

An elementary treatise on human anatomy / by Joseph Leidy.

Contributors

Leidy, Joseph, 1823-1891.
National Library of Medicine (U.S.)

Publication/Creation

Philadelphia : Lippincott, 1861.

Persistent URL

<https://wellcomecollection.org/works/pxpsmdeh>

License and attribution

This material has been provided by This material has been provided by the National Library of Medicine (U.S.), through the Medical Heritage Library. The original may be consulted at the National Library of Medicine (U.S.) where the originals may be consulted.

This work has been identified as being free of known restrictions under copyright law, including all related and neighbouring rights and is being made available under the Creative Commons, Public Domain Mark.

You can copy, modify, distribute and perform the work, even for commercial purposes, without asking permission.



Wellcome Collection
183 Euston Road
London NW1 2BE UK
T +44 (0)20 7611 8722
E library@wellcomecollection.org
<https://wellcomecollection.org>




NATIONAL LIBRARY OF MEDICINE
Bethesda, Maryland




Geo. C. Lippincott
Salem

May 5. 1873

N. J.



Sanctions, to which they were obliged for the faculty of doctors.
"Syphilis" a Latin poem by Fracastorius (an Italian) in 1530
Sinacra - first president of the Coll. Physicians formed in 1518 by Ho.



Geo. C. Lippincott
AN
Salem,
N.J.,

ELEMENTARY TREATISE

ON

HUMAN ANATOMY.

BY

JOSEPH LEIDY, M.D.,

PROFESSOR OF ANATOMY IN THE UNIVERSITY OF PENNSYLVANIA; CURATOR OF THE ACADEMY OF NATURAL SCIENCES; MEMBER OF THE AMER. PHILOS. SOC.; COL. OF PHYSICIANS, PHILADELPHIA; AMER. ACAD. OF ARTS AND SCIENCES; NAT. HIST. SOC., BOSTON; LYC. NAT. HIST., NEW YORK; ELLIOT NAT. HIST. SOC., CHARLESTON; MED. SOC. OF VIRGINIA; ACAD. OF SCIENCES, ST. LOUIS; IMP. SOC. OF NATURALISTS, MOSCOW; IMP. LEOPOLD. CAROL. ACAD. OF SCIENCES, JENA; ROY. ACAD. OF SCIENCES, MUNICH; BIOLOG. SOC., PARIS; SOC. OF ARTS AND SCIENCES, MONS; ZOOLOG. SOC., LONDON; UNIV. ZOOL. AND BOT. ASSOC., DUBLIN, ETC.

WITH THREE HUNDRED AND NINETY-TWO ILLUSTRATIONS.

PHILADELPHIA:


J. B. LIPPINCOTT & CO.

1861.

Entered, according to act of Congress, in the year 1860, by

JOSEPH LEIDY, M.D.,

In the Clerk's Office of the District Court of the United States for the Eastern
District of Pennsylvania.



PREFACE.

As indicated by its title, the present work is intended as an elementary treatise on human anatomy, and is not an elaborate system adapted to the use of those who have already advanced in anatomical knowledge. The author has attempted to prepare such a book as he feels would have been of service to himself in the commencement of his studies, and he hopes it may be found worthy of the approbation of students, for whom, and by whose frequent solicitation, it was written.

Much of the difficulty, of which we hear constant complaint, in the acquisition and retention of anatomical knowledge, arises from an excessive, and, in some other respects, objectionable nomenclature. Not only has the naming of comparatively unimportant parts been carried to an extreme, but, in numerous instances, the same parts are designated by a multitude of names, which are indiscriminately used by different writers. The nomenclature of anatomy has been founded on no particular system; the names having been chosen, according to the fancy of anatomists, from the shape, function, or supposed resemblance of the part, or in commemoration of the original investigator. In some measure to avoid the difficulty to which we refer, the author has adopted the plan of generally using a single name for each part;

25/11/11 X 00H
D + 51R

of the many names employed, to use that which is most expressive of the character of the part; and, when admissible, the name is anglicized. A copious synonymy is added, in foot-notes, which may be found useful for future reference.

Many of the drawings accompanying the work are original, and were made by the author, or by his friend Dr. H. D. Schmidt, favorably known for his anatomical investigations. The excellent wood engravings, with few exceptions, are from the masterly hand of August Wilhelm, a young artist of this city.

CONTENTS.

CHAPTER I.

	PAGE
INTRODUCTION - - - - -	17
Ultimate Chemical Elements of the Human Body - - - -	25
Proximate Chemical Elements of the Human Body - - - -	26
Group 1. Nitrogenized Elements peculiarly Organic - - -	26
“ 2. Non-Nitrogenized Elements peculiarly Organic - -	27
“ 3. Elements not peculiarly Organic - - - - -	28
“ 4. Elements arising from the disintegration of the different parts of the body, for the most part expelled in the excretion - - - - -	28
Ultimate Physical Elements of the Human Body - - - -	29
The Proximate Physical Elements of the Tissues of the Human Body -	32

CHAPTER II.

THE SKELETON - - - - -	33
Development and Growth of the Skeleton - - - - -	42
Articulations or Joints of the Skeleton - - - - -	46
Of the Relative Position of the Different Structures entering into the Composition of Articulations - - - - -	48
Bones of the Head or Skull - - - - -	50
Bones of the Cranium - - - - -	50
The Occipital Bone - - - - -	50
The Sphenoid Bone - - - - -	52
The Ethmoid Bone - - - - -	56
The Frontal Bone - - - - -	58
The Parietal Bone - - - - -	60
The Temporal Bone - - - - -	61
Structure and Articulation of the Bones of the Cranium - - -	65
General Conformation of the Cranium - - - - -	67
Mechanical Construction of the Cranium - - - - -	70
Development of the Cranium - - - - -	73
Supernumerary Bones of the Cranium - - - - -	75
Bones of the Face - - - - -	75
The Superior Maxillary Bone - - - - -	76
The Palate Bone - - - - -	78
The Lachrymal Bone - - - - -	80
The Nasal Bone - - - - -	81
The Turbinated Bone - - - - -	81
The Vomer - - - - -	82
The Malar Bone - - - - -	83

THE SKELETON—Continued.

	PAGE
The Inferior Maxillary Bone - - - - -	83
Structure and Articulation of the Bones of the Face - - - - -	85
The Temporo-maxillary Articulation - - - - -	86
General Conformation and Position of the Face - - - - -	87
The Side of the Skull - - - - -	88
The Base of the Skull - - - - -	90
The Orbits - - - - -	91
The Nasal Cavities - - - - -	92
Development of the Face - - - - -	94
Changes of the Skull at Different Periods of Life - - - - -	94
The Hyoid Bone - - - - -	96
The Trunk - - - - -	96
The Vertebral Column - - - - -	97
The True Vertebrae - - - - -	97
The Cervical Vertebrae - - - - -	99
The Dorsal Vertebrae - - - - -	102
The Lumbar Vertebrae - - - - -	103
The False Vertebrae - - - - -	103
The Sacrum - - - - -	104
The Coccyx - - - - -	105
Development of the Vertebrae - - - - -	106
Articulations of the Vertebral Column - - - - -	107
Articulations of the Occipital Bone, the Atlas, and the Axis - - - - -	111
The Vertebral Column viewed Entire - - - - -	113
The Ribs - - - - -	114
The Sternum - - - - -	117
Articulations of the Ribs with the Vertebrae and Sternum - - - - -	118
The Thorax - - - - -	119
The Hip or Innominate Bones - - - - -	121
Articulations of the Hip Bones - - - - -	125
The Pelvis - - - - -	126
Sexual Differences of the Pelvis - - - - -	128
The Upper Extremities - - - - -	129
Bones of the Shoulder - - - - -	129
The Clavicle - - - - -	129
The Scapula - - - - -	130
Bones of the Arm and Forearm - - - - -	132
The Humerus - - - - -	132
The Ulna - - - - -	134
The Radius - - - - -	135
Bones of the Hand - - - - -	136
Bones of the Carpus - - - - -	136
Bones of the Metacarpus - - - - -	138
Bones of the Fingers - - - - -	139
The Hand - - - - -	140
Development of the Bones of the Upper Extremities - - - - -	141
Articulations and Movements of the Upper Extremities.—The Sterno-clavicular Articulation - - - - -	141

CONTENTS.

vii

THE SKELETON—Continued.

	PAGE
The Scapulo-clavicular Articulation - - - - -	142
The Shoulder Joint - - - - -	143
The Elbow Joint - - - - -	144
The Superior Radio-ulnar Articulation - - - - -	145
The Middle " " - - - - -	145
The Inferior " " - - - - -	145
The Wrist Joint, or Radio-carpal Articulation - - - - -	146
The Intercarpal and Carpo-metacarpal Articulations - - - - -	147
The Metacarpo-phalangeal and Phalangeal Articulations - - - - -	147
The Lower Extremity - - - - -	148
The Femur - - - - -	148
The Patella - - - - -	150
The Bones of the Leg - - - - -	150
The Tibia - - - - -	150
The Fibula - - - - -	152
Bones of the Foot - - - - -	153
Bones of the Tarsus - - - - -	153
Bones of the Metatarsus - - - - -	156
Bones of the Toes - - - - -	157
The Foot - - - - -	157
Development of the Bones of the Lower Extremity - - - - -	158
Articulations and Movements of the Lower Extremities - - - - -	158
The Hip Joint - - - - -	159
The Knee Joint - - - - -	160
The Tibio-fibular Articulations - - - - -	163
The Ankle Joint - - - - -	163
The Intertarsal and Tarso-metatarsal Articulations—Articulations of the Astragalus, Calcaneum, and Scaphoid Bone - - - - -	164
Articulation of the Calcaneum and Cuboid Bone - - - - -	165
Articulation of the Scaphoid, Cuboid, and Cuneiform Bones together and with the Bases of the Metatarsal Bones - - - - -	165
Metatarso-phalangeal and Phalangeal Articulations - - - - -	166

CHAPTER III.

THE FIBROUS, CARTILAGINOUS, FIBRO-CARTILAGINOUS, ELASTIC, AND ADIPOSE

TISSUES - - - - -	167
Fibrous Tissue - - - - -	167
Cartilage and Fibro-cartilage - - - - -	171
Elastic Tissue - - - - -	175
Adipose Tissue - - - - -	176

CHAPTER IV.

THE MUSCULAR SYSTEM - - - - -	178
General Remarks on the Head - - - - -	183
Fascia of the Head - - - - -	185
Muscles of the Scalp - - - - -	185
Muscles of the Eyelids and Eyebrows - - - - -	187

THE MUSCULAR SYSTEM—Continued.	PAGE
Muscles of the Nose - - - - -	188
Muscles of the Lip and Cheek - - - - -	188
The Muscles of the Lower Jaw, or of Mastication - - - - -	191
The Neck - - - - -	193
Muscles and Fasciæ of the Neck.—The Subcutaneous Cervical Muscle	193
The Cervical Fascia - - - - -	194
The Sterno-mastoid Muscle - - - - -	195
Depressors of the Hyoid Bone and Larynx - - - - -	195
Elevators of the Hyoid Bone and Larynx - - - - -	196
Deep Muscles of the Front of the Neck - - - - -	197
Topographical Sketch of the Anatomy of the Neck - - - - -	199
Front of the Thorax - - - - -	200
Muscles of the Front and Sides of the Thorax - - - - -	201
The Back - - - - -	203
Superficial Muscles of the Back - - - - -	203
Deep Muscles of the Back, or Extensors of the Head and Trunk - - - - -	206
Muscles of the Ribs - - - - -	210
The Abdomen - - - - -	211
Superficial Fascia of the Abdomen - - - - -	212
Muscles of the Abdomen - - - - -	213
The Lumbar Fascia - - - - -	218
The Transverse Fascia of the Abdomen - - - - -	218
The Inguinal Canal - - - - -	219
Remarks on Inguinal Hernia - - - - -	220
The Diaphragm - - - - -	221
The Upper Extremity - - - - -	223
Fasciæ of the Upper Extremity - - - - -	224
Muscles of the Shoulder - - - - -	226
Muscles of the Arm - - - - -	227
Muscles of the Front of the Forearm - - - - -	230
Muscles of the Back of the Forearm - - - - -	233
Muscles of the Hand - - - - -	236
Muscles of the Ball of the Thumb - - - - -	236
Muscles of the Little Finger - - - - -	237
The Interosseous Muscles - - - - -	237
The Lower Extremities - - - - -	238
Fasciæ of the Lower Extremity - - - - -	238
Sketch of the Anatomy concerned in Femoral Hernia - - - - -	242
Muscles of the Buttock - - - - -	244
The Iliac Fascia - - - - -	247
Muscles of the Iliac Region and Loin - - - - -	247
Muscles on the Front of the Thigh - - - - -	248
Muscles on the Back of the Thigh - - - - -	250
Muscles of the Front and Outer Part of the Leg, and Upper Part of the	
Foot - - - - -	252
Muscles on the Back of the Leg - - - - -	254
Muscles of the Sole of the Foot - - - - -	256
The Interosseous Muscles of the Foot - - - - -	258

CHAPTER V.

	PAGE
ANATOMICAL ELEMENTS OF SEROUS AND MUCOUS MEMBRANES, THE GLANDS,	
THE LUNGS, AND THE SKIN - - - - -	259
Serous Membranes - - - - -	263
Mucous Membranes - - - - -	266
The Glandular System - - - - -	267
Unstriated Muscular Tissue - - - - -	271

CHAPTER VI.

THE ALIMENTARY APPARATUS - - - - -	273
The Mouth - - - - -	273
Muscles of the Palate and Fauces - - - - -	277
The Salivary Glands - - - - -	278
The Tongue - - - - -	280
Muscles of the Tongue - - - - -	283
The Teeth - - - - -	285
Characters of the Permanent Teeth - - - - -	286
Characters of the Temporary Teeth - - - - -	288
Structure of the Teeth - - - - -	289
Development of the Teeth - - - - -	292
The Pharynx - - - - -	294
Muscles of the Pharynx - - - - -	295
The Œsophagus - - - - -	297
The Cavity of the Abdomen - - - - -	298
The Peritoneum - - - - -	300
The Stomach - - - - -	305
The Small Intestine - - - - -	309
The Large Intestine - - - - -	315
The Rectum - - - - -	318
The Pancreas - - - - -	320
The Liver - - - - -	321
Structure of the Liver - - - - -	324
Biliary Ducts and Gall-bladder - - - - -	328
The Spleen - - - - -	329

CHAPTER VII.

THE VASCULAR SYSTEM - - - - -	332
General Character of the Arteries - - - - -	332
General Character of the Veins - - - - -	335
The Capillaries - - - - -	337
The Blood - - - - -	338
The Heart - - - - -	341
Structure of the Heart - - - - -	347
The Pericardium - - - - -	349
Mechanism of Action of the Heart - - - - -	349
The Arteries - - - - -	351

THE VASCULAR SYSTEM—Continued.	PAGE
The Aorta - - - - -	351
The Arch of the Aorta - - - - -	351
The Coronary Arteries - - - - -	353
The Innominate Artery - - - - -	353
The Common Carotid Artery - - - - -	354
The External Carotid Artery - - - - -	355
The Internal Carotid Artery - - - - -	363
The Subclavian Arteries - - - - -	367
The Axillary Artery - - - - -	372
The Brachial Artery - - - - -	374
The Radial Artery - - - - -	376
The Ulnar Artery - - - - -	379
Thoracic Aorta - - - - -	381
Abdominal Aorta - - - - -	383
The Cœliac Axis - - - - -	384
The Superior Mesentery Artery - - - - -	386
The Inferior Mesentery Artery - - - - -	388
The Middle Sacral Artery - - - - -	389
Arteries in Pairs from the Abdominal Aorta - - - - -	389
The Common Iliac Arteries - - - - -	390
The Internal Iliac Artery - - - - -	391
The External Iliac Artery - - - - -	395
The Femoral Artery - - - - -	396
The Popliteal Artery - - - - -	399
The Anterior Tibial Artery - - - - -	400
The Dorsal Pedal Artery - - - - -	401
The Posterior Tibial Artery - - - - -	402
The Pulmonary Artery - - - - -	405
The Veins - - - - -	405
The Coronary Vein - - - - -	405
The Superior Cava - - - - -	406
The Innominate Veins - - - - -	406
Veins of the Head and Neck - - - - -	408
The Internal Jugular Vein - - - - -	409
Sinuses of the Dura Mater - - - - -	409
Veins of the Brain - - - - -	412
The Diploic and Meningeal Veins - - - - -	413
The Ophthalmic Vein - - - - -	413
The External Jugular Vein - - - - -	413
The Facial Vein - - - - -	414
The Temporal Vein - - - - -	414
The Internal Maxillary Vein - - - - -	415
The Temporo-maxillary Vein - - - - -	415
The Posterior Auricular Vein - - - - -	415
The Occipital Vein - - - - -	416
The Veins of the Tongue - - - - -	416
The Pharyngeal Vein - - - - -	416
The Superior Thyroid Veins - - - - -	416

THE VASCULAR SYSTEM—Continued.	PAGE
The Veins of the Upper Extremities - - - - -	416
The Subclavian Vein - - - - -	417
The Deep Veins of the Upper Extremity - - - - -	417
The Superficial Veins of the Upper Extremity - - - - -	417
The Azygos Vein - - - - -	419
The Inferior Cava - - - - -	420
Branches of the Inferior Cava - - - - -	420
The Portal Vein - - - - -	421
The Veins of the Vertebral Column - - - - -	423
The Common Iliac Veins - - - - -	423
The Internal Iliac Vein - - - - -	424
The External Iliac Vein - - - - -	425
The Deep Veins of the Lower Extremity - - - - -	426
The Superficial Veins of the Lower Extremity - - - - -	426
The Pulmonary Veins - - - - -	428
The Lymphatic System - - - - -	428
The Trunks of the Lymphatic System - - - - -	430
The Thoracic Duct - - - - -	431
The Right Lymphatic Duct - - - - -	432
Lymphatics of the Head and Neck - - - - -	432
Lymphatics of the Cranial Cavity - - - - -	432
Lymphatics of the Exterior of the Cranium - - - - -	433
Lymphatics of the Face - - - - -	434
Lymphatics of the Neck - - - - -	434
Lymphatics of the Upper Extremities, and of the Exterior of the Thorax - - - - -	435
Lymphatics of the Cavity of the Thorax - - - - -	435
Lymphatics of the Lower Extremities and of the Pelvis - - - - -	437
Lymphatics of the Cavity of the Abdomen - - - - -	438

CHAPTER VIII.

THE VOCAL AND RESPIRATORY APPARATUS - - - - -	440
The Larynx - - - - -	440
Cartilages of the Larynx - - - - -	440
Articulations and Ligaments of the Larynx - - - - -	442
Muscles of the Larynx - - - - -	443
The Cavity of the Larynx - - - - -	445
The Organs of Respiration - - - - -	447
The Trachea - - - - -	447
The Lungs - - - - -	450
The Pleura - - - - -	454
The Thyroid Body - - - - -	455
The Thymus Body - - - - -	456

CHAPTER IX.

	PAGE
THE URINARY ORGANS - - - - -	458
The Kidneys - - - - -	458
The Urinary Bladder - - - - -	462
The Urethra - - - - -	465
The Supra-renal Bodies - - - - -	465

CHAPTER X.

THE GENERATIVE APPARATUS - - - - -	468
The Male Organs of Generation - - - - -	468
The Testicles - - - - -	468
The Seminal Vesicles and Ejaculatory Ducts - - - - -	473
The Penis - - - - -	475
The Urethra of the Male - - - - -	478
The Prostate and Suburethral Glands - - - - -	480
The Female Organs of Generation - - - - -	481
The Uterus - - - - -	481
Ligaments of the Uterus - - - - -	484
The Ovaries - - - - -	485
The Parovarium - - - - -	487
The Fallopian Tubes, or Oviducts - - - - -	488
The Vagina - - - - -	489
The Vulva - - - - -	491
The Cavity of the Pelvis - - - - -	494
The Perineum - - - - -	496
The Pelvic and Perineal Fasciæ - - - - -	496
Muscles of the Perineum - - - - -	498
The Mammæ - - - - -	499

CHAPTER XI.

THE NERVOUS SYSTEM - - - - -	503
General Character and Structure of the Cerebro-spinal Axis - - - - -	503
General Character and Structure of the Cerebro-spinal Nerves - - - - -	507
Origin and Termination of the Cerebro-spinal Nerves - - - - -	509
General Character and Structure of the Sympathetic Nerves - - - - -	511
General Character and Structure of the Ganglia - - - - -	512
The Cerebro-spinal Axis, or Brain and Spinal Cord - - - - -	513
The Brain - - - - -	514
The Cerebrum - - - - -	515
Fornix - - - - -	521
Pellucid Septum - - - - -	521
Lateral Ventricles - - - - -	521
Corpora Striata, or Striated Bodies - - - - -	523
Third Ventricle - - - - -	523
Thalami - - - - -	524
Quadrigeminal Body - - - - -	525

THE NERVOUS SYSTEM—Continued.

	PAGE
Pineal Gland - - - - -	526
Commissures of the Third Ventricle - - - - -	526
The Cerebellum - - - - -	526
Dentated Body - - - - -	528
Crura of the Cerebellum - - - - -	528
The Pons - - - - -	529
The Medulla Oblongata - - - - -	530
Fourth Ventricle - - - - -	531
The Spinal Cord - - - - -	533
Membranes of the Brain and Spinal Cord - - - - -	535
The Pia Mater - - - - -	535
Pia Mater of the Brain - - - - -	535
Pia Mater of the Spinal Cord - - - - -	536
The Ependyma - - - - -	537
The Dura Mater - - - - -	537
Dura Mater of the Brain - - - - -	537
Dura Mater of the Spinal Cord - - - - -	539
The Arachnoid Membrane - - - - -	539
The Nerves of the Brain, or the Cerebral Nerves - - - - -	540
The Olfactory, or First Pair of Nerves - - - - -	540
The Optic, or Second Pair of Nerves - - - - -	541
The Oculo-motor, or Third Pair of Nerves - - - - -	541
The Pathetic, or Fourth Pair of Nerves - - - - -	542
The Trifacial, or Fifth Pair of Nerves - - - - -	542
The Ophthalmic Nerve - - - - -	543
The Ophthalmic Ganglion - - - - -	544
The Superior Maxillary Nerve - - - - -	545
The Spheno-palatine Ganglion - - - - -	546
The Inferior Maxillary Nerve - - - - -	548
The Otic Ganglion - - - - -	550
The Submaxillary Ganglion - - - - -	550
The Abducent, or Sixth Pair of Nerves - - - - -	550
The Facial, or Seventh Pair of Nerves - - - - -	551
The Auditory, or Eighth Pair of Nerves - - - - -	553
The Glosso-Pharyngeal, or Ninth Pair of Nerves - - - - -	553
The Pneumogastric, or Tenth Pair of Nerves - - - - -	555
The Accessory, or Eleventh Pair of Nerves - - - - -	558
The Hypoglossal, or Twelfth Pair of Nerves - - - - -	559
The Spinal Nerves - - - - -	559
The Cervical Nerves - - - - -	561
Posterior Branches of the Cervical Nerves - - - - -	561
Anterior Branches of the Cervical Nerves - - - - -	562
The Cervical Plexus - - - - -	562
The Brachial Plexus - - - - -	563
The Thoracic Nerves - - - - -	570
Posterior Branches of the Thoracic Nerves - - - - -	571
Anterior Branches of the Thoracic Nerves - - - - -	571
The Intercostal Nerves - - - - -	571

THE NERVOUS SYSTEM—Continued.	PAGE
The Lumbar Nerves - - - - -	572
The Lumbar Plexus - - - - -	573
The Sacral and Coccygeal Nerves - - - - -	576
The Sacral Plexus - - - - -	577
The Sympathetic System of Nerves - - - - -	581
Cervical Portion of the Sympathetic Nerve - - - - -	582
The Cardiac Plexus - - - - -	584
Thoracic Portion of the Sympathetic Nerve - - - - -	585
The Solar Plexus - - - - -	585
Lumbar and Sacral Portions of the Sympathetic Nerves - - - - -	587
The Hypogastric Plexus - - - - -	587

CHAPTER XII.

THE ORGANS OF SPECIAL SENSE - - - - -	588
The Nose - - - - -	588
The Nasal Cavities - - - - -	591
The Eye - - - - -	594
The Eyebrows - - - - -	595
The Eyelids - - - - -	595
The Conjunctiva - - - - -	597
The Lachrymal Apparatus - - - - -	598
The Eyeball - - - - -	600
Muscles of the Eyeball - - - - -	601
The Sclerotica - - - - -	602
The Cornea - - - - -	603
The Choroidea - - - - -	604
The Iris - - - - -	607
The Retina - - - - -	608
The Aqueous Humor - - - - -	610
The Crystalline Lens - - - - -	610
The Vitreous Humor - - - - -	611
The Ear - - - - -	612
The External Ear - - - - -	612
The Middle Ear - - - - -	616
The Internal Ear - - - - -	621
The Organ of Taste - - - - -	628
The Skin and its Appendages - - - - -	628
The Dermis - - - - -	629
The Epidermis - - - - -	631
The Sweat Glands - - - - -	633
The Sebaceous Glands - - - - -	634
The Hairs - - - - -	636
The Nails - - - - -	640

LIST OF ILLUSTRATIONS.

[Those marked with an asterisk are by the author. The names opposite the others indicate the authorities from which they have been obtained. When the illustrations differ from the original drawings they have been altered by the author or by Dr. Schmidt.]

FIG.

- 1 *Monas crepusculum*.*
- 2 *Vibrios*.*
- 3 Diagram of a typical organic cell.*
- 4 *Trachelomonas volvocina*, from stagnant water.*
- 5 *Protococcus*, from damp pavements, multiplying by division.*
- 6 Ciliated epithelial cell.*
- 7 Progressive division or segmentation of the yolk in the human egg.*
- 8 Process of multiplication of cartilage cells.*
- 9 Process of development of an organic cell from a granule.*
- 10 Three secreting cells from the submaxillary salivary gland.*
- 11 A lymph corpuscle.*
- 12 Epithelial cells of a serous membrane.*
- 13 Exhibits the progressive development of the epidermis.*
- 14 Mode of development, from below upward, of columnar epithelial cells.*
- 15 Mode of development of unstriated muscular fibre.*
- 16 Nerve cell.*
- 17 Mode of development of capillary vessels from cells.*
- 18 Development of striated muscular fibre, from cells.*
- 19 Development of fibrous tissue.*
- 20 Longitudinal section of the proximal extremity of the femur. *Ibbotson*.
- 21 Horizontal section of the condyles of the femur. *Ibid.*
- 22 Vertical section, antero-posteriorly, of the calcaneum. *Ibid.*
- 23 Transverse section of the shaft of a phalanx.*
- 24 Transverse section of bone from the shaft of the femur.*
- 25 An osseous lacuna.*
- 26 Thin plate from the ethmoid bone.*
- 27 Development of the femur. *Wilhelm*.
- 28 Development of the vertebræ. *Quain & Sharpey*.
- 29 Development of the epiphyses to the vertebræ. *Ibid.*
- 30 External view of the occipital bone. *Wilson*.
- 31 Internal view of the occipital bone. *Ibid.*
- 32 Front view of the sphenoid bone. *Schmidt*.

FIG.

- 33 Upper view of the sphenoid bone.*
- 34 Upper view of the ethmoid bone. *Wilson.*
- 35 External view of the frontal bone. *Ibid.*
- 36 Internal view of the frontal bone. *Ibid.*
- 37 Outer view of the left parietal bone. *Ibid.*
- 38 Inner view of the left parietal bone. *Ibid.*
- 39 External view of the temporal bone of the right side.*
- 40 Internal view of the temporal bone of the left side. *Packard.*
- 41 Inferior view of the left temporal bone.*
- 42 Internal view of the base of the cranium of the left side. *Schmidt.*
- 43 External view of the base of the skull, right side. *Ibid.*
- 44 Antero-posterior section of the cranium.*
- 45 Horizontal section of the cranium.*
- 46 Transverse section through the front of the cranium.*
- 47 Transverse section in advance of the middle of the cranium.*
- 48 Transverse section through the middle of the cranium.*
- 49 Transverse section posterior to the middle of the cranium.*
- 50 Two pieces of the temporal bone. *Quain & Sharpey.*
- 51 Superior maxillary bone of the left side. *Schmidt.*
- 52 Superior maxillary bone of the left side. *Ibid.*
- 53 Posterior view of the right palate bone. *Wilson.*
- 54 Exterior view of the right palate bone. *Ibid.*
- 55 External view of the right lachrymal bone. *Ibid.*
- 56 Anterior view of the left nasal bone. *Ibid.*
- 57 External view of the right turbinated bone. *Horner.*
- 58 Left side of the vomer. *Wilson.*
- 59 Outer view of the right malar bone. *Ibid.*
- 60 Inferior maxillary bone. *Ibid.*
- 61 Vertical section of the articulation of the lower jaw. *Ibid.*
- 62 External view of the temporo-maxillary articulation. *Ibid.*
- 63 The skull, seen partly in front and on the right side. *Wilhelm.*
- 64 View of the right side of a portion of the face and cranium. *Schmidt.*
- 65 View of the right half of the base of the skull. *Ibid.*
- 66 Vertical section of the face. *Ibid.*
- 67 View of the outer wall of the right nasal fossa. *Ibid.*
- 68 The hyoid bone. *Wilson.*
- 69 The vertebral column. *Morton.*
- 70 Side view of a dorsal vertebra. *Wilson.*
- 71 Upper view of a cervical vertebra. *Ibid.*
- 72 Upper view of the atlas. *Ibid.*
- 73 Side view of the axis. *Ibid.*
- 74 Side view of a dorsal vertebra. *Ibid.*
- 75 Side view of a lumbar vertebra. *Ibid.*
- 76 Front view of the sacrum. *Ibid.*
- 77 Back view of the sacrum. *Ibid.*
- 78 Posterior view of the coccyx. *Morton.*

- FIG.
- 79 Development of the vertebræ. *Quain & Sharpey.*
 - 80 Development of the epiphyses to the vertebræ. *Ibid.*
 - 81 Upper view of a lumbar vertebra. *Ibid.*
 - 82 Vertical section of two lumbar vertebræ. *Ibid.*
 - 83 Three vertebral arches removed from as many dorsal vertebræ. *Wilson.*
 - 84 Portion of the occipital bone, with the atlas and axis. *Ibid.*
 - 85 Three dorsal vertebræ. *Ibid.*
 - 86 Portion of the cranium and of the atlas and axis. *Ibid.*
 - 87 Bodies of three dorsal vertebræ. *Ibid.*
 - 88 Portion of the occipital bone, with the atlas and axis. *Ibid.*
 - 89 Portion of the occipital bone and the upper three cervical vertebræ. *Ibid.*
 - 90 Portion of the skull, the atlas, and axis. *Ibid.*
 - 91 Front view of the thorax. *Ibid.*
 - 92 Anterior view of three dorsal vertebræ and their articulation with the ribs. *Ibid.*
 - 93 Posterior view of four dorsal vertebræ and their articulation with the ribs. *Ibid.*
 - 94 Front view of the thorax. *Ibid.*
 - 95 Inner view of the left hip or innominate bone. *Schmidt.*
 - 96 Outer view of the left hip or innominate bone. *Wilson.*
 - 97 Ligaments of the pelvis and hip joint. *Ibid.*
 - 98 Ligaments of the pelvis and hip joint. *Ibid.*
 - 99 Front view of a female pelvis. *Ibid.*
 - 100 Clavicle of the right side. *Ibid.*
 - 101 The scapula of the left side. *Ibid.*
 - 102 Anterior view of the scapula. *Ibid.*
 - 103 Humerus of the left side. *Ibid.*
 - 104 The two bones of the left forearm. *Ibid.*
 - 105 Bones of the carpus. *Ibid.*
 - 106 The left hand. *Ibid.*
 - 107 Sterno-clavicular, costo-clavicular, and costo-sternal articulations. *Ibid.*
 - 108 Scapulo-clavicular and scapulo-humeral articulations. *Ibid.*
 - 109 The elbow joint. *Ibid.*
 - 110 The same elbow joint. *Ibid.*
 - 111 Ligaments of the wrist and hand. *Ibid.*
 - 112 Femur of the right side. *Ibid.*
 - 113 Patella of the right side. *Ibid.*
 - 114 Tibia and fibula of the left leg. *Ibid.*
 - 115 Tibia and fibula of the right leg. *Ibid.*
 - 116 Dorsal surface of the right foot. *Ibid.*
 - 117 Sole of the left foot. *Ibid.*
 - 118 Ligaments of the hip. *Ibid.*
 - 119 The right knee joint. *Ibid.*
 - 120 Front view of the right knee joint. *Ibid.*
 - 121 Longitudinal section of the left knee joint. *Ibid.*
 - 122 Posterior view of the inferior tibio-fibular and ankle joints. *Ibid.*

- FIG.
- 123 External view of the right ankle joint. *Wilson.*
 - 124 Internal view of the ankle joint. *Ibid.*
 - 125 Ligaments of the sole of the foot. *Ibid.*
 - 126 Example of fibrous tissue.*
 - 127 Examples of fibrous tissue.*
 - 128 Portion of connective tissue.*
 - 129 Fibrous tissue.*
 - 130 Portion of connective tissue.*
 - 131 Crossing bands of fibrous tissue.*
 - 132 Cartilage.*
 - 133 Vertical section of articular cartilage.*
 - 134 Section of costal cartilage.*
 - 135 Section of costal cartilage.*
 - 136 Section of fibro-cartilage from the auricle of the ear.*
 - 137 Elastic tissue.*
 - 138 Elastic tissue. *Kölliker.*
 - 139 Elastic tissue. *Ibid.*
 - 140 Adipose tissue, with connective tissue.*
 - 141 Transverse section of the lower end of the ulno-carpal flexor.*
 - 142 Transverse section of a muscular fasciculus.*
 - 143 Two portions of a muscular fasciculus.*
 - 144 Two muscular fibres.*
 - 145 Fibrils from a muscular fibre of the axolotl. *Kölliker.*
 - 146 A muscular fibre of a salamander.*
 - 147 Muscles of the head and neck. *Sappey.*
 - 148 View of the interior part of the left side of the face. *Jamain.*
 - 149 View of the temporal muscle. *After Bonamy & Beau, Morton.*
 - 150 Inner part of the ramus of the lower jaw. *Wilson.*
 - 151 Front view of the muscles of the neck. *Ibid.*
 - 152 Deep muscles of the front of the neck. *Morton.*
 - 153 Muscles of the front of the thorax and abdomen. *Wilson.*
 - 154 Muscles of the back. *Ibid.*
 - 155 Extensor muscles of the back. *Ibid.*
 - 156 Muscles of the front of the trunk. *Ibid.*
 - 157 View of the left side of the abdomen. *Ibid.*
 - 158 View of the inguinal canal. *Sappey.*
 - 159 Inferior view of the diaphragm. *Wilson.*
 - 160 Muscles of the back of the scapula. *After Bonamy & Beau, Morton.*
 - 161 Muscles of the front of the scapula. *Ibid.*
 - 162 The deltoid muscle. *Ibid.*
 - 163 Muscles of the fore part of the arm. *Wilson.*
 - 164 View of the triceps extensor, on the back of the right arm. *Ibid.*
 - 165 Superficial muscles of the front of the forearm. *Ibid.*
 - 166 Deep muscles of the front of the forearm. *Ibid.*
 - 167 Metacarpal and phalangeal bones of the fingers, with their tendons and ligaments. *Quain & Sharpey.*

- FIG.
- 168 Muscles of the back of the forearm. *Wilson*.
- 169 Deep muscles of the back of the forearm. *Ibid*.
- 170 Muscles of the palmar surface of the hand. *Ibid*.
- 171 View of the inguinal canal. *Sappey*.
- 172 Muscles of the buttock. *Wilson*.
- 173 Muscles of the iliac region and front of the thigh. *Ibid*.
- 174 Muscles of the back of the right buttock and thigh. *Ibid*.
- 175 Muscles of the front of the leg and back of the foot. *Ibid*.
- 176 Superficial muscles on the back of the right leg. *Ibid*.
- 177 Deep muscles of the back of the leg. *Ibid*.
- 178 Muscles of the sole of the foot. *Ibid*.
- 179 Deep muscles of the sole. *Ibid*.
- 180 Diagram exhibiting the relative position of the common anatomical elements of serous and mucous membranes, the glands, the lungs, and the skin.*
- 181 Squamous epithelium.*
- 182 Pavement epithelium.*
- 183 Polyhedral epithelium.*
- 184 Diagram of a vertical section of mucous membrane of the small intestine.*
- 185 Diagram of a vertical section of the bronchial mucous membrane.*
- 186 Diagram of a section of the mucous membrane of the mouth.*
- 187 Diagram exhibiting the relation of a serous membrane, the pleura, to the organ it invests and the cavity it lines.*
- 188 Diagram of two simple tubular glands.*
- 189 Simple gland dilated into a pouch.*
- 190 Glands rendered slightly complex by division at bottom.*
- 191 Increase of complexity of glands.*
- 192 A tubular gland.*
- 193 Gland of complex form.*
- 194 Gland of complex form.*
- 195 Gland of complex character.*
- 196 A racemose gland.*
- 197 Unstriated muscular fibre.*
- 198 Vertical section of the face and neck, through the median line, antero-posteriorly, exposing to view the nose, mouth, pharynx and larynx. *Sappey*.
- 199 Section of a follicular gland from the root of the tongue. *Kölliker*.
- 200 Posterior view of the muscles of the palate and fauces. *After Bonamy & Beau, Morton*.
- 201 View of the upper surface of the tongue. *Sappey*.
- 202 Diagram of the papillæ of the tongue.*
- 203 Papillæ of the tongue.*
- 204 Side view of the muscles of the tongue. *After Bonamy & Beau, Morton*.
- 205 Upper and lower permanent teeth, exterior view. *Schmidt*.
- 206 Lateral views of same. *Ibid*.

- FIG.
 207 Temporary teeth of one side. *Schmidt*.
 208 Vertical section of a molar tooth.*
 209 Vertical section of the fang of a canine tooth.*
 210 Section of dentine.*
 211 Three enamel columns.*
 212 Section of enamel.*
 213 Diagram of the mode of development of the teeth. *After Goodsir, Kölliker*.
 214 Posterior view of the muscles of the pharynx. *Wilson*.
 215 Side view of the muscles of the pharynx. *Ibid*.
 216 Cavity of the abdomen laid open, with the viscera retained in their relative position. *Ibid*.
 217 Diagram of the reflections of the peritoneum in a vertical section of the abdomen.*
 218 The stomach and intestines. *Schmidt*.
 219 Wrinkled or rugous surface of the mucous membrane of the stomach. *Sappey*.
 220 Mammillæ of the mucous membrane of the stomach. *Ibid*.
 221 Small portion of the mucous membrane of the stomach, with the imbedded gastric glands.*
 222 A gastric gland.*
 223 Small portion of the mucous membrane from the upper part of the jejunum.*
 224 Portion of mucous membrane from the ileum.*
 225 Diagram of the structure of the mucous membrane of the ileum.*
 226 Portion of the duodenum. *Sappey*.
 227 A vertical section of the duodenum.*
 228 Portion of the mucous membrane from the upper part of the ileum. *Sappey*.
 229 Portion of the ileum. *Ibid*.
 230 The cæcum laid open, to expose the ileo-cæcal valve. *Morton*.
 231 Section of the mucous membrane of the colon.*
 232 Inferior surface of the liver.*
 233 Portion of the liver of the hog. *After Kiernan, Kölliker*.
 234 Portion of the liver of the hog. *Ibid*.
 235 Section of several lobules of the liver of the rabbit. *Kölliker*.
 236 Polyhedral epithelium.*
 237 Diagram representing the section of a lobule of the liver.*
 238 Diagram representing a transverse section of one of the cords of the hepatic cell-net.*
 239 Transverse section of the walls of the aorta. *Kölliker*.
 240 Elastic tissue from the middle coat of the popliteal artery. *Ibid*.
 241 Unstriated muscular fibres from the middle coat of the arteries. *Ibid*.
 242 Diagrams exhibiting the arrangement of the valves of veins. *Morton*.
 243 A small artery magnified. *Kölliker*.
 244 Red blood corpuscles.*
 245 Front view of the heart. *Quain & Sharpey*.

- FIG.
 246 Posterior or lower surface of the heart. *Quain & Sharpey*.
 247 View of the heart, with the anterior portions of the ventricles removed.
 Schmidt.
 248 Striated muscular tissue of the heart.*
 249 The aorta. *Bourgery*.
 250 Left common carotid dividing into the external and internal carotid arteries. *Ibid*.
 251 The external carotid artery and its branches. *Ibid*.
 252 Internal maxillary artery. *Ibid*.
 253 Arteries of the interior of the cranium. *Ibid*.
 254 View of the axillary artery. *Schmidt*.
 255 View of the axillary and brachial artery. *Ibid*.
 256 Arteries of the forearm. *Bourgery*.
 257 Arteries of the hand; palmar surface. *Ibid*.
 258 The aorta. *Ibid*.
 259 Distribution of the cœliac artery. *Wilson*.
 260 Distribution of the superior mesenteric artery. *Jamain*.
 261 Distribution of the inferior mesenteric artery. *Ibid*.
 262 View of the left side of the pelvis, the bladder, uterus, vagina, and rectum. *Ibid*.
 263 View of the perineum, exhibiting the distribution of the internal pudic artery. *Bourgery*.
 264 Arteries of the front of the thigh. *Jamain*.
 265 Arteries of the back of the thigh. *Ibid*.
 266 Arteries of the front of the leg. *Ibid*.
 267 Arteries of the back of the leg. *Ibid*.
 268 Arteries of the sole of the foot. *Ibid*.
 269 Veins of the thorax and abdomen. *Bourgery*.
 270 Veins of the head and neck. *Ibid*.
 271 Sinuses at the base of the cranium. *Schmidt*.
 272 Vertical section of the skull. *Ibid*.
 273 Superficial veins of the upper extremity. *Ibid*.
 274 Veins of the thorax and abdomen. *Bourgery*.
 275 The portal system of veins. *Quain & Sharpey*.
 276 Superficial veins of the back of the leg. *Bourgery*.
 277 Superficial veins of the inner part of the lower extremity. *Ibid*.
 278 Lymphatic capillary net-work of the skin of the ear. *Sappey*.
 279 View of the great lymphatic trunks. *Bourgery*.
 280 Lymphatics of the head and neck. *Ibid*.
 281 Cartilages of the larynx. *Quain & Sharpey*.
 282 View of the vocal membrane.*
 283 Muscles of the larynx.*
 284 Vertical section of the face and neck, through the median line antero-posteriorly, exposing to view the nose, mouth, pharynx and larynx.
 Sappey.
 285 Front of the larynx, trachea and bronchi, and back of the same. *Richardson*.

FIG.

- 286 The trachea, lungs and heart. *Bourger*.
- 287 Diagram of the two primary lobules of the lungs.*
- 288 Portion of the thyroid body in section. *Kölliker*.
- 289 One lobe of the thymus body, with its cavity laid open, and exhibiting the lobular recesses. *Ibid.*
- 290 Section of a lobule of the thymus body. *Ibid.*
- 291 Longitudinal section of a kidney.*
- 292 Diagram of the structure of the kidneys.*
- 293 Section of the cortical substance of a supra-renal body. *Kölliker*.
- 294 Cells from the supra-renal body. *Ibid.*
- 295 Testicle, with the vaginal tunic laid open. *Quain & Sharpey*.
- 296 Transverse section of the testicle. *Kölliker*.
- 297 Testicle, deprived of its tunics. *After Arnold, Kölliker*.
- 298 Portion of a seminiferous tubule. *Kölliker*.
- 299 Posterior view of the fundus of the bladder. *Cruveilhier*.
- 300 Spermatozooids. *Kölliker*.
- 301 Transverse section of the penis. *After Weber, Morton*.
- 302 Vertical section of the penis and bladder.*
- 303 Part of the bladder and penis, with the urethra laid open from above. *Wilson*.
- 304 Sketch of the uterus and its appendages. *Ibid.*
- 305 Section of the uterus antero-posteriorly, and section of the uterus from side to side.*
- 306 Transverse section of an ovary. *Kölliker*.
- 307 Human ovum. *Ibid.*
- 308 Two corpora lutea. *Ibid.*
- 309 Ovary, parovarium, and Fallopian tube of the left side.*
- 310 Section of female pelvis, from before backward. *Schmidt*.
- 311 External organs of generation.*
- 312 Side view of the male pelvis and its contents. *Wilson*.
- 313 View of the perineum. *Bourger*.
- 314 Several small lobules of the mammary gland of a pregnant woman. *After Langer, Kölliker*.
- 315 Diagram, exhibiting the course of a lactiferous duct. *After Cooper, Morton*.
- 316 Corpuscles observed in milk. *Kölliker*.
- 317 Nerve fibres of the white substance of the cerebrum.*
- 318 Portion of gray substance, from the exterior of the cerebellum.*
- 319 Large nerve cells from the anterior horns of the gray substance of the spinal cord. *Kölliker*.
- 320 Transverse section of the small sciatic nerve. *Ibid.*
- 321 Mode of anastomosis and branching of nerves.*
- 322 Structure of nerve fibres.*
- 323 Pacinian corpuscles.*
- 324 Elements of the sympathetic system. *Kölliker*.
- 325 Nerve cells from the semilunar ganglion of the trigeminal nerve. *Ibid.*

FIG.

- 326 Base of the brain. *After Hirschfeld, Sappey.*
- 327 Transverse section of the hemispheres of the cerebrum on a level with the corpus callosum.*
- 328 Section of the brain along the great longitudinal fissure. *After Hirschfeld, Sappey.*
- 329 Transverse section of the cerebral hemispheres, the corpus callosum removed, and the lateral ventricles exposed.*
- 330 Striated bodies, thalami, quadrigeminal body, and cerebellum. *After Hirschfeld, Sappey.*
- 331 Segment of the spinal cord.*
- 332 Oculo-motor and abducent nerve. *After Hirschfeld, Sappey.*
- 333 Trifacial nerve. *Ibid.*
- 334 Ophthalmic ganglion, the outer part of the right orbit removed. *Ibid.*
- 335 Superior maxillary nerve, the external wall of the left orbit and of the superior maxillary bone removed. *Ibid.*
- 336 View of the sphenopalatine ganglion, the outer wall of the left nasal cavity, and the olfactory nerve. *Ibid.*
- 337 Distribution of the inferior maxillary nerve. *Ibid.*
- 338 The facial nerve. *Ibid.*
- 339 The last four cerebral nerves, the facial nerve, the sympathetic, and the upper two cervical nerves. *Ibid.*
- 340 The pneumogastric nerve. *Ibid.*
- 341 The brachial plexus. *Ibid.*
- 342 Cutaneous nerves of the upper extremity. *Ibid.*
- 343 The same. *Ibid.*
- 344 External cutaneous, median, ulnar, and musculo-spiral nerves. *Ibid.*
- 345 The same. *Ibid.*
- 346 Cutaneous nerves of the front of the thigh. *Ibid.*
- 347 Lumbar plexus and its branches. *Ibid.*
- 348 External popliteal nerve and its branches. *Ibid.*
- 349 Popliteal nerves. *Ibid.*
- 350 Partition of the nose. *Sappey.*
- 351 Cartilages of the nose. *Ibid.*
- 352 Outer wall of the left nasal cavity. *Ibid.*
- 353 Nerves of the partition of the nose. *Ibid.*
- 354 The left eyelid and lachrymal gland, turned forward and inward so as to see their inner surface. *Ibid.*
- 355 The left eye, with a portion of the eyelids removed, to exhibit the lachrymal canals and sac. *Ibid.*
- 356 Muscles of the eye. *Morton.*
- 357 Vertical section antero-posteriorly of the eyeball. *Sappey.*
- 358 The choroidea and iris. *Ibid.*
- 359 Veins of the choroidea and iris. *Ibid.*
- 360 View from behind of the anterior part of the eyeball. *Ibid.*
- 361 The same view, with the crystalline lens and retina removed. *Ibid.*
- 362 Segment of the choroidea and iris, seen on its inner surface. *Ibid.*

FIG.

- 363 Arteries of the iris. *Sappey.*
- 364 The eyeball, with the sclerotica, cornea, choroidea, and iris removed. *Ibid.*
- 365 Retina, seen on its posterior inner surface. *Ibid.*
- 366 The crystalline lens. *Ibid.*
- 367 Crystalline lens, breaking up into segments. *Ibid.*
- 368 Segment of the crystalline lens. *Ibid.*
- 369 The auricle. *Ibid.*
- 370 General view of the ear, right side, laid open from the front. *Ibid.*
- 371 Cavity of the tympanum and mastoid sinuses. *Ibid.*
- 372 Small bones of the ear. *Ibid.*
- 373 The internal ear, consisting of the labyrinth and internal auditory meatus, laid open. *Ibid.*
- 374 Internal ear laid open. *Ibid.*
- 375 Nerves of the vestibule and semicircular canals. *Ibid.*
- 376 The cochlea, laid open, its summit turned upward. *Ibid.*
- 377 The cochlea, laid open, and viewed from its summit toward the base. *Ibid.*
- 378 Distribution of the cochlear nerve. *Ibid.*
- 379 Vertical section of the skin of the forefinger across two of the ridges of the surface.*
- 380 Scurf from the leg.*
- 381 Fragment of dandruff from the head.*
- 382 Sebaceous glands opening into the mouth of a hair follicle. *Todd & Bowman.*
- 383 A large sebaceous gland from the nose. *Kölliker.*
- 384 Sebaceous matter, from one of the sebaceous glands of the nose.*
- 385 Structure of the sebaceous glands. *Kölliker.*
- 386 Portion of the shaft of a light hair. *Ibid.*
- 387 Portion of a hair from the outer part of the thigh.*
- 388 Root of a hair lodged within its follicle. *Kölliker.*
- 389 Diagram of structure of the root of a hair within its follicle.*
- 390 Matrix of the nail. *Sappey.*
- 391 Under surface of the nail. *Ibid.*
- 392 Vertical section of the end of a finger. *Ibid.*

AN
ELEMENTARY TREATISE
ON
HUMAN ANATOMY.

CHAPTER I.

INTRODUCTION.

THE word **Anat'omy** means dissection; but it has become to be applied to the study of the physical structure of organized bodies. The word is variously modified, according to its application; and thus we have vegetable anatomy, comparative anatomy, human anatomy, pathological anatomy, etc.

Hu'man anat'omy, the special object of our attention, may be subdivided into general, special, and topographical anatomy.

Gen'eral anat'omy treats, in common, of the physical elements of structure of the various organs of the body. It is frequently named **Microscopic anatomy**, from the necessity of employing the microscope in its study. The term **Histology**, from the Greek *ἵστος*, the organic structure, and *λογος*, a description, is also applied to it.

Special or Descrip'tive anat'omy treats of the properties, such as form, color, size, and situation of the organs of the body arranged into systems; and thus we have the anatomy of the bones, of the muscles, etc.

Topograph'ical anat'omy treats of the relative position of organs in particular regions of the body. Thus, the topographical anatomy of the groin refers to all the organs in this region. It is also called **Surgical anatomy**, from its importance in surgery.

In commencing with the study of human anatomy, the author thinks it not amiss in directing the student to take a cursory glance at the general structure, characteristic phenomena, and conditions of existence of living bodies, of which man constitutes the highest or most complex type.

According to the present state of chemical knowledge, about sixty

different kinds of matter, the so-called simple or ultimate elements, enter into the composition of the earth. The phrase "kinds of matter" is expressive of the idea of the ponderable agencies of nature which are not reducible to a simpler condition with all the aids of modern science, are incapable of conversion into one another, and are indestructible.

All the material masses or bodies of the earth are divisible into two great groups—mineral bodies and organized bodies. The former are known as minerals, and comprehend the rocks, stones, ores, soils, water, air, and gasses; the latter are known as plants and animals, including all their parts.

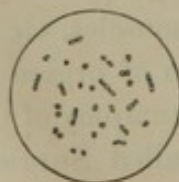
Mineral bodies, in contradistinction to organized bodies, are also called unorganized. They are homogeneous in structure; and, under ordinary circumstances, either have no definite form, expressed by the term amorphous, or they are crystalline; that is to say, they are of regular form, defined by plane surfaces and sharp angles. Under special circumstances, it is probable that all mineral bodies may assume a crystalline form. Thus, water and mercury, ordinarily liquid, at lower temperatures become crystalline solids; and even certain aeriform fluids, such as carbonic acid or nitrous oxide, under the combined influence of high pressure and intense cold, assume the condition of crystalline masses.

Organized bodies are composed of a few simple physical elements, which may be arranged as follows:—

1. Homogeneous liquid, and its transitions toward a solid condition.
2. Homogeneous granules.
3. Homogeneous filaments.
4. Homogeneous membrane.

Every organized body originates in a homogeneous liquid, the most complex as well as the most simple; and every one starts into definite existence as a homogeneous granule, invisible except with the aid of the microscope. The granule is the first appreciable step in the production of the seed of plants, and of the egg of animals. There are certain specific living beings, which, throughout their existence, appear to consist of a simple granule; as, for instance, the *Monas crepusculum*, represented in figure 1. This measures less than the 10,000th of an inch in diameter, or is so minute that 500,000,000 may be crowded in a drop of water, in which they are often observed endowed with the power of movement.

FIG. 1.



MONAS CREPUSCULUM.
Highly magnified.

Homogeneous filaments are the least frequent constituents of organized bodies. They constitute the vibrating appendages of certain microscopic

plants, of many animalcules, of the so-called ciliated cells of more complex animals, and of the spermatozooids of the male seminal liquid. They also appear to form the structure of areolar tissue.

Some of the simplest forms of specific organic life consist, apparently, of mere homogeneous filaments; as, for instance, the various species of *Vibrio*, (figure 2,) millions of which, endowed with the power of movement, may be observed in any organic infusion that has been exposed for a short time to the air. The thin, oil-like, iridescent film, often seen on standing water, is sometimes composed of these living homogeneous filaments, which, decomposing the rays of light falling on them, give rise to the characteristic hues of the rainbow.

Homogeneous membrane is an important solid element of organized structures, and is mostly the containing part when the other elements are in association with it.


Organized bodies derive their materials of composition from the mineral world, and they are subject to the control of the same laws which govern unorganized bodies. In the final dissolution of organized bodies, the material of composition again reverts to the mineral world.

Though we cannot comprehend the idea of a beginning to matter, it is nevertheless conceivable that organized bodies may have had a definite commencement or origin in time. Be this as it may, the nature of the origin of organized bodies in time is involved in the deepest obscurity. If the view of many cosmogenists and geologists be adopted, that the earth was once in a highly heated or incandescent condition, it is obvious such a state would have been incompatible with the contemporaneous existence of organized bodies; and it would follow, of necessity, that they were subsequently produced or introduced when the temperature of the earth was reduced to the condition favorable to the support of life.

Philosophers have contended that the simplest forms of organized bodies may originate directly and spontaneously from the mineral world, under the operation of ordinary physical causes. Aside from the important fact that it is never pretended that the more complex plants and animals spring into existence in this manner, no authentic evidence has yet been presented to us that microscopic organisms may originate spontaneously; but, on the contrary, all careful investigations and well-conducted experiments have so far tended to refute the hypothesis.

Organized bodies have existed for incalculable ages, as is proved by the great quantity and variety of their remains, which extend through an enormous depth of the stratified rocks composing the surface of the earth. Perhaps a more remarkable fact, ascertained in the exploration

FIG. 2.



VIBRIOS, from urine which had been exposed to the air for some hours. Highly magnified.

of the latter, is, that the earliest series of organized bodies became extinct to give place to a new series, which in like manner subsequently became extinct; and this process of the successive origin and extinction of races or series of species has continued without interruption down to the present period; from which it is probably not unsafe to infer the ultimate fate of the existing race of living beings.

For convenience in study and easy reference, organized bodies are arranged or classified in some system, which may vary according to our extent of knowledge of those bodies. Thus, we have kingdoms, classes, orders, families, genera, species, and varieties, each division exhibiting certain characters in common, by which its relative position is maintained and readily perceived. How far these divisions accord with any apparent natural plan, is a subject of much controversy.

The first grand division of organized bodies is into the vegetable and animal kingdom, or into plants and animals. This arrangement, however obvious it may appear, is not without its difficulties; for, although the higher types of both are readily distinguishable, it appears to be impossible, in the present condition of our knowledge, to indicate a positive separation between the lower types; and hence we find naturalists classifying the simplest forms of organized bodies indiscriminately as plants or animals.

As regards the subdivisions of the vegetable and animal kingdoms, though there is, perhaps, rather more concurrence of opinion, yet the attempt to define positive lines of separation frequently results in failure.

In accordance with the systematic labors of naturalists, who classify the material objects of nature, a species of organized body is one possessing some character by which it may be distinguished from another; and this character is constant, so far as the history of the species is known. Varieties are founded upon distinctive characters, which, as is known by their history, are temporary. A genus consists of a group of species possessing some structural characters in common; and, in like manner, a group of genera approaching in character makes a family; and thus we may advance to the starting-point of classification into kingdoms.

It has already been indicated that the matter of mineral or unorganized bodies, and that of organized bodies, is the same. When, however, we speak of the material of the latter, it is called organic matter, in contradistinction to that of the former, which is called inorganic matter. In other words, so long as the material constitutes mineral or unorganized bodies, it is inorganic matter; but, the same material having entered into the constitution of plants and animals, or organized bodies, is then named organic matter.

The derivation, directly or indirectly, of organized bodies from the inorganic world, is termed organization, and their reduction to the primitive condition, disorganization, or decomposition.

Of the sixty ultimate elements of the earth, less than a third enter into the composition of organized bodies—seventeen being the number usually detected. All the other elements of nature are unorganizable, or incapable of entering into the perfect constitution of plants and animals.

Of the seventeen organizable elements, **Ox'ygen**, **Hy'drogen**, **Car'bon**, and **Ni'trogen** are so universally existent in plants and animals, that they are viewed as the necessary or essential elements of every organized body. Coincident with this highly important circumstance, the four elements mentioned are the most widely diffused and abundant in nature.

The remaining or incidental chemical elements of organized bodies, arranged in the order of their relative importance, or frequency and quantity, are as follow: **Cal'cium**, **Potas'sium**, **So'dium**, **Chlo'rine**, **Phos'phorus**, **Sul'phur**, **Sil'icon**, **I'ron**, **Magne'sium**, **Manganese'**, **I'odine**, **Flu'orine**, and **Bro'mine**. These are almost never found in a simple condition, but are in combination with oxygen, hydrogen, and carbon, and with one another.

The ultimate elements by union constitute the proximate chemical elements of organized bodies, which are those entering immediately into the structure of the latter, and are obtained separately by the simplest methods of analysis.

The proximate elements of organized bodies are numerous, and in many instances are imperfectly known. They may be divided into four groups, as follow: 1. Nitrogenized elements peculiarly organic, such as gluten and legumen in plants, and fibrin and albumen in animals. 2. Non-nitrogenized elements peculiarly organic, such as cellulose, starch, sugar, and fats. 3. Elements not peculiarly organic, as water, carbonic acid, and phosphate of lime. 4. Elements resulting from the disintegration of the former during the ordinary vital actions, and mostly found in the secretions and excretions, such as urea, and uric acid in animals.

Through a variety of conditions—the agency of disease, spontaneously under ordinary circumstances after death, or aided by artificial means—the proximate principles are resolved into a vast number of new compounds, such as the ordinary fat acids, glycerin, gelatin, the alcohols, ethers, etc. etc.

Every organized body, in its construction, exhibits a series of phenomena called those of life, or vital; and hence, when an organized body presents such phenomena, it is said to live, or possess life or vitality—which terms are expressive of the actions peculiar to, or ob-

served only in association with, organic forms. Vital phenomena, or the display of the peculiar actions of organized bodies, require a constant supply of the elements of their structure in a liquid state, the influence of the air, and a certain range of temperature. Without these conditions vital activity cannot be maintained; and hence these conditions are viewed as essential to life. No one can be removed without a cessation of vital action—often forever—in some instances only while the condition is absent. Thus, a dried seed exhibits no vital activity, but may do so when the essential conditions are brought to play upon it.

Every organized body must have lived during the period of its construction; but it may be subsequently preserved without those actions which characterize life—such a condition being distinguished as that of death. Thus, the timbers of our buildings and the clothes we wear were once living, but are now dead organized bodies.

The phenomena which characterize life are as follow: the origin of the organized body from a parent; its successive development and growth; the processes of nutrition and assimilation; the combustion of effete particles of structure; and reproduction. The cessation of these phenomena constitutes death.

All living bodies proceed from parents, whose remotest ancestry cannot now be traced. All of them commence in or start from the condition of a homogeneous liquid; and the first defined step in organization is the appearance of a granule, whose form, beneath the highest powers of the microscope, appears to be spherical. The homogeneous liquid in which living bodies originate is the so-called nutritive matter.¹ It contains all the chemical elements of structure of the organized bodies in complete solution.

In the development and constitution of organized bodies, we find the four ultimate physical elements, previously mentioned, very generally, more or less associated in the composition of a common characteristic structure named the **organ'ic cell**. All organized bodies, except such as are of so simple a nature as to consist alone of isolated granules or filaments, are, for the most part, composed of organic cells and their transformations.

The primitive form of the organic cell, as represented in figure 3, is that of a spherical vesicle with a filamentary appendage. In this condition, however, the organic cell is not often observed, for generally the filamentary appendage is absent, and the spherical form of the vesicle is quickly modified after its development. The minute being, *Trachelo-*

¹ Plasma; Blastema.

monas volvocina, (figure 4,) found in stagnant water, may be viewed as a specific organized body consisting of a single typical organic cell. The minute plant, *Protococcus*, (figure 5,) which coats damp walls and pave-

FIG. 3.




DIAGRAM OF A TYPICAL
ORGANIC CELL.

FIG. 4.



TRACHELOMONAS VOLVOCINA,
FROM STAGNANT WATER.
Highly magnified.

FIG 5.



PROTOCOCCUS, FROM DAMP PAVE-
MENTS, MULTIPLYING BY DIVI-
SION. 1, a simple cell; 2, the
contents dividing; 3, the cell
contents dividing into four;
4, a cell dividing into two.

ments, in shaded places, with a green covering, consists of isolated organic cells without the filamentary appendage.

The outer portion of the vesicle of the organic cell, or the cell wall, is homogeneous membrane. The cell contents may be liquid, semi-liquid, granular, or filamentous. Among the cell contents very generally there is observed a second and much smaller vesicle, called the *nu'cleus*,¹ which though liable to transformation is much less so than the containing cell. The wall of the nucleus is also of homogeneous membrane, and its contents likewise liquid, semi-liquid, or granular. Occasionally organic cells are observed with several nuclei. Among the nuclear contents, almost always, a spherical granule, conspicuous for its size, may be distinguished from the others, and this is technically called the *nucle'olus*.

A ciliated epithelial cell, as seen in figure 6, from the mucous membrane of the nasal and bronchial passages, presents an association of all the ultimate physical elements of organized bodies. Thus we have homogeneous membrane in the cell wall and nuclear wall; homogeneous granules and liquid in the cell contents; and homogeneous filaments in the vibrating appendages.

In plants, organic cells are generally developed and multiplied through division and subdivision of the contents of pre-existing cells, which contents at the same time increase in bulk or grow through a constant supply of nutritive matter. The process is observed in the germination of seeds and the production of the stem, leaves, flowers, and fruit of plants. In the simplest of vege-

FIG. 6.



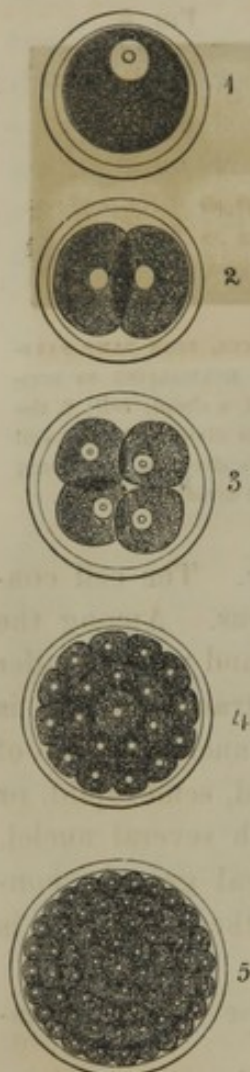CILIATED EPITHELIAL
CELL, from the pul-
monary mucous
membrane; exhibit-
ing the granular con-
tents, together with
the nucleus, and, at

the upper free extremity, the
vibrating appendages or cilia.

¹ Cytoblast.

tables, such as the *Protococcus*, as represented in figure 5, it is the mode of reproduction of the plant.

FIG. 7.

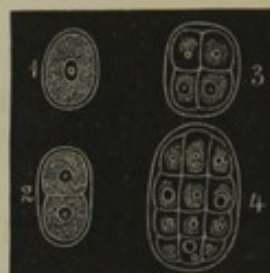


PROGRESSIVE DIVISION OR SEGMENTATION OF THE YOLK IN THE HUMAN EGG. 1, a ripe ovum; 2, the yolk divided into two; 3, the yolk divided into four; 4, 5, the yolk divided into numerous cells.

This method of production and multiplication of organic cells is also observed in the course of development of the embryo from the egg. After the latter has been fecundated or exposed to the influence of the male spermatic liquid, the yolk divides into two spheres; these subdivide into four, and this process continues until the yolk is reduced to the condition of a mass of nucleated cells, as represented in figure 7.

Another instance in which the multiplication of cells through division of the contents is strikingly observed in the animal, is in the development of the cartilages. In the early condition of cartilage, it consists of a homogeneous matrix with isolated nucleated cells imbedded. These multiply through division and form groups of from a pair to twenty or more, (figure 8,) as may be seen at any time in the permanent cartilages of the adult.

FIG. 8.




PROCESS OF MULTIPLICATION OF CARTILAGE CELLS. 1, simple cartilage cell from the embryo; 2, increase of cartilage cells by division of the primary cell; 3, 4, groups of cartilage cells, from an adult articular cartilage.

Another mode of production of cells, with a continual reproduction in the same manner, is observed in animals, in the formation and renovation of the epidermis and its appendages, the hairs and nails, of the epithelium of mucous and serous membranes, and of the secreting cells of glandular organs. In the deepest part of these structures, in the nutritive liquid constantly exuding from the capillary vessels, homogeneous granules originate. These, which constitute nucleoli, successively become nuclei and organic cells in the following manner. A granule or nucleolus first appears; and upon this a vesicular wall is developed, inclosing the nucleolus. In the liquid contents of the nucleus thus formed, granules may originate; and a second vesicular wall is developed, which incloses the nucleus and thus constitutes an organic cell. The contents of the latter, at first liquid, become more or less granular. The steps of the process just related are represented in figure 9.

Subsequent to the development of organic cells, they most usually

FIG. 9.



PROCESS OF DEVELOPMENT OF AN ORGANIC CELL FROM A GRANULE. 1, a granule; 2, a vesicle developed upon the granule: the two constituting the nucleus and contained nucleolus; 3, the same, increased in size; 4, 5, granules developed in the contained liquid of the nucleus; 6, the cell wall developed on the nucleus; 7, 8, 9, successive increase of the cell, and development of granular contents.

undergo more or less transformation in the production of the various parts of plants and animals. In some cases the modification is so slight that the original form remains manifest, as instanced, by the glandular cells generally, in animals. Thus in the figure

FIG. 10.



THREE SECRETING CELLS FROM THE SUB-MAXILLARY SALIVARY GLAND.

10, representing several secreting cells of the salivary glands, the typical organic cell form is readily recognized. In other instances the transformation of cells is so great that their existence would not be suspected from an examination alone of the structure produced from them. Thus the fibrous tissues, which consist of bundles of

the finest homogeneous filaments, are the result of the subdivision or splitting of organic cells.

Through continued reproduction, aggregation, and transformation of organic cells, the various textures or tissues are produced, which constitute the proximate physical elements of the various organs of animals.

ULTIMATE CHEMICAL ELEMENTS OF THE HUMAN BODY.

1. Oxygen.	5. Chlorine.	9. Sodium.	12. Iron.
2. Hydrogen.	6. Phosphorus.	10. Potassium.	13. Fluorine.
3. Carbon.	7. Sulphur.	11. Magnesium.	14. Silicon.
4. Nitrogen.	8. Calcium.		

Ox'ygen, **Hy'drogen**, and **Car'bon** are found in all the tissues and liquids of the human body. **Ni'trogen** is likewise found in all except fat.

Chlo'rine forms with hydrogen the chlorohydric acid of the gastric juice. It also exists in combination with sodium and potassium in most of the tissues and liquids of the body.

Phos'phorus, or **Sul'phur**, or both together, exist in all the nitrogenized proximate elements of the body.

Cal'cium, oxydized as lime, in the form of phosphate of lime, and in that of carbonate of lime, enters largely into the composition of the bones and teeth, and is also found in small quantities in some other parts of the body.

So'dium and **Potas'sium**, as common salt or chloride of sodium, and as chloride of potassium, exist in most of the tissues and liquids.

Magne'sium, as phosphate of magnesia, is found in the bones, and in small quantity elsewhere.

I'ron exists in the coloring matter of the blood corpuscles. **Flu'orine**, in small quantity, as fluoride of calcium, is found in bones. **Sil'icon**, as silica, is found in hairs.

PROXIMATE CHEMICAL ELEMENTS OF THE HUMAN BODY.

GROUP 1.—NITROGENIZED ELEMENTS PECULIARLY ORGANIC.

Fibrin.	Collagen.	Crystallin.	Pancreatin.
Albumen.	Chondrigen.	Keratin.	Pepsin.
Albuminose.	Elasticin.	Hæmatin.	Mucosin.
Casein.	Neurin ?	Ptyalin.	Melanin.
Musculin.	Globulin.		

Many of the elements belonging to this group are those which are least known. Thus the character of the albumenoid matter (Neurin) of the nervous system has not been ascertained, nor are we familiar with the important proximate constituents of the liver, kidneys, salivary glands, and some other organs. They all contain oxygen, hydrogen, carbon, and nitrogen; most of them sulphur; and many of them phosphorus.

Fi'brin exists in the blood and lymph in a liquid condition. Its most striking peculiarity is its spontaneous coagulation on being removed from the circulation.

Albu'men is found in the blood, lymph, and fluids of the serous cavities in a liquid condition. It coagulates above a temperature of 160° Fahr.; also through the agency of alcohol, tannin, the mineral acids, and the metallic salts.

Albu'minose is found in the blood and chyle in a liquid condition. It results from digestion, in the alimentary canal, of the albuminous, fibrinous, and caseous matters of food, and from flesh; and it differs from albumen in not being coagulable by heat.

Ca'sein is the most important constituent of milk, in which it exists in the fluid condition. It coagulates through the agency of acids, but not through heat, nor spontaneously. The curdling of milk is due to the development of lactic acid from the sugar of milk.

Mus'culin is the soft substance of flesh or muscles, endowed during life with the power of contractility. It is soluble in dilute muriatic acid; boiling in water renders it more solid.

Col'lagen is the principal constituent of the so-called bone cartilage, ligaments, tendons, fibrous membranes, the dermis, and the areolar tissue. By boiling in water it is resolved into gelatin or glue.

Chon'drigen is the basis of the true cartilages and of the cornea. Long

boiling resolves it into chondrin, which differs from gelatin in being precipitated from solution by acetic acid and some other agents not acting on the latter.

Elas'ticin is the peculiar solid material of the elastic tissue. It is remarkably insoluble in all ordinary menstrua.

Neu'rin? is the supposed albumenoid principle of the nervous system.

Glob'ulin forms with hæmatin the contents of the red blood corpuscles.

Crys'tallin is the basis of the crystalline lens of the eye. It is coagulable by heat and by alcohol; but unlike albumen, is precipitated from solution by carbonic acid.

Ker'atin is the principle which gives the horn-like character to the epidermis, nails, and hairs.

Hæm'atin is the coloring matter of the red blood corpuscles.

Pty'alín is found in the salivary glands and the saliva.

Pancrea'tin exists in the pancreas and its secretion.

Pep'sin is a peculiar principle of the gastric mucous membrane and gastric juice.

Mu'cosin is the viscid matter of mucus and the mucous epithelial membranes.

Mela'nin is the dark coloring matter of the choroid tunic of the eye and of the skin of the negro.

GROUP 2.—NON-NITROGENIZED ELEMENTS PECULIARLY ORGANIC.

Olein.	Stearin.	Glycogen.	Lactin.
Margarin.	Butyrin.	Glucose.	Inosit.

All of these have for their ultimate elements oxygen, hydrogen, and carbon.

O'lein, **Mar'garin**, and **Ste'arin**, mingled together, form the greater part of the fats of the human body—margarin being the most abundant, and stearin the least so. Olein remains liquid even below the freezing point; and at the ordinary temperature of the body it retains the other fatty matters in solution. Margarin, isolated, becomes a crystalline solid, below 118° Fahr.; and stearin assumes the same condition below 143° Fahr. With alkaline solutions, the three fatty substances mentioned undergo decomposition, evolving oleic, margaric, and stearic acids, which combine with the alkaline base, as in the ordinary formation of soaps. The original fat base, in combination with water, constitutes the peculiar sweet liquid, glycerin.

Bu'tyrin, in combination with margarin and stearin, forms the fatty part of cream or milk.

Glyc'ogen is a peculiar substance in the tissue of the liver, which undergoes transformation into glucose.

Glu'cose, commonly known as **grape sugar**, is found in the liver and the blood of the hepatic vein, and in less quantity in other blood.

Lac'tin, or **sugar of milk**, is developed in the mammary gland, and may be obtained from the whey of milk, in a crystalline condition. The souring of the latter liquid arises from the conversion of its sugar into lactic acid.

In'osit is a saccharine substance, incapable of vinous fermentation, found in the muscular structure of the heart.

GROUP 3.—ELEMENTS NOT PECULIARLY ORGANIC.

Water.	Phosphate of soda.	Carbonate of potassa.
Chloride of sodium.	Phosphate of potassa.	Fluoride of calcium.
Chloride of potassium.	Carbonate of lime.	Silica.
Phosphate of lime.	Carbonate of soda.	Chloro-hydric acid.
Phosphate of magnesia.		

Water is one of the most important proximate principles of the human and all other organized bodies. It is the vehicle through which all the other proximate elements, with perhaps the exception of a portion of the fatty matters, are rendered capable of entering into the composition of the body. The amount of water in the different parts of the latter varies. In blood it is equal to 795 parts in the thousand; in muscles about 750 parts; and in bones about 130 parts. The entire body consists of more than two-thirds its weight of water.

Chlo'ride of So'dium and of **Potas'sium**, and more especially the former, are contained in solution in most of the liquids of the animal body.

Phos'phate of Lime, of Magne'sia, of So'da, and of Potas'sa are found in solution in most of the animal liquids. The first of these elements is the chief material to which the hardness of the bones is due.

Car'bonate of Lime, of Soda, and of Potassa are found in comparatively small quantity in the human body—the first chiefly in the bones, the latter two in most of the tissues.

Flu'oride of Cal'cium and **Sil'ica** also exist, in small quantity, in the body—the former in bones, the latter in hairs.

Chlo'ro-hy'dric Acid exists in the gastric juice.

GROUP 4.—ELEMENTS ARISING FROM THE DISINTEGRATION OF THE DIFFERENT PARTS OF THE BODY, FOR THE MOST PART EXPELLED IN THE EXCRETIONS.

Urea.	Taurocholate of soda.	Butyric acid.
Creatin.	Urates of soda, potassa,	Formic acid.
Creatinin.	and ammonia.	Acetic acid.
Biliverdin.	Cholesterine.	Oxalate of lime.
Uroerythrin.	Lactic acid.	Carbonic acid.

Ure'a, with a composition of carbon, hydrogen, oxygen, and nitrogen, is the most important constituent of the urine—forming, as it does, about three-fourths of the solid matter left after the evaporation of the water. It crystallizes in the form of four-sided prisms. In small quantity, it is found in the blood and the humors of the eye, and is considered to be derived from the disintegration of the nitrogenized tissues.

Cre'atin and **Crea'tinin**, containing the same ultimate elements as the preceding, are two crystallizable principles found in the muscles, from which they appear to be given up to the blood, to be excreted in the urine.

Biliverd'in and **Uroer'ythrin** are coloring matters—the former of the bile, the latter of the urine. Both have the four ultimate elements—carbon, oxygen, hydrogen, nitrogen—entering into their composition.

Taurochol'ate of Soda, consisting of taurocholic acid, containing the same elements as the former substances, in combination with soda, is an important ingredient of the bile.

The **U'rates of Soda, Potassa, and Ammonia**, consisting of uric acid, with the same elements as the preceding, in combination with the alkaline bases, are found in the urine.

Chol'esterine is a crystallizable, fatty substance, with a composition of carbon, hydrogen, and oxygen, but is unsaponifiable. It is found in the juices of the nerve-centres and the blood, and is excreted in the bile.

Lac'tic Acid, with a composition of carbon, hydrogen, and oxygen, is found in the muscles and gastric juice.

Butyr'ic, Ace'tic, and Form'ic Acids, containing the ultimate elements, carbon, hydrogen, oxygen, are obtained from the juice of the muscles, and are excreted in the sweat.

Ox'alate of Lime is found in small quantity in the urine.

Carbon'ic Acid is found in the blood and other liquids of the body.

ULTIMATE PHYSICAL ELEMENTS OF THE HUMAN BODY.

1. Homogeneous liquid and its transitions to a solid condition.
2. Homogeneous granules.
3. Homogeneous filaments.
4. Homogeneous membrane.

Homoge'neous liquid is observed in the fluids of the body, varying in consistence in different cases, as instanced by the liquor of the blood and lymph, serum, mucus, and the juices of the tissues.

Homoge'neous gran'ules form an important constituent of many tissues, as in the contents of the secreting cells of glands, and epithelial cells, and in the ash-colored portion of the nervous system.

Homoge'neous fil'aments form the principal constituent of the true fibrous tissues, and the vibrating appendages of ciliated epithelial cells.

Homoge'neous mem'brane constitutes the basement membrane of the serous and mucous membranes, and glands. It also forms the wall of capillary vessels, the sheath of muscular and nerve fibres, and the parietes of organic cells.

The human body has its origin in the ovary of the mother, and starts into definite existence as a homogeneous granule, which, in course of development, becomes an organic cell. This constitutes the primitive ovum; which, after escaping from the ovary, traverses the oviduct, to be received into the uterus. Being subjected to the influence of the spermatic liquid of the male, its contents undergo a series of segmentations, resulting in the production of a mass of organic cells, inclosed within the parent cell. Continually imbibing nourishment from the exterior, the ovum gradually increases in size, and step by step the embryo is evolved, the development of all its parts being preceded by the production of organic cells, through division of previously existing cells. It thus follows, that all the organs and tissues of the human body—and this will equally well apply to all organized bodies, except the simplest forms before mentioned—are derived from organic cells.

The degree of transformation of organic cells, in the production of the fully-developed tissues of the human body, varies from a condition of no perceptible change in the typical form, through a gradation of conditions, to such as lose all trace of the original cell-form.

In the lymph corpuscles (figure 11) and the simple ganglionic cells, we have an instance of organic cells retaining, throughout their existence, the original form.

FIG. 11.

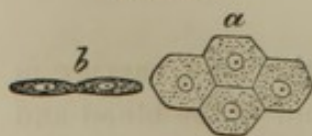


A LYMPH CORPUSCLE.

In the medullary cells of the spongy part of bones, the adipose cells, and the secreting cells of many glands, the original cell-form is simply modified, by mutual pressure, so as to assume a polyhedral appearance.

In the epithelium of serous membranes, the original cell-form is modified by its not only assuming the polyhedral outline, but from the breadth transcending the thickness, as represented in figure 12.

FIG. 12.

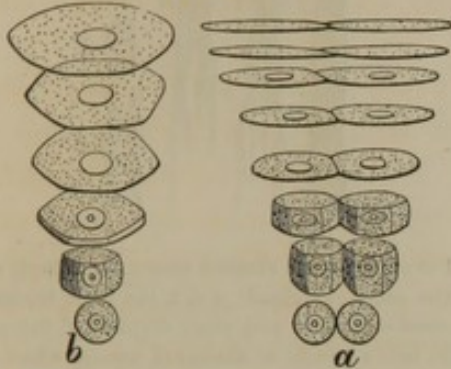


EPITHELIAL CELLS OF A SEROUS MEMBRANE. *a*, viewed on the broad surface; *b*, viewed in the thickness.

In the epidermis, and the epithelium of the mouth, the organic cells, which continually originate in the deep parts of these structures, as they rise toward the free surface, assume the form of broad scales, as represented by the diagrams in figure 13.

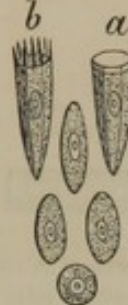In the epithelium of the stomach and intestines, the organic cells, which originate as in the former instance, assume the form of prismatic columns, as represented in figure 14, *a*.

FIG. 13.



EXHIBITS THE PROGRESSIVE DEVELOPMENT, FROM BELOW UPWARD, OF THE SCALES OF THE EPIDERMIS, OR THE SCALE-LIKE EPITHELIUM OF THE MOUTH. *a*, the thickness; *b*, the breadth.

FIG. 14.



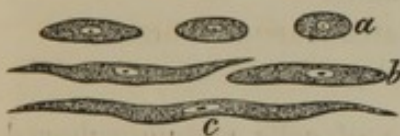
MODE OF DEVELOPMENT, FROM BELOW UPWARD, OF THE COLUMNAR EPITHELIAL CELLS. *a*, epithelial cell of the stomach and intestines; *b*, epithelial cell of the pulmonary mucous membrane.

In the epithelium of the air-passages, the organic cells undergo the same changes as in the case just mentioned; but, in addition, have developed, upon

their free extremities, vibrating appendages, as represented in figure 14, *b*.

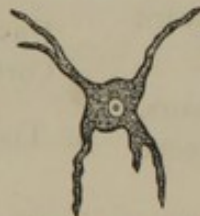In the formation of the unstriated muscular fibres, the organic cells become elongated into fusiform bands, as represented in figure 15, *a-c*.

FIG. 15.



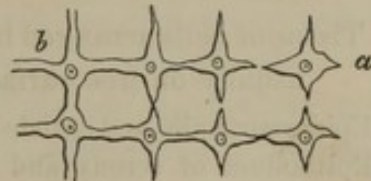
MODE OF DEVELOPMENT OF UNSTRIATED MUSCULAR FIBRE. *a*, *b*, *c*, cells successively elongating into a fusiform fibre.

FIG. 16.



NERVE CELL, from the ash-colored matter of the cerebrum.

FIG. 17.



MODE OF DEVELOPMENT OF CAPILLARY VESSELS FROM CELLS. *a*, cell with four prolongations; *b*, vessels formed from the conjunction of the prolongations of cells. The nuclei remain adhering to the structureless walls of the vessels.

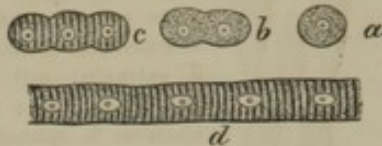
The caudated nerve cells are produced by the organic cells sending off a number of processes, as represented in figure 16.

In the formation of capillary vessels, organic cells protrude appendages, which unite with one another, and thus form an intercommunicating system of tubes, as represented by the diagram, figure 17.

In the development of the striated muscular fibres, cells arrange themselves in rows, and become united into continuous columns, as represented in figure 18, *a-d*.

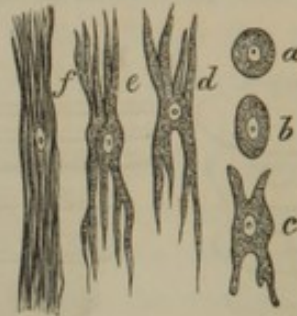In the formation of the fibrous tissues, constituting the ligaments, tendons, the dermis, and areolar tissue, organic cells split up into bundles of fine filaments, as represented in figure 19, *a-f*.

FIG. 18.



DEVELOPMENT OF STRIATED MUSCULAR FIBRE, FROM CELLS. *a*, simple cell; *b*, a pair of cells fused together; *c*, three cells fused, and their contents assuming the striated character; *d*, a muscular fibre, exhibiting its original composition of cells.

FIG. 19.



DEVELOPMENT OF FIBROUS TISSUE. *a*, simple cell; *b*, the same elongated; *c*, *d*, *e*, the same becoming successively more and more divided; *f*, the same split into a bundle of filaments, among which the nucleus remains.

THE PROXIMATE PHYSICAL ELEMENTS OR TISSUES OF THE HUMAN BODY.

1. Tissue of free cells floating in a liquid.
Blood corpuscles, with the containing liquor.
Lymph corpuscles, with the containing liquor.
2. Tissue of cells arranged in layers usually on free surfaces.
Epidermis, nails, and cuticle of hairs.
Epithelium of serous and mucous membranes.
Glandular cells.
Pigment cells.
Nerve cells of retina and labyrinth.
Enamel.
3. Tissue of cells aggregated in masses.
Adipose tissue.
Medullary tissue of spongy bones.
Medulla of hairs.
Ash-colored nerve tissue.
Closed gland tissue.
4. Tissue of cells imbedded in a solid non-cellular substance.
Cartilage.
Bone.
5. Tissue of cells forming fusiform bands.
Unstriated muscular fibres.
Cortical portion of hairs.
6. Tissue of cells metamorphosed into tubes with liquid, semi-liquid, or solid contents.
Capillaries.
Nerve fibres.
Striated muscular fibres.
Crystalline fibres.
Dentine.
7. Tissue of cells completely metamorphosed into filaments.
Fibrous tissue.
Elastic tissue.

CHAPTER II.

THE SKELETON.

THE **Skel'eton** is the frame-work of the body, and is composed of an articulated assemblage of hard organs, the **bones**. It serves to preserve the shape of the body; forms cases for the protection of the most important viscera; and gives attachment to muscles and forms levers of movement. For convenience of description and study it is usually considered in parts corresponding with the ordinary divisions of the body; as the head, trunk, and the upper and lower extremities.

The number of distinct pieces or bones composing the skeleton varies at different periods of life. Some remain distinct from the first moment of their development, such generally being of the simplest form, as the bones of the carpus, the parietal bone, and the patella. Others, which are viewed as single bones in the adult, not only consist of several pieces in the beginning, but in the progress of development have other pieces successively added, as in the case of the vertebræ and the thigh-bones. Again, bones considered as distinct pieces when the body has arrived at maturity, at a later period may become united with those which are contiguous, as in the co-ossification of the cranial bones.

The number of bones to which we usually refer in the description of the skeleton is as follows:—

For the head; including the hyoid bone and excluding the teeth and the small bones of the ear	23
For the trunk; counting the coccyx as four, the sternum as three, and including the hip-bones	59
For the upper extremities; including the sesamoid bones, thirty-four to each extremity	68
For the lower extremities; thirty-two to each	64
	214

The bones are connected together, in the construction of the skeleton, by various means, viz.: by cartilages, fibro-cartilages, and ligaments.

The connections are named the joints or articulations, and the parts of the bones involved are called the **artic'ular extremities, borders, or surfaces**, as the case may be.

The bones of the two sides of the skeleton are either in pairs, as the ribs and those of the extremities, or they are single and symmetrical; that is, they consist of two similar halves, as the *vertebræ*. They vary much in relative proportion and form, and in these respects are divisible into four classes: the **long bones**, such as the principal ones of the limbs; the **tabular bones**,¹ as those of the vault of the cranium; the **irregular bones**, as the *vertebræ*; and the **short bones**,² as those of the wrist.

The long bones have a more or less cylindroid or prismoid **shaft** or **body**; which latter term is also applied to the massive part of irregular bones. The extremities of a long bone are dilated, and support smooth articular surfaces. From their respective position in relation with the vertebral column, that which is nearer to the latter is called the **proximal extremity**, and the more distant, the **distal extremity**. If an extremity forms a single rounded prominence it is called a **head**; but if there are such a pair of prominences, they are called **con'dyles**; though this name is also applied to the single articular eminences of the occipital bone and the lower jaw, and even to the tubercles on each side of the distal end of the humerus. The narrow or constricted portion intervening between a head, condyles, or other articular eminence, and the principal part of a bone, is called the **neck**.

Any elevation or prominence may be termed a **proc'ess**.³ If this be narrow and tapering it is usually named a **spi'nous proc'ess**, though the term is frequently applied to an obtuse prominence, which is also called a **tu'bercle**, or a **tuberos'ity**. An eminence supporting an articular surface is termed an **artic'ular proc'ess**. An elevation extending some distance along the surface of a bone, or a prominent border, is named a **line, ridge, or crest**.

An aperture in a bone or between several bones is called a **fora'men**, (plural: **fora'mina**,) and if this is prolonged for some distance it becomes a **canal**, or **mea'tus**. A broad shallow depression is termed a **fos'sa**, (plural: **fos'sæ**,) and a cavity with a small external communication is a **si'nus**.

Bones in the fresh condition are white, with a faintly bluish translucency, tinged with pink from the blood with which they are supplied; and they are more pink or red the younger they are, from their greater degree of vascularity. When cleansed of their softer attachments by boiling or maceration, and dried, they lose in weight and become dull yellowish

¹ Synonym: Broad bones.

² Thick, or massive bones.

³ Apophysis.

white; and if exposed to the combined influence of the air, moisture, and light, they acquire a more or less chalk-white appearance. They are hard, tough, and moderately elastic, which qualities vary with their age; being tougher and more elastic the younger they are, and harder and more brittle the older they are.

Human bones are nearly twice as heavy as water, their specific gravity being 1.92. Their chemical composition at mature age, according to recent analyses, is as follows:—

Bone-cartilage and blood-vessels	32.56
Phosphate of lime	53.61
Carbonate of lime	9.41
Phosphate of magnesia, fluoride of calcium, chloride of sodium, soda, oxides of iron and manganese, traces of silex, and loss	4.42
	<hr/> 100.00

From this table it will be perceived that about one-third of peculiar animal matters and two-thirds of ordinary mineral matters enter into the composition of bones. The relative proportion of the different matters, however, varies with age. The skeleton commences in the embryo in a cartilaginous condition; the mineral matters are subsequently added in the course of development, and they increase in relative quantity with the advance of age. In the infant the different matters exist in the proportion of about half and half; from old bones as much as seven-eighths of mineral matters have been obtained.

To the peculiar animal matters, bones owe their tenacity and elasticity; to the mineral matters, their hardness and rigidity. These qualities vary in degree with age, in accordance with the difference in relative proportion of the two kinds of matters. Hence the great predominance of mineral matters in the bones of old persons is one of the reasons why they are so much more liable to fracture than in young persons.

When bones are burned, from the charring of their cartilage they become black and brittle; in this condition constituting the bone-black of the arts. If the bone cartilage is entirely consumed, the mineral matters remain, still preserving the original form of the bones, which have now become pure white and exceedingly friable. From such calcined bones the phosphorus of commerce is obtained.

When bones are steeped in diluted hydrochloric acid, most of the mineral matters are dissolved out, and the cartilage is left as a tough, flexible, gristle-like substance, retaining the original form of the bones. This bone cartilage, by boiling, is reduced into the condition of gelatin. When bones are boiled under high pressure, the gelatin is extracted; and it has been obtained in this manner for the making of jellies and

soups. Dogs, wolves, cats, and other carnivorous animals eat bones, from which the gastro-intestinal liquids thoroughly extract the gelatin, while the mineral matters are expelled as excrement.¹

The surface of bones, closely examined, exhibits a more or less distinctly fibrous appearance; and it is perforated with numerous minute foramina for the transmission of blood-vessels. The articular surfaces present an even or close structure, and in the recent condition are covered with plates of cartilage. The extremities of long bones and the bodies of irregular bones present numerous comparatively large foramina, which transmit blood-vessels, chiefly veins.

The bones are composed of an exterior more compact layer, and an interior looser arrangement of the same structure; the two being distinguished as the **compact** and **spongy substances**.

In the long bones the compact substance forms the wall of the hollow shaft, and gradually diminishes to a thin layer investing the extremities. The spongy substance forms the great bulk of the latter, and gradually diminishes in the interior toward the middle of the shaft.

The large hollow occupying the interior of the shaft of the long bones of the limbs is the **medullary cavity**. It is filled with a soft, yellow fat, the **marrow** or **medulla**.

At the sides, and especially at the ends, of the medullary cavity, a portion of spongy substance is found, consisting of a delicate network of fibres,² which appears to be serviceable in sustaining the position of the mass of marrow and supporting the blood-vessels that supply the latter.

The medullary cavity communicates with the exterior by means of one or more long, oblique canals, which pierce its wall from near the middle of the shaft, and accommodate the principal medullary nutritious blood-vessels.

The areolæ or interspaces of the spongy substance are occupied by a red, semi-solid marrow, resembling in chemical composition the extract of beef.

In the fœtus the medullary cavity does not exist, but is gradually formed through a solution or removal of spongy substance occupying the axis of the bone. It gradually increases in size with the advance of age; and in its progress successive layers of compact substance become spongy substance, which in turn becomes looser in structure, and is finally removed.

¹ This fact it appears is not sufficiently estimated in the question whether gelatin is nutritious or not.

² Cancellated or reticulated substance.

The broad bones are composed of an exterior moderately thick layer of compact substance, with an intervening layer of spongy substance.¹ The bodies of irregular bones, and the short bones, are composed of a mass of spongy substance enveloped with a comparatively thin layer of compact substance.

The spongy substance of bones generally is pervaded by irregular canals for the accommodation of veins. They are especially conspicuous in the bones of the cranial vault.²

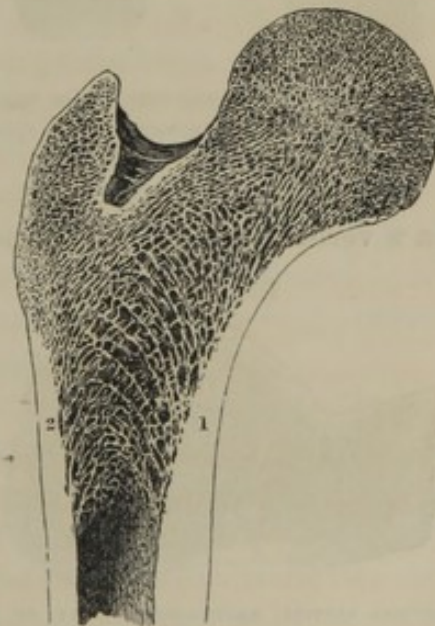
All the foramina of the surfaces of bones, canals, and areolæ of the spongy substance and medullary cavities, where they exist, freely intercommunicate ; so that if mercury be poured in at one extremity of a long bone deprived of its marrow, it may be observed to stream from the foramina at the other extremity.

The compact substance is relatively thickest or most abundant where bones are most slender or thin, in positions in which they are required to give the strongest support or offer the greatest degree of resistance to muscular action, and in parts of the body most exposed to injury from external violence.

The introduction of the spongy substance into bones increases their bulk to a convenient size without a proportionate increase in weight ; and the extension of surface produced by its presence where they articulate, very much reduces the liability of their displacement or dislocation. Further, the substitution of the spongy for the compact substance, very much reduces the force of concussion from blows or falls. In animals whose recumbent position renders them little liable to the latter accidents, the bones contain a comparatively small quantity of spongy substance, as in the alligator.

At first view it might be supposed that the spongy substance consisted of small plates and fibres of bone arranged without order, and even

FIG. 20.



LONGITUDINAL SECTION OF THE PROXIMAL EXTREMITY OF THE FEMUR, exhibiting the arrangement of the spongy substance. 1, 2, positions in which the compact substance appears to resolve itself into a series of arches.

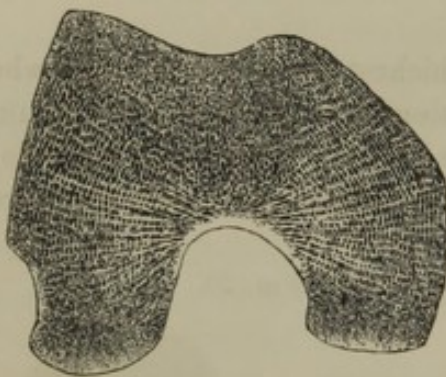¹ Diploe ; diploic structure.

² Where they are named the diploic sinuses.

thrown into the utmost confusion. This is, however, not the case, as it always has the same general arrangement in the corresponding bones; and this arrangement is of such a character that it contributes to give strength. Thus, if a longitudinal section be made of the proximal extremity of the femur, (figure 20,) it will be observed that, as the compact substance forming the walls of the shaft thins out, it appears to do so by sending off on each side successive arching plates, which, by crossing, not only mutually sustain one another, but also contribute to the support of the surfaces with which they are connected.

In a transverse section of the condyles of the same bone, (figure 21,)

FIG. 21.

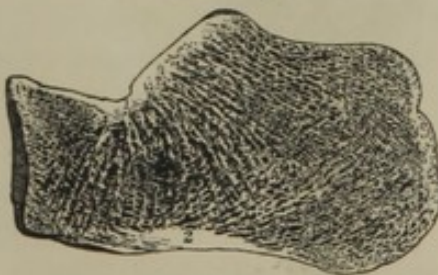


HORIZONTAL SECTION OF THE CONDYLES OF THE FEMUR, exhibiting the arrangement of the spongy substance.

it may be noticed that the exterior is formed of a layer of compact substance, very little thicker than the numerous plates of the spongy substance, which act as so many beams extending between the anterior and posterior surfaces. These antero-posterior plates are supported, at short distances, by cross-pieces; and the whole is further strengthened by numerous plates, radiating from a compact nucleus, situated at the bottom of the inter-condyloid notch.

In a vertical section, antero-posteriorly, of the calcaneum, (figure 22,)

FIG. 22.



VERTICAL SECTION, ANTERO-POSTERIORLY, OF THE CALCANEUM, exhibiting the arrangement of the spongy substance. 1, nucleus of compact substance below the articulation of the astragalus, from whence start off numerous radiating fibres; 2, nucleus of compact substance, sending off numerous arching fibres.

the bone will be seen to be composed of a thin exterior layer of compact substance, with thickened nuclei at the position of support of the astragalus, and at its base. From the upper nucleus, plates of the spongy substance radiate in all directions; and these are crossed by arching plates, proceeding from the nucleus at the base of the bone.

A vertical section, antero-posteriorly, of a vertebra, exhibits the body composed of an exterior thin

layer of compact substance, with the spongy substance composed of vertical and transverse columns, mutually supporting one another and the surfaces of the bone. The spinous process, which performs the part of a

lever for muscular action, is composed of a thick layer of compact substance, with a very small proportion of strong spongy substance.

The section of one of the tabular bones of the cranial vault presents two moderately thick plates of compact substance, mutually supported by intervening columns of spongy substance, with lateral offsets.

The examples thus given are amply sufficient to prove that the spongy substance possesses an admirable mechanical arrangement, adapted to contribute strength to the bones of which it forms a part.

The hollow, columnar condition of the shaft of the long bones of the limbs gives several advantages over a solid rod containing the same amount of material. Besides the increase of surface for muscular attachment, an increase of strength is obtained; as it is well known, in the mechanic arts, that a hollow column is much stronger, or capable of sustaining a much greater weight, than a solid column containing the same amount of material; and hence it is that metallic columns of support are made hollow. Another familiar application of this principle in nature is exhibited in the construction of the culm or stem of most grasses—so admirably adapted to the support of their treasures of grain, while they are yet so light as to bend beneath the gentlest breeze.

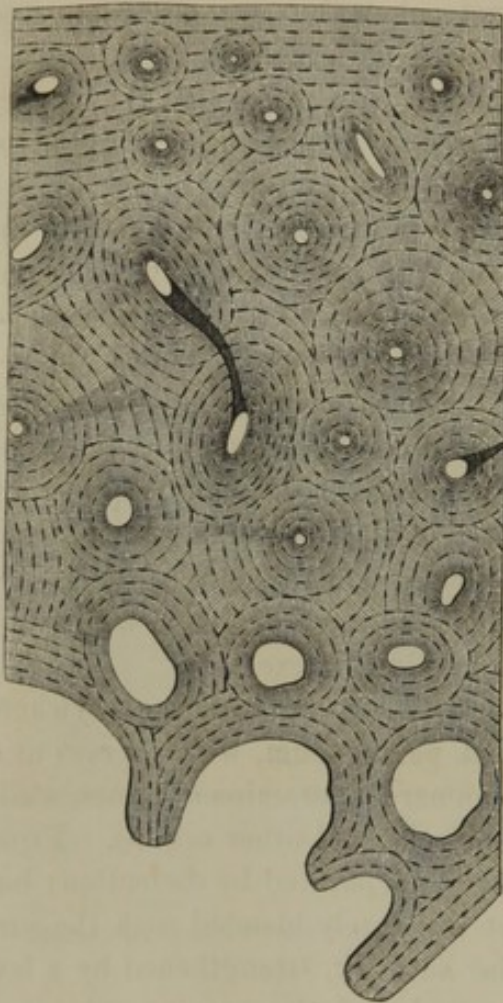
The exterior of bones, except at the articular surfaces, is everywhere invested with a fibrous membrane, called **perios'teum**, which serves as a nidus for the blood-vessels entering the numerous foramina of bones, while it affords a medium of attachment for muscles and other organs. From young bones, this membrane may be readily separated by dissection; but in the progress of age it becomes most intimately blended with the surface of the bones. The delicate vascular network, strengthened by a few filaments of fibrous tissue, lining the areolæ of the spongy substance and the medullary cavity, is called **endos'teum**.

The **marrow**, or **medul'la**, is of two kinds—that which fills the hollow shaft or medullary cavity of the long bones of the limbs, and that which fills the areolæ or interspaces of the spongy substance generally. The former is a soft, yellow fat, consisting of delicate adipose cells; the latter is a red, pulpy matter, which, in chemical composition, resembles the extract obtained in boiling meat. It also contains fat, which increases in quantity with the advance of age. Examined with the microscope, it is found to consist of nucleated cells.

The bones are pervaded by blood-vessels, which communicate with those of the periosteum and endosteum. The general course of these nutritious vessels corresponds with the fibrous arrangement more or less distinctly observable on the surface of bones; and hence it is, for the most part, longitudinal in the shaft of long bones.

The **osseous tissue** is arranged in concentric layers around the course of the **vascular canals**¹ of the bones ;

FIG. 23.



TRANSVERSE SECTION OF THE SHAFT OF A PHALANX, moderately magnified. The upper part of the figure corresponds with the exterior surface of the bone; the lower part with the interior spongy substance.

so that if a transverse section of the shaft of a long bone be made of sufficient thinness to transmit light, and be viewed with the microscope, it will be observed to be perforated with circular and oval orifices of the divided vascular canals, surrounded by rings of osseous tissue, as represented in figure 23. In a longitudinal section the vascular canals are seen generally pursuing the same direction, inclosed on each side with plates of osseous tissue.

In very many instances, in the transverse section of a bone, it may be observed that the outer laminae of a series of ossific plates surrounding the vascular canals are more or less interrupted, in their course, by the encroachment of contiguous laminae belonging to neighboring canals, apparently the result of absorption, from pressure, more or less mutual and outward, from the vascular canals.

In young and growing bones, in accordance with their greater degree of vascularity, the vascular canals are more numerous than in older ones. The surrounding osseous laminae are, however, less numerous; and these appear to increase in number with the development and growth of bones.

At the surface of bones, in transverse sections, parallel layers of osseous tissue, more or less interrupted, are observable, which are those last deposited by, or formed from, the periosteum.

The fibres and plates of the spongy substance are composed of laminae of osseous tissue, which appear to be the remains of concentric series of laminae that once surrounded vascular canals but now form walls to the areolae containing marrow.

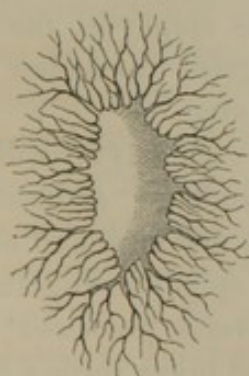
¹ Canals of Havers; Haversian canals.

In and between the laminae of osseous tissue, as seen in figure 24, there exist numerous minute lenticular excavations, called *lacu'næ*,¹ from which diverge a multitude of exceedingly fine branching tubes or *canalic'uli*, perforating the osseous laminae, and freely communicating with one another and with the vascular canals. By means of this arrangement a free intercommunication is established for the conveyance of nutritive matter throughout the osseous structure.

The lacunæ and canaliculi, when viewed in a section of bone by transmitted light, appear as black fusiform spots, with numerous minute diverging black lines. By reflected light they appear opaque white upon a more translucent ossific matrix.

The osseous laminae, when isolated and highly magnified, exhibit a

FIG. 25.

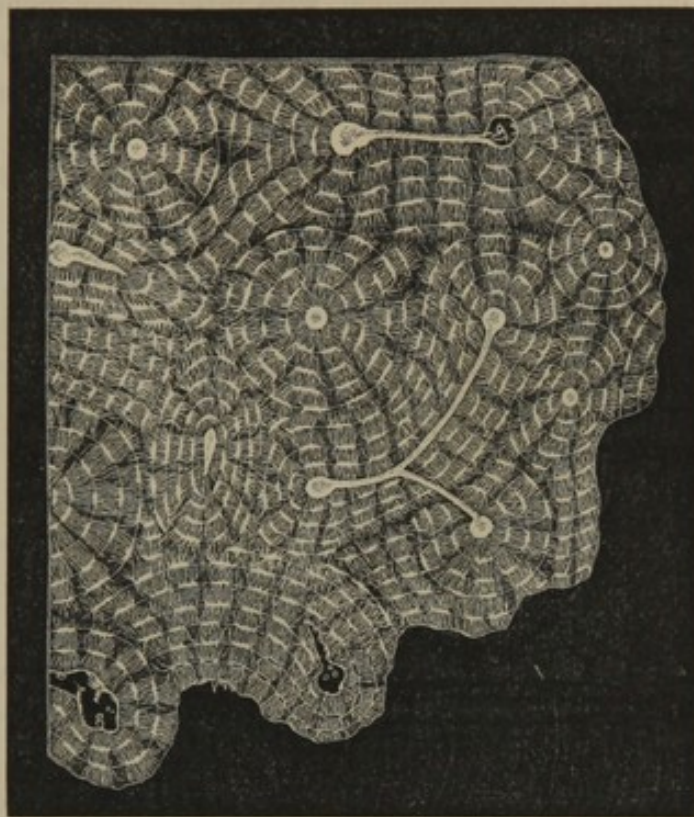


AN OSSEOUS LACUNA, exhibiting its numerous diverging canaliculi; highly magnified.

faintly longitudinal reticular arrangement, as if they were composed of an intertexture of filaments; and indeed when the cartilage of bone is macerated in diluted muriatic acid, it is resolved into a mass of the finest cotton-like filaments.

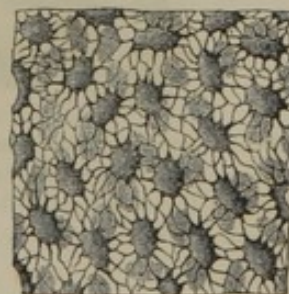
In positions where bones or parts of them are very thin, as in the lachrymal

FIG. 24.



TRANSVERSE SECTION OF BONE FROM THE SHAFT OF THE FEMUR, highly magnified. The large circular orifices are transverse sections of the vascular canals, surrounded by concentric layers of osseous substance. Between the latter are seen the lenticular excavations or lacunæ intercommunicating by means of canaliculi.

FIG. 26.



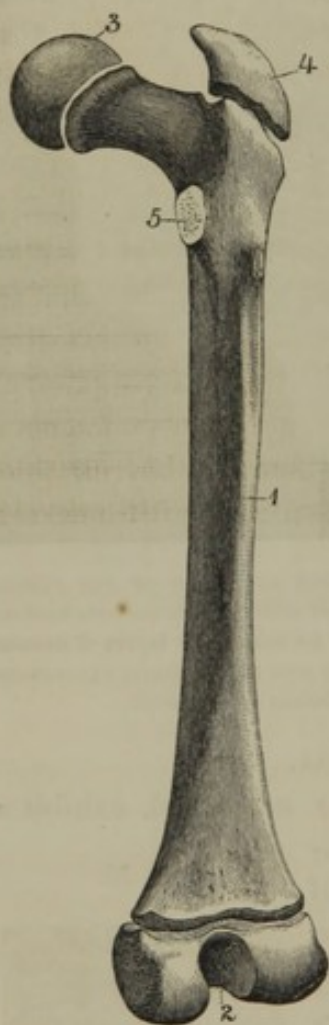
THIN PLATE FROM THE ETHMOID BONE, without preparation; highly magnified. Two planes of lacunæ visible, but one only in focus.

¹ Corpuscles of Purkinje.

bone, the edge of the squamous portion of the temporal bone, and the thin plates of the ethmoidal sinuses, (figure 26,) they are composed of parallel osseous laminae, with intervening lacunae, which communicate by means of their canaliculi with the exterior surfaces covered with periosteum, from the vessels of which they imbibe nutritive matter.

DEVELOPMENT AND GROWTH OF THE SKELETON.

FIG. 27.



FEMUR, from an individual about sixteen years of age, exhibiting the diaphysis (1,) distinct from the epiphyses, (2, 3, 4 5.)

The skeleton at its earliest period is perceptible as a soft cell structure, which soon assumes the more consistent character and composition of cartilage. **Ossification**, or the deposit of the calcareous matters, commences as early as the sixth or seventh week of embryonic life. The process occurs from one or more points for each bone, which are called the **centres of ossification**.¹

Bones of simple form generally have but a single centre of ossification, as the parietal and the carpal bones. The others are developed from a number of centres, in most cases holding a relationship with their degree of complexity. Ossification begins in the principal part of a bone, which is thence called the **diaphysis**.² The accessory portions, subsequently ossifying more or less in succession, are called **epiphyses**. Thus, for example, (figure 27,) the shaft or diaphysis of the thigh-bone first begins to ossify, then follow in succession, as epiphyses, the condyles, the head, the great trochanter, and finally the small trochanter.

In a vertebra, (figures 28, 29,) three diaphyses simultaneously undergo ossification; that is to say, the body and each half of the arch. Then follow the epiphyses together of the spinous and transverse processes; and lastly a thin plate of bone is added to the upper and lower surface of the body.

Epiphyses are united with their diaphysis by continuous cartilaginous

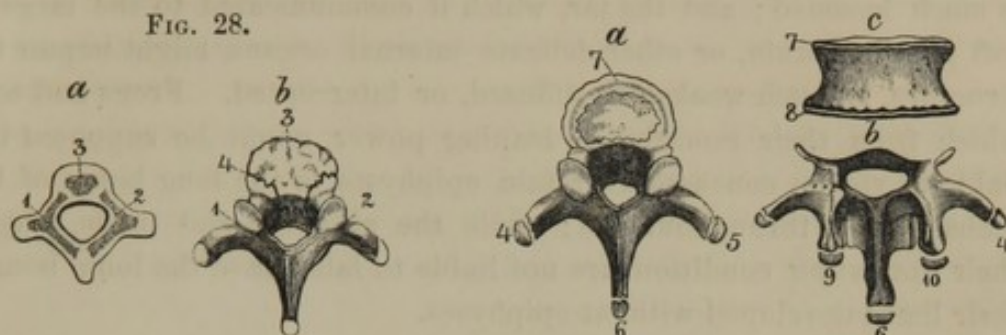
¹ Puncta ossificationis.

² Body; corpus ossis.

structure, which remains until both have reached their full development and growth, when they become united through ossification of the intervening cartilage.

FIG. 29.

FIG. 28.



DEVELOPMENT OF THE VERTEBRÆ. *a*, vertebra of a fœtus, in a cartilaginous condition, with three centres of ossification; 1, 2, lateral pieces; 3, the body; *b*, vertebra of an infant. The lateral pieces, 1, 2, are co-ossified at the spinous process, and join the body 3, at the sutures 4. The ends of the transverse and spinous processes yet in a cartilaginous state.

DEVELOPMENT OF THE EPIPHYSES TO THE VERTEBRÆ. *a*, dorsal vertebra, with the epiphyses 4, 5, to the transverse processes; 6, to the spinous process; and 7, to the body; *b*, arch with its processes; and *c*, body of a lumbar vertebra; 4, 5, epiphyses of the transverse processes; 6, of the spinous process; 7, 8, of the body; 9, 10, of tubercles of the upper articular processes.

Ossification commences in the skeleton with the clavicle and lower jaw as early as the sixth or seventh week of embryonic life; it then occurs successively in the vertebræ, humerus, femur, ribs, etc. At birth the diaphyses of most bones are ossified; but none of the epiphyses ordinarily have commenced the process, and this is also the case with the patella and the carpal and tarsal bones, except the calcaneum and astragalus.

Ossification of epiphyses commences with that of the condyles of the femur about the period of birth; and it occurs with the numerous others of the skeleton at different periods up to adult age.

The construction of bones from several centres of ossification facilitates the development of complex forms, though this means is not essential, for we find corresponding and equally complex bones in other animals developed from single centres. Thus the human humerus, which is developed from seven centres of ossification, and the femur from five, in birds, many lizards, and turtles, are developed from one.

In most instances, separate centres of ossification, or groups of such centres, are significant of permanently distinct bones in other parts of the same skeleton, or in the skeleton of other animals. Thus, as examples, we recognize the epiphysis of the olecranon of the ulna as representing the distinct patella; the coracoid epiphysis of the scapula represents the distinct coracoid bone of birds; the five divisions of the sacrum represent as many true vertebræ: in whales, dolphins, and serpents, always remaining as separate elements in the vertebral series.

The presence of epiphyses, and the intervening plates of elastic cartilage to the diaphyses, gives an important incidental condition in the protection of the body from injury at a period of life when it is most liable to falls or blows. Through this condition the shock from such accidents is much lessened; and the jar, which if communicated to the large and soft growing brain, or other delicate internal organs, might impair their structure, is much weakened, diffused, or intercepted. Frogs and toads, which from their remarkable leaping power might be supposed to be liable to violent concussions, retain epiphyses to the long bones of their limbs almost throughout life; while the alligator and turtle, which in their sprawling condition are not liable to falls, have the long bones of their limbs developed without epiphyses.

The cartilage of the embryonic skeleton consists of a comparatively soft, translucent, opalescent, homogeneous or faintly granular matrix, crowded with spherical or oval cells, which have finely granular contents and a central, nucleolated nucleus.

In the progress of development of the young being, the cartilage cells multiply through division, and the intercellular matrix increases so as gradually to widen the spaces between the groups or rows of cells.

In the cartilaginous diaphysis of long bones, the cartilage cells multiply in linear rows, generally parallel with one another and with the long diameter of the diaphysis. In epiphyses and short bones, the cartilage cells form oblong groups irregularly dispersed from the centre.

Just previous to ossification channels become developed in the intercellular matrix of the cartilage by resolution of its substance, and blood-vessels extend into them by continuous development from those of the exterior investing membrane.

The cartilage at the centres of ossification assumes a yellowish hue and an indistinct fibrous appearance; and at this time the chondrin is either converted into, or displaced by, the gelatinoid element. The calcareous substances are now deposited in the intercellular matrix as minute granules, which gradually become fused. The cartilage cells likewise receive the same deposit, and their walls coalesce with the ossified intercellular matrix. The remaining cavities of the cells, still filled with soft contents, constitute the lacunæ of bone. A few of the coarser canaliculi of the lacunæ appear to be narrow unossified tracts, along which, perhaps, there are comparatively strong currents of nutritive matter. Most of the canaliculi, however, apparently originate by a subsequent resolution of ossific substance.

The diaphysis of long bones grows in length by continuous development and ossification of cartilage at the extremities. Hence in the experiment, in which two holes are bored at a certain distance apart

in the shaft of a long bone of a young animal, after the latter has advanced in growth, the holes are found to remain the same distance from each other, while the shaft has increased in length in both directions.

Tabular bones extend in a similar manner at their borders; and short bones and epiphyses generally in all directions from their centres of ossification.

The diaphysis of long bones grows in thickness by the development from the under surface of the periosteum of successive layers of a substance, at first resembling incipient fibrous tissue, but subsequently embryonic ^{or bone} cartilage.¹ In the latter condition, this substance, which consists of a homogeneous matrix crowded with cartilage cells, and pervaded with vessels from the periosteum, undergoes ossification in the manner already described.

The tabular bones of the cranial vault and the bones of the face originate from the fibrous layers, which subsequently constitute their periosteum, in the same mode that the outer layers of the diaphysis of long bones are produced, as just described; and they afterwards grow in thickness through the same process.

The spongy substance of the bones is produced by a resolution of ossific structure, and the medullary cavity of long bones is formed by the gradual solution and absorption of spongy substance. At first the medullary cavities, as well as the interspaces of the spongy substance, are filled with a nutritive matter and numerous nucleated cells. The latter for the most part become converted into the adipose cells of the marrow of the medullary cavities.

At birth, the canal near the middle of the shaft of long bones, which contains the principal medullary nutritious vessels, is the largest space in their interior; and it is from this canal that the medullary cavity is gradually extended by absorption of the spongy substance occupying the axis of the bone.

As the diaphysis of the long bones of the limbs grows in length through ossification of the terminal cartilage, and grows in thickness through successive deposits from the periosteum, the medullary cavity increases almost as rapidly by absorption of previously formed osseous tissue. Therefore it is, before such a bone has reached its full growth, it appears to have been repeatedly absorbed and regenerated. Thus for example, the femur at the period of birth contains none of the osseous tissue of this bone in the embryo, and that of the child after a few years contains none

¹ Which differs from ordinary cartilage in yielding gelatin instead of chondrin by boiling.

of the osseous tissue which existed at birth, and before maturity the bone changes several times again.

After bones have reached their full growth, calcareous deposits continue still to be made gradually throughout life, thus rendering them harder and more brittle. The medullary cavities, and also in a less striking manner the interspaces of the spongy substance, slowly increase in size, so that the bones of old persons are rendered comparatively brittle from this circumstance, as well as from the increase of calcareous deposits.

ARTICULATIONS OR JOINTS OF THE SKELETON.

The **articula'tions** or **joints**¹ of the skeleton exhibit a gradation of union from those which are immovable to such as possess motion in all directions.

The most **immovable articulations**² are those which exist between the bones of the skull, constituting what are called the **sut'ures**.³ Many of the sutures are formed through indentations of the contiguous margins of the bones, which are mutually adapted to one another, often in a somewhat dovetailed manner. From their toothed appearance they are called **dent'ated** or **ser'rated sut'ures**.⁴ Examples of them are seen in the union of the frontal, parietal, and occipital bones. In other sutures the contiguous borders of bones are beveled off and mutually coadapted, as observed in the union of the sphenoid and temporal bones with the parietal. Such, from their scale-like arrangement, are called **squa'mous sutures**.⁵ In some sutures,⁶ plane borders of contiguous bones, slightly roughened, are coadapted, as in the union of the upper maxillary bones.⁷ Occasionally the border of one bone is grooved to receive the sharpened edge of another,⁷ as in the articulation of the vomer with the sphenoid bone.

The next form of articulation possesses more or less flexibility without allowing other motion. Such a joint is called a **sym'physis**,⁸ and is formed by the union of broad surfaces of contiguous bones through means of an intervening plate of fibro-cartilage. Examples of this mode of junction are presented in the union of the bones of the pelvis, the bodies of the vertebræ, and the pieces of the sternum.

In the **movable articulations**⁹ the bones have their opposed sur-

¹ Arthroses.

² Synarthroses.

³ Suturae.

⁴ S. dentatæ; s. serratæ.

⁵ S. squamosæ.

⁶ Harmonia; harmony; false suture.

⁷ Schindylesis.

⁸ Amphiarthrosis.

⁹ Diarthroses; diarthrodial articulations.

faces invested with cartilage, and their union is preserved by means of ligaments, which inclose the joints. Muscles or their tendons, which in many instances more or less surround these joints, very much contribute to the firmness of their union, and thus to prevent dislocation. To facilitate movement, they are lined with **syno'vial membrane**, which secretes a lubricating liquid, named the **syno'via**.

Of the movable articulations there are several varieties, which exhibit different degrees of mobility.

In some instances the movements are exceedingly limited, amounting only to a slight degree of gliding of the opposed surfaces upon each other, as instanced in most of the joints of the carpus and tarsus, and those of the articular processes of the vertebræ.

In other cases the joints are restricted to a hinge-like motion,¹ as observed in the elbow and knee joints, and those of the fingers and toes.² The hinge-like movement, together with a motion toward either side, is observed in the wrist and ankle joints.

Occasionally joints admit only of a rotary motion, as in the two radio-ulnar articulations and those between the atlas and axis.

The most movable articulations are the ball-and-socket joints,³ in which the head of one bone fits into a more or less deep cup-shaped concavity of the contiguous bone. Examples of such joints are presented in the shoulder and hip. The movements of these joints are those of flexion and extension, abduction and adduction, circumduction and rotation.

Of the different movements of the articulations, **flex'ion** is that in which one or more bones of a joint are made to describe an angle with others, in moving either backward or forward. Thus the bending of the bones of the forearm forward, is the flexion of the forearm upon the arm; the bending of the leg backward, is its flexion upon the thigh. **Exten'sion** is the opposite movement of flexion, in which the bones are generally brought into a line with one another. Thus the bending of the forearm backward after it has been flexed, so as to bring it on the same line with the arm, is the extension of the forearm.

Abduc'tion is that movement in which a bone is directed outwardly from another, or from the body; and **adduc'tion** is the opposite movement, in which a bone is directed inwardly. Thus the movement by which the thumb is moved outwardly from the fingers is abduction, and that by which it is made to approach them is adduction.

Circumduc'tion is that motion of a bone when its head acts as a pivot

¹ Ginglymus; ginglymoideus.

² Ginglymoid joints.

³ Enarthroses.

and the distal end is made to describe a circle. This character of movement is best exemplified with the humerus and glenoid cavity of the scapula. **Rota'tion** is the motion made by a bone when it rolls on its axis, as in the movements of the radius upon the ulna.

OF THE RELATIVE POSITION OF THE DIFFERENT STRUCTURES ENTERING INTO THE COMPOSITION OF ARTICULATIONS.

The bones articulating by suture are continuously associated by intervening cartilage, which is apt to ossify after the bones have reached maturity. The fibrous periosteum in all cases passes over the sutures, resembling in this position the capsular ligaments of movable joints. In symphyses an intervening plate of fibro-cartilage intimately connects the surfaces of the contiguous bones; and they are surrounded with bands of fibrous tissue, corresponding with the capsular ligaments of movable articulations.

In movable joints the opposed surfaces of the bones are invested with a layer of cartilage, which from its position is called **artic'ular car'tilage**.¹ When the cartilage covers a depressed or concave surface, it usually becomes thicker toward the borders, so as to deepen the concavity; but if it invests a head, condyle, or other articular prominence, it becomes thinner toward the margins.

The ligaments surrounding movable joints are of two kinds: the **cap'sular**² and **band-like lig'aments**.³ The former are cylindrical sacs, including by their extremities the borders of the articular surfaces of bones, where they become continuous with the periosteum of the latter, and frequently with the contiguous tendons of muscles. They vary in thickness; are composed of an intertexture of bundles of fibrous tissue, and are highly flexible and slightly extensible. In many positions, broad tendons of muscles, passing over joints, assume their place, as in the case of the tendon of the quadriceps extensor muscle of the thigh, and the extensor tendons on the backs of the phalangeal articulations. The band-like ligaments are accessory to the capsular ligaments, contributing to the strength of joints in particular positions. They are strong bundles of parallel filaments of fibrous tissue, quite flexible, but entirely inextensible. They constitute the numerous lateral ligaments of the joints.

The **syno'vial mem'branes** belong to the class of serous membranes. They line the interior of capsular ligaments; and in the adult are reflected upon the border of the articular cartilages; but in infancy they

¹ Diarthrodial cartilage.

² Capsulæ articulares.

³ Funicular ligaments.

invest the entire cavity of joints. They secrete a viscid, albuminoid liquid resembling the white of eggs, and called the **syno'via**, which lubricates the surfaces of joints, and, by lessening friction, facilitates motion.

The synovial, like other serous membranes, are composed of a delicate structureless layer, or basement membrane, attached beneath by a layer of connective tissue, in which blood-vessels are distributed, and invested on the free surface with several layers of pavement-like, nucleated cells. Their inner surface is smooth, and they possess no glands. At the borders of joints they are frequently thrown into folds and processes, containing connective tissue, fat, and an occasional isolated cartilage cell. These **syno'vial fringes**¹ apparently act as cushions to fill up interspaces, though from their greater comparative vascularity than other portions of the membrane, they are no doubt especially active in the production of synovia.

Concave articular surfaces are frequently rendered deeper by the provision of a band of fibro-cartilage tipping or surrounding their margin, as in the case of the glenoid cavity of the shoulder and the acetabulum of the hip-joint. Occasionally joints are partially or completely divided into two parts by the introduction of an inter-articular fibro-cartilaginous disk, as in the case of the articulation of the lower jaw and the knee-joint.

In some instances bones are connected by ligaments totally different from the ordinary ones, being composed of an elastic substance; such are the yellow ligaments which conjoin the vertebral arches; and such also is the nature of the nuchal ligament which sustains the head of quadrupeds.

The various structures which have been mentioned as entering into the composition of the articulations consist of bones, cartilages, fibro-cartilages, ligaments, and synovial membranes. The constitution of bones or of the osseous tissue has been described, but a consideration of the tissues comprising the remaining structures is deferred at present, on account of their entering into the constitution of many other organs. The structure of the cartilages and fibro-cartilages will be found under their appropriate head; the structure of ligaments in the description of the white fibrous, and yellow elastic tissues; and the synovial membranes are again mentioned in the account of the serous membranes.

¹ Synovial glands of Havers; Haversian glands; glandulæ articulares; synovial fimbriæ.

BONES OF THE HEAD OR SKULL.

The bones of the head or skull are twenty-two in number, and with one exception, that of the lower jaw, are firmly and immovably articulated. They form together cases for the reception and protection of the brain, the organs of especial sense, and the commencement of the alimentary and respiratory passages. They are divisible into two groups: those of the cranium or brain case, eight in number, and those of the face, fourteen in number.

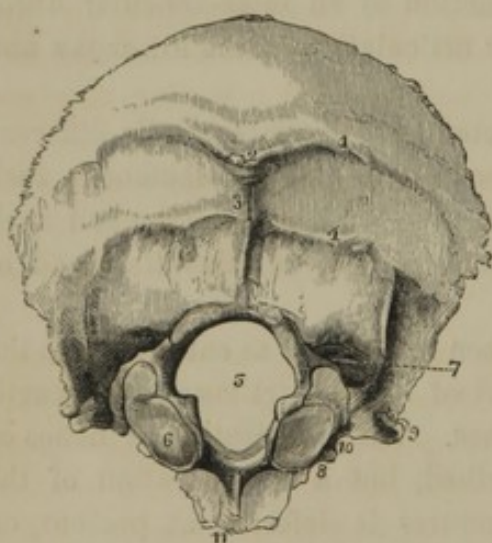
BONES OF THE CRANIUM.

Of the eight bones of the cranium, four are single and symmetrical: the occipital, sphenoid, ethmoid, and frontal bones, situated at the occiput, base, and forehead. The other bones are in pairs: the parietal and temporal bones, situated at the top and sides of the cranium.

THE OCCIPITAL BONE.

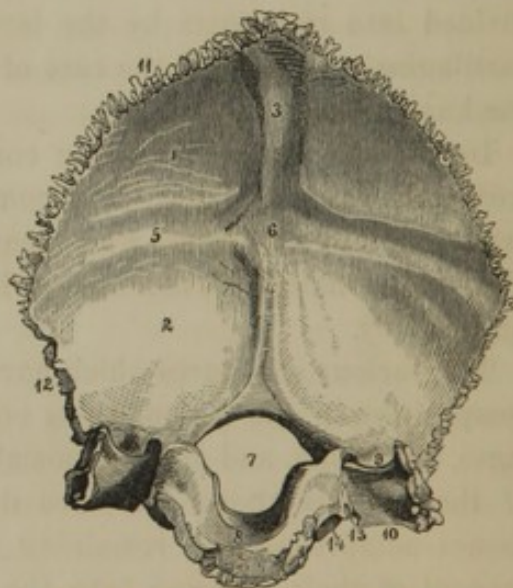
The **Occip'ital bone**¹ occupies the posterior extremity of the cranium,

FIG. 30.



EXTERNAL VIEW OF THE OCCIPITAL BONE. 1, superior curved line; 2, external occipital protuberance; 3, occipital crest; 4, inferior curved line; 5, occipital foramen; 6, condyle; 7, fossa behind the condyle, in which a venous foramen frequently opens; 8, position of condyloid foramen; 9, transverse process; 10, notch contributing to form the jugular foramen; 11, basilar process.

FIG. 31.



INTERNAL VIEW OF THE OCCIPITAL BONE. 1, fossa for the cerebrum; 2, fossa for the cerebellum; 3-6, occipital cross; 3, groove for the longitudinal sinus; 4, ridge for the attachment of the cerebellar falx; 5, groove for the lateral sinus; 6, internal occipital protuberance; 7, occipital foramen; 8, basilar process; 9, 10, groove for the lateral sinus, descending on the transverse process to the jugular notch; 11, border for the parietal bone; 12, border for the temporal bone; 13, position at which the ninth, tenth, and eleventh cerebral nerves pass through the jugular foramen; 14, condyloid foramen.

¹ *Os occipitis; os puppis; os memoriæ; os basilare; part of the os spheno-basilare; os lambdoides; os nervosum; os proræ; os pyxidis; os laudæ; os fibrosum; os pelvicephalicum; os sextum cranii.*

extending forward into the base of the latter. It has a general quadrate outline, with a convex external and a concave internal surface.

Its lower portion presents a large oval aperture, the **occip'ital fora'men**,¹ which gives transmission to the spinal cord, the spinal accessory nerves, and the vertebral arteries.

In advance of the foramen is a thick plate, the **bas'ilar proc'ess**,² the lateral borders of which are rough and contiguous to the petrous portion of the temporal bone; and its anterior extremity is rough and connected with the body of the sphenoid bone by means of an intervening plate of cartilage. The latter ossifies about the age of puberty, thus associating the occipital and sphenoid bones into one piece.³ The upper surface of the basilar process is a smooth, shallow groove,⁴ inclining to the occipital foramen, and supporting the medulla oblongata. The under surface⁵ is impressed by muscular attachments, and overhangs the pharynx.

On each side of the occipital foramen anteriorly, and on the under part of the bone, are situated the **con'dyles**. These are two oblong prominences, converging forward, with their lower surface convex, inclined outwardly, and covered with cartilage. Between them and the corresponding articulating processes of the atlas, the backward and forward movements of the head occur. At their inner border, they are roughened for the attachment of ligaments.

Piercing the bone, above the middle of the condyles, from within outwardly, is the **con'dyloid fora'men**,⁶ for the transmission of the hypoglossal nerve. Frequently at the back of the condyles there is another foramen,⁷ for the transmission of a vein.

To the outer side of the condyles is an angular prominence, the **trans'verse proc'ess**, which presents a ridge⁸ below for muscular attachment, a groove above to accommodate the termination of the lateral sinus, and an articular surface at the extremity covered with cartilage. In front of the process is a wide notch, which, with the contiguous border of the temporal bone, forms the **ju'gular fora'men**, for the conjunction of the lateral sinus with the jugular vein and the transmission of the spinal accessory, pneumo-gastric, and glosso-pharyngeal nerves.

The upper expanded portion of the bone is convex externally, and

¹ F. occipitale magnum; f. magnum.

² Pars basilaris; body of the occipital bone; basi-occipital bone; processus cuneiformis.

³ Os basilare; os spheno-occipitale.

⁴ Basilar fossa.

⁵ Basilar surface.

⁶ Anterior condyloid foramen.

⁷ Posterior condyloid foramen.

⁸ Jugular tubercle, or paramastoid process of lower animals.

presents just above its centre the **external occip'ital protu'berance**. From this a ridge, the **occip'ital crest**,¹ descends to the occipital foramen and gives attachment to the nuchal ligament. From the protuberance there extends outwardly the **superior curved line**,² so called in contradistinction to another lower down, the **inferior curved line**.³ These lines, which are only well marked in well-developed muscular individuals of mature age, together with the surfaces between and below them, give attachment to the muscles which sustain the erect position of the head.

The inner surface, of the expanded portion of the bone, is divided by ridges, forming the **occip'ital cross**, into four broad, shallow fossæ, of which the lower two accommodate the hemispheres of the cerebellum, and the upper two the posterior lobes of the cerebrum. The prominent centre of the cross is the **internal occip'ital protu'berance**, which is situated a little lower than the external one.

The upper limb of the occipital cross is marked by a groove indicating the course of the terminal portion of the longitudinal sinus; and it has attached to it the posterior extremity of the cerebral falx of the dura mater. The lower limb, extending to the occipital foramen, has the cerebellar falx attached to it. The lateral limbs are marked with grooves indicating the course of the lateral sinuses and the attachment of the tentorium.

The superior borders of the bone are dentated, and converge to form the **occip'ital angle**, which is received between the parietal bones. The lateral borders inferiorly articulate with the mastoid portions of the temporal bones.

The upper extremity of the occipital bone is occasionally found to be separated from the other portion by a transverse suture at any position down to the superior curved line. Such an anomalous piece corresponds with the interparietal bone of certain of the lower animals, as many rodents and ruminants. Occasionally the anomalous human interparietal bone is divided in the median line into two parts.

THE SPHENOID BONE.

The **Sphe'noid bone**⁴ is situated across the base of the cranium, and extended up on each side, just in advance of the middle. It contributes

¹ Occipital spine.

² Superior semicircular ridge.

³ Inferior semicircular ridge.

⁴ Os sphenoidum; os sphecoideum; os cuneiforme; os vespiforme; os basilare; os baxilare; os papillare; os mul-

tiforme; os azygos; os inconjugatum; os alatum; os alæforme; os polymorphon; os pterygoideum; os colatorii; os cuneo comparatum; sphenoidal part of the os sphenobasilare, or of the os sphenoccipitalis.

to the formation of the cranial cavity, the orbits, and the temporal, spheno-maxillary, and nasal fossæ.

From its complex form we may examine in succession its body, its small and great wings, its pterygoid processes, and its foramina.

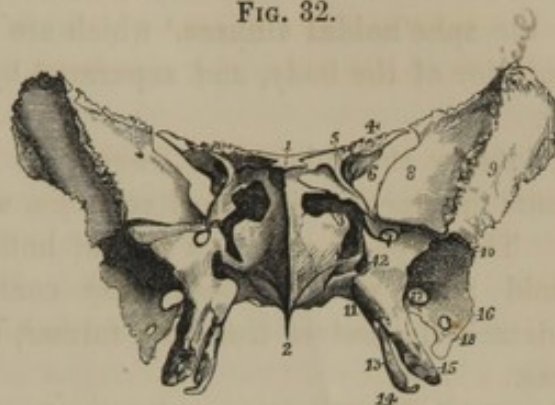
The **body**¹ or central portion of the bone is irregularly cuboidal, and articulates posteriorly by a rugged surface, in the manner previously mentioned, with the occipital bone. Its upper surface presents a deep excavation, the **pitu'itary fossa**,² which lodges the pituitary body of the brain. Posteriorly the fossa is bounded by an oblique plate, the **decliv'ity**,³ which continues the slope of the basilar process of the occipital bone, and supports the pons. The convex prominence in front, is the **ol'ivary proc'ess**,⁴ upon the slightly depressed surface of which the commissure of the optic nerve rests. In advance of this, is a smooth surface inclining toward the ethmoid bone, with which it articulates by its anterior border.

The prominent angles of the declivity are called the **posterior cli'noid proc'esses**,⁵ in contradistinction to the obtuse, backward projections, of the small wings, called the **anterior cli'noid proc'esses**.⁵

On each side of the body, below the pituitary fossa, there is a shallow groove,⁶ for the accommodation of the internal carotid artery, which curves from a notch at the back of the bone to the interval between the anterior clinoid and olivary processes.

The inferior surface of the body, which overhangs the posterior nares,

FIG. 32.



FRONT VIEW OF THE SPHENOID BONE. 1, 2, sphenoidal crest and rostrum for joining the nasal plate of the ethmoid bone and the vomer; 3, entrance of the sphenoidal sinuses; 4, small wing; 5, optic foramen piercing its base; 6, sphenoidal foramen; 7, rotund foramen; 8, orbital surface of the great wing; 9, temporal surface of the same; 10, ridge separating the temporal and spheno-maxillary fossæ; 11, position of the pterygo-palatine canal; 12, pterygoid canal; 13, internal pterygoid process, ending in a hook; 14; 15, external pterygoid process; 16, spinous process; 17, oval foramen; 18, spinous foramen.

¹ Basisphenoid bone; posterior or principal sphenoid bone; basis sive corpus partis sphenoidalis ossis spheno-occipitalis.

² Sella turcica; s. equina; ephippium.

³ Dorsum ephippii; clivus; clivus Blumenbachii.

⁴ Tuberculum ephippii.

⁵ Processus clinoides posteriores et anteriores; apophyses clinoides.

⁶ Sulcus caroticus.

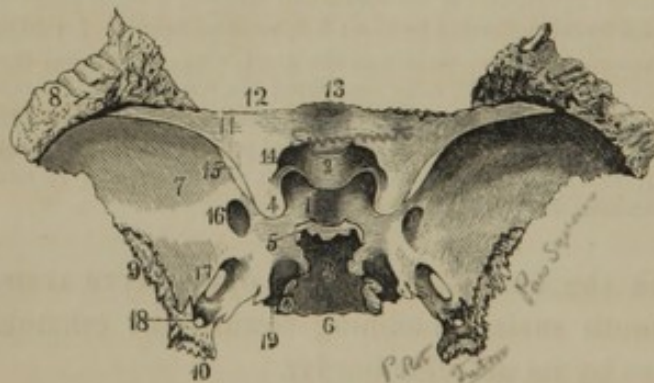
presents a median acute ridge, the **ros'trum**,¹ with which the expanded border of the vomer articulates; and on each side is a thin projecting plate, which joins the reflected margin of the same bone.

The anterior surface, directed toward the nasal fossæ, presents a median ridge, the **sphe'noidal crest**,² which articulates with the nasal plate of the ethmoid bone. On each side of the crest is an opening communicating with the **sphe'noidal sinuses**,³ which are two large cavities hollowed in the interior of the body, and separated by a usually unsymmetrical partition.

In infancy the sphenoidal sinuses do not exist; and the body then presents inferiorly a thick median ridge, with a triangular space on each side. These spaces receive a pair of hollow cones,⁴ projecting from the ethmoid bone, which subsequently coalesce with the sphenoid bone and detach themselves from the former, thus producing the sphenoidal sinuses.

The **small wings**⁵ of the sphenoid bone are two sabre-like processes,

FIG. 33.



UPPER VIEW OF THE SPHENOID BONE. 1, pituitary fossa; 2, olivary process; 3, declivity; 4, anterior clinoid process; 5, posterior clinoid process; 6, posterior border of the body; 7, cerebral surface of the great wing; 8, articular surface for the frontal bone; 9, articular border for the temporal bone; 10, spinous process; 11, small wing; 12, border articulating with the orbital plate of the frontal bone; 13, border joining the ethmoid bone; 14, optic foramen; 15, sphenoidal foramen; 16, rotund foramen; 17, oval foramen; 18, spinous foramen; 19, groove for the internal carotid artery.

which extend horizontally outward from the antero-lateral portion of the body. Their anterior rugged border articulates with the orbital plates of the frontal bone; and their posterior smooth and curved border is received into the fissure separating the anterior and middle lobes of the cerebrum. Their outer end is sharp pointed; and their posterior end forms the blunt **anterior cli'noid process**.

The **great wings**⁶ project laterally from the body, curve outward, forward, and upward, and present three important surfaces. The **superior**

¹ Processus azygos.

² Crista or spina sphenoidalis.

³ Sinus sphenoidales.

⁴ Ossicula Bertini; cornua sphenoi-

dalia; pyramids of Wistar; ossa triangularia.

⁵ Alæ minores; processus enciformes; apophyses Ingrassii.

⁶ Alæ magnæ, temporal wings.

or **cer'ebral surface**¹ is a crescentic concavity contributing to form the middle cerebral fossa. The **anterior** or **orb'ital surface**² is an oblique quadrate, vertical plane, forming part of the outer wall of the orbit. The **external** or **tem'poral surface**³ is divided by a ridge into two parts, of which the upper, slightly concave and directed outwardly, forms part of the temporal fossa, while the lower division directed downward forms part of the sphenomaxillary fossa.

From the back part of the great wing projects the thick, angular, **spinous process**,⁴ which is received in the interval between the squamous and petrous portions of the temporal bone.

Upon the broad rough surface inclining from the summit of the great wing forward, rest the anterior prolonged angle of the parietal bone and the orbital plate of the frontal bone. The anterior border of the orbital surface articulates with the malar bone, and its lower border forms the upper boundary of the sphenomaxillary fissure. The posterior concave border of the great wing joins the squamous portion of the temporal bone.

The **pter'ygoid proc'esses**⁵ project vertically downward from the junction of the great wings with the body. They consist of a pair of plates united at an angle anteriorly, and diverging posteriorly, so as to inclose an angular groove, the **pter'ygoid fossa**.⁶ The **external pter'ygoid process** is broad and thin, and directed outward and backward. The **internal pter'ygoid process** is longer and narrower than the other; and it forms the lateral border of the posterior nares. At its upper part behind is a fossa⁷ for the origin of the tensor muscle of the palate; and its lower part is prolonged into a hook⁸ around which the tendon of the latter muscle turns in its course to the palate.⁹ The pterygoid fossa at its lower part presents a deep angular notch,⁹ which is occupied by the pyramidal process of the palate bone.¹⁰

The foramina of the sphenoid bone are numerous and important.

The **op'tic fora'men**¹⁰ pierces the base of the small wing from the side of the olivary process outward and forward. It transmits the optic nerve and ophthalmic artery from the cranial cavity to the orbit.

The **sphenoid'al fora'men**¹¹ in the separated bone is open at its outer end, but is closed by the apposition of the frontal bone. It is club-

¹ Superficies cerebralis; s. interna.

² S. orbitalis; s. anterior.

³ S. temporalis; s. externa.

⁴ Lamina triangularis; spina angularis.

⁵ Processus pterygoidei; alae inferiores; a. palatinae; processus aliformes.

⁶ Fossa pterygoidea.

⁷ Scaphoid fossa.

⁸ Hamulus pterygoideus; hamular process.

⁹ Incisura pterygoidea; fissura pterygoidea.

¹⁰ Foramen opticum.

¹¹ F. sphenoidalis; f. orbitalis superior; f. lacerum superius.

shaped, with the broad end internal, and separates the small and great wings. It opens into the orbit and transmits the oculo-motor, pathetic, ophthalmic, and abducent nerves, and the ophthalmic vein.

The **rotund' fora'men**¹ pierces the great wing from behind forward, just below the inner extremity of the preceding foramen. It opens from the cerebral surface into the pterygo-maxillary fossa, and transmits the superior maxillary nerve.

The **oval fora'men**,² larger than the last, and less than half an inch behind it, pierces the great wing vertically, and transmits the inferior maxillary nerve. *Small meningeal artery*

The **spinous fora'men**,³ quite near the preceding, pierces the spinous process vertically, and transmits the great meningeal artery.

The **pter'ygoid canal**⁴ penetrates the root of the pterygoid processes from before backward, and transmits the pterygoid ^{or Vidianus} nerve.

The **pter'yo-pal'atine canal**⁵ is a small groove situated internally to the former, and converted into a complete canal by the apposition of the palate bone.

THE ETHMOID BONE.

The **Eth'moid bone**⁶ is situated at the anterior part of the base of the cranium, between the cavity of the latter and the nasal fossæ, and between the orbits. It is cuboidal in form, and is exceedingly light, in consequence of its excavated character.

We may consider, separately, its vertical lamina, its cribriform plate, and its lateral masses.

The **vertical lamina** occupies the median line. Its upper ^{1/5} portion, projecting into the cavity of the cranium, is the **ethmoid'al crest**,⁷ which is thick and prominent in front, and rapidly declines posteriorly. It separates the ethmoidal gutters, and has attached the anterior extremity of the cerebral falx. From its front project the **ethmoid'al wings**,⁸ two small processes resting against the frontal bone.

The lower four-fifths of the vertical lamina form the **na'sal plate**,⁹ which contributes about one-third to the extent of the nasal partition. ^{Fig. 66} Its posterior border joins the sphenoidal crest; its inferior, the vomer; and its anterior below, the triangular cartilage; and above, the nasal process of the frontal bone. Its superior border ^{on each side} is pierced by vertical canals, for the passage of branches of the olfactory nerves.

¹ F. rotundum.

² F. ovale.

³ F. spinosum.

⁴ Canalis pterygoideus; c. Vidianus.

⁵ Canalis pterygo-palatinus.

⁶ Os ethmoideum; os cribrosum; os

spongiosum; os cristatum; os cubicum; os colatorium; os foraminulentum; os coliforme; os multiforme.

⁷ Crista ethmoidalis; crista galli.

⁸ Processus alares.

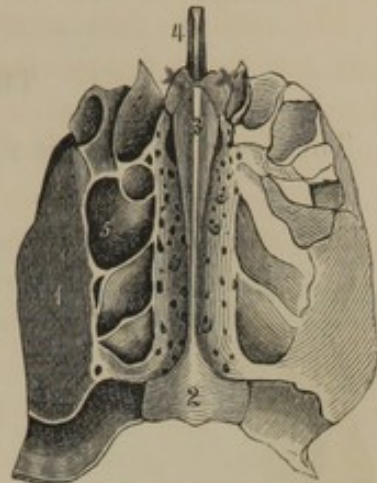
⁹ Lamella nasalis.

The **crib'riform plate**¹ is the horizontal perforated portion connecting the lateral masses with the vertical lamina, and occupying the interval of the orbital plates of the frontal bone. It separates the cavity of the cranium from the nasal fossæ, and is depressed on each side of the ethmoidal crest, so as to form the **ethmoid'al gutters**, for the lodgment of the olfactory bulbs. Its numerous **orifices**² transmit the nerves from the latter, except the larger anterior one, which gives passage to the ^{nasal} branch of the ophthalmic nerve.

The **lateral masses** consist of an aggregation of thin walled cavities, the **ethmoid'al si'nuses**,³ which are usually separated into three sets: the anterior, middle, and posterior. They are bounded externally by the **orbital plate**,⁴ which forms part of the inner wall of the orbit. The plate is square, but not being sufficiently extensive to close all the sinuses, this is done in front by the lachrymal and maxillary bones, above by the borders of the orbital plates of the frontal bone, and behind by the sphenoid and palate bones.

The inner or nasal surface of the lateral masses presents two oblique, scroll-like laminae, the **superior** and **inferior tur'binated proc'esses**.⁵ The former is posterior, shorter than the other, and is thin and narrow. The latter extends the length of the lateral mass, and presents a convex surface toward the nasal partition, a concave surface toward the ethmoidal sinuses, and a convoluted and rough border downward. Between the turbinated processes is an oblique fissure, the **superior mea'tus**⁶ of the nose, into which opens the posterior and middle ethmoidal sinuses. Above the processes, the surface is perforated by branches of the olfactory nerve. The inferior turbinated process forms the upper boundary of the **middle mea'tus**⁷ of the nose, into which opens the anterior, and sometimes the middle ethmoidal sinuses.

FIG. 34.



UPPER VIEW OF THE ETHMOID BONE
1, orbital surface of the lateral mass;
2, posterior extremity of the cribriform plate, which unites the lateral masses, and is depressed and perforated with numerous foramina on each side of the ethmoidal crest 3; the two oblique processes in advance of the latter are the ethmoidal wings; 4, anterior extremity of the nasal plate; 5, the ethmoidal sinuses.

¹ Lamina cribrosa.² Foramina cribrosa.³ Cellulae ethmoidales.⁴ Os planum; lamina papyracea.⁵ Superior and middle turbinated

bones; concha sup. et inf.; c. minor et major; ossa spongiosa sup. et medius; superior and middle spongy bones.

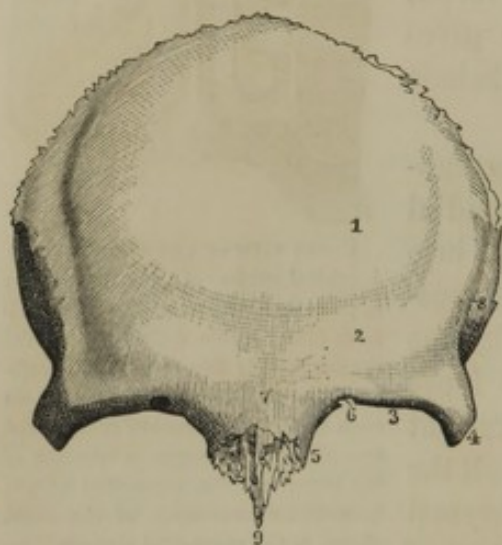
⁶ Meatus narium superior.⁷ M. n. medius.

From the lower portion of the lateral mass, where it rests upon the maxillary bone, one or two small irregular plates¹ project downward so as to diminish the size of the aperture of the maxillary sinus.

THE FRONTAL BONE.

The **Front'al bone**² is situated at the anterior part of the cranium, and forms the basis of the forehead, the root of the nose, and the roofs of the orbits.

FIG. 35.



EXTERNAL VIEW OF THE FRONTAL BONE. 1, situation of the frontal eminence; 2, situation of the superciliary ridge; 3, supra-orbital margin; 4, 5, external and internal angular processes; 6, supra-orbital notch or foramen; 7, nasal eminence; 8, temporal ridge; 9, nasal spine.

Externally it is convex and smooth, and presents on each side the **front'al eminence**,³ usually the most prominent part of the forehead, and especially well marked in the young.

At the lower border of the bone on each side is an arching ridge, the **supra-orb'ital margin**, the extremities of which terminate in the **external**⁴ and **internal angular processes**. At the inner part of the ridge is a foramen, or a notch converted into one by a ligament, the **supra-orb'ital fora'men**, which transmits an artery and nerve to the forehead.

Above the supra-orbital margin is an arching prominence, the **supercil'iary ridge**,⁵ which is situated just above the eyebrow, and varies in degree of development in different individuals. The prominence between the ridges of the two sides is the **nasal eminence**,⁶ the width of which has much influence in the intellectual expression of the face. Below, it terminates at the **root of the nose**,⁷ which is a rough surface, for articulating with the nasal and maxillary bones. From this surface projects the **nasal spine**,⁸ which serves as a point of support to the nasal bones, and joins behind the nasal plate of the ethmoid bone.

¹ Processus uncinatus; p. Blumenbachii.

² Os sincipitis; os coronale; os proræ; os puppis; os rationis; os inverecundum.

³ Tuber frontalis; frontal protuberance.

⁴ Processus zygomaticus.

⁵ Arcus superciliaris.

⁶ Nasal tuberosity; glabella; intercilium; metopium; mesophryon.

⁷ Pons nasalis.

⁸ Spina nasalis superior.

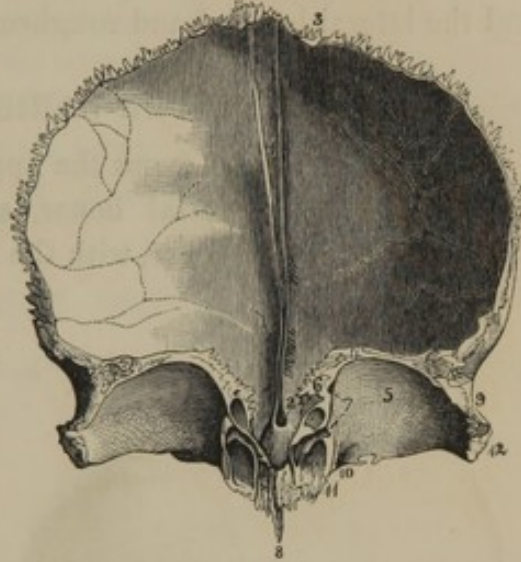
At the side of the bone, curving upward and backward from the external angular process, is the **tem'poral ridge**, which includes the anterior part of the temporal fossa.

The internal surface of the frontal bone is generally concave and impressed by the convolutions of the cerebrum. In its middle below is a ridge, the **front'al crest**,¹ which gives attachment to the cerebral falx, and disappears above at the sides of a shallow groove for accommodating the longitudinal sinus. At the bottom of the crest is a blind-pit,² or a canal,³ transmitting a vein from the nose to the latter sinus.

From the lower part of the internal surface project the two broad, arching **orb'ital plates**,⁴ which form the roofs of the orbits. They are separated by a wide interval, the **ethmoid'al fissure**.⁵ Above, they are convex, and strongly marked by the inferior convolutions of the anterior cerebral lobes. Below, they are concave and smooth, and are deeply depressed within the position of the external angular process for the accommodation of the lachrymal gland.⁶ Just above the internal angular process, on the same surface, is a small impression,⁷ made by the fibro-cartilaginous pulley of the superior oblique muscle of the eyeball.

The outer border of the orbital plate and the external angular process articulate with the malar bone; and the posterior border of the former joins the small wing of the sphenoid bone. Its inner border exhibits several superficial excavations, which form the upper boundary of the ethmoidal sinuses, and in front of them is the communication with the

FIG. 36.



INTERNAL VIEW OF THE FRONTAL BONE. 1, commencement of the groove for the longitudinal sinus, formed by the divergence of the frontal crest; 2, is placed in the ethmoidal fissure, and points to a small venous canal; 3, superior dentated border, articulating with the parietal bones; 4, posterior border of the orbital plate 5, which joins the small wing of the sphenoid bone; 6, irregular inner border of the same plate which covers the upper part of the ethmoidal sinuses; 7, points to the position of the ethmoidal foramina; 8, nasal spine; 9, thick rough border articulating with the great wing of the sphenoid bone; 10, refers to the black spot which indicates the position of a fossa for the trochlea of the superior oblique muscle; to its outer side is the supra-orbital notch; 11, internal angular process, and entrance to the frontal sinus; 12, external angular process.

¹ Crista frontalis.² Foramen cœcum.³ Porus cranio-nasalis.⁴ Partes orbitales or horizontales.⁵ Incissura ethmoidalis.⁶ Fovea glandulæ lachrymalis.⁷ Foveola trochlearis.

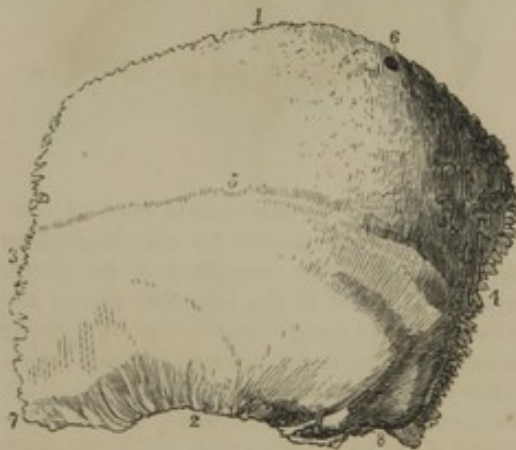front'al si'nus.¹ This cavity extends upward and outward within the position of the superciliary ridge, and varies in size in different individuals. Very rarely it does not exist; but not unfrequently it extends as high as the frontal prominence, and backward into the orbital plate. It is separated from the other by a partition, and communicates through the anterior ethmoidal sinuses with the nose.

The upper thick dentated border² articulates with the parietal bones, and the lateral beveled and roughened border with the sphenoid bone.

THE PARIETAL BONE.

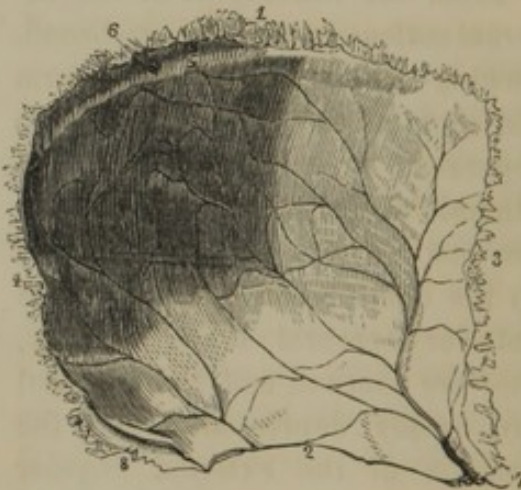
The **Pari'etal bone**³ forms the upper part of the cranial vault between the frontal and occipital bones, and is united with its fellow in the median line. It is square, with the external surface convex and smooth,

FIG. 37.



OUTER VIEW OF THE LEFT PARIETAL BONE. 1, upper border; 2, beveled lower border, which articulates with the squamous portion of the temporal bone; 3, anterior border, joining the frontal bone; 4, occipital border; 5, temporal ridge; 6, venous foramen; 7, prolonged anterior inferior angle joining the summit of the great wing of the sphenoid bone; 8, posterior inferior angle articulating with the mastoid portion of the temporal bone.

FIG. 38.



INNER VIEW OF THE LEFT PARIETAL BONE. 1-4, borders corresponding with same numbers in former figure; 5, groove for the longitudinal sinus, and communication with it, of a venous foramen; 6; 7, 8, anterior and posterior inferior angles; the groove on the latter accommodates the lateral sinus. The arborescent lines on the inner concave surface of the bone indicate grooves produced by the great meningeal artery.

and the internal surface concave, ridged, and impressed by the arborescent branches of the great meningeal artery.

Toward the middle of the bone externally is the most prominent part, named the **pari'etal eminence**;⁴ and just below this is a superficial curved

¹ S. superciliaris; s. pituitarii frontis; caverna frontis.

² Margo coronalis.

³ Os parietale; o. bregmaticum; o.

verticale; o. verticis; o. tetragonum; o. nervale.

⁴ Tuber parietale; parietal protuberance.

line, the **tem'poral ridge**, which defines the upper part of the temporal fossa.

Along the superior border internally, of the two bones in conjunction, a shallow groove is visible, indicating the course of the longitudinal sinus.

Of the four angles of the parietal bone, the anterior inferior is most prolonged, and articulates with the great wing of the sphenoid bone.

The posterior inferior angle joins the mastoid portion of the temporal bone, and internally is impressed by the lateral sinus.

Of the four borders of the bone, the anterior, superior, and posterior are nearly straight, thick, and dentated for articulation with the frontal, the opposite parietal, and the occipital bones. The inferior border is curved and beveled to a sharp edge for articulation with squamous portion of the temporal bone.

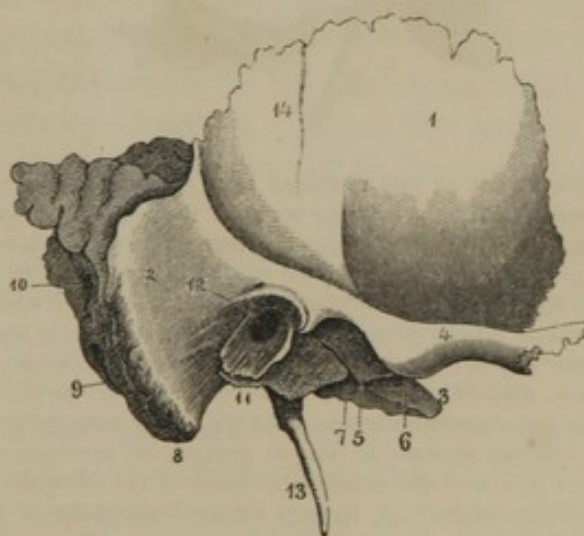
THE TEMPORAL BONE.

The **Tem'poral bone**¹ is situated at the side of the cranium, and extends into its base.

It is of complex form, and divisible into the squamous, mastoid, and petrous portions.

The **squa'mous por-tion**,² so named from its scale-like form, presents an external smooth surface, which contributes to the temporal fossa; and an internal surface, marked by the cerebral convolutions and great meningeal artery, forming part of the middle cerebral fossa. Its upper border is beveled to a thin edge, and overlaps the contiguous border of the parietal bone; and its anterior border, less beveled, articulates with the sphenoid bone. From near the

FIG. 39.



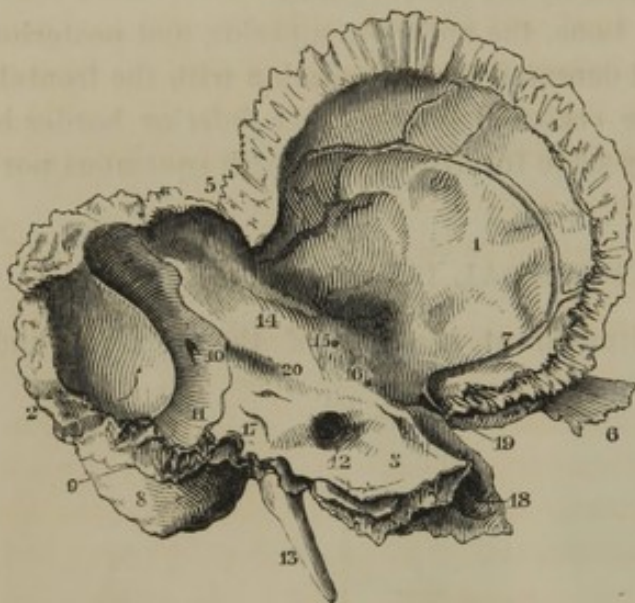EXTERNAL VIEW OF THE TEMPORAL BONE OF THE RIGHT SIDE. 1, squamous portion; 2, mastoid portion; 3, apex of the petrous portion; 4, zygomatic process; 5, glenoid cavity; 6, glenoid tubercle; 7, glenoid fissure; 8, mastoid process; 9, back part of digastric groove; 10, mastoid foramen; 11, auditory process, by extension inwardly, forming the vaginal process; 12, external auditory meatus; 13, styloid process; 14, slight impression of the deep temporal artery.

¹ *Os temporale*; *o. temporis*; *o. parietale inferius*; *o. lapidosum*; *o. squamosum*; *o. crotaphyticum*; *o. memento mori*; *o. mendosum*; *o. arcuale*; *o. armale*.

² *Pars squamosa*; *squama*; *lepisma*; *os lepidoides*; *os squamiforme*.

middle of its lower border externally, the **zygomatic process**¹ arches outward and forward to join the corresponding process of the malar bone, and thus form the **zygo'ma**² or yoke through which the temporal muscle proceeds to its insertion. Beneath and internal to the position of the root of the process, is a transverse concavity, the **gle'noid fossa**,³ and in advance of this a transverse eminence, the **gle'noid tubercle**,⁴ both of

FIG. 40.



INTERNAL VIEW OF THE TEMPORAL BONE OF THE LEFT SIDE.

1, squamous portion; 2, posterior border of the mastoid portion articulating with the occipital bone; 3, petrous portion; 4, beveled edge, which overlaps the lower edge of the parietal bone; 5, thick upper border of the mastoid portion, articulating with the posterior inferior angle of the parietal bone; 6, end of the zygomatic process; 7, groove produced by the great meningeal artery; 8, mastoid process; 9, digastric groove; 10, mastoid foramen opening into the groove 11, for the lateral sinus; 12, internal auditory meatus; 13, styloid process; 14, prominence produced by one of the semicircular canals of the labyrinth; 15, Fallopian hiatus; 16, foramen for the transmission of a branch of the tympanic nerve; 17, cleft which transmits a small blood-vessel to the vestibule of the labyrinth; 18, termination of the carotid canal; 19, Eustachian tube; 20, groove of the superior petrosal sinus.

mastoid portion forms part of the cerebellar fossa, and presents a wide

of which enter into the articulation of the lower jaw. Posteriorly, the fossa is separated from the petrous portion of the bone by the **gle'noid fissure**.⁵

The **mas'toid portion**,⁶ named from its nipple-like prominence, occupies the back part of the bone, and articulates with the parietal and occipital bones. It is thick, and occupied interiorly with the **mas'toid sinuses**,⁷ which communicate with the tympanum. The flattened nipple-shaped prominence, or **mas'toid process**,⁸ projects downward, and is roughened for muscular attachment. On its inner side is situated the **di-gas'tric groove**,⁹ for the origin of the correspondingly named muscle.

The inner surface of the

¹ Processus zygomaticus; p. jugalis.

² Arcus zygomaticus; zygomatic arch.

³ Fossa glenoidalis.

⁴ Tuberculum articulare.

⁵ Fissura Glasseri; Glasserian fissure.

⁶ Pars mastoidea; p. mammillaris.

⁷ Cellulæ mastoideæ; antrum mastoideum.

⁸ Processus mastoideus; apophysis mammillaris.

⁹ Digastric fossa; mastoid groove; incisura mastoidea.

descending groove,¹ which indicates the course of the lateral sinus. From the groove a foramen² generally perforates the border of the bone for the transmission of a vein from the scalp.

The **pe'trous portion**,³ named from its comparative hardness, contains the labyrinth and tympanum.⁴ It forms a prostrate, trilateral pyramid projecting into the base of the cranium inward and forward. Its base rests against the junction of the other two portions of the bone, and between these, externally, presents the **external aud'itory mea'tus**,⁵ a wide oval canal, directed inward and forward to the tympanum, and bounded below by a scroll-like plate, the **aud'itory process**, the border of which is rough, for the attachment of the auricle. The apex of the petrous portion is received in the interval between the spinous process of the sphenoid bone and the anterior part of the occipital bone.

Of the three surfaces of the petrous portion, the anterior forms part of the middle cerebral fossa; the posterior forms part of the cerebellar fossa; and the inferior surface is directed downward.

The anterior surface is an inclined plane with its inner end impressed by the semilunar ganglion of the trifacial nerve, and its upper part rendered prominent by one of the semicircular canals of the labyrinth. Its inner third presents an inconspicuous narrow groove,⁶ leading outwardly to a small foramen,⁷ which communicates with the Fallopian canal, and transmits a branch of the pterygoid nerve. Below the groove are one or two smaller foramina,⁸ likewise intended for the transmission of nerves.

The posterior surface also forms an inclined plane. At its inner third is an oblique canal directed outwardly, the **internal aud'itory mea'tus**,⁹ which transmits the auditory and facial nerve. The bottom¹⁰ of the meatus is divided by a transverse ridge into two pits, in the upper one of which commences the **Fallo'pian canal**,¹¹ for the further passage of the facial nerve. The canal is at first directed forward, and then turns abruptly backward and outward at the upper part of the tympanum, and subsequently descends to the stylo-mastoid foramen. The

¹ Sulcus sinus transversi; fossa sigmoidea.

² F. mastoideum.

³ Pars petrosa; pars pyramidalis; petrous process; os lapideum; o. durum; o. lithoides; o. saxeum; o. petrosum; o. praeruptæ rupi assimilatum; o. nervale.

⁴ See Organ of Hearing.

⁵ Meatus auditorius externus.

⁶ Semicanalisis nervi Vidiani.

⁷ Fallopian hiatus; hiatus Fallopii; hiatus canalis Fallopiæ; foramen Vidiani; apertura spuria; for. Tarini; f. anonymum Ferreinii.

⁸ Canaliculi petrosi.

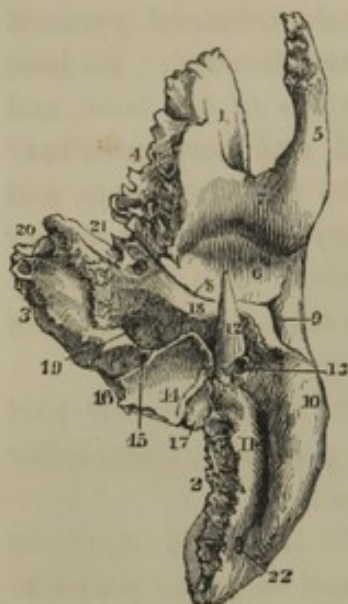⁹ Meatus auditorius internus; porus or sinus acusticus int.

¹⁰ Macula cribrosa.

¹¹ Canalis Fallopiæ; aqueductus Fallopiæ; can. facialis.

other portions of the bottom of the internal auditory meatus transmit the divisions of the auditory nerve to the labyrinth, in a manner more particularly described hereafter.¹ About

FIG. 41.



INFERIOR VIEW OF THE LEFT TEMPORAL BONE. 1, squamous portion; 2, mastoid portion; 3, petrous portion; 4, border articulating with the great wing of the sphenoid bone; 5, zygomatic process; 6, glenoid cavity; 7, glenoid tubercle; 8, glenoid fissure; 9, external auditory meatus; 10, mastoid process; 11, digastric groove; 12, styloid process; 13, stylo-mastoid foramen; 14, jugular fossa; 15, pit which transmits a vein from the cochlea of the vestibule; 16, position between which and the occipital bone the ninth, tenth, and eleventh cerebral nerves escape from the cavity of the cranium; 17, articular process; 18, vaginal process; 19, 20, entrance and exit of the carotid canal; 21, Eustachian tube; 22, mastoid foramen.

the fourth of an inch external to the entrance of the meatus there is a short cleft, which communicates with a small foramen² for the transmission of a vein from the vestibule of the labyrinth. At the upper border of this surface is a groove³ for conducting the superior petrosal sinus to the lateral sinus.

The inferior surface of the petrous portion of the bone presents many points of interest. At its anterior outer part is the plate of bone which forms the **aud'itory proc'ess**,⁴ defined above by the glenoid fissure, and below by a sharp crest named the **vag'inal process**,⁵ which partly ensheathes the base of the **sty'loid proc'ess**.⁶ The latter is a tapering spine, of variable length, projecting downward, forward, and inward, and connected to the hyoid bone by means of a round, fibrous cord, the **sty'lo-hy'oid lig'a-ment**.

Between the styloid and mastoid processes is the **sty'lo-mas'toid fora'men**,⁷ which is the termination of the Fallopiian canal, and gives exit to the facial nerve.

Behind the styloid process is a surface tipped with cartilage, the **artic'ular process**, which joins the transverse process of the occipital bone. To the inner side of this surface is a concave depression, the **ju'gular fos'sa**,⁸ in which the internal jugular vein commences. To the inner side of the fossa is a notch, part of the jugular foramen, containing a three-sided pit, at the bottom of which is a

foramen⁹ for the transmission of a vein from the cochlea of the labyrinth.

¹ See Organ of Hearing.

² Aqueductus vestibuli.

³ Sulcus petrosus superior.

⁴ Processus auditorius.

⁵ Processus vaginalis.

⁶ P. styloideus.

⁷ F. stylo-mastoideum.

⁸ Fossa jugularis; thimble-like cavity.

⁹ Aqueductus cochleæ.

Below the notch is the entrance of the **carot'id canal**,¹ which ascends and then turns at a right angle forward and inward to the apex of the petrous portion of the bone, and transmits the internal carotid artery to the cavity of the cranium.

In the crest, which separates the jugular fossa and carotid canal, is a small foramen,² which transmits the tympanic branch of the glossopharyngeal nerve to the tympanum.

The anterior border of the petrous portion, in the notch separating it from the squamous portion, exhibits the irregular orifice of a canal, which communicates with the tympanum and is divided into two parts by a partition.³ The upper division⁴ of the canal accommodates the tensor muscle of the tympanum, and the lower one forms part of the **Eustachian tube**.⁵

STRUCTURE AND ARTICULATION OF THE BONES OF THE CRANIUM.

The bones of the cranium, excepting when they are especially thin, as in the case of the ethmoid bone, the orbital plates of the frontal bone, the squamous portion of the temporal bone, and the cerebellar fossæ of the occipital bone, are composed, as in the case of tabular bones generally, of two layers of compact substance, with an intervening spongy substance.⁶ The outer table of compact substance is much more tenacious than the inner one, which from its comparative brittleness has received the name of the **vitreous table**. The spongy substance varies in the extent of its development in different individuals and races; and generally it is more abundant in the negro than in the white race.

The bones of the cranium are nearly all united by suture. Before puberty, the basilar process of the occipital bone articulates with the body of the sphenoid bone, by means of fibro-cartilage, which speedily ossifying, unites the two bones into one piece. The transverse process of the occipital bone is connected with the articular process of the temporal bone by cartilage, which likewise speedily ossifies. The anterior border of the petrous portion of the temporal bone is simply coadapted with the posterior border of the great wing of the sphenoid bone; but its apex and posterior border, as far as the jugular foramen, are united with the contiguous borders of the sphenoid and occipital

¹ Canalis caroticus.

² Canaliculus tympanicus.

³ Processus cochleariformis.

⁴ Semicanalis tensoris tympani.

⁵ Bony portion of the Eustachian tube.

⁶ Diplœ; diploic structure.

bones, by fibro-cartilage, which ordinarily remains to a late period of life.

In all other instances, the cranial bones are united by suture, generally of the dentated or serrated variety, in which the contiguous borders of the bones are jagged, and mutually knit together in such a manner as frequently to require considerable force to separate them. The remaining sutures are of the squamous, or scale-like variety, in which the contiguous borders of the bones are beveled off, roughened, and mutually coadapted.

The bones of the cranium are, however, not merely conjoined by suture—they are actually continuous through intervening cartilage; for if an unmacerated cranium be treated with muriatic acid, so as to remove the calcareous salts, the sutures disappear, and the cranium remains as a flexible case of bone-cartilage.

The principal sutures of the cranium are the **fronto-parietal**,¹ the **inter-parietal**,² the **occipito-parietal**,³ and **occipito-temporal**,⁴ which are of the dentated or serrated variety; and the **temporo-parietal**,⁵ and **spheno-parietal**, which are of the squamous variety. The **spheno-temporal**, **spheno-frontal**, and **fronto-ethmoidal** partake of both the dentated and squamous character.

The sutures of the cranial vault are remarkable for their exceedingly intricate and winding course, which has always rendered them one of the most striking characters in the anatomy of the skull. This intricacy is, however, confined to the exterior of the cranium, for it extends only through the outer layer of compact substance of the bones. In the interior of the cranium the same sutures present a merely waving, or slightly tortuous course.

In early life, the sutures are less intricate than later; and after the brain has reached its full development and growth, they gradually become more or less completely obliterated by the ossification of the intervening cartilage. This obliteration usually commences with the occipito-temporal suture, then occurs with the inter-parietal, then the fronto-parietal, and afterwards the occipito-parietal suture.

Occasionally the inter-parietal suture ossifies at a comparatively

¹ Coronal suture; sutura coronalis; s. arcualis.

² Sagittal suture; sutura biparietalis; s. virgata; s. rhabdoides; s. jugalis.

³ Lambdoidal suture; s. lambdoidalis; s. occipitalis.

⁴ Additamentum suturæ lambdoidalis.

⁵ Squamous suture; s. squamosa; s. mendosa; s. lepidoides. The part of the suture which is not squamous and unites the parietal bone with the mastoid portion of the temporal bone is the additamentum suturæ squamosæ.

early period, when, in consequence of the subsequent growth of the brain being less retarded antero-posteriorly, the cranium becomes more elongated than usual.

The frontal bone at birth consists of two distinct pieces united in the median line. The two pieces usually co-ossify before the third year of infantile life, but occasionally remain connected by serrated suture. In such cases the **front'al suture** is apt to be among the most permanent.

GENERAL CONFORMATION OF THE CRANIUM.

The **Cra'nium**¹ is egg-shaped or ovate; the long diameter being antero-posterior, and the narrow extremity forward. It is moulded upon its contents, so that its interior surface presents impressions corresponding with the form of the brain, and grooves corresponding with the sinuses and arteries of the dura mater. Its exterior, however, is not the exact counterpart of the interior, so that even if the different faculties of the brain were localized, as pretended by phrenologists, they could not be accurately determined by an examination of the cranium. Most of the perceptive faculties indeed would have nothing to do with the brain, if they were situated, as phrenologists have placed them, over the position of the vacant spaces constituting the frontal sinuses.

The interior surface of the vault or top of the cranium is marked by the cerebral convolutions. Along its median line may be observed the shallow groove impressed by the course of the longitudinal sinus. On each side of the position of this groove, more especially on the parietal bones, irregular depressions, resembling ulcerations, are not unfrequently observable. These are the result of absorption from the pressure of certain anomalous deposits of the membranes of the brain, called *Pachionian bodies*. *h 536*

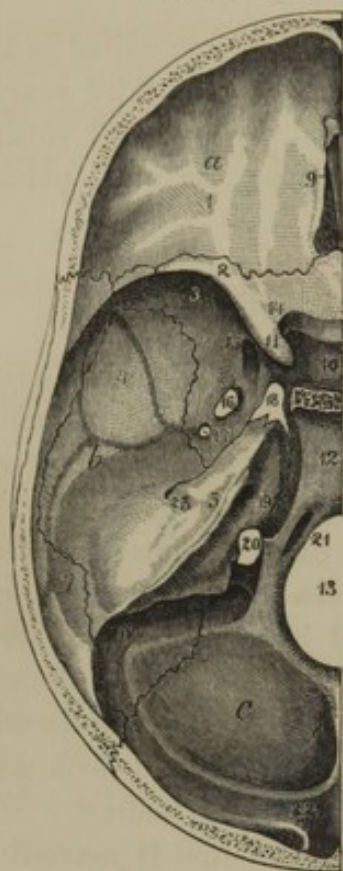The bottom of the cavity of the cranium presents three pairs of well-marked fossæ. The **anterior cranial fossæ**² accommodate the anterior cerebral lobes, and correspond with the roofs of the orbits. They are formed by the orbital plates of the frontal bone, strongly marked by cerebral convolutions, and the small wings of the sphenoid bone, which constitute their posterior boundary. Between them projects the ethmoidal crest, separating on each side the ethmoidal gutters, for the lodgment of the olfactory bulbs.

¹ The cranium proper; the brain pan; brain case; cranium; scaphion; conchus; theca cerebri; ollacapitis.

² Fossæ anteriores basis cranii; f. cerebrales anteriores.

The middle cranial fossæ,¹ which receive the middle cerebral lobes,

FIG. 42.



INTERNAL VIEW OF THE BASE OF THE CRANIUM OF THE LEFT SIDE. *a, b, c*, anterior, middle, and posterior cranial fossæ; 1, orbital plate of the frontal bone; 2, small wing of the sphenoid bone; 3, great wing of the same; 4, squamous portion of the temporal bone; 5, petrous portion of the same; 6, mastoid portion; 7, parietal bone; 8, occipital bone; 9, ethmoidal gutter and ethmoidal crest; 10, pituitary fossa; 11, anterior clinoid process; 12, declivity; 13, occipital foramen; 14, optic foramen; 15, rotund foramen; 16, oval foramen; 17, spinous foramen and groove from it, indicating the course of the great meningeal artery; 18, lacerated foramen; 19, internal auditory meatus; 20, jugular foramen; 21, condyloid foramen; 22, commencement of the groove for the lateral sinus. The course of the groove is observed along the horizontal limb of the occipital crest, the posterior inferior angle of the parietal bone, the mastoid portion of the temporal bone, and the transverse process of the occipital bone, terminating at the jugular foramen.

are formed by the great wings of the sphenoid bone, the squamous portions of the temporal bones, and the anterior surfaces of the petrous portions of the latter. Their anterior boundary is the sharp crescentic border of the small wings of the sphenoid bone, and their posterior boundary the upper border of the petrous portion of the temporal bones. They intercommunicate through the pituitary fossa.

Between the apex of the petrous portion of the temporal bone and the body and great wing of the sphenoid bone, there is a large irregular aperture, the **lacerated fora'men**,² which is closed below by a thin plate of cartilage, but is occupied at the upper part of its area by the internal carotid artery, as it proceeds from the carotid canal to the side of the body of the sphenoid bone.

From the spinous foramen, the groove for the middle meningeal artery ascends a short distance near the anterior border of the squamous portion of the temporal bone, when it divides into two branches. One of these continues along the squamous portion of the bone to its back part, when it mounts upon the parietal bone, subdividing in numerous branchlets. The other branch turns over the summit of the great wing of the sphenoid bone, and then, like the preceding, ascends on the parietal bone.

The **posterior cranial fossæ**,³ more capacious than the others, receive the lobes of the cerebellum. They are formed by the posterior surfaces of the petrous portions of the temporal bones, the mastoid portions of the latter, and the occip-

¹ F. med. basis cranii; f. cereb. med. ² Foramen lacerum; f. lacerum medius.

³ F. post. basis cranii; f. cerebelli.

ital bone below the lateral limbs of the occipital cross. They are separated posteriorly by the vertical limb of the latter, and anteriorly communicate through the inclined surface of the declivity of the sphenoid bone and the basilar process, upon which rest the medulla oblongata and the pons.

From the groove for the longitudinal sinus, that for the lateral sinus may be seen following the course of the horizontal limb of the occipital cross, then curving down upon the mastoid portion of the temporal bone, and over the transverse process of the occipital bone to the jugular foramen. Usually the groove upon the right side is larger than that upon the left.

The **ju'gular fora'men**¹ is an irregular orifice formed by the contiguity of two notches between the petrous portion of the temporal bone and the occipital bone. It is usually more or less subdivided by a short process projecting from near the middle of the notch of the petrous portion of the temporal bone. The outer and larger division admits of the termination of the lateral sinus in the internal jugular vein, and the inner division transmits the ninth, tenth, and eleventh cranial nerves. In accordance with the usually larger size of the right lateral sinus than the left one, the right jugular foramen and the right internal jugular vein are also larger than those of the left side.

The external surface of the **vault of the cranium**,² covered by the scalp, is smooth; and its front forms the forehead, its back the occiput, and its sides contribute to the **temporal fossæ**.³ The latter give origin to the temporal muscles, and are defined above by a superficial ridge or line commencing at the external angular process of the frontal bone, and arching upward and backward upon the parietal bone to the dividing line between the squamous and petrous portions of the temporal bone. Inferiorly the temporal fossa is defined by a ridge proceeding inward and forward from the root of the zygomatic process of the temporal bone, and becoming continuous with another dividing the external surface of the great wing of the sphenoid bone into two parts.

The exterior of the base of the cranium is exceedingly irregular. Transverse lines directed from external conspicuous points would indicate important parts as follows:—

1. A line between the ends of the mastoid processes would pass nearly through the middle of the occipital foramen.
2. A line between the external auditory meatuses would pass through the jugular foramina and the anterior part of the occipital foramen and condyles.

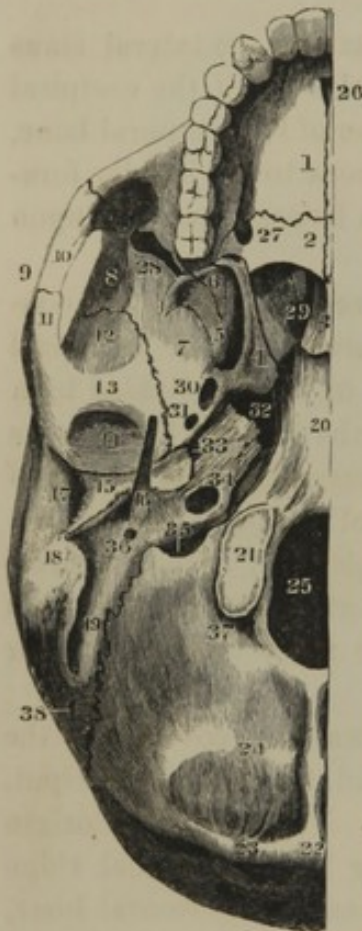
¹ F. jugulare; f. lacerum posterius. ² Skull cap; calvaria; calva; camera.

³ Fossæ temporales.

3. A line between the glenoid cavities would pass through the entrance of the carotid canals.

4. A line between the glenoid tubercles would pass through the exit of the carotid canals and the lacerated foramina.

FIG. 43.



EXTERNAL VIEW OF THE BASE OF THE SKULL, RIGHT SIDE. 1, palate plate of the superior maxillary bone; 2, palate plate of the palatine bone; 3, vomer; 4, 5, internal and external pterygoid processes; 6, pyramidal process of the palatine bone; 5, 6, occupy the pterygoid fossa; 7, under part of the great wing of the sphenoid bone, forming part of the sphenomaxillary fossa; 8, temporal surface of the great wing of the sphenoid bone; 9, zygoma; 10, zygomatic process of the malar bone; 11, zygomatic process of the temporal bone; 12, squamous portion of the temporal bone; 13, glenoid tubercle; 14, glenoid fossa; 15, auditory and vaginal process; 16, styloid process; 17, external auditory meatus; 18, mastoid process; 19, digastric fossa; 20, conjunction of the basilar process and body of the sphenoid bone; 21, occipital condyle; 22, occipital protuberance, and crest leading from it downward; 23, 24, superior and inferior semicircular ridges; 25, occipital foramen; 26, incisive foramen; 27, posterior palatine foramen; 28, sphenomaxillary fissure; 29, posterior naris; 30, oval foramen; 31, spinous foramen;

32, lacerated foramen; 33, Eustachian tube; 34, entrance of the carotid canal; 35, jugular foramen; 36, stylo-mastoid foramen; 37, pit with a posterior condyloid foramen; 38, mastoid foramen.

a groove which accommodates the inferior portion of the Eustachian tube.

MECHANICAL CONSTRUCTION OF THE CRANIUM.

A sphere is best adapted to resist pressure equally applied on all sides, and therefore of all abstract forms is the strongest. It or its modifications into the oval and ovate forms are constantly employed in the organic kingdom in the construction and protection of delicate structures, as instanced in the organic cell, the eggs of animals, etc.

Under special circumstances the oval or ovate forms are better adapted to the preservation of delicate structures than the perfect sphere.

The human cranium, especially adapted to the protection of the brain, is ovate, with the narrow end strongest and situated forward, where it is most liable to violence.

The cranium of the infant varies, from the more mature ovate form, in presenting a number of prominent points in positions liable to receive pressure during birth, or subsequently to receive the first impression from falls or blows.

Prior to co-ossification of the bones of the cranium, they are so intimately and admirably articulated, that it requires considerable force to separate any one of them, but after this is done the connection of the whole becomes more or less enfeebled.

The sphenoid bone is the most important agent of connection of the bones of the cranium; extending transversely across the base of the latter it articulates with all the other bones and its body appears to be a central point of support for the whole of them.

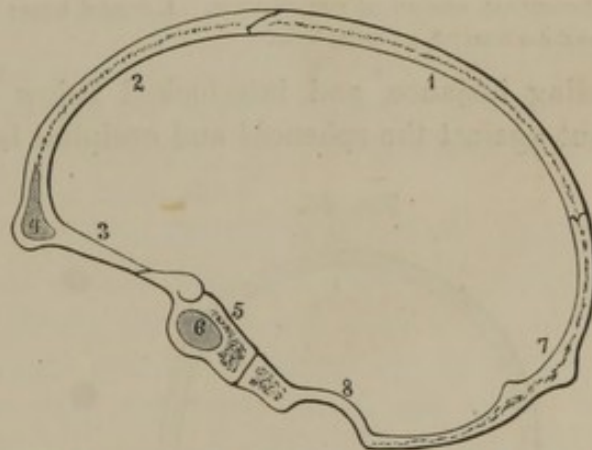
If sections are made in different directions through the cranium, they will exhibit the intimate relationship existing in the connection of the bones by which so many pieces are enabled to preserve the integrity of the cranium.

Thus a vertical antero-posterior section of the cranium exhibits a connection of its segments, as represented in figure 44. The upper border of the frontal bone rests upon the beveled contiguous border of the parietal bones, these behind abut against the occipital bone, and the circle, after bifurcating and

surrounding the occipital foramen, terminates in the basilar process, which is firmly supported against the body of the sphenoid bone. The latter by its lesser wings affords a support to the orbital processes of the frontal bone, and thus the circle is completed.

A horizontal circle of the cranium, as represented in figure 45, exhibits the borders of its frontal segment overlapped by the parietal segments, and these likewise slightly overlapped by the occipital segment. A circle lower down will exhibit the frontal segment overlapped by the great wings of the sphenoid bone, and these by the squamous portions

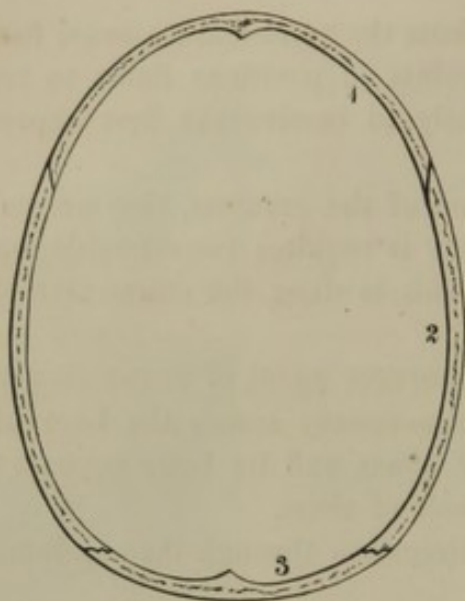
FIG. 44.



ANTERO-POSTERIOR SECTION OF THE CRANIUM, exhibiting the mode by which the connection of the different bones contributes to preserve its integrity. 1, parietal bone; 2, frontal bone; 3, its orbital plate; 4, frontal sinus; 5, body of sphenoid bone; 6, sphenoidal sinus; 7, occipital bone; 8, marginal ridge of the occipital foramen.

of the temporal bones, which likewise behind inclose the parietal bones, also slightly overlapped by the occipital bone.

FIG. 45.



HORIZONTAL SECTION OF THE CRANIUM. 1, frontal bone; 2, parietal bone; 3, occipital bone.

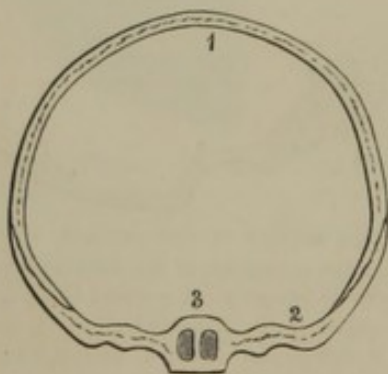
A vertical transverse circle at the front of the cranium, as represented in figure 46, exhibits a frontal arch interlocked by the sphenoid bone.

A second circle a short distance behind the preceding, as represented in figure 47, exhibits the parietal bones dove-tailed above, and interlocked by the sphenoid bone below.

A third circle further back, as represented in figure 48, exhibits the parietal bones articulating as in the preceding instance, and interlocked below by the temporal bones, which

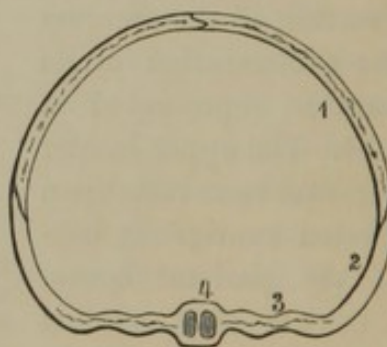
abut against the sphenoid and occipital bones.

FIG. 46.



TRANSVERSE SECTION THROUGH THE FRONT OF THE CRANIUM. 1, transverse arch formed by the frontal bone; 2, great wing of the sphenoid bone, including or overlapping the abutments of the frontal arch; 3, body of the sphenoid bone, with its sinuses.

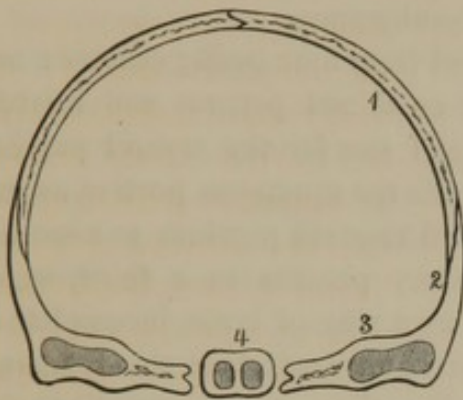
FIG. 47.



TRANSVERSE SECTION IN ADVANCE OF THE MIDDLE OF THE CRANIUM. 1, parietal bone forming with its fellow an arch; 2, great wing of the sphenoid bone; 3, horizontal portion of the wing; 4, body, with the sphenoidal sinuses.

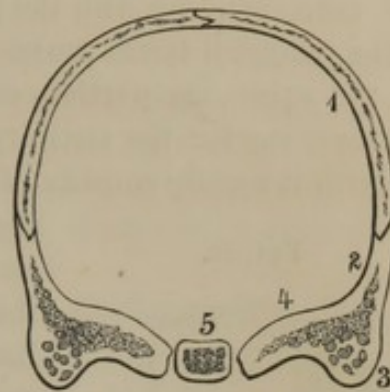
A fourth circle at the back of the cranium, as represented in figure 49, exhibits the parietal bones joined as in the two preceding instances, and fitting into a notch below, between the squamous and mastoid portions of the temporal bones, which, as before stated, abut against the sphenoid and occipital bones.

FIG. 48.



TRANSVERSE SECTION THROUGH THE MIDDLE OF THE CRANIUM. 1, parietal bone; 2, squamous portion of the temporal bone; 3, petrous portion; 4, body of the sphenoid bone.

FIG. 49.



TRANSVERSE SECTION POSTERIOR TO THE MIDDLE OF THE CRANIUM. 1, back part of the parietal bones; 2, mastoid portion of the temporal bone; 3, mastoid process with the sinuses; 4, petrous portion of the temporal; 5, sphenoidal body, or the basilar process of the occipital bone.

DEVELOPMENT OF THE CRANIUM.

The occipital bone is developed from seven distinct centres of ossification: four for the expanded portion, and three for the lower portion. At birth it consists of three pieces: the upper expanded portion,¹ the two condyloid portions,² and the basilar portion.³ They usually become united into one piece by the fifth or sixth year.

The sphenoid bone is developed from twelve ossific centres, including the formation of the sphenoidal sinuses from the ethmoidal pyramids. At birth it consists of three pieces: the body and small wings as one, and the great wing and pterygoid processes making one on each side. Subsequently, during the first year, the three pieces are united into one. The ethmoidal pyramids become the sphenoidal sinuses on the approach of puberty.

The ethmoid bone is developed from five centres of ossification, exclusive of the pyramids. At birth, its two lateral masses only are ossified, but during the first year the vertical and cribriform plates ossify and become united with the former.

The frontal bone is developed from two ossific centres, which correspond with the supra-orbital ridges. At birth it consists of two halves united at the median line. They usually co-ossify before the third year; but occasionally the suture remains as one of the least disposed to obliteration.

¹ Supra-occipital bone; inter-parietal bone; squama occipitalis.

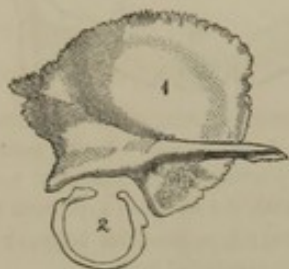
² Exoccipitals; lateral occipitals.

³ Basioccipital bone; basilar bone; inferior occipital bone.

The parietal bones are each developed from a single centre of ossification, corresponding with the parietal protuberance.

The temporal bones are each developed from four ossific centres: one for the squamous portion, one for the combined petrous and mastoid portions, one for the auditory process, and one for the styloid process. At birth it usually consists of three pieces: the squamous portion as one,

FIG. 50.



TWO PIECES OF THE TEMPORAL BONE, as observed about the period of birth; the third piece corresponding with the petrous and mastoid portions, not represented. 1, the squamous portion of the temporal bone; 2, the auditory process, in the form of an imperfect ring.

the petrous and mastoid portions as a second, and the auditory process as a third, which then appears as a ring of bone, incomplete at its upper part, and encircling the tympanic membrane. The three pieces speedily unite after birth, and the ring of bone encircling the tympanic membrane gradually elongates outward into the external auditory meatus. The styloid process subsequently ossifies, varies in its degree of development, and sometimes never unites with the temporal bone.

The tabular bones of the vault of the cranium, at the period of birth, present the appearance of depressed cones; being conspicuously prominent at their centres, which correspond with the frontal, parietal, and occipital protuberances. From the summits of the cones the ossific structure radiates in well-marked lines to the borders of the bones, which overlap instead of interlocking with each other, as they do subsequently. The parietals overlap both the frontals and the occipital. From this arrangement of the vault of the cranium, compression may reduce its diameters, which is an important provision in the passage of the head of the child through the pelvis of the mother. The bones at the base of the skull meet at their borders without overlapping so as not to permit diminution from pressure, which is not only unnecessary from the small size of the base compared with the vault, but which would prove injurious to the parts of the brain concerned in this position.

At or near the period of birth, there are several membranous spaces left in the line of the sutures, through which ossification has not extended, and which are named **font'anel's**.¹ The largest of these interspaces, the **anterior font'anel**,² is situated at the contiguous angles of the two frontals with the two parietal bones. It is quadrangular, with the anterior angle much prolonged and acute, and the posterior short and

¹ Fontanellæ; fonticuli; lacunæ.

² Great, sincipital, or frontal fontanel;

fons pulsatilis; vertex palpitans; fonticulus quadrangularis.

obtuse. It remains unossified for several months after birth; and at the membranous space, the pulsations of the brain may be felt. The **posterior font'anel**,¹ situated between the parietal bones behind, is usually closed at birth by the summit of the occipital bone.

The anterior fontanel, and the posterior one, or the three sutures which lead to its position, afford important means to the midwife in determining the relative position of the head of the child while within the pelvis of the mother.

At the sides of the cranium are the **lateral font'annels**, of which one is situated between the frontal, temporal, parietal, and sphenoid bones,² and the other is placed between the occipital, temporal, and parietal bones.³

The bones of the fœtal cranium consist of a single layer of compact substance; the spongy substance being developed in them subsequent to birth. The frontal and mastoid sinuses are developed by a resolution of the spongy substance.

SUPERNUMERARY BONES OF THE CRANIUM.

Not unfrequently there are found in the course of the sutures of the cranium supernumerary, islet-like bones,⁴ which have originated from distinct centres of ossification. They rarely occur in any other than the sutures of the vault of the cranium, and of these are most frequent in the course of the occipito-parietal suture. These bones vary much in number and size; and in hydrocephalic cases are often numerous and large. Frequently they may be found on the two sides of the cranium, alike or symmetrical in position. Occasionally one⁵ is found occupying the former position of the anterior fontanel.

2

BONES OF THE FACE.

Of the fourteen bones of the face, twelve are in pairs: the superior maxillary, palate, lachrymal, nasal, turbinated, and malar bones; the remaining two are single and symmetrical: the vomer, situated in the partition of the nose, and the inferior maxillary bone.

¹ Small, bregmatic, or occipital fontanel.

² Sphenoid fontanel.

³ Mastoid fontanel; fonticulus mastoideus; f. Casserii.

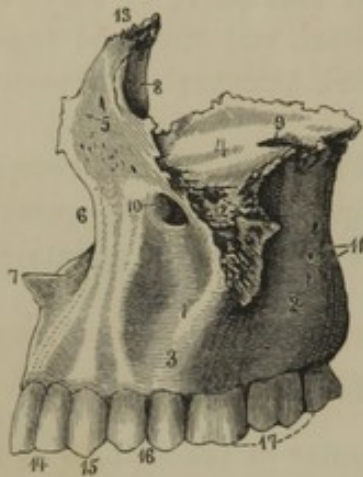
⁴ Ossa intercalaria; o. suturarum; o. Wormiana; o. triquetra; o. epactalia; o. raphogeminantia; o. triangularia Blasii; claves calvariae.

⁵ Os antiepilepticum.

THE SUPERIOR MAXILLARY BONE.

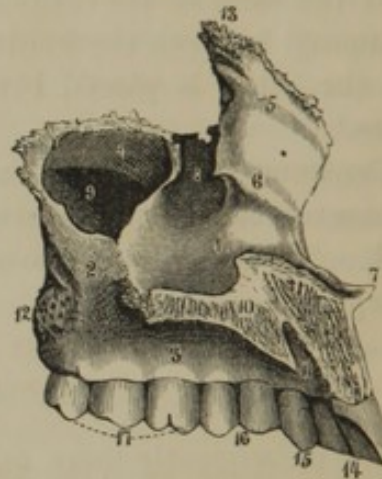
The **Superior Maxillary bone**¹ forms with its fellow the upper jaw, and contributes in the construction of the roof of the mouth, the nasal fossæ, the orbits, the cheeks, and the sphenomaxillary fossæ.

FIG. 51.



SUPERIOR MAXILLARY BONE OF THE LEFT SIDE, outer view. 1, body; 2, tuberosity; 3, alveolar border; 4, orbital plate; 5, nasal process; 6, nasal notch; 7, nasal spine; 8, lachrymal groove; 9, entrance of the infra-orbital canal; 10, infra-orbital foramen; 11, orifices of the posterior dental canals; 12, malar process; 13, articulation for the internal angular process of the frontal bone; 14, incisor teeth; 15, canine tooth; 16, premolar teeth; 17, large molar teeth.

FIG. 52.



SUPERIOR MAXILLARY BONE OF THE LEFT SIDE, inner view. 1, nasal surface of the body; 2, surface for the palate bone; 3, alveolar border; 4, orbital plate; 5, nasal process; 6, ridge for the articulation of the turbinated bone; 7, nasal spine; 8, groove contributing to form the lachrymo-nasal duct; 9, maxillary sinus; 10, palate plate, its articulating border for the right maxillary bone; 11, incisive foramen continuous with the nasopalatine canals; 12, tuberosity; 13, articular extremity for the internal angular process of the frontal bone; 14, incisor teeth; 15, canine tooth; 16, premolar teeth; 17, large molar teeth.

The **body** of the bone, independent of its processes, is wedge-shaped, and is hollowed into a large cavity, the **maxillary sinus**,² which communicates, by a large irregular orifice, through the inner wall, with the nasal fossa. Above the orifice just mentioned, the inner surface of the body articulates with the lachrymal and ethmoid bones, and behind it, with the palate bone.

The anterior surface of the body, forming part of the cheek, is depressed³ and is bounded above by the infra-orbital margin. Just

¹ Os maxillare superius; upper jaw-bone; maxilla sup.; mandibula sup.; maxilla syncrania.

² S. maxillaris; antrum Highmore-

num; antrum of Highmore; genyantrum; gnathantrum; sinus genæ pituitarius; antrum genæ.

³ Fovea maxillaris; canine fossa.

below the latter is the **in'fra-orb'ital fora'men**,¹ which transmits the infra-orbital nerve and blood-vessels.

The posterior convex surface of the body constitutes the **tuberos'ity**,² and contributes to form the speno-maxillary fossa. It presents a perforated surface; and several of the larger orifices are the commencement of the **posterior dent'al canals**,³ which are narrow passages transmitting nerves and arteries to the molar teeth.

The upper surface of the body, or **orb'ital plate**,⁴ forms the floor of the orbit, and terminates behind in an obtuse border, which is the lower boundary of the speno-maxillary opening. From the latter border, the **infra-orb'ital canal**,⁵ proceeds forward in the orbital plate, and terminates at the corresponding foramen. From the canal two fine passages, the **anterior dent'al canals**,⁶ descend in the outer wall of the body, and conduct arteries and nerves to the anterior teeth. Both the anterior and posterior dental canals are partially visible within the maxillary sinus.

At the lower part of the superior maxillary bone is the thick pyramidal ridge, called the **alve'olar border**,⁷ which arches from behind forward and inward, and projects obliquely downward and outward. The free margin presents the orifices of a number of deep conical pits, the **alve'oli**,⁸ or **sockets** for the insertion of the teeth. The outer surface of the border is marked by alternating vertical ridges and depressions, corresponding with the alveoli and their intervals. The posterior extremity of the border is rough, and abuts against the pyramidal process of the palate bone. The anterior extremity is likewise rough, and articulates with the corresponding border of the opposite bone.

Above the anterior extremity of the alveolar border is a pointed process, the **na'sal spine**,⁹ prolonged backward into a ridge, to which the cartilage of the partition of the nose is attached. To the outer side of the spine is a concave notch, which forms part of the anterior nasal orifice. The margin of the **na'sal notch** in the white race is usually acute, but is rounded off to the anterior surface of the alveolar border in the black race.

Above the notch just mentioned is a plate of bone, the **na'sal proc'ess**,¹⁰

¹ F. infra orbitale.

² Tuberositas maxillaris.

³ Canales, or canaliculi alveolares, or dentales posteriores.

⁴ Planum orbitale.

⁵ Canalis infra-orbitalis.

⁶ Canalis alveolaris, or dentalis medius et anterior.

⁷ Processus, or limbus alveolaris.

⁸ Alveoli dentis; cavernæ dentium; odontobothria; mortarioli.

⁹ Spina nasalis; s. nasalis anterior.

¹⁰ Processus nasalis; p. frontalis; p. ascendens.

which extends upward to join the internal angular process of the frontal bone. Its outer surface forms part of the side of the nose; and its inner surface, directed toward the cavity of the latter, is concave and bounded below by a ridge for the attachment of the turbinated bone. Its anterior border is thick and rough for junction with the nasal bone. Its posterior border joins the lachrymal bone, and is grooved to form part of the naso-lachrymal canal.

From the internal part of the base of the alveolar border there projects horizontally inward, the **pal'ate plate**,¹ which contributes to form the roof of the mouth and the floor of the nose. Its nasal surface is smooth and concave; and its oral surface, continuous with the inner one of the alveolar border, is vaulted and rough. Its inner border rises into a ridge which articulates with the vomer, and forms a thick rough surface for junction with that of the opposite bone. The posterior border is thin and rough, and joins the palate bone.

From the outer part of the body there projects a strong protuberance, the **ma'lar proc'ess**,² which presents a large trilateral roughened surface for the support of the malar bone.

Between the anterior extremity of the alveolar border and the palate plate of the superior maxillary bone, the **na'so-pal'atine canal**,³ descends from the nasal fossa, and, converging, forms with that of the opposite bone, in the intermediate suture, the **anterior pal'atine fora'men**.⁴ From the canal and foramen a fine fissure may be traced a short distance outwardly, which is a vestige of the separation, existing in other mammals, of that portion of the bone containing the incisive teeth, and called the intermaxillary bone. The representative of the latter is obscurely indicated in the human embryo prior to the third month; the line of its separation dividing off the incisive portion of the alveolar border and the lower third of the nasal process.

THE PALATE BONE.

The **Pal'ate bone**⁵ is situated at the back part of the superior maxillary bone, between it and the sphenoid bone. It contributes, with its fellow, to form the mouth, nasal fossæ, and orbits. It has the outline of the letter L, consisting of a horizontal and vertical plate, together with smaller processes.

¹ P. palatinus.

² P. zygomaticus.

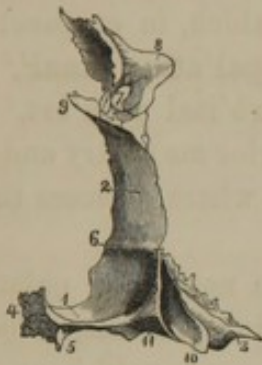³ Canalis, or ductus naso-palatinus, or incisivus.

⁴ F. palatinum anterius; f. incisivum; f. alveolare anterius; f. coecum.

⁵ Os palatinum; o. palati.

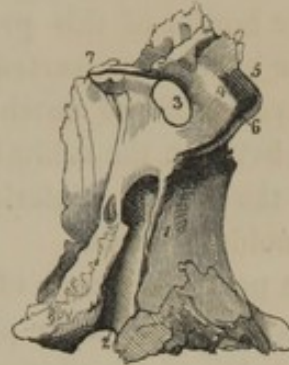The horizontal or **pal'ate plate**¹ is square, and contributes a smooth concave surface to the floor of the nose, and a smaller surface to the hard palate. Its inner border rises into a **crest**² and articulates with that of

FIG. 53.



POSTERIOR VIEW OF THE RIGHT PALATE BONE. 1, palate plate; 2, nasal plate; 3, pyramidal process; 4, articular border for the left palate bone; 5, palate spine; 6, ridge for junction with the turbinated bone; 7, spheno-palatine notch, between 8, the orbital, and 9, the sphenoidal process; 10, groove for the internal pterygoid process of the sphenoid bone; 11, position of the posterior palatine foramen.

FIG. 54.



EXTERIOR VIEW OF THE RIGHT PALATE BONE. 1, rough surface articulating with the superior maxillary bone, and diminishing the aperture of the maxillary sinus; 2, posterior palatine canal; completed by the tuberosity of the superior maxillary bone; 3, spheno-palatine notch; 4, 5, 6, orbital process; 4, surface directed toward the pterygo-maxillary fossa; 5, orbital surface; 6, maxillary border; 7, sphenoidal process; 8, pyramidal process.

the opposite side; the crests of the conjoined palate plates aiding in the support of the vomer, and projecting backward into a pointed process, the **palate spine**.³ The anterior border of the palate plate articulates with that of the superior maxillary bone; and the posterior crescentic border has the soft palate attached to it.

The vertical or **na'sal plate**⁴ is thinner than the other, and extends from it to the base of the cranium. Its inner or nasal surface is divided into two parts by a horizontal ridge,⁵ with which the turbinated bone articulates. Its outer surface is divided by a vertical ridge bounding a groove,⁶ which, by the approximation of the sphenoid and superior maxillary bones, is converted into the **posterior pal'atine canal**,⁷ descending from the pterygo-maxillary fossa to the hard palate.³ The posterior portion of the outer surface of the nasal plate articulates with the internal pterygoid process, and the anterior portion with the maxillary bone, partially closing the entrance of the maxillary sinus.

¹ Pars palati; p. horizontalis.

² Crista nasalis.

³ Spina palatina; s. nasalis posterior.

⁴ Pars nasalis; p. perpendicularis.

⁵ Crista turbinalis; c. t. inferior.

⁶ Sulcus pterygo-palatinus.

⁷ Canalis palatina posterior; c. pterygo-palatina.

At the upper border of the nasal plate is a large, round notch, which, in conjunction with the under part of the body of the sphenoid bone, is converted into the **sphe'no-pal'atine fora'men**¹ communicating from the pterygo-maxillary fossa with the nasal fossa.

Behind the notch just mentioned is the **sphenoid'al proc'ess**,² which articulates with the under part of the body of the sphenoid bone. In the upper border of this process is a groove, which, in conjunction with the latter bone, is converted into the **pter'ygo-pal'atine canal**.³

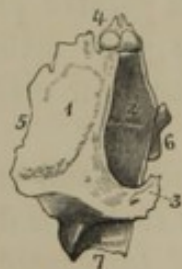In advance of the notch indicated, is the **orb'ital proc'ess**,⁴ which is received between the orbital plates of the superior maxillary and ethmoid bones at the posterior inferior part of the orbit, where it closes the posterior ethmoidal sinuses.

At the posterior angle of conjunction of the nasal and palate plates of the palate bone, there projects the **pyramidal proc'ess**,⁵ which occupies the notch of the pterygoid processes of the sphenoid bone. Sometimes it completely incloses the lower part of the posterior palatine canal; and not unfrequently it is pierced by one or two branches from the latter descending in the same direction.

THE LACHRYMAL BONE.

The **Lach'rymal bone**,⁶ the smallest of those of the face, is situated one at the fore part of the inner wall of each orbit. It contributes to form the latter, the lachrymo-nasal duct, the nasal fossa, and the anterior ethmoidal sinuses.

FIG. 55.



EXTERNAL VIEW OF THE RIGHT LACHRYMAL BONE. 1, orbital surface; 2, lachrymal fossa; 3, small process bounding the latter inferiorly; 4, frontal border; 5, ethmoidal border; 6, maxillary border; 7, process articulating with the turbinated bone.

It consists of a thin, oblong square plate, articulating above, behind, and below with the orbital plates of the frontal, ethmoid, and maxillary bones, and in front with the nasal process of the latter bone.

The outer surface forms part of the inner wall of the orbit, and in advance contributes a fossa or groove⁷ to the **lach'rymo-na'sal duct**.⁸ The outer surface closes in the anterior ethmoidal sinuses.

¹ F. speno-palatinum.

² Processus sphenoidalis; apophysis pterygoideus.

³ C. pterygo-palatina.

⁴ P. orbitalis.

⁵ Pterygoid process; apophysis sphenoidalis.

⁶ Os lachrymale; os unguis; unguiform bone.

⁷ Lachrymal fossa.

⁸ Ductus ad nasum.

From the anterior inferior angle a process¹ projects downward, which joins with one from the turbinated bone, and serves to prolong the lachrymo-nasal duct.

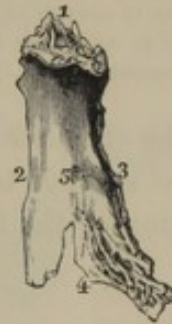THE NASAL BONE.

The **Na'sal bone**² projects from the root of the nose downward and forward, and with its fellow, together with the nasal processes of the superior maxillary bones, forms the bridge of the nose.

It is irregularly quadrate, and thicker and narrower above than below, and not unfrequently is so narrow as to assume a fan-like shape. In its length it presents a sigmoid curve, though occasionally it is simply concave in this direction. The outer surface is smooth, transversely convex, and generally presents a small but conspicuous foramen³ near its middle. The inner surface, directed toward the corresponding nasal fossa, is transversely concave, and presents a longitudinal groove for the accommodation of a branch of the nasal nerve.

The upper border of the nasal bone is thick and roughened for articulation with the frontal bone; the lower border is thin and notched, and forms the superior boundary of the anterior nasal orifice. The inner border is thick above, narrows off below, and conjoins with that of the opposite bone. The outer border is beveled off and overlapped by the corresponding border of the nasal process of the superior maxillary bone.

FIG. 56.



ANTERIOR VIEW OF THE LEFT NASAL BONE. 1, frontal border; 2, nasal border; 3, maxillary border; 4, lower border; 5, nasal foramen.

THE TURBINATED BONE.

The **Tur'binated bone**⁴ is quite rudimentary in comparison with the corresponding one of most other animals, in which it often acquires an extraordinary degree of development, as the student may observe in any of the common carnivorous animals—the cat, dog, weasel, bear, etc. It projects horizontally from the outer wall of the nasal fossa, and separates the middle and inferior meatus.

The bone presents the form of an irregular scroll, with a rough convex surface directed toward the partition of the nose, and a con-

¹ Hamulus lachrymalis.

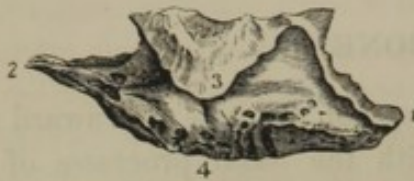² Os nasale; os nasi.

³ F. nasalis.

⁴ Os turbinatum; o. t. inferius; spongy bone; o. spongiosum; concha inferior; c. veneris; buccinum.

cave surface directed outwardly. Its lower part is thick and spongy;

FIG. 57.



EXTERNAL VIEW OF THE RIGHT TURBINATED BONE. 1, anterior extremity articulating with the superior maxillary bone; 2, posterior extremity articulating with the palate bone; 3, hook-like plate overhanging the lower border of the maxillary sinus. The process in advance of it above joins the lachrymal bone to contribute in the formation of the lachrymo-nasal duct. 4, inferior, obtuse border.

its anterior extremity joins the transverse ridge at the root of the nasal process of the superior maxillary bone; and its posterior narrower extremity articulates with a like ridge of the palate bone.

From the middle of the upper border a hook-like plate¹ overhangs the inferior edge of the entrance to the maxillary sinus; and a small process² ascending from this plate diminishes the aperture of the latter, and frequently joins a process

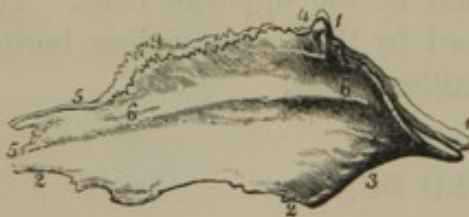from the ethmoid bone. In advance of the hook-like plate, another small process³ ascends to join one from the lachrymal bone, and assists in the formation of the lachrymo-nasal duct.

THE VOMER.

The **Vo'mer**⁴ is a lozenge-shaped plate of bone, situated at the back part of the partition of the nose.

Its lateral surfaces form part of the inner wall of the nasal fossæ.

FIG. 58.



LEFT SIDE OF THE VOMER. 1, 1, broad groove receiving the rostrum of the sphenoid bone; 2, 2, inferior border articulating with the palate plates of the superior maxillary and palate bones; 3, posterior border, the dividing line of the posterior nares; 4, 4, grooved border receiving a narrow slip of cartilage, situated between the vomer and the nasal plate of the ethmoid bone; 5, 5, border for the cartilaginous septum of the nose; 6, 6, nasal surface.

The upper border is grooved to receive the rostrum of the sphenoid bone, and its edges⁵ are reflected to join a thin plate springing out of the root of the pterygoid processes. The lower border articulates with the crest formed at the conjunction of the palate plates of both the superior maxillary and palate bones. The anterior border is grooved to receive the cartilage of the nasal partition, and at its upper part articulates with the nasal plate of the ethmoid bone. The posterior border is thin and crescentic, and

forms the oblique line of separation of the posterior nasal orifices.

¹ Processus maxillaris.

² P. ethmoidalis.

³ P. lachrymalis.

⁴ Os vomeris; aratrum.

⁵ Alæ vomeris.

THE MALAR BONE.

The **Ma'lar** or **cheek bone**¹ forms the most prominent part of the cheek, and contributes to the construction of the orbit and temporal fossa. It is quadrangular, and rests by a broad, trilateral, rough surface upon the malar process of the superior maxillary bone.

From the upper part a strong **front'al proc'ess** ascends to articulate with the external angular process of the frontal bone; and from the back part projects a strong **zygo-mat'ic proc'ess** to articulate with the corresponding process of the temporal bone.

The upper, anterior, concave border forms the inferior and external margin of the orbit. From this border there proceeds backward and inward the **orb'ital plate**, which separates the orbit from the temporal fossa, articulates with the corresponding plates of the maxillary, sphenoid, and frontal bones, and contributes to the spheno-maxillary foramen.

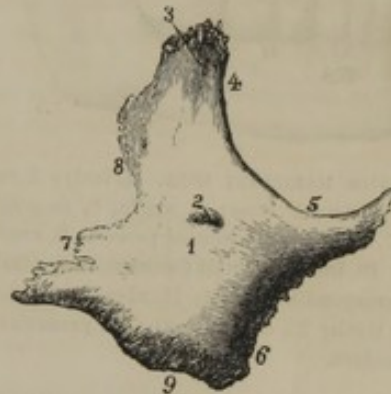
The posterior border of the bone, included between the frontal and zygomatic processes, is sigmoid, and gives attachment to the temporal fascia. The inferior border is convex and rugged, and contributes about one-half to the extent of the lower margin of the zygoma.

The **fa'cial surface**, directed more or less outwardly and forward, is for the most part convex, and pretty constantly presents one or two conspicuous foramina, which are continuous with canals² from the orbital and temporal surfaces. The **tem'poral surface** is concave, directed backward, and forms the anterior part of the temporal fossa.

THE INFERIOR MAXILLARY BONE.

The **Inferior Max'illary**, or **lower jaw bone**,³ is the second of the symmetrical bones of the face, in which it occupies the lower semi-

FIG. 59.



OUTER VIEW OF THE RIGHT MALAR BONE. 1, external or facial surface; 2, malar foramen; 3, frontal process; 4, 5, orbital border; 6, maxillary border; 7, zygomatic process; 8, temporal border; 9, inferior border.

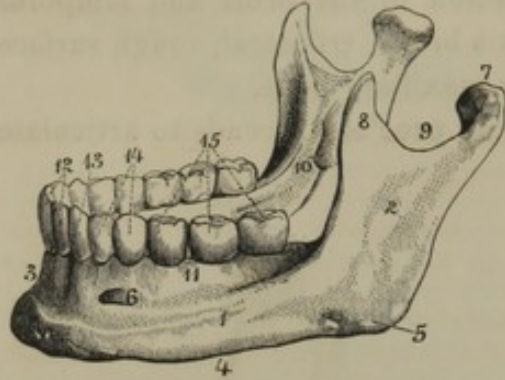
¹ Os malare; o. malæ; o. zygomaticum; o. jugale; o. suboculare; o. hypopium; o. pudicum; o. jugamentum; o. genæ.

² C. zygomaticus facialis, or temporalis.

³ Maxilla inferior; os maxillare inferius; inferior maxilla; mandibula.

circumference. It is also the largest and strongest bone of the face, and is the only movable one of the skull. From the other bones of the face

FIG. 60.



INFERIOR MAXILLARY BONE. 1, body; 2, ramus; 3, symphysis; 4, base; 5, angle; 6, mental foramen; 7, condyle; 8, coronoid process; 9, semilunar notch; 10, inferior dental foramen, the entrance of the corresponding canal; 11, alveolar border; 12, incisor teeth; 13, canine tooth; 14, premolars; 15, large molars.

it is actually isolated through contact of the teeth, and it articulates with the cranium at the glenoid cavities of the temporal bones. It is divisible for description into the body, and rami or branches.

The **body** is the curved portion of the bone supporting the teeth. Its outer surface is convex, and at the middle presents a prominent line, indicating the early separation of the bone into two pieces, and hence called the **sym'physis**. The prominent portion of the body in front is the **chin**,¹ which in the negro is vertical or even receding.

Its lower protuberant part is the **men'tal protu'berance**,² on each side of which is the **men'tal fora'men**,³ the termination of the inferior dental canal.

The inner surface of the body presents at the lower part of the symphysis the **men'tal tu'bercle**.⁴ On each side, below the position of the molar teeth, is the oblique **mo'lar ridge**,⁵ to which is attached the muscular floor of the mouth. Beneath the ridge the surface is slightly impressed by the position of the submaxillary gland, and the lower obtuse border of the bone is its **base**.

The upper portion of the body forms its **alve'olar border**,⁶ which is constructed on the same plan, and for the same purpose as in the superior maxillary bones. In relation with the corresponding part of the latter, it is usually vertical in position, though in the negro it is generally directed a little forward and upward.

The **ram'i**⁷ are the quadrate plates ascending from the posterior extremities of the body, reaching as high as the zygomatic arches. Their outer surface forms a nearly vertical plane. Near the middle of

¹ Mentum.

² Protuberantia mentalis.

³ F. mentale; f. maxillare anterius.

⁴ Spina mentalis interna; spinæ mentales; internal mental tubercle.

⁵ Mylo-hyoid ridge; linea mylohyoidea; l. obliqua interna.

⁶ Processus alveolaris.

⁷ The name rami is frequently applied by comparative anatomists to the two halves of the jaw.

the inner surface is the entrance¹ of the **inferior dent'al canal'**,² which descends to the body of the bone and proceeds beneath the alveolar border to terminate at the mental foramen. The entrance of the canal is bounded by a prominent crest,³ which gives attachment to the sphenomaxillary ligament; and below it, there descends a groove for the accommodation of a small nerve. *(Ramus, Angle, Angle Process)*

The posterior border of each ramus is obtuse, and terminates below in the **angle**,⁴ which is more or less obtuse in its relation with the base of the bone. The inner and outer surfaces of the angle are variably rugged, for the attachment of two of the masticating muscles. The anterior border of the ramus is sigmoid in its descent to the outer side of the body, where it terminates just exterior to the last tooth.

The upper border of the ramus exhibits a large **semilunar notch**,⁵ in advance of which is a flat conical eminence, the **cor'onoid proc'ess**,⁶ into which the temporal muscle is inserted. Posterior to the notch is another process, which supports a transverse articular convexity, the **con'dyle**,⁷ and its narrow part below constitutes the **neck**⁸ of the jaw, the inner side of which presents a depressed surface, directed forward, for the attachment of the external pterygoid muscle.

STRUCTURE AND ARTICULATION OF THE BONES OF THE FACE.

The bones of the face are remarkable for their light and laminar character, with the exception of the inferior maxilla, which is the stoutest and strongest bone of the skull, and contains within it, like most of the cranial bones, a quantity of spongy substance.

All the bones of the face, except the lower jaw, are firmly and immovably articulated with one another and with the cranium.

The face and cranium together constitute the **skull**, or bony portion of the head.

Across the root of the nose, at the external angular processes of the frontal bone, and at the zygomatic arches, the face articulates by well-marked serrate sutures⁹ with the cranium. Among themselves the bones of the face generally articulate by the mutual adaptation of more or less

¹ Foramen maxillare internum; inferior dental foramen.

² Canalis maxillaris; c. alveolaris inferior.

³ Lingula.

⁴ Angulus maxillæ.

⁵ Incisura semilunaris; i. sigmoidea.

⁶ Processus coronoideus.

⁷ Condylus; capitulum.

⁸ Cervix; collum.

⁹ The transverse facial suture.

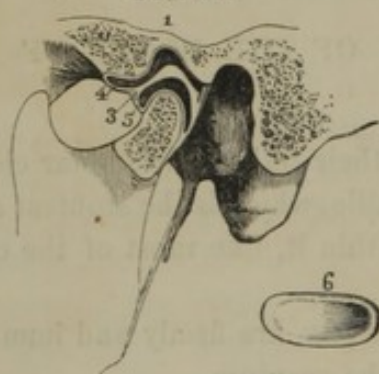
roughened borders.¹ The different sutures are named from the bones they connect, or from their position, and thus we have a *na'so-front'al su'ture*, an *intermax'illary su'ture*, a *middle* and *transverse pal'ate su'ture*, etc.

THE TEMPERO-MAXILLARY ARTICULATION.

The movable articulation of the inferior maxillary bone is formed between the condyle of the latter and the glenoid cavity and tubercle of the temporal bone, which are invested with cartilage. The motions of the lower jaw are as follows: 1. the opening and shutting of the mouth, in which the condyles roll on their axes in the glenoid cavities, as in the movement of a hinge; 2. the movement of the lower jaw forward and backward, in which the condyles move forward from the glenoid cavities upon the glenoid tubercles and back again; and 3. the movement from side to side, when the condyles move alternately and obliquely from the glenoid cavities to the glenoid tubercles and back again.

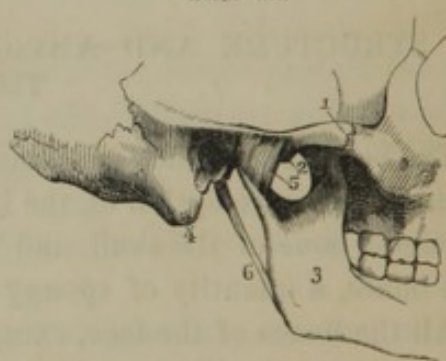
The hinge-like or downward and upward movement of the lower jaw is the act of biting; the movements of the jaw forward and backward, and from side to side, are those of mastication or chewing.

FIG. 61.



VERTICAL SECTION OF THE ARTICULATION OF THE LOWER JAW. 1, is placed above the glenoid cavity; 2, glenoid tubercle; 3, inter-articular cartilage dividing the joint into two cavities, 4 and 5; 6, an inter-articular cartilage separated from a joint, to exhibit its form.

FIG. 62.



EXTERNAL VIEW OF THE TEMPERO-MAXILLARY ARTICULATION. 1, zygoma; 2, glenoid tubercle, 3, ramus of the inferior maxillary bone; 4, mastoid process; 5, external lateral ligament; 6, stylo-maxillary ligament, a process of the cervical fascia.

The articulation of the lower jaw is rendered more movable by an *in'terartic'ular fi'bro-car'tilage*,² which is a discoidal plate horizontally dividing the joint into two cavities, each lined with a synovial membrane. The margin of the fibro-cartilage is thickened and attached to the capsular ligament; and it is sigmoid in section antero-posteriorly. It follows the movements of the condyle, and reduces the force of its impressions.

¹ Suturae harmoniae.

² Cartilago-interarticularis.

The **cap'sular lig'ament**, inclosing the joint, is thin and loose, and is attached above to the articular margin of the glenoid cavity and tubercle, and below to the neck of the lower jaw.

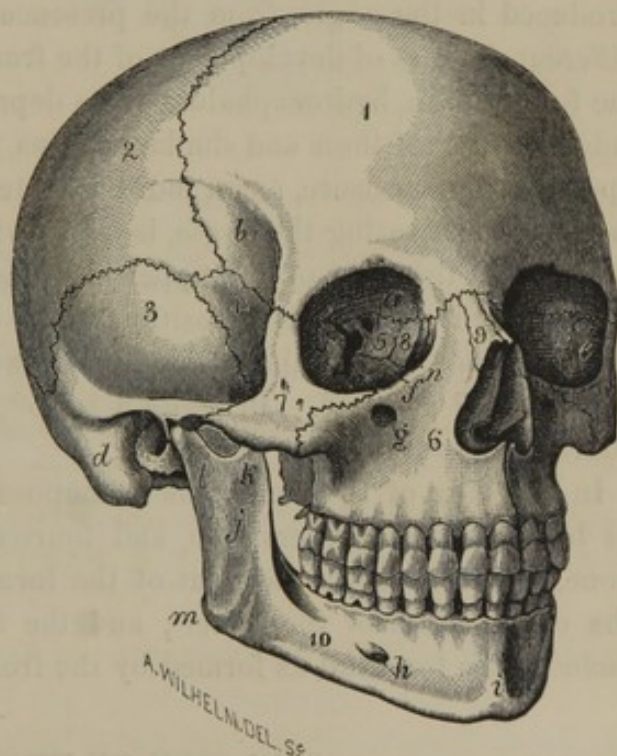
The **exter'nal lat'eral lig'ament**¹ strengthens the former on the outer side of the joint. It consists of a short, strong band attached to the root of the zygomatic process, and extending downward and backward to the neck of the lower jaw.

GENERAL CONFORMATION AND POSITION OF THE FACE.

The **Face** is placed beneath the fore part of the **cra'nium**, together with which it forms the **skull**, as previously stated. In outline it has the shape of a wedge-like segment from an oval figure. The rounded portion of the segment is formed by the front and sides of the face; the sectional surfaces are formed by the conjunction of the latter with the cranium and the base of the lower jaw; and the apex, which is truncated, is formed by the back borders of the rami of the lower jaw.

The face is mainly constituted of a series of receptacles for the accommodation and protection of the organs of sight, smell, taste, and others belonging to the commencement of the alimentary apparatus. In relation with the size of the cranium, it is smaller than in other mammals. In the white race it forms about one-fifth of the bulk of the skull, but in the inferior races is considerably larger. The greater its size in relation with that of the cranium, the

FIG. 63.



THE SKULL, SEEN PARTLY IN FRONT AND ON THE RIGHT SIDE. 1, frontal bone; 2, parietal bone; 3, temporal bone, its squamous portion; 4, the sphenoid bone, temporal surface of its great wing; 5, ethmoid bone, its orbital surface; 6, superior maxillary bone; 7, malar bone; 8, lachrymal bone; 9, nasal bone; 10, inferior maxillary bone. *a*, orbital plate of the frontal bone; *b*, temporal surface; *c*, orbital surface of the great wing of the sphenoid bone; *d*, mastoid portion of the temporal bone; *e*, orbital surface of the malar bone; *f*, orbital plate of the superior maxillary bone; *g*, infra-orbital foramen; *h*, mental foramen; *i*, symphysis; *j*, ramus; *k*, coronoid process; *l*, neck supporting the condyle; *m*, angle; *n*, lachrymo-nasal duct.

¹ Ligamentum maxillæ laterale externum; membrana articularis ligamentosa.

less does it project in advance of the latter; and with its proportionate diminution, as its front approaches a line vertical with the forehead, the nearer does it approximate the ideal standard of an intellectual countenance. Hence the advancing forehead and retiring face are most striking features in the white race, especially in its more cultivated families; while the prominent face, with large jaws, and receding forehead, are coexistent with the less intellectual character of the inferior races of men.

The angle of inclination of the fore part of the skull is viewed to determine the comparative degree of development of the face and cranium, and in some measure to form an estimate of the mental capacity of races and individuals. Though open to many objections, such as variations being produced in the angle, from the presence or absence of teeth, from the different degrees of development of the frontal sinuses, from projection of the forehead in hydrocephalus, or its depression by artificial means, yet independently of these and similar reasons, the **fa'cial angle**¹ is still looked upon, in some measure, as an index of intellectual character. The usual method of estimating the angle, is by drawing a line from the front of the forehead to the front of the upper jaw, and crossing this line by another proceeding from the latter position to the external auditory meatus. In the white race, the facial angle ranges between 75° and 85° ; in the negro, between 70° and 80° . In idiots it is 65° , or even much less; and in the adult orang-outang it is about 30° .

In speaking of the bones which compose the skull, eight were indicated as belonging to the cranium, and fourteen to the face. The ethmoid bone, included in the account of the former, really contributes more to the composition of the latter; and the face, as we usually refer to it, includes the forehead as formed by the frontal bone.



THE SIDE OF THE SKULL.

The **Tem'poral fos'sa**² occupies a great portion of the side of the skull, and is bounded above by the **tem'poral ridge**,³ and below by the **zygomat'ic arch**. The former proceeds from the external angular process of the frontal bone upward and backward upon the parietal bone to the dividing ridge between the squamous and mastoid portions of the temporal bone. The **tem'poral surface**, which gives origin to the temporal muscle, is formed by the frontal, sphenoid, parietal, and temporal bones; and it terminates inferiorly at a ridge proceeding from the root

¹ Facial angle of Camper; *angulus faciei Camperi*.

² *Fossa temporalis*.

³ *Linea temporalis*.

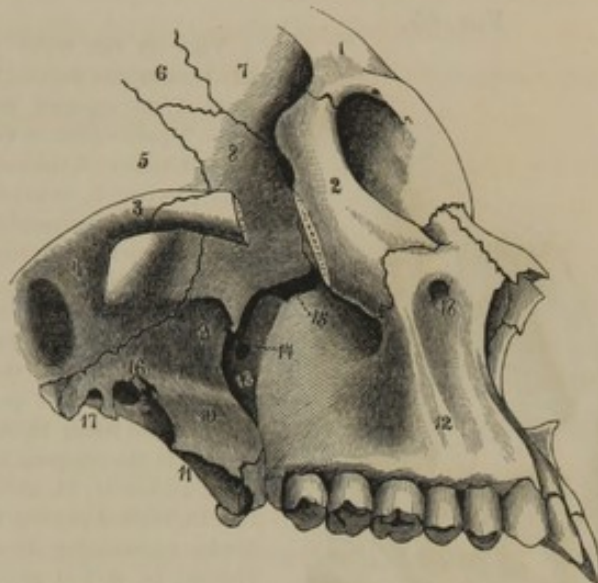
of the zygomatic process of the temporal bone, across the great wing of the sphenoid bone to the outer extremity of the sphenomaxillary foramen.

The **Zygomat'ic arch**,¹ beneath which passes the temporal muscle to its insertion, is formed by the zygomatic process of the temporal and the malar bone, and gives support to the cheek.

The **Sphe'no-max'illary fos'sa**² is the space between the bottom of the great wing and the external pterygoid process of the sphenoid bone, and the back part of the superior maxillary bone, and is occupied by the external pterygoid muscle. At its upper part anteriorly is a large aperture, the **sphe'no-max'illary fora'men**,³ which communicates with the orbit. It is bounded by the sphenoid, superior maxillary, malar, and palate bones; and corresponds to the free communication, or rather continuation, of the temporal fossa and orbit in most of the inferior mammals.

The **Ptery'go-max'illary fos'sa**⁴ is the deep, wedge-shaped fissure, at the bottom of the former fossa, extending from the inner extremity of the sphenomaxillary foramen downward, between the pterygoid processes of the sphenoid bone, and the superior maxillary and palate bone. It is beneath the apex of the orbit, and has, opening from its upper part backward, the pterygoid canal; and inward, the sphenopalatine foramen.

FIG. 64.



VIEW OF THE RIGHT SIDE OF A PORTION OF THE FACE AND CRANIUM. 1, frontal bone; 2, malar bone, a portion of its zygomatic process removed; 3, zygomatic process of the temporal bone; 4, glenoid tubercle, and back of it the glenoid cavity; 5, squamous portion of the temporal bone; 6, anterior inferior angle of the parietal bone; 7, temporal surface of the frontal bone; 8, temporal surface of the great wing of the sphenoid bone; 9, inferior surface of the great wing; 10, external pterygoid process; 11, internal pterygoid process; 12, superior maxillary bone; 13, pterygo-maxillary fossa; 14, sphenopalatine foramen; 15, sphenomaxillary foramen; 16, oval foramen; 17, spinous foramen; 18, infra-orbital foramen. Figures 5-8 occupy the fore part of the temporal fossa; the space between 9, 10, and 14, 15, is the sphenomaxillary fossa.

¹ Arcus zygomaticus; zygoma; pons zygomaticus.

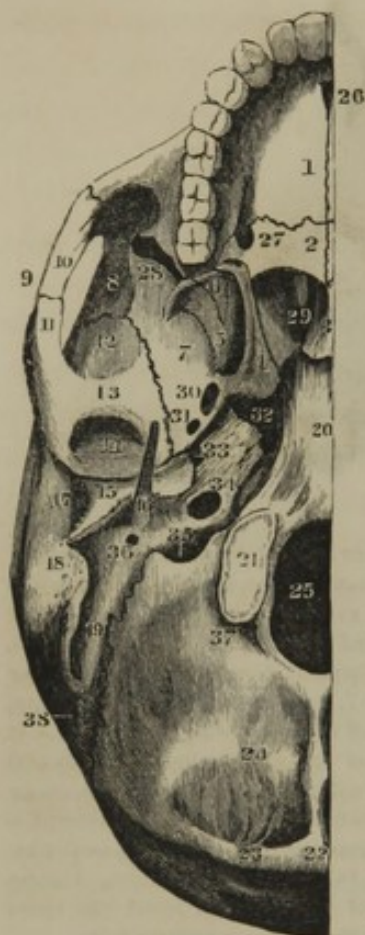
² Fossa sphenomaxillaris; zygomatic fossa.

³ Foramen sphenomaxillare; fissura orbitalis inferior, or sphenomaxillaris; foramen lacerum inferius.

⁴ Fossa pterygo-maxillaris; f. pterygo-palatina.

THE BASE OF THE SKULL.

FIG. 65.



tube; 34, carotid canal; 35, jugular foramen; 36, stylo-mastoid foramen; 37, 38, foramina for veins.

VIEW OF THE RIGHT HALF OF THE BASE OF THE SKULL. 1, palate plate of the superior maxillary bone; 2, palate plate of the palate bone; 3, vomer; 4, internal pterygoid process; 5, external pterygoid process; 6, pyramidal process of the palate bone; 7, under surface of the great wing of the sphenoid bone; 8, its temporal surface; 9, zygomatic arch; 10, zygomatic process of the malar bone; 11, zygomatic process of the temporal bone; 12, squamous portion of the temporal bone; 13, glenoid tubercle; 14, glenoid cavity; 15, vaginal process, its outer border constituting the auditory process; 16, styloid process; 17, external auditory meatus; 18, mastoid process; 19, digastric groove; 20, basilar process of the occipital bone co-ossified with the body of the sphenoid bone; 21, condyle; 22, occipital protuberance; 23, superior, and 24, inferior semicircular ridges; 25, occipital foramen; 26, incisive foramen; 27, posterior palatine foramen; 28, sphenomaxillary foramen; 29, posterior naris; 30, oval foramen; 31, spinous foramen; 32, lacerated foramen; 33, Eustachian

The **Base of the Skull**, included in the occipital and inferior maxillary outline, is ovate in form, and includes the palatine, guttural, and occipital regions.

The **Pal'atine or oral region**¹ is inclosed by the upper and lower jaws, and is bounded above by the vaulted hard palate. Its depth ordinarily is about two and a half inches, but before the protrusion of the teeth, and subsequent to their loss, it is reduced to an inch or less in depth. The **hard pal'ate**² presents a roughened surface, divided by the **middle and transverse pal'ate**

su'tures.³ At the fore part of the middle suture is the **anterior pal'atine fora'men**,⁴ which communicates above with the two naso-palatine canals entering the nasal fossæ. At the posterior part of the hard palate, on each side, is the **posterior pal'atine fora'men**,⁵ from which coarse grooves are directed forward for the accommodation of the palatine nerves and blood-vessels.

The **Gut'teral region**,⁶ so named because it forms the upper boundary

¹ Regio palatina: cavum oris.

² Palatum durum; p. osseum.

³ Sutura palatina cruciata.

⁴ F. palatinum anterior; f. incisivum.
f. alveolare anterius; f. coecum.

⁵ F. palatinum posterior, or descendens; f. palato-maxillare; f. alveolare posterius.

⁶ Regio gutturalis.

of the pharynx or throat, has the posterior nares opening into it in front, and is limited behind by the occipital foramen and condyles. On each side are the pterygoid processes, and above, it is bounded by the basilar process of the occipital bone and the body of the sphenoid bone.

The **Occip'ital region** includes that part of the base of the skull posterior to the occipital foramen and condyles.

THE ORBITS.

The **Orb'its**¹ are quadrately pyramidal cavities situated beneath the anterior part of the cranium, with their axes directed forward and outward.

The apex of each orbit corresponds with the optic foramen, and the base forms the **orb'ital entrance**.² This is situated beneath the forehead, and is transversely quadrate-oval, with a slight obliquity from the median line downward, and a direction forward and a little outward.

The roof of the orbit is vaulted, and is formed by the orbital plate of the frontal bone and the lesser wing of the sphenoid bone. The floor is slightly depressed below the infra-orbital margin, and is formed by the orbital plate of the superior maxillary bone and the orbital process of the palate bone. The inner wall is nearly vertical and parallel with that of the other orbit, and is formed by the nasal process of the superior maxillary bone, the lachrymal bone, the orbital plate of the ethmoid bone, and the body of the sphenoid bone. The outer wall is also nearly vertical, but is directed obliquely outward; and it is composed of the orbital plate of the great wing of the sphenoid bone and that of the malar bone.

At the bottom or apex of the orbit are the optic and sphenoidal foramina, already described, and between the outer wall and floor is the sphenomaxillary foramen, also previously described.

At the anterior part of the inner wall of the orbit is the **lach'rymona'sal duct**.³ Commencing as a fossa⁴ or groove between the nasal process of the superior maxillary and lachrymal bones, by the addition of a process of the turbinated bone, its lower half forms a complete tube. It descends with a slight inclination backward, and terminates at the anterior part of the inferior meatus of the nasal fossa.

At the upper border of the inner wall of the orbit, in the suture

¹ Orbitæ; trochiæ; conchi; cavitates, or foveæ, or pelvicolæ oculorum; orbital fossæ; orbital cavities.

² Apertura orbitalis.

³ Ductus or canalis lachrymo-nasalis, or naso-lachrymalis; ductus ad nasum; lachrymal duct; nasal duct; ductus nasalis orbitæ.

⁴ Fossa lachrymalis.

between the ethmoid and frontal bones, are the **anterior and posterior ethmoid'al fora'mina**,¹ for the transmission of a nerve and an artery.

THE NASAL CAVITIES.

The **Na'sal cavities** or **fos'sæ**² are two complicated spaces separated by a thin vertical partition, the **os'seous na'sal sep'tum**.³ They open on the front of the face by the **anterior na'sal or'ifice**, and communicate posteriorly with the guttural region by the **posterior na'sal or'ifices** or **na'res**. Communicating with them are the frontal, ethmoidal, sphenoidal, and maxillary sinuses, which are accessory chambers.

The height and depth of each nasal cavity are about two inches; the greatest width, which is below the turbinated bone, is about half an inch.

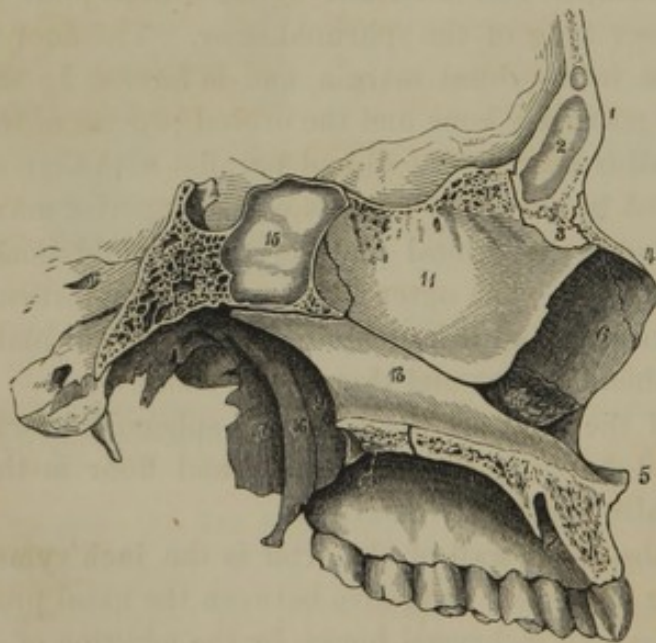
The **anterior na'sal or'ifice**⁴ is pyriform, and is bounded by the superior maxillary and na-

sar bones. Its border is thin and sharp; in the negro, however, it is rounded off at the bottom. From the middle of its base, the **na'sal spine**⁵ projects, for the attachment of the column of the nose.

The **posterior na'sal or'ifices**⁶ are quadrate apertures separated by the vomer, and, in addition to the latter, are bounded by the body and internal pterygoid processes of the sphenoid bone and the palate bones.

The **os'seous na'sal sep'tum** is formed by the nasal plate of the eth-

FIG. 66.



VERTICAL SECTION OF THE FACE, exhibiting the osseous nasal septum. 1, frontal bone; 2, frontal sinus; 3, nasal spine of the frontal bone; 4, nasal bone; 5, nasal spine of the superior maxillary bone; 6, nasal process of the same bone; 7, border of the palate plate of the same; 8, incisive foramen; 9, left posterior naris; 10, palate plate of the palate bone; 11, nasal plate of the ethmoid bone; 12, ethmoidal crest; 13, vomer; 14, left turbinated bone; 15, sphenoidal sinus; 16, internal pterygoid process; 17, external pterygoid process.

¹ F. ethmoidale anterius et posterius;
f. orbitale ant. et post.

² Cavi narium; nares internæ.

³ Septum narium osseum.

⁴ Apertura narium anterior.

⁵ Anterior nasal spine.

⁶ Posterior nares; aperturæ narium posteriores.

moid bone and the vomer, which have between them anteriorly a deep angular notch for the reception of the cartilaginous septum. Frequently the nasal septum is bent to one side, thus increasing the width of one cavity at the expense of the other.

The **roof** of the nasal cavities is antero-posteriorly concave, and is narrower and longer than any other portion. It is formed by the nasal bones, the nasal spine of the frontal bone, the cribriform plate of the ethmoid bone, and the body of the sphenoid bone.

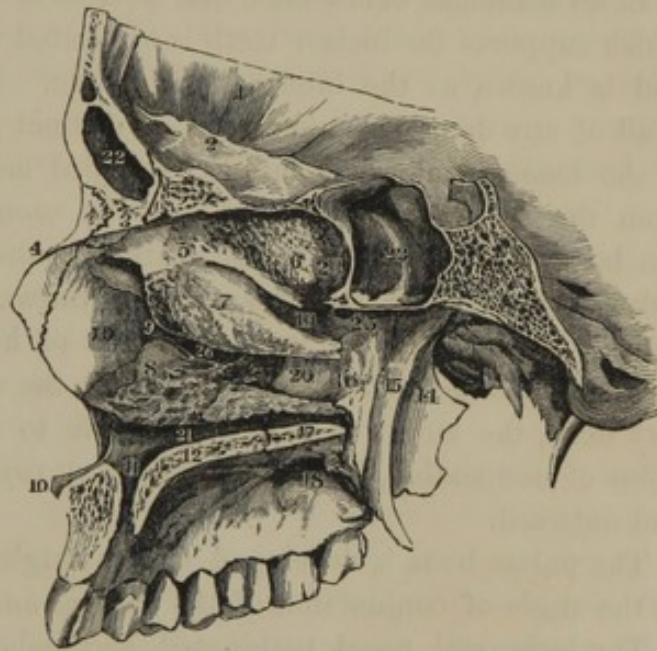
The **floor** of the nasal cavities is a little depressed below the level of the base of the anterior nasal orifice; and is formed by the palate plates of the maxillary and palate bones.

The **outer wall** is the most complicated portion of the nasal cavities. From it project inward and downward, like three scrolls, the turbinated processes of the ethmoid bone and the turbinated bone; and below these are situated the **na'sal mea'tuses**.¹

The **superior mea'tus** is the shortest, is situated at the upper back part of each cavity, and is directed obliquely downward and backward to the upper part of the corresponding posterior nasal orifice. Into it the posterior and middle ethmoidal sinuses open; and above its posterior extremity, the sphenoidal sinus communicates with the nose.

The **middle meatus** is situated between the ethmoid and turbinated bones along the middle of the nasal cavity. Into it open the anterior

FIG. 67.



VIEW OF THE OUTER WALL OF THE RIGHT NASAL FOSSA. 1, frontal bone; 2, its orbital plate; 3, its nasal spine; 4, nasal bone; 5, ethmoid bone; 6, its upper turbinated process; 7, its lower turbinated process; 8, turbinated bone; 9, process of the lachrymal bone, within the position of which is the lachrymo-nasal duct; 10, nasal spine of the superior maxillary bone; 11, naso-palatine canal; 12, palate plate of the superior maxillary bone; 13, nasal process of the latter; 14, external pterygoid process; 15, internal pterygoid process; 16, nasal plate of the palate bone; 17, its palate plate; 18, posterior palatine foramen; 19, superior meatus of the nose; 20, middle meatus; 21, inferior meatus; 22, frontal sinus; 23, sphenoidal sinus; 24, its communication with the upper back part of the nose; 25, sphenopalatine foramen; 26, orifice of the maxillary sinus.

¹ Meatus narium.

ethmoidal and frontal sinuses and the maxillary sinus. The orifice of the latter is much reduced in size compared with its condition in the isolated maxillary bone; the ethmoid, palate, turbinated, and lachrymal bones all contributing to its diminution.

The *inferior meatus*, situated below the turbinated bone, is transverse in its direction from before backward; and it has communicating with its anterior part, the lachrymo-nasal duct.

DEVELOPMENT OF THE FACE.

In all mammals below man, that portion of the superior maxillary bone which supports the incisor teeth is separated from the principal portion, and is known as the intermaxillary bone. It may be observed in the skull of any domestic animal. As a distinct piece, it is obscurely visible in the human embryo as late as the third month, and may be detached from the superior maxillary bone. It soon becomes co-ossified with the latter, and its line of separation is distinguishable subsequently only for a short distance transversely outward from the incisive foramen. Occasionally, as in some cases of hare-lip, the intermaxillary bone remains permanently distinct. To the main portion of the maxillary bone, the author has not been able to detect more than a single point of ossification, from which the bony rays shoot upward, backward, and outward.

The palate bone is developed from a single ossific point, commencing at the angle of junction of the vertical and horizontal portions.

The lachrymal, nasal, turbinated, and malar bones, and the vomer, are each developed from one centre of ossification.

In the development of the inferior maxillary bone, each half appears to originate in a single ossific point, which commences before any other in the skeleton, except that of the clavicle. At birth the lower jaw consists of two halves, united at the symphysis by fibro-cartilage, but which, during the first year, subsequently co-ossify.

CHANGES OF THE SKULL AT DIFFERENT PERIODS OF LIFE.

In the embryo and early fœtus the skull has a spheroidal figure, with a comparatively small conical prominence corresponding to the face. At birth, and for some time subsequently, the cranium is still more spheroidal than afterwards, and at this early period is much larger in comparison with the face than at maturity. The facial angle also is greater than it is at a later period.

The skull is composed of a greater number of pieces at birth than

afterwards, as already indicated in the account of the individual bones. The texture of these, due to their greater proportion of bone cartilage, is more flexible, and they are rather disposed to bend than to break. The bones likewise are more readily movable upon one another, so that from this and the preceding circumstance, the head in infancy is readily modified in shape artificially, as instanced in the change of form produced in the cranium, customary among the Flat-head Indians, and other savage tribes.

In the infant skull, the bones of the vault of the cranium are more conical than concavo-convex, as they afterwards become. The greatest transverse diameter of the skull is at the parietal protuberances; but later, is at the temporal fossæ. The latter are proportionately small, in accordance with the moderate development of the temporal muscles, which are not yet required for mastication. The face is low, and situated entirely beneath the cranium. The nasal cavities are small, and the various sinuses communicating with them only begin to be developed. The mouth or palatine region in vertical depth is not more than half an inch; and the rami of the lower jaw project comparatively little above its body, and are more oblique than afterwards. As the child grows, the bones of the skull acquire greater hardness, become thicker, and gradually develop their spongy substance and their sinuses.

With the development of the teeth and alveolar processes, and the protrusion of the former, the face becomes more prominent and deeper, the facial angle declines, and the spaces occupied by the masticating muscles enlarge. The rami of the lower jaw lengthen downward, and become less oblique; and the mouth increases to two and a half inches of vertical depth. With the advance of the face, there is also a recession of the cranium; and from the development of the frontal sinuses, the superciliary ridges become the most prominent portion of the forehead, instead of the frontal protuberances as in infancy.

From puberty to adult age, but little change occurs in the skull, except a comparatively slight and very gradual increase in size and strength. At maturity the sutures gradually disappear; and in old age a sort of retrograde metamorphosis occurs. The bones of the skull become thinner and more brittle, and the spongy substance decreases, though the sinuses enlarge. With a diminution in quantity of the brain, the cranium undergoes an actual reduction in size. The teeth drop out, and the alveolar borders of the jaws disappear, reducing the depth of the mouth almost to the condition of that in infancy. In consequence of these changes, the face loses much of its vertical extent, and the facial angle is increased. As the body of the lower jaw forms a much larger

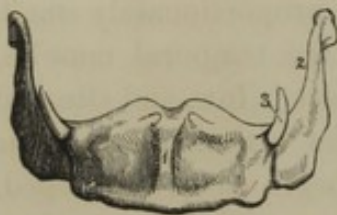
arch than the upper jaw, it mounts upon and incloses the latter, thus bringing the prominent chin just beneath the nose, as so strikingly observed in the aged.

THE HYOID BONE.

The **Hy'oid bone**¹ is situated in the front of the neck, at the root of the tongue, and is readily felt just above the larynx. It consists of a median symmetrical body, with a pair of horns on each side.

The **body**² is the middle piece in front, and is quadrate in outline.

FIG. 68.



THE HYOID BONE. 1, body; 2, greater horn; 3, lesser horn.

Anteriorly it is convex and impressed on each side by muscles, and posteriorly is concave.

The **greater horns**³ project backward from the ends of the body; and are comparatively long, thin processes ending in a tubercle. The **lesser horns**,⁴ usually in a cartilaginous condition until late in life, are conical, and project upward and backward from the junction of the body with the greater horns.

The lesser horns connect the hyoid bone with the styloid process of the temporal bone, by means of a long, narrow, fibrous cord, the **sty'lo-hy'oid liga'ment**.⁵ Generally they are only two or three lines long, and often vary in length and degree of ossification on the two sides. Sometimes ossification extends from them up the stylo-hyoid ligament, and rarely, its entire length.

THE TRUNK.

That division of the skeleton called the **trunk**⁶ is composed of the vertebral column, the ribs, the sternum, and the hip bones. Its upper extremity forms the bony axis of the neck; below this is the thorax or chest; then follows the axis of the loins; and the lower part of the trunk forms the pelvis.

¹ Os hyoides; os linguæ, or linguale; os ypsiloides; os gutteris, or gutterale; os bicornis; os lambdoides.

² Basis; ossiculum medium hyoidis.

³ Cornua majora; branches; rami.

⁴ Cornua minora; corpuscula, or graniticea; cornicula; ossa pisiformia linguaria; styloid cornua.

⁵ Ligamentum stylo-hyoideum.

⁶ Truncus.

THE VERTEBRAL COLUMN.

The **Vert'ebral column**¹ is the axis of support of the body, and is situated along the middle line of the trunk posteriorly. It is composed of twenty-nine symmetrical pieces, named **vert'ebræ**,² which are divided into twenty-four true and five false vertebræ.

In front, the vertebral column is composed of a series of half cylindroid segments conjoined by fibro-cartilage; posteriorly, of a series of arches supporting processes for mutual articulation, and others for muscular attachment. From the elongated spine-like character of its posterior median processes, the entire column is ordinarily named the **spine**.³

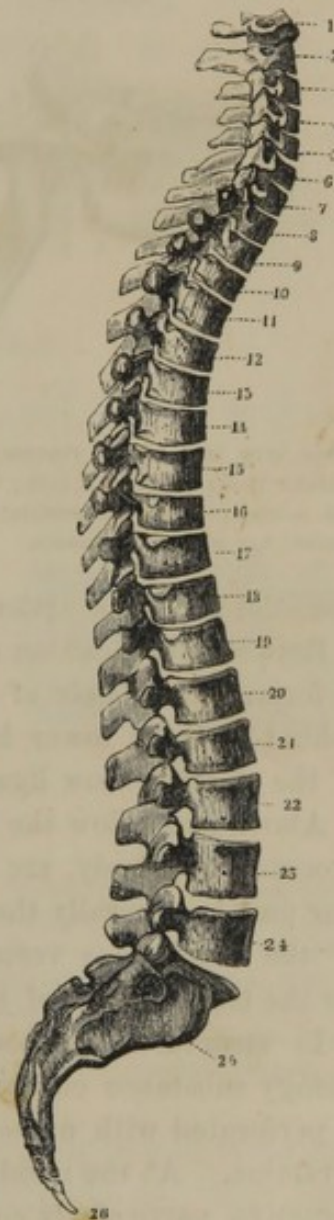
THE TRUE VERTEBRÆ.

The **True vert'ebræ**,⁴ twenty-four in number, extend from the skull to the pelvis, and gradually increase from the first to the last, which rests on the sacrum. From their relative position in the trunk they are divided into cervical or neck vertebræ, dorsal or thoracic vertebræ, and lumbar vertebræ.

The true vertebræ are composed of a body and an arch supporting seven processes.

The **body**⁵ is at the fore part, and usually possesses the form of a transverse segment of a half cylinder, concave posteriorly, and constricted at the front and sides. Its broad surface above and below is generally flat, with a slightly elevated border; and is conjoined with the contiguous vertebral body by means of a plate of fibro-cartilage.

FIG. 69.



THE VERTEBRAL COLUMN, lateral view; exhibiting the curvatures, 1 to 24, true vertebræ; 25, 26, false vertebræ; 1 to 7, cervical vertebræ; 8 to 19, dorsal vertebræ; 20 to 24, lumbar vertebræ; 25, sacrum; 26, coccyx.

¹ Columna vertebralis; spinal column; columna spinalis; columna dorsi; spine; spina dorsi; back bone; rachis; carina; dorsum; tergum; notos; acnestis; acantha; compages vertebrarum; sacra fistula; hiera syrinx.

² Spondyli; spondles; whetle bones.

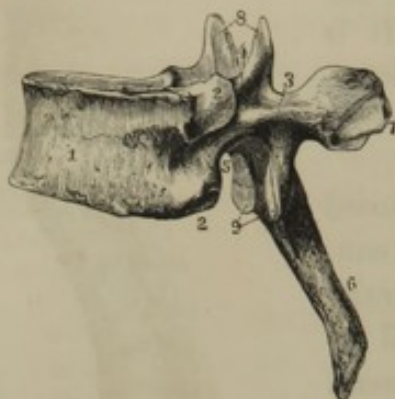³ Spina.

⁴ Vertebræ veræ.

⁵ Corpus vertebræ; centrum.

The arch¹ is attached to the sides of the body posteriorly by narrow ped'icles,² and the passage through it is the spi'nal fora'men,³ forming

FIG. 70.



SIDE VIEW OF A DORSAL VERTEBRA. 1, body; 2, articular facets for ribs; 3, arch; 4, 5, intervertebral notches; 6, spinous process; 7, transverse process; 8, 9, articular processes.

part of the spinal canal for containing the spinal cord. In form the arch is angular, and its sides expand below; so that in the vertebral column the arches together present a somewhat imbricated appearance.

From the summit of the arch posteriorly projects the spi'nous proc'ess,⁴ and from each side, the trans'verse proc'ess,⁵ all of which serve as points of attachment for muscles. Above and below, the arch supports a pair of artic'ular proc'esses,⁶ which present smooth

discoidal facets for articulation with those of the contiguous vertebræ.

Between the position of the articular and spinous processes, the arch is formed of a pair of shelving plates,⁷ of which the upper border behind and the lower border in front are roughened for the attachment of the elastic yellow ligaments.

Above and below the pedicles of the arch, and between the articular processes and body, are the intervert'ebral notches, of which the inferior pair is generally the deeper. By the approximation of the notches of the contiguous vertebræ they form the intervert'ebral fora'mina,⁸ for the transmission of the spinal nerves and blood-vessels.

In structure, the body of the vertebræ is composed of a mass of spongy substance covered with a thin layer of compact substance, which is perforated with numerous comparatively large nutritious or vascular foramina. At the middle of the body posteriorly there are two of these foramina particularly conspicuous, which communicate with channels for conducting veins from the spongy substance to the vertebral sinuses. The vertebral arch, together with its processes, requiring greater strength

¹ Arcus vertebræ; vertebral arch; neural arch.

² Neurapophyses.

³ Foramen spinale, or vertebrale; vertebral foramen.

⁴ Processus spinosus; neural spine.

⁵ P. transversus; diapophysis.

⁶ P. articulares; oblique processes; p. ascendentes et descendentes; zygapophyses.

⁷ Vertebral plates; laminæ; neurapophyses.

⁸ F. intervertebralia; f. vertebralia; f. conjugata.

than the body, have a predominance of compact substance composing them.

The characters, thus given of the true vertebræ, are modified in the three regions to which we have referred; so that the cervical, dorsal, and lumbar vertebræ will now require a special description. In each region, however, the characters are not constant for all the vertebræ, as we find those of contiguous regions assuming more or less the appearance of one another; and in several instances they are much modified, so as to be adapted to some special function, as in the case of the upper pair of the neck.

THE CERVICAL VERTEBRÆ.

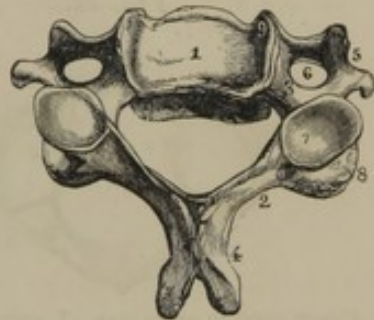
The *Cer'vical vert'ebræ*¹ are seven in number, and form the bony axis of the neck, extending from the skull to the thorax. The most striking peculiarity, by which they may be distinguished from those of the other regions of the trunk, is the large foramen in the transverse processes.

The body is widest transversely, and this disposition increases from the first to the last of the series. Its upper surface is rendered transversely concave from the elevation of the lateral borders; and its lower surface is in a less degree concave in the opposite direction from the prolongation of the anterior and posterior borders. From this arrangement the contiguous bodies interlock, thus affording a provision against dislocation where the vertebræ are smallest.

The arch is less deep, but wider than in the dorsal or lumbar vertebræ; and the spinal foramen is trilateral, with rounded angles, and larger than in the other true vertebræ. The upper and lower intervertebral notches are nearly equal in size.

The spinous process is comparatively short, and is bifid at the extremity. The transverse processes are also comparatively short, and they consist of two portions. The posterior portion,² springing from the pedicle of the vertebral arch, corresponds with the transverse processes of the dorsal vertebræ, while the anterior portion corresponds with the ribs.³ The two portions being conjoined by an isthmus, a foramen⁴ is formed,

FIG. 71.



UPPER VIEW OF A CERVICAL VERTEBRA, from the middle of the series. 1, body; 2, 3, arch; 4, spinous process; 5, transverse process; 6, its foramen; 7, superior articular process; 8, inferior articular process; 9, elevated lateral border of the body.

¹ *Vertebræ colli; v. cervicis.*

² *Diapophysis.*

³ *Parapophysis.*

⁴ *F. transversarium; f. vertebrale.*

which, in the case of the upper six vertebræ of the neck, transmits the vertebral artery.

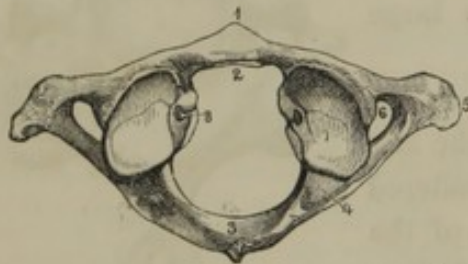
The upper articular processes have their facets directed obliquely backward and upward; the lower ones, downward and forward.

The description thus given of the cervical vertebræ applies especially to those from the third to the sixth inclusive; the remaining three possess peculiarities requiring special notice.

The first cervical vertebra is named the **At'las**,¹ from its supporting the head. It is an irregular ring, and is broader than any other of the vertebræ of the neck. The large space included by the ring is divided by the transverse ligament into two parts, of which that anterior is the smallest, and is occupied by the pivot-like odontoid process of the second vertebra; the posterior portion is the true spinal foramen.

Anteriorly, the atlas presents a short transverse bridge, with a tubercle in front, and a smooth articular facet behind, which moves on the odontoid process.

FIG. 72.



UPPER VIEW OF THE ATLAS. 1, anterior tubercle; 2, articular facet for the odontoid process; 3, arch, with its rudimentary spinous process; 4, groove for the vertebral artery; 5, transverse process; 6, its foramen; 7, superior articular process; 8, tuberosity for the transverse ligament.

The arch of the atlas is rounded, and its rudimentary spinous process is in the form of a small tuberosity. The transverse process is much prolonged beyond that of the other cervical vertebræ, and ends in a rounded tuberosity.

The upper articular processes form elliptical concavities inclining inwardly, and having their long

diameter directed forward and inward. They articulate with the occipital condyles, and are the centre of the backward and forward motion of the head. The lower articular processes have oval, slightly depressed facets, directed downward and inward.

The portions of the atlas forming the articular processes are the thickest and strongest of the bone; and they are adapted to sustain the pressure of the skull, which is subsequently transmitted, through the obliquity of the inferior articular processes, to the body of the second cervical vertebra, and thence through all the other vertebral bodies.

Between the position of the upper and lower articular processes internally, is a tuberosity, for the attachment of the transverse ligament, which retains the odontoid process in its place.

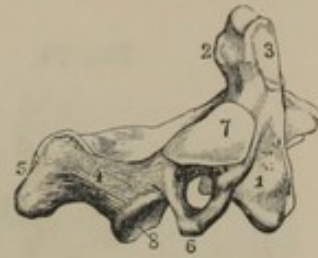
¹ Atlantion; astragalus.

The intervertebral notches of the atlas are behind the articular processes, those below being the smaller. The upper ones are continuous with a groove from the foramen of the transverse process, and transmit the vertebral arteries in their course to the occipital foramen. Sometimes these upper notches are converted by a bridge of bone into foramina.

The second cervical vertebra is called the **Ax'is**,¹ from its supporting the pivot upon which the atlas and the skull together rotate.

The body of the axis presents a median prominence in front, and its upper part is prolonged into the pivot-like **odon'toid proc'ess**,² which projects within the circle of the atlas. The process is conical, has a smooth facet in front to articulate with the bridge of the atlas, and another behind, against which the transverse ligament moves. The summit and sides are also impressed by the attachment of the ligaments which moderate the rotation of the head.

FIG. 73.



SIDE VIEW OF THE AXIS. 1, body; 2, odontoid process; 3, articular facet; 4, arch; 5, spinous process; 6, transverse process, with its foramen; 7, 8, superior and inferior articular processes.

The arch of the axis is more robust than in any other of the cervical vertebræ. The spinous process is comparatively very strong; and it has depressed sides, a deep groove below, and a cleft extremity. The transverse process is the shortest in the cervical series, and its foramen ascends at first beneath the upper articular processes, and then turns abruptly outward and backward.

The upper articular processes are oval in form and slightly convex, and rest obliquely upon the sides of the body and the pedicles. They are the circle of the rotary movements of the head, while the odontoid process is the centre.

The upper intervertebral notches are obsolete; while those below, and other parts of the bone in this position, correspond with the condition of the other vertebræ of the neck.

The last cervical vertebra³ partakes strongly of the characters of the dorsal series, and is particularly remarkable for the length of its spinous process, which is tuberos at the end, instead of being cleft as in the others.

¹ Vertebra dentata; epistropheus; axon; maschalista.

² P. odontoideus, or odontoides; p. dentatus; p. dentiformis; p. pyrenoides.

³ V. prominens.

THE DORSAL VERTEBRÆ.

The **Dor'sal vert'ebræ**,¹ twelve in number, form the bony axis of the thorax, and extend from the neck to the loins.

The most characteristic marks by which they may be distinguished from other vertebræ are the articular facets for the ribs.

The bodies decrease in breadth from the first to the third, then are nearly uniform in this respect to the fifth, and afterwards gradually increase to the last. They are more demi-cylindroid in form than either those of the neck or loins. Their upper and lower surfaces are flat.

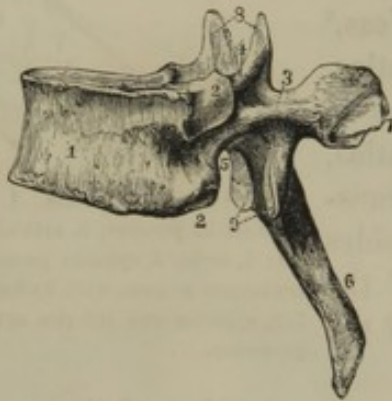

FIG. 74.
SIDE VIEW OF A DORSAL VERTEBRA. 1, body; 2, articular facets for ribs; 3, arch; 4, 5, intervertebral notches; 6, spinous process; 7, transverse process; 8, 9, articular processes.

The arches are smaller and stronger than in the cervical vertebræ. The spinal foramen is nearly circular, and is smaller than in the neck or loins.

The lower intervertebral notches are much larger than the upper ones.

The spinous processes are long and narrow, are trilateral, and have a tuberosus extremity. They are directed backward and downward, successively increasing in the latter inclination to the lower ones of the series. The transverse processes² are long and strong, and terminate in a thick tuberosity. They are directed outward, with a successively increasing inclination backward. The articular processes are nearly vertical; those above being directed backward, those below forward.

The articular facets for the ribs are situated one at the upper and lower margin of the body, on each side posteriorly, and another in front of the extremity of the transverse processes. The facets, at the sides of the bodies of contiguous vertebræ, together form pits,³ for the articulation of the head of the ribs. The facet of the transverse process articulates with the tubercle of the ribs.

The bodies of the first and last two dorsal vertebræ present each a complete articular facet for the heads of the corresponding ribs.

¹ V. dorsales; v. thoracis; thoracic vertebræ.

² Diapophyses.

³ Foveæ articulares.

THE LUMBAR VERTEBRÆ.

The **Lum'bar vert'ebræ**,¹ five in number, form the bony axis of the loins, and extend from the thorax to the pelvis. They are the largest of the true vertebræ, and are readily distinguished from the others by the absence of a foramen in the transverse processes and articular facets for ribs.

The bodies are oval in transverse section, and successively increase in size to the last. As in the dorsal series, their upper and lower surface is flat. The arches are strong, and increase in width from first to last.

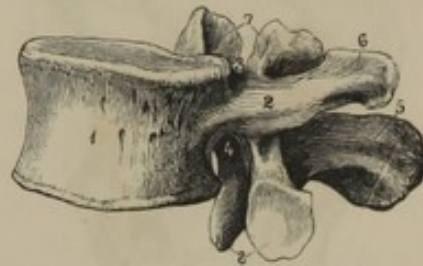The spinal foramen is large and trilateral. The intervertebral notches are large, and nearly equal in size above and below.

The spinous process forms a strong vertical plate projecting backward and ending in a thickened extremity.

The transverse processes² are narrow, directed outwardly, and successively increase in length to the middle of the series, and then diminish to the last. They represent ribs; while the part corresponding with the transverse processes of the dorsal vertebra is a tubercle projecting from the outer side of the upper articular process.

The articular processes are vertical; the upper ones being directed toward, while the lower ones are directed from each other, by which arrangement those of the contiguous vertebræ interlock, and thus aid in maintaining the articular integrity of the column, where it has no lateral support as in the thorax.

FIG. 75.



SIDE VIEW OF A LUMBAR VERTEBRA. 1, body; 2, side of the arch; 3, 4, intervertebral notches; 5, spinous process; 6, transverse process; 7, 8, articular processes.

THE FALSE VERTEBRÆ.

The **False vert'ebræ**³ are so called because they consist of nine segments corresponding with the true vertebræ, which in the mature condition are co-ossified into comparatively few pieces. The upper five pieces, co-ossified, constitute the sacrum; the lower four pieces form the coccyx.

¹ V. lumbales; vertebræ of the loins.

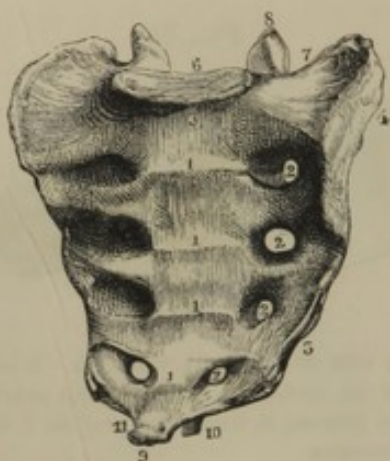
² Parapophyses.

³ V. spuriae.

THE SACRUM.

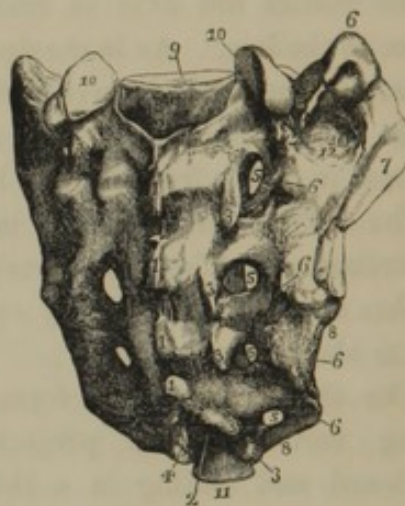
The *Sa'crum*¹ is a triangular bone, inserted obliquely backward and downward between the hip bones, at the posterior part of the pelvis. Its base is upward, joining the last lumbar vertebra; its apex downward, joining the coccyx.

FIG. 76.



FRONT VIEW OF THE SACRUM. 1, transverse ridges, indicating the original separation of the bone into five segments; 2, sacral foramina; 3, promontory; 4, articular surface for the hip bone; 5, sacral border of the sacro-sciatic notch; 6, base of the sacrum, with its articular surface for the last lumbar vertebra; 7, wing of the sacrum; 8, articular process; 9, apex of the sacrum, with its articular surface for the coccyx; 10, pedicle of the last vertebral arch of the sacrum; 11, notch for the last sacral nerve.

FIG. 77.



BACK VIEW OF THE SACRUM. 1, rudimentary spinous processes; 2, 2, sacral canal, terminating below in a notch between the pedicles, 3, 4, of the last vertebral arch; 3, 3, rudimentary articular processes; 5, sacral foramina; 6, 6, rudimentary transverse processes; 7, articular surface for the hip bone; 8, sacral border of the sacro-sciatic notches; 9, articular surface for the last lumbar vertebra; 10, articular processes for the latter bone; 11, apex of the sacrum; 12, rough surface on the wing of the sacrum, for the sacro-iliac ligaments.

It is curved forward, and has a broad, smooth, concave surface in front, and an irregular, narrower, convex surface behind. It varies in degree of curvature and relation of length with breadth in different individuals, as well as sexes. As a general rule, it is more curved and longer in proportion with its breadth in the male.

The bone corresponds with five vertebræ, whose elements are more or less obscured by co-ossification and feeble development.

The front surface of the sacrum exhibits four transverse lines, indicating the original separation of the bodies of the sacral vertebræ. The first division of the bone presents an oval articular surface for the

¹ Os sacrum; os latum; os clunium; os basilare; os alagas; vertebra magna; lus; luz; clunis; subvertebra; hieron osteon; albagiazi; vetula.

body of the last lumbar vertebra, and the last division a similar but smaller surface for the first piece of the coccyx.

The posterior part of the sacrum is composed of the co-ossified arches of the vertebral segments. The fifth arch is generally incomplete or open at its back part; and sometimes this condition extends to the arch above, or even through the others.

The continuation of the spinal canal is called the *sa'cral canal*,¹ and is trilateral. It diminishes in its descent, and terminates in the notch² produced by the incompleteness of the fifth sacral arch.

In front, and behind the sacrum, on each side, are the four *sa'cral fora'mina*,³ which communicate with the sacral canal, and correspond with the intervertebral foramina. They successively diminish in size from above downward, and transmit the sacral nerves and blood-vessels. The anterior ones are the larger, and lead outwardly into grooves.

The spinous processes successively diminish in size. The upper three are in the form of tubercles, and more or less confluent into a ridge. The fourth one is usually cleft into two tubercles, which likewise conjoin with those above.

The upper articular processes of the first sacral division form vertically concave facets directed backward and inward. They are separated by a wide notch, which is occupied by the last pair of the yellow ligaments. The other articular processes are rudimental, and are obscurely distinguishable bounding the inner side of the posterior sacral foramina.

The *wings*⁴ or lateral portions of the sacrum correspond with the ribs and transverse processes of the dorsal vertebræ, which are here fused together, so as to afford a broad surface of articulation for the hip bones. Below the surface for the latter, the obtuse margin of the bone gives attachment to the sacro-ischiatic ligaments. The rough surface behind the articulation gives attachment to the sacro-iliac ligaments.

THE COCCYX.

The *Coc'cyx*⁵ is situated at the lower end of the sacrum, from which it curves downward and forward. It corresponds with four of the true vertebræ, and though described as consisting of as many pieces, it presents a very variable condition of co-ossification of these.

The four bones successively decrease in size, and as vertebræ become

¹ Canalis sacralis.

² Hiatus sacralis.

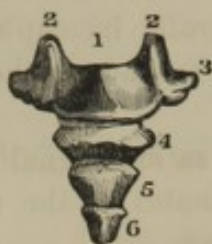³ F. sacralia.

⁴ Alæ sacraliæ.

⁵ Os coccygis; caudal vertebræ; crupper bone; rump bone; os alagas; ossis sacri acumen; cauda; cuculus; uropygion.

more rudimental. The first of the series has a compressed body, with oval

FIG. 78.



POSTERIOR VIEW OF THE COCCYX. 1, first piece; 2, 2, pedicles of a vertebral arch; 3, transverse processes; 4, 5, 6, lower three pieces of the coccyx, consisting of rudimental vertebral bodies.

articular faces for conjunction with the sacrum and the second bone of the coccyx. From each side projects a transverse process. This is not unfrequently co-ossified with the margin of the sacrum, giving rise to a fifth sacral foramen. Behind the body on each side is another short process,¹ which corresponds with the pedicle of a vertebral arch.

The remaining three bones present mere flattened bodies successively diminishing in size.

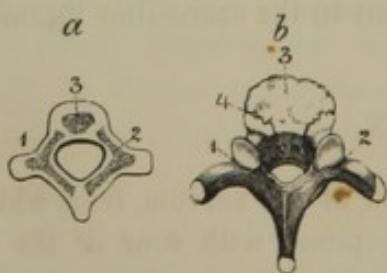
The pieces of the coccyx correspond with the caudal or tail vertebræ of lower animals.

DEVELOPMENT OF THE VERTEBRÆ.

Ossification commences in the vertebræ about the seventh or eighth week of embryonic life, and is not entirely completed until near the twenty-fifth year after birth.

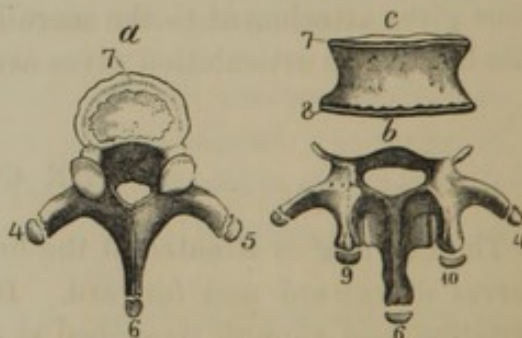
As a general rule, each true vertebra is developed from three principal ossific points, of which one belongs to the body, and one to each side of the arch with its processes. To these are added five epiphyses, of which three arise at the ends of the spinous and transverse processes, and the remaining two appear as thin plates on the articular surfaces of the body.

FIG. 79.



DEVELOPMENT OF THE VERTEBRÆ. *a*, vertebra of a fetus, in a cartilaginous condition, with three centres of ossification; 1, 2, lateral pieces; 3, the body; *b*, vertebra of an infant. The lateral pieces, 1, 2, are co-ossified at the spinous process, and join the body 3, at the sutures 4. The ends of the transverse and spinous processes yet in a cartilaginous state.

FIG. 80.



DEVELOPMENT OF THE EPIPHYSES TO THE VERTEBRÆ. *a*, dorsal vertebra, with the epiphyses 4, 5, to the transverse processes; 6, to the spinous process; and 7, to the body; *b*, arch with its processes; and *c*, body of a lumbar vertebra; 4, 5, epiphyses of the transverse processes; 6, of the spinous process; 7, 8, of the body; 9, 10, of tubercles of the upper articular processes.

¹ Cornua sacralia.

The atlas is usually developed from three principal points only. The axis has two additional points for the odontoid process. The anterior division of the transverse process of the last cervical vertebra sometimes has a distinct ossific point, and this is occasionally developed into a rudimentary and movable rib.

The lumbar vertebræ have epiphyses at the ends of the transverse processes corresponding with ribs, as well as those upon the tubercles which represent the true transverse processes.

The sacrum has three principal points of ossification for each division, as in the true vertebræ. In addition to these, epiphysial plates form on the articular surfaces of the bodies; points originate on each side of the upper three divisions representing ribs; and subsequently two epiphysial plates originate at each lateral border of the bone.

In the coccyx each bone is developed from a single ossific centre.

ARTICULATIONS OF THE VERTEBRAL COLUMN.

The ligaments which connect the different pieces of the vertebral column together and with the skull are as follows :—

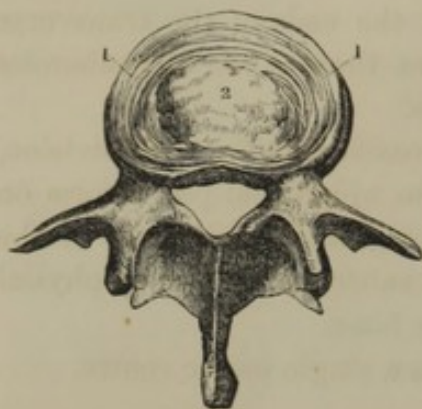
- Twenty-seven intervertebral ligaments.
- Twenty-three pairs of yellow ligaments.
- The anterior vertebral ligament.
- The posterior vertebral ligament.
- Twenty-five pairs of capsular ligaments.
- The supra-spinous ligament.
- The interspinous ligaments.
- The nuchal ligament.
- The anterior and posterior occipito-atloid ligaments.
- The anterior and posterior atlo-axoid ligaments.
- The transverse ligament.
- Three odontoid ligaments.

The **Intervert'ebral liga'ments**¹ or **disks** are plates of fibro-cartilage interposed between the bodies of the vertebræ, except the atlas and axis, constituting a most tenacious but pliant means of connection. They vary in thickness in different parts of the vertebral column; being thickest in the lumbar region, and thinnest in the coccyx and dorsal region. They also vary in this respect in different parts of themselves; thus, the disks of the cervical and lumbar regions are thickest in front, while those of the dorsal region are somewhat thicker behind. To this

¹ Ligmenta intervertebralia; fibro-cartilagine intervertebrales; intervertebral substance, cartilages, or fibro-cartilages.

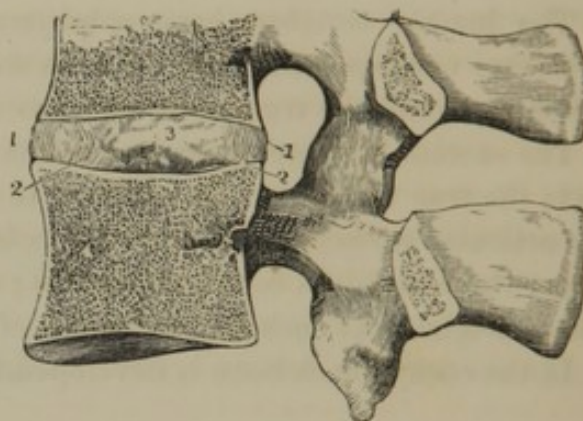
arrangement, together with the more or less wedge-like condition of the vertebral bodies, the curves of the vertebral column are due, excepting that of the sacrum, which belongs to the bending of the bone itself.

FIG. 81.



UPPER VIEW OF A LUMBAR VERTEBRA, with a horizontal section of an intervertebral ligament. 1, concentric layers of fibrous tissue; 2, pulpy fibro-cartilage.

FIG. 82.



VERTICAL SECTION OF TWO LUMBAR VERTEBRÆ, with the intervening intervertebral ligament. The intervening articular processes, enveloped by a capsular ligament, are also represented. 1,1, concentric layers of fibrous tissue, curving outwardly; 2,2, concentric layers curving inwardly; 3, pulpy fibro-cartilage in the middle.

Each intervertebral ligament is composed at the circumference of concentric layers of fibrous tissue, and at the centre of a pulp-like fibro-cartilage. The concentric layers consist of short bundles of fibres extended obliquely between the vertebræ and successively alternating in direction in the different layers, so that if the first proceeds from left to right, the second take their course in the reverse direction, and so on through the series. The concentric layers are not quite vertical, but the more superficial ones bend outwardly, while the deeper ones bend inwardly.

The interior pulp-like fibro-cartilage appears to be closely compressed in its position; so that when an intervertebral disk is cut through, the fibro-cartilage rises above the level of the exposed surface.

The intervertebral ligaments, while firmly associating the segments of the vertebral column, at the same time give it a decided though restricted flexibility. The exterior concentric fibrous layers strongly attach the vertebral bodies, while their alternately crossing arrangement permits a slight degree of torsion or twisting motion; and at the same time the interior compressed fibro-cartilage gives elasticity to the structure.

Under pressure of the body in its erect position, the curvature of the concentric layers of the intervertebral ligaments increases, and the fibrous bundles composing them become more depressed, so that the trunk diminishes in length. In the recumbent position, pressure being removed,

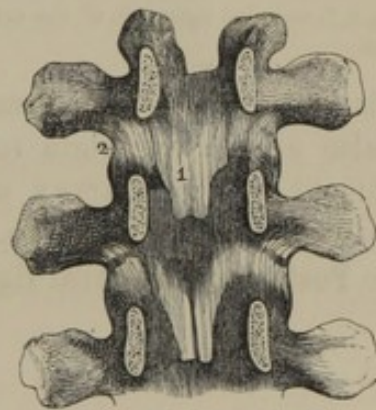
the condition is reversed; and in this manner may be explained the fact that a man is slightly taller on rising from bed in the morning than on retiring at night.

In the conjunction of the vertebral bodies by means of the intervertebral ligaments, we may discover some analogy to the ball-and-socket joint, which allows movement in all directions, though in this case it is of a very restricted character. The interior compressed fibro-cartilage of the disks between the resisting vertebral bodies serves the part of a ball, while the exterior concentric layers of alternately crossing fibrous bundles act as check ligaments. The entire arrangement is an admirable provision, to give a slight degree of movement in all directions to the vertebral column without endangering the integrity of the delicate nervous cord which it incloses and protects.

The **Yellow lig'aments**,¹ of which there are twenty-four pairs, situated between the vertebral arches from the axis to the sacrum, are most distinctly seen within the spinal canal. They are attached to the anterior surface of the lower part of the arches above, and the posterior surface of the upper part of those below, between the position of the spinous and transverse processes. They are composed of yellow, elastic tissue, the fibres of which are extended between the vertebral arches.

The **Anterior vert'ebral lig'a-ment**² is a strong band extending the entire length of the vertebral column, from the basilar process of the occipital bone to the end of the coccyx. Its upper extremity forms a rounded end, and is usually viewed as a distinct ligament.³ It widens in its descent, is thickest and most obvious opposite the vertebral bodies, thinnest upon the sacrum, and adheres most tightly to the intervertebral disks and the contiguous margins of the vertebral bodies. It is composed of closely associated bundles of fibres, of which the superficial

FIG. 83.



THREE VERTEBRAL ARCHES REMOVED FROM AS MANY DORSAL VERTEBRÆ, viewed in front, and exhibiting 1, the yellow ligaments; and 2, the capsular ligaments of the articular processes.

¹ L. flava; l. subflava; l. intercruralia.

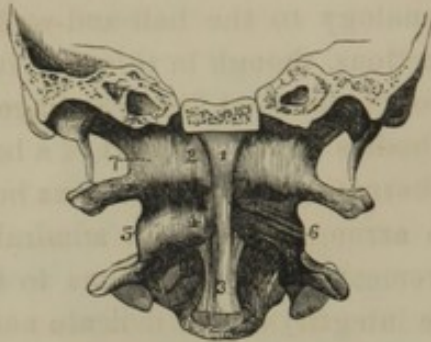
² Anterior common ligament; ligamentum longitudinale anterius; l. corporibus vertebrarum commune anterius;

fascia longitudinalis anterior. Its lower end, the l. sacro-coccygeum anterius.

³ Anterior middle occipito-atloid ligament.

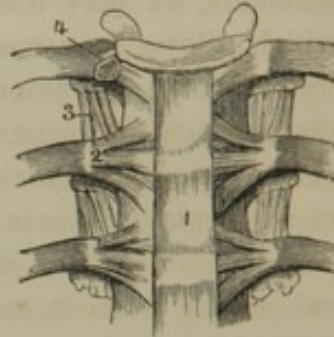
extend the length of three or four vertebræ; those deeper, the length of two or three; and the deepest, between the contiguous vertebræ.

FIG. 84.



PORTION OF THE OCCIPITAL BONE, WITH THE ATLAS AND AXIS, front view. 1, origin of the anterior vertebral ligament from the basilar process; 2, anterior occipito-atloid ligament on each side of the former; 3, widening of the anterior vertebral ligament from the axis; 4, anterior atlo-axoid ligament; 5, 6, 7, capsular ligaments of the articular processes.

FIG. 85.

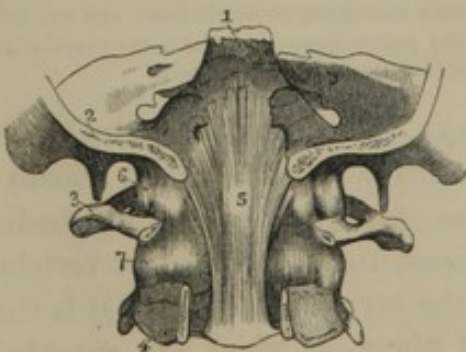


THREE DORSAL VERTEBRÆ, with the articulations of the ribs, viewed in front. 1, portion of the anterior vertebral ligament; 2, radiating ligament; 3, anterior costo-transverse ligament; 4, articulation of the head of the rib, laid open, and exhibiting the interarticular ligament separating two synovial cavities.

This ligament, besides forming a strong bond of union to the vertebræ, also affords an origin to the crura of the diaphragm, and gives attachment to the pharynx and œsophagus, the aorta, thoracic duct, azygos vein, and inferior cava.

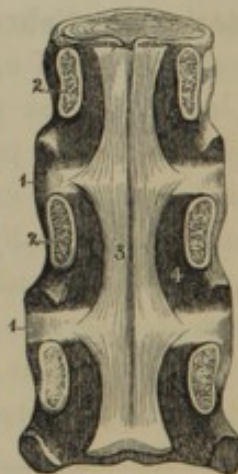
The **Posterior vert'ebral lig'ament**¹ is a strong fibrous band, with fes-

FIG. 86.



PORTION OF THE CRANIUM AND OF THE ATLAS AND AXIS, viewed from behind; the posterior portions of the occipital and two last bones removed. 1, declivity of the sphenoid bone; 2, occipital bone; 3, atlas; 4, axis; 5, origin of the posterior vertebral ligament from the basilar process; 6, 7, capsular ligaments of the articular processes.

FIG. 87.



BODIES OF THREE DORSAL VERTEBRÆ, connected by the intervertebral ligaments, viewed from behind; the vertebral arches having been removed. 1, intervertebral ligaments; 2, pedicles of the vertebral arches; 3, portion of the posterior vertebral ligament, exhibiting its lateral festooned borders, 4, interarticular ligament.

tooned margins, situated within the spinal canal, and extending from the inner surface of the basilar process of the occipital bone to the end of the coccyx. In its course it widens opposite the intervertebral disks, to which and the contiguous margins of the vertebral bodies it tightly adheres; and it narrows toward the middle of the latter, from which it is separated by the transverse veins of the spinal sinuses. + p 42

The articular processes of the vertebræ are invested with cartilage; and each joint possesses a synovial membrane and a thin capsular ligament.² The extent of motion in the joints formed by the vertebral articular processes generally is very feeble, consisting only of a slight gliding in the bending of the vertebral column.

The **Su'pra-spi'nous lig'ament**³ is a thin fibrous band connecting the summits of the spinous processes from the last cervical vertebra to the end of the coccyx. It is strongest in the lumbar region, and is continuous at its upper extremity with the nuchal ligament. Its lower extremity, by expanding, closes, in this position, the spinal canal.

The **Interspi'nous lig'aments**⁴ are thin fibrous membranes connecting the contiguous spinous processes of the vertebræ, and extending from the former ligament.

The **Nu'chal lig'ament**⁵ is a partition of loose fibrous tissue, separating the muscles of the two sides of the neck, and extending from the cervical spinous processes along the median line of the occipital bone to the occipital protuberance. In man this ligament is a mere rudiment of the powerful elastic nuchal ligament which sustains the pendant head in quadrupeds.

ARTICULATIONS OF THE OCCIPITAL BONE, THE ATLAS, AND THE AXIS.

The **Anterior and posterior occip'ito-at'loid lig'aments**⁶ are thin, broad fibrous membranes extended between the contiguous borders of the occipital foramen and atlas, before and behind the position of the condyles and articular processes.

¹ Posterior common ligament; l. longitudinale posterius; l. corporibus vertebrarum posterius; fascia longitudinalis postica. The upper extremity, usually described as distinct, with the names apparatus ligamentosus, membrana ligamentosa, and occipito-axoidean ligament.

² Ligamenta processuum obliquorum.

³ Ligamentum apicum; its lower end, the lig. sacro-coccygeum posticum.

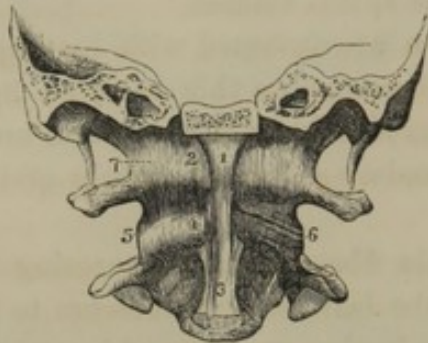
⁴ Lig. interspinalia; membrana interspinalis.

⁵ Lig. nuchæ; fascia nuchalis; paxywaxy; paxwax; packwax; faxwax; taxwax; lig. cervical; descending ligament of Diemerbroeck.

⁶ Membrana annuli anterioris et posterioris atlantis; m. obturatoria anterior et posterior.

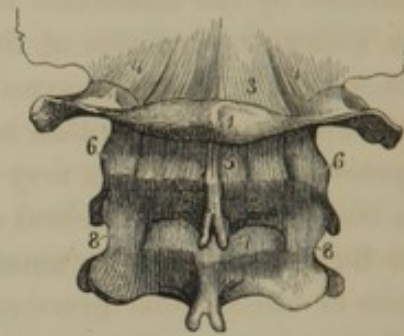
The **Anterior** and **posterior at'lo-ax'oid lig'aments** are likewise thin fibrous membranes, the former connecting the anterior bridge of the atlas with the front of the body of the axis, and the latter connecting the contiguous borders of the arches of the atlas and axis.

FIG. 88.



PORTION OF THE OCCIPITAL BONE, WITH THE ATLAS AND AXIS, front view. 1, origin of the anterior vertebral ligament; 2, anterior occipito-atloid ligament on each side of the former; 3, widening portion of the anterior vertebral ligament; 4, anterior atlo-axoid ligament; 5, 6, 7, capsular ligaments of the articular processes.

FIG. 89.

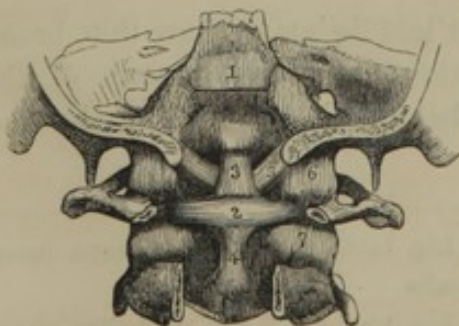


PORTION OF THE OCCIPITAL BONE AND THE UPPER THREE CERVICAL VERTEBRÆ. 1, atlas; 2, axis; 3, posterior occipito-atloid ligament; 4, capsular ligaments of the occipital condyles and articular processes of the atlas; 5, posterior atlo-axoid ligament; 6, capsular ligaments of the articular processes between the atlas and axis; 7, first pair of yellow ligaments; 8, capsular ligaments of the articular processes between the second and third cervical vertebrae.

The membranes constituting the above four ligaments are comparatively loose and flexible, so as not to interfere with the peculiar movements of the skull and first pair of cervical vertebrae.

The capsular ligaments of the articular processes of the occiput, atlas, and axis are likewise comparatively loose, so as to permit rotation, flexion, and extension of the head.

FIG. 90.



PORTION OF THE SKULL, THE ATLAS, AND AXIS, viewed from behind; the posterior portions of the occipital and two latter bones removed. 1, upper extremity of the posterior vertebral ligament; 2, transverse ligament, with its two appendices, 3 and 4; 5, odontoid ligaments; 6, 7, capsular ligaments.

The **Trans'verse lig'ament**¹ is a strong band extended between the tubercles on the inner side of the atlas, and serves the purpose of retaining the odontoid process of the axis in its proper position. To render its functions more effective, it sends from its middle a process upward, to be attached to the anterior border of the occipital foramen, and another one downward, to be attached at the root of the odontoid process, so that altogether it has a crucial form.²

¹ L. transversum atlantis; l. transversale.

² L. cruciatum.

The **Odon'toid lig'aments**¹ are three bands which ascend from the sides and summit of the odontoid process of the axis, to be attached to the anterior border of the occipital foramen. The lateral bands are much stronger than the middle one. These ligaments serve to limit the rotary movement of the head.

The contiguous surfaces of the odontoid process and atlas are invested with cartilage, and form a joint lined with a synovial membrane and encircled with a capsular ligament.² A similar joint is formed between the odontoid process and the transverse ligament.

The movements of flexion and extension of the head, as before indicated, occur between the occipital bone and atlas, for which the peculiar construction of the condyles of the former and articular processes of the latter are well adapted; while they are limited in extent by the capsular, occipito-atloid, and nuchal ligaments. The rotary movement of the head occurs between the atlas and axis; the centre of motion being the odontoid process, and the circle of rotation the contiguous articular processes. It is limited by the capsular, atlo-axoid, and odontoid ligaments. The general flexibility of the cervical portion of the vertebral column permits a slight increase in the movements indicated.

THE VERTEBRAL COLUMN VIEWED ENTIRE.

The **Vertebral column** averages about two and a quarter feet in length, and varies but little in this respect in comparison with the stature of persons, the difference depending more on the proportionate length of the lower extremities.

The first vertebra forms a capital to the column sustaining the head. The other true vertebræ successively increase in bulk, forming a tapering column resting with its base upon the sacrum, which, like the key-stone of an arch, is inserted between the hip bones.

The breadth of the vertebræ increases from the second to the seventh, then decreases to the fourth of the dorsal region, and afterwards gradually increases again to the sacrum, which rapidly diminishes to the end of the coccyx. The height of the cervical vertebræ is nearly uniform; the others gradually increase in this respect to the last.

The intervertebral ligaments gradually increase in thickness from the third dorsal vertebra to the sacrum. Above the former point they increase to the middle of the neck, and then again decrease.

¹ Ligamenta alaria and l. rectum medium; l. dentis suspensorium; moderator and middle straight ligaments.

² Vaginal ligament.

The intervals between the vertebral arches are occupied by the yellow ligaments. They are widest in the loins, and least so in the lower portion of the neck and back.

The **spi'nal canal**¹ is largest and is triangular in the neck and loins, is narrower and cylindrical in the dorsal region, and is smallest and triangular in the sacrum.

The intervertebral foramina increase in size from the first to the last; the sacral foramina successively decrease.

The spaces between the spinous and transverse processes constitute the vertebral gutters, and are occupied by the extensor muscles of the back.

Viewed in profile, the vertebral column presents a series of four curves, which, except in the case of the sacrum, depend on the difference in thickness between the fore and back parts of the vertebral bodies and the intervertebral disks. In the neck and loins the convexity of the curves is directed forward, in the dorsal region and pelvis backward. The strongest degree of convexity is that presented in the loins; its lower part being produced by the promontory of the sacrum.

The curvatures commence to become particularly evident with the first efforts of the child to stand or walk; prior to this period the vertebral column being nearly straight.

More or less lateral curvature is quite frequently observable in the dorsal region, most usually with the convexity toward the right. This abnormal character appears to depend on the excess of muscular action upon the side to which the convexity is directed.

The sacrum is the only portion of the vertebral column which is entirely immovable, and it is through this bone that the weight of the trunk is communicated to the lower extremities. The mobility in other portions of the vertebral column varies, being greatest in the cervical region, and least in the dorsal region.

The motions of the vertebral column, though very restricted, occur in all directions; being those of flexion and extension, bending to either side, and rotation upon its axis.

THE RIBS.

The **Ribs**,² of which there are twelve pairs, form a series of narrow arches on each side of the trunk, extending from the dorsal vertebræ toward the sternum. Anteriorly they are prolonged by the **cos'tal car'**-

¹ Vertebral canal; rachidian canal; canalis medullæ spinalis; specus pro medulla spinali, or vertebralis; solen.

² Costæ; pleuræ; pleurapophyses; pleuromata.

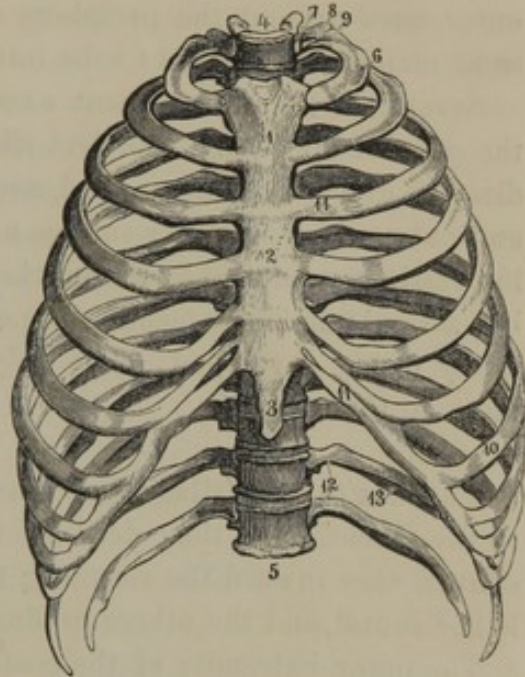
tilages.¹ The upper seven pairs join the side of the sternum through the latter, and are called **true** or **ster'nal ribs.**² Of the others, called **false** or **aster'nal ribs,**³ three successively join one another and the cartilage of the last true rib, by means of their cartilages. The remaining two have their cartilages unattached, and are thence called **free** or **floating ribs.**⁴

The ribs successively increase in length from the first to the eighth, and then decrease to the last one. In breadth and degree of curvature they gradually diminish from first to last. In direction from the vertebral column, they are first directed from the bodies outward and backward to the transverse processes, from thence outward and slightly forward, and subsequently more abruptly forward and inward. In proceeding from the vertebræ they likewise incline downward, so that their anterior extremity is lower than the posterior. In the latter direction the ribs exhibit a slight twist, so that they will not lie with their whole length in contact with a level surface.

The ribs have an outer and inner broad smooth surface; an upper rounded border and a lower sharp one. Within the greater part of the length of the lower border there is a groove⁵ for the intercostal blood-vessels.

The posterior extremity of a rib is the **head,**⁶ and this presents two articular facets, separated by a slight ridge, which articulate with the corresponding facets of a contiguous pair of vertebral bodies. The narrow part of the rib succeeding the head is its **neck,**⁷ and this is bounded externally by the **tu'bercle,**⁸ upon which is an articular facet for the transverse process of the lower of the two vertebræ joined by the

FIG. 91.



FRONT VIEW OF THE THORAX. 1, 2, 3, the three pieces of the sternum; 4, 5, the dorsal vertebrae; 6, the first true rib; 7, its head; 8, neck; 9, tubercle; 10, the seventh true rib; 11, costal cartilages; 12, the floating ribs; 13, groove for the intercostal blood-vessels.

¹ Cartilagines costarum; hæmapophyses.

² Costæ veræ; c. genuinæ; c. sternales.

³ Costæ spuris; c. mendosæ; c. aster-nales; nothæ costæ.

⁴ Costæ fluctuantes.

⁵ Sulcus costalis.

⁶ Capitulum costæ.

⁷ Cervix; collum.

⁸ Tuberculum.

head of the rib. Externally to the tubercle is a rough mark called the **angle**,¹ corresponding with the point at which the rib is rather abruptly directed forward. The distance of the angle from the tubercle successively increases from the first to the last rib.

The anterior extremity of the rib is the most compressed portion, is obtuse at both borders, and is continuous with its costal cartilage, which, after separation by maceration, leaves an elliptical pit at the end of the bone.

The broad surfaces of the ribs are so arranged in succession that the outer ones present the periphery of an oval, and the inner ones in the same manner are related to the interior of an oval.

Several of the ribs present exceptional characters to those given in the general account. The first rib has no twist, has its broad surfaces directed upward and downward, and its borders, which are narrow, inward and outward. The upper surface at its fore part is marked by two slight impressions produced by the subclavian blood-vessels. The head presents but a single articular facet. The eleventh and twelfth ribs are comparatively feebly developed; have only one articular facet to the head, and have no tubercle.

The **Cos'tal car'tilages**² successively increase in length from the first to the seventh, and then decrease to the last. Their direction is one of convergence toward the sternum; the first one descends, that succeeding is horizontal, and the others gradually become more and more ascending.

The outer extremity of the costal cartilages is absolutely continuous with the structure of the ribs. The inner extremity of those of the true ribs, except the first pair, forms a movable articulation with the side of the sternum. The inner end of the succeeding three pairs of cartilages is pointed and attached to the cartilage next above. The last two pairs of costal cartilages are pointed and free.

Between the fifth to the eighth pair of costal cartilages, processes usually exist blending their contiguous borders together.

The ribs commence ossification even before the vertebræ. They are formed from a principal piece, an epiphysis for the head, and another for the tubercle, except in the last two pairs, which have no epiphysis for the latter process.

Usually after the prime of life, in the male, the costal cartilages become partially ossified, but in the female this is much less liable to occur, and then only in advanced age.

¹ Angulus, or cubitus costæ.

² Cartilagines costarum; hæmapophyses.

THE STERNUM.

The **Ster'num** or **breast bone**¹ is situated in the median line, in front of the thorax, sloping from above downward and forward. It is long, broad, and nearly flat, and bears a general resemblance to the ancient broad-sword, from which the older anatomists called its three pieces the handle, the blade, and the point. Its anterior surface is slightly convex; its posterior surface slightly concave. In structure it is light and spongy, and is invested with a thin layer of moderately compact substance.

The **handle** or **first piece**² is the broadest and thickest bone of the sternum. It is irregularly hexahedral; slightly convex in front, and slightly concave behind. Its upper border is thick, rounded, and transversely concave;³ its lower border is straight, and joins the second bone of the sternum. The upper, short, lateral border slopes off and articulates with the clavicle.⁴ The lower, long, lateral border curves downward and inward; its upper end is continuous with the first costal cartilage; its lower end articulates with part of the second costal cartilage.

The **second piece** or **body**⁵ is the longest portion of the sternum. It is oblong, quadrate in form, and usually widest at its lower part. Its anterior and posterior surfaces are nearly flat, and are commonly more or less marked by several transverse lines indicating the original separation of the bone into parts. Its lateral borders present successively, first, at the upper end an articular surface forming part of the articulation for the second costal cartilage, then four notches for the third to the sixth costal cartilages inclusive, and finally, at the lower end a surface for part of the seventh costal cartilage. The distance between these articulations successively decreases from above downward.

The **third piece** or **point**⁶ of the sternum is usually the narrowest, thinnest, and shortest portion. It is quite variable in shape, being flat, long and pointed, or ensiform; tongue-shaped, or discoidal; or it is forked. It commences ossification several years after birth, and even in advanced age is rarely entirely ossified; hence its name of **en'siform car'tilage**.⁷ With the commencement of its lateral border, the seventh costal cartilage partially articulates.

The upper two pieces of the sternum commence ossification about the fifth or sixth month of foetal life; and they do so from a variable number

¹ Sternon; os pectoris; o. xiphoides; o. gladioli; o. ensiforme; o. asser; scutum pectoris, or cordis; hæmal spine.

² Manubrium; episternum.

³ Incisura semilunaris; os jugularis.

⁴ Incisura clavicularis.

⁵ Corpus; blade; mesosternum.

⁶ Processus xiphoides; p. mucronatus; p. ensiformis; hyposternum.

⁷ Cartilago ensiformis.

not so, this is a sword,
so called for its shape

of points. At puberty the handle forms a single bone; the body usually presents five segments, which successively co-ossify from below upward. Generally the three pieces or bones of the sternum remain separated, but frequently the upper two become united, and occasionally in old age all three are found co-ossified.

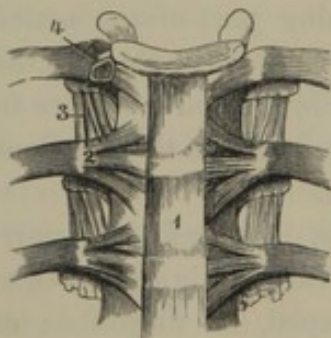
The sternum is variable in its form in different individuals, principally in the proportion of length and breadth of the different pieces.

Articulations of the Sternum.—The three pieces of the sternum are conjoined by fibro-cartilage, and are much strengthened in their union by a thick fibrous investment, partially derived from the costo-sternal ligaments.

ARTICULATIONS OF THE RIBS WITH THE VERTEBRÆ AND STERNUM.

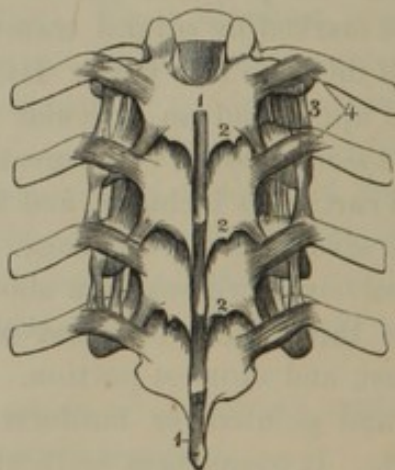
Costo-vertebral articulations.—The articulation between the head of the ribs and the bodies of the dorsal vertebræ is surrounded with a **cap'sular lig'ament**, and, except in the case of that of the first and the last two ribs, is divided into two parts by an **interartic'ular lig'ament**,¹

FIG. 92.



ANTERIOR VIEW OF THREE DORSAL VERTEBRÆ AND THEIR ARTICULATION WITH THE RIBS. 1, portion of the anterior vertebral ligament; 2, radiating ligament; 3, anterior costo-transverse ligament; 4, articulation of the head of the rib laid open, exhibiting the cavity divided into two by an interarticular ligament.

FIG. 93.



POSTERIOR VIEW OF FOUR DORSAL VERTEBRÆ AND THEIR ARTICULATION WITH THE RIBS. 1, supra-spinal ligament; 2, yellow ligament, seen just below the edge of the vertebral arches; 3, anterior costo-transverse ligaments; 4, posterior costo-transverse ligaments.

which is a short band connecting the ridge on the head of the ribs with the contiguous intervertebral disk. In front the articulation is strengthened by the **ra'diating lig'ament**,² consisting of three bands diverging

¹ L. interarticulare; l. transversum.

² L. capituli costæ anterioris; l. radiatum.

from the head of the rib to the sides of the contiguous pair of vertebral bodies and the intervertebral disk.

The slightly movable articulation between the tubercle of the upper ten ribs and the neighboring transverse processes of the dorsal vertebræ is likewise surrounded with a **cap'sular lig'ament**. Besides this, each rib is connected with the transverse processes by three ligaments, as follows:

The **anterior cos'to-trans'verse lig'ament**.¹—This is a membranous band connecting the neck of the rib with the transverse process above.

The **posterior cos'to-trans'verse lig'ament**.²—This is a short band connecting the tubercle of the ribs with the end of the contiguous transverse process.

The **middle cos'to-trans'verse lig'ament**.³—This consists of short fibres intervening between the neck of the rib and the contiguous transverse process.

Costo-sternal articulations.—The costal cartilages, except the first, form articulations with the side of the sternum surrounded by capsular ligaments and lined with synovial membranes. Behind, and especially in front, the articulations are strengthened by fibres radiating from the costal cartilages upon the sternum, constituting the **anterior and posterior cos'to-ster'nal lig'aments**.⁴ Those of the two sides blend together and with the aponeurotic origin of the pectoral muscles.

A thin fibrous band connecting the seventh costal cartilage with the third piece of the sternum is called the **cos'to-xi'phoid lig'ament**.⁵

The contiguous margins of the costal cartilages from the sixth to the ninth, if not blended together, have opposed articular surfaces surrounded with **cap'sular lig'aments**.

THE THORAX.

The **Tho'rax** or **chest**⁶ is a conical or ovoidal case, with its narrower part uppermost. It is flattened before and behind, which is the reverse of the condition observable in the lower mammals generally, and hence it is that man can readily lie on his back, while the lower animals cannot.

It is formed of the dorsal vertebræ, ribs, and sternum; and its sides are also called its walls.

¹ L. costo-transversale anterius; l. transversarium internum; int. costo-transverse ligament; l. costo-transversarium inferius.

² L. costo-transversale posterius; l. transversarium externum; ext. costo-transverse ligament.

³ L. costo-trans. medius; l. colli costæ; l. cervicum costæ.

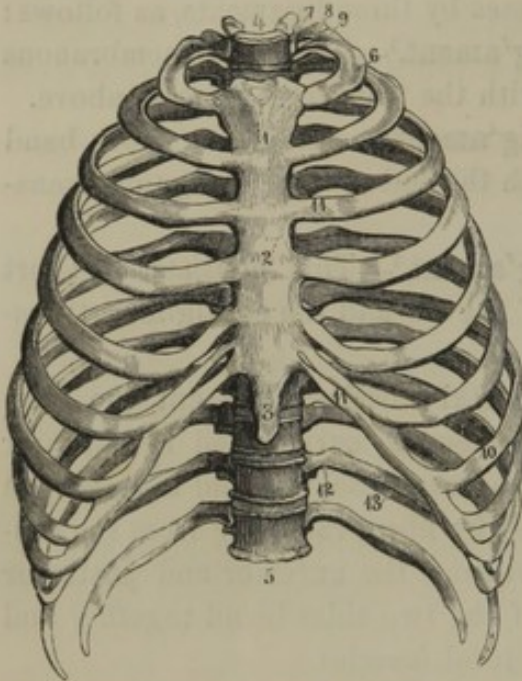
⁴ L. costo-sternalia ant. et post.; l. radiata.

⁵ L. costo-xiphoideum.

⁶ Pectus; stethus; cassa; venter medius; citharus; scutum pectoris; bir; chelys.

The **front wall** of the chest, or the **breast**, is flatter and shorter than any other portion, and is formed of the sternum and cartilages of the true ribs. It slopes forward and downward to such an extent that the

FIG. 94.



FRONT VIEW OF THE THORAX. 1, 2, 3, the three pieces of the sternum; 4, 5, the dorsal vertebræ; 6, the first true rib; 7, its head; 8, neck; 9, tubercle; 10, the seventh true rib; 11, costal cartilages; 12, the floating ribs; 13, groove for the intercostal blood-vessels.

lower end of the sternum is removed twice the distance of the upper end from the vertebræ.

The **posterior wall** is the **back**, in the most restricted use of the term. It is also flattened, is divided in the middle by the imbricating spinous processes of the dorsal vertebræ, and is defined on each side by the angles of the ribs, which indicate the extent to which the dorsal extensor muscles reach outwardly.

The **lateral walls** of the chest are the longest, most prominent, and convex.

The **cavity of the tho'rax**¹ is subdivided posteriorly by the intrusion of the bodies of the dorsal vertebræ; and it is open above, below, and between the ribs.

The **superior opening of the tho'rax**² is formed by the first dor-

sal vertebra, the first pair of ribs, and the first piece of the sternum. It is reniform, with its transverse diameter more than twice as great as the antero-posterior, and with its plane inclining a little downward and forward.

The **inferior opening**,³ by far the largest, is formed by the last dorsal vertebra, the last pair of ribs, the cartilages of all the false ribs, and the last piece of the sternum. It is likewise reniform, with its transverse diameter about one-third greater than the antero-posterior, and with its plane inclining upward and forward.

The **intercos'tal spaces**⁴ increase in width anteriorly, and are occupied by muscles of the same name.

The greatest circumference of the thorax is just below the middle, and not at the bottom or base. The ribs incline downward and forward in such a manner that the anterior extremity of the first rib is on a level

¹ Cavum thoracis.

² Apertura thoracis superior.

³ Apertura thoracis inferior.

⁴ Spatia intercostalia.

with the second dorsal vertebra, the anterior extremity of the seventh rib is on a level with the tenth dorsal vertebra, and the end of the last rib is on a level with the first lumbar vertebra.

The movements of the thorax consist of a moderate degree of elevation and depression of the ribs and sternum, as in inspiration and expiration. From the direction of the ribs, when their anterior part is raised they assume a more horizontal position, and the diameter of the chest is increased.

The thorax is more ovoidal and less compressed antero-posteriorly in the female than the male. Tight-lacing makes it still more assume the form of an oval.

THE HIP OR INNOMINATE BONES.

The **Hip** or **Innominate bones**,¹ though included in the account of the trunk, really belong to the lower extremities, holding the same relation to them that the shoulder bones do to the upper extremities. In the lower animals their presence is observed to be in a great measure dependent on the existence of hinder extremities.² Together with the sacrum, they constitute the pelvis, which incloses a portion of the digestive and genito-urinary apparatus. For convenience of description they are viewed as consisting of three parts: the **il'ium**, **is'chium**, and **pu'bis**, corresponding with the original divisions of the bones as existing in infancy.

The **Il'ium**³ is a broad, thick plate forming the upper part of the hip bone. Its inner side presents three surfaces: an anterior, broad, smooth concavity, called the **il'iac fos'sa**;⁴ a posterior, uneven surface, partly devoted to articulation with the sacrum, and partly to ligamentous attachment; and an inferior, small, nearly plane surface, forming part of the true pelvis.

The outer or dorsal surface of the ilium is convex at its fore part, and concave behind. It is marked by two feeble ridges, called the **superior** and **inferior curved lines**.⁵ The space between them gives origin to the small gluteal muscle; the space above them to the middle gluteal muscle, except a rough surface at the posterior superior part of the bone, which gives attachment to the great gluteal muscle.

¹ Ossa innominata; ossa anonyma; o. coxarum; o. lateralia pelvis; the haunch bones.

² In some animals hip bones exist without the presence of limbs, but in such cases they are quite rudimentary; as in the dolphin, whale, and glass snake.

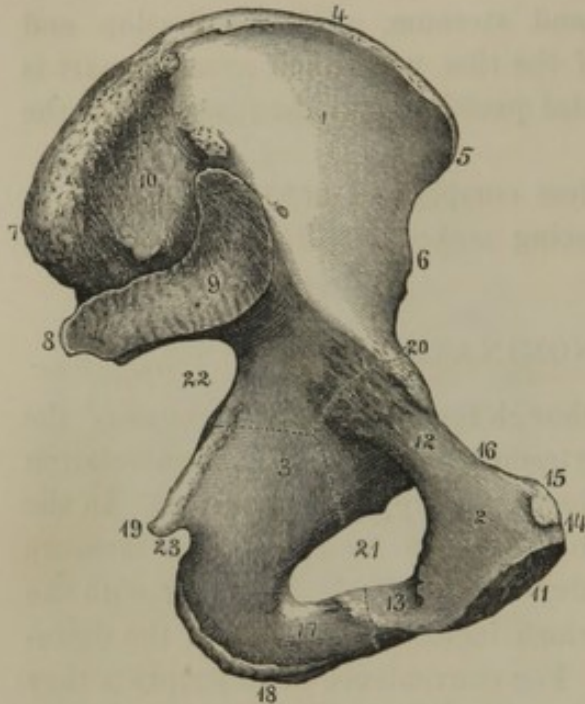
³ Os ilium; os ilei; ileum; ileon; haunch; haunch bone.

⁴ Fossa iliaca.

⁵ Lineæ arcuatæ; l. semicircularis superior et inferior.

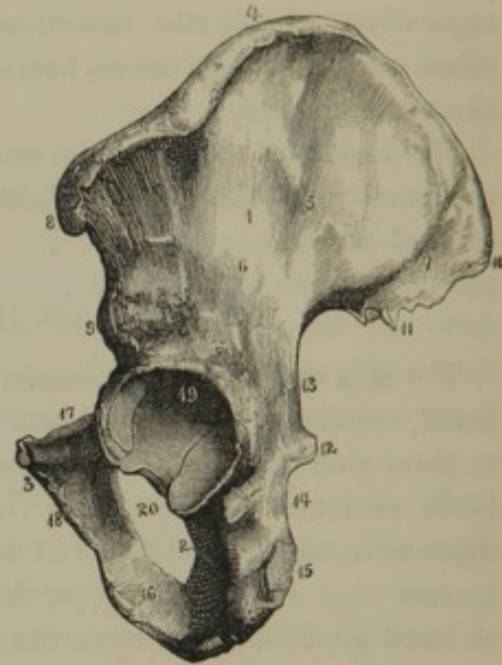
The upper border, or **crest of the il'ium**,¹ is thick and rounded, and is convex and sigmoid in its course. It gives attachment to the broad

FIG. 95.



INNER VIEW OF THE LEFT HIP OR INNOMINATE BONE. The dotted line indicates its division into three parts: 1, the ilium, 2, the ischium, and 3, the pubis. (1, iliac fossa:) 4, crest of the ilium; 5, 6, anterior superior, and inferior spinous processes; 7, 8, posterior superior, and inferior spinous processes; 9, articular surface for the sacrum; 10, rough surface for the attachment of ligaments. (2, body of the pubis:) 11, symphysis; 12, horizontal, and 13, descending ramus; 14, upper border of the body; 15, spine of the pubis; 16, pectineal line. (3, plane of the ischium:) 17, ramus of the ischium; 18, tuberosity; 19, spine of the ischium; 20, ilio-pubic eminence; 21, obturator foramen; 22, great sciatic notch; 23, lesser sciatic notch.

FIG. 96.



OUTER VIEW OF THE LEFT HIP OR INNOMINATE BONE 1, ilium; 2, ischium; 3, pubis. (1, dorsal surface of the ilium:) 4, crest of the ilium; 5, 6, superior and inferior curved lines; 7, surface of the great gluteal muscle; 8, 9, anterior superior, and inferior spinous processes; 10, 11, posterior superior, and inferior spinous processes. (2, body of the ischium:) 12, spine of the ischium; 13, great sciatic notch; 14, lesser sciatic notch; 15, tuberosity of the ischium; 16, ramus of the ischium. (3, body of the pubis:) 17, horizontal ramus of the pubis; 18, descending ramus; 19, acetabulum; 20, obturator foramen.

muscles of the abdomen, and terminates at each end in a prominence, called the **anterior superior, and posterior superior spi'nous proc'ess**.² Below these processes is a notch, succeeded by the **anterior inferior, and posterior inferior spi'nous proc'ess**.³ Following these processes are other notches: one anteriorly, terminated below by the ilio-pubic eminence; the other posteriorly being the **great sciat'ic notch**.⁴

¹ Crista ilei.

² Processus spinosus ant. sup. et post. sup.; spina ant. sup. et post. sup.

³ P. s. ant. inf. et post. inf.; spina ant. inf. et post. inf.

⁴ Incisura ischiadica major; incisura iliaca; part of the sacro-sciatic notch.

The **Is'chium**¹ forms the inferior part of the hip bone, and consists of a **body** and a **ramus**, united in the form of a hook. The **body**² is the posterior thicker portion joining the ilium. It is trilateral, one side looking outward, another inward, and the third backward. Below, it forms a strong prominence, the **tuberos'ity**,³ upon which we sit, and which gives origin to the flexor muscles of the back of the thigh. Behind, the ischium possesses a strong process, the **spine**,⁴ which separates the **greater sciat'ic notch**⁵ above from the **lesser sciat'ic notch**⁶ below.

The **ra'mus**⁷ of the ischium proceeds from the lower extremity of the body upward and forward to the pubis. It presents an inner and an outer surface, and an anterior thick border, which gives attachment to the crus of the penis.

The **Pu'bis**⁸ is situated at the anterior part of the hip bone, and consists of a **body** and two **ra'mi** or **branches**. The **body** is the inner expanded part, flattened before and behind, and having at its inner border an uneven articular surface, forming part of the **sym'physis**, or junction of both pubes. The upper part of the body forms an obtuse ridge⁹ terminating externally in a small eminence, the **spine**,¹⁰ which gives attachment to the lower end of Poupart's ligament.

The **horizontal ra'mus** of the pubis proceeds outward from the body, and at its junction with the ilium forms the **il'io-pu'bic eminence**.¹¹ It is three sided, and presents three margins, of which one is inferior, another is obtuse and proceeds from the spine of the pubis outwardly to the acetabulum, and the third is sharp and is called the **pecti'neal line**.¹² This proceeds from the spine of the pubis to the inner side of the ilio-pubic eminence, and at its commencement gives attachment to Gimbernat's ligament.

The **descending ra'mus** of the pubis proceeds outward and downward to join the ramus of the ischium. It is small and flattened from without inward.

Having described the separate divisions of the hip bones, it remains to point out some anatomical characters formed by their conjunction.

At the union of the three pieces of the hip bone, externally there is

¹ Os ischii; os coxendicis; ischion; huckle bone; seat bone.

² Ramus descendens.

³ Tuberositas or tuber ischii; os sedentarium.

⁴ Spina ischii: spinous process.

⁵ Incisura ischiadica major.

⁶ In. isch. minor; luna Albini.

⁷ Ramus ascendens.

⁸ Os pubis; os pectinis; pecten; epischion.

⁹ Crest; crista pubis.

¹⁰ Tuberosity of the pubis; tuberculum pubicum; spina pubis.

¹¹ Ilio-pectineal protuberance; tuberculum ilio-pubicum; tub. ilio-pectineum.

¹² Crista; pecten; linea pectinea; crista ilio-pectinea.

situated a hemispherical or cup-shaped cavity, the **acetab'ulum**,¹ for articulation with the head of the thigh bone. To it, the pubis contributes one-fifth, and the ilium and ischium contribute each about two-fifths. It is bounded by a prominent margin,² except internally, where it is deeply notched.³ The greater part of the surface of the acetabulum is smooth and covered with cartilage, but at its bottom there is an irregular pit,⁴ communicating with the notch of its margin, which is occupied by a cushion of fat.

In advance of the acetabulum, between the pubis and ischium, is a large hole, the **obtura'tor fora'men**,⁵ which is closed by a fibrous membrane. It is oval, with a tendency to assume a trilateral form, especially in the female.

Above the position of the acetabulum is the **il'io-pu'bic emi'nence**,⁶ corresponding with the union of the horizontal ramus of the pubis with the ilium. To the inner side of this eminence there proceeds forward and backward the ilio-pectineal line, which separates the true and false pelvis.

Internal to the position of the acetabulum, within the pelvis, there is a vertical surface formed by the ilium and ischium, and called by obstetricians the **plane of the is'chium**. Behind it, formed between the posterior inferior spinous process of the ilium and the spine of the ischium, is the great sciatic notch.

The hip bone is composed of spongy substance with a moderately thick investment of compact substance, which is perforated in many places with large foramina for nutritious blood-vessels. Frequently the two plates of compact substance come into contact at the middle of the iliac fossa, and in this position are so thin as to be translucent.

The hip bone is ossified from three principal pieces, corresponding with its divisions indicated, and four epiphyses. Ossification commences early in foetal life, and is not completed until after adult age. The epiphyses, which begin to appear subsequent to puberty, consist of one for the crest of the ilium, another for the tuberosity, and small ones for the anterior inferior spinous process and the pubic symphysis.

¹ Cotyle; cotyloid cavity; fossa cotyloidea; sinus coxæ; acetabulum pyxis.

² Supercilium acetabuli.

³ Incisura acetabuli.

⁴ Fossa acetabuli.

⁵ F. obturatum or obturatorium; f. ovale; f. thyroideum; f. infra-pubianum; f. amplum pelvis.

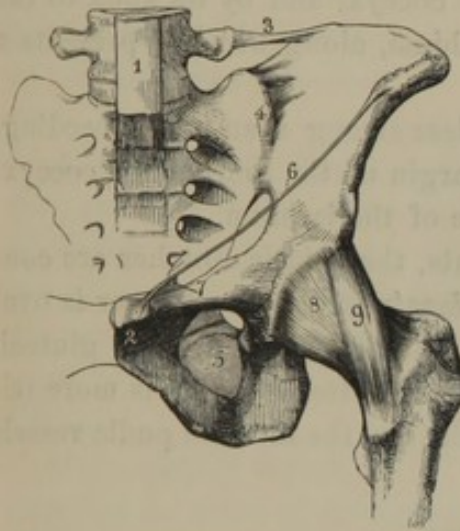
⁶ Ilio-pectineal eminence.

ARTICULATIONS OF THE HIP BONES.

The hip bones are immovably articulated together and with the sacrum by means of fibro-cartilaginous plates and strong ligaments.

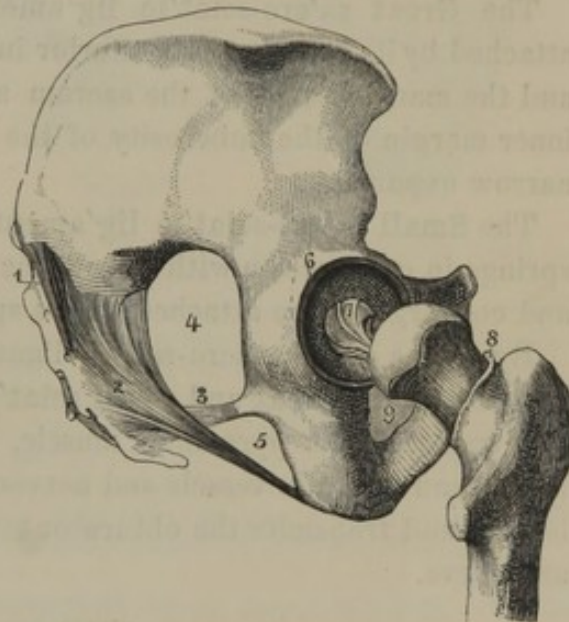
The **Pu'bic sym'physis**¹ is formed by the conjunction of the pubes through a thick plate of fibro-cartilage, as in the union of the vertebral bodies. It is strengthened by fibrous bands passing from one bone to the other, constituting the **pu'bic lig'aments**, which are named, from their relative position to the symphysis, **anterior**, **posterior**, etc. The **inferior** or **sub-pubic ligament**² is the strongest.

FIG. 97.



LIGAMENTS OF THE PELVIS AND HIP JOINT. 1, lower part of the anterior vertebral ligament; 2, pubic symphysis; 3, ilio-lumbar ligament; 4, sacro-iliac symphysis, with the anterior sacro-iliac ligament; 5, obturator membrane; 6, edge of the tendon of the external oblique muscle of the abdomen, technically named Poupart's ligament; 7, extension of the latter along the pectineal line named Gimbernat's ligament; 8, capsular ligament of the hip joint; 9, a strong accessory band of the latter ligament.

FIG. 98.



LIGAMENTS OF THE PELVIS AND HIP JOINT. 1, posterior sacro-iliac ligament; 2, great sacro-sciatic ligament; 3, small sacro-sciatic ligament; 4, great sacro-sciatic foramen; 5, small sacro-sciatic foramen; 6, cotyloid ligament surrounding the border of the acetabulum; 7, round ligament; 8, cut edge of the capsular ligament; 9, obturator membrane.

The **Obtura'tor mem'brane**³ is a fibrous structure, closing the obturator foramen, except at its upper and outer part, where there is an orifice⁴ for the passage of the obturator vessels and nerve. The surfaces of the membrane give origin to the obturator muscles.

The **Sa'cro-il'iac sym'physis**⁵ is formed by the union of the corre-

¹ Symphysis pubis.

² Lig. arcuatum.

³ Membrana obturatoria; ligamentum obturatorium; sub-pubic membrane.

⁴ Canalis obturatorius.

⁵ Symphysis sacro-iliaca.

sponding articular surfaces of the ilium and sacrum through means of fibro-cartilage, which is separable by force into two plates adhering one to each bone. The joint is strengthened by the **anterior** and **posterior sa'cro-il'iac lig'aments**.¹ The former consists of short bands uniting the contiguous bones in front of the symphysis. The latter is composed of strong bands passing transversely and obliquely from the posterior spinous processes and contiguous uneven surface of the ilium to the corresponding surface of the sacrum, behind the symphysis.

The **Il'io-lum'bar lig'ament**² is a fibrous band springing from the end of the transverse process of the last lumbar vertebra, and expanding outwardly to be attached to the posterior part of the crest of the ilium.

The **Great sa'cro-sciat'ic lig'ament**³ is a strong triangular band attached by its base to the posterior inferior spinous process of the ilium and the margin below of the sacrum and coccyx, and by its apex to the inner margin of the tuberosity of the ischium, along which it presents a narrow expansion.

The **Small sa'cro-sciat'ic lig'ament**,⁴ less strong than the preceding, springs in conjunction with it from the margin of the sacrum and coccyx, and converges to be attached to the spine of the ischium.

By means of the sacro-sciatic ligaments, the sciatic notches are converted into the **great** and **small sciatic fora'mina**.⁵ The former is oval and transmits the pyramidal muscle, the sciatic nerve, and the gluteal, pudic, and ischiatic vessels and nerves. The latter foramen is more triangular, and transmits the obturator muscle, and the internal pudic vessels and nerve.

THE PELVIS.

The **Pel'vis**⁶ is the basin-like portion of the trunk formed by the hip bones, the sacrum, and the coccyx. It is situated in an oblique position from the vertebral column, downward and backward, so that the end of the coccyx is nearly on a level with the middle of the pubic symphysis.

By means of the **il'io-pectine'al line**,⁷ and the upper projecting part of the sacrum, called its **promontory**,⁸ the pelvis is divided into the **superior** or **false**, and the **inferior** or **true pel'vis**.

¹ Lig. sacro-iliacum ant. et post.; the posterior consisting of the lig. sacro-iliacum longum et breve.

² L. ilio-lumbale.

³ L. sacro-ischiaticum majus; l. posticus; l. tuberoso-sacrum.

⁴ Lig. sacro-ischiaticum minus, or anticus, or internum; l. spinoso-sacrum.

⁵ Foramina sciatica, or ischiatica, or ischiadicum majus et minus, or major et minor.

⁶ Choana; pyclos; lecané.

⁷ Linea arcuata interna; l. innominata; l. terminalis.

⁸ Promontorium.

The **superior pel'vis**¹ is formed on each side by the ilium, and is completed by the lumbar vertebræ and the soft walls of the abdomen.

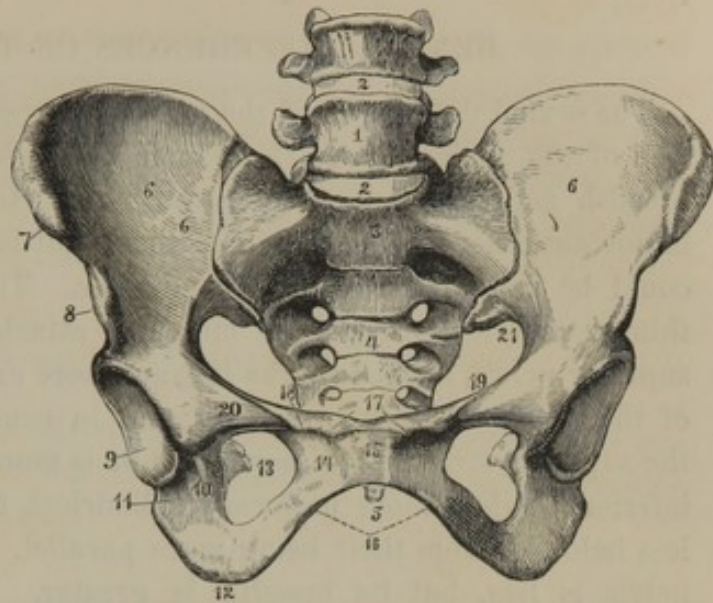
The **inferior pel'vis**² is composed of the pubes and ischia, the sacrum and coccyx. Its cavity is curved cylindrical, narrowing below and becoming deeper from before backward. Its **inlet** and **outlet** are also called the superior and inferior straits, the ideal planes of which converge anteriorly.

The **superior strait**³ corresponds with the iliopectineal line and promontory of the sacrum, the projection of which gives it a cordiform outline.

The **inferior strait**⁴ is bounded by three prominences, separated by as many notches. Of the prominences, two are lateral and correspond with the tuberosities of the ischia, and the other is formed by the sacrum and coccyx. Of the notches, one is the **pu'bic arch**,⁵ bounded on each side by the rami of the ischium and pubis. It is triangular, and has for its apex the symphysis of the pubes. The other notches, called from their position **sa'cro-sci-at'ic**, by means of ligaments of the same name are converted into foramina likewise distinguished by the same designation.

The **axis** of the inferior pelvis constitutes a curved line⁶ passing out at the centre of the straits.

FIG. 99.



FRONT VIEW OF A FEMALE PELVIS. 1, last lumbar vertebra; 2, intervertebral ligaments; 3, sacrum, the figure being placed on its promontory; 4, transverse lines indicating the original separation of the sacrum into five vertebral segments; 5, end of the coccyx; 6, iliac fossa; 7, 8, anterior superior, and inferior spinous processes; 9, acetabulum; 10, its notch on the inner side; 11, body of the ischium; 12, tuberosity of the ischium; 13, spine of the ischium, seen through the obturator foramen; 14, body of the pubis; 15, symphysis of the pubis; 16, arch of the pubis; 17, upper part of the body of the pubis; 18, spine of the pubis; 19, pectineal line; 20, ilio-pubic eminence; 21, great sacro-sciatic notch.

¹ The great, or greater pelvis; false pelvis; labrum pelvis.

² The small, or lesser pelvis; pelvis minor; p. vera.

³ Brim of the pelvis; apertura pelvis superior; introitus; angustia abdominalis; upper opening.

⁴ Apertura pelvis inferior; lower opening; exitus; angustia perinæalis.

⁵ Arcus ossium pubis; arch of the pubis.

⁶ The curve of Carus.

In the infant the capacity of the inferior pelvis is so small that the urinary bladder for the most part occupies the space of the superior pelvis.

SEXUAL DIFFERENCES OF THE PELVIS.

The sexual differences of the pelvis are greater than in any other portion of the skeleton. In the female the pelvis is more capacious in its breadth and less deep than in the male. In consequence of this most important difference, the birth of the infant is easier and quicker than it could be under the opposite conditions. The bones of the pelvis are thinner and less marked by muscular attachments. The sides of the superior pelvis, formed by the ilia, are more expanded. The promontory of the sacrum is less projecting, and in consequence of this difference the superior strait is less cordiform or is more oval. The cavity of the inferior pelvis is more uniformly cylindrical, from the ischia converging less below or from their being more parallel. The depth of the inferior pelvis is less, but its breadth is greater. The diminution in depth depends on the less extent of the ischia. The sub-pubic arch is lower, wider, more obtuse at the summit, and less everted at the sides. The sacrum and coccyx are shorter and wider; the ilio-pectineal line is longer; and the obturator foramen is more trilateral. The following table gives the comparative measurements of the inferior pelvis in the two sexes:—

SUPERIOR STRAIT.					MALE.	FEMALE.
Antero-posterior diameter ¹	4 inches.	4 $\frac{1}{4}$ inches.
Transverse diameter	4 $\frac{3}{4}$ "	5 $\frac{1}{4}$ "
Oblique diameter	4 $\frac{1}{2}$ "	4 $\frac{3}{4}$ "
Circumference	15 "	16 $\frac{1}{2}$ "
CAVITY.						
Antero-posterior diameter	4 $\frac{1}{4}$ inches.	4 $\frac{1}{2}$ inches.
Transverse diameter	4 "	4 $\frac{1}{2}$ "
Depth at the pubic symphysis	1 $\frac{3}{4}$ "	1 $\frac{1}{2}$ "
Depth posteriorly	5 $\frac{1}{4}$ "	5 "
Depth at the sides	4 "	3 $\frac{1}{2}$ "
Circumference	13 $\frac{1}{2}$ "	15 $\frac{1}{2}$ "
INFERIOR STRAIT.						
Antero-posterior diameter; from the mobility of the coccyx capable of being extended an additional inch	3 $\frac{1}{4}$ inches.	4 $\frac{1}{4}$ inches.
Transverse diameter	3 $\frac{1}{4}$ "	4 $\frac{1}{4}$ "

At the approach of the end of pregnancy, the symphyses of the pelvis undergo a slight degree of relaxation, which facilitates child-birth.

¹ Conjugate diameter.

THE UPPER EXTREMITIES.

The **Upper extremities** are suspended from the thorax at the sides of the skeleton, with which they articulate only by the inner end of the clavicle, so that when this bone is absent, as in many quadrupeds, the fore legs have no ligamentous union with the other part of the skeleton.

Each upper extremity consists of two bones to the shoulder, one to the arm, two to the forearm, and twenty-nine to the wrist and hand.

BONES OF THE SHOULDER.

The two bones of the shoulder are the clavicle and scapula. By means of the former it is connected with the sternum and first rib, and by means of the latter with the arm bone.

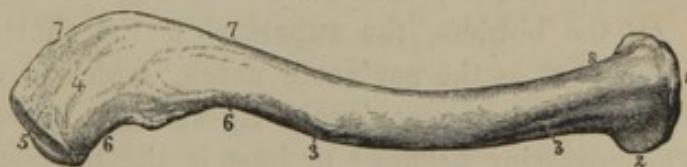THE CLAVICLE.

The **Clav'icle**¹ or **collar bone** is situated in front of the upper part of the thorax, extended transversely between the sternum and the acromion of the scapula. It is cylindroid, with a sigmoid curve; is more curved and robust in the male, and most so in vigorous persons.

The **ster'nal end**² is thickened, and presents an irregular triangular surface, partly for articulation with the sternum, and partly for the attachment of ligaments. The **acro'mial end**³ is compressed from above downward, and has a small articular surface for union with the acromion.

The upper surface of the clavicle is covered only by the skin and subcutaneous fascia. The lower surface is directed toward the first rib and the coracoid process of the scapula, and is marked by the ligamentous attachments with these bones. In the curvatures of the clavicle, the convexity of its acromial extremity is directed backward; that of the sternal extremity forward.

FIG. 100.



CLAVICLE OF THE RIGHT SIDE, upper view. 1, sternal end; 2, portion which joins the cartilage of the first rib; 3, anterior convexity and line of attachment of the great pectoral muscle; 4, upper surface of the acromial end; 5, its articular surface; 6, anterior concavity, giving attachment to the deltoid muscle; 7, posterior convexity, giving attachment to the trapezius muscle; 8, position of origin of the sterno-mastoid muscle.

¹ Clavicula; clavis; furcula; ligula;
os juguli; jugulum; cleidion.

² Extremitas sternalis.

³ Extremitas acromialis.

The clavicle is a most important agent in maintaining the position of the upper extremity; removing the shoulder joint a convenient distance from the thorax, thus contributing to the greater range and freedom of movement of the limb. If it is removed or broken, the shoulder is depressed, and the head of the arm bone falls against the side of the thorax and is much restricted in its movements.

In animals which use the fore legs only for support, the clavicle does not exist, as in the ruminants and the horse; its degree of development is intimately related with the freedom of movement of the fore extremities of other animals. Thus it is well developed in squirrels, bats, and birds, and is feebly developed in dogs and cats.

THE SCAPULA.

The **Scap'ula**¹ or **shoulder blade** is situated at the upper back part of the thorax, extending from the position of the second to the seventh rib. It is broad, flat, thin, and triangular, and presents two surfaces, three borders, three angles, and three processes.

Of the surfaces, the **anterior**² forms the shallow **subscap'ular fos'sa**,³ which is crossed by ridges,⁴ and gives attachment to the subscapular muscle. The **posterior surface**⁵ is divided by a projecting plate, the **spine**, into two unequal parts, of which the upper and smaller is called the **su'pra-spi'nous fos'sa**,⁶ and the lower the **in'fra-spi'nous fossa**;⁷ both being occupied by like-named muscles.

Of the borders, the **superior**⁸ is the shortest and thinnest. At its outer part is the **cor'acoid notch**,⁹ which is converted by a transverse fibrous band, the **cor'acoid lig-ament**,¹⁰ into the **cor'acoid fora'men**.¹¹ The **posterior border**¹² or **base** is the longest, is irregularly convex in its course, and gives attachment to muscles. The **inferior border**¹³ inclines toward the axilla, and is thick and partially grooved. At its upper part is a rough impression produced by the attachment of the long head of the triceps extensor muscle.

¹ Scapulum; spatula; scaptula; plata; omoplata; pterygium; chelonium; epinotium; os latum humeri; scutum thoracis; latitudo humeri; blade bone; plate bone; spade bone; shield bone.

² Venter.

³ Fossa subscapularis.

⁴ Costæ scapulares.

⁵ Dorsum; dorsal surface; testudo scapulæ.

⁶ Fossa supra-spinatus.

⁷ F. infra-spinatus.

⁸ Costa superior; cervical border.

⁹ Incisura coracoidea; i. scapulæ; lunula; supra-scapular notch.

¹⁰ Lig. coracoideum.

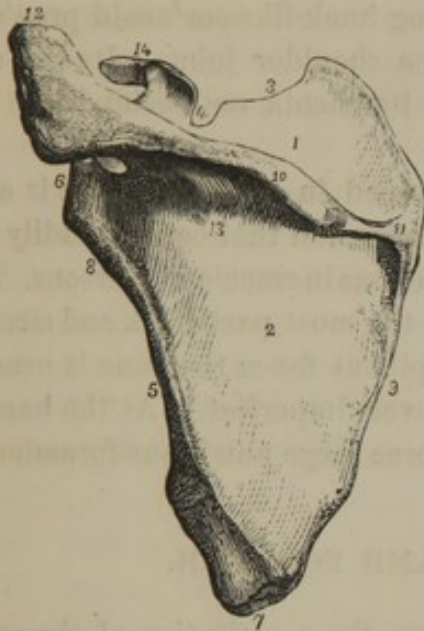
¹¹ Foramen coracoideum.

¹² Vertebral border.

¹³ Costa inferior; axillary border.

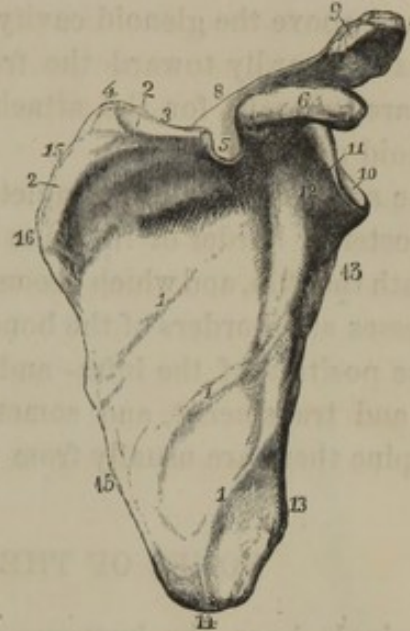
Of the angles, the **superior** is thin, and is formed at the conjunction of the upper border and base. The **inferior angle** is thick, and expanded

FIG. 101.



THE SCAPULA OF THE LEFT SIDE, posterior view. 1, supra-spinous fossa; 2, infra-spinous fossa; 3, superior border; 4, coracoid notch; 5, inferior border; 6, glenoid cavity; 7, inferior angle; 8, neck of the scapula; 9, posterior border or base; 10, spine; 11, its triangular commencement, upon which the tendon of the trapezius muscle moves; 12, acromion; 13, one of the nutritious foramina; 14, coracoid process.

FIG. 102.



ANTERIOR VIEW OF THE SCAPULA. 1, ridges crossing the subscapular fossa; 2, upper boundary of the latter; 3, superior border; 4, superior angle; 5, coracoid notch; 6, coracoid process; 7, acromion; 8, spine of the scapula; 9, articular surface for the clavicle; 10, glenoid cavity; 11, elevated border of the same; 12, neck; 13, inferior border; 14, inferior angle; 15, base; 16, position at which the spine commences posteriorly.

at its outer part, where it gives origin to the greater terete muscle. The **external angle**¹ is massive, and supports a vertically ovate, shallow, concave surface, the **gle'noid cavity**,² forming part of the shoulder joint. The cavity has an obtuse prominent border, and is supported by a narrowed portion of the bone, named the **neck of the scap'ula**.³

Of the processes, the **spine**⁴ is the most conspicuous, consisting of a strong triangular plate springing backward and a little upward from the posterior surface of the scapula and separating the supra- and infra-spinous fossæ. Its anterior border curves over the neck of the scapula, and is thick and rounded. Its posterior border commences in a triangular expansion at the base of the bone, is thick and strong, and has attached

¹ Corpus scapulæ.

² Cavitas, or fossa glenoidea; acetabulum humeri; cavitas humeri glenoides; omocotyle; entyposis.

³ Cervix, or collum scapulæ.

⁴ Spina scapulæ.

the trapezius and latissimus muscles. The angle of conjunction of the anterior and posterior borders is prolonged outwardly and expanded into a broad process, the **acro'mion**,¹ which forms the summit of the shoulder and overhangs the joint.

From above the glenoid cavity the strong hook-like **cor'acoid proc'ess**² curves outwardly toward the front of the shoulder joint. Its end and base are tuberosus for the attachment of ligaments, and behind it is the coracoid notch.

The scapula is almost completely enveloped in muscles, and it is only the posterior border of its spine and the acromion that can be readily felt beneath the skin, and which become conspicuous in emaciated persons. The processes and borders of the bone are for the most part thick and strong. In the position of the infra- and supra-spinous fossæ the bone is usually thin and translucent, and sometimes is even imperfect. At the base of the spine there are usually from one to three large nutritious foramina.

BONES OF THE ARM AND FOREARM.

A single bone, the humerus, enters into the constitution of the **arm**.³ It joins the glenoid cavity of the scapula, from which it extends vertically, with a slight inclination inward, to join the bones of the **forearm**.⁴ These are the radius and ulna, which lie side by side, separated by an interspace, and extend downward to the wrist with a slight inclination outward and forward.

THE HUMERUS.

The **Hu'merus**⁵ or **arm bone** is long and cylindroid, and presents for special examination its shaft and extremities.

The **shaft** or **body** is rounded at its upper, and trilateral at its lower part. The **posterior surface** is smooth, rounded above and flattened below, and is occupied its entire extent by the triceps extensor muscle. The **anterior surface** below inclines on each side to a ridge separating it from the posterior surface, and is occupied by the brachial muscle. Near the middle of the shaft internally, is a slight roughness

¹ Acromium; acrocolium; os acromii; humerus, or armus summus; caput scapulæ; mucro humeri; rostrum porcinum.

² Processus coracoideus; p. uncinatus; p. cornicularis; p. anchoralis; p. rostriformis; p. ancyroides.

³ Brachium.

⁴ Antibrachium.

⁵ Os brachii; os brachiale; os humeri; os adjutorium; brachium; lacertus; shoulder bone.

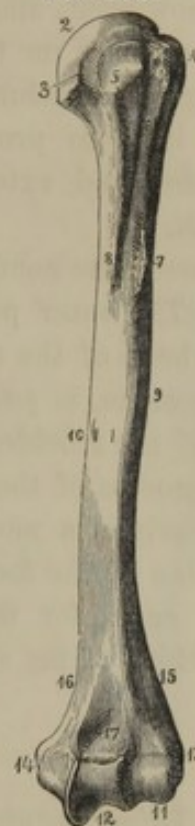
produced by the insertion of the coraco-brachial muscle. Above the middle, on the outer aspect, is a broad, superficial, rough eminence,¹ into which the deltoid muscle is inserted. Between this eminence and the ridge descending to the outer condyle, the shaft presents a slight spiral tract, from its upper back part outwardly to its lower front part, indicating the course of the superior profound artery and the musculo-spiral nerve. At the upper third of the shaft is a longitudinal gutter, the **bicip'ital groove**,² which accommodates the tendon of the long head of the biceps muscle. The groove is bounded by ridges,³ of which the outer one gives attachment to the great pectoral muscle, and the inner one to the latissimus and greater terete muscles.

The **upper extremity** of the bone expands and supports a large hemispherical eminence, the **head**,⁴ which is directed backward and inward, and forms part of the shoulder joint. To the outer side of the head, and separated from it by a slight groove corresponding with the **neck**⁵ of the bone, are the **tuberos'ities**, separated from each other by the bicipital groove. The **greater tuberosity**⁶ is external to the other, and at its upper part presents three impressions for the attachment of the supra- and infra-spinous and lesser terete muscles. The **smaller tuberosity**⁷ gives attachment to the subscapular muscle.

Surgical writers apply the term **neck**⁸ to that portion of the bone just below the tuberosities, which, though not anatomically correct, is convenient for practical purposes.

The **lower extremity** of the humerus is expanded laterally, and presents at the sides prominent tuberosities, the **con'dyles**, from which

FIG. 103.



HUMERUS OF THE LEFT SIDE, viewed in front. 1, shaft; 2, head; 3, neck; 4, greater tuberosity; 5, lesser tuberosity; 6, bicipital groove; 7, 8, ridges bounding the latter and giving attachment to muscles; 9, position of insertion of the deltoid muscle; 10, principal nutritious foramen; 11, articular eminence for the radius; 12, trochlea for the ulna; 13, 14, external and internal condyles; 15, 16, condyloid ridges ascending from the latter; 17, fossa for the coronoid process of the ulna.

¹ Tuberositas.

² Sulcus, or fossa bicipitalis; sulcus intertubercularis.

³ Bicipital ridges; spina tuberculi majoris et minoris.

⁴ Caput.

⁵ Cervix humeri anatomicum.

⁶ Tuberculum majus.

⁷ Tuberculum minus.

⁸ Cervix humeri chirurgicum.

ascend the **con'dyloid ridges**. The **internal con'dyle**¹ is more prominent than the other, gives attachment to the internal lateral ligament of the elbow joint, and gives origin to the short pronator and most of the flexor muscles on the inner part of the forearm. The **external con'dyle**² gives attachment to the external lateral ligament, and the ridge above it, more prominent than the opposite one, gives origin to the supinator and extensor muscles on the outer and back part of the forearm.

Between the condyles is the articular surface for the bones of the forearm. The outer portion of this surface is a convex eminence³ adapted to the head of the radius. The inner portion, the **troch'lea**, as expressed by the name, is pulley-like, and articulates with the ulna. Above the front of the trochlea is a pit⁴ which accommodates the point of the coronoid process of the ulna in the flexion of the forearm; and above it posteriorly is a more extensive fossa⁵, which receives the olecranon in extension of the forearm.

The canal for the nutritious artery of the marrow descends at the lower third of the shaft internally.

THE ULNA.

The **Ul'na**⁶ occupies the inner side of the forearm, and is a little longer than the radius. It is prismoid in form, and diminishes toward its lower extremity.

Its **shaft** presents three surfaces separated by prominent borders. The **anterior surface** is slightly depressed, and gives origin to the deep flexor of the fingers. The **inner surface** above is expanded for the origin of the latter muscle, and below is rounded and subcutaneous. The **posterior surface** above presents an elongated, shallow depression, which accommodates the anconeus muscle, and below this a flattened surface for the extensor muscles of the thumb. Of the three borders, the inner two are obtuse, and the outer one is acute and gives attachment to the interosseous membrane.

The **upper extremity**, which is the thickest portion of the ulna, terminates in two robust processes inclosing the articular surface for the

¹ Condylus internus; c. flexorius.

² Condylus extensus; c. extensorius.

³ Eminentia capitata; capitellum; the little head; rotula.

⁴ Fovea supra-trochlearis anterior; lesser sigmoid cavity.

⁵ Fovea supra-trochlearis posterior; greater sigmoid cavity.

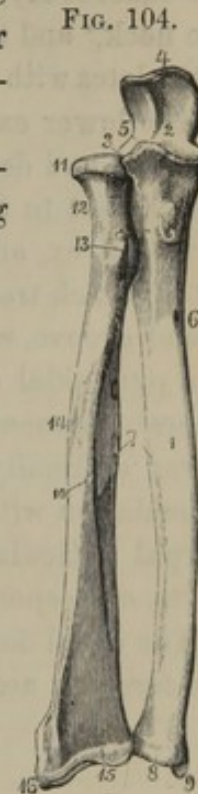
⁶ Cubitus; focii majus or inferius; canna major brachii; os cubiti inferius; cubit; os procubitale; arundo brachii major; olene.

humerus. The posterior and larger process, the **olec'ranon**,¹ is on a line with the shaft of the bone. Its upper part is truncated and receives the insertion of the triceps extensor muscle. Its back part presents a trilateral surface, which is subcutaneous. The **cor'onoid process**² projects from the front of the bone, and is roughened³ at the fore part of its base for the insertion of the brachial muscle.

Between the olecranon and coronoid processes is the **greater sig'moid cavity**,⁴ which articulates with the trochlea of the humerus. Its outer side is continuous with the **lesser sig'moid cavity**,⁵ a transverse concave surface, which articulates with the head of the radius.

The **lower extremity** of the ulna is narrow and cylindrical. It terminates in a rounded **head** articulating with the radius, and a conical **sty'loid process**,⁶ to which is attached the internal lateral ligament of the wrist. Between the styloid process and head is a depression, into which is inserted a fibrocartilage separating the radio-ulnar from the radio-carpal articulation. Behind the styloid process is a groove which transmits the tendon of the ulno-carpal extensor.

THE TWO BONES OF THE ~~FORE~~ FORE-ARM, viewed in front; the ulna to the right and the radius to the left of the figure. 1, shaft of the ulna; 2, greater sigmoid cavity; 3, lesser sigmoid cavity articulating with the head of the radius; 4, olecranon; 5, coronoid process; 6, nutritious foramen; 7, sharp ridges of both bones of the forearm for the attachment of the interosseous membrane; 8, head of the ulna; 9, styloid process; 10, shaft of the radius; 11, head of the same; 12, neck; 13, tuberosity; 14, roughened attachment of the terete pronator muscle; 15, carpal extremity of the bone; 16, its styloid process.



THE RADIUS.

The **Ra'dius**⁷ is placed at the outer side of the ulna, and extends a little lower in the forearm.

Its **shaft** is trilateral, with an acute border internally for the attach-

¹ Olecranon; o. mobile; olecranium; acrolenion; ancon; processus anconæus; p. uncinatus ulnæ; glans ulnæ; corona ulnæ; corona posterior ulnæ; additamentum necatum, or uncatum ulnæ; vertex cubiti; patella fixa; rostrum externum, or posterius; top of the cubit.

² Processus coronoideus.

³ Tuberositas ulnæ.

⁴ Cavitas sigmoidea major; c. lunata major; semilunar fossa: olecranoid cavity.

⁵ Cavitas sigmoidea minor; c. lunata minor.

⁶ Processus styloideus.

⁷ Manubrium manus; focile minus, or superius; additamentum ulnæ; canna minor; cercis; os ad cubitale; arundo brachii minor; parapechyon.

ment of the interosseous membrane. The **external surface** is rounded, and near its middle is impressed by the insertion of the terete pronator muscle. The **anterior surface** is flattened, expands below, and is slightly grooved at the middle for the origin of the long flexor of the thumb. The posterior surface is rounded above, and is flattened below, where it accommodates the extensor of the thumb.

The **upper extremity** of the bone in front presents a rough eminence, the **tuberosity**,¹ into which the biceps muscle is inserted. Above it is the **neck**,² and this supports a discoidal **head**,³ the wide margin of which articulates with the ulna, and the upper concave surface with the humerus.

The **lower extremity** of the radius is its thickest portion. In front, it is broad and depressed, and bounded below by a prominent ridge giving attachment to the capsular ligament of the wrist. Behind, it is irregularly convex, and exhibits a narrow groove separating two broad ones, all of which transmit extensor tendons. Its outer side presents another broad groove, which likewise transmits tendons. Below the latter groove is a pyramidal eminence, the **styloid process**,⁴ with which the external lateral ligament of the wrist is connected. On the inner side of the lower extremity is a transverse excavation, the **semilunar cavity**,⁵ for articulation with the head of the ulna. Below is a large concavity, the **carpal articular surface**,⁶ which is divided by a slight ridge into two parts, corresponding with the position of the scaphoid and lunar bones.

The canal for the nutritious artery of the marrow, in both bones of the forearm, ascends from the front of their upper third.

BONES OF THE HAND.

The bones of the hand are situated in the same general plane with those of the forearm, and are subdivided into those of the carpus, of which there are eight; of the metacarpus, of which there are five; and of the fingers, of which there are sixteen.

BONES OF THE CARPUS.

The **Carpal bones**,⁷ or those of the **carpus** or **wrist**,⁸ eight in number, are arranged in two rows, of which one joins the forearm, the other the metacarpus. Those of the first row, indicated from the outer side of

¹ Tuberositas; bicipital tuberosity.

² Cervix; collum.

³ Caput.

⁴ Processus styloideus.

⁵ Incisura semilunaris.

⁶ Fossa scaphoidea; f. navicularis.

⁷ Ossa carpi.

⁸ Carpismus; brachiale; raseta.

the wrist, are the scaphoid, lunar, cuneiform, and pisiform bones; and those of the second row, in the same direction, are the trapezial, trapezoid, capitate, and unciform bones.

The **Scaphoid bone**¹ is the largest of the first row of the carpus, and is oblique in its position. It is oblong, concavo-convex, with a tubercle on the outer end for the attachment of the annular ligament. It articulates with the radius above, the lunar bone within, and the trapezial, trapezoid, and capitate bones below.

The **Lunar bone**² is the second in size of the first carpal row, and is square and concavo-convex. It articulates with the radius above, the scaphoid bone on its outer, and the cuneiform bone on its inner side, and the capitate and unciform bones below.

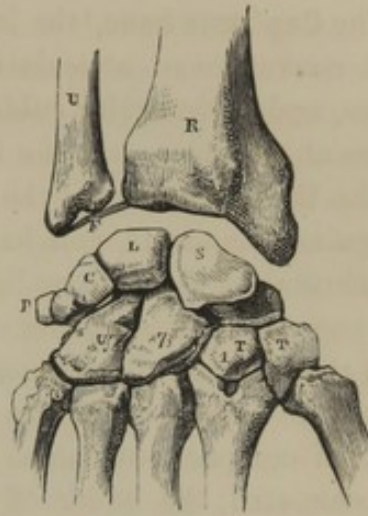The **Cu'neiform bone**³ is irregularly pyramidal, and articulates with the lunar and unciform bones on its outer side, and the pisiform bone in front.

The **Pis'iform bone**,⁴ irregularly rounded, is the smallest of the first carpal row, and articulates alone with the cuneiform bone.

The **Trape'zial bone**⁵ is the third in size of the second carpal row, and is irregular in form. In front it has a groove, which accommodates the tendon of the radio-carpal flexor, bounded by a ridge externally, which gives attachment to the annular ligament. It articulates above with the scaphoid bone, below with the first metacarpal bone, and on the inner side with the trapezoid and second metacarpal bones.

The **Trap'ezoid bone**⁶ is the smallest of the second carpal row, and is

FIG. 105.



BONES OF THE CARPUS, and those with which they articulate; right hand, posterior view. Of the upper bones U is the lower end of the ulna, and R is the lower end of the radius; F indicates the position of a fibro-cartilage which separates the radio-carpal from the radio-ulnar articulation. Of the bones of the carpus, in the first row, S is the scaphoid, L the lunar; C the cuneiform, and P the pisiform bone; and in the second row, T T are the trapezial and trapezoid bones, 7 the capitate, and U the unciform bones. Below, are the bases of the metacarpal bones.

¹ Os scaphoideum; os scaphoides; os naviculare; os cotyloides; os cymbiforme; boat-like bone.

² Os lunatum, or lunare; os semilunatum, or semilunare.

³ Os cuneiforme; os triquetrum; os pyramidale; os cubitale; os triangulare.

⁴ Os pisiforme; os subrotundum; os orbiculare; os lentiforme; os extra ordinem carpi.

⁵ Trapezium; os trapezium, or trapezoides; os multangulum majus; os rhomboides.

⁶ Os trapezoides; os multangulum minus; os trapezium; os pyramidale.

an irregular truncated pyramid, wedged, with its narrow end forward, between the scaphoid bone above and the second metacarpal bone below, the trapezial bone on its outer side and the capitate bone on its inner side.

The **Cap'itate bone**,¹ the largest of the second carpal row, has a prominent convex head articulating with the scaphoid, lunar, and unciform bones, and an irregular cubical base joining the trapezoid and unciform bones at the sides, and the intermediate three metacarpal bones below.

The **Un'ciform bone**,² the second in size of the second carpal row, is irregularly quadrate, and has a broad hook-like process in front for the attachment of the annular ligament. It articulates above with the lunar and cuneiform bones, on its outer side with the capitate bone, and below with the last pair of metacarpal bones.

All the carpal bones are composed of spongy substance, with a thin layer of compact substance.

Associated, the bones of the carpus form a convexity on the dorsal surface, and a concavity toward the palmar surface. The concavity on the inner side is bounded by the pisiform bone and the hook-like process of the unciform bone; on the outer side by the tuberosity of the scaphoid bone and the ridge of the trapezial bone. Between the two sides a strong fibrous band, the **anterior annular ligament**, is extended, converting the carpal concavity into a canal, through which the flexor tendons reach the palm of the hand.

The upper border of the carpus, as formed by the scaphoid, lunar, and cuneiform bones, is convex, and forms the lower part of the radio-carpal articulation, with which the pisiform bone has no connection. The lower border of the carpus forms an irregular transverse plane, with which the metacarpus articulates. The capitate and unciform bones together form a convex prominence received into a concavity formed by the scaphoid, lunar, and cuneiform bones, an arrangement of the two rows of carpal bones which contributes to the strength of their articulation.

BONES OF THE METACARPUS.

The **Metacar'pal bones**,³ or those which compose the **metacar'pus**,⁴ correspond in number with the fingers, which they join below. They belong to the class of long bones, and are slightly bent forward. Their **shaft** is trilateral, convex behind, and sloping off on each side

¹ Os capitatum; os magnum. In some animals the smallest bone of the wrist.

² Os unciforme, or uncinatum; os hamatum; os cuneiforme.

³ Ossa metacarpi.

⁴ Metacarpion; postcarpium; postbrachiale; torsus manus.

anteriorly. Their **upper extremity** or **base** is quadrate, and varies in character with the difference of articulation with the carpus. Their **lower extremity** forms a spheroidal **head**,¹ with a pit and pair of tubercles on each side for ligamentous attachment.

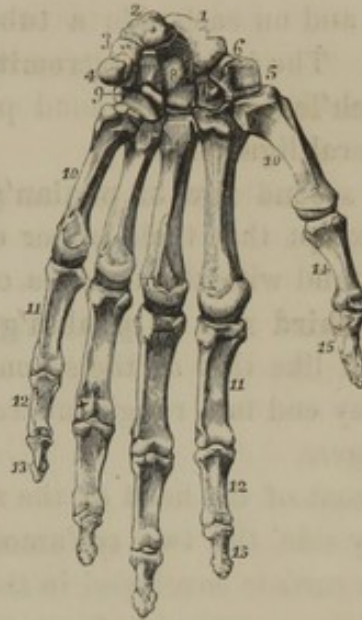
The metacarpal bone of the thumb² is the shortest and most robust. It is also disconnected and divergent from the others. The succeeding bones gradually diminish in size to the last, and lie nearly parallel to one another. They are articulated at their contiguous extremities, and form the least movable portion of the hand.

The spaces between the metacarpal bones are called **interosseous**, are numbered from without inward, and are occupied by muscles.

BONES OF THE FINGERS.

The **Fingers**³ are named, in succession, the **thumb**,⁴ the **index** or **forefinger**,⁵ the **middle finger**,⁶ the **ring finger**,⁷ and the **little finger**.⁸ Each has three bones, called **phalan'ges**,⁹ or **joints**, except the thumb, which has two. The middle finger is the longest, the index and ring fingers are next in length and nearly equal. The three bones of the little finger are longer than the two of the thumb, but these are much more robust, and the last **phal'anx** of the latter is larger than the corresponding bone of any of the other fingers.

FIG. 106.



THE LEFT HAND, viewed in front, or on the palmar surface. 1, scaphoid bone; 2, semilunar; 3, cuneiform; 4, pisiform; 5, trapezium; 6, groove in the latter; 7, trapezoid; 8, capitate; 9, unciform; 10, the five metacarpal bones; 11, first row of phalanges of the fingers; 12, second row; 13, last row; 14, 15, phalanges of the thumb.

¹ Capitulum.

² Os metacarpi pollicis.

³ Digiti, dactyli.

⁴ Pollex; allus pollex; digitus primus, or magnus; promanus; anticheir; manus parva majori adjutrix.

⁵ Digitus index, secundus, salutaris, or demonstratorius; indicator; demonstrator; lichanos.

⁶ Digitus medius, tertius, famosus, infamis, impudicus, obsœnus, or verpus; long finger.

⁷ Digitus annularis, quartus, medicus, or cordis; paramesos; iatricus.

⁸ Digitus parvus, minimus, quintus, auricularis, myops, or otites.

⁹ Phalangeal bones; ossa, nodi, internodia, articuli, condyli, agmina, acies, scutulæ, or scytalides digitorum manus.

The **first row of phalan'ges**¹ are the largest. They have a demi-cylindrical **shaft**, convex behind and flattened in front, with a ridge on each side for the attachment of the vaginal ligaments. The **upper extremity** or **base** is the most expanded portion of these bones, and supports a concave articular surface for the head of the metacarpal bones, and on each side a tubercle for the attachment of lateral ligaments. The **inferior extremity** presents a pulley-like articular surface, or **troch'lea**, for the second phalanges, and a slight fossa on each side for lateral ligaments.

The **second row of phalan'ges**² are constructed like those of the first row, except that their upper extremity supports a double concavity, to correspond with the trochlea of the former.

The **third row of phalan'ges**³ are the shortest. Their base is constructed like that of the second row, their shaft is compressed conical, and they end in a rough tuberosity for the attachment of the soft tips of the fingers.

In front of the head of the metacarpal bone of the thumb are placed, side by side, the two **ses'amoid bones**.⁴ They are oval, with a palmar convex surface enveloped in the tendon of the short flexor of the thumb, and with an articular facet moving upon the head of the metacarpal bone.

THE HAND.

The **Hand** at rest occupies the same plane as the forearm, but by means of the mobility of the radio-carpal articulation or wrist joint it may be brought nearly to a right angle before and behind, and also may be moved at an obtuse angle outward and inward.

The **dorsal surface** or **back of the hand** is convex. When the hand is closed as in forming the **fist**, the heads of the metacarpal bones and extremities of the phalanges become prominent, as the **knuckles**. The **inner** or **palmar surface** is concave, and is rendered more so by the flexion of the fingers. The concavity of the metacarpus is the basis of the **palm**⁵ or **hollow of the hand**.

The fingers may all be flexed or bent inward at a right angle to the metacarpus, but cannot be extended or bent backward beyond the line of the latter. They are all capable of convergence and divergence, or of adduction and abduction. The phalanges may be flexed at right

¹ Metacarpal phalanges; procondyli.

² Middle phalanges; mesocondyli.

³ Phalanges unguium; metacondyli.

⁴ Ossa sesamoidea.

⁵ Palma; vola; platea; thenar; poculum; patera; supellex Diogenis.

angles with one another, and extended back to their former straight line, but have no other movement.

From the mobility of the first metacarpal on the trapezial bone, the thumb is opposable to the other fingers, and enjoys a greater range of movement. The different length of the fingers makes their tips correspond with the hollow of the hand when this is closed, and perhaps adapts them better for seizing objects of varied forms; and thus when a spherical body is clasped it will be found that the tips of the fingers are brought to the same plane.

DEVELOPMENT OF THE BONES OF THE UPPER EXTREMITIES.

The clavicle commences to ossify earlier than any other bone. It is developed from a principal piece, and an epiphysis which appears at the sternal end on the approach of adult age.

The scapula commences ossification about the same time as the vertebrae. It is formed from a principal piece, and several epiphyses added subsequent to birth. The acromion and coracoid process are each formed from two epiphyses, another is developed at the lower angle, and one along the base of the scapula.

The humerus commences to ossify after the clavicle, and before the vertebrae. At birth the shaft is ossified, but the extremities are cartilaginous. The head and tuberosities are formed from two ossific centres; the condyles and lower articular extremity from four centres.

The radius and ulna begin to ossify shortly after the humerus. Their extremities are cartilaginous at birth, and an epiphysis is formed for each.

The carpus is cartilaginous at birth, and ossification commences with the capitate bone during the first year. Each bone is developed from a single ossific centre.

At birth the shaft of the metacarpal bones and phalanges is ossified. Subsequently the head of the inner four metacarpal bones is formed as an epiphysis; but in the first metacarpal bone and the phalanges, it is the base which appears as an epiphysis.

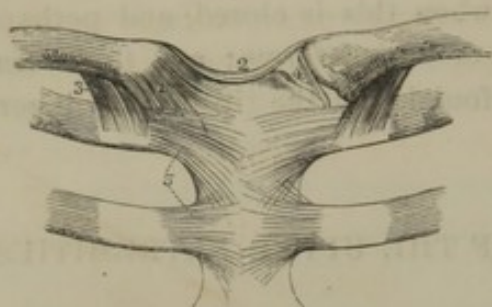
ARTICULATIONS AND MOVEMENTS OF THE UPPER EXTREMITY.

THE STERNO-CLAVICULAR ARTICULATION.

The joint formed between the upper angle of the sternum and the end of the clavicle is surrounded by a *cap'sular lig'ament*, the stronger por-

tions of which constitute the **anterior** and **posterior ster'no-clavic'ular lig'aments**. The joint is divided into two parts by a biconcave

FIG. 107.



STERNO-CLAVICULAR, COSTO-CLAVICULAR, AND COSTO-STERNAL ARTICULATIONS. 1, capsular ligament of the sternoclavicular articulation; 2, inter-clavicular ligament; 3, costo-clavicular ligament; 4, inter-articular fibro-cartilage; 5, anterior costosternal ligaments.

inter-artic'ular fi'bro-car'tilage, which is attached by its margin to the capsular ligament, the first costal cartilage, and the upper border of the clavicle.

The sternoclavicular articulation is further strengthened by two accessory ligaments: the **inter-clav'ic'ular lig'ament**,¹ a narrow band connecting both clavicles across the upper part of the sternum; and the **cos'to-clavic'ular ligament**,² a strong band connecting the first costal cartilage with the under part of the clavicle.

Notwithstanding the strong ligamentous union of this joint, which is the only one between the trunk and the upper extremity, it possesses a considerable degree of mobility in every direction. In this motion the entire limb participates, while the sternum is passive.

THE SCAPULO-CLAVICULAR ARTICULATION.

The joint formed between the acromion and clavicle is surrounded by a **cap'sular lig'ament**, the stronger portions of which are the **superior** and **inferior acro'mio-clavic'ular lig'aments**. It possesses but little mobility, and is further restricted by the **cor'aco-clavic'ular ligament**,³ which consists of two strong fibrous bands passing between the base of the coracoid process and the under surface of the clavicle.

In the movements of the bones of the shoulder the centre of motion is the sternoclavicular articulation. The clavicle and scapula from this point move upward and downward, forward and backward. In the movements of the scapula, it glides upward and downward, or forward and outward; or it rotates on its axis, as in the shrugging of the shoulders.

¹ L. interclaviculare.

² L. costo-claviculare; l. rhomboides.

³ L. coraco-claviculare; l. conoides et trapezoides; l. scapulæ commune conoides et trapezoides.

THE SHOULDER JOINT.

The **Scapulo-humeral articulation** or **shoulder joint** is surrounded by a thin, loose **cap'sular lig'ament**,¹ which is attached above to the margin of the glenoid cavity, and below to the neck of the humerus. Its upper part is much strengthened by a broad band, the **cor'aco-hu'-meral lig'ament**,² which extends between the coracoid process and the greater tuberosity of the humerus.

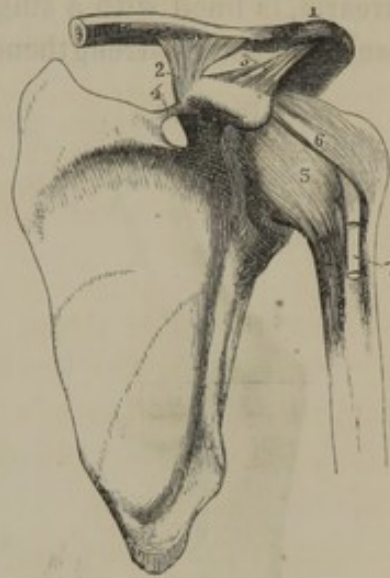The shoulder joint is the most movable one of the body; possessing a wide range of motion in every direction. From this circumstance it is very liable to dislocation, notwithstanding its many means of protection.

The head of the humerus has more than three times as much surface as the glenoid cavity upon which it moves. To deepen the cavity, a prismoid, fibro-cartilaginous band, the **gle'noid lig'ament**,³ is attached around its margin. The upper part of this ligament gives origin to the tendon of the long head of the biceps flexor muscle, which passes through the shoulder joint to the bicipital groove of the humerus, and acts functionally the part of a ligament. As it passes through the joint it is separated from the cavity by a reflection of the synovial membrane.

A strong, triangular, fibrous band, the **cor'aco-acromial lig'ament**,⁴ is attached by its apex to the acromion, and by its base to the coracoid process. The two processes thus associated form a wide arch above the shoulder joint, which prevents the dislocation of the humerus in this direction, unless the arch is broken. The deltoid muscle also contributes greatly to the strength and protection of the upper part of the shoulder joint.

In front and behind, the latter is closely enveloped by the tendons of the subscapular, supra- and infra-spinous, and lesser terete muscles, as

FIG. 108.



SCAPULO-CLAVICULAR AND SCAPULO-HUMERAL ARTICULATIONS. 1, acromio-clavicular articulation, surrounded with its capsular ligament; 2, coraco-clavicular ligament; 3, coraco-acromial ligament; 4, coracoid ligament; 5, capsular ligament of the shoulder joint; 6, coraco-humeral ligament; 7, tendon of the biceps flexor muscle.

¹ L. capsulare magnum.

² L. ascititium; accessory ligament.

³ L. glenoides.

⁴ L. coraco-acromiale; 1. triangulare;
1. scapulæ proprium anterius.

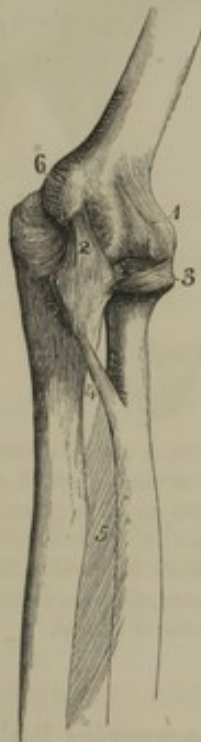they proceed to be inserted into the tuberosities of the humerus. Inferiorly the joint is in relation with the long head of the triceps extensor muscle. If the muscles surrounding the shoulder joint are detached, on account of the looseness of the capsular ligament, the head of the humerus falls nearly an inch below its usual point of contact with the glenoid cavity.

The movements of the shoulder joint are forward, backward, outward, upward, and downward, and those of circumduction and rotation.

THE ELBOW JOINT.

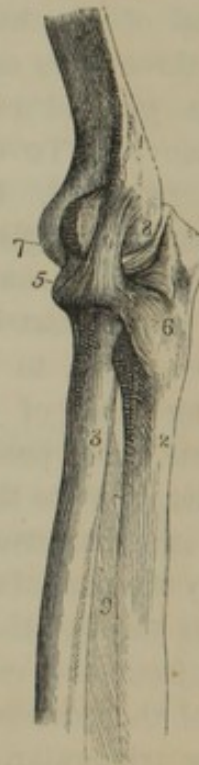The **Elbow joint** is formed between the humerus and both bones of the forearm, is lined with a single synovial membrane, and is inclosed by a capsular ligament strengthened with lateral ligaments.

FIG. 109.



THE ELBOW JOINT, *left* side, viewed antero-internally. 1, the capsular ligament in front; 2, internal lateral ligament; 3, annular ligament; 4, round ligament; 5, interosseous membrane; 6, ~~internal~~ condyle.

FIG. 110.



THE ~~SAME~~ ELBOW JOINT, viewed externally. 1, posterior surface of the humerus; 2, ulna; 3, radius; 4, external lateral ligament; 5, 6, annular ligament; 7, 8, capsular ligament; 9, interosseous membrane.

The **cap'sular lig'ament**,¹ thin and loose, is attached above the articular surface of the humerus, including the pits for the accommodation of the olecranon and coronoid process; and is attached below to the margin of the sigmoid cavities of the ulna and to the annular ligament. Its back portion is much weaker than its fore part.

¹ Membrana capsularis cubiti.

The **internal lateral ligament**¹ is a strong band radiating from the internal condyle of the humerus to the inner margin of the greater sigmoid cavity of the ulna, between the olecranon and coronoid process. The **external lateral ligament**² is a narrow band extended between the external condyle and the annular ligament surrounding the head of the radius.

The ordinary movements of the bones of the forearm upon the humerus are those of flexion and extension. The motions of the ulna are restricted to these alone, but the radius has in addition a rotary movement occurring upon the ulna and humerus together.

THE SUPERIOR RADIO-ULNAR ARTICULATION.

The **superior radio-ulnar articulation** forms part of the elbow joint, one synovial membrane and capsular ligament being common to both. The head of the radius and the lesser sigmoid cavity of the ulna form this articulation, the former being surrounded by a strong fibrous band, the **an'nular ligament**,³ the extremities of which are attached to the ulna before and behind the latter cavity.

THE MIDDLE RADIO-ULNAR ARTICULATION.

The lower four-fifths of the interval of the radius and ulna are occupied by the **interos'seous membrane**,⁴ which is thin but strong, and is composed of oblique fibres descending from the sharp edge of the radius to the opposed edge of the ulna. It is perforated by blood-vessels, and serves to give origin to some of the muscles of the forearm, as well as to connect the bones.

At the upper part of the interosseous space an oblique band, the **round ligament**,⁵ descends from the coronoid process of the ulna to the radius below its tuberosity.

THE INFERIOR RADIO-ULNAR ARTICULATION.

The **inferior radio-ulnar articulation** is separated from the wrist joint by a triangular, interarticular fibro-cartilage, the base of which is attached to the lower margin of the semilunar cavity of the radius, and the apex to the pit between the styloid process and head of the ulna. This articulation is surrounded by a loose **capsular ligament**⁶ connected with the articular margins of the radius, ulna, and fibro-cartilage.

¹ L. laterale internum; l. brachio-cubitale; l. radiatum; l. triangulare.

² L. laterale externum; l. brachio-radiale.

³ L. annulare; l. orbiculare.

⁴ L. interosseum; membrana interossea.

⁵ L. teres; l. obliquum; chorda transversalis.

⁶ Membrana capsularis sacciformis.

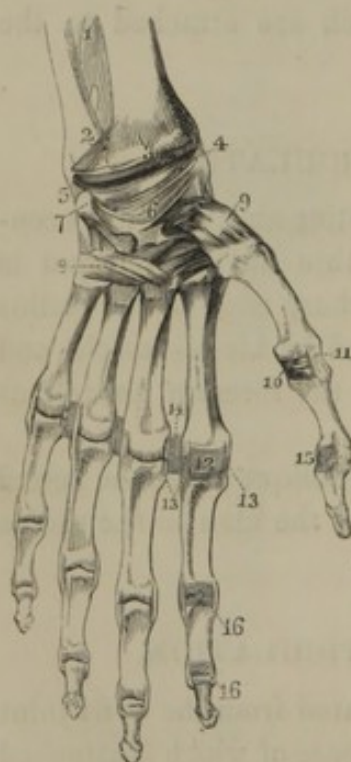
The radius rotates inwardly upon the ulna and becomes obliquely crossed in front of it. The hand follows the motion of the radius, in the pendant condition of the upper extremity the palm becoming directed backward; and this constitutes the movement of pronation. The reverse motion, by which the radius assumes a position parallel to the outer side of the ulna, and the palm of the hand is directed forward, is called that of supination.

In these movements of the radius, its head rotates upon the humerus and the lesser sigmoid cavity of the ulna within the annular ligament, and its lower extremity rotates upon the head of the ulna.

THE WRIST JOINT, OR RADIO-CARPAL ARTICULATION.

The **Wrist joint** is formed above by the radius and triangular fibro-

FIG. 111.



LIGAMENTS OF THE WRIST AND HAND, anterior view. 1, lower part of the interosseous membrane; 2, lower radio-ulnar articulation inclosed by a capsular ligament; 3, fore part of the radio-carpal joint inclosed by a capsular ligament; 4, external lateral ligament of the wrist; 5, internal lateral ligament; 6, palmar portion of the capsular ligament of the carpus; 7, pisiform bone with its capsular ligament; 8, palmar portion of the capsular ligament connecting the carpus with the base of the metacarpus; 9, capsular ligament of the trapezial and metacarpal bone of the thumb; 10, palmar or anterior ligament of the metacarpo-phalangeal articulation of the thumb; 11, external lateral ligament of the same joint; 12, palmar or anterior ligament of the corresponding joint of the index finger, represented as removed

in the other fingers; 13, lateral ligaments of the same articulation; 14, transverse ligaments connecting the heads of the contiguous metacarpal bones; 15, 16, palmar or anterior ligaments and lateral ligaments of the phalangeal articulations.

cartilage connecting it with the ulna; and below by the scaphoid, lunar, and cuneiform bones. It is inclosed by a loose **cap'sular lig'ament**¹ connected with the contiguous margins of the articular surfaces. It is strengthened by a strong, rounded, **internal lateral ligament**,² connecting the styloid process of the ulna with the cuneiform bone; and a strong **external lateral ligament**,³ extended between the styloid process of the radius and the scaphoid bone.

A single synovial membrane lines the radio-carpal articulation, and neither communicates with

the radio-ulnar articulation nor extends between that of the carpal bones.

¹ Anterior and posterior radio-carpal ligaments; l. accessorium rectum et obliquum et rhomboideum; membrana articuli cubiti et carpi capsularis.

² L. laterale internum; l. laterale ulnare; funiculus ligamentosus.

³ L. laterale externum; l. laterale radiale.

The movements of the wrist joint are flexion and extension, abduction and adduction, and circumduction. The turning of the hand depends on the rotation of the radius.

THE INTERCARPAL AND CARPO-METACARPAL ARTICULATIONS.

The pisiform bone forms a distinct joint with the cuneiform bone, surrounded by a strong capsular ligament lined with synovial membrane.

The scaphoid, lunar, and cuneiform bones of the first row of the carpus are connected at their upper part by intervening **interos'eous ligaments**. In the same manner the trapezoid, capitate, and unciform bones of the second row are connected at their middle, and this is likewise the case with the bases of the inner four metacarpal bones.

All the carpal bones except the pisiform bone, and the bases of all the metacarpals, except that of the thumb, are connected with one another by short fibrous bands constituting the **pal'mar and dor'sal ligaments**. The association of these ligaments forms a sort of capsular ligament investing the carpus and base of the metacarpus.

A single synovial membrane lines the intercarpal and carpo-metacarpal articulations. These joints possess but little mobility, except the one between the two rows of carpal bones, which has a hinge-like motion.

The metacarpal bone of the thumb forms, with the trapezial bone, a freely movable joint surrounded with a capsular ligament. Each articulating surface is convex in one direction and concave in the other, and the two surfaces are applied in a crossing manner, allowing the metacarpal bone to be moved backward or forward, inward or outward, thus rendering the thumb opposable to the other fingers.

The heads of the inner four metacarpal bones are associated in front by thin and rather loose **transverse ligaments**.

THE METACARPO-PHALANGIAL, AND PHALANGIAL ARTICULATIONS.

The **metacarpo-phalangial**, and **phalangial articulations**, are connected by strong **lateral ligaments**, which descend from the sides of the bones above, obliquely forward to the sides of the bones below. The fore part of these articulations is protected by a thick, fibro-cartilaginous **palmar ligament**,¹ extended between the position of the lateral ligaments. It is firmly attached to the margin of the bone below the joint, and but slightly to that above; and it is grooved on its palmar aspect

¹ Anterior ligament.

for the passage of the flexor tendons. The back part of these articulations is covered by the expanded extensor tendons, which act in this position as ligaments.

The spheroidal head of the metacarpal bones, and the single concavity of the bases of the first row of phalanges, permit the movements of flexion and extension, abduction and adduction.

The phalangeal articulations or finger joints possess only the movements of flexion and extension.

THE LOWER EXTREMITY.

The lower extremity extends from below the pelvis, with which it articulates by means of the head of the thigh bone. Each consists of a single bone to the **thigh**, one to the **knee**, two to the **leg**, and twenty-eight to the **foot**.

THE FEMUR.

The **Fe'mur**, or **thigh bone**,¹ is the largest and longest bone of the skeleton, and extends from the hip bone downward, with an inward inclination, to the tibia.

The **shaft** is cylindrical, with a prominent crest behind, called the **as'perous ridge**, (*linea aspera*.) Its front and sides are smooth, and occupied by the quadriceps extensor muscle. The asperous ridge, for the attachment of muscles, is acute at the middle, and is rough only at its upper part, which diverges in two divisions to the trochanters. Its lower part is less well developed, and diverges in two divisions to the condyles, inclosing a triangular surface forming the basis of the popliteal space.

The upper extremity of the shaft terminates in two processes, called **trochan'ters**.² The **greater trochan'ter** is situated at the highest part of the shaft externally. It is convex and rugged on its outer surface, and presents an oblique ridge for the attachment of the middle gluteal muscle. Its inner surface, less extensive, exhibits a pit, the **trochanter'ic fos'sa**,³ into which the small rotary muscles of the thigh are inserted. The **smaller trochan'ter**⁴ is a rounded eminence situated at the posterior and inner side of the bone, and gives attachment to the tendon of the psoas and iliac muscles.

In front and behind, the trochanters are conjoined by the **intertrochanter'ic ridges**, of which the **posterior** is much the most prominent,

¹ Os femoris; merium.

² Trochanteres; rotatores.

³ Fossa trochanterica. *f. sigillata* - Gray

⁴ Lineæ trochantericæ.

and gives attachment to the quadrate femoral muscle. The **anterior ridge** is feebly developed, but is longer than the other.


From the trochanters and their associating ridges the **neck of the femur**¹ projects upward and inward at an obtuse angle from the shaft. It is cylindrical, compressed from before backward, and joins the latter by a strong, expanded base. It supports a spherical **head**,² which is covered with cartilage, and articulates with the acetabulum. On the inner side of the head is a pit for the attachment of the round ligament of the hip joint.

The **lower extremity** of the femur is the most expanded and massive portion of the bone. It terminates in two large eminences, the **con'dyles**, which are separated behind by a deep notch, the **intercon'dyloid fos'sa**.³ The articular surfaces of the condyles are continuous in front by a pulley-like surface, the **troch'lea**, upon which the knee-cap moves. The **internal con'dyle** is the larger, but the **external con'dyle** projects most anteriorly. On the remote sides of the condyles is a **tuberos'ity**⁴ for the attachment of the lateral ligaments of the knee joint. Below the external tuberosity is a crescentic fossa, which gives origin to the tendon of the popliteal muscle.

When the femur is placed vertically, the internal condyle appears much longer than the external, and the summit of the greater trochanter rises nearly as high as the head of the bone. The natural position of the latter is oblique, so that the lower extremities of both thigh bones are brought nearly into contact, and the upper extremities are the most remote from each other. In this position the articulating surfaces of the condyles are on a level, and the summit of the greater trochanter is on the same line with the centre of the head.

In the female the neck of the femur is longer and more rectangular

FIG. 112.



FEMUR OF THE RIGHT SIDE, front view. 1, the shaft; 2, head; 3, neck; 4, great trochanter; 5, anterior inter-trochanteric ridge; 6, lesser trochanter; 7, external, and 8, internal condyles; 9, tuberosity for the external lateral ligament; 10, groove for the popliteal tendon; 11, tuberosity for the internal lateral ligament.

¹ Cervix, or collum femoris.

² Caput femoris.

³ Fossa intercondyloidea; f. poplitea.

⁴ Tuberositas condyli.

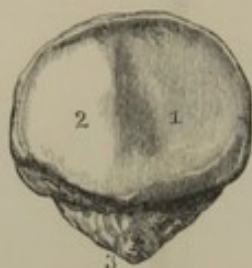
in its relation with the shaft than in the male, so that the thigh bones in the former sex are more oblique or more divergent above.

One or two canals, for the principal medullary nutritious vessels, ascend at the inner side of the asperous ridge, in the vicinity of its middle.

THE PATELLA.

The **Patel'la**, or **knee-cap**,¹ viewed by some anatomists as the representative of the olecranon, by others as a sesamoid bone of the tendon of the quadriceps ex-

FIG. 113.



PATELLA OF THE RIGHT SIDE, posterior view. 1, 2, articular faces for the trochlea of the femur; 3, apex of the bone roughened for the attachment of its ligament.

tensor muscle, is situated in front of the knee joint. It is a chestnut-shaped bone, with its apex downward and attached by a strong ligament to the tibia. Its base is thick, and has inserted into it the tendon of the quadriceps extensor. Its fore part is convex and rough; and its back part presents a transversely oval articular surface, elevated from each side into a median ridge so as to correspond with the trochlea of the femur, upon which it moves.

The patella is composed of a mass of spongy substance enveloped in a thin layer of compact substance.

THE BONES OF THE LEG.

The bones of the leg consist of the tibia and fibula, placed side by side. The tibia joins the femur above, and, together with the fibula, joins the astragalus below. The former alone receives the pressure of the upper part of the body, and transmits it to the foot; while the latter appears mainly of importance in extending the surface of the leg for muscular attachment.

THE TIBIA.

The **Tib'ia**, or **shin bone**,² situated at the fore and inner part of the leg, extends in a straight line from the thigh bone to the tarsus, and is the second largest and longest bone of the skeleton. Its shaft is a trilateral prismatic column, with sharp borders, and is most expanded toward the upper extremity. The **inner surface**, smooth and slightly rounded, is

¹ Rotula; epigonis; caucaloides; supergenualis; acromyle; mylacris; myle; mola; gamba; concha; oculus; orbis, orscutum genu; osscutiforme, disciforme,

thyroides, or sesamoideum magnum; olecranon mobile.

² Cneme; procnemium; focile majus; arundo, or canna major; canna domestica cruris.

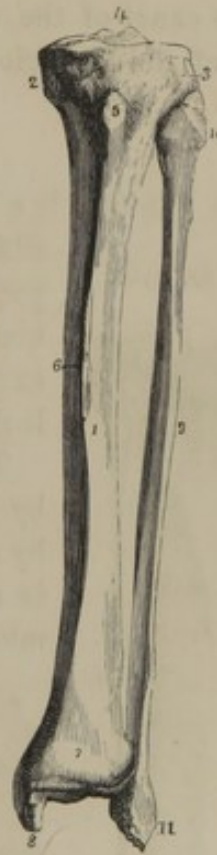subcutaneous. The **outer surface**, occupied by muscles, is slightly grooved above, and is rounded below, where it inclines forward. The **posterior surface** is flat and covered with muscles, and at the upper part is marked by a feeble, oblique ridge, indicating the lower border of attachment of the popliteal muscle. The **anterior border**, called the **crest** or **shin**,¹ is waving in its course, and acute at the middle. The **outer border** gives attachment to the interosseous membrane; the posterior border, less sharp than the others, gives attachment to muscles.

The **superior extremity** expands into the **head**, which is the most massive portion of the bone, and appears as if it were pressed backward, so that its front is flattened and it overhangs the posterior surface of the shaft. Its prominent lateral portions constitute the **con'dyles**,² which have thick porous borders, and support a pair of smooth, oval surfaces,³ invested with cartilage, for articulation with the condyles of the femur. The inner articular surface is the longer antero-posteriorly, and is slightly concave in this direction; while the other is slightly convex. Both are elevated at the middle of their approximate border upon a small pyramidal eminence, the **spi'nous proc'ess**,⁴ the base of which is the centre of attachment for the semilunar cartilages and crucial ligaments. The articular surfaces are separated by a rough, depressed tract, which crosses the spinous process and expands on the fore and back part of the head. Below the back part of the external condyle is a small, smooth surface, covered with cartilage, for articulation with the head of the fibula.

Below the head, in front, at the commencement of the crest, is a conspicuous eminence, the **tuberos'ity**,⁵ into which the ligament of the patella is inserted.

The **lower extremity** of the tibia is expanded, and at its termination is quadrate. In front it is smooth and convex, and bounded below by a prominent mar-

FIG. 114.



TIBIA AND FIBULA OF THE LEFT LEG. 1, shaft of the tibia; 2, 3, condyles; 4, spinous process; 5, tuberosity; 6, crest or shin; 7, lower extremity of the bone; 8, internal malleolus; 9, shaft of the fibula; 10, its head; 11, external malleolus.

¹ Crista; spina.

² Condyli; tuberosities.

³ Condyli.

⁴ Acclivitas, or eminentia condyloidea, or intercondyloidea; spine.

⁵ Tuberositas tibiæ; tuberculum; tubercle.

gin for the attachment of the capsular ligament of the ankle joint. Behind, it slopes to an obtuse border, for the same purpose as the latter, and its outer side is excavated and roughened for ligamentous attachment with the fibula. Its inner part is prolonged into a strong prominence, the **internal malle'olus** or **ankle**.¹ The inner surface of this process is convex and subcutaneous; and behind, is marked with a groove for the tendon of the posterior tibial muscle.

At the bottom of the tibia is the **tar'sal articular surface**, a quadrilateral concavity, which at its inner side is prolonged downward on the malleolus. It is covered with cartilage, and joins the upper and inner side of the astragalus.

The canal of the medullary nutritious vessels is situated at the upper third of the posterior surface of the shaft, and is directed downward.

THE FIBULA.


The **Fib'ula**² is a long, slender bone, situated at the outer side of the tibia. Its upper extremity articulates beneath the back part of the head of the latter; but, in descending, the bone gradually advances in position, so that its lower extremity is nearly as far forward as the internal malleolus, and extends rather lower than this.

The **shaft** presents three irregular surfaces separated by prominent borders. The **inner surface** is divided by an oblique ridge, to which the interosseous membrane is attached. The **outer surface** is grooved above the middle; at its upper part inclines forward, and at its lower part inclines backward.

The **posterior surface** is convex; its upper part inclining outward, its lower part inward.

The **upper extremity** expands into the **head**,³ which is prominent at the sides for the attachment of ligaments and the tendon of the biceps flexor; and supports at its inner part a small smooth

FIG. 115.



TIBIA AND FIBULA OF THE RIGHT LEG, posterior view. 1, 2, articular surfaces for the condyles of the femur separated by the spinous process; 3, the inner condyle of the tibia; 4, surface occupied by the popliteal muscle defined by the oblique line 5; 6, nutritious foramen; 7, surface covered by the flexors of the toes; 8, internal malleolus; 9, grooves for tendons; 10, shaft of the fibula; 11, its head; 12, subcutaneous surface at the lower part of the bone; 13, external malleolus; 14, groove for tendons.

surface for articulation with the external condyle of the tibia.

¹ Inner ankle bone.

² Os perone; peroneum; canna, or arundo minor; sura; fistula cruris; cru-

ris radius; focile minus; tibia minima; spell, or splinter bone.

³ Capitulum.

The **lower extremity**, rather larger than the other, is prolonged, below its junction with the tibia, into the **external malle'olus** or **ankle**.¹ This is longer and more prominent than the internal one, and supports a smooth, triangular, articular facet, which joins the outer side of the astragalus and forms part of the ankle joint. Behind the articular surface is a fossa for the attachment of the external lateral ligament of the ankle joint, and above it is a convexity, which is conjoined with the tibia by means of a ligament. The fore part of the malleolus is convex and subcutaneous; and its back part is marked by a groove for the tendons of the peroneal muscles.

The canal for the medullary nutritious vessels is situated near the middle of the posterior surface of the shaft, and, like that of the tibia, is directed downward.

BONES OF THE FOOT.

The bones of the foot are situated at a right angle with those of the leg, and are subdivided into those of the tarsus, of which there are seven; those of the metatarsus, of which there are five; and those of the toes, of which there are sixteen.

BONES OF THE TARSUS.

The **Tarsal bones**,² or those composing the **tarsus**, seven in number, consist of the astragalus and calcaneum, the scaphoid, cuboid, and three cuneiform bones.

The **Astragalus**,³ or **ankle bone**, is the only one of the tarsus which articulates with those of the leg; and is the highest and second in size of the former. Its posterior part, or **body**, is quadrate, and is received between the two malleoli. Its upper articular surface, for the tibia, is antero-posteriorly convex, transversely slightly concave, and is continuous at the sides with vertical articular surfaces for the malleoli. Beneath the body, at its back and outer part, is a concave articular surface, which rests on the calcaneum. In advance of the body is the **neck** terminating in the **head**, which supports an anterior, convex, articular surface for the scaphoid bone, and an inferior articular surface for the calcaneum. The latter surface and that beneath the body are separated by a deep groove, corresponding with a similar one of the calcaneum, for an interosseous ligament.

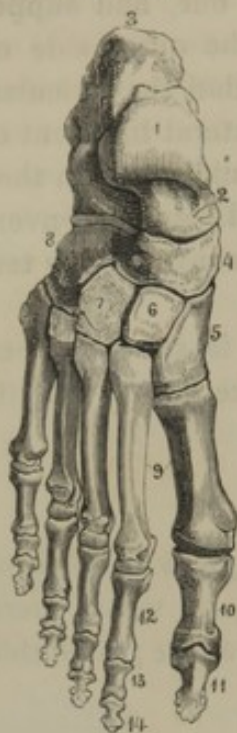¹ Outer ankle bone.

² *Ossa tarsi*; *planta prima*; *rasceta pedis*; *pedium*; *caviculæ pedis nodus*.

³ *Talus*; *quatrio*; *diabebos*; *cavicula*; *cavilla*; *tetroros*; *astrion*; *os balistæ*; *os tesseræ*; *sling bone*; *huckle bone*.

The **Calcan'eum**, or **heel bone**,¹ is the largest one of the tarsus. It is

FIG. 116.



DORSAL SURFACE OF THE RIGHT FOOT.
1, body of the astragalus; 2, its head; 3, calcaneum; 4, scaphoid bone; 5, 6, 7, internal, middle, and external cuneiform bones; 8, cuboid bone; 9, metatarsal bones; 10, 11, phalanges of the great toe; 12, 13, 14, phalanges of the other toes.

placed beneath the astragalus, extends nearly as far forward, and posteriorly extends far beyond, where it forms the basis of the heel. It is irregularly oblong quadrate. At its upper part in front is a large, irregular fossa, containing two articular surfaces, for the astragalus, separated by a rough tract.² The larger articular surface is convex, and situated at the back of the fossa; the other is narrow and concave, and rests on a **lateral process**³ internally. In advance of the fossa is a vertical articular surface for junction with the cuboid bone. Posteriorly, the calcaneum terminates in a large, convex **tuberosity**,⁴ the lower part of which gives attachment to the "tendon of Achilles." The upper surface of the tuberosity is saddle like, and corresponds with the depression above each side of the heel. The bottom of the tuberosity is subdivided into two **tubercles**,⁵ which give attachment to the plantar fascia and muscles. In advance of the tubercles, the under surface of the bone forms an obtuse ridge. The outer surface of the calcaneum is vertical and rough. Its inner surface forms, with the lateral process, a **concavity**,⁶ which transmits the tendons of the flexor muscles and the plantar vessels and nerves.

The **Scaph'oid bone**,⁷ situated at the inner side of the tarsus, is ovoid in outline, with a posterior concave articular surface for the head of the astragalus, and an anterior convex surface, divided into three facets, for junction with the cuneiform bones. Its upper and lower borders are rough; and its inner part forms a **tuberosity** for the insertion of the posterior tibial muscle.

The **Cu'bold bone**⁸ is situated at the anterior outer part of the tarsus,

¹ Os calcis; calcaneus; calcar pedis; calcia; ichnis; pternium.

² Sulcus calcanei.

³ Processus lateralis; sustentaculum tali; small apophysis.

⁴ Tuberositas calcanei; talus; calx; heel.

⁵ Greater and lesser tuberosity.

⁶ Sinuosity.

⁷ Os scaphoides; os scaphoideum; os naviculare; os cymbiforme; boat-like bone.

⁸ Os cuboides; os cubiforme; os cuboideum; os cyboides; os cyrtoides; os grandinosum; os tesseræ; os varium.

and is the third in size of the tarsal bones. Its upper surface inclines outwardly, and is rough. Its under surface, also rough, presents a **tuberosity** for the attachment of the calcaneo-cuboid ligament, and, in advance of this, a **groove** for the transmission of the tendon of the long peroneal muscle. Posteriorly it has a vertical articular facet for the calcaneum; and anteriorly, another, which is subdivided to join the outer two metatarsal bones. Its inner surface is rough, and near the middle has a small articular facet for the ~~internal~~ ^{Scaphoid} cuneiform bone.

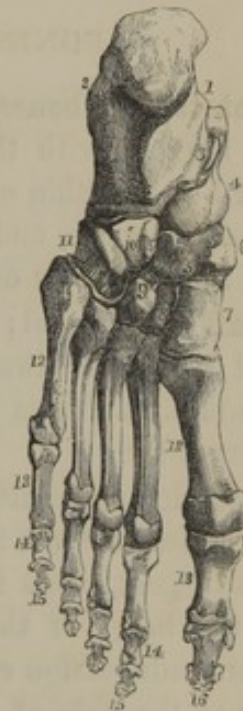The three **Cu'neiform bones**¹ are situated in a row in front of the scaphoid bone, with which they articulate. As expressed by the name, they are wedge shaped. The **internal cuneiform bone**² is the largest, and has its base downward; the **middle cuneiform bone**³ is the smallest, and it, with the **external cuneiform bone**,⁴ have their base upward. The three bones together contribute to the dorsal convexity of the tarsus, and to its plantar concavity. Anteriorly they articulate with the inner three metatarsal bones, and the ^{*}external one also articulates with the cuboid bone.

All the tarsal bones are composed of masses of spongy substance with a comparatively thin investment of compact substance, which presents many perforations for the transmission of vessels.

The tarsus forms one-half of the length of the foot, and is connected near its middle with the leg. Behind the bones of the latter, a small portion of the astragalus and about one-half the length of the calcaneum project, and in front of them project the head of the astragalus, a small portion of the calcaneum, and the five smaller tarsal bones.

The portion of the tarsus in front of the ankle joint, or the **instep**,⁵ is convex on its dorsal surface and concave on its plantar surface. On the

FIG. 117.



SOLE OF THE LEFT FOOT. 1, concavity of the calcaneum; 2, outer face of the same; 3, groove for the tendon of the long flexor of the toes; 4, head of the astragalus; 5, scaphoid bone; 6, its tuberosity; 7, 8, 9, internal, middle, and external cuneiform bones; 10, cuboid bone; 11, its groove for the tendon of the long peroneal muscle; 12, metatarsal bones; 13, first row of phalanges; 14, second row; 15, last row; 16, last phalanx of the great toe.

¹ Ossa cuneiformia; ossa, or ossicula chalcoida.

² Os cuneiforme internum, primum, or magnum.

³ Os cuneiforme medium, secundum, or minus.

⁴ Os cuneiforme externum, or tertium.

⁵ Collum pedis; neck of the foot.

outer part of the tarsus, between the astragalus and calcaneum, is a large space or **sinus**,¹ which narrows into a canal, proceeding obliquely inward and backward to the inner side of the tarsus. Both sinus and canal are occupied by interosseous ligaments connecting the astragalus and calcaneum. Back of the astragalus a groove is observable, leading toward another beneath the lateral process of the calcaneum, both of which accommodate the tendon of the long flexor of the great toe.

The articulation of the astragalus and calcaneum with the other bones of the tarsus is so nearly in a direct line, that it affords a convenient position for disarticulation, when necessary, from injuries of the foot.

BONES OF THE METATARSUS.

The **Metatar'sal bones**,² or those composing the **metatar'sus**,³ correspond in number with the toes, which they join in front. They are enumerated from within outward, have the same general construction as the metacarpal bones, and are slightly bent in their length so as to contribute to the concavity of the sole of the foot.

The **shaft** is trilateral; one surface presenting downward, another outward, and the third inward and upward. The shaft of the outer four bones gradually narrows to its head; that of the great toe is more uniform in diameter.

The **posterior extremity**, or **base**, is the most expanded part, is quadrate, and varies in form with the different bones. The base of the first, at its lower part, has a **tubercle** for the insertion of the long peroneal tendon; the bases of the succeeding three are wedge shaped, and by their lateral adaptation contribute to the convexity of the back and the concavity of the sole of the foot. The base of the last metatarsal is prolonged outward and backward into a **tuberosity** for the insertion of the short peroneal tendon. The bases of the outer four metatarsals articulate with one another by opposed smooth surfaces: those of the inner three metatarsals articulate with the cuneiform bones; and those of the outer two with the cuboid bone.

The **anterior extremity**, or **head**, is constructed like the corresponding part of the metacarpal bones, but is smaller, in proportion with the length of the bones, except in the case of that of the great toe.

The first metatarsal bone is the shortest, but is twice as robust as the others; the second and fifth metatarsals are the longest, and are nearly equal; the third and fourth are next in length, and are also nearly equal. All the metatarsals lie parallel to one another, and they contribute in

¹ Sinus tarsi.

² Ossa metatarsi.

³ Metatarsium; metapedium; præcordium, solum, or vestigium pedis.

their union to the convexity of the back and the concavity of the sole of the foot. The **interos'eous spaces** are enumerated from within outward.

BONES OF THE TOES.

The **Toes**¹ are enumerated from within outward, as the **first** or **great toe**,² the **second**, **third**, **fourth**, and **fifth** or **little toe**. They diminish in length from first to last, and possess the same number of bones as the fingers. The **phalan'ges**,³ or **joints**, of the toes have the same general form as those of the fingers, but are smaller, except those of the great toe, which are as long and of more robust proportions than those of the thumb.

In the first row of phalanges, except in the great toe, the shaft resembles that of the corresponding bones of the fingers, but compressed laterally so as to assume a more cylindroid form.

In the second and third rows of phalanges of the outer two or three toes, the characteristic extremities are so nearly approached that the shaft is more or less obsolete. The second and third phalanges of the little toe are frequently co-ossified.

The two **ses'amoid bones** of the great toe are like those of the thumb, and occupy a corresponding position in the sole of the foot.

THE FOOT.

The **Foot** is placed at a right angle with the leg, and rests upon the ground with the tuberosity of the calcaneum, the heads of the metatarsal bones, and the under parts of the phalanges. The heel projects behind the leg at the outer part of the foot, of which it is the narrowest portion. From the fore part of the tarsus, or the **instep**, the foot in advance gradually expands in breadth and becomes thinner. The **upper** or **dorsal surface**, or **back of the foot**, is convex in its length and breadth; and the **under** or **plantar surface**, or **sole**, in the same direction is concave. The **arch** formed by the foot is higher and more open on the inner side. When covered with soft parts, the heel, outer border of the foot, and the under part of the toes touch the ground; the inner archway constituting the **hollow of the foot**. The feet of the two sides diverge from each other in front, in consequence of the rotary muscles of the thigh directing the limbs outwardly. The hinge-like joint of the ankle

¹ Digiti pedis.

² Pollex pedis; hallux, or hallus.

³ Ossa, articuli, or internodia digitorum pedis.

allows flexion and extension of the foot. In the former movement the foot is bent forward; in the latter the back of the foot approaches the same line as the front of the leg. The movement of the foot directing its sole inward and in a feebler degree outward, occurs between the astragalus and the tarsal bones with which it articulates. The bones of the tarsus and metatarsus together exhibit but very little movement among themselves, with the exception just mentioned. The toes present a greater degree of extension upon the metatarsus than the fingers on the metacarpus, but their power of flexion is much more limited, and that of abduction and adduction are feeble. The phalanges of the toes have the same movements among themselves as those of the fingers, but are restricted from their comparatively feeble development. A continuance of extension of the toes flexes the foot; the reverse action of the toes extends the foot. When the toes are covered with their soft parts, the second appears a little longer than the first, a feature which has not escaped the attention of artists, but the great toe of the skeleton is actually the longer.

DEVELOPMENT OF THE BONES OF THE LOWER EXTREMITY.

The femur begins to ossify about the middle of the second month of embryonic life, being earlier than the vertebral column. At birth its shaft is formed, and an ossific centre has appeared in the lower extremity as an epiphysis. Subsequently the head, the greater and the smaller trochanter successively ossify as epiphyses.

The patella is formed from a single centre of ossification, appearing several years after birth.

The shaft of the tibia commences ossification about the same time as that of the femur, and the shaft of the fibula begins the process a little later. In both bones, after birth, the extremities ossify as epiphyses.

The astragalus and calcaneum begin to ossify before birth; the other tarsal bones subsequently. An epiphysis is developed upon the tuberosity of the calcaneum. The metatarsal and phalangeal bones are ossified in the same manner as the corresponding bones of the hand.

ARTICULATIONS AND MOVEMENTS OF THE LOWER EXTREMITIES.

The support of the trunk of the body requires that the articulations of the lower extremities should be more extensive, and stronger than those of the upper extremities, a condition which has been gained at the expense of comparative freedom in movement. The hip bones,

described as part of the trunk, but which correspond with the bones of the shoulder, are entirely immovable.

THE HIP JOINT.

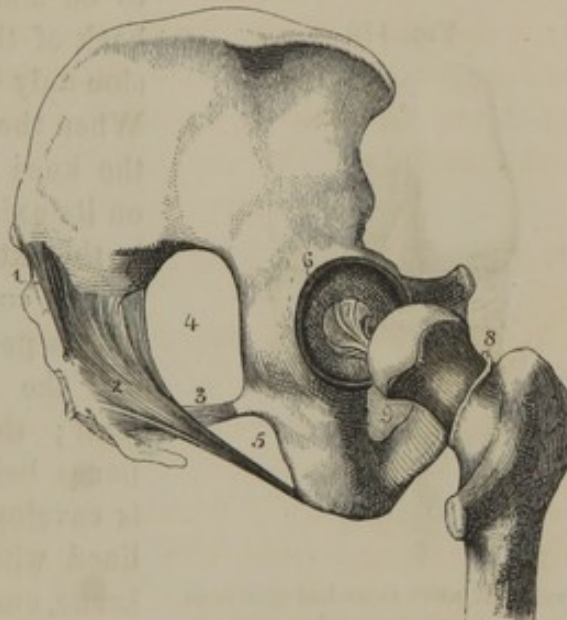
The **Hip joint**,¹ formed between the acetabulum and the head of the thigh bone, is the strongest articulation of the body, and the best instance of a ball-and-socket joint. Though admitting of movement in every direction, it is nevertheless much restricted in this respect in comparison with the shoulder joint.

The acetabulum is deepened by a prismatic fibro-cartilaginous ring, the **cot'yloid lig'ament**,² attached around its margin. As the ligament passes over the cotyloid notch, this is converted into a foramen, which transmits articular vessels into the joint.

From the pit on the head of the femur, a strong fibrous cord, the **round lig'ament**,³ diverges inwardly to be attached to the margins of the cotyloid notch.

The **cap'sular lig'ament**⁴ of the hip joint is the strongest one of the body. It is attached by its upper extremity around the border of the acetabulum, inclosing the cotyloid ligament; and by its lower extremity is attached to the anterior inter-trochanteric ridge of the femur, and less strongly to the neck of the latter just above the posterior inter-trochanteric ridge. In front of the joint it is strengthened by a broad fibrous band, the **ac'cessory lig'ament**,⁵ which is extended between the anterior inferior spinous process of the ilium and the anterior inter-trochanteric ridge. The capsular ligament is surrounded

FIG. 118.



LIGAMENTS OF THE HIP. 1, portion of the posterior sacrospinous ligament; 2, the greater sacrospinous ligament; 3, the lesser sacrospinous ligament; 4, the greater sacrospinous foramen; 5, the lesser sacrospinous ligament; 6, the cotyloid ligament surrounding the acetabulum; 7, the round ligament; 8, attachment of the capsular ligament of the hip joint to the neck of the femur; 9, obturator membrane.

¹ Coxo- or ilio-femoral articulation.

² Labrum cartilagineum.

³ Lig. teres; interarticular ligament.

⁴ Membrana capsularis femoris.

⁵ Superior ligament; ilio-femoral ligament.

with large muscles, which contribute to the strength of the joint. Internally it is lined with synovial membrane, which also invests the neck of the femur, and is reflected upon the round ligament.

Even when all the muscles, together with the capsular ligament surrounding the hip joint, are cut away, it requires considerable force to remove the head of the femur from its socket, in consequence of the pressure of the atmosphere retaining it in position.

THE KNEE JOINT.

The **Knee joint** is the largest and most complex of the articulations. It is hinge like and slightly rotary in its movements. It allows the leg

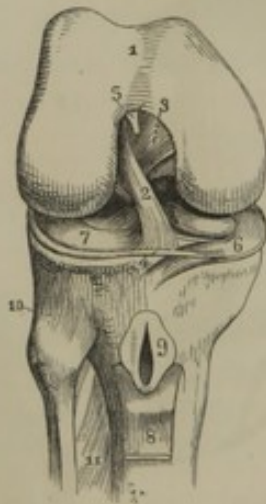
to be almost doubled in flexion on the back of the thigh, but permits its extension only to a straight line with the latter. When the leg is flexed the articulation of the knee permits it to rotate moderately on its axis from side to side, but not when in the extended condition.

The condyles of the femur and tibia, with a pair of interposed fibro-cartilages, and the patella, form the basis of the joint; the contiguous surfaces of the bones being invested with cartilage. It is enveloped in a thin capsular ligament lined with an extensive synovial membrane, and is strengthened by strong cord-like ligaments and the contiguous tendons of muscles.

Upon the condyles of the tibia rest the **semilu'nar fi'bro-cartilages**,¹ a pair of prismoid, C-like plates, with their extremities attached in front and back of the spinous process.² Their exterior border is thick, and they slope off to a

thin interior edge, by which arrangement they deepen the shallow articular surfaces of the tibia into suitable concavities for the play of the

FIG. 119.



THE RIGHT KNEE JOINT, laid open from the front. 1, articular surface of the femur; 2, 3, crucial ligaments; 4, insertion of one of these ligaments into the tibia; 5, attachment of the alar folds of the synovial membrane to the femur; 6, 7, internal and external semilunar fibro-cartilages; 8, ligament of the patella turned down, so as to exhibit the synovial bursa (9) beneath; 10, superior tibio-fibular articulation; 11, interosseous membrane.

¹ Fibro-cartilaginee, or cartilaginee semilunares, interarticulares, falcatae, lunatae, meniscoideae, or sigmoideae.

² The attachments of these fibro-cartilages constitute the ligamenta cartilaginum semilunatarum. A connection of the two in front, the lig. transversum.

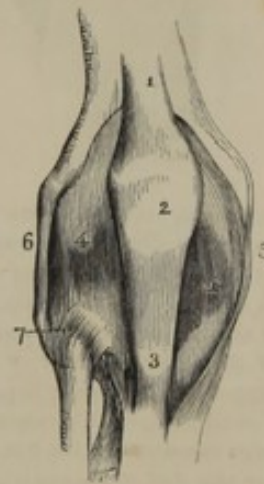
condyles of the femur. The inner fibro-cartilage is adherent by its circumference to the capsular and lateral ligaments; the outer one is not so much adherent, and therefore glides more freely to and fro with the movements of the femur. Besides adapting the condyles of the tibia to those of the femur, the semilunar fibro-cartilages protect the condyles from attrition, act as elastic cushions to reduce the force of concussions, and prevent the atmosphere from pressing the capsular ligament between the bones.

From the sides of the intercondyloid fossa of the femur a pair of strong, fibrous cords, the **cru'cial lig'a-ments**,¹ cross each other and descend to be attached in front and behind the spinous process of the tibia. These ligaments restrict the flexion and extension of the leg, and give firmness to the joint, especially when the limb is flexed.

The **cap'sular lig'ament**² is a thin, capacious envelope, attached to the rough borders of the condyles of the femur and tibia, and the sides of the patella, and associated with the tendons of the various muscles attached in the vicinity of the articulation. It is so thin as to appear to be a mere continuation of the periosteum of the contiguous bones strengthened at particular points with processes from neighboring tendons. A process³ of this kind, at the back of the joint, is derived from the tendon of the semi-membranous muscle, and is extended between the external condyle of the femur and the internal condyle of the tibia.

Above the patella, the tendon of the quadriceps extensor occupies position and function of a strong ligament to the knee joint; below is the **lig'ament of the patel'la**,⁴ a broad, thick, fibrous band, which is an extension of the tendon of the muscle just mentioned descending from the apex and front of the patella to the tuberosity of the tibia. Just above its insertion the ligament is separated from the head of the tibia by a synovial bursa, not communicating with the knee joint.

FIG. 120.



FRONT VIEW OF THE RIGHT KNEE JOINT. 1, tendon of the quadriceps extensor muscle; 2, patella; 3, ligament of the patella, or tendinous insertion of the muscle just mentioned; 4, capsular ligament; 5, 6, internal and external lateral ligaments; 7, superior tibio-fibular articulation.

¹ L. cruciata.

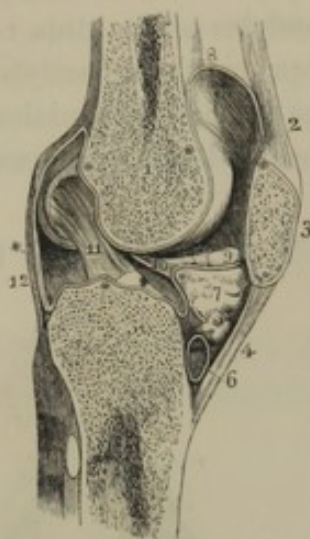
² Membrane capsularis genu.

³ Lig. posticum Winslowii; l. popliteum; posterior ligament.

⁴ Lig. patellæ.

The **internal lateral ligament**¹ of the knee joint is a long, broad, and

FIG. 121.



LONGITUDINAL SECTION OF THE LEFT KNEE JOINT. 1, femur; 2, tendon of the quadriceps extensor muscle; 3, patella; 4, ligament of the patella; 5, tibia; 6, synovial bursa; 7, cushion of fat occupying the angular interval between the patella and head of the tibia; * * * * * reflections of the synovial membrane; 8, pouch of this membrane extending upward between the tendon of the quadriceps extensor and the front of the femur; 9, the outer alar fold of the synovial membrane; 10, connection of the alar folds with the femur; 11, crucial ligament; 12, back of the capsular ligament.

a conical, cord-like process,⁴ ascending obliquely backward, to be attached to the front margin of the intercondyloid fossa of the femur. Above the patella and its trochlea the synovial membrane is reflected as a pouch for several inches upward, between the tendon of the quadriceps extensor and the femur. In the flexion of the leg this pouch is drawn down to the edge of the trochlea of the femur; and in extension is again drawn up by fleshy slips⁵ of the quadriceps muscle. Behind the joint, the synovial membrane extends upward between the condyles of the femur and the tendinous heads of the origin of the gastrocnemius muscle.

strong band, extended between the tuberosity of the internal condyle of the femur and the upper part of the inner border of the tibia. The **external lateral ligament**² is a rounded cord, extended between the tuberosity of the external condyle of the femur and the head of the fibula. These ligaments sustain the firmness of the articulation, more especially in the extended condition of the leg.

The synovial membrane of the knee joint lines the capsular ligament, and is reflected upon the semilunar fibro-cartilages and crucial ligaments. It is also reflected upon a mass of fat intervening between the ligament of the patella and the front of the head of the tibia, and is extended along the sides of the joint as two crescentic appendages named the **a'lar folds**.³

These unite and are prolonged in

¹ L. laterale internum.

² L. laterale externum.

³ Ligamenta alaria; l. alare majus internum et minus externum.

⁴ Mucus ligament; ligamentum mucosum.

⁵ Musculi subcrurales; m. articulares genu.

THE TIBIO-FIBULAR ARTICULATIONS.

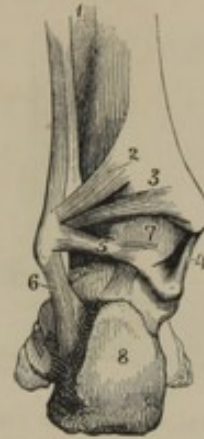The fibula articulates immovably with the tibia.

The **superior tib'io-fib'ular articulation**,¹ between the head of the former and the outer condyle of the latter, has the opposed surfaces covered with cartilage. It is inclosed in a capsular ligament, the stronger portions of which constitute the **anterior** and **posterior ligaments**.

The wide interval between the two bones of the leg is occupied by an **interos'eous membrane**,² composed of parallel fibres descending obliquely from the outer border of the tibia to the opposed border of the fibula. The membrane is perforated above for the passage of the anterior tibial vessels. It gradually narrows below, and between the inferior extremities of the bones consists of short, strong fibres³ firmly connecting them together.

The **inferior tib'io-fib'ular articulation** is strengthened by the **anterior ligament**,⁴ which is an oblique band extending from the front of the tibia downward to the external malleolus; and the **posterior ligament**,⁵ which consists of two bands pursuing the same course behind the bones.

FIG. 122.



POSTERIOR VIEW OF THE INFERIOR TIBIO-FIBULAR AND ANKLE JOINTS. 1, interosseous membrane; 2, 3, two fasciculi of the posterior tibio-fibular ligament; 4, internal lateral ligament of the ankle joint; 5, 6, posterior and outer fasciculi of the external lateral ligament; 7, capsular ligament of the ankle joint; 8, calcaneum.

THE ANKLE JOINT.

The **Ankle joint**⁶ is formed by the transverse arch between the malleoli and the body of the astragalus. It is a simple hinge-like articulation, permitting flexion and extension.

The joint is surrounded by a thin **cap'sular lig'ament**, connecting the contiguous borders of the articular surfaces of the bones, strengthened by lateral ligaments.

¹ Peroneo-tibial articulation.

² Membrana interossea; septum longitudinale interosseum.

³ Inferior interosseous ligament.

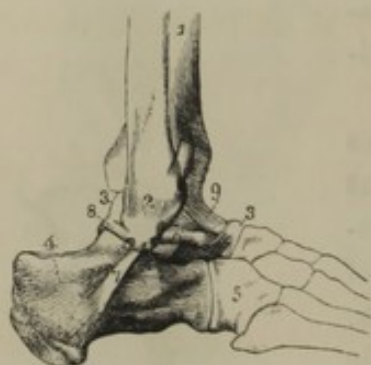
⁴ L. tibio-fibulare anticum superius et inferius; l. malleoli interni anticum.

⁵ L. tibio-fibulare posticum superius et inferius; the posterior and transverse ligaments; l. malleoli interni anticum.

⁶ Articulatio pedis; articulatio talocruralis.

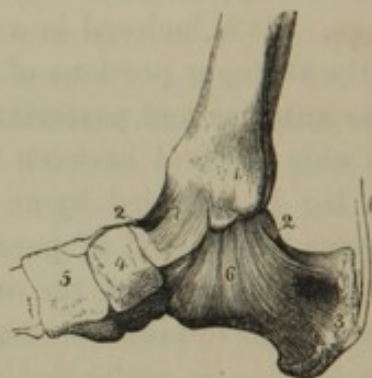The **external lateral ligament**¹ consists of three strong fibrous bands diverging from the outer malleolus; one proceeding backward to the posterior border of the astragalus, a second descending to the outer part of the calcaneum, and the third passing forward to the anterior border of the astragalus.

FIG. 123.



EXTERNAL VIEW OF THE RIGHT ANKLE JOINT. 1, tibia; 2, external malleolus of the fibula; 3, astragalus; 4, calcaneum; 5, cuboid bone; 6, 7, 8, three fasciculi of the external lateral ligament; 9, front of the capsular ligament.

FIG. 124.



INTERNAL VIEW OF THE ANKLE JOINT. 1, internal malleolus of the tibia; 2, astragalus; 3, calcaneum; 4, scaphoid bone; 5, internal cuneiform bone; 6, internal lateral ligament; 7, capsular ligament; 8, Achilles' tendon.

The **internal lateral ligament**² is a strong band diverging from the lower border of the inner malleolus to the corresponding side of the astragalus and the lateral process of the calcaneum.

THE INTERTARSAL AND TARSO-METATARSAL ARTICULATIONS.

ARTICULATIONS OF THE ASTRAGALUS, CALCANEUM, AND SCAPHOID BONE.

The astragalus and calcaneum are conjoined by a thick **interos'eous lig'ament**, occupying the sinus formed by the contiguous grooves of those bones. The ligament separates two joints, of which the posterior is surrounded by a short, thin **cap'sular lig'ament**, lined with a synovial membrane. The other joint is continuous inferiorly with that between the head of the astragalus and the scaphoid bone; both being enveloped in a common **cap'sular lig'ament**, and lined with a continuous synovial membrane. This articulation is strengthened above by a broad fibrous band, the **astrag'alo-scaph'oid lig'a-**

¹ L. laterale externum; l. fibulare tali posticum et anticum et l. fibulare calcanei; l. malleoli externi posticum, medium,

et anticum; l. fibulae posticum, medium, et anticum.

² L. laterale internum; l. deltoides; l. tibio-tarsium.

ment;¹ at its outer side by the **external calcan'eo-scaph'oid lig'ament**,² connecting the corresponding bones in the interval between the astragalus and cuboid bone. Below the articulation is the **inferior calcan'eo-scaph'oid ligament**,³ which is a strong, broad band proceeding from the lateral process of the calcaneum, beneath the head of the astragalus, to the scaphoid bone.

ARTICULATION OF THE CALCANEUM AND CUBOID BONE.

The intervening articulation of the calcaneum and cuboid bone is surrounded by a short **cap'sular lig'ament**, strengthened above and below by a broad band of fibres constituting the **superior and inferior calcan'eo-cu'boid lig'ament**.⁴

ARTICULATION OF THE SCAPHOID, CUBOID, AND CUNEIFORM BONES TOGETHER AND WITH THE BASES OF THE METATARSAL BONES.

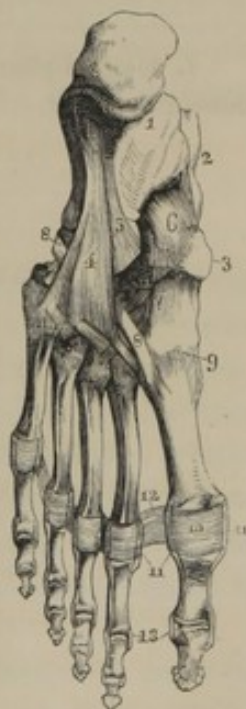All the bones here mentioned, with the exception of the first metatarsal, are joined with one another, on the back and sole of the foot, by fibrous bands associating those contiguous, and constituting the **dor'sal and plan'tar lig'aments**,⁵ which together form a sort of capsular ligament.

Interos'eous lig'aments,⁶ consisting of short intervening fibres, conjoin the scaphoid with the cuboid bone, the latter with the external cuneiform bone, the three cuneiform bones with one another, and the bases of the outer four metatarsal bones.

The synovial membrane of the articulation of the scaphoid and cuneiform bones is prolonged to that

LIGAMENTS OF THE SOLE OF THE FOOT. 1, calcaneum; 2, astragalus; 3, scaphoid bone; 4, long plantar ligament; 5, inferior calcaneo-cuboid ligament; 6, inferior calcaneo-scaphoid ligament; 7, plantar ligaments between the cuneiform bones and base of the metatarsus; 8, tendon of the long peroneal muscle passing through a groove of the cuboid bone above the long plantar ligament to be inserted into the first metatarsal bone; 9, capsular ligament between the latter and the internal cuneiform bone; 10, plantar ligaments, having the same relationship with the metatarso-phalangeal and phalangeal articulations that the palmar ligaments have with the corresponding joints of the fingers; 11, lateral ligaments; 12, transverse ligaments; 13, lateral ligaments of the phalangeal articulations.

FIG. 125.



¹ L. astragalo-scaphoideum.

² L. calcaneo-scaphoideum externum, interosseum, or dorsale; 1. calcaneo-naviculare interosseum.

³ L. calcaneo-scaphoideum inferius; 1. calcaneo-naviculare plantare.

⁴ L. calcaneo-cuboideum superius et inferius, or dorsale et plantare, or breve.

⁵ L. dorsalia et plantaria.

⁶ L. interossea.

of the cuboid and external cuneiform bone, and also to the articulation between the outer two cuneiform and the second and third metatarsal bones. Another synovial membrane lines the joint of the cuboid and outer pair of metatarsal bones.

The first metatarsal bone and internal cuneiform bone form a separate joint surrounded by a **capsular ligament** with a distinct synovial membrane.

The **Long Plan'tar lig'ament**,¹ the most conspicuous of the ligaments of the foot, commences on the under surface of the calcaneum, and proceeds forward, gradually expanding, to be attached to the tuberosity of the cuboid bone and the bases of the last two metatarsal bones. It converts the groove of the cuboid bone into a canal, through which passes the tendon of the long peroneal muscle.

METATARSO-PHALANGIAL AND PHALANGIAL ARTICULATIONS.

The **metatar'so-phalan'gial** and **phalan'gial articulations** are constructed exactly like the corresponding joints of the hand.

¹ L. longum-plantæ; l. calcaneo-cuboideum plantare; inferior or long calcaneo-cuboid ligament.

CHAPTER III.

THE FIBROUS, CARTILAGINOUS, FIBRO-CARTILAGINOUS, ELASTIC, AND ADIPOSE TISSUES.

IN describing the articulations of the skeleton, many structures were mentioned, which enter into their composition, in addition to the bones. As these structures likewise enter into the constitution of many other parts of the body, it has appeared to us convenient to defer an examination of their nature until the present moment. Those to which we especially refer are the fibrous, cartilaginous, fibro-cartilaginous, and elastic tissues. To these we might add the serous, adipose, and muscular tissues, but an account of the former and latter will be deferred to other opportunities; while the adipose tissue, which appears to be unessential to the constitution of any organ, may be conveniently described in the present chapter.

FIBROUS TISSUE.

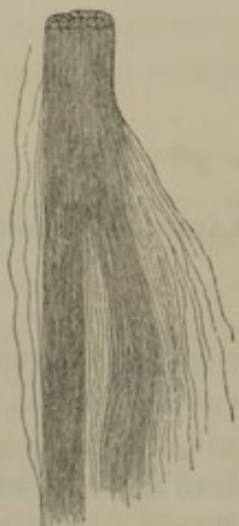Fi'brous tis'sue¹ is one of the most abundant and extensively diffused materials of structure of the body. It mainly composes the dermis or true skin; the superficial and deep fasciæ; the periosteum and perichondrium; nearly all the ligaments; the sheaths of blood-vessels and nerves; the tendons, aponeuroses, and sheaths of muscles; the dura mater, sclerotica, and the outer layer of the pericardium; the capsules of the spleen, kidneys, testes and ovaries; the submucous, subserous, and subglandular tissues; and the general connective or areolar tissue of most organs of the body.

Fibrous tissue is white, bluish white, or yellowish white, and more or less glistening. When dried it becomes hard, yellow, and transparent; but assumes its former appearance on the imbibition of water. It is the strongest and most tenacious of all animal tissues, is very inextensible, but highly flexible. From these physical properties it is admirably adapted to the various purposes for which it is employed in the

¹ White fibrous tissue.

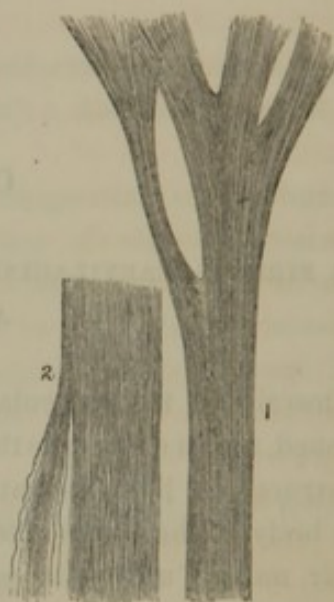
body, viz., the protection, sustaining, and connection of other tissues and organs.

FIG. 126.



EXAMPLE OF FIBROUS TISSUE. Portion of one of the lateral ligaments of a phalangeal articulation, exhibiting its composition of bundles of parallel filaments of fibrous tissue; highly magnified.

FIG. 127.



EXAMPLES OF FIBROUS TISSUE. 1, a small tendinous cord from the right ventricle of the heart. The upper extremity exhibits its division and expansion into the edge of the tricuspid valve. 2, a portion of the dura mater of the spinal cord.

The great strength, tenacity, and durability of fibrous tissue have rendered it of important service in the arts. The so-called "cat-gut," fiddle strings, and the like, are the twisted fibrous structure of the small intestine of the sheep. All varieties of leather consist of the fibrous derm of the skins of animals, rendered less liable to the ordinary causes of decay by union with certain chemical substances, such as tannin. Parchment is likewise derived from the same source; and the savage finds it invaluable as a bow-string.

By boiling fibrous tissue it is resolved into gelatin; and hence fragments of skin, tendons, and ligaments are the chief source of the glue of commerce.

Fibrous tissue is mainly composed of exceedingly fine homogeneous filaments, measuring from the $\frac{1}{300000}$ to the $\frac{1}{100000}$ of an inch in diameter, collected into minute inextensible bundles, which may be associated into larger bundles, as in the formation of tendons and ligaments, or they may interlace with one another into more or less extensible membranes. The intervals of the bundles of filaments of fibrous tissue are occupied by a colorless homogeneous liquid resembling serum, but its exact nature has not been positively determined.

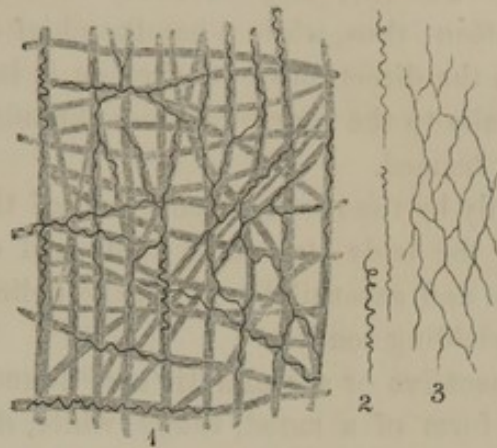
All structures of fibrous tissue contain more or less intermingled elastic tissue in the character of slender fusiform fibres, or as fine networks. The elastic tissue is rendered evident, on treating portions of any of the fibrous structures with acetic acid, beneath the microscope. By this process the fibrous tissue is rendered so transparent as to appear indistinct, while the fibres of the elastic tissue become sharply defined.

In the formation of tendons, the primary bundles of fibrous tissue are closely associated parallel to one another, thus producing strong inextensible cords, admirably adapted to convey the muscular power to the bone or other part to be moved. Likewise in the construction of the band-like ligaments, intended to unite the bones in the strongest manner, the fibrous tissue is collected into parallel bundles, permitting free flexibility, but no stretching or extensibility.

In the constitution of aponeuroses, the deep fasciæ, and the dura mater, bundles of fibrous tissue are arranged parallel to one another in layers, and crossed by bundles which closely associate the former together.

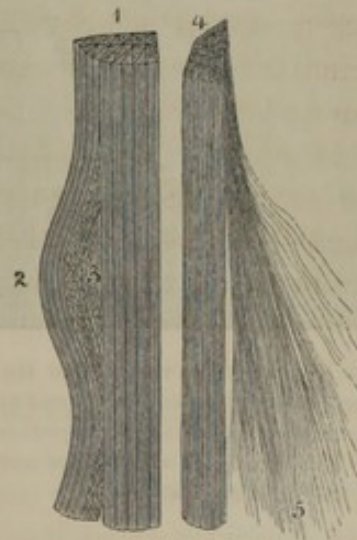
In most other fibrous structures, the filaments and bundles of fibrous tissue interlace with one another in such a manner as to permit of more or less extensibility. This property

FIG. 128.



1, PORTION OF CONNECTIVE TISSUE, from that which envelops the flexor tendons of the fingers as they pass beneath the annular ligament, treated with acetic acid. The pale, dotted portion is intended to represent the fibrous element fading away; the blacker tortuous lines and nets represent the mixture of elastic tissue. 2, 3, simple tortuous fibres, and a net of elastic tissue, isolated from the preceding specimen.

FIG. 129.



FIBROUS TISSUE. 1, portion of tendon exhibiting its composition of prismatic bundles of fibrous tissue, the filaments all parallel to one another; 2, a few bundles drawn from the others, exhibiting their union by delicate crossing filaments of connective tissue, (3) one of the varieties of fibrous tissue; 4, a single bundle, more highly magnified, with a portion (5) of the filaments fretted out.

is, however, entirely dependent on the arrangement alone of the fibrous tissue, as it is in all cases entirely inextensible in the direction of its filaments. The fact may be easily understood by referring to a familiar illustration: thus, while a handkerchief or other similar fabric is inextensible in the direction of its threads, it is quite extensible and contractile diagonally to the course of those threads, or in the bias direction, as it is usually termed.

Simply by the arrangement then of the filaments of fibrous tissue, we find in the body structures composed of it exhibiting every degree of softness and extensibility, from the delicate, cottony connective tissue, to the unyielding tendon.

Connect'ive or are'olar tis'sue,¹ found almost everywhere in the body in the form of a moist, tough, white, downy substance, is composed of

FIG. 130.



PORTION OF CONNECTIVE TISSUE, from the axilla, exhibiting its composition of bundles and filaments of fibrous tissue crossing in every direction. The rounded bodies represent a single row and a portion of a small group of fat cells.

FIG. 131.



CROSSING BANDS OF FIBROUS TISSUE, from the external, or fibrous coat of the facial artery. Intervals are left in the drawing to exhibit clearly that there are two layers of fibrous tissue, of which the filaments cross one another in their spiral course around the vessels.

interlacing bundles of fibrous tissue, and of all materials is the best adapted, from its combined strength, softness, and yielding character, to connect, sustain, and strengthen organs, while it permits a certain degree of mobility among them. Thus it tenaciously holds together the vessels,

¹ Cellular tissue; *tela cellulosa*, or *cellularis*; reticulated, filamentous, laminated, or porous tissue; cellular, or reticular substance; *contextus cellulosus*; *ethmype*, *tela Hippocratis cribrosa*.

nerves, muscles, bones, and skin, fills up intervals and forms soft beds of support for them, and yet allows them moderate freedom of movement. In like manner it holds together the muscular fibres, the nerve fibres, and the constituents of other tissues, and gives them strength without inconveniently impeding their movements. Comprising as it does the submucous and subserous layers of the hollow viscera, while these derive from it their main strength, it yet permits their expansion.

In the sheath of blood-vessels and muscular fasciculi, the filaments of fibrous tissue cross one another diagonally to the course of the former in a most beautiful manner, and while they give strength they allow movement in all directions. While the band-like ligaments, composed of parallel bundles of fibrous tissue, firmly unite the bones and are simply flexible, the capsular ligaments, composed of interlacing bundles of the same material, are moderately extensible. The tendon, composed of closely parallel bundles of fibrous tissue, does not stretch, but follows the contraction of the muscle whose swelling form is observed through the more yielding fasciæ and skin.

The fibrous tissues are furnished with comparatively few and small blood-vessels; the large arteries and veins frequently observed in them, as for instance in the submucous tissues and the dura mater, being destined to supply the contiguous structures. The nerves are also few, and hence the sensibility of these tissues is of the feeblest character. The dermis would appear to be an exception in comparison with other fibrous structures, but the vessels and nerves in this case are rather intended for the functions of various accessory parts, as for example the papillæ of touch and of the hairs, the glands, and the epidermis.

Fibrous tissue, of all others, appears to be the most easily reproduced in cases where it has been destroyed. It forms the structural element of most cicatrices, false membranes, adhesions, etc.

CARTILAGE AND FIBRO-CARTILAGE.

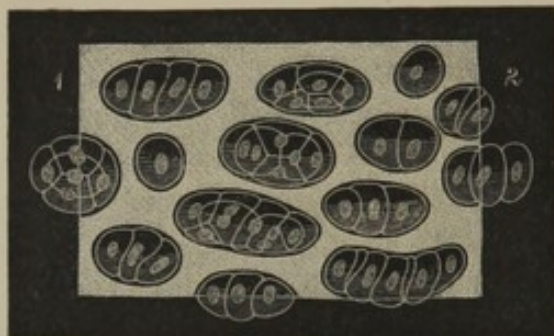
Car'tilage or **gristle**¹ is a dense substance, of less hardness than bone, of a bluish-white or yellow color, with an opalescent or pearly appearance. It is elastic, flexible but inextensible, and, though of firm consistence, is less tough than fibrous tissue. Easily cut or sliced with the knife, in thin pieces it is translucent; and to the naked eye appears homogeneous in structure. By drying it becomes very hard, yellow, and

¹ Cartilago; chondros.

transparent, but readily assumes its former condition through the imbibition of water.

From its physical properties cartilage is admirably adapted to con-

FIG. 132.



CARTILAGE; section through the thickness of the oval cartilage of the nose. 1, toward the exterior; 2, toward the interior surface; highly magnified. It exhibits groups of cartilage cells imbedded in a homogeneous or faintly granular matrix.

tribute to the formation of the joints of the skeleton, and to give form and strength to other organs, without too great a degree of rigidity. It constitutes the articular cartilages, the cartilages of the ribs, those of the larynx, except the epiglottis, those of the trachea and its divisions, and those of the nose.

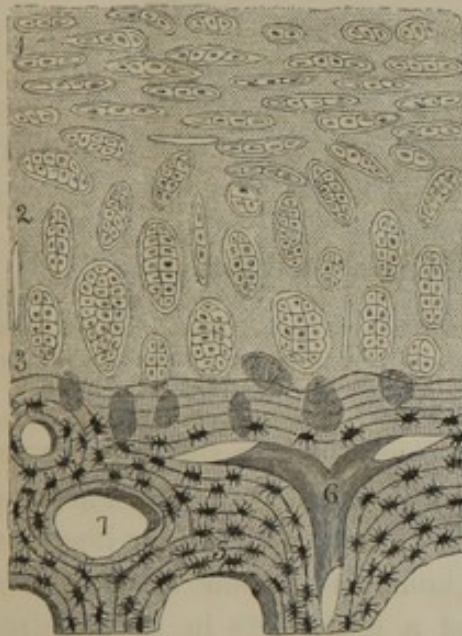
In association with fibrous tissue it forms the fibro-cartilages, as the intervertebral disks, the fibro-cartilages of the symphyses, the inter-articular fibro-cartilages, the epiglottis, the cartilages of the ear and Eustachian tube, and those of the eyelids.

The bones originate, for the most part, in the condition of cartilage, and to a much less degree in the form of fibrous tissue; and their subsequent development and growth are step by step preceded by a production of the latter tissues. The cartilages which ossify and form part of the skeleton are commonly termed **temporary car'tilages**; although the others, named in contradistinction **permanent car'tilages**, in many cases at a later period of life become ossified, or show more or less disposition to do so. Thus the cartilages of the larynx may become completely ossified, and the costal cartilages are liable to partial ossification. The articular cartilages, the cartilages of the nose, and the fibro-cartilages exhibit no tendency to ossification, at least under ordinary circumstances.

In structure, cartilage consists of a solid matrix with imbedded nucleated cells. The matrix is colorless and translucent, or resembles in appearance ground glass, or it is faintly amber colored. It is amorphous, indistinctly granular, or obscurely filamentous, passing into a distinctly fibrous condition. The nucleated cells may be single, but are usually in compressed, elongated oval groups, which seem as if they had originated through the division of simple cells, as they are seen in the earliest condition of cartilage. In the deeper part of the articular cartilages, and the more interior part of the others, the groups of cells are arranged vertically to the direction of the free surfaces; but, approaching the latter, they become more numerous and parallel to them. The car-

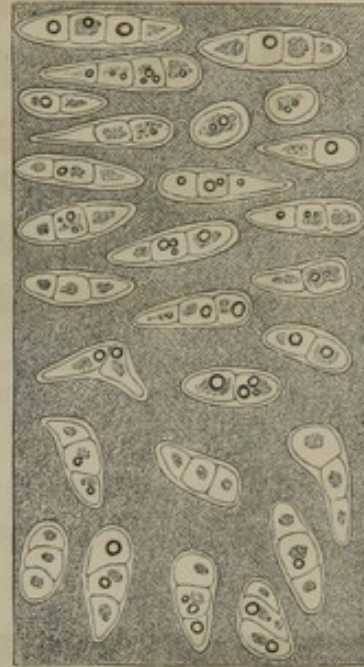tilage cells are observable from single ones up to groups of twenty or more. They have more or less thickened walls, with faintly granular contents, usually a nucleus, and frequently one or more oil globules.

FIG. 133.



VERTICAL SECTION OF ARTICULAR CARTILAGE, from the carpal surface of the radius. 1, 2, 3, articular cartilage; below this is a portion of the bone, 5, 6, 7. 1, exterior portion of the cartilage, exhibiting the groups of cells lying parallel to the slightly irregular free surface; 2, 3, the cells arranged vertically in the deeper part of the cartilage; 4, groups of cells obscured by osseous deposits; 5, structure of the bone, exhibiting the concentric laminae, and lacunae; 6, a vascular canal; 7, a marrow areola of the spongy substance of the bone. The specimen is highly magnified, but the depth of the articular cartilage is proportionately reduced, so as to exhibit the relation of all the parts without making too large a figure.

FIG. 134.



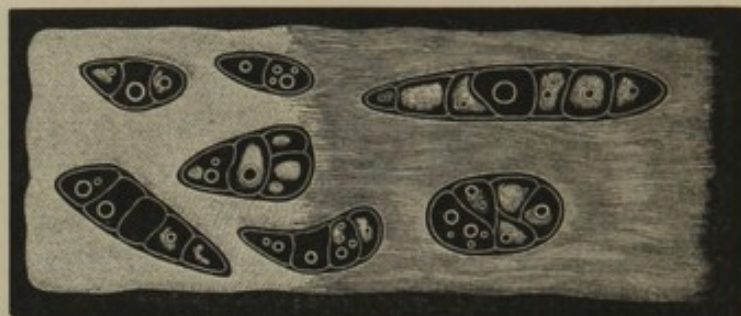
SECTION OF COSTAL CARTILAGE. The upper part is toward the exterior surface, where the groups of cells are arranged parallel to it; the lower part is toward the interior, where the groups are arranged vertically to the free surfaces; highly magnified.

Fi'bro-car'tilage consists of a more or less dense fibrous matrix, with imbedded cartilage cells. Between pure fibrous tissue and pure cartilage we may distinguish very various degrees of intermixture of

the two elements in the constitution of the fibro-cartilages. Thus the cartilages of the eyelids, and the semilunar and other interarticular cartilages, are almost entirely composed of fibrous tissue. This is likewise the case with the exterior of the intervertebral disks, but the more pulp-like central portion contains numerous mingled cartilage cells. In the cartilages of the ear and the epiglottis a more equal admixture of the two elements is observable, groups of cells being contained in the meshes of an intricate intertexture of fibres. Even in the costal cartilages, classed with the pure cartilages, portions of the interior not unfrequently present a decidedly fibrous matrix, including the cell groups.

Fibro-cartilages combine the elasticity of cartilage with the tenacity of fibrous tissue, and are well adapted for the firmest union of bones, accompanied with a moderate degree of flexibility.


FIG. 135.



SECTION OF COSTAL CARTILAGE, crossing the free surfaces, but taken from near the centre. To the left, which was toward the exterior surface, the groups are imbedded in a homogeneous matrix; toward the right, the matrix has assumed a decidedly fibrous character. Specimen from an adult of about forty years of age.

By long boiling cartilage is resolved into chondrin, a substance resembling gelatin, but, unlike it, is precipitable by the mineral acids. The mineral salts of cartilage are like those of bone, and amount to about three and a half parts in the hundred.

FIG. 136.



SECTION OF FIBRO-CARTILAGE FROM THE AURICLE OF THE EAR. The cells are seen imbedded in a fibrous matrix. 1, exterior surface, where the cells are parallel to it; 2, toward the middle. Highly magnified.

Fibro-cartilage, by boiling is resolvable into gelatin.

The **articular cartilages** consist of thin layers covering the articular surfaces of bones in the construction of movable joints. They are entirely non-vascular, and devoid of nerves; but they derive nourishment from the blood-vessels in contact with their surface beneath or continuous with the bones. The

other cartilages are invested with a fibrous membrane, named the **perichon'drium**, which serves as a means of attachment with contiguous parts, and as a nidus to the blood-vessels nourishing the cartilages. The comparatively thick costal cartilages are pervaded with vascular canals, continuous with those of the ribs, and contain nutrient vessels communicating with those of the latter and of the perichondrium. Fibro-cartilages receive more vessels than the true cartilages, but the number of them is very small.

ELASTIC TISSUE.

The **Elas'tic tissue**,¹ though widely distributed in the body, seldom forms masses of any important size. It composes the yellow ligaments of the vertebral arches; is the chief component of the thyro-hyoid ligament, the vocal membrane, and the structure conjoining the rings of the trachea and bronchia; and it enters largely, in association with muscular tissue, in the formation of the middle coat of the blood-vessels. In small quantity it is found mingled with most of the fibrous structures, as the dermis, the superficial fasciæ, etc.

In its most striking condition of development it is observed composing the nuchal ligament of quadrupeds, especially the more bulky ones, as the elephant, elk, and the ox, in which, through its elasticity, it sustains the weight of the head, and thus economizes muscular power. In the same animals it also constitutes a strong layer in the abdominal wall, where it sustains the pressure of the contained viscera.

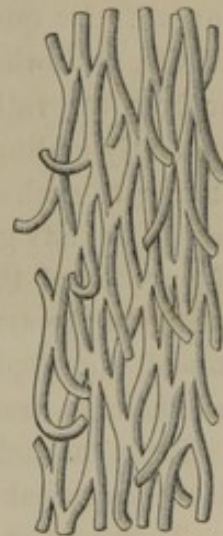
Elastic tissue in its ordinary condition is dull yellow, opaque, tough, and coarsely fibrous. Viewed by means of the microscope, it is found to be composed of reticulating fibres, the abruptly broken ends of which appear curled. The fibres vary exceedingly in diameter in different parts of the body. Those found in the subserous or submucous tissues form nets of filaments almost as fine as those of fibrous tissue. Those of the yellow ligaments of the vertebræ measure about the $\frac{1}{5000}$ of an inch in diameter. Finally, in the middle coat of the blood-vessels the elastic tissue in part consists of wide reticular bands, together having the appearance of a perforated membrane.²

In the formation of ligaments and membranes, the bundles of elastic tissue composing them are associated by areolar tissue, and the former also are invested with the same material as the latter.

Long boiling resolves elastic tissue into a brownish liquid, which smells like glue, but does not form a jelly on cooling.

The structures composed of elastic tissue are furnished with few blood-vessels, the capillaries of which pursue the general course of the fibres

FIG. 137.



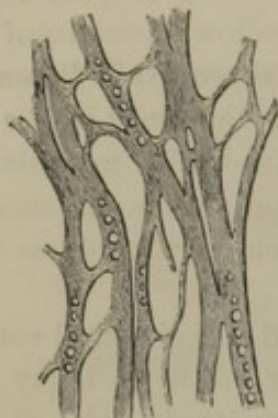
ELASTIC TISSUE, highly magnified, from the yellow ligaments of the vertebræ. The specimen is observed to be composed of coarse anastomosing fibres.

¹ Yellow elastic tissue. ² Perforated, or fenestrated membrane; striated membrane.

of the former. The supply of nerves is small, and little is known in regard to them.

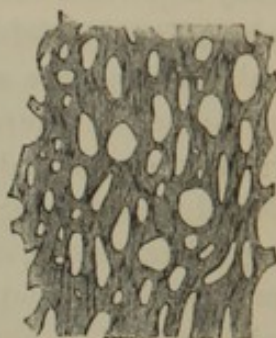FIG. 138.

Fig 240



ELASTIC TISSUE, from the middle coat of the pulmonary artery of the horse; highly magnified.

FIG. 139.



ELASTIC TISSUE, from the middle coat of the carotid artery of the horse; highly magnified.

ADIPOSE TISSUE.

Ad'ipose or **fat tis'sue** is remarkable as a physical element of the body, from the fact that it does not appear to be essential to the constitution of any organ. Its quantity depends much upon the condition of health, habits of life, and other circumstances of the individual; in certain diseases, or from starvation, disappearing almost entirely; in healthy persons frequently adding greatly to the bulk of the body, and sometimes accumulating to such an extent as in the condition itself to be viewed as a disease. It exists generally wherever connective tissue is found, occupying the areolæ of the latter, and filling the interspaces of organs, thus contributing to the symmetry of form of the body.

Examined microscopically, adipose tissue is observed to consist of masses of delicate, transparent vesicles, distended with a liquid, yellowish fat. From mutual pressure the fat vesicles are polyhedral, but when isolated are spherical and of variable diameter, but average the $\frac{1}{400}$ of an inch. They consist of nucleated cells, the nuclei of which are attached to the walls of the latter, and are rendered invisible by the presence of the contained oil. In emaciated or dropsical subjects these cells may often be detected with the nucleus distinctly visible, and with the cell contents consisting of a serous liquid and one or more drops of yellow oil.

Adipose tissue forms a considerable and continuous layer¹ beneath the skin, lodged in the meshes of the dermis and in the adjacent connective tissue. In this position it is most abundant in the female, contributing

¹ Panniculus adiposus.

mainly to her characteristic, rounded symmetry of form. It is especially thick beneath the skin of the breast, abdomen, and buttocks. In the palms of the hands and soles of the feet, it serves as an elastic cushion to relieve the influence of pressure, and is always present, even under the greatest extent of emaciation. Mostly it is confined to the subcutaneous layer of the superficial fascia, and only when excessive does it pervade the deeper layer of the same fascia.

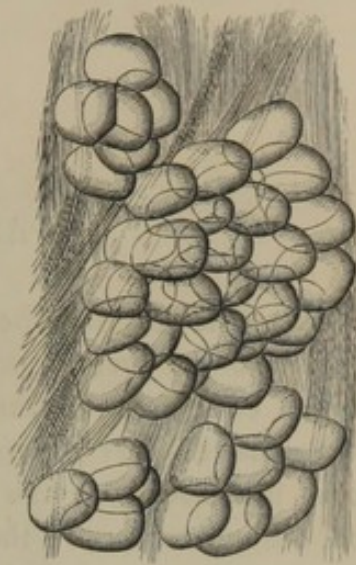
The adipose tissue also occupies the intervals of muscles, the hollows of the temples and cheeks, and the interspaces of the important organs of the orbits. The disappearance of this material in disease gives rise to the sunken appearance of the eyes, the cheeks, and the temples.

Adipose tissue also collects along the course of the blood-vessels and nerves, especially those of the heart and intestines. It often accumulates in large quantity around the kidneys and the lower extremity of the rectum, and between the folds of the peritoneum; according to its extent in these positions producing in a great measure the protuberant abdomen of fat persons. It likewise constitutes the marrow of the medullary cavities of bones, fills up intervals about the joints, and occupies the synovial folds; but surrounding the articulations it is usually in less quantity than elsewhere subjacent to the skin.

In the healthy condition, no adipose tissue exists in the subcutaneous connective tissue of the eyelids, and of the penis and scrotum. It also does not exist in the submucous connective tissue; nor is it found in the interior of the cranium, the dura mater of the spinal cord, the eyeball, or the lungs.

The blood-vessels of the adipose tissue form a capillary net, with polyhedral meshes, including the fat vesicles. Nerves are transmitted to important structures through adipose tissue, but appear to give it no branches.

FIG. 140.



ADIPOSE TISSUE, WITH CONNECTIVE TISSUE, from the superficial fascia of the abdomen; highly magnified. The groups of fat vesicles are observed contained in the meshes of connective tissue.

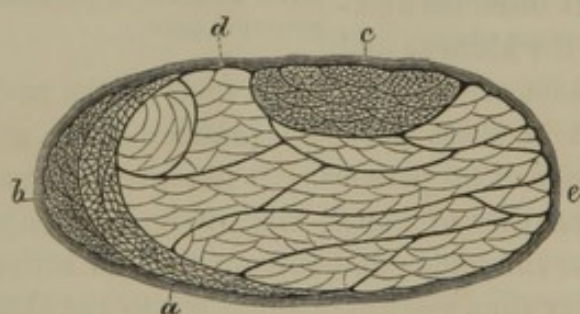
CHAPTER IV.

THE MUSCULAR SYSTEM.

THE **Mus'cles**¹ are the principal organs of motion in animals. They constitute the greater portion of the human body, and in an important degree contribute to the production of its outward form. They are numerous, of very different sizes, and of various shapes, dependent in some measure upon the position they occupy. They consist of a soft, red, fleshy part, named the **belly**,² usually attached, by means of **ten'dons**, between two or more points of the skeleton. The substance of the muscular belly, named **flesh** or **mus'cle**, is the active agent of motion, while

the tendons are entirely passive, simply communicating the power of the former to the part to be moved.

FIG. 141.



TRANSVERSE SECTION OF THE LOWER END OF THE ULNO-CARPAL FLEXOR, moderately magnified. *a*, section of tendon appearing as two crescents, composed of prismatic fasciculi of fibrous tissue; *b*, a secondary fasciculus of crescentic shape, consisting of primary bundles of muscular fibres; *c*, a flattened cylindrical secondary fasciculus, consisting of primary bundles of muscular fibres; *d*, secondary and primary bundles in outline; *e*, sheath of the muscle, composed of fibrous tissue.

FIG. 142.



TRANSVERSE SECTION OF A MUSCULAR FASCICULUS, exhibiting its prismoid form, and its composition of prismatic muscular fibres. From the biceps flexor of the arm. Highly magnified.

The belly of a muscle is composed of an aggregation of peculiar, soft, red fibres, named **mus'cular fi'bres**.³ These are collected into **primary bundles**, or **fascic'uli**,⁴ which are associated into larger or **secondary fascic'uli**, and these again may unite in the formation of still coarser bundles, as those of the great gluteal muscle. The fibres and fasciculi

¹ Musculi. Singular: musculus; laceratus; torus; mys.

² Venter, or medium musculi.

³ Fleshy fibres. Sing.: fibrum musculare; fibrilla muscularis.

⁴ Lacerti musculorum.

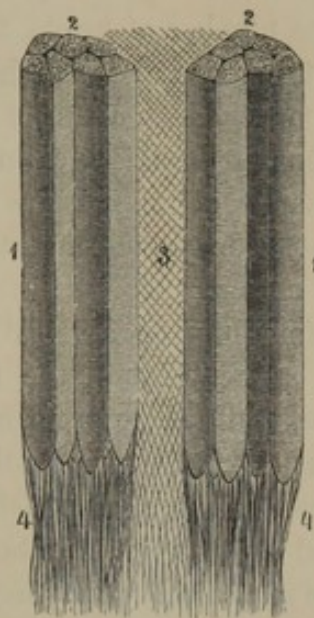
are held together and enveloped with delicate connective tissue, the filaments of which cross one another diagonally to the direction of the former, as represented in figure 143, so as to interfere in the least degree with muscular movement. The prismatic form of the fibres and fasciculi enables them to give the most compact condition to the muscles, and thus economize space.

In some muscles the fasciculi run parallel to one another throughout the length of the former, as in the sartorius and gracilis muscles. In others, they converge from one attachment to the other, producing a triangular or *ra'diated mus'cle*,¹ as in the temporal and pectoral muscles. In some, the fasciculi converge toward both attachments, as in the biceps flexor of the arm. In others, the fasciculi converge from each side of a muscle to a median tendon, producing what is called a *pen'niform mus'cle*,² from its resemblance in arrangement to a feather, as in the rectus muscle of the thigh, or the dorsal interosseous muscles of the hand. When the fasciculi of a muscle proceed obliquely from one attachment to a tendon on the other side, a *semi-pen'niform mus'cle* is produced,³ as in the case of the peroneal muscles of the leg.

From their extent, muscles are often mentioned as **long, short, and broad muscles**; from their form, as **triangular, quadrate, terete or rounded, fusiform, and ribbon-like muscles**; and from the direction of their fasciculi, as **straight, oblique, and transverse muscles**.

The point of attachment of a muscle from which it ordinarily acts is called its **origin**, and the corresponding extremity of the muscle is named its **head**. The point of attachment which is to be moved is called the **insertion**. Generally, the origin is the point of attachment nearest the vertebral column. Functionally, the origin and insertion, if these be viewed as the fixed and moving points, will vary according to the circumstances in

FIG. 143.



TWO PORTIONS OF A MUSCULAR FASCICULUS, from the trapezius muscle; highly magnified. 1, two portions of a muscular fasciculus, composed of prismatic striated fibres terminating below, in rounded extremities, among the fibrous tissue of the commencing tendon; 2, cut extremities of the fibres, showing their prismatic form; 3, delicate sheath composed of obliquely crossing filaments of fibrous tissue; 4, the fibres of the commencing tendons. Partly a diagram.

¹ M. radiatus.² M. penniformis; m. pennatus.³ M. semi-penniformis.

which the body is placed. Thus, the muscles emanating from the trunk and shoulders, which ordinarily raise the arms, by fixing the latter, may be made to raise the body, as instanced in the experiment of elevating the head to the level of a horizontal bar placed above it.


The number of points of attachment of muscles varies, and thus the latter are said to **arise** by one, two or more heads, as the case may be. From the number of heads, the muscles are mentioned as **single headed**, **biceps**, **triceps**, and **many headed**. The number of insertions likewise vary, a muscle with a single head not unfrequently ending in a number of tendons of insertion, as in the common extensor of the fingers.

The names of the muscles are derived from some prominent character, as the position, direction, form, attachments, number of heads, or physiological action.

The **ten'dons** or **sinews**¹ vary in character, some consisting of the shortest attachment of the muscular belly to the points of origin and insertion, while some are spread out in broad membranous expansions, named **aponeuro'ses**,² and others form strong, flattened, cylindrical cords. They are bluish or yellowish white, longitudinally striated, and glistening; and are very flexible but entirely inextensible. In their connection with the muscular bellies they usually commence in the interior as a wide expansion, or upon the exterior as an aponeurotic facing. From the belly, the tendons may continue with the same width to their origin and insertion, but frequently become gradually narrowed into flattened, cylindrical cords.

As relates to the more intimate structure of the muscles, an examination of both the muscular and tendinous tissue is required.

FIG. 144.



TWO MUSCULAR FIBRES, from the lower end of the ulno-carpal flexor; highly magnified. To the right of the figure, the muscular substance is observed to be gradually resolved among the fibrous tissue of the commencing tendon.

The muscular fibres, viewed with the microscope, are found to be of variable diameter, though uniform in each case, and they average about the $\frac{1}{400}$ of an inch. They appear moderately translucent, pale

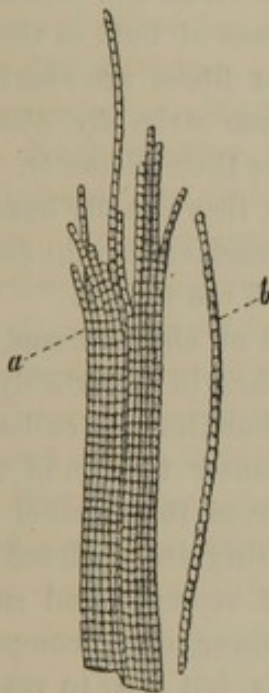
¹ Leaders; thews. Sing.: tendo; tenon; pronervatio.

² Sing.: expansio nervosa; denervatio; pronervatio.

reddish, faintly striated longitudinally, and distinctly and regularly striated transversely, whence the name applied to them of **striated muscular fibres**,¹ in contradistinction to those of the hollow viscera, which for the most part are unstriated.

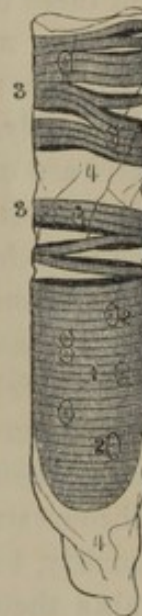A further analysis of the muscular fibres proves each to consist of a bundle of numerous and exceedingly minute filaments, named **muscular fi'brils**, inclosed together in a delicate wall of structureless membrane called the **myolem'ma**.² The muscular fibrils are composed of highly refractive particles³ of uniform size and arrangement, to which is due the regularly transverse striated appearance of the muscular fibres.

FIG. 145.



FIBRILS FROM A MUSCULAR FIBRE OF THE AXOLOTL, a batrachian reptile; highly magnified. *a*, Bundle of fibrils; *b*, an isolated fibril.

FIG. 146.



A MUSCULAR FIBRE OF A SALAMANDER, a batrachian reptile, which had been long kept in weak alcohol. 1, muscular substance; 2, nuclei; 3, muscular substance split into disks; 4, the myolemma.

Occasionally the latter are broken in the direction of their transverse striæ, when they appear as if composed of a series of superimposed disks, as represented in figure 146.

The muscular fasciculi, in approaching their tendinous connections, become pointed, from one muscular fibre after another ceasing in the tendinous structure. In many instances the muscular fibres terminate in rounded or bluntly-pointed extremities, but in other instances the fibrils of the fibres appear gradually to resolve themselves among the tendinous structure.

¹ Striped muscular fibres.

² Sarcolemma.

³ Myoline; sarcous element, matter, or substance.

When treated with acetic acid the muscular fibres are rendered more translucent, and a number of elongated nuclei, imbedded among the fibrils, are brought into view. These nuclei remain from the organic cells, from which the muscular fibres were originally developed.

Muscular fibres possess the property named **contractility**, which is excited ordinarily during life through impressions received from the nervous system, though a variety of stimuli, as mechanical irritation, chemical agencies, change of temperature, and electricity, are capable of calling it into action. By this property the muscles shorten or contract, and thus by approaching the two extremities move the insertion. When the contraction ceases, the muscles again become elongated, and the contractile power is lost only with the death of the muscular tissue. With the contraction there is a corresponding increase of bulk in the breadth and thickness of the muscle. When muscular fibres are observed contracting beneath the microscope, the transverse striæ are observed to approach more closely, while the fibres increase their diameter.

When muscles are inserted into soft organs, they usually have no tendinous attachment, but their fibres resolve themselves into the contiguous parts, as in the insertion of the muscles around the mouth.

The **tendons** are composed of dense bundles of fibrous tissue, the filaments of which are associated with one another in a perfectly parallel manner. In the thicker tendons the finer bundles are collected into coarser prismatic fasciculi, associated by a looser texture of the same material, forming their connective tissue. From the parallel arrangement of the fibrous structure of the tendons they are rendered inextensible, which quality, together with their great strength and small size, admirably adapts them to communicate the power of the comparatively bulky muscular belly not only to distant parts, but also to very limited points of insertion.

The muscles are invested with fibrous sheaths, continuous with those of the muscular fasciculi and with one another. Portions of these sheaths between muscles in many instances present a tendinous or aponeurotic character, constituting the so-called **intermuscular partitions**, from which the muscles in part frequently arise. The groups of muscles in different regions of the body are enveloped together in fibrous sheaths, named the **fas'ciæ**, as the brachial fascia, the femoral fascia, etc. These fasciæ are usually denser or more aponeurotic in their character than the sheaths of the individual muscles. In many instances the latter partly arise from the fasciæ, or are partly and even wholly inserted into them.

To preserve the position of tendons in their course they are frequently confined in grooves, or upon narrow surfaces of the bones, by means of

appropriate ligaments, as in the passage of the extensor tendons through grooves at the carpal extremity of the radius, and the passage of the flexor tendons of the fingers beneath the annular ligament of the wrist and the vaginal ligaments of the phalanges.

When muscles or their tendons pass over prominences of the bones, thin walled, serous pouches, named **syno'vial bur'sæ**,¹ intervene, with the object of alleviating friction. Similar bursæ are reflected upon tendons as they pass through grooves or beneath annular and vaginal ligaments. In some instances these bursæ are much divided or folded, as in the reflection of the synovial bursa upon the flexor tendons of the fingers as they pass beneath the annular ligament of the wrist.

When muscles are accidentally torn, they are not restored by the reproduction of muscular tissue, but the parts are reunited by means of ordinary fibrous tissue.

The muscles are highly vascular, in accordance with their great activity. Their capillary blood-vessels generally pursue a course parallel to and between the muscular fibres, and frequently anastomose across the latter. The tendons are but slightly vascular. The lymphatic vessels are few in the muscles, and have not been detected in the tendons.

Though possessing only a moderate degree of sensibility, the muscles are abundantly supplied with nerves, their office, however, being mainly to convey motor impressions. The terminal branches of the nerves anastomose with one another and form intricate plexuses among the muscular fibres. The tendons are almost devoid of nerves, and, at least in a condition of health, are entirely insensible.

GENERAL REMARKS ON THE HEAD.

The **Head**² is composed of the skull with its contents, covered with muscles and the skin. The cranial vault is covered with the occipito-frontal, temporal, and auricular muscles, and the scalp. The front of the cranium is the forehead, its back the occiput, and its sides the **temples** or **tem'poral regions**. The **forehead**³ terminates below with the eyebrows and the intervening space, named **glabel'la**; on each side is bounded by the temple, and above by the scalp. The **occiput**⁴ extends between the position of the ears posteriorly, and is covered at its lower part by the muscles of the neck. The **temple**,⁵ so called from the Latin *tempus*, time, because in this region white hairs first appear, is defined above by the course of the temporal ridge, below by the zygoma.

¹ Bursæ mucosæ.

² Caput; cephale; poll.

³ Sinciput; front; frons; brow.

⁴ Occipitum; regio occipitalis; inion.

⁵ Regio temporalis; crotaphus.

The **Face**,¹ formed by the forehead above, bounded by the base of the lower jaw below, and the ear on each side, presents to us in succession beneath the glabella: the **root of the nose**, which is its origin from the forehead; the **bridge or back of the nose**;² the **column of the nose**,³ which separates the **nostrils or anterior nares**; the **labial groove**⁴ of the upper lip; and the **labio-mental groove**,⁵ between the lower lip and the chin. From the bridge slope off the **sides of the nose**, connected below with the dilated **wings**, which bound the nostrils externally. The **fissure of the mouth** is terminated on each side by the conjunction of the lips, named the **angles of the mouth or oral angles**.⁶ The upper lip is defined on each side by the **naso-labial furrow**,⁷ which becomes more marked with the advance of age. Below the **eyebrows** are the **eyelids**, separated by the **pal'pebral fissure**, the extremities of which are the **angles or canthi of the eye, or of the orbit**. The **cheeks** are bounded by the zygoma, the ear, the angle and base of the lower jaw, the chin, lips, and nose. The space in the vicinity of the ear extending to the angle of the jaw and the sterno-mastoid prominence of the neck, is the **parotid region**.

The **scalp**⁸ or skin of the vault of the cranium where covered with hair, is thick, dense, and inextensible; and its deeper part is filled with hair follicles, sweat glands, and sebaceous glands, associated with adipose tissue. On the forehead and temples it is thinnest and most extensible. The hairs of the scalp diverge in whorls from a central point at the top of the head, called the **crown or vertex**.⁹ The scalp tightly adheres by short connective tissue to the occipito-frontal muscles, and follows all their movements; but the skin alone of the forehead is thrown into transverse wrinkles by the contraction of their frontal bellies. The skin of the eyebrows is thick and dense, and is moved with that of the forehead. The skin of the eyelids is thin, and the connective tissue attaching it to the orbicular muscle beneath is devoid of fat. In injuries about the entrance of the orbit, blood readily pervades this connective tissue, giving rise to what is commonly called "black eye." The skin of the nose is thin and movable above, but is thicker, more dense, and intimately connected with the subjacent part below, in which position it is filled with large sebaceous glands. The skin

¹ *Facies*; *vultus*; *prosopon*.

² *Dorsum nasi*.

³ *Columna nasi*.

⁴ *Philtrum*; *amatorium*; *amabile*; *sulcus*, or *lacuna labii superioris*.

⁵ *Sulcus mento-labialis*.

⁶ *Commissures of the mouth*.

⁷ *Sulcus naso-labialis*.

⁸ *Capillitium*.

⁹ *Spondylus*.

of the lips, where furnished with large hairs, is thick ; but at the borders is very thin and closely adherent to the orbicular muscle. The skin of the chin is thick, filled with hair follicles, sebaceous and sweat glands, and is most intimately blended with the muscles beneath. The skin of the cheeks is thin, and closely associated with a thick subcutaneous adipose layer involving several of the muscles ; and in the interval of the masseter and buccinator muscles, the cheek is occupied with a large mass of soft fat tissue. The skin at the back part of the cheek is like that of the chin, though less dense, and is not blended with the contiguous muscles.

220
p. 503
+ 1907
275

FASCIA OF THE HEAD.

Fasciæ readily separated from the contiguous parts as distinct layers, on the head are found only in the temporal region. In other positions they are represented by the thin and closely adherent investments of the muscles of the scalp and face, and by the subcutaneous adipose layer.

The **Superficial temporal fascia**¹ is a thin but distinct layer of loose fibrous tissue beneath the skin of the temple. It is attached above to the aponeurosis of the occipito-frontal muscle, and is continuous with the thin layers of connective tissue investing the fleshy bellies of the latter and the palpebral orbicular muscle. It incloses the auricular muscles and the superficial temporal blood-vessels.

The **Deep temporal fascia**² is a strong, bluish-white and shining fibrous membrane extended between the curved boundary of the temporal fossa and the zygoma. Its lower part is divided into two layers, between which is some loose areolar tissue and more or less fat. The inner surface of the fascia affords a point of origin to the temporal muscle.

MUSCLES OF THE SCALP.

The **Occip'ito-front'al mus'cle**³ extends from the occiput to the forehead, and consists of two fleshy bellies connected by an intermediate aponeurosis.

The occipital belly,⁴ shorter and narrower than the other, arises from the superior semicircular ridge of the occipital bone, and ascends in an inward direction to its aponeurosis.

¹ Fascia temporalis superficialis.

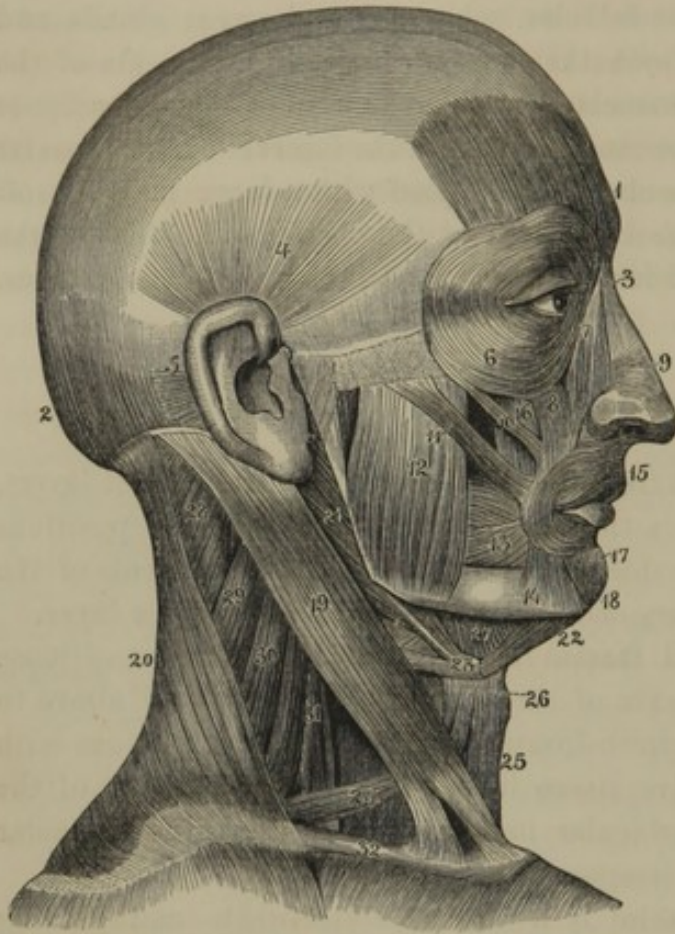
² Fascia temporalis profunda ; f. temporalis ; temporal aponeurosis.

³ M. occipito frontalis ; m. epicranius ; m. digastricus cranii.

⁴ M. occipitalis.

The frontal belly,¹ paler than the former, arises from the internal angular

FIG. 147.



MUSCLES OF THE HEAD AND NECK. 1, 2, occipito-frontal muscle: 1, its frontal belly; 2, its occipital belly; 3, nasal pyramidal muscle; 4, superior, and 5, posterior auricular muscles; 6, labio-nasal elevator; 7, elevator of the upper lip; 8, nasal compressor; 9, 10, 11, zygomatic muscles; 12, masseter muscle; 13, buccinator; 14, depressor of the oral angle; 15, oral orbicular muscle; 16, elevator of the oral angle; 17, 18, depressor of the lower lip; 19, sternomastoid muscle; 20, trapezius; 21, posterior belly of the digastric and the stylo-hyoid muscle; 22, anterior belly of the former; 23, loop of fibrous tissue attaching the tendon of the digastric muscle to the hyoid bone; 24, omo-hyoid muscle; 25, sterno-hyoid; 26, sterno-thyroid, seen to the outer side and behind the anterior belly of the omo-hyoid; 27, mylo-hyoid; 28, splenius; 29, elevator of the scapular angle; 30, 31, middle and anterior scalene muscles; 32, clavicle.

process and superciliary ridge of the frontal bone, and ascends to its aponeurosis. A prolongation from this belly, at the root of the nose to the nasal compressor muscle, is usually described as distinct, under the name of the **nasal pyramidal muscle**.²

The occipito-frontal aponeurosis³ is a thin sheet of tendinous fibres covering the upper part of the head continuously from side to side. Between the occipital bellies of the two muscles it is attached to the occipital protuberance, and in the vicinity of the temporal ridge on each side is blended with the superficial temporal fascia. It is loosely attached to the periosteum beneath, but is closely adherent to the integument above, so that in the action of its muscular bellies the scalp is moved backward and forward on the cranium.

¹ M. frontalis.

² M. pyramidalis nasi; m. nasum dilatans; m. processus nasi; fronto-nasal muscle.

³ Epicranial aponeurosis; membrana epicrania; galea capitis; galea aponeurotica capitis; g. tendinea Santorini.

MUSCLES OF THE EYELIDS AND EYEBROWS.

The **Pal'pebral Orbic'ular muscle**¹ forms a thin elliptical layer surrounding the entrance of the orbit, immediately beneath the skin. It arises from the internal angular process of the frontal bone, the nasal process of the superior maxillary bone, and the internal palpebral ligament. From this origin the muscle proceeds outwardly in the upper eyelid and the eyebrow, and returns below the palpebral fissure to be inserted into the same points from which it started. The portion corresponding with the eyelids is thinner and paler than elsewhere, and has been described as distinct under the name of the **cil'iary muscle**.² A fasciculus or offset, springing from the back part of the lachrymal bone and passing upon the eyelids along the course of the lachrymal canals, was particularly described, by the late Professor Horner, under the name of the **tar'sal ten'sor**.³

The palpebral orbicular muscle closes the eyelids and draws the skin in a radiating manner toward the inner angle. The ciliary portion is constantly engaged in the act of winking.

The **Pal'pebral Ele'vator muscle**⁴ is contained within the orbit. It arises above the optic foramen, and passes forward beneath the roof of the orbit; expanding in its course, and terminating in a broad, thin tendon, it is inserted into the edge of the superior palpebral cartilage. As indicated by the name, the muscle raises the upper eyelid.

The **Supercil'iary muscle**⁵ arises from the inner extremity of the superciliary ridge, and proceeds outwardly and a little upward to become blended with the palpebral orbicular and occipito-frontal muscles, between which and the bone it is situated.

The muscles of the two sides throw the skin at the middle of the forehead into vertical wrinkles, as in frowning.

¹ M. orbicularis palpebrarum; m. o. oculi; m. pal. ciliaris; m. palpebralis; m. naso-palpebralis; m. maxillo-palpebralis; m. orbicularis latus; palpebrarum duo muscoli; sphincter, or constrictor palpebrarum, or oculi.

² M. ciliaris.

³ M. tensor tarsi; m. Horneri; m. sacci lachrymalis.

⁴ M. levator palpebræ superioris; palpebræ superioris primus; apericus palpebrarum rectus; secluser palpebrarum; apertor oculi; orbito-palpebral muscle.

⁵ M. superciliaris; m. supercilii; m. corrugator supercilii; m. c. frontis; m. c. Coiterii; m. cutaneo- or fronto-superciliaris; m. frontalis verus.

MUSCLES OF THE EYEBALL.

See the Account of the Eye.

MUSCLES OF THE EAR.

See the Account of the Ear.

MUSCLES OF THE NOSE.

The **Na'sal Compress'or**¹ is a thin, triangular muscle arising from the fore part of the superior maxillary bone and diverging upon the side of the nose. On the back of the latter it terminates in a thin aponeurosis, which conjoins that of the opposite side, is attached to the tip of the nose, and is connected with a pair of fleshy slips² from the occipito-frontal muscles.

The **Na'sal Dila'tor**³ consists of short, indistinct muscular fibres, situated between the cartilages of the wing of the nose and the skin, with which they are intimately blended.

MUSCLES OF THE LIPS AND CHEEK.

The **O'ral Orbic'ular muscle**⁴ is an elliptical fasciculus of fibres surrounding the mouth, and blended with all the muscles which converge to it. At the angles of the mouth its fibres, except the most superficial ones, decussate with those of the buccinators, and with the elevators and depressors of the oral angles.

This muscle is a sphincter, and antagonizes all the other muscles of the mouth. When closely contracted, it projects the lips as in the acts of kissing and sucking.

The **Lab'io-na'sal el'elevator**⁵ arises from the nasal process of the supe-

¹ M. compressor naris; m. transversalis nasi; m. triangularis nasi; m. nasalis; m. rinalus; m. myrtiformis; m. constrictor naris; m. dilatator alæ nasi.

² Nasal pyramidal muscles.

³ M. levator proprius alæ nasi anterior et posterior; m. dilatator naris ant. et post.; m. pinnæ dilatator.

⁴ M. orbicularis oris; m. constrictor oris; m. sphincter labiorum; m. osculatorius; m. basiator; m. labialis; m. semior demi-orbicularis; m. supra-semi-orbicularis.

⁵ M. levator labii superioris alæque nasi; elevator of the upper lip and wing of the nose; m. incisivus lateralis et pyramidalis.

rior maxillary bone, and as it descends separates into two fasciculi, of which one is inserted into the wing of the nose, while the other is prolonged to the upper lip, where it is blended with the contiguous muscles.

The **La'bio-na'sal depress'or**¹ is a small muscular slip situated just exterior to the mucous membrane of the upper lip at the side of the frænum. It arises from the point of the incisive alveoli of the superior maxillary bone, and ascends to be inserted into the wing and column of the nose and become blended with the upper margin of the oral orbicular muscle.

The **El'elevator of the Upper Lip**² arises from the malar and superior maxillary bones just above the infra-orbital foramen, and descends to become blended with the contiguous muscles of the upper lip.

The **El'elevator of the O'ral Angle**³ is partially concealed by the preceding muscle. It arises from the superior maxillary bone below the infra-orbital foramen, and descends in a convergent manner to the angle of the mouth. Between it and the elevator of the upper lip are the infra-orbital nerve and artery.

The **Zygomat'ic muscles** are two narrow fasciculi extending obliquely from the most prominent part of the cheek to the angle of the mouth.

The **Larger Zygomat'ic muscle**,⁴ external to the smaller one, arises from the zygomatic process of the malar bone, and, after reaching the angle of the mouth, becomes blended with the contiguous muscles.

The **Smaller Zygomat'ic muscle**⁵ is inconstant in size and exact position, and occasionally is absent. It arises from the malar bone, and terminates near the angle of the mouth by blending with the elevator of the upper lip.

The zygomatic muscles elevate the angles of the mouth outwardly, as in smiling.

The **Depress'or of the Lower Lip**,⁶ a square muscle situated at the

¹ M. depressor labii superioris alæque nasi; depressor of the upper lip and of the wing of the nose; m. depressor alæ nasi; m. myrtiformis.

² M. levator labii superioris; m. incisivus.

³ M. levator anguli oris; elevator of the angle of the mouth; m. caninus; m.

abducens labiorum; m. elevator labiorum communis.

⁴ M. zygomaticus major; m. distortor oris; zygomato-labial muscle.

⁵ M. zygomaticus minor; small zygomato-labial muscle.

⁶ M. depressor labii inferioris; m. quadratis menti; m. mento-labialis.

side of the chin, arises from the base of the lower jaw and ascends inwardly to be inserted into the lower lip.

The **El'elevator of the Lower Lip**¹ is a small square muscle situated just exterior to the mucous membrane of the lower lip at the side of the frænum. It arises from the front of the outer incisive and canine alveoli of the lower jaw, and descends inwardly to be inserted into the lower lip.

The **Depress'or of the O'ral Angle**² is a triangular muscle, which arises from the base of the lower jaw at the side of the chin, and is inserted by its apex into the angle of the mouth, where it blends with the contiguous muscles.

The **Buccina'tor muscle**³ contributes to the formation of the cheek. It arises from the pterygo-maxillary ligament and from the alveolar border of both jaws as far forward as the first molar tooth. From these points the fibres proceed forward and converge to the angle of the mouth, where they cross one another and become confluent with the oral orbicular muscle.

Internally it is in contact with the mucous membrane of the mouth, and externally is closely invested with a thin fascia. Its back part is separated from the ramus of the lower jaw by means of a mass of fat, remarkable for its softness and slight attachment to the contiguous structures. The disappearance of this fat in emaciation gives rise to the hollow cheek. Opposite the second molar tooth of the upper jaw the buccinator is perforated by the termination of the parotid duct.

When the buccinators alone contract, they widen the mouth; but if they contract in conjunction with the oral orbicular muscle, they press the cheeks close to the jaws; or if the mouth is filled with air, this is compressed, as in the acts of blowing and whistling.

The **Pter'yo-max'illary lig'ament** is a fibrous band, extended between the external pterygoid process of the sphenoid bone and the posterior end of the molar ridge of the lower jaw, serving as a common origin to the buccinator muscle and the superior constrictor of the pharynx.

¹ M. levator labii inferioris; m. levator menti; m. incisivus inferior; m. penicillatus; mento-labial muscle.

² M. depressor anguli oris; depressor of the angle of the mouth; m. triangulus oris;

m. maxillo-labialis; m. depressor labiorum communis.

³ M. retractor anguli oris; m. bucco-alveolo-maxillaris; m. alveolo-labialis; m. mansorius.

1884 +
275

THE MUSCLES OF THE LOWER JAW, OR OF MASTICATION.

The **Mass'eter muscle**,¹ thick and oblong square, is situated at the back of the cheek, and extended between the zygoma and angle of the lower jaw. It has a number of tendinous bands interspersed with its structure, and is separable into two portions, the fibres of which pursue a different course.

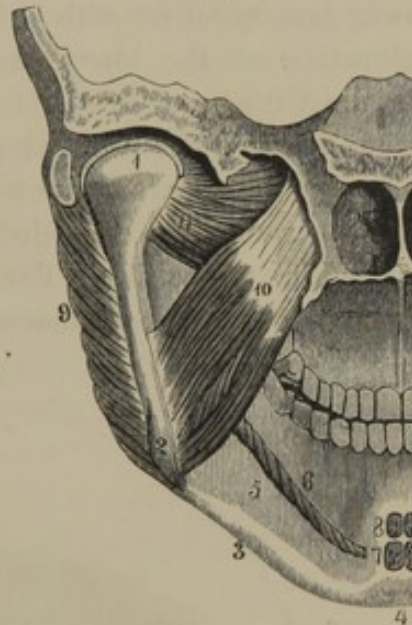
The superficial and larger portion of the muscle arises tendinously from the upper maxillary bone and the lower margin of the malar bone, and descends backward to be inserted into the lower half of the ramus and angle of the lower jaw. The deeper portion arises from the zygomatic process of the temporal bone, and descends a little forward to be inserted into the upper half of the ramus of the lower jaw.

The **External Ptery'goid muscle**² is short, thick, and triangular, and occupies the upper part of the sphenomaxillary fossa. It arises from the under surface of the great wing and the outer surface of the external pterygoid process of the sphenoid bone, and converges to be inserted, by means of a short, thick tendon, into the depressed surface of the front of the neck of the lower jaw.

Externally this muscle is crossed by the internal maxillary artery and the tendon of the temporal muscle; and internally it is in contact with the internal pterygoid muscle and the inferior maxillary nerve.

The **Internal Pter'ygoid muscle**³ is square and thick, and is situated within the position of the ramus of the jaw. It arises from the ptery-

FIG. 148.



VIEW OF THE INTERIOR PART OF THE LEFT SIDE OF THE FACE. 1, condyle of the lower jaw; 2, angle of the jaw; 3, base; 4, symphysis; 5, sub-maxillary fossa; 6, attachment of the mylo-hyoid muscle to the corresponding ridge; 7, origin of the genio-hyoid muscles; 8, origin of the genio-glossal muscles; 9, masseter muscle; 10, internal pterygoid muscle; 11, external pterygoid muscle.

¹ M. mandibularis; m. zygomatico-maxillaris.

² M. pterygoideus externus, or minor; m. pterygo-colli-maxillaris; m. pterygo-maxillaris minus; m. alaris, or aliformis minor.

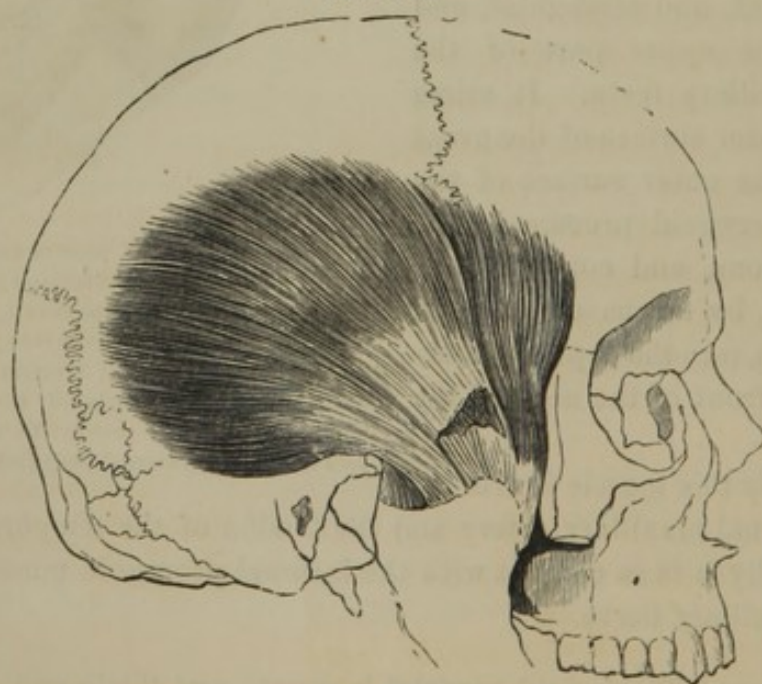
³ M. pterygoideus internus, or major; m. masseter internus; m. latens in ore; m. pterygo-anguli-maxillaris; m. pterygo-maxillaris majus; m. alaris, or aliformis major.

goid fossa, and descends outward and backward to be inserted into the inner surface of the ramus and angle of the lower jaw.

The **Tem'poral muscle**¹ occupies the temporal fossa, and is covered by the temporal fascia. It arises from the entire surface of the former and from the upper part of the latter, and converges to an interior tendinous layer, which becomes a thick, flattened fasciculus, descending to be inserted into the inner surface and anterior border of the coronoid process of the lower jaw.

The temporal, masseter, and pterygoid muscles are the active agents in mastication. The movements produced are those of elevation of the lower jaw, together with a lateral, forward and backward motion. The elevation of the lower jaw, productive of firm pressure of the lower against the upper teeth, is the result of the contraction of the temporal muscles and the internal portions of the masseters. Depression of the lower jaw occurs by its weight alone, though aided by the digastric and other muscles extended between it and the hyoid bone, when this is fixed in its position. The grinding movement of the lower jaw is performed by the pterygoid, masseter, and temporal muscles. The external

FIG. 149.



VIEW OF THE TEMPORAL MUSCLE. The temporal fascia and zygoma removed.

pterygoid muscles and the external portions of the masseter muscles draw the jaw forward; the temporal muscles and internal portions of the masseters draw it back again; and the internal pterygoid muscles, contracting alternately, draw the jaw to either side.

¹ M. temporalis; m. crotaphites; m. arcadi-temporo-maxillaris; m. temporo maxillaris.

THE NECK.

The **Neck**,¹ which forms the short cylindrical column connecting the head with the thorax, varies in length and thickness in different individuals of the same age and sex. Its bony axis is situated more posteriorly than anteriorly, in consequence of which the head is disposed to fall forward.

The front of the neck, or the **throat**,² presents a prominence in the adult male, commonly called "Adam's apple."³ This is produced by the larynx, which, from its less degree of development before puberty, and at all periods of life in the female, is not evident externally.

The elevation on each side of the neck, descending from behind the position of the ear to the sternum, is produced by the sterno-mastoid muscles. The concavity between the latter just above the breast is the **ju'gular fossa**;⁴ and the shallower depression outside of the muscle above the clavicle is the **supra-clavic'ular fossa**.⁵

The skin of the neck is thin and movable, and is readily elevated into folds. The two conspicuous folds, observed in old people, descending from the sides of the chin toward the lower part of the neck, are produced upon the anterior borders of the subcutaneous cervical muscles, which become extended through elevation of the lower jaw consequent on the loss of the teeth and their alveoli in both jaws. Beneath the muscles just mentioned is the cervical fascia, which incloses the sterno-mastoid muscles.

The middle of the neck in front of the vertebræ is occupied by the pharynx and œsophagus, the root of the tongue, the hyoid bone, the larynx and trachea, and the thyroid body. At the sides of these parts the principal cervical blood-vessels and nerves are situated, enveloped in the deep cervical fascia.

MUSCLES AND FASCLE OF THE NECK.

THE SUBCUTANEOUS CERVICAL MUSCLE.

The **Subcuta'neous Cer'vical muscle**⁶ is a broad, thin, and pale lamina arising in the connective tissue covering the upper part of the deltoid and pectoral muscles. Passing over the clavicle, it ascends the

¹ Collum; cervix; trachelos; anchen.

² Guttur; jugulum.

³ Pomum Adami; eminentia thyroidea; nodus gutturis.

⁴ Fossa jugularis.

⁵ Fovea supra-clavicularis.

⁶ M. s. cervicis, or colli; m. platysma myoides; m. cutaneus; m. latissimus colli; m. peaucier.

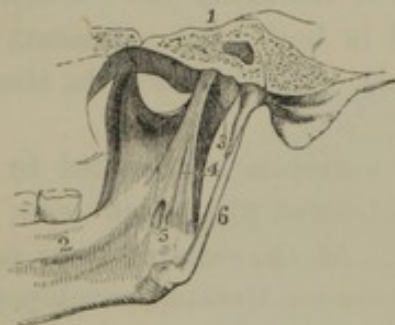neck inwardly to the lower jaw, where its most anterior fibres join those of the opposite muscle, while others are inserted into the side of the chin, and become blended with the depressors of the lower lip and oral angle, and the most posterior ones terminate in the fascia investing the masseter muscle and parotid gland. A small offset¹ crosses the cheek transversely from over the masseter muscle to the vicinity of the angle of the mouth.

This muscle will aid the depression of the lower jaw; but its main purpose appears to be to extend the skin of the neck between the clavicle and lower jaw, thus elevating it from the influence of exterior pressure upon the air-passages and blood-vessels.

THE CERVICAL FASCIA.

Upon removing the subcutaneous cervical muscle, the **Cer'vical fas'cia**² is exposed to view. Its upper part forms a sheath for the parotid and submaxillary glands, which are separated from each other by a well-marked process of the fascia, called the **sty'lo-max'illary lig'ament**,³ which extends from the styloid process of the temporal bone to the angle

FIG. 150.



INNER PART OF THE RAMUS OF THE LOWER JAW, right side. 1, temporal bone; 2, lower jaw; 3, capsular ligament of the articulation of the latter; 4, stylo-maxillary ligament; 5, entrance of the inferior dental canal; 6, stylo-maxillary ligament.

of the lower jaw^{Fig 62} and inwardly to the sheath of the principal cervical blood-vessels. In advance of the parotid gland, the fascia invests the masseter muscle and adheres along the base of the lower jaw. At the lower part of the neck the fascia adheres along the upper border of the sternum and clavicle, and is continuous in front of these bones with the thoracic fascia. Behind the neck, it is continuous with the layer inclosing the trapezius muscle; and in proceeding forward it

incloses the sterno-mastoid muscle, and the elevators and depressors of the hyoid bone and larynx. Processes of the fascia, continued inwardly, inclose the trachea and larynx, the œsophagus and pharynx; form the sheath of the large cervical blood-vessels, and become continuous with the fibrous investment of the muscles in front of the cervical vertebræ.

¹ M. risorius Santorini.

² Fascia cervicalis; fascia colli; fascia superficialis et profunda cervicis; superficial and deep or proper cervical fascia.

³ Ligamentum stylo-maxillare.

Another process, separating the pterygoid muscles, and extended from the spinous process of the sphenoid bone to the lower jaw at the inner border of the dental foramen, constitutes the **sphe'no-max'illary lig'a-ment**.¹

THE STERNO-MASTOID MUSCLE.

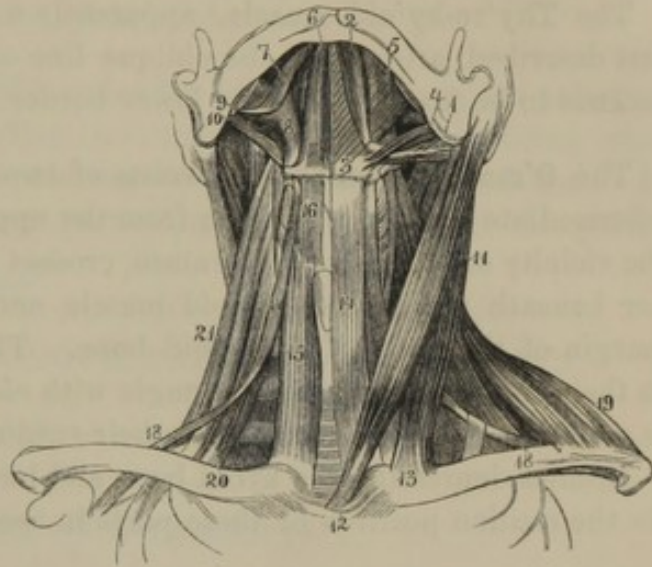
The **Ster'no-mas'toid muscle**² is the largest and most conspicuous of the muscles of the neck. It arises by a flat tendon from the upper fore part of the sternum, and tendinous and fleshy from the inner third of the clavicle. The two portions are separated at their origin by an angular interval, but as the clavicular portion ascends nearly vertically, while the sternal portion inclines backward in its ascent, the two conjoin about the middle of the neck and form a single thick rounded belly, which proceeds to be inserted into the mastoid process and the superior semicircular line of the occipital bone.

When the muscles of the two sides act together, the head is drawn downward; but when one alone contracts, the face is directed toward the opposite side.

DEPRESSORS OF THE HYOID BONE AND LARYNX.

The **Ster'no-hy'oid muscle**³ is a flat band arising from the inner surface of the upper part of the sternum and the contiguous portion of the

FIG. 151.



FRONT VIEW OF THE MUSCLES OF THE NECK. 1, posterior, and 2, anterior belly of the digastric; 3, its intermediate tendon attached to the hyoid bone and passing through the insertion of the stylo-hyoid muscle, 4; 5, mylo-hyoid; 6, genio-hyoid; 7, genio-glossal muscle of the tongue; 8, hyo-glossal; 9, stylo-glossal; 10, stylo-pharyngeal muscle; 11, sterno-mastoid muscle; 12, its sternal origin; 13, its clavicular origin; 14, sterno-hyoid; 15, sterno-thyroid; 16, thyro-hyoid; 17, 18, omo-hyoid muscle; 19, trapezius; 20, anterior scalene muscle; 21, middle scalene muscle.

¹ Erroneously described under the name of internal lateral ligament of the articulation of the lower jaw.

² M. sterno-mastoideus; m. sterno-

cleido-mastoideus; m. cleido-mastoideus; m. mastoideus; m. metator capitis.

³ M. sterno-hyoideus; m. sterno-cleido-hyoideus; m. hyoides primus.

clavicle. Ascending the neck inwardly, it is inserted into the lower border of the body of the hyoid bone.

The **Ster'no-thy'roid muscle**,¹ broader than the preceding, arises from the inner surface of the upper part of the sternum, and ascends the neck between the former muscle and the trachea, to be inserted into the oblique line at the side of the thyroid cartilage.

The **Thy'ro-hy'oid muscle**,² apparently a continuation of the muscle just described, arises from the oblique line of the thyroid cartilage, and ascends to be inserted into the lower border of the hyoid bone.

The **O'mo-hy'oid muscle**³ consists of two fleshy bellies united by an intermediate tendon. It arises from the upper border of the scapula, in the vicinity of the coracoid foramen, crosses the neck in an oblique manner beneath the sterno-mastoid muscle, and is inserted into the lower margin of the body of the hyoid bone. The two bellies of the muscle in their course form an obtuse angle with each other, and this position is maintained by a connection of their tendon with the cervical fascia.

Besides depressing the hyoid bone and larynx, the omo-hyoid muscles fix the median position of these parts in the neck.

ELEVATORS OF THE HYOID BONE AND LARYNX.

The **Digas'tric muscle**,⁴ as indicated by the name, consists of two fleshy bellies which are united by an intermediate rounded tendon. The posterior belly arises from the digastric fossa of the temporal bone, and the anterior belly from the inner surface of the lower jaw near its symphysis. Both descend to the side of the hyoid bone, where their intervening tendon passes through the insertion of the stylo-hyoid muscle, and is attached to the former by means of a fibrous band. A thin aponeurosis, continuous with the latter, is extended between the anterior bellies of the two muscles.

The **Sty'lo-hy'oid muscle**⁵ lies in contact with the posterior belly of the preceding muscle. It arises from the middle of the styloid process of

¹ M. sterno-thyroideus; m. bronchius.

² M. thyro-hyoideus; m. hyo-thyroideus.

³ M. omo-hyoideus: m. coraco-hyoideus; m. scapula-hyoideus; m. hyoidus quartus.

⁴ M. digastricus; m. biventer; m. b. maxillæ; m. deprimens maxillæ biventer; m. bigaster.

⁵ M. stylo hyoideus; m. stylo-hyoideus major; m. stylo-ceratoideus; m. stylo-cerato-hyoideus.

the temporal bone, and descends to be inserted into the side of the body of the hyoid bone, where it is perforated by the tendon of the digastric muscle.

The **My'lo-hy'oid muscle**¹ is a triangular layer, forming with its fellow of the opposite side the muscular floor of the mouth. It arises from the molar ridge of the lower jaw, from whence its fibres proceed obliquely inward to conjoin with those of the opposite muscle, in the median line, extending from the chin to the hyoid bone.

The **Geni'o-hy'oid muscle**² is a slender band arising from the posterior mental tubercle, and descending in contact with the corresponding muscle of the other side, to be inserted into the body of the hyoid bone. It is situated between the inner part of the mylo-hyoid and the genio-glossal muscle.

line

MUSCLES OF THE TONGUE, PALATE, AND PHARYNX.

See the account of these different organs.

MUSCLES OF THE LARYNX.

See the account of this organ.

DEEP MUSCLES OF THE FRONT OF THE NECK.

The **Anterior Scalene' muscle**³ is deeply situated at the lower part of the side of the neck. It arises from the transverse processes of the third to the sixth cervical vertebræ inclusively, and descends to be inserted into the anterior part of the first rib.

In front of the insertion of this muscle the subclavian vein passes over the first rib.

The **Middle Scalene' muscle**⁴ arises from all the cervical transverse processes, usually excepting the first, and descends behind the preceding muscle to be inserted into the posterior half of the first rib.

Between the anterior and middle scalene muscles the axillary plexus of nerves and the subclavian artery take their course.

¹ M. mylo-hyoideus; m. mylo-pharyngeus.

² M. geni-hyoideus; m. mento-bicorneus.

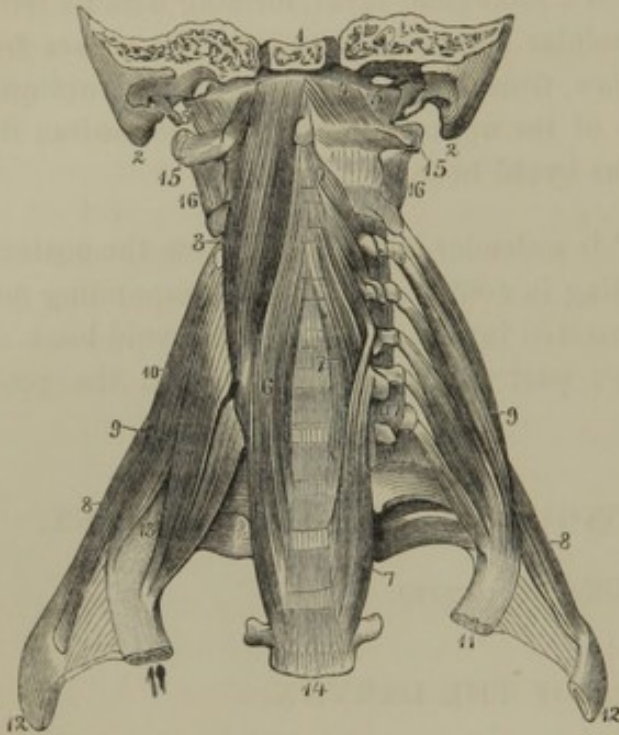
³ M. scalenus anticus; m. s. prior; m. costo-trachelius.

⁴ M. scalenus medius; m. s. secundus.

The **Posterior Scalene' muscle**,¹ small and thin, arises from the two or three lower cervical transverse processes, and descends to be inserted into

the back part of the second rib.

FIG. 152.



DEEP MUSCLES OF THE FRONT OF THE NECK. 1, basilar process of the occipital bone; 2, mastoid process; 3, larger straight muscle; 4, smaller straight muscle; 5, lateral straight muscle; 6, 7, long cervical muscles; 8, posterior scalene muscle; 9, anterior scalene muscle; 10, middle scalene muscle; 11, 12, first and second ribs; 13, position at which the subclavian artery and axillary plexus of nerves emerge over the first rib, between the anterior and middle scalene muscles; 14, third dorsal vertebra; 15, atlas; 16, 17, intertransverse muscles.

The scalene muscles acting from above elevate the ribs; but acting from below they flex the neck.

The **Larger Straight muscle**² arises by as many distinct tendinous heads, from the third to the sixth cervical transverse processes inclusively, and ascends inwardly to be inserted into the basilar process of the occipital bone.

The **Smaller Straight muscle**³ arises from the side of the atlas, and ascends inwardly to be inserted into the basilar process, beneath the last muscle.

The two straight muscles are flexors of the head.

The **Long Cer'vical muscle**⁴ extends along the side of the neck, and is quite complex in its arrangement. It consists of two portions, of which one arises from the side of the bodies of the three upper dorsal and the three lower cervical vertebræ, and ascends to be inserted by distinct tendons into the fourth and fifth cervical transverse processes, and partially tendinous and fleshy into the bodies of the second, third, and fourth cervical vertebræ. The remaining portion arises by distinct ten-

¹ M. scalenus posticus; m. s. tertius.

² M. rectus capitis anticus major; m. r. c. internus major; m. r. c. anterior longus; m. trachelo-basilaris; larger anterior straight muscle.

³ M. rectus capitis anticus minor; m.

r. c. internus minor; m. r. c. anterior brevis; m. trachleo-basilaris minus; m. rennuens; m. annuens; smaller anterior straight muscle.

⁴ M. longus colli; m. pre-dorso-cervicalis; m. pre-dorso-atloideus.

dons from the third, fourth, and fifth cervical transverse processes, and ascends to conjoin with the preceding portion and to be inserted in front of the atlas.

This muscle bends the neck forward.

TOPOGRAPHICAL SKETCH OF THE ANATOMY OF THE NECK.

Upon removing the skin of the neck and the subcutaneous cervical muscle, the cervical fascia is exposed, with the external jugular vein descending from behind the angle of the jaw to about the middle of the clavicle, where it dips inward to join the subclavian vein. Upon removing the superficial layer of the cervical fascia, the sterno-mastoid muscle is seen pursuing its course from the sternum to the mastoid process, and beneath it, crossing the neck in an opposite direction, is the omo-hyoid muscle. If the line of the latter be continued to the chin, the side of the neck will be divided by the two muscles into four triangles.

The **posterior cer'vical triangle** is occupied with muscles, to be described in the account of the back.

The **anterior cer'vical triangle** contains the root of the tongue, the hyoid bone, larynx and trachea, and, behind these, the pharynx and œsophagus. The larynx and trachea are covered by the depressor muscles of those organs; and beneath them, on the trachea, is the thyroid gland. The lower part of this triangle corresponds with the depression above the sternum, called the **ju'gular fossa**.

The **inferior cer'vical triangle** corresponds with the **supra-clavic'ular fossa**. The deeper layer of the cervical fascia being removed from it, a quantity of loose areolar tissue, containing the supra-clavicular lymphatic glands, is exposed. Upon removing the latter, the triangle will be found to extend into a deep fossa between the clavicle and first rib, and continuous outwardly with the axilla. The extent of the fossa varies with the position of the shoulder. If this is elevated and thrown back, the fossa is deepened and narrowed; if depressed and thrown forward, the fossa is rendered shallower and broader, and its parts become more distinctly visible. Crossing the lower part of the triangle are the supra-scapular and transverse cervical blood-vessels. At the outer part of the triangle the scalene muscles are seen descending from the cervical vertebræ to the first rib. In front of the insertion of the anterior scalene muscle the subclavian vein passes over the first rib. Between the anterior and middle scalene muscles the subclavian artery and axillary plexus of nerves emerge in their course to the axilla.

The **superior cer'vical triangle** corresponds with the **submax'illary fossa**. Its upper part contains the submaxillary gland, lodged in an oval

depression of the deeper layer of the cervical fascia, the outer portion of which is a partition separating it from the parotid gland, and corresponding with the **sty'lo-max'illary ligament**. If the deeper layer of the cervical fascia is removed, above the submaxillary gland, the muscular floor of the mouth is seen, formed by the mylo-hyoid muscle; and below the gland are the stylo-hyoid and digastric muscles. At the outer border of the triangle is the external carotid artery, from which diverge forward, in succession from below, the superior thyroid, lingual, and facial arteries. Curving across the triangle below the digastric muscle is seen the hypo-glossal nerve, giving off a descending branch ^{to the depressor} ~~to the depressor~~ muscles of the hyoid bone.

Upon detaching the sterno-mastoid muscle, the great cervical vessels are observed inclosed within a sheath and ascending the neck from the position of the sterno-clavicular junction toward the angle of the jaw. The sheath being opened, is seen to contain the primitive carotid artery at the inner side, the internal jugular vein to the outer side, and the pneumogastric nerve between them. The primitive carotid artery divides opposite the upper border of the larynx into the external and internal carotids, the former of which ascends to penetrate the parotid gland; the latter takes a deeper course to reach the carotid canal of the temporal bone. Behind the great cervical vessels lies the sympathetic nerve, and to their outer side a chain of lymphatic glands.

FRONT OF THE THORAX.

The front of the **Thorax** or **chest**, usually called the **breast** or **bosom**, on each side extends to the **shoulder**, the **armpit**, and the **back**. Below the clavicle it is slightly depressed, forming there the **infra-clavicular fossa**. In lean persons it exhibits the outlines of the sternum and ribs, in vigorously muscular men the outlines of the superficial muscles, and in fat persons hemispherical elevations corresponding with the *mammæ*. At the lower part of the sternum, over the position of the ensiform cartilage, is a depression, "**the pit of the stomach**."¹ From this the lower border of the thorax slopes off on each side downward and outward. The skin of the breast is thin, readily raised into folds on each side, but adheres more closely over the sternum. Beneath it, is a layer of fascia containing more or less fat, excepting over the position of the sternum. Beneath the fatty layer² is a thin layer of fascia investing the muscles.

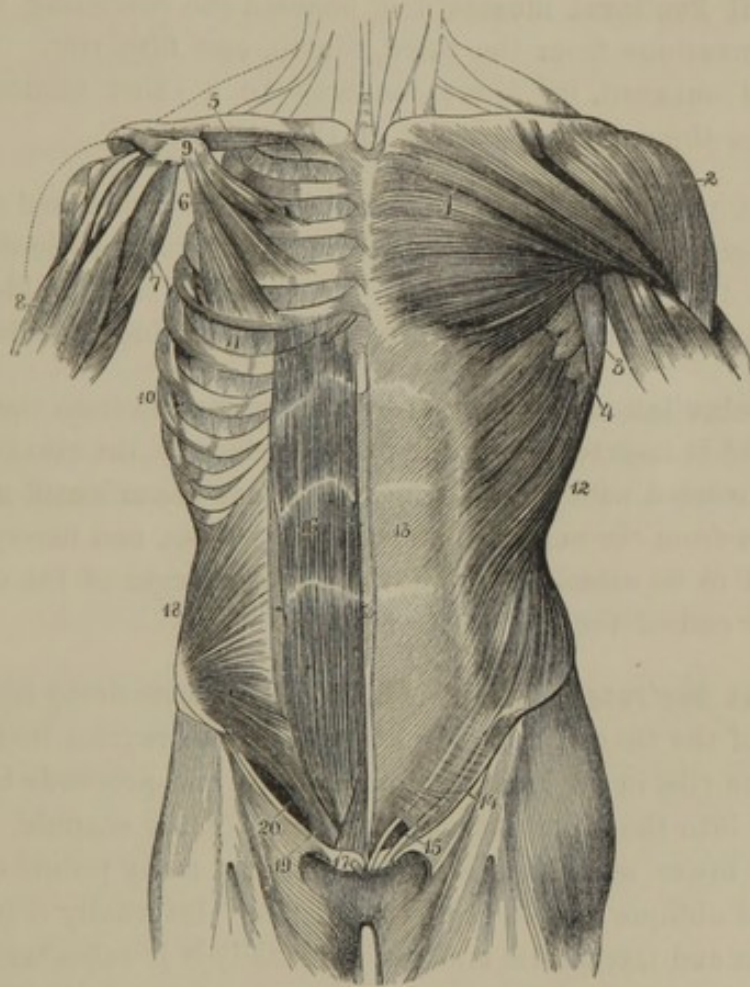
¹ Scrobiculus cordis; procardium; anticardium.

² Panniculus adiposus.

MUSCLES OF THE FRONT AND SIDES OF THE THORAX.

The **Great Pec'toral muscle**¹ occupies the front of the upper part of the chest and axilla. It arises from the sternal two-thirds of the clavicle, the front of the sternum and the upper six costal cartilages, and

FIG. 153.



MUSCLES OF THE FRONT OF THE THORAX AND ABDOMEN. 1, great pectoral muscle; 2, deltoid muscle; 3, latissimus muscle; 4, great serrated muscle; 5, subclavian muscle; 6, small pectoral muscle; 7, coraco-brachial muscle; 8, biceps flexor; 9, coracoid process of the scapula; 10, origin of the great serrated muscle; 11, intercostal muscles; 12, external oblique muscle of the abdomen; 13, its aponeurosis; 14, lower border of the latter, named Poupart's ligament; 15, external abdominal ring, the lower extremity of the inguinal canal; 16, straight muscle of the abdomen; 17, pyramidal muscle; 18, internal oblique muscle; 19, conjoined tendon of the internal oblique and transverse muscles; 20, position of the inguinal canal below the arching edges of the preceding two muscles.

from the aponeurosis of the external oblique muscle of the abdomen. Proceeding outwardly, its fleshy fasciculi converge to a broad tendon,

¹ Greater pectoral muscle; m. pectoralis major; m. adductor brachii; m. sterno-humeralis; m. sterno-costo-clavi-humeralis; m. sterno-cleido-brachialis.

which is inserted into the anterior margin of the bicipital groove of the humerus.

The clavicular portion of the muscle is separated from the other by an interval filled with connective tissue. The outer portion of the muscle, with its tendon, is doubled on itself so as to produce the thick anterior fold of the axilla, and the lower fleshy fasciculi by this arrangement become inserted into the humerus higher than the upper ones.

The **Small Pec'toral muscle**¹ lies beneath the preceding muscle, and arises by serrations from the third, fourth, and fifth ribs. Proceeding upward and outward, its fibres converge to a short tendon, which is inserted into the coracoid process of the scapula.

The great pectoral muscle draws the arm downward and forward, in which movement it is aided by the small pectoral muscle drawing the shoulder in the same direction. If the bones of the shoulder and arm are fixed, the pectorals aid in respiration by elevating the ribs.

The **Sub-clav'ian muscle**² arises by a short tendon from the first costal cartilage, and is inserted along the under surface of the clavicle. Externally it is invested with a strong fascia, the **cos'to-cor'acoid membrane**,³ which starts from the end of the coracoid process, and diverges upward and inward to be attached along the under margin of the clavicle and the anterior end of the first rib.

The **Great Ser'rated muscle**⁴ is a broad quadrate fleshy layer situated at the side of the thorax. It arises by angular serrations from the upper eight or nine ribs in advance of their middle, and proceeds backward to be inserted into the inner aspect of the base of the scapula.

The five lower serrations alternate with as many points of origin of the external oblique muscle of the abdomen. Internally it is in contact with the ribs and intercostal muscles, externally it is subcutaneous, reaching upward into the axilla between the pectoral and latissimus muscles.

It draws the scapula, and with it the whole shoulder, forward, or, if the latter is fixed, it may contribute to respiration by aiding the pectoral muscles in elevating the ribs, and thus increasing the capacity of the thorax.

¹ Smaller pectoral muscle; m. pectoralis minor; m. serratus anticus minor; m. costo-coracoideus.

² M. subclavius, subclavicularis, or subclavianus; m. costo-clavicularis.

³ Ligamentum costo-coracoideum; cla-

vicular fascia; bifid ligament; ligamentum bicorné.

⁴ Anterior great serrated muscle; m. serratus magnus anticus; m. s. major; m. costo-scapularis; m. costo-basi-scapularis.

THE BACK.

The **Back**,¹ as the term is commonly used, applies to the posterior part of the trunk, but, in its most restricted sense, refers to the posterior part of the thorax.² A groove descends along the median line of the back, which is deepened in fat persons from the deposit of adipose tissue occurring on each side, while the skin tightly adheres to the summits of the spinous processes. On each side of the thorax, the scapula and its muscles produce a prominence, which is convex in stout individuals, but exhibits the outline of the scapula, with its projecting spine, in thin persons.

The skin of the back is thicker and denser than in any other position of the body. It is attached to the parts beneath by long, extensible connective tissue, which allows it readily to be moved or raised into folds.

The muscles of the back are invested with a thin layer of fascia, independently of the extensible areolar tissue just mentioned. They are divided into superficial and deep muscles; the former being broad, and for the most part intended to move the upper extremities. The latter are comparatively long and narrow, occupy the gutters along the vertebral column, and are intended to maintain the erect position of this and the head.

SUPERFICIAL MUSCLES OF THE BACK.

The **Trape'zius muscle**³ arises from the superior curved line and protuberance of the occipital bone, the nuchal ligament, and the summits of the spinous processes of the dorsal vertebræ. From this extensive origin it converges, to be inserted into the outer third of the clavicle and into the upper margin of the acromion and spine of the scapula.

Between the spinous processes, the muscles of the two sides conjoin by means of intervening tendinous fibres.

The lower fibres of the muscle, in their ascent, as they approach the scapula, become tendinous, and glide upon the triangular surface at the commencement of its spine.

The muscles of the two sides together have the outline of a trapezium, whence their name. They fix the position of the shoulders, in the respiratory action of the pectoral and great serrated muscles. They also draw them upward, directly backward, or downward, according as their upper, middle, or lower fasciculi contract separately. If the

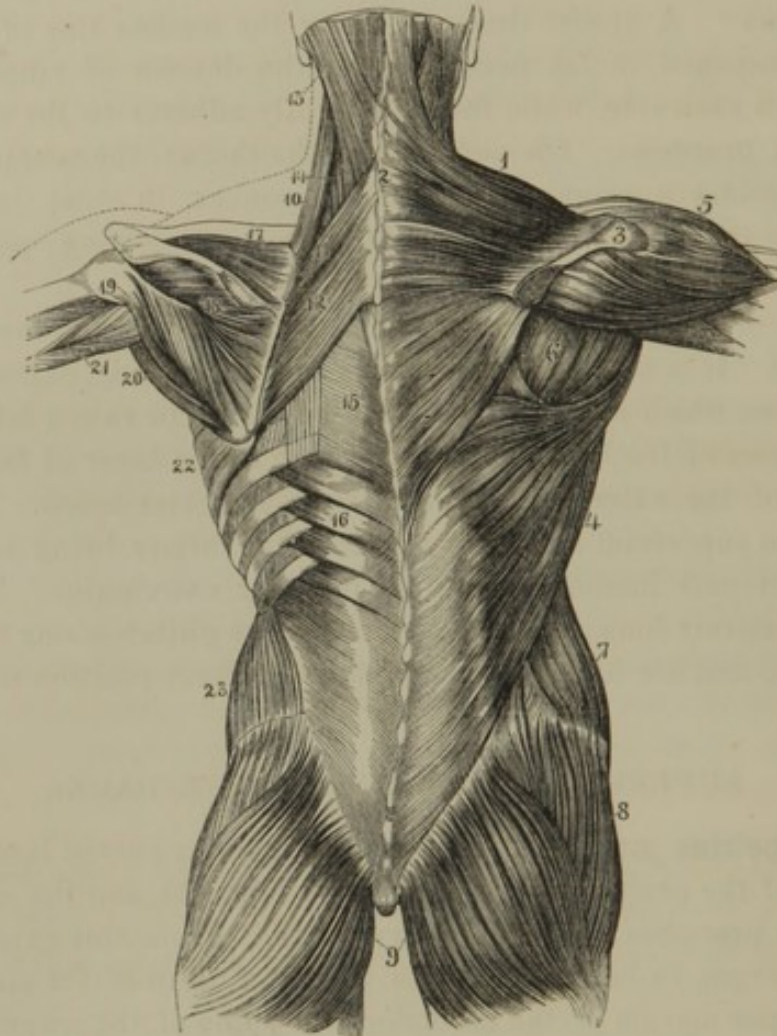
¹ Dorsum; tergum; notos; noton; metaphrenon.

² Dorsum; dorsal region.

³ M. trapezius; m. cucullaris; m. mensalis; m. dorso-supra-acromialis; m. occipito-dorsi-acromialis.

shoulders are fixed, they may draw the head backward; or, if one alone acts, it may draw the latter to one side.

FIG. 154.



MUSCLES OF THE BACK. 1, 2, trapezius; 3, acromion; 4, latissimus; 5, deltoid; 6, infra-spinous, and to its outer side the terete muscles; 7, external oblique muscle of the abdomen; 8, middle gluteal; 9, external gluteal muscle; 10, elevator of the scapular angle; 11, 12, rhomboid muscles; 13, 14, splenius; 15, aponeurosis extending from the superior to the inferior serrated muscle, 16; 17, supra-spinous; 18, infra-spinous muscle; 19, lesser terete, and 20, greater terete muscle; 21, triceps extensor; 22, great serrated muscle; 23, internal oblique muscle of the abdomen.

The **Latis'simus muscle**¹ occupies the lower part of the back, extending upwardly along the side of the thorax to the back of the humerus. It arises by a thin aponeurosis from the spinous processes of the lower six dorsal vertebræ, and all of those of the lumbar vertebræ and sacrum; from the posterior third of the crest of the ilium, and from the lumbar fascia. Its broad, fleshy belly ascends outwardly, in its course receiving

¹ M. latissimus dorsi; m. dorsi-lumbo-sacro-humeralis; m. lumbo-humeralis; m. scalptor ani; m. tursor ani; m. brachium movens quartus.

fasciculi from the lower three ribs. It glides over the inferior angle of the scapula, from which it also usually receives a slip, and converges to a broad, tendinous band inserted into the posterior border of the bicipital groove of the humerus. Folding around the greater terete muscle, it forms the posterior boundary of the axilla; and, like the great pectoral muscle, it has its lowest fasciculi inserted highest into the humerus.

A synovial bursa is interposed between the muscle and the inferior angle of the scapula, and another between its tendon and that of the greater terete muscle.

The latissimus muscle draws the humerus downward and backward. In conjunction with the pectoral muscles, it is the chief agent in climbing and in walking with crutches.

The **Rhom'boid muscle**¹ is situated beneath the trapezius muscle. It arises from the lower extremity of the nuchal ligament and the spinous processes of the upper four dorsal vertebræ, and proceeds obliquely downward and outward to be inserted into the base of the scapula from its spine to its inferior angle.

The muscle draws the scapula backward and upward.

The fasciculus derived from the nuchal ligament is frequently more or less separated by a narrow interval from the lower portion of the muscle, leading to the usual division of the latter into the **lesser** and **greater rhomboid muscles**.²

The **Elevator of the Scap'ular angle**³ is situated at the side of the neck, and consists of a thick, fleshy bundle arising tendinously from the transverse processes of the upper four cervical vertebræ, and descending to be inserted into the upper angle of the scapula.

The **Superior Ser'rated muscle**⁴ is situated beneath the rhomboid muscle. It arises by a thin aponeurosis from the lower part of the nuchal ligament and the upper three dorsal spinous processes, and descends obliquely outward to be inserted, by angular serrations, into the upper border of the second, third, fourth, and fifth ribs, beyond their angle.

A thin aponeurosis extends between this and the succeeding muscle, covering the extensors beneath.

¹ M. rhomboideus; m. cervici-dorso-scapularis.

² M. rhomboideus minor and major, or superius and inferius.

³ M. levator scapulæ; m. l. anguli scapulæ; m. l. proprius scapulæ; m. an-

gularis; m. patientiæ; m. trachelo-scapularis; elevator muscle of the angle of the scapula.

⁴ M. serratus posticus superior; m. dorso-costalis; m. cervici-dorso-costalis.

The **Inferior Ser'rated muscle**¹ is situated at the lower part of the back, beneath the latissimus muscle. It arises by a thin aponeurosis from the lower two dorsal and the upper three lumbar spinous processes, and ascends obliquely outward to be inserted by serrations into the lower border of the four inferior ribs.

The two serrated muscles are antagonistic in their action. The superior one aids in elevating the ribs, the inferior in depressing them, and thus both assist in respiration.

DEEP MUSCLES OF THE BACK, OR EXTENSORS OF THE HEAD AND TRUNK.

The extensor muscles, which maintain the erect position of the head and trunk, are situated at the back of the latter, and occupy the sides of the neck, the intervals between the angles of the ribs and spinous processes of the vertebræ, and the sides of the loins, extending into the angular intervals of the sacrum and hip bones.

They lie beneath the trapezius, latissimus, rhomboid, and serrated muscles, and consist of numerous fleshy and tendinous fasciculi, which are more or less intimately connected, so that they may be described as comparatively few or many distinct muscles.

The **Dor'sal Exten'sor**² is a large muscle occupying the groove of the back at the side of the vertebral column. It is exceedingly complex in its arrangement, consisting of intermingled fleshy fasciculi and tendinous bands, and having many points of attachment to the vertebral column and ribs. Its lower portion is superficially composed of a strong aponeurosis, from which many fleshy fasciculi have their origin.

The muscle commences in a pointed manner upon the sacrum, is thickest in the loins, and gradually thins away on the thorax, from which, by accessory fasciculi, it is continued to the neck. It arises from the posterior surface of the sacrum, the posterior third of the crest of the ilium, and the spinous processes of the lumbar and lower two or three dorsal vertebræ, and in the vicinity of the last rib divides into two portions, named the longissimus and sacro-lumbar muscles.

The **Longis'simus muscle**³ is the internal and larger portion of the dorsal extensor. It is inserted into the transverse processes of the

¹ M. serratus posticus inferior; m. lumbo-costalis; m. dorso-lumbo-costalis.

² M. extensor dorsi, or trunci communis; m. erector spinæ; m. sacro-spinalis; m. lumbo-costalis; m. opisthothenar.

³ M. longissimus dorsi; m. semi-spinatus; m. lumbo-dorso-trachelius; m. extensor dorsi internus.

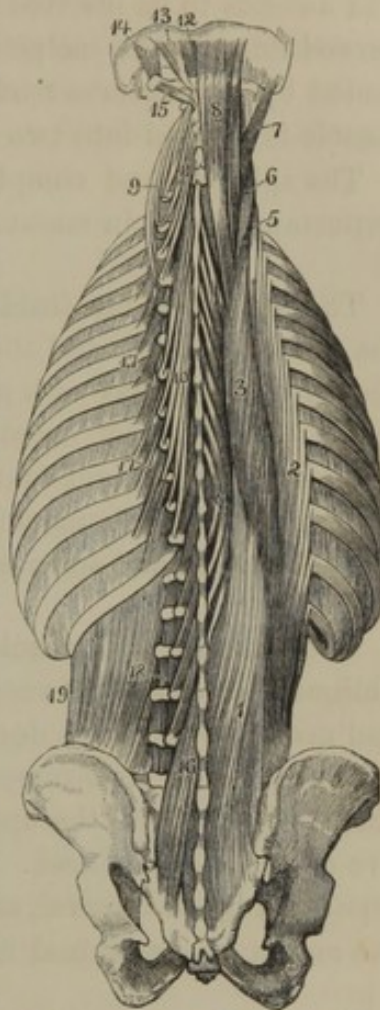
(lumbar³ and) dorsal vertebræ, into the ends of the upper dorsal spinous processes,¹ into the ribs within the position of their angles; and by accessory slips, derived from the upper dorsal transverse processes, is prolonged to the lower four or five cervical transverse processes.²

The **Sa'cro-lum'bar muscle**,³ in its ascent, receives accessory slips⁴ from the upper border of the ribs, and is inserted by a series of tendons into the angles of the ribs and into the four or five lower cervical transverse processes.⁵

The **Sple'nus muscle**⁶ is situated at the back of the neck, beneath the trapezius muscle. It arises from the upper six dorsal spinous processes and the lower half of the nuchal ligament. Proceeding upward and outward, it divides into two portions, of which one⁷ is inserted into the upper four cervical transverse processes, and the other⁸ is inserted into the mastoid portion of the temporal bone and the contiguous part of the surface between the curved lines of the occipital bone.

EXTENSOR MUSCLES OF THE BACK. 1, 2, 3, 4, 5, 6, the dorsal extensor muscle. 1, origin from the ilium, sacrum, lumbar, and lower dorsal vertebræ; 2, insertion into the ribs, named the sacro-lumbar muscle; 3, insertion, named the longissimus muscle; 4, offset, named the dorsal spinal muscle; 5, 6, prolongations to the neck, named the ascending and transverse cervical muscles; 7, trachelo-mastoid muscle; 8, complex muscle; 9, prolongation of the longissimus, named the transverse cervical muscle; 10, 11, semispinal muscle; 12, 13, smaller and larger straight muscles of the head; 14, 15, superior and inferior oblique muscles; 16, multifid-spinal muscle; 17, elevators of the ribs; 18, inter-transverse muscles; 19, quadratus lumbar muscle.

FIG. 155.



¹ *M. spinalis dorsi*. Usually described as distinct, ascending from the upper two lumbar and the three lower dorsal spinous processes, to the upper eight or nine dorsal spinous processes.

² *M. transversalis cervicis*, or *colli*; *m. t. major colli*, are names given to the portion prolonged to the neck.

³ *M. sacro-lumbalis*; *m. sacro-costalis*; *m. ilio-costalis*; *m. lumbo-costo-trachelius*; *m. extensor dorsi externus*.

⁴ *M. accessorii*, or *additamentum ad sacro-lumbalem*.

⁵ *M. cervicalis ascendens*, or *descendens Diemerbroeckii*; *m. accessorius ad sacro-lumbalem*; *m. transversalis collateralis colli*, are names given to the portion prolonged into the neck.

⁶ Posterior mastoid muscle; *m. cervico-dorso-mastoideus*.

⁷ *M. splenius colli*; *m. dorso-trachelius*.

⁸ *M. splenius capitis*; *m. cervico-mastoideus*.

The **Com'plex muscle**,¹ partly concealed by the last, arises from the transverse processes of the upper four to six dorsal vertebræ and the transverse and articular processes of the lower four cervical vertebræ, and ascends to be inserted into the inner part of the surface between the curved lines of the occipital bone. Its upper portion is partially intersected by a transverse tendinous structure; and a large fasciculus of the muscle is divided into two bellies by an intermediate tendon.²

The splenius and complex muscles of the two sides of the neck are important agents in maintaining the erect position of the head.

The **Trache'lo-mas'toid muscle**,³ situated between the upper end of the dorsal extensor and the complex muscle, is intimately connected with the former, and may with propriety be considered its prolongation to the head. It arises by narrow tendons from the roots of the transverse processes of the lower four cervical vertebræ, and ascends outwardly to be inserted into the mastoid process of the temporal bone beneath the sterno-mastoid and splenius muscles.

The **Semispi'nal muscle**⁴ consists of fleshy and tendinous fasciculi, obliquely extended between transverse and spinous processes in the back and neck, beneath the dorsal extensor and complex muscles. It arises from the dorsal transverse processes, except the one or two lower ones, and is inserted into the upper five dorsal spinous processes and the lower five of those of the neck. The upper and lower portions are sometimes separated by an interval, and these are usually described as distinct, with the names of **semispinal muscle of the neck**⁵ and of **the back**.⁶

The **Mul'tifid spi'nal muscle**,⁷ partially concealed beneath the last, consists of numerous short, oblique fasciculi, extended from the transverse and articular processes to the contiguous spinous processes, from the sacrum to the axis. The fasciculi vary in length, some extending

¹ M. complexus; m. c. major; m. trachelo-occipitalis; m. dorso-trachelo-occipitalis.

² This double-bellied fasciculus constitutes the m. biventer cervicis.

³ M. trachelo-mastoideus; m. complexus minor.

⁴ M. semispinalis dorsi et colli.

⁵ M. semispinalis colli, or cervicis; m. spinalis, or transversalis colli, or cervicis; m. transverso- or articulo-spinalis colli; m. semispinatus colli.

⁶ M. semispinalis dorsi, or externus; m. transverso-spinalis dorsi; m. semispinatus dorsi.

⁷ M. multifidus spinæ; m. transversalis dorsi; m. transverso-spinalis; m. t. s. lumbarum dorsi et colli; m. spinales et transversales lumbarum; m. sacer; m. semispinalis internus et transverso-spinalis colli pars interna; m. lumbo-dorsispinalis; lumbo-cervical portion of the spinal muscle; in part, the muscoli rotatores spinæ.

between two vertebræ, others between three, and a few between four, or even five.

This and the preceding muscles are extensors of the vertebral column.

The **Inter-spi'nal muscles**¹ consist of short, fleshy bundles, situated in pairs between the contiguous spinous processes of the vertebræ. They are best developed in the neck, and usually are obsolete in the dorsal region.

The **Inter-trans'verse muscles**² consist of short, fleshy bundles, occupying the intervals of the contiguous transverse processes. They are best developed in the neck, where they are double, are rudimental in the dorsal region, and are well marked in the loins.

These and the preceding small muscles aid in the extension of the vertebral column.

The **Larger Straight muscle**³ arises tendinously from the spinous process of the axis, and ascends to be inserted into the inferior curved line of the occipital bone.

The **Smaller Straight muscle**⁴ arises from the rudimental spinous process of the atlas, and is inserted into the occipital bone below its inferior curved line.

The **Lateral Straight muscle**⁵ arises from the transverse process of the atlas, and is inserted into a ridge of the corresponding process of the occipital bone.

The **Superior Oblique muscle**⁶ arises from the extremity of the transverse process of the atlas, and ascends obliquely inward to be inserted into the outer part of the surface between the curved lines of the occipital bone.

The **Inferior Oblique muscle**⁷ arises from the spinous process of the

¹ M. interspinales; m. i. colli, dorsi et lumbarum.

² M. intertransversarii.

³ M. rectus major; m. rectus capitis posticus major; m. axoideo-occipitalis; m. spini-axoideo-occipitalis; larger posterior straight muscle.

⁴ M. rectus minor; m. r. c. p. minor; m. atlo-occipitalis; m. tuber-atloideo-occipitalis; smaller posterior straight muscle.

⁵ M. rectus lateralis; m. rectus capitis lateralis; m. lateralis Fallopii; m. transversalis anticus primus; m. trachelo-atloido-basilaris; m. atloido-suboccipitalis.

⁶ M. obliquus capitis superior, or minor; m. atlo-, post-, or submastoideus; m. trachelo-atloido-occipitalis.

⁷ M. o. c. inferior, or major; m. axo-atloideus; m. spini-axoideo-tracheli-atloideus.

axis, and passes obliquely outward and upward to be inserted into the extremity of the transverse process of the atlas.

The straight and oblique muscles contribute to maintain the erect condition of the head. The inferior oblique and larger straight muscles rotate the latter, together with the atlas upon the axis.

MUSCLES OF THE RIBS.

The **Intercos'tal muscles**, of which there are eleven pairs on each side of the thorax, occupy the intervals of the ribs. They consist of two planes of short, fleshy and tendinous fibres, extended between the contiguous borders of the ribs and costal cartilages.

The **External Intercos'tal muscles**¹ commence at the tubercles of the ribs, and, with their fibres directed obliquely downward and forward, advance to the costal cartilages, between which they terminate in a thin aponeurosis.

The **Internal Intercos'tal muscles**² commence at the sternal ends of the costal cartilages, and, with their fibres directed obliquely downward and backward, crossing the course of those of the preceding muscles, proceed to the angles of the ribs, where they terminate in a thin aponeurosis, extending to the vertebræ.

On the inner surface of the ribs, more or less frequently, a variable number of fasciculi of fibres of the internal intercostals extend over two or even three intercostal spaces.³

Between the intercostal muscles the intercostal blood-vessels and nerves pursue their course. The internal intercostal muscles are in contact with the pleura; the external ones with the pectoral and great serrated muscles.

The **Ster'no-cos'tal muscle**,⁴ variable in its extent and attachments, is situated within the front of the thorax. It arises by a thin aponeurosis from the inner surface of the lower two divisions of the sternum and the contiguous ends of the costal cartilages, whence its fibres diverge upward and outward, to be inserted by digitations into the costal cartilages from the fifth to the second inclusively.

The **Cos'tal El'eiators**⁵ are twelve in number, on each side of the thorax, and lie beneath the extensor muscles of the back. They con-

¹ M. intercostales externi.

² M. intercostales interni; m. interpleuro-costales.

³ M. infracostales; m. subcostales.

⁴ M. sterno-costalis; m. triangularis sterni; m. pectoralis internus.

⁵ Elevator muscles of the ribs; m. levatores costarum breviores et longiores; m. supra-costales.

sist of narrow bundles arising tendinously from the ends of the transverse processes of the last cervical and all the dorsal vertebræ, except the last one. Descending obliquely outward, their fibres diverge to be inserted into the contiguous ribs, between their tubercles and angles. The lower muscles of the series send an additional fasciculus to the second ribs below their origin.

The intercostal muscles act together, and either raise or depress the ribs according as the first or last of the series of the latter becomes the more fixed point of action. Thus, if the scalene muscles draw up the first and second ribs, this will determine the intercostals to raise all the ribs. If, on the other hand, the quadratus lumbi muscles draw down the last ribs, then all the others will be depressed by the intercostals.

The costal elevators, as expressed by their name, and the superior serrated muscles, raise the ribs. The sterno-costal and inferior serrated muscles depress the ribs.

From the above, it will have been perceived that all the muscles mentioned concur in promoting the function of respiration.

THE ABDOMEN.

The **Abdo'men** or **belly**¹ is that part of the trunk which is included between the thorax and pelvis.

The large vacuity observed in the skeleton between the inferior margin of the thorax and the superior border of the pelvis, is closed by the soft, extensible **abdom'inal pari'etes** or **walls**, composed of skin, the superficial fascia, six pairs of muscles, the transverse fascia, and the peritoneum. The abdominal parietes are longest anteriorly, and become gradually shortened as they approach the back part, named the **loins** or **lumbar regions**,² situated on each side of the vertebral column. In the upright position the abdominal walls are convex and protuberant, varying in these respects according to the fatness of the individual. In the recumbent position they sink inwardly, and in very lean persons even the vertebral column may be felt through them. Inspiration increases their protuberance, and expiration their depression.

In vigorous men, the outlines of the muscular bellies of the abdominal parietes are visible through the skin. In fat persons, usually including healthy women, these are obscured by the subcutaneous fat. Over the position of the end of the sternum is a depression called the **pit of the**

¹ Venter; gaster; abdomen; alvus; venter imus, or infimus; epischion; hypogastrion; hypocoelium; hypoutrion; hypochoilion; etron; nedys; neira; physce.

² Lumbi; lendis; psoæ; reins.

stomach,¹ which becomes more evident with an increase of fat. Near the centre of the abdomen, in front, is the **umbili'cus** or **navel**,² which is a cicatrix remaining from the connection of the umbilical cord of the foetus. From the close adhesion of the skin to the umbilicus, its depth increases with the accumulation of fat around.

The lower part of the abdominal walls is defined on each side by the prominence corresponding with the crest of the ilium and named the **hip**; and in advance of this by the groin and prominence of the pubes.

The **groin** or **in'guinal region**³ corresponds with the crease descending from the hip to the pubis and separating the abdomen from the front of the thigh.

The skin of the abdomen is rather thin and moderately extensible; in lean persons is readily elevated into folds, but not in fat persons. Its extensibility is not so great as might be supposed from the frequent occurrence of distention of the abdominal walls from the accumulation of fat, pregnancy, dropsy, or other causes. In such cases partial ruptures of the dermis take place; and even after the distention is removed, the position of these ruptures is indicated by their cicatrix-like marks on the skin.

SUPERFICIAL FASCIA OF THE ABDOMEN.

The **Superficial Fascia**⁴ is well developed, especially toward the lower part of the abdomen, where it is observed to consist of two distinct layers. It is continuous above with the superficial fascia of the thorax, and behind with that of the back. Its two layers, blended together, adhere along the median line of the abdomen, along the crest of the ilium, and Poupart's ligament, and become continuous with the superficial fascia of the thigh, that of the spermatic cord, and the penis. Where the two layers are separable, the subcutaneous one is found to be composed of loose areolar tissue containing more or less fat, which increases in descending toward the pubis. At the umbilicus it never contains fat, so that the fatter the individual the more depressed the umbilicus will appear. The deeper layer is thinner and more membranous in its character than the other, and is not disposed to the development of fat in its interstices. Between the two layers are contained the subcutaneous blood-vessels, among which, the superficial epigastric artery and vein are conspicuously observed ascending obliquely from the groin.

¹ Scrobiculus cordis.

³ Inguen; plica inguinalis; bubo.

² Umbilic; umbo; omphalos; mesomphalium; radix, or medium ventris.

⁴ Fascia superficialis abdominis.

MUSCLES OF THE ABDOMEN.

The front and lateral walls of the abdomen are composed of six pairs of muscles, of which three are broad muscles, and the others are long ones.

The **External Oblique muscle**,¹ the stoutest of the three broad abdominal muscles, consists of a fleshy portion occupying the side of the abdomen, and a strong aponeurotic portion extending over the front of the latter.

It arises by angular digitations from the outer surface of the lower eight ribs; the digitations being received between similar processes of the origin of the great serrated and latissimus muscles. The fleshy fasciculi incline downward and inward, the lowest ones being inserted into the crest of the ilium, while the others terminate in an aponeurosis, which extends to the median line of the abdomen, from the sternum to the pubis, and conjoins with that of the opposite side.

The upper three-fourths of the aponeurosis present the appearance of a broad band at the side of the median line of the abdomen; and its lower fourth widens outward to the anterior superior spinous process of the ilium. Though mainly composed of fibres continuing in the direction of the fleshy fasciculi, it nevertheless contains many crossing ones, apparently derived from the aponeurosis of the opposite muscle. In several positions the fibres by their separation leave small square intervals, through which blood-vessels reach the superficial fascia and integument.

The upper part of the aponeurosis is connected with the origin of the great pectoral muscle, and is attached to the third piece of the sternum.

As the aponeurosis approaches the pubis its fibres diverge, leaving between them a triangular interval, the **external abdom'inal ring**,² which gives passage to the spermatic cord of the male, and the round ligament of the uterus of the female. The direction of the ring is obliquely downward and inward; its base being formed by the body³ of the pubis, and its sides or **columns**⁴ by the diverging fibres of the aponeurosis. The **inner or upper column** is attached in front of the pubic symphysis, and interlaces with the corresponding insertion of the opposite muscle. The **outer or lower column** is formed by the inferior and somewhat thick-

¹ M. obliquus abdominis externus, descendens, or major; m. costo-abdominalis; m. ilio-pubo-costo-abdominalis.

² Abdominal ring; annulus abdominis, or inguinalis; inguinal ring.

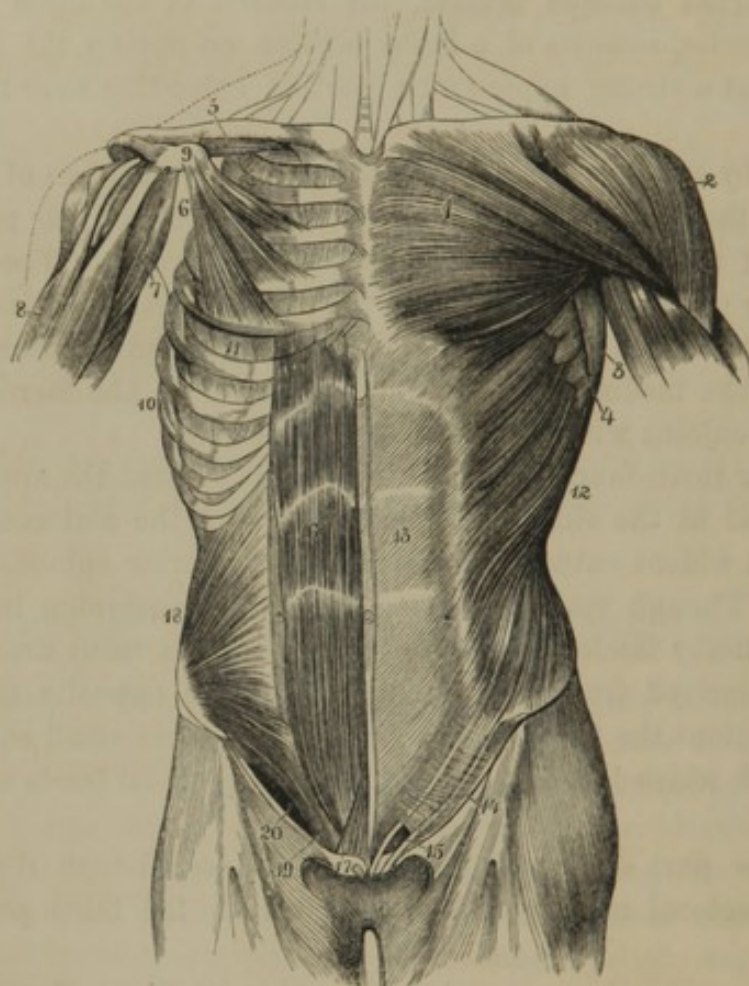
³ Crest of the pubis.

⁴ Pillars; crura.

*As also do the pectoral and
serratus branches at times cross
over the median line, &c.*

ened fibres of the aponeurosis, extended between the anterior superior spinous process of the ilium and the spine of the pubis, constituting the so-called **Poupart's ligament**¹ or **femoral arch**,² important in its relations with inguinal and femoral herniæ

FIG. 156.



MUSCLES OF THE FRONT OF THE TRUNK; on the left side are seen the superficial muscles, on the right the deeper ones. 1, great pectoral; 2, deltoid; 3, latissimus; 4, great serrated; 5, subclavian; 6, small pectoral; 7, coraco-brachial; 8, biceps flexor muscle; 9, coracoid process; 10, great serrated muscle; 11, intercostals; 12, external oblique; 13, its aponeurosis; 14, Poupart's ligament; 15, external abdominal ring; the figure rests upon the falciform process of the fascia of the thigh bounding the saphenous opening externally; 16, straight muscle of the right side, exposed by removing the front of its sheath, which remains on the left side; 17, pyramidal muscle; 18, internal oblique; 19, conjoined tendon of the internal oblique and transverse muscles; 20, position of the inguinal canal below the arching edges of the muscles just named.

Above the position of the external abdominal ring, transversely crossing fibres proceed from the line of Poupart's ligament toward the median line of the abdomen, apparently with the object of preventing a greater separation of the columns of the ring. From the edges of the latter, a

¹ Ligament of Fallopius.

² Crural, or inguinal arch.

thin layer of connective tissue¹ is prolonged upon the spermatic cord, or round ligament.

Poupart's ligament in its course makes a curve with the convexity downward, and is somewhat inflected or directed inwardly. Below, it is continuous with the femoral fascia. At its insertion, a process of the same structure extends a short distance along the pectineal line of the pubis, and terminates in a crescentic margin, constituting the so-called **Gimbernat's ligament**,² important in its relations with femoral hernia.

The **Internal Oblique muscle**³ is placed beneath the last, and, like it, is fleshy at the side of the abdomen, and aponeurotic in front.

It arises from the outer half of Poupart's ligament, the crest of the ilium, and the lumbar fascia. From this origin the fleshy fasciculi radiate forward, the more posterior ascending obliquely and becoming attached to the margin of the lower four costal cartilages contiguous to their internal intercostal muscles, while the others terminate in an aponeurosis extending from the sternum to the pubis. At its upper extremity the aponeurosis is attached to the end of the sternum and the seventh and eighth costal cartilages. For three-fourths of its extent it splits at the semilunar line into two laminae, of which one proceeds in front of the straight muscle and identifies itself with the aponeurosis of the external oblique muscle, while the other proceeds behind the straight muscle, and in like manner identifies itself with the aponeurosis of the transverse muscle. The lower fourth of the aponeurosis passes without division in front of the straight muscle.

The inferior fibres of the internal oblique muscle arch forward and downward over the course of the spermatic cord, or round ligament of the uterus, and, in conjunction with corresponding fibres of the transverse muscle, form the **conjoined tendon**,⁴ which is inserted into the body and pectineal line of the pubis, within the position of the external abdominal ring, thus affording a protection against the escape of any portion of the bowels through this aperture.

The **Transverse muscle**⁵ lies beneath the preceding muscles, and like them presents the same relation of fleshy and aponeurotic portions.

It arises from the outer half of Poupart's ligament, the crest of the ilium, the lumbar fascia, and the inner surface of the lower six costal

¹ Intercolumnar fascia; fascia spermatica.

² Hey's ligament. *Not a ligament.*

³ M. obliquus abdominis internus, ascendens, or minor; m. ilio-abdominalis;

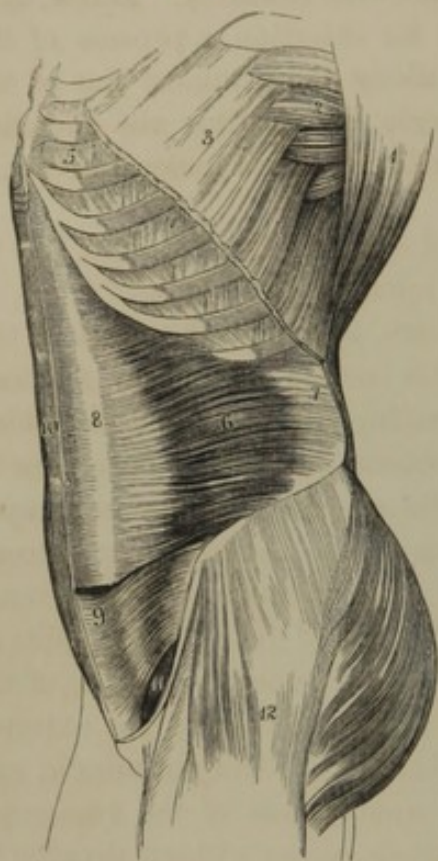
m. ilio-lumbo-costo-abdominalis; m. acclivis.

⁴ Superficies intercruralis.

⁵ M. transversalis abdominis; m. lumbo-abdominalis.

cartilages, where it indigitates with the origin of the diaphragm. The fleshy fasciculi, as indicated by the name of the muscle, proceed trans-

FIG. 157.



VIEW OF THE LEFT SIDE OF THE ABDOMEN. 1, portion of the latissimus muscle; 2, origin of the great serrated muscle; 3, origin of the external oblique; 4, external intercostals; 5, internal intercostals; 6, transverse muscle; 7, its aponeurotic origin; 8, its aponeurotic insertion; 9, lower part of the internal oblique muscle; 10, straight muscle of the right side; 11, position of the inguinal canal between the arched border of the internal oblique and transverse muscles and Poupart's ligament; the figure rests on the transverse fascia; 12, the gluteal muscles.

versely forward and terminate in an aponeurosis, of which the upper three-fourths join the posterior lamina of the aponeurosis of the internal oblique muscle, and with it proceed to the median line of the abdomen, while the lower fourth passes in front of the straight muscle, and, in conjunction with the corresponding portion of the aponeuroses of the other broad muscles, likewise proceeds to the median line of the abdomen.

The inferior fibres of the transverse muscle, like those of the internal oblique, arch forward and downward to the conjoined tendon.

Internally this muscle is invested with a thin, fibrous membrane, the **transverse fascia**,¹ which attaches it to the peritoneum.

The **Straight muscle**² is a broad, fleshy band, situated at the side of the median line of the abdomen, and extending from the pubis to the front of the thorax. It arises by a flat tendon from the symphysis and body of the pubis, expands gradually to the breadth of three or four inches, and ascends to be

inserted in front of the fifth, sixth, and seventh costal cartilages. In its course it presents three or four short tendinous intersections,³ which extend through the breadth and thickness of the muscle, and adhere tightly to the aponeurosis covering the latter. These tendinous intersections appear to represent the abdominal ribs of lizards.

The straight muscle is inclosed in a sheath,⁴ formed by the aponeu-

¹ Fascia transversalis.

² M. rectus abdominis; m. pubio-sternalis.

³ Inscriptiones tendineæ.

⁴ Vagina musculi recti.

roses of the broad muscles, which is incomplete, however, at its lower fourth posteriorly, where the muscle is in contact with the transverse fascia. The deficiency in the sheath is more or less defined by a thin, lunated edge,¹ which is confluent with the transverse fascia extending toward the pubis.

In consequence of the deficiency in the aponeurotic sheath of the straight muscle a space is left, recently described² as the **preperitone'al cavity**,³ which accommodates the urinary bladder in a distended condition.

The **Pyram'idal muscle**⁴ is situated beneath the aponeuroses of the broad muscles upon the lower extremity of the straight muscle. It arises from the symphysis and body of the pubis, and ascends one-third the distance toward the umbilicus, to be inserted into the median line of the abdomen. This muscle sometimes exists only on one side, and not unfrequently it is altogether absent.

At the **median line** of the abdomen, the aponeuroses of the three pairs of broad muscles are intimately associated with one another, the tendinous fibres of one side crossing and intersecting those of the opposite side. From its white appearance, rendered more conspicuous by the dark color of the straight muscle being seen through the aponeurosis on each side, it is named the **linea alba**.⁵ This is wide above but narrow below, and separates the straight muscles. Near its middle the umbilicus appears as a fibrous cicatrix.

The aponeuroses of the broad muscles commence nearly in the same position, corresponding with the outer border of the straight muscles. This position also appears as a white line, in contrast with the fleshy bellies on each side, and is named, from its curving inwardly as it approaches the pubis, the **semilunar line**.⁶

Crossing from the semilunar to the median line, the tendinous intersections of the straight muscle are seen through the aponeurosis investing the latter, and are named, from their course, the **transverse lines**.⁷ One of these exists nearly opposite the lower end of the sternum, a second about half the distance from this to the umbilicus, a third nearly on a level with the latter, and usually an imperfect one half way between the umbilicus and pubis. They intimately adhere to the aponeurosis in front

¹ Linea semicircularis; linea Douglasii; plica semilunaris Douglasii.

² Sitzungsberichte der K. Akad. der Wissenschaften. Wien, 1858, page 259.

³ Cavum præperitoneale; c. p. Retzii; porta vesicæ; p. v. Retzii.

⁴ M. pyramidalis abdominis; m. pubio-umbilicalis; m. Fallopii; m. succenturiatus; m. auxiliarius.

⁵ L. centralis; l. candidula.

⁶ L. semilunaris.

⁷ L. transversæ.

of the straight muscle, and, in powerfully muscular men, together with the median and semilunar lines, indicate the position of the intervening fleshy bellies, even through the tegumentary covering of the abdomen.

The **Quad'rate Lum'bar muscle**¹ is situated at the side of the lumbar vertebræ, and is inclosed in a sheath formed by the lumbar fascia. It arises tendinously from the crest of the ilium back of its middle, and ascends to be inserted into the last rib and the transverse processes of the lumbar vertebræ, except the last one.

The muscles of the abdomen support and compress the viscera of its cavity. By depressing the ribs and elevating the abdominal viscera, they antagonize the action of the diaphragm, and thus become the principal muscles in expiration. They act also in the expulsion of the contents of the bowels and urinary bladder, in the birth of the child, in vomiting, etc.

THE LUMBAR FASCIA.

The **Lum'bar fas'cia**² consists of two fibrous layers inclosing the quadrate lumbar muscle, and forming part of the origin of the internal oblique, transverse, and latissimus muscles. The anterior layer is attached to the front of the roots of the transverse processes of the lumbar vertebræ, the crest of the ilium, and the last rib; in which latter position its thickened margin constitutes the **external arc'uate ligament**.³ The posterior layer, thicker and more aponeurotic than the other, is attached to the ends of the transverse processes of the lumbar vertebræ, the crest of the ilium, and the last rib. It separates the quadrate lumbar muscle from the dorsal extensor, and is joined at the outer border of the former by the anterior layer, in which position it gives origin to the muscles above mentioned.

THE TRANSVERSE FASCIA OF THE ABDOMEN.

The **Transverse fascia**⁴ of the abdomen is a thin, fibrous membrane investing the inner surface of the transverse muscles, and attaching them to the peritoneum. It is strongest in the inguinal region, and in this position is important in its relations with hernia. It invests the straight muscle where its sheath is incomplete, and closely adheres to the lunated margin of the latter, as it does also to the body and pectineal line of the pubis, behind the tendon of the straight muscle and the conjoined tendon

¹ *M. quadratus lumborum, or dorsi; m. lumbaris externus; m. flectans par lumborum; m. ilio-costalis; m. ilio-lumbo-costalis.*

² *F. lumborum.*

³ *L. arcuatum externum.*

⁴ *F. transversa; f. transversalis; f. Cooperi; f. endogastrica.*

of the internal oblique and transverse muscles. Traced upward, it becomes thinner, and is continuous with the fibrous attachment of the peritoneum to the diaphragm. Traced toward the loins, it becomes thinner and looser in texture. It tightly adheres to the crest of the ilium and Poupart's ligament, and from these positions is continuous with the iliac fascia.

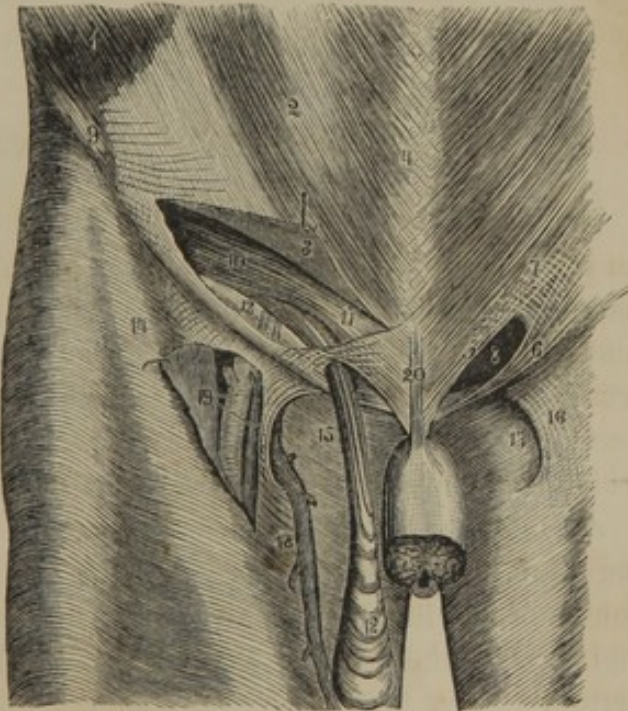
Half way between the anterior superior spinous process of the ilium and the symphysis of the pubis, just above Poupart's ligament, the transverse fascia is prolonged downward and inward as a sheath¹ to the spermatic cord. The entrance of this prolongation, viewed as an orifice, is named the **internal abdom'inal ring**, the commencement of the inguinal canal.

THE INGUINAL CANAL.

The **In'guinal canal**² is the space in the lower part of the abdominal walls which gives passage to the spermatic cord of the male, and the round ligament of the uterus in the female. It is narrower in the latter, in accordance with the smaller size of the round ligament than the spermatic cord.

FIG. 158.

VIEW OF THE INGUINAL CANAL. 1, portion of the fleshy belly of the external oblique muscle; 2, its aponeurosis; 3, portion of the latter raised up, exposing the inguinal canal; 4, linea alba; 5, insertion of the aponeurosis of the external oblique into the body of the pubis; 6, its insertion into the spine of the pubis, named Poupart's ligament; 7, division of the fibres of the aponeurosis crossed by transverse fibres; 8, external abdominal ring, the termination of the inguinal canal; 9, anterior superior spinous process, the origin of Poupart's ligament; 10, arching lower border of the internal oblique and transverse muscles; 11, conjoined tendon of the latter muscles; 12, fibres of the cremaster muscle descending on the spermatic cord from the edges of the muscles just named; 13, rests on the transverse fascia; to its right are the epigastric vessels crossing the course of the inguinal canal; 14, iliac portion of the femoral fascia; 15, pubic portion; 16, falciform process; 17, saphenous opening; 18, saphenous vein joining the femoral vein through the saphenous opening; 19, the femoral artery and vein exposed by raising the portion of fascia which forms the falciform process; 20, suspensory ligament of the penis.



The canal is about an inch and a half long; its upper extremity being the **internal abdom'inal ring**,³ and its lower extremity the **external**

¹ Infundibuliform fascia; fascia spermatica interna, or propria.

² Canalis inguinalis; spermatic canal.

³ Apertura interna; a. abdominalis.

abdom'inal ring.¹ In front it is bounded by the aponeurosis of the external oblique muscle, behind by the transverse fascia and conjoined tendon of the internal oblique and transverse muscles, above by the arching borders of the latter muscles, and below by Poupart's ligament.

The middle of the inguinal canal is crossed behind by the epigastric blood-vessels, which pursue their course, involved in the structure of the transverse fascia, from the external iliac blood-vessels, upward and inward toward the umbilicus.

p 302+ The interior surface of the abdominal wall, in the inguinal region, presents a slight fold of peritoneum pursuing the same course as the epigastric blood-vessels, and hence called the **epigas'tric fold.**² The fold divides the inguinal region into two shallow depressions named the **internal** and **external in'guinal fossæ.**³

The deeper part of the **internal in'guinal fossa**⁴ corresponds with the position of the external abdominal ring, and is the point at which direct inguinal hernia occurs.

The deeper part of the **external in'guinal fossa** corresponds with the position of the internal abdominal ring, into which the peritoneum is sometimes prolonged, especially in the female, as a small funnel-like pit;⁵ and at this point oblique inguinal hernia has its commencement.

REMARKS ON INGUINAL HERNIA.

The protrusion of any portion of the contents of the abdomen through an opening in its parietes is called a **her'nia**; the varieties of which are named from the particular positions of their occurrence, and thus we have umbilical hernia, inguinal hernia, femoral hernia, and others. The protruding part pushes before it the membranous structures it meets in its passage, and these furnish coverings to the hernia. The peritoneum, which is the membrane first protruded, forms the so-called **her'nial sac.**

An inguinal hernia may occur either from the internal or the external inguinal fossa. Most frequent from the latter position, it follows the course of the inguinal canal, and emerges at the external abdominal ring, and receives the name of **oblique in'guinal her'nia.** In this variety the hernial sac has for its coverings, in the order of their protrusion: first, a membrane, more or less distinct, formed by the association of the transverse and intercolumnar fasciæ, including the fibres of the cremaster muscle; second, the superficial fascia; and third, the skin.

¹ Annulus inguinalis; apertura externa.

² Plica epigastrica.

³ Foveæ inguinales.

⁴ Triangle of Hesselbach.

⁵ Canal of Nuck.

The protrusion of a hernia directly through the external abdominal ring occurs from the internal inguinal fossa, and receives the name of **direct in'guinal hernia**.¹ The coverings of the hernial sac in this variety, in the order of protrusion, are: first, a membranous investment, derived from the transverse fascia and the intercolumnar fascia, including some loose fibres of the conjoined tendon; second, the superficial fascia; and, third, the skin. If the protrusion occurs through a separation or interval of the fibres of the conjoined tendon, this structure would not contribute to form the first covering of the hernial sac.

In consequence of the comparative narrowness of the inguinal canal and smallness of the abdominal rings, inguinal hernia is of rare occurrence in the female.

In oblique inguinal hernia, the excretory duct of the testicle and vessels of the spermatic cord and the epigastric blood-vessels lie at the inner side of the neck of the hernia; but in direct inguinal hernia, the spermatic cord and epigastric vessels are at the outer side.

THE DIAPHRAGM.

The **Di'aphragm**² is a muscular partition separating the thorax and abdomen. Its under or abdominal surface is deeply vaulted, and is invested by the peritoneum; its upper surface is convex, and is covered by the two pleuræ and the pericardium. Its centre rises to a level with the fifth costal cartilages; and on the right side, apparently to accommodate the liver, it rises higher than upon the left.

The origin of the diaphragm is from the inferior margin of the thorax as constituted by the end of the sternum and the lower six ribs, from the arcuate ligaments, and from the bodies of the upper four lumbar vertebræ. From this extensive circle the fleshy fasciculi ascend and converge to a central tendon.

The origin from the ribs is by fleshy serrations included between similar processes of the transverse muscles of the abdomen.

The **arc'uate ligaments**³ are thin and narrow fibrous arches, of which the inner one extends over the upper extremity of the psoas muscle from the body of the first lumbar vertebræ to its transverse process; the outer one forms the upper edge of the anterior layer of the lumbar fascia,

¹ Internal inguinal hernia; ventro-inguinal hernia.

² Diaphragma; musculus phrenicus; midriff; diaphragm; disseptum; discretorium; hypozoma; perizoma; diazomo;

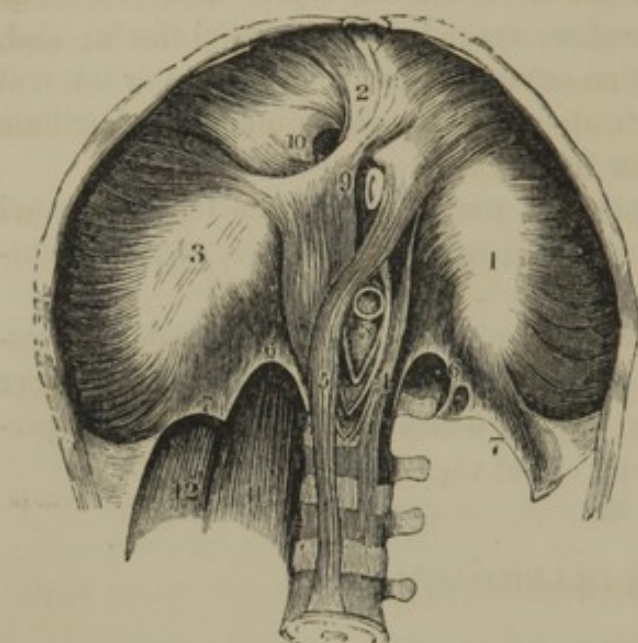
phrenes; præcordia; præcinctus; succentura; musc. succinctus; septum transversum; respiratorium ventris.

³ Ligamenta arcuata.

extended from the transverse process of the first lumbar vertebra to the end of the last rib.

The portions of the diaphragm proceeding from the lumbar vertebræ

FIG. 159.



INFERIOR VIEW OF THE DIAPHRAGM. 1, 2, 3, the three lobes of the central tendon, surrounded by the fleshy fasciculi derived from the inferior margin of the thorax, the crura, 4, 5, and the arcuate ligaments, 6, 7; 8, aortic orifice; 9, oesophageal orifice; 10, quadratus foramen; 11, psoas muscle; 12, quadratus lumbis muscle.

are named its **crura**.¹ The **right crus** is the larger, and arises tendinously from the bodies and intervening fibro-cartilages of the upper four lumbar vertebræ; the **left crus** arises in the same manner from the upper three.

The **central tendon**² of the diaphragm is a broad aponeurosis, composed of converging and interwoven fibrous bands, and is entirely surrounded by the fleshy part of the muscle. It is usually described as somewhat heart shaped, with the notch directed backward, or more correctly as trilobed, one

lobe being directed forward, and one backward on each side.

Three important orifices exist in the diaphragm for the passage of the aorta, oesophagus, and inferior cava.

The **aortic orifice**³ is formed between the crura of the diaphragm in front of the first lumbar vertebra. The tendons of origin of the crura meet behind the aorta, and conjoin in a narrow arch in front of it, so that the vessel is inclosed by fibrous structure and is not liable to constriction from the action of the fleshy portion of the muscle. Besides the aorta, the thoracic duct passes through the aortic orifice of the diaphragm.

The **oesophageal orifice**⁴ is an elliptical opening, situated above and a little to the left of the aortic orifice, in the muscular structure of the diaphragm. In the ascent of the crura of the latter, their fleshy fasciculi cross in front of the aortic orifice, and then, proceeding upward to

¹ Pillars; columns; pars lumbalis.

² Centrum tendineum, phrenicum, or nerveum; pars tendinea; tendo diaphragmatis; speculum Helmontii; cordiform tendon; phrenic centre.

³ Hiatus aorticus; semicirculus exculptus.

⁴ Oesophageal aperture or foramen; for. oesophageum.

reach the central tendon, leave between them the œsophageal orifice. The fleshy constitution of the borders of this aperture adapts it to act the part of a sphincter muscle to the œsophagus.

The remaining orifice, which transmits the ascending cava, is situated in the central tendon, to the right of its middle. Formed between the crossing fibrous bands of the tendon, it is somewhat square, with rounded angles, and hence is named the **quad'rate foramen**.¹

Besides the orifices described, the crura of the diaphragm are pierced by the great sympathetic nerves and azygos veins.

The diaphragm is the most important of the respiratory muscles. In contracting it descends, and thus increases the capacity of the chest, and produces inspiration. The abdominal muscles are the chief antagonists to its action. It performs an important part in coughing, laughing, sneezing, yawning, sighing, crying, sobbing, hiccoughing, singing, vomiting, the voiding of the excrement, and the expulsion of the fœtus.

MUSCLES OF THE PERINEUM.

See the article Perineum, after the account of the generative apparatus.

THE UPPER EXTREMITY.

The **Upper Extremity** commences with the prominence of the **shoulder**, beneath which is the **axil'la**² or **armpit**, bounded in front and behind by thick borders, the **ax'illary folds**. The **arm**³ is cylindrical, and terminates in the **bend of the arm** or **elbow**, which is bounded on each side by the prominences of the condyles, and behind by the prominence of the olecranon, the **elbow**. The **forearm**⁴ is club shaped, and compressed from within outwardly. Its prominent inner portion above is produced by the flexor and pronator muscles; its corresponding outer portion, by the extensor and supinator muscles. The **back** or **dorsal surface of the hand** is broad and convex, and presents no indication of the separation existing between the carpus and metacarpus. The **palm** or **palmar surface** exhibits the **hollow of the hand**, bounded above by the prominence of the **carpus** or **wrist**, and at the sides by the **ball of the thumb**⁵ and **little finger**.⁵

The wrist joint, or radio-carpal articulation, is indicated in front by transverse furrows of the skin. The metacarpo-phalangeal articulations are indicated by the **knuckles** behind, and transverse furrows at the ante-

¹ F. quadratum; f. venosum.

² Assella; fovea axillaris; cordis emunctorium; hypomia; male; maschalis.

³ Brachium.

⁴ Antibrachium; pars inferior brachii; cubitus.

⁵ Thenar and hypothenar eminences.

rior third of the palm. The phalangeal articulations are likewise indicated by **knuckles**, and by transverse furrows of the skin before and behind.

The fingers, as previously mentioned, are named in succession, the **thumb**,¹ the **index** or **fore finger**,² the **middle**,³ the **ring**,⁴ and the **little fingers**.⁵

The skin of the upper extremity is moderately thick and dense externally or posteriorly; thin and extensible internally or anteriorly. It is readily movable to and fro on the parts beneath, except in the palm of the hand.

FASCIÆ OF THE UPPER EXTREMITY.

The **Superficial fascia** of the upper extremity is a rather loose layer of areolar tissue connecting the skin with the deep fascia and with the various subcutaneous prominences and ridges of the bones. Its superficial portion contains more or less fat, the superficial venous trunks, and the cutaneous nerves in their course to the skin. Accumulation of fat involves the veins just mentioned, and, occupying the angular intervals of the different groups of muscles, gives the characteristic rounded form to the limbs of young children, well-developed women, and fat men. The deeper portion of the fascia is more membranous in character, and defines the fatty layer from the parts beneath. Upon the acromion and olecranon the superficial fascia is always devoid of fat; and in the latter position it contains an irregular synovial bursa, devoid of an epithelium.

Approaching the wrist and hand, the fatty layer of the superficial fascia decreases, but is never absent from the palm of the hand, where it is intimately blended with the under surface of the skin.

The **Deep fascia**⁶ of the upper extremity is a continuation of the thin membrane investing the pectoral, trapezius, latissimus, and great serrated muscles. Adhering to the clavicle, acromion, and spine of the scapula, it gives the deltoid muscle a thin covering, and extends downward upon the arm. A portion invests the subscapular and terete muscles; but stronger portions cover the supra- and infra-spinous muscles, adhering intimately to the borders of the fossæ whence the muscles arise. It incloses the axilla by crossing from the pectoral to the latissimus muscle, and it is intimately associated with the sheath of the axillary and brachial vessels and nerves. It is thin upon the inner part of the arm, is thicker on the back part, and increases in strength as it approaches the elbow,

¹ Pollex.

² Digitus indicis.

³ D. medius.

⁴ D. annularis.

⁵ D. minimus.

⁶ Brachial and antebrachial fascia.

where it adheres to the olecranon, the condyles, and the condyloid ridges,—the attachments to the latter constituting intermuscular partitions. It receives offsets from the tendons of insertion of the pectoral, latissimus, and triceps muscles, and also gives origin to some of the fleshy fasciculi of the latter.

In the forearm the deep fascia has an aponeurotic appearance; is bluish white, and shining, and is composed of transverse fibres conjoined by others running longitudinally. From the tendon of the biceps it receives a conspicuous offset, which expands upon the muscles arising from the internal condyle, and separates the median basilic vein from the brachial vessels and median nerve. Extensions of the fascia inwardly between the muscles constitute **intermuscular partitions**, which, together with the inner surface of the fascia afford origin to many of the fleshy fasciculi of the muscles.

At the wrist, by strong accessions of transverse fibres, the deep fascia forms the annular ligaments, which serve to maintain the position of the flexor tendons in their course to the hand.

The **Anterior an'nular ligament**¹ is a strong, thick, and wide band extended from the inner to the outer side of the front of the carpus, being attached by one extremity to the pisiform and unciform bones, by the other to the trapezial and scaphoid bones. With the concavity of the carpus it forms a canal for the passage of the flexor tendons and median nerve to the palm of the hand.

The **Posterior an'nular ligament**,² less distinct and strong than the preceding, is a wide band of oblique fibres extended from the outer border of the lower end of the radius to the inner side of the ulna and the pisiform bone. As it crosses the radius and ulna, it tightly adheres to the parallel ridges at their lower ends, thus converting the intermediate grooves into canals, through which the extensor tendons pass to the back of the hand.

The deep fascia on the back of the hand extends as a thin layer from the ligament just described to the fingers, and is intimately connected with the extensor tendons beneath. The **palmar fascia**³ extends from the annular ligament, as a thin investment to the ball of the thumb and little finger. The middle portion is a strong, triangular aponeurosis, composed of fibres diverging from the annular ligament and connected by transverse fibres. Its apex partly receives the insertion of the tendon of the long palmar muscle; its base divides into four processes, each of which subdivides upon the flexor tendons as these diverge to the fingers,

¹ L. annulare, or transversum anterius; l. commune, or carpi volare.

² L. annulare, or transversum posterius; l. commune, or carpi dorsale.

³ Aponeurosis palmaris.

and the subdivisions are attached to the vaginal ligaments and those of the metacarpo-phalangeal articulations.

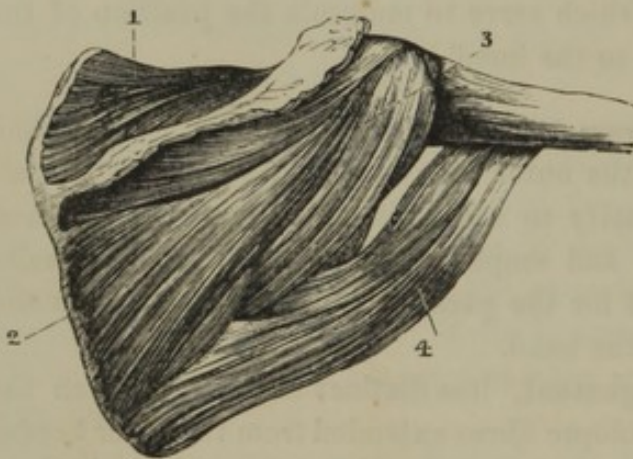
The **Vag'inal ligaments**¹ are fibrous sheaths, inclosing the flexor tendons, in front of the phalanges, with the lateral edges of which they are firmly attached. They are composed of transverse and obliquely crossing bands, thick and strong in front of the phalanges, but thin upon the articulations, so as not to impede the movement of the latter.

The tendons of the flexor and extensor muscles, as they pass through the canals formed by the annular and vaginal ligaments, are invested with synovial sheaths.²

MUSCLES OF THE SHOULDER.

The **Supra-spi'nous muscle**³ arises from the corresponding fossa of the

FIG. 160.



MUSCLES ON THE BACK OF THE SCAPULA. 1, supra-spinous muscle; 2, infra-spinous muscle; 3, lesser terete muscle; 4, greater terete muscle.

scapula and from an investing aponeurosis. Its fleshy fasciculi converge to a tendon which proceeds beneath the acromion, adheres to the capsular ligament of the shoulder joint, and is inserted into the upper part of the greater tuberosity of the humerus.

The **Infra-spi'nous muscle**⁴ arises from the corresponding fossa of the scapula and converges to a tendon, which, proceeding over the capsular ligament of the shoulder joint, is inserted into the middle part of the greater tuberosity of the humerus.

The **Lesser Te'rete muscle**⁵ arises from the upper part of the outer border of the scapula, and, in contact with the preceding muscle, frequently more or less conjoined with it, ascends to be inserted into the lower part of the greater tuberosity of the humerus.

The **Subscap'ular muscle**⁶ arises by broad fasciculi from the corre-

¹ L. vaginalia; vaginal and crucial ligaments.

² Vaginæ synoviales.

³ M. supra-spinatus; m. supra-scapularis; m. superscapularis superior.

⁴ M. infra-spinatus; m. superscapularis inferior.

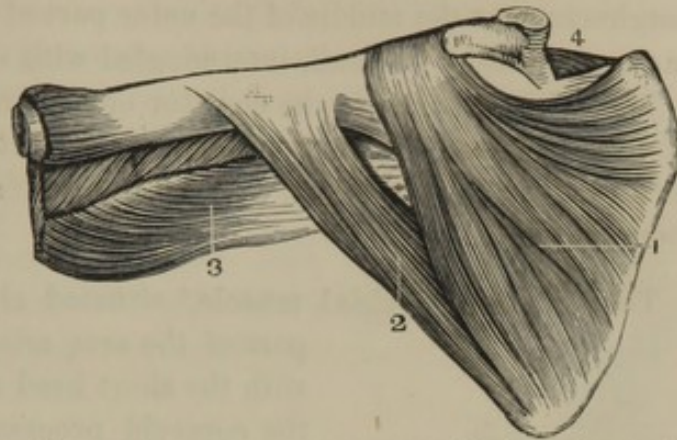
⁵ M. teres minor.

⁶ M. subscapularis.

sponding fossa of the scapula, and converges to a strong tendon, which passes in front of the shoulder joint, and is inserted into the lesser tuberosity of the humerus.

It lies upon the great serrated muscle, from which it is separated by a thin fascia¹ and some loose areolar tissue extending from the axilla. Between its tendon and the neck of the scapula a synovial bursa is interposed.

FIG. 161.



MUSCLES ON THE FRONT OF THE SCAPULA. 1, subscapular muscle; 2, greater terete muscle; 3, upper part of the triceps extensor; 4, supra-spinous muscle.

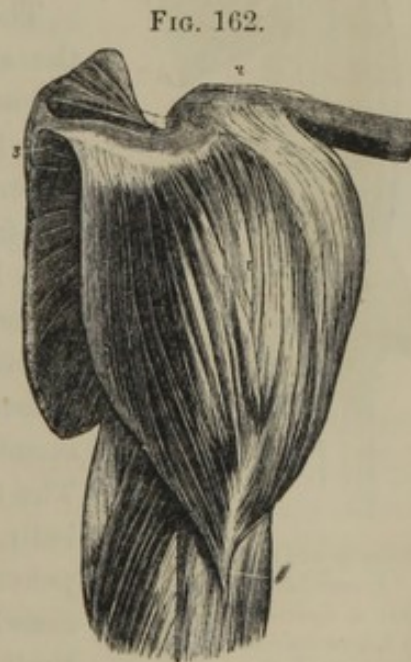The subscapular muscle rotates the arm inwardly, and the supra-spinous, infra-spinous, and lesser terete muscles rotate it outwardly. The tendons of these four muscles, as they approach their insertion, partially surround the shoulder joint, form an intimate connection with its capsular ligament, and contribute very greatly to its strength.

MUSCLES OF THE ARM.

The **Greater Te'rete muscle**² forms part of the posterior fold of the axilla. It arises from the lower part of the inferior border and angle of the scapula, ascends beneath the latissimus muscle, and terminates in a broad tendon, which is inserted into the posterior bicipital ridge of the humerus, in contact with the tendon of the latissimus. The long head of the triceps separates the greater from the lesser terete muscle.

The greater terete muscle assists the latissimus in its action.

The **Del'toid muscle**³ forms the convex prominence of the shoulder.



THE DELTOID MUSCLE. 1, its insertion; 2, its origin from the clavicle; 3, origin from the spine and acromion of the scapula.

¹ Fascia subscapularis.

² M. teres major; m. scapulo-humeralis.

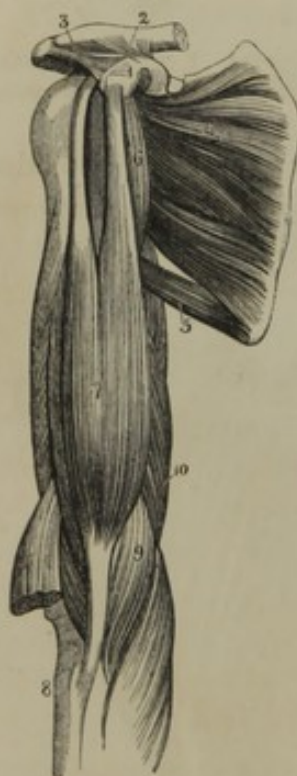³ M. deltoideus; m. deltiformis; m. supra-acromio-humeralis; m. attollens humeri.

It arises, partially tendinous and fleshy, from the outer third of the clavicle, the acromion, and the lower margin of the spine of the scapula, and converges to be inserted, partially tendinous and fleshy, into the roughness near the middle of the outer part of the humerus. The muscle has coarse, fleshy fasciculi, intermingled with tendinous fibres.

The deltoid muscle is the elevator of the arm, and may raise the limb to a vertical position. It is also an efficient aid in drawing the arm backward or forward, and greatly contributes to the strength of the shoulder joint.

The **Cor'aco-bra'chial muscle**,¹ situated along the upper and inner part of the arm, arises tendinously, in common

FIG. 163.



MUSCLES OF THE FORE PART OF THE ARM. 1, coracoid process of the scapula; 2, coraco-clavicular ligament; 3, coraco-acromial ligament; 4, subscapular muscle; 5, greater terete muscle; 6, coraco-brachial muscle; 7, biceps flexor; 8, its insertion into the tuberosity of the radius; 9, brachial muscle; 10, triiceps extensor.

with the short head of the biceps muscle, from the coracoid process of the scapula, and proceeds downward to be inserted about the middle of the inner side of the humerus. It is usually perforated by the external cutaneous nerve in its course to the outer part of the arm.

The **Bi'ceps Flex'or**² is situated in front of the arm, extending from the scapula to the forearm. As the name indicates, it arises by two heads, of which the internal or short one is derived, in common with the preceding muscle, from the coracoid process of the scapula. The long head arises from the summit of the glenoid cavity, by a narrow tendon which passes through the upper part of the shoulder joint, insheathed by the synovial membrane, and descends along the bicipital groove of the humerus. The two heads conjoin and form a thick, fleshy belly, terminating in a strong tendon, which penetrates between the supinator and flexor muscles of the forearm, to be inserted into the back part of the tuberosity of the radius.

Between the tendon of insertion and the fore part of the latter tuberosity, a synovial bursa is interposed; and from the commencement of the same tendon an aponeurotic process is given off to the fascia of the forearm just below the internal condyle.

¹ M. coraco-brachialis, or humeralis; m. perforatus, or m. p. Casserii.

² M. biceps flexor cubiti; m. biceps brachialis; m. biceps internus; m. coraco-radialis; m. scapulo-radialis; the biceps.

The **Bra'chial muscle**¹ lies beneath the biceps muscle at the lower part of the arm, and covers the front of the elbow joint. It arises from the humerus each side of the insertion of the deltoid muscle and from the surface of the bone below, and converges to be inserted tendinously into the fore part of the ~~coracoid~~ process of the ulna.

Coronoid

The coraco-brachial muscle draws the arm inwardly. If the hand is prone, the biceps supinates it by rotating the radius outwardly, and if the action of the muscle continues, the forearm is flexed. The brachial muscle is also a flexor of the forearm, and from its position greatly contributes to the strength of the elbow joint.

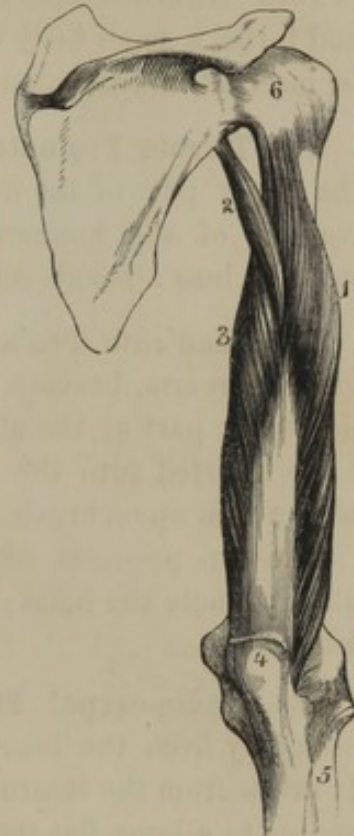The **Tri'ceps Extensor**² forms the whole of the fleshy mass on the posterior part of the arm, and, as the name implies, arises by three heads.

The **external head**³ arises from the humerus, below the greater tuberosity; the **short head**⁴ arises from the humerus, below the greater terete muscle; and the **long head**⁵ arises from the border of the scapula, below the glenoid cavity. The three heads conjoin in one fleshy belly, which in its descent receives a constant accession of fasciculi from the surface of the humerus, and terminates in a strong aponeurotic band facing the muscle posteriorly and inserted into the olecranon process of the ulna. Between the tendinous insertion and the top of the process, a synovial bursa is introduced.

This muscle is the extensor of the forearm.

The **Ancone'us muscle**⁶ appears to be a continuation of the triceps below the outer part of the elbow. It arises

FIG. 164.



VIEW OF THE TRICEPS EXTENSOR, ON THE BACK OF THE RIGHT ARM. 1, external head; 2, long head; 3, short head; 4, insertion of the muscle into the olecranon of the ulna; 5, radius; 6, capsular ligament of the shoulder joint.

¹ M. brachialis anticus; m. b. internus; m. b. humero-cubitalis; m. brachiaeus; anterior brachial muscle.

² M. triceps extensor cubiti, or brachii; m. triceps brachialis.

³ Caput externum; anconeus externus; vastus externus; short head of the biceps externus.

⁴ C. internum; internal head; anc. internus; v. int.; brachialis externus.

⁵ C. longum; c. medius; middle head; first head; long head of the biceps externus; anconeus longus, or major.

⁶ M. anconeus; m. a. quartus, or minor; m. brevis cubiti; m. cubitalis Riolani.

from the external condyle of the humerus, and is inserted into the triangular space at the upper and outer part of the ulna.

It acts with the triceps, and was formerly described as a fourth head to this muscle.

MUSCLES OF THE FRONT OF THE FOREARM.

The **Long Pal'mar muscle**¹ lies between the radio- and ulno-carpal flexors. It arises from the internal condyle and intermuscular partitions, and forms a small belly terminating in a long tendon, which descends to be inserted into the annular ligament of the wrist and the palmar fascia.

The **Te'rete Pro'nator**² is a small muscle extended obliquely across the upper part of the front of the forearm. It arises from the internal condyle of the humerus, and passes outward and downward to be inserted into a rough surface on the outer side of the radius.

The **Quad'rate Pro'nator**³ is a square muscle crossing the lower part of the forearm, beneath the flexor muscles. It arises from the front of the lower part of the ulna, and passes over the interosseous membrane to be inserted into the front of the radius. Superficially it is invested with a thin aponeurosis.

The two pronator muscles, by rotating the radius inwardly upon the ulna, pronate the hand; or, in other words, turn it with the palm downward.

The **Radio-carpal Flexor**⁴ lies in front of the forearm, extending obliquely from the inner condyle to the outer side of the metacarpus. It arises from the internal condyle and intermuscular partitions, and converges to a long, flat tendon, which, after passing through a fibrous canal at the outer part of the carpus, is inserted into the base of the second metacarpal bone.

The **Ulno-carpal Flexor**⁵ lies superficially on the ulnar side of the forearm. It arises from the internal condyle and the olecranon and by a strong aponeurosis from the upper part of the inner border of the ulna. Its belly terminates in a tendon, which is inserted into the pisiform bone and base of the last metacarpal bone.

¹ *M. palmaris longus*; *m. ulnaris gracilis*; *latescentis chordæ*; *m. epitrochlo-carpi-palmaris*.

² *M. pronator radii teres*; *m. pronator rotundus*; *m. p. obliquus*; *m. epitrochlo-radialis*.

³ *M. pronator radii quadratus*; *m.*

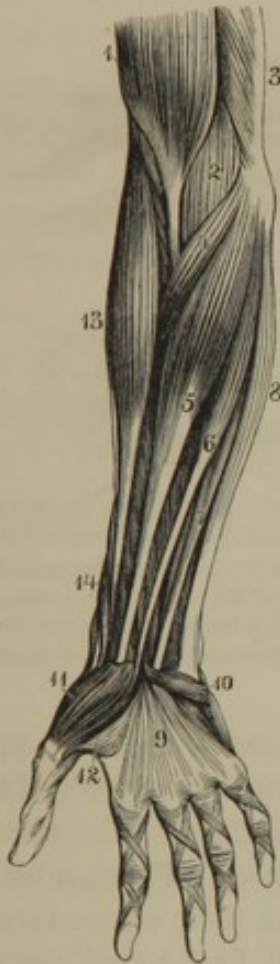pronator transversus; *m. quadratus radii*; *m. cubito-radialis*.

⁴ *M. flexor carpi-radialis*; *m. radialis internus*; *m. palmaris magnus*.

⁵ *M. flexor carpi-ulnaris*; *m. ulnaris internus*; *m. cubitalis internus*, or anterior.

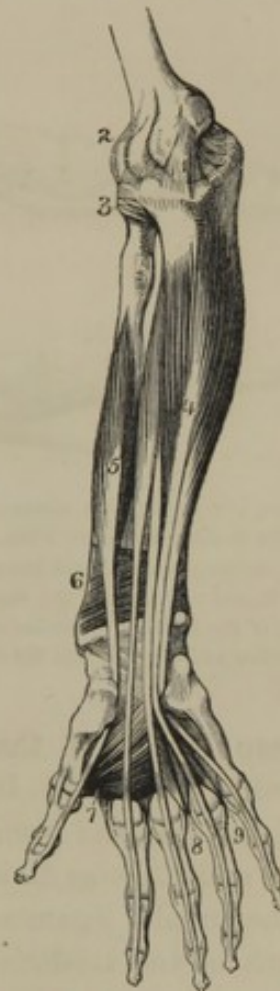Between the origin of this muscle from the humerus and the ulna, the ulnar nerve takes its course.

FIG. 165.



SUPERFICIAL MUSCLES OF THE FRONT OF THE FORE-ARM. 1, lower part of the biceps flexor; 2, brachial muscle; 3, lower part of the triceps extensor; 4, terete pronator; 5, radio-carpal flexor; 6, long palmar muscle; 7, superficial flexor of the fingers; 8, ulno-carpal flexor; 9, palmar fascia; 10, short palmar muscle; 11, abductor of the thumb; 12, short flexor of the thumb; 13, long supinator; 14, extensors of the thumb. The crossing and transverse bands on the fingers are the vaginal ligaments inclosing the flexor tendons.

FIG. 166.



DEEP MUSCLES OF THE FRONT OF THE FOREARM. 1, internal lateral ligament of the elbow joint; 2, capsular ligament of the same; 3, annular ligament inclosing the head of the radius; 4, deep flexor of the fingers; 5, long flexor of the thumb; 6, quadrate pronator; 7, adductor of the thumb; 8, 9, interosseous muscles.

The Superficial Flexor of the Fingers¹ is situated in front of the

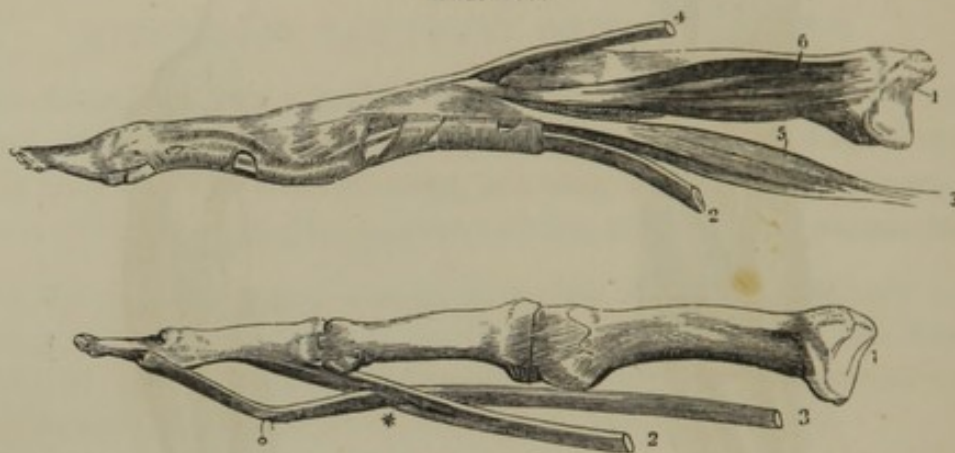
forearm, between the preceding muscles. It arises from the internal condyle, the internal lateral ligament, the coronoid process of the ulna, and the radius below its tuberosity. The fleshy belly at the lower third of the forearm divides into four tendons, which proceed together beneath the annular ligament of the wrist, and diverge to be inserted into the base

¹ M. flexor sublimus perforatus; m. f. digitorum sublimus, or perforatus.

of the second phalanges of the fingers. In front of the first phalanges the tendons are split, to give passage to the tendons of the deep flexor.

Between the ulnar and radial origin of this muscle the median nerve pursues its course.

FIG. 167.



METACARPAL AND PHALANGIAL BONES OF THE FINGERS, WITH THEIR TENDONS AND LIGAMENTS. In the upper figure the flexor tendons are retained in position by the vaginal ligaments composed of transverse and obliquely crossing bands; in the lower figure the flexor tendons are freed from the vaginal ligaments. 1, metacarpal bone; 2, tendon of the superficial flexor; 3, tendon of the deep flexor, passing through a perforation (*) of the former; 4, tendon of the common extensor; 5, a lumbrical muscle, arising from the deep flexor tendon and inserted into the extensor tendon; 6, an interosseous muscle, also inserted into the latter tendon.

The **Deep Flexor of the Fingers**¹ is stronger than the preceding muscle, and is beneath it. It arises from the upper two-thirds of the front surface of the ulna and from the contiguous portion of the interosseous membrane, and likewise divides into four tendons. These, after passing through the annular ligament of the wrist, take their course through the perforations of the tendons of the superficial flexor, and are inserted into the base of the last phalanges.

The **Lum'brical muscles**,² as implied by the name, are worm-like, fleshy fasciculi, four in number, situated in the palm of the hand. They arise from the radial side of the tendons of the deep flexor, and proceed to be inserted into the corresponding side of the tendinous expansions on the back of the fingers.

The **Long Flexor of the Thumb**,³ situated at the outer side of the deep flexor of the fingers, arises from the front of the radius and the contiguous portion of the interosseous membrane. The fleshy belly terminates in a tendon, which passes beneath the annular ligament of the

¹ M. flexor profundus perforans; m. f. digitorum profundus, or perforans; m. f. tertii internodii digitorum; m. perforans manus.

² M. lumbricales; m. fidicinales.

³ M. flexor longus pollicis; m. f. tertii internodii, or longissimus pollicis.

wrist, turns outwardly, and proceeds between the two portions of the short flexor to be inserted into the base of the last phalanx of the thumb.

The tendons of the flexor muscles proceeding to the fingers are retained in their position by the vaginal ligaments.¹ In their passage beneath the latter they are attached to the front of the phalanges by narrow, accessory bands,² apparently serving to conduct nutritious vessels to the tendons. Synovial bursæ³ lining the vaginal ligaments and fronts of the phalanges are thence reflected upon the flexor tendons and their accessory bands.

MUSCLES OF THE BACK OF THE FOREARM.

The **Common Extensor of the Fingers**⁴ arises from the external condyle, contiguous intermuscular partitions, and the fascia of the forearm. Below the middle of the latter its fleshy belly separates into four tendons, which pass beneath the posterior annular ligament, and diverge to the fingers, upon the backs of which they expand. As they pass over the first phalanges they receive an addition of fibres at the sides from the lumbrical and interosseous muscles, and their middle portion is inserted into the base of the second phalanges, while the lateral portions proceed onward and converge to be inserted together into the base of the last phalanges. On the back of the hand the inner three of the tendons are connected together by short, intervening bands, which associate their action much more than with the remaining tendon.

The **Long Supinator**⁵ lies on the radial side of the forearm, and extends from near the middle of the humerus to the wrist. It arises from the external condyloid ridge below the insertion of the deltoid muscle, and converges to a long, flat tendon, which is inserted into the base of the styloid process of the radius.

The **Longer Radio-carpal Extensor**⁶ is partially covered by the preceding muscle, and arises just below it from the same ridge. Its belly converges to a long, flat tendon, which descends along the radius, and is inserted into the base of the second metacarpal bone.

The **Shorter Radio-carpal Extensor**,⁷ partially concealed by the last

¹ Ligamenta vaginalia.

² Vincula vasculosa; v. accessoria tendinum; tenacula.

³ Vaginæ synoviales.

⁴ M. extensor digitorum communis; m. digitorum tensor.

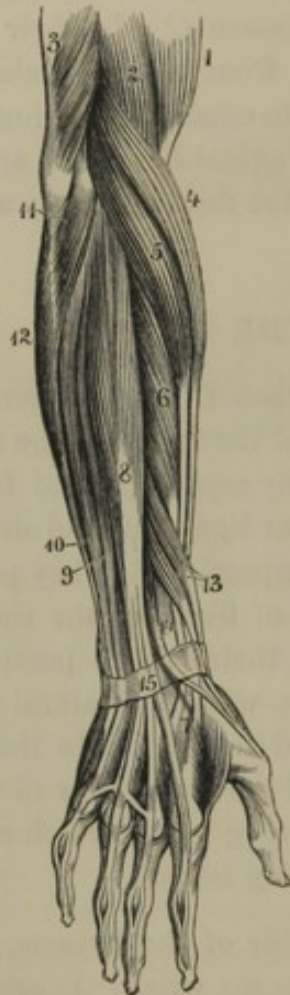⁵ M. supinator longus; m. s. radii longus; m. s. major; m. brachio-radialis.

⁶ M. extensor carpi-radialis longior; m. radialis externus longior, or primus.

⁷ M. extensor carpi-radialis brevior; m. radialis externus brevior, or secundus.

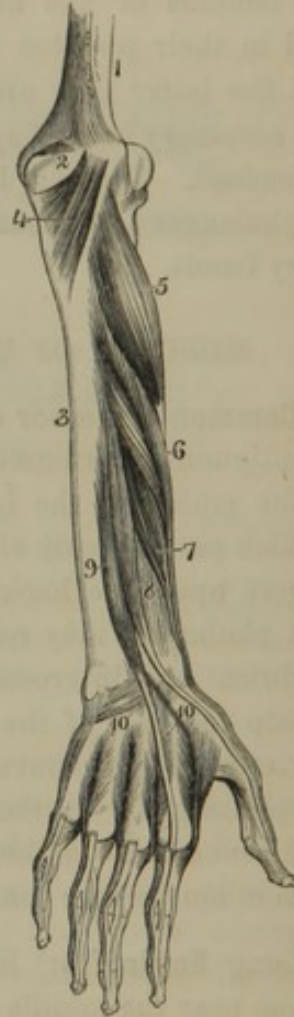muscle, arises from the external condyle of the humerus, and is inserted by a flat tendon into the base of the third metacarpal bone.

FIG. 168.



MUSCLES OF THE BACK OF THE FOREARM. 1, biceps flexor; 2, brachial muscle; 3, triceps extensor; 4, long supinator; 5, longer radio-carpal extensor; 6, shorter radio-carpal extensor; 7, insertion of the tendons of the last two muscles; 8, common extensor of the fingers; 9, extensor of the little finger; 10, ulno-carpal extensor; 11, short supinator; 12, ulno-carpal flexor; 13, metacarpal and first phalangeal extensors of the thumb; 14, second phalangeal extensor of the thumb; 15, posterior annular ligament.

FIG. 169.



DEEP MUSCLES ON THE BACK OF THE FOREARM. 1, humerus; 2, olecranon; 3, ulna; 4, anconeus muscle; 5, short supinator; 6, metacarpal extensor of the thumb; 7, first phalangeal extensor; 8, second phalangeal extensor of the thumb; 9, extensor of the index finger; 10, the dorsal interosseous muscles between the metacarpal bones.

The **Ulnocarpal Extensor**¹ lies at the ulnar side of the forearm, and arises from the external condyle, the upper part of the inner border of the ulna, and the fascia of the forearm. Its belly converges to a long, flat tendon, which descends to be inserted into the base of the last metacarpal bone.

¹ M. extensor carpi-ulnaris; m. ulnaris externus; m. cubitalis externus, or posterior.

The **Extensor of the Little Finger**¹ lies at the ulnar side of the common extensor, with which it has its origin; and its tendon, after passing through a separate canal of the annular ligament, conjoins the fourth tendon of the common extensor.

The **Short Supinator**² is concealed by the long supinator and the radial extensors. It arises from the external condyle of the humerus, the external lateral ligament of the elbow joint, and the ulna, and winds obliquely outward and downward upon the radius, into the upper third of which it is inserted.

The **Metacarpal Extensor of the Thumb**³ crosses the forearm obliquely below the preceding muscle, and arises from the ulna, the interosseous membrane, and the radius. Its belly terminates in a tendon, which crosses those of the radio-carpal extensors, and, after passing through a groove in front of the styloid process of the radius, is inserted into the base of the metacarpal bone of the thumb.

The **First Phalan'gial Extensor of the Thumb**⁴ is a small muscle situated below the preceding to its ulnar side, and has the same points of origin. Its fleshy belly terminates in a narrow tendon, which accompanies that of the preceding muscle, and is inserted into the base of the first phalanx of the thumb.

The **Second Phalan'gial Extensor of the Thumb**⁵ arises below the preceding muscle from the ulna and interosseous membrane. Its belly terminates in a tendon, which passes through a distinct canal of the annular ligament from that occupied by the tendons of the first phalangeal and metacarpal extensors, and proceeds to be inserted into the base of the last phalanx of the thumb.

The **Extensor of the Index Finger**⁶ lies at the ulnar side of the preceding muscle, and has the same points of origin. Its tendon of insertion passes through a groove of the radius, and conjoins the tendon of the common extensor to the index finger.

¹ M. extensor minimi digiti, or m. e. proprius m. d.; m. auricularis.

² M. supinator radii brevis, or minor; m. epicondylo-radialis.

³ M. extensor ossis metacarpi pollicis; m. abductor longus pollicis; m. e. primi internodii ossis pollicis.

⁴ M. extensor primi internodii pollicis; m. extensor brevis, or minor pollicis; m. e.

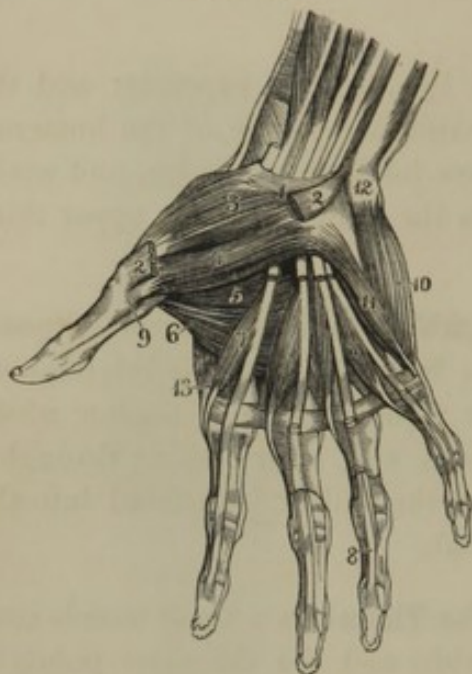
pollicis primus; m. e. secundi internodii ossis pollicis.

⁵ M. extensor secundi internodii pollicis; m. extensor longus, or major pollicis; m. e. pollicis secundus; m. e. tertii internodii ossis pollicis.

⁶ M. extensor indicis; indicator; m. ext. proprius indicis; m. e. p. primi digiti.

MUSCLES OF THE HAND.

FIG. 170.



The **Short Pal'mar muscle**¹ is a thin layer of fleshy fibres situated beneath the skin at the inner side of the palm of the hand. It arises from the annular ligament and palmar fascia, and proceeds inwardly to be attached to the integument.

MUSCLES OF THE PALMAR SURFACE OF THE HAND. 1, anterior annular ligament; 2, origin and insertion of the abductor of the thumb; its belly removed so as to expose 3, the metacarpal flexor; 4, 5, two bellies of the short flexor; 6, adductor of the thumb; 7, lumbrical muscles; 8, tendons of the deep flexor of the fingers passing through the slits of the superficial tendons; 9, tendon of the long flexor of the thumb, passing from between the bellies of the short flexor; 10, abductor of the little finger; 11, short flexor of the little finger, with the edge of the adductor seen beneath; 12, pisiform bone; 13, first interosseous muscle.

MUSCLES OF THE BALL OF THE THUMB.

The **Abductor**² is the most superficial and external of the muscles of the ball of the thumb. It arises from the annular ligament of the wrist, and is inserted into the base of the first phalanx of the thumb.

The **Metacarpal Flexor**,³ beneath the preceding, arises from the same source, and is inserted into the length of the metacarpal bone of the thumb.

The **Short Flexor**⁴ consists of two portions, between which lies the tendon of the long flexor of the thumb. It arises from the annular ligament and the second row of carpal bones, and is inserted tendinously into the base of the first phalanx of the thumb. Within its tendinous insertion the sesamoid bones are imbedded.

The **Adductor**⁵ is a triangular muscle, arising from the length of the

¹ M. palmaris brevis; caro quadrato; m. carpæus.

² M. abductor pollicis; m. a. brevis pollicis; m. a. brevis alter p.; m. scapho-carpo-superphalangeus pollicis.

³ M. flexor ossis metacarpi pollicis; m.

opponens pollicis; m. f. primi internodii pollicis; m. antithenar.

⁴ M. flexor brevis pollicis; m. f. secundi internodii p.; m. f. primi et secundi i. p.; m. thenar.

⁵ M. adductor pollicis; m. metacarpo-phalangeus pollicis.

middle metacarpal bone, and converging to be inserted into the base of the first phalanx of the thumb.

MUSCLES OF THE LITTLE FINGER.

The **Abductor**¹ lies on the margin of the palm. It arises from the pisiform bone, and is inserted into the base of the first phalanx and extensor tendon of the little finger.

The **Short Flexor**² arises from the annular ligament of the wrist and the unciform bone, and is inserted into the base of the first phalanx of the little finger. It is not unfrequently inseparable from the preceding muscle.

The **Adductor**³ arises from the same points as the preceding muscle, and is inserted into the length of the metacarpal bone of the little finger.

THE INTEROSSEOUS MUSCLES.

The **Interos'seous muscles**⁴ are seven in number, and, as implied by their name, are situated in the intervals of the metacarpal bones—four on the back, and three on the palm of the hand.

The **Dorsal Interos'seous muscles**,⁵ four in number, arise from the contiguous sides of the metacarpal bones, and each forms a penniform belly, terminating in a tendon, which partially conjoins the extensor tendons on the back of the finger, and is partially inserted into the base of the first phalanx.

The first of this series is inserted into the radial side of the index finger, and is an abductor; the succeeding two are inserted into the opposed sides of the middle finger, and act as an abductor and adductor; and the last one is inserted into the ulnar side of the ring finger, and is an adductor.

The **Palmar Interos'seous muscles**,⁶ three in number, arise from a single side of the metacarpal bones of the index, ring, and little fingers, and terminate in the same manner as the dorsal series. The first is on the ulnar side, and is an adductor, and the other two are on the radial side, and are abductors.

¹ M. abductor minimi digiti; m. extensor tertii internodii m. d.; m. carpo-phalangeus m. d.; m. hypothenar minor metacarpeus.

² M. flexor brevis, or parvus minimi digiti.

³ M. adductor minimi digiti; m. a. metacarpi m. d.; m. carpo-metacarpeus m. d.

⁴ M. interossei.

⁵ M. i. externi; m. i. bicipites.

⁶ M. i. interni.

THE LOWER EXTREMITIES.

The **Lower Extremities**, which support and carry the other portions of the body, are accordingly larger and stronger, and provided with more powerful muscles than the upper extremities. At the back part of the hips are the **buttocks** or **nates**,¹ separated by the **fissure of the anus**, and from the thighs below by the **sub-ischiatic grooves**. The **thigh**² is separated from the abdomen by the **groin** or **inguinal region**, and gradually becomes narrowed to the **knee**.³ Behind the latter is the space called the **poplite'al region**, or **hollow of the knee**,⁴ bounded on each side by the "**ham-strings**." The condyles of the femur and tibia produce the lateral prominences of the **knee**, the **knee-cap** producing the eminence in front. The **calf**⁵ or thick mass of the **leg**⁶ narrows downward to the "**tendon of Achilles**," which terminates at the **heel**.⁷ The **ankles** correspond with the malleoli of the tibia and fibula.

The skin of the buttock is thick, but becomes thin in the fissure of the anus. Upon the outer part of the thigh and leg it is thick, dense, and comparatively dull in sensibility; becomes thinner, more extensible, and sensitive toward the inner part, and is everywhere quite movable. Upon the back of the foot the skin is thin and extensible; but upon the sole, is thick, inextensible, and quite immovable.

FASCIÆ OF THE LOWER EXTREMITY.

The **Superficial fascia** of the lower extremity, as in other divisions of the body, is in most parts separable into two layers, of which the inner one is thin and membranous, the outer one loose in texture, and more or less filled with fat.

Upon the buttock the superficial fascia is ordinarily occupied with a large quantity of fat. Upon the thigh and leg it also usually contains much fat, except over the great trochanter and the patella, in which positions synovial bursæ are substituted. In the sole of the foot it is always occupied with fat, and is most intimately blended with the structure of the skin. At the heel, and bend of the first and last metatarsal bones, it contains synovial bursæ. Between the fatty and membranous layers of the superficial fascia, the superficial veins and cutaneous nerves have their course.

¹ Glutia; sedilia; clunes; podex; posteriors; bottom.

² Femur; crus; merus.

³ Genu.

⁴ Popliteal fossa; the hock; the hough; the ham.

⁵ Sura; gastrocnemium.

⁶ Crus; scelos; cneme.

⁷ Calx; talus.

The fatty layer at the groin and hip is continuous with the corresponding layer of the superficial fascia of the abdomen. The deeper or membranous layer adheres to Poupart's ligament and the crest of the ilium. At the saphenous opening it is pierced by the cutaneous vessels of the contiguous regions, from which circumstance this perforated portion of the superficial fascia is called the **crib'riform fascia**.¹

The **Deep fascia** of the lower extremity, like that of the upper extremity, forms a complete envelope to the limb, sends partitions between the muscles, and gives sheaths to the great blood-vessels. It is called, from its relative positions, the **femoral fascia**, the **crural fascia**, and the **fascia of the foot**.

The **Fem'oral fas'cia** or **fas'cia la'ta**,² is attached along the crest of the ilium, the back of the sacrum and coccyx, the border of the ischium and pubis and Poupart's ligament, with which it is continuous. Upon the great gluteal muscle it forms a thin investment; but in advance of this, and extending in the same line the entire length of the outer part of the thigh, it is so thick and strong as to appear like an aponeurosis. This portion of the fascia is composed of longitudinal fibres strengthened by transverse ones; gives partial origin to the middle gluteal muscle; receives, over the position of the great trochanter, part of the insertion of the great gluteal muscle; and after insheathing its own peculiar tensor muscle, receives the insertion of this altogether. In passing from the outer to the inner part of the thigh, the femoral fascia becomes gradually thinner, and is mainly composed of transverse fibres.

Between all the muscles it sends partitions, among the most important of which are the so-called **external** and **internal intermuscular partitions**.³ The former of these is a strong process separating the quadriceps extensor and the biceps flexor, and attaching itself to the asperous ridge from the insertion of the great gluteal muscle to the outer condyle of the femur. The other is a thinner partition separating the quadriceps extensor from the adductor muscles, and connecting itself with the asperous ridge leading to the inner condyle. At the knee the fascia receives offsets from the extensor and flexor tendons, forms a general envelope⁴ to the joint, and becomes continuous with the crural fascia.

Below the groin, the femoral fascia is so important in its relations with the femoral blood-vessels and the subject of femoral hernia, that it requires special attention. The inner and outer portions of the fascia,

¹ Fascia cribrosa.

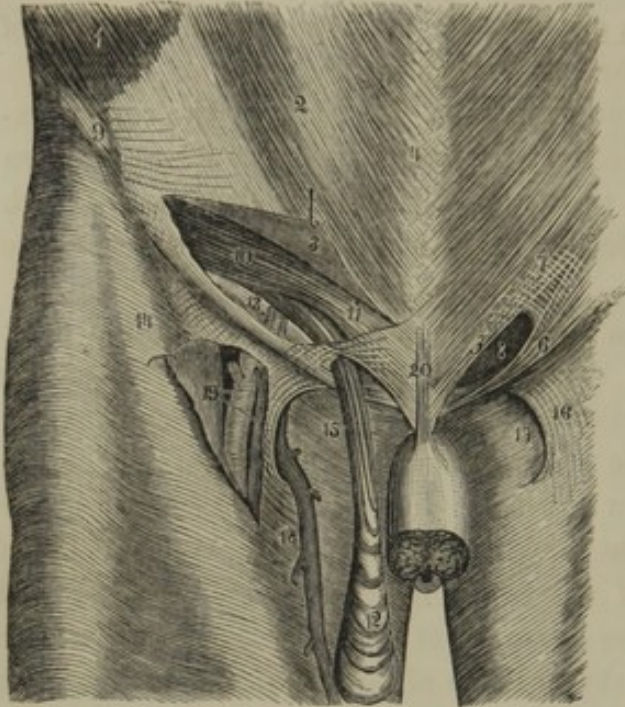
² Fascia femoris; f. lata aponeurosis;
f. aponeurotica femoris; vagina femoris;
crural, or femoral aponeurosis.

³ Ligamentum intermusculare externum et internum.

⁴ Involucrum generale.

from the muscles they immediately invest, are conveniently named the pectineal and sartorial fascia.

FIG. 171.



VIEW OF THE INGUINAL CANAL. 1, portion of the fleshy belly of the external oblique muscle; 2, its aponeurosis; 3, portion of the latter raised up, exposing the inguinal canal; 4, linea alba; 5, insertion of the aponeurosis of the external oblique into the body of the pubis; 6, its insertion into the spine of the pubis, named Poupart's ligament; 7, division of the fibres of the aponeurosis crossed by transverse fibres; 8, external abdominal ring, the termination of the inguinal canal; 9, anterior superior spinous process, the origin of Poupart's ligament; 10, arching lower border of the internal oblique and transverse muscles; 11, conjoined tendon of the latter muscles; 12, fibres of the cremaster muscle descending on the spermatic cord from the edges of the muscles just named; 13, rests on the transverse fascia; to its right are the epigastric vessels crossing the course of the inguinal canal; 14, iliac portion of the femoral fascia; 15, pubic portion; 16, falciform process; 17, saphenous opening;

18, saphenous vein joining the femoral vein through the saphenous opening; 19, the femoral artery and vein exposed by raising the portion of fascia which forms the falciform process; 20, suspensory ligament of the penis.

The *pectine'al fas'cia*¹ invests the corresponding muscle behind the femoral blood-vessels. It is attached along the body and pectineal line of the pubis, and at its outer border becomes continuous with the iliac fascia investing the psoas and iliac muscles, and with the posterior layer of the sartorial fascia.

The *sarto'rial fas'cia*,² after including the corresponding muscle, in the groin is attached along Poupart's ligament and extends in front of the femoral blood-vessels. A couple of inches below the pubis, it becomes continuous with the pectineal fascia, and between these two points includes an oval space named the *saphe'nous opening*,³ from the long saphenous vein entering at this position to join the femoral vein. The outer part of the saphenous opening is defined by a lunated edge of the sartorial fascia, named the *fal'ciform process*,⁴ the upper extremity⁵ of

¹ Pubic portion of the femoral fascia, or fascia lata; fascia ischio-pubica.

² Iliac portion of the femoral fascia, or fascia lata; fascia ilio-pectinea.

³ Fossa ovalis; inferior orifice of the crural canal.

⁴ Plica falciformis; falciform expansion, or semilunate edge of the fascia lata.

⁵ Cornu superius; upper horn; Hey's ligament; femoral ligament.

which is continuous with Gimbernat's ligament; the lower extremity,¹ with the pectineal fascia. The inner part and bottom of the opening are formed by the latter fascia as it dips from within, outwardly, behind the femoral blood-vessels.

The saphenous opening is occupied with a portion of the superficial fascia, called **crib'rifform fascia**,² from its being perforated by many small superficial vessels passing between the contiguous parts and the femoral vessels. The cribriform fascia is continuous with the falciform process, and careful manipulation is required to distinguish the lunated edge of the latter. When the fascia is removed, the falciform process is observed to overlie the femoral vessels; its upper and lower extremities are usually well marked, while the middle portion is less defined.

The **Cru'ral fascia**³ or **deep fascia of the leg**, for the most part well marked and strong, adheres to the heads of the tibia and fibula, to the anterior and internal borders of the former bone, and to both malleoli. It receives offsets from the tendons of insertions of the sartorius, gracilis, semitendinous, and biceps muscles, and is mainly composed of transverse fibres. It is strongest in the outer part of the leg, where it gives partial origin to the heads of the muscles, and is continuous with their intermuscular partitions. It is thinnest on the back of the leg,⁴ where it consists of a layer investing the muscles of the calf, and another⁵ separating the latter from the deeper muscles.

In the vicinity of the ankle joint, the crural fascia receives an accession of fibres, much increasing its strength, and constituting the annular ligaments, which bind down the tendons of the muscles as they turn forward from the leg to the foot.

The **anterior an'nular ligament**⁶ is a strong band extending obliquely in front of the ankle joint, from the inner malleolus to the anterior and outer part of the calcaneum. It consists of two layers, which inclose the tendons in several compartments as they cross the ankle joint. Thus the tendons of the long extensor of the toes occupy a compartment next to the fibula, that of the anterior tibial muscle occupies another next to the tibia, and the tendon of the extensor of the great toe an intermediate compartment. The anterior tibial blood-vessels and nerve are behind the ligament. A band of fibres,⁷ above the ankle joint, extended between the front of the tibia and the fibula, is sometimes described as a portion of the anterior annular ligament; and another band crosses

¹ Cornu inferius; lower horn.

² F. cribriformis.

³ Fascia cruralis.

⁴ In this position called sural fascia;
f. suralis.

⁵ Deep fascia of the leg; deep crural fascia.

⁶ Lig. annulare anterius; annular ligament of the tarsus.

⁷ Lig. transversum.

the annular ligament from the external malleolus to the inner side of the tarsus.¹

The **internal an'nular ligament**² is a band of loose fibres extending from the internal malleolus to the back of the astragalus and the inner side of the calcaneum. It converts the groove at the back of the internal malleolus into a canal for the passage of the tendons of the posterior tibial and long flexor muscles; and the grooves at the back of the astragalus and beneath the calcaneum into a canal for the passage of the tendon of the long flexor of the great toe. Between these two canals the ligament transmits the posterior tibial vessels and nerves. A thin offset from the ligament extends superficially to the tendon of Achilles and the tuberosity of the calcaneum.

The **external an'nular ligament**³ is less marked than the preceding, and consists of a band of loose fibres starting from the external malleolus to be attached to the outer part of the calcaneum, and binding down the tendons of the peroneal muscles.

As the tendons of the muscles pass in their course from the leg to the foot, beneath the annular ligaments, they are invested with synovial bursæ.

The fascia on the back of the foot is a thin extension from the anterior annular ligament. The **plantar fascia**⁴ consists of three portions, as in the case of the palmar fascia. The inner and outer portion is thin, and invests the small muscles of the toes. The middle portion is strongest, and resembles the corresponding portion of the palmar fascia. It is composed of longitudinal, diverging fibres, strengthened with transverse ones, and forms a triangular investment to the short flexor of the toes, to which it gives partial origin. Its apex is attached to the tuberosity of the calcaneum, and its base divides into five processes, each of which subdivides to be inserted into the metacarpo-phalangeal and contiguous vaginal ligaments. At the sides it is continuous with the lateral portions of the fascia, and with intermuscular partitions dipping into the sole.

The **vag'inal ligaments** which inclose the flexor tendons of the toes have the same arrangement as those of the fingers.

SKETCH OF THE ANATOMY CONCERNED IN FEMORAL HERNIA.

The position of the groin is defined by **Poupart's ligament**,⁵ which is the line of continuity of the aponeurosis of the external oblique muscle

¹ Forming with the annular ligament, the lig. cruciatum.

² Lig. annulare internum; l. lacinia-tum internum.

³ Lig. annulare externum; l. lacinia-

tum externum; retinaculum tendinum peroneorum.

⁴ Aponeurosis plantaris.

⁵ Lig. Pouparti; l. Fallopii; crural arch.

of the abdomen with the femoral fascia, extending from the anterior superior spinous process of the ilium to the spine of the pubis.

Poupart's ligament constitutes the **femoral arch**,¹ the bottom of which is formed by the anterior border of the ilium and the horizontal ramus of the pubis. The inner part of the arch is formed by **Gimbernati's ligament**,² which is a triangular process from Poupart's ligament, extending a short distance outwardly along the pectineal line of the pubis.

The femoral arch is occupied externally by the iliac and psoas muscles, with the anterior crural nerve situated in the angular interval of their conjunction. Internally it is occupied by the femoral artery, vein, and lymphatics, inclosed together within a sheath, and resting on the **pectine'al fascia**,³ which invests the corresponding muscle.

Below the inner part of Poupart's ligament is the oval space, named the **saphe'nous opening**, from its admitting the saphenous vein to join the femoral vein. The opening is defined externally by the lunated edge of the **falciform process**⁴ of the **sarto'rial fascia**.⁵ The upper end⁶ of this process is continuous with both Gimbernati's and Poupart's ligament, and its lower end is continuous with the pectineal fascia. The saphenous opening is occupied by the **crib'riform fascia**,⁷ a portion of the superficial fascia, so named from its perforated condition, arising from the transmission of the superficial vessels of the neighboring parts.

Behind the falciform process, from without inwardly, lie in succession the femoral artery, vein, and lymphatics, which together are inclosed in a **sheath**⁸ closely connected with the contiguous fasciæ. The femoral vessels included within their sheath may be viewed as occupying the tube of a membranous funnel whose expanded portion is formed by the transverse, iliac, and pelvic fascia of the abdomen and pelvis. Between the femoral vein and Gimbernati's ligament, within the sheath of the femoral vessels, is a small space named the **fem'oral ring**.⁹ This is occupied with lymphatic vessels, and a gland enveloped in some loose connective tissue,¹⁰ and is the position at which **femoral hernia** occurs.

When the femoral ring is cleared of its contents, the end of the little finger may be introduced into it from the abdomen to the upper part of

¹ Crural arch.

² Lig. Gimbernati; ~~Hey's~~ **ligament**.

³ Pubic portion of the fascia lata.

⁴ Plica falciformis; lunated edge of the fascia lata.

⁵ Iliac portion of the fascia lata.

⁶ Hey's ligament. *correct*

⁷ F. cribrosa.

⁸ Femoral sheath; vagina vasorum cruralium.

⁹ Crural ring; annulus cruralis.

¹⁰ Septum crurale; septum transversum; crural septum.

the saphenous opening, a depth of about half an inch.¹ Its internal and anterior boundary² is the edge of Gimbernat's ligament continuous with the edge of the falciform process; its outer boundary the femoral vein, and its posterior boundary the pubis and pectineal fascia.

When the lower limb is extended and rotated with the toes directed outwardly, the falciform process and Gimbernat's ligament become tense, and the femoral ring is narrowed; and when the limb is flexed and rotated with the toes directed inwardly, the same points become relaxed, and the ring is widened.³ As the seat of constriction or strangulation of femoral hernia occurs within the circle of the femoral ring, the facts just mentioned afford important indications as to the mode of treatment.

Besides the femoral vein, other blood-vessels in relation with the femoral ring are the epigastric artery and veins situated above it externally. When, as occasionally happens, the obturator artery is derived from the external iliac, as this is about to emerge from the femoral arch, it descends at the outer or sometimes at the inner side of the femoral ring.

In femoral hernia, the **hernial sac**, consisting of a pouch of peritoneum containing a portion of the bowels, descends through the femoral ring within the sheath of the femoral blood-vessels. Arriving at the saphenous opening, and finding least resistance in front, it protrudes forward, and subsequently, as it increases, extends outwardly in the course of the groin. Such a hernia has for its coverings from without inwardly, the skin, the subjacent fatty layer of the superficial fascia, and lastly, a fibrous layer,⁴ more or less distinct, and derived from the cribriform fascia and the sheath of the femoral blood-vessels.

MUSCLES OF THE BUTTOCK.

The **Great Glu'teal muscle**⁵ is a thick, lozenge-shaped mass, composed of coarse fleshy fasciculi, and extending from the back of the pelvis to the upper and outer part of the thigh. It arises from the posterior fourth of the crest of the ilium, the posterior surface of the sacrum and

¹ The depth of space has been named the femoral canal, its upper orifice being the femoral ring, its lower orifice the saphenous opening.

² Usually stated to be Poupart's ligament, but as the falciform process is continuous with both Gimbernat's and Poupart's ligament, the anterior boundary may be considered as stated in the text.

³ The falciform process forms, with

Gimbernat's ligament, a semispiral edge, which becomes more enrolled, and consequently includes a narrower space, when the limb is rotated outwardly, and becomes partially unwound when the limb is rotated inwardly.

⁴ Fascia propria of femoral hernia.

⁵ *M. glutæus magnus, major, maximus, or extimus; m. sacro-femoralis; m. ilio-sacro-femoralis.*

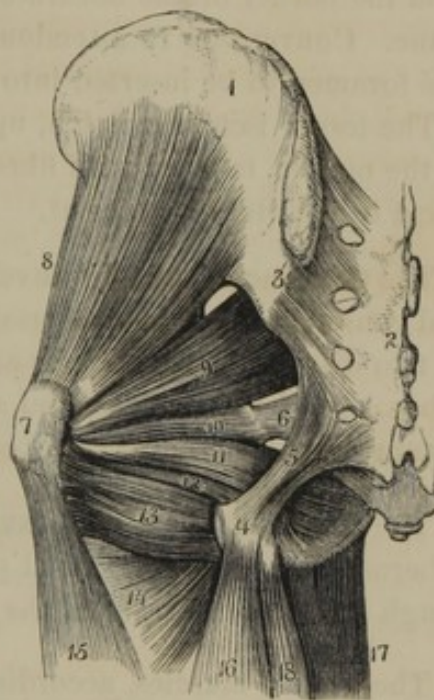
Franken Printer set this up
 but the middle and small gluteal muscles may rotate them either inwardly or outwardly, according as their posterior or anterior fibres are brought coe'yx, and from the greater sacro-ischiatic ligament. From this origin its fleshy fasciculi proceed outward and downward, and terminate in a thick aponeurosis, which is inserted into the femoral fascia over the greater trochanter of the femur, and into the rough surface extending from the latter process to the asperous ridge. — See Fig 174

The lower border of this muscle forms the fold of the buttock, and in the erect position of the body covers the tuberosity of the ischium, but glides from it in the sitting position. Between its tendon and the greater trochanter of the femur a large synovial bursa is interposed, and another is situated between the muscle and the tuberosity of the ischium.

The **Middle Glu'teal muscle**,¹ covered at its fore part by a thick portion of the femoral fascia, and at its back part by the preceding muscle, arises from the dorsal surface of the ilium, between the crest of the latter and the superior curved line, and from the investing femoral fascia. Descending, its fasciculi converge to a short, thick tendon, which is inserted into the outer surface of the greater trochanter. Between the upper part of the latter and the tendon, a synovial bursa is interposed.

The **Small Glu'teal muscle**,² concealed by the preceding, arises from the dorsal surface of the ilium between the superior and inferior curved lines, and converges to a tendon, which is inserted into the inner part of the summit of the greater trochanter. Between the latter and the tendon a synovial bursa is interposed.

FIG. 172.



MUSCLES OF THE BUTTOCK. 1, ilium; 2, sacrum; 3, posterior sacro-iliac ligament; 4, tuberosity of the ischium; 5, great sacro-ischiatic ligament; 6, small sacro-ischiatic ligament; 7, greater trochanter; 8, small gluteal muscle; 9, pyriform muscle; 10, 12, geminus muscle, including between its two fasciculi the termination, 11, of the internal obturator muscle; 13, quadratus femoral muscle; 14, upper part of the great adductor of the thigh; 15, external vastus muscle; 16, biceps flexor; 17, gracilis; 18, semi-tendinous muscle.

¹ M. glutæus medius, or secundus; m. ilio-trochanterius.

² M. glutæus minimus, minor, tertius, or intimus; m. ilio-ischio-trochanterius.

The **External Obtur'ator muscle**¹ is situated exterior to the cavity of the pelvis, and arises from the borders of the obturator foramen and from the obturator membrane. Converging to a tendon, it passes behind the neck of the femur to be inserted into the trochanteric fossa.

The **Pyr'iform muscle**² arises within the pelvis from the front surface of the second, third, and fourth divisions of the sacrum, and from the lower part of the sacro-iliac symphysis. Passing from the pelvis through the greater sacro-ischiatic foramen, it converges, to be inserted, by a round tendon, into the greater trochanter, beneath the small gluteal muscle.

The **Internal Obtura'tor muscle**³ arises within the cavity of the pelvis from the border of the obturator foramen and from the obturator membrane. Converging to a tendon, it passes through the lesser sacro-ischiatic foramen to be inserted into the trochanteric fossa. *(upper border of great trochanter)*

The lesser ischiatic notch, upon which the tendon plays in the action of the muscle, is faced with fibro-cartilage, and furnished with a synovial bursa to facilitate movement.

The **Gem'inous muscle**⁴ envelops the tendon of the preceding muscle, and consists of a pair of accessory fleshy fasciculi to it, usually described as two distinct muscles.⁵ It arises from the spine and back part of the tuberosity of the ischium, and after including the tendon of the internal obturator muscle, is inserted in company with it into the trochanteric fossa.

The **Quadrata Fem'oral muscle**⁶ arises from the outer border of the tuberosity of the ischium, and proceeds outwardly to be inserted into the rough line descending from the greater trochanter.

The gluteal muscles, accordingly as they act from their origin or insertion, are abductors of the thighs, or they ~~fix~~ ^{tear} the pelvis, and with it the trunk upon the lower extremities. They also rotate the thighs outwardly,

¹ M. obturator, or obturatorius externus; m. sub-pubio-trochantereus externus; m. extra-pelvio-pubio-trochantereus.

² M. pyriformis; m. pyramidalis; m. p. femoris; m. iliacus externus; m. sacro-trochantereus; m. primus et superior quadrigeminus.

³ M. obturator, or obturatorius internus; m. sub-pubio-trochantereus internus; m. marsupialis; m. bursalis; m. intro-pelvio-trochantereus.

⁴ M. geminus, or gemellus; m. gemini, or gemelli; marsupium carneum; m. marsupialis; m. ischio-spini-trochantereus; m. canaliculatus; m. accessorius obturatoris interni.

⁵ M. geminus, or gemellus superior and inferior; m. secundus et tertius quadrigeminus.

⁶ M. quadratus femoris; m. tuber-ischio-trochantereus; m. ischio-subtrochantereus; m. quartus quadrigeminus quadratus.

but the middle & small gluteal muscles may rotate them either inwardly or outwardly according as their posterior or anterior fibres are brought into action. The obturator, pyriform, geminous, and quadrate femoral muscles rotate the thighs outwardly.

THE ILIAC FASCIA.

The **Il'iac fas'cia**¹ invests the iliac and psoas muscles, and is a continuation of the same fibrous membrane, constituting in other positions the transverse and pelvic fasciæ. It adheres to the lumbar fascia, the arcuate ligaments, the vertebral column, the crest of the ilium, Poupart's ligament, and the pubis. Together with the transverse and pelvic fascia it converges to become the sheath of the femoral blood-vessels.

MUSCLES OF THE ILIAC REGION AND LOIN.

The **Il'iac muscle**² arises from the corresponding fossa of the ilium, and converges to the femoral arch, under which it passes to be inserted, in conjunction with the psoas muscle, into the smaller trochanter of the femur.

The **Pso'as muscle**³ arises from the sides of the bodies and transverse processes of the last dorsal and the lumbar vertebræ, and the intermediate intervertebral disks. Descending from the loins along the brim of the pelvis, it passes under the femoral arch and terminates in a tendon, which, being joined by the preceding muscle, is inserted into the back part of the smaller trochanter.

The upper extremity of the muscle has the internal arcuate ligament of the diaphragm extended across it. At the origin from the sides of the vertebræ, tendinous arches separate it from the lumbar arteries and veins and the anastomotic filaments of the sympathetic nerve. Between the tendon of insertion and the smaller trochanter, a synovial bursa is interposed.

Occasionally, a **Small Pso'as muscle**⁴ is situated in front of the former. It arises from the sides of the bodies of the upper two lumbar vertebræ, and terminates in a thin tendon, which expands at the brim of the pelvis into the iliac fascia, and is connected with the ilio-pubic eminence.

The iliac and psoas muscles, according to the fixation of their origin or insertion, bend either the trunk or the lower extremities forward. They also rotate the thighs outwardly, by drawing the smaller trochanter forward. In conjunction with the gluteal muscles they maintain the erect condition of the body.

¹ Fascia iliaca.

² M. iliacus; internal iliac muscle; m. iliacus internus; m. ilio-trochantereus; part of the m. flexor femoris; m. femur moventium septimus.

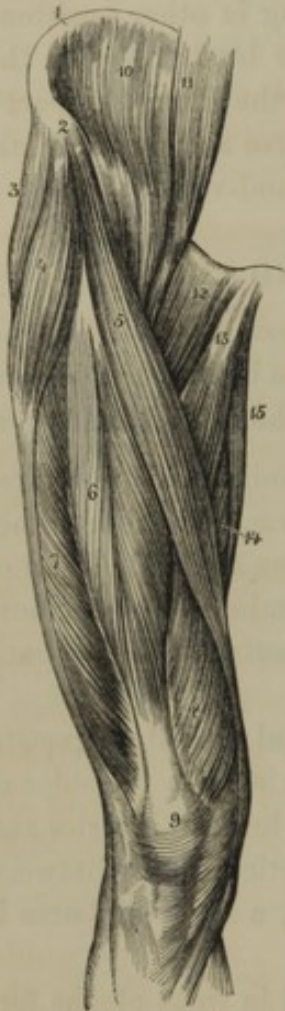³ Greater psoas muscle; m. psoas major; m. lumbalis; m. prælumbo-trochantereus; part of the m. flexor femoris; m. femur moventium sextus.

⁴ M. psoas parous; m. præ-lumbo-pubius.

MUSCLES ON THE FRONT OF THE THIGH.

The **Ten'sor of the Fem'oral Fas'cia**¹ is a short, flat muscle, situated at the upper and outer part of the thigh, and inclosed in a sheath of the femoral fascia. It arises from the anterior superior spinous process of the ilium, between the sartorius and gluteal muscles, and descends in front of the greater trochanter, to terminate in the femoral fascia, a short distance below the latter.

FIG. 173.



MUSCLES OF THE ILIAC REGION AND FRONT OF THE THIGH. 1, crest of the ilium; 2, anterior superior spinous process; 3, middle gluteal muscle; 4, tensor of the femoral fascia; 5, sartorius; 6, rectus; 7, external vastus; 8, internal vastus; 9, insertion of the quadriceps extensor into the patella; 10, iliac muscle; 11, psoas muscle; 12, pectineal muscle; 13, long adductor; 14, great adductor; 15, gracilis muscle.

The **Sarto'rius muscle**² arises tendinously from the anterior superior spinous process of the ilium, and in the form of a long fleshy band descends obliquely across the thigh to the inner side of the knee, where it terminates in a tendon, which expands to be inserted on the inner side of the tibia, just below its tuberosity.

The tendon of insertion gives off a process to the crural fascia, and between it and the tendon of the succeeding muscle a synovial bursa is interposed.

The sartorius flexes the leg upon the thigh, and if it continues its action the leg is drawn across the opposite thigh.

The **Grac'ilis muscle**³ arises by a thin aponeurosis from the margin of the symphysis and descending ramus of the pubis. In the form of a long fleshy band it passes down on the inner part of the thigh, and terminates at the knee in a narrow tendon, which expands to be inserted beneath the sartorius tendon. Between its tendon and the tibia a synovial bursa is placed.

The gracilis adducts the thigh, and assists the action of the preceding muscle.

¹ M. tensor vaginæ femoris; m. t. fasciæ latæ; m. fasciæ latæ; m. membranosus; m. fascialis; m. aponeurosis; m. ilio-aponeurosi femoralis.

² M. sartorius; m. fascialis; m. f. longus; m. longissimus femoris; m. cristo-tibialis; m. ilio-præ-tibialis.

³ M. gracilis, or rectus internus, or interior; m. pubio-præ tibialis.

The **Quad'riceps Exten'sor**¹ occupies the whole front and sides of the thigh, and, as implied by its name, has four heads of origin, called the rectus, the external and internal vastus, and the cruralis.

The **Rec'tus**² arises, by two short thick tendons, from the anterior inferior spinous process of the ilium and the summit of the acetabulum. Descending in front of the thigh, its fleshy fasciculi form a penniform belly ending in a stout, flat tendon, which is joined by the tendons of the other heads of the quadriceps, just above the knee. The remaining three heads, more intimately associated with one another than with the rectus, are sometimes described as a distinct muscle.³

The **External Vas'tus**,⁴ the largest portion of the quadriceps, arises by an aponeurosis from the base of the greater trochanter and from the outer border of the asperous ridge. The **Internal Vas'tus**⁵ arises from the inner border of the asperous ridge; and the **Crura'lis**⁶ arises from the front of the femur, between the two preceding heads of the quadriceps. The fleshy fasciculi of the internal and external vastus proceed downward and forward, those of the cruralis proceed directly downward, and all together terminate in a broad tendon, which conjoins with that of the rectus to be inserted into the base, sides, and front of the patella.

Viewing the **ligament of the patella** as a continuation of the tendon of the quadriceps, this is then inserted into the tuberosity of the tibia.

The quadriceps extends the leg upon the thigh. Some detached fasciculi⁷ of the muscle descend from the lower part of the femur to the synovial capsule of the knee joint, and serve to retain this capsule in its proper position.

The **Pectine'al muscle**⁸ arises from the horizontal ramus of the pubis, between its spine and the ilio-pectineal eminence, and descends on the inner side of the femur to be inserted into the line leading from the smaller trochanter to the asperous ridge.

The **Long Adduc'tor**,⁹ situated on the same plane as the former muscle, arises tendinously from the front of the pubis, and descends

¹ M. quadriceps extensor cruris.

² M. rectus femoris; m. rectus, or gracilis anterior, or cruris; m. ilio-rotuleus; anterior straight muscle.

³ M. triceps extensor cruris; m. femoralis, or cruralis; m. trifemoro-rotuleus, or tibio-rotuleus.

⁴ M. vastus, or venter externus.

⁵ M. vastus, or venter internus.

⁶ M. vastus medius; m. venter posterior; m. cruræus.

⁷ M. suberureus, or subcruralis; m. articulares genu.

⁸ M. pectineus, or pectinalis; m. pubio-femoralis; m. lividus.

⁹ M. adductor longus; m. a. femoris primus; caput longum m. ad. tricipitis; m. ad. primus; m. pubio-femoralis.

obliquely to be inserted into the middle third of the asperous ridge of the femur.

The **Short Adduc'tor**,¹ concealed by the preceding two muscles, arises from the body and descending ramus of the pubis, and descends obliquely to be inserted into the upper third of the asperous ridge of the femur.

The **Great Adduc'tor**² is a large, triangular muscle, forming a partition between the front and back part of the thigh. It arises from the descending ramus of the pubis and the ramus and tuberosity of the ischium, and radiates outward and downward to be inserted tendinously into the whole length of the asperous ridge of the femur, extending also by a tendinous cord to the internal condyle.

The lower third of the insertion of the great adductor is perforated for the passage of the femoral blood-vessels; besides which there are several smaller openings in the tendinous insertion of this muscle for the transmission of the perforating arteries and their companion veins.

The pectineal and adductor muscles bend the thigh on the pelvis, rotate it outwardly, and act as powerful adductors.

MUSCLES ON THE BACK OF THE THIGH.

The **Bi'ceps Flex'or**,³ as expressed by the name, arises by two heads. The long head arises by a tendon, common to it and the semitendinous muscle, from the back part of the tuberosity of the ischium; the short head arises from the lower two-thirds externally of the asperous ridge of the femur. The fleshy fasciculi terminate in an aponeurosis narrowing into a stout tendon, which is inserted into the head of the fibula. From the tendon of insertion proceed two processes, of which one is inserted into the head of the tibia, and the other is continuous with the crural fascia.

The **Semiten'dinous muscle**⁴ arises, in common with the tendon of the long head of the biceps flexor, from the tuberosity of the ischium, and descends upon the inner back part of the thigh. Just below the middle of the latter its fleshy belly ends in a long tendon, which proceeds to be

¹ M. adductor brevis; m. a. femoris secundus; caput breve m. ad. tricipitis; m. ad. secundus; m. subpubio-femoralis.

² M. adductor magnus; m. a. femoris tertius et quartus; caput magnum mus-

culi adductor tricipitis; m. ischio-femoralis.

³ M. biceps femoris, or flexor cruris; m. ischio-femoro-peronealis.

⁴ M. semitendinosus; m. ischio-præ-tibialis; m. seminervosus.

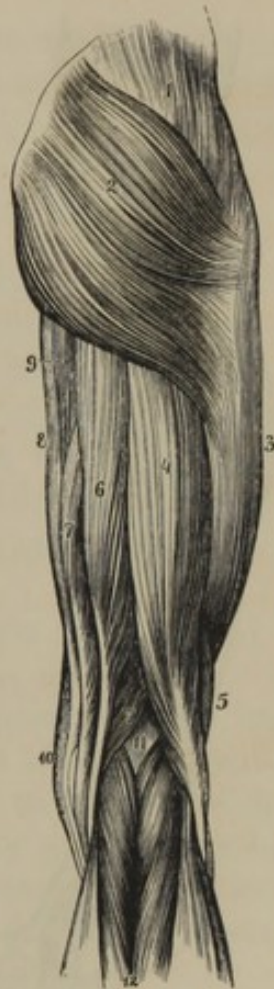inserted into the inner side of the tibia below its tuberosity and beneath the insertion of the gracilis tendon

The semitendinous, gracilis, and sartorius muscles arise from remote and nearly equidistant points of the hip bone, and converge to be inserted into the same point of the tibia. Acting together, they cross the leg upon the opposite thigh.

The **Semimem'branous muscle**,¹ situated on the inner side of the preceding muscle, arises from the back part of the tuberosity of the ischium by a broad tendon, which expands into an aponeurosis. From this a fleshy belly, composed of short fasciculi, proceeds to another aponeurosis narrowing into a cord-like tendon, which is inserted into the inner side of the head of the tibia. The tendon of insertion gives off processes to the back part of the capsular ligament of the knee joint and the fascia investing the popliteal muscle.

The biceps flexor, semitendinous, and semimembranous muscles are all flexors of the leg upon the thigh. The tendon of insertion of the biceps is named the **outer ham string**; the corresponding tendons of the semitendinous and semimembranous muscles, the **inner ham strings**. The space included by the ham strings is the **poplite'al region**² or the **ham**.

FIG. 174.



MUSCLES OF THE BACK OF THE RIGHT BUTTOCK AND THIGH. 1, middle gluteal muscle; 2, great gluteal muscle; 3, external vastus, covered by the femoral fascia; 4, long head of the biceps flexor; 5, its short head; 6, semitendinous, and 7, semimembranous muscles; 8, gracilis muscle; 9, inner border of the great adductor; 10, lower extremity of the sartorius muscle; 11, popliteal space; 12, gastrocnemius muscle.

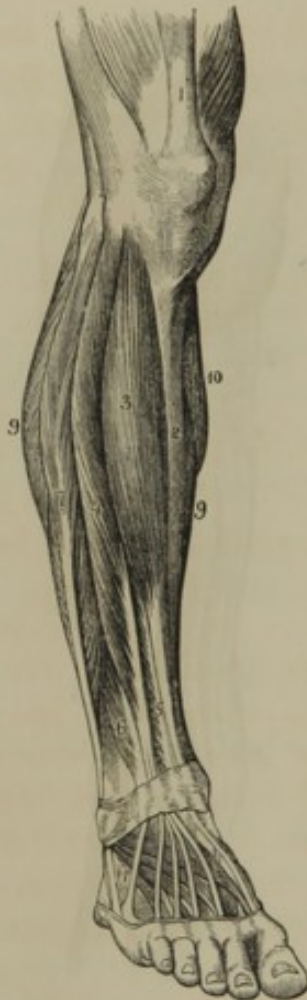¹ M. semimembranosus; m. ischio-poplito-tibialis.

² Popliteal fossa; fossa genu; hock; hoff; garetum; ignys; suffrago; hollow of the knee.

MUSCLES OF THE FRONT AND OUTER PART OF THE LEG, AND UPPER PART OF THE FOOT.

The **Anterior Tib'ial muscle**¹ arises from the upper two-thirds of the

FIG. 175.



MUSCLES OF THE FRONT OF THE LEG AND BACK OF THE FOOT. 1, tendon of the rectus muscle of the thigh; 2, subcutaneous inner surface of the tibia; 3, anterior tibial muscle; 4, long extensor of the toes; 5, long extensor of the great toe; 6, anterior peroneal muscle; 7, long peroneal muscle; 8, short peroneal muscle; 9, borders of the soleus; 10, border of the inner belly of the gastrocnemius; 11, short ~~flexor~~ ^{extensor} of the toes, beneath the tendons of the long ~~flexor~~ ^{extensor}.

This muscle aids the anterior tibial in flexing the foot.

¹ M. tibialis anticus; m. flexor tarsi-tibialis; m. tibio-supertarseus; m. tibio-supra-metatarsus; m. hippicus; m. catenæ.

outer part of the tibia, from the interosseous membrane and the crural fascia. Its fleshy belly descends the leg and ends in a flat tendon, which passes beneath the annular ligament of the ankle to the inner side of the foot, where it is inserted into the ^{upper surface of the} internal cuneiform bone and the base of the metatarsal bone of the great toe. This muscle flexes the foot.

The **Long Exten'sor of the Toes**² arises from the head of the tibia, the upper three-fourths of the length of the fibula, and from the interosseous membrane and crural fascia. Its fleshy fasciculi terminate in a tendon, which descends beneath the annular ligament of the ankle and divides into four tendons diverging to the four lesser toes, over the backs of which they expand in the manner of the extensor tendons of the fingers.

The **Anterior Perone'al muscle**³ arises from the fibula, below the preceding, and ends in a tendon, which descends beneath the annular ligament to be inserted into the base of the last metatarsal bone.

² M. extensor longus, or communis digitorum pedis; m. enemodactylæus.

³ M. peroneus anticus, or tertius; m. tarsi-fibularis; m. peroneo-supra-metatarsus brevis; m. nonus Vesalii.

The **Exten'sor of the Great Toe**¹ lies between the anterior tibial and long extensor muscles. It arises from the lower two-thirds of the fibula and the interosseous membrane, and ends in a flat tendon, which descends beneath the annular ligament of the ankle and expands on the back of the great toe, being finally inserted into its last phalanx.

The **Short Exten'sor of the Toes**² is situated on the back of the foot. It arises from the outer side of the calcaneum and the annular ligament of the ankle, and forms four fleshy bellies, each of which ends in a tendon proceeding to join the extensor tendons of the great toe and the succeeding three toes.

The **Long Perone'al muscle**,³ situated at the outer part of the leg, arises from the upper two-thirds of the fibula, from the contiguous intermuscular partitions and the crural fascia. Its fleshy belly ends in a long tendon, which descends through a groove at the back of the external ankle, then proceeds along another groove on the outer surface of the calcaneum, and turns beneath the sole of the foot. Entering the groove of the cuboid bone, it passes obliquely forward and inward to be inserted into the base of the first metatarsal bone.

In the course of the tendon, it twice changes its direction; once at the lower end of the fibula, and again at the cuboid bone. In these positions it acquires a thickened fibro-cartilaginous character, and at the turn of the cuboid bone not unfrequently has a sesamoid bone developed in it. The grooves behind the external ankle and the outer face of the calcaneum, through which the tendons pass, are converted by fibrous bands into canals lined with synovial bursæ. The groove of the cuboid bone is converted into a canal by the long plantar ligament, and is likewise provided with a synovial bursa.

The **Short Perone'al muscle**⁴ arises from the lower half of the outer surface of the fibula, and the contiguous intermuscular partitions. Its fleshy belly terminates in a tendon, which descends, in company with that of the preceding muscle, behind the external ankle, and passes along the outer surface of the calcaneum to be inserted into the base of the last metatarsal bone.

The long and short peroneal muscles extend the foot, and are the antagonists of the anterior peroneal and tibial muscles.

¹ M. extensor proprius pollicis, or hallucis; m. e. longus hallucis.

² M. extensor brevis digitorum pedis; m. pedicus.

³ M. peroneus longus, primus, posticus,

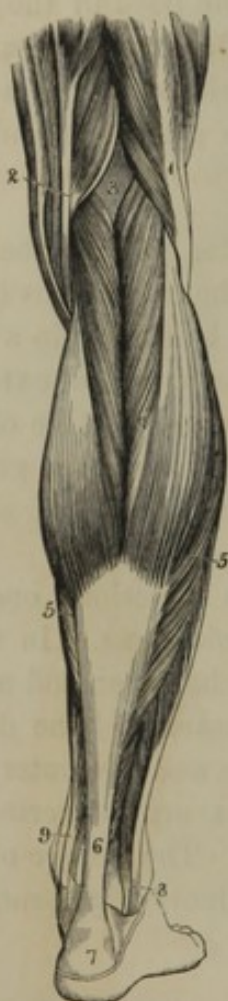or maximus; m. peroneo-sub-tarseus; m. extensor tarsi-fibularis longior.

⁴ M. peroneus brevis, secundus, or medius; m. semifibulæus; m. extensor tarsi-fibularis brevior.

MUSCLES ON THE BACK OF THE LEG.

The **Tri'ceps Su'ral muscle**,¹ as expressed in the name, has three heads, the fleshy bellies of which form the **calf of the leg**.² Two of the bellies

FIG. 176.



are superficial, and constitute the **gastrocnemius muscle**, while the third is under cover of the former, and is named the **soleus muscle**.

The **Gastrocne'mius muscle**³ arises tendinously just above the condyles of the femur; and its two fleshy bellies descend in contact with each other to terminate in a strong aponeurosis.

The **Sole'us muscle**⁴ arises from the head and half the length of the fibula, from the oblique line of the tibia just below the popliteal muscle, and from the inner border of the tibia for several inches below the latter. From this origin the fleshy fasciculi descend obliquely, and terminate in an aponeurosis facing the muscle posteriorly.

SUPERFICIAL MUSCLES ON THE BACK OF THE RIGHT LEG. 1, biceps flexor; 2, tendons of the semitendinosus, semimembranosus, gracilis, and sartorius muscles; 3, popliteal space; 4, gastrocnemius; 5, soleus; 6, tendon of Achilles; 7, calcaneum; 8, tendons of the long and short peroneal muscles passing behind the outer ankle; 9, tendons of the posterior tibial muscle and long flexor of the toes passing behind the inner ankle.

The aponeuroses of the gastrocnemius and soleus muscles conjoin in the formation of the strongest cord-like tendon of the body, named the **tendon of Achilles**,⁵ which descends to be inserted into the lower part of the tuberosity

of the calcaneum. Between the upper part of the tuberosity and the tendon a synovial bursa is interposed.

The triceps sural muscle by drawing on the calcaneum elevates the body upon the toes, as in walking. Dancing, jumping, or other active movements of the kind tend greatly to increase its size.

¹ M. extensor pedis; m. triceps suræ; m. suræ, or suralis; m. extensor tarsi magnus.

² Sura; gastrocnemium.

³ M. gastrocnemius externus; m. gemellus suræ; m. gemellus externus and internus; m. bi-femoro-calcaneus.

⁴ M. gastrocnemius internus; m. tibio-calcaneus; m. tibio-peroneo-calcaneus.

⁵ Tendo Achilles; Achilles' tendon; chorda, or funis Hippocratis; corda magna; nervus latus.

The **Plantar muscle**¹ arises from the femur just above the outer condyle, and from the contiguous portion of the capsular ligament of the knee joint. Its short, fleshy belly ends in a long, delicate tendon, which, after passing between the gastrocnemius and soleus muscles, descends at the inner margin of the tendon of Achilles to be inserted, in company with it, into the calcaneum.

This muscle corresponds to the long palmar muscle of the forearm, but it is only in some of the lower animals that its tendon joins the plantar aponeurosis.

The **Poplite'al muscle**² is situated immediately below the knee joint posteriorly, and is invested with a thin aponeurosis connected with the tendon of the semimembranous muscle. It arises by a tendon from the groove on the outer side of the external condyle of the femur, beneath the contiguous lateral ligament of the knee joint, and expands upon the triangular surface at the upper part of the tibia, into which it is inserted.

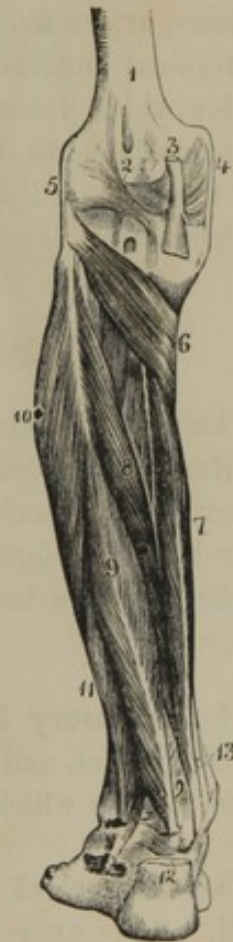The tendon of origin is attached to the external semilunar fibro-cartilage, and is invested by the synovial membrane of the knee joint.

The popliteal muscle flexes the leg and rotates it inwardly.

The **Long Flexor of the Toes**,³ situated under cover of the muscles of the calf, and below the popliteal muscle, arises from the tibia to within a short distance of its lower

extremity. The fleshy fasciculi proceed obliquely to a tendon, which descends behind the inner ankle and turns beneath the concavity of the calcaneum into the sole of the foot. Receiving a process from the tendon of the long flexor of the

FIG. 177.



DEEP MUSCLES OF THE BACK OF THE LEG. 1, femur; 2, posterior portion of the capsular ligament; 3, tendon of the semimembranous muscle inserted into the head of the tibia, and giving an offset to the capsular ligament; 4, 5, internal and external lateral ligaments; 6, popliteal muscle; 7, long flexor of the toes; 8, posterior tibial muscle; 9, long flexor of the great toe; 10, 11, long and short peroneal muscles; 12, tendon of Achilles; 13, tendons of the long flexor of the toes, and the posterior tibial muscle, just before passing beneath the internal annular ligament.

¹ M. plantaris; m. p. gracilis; m. extensor tarsi minor; m. gracilis suræ; m. tibialis gracilis; m. femoro-calcaneus brevis.

² M. popliteus; m. sub-popliteus; m. femoro-popliti-tibialis.

³ M. flexor longus digitorum; m. f. l. d. pedis profundus perforans; m. flexor tertii internodii digitorum pedis; m. peronodactylus.

great toe, it then divides into four tendons, which proceed forward and pass through perforations in the tendons of the short flexor of the toes, finally to be inserted into the bases of the last phalanges of the four lesser toes.

The **Long Flexor of the Great Toe**,¹ situated at the outer side of the preceding muscle, arises from the lower two-thirds of the fibula, and ends in a tendon which descends behind the inner ankle to the concavity of the calcaneum. Turning forward in the sole of the foot, after giving off a process to the tendon of the long flexor of the toes, it proceeds to be inserted into the base of the last phalanx of the great toe.

The **Posterior Tib'ial muscle**,² situated between the preceding pair of muscles, arises from the surface of the interosseous membrane and the contiguous borders of the tibia and fibula. Its fleshy fasciculi end in a tendon which descends through a groove behind the inner ankle, then proceeds beneath the calcaneum to be inserted into the scaphoid bone and the base of the first metatarsal bone. *internal cuneiform bone - Gray*

This muscle is an extensor of the foot.

MUSCLES OF THE SOLE OF THE FOOT.

The **Short Flexor of the Toes**³ is covered by the middle portion of the plantar fascia, from which and the inner tubercle of the calcaneum it has its origin. Proceeding forward, it terminates in four tendons, which, after being perforated for the passage of the tendons of the long flexor of the toes, are inserted into the bases of the second phalanges of the latter.

The **Accessory Flexor**⁴ arises from the concavity and under part of the calcaneum, and is inserted into the tendon of the long flexor of the ~~great~~ toes, to which, as the name indicates, it is an accessory head.

The **Lumbrical muscles**⁵ are four fleshy fasciculi like those of the hand. They arise from the tendons of the long flexor of the toes, and

¹ M. flexor longus pollicis pedis; m. f. l. hallucis pedis.

² M. tibialis posticus; m. nauticus; m. extensor tarsi-tibialis; m. tibio-sub-tarsus.

³ M. flexor brevis digitorum pedis; m. f. b. d. p. perforatus; m. f. sublimus d. p.

perforatus; m. flexor secundi internodii digitorum pedis.

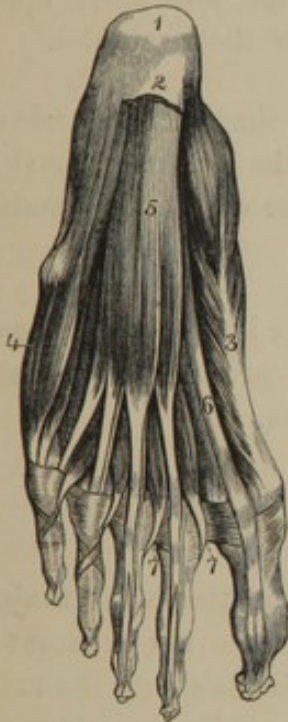⁴ M. flexor accessorius; m. accessorius flexoris longi digitorum pedis; massa carnea Jacobi Sylvii; caro quadrata Sylvii; caro accessoria; m. plantaris verus.

⁵ M. lumbricales pedis.

proceed to be inserted into the corresponding extensor tendons and the bases of the first phalanges of the toes.

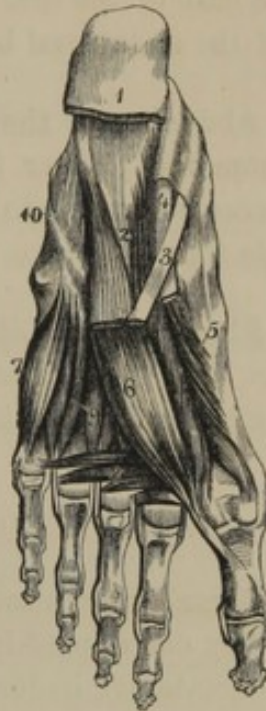The **Abduc'tor of the Great Toe**,¹ the most superficial of the muscles on the inner side of the sole of the foot, arises from the calcaneum, the scaphoid and internal cuneiform bones, and the plantar fascia, and proceeds forward to be inserted by a tendon into the base of the first phalanx of the great toe.

FIG. 178.



MUSCLES OF THE SOLE OF THE FOOT. 1, calcaneum; 2, posterior extremity of the plantar fascia; 3, abductor of the great toe; 4, abductor of the little toe; 5, short flexor of the toes; 6, tendon of the long flexor of the great toe; 7, insertion of the lumbrical muscles, which are seen to the right of the tendons of the short flexor of the toes.

FIG. 179.



DEEP MUSCLES OF THE SOLE. 1, attachment of the plantar fascia and short flexor of the toes; 2, accessory flexor; 3, tendon of the long flexor of the toes; 4, tendon of the long flexor of the great toe; 5, two heads of the short flexor of the same; 6, adductor of the great toe; 7, flexor of the little toe; 8, transverse muscle; 9, interosseous muscles; 10, course of the tendon of the long peroneal muscle, seen through the long plantar ligament.

The **Short Flexor of the Great Toe**² arises, as a pair of fleshy bellies, from the cuboid and outer two cuneiform bones, and proceeds forward to be inserted tendinously into the base of the first phalanx of the great toe. Between the two bellies of this muscle lies the tendon of the long flexor.

The **Adduc'tor of the Great Toe**³ arises from the cuboid bone and the

¹ M. abductor pollicis pedis; m. calco-sub-phalangeus pollicis.

² M. flexor brevis pollicis, or hallucis pedis.

³ M. adductor pollicis, or hallucis pedis; m. antithenar; m. metatarso-sub-phalangeus pollicis.

bases of the third and fourth metatarsal bones, and is inserted tendinously into the base of the first phalanx of the great toe.

The **Transverse muscle**¹ consists of several fasciculi arising from the heads of the second, third, and fourth metatarsal bones, and inserted tendinously into the base of the first phalanx of the great toe.

The sesamoid bones are inclosed within the insertion of the muscles into the base of the first phalanx of the great toe, and move upon the head of the metatarsal bone during the action of those muscles.

The **Abduc'tor of the Little Toe**² arises from the outer tubercle of the calcaneum, the plantar fascia, and the base of the last metatarsal bone, and proceeds forward to be inserted into the base of the first phalanx of the little toe.

The **Flexor of the Little Toe**³ arises from the long plantar ligament and the base of the last metatarsal bone, and proceeds to be inserted into the base of the first phalanx of the little toe.

THE INTEROSSEOUS MUSCLES OF THE FOOT.

The **Dorsal Interos'seous muscles** occupy the metatarsal intervals, with which they correspond in number. They arise from the adjacent sides of the metatarsal bones, and are inserted tendinously into the extensor tendons and bases of the first phalanges of the middle three toes.

The first dorsal interosseous muscle is inserted on the inner side of the second toe, and acts as an adductor; while the others are inserted into the outer side of the second, third, and fourth toes, and act as abductors.

The **Plantar Interos'seous muscles**, three in number, lie on the outer three metatarsal bones and arise from their inner side, from whence they proceed forward to be inserted into the extensor tendons and bases of the first phalanges of the corresponding toes, to which they act as adductors.

¹ M. transversalis, or transversus pedis; m. scandularius; m. metatarso-subphalangeus.

² M. abductor minimi digiti pedis.

³ M. flexor minimi digiti pedis.

CHAPTER V.

ANATOMICAL ELEMENTS OF SEROUS AND MUCOUS MEMBRANES, THE GLANDS, THE LUNGS, AND THE SKIN.

SEROUS and mucous membranes, glands, the lungs, and the skin possess common anatomical elements, which hold the same relative position with one another. These elements are as follows: a cellular layer, a basement membrane, a fibrous layer, and blood-vessels, lymphatics, and nerves.

The **Cel'lular layer**¹ occupies the free surface of the structures above mentioned, and is named **epithe'lium**,² except on the skin, where it is called **epider'mis**. It consists of from one to many layers of cells, of different forms in the various structures indicated. The epithelium of the uriniferous tubules of the kidneys presents an example of a single layer of cells; the serous membranes, from one to four layers; the mucous membrane of the stomach, several layers in different stages of development; the mucous membrane of the mouth, many layers; and the epidermis, above all similar structures, presents the greatest number of layers of cells.

From difference in form, and other peculiarities, the epithelium is

FIG. 180.




DIAGRAM EXHIBITING THE RELATIVE POSITION OF THE COMMON ANATOMICAL ELEMENTS OF SEROUS AND MUCOUS MEMBRANES, THE GLANDS THE LUNGS, AND THE SKIN. 1, epithelium, secreting cells, or epidermis, as the case may be, composed of nucleated cells, and occupying the free surface of the structure mentioned; 2, basement layer, in this and other diagrams purposely represented much thicker than natural, in comparison with the other layers; 3, fibrous layer, in which the arteries and veins (4) terminate in a capillary net-work.

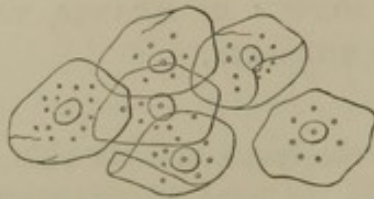¹ Implying its composition of organic cells, and not to be confounded with areolar or connective tissue, which, until within a comparatively short period, was called cellular tissue.

² Epithelium; endepidermis.

divided into the following varieties: squamous epithelium; pavement epithelium; spheroidal, polyhedral, and irregular epithelium; columnar epithelium; and ciliated epithelium.

The **Squa'mous epithe'lium**¹ consists of many layers of broad, thin scales, which are flattened cells, containing a nucleus and a few scattered coarse granules. This variety forms the epithelium of the mucous membrane of the mouth, lower part of the pharynx, œsophagus, vagina, vulva, entrance of the urethra, conjunctiva, and entrance of the nose.

FIG. 181.



SQUAMOUS EPITHELIUM, consisting of nucleated cells transformed into broad scales. From the mucous membrane of the mouth, highly magnified.

FIG. 182.



PAVEMENT EPITHELIUM, from a serous membrane, highly magnified, and seen to consist of flat, six-sided nucleated cells.

The **Pavement epithe'lium**² consists of from one to four layers of flat nucleated cells, usually six-sided, and regularly arranged like the blocks of a pavement, whence the name. Such an epithelium forms the free surface of the serous membranes, including the synovial membranes and the lining membrane of the vascular system; it likewise constitutes the epithelium of the uriniferous tubules, sweat glands, and air-cells of the lungs.

The **Spheroidal, polyhedral, and irregular epithe'lium** are modifications of the same form. The spheroidal epithelium constitutes the secreting cells of the salivary glands and pancreas, but they are more or less modified into the polyhedral form by mutual pressure. The secreting cells of the liver are polyhedral, but more or less irregular. The epithelium of the excretory duct of the kidney and of the bladder exhibits singularly irregular forms of cells.

The **Columnar epithe'lium**³ consists of a single layer of six-sided columnar cells, with a conical prolongation. The broad end of the cells is free, the sides are in contact, and the narrow end is imbedded in a progeny of developing cells. The columnar cells are more delicate than most other kinds, are provided with granular contents, and possess a large oval nucleus. Such an epithelium is found on the mucous mem-

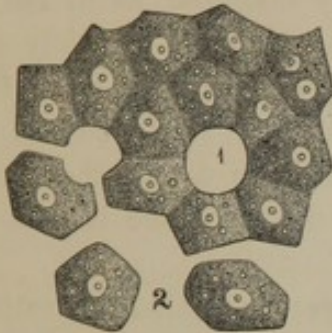
¹ Scaly, lamellar, tabular, flattened, pavement, or tessellated epithelium.

² Tessellated epithelium.

³ Cylinder, prismatic, conical, or tubular epithelium; simple columnar epithelium.

brane of the stomach, small and large intestines; in many glands, as the tubular glands of the intestines; in the ducts of most glands; in the gall-bladder; and in the urethra.

FIG. 183.



POLYHEDRAL EPITHELIUM, exemplified by secreting cells of the liver. The arrangement is ideal. 1, space occupied by a blood-vessel; 2, isolated cells.

The *Cil'iated epithe'lium*¹ differs from the preceding, in the cells possessing at their free extremity a number of exceedingly fine filamentous appendages, named, from their resemblance to the eyelashes, *cil'ia*.² These are processes of the cell wall of uniform size, and during life are endowed with the power of rapidly and incessantly moving backward and forward. This vibratory movement is always uniform and wave-like in a long series of cells, so that when seen over a surface of some extent, it reminds one of the movement of a field of grain under the influence of a gentle breeze. The vibration of the cilia produces currents in the liquids in contact with them, and thus conveys the liquids from one position to another. The *cil'iary motion* even continues for some time after the cells have been scraped from the membrane of which they form a part; and the resistance of the liquid to the vibrating cilia of the detached cells causes these to move freely about, as if endowed with voluntary power. A ciliated epithelium exists on the mucous membrane of the upper part of the nose and pharynx, the tympanum and Eustachian tube, the larynx, trachea, bronchi and their ramifications, and the cavity of the uterus and Fallopian tubes.

The epidermis will be particularly described in the account of the skin.

FIG. 184.

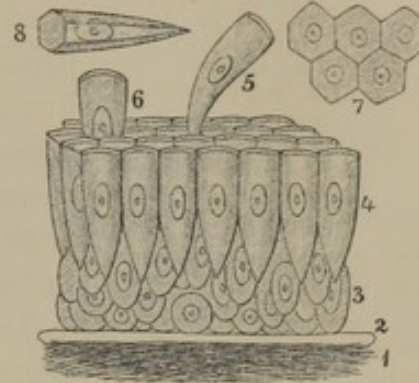


DIAGRAM OF A VERTICAL SECTION OF MUCOUS MEMBRANE OF THE SMALL INTESTINES, highly magnified. 1, fibrous layer, in which the blood-vessels are distributed; 2, basement membrane; 3, young nucleated cells; 4, layer of columnar cells; 5, 6, cells in the act of being shed or thrown off; 7, free ends of the columnar cells, exhibiting their six-sided form; 8, a single columnar cell, exhibiting its actual form at all parts

¹ Vibratile epithelium.

² Vibratile cilia; vibrillæ. *cils*

Basement membrane¹ is a thin, homogeneous layer, or one devoid of visible structure, supporting the cellular layer of the serous and mucous

FIG. 185.

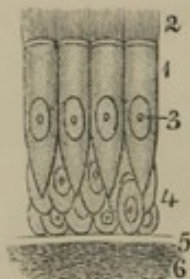


DIAGRAM OF A VERTICAL SECTION OF THE BRONCHIAL MUCCOUS MEMBRANE, highly magnified. 1, columnar ciliated epithelial cells; 2, cilia; 3, nuclei; 4, young cells; 5, basement membrane; 6, fibrous layer.

membranes, the skin, and other organs above mentioned; and resolving itself beneath into the fibrous layer. In some instances it is very distinct and readily observed, as in the uriniferous tubules; in others it certainly exists, but is not so easily demonstrable as in the mucous membranes and skin; and in some cases it is so difficult to detect, that in such positions by many its existence is denied, as in the liver.

The **fibrous layer**,² situated beneath and supporting the basement membrane and epithelial layer, is composed of an intertexture of bundles of fibrous tissue mingled with fine networks of elastic tissue. This layer, for the most part, is absent in the liver, exists in very small quantity in the kidneys, is well developed in other glands, and in the serous and mucous membranes, and reaches its greatest extent in the formation of the dermis. The fibrous layer gives strength and stability to the other structures, and in it, or in a corresponding position if it is absent, the blood-vessels, lymphatics, and nerves are distributed, and never penetrate the basement membrane or epithelial layer. The blood-vessels form capillary nets, which have the closest meshes in the glands, mucous membranes, lungs, and skin. The lymphatics are more numerous in these than any other structures. The nervous supply is also abundant.

Most or perhaps all the structures, whose elements have been described above, lose the superficial portion of their cellular layer from time to time, which is as constantly renewed. The process is not very evident in the cellular layer of glands, nor is it much more clear in the pavement epithelium of serous membranes and allied structures. The columnar epithelium, including its ciliated variety, exhibits strong evidences of the process, but it is most strikingly obvious in the squamous epithelium and the epidermis.

In a vertical section of the mucous membrane of the mouth, the cells of the epithelium in contact with the basement membrane are observed to be comparatively soft, polyhedral from mutual pressure, and of uniform

¹ Structureless, or amorphous membrane; homogeneous layer; membrana intermedia, or limitans; primary or limitary membrane.

² Membrana propria.

diameters; the layers of cells in succession increase in breadth at the expense of their depth; and the superficial cells form the broad thin scales characteristic of the squamous epithelium, of which shreds or flakes are constantly being cast off while they are renewed from beneath.

FIG. 186.

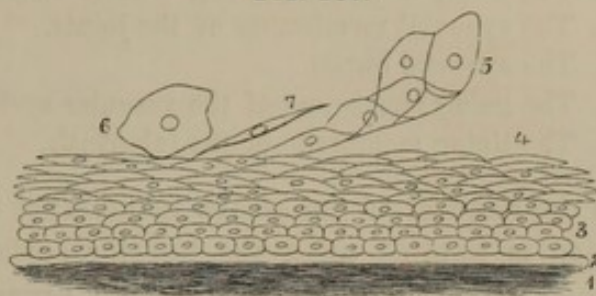


DIAGRAM OF A SECTION OF THE MUCOUS MEMBRANE OF THE MOUTH, highly magnified. 1, fibrous layer, in which the blood-vessels are distributed; 2, basement layer; 3, young cells of the epithelium; 4, older cells transformed into scales; 5, shred of epithelium cast off; 6, a single scale, seen on its broad surface; 7, a similar scale, seen in its thickness.

In a vertical section of the mucous membrane of the small intestine, several layers of cells are observable, in the deeper part of the epithelium, in various stages of development, from the simple spheroidal form to the columnar cells, which always exist in a single layer at the free surface of the epithelium. How, or whether these columnar epithelial cells are shed, has not been positively determined. On several occasions, the author, in some examinations of the structure of the small intestine in the lower animals, has observed isolated columnar cells apparently crowded from their position by pressure laterally and beneath, as represented in figure 184. Perhaps from these instances we may not be wrong in suspecting that the older or effete cells are thus pushed one after another from their place by the more vigorous cells around and the developing ones beneath.

SEROUS MEMBRANES.

The **Serous membranes**,¹ named from the character of the liquid bathing their free surface, line cavities of the body having no exterior communication, and are therefore closed sacs. They serve to lubricate organs which move upon one another, and in many instances form folds, which retain the organs in their position, and from this circumstance, in some cases are named ligaments, as in the case of the suspensory ligament of the liver.

The serous membranes are as follows:—

1. The two pleuræ lining the sides of the thorax and investing the lungs.
2. The pericardium surrounding the heart.
3. The peritoneum lining the cavity of the abdomen and reflected upon its viscera.

¹ Membranæ serosæ.

4. The vaginal tunic of each testicle.
5. The arachnoid membrane of the brain and spinal cord.
6. The lining membrane of the ventricles of the brain.
7. The synovial membranes of the joints.
8. The synovial bursæ.
9. The lining membrane of the vascular system.
10. The lining membrane of the labyrinth.

In the relation of the serous membranes to the contiguous parts, one portion is applied upon the interior surface of the cavity it lines, and another portion is reflected upon the organ or organs contained within the cavity. The former is named its **pari'etal** or **lining portion**; the latter, its **reflected** or **vis'ceral portion**. From this arrangement, the organs are not contained within the cavity of the serous sacs, but are excluded by the membrane being reflected over them.

The outer surface of the serous membrane is attached to the neighbor-

FIG. 187.

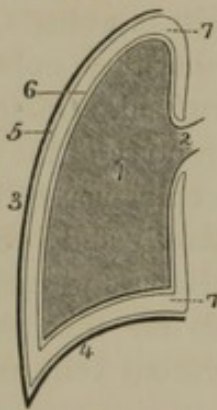


DIAGRAM EXHIBITING THE RELATION OF A SEROUS MEMBRANE, THE PLEURA, TO THE ORGAN IT INVESTS AND THE CAVITY IT LINES. 1, lung; 2, root of the lung, which is the only attached portion of the organ, all others being free; 3, side of the thorax; 4, diaphragm; 5, parietal pleura; 6, pulmonary or reflected pleura; 7, cavity of the pleura.

ing parts by connective tissue, named from its position **sub-serous tissue**; the inner surface is free, smooth, shining, and moistened with a serous liquid elaborated by the membrane itself. The free surfaces of the parietal and reflected portions of the serous membrane come into contact, so that the organs easily and smoothly move upon one another, and against the walls of the cavity containing them; the movement being facilitated by the liquid lubricating the surfaces.

The liquid of the serous cavities resembles the serum of the blood in appearance and composition, but in some instances is more viscid, as in the case of that of the synovial membranes.

The sub-serous connective tissue usually attaches the serous membranes closely to the adjacent parts. In the case of the arachnoid membrane attached to the pia mater, it consists of scattered bands, the **sub-arach'noid tissue**, with the intervals occupied by a liquid like that contained within the cavity of the arachnoid membrane.

When serous membranes invest the interior surface of fibrous membranes, as in the case of the arachnoid and dura mater, and the serous and fibrous pericardium, the two together are often named **fibro-serous membranes**.

The serous membranes are thin, transparent, and colorless, moderately

strong, extensible and elastic. In structure they consist of one or more layers of pavement epithelium composed of six-sided cells; a thin basement membrane, and a layer of fibrous tissue with mingled elastic fibres. The blood-vessels are comparatively few, and form capillary nets, with wide meshes, in the fibrous layer. Numerous lymphatics and fine plexuses of nerves also pervade the latter, though the serous membranes are quite devoid of sensibility in a condition of health. The liquid of serous membranes consists of water, with from one to six percentage of albumen, chloride of sodium, and phosphate of soda and lime.

Syno'vial membranes¹ line the interior of the joints, but do not cover the articular cartilages. Their lubricating liquid, named **syno'via**,² is more viscid than the liquid of other serous membranes. At the margin of the articulations the membrane frequently forms one or more folds containing fat, and named **synovial fringes**.³ These are yellow or reddish yellow, more vascular than other portions of the synovial membrane, and apparently more active in the production of synovia.

Syno'vial bur'sæ⁴ occur where muscles or tendons move upon bones, fibro-cartilages, or ligaments, or frequently upon one another. In many positions they appear as simple, flattened spheroidal sacs, tightly adherent by one side to the moving organ, and by the other side to the part against which the organ moves. Instances of this kind are seen in the bursa beneath the deltoid muscle, and that between the insertion of the biceps flexor tendon and the tuberosity of the radius.

When tendons move through grooves of bones, or beneath annular or vaginal ligaments, the synovial bursa⁵ lines the groove or canal and is thence reflected upon the tendons. In the vicinity of joints the bursæ often communicate with their cavity.

In positions in which a number of tendons move upon one another, as in the case of the flexor tendons in the vicinity of the wrist, a highly extensible, fibro-elastic membrane⁶ is folded around and among them, which appears to have the same function as the synovial bursæ, but presents no trace of an epithelium. Beneath the skin also in certain positions, as between that of the elbow and the olecranon, or that of the knee and the patella, pouches⁷ exist, apparently of the nature of

¹ Capsulæ synoviales.

² Mucilago; humor, unguentum, smegma, axungia, gluten, or humidum nativum articulorum; hydrarthrus; arthrohydrine.

³ Synovial glands of Havers; Haversian glands; glandulæ articulares; synovial fimbriæ; plicæ synoviales, adiposæ, or vasculosæ; ligamenta mucosa.

⁴ Bursæ mucosæ; b. m. vesiculares; b. or capsulæ synoviales; sacci mucosi; synovial crypts or follicles; blennocystides; vesicæ unguinosæ tendinum.

⁵ Vaginæ synoviales or mucilaginosæ.

⁶ Bursæ mucosæ tendinosæ.

⁷ B. m. subcutanæ.

synovial bursæ. These have a ragged-looking internal surface devoid of an epithelium.

MUCOUS MEMBRANES.

Mucous membranes, though possessing common physical or anatomical elements, like the serous membranes, differ in most other respects. They line internal cavities and passages communicating with the exterior, together with various receptacles and glandular ducts opening on the surfaces of the former. They never form completely closed sacs, as the serous membranes, and are all continuous with one another and the skin. Habitually exposed to the contact of materials foreign to their structure, such as food, air, dust, the secretions and excretions of glands, their free surface is bathed with a viscous liquid named **mucus**, which is usually more consistent than the liquid of serous membranes.

Mucous membrane lines the cavity of the nose and its communicating sinuses, the front of the eye and the lachrymo-nasal duct, the tympanum, mastoid sinuses and Eustachian tube, the mouth, pharynx, œsophagus, stomach, and intestines, the larynx, trachea, bronchi and their ramifications, the salivary, pancreatic, and bile ducts, and the gall-bladder, the pelvis of the kidneys, ureters, urinary bladder and urethra, the seminal ducts and vesicles, the vagina, uterus, and Fallopian tubes, and the ducts of the mammary glands. From their isolation, all these mucous membranes together are divided into three groups, generally designated as the **gastro-pulmonary**, **genito-urinary**, and **mammary mucous membranes**. At the edges of the eyelids, nostrils, mouth, anus, vulva, urethra, and orifices of the milk ducts, the mucous membranes become continuous structures with the skin.

All the mucous membranes possess a free surface formed of an epithelium resting on a basement membrane, beneath which is a fibrous layer adhering to the contiguous parts by connective tissue, named from its position the **submucous tissue**.¹ In the hollow viscera the latter forms an abundant and distensible layer, permitting considerable enlargement of the visceral cavities, as in the case of the stomach and urinary bladder. In contraction of organs lined with mucous membrane this becomes rugose, or thrown into folds, which are effaced on distention. These folds, however, should not be confounded with others of a permanent character existing in some of the mucous membranes, as for instance, the **val'vulæ conniven'tes** of the small intestine.

The mucous membranes are less transparent in general than the serous

¹ *Textus cellularis submucosus*; *tunica cellularis*; fibrous coat; cellular coat.

membranes; are more vascular, and are also well supplied with lymphatics and nerves. They vary from a white, grayish white and pale pink, to dark red, the shade or depth of redness depending mainly on the amount of blood supplied. Excitation heightens their color, and contact with the air favors their permanent redness.

Nearly all mucous membranes are abundantly supplied with minute glands imbedded in their fibrous layer or the contiguous submucous tissue, and opening on their free surface.

The epithelium of mucous membranes presents most of the varieties of cells which have been described. Those provided with a columnar epithelium are usually softer and more moist than the others. The basement membrane and fibrous layers of structure are sufficiently evident in all mucous membranes.

Mucus, the material elaborated by the mucous membranes, and apparently by many of their glands, is a clear, colorless, transparent, viscid liquid, frequently rendered more or less turbid by cast-off epithelial cells, and isolated nuclear bodies, commonly called **mucous corpuscles**. It is composed of water, the peculiar organic principle mucosin, and alkaline salts.

THE GLANDULAR SYSTEM.

The name of **Gland** has been indiscriminately applied to almost every rounded, massive organ, if it was only supposed to elaborate certain liquid materials from the blood. Thus the liver, which produces the bile, the thyroid body whose office is unknown, the rounded masses situated in the course of the lymphatics, and the pituitary body, a portion of the brain, have all been and yet continue to be called glands. In this confusion of parts with one general name, it is our object at present only to describe those which are commonly distinguished as the **true glands**. These may be defined to be organs which elaborate from the blood liquid matters poured forth by one or more ducts or orifices opening on the surface of the mucous membranes or skin. The material elaborated by a gland is called a **secretion**, and the same name is given to the act of elaboration. If the secretion is to be rejected from the body as useless, it is also called an **excretion**. The term secretion is likewise applied to mucus and serum, and to the elaboration of these by their appropriate membranes.

In general, the glands may be described as consisting of a tube or series of tubes of basement membrane lined with nucleated cells, and invested externally with a fibrous layer in which are distributed the blood-vessels from which the glands elaborate their secretions. The difference

in the complexity and extent of glands depends mainly on the difference in number, length, and arrangement of the tubes.

FIG. 188.

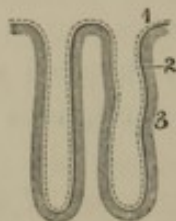


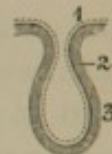
DIAGRAM OF TWO SIMPLE TUBULAR GLANDS. The dotted line 1 indicates the glandular epithelium or secreting cells; the thicker continuous line 2, is the basement membrane, and the shaded portion of the figure 3 represents the fibrous tissue in which the blood-vessels are distributed which supply the glands.

the tubular glands of the small intestines. The complexity is slightly increased if the tube is dilated into a purse-like pouch, as in the simple sebaceous glands of the skin.

If the simple tube or pouch is divided at bottom into two or more similar parts, the complexity is increased according to the number of the latter, as seen in the gastric glands, and compound sebaceous glands of the skin.

The glandular tube may be rendered complex by becoming more or less elongated and convoluted, as in the case of the sweat glands. If

FIG. 189.



SIMPLE GLAND DILATED INTO A POUCH. References as in the preceding figure.

The simplest form of a gland consists of a short, straight tube, closed at one end, and opening at the other upon the surface of a mucous membrane, as instanced in

FIG. 190.

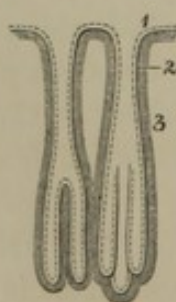


FIG. 191.

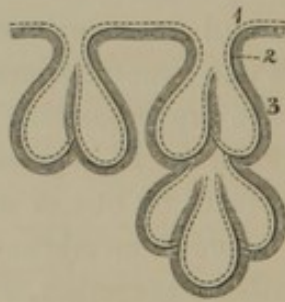


FIG. 192.

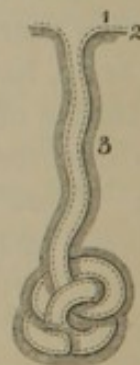

Fig. 190. GLANDS RENDERED SLIGHTLY COMPLEX BY DIVISION AT BOTTOM. References as in figure 188.

Fig. 191. INCREASE OF COMPLEXITY OF GLANDS BY THE ADDITION OF SIMILAR PARTS. References as before.

Fig. 192. A TUBULAR GLAND RENDERED COMPLEX BY BECOMING ELONGATED AND CONVOLUTED. Same references.

the tube divide and subdivide, and the ultimate branches become elongated and convoluted, the gland is rendered complex according to the extent of branching and convolution, as exemplified by the kidneys and testicles.

If the glandular tube divide and subdivide, and the terminal branches

dilate into vesicles, a complex arrangement is produced resembling in appearance a bunch of grapes, as represented in the construction of the salivary glands. If, on the other hand, the branching tubes form a network, a complex arrangement results such as is seen in the construction of the liver.

FIG. 193.

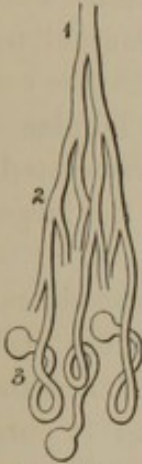

FIG. 194.

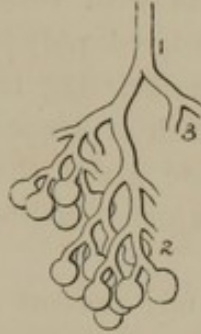

FIG. 195.

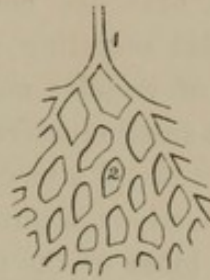

Fig. 193. GLAND OF COMPLEX FORM; the tubes branching and the terminal ones convoluted and dilated at the extremities. 1, main tube or duct; 2, branches; 3, convoluted portions dilated at the extremities.

Fig. 194. GLAND OF COMPLEX FORM, whose arrangement resembles that of a bunch of grapes. 1, duct; 2, branches ending in vesicles; 3, branch of another lobule.

Fig. 195. GLAND OF COMPLEX CHARACTER in which the tubes anastomose, and thus form a net-work 1, duct; 2, net-work of tubes.

The glands may be classified according to their structural arrangement, though it should be fairly understood that the different forms are not separated by trenchant characters, but pass by gradations into one another. The principal forms are as follows: the tubular, racemose, convoluted, and reticular glands.

The **Tubular glands** consist of simple, straight or slightly tortuous tubes closed at one end, and opening at the other on the surface of a mucous membrane. They are usually short, of uniform diameter throughout, or slightly dilated toward the closed extremity; or in the latter position they may divide into several tubular offsets or prolongations. They are imbedded in the fibrous layer of mucous membranes, and in most instances are provided with a columnar epithelium, besides the basement membrane and fibrous coat. Such are the tubular glands of the large and small intestine, the gastric glands, and the tubular glands of the nose and uterus.

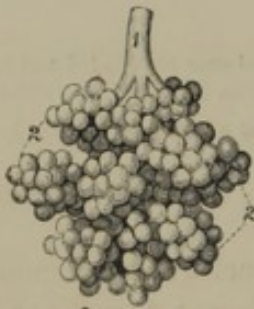The **Follic'ular glands**, intermediate to the former and the succeeding variety, and passing insensibly from one into the other, are composed of one or more purse-like pouches lined with a spheroidal epithelium. When the pouches are numerous, they are usually collected into small groups or **lobules** opening into a common canal or duct, which conveys

the secretion to the surface of the skin or mucous membrane. To this variety belong the sebaceous glands of the skin, the follicular glands of the root of the tongue, soft palate and pharynx, and the tonsils.

The **Rac'emo**se glands are named from their structure resembling in arrangement the appearance of a raceme or cluster of grapes. In the construction of such glands, a tube divides and subdivides, and the smallest branches communicate with vesicular dilatations lined with spheroidal secreting cells, rendered polyhedral from mutual pressure. Groups of vesicles and their associating tubes, which may be compared with the small clusters of a bunch of grapes, are named **lobules**. In the construction of a large racemose gland, the latter are associated in still larger portions, a number of which together may form the largest divisions or **lobes** of the gland.

The simplest racemose glands present a striking resemblance to a

FIG. 196.



A RACEMOSE GLAND. 1, duct; 2, lobules composed of the terminal divisions of the ducts, ending in vesicles.

bunch of grapes, but the more compound glands, or those consisting of a number of lobules and lobes, are modified in form from mutual pressure. The commencing vesicles are polyhedral, the lobules and lobes are pyramidal, and the whole are associated, by intervening connective tissue, into a more or less solid mass. The tubes or **ducts**, which collect the secretion from the commencing vesicles, finally emerge from the lobules and collect into a principal **duct**, or sometimes several, issuing from the gland and opening on some mucous membrane.

The duct or ducts of the racemose glands have fibrous walls lined with mucous membrane, usually provided with a columnar epithelium. A few of the principal ducts in addition are furnished with unstriated muscular fibres.

To the racemose glands belong the pancreas, the salivary glands, the lachrymal gland, the labial, buccal, palatine, lingual, pharyngeal, œsophageal, and duodenal glands, the tracheal and bronchial glands, the vaginal, prostatic, and urethral glands.

The **Convolute**d glands are composed of simple or branching tubes, which, at their commencement, are enrolled upon themselves or convoluted into masses. The simplest forms are the sweat glands; the compound forms are the kidneys and testicles.

The only gland exhibiting a reticular arrangement in its intimate structure is the liver. This organ is divided on the surface into several lobes, and these are composed of an aggregation of small and closely

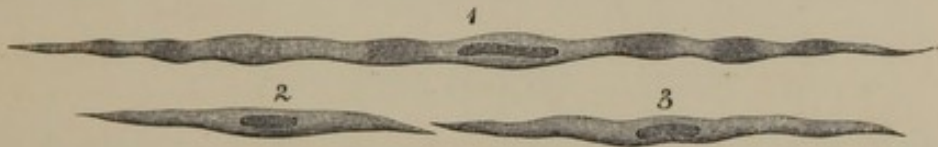
adherent polyhedral **lobules** or **acini**. Independently of the blood-vessels, the acini consist of a net-work of polyhedral glandular cells; but whether they occupy the interior of tubes of basement membrane, as in other glands, is still a point which remains undetermined to the satisfaction of most anatomists. Ducts proceeding from the acini, as in other secretory organs, converge to trunks composed of fibrous walls, with a lining of mucous membrane.

The glands are most richly furnished with blood-vessels, which form capillary nets around or among the glandular tubes. They likewise possess numerous lymphatics, and are also supplied with nerves.

UNSTRIATED MUSCULAR TISSUE.

Most of the hollow viscera, including the vascular system and a few other parts, are provided with muscular layers of a different structure

FIG. 197.



UNSTRIATED MUSCULAR FIBRE. 1, from the small intestine; 2, from the middle coat of an artery; 3, from a vein.

from that already described, and named, in contradistinction, the **unstriated muscular tissue**.¹ The **unstriated muscular fibres** of the latter consist of fusiform, rounded, or slightly prismoid columns or bands, varying considerably in the proportions of length and breadth in the different organs. They range from the $\frac{1}{80}$ to the $\frac{1}{10}$ of a line in length, are faintly yellowish or colorless, homogeneous, or indistinctly granular, and present no trace of transverse striation. They consist of single, elongated cells, pointed at the extremities, and always provided with a central, oblong oval nucleus.

The unstriated muscular fibres are usually associated into fasciculi, and these are arranged into layers or membranes, having a yellowish-brown appearance. These muscular layers are abundantly supplied with blood-vessels and nerves, which have the same general arrangement as in the striated muscles. The unstriated muscular tissue is excited to contraction usually through reflex impressions, but may also be excited by the direct impression of most of the stimuli operating on the striated muscles, except the will.

¹ Unstriped, or non-striated muscular tissue or fibres; smooth muscles, or muscular fibres; organic muscular tissue or fibres; muscular tissue of organic life.

Unstriated muscular tissue constitutes the muscular coat of the stomach, small and large intestine, and the muscular fibres noticed in the mucous membrane of these organs. A thin layer is also found on the gall-bladder and in certain glandular ducts. It forms the muscular coat of the urinary bladder, the walls of the uterus, and a layer to the Fallopian tubes, vagina, and urethra. In association with elastic tissue, it composes the middle coat of the blood-vessels and lymphatics, and further constitutes the muscular structure of the trachea, bronchi and their ramifications. Finally, it forms the dartos layer of the scrotum, and is found in other parts of the skin, especially in the walls of the odoriferous glands of the axillæ.

CHAPTER VI.

THE ALIMENTARY APPARATUS.

THE **Aliment'ary apparatus** consists of the **aliment'ary canal**,¹ together with a number of accessory organs. The former comprises two divisions, of which one is constituted by the mouth and the **organs of degluti'tion**, consisting of the pharynx and œsophagus; the other, by the **diges'tive organs**,² contained within the abdomen, and composed of the stomach and the small and large intestines. The accessory organs are those of **mastica'tion**, consisting of the teeth, jaws, and appropriate muscles, and the tongue, salivary glands, pancreas, and the liver.

THE MOUTH.

The **Mouth**³ is the space included between the lips in front, the pharynx behind, and the cheeks at the sides. Above, it is bounded by the roof or palate, inclosed by the upper teeth and alveolar arch; below, is its floor, upon which rests the tongue, included within the lower teeth and alveolar arch. The closed jaws and teeth divide the mouth into two portions: the narrow interval⁴ between the lips, cheeks, and the jaws, and the larger cavity within the latter, containing the tongue.

The cavity of the mouth,⁵ except on the teeth, is everywhere invested with a highly vascular mucous membrane, provided with a squamous epithelium. It is also furnished with conical papillæ, for the most part minute and concealed beneath the epithelium, except at the margins of the gums, and more especially on the upper surface of the tongue, where they become conspicuous as the chief organs of taste.

The **Gums**⁶ consist of reflections of the oral mucous membrane upon the alveolar arches. They closely adhere to the periosteum beneath, and form circular doublings or collars around the necks of the teeth, with which they are intimately connected.

¹ Canalis, tubus, or ductus alimentarius, ciliarius, digestivus, or intestinum; digestive canal; intestinal canal; primæ viæ.

² Organon digestionis.

³ Os; stoma; cavum oris.

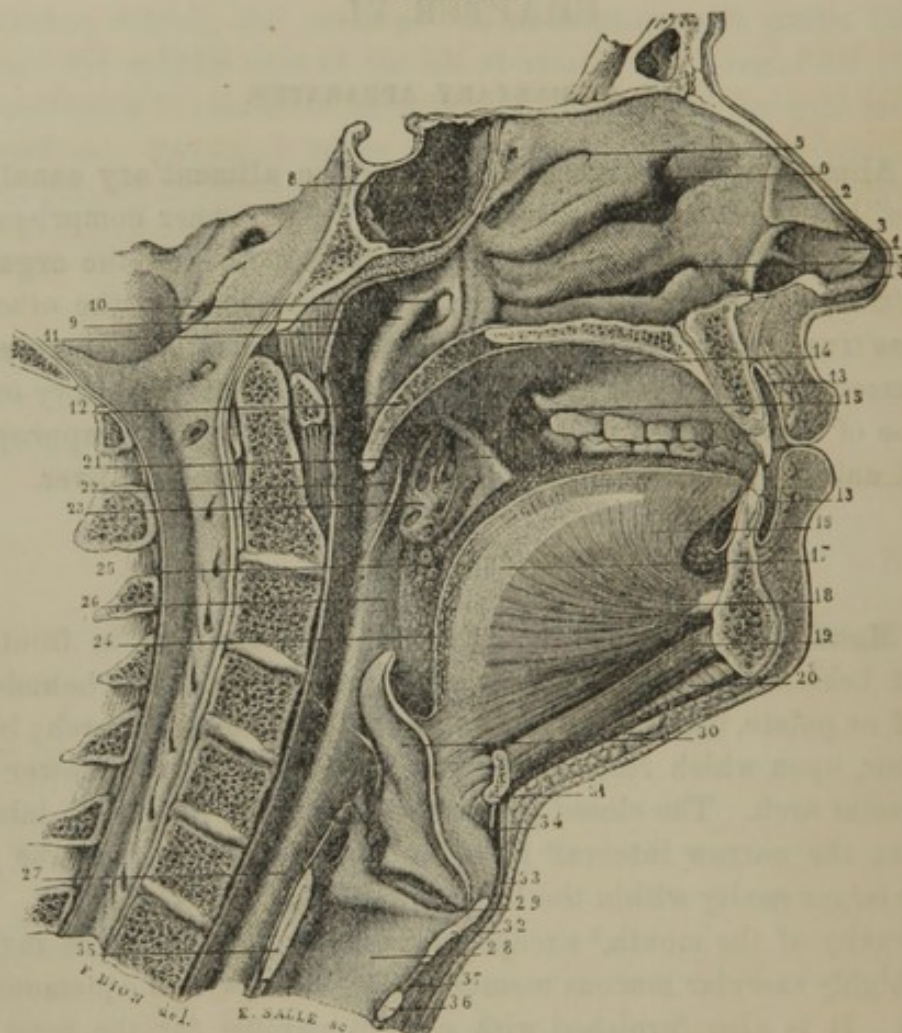
⁴ Vestibulum oris.

⁵ Cavum, or spatium oris.

⁶ Gingivæ; carnicula; ula.

The **Lips**¹ are separated by the **oral fissure**,² the extremities of which constitute the **oral angles** or **commissures**.³ Besides the exterior skin, with its subjacent connective tissue and fat, the lips are composed of various muscles converging to and surrounding the oral fissure, together with

FIG. 198.



VERTICAL SECTION OF THE FACE AND NECK, THROUGH THE MEDIAN LINE ANTERO-POSTERIORLY, EXPOSING TO VIEW THE NOSE, MOUTH, PHARYNX, AND LARYNX. 1, oval cartilage of the left nostril; 2, triangular cartilage; 3, line of separation between the two; 4, prolongation of the oval cartilage along the column of the nose; 5, superior meatus of the nose; 6, middle meatus; 7, inferior meatus; 8, sphenoidal sinus; 9, posterior part of the left nasal cavity, communicating with the pharynx; 10, orifice of the Eustachian tube; 11, upper extremity of the pharynx; 12, soft palate, ending below in the uvula; 13, interval of the mouth between the lips and jaws; 14, roof of the mouth, or hard palate; 15, communication of the cavity of the mouth with the interval between the jaws and cheek; 16, tongue; 17, fibrous partition in the median line of the latter; 18, genio-glossal muscle; 19, genio-hyoid muscle; 20, mylo-hyoid muscle; 21, anterior half arch of the palate; 22, posterior half arch of the palate; 23, tonsil; 24, 25, floor of the fauces; 26, 27, pharynx; 28, cavity of the larynx; 29, ventricle of the larynx; 30, epiglottis; 31, hyoid bone; 32, 33, thyroid cartilage; 34, thyro-hyoid membrane; 35, 36, cricoid cartilage; 37, vocal membrane.

¹ Sing.: labium; pl.: labia; labrum, cheilos; upper and under lip; anocheilos and catacheilos.

² Rima, apertura, orificium, or hiatus oris; os; peristomium.

³ Angles, or commissures of the mouth or of the lips; commissura labiorum; prostomia.

the lining mucous membrane and a number of glands. The orbicular muscle borders the oral fissure or orifice of the mouth, and is covered by thin skin, gradually passing into mucous membrane. Between the lips and jaws, in the median line, the mucous membrane forms doublings, named the **superior** and the **inferior labial fræ'num**.¹

The **Cheeks**² have a composition similar to the lips, and their principal muscle is the buccinator. At their back part they include the ramus of the lower jaw and its muscles, and also, usually between these and the buccinator muscle, a mass of soft adipose tissue.

Beneath the mucous membrane of the lips and cheeks there are numerous small, rounded, pinkish racemose glands, opening by their ducts into the mouth, and named from their position the **labial**³ and **buccal glands**.⁴ Though they are supposed to secrete mucus, their office has not been satisfactorily determined.

The **Palate**, or **roof of the mouth**,⁵ comprises two parts, called the hard and soft palate.

The **Hard palate**⁶ is deeply vaulted, and is lined with a smooth mucous membrane, except at its fore part, where it is roughened by transverse ridges. It is divided by a faintly-marked median line,⁷ ending in a small prominence, corresponding with the position of the incisive foramen. Its osseous basis is formed by the palate plates of the superior maxillary and palate bones, to which the mucous membrane adheres by a dense layer of fibrous tissue, containing numerous small racemose glands, named from their position the **palatine glands**.⁸

The **Soft palate**⁹ is composed of a doubling of mucous membrane, inclosing a fibro-muscular layer, together with many small racemose and follicular glands. It projects as a freely movable partition obliquely downward and backward from the hard palate, between the mouth and posterior nasal orifices.

The **U'vula**¹⁰ is the small, tongue-like appendage projecting from the

¹ Frænum, or frænulum labii superioris et inferioris.

² Genæ; malæ.

³ Glandulæ labiales.

⁴ Glandulæ buccales.

⁵ Palatum; fossa palatina; uraniscos; hyperoa.

⁶ Palatum durum, or stabile.

⁷ Raphe.

⁸ Glandulæ palatinæ.

⁹ Palatum molle, mobile, or pendulum;

velum palatinum, pendulum, or staphylinum; velum palati, or pendulum palati; pendulum, or claustrum palati; pendulous veil of the palate.

¹⁰ Uva; uvigena; uvigera; staphyle; columella, or columna oris; sublingua; tintinnabulum; gargarlon; gurgulis; interseptum; processus, or cartilago uvifer; pinnaculum fornicis gutturalis; himas; plestrum; pap of the throat; the palate.

+185+190

middle of the soft palate, and consists of a pair of muscles inclosed in a pouch of mucous membrane.

The **Half arches of the Palate** are two crescentic folds of mucous membrane, inclosing muscular fasciculi, and diverging from the base of the uvula, on each side of the palate, outward and downward, one to the side of the tongue, the other to the side of the pharynx. The anterior pair inclose the palato-glossal muscles, and together constitute the **anterior palatine arch**;¹ the posterior pair inclose the palato-pharyngeal muscles, and constitute together the **posterior palatine arch**.²

The **Fau'ces**³ are the straits or passage leading from the mouth to the pharynx, and correspond with the space included between the palatine arches.

The **Ton'sils**⁴ are two glandular organs, about the size and shape of an almond kernel, situated one on each side of the fauces, inclosed in the triangular recess between the half arches of the palate. They are in contact externally with the superior constrictor muscles of the pharynx, and move with the contraction of these muscles. Their surface toward the fauces presents a coarsely reticular appearance, due to a number of large orifices communicating with pouches, in the bottom of which the orifices of smaller pouches are visible. They are large compound follicular glands of peculiar constitution.

Simple follic'ular glands of the same character as the tonsils occupy the floor of the fauces or the root of the tongue, the palate, and the pharynx. These are distinguished as rounded prominences of the mucous membrane, with an orifice communicating with the mouth or pharynx. They consist of a purse or bottle-like inflection of the mucous membrane, and contain in their thick walls of submucous tissue a number of spheroidal capsules or vesicles resembling in composition the solitary glands of the intestines. The tonsils differ from the simple follicular glands only in their compound form, or, in other words, they consist of an aggregation of such bodies as constitute the glands just named.

The recesses of the tonsils and simple follicular glands ordinarily appear to elaborate mucus, which lubricates the fauces in the passage of food. Under the influence of cold, these glandular organs are very sus-

¹ Arcus palatinus anticus; a. palato-glossus.

² Arcus palatinus posticus; a. palato-pharyngeus.

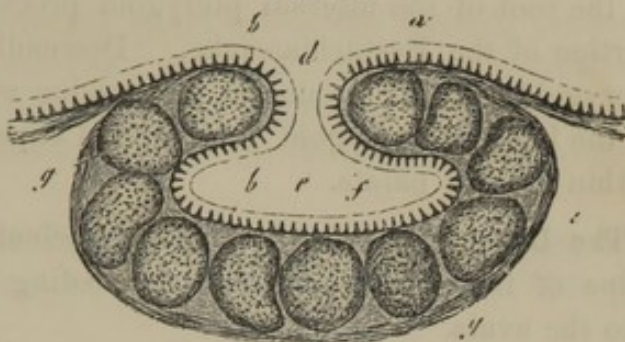
³ Isthmus of the fauces; i. faucium; claustrum gutturis.

⁴ Sing.: tonsilla; amygdala; paristhmia; tola; spongios; antias; amphibranchium; glandula colli; almond of the throat or of the ear.

ceptible to inflammation and chronic enlargement. In the unhealthy condition their recesses frequently become filled with a dirty-white tallow-like matter, which is from time to time expectorated in the form of small, rounded balls.

These, when crushed, exhale a heavy, disagreeable odor, indicating a source of foul breath, independent of the more ordinary one. The material examined beneath the microscope exhibits nothing but squamous epithelial cells, together with some oil globules, and minute, parasitic, filamentous plants.

FIG. 199.

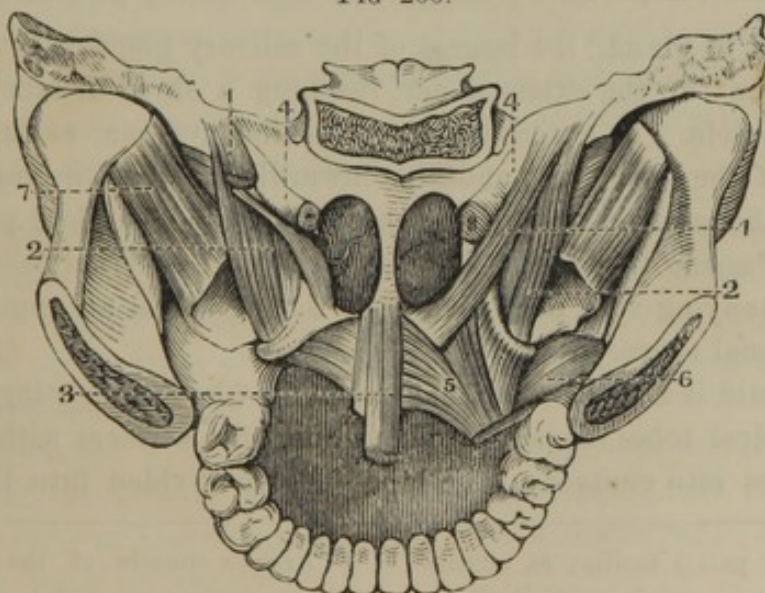


SECTION OF A FOLLICULAR GLAND FROM THE ROOT OF THE TONGUE. *a*, epithelium; *b*, papillæ imbedded in the latter; *c*, outer part of the thick wall of the gland composed of connective tissue; *d*, mouth of the gland; *e*, its cavity; *f*, epithelium lining the latter; *g*, vesicular bodies resembling the solitary glands of the intestines. Highly magnified.

MUSCLES OF THE PALATE AND FAUCES.

The **Eleva'tor of the Palate**¹ is a thin, flat muscle, which arises from the end of the petrous portion of the temporal bone and the contiguous

FIG 200.



POSTERIOR VIEW OF THE MUSCLES OF THE PALATE AND FAUCES. 1, elevator of the palate, on the left side its origin only remaining; 2, tensor of the palate, winding around the hook of the internal pterygoid process and ending in the soft palate; 3, uvular muscles; 4, Eustachian tube; 5, origin of the palatopharyngeal and palato-glossal muscles; 6, part of the origin of the superior constrictor of the pharynx; 7, external pterygoid muscle.

¹ *M. levator palati mollis*; *m. salpingo-staphylinus*; *m. s.-s. internus*; *m. petro-salpingo-staphylinus*; *m. pterygo-staphylinus externus*; *m. spheno-staphylinus*; *m. spheno-palatinus*; *m. peristaphylinus internus superior*; *m. petro-staphylinus*.

portion of the Eustachian tube, and descends at the side of the posterior nasal orifice to expand in the structure of the soft palate.

The **Ten'sor of the Palate**¹ is a narrow muscle arising from the ^{sphenoid} fossa, at the root of the internal pterygoid process, and from the contiguous portion of the Eustachian tube. Descending at the inner side of the pterygoid fossa, it terminates in a tendon which winds around the hook of the internal pterygoid process, and expands into a thin aponeurosis within the soft palate.

The **U'vular muscle**² is a fleshy fasciculus arising from the palate spine of the palate bone, and descending in company with its fellow into the uvula.

The **Pal'ato-glos'sal muscle**³ is situated within the anterior half arch of the palate, extending from the side of the soft palate to the tongue.

The **Floor of the mouth**, included within the lower jaw, is formed by the skin, the mylo- and genio-hyoid muscles, and the mucous membrane reflected from the gum to the under part of the tongue.

THE SALIVARY GLANDS.

Opening into the cavity of the mouth there are three pairs of salivary glands, named the parotid, submaxillary and sublingual glands.

The **Parot'id gland**,⁴ the largest of the salivary glands, occupies a position in front of the external ear, reaching a short distance over the masseter muscle. It extends as high as the zygoma, as far down as the angle of the lower jaw, and dips inwardly between the ramus of the latter and the mastoid process to the position of the styloid process and muscles. Passing through its length, we find the external carotid artery and accompanying vein, and, diverging through it in an opposite direction, the facial nerve.

The parotid is a large compound racemose gland, consisting of numerous polyhedral lobes, closely moulded upon the surfaces with which the gland comes into contact. The lobes are subdivided into lobules, the

¹ M. tensor palati mollis; m. circumflexus palati; m. salpingo-staphylinus; m. petro-salpingo-staphylinus; m. pterygo-staphylinus; m. spheno-salpingo-staphylinus; m. peristaphylinus externus or inferior; m. staphylinus externus; m. palato-salpingeus; m. spheno-ptyergo-palatinus; m. tubæ novæ.

² Azygos muscle of the uvula; m. azygos uvulæ; m. palato-staphylinus; m. staphylinus; m. epistaphylinus; m. staphylinus medius.

³ M. palato-glossus; m. constrictor isthmii faucium; m. glosso-staphylinus; m. glosso-palatinus.

⁴ Glandula parotidea; g. adares; parotis; animellæ; lacticinia.

whole being connected together by dense areolar tissue, continuous externally with that enveloping the gland and adhering to the contiguous parts.

The **Parot'id duct**,¹ about the diameter of a crow-quill, and two inches in length, passes forward from the gland across the masseter muscle, a short distance below the zygoma, and opens into the mouth by perforating the buccinator. Its orifice, somewhat contracted, is indicated by a small prominence opposite the position of the second upper large molar tooth.

Usually a detached portion of the gland, named the **accessory parotid**,² rests on the masseter muscle, and communicates by its duct with the main one.

The **Submax'illary gland**,³ about a third the size of the preceding, and separated from it by a strong process of the deep cervical fascia, is situated just within and below the base of the lower jaw. It is beneath the mylo-hyoid muscle; is included below in the curve of the digastric muscle, and externally is covered by the subcutaneous cervical muscle and skin. Its structure is like that of the parotid gland, but its lobes are coarser, its connective tissue much less in quantity, and its attachment to the contiguous parts comparatively feeble.

The **Submax'illary duct**,⁴ about two inches in length, passes backward, turns over the posterior edge of the mylo-hyoid muscle, and is then directed forward between this and the hyo-glossal muscle to the side of the lingual frænum, where it terminates at the summit of a small prominence.⁵ An accessory portion of the gland follows the duct a short distance and communicates with it.

The **Sublin'gual gland**,⁶ the smallest of the salivary glands, is narrow oblong in shape, and rests on the floor of the mouth, projecting into its cavity as a conspicuous ridge beneath the side of the tongue. It extends from the position of the lingual frænum to the submaxillary gland, and is in contact with the duct of the latter.

The sublingual gland has the same structure as the other salivary glands; but its lobules are less closely associated. It communicates with the cavity of the mouth by about half a dozen small ducts,⁷ which

¹ Duct of Steno; ductus Stenonianus; d. salivalis superior.

² Glandula socia parotidis; accessory gland of the parotid; g. parotis accessoria.

³ Glandula submaxillaris; g. angularis; g. maxillaris; hypognathaden; hypopaladen.

⁴ Duct of Wharton; ductus Whartonianus; d. salivalis inferior.

⁵ Caruncula sublingualis.

⁶ Glandula sublingualis; in part, the glands of Rivinus.

⁷ Ductus Rivini; d. Waltheriani.

*Submaxillary
duct
Steno*

open upon the ridge indicating its position. Frequently several of the ducts unite into a single one,¹ terminating near to, or in conjunction with, the submaxillary duct.

The secretion of the salivary glands, the **sali'va**,² is a colorless liquid of slightly alkaline reaction. It is rendered more or less viscid by the mixture of mucus, and contains a few epithelial scales and so-called mucous corpuscles or free nuclei.

The parotid gland is supplied with arteries from the external carotid, the submaxillary gland from the facial, and the sublingual gland from the sublingual artery. The veins terminate in those accompanying the corresponding arteries. The nerves are derived from the contiguous vascular plexuses of the sympathetic, in conjunction with filaments of the trifacial nerve.

THE TONGUE.

The **Tongue**³ is a muscular organ invested with mucous membrane,⁴ and ordinarily, when at rest, occupies a position within the arch of the lower jaw. From its freedom of movement it aids in the process of mastication and deglutition, and contributes to articulation in speech; from the papillæ of its surface it constitutes the organ of taste.

The posterior part of the tongue attached to the hyoid bone is named its **root** or **base**,⁵ and that which is attached along the middle to the floor of the mouth is the **body**. The **tip**,⁶ **sides**,⁷ and **upper surface**⁸ are free, and invested with mucous membrane, which, from beneath the tongue, is reflected to the lower gum.

Between the root of the tongue and the epiglottis, the mucous membrane forms three folds, named the **glos'so-epiglot'tic fræ'na**;⁹ and beneath the tip of the tongue a median fold passes to the gum, and is called the **lin'gual fræ'num**.¹⁰

The mucous membrane of the under part of the tongue is thin and translucent, and permits the blood-vessels, especially the ranine veins, and a number of small racemose glands, distinctly to be seen through it. Beneath the tip it forms a slightly elevated **median line** or **raphe'** which is continuous with the lingual frænum.

¹ Ductus Bartholini.

² Sputum; sputamentum; ptyalon; sialon; spit; spittle.

³ Lingua; glossa; glotta.

⁴ Periglottis; membrana, or tunica vaginalis; involucrum; cutis; epidermis; crusta villosæ.

⁵ Radix; hyoid extremity.

⁶ Dental extremity; point.

⁷ Margins.

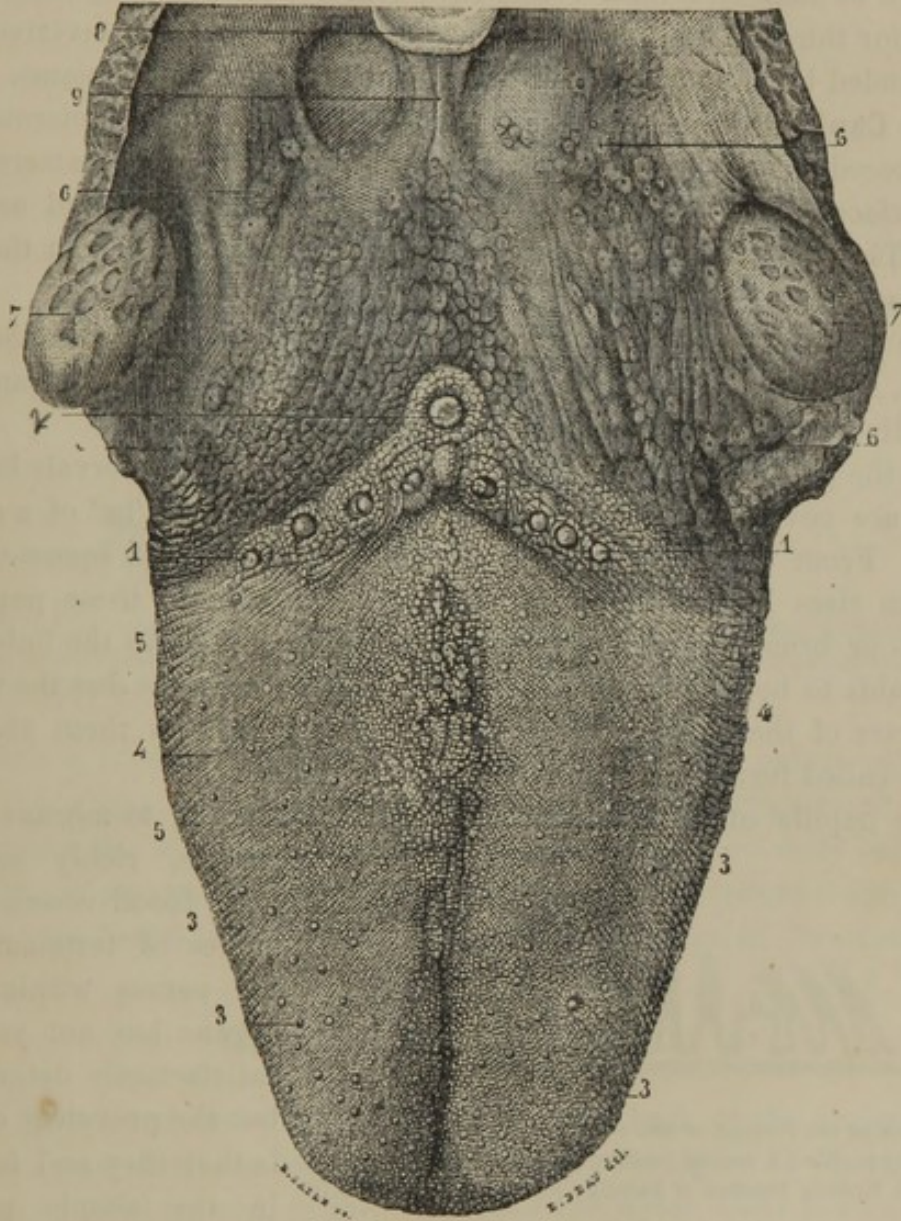
⁸ Dorsum.

⁹ Glosso-epiglottic ligaments; fræna, or frænula epiglotidis; ligamenta membranacea; velamenta linguæ.

¹⁰ Frænum, frænulum, or vinculum linguæ; glossodesmus; filetum.

The upper surface or back of the tongue¹ is marked along the middle by a slight furrow,² which corresponds in position with a thin fibrous partition,³ dividing the organ into symmetrical halves.

FIG. 201.



VIEW OF THE UPPER SURFACE OF THE TONGUE. 1, 2, V-like row of the circumvallate papillæ; 3, capitate papillæ; 4, 5, conical papillæ; 6, 6, floor of the fauces, with numerous simple follicular glands; 7, tonsils; 8, summit of the epiglottis; 9, the middle glosso-epiglottic frænum, with depressions on each side bounded externally by the lateral fræna.

Upon the anterior two-thirds of the upper surface of the tongue, the mucous membrane adheres most intimately to the muscular structure beneath, and is especially remarkable from its being densely beset with

¹ Dorsum.

² Linea mediana; raphe.

³ Septum linguæ; cartilago linguæ; c. mediana; lingual fibro-cartilage.

small processes, named, from their function, the **papillæ of taste**.¹ The principal of these are of a composite character, and present three varieties, called the circumvallate, capitate, and conical papillæ.

The **Circumvallate papillæ**,² the largest of the varieties, and about a dozen in number, form a V-like row, defining the papillary layer at the posterior third of the tongue. They have the form of an inverted cone, surrounded by an annular, wall-like elevation, whence their name.

The **Capitate papillæ**,³ the second in size, and more numerous than the preceding, are conspicuous as small, red eminences, scattered over the surface of the tongue, but are especially numerous at and near the tip. They are rounded at the free extremity, and narrower at the basis of attachment.

The **Conical papillæ**,⁴ smaller and much more numerous than the others, are crowded in the intervals between them, but are arranged in rows diverging from the median line of the tongue.

All the papillæ of taste, as described above, and the intervals between them, are covered with numerous minute, **simple papillæ**⁵ of a conical form. From those surmounting the conical papillæ, the squamous epithelium rises in hair-like appendages, which give to these papillæ a pencil- or brush-like arrangement, admirably adapted to the imbibition of liquids to be tasted. To these hair-like processes is due the velvety character of the surface of the tongue; and it is upon them also that the so-called furred condition of the latter depends.

The papillæ of taste are processes of the mucous membrane of the tongue, richly supplied

FIG. 202.

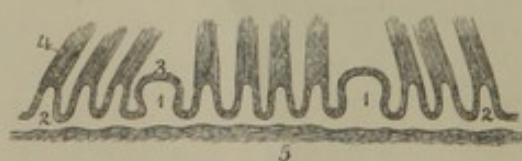


DIAGRAM OF THE PAPILLÆ OF THE TONGUE, moderately magnified. 1, capitate papillæ; 2, conical papillæ; 3, epithelium; 4, the same structure forming bunches of hair-like processes; 5, connective tissue.

with blood-vessels. The modes of termination of the nerves within these organs has not yet been satisfactorily determined, but the prevalent opinion is that they end in loops in the simple papillæ.

The capillary blood-vessels distinctly appear within the latter in the form of loops communicating with the vascular trunks at their base.

¹ Papillæ gustatoriæ.

² P. circumvallatæ: p. vallatæ; p. maxillæ; p. truncatæ; p. calyciformes; p. mucosæ; p. lenticulares.

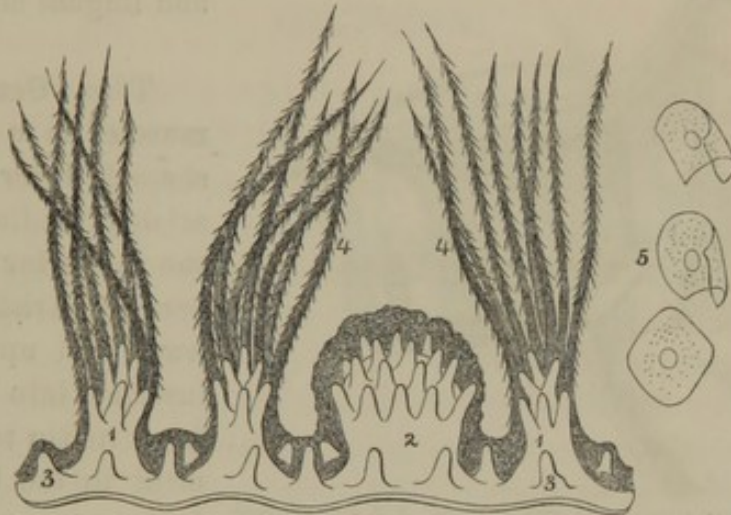
³ P. capitatæ; p. fungiformes; p. clavatæ; p. mediæ; p. semilenticulares.

⁴ P. conicæ; p. minimæ; p. pyramidales; p. villosæ; p. conicæ et filiformes.

⁵ P. filiformes; filla; villi linguæ.

Back of the position of the circumvallate papillæ, corresponding with the floor of the fauces, the tongue is provided with numerous glands, named the **lingual glands**.¹ These are of two kinds: racemose glands, probably secreting mucus; and follicular glands, which have the peculiar

FIG. 203.



PAPILLÆ OF THE TONGUE, highly magnified. 1, conical papillæ; 2, capitate papilla; 3, simple papillæ, occupying the intervals of the compound papillæ; 4, epithelium ascending from the conical papillæ in hair-like processes; 5, isolated epithelial scales from the latter.

constitution of the tonsils, the follicular glands of the palate and pharynx. A group of the lingual glands usually opens into a small pouch² just behind the middle circumvallate papilla. As previously indicated, a number of racemose glands also exist beneath the tongue; and others likewise are found imbedded in the muscular structure of its sides.

MUSCLES OF THE TONGUE.

The muscles of the tongue form the great bulk of the organ. For the most part they are inserted into the fibrous layer of its investing mucous membrane, and, as they approach the latter, their fasciculi form an intricate intertexture, associated with many bundles of **transverse**,³ **longitudinal**,⁴ and **vertical muscular fibres**.⁵ Mingled with these fibres there is a quantity of adipose tissue, which in some measure appears to take the ordinary position of connective tissue.

¹ Glandulæ linguales.

² Foramen cœcum; f. Morgagni.

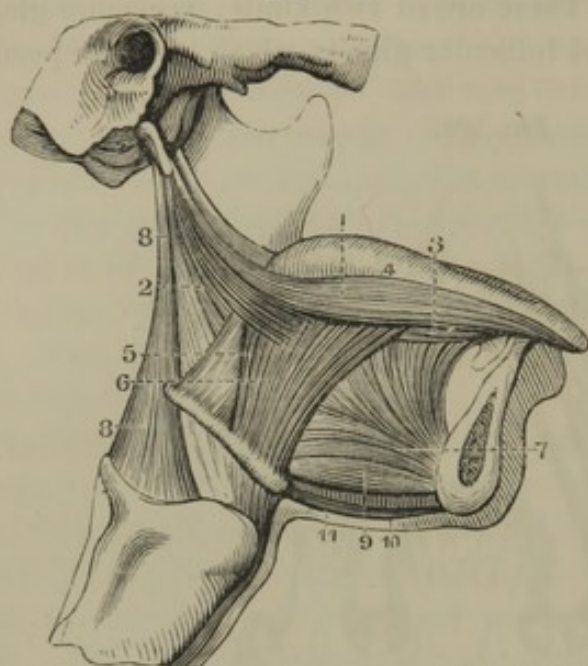
³ Musculus transversus linguæ; musculi transversales.

⁴ M. longitudinalis superior; m. chondroglossus; m. superficialis linguæ; musculi longitudinales.

⁵ Musculi verticales.

The **Hyo-glos'sal muscle**¹ is a quadrilateral plane of fibres arising

FIG. 204.



SIDE VIEW OF THE MUSCLES OF THE TONGUE. 1, 2, stylo-glossal muscle; 3, lingual muscle; 4, upper part of the tongue; 5, 6, hyo-glossal muscle; 7, genio-glossal muscle; 8, stylo-pharyngeal muscle; 9, genio-hyoid muscle; 10, 11, median line of the mylo-hyoid muscles.

from the great horn and body of the hyoid bone, and ascending to expand in the side of the tongue, between the stylo-glossal and lingual muscles.

The **Geni'o-glos'sal muscle**² is a thick, fan-shaped layer of fibres, arising tendinously from the posterior mental tubercle, and radiating backward and upward to be inserted into the tongue from its tip to its attachment to the hyoid bone. It is separated from the muscle of the opposite side by a thin partition of fibrous tissue.

The **Lin'gual muscle**³ is a narrow fasciculus of fibres, situated between the insertion of the hyo-glossal and genio-glossal muscles, and extending from the hyoid bone to the tip of the tongue.

The **Sty'lo-glos'sal muscle**⁴ arises from the extremity of the styloid process of the temporal bone and from the stylo-maxillary ligament, and descends to expand in the side of the tongue externally to the hyo-glossal muscle.

The genio-glossal muscles, when the mouth is open, will protrude the tongue, and the hyo-glossal and lingual muscles will retract it again. The anterior portion of the genio-glossal muscles when alone contracting will draw down the tip of the tongue. The stylo-glossal muscles draw the sides of the tongue upward and backward.

The arteries of the tongue are derived from the lingual branches of

¹ M. hyo-glossus; m. basio-glossus, cerato-glossus, et chondro-glossus; m. hyoideo-glossus; m. hyo-chondro-glossus; m. hypsilo-glossus.

² M. genio-glossus; m. genio-hyo-glossus; m. meso-glossus; m. nonus linguæ.

³ M. lingualis; m. basio-glossus; m. glossianus; m. longitudinalis inferior.

⁴ M. stylo-glossus.

the external carotids. The principal veins are the ranine, which usually join the facial vein on each side of the head. The nerves are the lingual branch of the inferior maxillary, the lingual branches of the glosso-pharyngeal, and the hypoglossal nerve. The former two supply the mucous membrane and papillæ of taste; the latter supplies the muscular structure.

THE TEETH.

Teeth¹ have so close a relationship with the nature of the food and the habits of animals, that they present to the zoologist most important distinctive characters in classification. Three different substances generally enter into their constitution: **cement**, a material resembling bone; **dentine**, a harder material forming the ivory of the tooth; and **enamel**, not only the hardest material of teeth, but the hardest of all organic substances. In the grinding teeth of herbivorous animals, as the horse, ox, and elephant, the three substances alternate with one another in such a manner that, as the teeth are worn, an uneven triturating surface is always preserved. In carnivorous and omnivorous animals, as the cat, dog, and hog, the body of the teeth is composed of dentine, while the crown or exposed part is capped with enamel, and the roots are covered with a thin film of cement.

The teeth are properly appendages of the mucous membrane of the alimentary canal, and are developed from it. They are inserted into a portion of the skeleton so as to give them a firmly-fixed position. In birds and turtles we find their place on the jaws occupied by a corneous bill, which, like nails and hairs, is an appendage of the skin. In granivorous birds, as the common fowl, pebbles swallowed with the food are a substitute for teeth. The gizzard, which is a powerfully muscular stomach with a thick epidermis-like lining, triturates the hard food through the aid of the pebbles.

Man and almost all other mammals, in the course of life, are provided with two sets of teeth, of which the first are the **temporary** or **milk teeth**; the second, the **permanent teeth**. Reptiles and fishes are provided with numerous sets, which succeed one another through life.

The teeth are divided into four kinds, named **inci'sors**, **canines'**, **pre-mo'lars** or **bicus'pids**, and **mo'lars**.

The protruding portion of the teeth is named the **crown** or **body**;² the portion inserted into the alveoli or sockets of the jaws, is the **fang**

¹ Sing.: dens; odous; pl.: dentes; odontes; mordices.

² Corona.

or **root**;¹ and the slightly constricted portion clasped by the gums, is the **neck**.² The crown varies in form in the different kinds of teeth. The fang gradually tapers to its extremity, and is firmly attached to the sides of the alveolus, in which it is inserted, by fibrous tissue continuous with the periosteum of the jaws and the submucous tissue of the gums. At the neck of the tooth a slight accumulation of this tissue constitutes the **dental ligament**.

The teeth have in their interior a small hollow called the **pulp cavity**,³ which has the general form of the teeth, and contains a soft, highly sensitive, and vascular structure named the **pulp**.⁴ This receives its blood-vessels and nerves through a narrow canal⁵ opening at the extremity of the fangs.

The teeth in each jaw form an unbroken arch, which is rarely the case in any of the inferior animals. The upper arch is larger than the lower one, and projects slightly beyond it. This difference is mainly due to the obliquity forward of the upper front teeth, while the corresponding ones below are vertical, and those behind slightly inclined inward. When the jaws are shut, the upper incisors inclose those below, while the succeeding upper teeth alternate with those below; the triturating surfaces of the molars being in contact.

CHARACTERS OF THE PERMANENT TEETH.

The **Permanent teeth**⁶ are thirty-two in number, sixteen in each jaw, or eight on each side of each jaw, as follows: two incisors, one canine, two premolars, and three molars. Occasionally there is a diminution or an increase in the number. When there are supernumerary teeth, they are usually small, and provided with a single fang.

The **Inci'sors**,⁷ eight in number, are the four **front teeth** of each jaw, and are so named from their being adapted to cutting or biting the food. Their crown is wedge-shaped or chisel-like, being convex in front, beveled behind, and triangular at the sides. The cutting edge at first is narrow, and provided with three small tubercles, but these are soon obliterated from use, and the edge gradually widens. The fang is long, conical, and compressed at the sides.

¹ Radix.

² Cervix; collum.

³ Cavitas pulpæ; cavum dentis; antrum dentale.

⁴ Pulpa; blastema dentis.

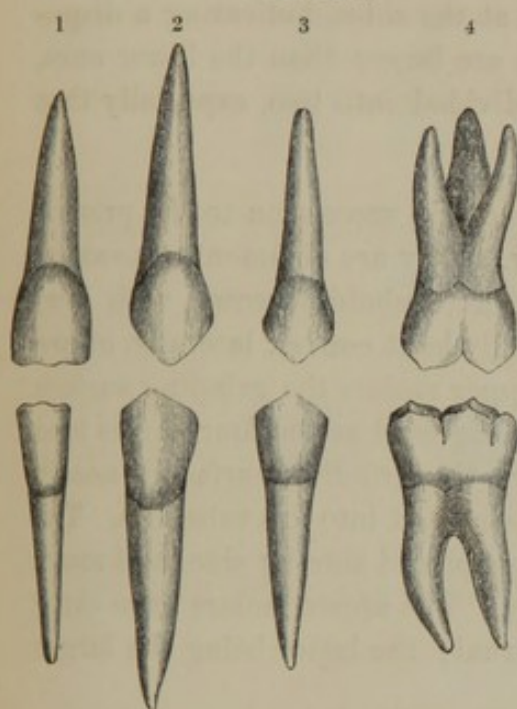
⁵ Canalis radialis, or dentalis.

⁶ Second teeth; last teeth; dentes permanentes; d. serotini.

⁷ Incisive teeth; dentes incisivi, or incisores; d. primores; d. tomici, rasoires, gelasini, ctenes, or dichasteres.

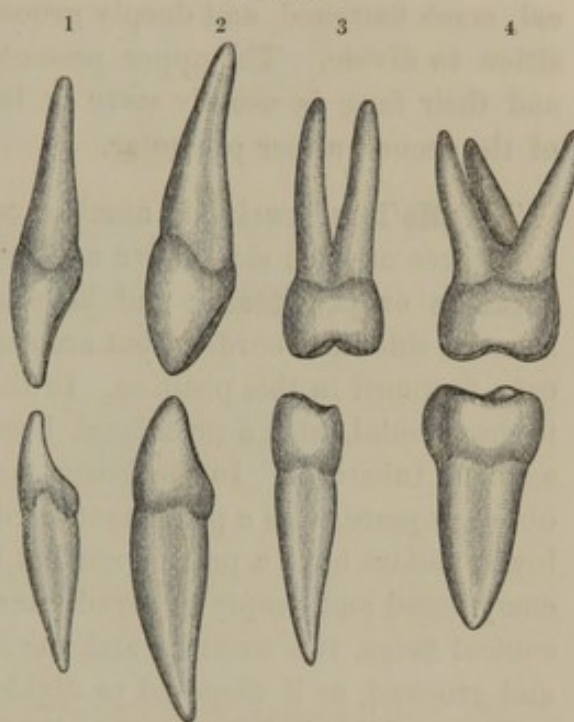
The upper incisors are larger than the lower ones, and of the former the central incisors¹ are the larger, while the lateral ones are the larger in the case of the lower incisors. The upper incisors are directed downward and forward, while the lower ones occupy a vertical position.

FIG. 205.



UPPER AND LOWER PERMANENT TEETH, EXTERIOR VIEW. 1, first incisors; 2, canines; 3, first premolars; 4, middle molars.

FIG. 206.



LATERAL VIEW of the same teeth, as in the preceding figure.

The **Canine' teeth**,² four in number, are larger than the incisors, and succeed them in position, one on each side above and below. Their crown is blunt, conical, beveled behind, and becomes more blunt from attrition. Their fang is conical, compressed at the sides, and longer than in any of the other teeth. It is also marked laterally by a slight furrow, as if indicating a disposition to divide into two.

The upper canines, commonly called **eye teeth**, are larger and longer than the lower ones, which are commonly known as the **stomach teeth**.

In carnivorous animals the canine teeth are remarkable for their length and strength, and are admirably adapted to seizing, retaining, and tearing living prey. From their conspicuous character in the canine or dog tribe they have received their name.

The **Premo'lars**, or **bicus'pid teeth**,³ eight in number, succeed the ca-

¹ Butter teeth.

² Cuspid teeth; dentes cuspidati; canini; angulares, or laniarii; d. columel-

lares; oculares, or mordentes; cynodontes; pug teeth.

³ Small molars; dentes bicuspidati; d. buccales.

nines in position, two on each side above and below. Their crown is cubical with rounded borders, prominently convex externally and internally, and less so or flattened at the sides. The triturating surface has a prominent border elevated before and behind into a pair of tubercles, of which the outer one is the larger and higher. The fang is conical, much flattened, and deeply grooved at the sides, indicating a disposition to divide. The upper premolars are larger than the lower ones, and their fang is usually more or less divided into two, especially that of the second upper premolar.

The **Mo'lars**,¹ twelve in number, are next in succession to the premolars, three on each side above and below. They are commonly known as **grinders** or **jaw teeth**; and have a large, cuboidal crown, with low, rounded sides and borders, but are generally least convex laterally, or are even flattened in this position. In the upper molars the grinding surface is rhomboidal, with a prominent border, elevated at the four angles into as many tubercles. In the lower molars, the grinding surface is nearly oblong square, with a prominent border elevated into five tubercles. The lower molars have a pair of conical fangs placed side by side, and much compressed and deeply grooved laterally. The upper molars have three conical fangs, two external and one internal; the latter being the larger and grooved, as if disposed to divide.

The molars slightly decrease in size from first to last, and the lower ones are larger than the upper ones. The last of the series, from its comparatively late appearance in life, is named the **wisdom tooth**.² It is liable to considerable variation in size and form, more especially in the case of the upper one. Its fangs are usually more or less confluent into a single cone.

CHARACTERS OF THE TEMPORARY TEETH.

The **Temporary** or **milk teeth**³ are twenty in number, ten in each jaw, or five on each side of each jaw, as follows: two incisors, one canine, and two molars.

The incisors and canines correspond in number with those of the permanent set, which they also resemble in form; but they are smaller, and the crowns are broader in proportion to their length.

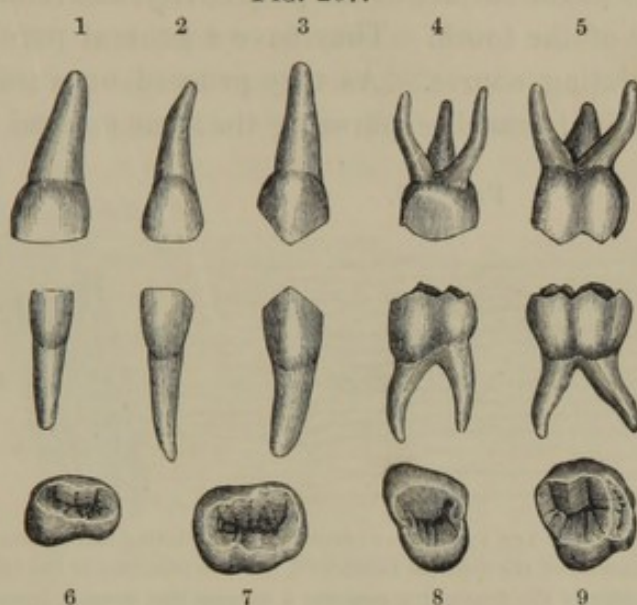
¹ Dentes molares; large molars; true molars; dentes multicuspidati; d. maxillares, clavales, or gomphii; molæ; mylodontes; mylacri; momisci; cheek teeth; axle teeth; wall teeth; log teeth; grinding teeth.

² Dens sapientiæ; d. serotinus; d. sophroreticus; d. sophronista; wit tooth; last tooth.

³ Dentes lactei; d. caduci; d. temporarii; deciduous teeth; primary, or shedding teeth.

No premolars belong to the temporary set of teeth. The molars are eight in number, succeeding the canines in position, two on each side above and below.

FIG. 207.



TEMPORARY TEETH OF ONE SIDE. 1, 2, upper and lower incisors; 3, upper and lower canine; 4, 5, upper and lower molars; 6, 7, triturating surface of the lower molars; 8, 9, triturating surface of the upper molars.

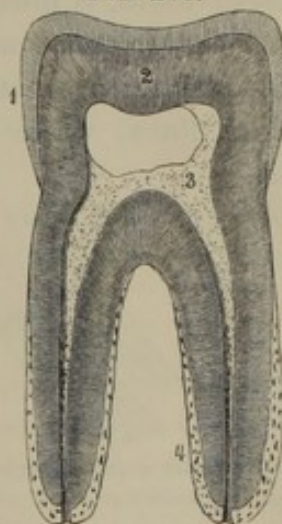
STRUCTURE OF THE TEETH.

On splitting a tooth longitudinally, the exposed surface exhibits, besides the pulp cavity, three different substances. The greater portion of the tooth appears to be composed of a yellowish-white substance, which is called **dent'ine**; the crown is capped with a harder and whiter layer, named the **enam'el**; and a thin, translucent investment to the fang is the **cement'**.

The **Dent'ine**, or **ivory**,¹ forms the principal bulk of the tooth, giving to it the general shape, and containing the pulp cavity. It is yellowish-white, and has the appearance of dense bone, which it further resembles in chemical composition. It consists of about twenty-eight parts of bone cartilage and seventy-two parts of earthy matters; mostly phosphate of lime, with a little carbonate of lime.

In thin section, beneath the microscope, the

FIG. 208.



VERTICAL SECTION OF A MOLAR TOOTH, moderately magnified. 1, enamel, the lines of which indicate the arrangement of its columns; 2, dentine, the lines indicating the course of its tubules; 3, thin lamina of the dentine forming the wall of the pulp cavity, the dots indicating the orifices of the dentinal tubules; 4, cement.

¹ Ebur; substantia ossea, or eburnea; tooth bone; proper tooth substance; osseous substance.

dentine is found to be composed of a translucent, amorphous substance, pervaded with a multitude of fine canals, possessing distinct walls from the intervening material. The canals, named **dent'inal tu'bules**,¹ commence with open orifices at the surface of the pulp cavity, and radiate from thence to the periphery of the tooth. They have a general parallel and gently waving or undulating course. As they proceed outwardly, they divide into several principal branches, pursuing the same general parallel course

FIG. 209.

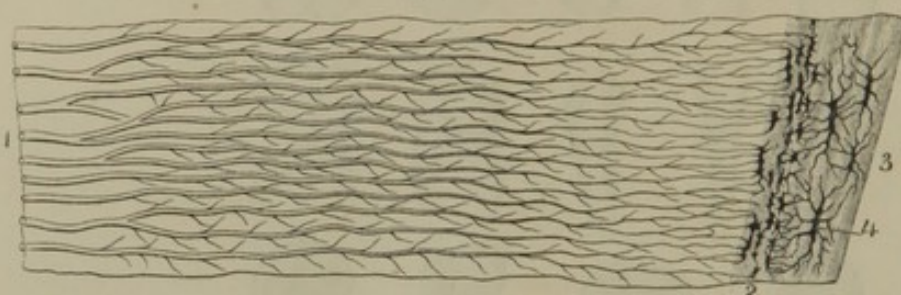


Fig. 209. VERTICAL SECTION OF THE FANG OF A CANINE TOOTH, exhibiting the structure of the dentine and cement. 1, inner extremities of the dentinal tubules; 2, outer extremities of the tubules, terminating in interspaces at the boundary of the dentine; 3, cement; 4, lacunæ like those of bone. Highly magnified.

FIG. 210.

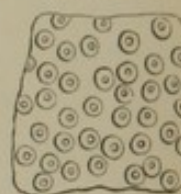
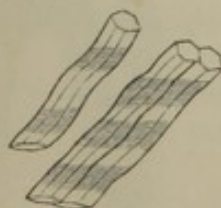

Fig. 210. SECTION OF DENTINE, cutting across the direction of its tubules, very much magnified. The tubules are seen to have thick walls, distinct from the intervening material.

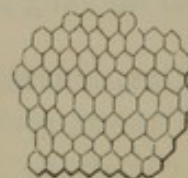
to one another. They also gradually become narrower, and give off innumerable, fine, divergent branches, which anastomose with one another. The walls of the tubules are nearly as thick as their calibre, which, in the fresh tooth, is filled with a colorless liquid, replaced by air in dried specimens. In consequence of the latter condition, the dried microscopic sections of teeth, when viewed by transmitted light, appear pervaded by black lines; while by reflected light, the same lines appear silvery white.

FIG. 211.



THREE ENAMEL COLUMNS, highly magnified; exhibiting the six-sided prismatic and waving character.

FIG. 212.



SECTION OF ENAMEL, highly magnified, at right angles to the course of its columns; exhibiting the six-sided character of the latter.

The **Enam'el**² is the glistening-white or bluish-white substance investing the crowns of the teeth. It is thickest on the triturating surface, and gradually diminishes toward the neck, where it terminates by a

¹ Canaliculi dentium.

s. filamentosa; cortex; c. striata; crusta

² Substantia vitrea; s. adamantina;

adamantina; nitor dentium.

sharply defined edge. As previously mentioned, enamel is not only the hardest of all the dental structures, but it is the hardest of all organized substances. In chemical composition it consists of only five parts of bone cartilage, with ninety-five parts of earthy matters, mostly phosphate of lime.

Viewed with the microscope, enamel is found to consist of solid, hexahedral columns, resting with one extremity on the dentine of the crown, and with the other extremity free. The columns are not straight, but undulating in their course; and at the sides they present a faint, transversely striated appearance.

The arrangement of the enamel columns is the most favorable that could have been adopted to prevent their detachment and rapid abrasion; though this arrangement, together with the great deficiency of bone cartilage, renders the enamel brittle, and, under extremes of temperature, to which it is often subjected in the use of hot and cold food, it is liable to crack.

The exterior surface of the unworn enamel, when treated with hydrochloric acid, so as to remove its calcareous salts, separates in the form of a thin, homogeneous membrane,¹ which, though it is intimately blended with the exterior ends of the enamel columns, appears to be an independent structure.

The **Cement**² is a very thin layer of osseous substance investing the fangs of the teeth, commencing at the neck, and gradually becoming thicker to the extremities of the fangs. In the latter position, in the teeth of old persons, it frequently becomes much increased in thickness, and sometimes forms a nodular mass. Like true bone, the cement contains branching lacunæ, but vascular canals pervade it only when it becomes much thickened.

The teeth, like the epithelium of a mucous membrane, are entirely non-vascular, and their fluids are obtained by imbibition from the dental pulp and the periosteum of the fangs.

The **Dent'al pulp**³ is a soft, translucent, reddish-white substance, filling the pulp cavity of the teeth. It is composed of an exterior layer of nucleated cells, with an interior mass of indistinctly defined areolar tissue, mingled with many nuclei, and containing an abundant colorless liquid. Highly sentient and vascular, its nerves and blood-vessels, entering the fine aperture at the ends of the fangs, are derived from the dental nerves of the trifacial, and the dental arteries of the internal maxillary artery.

¹ Nasmyth's membrane; cuticle of the enamel; skin of the teeth.

crusta petrosa; cortical substance; substantia ostoidea.

² Cementum; crusta ostoides radialis;

³ Pulpa dentis.

DEVELOPMENT OF THE TEETH.

The temporary teeth commence their development from the sixth to the tenth month of embryonic life, originating in a corresponding number of papillæ from the bottom of the **dental groove**,¹ which is a semi-circular inflection of the mucous membrane at the margin of the gums. Processes² from the dental groove gradually inclose the papillæ in separate compartments, which contract in the course of the fourth month, and include the papillæ in distinct cavities, named the **dental sacs**. The

FIG. 213.

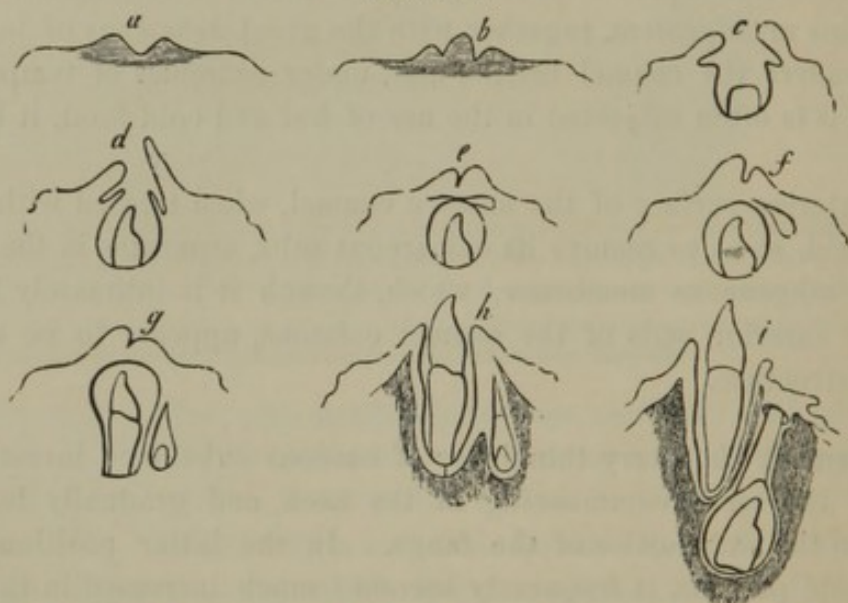


DIAGRAM OF THE MODE OF DEVELOPMENT OF THE TEETH. *a*, section across the dental groove; *b*, papilla developed in the latter; *c*, the groove deepened and processes forming which ultimately close it; *d*, the groove becoming closed; *e*, dental sac containing a dental pulp, which is the rudiment of the crown of a temporary incisor; the cavity above is reserved for a permanent incisor; *f*, the crown of the temporary incisor fully formed, and the reserved cavity for the permanent tooth moving backward; *g*, fang of the temporary incisor produced, and origin of the dental papilla of the future permanent tooth; *h*, eruption of the temporary incisor, and the alveoli produced for both teeth; *i*, the temporary incisor occupying its functional position, and the crown of the permanent incisor developed.

papillæ, now called **dental pulps**, gradually assume the form and size of the crowns of the future teeth, and are defined by a delicate basement membrane.³ The enlarging dental sacs, closely applied to the included pulps, also undergo a change in structure; and they are supplied with blood-vessels from the dental arteries as well as from those of the gums.

From the fifth to the eighth month of fœtal life the dental pulps commence transformation into dentine by the deposit of calcareous salts. This transformation begins at the summit of the pulps and proceeds toward their base, and from without inwardly.

¹ Primitive dental groove.² Opercula.³ Membrana præformativa.

While this process is going on, the thick internal layer of the dental sacs, named the **enamel organ**,¹ undergoes transformation into enamel, from within outwardly.

The crown of the tooth being produced, the dental pulp now grows in length, and as it gradually develops the shape of the future fang, it is transformed into dentine, from without inwardly, and from the base toward the end of the fang.

The lengthening of the fang occasions the **eruption** or so-called **cutting of the teeth**,² in which process the latter burst their sacs and protrude from the gums.

The **eruption of the temporary teeth**³ occurs after birth, during the period between six months and two and a half years; usually in the following order, the lower teeth generally taking precedence of the upper ones :—

- The central incisors from the sixth to the eighth month;
- The lateral incisors from the seventh to the ninth month;
- The first molars from the twelfth to the fourteenth month;
- The canines from the sixteenth to the twentieth month;
- The last molars from the twentieth to the thirtieth month.

During the fourth and fifth months of foetal life, in the progress of development of the dental sacs of the temporary teeth, a corresponding number of cavities⁴ are developed in the **dental groove**⁵ over them. These **reserved cavities** subsequently become the dental sacs of permanent teeth; those of the upper jaw receding behind and above the position of the temporary teeth; those of the lower jaw receding behind and below the temporary teeth. The dental sacs just indicated are finally inclosed in osseous cavities of the jaws, communicating by canals⁶ with the margin of the latter. The canals contain a narrow pedicle,⁷ which is the closed and elongated neck of the dental sacs continuous with the gum behind the corresponding temporary teeth.

The three permanent molar teeth on each side, above and below, originate in succession from the posterior extremity of the dental groove.

The permanent teeth are developed from their dental sacs and pulps in the same manner exactly as the temporary teeth. Calcification commences in the different ones from a period prior to birth up to the twelfth year subsequently.

At six years, when the temporary teeth are usually still preserved, the

¹ Organon adamantinæ.

² Teething; dentition; odontophyia.

³ First dentition; odontia dentitionis lactantium.

⁴ Cavities of reserve.

⁵ Secondary dental groove

⁶ Itinera dentium.

⁷ Gubernaculum dentis.

jaws contain besides, the crowns of all the permanent teeth except the last molars or wisdom teeth. The subsequent development of the fangs of the permanent teeth causes a gradual advancement of their crowns toward the gums. Those which come into contact with and press against the temporary teeth excite a gradual absorption of the fangs of the latter. Continuing to advance, the permanent teeth detach the loosened crowns of the temporary set, and protrude from the gums in their place.

The **eruption of the permanent teeth**¹ and the shedding of the temporary set commences between the fifth and seventh years after birth. The first permanent molars usually protrude before any of the temporary teeth are shed, and it is perhaps partly due to this circumstance that these teeth are usually the first to undergo decay. The course of eruption of the permanent teeth is commonly as follows, the lower ones preceding the upper:—

- The first molars from the fifth to the seventh year ;
- The central incisors from the sixth to the eighth year ;
- The lateral incisors from the seventh to the ninth year ;
- The first premolars from the eighth to the tenth year ;
- The second premolars from the tenth to the twelfth year ;
- The canines from the eleventh to the twelfth year ;
- The second molars from the twelfth to the fourteenth year ;
- The last molars or wisdom teeth from the seventeenth to the twenty-second year.

THE PHARYNX.

The **Pha'rynx**² or **throat** is the funnel-like cavity occupying the guttural region of the skull, and extending from its base down to a level with the fifth cervical vertebra, where it terminates in the œsophagus. Behind it is the vertebral column, and on each side the great blood-vessels and nerves of the neck. Communicating with it in front, in succession from above downward, are the nasal fossæ, the mouth, and the larynx; and opening into it on each side of the nasal fossæ is the Eustachian tube. Its upper extremity is attached to the basilar process of the occipital bone; and on each side it is attached in succession to the petrous portion of the temporal bone, the internal pterygoid process, the pterygo-maxillary ligament, the back part of the molar ridge of the lower jaw, the root of the tongue, the hyoid bone, and the larynx. With the surrounding parts it is connected by areolar tissue.

¹ Second dentition; odontia dentitionis puerilis; dedentition.

² Pharus; pharyngethros; fauces; gula; isthmus; læmos; ingluvies; gurgus; os posterum; principium gulæ; communis æris et nutrimentorum via.

The walls of the pharynx are musculo-membranous. Exteriously it is provided with a thin, fibrous investment, which at its attachment to the base of the skull assumes a stronger and more aponeurotic character. Within this structure succeeds a moderately thick, muscular layer, separable into five pairs of distinct muscles, presently to be described.

The lining mucous membrane of the pharynx is soft and red, and is connected with the muscular layer by a strong submucous tissue containing many glands. As low down as the floor of the nose the mucous membrane is furnished with a columnar ciliated epithelium, but in the lower portion of the pharynx it resembles that of the mouth, being furnished with minute papillæ imbedded in a squamous epithelium.

The **pharyn'geal glands** are of the racemose and follicular kind; the latter variety being simple and compound, having the peculiar constitution of the tonsils and follicular glands of the palate and tongue.

The blood-vessels of the pharynx are derived from the pharyngeal, inferior palatine, and thyroid arteries. The nerves are supplied from the glosso-pharyngeal, pneumo-gastric, and sympathetic system.

MUSCLES OF THE PHARYNX.

The **Pal'ato-pharyn'geal muscle**¹ originates in the soft palate, and descends within the posterior half arch of the palate to be inserted, in conjunction with the succeeding muscle, into the side of the pharynx and the upper part of the thyroid cartilage.

The **Sty'lo-pharyn'geal muscle**² arises from near the root of the styloid process of the temporal bone, and descends between the superior and middle constrictors of the pharynx, to expand upon the mucous membrane of the latter, and partially to be inserted into the upper part of the thyroid cartilage.

The **Superior Constrict'or of the Pharynx**³ is a thin, quadrilateral muscle arising from the pterygo-maxillary ligament and the lower half of the internal pterygoid process. Proceeding backward, it conjoins the muscle of the opposite side, and is prolonged to be attached to the basilar process of the occipital bone.

¹ M. palato-pharyngeus; m. pharyngo-staphylinus; m. staphylino-pharyngeus; m. thyro-pharyngo-staphylinus; m. hy-petro-pharyngeus in part.

² M. stylo-pharyngeus; m. stylo-thy-ro-pharyngeus.

³ M. constrictor pharyngeus superior; m. cephalo-pharyngeus; m. glosso-pharyngeus; m. mylo-pharyngeus; m. pterygo-pharyngeus; m. pterygo-syndesmo-staphili-pharyngeus.

The **Middle Constrictor of the Pharynx**¹ is a fan-shaped muscle, arising from the great and small horns of the hyoid bone, from whence it radiates to conjoin the muscle of the opposite side in the posterior median line of the pharynx.

The lower fibres of the muscle are concealed by the inferior constrictor; the middle ones are nearly horizontal; and the upper ones overlap the superior constrictor.

FIG. 214.

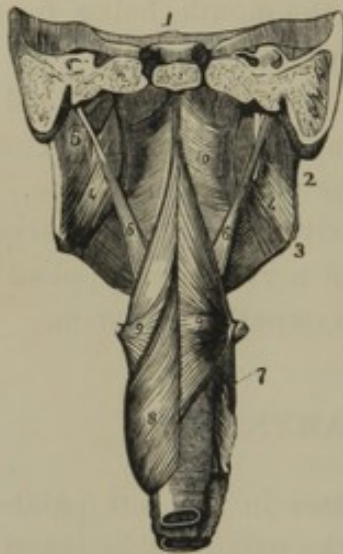


Fig. 214. POSTERIOR VIEW OF THE MUSCLES OF THE PHARYNX. 1, vertical section, transversely, of the base of the skull, just in advance of the cervical vertebræ; 2, 3, posterior border and angle of the lower jaw; 4, internal pterygoid muscle; 5, styloid process giving attachment to 6, the stylo-pharyngeal muscle; 7, larynx; 8, inferior constrictor of the pharynx; 9, middle constrictor; 10, superior constrictor.

FIG. 215

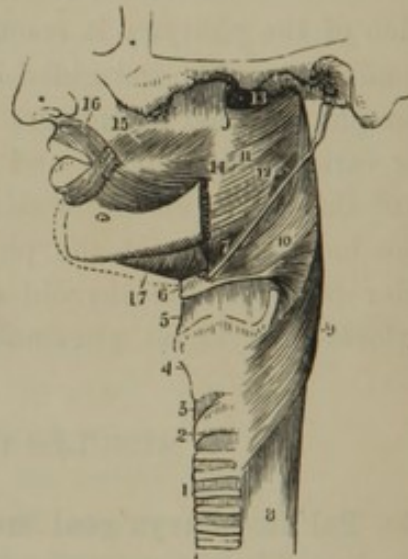


Fig. 215. SIDE VIEW OF THE MUSCLES OF THE PHARYNX. 1, trachea; 2, cricoid cartilage; 3, vocal membrane; 6, hyoid bone; 7, stylo-hyoid ligament; 8, œsophagus; 9, inferior constrictor of the pharynx; 10, middle constrictor; 11, superior constrictor; 12, portion of the stylo-pharyngeal muscle observed passing into the interval between the superior and middle constrictors; 13, upper extremity of the pharynx; 14, pterygo-maxillary ligament; 15, buccinator muscle; 16, oral orbicular muscle; 17, mylo-hyoid muscle.

The **Inferior Constrictor of the Pharynx**² arises from the upper one or two rings of the trachea, the side of the cricoid cartilage, and an oblique line of the thyroid cartilage. From this origin it curves backward, expanding in its course, and conjoins the muscle of the opposite side in the posterior median line of the pharynx.

The inferior fibres of the muscle are horizontal, and inclose the commencement of the œsophagus; and the upper fibres ascend, gradually

¹ M. constrictor pharyngeus medius; m. hyo-pharyngeus; m. cerato-pharyngeus; m. chondro-pharyngeus; m. syndesmo-pharyngeus; m. hyo-glosso-basi-pharyngeus.

² M. constrictor pharyngeus inferior; m. laryngo-pharyngeus; m. thyro- et crico-pharyngeus; m. crico-thyro-pharyngeus.

increasing in obliquity, and overlap the lower part of the middle constrictor.

The muscles of the soft palate, fauces, and pharynx, together with those of the tongue and the elevators of the hyoid bone and larynx, are concerned in the action of deglutition, or swallowing.

The genio-glossal muscles, drawing the tongue forward and upward, press the food against the hard palate, and from thence into the fauces. The stylo-glossal muscles now contract, narrowing the entrance of the fauces; and the stylo-glossal muscles draw the tongue backward and upward. The soft palate is drawn upward and backward, and made tense by the action of its elevators and tensors. At the same time, the palatopharyngeal muscles cause the posterior half arches of the palate to approach each other, leaving only a small interval, which is closed by the uvula, and thus the communication of the pharynx with the nasal cavities is cut off. The pharynx and larynx are drawn up by the stylopharyngeal, stylo-hyoid, digastric, genio-hyoid, and mylo-hyoid muscles, through which action the former cavity is widened, and the latter is closed by pressure against the epiglottis. The food received into the pharynx is passed downward into the œsophagus by the action of its constrictors,¹ after which the parts resume their ordinary position.

THE ŒSOPHAGUS.

The *Oesoph'agus* or *gullet*² is a musculo-membranous tube descending from the pharynx in a slightly flexuose course through the neck and posterior mediastinal cavity to the stomach. It commences on a level with the fifth cervical vertebra and the cricoid cartilage of the larynx, proceeds downward in contact with the vertebral column, and opposite the ninth dorsal vertebra passes through the œsophageal orifice of the diaphragm. In the neck, the trachea is in front, and the primitive carotid artery on each side of it; in the thorax, the pericardium is in front, the descending aorta to its left, and the azygos vein to its right.

The œsophagus is about nine inches long, and rather less than an inch in diameter. It is narrowest at its commencement, gradually widens in its descent, but is slightly constricted as it passes through the diaphragm, after which it quickly expands into the stomach. In the state of rest it is flattened from before backward; but when distended, is cylindroid in shape.

¹ *Musculus sphincter gulæ.*

² *Gula; fistula cibalis; f. ventriculi; infundibulum ventriculi; via stomachi et ventris; gluttus.*

The œsophagus is provided externally with a thin, fibrous investment, inclosing the œsophageal plexus of nerves, and adhering to the contiguous parts. Succeeding this investment is the **muscular coat**,¹ which is about three-fourths of a line thick, and composed of two layers. The external layer consists of longitudinal fibres, which originate in three fasciculi from the cricoid cartilage and inferior constrictors of the pharynx, and surround the œsophagus uniformly to the stomach. The internal layer, thinner than the other, consists of transverse or circular fibres, continuous with the inferior constrictors of the pharynx, and extending to the stomach.

In the upper part of the œsophagus the muscular coat is exclusively composed of striated fibres, but in its descent unstriated fibres become mingled with the latter, and finally predominate.

The mucous membrane lining the œsophagus is much paler than in the pharynx or mouth, though it has the same structure, being provided with minute papillæ and a squamous epithelium which completely conceals the latter. When the œsophagus is at rest, the mucous membrane is thrown into slight longitudinal folds, which disappear in the distended condition of the organ. Beneath the mucous membrane is a moderately thick layer of sub-mucous tissue, connecting it to the muscular coat, and containing some small, scattered, racemose glands, named from their position the **œsophage'al glands**.²

The blood-vessels of the œsophagus are derived from the inferior thyroid and œsophageal arteries. The nerves are supplied by the pneumo-gastrics and the sympathetics.

THE CAVITY OF THE ABDOMEN.

The **Cavity of the Abdomen, or of the belly**,³ the most extensive space of the body, is occupied by the greater portion of the alimentary and uro-genital apparatus. It is lined with an extensive serous membrane, the **peritoneum**, which, from its relationship with the many viscera it invests, is very complex in its arrangement.

The viscera of the abdominal cavity leave no unoccupied vacuity or space filled with air; they follow the movements of the muscular walls of the abdomen; and the enlargement or decrease of any one results in the displacement of those around.

In consequence of the great extent of the abdomen, and the frequent necessity of referring to the relative position of the organs which occupy the different parts of its cavity, it is artificially divided into regions,

¹ Tunica vaginalis gulæ.

² Glandulæ œsophageales.

³ Cavum abdominis.

indicated by lines drawn on the abdominal walls. Transverse lines encircling the body, one at the lower margin of the thorax, the other at the hips or crest of the ilium on each side, divide the abdomen into three zones. A vertical plane, ascending on each side from the anterior inferior spinous process of the ilium, will divide each zone into three parts, and in this manner nine regions will be defined.

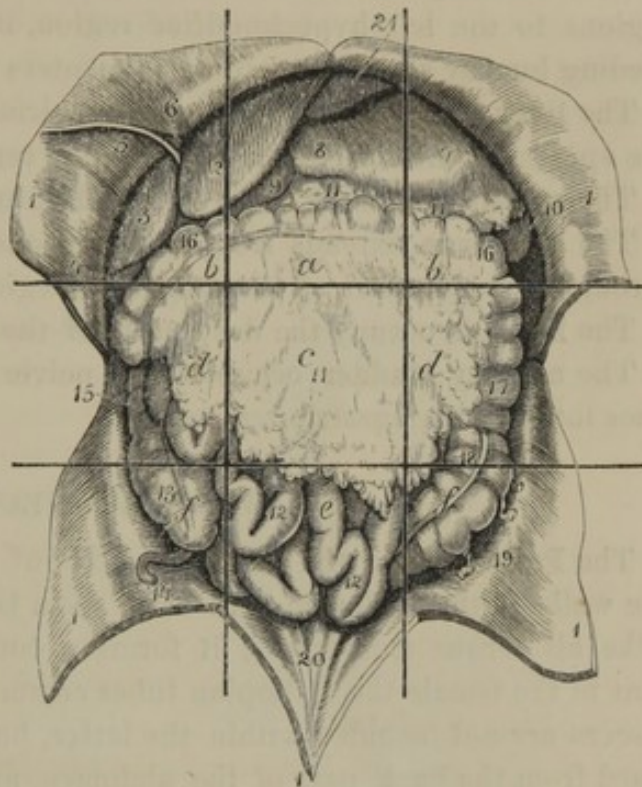
Of the middle regions, the upper one is the **epigas'tric region**;¹ the succeeding one, the **umbil'ic-al region**;² and the lowest, the **hypogas'tric region**.³ Of the lateral regions, the upper pair are the **right and left hypochon'driac regions**;⁴ those succeeding, the **lum'bar regions**;⁵ and the lowest, the **il'iac regions**.⁶

The different organs occupying these regions are as follows:—

The **stomach** occupies the left hypochondriac, epigastric, and a small part of the right hypochondriac regions. In a distended condition, with the small intestine empty, it encroaches on the umbilical region.

The **small intestine** forms a convoluted mass, occupying the umbilical region and the contiguous borders of the surrounding regions. When

FIG. 216.



CAVITY OF THE ABDOMEN LAID OPEN, WITH THE VISCERA RETAINED IN THEIR RELATIVE POSITION. The straight lines indicate the regions of the abdomen. *a*, epigastric region; *b*, hypochondriac regions; *c*, umbilical region; *d*, lumbar regions; *e*, hypogastric region; *f*, iliac regions. 1, flaps of the abdominal wall turned aside; 2, 3, left and right lobes of the liver; 4, fundus of the gall-bladder; 5, round ligament of the liver; 6, part of the suspensory ligament of the liver; 7, 8, stomach; 9, commencement of the duodenum; 10, spleen; 11, great omentum; 12, small intestine; 13, cæcum; 14, vermiform appendix; 15, ascending colon; 16, transverse colon; 17, descending colon; 18, sigmoid flexure; 19, epiploic appendages; 20, ridges indicating the course of the remains of the urachus and umbilical arteries; 21, diaphragm.

¹ Regio epigastrica; *r. cardiaca*; *r. stomachica*; epigastrium.

² *R. umbilicalis*; *r. mesogastrica*; *r. gastrica*; mesogastrium.

³ *R. hypogastrica*; *r. pubis*; hypogastrium; rumen; venter parvus, or imus.

⁴ *Regiones hypochondriacæ*; *r. subcartilagineæ*; hypochondria.

⁵ *R. lumbares*, or *lumbales*; *lumbi*; *lendis*; *psoæ*; *loins*; *flanks*; *reins*; *lappara*.

⁶ *R. iliacæ*; *inania*; *flanks*.

the viscera of the pelvis are empty, a portion of the small intestine descends into that cavity.

The **large intestine**, commencing in the right iliac region, ascends through the corresponding lumbar into the right hypochondriac region. Thence crossing through the boundary of the epigastric and umbilical regions to the left hypochondriac region, it descends through the succeeding lumbar and iliac regions, and enters the pelvis at its back part.

The **liver** occupies the right hypochondriac region, and extends across the epigastric into the left hypochondriac region.

The **spleen** is situated deeply in the left hypochondriac region.

The **pancreas** extends from one hypochondriac region to the other, through the deep part of the epigastric region.

The **kidneys** occupy the deep parts of the lumbar regions or loins.

The **urinary bladder** occupies the pelvic cavity, but when distended rises into the hypogastric region.

THE PERITONEUM.

The **Peritone'um**,¹ the most extensive of all serous membranes, lines the walls of the abdomen, and from them is reflected upon the viscera. Like all serous membranes, it forms a completely closed sac, except that in the female the Fallopian tubes communicate with its cavity. The viscera are not included within the latter, but are, as it were, thrust forward from the back part of the abdomen, and inclosed by inflections of the peritoneum projecting into its own cavity. It is to these numerous inflections inclosing the viscera that the peritoneum owes the complexity of its arrangement. That portion of the membrane investing the viscera is named the **vis'ceral peritone'um**,² and that lining the abdominal walls is the **parie'tal peritone'um**;³ and both portions on the interior of the peritoneal cavity are in close contact with each other. Their opposed surfaces are smooth and shining, and are bathed with a serous liquid, which give the organs they invest a slippery feeling, and adapts them favorably to move on one another. The attached surface of the peritoneum adheres closely to the contiguous parts by thin, connective tissue.⁴ Its numerous doublings or folds,⁵ associated by connective tissue, often

¹ Peritonæum; membrana abdominis; velamentum abdominale; tunica prætensa; operimentum prætensum; pagos; syphar; zepach.

² P. viscerale, or intestinale.

³ P. parietale.

⁴ Textus cellulosus subperitonealis, or subserosus; lamina externa peritonei;

subperitoneal membrane; retro-peritoneal membrane.

⁵ Omenta; epiploones, ligaments, and mesenteries. Sing.: omentum; epiploon; rete; reticulum; dertron; gangamum; zirbus; operimentum intestinorum; sacculus epiploicus; sagena; caul.

containing much fat, inclose and sustain the position of the viscera, and likewise include the blood-vessels, lymphatics, and nerves passing to and from the latter.

In tracing the reflections of the peritoneum from the abdominal walls, and from one organ to another, in any direction, its complete continuity will be discovered. Thus the peritoneum, in ascending from the front and sides of the abdominal parietes, invests the diaphragm, and is thence reflected to the liver, producing three folds, named the **suspensory** and **lateral ligaments of the liver**. After inclosing the liver, it is reflected as a doubling, the **gas'tro-hepat'ic omen'tum**, from the transverse fissure of the liver to the small curvature of the stomach. Enveloping the latter, the peritoneum then passes from its great curvature, and makes a quadruple fold, named the **great omen'tum**. This is suspended as a broad, apron-like process in front of the intestines, and has its posterior division above, inclosing the transverse colon. Passing thence to the back of the abdomen, the doubling named the **transverse mesoco'lon** is produced. Of the two layers of this doubling, the upper one proceeds to the back of the liver, there forming the posterior part of its lateral ligaments. The other layer of the transverse mesocolon descends, and, passing off laterally, incloses the colon on each side and forms the **ascending** and **descending mesoco'lon**. The peritoneum, from the intervening portions of the mesocolon reflected forward from the vertebral column to the small intestine, forms the extensive fold named the **mes'en'tery**. From the root of the latter the peritoneum descends to the rectum, and, binding this to the posterior part of the pelvis, forms the **mesorec'tum**. The peritoneum is then reflected from the rectum to the bladder, or in the female to the uterus, and

FIG. 217.

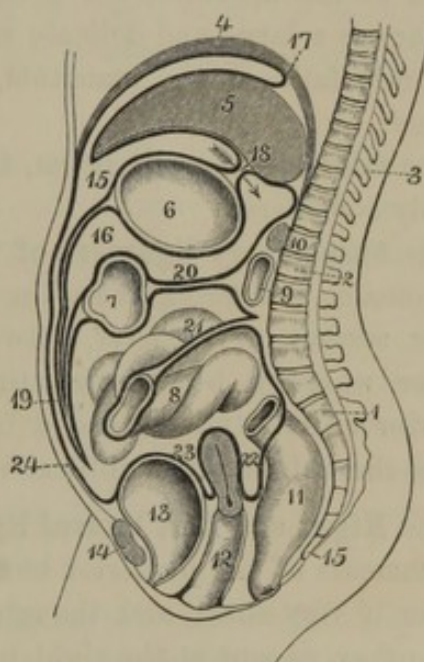


DIAGRAM OF THE REFLECTIONS OF THE PERITONEUM IN A VERTICAL SECTION OF THE ABDOMEN, the peritoneum represented by the thick, black line. 1, upper segment of the sacrum; 2, first lumbar vertebra; 3, dorsal vertebrae; 4, diaphragm; 5, liver; 6, stomach; 7, transverse colon; 8, small intestine; 9, duodenum; 10, pancreas; 11, rectum; 12, vagina and uterus; 13, urinary bladder; 14, pubis; 15, greater cavity of the peritoneum; 16, lesser cavity; 17, section of a lateral ligament of the liver; 18, gastro-hepatic omentum: the arrow indicates the communication, at the right border of the latter, of the great and lesser cavities of the peritoneum; 19, great omentum; 20, transverse mesocolon; 21, mesentery; 22, recto-uterine pouch; 23, vesico-uterine pouch; 24, portion of peritoneum lining the anterior wall of the abdomen.

thence to the bladder, and from this it ascends to the anterior wall of the abdomen.

In figure 217, representing the course of the reflections of the peritoneum, it would appear as if the latter formed a small cavity¹ behind the stomach, distinct from the greater peritoneal cavity. This is, however, not the case, as the two communicate by an aperture, named the **foramen of Winslow**,² behind the right border of the gastro-hepatic omentum. A finger passed through this opening, and downward between the stomach and colon, gains access to the space between the two divisions of the great omentum, or if in the new-born child a blow-pipe be introduced at the aperture, the great omentum may be inflated, and then appears as a large and delicate sacculated vesicle. The experiment subsequently fails, as the omentum, in the progress of life, becomes perforated.

The folds of the peritoneum, from their importance, may now be separately considered.

The **Suspen'sory ligament of the liver**³ is a falciform doubling of the peritoneum, extending from the median line of the diaphragm to the upper surface of the liver, between its anterior notch and its posterior border, where it becomes continuous with the lateral ligaments. Its anterior extremity is extended from the liver to the umbilicus, and incloses the obliterated umbilical vein.

The **Right and Left lateral ligaments**⁴ of the liver are the peritoneal attachments of the posterior border of the liver to the diaphragm. The former is very short, and though of two layers, these are remote from each other, except at the right border of the liver. The other is longer, and suspends the left lobe of the liver loosely.

The **Suspen'sory ligament of the spleen**⁵ is a doubling of peritoneum passing from the diaphragm to the upper part of the spleen; and it is continuous with the left lateral ligament of the liver.

The **Gas'tro-hepat'ic omen'tum**⁶ is a thin doubling of the peritoneum, extended between the transverse fissure of the liver and the small curvature of the stomach. Its left border is short, and incloses the cardiac orifice. Its right border is long, bounds the foramen of Winslow, and incloses the common biliary duct, the portal vein, and the hepatic artery.

¹ Bursa omentalis; saccus retro-ventricularis; sac of the omentum.

² F. Winslovii; hiatus of Winslow.

³ Ligamentum suspensorium hepatis; broad ligament; l. triangulare.

⁴ L. lateralia hepatis.

⁵ L. phrenico-lienale; phrenico-splenic ligament.

⁶ Lesser omentum; omentum minus, or gastro-hepaticum; gastro-hepatic epiploon; membrana macilentior; small epiploon.

The **Gas'tro-splen'ic omen'tum**¹ is a doubling of peritoneum passing from the cul-de-sac of the stomach to the hilus of the spleen, and contains the splenic blood-vessels.

The **Great omen'tum**, or **gas'tro-col'ic omen'tum**,² is a quadruple doubling of peritoneum suspended from the great curvature of the stomach and transverse colon downward in front of the small intestine, nearly to the pelvis. It is a broad, thin, apron-like process, with its four layers inseparably united in the adult. It frequently presents a perforated, lace-like appearance, crossed with reticular lines of fat, indicating the course of long, narrow vessels, which are branches of the gastro-epiploic arteries and veins. In fat persons it contains a large accumulation of fat. Not unfrequently it is found tucked up above the small intestine.

The **Mes'entery**³ is a large doubling of the peritoneum, which is reflected from the front of the vertebral column over the small intestine. Its **root** is about six inches wide, and extends obliquely from the left side of the second lumbar vertebra to the right iliac region. From the vertebral column the mesentery extends about four inches to its intestinal border, which corresponds in length with that of the small intestine it involves. Between the layers of the mesentery there are contained, besides areolar tissue and fat, the superior mesenteric blood-vessels and their accompanying plexus of nerves, the lacteals, and numerous lymphatic glands.

The **Mesoco'lon**⁴ is the portion of peritoneum which binds the colon to the back part of the abdomen. The **transverse mesoco'lon**⁵ is a wide doubling, the layers of which, in front, after inclosing the transverse colon, become continuous with the posterior layer of the great omentum; while behind they diverge over the position of the pancreas and duodenum. The **ascending**⁶ and **descending mesoco'lon**⁷ is for the most part so short, that its two layers do not come into contact behind the corresponding portions of the intestine, which, in consequence, are closely bound to the posterior wall of the abdomen. In the left iliac region,

¹ Omentum gastro-lienale; o. gastro-splenicum; gastro-splenic epiploon; g. s. ligament.

² Omentum majus; o. gastro-colicum; great, or gastro-colic epiploon; rete majus; peritonæum duplicatum; zirbus adipinus.

³ Mesenterium; mesaræum; media-

num; membrana pinguis intestinorum; medius intestinum; lactes; epichordis.

⁴ Mesenterium crassum.

⁵ Mesocolon transversum.

⁶ Right lumbar mesocolon; right ligament of the colon; colic omentum, or epiploon; third omentum, or epiploon.

⁷ Left lumbar mesocolon and iliac mesocolon; left ligament of the colon.

however, it becomes so broad as to suspend the colon in a sigmoid flexure.

The **Meso-rec'tum** is an extension of the descending mesocolon, connecting the upper part of the rectum closely to the sacrum.

The **Rec'to-ves'ical folds**,¹ as expressed by the name, are two duplicatures of peritoneum which extend between the sides of the rectum and bladder. They include between them a pouch of peritoneum, named the **rec'to-ves'ical pouch**, which extends downward between the rectum and bladder, nearly to the position of the prostate gland. When the bladder and rectum are empty, the recto-vesical folds form together a crescentic line, and a portion of the small intestine occupies the recto-vesical pouch.

In the female, the pouch just mentioned is divided, by the presence of the uterus and vagina, into two portions, which are named, from their position, the **rec'to-u'terine** and **ves'ico-u'terine pouches**. The former is the deeper, extending downward between the rectum and the upper part of the vagina while the other extends between the body of the uterus and the bladder. Instead of the recto-vesical folds, their place in the female is substituted by the **rec'to-u'terine**² and **ves'ico-u'terine folds**.³

The **Broad ligaments of the uterus** are two folds of peritoneum passing from the sides of the uterus to those of the pelvis. They inclose the ovaries and the Fallopian tubes.

From the summit and sides of the bladder a slight fold⁴ of peritoneum ascends to the umbilicus, and incloses the obliterated urachus and umbilical arteries of the fœtus. Likewise a pair of slight folds⁵ ascend to the umbilicus, over the position of the epigastric blood-vessels. The latter folds cross the course of the inguinal region, and divide it into two shallow fossæ, called, from their relative position, the **internal** and **external in'guinal fossæ**.⁶ The former corresponds in position with the external abdominal ring, the latter with the internal abdominal ring; and here the peritoneum often presents a short, conical pouch, which was once continuous with the vaginal tunic of the testicle. In the female, the pouch just mentioned is sometimes lengthened into a blind sac⁷ accompanying the round ligament of the uterus a short distance into the inguinal canal.

¹ Posterior false ligaments of the bladder; plicæ semilunares.

² Posterior ligaments of the uterus; plicæ semilunares.

³ Anterior ligaments of the uterus.

⁴ Plica vesico-umbilicalis media; liga-

mentum suspensorium vesicæ; superior false ligament of the bladder.

⁵ Plicæ vesico-umbilicales laterales; plicæ epigastricæ.

⁶ Fovea inguinalis interna et externa.

⁷ Canal of Nuck.

THE STOMACH.

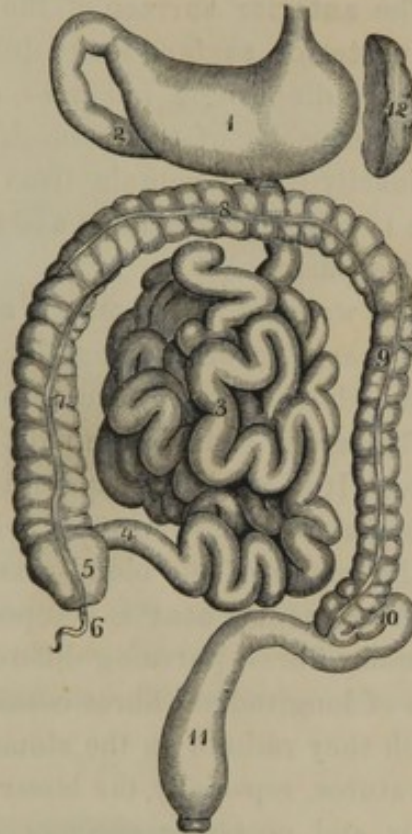
The **Stom'ach**¹ is a large musculo-membranous pouch, situated within the abdomen, and extending from the œsophagus to the small intestine. It is the most capacious portion of the alimentary canal, and is a receptacle in which the food is submitted to the chemical action of liquids elaborated in its walls. It occupies the left hypochondriac region extending through the epigastria into a small part of the right hypochondriac region. Above it is the diaphragm and liver; below, the transverse colon; in front, the abdominal wall; behind, the pancreas; to the right the liver, and to the left the spleen. In shape it is conical, curved upwardly on itself, and is extended obliquely from left to right.

The different parts of the stomach, to which we usually refer in speaking of the organ, are its greater and lesser extremities, its greater and lesser curvatures, its anterior and posterior surfaces, and its cardiac and pyloric orifices.

The **greater extremity** of the stomach is to the left, and communicates with the œsophagus by the **car'diac orifice**;² the **lesser extremity**, also named **pylor'ic extremity**,³ is to the right, and communicates with the small intestine by the **pylor'ic orifice**.⁴

The greater extremity of the stomach projects several inches to the left of the œsophagus, and in this position is named the **fundus**.⁵ The terminal portion of the lesser extremity, for about two inches of its

FIG. 218.



THE STOMACH AND INTESTINES. 1, stomach; 2, duodenum; 3, small intestine; 4, termination of the ileum; 5, cæcum; 6, vermiform appendix; 7, ascending colon; 8, transverse colon; 9, descending colon; 10, sigmoid flexure of the colon; 11, rectum; 12, spleen.

¹ Stomachus; ventriculus; gaster; anocœlia; nedys; gluttupatens; maw.

² Cardia; œsophageal orifice; upper, or left orifice; os ventriculi; ostium œsophageum.

³ Pars pylorica.

⁴ Pylorus; intestinal orifice, lower, or right orifice; ostium duodenale.

⁵ Cul-de-sac; great tuberosity.

length, is slightly constricted from the rest, and is named the **pyloric antrum**.¹

The **lesser curvature**² of the stomach is directed upward and backward, and has attached the smaller omentum; the **greater curvature**³ is directed forward and downward, and has attached the anterior division of the great omentum.

The **anterior surface** of the stomach presents forward and upward; the **posterior surface** looks downward and backward, and is in contact with the diaphragm, pancreas, duodenum, and left kidney.

The capacity of the stomach varies with the degree of distention, but ordinarily it will contain from one to two quarts, and measures from nine to twelve inches long, and from four to five inches in diameter where most capacious.

The walls of the stomach are composed of four coats, named from their character serous, muscular, fibrous, and mucous, all of which adhere intimately together by means of connective tissue.

The **serous coat**⁴ is the most external, and is derived from the peritoneum. It is a thin, transparent membrane closely investing the stomach, except along the curvatures, where it leaves a narrow interval occupied by the trunks of the blood-vessels, lymphatics, and nerves of the organ.

The **muscular coat**⁵ is composed of three layers of pale-red, unstriated muscular fibres, pursuing different directions. The **external layer** consists of longitudinal fibres continuous with those of the œsophagus, from which they radiate on the stomach. They are most numerous along the curvatures, especially the lesser one, and are thinly scattered on the anterior and posterior surfaces. The **middle layer**, more uniform and important than the former, consists of circular fibres. Commencing thinly at the fundus, they gradually accumulate toward the pyloric extremity, and at the pyloric orifice form a thick fasciculus named the **pylor'ic sphinc'ter**.⁶ The **internal layer** consists of oblique fibres, continuous with the circular fibres of the œsophagus. They form a wide band embracing the cardiac orifice on the left, and spreading obliquely downward and to the right on the anterior and posterior surfaces of the stomach.

The **fibrous coat**⁷ is a thick, submucous tissue, forming an extensible layer upon which the strength of the stomach mainly depends.

¹ Antrum pylori, or pyloricum; lesser cul-de-sac; lesser tuberosity.

² Curvatura superior; superior, or diaphragmatic margin.

³ Curvatura inferior; inferior, or colic margin.

⁴ Tunica serosa.

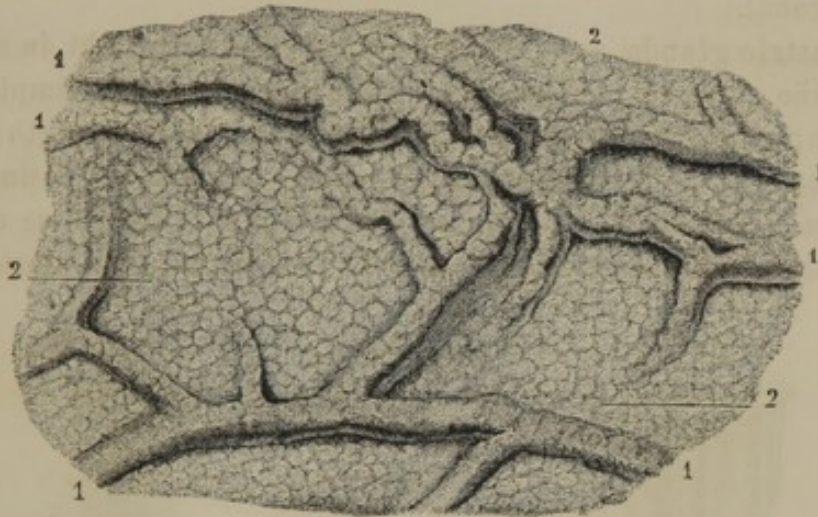
⁵ Tunica musculosa; stratum musculare.

⁶ Sphincter pylori.

⁷ Tunica fibrosa; t. nervosa, or nervea.

The **mucous coat**¹ or lining membrane of the stomach is soft and pulpy to the touch, and is of a pale-pinkish ash color. Under excitement it becomes more reddened, as during digestion; and in inflammation it assumes a deep-red hue. It is thin at the fundus, and gradually thickens

FIG. 219.

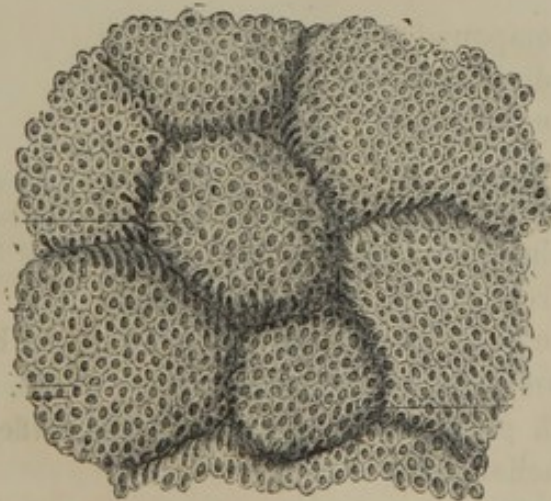


WRINKLED OR RUGOUS SURFACE OF THE MUCOUS MEMBRANE OF THE STOMACH. 1, wrinkles, or superficial folds; 2, mammillated surface.

toward the pyloric extremity, where it is from three-fourths of a line to one line in thickness. In the latter position, ordinarily, it presents numerous contorted reticular ridges or **wrinkles**,² the larger of which are longitudinal, and gradually fade away toward the fundus of the stomach. These ridges multiply and increase in size with the extent of contraction of the organ, and decrease or even disappear with its distention.

At the pyloric orifice a thick, circular fold, or sometimes a pair of crescentic folds, acts the part of a valve, and hence is named the **pylor'ic valve**.³ It contains the thick muscular fasciculus constituting the pyloric sphincter.

FIG. 220.



MAMMILLÆ OF THE MUCOUS MEMBRANE OF THE STOMACH, moderately magnified, exhibiting the orifices of the gastric glands.

¹ Tunica mucosa; crusta villosa ventriculi; gastro-mycoderis.

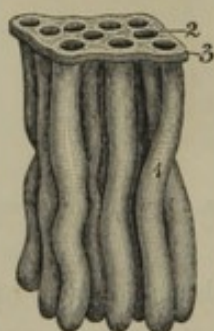² Rugæ; plicæ.

³ Valvula pylori.

The free surface of the gastric mucous membrane exhibits a feebly mammillated appearance, well represented in figure 219; and it is everywhere minutely punctured by the orifices of glands. It is provided with a columnar epithelium, which commences at the cardiac orifice and subsequently continues throughout the remainder of the alimentary canal.

The **gastric glands**¹ are tubular, and closely set upright in the thickness of the mucous membrane. They are generally simple, nearly straight or slightly tortuous, and gradually increase in length from the cardiac toward the pyloric orifice, to which circumstance is due the difference in thickness of the mucous membrane in the same direction. Some of the glands, both in the vicinity of the cardiac and pyloric orifices,

FIG. 221.



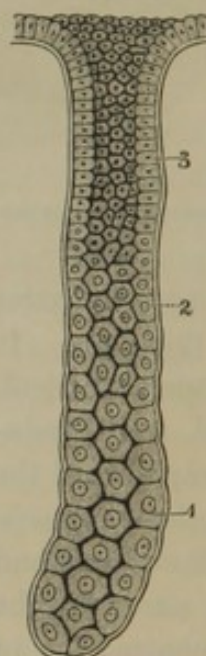
SMALL PORTION OF THE MUCOUS MEMBRANE OF THE STOMACH, WITH THE IMBEDDED GASTRIC GLANDS. 1, the glands; 2, orifices of the glands; 3, epithelium of the mucous membrane; moderately magnified.

are compound, consisting of a main tube dividing at bottom in from two to four branches.

Many of the gastric tubular glands are lined throughout with a columnar epithelium, not differing from that of the mucous membrane of the stomach. Most of them,² however, are provided in their deeper part with comparatively large, rounded or polyhedral cells,³ which gradually merge toward the orifices of the glands into columnar epithelial cells.

Besides the tubular glands, the stomach contains at its pyloric end a few minute racemose glands; and not unfrequently in the same position there may be detected a few small, rounded, whitish bodies, resembling the solitary glands of the intestines.

FIG. 222.



A GASTRIC GLAND, highly magnified. 1, large nucleated cells at the bottom of the gland, gradually merging 2 into the columnar cells 3, at the upper part of the gland.

¹ Gastric follicles; *glandulae gastricae*.

² Peptic glands.

³ Peptic cells.

The stomach is very vascular, the blood-vessels reaching it along the line of attachment of its omenta. The gastro-epiploic arteries together form an arch along the greater curvature; the coronary and pyloric arteries form a second along the lesser curvature, and the short gastric arteries reach the fundus. The branches from these vessels diverge to the surfaces of the stomach, and form together, between its coats, a vascular net, from which the capillary nets of the serous, muscular, and mucous coats originate. The veins correspond with the arteries and pursue the same course. The lymphatics are likewise numerous; their trunks also running along the curvatures. The nerves are derived from the terminal portion of the pneumogastric and the solar plexus of the sympathetic nerves.

The liquid elaborated by the glandular structure of the mucous membrane is named the **gastric juice**.¹ Free from foreign matters derived from the food, it is a clear, colorless liquid, rendered slightly viscid from the mixture of mucus, and has a decidedly sour taste. It consists of water holding in solution a peculiar nitrogenized principle named **pepsin**,² free chlorohydric and lactic acids, and a number of chloride and phosphatic salts. Its operation consists mainly in the solution of albuminoid substances, such as flesh, cheese, eggs, and the gluten of vegetables.

THE SMALL INTESTINE.

The **Small intes'tine**³ is a cylindrical and much convoluted tube, occupying the umbilical region and continuous borders of the surrounding regions, and suspended by the mesentery from the vertebral column. It measures about twenty-five feet in length, and from one to one and three-quarters of an inch in diameter; becomes slightly narrower in its descent; and terminates by joining the large intestine. It is divided into three portions: the **duodenum**, **jejunum**, and **ileum**, and although there is no distinct separation between these, each presents some peculiarity of character.

The **Duode'num**,⁴ as expressed by the name, is about twelve fingers'-breadth in length, and it is the widest portion of the small intestine. Commencing at the pyloric orifice, it ascends to the right and backward, until it reaches the neck of the gall-bladder. It then abruptly turns

¹ Succus gastricus; menstruum, or fermentum ventriculi; gastric acid.

² Gasterase; chymosin; the digestive principle.

³ Intestinum tenue; i. gracile; intestines; small gut; guts; enteron.

⁴ Ventriculus succenturiatus; dodecadactylon; portonarium; appendix, processus, or ecphysis ventriculi.

downward in front of the right kidney, makes another turn to the ^{left} ~~right~~ side, opposite the second lumbar vertebra, and terminates in the jejunum.

The ascending portion of the duodenum has the liver and gall-bladder in front and above it, and after death is usually found stained, with bile exuding from the latter. The descending portion has attached to it, on the left, the head of the pancreas; and into its lower part the duct of the latter, together with the common biliary duct, opens. The transverse portion is behind the transverse mesocolon, and is attached by areolar tissue to the crura of the diaphragm and vessels in front of the vertebral column. Along its upper border is the pancreas, and the superior mesenteric blood-vessels cross from beneath the latter over its termination.

The **Jeju'num**¹ and **Il'eum**² are the remaining portions of the small intestine, and though they pass insensibly into each other, the former is viewed as consisting of two-fifths, the latter of three-fifths of the length of the tube. The jejunum is wider than the ileum, feels thicker between the fingers from the more folded condition of its mucous membrane, and is further generally characterized by the absence of agminated glands. The ileum terminates in the right iliac region, by joining the large intestine nearly at a right angle.

Like the stomach, the small intestine has four distinct coats composing its walls: serous, muscular, fibrous, and mucous.

The external or **serous coat**, derived from the peritoneum, adheres closely around the intestine, leaving only a narrow space along the attachment of the mesentery for the passage of vessels and nerves. The duodenum is invested with peritoneum only at its extremities; the descending and transverse portions, for the most part, being destitute of a serous covering.

The **muscular coat** is composed of two layers of pale-red, unstriated fibres. The external layer consists of thinly-scattered, longitudinal fibres; the internal layer, thicker and quite distinct, consists of circular fibres.

The **fibrous coat**, less thick than that of the stomach, is nevertheless a strong, extensible layer.

The **mucous coat**, or lining membrane of the small intestine, is thinner and redder than that of the stomach, and, like it, possesses a columnar epithelium. It is thrown into numerous, transverse, crescentic folds or doublings, named **val'vulæ conniven'tes**.³ These are widest and most abundant in the upper part of the small intestine, where they

¹ Nestis.

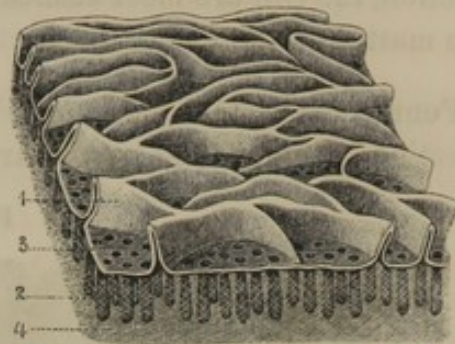
² Ileon; intestinum circumvolutum.

³ V. c. Kerkringii; plicæ conniventes; Kerkringian valves.

even overlap at the edges. In descending, they gradually diminish in number and width; and in the ileum they become indistinct, and finally disappear. These folds are permanent, and not due to contraction of the intestinal wall. They increase the extent of absorbing and secreting surface, and further retard the passage of the food.

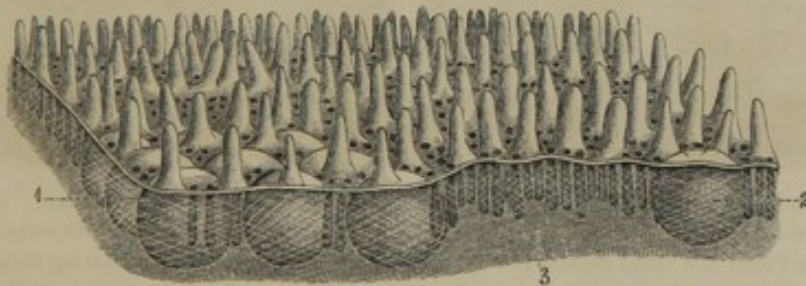
The mucous membrane of the small intestine, including its valvulæ conniventes, is everywhere provided with minute elevations, named vil'li.¹ These give to the surface a velvety appearance, which may be favorably observed, by examining a portion of intestine, after it is cleansed from mucus, beneath water. In the

FIG. 223.



SMALL PORTION OF THE MUCOUS MEMBRANE FROM THE UPPER PART OF THE JEJUNUM, moderately magnified. 1, villi, resembling valvulæ conniventes in miniature; 2, tubular glands; their orifices, 3, opening on the free surface of the mucous membrane; 4, fibrous tissue.

FIG. 224.



PORTION OF THE MUCOUS MEMBRANE FROM THE ILEUM, moderately magnified, exhibiting the villi on its free surface, and between them the orifices of the tubular glands. 1, portion of an agminated gland; 2, a solitary gland; 3, fibrous tissue.

upper part of the small intestine the villi appear as fine, serpentine folds, frequently interrupted in their course, and often conjoined in a reticular manner. Descending the intestine, the fold-like villi become more frequently interrupted or broken, and finally, in the ileum, they appear as flattened, conical, or tongue-like processes.

The villi are from one-fourth to one-third of a line high, and in structure are processes of the intestinal mucous membrane. Provided with the columnar epithelium, they contain on their interior a capillary net of vessels, in the form of the villi. They likewise contain the commencement of those lymphatics called lacteals, but the manner in which these originate has not been satisfactorily determined. According to one

¹ Villi intestinales; flocculi.

view, they commence as one or two cæcal branches for each villus; and according to a second view, they commence in a reteform plexus. In function, the villi are most efficient organs in the absorption of the nutritive matter of the food.

Four kinds of glands are found in the mucous membrane of the small intestine: the **duode'nal**, **tubular**, **solitary**, and **ag'minated** glands.

FIG. 225.

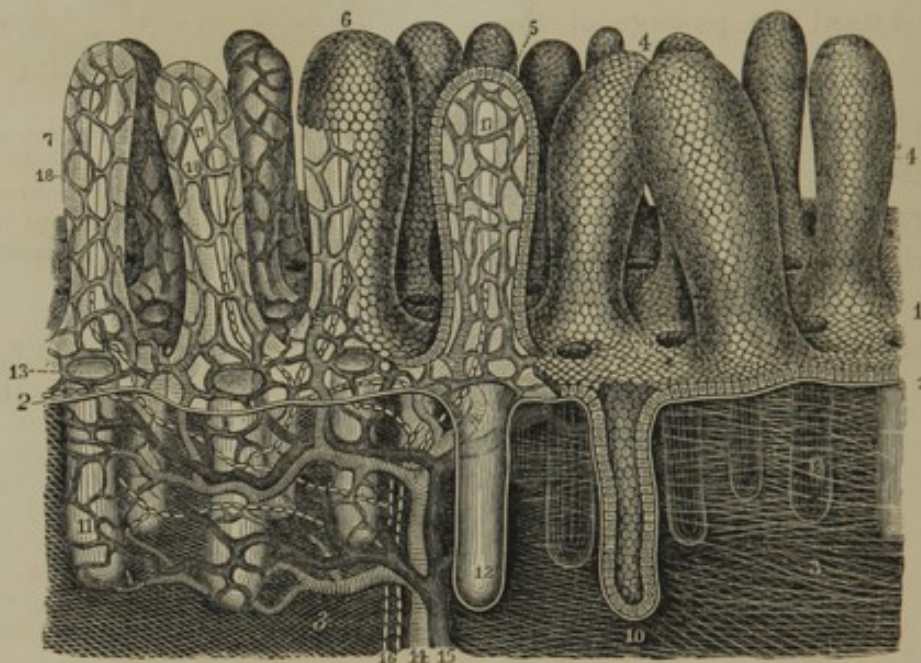


DIAGRAM OF THE STRUCTURE OF THE MUCOUS MEMBRANE OF THE ILEUM, highly magnified. 1, epithelium forming the free surface of the mucous membrane; 2, basement membrane; 3, fibrous layer; 4, villi covered with epithelium; 5, a villus deprived of one-half of its epithelium, and exhibiting through its basement layer the blood-vessels; 6, a villus partially deprived of its epithelium; 7, villi totally deprived of their epithelium, but retaining their basement membrane; 8, tubular glands imbedded in the fibrous layer of the mucous membrane; 9, orifices of the tubular glands opening on the free surface of the mucous membrane between the villi; 10, section of a tubular gland, with its epithelial lining; 11, tubular glands stripped of the latter, but retaining their basement membrane; 12, one of the glands in section, without its epithelium; 13, capillaries surrounding the orifices of the tubular glands; 14, an artery; 15, a vein; 16, lymphatics or lacteals; 17, commencement of the latter within the villi; 18, capillary blood-vessels of the villi.

The **Duode'nal glands**¹ (Brunner's) are small, racemose glands, occupying the submucous tissue, and opening into the duodenum. They are most numerous at the commencement of the latter, where they form a nearly continuous layer; gradually diminishing in number and size, they disappear altogether approaching its termination.

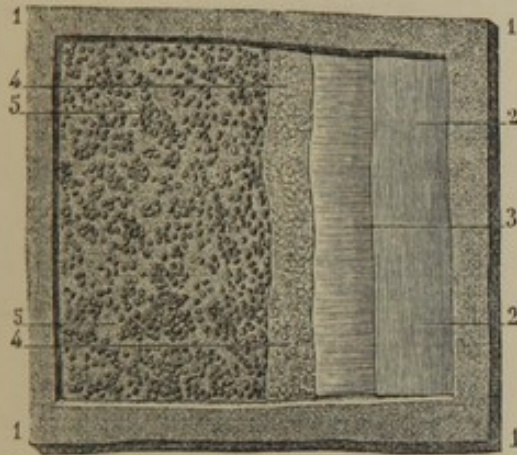
The **Tubular glands**² are the most numerous of those of the small intestine, and are found throughout its whole tract. They are situated

¹ Glands of Brunner; glandulæ Brunneri; second pancreas.

² Glands, or follicles of Lieberkühn; glandulæ, or cryptæ Lieberkühnianæ; cryptæ mucosæ.

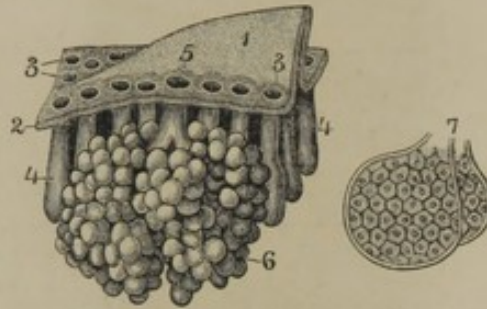
upright in the thickness of the mucous membrane, and open in the intervals of the villi, to which spaces they give a perforated appearance. They are simple, straight glands, provided with a columnar epithelium; and secrete a clear liquid, called the **intestinal juice**.¹

FIG. 226.



PORTION OF THE DUODENUM, viewed from without, natural size. 1, thickness of the duodenum; 2, 3, longitudinal and transverse layers of fibres of the muscular coat; 4, fibrous coat; 5, exterior of the mucous membrane, with the duodenal glands imbedded.

FIG. 227.



A VERTICAL SECTION OF THE DUODENUM, highly magnified. 1, a fold-like villus; 2, epithelium of the mucous membrane; 3, orifices of the tubular glands; 4, 5, orifice of a duodenal racemose gland; 6; 7, two vesicles of the latter, more highly magnified, exhibiting the epithelial cells lining their internal surface.

The **Solitary glands**² are minute, whitish, oval or rounded bodies scattered singly throughout the small intestine. They are closed vesicles imbedded in the submucous tissue. In structure, they consist of an exterior fibrous capsule, containing rounded, nucleated cells, free nuclei, and granules; and fine vessels penetrate into their interior. Their function is unknown.

The **Ag'minated glands**³ (Peyer's) consist of vesicular bodies like those just described, arranged in elliptical patches. Ordinarily there are from fifteen to thirty of these patches, from half an inch to two inches in length, and about half an inch in breadth. Usually occupying the ileum, they are always situated opposite the attachment of the mesentery, with their length parallel to that of the intestine. For the most part, the largest patches are the lowest in the ileum, and in ascending

¹ Succus entericus.

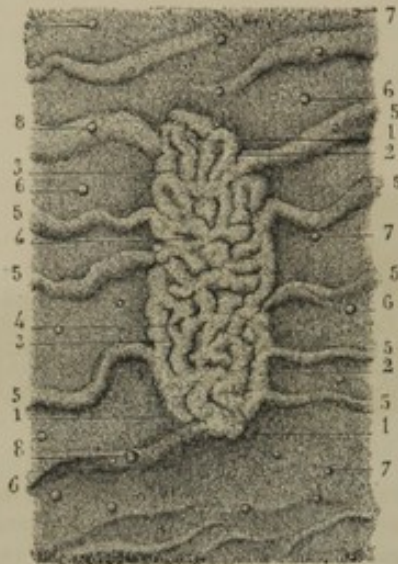
² Glandulæ solitariae; incorrectly Brunner's glands; solitary follicles.

³ Peyer's glands; glandulæ Peyer, or Peyerianæ; g. sociæ Peyer; g. agminatæ; g. mucosæ coagminatæ; g. muciparæ racematim congestæ; g. intesti-

nales plexiformes; g. plexus intestinales; g. int. spuria; g. in agmen congregatæ; corpuscula glandularium similia; enteradenes; aggregate or aggregated glands; patches of Peyer; Peyer's plaques; agminæ Peyer.

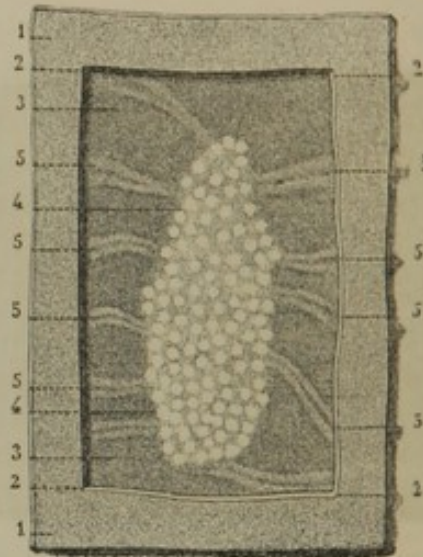
they become more distant, smaller, and more circular. When found in the jejunum, they are few in number, and small in size. Upon the inner surface of the intestine the agminated glands appear depressed below

FIG. 228.



PORTION OF THE MUCOUS MEMBRANE FROM THE UPPER PART OF THE ILEUM, exhibiting very well the appearance presented to the naked eye when the specimen is floated in water. 1, 2, 3, 4, an agminated gland; 5, valvulae conniventes, becoming much contorted over the gland; the short lines everywhere covering the surface of the mucous membrane, including the valvulae and the gland, represent villi; 6, 7, solitary glands.

FIG. 229.



PORTION OF THE ILEUM, viewed from without; the serous and muscular coats removed over the position of an agminated gland. 1, exterior surface of the ileum; 2, cut edge of the serous and muscular coats; 3, exterior surface of the mucous membrane; 4, an agminated gland; 5, valvulae conniventes.

the general level of the mucous membrane; but they give rise to a slight prominence externally. The valvulae conniventes, in approaching them, are usually interrupted, or if they pass upon them are reduced in size, and much contorted. Their function is unknown; and they are remarkable for the changes they undergo in certain diseases, as, for instance, typhoid fever.

The arteries of the small intestine are numerous, and are derived from the pancreatico-duodenal, pyloric, and superior mesenteric arteries. Diverging from the mesentery upon the intestine, in the intervals of its coats they form vascular nets, from which are derived the three capillary nets of the mucous, muscular, and serous layers. The veins accompany the arteries. The lymphatics are numerous, and are derived from the three sources supplied by the arteries. The nerves are furnished by the solar plexus of the sympathetic system.

THE LARGE INTESTINE.

The **Large intestine**¹ is a cylindrical tube, strikingly differing from the small intestine in its greater capacity and sacculated appearance. It is about five feet in length, nearly encircles the abdomen in its course from the small intestine to the anus, and is retained in position by the mesocolon. Commencing in the right iliac region, it ascends in front of the right kidney to the under part of the liver, then crosses through the upper boundary of the umbilical region to the left hypochondriac region. Descending from the latter, in front of the left kidney to the left iliac region, it here forms an S-like convolution, and then dipping into the pelvis, passes down in front of the sacrum to terminate at the anus. It is divisible into three portions: the cæcum, colon, and rectum.

The **Cæcum** or **head of the colon**² is the most capacious portion of the large intestine, and consists of a large pouch occupying the right iliac region below the termination of the ileum. It is retained in position by a fold of the peritoneum reflected in front, and by an attachment of loose connective tissue to the iliac fossa; though sometimes the peritoneum produces a doubling behind which renders the cæcum less fixed than ordinarily.

The cæcum is about two and a half inches in length and breadth, and toward its bottom curves inwardly and backward, and is abruptly reduced into a worm-like prolongation, named the **vermiform appendix**.³ This is four or five inches long, as thick as a goose-quill, and is usually somewhat coiled, in which condition it is retained by a fold of peritoneum. Its calibre is narrow, and its comparatively thick wall has the same structure as other portions of the large intestine. It is viewed as the rudiment of the much-elongated cæcum of lower mammals.

The **Co'lon**⁴ is the second and longest division of the large intestine, and extends from the cæcum to the rectum. In the different parts of its course it is called the **ascending, transverse, and descending colon**, and the **sigmoid flexure**. It is most capacious at its commencement,

¹ Intestinum crassum; megalocœlia.

² Cæcum; caput coli; monocolon; monomacum; typhlœnterum; typhloteron monocolon; initium intestini crassi; sacculus intestini crassi, or coli; prima cella coli; initium extuberans coli; the blind gut.

³ Appendix, or appendicula vermi-

formis; processus, or tubus vermicularis; appendix cæci; additamentum coli; ecphyas; digital appendix; vermiform, or vermicular process.

⁴ Colum; intestinum crassum et plenum; i. majus; i. grande; i. laxum; i. cellulatum; colon cæcum; monenterum; physce.

where it is about two and a half inches in diameter, and gradually diminishes to its termination, where it is an inch less in breadth. It exhibits three ranges of sacculæ or pouches,¹ alternating with as many equidistant longitudinal bands² proceeding from the base of the vermiform appendix. The constrictions between the sacculæ appear on the interior of the colon as crescentic doublings³ of its walls.

The **ascending colon**⁴ occupies the right side of the abdomen, attached to its posterior wall by loose connective tissue, and further retained in position by the peritoneum passing over the sides and in front of the intestine. Behind, it is in relation with the quadrate lumbar muscle and kidney; in front with the small intestine.

The **transverse colon**⁵ passes obliquely across the abdomen at the upper boundary of the umbilical region. It is closely attached to the back part of both hypochondriac regions, and arches forward toward its middle, where it is loosely suspended by the transverse mesocolon. Above it are the liver and the stomach; below, the small intestine; and descending from its outer border is the posterior fold of the great omentum.

The **descending colon**⁶ occupies the left side of the abdomen, to the back part of which it is closely attached by connective tissue, and by the peritoneum passing over its sides and front. Its upper part is in contact with the spleen; behind it are the left kidney and quadrate lumbar muscle; and in front is the small intestine.

The **sigmoid flexure of the colon**⁷ is an S-like convolution of the intestine attached by a wide fold of peritoneum to the left iliac fossa. It is the narrowest and least sacculated portion of the colon; and terminates opposite the left sacro-iliac symphysis in the rectum.

The **Il'eo-col'ic valve**. The ileum opens into the left side of the colon just above the cæcum, the orifice being provided with a pair of semilunar folds, which constitute the **ileo-colic valve**.⁸ The folds are transverse, and project from the borders of the aperture toward each other into the colon. The free edges of the folds are concave, and their contiguous extremities coalesce and are prolonged a short distance as a narrow doubling on the interior surface of the colon. The aperture

¹ Cellulæ, haustra, or loculamenta coli.

² Tæniæ Valsalvæ; tæniæ, or fasciæ ligamentosæ coli; ligamenta coli.

³ Plicæ sigmoideæ.

⁴ Colon ascendens; c. dextrum; right lumbar colon.

⁵ Colon transversum; transverse arch of the colon.

⁶ Colon descendens; c. sinistrum; left lumbar colon.

⁷ Flexura sigmoidea; f. S romanum; iliac colon.

⁸ Ileo-cæcal valve; valve of Bauhin, of Tulpus, of Fallopius, or of Varolius; valvula ilei; v. coli; v. cæci; operculum ilei; sphincter ilei.

Med. 364 Lect.

separating the folds is elliptical; but when closed, the free edges of the valve come into contact so as to prevent the return of matters from the large into the small intestine.

The third division of the large intestine, the rectum, possesses so many peculiarities that its description is reserved for a special section of our chapter.

The cæcum and colon, like the small intestine, have four coats holding the same relationship with one another.

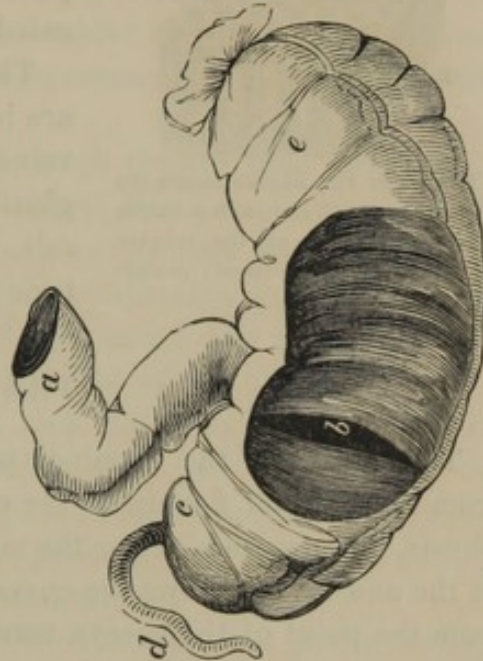
The **serous coat**, derived from the peritoneum, closely invests the colon except at the back part of the cæcum, and of the ascending and descending colon. Along its course, it exhibits a series of irregular, pendulous pouches containing fat, and named the **epiploic appendages**.¹

The **muscular coat** is composed of two layers of pale-red, unstriated fibres. The external longitudinal fibres, after forming a uniform layer to the vermiform appendix, are collected into three separate bands, which proceed equidistant from one another along the course of the cæcum and colon. These bands are much shorter than the intestine would be if deprived of them, and serve to maintain its sacculated condition. The internal muscular fibres are circular, and form a continuous layer to the cæcum and colon, dipping into the constrictions between their saccules, and into the folds of the ileo-colic valve.

The **fibrous coat** is like that of the small intestine.

The **mucous membrane** is soft, smooth, and of a pale-pinkish ash color. It is without villi or other doublings than those produced by the constrictions separating the saccules. Its free surface everywhere exhibits a finely-punctured or sieve-like appearance, with here and there small whitish spots. It is provided with a columnar epithelium and two

FIG. 230.

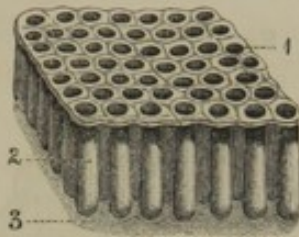


THE CÆCUM LAID OPEN, TO EXPOSE THE ILEO-CÆCAL VALVE. *a*, Termination of the ileum; *b*, slit-like orifice between the two folds of the ileo-cæcal valve; *c*, cæcum; *d*, vermiform appendix; *e*, ascending colon.

¹ Appendices, or appendiculæ epiploicæ, or pinguedinosæ; appendices coli adiposæ; supplementa epiploica; fimbriæ carnosæ; omentula.

kinds of glands, **tubular**¹ and **solitary glands**,² which are like those of the small intestine. The former are closely

FIG. 231.



SECTION OF THE MUCOUS MEMBRANE OF THE COLON. 1, free surface exhibiting the orifices of the tubular glands 2; 3, fibrous tissue; moderately magnified.

set together in the thickness of the mucous membrane, and give to its free surface the punctured appearance; the latter are indicated by the scattered whitish spots.

The blood-vessels of the cæcum and colon are branches of the mesenteric arteries and veins. The lymphatics communicate with glands lying in the course of the former vessels. The nerves are derived from the mesenteric plexuses of the sympathetic system.

THE RECTUM.

The **Rec'tum**,³ the terminal portion of the large intestine, proceeds from the sigmoid flexure of the colon, opposite the left sacro-iliac symphysis, and descends along the middle of the sacrum and coccyx, to end at the anus. It follows the curvatures of the bones just mentioned, and from the point of the coccyx turns backward and downward. It is not sacculated like the colon, though it usually exhibits three constrictions, corresponding with crescentic folds on its interior. It is from six to eight inches long, and when distended is club-shaped, being narrow above and expanded just before it contracts to the anus. In front of it, in the male, are the urinary bladder, seminal vesicles, and prostate gland; in the female, the uterus and vagina.

The **a'nus**⁴ is a dilatable aperture, situated about an inch from the end of the coccyx. It is encircled by a sphincter muscle, covered below by thin, dark-colored skin, gradually merging into the mucous membrane of the rectum. In the condition of rest, this skin is puckered or folded; but in the act of defecation the folds are expanded, and the mucous membrane at the verge of the anus is everted.

The upper part of the rectum is invested by the peritoneum, which attaches it to the sacrum by a doubling named the **mes'o-rec'tum**. Subsequently the peritoneum extends down the sides, and finally only on the front of the rectum, and is thence reflected to the bladder of the

¹ Glands or follicles of Lieberkühn.

² Solitary follicles; glandulæ simplices majores.

³ Intestinum rectum; longanon; archos; cysaros; princeps; enthyenteron; apenthysmenos.

⁴ Podex; archos; sedes; culus; proctos; molyne; dactylios; cathedra; cyrcion; cysaros; cysthos; aphedra; hedra; the seat, fundament, or body.

male, or the vagina and uterus of the female. The lower part of the rectum is destitute of a peritoneal investment, and is attached to the contiguous structures by areolar tissue, usually accompanied with much adipose tissue.

In the male, the portion of the rectum unprovided with peritoneum is in contact in front with the base of the bladder, the seminal vesicles, and the prostate gland; in the female, it is in contact in the same position with the vagina.

The **muscular coat** of the rectum is much thicker than elsewhere in the large intestine. Its external longitudinal fibres, continuous with the longitudinal bands of the colon, form a continuous and well-marked layer. The circular fibres likewise form a continuous layer, and gradually increase in descending upon the rectum, and finally accumulate in a thick fasciculus, named the **internal sphinc'ter of the a'nus**.¹

Between the two sphincters of the anus the longitudinal muscular fibres of the rectum terminate, except a few, which turn around the lower border of the internal sphincter and ascend a short distance between it and the mucous membrane. In the same position the rectum is embraced from each side by the insertion of the anal elevator muscles.

The **fibrous coat** of the rectum is thicker than in other portions of the large intestine, and is strong and extensible.

The **mucous membrane** of the rectum has the same structure as that of the colon, but is more vascular, and becomes bright red at the lower extremity. It exhibits many irregular wrinkles, which are obliterated on distention of the bowel. Approaching the anus, it is thrown into convergent longitudinal folds, named the **columns of the rec'tum**,² which are often continuous below, so as to form small recesses between them, called the **pouches of the a'nus**.³

Corresponding in position with the three constrictions usually observed on the exterior of the rectum, its mucous membrane is provided with as many wide, crescentic folds, which may act the part of a valvular apparatus.

The arteries of the rectum are the hæmorrhoidal branches of the inferior mesenteric, internal iliac, and internal pudic arteries. The veins are numerous, and at the lower part of the rectum form an intricate net-work, named the **hæmorrhoi'dal plexus**, which returns its blood through the inferior mesenteric and internal iliac veins. Enlargement of the veins of the hæmorrhoidal plexus at the verge of the anus constitute hæmorrhoids or piles. The lymphatics of the rectum proceed to the sacral and

¹ Musculus sphincter ani internus, or superius.

² Columnæ carneæ Morgagni.

³ Sinus Morgagni; lacunæ.

lumbar glands. The nerves are numerous, and are derived from the hypogastric plexus of the sympathetic system and the contiguous spinal nerves.

The muscles of the anus will be more particularly described in the account of the perineum.

THE PANCREAS.

The **Pan'creas**¹ is a long, flat gland, situated behind the stomach, opposite the first lumbar vertebra. It extends from the descending portion of the duodenum in the right hypochondriac region, along the transverse portion of the duodenum through the epigastric region, and reaches the spleen in the left hypochondriac region. It closely adheres to the duodenum, and is loosely attached behind by connective tissue to the crura of the diaphragm, aorta, inferior cava, and superior mesenteric vessels. The latter are included in a groove of the gland, and sometimes in a complete canal. In front, the pancreas is connected with the ascending layer of the transverse mesocolon; and its upper border is grooved to accommodate the splenic blood-vessels.

The pancreas is pinkish white, and is less consistent and of looser texture than the salivary glands, which it resembles in composition. It is from six to eight inches long, is largest at the right extremity, named its **head**,² and gradually narrows toward the left extremity, named its **tail**.³ Its average depth is about one and a half inches; its thickness about half an inch; and it weighs between two and three ounces.

The head of the pancreas adheres closely to the inner side of the descending portion of the duodenum, and is frequently partially divided from the body of the gland, when it is named the **lesser pan'creas**.⁴

In structure the pancreas is a racemose gland, and consists of many polyhedral lobes and lobules loosely associated by connective tissue.

The **pancreat'ic duct**⁵ usually possesses two principal branches, of which the longer and larger proceeds transversely through the body of the gland from left to right, and is joined near its termination by the smaller branch⁶ derived from the head of the pancreas. Upon emerging from the pancreas, the duct penetrates the wall of the duodenum, opening into it near to or in conjunction with the common biliary duct, about four inches from the stomach.

¹ Sweetbread; pancratium; pancrene; calliareas; lactes; totum carnosum; pulvinar ventriculi; glandula salivalis abdominis.

² Caput pancreatis.

³ Cauda.

⁴ Pancreas minus; pancreas of Asseli.

⁵ Ductus pancreaticus; d. Wirsungianus; canal, or duct of Wirsung.

⁶ Ductus Santorini.

The arteries of the pancreas are derived from the pancreatico-duodenal and splenic arteries. The veins join the splenic and superior mesenteric veins. Its lymphatics communicate with the lumbar glands, and its nerves are branches from the solar plexus of the sympathetic system.

The **pancreat'ic juice**¹ is a clear, colorless, slightly viscid liquid, with a distinctly alkaline reaction. It contains a peculiar nitrogenized principle, named **pancreatin**, and is an important emulsifying agent of the fatty materials of the food.

THE LIVER.

The **Liver**² is the largest true glandular organ of the body. It occupies the greater part of the right hypochondriac region, and extends through the epigastric into a small portion of the left hypochondriac region. It is half ovoidal in shape, with its long diameter transverse, its convex surface accurately applied to the diaphragm, and its nearly flat or slightly concave surface in contact with the stomach, duodenum, colon, and right kidney. In front, it is in relation with the ensiform and costal cartilages, and behind, with the crura of the diaphragm, aorta, and inferior cava. It is suspended from the diaphragm by reflections of the peritoneum named the **suspensory**, the **right** and **left lateral ligaments**, and by a further attachment of connective tissue at its posterior border.

The right portion of the liver is much larger than the left, and is thicker, more fixed in position, and extends lowest in the abdomen as well as highest in the thorax. The posterior and right borders are thick and rounded; the anterior and left borders are thin and acute, and the most movable parts of the organ.

The liver is of firm, solid texture, smooth on the surface, and of a reddish-brown color. It often has more or less of a yellowish hue, apparently dependent on the presence of fat in the hepatic substance, and sometimes exhibits superficial livid bluish or purplish patches and borders. It weighs between three and four pounds, and measures ten to twelve inches from right to left, about six inches from back to front, and about three inches at its thickest part. In the female it is usually about a fifth less in weight and size.

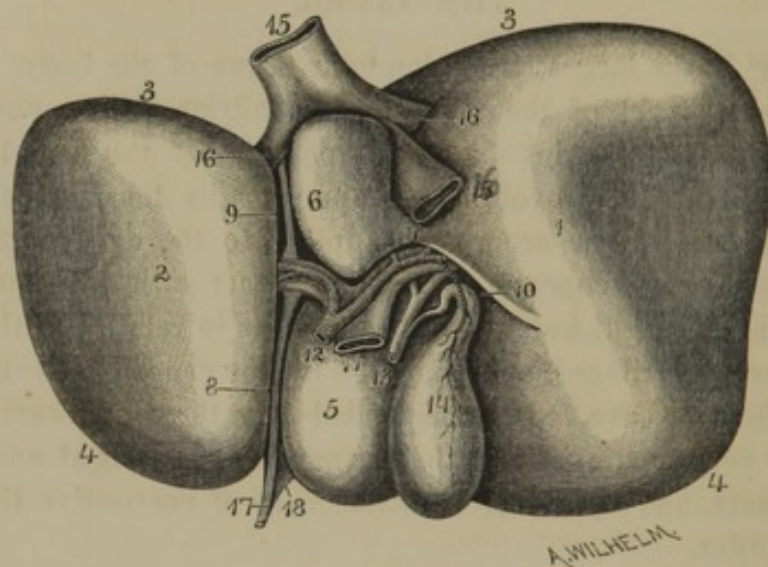
The suspensory ligament, extending from the median line of the diaphragm to the upper surface of the liver, together with the longitudinal fissure pursuing the same direction on the under surface, divide the organ into two unequal parts, named the right and left lobes.

¹ Succus, or liquor pancreaticus.

² Hepar; jecur; jecinus.

The **right lobe of the liver**,¹ four or five times the size of the left, is square in outline, and is closely adherent at its posterior border, by connective tissue, to the diaphragm, between the widely-separated reflections of the right lateral ligament. Its upper surface is convex; its lower surface is in contact with the right kidney, the pyloric extremity of the stomach, and the colon. At the fore part of its inferior surface the gall-bladder reposes in a fossa;² and to the left and back of this it presents two small subdivisions named the quadrate and caudate lobes.

FIG. 232.



INFERIOR SURFACE OF THE LIVER. 1, right lobe; 2, left lobe; 3, posterior margin; 4, anterior margin; 5, quadrate lobe; 6, caudate lobe; 7, isthmus, or caudate process, connecting the latter with the right lobe; 8, 9, longitudinal fissure; 10, transverse fissure; 11, portal vein; 12, hepatic artery; 13, common biliary duct formed by the union of the hepatic and cystic ducts; 14, gall-bladder; 15, inferior cava; 16, hepatic veins; 17, round ligament; 18, anterior part of the suspensory ligament.

The **left lobe of the liver**³ is comparatively thin, trilateral in outline, and movably suspended by the left lateral ligament. Its lower surface is in contact with the anterior part of the stomach, and behind, it is in relation with the cardiac orifice of this organ.

Besides the suspensory ligament and longitudinal fissure, the right and left lobes are separated at the anterior and posterior borders of the liver by notches. The **anterior notch** is acute, and continuous below with the longitudinal fissure; the **posterior notch** is broad and concave, and accommodates the vertebral column and the great blood-vessels in front of it. The inferior cava occupies a deeper portion of the posterior notch, excavated in the right lobe of the liver; and sometimes the hepatic substance extends around the vein so as to inclose it in a complete tube.

¹ Lobus dexter; large, or colic lobe.

² Fossa longitudinalis dextra.

³ Lobus sinister.

Above the posterior notch, the two layers of the suspensory ligament diverge¹ and become continuous with the anterior reflections of the lateral ligaments, leaving a triangular interval at which the liver is attached to the diaphragm by connective tissue.

The **Longitudinal fissure**² is a deep groove on the under part of the liver extending between the anterior and posterior notches, and separating the right and left lobes. Its fore part³ is frequently crossed by a bridge⁴ of hepatic substance, and it contains a fibrous cord named the **round ligament**,⁵ which is the obliterated umbilical vein of foetal life. Its back part⁶ also contains a fibrous cord, which is the obliterated **ductus venosus** of the foetus.

The **Transverse fissure**⁷ is a deep groove passing at a right angle from the longitudinal fissure, between the quadrate and caudate lobes, to terminate on the under part of the right lobe. This fissure is the position at which the blood-vessels and nerves enter the liver, and the lymphatics and excretory duct emerge.

The **Quadrate lobe of the liver**⁸ is a square portion of hepatic substance situated between the gall-bladder on the right and the longitudinal fissure on the left, and extending from the anterior border of the organ back to the transverse fissure.

The **Caudate lobe**⁹ is a small blunt pyramidal mass of hepatic substance behind the transverse fissure, extending to the posterior notch of the liver, and having to its left the longitudinal fissure, and to its right the groove for the inferior cava. A short isthmus or **caudate process**¹⁰ associates it, in front of the latter vessel, with the under surface of the right lobe.

¹ This divergence is usually and incorrectly described as if it were a distinct structure, under the name of the coronary ligament; l. coronarium.

² Great, or horizontal fissure, furrow, or sulcus; fossa umbilicalis; sulcus antero-posterior jecoris; sulcus sinister, or umbilicalis jecoris.

³ Fossa longitudinalis sinistra.

⁴ Pons, or isthmus hepatis.

⁵ Ligamentum teres.

⁶ Fossa ductus venosi.

⁷ Sulcus transversus; fossa transversa; sinus portarum; porta; p. hepatis, or

jecoris; manus hepatis, or jecoris; principal fissure; fissure or fossa of the portal vein; portal fissure or fossa.

⁸ Lobulus quadratus; l. anonymous; l. accessorius anterior quadratus; anterior portal eminence; auriga anonymous.

⁹ Lobulus Spigelii; the Spigelian lobe; lobulus porticus papillatus; tuberculum papillare; posterior portal eminence; small, duodenal, or pancreatic lobe.

¹⁰ Lobulus caudatus; lobus, or processus caudatus; tuberculum caudatum.

notes in fig 232

The liver derives its blood from two different sources, in this respect being quite peculiar among the organs of the body. It is supplied with red blood by a proportionately small vessel, the **hepatic artery**, and is provided with dark blood by a larger vessel, the **portal vein**. The two vessels together enter the transverse fissure of the liver, the artery in front of the vein, and both divide into two branches, which pass to the right and left lobes, and ramify through them in a divergent manner from below upward, and toward the borders of the organ.

The **bile ducts**,¹ originating in the hepatic substance, converge in the course of the vessels just mentioned, and emerge into the transverse fissure of the liver; a branch from the right and another from the left lobe conjoining to form the trunk of the **hepat'ic duct**.

Numerous lymphatics, and nerves from the pneumogastrics and sympathetics, pursue the same course as the above-mentioned blood-vessels and ducts, the whole together being enveloped by connective tissue.²

The **hepat'ic veins** collect the blood from the substance of the liver and return it to the general circulation. Commencing at the periphery of the organ, they emerge from before backward, and terminate, at the posterior notch of the liver, in two principal trunks which join the inferior cava.

The relative position of the hepatic veins with the other vessels of the liver bears a resemblance to a prostrate tree whose boughs and branches are entangled among those of a clump of upright trees.

STRUCTURE OF THE LIVER.

The liver is closely invested with a serous coat derived from the peritoneum, which everywhere covers it except along the posterior border, in the intervals of the suspensory and lateral ligaments, and at the bottom of its fissures. The subserous connective tissue³ is feebly developed, but a stronger and distinct extension of the same structure invests those portions of the liver which are destitute of peritoneum. In the transverse fissure the investing connective tissue of the liver is continuous with that enveloping the vessels and ducts.

The material composing the liver, and named the **hepat'ic substance**,⁴ has a reddish-brown color tinged with yellow, and has a finely and uniformly mottled aspect, which is much more evident in some of the infe-

¹ Biliary ducts: *pori biliarii*; *ductus biliarii*.

² Capsule of Glisson; *c. communis Glissoni*; *vagina portæ*; *v. Glissoni*.

³ *Tunica propria*.

⁴ *Parenchyma hepatis*; *parenchyma of the liver*.

rior animals than in man, as for instance in the hog. It is readily torn, and in this condition presents a coarsely granular appearance. The coarse granules corresponding with the distinct spots seen on the surface of the liver are polyhedral, from half a line to one line in diameter, and are named the *lob'ules of the liver*.¹

FIG. 233.

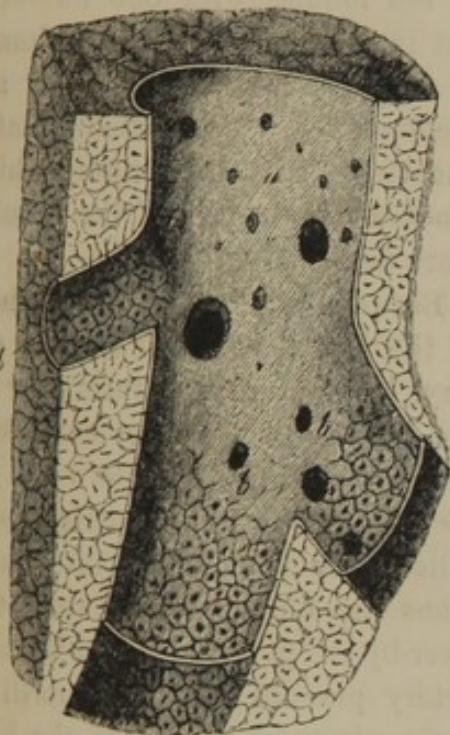


FIG. 234.

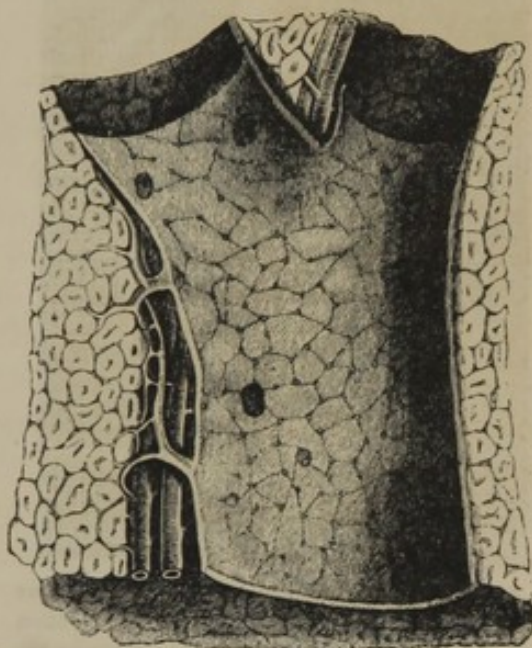


Fig. 233. PORTION OF THE LIVER OF THE HOG, exhibiting the lobular structure and the section of a hepatic vein, somewhat magnified. *a*, Large branch of the hepatic vein; the orifices belong to other branches; *b*, branches exhibiting through their thin walls the outlines of the lobules; the dots in the centre of the latter are orifices of the veins commencing within the lobules.

Fig. 234. PORTION OF THE LIVER OF THE HOG, exhibiting the lobular structure. The large vessel is a branch of the portal vein, the outlines of the lobules being seen through its transparent wall. The orifices, large and small, seen in the portal vein, are fine branches sent between the lobules. The two vessels lying to the left of the portal vein are branches of the hepatic artery and duct.

In tracing the relation of the hepatic lobules with the blood-vessels and ducts of the liver, it is found that an extreme branch² of the hepatic veins commences in the axis of every lobule, and emerges at its base to join a larger branch.³ This arrangement of the hepatic lobules and veins resembles the attachment of leaves by their midribs and stems to the branches of a tree. The portal vein, hepatic artery, and hepatic duct, associated together by connective tissue,⁴ ramify through appropriate canals⁵ of the hepatic substance, pursuing the same general course

¹ Acini.

² Intra-lobular vein; vena centralis.

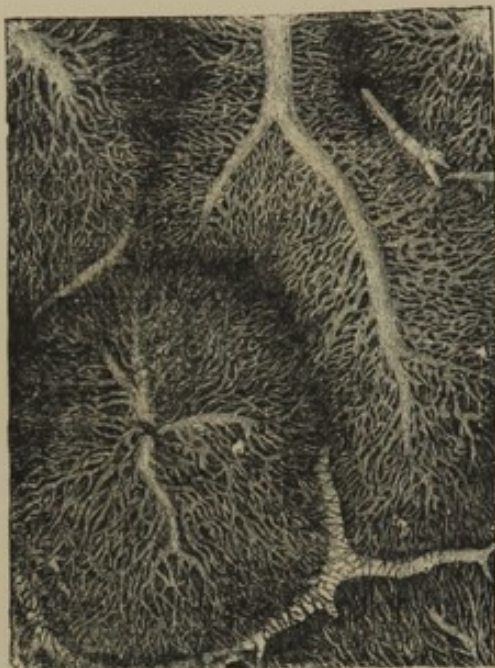
³ Sub-lobular vein.

⁴ Capsule of Glisson.

⁵ Portal canals.

in relation with the branches of the hepatic veins which has been indicated in the account of the arrangement of their trunks. Finally, the portal vein, hepatic artery, and the bile ducts ramify in the interspaces¹ of the lobules, forming plexuses,² and associating the latter together.

FIG. 235.



SECTION OF SEVERAL LOBULES OF THE LIVER OF THE RABBIT, the vessels injected, and the preparation magnified. The intricate capillary net-works are formed from the portal veins between the lobules, and the hepatic veins within them.

In the human liver, these intervening vessels are the chief connection of the lobules with one another; but in some of the lower animals, as for instance the hog, they are accompanied with a much greater quantity of connective tissue, which renders the outlines of the lobules more defined.

Between the terminal branches³ of the portal vein and hepatic artery, occupying the intervals⁴ of the lobules and the commencing branches⁵ of the hepatic veins in the axis of the latter, intricate capillary vascular nets⁶ intervene. Thus the blood which enters the liver by the portal vein and hepatic artery pursues its course until it arrives in the intervals of the lobules, when it meanders through the capillary nets to the commencement

of the hepatic veins in the interior of the lobules.

The meshes or interspaces of the capillary vascular nets are occupied by the proper secreting substance of the liver, constituting the **hepatic cells**.⁷ These are irregularly polyhedral, from the $\frac{1}{2000}$ to the $\frac{1}{1000}$ of an inch in diameter, with soft granular contents, some minute oil globules, and a nucleus. Generally, two hepatic cells are about equal to the diameter of the meshes they occupy, though frequently a single cell is observed extending across the interval.

From the description given, it may be readily comprehended that the hepatic lobules are composed of capillary vascular nets, intercalated

¹ Interlobular spaces.

² Interlobular veins, arteries, and ducts.

³ Interlobular veins and arteries.

⁴ Interlobular spaces.

⁵ Intralobular veins.

⁶ Lobular plexuses.

⁷ Liver cells; hepatic corpuscles.

with hepatic cell-nets, as represented in the diagram, figure 237. So far, anatomists concur in their observations on the structure of the liver; but in regard to the exact relationship of the hepatic cell-nets with the bile ducts¹ there exists much conflict of opinion. According to one view, the hepatic cell-nets are solid, and the bile ducts originate at the boundaries of the lobules. In a second view, intercellular passages of the hepatic cell-nets communicate with the commencement of the bile ducts in the interspaces of the lobules. According to a third view, a third net, composed of very fine tubes of basement membrane, is intercalated with the capillary vascular, and hepatic cell nets, and joins the bile ducts in the interspaces of the lobules. Finally, in a fourth view, as in other true glands, the hepatic cells are considered as lining tubes of basement membrane, from which the bile ducts originate in the intervals of the lobules.

FIG. 237.

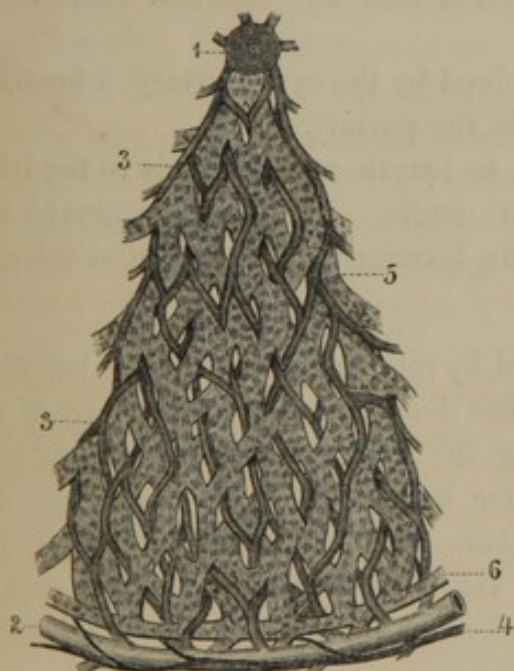

Fig. 237. DIAGRAM REPRESENTING THE SECTION OF A LOBULE OF THE LIVER, exhibiting the relative position of the hepatic cell-nets with the vascular nets. 1, section of a hepatic vein in the centre of a lobule; 2, branch of the portal vein at the circumference of the lobule; 3, capillary net formed between the portal and hepatic veins; 4, branch of the hepatic artery; 5, hepatic cell-net in the interior of the lobule; 6, a bile duct at the boundary of the latter.

FIG. 238.

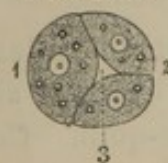

Fig. 238. DIAGRAM REPRESENTING A TRANSVERSE SECTION OF ONE OF THE CORDS OF THE HEPATIC CELL-NET, showing how a few cells may form a hollow tube. 1, large cell; viewed from this side the tubes would appear to be the breadth of a single cell; 2, two cells the diameter of the tube; 3, passage-way for the bile.

¹ Interlobular ducts; pori biliarii.

BILIARY DUCTS AND GALL-BLADDER.

The **Hepat'ic duct**,¹ commencing by two branches in the transverse fissure of the liver, descends within the right border of the gastro-hepatic omentum, in advance of the portal vein and to the right of the hepatic artery. It is about two inches in length, and terminates, by joining with the **cyst'ic duct** from the gall-bladder, to form the **common bil'iary duct**.

The **Gall-bladder**,² the receptacle of the bile, is a pyriform sac, partially lodged in a fossa on the under part anteriorly of the right lobe of the liver. Its **fundus** or base projects beyond the anterior border of the latter, in the vicinity of the tenth costal cartilage; and its **body** or main portion extends in a backward direction. Its neck forms an S-like convolution, and terminates at the transverse fissure by becoming the **cyst'ic duct**.

The gall-bladder is attached in its fossa of the hepatic substance by connective tissue, and its free part, including the fundus, is covered by the peritoneum. Independent of the latter membrane, its wall is provided with a strong layer of fibrous tissue, and a thin, diffuse stratum of pale unstriated muscular fibres. Its lining mucous membrane, stained yellow from the bile, is uniformly covered with fine reticular folds, and has a columnar epithelium.

The gall-bladder is supplied with blood by the cystic artery, a branch of the hepatic.³ Its veins terminate in the portal vein.

The **Cyst'ic duct**³ is about an inch in length, and descends to the left to join the hepatic duct at an acute angle. Its lining membrane is thrown into a series of oblique folds, forming a sort of spiral valve,⁴ which retards the flow of the bile.

The **Common bil'iary duct**,⁵ formed by the conjunction of the hepatic and cystic ducts, is about three inches long, and of the diameter of a large goose-quill. Continuing along the right border of the gastro-hepatic omentum, it pursues its course behind and to the inner side of the descending portion of the duodenum, and terminates in the latter, about four inches from the stomach. Its lower portion is involved in the head of the pancreas, and then perforates the wall of the duodenum

¹ Ductus hepaticus.

² Vesicula bilis; v. or folliculus fellis; vesica fellea; v. biliaria; cystis fellea; cholecystis.

³ Ductus cysticus; meatus cysticus.

⁴ Valvulus spiralis Heisteri.

⁵ Ductus communis choledochus; d. choledochus; d. hepato-cysticus; choledochus; common bile duct.

obliquely. Its orifice is narrowed, and opens at the summit of a slight papillary eminence.

The common biliary, cystic, and hepatic duct and its branches have the same structure. They have a strong fibrous coat, with a few unstriated muscular fibres, and a lining mucous membrane. The latter is provided with many minute racemose glands; and it has a columnar epithelium, except in the small bile ducts, where the epithelium assumes the tessellated form.

The secretion of the liver, named the **bile**,¹ as obtained from the human gall-bladder, is a thin, glairy, dark, yellowish-brown liquid, of bitter taste, and nearly neutral in reaction when fresh. It is exceedingly complex in chemical composition; and though an abundant secretion, and a very constant one in animals, its uses have not yet been satisfactorily determined.

THE SPLEEN.

The **Spleen**² is a half-ovoidal body, deeply situated in the left hypochondriac region. It is of comparatively soft consistence, and of a livid, purplish color. Its long diameter is vertical, with the larger extremity upward and attached to the diaphragm by a doubling of peritoneum, the **suspensory ligament**. Its external convex surface is directed toward the left side, and is in contact with the diaphragm opposite the three or four lower ribs. Its internal surface, slightly depressed in front and behind and elevated toward the middle, is directed to the right side, and applied to the fundus of the stomach, to which it adheres by the **gastro-splenic omentum**. Its posterior border is thick and rounded, and rests against the contiguous kidney and the diaphragm; its anterior border is thinner, and at the lower part usually exhibits one or two notches or clefts.

Along the middle of the internal surface of the spleen, usually indicated by a slight groove named the **hilus**,³ the splenic vessels and nerves pass to and from the organ.

The spleen is very variable in size, even in the condition of health, and is liable to great changes in this respect in certain diseases. Ordinarily it is four or five inches long, three or four broad, and from one to one and a half thick; and weighs about six ounces.

The spleen is provided with two coats, of which the outer is serous,

¹ Bilis; cholos; fel; the gall.

² Lien; splen; hepar sinistrum; h. adulterinum; fomes ventriculi; milt.

³ Porta lienis.

and the inner one fibro-elastic. The **serous coat** derived from the peritoneum is thin, transparent, smooth, and tightly adherent to the contiguous structure beneath.

The **fibro-elastic coat**¹ is a moderately strong, extensible layer, composed of interlacing bundles of fibrous tissue mingled with fibres of elastic tissue. At the hilus it becomes continuous with a similar investment to the splenic blood-vessels as they ramify through the organ.

The spleen is easily torn; its lacerated surface presenting a deep reddish-black, or brown, pulpy appearance, resembling coagulated blood or dark currant-jelly. This dark substance, named the **splenic pulp**,² may be scraped from the torn surface, or it may be removed from portions of the spleen by maceration or repeated washings, leaving a spongy mass, composed of the splenic blood-vessels, associated with numerous bundles of fibro-elastic tissue. These bundles, named **trabec'ulæ**, spring from the interior surface of the fibro-elastic coat of the spleen, and form an intricate net-work or sponge-like arrangement which supports the splenic blood-vessels and contains within its meshes the splenic pulp.

The **pulp of the spleen**, examined with the microscope, is found to consist of the following elements: 1, numerous blood-corpuscles, for the most part unchanged, but many apparently exhibiting various conditions of disintegration; 2, finely granular matter, partly colorless, but mostly of various shades of red passing into brown; 3, numerous isolated nuclear bodies; 4, colorless nucleated cells; 5, a few cells containing blood-corpuscles apparently in a state of disintegration; and 6, occasionally red acicular crystals, derived from the decomposition of blood-corpuscles.

The arrangement of these different elements of the splenic pulp, in their relationship with one another and with the blood-vessels, has not yet been determined in a satisfactory manner.

Adhering to the sides of the smallest arteries of the spleen, and imbedded in the pulp, there exist certain small, rounded, whitish bodies, named **splenic corpuscles**.³ These are variable in number and size, usually measure about one-sixth of a line in diameter, and resemble, in composition, the solitary glands of the intestines.

In proportion to its size, the spleen is the most vascular organ of the body. The splenic artery divides into a half dozen or more branches, which diverge along the hilus and enter the spleen. Spreading through the organ in numerous ramifications, those of the different principal branches not anastomosing, they finally break up into a multitude of

¹ Tunica propria; t. albuginea.

² Pulpa lienis.

³ Corpuscles of Malpighi; Malpighian bodies.

pencil-like bundles of delicate vessels, which terminate in the capillaries of the splenic pulp. The veins return in the course of the arteries, with which they correspond in number, but are larger. The lymphatics are few in comparison with those of the other abdominal viscera. The nerves are derived from the solar plexus of the sympathetic system.

The function of the spleen, though the subject of numerous and laborious investigations, yet remains unknown. It has been supposed that the spleen acts as a reservoir or diverticulum to the blood during the state of rest of the digestive organs, and during those conditions in which the blood retires from the surface toward the interior of the body. It has also been looked upon as being the position in which the blood-corpuscles, after having fulfilled their function in the economy, undergo dissolution, yielding their chemical elements to the circulating liquor sanguinis. Further, it has been supposed to be the organ in which the blood-corpuscles have their origin.

CHAPTER VII.

THE VASCULAR SYSTEM.

THE **Vas'cular system** consists of the heart, blood-vessels, lymphatics, and their contained liquids, the blood and lymph. The heart is a powerful muscular organ, and is the chief agent in the circulation of the blood. The blood-vessels consist of branching tubes, named arteries and veins, and an intermediate set of tubes, called capillaries. The lymphatics consist of vessels and peculiar bodies, named lymphatic glands.

GENERAL CHARACTERS OF THE ARTERIES.

The **Ar'teries**¹ are cylindrical, membranous tubes, which commence in two great trunks, the aorta and pulmonary artery. They undergo division as in the branching of a tree, and distribute the blood throughout the body, terminating in the capillaries. Their branches mostly come off at acute angles, are commonly of uniform diameter in each case, but successively diminish after and in consequence of division; and in this manner gradually merge into the capillary system. As a general rule, the combined area of the branches is greater than that of the vessel from which they emanate, and hence the collective capacity of the arterial system increases with its distribution. This arrangement facilitates the circulation; for the increasing capacity of the vessels in their course compensates for the retarding influence of friction.

Arteries have comparatively thick walls, and even when emptied, as is usually the case after death, they for the most part maintain their open calibre. Generally they pursue a straight course, but are often curved, and are sometimes tortuous, especially in positions liable to frequent change of volume, or of expansion and contraction; as in the lips, the urinary bladder, the uterus, etc. The larger arteries are generally deeply situated, and frequently pursue their course along the bones, where they are protected from undue extension. In the limbs they occupy the sides of

¹ Sing.: arteria; pl.: arteriæ.

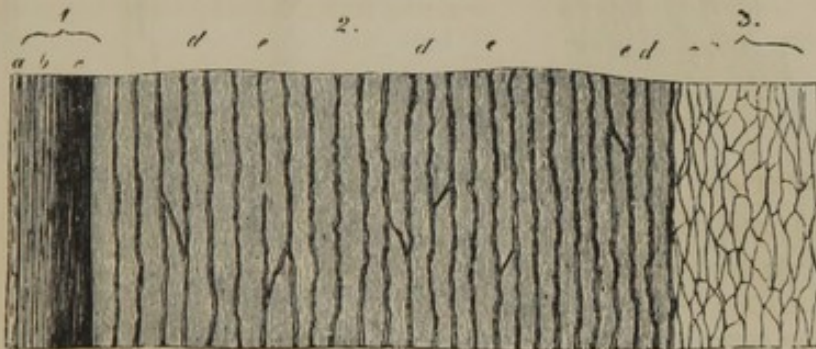flexion, where they are less exposed to a variety of accidents than if situated on the sides of extension.

Arteries, in their course of distribution, form intercommunications, named *anastomo'ses*,¹ which become more frequent as the vessels diminish in size. Even in many large vessels anastomoses are numerous, where it is important that the blood should be incessantly supplied to organs, as in the case of the arteries of the brain; or where the vessels are constantly exposed to the liability of pressure, as in the arteries of the hand and foot, those around the joints, and those of the abdominal viscera.

The arteries are highly elastic, being extensible and retractile both in length and breadth. During life, from their being provided with muscular tissue, they are also contractile.

The walls of the arteries are composed of three coats, which vary in vessels of different sizes.

FIG. 239.



TRANSVERSE SECTION OF THE WALLS OF THE AORTA, treated with acetic acid, and magnified. 1, internal coat: *a*, epithelium and basement membrane; *b*, *c*, layers of elastic tissue. 2, middle coat: *d*, layers of elastic tissue; *e*, muscular and connective tissue. 3, external coat, composed of fibrous tissue and fine nets of elastic tissue.

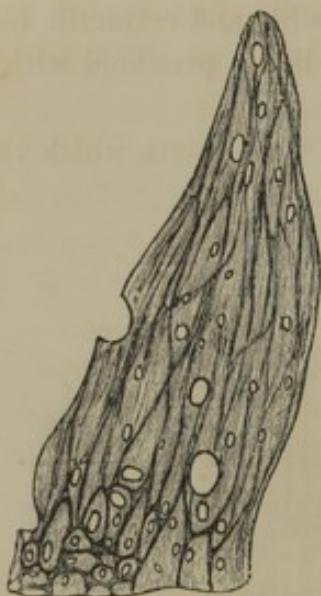The **external coat**² is comparatively thin in the largest arterial trunks; increases to half the thickness of the walls in the medium-sized arteries; becomes relatively thicker in the smaller branches; but finally disappears in those which merge into the capillaries. It is mainly composed of fibrous tissue, the bundles and filaments of which pursue a spiral direction, crossing one another from opposite sides of the vessel. Its exterior portion is of looser texture, and adheres to the surrounding parts; its interior portion is intimately blended with the middle coat. It contains fine nets of elastic tissue, which are most abundant toward the interior. To this coat the arteries chiefly owe their tenacity.

¹ Interosculation; inosculation; reuiones vasorum; exanastomoses; concursi.

² Tunica adventitia; t. externa; t. cellularis; vagina cellularis.

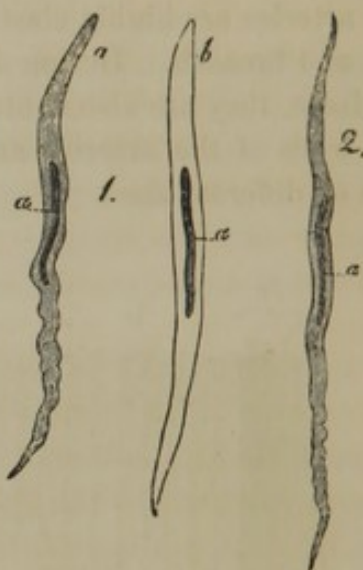
The **middle coat**¹ forms the principal thickness of the walls of the largest arterial trunks, gradually diminishes in their branches, and finally disappears. In the largest arteries it is of a yellowish color, and is mainly composed of elastic tissue, with a small proportion of unstriated muscular tissue and some connective tissue. In the medium-sized and smaller arteries it is of a reddish hue, and chiefly consists of muscular tissue, with a small proportion of elastic and connective tissue. In the smallest arteries the middle coat consists alone of muscular tissue.

FIG. 240.



ELASTIC TISSUE FROM THE MIDDLE COAT OF THE POPLITEAL ARTERY, highly magnified. The dark reticular lines indicate a narrow net of elastic tissue; the other part of the figure represents a layer of perforated membrane, which is a variety of the same tissue.

FIG. 241.



UNSTRIATED MUSCULAR FIBRES FROM THE MIDDLE COAT OF THE ARTERIES, highly magnified. 1, from the popliteal artery: *a*, without, and *b*, treated with acetic acid; 2, from a branch of the anterior tibial artery: *a*, pointing to the centre in all the figures, indicates the nucleus.

The elastic and muscular tissues are arranged in layers varying in number according to the thickness of the coat, and their fibres pursue a circular course around the vessels. The muscular fibres are fusiform, with elongated oval nuclei. The elastic tissue exhibits all varieties of form, from fine nets to broad-banded ones, constituting the so-called **perforated or fenes'trated membranes**.

To the middle coat arteries owe their contractility, most of their elasticity, and much of their strength; though it is of such a brittle character that the application of a ligature cuts or breaks it through.

The **internal coat**² of the arteries is the thinnest, most transparent, and elastic. It is composed of a lining epithelium, a basement membrane,

¹ T. media; t. elastica.

² Tunica intima; t. glabra; endangium.

and layers of elastic tissue. The epithelium consists of a single layer of elongated, lozenge-shaped cells, which are narrowest in the smallest arteries. The basement membrane is homogeneous and elastic, and is the last structure of the arteries becoming continuous with the capillaries. The elastic tissue consists of fibres, nets, and the so-called perforated membranes, pursuing a longitudinal direction, and intimately associated with the middle coat.

The larger arteries have their walls furnished with nutrient vessels, which are derived from small neighboring arteries, and not from the trunks they supply. The nutrient vessels form a net-work of capillaries, from which veins arise to empty into the contiguous larger venous branches. The arteries are accompanied by many nerves, chiefly from the sympathetic system, but to what extent their walls are supplied by them has not been satisfactorily determined.

The elasticity of the arteries allows them to dilate as each impulse of the heart sends an additional supply of blood to their circulating current. The dilatation moves rapidly onward in a wave-like manner, and insensibly decreases until it is entirely lost in the smallest arteries. It is followed by contraction of the arterial walls upon their contents, both in consequence of their elasticity and the excitation of their muscular structure. The alternation of dilatation and contraction of the arteries constitutes **pulsation or the pulse.**¹

GENERAL CHARACTER OF THE VEINS.

The **Veins**² are branching tubes like the arteries, but are generally larger, more numerous, and consequently more capacious. They commence in the capillary vessels, gradually converge in a reverse course mostly along side of the arteries, and, with one exception, terminate in the heart by seven trunks. Four of the latter are the pulmonary veins; the two largest ones are the superior and inferior cava, and the smallest is the coronary vein, derived from the walls of the heart itself. The exception is the portal vein, which derives its branches from the bowels, and is distributed through the liver.

The larger veins consist of a superficial and deep series; the former unassociated with arteries, and running immediately beneath the skin, the latter usually accompanying the arteries, and thence named **companion veins.**³ The arterial trunks and their large branches generally

¹ Pulsus; pulsatio; ictus, or incursus arteriarum.

² Sing.: vena; pl.: venæ; phlebs.

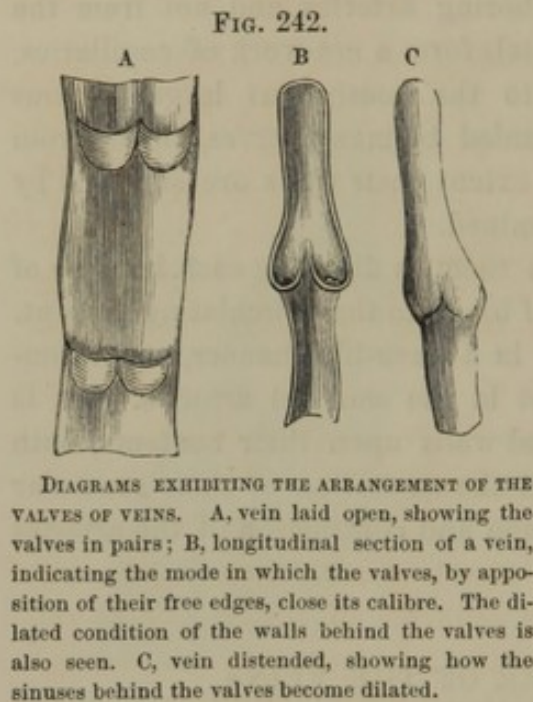
³ Venæ satellites; v. comites; v. concomites.

have one companion vein; but the medium-sized and smaller arteries usually possess a pair, arranged one on each side of the artery.

Anastomoses between veins of comparatively large size are much more frequent than among corresponding arteries; and in some positions they form coarse, intricate nets, named **venous plexuses**.

The veins have much thinner, but relatively stronger, walls than the arteries, and, after death, according to the quantity of their remaining contents, are found collapsed. Many of the larger ones are provided

with **valves**, which are so arranged as to prevent the reflux of blood. The valves are usually in pairs, opposite each other, and consist of crescentic doublings of the lining membrane of the veins, strengthened with some intervening fibro-elastic tissue. The convex border of the valves is attached; the concave border is free, and directed from the periphery of the body toward the heart. Behind each valve the vein is dilated into a pouch or sinus, which prevents the adherence of the valve to the side of the vein when the blood pursues its proper course. If the vein is



compressed, the blood driven back enters the sinus and presses the valve inward, so as to meet the opposite one in the middle of the channel, and thus close it.

The pulmonary veins throughout possess no valves, and this also is the case with the superior and inferior cava, the portal vein and its branches, the hepatic, renal, uterine, and spinal veins, and most of those of the head and neck. They are more abundant in the veins of the lower than in those of the upper extremities.

In certain membranes and some other organs, channels exist lined with an extension of the internal coat of the blood-vessels, and serving the function of veins. These channels are usually termed **venous sinuses**, as the sinuses of the dura mater, those of the bones, and of the uterus.

The walls of the veins, as in the arteries, are composed of three coats, having the same general character.

The **external coat** is the thickest, and gradually increases in this respect from the smallest to the largest veins. As in the arteries, it consists of fibrous tissue, with longitudinal nets of elastic tissue. In the

larger veins of the abdominal cavity it is also provided with unstriated muscular tissue, the lamina of which pursue a longitudinal direction.

The **middle coat** is best developed in the medium-sized veins, and disappears altogether in the smallest ones. As in the arteries, it consists of unstriated muscular, elastic, and connective tissue, the elements of which usually pursue a circular direction, though laminae of the elastic tissue also have a longitudinal direction. In the largest veins the middle coat contains a large proportion of connective tissue, and is sparingly provided with muscular tissue.

The **internal coat**, like that of the arteries, consists of a lining epithelium, an elastic basement membrane, and longitudinal laminae of elastic tissue, which, however, do not form fenestrated membranes.

The walls of the veins are furnished with nutritive vessels. A few nerves have been traced only in the larger veins. Both arteries and veins are insensible to painful impressions in a condition of health. The acute pain often evinced in the ligation of an artery is due to the inclusion of accompanying nerves.

THE CAPILLARIES.

The **Cap'illaries**¹ are minute blood-vessels usually arranged in the form of nets among the proper tissue elements of the organs of the body. They communicate with the termination of the arteries and the commencement of the veins, but are otherwise closed, or never communicate by open orifices with the structures in which they are distributed. The proper tissue elements are in all cases exterior to the capillary vessels, or occupy the meshes of the capillary nets; and they obtain their nutritive material simply by imbibition through the walls of the capillaries.

In any special structure the capillaries are remarkable for the general uniformity of their size, but in the different structures of the body they range from the $\frac{1}{300}$ to the $\frac{1}{100}$ of a line in diameter. The smallest admit the passage of blood corpuscles, though but a short time has elapsed since the opinion universally prevailed that in all structures of the body capillaries² existed which only transmitted the liquor sanguinis.

In structure the capillaries consist of tubes of transparent, elastic, structureless membrane with scattered oval nuclei. There is no lining epithelium, but only the single layer of membrane just described, which

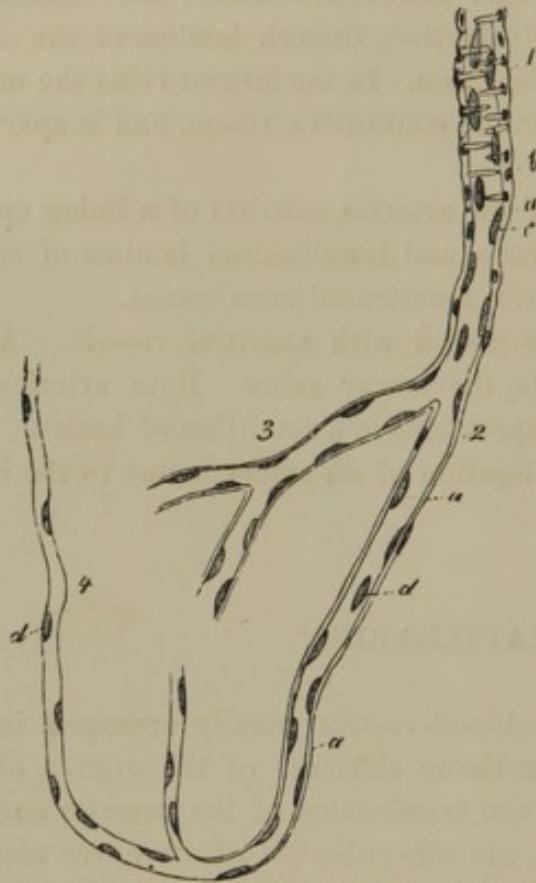
¹ Vasa capillaria; micrangia; trichangia.

² Vasa serosa.

is continuous with the basement layer of the internal coat of the arteries and veins.

The form of the capillary nets is in a measure dependent upon the ar-

FIG. 243.



A SMALL ARTERY gradually passing into the structure of the capillary vessels. 1, artery with transverse muscular fibres; *a*, structureless membrane; *b*, nuclei of transverse muscular fibres; *c*, nuclei of structureless membrane; 2, 3, 4, capillaries composed of structureless membrane (*a*) with scattered nuclei (*d*).

angement of the proper elements of the tissues they supply. Thus, in the lungs, the nets accommodate themselves to the form of the air-cells; in the muscles, they have elongated meshes, most of the vessels pursuing the course of the muscular fibres, and being connected by short ones crossing the latter, etc.

In many instances, especially within papillary eminences, the capillaries form loops, as in the papillæ of taste and of touch.

The greater the vital activity of an organ, the more dense or close is the capillary net; or, in other words, the greater is its degree of vascularity. The capillary net or plexus is closest in the lungs, the

glands, especially the liver and kidneys, the skin and mucous membranes, the muscles, and the gray nerve substance. In the fibrous tissues and the bones the nets have wide meshes, and, of course, comparatively few vessels.

THE BLOOD.

The **Blood**¹ constitutes the circulating contents of the heart, arteries, capillaries, and veins. It is a highly complex liquid, furnishing nutritive material to all the tissues of the body. It is somewhat viscid, and heavier than water—its specific gravity being about 1055. When fresh, it appears to the naked eye perfectly homogeneous, and of a more or

¹ Sanguis; cruor; hæma; lapis animalis.

less deep-red hue. It has an alkaline reaction, a saline taste, and a feeble peculiar odor. Its color varies in different vessels, and according to its degree of accumulation. A thin stratum always appears light red, and the color is deepened by an increase in the thickness of the stratum. In the pulmonary veins, the renal veins, the aorta and its branches, it appears bright red; in the superior and inferior cavæ and their branches generally, in the portal veins and the pulmonary arteries, it resembles in color the pulp of the black-heart cherry, or is of a deep-maroon hue.

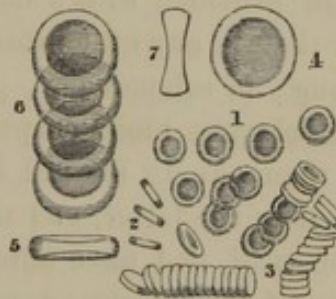
The amount of blood in the adult varies with the bulk and organic activity of the individual, but may be stated to be about equal in weight to one-tenth of the body.

When the blood is examined by means of the microscope, spread in a thin layer on a plate of glass, or while circulating in the capillaries, it is observed to consist of a colorless liquid, named the *liquor sang'-uinis*, and a multitude of minute circular bodies called *blood cor'-puscles*.¹ These are of two kinds, red and colorless corpuscles, of which the former very greatly predominate and give to the blood its color.

The *red blood cor'puscles*² are so exceedingly small and numerous that a single drop of blood a couple of lines in diameter contains about 100,000,000 of them. They are biconcave disks with rounded borders, resembling in shape the familiar article of food commonly known as the water cracker. They vary in diameter, but average about the $\frac{1}{300}$ of a line in breadth, with about a fourth of that thickness. They are elastic, and appear homogeneous, presenting no trace of granular contents or nucleus. Isolated, they appear of a yellowish hue, and it is only by their accumulation that they give rise to the decided red color of the blood.

Through evaporation of the containing liquid, as exposed upon the slip of glass on which the blood corpuscles are observed, they assume a

FIG. 244.



RED BLOOD CORPUSCLES, highly magnified. 1, corpuscles seen on their broad surface; 2, seen on their edge; 3, rolls of corpuscles, indicating the manner in which they are frequently observed to arrange themselves. The remaining figures more highly magnified: 4, corpuscle seen on its broad surface; 5, seen on its edge; 6, a series of corpuscles; 7, a corpuscle in section, indicating its biconcave discoidal form.

¹ Blood globules, or vesicles; globuli, vesiculæ, sphærulæ, corpuscula, folliculi, cellulæ, particulæ, or granula sanguinis.

² Blood disks

tuberculated and irregular stellated appearance. In water they swell up, become paler and spherical, and finally burst, exuding a faintly-colored liquid, and leaving a structureless membrane of extreme tenuity behind. When viewed in any quantity on a glass slide beneath the microscope, the blood corpuscles are frequently observed with a disposition to arrange themselves into piles or columns, a tendency which becomes more marked in the blood of inflammation.

The size, form, and constitution of the red blood corpuscles vary in different animals. In all mammals except the camel tribe, they are circular, and have the same constitution as in man, but are generally smaller. In the elephant they are larger, though there is no general relationship between the size of the corpuscles and that of the animal; thus, they are larger in the rat than in the horse, and are smallest in the musk deer. In the camel tribe, birds, reptiles, and fishes, they are elliptical, and are provided with a nucleus. In the batrachian reptiles they are larger than in any other animals; thus, in frogs they measure the $\frac{1}{80}$ of a line long; in salamanders, $\frac{1}{50}$; and in the proteus, $\frac{1}{40}$ of a line.

The **colorless blood corpuscles**¹ are comparatively few in number—not more than one to several hundred of the red corpuscles. They are larger than the latter, and measure about the $\frac{1}{250}$ of a line in diameter, are spherical, and have faintly granular contents and a nucleus.

Most of the colorless corpuscles are derived from the lymph, which, as will hereafter be seen, pours into the blood-vessels; but some of them also appear to originate in the spleen. According to the observations of T. W. Jones, their nuclei finally become red blood corpuscles.

The **liquor sang'uinis**,² or **blood liquor**, is a pale, amber-colored liquid which holds the blood corpuscles in suspension. It is remarkable for its tendency to coagulate or assume the solid condition upon removal from the circulating current, which change depends on its holding fibrin in solution. It is highly important as being the nutritive liquid which is imbibed from the capillaries by all the tissues of the body.

When blood is removed from the circulation it ordinarily coagulates or solidifies in a few moments. The **coag'ulum** or **clot**³ then slowly contracts, and expresses from the mass a clear amber-colored liquid, called the **serum**, in which the remainder of the clot floats.

The **se'rum**⁴ is the liquor sanguinis deprived of its fibrin, which in

¹ White globules; leucocytes; lymph corpuscles.

² Plasma; coagulable lymph; plastic lymph; hæmatoplasma; mucago; mucilage; intercellular fluid.

³ Crassamentum; cruor; insula; thrombus; placenta sanguinis, or cruoris; hepar sanguinis.

⁴ Ichor sanguinis; hæmydor.

coagulation entangles the blood corpuscles and thus forms the clot. The relation of the different constituents of liquid and coagulated blood may be understood by reference to the following plan :—

Liquid blood {	Corpuscles	} Clot	} Coagulated blood.
	Liquor sanguinis... { Fibrin Serum		

The coagulated fibrin of the blood, examined with the microscope, exhibits a fibrillated appearance, thus apparently indicating that the ready coagulation of this material is a step toward organization, or the production of definite form in a living body.

The blood of the hepatic veins, and that which escapes from the torn vessels of the uterine mucous membrane during the menstrual period, ordinarily does not coagulate, thus indicating the absence of fibrin.

The composition of the blood varies in the quantity of its chemical ingredients not only in different sexes, ages, individuals, and conditions of health, but also in different parts of the body.

A thousand parts of blood by evaporation are found to contain on an average about 790 parts of water and 210 parts of solid materials. The same quantity of blood consists of about 513 parts of blood corpuscles and 487 parts of liquor sanguinis. The chemical constituents of these, according to recent analyses, appear to be as follows :—

513 parts of blood corpuscles contain :	Water.....	350
	Globulin with Iron.....	151
	Hæmatin with Iron	8
	Chloride of potassium; phosphates of potasssa, soda, lime, and magnesia; soda, and sulphate of potassa.....	4
	Water.....	440
487 parts of liquor sanguinis contain :	Albumen.....	40
	Fibrin.....	3
	Chloride of sodium and potassium; phosphates of soda, lime, and magnesia; soda, and sulphate of potassa.....	4

THE HEART.

The **Heart**,¹ the great central power of the circulation of the blood, is situated within the cavity of the thorax, inclosed by a fibro-serous sac, the pericardium. It lies between the lungs, resting upon the diaphragm, and encroaches more on the left than on the right side. Its shape is conical, and its position oblique. It is everywhere free or un-

¹ Cor; cardia.

attached except at the base, by which it is suspended, through means of the blood-vessels emanating therefrom, to the front of the vertebral column.

FIG. 245

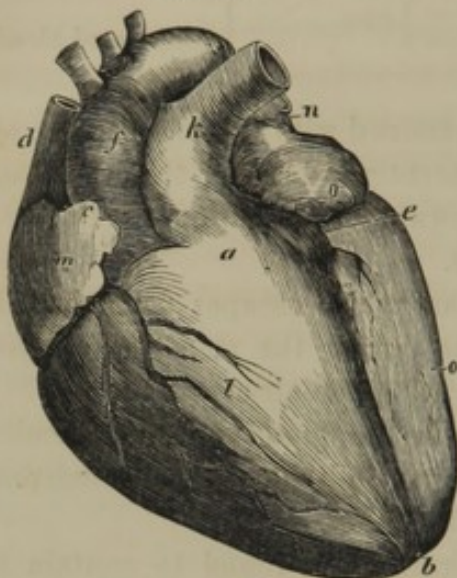


FIG. 246.

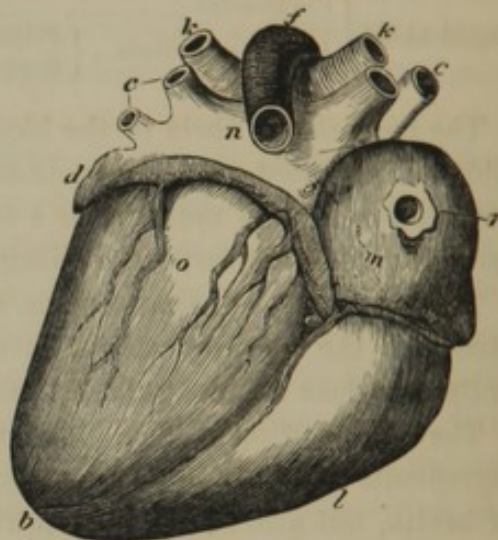


Fig. 245. FRONT VIEW OF THE HEART. *a*, base of the ventricles; *b*, apex; *c*, auricular appendage of the right auricle; *d*, superior cava; *e*, longitudinal groove separating the ventricles; *f*, aorta; *k*, pulmonary artery; *l*, right ventricle; *m*, right auricle; *n*, left auricle; *o*, its auricular appendage; the second letter *o* below indicates the left ventricle.

Fig. 246. POSTERIOR OR LOWER SURFACE OF THE HEART. *b*, apex of the heart; *c*, the four pulmonary veins; *d*, left auricular appendage; *e*, termination of coronary vein into the right auricle; *f*, aorta; *k*, right and left pulmonary arteries; *l*, right ventricle; *m*, right auricle; *n*, left auricle; *o*, left ventricle; *r*, orifice of the inferior cava.

The **base** of the heart is directed upward, backward, and to the right, and reaches from about the fourth to the eighth dorsal vertebra. The **apex** or **point**¹ is directed downward, forward, and to the left, and is opposite the sixth costal cartilage. The **anterior surface** is convex, and directed upward and forward; the **posterior surface** is flattened, and in contact with the diaphragm. Of the two **sides** or **borders** the left one² is the more obtuse, and is directed obliquely upward; the right one³ is the longer, and is directed obliquely downward.

The heart is a hollow muscular organ with a membranous investment and lining. It is brown in color, marked with white membranous streaks or patches, often rendered yellow from the presence of adipose tissue. Its average weight is about ten ounces; its length about five inches, and its breadth about three and a half inches. Its surface exhibits a **longitudinal** and a **transverse groove**⁴ which indicate a division of the organ into four parts, named auricles and ventricles.

¹ Mucro.² Margo obtusus.³ Margo acutus.⁴ Sulcus longitudinalis, and circularis, or coronalis.

The **Au'ricles**¹ are thin-walled cavities forming the basal portion of the heart, and are so called from their fore part being prolonged into an auricular or ear-like appendage. They are separated by a partition,² and are connected with the great venous trunks—the cavæ and pulmonary veins, through which they receive the blood from all parts of the body. They communicate with the ventricles, each by a large aperture, the **auric'ulo-ventric'ular orifice**,³ which is furnished with a remarkable mechanism of valves, allowing the transmission of the blood from the auricles into the ventricles, but preventing it in a reverse course.

The **Ven'tricles**⁴ are thick-walled cavities, forming the more massive portion of the heart toward the apex. They are separated by a partition,⁵ and are connected with the great arterial trunks—the pulmonary artery and aorta—by which they send the blood to all parts of the body. Another remarkable arrangement of valves at the mouths⁶ of the vessels just named prevents the reflux of the blood into the ventricles.

The **Right Au'ricle**⁷ consists of an oblong portion, the **si'nus**,⁸ with a triangular, somewhat indented **auric'ular appendage**,⁹ which projects forward to the outer side of the origin of the aorta. Its walls are thin and translucent, but are more thickened at the fore and outer part, and in the auricular appendage, by means of isolated fleshy fasciculi named **pectinate muscles**.¹⁰ When these are present, the interior surface of the auricle is rendered uneven by their prominence, but elsewhere it is smooth.

Into the back part of the right auricle the superior and inferior cavæ open with a direction forward, and thus produce between them an obtuse angle,¹¹ which is slightly prominent on the interior of the auricle. The orifices of the two veins are unprotected by valves, but from the direction of the two vessels their currents of blood are not opposed, but cross each other as they enter the auricle.

On the interior surface of the right auricle, corresponding with the partition separating it from the left auricle, there exists a shallow **oval fossa**¹² or depression, surrounded by a prominent border.¹³ The fossa

¹ Atria; sinus; cor venosum; cor membranosum; cavitates innominatæ.

² Septum atriorum.

³ Ostium atrio-ventriculare; o. ventriculi venosum; ostium venosum.

⁴ Ventriculi; cor arteriosum; cor musculosum; specus cordis.

⁵ Septum ventriculorum.

⁶ Ostia arteriosa.

⁷ Atrium dextrum; a. anterius; a. venarum cavarum.

⁸ Sinus dexter cordis; sinus, or saccus venarum cavarum; sinus venosus.

⁹ Auricula cordis dextra.

¹⁰ Musculi pectinati; trabeculæ carneæ.

¹¹ Tuberculum Loweri.

¹² Fossa, or fovea ovalis.

¹³ Annulus ovalis; limbus foraminis ovalis; isthmus Vieussenii.

indicates the position during foetal life of an orifice, named the **oval foramen**,¹ by which the two auricles communicate. The thin, translucent bottom of the fossa, in the foetus, forms a valve² which prevents a reflux of blood through the oval foramen. Not unfrequently the upper part of the fossa is found to have an oblique slit remaining as part of the free communication of the auricles in foetal life.

Anterior to birth, a crescentic, membranous fold, named the **Eustachian valve**,³ extends from the right of the orifice of the inferior cava, along its anterior border to the oval foramen, and serves to direct the current of blood from that vessel through the foramen. In the adult, the remains of this valve, usually more or less perforated in a reticular manner, are still observable.

Between the left extremity of the Eustachian valve and the auriculo-ventricular orifice is situated the aperture⁴ of the coronary vein, protected by a crescentic valve.⁵ A number of apertures⁶ of small veins are also to be detected at various points of the interior surface of the right auricle.

The **right auric'ulo-ventric'ular orifice**⁷ is placed in advance and to the left of that of the inferior cava. It is oval, about an inch in diameter, and has a smooth, slightly prominent border,⁸ giving attachment to the tricuspid valve.

The **Left Auricle**⁹ has a cuboidal **sinus**¹⁰ and an elongated, indented **auricular appendage**, projecting forward to the left of the origin of the pulmonary artery. Its walls are thicker, and not so translucent as in the right auricle. The interior surface is smooth, except within the auricular appendage,¹¹ which is provided with **pectinate muscles**.

At the back part of the left auricle the four pulmonary veins open, two on each side; and their orifices are unprotected by valves. At the lower fore part of the cavity is situated the **left auriculo-ventricular orifice**,¹² which is constructed like that in the right side of the heart.

x

The **Right Ven'tricle**¹³ is pyramidal, with its base upward and back-

¹ Foramen ovale; f. Botale; f. of Botal.

² Valvula foraminis ovalis.

³ Valvula Eustachii; valvula foraminis ovalis anterior.

⁴ Orificium venæ magnæ coronariæ.

⁵ Valvula Thebesii.

⁶ Foramina Thebesii.

⁷ Ostium atrio-ventriculare dextrum; ostium venosum dextrum.

⁸ Annulus fibro-cartilagineus; tendo

cordis venosus; circulus callosus Halleri.

⁹ Atrium sinistrum.

¹⁰ Sinus sinister cordis; s. pulmonalis; s., or saccus venarum pulmonalium; s. arteriosus; atrium cordis sinistrum.

¹¹ Auricula cordis sinistra.

¹² Ostium venosum sinistrum.

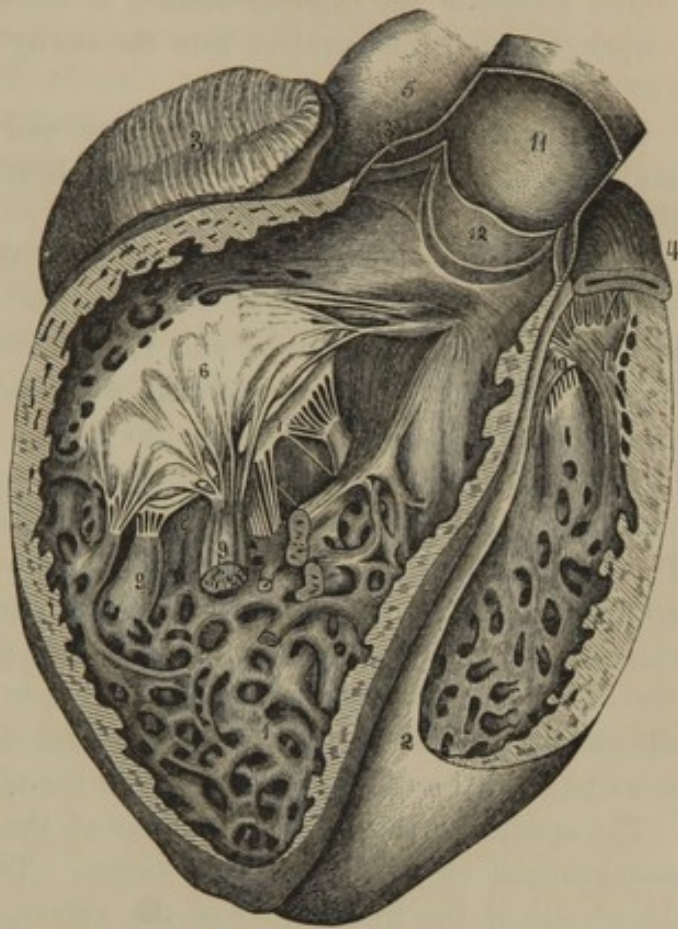
¹³ Ventriculus dexter; v. anterior; v. pulmonalis; v. primus; cor venosum; cor pulmonale.

ward, and joined to the corresponding auricle; its apex is downward and forward, and does not quite reach the point of the heart. It occupies more of the front surface of the heart than the left ventricle; and its walls, much thinner than in the latter, are about the fourth of an inch in thickness. The left wall, which forms the **partition**¹ between the ventricles, bulges into its cavity, so that this appears crescentic in a transverse section.

The interior surface of the right ventricle is rendered exceedingly uneven by numerous projecting, rounded, fleshy fasciculi, named the **carneous columns**.² These are of various sizes, and pursue different directions—springing from one part of the walls, sinking into another, and producing an intricate interlacement. Some of them, larger than the others, and named from their shape **papillary muscles**,³ project from the ventricular wall and end in narrow **tendinous cords**, which are inserted into the free borders of the tricuspid valve.

The **right auric'ulo-ventric'ular orifice**⁴ opens into the ventricle at the lower back part of its base. From its boundary projects a broad membranous fold, irregularly divided into three parts, and named, from this circumstance, the **tricuspid valve**.⁵ The free borders and

FIG. 247.



VIEW OF THE HEART, WITH THE ANTERIOR PORTIONS OF THE VENTRICLES REMOVED. 1, interior of the right ventricle, exhibiting its carneous columns; 2, left ventricle; 3, right auricle; 4, left auricle; 5, aorta; 6, 7, 8, tricuspid valve; 9, papillary muscles attached by tendinous cords to the tricuspid valve; 10, mitral valve; 11, pulmonary artery laid open; 12, one of the semilunar valves: the other two are seen in section on each side of the former; 13, sinus or dilatation of the artery behind one of the semilunar valves.

¹ Septum ventriculorum.

² Columnæ carneæ; trabeculæ carneæ; columnæ, trabeculæ, trabes, funes, fasciculi teretes, lacerti, or lacertuli cordis.

³ Musculi papillares.

⁴ Ostium atrio-ventriculare dextrum.

⁵ Valvula tricuspidalis; valvulæ tricuspidæ; v. trisulcæ; v. triglochines.

contiguous under surface of the valve are attached by numerous **tendinous cords**,¹ as above indicated, to the papillary muscles, and also to intervening points of the interior surface of the ventricle. When the valve is open, the divisions project into the cavity of the ventricle in contact with its sides.

In structure, both the tricuspid valve and tendinous cords consist of doublings of the lining membrane of the heart, strengthened by included fibrous tissue.

From the anterior angle of the base of the right ventricle, the pulmonary artery has its origin. The orifice² of this vessel is provided with three semilunar valves, and the interior surface of the ventricle conducting to it is smooth, so that no impediment is presented to the current of blood in its passage to the artery.

The **semilunar valves**³ of the pulmonary artery, as expressed in the name, are three crescentic membranous doublings arranged in a circle. Their convex border is attached around the boundary of the orifice of the artery, and their free border is directed into the latter. Behind each valve the artery is dilated into a shallow pouch or **sinus**,⁴ which prevents the valve, when open, from adhering to the side of the artery, and allows the blood in its reflux to get behind the valve and press it down, so as to meet the others and thus close the orifice.

The semilunar valves are doublings of the vascular lining membrane, strengthened by included fibrous tissue. The latter forms a nodule⁵ at the middle of the free border of the valves, which serves as a common central point of contact when they are closed. Between the nodule and the ends of each valve, just within the position of the free border, there exists a pair of thin lunated spaces,⁶ arising from a deficiency of the fibrous basis of the valve. When the valves are shut, these spaces are applied by their opposed surfaces to one another, and completely prevent the entrance of blood into the ventricle; while the force of the reflux is sustained by the stronger portions of the valves.

The **Left Ven'tricle**⁷ is conical, with its base connected to the corresponding auricle, and its apex forming the point of the heart. It is longer, and contributes more to the posterior surface of the heart than

¹ Chordæ tendineæ.

² Ostium arteriosum dextrum.

³ Valvulæ semilunares; v. sigmoideæ; processus sigmoideus.

⁴ Sinus of Valsalva; sinus pulmonalis.

⁵ Corpusculus, globulus, or nodulus

Arantii, or Morgagni; corpusculum sesamoideum.

⁶ Lunulæ.

⁷ Ventriculus sinister; v. aorticus; v. posterior; v. secundus; cor arteriosum; c. aorticum.

the right ventricle. Its walls are three times as thick as those of the latter, and its transverse section is circular. Its interior surface is furnished with more numerous and stronger **carneous columns**, which further have a more complex arrangement; and its two or three **papillary muscles** are also more robust.

The **left auric'ulo-ventric'ular orifice**,¹ placed at the back part of the ~~right~~ ventricle, is provided with a pair of membranous folds, constituting the **mi'tral valve**.² This has the same mechanism and purposes as the tricuspid valve, but is stronger.

In advance and to the right of the orifice just indicated, is the origin of the aorta, which is provided with **semilunar valves**, identical in character with those of the pulmonary artery, and differ only in being stronger.

STRUCTURE OF THE HEART.

As previously mentioned, the heart is muscular, with an exterior investment of serous membrane derived from the pericardium, and with its cavities lined by the **endocar'dium**. This is a thin, translucent membrane, continuous with that of the blood-vessels.

Doublings of the endocardium, thickened with intervening fibrous tissue, constitute the various valves of the interior of the heart and the vascular orifices communicating therewith. In structure the endocardium consists of an epithelium and a fibro-elastic layer. The epithelium is composed of a layer of elongated, flattened, polygonal, pavement-like cells. The fibro-elastic layer adheres closely to the muscular structure beneath, and appears to be defined next the epithelium by an exceedingly delicate basement membrane. At the auriculo-ventricular orifices, and those of the pulmonary artery and aorta, the fibro-elastic tissue forms a slightly prominent ring,³ which gives attachment to the valves, and affords a point⁴ of departure for most of the muscular fibres of the heart.

The muscular structure of the heart is composed of transversely striated fibres, which exhibit the peculiarity of anastomosing, or of being connected by means of numerous short oblique offsets, as represented in figure 248. The muscular fibres are much smaller than those of the voluntary muscles, and are not collected into bundles as in

¹ Ostium atrio-ventriculare sinistrum; ostium venosum sinistrum.

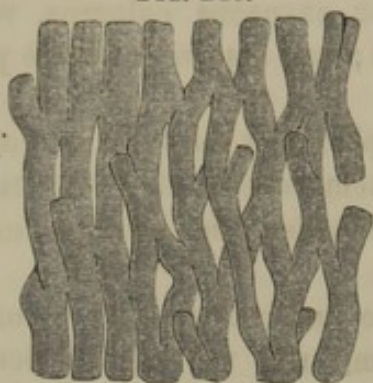
² Valvula mitralis; v. bicuspidalis; valvulae mitrales; v. bicuspidatae; v. episcopales.

³ Tendo cordis venosus et coronarius; annulus fibro-cartilagineus; circulus callosus Halleri.

⁴ Punctum fixum.

the latter, but are closely approximated with comparatively little intervening connective tissue.

FIG. 248.



STRIATED MUSCULAR TISSUE OF THE HEART, highly magnified.

The arrangement of the muscular fibres of the heart is exceedingly complex. In the auricles a thin layer of transverse muscular fibres encircles both together. Beneath this layer is another, thicker in the left than the right auricle, consisting of loop-like fibres crossing the direction of the former, and attached by their ends to the fibrous rings of the auriculo-ventricular

orifices. Other muscular fibres are arranged in circles around the origin of the great veins and the auricular appendages.

In the ventricles, some of the muscular fibres are common to both, while others belong exclusively to each—the left one possessing many more than the right one. Most of the muscular fibres may be traced from the fibrous rings of the auriculo-ventricular orifices, and those of the pulmonary artery and aorta. Those seen on the fore part of the heart pursue a course downward, from right to left; while those on the back of the heart take a more longitudinal course in the opposite direction. At the apex of the heart they penetrate in a whorl to the interior of the ventricles, where they terminate in the carneous columns, some of them forming the papillary muscles, and others ascending to the point from which they started, thus describing in their course a twisted loop like the Greek letter μ .

The arteries supplying the structure of the heart are the right and left coronary. The course of their trunks will be given hereafter. Their branches are numerous, and the capillaries in which they terminate generally pursue a course parallel to the direction of the muscular fibres, as in other muscular structures. Most of the returning blood is emptied directly into the right auricle by the great coronary vein, and the remainder is returned to the same cavity by a number of minute veins.

The lymphatics are numerous, the principal ones following the direction of the coronary veins along the grooves of the heart. Those of the right and front of the heart for the most part join the anterior mammary lymphatic glands; those of the left and back of the heart join the bronchial glands.

The nerves of the heart are numerous but small, and are derived from the cardiac plexuses of the pneumo-gastric, spinal, and great sympathetic nerves.

THE PERICARDIUM.

The **Pericar'dium**¹ is the fibro-serous sac inclosing the heart, and is attached by connective tissue to the pleura of each side, and the tendinous centre of the diaphragm below. It has the form of the heart, a bluish-white color, and consists of two layers.

The **exterior fibrous layer**² is a strong inextensible membrane composed of interlacing bundles of fibrous tissue, generally pursuing a longitudinal course. It embraces the origin of the great blood-vessels at the base of the heart, and becomes continuous with their external tunic.

The **internal serous layer**³ of the pericardium has the general arrangement and constitution of serous membranes generally. One portion closely invests the heart and the commencement of the great blood-vessels at its base, from which it is reflected on the interior of the fibrous layer of the pericardium.

The cavity of the pericardium presents smooth, opposed surfaces, bathed with a serous fluid, the **pericardial liquor**,⁴ which facilitates the movements of the heart.

MECHANISM OF ACTION OF THE HEART.

The heart, by alternate **contraction**⁵ and **dilatation**,⁶ is the motive power in the circulation of the blood, though there are also several other means which facilitate the latter. The motive power of the heart resides in its muscular walls, which, in the different cavities, correspond in strength with the distance to which the blood is to be sent. Thus, as the auricles transmit the blood only into the adjacent cavities, they possess thin walls, while those of the right ventricle, which sends the blood to the lungs, are thick—and those of the left ventricle are thickest, because this portion of the heart transmits the blood to the remotest parts of the body.

The **pectinate** muscles and carneous columns are accessory powers to the general walls, but are always so situated as not to interfere by their

¹ Pericardion; capsule, or sac of the heart; peribole; membrana cor circumflexa; involucrum, arca, arcula, capsula, camera, indumentum, panniculus, membrana, theca, saccus, sacculus, scrotum, vagina, vesica, thalamus regalis, bursa, or amphiesma cordis.

² Fibrous pericardium.

³ Serous pericardium.

⁴ Liquor pericardii; aqua, humor, lymphe, or urina pericardii; hydrocardia.

⁵ Systole; systalsis, contractio, contractio, angustatio, submissio, or micatio cordis.

⁶ Diastole; relaxatio, or remissio cordis; motus cordis diastalticus.

projection with the course of the currents of blood passing through the heart. Thus the spaces between the two cavæ and the four pulmonary veins are smooth, as are, likewise, the approaches to the auriculo-ventricular orifices, the pulmonary artery, and aorta.

The uniform direction of the circulation of the blood is maintained by the admirable mechanism of valves situated in the heart, at the origin of the great arterial trunks, and in the veins.

The auricles dilate and receive the blood simultaneously¹—the right one through the two cavæ and the coronary vein, the left one through the four pulmonary veins. The auricles then contract together, and transmit the blood through the auriculo-ventricular orifices into the ventricles. These becoming distended now contract²—the right one sending dark blood through the pulmonary artery to the lungs, the left one sending bright red blood through the aorta to the body generally.

In the contraction of the ventricles the auriculo-ventricular orifices are closed by the tricuspid and mitral valves, which are pressed with their edges together by the reflux of blood, and are kept stretched by the tendinous cords, just as the sail of a boat is kept stretched against the wind by the sheet line.

While the ventricles contract the auricles are refilling.³

The blood forced by the ventricles into the pulmonary artery and aorta pushes onward the column of blood which already fills these vessels, and likewise causes their expansion.

The arteries subsequently react or contract upon their contents, and thus continue the onward impulse of the current of blood, while its reflux closes the semilunar valves and prevents regurgitation into the ventricles. This alternate expansion and contraction of the arteries constitutes their **pulsation**, or the **pulse**.

The number of dilatations and contractions of the auricles and ventricles corresponds with the pulsations of the arteries—in the healthy adult amounting to from sixty to eighty in the minute.

The action of the heart gives rise to an impulse which may be felt on the left side of the thorax below the nipple, opposite the interspace of the fifth and sixth costal cartilages.

In the circulation of the blood from the heart to the lungs and body generally, and then back again, it performs two circles. The smaller of these, named the **lesser** or **pulmonary circulation**, is from the right ventricle through the pulmonary artery to the lungs, and back again by the pulmonary veins to the left auricle. The larger circle, named the **greater**

¹ Synchronous action of the auricles.

² Synchronous action of the ventricles.

³ Isochronous action of the ventricles and auricles.

or **systemic circulation**, is from the left ventricle through the aorta to all parts of the body, and thence back by the two cavæ to the right auricle.

Following the course of the blood in succession, and starting from the right auricle, this receives the dark blood of the body through the superior and inferior cava. Contracting, the right auricle sends the blood into the corresponding ventricle, which in turn sends it through the pulmonary artery to the lungs. Here acquiring a bright-red hue, the blood returns through the four pulmonary veins to the left auricle, which then transmits it to the left ventricle, to be propelled through the aorta to all parts of the body, from whence it regains the heart by the two cavæ.

THE ARTERIES.

The **Ar'teries** consist of two great trunks and their branches. One of these trunks is the aorta, by whose branches blood is conveyed to all parts of the body for the nutrition of the organs; the other is the pulmonary artery, which distributes the blood through the lungs to be aerated.

THE AORTA.

The **Aor'ta**¹ is the main trunk of the arterial system supplying blood to the body. It springs from the left ventricle of the heart, ascends and arches obliquely from the right to the left of the vertebral column, upon which it then descends to the fourth lumbar vertebra, and there divides into the common iliac arteries. The first portion of its course is named the arch of the aorta; and the descending portion² is named, from the cavities through which it passes, the thoracic and abdominal aorta.

THE ARCH OF THE AORTA.

The **Arch of the Aorta**³ ascends from the heart with a slight inclination toward the right side, curves obliquely backward to the left side over the right pulmonary artery and left bronchus, and descends to the left side of the third dorsal vertebra, where it becomes the thoracic aorta. Its commencement is concealed by the root of the pulmonary artery and right auricular appendage, and when exposed is observed to present a bulbous appearance,⁴ due to the dilatations⁵ behind the semilunar valves.

¹ Arteria magna; a. maxima; a. crassa; hæmal axis.

² Aorta descendens.

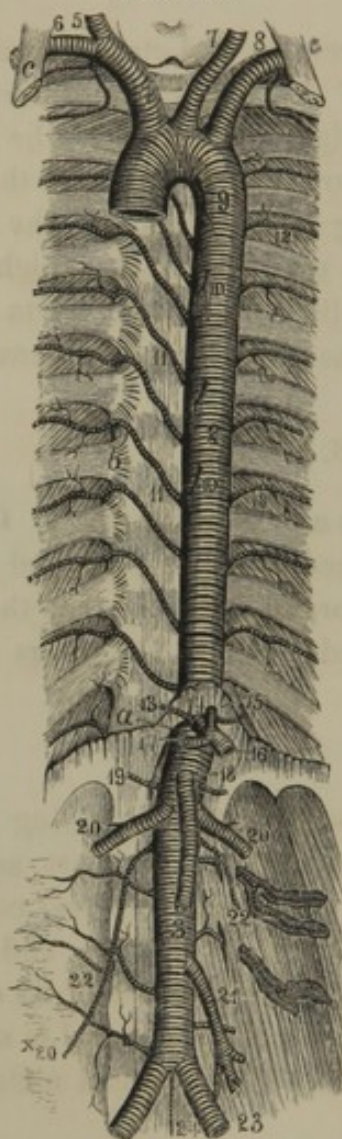
³ Arcus aortæ.

⁴ Bulbus aortæ.

⁵ Sinuses of Valsalva; lesser sinuses of Valsalva.

The ascending portion¹ of the arch is in relation behind with the right

FIG. 249.



THE AORTA. 1, arch of the aorta; 2, thoracic aorta; 3, abdominal aorta; 4, innominate artery; 5, right common carotid; 6, right subclavian; 7, left common carotid; 8, left subclavian; 9, bronchial artery, a small branch of the aorta; 10, oesophageal arteries; 11, intercostal arteries of the right side; 12, of the left side; 13, phrenic arteries; 14, coeliac axis; 15, coronary artery; 16, splenic artery; 17, hepatic artery; 18, superior mesenteric artery; 19, supra-renal arteries; 20, spermatic arteries; 21, inferior mesenteric artery; 22, lumbar arteries; 23, common iliac arteries; 24, middle sacral artery. *a*, aortic orifice of the diaphragm; *b*, articulation of the head of the ribs; *c*, anterior scalene muscle.

pulmonary artery and veins, to the right with the superior cava, and to the left with the trunk of the pulmonary artery. The transverse portion of the arch rests in the bifurcation of the pulmonary artery; is in relation above with the left innominate vein, behind with the division of the trachea, and in front with the upper part of the sternum. The descending portion of the arch is in relation with the œsophagus and thoracic duct to the right, and with the root of the left lung to the left and in front.

Frequently the right portion of the aortic arch exhibits a conspicuous dilatation,² resembling an incipient aneurism, but which is a natural condition, though not a constant one.

From the summit of the arch of the aorta spring forth the large vessels which supply the head and upper extremities, and much reduce the diameter of the descending portion of the arch.

The branches given in succession from the arch of the aorta are as follow:—

The right coronary artery.

The left coronary artery.

* The innominate artery.

* The right common carotid artery.

* The right subclavian artery.

The left common carotid artery.

The left subclavian artery.

The coronary arteries arise from the aorta, just above the position of the semilunar valves, and supply the walls of the heart. The other

¹ Aorta ascendens.

² Sinus of Valsalva; greater sinus of Valsalva.

three branches spring from the summit of the arch in close succession, and are the large vessels which supply the head and upper extremities.

THE CORONARY ARTERIES.

The **Right Cor'onary artery**¹ arises from the aorta just above its right semilunar valve, and winds along the groove between the right auricle and ventricle, until it reaches the posterior median groove of the ventricles, along which it proceeds to the apex of the heart, and anastomoses with the left coronary artery. It supplies the right side of the heart and the posterior portion of the left ventricle.

The **Left Cor'onary artery**² arises from the left side of the aorta and passes forward between the pulmonary artery and the left auricular appendage, and divides into two branches. One of these descends the anterior median groove of the ventricles to the apex of the heart, where it anastomoses with the right coronary artery. The other branch winds along the groove between the left auricle and ventricle to the back of the heart, where it anastomoses with the right coronary artery.

THE INNOMINATE ARTERY.

The **Innom'inate artery**³ is the first of the three large vessels springing from the summit of the arch of the aorta, and corresponds with the other two in supplying branches to one-half of the head and neck, and one upper extremity. It is about an inch and a half in length; ascends obliquely toward the right side, in front of the trachea and behind the left innominate vein, and divides into the right subclavian and right common carotid arteries opposite the right sterno-clavicular articulation.

As an occasional variation, the innominate artery gives off the left common carotid artery; more frequently it is represented by its ordinary divisions springing directly from the aorta, as in the case of the corresponding arteries of the left side.

¹ Arteria coronaria dextra.

² A. coronaria sinistra.

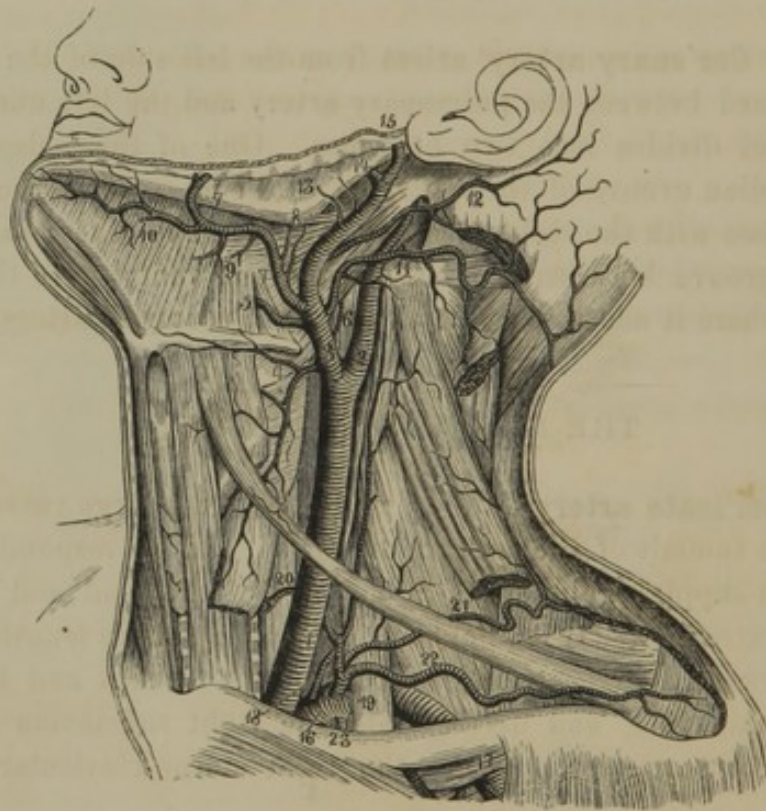
³ A. innominata; a. anonyma; a. brachio-cephalica; truncus brachio-cephalicus; right subclavian artery.

THE COMMON CAROTID ARTERY.

The **Right Common Carot'id artery**¹ is one of the divisions of the innominate artery, and ascends the neck to the upper border of the larynx, where it divides into the external and internal carotid arteries.

The **Left Common Carot'id artery**² is derived from the arch of the aorta next in succession to the innominate artery. It is longer, deeper, and more vertical in its ascent than the former, and divides in the same position and manner.

FIG. 250.



LEFT COMMON CAROTID DIVIDING INTO THE EXTERNAL AND INTERNAL CAROTID ARTERIES. 1, common carotid artery; 2, internal carotid; 3, external carotid; 4, superior thyroid; 5, lingual; 6, pharyngeal artery; 7, facial; 8, inferior palatine and tonsillar arteries; 9, submaxillary; 10, submental; 11, occipital; 12, posterior auricular; 13, parotid branches; 14, internal maxillary; 15, temporal artery; 16, subclavian artery; 17, axillary; 18, vertebral artery; 19, thyroid axis; 20, inferior thyroid giving off the ascending cervical; 21, transverse cervical; 22, supra-scapular; 23, internal mammary artery.

The **Common Carot'id arteries**,³ in ascending the neck, rest upon the muscles in front of the cervical vertebræ. At their inner side the trachea, larynx, and œsophagus are situated; at their outer side is the

¹ A. carotis communis dextra; a. c. primitiva dextra.

² A. c. c. sinistra; a. c. p. sinistra.

³ Primitive carotid arteries; a. caro-

tides; a. caroticæ; a. capitales; a. cephalicæ; a. jugulares; a. soporales; a. somniferæ; a. lethargicæ; a. apoplecticæ.

internal jugular vein, which is inclosed in the same sheath, with the pneumogastric nerve interposed. Behind them is the great sympathetic nerve; and in front they are crossed by the omo-hyoid muscle, and covered by the sterno-mastoid muscle.

They give off no branches until they reach the upper margin of the larynx, where they divide into the external and internal carotid arteries.

THE EXTERNAL CAROTID ARTERY.

The **External Carot'id artery**¹ on each side supplies all the parts of the head, with the exception of the brain and the contents of the orbits. Commencing opposite the upper border of the larynx, it ascends nearly vertically to the space between the neck of the lower jaw and the auditory meatus, where it divides into the temporal and internal maxillary arteries. It lies in front and to the inner side of the internal carotid artery, close to the pharynx. In the first part of its course it is covered only by the cervical fascia, subcutaneous cervical muscle, and skin; then is crossed by the stylo-hyoid and digastric muscles and the hypoglossal nerve; and afterwards passes through the substance of the parotid gland, in which it is crossed by the facial nerve.

The branches given off by the external carotid artery are as follow :—

1. Superior thyroid artery.
2. Lingual artery.
3. Pharyngeal artery.
4. Facial artery.
5. Occipital artery.
6. Posterior auricular artery.
7. Muscular branches.
8. Parotid branches.
9. Temporal artery.
10. Internal maxillary artery.

1. The **Superior Thy'roid artery**² comes off from the front of the external carotid, just above its commencement, and descends obliquely forward and inward, to the thyroid body, in which it is mainly distributed; anastomosing with the other arteries of that organ. In its course it is crossed by the omo-hyoid muscle, and gives off the following named branches :—

- a. Hyoid branch.
- b. Muscular branches.
- c. Laryngeal artery.

¹ A. carotis externa; a. carotis facialis; a. pericephalica.

² A. thyroidea superior; a. laryngea superior; a. gutturalis superior.

a. The **Hy'oid branch**¹ is a small vessel running along the side of the hyoid bone, and supplying the contiguous parts. It is frequently a branch of the lingual artery.

b. The **Muscular branches**² are distributed to the sterno-mastoid muscle and the depressors and elevators of the hyoid bone and larynx.

c. The **Larynge'al artery**³ pierces the thyro-hyoid membrane, and supplies the small muscles and mucous membrane of the larynx.

2. The **Lin'gual artery**,⁴ larger than the preceding branch of the carotid, comes off next to it, on a line with the side of the hyoid bone. After advancing just above the great horn of the latter, it ascends between the hyo-glossal muscle and the middle constrictor of the pharynx, to the under part of the tongue, along which it proceeds to the tip. Its branches are as follow :—

a. Dorsal lingual artery.

b. Sublingual artery.

c. Ranine artery.

a. The **Dorsal lin'gual artery**,⁵ frequently represented by several small branches, supplies the root of the tongue.

b. The **Sublin'gual artery**⁶ passes between the mylo-hyoid muscle and the sublingual gland, and supplies both with branches.

c. The **Ran'ine artery**⁷ is the continuation forward of the lingual, between the hyo-glossal and genio-glossal muscles, to the tip of the tongue. It has a tortuous course; and at the side of the frænum of the tongue is covered only by the mucous membrane.

3. The **Pharynge'al artery**⁸ is a long, narrow vessel, derived from the inner side of the external carotid artery, nearly on a level with the preceding branch. It lies concealed in the ordinary view of the vessels, and ascends deeply in the neck, on the surface of the pharynx, to the base of the skull. In its course it supplies branches to the pharynx,⁹ soft palate, and tonsils, the muscles in front of the cervical vertebræ, and the nerves which pass through the jugular foramen. It also gives small branches¹⁰ to the dura mater through the jugular and lacerated foramina.

¹ Ramus hyoideus.

² R. musculares.

³ R. laryngea; r. l. superior.

⁴ A. lingualis.

⁵ A. dorsalis linguæ.

⁶ A. sublingualis.

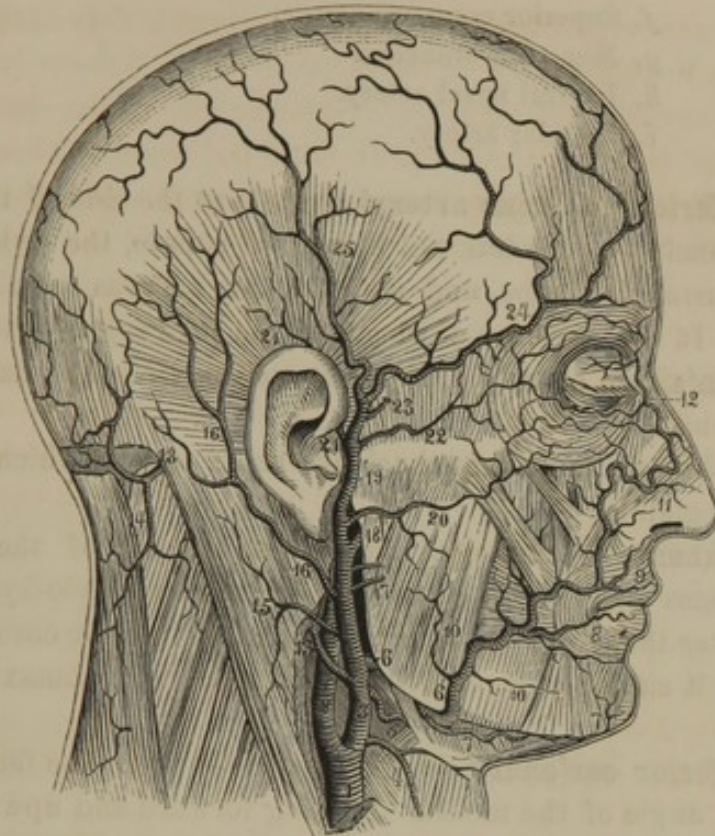
⁷ A. ranina; a. profunda linguæ.

⁸ A. pharyngea; a. pharyngea ascendens, or inferior.

⁹ Rami pharyngei.

¹⁰ A. meningeæ posteriores

FIG. 251.



THE EXTERNAL CAROTID ARTERY AND ITS BRANCHES. 1, right common carotid; 2, internal carotid; 3, external carotid; 4, superior thyroid; 5, lingual; 6, facial; 7, submental; 8, inferior coronary; 9, superior coronary; 10, muscular branches; 11, lateral nasal artery; 12, angular artery; 13, occipital artery; 14, descending cervical; 15, muscular branch; 16, posterior auricular artery; 17, parotid branches; 18, internal maxillary; 19, temporal; 20, transverse facial; 21, anterior auricular; 22, supra-orbital; 23, middle temporal; 24, anterior temporal; 25, posterior temporal artery.

4. The **Fa'cial artery**¹ comes from the external carotid just above the lingual, and is about the same size as this. It passes upward and forward through the submaxillary gland, curves over the base of the lower jaw in advance of the insertion of the masseter muscle, and ascends upon the face in a tortuous manner to the angle of the mouth, and thence to the inner angle of the eye. Below the jaw it passes beneath the stylo-hyoid and digastric muscles; at the base of the jaw is only covered by the skin and subcutaneous cervical muscle; and at the angle of the mouth is beneath the depressor of the oral angle and the zygomatic muscles. Its principal branches are as follow :—

- a. Inferior palatine artery.
- b. Tonsillar artery.
- c. Submaxillary branches.
- d. Submental artery.

¹ A. facialis; a. maxillaris externa; a. labialis; a. angularis; a. palato-labialis.

- e.* Inferior coronary artery.
- f.* Superior coronary artery.
- g.* Muscular branches.
- h.* Lateral nasal artery.
- i.* Angular artery.

a. The **Inferior pal'atine artery**¹ ascends at the side of the pharynx, and gives branches to the internal pterygoid muscle, the styloid muscles, the tonsil, Eustachian tube, and muscles and mucous membrane of the soft palate. It is sometimes a branch of the pharyngeal artery.

b. The **Ton'sillar artery**² ascends at the side of the pharynx to the fauces and tonsil.

c. The **Submax'illary branches**³ are small vessels which supply the submaxillary gland.

d. The **Submen'tal artery**,⁴ larger than any of the preceding branches, passes forward between the digastric and mylo-hyoid muscles, and winds over the chin to anastomose with the inferior coronary artery. In its course it supplies the contiguous muscles, the submaxillary gland, and the chin.

e. The **Inferior cor'onary artery**⁵ is derived from the facial as it approaches the angle of the mouth. Passing forward and upward, beneath the depressor of the oral angle, it enters the orbicular muscle of the lower lip, and pursues a tortuous course to join its fellow of the opposite side.

f. The **Superior cor'onary artery**⁶ comes from the facial at the angle of the mouth, and pursues a tortuous course in the upper lip to join the corresponding vessel of the other side. Besides supplying the lip, it gives a branch to the partition of the nose.⁷

g. The **Muscular branches**⁸ are small and variable vessels supplying the depressor of the oral angle, the masseter, buccinator, zygomatic, and other muscles.

h. The **Lateral na'sal artery**,⁹ frequently represented by several smaller branches, passes inward, and supplies the side of the nose.

i. The **Angular artery**,¹⁰ the termination of the facial, inosculates with branches of the ophthalmic artery.

¹ A. palatina inferior, or ascendens; a. pharyngo-palatina.

² A. tonsillaris.

³ Rami submaxillares; r. glandulares.

⁴ A. submentalis.

⁵ A. coronaria inferior; a. labialis inferior.

⁶ A. coronaria superior; a. labialis superior.

⁷ A. septi narium.

⁸ Rami musculares; r. buccales, masseterici, etc.

⁹ A. nasalis lateralis, or externa and rami pinnales and dorsales nasi.

¹⁰ A. angularis.

5. The **Occip'ital artery**¹ springs from the back part of the external carotid, about as high as the former branch, and passes backward beneath the muscles attached to the mastoid process of the temporal bone. Pursuing its course between the splenius and complex muscles, at the back of the neck, it pierces the cranial attachment of the trapezius muscle, and ascends beneath the skin of the occipital region, where it divides into many branches, which anastomose with the posterior auricular and temporal arteries.

In its course it gives off the following branches:—

- a. Muscular branches.
- b. Descending cervical artery.
- c. Meningeal branch.

a. The **Muscular branches**² go to the sterno-mastoid, digastric, and other muscles.

b. The **Descending cer'vical artery**³ passes down the back of the neck, and divides into branches which supply the complex, splenius, and other muscles.

c. The **Menin'geal branch**⁴ is a small vessel ascending through the jugular foramen to be distributed to the dura mater.

6. The **Posterior Auric'ular artery**⁵ is a small vessel which comes off from the external carotid a short distance above the former branch. It ascends between the lower part of the parotid gland and the mastoid process to the side of the head behind the ear, where it divides into branches supplying the latter, and anastomosing with the occipital artery. In its course it gives off a small but important branch, as follows:—

a. The **Sty'lo-mastoid artery**,⁶ which enters the foramen of that name, and ascends to supply the tympanum and its contents, and the mastoid sinuses.

7. The **Muscular branches**⁷ of the external carotid, irregular in size and disposition, supply the sterno-mastoid, masseter, and pterygoid muscles.

8. The **Parot'id branches**⁸ are small vessels given to the parotid gland in the course of the carotid artery through it.

¹ A. occipitalis.

² Rami musculares; r. cervicales; r. sterno-mastoideus, etc.

³ A. cervicalis descendens; a. cervicalis superior profunda and superficialis; a. princeps cervicis.

⁴ A. meningea; a. m. posterior externa; ramus meningeus.

⁵ A. auricularis posterior.

⁶ A. stylo-mastoidea.

⁷ Rami musculares; ramus sterno-mastoideus, massetericus, etc.

⁸ R. parotidei.

9. The **Tem'poral artery**,¹ the apparent continuation of the external carotid, ascends through the parotid gland in front of the ear to the temple, where it is situated between the skin and temporal fascia. A short distance above the zygoma it divides into two branches, which ramify on the side of the head immediately beneath the integument. The branches of the temporal artery, including the terminal ones, are as follow :—

- a. Transverse facial artery.
- b. Anterior auricular arteries.
- c. Supra-orbital artery.
- d. Middle temporal artery.
- e. Anterior temporal artery.
- f. Posterior temporal artery.

a. The **Transverse fa'cial artery**² arises from the temporal, while it is involved in the parotid gland, and passes across the masseter muscle, between the zygoma and parotid duct, to the upper part of the cheek. It supplies the parotid gland, masseter, palpebral orbicular, and other muscles, and anastomoses with branches of the ophthalmic and facial arteries. It is often represented by several smaller branches.

b. The **Anterior auric'ular arteries**³ are several small vessels distributed to the front of the ear and the auditory meatus.

c. The **Supra-orb'ital artery**⁴ arises above the zygoma and ascends to the supra-orbital margin, where it anastomoses with branches of the ophthalmic and anterior temporal arteries.

d. The **Middle tem'poral artery**⁵ perforates the temporal fascia, just above the zygoma, and is distributed to the temporal muscle.

e. The **Anterior tem'poral artery**,⁶ one of the terminal branches of the temporal, curves forward and upward upon the temple and forehead, and divides into numerous branches, supplying the scalp and contiguous muscles, and anastomosing with branches of the ophthalmic and posterior temporal arteries.

f. The **Posterior tem'poral artery**,⁷ larger than the former, turns upward and backward at the side of the head, and divides into numerous branches, anastomosing with the anterior temporal, posterior auricular, and occipital arteries.

¹ A. temporalis; a. crotaphitica.

² A. transversa faciei.

³ A. auriculares anteriores; a. auriculares anteriores inferiores, and a. auricularis anterior superior.

⁴ A. supra-orbitalis; a. supra-orbitalis externa; a. zygomatico-orbitalis.

⁵ A. temporalis media.

⁶ A. temporalis anterior; a. t. superficialis anterior; a. t. frontalis; a. t. interna.

⁷ A. temporalis posterior; a. t. superficialis posterior; a. t. occipitalis; a. t. externa.

10. The **Internal Max'illary artery**,¹ the larger division of the external carotid, passes behind the neck of the jaw, horizontally forward between the pterygoid muscles. It then ascends a short distance, and again turns forward and inward to the upper part of the pterygo-maxillary fossa, where it divides into two terminal branches—the descending palatine and the sphenopalatine arteries. Including the latter, the internal maxillary gives off the following branches:—

- a. Tympanic artery.
- b. Great meningeal artery.
- c. Small meningeal artery.
- d. Inferior maxillary artery.
- e. Muscular branches.
- f. Superior maxillary artery.
- g. Infra-orbital artery.
- h. Descending palatine artery.
- i. Sphenopalatine artery.

a. The **Tym'panic artery**,² a small vessel given from the internal maxillary near its origin, ascends behind the maxillary articulation and passes through the glenoid fissure to be distributed to the tympanum.

b. The **Great menin'geal artery**³ comes from the internal maxillary, a short distance from the preceding, and ascends to the spinous foramen of the sphenoid bone, through which it enters the middle cerebral fossa of the cranial cavity. It here curves forward and outward between the dura mater and the temporal bone, and divides into two branches, which ascend and ramify between the membrane just mentioned and the parietal bone. It produces the arborescent channels on the interior surface of the latter, and supplies both the dura mater and the cranial vault.

In its course it gives branches to the elevator and tensor muscles of the palate, and to the semilunar ganglion of the trifacial nerve.

c. The **Small menin'geal artery**,⁴ frequently a branch of the preceding, enters the cranium through the oval foramen, and supplies the dura mater of the middle cerebral fossa.

d. The **Inferior max'illary artery**⁵ comes from the internal maxillary nearly opposite the meningeals, and descends, in company with the inferior dental nerve, to enter the dental canal of the lower jaw. In its

¹ A. maxillaris interna: a. gutturo-maxillaris.

² A. tympanica.

³ A. meningea magna; a. m. media;

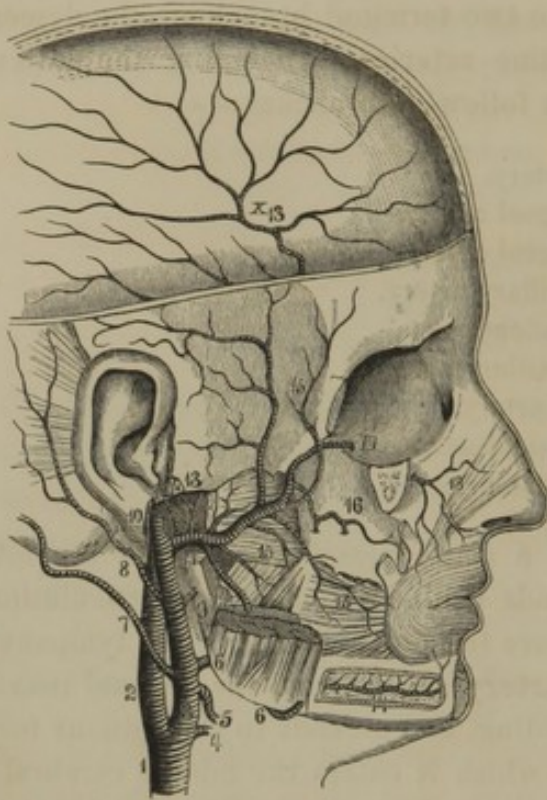
a. m. spinosa; a. spinosa; a. sphenospinosa; a. duræ matris media maxima.

⁴ A. meningea parva.

⁵ A. maxillaris inferior; a. dentalis, or alveolaris inferior.

passage through this canal it gives off the fine **dental arteries**¹ to the teeth, and finally emerges at the mental foramen to terminate in the chin,²

FIG. 252.



INTERNAL MAXILLARY ARTERY. 1, right common carotid; 2, internal carotid; 3, external carotid; 4, superior thyroid; 5, lingual; 6, facial; 7, occipital; 8, posterior auricular; 9, parotid branch; 10, temporal artery; 11, internal maxillary; 12, tympanic; 13, the great and small meningeal arteries from a common branch; 14, inferior dental artery; 15, muscular branches; 16, superior maxillary artery giving off the posterior dental arteries; 17, 18, infra-orbital artery.

teries which enter small foramina of the bone to supply the maxillary sinus and the molar teeth.

g. The **Infra-orbital artery**¹⁰ arises near the preceding, and enters the infra-orbital canal, along which it runs to the face. In its course through the canal it gives off the **anterior dental arteries** to the front teeth, and small branches to the inferior straight and oblique muscles of the orbit.

where it anastomoses with the submental and inferior coronary arteries. Before entering the dental canal it gives off a branch³ which runs along the molar ridge and supplies the gum and the mylo-hyoid muscle.

e. The **Muscular branches**,⁴ given off between the pterygoid muscles, usually consist of two⁵ to the latter, two⁶ to the temporal muscle, one⁷ to the masseter, and one⁸ to the buccinator.

f. The **Superior maxillary artery**⁹ is given off from the internal maxillary as it escapes from between the pterygoid muscles. It descends upon the tuberosity of the maxillary bone, and gives off branches to the gum, and the **posterior dental ar-**

¹ A. dentales; rami alveolares.

² A. mentalis.

³ A. mylohyoidea.

⁴ Rami musculares.

⁵ A. pterygoideæ.

⁶ A. temporales profundæ; a. temporalis profunda posterior and anterior.

⁷ A. masseterica.

⁸ A. buccinatoria; a. buccalis.

⁹ A. maxillaris superior; a. supra-maxillaris; a. dentalis; a. alveolaris superior.

¹⁰ A. infra-orbitalis.

On the face it gives branches to the lower eyelid and upper lip, and anastomoses with branches of the facial and ophthalmic arteries.

h. The **Descending pal'atine artery**,¹ one of the terminal branches of the internal maxillary, descends through the posterior palatine canal and is distributed to the soft and hard palate. One² of its branches reaches the front of the hard palate, and anastomoses, through the anterior palatine foramen, with the arteries of the nose. Another branch,³ near the origin of the artery, turns back through the pterygoid canal and reaches the top of the pharynx.

i. The **Spheno-pal'atine artery**,⁴ the second division of the internal maxillary, passes into the cavity of the nose through the spheno-palatine foramen, and, after sending a small branch⁵ backward through the pterygo-palatine canal to the upper part of the pharynx, divides into two branches. One⁶ of these is distributed to the lateral wall and floor of the nose, and to the maxillary sinus. The other branch⁷ descends upon the partition of the nose to which it is distributed, anastomosing, through the anterior palatine foramen, with a branch of the descending palatine artery.

new 6.14.73

THE INTERNAL CAROTID ARTERY.

The **Internal Carot'id artery**,⁸ the second division of the common carotid artery, destined to supply the brain and contents of the orbit, ascends in a nearly straight line to the carotid canal of the temporal bone. Winding through this canal, it enters the cranial cavity above the lacerated foramen, and proceeds forward along the side of the body of the sphenoid bone to the anterior clinoid process, where it turns upward to the fissure separating the anterior and middle lobes of the brain, and divides into the anterior and middle cerebral arteries.

In the neck the internal carotid gives off no branches, and rests against the muscles in front of the cervical vertebræ. To its inner side is the pharynx; in front of it the external carotid artery; and externally and behind are the internal jugular vein and the last four cerebral nerves. At the side of the body of the sphenoid bone, it is inclosed in the lower wall of the cavernous sinus, and at the anterior clinoid process pierces the dura mater to reach the brain.

¹ A. palatina descendens; a. palatina superior; a. pterygo-palatina.

² A. palatina anterior.

³ A. Vidian.

⁴ A. spheno-palatina; a. nasalis posterior.

⁵ A. pharyngea suprema, or descendens.

⁶ A. nasalis posterior externa, or lateralis.

⁷ A. septi narium posterior.

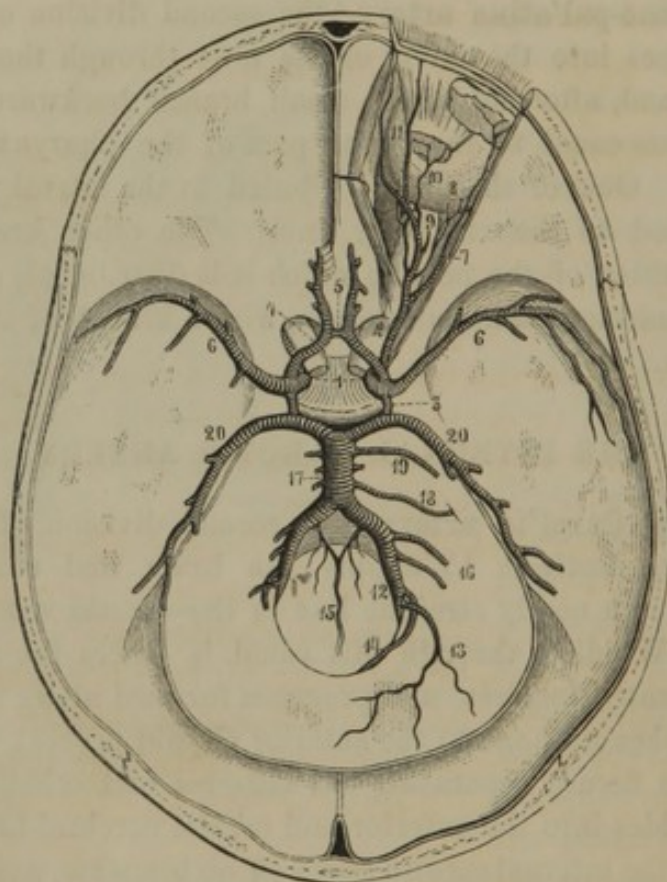
⁸ A. carotis interna; a. carotis cerebialis; a. cerebialis; a. encephalica.

The branches of the internal carotid artery are as follow :—

1. Ophthalmic artery.
2. Posterior communicating artery.
3. Choroid artery.
4. Anterior cerebral artery.
5. Middle cerebral artery.

1. The **Ophthalmic artery**¹ springs from the internal carotid, within the position of the anterior clinoid process, immediately after it pierces

FIG. 253.



ARTERIES OF THE INTERIOR OF THE CRANIUM. 1, internal carotid arteries; 2, ophthalmic artery; 3, posterior communicating arteries; 4, anterior cerebral arteries; 5, anterior communicating artery; 6, middle cerebral arteries; 7, lachrymal; 8, short ciliary arteries piercing the back part of the eyeball; 9, central retinal piercing the optic nerve to reach the interior of the eyeball; 10, muscular artery; 11, frontal and nasal artery; 12, vertebral arteries; 13, posterior meningeal artery; 14, posterior spinal artery; 15, anterior spinal arteries conjoining in a single one; 16, inferior cerebellar arteries, 17 basilar artery formed by the union of the vertebrals; 18, internal auditory; 19, superior cerebellar; 20, posterior cerebral arteries.

the dura mater, and passes through the optic foramen beneath and to the outer side of the optic nerve. Within the orbit it pursues a tortuous course above the optic nerve and along the inner wall, and divides into two terminal branches—the frontal and nasal. The branches of the ophthalmic artery, including the latter, are as follow :—

¹ A. ophthalmica; a. orbitalis.

- a. Lachrymal artery.
- b. Central retinal artery.
- c. Long ciliary arteries.
- d. Short ciliary arteries.
- e. Muscular arteries.
- f. Supra-orbital artery.
- g. Posterior ethmoidal artery.
- h. Anterior ethmoidal artery.
- i. Palpebral arteries.
- j. Frontal artery.
- k. Nasal artery.

a. The **Lach'rymal artery**¹ passes along the outer part of the orbit to the lachrymal gland, in which it is mainly distributed. Some of its branches supply several of the contiguous muscles; others pass through the foramina of the malar bone to anastomose with branches of the facial and internal maxillary arteries; some pierce the sclerotic tunic as **ciliary arteries**, and, finally, others² pass from the outer canthus of the eye to the eyelids.

b. The **Central ret'inal artery**³ penetrates the optic nerve, and through it enters the eyeball to ramify in the inner layer of the retina. In the fœtus a branch of it passes through the axis of the vitreous humor to reach the capsule of the crystalline lens.

c. The **Long cil'iary arteries**,⁴ two in number, pierce the back of the eyeball and run forward, one on each side, between the choroid and sclerotic coat, to the iris, in which they are distributed.

d. The **Short cil'iary arteries**,⁵ three or four in number, pierce the back of the sclerotic coat, and are distributed to the choroid.

e. The **Muscular arteries**⁶ are given off to all the muscles of the eyeball. From these arise the **anterior ciliary arteries**,⁷ which consist of from five to ten minute branches penetrating the front of the sclerotic coat to be distributed to the iris.

f. The **Supra-orb'ital artery**⁸ passes along the roof of the orbit, and through the supra-orbital foramen, to the skin and muscles of the eyebrow and forehead.

g. The **Posterior ethmoid'al artery**⁹ enters the corresponding foramen, and is distributed to the posterior ethmoidal sinuses and the dura mater.

¹ A. lachrymalis.

² A. palpebralis externa superior and inferior.

³ A. centralis retinæ; a. c. Zinnii.

⁴ A. ciliares posticæ longæ; a. iridis.

⁵ A. ciliares posticæ breves; a. uveales.

⁶ A. musculares.

⁷ A. ciliares anteriores.

⁸ A. supra-orbitalis; a. superciliaris.

⁹ A. ethmoidalis posterior.

h. The **Anterior ethmoid'al artery**¹ enters the corresponding foramen, and gives off a **menin'geal branch**² to the dura mater, and the **anterior nasal artery**,³ which enters the nose, through the most anterior of the foramina of the cribriform plate, to be distributed to the front part of the nose and the anterior ethmoidal and frontal sinuses.

i. The **Pal'pebral arteries**⁴ come from the ophthalmic at the inner canthus, and are distributed one to each eyelid.

j. The **Front'al artery**,⁵ one of the terminal branches of the ophthalmic, passes from the orbit at the inner canthus and ascends upon the forehead beneath the muscles, to which and the skin it is distributed.

k. The **Na'sal artery**,⁶ the remaining branch of the ophthalmic, passes from the orbit above the internal palpebral ligament, and descends upon the bridge of the nose, where it anastomoses with the angular artery.

2. The **Posterior Communicating 'artery'** is a small branch of the internal carotid proceeding backward at the side of the infundibulum to join the posterior cerebral artery.

3. The **Cho'roid artery**,⁸ the smallest branch of the internal carotid, ascends on the outer side of the cerebral crus, and enters the descending horn of the lateral ventricle to be distributed to the choroid plexus.

4. The **Anterior Cer'ebral artery**,⁹ a terminal branch of the internal carotid, ascends the longitudinal fissure of the cerebrum, across which it is connected with the corresponding artery of the other side, by a trunk not more than a line or two long, called the **anterior communicating artery**.¹⁰ It then turns over the front of the corpus callosum, and runs backward between this and the cerebral hemisphere, in its course giving off numerous branches, and anastomosing with the posterior cerebral artery.

5. The **Middle Cer'ebral artery**,¹¹ the remaining branch of the internal carotid, ascends the fissure separating the anterior and middle cerebral lobes, and divides into branches which supply the latter.

¹ A. ethmoidalis anterior.

² A. meningea anterior.

³ A. nasalis anterior.

⁴ A. palpebrales; a. palpebralis interna superior et inferior. These form with the palpebral branches of the lachrymal artery the arcus tarseus superior and inferior.

⁵ A. frontalis; a. supra-orbitalis.

⁶ A. nasalis; a. dorsalis nasi.

⁷ A. communicans posterior; a. c. Willisii.

⁸ A. choroidea.

⁹ A. cerebri anterior; a. corporis callosi.

¹⁰ A. communicans anterior.

¹¹ A. cerebri media; a. c. transversa; a. fossæ Sylvii; a. Sylviana.

THE SUBCLAVIAN ARTERIES.

The **Right Subclavian artery**¹ springs from the innominate artery, and curves outwardly to the interval of the anterior and middle scalene muscles, between which it passes over the first rib and assumes the name of axillary artery. It commences opposite the right sterno-clavicular articulation; and is in relation in front with the union of the internal jugular and subclavian veins, and is crossed in the same position by the pneumogastric nerve. Behind and above it are the brachial plexus and the great sympathetic nerve.

The **Left Subclavian artery**² is the third vessel arising in succession from the summit of the aortic arch. In consequence of its direct origin from the latter, it is longer than the right subclavian, and is also more deeply situated. It ascends vertically to a distance equal with the length of the innominate artery, and then pursues a similar course to the right subclavian. Its ascending portion is in relation with the left common carotid and the trachea on its right; and it has the pneumogastric nerve in front.

In the rare cases in which the innominate artery is represented by its ordinary divisions, the right subclavian commonly springs from the arch of the aorta after all the other branches, and reaches its usual destination by passing to the right side between the œsophagus and the cervical vertebræ.

No branches are given off by the ascending portion of the left subclavian artery, but in the subsequent part of its course, as in the case of the right subclavian, the following arise :—

1. Vertebral artery.
2. Thyroid axis.
3. Inferior thyroid artery.
4. Supra-scapular artery.
5. Transverse cervical artery.
6. Ascending cervical artery.
7. Internal mammary artery.
8. Superior intercostal artery.

1. The **Vertebral artery**,³ the largest branch of the subclavian, passes behind the common carotid artery, and enters the foramen in the transverse process of the sixth cervical vertebra. Ascending through

¹ A. subclavia dextra.

² A. subclavia sinistra.

³ A. vertebralis; posterior cerebral artery.

the foramina of the other transverse processes, it winds backward around the upper articular process of the atlas, perforates the dura mater, and enters the cranium through the occipital foramen. It then proceeds upward and forward, turns around the side of the medulla oblongata, and converges to join its fellow at the lower border of the pons, forming by this conjunction the basilar artery. Occasionally the vertebral artery arises directly from the arch of the aorta, especially the left one.

The branches of the vertebral artery are as follow :—

- a.* Muscular branches.
- b.* Spinal branches.
- c.* Posterior meningeal artery.
- d.* Posterior spinal artery.
- e.* Anterior spinal artery.
- f.* Inferior cerebellar arteries.

a. The **Muscular branches**,¹ derived from the vertebral artery in the neck, are small vessels which supply the muscles attached to the cervical transverse processes.

b. The **Spinal branches**,² also derived from the vertebral artery in the neck, are small vessels which pass through the neighboring intervertebral foramina to supply the spinal cord and its membranes.

c. The **Posterior menin'geal artery**³ is given off between the atlas and occipital foramen, and passes through the latter to the dura mater of the cerebellar fossa.

d. The **Posterior spi'nal artery**,⁴ the first branch of the vertebral within the cranium, descends on the posterior surface of the spinal cord, anastomosing in its course with the spinal branches derived from the vertebral artery in the neck.

e. The **Inferior cerebel'lar arteries**,⁵ usually two in number, wind around the upper part of the medulla oblongata to the under surface of the cerebellum, to which they are distributed.

f. The **Anterior spi'nal artery**,⁶ the last branch of the vertebral, unites with its fellow of the opposite side in front of the medulla oblongata, and the common vessel thus formed descends in a tortuous manner in front of the spinal cord, to which it is distributed.

The **Bas'ilar artery**,⁷ formed by the union of the two vertebrals, rests

¹ Rami musculares.

² Rami spinales.

³ A. meningea posterior.

⁴ A. spinalis posterior; posterior median artery.

⁵ A. cerebelli inferiores; a. c. inferior

posterior and anterior; inferior cerebellous arteries.

⁶ A. spinalis anterior; ant. median artery.

⁷ A. basilaris; a. cervicalis; a. mesocephalica.

in the median furrow of the pons, to which it gives small branches, besides sending off the following in pairs :—

- a. Internal auditory arteries.
- b. Superior cerebellar arteries.
- c. Posterior cerebellar arteries.

a. The **Internal auditory artery**¹ is a small vessel which accompanies the auditory nerve in the corresponding meatus, and is distributed, in company with the nerve, to the labyrinth.

b. The **Superior cerebellar artery**² passes outwardly at the fore part of the pons to the upper surface of the cerebellum, to which it is distributed.

c. The **Posterior cerebral artery**³ results from the division of the basilar artery. Diverging from its fellow of the opposite side, it receives the posterior communicating artery from the internal carotid, and winds around the cerebral crus outward and backward to the under part of the posterior lobe of the cerebrum. In this position it divides into many branches, supplying the latter and anastomosing with the other cerebral arteries.

In the early part of its course, the posterior cerebral artery sends a small branch⁴ beneath the back part of the corpus callosum to the interposed velum of the pia mater and the choroid plexus.

The union of the anterior cerebral arteries by the anterior communicating artery, and the union of the internal carotids with the posterior cerebrals by the posterior communicating artery, produce together an arterial circle at the base of the brain, around the position of the pituitary fossa. This remarkable series of anastomoses, known as the **circle of Willis**,⁵ associates the circulating currents of the internal carotid and vertebral arteries in such a manner that if any one of these vessels becomes obstructed, those remaining are still able to convey blood to all parts of the brain.

2. The **Thyroid axis**⁶ is a short, thick vessel springing from the fore part of the subclavian artery near the anterior scalene muscle. Immediately after its origin it divides into the inferior thyroid, supra-scapular, transverse cervical, and ascending cervical arteries. Occasionally another

¹ A. auditiva interna.

² A. cerebelli superior; superior cerebellous artery.

³ A. cerebri posterior; a. profunda cerebri; a. cerebri inferior.

⁴ A. choroidea posterior.

⁵ Circulus arteriosus Willisii; arterial hexagon.

⁶ Truncus thyro-cervicalis; a. thyroidea inferior

branch comes from the axis; and any of the branches indicated may arise independently from the subclavian artery.

3. The **Inferior Thy'roid artery**¹ ascends obliquely behind the common carotid to the lower part of the thyroid body, to which it is distributed, anastomosing freely with the superior thyroid. It likewise gives small branches to the trachea, larynx, and œsophagus.

4. The **Supra-scap'ular artery**² passes outwardly behind the clavicle and between the sterno-mastoid and scalene muscles to the upper border of the scapula, over which it turns to the supra-spinous fossa. In this it lies close to the bone, and is chiefly spent on the supra-spinous muscle. In its course it gives a small branch³ to the subcutaneous surface of the acromion; and a larger branch descends behind the neck of the scapula to the infra-spinous muscle.

Occasionally the supra-scapular comes directly from the subclavian artery, or from some of its other branches; and sometimes it arises from the axillary artery.

5. The **Transverse Cer'vical artery**⁴ passes outwardly above and parallel to the preceding, and crosses the scalene muscles and brachial plexus of nerves beneath the trapezius muscle to the upper angle of the scapula. Occasionally it is a branch directly of the subclavian artery; and it divides into the following branches:—

- a. ^{lateral}Superior cervical artery.
- b. Posterior scapular artery.

a. The **Superficial cer'vical artery**,⁵ often a branch of the ascending cervical, passes upwardly beneath the outer border of the trapezius muscle, and supplies this, the elevator of the scapular angle, the sterno-mastoid muscle, the contiguous lymphatic glands, and the skin.

b. The **Posterior scap'ular artery**⁶ descends along the base of the scapula under the rhomboid muscle, and supplies this, the great serrated, and latissimus muscles, and anastomoses with the supra- and subscapular arteries.

¹ A. thyroidea inferior; ramus thyreoideæ thyroideus.

² A. supra-scapularis; a. transversa scapulæ; ramus transversus scapularis.

³ Ramus acromialis; r. supra-acromialis.

⁴ A. transversa cervicis, or colli; a. cervico-scapularis.

⁵ A. superficialis cervicis; a. cervicalis posterior.

⁶ A. scapularis posterioris; a. dorsalis scapulæ.

6. The **Ascending Cer'vical artery**,¹ a small vessel derived from the thyroid axis, or the inferior thyroid artery, or less frequently from one of the other branches of the subclavian, passes up the neck in front of the origin of the scalene muscles, to which, and other contiguous muscles, and the lymphatic glands, it is distributed.

7. The **Internal Mam'mary artery**² is given from the subclavian, opposite the thyroid axis. It descends behind the clavicle and costal cartilages, a short distance from the sternum, and near the lower end of the latter divides into the musculo-phrenic and superior epigastric arteries. The branches derived from this vessel in its course, together with the terminal ones, are as follow:—

- a.* Mediastinal arteries.
- b.* Superior phrenic arteries.
- c.* Perforating arteries.
- d.* Anterior intercostal arteries.
- e.* Musculo-phrenic artery.
- f.* Superior epigastric artery.

a. The **Medias'tinal arteries**³ are minute branches supplying the parts of the anterior mediastinal space, including the thymus gland, bronchus, pericardium, pleura, sterno-costal muscle, and sternum.

b. The **Superior phren'ic artery**⁴ is a thread-like vessel descending in company with the phrenic nerve to the diaphragm.

c. The **Perforating arteries**⁵ consist of five or six small vessels perforating the corresponding upper intercostal spaces near the sternum, to supply the origin of the great pectoral muscle and the contiguous skin. In the female, the intermediate three or four vessels are larger than in the male, and contribute to supply the mammary gland. During lactation they increase in size.

d. The **Anterior intercos'tal arteries**,⁶ usually two in each intercostal space, arise together from the mammary, or separately, or in common with the perforating arteries. Proceeding outwardly in the upper five or six intercostal spaces, they anastomose with the aortic intercostal arteries, and supply the intercostal and pectoral muscles, the mammary gland, and the skin.

¹ A. cervicalis ascendens; a. c. anterior; a. dorsalis suprema; ramus thyroideæ ascendens.

² A. mammaria interna; a. sternalis; a. substernalis; a. thoracica interna.

³ A. mediastinicae; a. thymicae, bron-

chialis anterior, pericardiacæ, et sternales.

⁴ A. phrenica superior; a. pericardiacophrenica.

⁵ A. perforantes et mammariae externæ; mammary arteries.

⁶ A. intercostales anteriores.

e. The **Mus'culo-phren'ic artery**,¹ the outer of the terminal pair of branches of the mammary artery, inclines downward and outward behind the costal cartilages of the lower ribs to the last intercostal space. In its course it gives branches to the lower five intercostal spaces and to the attachments of the diaphragm and abdominal muscles.

f. The **Superior epigas'tric artery**² continues in the direction of the mammary artery to the abdominal parietes back of the straight muscle, to which it is mainly distributed, anastomosing also with the epigastric branch of the external iliac artery, and with others supplying the abdominal walls.

8. The **Superior Intercos'tal artery**³ arises from the back part of the subclavian, descends in front of the neck of the first rib, and divides into two branches, which supply the first pair of intercostal spaces.

9. The **Profound Cer'vical artery**,⁴ frequently originating in common with the preceding vessel, penetrates beneath the transverse process of the last cervical vertebra to the back of the neck, where it ascends between the transverse and spinous processes to supply the contiguous muscles.

THE AXILLARY ARTERY.

The **Ax'illary artery**⁵ is the continuation of the subclavian from the outer border of the first rib to the lower margin of the axilla, after which it assumes the name of brachial artery. In its course through the armpit it rests on the great serrated, subscapular, latissimus, and greater terete muscles, and is under cover of the pectoral muscles. In front of it is the axillary vein; and the brachial plexus at first is behind, and afterwards surrounds it.

The most important deviation from the ordinary arrangement of the axillary artery consists in its giving off a large branch, which corresponds with the radial artery of the forearm, or less frequently with the ulnar artery, or rarely with the interosseous artery. In some instances the large branch is the common source of several or all of the smaller ones, commonly derived separately from the axillary and brachial arteries.

Besides several small and inconstant twigs⁶ to the contiguous muscles

¹ A. musculo-phrenica.

² A. epigastrica superior.

³ A. intercostalis superior, or suprema; a. i. subclavia.

⁴ A. profunda cervicis; a. cervicalis

posterior; a. transversalis colli; a. trachelo-cervicalis.

⁵ A. axillaris.

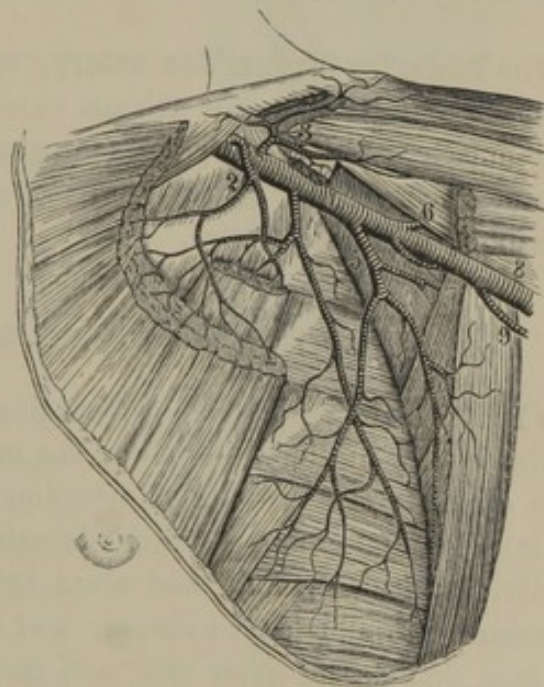
⁶ Muscular branches and axillary thoracic artery; a. thoracica axillaris, or alaris; a. ultima thoracicarum.

and lymphatic glands of the armpit, the axillary artery usually gives off in succession the following branches:—

1. Superior thoracic artery.
2. Acromial thoracic artery.
3. Long thoracic artery.
4. Subscapular artery.
5. Anterior circumflex artery.
6. Posterior circumflex artery.

1. The **Superior Thoracic artery**,¹ sometimes substituted by two branches, and frequently arising in common with the succeeding artery, passes between the subclavian and small pectoral muscles to supply the latter, the great pectoral muscle, and the mammary gland.

FIG. 254.



2. The **Acromial Thoracic artery**² ascends to the space above the small pectoral muscle, and divides into branches, which supply the pectoral and deltoid muscles, the shoulder joint, and the subcutaneous surface of the acromion. In the latter position it anastomoses with branches of the supra-scapular artery, forming together a fine vascular net.³

VIEW OF THE AXILLARY ARTERY, portions of the pectoral and deltoid muscles removed. 1, axillary artery; 2, superior thoracic; 3, acromial thoracic; 4, long thoracic; 5, subscapular; 6, anterior circumflex; 7, posterior circumflex; 8, brachial artery; 9, superior profound artery.

3. The **Long Thoracic artery**⁴ descends along the small pectoral muscle, and is distributed to the mammary gland, both pectoral, and the great serrated muscles.

¹ A. thoracica superior; a. t. externa superior; first thoracic artery.

² A. thoracica acromialis; a. t. humeralis; a. acromialis; external scapular, or third thoracic artery.

³ Rete acromiale.

⁴ A. thoracica longa; a. t. inferior; a. t. externa inferior; a. mammaria externa; second thoracic artery.

4. The **Subscap'ular artery**,¹ the largest branch of the axillary, descends along the outer border of the scapula, and is distributed to the subscapular, great serrated, greater terete, and latissimus muscles. In its course it gives off a large branch, as follows:—

a. The **Dorsal scap'ular artery**.²—This passes between the greater terete and subscapular muscles around the outer border of the scapula to the infra-spinous fossa, to the muscle of which it is distributed, and anastomoses with the supra- and posterior scapular arteries.

5. The **Anterior Circum'flex artery**³ is a small branch winding forward and outward around the humerus below its tuberosities, supplying the shoulder joint and inosculating with the succeeding artery.

6. The **Posterior Circum'flex artery**,⁴ much larger than the preceding, turns backward between the triceps extensor and the humerus to the deltoid muscle, which it supplies, also giving branches to the shoulder joint, and anastomosing with the anterior circumflex, the supra-scapular, and acromial thoracic arteries.

THE BRACHIAL ARTERY.

The **Bra'chial artery**,⁵ the continuation of the axillary, extends from the outer border of the axilla along the inner side of the arm. It commences opposite the tendons of insertion of the latissimus and greater terete muscles, and, about a finger's-breadth below the bend of the elbow joint, divides into the radial and ulnar arteries. In its course it lies on the coraco-brachial, triceps extensor, and brachial muscles. The median nerve is at first on its outer side, and then crosses in front to its inner side. The ulnar nerve is in the latter position, but gradually diverges in approaching the elbow.

The brachial artery is accompanied by two companion veins, which lie in close contact with it; and the basilic vein is placed over it. In nearly its whole length it is only covered by the brachial fascia and skin, and in an operation may readily be exposed without cutting the neighboring muscles. In front of the elbow joint it dips between the terete pronator and long supinator, and is covered by the offset from the tendon of the biceps flexor to the fascia of the forearm.

¹ A. subscapularis; a. scapularis inferior; a. s. communis; a. s. internus; a. thoracica axillaris, or alaris.

² A. dorsalis scapulæ; a. circumflexa scapulæ.

³ A. circumflexa anterior; a. articularis anterior.

⁴ A. circumflexa posterior; a. articularis posterior.

⁵ A. brachialis; a. humeralis.

As an important variation from the ordinary arrangement of the brachial artery, it may divide into its two principal branches in any position along the arm.

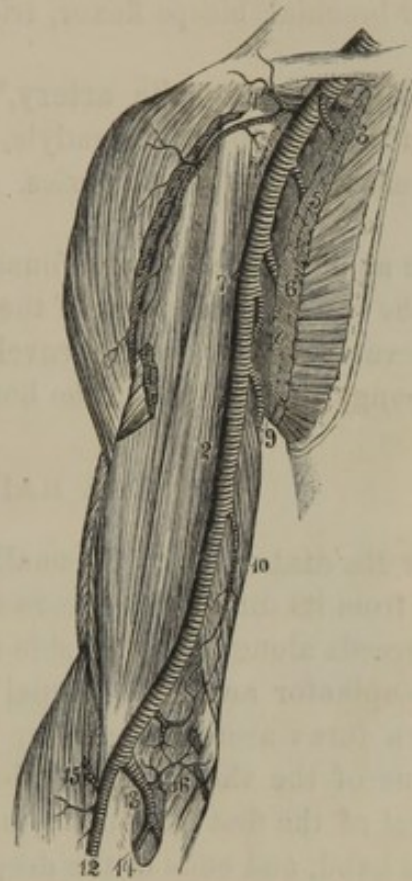The number of branches of the brachial artery and the order of their succession is variable, but usually they will be found to accord with the following series:—

1. Superior profound artery.
2. Inferior profound artery.
3. Medullary artery.
4. Muscular arteries.
5. Anastomotic artery.
6. Radial artery.
7. Ulnar artery.

1. The **Superior Profound artery**,¹ the largest branch of the brachial except its ultimate divisions, accompanies the musculospiral nerve between the triceps extensor and the humerus to the outer part of the arm, where it descends between the long supinator and brachial muscle to the elbow. In its course it supplies the coracobrachial, triceps extensor, brachial, and long supinator muscles, and at the elbow anastomoses with the radial, interosseous and ulnar recurrent, the inferior profound, and anastomotic arteries.

2. The **Inferior Profound artery**,² a small vessel from near the middle of the brachial, descends along the inner side of the triceps extensor, in company with the ulnar nerve, to the interval of the internal condyle and olecranon. It supplies the brachial muscle, and anastomoses with the ulnar recurrent and anastomotic arteries.

FIG. 255.



VIEW OF THE AXILLARY AND BRACHIAL ARTERY, portions of the pectoral and deltoid muscles removed. 1, axillary artery; 2, brachial artery; 3, superior thoracic artery; 4, acromial thoracic; 5, long thoracic; 6, subscapular; 7, anterior circumflex; 8, posterior circumflex; 9, superior profound, the first branch of the brachial artery; 10, inferior profound; 11, anastomotic; 12, radial; 13, ulnar; 14, interosseous; 15, recurrent radial; 16, recurrent ulnar artery.

¹ A. profunda superior; a. p. major humeri; a. p. brachii; a. collateralis magna; a. c. externa; a. spiralis; great muscular artery of the arm.

² A. profunda inferior; a. p. minor; a. collateralis prima; a. c. superior; large communicating ulnar artery; profunda-ulnar artery.

3. The **Med'ullary artery**,¹ a small vessel from near the middle of the brachial, or from one of its other branches, proceeds through the medullary foramen of the humerus to the marrow, which it supplies.

4. The **Muscular arteries**² consist of several small branches to the coraco-brachial, biceps flexor, triceps extensor, and brachial muscles.

5. The **Anastomot'ic artery**,³ from the lower part of the brachial, descends to the internal condyle, and there anastomoses with the ulnar recurrent and profound arteries.

The anastomotic and profound branches of the brachial artery form, with the recurrent branches of the radial, ulnar, and interosseous arteries, a fine vascular net,⁴ which envelops and supplies the elbow joint and the spongy extremities of the bones.

THE RADIAL ARTERY.

The **Ra'dial artery**,⁵ the smaller of the ultimate divisions of the brachial, from its direction appears as if it were a continuation of the latter. It proceeds along the outer side of the front of the forearm, between the long supinator and radio-carpal flexor to the lower end of the radius. It then turns around the outer side of the wrist beneath the extensor tendons of the thumb, to the back of the carpus, where, reaching the interval of the first pair of metacarpal bones, it penetrates to the palm of the hand, and ends in the deep palmar arch.

In the early part of its course it rests on the tendon of the biceps flexor and the insertion of the ^{triste}(round) pronator, and is overlapped by the fleshy part of the long supinator. Subsequently it rests on the long flexor of the thumb, the quadratus pronator, and the radius, and is covered alone by the fascia and skin. Near the wrist, during life, this artery is found very convenient, to determine the condition of the circulation as indicated by the pulse. It is accompanied by a pair of companion veins, and part of the way by the radial nerve.

In those cases in which the radial artery is derived from the brachial above its ordinary source, it passes along the inner side of the latter, and then crosses to its outer side. Reaching the elbow, it usually pierces the brachial fascia, and proceeds between it and the skin down the outer

¹ A. nutritia humeri.

² Rami musculares.

³ A. anastomotica; ramus anastomoti-

cus magnus; a. collateralis internus; a. c. ulnaris secunda; a. c. u. inferior.

⁴ Rete articulare cubiti.

⁵ A. radialis; a. externa cubiti.

side of the forearm; or, less frequently, from the position of the elbow it pursues the ordinary course.

The branches of the radial artery are as follow:—

1. Radial recurrent artery.
2. Muscular branches.
3. Anterior carpal artery.
4. Volar artery.
5. Posterior carpal artery.
6. Metacarpal artery.
7. Principal artery of the thumb.
8. Radial index artery.
9. Deep palmar arch.

1. The **Ra'dial Recur'rent artery**,¹ derived from near the commencement of the radial, ascends between the long and short supinators to the external condyle. It supplies the contiguous parts of the supinator and extensor muscles, and anastomoses with the superior profunda artery.

2. The **Muscular branches** are small vessels given to the neighboring muscles in the course of the radial artery.

3. The **Anterior Car'pal artery**² is a small branch from the lower part of the radial, descending to the front of the radio-carpal articulation, where it forms an anastomosis³ with a similar branch from the ulnar artery, and supplies the wrist joint.

4. The **Vo'lar artery**,⁴ very variable in its size and arrangement, is usually a small vessel derived from the radial just before it turns to the back of the carpus. Descending in front of the ball of the thumb, it supplies the small muscles of the latter, and contributes to form the superficial palmar arch.

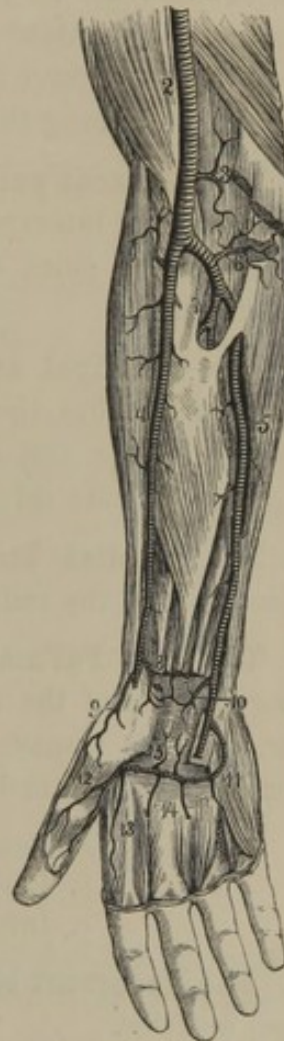
¹ A. recurrens radialis; recurrent artery of the epicondyle.

² A. carpea anterior; a. c. volaris; a. radio-carpalis; a. transversa-carpi anterior.

³ Anterior carpal arch; rete carpi volare.

⁴ A superficialis volæ; superficial volar artery; ramus volaris; a. radio-palmaris; external superficial artery of the palm.

FIG. 256.



ARTERIES OF THE FOREARM. 2, brachial artery; 3, anastomotic artery; 4, radial artery; 5, ulnar artery; 6, recurrent ulnar; 7, interosseous; 8, anterior carpal; 9, superficial volar; 10, anterior carpal branch of the ulnar; 11, superficial palmar arch; 12, principal artery of the thumb; 13, radial index artery; 14, digital arteries; 15, recurrent branches.

5. The **Posterior Carpal artery**¹ is a small branch from the posterior portion of the radial, which crosses the back of the carpus beneath the extensor tendons, to join with a similar branch of the ulnar artery. From this conjunction² twigs supply the wrist joint; and branches³ proceed to the outer three metacarpal interspaces, each dividing into a pair,⁴ which descend along the contiguous sides of the backs of the fingers.

6. The **Metacarpal artery**⁵ is a small vessel descending upon the first metacarpal interspace, and dividing into three branches,⁶ which proceed along the sides of the thumb and the approximate side of the index finger.

7. The **Principal artery of the Thumb**⁷ is derived from the radial just after it reaches the palm of the hand. It descends along the first metacarpal bone, and divides into two **digital arteries**,⁸ which proceed along the opposite sides of the thumb to its extremity.

8. The **Radial Index artery**⁹ arises close to the preceding and descends along the radial border of the index finger to its extremity.

9. The **Deep Palmar Arch**¹⁰ is formed by the conjunction of the terminating portion of the radial with the **communicating artery** from the ulnar. It lies transversely across the upper part of the metacarpus, beneath the flexor tendons, and gives off the following branches:—

- a. Recurrent branches.
- b. Perforating branches.
- c. Interosseous arteries.

a. The **Recurrent branches**¹¹ ascend and anastomose with the anterior carpal arteries.

b. The **Perforating branches**¹² pass through the upper part of the interosseous spaces and join the branches of the posterior carpal arteries.

c. The **Interosseous arteries**¹³ supply the corresponding muscles, and anastomose with the digital branches of the superficial palmar arch.

¹ A. carpæ posterior; a. c. dorsalis; a. transversa carpi-dorsalis; a. dorsalis carpi-radialis.

² Posterior carpal arch; rete carpi dorsale; r. carpeum posterius.

³ A. interosseæ dorsales.

⁴ A. digitales dorsales.

⁵ A. interosseæ dorsalis prima.

⁶ A. dorsalis pollicis et indicis; a. dorsalis pollicis radialis et ulnaris, et indicis radialis.

⁷ A. princeps pollicis; a. magna pollicis; a. pollicaris.

⁸ A. volaris pollicis radialis and ulnaris.

⁹ A. radialis indicis; a. volaris indicis radialis.

¹⁰ Arcus palmaris profundus; a. volaris profundus; profound, or radial palmar arch.

¹¹ Rami recurrentes; r. retrogradi.

¹² Rami interossei perforantes; r. perforantes superiores.

¹³ A. interosseæ volares.

THE ULNAR ARTERY.

The **Ul'nar artery**,¹ the second division of the brachial, turns inwardly beneath the muscles springing from the internal condyle, and descends on the inner side of the forearm between the ulno-carpal and superficial flexor of the fingers to the wrist. Passing over the anterior annular ligament at the side of the pisiform bone to the palm of the hand, it terminates in the formation of the superficial palmar arch. In the early part of its course it rests on the insertion of the brachial muscle, and afterwards on the deep flexor of the fingers. It is accompanied by two companion veins, and in the greater part of its course by the ulnar nerve.

In those anomalous instances in which the ulnar artery comes from the brachial above its ordinary position, as it approaches the elbow it inclines inwardly, and passes over the heads of the flexor muscles instead of beneath them, and then pursues the usual course down the forearm.

The branches given from the ulnar artery are as follow :—

1. Ulnar recurrent artery.
2. Common interosseous artery.
3. Muscular branches.
4. Posterior carpal artery.
5. Anterior carpal artery.
6. Communicating artery.
7. Superficial palmar arch.

1. The **Ulnar Recur'rent artery**,² frequently substituted by a pair of branches, comes from the ulnar just below the elbow, and ascends beneath the muscles arising from the internal condyle. It supplies the heads of the flexor muscles, and anastomoses with the inferior profound, anastomotie, and other arteries about the elbow joint.

2. The **Common Interos'seous artery**³ comes from the ulnar near the tuberosity of the radius, and shortly afterwards divides into the anterior and posterior interosseous arteries. Occasionally the common interosseous artery is a branch of the brachial; and when the ulnar artery derives its origin above the usual position, the common interosseous and radial arteries appear as the terminal divisions of the brachial.

a. The **Anterior interos'seous artery**⁴ descends in front of the inter-

¹ A. ulnaris; cubital artery; a. cubitalis.

² A. recurrens ulnaris; a. r. u. anterior and posterior; a. r. epitrochlæ; a. r. cubitalis anterior and posterior.

³ A. interossea communis; a. interossea antibrachii communis; a. interossea.

⁴ A. interossea anterior, or interna.

osseous membrane as far as the quadratus pronator, when it pierces the former and passes to the back of the wrist, where it anastomoses with the posterior carpal arteries. In its course it gives branches to the neighboring muscles.

b. The **Posterior interosseous artery**¹ passes to the back of the forearm through the opening at the upper part of the interosseous membrane, and descends beneath the common extensor of the fingers to the wrist, supplying in its course the contiguous muscles, and anastomosing with the anterior interosseous and posterior carpal arteries. At its upper part it gives off the **Interosseous recurrent artery**,² which ascends beneath the short supinator and anconeus muscles to the interval of the olecranon and external condyle, and anastomoses with the superior profound and radial recurrent arteries.

3. The **Muscular branches** of the ulnar artery are small vessels given to the neighboring muscles.

4. The **Posterior Carpal artery**,³ of variable size, comes from the lower part of the ulnar artery and turns beneath the tendon of the ulnocarpal flexor to the back of the wrist. It sends a metacarpal branch to the inner side of the hand and little finger, and terminates by joining the corresponding branch of the radial artery.

5. The **Anterior Carpal artery**,⁴ smaller than the preceding, passes outwardly to the front of the wrist, where it joins the anterior carpal branch of the radial artery.

6. The **Communicating artery**⁵ is derived from the ulnar just after passing the pisiform bone, and dips between the short flexor and abductor of the little finger to contribute in the formation of the deep palmar arch.

7. The **Superficial Palmar arch**,⁶ the terminating portion of the ulnar artery, curves internally in the palm of the hand, upon the flexor tendons and beneath the palmar fascia, and joins the volar artery of the radial. The branches given from the arch are four digitals.⁷

¹ A. interossea posterior, or externa; a. perforans suprema.

² A. interossea recurrens; a. recurrens olecranea; a. r. radialis posterior.

³ A. carpea posterior; ramus dorsalis.

⁴ A. carpea anterior.

⁵ A. communicans; a. cubitalis manus profunda.

⁶ Arcus palmaris superficialis; arcus volaris sublimis; a. v. superficialis; ramus volaris superficialis.

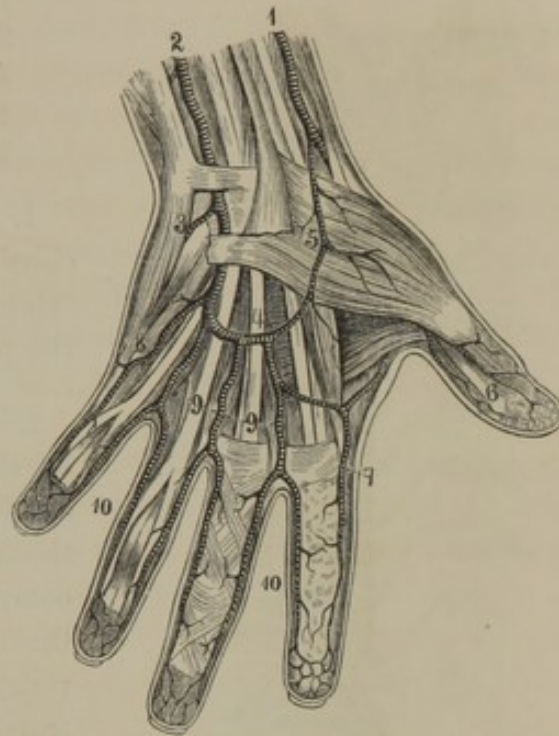
⁷ A. digitales volares; a. d. communes.

The first **Dig'ital artery** runs along the ulnar side of the hand and little finger to its extremity.

The remaining **Dig'ital arteries** descend along the metacarpal interspaces, except the first, to the roots of the fingers, where each divides into two branches¹ which run along the contiguous sides of the fingers to their tips.

The arteries of the hand exhibit frequent variations in their arrangement. In some instances the contribution of the ulnar artery to the superficial arch is much reduced, and that from the radial artery is in a corresponding degree increased. In other instances the contributions of both are reduced, even to a want of continuity in the superficial arch, and each supplies its own side of the hand; or the deep arch is larger, and then appears mainly to supply the hand and fingers.

FIG. 257.



ARTERIES OF THE HAND; PALMAR SURFACE. 1, radial artery; 2, ulnar; 3, communicating branch with the deep palmar arch; 4, superficial palmar arch; 5, superficial volar artery; 6, digital arteries of the thumb; 7, radial index artery; 8, digital artery to the little finger; 9, common digital arteries; 10, digitals to the fingers.

THORACIC AORTA.

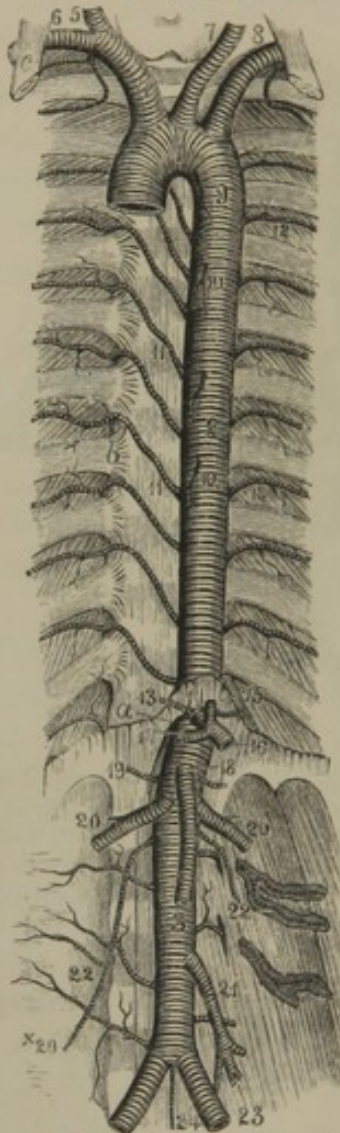
The **Thorac'ic Aor'ta**² commences with the termination of the arch of the aorta on the left side of the third dorsal vertebra. Descending on the left of the vertebral column, in the lower part of its course it gradually inclines toward the median line, which it nearly reaches opposite the last dorsal vertebra, and there passes through the aortic orifice of the diaphragm to assume the name of abdominal aorta. It is situated in the posterior mediastinal space behind the pericardium and the root of the left lung. It is in relation on the right with the œsophagus, azygos vein, and thoracic duct; on the left with the corresponding pleura and lung.

¹ Collateral digital arteries.

² Aorta thoracicus.

The branches of the thoracic aorta are all of small size, and come off in succession, as follow:—

FIG. 258.



THE AORTA. 1, arch of the aorta; 2, thoracic aorta; 3, abdominal aorta; 4, innominate artery; 5, right common carotid; 6, right subclavian; 7, left common carotid; 8, left subclavian; 9, bronchial artery, a small branch of the aorta; 10, oesophageal arteries; 11, intercostal arteries of the right side; 12, of the left side; 13, phrenic arteries; 14, coeliac axis; 15, coronary artery; 16, splenic artery; 17, hepatic artery; 18, superior mesenteric artery; 19, supra-renal arteries; 20, ~~spermatic~~ arteries; 21, inferior mesenteric artery; 22, lumbar arteries; 23, common iliac arteries; 24, middle sacral artery. *a*, aortic orifice of the diaphragm; *b*, articulation of the head of the ribs; *c*, anterior scalene muscle. *20 + Spermatic A.*

1. Pericardiac arteries.
2. Bronchial arteries.
3. Oesophageal arteries.
4. Mediastinal arteries.
5. Intercostal arteries.

1. The **Pericar'diac arteries**¹ consist of a few fine vessels ramifying on the contiguous portion of the pericardium.

2. The **Bron'chial arteries**,² two or three in number, occasionally originating in one trunk, apply themselves to the bronchi and accompany them in their ramification through the lungs. Sometimes the right bronchial artery is derived from the corresponding third intercostal artery.

3. The **Oesophage'al arteries**,³ four or five in number, supply the oesophagus.

4. The **Medias'tinal arteries**⁴ consist of a number of fine vessels distributed on the neighboring pleuræ and lymphatic glands.

5. The **Intercos'tal arteries**,⁵ of which there are ten on each side, including the one below the last rib, come off from the back of the aorta opposite the vertebral bodies. Those of the left side are shorter than the right ones in consequence of the position of the aorta on the left of the median line. They pass

¹ A. pericardiacæ; a. pericardiacæ posteriores.

² A. bronchiales; a. b. posteriores.

³ A. oesophageæ.

⁴ A. mediastinicae.

⁵ A. intercostales; a. i. inferiores, or aorticæ.

from their origin upward and outward to the commencement of the intercostal spaces, and divide into an anterior and a dorsal branch.

a. The **anterior branch**¹ passes outwardly beneath the pleura, enters between the two intercostal muscles, and then runs along the lower border of the uppermost rib. In its course it gives branches to the intercostal, pectoral, and great serrated muscles; a moderate-sized one² which descends and runs along the border of the rib below; and others which anastomose with the anterior intercostal branches of the internal mammary artery, and the thoracic branches of the axillary artery. The lower three of the anterior branches extend into the abdominal muscles, where they anastomose with the epigastric arteries. In the female, the anterior branches from the third to the sixth give off considerable twigs³ to supply the mammary gland.

b. The **dorsal branch**³ of the intercostals, after transmitting a **branch**⁴ through the intervertebral foramina to the contents of the spinal canal, passes backward between the transverse processes of the vertebræ, and is distributed to the muscles of the back.

ABDOMINAL AORTA.

The **Abdom'inal Aor'ta**⁵ commences in the termination of the thoracic aorta as it emerges through the aortic orifice of the diaphragm opposite the last dorsal vertebra. Descending in front of the vertebral column with a slight inclination to the left side, opposite the fourth lumbar vertebra it divides into the two common iliac arteries. In front it is in relation with the liver, splenic vein, pancreas, duodenum, left renal vein and peritoneum; and to its right is the inferior cava, with the right crus of the diaphragm, commencement of the thoracic duct and azygos vein interposed above.

The branches of the abdominal aorta are numerous, and many of them of large size. Four of them are symmetrical and median in their origin; the others are in pairs. The symmetrical branches are as follow:—

Cœliac axis.
Superior mesenteric artery.
Inferior mesenteric artery.
Middle sacral artery.

The branches in pairs are as follow:—

¹ Ramus anterior, or intercostalis.

² Rami mammarii externi.

³ R. dorsalis; r. posterior.

⁴ R. spinalis; r. vertebralis.

⁵ Aorta abdominalis; abdominal portion of the descending aorta.

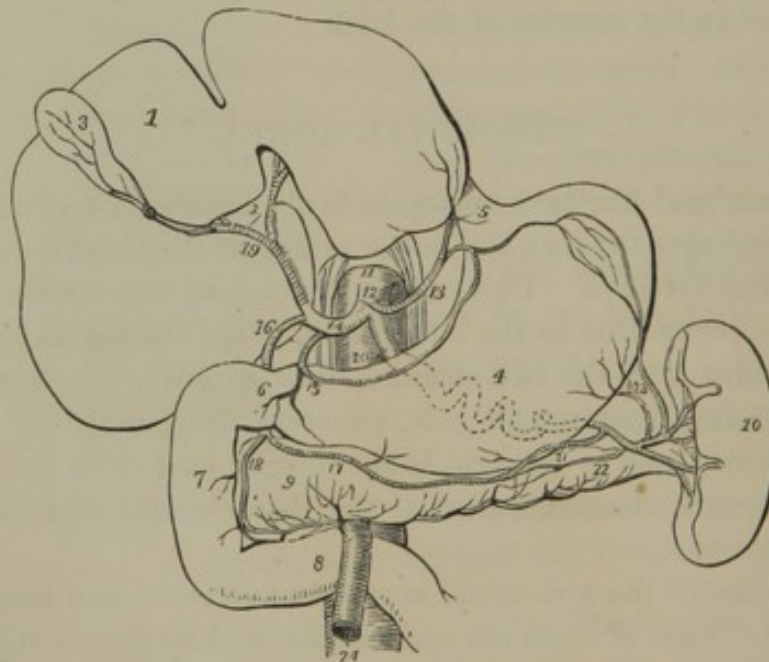
Phrenic arteries.
 Supra-renal arteries.
 Renal arteries.
 Spermatic arteries.
 Lumbar arteries.

THE CŒLIAC AXIS.

The **Cœ'liac axis**¹ is a short, thick trunk, projecting forward from the commencement of the abdominal aorta. It is in relation below with the pancreas, and with the semilunar ganglion on each side. It divides into three diverging branches as follow:—

1. Coronary artery.
2. Hepatic artery.
3. Splenic artery.

FIG. 259.



DISTRIBUTION OF THE CŒLIAC ARTERY. 1, liver turned upward, and showing its lower surface; 2, transverse fissure; 3, gall-bladder; 4, stomach; 5, œsophagus; 6, 7, 8, duodenum; 9, pancreas; 10, spleen; 11, aorta; 12, cœliac artery; 13, coronary artery; 14, hepatic artery; 15, pyloric artery; 16, gastro-duodenal artery; 17, right gastro-epiploic artery; 18, pancreatico-duodenal artery; 19, hepatic artery dividing into the right and left branches for the liver; 20, splenic artery; its course indicated behind the stomach by dotted lines; 21, left gastro-epiploic artery; 22, pancreatic branch; 23, gastric branches; 24, superior mesenteric artery, emerging from between the pancreas and duodenum.

1. The **Cor'onary artery**,² the smallest of the divisions of the cœliac axis, turns upward and to the left side toward the cardiac orifice of the

¹ A. cœliaca; tripus Halleri; a. epis-togastricus.

² A. coronaria; a. c. ventriculi; a. c. v. sinistra; a. gastrica major; a. g. sinistra superior; a. stomogastrica.

stomach, and then runs along its lesser curvature. Situated between the layers of the lesser omentum, it divides into numerous branches, which supply the lower part of the œsophagus¹ and both sides of the stomach,² and anastomose with all the other arteries of the latter.

2. The **Hepat'ic artery**,³ the second in size from the cœliac axis, inclines upwardly within the right border of the lesser omentum, and divides into two branches which enter the transverse fissure of the liver. Behind it is the portal vein, and to its right the bile duct. Its branches, including the terminal pair, are as follow :—

- a. Pyloric artery.
- b. Gastro-duodenal artery.
 - c. Pancreatico-duodenal artery.
 - d. Right gastro-epiploic artery.
- e. Right branch.
- f. Cystic artery.
- g. Left branch.

a. The **Pylor'ic artery**⁴ is a small branch which turns downward and runs along the lesser curvature of the stomach from right to left, anastomosing with the coronary artery.

b. The **Gas'tro-duode'nal artery**,⁵ a large branch, descends behind the pylorus, and divides into the following two vessels :—

c. The **Pancreat'ico-duode'nal artery**⁶ passes between the head of the pancreas and the duodenum, and supplies both with branches.⁷

d. The **Right gas'tro-epip'loic artery**⁸ runs along the greater curvature of the stomach from right to left, and terminates by conjunction with the left gastro-epiploic. It gives many branches⁹ to both surfaces of the stomach which anastomose with those from the lesser curvature, and it also sends long thread-like vessels¹⁰ downward to the great omentum.

e. The **Right branch**¹¹ of the hepatic artery enters the right side of the transverse fissure of the liver, and divides into two or three branches, which penetrate into the right lobe of the liver.

f. The **Cys'tic artery**,¹² a branch of the preceding, turns forward to supply the gall-bladder.

¹ Rami œsophagei inferiores.

² Rami cardiaci and gastrici.

³ A. hepatica.

⁴ A. pylorica; a. p. superior; a. coronaria dextra; a. c. ventriculi; a. gastrica dextra superior.

⁵ A. gastro-duodenalis.

⁶ A. pancreatico-duodenalis.

⁷ Rami pancreatici dextri and r. duodenales.

⁸ A. gastro-epiploica dextra; a. coronaria dextra inferior; a. c. ventriculi, or gastrica dextra inferior.

⁹ Rami gastrici.

¹⁰ Rami epiploici.

¹¹ A. hepatica dextra.

¹² A. cystica.

g. The **Left branch**¹ of the hepatic artery, smaller than the other, enters the left of the transverse fissure to be distributed to the corresponding lobe of the liver.

3. The **Splen'ic artery**,² the largest branch of the cœliac axis, passes toward the left side in a tortuous manner along the upper border of the pancreas to the hilus of the spleen. Its branches are as follow :—

- a.* Pancreatic arteries.
- b.* Left gastro-epiploic artery.
- c.* Short gastric arteries.
- d.* Splenic branches.

a. The **Pancreat'ic arteries**,³ variable in size and number, are given from the splenic in its course along the pancreas.

b. The **Left gas'tro-epip'loic artery**⁴ runs from left to right along the greater curvature of the stomach, and terminates by joining the right gastro-epiploic, like which it is also distributed.

c. The **Short gas'tric arteries**,⁵ three to six in number, are directed from the termination of the splenic artery, or some of its branches, to the fundus of the stomach, where they anastomose with the other arteries of that organ.

d. The **Splen'ic branches**,⁶ five or more in number, diverge from the parent vessel and enter the hilus of the spleen.

THE SUPERIOR MESENTERIC ARTERY.

The **Superior Mes'enteric artery**,⁷ a large vessel, springs from the front of the aorta just below the cœliac axis, and supplies the small intestine and the right portion of the large intestine. It descends behind the pancreas and in front of the duodenum, and then proceeds within the mesentery in a curved line, at first downward and to the left, and then toward the right iliac region, where it inosculates with its own ileo-colic branch.

The superior mesenteric artery gives off the following branches :—

- 1. Duodenal artery.
- 2. Jejunal and ileal arteries.
- 3. Ileo-colic artery.
- 4. Right colic artery.
- 5. Middle colic artery.

¹ A. hepatica sinistra.

² A. splenica; a. lienalis.

³ A. pancreaticæ.

⁴ A. gastro-epiploica sinistra; a. coronaria sinistra inferior; a. c. ventriculi, or gastrica sinistra inferior.

⁵ A. gastricæ breves; vasa brevia.

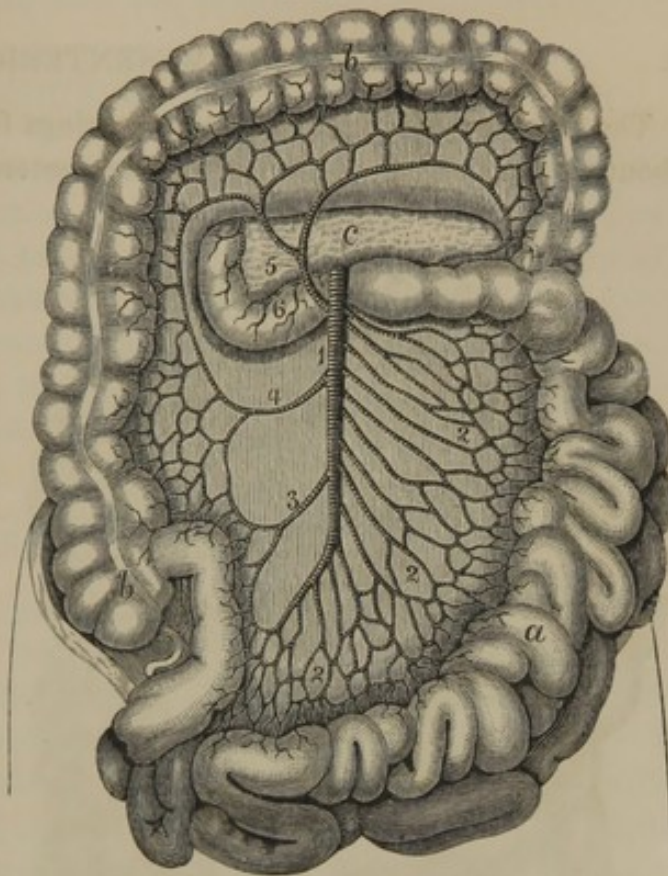
⁶ Rami splenici; r. lienales.

⁷ A. mesenterica superior; a. mesara-ica sup.

1. The **Duode'nal artery**¹ turns back along the course of the duodenum, and gives branches both to it and the pancreas.

FIG. 260.

2. The **Jeju'al and Il'eal arteries**,² fifteen or more in number, diverge from the convexity of the parent vessel, and supply almost the whole length of the small intestine. In their course within the mesentery they divide, and the contiguous branches conjoin so as to form a series of arches. From these spring forth a greater number of branches, which subdivide, and, in the manner just indicated, form a second series of arches, and from these again a third series is formed. Each series of arches becomes successively more numerous and smaller, and from the last series originate a multitude of intestinal branches which diverge upon the sides of the jejunum and ileum, where they freely anastomose with one another.



DISTRIBUTION OF THE SUPERIOR MESENTERIC ARTERY. 1, superior mesenteric artery; 2, jejunal and ileal arteries; 3, ileo-colic artery; 4, right colic; 5, middle colic artery; 6, duodenal artery. a, small intestine turned to the left; b, large intestine; c, pancreas.

3, 4, 5. The **Il'eo-colic**,³ **Right Colic**,⁴ and **Middle Colic arteries**⁵ arise in succession from the right side or concavity of the superior mesenteric artery. Each divides into two branches, of which those contiguous, together with the termination of the parent vessel and the upper branch of the left colic artery, conjoin so as to form four large arches. Upon these, in the manner indicated in the account of the preceding arteries, a more numerous and smaller row of arches is formed, from

¹ A. duodenalis inferior; a. pancreatico-duodenalis inferior.

² A. jejunaes et ileæ; a. intestinales; vasa intestini tenuis.

³ A. ileo-colica; a. colica dextra inferior; a. cæcalis.

⁴ A. colica dextra; a. c. d. media; a. media anastomotica.

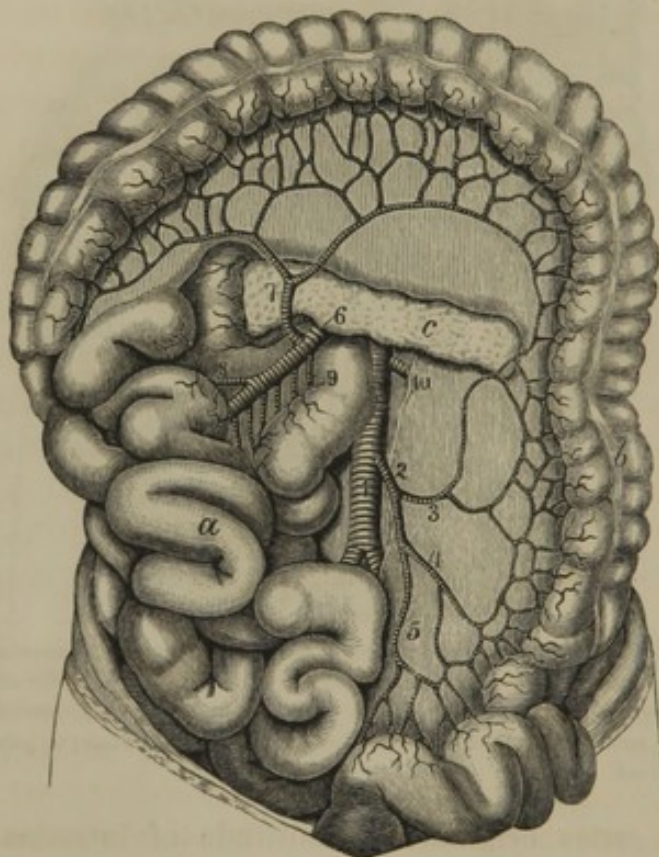
⁵ A. colica media; a. colica dextra superior; a. mesocolica.

which emanate many branches to supply the termination of the ilium, the cæcum, and the ascending and transverse colon.

THE INFERIOR MESENTERIC ARTERY.

The **Inferior Mes'enteric artery**¹ springs from the front of the aorta about two inches below the superior mesenteric, and is destined to supply the descending colon and the rectum. It descends toward the left iliac region and gives off the following branches:—

FIG. 261.



DISTRIBUTION OF THE INFERIOR MESENTERIC ARTERY. 1, aorta; 2, inferior mesenteric artery; 3, left colic artery; 4, sigmoid artery; 5, superior hæmorrhoidal artery; 6, superior mesenteric artery; 7, middle colic artery anastomosing with the left and the right (8) colic arteries; 9, branches to the small intestine; 10, left renal artery. *a*, small intestine turned to the right side; *b*, large intestine; *c*, pancreas.

ing in common with the former, and sometimes represented by two branches, inosculates with the left colic and superior hæmorrhoidal arteries, thus producing arches from which branches proceed to the sigmoid flexure of the colon.

3. The **Superior hæmorrhoidal artery**,⁴ the terminal portion of the

1. Left colic artery.
2. Sigmoid artery.
3. Superior hæmorrhoidal artery.

1. The **Left Col'ic artery**,² directed to the left side, divides into two branches, of which one joins the middle colic artery, and the other joins the sigmoid artery, thus contributing to form a pair of arches. Upon these a series of irregular and smaller arches is formed, from which branches proceed to the descending colon.

2. The **Sig'moid artery**³ sometimes originat-

¹ A. mesenterica, or mesaraica inferior.

² A. colica sinistra; a. c. s. superior; a. c. sinistra magna and media.

³ A. colica sinistra inferior; a. c. s. parva.

⁴ A. hæmorrhoidalis superior, or interna.

inferior mesenteric, after anastomosing with the former, descends behind the rectum and divides into two branches, distributed on the sides of the latter, and anastomosing with the middle and inferior hemorrhoidal arteries.

THE MIDDLE SACRAL ARTERY.

The **Middle Sac'ral artery**¹ is a small vessel descending from behind the bifurcation of the aorta along the middle of the sacrum and coccyx. It is really a rudimental termination of the aorta, and appears as a gradual prolongation of the latter in whales, snakes, and other animals in which hinder extremities do not exist or are feebly developed in comparison with the tail. In its course it gives off branches which anastomose with the lateral sacral arteries.

ARTERIES IN PAIRS FROM THE ABDOMINAL AORTA.

The **Phren'ic arteries**² are two small vessels arising from the sides of the abdominal aorta near the cœliac axis, or from the latter itself. Diverging on the crura of the diaphragm, the right one passes behind and to the outer side of the inferior cava, while the left one proceeds in like manner in relation with the œsophagus, and both divide into branches supplying the diaphragm, anastomosing with the phrenic branches of the internal mammary and the terminations of the intercostals.

In their course they give small branches³ to the supra-renal bodies.

The **Lum'bar arteries**⁴ correspond very nearly with the intercostals in their manner of origin, direction, and distribution. There are four pairs of them, and they cross the bodies of the lumbar vertebræ beneath the origin of the crura of the diaphragm and the psoas muscles, to the interspaces of the transverse processes, where they divide into an anterior and a posterior branch.

The **anterior branch**⁵ passes outwardly behind the quadrate lumbar muscle, ramifies in the broad abdominal muscles, and anastomoses with the epigastric arteries.

The **posterior branch**,⁶ after giving off a **spinal branch**,⁷ through the intervertebral foramina, to the spinal cord and membranes, is distributed to the muscles and skin of the back.

¹ A. sacralis media; a. s. anterior; median artery of the sacrum.

² A. phrenicæ: a. p. inferiores, or magnæ; a. diaphragmaticæ.

³ A supra-renales superiores.

⁴ A. lumbares, a. lumbales.

⁵ Ramus lumbaris, or abdominalis.

⁶ Ramus dorsalis.

⁷ R. spinalis.

The **Supra-re'nal arteries**¹ are two small vessels coming from the aorta on a level with the superior mesenteric artery, and proceed outward to be distributed to the supra-renal bodies.

The **Re'nal arteries**² are two large vessels coming from the sides of the aorta, a short distance below the position of the superior mesenteric artery. The right one is usually a little lower than the left one, and is longer in consequence of the position of the aorta on the left side of the vertebral column. Passing directly outward and backward in front of the crura of the diaphragm, they divide into four or five branches, which enter the sinus of the kidney and are distributed through the organ. They also give small branches to the supra-renal body,³ the kidney fat,⁴ and the pelvis and ureter.

The **Sperma'tic arteries**⁵ are long, slender vessels which spring one from each side of the front of the aorta, a short distance below the renal arteries. Each descends outwardly upon the psoas muscle, in company with the ureter, but leaves the latter at the brim of the pelvis, and proceeds to the internal abdominal ring, where it becomes one of the constituents of the spermatic cord, and descends to be distributed to the testicle. It gives fine twigs to the ureter; near the testicle, becomes quite tortuous, and gives branches to the vaginal tunic of the organ.

The **Ova'rian arteries**⁶ of the female correspond with those just described of the male. They have the same origin, and, likewise, the same course as the spermatic arteries to the brim of the pelvis, after which they proceed in a tortuous manner between the folds of the broad ligament to the ovary, the Fallopian tube, and the uterus.

THE COMMON ILIAC ARTERIES.

The **Common Il'iac arteries**⁷ are the terminal branches of the abdominal aorta, and are given off opposite the body of the fourth lumbar vertebra, slightly to the left of the median line. The two vessels diverge on the sides of the fifth lumbar vertebra; and just above the sacro-iliac symphysis each divides into the internal and external iliac arteries.

¹ A. supra-renales; a. s. mediæ, or aorticæ; a. capsulares; a. atrabiliaræ.

² A. renales; a. emulgentes.

³ A. supra-renales inferiores.

⁴ A. adiposæ.

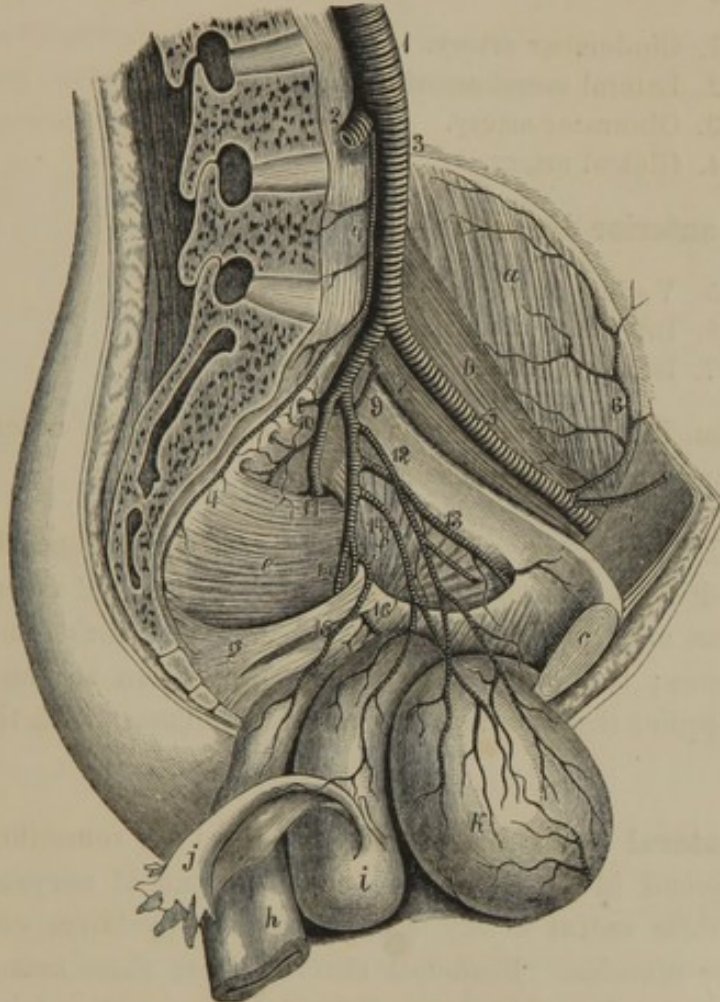
⁵ A. spermaticæ; a. s. internæ; a. præparantes; a. testiculares.

⁶ A. ovariana; a. spermatica.

⁷ A. iliacæ communes; a. i. primitivæ; primitive or primary iliac arteries; a. pelvicurales.

The common iliacs are about two inches in length, and are covered by the peritoneum and intestines. The right one crosses over both common iliac veins as these converge to the inferior cava.

FIG. 262.



VIEW OF THE LEFT SIDE OF THE PELVIS, THE BLADDER, UTERUS, VAGINA, AND RECTUM, turned downward so as to exhibit the distribution of the internal iliac artery. 1, aorta; 2, right common iliac artery; 3, left common iliac; 4, middle sacral; 5, external iliac; 6, circumflex iliac; 7, epigastric; 8, internal iliac; 9, ilio-lumbar; 10, lateral sacral arteries; 11, gluteal artery passing from the pelvis, above the pyriform muscle, at the upper part of the great sacro-sciatic foramen; 12, superior vesical artery; the branch cut off is extended into the remains of the umbilical artery; 13, obturator artery; 14, inferior vesical artery giving off the uterine artery to the vagina and uterus; 15, middle hæmorrhoidal artery; 16, internal pudic artery, seen emerging from and again entering the pelvis; 17, ischiatic artery. *a*, iliac muscle; *b*, psoas muscle; *c*, symphysis of the pubis; *d*, sacrum; *e*, pyriform muscle; *f*, internal obturator muscle; *g*, sacro-sciatic ligaments; *h*, rectum; *i*, uterus and vagina; *j*, Fallopian tube; *k*, bladder.

THE INTERNAL ILIAC ARTERY.

The **Internal Iliac artery**¹ is a short, stout vessel which descends from the common iliac into the pelvis, the contents of which, the but-

¹ *A. iliaca interna*; *a. i. posterior*; *a. hypogastrica*; *a. pelvica*.

tocks, and the generative apparatus it supplies. It extends in front of the sacro-iliac symphysis toward the great sacro-sciatic foramen, and divides into two portions, which usually give off branches in the following order:—

From the **posterior division**:—

1. Ilio-lumbar artery.
2. Lateral sacral arteries.
3. Obturator artery.
4. Gluteal artery.

From the **anterior division**:—

5. Vesical arteries.
6. Internal pudic artery.
7. Ischiatic artery.

In addition, in the female there come off from the anterior division the uterine and vaginal arteries.

1. The **Ilio-lum'bar artery**¹ passes outward beneath the psoas muscle, and divides into two branches. Of these, one² ascends and supplies the psoas and quadratus-lumbar muscles, and anastomoses with the lumbar arteries; the other³ crosses the iliac fossa to the crest of the ilium and supplies the iliac muscles, and anastomoses with the circumflex iliac artery.

2. The **Lateral Sac'ral arteries**,⁴ usually two, sometimes arising in common, descend in front of the sacral plexus of nerves, anastomose with the middle sacral artery, and supply the pyriform, coccygeal, and anal elevator muscles. Branches derived from these arteries enter the sacral foramina and supply the contained nerves and membranes, and in part pass out at the posterior foramina to terminate in the neighboring muscles and skin.

3. The **Obtura'tor artery**,⁵ often a branch of the anterior division of the internal iliac, passes forward along the side of the pelvis to the obturator foramen, through which it emerges and divides into two branches. Of these, the **internal branch**⁶ is distributed to the adductor, pectineal, and gracilis muscles, and anastomoses with the internal circumflex artery. The **external branch**⁷ is distributed to the obturator, quadratus femoral,

¹ A. ilio-lumbaris; a. ilia parva.

² Ramus ascendens; r. lumbaris.

³ R. transversalis; r. iliacus.

⁴ A. sacrales laterales.

⁵ A. obturatoria; a. sub-pubio-femoralis.

⁶ Ramus internus; r. anterior.

⁷ R. externus; r. posterior.

and geminous muscles, to the hip joint, and to the heads of the flexors attached to the tuberosity of the ischium. Within the pelvis the obturator artery gives small branches to the iliac, internal obturator, and anal elevator muscles.

Frequently the obturator artery arises, in common with the epigastric, from the termination of the external iliac artery, in which cases it descends behind the pubis to the obturator foramen, from whence it pursues the ordinary course.

4. The **Glu'teal artery**,¹ the continuation of the posterior division of the internal iliac, turns out of the pelvis at the upper part of the great sacro-sciatic foramen, and divides into two branches. The **superficial branch** runs backward between the middle and great gluteal muscles, which it supplies, together with the skin of the gluteal and sacral regions. The **deep branch** passes forward between the middle and small gluteal muscles, diverging into many branches,² which supply the latter and anastomose with the ischiatic and circumflex arteries.

5. The **Ves'ical arteries**³ are generally two in number. The **superior ves'ical artery**⁴ extends through the remains of the umbilical artery of the fœtus to the side of the urinary bladder, to which it is distributed. In its course it gives the **deferent artery** to the spermatic duct, and a branch to the ureter. The **inferior ves'ical artery**⁵ proceeds to the lower part of the bladder, and also supplies the prostate gland and seminal vesicles.

6. The **Internal Pu'dic artery**,⁶ one of the terminal branches of the anterior division of the internal iliac, descends to the lower part of the great sacro-sciatic foramen, and thence passes from the pelvis. Winding around the spine of the ischium, it again enters the pelvis through the small sacro-sciatic foramen, ascends along the inner side of the rami of the ischium and pubis, and divides into the cavernous and dorsal arteries of the penis. Its branches, including the terminal ones, are as follow:—

- a. Middle hæmorrhoidal artery.
- b. Inferior hæmorrhoidal artery.
- c. Perineal artery.
- d. Bulbo-urethral artery.
- e. Cavernous artery.
- f. Dorsal artery of the penis, or clitoris.

¹ A. glutæa; a. g. superior; a. iliaca posterior.

² Deep superior and inferior branches.

³ A. vesicæ; a. vesicales.

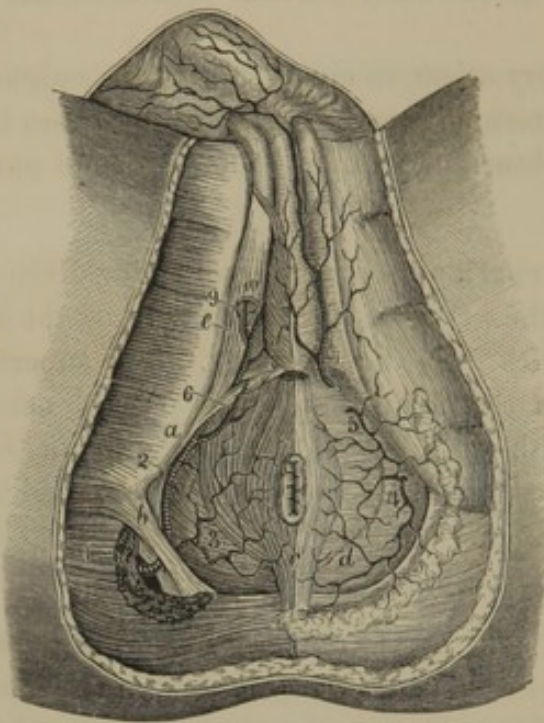
⁴ A. v. superior.

⁵ A. v. inferior.

⁶ A. pudica interna; a. pudica; a. pudenda; a. p. interna; a. p. communis; a. p. circumflexa; a. hæmorrhoidæ externa.

a. The **Middle hæmorrhoid'al artery**¹ proceeds from the pudic before

FIG. 263.



VIEW OF THE PERINEUM, EXHIBITING THE DISTRIBUTION OF THE INTERNAL PUDIC ARTERY. 1, the internal pudic issuing from the pelvis at the lower part of the great sacro-sciatic foramen; 2, the same vessel after it has returned into the pelvis through the small sacro-sciatic foramen; 3, inferior hæmorrhoidal artery; 4, 5, superficial perineal branches to the perineum; 6, transverse perineal; 7, perineal branch to the scrotum and skin of the penis; 8, bulbo-urethral artery; 9, cavernous artery; 10, dorsal artery of the penis. a, tuberosity of the ischium; b, greater sacro-sciatic ligament; c, sphincter of the anus; d, perineal fascia, which is removed on the opposite side so as to expose the anal elevator muscle; e, ischio-cavernous muscle; f, bulbo-urethral muscle.

it issues from the pelvis, and supplies the lower part of the rectum, the fundus of the bladder, and the prostate gland. It anastomoses with the superior and inferior hæmorrhoidal arteries. Sometimes it comes directly from the internal iliac, or it may come off in common with the inferior vesical artery.

b. The **Inferior hæmorrhoid'al artery**² is a small branch which comes from the pudic after it re-enters the pelvis, and is distributed to the parts about the anus.

c. The **Perine'al artery**³ becomes superficial by piercing the deep perineal fascia, and is distributed to the perineum and back part of the scrotum,⁴ or labia.⁵ A branch crossing the perineum on the trans-

verse perineal muscle, and important in its surgical relations, is named the **transverse perineal artery**.⁶

d. The **Bul'bo-ure'thral artery**,⁷ derived from the pudic just before its division, or from one of its terminal branches, passes transversely inward, and pierces the triangular ligament to reach the bulb of the spongy body, which it penetrates to supply the erectile tissue.

e. The **Cav'ernous artery**,⁸ a terminal branch of the pudic, runs a

¹ A. hæmorrhoidalis media.

² A. hæmorrhoidalis inferior; a. h. externa.

³ A. perinei; a. superficialis perinei.

⁴ A. scrotales posteriores et a. septi.

⁵ A. labiales posteriores.

⁶ A. transversa perinei.

⁷ Artery of the bulb; bulbar artery; a. bulbosa; a. bulbo-urethralis.

⁸ A. cavernosa; a. profunda penis.

short distance between the ramus of the ischium and the crus of the cavernous body, and enters this to supply its erectile tissue.

f. The **Dorsal artery of the penis**,¹ or **clitoris**,² the second terminal division of the pudic, ascends between the pubis and cavernous body to the back of the latter, along which it proceeds to the glans. It supplies the fibrous investment of the cavernous body, the glans, and the skin, and anastomoses with branches of the bulbo-urethral and cavernous arteries.

7. The **Ischiatic artery**,³ the remaining branch of the anterior division of the internal iliac, passes from the pelvis in company with the pudic artery and great sciatic nerve, at the lower part of the great sacro-sciatic foramen. Descending in the interval of the tuberosity of the ischium and the great trochanter, covered by the great gluteal muscle, it gives branches to the latter, the small rotators upon which it rests, the skin about the coccyx,⁴ the sciatic nerve,⁵ and hip joint, and it anastomoses with the gluteal and circumflex arteries.

8. The **Uterine artery**,⁶ a branch of the anterior division of the internal iliac, sometimes arising in common with the ^{inferior} ~~superior~~ vesical artery, passes within the broad ligament and ascends in a tortuous manner to the side of the uterus. It also gives branches to the vagina, Fallopian tube, round ligament, and ovary, and anastomoses with the ovarian artery.

9. The **Vaginal artery**,⁷ a branch of the anterior division of the internal iliac, sometimes arising in common with the uterine, inferior vesical, or middle hæmorrhoidal artery, supplies the walls of the vagina and the contiguous parts of the rectum and urinary bladder.

THE EXTERNAL ILIAC ARTERY.

The **External Iliac artery**,⁸ the second division of the common iliac, runs along the brim of the pelvis, resting against the psoas muscle, to the femoral arch, beneath which it passes out to assume the name of femoral artery. The corresponding iliac vein at first is behind it, and afterwards to its inner side. It gives off no branches of importance until it is about passing under the femoral arch, when it sends off the epigastric and circumflex iliac arteries.

¹ A. dorsalis penis.

² A. d. clitoridis.

³ A. ischiadica; a. glutæa inferior; a. sciatica; a. femoro-poplitea.

⁴ A. coccygeæ.

⁵ Comes nervis ischiadici.

⁶ A. uterina; a. u. hypogastrica.

⁷ A. vaginalis.

⁸ A. iliaca externa; a. i. anterior; crural artery; a. cruralis; a. c. iliaca.

1. The **Epigas'tric artery**¹ springs from the fore part of the external iliac, and ascends obliquely inward, between the peritoneum and transverse fascia, to the straight muscle of the abdomen. Piercing the sheath of this muscle, and ascending behind it, the artery mainly supplies the latter, and anastomoses with the termination of the mammary artery. In its course it crosses the inguinal canal and gives a branch² to the spermatic cord. Subsequently it gives branches to the broad abdominal muscles, which anastomose with the lumbar and circumflex iliac arteries.

2. The **Cir'cumflex Il'iac artery**,³ smaller than the preceding, runs outward from the external iliac, behind Poupart's ligament, to the crest of the ilium. Proceeding along the latter, it gives branches to the iliac and abdominal muscles, and anastomoses with the ilio-lumbar, lumbar, and epigastric arteries.

THE FEMORAL ARTERY.

The **Fem'oral artery**,⁴ the continuation of the external iliac, proceeds from the femoral arch, downward and inward, in the groove of the thigh, between the extensor and adductor muscles. Becoming gradually deeper in its descent, at about the commencement of the lower third of the thigh it pierces the insertion of the great adductor muscle, and assumes the name of popliteal artery. It passes through the middle of a triangular space, whose base is formed by Poupart's ligament, the outer side by the sartorius muscle, and the inner side by the border of the adductor muscles. A line extended from the middle of the groin to the inner side of the knee-cap would nearly indicate its course. In succession, it rests on the pectineal, long adductor, and great adductor muscles. At the femoral arch the corresponding vein lies at its inner side, but gradually assumes a position behind as it approaches the perforation of the great adductor. At the upper third of the thigh it is covered by the skin and fasciæ; lower down, in addition, by the sartorius muscle.

The branches of the femoral artery are as follow:—

1. External pudic arteries.
2. Superficial epigastric artery.
3. Superficial circumflex iliac artery.
4. Profound femoral artery.
5. Muscular branches.
6. Anastomotic artery.

1. The **External Pu'dic arteries**⁵ are two or three small vessels

¹ A. epigastrica; a. e. inferior; a. e. i. interna.

² A. spermatica externa.

³ A. circumflexa iliaca.

⁴ A. femoralis; a. cruralis; a. pelvi-cruralis.

⁵ A. pudendæ externæ; a. pudenda externa superior et inferior; a. scrotales et labiales anteriores.

from the commencement of the femoral artery, which pass through the pectineal and cribriform fasciæ to the region of the pubis, where they are distributed to the skin of the penis and scrotum, or, in the female, to the mons veneris and labia.

2. The **Superficial Epigas'tric artery**¹ arises a little below the femoral arch, perforates the falci-form process, and ascends in the superficial fascia of the abdomen toward the umbilicus.

3. The **Superficial Cir'cumflex il'iac artery**,² often a branch of the preceding, follows the course of Poupart's ligament to the ilium, dividing into branches which pierce the fascia and supply the groin³ and integument.

ARTERIES OF THE FRONT OF THE THIGH. 1, femoral artery; 2, popliteal artery; 3, posterior tibial artery; 4, superficial epigastric artery; 5, superficial circumflex iliac; 6, external pudics; 7, profound femoral artery; 8, 9, external and internal circumflex arteries; 10, perforating arteries; 11, muscular branches; 12, anastomotic artery; 13, 14, internal articular arteries; 15, small branch from the epigastric; 16, dorsal arteries of the penis. *a*, rectus muscle; *b*, internal vastus; *c*, *d*, *e*, adductor muscles; *f*, semi-tendinous muscle; *g*, sartorius muscle.

4. The **Profound Fem'oral artery**⁴ comes from the outer back part of the femoral, an inch or two below Poupart's ligament, and is nearly as large as the continuation of the parent trunk. It descends behind the latter, proceeds between the short and long adductors, and thence upon the great adductor, which is perforated by its terminal branches. In its course it is distributed through the following-named branches:—

¹ A. epigastrica superficialis; a. abdominalis subcutanea; a. ad cutem abdominis.

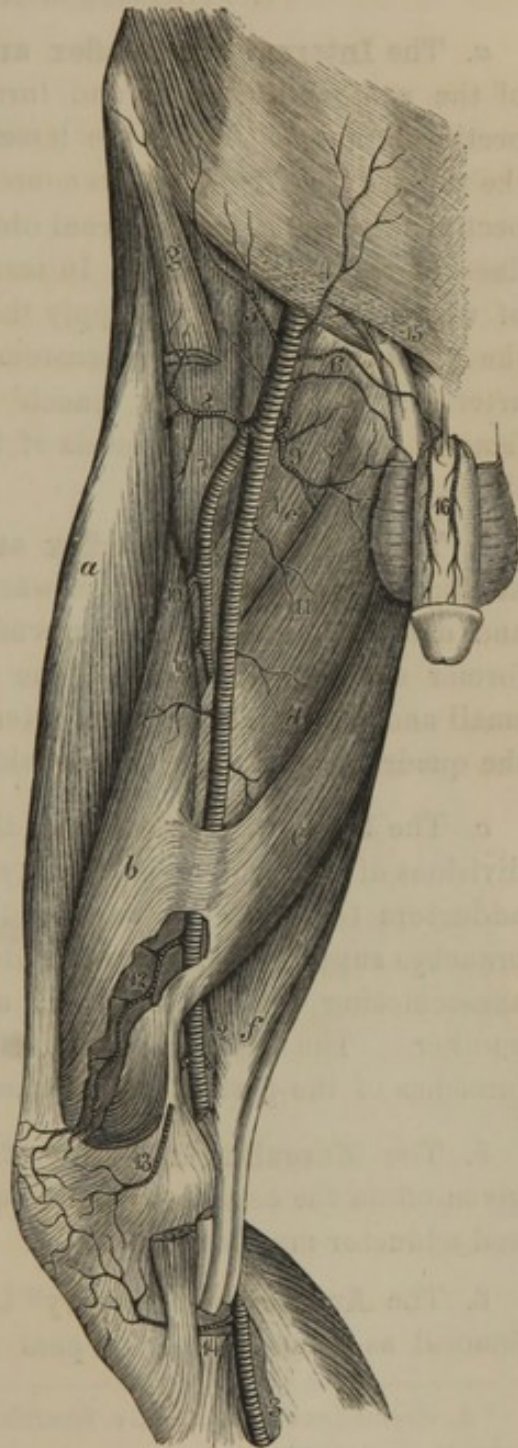
² A. circumflexa ilii superficialis or

externa; ramus iliacus of the sup. epigastric.

³ A. inguinales.

⁴ A. profunda femoris; a femoralis profunda.

FIG. 264.



- a. Internal circumflex artery.
- b. External circumflex artery.
- c. Perforating arteries.

a. The **Internal cir'cumflex artery**¹ comes from the commencement of the profound femoral, and turns backward between the psoas and pectineal muscles, above the lesser trochanter, to the posterior part of the neck of the femur. In its course it gives branches to the iliac, psoas, pectineal, gracilis, and external obturator muscles,² the heads of the adductors, and the hip joint.³ In terminating it divides into two branches, of which one⁴ ascends to supply the small rotators and the lower part of the great gluteal muscle, anastomosing with the ischiatic and gluteal arteries; while the other branch⁵ descends and supplies the quadrate femoral muscle and the heads of the great adductor and flexors of the thigh.

b. The **External cir'cumflex artery**,⁶ larger than the preceding, and arising a little lower, passes outward between the iliac and rectus muscles and divides into a series of ascending and descending branches. The former supply the tensor of the femoral fascia, the sartorius, rectus, small and middle gluteal, and external vastus muscles; the latter supply the quadriceps extensor and the skin on the outer part of the thigh.

c. The **Perforating arteries**,⁷ three or four in number, are successive divisions of the profound femoral artery which pierce the insertion of the adductors to reach the back of the thigh, where they are resolved in branches supplying the great gluteal, adductor, and flexor muscles, and anastomosing with the ischiatic and circumflex arteries and with one another. The **med'ullary nutrit'ious arteries of the femur**⁸ are branches of the perforating arteries.

5. The **Muscular branches**⁹ of the femoral artery are small vessels given off in the course of the latter to the sartorius, gracilis, extensor, and adductor muscles.

6. The **Anastomot'ic artery**¹⁰ is a slender vessel springing from the femoral as this is about to pass through the perforation of the great

¹ A. circumflexa interna; a. c. femoris interna, or posterior.

² Ramus superficialis.

³ A. articularis; a. acetabuli.

⁴ Ramus trochantericus.

⁵ R. descendens.

⁶ A. circumflexa externa; a. c. femoris externa, or anterior.

⁷ A. perforantes; a. perforans prima, secunda, et tertia.

⁸ A. nutritiæ; a. nutritia femoris superior et inferior, or magna.

⁹ Rami musculares.

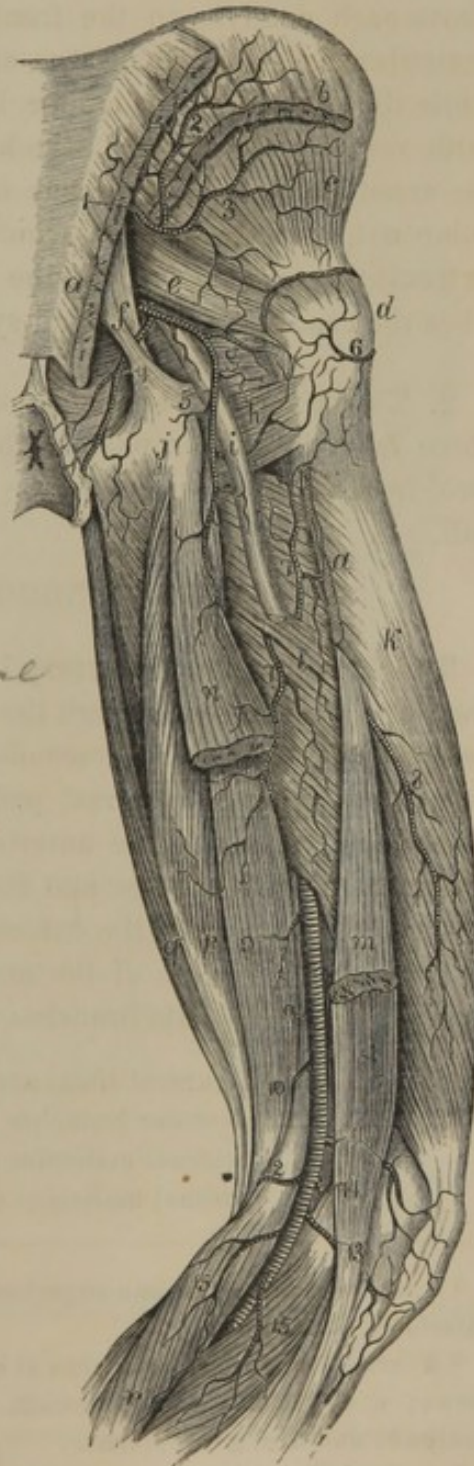¹⁰ A. anastomotica magna; ramus musculo-articularis and a. articularis genu superficialis, or a. a. g. s. superior interna or prima.

adductor. Descending upon the tendon of the latter and giving it branches, it also supplies the internal vastus, sartorius, and gracilis muscles, and terminates at the knee by anastomosing with all the other contiguous arteries.

THE POPLITEAL ARTERY.

ARTERIES OF THE BACK OF THE THIGH. 1, gluteal artery; 2, 3, its superficial and deep branch; 4, internal pudic artery; 5, ischiatic artery; 6, branch of the external circumflex; 7, 8, terminal branches of the perforating arteries; 9, popliteal artery; 10, 11, superior internal and external articular arteries; 12, 13, inferior internal and external articular arteries; 14, middle articular artery; 15, gastrocnemial branches. *a*, origin and insertion of the great gluteal muscle; *b*, origin of the middle gluteal muscle; *c*, small gluteal muscle; *d*, great trochanter; *e*, piriform muscle; *f*, sacro-sciatic ligaments; *g*, internal obturator muscle; *h*, quadrate femoral muscle; *i*, sciatic nerve; *j*, tuberosity of the ischium; *k*, external vastus muscle; *l*, great adductor; *m*, short head of the biceps; *n*, long head; *o*, *p*, semi-membranous and semi-tendinous muscles; *q*, gracilis; *r*, gastrocnemius.

FIG. 265.



The **Poplite'al artery**¹ is the name assumed by the femoral after its passage through the tendon of the great adductor *by Hunter's Canal* at the lower third of the thigh. It extends along the back of the latter, behind the middle of the knee joint, to the lower border of the popliteal muscle, where it divides into the anterior and posterior tibial arteries. Occupying the deepest part of the popliteal space, it rests in succession against the femur, the capsular ligament of the knee joint, and the popliteal muscle. In contact with it posteriorly is the corresponding vein; between which and the skin is the posterior tibial nerve. The branches of the popliteal artery, including the terminal ones, are as follow:—

¹ A. poplitea; popliteal portion of the crural artery.

1. Articular arteries.
2. Muscular branches.
3. Anterior tibial artery.
4. Posterior tibial artery.

1. The **Artic'ular arteries**¹ are five small vessels which spring from the popliteal artery and supply the knee joint and its contiguous structures. The **superior articular arteries**² wind around the femur, one above each condyle, to the front of the knee joint. Of the **inferior articular arteries**,³ one turns around the external semilunar cartilage, while the other takes its course below the internal condyle of the tibia; both reaching the front of the knee. These four vessels, together with the anastomotic and recurrent tibial arteries, produce an intricate vascular net,⁴ enveloping the front and sides of the knee. The **middle articular artery**⁵ penetrates the back of the capsular ligament and supplies the crucial ligaments and synovial folds of the knee joint.

2. The **Muscular branches** of the popliteal artery consist of two or three from its upper part to the flexor and vasti muscles, and one or two⁶ from its lower part to the gastrocnemius muscle and skin of the calf.

THE ANTERIOR TIBIAL ARTERY.

The **Anterior Tib'ial artery**,⁷ the smaller of the terminal divisions of the popliteal, passes through the opening at the upper part of the interosseous membrane, and descends in front of this to the instep, where it assumes the name of dorsal pedal artery. It is accompanied by two companion veins and the anterior tibial nerve; at first lies between the long extensor of the toes and the anterior tibial muscle, and afterwards between the latter and the extensor of the great toe. At the ankle it is crossed by the tendon of the muscle last named, and is covered by the annular ligament. Its branches are as follow:—

1. Recurrent tibial artery.
2. Muscular branches.
3. **External malleolar artery.**
4. **Internal malleolar artery.**

¹ A. articulares; a. a. genu superiores, inferiores, et media.

² A. articularis superior interna et externa; a. a. genu sup. int. secunda or profunda and a. a. g. s. externa.

³ A. art. inferior interna et externa.

⁴ Rete articulare genu.

⁵ A. art. genu media; a. a. genu azygos.

⁶ A. surales; a. gemellæ; a. surales profundæ et superficialis; gastrocnemial or sural arteries.

⁷ A. tibialis antica.

1. The **Recurrent Tib'ial artery**¹ ascends beneath the origin of the anterior tibial muscle to the front of the knee, and is there distributed, anastomosing with the articular arteries.

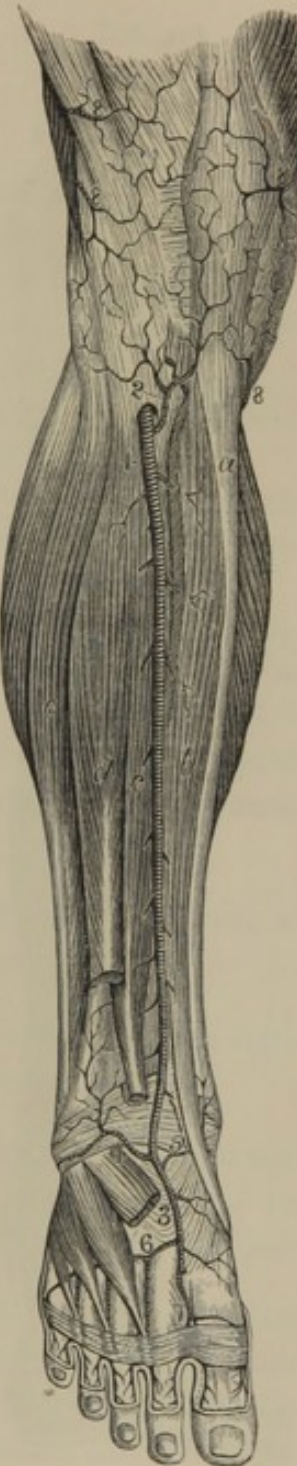2. The **Muscular branches** are numerous small vessels to the contiguous muscles.

3. The **External Malle'olar artery**² passes outwardly at the lower part of the leg, beneath the extensor tendons, and ramifies on the external ankle, supplying the neighboring structures, and anastomosing with the peroneal and tarsal arteries.

4. The **Internal Malle'olar artery**,³ smaller than the preceding, passes beneath the tendon of the anterior tibial muscle and ramifies over the internal ankle, anastomosing with branches of the posterior tibial and tarsal arteries.

ARTERIES OF THE FRONT OF THE LEG.
1, anterior tibial artery; 2, recurrent tibial; 3, dorsal pedal; 4, 5, external and internal malleolar arteries; 6, metatarsal artery; 7, dorsal artery of the great toe; 8, terminal branches of the articular arteries. *a*, tibia; *b*, anterior tibial muscle; *c*, extensor of the great toe; *d*, long extensor of the toes: the short extensor occupies the back of the foot; *e*, peroneal muscles: on each side of the leg the bellies of the gastrocnemius are visible.

FIG. 266.



THE DORSAL PEDAL ARTERY.

The **Dorsal Pe'dal artery**,⁴ the continuation of the anterior tibial, extends from the bend of the ankle over the instep to the commencement of the first interosseous space, where it dips to the sole of the foot to contribute in the formation of the plantar arch. Its branches are as follow:—

1. Tarsal arteries.
2. Metatarsal artery.
3. Dorsal artery of the great toe.

1. The **Tar'sal arteries**⁵ consist of several small branches to the inner

¹ A. tibialis recurrens.

⁴ A. dorsalis pedis.

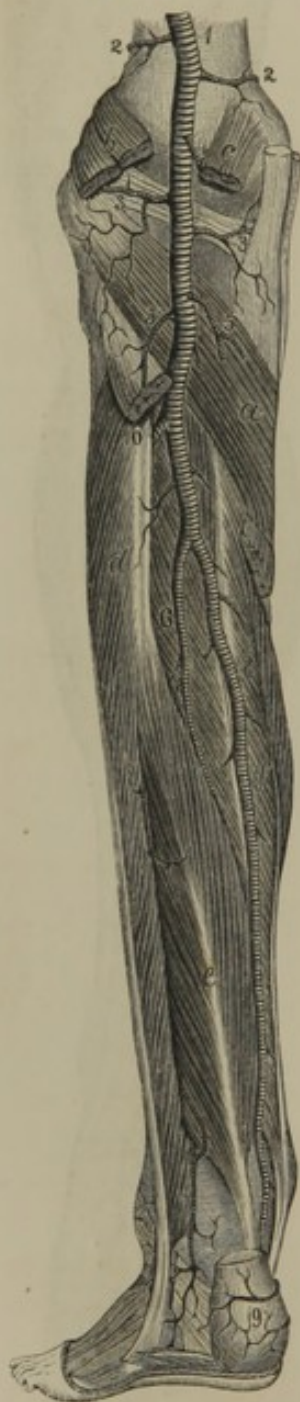² A. malleolaris externa.

⁵ A. tarseæ; a. t. internæ and externæ.

³ A. malleolaris interna.

side of the tarsus, and a large branch which crosses the latter beneath the short extensor of the toes and supplies the outer part of the tarsus.

FIG. 267.



2. The **Metatar'sal artery**¹ crosses the base of the metatarsus and supplies the outer part of the foot, anastomosing with the tarsal and external plantar arteries. In its course it gives off branches² to the outer three metatarsal spaces, which subsequently subdivide³ to supply the contiguous sides of the outer four toes and the outer side of the little toe.

3. The **Dorsal artery of the great toe**⁴ runs forward on the first interosseous space, and supplies the inner and outer sides of the great toe and the adjoining side of the second toe.⁵

THE POSTERIOR TIBIAL ARTERY.

ARTERIES OF THE BACK OF THE LEG.

1, popliteal artery; 2, 2, superior internal and external articular arteries; 3, 3, inferior internal and external articular arteries; 4, middle articular artery; 5, gastrocnemial arteries; 6, peroneal artery; 7, posterior peroneal branch; 8, posterior tibial artery; 9, calcanean branches. *a*, popliteal muscle; *b*, *c*, origin of the gastrocnemius; *d*, peroneal muscles; *e*, long flexor of the great toe; *f*, long flexor of the toes; that between the two latter is the posterior tibial muscle.

The **Posterior Tibial artery**,⁶ the remaining division of the popliteal, and appearing as a continuation of it, descends the back of the leg, curves around the inner ankle to the concavity of the calcaneum, and divides into

the two plantar arteries. It is accompanied by two veins and the posterior tibial nerve, and is situated behind the tibia, with the posterior tibial and long flexor muscle of the toes interposed. Its upper part is covered by the muscles of the calf, but behind the inner ankle is covered only by the skin and fascia. Its branches are as follow:—

¹ A. metatarsæ.

² A. interosseæ.

³ A. digitales dorsales; dorsal collateral digital branches.

⁴ A. dorsalis hallucis or pollicis pedis;

a. interossea dorsalis prima.

⁵ A. digitales dorsales; dorsal collateral digital branches.

⁶ A. tibialis postica.

1. Peroneal artery.
2. Muscular branches.
3. Medullary nutritious artery.
4. Calcanean arteries.
5. Internal plantar artery.
6. External plantar artery.

1. The **Perone'al artery**¹ arises an inch or two below the commencement of the posterior tibial, and turns outward to descend along the back of the fibula. In the first part of its course it rests on the posterior tibial muscle, covered by the soleus; subsequently lies on the interosseous membrane close to the fibula, and is covered by the long flexor of the great toe. It gives branches to the contiguous muscles, and finally divides into the anterior and posterior peroneal arteries.

a. The **Anterior perone'al artery**² pierces the interosseous membrane at the lower part of the leg, and is distributed in front of the outer ankle, anastomosing with the external malleolar and tarsal arteries.

b. The **Posterior perone'al artery**³ descends along the back of the outer ankle to the side of the calcaneum, distributing branches to the heel⁴ and parts about the external ankle.⁵ By a short transverse branch⁶ it anastomoses with the posterior tibial artery; and by other and smaller branches it inosculates with the external malleolar, tarsal, and external plantar arteries.

2. The **Muscular branches** of the posterior tibial artery consist of about a dozen small vessels sent to the contiguous muscles.

3. The **Med'ullary Nutri'tious artery**⁷ enters the corresponding foramen, at the upper part of the tibia, to supply the marrow.

4. The **Calca'nean arteries**⁸ are two or three branches from the lower part of the posterior tibial artery, passing inward to be distributed to the heel, the tarsus, and the heads of the muscles of the sole of the foot.

5. The **Internal Plant'ar artery**,⁹ one of the terminal divisions of the posterior tibial, runs along the inner side of the sole of the foot above the abductor of the great toe. In its course it gives deep branches to the tarsus, and superficial ones to the contiguous muscles and skin, and ends by anastomosing with the digital arteries of the great toe.

¹ A. peronea; a. fibularis.

² A. peronea antica; a. p. perforans.

³ A. p. postica.

⁴ Rami calcanei externi.

⁵ R. malleolares externi postici.

⁶ R. anastomoticus transversus.

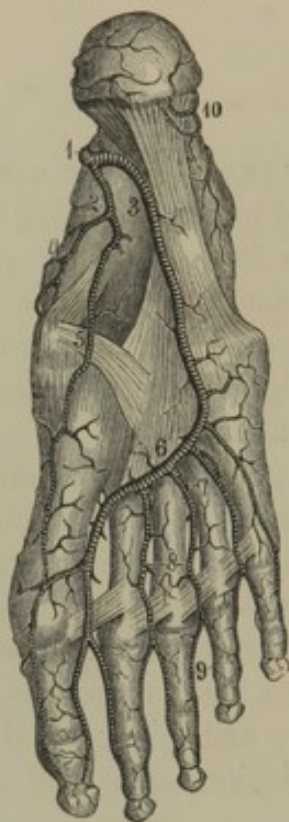
⁷ A. nutritia tibiæ; nutritious artery.

⁸ Rami calcanei interni.

⁹ A. plantaris interna.

6. The **External Plant'ar artery**,¹ larger than the preceding, inclines

FIG. 268.



ARTERIES OF THE SOLE OF THE FOOT. 1, posterior tibial artery dividing into 2 the internal, and 3 the external plantar arteries; 4, branch to the inner side of the foot; 5, branch to the great toe; 6, plantar arch; 7, perforating arteries; 8, common digitals; 9, digitals to the contiguous sides of the toes; 10, calcaneal branches of the peroneal and posterior tibial arteries.

outward and forward to the base of the last metatarsal bone, and then curves inwardly to form, in conjunction with the termination of the dorsal pedal artery, the plantar arch. In its course it lies between the short flexor of the toes and the accessory flexor, and subsequently between the latter and the short flexor of the little toe. To these and other muscles, and the skin on the inner side of the foot, it gives branches, as well as a **digital branch**² to the outer side of the little toe.

The **Plant'ar arch**,³ formed by the union of the external plantar and dorsal pedal arteries, lies against the interosseous muscles at the base of the metatarsus, covered by the flexor muscles and tendons. Besides giving branches to the contiguous muscles and articulations, it sends off the perforating and digital arteries.

a. The **Perforating arteries**⁴ are small vessels which penetrate between the bases of the metatarsal bones to anastomose with the interosseous branches of the metatarsal artery.

b. The **Digital arteries**,⁵ four in number, advance in the corresponding spaces to the clefts of the toes, and there divide into **digital branches**⁶ which run along the contiguous sides of the latter. The **first digital artery**⁷ also gives a **digital branch**⁸ to the inner side of the great toe.

¹ A. plantaris externa.

² A. digitalis plantaris externa.

³ Arcus plantaris.

⁴ A. perforantes.

⁵ A. interosseæ.

⁶ A. digitales pedis plantares; plantar collateral digital branches.

⁷ A. magna pollicis.

⁸ A. digitalis plantaris interna.

THE PULMONARY ARTERY.

The **Pul'monary artery**, one of the main trunks of the arterial system, conveys dark blood from the heart to the lungs. It is a short, wide vessel springing from the anterior part of the base of the right ventricle, and curves for about two inches upward, backward, and to the left side. Its origin conceals that of the aorta, but higher it crosses to the left side of the latter vessel, in front of the left auricle, and finally divides beneath the arch of the aorta into two branches—the right and left pulmonary arteries. At its bifurcation it is connected to the under side of the aortic arch by a short fibrous cord, which is the remains of a vessel of foetal life named the **ductus arteriosus**.

The **Right Pulmonary artery**, longer than the left, passes nearly transversely outward behind the ascending aorta and superior cava to the root of the right lung, of which it forms a part.

The **Left Pulmonary artery** passes transversely in front of the descending aorta into the root of the left lung.

THE VEINS.

The **Veins** comprise eight trunks, with their branches, as follow :—

The **Cor'onary vein**, which, with its branches, collects blood from the walls of the heart and conveys it to the right auricle.

The **Superior and Inferior Cava**, by whose branches blood is collected from most all parts of the body, and is then conveyed to the right auricle of the heart.

The **Port'al vein**, which originates by many branches from the stomach, intestines, spleen, and pancreas, and is distributed by another series of branches through the liver.

The four **Pul'monary veins** which convey the aerated blood from the lungs to the left auricle of the heart.

THE CORONARY VEIN.

The **Cor'onary vein**¹ commences at the apex of the heart, ascends in the groove between the ventricles in front, and then winds around the left auriculo-ventricular groove to the back of the heart, where it terminates in the right auricle. In its course it receives **car'diac branches**

¹ Vena coronaria; v. c. magna; v. cordis magna; great cardiac vein; coronary sinus of the heart.

from both ventricles, and from the left auricle. Its orifice is protected by a valve.¹

The **Posterior Car'diac vein**² commences at the apex of the heart, and ascends between the ventricles posteriorly to terminate in the coronary vein. In its course it receives **cardiac branches** from both ventricles.

The **Anterior Car'diac vein**,³ frequently represented by a pair of veins, runs from the front of the heart along the right auriculo-ventricular groove to terminate posteriorly in the coronary vein. In its course it receives **cardiac branches** from the right auricle and ventricle. Besides these several small **cardiac veins**⁴ ascend from the right ventricle to open separately into the right auricle.

THE SUPERIOR CAVA.

The **Superior Cava**⁵ is the great venous trunk which derives its branches from the head, neck, upper extremities, and walls of the thorax. It is placed to the right of the aortic arch in front of the root of the right lung, and commences behind the first costal cartilage of the right side by the conjunction of the two innominate veins. In its descent it receives the azygos vein, and terminates at the upper back part of the right auricle of the heart. It is less voluminous than the arch of the aorta, and is destitute of valves.

THE INNOMINATE VEINS.

The **Innom'inate veins**⁶ commence one on each side, behind the sterno-clavicular articulation, by the union of the internal jugular and subclavian veins. The **Right innom'inate vein**⁷ descends in front of the corresponding artery; the **Left innom'inate vein**,⁸ much longer than the other, crosses in front of the arteries springing from the summit of the aortic arch to the right side, where it joins its fellow to form the superior cava.

The innominate veins are destitute of valves, and, besides the branches

¹ Valvula Thebesii; v. Guiffartiana; v. venæ magnæ.

² V. cordis media; middle cardiac vein.

³ V. cordis parva; small, or anterior cardiac vein.

⁴ V. cordis minimæ; smallest cardiac veins.

⁵ Vena cava superior; v. c. descendens; v. c. thoracica; v. hepaticæ.

⁶ Venæ innominatæ; v. anonymæ; v. brachio-cephalicæ.

⁷ V. innominata dextra.

⁸ V. innominata sinistra; v. transversa; the transverse vein.

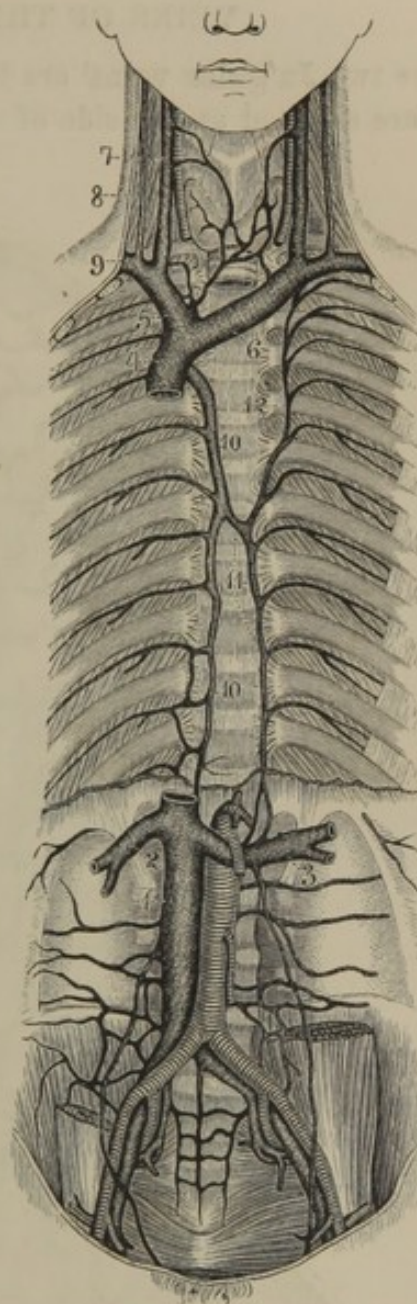
which conjoin in their formation, they receive the internal mammary, vertebral, and inferior thyroid veins, and usually the left superior intercostal vein.

The **Internal Mammary veins**,¹ a pair of companions to the corresponding artery, receive branches in accordance with the distribution of the latter, and finally unite to terminate in the innominate vein; though frequently the left one joins the superior cava.

The **Ver'tebral vein**² is a small vessel occupying the foramina of the transverse processes of the cervical vertebræ in company with the vertebral artery. It commences from branches on the occiput, receives others in its course down the neck from the neighboring muscles and spinal sinuses, and terminates in the innominate or subclavian vein.

The **Inferior Thy'roid vein**,³ formed by numerous branches in the thyroid gland, also receives others from the pharynx, larynx, œsophagus, and trachea, and terminates in the innominate vein. Sometimes the veins of the two sides conjoin in a single vessel⁴ descending in front of the trachea to end in the middle of the left innominate vein.

FIG. 269.



VEINS OF THE THORAX AND ABDOMEN. 1, inferior cava; 2, right, 3 left renal veins; 4, superior cava; 5, right, 6 left innominate veins; 7, internal veins; 8, external jugular veins; 9, subclavian vein; 10, azygos vein; 11 inferior, 12 superior hemiazygos veins.

¹ V. mammariae internæ.

² V. vertebralis.

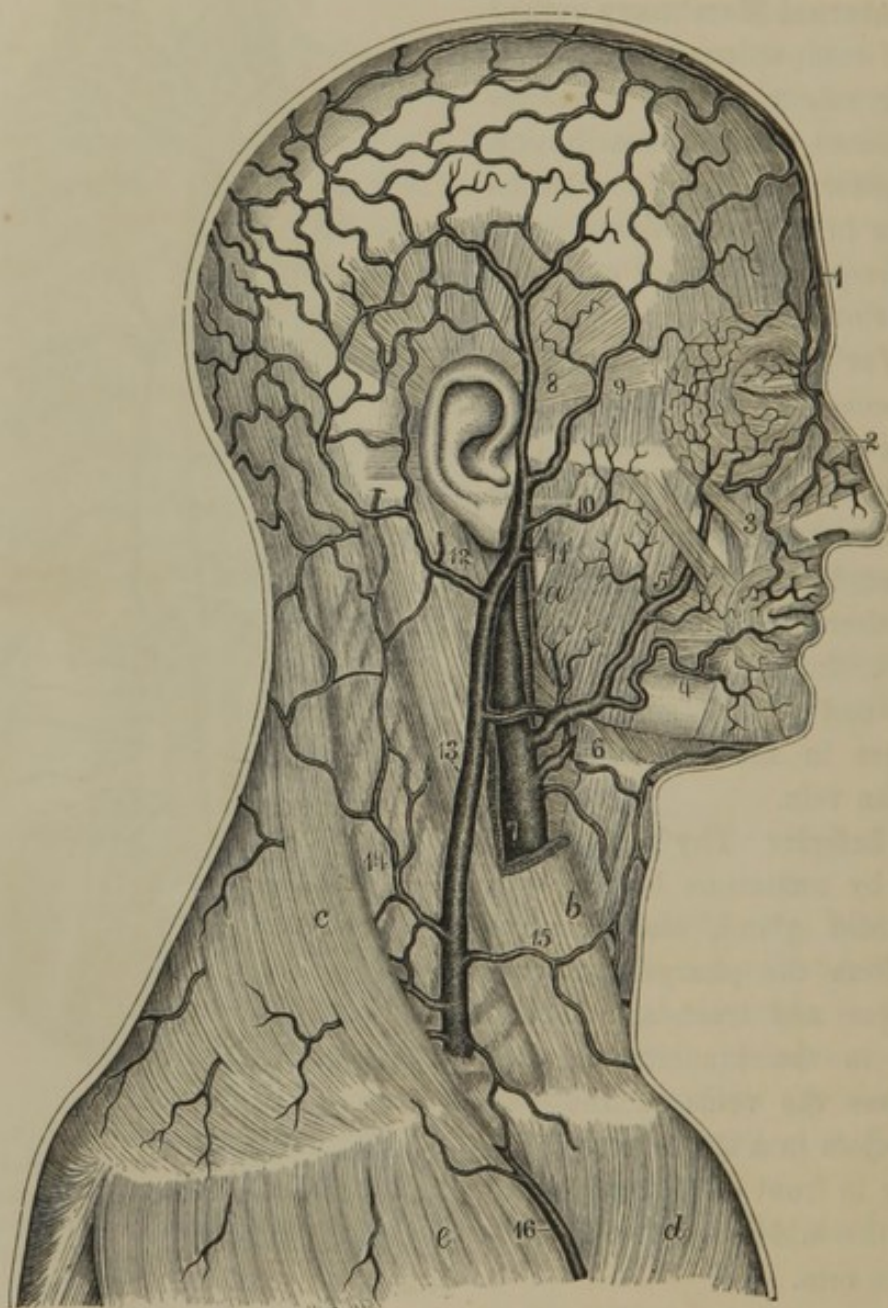
³ V. thyroidea inferior.

⁴ V. thyroidea ima; v. t. impar; v. t. axygos.

VEINS OF THE HEAD AND NECK.

The two **Ju'gular veins**¹ are the principal ones of the head and neck, and are situated at the side of the latter. The **internal jugular vein**

FIG. 270.



VEINS OF THE HEAD AND NECK. 1, frontal vein; 2, nasal vein; 3, 4, labial veins; 5, facial vein; 6, lingual vein; 7, internal jugular vein; 8, 9, posterior and anterior temporal veins; 10, transverse facial vein; 11, internal maxillary vein; 12, posterior auricular vein; 13, external jugular vein; 14 posterior, 15 anterior jugular veins. *a*, external carotid artery; *b*, sterno-mastoid muscle; *c*, trapezius; *d*, pectoral muscle; *e*, deltoid muscle.

corresponds with the deep veins which accompany the large arteries of the limbs. It receives the blood from the interior of the cranium and

¹ V. jugulares; v. soporales; v. apoplecticæ; v. sphagitides.

orbit—usually the greater part of that of the exterior of the cranium, and generally most of that of the face and neck. The **external jugular vein** corresponds with the large superficial veins of the limbs, and receives a portion of the blood from the exterior of the cranium, and usually from the face and neck.

All the veins of the head and neck, except the jugulars, are destitute of valves.

THE INTERNAL JUGULAR VEIN.

The **Internal Ju'gular vein**¹ commences in a bulb-like dilatation² at the jugular foramen of the cranium, and there receives the blood of the sinuses of the dura mater. It descends the neck at the outer side of the internal and common carotid arteries, and finally conjoins with the subclavian to form the innominate vein. In its course down the neck it generally receives the facial, lingual, pharyngeal, superior thyroid, and occipital veins, and sometimes the tempero-maxillary vein in whole or part.

The internal jugular vein varies in size reciprocally with that of the opposite side, and with the size of the external jugular vein. More frequently that of the right side is the larger. Further, it often varies in the number of branches which conjoin to form it on the two sides of the neck. Its lower part is frequently more or less dilated, and at the termination is provided with a pair of valves.

SINUSES OF THE DURA MATER.

The **Si'nuses of the Dura Mater**³ are venous channels formed between the layers of the latter membrane and lined with a continuation of the ordinary lining membrane of blood-vessels. They receive the veins of the brain and its membranes, those of the bones of the cranium, and those of the orbit; and the blood obtained from all these sources they convey to the internal jugular veins. They are destitute of valves, and do not accompany corresponding arteries.

The **Lateral Sinus**,⁴ on each side of the cranial cavity, is the main channel to which all the other sinuses converge. It commences at the internal occipital protuberance, in the so-called **confluence of the**

¹ V. jugularis interna; v. j. magna; v. j. cerebialis; v. cephalica; v. apoplectica.

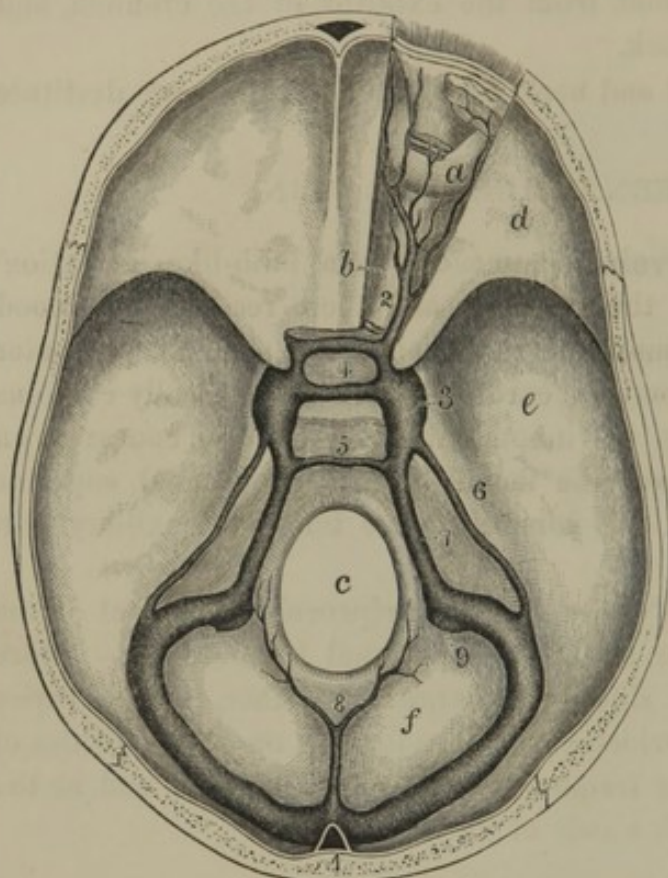
² Bulbus venæ jugularis; gulf or sinus of the jugular vein.

³ Sinus duræ matris; fistulæ, cavitates, ventriculi, tubuli, sanguiductus, or receptacula duræ matris.

⁴ S. lateralis; s. transversus; s. tentorii posterior; s. t. sigmoidus; s. magnus.

sinuses,¹ which is produced by the union of the superior longitudinal, straight, and posterior occipital sinuses. Proceeding outwardly along

FIG. 271.



SINUSES AT THE BASE OF THE CRANIUM, with the right orbit exposed. *a*, eyeball; *b*, optic nerve; *c*, occipital foramen; *d, e, f*, anterior, middle, and posterior cranial fossæ. 1, confluence of the sinuses from which the lateral sinus on each side passes off to terminate at the jugular foramen; 2, ophthalmic vein; 3, cavernous sinus; 4, circular sinus surrounding the pituitary fossæ; 5, anterior occipital sinus; 6, 7, superior and inferior petrosal sinuses; 8, posterior occipital sinus; 9, commencement of the internal jugular vein.

the groove of the transverse limb of the occipital cross, it then curves downward and inward in the groove of the mastoid portion of the temporal bone, and terminates at the jugular foramen by joining the jugular vein.

The **Superior Longitudinal sinus,**² a single channel for the two sides of the cranial cavity, commences at the bottom of the frontal crest, and proceeds backward along the convex border of the cerebral falx to the confluence of the sinuses. It is tri-lateral, increases in size from before backward, and gives rise to the shallow groove along the median line of the cranial vault. It receives the superior and median cerebral veins.

The **Inferior Longitudinal sinus**³ is a single small vessel which runs along the concave border of the cerebral falx, and terminates posteriorly in the straight sinus.

The **Straight sinus,**⁴ single for the two sides of the cranium, is situated along the conjunction of the cerebral falx with the tentorium, and

¹ Confluens sinuum; torcular Herophili; wine-press of Herophilus; fourth sinus.

² Sinus longitudinalis superior; s. fal-ciformis; s. f. superior; s. triangularis; s. medianus.

³ S. longitudinalis inferior; s. fal-ciformis; s. f. inferior; s. minor; vena falcis cerebri.

⁴ S. rectus; s. quartus; s. tentorii; s. perpendicularis; s. obliquus; s. choroideus.

terminates in the confluence of the sinuses. It is trilateral—at its commencement receives the preceding sinus and the ventricular veins, and in its course receives veins from the neighboring parts of the cerebrum and cerebellum.

The **Cav'ernous sinus**¹ is situated at the side of the pituitary fossa, and is short but capacious. Its cavity is crossed by fibrous bands or offsets of the dura mater, from whence the sinus derives its name. A more remarkable peculiarity consists in its walls inclosing the ophthalmic, pathetic, oculo-motor, and abducent nerves, and the internal carotid artery, which, however, are separated from its cavity by the lining membrane. Its fore part receives the ophthalmic vein, and its back part communicates with the petrosal sinuses.

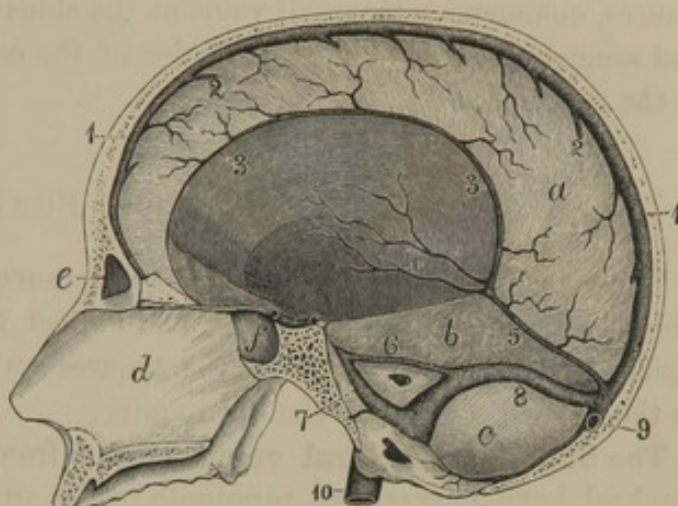
The **Circular sinus**² surrounds the pituitary body, and communicates on each side with the cavernous sinus.

The **Superior Petro'sal sinus**³ is a narrow channel which extends from the cavernous sinus, along the border of the tentorium attached to the edge of the petrous portion of the temporal bone, to the lateral sinus.

The **Inferior Petro'sal sinus**⁴ extends from the cavernous sinus along the lower border posteriorly of the petrous portion of the temporal bone to join the termination of the lateral sinus.

The **Anterior Occip'ital sinus**,⁵ sometimes represented by a pair of

FIG. 272.



VERTICAL SECTION OF THE SKULL, exhibiting the sinuses of the dura mater. 1, superior longitudinal sinus; 2, termination of the superior cerebral veins; 3, inferior longitudinal sinus; 4, internal cerebral veins; 5, straight sinus; 6, 7, superior and inferior petrosal sinuses of the right side; 8, right lateral sinus; 9, commencement of the left lateral sinus; 10, internal jugular vein. *a*, cerebral falx; *b*, tentorium; *c*, cerebellar fossa; *d*, partition of the nose; *e*, frontal sinus; *f*, sphenoidal sinus.

¹ S. cavernosus; receptaculum.

² S. circularis; s. c. Ridleyi; s. coronarius; s. ellipticus.

³ S. petrosus superior; s. tentorii lateralis.

⁴ S. p. inferior.

⁵ S. occipitalis anterior; s. basilaris; s. transversus.

sinuses, is a transverse channel of communication between the inferior petrosal sinuses, across the basilar process of the occipital bone.

The **Posterior Occip'ital sinus**,¹ frequently represented by a pair of sinuses, commences in small veins at the sides of the occipital foramen, and ascends along the convex border of the cerebellar falx to terminate in the confluence of the sinuses.

VEINS OF THE BRAIN.

The veins which emanate from the substance of the brain form an intricate net-work in the pia mater, and collect into large branches which generally follow the course of the fissures on the surface of the brain to the nearest sinuses of the dura mater.

The **Superior Cer'ebral veins**² ascend from the outer surface of the cerebral hemispheres, and terminate in the superior longitudinal sinus. They pierce the dura mater obliquely and open forward into the sinus.

The **Median Cer'ebral veins**³ ascend from the sides of the longitudinal fissure to the superior longitudinal sinus.

The **Inferior Cer'ebral veins**⁴ open into the nearest sinuses: those from the fore part of the cerebrum into the cavernous sinuses, those from the back part into the lateral and straight sinuses, and those intermediate into the superior petrosal sinuses.

The **Internal Cer'ebral veins**,⁵ two in number, pass backward along the middle of the choroid membrane of the third ventricle, and, united in a short trunk,⁶ or separately, terminate in the commencement of the straight sinus. They derive branches from the choroid plexuses, striate bodies,⁷ thalami, fornix, and cerebral crura.

The **Superior Cerebel'lar veins**⁸ terminate in the straight sinus.

The **Inferior Cerebel'lar veins**,⁹ together with branches from the pons and medulla oblongata, end in the inferior petrosal, posterior occipital, and lateral sinuses.

¹ S. occipitalis; s. o. posterior.

² V. cerebrales superiores.

³ V. c. medianæ.

⁴ V. c. inferiores.

⁵ V. cerebri internæ; v. c. magnæ; v. Galeni; v. choroideæ.

⁶ V. magna Galeni.

⁷ Vena choroidea et corporis striati.

⁸ V. cerebelli superiores.

⁹ V. cerebelli inferiores.

THE DIPLOIC AND MENINGEAL VEINS.

The **Dip'loic veins**¹ ramify in the spongy structure of the bones of the cranium, and communicate with the neighboring veins of the scalp, orbit, and dura mater, or with the sinuses of the latter membrane.

The **Menin'geal veins**,² of which two accompany each corresponding artery, continue in the course of the arteries or terminate in the sinuses of the dura mater. The **Great menin'geal veins**³ either terminate in the internal maxillary vein or in the cavernous sinus.

THE OPHTHALMIC VEIN.

The **Ophthal'mic vein**,⁴ possessing the same general arrangement as the corresponding artery, commences at the internal canthus of the eye, where it anastomoses with the facial vein. Passing back along the inner part of the orbit, it emerges at the sphenoidal foramen to end in the cavernous sinus.

THE EXTERNAL JUGULAR VEIN.

The **External Ju'gular vein**,⁵ much smaller than the internal jugular, is formed by the union in whole or part of the tempero-maxillary with the posterior auricular vein, or it may be a continuation of the latter alone or in union with the facial vein.

It descends from the vicinity of the angle of the jaw, crossing the sterno-mastoid muscle under cover of the subcutaneous cervical muscle, and terminates behind the middle of the clavicle by joining the sub-clavian vein. It usually possesses a valve about the middle of its course, and another at its termination. Besides its branches of origin, it generally receives the following:—

The **Anterior jugular vein**,⁶ from the front of the neck.

The **Posterior jugular vein**,⁷ from the back of the neck.

The **Supra-scap'ular vein**,⁸ pursuing the direction of the corresponding artery.

The **Transverse cer'vical vein**,⁹ likewise a companion of the corresponding artery.

¹ V. diploeticæ.

² V. meningeæ.

³ V. m. magnæ; v. m. mediæ.

⁴ V. ophthalmica.

⁵ V. jugularis externa; v. cutanea colli posterior; v. trachelo-subcutanea.

⁶ V. jugularis anterior; v. j. mediana colli; v. cutanea colli anterior.

⁷ V. jugularis posterior.

⁸ V. supra-scapularis.

⁹ V. transversa cervicis.

THE FACIAL VEIN.

The **Fa'cial vein**¹ pursues the general course of the facial artery, but is less tortuous, and is more posteriorly situated. It commences at the internal canthus of the eye, under the name of the **Angular vein**,² which is usually visible during life through the skin. In this position it anastomoses with the ophthalmic vein, and commonly receives the **Frontal vein**.³ The latter communicates with the temporal veins, and descends near the middle of the forehead to the root of the nose, across which it frequently anastomoses with the opposite vein; and it often terminates in the ophthalmic vein.

Near the angle of the jaw the facial vein most frequently ends in the internal jugular, and sometimes joins the tempero-maxillary vein to empty with it into the external jugular, or it may terminate in the latter alone. In its course it generally receives the following branches:—

The **Supra-orb'ital vein**,⁴ which runs along the superciliary ridge and receives the **superior pal'pebral veins**⁵ from the upper eyelid.

The **Na'sal veins**,⁶ from the side of the nose.

The **Inferior pal'pebral veins**,⁷ from the under eyelid.

The **Masseter'ic and Buc'cal veins**,⁸ from the cheek.

The **Labial veins**,⁹ from the lips.

The **Submen'tal vein**,¹⁰ from the vicinity of the chin.

The **Submax'illary veins**,¹¹ from the corresponding gland.

The **Pal'atine vein**,¹² from the soft palate and tonsil.

THE TEMPORAL VEIN.

The **Tem'poral vein**¹³ and its branches have the same general course as the corresponding arteries, but are less tortuous. The **anterior temporal vein**¹⁴ anastomoses with the frontal vein; the **posterior temporal**¹⁵ with the occipital vein. The common temporal penetrates the parotid gland, and at the neck of the lower jaw usually unites with the internal maxil-

¹ V. facialis; v. f. anterior, or interna;
v. palato-labialis.

² V. angularis.

³ V. frontalis; v. preparata.

⁴ V. supra-orbitalis.

⁵ V. palpebrales superiores.

⁶ V. nasalis dorsalis et lateralis, pin-
nalis, or alaris.

⁷ V. palpebrales inferiores.

⁸ V. massetericæ et buccales.

⁹ V. labiales.

¹⁰ V. submentalis.

¹¹ V. submaxillares.

¹² V. palatina.

¹³ V. temporalis; v. facialis posterior;
v. f. externa; v. carotis externa.

¹⁴ V. temporalis superficialis anterior.

¹⁵ V. t. s. posterior.

lary vein to form the tempero-maxillary vein. In its course it receives the following branches:—

The **Artic'ular veins**,¹ from a plexus² behind the articulation of the lower jaw.

The **Anterior auric'ular veins**,³ from the front of the auricle or ear.

The **Middle tem'poral vein**,⁴ following the course of the artery of the same name.

The **Transverse fa'cial vein**,⁵ likewise following the corresponding artery.

The **Parot'id veins**,⁶ from the parotid gland.

THE INTERNAL MAXILLARY VEIN.

The **Internal Max'illary vein**⁷ springs from a plexus which is situated between the pterygoid muscles, in contact with the maxillary artery, and receives the veins which accompany the latter. It is a short vessel which passes behind the neck of the lower jaw, and joins the temporal vein within the parotid gland, or it is represented by a pair of vessels, both joining the temporal vein, or one may join the latter and the other may descend to near the angle of the jaw, to end in the internal jugular vein.

THE TEMPERO-MAXILLARY VEIN.

The **Tem'pero-max'illary vein**,⁸ formed by the conjunction of the temporal with the whole or part of the internal maxillary vein, descends, in company with the external carotid artery, through the parotid gland, and joins with the posterior auricular vein to form the external jugular vein. Sometimes it divides, partly to contribute in the formation of the latter, and partly to join with the facial vein to empty into the internal jugular vein; and not unfrequently it entirely joins with the facial vein to terminate in the internal jugular.

THE POSTERIOR AURICULAR VEIN.

The **Posterior Auric'ular vein**,⁹ pursuing the course of the corresponding artery, joins with the tempero-maxillary vein, in whole or part,

¹ V. articulares.

² Plexus articularis posterior.

³ V. auriculares anteriores et v. auricularis profunda.

⁴ V. temporalis media or profunda.

⁵ V. transversa faciei.

⁶ V. parotidæ.

⁷ V. maxillaris interna; deep branch of the posterior facial vein.

⁸ V. tempero-maxillaris; v. facialis posterior.

⁹ V. auricularis posterior.

to form the external jugular vein; or, in those cases in which the former terminates in conjunction with the facial in the internal jugular vein, it is the sole origin of the external jugular.

THE OCCIPITAL VEIN.

The **Occip'ital vein**¹ follows the general course of the corresponding artery, and usually terminates in the internal jugular vein, but sometimes in the external jugular. (A communication between it and the lateral sinus is established by means of the **mastoid vein**, which passes through a foramen of the temporal bone.) — see fig 40

THE VEINS OF THE TONGUE.

The **Dorsal Lin'gual vein**² receives its branches from the upper part of the tongue, the tonsils, and epiglottis, and pursues the course of the lingual nerve, to end in the facial, pharyngeal, or either jugular vein.

The **Ranine vein**³ commences under the tip of the tongue, where it is visible through the mucous membrane, and passes back in the course of the hypoglossal nerve to terminate in the facial or either jugular vein.

THE PHARYNGEAL VEIN.

The **Pharynge'al vein**⁴ is derived from a plexus on the sides and back of the pharynx, and descends to terminate on a level with the hyoid bone in the internal jugular vein.

THE SUPERIOR THYROID VEINS.

The **Superior Thy'roid veins**,⁵ usually two in number, are derived from the upper part and side of the thyroid gland, and from the larynx and trachea, and terminate in the internal jugular vein, or occasionally in the lingual or facial vein.

THE VEINS OF THE UPPER EXTREMITIES.

The veins of the upper extremities consist of a deep and a superficial series, of which the former follow the arteries, while the latter pursue an independent course beneath the skin, but finally terminate in the main

¹ V. occipitalis.

² V. dorsalis linguæ.

³ V. ranina.

⁴ V. pharyngea.

⁵ V. thyroidea superiores; v. thyroidea superior et media et v. laryngea et v. pharyngea inferior.

trunk of the deep veins. The two series have frequent anastomotic communications, and are provided with many valves, which are more numerous in the deep veins.

THE SUBCLAVIAN VEIN.

The **Subcla'vian vein**¹ is the continuation of the axillary vein, and usually receives at its commencement the external jugular vein. As it passes over the first rib it is separated from the subclavian artery by the insertion of the anterior scalene muscle. It is destitute of valves, and by conjunction with the internal jugular forms the innominate vein.

THE DEEP VEINS OF THE UPPER EXTREMITY.

The **Deep Veins of the upper extremity** closely follow the arteries, every one of these except the axillary artery possessing a pair of companion veins which anastomose with each other by occasional transverse offsets crossing the vessel they accompany.

Of the two **Bra'chial veins**, the internal one is the larger, and usually just above the middle of the arm it receives the basilic vein, which belongs to the superficial set. In the axilla the two brachial veins unite to form the **Ax'illary vein**, and as this passes beneath the clavicle it receives the cephalic vein of the superficial set, and finally becomes the subclavian vein.

THE SUPERFICIAL VEINS OF THE UPPER EXTREMITY.

The **Superficial veins of the upper extremity** are generally larger than the deep ones, and are not the companions of arteries. Through numerous anastomoses they form a net-work enveloping the limb beneath the skin. In fat persons they are inclosed in the adipose layer of the superficial fascia, but in thin persons, and under ordinary circumstances, are for the most part visible through the integument. They have frequent anastomotic communication with the deep veins, and finally terminate in the main trunks of the latter.

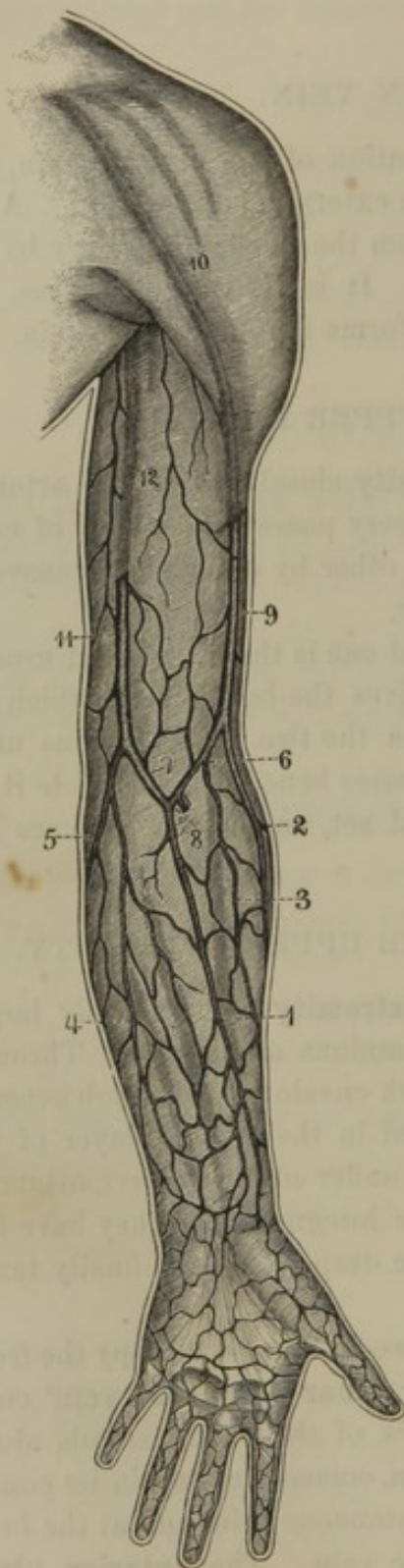
The **Ul'nar cuta'neous veins**,² usually two in number, occupy the front and back of the forearm. The **posterior ulnar cutaneous vein**³ commences from the outer portion of the back of the hand, ascends along the ulnar border of the back of the forearm, communicating in its course with anastomotic branches of the radial cutaneous vein, and at the bend of the elbow assumes the name of basilic vein. The **anterior ulnar**

¹ V. subclavia.

² V. ulnares cutaneæ; v. ulnaris cutanea; v. basilica.

³ V. ulnaris cutanea posterior; v. salvatella.

FIG. 273.



cutaneous vein¹ commences in front of the wrist, ascends along the forearm, anastomosing in its course with the preceding, and either terminates by joining the posterior ulnar cutaneous vein or the median vein.

SUPERFICIAL VEINS OF THE UPPER EXTREMITY. 1, median vein; 2, 3, radial cutaneous veins; 4, 5, ulnar cutaneous veins; 6, median-cephalic vein; 7, median-basilic vein; 8, anastomosis with the deep veins; 9, cephalic vein; 10, its further course seen through the brachial fascia; 11, 12, basilic vein.

The **Basil'ic vein²** ascends from the posterior ulnar cutaneous vein along the inner border of the biceps muscle, and perforates the brachial fascia, to join above the middle of the arm one of the brachial veins.

The **Radial cuta'neous vein³** commences from the radial side of the back of the hand, ascends along the outer border of the forearm, receiving in its course many branches from the front and back of the latter, and at the bend of the elbow assumes the name of cephalic vein. Sometimes there are two radial cutaneous veins which either conjoin near the bend of the elbow, or the anterior one joins the median vein.

The **Cephal'ic vein,⁴** ascending from the former along the outer border of the biceps muscle, and then in the groove between the deltoid and great pectoral muscles, dips inwardly below the clavicle and terminates in the axillary vein.

¹ V. ulnaris cutanea anterior.

² V. basilica; v. cutanea cubitalis; v. cubiti interior.

³ V. radialis cutanea; v. cephalica.

⁴ V. cephalica; v. cutanea radialis; v. capitis.

The **Me'dian veins**¹ occupy the front of the forearm in the interval of the ulnar and radial cutaneous veins, with which they freely anastomose. They are very variable in number, arrangement, and method of termination. Frequently they collect into a parent stem² which forks at the bend of the arm—one division, named the **median-cephal'ic vein**,³ proceeds obliquely upward and outward to join the cephalic vein, while the other, named the **median-basil'ic vein**,⁴ passes upward and inward to join the basilic vein. At other times the median vein or veins terminate in an oblique vessel proceeding across the bend of the arm upward and inward from the radial cutaneous vein to the basilic vein. The middle of the oblique vessel or the angle of the forked median vein anastomoses at the bend of the arm with the brachial veins.

The median-basilic vein or the inner portion of the oblique vessel is larger than the median-cephalic vein, and is usually chosen in the operation of bleeding from the arm. It crosses the brachial artery, from which it is only separated by the offset from the tendon of the biceps muscle to the brachial fascia. Important branches of the internal cutaneous nerve pass above and below it.

THE AZYGOS VEIN.

The **Az'ygos vein**⁵ commences on the right side of the vertebral column, in an anastomotic communication with the lumbar veins, the renal vein, or the inferior cava. Passing from the abdomen through the aortic orifice of the diaphragm, or through a distinct aperture in the right crus of the latter, it ascends on the dorsal vertebræ and arches forward over the root of the right lung to terminate in the superior cava. To its right are situated the thoracic duct, the aorta, and the œsophagus, and in its course it receives the following branches:—

The **Right intercostal veins**. Sometimes the upper two or three conjoin in a trunk, which opens into the right innominate vein.

The **Oesophageal veins**.

The **Right bronchial vein**.

The **Hemi-az'ygos veins**, of which there are two situated on the left side of the vertebral column. The **inferior hemi-az'ygos vein**⁶ arises in the same manner as the azygos vein, and like it enters the thorax, when it ascends to about the middle of the dorsal vertebræ, and then

¹ V. medianæ; v. mediana.

² V. mediana communis.

³ V. mediana cephalica.

⁴ V. mediana basilica.

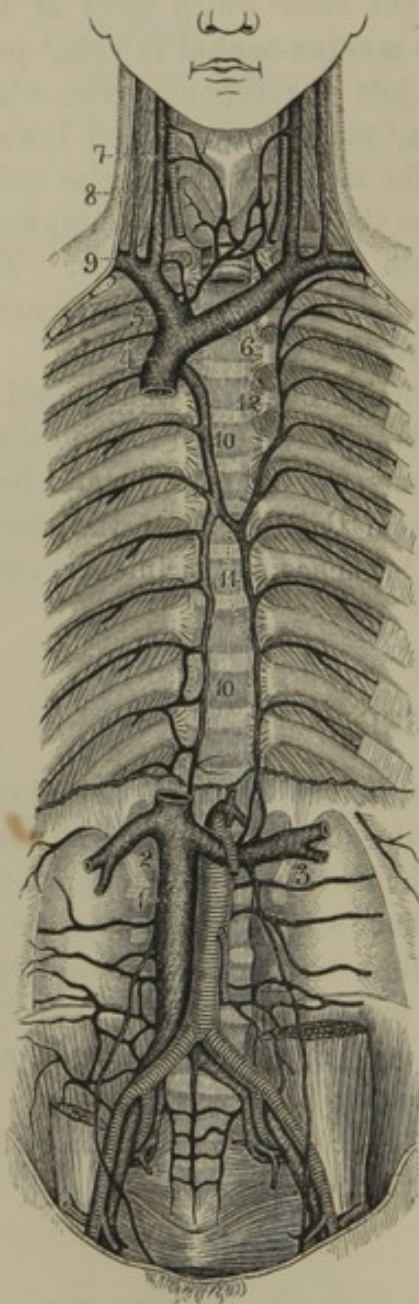
⁵ V. azygos; v. azyga; v. sine pari; v. pari careus; v. prelombo-thoracica.

⁶ V. hemi-azygos; v. hemi-azyga; v. azygos sinistra, or parva.

crosses the column beneath the aorta to join the azygos vein. It receives in its course the lower five or six **left intercostal veins**. The **superior hemi-az'ygus vein**¹ is formed

by the union of the upper **left intercostal veins** which do not join the former. It terminates in the left innominate, the inferior hemi-azygos, or the azygos vein.

FIG. 274.



VEINS OF THE THORAX AND ABDOMEN. 1, inferior cava; 2, right, 3 left renal veins; 4, superior cava; 5, right, 6 left innominate veins; 7, internal veins; 8, external jugular veins; 9, subclavian vein; 10, azygos vein; 11 inferior, 12 superior hemiazygos veins.

THE INFERIOR CAVA.

The **Inferior cava**,² the ascending trunk of the venous system, collects the blood from the inferior extremities, pelvis, and abdomen. It commences by the confluence of the common iliac veins at the ^{right} side of the fourth lumbar vertebra, ascends upon the vertebral column to the right of the aorta, and passes through the quadrate foramen of the diaphragm to terminate in the right auricle of the heart. It is larger than the aorta or the superior cava, and is possessed of no valves. Exclusive of the common iliac veins, in its course it receives a number of branches.

BRANCHES OF THE INFERIOR CAVA.

The **Middle sacral vein**³ follows the course of the corresponding artery, and opens into the commencement of the inferior cava. Sometimes it terminates in the left common iliac vein.

¹ V. hemi-azygos superior; superior intercostal vein; v. semi- or demi-azygos.

² Cava inferior; vena cava inferior, ascendens, or abdominalis; v. hepatices.

³ V. sacralis media.

The **Lumbar veins**¹ are three or four in number on each side, and follow the like-named arteries. They anastomose with one another, and with the common iliac, azygos, and hemi-azygos veins, thus forming a plexus.²

The **Spermatic veins**³ derive their blood from the testicles. Each originates in the **spermatic plexus**,⁴ and follows the corresponding artery—the right one to terminate in the inferior cava, the left one in the left renal vein.

The **Ova'rian veins**,⁵ of the female, originate in the **ovarian plexus** contained in the broad ligament, and follow the same course as the preceding veins.

The **Re'nal veins**⁶ are short, capacious trunks, formed by the convergence of several branches emerging from the sinus of the kidneys. They are nearly transverse in their direction, and the left one is the longer, and crosses in front of the aorta to reach its destination.

The **Supra-renal veins**⁷ consist of several branches from the supra-renal bodies terminating in the inferior cava, the renal veins, and those succeeding.

The **Phren'ic veins**⁸ consist of two companions for each corresponding artery, and terminate in the inferior cava just below the following.

The **Hepat'ic veins**⁹ are two or three trunks which emerge from the posterior notch of the liver, and immediately terminate in the inferior cava, just as it enters the quadrate foramen of the diaphragm.

THE PORTAL VEIN.

The **Portal vein**¹⁰ is a short, capacious trunk, about three inches in length, derived from the convergence of the veins of the stomach, the small and large intestines, the spleen, and the pancreas. It commences by the conjunction of the splenic and superior mesenteric veins behind the pancreas, and ascends in the right border of the lesser omentum to the transverse fissure of the liver, where it¹¹ divides into two principal branches,

¹ V. lumbares.

² Plexus lumbaris et v. lumbaris ascendens.

³ V. spermaticæ; v. s. internæ.

⁴ Plexus spermaticus; p. pampiniformis.

⁵ V. ovaria.

⁶ V. renales; v. emulgentes.

⁷ V. supra-renales; v. capsulares; v. atrabiliaria.

⁸ V. phrenicæ; v. p. inferiores; v. diaphragmaticæ.

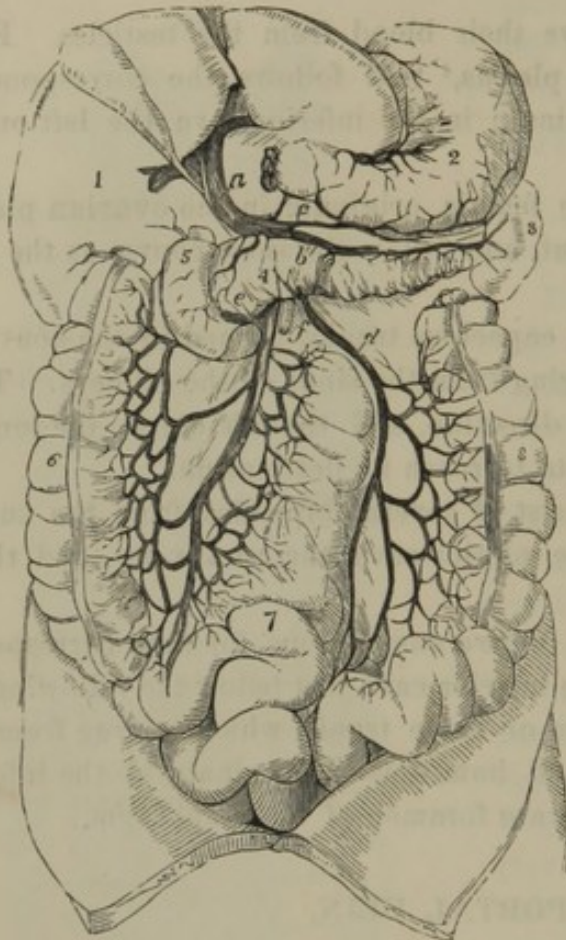⁹ V. hepaticæ; v. cavæ hepaticæ; v. supra-hepaticæ.

¹⁰ V. portalis, porta, portæ, portarum, or ad portas; v. lactea; v. arterialis; v. ostiaria; v. magna; manus jecoris or hepatis; ramalis vena; janitrix; portal system; abdominal venous system; system of the vena porta.

¹¹ Sinus venæ portarum.

which diverge right and left to be distributed throughout the organ.

FIG. 275.



THE PORTAL SYSTEM OF VEINS. *a*, portal vein; *b*, splenic vein; *c*, right gastro-epiploic vein; *d*, inferior mesenteric vein; *e*, superior mesenteric vein; *f*, trunk of the superior mesenteric artery. 1, liver; 2, stomach; 3, spleen; 4, pancreas; 5, duodenum; 6, ascending colon: the transverse colon is removed; 7, small intestine; 8, descending colon.

The **Inferior Mes'enteric vein**,⁶ pursuing the course of the corresponding artery, terminates in the splenic or the superior mesenteric vein.

The portal vein and its branches are destitute of valves.

The blood thus conveyed to the liver, together with that of the hepatic artery, is returned to the general system by means of the hepatic veins.

The **Splen'ic vein**¹ is derived from branches corresponding with those of the splenic artery, and pursues the same course as this until it joins the portal vein.

The **Superior mes'enteric vein**² pursues the same course as the like-named artery, and joins with the preceding vein to form the portal vein.

The **Cor'onary vein**³ of the stomach terminates either in the splenic vein or the portal vein.

The **Right Gastro-epip'loic vein**⁴ joins the superior mesenteric vein or the portal vein.

The **Cystic vein**,⁵ from the gall-bladder, joins the latter vessel.

¹ V. splenica; v. lienalis.

² V. mesenterica superior; v. mesenterica; v. m. magna.

³ V. coronaria; v. gastrica superior.

⁴ V. gastro-epiploica dextra; v. gastrica dextra inferior.

⁵ V. cystica.

⁶ V. mesenterica inferior; v. m. minor; v. colica sinistra.

THE VEINS OF THE VERTEBRAL COLUMN.

The **Dorsi-spinal plexus**¹ is a net-work of veins embracing the vertebral arches and their processes posteriorly. It receives the veins from the muscles of the back, and communicates by frequent anastomoses with the intra-spinal plexus, the vertebral, intercostal, lumbar, and sacral veins, and the superficial veins of the back.

The **Intra-spinal plexus**² is an intricate net-work of veins, situated within the spinal canal, between the dura mater and the vertebræ. It is composed of four longitudinal veins, two in front and two behind, extending the entire length of the spinal canal, and frequently communicating with one another by transverse veins. The **anterior longitudinal veins**³ occupy the sides of the vertebral bodies and present a festooned appearance from their curving round the abutments of the vertebral arches. Opposite the vertebral bodies they are associated by transverse veins, which pass beneath the vertebral ligament and receive the **diploic veins**⁴ from the interior of the vertebræ. The **posterior longitudinal veins**⁵, smaller than the anterior, occupy the sides of the vertebral arches, and conjoin by transverse branches crossing the latter, and likewise join the anterior longitudinal veins by lateral branches. The complexity of the intra-spinal plexus is increased by frequent division and reunion of both the longitudinal and transverse veins as they pursue their course.

The intra-spinal plexus receives veins⁶ from the spinal cord and its membranes, and communicates through the intervertebral foramina with the vertebral, intercostal, lumbar, and sacral veins, and with the occipital sinuses of the cranium.

THE COMMON ILIAC VEINS.

The **Common Il'iac veins**⁷ are formed by the confluence of the internal and external iliac veins opposite the ^{right} sacro-iliac articulation. Con-

¹ Venæ dorsi-spinales; plexus spinalis posterior; p. spinales externi posteriores; plexus rachidian externi posterieur, Breschet.

² Plexus spinalis internus; p. spinales interni; p. s. i. anteriores et posteriores; veines intra-rachidiennes fr.; meningo-rachidian veins.

³ V. longitudinales anteriores; sinus longitudinales; plexus longitudinales anteriores; great spinal veins; grandes veines rachidiennes longitudinales ante-

rieures, Breschet; sinus columnæ vertebralis.

⁴ Venæ basi-vertebrales; v. basis vertebrarum.

⁵ V. longitudinales posteriores; plexus spinales interni posteriores; posterior spinal veins; veines longitudinales rachidiennes posterieures, Breschet.

⁶ Medulli-spinal veins; v. medullispinales.

⁷ V. iliacæ communes; v. i. primitivæ.

verging, they ascend and pass beneath the right common iliac artery, and to the right of the median line, on the last lumbar vertebra, unite to form the inferior cava.

The right vein is shorter and more vertical in its ascent than the left; and is at first behind the corresponding artery, and then gets to its outer side. The left vein is situated at the lower part of the inner side of its accompanying artery. Both are destitute of valves.

THE INTERNAL ILIAC VEIN.

The **Internal Il'iac vein**¹ corresponds in its arrangement with the distribution of the like-named artery, posteriorly to which it is situated, ascending on a line with the sacro-iliac articulation to terminate in the common iliac vein. It receives the double companion veins of the gluteal, ilio-lumbar, lateral sacral, obturator, and ischiatic arteries, which generally conjoin with each other shortly before terminating in the main trunk.

The ilio-lumbar veins anastomose with the lateral sacral and lumbar veins, and frequently terminate in the common iliac vein. The lateral sacral veins form with the middle ones a **plexus**,² which communicates with the hæmorrhoidal plexus.

The veins of the rectum, bladder, and organs of generation are exceedingly numerous and large, and in several positions form very intricate and capacious plexuses.

The **Hæmorrhoid'al plexus**³ embraces the rectum, and is especially well developed at the lower part of the latter, where it is the frequent seat of varicose enlargements, constituting hæmorrhoids or piles. It communicates with the sacral and prostatic plexuses; and veins⁴ proceed from it to the inferior mesenteric vein, the internal iliac veins, and the pudic veins.

The **Prostat'ic plexus**⁵ is an intricate and capacious net-work of veins, embracing the membranous portion of the urethra, the neck of the bladder, the prostate body, and the seminal vesicles. It communicates freely with the vesical plexus, joins the hæmorrhoidal plexus, and terminates in the internal iliac and pudic veins.

The **U'tero-vag'inal plexus**⁶ corresponds in the female with the preceding, and embraces the vagina and uterus. It communicates with the

¹ V. iliaca interna; v. hypogastrica.

² Plexus sacralis.

³ P. hæmorrhoidalis.

⁴ V. hæmorrhoidales sup. med. et inf.;
v. h. internæ et externæ.

⁵ P. prostaticus; p. pudendalis; part
of vesico-prostatic plexus.

⁶ P. utero-vaginalis; p. uterinus et p.
vaginalis.

ovarian and the pudic veins, and, by means of the so-called **uterine veins**,¹ joins the internal iliac veins. During pregnancy, the veins of the uterine plexus become exceedingly enlarged, forming capacious sinuses,² but they do not pursue a tortuous course like the arteries.

The **Ves'ical plexus**³ embraces the bladder, but is especially well developed at the fundus of the latter, where it joins the prostatic or vaginal plexus. From it proceed several vesical veins to terminate in the internal iliac veins.

The **Pu'dic vein**⁴ pursues the course of the corresponding artery, and is formed of branches which accompany the deep arteries of the penis and those of the perineum. It communicates with the prostatic and hæmorrhoidal plexuses, and terminates in the internal iliac vein. It has a corresponding origin, in the female, from the clitoris and perineum, and communicates with the vaginal plexus.

Larger veins than those which follow the deep arteries of the penis emerge from its erectile tissue to pursue a different course. Those from the spongy body issue at the base of the glans and converge to form the **Dorsal vein of the penis**,⁵ which runs along the dorsal groove of the organ beneath the arch of the pubis. After perforating the triangular ligament, it divides into two branches, which terminate in the prostatic plexus. The veins from the cavernous bodies emerge at the lower groove and turn round their outer side to join the dorsal vein. The **Dorsal vein of the clitoris**⁶ has a corresponding origin and course as the preceding, and terminates in like manner in the vaginal plexus.

THE EXTERNAL ILIAC VEINS.

The **External Il'iac vein**⁷ collects the blood from the lower extremity, and is the continuation of the femoral vein. Commencing beneath Poupart's ligament at the inner side of the corresponding artery, it ascends behind the latter to join with the internal iliac in the formation of the common iliac vein. At its commencement it receives the double companion veins of the circumflex iliac and epigastric arteries.

¹ V. uterinæ.

² Uterine sinuses.

³ P. vesicalis; part of vesico-prostatic plexus.

⁴ V. pudica.

⁵ V. dorsalis penis.

⁶ V. dorsalis clitoridis.

⁷ V. iliaca externa.

THE DEEP VEINS OF THE LOWER EXTREMITY.

The **Deep veins of the lower extremity** pursue the exact course of the corresponding arteries; every one of these, excepting the popliteal artery and its continuation the femoral having two companions which anastomose with each other across the vessel they accompany.

The **Poplite'al vein**,¹ formed by the conjunction of the companion veins of the anterior and posterior tibial arteries, is situated behind the corresponding artery, and passes in company with it through the perforation of the great adductor muscle to assume the name of femoral vein.

The **Fem'oral vein**² at first lies behind its accompanying artery, but gradually inclines to the inner side during its ascent, and at Poupart's ligament assumes the name of external iliac vein.

THE SUPERFICIAL VEINS OF THE LOWER EXTREMITY.

The **Superficial veins of the lower extremity** have the general plexiform arrangement, relation of position to the skin, and other characters indicated in the account of those of the upper extremity. Two principal trunks, the saphenous veins, collect the blood of the superficial veins and empty it into the main trunk of the deep veins.

The **Short saphe'nous vein**³ proceeds from branches along the outer part of the back of the foot, passes behind the outer ankle, ascends the back of the leg, and dips between the heads of the gastrocnemius muscle to terminate in the popliteal vein. It collects the blood of the superficial veins of the outer part of the foot, and the outer and back part of the leg, and anastomoses freely with branches joining the succeeding vein.

The **Long saphe'nous vein**,⁴ more capacious than the other, springs from branches on the back and inner side of the foot. Passing in front of the inner ankle, it ascends along the tibia to the knee, where it inclines backward, and then ascends upon the thigh to the saphenous opening. Through this it dips to terminate in the femoral vein. It receives the veins from the inner side of the foot, the greater number of those of the leg, all those of the thigh, the external pudic veins, and many of those of the abdomen.

¹ V. poplitea.

² V. femoralis; v. cruralis.

³ V. saphena parva; v. s. externa; v. peroneo-malleolaris; lesser saphena vein; external saphenous vein.

⁴ V. s. longa; v. saphena interna; v. s. magna; v. tibio-malleolaris; great saphena vein; internal saphenous vein.

FIG. 276.

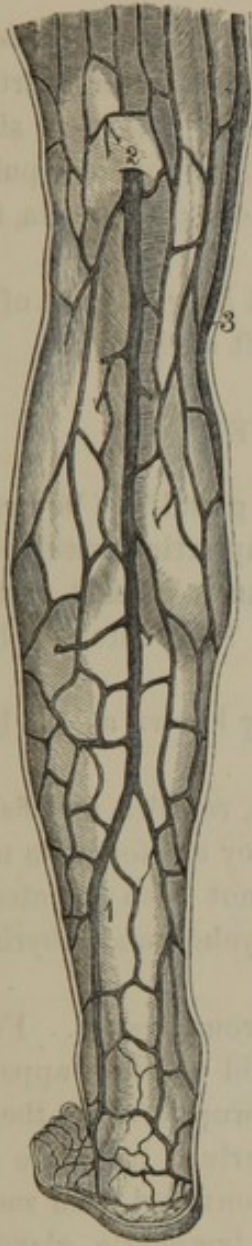

Fig. 276. SUPERFICIAL VEINS OF THE BACK OF THE LEG. 1, short saphenous vein; 2, position at which it terminates in the popliteal vein; 3, long saphenous vein.

FIG. 277.

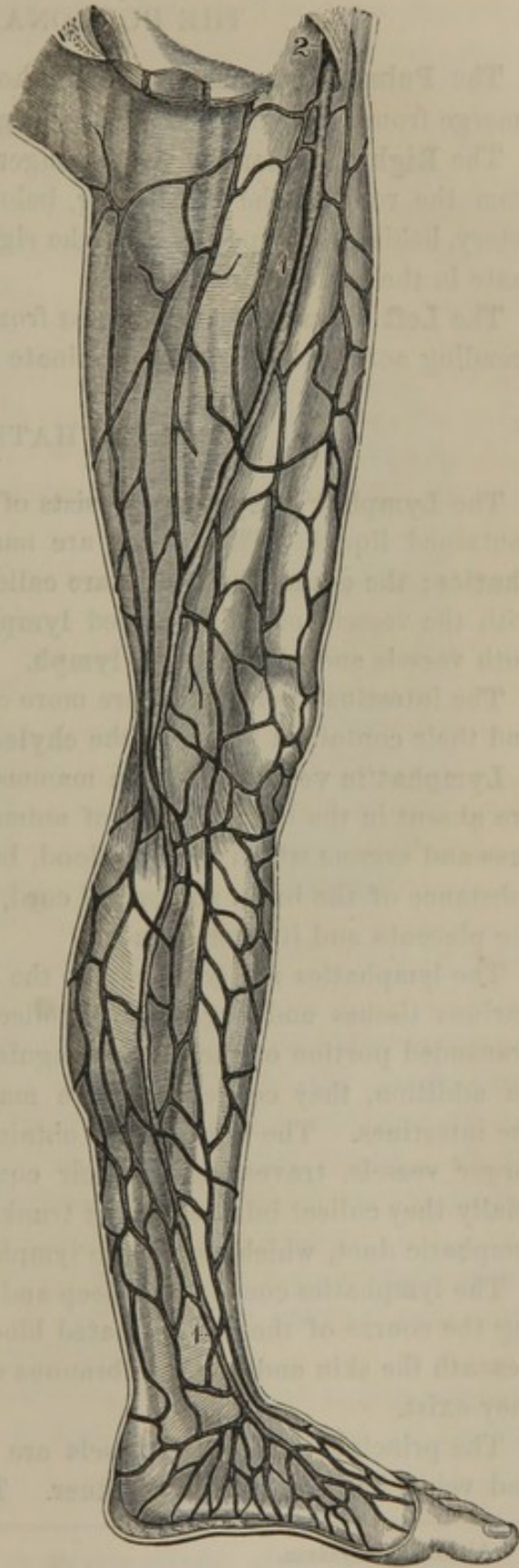


Fig. 277. SUPERFICIAL VEINS OF THE INNER PART OF THE LOWER EXTREMITY. 1, long saphenous vein; 2, its termination at the saphenous opening into the femoral vein.

THE PULMONARY VEINS.

The **Pulmonary veins** are four short venous trunks, of which two emerge from each lung and convey bright-red blood to the heart.

The **Right Pulmonary veins**, longer than those of the left side, pass from the root of the right lung, below the corresponding pulmonary artery, behind the superior cava, the right auricle and the aorta, to terminate in the left auricle.

The **Left Pulmonary veins** pass from the left lung in front of the descending aorta, and likewise terminate in the left auricle.

THE LYMPHATIC SYSTEM.

The **Lymphat'ic System**¹ consists of vessels, gland-like bodies, and a contained liquid. The former are named **lymphatic vessels** or **lymphatics**; the gland-like bodies are called **lymphatic glands**, or, together with the vessels, are also named **lymphatics**. The contained liquid of both vessels and glands is the **lymph**.

The intestinal lymphatics are more commonly known as the **lacteals**, and their contained liquid as the **chyle**.

Lymphat'ic vessels² exist in mammals, birds, reptiles, and fishes, but are absent in the lower classes of animals. They are found in most tissues and organs which receive blood, but have not been detected in the substance of the brain and spinal cord, in the eyeball and labyrinth, nor the placenta and its membranes.

The lymphatics are accessory to the sanguiferous system. From the various tissues and organs they collect a liquid which is apparently a transuded portion of the liquor sanguinis unappropriated by the tissues. In addition, they collect nutritive material derived from the food in the intestines. The liquids thus obtained are conveyed from smaller to larger vessels, traversing in their course the lymphatic glands, until finally they collect into two great trunks, the thoracic duct and the right lymphatic duct, which empty the lymph into the veins.

The lymphatics consist of a deep and superficial set, the former following the course of the deeply-seated blood-vessels, and the latter running beneath the skin and the membranous envelopes of the organs in which they exist.

The principal lymphatic vessels are more numerous than the arteries and veins, but are very much finer. They are long, thread-like, trans-

¹ Absorbent system.

² Absorbent vessels, or absorbents; vasa lymphatica; venæ lymphaticæ; vasa resorbentia; v. hydragoga; ductus serosi; lymphæ-ductus; lymphangia; hydrangia.

parent tubes, of difficult detection unless some colored substance is injected into them. They are remarkable also for their great number of valves, which are constructed like those of the veins, and prevent a retrograde course of the lymph. The valves are arranged in pairs at short distances apart, and the vessels behind them are dilated so that they present a beaded appearance when distended.

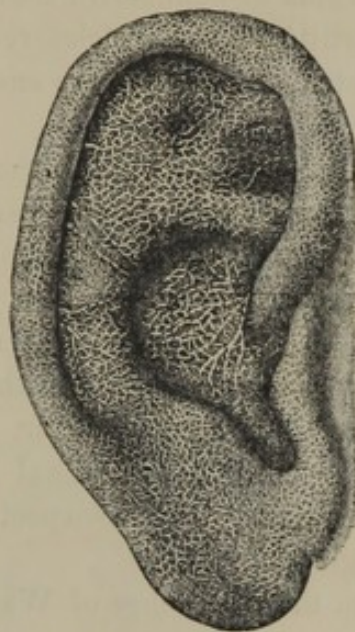
The mode in which the lymphatics commence has been imperfectly ascertained in consequence of the extreme tenuity and transparency of the vessels and the impossibility of injecting colored liquids in a direction opposed to the opening of the many valves which occupy the larger branches. For the most part they appear to originate in close capillary nets, intercalated with the sanguiferous capillaries, but having no communication with them. In the villi of the intestines the capillary lymphatics apparently commence as single club-like tubes with the extremity closed. The lymphatic capillaries are even larger than the sanguiferous capillaries, and like them are destitute of valves.

Nearly all the principal lymphatic vessels, in their course to the great trunks, pass through lymphatic glands which occupy convenient positions in the various recesses and cavities of the body. As they approach near to the glands, they divide and subdivide before entering the latter, and in emerging at the opposite side many branches converge to form larger vessels. Those which enter are named **afferent vessels**,¹ and those which emerge are the **efferent vessels**,² and are fewer and larger than the former.

In structure the lymphatic vessels resemble the blood-vessels, more especially the veins. According to Kölliker, their external coat contains longitudinal bundles of muscular fibres.

The **Lymphatic glands**³ are moderately hard, pinkish bodies, varying in size from that of a hemp-seed to that of an almond, and are mostly

FIG. 278.



LYMPHATIC CAPILLARY NET-WORK OF THE SKIN OF THE EAR.

¹ Vasa afferentia; v. inferentia.² Vasa efferentia.³ Lymphatic ganglions; conglobate, or globate glands; glandulæ lymphaticæ; g. conglobatæ.

compressed spheroidal or ovoidal. They are generally situated along the course of the larger blood-vessels, and exist in considerable numbers within the thorax and abdomen, but likewise are found in the neck, the axilla, groin, bend of the elbow, and the popliteal space.

The structure of the lymphatic glands has not yet been positively demonstrated. According to recent investigations, they appear to consist of a multitude of vesicles or pouches which communicate with one another, with the termination of the afferent vessels, and with the commencement of the efferent vessels. The vesicles occupy the interspaces of a stroma of connective tissue abundantly supplied with blood-vessels. In constitution the vesicles resemble those which form the solitary and agminated glands, and are suspected to be the source of the lymph corpuscles.

Lymph¹ possesses nearly the same physical and chemical properties as liquor sanguinis. After passing through the lymphatic glands it is found to have acquired numerous bodies, named **lymph corpuscles**.² These are faintly granular nucleated cells like the colorless corpuscles of the blood. They are also identical in character with the nucleated cells of the vesicular structure in the lymphatic glands, and are hence inferred to be derived from the latter. A few corpuscles of the same kind have been noticed in the intestinal lymphatic vessels before reaching the mesenteric glands, and are suspected of originating in the solitary and agminated glands.

From the researches of Wharton Jones, published more than a dozen years ago, the lymph corpuscles ultimately undergo solution, and leave their nuclei transformed into blood disks. Though these researches appear to be but little noticed, the opinion gains ground that the lymph corpuscles constantly poured into the blood are the source of its red corpuscles.

Chyle³ is the lymph of the intestinal canal modified by admixture of the absorbed nutritive liquid of the food. From the presence of innumerable fat particles, it is commonly of a milk-white color, whence the name of **lacteals**,⁴ given to the lymphatic vessels which convey it to the thoracic duct.

THE TRUNKS OF THE LYMPHATIC SYSTEM.

The lymphatic system has two main trunks, of which one is comparatively long and large, and is named the **thoracic duct**, while the other is quite small, and is called the **right lymphatic duct**.

¹ Lympha; white blood.

² Lymph globules; white corpuscles.

³ Chylus; succus nutritius.

⁴ Vasa chylifera; chyliiferous vessels; vasa lactea.

THE THORACIC DUCT.

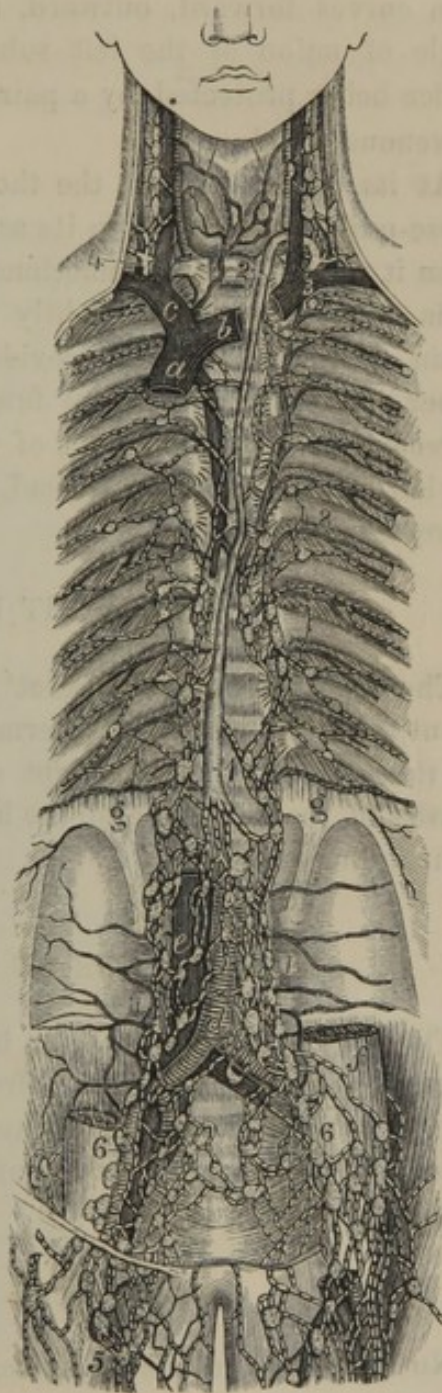
VIEW OF THE GREAT LYMPHATIC TRUNKS. 1, 2, thoracic duct; 3, its termination at the angle of conjunction of the left internal jugular and subclavian veins; 4, the right lymphatic duct; 5, lymphatics of the thigh; 6, iliac lymphatics; 7, lumbar lymphatics; 8, intercostal lymphatics. *a*, superior cava; *b*, left innominate vein; *c*, right innominate vein; *d*, aorta; *e*, inferior cava; *f*, psoas muscle; *g*, origin of the diaphragm.

The **Thoracic duct**¹ commences in front of the second lumbar vertebra, between the aorta and inferior cava, through the union of the two lumbar lymphatic trunks with the intestinal lymphatic trunk; the former being derived from the lymphatics of the pelvis and lower extremities, the latter from the visceral lymphatics.

The intestinal lymphatic trunk alone, or in conjunction with one or both of the lumbar lymphatic trunks, usually forms an oblong dilatation, called the **Receptacle of the Chyle**.² This dilatation, is of variable size, but generally measures from one to two inches in length, by the fourth of an inch in width.

After its origin, the thoracic duct passes through the aortic orifice of the diaphragm, and ascends in front of the vertebral column, between the aorta and azygos vein, and behind the œsophagus. From

FIG. 279.



¹ Ductus thoracicus; d. t. posterior; d. lymphaticus sinister; d. rorifer; d. vertebralis; d. chyli; d. chyliferus; d. lacteus; d. Pecquetianus; vena alba thoracis Eustachii; distributoria lactea thoracica; galaxia; duct of Pecquet; alimentary duct.

² Receptaculum chyli; r. Pecqueti; cisterna Pecqueti; c. chyli; c. lumbaris; sacculus lacteus, chyliferus, or rorifer; diversorium, stagnum, vesicula, or ampulla chyli; utriculus lacteus; alveus ampulosus; chylocistis; chylodochium; latices lactei; reservoir of the chyle, or of Pecquet.

the position of the fourth dorsal vertebra it inclines to the left side, passes behind the arch of the aorta, and ascends between the œsophagus and left subclavian artery, as high as the last vertebra of the neck. It then curves forward, outward, and downward, and terminates in the angle of union of the left subclavian and internal jugular veins, its orifice being protected by a pair of valves, which prevent the entrance of venous blood.

At its commencement the thoracic duct is about the diameter of a goose-quill, but narrows in its ascent to about the middle of its course, when it widens again—sometimes becoming in a marked degree dilated. It is not straight, but slightly tortuous; and occasionally subdivides, again to reunite. It is provided with valves, more especially in the upper part of its course, but fewer than in lymphatic vessels generally. It receives all the lymphatics of the body below the diaphragm, those of the left side of the thorax, head, and neck, and those of the left upper extremity.

THE RIGHT LYMPHATIC DUCT.

The **Right lymphatic duct**¹ is about half an inch in length, and about a line in width; and terminates, in a corresponding manner with the thoracic duct, on the right side of the body. It receives the lymphatics of the right side of the head, neck, and thorax, and those of the right upper extremity.

LYMPHATICS OF THE HEAD AND NECK.

The lymphatic vessels of the head and neck from particular localities terminate in groups of glands, from which efferent vessels proceed to the next group of glands below, and so on until a few trunks are formed which terminate at the bottom of the neck in the thoracic duct and the right lymphatic duct.

LYMPHATICS OF THE CRANIAL CAVITY.

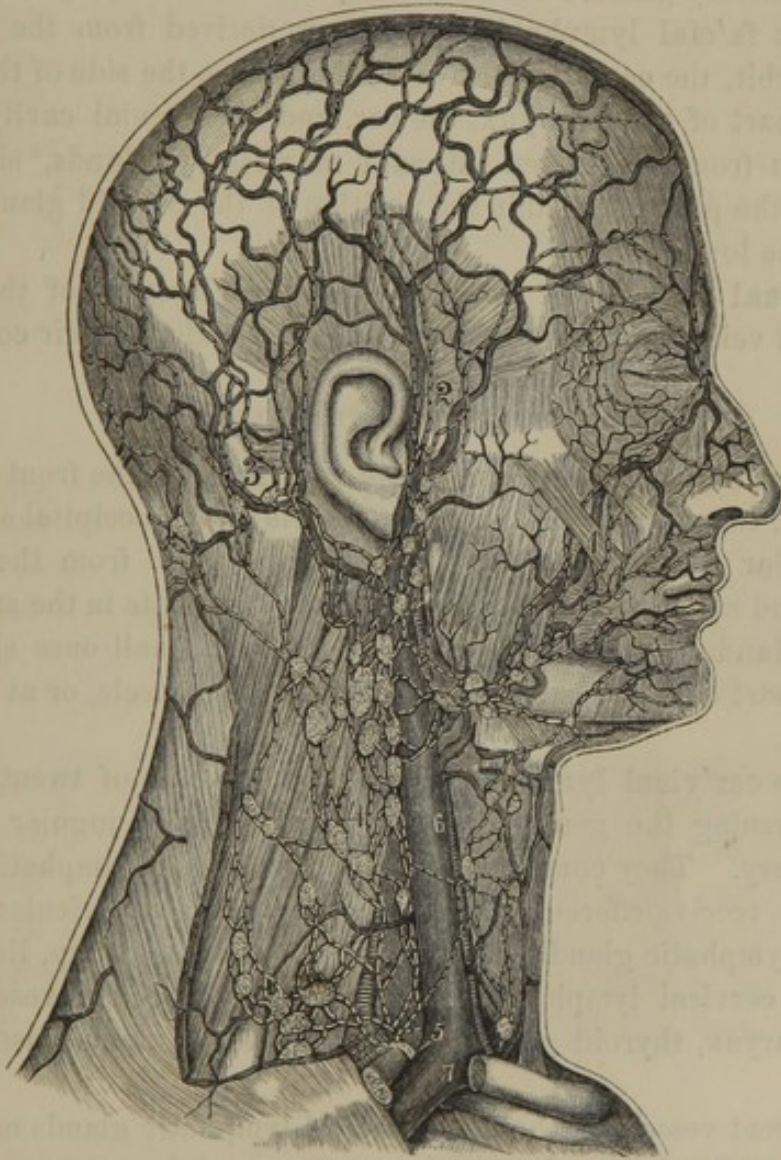
No lymphatic vessels have been detected in the brain, though they are numerous in the pia mater, in which they pursue the course of the principal veins, and emerge from the cranium through foramina giving passage to arteries and veins.

¹ Ductus lymphaticus dexter; d. thoracicus dexter; d. t. minor; truncus lymphaticus dexter.

LYMPHATICS OF THE EXTERIOR OF THE CRANIUM.

The **occip'ital lymphat'ic vessels** are derived from the back of the head, and terminate in the **occip'ital and posterior auric'ular glands**.¹ Of these there are four or five small ones situated in the vicinity of the mastoid process on the sterno-mastoid and trapezius muscles.

FIG. 280.



LYMPHATICS OF THE HEAD AND NECK. 1, facial lymphatics; 2, temporal lymphatics; 3, posterior auricular and occipital lymphatics; 4, cervical lymphatics; 5, the right lymphatic duct; 6, internal jugular vein; 7, subclavian vein.

The **temporal lymphat'ic vessels** are derived from the side of the

¹ Glandulæ occipitales, or cervicales, and g. auriculares posteriores, or subauriculares, or mastoideæ.

head, and terminate in the **anterior auricular glands**,¹ of which there are two or three situated on the parotid gland in front of the ear.

LYMPHATICS OF THE FACE.

The **superficial fa'cial lymphat'ic vessels**, derived from the forehead, eyelids, nose, lips, cheek, and chin, terminate in the **submax'illary lymphat'ic glands**.² Of these there are six or more, situated upon the submaxillary salivary gland, from which they also receive lymphatic vessels.

The **deep fa'cial lymphat'ic vessels** are derived from the temporal fossa, the orbit, the cavity of the nose, the palate, the side of the mouth, the upper part of the pharynx, the ear, and the cranial cavity. They terminate in from five to ten **internal max'illary glands**,³ situated at the side of the pharynx, within the position of the parotid gland and the ramus of the lower jaw.

The **lingual lymphat'ic vessels** follow the direction of the lingual arteries and veins, and traverse three or four glands⁴ in their course.

LYMPHATICS OF THE NECK.

The **superficial cer'vical lymphatic vessels**, from the front and back of the neck, together with the efferent vessels of the occipital and posterior auricular lymphatic glands, and part of those from the anterior auricular and submaxillary lymphatic glands, terminate in the **superficial cer'vical glands**.⁵ Of these there are five or six small ones situated at the upper part of the neck on the sterno-mastoid muscle, or at its posterior border.

The **deep cer'vical lymphatics**⁶ consist of a chain of twenty or more glands⁷ pursuing the general course of the internal jugular vein and carotid artery. They communicate with the axillary lymphatics, and in their course receive efferent vessels from the anterior auricular and submaxillary lymphatic glands, those of the internal maxillary, lingual, and superficial cervical lymphatic glands, and the lymphatic vessels of the larynx, pharynx, thyroid gland, trachea, œsophagus, and muscles of the neck.

The efferent vessels of the deep cervical lymphatic glands unite in the **ju'gular lymphatic trunk**,⁸ which terminates on the corresponding side in the thoracic duct, or the right lymphatic duct.

¹ G. auriculares anteriores; g. faciales superficiales; g. zygomaticæ.

² G. submaxillares.

³ G. maxillares internæ; g. faciales profundæ.

⁴ G. linguales.

⁵ G. cervicales superficiales; plexus jugularis externus.

⁶ Plexus jugularis internus.

⁷ G. c. profundæ; g. c. p. superiores and inferiores, or supra-claviculares.

⁸ Truncus l. jugularis.

LYMPHATICS OF THE UPPER EXTREMITIES, AND OF THE EXTERIOR OF THE THORAX.

The lymphatics of the upper extremity consist of a superficial and deep series, which pursue the general direction of the corresponding arterial and venous trunks.

The principal **superficial lymphatic vessels** in ascending the upper extremity are directed to its inner side, most of them pursuing the course of the ^{basilic}~~brachial~~ and cephalic veins. In front of the internal condyle a few of them traverse a lymphatic gland;¹ and nearly all converge to enter the lower lymphatic glands of the axilla. Some of them accompanying the cephalic vein, together with others from the shoulder, join the axillary lymphatic glands below the clavicle, or communicate with those of the neck.

The **deep lymphatic vessels** of the upper extremity, following the direction of the arteries and their companion veins, after traversing three or more lymphatic glands² in the vicinity of the elbow, terminate in the axillary lymphatic glands.

The **superficial lymphatic vessels** of the thorax commence beneath the skin of the upper part of the abdomen and breast. The **deep vessels** are derived from the mammary gland and the pectoral and neighboring muscles. Most of these lymphatics pass outward and upward to the axillary lymphatic glands, and a few of them terminate in the glands below the clavicle.

The **axillary glands**,³ which receive the lymphatic vessels of the upper extremity and exterior of the thorax, number from eight to a dozen, and are enveloped in the loose areolar tissue and fatty matter of the armpit. They extend from the lower part of the latter to the clavicle, and communicate with the deep cervical lymphatic glands. Their efferent vessels, following the direction of the subclavian vein, unite in the **subclavian lymphatic trunk**,⁴ which terminates in the thoracic duct, or the right lymphatic duct.

LYMPHATICS OF THE CAVITY OF THE THORAX.

The **intercos'tal lymphatic vessels** pursue the course of the corresponding veins, and are derived from the sides of the thorax and abdomen, the diaphragm, pleura, muscles of the back, and spinal canal.

¹ G. cubitalis superficialis.

³ G. axillares and g. infra-claviculares.

² G. cubitales profundæ and g. humerales.

⁴ Truncus lymphaticus subclavius.

In the vicinity of the heads of the ribs they traverse fifteen or more **intercostal glands**,¹ the efferent vessels of which terminate for the most part in the thoracic duct.

Between the intercostal lymphatic glands of the two sides, and communicating with them, there are about a dozen **posterior medias'tinal glands**,² which receive lymphatic vessels from the diaphragm, pericardium, and œsophagus. Some of the efferent vessels of these glands terminate in the thoracic duct, while others join the bronchial lymphatic glands.

The **anterior medias'tinal lymphatic vessels**³ are derived from the front wall of the abdomen, the upper surface of the liver through the suspensory ligament, the front wall of the thorax, the diaphragm, pericardium, heart, and thymus gland. They traverse about twenty **anterior medias'tinal glands**,⁴ situated in the course of the internal mammary blood-vessels, on the pericardium, and in front of the great blood-vessels emanating from the base of the heart. Their efferent vessels terminate in the thoracic and the right lymphatic ducts.

The **pul'monary lymphatic vessels** consist of a superficial and deep series. The former arise from an intricate net-work beneath the pulmonary pleura, and are directed toward the root of the lung, where they meet the deep vessels. These pursue the ramifications of the pulmonary blood-vessels and bronchi, traversing in the terminal portion of their course a number of small **pulmonary glands**.⁵ At the bifurcation of the trachea, on the bronchi, and at the root of the lungs, there are twenty or more **bron'chial glands**,⁶ which receive the lymphatic vessels of the lungs and of the bronchi, and some of those of the trachea, œsophagus, and heart. These glands are comparatively large; in infancy have the same color and consistence as those of other parts of the body, but in the progress of life gradually assume a gray and finally a black color, arising from a deposit of fine particles of pigmentary matter. They also frequently become the seat of calcareous or tubercular deposits. Their efferent vessels on the left side terminate in the thoracic duct, but on the right side unite to form the **broncho-medias'tinal trunk**,⁷ which ascends behind the innominate vein to join the right lymphatic duct.

¹ G. intercostales.

² G. mediastinæ posteriores.

³ Internal mammary lymphatic vessels.

⁴ G. mediastinæ anteriores and g. sternales.

⁵ G. pulmonicæ.

⁶ G. bronchiales and tracheales; g. Vesalianæ.

⁷ Truncus broncho-mediastinus.

LYMPHATICS OF THE LOWER EXTREMITIES AND OF THE PELVIS.

The **superficial lymphatic vessels** originating on the back of the foot ascend in the course of the long saphenous vein to terminate in the superficial inguinal glands. Those originating from the sole of the foot accompany the short saphenous vein and partly join the former series; while others terminate in the popliteal glands.

The **deep lymphatic vessels** follow the course of the corresponding blood-vessels, traverse from two to four **poplite'al glands**¹ in their course, and finally join the deep inguinal glands.

The **superficial in'guinal glands**,² from six to a dozen in number, are situated in the saphenous opening of the crural fascia and extend outwardly in the groin. Besides receiving the superficial lymphatic vessels ascending from the lower extremity, they receive the superficial lymphatic vessels of the lower part of the abdomen, the loins, and the buttocks, and those of the integument of the penis and scrotum, or of the clitoris and labia in the female.

The **deep in'guinal glands**,³ of which there are two or three, are situated upon the femoral blood-vessels. They receive the deep lymphatics of the lower extremity, and communicate with the superficial glands.

The efferent vessels of the inguinal glands ascend beneath the femoral arch and enter a chain of six or more **external iliac glands**.⁴ These are situated in the course of the corresponding blood-vessels, and further receive lymphatic vessels from the front and side of the abdomen internally.

The lymphatic vessels of the perineum, of the penis or the clitoris, of the back portion of the scrotum or labia, of the bladder, of the prostate gland and seminal vesicles, or the vagina and uterus, of the muscles of the buttocks, and of the rectum, converge to a dozen or more **internal il'iac glands**.⁵ These are situated at the side of the pelvis, about the corresponding blood-vessels, and communicate with the glands of the opposite side in front of the sacrum, and with the external iliac glands.

¹ G. popliteæ.

² G. inguinales superficiales.

³ G. inguinales profundæ.

⁴ G. iliacæ externæ; plexus iliacus externus.

⁵ G. iliacæ internæ, or hypogastricæ, and g. sacrales; plexus hypogastricus and sacralis.

LYMPHATICS OF THE CAVITY OF THE ABDOMEN.

The efferent vessels of the external and internal iliac glands become the afferent vessels of the **lumbar glands**.¹ Of these there are about twenty-five situated on each side of the vertebral column and great blood-vessels, upon the origin of the diaphragm, and upon the psoas and quadratus lumbar muscles. The glands of the opposite sides freely communicate; and besides the vessels mentioned, they receive lymphatic vessels from the loins, the kidney and ureter, the supra-renal body, and the testicle or the ovary.

The efferent vessels of the lumbar glands, on each side of the abdomen, conjoin to form the **lumbar lymphatic trunk**,² frequently represented by several smaller ones, terminating in the thoracic duct or the receptacle of the chyle.

The **lymphatic vessels of the stomach** pursue the direction of its blood-vessels, traversing in their course a number of small glands.³ Those from the lesser curvature and the right side of the greater curvature terminate in the mesenteric glands; those from the left extremity join the splenic lymphatics.

The lymphatic vessels of the small intestine are usually called the **lac'teals**,⁴ from the fact of their conveying the chyle, which gives them the appearance of being filled with milk. From the intestine they proceed between the layers of the mesentery, traversing in their course one hundred and thirty or more **mesenteric glands**.⁵ These are irregularly arranged in three rows, of which the first contains the smallest glands but the greatest number, and the last the fewest and largest. Their efferent vessels terminate in the cœliac glands.

The **lymphatic vessels of the large intestine** traverse about thirty **mesocol'ic glands**,⁶ and terminate for the most part in the superior mesenteric glands; those from the greater portion of the descending colon terminating in the left lumbar glands.

The lymphatic vessels of the spleen and pancreas follow the direction of the splenic vein, traversing in their course a number of small glands,⁷ and terminate in the cœliac glands.

The **lymphatic vessels of the upper surface of the liver**, as before mentioned, for the most part ascend through the suspensory ligament to

¹ G. lumbaris; plexus lumbaris.

² Truncus lymphaticus lumbaris.

³ G. gastro-epiploicæ superiores and inferiores.

⁴ Vasa lactea; v. chyliifera; chyliiferous vessels.

⁵ G. mesentericæ or meseraicæ.

⁶ G. mesocolicæ.

⁷ G. splenico-pancreaticæ.

join the anterior mediastinal glands. Those of the lower surface and the **deep vessels** emerging from the transverse fissure of the liver, after traversing a few small glands,¹ associate with the lymphatics of the lesser curvature of the stomach, and terminate in the mesenteric glands.

The **cœ'liac glands**,² from fifteen to twenty in number, are situated behind the duodenum and pancreas, upon the aorta, the cœliac and superior mesenteric arteries, and the portal vein, and are intimately associated with the lumbar glands on each side. Their efferent vessels conjoin to form the **intestinal lymphatic trunk**,³ frequently represented by two or more smaller ones, terminating in the receptacle of the chyle.

¹ G. hepaticæ.

² G. cœliacæ; plexus cœliacus.

³ Truncus lymphaticus intestinalis, or abdominalis.

CHAPTER VIII.

THE VOCAL AND RESPIRATORY APPARATUS.

THE LARYNX.

THE **Lar'ynx**,¹ the organ of the voice, is situated at the top of the trachea, below the root of the tongue and the hyoid bone. At the period of puberty it becomes much larger in the male than the female, and in the former produces the conspicuous prominence in the middle of the neck, commonly known as "Adam's apple."² It is bounded behind by the pharynx, with which it communicates above, and it opens below into the trachea.

In composition the larynx consists of a frame-work of cartilages connected by ligaments, provided with appropriate muscles, blood-vessels, and nerves, and lined with mucous membrane.

CARTILAGES OF THE LARYNX.

The **Cartilages of the larynx** consist of three symmetrical pieces, named the thyroid, cricoid, and epiglottic cartilages, and a pair called the arytenoid cartilages.

The **Thy'roid cartilage**,³ the largest of those of the larynx, is situated at the upper fore part of the latter, and consists of two lateral wing-like plates conjoined in front and diverging behind. In the male, after puberty, the line of union of the two plates forms an acute prominence above, and gradually recedes and becomes more obtuse below. In the female and young male it is less prominent above, and more uniformly rounded or obtuse.

Each half of the thyroid cartilage is a quadrilateral plate, with the inner and outer surfaces sloping, and the borders rounded. The outer surface presents an oblique ridge for the attachment of muscles. The

¹ Pars prima asperæ arteriæ; caput, operculum, initium, finis superior, or terminus superior asperæ arteriæ.

² Nodus gutturis; promenentia laryngis.

³ Adami morsus os; scutum; cartilago-scutiformis; c. clypealis; c. peltalis.

posterior angles are prolonged into blunt processes, named the **horns**,¹ of which the superior are the longer. The borders are sigmoid in their course; the upper one being so to the greatest degree, and meeting that of the opposite side in a deep notch in front of the thyroid cartilage.

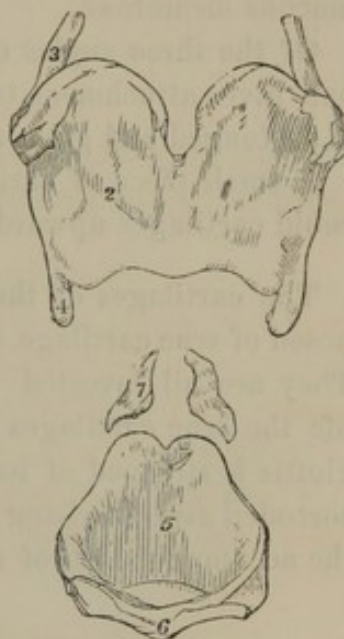
The **Cri'coid cartilage**,² situated below the former, and connected with the first ring of the trachea, in shape resembles a seal-ring. It is narrow in front, and gradually deepens posteriorly. Its lower border, somewhat waving in its course, is horizontal. The upper border ascends from the front, and at the back part is provided with a pair of convex, oval prominences, which articulate with the arytenoid cartilages.

On each side externally of the cricoid cartilage there is a slightly prominent circular facet for articulation with the inferior horns of the thyroid cartilage. The posterior surface is divided by a slight vertical ridge giving attachment to the œsophagus; and on each side of this ridge is a broad, shallow depression, accommodating the posterior crico-arytenoid muscle.

The **Epiglott'tis**³ is a somewhat spoon-shaped plate of fibro-cartilage invested with mucous membrane, projecting above the aperture of the larynx, which is closed against it in the act of swallowing. In the ordinary condition of rest it occupies an oblique position behind the body of the hyoid bone, with its free extremity bent toward the root of the tongue. Its outline is ovoid, with the broader extremity free, and the narrower extremity prolonged and attached by a band of fibro-elastic tissue to the thyroid cartilage within the entering angle of its two halves. The free borders of the epiglottis are thin and slightly everted. The surface directed forward or toward the mouth is convex, and that toward the aperture of the larynx is concave.

The **Aryt'enoid cartilages**,⁴ smaller than the others, are situated on

FIG. 281.



CARTILAGES OF THE LARYNX, front view. 1, thyroid cartilage; 2, its right side; 3, superior horn; 4, inferior horn; 5, posterior portion of the cricoid cartilage; 6, its anterior narrow portion; 7, the two arytenoid cartilages.

¹ Cornua; cornu longum, or superius and c. breve, or inferius; greater and lesser cornu.

² Cartilago cricoideus; c. annularis; c. cymbalaris; c. innominata.

³ Epiglottic cartilage; operculum laryngis; lingua exigua; sublinguum; lingula fistulæ; lingula; superligula.

⁴ Cartilagine arytenoides; c. gutturales; c. triquetrae; c. pyramidales; gutturnia.

the summit of the cricoid cartilage posteriorly. They are three sided, pyramidal, and curved. Their base is concave, and articulates with a corresponding prominence of the cricoid cartilage. Their apex is bent backward, and is surmounted with a nodule of cartilage¹ attached by means of a ligament. The posterior surface is concave, and accommodates the arytenoid muscles; the anterior surface is convex, and has attached the thyro-arytenoid muscle; and the inner surface is opposed to that of the opposite cartilage, leaving an intervening notch lined with mucous membrane.

Of the three angles of the base of the arytenoid cartilages, the outer one² gives attachment to the crico-arytenoid muscles, and the anterior³ is prolonged and gives attachment to the vocal membrane.

A small piece of cartilage⁴ frequently exists extending from the arytenoid cartilages upward into the aryteno-epiglottic folds.

The cartilages of the larynx, as they are commonly named, are composed of true cartilage, except the epiglottis, which is fibro-cartilaginous. They are all invested with a perichondrium, and with the advance of life the true cartilages are strongly disposed to ossify. When the epiglottis is stripped of its membranous investment, it is seen to present a corroded aspect arising from the existence of numerous irregular pits for the accommodation of small racemose glands.

ARTICULATIONS AND LIGAMENTS OF THE LARYNX.

The **Thyro-hyoid membrane**⁵ is a rather loose fibro-elastic structure connecting the upper border of the thyroid cartilage with the inner surface of the hyoid bone. It is thickest and most dense in front, and is thin at the sides.

The **Thyro-hyoid ligaments**⁶ are cylindrical, fibro-elastic cords, joining the superior horns of the thyroid cartilage with the ends of the great horns of the hyoid bone. At their middle they usually contain an imbedded nodule of cartilage,⁷ which is sometimes ossified.

The **Crico-thyroid articulation** is formed on each side of the larynx, between the inferior horn of the thyroid cartilage and the side of the cricoid cartilage. It is lined with a synovial membrane, and surrounded

¹ Corniculum laryngis; tuberculated, or supra-arytenoid cartilage; cartilage of Santorini; capitulum Santorini.

² Processus muscularis.

³ Processus vocalis.

⁴ Cuneiform cartilage; cartilage of Wrisberg.

⁵ Middle thyro-hyoid ligament.

⁶ Lateral thyro-hyoid ligaments.

⁷ Cartilago triticea.

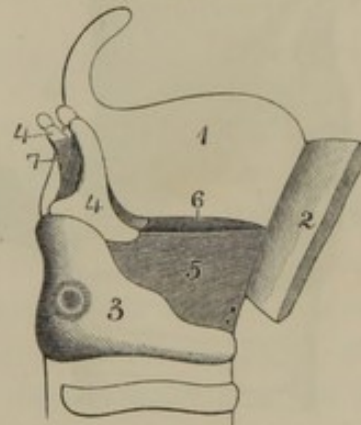
by a capsular ligament. This joint permits a movement of the thyroid cartilage downward and forward, and in the reverse direction.

The **Crico-aryt'enoid articulation** is a ball-and-socket joint, formed on each side of the larynx between the hollow base of the arytenoid cartilage and a corresponding convexity of the cricoid cartilage. It is lined with synovial membrane, and surrounded by a capsular ligament. The joint allows movement of the arytenoid cartilage in all directions.

The **Thyro-epiglottic ligament**¹ is a fibro-elastic band attaching the narrow extremity of the epiglottis to the upper part of the entering angle of the thyroid cartilage.

The **Vocal membrane**,² composed of elastic tissue, springs from the front and sides of the upper border of the cricoid cartilage, and extends upward to the bases of the arytenoid cartilages and the lower part of the entering angle of the thyroid cartilage. Its inferior portion is strongest, and is visible in the interval of the cricoid and thyroid cartilages at the front of the larynx. Its lateral portions are thin, and are separated from the sides of the thyroid cartilage by the intervening thyro-arytenoid muscles. Its upper margins, somewhat thickened, extend between the entering angle of the thyroid cartilage and the anterior prominent angle of the base of the arytenoid cartilages. These margins correspond in position with the lower edge of the ventricles of the larynx, and are almost universally described as the "**vocal cords**,"³ which, as peculiar or separate organs, do not exist.

FIG. 282.



VIEW OF THE VOCAL MEMBRANE. 1, left half of the thyroid cartilage; 2, right half turned forward and partly cut away; 3, cricoid cartilage; 4, arytenoid cartilages; 5, right half of the vocal membrane; 6, upper border of the left half; 7, arytenoid muscle. The upper borders of the vocal membrane, extended between the arytenoid cartilages and the thyroid, constitute the so-called "true vocal cords."

MUSCLES OF THE LARYNX.

The muscles of the larynx, except the arytenoid muscle, are in pairs, situated on each side of the larynx.

¹ Lig. thyro-epiglotticum.

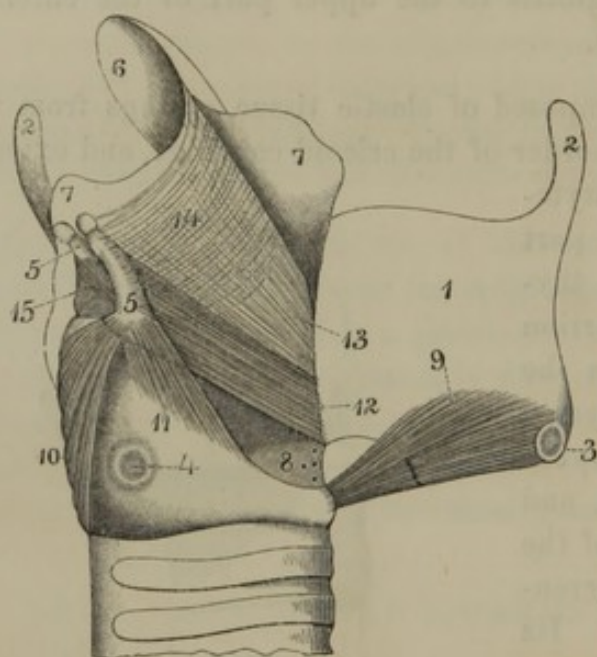
² Membrana vocalis; phonetic membrane; crico-thyroid membrane, or ligament; conoid, or pyramidal ligament.

³ Chordæ vocales; c. v. veræ: c. Ferreinii; superior thyro-arytenoid ligaments; inferior ligaments of the larynx; lips of the glottis.

The **Crico-thyroid muscle**¹ arises from the front and side of the cricoid cartilage, and ascends outward and backward to be inserted into the lower border of the thyroid cartilage. It draws the latter downward and forward, the centre of motion being the articulation between the inferior horn of the thyroid and the side of the cricoid cartilage. The result of the movement is to render the vocal membrane tense.

The **Posterior Crico-aryt'enoid muscle**² arises from the broad depression at the side, posteriorly of the cricoid cartilage, and converges upward and outward to be inserted into the external angle of the base of the arytenoid cartilage. It rotates the latter on its base outward and backward, rendering the vocal membrane tense, and widening the glottis.

FIG. 283.



MUSCLES OF THE LARYNX. 1, right half of the thyroid cartilage, turned forward; 2, superior horns; 3, inferior horn marked by the crico-thyroid articulation; 4, the other portion of the latter on the side of the cricoid cartilage; 5, arytenoid cartilages, surmounted by nodules of the same substance; 6, epiglottis; 7, the two laminae of the aryteno-epiglottic fold separated so as to expose the muscles; 8, lower part of the vocal membrane; 9, crico-thyroid muscle; 10, posterior crico-arytenoid muscle; 11, lateral crico-arytenoid; 12, thyro-arytenoid; 13, thyro-epiglottic muscular fibres; 14, aryteno-epiglottic muscular fibres; 15, arytenoid muscle.

It rotates the latter on its base outward and forward, relaxing the vocal membrane and widening the glottis.

The **Thyro-aryt'enoid muscle**,⁴ situated immediately above the pre-

¹ M. crico-thyroideus; anterior dilator of the larynx.

² M. crico-arytænoideus posticus; posterior dilator of the larynx,

³ M. crico-arytænoideus lateralis.

⁴ M. thyro-arytenoidæus.

ceeding, arises from the inner surface of the thyroid cartilage at its entering angle, and from the contiguous portion of the vocal membrane, and passes backward to be inserted into the outer surface and base of the arytenoid cartilage. It draws the latter forward, and relaxes the vocal membrane.

The **Aryt'enoid muscle**¹ consists of several transverse and obliquely crossing fasciculi, passing between the posterior concave faces of the arytenoid cartilages. It draws the latter together, and thus narrows the glottis.

Besides the preceding well-characterized muscles, there exist some thin fleshy fasciculi which are not constant in extent or arrangement. Some of these diverge from the entering angle of the thyroid cartilage to the sides of the epiglottis,² while others pass from the latter to the sides of the arytenoid cartilages.³

THE CAVITY OF THE LARYNX.

The lining mucous membrane of the larynx is continuous with that of the pharynx and trachea. Extending from the root of the tongue to the epiglottis, it forms the three **glosso-epiglot'tic folds**.⁴ Reflected from the sides of the epiglottis to the summits of the arytenoid cartilages, it forms the **aryt'eno-epiglot'tic folds**.⁵ Dipping into a notch between the summits of the arytenoid cartilages, it extends from the front of these into the cavity of the larynx, and behind them into the pharynx toward the commencement of the œsophagus.

The **aperture of the larynx**,⁶ communicating with the pharynx, is triangular and oblique. Its base or wider portion above is formed by the epiglottis, its sides by the aryteno-epiglottic folds, and its apex or narrow extremity by the notch separating the summits of the arytenoid cartilages.

Descending from the aperture into the cavity of the larynx, the mucous membrane is reflected at each side, outward and upward, forming a pair of pouches named the **ventricles of the larynx**.⁷ These are half

¹ M. arytaenoideus; m. arytaenoidei transversi and obliqui.

² M. thyro-epiglottideus.

³ M. aryteno-epiglottideus; compressor sacculi laryngis; m. ary-epiglottidæus

⁴ Glosso-epiglottic fræna; ligamenta glosso-epiglottica.

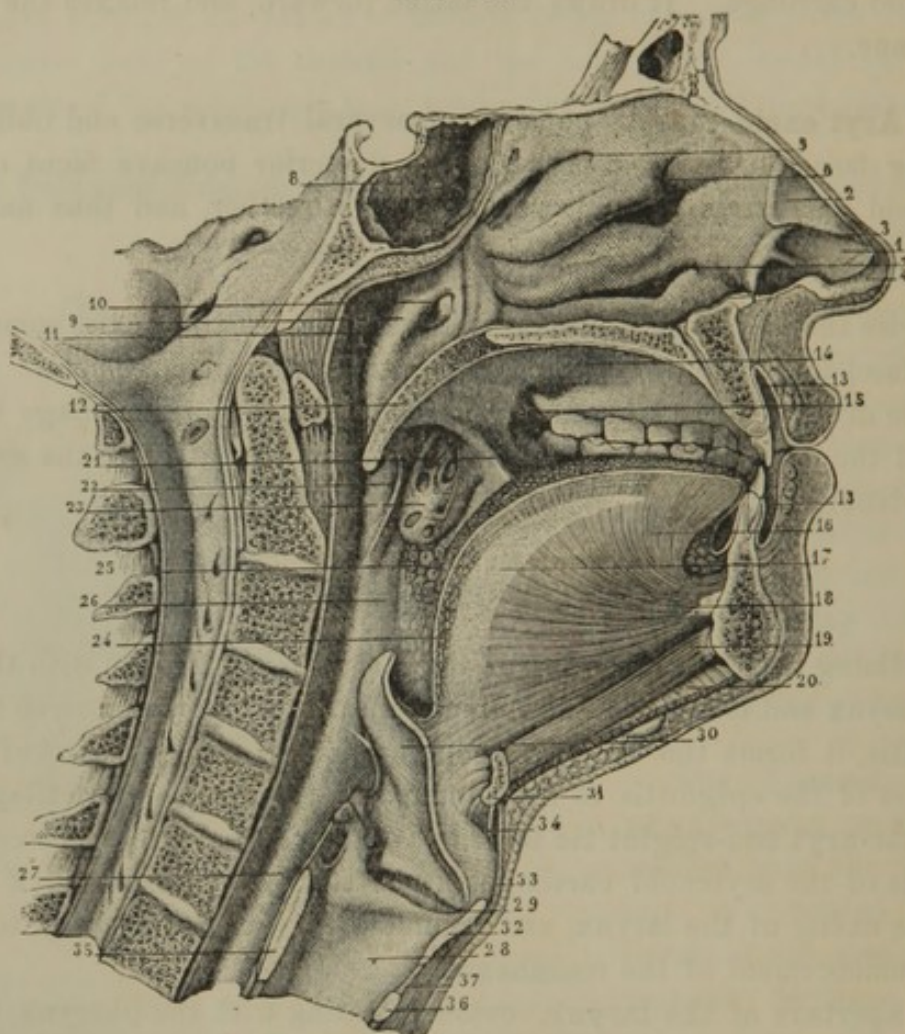
⁵ Ligamenta epiglottideo-arytaenoidea.

⁶ Superior aperture of the larynx; aditus laryngis.

⁷ Ventriculi laryngis; sacculi laryngis; sinuses of the larynx; laryngeal pouches; ventriculi Morgagni, or Galeni.

oval recesses communicating with the cavity of the larynx by a transverse elliptical orifice. The lower edge of the latter corresponds with

FIG. 284.



VERTICAL SECTION OF THE FACE AND NECK, THROUGH THE MEDIAN LINE ANTERO-POSTERIORLY, EXPOSING TO VIEW THE NOSE, MOUTH, PHARYNX, AND LARYNX. 1, oval cartilage of the left nostril; 2, triangular cartilage; 3, line of separation between the two; 4, prolongation of the oval cartilage along the column of the nose; 5, superior meatus of the nose; 6, middle meatus; 7, inferior meatus; 8, sphenoidal sinus; 9, posterior part of the left nasal cavity, communicating with the pharynx; 10, orifice of the Eustachian tube; 11, upper extremity of the pharynx; 12, soft palate, ending below in the uvula; 13, interval of the mouth between the lips and jaws; 14, roof of the mouth, or hard palate; 15, communication of the cavity of the mouth with the interval between the jaws and cheek; 16, tongue; 17, fibrous partition in the median line of the latter; 18, genio-glossal muscle; 19, genio-hyoid muscle; 20, mylo-hyoid muscle; 21, anterior half arch of the palate; 22, posterior half arch of the palate; 23, tonsil; 24, 25, floor of the fauces; 26, 27, pharynx; 28, cavity of the larynx; 29, ventricle of the larynx; 30, epiglottis; 31, hyoid bone; 32, 33, thyroid cartilage; 34, thyro-hyoid membrane; 35, 36, cricoid cartilage; 37, vocal membrane.

the upper border of the vocal membrane, or with what are commonly termed, on the two sides together of the larynx, the **vocal cords**.¹ The upper edge of the orifice of the ventricles is rendered slightly prominent

¹ Chordæ vocales; c. v. veræ; ligamenta glottidis veræ; l. thyro-arytenoideæ inferiora; inferior, or true vocal cords; lips of the glottis; chordæ Ferreinii.

by an accumulation of the subjacent connective tissue, usually called, on the two sides of the larynx, the **false vocal cords**.¹

From the ventricles of the larynx, the mucous membrane extends downward, lining the vocal membrane and the cricoid cartilage, and becoming continuous with that of the trachea.

The cavity of the larynx gradually narrows from its aperture downward to the space between the inferior edges of the orifices of the laryngeal ventricles. The narrowest portion of this space, named the **glottis**,² forms an isosceles triangle, of which the apex is at the entering angle of the thyroid cartilage; the sides correspond with the edges of the vocal membrane, and the base is in relation with the arytenoid cartilages. Below the glottis the cavity of the larynx gradually widens and assumes the circular form of the interior of the cricoid cartilage.

The mucous membrane of the larynx is soft, thin, and pale red. It adheres tightly to the epiglottis, the vocal membrane, and the interior of the cricoid cartilage, but in other positions is more loosely attached to the parts beneath by an abundant connective tissue. It is provided with numerous small racemose glands, and its epithelium is of the ciliated columnar form.

Between the lower part of the epiglottis and the root of the tongue there is an abundant deposit of connective, elastic, and adipose tissue, and a similar deposit, with many racemose glands, is situated beneath the mucous membrane in front of the arytenoid cartilages.

The arteries of the larynx are derived from the superior and inferior thyroid. The veins are branches of the thyroid veins. The lymphatics enter the cervical glands. The nerves are derived from the laryngeal branches of the pneumogastric and the sympathetic nerves.

THE ORGANS OF RESPIRATION.

The respiratory apparatus consists of the trachea and lungs, together with the thorax and appropriate muscles. The latter have already been described, and it now remains to examine the former.

THE TRACHEA.

The **Tra'chea** or **Windpipe**,³ the main air-passage of the lungs, is a cylindrical tube descending the neck in front of the œsophagus into the

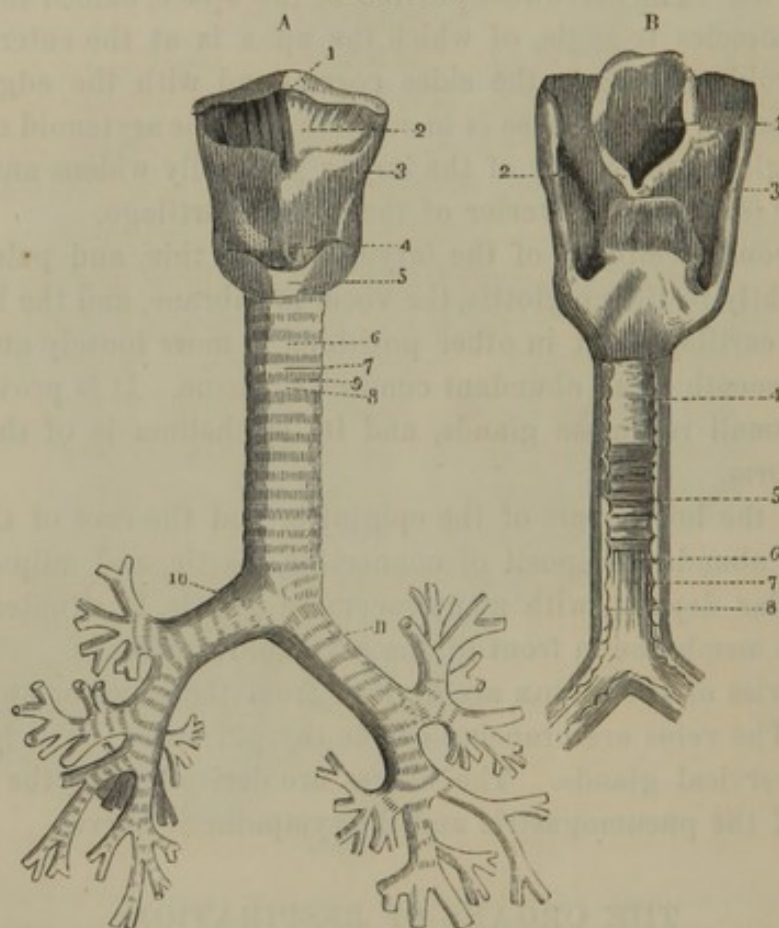
¹ Chordæ vocales spuriae; ligamenta glottidis spuriae; l. thyro-arytenoideæ superiora; superior, or false vocal cords.

² Glottis vera; rima glottidis; fissure of the glottis; true glottis; ligula.

³ Aspera arteria; fistula pulmonalis, or spiritalis; canna; syrinx; weasand; throttle; bronchus.

thorax. Commencing at the larynx opposite the fifth cervical vertebra, it terminates by dividing into the two bronchi opposite the third dorsal vertebra. Its length is about four inches; its breadth, less in the female than the male, is from three-fourths to one inch. In the neck it is bounded on each side by the great blood-vessels; and in the thorax is just behind the upper part of the sternum.

FIG. 285.



A.—FRONT OF THE LARYNX, TRACHEA, AND BRONCHI. 1, hyoid bone; 2, thyro-hyoid membrane; 3, thyroid cartilage; 4, lower part of the vocal membrane; 5, cricoid cartilage; 6, trachea; 7, 8, two cartilaginous rings; 9, intervening fibro-elastic membrane connecting the rings; 10, 11, right and left bronchi dividing into the bronchial tubes.

B.—BACK OF THE LARYNX, TRACHEA, AND BRONCHI. 1, aperture of the larynx; 2, 3, spaces between the sides of the thyroid cartilage, and the cricoid and arytenoid lined with mucous membrane extending downward to the œsophagus; 4, membranous space at the back of the trachea; 5, muscular fibres passing across the space and exposed by removing a fibrous layer containing the tracheal glands; 6, outer surface of the mucous membrane within the muscular layer; 7, 8, ends of the cartilaginous rings.

The **Bron'chi**¹ diverge from the trachea to the lungs, behind the great blood-vessels emanating from the base of the heart. The **right bron'-chus**,² about an inch in length, passes nearly at a right angle to the root of the corresponding lung, on a level with the fourth dorsal vertebra,

¹ Bronchia; bronchiæ; cannulæ pulmonum.

² Bronchus dexter.

and behind the right pulmonary artery. The **left bron'chus**,¹ narrower than the right, but about twice its length, passes downward and outward beneath the arch of the aorta to the root of the corresponding lung, on a level with the fifth dorsal vertebra and behind the left pulmonary artery.

The trachea and bronchi are composed of a series of cartilaginous rings connected by a fibro-elastic membrane, and lined with mucous membrane.

The **cartilaginous rings**² encircle the trachea and bronchi, but are imperfect at their posterior third. They are flat on their outer surface and convex on their inner surface, and therefore appear more prominent in the latter position. A strong fibro-elastic membrane connects their adjacent edges, and in a thinned condition extends over them. The posterior interval of the cartilaginous rings is occupied by a loose fibrous membrane and an internal layer of pale, unstriated muscular fibres having a transverse direction.

The last of the cartilaginous rings of the trachea is modified in form so as to accommodate itself to the two first rings of the bronchi; its lower margin being prolonged in front to a median point, which is bent backward.

The **mucous membrane of the trachea and bronchi** is pinkish white, and smooth, except that there are some fine longitudinal ridges at their posterior or membranous part, produced by reticular bundles of sub-mucous elastic tissue, which conspicuously occupy this position. The epithelium is of the ciliated columnar form; the vibrating movement of the cilia during life being directed upward.

The trachea and bronchi are provided with numerous minute racemose glands³ which open upon the surface of the mucous membrane. The largest of these are imbedded in the posterior fibrous membrane; and their terminal orifices are distinctly visible as numerous fine punctures on the free surface of the contiguous mucous membrane. Smaller glands occupy the intervals of the rings, and likewise distinctly exhibit their terminal orifices on the adjacent mucous membrane.

The trachea and bronchi are supplied by the inferior thyroid and bronchial arteries; their veins terminate in the thyroid and bronchial veins; and their nerves are derived from the pneumogastric and sympathetic nerves.

¹ Bronchus sinister.

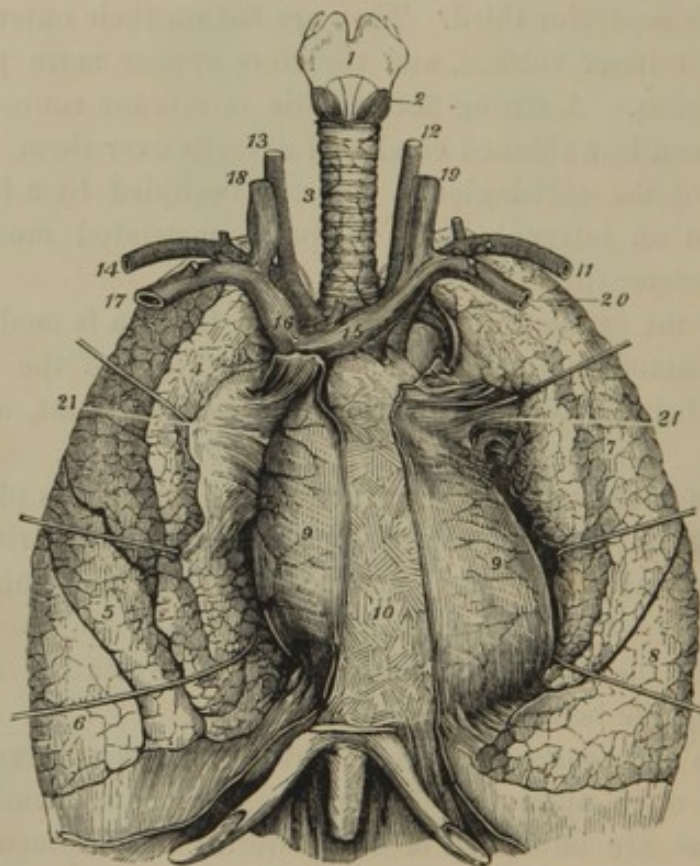
² Annuli cartilaginei; segmenta cartilaginea; orbes cartilaginei.

³ Tracheal and bronchial glands; glandulæ muciparæ tracheales et bronchiales.

THE LUNGS.

The **Lungs**¹ occupy the cavity of the thorax on each side, separated by the heart and great blood-vessels. They accurately fill the spaces which contain them in the constantly changing capacity of the chest during respiration. They are free or unattached everywhere except at their root, and are closely invested with a serous membrane, the pleura.

FIG. 286.



THE TRACHEA, LUNGS, AND HEART. 1, larynx; 2, crico-thyroid muscle; 3, trachea; 4, 5, 6, upper, middle, and lower lobes of the right lung; 7, 8, upper and lower lobes of the left lung; the anterior part of both lungs is drawn aside by hooks so as to expose to view 9, the heart contained within its pericardium; 10, anterior mediastinal space, the line on each side indicating the position at which the pleuræ are reflected from the pericardium to the front wall of the thorax; 11, left subclavian artery; 12, left common carotid; 13, right common carotid; 14, right subclavian; 15, left innominate vein; 16, right innominate vein; 17, 18, left subclavian and internal jugular veins; 19, 20, right internal jugular and subclavian veins; 21, root of the lung.

The **root**² of each lung is situated near its middle internally, and consists of the corresponding bronchus, pulmonary artery and veins, the bronchial blood-vessels, nerves, and lymphatics, surrounded by a

¹ Pulmones; pulmo dexter and sinister; pneumones; pleumones; lights; spiramenta animæ; flabella et ventilabra cordis; ergasteriones spiritus.

² Radix, or pedunculus pulmonis.

reflection of the pleura. The root of the right lung is behind the superior cava, and has the azygos vein arching over it as this communicates with the former vessel. The root of the left lung lies partly beneath the arch and partly in front of the descending portion of the aorta.

In the root of the right lung the bronchus is highest, the pulmonary artery is next, and the pulmonary veins are lowest. In the root of the left lung the pulmonary artery is highest, and then follows the bronchus, succeeded by the veins.

Before entering a depression at the root of the lungs, named the **hilus**,¹ the bronchi subdivide: the right into three branches, the left into two, in correspondence with the number of lobes of each lung. The pulmonary blood-vessels also commence subdivision before entering the lungs.

Each lung is conical, with a broad, concave base resting on the diaphragm; a rounded apex extending above the level of the first rib into the neck; an outer convex surface; and an inner concave surface directed toward the heart. The posterior border is long, thick, and convex, and occupies the side of the vertebral column; the anterior border is thin and sharp, and folds around the heart included within its pericardium. The margin of the base is acute, and outwardly occupies the narrow angular interval between the origin of the diaphragm and the inferior border of the thorax.

The lungs vary in weight and capacity according to many conditions, such as age, sex, size of the individual, state of health, and habit of exercise. In the adult their approximate weight is about two and a half pounds, and their total capacity about three hundred cubic inches. Their long diameter is the greatest, and is deepest posteriorly. The right lung is shorter than the left, but wider, and of somewhat greater bulk.

Each lung is divided by a fissure, commencing a short distance below the apex posteriorly and descending obliquely forward to the base anteriorly. The right lung is further divided by a fissure proceeding from the first obliquely forward to its anterior margin. Thus the right lung has three **lobes**,² of which the middle one is the smallest and the lowest one is the largest; the left lung has two **lobes**,² of which the lower is the larger. Between the lobes of the left lung in front there exists a large angular notch, corresponding with the position at which the impulse of the heart is felt against the walls of the chest during life.

In infancy the lungs are of a pale-rose color; but as life advances they assume a pinkish-gray or more or less leaden hue, variegated with spots and streaks of a dark-slate or bluish-black color. This change is

¹ Porta pulmonis.

² Lobi, or alæ pulmonum.

due to the gradual deposition in the structure of the lungs of minute granules of a black pigmentary matter. The surface of the lungs is smooth and shining, and distinctly marked with polyhedral outlines, indicating a lobular constitution in these organs.

The lungs are highly elastic, so that if the cavities containing them are opened, they collapse to about one-third of their previous bulk; and they may again be readily inflated by artificial means. Their substance is of a sponge-like consistence, readily floats in water, and imparts a crackling sensation when compressed between the fingers. In the fœtus before birth, or before respiration has taken place, they are heavier than water and sink in that fluid. A similar condition is observed in certain diseases, in which from congestion or effusion the lungs become more or less consolidated. On cutting a healthy lung and compressing it, a reddish, frothy liquid exudes, consisting of mucus mingled with blood and air bubbles.

The lungs are composed of numerous small, polyhedral **primary lobules**,¹ which unite into larger **secondary lobules** of the same general form. The latter give

FIG. 287.

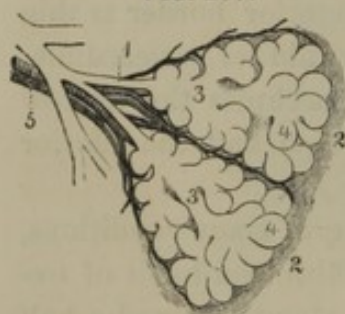


DIAGRAM OF TWO PRIMARY LOBULES OF THE LUNGS, magnified. 1, bronchial tube; 2, a pair of primary lobules connected by fibro-elastic tissue; 3, intercellular air-passages; 4, air-cells; 5, branches of the pulmonary artery and vein.

rise to the polyhedral markings on the surface of the lungs, and close inspection will lead to the discovery of the outlines of the primary lobules composing them. Both the primary and secondary lobules are associated by means of connective tissue;² they are most distinctly observed in the young, but become less evident in advancing life.

Every primary lobule of a lung represents in its structure the entire organ, and consists of a bronchial tube opening into an air-passage which communicates with a multitude of air-cells.

The **Air-cells**,³ the ultimate recesses of the lungs reached by the air in respiration, are rounded polyhedral sacs. They approach an average of about the one-tenth of a line in diameter, but vary much in size, being larger near the surface than in the deeper part of the lungs. They further increase in size with the advance of age; and they become much enlarged in ~~asthmatic~~ ^{(probably) emphysematous} persons. They communicate with a common, somewhat ramifying, inter-cellular air-passage, which ends in a bronchial

¹ Lobuli, or insulæ pulmonales.

² Interlobular connective, or areolar tissue.

³ Cellulæ, or vesiculæ aeræ; cellulæ terminales and parietales; alveolæ pulmonales; spiramina, or cellulæ pulmonum.

tube emanating from a primary lobule. They are connected together by an intervening fibro-elastic tissue, to which the elasticity of the lungs is mainly due; and they are composed of a basement membrane with a lining squamous epithelium. Exteriorly they are surrounded by fine nets of capillary blood-vessels, which intervene between the terminal branches of the pulmonary arteries and the commencing ones of the pulmonary veins.

The **Bron'chial tubes**,¹ formed from the subdivision of the two bronchi, ramify throughout the lungs without anastomosing, and finally end in the primary lobules, where they communicate with the intercellular air-passages. They have the same structure as the trachea and bronchi, except that their cartilages are subdivided into several pieces distributed around the tube instead of forming C-like rings; and their muscular fibres form a continuous layer. At the division of the bronchial tubes the cartilages assume a crescentic shape, and are so placed as to maintain the orifices of the tubes open. As the bronchial tubes become smaller, the cartilaginous element of structure decreases, and finally disappears, when they consist alone of fibro-elastic membrane with muscular fibres and a lining mucous membrane.

The **Pul'monary artery**, specially devoted to the conveyance of dark blood from the heart to the lungs, ramifies in company with the bronchi and terminates in the capillary vascular nets inclosing the air-cells.

The **Pul'monary veins** originate in the capillary nets just mentioned, and pursue the course of the bronchial tubes until they emerge from the lungs, when they convey the aerated, scarlet blood to the heart.

The **Bron'chial arteries**, which are small vessels compared with the preceding, come off from the aorta, and follow the ramifications of the bronchial tubes, the tissues of which they chiefly supply.

The **Bron'chial veins**, returning most of the blood of the corresponding arteries, terminate in the azygos vein on the right, and the superior hemiazygos vein on the left side.

The lymphatics of the lungs are numerous. The superficial ones converge toward the root; the deep ones follow the course of the bronchial tubes; and both enter numerous lymphatic glands situated about the bronchi and bifurcation of the trachea. These bronchial glands in early life do not differ in appearance from those elsewhere, but in the advance of age they assume a darker color than the lungs, and not unfrequently are found to contain calcareous deposits.

The nerves of the lungs are derived from the pneumogastric with

¹ Bronchi; syringes, or canales aeriferi.

branches of the sympathetic. These nerves form the anterior and posterior pulmonary plexuses, of which the latter is the larger, and both follow the course of the bronchi and pulmonary blood-vessels in their ramifications.

THE PLEURA.

The **Pleu'ra**¹ is a serous membrane which lines the sides of the cavity of the thorax, and is thence reflected from the root over the corresponding lung. It closely adheres to the subjacent structures, and in its different positions receives the names of **costal**, **diaphragmat'ic**,² **medias'tinal**, and **pulmonary pleura**. From the root of the lung a fold of the membrane extends downward to the diaphragm, and is called the **pulmonary ligament**.³ The cavity of the pleura is bathed with a thin serous secretion which lubricates the surface of the lungs, and thus facilitates their movements during respiration.

By the approximation of the two pleuræ in the median line, they form the **mediasti'num**,⁴ or partition of the thorax, which contains the heart included within its pericardium.

The intervals between the two pleuræ in front of, behind, above, and that occupied by the heart, are named from their relative position the anterior, posterior, superior, and middle mediastinal cavities. Above the middle of the sternum, for a short distance, the two pleuræ come into contact and are associated by connective tissue.

The **Anterior medias'tinal cavity**⁵ is bounded in front by the sternum, on each side by the pleura, and is occupied by some loose areolar tissue.

The **Posterior medias'tinal cavity**⁶ is bounded behind by the vertebral column, on each side by the pleura, and in front by the pericardium. It contains the aorta, the azygos and hemiazygos veins, the thoracic duct, the œsophagus, and the pneumogastric and splanchnic nerves.

The **Superior medias'tinal cavity**⁷ is bounded on each side by the apex of the pleura, behind by the vertebral column, and in front by the

¹ Pleurum; pleuroma; membrana pleuritica succingens; m. p. costas succingens; m. costalis, or subcostalis; hy-popleurios.

² Phrenic.

³ Ligamentum pulmonale.

⁴ Medianum; mesodne; mesotœchium; septum, or dissipimentum thoracis; membrana thoracem intersepiens; m.

diaphratton; intersepimentum thoracis; hymen diaphratton; diribitorium.

⁵ Anterior mediastinum; cavum mediastini anterioris; mediastinum pectorale.

⁶ Posterior mediastinum; m. dorsale; cavum mediastini posterioris.

⁷ Superior mediastinum; cavum mediastini superioris.

sternum. It contains the bifurcation of the trachea, the œsophagus, and great blood-vessels connected with the base of the heart.

The **Middle medias'tinal cavity**¹ is occupied by the heart within its pericardium.

THE THYROID BODY.

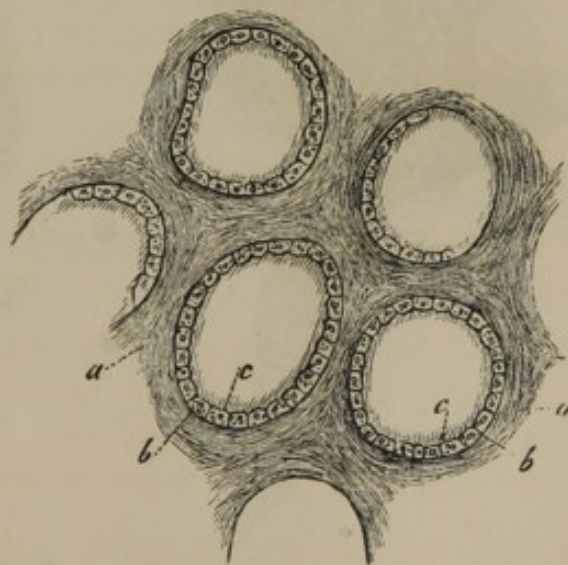
The **Thy'roid body**² is a moderately soft, reddish organ, of unknown function, embracing the front and sides of the upper extremity of the trachea, and extending to the sides of the larynx. It consists of a pair of lateral lobes united at their lower part by a transverse **isthmus**. Its outer surface is convex, and its inner surface in contact with the trachea and larynx is concave. It adheres to the adjacent parts by connective tissue, and is covered by the sterno-hyoid, sterno-thyroid, and omo-hyoid muscles, and is in relation at its posterior borders with the great blood-vessels of the neck.

The **lateral lobes**³ are oblong oval, thicker below than above, and usually of unequal length. They commonly measure about two inches long, and extend from the sixth cartilaginous ring of the trachea to the lower part of the thyroid cartilage. From the **isthmus** associating the lobes, a process⁴ of the body frequently extends upward to the hyoid bone, to which it is attached by a fibrous band, occasionally containing some muscular fibres.⁵

The weight of the thyroid body is ordinarily from one to two ounces, but is larger in the female. It is very liable to enlargement, especially in the latter sex, constituting the affection called goitre.

The thyroid body is a highly vascular organ, invested with a thin, fib-

FIG. 288.



PORTION OF THE THYROID BODY IN SECTION, highly magnified. *a*, fibrous stroma; *b*, vesicles; *c*, the epithelium and liquid contents.

¹ Middle mediastinum; cavum mediastini medius.

² Corpus thyroideum; glandula thyroidea; ganglion vasculosum.

³ Cornua lateralia.

⁴ Cornu medium; processus pyramidalis.

⁵ Levator glandulæ thyroideæ.

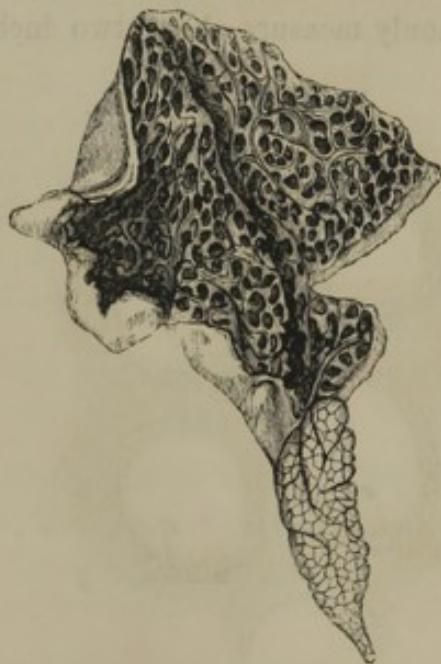rous membrane,¹ and composed of a fibrous stroma, in the meshes of which a multitude of minute, closed vesicles are imbedded. The vesicles² consist of a basement membrane³ lined with an epithelium consisting of a single layer of nucleated cells; and they are filled with a viscid amber-colored liquid.

The arteries and veins of the thyroid body are branches of the superior and inferior thyroids. The lymphatics are numerous, and communicate with the cervical glands. The nerves are derived from the pneumogastric and great sympathetic.

THE THYMUS BODY.

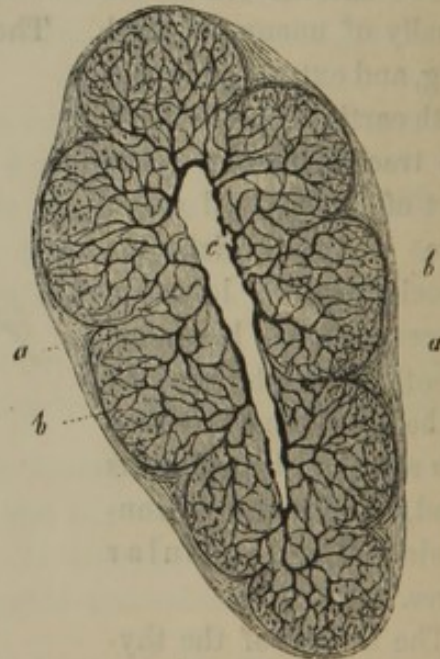
The **Thy'mus body**⁴ is a temporary organ of unknown function, which increases in size from the embryonic period up to two years after birth, and subsequently dwindles away. It occupies the upper part of the

FIG. 289.



ONE LOBE OF THE THYMUS BODY, WITH ITS CAVITY LAID OPEN, AND EXHIBITING THE LOBULAR RECESSES. The lower extremity of the figure exhibits the outlines of the lobules.

FIG. 290.



SECTION OF A LOBULE OF THE THYMUS BODY, magnified. *a*, fibrous investment of the lobule; *b*, acini penetrated by blood-vessels; *c*, the lobular recess.

anterior mediastinal cavity behind the sternum, and extends into the neck, frequently to the thyroid gland. It rests upon the pericardium, aorta, left innominate vein, and the trachea. It is a flat triangular body

¹ Tunica propria.

² Gland vesicles.

³ Membrana propria.

⁴ Corpus thymicum; thymus gland; glandula thymus; thymus; corpus incomprehensibile; the sweetbread.

consisting of a pair of lateral and usually unequal lobes. It is of a pinkish cream color, and varies in size and weight, not only according to age, but also in different individuals of the same age. At birth it is commonly about two inches long, one and a half inches wide at the lower part, and two or three lines thick, and its weight is about half an ounce.

The thymus body is provided with a thin investing fibrous membrane, and is composed of numerous compressed angular lobules, associated by connective tissue, which give it the aspect of a racemose gland. Each lateral lobe commonly exhibits an interior cavity¹ of variable extent, communicating with recesses in the lobules. Further than this, the structure of the thymus body has not been satisfactorily determined. The thick walls of the lobular recesses appear to consist of **acini**² or coarse granules, comparable to the vesicles of the thyroid body or those of racemose glands. The **acini** are composed of free nuclei and nucleated cells, and are penetrated by blood-vessels. The recesses of the lobules and the cavities of the lobes are filled with a thick milk-like liquid, mingled with numerous nuclei and nucleated cells.

The arteries³ of the thymus body are derived from the internal mammary, pericardiac, and inferior thyroid arteries. The veins empty into the left innominate vein. The lymphatic vessels terminate in the internal mammary lymphatics. The nerves are derived from the pneumogastrics and great sympathetics.

¹ Reservoir of the thymus.

² Incorrectly called cells, or vesicles.

³ Thymic arteries.

CHAPTER IX.

THE URINARY ORGANS.

THE urinary organs consist of the **kidneys**, which secrete the urine; the **ureters** or excretory ducts of the former; the **bladder**, a receptacle for the urine; and the **urethra**, the canal through which the latter liquid is discharged.

THE KIDNEYS.

The **Kidneys**¹ are two glandular organs, deeply situated in the lumbar regions, lying one on each side of the vertebral column; the right a little higher than the left. They are opposite the upper two or three lumbar and the last dorsal vertebræ, inclining toward each other above, and are maintained in this position by their vessels, together with a quantity of loose areolar tissue usually containing much fat.² Their anterior surface is more convex than the posterior, and their upper extremity is larger than the lower, and has attached to it the supra-renal body.

The right kidney in front is in contact with the liver, the descending portion of the duodenum, and the ascending colon; the left with the spleen, pancreas, stomach, and descending colon.

The kidneys are smooth, dark red, compressed oval bodies with a notch on the inner side; the form being so characteristic that similar shaped bodies are commonly called kidney-shaped or reniform. They vary in size, but ordinarily measure about four inches in length, two inches in breadth, and one inch in thickness, and weigh about four ounces.

The notch on the inner side of the kidneys is named the **hilus**,³ and communicates with an interior cavity, the **sinus**, at which the vessels, nerves, and excretory duct of the organs have their entrance and exit.

Besides the general envelope of areolar tissue and fat, the kidneys are furnished with a special **fibrous coat**.⁴ This is a thin, moderately firm,

¹ Renes. Singular: ren; nephros; protmesis.

² Tunica, or capsula adiposa.

³ Porta renis.

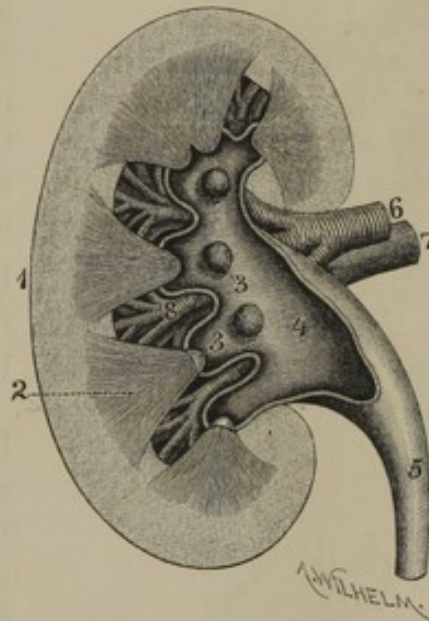
⁴ Tunica propria; capsula fibrosa.

uniform layer of fibrous tissue adhering slightly to the glandular structure beneath. It extends from the hilus into the sinus, and at the bottom of this cavity becomes continuous with the fibrous investment of the vessels and duct of the organs.

Upon dividing a kidney in its breadth longitudinally, the cut surface is observed apparently to consist of two substances: an exterior more granular looking portion, named from its relative position the **cortical substance**,¹ and an interior striated portion, called the **medullary substance**.² The latter is arranged into conical masses, the **renal pyramids**,³ the bases of which are enveloped in the cortical substance,⁴ while the free summits, named **renal papillæ**,⁵ project into the sinus of the kidney.

The **renal pyramids**³ vary in size and number—there usually being from ten to fifteen—and sometimes a pair of them are confluent. They are arranged in three irregular series, with their bases directed exteriorly and their summits converging toward the sinus of the kidney. Together with the enveloping cortical substance at their base, they correspond with so many lobules which are attached by connective tissue in the fœtus, but subsequently become indissolubly blended. In many of the lower animals the lobules remain permanently and distinctly separated; and not unfrequently the surface of the adult human kidney presents more or less distinct traces of the original lobular isolation.

FIG. 291.



LONGITUDINAL SECTION OF A KIDNEY. 1, cortical substance; 2, renal pyramid; 3, renal papillæ; 4, pelvis; 5, ureter; 6, renal artery; 7, renal vein; 8, branches of the latter vessels in the sinus of the kidney.

¹ Substantia corticalis vasculosa, glandulosa, or glomerulosa; glandular, discerning, or vascular substance.

² Substantia medullaris, tubulosa, fibrosa, or radiata; uriniferous, or conoidal substance.

³ Pyramids of Malpighi.

⁴ The cortical substance projecting between the bases of the renal pyramids forms the columnæ, or septa Bertini.

⁵ Papillæ, or mammillæ renales.

The substance¹ of the kidney is mainly composed of secretory tubes, named **urin'iferous tubules**,² and blood-vessels, associated with comparatively little connective tissue. The terminal orifices of the uriniferous tubules may be observed, to the number of several hundred, at the summit of each renal papilla. Tracing the tubules from their terminal

FIG. 292.

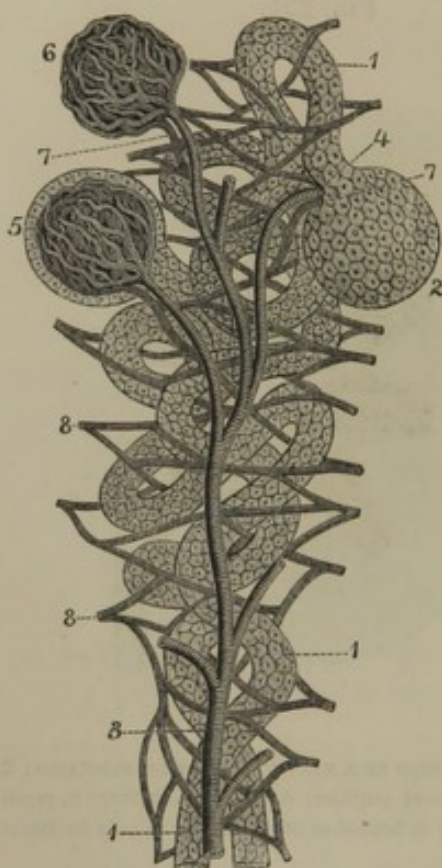


DIAGRAM OF THE STRUCTURE OF THE KIDNEYS. 1, two uriniferous tubules of the cortical substance lined with a pavement epithelium; 2, dilatation of a tubule inclosing a renal glomerule; 3, branch of the renal artery ending in vessels which enter the glomerules as seen at 4, 5; 6, knot of blood-vessels freed from its investment; 7, veins emerging from the vascular knots; 8, plexus formed by the latter veins among the uriniferous tubules, from which plexus originate the branches of the renal vein.

orifices backward, they are found to pursue a nearly straight but slightly divergent course in the renal pyramids, dividing repeatedly at acute angles, and diminishing in size. Approaching the bases of the pyramids, they assume a slightly tortuous course, subsequently become much convoluted, and finally cease in the cortical substance, each in a pouch-like dilatation, inclosing a **renal glom'erule** (**Malpighian corpuscle**.)

The straight course of the uriniferous tubules in the renal pyramids, and their subsequent convoluted course, give rise to the difference of appearance in the renal substance distinguished as the medullary and cortical portions. The uriniferous tubules are composed of a delicate wall of basement membrane lined with a pavement epithelium, and at their pouch-like extremity the wall is inflected upon the inclosed renal glomerule.

The kidneys are very vascular, and obtain their blood through the renal arteries, which are large in proportion with the organs they

supply. Approaching the hilus of a kidney, the renal artery divides into several branches, which subdivide, enter the sinus, and penetrate

¹ Secreting parenchyma.

² Tubuli uriniferi; uriniferous canals. Those of the medullary substance are named tubuli recti, or Belliniani, or ducts of Bellini. The bundles formed

by the divisions of these tubes are called the pyramids Ferreinii. The uriniferous tubules of the cortical substance are the tubuli contorti, corticales, or Ferreinii.

the renal substance between the renal papillæ. Ramifying through the cortical substance, they finally terminate by forming most remarkable plexuses, named the **renal glom'erules**.¹ Each **glomerule** is a spheroidal knot of about $\frac{1}{100}$ of an inch in diameter, consisting of an intricate and close convolution of capillary vessels, inclosed by the pouch-like dilatation of a uriniferous tubule. From each glomerule there emerges an efferent vessel, which, together with others, forms a capillary net-work between and along the course of the uriniferous tubules. From this capillary net-work the renal veins originate and converge from the exterior surface of the kidney toward the base of the renal pyramids; then pursue the course of the arteries and emerge into the sinus of the kidney, from which they make their exit in a single trunk.

The excretory duct of the kidney, called the **ure'ter**, appears at the hilus as a compressed funnel-shaped pouch, named the **pelvis**.² Within the sinus, the wide mouth of the pelvis divides into two or three portions, which subdivide into several smaller funnels, or **cal'yces**.³ Into each **cal'yx** one or two renal papillæ project, so that the urine dribbling from the orifices of the uriniferous tubules is received by the calyces, conveyed to the pelvis, and thence runs down the ureter.

The **cal'yces**, **pelvis**, and **ure'ter** have the same structure, consisting of an exterior fibrous layer, a succeeding stratum of unstriated muscular fibres, and a lining mucous membrane. The fibrous layer of the calyces at the base of the renal papillæ becomes continuous with the fibrous investment of the sinus of the kidney. The muscular layer thins away from the pelvis, and ceases at the base of the renal papillæ, while the mucous membrane is reflected upon the latter and becomes continuous with the uriniferous tubules at their orifices.

In the hilus and sinus of the kidney, the pelvis is posterior to the position of the renal blood-vessels. The renal vein is in advance of the corresponding artery at the hilus, but within the sinus their branches intermingle. The nerves of the kidney are derived from the renal plexus of the sympathetic system; the lymphatics communicate with the lumbar glands.

The **Ure'ter**⁴ is a cylindrical tube from each kidney, which conveys the

¹ Glomeruli renales; corpuscula Malpighii; corpora Malpighiana; Malpighian bodies or corpuscles; glandules, glomerules, or acini of Malpighi.

² Pelvis renalis; sinus, venter, or alvus renum.

³ Infundibula; calyces renales minores et majores; canales, or cylindri membranacei renum; tubuli pelvis renum; fistulæ ureterum renum.

⁴ Ductus urinæ; vas urinarium; urina: canalis nerveus fistulosus renum; vena alba renum.

urine to a common receptacle, the bladder. It measures from fifteen to eighteen inches long, and is about the diameter of a goose-quill. Descending obliquely inward, it enters the pelvic cavity and curves forward and downward to the fundus of the bladder, into which it opens. In its course it lies behind the peritoneum, loosely attached to contiguous parts by areolar tissue, and is crossed in front by the spermatic vessels. First resting on the psoas muscle, it then crosses the iliac blood-vessels, and is afterwards included by the recto-vesical or recto-uterine fold of the peritoneum, according to the sex. Approaching the bladder, in the male it crosses to the outer side of the spermatic duct, in the female runs along the side of the neck of the uterus, and terminates, after penetrating the wall of the bladder obliquely, about one and a half inches behind the orifice of the urethra, and about the same distance from its fellow.

The fibrous coat of the ureter is strong, and pinkish white in color. The muscular coat, consisting of pale, unstriated, longitudinal and transverse fibres, slightly thickens in its descent. The mucous membrane is without glands, and is provided with an epithelium whose cells exhibit a remarkable variety in form and size.

The arteries of the pelvis and ureter are small branches derived from the renal, spermatic, and vesical arteries. The nerves are derived from the sympathetic system.

The **U'rine**, secreted by the kidneys and accumulated in the bladder, is a transparent, amber-colored liquid, highly complex in its chemical composition. Its most characteristic constituent is a peculiar nitrogenized principle called **u'rea**.

THE URINARY BLADDER.

The **U'rinary Bladder**¹ is a musculo-membranous sac which serves as a reservoir to the urine as it is excreted by the kidneys. Its size and form vary with its condition of distention or collapse. When empty, it lies in the pelvic cavity, appearing as a flattened, triangular body, with the apex extending upward behind the pubic symphysis. When moderately distended, it assumes a rounded form, and still occupies the pelvic cavity; but when completely filled, it becomes ovoidal, and its summit extends above the pubes into the pre-peritoneal space of the hypogastric region. Its long diameter is directed from the latter downward and backward toward the anus; but from its summit to its termination in the urethra its axis is somewhat curved.

¹ Vesica urinaria; bladder; urocystis; cystis.

In the female the bladder approaches a more spheroidal form than in the male, and in both sexes its capacity is about equal to one pint.

The upper extremity or **summit**¹ of the bladder is connected with a fibrous cord ascending behind the **linea alba** to the umbilicus. This cord is an obliterated tube, the **urachus**, which in the embryo extends between the bladder and a pouch, named the **allantois**, situated exteriorly to the abdomen.

The **base** or **fundus**² of the bladder is the widest part of the organ, and is in contact, in the male, with the lower end of the rectum; in the female, with the vagina.

The portion of the bladder intervening to the fundus and summit is the **body**, and is more convex in front than behind.

In advance of the fundus, the bladder is narrowed in a funnel-like manner, and is named the **neck**.³ In the male this is nearly horizontal, the fundus extending slightly below its level; but in the female the neck descends obliquely forward and is the lowest part of the organ.

The bladder is maintained in position by reflections of the peritoneum and recto-vesical fascia, by connective tissue attaching its front and fundus to the contiguous organs, by the obliterated umbilical arteries and urachus, and by the neck becoming continuous with the urethra.

The recto-vesical fascia passing from the back of the pubis to the prostate gland and neck of the bladder forms two small processes, named the **anterior ligaments of the bladder**. A continuation of these to the sides of the fundus, reflected from the inner surface of the anal elevator muscles, constitutes the **lateral ligaments of the bladder**.

The so-called false ligaments of the bladder are folds of peritoneum produced in its reflection upon this viscus. The **recto-vesical folds**⁴ pass from the sides of the rectum to the sides of the bladder; or instead of them, in the female, the **utero-vesical folds** pass from the sides of the uterus to the sides of the bladder. These folds contain the ureters, vessels and nerves of the bladder, and the commencement of the obliterated umbilical arteries. A slight fold is also produced by the subsequent course of the latter together with the urachus, toward the umbilicus.

The peritoneum is reflected from the rectum or uterus to the back, the sides, and the summit of the bladder, and thence to the sides of the pelvis⁵ and the anterior parietes of the abdomen. Where destitute of peritoneum, the bladder is invested with a thin, feeble layer of fibrous tissue,

¹ Superior fundus.

² Inferior fundus; bas-fond.

³ Cervix.

⁴ Plicæ semilunares.

⁵ The reflections to the side of the pelvis constitute the lateral false ligaments of the bladder.

constituting a portion of the recto-vesical fascia and continuous with the subserous connection of the former. When the bladder becomes distended, its summit elevates the peritoneum from the abdominal wall in the hypogastric region, so that the organ, in an operation, may be reached above the pubis without interfering with the latter membrane.

Succeeding the peritoneum and vesical fascia, the bladder possesses a strong **muscular coat**, consisting of reddish-brown unstriated fibres which are collected into various sized fasciculi conjoining in a reticular manner, and are arranged in two different directions. The external longitudinal fibres diverge from the neck and anterior ligaments of the bladder, and again converge to its summit about the attachment of the urachus. The internal circular fibres are less numerous than the former, are transverse and oblique; and at the neck of the bladder accumulate in a dense bundle, constituting the **vesical sphincter**.¹

Succeeding the muscular coat, and adhering closely to it, the bladder is provided with a moderately thick, strong, and extensible layer of fibrous tissue mingled with elastic fibres.

The lining **mucous membrane** of the bladder is smooth, pale rose red, and closely adherent to the fibrous layer beneath. It has an epithelium, like that of the ureters and pelves of the kidneys, consisting of several layers of cells, of which the deeper ones are columnar, and the superficial ones larger and tessellated. In the neck of the bladder it is also provided with a few minute racemose glands.

In the empty condition of the bladder its mucous membrane is thrown into wrinkles, which disappear as the organ undergoes distention. Sometimes it presents reticular ridges corresponding with the arrangement of the fasciculi of the muscular coat; a condition usually due to inordinate action of the latter arising from obstruction to the emission of the urine.

At the bottom of the bladder, extending from the neck toward the fundus, a slightly elevated triangular space is observable, named the **vesical triangle**.² The apex of this constitutes the **vesical uvula**,³ a small, rounded elevation projecting into the orifice of communication of the bladder with the urethra. The basal angles of the vesical triangle are formed by the **orifices of the ureters**, which appear as oblique slits the one-eighth of an inch long. The muscular structure⁴ beneath the mucous membrane of the vesical triangle is thick, and often presents fasciculi⁵ diverging from the vesical uvula to the orifices of the ureters.

¹ Musculus sphincter vesicæ.

³ Uvula vesicæ.

² Trigonum vesicæ; t. Lieutaudi; corpus trigonum.

⁴ Muscle of the vesical triangle.

⁵ Muscles of the ureters.

THE URETHRA.

The **Ure'thra**¹ in the male serves as a passage for the urine and the spermatic liquid. As its anatomical relations may be best understood after describing the penis, an account of it is reserved for the chapter on the organs of generation.

The **Ure'thra of the female** serves alone for the passage of the urine. In consequence of the divided condition of the spongy body of the clitoris it does not extend through this organ, as the male urethra does through the spongy body of the penis; and it therefore corresponds only with the prostatic and membranous portions of the urethra of the male. It is about an inch and a half long and three or four lines wide, though it is capable of greater distention. From the bladder it curves downward and forward beneath the pubic arch, and terminates at the middle of the base of the vestibule just above the orifice of the vagina. It lies imbedded in the anterior wall of the latter canal, and pierces the triangular ligament, its external orifice² being indicated by a slight papillary eminence about an inch behind the glans of the clitoris or twice that distance from the anterior commissure of the vulva.

The lining mucous membrane of the urethra is longitudinally folded, reddish, and provided with minute racemose glands.³ Its epithelium is squamous toward the external orifice, and assumes the character of that of the bladder toward its inner orifice. Exterior to the mucous membrane is a layer of fibrous tissue containing many blood-vessels, especially veins forming a plexus. The urethra is also furnished with a layer of unstriated muscular fibres mingled with elastic and fibrous tissue.

THE SUPRA-RENAL BODIES.

The **Supra-re'nal bodies**⁴ are a pair of flattened triangular organs, situated one upon the upper extremity of each kidney, and inclined inwardly toward the vertebral column. Their upper border is thin and convex; their lower border or base is thick and concave, and is attached by long, loose areolar tissue to the corresponding kidney. Their posterior surface, moderately convex, rests against the crura of the diaphragm; their anterior surface, more flat, on the right side is in contact with the liver, on the left side with the pancreas and spleen. The surfaces present

¹ Meatus, or ductus urinarius.

² Meatus urinarius; urethral orifice.

³ Glands of Littre.

⁴ Supra-renal capsules, or glands;

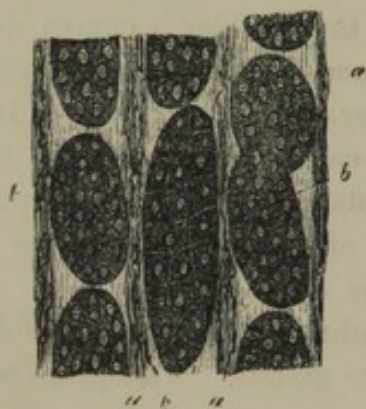glandulæ supra-renales; capsulæ atrabiliaræ, renales, or supra-renales; renal glands, or capsules; renes succenturiati; nephridi.

vascular furrows, the largest of which at the base is distinguished as the **hilus**.

The supra-renal bodies are brownish yellow in color, of moderately firm consistence, and vary in size in different individuals, and slightly on the two sides. Generally they are about one and a half inches in breadth and height, and about one-fourth of an inch thick. Besides a quantity of loose areolar tissue, often mingled with fat, connecting them with contiguous parts, they have a thin but strong fibrous coat.

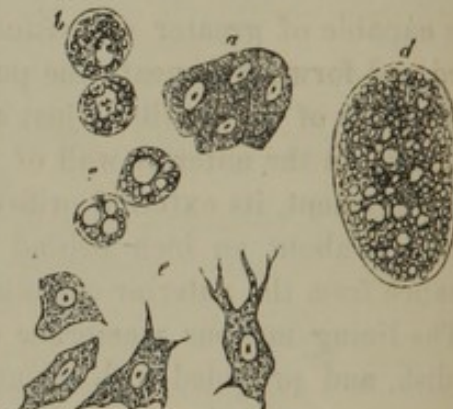When a section is made across the supra-renal bodies, they are found to be composed of an external layer, named the cortical substance, and an internal softer material, the medullary substance.

FIG. 293.



SECTION OF THE CORTICAL SUBSTANCE OF A SUPRA-RENAL BODY, highly magnified. *a*, stroma of fibrous tissue; *b*, oblong oval receptacles occupied by groups of cells.

FIG. 294.



CELLS FROM THE SUPRA-RENAL BODY, highly magnified. *a*, nucleated cells from the cortical substance; *b*, *c*, *d*, cells from the same containing fat; *e*, cells from the medullary substance.

The **cor'tical layer**¹ is yellow in color, of moderately firm consistence, and is striated, or presents a columnar appearance at right angles to the surfaces of the layer. Examined with the aid of the microscope, it exhibits oblong receptacles occupying a fibrous stroma continuous with the fibrous coat of the body. These receptacles have their long diameter vertical to the surface of the cortical substance, and are filled with fine granular matter, nuclei, oil globules, and pigment granules. According to Kölliker, all of these elements are the contents of groups of cells occupying the receptacles of the cortical stroma.

The **med'ullary substance**² is a dark-brown, pulpy matter, so easily broken that the cavity frequently observed in its interior is usually viewed as being an accidental laceration. It consists of a fine stroma of areolar tissue continuous with that of the cortical substance, and containing in its meshes fine granular matter, pigment granules, oil globules, and nucleated cells somewhat resembling those of the nerve centres.

¹ Substantia corticalis; cortex.

² Substantia medullaris.

The blood-vessels of the supra-renal bodies are numerous. Each is supplied by the supra-renal artery from the aorta, together with branches from the contiguous phrenic and renal arteries. Upon entering the organ the arteries ramify through its fibrous stroma, and terminate in capillaries surrounding the receptacles of granular and cell contents. The veins emanating from the organ usually form a single trunk, which terminates on the right in the inferior cava, on the left in the corresponding renal vein. Few lymphatics have been noticed. The nerves are chiefly derived from the solar and ^{lumbar} renal plexuses of the sympathetic system, and are so numerous as to have given rise to the impression that the supra-renal bodies may have some important function in connection with the nervous system, otherwise the use of these organs remains totally unknown.

+ p. 526

CHAPTER X.

THE GENERATIVE APPARATUS.

THE MALE ORGANS OF GENERATION.

THE organs of generation of the male consist of the testicles and penis, together with certain accessories.

THE TESTICLES.

The **Tes'ticles**¹ are two glandular bodies which secrete the spermatie liquid, and are suspended within the scrotum, one on each side, by the spermatie cords.

The **Scro'tum**² is the pendant pouch below the pubes, containing the testicles. The skin of the scrotum is thin, darker than elsewhere, and more or less wrinkled. It is marked in the median line by a slight ridge, the **raphé**, which is continued forward on the under part of the penis, and backward to the anus, and is an indication of original separation of the two halves of the scrotum in the embryo. From the surface of the skin project scattered crisp hairs, whose roots are surrounded by groups of sebaceous glands, appearing as whitish eminences on the scrotum.

The inner portion of the skin of the scrotum is composed of pale-red, unstriated muscular fibres, constituting the **dar'tos**.³ This structure fades away at the borders of the scrotum into the neighboring superficial fascia. In the median line, mixed with fibrous tissue, it forms the **scro'tal partition**,⁴ which divides the scrotum into two recesses lodging the testicles.

Upon the presence of the dartos depends the contractility of the

¹ Testiculi; testes; sing.: testiculus; testis; t. virilis; orchis; didymus; pommum amoris; hernia; pl.: gemini; stones.

² Scortum; scorium; oschus; marsupium; bursula; bursa testium; b. viri-

lis; folliculus genitalis; the purse; the cods; the bags.

³ Tunica dartos; t. muscularis; t. rubicunda scroti; membrana carnea; marsupium musculosum.

⁴ Septum scroti.

scrotum; and ordinarily, under the influence of cold, it is observed to throw the skin on each side of the raphé into transverse, corrugated wrinkles; but from the impression of warmth it becomes relaxed and the scrotum elongates.

The **Spermat'ic cord**¹ consists of the excretory duct, blood-vessels, lymphatics, nerves, and cremaster muscle of each testicle. From the internal abdominal ring it pursues its course through the inguinal canal and external abdominal ring downward to the back part of the testicle.

The constituents of the spermatic cord and the testicle are enveloped in an abundance of areolar tissue, the **spermatic fascia**,² which is continuous at the abdomen with the superficial and transverse fasciæ. Involved between the layers of the spermatic fascia are the thin, scattered fasciculi of the **cremas'ter muscle**.³ This arises within the inguinal canal, from Poupart's ligament and the spine of the pubis, and descends along the spermatic cord to end in loops upon the testicle. It is composed of striated fibres, and acts in raising the testicles; in some individuals being under the control of the will.

Succeeding the spermatic fascia, the testicle is inclosed in a serous membrane, the **vag'inal tunic**.⁴ This, after investing the organ and adhering closely to it, is reflected from its back part so as to form a sac, the cavity of which contains a serous liquid secreted by the vaginal tunic. The outer part of the latter is loosely attached to the spermatic fascia, except at the lower part of the testicle, where a broad band of areolar tissue connects it more firmly with the bottom of the scrotum. This band is the remains of the **gubernac'ulum of the testicle**,⁵ a structure of foetal life, apparently intended to determine the future position of the organ with which it is attached.

The **Testicles**, connected with the spermatic cords, hang obliquely, their upper extremity being directed forward and outward; and the left one usually is lower than the right one. They are oval, laterally compressed, measure about an inch and a half long, and weigh each about three-fourths of an ounce.

Each testicle consists of an anterior oval **body**, properly named the **testis**, and a posterior elongated portion clasping the former, and called

¹ Funiculus spermaticus; testicular cord; corpus varicosum.

² Spermatic fascia in part; tunica vaginalis communis testis.

³ Musculus cremastericus testis, or testicondus; suspensiculum; suspensio-

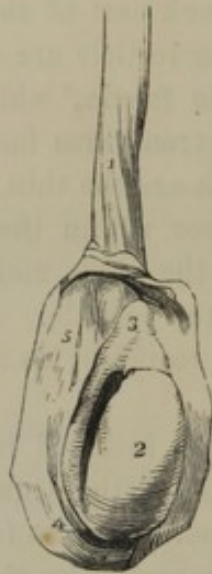rium testis; elevator testiculi; tunica erythroides.

⁴ Tunica vaginalis; t. v. propria; t. adnata testis and t. v. reflexa.

⁵ Gubernaculum testis; g. Hunteri; ligamentum suspensorium testis.

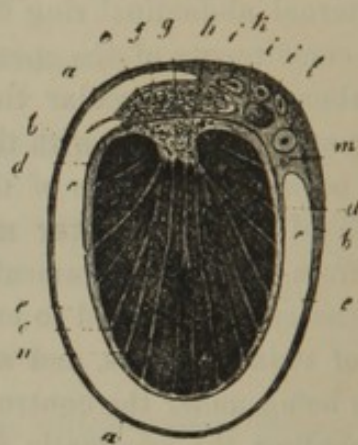the **epidid'ymis**.¹ The upper extremity of this, named the **head**,² is the larger, and closely adheres to the contiguous part of the testis; its lower extremity, or **tail**,³ loosely adheres to the latter, and turns upward on itself to become the spermatic duct. The portion of the epididymis between its head and tail is the **body**, and is separated from the testis by an interval into which the vaginal tunic is reflected.

FIG. 295.



TESTICLE, WITH THE VAGINAL TUNIC LAID OPEN. 1, lower part of the spermatic cord; 2, body of the testicle; 3, body, and 4, tail, of the epididymis; 5, reflected portion of the vaginal tunic.

FIG. 296.



TRANSVERSE SECTION OF THE TESTICLE. *a*, spermatic fascia; *b*, reflected portion of the vaginal tunic; *c*, cavity of the latter; *d*, investing portion of the same membrane; *e*, albugineous tunic; *f*, vaginal and albugineous tunics of the epididymis; *g*, its interior tubular structure; *h*, mediastinum; *i*, branches of the spermatic artery; *k*, spermatic vein; *l*, spermatic duct; *m*, artery of the latter; *n*, lobules of the testis; *o*, septula separating the latter.

The testis is invested with a dense, white membrane, the **albugin'eous tunic**,⁴ which is composed of interlacing bundles of fibrous tissue, and serves by its strength to protect the soft glandular structure within. At the upper part of the testis it is continuous with a thinner investment of the same kind on the epididymis; and at the back part forms a process named the **mediasti'num**.⁵ This projects into the glandular substance of the testis so as to produce an incomplete vertical partition, and from it diverge numerous fibrous bands, named **sep'tula**,⁶ which are inserted into the inner surface of the albugineous tunic, and serve to sustain the delicate secretory structure of the organ.

¹ Didymis; parastata; testiculus accessorius; caput testis; corpus varicosum testis; supergeminalis.

² Globus major; caput.

³ Globus minor; cauda.

⁴ Tunica albuginea; peritestis; dura mater testis; membrana capsularis testis; albuginea testis; perididymis.

⁵ M. testis; corpus Highmori, or Highmorianum; meatus seminarius.

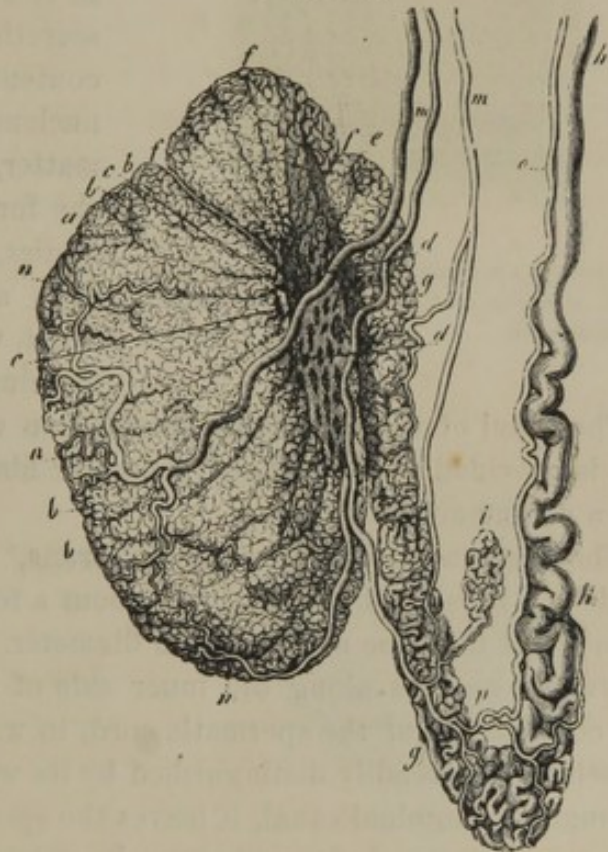
⁶ Septula testis.

Upon the inner surface of the albugineous tunic, mediastinum, and septula is spread a delicate **vascular tunic**,¹ formed by the spermatic blood-vessels, which pass to and from the testis through the mediastinum.

(The vascular tunic holds the same relation to the secretory substance of the testicle that the pia mater does to the brain; that is to say, it is the point of departure and termination of the capillary blood-vessels of the organ.) * p. 507

The **Glandular structure** of the testis is a soft, reddish-yellow, inelastic mass, divided into several hundred pyramidal or conoidal **lobules**,² which converge toward the mediastinum. Each lobule consists of from one to three **seminiferous tubules**,³ occasionally branching and exceedingly convoluted. At the narrow extremity of the lobules the tubules end in **straight tubes**,⁴ which enter the mediastinum and form together within its length a **reteform plexus**.⁵ From the upper part of this plexus about a dozen **efferent canals**⁶ emerge and pass out of the testis to the head of the epididymis. Within the latter the efferent canals become convoluted into a series of **spermatic cones**.⁷ These successively end in a single, coarse, and much convoluted tube forming the **body and tail of the epididymis**, which finally terminates in the straight spermatic duct.

FIG. 297.



TESTICLE, DEPRIVED OF ITS TUNICS. *a*, body of the testicle, or the testis; *b*, lobules; *c*, position at which they end in the straight tubes; *d*, reteform plexus; *e*, efferent canals; *f*, spermatic cones; *g*, epididymis; *h*, commencement of spermatic duct; *i*, a spermatic cone unattached to the testis; *m*, *n*, branches of the spermatic artery; *o*, deferent artery; *p*, anastomosis between the two latter vessels.

¹ Tunica vasculosa.

² Lobuli testis.

³ Tubuli or canaliculi seminiferi; seminal tubes or canaliculi; vasa seminalia; vascula serpentina.

⁴ Vasa, or ductuli recti.

⁵ Plexus reteformis; rete vasculosum testis; r. v. Halleri.

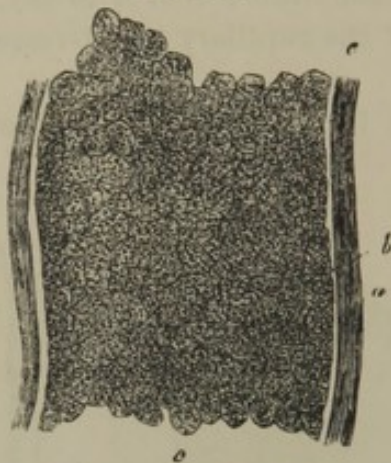
⁶ Vasa efferentia.

⁷ Coni vasculosi; c. v. Halleri.

Usually there is a spermatic cone joining the epididymis below the others, which has no connection with the testis.¹

The **seminiferous tubules** are about one-tenth of a line in diameter,

FIG. 298.



PORTION OF A SEMINIFEROUS TUBULE, highly magnified. *a*, fibrous coat; *b*, basement membrane; *c*, spermatic cells.

and are composed of a basement membrane strengthened with a delicate layer of fibrous tissue, and lined with soft, polyhedral secreting cells. These, which are named **sperm cells**, elaborate the **spermat'ic** or **sem'inal liquid**, the peculiar secretion of the testicles. The contents of the cells, besides the nucleus, consist of finely granular matter, which subsequently assumes the form of bundles of filamentary bodies, named **spermatozo'ids**. The cells are constantly cast off and burst, while others are successively developed.

The canal of the epididymis, besides an external layer of fibrous tissue, is provided with unstriated muscular fibres; and its lining membrane has a columnar epithelium.

The **Spermat'ic duct**, or **vas def'erens**,² is the excretory duct of the testicle. It is a cylindrical tube, about a foot and a half in length and from a line to a line and a half in diameter. From the tail of the epididymis it ascends along the inner side of the latter and forms one of the constituents of the spermatic cord, in which it lies behind the blood-vessels, and is readily distinguished by its wire-like feel. Having passed through the inguinal canal, it leaves the spermatic vessels at the internal abdominal ring and descends into the pelvis. Reaching the side of the bladder, it curves backward and downward beneath the fundus, and passes forward in a convergent manner to form, in conjunction with the duct of the seminal vesicle, the ejaculatory duct.

The walls of the spermatic duct are exceedingly thick, and its calibre is about equal to the size of an ordinary bristle. For the greater part of its length the duct is straight, but beneath the bladder it becomes enlarged, tortuous, and more or less sacculated. In this latter position its walls are thinner and its capacity greater than elsewhere; but approaching its termination it again becomes narrower.

¹ Vasculum, or vas aberrans; v. a. Halleri.

² Canalis, or ductus deferens; vibrator.

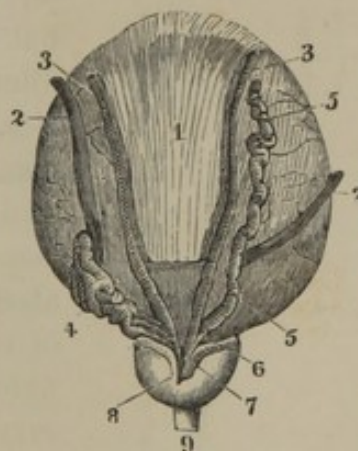
The structure of the vas deferens is the same as that of the epididymis; consisting of an external fibrous coat, an unstriated muscular layer, and a lining mucous membrane. The latter is thrown into fine longitudinal folds; and in the terminal, sacculated portion of the tube, exhibits fine reticular folds.

The testicle receives blood from the spermatic artery. The spermatic duct is supplied by the **deferent artery**,¹ a long, thread-like vessel derived from the superior vesical artery. After giving branches to the epididymis, the remainder of the spermatic artery penetrates the testis through the mediastinum, and ramifies in the vascular tunic. The spermatic veins, emerging from the back of the testicle as they ascend the spermatic cord, form an intricate anastomosis, named the **pampiniform plexus**.² The lymphatics of the testicle are numerous and large, and communicate with the lumbar ganglia. The nerves are derived from the spermatic plexus of the sympathetic.

THE SEMINAL VESICLES AND EJACULATORY DUCTS.

The **Seminal vesicles**³ are two compressed, ovoidal bodies, closely adhering to the under surface of the fundus of the bladder. They are quite near each other behind the prostate gland, but diverge posteriorly so as to include a triangular space. They are separated from the rectum only by the thin rectovesical fascia; and to their inner side lies the terminal sacculated portion of the spermatic ducts. They vary in size, but usually are about two inches long and half an inch wide. Their posterior extremity is obtuse; and their anterior extremity narrows into a short duct, which joins with the corresponding spermatic duct, at a very acute angle, to form the ejaculatory duct.

FIG. 299.



POSTERIOR VIEW OF THE FUNDUS OF THE BLADDER
1, peritoneum extending as far down as the transverse line; 2, ureters; 3, spermatic ducts; 4, seminal vesicle of the left side; 5, right seminal vesicle dissected so as to show its tubular character; 6, duct of the seminal vesicle, joining the spermatic duct to form 7, the ejaculatory duct; 8, prostate gland; 9, membranous portion of the urethra.

The seminal vesicles consist each of a coarse tube closed at the posterior extremity, and convoluted into a mass. When unraveled, the

¹ A. vasis deferentis Cooperi.

² Corpus pampiniforme.

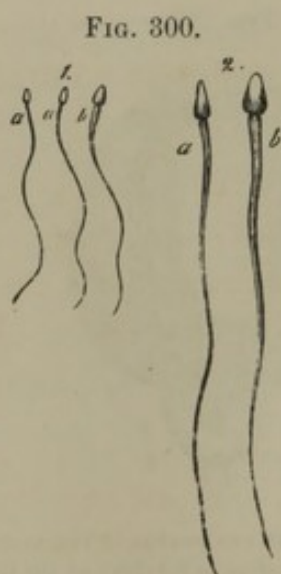
³ Vesiculæ, or capsulæ seminales; v. spermaticæ; conceptacula seminaria; gonecystides.

tube is found to be three or four inches long, the diameter of an ordinary goose-quill, and provided with a few simple and branching cœcal appendages. In structure, they are like the sacculated terminal portion of the spermatic ducts, except that their wall is thinner.

The **Ejac'ulatory ducts**¹ are formed by the conjunction, on each side, of the corresponding spermatic duct with that of the seminal vesicle. They are nearly an inch long, and converge to the prostate gland, through which they pass side by side to terminate at the border of the orifice of the **utricle** communicating with the urethra. They have thin walls, gradually become narrower in their course, and end each in a slit-like aperture.

The seminal vesicle and ejaculatory ducts receive blood through branches of the inferior vesical and middle hæmorrhoidal arteries. Their nerves are derived from the hypogastric plexus of the sympathetics.

The testicles secrete the spermatic liquid, which accumulates in the sacculated terminal portions of the spermatic ducts, and in the seminal vesicles. The latter, however, not only



SPERMATOZOIDS. 1, magnified 350 diameters; 2, magnified 800 diameters; *a*, viewed on the narrower side; *b*, on the broader side.

serve as reservoirs to the spermatic liquid, but likewise secrete a fluid which serves to dilute the more viscid secretion of the testicles. The ejaculated **spermat'ic liquid** or **semen**² is a whitish, viscid matter, mainly consisting of a colorless liquid containing immense numbers of minute bodies named **spermatozo'ids**.³ These are the essential constituent of the spermatic liquid of animals—that upon which its fecundating power depends. They vary in form and size in different animals, and are endowed with inherent power of movement. In man they are about the $\frac{1}{3000}$ of an inch long, and consist of an ovoidal **head**, with a long, filamentary appendage or **tail**, which vibrates with wonderful rapidity. The spermatozooids

are not properly independent animals, as was once generally supposed, but simply particles of the structure of an animal; a constituent portion of the contents of the spermatic cells of the testicles. In the case of

¹ Ductus, or canales ejaculatorii; common seminal ducts.

² Sperma; sperm; seminal fluid; seed; semen virile, masculinum, or genitale.

³ Spermatozoa; spermatic filaments.

ciliated epithelial cells we have more complex particles of an animal structure, also endowed with movement, and although ordinarily fixed, when artificially detached, they move in liquids in the same manner as the spermatozooids. The quivering of a detached fragment of muscle is no indication of its being an independent animal!

THE PENIS.

The **Penis**¹ is composed of three columnar bodies invested by skin and filled with a peculiar, vascular, sponge-like structure, upon the distention or emptying of which the erection or collapse of the organ depends.

The attachment of the penis to the pubic arch and symphysis is named its **root**; the free extremity is its **glans** or **head**; and the intermediate portion is the **body**. The surface of the latter, directed forward in a collapsed state of the organ, but backward in its erect condition, is named the **dorsum** or **back**.

The **Glans**² is a blunt cone with an expanding base, named the **corona**,³ beneath which is the constriction, named the **cervix** or **neck**.⁴ The summit⁵ of the glans presents a vertical slit-like orifice,⁶ which is the termination of the urethra.

The skin of the penis is thin, and adheres to the organ by a loose superficial fascia allowing much freedom of movement. At the free extremity of the penis it forms a loose cup-like fold, named the **pre'puce**,⁷ after which it is reflected on the cervix and upon the glans. To the latter it firmly adheres; and from below the urinary meatus it extends in a median fold, named the **prepu'tial frænum**.⁸

In front of the pubis the skin invests a thick accumulation of fat, and is abundantly provided with crisp hairs, projecting from among whitish groups of sebaceous glands. On the body of the penis the skin is always free from fat, and is provided with scattered crisp hairs, which diminish and finally disappear anteriorly. It also presents many whitish groups of sebaceous glands, which are especially congregated about the roots of the hairs, and on the under part of the penis.

¹ Membrum virile; phallus; mentula; priapus; veretrum; virga; coles; verpes; nervus; cauda; the yard; the male organ, etc.

² Balanus; caput penis.

³ Corona glandis.

⁴ Collum; sulcus retro-glandularis.

⁵ Apex glandis.

⁶ Meatus urinarius; orificium urethræ.

⁷ Præputium; foreskin.

⁸ Frænum, or frænulum præputii.

At the free border of the prepuce, the skin, as it folds inwardly, assumes more the character of a mucous membrane, becoming softer, thinner, and more moist, and it is destitute of perspiratory glands and hairs. At the cervix and corona, it is abundantly furnished with sebaceous follicles, named the **prepu'tial glands**.¹ The secretion of these, together with the desquamated epidermal cells of the cervix, constitute the **smegma**,² a white caseous substance, readily decomposing, and emitting a strong odor. Upon the glans, the skin becomes most vascular and sensitive, and is devoid of glands.

The **superficial fascia** of the penis is continuous with that of the abdomen and perineum, and with the dartos of the scrotum, and is always free from fat. From the lower part of the linea alba, and the front of the pubes, a fibro-elastic fasciculus, named the **suspens'ory ligament**,³ descends to the root of the penis and becomes continuous with its superficial fascia.

The **Cav'ernous bodies**⁴ are two long fusiform columns, whose posterior extremities, named **crura**, spring from the inner border of the rami of the ischia and pubes. Converging, the crura join each other in the median line, after which the cavernous bodies lie side by side, intimately associated, until they terminate in a common conical extremity, which is capped by the glans. The crura have a firm tendinous attachment to the pubic arch, and each crus is somewhat swollen⁵ before it conjoins with the other. A slight groove between the cavernous bodies on the dorsum of the penis is occupied by the dorsal blood-vessels, and a deeper groove below accommodates the spongy body.

The cavernous bodies have a strong exterior wall, consisting of a dense, tendon-like, fibrous membrane. Where they conjoin, the latter forms an intervening vertical partition, which is complete and is thickest posteriorly; but anteriorly its fasciculi are separated by clefts, which give the partition a comb-like arrangement; hence the name of **pectini-form septum**.⁶ From this septum bands diverge to the interior surface of the cavernous walls, besides which other bands pass in all directions through the interior of the cavernous bodies. The bands, composed of fibro-elastic tissue, are named **trabec'ulæ**, and these, together with blood-vessels occupying their intervals, form a soft, red, spongy substance, the **erect'ile tissue**⁷ of the cavernous bodies.

¹ Glandulæ præputiales; g. odoriferæ præputii; g. o. Tysoni; g. Tysonianæ; g. sebaceæ glandis; g. coronæ penis.

² Sebum præputiale.

³ Ligamentum suspensorium penis.

⁴ Corpora cavernosa; c. nervosa; c. nerveo-spongiosa; corpus carvernosum.

⁵ Bulb of the cavernous body.

⁶ Septum pectiniforme; s. penis.

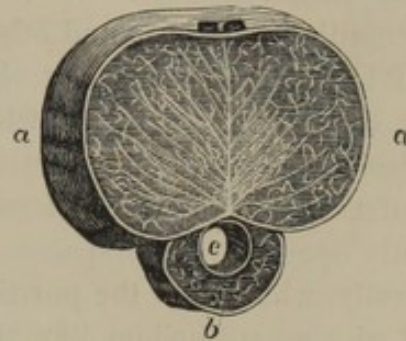
⁷ Textus, or tela erectilis.

The **Spongy body**¹ commences in front of the triangular ligament of the pubis, below the crura of the cavernous bodies, in an enlargement named the **bulb**.² From this it extends along the groove below the cavernous bodies, cylindroid in form but slightly narrowing, and at the anterior extremity of the latter expands into the glans. The base of the bulb is divided by a median groove, and is in contact with the triangular ligament. The base of the glans is excavated, and fits upon the conical termination of the cavernous bodies.

The urethra enters the spongy body above and in advance of the base of its bulb, and then traverses the entire length of the former to terminate at the summit of the glans.

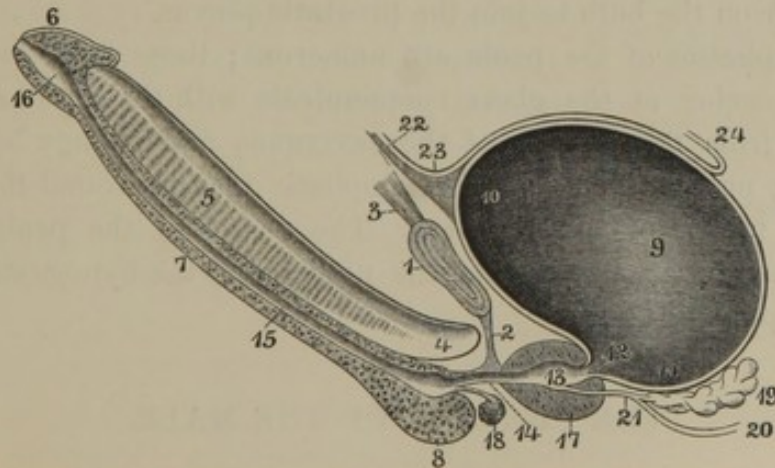
The spongy body is provided with an exterior fibrous wall and an interior erectile tissue, like the cavernous bodies; but the former is much thinner and the latter more delicate than in these.

FIG. 301.



TRANSVERSE SECTION OF THE PENIS. *a*, cavernous bodies: the vertical line in the middle is the pectiniform septum; those diverging from it are the trabeculae; the intervening spaces are occupied by erectile tissue; *b*, spongy body; *c*, urethra.

FIG. 302.



VERTICAL SECTION OF THE PENIS AND BLADDER. 1, pubic symphysis; 2, triangular ligament; 3, abdominal muscles; 4, crus of the right cavernous body; 5, pectiniform septum; 6, glans; 7, spongy body; 8, its bulb; 9, bladder; 10, its summit; 11, its fundus; 12, its neck; 13, prostatic portion of the urethra; 14, membranous portion; 15, spongy portion; 16, navicular fossa; 17, prostate gland; 18, suburethral gland; 19, right seminal vesicle; 20, spermatic duct; 21, ejaculatory duct; 22, urachus; 23, peritoneum; 24, its recto-vesical fold.

The cavernous bodies are supplied with blood by the cavernous arteries, together with a few small branches from the dorsal arteries of

¹ Corpus spongiosum; c. s. urethræ; c. cavernosum urethræ; substantia spongiosa urethræ.

² Bulbus urethræ.

the internal pudics. The cavernous arteries enter the crura of the cavernous bodies and advance near the pectiniform septum, ramifying in their course. The spongy body is mainly supplied by the bulbo-urethral arteries, which penetrate the bulb. The arteries of both the cavernous and spongy bodies terminate finally in the interspaces of the erectile tissue.

According to Müller and other excellent authorities, many of the arterial branches, especially at the root of the penis, form short convolutions, the **hel'icine arteries**, which occupy intervals of the erectile tissue and become distended in erection. According to Kölliker, the extremities of the helicine arteries terminate in much finer vessels, which subsequently open into interspaces of the erectile tissue. From the latter generally, which hold the position of ordinary capillaries, but which are lined with an epithelium like that of the larger blood-vessels, the veins of the penis may be said to originate. Those of the cavernous bodies partly pass out between these and the spongy body, and wind around the sides of the penis to join the dorsal veins. Short ones penetrate the cavernous walls and immediately join the latter; but most of the cavernous veins pass from the crura and join the prostatic plexus. The veins from the spongy body mainly converge from the base of the glans around the cervix to form the commencement of the dorsal veins; a few join the latter in their course from the sides of the spongy body; and others pass back from the bulb to join the prostatic plexus.

The lymphatics of the penis are numerous; those from beneath the skin, commencing at the glans, communicate with the inguinal glands; and those from the interior of the cavernous and spongy bodies pass beneath the pubic arch to join the lymphatic plexus around the prostate gland and fundus of the bladder. The nerves of the penis are also numerous, and are derived from the pudics and the hypogastric plexus of the sympathetics.

THE URETHRA OF THE MALE.

The **Ure'thra**,¹ a canal common to the emission of urine and of semen, extends from the neck of the bladder to the summit of the glans penis. It is from seven to ten inches in length, and comprises three divisions: the prostatic, membranous, and spongy portions.

The **Prostat'ic portion of the Ure'thra**² proceeds from the neck of the bladder through the upper part of the prostate gland, whence its

¹ Meatus, ductus, or canalis urinarius; fistula urinaria; iter urinarium.

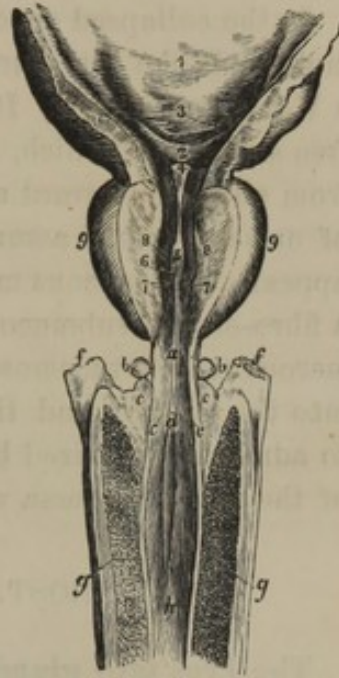
² Pars prostatica urethræ.

name. It is barrel shaped, from one to one and a half inches in length, and is not only the widest, but the most dilatable portion of the canal. At the bottom it presents a longitudinal ridge, named the **ure'thral crest**,¹ in the front of which is a small pouch, viewed as analogous with the uterus of the female, and named the **u'tricle**.² This extends between the urethral crest and prostate gland, a depth of from one-fourth to one-half an inch, and has the orifices of the ejaculatory ducts opening into it on each side of its communication with the urethra.

The **Membranous portion of the ure'thra**,³ continuous from the former, passes out of the pelvic cavity, traversing the triangular ligament about an inch beneath the symphysis of the pubes. It is about three-fourths of an inch long, and extends from the apex of the prostate gland to the spongy body of the penis, above and in advance of the base of the bulb. It is cylindrical, curved, with the convexity ~~downward~~, and is the least dilatable portion of the urethra. Besides its lining membrane, it has an exterior layer of unstriated muscular fibres, a thin layer of erectile tissue continuous with that of the spongy body, and a fibrous investment continuous with the triangular ligament.

The **Spongy portion of the ure'thra**,⁴ the most variable in its length and direction, includes the remainder of the canal, extending from the membranous portion through the interior of the spongy body of the penis to the summit of the glans. Within the bulb it is somewhat dilated; then very gradually diminishes to the glans, in which it forms an abrupt expansion, the **navic'ular fossa**,⁵ terminating in the

FIG. 303.



PART OF THE BLADDER AND PENIS, WITH THE URETHRA LAID OPEN FROM ABOVE. 1, internal surface of the bladder; 2, space called the vesical triangle; 3, position of the orifice of the ureter on each side; 4, vesical uvula; 5, urethral crest; 6, position of the utricle; 7, 8, prostatic portion of the urethra on each side of the crest; 9, prostate gland. *a*, membranous portion of the urethra; *b*, suburethral glands; *c*, position at which the ducts of the latter open; *d*, spongy portion of the urethra within the bulb, *e*; *f*, crura of the cavernous bodies, *g*; *h*, continuation of the spongy portion of the urethra.

¹ Crista urethralis; caput gallinaginis; verumontanum; caruncula, or colliculus seminalis.

² Utriculus; u. prostaticus; uterus masculinus; sinus pocularis, or prostatae; vesicula, or vesica prostatica; corpusculum Weberianum; organ of Weber.

³ Pars membranacea urethrae; isthmus urethrae.

⁴ Pars spongiosa urethrae; pars cavernosa urethrae.

⁵ Fossa navicularis, or scaphoides; navicula; scaphula; fossa of Malpighi, or Morgagni.

external **ure'thral orifice**.¹ This is a vertical aperture, and is the narrowest point of the urethra; an instrument, under ordinary circumstances, being capable of passing the entire length of the canal if readily introduced at the urethral orifice.

In the collapsed condition of the penis the entire urethra forms a sigmoid or S-like curvature, but in the erect condition of the organ it forms a U-like curvature. It is lined with a smooth mucous membrane, the free surfaces of which, in the greater part of the urethra, are in contact from above downward and wrinkled longitudinally. During the emission of urine the canal assumes a more cylindrical form and the wrinkles disappear. The mucous membrane is provided with a columnar epithelium, a fibro-elastic submucous layer with unstriated muscular fibres, and numerous minute racemose glands.² The ducts³ of the latter open forward into the urethra, and the mouths of many of them are sufficiently large to admit a good-sized bristle; an especially large one⁴ at the upper part of the navicular fossa will admit the end of an ordinary surgical probe.

THE PROSTATE AND SUBURETHRAL GLANDS.

The **Pros'tate gland**⁵ resembles in size and form a Spanish chestnut, and is within the pelvic cavity, between the neck of the bladder and the triangular ligament surrounding the first portion of the urethra. It is usually from one to one and a half inches in length and breadth, and about three-fourths of an inch in thickness. Its apex adheres to the triangular ligament, and its notched base encircles the neck of the bladder. Its flat or slightly concave under surface rests against the rectum, through the front wall of which it may readily be felt. The sides of the prostate gland are prominently convex; and they project backward to such an extent as to lead to their being distinguished as the **lateral lobes**. These are united beneath the neck of the bladder by a prominent isthmus, named the **middle lobe**, which corresponds in position with the vesical uvula. When enlarged from disease, to which it is liable, this third lobe of the prostate projects into the neck of the bladder so as to impede the emission of urine.

The prostate gland is invested with a fibrous membrane, continuous in front with the triangular ligament, behind with the recto-vesical fascia, at the sides and above with the lateral and anterior ligaments of the

¹ Meatus urinarius.

² Glands of Littre; glandulæ Littrianæ; urethral glands.

³ Lacunæ or sinuses of Morgagni.

⁴ Lacuna magna.

⁵ Prostata; glandula prostata; prostata adenoides; parastata; adstans; testis minor; corpus glandulosum; c. adenoides; assistentes glandulæ; adstites glandulosi.

bladder. Its structure is of firm consistence, of a pale, reddish-gray color, and consists of a mass of fibro-muscular tissue with imbedded racemose glands. The muscular fibres, which are unstriated, are partly longitudinal; and in the vicinity of the urethra are circular, and become continuous with those of the sphincter of the bladder. The racemose glands are numerous, and open into the urethra at the sides of the urethral crest.

The prostate gland is probably the homologous structure with the walls of the uterus and vagina of the female. It is supplied with blood from the vesical, hæmorrhoidal, and pudic arteries; and its veins form a remarkably intricate plexus communicating with the internal iliac veins.

The **Subure'thral glands**¹ (Cowper's) are two compact, rounded bodies of a pinkish-yellow color, and about the fourth of an inch in diameter, situated just behind the bulb of the spongy body and below the membranous portion of the urethra. They are racemose glands, and empty their secretion, by a long duct, into the urethra within the bulb of the spongy body.

THE FEMALE ORGANS OF GENERATION.

The organs of generation of the female partly occupy the interior of the pelvis and partly the exterior, whence their division into the internal and external organs. The former consist of the uterus, ovaries, Fallo-pian tubes, and vagina, together with certain accessories; the latter, comprised under the general name of **vulva**, consist of the mons veneris, labia, clitoris, and nymphæ.

THE UTERUS.

The **U'terus**, or **womb**,² is a symmetrical, hollow, muscular organ provided for the reception of the ovum, and the development of the foetus. It ordinarily occupies the cavity of the pelvis between the rectum and bladder, but during pregnancy greatly increases in size, and rises into the cavity of the abdomen.

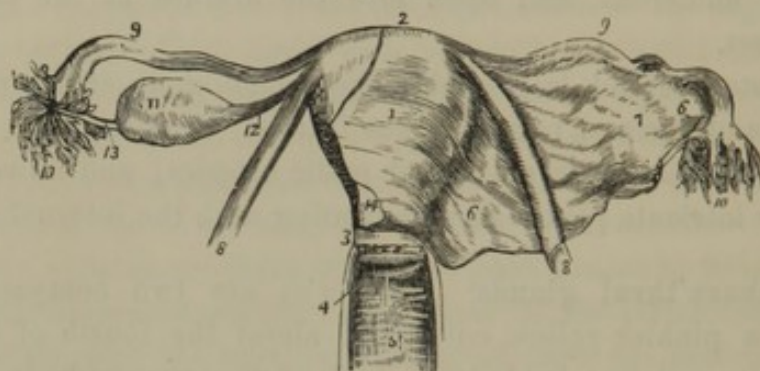
The adult unimpregnated, or virgin uterus, holds an oblique position in the axis of the pelvis, with its upper extremity inclining forward and its lower extremity directed backward. It is maintained in position by

¹ Glandulæ Cowperi; g. ante-prostatæ;
g. prostatæ inferiores; small prostate
glands; accessory glands.

² Utriculus; matrix; hystera; metra;
mater; mother; venter; alvus; gaster;
loci; conceptaculum.

its attachment to the vagina, by the reflections of peritoneum between it, the bladder and the rectum, by the round ligaments, but more especially by the broad ligaments. In front it is in contact with the bladder, behind with the rectum, and above with the small intestine.

FIG. 304.



SKETCH OF THE UTERUS AND ITS APPENDAGES. 1, uterus, with its peritoneal covering partially retained; 2, its fundus; 3, its neck, with the fore part of the attachment of the vagina removed; 4, mouth of the uterus; 5, interior of the vagina; 6, broad ligament, removed on the opposite side; 7, position of the ovary behind the broad ligament; 8, round ligament; 9, oviduct or Fallopian tube; 10, its fimbriated extremity; 11, ovary; 12, ovarian ligament; 13, process connecting the fimbriated extremity with the ovary; 14, cut border of the broad ligament.

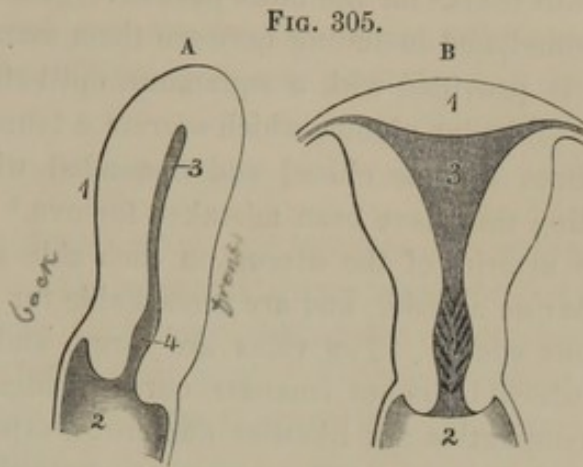
The uterus is pyriform, but compressed from before backward. Its narrow extremity below is the **neck**;¹ its upper broad extremity, the **fundus**;² and the intervening portion is the **body**.³ Its length is about two and a half inches, of which the body comprises one and a half inches or more, and approaches two inches in its greatest breadth, and one inch in thickness.

The **body of the uterus** is less convex in front than behind, and is inclosed in a doubling of peritoneum, which, passing off at the sides, produces the broad ligaments. The **fundus** is convex, and at the sides is continuous with the Fallopian tubes and the round ligaments. The **neck** is cylindroid, and partly projects into the vagina, with which it is continuous. The lower end of the neck exhibits a transverse elliptical orifice, the **mouth of the uterus**,⁴ which opens into the vagina, and is bounded by a pair of thick, smooth lips. The **anterior lip** is the longer, and descends more deeply into the vagina than the **posterior lip**. This, however, projects more into the vagina in consequence of the walls of the latter being connected higher with the neck of the uterus behind than in front.

The **cavity of the uterus** is a narrow space included by thick walls, which come into contact by their inner surfaces anteriorly and poste-

¹ Cervix.² Base.³ Corpus.⁴ Os uteri; o. u. externum; os tincæ; orificium vaginale.

riorly. The **cavity of the body** from side to side is triangular, but in section from before backward appears as a mere slit. The sides of the triangular cavity are convex inwardly, and the angles are prolonged—the two upper ones to communicate with the Fallopian tubes, the lower one to form the **internal mouth of the uterus**.¹ The **cavity of the neck**,² with which the latter communicates, from side to side is longitudinally oval, and from before backward in section appears as a wide fissure.



A. SECTION OF THE UTERUS ANTERO-POSTERIORLY. 1, back part of the uterus; 2, vagina; 3, cavity of the body; 4, cavity of the neck.

B. SECTION OF THE UTERUS FROM SIDE TO SIDE. 1, fundus; 2, vagina; 3, cavity of the body; 4, cavity of the neck.

The walls of the uterus average about half an inch in thickness, and give to the organ a remarkably firm and solid consistence. They are mainly muscular, but externally are provided with a partial investment of peritoneum, and internally are lined with a mucous membrane. In section they appear of a pale reddish hue, and present the orifices of numerous vessels, especially near the lateral borders of the organ.

The muscular portion of the uterine walls is formed of an intricate arrangement of short, fusiform, unstriated muscular fibres, associated with connective tissue and blood-vessels. In the enlargement of the uterus during pregnancy, the muscular fibres undergo a remarkable development in length.

The peritoneum invests the body and the upper portion of the neck of the uterus, and intimately adheres to the muscular structure beneath, except at the lateral borders, where it forms the broad ligaments.

The mucous membrane of the cavity of the body is thin, soft, smooth, and of a pale-red color. It intimately adheres to the subjacent muscular structure without the intervention of a fibrous layer, and is continuous with the mucous membrane of the Fallopian tubes, and that of the neck of the uterus. It is provided with a ciliated columnar epithelium, and numerous tubular glands, the orifices of which give to the membrane a finely punctated appearance. The glands are generally simple, a few being divided at their deeper part, where they are somewhat tortuous.

¹ Os uteri internum; ostium, or isthmus uteri; orificium uterinum.

² Canalis cervicis.

In the cavity of the neck of the uterus, the mucous membrane is thicker, less soft, and paler than that of the body. It is thrown into numerous folds,¹ for the most part divergent from a median fold in front and behind, and including between them many smaller folds. The membrane is provided with a squamous epithelium, and numerous minute, simple follicular glands, which secrete a tenacious mucus. These glands sometimes become closed and distended with their contents, in which condition they have been mistaken for ova.²

The arteries of the uterus on each side are branches of the ovarian and uterine arteries, and are remarkable for their many anastomoses and tortuous course. The veins are large, and form an intricate plexus, from which branches emanate corresponding with the uterine arteries. The lymphatics are likewise numerous, especially in the pregnant condition of the organ. The nerves are derived from the ovarian and hypogastric plexuses of the sympathetic system.

LIGAMENTS OF THE UTERUS.

The **Broad ligaments**³ consist of the doubling of peritoneum which passes from each side of the uterus to the sides of the pelvis. They contain the Fallopian tube, the ovary, parovarium, round ligament, the uterine blood-vessels, lymphatics and nerves, together with connective and some unstriated muscular tissue, which unite the two layers of the broad ligaments.

The **Recto-uterine**, and **Vesico-uterine folds**⁴ of peritoneum, acting the part of ligaments, pass respectively between the sides of the uterus, rectum, and bladder. These folds contain extensions of fibrous tissue from the uterus to the neighboring parts, which have likewise been described as ligaments.⁵

The **Round ligament**⁶ is an extension of the structure of the uterus, consisting of a flattened cord of unstriated muscular and fibrous tissue. It commences at the side of the fundus of the uterus, a little below and in front of the connection of the Fallopian tube, and proceeds outwardly within a slight fold of the anterior layer of the broad ligament, to the

¹ Arbor vitæ.

² Ovula Nabothi; glandulæ Nabothi; glands, or eggs of Naboth; hydatides, glandulæ, vesiculæ, or bullæ rotundæ cervicis uteri; folliculi rotundi and oblongi; vesiculæ seminales mulierum; corpuscula globosa.

³ Ligamenta lata; alæ vespertilionis; retia uteri.

⁴ Anterior and posterior ligaments; plicæ semilunares.

⁵ Utero-sacral and utero-vesical ligaments.

⁶ Ligamentum rotundum.

inguinal canal. Through this it descends and fades away in the subcutaneous tissue of the pubis. A pouch of peritoneum¹ occasionally accompanies it into the canal in young persons, which is usually obliterated in the adult. This pouch may become the avenue of the abnormal descent of the ovary into the labium, or it may be the seat of hernia.

THE OVARIES.

The **O'varies**² are to the female what the testicles are to the male: organs for the production of the germs of future offspring. They are two compressed ovoid bodies, suspended behind the broad ligaments, inclosed in a pouch of their posterior layer. They are situated nearly horizontally from half an inch to an inch or more from the uterus, and a little below the Fallopian tube.

The **ovary** varies in dimensions and appearance at different ages, and in different individuals. It is largest in the virgin between the period of puberty and adult age, and is then pearly white, smooth, and plump in appearance. From the period of puberty, ova periodically escape through ruptures of the surface of the ovary, a process which continues up to nearly fifty years of age. The effect of the frequent ruptures and their cicatrization is to give the ovary a scarred appearance, which increases with the advance of age until the organ is finally reduced and shriveled to less than half its original size.

The fully-developed ovary, unaffected by its function, measures about an inch and a third transversely, three-fourths of an inch in depth, and about five lines in thickness. Its lower border and outer extremity nearly form a semicircle; its inner extremity is narrowed and connected with the ovarian ligament; the upper border is straight, and is the part by which the ovary is suspended from the broad ligament. The anterior and posterior surfaces are free, and the latter is the more convex.

The **ova'rian ligament** is a fibrous band mingled with muscular fibres, which extends from the narrow end of the ovary to the side of the uterus just below and behind the connection of the Fallopian tube.

Beneath the peritoneal coat, derived from the posterior layer of the broad ligament, the ovary is provided with a dense **fibrous tunic**,³ intimately associated with its serous investment and the contents of the ovary. At the upper border⁴ of the latter the fibrous tunic is perforated by the passage of the ovarian blood-vessels and nerves.

The contents of the ovary consist of a reddish, spongy, fibrous **stroma**,⁵

¹ Canal of Nuck.

² Ovaria. Sing: ovarium; testis muliebris, or femineus; vesicarium.

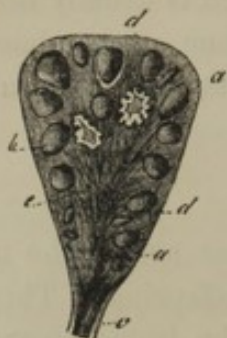³ Tunica albuginea.

⁴ Hilus ovarii.

⁵ Parenchyma.

abundantly supplied with blood-vessels, and containing numerous closed

FIG. 306.



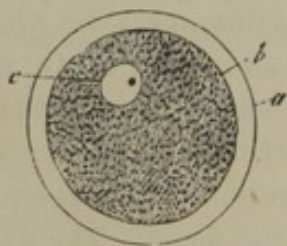
TRANSVERSE SECTION OF AN OVARY, from a case in the fifth month of pregnancy. *a*, *b*, ovisacs; *c*, ovarian ligament; *d*, stroma. In the interior, two old corpora lutea are visible.

vesicular bodies named **o'visacs**.¹ These are especially abundant in the peripheral portion of the stroma, are spherical, and vary from a microscopical size to the fourth of an inch in diameter. The walls of the ovisacs are composed of a fibro-vascular layer² continuous with the stroma of the ovary, a basement membrane,³ and an internal layer of polyhedral epithelial cells.⁴ The interior of the ovisacs is filled with a serous liquid⁵ containing some granules, nuclei, and cells apparently detached from the epithelium. The latter, on the side of the ovisac next the ovarian surface, presents an accumulation of cells named the **germinal emi-**

nence,⁶ within which is enveloped the **o'vum** or **egg**.

From the commencement of puberty, the ovisacs in succession gradually approach the surface of the ovary, and become enlarged to the third of an inch or more in diameter. The envelopes of the ovary next the ovisacs gradually thin away, and the latter project from the surface of the former. Finally, the ovisacs burst, and their contents escape into

FIG. 307.



HUMAN OVUM, highly magnified. *a*, vitelline membrane; *b*, yolk; *c*, germinal vesicle containing the germinal spot.

the abdominal cavity, and are thence received into the pavilion or expanded mouth of the Fallopian tube. The rupture or **dehiscence** of the ovisacs is periodical, and is attended with a general afflux of blood to the whole generative apparatus, together with an escape of a portion of that liquid from distended capillaries of the cavity of the uterus.

The **O'vum**,⁷ discharged from the ovisac, usually retains the germinal eminence⁸ and some additional shreds⁹ of epithelium attached. These are subsequently rubbed off, and the isolated ovum appears as a spheroidal body about

¹ Graffian vesicles, or follicles; ovisacci; folliculi Graffiani, or ovarii; vesicles of De Graaf.

² Vascular, or fibrous coat; tunica fibrosa; theca folliculi; ovisac; tunica of the ovisac.

³ Membrana propria.

⁴ Granular layer; membrana granulosa.

⁵ Liquor folliculi.

⁶ Cumulus, or discus proligerus; tunica granulosa; germinal disk.

⁷ Ovulum; ovule.

⁸ Cumulus, or discus proligerus; tunica granulosa.

⁹ Retinacula.

the tenth of a line in diameter, and with all the characters of an organic cell.

The exterior of the ovum consists of an unusually thick, elastic, structureless wall named the **vit'elline membrane**,¹ which, when viewed beneath the microscope, appears as a broad, transparent zone² encircling the egg. The contents of the ovum consist of a pale-yellowish **yelk**,³ composed of a viscid liquid mingled with a multitude of granules. Within the yelk is a large, clear nucleus, called the **germinal vesicle**,⁴ containing a nucleolus named the **germinal spot**.⁵

With the escape of the contents of the ovisac, it fills with blood, which coagulates. The walls of the ovisac subsequently become thickened, corrugated, and contracted upon the blood clot. This loses its color, and, together with the thickened walls of the ovisac, gradually assumes the appearance of a spheroidal, corrugated, yellowish body, named the **corpus lu'teum**. The latter afterwards becomes atrophied, and is finally resolved into the stroma of the ovary. The corpus luteum,⁶ in the pregnant condition, apparently from the more continued afflux of blood to the part, undergoes a greater development, and disappears less rapidly than the corpus luteum⁷ produced without pregnancy.

The ovaries are supplied by the ovarian arteries, which freely anastomose with branches of the uterine arteries. The veins form an intricate plexus from which the main vessels pursue the course of the ovarian arteries. The nerves are derived from the ovarian and hypogastric plexuses of the sympathetic system.

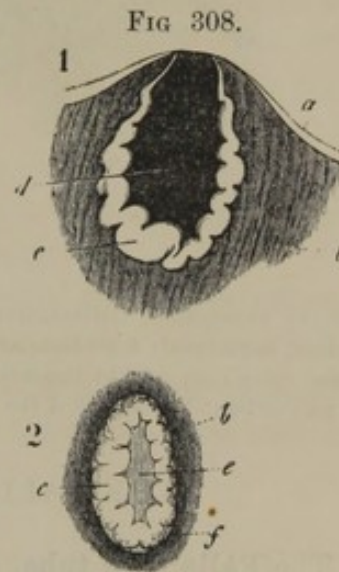


FIG 308.
TWO CORPORA LUTEA; in section, natural size. 1, eight days after conception; 2, at the fifth month of pregnancy. *a*, fibrous tunic of the ovary; *b*, stroma; *c*, thickened and plicated membrane of the ovisac; *d*, blood clot; *e*, the same, later, without its red color; *f*, fibrous coat bounding the corpus luteum.

THE PAROVARIIUM.

The **Parova'rium**⁸ is situated between the layers of the broad ligament, and consists of a series of whitish, tortuous tubes diverging from

¹ Membrana vitellina; oolemma pellucidum; chorion.

² Zona pellucida.

³ Vitellus; yolk.

⁴ Vesicula germinativa, or prolifera; Purkinjean vesicle; germ cell.

⁵ Macula germinativa; nucleus ger-

minativus; blasto-cardia; corculum germinis.

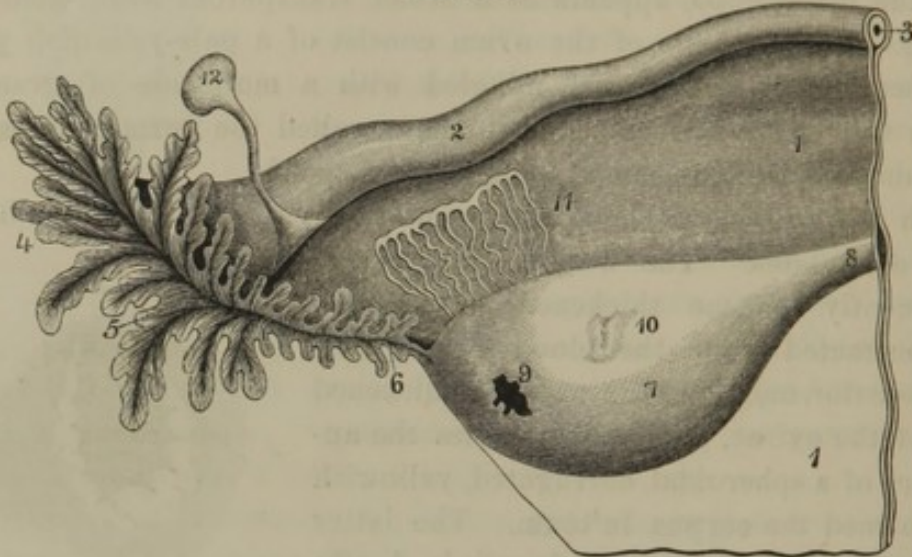
⁶ True corpus luteum.

⁷ False corpus luteum.

⁸ Corpus conicum; organ of Rosenmüller; paroärrion; corpusculum conicum Rosenmülleri.

see fig. 83. } the ovary to a main trunk in the vicinity of the Fallopian tube. It is the remains of an organ of embryonic life, named the Wolffian body, which in the male becomes the epididymis.

FIG. 309.



OVARY, PAROVARIIUM, AND FALLOPIAN TUBE OF THE LEFT SIDE. 1, broad ligament; 2, Fallopian tube, or oviduct; 3, its canal; 4, its fimbriated extremity; 5, mouth of the latter, or pavilion; 6, process attached to the ovary; 7, 8, ovarian ligament; 9, orifice from which an ovum recently escaped; 10, a cicatrix; 11, parovarium; 12, remains of the duct of Müller. From a virgin of about eighteen years of age.

THE FALLOPIAN TUBES, OR OVIDUCTS.

The **Fallo'pian tube**, or **O'viduct**,¹ intended to convey the ovum from the ovary to the uterus, is inclosed in the upper border of the broad ligament. It is a trumpet-shaped tube of about four inches in length. Commencing above and externally to the ovary, it gradually narrows and pursues a curvilinear and slightly undulating course to the side of the fundus of the uterus, with which it is connected. The outer extremity is free, expanded, and opens into the abdominal cavity; and its margin is fringed with a number of irregular processes,² whence it is named the **fim'briated extremity**.³ One⁴ of the longest of the processes, with fringed edges and doubled so as to include a furrow, extends along the border of the broad ligament to become attached to the outer extremity of the ovary. The expanded, funnel-shaped orifice or **pavilion**⁵

¹ Tuba Fallopianæ, uteri, or cæca; oviductus muliebris; vas spermaticus, ejaculans, or deferens mulieris; meatus seminalis; m. seminarius uteri; ductus varicosus uteri; processus lateralis uteri; vector canal; uterine canal.

² Fimbriæ; laciniae; vexillæ; digitationes.

³ Morsus diaboli; foliaceum ornamentum.

⁴ Tubo-ovarian ligament, or fringes.

⁵ Infundibulum; ostium abdominale; corolla infundibuliformis.

of the fimbriated extremity narrows into the canal of the tube, which at its communication¹ with the cavity of the uterus is so small as hardly to permit the passage of a fine bristle. The lining membrane of the canal is longitudinally plaited or provided with narrow folds, which extend from the uterine orifice of the tube to the fringed processes of its fimbriated extremity.

In structure the oviducts, besides their peritoneal investment, have a fibro-muscular coat and a lining mucous membrane. The peritoneal or serous tunic formed by the upper border of the broad ligament is loosely attached to the tube. The middle coat is the thickest and strongest, and is an extension of the structure of the uterine walls, consisting of fibrous tissue associated with unstriated muscular fibres. The lining mucous membrane is soft, pinkish white, and furnished with a ciliated columnar epithelium.

The oviducts are supplied with branches of the uterine arteries. Their veins pursue the same course as the latter. The nerves are derived from the same source as those of the uterus and ovaries.

Near the fimbriated extremity of the oviduct there usually exists an appendage, consisting of a small sac attached by a long pedicle. This has generally been looked upon as a hydatid, but recent researches prove it to be the remains of an organ of the embryo, which has been named the **duct of Müller**.

THE VAGINA.

The **Vagi'na**² is a cylindroid canal extending from the vulva to the uterus, the neck of which projects into it. Behind it is in relation with the bottom of the recto-uterine pouch of the peritoneum, and below this adheres by loose connective tissue to the rectum. In front it adheres to the base of the bladder and urethra, and at the sides is in relation with the bottom of the broad ligaments, pelvic fascia, and anal elevator muscles. It curves upward and backward in the direction of the axis of the pelvis, is attached to the neck of the uterus higher posteriorly than anteriorly, and in consequence has a greater length behind than in front.

The vagina is most capacious at the middle, where its transverse diameter is greatest; and it slightly narrows toward the extremities. Ordinarily its anterior and posterior walls are in contact, and it varies in size according to circumstances, being capable of much enlargement. In the virgin adult it measures about four inches in length by an inch

¹ Ostium uterinum; internal or uterine orifice.

² Vagina uteri, muliebris, or penis; sinus muliebris, pudoris, or pudendi; vulvo-uterine canal.

and a quarter in its breadth. After frequent intercourse or child-birth these dimensions are much exceeded.

The lower orifice or entrance of the vagina is constricted in the virgin state by a fold of the lining membrane, named the **hymen**.¹ This usually appears in the adult as a crescentic process at the posterior part of the entrance of the vagina, including an antero-posteriorly elliptical orifice. The younger the individual, the more does this process approach the form of a complete circular zone, which is the ordinary condition of the hymen in the infant. Sometimes this zone-like form is retained to adult age; and not unfrequently it presents a puckered appearance toward the central aperture. Commonly the hymen is obliterated by intercourse, child-birth, or other means; and if its free edges are thin, in the process of dilatation, these may be torn. As an abnormal condition, the hymen is occasionally imperforate; and in rare instances it is so strong that impregnation may occur without its being destroyed. Its existence is no evidence of virginity, nor its absence any to the contrary!

The upper extremity² of the vagina is circular, and is reflected smoothly around the neck of the uterus, which projects into it as a short blunt cone.

The internal surface of the vagina on its anterior and posterior wall is roughened with numerous transverse folds³ passing off from a slight median ridge,⁴ and arranged with a certain degree of regularity. The folds are often interrupted or broken into wart-like eminences; and they are remarkable for their rigidity in comparison with similar processes of other mucous membranes. They are most numerous near the entrance of the vagina, where some of them are named the **myr'tiform car'uncles**,⁵ though these are usually looked upon as the remains of the hymen. From repeated child-birth the folds of the posterior wall of the vagina become completely obliterated: those of the anterior wall partially. Frequent intercourse to a less extent produces the same result.

The walls of the vagina average about one line in thickness, and are composed of three coats. The outer coat, adherent to the contiguous organs, consists of fibro-elastic tissue. The middle coat consists of

¹ Valvula, or membranula lunata vaginæ; claustrum, custodia, columna, flos, sigillum, or zona virginitatis; circulus membranosus; interceptum virginalis; cento, or flos virginalis; argumentum integritatis; zona, or munimentum castitatis; panniculus hymenæus, or virginalis; virginia; virginal membrane.

² Fundus; fornix.

³ Rugæ.

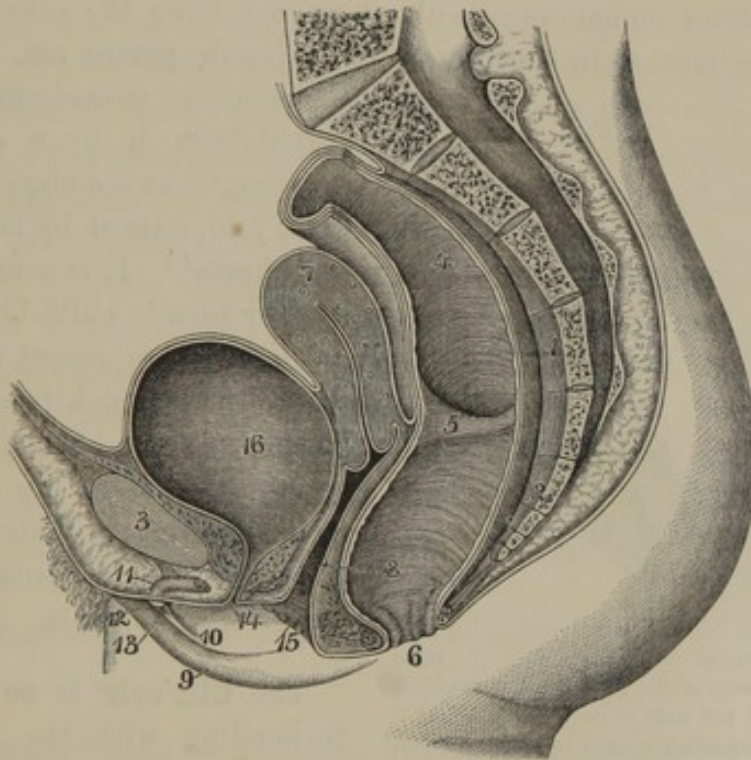
⁴ Columna rugarum; column of the vagina.

⁵ Carunculæ myrtiformes; c. vaginales; glandulæ myrtiformes.

unstriated muscular fibres, associated with fibro-elastic tissue and blood-vessels, and is continuous with the corresponding structure of the uterus. The inner coat is a mucous membrane provided with a multitude of minute conical papillæ, imbedded beneath a squamous epithelium.

The vagina is supplied with arteries from the vaginal, uterine, vesical, and internal pudics. The veins on each side form an intricate plexus, from which vessels proceed in the course of the arteries. The nerves are derived from the hypogastric plexus of the sympathetic system, the fourth and fifth sacral, and the internal pudic nerves.

FIG. 310.



SECTION OF FEMALE PELVIS, FROM BEFORE BACKWARD. 1, sacrum; 2, coccyx; 3, pubic symphysis; 4, rectum; 5, one of its valvular folds; 6, anus; 7, uterus; 8, vagina; 9, right labium; 10, right nympha; 11, clitoris, attached by the suspensory ligament to the front of the pubic symphysis; 12, glans; 13, prepuce; 14, urethra; 15, entrance of the vagina; 16, bladder.

THE VULVA.

As previously mentioned, the external organs of generation of the female are comprised under the general name of **vulva**,¹ and consist of the mons veneris, labia, clitoris, and nymphæ.

The **Mons ven'eris**² is the prominence of skin over the position of the

¹ Pudendum; p. muliebre; female organs, or parts.

² Monticulus veneris; supra-pubic eminence.

pubic symphysis, to which it is attached by areolar tissue containing an abundance of adipose tissue. Its surface is provided with crisp hairs and large sebaceous glands.

The **Labia**¹ are two parallel, rounded prominences of the integument bounding the vertical **fissure of the vulva**,² and united above and below; the points of union being named the **com'missures**.³ They are composed of a quantity of areolar and adipose tissue covered externally with common skin and internally with the commencement of the genito-urinary mucous membrane. Their surface is supplied with many sebaceous glands, and the external skin is furnished with scattered crisp hairs.

The posterior commissure is about an inch from the anus; the intervening space, marked by a median **raphé**, being the **perine'um**. Just within

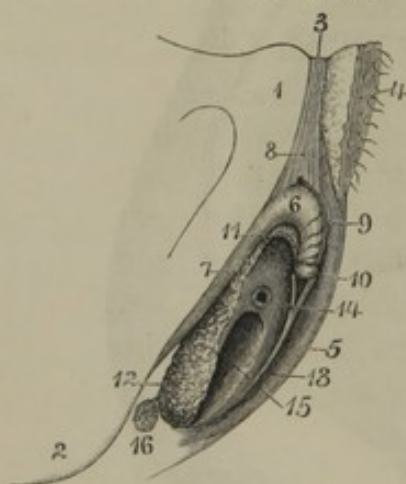
the posterior commissure, and separated from it by a shallow depression,⁴ is an inconspicuous transverse fold, named by midwives the **fourchette**.⁵ It is usually obliterated or torn in child-birth.

The labia represent the scrotum of the male, which is also divided in the embryo. The raphé of the scrotum indicates the line of confluence of the two halves, which as the labia, remain permanently separated in the female.

The **Clit'oris**⁶ is an organ corresponding with the male penis, which it resembles in general form, structure, and connections. It is situated at the upper part of the fissure of the vulva, concealed by the labia. When these are sep-

arated, it is seen through the mucous membrane as a slight vertical

FIG. 311.



EXTERNAL ORGANS OF GENERATION. 1, right pubis; 2, tuberosity of the ischium; 3, symphysis of the pubes; 4, left half of the mons veneris; 5, left labium; 6, clitoris; 7, crus of the right cavernous body; 8, suspensory ligament; 9, dorsal vein; 10, glans; 11, pedicle of the right half of the spongy body; 12, right semi-bulb; 13, left nympha, terminating above in the prepuce; 14, urethral orifice at the base of the vestibule; 15, vagina; 16, right suburethral gland.

¹ Labia pudendi; l. majora; l. externa.

² Fissura, or f. magna vulvæ; rima, or r. magna vulvæ; sinus vulvæ; introitus; scapha.

³ Commissuræ vulvæ; c. labiorum.

⁴ Fossa navicularis.

⁵ Frænulum, or frænulum pudendi; furcula labiorum.

⁶ Penis muliebris, or femineus; mentula muliebris; membrum muliebre; superlabia.

prominence terminating below in the glans. It is about two inches in length, and consists of a pair of cavernous bodies and a bipartite spongy body ending in a glans.

The **Cav'ernous bodies**¹ have the same constitution, attachment, and relation with each other as their representatives in the penis. From their ascending crura, which constitute about half their length, they bend abruptly downward, and, lying parallel together, form the **body** of the clitoris. The crura and body are thus arranged so as to resemble a tripod; and from the bend of the organ a strong fibro-elastic **suspensory ligament**² ascends to be attached to the pubic symphysis.

The **Glans**,³ constituted like that of the penis, is a small, conical eminence capping the lower extremity of the cavernous bodies, and situated about an inch beneath the anterior commissure. It is imperforate in consequence of the divided condition of the spongy body, and is surrounded by a **pre'puce**⁴ continuous at the sides with the nymphæ.

The **Spongy body**⁵ extends from the glans as a narrow, **intermediate portion** or pedicle, along each side of the under part of the body of the clitoris, and expands in the semi-bulbs. The **intermediate portions**⁶ consist of a plexus of veins communicating with the erectile tissue of the glans and cavernous bodies enveloped in a thin, fibrous membrane. The **semi-bulbs**⁷ are situated beneath the vestibule, and embrace the urethral and vaginal orifices. They are about the size and form of a large almond kernel, and consist of an erectile tissue continuous with the plexus of veins of the pedicles, and invested with a thin fibro-elastic membrane.

The arteries, veins, and nerves of the clitoris correspond with those of the penis.

The **Nymphæ**⁸ are two crest-like folds of mucous membrane diverging from the prepuce of the clitoris downward and outward upon the inner border of the labia. Together with the prepuce and the mucous membrane enveloping the clitoris, they correspond with the integument of the penis. The raphé of the latter represents the separation of the nymphæ.

¹ Corpora cavernosa clitoridis.

² Ligamentum suspensorum clitoridis.

³ Glans clitoridis.

⁴ Præputium clitoridis.

⁵ Corpus spongiosum clitoridis.

⁶ Pars intermedia of Kobelt.

⁷ Bulbi vestibuli; plexus retiformes;

crura clitoridis interna; erectile tissue of the vestibule, or vagina.

⁸ Labia minora; l. pudendi minora; l. interna; cristæ clitoridis; alæ minores clitoridis; colliculi vaginæ; carunculæ cuticulares.

Between the nymphæ is the triangular space named the **vestibule**.¹ It is covered by mucous membrane continuous with the inner surface of the nymphæ. At the middle of its base, about an inch below the glans, is situated the urethral orifice, which has an elevated border, so that to the touch it appears like a papillary eminence.

Just below the vestibule and the urethral orifice is the entrance of the vagina, which may be narrowed by the presence of the hymen to a small aperture; or, if this is obliterated, it appears as an antero-posteriorly elliptical orifice an inch and a half or more in diameter.

The mucous membrane, traced inwardly from the labia, covers the clitoris, forms the nymphæ and prepuce, invests the vestibule, and is then continuous with that of the vagina and urethra. It is smooth, and pink in color, and is furnished with a squamous epithelium and many sebaceous glands.² Small racemose glands, secreting mucus, also open on the mucous membrane of the vestibule and around the urethral and vaginal orifices.

The **Subure'thral glands** (Bartholine's)³ are two spheroidal racemose glands, about a third of an inch in diameter and of a yellowish-pink hue, situated just behind the lower part of the semi-bulbs of the spongy body. Their duct is about three-fourths of an inch long, and opens between the nymphæ and the vaginal orifice. They appear to secrete mucus, and in advanced age become atrophied.

The blood-vessels and nerves of the vulva correspond closely with those of the penis and scrotum.

THE CAVITY OF THE PELVIS.

The **Cavity of the pelvis**⁴ is a short, wide, and curved canal, the concavity of which is directed forward and downward. Its posterior wall corresponds in length with the curve of the sacrum and coccyx; its anterior wall with the pubic symphysis. It is longer, narrower, and perhaps generally more curved in the male than the female. The **entrance** or **superior strait** of the pelvis is cordiform, the notch of this outline corresponding with the promontory of the sacrum. The **exit** or **inferior strait** is likewise cordiform, the notch being produced by the coccyx, and it is narrower than the superior strait.

¹ Vestibulum; v. vaginæ; atrium vaginæ; ambitus genitalis muliebris.

² Glandulæ odoriferæ; g. o. Tysoni.

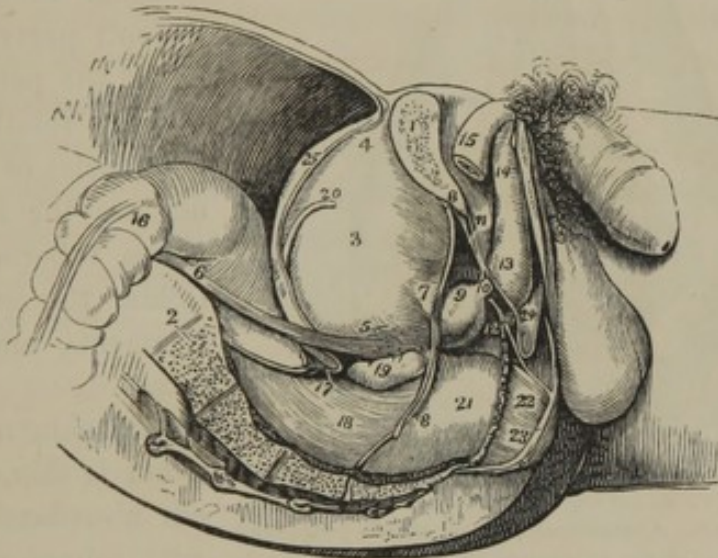
³ Glandulæ Cowperi; Cowper's glands

of the female; glands of Duverney; glands of Mery; vulvo-vaginal glands; prostata muliebris.

⁴ True pelvis.

In the male the cavity of the pelvis is occupied posteriorly by the rectum, in front by the bladder, and between these is the recto-vesical pouch of the peritoneum. Beneath the bladder are the seminal vesicles, and in front of them, surrounding the commencement of the urethra, is the prostate gland. In the female pelvis, between the rectum and bladder are the uterus and vagina, together with the broad ligaments, Fallopian tubes, and ovaries. Between the rectum, uterus, and bladder are the recto- and vesico-uterine pouches of peritoneum.

FIG. 312.



SIDE VIEW OF THE MALE PELVIS AND ITS CONTENTS. 1, the right pubis sawed through; 2, sacrum; 3, bladder; 4, its summit; 5, its fundus; 6, right ureter; 7, neck of the bladder; 8, attachment of the pelvic fascia; 9, prostate gland; 10, membranous portion of the urethra; 11, triangular ligament; 12, suburethral gland between the two layers of the latter; 13, 14, spongy body; 15, right cavernous body; 16, sigmoid flexure of colon; 17, recto-vesical fold of peritoneum; 18, rectum, with its muscular coat seen; 19, right seminal vesicle; 20, spermatic duct; 21, pelvic fascia descending to the rectum; 22, anal elevator muscle; 23, anal sphincter; 24, union of the superficial perineal fascia with the triangular ligament or deep fascia; 25, peritoneum passing from the summit of the bladder to the anterior abdominal wall.

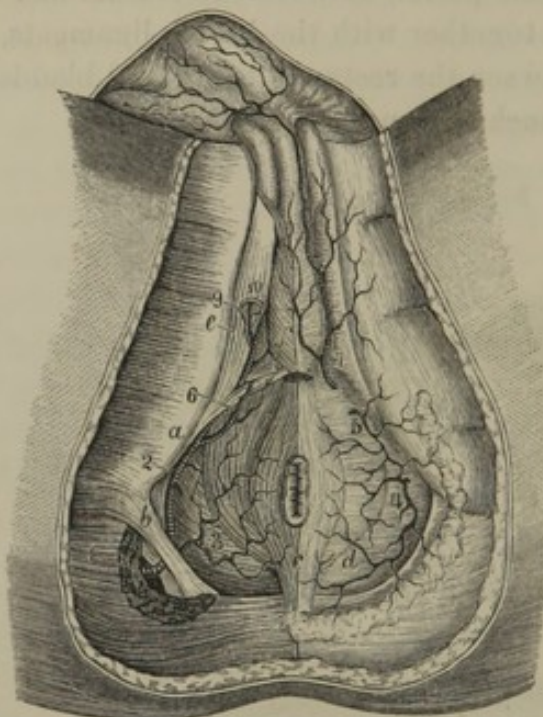
When the viscera of the pelvis above mentioned are emptied, a portion of the small intestine descends into the peritoneal pouches between them.

The sides of the cavity of the pelvis are occupied by the pyriform, internal obturator, and anal elevator muscles, the internal iliac blood-vessels and lymphatics, and the sacral plexus of nerves.

THE PERINEUM.

In its most restricted sense, the term **perine'um**¹ is applied to the

FIG. 313.



VIEW OF THE PERINEUM; the superficial fascia removed from the left side of the figure. *a*, transverse perineal muscle proceeding from the tuberosity of the ischium to the perineal centre; *b*, greater sacro-sciatic ligament; *c*, anal sphincter; *d*, anal elevator; *e*, ischio-cavernous muscle; *f*, bulbo-urethral muscle inclosing the bulb of the spongy body. 1, 2, internal pudic artery; 3, inferior hæmorrhoidal artery; 4, 5, 6, 7, superficial perineal branches; 8, bulbo-urethral artery; 9, cavernous artery; 10, dorsal artery of the penis.

space between the anus and scrotum in the male; between the anus and vulva in the female. In a broader view of the anatomy of the perineum, it is usual to describe all the soft parts at the outlet of the pelvis, so that in this relationship the boundaries of the perineum are the arch of the pubes, tuberosities of the ischia, the sacro-sciatic ligaments, and the coccyx.

The skin of the perineum is thin, dark colored, abundantly supplied with sebaceous and perspiratory glands, and is marked in the middle by a slightly elevated line called the **raphe**.²

THE PELVIC AND PERINEAL FASCIÆ.

The **Pelvic fascia**³ is attached to the brim of the pelvis, and is there continuous with the transverse and iliac fasciæ. Posteriorly it descends upon the sacrum and pyriform muscles of the two sides, giving them an investment. It is also continuous with the fibrous sheaths of the internal iliac vessels and sacral plexuses of nerves. Behind the pubes it descends and attaches itself by two short, narrow processes⁴ to the sides

¹ Perinæum; interfoemineum; interforamineum; regio perinæi; foemen; perin; mesomerion; mesocelon: gressura; amphiplex; plichos; cochone; tauros; anterior and posterior perineum.

² Tramis.

³ Fascia pelvis; f. hypogastrica.

⁴ The anterior and lateral true ligament of the bladder; ligamentum puboprostaticum medium et laterale, in the male; l. pubo-vesicale medium et laterale, in the female.

of the prostate gland and neck of the bladder. At the sides of the pelvis it descends on the obturator muscle, and forms a narrow **tendinous arch**,¹ which curves from the pubis downward and backward to the spine of the ischium. From the tendinous arch emanate the recto-vesical and ischio-rectal fasciæ, and between these originates the anal elevator muscle.

The **recto-vesical fascia**² is an extension of the pelvic fascia descending on the inner surface of the anal elevator muscle to the prostate gland, neck and fundus of the bladder, and side of the rectum in the male; to the bladder, vagina, and rectum in the female. From the point of contact of the recto-vesical fascia with the organs just named it becomes continuous with their fibrous investments.

The **ischio-rectal fascia** lines the corresponding space throughout. Starting from the tendinous arch of the pelvic fascia, one lamina invests the outer surface of the anal elevator, and becomes continuous with the bottom of the deep perineal fascia and the thin connective tissue of the anal sphincter; another lamina³ descends on the lower part of the internal obturator muscle, and attaches itself to the tuberosity of the ischium.

The **Superficial perine'al fascia** consists of a subcutaneous adipose layer, and a deeper membranous layer. The former is continuous with the same structure of the buttocks and thighs, and, in the female, of the labia. Approaching the scrotum it gradually merges into the deeper membranous layer, and posteriorly it dwindles into the thin connective tissue of the anal sphincter. On each side of the latter it is continuous with a mass of areolar and adipose tissue occupying the **ischio-rectal fossa**—a depression several inches in depth between the ischium and rectum.

The membranous layer of the superficial fascia is thin and moderately strong. It is connected with the rami of the pubes and ischia, and with the tuberosities of the latter; invests the ischio-cavernous and bulbo-urethral muscles, and is continuous with the fascia of the spongy and cavernous bodies. Posteriorly, after investing the transverse perineal muscle, it becomes continuous with the bottom of the deep perineal fascia, the connective tissue of the anal sphincter, and the ischio-rectal fascia.

The **Deep perine'al fascia, or triangular ligament**,⁴ is a strong membrane extended across the arch of the pubis. It is pierced by the mem-

¹ Arcus tendineus; ischio-pubic arch, or band.

² Fascia recto-vesicalis; diaphragma pelvis; visceral layer of the pelvic fascia; vesical fascia.

³ Obturator fascia.

⁴ Fascia perinæi profunda; ligamentum Camperi; l. triangulare urethræ; l. infra-pubianum; perineal ligament.

branous portion of the urethra; and this receives from it an investment which is continuous with the fascia of the prostate gland. It further incloses the suburethral glands; and externally is continuous with the fascia of the spongy body. In the female it is pierced by the extremity of the urethra, and is continuous with the fascia of the vagina. Its lower border is continuous with the superficial perineal fascia.

MUSCLES OF THE PERINEUM.

The **Ischio-cav'ernous muscle**¹ arises tendinously from the inner part of the tuberosity and ramus of the ischium, and from the commencement of the crus of the cavernous body of the penis. Its fleshy fibres form a thin layer covering the under part of the crus, and proceed to terminate in the fibrous investment of the cavernous body.

In the female the muscle² has similar relations with the clitoris.

The action of the muscle is usually considered as aiding to maintain the erect condition of the penis through compression of the commencement of the cavernous body. Under ordinary circumstances it would appear to retract or draw down the organ.

The **Bulbo-ure'thral muscle**³ is single, or rather consists of two muscles united by a median tendinous line, beneath the bulb of the spongy body. Its fleshy fibres arise from the perineal centre and from the line just mentioned, and proceed obliquely outward and forward, inclosing the bulb of the spongy body, and terminate in the fibrous structure on the back of the latter. A loop of the most anterior of the fibres passes around the cavernous bodies and dorsal vein of the penis, so that this vessel is compressed in the contraction of the muscle.

By compression of the bulb of the spongy body and the dorsal vein the bulbo-urethral muscle contributes to maintain the erect condition of the penis. Voluntarily it acts in expelling the last portion of urine, and involuntarily in the emission of spermatic liquid.

The **Vag'inal Constrictor**⁴ is the representative of the foregoing muscle in the female; the corresponding halves of the bulbo-urethral muscle being separated in the median tendinous line of origin so as to inclose the semi-bulbs of the spongy body and embrace the orifice of the

¹ Musculus ischio-cavernosus; m. erector, director, or sustentator penis; m. ischio-urethralis.

² M. erector, sustentator, or superior rotundus clitoridis; m. ischio-clitoridis, or ischio-sub-clitoridis.

³ M. bulbo-urethralis; m. accelerator urinæ; m. ejaculator seminis; m. bulbo-cavernosus; m. bulbo-syndesmo cavernosus.

⁴ M. constrictor, or constrictores vaginæ, or vulvæ; sphincter vaginæ; m. lati et plani inferiores clitoridis.

vagina. A slip of the muscle¹ likewise passes around the body of the clitoris and its dorsal vein.

The **Transverse perine'al muscle**² arises from the inner part of the ramus of the ischium, and proceeds to the perineal centre. Frequently one or two offsets³ are situated in advance, and somewhat higher than the main portion of the muscle.

The **Anal Sphincter**⁴ is an elliptical ring of fleshy fibres inclosing the anus. Its posterior extremity is attached to the subcutaneous tissue at the end of the coccyx, and its anterior extremity blends with the other muscles connected with the perineal centre.

The **Anal Elevator**⁵ is a broad, thin plane of muscular fibres situated within the cavity of the pelvis. It arises from the inner surface of the body and descending ramus of the pubis, the tendinous arch of the pelvic fascia, and the spine of the ischium. Descending from this wide origin, it converges to be inserted into the end of the coccyx, the side of the anus, the neck of the bladder, and the prostate gland. In the female, instead of the latter, it is attached to the vagina.

This muscle raises the whole perineum, in which action it is aided by the transverse perineal muscle. Anterior offsets have been described as special muscles of the urethra.⁶

The **Coccyge'al muscle**⁷ is a posterior offset of the preceding muscle. It arises from the spine of the ischium and the lesser sacro-sciatic ligament, and passes with this to be inserted into the side of the coccyx.

THE MAMMÆ.

The **Mammæ** or **breasts**,⁸ the milk-secreting organs of the female, exist only in a rudimental condition in the male. Their presence is characteristic of the highest order of animals, which are thence named

¹ *M. attrahens clitoridis.*

² *M. transversus perinei; m. perinæus superficialis, or posterior; m. ischio-perinæus; m. levator ani parvus.*

³ *M. transversus perinei alter; m. perinæus profundus, or anterior.*

⁴ Sphincter of the anus; *m. sphincter ani; m. s. a. externus, or cutaneus; m. constrictor ani; m. orbicularis recti; m. coccygio-ani; m. aspidiscus.*

⁵ Elevator of the anus; *m. levator ani; m. l. a. magnus, or internus; m. latus*

ani; m. sedem attolens. In part *m. adductor, levator, or compressor prostatæ.*

⁶ *M. compressor urethræ; m. c., or constrictor isthmi urethræ; m. constrictor urethræ membranacæ; m. pubio-urethrales; transverse compressor muscle; Guthrie's muscles; Wilson's muscles.*

⁷ *M. coccygeus; m. ischio-coccygeus; m. levator, or triangularis coccygis.*

⁸ Sing.: *masthus; mastus; ruma; uber.*

mammals or mammalia. In most of these they are attached to the parietes of the abdomen, but in apes and man they occupy the front of the thorax.

When fully developed in the human female, the mammæ form a pair of hemispherical prominences slightly divergent from each other and surmounted by a conical eminence, the nipple. They are separated by a groove in front of the sternum, and extend outwardly nearly to the axilla. Their base rests against the great pectoral muscle, extending from about the third to the seventh rib.

The **Nipple**¹ is of a roseate or brownish hue, and is surrounded by an **areola** of skin of the same color. Both enlarge and become darker in pregnancy, and the change to some degree is permanent. The skin of the nipple is smooth in the virgin, but after pregnancy becomes more or less wrinkled. It is thin, and furnished with numerous sensitive papillæ; is highly vascular, and, under excitement, capable of erection. At its summit are situated the mouths of the milk ducts, of which there are fifteen or twenty.

The skin of the areola is thin, and exhibits scattered, whitish, pimple-like eminences,² which are sebaceous glands. These enlarge during suckling, and secrete a peculiar fatty substance which protects the parts from the liability to excoriation. Beneath the skin of the mammæ there is a variable amount of adipose tissue, upon the extent of which the size and form of the breasts greatly depend. It is divided into lobular masses by laminæ of fibrous tissue extended between the skin and the mammary gland. In thin persons this adipose tissue is absent, and its position is occupied by an abundance of areolar tissue.

The **Mam'mary gland**³ is circular, with its external surface convex and prolonged to the nipple. Its internal surface is flattened, and adheres to the pectoral muscle by connective tissue, which may become much elongated during pregnancy, from the increasing weight of the mammæ, unless they are supported by artificial means. From such an elongation of the connection of the mammæ they hang purse-like from the front of the thorax, with the nipples directed downward.

The mammary gland is of firm consistence, and of a pinkish-white color. It is a racemose gland, composed of from fifteen to twenty lobes closely associated by connective tissue. The lobes are subdivided into lobules, and these consist of the ultimate vesicular structure observed in

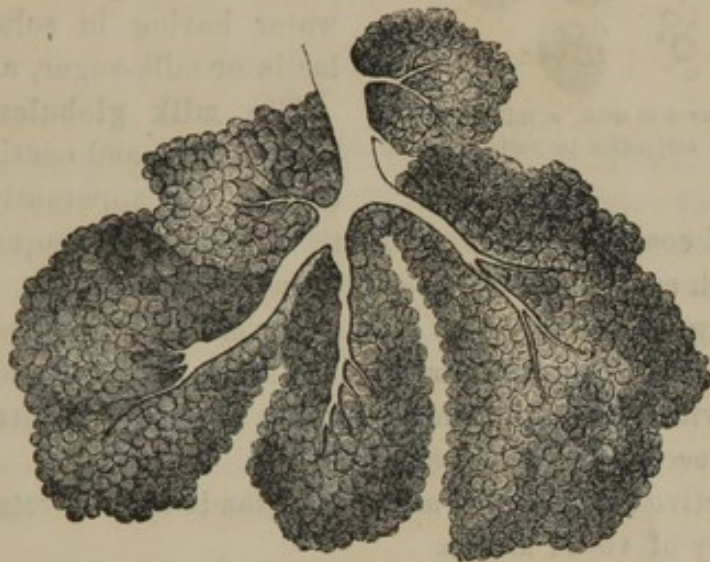
¹ Teat; titty; dug; pap; mammilla; papilla.

² Tubercles of the areola.

³ Glandula lactifera.

other racemose glands, but the whole are so closely united as to appear homogeneous. Under the active state, however, the lobular constitution becomes more evident. From each lobe proceeds a **lactiferous duct**¹ toward the summit of the nipple, where it terminates by a small orifice, and thus the number of orifices in the latter position correspond with the number of lobes and ducts of the gland. Beneath the areola, the ducts

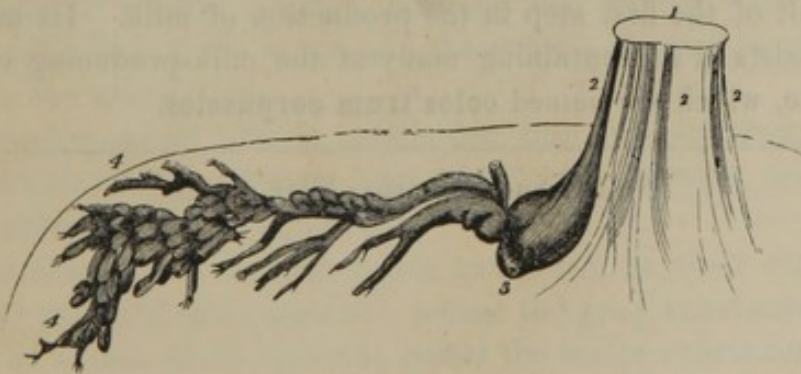
FIG. 314.



SEVERAL SMALL LOBULES OF THE MAMMARY GLAND OF A PREGNANT WOMAN, highly magnified.

become enlarged, especially during lactation, forming the so-called **lactiferous sinuses**.² These are comparatively small in the human female, but in some of the lower animals, as in the cow, they form large reservoirs for the milk.

FIG. 315.



DIAGRAM, EXHIBITING THE COURSE OF A LACTIFEROUS DUCT. 1, summit of the nipple; 2, course of the ducts through the latter; 3, a lactiferous sinus; 4, origin of the ducts toward the periphery of the gland.

The arteries of the mammary gland are the long thoracic, together with other branches of the axillary, and of the internal mammary and

¹ Galactophorous ducts; ductus galactophorus.

² Galactophorous sinuses; sinus lactei.

intercostal arteries. The veins correspond with the arteries. The nerves are derived from the intercostals.

Milk,¹ the secretion of the mammary glands, consists of a colorless liquid, the milk plasma, holding in suspension innumerable fat-like corpuscles, named the milk globules.

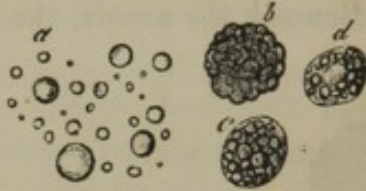

FIG. 316.
CORPUSCLES OBSERVED IN MILK. *a*, milk globules; *b*, *c*, *d*, colostrum corpuscles in various stages. Highly magnified.

The **milk plasma** consists of water having in solution casein, lactin or milk-sugar, and salts.

The **milk globules** are of no definite size, and consist of minute drops of fat apparently inclosed in

a thin film of coagulated casein. To them is due the opaque-white color of milk, which constitutes a sort of an emulsion.

The souring of milk depends on the conversion of its sugar into lactic acid, which separates the casein from the milk globules, and coagulates it, together with that of the milk plasma, into a finely granular mass, while the oil accumulates as **cream**.

In the inactive state of the mammary glands they secrete only a very small quantity of viscid mucus.

The formation of milk occurs through the elaboration of its constituents within the secreting cells of the ultimate gland vesicles, which cells successively advance into the lactiferous ducts and there burst, yielding up their contents in the form of milk.

At the commencement of lactation, the liquid first discharged from the mammæ has a thin, yellowish aspect, and is called **colos'trum**. This is the result of the first step in the production of milk. Its main peculiarity consists in its containing many of the milk-producing cells in an entire state, which are named **colos'trum corpuscles**.

¹ Lac; humor lacteus; latex niveus.

CHAPTER XI.

THE NERVOUS SYSTEM.

THE **Nervous system**¹ is subdivided into the **cer'ebro-spinal** and **sympathetic** systems. The former consists of the **cer'ebro-spinal axis**,² or the **brain** and **spinal cord**, and the **nerves**³ distributed thence throughout the body; the latter is composed of an intricate arrangement of **nerves** and **ganglia**, intercommunicating with the cerebro-spinal system, and mainly distributed upon the viscera of the great cavities. Ganglia are likewise found upon most of the cerebro-spinal nerves, several of which, however, are by some anatomists described as belonging to the sympathetic system.

GENERAL CHARACTERS AND STRUCTURE OF THE CEREBRO-SPINAL AXIS.

The **Cer'ebro-spinal axis**, or the **brain**, with its prolongation the **spinal cord**, is a large mass of matter of peculiar anatomical and chemical constitution. It is of about the consistency of newly-pressed cheese, and is readily crushed between the fingers. Its substance, together with that of the nerves and the ganglia situated on their course, constitute the nerve tissue.

The cerebro-spinal axis is subdivided into the cerebrum and cerebellum, which form the greater part of the nervous mass, and the pons, medulla oblongata, and spinal cord.

The cerebrum and cerebellum are composed, on their exterior, of a reddish or brownish-gray material, named the **gray substance**; on their interior, of a milk-white material, called the **white substance**, which includes a number of nuclei, laminæ, and streaks of the gray substance. The pons, medulla oblongata, and spinal cord are composed, exteriorly, of the white substance, and contain gray substance interiorly.

The two kinds of nerve substance, in an unaltered condition, to the eye

¹ Systema nervosum.

² S. n. centrale; neural axis; cranio-spinal axis.

³ S. n. periphericum.

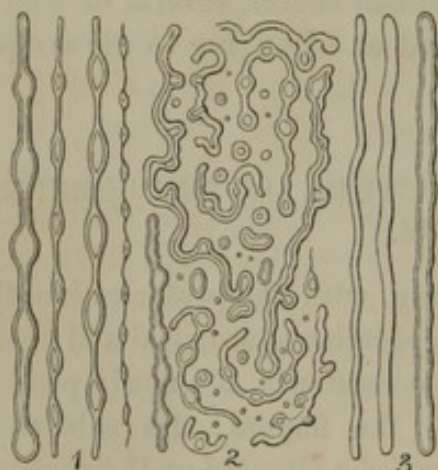
appear perfectly homogeneous, but when hardened by the action of alcohol or other means, the white substance readily tears into fibrils, having a determinate direction in every position; while the gray matter assumes a more granular aspect.

The chemical composition of the nerve substance of the cerebro-spinal axis approximates the following:—

Water	80
Albuminous matter	7
Peculiar fatty matters in association with phosphorus	7
Osmazome	1
Phosphates of potassa, lime, and magnesia, chloride of sodium, and sulphur	5
	<hr/> 100

The **White substance**¹ of the brain and spinal cord is of comparatively simple anatomical constitution. Under ordinary circumstances,

FIG. 317.



NERVE FIBRES OF THE WHITE SUBSTANCE OF THE CEREBRUM. 1, beaded appearance presented by the fibres, which are of various sizes; 2, various irregular forms assumed by the fibres as they ordinarily appear when examined mingled with a little water; 3, ideal representation of the unchanged fibres.

when examined beneath the microscope, it appears to be composed of transparent beaded filaments² of various sizes. The larger filaments, and the bead-like dilatations of the smaller ones, exhibit a double outline or contour, as if they were hollow and filled with a transparent homogeneous substance. The filaments are soft, and with the slightest violence are broken up into fragments, which partially exude their contents and assume a multitude of irregular forms, as represented in figure 317. Careful investigation shows that the filaments are tubular, and are like those

composing the nerves, whence they are named **nerve fibres**.³ These, in the unaltered condition, are separately of uniform diameter, and exhibit a range in different ones of from the $\frac{1}{10000}$ to the $\frac{1}{4000}$ of an inch. They are arranged parallel to one another, and have straight, or at most only slightly undulating sides. They are provided with a structureless

¹ Medullary substance; tubular nerve substance.

² *Fibræ nervosæ varicosæ*; varicose nerve fibres.

³ Nerve tubules, or tubes; ultimate, or primitive nerve fibres or tubes; *fibræ nervosæ primitivæ*; f. n. centrales.

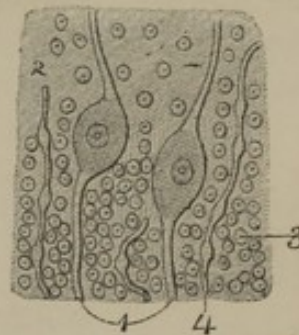
membrane of extreme tenuity, called the **neurilem'ma**,¹ and colorless, apparently homogeneous contents, named the **nervous matter**.² After death this matter in the larger nerve tubes is observed to consist of two portions, which have been named the **med'ullary sheath**³ and the **axis fibre**.⁴ The former incloses the latter, and has its outer limit undefined from the equally refractive neurilemma. It appears like viscid oil, and escapes from the ruptured nerve tubes in thickly outlined drops of various shapes. The axis fibre is solid, translucent, homogeneous, or sometimes appears faintly granular, and is elastic. From the broken ends of nerve fibres it is not unfrequently seen projecting beyond the exuded drops of the substance of the medullary sheath.

Whether the axis fibre and medullary sheath are separate structures during life, or whether they are actually the result of a sort of coagulation of the nervous matter subsequent to death, is a much disputed question.

The **Gray substance**⁵ of the cerebro-spinal axis is of complex constitution, and is composed of nerve cells, nuclei, granular matter, and nerve fibres. The exact relationship of these different elements is among the most difficult anatomical subjects of investigation, and their signification is variously estimated. By some authorities the larger cells and the nerve fibres are alone considered as true elements of nerve structure, while the abundant granular matter, nuclei, and smaller cells are viewed as a matrix allied to ordinary connective tissue.

The **Nerve cells**⁶ of the gray substance range from about the $\frac{1}{500}$ to the $\frac{1}{20}$ of a line in diameter, and in most instances are provided with one,

FIG. 318.



PORTION OF GRAY SUBSTANCE, FROM THE EXTERIOR OF THE CEREBELLUM. 1, two nerve cells with bipolar prolongations; 2, granular matter; 3, nuclear bodies; 4, nerve fibres.

¹ Coat, sheath, or tunic of nerve fibres; limitary membrane; primitive sheath; vagina interna.

² Neurine; contentum nervosum; c. fibrarum nervosarum.

³ White substance of Schwann; nerve medulla; n. pulp.

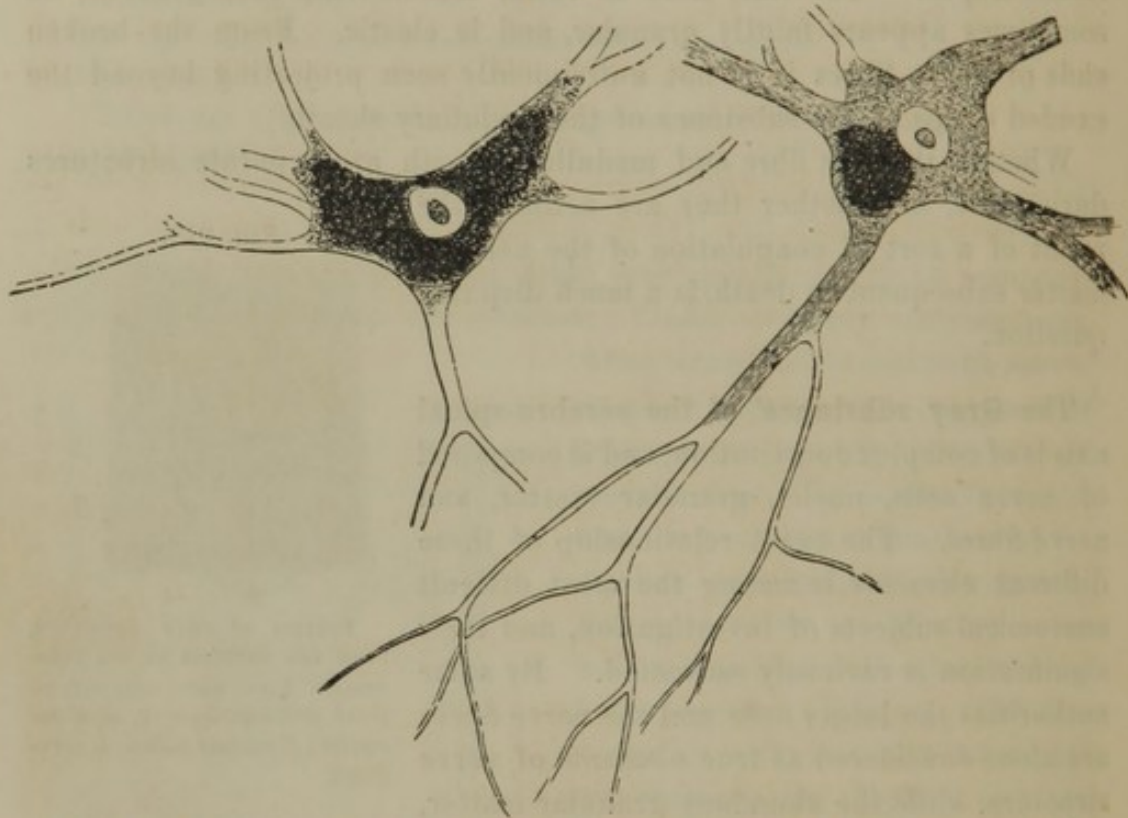
⁴ Cylinder axis; central fibre; primitive band; axis band; fibra primitiva fibræ nervosæ; fascia primitiva.

⁵ Substantia grisea; s. cinerea; s. corticalis; the cineritious substance. Also the varieties: substantia ferruginea, flava, ochracea, nigra, cœrulea, violacea, spongiosa, and gelatinosa; vesicular neurine.

⁶ Ganglion globules; nerve globules, cells, corpuscles, or vesicles; corpuscula nervea; c. nervosa centralia; globuli nervosi nucleati; g. explementorii; g. nucleati centrales.

two, or more processes, from which they are called **unipolar**, **bipolar**, and **multipolar cells**. They have a delicate wall and soft granular contents, with or without pigmentary matter, upon which the color of the gray substance is partly due. They generally possess a single large, spherical nucleus; but some of the smaller cells in the central portion¹ of the gray substance of the spinal cord have several nuclei.

FIG. 319.



LARGE NERVE CELLS FROM THE ANTERIOR HORNS OF THE GRAY SUBSTANCE OF THE SPINAL CORD, highly magnified.

The processes of the nerve cells are from one to twenty or more, and start from any part of their periphery. They appear as hollow prolongations, with the ordinary cell contents, or are filled with homogeneous substance, or partly with both. The relation of these processes to contiguous structures has not been definitely settled. Many appear to conjoin with those of other cells, thus forming **commissures**; some become continuous with the axis fibre of nerve fibres, but in the smallest cells they appear to end without being connected with other parts. They are often of considerable length, simple or branched, and usually continue some distance, especially in the larger cells, before becoming attenuated; which they, however, do not do at all when they join nerve fibres.

¹ Substantia grisea centralis; gray central nucleus of the cord.

The larger nerve cells, generally acknowledged as being the most important element of the gray substance, are abundant in the anterior horns of the gray matter of the spinal cord, the base of the posterior horns, the surface of the fourth ventricle, the gray matter of the medulla oblongata and pons, the dentate body of the cerebellum, the deeper part of the outer layer of the cortical gray substance of the latter, and in the gray matter of the cerebrum. The smaller cells are most numerous in the central portion, and extremities of the posterior horns, of the gray substance of the spinal cord, in the outer layer of the cortical gray substance of the cerebellum, and throughout the cortical layer of the cerebrum.

The **nuclei** of the gray substance of the cerebro-spinal axis are more numerous than the nerve cells, and are everywhere abundant, but especially in the deeper layer of the cortical gray substance of the cerebrum and cerebellum. They are mostly smaller than those contained within the nerve cells, but also reach the size of those belonging to the latter. They have finely granular contents and a nucleolus.

The **granular** matter of the gray substance forms a kind of matrix in which the elements above described are imbedded. It is exceedingly fine and soft, resembling that contained within the nerve cells. It is everywhere abundant, but in the superficial portion of the cortical gray substance of the cerebrum and cerebellum is especially large in quantity.

The **nerve fibres** of the gray substance have the same constitution as, and are continuous with, those of the white substance, but are much attenuated, so as generally not to be more than half the diameter of the latter. They form half the bulk of the gray substance of the spinal cord and a large portion of the deeper layer of the cortical gray substance of the cerebrum and cerebellum.

The brain and spinal cord are among the most vascular of organs, and their capillary blood-vessels are the finest in the body. These vessels are most numerous in the gray substance, everywhere form an intricate net-work, and (are supplied from the vessels of the pia mater, to which they again return the blood.) *471 N

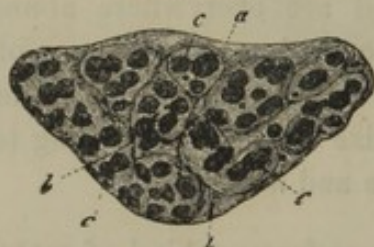GENERAL CHARACTERS AND STRUCTURE OF THE CEREBRO-SPINAL NERVES.

The **Cer'ebro-spinal nerves** are connected in pairs with the brain and spinal cord by their larger extremity, and are thence distributed throughout the body. They are white or cream colored, mostly flattened cylin-

drical cords, branching in their course at acute angles, and disseminated in fine filaments in the various organs and tissues. With few exceptions they anastomose with one another a short distance after their origin, forming **plexuses**; but subsequently anastomoses in the larger branches of most nerves are comparatively unfrequent. Many of the nerves pursue the same general course as the principal blood-vessels; and usually the nerves, blood-vessels, and lymphatics of an organ are observed associated together with connective and some adipose tissue.

The nerves are composed of bundles of nerve fibres, the larger ones, like the muscles, being composed of primary and secondary bundles, which are associated with an abundance of connective, mingled with

FIG. 320.

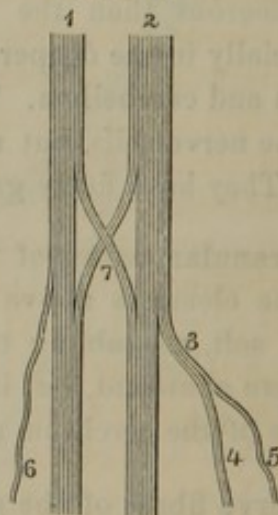


TRANSVERSE SECTION OF THE SMALL SCIATIC NERVE, magnified fifteen diameters. *a*, general sheath of the nerve; *b*, sheath of the secondary bundles; *c*, the primary bundles of nerve fibres. From the calf.

some elastic tissue, which constitute their sheath.¹ The sheath of the primary bundles is delicate, transparent, and assumes the character of structureless membrane² with scattered nuclei. The larger the nerve, the greater is its number of bundles of nerve fibres; and the branching of a nerve is the sending off of such bundles, and finally of the individual nerve fibres. The anastomosis of nerves consists of an interchange of bundles of nerve fibres. In the course of a nerve trunk the primary bundles frequently subdivide and anastomose; but in all cases the nerve fibres retain their continuity.

The **nerve fibres**³ of the nerves have the same constitution as those of the white substance of the brain and spinal cord, but are generally

FIG. 321.



MODE OF ANASTOMOSIS AND BRANCHING OF NERVES. 1, 2, two fasciculi of nerve fibres; 3, a branch of three fibres; 4, branch of two fibres; 5, 6, branches of single fibres; 7, anastomosis between two nerves.

¹ Neurilemma; neurymen; perineurion; tunica, membrana, involucrum, vagina, capsula, fistula, tubulus, or indumentum nervorum.

² Perineurium.

³ Ultimate or primitive nerve fibres; nerve tubes, or tubules; fibræ nervocæ; tubuli nervei; fila nervea; tubular nerve fibres.

much larger. In every case they continue undivided, and of nearly uniform diameter from their origin to their destination. The difference in strength of the nerves and white substance of the cerebro-spinal axis depends on the association of connective tissue with the former, and its absence in the latter. For the same reason, a house-fly or other insect, with its complex muscular and nervous system, its digestive and vascular apparatus, is readily crushed between the fingers; while the more bulky vertebrate animal is protected from the same easy destruction by what might be called its skeleton of bone, gristle, and fibrous tissue.

The nerves are duller, less glistening and dense than tendons, with which the unaccustomed eye is apt to confound them. The transverse striation exhibited by their primary bundles depends on the slightly wavy or undulant course of the nerve fibres, and is found to disappear on stretching the nerves.

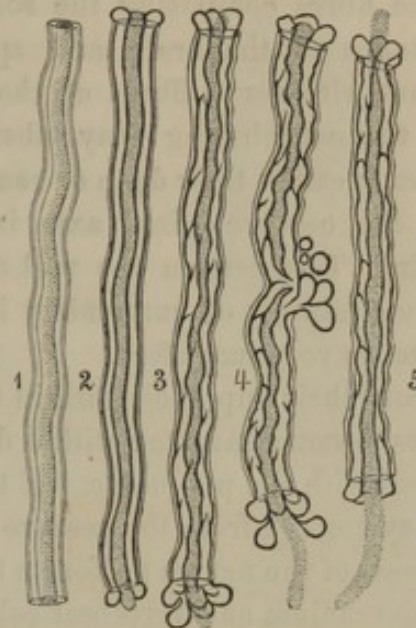
The nerves are abundantly supplied with blood-vessels, which form a capillary net-work, with elongated meshes, among the bundles of nerve fibres.

ORIGIN AND TERMINATION OF THE CEREBRO-SPINAL NERVES.

The extremity of the cerebro-spinal nerves connected with the brain and spinal cord is called their **origin** or **root**, while the peripheral extremity is named their **termination**. These terms are employed independently of their functional significance, as most nerves are composed of fibres, of which different ones transmit impressions in opposite directions, and therefore the extremities would more properly be designated their central and peripheral connections.

A nerve is said to originate by a single root when its bundles of fibres emanate from one spot or along the same line of the cerebro-spinal axis; and it is said to arise by two or more roots, when its bundles of fibres

FIG. 322.



STRUCTURE OF NERVE FIBRES, partly ideal. 1, a nerve fibre represented in the fresh condition, exhibiting in succession its neurilemma, medullary sheath, and axis fibre; 2, 3, 4, 5, exhibit the same constituents; the medullary sheath indicated, as it appears shortly after death, by heavy outlines; the axis fibre represented as dotted. In 4, 5, the axis fibre is seen projecting from the cut ends of the nerve fibres. In 4, the medullary sheath is seen exuding in drops through a rupture of the neurilemma.

form a corresponding number of series emanating from different points of the cerebro-spinal axis.

The fibres composing the roots of the nerves are traceable into the substance of the brain and spinal cord, within which they are continuous with nerve fibres of the white substance, or become connected with the neighboring gray substance. This interior connection of the nerves is called their **deep** or **real origin**, while their exterior connection with the cerebro-spinal axis is named their **superficial** or **apparent origin**. To ascertain the real origin of the nerves is among the most difficult subjects of anatomical investigation, and our knowledge in this respect is very imperfect.

From their superficial origin the bundles of fibres of the roots of the nerves become invested with a delicate sheath of connective tissue, continuous with the pia mater. If the bundles of nerve fibres are separated as they emerge from the cerebro-spinal axis they converge together, and the roots of the nerves perforate the dura mater, to pass through foramina of the cranium and vertebral column. In the course of the roots of the nerves to the dura mater, the arachnoid membrane is reflected around them. Externally to the dura mater, the nerves become invested with a strong sheath of connective tissue, which is continuous with the latter membrane, and much increases the size of the nerves.

Approaching their termination in the different organs, the nerves form frequent anastomoses; but, as in the case of the trunks and larger branches of the nerves, these anastomoses consist alone of an interchange of nerve fibres. The mode in which the latter end in the various tissues, for the most part remains an unsettled question. Until within a short period it was asserted, and the view generally adopted, that the nerves terminated in loops: that is to say, pairs of nerve fibres finally conjoined in an arching or sling-like manner. Recent observations are not confirmatory of such a conclusion. In the muscles, the nerve fibres sent off separately subdivide, and finally lose their medullary sheath, the axis fibre alone ending among the muscular fibres.

In some instances, the nerves terminate in peculiar capsular bodies, of which three varieties have been detected.

The most remarkable of the **nerve capsular bodies** are the so-called **Pacin'ian corpuscles**,¹ attached in greatest number along the digital nerves of the fingers and toes, and occasionally on other nerves. These corpuscles are oval, pyriform, or reniform, from half a line to a line long, of a pearly lustre, and consist of a series of capsules or concen-

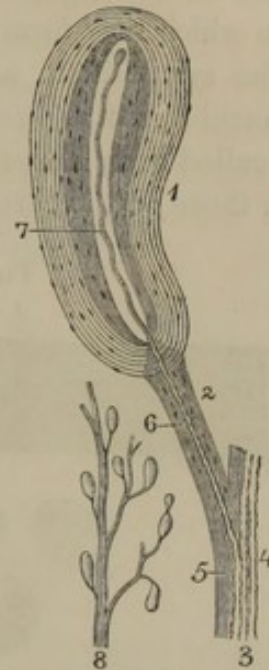
¹ Pacinian bodies; corpuscles of Vater; Vaterian corpuscles; Vater-Pacini'schen Körperchen; papillæ nerveæ.

tric layers of fibrous tissue with scattered nuclei. The outer capsules are separated more widely than the inner ones, and the interspaces, as well as the central cavity of the corpuscle, are filled with a colorless liquid. Each corpuscle is attached to the nerves by a pedicle of fibrous tissue, through which extends a single nerve fibre. The latter, after penetrating the series of capsules, terminates by sending its axis fibre into the central cavity of the corpuscle, at the top of which it ends by a simple or divided extremity.

The second variety of nerve capsular bodies are the so-called **tactile corpuscles**.¹ These are oval bodies found in many of the papillæ of touch of the fingers and palms of the hands, and the toes and soles of the feet. They average the $\frac{1}{40}$ of a line long, and consist of a single capsule of structureless membrane with transverse nuclei. They are filled with a finely-granular matter, and have entering into them usually two, but sometimes one, or even three or four, nerve fibres.

The third variety² of the nerve capsular bodies are transparent, spherical corpuscles of about the $\frac{1}{50}$ of a line in diameter, discovered in the conjunctiva of the eyeball, the mucous membrane of the root of the tongue and soft palate, and the skin of the glans penis and clitoridis. They are filled with a soft, transparent, homogeneous substance, and have entering into them one or two branches of a nerve fibre.

FIG. 323.



PACINIAN CORPUSCLES, from the digital nerve of the finger of a new-born child. 1, much magnified corpuscle, which was reniform; 2, the pedicle; 3, portion of the digital nerve; 4, several nerve fibres; 5, the fibrous sheath; 6, nerve fibre to the corpuscle; 7, axis fibre of the nerve fibre; 8, portion of a digital nerve with Pacinian corpuscles attached, of the natural size.

GENERAL CHARACTER AND STRUCTURE OF THE SYMPATHETIC NERVES.

The nerves of the sympathetic system are mostly reddish gray³ or grayish white,³ a few of the larger trunks being white, as in the case of the cerebro-spinal nerves. They are generally much smaller than the

¹ *Corpuscula tactus*; tactile corpuscles of Wagner, or of Meissner; Wagner-Meissner'schen Tastkörperchen!; axile bodies; touch corpuscles.

² Corpuscles of Krause; Krause'schen Endkolben.

³ *Nervi molles*; *n. grisei*; fasciculi nervosi molles.

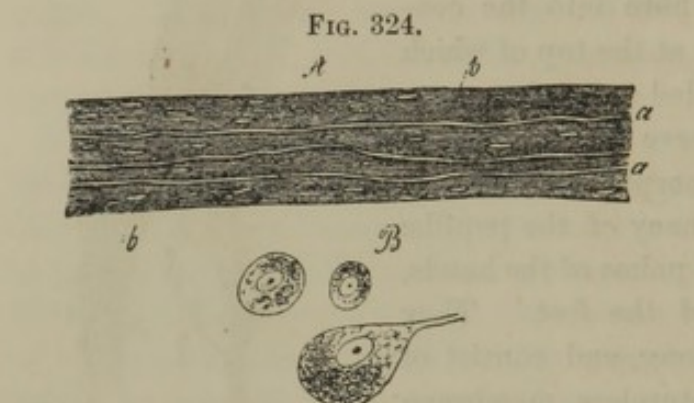
latter, and are associated with many ganglia, from which the sympathetic has likewise been called the **gan'glion'ic system of nerves**. In their course to the organs they supply, they usually follow the blood-vessels, upon which they form exceedingly intricate plexuses.

The sympathetic nerves are composed of nerve fibres, like those of the cerebro-spinal system in association with others of peculiar character, called **gray fibres**.¹ The white nerve fibres are generally much finer than those of the cerebro-spinal nerves, are most numerous in the white

trunks of the sympathetic system, and are comparatively few in the reddish-gray nerves.

The **gray fibres**¹ are far more numerous than the white ones in the reddish-gray and grayish-white sympathetic nerves.

They exist in the form of bands, averaging the $\frac{1}{500}$ of a line in breadth. In structure they appear



ELEMENTS OF THE SYMPATHETIC SYSTEM. A, portion of a nerve highly magnified: *a*, nerve fibres; *b*, gray fibres with nuclei. B, three nerve cells from a ganglion.

faintly granular, indistinctly striated or homogeneous, and are provided with elongated oval nuclei. Whether the gray fibres are a peculiar element of the nervous structure, or whether they are to be viewed as a variety of connective tissue, is a much-disputed question.

GENERAL CHARACTER AND STRUCTURE OF THE GANGLIA.

The **Gan'glia**, or **gan'glions**,² are rounded bodies situated in the course of many of the nerves. Thus, several belong to the trifacial, glosso-pharyngeal, and pneumogastric nerves; one exists on the posterior root of each spinal nerve; and a numerous series are found on the sympathetic nerves. They are mostly elliptical or spheroidal, but present many varieties of form.

The ganglia are viewed as sources of nerve power, and hence, like the brain and spinal cord, are frequently called nerve centres. The term is likewise often applied to the collections of gray substance of the cerebro-spinal axis.

¹ Fibres of Remak; gelatinous fibres.

² Ganglia nervorum; nervous ganglions; ganglia, gangliones, nodi, noduli, or tubercula nodosa nervorum; tumores,

or plexus ganglioformes; diverticula spirituum animalium; ganglia of increase; formative ganglia.

The ganglia are reddish gray or grayish white, and of firm consistence. They appear like knots or swellings in the course of the nerves, and are furnished with a tightly-adherent membrane continuous with the sheath of the latter. In structure they consist of a mass of nerve cells imbedded in a stroma of connective tissue, and are traversed by nerve fibres associated with gray fibres.

The nerve cells of the ganglia resemble those of the gray substance of the cerebro-spinal axis, but are more uniformly of large size, ranging from about the $\frac{1}{1000}$ to the $\frac{1}{300}$ of an inch. They are globular or oval, and generally unipolar or bipolar, though both apolar and multipolar cells also appear to exist. The processes of the nerve cells are continuous with the nerve fibres passing to and from the ganglion.

In the ganglia of the cerebro-spinal nerves, the cells are generally larger than in those of the sympathetic system.

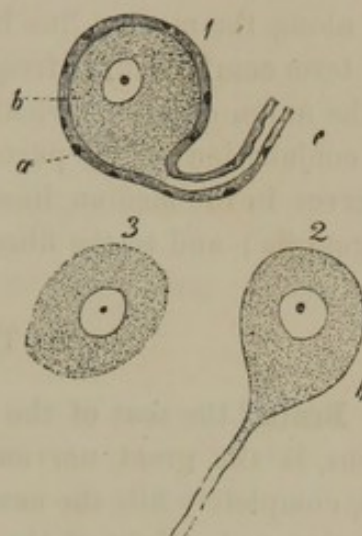
The nerve fibres partly traverse the ganglia without forming any attachment to the cells, while others are continuous with them.

The gray fibres of the ganglia are like those of the sympathetic nerves, and are especially abundant in the sympathetic ganglia, in which they occupy the position of a stroma to the nerve cells.

The stroma of the cerebro-spinal nerves appears as a homogeneous or feebly striated connective tissue furnished with nuclei, and on isolated nerve cells looks like an especial investment to them.

Like other nerve centres, the ganglia are abundantly furnished with capillary blood-vessels.

FIG. 325.



NERVE CELLS FROM THE SEMILUNAR GANGLION OF THE TRIGEMINAL NERVE OF A CAT, highly magnified. 1, nerve cell exhibiting the origin of a nerve fibre: *a*, sheath of the cell and nerve fibre with nuclei; *b*, the nerve cell within; *c*, the nerve fibre within its sheath; 2, cell with the origin of a nerve fibre deprived of its sheath; 3, nerve cell without sheath or nerve fibre.

THE CEREBRO-SPINAL AXIS, OR BRAIN AND SPINAL CORD.

The **Cer'ebro-spinal axis** consists of the **brain**, which occupies the cavity of the cranium, and the **spinal cord**, which is a prolongation of the former extending downward into the vertebral canal. Besides the

skull and vertebral column, the cerebro-spinal axis is further enveloped in three membranes, the dura mater, arachnoid, and pia mater. From it originate the **cerebro-spinal nerves**, or the **cer'ebral nerves** and the **spinal nerves**. It is symmetrical, the two halves being in contact, and united along the median line by commissures of nerve substance.

The term **com'missure**,¹ frequently employed in anatomy, generally implies the union of symmetrical parts. In the nervous system it applies to the conjunction of two parts of the brain or spinal cord; the union of two nerves in the median line of the body, to nerves between two or more ganglia; and to the fibres uniting nerve cells.

THE BRAIN.

The **Brain**,² the seat of the intellect, the will, the sensations, and the emotions, is the great nervous mass which, with its enveloping membranes, completely fills the cavity of the cranium.

The size and weight of the brain varies with the race, sex, age, and individual. It is largest in the white race; and, all other circumstances being equal, such as race, sex, age, size of body, and health, its bulk bears a general relationship with the development of intellect.

Its weight in the adult white male averages near fifty ounces avoirdupois; in the female, forty-five ounces. In its relation with the weight of the body, the difference between the two sexes is very little. In relation with the size of the body at birth, the brain bears the proportion of one to twenty; in the adult, of one to thirty-five.

The human brain is larger than in any other animal except the species of elephants and whales; but in relation with the size of the nerves given off from its base, it is larger than in any animal without exception. In relation with the size of the body, the brain is larger in some small mammals and birds than in man, as for instance, in the little monkey *Oustiti*, the field mouse, and the canary bird.

In the infant the brain is of a soft, pulpy consistence, but gradually assumes the firmness, in the adult, of newly-pressed cheese. Its specific gravity is about equal to or a very little greater than water. It is for the most part of a reddish-ash color on the exterior, and is generally ovoid in form, with the broader extremity posterior. Its upper part is uniformly convex, but its lower part, called the **base**, is uneven. It exhibits four well-marked divisions of unequal size, named the **cerebrum**, **cerebellum**, **pons**, and **medulla oblongata**.

¹ Commissura.

² Encephalon; cerebrum.

THE CEREBRUM.

The **Cer'ebrum**¹ forms about six-sevenths of the mass of the brain, and extends the whole length and breadth of its upper part. It is half ovoid, with the narrow extremity forward, the convex side upward, the base downward, and the broadest part opposite the parietal protuberances.

A deep cleft, the **great longitudinal fissure**,² extends the entire length of the upper part of the cerebrum, and the whole depth of its fore and back part. It accommodates the cerebral falx, and along its upper boundary the superior longitudinal sinus.

The lateral halves of the cerebrum are named its **hemispheres**.³ These form vertical planes next the longitudinal fissure, have their outer surface convex, and their under part forming the three pairs of **cer'ebral lobes**.

The **anterior lobes**⁴ of the cerebrum occupy the anterior fossæ of the base of the cranium, and therefore rest above the position of the orbits.

The **middle lobes**⁵ occupy the middle fossæ of the cranial cavity, and are the deepest portions of the cerebrum. They are separated from the anterior lobes by the **Syl'vian fissure**,⁶ which curves outwardly, and receives the small wings of the sphenoid bone.

The **posterior lobes**⁷ have no dividing line from those in advance, and are constituted by the portions of the cerebrum resting upon the tentorium, or situated above the cerebellum. In the upper view of the brain they completely conceal the latter, and their under surface is somewhat hollowed, to accommodate the prominent upper part of the cerebellum.

The cerebral hemispheres have their surface everywhere thrown into winding eminences called **convolutions**,⁸ separated by deep **fissures**,⁹ which receive processes of the pia mater.

¹ Cerebrum magnum; encephalon; the brain; the great brain.

² Superior longitudinal sinus; fissura, or scissura cerebri longitudinalis; f. c. l. superior, inferior, et horizontalis posterior; interlobular fissure.

³ Hemisphæria cerebri; h. c. et pars media cerebri.

⁴ Lobi anteriores; l. minores.

⁵ Lobi medii; l. descendentes.

⁶ Fissura, or fossa Sylvii; fissura anterior; f. a. inferior et externa; f. inferior; f. transversa.

⁷ Lobi posteriores. The middle and posterior together named lobi posteriores; l. majores; l. temporo-occipitales.

⁸ Cerebral circonvolutions; gyri; processus enteroides cerebri.

⁹ Sulci; anfractuosities.

Deuss a French Physician - wrote to Francis & Taylor
 (Dubois) Anatomist in University of Paris in 1820

The **Convolutions** of the cerebrum are nearly of uniform diameter, and are rounded at the borders of the fissures separating them, but are rather flattened at the summit. Their course is, however, not symmetrical on the two hemispheres, nor are they alike in two individuals, though there is sufficient correspondence in their position and general direction to permit of their being identified. One¹ of the most characteristic of these convolutions arches over the corpus callosum on each side; another,² less well-marked, borders the great longitudinal fissure; and a third³ borders the Sylvian fissure, and incloses a small group of convolutions⁴ concealed within the latter.

The exterior of the cerebrum is composed of gray substance called, from its position, **cortical**,⁵ while the interior consists of white substance named, in contradistinction, **medullary**.⁶ In a horizontal section of the cerebral hemispheres, they exhibit a central oval surface⁷ of white substance spotted with minute red points arising from the division of blood-vessels. The circumference of the plane of white substance is observed to form many processes corresponding with the divided convolutions. These processes are further noticed to be everywhere inclosed by the cortical gray matter, which forms a layer of uniform thickness, and follows the course of all the convolutions and fissures of the cerebral hemispheres. In a section of the hemispheres, on a level with the corpus callosum, this appears as a bridge of white substance associating the oval centres⁸ of the same material of the cerebrum.

In a view of the base of the brain, the posterior lobes of the cerebrum are concealed by the cerebellum. In advance of this are the medulla oblongata and pons, and in front of the latter, along the median part of the cerebrum, the following are observed in succession: the cerebral crura, the mammillary eminences, the infundibulum, the pituitary body, the optic nerves and commissure, and the olfactory nerves.

The **Crura of the cer'ebrum**⁹ are two large cylindroid bodies diverg-

¹ Great convolution of the corpus callosum; internal convolution of the hemispheres; gyrus fornicatus; processus cristatus.

² Great convolution of the circumference of the hemispheres; marginal convolution of the longitudinal fissure.

³ Convolution of the Sylvian fissure.

⁴ Island of Reil; insula; i. Reilii; gyri operi.

⁵ Cineritious, or vesicular substance.

⁶ Tubular, or fibrous substance; medulla cerebri.

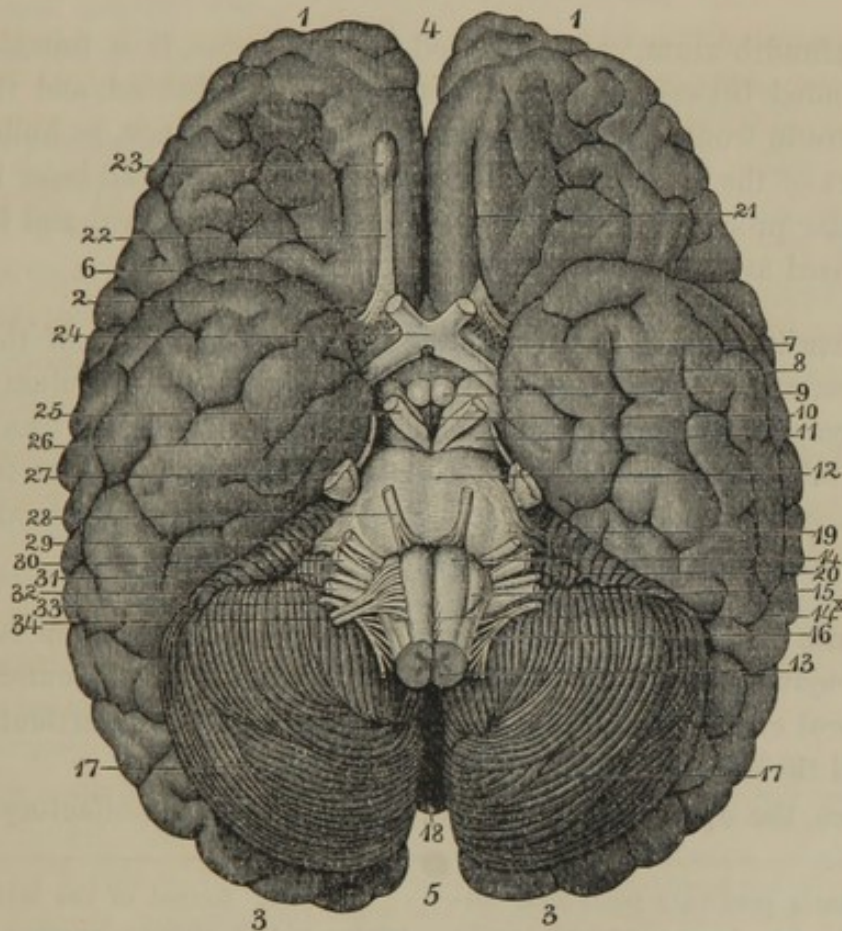
⁷ Centrum semi-ovale; c. ovale Vieussenii; c. ovale minus; lesser oval centre of Vicq-d'Azyr.

⁸ Greater oval centre; centrum ovale Vieussenii.

⁹ Crura cerebri; pedunculi cerebri; processus medullares cerebri; caudex cerebri; crura anteriora medullæ oblongatæ; peduncles of the brain; cerebral peduncles.

ing from the fore part of the pons into the cerebral hemispheres, at the inner side of their middle lobes. They are longitudinally striated, and composed, on the exterior, of white substance. On the interior they contain a collection of gray substance,¹ which appears as a crescentoid layer in a transverse section through them.

FIG. 326.



BASE OF THE BRAIN. 1, anterior lobes of the cerebrum; 2, middle lobes; 3, posterior lobes; 4, 5, anterior and posterior extremities of the great longitudinal fissure; 6, Sylvian fissure; 7, anterior perforated space; 8, infundibulum; 9, mammillary eminences; 10, posterior perforated space; 11, crura of the cerebrum; 12, pons; 13, medulla oblongata; 14, pyramidal bodies; 14*, decussation of the pyramids; 15, olivary body; 16, restiform body; 17, hemispheres of the cerebellum; 18, vermiform process at the bottom of the fissure separating the latter; 19, crus of the cerebellum; 20, pneumogastric lobule of the cerebellum; 21, fissure which accommodates the olfactory nerve; 22, 23, bulb of the olfactory nerve; 24, optic commissure; 25, oculo-motor nerve; 26, pathetic nerve; 27, trifacial nerve; 28, abducent nerve; 29, facial nerve; 30, auditory nerve; 31, glosso-pharyngeal nerve; 32, pneumogastric nerve; 33, accessory nerve; 34, hypoglossal nerve.

The interval² separating the crura at its fore part includes the mammillary eminences and the infundibulum. At its posterior angle it forms a deep pit, which is separated from the third ventricle by some mingled

¹ Locus niger; substantia nigra; stratum nigrum.

² Interpeduncular space.

gray and white substance perforated by a number of small blood-vessels, and hence named the **posterior perforated space**.¹

The **Mam'millary eminences**² are two small, white, spherical bodies, in contact with each other, immediately in advance of the space just mentioned. They are connected above with the anterior crura of the fornix, and contain some gray substance.³

The **Infundib'ulum**,⁴ as expressed by the name, is a funnel-shaped body included between the mammillary eminences behind, and the optic commissure in front. It is composed of gray substance, is hollow, and forms part of the bottom of the third ventricle. Its broad base⁵ narrows to a tubular process, which is directed obliquely downward and forward, and is closed at the extremity.

The **Pitu'itary body**⁶ occupies the corresponding fossa of the sphenoid bone, and is connected with the end of the infundibulum. It is reddish gray, of firm consistence, and presents an anterior transversely reniform lobe, and a smaller posterior rounded one. Its structure consists of a stroma of connective tissue, with many capillary blood-vessels mingled with granular matter, nuclei, and nucleated cells.

The **Optic com'missure**,⁷ situated in front of the infundibulum, is formed by the conjunction of the optic tracts converging from the outer side of the cerebral crura. It and its connections will be more particularly described in the account of the optic nerves.

Between the optic commissure and the roots of the olfactory nerves,

¹ Substantia perforata postrema, posterior, or media: basis ventriculi tertii; antrum; pons Tarini.

² Eminentiae mammillares, candicantes, glandulosæ, papillares, or medullares; bulbi fornicis; bulbs of the fornix; b. priorum crurum fornicis; globuli medullares; g. albi; corpora alba, mammillaria, albicantia, or glandularia; protuberantiæ crurum medullæ oblongatæ; p. glandulosæ; p. orbiculares; tubercula mammillaria, hemispherica, or pisi-formia; prominentiæ albicantes; glandulæ sub-infundibulo; g. candicantes; processus glandulosi; protensiones glandulares; testiculi cerebri; mammæ muliebres.

³ Nucleus griseus.

⁴ Funnel; funnel of the middle ventricle; pelvis, choana, cyathus, concha, scyphus, lacuna, aquæductus, embolum, labrum, concavitas conchularis, or processus orbicularis cerebri; tubercineum cum infundibulo.

⁵ Tuber cinereum; substantia perforata media posterior.

⁶ Glandula pituitaria, pituitosa, or basilaris; hypophysis, appendix, or appendicula cerebri; caput rosæ; colatorium; labrum; lacuna; infusorium; concha; pelvis; p. colatoria; sentina encephali.

⁷ Chiasma opticum; chiasm of the optic nerves; chiasma nervorum optico-rum.

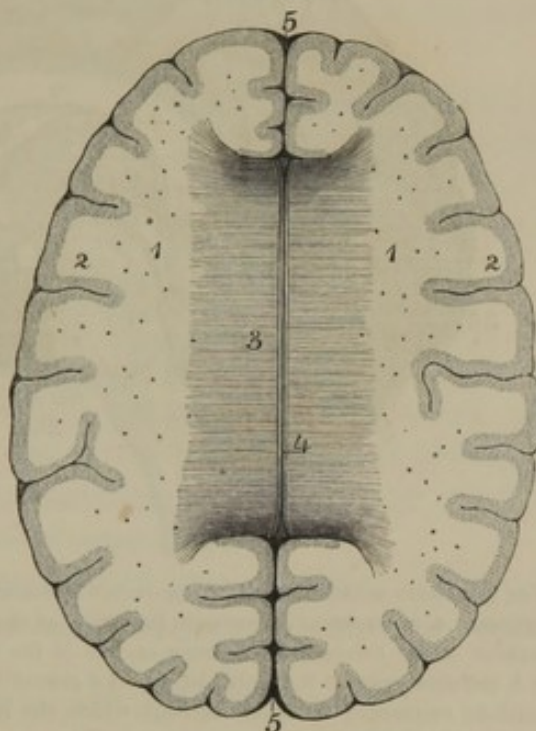
on each side, are the **anterior perforated spaces**,¹ so called from their presenting numerous small apertures for vessels which penetrate to the interior of the cerebrum.

On pressing apart the cerebral hemispheres, at the bottom of the great longitudinal fissure, a convex white body, the corpus callosum, is observed to connect the former, and extend for several inches along the latter.

The **Corpus callo'sum**,² or **great cer'ebral com'-missure**, in a section of the brain on a level with it, appears as a bridge of white substance, about three inches long and three-fourths of an inch wide, uniting the central white masses of the cerebral hemispheres. It reaches farther forward than backward, and is narrower anteriorly. Its upper surface³ arches in the length, and is transversely striated,⁴ but exhibits on each side of the median line⁵ a narrow tract of longitudinal striæ.⁶ Its anterior and posterior borders are thick and rounded, and are separated by fissures from the contiguous gray substance of the cerebral hemispheres.

In a vertical section of the brain, along the great longitudinal fissure,

FIG. 327.



TRANSVERSE SECTION OF THE HEMISPHERES OF THE CEREBRUM ON A LEVEL WITH THE CORPUS CALLOSUM. 1, white substance of the hemispheres, dotted with divided capillary vessels; 2, gray substance on the convoluted exterior; 3, corpus callosum, with the direction of its fibres indicated by transverse striæ; 4, longitudinal median striæ; 5, anterior and posterior portions of the great longitudinal fissure.

¹ Substantia perforata anterior; s. cribrosa anterior; lamina cribrosa cerebri; substantia perforata antica media, et partes laterales substantiæ perforatæ anticæ.

² Commissura magna, or maxima cerebri; trabs cerebri; t. medularis; cupula alba, or magna cerebri: great commissure of the brain; mesolobe.

³ Facies, or superficies superior, or libera.

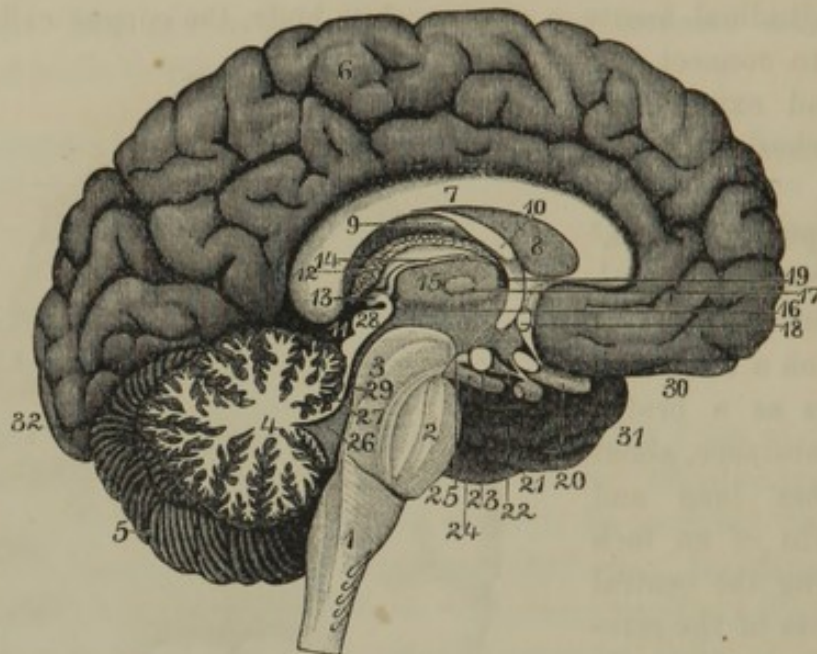
⁴ Striæ, or chordæ transversales Willisii.

⁵ Raphé; r. externa; linea, or chorda longitudinalis.

⁶ Striæ longitudinales Lancisii, internæ, or liberæ; nerves of Lancisi.

the corpus callosum is observed to be a thick layer of white substance passing beneath an arching convolution of each cerebral hemisphere. Its anterior part¹ appears doubled on itself producing a thick fold, the

FIG. 328.



SECTION OF THE BRAIN ALONG THE GREAT LONGITUDINAL FISSURE. 1, medulla oblongata; 2, pons; 3, crus of the cerebrum; 4, arborescent appearance in section of the fundamental portion of the cerebellum; 5, left hemisphere of the cerebellum; 6, inner surface of the left hemisphere of the cerebrum; 7, corpus callosum; 8, pellucid septum; 9, fornix; 10, anterior crus of the fornix descending to join the corresponding mammillary eminence; 11, fissure through which the interposed ~~ventricle~~ ^{velum} 12 is introduced into the third ventricle; 13, pineal gland; 14, its peduncle; 15, rests on the thalamus within the third ventricle; 16, posterior commissure of the latter; 17, middle commissure; 18, anterior commissure; 19, foramen of communication between the third and lateral ventricles; 20, optic nerve; 21, pituitary body; 22, infundibulum; 23, mammillary eminence; 24, oculo-motor nerve; 25, posterior perforated space; 26, fourth ventricle; 27, valve of the brain; 28, quadrigeminal body; 29, entrance from the third to the fourth ventricle; 30, 31, 32, anterior, middle, and posterior lobes of the cerebrum.

under portion² of which becomes continuous with a thin lamina³ curving downward to the optic commissure, and closing the front of the third ventricle. - The posterior part⁴ is seen to reach the base of the cerebrum, just above the position of the quadrigeminal body and the most prominent portion of the cerebellum.

In structure the corpus callosum consists of a thick stratum of nerve fibres diverging through the white substance of the cerebral hemispheres to their cortical gray substance.

¹ Genu corporis callosi.

² Rostrum corporis callosi; apex genu.

³ Lamina genu; lamina cinerea et pedunculi corporis callosi.

⁴ Splenium, or tuber corporis callosi.

FORNIX.

Continuous with the back part of the corpus callosum, and arching forward beneath nearly to its anterior part, is a thin layer of white substance, the **fornix**.¹ Viewed from above or below it is triangular. Its upper surface along the middle is continuous with the corpus callosum and pellucid septum, and on each side forms part of the floor of the lateral ventricles. Its lower vaulted surface² is longitudinally and transversely striated, and forms the roof of the third ventricle.

The apex of the fornix divides into two portions, its **anterior crura**,³ which descend with a slight divergence to the mammillary eminences. The basal angles are prolonged, as its **posterior crura**,⁴ into the middle horns of the lateral ventricles, and become continuous with the fimbriated body.

PELLUCID SEPTUM.

The interval between the corpus callosum and fornix, in the median line of the brain, is occupied by the **pellucid septum**,⁵ a thin partition of nerve substance separating the lateral ventricles. It includes a narrow cavity or fissure, the **fifth ventricle**,⁶ which is closed at all points, and is lined with a delicate serous membrane.

The pellucid septum is composed of gray substance on its exterior surface, and of white substance on the surface next the fifth ventricle.

LATERAL VENTRICLES.

Beneath the corpus callosum on each side is a cavity with prolongations extending into the three lobes of the cerebral hemispheres. The cavities are the **lateral ventricles**;⁷ the prolongations are named the **horns**.⁸

¹ Fornix cerebri, trilateralis, or tricuspidalis; arcus medullaris; camera; cornix; corpus psaloides; c. camera-tum; trigonum cerebrale; testudo; communio cerebris.

² Lyra; psalterium; corpus psalloideum; lamina medullaris; l. triangularis; membrana medullaris inter crura posteriora fornicis.

³ Crura or cornua anteriora fornicis; cornua fornicis; columnæ fornicis; anterior pillars or pillar; crus, or columna fornicis.

⁴ Crura posteriora fornicis; crura fornicis; posterior pillars.

⁵ Septum pellucidum, or lucidum; diaphragma cerebri; d. ventriculorum lateralium; speculum; corpus speculare; mediastinum; septum medium; s. tenue; tympanum; septum medullare triangulare.

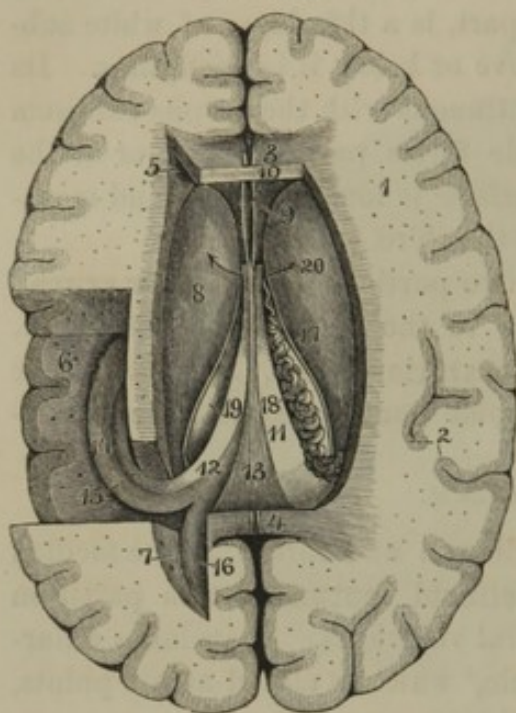
⁶ Ventriculus quintus; ventriculus, camera, or sinus septi pellucidi; incisura septi; cavitas Vieussenii, Sylvii, Duncani, prima, or quinta.

⁷ Ventriculi laterales; v. anteriores; v. magni; v. majores; v. priores; v. superiores; v. tricornes; sinus anteriores.

⁸ Cornua; c. laterales; partes laterales.

Each lateral ventricle has for its roof¹ the corpus callosum, its floor the fornix, its inner wall the pellucid septum, and its outer wall the striated body.

FIG. 329.



TRANSVERSE SECTION OF THE CEREBRAL HEMI-SPHERES, THE CORPUS CALLOSUM REMOVED, AND THE LATERAL VENTRICLES EXPOSED. 1, white substance of the interior of the cerebral hemispheres; 2, gray substance of the exterior convoluted surface; 3, 4, anterior and posterior extremities of the corpus callosum; 5, anterior horn of the left lateral ventricle; 6, middle or descending horn; 7, posterior horn; 8, striated body; 9, pellucid septum; 10, fifth ventricle; 11, fornix; 12, posterior crus of the fornix; 13, attachment of the fornix to the under part of the corpus callosum; 14, hippocampus; 15, fimbriated body; 16, ergot; 17, semi-circular line; 18, choroid plexus; 19, edge of the thalamus. 20 Foramen Monroii

The **anterior horn**² of the lateral ventricle, less conspicuous than the others, is simply the extension of the cavity around the anterior extremity of the striated body.

The **middle horn**³ curves downward into the middle cerebral lobe. From the inner part of its floor projects a thick convex ridge, indented at its lower end,⁴ and named the **hippocampus**.⁵ The upper border of the ridge is provided with a white band, named the **fimbriated body**,⁶ which is continuous with the posterior crus of the fornix.

The hippocampus is composed of white substance⁷ on the surface, of gray substance within, and the latter appears superficially as a **dentated band**⁸ on the inner or concave side of the hippocampus.

The **posterior horn**⁹ curves inwardly as it passes into the pos-

¹ Tegumentum cellæ lateralis; t. ventriculi lateralis.

² Cornu anterius.

³ Cornu medium, inferius, descendens, magnum, or laterale; sinus inferior hippocampi; s. cornu Ammonis; ventriculus inferior hippocampi; v. bombycinus.

⁴ Digiti cornu Ammonis; colliculi fissi interni; uncus; pes hippocampi.

⁵ Hippocampus major; pes hippocampi; p. h. major; cornu Ammonis; c. arietis; vermis, or appendix bombyci-

nus; bombyx; processus cerebri lateralis; protuberantia cylindroides; pes hippocotami major.

⁶ Fimbria, or tænia hippocampi; limbus, or corpus fimbriatum; c. f. Sylvii.

⁷ Lamina medullaris superficialis cornu Ammonis.

⁸ Fascia dentata; margo denticulatus Tarini.

⁹ Cornu posterius; cavitas digitalis; c. ancyroidea; diverticulum.

terior cerebral lobe. From its inner side projects a white, spur-like ridge, named the **ergot**.¹

The lateral ventricles communicate with each other and with the third ventricle by a foramen² beneath the anterior crura of the fornix. In all other positions they are closed, and are lined throughout with a delicate serous membrane.

CORPORA STRIATA, OR STRIATED BODIES.

Projecting into each lateral ventricle from the outer wall is a half-pyriform prominence, named, from its appearance in section, the **cor'pus stria'tum**, or **striated body**.³ Its larger portion⁴ is anterior, and its narrower portion⁵ curves backward to the outer side of the thalamus. Some depth from the ventricular surface it is composed of gray substance,⁶ beneath which is a layer of white substance,⁷ succeeded by a **lenticular nucleus**⁸ of gray substance. The latter is penetrated by the diverging fibres of the cerebral crus, giving to it in section a striated appearance. Below the fore part of the lenticular nucleus is a smaller accumulation of gray substance,⁹ and to its outer side is another collection.¹⁰

On the floor of each lateral ventricle is a remarkable vascular appendage of the pia mater, named the **choroid plexus**. This extends from the foramen beneath the anterior crura of the fornix along the side of the latter, and descends to the bottom of the middle horn of the lateral ventricle. It is continuous beneath the fornix with the interposed velum of the pia mater, and is separated from the cavity of the lateral ventricle by its lining membrane.

THIRD VENTRICLE.

Beneath the fornix is the **third ventricle**¹¹ of the brain. This is a narrow triangular cavity, with its apex forward and its base corresponding with the fissure between the posterior border of the corpus callosum

¹ Hippocampus minor; calcar; c. avis; unguis; u. avis; u. Halleri; ocrea; pes hippocampi minor; eminentia minor digitata; e. unciformis; ocrea; colliculus.

² Foramen of Monro; f. Monroi; f. anterius; vulva.

³ Pl.: corpora striata; eminentiæ striatæ; e. pyriformes; e. similes coxis humani; e. lenticulares; prominentiæ lentiformes; apices medullæ oblongatæ; processus anteriores medullæ oblongatæ; ganglia magna superiora cerebri; g. cerebralia anteriora; colliculi nervo-

rum ethmoidalium; apices crurum medullæ oblongatæ.

⁴ Caput.

⁵ Cauda

⁶ Nucleus caudatus; n. intraventricularis.

⁷ Capsula medullaris nuclei lentiformis; capsula externa.

⁸ Nucleus lentiformis; n. extraventricularis.

⁹ Nucleus amygdalæ.

¹⁰ Claustrum; nucleus tæniæformis.

¹¹ Ventriculus tertius; v. medius cerebri.

and the quadrigeminal body. Its fore part is closed by the anterior descending portion of the corpus callosum. Its floor is formed in succession from before backward by the optic commissure, infundibulum,¹ mammillary eminences, posterior perforated space, and cerebral crura. Behind the latter and beneath the quadrigeminal body it communicates² with the fourth ventricle by a narrow passage,³ the sides of which are coated with gray substance.⁴ As previously mentioned, beneath the anterior crura of the fornix it opens on each side into the lateral ventricles.

At the fissure,⁵ between the posterior border of the corpus callosum and the cerebellum, a process of pia mater, the **interposed velum**,⁶ is introduced along the under surface of the fornix, which forms the vaulted roof of the third ventricle.

THALAMI.

The outer walls of the third ventricle are formed by a large, oval prominence, the **thal'amus**,⁷ which is supported on the inner side of the diverging cerebral crus. Its ventricular surface, for the most part, is composed of white substance,⁸ but on the inner side exhibits some gray substance. Its interior is composed of mingled white and gray substance.⁹

In front and to the outer side the thalamus is separated from the striated body by a narrow **semicircular band**¹⁰ of white substance. The anterior and posterior more prominent portions of the thalamus are named its **tubercles**.¹¹ Beneath the posterior tubercle are two convex white eminences, the **genic'ulate bodies**,¹² which give partial origin to the optic tracts.

¹ Aditus ad infundibulum.

² Aditus ad aquæductum Sylvii; introitus.

³ Iter e tertio ad quartum ventriculum; aquæductus Sylvii; fistula sacra; ventriculus subter nates et testes; transitus ad ventriculum quartum; aquæ emissorium; canalis medianus; incile, or canalis tuberculorum; c. corporum quadrigeminarum.

⁴ Substantia feruginea superior.

⁵ Transverse fissure of the cerebrum.

⁶ Velum interpositum; tela choroidea.

⁷ Optic thalamus; pl.: thalami nervorum opticorum; ganglia magna inferiora cerebri; g. cerebri media; g. c. postica; protuberantiæ striatæ; eminentiæ mag-

næ cerebri; corpora striata superna posteriora; c. s. posteriora interna; colliculi nervorum opticorum; capita, or crura medullæ oblongatæ; juga crurum medullarium; secundum par tuberculorum; secunda sectio crurum medullarium.

⁸ Stratum zonale.

⁹ Nuclei cinerei.

¹⁰ Tænia semicircularis; t. terminalis; lamina cornea; centrum geminum semicirculare; stria cornea. In part: acies, flabellum, and penicillus.

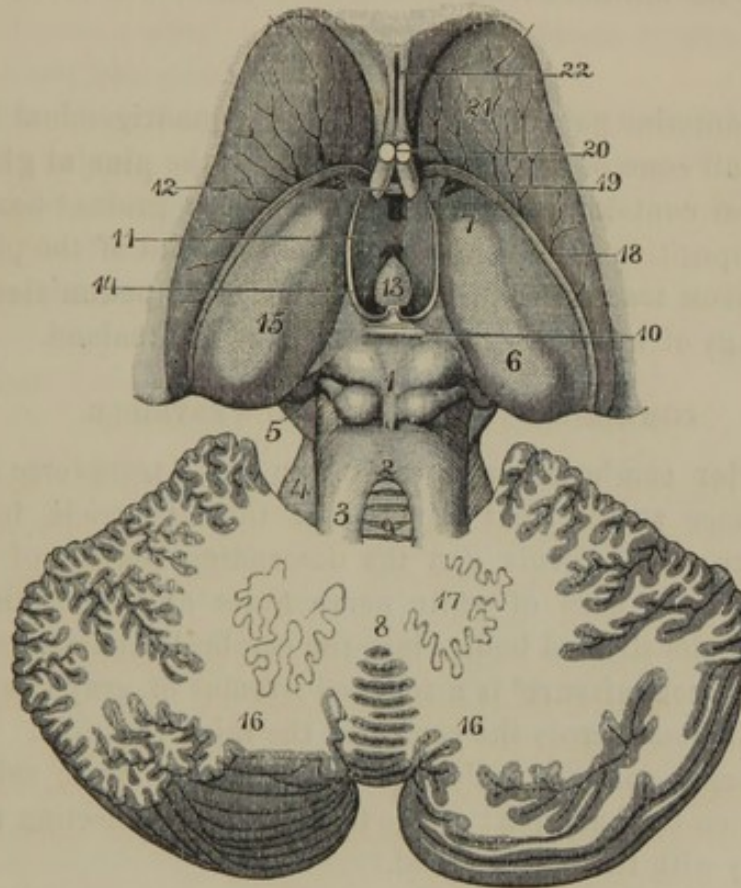
¹¹ Tuberculum superius anterius and t. s. posterius, or pulvinar.

¹² Corpus geniculatum internum and c. g. externum; corpora geniculata.

QUADRIGEMINAL BODY.

At the back part of the third ventricle is situated a quadrate, white mass, divided on its upper surface by a crucial gutter¹ into four emi-

FIG. 330.



STRIATED BODIES, THALAMI, QUADRIGEMINAL BODY, AND CEREBELLUM. 1, quadrigeminal body; 2, valve of the brain; 3, superior peduncle of the cerebellum; 4, superior portion of the middle peduncle; 5, superior portion of the crus of the cerebrum; 6, posterior tubercle of the thalamus; 7, anterior tubercle; 8, fundamental portion of the cerebellum; 9, process of gray substance resting on the valve of the brain; 10, posterior commissure of the third ventricle; 11, middle commissure; 12, anterior commissure; 13, pineal gland turned forward; 14, its peduncle; 15, thalamus; 16, hemispheres of the cerebellum; 17, dentated body; 18, semicircular line; 19, vein of the striated body; 20, anterior crura of the fornix; 21, striated body; 22, fifth ventricle between the layers of the pellucid septum.

nences, from whence it derives the name of **quadrigem'inal body** or **bodies**.² It extends obliquely from the thalami toward the cerebellum, with which it is connected by the superior peduncles. At the sides it is

¹ Sulcus longitudinalis et s. transversus corporum quadrigeminae.

² Corpora, or tubercula quadrigemina; c. bigemina; c. anteriores; protuberantiae; processus natiformes et testiformes; tubercula; t. anteriora et posteriora;

prominentiae; p. orbitales; p. encephalici; nates et testes; prominentiae, eminentiae, or corpora superiores et inferiores, majores et minores, or natiformes et testiformes; pons Sylvii.

attached to the thalami and geniculate bodies; and by means of a band¹ of white substance joins the back part of the pons between the crura of the cerebrum and cerebellum. Between it and the posterior border of the corpus callosum is the fissure through which the interposed velum of the pia mater is introduced along the roof of the third ventricle. Beneath it is the entrance from the latter to the fourth ventricle.

PINEAL GLAND.

Upon the anterior pair of eminences of the quadrigeminal body there reposes a small cone of gray substance, named the **pine'al gland**.² It is remarkable for containing a quantity of sand-like grains,³ having nearly the same composition as bone earth. From the front of the pineal gland a pair of narrow tracts of white matter, named its **pedun'cles**,⁴ diverge, like the prongs of a fork, to the inner sides of the thalami.

COMMISSURES OF THE THIRD VENTRICLE.

The **anterior com'missure**⁵ appears as a small transverse cylinder of white substance at the front part of the third ventricle, between the anterior crura of the fornix and the descending portion of the corpus callosum. It is a cord of white nerve fibres extending through the lower part of the striated bodies into the cerebral hemispheres.

The **middle commissure**⁶ is a rounded isthmus of gray substance connecting the thalami across the centre of the third ventricle.

The **posterior commissure**⁷ is a thin lamina of white substance extended between the back part of the thalami, and connecting the quadrigeminal body with the pineal gland.

THE CEREBELLUM.

The **Cerebel'lum**⁸ forms about one-eighth of the bulk of the brain, and occupies the posterior fossæ of the cranial cavity, beneath the ten-

¹ Lemniscus; fillet; laqueus; fasciculus triangularis lateralis; ribbon of Reil.

² Glandula pinealis; conarium; pinus; penis; cerebral epiphysis; corpus conoides; c. turbinatum; turbo cerebri; virga.

³ Cerebral sand; acervulus cerebri; concrementa pinealia; sabulous matter; brain sand; pineal sand; sabulum conarii; lapilli glandulæ pinealis.

⁴ Pedunculi conarii; striæ, or tæniæ medullares; habenula; reins.

⁵ Commissura anterior.

⁶ Commissura media; c. mollis; chordæ Willisii; unio thalamorum nervorum opticorum.

⁷ Commissura posterior.

⁸ Cerebrum parvum; c. posterius; appendix ad cerebrum; encranion; epen-cranis; parencephalum; encephalum; micrencephalum; encephalus opisthius; little brain; after brain.

torium, which separates it from the posterior lobes of the cerebrum. Like the latter, it consists of two lateral portions, named **hemispheres**,¹ which are separated behind and below by a wide, deep groove, named the **valley**.²

The hemispheres are associated by an intermediate or **fundamental portion**,³ which is not distinctly evident above, but appears at the bottom of the valley as a thick, worm-like ridge, whence it receives the name of the **vermiform process**.⁴

The superior cerebellar surface⁵ is moderately convex, is most prominent at its anterior portion,⁶ and inclines from the median line of union⁷ of the hemispheres to their lateral border. The lower and outer surfaces⁸ are prominently convex.

The exterior of the cerebellum presents the same gray color as that of the cerebrum, and is divided by numerous fissures⁹ into nearly parallel **laminæ**,¹⁰ having a general transverse direction.

When the constitution of the hemispheres is examined, it is found that each consists of an interior prismoid trunk¹¹ of white substance, from the sides of which emanate about a dozen broad, thin, divergent laminæ of the same material. These divide into a second series of thinner laminæ, which in many cases subdivide. Around the laminar divisions of white substance the **cortical gray substance** of the cerebellum is folded, the intervals of the folds corresponding with fissures of the cerebellar surface. In consequence of this arrangement, a vertical section of the hemispheres exhibits an arborescent appearance,¹² while a transverse section simply presents a broad surface of the **medullary white substance** bordered by gray substance.

The fundamental portion of the cerebellum exhibits the same arrangement of structure as the hemispheres, and differs only in accordance with the comparative size of the part.

At the anterior extremity of the valley, the hemispheres form a pair of rounded eminences, including between them a more prominent por-

¹ Hemisphæria cerebelli; pontes laterales.

² Vallis; vallicula; scissura cerebelli longitudinalis.

³ Ambitus vermis; vermiform process.

⁴ Inferior vermiform process; the worm; vermis inferior; protuberantia vermiformis; pyramid of Malacarne; pyramid, uvula, and nodulus.

⁵ Superficies cerebelli superior.

⁶ Culmen; monticulus.

⁷ Monticulus; superior vermiform process; vermis superior; protuberantia vermiformis superior.

⁸ Superficies cerebelli inferior.

⁹ Sulci.

¹⁰ Gyri; convolutions; circonvolutions.

¹¹ Stratum medullare; medullium laterale.

¹² Arbor vitæ.

tion of the vermiform process, which together, from their resemblance in relative position, have been named **tonsils**¹ and **uvula**. Above the tonsils anteriorly, and separated from them by a fissure² proceeding from the cerebellar crura outwardly, each hemisphere presents the **pneumogas'tric lobule**,³ so named from its vicinity to the corresponding nerve.

DENTATED BODY. *

Within the trunk of white substance of each hemisphere of the cerebellum there is a plicated pouch-like layer⁴ of gray substance. In section this appears as an indented nucleus of white substance⁵ bordered by gray substance, whence its name of the **dentated body**.⁶ The gray layer is open at its upper and inner part, in which position the nerve fibres of the white substance gain admission to its interior surface.

CRURA OF THE CEREBELLUM.

At the base of the brain, the pons extends laterally as a pair of cylindroid processes of white substance, diverging posteriorly, and entering the hemispheres of the cerebellum. These processes are the **crura**, or **middle pedun'cles of the cerebellum**.⁷ They are longitudinally striated, and consist of large bundles of nerve fibres proceeding from the pons to the white substance of the cerebellar hemispheres.

Behind the crura are situated the superior and inferior peduncles of the cerebellum.

The **Superior pedun'cles**⁸ are two flattened, cylindrical, white bands, ascending obliquely in a converging manner from the interior white substance of the hemispheres of the cerebellum to the quadrigeminal body. The triangular interval of these peduncles, and the fundamental portion of the cerebellum, is closed by a thin lamina of white matter, incorrectly

¹ Tonsillæ; amygdalæ; lobi medullæ oblongatæ; lobi interni cerebelli.

² Sulcus horizontalis; s. perpendicularis; s. magnus cerebelli.

³ Lobuli nervi-pneumogastrici; appendices lobulares anteriores; flocculi; subpeduncular lobes.

⁴ Fascia dentata cinerea, or fimbriata.

⁵ Medulla centralis, or ciliaris.

⁶ Corpus dentatum, denticulatum, rhomboideum, ciliare, or mixtum; nucleus dentatus, rhomboidalis, lenticulatus, fimbriatus, or centralis; ganglion

ciliare; g. cerebelli; substantia rhomboidea.

⁷ Crura cerebelli; c. c. ad pontem; c. media; c. lateralia; c. posteriora; brachia pontis.

⁸ Anterior peduncles; crura, or brachia cerebelli ad corpora quadrigemina; crura superiora; c. anteriora; c. ascendencia; commissura cerebelli et cerebri; brachia conjunctoria, or copulativa; processus cerebelli ad testes; processus ad testes; columnæ valvulæ Vieussenii; oblique intercerebral commissures.

named the **valve of the brain**.¹ This so-called valve is attached at all its borders, and is situated over the fourth ventricle. Upon its upper surface a tongue-like process² of gray substance, transversely ridged, is extended from the cerebellum.

The **Inferior peduncles of the cerebellum**,³ smaller than the others, are two narrow, white bands, which proceed from the interior of the hemispheres, and descend to become continuous with the restiform bodies of the medulla oblongata.

THE PONS.

The **Pons**⁴ is a quadrate white body, situated back of the middle of the base of the cerebrum, and in advance of the cerebellum. It rests on the upper part of the basilar process of the occipital bone, and the declivity of the sphenoid bone. Its under surface is convex and transversely striated,⁵ and its anterior and posterior borders are rounded. Along the median line of the under surface it presents a shallow groove,⁶ which accommodates the basilar artery, and also exhibits small perforations transmitting branches of the latter.

The superficial or lower portion of the pons is composed of transverse nerve fibres, which at the sides diverge as the crura or middle peduncles of the cerebellum.

The association of the hemispheres of the cerebellum through its middle peduncles is the origin of the name pons, signifying a bridge, though the term is extended in its application to the deeper parts, or those within the superficial portions of the structure. The latter, which constitutes a transverse commissure conjoining the hemispheres of the cerebellum, depends on these for its existence; and therefore in birds, in which the cerebellar hemispheres do not exist, the transverse commissural portion of the pons is absent.

¹ Valvula cerebelli; v. Vieussensii; v. Willisiana; v. cerebri; v. magna cerebri; velum medullare anterius; v. Vieussensii; v. interjectum cerebelli; v. apophysi vermiformi obtentum; lacunar ventriculi quarti superior.

² Lingula; linguetta laminosa.

³ Pedunculi cerebelli sensu strictiori; crura cerebelli ad medullam oblongatam; c. c. ad medullam spinalem; crura inferiora; c. posteriora.

⁴ Pons Varolii; p. cerebelli; nodus encephali; n. cerebri; protuberantia annularis; p. a. Willisii; p. basilaris; annular protuberance; processus, eminentia, or prominentia annularis; tuber annulare; corpus annulare; commissura hemisphæriorum cerebelli; c. cerebelli; mesocephalon; Varoli's bridge; cerebral protuberance.

⁵ Sulci transversi; s. obliqui; s. minores pontis.

⁶ Sulcus basilaris.

From the front of the pons, the crura of the cerebrum appear to emerge, and this is found actually to be the case on removal of the superficial portion of the pons; for within this, longitudinal fasciculi of fibres, intermingled with gray matter, extend from the medulla oblongata upward to become continuous with the cerebral crura.

THE MEDULLA OBLONGATA.

The **Medul'la oblonga'ta**¹ is the smallest of the four divisions of the brain, and is a white, pyriform body, situated in front of the cerebellum, and extending from the pons to the spinal cord, with which it is continuous. It is a little over an inch in length, and rests in the groove of the basilar process of the occipital bone. It is divided into two lateral portions by an **anterior** and a **posterior median fissure**, continuous below with the corresponding fissures of the spinal cord.

The medulla oblongata is further divided on each side into the pyramidal, olivary, and restiform bodies, and the posterior pyramids.

The **Pyram'idal bodies**² appear on each side of the anterior median fissure as a club-shaped, white mass, continuous below with the anterior and lateral columns of the spinal cord. Their upper and thicker extremity is rounded, and is connected with the pons.

At the lower part of the median fissure portions of the white substance of the pyramidal bodies cross from side to side, producing the **decussation of the pyramids**.³

In structure the pyramidal bodies are three-sided prismatic bundles of nerve fibres, ascending from the anterior and lateral columns of the spinal cord to the pons. The inner fibres ascend from the lateral columns of the cord, and cross to the opposite side, thus producing the decussation above mentioned; the lateral fibres ascend from the anterior columns of the spinal cord of the same side.

The **Ol'ivary bodies**⁴ appear as oval, white prominences to the outer side of the pyramidal bodies. They are composed of white substance, and contain a plicated, pouch-like layer of gray substance. In section

¹ Bulbus rachidicus; caudex encephali communis; medulla respiratoria; oblong medulla; cerebrum elongatum; centrum vitale.

² Corpora pyramidalia; c. p. anteriora; c. p. interna; eminentiæ pyramidales; e. oblongæ; e. medianæ internæ.

³ Decussatio pyramidum; decussation of Mistichelli.

⁴ Corpora olivaria; eminentiæ olivares; e. ovales; e. o. laterales; olivæ; corpora ovata, or semiovalia; funiculi, or fasciculi ovales.

the latter gives the central mass of the olivary bodies the appearance of an indented oval nucleus, whence its name of the **dentated body**.⁴ An additional small accumulation of gray substance within the olivary bodies, distinct from the former, is named the **accessory olivary nucleus**.

The white substance of the olivary bodies is continuous with that of the anterior columns of the spinal cord, and forms a fasciculus, which may be traced through the pons to the crura of the cerebrum and the quadrigeminal body.

The **Res'tiform bodies**,¹ situated to the outer side, posteriorly, of the olivary bodies, ascend from the spinal cord in a divergent manner, and become continuous with the inferior peduncles of the cerebellum. They are composed of white substance continuous with that of the spinal cord, and contain some gray substance² continuous with the posterior horns of the latter.

The **Posterior pyramids**³ are situated behind the preceding bodies, on each side of the posterior median fissure, and diverge at the sides of the fourth ventricle. They consist of two narrow fasciculi of white substance, continuous with the posterior median columns of the spinal cord, and appear to merge in the inferior peduncles of the cerebellum.

At the sides of the medulla oblongata, below the olivary bodies, or even crossing their lower part, there usually exist some arching fibres connecting the pyramidal and restiform bodies, and named **arciform fibres**.⁴ Other fibres also pass transversely from before backward, within the median fissures of the medulla oblongata, and are named **septal fibres**.

FOURTH VENTRICLE.

The triangular space included between the medulla oblongata and pons in front, and the cerebellum behind, is called the **fourth ventricle**.⁵

¹ Corpora restiformia; pyramides laterales; fasciculi, or funiculi pyramidales; fasciculi laterales et cuneati; corpora pyramidalia posteriora; processus a cerebelli ad medullam oblongatam; peduncles of the medulla oblongata; inferior peduncles of the cerebellum.

² Nucleus, or corpus cinereus; partially the tubercula cinerea of Rolando.

³ Fasciculi graciles.

⁴ Fibrae transversae arciformes; stratum zonale medullae oblongatae; ponticulus.

⁵ Ventriculus quartus; v. Arantii; v. calami-scriptorii; v. rhomboidalis; v. cerebelli; ventricle of the cerebellum.

It communicates, by a narrow passage¹ ascending beneath the quadrigeminal body, with the third ventricle, and is lined with a delicate serous membrane, continuous with that of the latter cavity, and opening below into the subarachnoid space of the spinal cord.

The posterior sloping **roof** of the fourth ventricle is formed by the superior peduncles of the cerebellum, and the intervening "valve" of the brain. Its sides, posteriorly, are formed by the inferior peduncles of the cerebellum.

The anterior part, or **floor of the fourth ventricle**,² is formed by the back of the medulla oblongata and pons. It is lozenge shaped in outline, and is bounded laterally above by the superior peduncles of the cerebellum; below by the inferior peduncles, the restiform bodies, and posterior pyramids. The sides of the floor incline to the **posterior median fissure**,³ which is continuous below with that of the spinal cord, and becomes obsolete above.

The surface of the floor is rendered uneven by several slight convex eminences,⁴ and is invested with a layer of gray substance⁵ continuous with that of the spinal cord. On each side it is crossed by a series of transverse white lines⁶ which are connected with the origin of the auditory nerves.

At the lower angle⁷ of the floor is a small pit,⁸ which is the upper extremity of a canal⁹ existing during foetal life along the centre of the spinal cord.

The lower portion of the fourth ventricle is closed by the arachnoid membrane, but, as previously indicated, it communicates with the subarachnoid space of the spinal cord.

¹ *Meatus conjunctorius ventriculi quarti et tertii medii; aquæductus Sylvii; iter e tertio ad quartam ventriculam.*

² *Sinus, fovea, fossa, or cavitas rhomboidalis; scrobs, or fovea ventriculi quarti; area, or semicanalis medullæ oblongatæ.*

³ *Sulcus, or fissura longitudinalis; s. or f. medius fossæ rhomboidalis.*

⁴ These comprise—1, the *eminentiæ teretes, semiteretes, perpendiculares, or longitudinales; funiculi, or fasciculi teretes, or the corpora teretia*; 2, the *emi-*

nentiæ cuneiformes cinereæ; alæ cinereæ, or folia cinerea lanceolata.

⁵ Comprising the *substantia cinerea ochracea; locus cinereus, or cœruleus, or substantia ferruginea; and the fasciolæ cinereæ.*

⁶ *Striæ, tæniæ, or fibræ medullares, or acusticæ; fasciculi et fibrillæ filiformes nervi acustici.*

⁷ *Calamus scriptorius.*

⁸ *Ventriculus Arantii.*

⁹ *Canalis medullæ spinalis.*

THE SPINAL CORD.

The **Spinal cord**,¹ the centre of excito-motor impulses, with its membranes, occupies the vertebral canal. It is continuous with the medulla oblongata, and extends from the occipital foramen to the lower part of the first lumbar vertebra.

In the embryo the spinal cord corresponds in length with the vertebral column, but subsequent to the third month the latter grows more rapidly than the former, so that at birth the cord extends only as far as the third lumbar vertebra.

The length of the spinal cord of the adult is from fifteen to eighteen inches, and its weight about an ounce and a half avoirdupois. In general form it is cylindrical, compressed from before backward, and it varies in diameter in different positions. In the region of the neck it presents the **cervical enlargement**² extending from about the third cervical to the first dorsal vertebra. Below this position it is of nearly uniform diameter, until it forms the **lumbar enlargement**,³ which is opposite the last dorsal vertebra, and subsequently it tapers to a conical point.⁴

The cervical and lumbar enlargements correspond with the large nerves connected with these portions of the spinal cord. Where other nerves emanate from the latter, it exhibits slight enlargements, which give to the sides of the cord a somewhat undulating appearance.

Exteriorly the spinal cord is composed of white nerve substance; interiorly, of gray substance—the former being the more abundant, especially in the cervical region.

In front and behind, the spinal cord is divided by fissures into lateral symmetrical halves.

The **anterior median fissure**⁵ penetrates about one-third the thickness of the cord, but becomes deeper toward its lower extremity. The white substance at its bottom associating the two sides of the cord is named the **anterior or white commissure**.⁶

The **posterior median fissure**,⁷ narrower, and for the most part deeper than the anterior, becomes shallower toward its lower end.

¹ Medulla spinalis; spinal marrow; corda spinalis; medulla dorsalis; m. spinæ; caudex dorsalis; funiculus spinalis; cerebrum longum, or oblongum; nucha; myelus; myelon; notomyelus; rhacites; rhachetrum; processus rachidianus; funis argenteus; sacra fistula; vertebral marrow.

² Intumescentia cervicalis.

³ Intumescentia lumbaris, or cruralis.

⁴ Conus medullaris; c. terminalis medullæ spinalis.

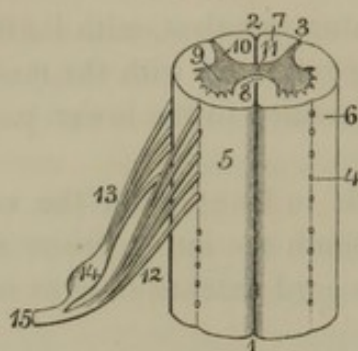
⁵ Fissura longitudinalis anterior, or mediana.

⁶ Commissura anterior.

⁷ Fissura longitudinalis posterior; sulcus longitudinalis medianus; fis. long. post. superior et inferior.

From each side of the cord, the spinal nerves originate by a series of

FIG. 331.



SEGMENT OF THE SPINAL CORD. 1, anterior median fissure; 2, posterior median fissure; 3, postero-lateral fissure; 4, antero-lateral fissure; 5, anterior column; 6, lateral column; 7, posterior column; 8, anterior commissure; 9, anterior horns of the gray substance; 10, posterior horns; 11, gray commissure; 12, anterior root of a spinal nerve springing by a number of filaments from the antero-lateral fissure; 13, posterior root from postero-lateral fissure; 14, ganglion on the posterior root; 15, spinal nerve formed by the union of the two roots.

spinal nerves are the **lateral columns**,³ and those between the posterior median and postero-lateral fissures are the **posterior columns**.⁴ In consequence of the feebly-marked character of the antero-lateral fissures, the anterior and lateral portions of the cord are usually referred to under the name of the **antero-lateral columns**.

At the upper part of the cord, a pair of narrow, white tracts are observed separated by the posterior median fissure. These are named the **posterior median columns**,⁵ and are continuous with the posterior pyramids of the medulla oblongata.

In a transverse section of the spinal cord, the gray substance is noticed to be arranged in the form of two irregular crescentoid bars, situated one on each side, with their convexities conjoined by a transverse bar. The extremities of the crescentoid bars are called **horns**,⁶ and the intervening transverse bar is the **posterior or gray commissure**.⁷

The **anterior horns**⁸ are short, broad, and obtuse, and are inclosed

anterior and posterior roots, the attachments of which give rise to slight furrows named the **anterior and posterior lateral fissures**.¹ Of these the posterior is the more evident from the gray substance of the interior of the cord extending to its bottom, so as to isolate the white substance of the posterior part of the cord from the antero-lateral part.

The fissures of the spinal cord have led to its division into **columns**. The portions included between the anterior median fissure and the antero-lateral fissures constitute the **anterior columns**,² those at the sides between the lateral fissures or the roots of the

¹ Fissura lateralis anterior et posterior.

² Funiculi anteriora.

³ Funiculi lateralia.

⁴ Funiculi posteriora.

⁵ Fasciculi graciles.

⁶ Cornua; crura.

⁷ Commissura cinerea. Its central portion is the nucleus cinereus; centrum cinereum; commissura gelatinosa; substantia grisea centralis; gray central nucleus; gelatinous central cord of the gray commissure.

⁸ Cornua anteriora.

within the antero-lateral columns of the cord. The **posterior horns**¹ are longer and narrower, and are capped at the extremity by a more translucent portion of the gray substance, called the **gelatinoid substance**.² They separate the antero-lateral from the posterior columns, and reach the bottom of the postero-lateral fissures.

Toward the lower extremity of the spinal cord, the crescentoid appearance of the lateral bars of gray substance becomes indistinct, and the relative quantity of the white substance is diminished.

MEMBRANES OF THE BRAIN AND SPINAL CORD.

THE PIA MATER.

The **Pia mater**³ is a delicate fibro-vascular membrane closely investing the brain and spinal cord, contributing to sustain their structure, and serving as a point of departure and termination to their numerous capillary blood-vessels.

PIA MATER OF THE BRAIN.

The branches of the internal carotid and vertebral arteries destined to supply the brain with blood, by frequent anastomosis form upon its surface an intricate net-work. This vascular net, in conjunction with numerous veins, and strengthened with delicate, interlacing bundles of fibrous tissue, constitutes the **pia mater of the brain**. Processes of the membrane extend into all the fissures of the brain, and its vessels supply and return the blood of the capillaries of the latter. When the pia mater is detached, the torn capillaries from the brain give its inner surface a flocculent appearance.

A process of the pia mater, named the **interposed velum**,⁴ dips from between the cerebrum and cerebellum, beneath the posterior border of the corpus callosum, and above the quadrigeminal body, into the third ventricle. The velum extends along the under surface of the fornix, and has the same form. In the median line it incloses the two ventricular veins, which lie parallel to each other, and end in a short trunk⁵ which opens into the straight sinus of the dura mater.

On each side the velum projects beyond the lateral borders of the for-

¹ Cornua posteriora.

² Substantia cinerea gelatinosa.

³ Pia meninx; mollis, or tenuis mater; tunica, or meninx interior, vasculosa, or choroides; membrana vasculosa cerebri; m. cerebri tenuis, mollis, or propria;

inner lamina of the meninges; tunica cerebri et medullæ spinalis propria.

⁴ Velum interpositum, triangulare, or choroides; tela choroidea; t. c. superior; plexus choroideus medius; rete mirabile; r. choroideum.

⁵ Vena Galeni.

nix, and forms the **choroid plexuses of the lateral ventricles.**¹ These plexuses are two remarkable vascular appendages, which resemble in appearance pieces of knotted red worsted cord. They extend from the foramen beneath the anterior crura of the fornix, along the floor of the lateral ventricles at the side of the latter, and descend to the bottom of the middle horns of the ventricles. Narrow at their commencement, they increase in bulk until they reach the middle horns of the lateral ventricles, and then decrease to their termination. In structure the choroid plexuses consist of portions of the interposed velum, furnished with many villous processes, and containing tortuous blood-vessels. The villous processes, in an advanced period of life, are frequently found more or less dilated into spherical bodies, from the size of a pin-head to that of a pea, and have been mistaken for hydatid parasites.

On the under-surface of the interposed velum are situated the **choroid plexuses of the third ventricle.**² These are two narrow, vascular appendages, extending from those of the lateral ventricles backward along the course of the ventricular veins.

The **choroid plexuses of the fourth ventricle**³ extend from the pneumogastric lobule of the cerebellum, join each other across the vermiform process, and are prolonged a short distance along the sides of the latter.

Connected with the pia mater at the borders of the great longitudinal fissure, there is found a variable number of coarse, rounded granules, called **Pacchio'nian bodies.**⁴ These are usually collected in groups, and frequently protrude through openings of the dura mater into the longitudinal sinus. The openings just indicated appear to result from pressure of the Pacchionian bodies, and absorption of the contiguous osseous wall of the cranium is also occasionally produced by them. They were formerly supposed to be glandular in character, but as they do not exist at birth, they are perhaps to be viewed as a pathological production, notwithstanding their frequency.

PIA MATER OF THE SPINAL CORD.

The **pia mater of the spinal cord** has fewer vessels and more fibrous tissue entering into its composition than that of the brain, and therefore appears denser, stronger, and less vascular. Thin processes of the membrane dip into the anterior and posterior median

¹ Plexus choroideus, or choroides; p. c. lateralis dexter et sinister; p. choroiformes; p. reticularis; p. reteformes; p. glandulares; vermes cerebri; retia mirabilia.

² Plexus choroideus ventriculi tertii.

³ Plexus choroideus ventriculi quarti.

⁴ Glandulæ Pacchionii; glands of Pacchioni; glandulæ duræ matris; g. duræ meningis; tubercula parva; corpora glandiformia; cerebral granulations.

fissures. In front it exhibits a longitudinal fibrous band,¹ and on each side, between the roots of the spinal nerves, it forms the **denticulate ligament**.² This is a projecting fibrous band deeply toothed in a saw-like manner at its outer part, the points of the dentations being attached to the dura mater in the intervals of the spinal nerves.

From the lower end of the spinal cord the pia mater is continued, as a partially hollow, thread-like prolongation,³ to the termination of the vertebral canal, where it is attached to the dura mater. The hollow of the prolongation is apparently occupied by a continuation of the gray substance of the spinal cord.

THE EPENDYMA.

The **Epen'dyma**⁴ is the delicate, transparent, serous membrane, lining the ventricles of the brain and the central canal of the spinal cord of the embryo. At birth its epithelium consists of ciliated cells, but at a later period the cilia are obliterated.

THE DURA MATER.

The **Dura mater**,⁵ the exterior investment of the brain and spinal cord, is a dense, strong, inextensible bluish-white membrane, composed of an intertexture of bundles of fibrous tissue.

DURA MATER OF THE BRAIN.⁶

This consists of two intimately adherent layers, of which the outer corresponds with the periosteum in other parts of the skeleton, while the inner alone corresponds with the spinal dura mater. The adhesion of the dura mater to the inner surface of the cranium depends on the many minute blood-vessels and fibrous processes passing between the two. The connection is closest along the sutures, and at the borders of the foramina, and is especially well marked at the base of the cranium.

The inner layer of the dura mater has a smooth internal surface closely invested by the arachnoid membrane. Between the cerebrum and cerebellum and their hemispheres it sends strong partitions which contribute to sustain the mass of the brain.

¹ Linea splendens Halleri.

² Ligamentum denticulatum; l. serratum; l. dentatum; membrana dentata.

³ Filum terminale; nervus impar.

⁴ Endyma, or indumentum ventriculorum.

⁵ Dura meninx; meninx exterior; m. sclera; m. dermatodes; m. pacheia; crassa meninx; cuticularis membrana; membrana externa; m. dura; m. fibrosa.

⁶ Dura mater cerebri; d. m. sensu strictiori; d. membrana cerebrum ambiens.

The **Cer'ebral falx**,¹ one of the partitions just indicated, occupies the great longitudinal fissure, and separates the hemispheres of the cerebrum. Commencing at the ethmoidal crest, to which it tightly adheres, it extends along the course of the superior longitudinal sinus, gradually increasing in breadth until it joins the tentorium. It is thus shaped like a sickle, from whence its name is derived.

The **Cerebel'lar falx**² is a thick fold of the dura mater occupying the valley, and separating the hemispheres of the cerebellum. It extends from the tentorium downward to the occipital foramen.

The **Tento'rium**³ is a broad partition of the dura mater separating the cerebrum from the cerebellum. It is continuous along its median line with the cerebral falx, from which it inclines on each side downward, outward, and backward. It is attached along the horizontal limbs of the occipital cross, and the superior border of the petrous portion of the temporal bones, extending to the posterior clinoid processes. Its inner border includes a large oval space⁴ through which the cerebral crura diverge from the pons to the hemispheres of the cerebrum.

Through separation of the layers of the dura mater in certain positions, channels are formed named the **sinuses of the dura mater**. These perform the office of veins, and are lined with a continuation of the ordinary epithelium of blood-vessels. In them terminate the veins of the pia mater, which return the blood from the capillary vessels of the brain.

The superior longitudinal, straight, and lateral sinuses are three sided, from their occupying the angular intervals along the lines of departure of the cerebral falx and tentorium. The remaining sinuses, smaller than those just mentioned, are generally cylindroid, and occupy the base of the cranial cavity. A description of the course of the sinuses of the dura mater is given in the account of the venous system, page 409.

The meningeal arteries of the dura mater, which give rise to the arborescent channels on the interior surface of the cranium, not only supply the membrane, but are also destined to supply the bones of the latter.

¹ Falx cerebri, major, or magna; processus falciformis cerebri; septum, or mediastinum cerebri; vertical superior longitudinal process.

² Falx cerebelli; f. minor; processus falciformis cerebelli; septum cerebelli; s. parvum occipitale; median septum of the cerebellum.

³ T. cerebelli; t. cerebello super extensum; tentaculum cerebelli; septum encephali; diaphragma cerebri; inter-septa horizontalia Pacchioni; processus transversus; lateral processes; transverse septum.

⁴ Incisura tentorii.

In the passage of vessels and nerves through foramina at the base of the cranium, the dura mater becomes continuous with their fibrous sheaths.

DURA MATER OF THE SPINAL CORD.¹

This corresponds alone with the internal layer of the dura mater of the brain, with which it is continuous through the occipital foramen. Firmly attached to the border of the latter, the spinal dura mater extends to the end of the vertebral canal, and forms a loose sheath for the spinal cord and its nerves. It is unattached to the periosteum of the vertebral canal, except at the occipital foramen, the interval of the two membranous layers being occupied by the intra-spinal plexus of veins, together with some loose areolar and adipose tissue.

Opposite the intervertebral foramina the dura mater is pierced separately by the roots of the spinal nerves, but prolongations of the membrane extend as sheaths of the latter and become firmly attached to the periosteum bordering the intervertebral foramina.

THE ARACHNOID MEMBRANE.

The **Arach'noid membrane**² is a delicate, transparent, and colorless, serous tunic, intervening between the pia mater and the dura mater. Its reflected portion adheres closely to the internal surface of the latter membrane; while its investing portion is connected with the pia mater without dipping into any of the fissures or depressions of the brain and spinal cord, except those which receive the cerebral falx, the cerebellar falx, and the tentorium.

The arachnoid membrane is especially remarkable among serous membranes from its loose attachment to the structure beneath. Being connected with the pia mater by scattered bands of fibrous tissue and blood-vessels, an interval is left between the two membranes, called the **subarach'noid space**. This varies in extent in different positions, but is most capacious along the middle part of the base of the brain, at the bottom of the superior longitudinal fissure, and on the spinal cord.

A serous fluid, the **cer'ebro-spinal liquid**, amounting to several ounces, occupies both the cavity of the arachnoid membrane and the subarachnoid space.

The bottom of the fourth ventricle is closed by the arachnoid membrane, but the cavity of the former communicates with the subarachnoid space.

¹ Dura mater spinalis; pars spinalis duræ matris.

² Membrana, or tunica arachnoidea; m. media; t. mucosa; t. serosa; t. aranea; t. crystallina; meninx media; m. serosa; meningion.

The roots of the cerebro-spinal nerves are loosely invested with tubular sheaths of the arachnoid membrane, extending from the pia mater to their exit through the dura mater.

THE NERVES OF THE BRAIN, OR THE CEREBRAL NERVES.

The **Nerves of the Brain**, usually called the **Cerebral nerves**,¹ consist of twelve pairs,² and are either named numerically from before backward, or from their function, destination, or other special character.

THE OLFACTORY, OR FIRST PAIR OF NERVES.

The **Olfac'tory nerves**³ are situated beneath the anterior cerebral lobes, and appear rather as appendages of the brain than as true nerves. They are small in comparison with those of most lower mammals, in accordance with the less acute sense of smell in man. They occupy a groove a short distance from the longitudinal fissure, and rest in the ethmoidal gutters.

Each nerve is a club-shaped body, with a three-sided handle or **pedicle**, and an oval head or **bulb**.

The **pedicle** of the olfactory nerve is composed of white substance or nerve fibres below, and of gray substance above. The nerve fibres originate by a pair of roots⁴ converging from the sides of the anterior perforated space at the inner part of the Sylvian fissure; the gray substance communicates by a single root⁵ with the space just mentioned.

The **bulb**⁶ forms the free extremity of the olfactory nerve anteriorly. It is oval, soft, and composed of gray substance. From it emanate many branches,⁷ which descend through the foramina of the cribriform plate of the ethmoid bone to be distributed to the mucous membrane of the upper part of the nose.

¹ Cranial, or encephalic nerves.

² Nine pairs of Willis.

³ Nervi olfactorii; n. odoratorii; processus mammillares; p. m. cerebri ad nares; p. papillares; carunculæ mammillares; ethmoidal nerves; par primum nervorum cerebri; first pair of encephalic

lic nerves; nerves of smelling, or olfaction.

⁴ Radix externa, or longa, and radix interna, or brevis.

⁵ Radix media, grisea, or superior.

⁶ Bulbus olfactorius; b. cinereus; olfactory tubercle or lobe.

⁷ Nervi olfactorii; rami bulbi.

THE OPTIC, OR SECOND PAIR OF NERVES.

The **Optic nerves**,¹ among the largest of those of the brain, originate each in a white band, named the **optic tract**.² This starts from the quadrigeminal and geniculate bodies, winds around the outer side of the crus of the cerebrum, and converges to join that of the opposite side in front of the base of the infundibulum. The conjunction of the tracts forms the **optic commissure**,³ from which the **optic nerves** diverge to pass through the optic foramina into the orbits. The optic tracts and commissure throughout their course intimately adhere to the contiguous structures of the brain, from which they receive additional nerve fibres.

In the optic commissure some of the nerve fibres cross from one side to the other, or decussate; another set proceed directly from the optic tracts to the corresponding nerves; a third series, in the form of loops, appear to associate the tracts together; and a fourth series, in the same manner, conjoin the two nerves independently of the tracts.

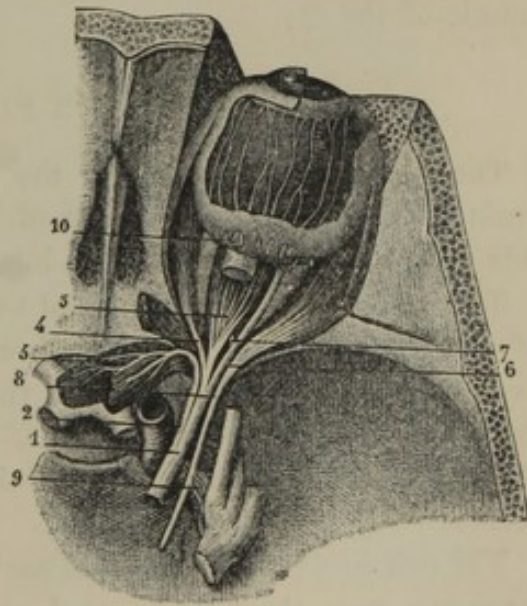
The optic nerves are those of vision, and terminate in the retina of the eyeball.

THE OCULO-MOTOR, OR THIRD PAIR OF NERVES.

The **Oc'ulo-motor nerves**⁴ appear at the surface of the brain, springing from the inner side of the cerebral crura, just in advance of the pons. Their nerve fibres are

OCULO-MOTOR AND ABDUCENT NERVE, the upper part of the right orbit removed. 1, oculo-motor nerve; 2, 3, branch to the superior straight and oblique muscles; 4, 5, branches to the internal and inferior straight muscles; 6, branch to the inferior oblique muscle; 7, branch from the latter to the ophthalmic ganglion; 8, abducent nerve to the external straight muscle; 9, communicating filaments between the abducent nerve and the carotid plexus of the sympathetic. To their outer side is the tri-facial nerve. 10, ciliary nerves perforating the sclerotic coat of the eyeball, and passing forward between it and the choroid to the ciliary muscle and iris.

FIG. 332.



traceable to the gray substance in the interior of the crura of the cerebrum and the pons.

¹ Nervi optici; n. visorii; par secundum, opticum, or visorium; ocular nerves; nerves of sight or vision.

² Tractus opticus.

³ Chiasma, or commissura nervorum opticorum.

⁴ Nervi oculo-motores; n. motores oculorum; n. oculares communes; n. ophthalmici externi; common oculo-muscular nerves; par tertium.

Passing obliquely forward and outward, the oculo-motor nerve pierces the dura mater in front of the posterior clinoid process, and, after traversing the outer wall of the cavernous sinus, it divides into two branches, which enter the orbit through the sphenoidal foramen.

Of the two branches, the upper and smaller is distributed to the palpebral elevator and superior straight muscles; while the lower one supplies the internal and inferior straight and the inferior oblique muscles, and is connected by a short branch¹ with the ophthalmic ganglion.

The name of the oculo-motor nerve indicates its function.

THE PATHETIC, OR FOURTH PAIR OF NERVES.

The **Pathet'ic nerves**,² the smallest of those connected with the brain, start from the upper part of the "valve of the brain," immediately behind the quadrigeminal body. Their fibres are traceable to the gray substance of the pons and the floor of the fourth ventricle.

Each pathetic nerve appears like a white thread winding around the outer side of the crus of the cerebrum. Piercing the dura mater just behind the oculo-motor nerve, it accompanies this through the outer wall of the cavernous sinus and the sphenoidal foramen into the orbit. It is motor in its function, and is distributed to the superior oblique muscle of the eye.

THE TRIFACIAL, OR FIFTH PAIR OF NERVES.

The **Trifa'cial nerves**³ are the largest of those derived from the brain. They arise by two roots of unequal size, which emerge from the side of the pons at its fore part inferiorly.

The **large root**⁴ of the trifacial nerve, sensory in its function, consists of numerous bundles of nerve fibres, which may be traced through the pons into the restiform body and the gray substance of the floor of the fourth ventricle. The **small root**,⁵ motor in its function, though traceable through the pons to the medulla oblongata, has not had its origin satisfactorily determined.

The two roots of the trifacial nerve, the smaller concealed behind the large one, pass through an oval aperture of the dura mater, near the

¹ Radix brevis ganglii ciliaris; short root of the ophthalmic ganglion.

² Nervi pathetici; n. trochleares; n. oculo-musculares superior, minimi, or interni; par quartum.

³ N. trifaciales; n. trigemini; trigeminal nerves; n. gustatorii; par quintum;

par trigeminum; par trium funiculorum. Sing.: n. divisus; n. trimellus; n. mixtus; n. quintus; n. sympatheticus medius; n. anonymus; n. innominatus.

⁴ Radix major, posterior, inferior, or longior.

⁵ Radix minor, anterior, or superior.

apex of the petrous portion of the temporal bone. The large root terminates in the **semilunar ganglion**, which rests in a slight depression in front of the apex of the petrous portion of the temporal bone; while the small root passes beneath the ganglion, and simply lies in contact with it.

The **semilunar ganglion**¹ of the trifacial nerve is a large crescentic body, with its concavity upward, and receiving the diverging fibres of the large root of the nerve. From its convexity emanate the **ophthalmic** and **superior maxillary nerves**, and a third branch, which joins the small root of the trifacial to form the **inferior maxillary nerve**.

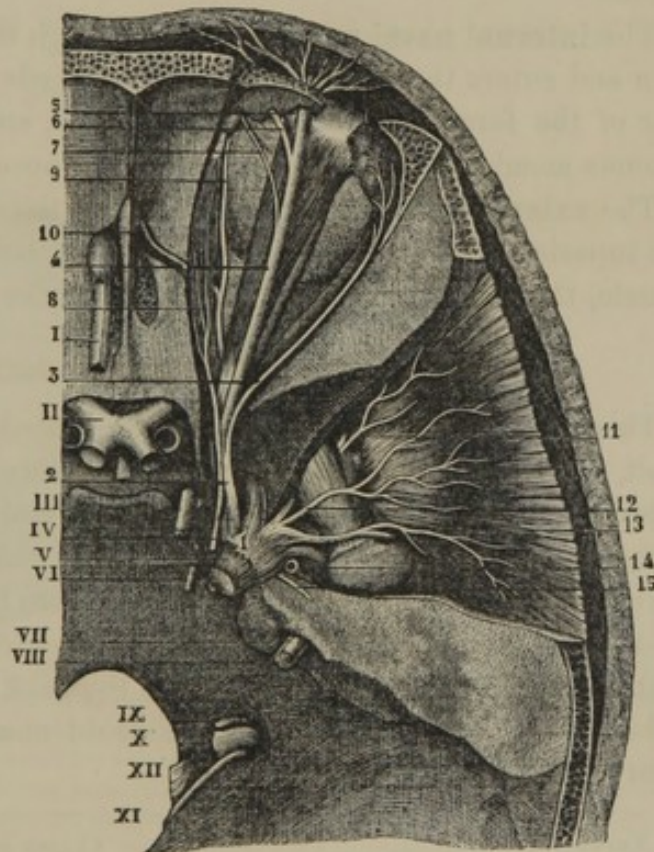
THE OPHTHALMIC NERVE.²

This is the first division of the trifacial nerve, and the smallest branch from the semilunar ganglion. After traversing the outer wall of the cavernous sinus, it divides into three branches, which pass through the sphenoidal foramen into the orbit.

TRIFACIAL NERVE, the upper part of the orbit and temporal fossa removed. 1, semilunar ganglion; 2, ophthalmic nerve; 3, lachrymal nerve; 4, frontal nerve; 5, 6, its two principal branches; 7, a branch passing from the orbit above the pulley of the superior oblique muscle; 8, nasal nerve; 9, its external nasal branch; 10, course of the internal nasal nerve from the orbit into the cranium, and nose; 11, 12, 13, temporal branches of the inferior maxillary nerve; 14, commencement of the auriculo-temporal nerve; 15, greater petrosal nerve; I, olfactory nerve; II, optic nerves; III, oculo-motor nerve; IV, pathetic nerve to the superior oblique muscle of the eye; V, trifacial

nerve; its small root visible beneath the cut end of the large root, which forms the semilunar ganglion dividing into the ophthalmic, superior and inferior maxillary nerves; VI, abducent nerve; VII, facial, included in a groove of the auditory nerve, VIII, both entering the auditory meatus; IX, glosso-pharyngeal, X, pneumogastric, and XI, accessory nerves emerging at the jugular foramen; XII, hypoglossal nerve.

FIG. 333.



¹ G. semilunare; g. Gasseri: Gasserian ganglion; ganglion of Gasser; intumescencia, or moles gangliiformis; i. semilunaris; tænia nervosa Halleri; ganglion of the fifth nerve.

² Nervus ophthalmicus; n. orbito-frontalis.

The **Lach'rymal nerve**,¹ one of the branches of the ophthalmic, passes along the outer part of the orbit to be distributed to the lachrymal gland and upper eyelid.

The **Frontal nerve**,² the largest branch of the ophthalmic, passes along the roof of the orbit, and divides into two branches, of which one³ emerges at the supra-orbital foramen, the other⁴ between the latter and the pulley of the superior oblique muscle, and both are distributed to the skin and muscles of the forehead and upper eyelid.

The **Nasal nerve**,⁵ the remaining branch of the ophthalmic, passes above the optic nerve and along the inner side of the orbit to the anterior ethmoidal foramen, where it divides into the internal and external nasal nerves. In its course within the orbit it is connected by an anastomotic filament⁶ with the ophthalmic ganglion, and gives off two or three ciliary nerves.⁷

The **internal nasal nerve**⁸ passes through the anterior ethmoidal foramen and enters the cranium, when it proceeds forward to the most anterior of the foramina of the ethmoid bone, and descends to supply the mucous membrane at the fore part of the nose.

The **external nasal nerve**⁹ passes from the orbit beneath the pulley of the superior oblique muscle, and is distributed to the eyelids with their muscle, the lachrymal sac, and the skin of the nose.

THE OPHTHALMIC GANGLION.¹⁰

This is a small, reddish-gray body, situated at the back part of the orbit, between the optic nerve and the external straight muscle. It is imbedded in areolar and adipose tissue, and is connected by branches with the nasal nerve of the ophthalmic, the oculo-motor nerve, and the carotid plexus of the sympathetic. From its fore part emanate about a dozen **cil'iary nerves**.¹¹ These, together with the two or three **ciliary branches** from the nasal nerve, pierce the back part of the sclerotic coat, and advance between it and the choroid coat to be distributed to the ciliary muscle and iris.

¹ Nervus lachrymalis.

² N. frontalis; n. fronto-palpebralis.

³ N. supra-orbitalis; n. frontalis externus, or major.

⁴ N. supra-trochlearis; n. frontalis internus, or minor.

⁵ N. nasalis; n. nasarius; n. naso-ciliaris; n. naso-ocularis.

⁶ Long root of the ophthalmic ganglion.

⁷ Long ciliary nerves.

⁸ N. nasalis internus; n. ethmoidalis.

⁹ N. infra-trochlearis; n. nasalis externus.

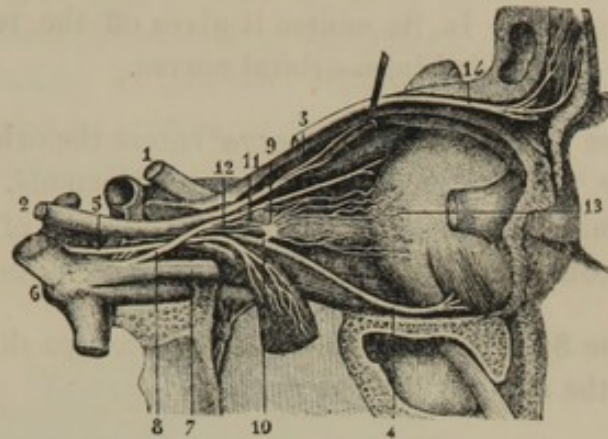
¹⁰ Ganglion ophthalmicum; g. ciliare; g. lenticulare; g. semilunare; g. orbitale; ciliary or lenticular ganglion.

¹¹ Short ciliary nerves; nervi ciliares breves.

OPHTHALMIC GANGLION—THE OUTER PART OF THE RIGHT ORBIT REMOVED.

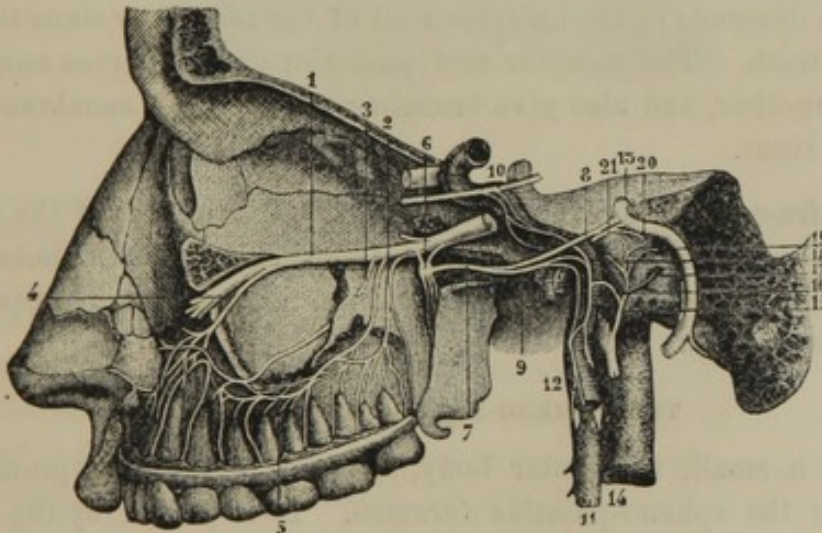
1, optic nerve; 2, oculo-motor nerve; 3, branch to the superior straight and oblique muscles; 4, branch to the inferior oblique muscle; 5, abducent nerve to the external straight muscle; 6, trifacial nerve, its ganglion and three principal branches; 7, ophthalmic nerve; 8, nasal nerve; 9, ophthalmic ganglion; 10, its communicating branch with the oculo-motor nerve; 11, do. with the ophthalmic nerve; 12, do. with the carotid plexus of the sympathetic; 13, the ciliary nerves; 14, frontal nerve.

FIG. 334.

THE SUPERIOR MAXILLARY NERVE.¹

This is the second division of the trifacial nerve, and is intermediate in size and position to the others. Starting from the middle of the

FIG. 335.



SUPERIOR MAXILLARY NERVE—THE EXTERNAL WALL OF THE LEFT ORBIT AND OF THE SUPERIOR MAXILLARY BONE REMOVED. 1, superior maxillary nerve in its course through the infra-orbital canal; 2, 3, posterior dental nerves; 4, anterior dental nerve; 5, anastomosis between the dental nerves; 6, sphenopalatine ganglion; the branch from the superior maxillary nerve above is the commencement of the temporo-malar nerve; 7, pterygoid nerve; 8, greater petrosal nerve joining the facial nerve; 9, deep petrosal nerve joining the carotid plexus of the sympathetic; 10, abducent nerve with its communicating branches of the latter plexus; 11, superior cervical ganglion; 12, ascending branches to the carotid plexus; 13, facial nerve; 14, glossopharyngeal nerve; 15, the tympanic nerve; 16, branch to the carotid plexus; 17, 18, 19, branches to the round and oval windows and Eustachian tube; 20, branch to the smaller petrosal nerve, 21.

semilunar ganglion as a flattened cord, it assumes a rounded form, and passes from the cavity of the cranium through the rotund foramen of the sphenoid bone. It then crosses the upper part of the pterygo-max-

¹ Nervus maxillaris superior.

illary fossa, and enters the infra orbital canal,¹ through which it advances to the face. In its course it gives off the temporo-malar, sphe-no-palatine, dental, and infra-orbital nerves.

The **Temporo-ma'lar nerve**² enters the orbit through the sphe-no-maxillary foramen, and divides into filaments, which are transmitted by foramina of the malar bone to the skin of the temple and cheek. It anastomoses with the lachrymal and facial nerves.

The **Sphe'no-pal'atine nerves**³ are two short branches descending to join the sphe-no-palatine ganglion.

The **Dental nerves**⁴ consist of posterior and anterior branches. The **posterior dental nerves**,⁵ of which there are two or three, descend behind the tuberosity of the superior maxillary bone, and enter small canals in the outer wall of the maxillary sinus to supply the back teeth. One of the branches also supplies the upper gum. The **anterior dental nerve**⁶ comes off from the superior maxillary within the infra-orbital canal, and descends in the anterior wall of the maxillary sinus to supply the front teeth. The anterior and posterior dental nerves anastomose with one another, and also give branches to the lining membrane of the maxillary sinus.

The **Infra-orbital nerves**⁷ are the terminal branches of the superior maxillary, emerging at the infra-orbital foramen to be distributed to the lower eyelid, the upper lip, the side of the nose, and the mucous membrane of the cheek.

THE SPHENO-PALATINE GANGLION.⁸

This is a small, triangular body, situated in the pterygo-maxillary fossa, near the sphe-no-palatine foramen. It is joined by the sphe-no-palatine branches of the superior maxillary nerve, and besides giving small filaments⁹ to the upper part of the pharynx, sends off the nasal, palatine, and pterygoid nerves.

¹ Within which it is usually called the infra-orbital nerve; *nervus infra-orbitalis*.

² *N. subcutaneus malæ; n. orbitarius*.

³ *Nervi sphe-no-palatini; n. pterygo-palatini*.

⁴ *N. dentales; n. d. superiores; n. alveolares superiores*.

⁵ *N. dentales, or alveolares superiores posteriores*.

⁶ *N. dentalis, or alveolaris superior anterior*.

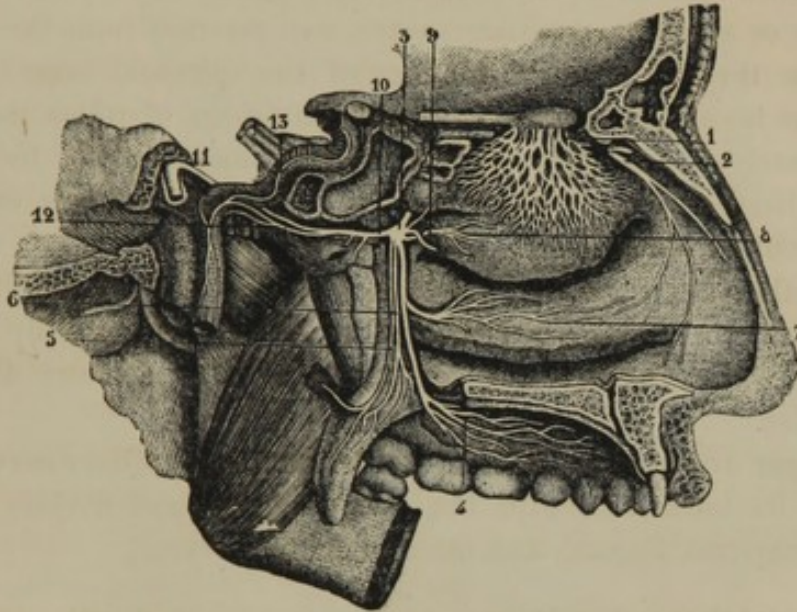
⁷ *N. infra-orbitales*.

⁸ *G. sphe-no-palatinum; g. pterygo-palatinum; g. Meckelii; Meckel's ganglion; ganglion of Meckel; g. nasale; g. rhinicum; g. sphenoidale*.

⁹ *Rami pharyngei*.

The **Nasal nerves**¹ consist of half a dozen or more small branches, which pass through the sphenopalatine foramen to supply the mucous membrane of the nose, including its partition, its outer wall, and the ethmoidal and sphenoidal sinuses. One² of the branches, descending obliquely on the partition, passes through the naso-palatine canal to the roof of the mouth.

FIG. 336.



VIEW OF THE SPHENO-PALATINE GANGLION, THE OUTER WALL OF THE LEFT NASAL CAVITY, AND THE OLFACTORY NERVE. 1, olfactory nerve; 2, nasal branch of the ophthalmic nerve; 3, sphenopalatine ganglion; 4, 5, 6, palatine nerves; 7, branch to the nose; 8, nasal nerve to the outer wall of the nose; 9, do. to the inner wall; 10, pterygoid nerve; 11, facial nerve; 12, deep petrous nerve joining the carotid plexus, 13; the other branch of the pterygoid is the larger petrosal nerve, which joins the facial.

The **Pal'atine nerves**,³ of which there are usually three, descend through the posterior palatine canal and its divisions to be distributed to the hard and soft palate, the palatine arches, the uvula, and the tonsil. From the largest palatine nerve,⁴ in its course one or two branches⁵ are given off to the outer wall of the nose.

The **Pter'ygoid nerve**⁶ proceeds from the sphenopalatine ganglion backward through the pterygoid canal of the sphenoid bone, and divides into two branches. One of these, the **deep petrous nerve**,⁷ pierces the cartilage occupying the lacerated foramen, and joins the carotid plexus of the sympathetic nerve. The other branch, named the **greater petro-**

¹ N. nasales superiores anteriores et posteriores, et naso-palatinus.

² N. naso-palatinus; n. naso-palatinus Scarpæ; n. septi narium.

³ N. palatini; n. p. anterior et medius, posterior, or minus posterior et minimus exterior.

⁴ N. palatinus anterior, or major.

⁵ N. nasales inferiores.

⁶ N. pterygoideus; n. Vidianus; Vidian nerve; n. recurrens Vidianus.

⁷ Ramus sympathicus; r. profundus nervi Vidiani.

sal nerve,¹ enters the cranial cavity through the cartilage of the lacerated foramen, and passes into a canal on the front of the petrous portion of the temporal bone to join the facial nerve.

THE INFERIOR MAXILLARY NERVE.²

This is formed by the union of the small root of the trifacial nerve with the third branch of its semilunar ganglion. It is larger than the ophthalmic or superior maxillary nerve, and emerges from the cavity of the cranium through the oval foramen of the sphenoid bone. Immediately after its exit it separates into two divisions, of which the smaller receives nearly all the fibres of the small or motor root of the trifacial nerve; while the larger division receives most of the fibres emanating from the semilunar ganglion.

The **smaller division** of the inferior maxillary nerve resolves itself into a number of **muscular branches**,³ of which two⁴ supply the temporal muscle, one⁵ the masseter, one⁶ the buccinator, and two⁷ the pterygoid muscles.

The **larger or sensory division** of the inferior maxillary nerve is connected on its inner side with the otic ganglion, and divides into the auriculo-temporal, lingual, and inferior dental nerves.

The **Auric'ulo-tem'poral nerve**,⁸ the smallest of the three branches just indicated, is directed outwardly between the ear and the articulation of the lower jaw, and ascends to be distributed to the skin of the temple. In its course it gives branches to the external ear, the articulation of the lower jaw, and the parotid gland; and it anastomoses with the facial nerve.

The **Lin'gual nerve**⁹ curves downward and forward between the pterygoid muscles to the side of the tongue, along which it continues to the tip, beneath the sublingual gland and in contact with the mucous membrane of the mouth. In its course it is joined by the tympanic branch¹⁰ of the facial nerve, and gives small branches to the mucous

¹ Greater superficial petrosal nerve; *nervus petrosus superficialis major*; *n. superior*, or *superficialis nervi Vidiani*.

² *Nervus maxillaris inferior*; *n. crotaphitico-buccinatorius et maxillaris inferior*; *ramus tertius nervi quinti*; third branch of the fifth, or trigeminal nerve.

³ *Rami musculares*.

⁴ *N. temporalis profundus anterior et posterior*.

⁵ *N. massetericus*.

⁶ *N. buccinatorius*.

⁷ *N. pterygoideus internus et externus*.

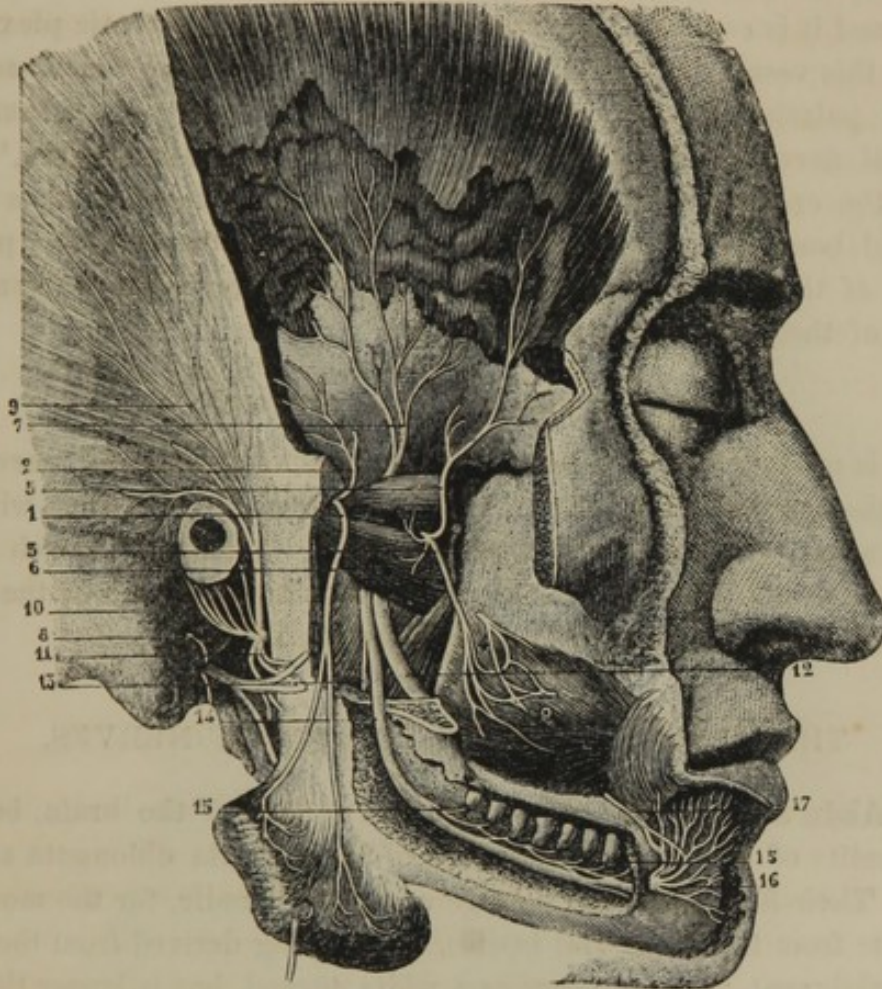
⁸ *N. auriculo-temporalis*; *n. temporalis superficialis*; *n. auricularis anterior*.

⁹ *N. lingualis*; *n. gustatorius*; gustatory nerve.

¹⁰ *Chorda tympani*.

membrane of the mouth, sublingual gland, and the submaxillary ganglion. Its terminal branches perforate the muscular structure of the tongue, and ascend almost vertically to end in the papillæ of taste.

FIG. 337.



DISTRIBUTION OF THE INFERIOR MAXILLARY NERVE. 1, muscular branch to the masseter muscle; 2, 5, 7, branches to the temporal muscle; 3, branch to the buccinator, anastomosing with one from the facial at 4; 6, external pterygoid muscle; 8, auriculo-temporal nerve; 9, branches to the temple; 10, branches to the ear; 11, its anastomosis with the facial; 12, lingual nerve; 13, branch to the mylo-hyoid muscle from the inferior dental nerve, 14; 15, branches to the teeth; 16, terminal branches to the lower lip and chin.

The **Inferior dental nerve**,¹ a little larger than the lingual, descends in company with it, but diverges to enter the dental canal of the inferior maxillary bone. In its course through the canal it supplies the lower teeth; and it finally emerges at the mental foramen to be distributed to the lower lip and chin. Before entering the dental canal it gives a branch² to the muscles and skin of the floor of the mouth.

¹ N. dentalis inferior; n. maxillaris inferior; n. mandibularis.

² Ramus mylo-hyoideus.

THE OTIC GANGLION.¹

This is a small, flattened, oval body, situated on the inner side of the sensory division of the inferior maxillary nerve, with which it is connected by several short filaments. Behind it is the great meningeal artery, and it is connected by a filament with the sympathetic plexus following this vessel. It gives branches to the tympanic tensor and circumflex palatine muscles, and an anastomotic filament to the auriculo-temporal nerve. From it emanates the **small petrosal nerve**,² which enters the cranium through a fine canal in the spinous process of the sphenoid bone, and then traverses a canal in the front of the petrous portion of the temporal bone, to join the facial nerve and the tympanic branch of the glosso-pharyngeal nerve.

THE SUBMAXILLARY GANGLION.³

This is a minute body situated on the trunk of the lingual nerve, just above the submaxillary gland. It is connected by filaments with the lingual nerve, which are partly traceable to the tympanic branch of the facial. It is also connected with the sympathetic plexus of the facial artery, and sends all its branches to the submaxillary gland.

THE ABDUCENT, OR SIXTH PAIR OF NERVES.

Fig. 326 * The **Abdu'cent nerves**⁴ appear at the surface of the brain, between the summits of the pyramidal bodies of the medulla oblongata and the pons. Their fibres, forming a large and small bundle, for the most part originate from the pyramidal bodies, a few being derived from the pons.

The abducent nerve appears as a white thread, but is larger than the pathetic nerve. It proceeds forward, traverses the cavernous sinus, from the cavity of which it is separated by the lining membrane, and passes through the sphenoidal foramen into the orbit. In the cavernous sinus it lies at the outer side of the internal carotid artery, and is connected with its sympathetic plexus by a pair of filaments. In the orbit it passes between the two heads of the external straight muscle, to which it is distributed.

¹ Ganglion oticum; g. auriculare; g. Arnoldi; ganglion of Arnold; otoganglion; g. maxillo-tympanicum.

² Small superficial petrosal nerve; nervus petrosus superficialis minor.

³ G. submaxillare; g. linguale; g. mi-

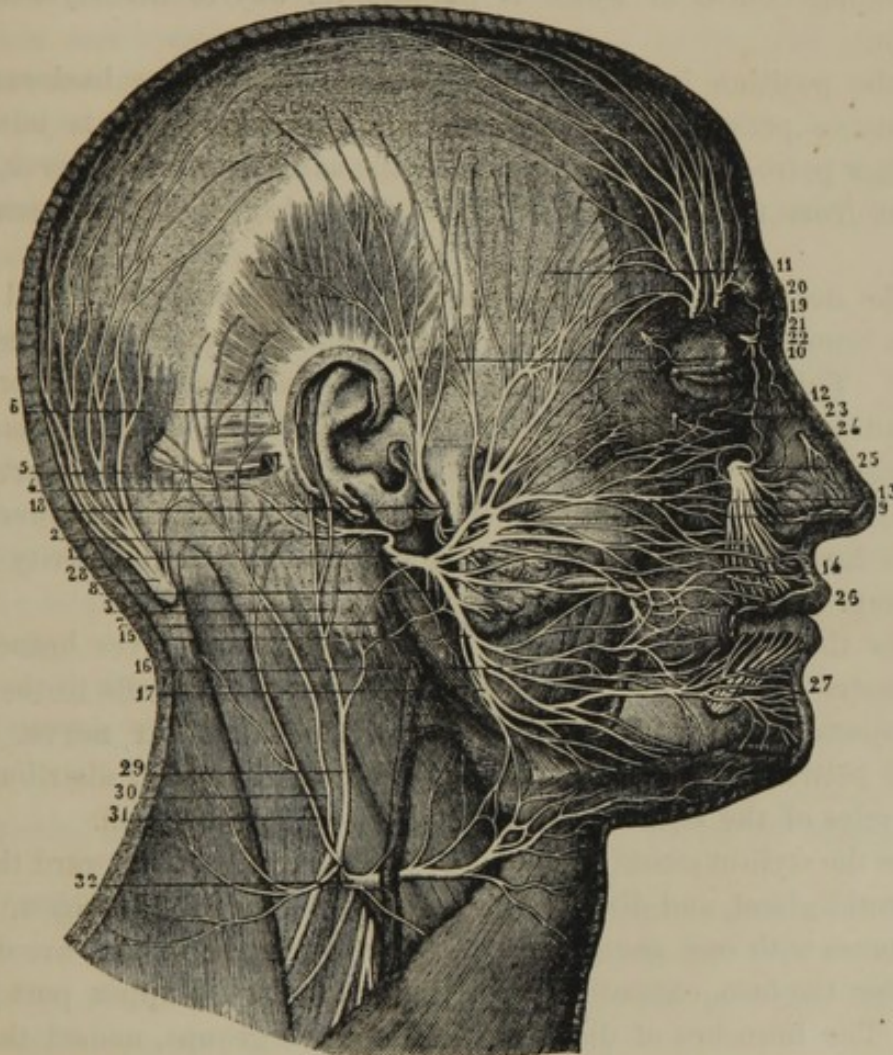
nus Meckelii; plexus gangliosus submaxillaris.

⁴ Nervi abducentes. Sing.: nervus abducens; n. oculo-muscularus externus or posterior; n. ocularis externus; n. motor-oculi externus; n. timidus.

THE FACIAL, OR SEVENTH PAIR OF NERVES.

The **Facial nerves**¹ emerge from the depression immediately back of the pons, between the olivary and restiform bodies. They have a large

FIG. 338.



THE FACIAL NERVE. 1, trunk of the nerve emerging at the stylo-mastoid foramen; 2, its deep auricular branch; 3, anastomosis of the latter with the great auricular nerve of the cervical plexus; 4, 5, 6, branches to the contiguous muscles; 7, 8, branches of the facial to the digastric and stylo-hyoid muscles; 9, temporo-facial division of the nerve; 10, branch to the temple, anastomosing with the auriculo-temporal nerve; 11, temporal branches; 12, zygomatic branches; 13, infra-orbital branches; 14, 15, cervico-facial division of the facial nerve; 14, buccal branches; 16, inferior maxillary branches; 17, cervical branches; 18, auriculo-temporal nerve; 19, 20, terminal branches of the frontal nerve; 21, terminal branch of the lachrymal nerve; 22, external nasal nerve; 23, branch of the temporo-malar nerve; 24, terminal branch of the internal nasal nerve; 25, infra-orbital nerves; 26, anastomosis between the buccal branch of the inferior maxillary nerve and the buccal branches of the facial nerve; 27, terminal branches of the inferior dental nerve; 28, great occipital nerve; 29, 31, branches of the great auricular nerve; 30, small occipital nerve; 32, superficial cervical nerve, anastomosing with the facial nerve.

¹ *Nervi faciales*; *par septimum*; *p. faciale*. Sing.: *portio dura nervi septimi*; *n. communicans faciei*; *n. primus paris septimi*; *n. sympathicus parvus*

or *minor*; *ramus durior septimæ conjugationis*; respiratory nerve of the face; *portio dura nerve*; *portio dura* of the seventh pair of nerves.

root whose fibres are derived from the restiform body, and a small root from the floor of the fourth ventricle. The two roots together accompany the auditory nerve, lying in a groove on its upper part, and pass down the internal auditory meatus. At the bottom of this passage the facial leaves the auditory nerve and enters the Fallopian canal, through the winding course of which it pursues its way to the stylo-mastoid foramen.

At the position in which the Fallopian canal turns backward, the facial nerve presents a **gangliform enlargement**,¹ which is joined by the larger petrosal nerve, a branch of the smaller petrosal nerve, and a filament from the sympathetic plexus following the great meningeal artery.

In the descending portion of the Fallopian canal the facial nerve sends a branch to the stapedius muscle, and gives off the **tympanic nerve**.² This enters the tympanum through a foramen near the pyramid, and proceeds forward to emerge at the glenoid fissure, from which it descends between the pterygoid muscles to join the lingual nerve. In its course it lies in contact with the tympanic membrane, between this and the handle of the mallet, and is separated from the cavity of the tympanum by its lining mucous membrane.

Below the stylo-mastoid foramen the facial nerve gives branches to the digastric and stylo-hyoid muscles, anastomotic filaments to the auriculo-temporal nerve, and sends off the **deep auricular nerve**.³ This ascends between the ear and the mastoid process, and is distributed to the muscles of the back of the ear and the occipital region.

From the stylo-mastoid foramen the facial nerve turns forward through the parotid gland, and divides into numerous diverging branches,⁴ which anastomose with one another on the side of the cheek, and are distributed over the face, extending from the temple to the upper part of the neck. The branches of distribution form two groups, named the temporo-facial and cervico-facial divisions of the nerve.

The **Temporo-facial division** of the facial nerve ramifies on the side of the face from the temple to the vicinity of the mouth, forming an intricate plexus, and anastomosing with the contiguous terminal branches of the trifacial nerve. Its branches, mainly distributed to the muscles of the temple, forehead, eyelids, cheek, nose, and upper lip, are named, from their special position, **temporal, zygomatic, and infra-orbital**.

¹ Intumescencia gangliiformis; ganglion geniculare.

² Chorda tympani; funiculus tympani.

³ Nervus auricularis profundus; posterior, or exterior.

⁴ Pes anserinus; plexus parotideus.

The **Cervico-facial** division of the facial nerve is distributed to the lower part of the face and the upper part of the neck. Its upper or **buccal branches** anastomose with the lower ones of the preceding division, and supply the muscles of the cheek, nose, and upper lip. The **inferior maxillary branches** supply the muscles of the lower lip and chin, and anastomose with the inferior dental nerve. The **cervical branches** anastomose with the upper cervical nerves, and supply the subcutaneous cervical muscle.

The facial nerve is the motor nerve of the face, and is the avenue through which its muscles are acted upon by the emotions. A few sensory filaments which it contains are derived through anastomosis with the pneumogastric and trifacial nerves.

THE AUDITORY, OR EIGHTH PAIR OF NERVES.

The **Aud'itory nerves**¹ have their origin in the transverse white striæ of the floor of the fourth ventricle, and turn forward around the restiform bodies, from which they also receive a few fibres. Each nerve is then directed outwardly, in company with the facial nerve, and passes into the internal auditory meatus, from whence it is distributed to the labyrinth.

The auditory nerve is the special one of hearing, and is more particularly described in the account of the ear.

THE GLOSSO-PHARYNGEAL, OR NINTH PAIR OF NERVES.

The **Glosso-pharynge'al nerves**² arise by about a half dozen cords from the restiform body, just behind the olivary body. They issue from the cavity of the cranium, in company with the pneumogastric and accessory nerves, through the jugular foramen.

Within the latter foramen, some of the fibres of the glosso-pharyngeal nerve become mingled with nerve cells, forming a small ganglion,³ but its presence is inconstant.

As it emerges from the jugular foramen, the glosso-pharyngeal nerve

¹ Nervi auditorii. Sing.: n. auditorius; n. acusticus; portio mollis paris septimi, or nervi auditorii; portio mollis nerve: portio mollis of the seventh pair of nerves; acoustic nerve.

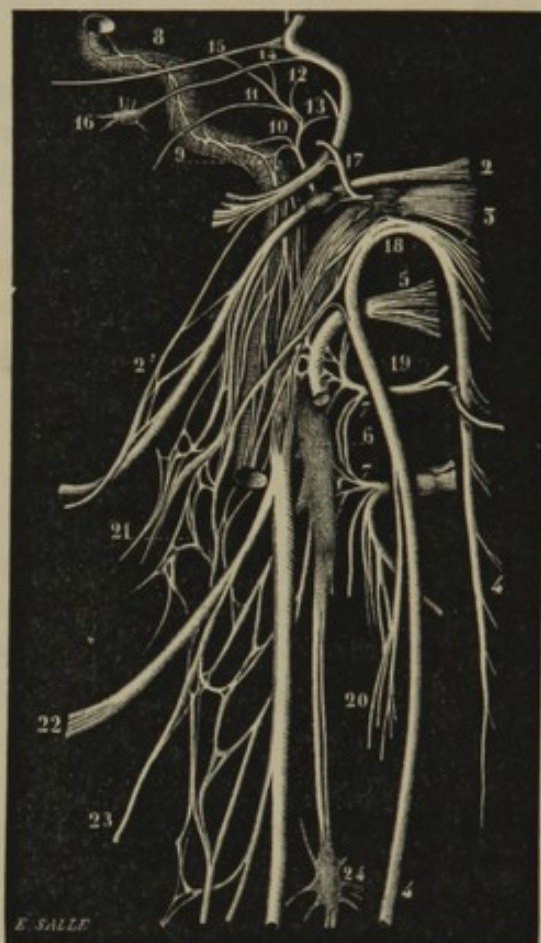
² N. glosso-pharyngei; par nonum. Sing.: n. pharyngo-glossus; n. lingualis lateralis; n. sensualis linguæ; n. gus-

tatorius linguæ; n. lingualis paris octari; n. lingualis paris noni; n. lingualis pneumogastrici; first branch of the eighth pair of nerves.

³ Ganglion superius nervi glosso-pharyngei; g. jugulare superius; g. Ehrenritteri; g. Mülleri; ganglion of Ehrenritter.

enlarges into the **petrous ganglion**,¹ which is connected by fine filaments

FIG. 339.



THE LAST FOUR CEREBRAL NERVES, THE FACIAL NERVE, THE SYMPATHETIC, AND THE UPPER TWO CERVICAL NERVES. 1, facial nerve; 2', anastomosis between branches of the facial and glosso-pharyngeal nerve; 2, glosso-pharyngeal; 3, pneumogastric; 4, accessory; 5, hypoglossal; 6, first cervical ganglion of the sympathetic; 7, first and second cervical nerves; 8, carotid plexus of the sympathetic on the internal carotid artery; 9, tympanic nerve from the petrous ganglion of the glosso-pharyngeal; 10, its connection with the carotid plexus; 11, branch to the Eustachian tube; 12, 13, branches to the round and oval windows of the ear; 14, 15, branches joining the small and greater petrosal nerves; 16, otic ganglion; 17, auricular branch from the jugular ganglion, connected by filaments with the petrous ganglion and the facial nerve; 18, anastomosis of the accessory with the pneumogastric; 19, anastomosis of the first cervical nerve with the hypoglossal; 20, anastomosis of the second cervical nerve with a branch of the accessory; 21, pharyngeal plexus; 22, superior laryngeal nerve; 23, its external branch; 24, second cervical ganglion of the sympathetic.

sympathetic, and gives branches to the muscles and mucous membrane

with the pneumogastric and sympathetic nerves, and gives off an important branch, named the **tympanic nerve**.² This ascends through a fine canal of the petrous portion of the temporal bone to the tympanum, and expands upon the promontory into a number of branches, which supply the lining membrane of the tympanum, the round and oval windows, and the Eustachian tube. It is also connected with the sympathetic plexus of the internal carotid artery, and with the smaller petrosal nerve.

From the petrous ganglion, the glosso-pharyngeal nerve passes between the jugular vein and the internal carotid artery, and descends in a curve to the root of the tongue, on the inner side of the stylo-pharyngeal muscle, and beneath the tonsil. In its course it is connected by anastomotic filaments with the pneumogastric nerve and the carotid plexus of the

¹ G. inferius nervi glosso-pharyngei; g. petrosum; g. Anderschii; neuronodus petrosus; ganglion of Andersch.

² Nerve of Jacobson; ramus tympanicus; nervus tympanicus superior; ramus anastomoticus Jacobsonii; nervus Jacobsonii.

of the pharynx. 'Its terminal branches are distributed to the tonsils and the mucous membrane of the root of the tongue, including the circumvallate papillæ.

The glosso-pharyngeal nerve is sensory-motor in its function; and its terminal branches are by many believed to participate with the lingual nerve in the sense of taste.

THE PNEUMOGASTRIC, OR TENTH PAIR OF NERVES.

The **Pneumogas'tric nerves**¹ extend from the cavity of the cranium, through the neck and thorax, into the abdomen, and are distributed to the organs of voice and respiration, the heart, and the alimentary canal from the pharynx to the stomach inclusively. They spring by from ten to fifteen cords from the groove behind the olivary body, and pass from the cranium, in company with the glosso-pharyngeal and accessory nerves, through the jugular foramen. From thence they descend within the sheath of the great blood-vessels of the neck, lying posteriorly between the carotid arteries and jugular vein.

At the bottom of the neck the **right pneumogastric nerve** enters the posterior mediastinal cavity between the corresponding subclavian artery and vein. It then descends behind the root of the right lung to the posterior surface of the œsophagus, which it accompanies to the stomach.

The **left pneumogastric nerve** descends, in front of the left subclavian artery and the arch of the aorta, into the posterior mediastinal cavity, and passes behind the root of the left lung to the front of the œsophagus, along which it continues to the stomach.

Within the jugular foramen the pneumogastric nerve presents an ovoidal, grayish body, the **jugular ganglion**.² This resembles in appearance the ganglia of the spinal nerves, and like them it gives additional fibres to the trunk upon which it is situated. It gives off an **auricular branch**,³ which, after being joined by filaments from the petrous ganglion and the facial nerve, is distributed to the external auditory meatus.

Having emerged from the jugular foramen, the pneumogastric nerve receives an accession of fibres from the accessory and hypoglossal nerves, and dilates into a fusiform enlargement called the **gangliform plexus**.⁴ This

¹ Nervi pneumogastrici; par vagum; par undecimum. Sing.: nervus vagus; n. ambulatorius; n. decimus; n. sympathicus medius; second branch of the eighth pair of nerves.

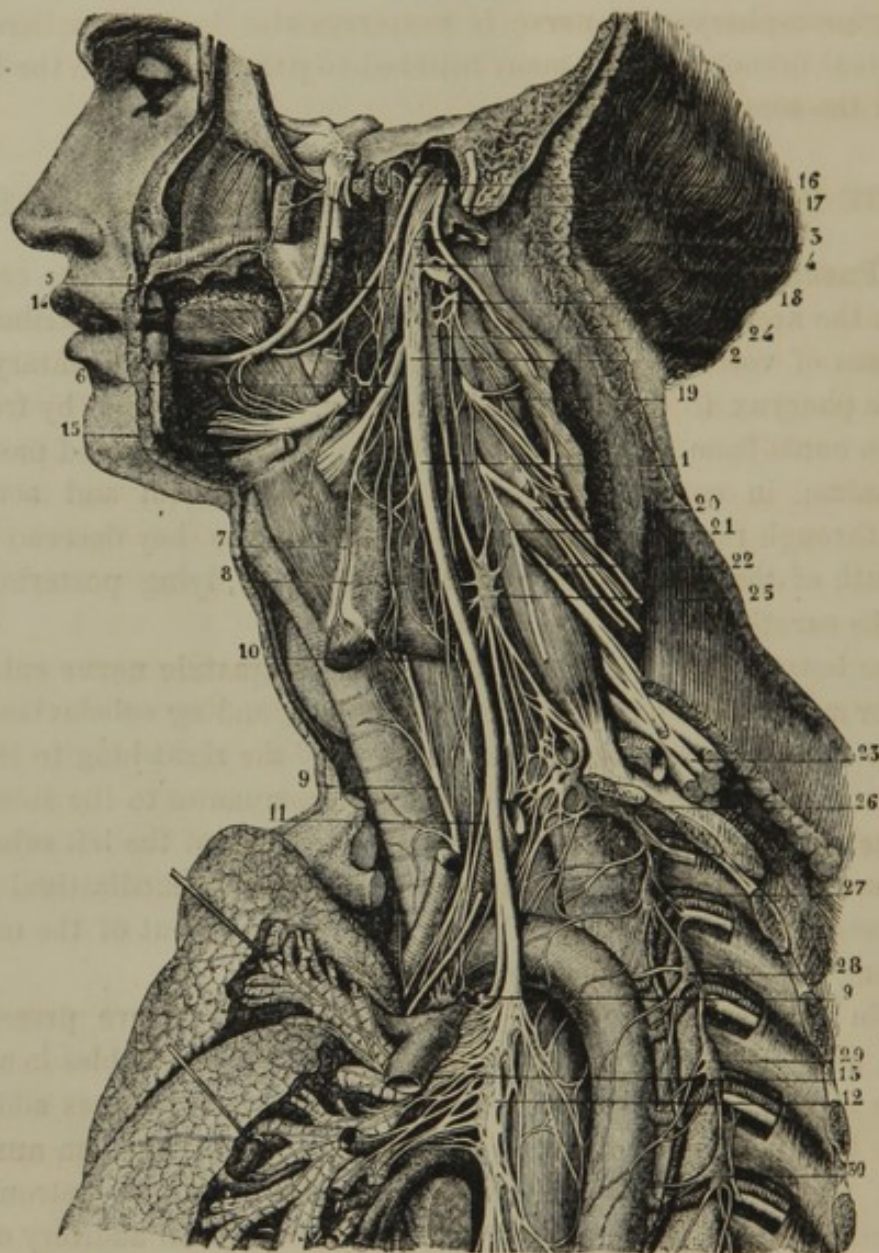
² G. jugulare nervi vagi; g. superius nervi vagi; g. nervi vagi.

³ Ramus auricularis; auricular nerve of Arnold.

⁴ Plexus gangliiformis; p. nodosus; ganglion inferius nervi vagi; g. tunici nervi vagi.

is about three-fourths of an inch long, of comparatively loose texture, and contains mingled nerve cells.

FIG. 340.



THE PNEUMOGASTRIC NERVE. 1, trunk of the pneumogastric; 2, gangliform plexus; 3, anastomosis of the latter with the accessory nerve; 4, anastomosis with the hypoglossal; 5, pharyngeal nerve; 6, superior laryngeal nerve; 7, its external branch; 8, pharyngeal plexus; 9, inferior laryngeal nerve; 10, 11, filaments to the cardiac plexus; 12, commencement of the oesophageal plexus; 13, pulmonary plexus; 14, lingual nerve; 15, lower part of the hypoglossal nerve; 16, glosso-pharyngeal nerve; 17, accessory nerve; 18, 19, 20, second, third, and fourth cervical nerves; 21, commencement of the phrenic nerve; 22, 23, the lower four cervical nerves which with the first thoracic nerve form the brachial plexus; 24, 25, first and second cervical ganglia of the sympathetic; 26, third cervical united with the first thoracic ganglion; 27-30, second to the fifth thoracic ganglia.

The gangliform plexus receives anastomotic branches from the glosso-pharyngeal nerve, the first cervical ganglion of the sympathetic, and the upper part of the cervical plexus, and it gives off the pharyngeal and superior laryngeal nerves.

The **Pharynge'al nerve** or **nerves**,¹ from one to three in number, descend upon the side of the pharynx, anastomose with the pharyngeal branches of the glosso-pharyngeal nerve, and supply the constrictor muscles and mucous membrane of the pharynx.

The **Superior Larynge'al nerve**² curves downward and forward to the side of the larynx. After giving a branch to the inferior constrictor of the pharynx, the crico-thyroid muscle, and the thyroid body, it pierces the thyro-hyoid membrane, and is expended in numerous filaments to the mucous membrane of the larynx.

Descending the neck, the pneumogastric nerve gives off several filaments³ which join the cardiac nerves of the sympathetic, or descend the neck to the cardiac plexus. It also gives off an anastomotic branch to the descending cervical nerve of the hypoglossal. At the bottom of the neck it gives off a large branch, the **Inferior Larynge'al nerve**.⁴ This, on the right side, descends in front of the subclavian artery, and winds around it posteriorly from beneath; on the left side, in the same manner, the nerve winds around the arch of the aorta. It then ascends the neck, in the interval laterally of the trachea and œsophagus, to the larynx. In its course it is connected by anastomotic filaments with the last cervical ganglion, and the cardiac plexus of the sympathetic, and gives branches to the trachea and œsophagus. Its terminal branches supply most of the muscles of the larynx, a few of them being distributed to the mucous membrane, and anastomosing with the superior laryngeal nerve.

In the thorax the pneumogastric nerve gives off cardiac and pulmonary branches, and then with its fellow forms the œsophageal plexus.

The **cardiac branches**⁵ are derived from the pneumogastric nerve below the inferior laryngeal. They anastomose with the cardiac branches of the sympathetic, and contribute to form the cardiac plexus of the latter.

The **pulmonary branches**⁶ are numerous, and enter the root of the lung upon the bronchus, a few in front, but mainly at its back part. They are joined by filaments from the upper thoracic ganglia of the sympathetic, and form on the bronchus the **pulmonary plexus**,⁷ from

¹ Nervi pharyngei.

² Nervus laryngeus superior.

³ Rami cardiaci.

⁴ Nervus laryngeus inferior, or recurrent; recurrent laryngeal nerve.

⁵ Rami cardiaci; r. c. profundi inferiores.

⁶ Rami pulmonarii.

⁷ Plexus pulmonalis anterior et posterior.

which the nerves follow the ramifications of the bronchial tubes throughout the lungs.

After the origin of the pulmonary branches, the pneumogastric nerve of the right side applies itself to the back of the œsophagus, while that of the left side applies itself to the front. By division and reunion of branches, the two nerves form the intricate **œsophage'al plexus**,¹ which surrounds the œsophagus and supplies its walls.

The terminal branches² of the right pneumogastric nerve, after leaving the œsophageal plexus, are distributed to the posterior part of the stomach, and are connected with the solar plexus of the sympathetics.

The terminal branches² of the left pneumogastric nerve, descending from the œsophagus, supply the front surface and pyloric extremity of the stomach, and partly proceed along its lesser curvature to join the hepatic plexus of the sympathetics.

The pneumogastric nerve is sensory-motor in its function, and presides over the general sensibility and muscular actions of the pharynx, œsophagus, stomach, larynx, trachea, ^{heart} and lungs.

THE ACCESSORY, OR ^{eleventh} ~~TWELFTH~~ PAIR OF NERVES.

The **Ac'cessory nerves**³ are somewhat variable in extent and origin, and not unfrequently differ on the two sides. They arise by a series of filaments from the lateral columns of the spinal cord, and from the medulla oblongata, below and behind the olivary bodies. The filaments of origin may commence as low as from the third to the last cervical vertebra, and are situated between the posterior roots of the spinal nerves and the denticulated ligament. They are successively collected into an ascending cord, which enters the cranium through the occipital foramen. The accessory nerve then passes through the jugular foramen, in company with the glosso-pharyngeal and pneumogastric nerve, and divides into two branches. One of these joins the gangliform plexus of the pneumogastric nerve; the other branch turns outwardly behind the jugular vein, and pierces the sterno-mastoid muscle above its middle. After supplying the latter with filaments, it proceeds through the supra-clavicular fossa to the trapezius muscle, in which it terminates.

Besides its connection with the pneumogastric, the accessory nerve anastomoses with the upper four cervical nerves. Occasionally it pre-

¹ Plexus œsophageus.

² Rami gastrici.

³ Spinal accessory nerves; nervi accessorii; par undecimum; eleventh pair of encephalic nerves. Sing.: accessory

of the par vagum, or eighth pair; nervus accessorius Willisii; n. a. ad par octavum; n. spinalis; superior respiratory nerve; third branch of the eighth pair of nerves.

sents a ganglion upon its trunk. In function it is a motor nerve, though it appears also to contain a few sensory fibres.

THE HYPOGLOSSAL, OR TWELFTH PAIR OF NERVES.

The **Hypoglossal nerves**,¹ the last pair of the cerebral series, arise by a number of filaments from the fissure between the pyramidal and olivary bodies. The filaments converge into two bundles, which, after passing through the condyloid foramen of the occipital bone, unite in a rounded cord.

From the condyloid foramen the hypoglossal descends behind the pneumogastric nerve, and then curves downward and forward to the outer side of the latter, between the internal carotid artery and jugular vein, to the under part of the tongue. It is here situated above the hyoid bone, on the outer side of the hyo-glossal muscle, and penetrates the genio-glossal muscle, to which, and the other muscular structure of the tongue, it is distributed.

After its exit from the cranium, the hypoglossal nerve is connected by anastomotic filaments with the first cervical ganglion of the sympathetic, the gangliform plexus of the pneumogastric, and the upper two cervical nerves. Lower in its course it gives off the **descending cervical nerve**,² which crosses to the outer side of the great blood-vessels of the neck, and, after being joined by filaments from the pneumogastric and cervical plexus of nerves, is distributed to the omo-hyoid, sterno-hyoid, and sterno-thyroid muscles.

The hypoglossal nerve, as indicated by its distribution, is motor in function.

THE SPINAL NERVES.

Of **Spinal nerves**³ there are thirty-one pairs, divided, according to their relation with the vertebral column, into eight cervical, twelve thoracic, five lumbar, five sacral, and one coccygeal nerve.

Every spinal nerve originates by an anterior and a posterior root from the corresponding lateral grooves of the spinal cord. Each root is composed of a vertical series of flattened threads, which converge together from their origin. The anterior roots, except those of the upper two cervical nerves, are larger and composed of a greater number of threads than the posterior roots.

¹ Nervi hypoglossi; par nonum; ninth pair of nerves. Sing.: nervus lingualis; n. l. medius; n. motorius linguæ; n. sublingualis; n. loquax; hypoglossus; myoglossus; gustatory nerve.

² Descendens noni; ramus descendens.

³ Vertebral nerves; intervertebral nerves.

The largest roots of the spinal nerves are those of the lower four cervical and the first thoracic nerve, which supply the upper extremities; and those of the lower three lumbar and upper two sacral nerves, which supply the lower extremities.

The anterior and posterior roots converge and pass side by side through separate apertures of the dura mater, opposite the intervertebral and sacral foramina, but are accompanied by tubular sheaths of that membrane.

In consequence of the comparative shortness of the spinal cord, the roots of the spinal nerves, in order to reach their place of exit from the dura mater, successively increase in length from the first to the last. From this arrangement they also incline more and more from a horizontal course, until they finally assume a vertical direction, and thus the roots of the lumbar, sacral, and coccygeal nerves are collected into a thick bundle¹ occupying the lower part of the sheath of the dura mater.

The posterior roots of the spinal nerves are provided with a reddish-gray, oval ganglion, which contributes additional fibres to the roots as they proceed from them. The ganglia, except those of the sacral and coccygeal nerves, are situated within the intervertebral foramina. Those of the sacral nerves are contained within the spinal canal, and that of the coccygeal nerve is even placed within the sheath of the dura mater of the spinal cord.

The anterior root of the spinal nerves lies in contact with the ganglion of the posterior root, but neither contributes to nor receives fibres from it. Immediately beyond the ganglion, the two roots unite in a common trunk, which is a short, rounded cord, composed of an intermixture of the nerve fibres of both roots.

The spinal nerves thus formed emerge from the intervertebral foramina, the sacral and coccygeal nerves excepted, which divide within the vertebral canal into anterior and posterior branches, and then escape through the corresponding sacral foramina.

The nerves which pass through the intervertebral foramina immediately afterwards divide into an anterior and a posterior branch. With the exception of those of the first two pairs of spinal nerves, the anterior branches are much the larger, and are destined to supply the trunk in advance of the vertebral column, and the limbs; the posterior branches are distributed to the back of the trunk.

The anterior roots of the spinal nerves are motor in function; the posterior roots are sensory. The association of the two roots renders

¹ Cauda equina.

the spinal nerves sensory-motor; and with this endowment the nerves are distributed to the muscles and skin of the body, from the head downward.

THE CERVICAL NERVES.

Of the **Cer'vical nerves**¹ there are eight pairs, of which the **first pair**, or **suboccip'ital nerves**,² emerge from the vertebral canal, between the occipital bone and atlas; and the **last pair** escape through the intervertebral foramina, between the last cervical and first dorsal vertebræ. They increase successively from above downward, and, after passing from the vertebral canal, as already indicated, they divide into an anterior and a posterior branch.

POSTERIOR BRANCHES OF THE CERVICAL NERVES.

The **posterior branch** of the **first cervical**, or **suboccip'ital nerve**,² is larger than the anterior branch. After issuing from between the arch of the atlas and the vertebral artery, it is expended in filaments on the contiguous straight, oblique, and complex muscles; one of them descending to communicate with the second cervical nerve.

The **posterior branch** of the **second cervical nerve** is the largest of the corresponding branches of the cervical series. Emerging from between the arches of the atlas and axis, it receives a communicating filament from the first cervical nerve, and then divides into two branches. Of these, the **external branch** is expended in the complex, splenius, and trachelo-mastoid muscles. The **internal branch**, or **great occip'ital nerve**,³ pierces the complex and trapezius muscles, and accompanies the occipital artery to be distributed to the muscle and skin of the occipital region.

The **posterior branches** of the **lower six cervical nerves**, after passing backward between the transverse processes of the vertebræ, divide into external and internal branches.

The **external branches** supply the ascending cervical, transverse cervical, and trachelo-mastoid muscles. The **internal branches** are larger than the preceding. These, from the third, fourth, and fifth cervical nerves, turn inwardly toward the spinous processes of the vertebræ, and are then directed outwardly to be distributed to the skin; while those from the lower three cervical nerves terminate in the complex, semispinal, and multifid spinal muscles.

¹ Nervi cervicales: n. cervicis; n. nuchæ; n. intervertebrales colli.

² N. cervicalis primus; n. c. supremus; n. infra-occipitalis.

³ N. occipitalis magnus or maximus.

ANTERIOR BRANCHES OF THE CERVICAL NERVES.

The **anterior branches** of the cervical nerves successively increase in size from first to last. They turn forward to the outer side of the vertebral artery, except the first of the series, which is situated beneath the horizontal turn of that vessel above the atlas.

The **anterior branches** of the **upper four cervical nerves** divide and anastomose with one another in such a manner as to form a series of loops, constituting the **cervical plexus**, which is situated in front of the attachment of the muscles to the transverse processes of the vertebræ. The plexus is connected by anastomotic filaments with the superior cervical ganglion and trunk of the sympathetic, and with the pneumogastric, accessory, and hypoglossal nerves. It supplies an offset to the brachial plexus, and gives off numerous branches; which are mainly distributed to the front and side of the neck.

The **anterior branches** of the **lower four cervical nerves** are much larger than the preceding. Through anastomosis together, and with the **anterior branch** of the **first thoracic nerve**, they form the **brachial plexus**, mainly destined to supply the upper extremity. The nerves forming the brachial plexus communicate by filaments with the second and third cervical and first dorsal ganglia of the sympathetic.

THE CERVICAL PLEXUS.

The **Cer'vical plexus**,¹ as above mentioned, is formed by division and anastomosis of the anterior branches of the upper four cervical nerves. It is situated beneath the sterno-mastoid muscle, and rests upon the middle scalene muscle and the elevator of the scapular angle, opposite the upper four cervical vertebræ.

From the cervical plexus are derived the following nerves :—

1. Muscular branches.
2. The superficial cervical nerve.
3. The great auricular nerve.
4. The small occipital nerve.
5. The supra-clavicular nerves.
6. The phrenic nerve.

1. The **Muscular branches** supply the scalene and long cervical muscles, the anterior and lateral straight muscles, the elevator of the scapular angle, and the sterno-mastoid and trapezius muscles.

¹ Plexus cervicalis.

2. The **Superficial Cer'vical nerve**,¹ derived from the anastomosis of the second and third cervical nerves, is directed around the posterior border of the sterno-mastoid muscle, and passes forward between it and the subcutaneous cervical muscle. Dividing into **ascending** and **descending branches**, the former supply the subcutaneous cervical muscle and the skin at the upper fore part of the neck, and anastomose with filaments of the facial nerve; the latter supply the skin of the lower fore part of the neck.

3. The **Great Auric'ular nerve**,² from the cervical plexus, winds around the posterior border of the sterno-mastoid muscle, and ascends on its outer surface to be distributed to the external ear and the skin over the parotid gland and mastoid process. Some of its filaments anastomose with branches of the facial and pneumogastric nerves.

4. The **Small Occip'ital nerve**,³ derived from the second cervical nerve, ascends along the posterior border of the sterno-mastoid muscle, and is distributed to the skin and muscles of the occipital region, anastomosing with the great occipital and great auricular nerves.

5. The **Supra-clavic'ular nerves**,⁴ of which there are usually three, spring from the fourth cervical nerve, and descend in the interval of the sterno-mastoid and trapezius muscles to be distributed to the skin over the clavicle, the breast, and shoulders.

6. The **Phrenic nerve**,⁵ the most important branch of the cervical plexus, springs from the third and fourth cervical nerves, and further receives an offset from the fifth cervical nerve or the commencement of the brachial plexus. Descending upon the anterior scalene muscle, it enters the thorax between the subclavian artery and vein, and proceeds downward in front of the root of the lung, included between the pleura and pericardium until it reaches the diaphragm, to which it is distributed. In its course it receives anastomotic filaments from the lower two cervical ganglia of the sympathetic, and gives filaments to the pericardium.

THE BRACHIAL PLEXUS.

The **Bra'chial plexus**,⁶ which mainly supplies the upper extremity, is formed through anastomosis of the anterior branches of the lower four

¹ N. superficialis colli; n. subcutaneus colli superior, medius, et infimus.

² N. auricularis magnus; n. a. posterior.

³ N. occipitalis minor.

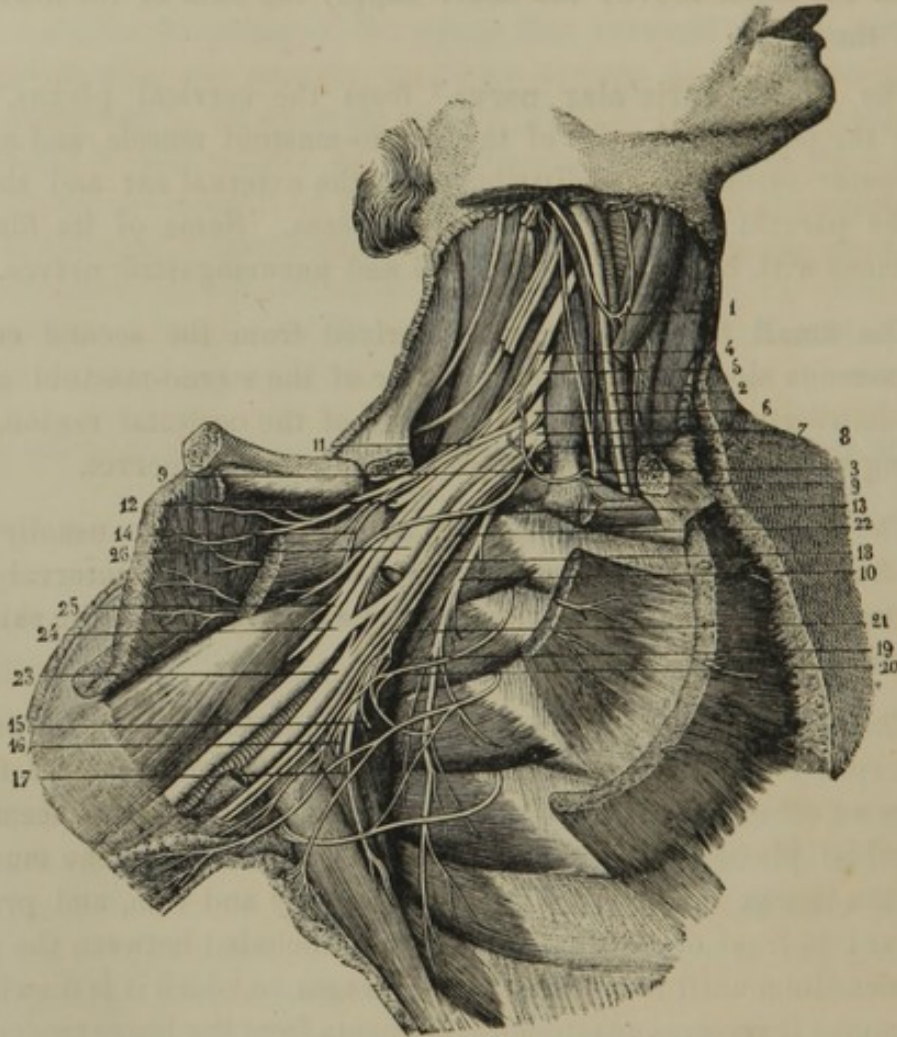
⁴ N. supra-claviculares; n. s. c. anteriores, medii, et posteriores.

⁵ N. phrenicus; n. diaphragmaticus; n. respiratorius internus; internal respiratory nerve of Bell.

⁶ Plexus brachiales; p. axillaris.

cervical nerves, together with the corresponding branch of the first thoracic nerve. It extends from the side of the cervical vertebræ to the axilla, and opposite the coracoid process separates into large offsets for the upper extremity. In its course it passes outwardly between the anterior and middle scalene muscles, and descends obliquely beneath the

FIG. 341.



THE BRACHIAL PLEXUS. 1, anastomosis between the descending cervical branch of the hypoglossal and a branch of the cervical plexus; 2, pneumogastric nerve; 3, phrenic nerve; 4-8, the lower four cervical, and the first thoracic nerves, forming the brachial plexus; 9, branch to the subclavian muscle giving a filament to the phrenic nerve; 10, posterior thoracic nerve; 11, 13, anterior thoracic nerves; 14, anastomosis between the latter; 12, supra-scapular nerve; 15-17, subscapular nerves; 18, small cutaneous nerve; 19, anastomosis of a branch of the latter with the intercosto-humeral nerve, 20; 21, continuation of the small cutaneous nerve in company with the internal cutaneous, 22; 23, ulnar nerve; 24, median; 25, external cutaneous; 26, musculo-spiral nerve.

clavicle into the axilla. It is at first situated above and partially behind the subclavian blood-vessels, then behind the axillary vessels, and finally, it surrounds the latter as it is about to expend itself in branches.

In its modes of formation the brachial plexus is subject to variation, but the most frequent arrangement is that which follows. The fifth cer-

vical nerve descends obliquely and joins the sixth, and the trunk thus formed is shortly after joined by the seventh cervical nerve. The first thoracic nerve ascends obliquely to join the eighth cervical nerve. The two trunks thus produced then send off each a branch which joins with its fellow to form a third trunk. Of the three trunks, one is placed on the outer side of the axillary artery; another on the inner side; and the third behind the vessel; and from them diverge the branches to the limb.

The branches given off from the brachial plexus above the clavicle are, for the most part, destined to supply the side of the thorax and shoulder; those given off below the clavicle are its terminal divisions, and mostly extend the length of the upper extremity.

The branches of the brachial plexus are as follow:—

1. Muscular branches.
2. Supra-scapular nerve.
3. Thoracic nerves.
4. Subscapular nerves.
5. Small cutaneous nerve.
6. Internal cutaneous nerve.
7. External cutaneous nerve.
8. Circumflex nerve.
9. Median nerve.
10. Ulnar nerve.
11. Musculo-spiral nerve.

1. The **Muscular branches** given off from the commencement of the brachial plexus supply the scalene, long cervical, rhomboid, superior serrate, and subclavian muscles.

2. The **Supra-scap'ular nerve**,¹ from the upper trunk of the brachial plexus, passes outward and backward, and proceeds through the supra-scapular foramen to supply the supra- and infra-spinous muscles.

3. The **Thorac'ic nerves** consist of posterior and anterior branches. The **posterior** or **long thoracic nerve**,² larger than the others, is derived from the fifth and sixth cervical nerves, and descends along the fore part of the great serrated muscle, to which it is distributed. The **anterior thoracic nerves**,³ of which there are two, spring from the inner and outer trunks of the brachial plexus, and pass beneath the clavicle to supply the pectoral muscles.

¹ N. supra scapularis; n. scapularis.

² N. thoracicus posterior, or longus; n. respiratorius externus; external respiratory nerve of Bell.

³ Nervi thoracici; n. pectorales anteriores.

4. The **Subscap'ular nerves**,¹ of which there are three, originate by filaments from all the cords of the brachial plexus, except the first thoracic nerve. The largest branch descends along the outer border of the subscapular muscle to be distributed to the latissimus muscle, some of its filaments reaching the inferior serrated muscle. The other two nerves enter the upper part of the subscapular and terete muscles, which they supply.

5. The **Small Cuta'neous nerve**,² derived from the first thoracic nerve of the brachial plexus, descends along the inner side of the axillary and brachial blood-vessels to near the middle of the arm. It then pierces the fascia of the latter, and proceeds beneath the skin to the elbow between the internal condyle and olecranon. In its course it anastomoses with the intercosto-humeral nerve, and it supplies the skin on the lower inner part of the arm.

The remaining branches of the brachial plexus come off at the lower or outer part of the axilla, and appear as its terminal divisions, for the most part extending the length of the upper extremity.

6. The **Internal Cuta'neous nerve**,³ from the lower trunk of the brachial plexus, is its smallest terminal branch. It descends on the inner side of the brachial blood-vessels, near the middle of the arm, pierces the fascia, and divides into two branches. Of these the **smaller branch** descends to the inner side of the basilic vein and behind the internal condyle, to be distributed to the skin on the back of the forearm. The **larger branch**, apparently the continuation of the main nerve, descends along the inner front part of the arm and forearm, and is expended in the contiguous skin. At the bend of the elbow one of its branches usually passes above, and another beneath the median basilic vein, near the termination of this vessel in the basilic vein.

7. The **External Cuta'neous nerve**,⁴ larger than the preceding, and derived from the upper cord of the brachial plexus, perforates the coraco-brachial muscle, and passes between the biceps flexor and brachial muscle to the outer part of the arm. It here perforates the brachial fascia, and divides into two branches, of which one passes in

¹ N. subscapulares.

² N. cutaneus minor; n. c. internus minor; n. c. brachii internus; n. c. ulnaris Wrisbergii.

³ N. cutaneus internus; n. c. i. major; n. c. brachii medius.

⁴ N. cutaneus externus; n. musculo-cutaneus; n. perforans Casserii; ramus magnus nervi mediani.

front, the other beneath the median cephalic vein, and both descend along the outer part of the forearm to the wrist.

FIG. 342.

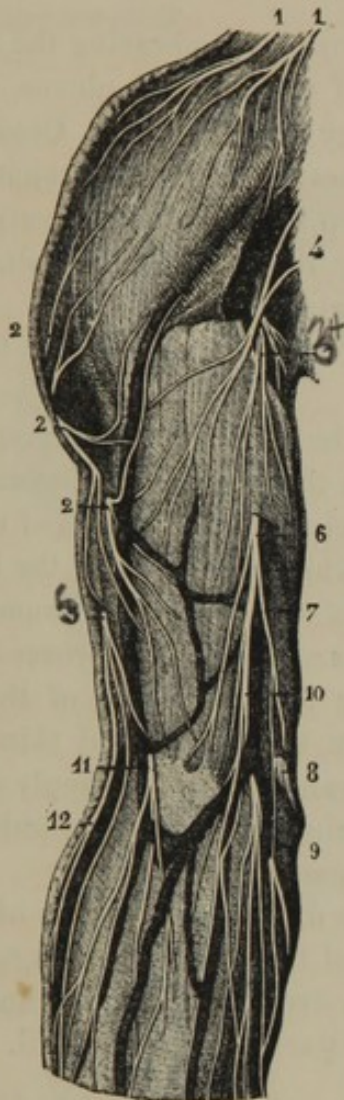
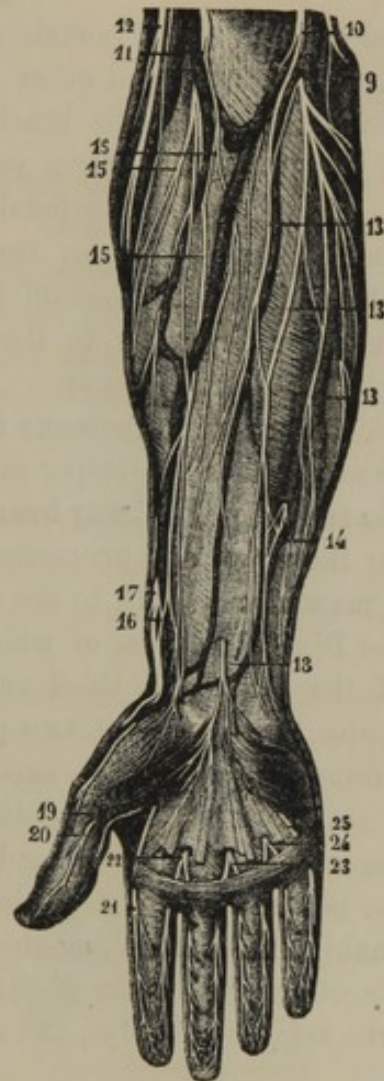

FIG. 343.



CUTANEOUS NERVES OF THE UPPER EXTREMITY. 1, supra-clavicular nerves of the cervical plexus; 2, cutaneous branches of the circumflex nerve; 3, branch of the internal cutaneous nerve; 4, small cutaneous nerve, with its anastomosis from the intercosto-humeral; 5, cutaneous branch of the musculo-spiral nerve; 6, internal cutaneous nerve piercing the brachial fascia; 7, posterior branch anastomosing with 8, the ulnar nerve, and 9, the anterior branch; 10, the internal cutaneous dividing into branches, some passing in front and others behind the median basilic vein; 11, external cutaneous nerve; 12, cutaneous branch of the musculo-spiral nerve; 13, branches of the internal cutaneous to the front of the forearm; 14, anastomosis of one of the latter branches with one from the ulnar nerve; 15, terminal branches of the external cutaneous nerve; 16, 17, anastomosis between the latter and the radial nerve; 18, superficial palmar branch of the median nerve; 19-25, digital nerves.

In its course it gives branches to the coraco-brachial, biceps flexor, and brachial muscles, and its terminal branches supply the skin on the outer part of the forearm—some of them anastomosing with filaments of the radial and musculo-spiral nerves.

8. The **Circumflex nerve**¹ accompanies the posterior circumflex blood-vessels around the upper extremity of the humerus, and is distributed to the lesser terete and deltoid muscles, some of the branches also supplying the shoulder joint and the skin on the back of the arm.

9. The **Median nerve**² commences by two roots embracing the axillary artery from the inner and outer trunks of the brachial plexus, and descends in contact with the brachial artery to the elbow. Crossing in front of the latter, the nerve passes beneath the terete pronator, and proceeds between the superficial and deep flexors of the fingers to the wrist, and then passes under the annular ligament to the palm of the hand. In its course it gives off the following branches:—

a. **Muscular branches** to the muscles on the front of the forearm, except the ulno-carpal flexor.

b. The **anterior interosseous nerve**,³ which follows the corresponding artery, and supplies the deeper muscles on the front of the forearm.

c. The **superficial palmar branch**,⁴ which pierces the fascia of the forearm near the wrist, and proceeds to the skin of the palm of the hand.

d. A **muscular branch** to the muscles of the ball of the thumb.

e. The **Digital nerves**, of which there are five. Two proceed to the sides of the thumb; a third runs along the outer side of the index finger; and the remaining two pass down the second and third metacarpal intervals, and divide each into **branches**, which supply the contiguous sides of the index, middle, and ring fingers. The fifth digital nerve receives a communicating branch from the ulnar nerve.

At the bases of the first phalanges, the digital nerves give off a **dorsal branch**, which runs along the border of the back of the fingers. At the ends of the latter the digital nerves divide into two **branches**, of which one supplies the tips, the other the part beneath the nail.

10. The **Ulnar nerve**,⁵ from the lower and ~~outer~~^{inner} trunks of the brachial plexus, is smaller than the preceding, and gradually diverges from it on the inner part of the arm to the interval of the olecranon and internal condyle. In this position it may be compressed against the latter through the skin, giving rise to the sensation which has led the part commonly to be called the "crazy bone."

Piercing the origin of the ulno carpal flexor, the ulnar nerve proceeds between this muscle and the deep flexor of the fingers to the wrist, where

¹ N. circumflexus; n. axillaris; n. scapulo-humeralis.

² N. medianus.

³ N. interosseus internus; n. i. profundus.

⁴ N. palmaris superficialis; n. cutaneus palmaris; n. c. p. longus.

⁵ N. ulnaris; n. cubitalis; cubito-digital nerve.

it passes over the annular ligament close to the pisiform bone, and reaches the palm of the hand. Its branches are as follow:—

a. **Articular, muscular, and cutaneous branches** to the elbow joint, ulno-carpal and deep flexor of the fingers, and the skin on the inner part of the forearm.

FIG. 344.

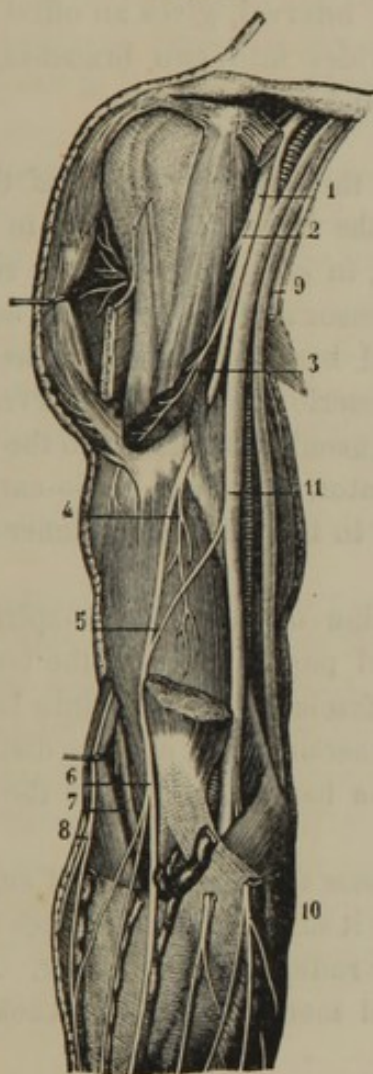
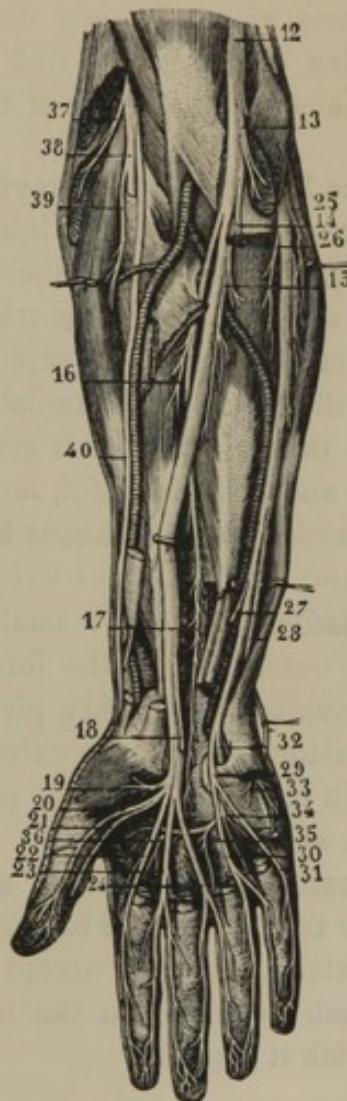


FIG. 345.



EXTERNAL CUTANEOUS, MEDIAN, ULNAR, AND MUSCULO-SPIRAL NERVES. 1, external cutaneous nerve; 2, 3, 4, muscular branches; 5, anastomotic filament from the median; 6, division of the external cutaneous nerve into branches to the forearm; 7, musculo-spiral nerve; 8, cutaneous branch of the latter; 9, internal cutaneous nerve; 10, its branches to the forearm; 11, median and ulnar nerves; 12, median nerve; 13-16, muscular branches; 17, anterior interosseous nerve; 18, superficial palmar branch; 19, branch to the muscles of the ball of the thumb; 20-24, digital nerves of the thumb, index, middle, and one side of the ring finger; 25, ulnar nerve; 26, muscular branches; 27, 28, cutaneous and dorsal branches; 30, 31, digitals to the little and ring fingers; 32, deep palmar branch; 33-36, muscular branches from the latter; 37, musculo-spiral nerve; 38, its posterior interosseal division; 39, a muscular branch of the latter; 40, radial nerve.

b. A **dorsal branch**,¹ which passes beneath the tendon of the ulno-carpal flexor to supply the skin on the back of the hand.

¹ N. dorsalis manus; cubito-dorsal nerve.

c. The **deep palmar branch**, which follows the corresponding blood-vessels, and supplies the small muscles of the little finger, the interosseal and lumbrical muscles.

d. The **Digital nerves**, of which there are two. One of these supplies twigs to the short palmar muscle and the skin on the inner part of the hand, and then runs along the inner side of the little finger. The other passes along the last metacarpal interval, gives an offset to the last median digital nerve, and then divides into two branches, which supply the contiguous sides of the ring and little fingers.

11. The **Musculo-spiral nerve**,¹ from the posterior trunk of the brachial plexus, is the largest branch of the latter. It winds in a half spiral around the back of the humerus, in company with the superior profunda artery, between the triceps extensor and the bone, and descends in the interval of the long supinator and brachial muscle to the elbow, where it divides into the radial and posterior interosseal nerves. In its course through the arm it gives off **muscular branches** to the triceps extensor, anconeus, brachial, long supinator, and long radio-carpal extensor muscles, and **cutaneous branches** to the skin on the inner side of the arm and forearm to the wrist.

The **Radial nerve**, the smaller division of the musculo-spiral, runs along the outer part of the forearm, and passes beneath the tendon of the long supinator. It then pierces the fascia, and divides into branches which anastomose with the external cutaneous nerve, and are distributed to the skin on the outer back part of the hand, the back of the thumb, the index and middle fingers.

The **Posterior Interos'eal nerve** passes through the short supinator muscle to the back of the forearm, where it divides into branches supplying the extensor muscles, except the long radio-carpal extensor. A terminal branch descends on the interosseal membrane to the back of the wrist, which it supplies.

THE THORACIC NERVES.

There are twelve pairs of **thorac'ic nerves**,² of which the first pair issue from the intervertebral foramina, between the upper two dorsal vertebræ, and the last pair between the last dorsal and first lumbar vertebra. The first pair is much the largest; the others are nearly of uniform size. After escaping from the intervertebral foramina they divide into **anterior** and **posterior branches**.

¹ N. musculo-spiralis; n. radialis; n. spiralis.

² Dorsal nerves; nervi thoracis, or dorsales.

POSTERIOR BRANCHES OF THE THORACIC NERVES.

The **Posterior branches** of the **thoracic nerves**, like those of the other spinal nerves generally, are smaller than the anterior branches. Turning backward between the transverse processes of the vertebræ, they divide into external and internal branches.

The **external branches** successively increase in size from first to last, and appear in the interval of the longissimus and sacro-lumbar muscles, which they supply. The lower six of the series further give off **cutaneous branches**, which pierce the inferior serrated and latissimus muscles to supply the skin contiguous to the angle of the ribs.

The **internal branches** of the upper six thoracic nerves appear in the interval of the multifid and semi-spinal muscles, to which they give filaments, and then supply the skin in the vicinity of the spinous processes of the vertebræ. The corresponding branches of the lower six thoracic nerves terminate in the multifid spinal muscle.

ANTERIOR BRANCHES OF THE THORACIC NERVES.

The **anterior branches** of the **thoracic nerves** remain distinct from one another, or do not anastomose and form plexuses as in the case of the other spinal nerves. Near their commencement each communicates, by means of a pair of anastomotic filaments, with the contiguous thoracic ganglia of the sympathetic.

The **anterior branch** of the **first thoracic nerve**, much larger than the others, as previously indicated, ascends over the first rib to form part of the brachial plexus. In its course it gives off a small branch, the **first intercostal nerve**, which runs along the first intercostal space.

The **anterior branches** of the **succeeding thoracic nerves** are of nearly uniform size, and, with the exception of the last one, pass outwardly in the intercostal spaces as **intercostal nerves**.

The **anterior branch** of the **last thoracic nerve** is situated below the last rib. After crossing the quadratus lumborum muscle, it advances between the internal oblique and transverse muscles in the same manner as the intercostal nerves. At its commencement it frequently sends an anastomotic filament to the first lumbar nerve.

THE INTERCOSTAL NERVES.

The **first intercostal nerve** is a small branch given off from the anterior branch of the first thoracic nerve, and supplies the muscles of the corresponding intercostal space.

The **lower ten intercostal nerves**¹ are constituted by the anterior branches of the thoracic nerves, from the second to the eleventh inclusive, and pass outwardly in the lower ten intercostal spaces. They first rest against the external intercostal muscle, and proceed between the two intercostal muscles in company with the corresponding blood-vessels, below which they are situated. They then penetrate the internal intercostal muscle, and continue forward between it and the pleura.

The **upper intercostal nerves** finally perforate the fore part of the intercostal spaces and the greater pectoral muscle, and terminate in the skin of the breast as the **anterior cutaneous nerves of the thorax**.²

The **lower intercostal nerves** pass over the cartilages of the ribs at the inferior margin of the thorax, and advance between the internal oblique and transverse muscles of the abdomen to the straight muscle. Penetrating this, they finally end near the median line as the **anterior cutaneous nerves of the abdomen**.²

In their course the intercostal nerves supply the contiguous muscles, and give off **lateral cutaneous branches**.³ These perforate the external intercostal muscles, and pass between the fasciculi of the great serrated muscle above and the external oblique muscle below, and are distributed to the skin on the side of the thorax and abdomen.

The lateral cutaneous branch of the second intercostal nerve constitutes the **intercosto-humeral nerve**, which extends across the axillary space, anastomoses with the small cutaneous nerve, and is distributed to the skin on the inner part of the arm.

THE LUMBAR NERVES.

Of the five pairs of **lumbar nerves**,⁴ the first issue from the intervertebral foramina, between the first and second lumbar vertebræ, and the last pair between the fifth lumbar vertebra and the sacrum. Like the cervical and thoracic nerves they divide into an anterior and a posterior branch.

The **posterior branches** of the **lumbar nerves** decrease in size from above downward, and pass backward between the transverse processes of the vertebræ. Penetrating the interstice of the longissimus and sacrolumbar muscles, they supply them with branches and send filaments to the contiguous skin.

The **anterior branches** of the **lumbar nerves** successively increase in size; and at their commencement each communicates by a pair of anas-

¹ N. intercostales; n. subcostales.

³ Rami cutanei laterales.

² Rami cutanei interni; reflected nerves.

⁴ N. lumbares; n. abdominales.

tomotic filaments with the neighboring lumbar ganglia of the sympathetic. They pursue an oblique course outward and downward, partly through and partly behind the psoas muscle. In this position each nerve above sends an offset to the one next below, and by this mode of anastomosis the upper four lumbar nerves, in conjunction with a filament from the last thoracic nerve, form the **lumbar plexus**. The offset from the fourth lumbar nerve joining the fifth, together¹ form part of the sacral plexus.

THE LUMBAR PLEXUS.

The **Lumbar plexus**,² formed, as above mentioned, by the anastomosis of the anterior branches of the upper four lumbar nerves with a filament from the last thoracic nerve, besides supplying the psoas and quadrate lumbar muscles, gives off the following branches :—

1. Ilio-hypogastric nerve.
2. Ilio-inguinal nerve.
3. Genito-crural nerve.
4. External cutaneous nerve.
5. Obturator nerve.
6. Anterior crural nerve.

1. The **Ilio-hypogas'tric nerve**³ springs from the first lumbar nerve, passes through the psoas muscle, and crosses the quadrate lumbar muscle to the crest of the ilium. It then perforates the transverse muscle of the abdomen, and proceeds between it and the internal oblique muscle to the inguinal canal, through which it descends, or it pierces the tendon of the external oblique muscle, to supply the skin over the pubis.

2. The **Ilio-in'guinal nerve**,⁴ from the same source as the preceding, passes through the psoas muscle and across the iliac muscle to Poupart's ligament. It then perforates the transverse muscle, and descends the inguinal canal to supply the skin of the penis and scrotum, or the labium of the female.

This and the ilio-hypogastric nerve are of variable size, and usually a diminution of one is compensated by an increase of the other.

3. The **Genito-crural nerve**⁵ springs from the second lumbar nerve, and pierces the psoas muscle to descend on its anterior surface, upon

¹ The lumbo sacral cord.

² Plexus lumbaris.

³ N. ilio-hypogastricus; n. musculo-cutaneus superior.

⁴ N. ilio-inguinalis; n. musculo-cutaneus inferior.

⁵ N. genito-cruralis; n. pudendis externus; n. spermaticus externus; n. inguinalis externus.

which it divides into two branches. Of these, the **genital branch**¹ crosses to the inner side of the external iliac artery, and enters the inguinal canal, through which it proceeds to be distributed to the spermatic cord and the coverings of the testicle, or in the female to the round ligament, mons veneris, and labium. The **crural branch**² descends on the outer side of the external iliac artery, and passes beneath Poupart's ligament to supply the skin in front of the thigh.

4. The **External cutaneous nerve**,³ derived from the second and third lumbar nerves, crosses the iliac muscle to the notch below the anterior superior spinous process of the ilium, and thence escapes from the abdomen. Piercing the femoral fascia below Poupart's ligament, it divides into two branches, of which one supplies the skin on the outer part of the thigh, while the other supplies the skin on the fore part as low as the knee.

5. The **Obtura'tor nerve**,⁴ larger than the preceding branches of the lumbar plexus, is derived from the second, third, and fourth lumbar nerves. Emerging from beneath the inner border of the psoas muscle, it runs along the side of the pelvis, and escapes, in company with the obturator blood-vessels, through the foramen of the obturator membrane. Reaching the thigh, it divides into two branches,⁵ of which one supplies the great adductor and external obturator muscles, and gives filaments to the hip joint, while the other supplies the long and short adductor, the pectineal, and gracilis muscles, and furnishes filaments to the skin on the inner side of the thigh.

6. The ^{anterior} **Crural nerve**,⁶ the largest branch of the lumbar plexus, is derived from the second, third, and fourth lumbar nerves. Passing from beneath the psoas muscle, it descends in the groove between this and the iliac muscle, and emerges from the pelvis under Poupart's ligament. In this position it is situated a short distance to the outer side of the femoral artery, beneath the femoral fascia, and divides into numerous branches.

Within the pelvis it supplies the iliac muscle; externally it gives **muscular branches** to the quadriceps extensor, the sartorius, and pectineal muscles, besides which it gives off the following:—

¹ Ramus pudendus externus; n. spermaticus externus.

² Ramus lumbo-inguinalis.

³ Nervus cutaneus externus; n. c. anterior.

⁴ N. obturatorius; n. cruralis posterior; n. c. internus.

⁵ Ramus anterior et posterior.

⁶ N. cruralis; n. c. anterior; the anterior crural nerve; n. femoralis; n. musculo-cutaneus femoris.

a. The **Middle cutaneous nerve**,¹ which perforates the sartorius muscle and femoral fascia to supply the skin on the front of the thigh as low as the knee.

FIG. 346.

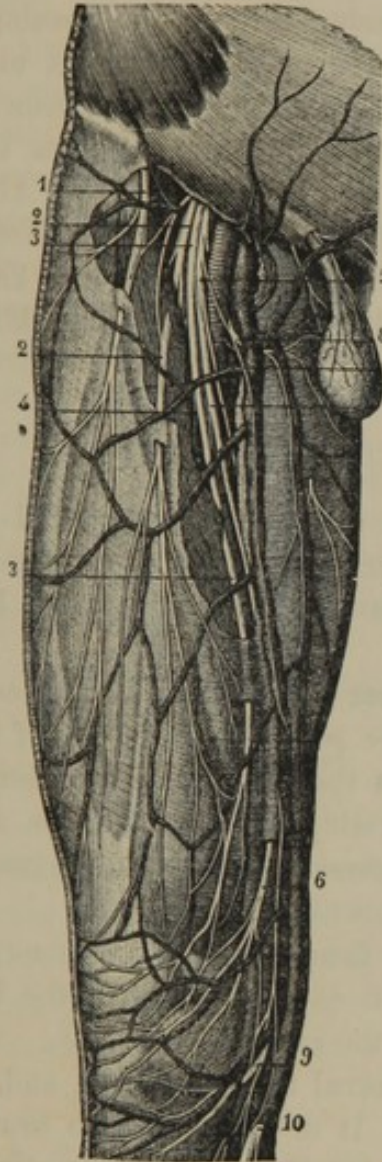


FIG. 347.

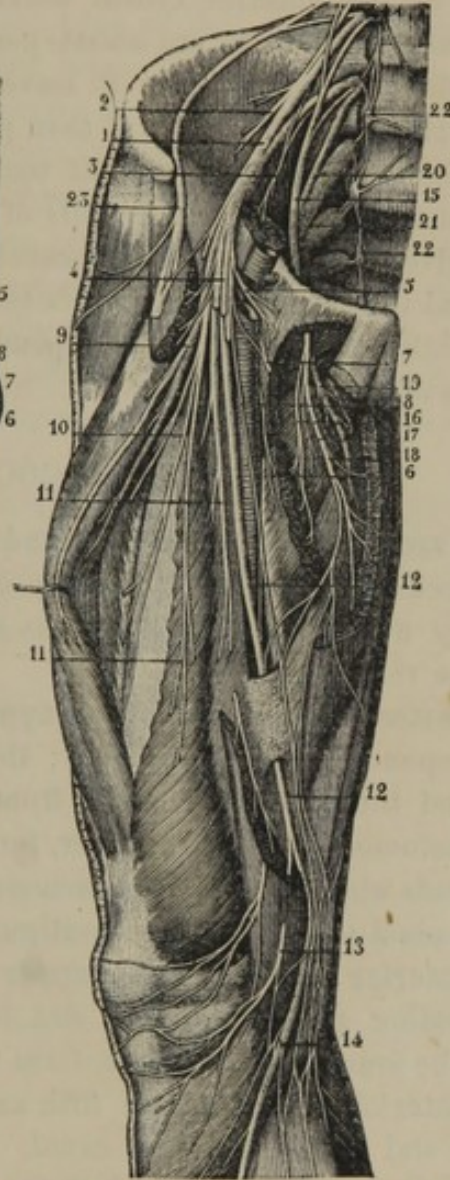


Fig. 346.—CUTANEOUS NERVES OF THE FRONT OF THE THIGH. 1, external cutaneous nerve; 2, middle cutaneous nerve; 3, 4, 5, 6, 7, internal cutaneous nerve and its branches; 8, cutaneous filaments to the inner part of the thigh; 9, 10, branches of the long saphenous nerve.

Fig. 347.—LUMBAR PLEXUS AND ITS BRANCHES. 1, crural nerve; 2, 3, branches to the iliac and psoas muscles; 4, the cutaneous nerves cut away; 5, 6, small muscular filaments to the pectineal and adductor muscles; 7, origin of the cutaneous filaments seen in the preceding figure on the inner part of the thigh; 8, cutaneous filament descending to the inner part of the knee; 9, 10, 11, muscular branches of the crural to the quadriceps extensor; 12, long saphenous nerve; 13, branch to the knee; 14, branch descending the leg in company with the saphenous vein; 15, obturator nerve; 16, 17, 18, 19, branches to the adductor and gracilis muscles; 20, branch of the fourth lumbar nerve, with the fifth lumbar nerve descending to join the first sacral nerve, 21; 22, lumbar and sacral ganglia of the sympathetic; 23, external cutaneous nerve.

¹ N. cutaneus medius; n. perforans.

b. The **Internal cutaneous nerve**,¹ which descends inwardly across the femoral blood-vessels, and perforates the fascia to supply the skin on the inner part of the thigh to the knee.

c. The **Long Saphenous nerve**,² which is the largest of the cutaneous branches of the anterior crural nerve. It accompanies the femoral blood-vessels until these are about passing through the opening of the great adductor muscle, when it leaves them, and descends under the sartorius muscle to the knee. It then pierces the fascia between the tendons of the sartorius and gracilis muscles, and accompanies the long saphenous vein down the inner side of the leg to the foot. Above the knee it gives off a considerable branch, which perforates the sartorius muscle and the fascia, and is distributed to the skin over the knee. In the remainder of its course it is expended in branches to the skin on the inner side of the leg and foot.

THE SACRAL AND COCCYGEAL NERVES.

There are five pairs of **sacral**,³ and one pair of **coccyge'al nerves**,⁴ which successively diminish in size; and they differ from other spinal nerves by undergoing division into anterior and posterior branches within the vertebral canal.

The **posterior branches** of the **upper four sacral nerves** emerge at the corresponding sacral foramina; the **posterior branches of the fifth sacral** and the **coccygeal nerve** from the end of the vertebral canal. They anastomose with one another, forming a series of loops, and give off filaments which supply the commencement of the dorsal extensor and multifid-spinal muscle, and the contiguous skin.

The **anterior branches** of the **upper four sacral nerves** emerge at the corresponding sacral foramina, and, in conjunction with the fifth, and part of the fourth lumbar nerve, form the **sacral plexus**.

The **anterior branch** of the **fifth sacral nerve** is small, and emerges from the end of the vertebral canal. It divides into two branches, of which one joins with a filament of the fourth sacral nerve to end in the hypogastric plexus of the sympathetic, and the other joins the coccygeal nerve.

The **anterior branch** of the **coccygeal nerve**, smaller than the preceding, also emerges at the end of the vertebral canal. Being joined by a branch of the last sacral nerve, it perforates the coccygeal muscle and the great sacro-sciatic ligament, to terminate in the contiguous skin of the buttock.

¹ N. cutaneus internus; n. saphenus minor.

³ N. sacrales.

² N. saphenus longus; n. s. major. *n. s. internus*

⁴ N. coccygei.

THE SACRAL PLEXUS.

The **Sacral plexus**,¹ as previously mentioned, is formed by the conjunction of the anterior branches of the upper four sacral nerves with the anterior branch of the fifth and part of that of the fourth lumbar nerves. These converge from their respective foramina into a broad, flat cord, which passes from the cavity of the pelvis through the great sacro-sciatic foramen, and mainly ends in the great sciatic nerve.

The sacral plexus is triangular, rests against the pyriform muscle, and is separated from the internal iliac blood-vessels and the neighboring viscera by the pelvic fascia. Its upper divisions, formed by the lowest lumbar and upper sacral nerves, are of large and nearly uniform size. The division formed by the third sacral nerve is considerably smaller than those above, and that formed by the fourth sacral nerve is less than half the size of the preceding.

Besides giving off small branches, chiefly from the lower part of the plexus, to the hypogastric plexus of the sympathetic, the pyriform, internal obturator, elevator and sphincter anal, geminous, and quadrate femoral muscles, it terminates in the following branches :—

1. Superior gluteal nerve.
2. Pudic nerve.
3. Small sciatic nerve.
4. Great sciatic nerve.

1. The **Superior Gluteal nerve**² is derived from the upper part of the sacral plexus, and passes from the pelvis in company with the gluteal blood-vessels at the upper part of the great sciatic foramen. Dividing into two branches, these advance between the middle and small gluteal muscles, to which, and the tensor of the femoral fascia, they are distributed.

2. The **Pudic nerve**³ leaves the lower part of the sacral plexus, and passes from the pelvis through the great sciatic foramen below the pyriform muscle. Turning behind the spine of the ischium, it re-enters the pelvis through the small sciatic foramen, and accompanies the internal pudic artery along the outer part of the ischio-rectal fossa. Its branches are as follow :—

a. The **inferior hæmorrhoidal nerve**,⁴ which is given off near the

¹ Plexus sacralis; p. ischiaticus; p. femoralis inferior.

² Nervus glutæus superior.

³ N. pudendus; n. spermaticus communis.

⁴ N. hæmorrhoidalis imus.

commencement of the pudic, or sometimes directly from the sacral plexus. Accompanying the trunk of the pudic through the small sciatic foramen, it descends to the extremity of the rectum, and terminates in the sphincter of the anus and the adjacent integument.

b. The **perineal nerve**.¹ This divides into **superficial branches**, which are distributed to the skin of the perineum; and **deep branches**, which supply the muscles of the perineum and penis, and the posterior part of the scrotum. In the female, in correspondence with the latter parts, it supplies the muscles of the vagina and clitoris, the vestibule, the nymphæ, and the labia.

c. The **dorsal nerve of the penis**,² or of the **clitoris**.³ This accompanies the corresponding artery between the cavernous and spongy bodies to the back of the organ, along which it proceeds to the glans. It supplies the cavernous and spongy bodies, the glans and prepuce, the skin of the penis, or the upper part of the nymphæ.

3. The **Small Sciatic nerve**⁴ is derived from the lower part of the sacral plexus, through the union of two or three narrow offsets. Passing from the cavity of the pelvis through the great sciatic foramen, below the pyriform muscle, it descends upon the back of the thigh and leg.

At the upper part of its course it is under the great gluteal muscle, and gives off the inferior gluteal and pudendal nerves. It then proceeds downward beneath the femoral fascia, and is resolved into many small cutaneous branches, which pierce the latter and supply the contiguous skin of the thigh and leg.

The **inferior gluteal nerves**,⁵ usually two in number, come from the commencement of the small ischiatic nerve or directly from the sacral plexus close to it, and are distributed to the great gluteal muscle.

The **pudendal nerve**,⁶ a large, cutaneous branch of the small sciatic, curves forward below the tuberosity of the ischium, and is distributed to the scrotum, or the labia.

4. The **Great Sciatic nerve**⁷ appears as a prolongation of the sacral plexus, and is the largest nerve of the body. It escapes from the pelvis

¹ N. pudendus inferior; n. spermaticus inferior; n. ovaricus inferior; n. o. internus.

² N. pudendus superior; n. spermaticus superior; n. ovaricus superior; n. o. externus; n. dorsalis penis.

³ N. clitoridis.

⁴ N. glutæus inferior et n. cutaneus posterior; n. ischiadicus minor.

⁵ N. glutæi inferiores.

⁶ N. cutaneus femoris posterior; n. pudendalis longus inferior; inferior pudendal nerve.

⁷ N. ischiadicus major; n. ischiadicus; great femoro-popliteal nerve.

through the great sciatic foramen, below the pyriform muscle, descends through the middle of the interval between the tuberosity of the ischium and the great trochanter, and continues along the back of the thigh to its lower part, where it divides into the external and internal popliteal nerve. The division of the sciatic nerve may occur at any point between the ordinary one just stated and its commencement in the sacral plexus.

In its course down the thigh the great sciatic nerve gives **articular filaments** to the hip joint, and **muscular branches** to the flexors and great adductor.

The **External Poplite'al nerve**¹ is the smaller terminal division of the great sciatic. Descending obliquely along the outer part of the popliteal space to the fibula below its head, it passes between that bone and the long peroneal muscle, and divides into the anterior tibial and musculo-cutaneous nerves. In its course it gives off several **articular branches** to the knee joint, a couple of **cutaneous branches**² to the skin on the outer part of the leg, and the **peroneal communicating branch**,³ which descends the back of the leg to join the short saphenous nerve.

The **anterior tibial nerve**⁴ passes beneath the long extensor of the toes, and reaches the fore part of the interosseal membrane, to accompany the anterior tibial vessels down the leg. In its course it furnishes filaments to the contiguous muscles, and in front of the ankle joint divides into two branches, of which one supplies the short extensor of the toes, and the other follows the dorsal pedal artery, and supplies the inner part of the foot.

The **musculo-cutaneous nerve**⁵ descends between the peroneal muscles and the long extensor of the toes, giving them branches, and reaches the lower third of the front of the leg, where it perforates the fascia and becomes subcutaneous. Continuing its descent, it divides into two branches, which supply the skin on the back of the foot and toes.

The **Internal Poplite'al nerve**,⁶ the larger of the terminal divisions of the great sciatic nerve, is continued in the direction of the parent trunk. It occupies the middle of the popliteal space, more superficially than the blood-vessels, and at the lower margin of the popliteal muscle assumes the name of the posterior tibial nerve. It gives off two or three **ar-**

¹ N. popliteus externus; n. peroneus; n. fibularis; n. ischiadicus minor.

² Peroneo-cutaneous nerves.

³ N. communicans fibularis. or

" Peroneal

⁴ N. tibialis anterior; n. peroneus profundus; n. interosseus.

⁵ N. musculo-cutaneus; m. peroneus superficialis.

⁶ N. popliteus internus; n. tibialis.

ticular branches to the knee joint, and muscular branches to the gastrocnemius, soleus, plantar, and popliteal muscles. It also gives off the short saphenous nerve,¹ which descends between the gastrocnemius

FIG. 348.

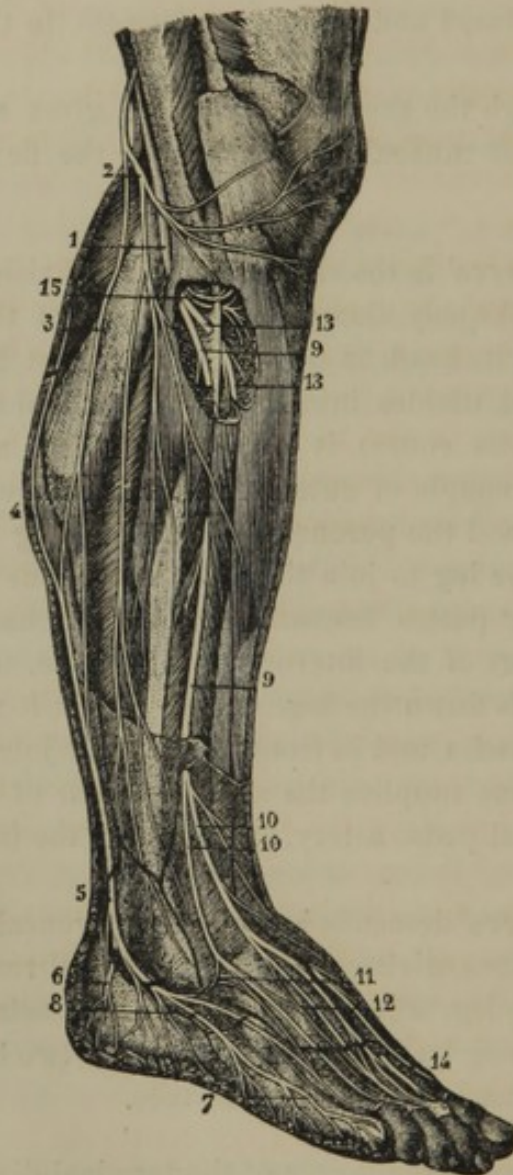


FIG. 349.

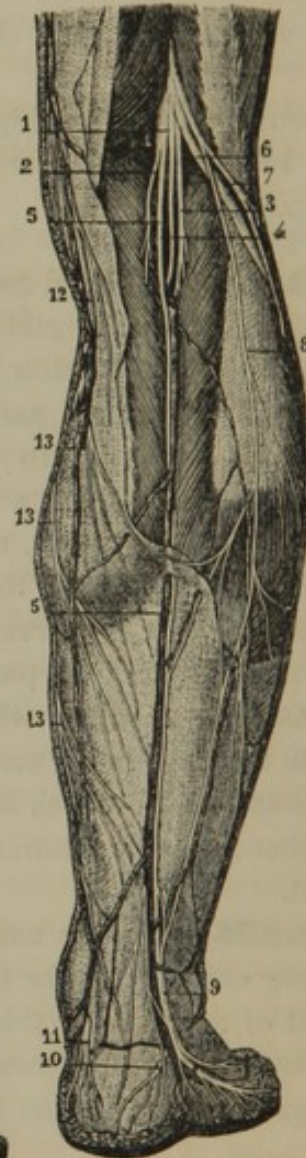


Fig. 348. EXTERNAL POPLITEAL NERVE AND ITS BRANCHES. 1, external popliteal nerve; 2, cutaneous branch to the outer part of the leg; 3, peroneal communicating branch anastomosing with the short saphenous nerve 4, 5; 6, 7, 8, terminal branches of the latter to the outer part of the foot; 9, musculo-cutaneous nerve; 10, 11, 12, terminal branches to the back of the foot; 13, anterior tibial nerve; 14, terminal branch of the latter anastomosing with branches of the musculo-cutaneous nerve; 15, muscular branches.

Fig. 349. POPLITEAL NERVES. 1, internal popliteal nerve; 2, 3, 4, muscular branches; 5, short saphenous nerve; 6, external popliteal nerve; 7, cutaneous branch; 8, peroneal communicating branch joining the short saphenous nerve; 9, common trunk of the peroneal communicating and saphenous nerves to the outer part of the foot; 10, branch to the heel; 11, cutaneous branch from the posterior tibial nerve; 12, 13, branches of the long saphenous nerve.

¹ N. saphenus externus; n. s. brevis; n. communicans tibialis; ramus communicans nervi tibici; n. cutaneus longus cruris et pedis.

muscle and the fascia, and about the middle of the leg perforates the latter and becomes subcutaneous. It then usually receives the **peroneal communicating branch**¹ of the external popliteal nerve, and descends, in company with the short saphenous vein, to the outer side of the foot, to which it is distributed.

The **Posterior Tibial nerve** is the continuation of the internal popliteal nerve from the lower margin of the popliteal space. It descends the back of the leg, in company with the posterior tibial vessels, supplying in its course **muscular branches** to the posterior tibial and long flexor muscles of the toes, and a cutaneous branch to the skin of the heel. Behind the inner ankle it divides into the two plantar nerves.

The **Internal plantar nerve**² accompanies the corresponding artery in the sole of the foot, in its course giving branches to the short flexor of the toes, the abductor of the great toe, and the skin of the sole. At the back part of the metatarsus it divides into **four digital nerves**, of which one courses along the inner side of the great toe, while the other three pass forward in the succeeding three metatarsal intervals, and bifurcate to supply the contiguous sides of the corresponding toes. These digital nerves also supply the short flexor muscle of the great toe and the contiguous lumbrical muscles.

The **External plantar nerve**,³ the smaller of the terminal divisions of the posterior tibial, passes between the short digital and accessory flexors to the outer side of the foot. In its course it gives **muscular branches** to the short and accessory flexors of the toes, the muscles of the little toe, the adductor of the great toe, and the interosseal, transverse, and outer lumbrical muscles. It also gives **cutaneous filaments** to the outer part of the sole, and terminates in two **digital nerves**, which supply the outer side of the little toe and the contiguous sides of this and the adjoining toe.

THE SYMPATHETIC SYSTEM OF NERVES.

The **Sympathetic system of nerves**⁴ is mainly devoted to supply the viscera of the great cavities of the body, though the respiratory organs, the heart, and the extremities of the alimentary canal also receive nerves from the cerebro-spinal system. The nerves of the sympathetic system are generally much smaller, less strong, and less distinctly observable

¹ N. communicans fibularis.

² N. plantaris internus.

³ N. plantaris externus.

⁴ Great sympathetic nerves; tri-splanchnic nerves; ganglionic nerves;

organic nervous system; nervous system of the automatic functions; nerves of organic life; great intercostal nerves; vertebral nerves; vaso-motor nerves.

than those of the cerebro-spinal system. Usually they possess a more or less grayish aspect, closely adhere to contiguous structures by a profusion of connective tissue, and are connected with many ganglia.

Like the cerebro-spinal system, the sympathetic system is double. It consists of a **gangliated cord**, extending on each side of the body the entire length of the vertebral column, intercommunicating with the neighboring cerebro-spinal nerves by means of anastomotic filaments,¹ and sending off numerous branches, which form intricate plexuses often associated with additional ganglia, and usually following the course of the blood-vessels to the viscera.

The gangliated cords of the two sympathetics lie nearly parallel to each other as far down as the sacrum, upon which they gradually converge and conjoin in a single minute ganglion resting on the coccyx. The ganglia of each cord correspond in number, and nearly in position with the segments of the vertebral column, except in the neck, where there are but three. These ganglia intercommunicate with the contiguous cerebro-spinal nerves by means of short, narrow cords, composed of an interchange of nerve fibres of the two systems, which thus become closely associated.

Many of the nerves from the gangliated cords at once follow the course of the contiguous blood-vessels to their ultimate destination; but the greater number and larger ones contribute to the formation of three most intricate plexuses common to the two sympathetic nerves. These symmetrical plexuses are situated in front of the vertebral column, within the thorax, abdomen, and pelvis, and are successively named the cardiac, solar, and hypogastric plexuses. With them are associated many ganglia, and they are resolved into smaller plexuses, which accompany the contiguous blood-vessels to the neighboring organs.

The gangliated cord of the sympathetics, from the different positions it occupies in its course, for description is conveniently divided into the cervical, dorsal, lumbar, and sacral portions. These, with the three great symmetrical plexuses above indicated, will be separately considered.

(For the upper part of the sympathetic nerve see figures 339, 340.)

CERVICAL PORTION OF THE SYMPATHETIC NERVE.

In the neck the gangliated cord of the sympathetic nerve rests upon the muscles in front of the cervical vertebræ, behind the great blood-vessels. It possesses three ganglia, which are called, from their relative position, superior, middle, and inferior.

¹ Rami communicantes.

The **Superior cer'vical ganglion**¹ is the largest of the cervical series, and is usually fusiform. It rests on the greater straight muscle in front of the second and third cervical vertebræ and behind the internal carotid artery. It is connected by intervening filaments with the upper four spinal nerves, the petrosal ganglion of the glosso-pharyngeal, the ganglia of the pneumogastric, and with the hypoglossal nerve. Besides the cord of communication with the second cervical ganglion, it gives off an ascending branch, vascular branches, pharyngeal nerves, and the superior cardiac nerve.

1. The **Ascending branch**² of the superior cervical ganglion appears as the continuation of the sympathetic accompanying the internal carotid artery through the carotid canal of the temporal bone. It divides into two branches, which subdivide and communicate with one another around the artery, and thus form the **carotid plexus**. This plexus, by means of one or two filaments, joins the abducent nerve; and, through the deep petrosal branch of the pterygoid nerve, it joins the spheno-palatine ganglion. The continuation of the plexus upon the same artery in the cavernous sinus constitutes the **cavernous plexus**, and this communicates through fine filaments with the semilunar ganglion of the trifacial nerve, with the oculo-motor, the pathetic, and the ophthalmic nerves, and with the ophthalmic ganglion. From the carotid and cavernous plexuses fine filaments are given off, which accompany all the branches of the internal carotid artery.

2. The **Vascular branches**³ of the first cervical ganglion apply themselves to the external carotid artery, and form plexuses upon it and its ramifications. By means of the plexuses on the facial and internal maxillary arteries, the sympathetic nerve is brought into communication with the submaxillary and otic ganglia.

3. The **Pharynge'al nerves**,⁴ of which there are two or three, descend to the side of the pharynx, and, in conjunction with the branches derived from the glosso-pharyngeal and pneumogastric nerves, form the **pharyngeal plexus**, which supplies the mucous membrane and constrictor muscles of the pharynx.

4. The **Superior cardiac nerve**⁵ is derived from the first cervical ganglion and the cord below it by two or three filaments, and descends the

¹ Ganglion cervicale superius.

² Ramus ascendens; cranial branch.

³ Nervi molles.

⁴ Rami pharyngei.

⁵ Nervus cardiacus superficialis, superior, supremus, or magnus.

neck behind the great blood-vessels, to enter the thorax. On the right side it passes either in front of or behind the subclavian artery, and then along the innominate artery to the back of the arch of the aorta, where it ends in the deeper part of the cardiac plexus. On the left side, the nerve follows the carotid artery to the arch of the aorta, and usually ends in the superficial part of the cardiac plexus. In its course down the neck, the superior cardiac nerve receives branches from the pneumogastric nerve, and it gives filaments to the inferior thyroid artery.

The **Middle cervical ganglion**¹ is small, and is connected with the third ganglion by several branches. Sometimes it is indistinct, and appears to be associated with the third ganglion. It rests against the inferior thyroid artery, opposite the fifth cervical vertebra, and is usually connected by intervening filaments with the fifth and sixth spinal nerves. Besides giving branches to the inferior thyroid artery, following that vessel to the thyroid body, it gives off the **Middle cardiac nerve**.² This descends to the root of the neck, communicates with the superior and inferior cardiac and pneumogastric nerves, and ends in the deeper part of the cardiac plexus.

The **Inferior cervical ganglion**,³ irregularly crescentic in form, is situated between the transverse process of the last cervical vertebra and the first rib, behind the vertebral artery. It is connected with the first thoracic ganglion by several branches, some of which pass in front and some behind the subclavian artery. It communicates by short cords with the seventh and eighth spinal nerves. Besides sending filaments to contribute in the formation of the plexus accompanying the vertebral artery, it gives off the **Inferior cardiac nerve**,⁴ which, after communicating with the middle cardiac and inferior laryngeal nerves, terminates in the deeper part of the cardiac plexus. It sometimes receives a contribution from the first thoracic ganglion; and on the left side is often blended with the middle cardiac nerve.

THE CARDIAC PLEXUS.

The **Cardiac plexus**⁵ of the sympathetic nerve is situated behind and beneath the arch of the aorta, and is formed from the three cardiac nerves derived from the cervical ganglia, together with branches derived from the first thoracic ganglia and pneumogastric nerves. Beneath

¹ Ganglion cervicale medium; g. thyroideum.

² Nervus cardiacus medius, profundus, or magnus.

³ Ganglion cervicale inferum, inferius,

ultimum, thyroideum, vertebrale, stellatum, or cardiacum tertium.

⁴ Nervus cardiacus inferius.

⁵ Superficial and deep cardiac plexus; plexus cardiacus superficialis et magnus profundus.

the arch of the aorta, above the point of division of the pulmonary artery, the plexus contains one or two small ganglia,¹ called cardiac from their position. From the cardiac plexus prolongations accompany the coronary arteries, and are named the **coronary plexuses**.

THORACIC PORTION OF THE SYMPATHETIC NERVE.

In the thorax the gangliated cord of the sympathetic nerve is situated at the side of the vertebral column, along the line of the heads of the ribs, and is covered by the pleura. The ganglia, twelve in number, rest on the heads of the ribs. They are irregularly triangular, and are generally associated, each by means of two narrow cords, with the nearest intercostal nerve. The first thoracic ganglion joins the last cervical ganglion, as previously stated; the last one communicates through the diaphragm with the first lumbar ganglion.

The upper six thoracic ganglia give off small branches to the aorta, the intercostal blood-vessels, and the œsophageal and pulmonary plexuses of the pneumogastric nerve. The lower six ganglia, besides furnishing filaments to the aorta, give off branches which conjoin to form the three splanchnic nerves.

The **Great Splanchnic nerve**² derives its roots from the sixth to the tenth thoracic ganglia. Descending obliquely over the bodies of the dorsal vertebræ, it perforates the crus of the diaphragm, and terminates in the semilunar ganglion.

The **Small Splanchnic nerve**³ derives its roots from the tenth and eleventh thoracic ganglia, and accompanies the preceding nerve through the diaphragm, and terminates in the solar plexus.

The **Third Splanchnic nerve**⁴ comes from the twelfth thoracic ganglion, and, after piercing the diaphragm, ends in the renal plexus. Its place is sometimes supplied by a branch from the preceding nerve.

THE SOLAR PLEXUS.

The **Solar plexus**⁵ is the most extensive of those of the sympathetic system, and is so named from the multitude of filaments radiating there-

¹ Ganglion cardiacum Wrisbergii; g. c. magnum; g. c. inferius; g. thoracicum rami cardiaci superioris.

² N. splanchnicus maximus, major, superior, or primus.

³ N. splanchnicus medius, minor, or inferior.

⁴ N. splanchnicus inferior, inferius, or minimus; least splanchnic nerve.

⁵ Plexus solaris; p. epigastricus; centrum commune.

from. It is situated behind the stomach, in front of the aorta and the crura of the diaphragm, surrounding the celiac and commencement of the superior mesenteric artery, and extending between the supra-renal bodies. It is composed of a highly intricate intertexture of nerves associated with ganglia; and on both sides it receives the great and small splanchnic nerves, together with some filaments from the pneumogastric nerves. Among the ganglia, which are variable in size and number, generally there is one on each side of the plexus conspicuous for its size and shape, named the **semilunar ganglion**.¹ This is situated at the side of the celiac and superior mesenteric arteries, and receives the great splanchnic nerve.

From the solar plexus emanate a multitude of nerves, which pursue the course of the neighboring arteries, form plexuses upon them, and partake in their ultimate distribution to the viscera. These secondary plexuses are as follow :—

The **Phrenic plexus**,² accompanying the corresponding artery on each side to the diaphragm.

The **Coronary, Hepatic, and Splenic plexuses**, pursuing the like-named arteries to the stomach, liver, pancreas, and spleen.

The **Supra-renal plexus** to the supra-renal body. This is large in comparison with the organ it supplies, and usually contains a ganglion.³

The **Renal plexus**, which accompanies the renal artery to the kidney. It receives the third splanchnic nerve, and contains several small ganglia. An offset, pursuing the course of the spermatic artery, constitutes the **spermatic plexus**.

The **Superior mesenteric plexus**, following the corresponding artery and its branches to the intestines. With its commencement several small ganglia are associated.

The **Aortic plexus**, which is the continuation of the solar plexus, descending upon the aorta. It is intimately associated with the renal plexus on each side, receives branches from the lumbar ganglia, and terminates below in the hypogastric plexus. From it is derived the **Inferior mesenteric plexus**, which follows the corresponding artery to the large intestine.

¹ Ganglion semilunare; g. magnum; g. medium; g. splanchnicum; g. solare; g. transversale; g. abdominale maximum; cerebrum abdominale; centrum nervosum.

² Diaphragmatic plexus.

³ Ganglion splanchnico-supra-renale.

LUMBAR AND SACRAL PORTIONS OF THE SYMPATHETIC NERVES.

The gangliated cord of the sympathetic nerve in the lumbar region, continued from that in the thorax, rests at the side of the lumbar vertebræ along the front edge of origin of the psoas muscle. Its four or five ganglia are oblong, oval, and small, and are situated at the sides of the vertebræ. Each is connected by a pair of communicating filaments with the nearest lumbar nerve, and gives off branches to the neighboring aortic plexus and the hypogastric plexus.

The sacral portion of the gangliated cord lies to the inner side of the anterior sacral foramina, and terminates in front of the coccyx in a small ganglion common to the two sympathetic nerves. Besides the latter, it usually possesses four ganglia, which successively decrease in size. The sacral and coccygeal ganglia are each connected with the contiguous spinal nerves by a pair of communicating filaments, and they give off branches to the hypogastric plexus.

THE HYPOGASTRIC PLEXUS.

The **Hypogas'tric plexus**,¹ more intricate than the preceding great plexuses of the sympathetic, is situated between the common iliac blood-vessels, and extends² downward on each side of the rectum. It is formed from the termination of the aortic plexus in conjunction with branches from the lower lumbar ganglia, the sacral ganglia, the lower two or three sacral nerves, and the inferior mesenteric plexus. It is mingled with much loose connective tissue, contains a number of minute inconspicuous ganglia, and gives off the following secondary plexuses:—

The **Vesico-prostat'ic plexus**,³ which extends to the sides of the bladder, the prostate gland, and the seminal vesicles.

The **Vesico-vag'inal plexus**,⁴ which represents the preceding in the female, and extends to the sides of the vagina and bladder.

The **Uterine plexus**,⁵ which extends between the layers of the broad ligament to the uterus.

¹ Plexus hypogastricus; p. h. superior, communis, uterinus, medius, or impar; inferior aortic plexus; plexus divisionis aortæ.

² The extensions on each side downward are the inferior hypogastric plexuses; p. hypogastricus inferior; p. h.

lateralis inferior; p. ganglionus inferior; pelvic plexus.

³ Plexus vesicalis et prostaticus, et vesiculæ seminalis.

⁴ Plexus vesicalis et vaginalis.

⁵ Plexus uterina.

CHAPTER XII.

THE ORGANS OF SPECIAL SENSE.

THE NOSE.

THE **Nose**¹ is the special organ of the sense of smell, though it participates in other functions, as those of respiration, and the voice. For convenience of description the term is restricted to the pyramidal eminence of the face, extending from the forehead to the upper lip, while the other portions of the organ are separately considered as the nasal cavities.

THE NOSE.

The **nose**² varies in its exact shape and size in different races, sexes, and individuals, and forms one of the most expressive features of the face. Its upper part, firm and immovable, has for its basis the nasal bones and the nasal processes of the superior maxillary bones; its lower part, quite movable, is sustained by cartilages and tough fibrous membrane. Externally the nose is covered by the skin, and is furnished with muscles, and internally is lined by an extension of the mucous membrane of the nasal cavities.

The upper extremity of the nose, forming an indentation below the forehead, is its **root**;³ the convexity between the eyes is the **bridge**, from which the **back**⁴ extends to the **tip**⁵ and the **sides**, terminated below by convex prominences named the **wings**.⁶ At the lower part of the nose are the **nostrils** or **anterior nares**,⁷ a pair of elliptical orifices directed downward, and separated by a thick ridge named the **column of the nose**.⁸

The skin of the nose is thin above, and readily movable on the parts beneath; but is much thicker below, and firmly adherent to the cartilages, and other subjacent structures. As elsewhere, generally, it is furnished with perspiratory and sebaceous glands and hairs. The seba-

¹ Nasus; organon olfactorium; emunctorium cerebri.

² Nasus; rhin; promonitorium faciei; snout.

³ Radix.

⁴ Dorsum; rachis.

⁵ Lobulus; lobe; globulus; apex; point of the nose.

⁶ Alæ; pinnæ.

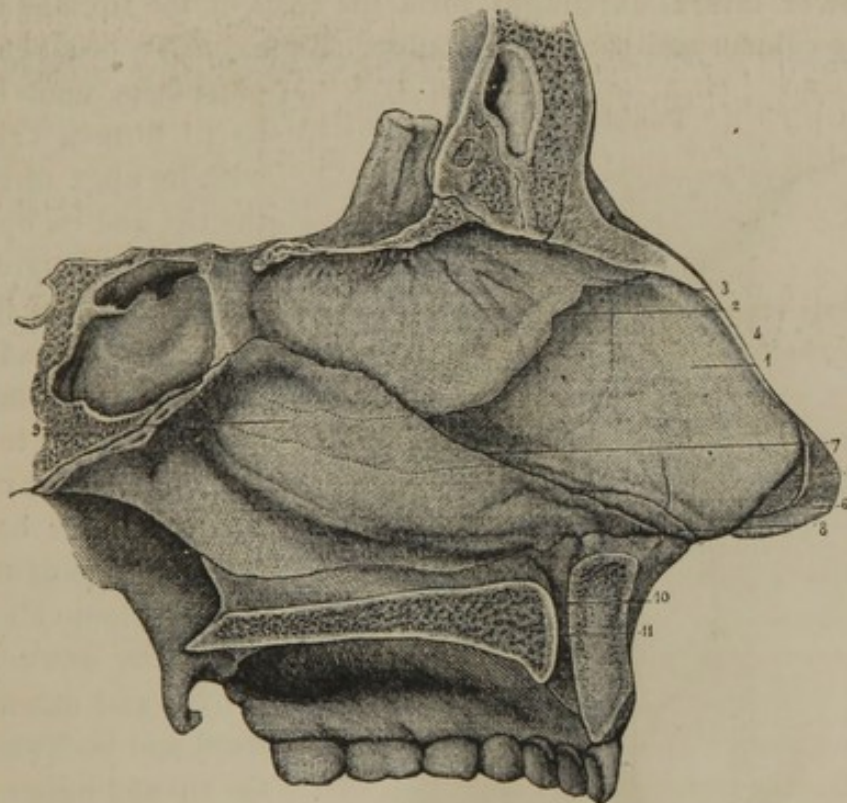
⁷ Nares; aperturæ nasi externæ; rhines; narium aditus.

⁸ Columna nasi.

aceous glands are comparatively large and numerous at the lower part of the nose, more especially along the groove above the wing. The hairs for the most part are exceedingly minute, except within the margin of the nostrils, where they are well developed and project from all sides, and in some measure serve the purpose of a sieve in preventing the entrance of dust.

The muscles of the nose have already been described in the general account of the muscles of the face, to which the student is referred, pages 186, 188, 189. They are the nasal pyramidal, nasal compressor, nasal dilator, labio-nasal elevator, and the labio-nasal depressor muscles.

FIG. 350.



PARTITION OF THE NOSE. 1, cartilage of the partition; 2, its junction with the nasal plate of the ethmoid bone; 3, its junction with the nasal bones; 4, margin of continuation with the upper lateral cartilage; 5, fibrous membrane connecting the cartilage of the partition with the lower lateral cartilage; 6, inner portion of the left lower lateral cartilage; 7, anterior border of the vomer; 8, an accessory cartilage; 9, prolongation of the cartilage of the partition, in a groove between the vomer and nasal plate of the ethmoid bone; 10, naso-palatine canal of the right side opening into the anterior palatine foramen, 11.

The cartilages of the nose are the main support of the lower part of the organ, and are situated in front of the anterior nasal orifice of the skull. They consist of a cartilage to the partition, and two pairs of lateral cartilages, besides several small accessory pieces.

The cartilage of the partition¹ of the nose occupies the angular in-

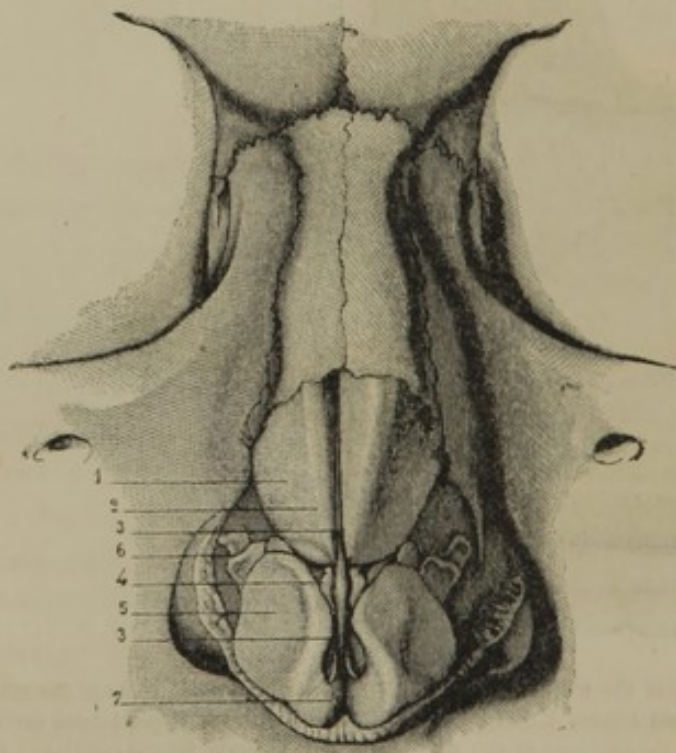
¹ Septum cartilagineum; cartilage of the septum; cartilago septi narium.

terval between the nasal plate of the ethmoid bone and the vomer. It is continued forward along the median line of the nasal bones; below these is continuous with the upper lateral cartilages, and inferiorly contributes to form the column of the nose. It is trapezoidal in outline, and constitutes about one-third of the partition of the nose.

The **upper lateral cartilages**¹ are continuous with the anterior border of the cartilage of the partition, and are reflected one on each side outwardly to be attached along the margin of the nasal bone and the nasal process of the superior maxillary bone. They are triangular, and are connected with the tip and wings of the nose by tough fibrous membrane.

The **lower lateral cartilages**² form the basis of the tip, and contribute to the column and wings of the nose. Each consists of an elongated

FIG. 351.



CARTILAGES OF THE NOSE. 1, upper lateral cartilage; 2, its anterior border; 3, anterior margin of the cartilage of the septum appearing between the lateral cartilages; 4, small accessory cartilage; 5, lower lateral cartilage, back of which is the wing of the nose; 6, accessory cartilages; 7, tip of the nose where the lower lateral cartilages are bent inwardly along the column.

plate bent upon itself so as to form a triangle, with its apex directed to the tip, and its open base directed backward. The inner portion of the plate is narrow, extends along the column of the nose, and is attached to that of the opposite cartilage and the lower border of the cartilage of the partition by loose fibrous tissue. The outer portion is oval, and extends outward and backward upon the tip and upper portion of the wing. Its upper border and posterior extremity are attached by tough fibrous membrane to the upper lateral cartilage and the margin of the nasal process of the maxillary bone.

Between the two lower lateral cartilages, which adhere to each other

¹ Cartilagine nasales laterales; c. laterales superiores; c. triangulares.

² Cartilagine alarum nasi; c. pinnalles; c. laterales inferiores; oval cartilages.

by fibrous tissue, an angular cleft is left at the tip of the nose, in which the skin often appears depressed.

The **accessory cartilages**¹ consist of two or three small pieces² imbedded in the fibrous membrane behind the posterior extremity of the outer portion of the lower lateral cartilages—occasionally a small nodule above the latter—and a small slip³ on each side of the lower margin posteriorly of the cartilage of the partition. The cartilages of the nose are composed of pure cartilage, and are enveloped in a perichondrium continuous with the periosteum of the contiguous bones. The cartilage of the septum forms a continuous structure with the upper lateral cartilages, the vomer, and the nasal plate of the ethmoid bone.

The **wings of the nose**⁴ are the convex prominences bounding the nostrils externally, and separated from the sides above by a furrow. They are composed of a doubling of thick skin containing a mass of tough connective tissue mingled with adipose tissue and muscular fibres forming part of the insertion of the nasal muscles.

The cartilages and wings of the nose give to the lower part of the organ its flexibility, and while they ordinarily preserve the open condition of the nostrils, they permit their contraction and expansion.

THE NASAL CAVITIES.

The **Nasal cavities**⁵ are two narrow but extensive and complex spaces, communicating with the exterior in front by the anterior nares, and with the pharynx behind by the posterior nares. Their **roof** is formed by the nasal bones, the cribriform plate of the ethmoid bone, and the body of the sphenoid bone; their **floor** is formed by the palate processes of the superior maxillary and palate bones. They are separated from each other by the **nasal partition**;⁶ their **outer wall** supports the **turbinated processes and bone**, between which are the three **meatuses**; and with them communicate the **sphenoidal, ethmoidal, frontal, and maxillary sinuses**. The mode of construction of the nasal cavities by the surrounding bones has already been described in the account of the skull, page 92.

The anterior nares are placed below the level of the floor of the nose,

¹ Cartilaginee sesamoideæ; c. epac-
tiles; c. accessorii.

² C. sesamoideæ; c. quadratæ.

³ Vomer cartilagineus dexter et sinister.

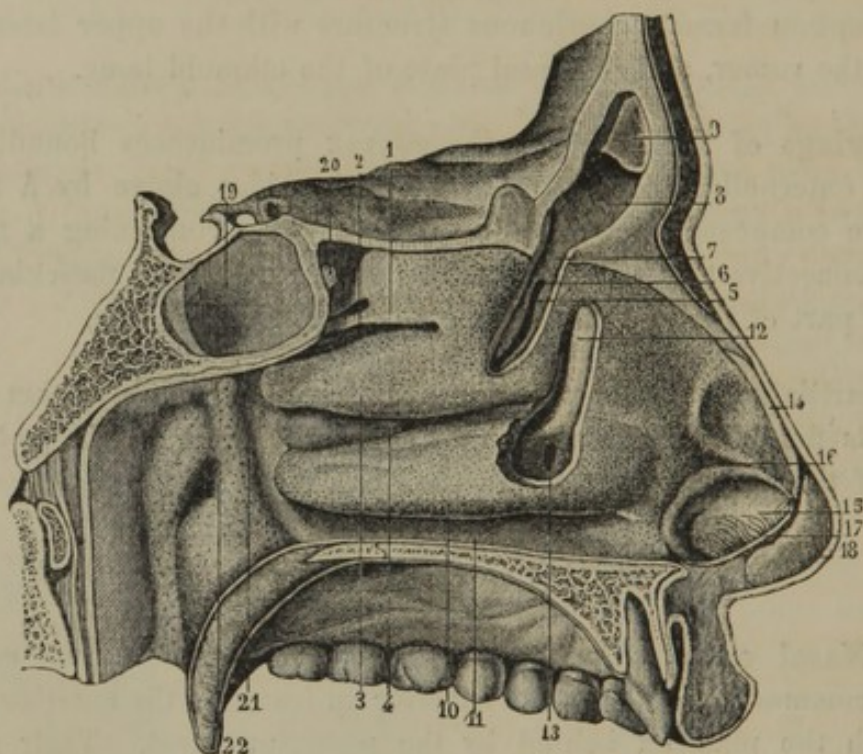
⁴ Alæ nasi; pinnæ.

⁵ Fossæ nasales; nasus internus: cavi-
narium; caverna narium.

⁶ Nasal septum.

at the most advanced position of the organ, and are directed downward. The posterior nares occupy the posterior inferior extremity of the organ, and are directed backward and downward. Inspired currents of air describe a semicircle in passing through the nasal cavities, ascending from the nostrils to the roof, and descending to the posterior nares. The turbinated processes break up the currents, and the air passes through the meatuses and into the various sinuses, so that all parts of the nasal surfaces may receive odorous particles conveyed into the nose.

FIG. 352.



OUTER WALL OF THE LEFT NASAL CAVITY. 1, superior turbinated process; 2, superior meatus; 3, inferior turbinated process; 4, middle meatus; 5, portion of the turbinated processes of the ethmoid bone, removed to exhibit the orifice of communication 6, with the anterior ethmoidal sinuses; 7, communication with the frontal sinus; 8, left frontal sinus; 9, part of the unsymmetrical partition which separates the frontal sinuses; 10, turbinated bone; 11, inferior meatus; 12, lachrymo-nasal duct exposed by removing a portion of the bones; 13, its termination; 14, edge of the upper lateral cartilage; 15, outer part of the left nostril; 17, cut edge of the cartilage of the partition; 18, inner portion of the left lower lateral cartilage; 19, sphenoidal sinus; 20, its orifice; 21, pharynx; 22, orifice of the Eustachian tube.

The nasal cavities are lined throughout with a highly vascular mucous membrane intimately adherent to the subjacent periosteum and perichondrium. At the nostrils it gradually merges into the skin, at the posterior nares is continuous with the mucous membrane of the pharynx, and through the lachrymo-nasal duct and lachrymal canals with the conjunctiva.

The **nasal mucous membrane**¹ is red, but varies in thickness, vascularity, and special structure in different positions. It is thickest and most vascular upon the turbinated processes, but especially on the turbinated bone; and at their inferior borders and posterior extremities it forms quite thick doublings, which much increase the extent of the nasal surface. On the partition it is also moderately thick, but in other positions is thinner; and in the sinuses it is so delicate and transparent as to assume more the appearance of a serous membrane. The foramina communicating with the sinuses are much reduced in size, from what they appear in the macerated skull, by the reflection of the mucous membrane at their edges.

Approaching the anterior nares the mucous membrane is comparatively dry, and is provided with a squamous epithelium. In other positions, including the sinuses but excluding the olfactory region, it is provided with a ciliated columnar epithelium, and is furnished with minute racemose glands,² which are most numerous where the membrane is thickest. In the **olfac'tory region**,³ which corresponds with the convex surface of the turbinated processes and the surface of the nasal plate of the ethmoid bone, the mucous membrane⁴ has a columnar epithelium devoid of cilia, and is furnished with simple tubular glands.⁵

The principal arteries which supply the nasal mucous membrane are the sphenopalatine branches of the internal maxillary, but it also receives the ethmoidal branches of the ophthalmic, branches from the descending palatine and dental arteries of the internal maxillary, and branches from the superior coronary and lateral nasal arteries of the facial. The veins of the nasal mucous membrane are larger and more numerous than the arteries, and form a plexus between the membrane and the periosteum, which is especially well developed upon the turbinated processes and bone, and the partition. They communicate with veins pursuing the course of the sphenopalatine artery, and by ethmoidal branches with the ophthalmic vein.

The nerves of the nasal mucous membrane are numerous, and are of two kinds—those of general, and those of special sensibility. The former are the nasal branches of the sphenopalatine ganglion, a branch from one of the palatine nerves, and the internal nasal division of the nasal nerve of the ophthalmic, besides filaments from the superior dental nerves.

¹ Schneiderian membrane; pituitary membrane; membrana pituitaria; m. olfactoria; m. mucosa nasi; m. Schneideriana.

² Glandulæ muciparæ aggregatæ.

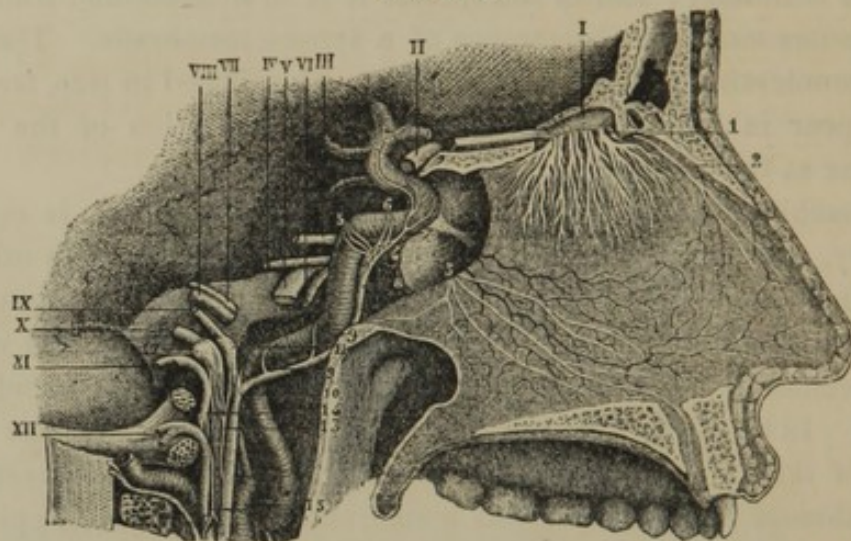
³ Regio olfactorio.

⁴ Olfactory mucous membrane.

⁵ Bowman's glands.

The olfactory nerves are those of special sensibility. The branches of each pass through the foramina of the cribriform plate of the ethmoid bone in two groups, of which one is destined to the inner, the other to the outer wall of the nasal cavity. At first the branches descend in grooves of the surfaces of the bones beneath the nasal mucous

FIG. 353.



NERVES OF THE PARTITION OF THE NOSE. I, olfactory nerve; 1, its branches descending to the nasal mucous membrane; 2, internal nasal branch of the nasal nerve of the ophthalmic; 3, nasal branches from the sphenopalatine ganglion. II, optic nerve; III, oculo-motor; IV, trochlear; V, trigeminal; VI, abducent; VII, facial; VIII, auditory; IX, glossopharyngeal; X, pneumogastric; XI, accessory; XII, hypoglossal. 4, cavernous plexus of the sympathetic; 5, filaments of communication with the semilunar ganglion of the trigeminal; 6, filaments of communication with the oculo-motor nerve; 7, branches of the sympathetic following the internal carotid artery; 8, branch connected with the superior cervical ganglion; 9, 10, filaments forming a plexus upon the internal carotid artery; 11, petrous ganglion of the glossopharyngeal; 12, jugular ganglion of the pneumogastric nerve; 13, 14, 15, anastomotic filaments between the sympathetic, the glossopharyngeal, pneumogastric, accessory, and hypoglossal nerves.

(For the nerves of the outer wall of the nose see figure 336, page 547.)

membrane, and then penetrate into the fibrous layer of the latter. The inner group subdivide into flattened tufts of filaments, which spread laterally in a fan-like manner, but appear not to descend below the nasal plate of the ethmoid bone. The outer group subdivide, and, through frequent anastomoses, produce a plexus or net-work which covers the external surface of the turbinated processes of the ethmoid bone.

THE EYE.

The **Eye**,¹ or organ of sight, includes the **eyeball** and the surrounding structures, named its **appendages**,² which consist of the muscles of the eyeball, the eyebrows and eyelids with their muscles, and the lachrymal apparatus.

¹ Oculus; ophthalmus; ops; organum visus.

² Tutamina oculi.

THE EYEBROWS.

The **Eyebrow**¹ is the arching prominence resting upon the superciliary ridge and supra-orbital margin, between the forehead and upper eyelid. It is composed of skin thickly provided with hairs, some subcutaneous connective and adipose tissue, a portion of the palpebral orbicular, and the superciliary muscle.

The hairs of the eyebrow are stiff, compressed, and pointed, project very obliquely from the skin, so as to lie in contact with it, and are generally directed along the line of the arch from within outwardly.

THE EYELIDS.

The **Eyelids**² are a pair of horizontal curtains placed in front of the eye or of the orbit, are separated by the palpebral fissure, and are fringed at their free margins by the eyelashes.

The upper eyelid³ is larger than the lower one,⁴ and is more movable, in consequence of its being provided with a special muscle, the **pal'pebral elevator**.

The **pal'pebral fissure**⁵ varies in length, and thus mainly gives rise to the apparent difference of size of the eye in different races and individuals. The extremities are named the **angles of the eye**,⁶ of which the **external**⁷ is acute and the **internal**⁸ is prolonged and rounded. The edges of the eyelids⁹ are straight, so that when they are closed the palpebral fissure appears as a transverse slit fringed with a double row of eyelashes.

Where the palpebral fissure commences to be prolonged to form the internal angle, the border of each eyelid presents a slight mammillary eminence, named the **lach'rymal papilla**.¹⁰ At the summit of this is a minute aperture, the **lach'rymal orifice**,¹¹ which is the commencement of the corresponding lachrymal canal.

In structure the eyelids consist of skin, the palpebral orbicular muscle, the palpebral cartilages and glands, and a portion of the conjunctiva.

¹ Supercilium; ophrys.

² Palpebræ; opercula.

³ Palpebra superior; p. major; epicoelis.

⁴ Palpebra inferior; p. minor; hypocoelis.

⁵ Fissura palpebrarum.

⁶ Anguli; canthi.

⁷ External, lesser, or temporal canthus.

⁸ Internal, greater, or nasal canthus; canthus; epicanthus; angulus ocularis; fons lacrymarum.

⁹ Margo palpebrarum.

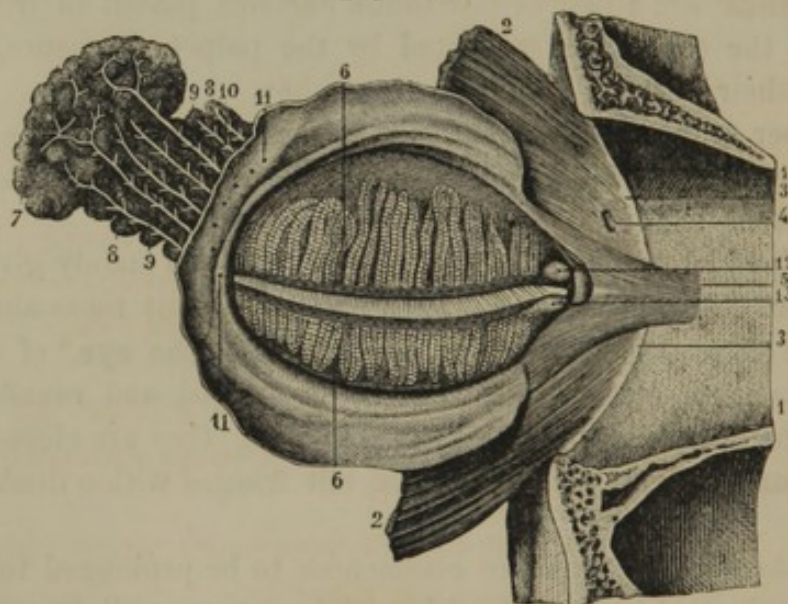
¹⁰ Papilla lacrymalis; tuberculum lacrymale.

¹¹ Punctum lacrymale.

The skin of the eyelids is thin, delicate, semitransparent, and without subcutaneous adipose tissue; and at the edges of the lids it becomes continuous with the conjunctiva. Subjacent to the skin is the palpebral orbicular muscle, which in this position is thin and pale, and specially concerned in the act of winking.

The **Pal'pebral cartilages**,¹ succeeding the muscle just indicated, are two thin plates of fibro-cartilage, which give form and firmness to the eyelids. They are thickest at their free margin, and have the conjunctiva intimately adherent to their inner surface. By their orbital margin they are continuous with an extension² of the periosteum of the orbit and face. Their inner extremity is attached by a round fibrous cord, the **internal pal'pebral ligament**,³ with the inner border of the orbit;

FIG. 354.



THE LEFT EYELID AND LACHRYMAL GLAND, TURNED FORWARD AND INWARD SO AS TO SEE THEIR INNER SURFACE. 1, upper and lower part of the orbit; 2, portion of the palpebral orbicular muscle; 3, attachment of this muscle to the inner margin of the orbit; 4, perforation for the passage of the external nasal nerve; 5, offset described as the tensor muscle of the eyelids; 6, palpebral glands; 7, posterior, and 8, anterior portions of the lacrimal glands; 9, 10, ducts; 11, orifices opening on the inner surface of the upper eyelid; 12, 13, the lacrimal orifices at the summits of the lacrimal papillæ.

and their outer extremity is connected with the contiguous border of the orbit by a somewhat thickened extension of the periosteum, named the **external pal'pebral ligament**.⁴

The **upper pal'pebral cartilage**⁵ is the larger, has the shape of the

¹ Tarsi: tarsal cartilages or fibro-cartilages; coronæ, chelæ, crepidines, or ungulæ palpebrarum.

² Ligamenta tarsorum superius et inferius; superior and inferior palpebral ligaments.

³ Ligamentum palpebrale, interpalpebrale, or angulare internum; tendo palpebralis.

⁴ L. palpebrale, interpalpebrale, or angulare externum.

⁵ Tarsus superior.

long half of an oval, and is about five lines wide at the middle. Into its upper convex border the broad, thin tendon of the palpebral elevator muscle is inserted. The **lower pal'pebral cartilage**¹ is a band about a line in width, and has its borders nearly parallel.

The **Pal'pebral glands**,² about twenty to each eyelid, are situated between the palpebral cartilages and the conjunctiva, through which they appear as vertical, parallel bodies, of a yellowish color and granular aspect. They are sebaceous glands lodged in grooves of the palpebral cartilages, with the depth of which they correspond in length. Each gland consists of a series of pyriform pouches communicating with a median duct extending the length of the gland and opening at the margins of the eyelids. They secrete an oleaginous matter,³ which prevents the overflow of the tears from the margins of the eyelids.

The **Eyelashes**⁴ are the stiff, curved hairs projecting from the borders of the eyelids along the line of union of the skin with the conjunctiva. Those of the upper lid are more numerous and longer, and have their convexity directed downward; those of the lower lid have their convexity directed upward. Associated with the roots of the eyelashes are numerous minute sebaceous glands, distinguishable as yellowish granules along the edges of the eyelids.

The muscles of the eyebrows and eyelids are the palpebral orbicular, superciliary, and palpebral elevator muscles, which are described in the account of those of the face, page 187.

THE CONJUNCTIVA.

The **Conjuncti'va**⁵ is the mucous membrane which lines the eyelids, and is thence reflected over the front of the eyeball. It is provided with a squamous epithelium, but otherwise varies in character in different positions.

The **palpebral portion**⁶ of the conjunctiva is red and highly vascular, and is closely adherent to the inner surface of the palpebral cartilages.

¹ Tarsus inferior.

² Glands of Meibomius; Meibomian glands; glandulæ Meibomianæ; g. ciliares; folliculi ciliares; glandulæ sebaceæ palpebrarum; g. s. ciliares; intestinula Meibomii; lacunæ palpebrarum.

³ Gum; eye-gum; lippitudo; lema; sebum palpebrale.

⁴ Cilia; epicærides; pili palpebrarum; blepharides; wickers.

⁵ Conjunctival membrane; membrana, or tunica conjunctiva; tunica adnata; circumcaulalis.

⁶ Conjunctiva palpebrarum.

It is furnished with minute conical papillæ, and is the most sensitive portion of the membrane.

At the inner angle of the eye the conjunctiva covers a group of sebaceous glands, which together form the **lach'rymal car'uncle**.¹ This is the soft, red eminence occupying the interval of the internal angle. It is furnished with minute hairs, and secretes an oleaginous material, which bathes the lachrymal papillæ.

At the outer side of the caruncle the conjunctiva forms a narrow, red doubling, the **semilunar fold**,² which is a rudiment of the third eyelid, or nictitating membrane of lower animals.

From the eyelids the conjunctiva is reflected over the front part of the sclerotica and cornea of the eyeball. Along the line of reflection at the bottom of the eyelids it contains a few small racemose glands.

The **sclerotic portion**³ of the conjunctiva is thin, transparent, devoid of papillæ, and less vascular than the palpebral portion. It adheres loosely to the sclerotica, which, seen through the transparent membrane, constitutes the **white of the eye**. The few large vessels ordinarily observed in the sclerotic portion of the conjunctiva are branches of the ophthalmic artery, which terminate in a fine capillary net-work bordering the cornea, but not extending beyond it in a state of health.

The **corneal portion**⁴ of the conjunctiva is non-vascular, highly transparent, and adheres so intimately to the cornea as to appear to be a part of its structure.

THE LACHRYMAL APPARATUS.

The **Lach'rymal apparatus**⁵ consists of the lachrymal gland, the lachrymal canals, the lachrymal sac and its continuation the lachrymo-nasal duct. The lachrymal gland secretes the tears, which moisten the conjunctiva, an excess ordinarily finding its way through the lachrymal canals and sac into the nose. Under the emotion of grief the gland is excited to an inordinate flow of tears, which then trickle over the edges of the eyelids.

The **Lach'rymal gland**⁶ is situated at the upper outer part of the orbit, and consists of two portions, of which the posterior⁷ is about the size and form of an almond kernel; the anterior⁸ is thinner and irreg-

¹ Caruncula lacrymalis.

² Plica, valvula, or membrana semilunaris; palpebra tertia. *ms. nictitans*

³ Conjunctiva scleroticæ.

⁴ Conjunctiva cornæ.

⁵ Organa lacrymalia.

⁶ Glandula lacrymalis.

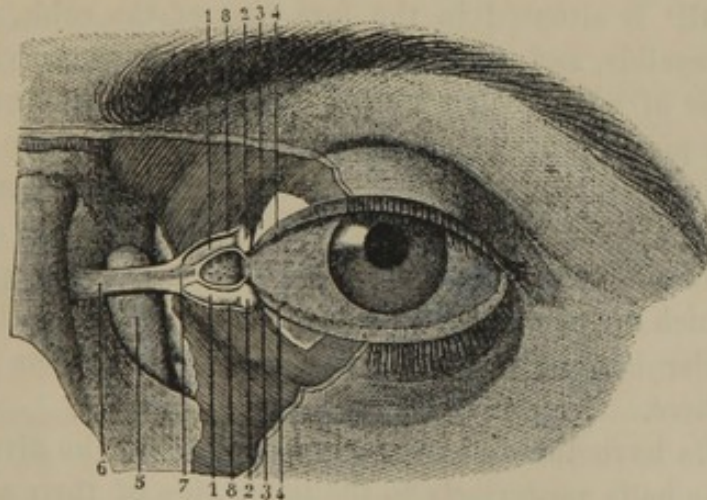
⁷ G. l. superior; g. innominata Galeni.

⁸ G. l. inferior Rosenmülleri; g. congregatæ Monroi.

ularly square. Its upper surface applied to the roof of the orbit is convex; while its lower surface, accommodating itself to the eyeball, is concave. It is a lobulated, racemose gland, of a pinkish hue, and is provided with a transverse series of about half a dozen **ducts**,¹ which proceed forward to open at the outer part of the reflection of the conjunctiva from the upper eyelid to the eyeball.

The **Lach'rymal canals**,² which ordinarily convey the tears from the front of the eye, commence at the summit of the **lachrymal papillæ**³ by a minute aperture, named the **lachrymal orifice** or **point**.⁴ The upper canal ascends within the corresponding eyelid; the lower one descends, and both then abruptly converge inwardly and terminate by separate apertures into the lachrymal sac. The canals expand after their origin, and are composed of an exterior fibrous tunic and a lining mucous membrane. They include between them the lachrymal caruncle, and are covered in front by the palpebral orbicular muscle.

FIG. 355.



THE LEFT EYE, WITH A PORTION OF THE EYELIDS REMOVED, TO EXHIBIT THE LACHRYMAL CANALS AND SAC. 1, lachrymal canals; 2, commencement of these at the summit of the lachrymal papillæ; 3, palpebral cartilages; 4, edges of the eyelids; 5, lachrymal sac; 6, internal palpebral ligament; 7, its point of division in front of the lachrymal canals; 8, branches of the ligament giving attachment to the fibres of the palpebral orbicular muscle.

The **Lach'rymal sac**⁵ is the commencement of the passage which conducts the tears from the front of the eye to the nose. It occupies the

¹ Ductus lacrymales.

² Canaliculi lacrymales; c. l. superior et inferior; c. limacum; canales, or ductus lacrymales; d. l. laterales; d. or collicie punctorum lacrymalium; cornua lacrymalia; c. limacum; spiracula; hircui; lachrymal ducts.

³ Papilla lacrymalis; tuberculum lacrymale.

⁴ Punctum lacrymale; spiramen palpebræ.

⁵ Saccus lacrymalis; sinus, or lacus lacrymalis; utriculus lacrymarum; infundibulum lacrymale; lacrycystis.

fossa between the lachrymal and superior maxillary bones, and is about half an inch in length. It is cylindrical, with a rounded, closed summit projecting a short distance above the entrance of the lachrymal canals.

The **Lach'rymo-nasal duct**¹ is formed by the lachrymal, superior maxillary, and turbinated bones, and is about half an inch in length. It is lined by a continuation of the lachrymal sac, and descends to terminate at the anterior extremity of the inferior meatus of the nose.

The lachrymal sac and lachrymo-nasal duct together have a nearly vertical direction, but in their descent incline slightly inward and backward. They are lined with mucous membrane intimately adherent to the subjacent periosteum, and continuous above with the mucous membrane of the lachrymal canals, below with that of the nose. The membrane is pale red, is provided with a columnar, ciliated epithelium, and sometimes has one or two slight transverse folds.

THE EYEBALL.

The **Eyeball**² is situated in the fore part of the orbit, protected in front by the eyelids, and resting behind in what may be viewed as the excavated base of a conical cushion of adipose and areolar tissue. It is maintained in position by the cushion just indicated, by the optic nerve and eyelids, but mainly by the muscles which surround and serve to move it in various directions. Its shape is nearly spherical, with a diameter a little less than an inch. Viewed in profile, it presents parts of two spheres, of which the posterior and larger corresponds with the sclerotica, and the smaller is formed by the cornea projecting from the front of the larger sphere.

The eyeballs have their axes³ nearly parallel, but the diverging optic nerves join the balls posteriorly to the inner side of their axes, and are thus brought several lines nearer the internal than the external border of the cornea.

In composition the eyeball consists of a series of concentric **tunics** inclosing three perfectly transparent and colorless media, named the **humors of the eye**. The tunics in succession are, firstly, the sclerotica and the cornea; secondly, the choroid coat and the iris; and thirdly, the retina. The humors are the aqueous humor, the crystalline lens, and the vitreous humor.

¹ Ductus naso-lacrymalis; d. lacrymalis; d. nasalis; d. n. orbitæ; d. ad nasum; nasal canal or duct; lachrymal duct; canalis lacrymalis; c. l. membranaceus; c. orbitæ nasalis.

² The eye; ball, globe, or bulb of the eye; bulbus oculi.

³ Visual axes.

MUSCLES OF THE EYEBALL.

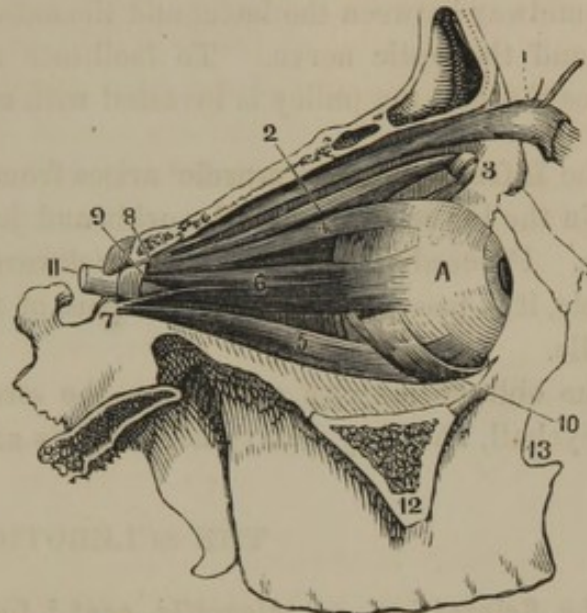
The **Straight muscles**¹ of the eyeball, of which there are four, are named from their relative position the **Superior**,² **Inferior**,³ **External**,⁴ and **Internal**.⁵ They arise tendinously around the optic foramen, and diverge forward equidistant from each other, to be inserted by tendons into the sclerotica a short distance from the cornea.

The external straight muscle has its origin divided into two parts, between which pass the oculo-motor and abducent nerves and the nasal branch of the ophthalmic.

The superior and inferior straight muscles of the two eyes act together, and draw the balls upward or downward. The external straight muscle draws the eyeball outward; the internal draws it inward, but the external muscle of one eye acts in conjunction with the internal muscle of the other eye. The united action of the straight muscles draws the eyeball toward the bottom of the orbit, which action, in a measure, is antagonized by the oblique muscles.

The **Superior Oblique muscle**⁶ arises tendinously above the optic fora-

FIG. 356.



MUSCLES OF THE EYE. 1, the palpebral elevator muscle; 2, the superior oblique; 3, the pulley through which the tendon of insertion plays; 4, superior straight muscle; 5, inferior straight muscle; 6, external straight muscle; 7, 8, its two points of origin; 9, interval through which pass the oculo-motor and abducent nerves; 10, inferior oblique muscle; 11, optic nerve; 12, cut surface of the malar process of the superior maxillary bone; 13, the nasal orifice. A, the eyeball.

¹ Musculi recti oculi.

² Musculus rectus superior; m. attollens oculi; m. levator oculi; m. superbus; m. oculus movens tertius; elevator muscle of the eyeball.

³ M. rectus inferior; m. depressor oculi; m. deprimens; m. humilis; m. timidus; m. oculus movens quartus; depressor muscle of the eyeball.

⁴ M. rectus externus; m. abductor oculi; m. indignabundus; m. indignato-

rius; m. iracundus; m. oculus movens secundus; abductor muscle of the eyeball.

⁵ M. rectus internus; m. adductor oculi; m. adducens oculi; m. bibitorius; m. oculus movens primus; adductor muscle of the eyeball.

⁶ M. obliquus superior oculi; m. o. major oculi; m. trochlearis; m. trochleator; m. amatorius; m. circumductionis opifex; m. longissimus oculi.

men, and advances along the upper and inner part of the orbit. Terminating in a round tendon, this passes through a **fibro-cartilaginous ring** or **pulley**,¹ situated in a depression just within the inner extremity of the supra-orbital margin. The tendon then turns backward and outward beneath the superior straight muscle, and is inserted into the eyeball, midway between the latter and the external straight muscle, the cornea and the optic nerve. To facilitate movement, the tendon as it passes through the pulley is invested with a synovial bursa.

The **Inferior Oblique muscle**² arises from the superior maxillary bone within the lower margin of the orbit and just external to the lachrymal fossa. Proceeding outward and backward below the inferior straight muscle, it is inserted into the outer part of the eyeball a little back of its middle.

The oblique muscles antagonize the straight muscles by protruding the eyeball, and they also rotate it on its axis in opposite directions.

THE SCLEROTICA.

The **Sclerot'ica**, or **sclerot'ic coat**,³ forms the posterior four-fifths of the exterior wall of the eyeball. It is a strong, white, opaque, inextensible membrane, composed of interlacing bundles of fibrous tissue, and is adapted to give form and solidity to the eyeball. Its front part, seen through the conjunctiva, is commonly called the **white of the eye**.⁴ It is thickest posteriorly, and gradually becomes thinner anteriorly, in which position the tendons of the straight and oblique muscles are inserted. Its back part admits the optic nerve through a funnel-shaped opening; and the sheath of the nerve becomes continuous with the sclerotica. Into a circular aperture at its fore part the cornea is inserted, in the manner of a watch-crystal in its frame. The margin of the aperture is beveled inwardly, so as to inclose the corresponding margin of the cornea. In the vicinity of the optic nerve and near the cornea, the sclerotica is pierced by the ciliary blood-vessels and nerves. Its inner surface is brownish, and is attached to the choroid tunic by a small quantity of delicate connective tissue.⁵

The sclerotica is supplied with blood from branches of the ciliary arteries; and its veins join the choroid and ciliary veins.

¹ Trochlea.

² M. obliquus inferior oculi; m. o. minor oculi.

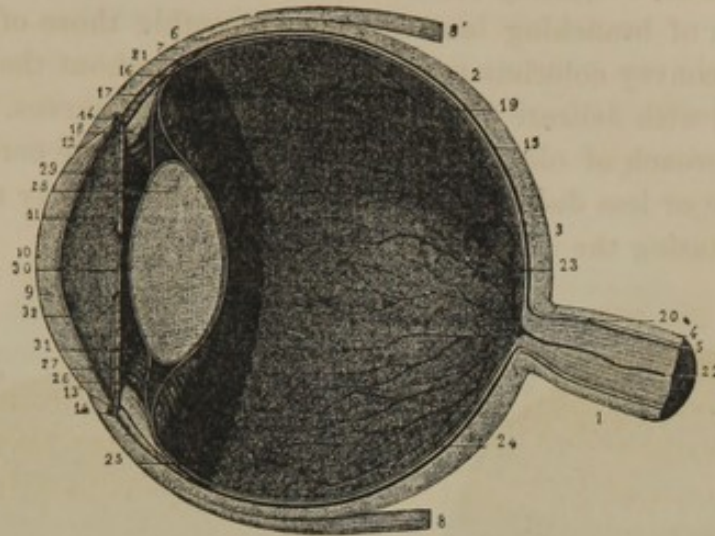
³ Tunica sclerotica; t. albuginea; t. dura, durior, crassior, alba, extima,

candida, or innominata oculi; cornea opaca.

⁴ Album, or albumen oculi; lachrymæ.

⁵ Lamina, or membrana fusca.

FIG. 357.



VERTICAL SECTION ANTERO-POSTERIORLY OF THE EYEBALL. 1, optic nerve; 2, sclerotica; 3, its posterior thicker portion; 4, sheath of the optic nerve continuous with the sclerotica; 5, the nerve within the sheath; 6, insertion of the straight muscles into the sclerotica; 7, 8, superior and inferior straight muscles; 9, cornea; 10, its conjunctival surface; 11, membrane of the aqueous humor; 12, 13, beveled edge of the cornea fitting into the sclerotica; 14, circular sinus of the iris; 15, choroidea; 16, the anterior portion of the same, constituting the ciliary body; 17, the ciliary muscle; 18, the ciliary processes; 19, retina; 20, its origin; 21, its anterior border; 22, central retinal artery; 23, vitreous humor; 24, 25, hyaloid tunic; 26, 27, its separation into two laminae, which inclose the crystalline lens, 28; 29, iris; 30, pupil; 31, posterior chamber, and 32, anterior chamber occupied by the aqueous humor.

THE CORNEA.

The **Cor'nea**¹ is the transparent membrane at the front of the eyeball, the exterior wall of which it constitutes the most prominent fifth part. By a beveled margin it fits into the circular aperture adapted to it in the sclerotica. Externally the conjunctiva² is reflected over it; and internally it is lined by an equally transparent layer named the **membrane of the aqueous humor**.³ Independently of the two layers just mentioned, the cornea⁴ is composed of a fibrous tissue much resembling in appearance and chemical constitution that not unfrequently observed in the matrix of cartilages. The fibrous tissue has a lamellar arrangement, so that the cornea may be dissected into a number of layers, varying with the delicacy of manipulation. At the conjunction of the cornea and sclerotica the two become intimately associated, and in this position inclose a venous channel, called the **circular sinus of the iris**.⁵

¹ C. pellucida, lucida, or transparen; membrana cornea; sclerotica ceratoides; ceratoides; membrana ceratoides; ceratomeninx; the sight.

² Conjunctival portion of the cornea.

³ Membrana, tunica propria, vagina, or capsula humoris aquei; m. Descemeti; m. Demoursii; m. Duddeliana; m. Demu-

riana; proper membrane of Descemet; posterior elastic lamina of the cornea; capsula aquea cartilaginosa; c. præaqueosa.

⁴ Cornea propria.

⁵ Canalis Schlemmii; c. Fontanæ; sinus venosus Hovii; circulus venosus orbiculi iridis, or ciliaris. *Ann. Ocul. Indis.*

The cornea in a healthy condition is non-vascular, but is pervaded with a system of branching lacunæ which resemble those of the bones, and serve to convey colorless nutritive liquid throughout the membrane. It is supplied with delicate filaments from the ciliary nerves.

On the approach of old age the circumference of the cornea usually becomes more or less dull or opaque by the deposit of fatty matter in its tissue, constituting the so-called **arcus senilis**.¹

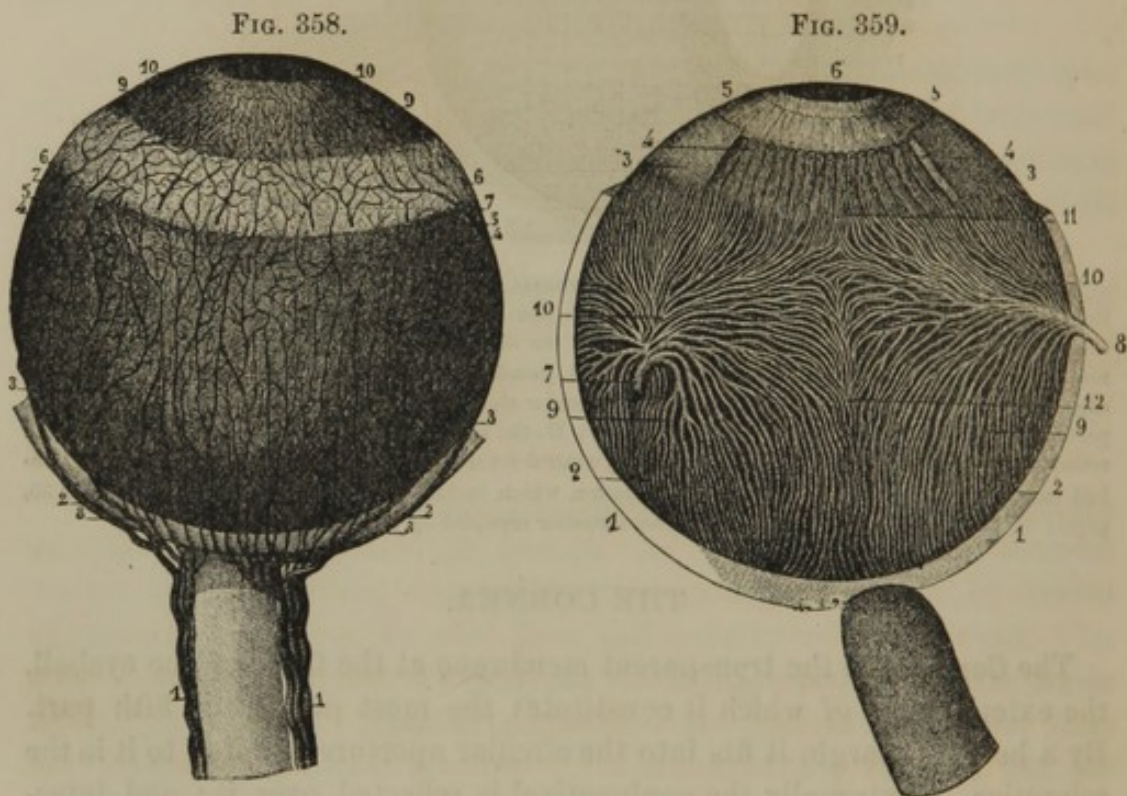


Fig. 358.—THE CHOROIDEA AND IRIS. 1, ciliary arteries situated at the sides of the optic nerve; 2, the long ciliary arteries; 3, the same after having pierced the sclerotica; 4, 5, the main divisions of the same vessels; 6, the ciliary muscle; 7, the anterior ciliary arteries; 8, the short ciliary arteries to the choroidea; 9, the iris supplied by the long and anterior ciliary arteries; 10, the pupil.

Fig. 359.—VEINS OF THE CHOROIDEA AND IRIS. 1, sclerotica; 2, choroidea; 3, ciliary muscle, of which a portion has been removed to exhibit the ciliary processes; 4, 5, the iris; 6, pupil; 7, 8, trunks of the choroid veins; 9, 10, vorticosæ vessels; 11, their conjunction with the veins of the ciliary processes; 12, anastomosis between the groups of vorticosæ vessels.

THE CHOROIDEA.

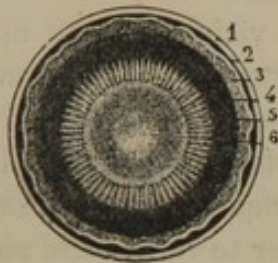
The **Choroi'dea**, or **choroid coat**,² is a thin, black, and highly vascular membrane succeeding the sclerotica and separating it from the retina. It is perforated behind for the passage of the optic nerve, and terminates

¹ Gerontoxon; macula corneæ arcuata; leucoma gerontotoxon.

² The choroid; tunica or membrana choroidea; t. vasculosa; t. aciniformis; t. rhagoides; uvea.

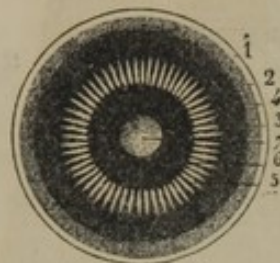
in front in the ciliary muscle and body. Its outer surface,¹ of a brownish-black hue, is attached to the sclerotica, loosely at the fore part, more intimately behind, by delicate connective tissue and blood-vessels. The inner surface is smooth, shining, intensely black, and is simply applied to the contiguous surface of the retina.

FIG. 360.



VIEW FROM BEHIND OF THE ANTERIOR PART OF THE EYEBALL. 1, sclerotica; 2, choroidea; 3, retina; 4, its anterior border; 5, ciliary processes; 6, the crystalline lens placed back of the iris and pupil.

FIG. 361.



THE SAME VIEW, WITH THE CRYSTALLINE LENS AND RETINA REMOVED. 1, sclerotica; 2, choroidea; 3, ciliary body; 4, line at which the retina ceases; 5, ciliary processes; 6, iris; 7, cornea seen through the pupil.

The **ciliary muscle**² is a whitish zone connecting the anterior part of the choroidea with the circumference of the iris and the conjunction of the sclerotica and cornea. It is composed of pale, unstriated muscular fibres, and is abundantly supplied with nerves and blood-vessels.

Within the position of the ciliary muscle the choroidea constitutes the so-called **ciliary body**,³ of which the fore part⁴ is thrown into about sixty convergent folds,⁵ named **ciliary processes**.⁶ These are received into corresponding grooves of the vitreous humor in advance of the retina, and serve to retain it in position. Their anterior extremities⁷ are free, suspended behind the iris, and are bathed in the aqueous humor of the posterior chamber of the eye.

In structure the choroidea consists of a vascular lamina lined on the interior with a pigmentary layer.

¹ Lamina fusca: l. supra-choroidea; l. cellulosa; l. arachnoidea chorioideæ; l. villosoglandulosa.

² Musculus ciliaris; ciliary ligament; ligamentum ciliare; l. sclerotico-chorioidale; l. iridis; annulus, circulus, orbiculus, or plexus ciliaris; interstitium ciliare, or iridis; tensori chorioideæ; circulus chorioideæ; annulus cellulosus; commissure of the uvea; ciliary circle, or ring.

³ Corpus ciliare; corona ciliaris; orbiculus ciliaris; tunica ciliaris; ciliary disk.

⁴ Pars plicata corporis ciliaris.

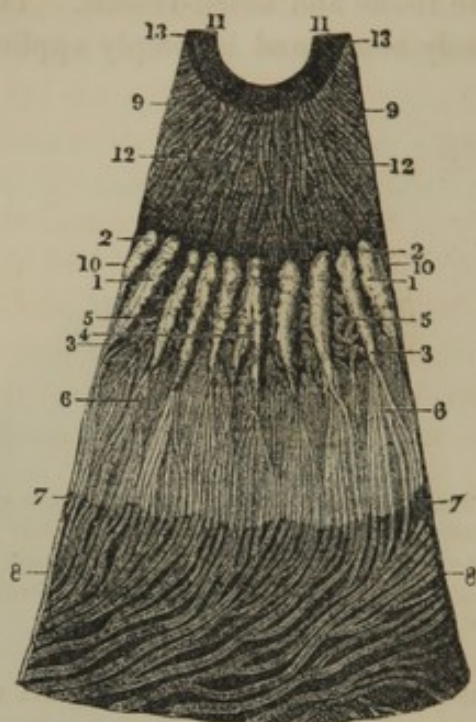
⁵ Plicæ ciliares; ciliary folds.

⁶ Processus ciliares; plicæ ciliares; p. corporis ciliaris; radii ciliares; striæ ciliares, ligamenta ciliaria; fibræ pallidæ.

⁷ Processus ciliares.

The **vascular lamina**¹ is composed of blood-vessels mingled with

FIG. 362.



SEGMENT OF THE CHOROIDEA AND IRIS, SEEN ON ITS INNER SURFACE, magnified four diameters. 1, ciliary processes; 2, their free extremities behind the iris; 3, 4, commencement of the processes; 5, intervening reticular folds; 6, veins of the ciliary processes; 7, posterior margin of the ciliary body; 8, choroidea with its veins; 9, iris; 10, its outer border; 11, the pupillary border; 12, radiating fibres of the iris; 13, circular fibres.

a stroma of fusiform and stellate cells, apparently an incipient form of connective tissue. The arterial branches of the vascular lamina are derived from the short ciliary arteries, which pierce the sclerotica in the vicinity of the optic nerve, and, after repeated branching, end in a fine capillary net-work.² The veins derived from the latter form an intricate and remarkable plexus exterior to it, and are named, from their peculiar whorled arrangement, the **vorticose vessels**.³ These form four groups,⁴ and converge in curving lines to four equidistant trunks, which perforate the sclerotica midway between the cornea and optic nerve, and end in the ophthalmic vein.

The ciliary processes are equally vascular with other portions of the choroidea. The arteries proceeding from the latter into the processes become convoluted, inoscu-

late, and finally terminate in veins which pursue a reverse course to join the vorticose vessels. The ciliary muscle is supplied by terminal branches of the short ciliary and the anterior ciliary arteries.

The **pigmen'tary layer**⁵ of the inner surface of the choroidea also envelops the ciliary processes. It consists of flattened, regularly hexahedral nucleated cells, filled with brownish-black granular contents, which give to the choroidea its intensely black color. In albinos the pigmentary granular matter is absent, and the choroidea presents a red color, due to its vascularity.

In many of the lower animals the inner surface of the choroidea at its back part exhibits a patch of metallic color and brilliancy, named the

¹ Tunica vasculosa Halleri; t. chorioidea propria; external layer; proper vascular layer.

² Membrana chorio-capillaris; m. Hovii; m. Ruyschii; tunica Ruyschiana.

³ Vasa vorticosa; venæ vorticosæ; v. tortuosæ.

⁴ Stellulæ vasculosæ Winslowii.

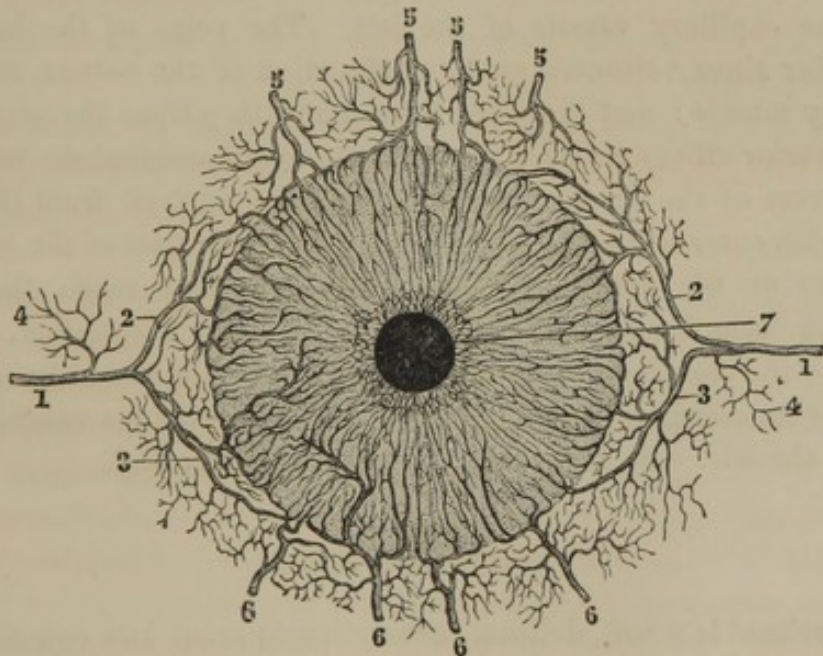
⁵ Stratum pigmenti; pigmentum nigrum; membrana Döellingeriana.

tape'tum.¹ In this the black pigmentary matter is replaced by colorless granules, which reflect the rays of light falling upon them, and thus give rise to that shining of the eyes of animals in the dark, which has proved to be so fertile a source of terror to the superstitious.

THE IRIS.

The **Iris**² is a flat disk with a central aperture, and regulates the amount of light received by the retina from its being endowed with the power of contracting or dilating. It is inserted into the anterior border of the ciliary muscle, is vertical in position, and is bathed in the aqueous humor. The anterior surface is divided into two zones,³ of which the outer one is the broader. It also appears striated from the circumference

FIG. 363.



ARTERIES OF THE IRIS. 1, long ciliary arteries; 2, 3, their principal divisions; 4, small branches to the ciliary muscle; 5, 6, anterior ciliary arteries; 7, the pupil.

toward the pupil, and in different individuals presents various shades of gray, blue, or brown passing into black. The posterior surface is intensely black, arising from the presence of a layer of pigment cells like those of the choroidea.

The central aperture of the iris, named the **pupil**,⁴ is circular, and in

¹ Membrana versicolor.

² Tunica cœrulea; uvea.

³ Annuli iridis; annulus major et minor iridis; a. externus et internus; a. ciliaris et pupillaris.

⁴ Pupila; pupula; fenestra nigrum; foramen oculi; prunella; sight of the eye.

the living eye appears as a black spot. Under the influence of light it decreases, and with the diminution of that agency it enlarges.

The iris is a highly vascular fibro-muscular structure, with its surfaces covered by an epithelium. The posterior layer¹ of the latter consists of black pigment cells; the anterior layer is composed of colorless pavement cells. The muscular fibres of the iris are unstriated; form a circular layer² around the pupil, and radiate³ toward the circumference of the iris.

The blood of the iris is derived from the long and anterior ciliary arteries. The former pierce the back of the sclerotica, one on each side, and advance on the outer surface of the choroidea to the ciliary muscle, when they bifurcate and form together an arterial circle, from which numerous branches proceed to the iris. The anterior ciliary arteries, about half a dozen in number, pierce the sclerotica in the vicinity of the cornea, and, after anastomosing with the branches of the long ciliary arteries, end in the capillary vessels of the iris. The veins of the latter join the **circular sinus**,⁴ situated at the conjunction of the cornea, sclerotica, and ciliary muscle; and the veins from the sinus pursue the same course as the anterior ciliary arteries to terminate in the ophthalmic vein.

The nerves of the iris are numerous, and are derived from the ciliary nerves which enter the eyeball by piercing the back part of the sclerotica. Advancing on the exterior of the choroidea, they reach the ciliary muscle and there form a plexus from which the iris is supplied.

Prior to the eighth month of foetal life the pupil is closed by a delicate **pu'pillary membrane**,⁵ which appears to be a continuous vascular structure with the iris. At birth it is completely obliterated.

THE RETINA.

The **Ret'ina**⁶ is a soft, delicate, nearly transparent and colorless membrane, which extends from the optic nerve on the inner surface of the choroidea to the ciliary body, where it terminates in a waving margin.⁷ After death it loses much of its transparency, and assumes the appearance of ground glass.

¹ Uvea; pigmentum nigrum; membrana pigmenti.

² Sphincter pupillæ; oclussor muscle of the pupil; fibræ circulares.

³ Dilator pupillæ; fibræ radiatæ; f. longitudinales iridis.

⁴ Canal of Fontana, or of Schlemm; canalis Fontanæ; c. Schlemmii.

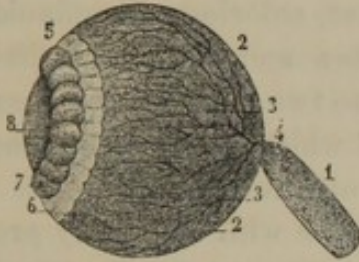
⁵ Membrana pupillaris; m. Wachen-dorfiana; pupillæ velum.

⁶ Tunica retina; t. reticularis or retiformis; t. nervea; t. arachnoidea; t. intima oculi.

⁷ Ora serrata; margo dentatus; m. undulato-dentatus.

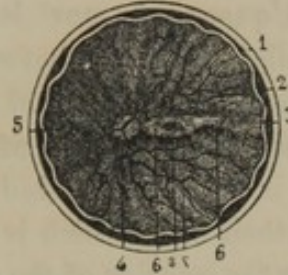The surfaces of the retina are simply in contact with the contiguous structures, and in the living or perfectly fresh state are smooth. Shortly after death a small fold¹ appears on the inner surface, extending a little distance outwardly from the entrance of the optic nerve. Upon the summit of this fold, in the axis of the eyeball, there is a **yellow spot**,²

FIG. 364.



THE EYEBALL, WITH THE SCLEROTICA, CORNEA, CHOROIDEA, AND IRIS REMOVED. 1, optic nerve; 2, 3, retina; 4, central retinal artery entering the eyeball through the optic nerve and distributed to the retina; 5, 6, ciliary zone, at which the ciliary folds of the choroidea impress the vitreous humor; 7, space of the hyaloid tunic at the circumference of the crystalline lens, 8, artificially inflated, and assuming the form of a beaded canal.

FIG. 365.



RETINA, SEEN ON ITS POSTERIOR INNER SURFACE. 1, sclerotic; 2, choroidea; 3, retina; 4, white spot indicating the entrance of the optic nerve; 5, central retinal artery; 6, a slight fold of the retina, upon which is situated, in the axis of the eye, the yellow spot, 7; 8, its minute central aperture.

with an apparent central aperture³ depending on a thinning of the retina. The entrance of the optic nerve is seen as an opaque, white spot,⁴ from the centre of which diverge the branches of the central retinal artery.

The structure of the retina is exceedingly complex, and consists of a series of elements, enumerated from without inwardly, as follows: 1, a layer composed of narrow, vertical, columnar cells;⁵ 2, a granular layer;⁶ 3, a layer of nerve cells with caudate appendages;⁷ 4, nerve fibres derived from the expansion of the optic nerve;⁸ 5, a structureless, limiting membrane.⁹

The blood-vessels derived from the central retinal artery form a cap-

¹ *Plica centralis retinæ*; *p. transversa retinæ*.

² *Macula lutea*; *m. flava centralis retinæ*; *limbus luteus foraminis centralis*.

³ *Foramen centrale Sæmmerringii*; *fovea centralis retinæ*.

⁴ *Papilla*, or *colliculus nervi optici*.

⁵ *Tunica Jacobi*; *Jacob's membrane*; *basillar layer*; *stratum basillorum*; *basilli et coni*; rods and cones; *prisma-*

ta præacuta et coni gemini; layer of rods and cones.

⁶ *Stratum granulosum*.

⁷ The layer of cineritious cerebral substance of Kölliker; layer of gray nerve substance; *stratum globulosum*.

⁸ Expansion of the optic nerve; *stratum fibrillosum*; *s. vasculoso-nerveum*; *stratum medullare*.

⁹ *Membrana limitans*.

illary net-work in the nervous layers of the retina;¹ and the veins return in the course of the corresponding arteries.

The retina is the sensitive membrane of the eyeball—that which receives the impression of light, the form and color of exterior objects.

THE AQUEOUS HUMOR.

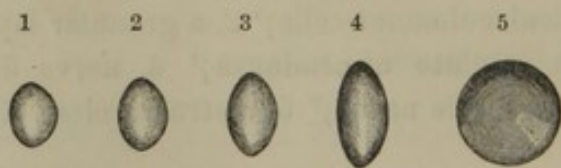
The **A'queous humor**² is a transparent, colorless, albuminoid liquid, which fills the space between the cornea and crystalline lens. The space it occupies is divided by the iris into two parts, named the **anterior** and **posterior chambers of the eye**,³ of which the former is the larger. The iris is freely suspended in the aqueous humor, both of its surfaces being bathed in it, which is likewise the case with the ciliary processes.

Lining the interior of the cornea, and continuous with the anterior layer of the iris, is the so-called **membrane of the aqueous humor**.⁴ It is an elastic membrane, consisting of a structureless basement layer and a pavement epithelium. Its border is resolved into a fine net-work of fibres,⁵ which are reflected upon, and become continuous with, the anterior surface of the iris.

THE CRYSTALLINE LENS.

The **Crys'talline lens**⁶ succeeds the aqueous humor from behind, and is the most consistent of the humors of the eye. It is a double convex

FIG. 366.



THE CRYSTALLINE LENS. 1, lens of a fetus of seven months; 2, lens of a fetus of nine months; 3, lens of a child of ten years of age; 4, lens of an adult viewed in profile; 5, the same seen on its anterior surface.

lens, of which the posterior surface is the more convex, and is received into a depression⁷ of the vitreous humor; while its anterior surface is bathed by the aqueous humor. It is retained in position by the hyaloid tunic of the vitreous humor, which

is reflected from its border to its anterior and posterior surfaces.

¹ Lamina vasculosa retinæ.

² Humor aquosus; h. oviformis; h. ovatus; h. oodes; h. hydatodes; albumineous humor.

³ Cameræ oculi.

⁴ Membrane of Descemet. See page 603.

⁵ Ligamentum pectinatum iridis; processus peripherici; pillars of the iris.

⁶ Lens crystallina; corpus crystallinum; crystalline humor or body; the crystallinus; corpus discoides or phacoides; phacus; gemma oculi.

⁷ Fossa lenticularis; f. patellaris.

From foetal life to the adult period the lens gradually diminishes in its degree of convexity, and increases in breadth; and in the advance of life it continues to decline in convexity. It is perfectly transparent and colorless, though in old age it is apt to assume a yellowish hue. Boiling water or alcohol coagulate it and render it hard and opaque white.

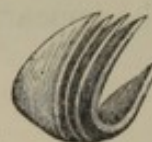The lens is provided with a transparent membranous **capsule**,¹ which is structureless, and is thickest anteriorly. The substance² of the lens is composed of concentric laminæ, which increase in density toward the centre. The laminæ are composed of hexahedral fibres, with corrugated sides closely adapted to one another. In fishes this corrugated character is much exaggerated, and the fibres indigitate by serrated processes.

FIG. 367.



CRYSTALLINE LENS, BREAKING UP INTO SEGMENTS.

FIG. 368.



SEGMENT OF THE CRYSTALLINE LENS, exhibiting the concentric arrangement of the laminæ.

Not unfrequently, in dissections, the lens is observed with a disposition to separate into segments from its axis, and this appears to indicate the arrangement of structure. The segments are composed of the concentric laminæ above described, and these consist of the hexahedral fibres, which pursue a direction from the bases of the segments to their summits and lateral edges. The intervals of the segments are occupied with a mingled amorphous and finely granular matter.

Between the front of the lens and its capsule there exists a layer of delicate epithelial cells,³ which, after death, become detached and mingled with some liquid⁴ exuding from the contiguous structures.

In foetal life, a vessel from the central retinal artery traverses the axis of the vitreous humor, and is distributed to the capsule of the lens; but it is obliterated before birth.

THE VITREOUS HUMOR.

The **Vit'reous humor**,⁵ less consistent than the crystalline lens, but more so than the aqueous humor, is equally transparent and colorless.

¹ Capsula lentis; tunica crystalloidea; t. arachnoidea.

² Humor crystallinus; h. glacialis.

³ Globuli lentis.

⁴ Liquor or aqua Morgagni.

⁵ Corpus vitreum; c. hyaloideum; humor vitreus; h. hyalinus; h. glacialis.

It occupies all the space included within the expanse of the retina and the ciliary body, and consists of a viscid albuminoid liquid¹ contained in the meshes of a delicate membranous structure, named the **hy'aloïd tunic.**² This is homogeneous, and, besides forming partitions³ through the mass of the vitreous humor, affords it an exterior investment. In advance of the retina the hyaloïd tunic is thicker than elsewhere, and forms the **ciliary zone.**⁴ This is in contact externally with the ciliary body, and is impressed by its processes, which, being received into corresponding grooves of the zone, contribute to maintain the position of the vitreous humor. In front, the tunic separates into two laminae, which diverge upon the border of the crystalline lens, and become confluent with the anterior and posterior surfaces of its capsule. The angle of separation⁵ of the two laminae is partially interrupted at short distances, so that when inflated it assumes the appearance of a beaded canal⁶ at the circumference of the lens.

THE EAR.

The **Ear** or organ of hearing is exceedingly complicated in its structure, and is for the most part concealed from view within the petrous portion of the temporal bone. It is divisible into the external, middle, and internal ear.

THE EXTERNAL EAR.

The **External ear** consists of the auricle and the external auditory meatus.

The **Auricle,**⁷ or ear of common language, joins the external auditory meatus between the articulation of the lower jaw and the mastoid process. It resembles the expanded mouth of a trumpet crushed inwardly, and mainly derives its peculiar form from a fibro-cartilage. The winding ridges and hollows of its outer surface correspond with reverse characters on the inner surface or back of the ear. Its lower pendant portion, named the **lobe,**⁸ is a pouch of skin filled with connective tissue and fat.

¹ Vitrina ocularis.

² Tunica hyaloïdea; t. vitrea; membrana arachnoïdea.

³ Hyaloïdea interna; pars cellularis hyaloïdæ; cellularis corporis vitrei; tunica arachnoïdea.

⁴ Zona ciliaris; pars ciliaris hyaloïdæ; corpus ciliare hyaloïdæ; zonula Zinni; zonula, or zone of Zinn; lamina

ciliaris; membranula coronæ ciliaris; corona ciliaris; orbiculus capsulo-ciliaris; ligamentum suspensorium lentis.

⁵ Canal of Petit; canalis Petitianus; circulus Petiti; camera tertia aquosa.

⁶ Bullular canal of Petit.

⁷ Auricula; pavilion; pinna; ala; otium.

⁸ Lobulus auriculæ.

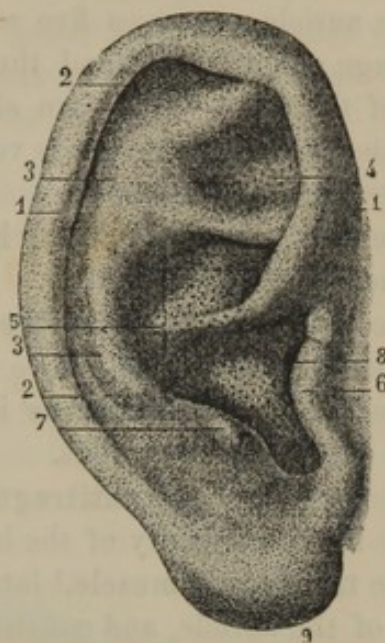
The inflected border of the auricle, curving from above the auditory meatus upward, backward, and downward, is the **helix**.¹ Separated from this by a groove² is the ridge named the **antihelix**, which bifurcates above,³ and includes a triangular fossa.⁴ In front of the auditory meatus is a conical eminence, the **tragus**;⁵ and separated from this by a rounded notch, and situated below the antihelix, is another eminence, the **antitragus**. The deep concavity within the position of the antihelix, and presenting a semispiral course toward the entrance of the auditory meatus, is the **concha**.

The auricle, excepting its lobe, consists of a plate of fibro-cartilage, invested with a perichondrium, to which the skin tightly adheres. Several fissures or intervals exist in the fibro-cartilage, occupied by connective tissue. Thus the fibro-cartilage is deficient between the tragus and the commencement of the helix, and between the lower end of the latter and the antitragus. Short fissures also exist on the tragus and the fore part of the helix. In the last-mentioned position there is a small conical eminence, named the **process of the helix**.

The fibro-cartilage of the auricle is thin, and rather brittle, but is rendered more tenacious by its perichondrium. The skin is thin, and, as elsewhere generally, is furnished with minute hairs and sebaceous glands. The latter are well developed in the fossæ of the auricle, more especially in the concha.

Besides the connection of the skin, the auricle is attached to the side of the head by ligamentous bands. The **anterior ligament**, broad and strong, extends from the process of the helix to the root of the zygo-

FIG. 369.



THE AURICLE. 1, helix; 2, fossa of the helix; 3, antihelix; 4, fossa of the antihelix; 5, concha subdivided by the commencement of the helix; 6, tragus; 7, antitragus; 8, entrance of the external auditory meatus; 9, the lobe. The large dots in the concha and fossa of the antihelix are the orifices of sebaceous glands.

¹ Capreolus.

² Fossa navicularis, scaphoides, or innominata; fossa of the helix.

³ Crura furcata.

⁴ Fossa of the antihelix; fossa triangularis, or ovalis.

⁵ Hircus.

matic process. The **posterior ligament** attaches the convexity of the concha to the root of the mastoid process.

The auricle possesses five small muscles situated between the fibro-cartilage and the skin, and three larger ones which connect it with the side of the head. They are all composed of striated fibres, and while the function of the former is very obscure, the latter are generally quite inactive.

The **smaller muscle of the helix**¹ is a short fasciculus situated on the commencement of the latter.

The **greater muscle of the helix**² is a narrow band situated on the fore part of the auricle, above the process of the helix.

The **muscle of the tragus**³ is a short plane of fibres situated on the outer surface of the tragus.

The **muscle of the antitragus**⁴ is a band extended from the antitragus to the lower extremity of the helix.

The **transverse muscle**,⁵ larger than the preceding, is situated on the back of the auricle, and consists of a plane of fibres extending from the concha to the ridge bounding the groove of the antihelix.

The **superior auric'ular muscle**⁶ is a broad, thin, and pale fan-like plane of fibres, arising from the border of the occipito-frontal aponeurosis, and descending to be inserted back of the fossa of the antihelix. In action, it will draw the auricle upward.

The **anterior auric'ular muscle**,⁷ generally less distinct than the preceding, is a thin, transverse fasciculus arising from the temporal fascia, and inserted into the helix and concha. In action it would draw the auricle forward.

The **posterior auric'ular muscle**,⁸ stronger and less pale than the others, consists of two or three fasciculi arising from the mastoid process, and inserted into the back of the concha. In action it draws the auricle backward.

The auricle is abundantly supplied with blood-vessels and nerves. Its

¹ M. helicis minor.

² M. helicis major.

³ M. tragicus.

⁴ M. antitragicus.

⁵ M. transversus auriculæ; m. t. and obliquus auris.

⁶ M. auricularis superior; m. attollens auriculæ, or aurem; m. levator, or superior auris; m. temporo-auricularis.

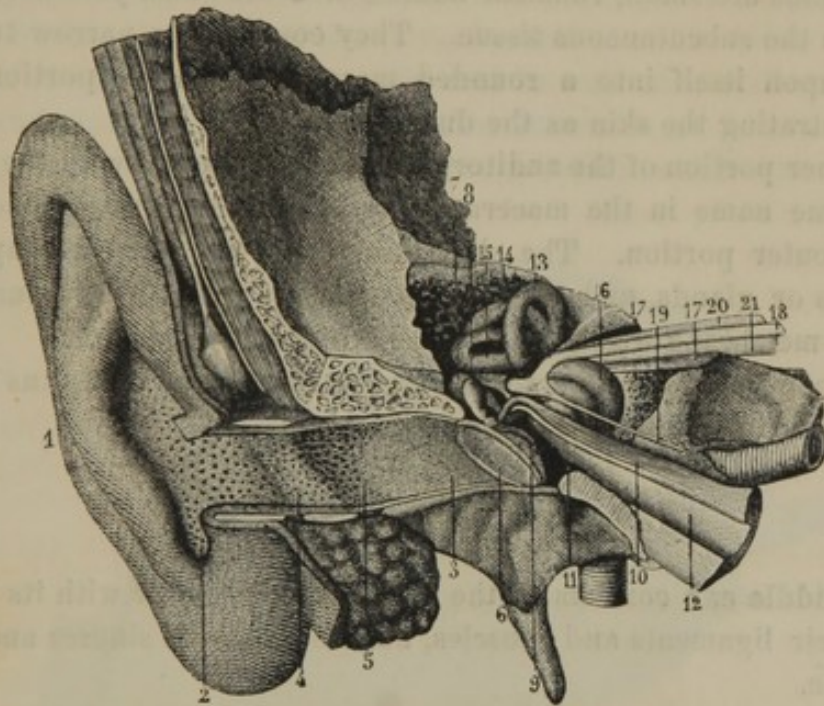
⁷ M. auricularis anterior; m. attrahens auriculæ; m. anterior auris; m. zygomato-auricularis.

⁸ M. auricularis posterior; m. retrahens, or retrahentes auriculæ; m. posterior auris; m. mastoido-auricularis; m. deprimens auriculæ; m. bicaudalis, triceps, or tricaudalis auris; m. proprius auris externæ; m. secundus propriorum auriculæ.

arteries form a conspicuous net-work upon the fibro-cartilage, and are derived from the anterior and posterior auricular branches of the temporal and external carotid arteries. Its veins terminate in the temporal vein. The nerves are derived from the great auricular branch of the cervical plexus, the posterior auricular branch of the facial nerve, and the auriculo-temporal branch of the inferior maxillary nerve.

The **External aud'itory mea'tus**¹ is a canal extending from the concha to the tympanum, and serves to conduct sounds to the latter which

FIG. 370.



GENERAL VIEW OF THE EAR, RIGHT SIDE, LAID OPEN FROM THE FRONT. 1, auricle; 2, concha; 3, 4, external auditory meatus; 5, ceruminous glands; 6, tympanic membrane; 7, anvil; 8, mallet; 9, its handle inserted into the tympanic membrane; 10, tensor muscle of the latter; 11, cavity of the tympanum; 12, Eustachian tube; 13, 14, 15, the three semicircular canals; 16, cochlea; 17, the internal auditory meatus; 18, facial nerve occupying a groove of the auditory nerve, 20, 21.

are collected by the auricle. It is about an inch in length, is directed inward and forward, and curves in its course upward and downward. Its commencement is vertically oval, its middle is the narrowest part, and its bottom is closed by the tympanic membrane.

The meatus consists of an outer shorter portion, which is a prolongation of the auricle, and an inner portion composed of the osseous auditory meatus lined with an extension of the skin.

The outer portion of the meatus, independently of the skin, is com-

¹ Meatus auditorius externus; external auditory canal; auricular canal; alvearium; scapha.

posed of a scroll of fibro-cartilage, open above, and continuous by a narrow slip with that of the auricle. The interval of the scroll is occupied with fibrous membrane, thus producing a complete tube. The fissures intervening between the outer part of the latter and the concha are likewise occupied with fibrous membrane, and its inner extremity is connected by an **annular ligament** with the orifice of the osseous meatus.

The skin of the outer portion of the auditory meatus is comparatively thick, and is furnished with numerous hairs and sebaceous glands. Its surface presents a punctated appearance, from the many orifices of the **ceru'minous glands**,¹ which secrete the **ceru'men** or **ear-wax**.² These glands are small, rounded bodies, of a brownish-yellow color, imbedded in the subcutaneous tissue. They consist of a narrow tube convoluted upon itself into a rounded mass, the terminal portion of the tube penetrating the skin as the duct of the gland.

The inner portion of the auditory meatus corresponds with the passage of the same name in the macerated bone, and is narrower and longer than the outer portion. The skin lining it is very thin, is unprovided with hairs or glands, and becomes continuous with the structure of the tympanic membrane which closes the bottom of the meatus.

The blood-vessels and nerves of the external auditory meatus have the same derivation as those of the auricle.

THE MIDDLE EAR.

The **Middle ear** consists of the tympanum, together with its inclosed bones, their ligaments and muscles, and the mastoid sinuses and Eustachian tube.

The **Tym'panum**, or **drum of the ear**,³ is an irregular cavity in the interior of the petrous portion of the temporal bone. It is about half an inch in height and breadth, and one to two lines from without inward. Its roof is a plate of bone separating it from the cranial cavity; its floor is a groove between the outer and inner walls. Into its upper back part open the mastoid sinuses; and in front it narrows into the Eustachian tube. The outer wall is formed by the tympanic membrane, and its inner wall bounds the labyrinth.

The **tym'panic membrane**, or **membrane of the tym'panum**,⁴ is a cir-

¹ Glandulæ, or folliculæ ceruminosæ.

² Cerea; sordes, sordiculæ, or marmorata aurium; ceruminous humor; cypsele, or cypselis; fugile.

³ Cavum, or cavitas tympani; cavity of the tympanum, or drum; barrel of

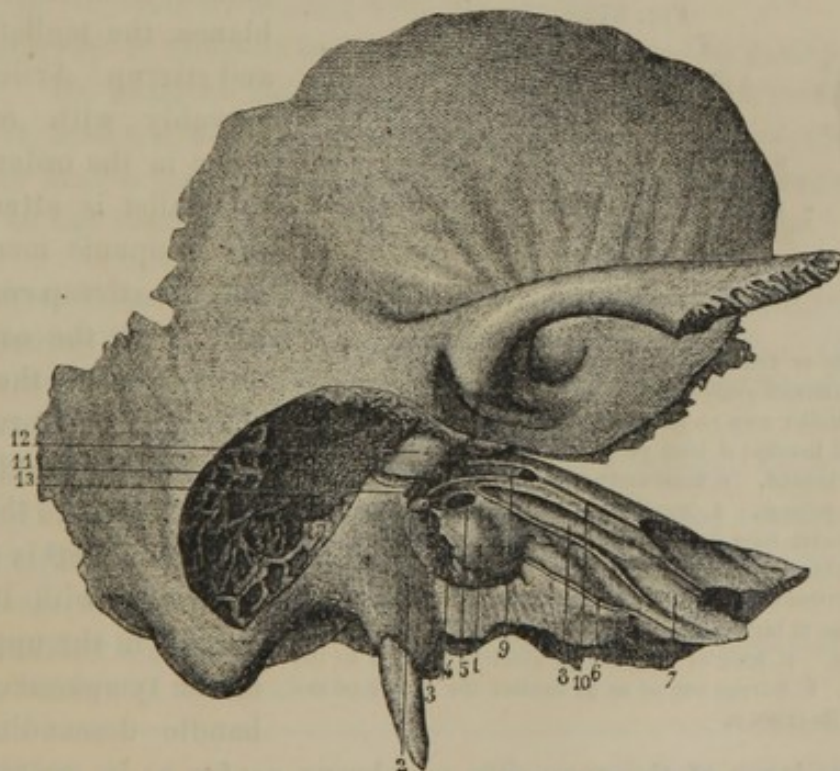
the ear; antrum, or cavitas antrosa auris.

⁴ Membrana tympani; membrane of the drum; diaphragma, mediastinum, or tegumentum auris; myringa; myrinx.

cular partition separating the cavity of the tympanum from the external auditory meatus, from which it receives transmitted sounds. It is not flat, but slightly funnel shaped, and is situated obliquely, so that its outer, depressed surface¹ is directed downward and forward. The greater part of its circumference is inserted into a fine groove, which in the newborn child is included by an osseous ring, subsequently developed, by + p. 7
prolongation outwardly, into the osseous auditory meatus. Into its upper part, descending as far as the centre, the handle of the mallet is inserted, so that vibrations of the tympanic membrane are communicated to the latter.

The tympanic membrane is thin and translucent, and is composed of a layer of fibrous tissue invested externally with a continuation of the epidermis of the meatus, and internally with an extension of the lining mucous membrane of the tympanum. Its fibrous layer consists of fibres radiating from the centre, with some concentric fibres at its circumference.

FIG. 371.



CAVITY OF THE TYMPANUM AND MASTOID SINUSES, right side. The auditory meatus, tympanic membrane, small bones, and outer wall of the mastoid sinuses removed. 1, promontory; 2, pyramid; 3, ridge within which descends the Fallopian canal; 4, round window; 5, oval window; 6, osseous portion of the Eustachian tube; 7, surface of attachment of the cartilage of the latter; 8, canal above the tube which lodges the tensor muscle of the tympanum; 9, Fallopian canal laid open; 10, canal occupied by the greater petrous nerve; 11, mastoid sinuses; 12, communication of the latter with the tympanum; 13, orifice through which the tympanic branch of the facial nerve enters the tympanum.

The inner wall of the tympanum presents a convex eminence, the *prom'ontory*,² produced by the projection of the cochlea. Above the

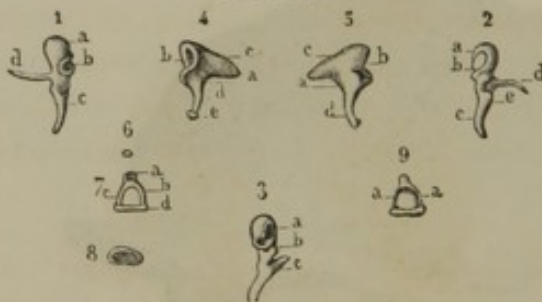¹ Umbo.² Promontorium; tuber, or tuberositas tympani.

back of the promontory is an orifice, the **oval window**,¹ which communicates with the vestibule, but is closed by the application of the base of the stirrup. Above the oval window and promontory is a ridge, passing from before backward, produced by the course of the Fallopian canal, which transmits the facial nerve. Behind the lower part of the promontory is a pit, at the bottom of which is an aperture named the **round window**.² This communicates with the cochlea, but is closed by the **secondary tympanic membrane**,³ which consists of a fibrous layer, invested externally with the lining membrane of the tympanum, internally with that of the cochlea.

At the back part of the tympanum a descending ridge indicates the continuation of the Fallopian canal to the stylo-mastoid foramen. From the ridge there projects forward a hollow, conical eminence, named the **pyramid**.⁴

The small bones⁵ occupy the upper part of the tympanum, and are

FIG. 372.



SMALL BONES OF THE EAR. 1. Mallet seen on its inner surface. *a*, head; *b*, articular surface for the anvil; *c*, handle; *d*, the long process. 2. Mallet seen on its outer surface. *a*, head; *b*, articular surface; *c*, handle; *d*, long process; *e*, short process. 3. Mallet seen from behind. *a*, head and articular facet; *b*, short process; *c*, long process. 4. Anvil seen on its inner surface. *a*, body; *b*, articular facet for the mallet; *c*, short process; *d*, long process; *e*, orbicular process. 5. Anvil seen on its outer surface. *a*, body; *b*, articular facet; *c*, *d*, short and long processes. 6. Orbicular process, at birth a distinct bone. 7. Stirrup. *a*, head; *b*, *c*, crura; *d*, base. 8. Base of the stirrup, which is applied to the oval window. 9. Stirrup cut so as to exhibit the groove on the inner side of its crura *a*.

named, from their resemblance, the mallet, anvil, and stirrup. Articulating movably with one another in the order given, the mallet is attached to the tympanic membrane, and the stirrup communicates with the oval window, so that the vibrations of the former are continued through the series of bones to the latter.

The **Mallet**⁶ is situated vertically, with its head lodged in the upper part of the tympanum, and its handle descending into

the fibrous layer of the tympanic membrane as far as its centre. The

¹ Fenestra ovalis, or vestibularis; foramen ovale.

² Fenestra rotunda, triquetra, or cochlearis; foramen rotundum.

³ Membrana tympani secundaria; m. fenestræ rotundæ; tympanum minus, or secundarium.

⁴ Pyramis; eminentia pyramidalis tympani.

⁵ Ossiculi auditus; o. auris.

⁶ Malleus, malleolus; ossiculum malleolo-assimilatum; the hammer.

head is rounded, and at its back part has an oval facet invested with cartilage, for articulation with the anvil. The **handle**¹ is a tapering process, slightly twisted and compressed. The **neck** is slightly constricted, and gives off two processes. The **long process**² is a slender spine projecting nearly at a right angle from the neck, and enters the glenoid fissure; the **short process**³ is a conical eminence at the root of the neck.

The **Anvil**⁴ is situated behind the mallet, near the entrance to the mastoid sinuses. Its **body** is irregularly square, and at its fore part has an oval articular surface for the head of the mallet. Behind, it has a pair of diverging processes, of which the lower is the longer. The **short process**⁵ projects backward, and is connected by a ligamentous band to the posterior part of the tympanum. The **long process**⁶ is curved and tapering, and descends nearly parallel to the handle of the mallet. Its end internally supports an **orbicular process**,⁷ which articulates with the head of the stirrup. At birth the latter process is a distinct bone, but it soon becomes co-ossified with the anvil.

The **Stirrup**⁸ is directed horizontally inward from the anvil to the oval window. Its **head** is flattened, and at the summit has a concave articular facet, invested with cartilage, for the orbicular process of the anvil. From the head a pair of **crura** curve inwardly to join the **base**, which is applied to the oval window.

The three bones just described have movable articulations, surrounded by a capsular ligament and lined with synovial membrane. The articulation between the mallet and anvil is hinge like; that between the latter bone and the stirrup is a ball-and-socket joint.

The **suspensory ligament**⁹ of the mallet is a slender band of fibres, extending from the head of the bone to the roof of the tympanum.

The **suspensory ligament**¹⁰ of the anvil extends from its short process to the back part of the tympanum.

The **annular ligament**¹¹ of the stirrup connects the margin of the base with the border of the oval window.

¹ Manubrium.

² Processus, or apophysis longus, gracilis, Folii, or Rauii.

³ P. brevis; p. obtusus.

⁴ Incus; acmon; os incude simile; ossiculum incudi, or molari denti comparatum.

⁵ Ramus horizontalis.

⁶ Ramus verticalis.

⁷ Os, or ossiculum orbiculare, lenticulare, squamosum, cochleare, or quartum; processus lenticularis; ossiculum orbiculare or lenticulare Sylvii; globulus stapedis; epiphysis cruris longioris incudis.

⁸ Stapes; stapha; staffa.

⁹ Ligamentum superiores, or teres.

¹⁰ Posterior ligament.

¹¹ L. annulare, or orbiculare baseos stapedis.

Three minute muscles, composed of striated fibre, are connected with the bones of the ear, to regulate their movements. Others¹ have been described, but their existence is not usually acknowledged.

The **tensor muscle**² arises from the end of the cartilage of the Eustachian tube and the contiguous surfaces of the sphenoid and temporal bone. Passing through an osseous canal of the latter, above the Eustachian tube, it ends in a tendon which enters the tympanum and turns outwardly to be inserted into the neck of the mallet. Its contraction increases the tensity of the tympanic membrane.

The **laxa'tor muscle**³ arises from the spinous process of the sphenoid bone, passes upward and outward, and enters the glenoid fissure, to be inserted into the long process of the mallet. In action it relaxes the tympanic membrane.

The **stape'dius muscle**⁴ arises within the hollow of the pyramid, and is inserted into the head of the stirrup. It regulates the pressure of the base of the latter against the oval window.

The cavity of the tympanum is everywhere lined with a delicate mucous membrane, which likewise invests the small bones, stretching across the aperture of the stirrup,⁵ and covering the muscles and ligaments. It is pink in color from its vascularity, and is provided with a pavement-like epithelium. The arteries of the tympanum, though small, are numerous. They are derived from the tympanic branch of the internal maxillary artery, the stylo-mastoid artery, the great meningeal and descending palatine arteries, and from the internal carotid artery as it passes through the carotid canal. The veins communicate with the great meningeal and pharyngeal veins, and through a plexus, near the glenoid articulation, with the internal jugular vein. The nerves are derived from the tympanic branch of the glosso-pharyngeal, and the carotid plexus of the sympathetic nerve.

The **Mastoid sinuses**⁶ consist of numerous irregular cavities in the interior of the mastoid portion of the temporal bone, communicating by a large orifice⁷ with the upper back part of the tympanum. They are

¹ Laxator tympani minor.

² M. tensor tympani; m. internus mallei; m. tensor auris internus; m. salpingo-mallei.

³ M. laxator tympani; m. l. t. major; anterior ligament of the malleus; m. mallei externus, or anterior; m. obliquus, or externus auris; m. laxator auris in-

ternus; m. Eustachii; m. spheni-salpingo-mallei.

⁴ M. stapedius, or pyramo-stapedius.

⁵ Membrana obturatoria, or propria stapedis.

⁶ Mastoid cells; cellulæ mastoideæ; antrum mastoideum.

⁷ Petro-mastoid canal.

lined throughout with a delicate mucous membrane, provided with a pavement epithelium.

The **Eusta'chian tube**¹ is a trumpet-shaped canal, rather over an inch and a half long, extending from the fore part of the tympanum obliquely inward, forward, and downward to the pharynx. Its upper section is formed by an osseous canal in the petrous portion of the temporal bone, which communicates at its outer end with the tympanum, and narrows to its union with the other section in the angle between the squamous and petrous portions of the temporal bone.

The lower and longer section of the Eustachian tube proceeds from the angle mentioned along the posterior border of the sphenoid bone to the inner side of the internal pterygoid process. Gradually expanding in its course, it terminates by an oval orifice, with a prominent border, at the side of the pharynx, on a level with the turbinated bone, just back of the posterior nasal orifice. It is composed of a triangular plate of cartilage, bent into a gutter, open at its outer part, but converted into a complete tube by fibrous membrane.

The Eustachian tube is lined with mucous membrane, provided with a ciliated epithelium, and is continuous with that of the pharynx and tympanum.

THE INTERNAL EAR.

The **Internal ear** includes the labyrinth and the internal auditory meatus.

The **Lab'yrinth**,² named from its highly complex character, is the most important portion of the organ of hearing, as it contains the entire distribution of the auditory nerve. It is imbedded in the petrous portion of the temporal bone, and consists of three parts, named the vestibule, the semicircular canals, and the cochlea. Though these may be described as cavities, it should be understood that the labyrinth has osseous walls independent of the bony structure embracing it. At birth it may be readily excavated from the looser surrounding osseous substance; but at a later period this substance becomes condensed and confounded with the exterior surface of the labyrinth.

The **Ves'tibule**³ is an irregularly oval cavity, situated between the tympanum and the bottom of the internal auditory meatus, and joining

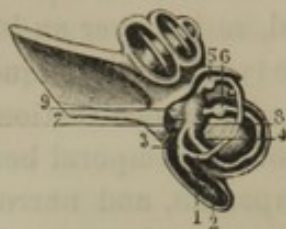
¹ Tuba Eustachiana, or Aristotelica; canalis gutturalis; meatus cæcus: iter a palato ad aurem; ductus auris palatinus; syrinx; syringa.

² Labyrinthus; l. auris intimæ; labyrinthic cavity; pars intima organi auditus; antrum buccinosum.

³ Vestibulum labyrinthi.

the semicircular canals postero-externally, the cochlea antero-internally.

FIG. 373.



THE INTERNAL EAR, CONSISTING OF THE LABYRINTH AND INTERNAL AUDITORY MEATUS, LAID OPEN. The lower part of the figure exhibits the three osseous semicircular canals containing the membranous semicircular canals. 1, 2, two semicircular canals, ending in a common tube, 3; 4, simple extremity of one of the canals; 5, 6, 7, dilated extremities or ampullæ of the canals; 8, elliptical, and 9, hemispherical saccules contained in the vestibule. Above the latter is the cochlea; and to its left the internal auditory meatus.

Through its outer wall it communicates with the tympanum by the oval window.

A slight semicircular ridge or **crest**¹ springs from the floor of the vestibule, ascends on its inner wall to the roof, and terminates in a small **pyram'idal eminence**.² The latter presents a group of minute foramina communicating with the internal auditory meatus, and named the **superior crib'riform spot**.³ The crest separates two recesses, called, from their shape, the **hemispherical**⁴ and **hemielliptical fossa**.⁵ The former is the smaller, and occupies the antero-internal portion of the vestibule; the latter occupies the postero-external portion. Just below the centre of the hemispherical fossa is a second group of minute foramina communicating with the internal auditory meatus, and named the **middle crib'riform spot**.⁶ Immediately in advance of the

fossa, the orifice⁷ of the vestibular scala of the cochlea communicates with the vestibule. Into the hemielliptical fossa open the orifices of the semicircular canals and the aperture⁸ of a small vascular canal⁹ which communicates with the posterior surface of the petrous portion of the temporal bone, and transmits the vestibular vein to the inferior petrosal sinus.

The **Semicircular canals**,¹⁰ three in number, are situated postero-externally to the vestibule and above the inner back part of the tympanum. From their position they are named **superior**,¹¹ **posterior**,¹² and **inferior**,¹³ the former two being vertical, the last horizontal. They are so

¹ Crista vestibuli.

² Eminentia pyramidalis; pyramis vestibuli.

³ Macula cribrosa superius.

⁴ Fossa, or fovea hemispherica; recessus hemisphericus; sinus rotundus.

⁵ Fossa, or fovea hemielliptica, semielliptica, or elliptica; recessus hemiellipticus; sinus ovatus.

⁶ Macula cribrosa media.

⁷ Apertura scalæ vestibuli.

⁸ Recessus, or fovea sulciformis.

⁹ Aqueduct of the vestibule; aqueductus vestibuli, or Cotunnii; canal of Cotunnus.

¹⁰ Canales, or ductus semicirculares, circulares, or tubæformes; semicirculari ossei; funes, or canaliculi semicirculares labyrinthi.

¹¹ Also vertical, or superior vertical.

¹² Also posterior vertical, or oblique.

¹³ Also external, or horizontal.

related with one another as to correspond with the inner, back, and lower faces of a cube.

Each canal is rather more than half a circle, and forms at one extremity a bottle-like dilatation, named the **ampul'la**, which communicates with the vestibule. Of the undilated extremities, two conjoin, and, with the remaining extremity, likewise open into the vestibule; and thus the three canals communicate with the latter by five orifices.

Within the ampulla of the posterior semicircular canal there is a third group of minute foramina communicating with the internal auditory meatus, and named the **inferior crib'riform spot**.¹

The interior of the vestibule and the semicircular canals is lined with a delicate membrane, resembling a serous membrane. It consists of a fibrous layer adhering to the osseous surface as a periosteum, a structureless basement layer, and a tessellated epithelium. Within this membrane the cavity is occupied by a serous liquid, named the **perilymph**,² from its surrounding a secondary structure, known as the **membranous lab'yrinth**. This consists of a pair of communicating pouches,³ contained in the vestibule, and three semicircular canals, of the same form as the osseous canals which contain them. The smaller pouch occupies the hemispherical fossa, and is named the **spherical saccule**;⁴ while the other pouch, occupying the hemielliptical fossa, is named the **elliptical saccule**,⁵ and is joined by three **membranous semicircular canals**.

The membranous labyrinth consists of an outer fibrous structure, lined internally with a tessellated epithelium, and filled with a serous liquid, named the **endolymph**.⁶

The **vestibular branch** of the internal auditory nerve is distributed to the membranous labyrinth, and maintains its floating position in the perilymph. This nerve divides at the bottom of the internal auditory meatus into three branches, of which one enters the vestibule at the superior cribriform spot, to be distributed to the elliptical saccule and the ampullæ of the superior and inferior semicircular canals; a second enters at the middle cribriform spot, and is distributed to the

¹ Macula cribrosa inferius.

² Liquor, or aquula Cotunnii; aqua, or aquula acustica, or auditoria; aquula.

³ Sacculus vestibuli.

⁴ Sacculus sphaericus; sacculus; saccule.

⁵ Sacculus ellipticus; s. vestibuli;

utriculus, sinus, or alveus communis; utricle; sinus, or alveus utriculosus; median sinus.

⁶ Endolympha; vitrina auditiva; aquula vitrea auditiva; aqua labyrinthi membranacei; humor vitreus auris; liquor of Scarpa.

hemispherical saccule; and the third enters at the inferior cribriform spot, and is distributed to the ampulla of the posterior semicircular canal.

FIG. 374.

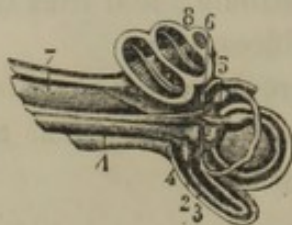


FIG. 375.

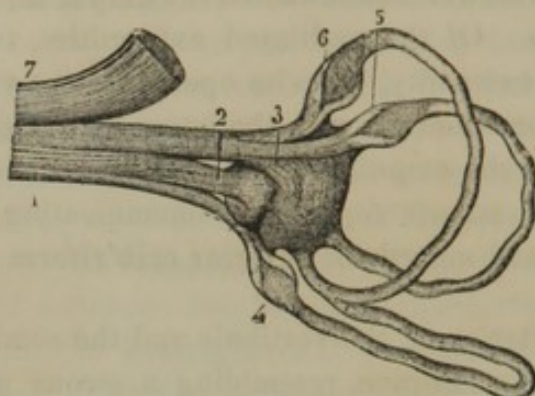


Fig. 374.—INTERNAL EAR LAID OPEN. 1, vestibular branch of the auditory nerve; 2, branch to the spherical saccule; 3, branch to the elliptical saccule; 4, 5, 6, branches to the ampullae of the membranous semicircular canals; 7, cochlear branch of the auditory nerve; 8, cochlea.

Fig. 375.—NERVES OF THE VESTIBULE AND SEMICIRCULAR CANALS, magnified three diameters. 1, vestibular branch of the auditory nerve; 2, branch to the spherical saccule; 3, branch to the elliptical saccule; 4, 5, 6, branches to the ampullae of the semicircular canals; 7, cochlear nerve.

Adhering to the inner surface of the two saccules of the vestibule, at the point of entrance of the nervous filaments from the cribriform spots, are two white discoidal masses, consisting of minute crystalline particles, called *o'tolites*.¹ These cohere, and appear to be in contact with the nervous filaments distributed to the saccules. They are composed of carbonate of lime, and are an important element of structure to the organ of hearing, as they are found in the ear of most animals.

The arteries of the vestibule and semicircular canals are derived from the vestibular branches of the auditory artery accompanying the branches of the vestibular nerve. The veins partly terminate in the venous sinus of the cochlea, and partly in the vestibular vein, which communicates with the inferior petrosal sinus.

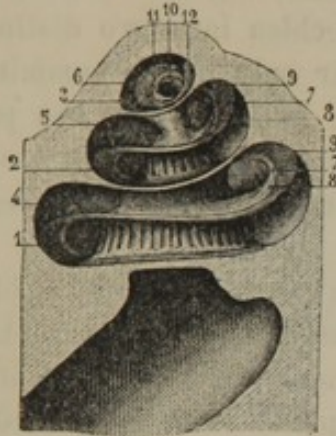
The *Coch'lea*² is the inner portion of the labyrinth, and is named from its resemblance to a snail-shell. Its base is applied to the bottom of the internal auditory meatus, and its apex is directed forward and slightly outward. It consists of an osseous tube, about an inch and a half long, wound nearly three times around a central *axis*, with each turn successively rising. The commencement of the tube is connected with the fore part of the vestibule, and produces the promontory of the

¹ Otolithi; otoliths; otoconia; otoconites.

² Concha auris interna; c. labyrinthi; cavitas cochleata, or buccinata; trochlea labyrinthi; antrum buccinosum.

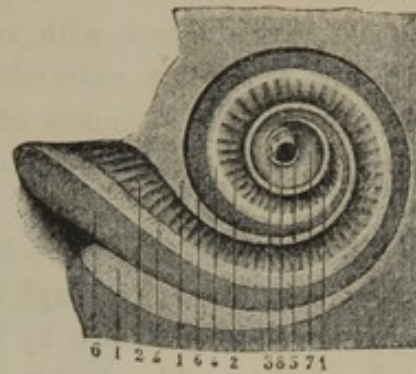
(out to in) in both right and left
 tympanum. Turning from right to left in the right ear, and the reverse direction in the left ear, it ends in a closed extremity, named the **cupola**, which nearly reaches the front surface of the petrous portion of the temporal bone above the ascending part of the carotid canal.

FIG. 376.



THE COCHLEA, LAID OPEN, ITS SUMMIT TURNED UPWARD, magnified three diameters. 1, 2, 3, the tympanic scala; 4, 5, 6, the vestibular scala; 7, 8, osseous spiral lamina; 9, membranous spiral lamina; 10, orifice of communication of the two scalæ at the summit of the cochlea; 11, 12, termination of the osseous and membranous spiral laminae.

FIG. 377.



THE COCHLEA, LAID OPEN, AND VIEWED FROM ITS SUMMIT TOWARD THE BASE. 1, cut edges of the osseous wall of the cochlea; 2, osseous spiral lamina, seen within the vestibular scala; 3, end of the lamina; 4, 5, its outer border; 6, membranous spiral lamina; 7, its end; 8, foramen of communication with the tympanic scala.

The **axis of the coch'lea**¹ is conical, its base forming the spiral tract at the bottom of the internal auditory meatus, and its summit becoming continuous with the inner wall of the last turn of the canal of the cochlea.² It is traversed by numerous fine canals, continuous with the foramina of the spiral tract and transmitting the filaments of the cochlear nerve, together with the cochlear branches of the auditory artery. A central canal,³ larger than the others, extends the entire length of the axis, and transmits a branch of the latter vessel.

An **osseous spiral lamina**⁴ commences just below the hemispherical fossa of the vestibule, winds around the axis of the cochlea, extending about half way across its canal, and terminates in a pointed process⁵ at the summit of the latter. The lamina is traversed by a multitude of fine anastomosing canals, which are continuous with those of the axis of the cochlea, and open into a groove at the free margin of the lamina.

¹ Column of the cochlea: axis, columella, or pyramis cochleæ; modiolus.

² The last turn of the inner wall of the cochlea upon its axis forms the infundibulum, or scyphus Vieussenii, or auditorius.

³ Canalis centralis modioli.

⁴ Lamina spiralis ossea; septum scalæ, or cochlæ auditoriæ; zona ossea.

⁵ Hamulus.

The interior of the cochlea is lined by a delicate membrane continuous with, and like that of the vestibule. After investing the two surfaces of the osseous spiral lamina, it is extended in a double layer from the free border of the latter across the canal of the cochlea to the outer wall, where it is firmly attached. This extension of the membrane, which is named the **membranous spiral lamina**,¹ together with the osseous spiral lamina, divides the canal of the cochlea into two distinct passages, which communicate with each other only at the summit of the cochlea.² At the lower extremity of the latter, one of the passages terminates at the round window of the tympanum, and is thence named the **tym'panic sca'la**,³ while the other opens into the vestibule, and is called the **vestib'ular sca'la**.⁴

Both **scalæ**⁵ of the cochlea are filled with a limpid serous liquid, which communicates with the perilymph of the vestibule, but is prevented from escaping at the round window by the secondary tympanic membrane.

The axis of the cochlea within the tympanic scala is pierced with a series of foramina, transmitting veins from the lining membrane of the cochlea to a spiral sinus⁶ within the axis. At the lower extremity of the same scala is the orifice of a canal⁷ which ends in a triangular pit in advance of the jugular foramen, and transmits a vein from the spiral sinus just mentioned to the inferior petrosal sinus.

The **cochlear branch** of the internal auditory nerve is resolved into a multitude of filaments, which, together with branches of the corresponding artery, enter the foramina of the spiral tract at the bottom of the internal auditory meatus. Ascending the canals of the axis of the cochlea, they are reflected outwardly to the osseous spiral lamina, within which they form an intricate plexus, and become associated near its free border with a series of nerve cells. From these the nerve fibres emerge, and enter the membranous spiral lamina, where, with pe-

¹ Lamina spiralis membranacea; zona membranacea, or mollis; zona choriacea and pars membranacea; z. cartilaginea and membranacea; z. media and membranacea; z. nervea and cartilaginea; z. denticulata and pectinata; habenula interna, or sulcata, and h. externa, denticulata, or perforata, are subdivisions of the zona denticulata.

² The communication is named the Helicotrema.

³ Scala tympani, posterior, interna, or superior; incorrectly inferior.

⁴ Scala vestibuli, anterior, externa, or inferior; incorrectly superior.

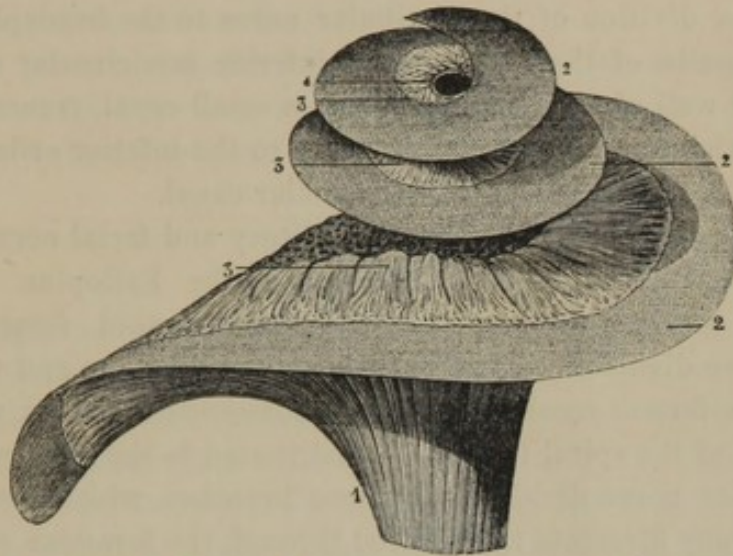
⁵ Gyri; ductus spirales; canales.

⁶ The canal containing the sinus is the canalis Rosenthalianus, or c. spiralis modioli.

⁷ Aqueduct of the cochlea; aquæductus cochleæ.

cular nerve cells, they form a complex arrangement, the character of which has not yet been conclusively determined.¹

FIG. 378.



DISTRIBUTION OF THE COCHLEAR NERVE. 1, trunk of the cochlear nerve; 2, membranous spiral lamina; 3, terminal filaments of the cochlear nerve emerging from the osseous spiral lamina to spread themselves in the membranous lamina; 4, orifice of communication of the tympanic and vestibular scale.

The **arteries** of the cochlea are mainly derived from the cochlear branches of the auditory artery, and, as previously indicated, they follow the course of the cochlear branch of the auditory nerve. They terminate in a capillary net of the lining membrane and spiral lamina of the cochlea, from which veins originate and join the spiral venous sinus within the axis of the cochlea. The spiral sinus communicates by means of a vein with the inferior petrosal sinus.

The **Internal aud'itory mea'tus**² is a cylindroid canal about three-fourths of an inch in length, leading from the posterior surface of the petrous portion of the temporal bone, obliquely downward, forward, and outward to the position of the labyrinth. Its bottom is unequally divided by a prominent, transverse, crescentic crest into two compartments, of which the lower is the larger. The upper compartment is subdivided by a vertical ridge into two pits, of which the inner one is the commencement of the Fallopian canal for the transmission of the facial nerve, and the outer one corresponds with the superior cribriform spot of the vestibule for the transmission of the superior division of the ves-

¹ For a more intimate description of this structure see the admirable researches of Corti and Kölliker.

² Meatus auditorius internus; foramen, porus, or sinus acusticus.

tibular nerve to the elliptical sacculæ. The lower compartment internally is occupied by a **spiral tract**,¹ pierced with a multitude of minute foramina, for the transmission of the cochlear nerve; externally is a fossa corresponding with the middle cribriform spot for the transmission of the inferior division of the vestibular nerve to the hemispherical sacculæ and ampullæ of the superior and inferior semicircular canals. In the posterior wall of the meatus there is a small canal, transmitting the posterior division of the vestibular nerve to the inferior cribriform spot of the ampulla of the posterior semicircular canal.

The auditory meatus transmits the auditory and facial nerves, and the auditory artery. The facial nerve enters the Fallopian canal, and pursues its course to emerge at the stylo-mastoid foramen. The auditory nerve divides into two branches, the **coch'lear** and **vestib'ular nerves**. The former resolves itself into numerous filaments, which enter the foramina of the spiral tract to be distributed in the manner indicated. The vestibular nerve divides into three branches, which resolve themselves into many filaments transmitted through the foramina of the three cribriform spots as above mentioned.

The auditory artery, a branch of the basilar, divides into cochlear and vestibular branches, which accompany the corresponding nerves.

THE ORGAN OF TASTE.

(For an account of the organ of taste, the student is referred to the description of the tongue, page 280.)

THE SKIN AND ITS APPENDAGES.

The **Skin**² is the organ of touch,³ and in the healthy condition of the body is among the most sensitive to the impression of pain, through which quality we are led to avoid agencies injurious or destructive to life. By its peculiar constitution it prevents evaporation of the liquids of the body, and yet holds a correlation with other organs in getting rid of an excess of those liquids. In general it is thickest on the most exposed parts—on the back of the trunk, outer part of the limbs, palms of the hands and soles of the feet. It is thinnest on the eyelids, lips, inner surface of the prepuce, and glans penis. It is flexible, moderately extensible, slightly elastic, semitransparent, and varies in color in different races and individuals. On the palms and soles it is closely covered with

¹ Tractus spiralis foraminulosus.

² Cutis; derma; deris; corium; pellis; integumentum commune.

³ Organon tactus.

fine parallel ridges, mostly arranged in curving lines, and with peculiar regularity. In other positions it presents fine reticular furrows, and pits from which hairs project. In parts exposed to frequent doubling or flexion it becomes more or less coarsely furrowed or wrinkled, as around many of the joints, and on the forehead.

The skin is composed of two principal layers, the dermis and epidermis; is provided with two kinds of glands, the sweat and sebaceous glands; and is furnished with two varieties of appendages, the hairs and nails.

THE DERMIS.

The **Dermis**¹ constitutes the deeper layer of the skin, and is thickest where the entire skin presents that condition. It is about one-sixth of a line thick on the eyelids, from one-fourth to one-half a line on the front of the body, and from one-half a line to one and a half lines on the back of the body and the heels. It is thinner in the female than the male; in children, is about half as thick as it is in adult age, and it becomes thinner in old age. It is of a pinkish cream color, and varies in the depth of pinkish hue in different positions according to its degree of vascularity.

The dermis is mainly composed of a dense intertexture of bundles of fibrous tissue, which cross one another at acute angles, in different directions. It is mingled with some elastic tissue, which is most abundant on the front of the body and about the joints. It also contains unstriated muscular fibres, which descend from the more superficial part of the dermis to the bottom of the hair follicles. When excited to contraction, through the impression of cold, the emotion of fear, or the influence of electricity, these muscular fibres elevate the hairs and produce the phenomenon of "goose flesh."²

The dermis is densest approaching its exterior surface, which is defined by a more homogeneous layer or basement membrane. Its interior surface is continuous with the connective tissue of the adipose layer of the superficial fascia, or in positions in which the adipose layer is absent it adheres to the deeper layer of the superficial fascia, or other subjacent structure, by more or less long and loose connective tissue, which allows the skin to be moved backward and forward. The interior surface, when freed from its connections, presents the appearance of a coarsely-corded net, with the meshes occupied by small, round masses of adipose tissue.

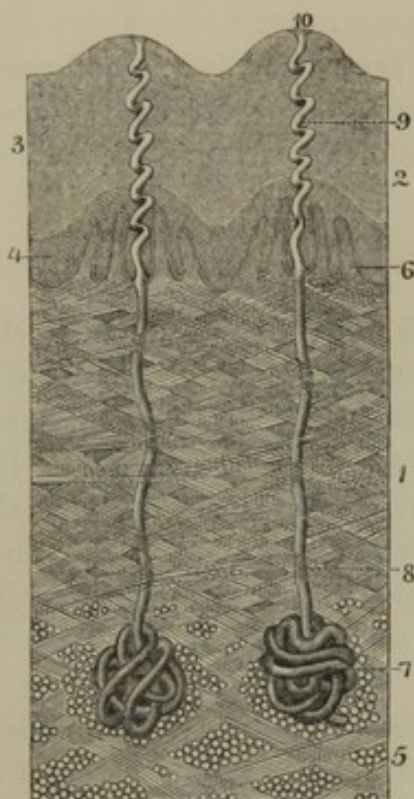
The outer surface of the dermis is provided with a multitude of mi-

¹ Derma; dermat; cutis; cutis vera; corium; true skin.

² Cutis anserina.

nute processes, which, from their function, have been named the **tactile papillæ**.¹ They vary in number and degree of development in different

FIG. 379.



VERTICAL SECTION OF THE SKIN OF THE FORE-FINGER ACROSS TWO OF THE RIDGES OF THE SURFACE, highly magnified. 1, dermis composed of an intertexture of bundles of fibrous tissue; 2, epidermis; 3, its cuticle; 4, its soft layer; 5, subcutaneous connective and adipose tissue; 6, tactile papillæ; 7, sweat glands; 8, duct; 9, spiral passage from the latter through the epidermis; 10, termination of the passage on the summit of ridge.

brane, and receive terminal filaments of the cutaneous nerves, and each a looped capillary blood-vessel. Some of the papillæ of the palm and sole contain peculiar bodies, which have already been described as **tactile corpuscles** on page 511.

The dermis is richly supplied with blood-vessels, lymphatics, and nerves. The arteries of the skin penetrate from beneath, and end in a capillary net-work, which becomes more close the nearer it approaches the exterior surface of the dermis, and from this net-work single loops enter the tactile papillæ. The veins emerging from the skin are more

parts of the body. They are most numerous and longest on the palms and soles, where they are arranged in double rows supported on linear ridges of the dermis, corresponding with those seen on the surface of the skin. They are also numerous on the prepuce, glans penis, nymphæ, clitoris, and nipple. In other positions they are more widely set apart, less well developed, and on the face are nearly obsolete.

The largest or best developed papillæ are conical, and either simple or compound—the latter consisting of two, three, or even more, springing from a common base. The less well developed papillæ are mammillary or wart like, and degenerate into feeble ridges of the surface. In the palms and soles they measure from the one-thirtieth to the one-tenth of a line long, and in other positions descend from the one-thirtieth to one-eighthieth of a line. They are composed of a continuation of the fibrous structure of the dermis, defined by structureless basement mem-

¹ Papillæ tactus; papillæ of touch; papillary layer of the derm; corpus papillare.

numerous and much larger than the arteries, and end in the superficial venous trunks beneath. The lymphatics also form an intricate net-work in the dermis, and are most numerous on the fore and inner part of the body and limbs, especially in the palms and soles. The nerves are abundant, and are derived from the various cutaneous branches described in the account of the nervous system. They extend to the exterior surface of the dermis, and into the tactile papillæ; but their mode of termination has not been accurately ascertained.

By boiling, the dermis is resolved into gelatin, and indeed the main source of glue used in the arts is obtained from fragments of the skin of animals. By tanning, the dermis is converted into leather; deprived of fatty and other matters, and properly thinned, it forms parchment. The cut edge and rough surface of a piece of leather illustrates the arrangement of the fibrous structure of the dermis, and its smooth outer surface frequently exhibits the mouths of the hair follicles, papillæ, and other marks.

THE EPIDERMIS.

The **Epider'mis**¹ constitutes the superficial layer of the skin, and holds the same relation to the dermis that the epithelium does to the deeper layer of the mucous membranes. It is thickest in the palms and soles, where it measures from the one-tenth to one line or more, and in other positions forms a thin layer ranging from about $\frac{1}{60}$ to $\frac{1}{10}$ of a line. The thickness is however in some measure dependent on the pressure or friction to which the skin is subjected, and thus it becomes thicker in the palm of the laborer and the sole of the plowman than in most other persons. Corns are much-thickened portions of the epidermis in particular spots, which are exposed to excessive pressure or friction. They are not necessarily confined to the feet, but are produced on the knee of the shoemaker from frequent hammering, or in front of the clavicle of the soldier from the pressure of his musket. The pain so frequently induced by their presence is due to their exciting inflammation in the sensitive dermis upon which they press, just as a pebble does under the same circumstances.

The epidermis is entirely non-vascular, but derives its nutritive liquid by imbibition from the vessels of the dermis. It is without nerves, and therefore completely insensible; but it transmits impressions through pressure to the exquisitely sensitive dermis, the soft and delicate struc-

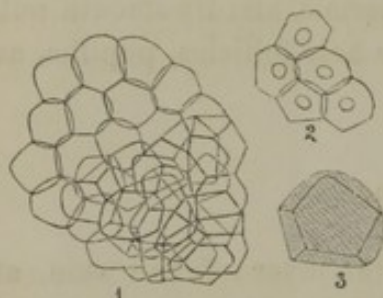
¹ Cuticula; cuticle; epiderma; epichorium; cutis extima; pellis summa; lamina prima cutis; scarf skin.

ture of which it protects from laceration or drying. If removed, the contact of the atmosphere is sufficient to produce inflammation of the dermis, and after death the latter speedily dries.

The epidermis consists of two layers, quite different in many respects; one being named the cuticle, the other the soft epidermic layer.

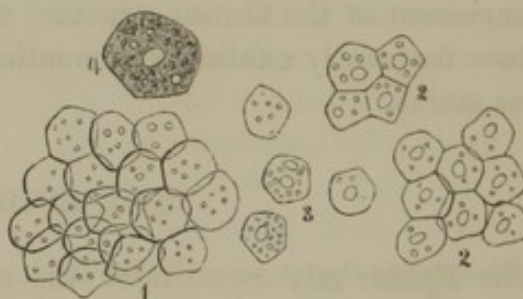
The **Cu'ticle**¹ is a nearly dry, yellowish, translucent, horn-like membrane, well illustrated by the slice of a corn. Its deeper surface is continuous with the soft epidermic layer from which it is incessantly renewed, while from its free surface it is constantly worn away, or is shed in small flakes, constituting the so-called scurf and dandruff. In many lower animals, as for instance serpents, it exfoliates from time to time in an

FIG. 380.



SCURF FROM THE LEG. 1, a fragment of scurf, consisting of dried, flattened, non-nucleated cells or scales; 2, a few cells with a nucleus; 3, a cell more highly magnified, to exhibit its polyhedral form.

FIG. 381.



FRAGMENT OF DANDRUFF FROM THE HEAD. 1, portion of dandruff, consisting of non-nucleated cells; 2, several fragments, consisting of nucleated cells; 3, isolated cells, some with and without nuclei; 4, a cell more highly magnified, exhibiting granular contents and a nucleus.

entire state. It consists of numerous laminae, according to its degree of thickness, of minute scales, which are completely flattened and nearly dried organic cells. These have a small quantity of granular contents, but usually no nucleus, though frequently the remains of one, especially in the deeper part of the cuticle, may be detected.

By treatment with a solution of potash, the scales of the cuticle separate from one another, and swell into spheroidal vesicles. Hence it is that alkaline solutions remove the epidermis. A blister or burn produces inflammation of the dermis and effusion of liquid, which breaks up the soft epidermic layer, and elevates the cuticle.

By maceration of the skin after death, the cuticle becomes detached from the dermis through disorganization of the soft epidermic layer. When the cuticle is sufficiently thick and strong to sustain itself, it may be removed in large pieces, and thus from the hand it may be stripped off like a glove.

¹ Cuticula.

The **Soft epidermic layer**¹ consists of many laminae of delicate polyhedral cells with soft granular contents and a nucleus. The upper laminae of cells are successively more and more flattened, and are incessantly transformed into the comparatively dry scales of the cuticle, while they are as constantly reproduced from the surface of the dermis.

In the white race the soft epidermic layer is colorless, and, like the cuticle, translucent, and hence it allows the color and vascularity of the dermis to be seen. In the negro, its cells, especially the deeper ones, are filled with brown or black pigmentary matter, which produces the characteristic color of the race. Smaller quantities of the same material give rise to the various shades of complexion of other races, of different individuals, and even different parts of the skin of the same person. The sun-burnt complexion is due to the development or increase of the same coloring matter; and in freckles it is accumulated in spots. As the soft epidermic layer is transformed into the cuticle, the pigmentary matter disappears from its cells.

THE SWEAT GLANDS.

The **Sweat or perspi'ratory glands**² exist almost everywhere in the skin, and number a million or more. They are yellowish-red, spheroidal bodies, averaging about one-sixth of a line in diameter, and are lodged in interspaces of the deep part of the dermis, usually surrounded by adipose tissue. Each gland consists of a tube convoluted into a ball, and afterwards ascending, as the **sweat duct**, in a slightly tortuous manner, to the exterior surface of the dermis. The tube is composed of an exterior fibrous layer, succeeded by one of basement membrane; and is lined with a pavement epithelium, consisting of polyhedral cells containing a nucleus, and granular contents mingled with some yellowish pigment particles.

From the sweat duct opening on the surface of the dermis a passage way conducts to the exterior of the epidermis. When the latter is thin, the passage is straight; but when thick, as in the palms and soles, it pursues a spiral course, and terminates in a funnel-shaped orifice. The apertures of the ducts are distinctly visible with a common pocket lens, in

¹ Rete mucosum; r. Malpighi; corpus, or stratum Malpighi; corpus mucosum; c. reticulare; reticulum cutaneum; r. mucosum; mesodermum; mucous web; tunica albida superficialis et profunda, et gemmula, et bourgeons sanguins.

² Glandulae sudoriparæ; g. miliaria; g. hydrophoræ; organa sudoripara; sudoriparous glands; diapnogenous apparatus; perspiratory organs; fontes sudoris.

a single row on the summits of the ridges of the palms and soles; but in other positions are not so readily distinguished.

A modification of the sweat glands constitutes the ceruminous glands, described in the account of the ear, and the **odoriferous glands** of the **axilla**.¹ These form a patch, an inch and a half or more in diameter, situated in the subcutaneous connective and adipose tissue of the hairy part of the armpit. They are largest near the centre of the patch, and gradually diminish toward the circumference, where they merge into the ordinary sweat glands. They are usually much better developed in the negro, in whom the largest reach the size of a small pea. They are of a dusky, yellowish-red color, and, like the sweat glands, are composed of a tube coiled into a ball, from which the tube continues as the duct to open on the exterior surface of the skin. The tube of the gland contains unstriated muscular fibres in its wall; and its cavity is filled with a finely granular matter mingled with brown or yellow pigment and fat particles. Besides an abundance of sweat, these glands yield a strongly odorous substance, which is somewhat peculiar in the different races.

Sweat² is a clear, watery liquid, with an acid reaction and a saline taste. It contains formic, butyric, and acetic acids, and a number of salts, of which the most abundant is chloride of sodium.

THE SEBACEOUS GLANDS.

The **Seba'ceous glands**³ of the skin are very numerous, and exist almost everywhere, except in the palms and soles. They are mostly associated with the hair follicles, being situated around them in groups from two to eight for each follicle, imbedded in the more superficial part of the dermis. Generally the largest glands are found with the smallest hair follicles, so that these appear of secondary importance, while the smallest glands exist in pairs in connection with the hairs of the scalp.

The largest sebaceous glands are those of the nose, concha of the ear, skin of the penis, the scrotum, labia, and areola surrounding the female nipple. The groups of glands connected with each hair follicle appear as rounded whitish bodies imbedded in the semitransparent skin, and measure from one-tenth to one-half a line or more in diameter.

¹ Glandulæ odoriferæ of Horner.

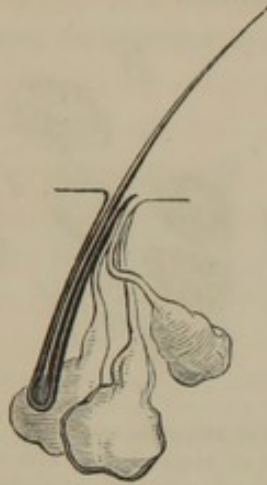² Sudor; perspiration; perspiratory fluid.

³ Glandulæ sebaceæ; g. sebiparæ; g.

sebiferæ; cryptæ sebaceæ; folliculi sebaceæ; sebiparous, or sebiferous glands; sebaceous follicles, or crypts; miliary glands; oil glands.

The sebaceous glands are simple or compound, being composed of one or more purse-shaped pouches, the ducts of which open into the

FIG. 382.

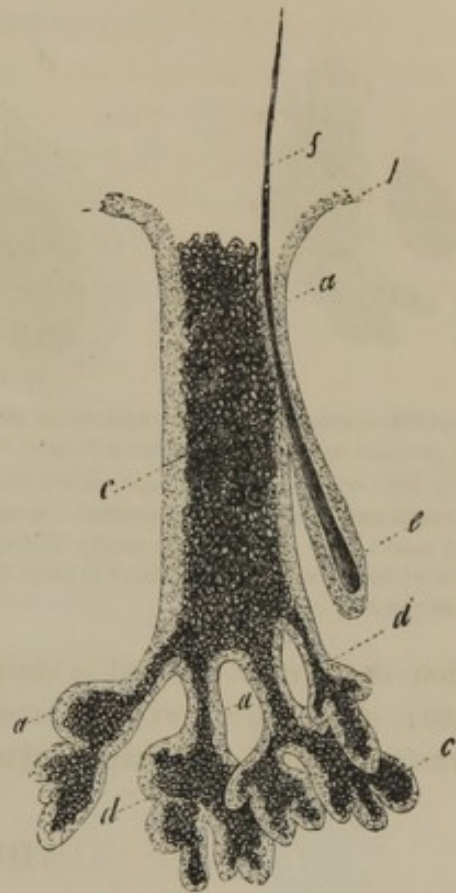


SEBACEOUS GLANDS OPENING INTO THE MOUTH OF A HAIR FOLLICLE, much magnified.

mouths of the hair follicles, or in the case of the largest glands, together with the latter they open on the surface of the skin. In structure the glands possess a delicate wall of fibrous tissue, defined by a basement membrane, and are lined with an epithelium consisting of polyhedral, nucleated cells with granular contents. The cavity of the glands is filled with **sebaceous matter**,¹ consisting of cells and oil globules. Of the cells, some contain finely granular matter mingled with oil drops, while others are distended with oil.

The sebaceous matter anoints the hairs with oil in their progress of growth from the skin, and also imbues the cuticle, by which it is rendered repellant of water. The greasiness of the surface of the skin, occasioned by this material, permits the ready adhesion of dust and dirt, and renders the employment of soaps necessary for easy removal of its excess. The too free use of alkaline washes, by depriving the cuticle of its oil, produces a dry and harsh feeling in the skin. The sebaceous matter often becomes inspissated and distends the glands, most frequently in the face, and especially on the nose; and at the mouths of the ducts it

FIG. 383.



A LARGE SEBACEOUS GLAND FROM THE NOSE, viewed by transmitted light, and highly magnified. *a*, epithelium of the gland; *b*, the same continuous with the epidermis; *c*, the sebaceous matter; *d*, subdivisions of the gland; *e*, a hair follicle; *f*, a hair.

¹ Sebum, or smegma cutaneum.

becomes incorporated with dirt. By pressure it is squeezed out, and from its assuming the form of the duct, is vulgarly taken for a worm, of

FIG. 384.

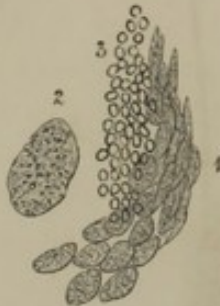

FIG. 385.

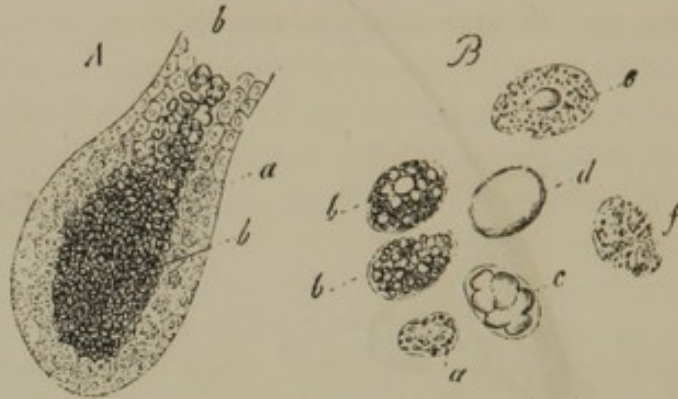

Fig. 384.—SEBACEOUS MATTER, FROM ONE OF THE SEBACEOUS GLANDS OF THE NOSE, magnified. 1, cells filled with granular matter; 2, one of the cells more highly magnified; 3, oil drops mingled with the cells.

Fig. 385.—STRUCTURE OF THE SEBACEOUS GLANDS. A, a simple sebaceous gland, or one of the divisions of a compound gland, highly magnified. *a*, epithelial cells; *b*, sebaceous matter. B, sebaceous cells, much more highly magnified. *a*, small cells from the epithelial layer; *b*, larger cells abounding in fat; *c*, cell in which the fat has accumulated in large drops; *d*, cell distended with fat; *e*, *f*, cells from which the fat has partially escaped.

which the dirt at the end is supposed to be the head. The sebaceous matter, nevertheless, even in most healthy individuals, contains a curious parasitic animal, the **pimple mite**.¹

THE HAIRS.

The **Hairs**² are solid, thread-like appendages of the skin, projecting from almost every part of its surface except the palms and soles. They are flexible, elastic, and shining, but vary in degree of development, fineness, color, form, and arrangement in different races, sexes, individuals, and parts of the body. From the long hairs of the head³ they exist of every gradation of size to such⁴ as are hardly visible.

The portion of a hair projecting from the skin is its **shaft** or **stem**⁵ terminated by the **point** or **end**; the portion inserted into the skin is the **root**,⁶ which begins in a club-like expansion, named the **bulb**.⁷

The hairs generally project obliquely from the skin, singly, or in groups of two, three, or more. They are regularly arranged in the different parts of the body, mostly in curving lines or whorls from particular points.

¹ *Acarus folliculorum*; *Demodex folliculorum*.

² *Pili*; the hair; *crinis*; pile; *thrix*.

³ *Capilli*.

⁴ *Lanugo*; down.

⁵ *Scapus*.

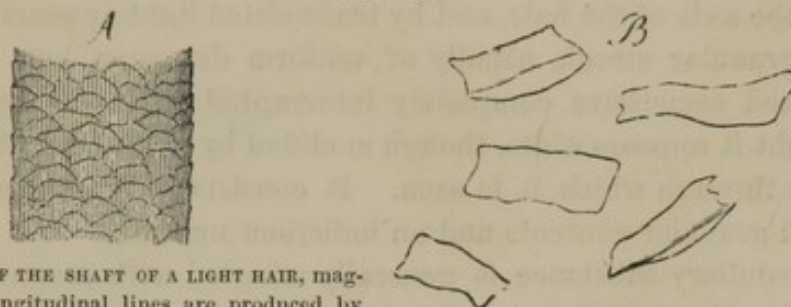
⁶ *Radix pili*.

⁷ *Bulbus pili*; button.

The fine silken hair of the head of the white race is cylindrical; the crisp, curling hair of the beard, other parts of the body, and the head of the negro, is more or less flattened cylindrical.

In structure the hairs consist of an exterior cuticle, a cortical substance, and an interior medullary substance.

FIG. 386.



A. PORTION OF THE SHAFT OF A LIGHT HAIR, magnified. The longitudinal lines are produced by the cortical substance; the transverse, undulating lines, by the cuticle. B. Isolated scales of the cuticle.

The **cuticle** of the hair consists of a single layer of thin, colorless, quadrilateral scales or completely flattened cells, which overlap like the shingles of a roof. The projecting edges of these scales are directed upward and outward along the shaft; and in a hair examined beneath the microscope are seen as irregularly undulating and intersecting transverse lines. As feebly as their edges appear to project, they nevertheless present an obstacle to the hair being moved in any other direction than with its root forward, when rubbed between two surfaces. It is upon a similar condition that the felting of the hair and wool of various animals depends.

The **cortical substance**¹ makes the chief bulk of the hair, and is that upon which the color mainly depends in different races and individuals. When sufficiently translucent, as in white or light-colored hairs, beneath the microscope it presents a longitudinally striated appearance. It is composed of layers of flexible fibres, into which it is not unfrequently found more or less split at the ends of hairs, as the result of drying and friction. The fibres consist of much elongated, fusiform cells containing a linear nucleus. The coloring matter is usually dif-

FIG. 387.



PORTION OF A HAIR FROM THE OUTER PART OF THE THIGH, magnified. 1, shaft of the hair covered with transverse markings indicating the projecting edges of the cuticular scales; 2, cortical substance at the end of the hair broken up into coarse fibres as the result of friction of the clothing.

¹ Cortex.

fused through the cortical substance, though it is also often accumulated in streaks or spots. With the loss of the coloring matter, generally occurring in the advance of age, the cortical substance becomes white.

The **medullary substance**¹ is frequently absent, especially in dark-colored hairs of the head, and in fine down-like hairs of the body. It occupies the axis of the hair, and by transmitted light appears as a dark, coarsely granular streak, usually of uniform diameter, but often contracted, and sometimes completely interrupted in its course. By reflected light it appears white, though modified by the color of the cortical substance through which it is seen. It consists of somewhat cuboidal cells, with granular contents and an indistinct nucleus.

The medullary substance is generally mingled with more or less air, in small bubbles, which penetrates from the ends of the hairs, and gives to these when white the characteristic silvery lustre.

The root of the hair is lodged in a flask-shaped receptacle of the skin called the **hair follicle**,² at the bottom of which is a papilla from which the hair grows. The hair follicles are imbedded in the dermis, or, in the case of the large hairs, extend into the subcutaneous connective and adipose tissue. They may be viewed as inflections of the skin, and the hair papilla at their bottom as a modified tactile papilla.

The wall of the hair follicle is composed of a fibrous layer defined by a basement membrane, and lined with an inflection³ of the epidermis. The cuticular portion⁴ of this inflection is remarkably modified from the corresponding layer on the free surface of the skin. It forms a comparatively thick, transparent, elastic membrane, composed of somewhat elongated non-nucleated cells, adhering to one another in such a manner as to assume the appearance of fenestrated membrane. The elastic cuticular layer merges into the softer epidermic layer beneath, and tightly clasps the root of the hair. It perhaps acts upon the latter as it is projected in its growth from the papilla, as a wire is acted upon when it is protruded through a draw-plate.

The **hair papilla**⁵ is ovoid, of soft consistence, and supplied with both capillary vessels and nerves. The hair bulb caps or incloses the papilla,

¹ Medulla.

² Folliculus pili.

³ Root sheath of the hair; vagina pili.

⁴ Inner root sheath of the hair. The softer cells beneath constitute the outer root sheath.

⁵ Papilla pili; pulpa, or blastema pili.

and in the extraction of a hair it is traction on the latter which gives rise to the pain.

The root of the hair is softer and thicker than the shaft, the character of which it assumes in its growth. The hair bulb is soft, translucent, and is continuous at the bottom of the hair papilla with the epidermic layer of the hair follicle. It is composed of soft, polyhedral nucleated cells, which exhibit a gradual and successive transition into the cuticle, cortical and medullary substances of the root above. By the

FIG. 388.

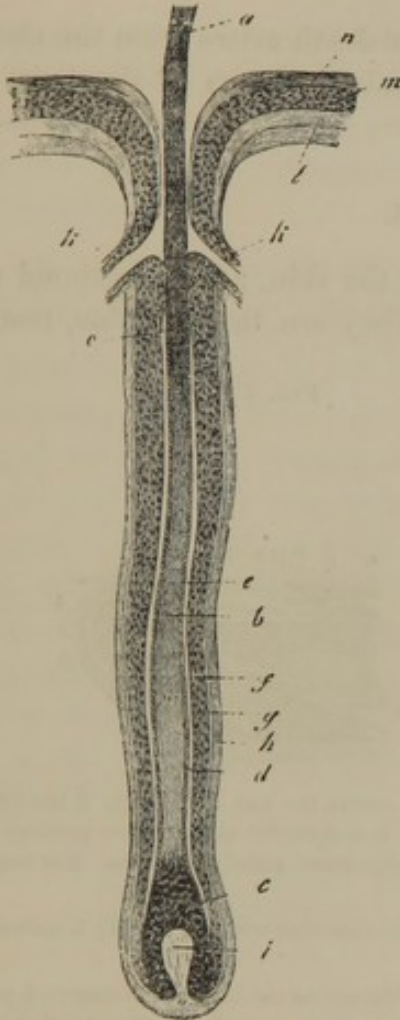


Fig. 388. ROOT OF A HAIR LODGED WITHIN ITS FOLLICLE, magnified. *a*, shaft of the hair; *b*, root; *c*, bulb; *d*, cuticle of the hair; *e, f*, epidermic lining of the follicle; *g*, basement membrane; *h*, fibrous layer of the wall of the hair follicle; *i*, hair papilla; *k*, mouths of two sebaceous glands; *l*, dermis; *m*, soft layer of the epidermis; *n*, cuticle of the epidermis.

FIG 389.

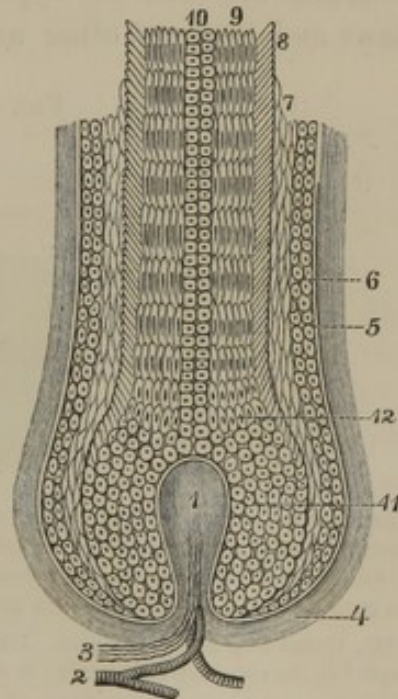


Fig. 389. DIAGRAM OF STRUCTURE OF THE ROOT OF A HAIR WITHIN ITS FOLLICLE. 1, hair papilla; 2, capillary vessel; 3, nerve fibres; 4, fibrous wall of the hair follicle; 5, basement membrane; 6, soft epidermic lining of the follicle; 7, its elastic cuticular layer; 8, cuticle of the hair; 9, cortical substance; 10, medullary substance; 11, bulb of the hair composed of soft polyhedral cells; 12, transition of the latter into the cortical substance, medullary substance, and cuticle of the hair.

transformation of the cells into the elements just mentioned, and the production of new cells from the papilla, the hair constantly grows in length.

Like the epidermis the hairs receive nutriment by imbibition—the liquids being transmitted from one cell element to another in gradually diminishing quantity throughout the length of the hair.

The hairs are not only renewed by constant growth, but in many instances, even in the healthy condition, but especially after diseases, they are cast off or shed, and new ones are produced. In such instances, likewise when the hairs are violently extracted, the new hairs are produced from the same hair follicles, but sometimes at least from new papillæ. Permanent baldness, so often occurring in the advance of age, arises from atrophy of the hair papillæ.

The apparent growth of the beard after death arises from the shrinking of the skin, which protrudes the remaining roots of the hairs the eighth of an inch or more.

THE NAILS.

The **Nails**¹ are corneous appendages of the skin, and correspond with the claws and hoofs of other animals. They are thin, flexible, translu-

FIG. 390.

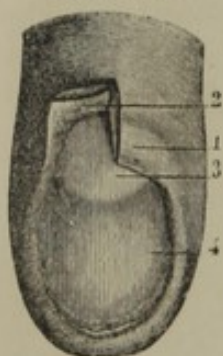


FIG. 391.

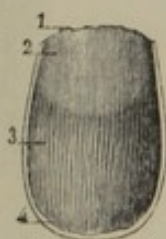


FIG. 392.

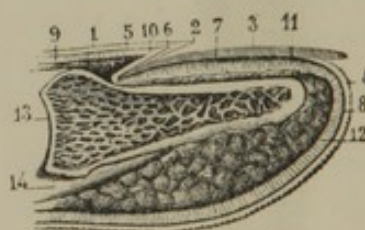


Fig. 390. MATRIX OF THE NAIL. 1, fold of the skin which covers the root of the nail; 2, the fold partially turned up to show the depth of the groove beneath; 3, 4, posterior and anterior portions of the matrix, the former the less vascular, and giving rise to the appearance called the lunula. The longitudinal lines indicate the ridges bordered with papillæ.

Fig. 391. UNDER SURFACE OF THE NAIL. 1, root; 2, part corresponding with the lunula; 3, grooved surface adapted to the ridges of the matrix; 4, free border.

Fig. 392. VERTICAL SECTION OF THE END OF A FINGER. 1, epidermis on the back of the finger; 2, point at which it is reflected to become continuous with the nail; 3, the nail; 4, epidermis at the end of the finger; 5, 6, 7, 8, surface of the dermis corresponding with the position of the soft epidermic layer; 9, 10, 11, 12, dermis; 13, last phalanx; 14, flexor tendon.

cent, quadrilateral plates continuous with the epidermis, and resting on a depressed surface of the dermis, called the **matrix** or **bed**.

The exposed portion of the nail, named its **body**, is terminated anteriorly by the **free border**. The posterior third or fourth of the nail, named its **root**, is lodged in a deep groove² of the matrix, and the lateral borders are received into shallow grooves. From the body of the nail the root gradually thins away to a sharp edge, and the lateral borders more abruptly thin out.

¹ Ungues.

² Vallecula unguis; nail follicle.

The translucency of the nail permits the redness of the matrix to be seen, which color is due to vascularity of the part. The less degree of vascularity of the matrix at the root, defined by a semicircular line, gives rise to the whitish spot called the *lu'nula*.¹ The free surface of the body of the nail is shining and faintly striated longitudinally; its under surface is finely grooved in the same direction.

The matrix of the nail, constituted by a highly vascular portion of the dermis, is covered with fine longitudinal ridges beset with a multitude of minute papillæ. The ridges and papillæ fit into the grooves of the under surface of the nail, and correspond with the tactile papillæ in other positions.

By maceration the nails become detached continuously with the epidermis from the dermis. They consist of a thick horny layer attached by a delicate soft layer to the dermis.

The **horny layer** answers to the cuticle of the epidermis, and is composed of numerous intimately associated laminæ of flattened nucleated cells or scales, which can only be distinguished microscopically after treatment with certain chemical reagents, as the alkalies.

The **soft layer**² of the nails corresponds with that of the epidermis, and like it is composed of delicate, polyhedral nucleated cells. These are incessantly transformed into the scales of the horny layer, and are renewed from the surface of the dermis. By the constant addition of cells at the root, the nail grows in length; by addition beneath, they grow in thickness.

¹ Semilunula; arcus; albedo unguium.

² Stratum Malpighi; soft mucous layer; stratum mucosum.

INDEX.

ABDOMEN	211	Angles of the eye.....	595
cavity of.....	298	Ankle.....	152, 153, 238
Abdominal parietes	211	Ankle bone	153
ring, external	213, 220	joint.....	163
internal	219	Antihelix	613
walls.....	211	Antitragus.....	613
Abduction	47	Anus.....	318
Abductor of great toe.....	257	internal sphincter of.....	319
of little finger.....	237	pouches of	319
of little toe	258	Anvil	619
of thumb	236	Aorta	351
Accessory flexor of the foot.....	256	abdominal.....	383
parotid gland	279	thoracic	381
Acetabulum.....	124	Aortic orifice.....	222
Acid, butyric.....	29	Aperture of the larynx.....	445
carbonic.....	29	Aponeuroses	180
chloro-hydric.....	28	Apparatus, lachrymal.....	598
formic.....	29	Appendages of the eye.....	594
lactic.....	29	Aqueous humor.....	610
Acini of thymus body.....	457	Arachnoid membrane.....	539
Acromion.....	132	Arch of aorta.....	351
Adduction	47	deep palmar.....	378
Adductor of great toe	257	plantar.....	404
of little finger.....	237	superficial palmar.....	380
of thumb.....	236	zygomatic.....	88, 89
great.....	250	Arches, palatine.....	276
long.....	249	Arciform fibres.....	531
short.....	250	Arcus senilis.....	604
Adam's apple.....	193, 440	Areola.....	500
Adipose tissue.....	176	Areolar tissue.....	170
Afferent vessels.....	429	Arm	223
Air-cells.....	452	Arm bone.....	132
Alar folds.....	162	Armpit.....	223
Albumen.....	26	Arteries.....	332, 351
Albuminose	26	anterior intercostal.....	371
Albugineous tunic of testis.....	470	articular.....	400
Alimentary apparatus.....	273	bronchial	382, 453
canal	273	calcanean.....	403
Allantois	463	cerebellar, inferior.....	368
Alveolar border.....	77, 84	common iliac.....	390
Alveoli.....	77	digital of superficial palmar	
Ammonia, urate of.....	29	arch	381
Ampulla.....	623	of plantar arch	404
Anatomy	17	external pudic.....	396
Anastomoses	333	helicine.....	478
Angle, facial	88	ileal.....	387

- | | | | |
|-----------------------------------|----------|-----------------------------------|----------|
| Arteries, inferior articular..... | 400 | Artery, interosseous..... | 379 |
| intercostal..... | 382 | communicating..... | 380 |
| anterior branches of..... | 383 | coronary..... | 384 |
| dorsal branches of..... | 383 | left..... | 353 |
| interosseous, of palmar arch... | 378 | right..... | 353 |
| jejunal..... | 387 | cystic..... | 385 |
| lateral sacral..... | 392 | deferent..... | 393, 473 |
| lumbar..... | 389 | dental, of inferior maxillary ... | 362 |
| anterior branches of..... | 389 | descending palatine..... | 363 |
| posterior branches of..... | 389 | cervical..... | 359 |
| spinal branches of..... | 389 | dorsal lingual..... | 356 |
| mediastinal..... | 371, 382 | dorsal, of clitoris..... | 395 |
| œsophageal..... | 382 | of great toe..... | 402 |
| ovarian..... | 390 | of penis..... | 395 |
| pancreatic..... | 386 | pedal..... | 401 |
| perforating, of internal mam- | | scapular..... | 374 |
| mary..... | 371 | duodenal..... | 387 |
| of plantar arch..... | 404 | epigastric..... | 396 |
| of profound femoral..... | 397 | external carotid..... | 355 |
| pericardiac..... | 382 | iliac..... | 395 |
| phrenic..... | 389 | malleolar..... | 401 |
| renal..... | 390 | plantar..... | 404 |
| short gastric..... | 386 | facial..... | 357, 358 |
| spermatic..... | 390 | femoral..... | 396 |
| splenic branches of splenic.... | 386 | frontal..... | 366 |
| superior articular..... | 400 | gastro-epiploic, right..... | 385 |
| supra-renal..... | 390 | duodenal..... | 385 |
| tarsal..... | 401 | gluteal..... | 393 |
| vesical..... | 393 | great meningeal..... | 361 |
| Artery, angular..... | 358 | hæmorrhoidal, inferior..... | 394 |
| acromial thoracic..... | 373 | middle..... | 394 |
| anastomotic..... | 376, 398 | superior..... | 388 |
| anterior auricular..... | 360 | hepatic..... | 385 |
| carpal..... | 377, 380 | left..... | 386 |
| cerebral..... | 366 | right..... | 385 |
| ciliary..... | 365 | hyoid branch of superior thyroid | 356 |
| circumflex..... | 374 | ilio-colic..... | 387 |
| communicating..... | 366 | ilio-lumbar..... | 392 |
| dental, of infra-orbital..... | 362 | inferior coronary..... | 358 |
| ethmoidal..... | 365 | maxillary..... | 361 |
| interosseous..... | 379 | mesenteric..... | 388 |
| nasal..... | 366 | palatine..... | 358 |
| spinal..... | 368 | profound..... | 375 |
| temporal..... | 360 | thyroid..... | 370 |
| tibial..... | 400, 401 | vesical..... | 393 |
| ascending cervical..... | 371 | infra-orbital..... | 362 |
| axillary..... | 372 | innominate..... | 353 |
| basilar..... | 368 | ischiatric..... | 395 |
| brachial..... | 374, 376 | internal auditory..... | 369 |
| bulbo-urethral..... | 394 | carotid..... | 363 |
| cavernous..... | 394 | circumflex..... | 398 |
| central retinal..... | 365 | iliac..... | 391 |
| choroid..... | 366 | malleolar..... | 401 |
| ciliary arteries..... | 365 | mammary..... | 371 |
| long..... | 365 | maxillary..... | 361, 362 |
| short..... | 365 | plantar..... | 403 |
| circumflex iliac..... | 396 | pudic..... | 393 |
| colic, left..... | 388 | interosseous recurrent..... | 380 |
| middle..... | 387 | lachrymal..... | 365 |
| right..... | 387 | laryngeal..... | 356 |
| common carotid, left..... | 354 | lateral nasal..... | 358 |
| right..... | 354 | lingual..... | 356 |

- | | | | |
|-----------------------------------|----------|--------------------------------------|----------|
| Artery, long thoracic..... | 373 | Artery, sub-maxillary branches of | |
| medullary | 376 | facial..... | 358 |
| nutritious | 403 | submental..... | 358 |
| meningeal..... | 268 | subscapular..... | 374 |
| branches of anterior eth- | | superficial circumflex..... | 397 |
| moidal..... | 366 | epigastric..... | 397 |
| branches of occipital..... | 359 | superior cerebellar..... | 369 |
| metacarpal..... | 378 | cervical | 370 |
| metatarsal..... | 402 | coronary | 358 |
| middle articular of popliteal.... | 400 | epigastric..... | 372 |
| cerebral | 366 | intercostal..... | 372 |
| sacral..... | 389 | maxillary..... | 362 |
| temporal..... | 360 | mesenteric..... | 386 |
| muscular branches of superior | | phrenic..... | 371 |
| thyroid..... | 356 | profound | 375 |
| musculo-phrenic..... | 372 | thoracic | 373 |
| nasal | 366 | thyroid..... | 355 |
| obturator..... | 392 | vesical | 393 |
| occipital..... | 359 | stylo-mastoid..... | 359 |
| ophthalmic..... | 364, 365 | supra-orbital | 360, 365 |
| pancreatico-duodenal..... | 385 | supra-scapular | 370 |
| palpebral..... | 366 | temporal..... | 360 |
| parotid branches of external | | tonsillar..... | 358 |
| carotid..... | 359 | transverse facial..... | 360 |
| perineal..... | 394 | perineal..... | 394 |
| peroneal anterior..... | 403 | tympanic..... | 361 |
| posterior..... | 403 | ulnar, and ulnar recurrent..... | 379 |
| pharyngeal | 356 | uterine..... | 395 |
| popliteal | 399, 400 | vaginal..... | 395 |
| posterior auricular..... | 359 | vertebral..... | 367, 368 |
| carpal..... | 378, 380 | volar..... | 377 |
| cerebellar | 369 | Articular borders | 34 |
| circumflex | 374 | cartilage..... | 48, 174 |
| communicating | 366 | extremities..... | 34 |
| dental, of superior maxil- | | process..... | 34 |
| lary | 362 | surfaces | 34 |
| ethmoidal..... | 365 | Articulation, carpo-metacarpal | 147 |
| interosseous | 380 | crico-arytenoid..... | 443 |
| scapular..... | 370 | crico-thyroid..... | 442 |
| temporal. | 360 | inferior radio-ulnar | 145 |
| tibial..... | 402, 403 | tibio-fibular..... | 163 |
| principal, of the thumb..... | 378 | intercarpal..... | 147 |
| profound cervical..... | 372 | middle radio-ulnar..... | 145 |
| femoral..... | 397 | radio-carpal..... | 146 |
| pulmonary..... | 453 | scapulo clavicular..... | 142 |
| left | 405 | sterno-clavicular..... | 141 |
| right | 405 | superior radio-ulnar | 145 |
| pyloric..... | 385 | tibio fibular..... | 163 |
| radial..... | 376, 377 | temporo-maxillary. | 86 |
| recurrent..... | 377 | Articulations..... | 46 |
| index..... | 378 | costo-sternal | 119 |
| ranine..... | 356 | costo-vertebral | 118 |
| recurrent tibial..... | 401 | immovable.... | 46 |
| sigmoid..... | 388 | intertarsal | 164 |
| small meningeal..... | 361 | metacarpo-phalangeal..... | 147 |
| spheno-palatine.... | 363 | metatarso-phalangeal..... | 166 |
| spinal..... | 368 | movable | 46 |
| branches of vertebral | 368 | of the atlas..... | 111 |
| splenic..... | 386 | axis..... | 111 |
| subclavian, left..... | 367 | hip bones..... | 125 |
| right | 367 | lower extremities..... | 158 |
| sublingual..... | 356 | occipital bone..... | 111 |

- | | | | |
|---|----------|--------------------------------------|-----|
| Articulations of the ribs..... | 118 | Body, striated | 523 |
| of the sternum | 118 | thymus..... | 456 |
| upper extremities..... | 141 | thyroid..... | 455 |
| vertebral column..... | 107 | Bone, occipital | 50 |
| Arytenoid cartilages..... | 441 | arm..... | 132 |
| Auditory meatus, external..... | 63 | canaliculi of..... | 41 |
| internal..... | 63 | capitate | 138 |
| process | 63, 64 | collar | 129 |
| Axis..... | 101 | cuboid | 154 |
| cerebro-spinal..... | 503, 513 | cuneiform..... | 137 |
| coeliac..... | 384 | ethmoid | 56 |
| fibre | 505 | frontal | 58 |
| of the pelvis..... | 127 | hip | 121 |
| Aryteno-epiglottic folds..... | 445 | hyoid | 96 |
| Astragalus..... | 153 | inferior maxillary..... | 83 |
| Asperous ridge..... | 148 | innominate..... | 121 |
| Atlas..... | 100 | lachrymal..... | 80 |
| Auricle of the ear..... | 612 | lacunæ of..... | 41 |
| of the heart..... | 343 | lunar..... | 137 |
| left..... | 344 | malar | 83 |
| right..... | 343 | nasal | 81 |
| Auricular appendage | 343, 344 | palate..... | 78 |
| Auriculo-ventricular orifice, left..... | 344, 347 | parietal..... | 60 |
| right | 344, 345 | pisiform..... | 137 |
| Axilla..... | 223 | scaphoid, of carpus..... | 137 |
| | | scaphoid, of tarsus..... | 154 |
| BASILAR process | 51 | shin..... | 150 |
| Base of the skull | 90 | sphenoid..... | 52 |
| Basement membrane..... | 262 | superior maxillary..... | 76 |
| Band, semicircular.. .. | 524 | temporal..... | 61 |
| Back | 200, 203 | thigh..... | 148 |
| of hand.. .. | 223 | trapezial..... | 137 |
| Ball of the thumb..... | 222 | trapezoid..... | 137 |
| Band-like ligaments..... | 48 | turbinated..... | 81 |
| Belly..... | 211 | unciform | 138 |
| cavity of..... | 298 | vascular canals of..... | 40 |
| muscles of | 178 | Bones, articular extremities of..... | 34 |
| Bile ducts..... | 324 | articular process of... .. | 34 |
| Biliary duct, common..... | 328 | body of..... | 34 |
| Biliverdin..... | 29 | borders of..... | 34 |
| Bladder, ligaments of..... | 463 | canal of..... | 34 |
| urinary..... | 300, 462 | canaliculi of..... | 41 |
| Blood | 338 | carpal..... | 136 |
| corpuscles | 339 | compact substance of..... | 36 |
| colorless | 340 | condyles of..... | 34 |
| red | 339 | crest of..... | 34 |
| liquor..... | 340 | cuneiform, of tarsus..... | 155 |
| Bodies, geniculate..... | 524 | diaphysis of..... | 42 |
| nerve capsular..... | 510 | distal extremity of..... | 34 |
| olivary..... | 530 | endosteum of..... | 39 |
| Pacchionian | 536 | epiphyses of..... | 42 |
| pyramidal | 530 | foramen of..... | 34 |
| quadrigeminal | 525 | fossa of..... | 34 |
| restiform..... | 531 | head of..... | 34 |
| striated..... | 523 | irregular | 34 |
| supra-renal..... | 465 | lacunæ of..... | 41 |
| Body, ciliary..... | 605 | line of..... | 34 |
| dentated..... | 528, 531 | long | 34 |
| of bone..... | 34 | marrow of..... | 36 |
| of teeth | 285 | meatus of..... | 34 |
| quadrigeminal..... | 525 | medulla of..... | 36 |
| pituitary | 518 | medullary cavity of..... | 36 |

- Bones, metacarpal..... 138
 metatarsal..... 156
 neck of..... 34
 periosteum of..... 39
 process of..... 34
 proximal extremity of..... 34
 ridge of..... 34
 sesamoid..... 140, 157
 shaft of..... 34
 short..... 34
 sinus of..... 34
 spinous process of..... 34
 spongy substance of..... 36
 surface of..... 34
 tabular..... 34
 tubercle of..... 34
 tuberosity of..... 34
 vascular canals of..... 40
 Brain..... 503, 513, 514
 gray substance of..... 503, 505
 white substance of..... 503, 504
 ventricles of..... 521, 523, 531
 Breasts..... 499
 Bromine..... 21
 Bronchi..... 448
 Bronchial arteries..... 453
 tubes..... 453
 veins..... 453
 Bronchus, left..... 449
 right..... 448
 Brunner's glands..... 312
 Bulb, olfactory..... 540
 Bundles of muscles..... 178
 Bursæ, synovial..... 183, 265
 Buttocks..... 238
 Butyryn..... 27

 CÆCUM..... 315
 Calcaneum..... 154
 Calcium..... 21, 25
 Calyces..... 461
 Canal, alimentary..... 273
 anterior dental..... 77
 carotid..... 65
 infra-orbital..... 77
 inguinal..... 219
 lachrymal..... 599
 naso-palatine..... 78
 posterior dental..... 77
 posterior palatine..... 79
 pterygoid..... 56
 pterygo-palatine..... 56, 80
 sacral..... 105
 semicircular..... 623
 spinal..... 114
 Canals, semicircular..... 622, 623
 vascular of bone..... 40
 Canine teeth..... 287
 Capillaries..... 337
 Capitate papillæ..... 282
 Capsular ligaments..... 48
 Capsule of the lens..... 611

 Carbon..... 21, 25
 Carbonate of lime..... 28
 of magnesia..... 28
 of soda..... 28
 Carbonic acid..... 29
 Cardiac orifice of stomach..... 305
 Carneous columns..... 345
 Carotid canal..... 65
 Carpal bones..... 136
 Carpus..... 136, 223
 Cartilage..... 171
 articular..... 48, 174
 ensiform..... 117
 Cartilages, costal..... 114, 116
 of the larynx..... 440
 of the nose..... 589
 palpebral..... 596
 permanent..... 172
 temporary..... 172
 Cartilaginous rings of bronchi..... 449
 Caruncle, lachrymal..... 598
 Caruncles, myrtiform..... 490
 Casein..... 26
 Cava, inferior..... 420
 superior..... 406
 Cavernous bodies..... 476
 of clitoris..... 493
 of penis..... 476
 Cavities, nasal..... 591
 Cavity of the uterus..... 482
 Cell, hepatic..... 326
 organic..... 22
 Cells, spermatic..... 472
 Cellular layer of membranes..... 259
 Cement of teeth..... 289, 291
 Centres of ossification..... 42
 Cerebellar falx..... 538
 Cerebellum..... 526
 cortical substance of..... 527
 medullary substance of..... 527
 Cerebral falx..... 538
 Cerebro-spinal axis..... 503, 513
 liquid..... 539
 Cerebrum..... 515
 convolutions of..... 515, 516
 cortical substance of..... 516
 crura of..... 516
 hemispheres of..... 515
 lobes of..... 515
 medullary substance of..... 516
 Cerumen..... 616
 Cervical vertebræ..... 99
 triangles..... 199
 Chambers of the eye..... 610
 Cheek bone..... 83
 Cheeks..... 275
 Chest..... 119, 200
 Chlorine..... 21, 25
 Chloride of sodium..... 28
 of potassium..... 28
 Chloro-hydric acid..... 28
 Cholesterine..... 29

- | | | | |
|-----------------------------------|----------|-----------------------------------|---------------|
| Chondrigen..... | 26 | Corpuscles, colostrum..... | 502 |
| Choroid coat..... | 604 | lymph..... | 430 |
| plexuses..... | 523, 536 | mucous..... | 267 |
| Choroidea..... | 604 | of blood..... | 339 |
| Chyle..... | 430 | Pacinian..... | 510 |
| receptacle of..... | 431 | splenic..... | 320 |
| Ciliary body..... | 605 | tactile..... | 511, 630 |
| motion..... | 261 | Cortical layer of the supra-renal | |
| muscle..... | 605 | bodies..... | 466 |
| processes..... | 605 | substance of cerebellum..... | 527 |
| zone..... | 612 | of cerebrum..... | 516 |
| Circle of Willis..... | 369 | of hair..... | 637 |
| Circumduction..... | 47 | of the kidneys..... | 459 |
| Circumvallate papillæ..... | 282 | Costal cartilages..... | 116 |
| Clavicle..... | 129 | Cranial fossa, anterior..... | 67 |
| Clinoid processes..... | 53 | middle..... | 68 |
| Clitoris..... | 492 | posterior..... | 68 |
| Clot of blood..... | 340 | Cranium..... | 67 |
| Coagulum..... | 340 | vault of..... | 69 |
| Coats of the arteries..... | 333 | Cream..... | 502 |
| of the veins..... | 336 | Creatin..... | 29 |
| Coccyx..... | 105 | Creatinin..... | 29 |
| Cochlea..... | 624 | Crest of bone..... | 34 |
| axis of..... | 625 | ethmoidal..... | 56 |
| Cœliac axis..... | 384 | frontal..... | 59 |
| Collagen..... | 26 | occipital..... | 52 |
| Collar bone..... | 129 | sphenoidal..... | 54 |
| Colon..... | 315 | urethral..... | 479 |
| Colostrum..... | 502 | Cribriform fascia..... | 239, 241, 243 |
| corpuscles..... | 502 | plate of ethmoid bone..... | 57 |
| Column, vertebral..... | 97, 113 | spot, inferior..... | 623 |
| Commissure..... | 514 | middle..... | 622 |
| optic..... | 518 | superior..... | 622 |
| great cerebral..... | 519 | Cricoid cartilage..... | 441 |
| Commissures of brain and spinal | | Cross, occipital..... | 52 |
| cord..... | 514 | Crown of head..... | 184 |
| of mouth..... | 274 | of teeth..... | 285 |
| of the third ventricle..... | 526 | Crus of diaphragm, left..... | 222 |
| of vulva..... | 492 | right..... | 222 |
| Companion veins..... | 335 | Crura of cerebellum..... | 528 |
| Concha..... | 613 | of cerebrum..... | 516 |
| Condyles..... | 34 | of diaphragm..... | 222 |
| occipital..... | 51 | of fornix..... | 521 |
| of femur..... | 149 | Crystalline..... | 27 |
| of humerus..... | 133 | lens..... | 610 |
| of inferior maxillary bone..... | 85 | Cuticle..... | 632 |
| Condylloid foramen..... | 51 | of hair..... | 637 |
| ridges of humerus..... | 134 | Cystic duct..... | 328 |
| Confluence of the sinuses..... | 409 | DARTOS..... | 468 |
| Conical papillæ..... | 282 | Dehiscence of ovaries..... | 486 |
| Conjoined tendon..... | 215 | Dental canals, anterior..... | 77 |
| Conjunctiva..... | 597 | posterior..... | 77 |
| Connective tissue..... | 170 | groove..... | 292, 293 |
| Contraction of the heart..... | 349 | ligament..... | 286 |
| Convolutions of the cerebrum..... | 515, 516 | pulp..... | 291, 292 |
| Coracoid foramen..... | 130 | sacs..... | 292 |
| ligament..... | 130 | Dentated band..... | 522 |
| notch..... | 130 | body..... | 528 |
| Cornea..... | 603 | Dentinal tubules..... | 290 |
| Corpus callosum..... | 519 | Dentine..... | 289 |
| luteum..... | 487 | Dermis..... | 629 |
| striatum..... | 523 | | |

Descriptive anatomy.....	17	Erectile tissue.....	476
Diaphragm.....	221	Ergot.....	523
Diaphysis of bones.....	42	Eruption of temporary teeth.....	293
Dilatation of heart.....	349	permanent teeth.....	294
Disks, intervertebral.....	107	Ethmoidal crest.....	56
Dorsal vertebræ.....	102	fissure.....	59
Drum of the ear.....	616	gutters.....	57
Duct, common biliary.....	328	sinuses.....	57
cystic.....	328	wings.....	56
hepatic.....	324, 328	Ethmoid bone.....	56
lachrymo-nasal.....	91, 600	Eustachian tube.....	65, 621
lactiferous.....	501	valve.....	344
of glands.....	269	Excretion.....	267
of Müller.....	489	Extremities, lower.....	238
pancreatic.....	320	upper.....	223
parotid.....	279	Eye.....	594
right lymphatic.....	430, 432	Eyeball.....	594, 600
spermatic.....	472	Eyebrow.....	595
submaxillary.....	279	Eyelashes.....	597
thoracic.....	430, 431	Eyelids.....	595
Ducts, ejaculatory.....	474	Eye teeth.....	287
Duodenal glands.....	312	FACE.....	87
Duodenum.....	309	Facial angle.....	88
Dura mater.....	537	Falciform process.....	240, 243
EAR.....	612	Fallopian canal.....	63
external.....	612	tube.....	488
internal.....	621	False vocal cords.....	447
ligaments of.....	613, 619	Falx, cerebellar.....	538
middle.....	616	cerebral.....	538
muscles of.....	614, 620	Fang of tooth.....	285
small bones of.....	618, 619	Fascia.....	182
wax.....	616	cervical.....	194
Efferent lymphatic vessels.....	429	cribriform.....	239, 241
Egg.....	486	crural.....	239, 241
Ejaculatory ducts.....	474	deep.....	224, 239
Elastic tissue.....	175	perineal.....	497
Elbow joint.....	144	temporal.....	185
Eminence, nasal.....	58	femoral.....	239
parietal.....	60	ischio-rectal.....	497
pyramidal.....	622	lata.....	239
Eminences, mammillary.....	518	lumbar.....	218
Enamel.....	285, 289, 290	of the foot.....	239
organ.....	293	palmar.....	225
Endocardium.....	347	pectineal.....	240, 243
Endolymph.....	623	pelvic.....	496
Endosteum.....	39	plantar.....	242
Ependyma.....	537	recto-vesical.....	497
Epidermis.....	259, 631	sartorial.....	240, 243
Epigastric fold.....	220	spermatic.....	469
region.....	299	superficial.....	212, 224, 238
Epiglottis.....	441	superficial perineal.....	497
Epiphyses of bones.....	42	superficial temporal.....	185
Epiploic appendages.....	317	transverse.....	216, 218
Epithelium.....	259	Fasciculi of muscular fibres.....	178
ciliated.....	261	Fat tissue.....	176
columnar.....	260	Fauces.....	276
irregular.....	260	Femoral arch.....	214, 243
pavement.....	260	hernia.....	243, 244
polyhedral.....	260	ring.....	243
spheroidal.....	260	Femur.....	148
squamous.....	260	Fenestrated membranes.....	334

- | | | | |
|-----------------------------------|---------------|-----------------------------------|--------------|
| Fibre, muscular..... | 178 | Foramen, quadrate..... | 223 |
| Fibres, striated muscular..... | 181 | rotund..... | 56 |
| unstriated muscular..... | 271 | sphenoidal..... | 55 |
| Fibrils, muscular..... | 181 | spheno-palatine..... | 80 |
| Fibro-cartilage..... | 173 | spheno-maxillary..... | 89 |
| interarticular..... | 86, 142 | spinous..... | 56 |
| semilunar..... | 160 | spinal..... | 98 |
| Fibro-serous membranes..... | 264 | stylo-mastoid..... | 64 |
| Fibrous tissue..... | 167 | supra-orbital..... | 58 |
| Fibula..... | 152 | Foramina, inter-vertebral..... | 98 |
| Filaments, homogeneous..... | 30 | great sciatic..... | 126 |
| Fimbriated extremity of Fallopian | | sacral..... | 105 |
| tube..... | 488 | small sciatic..... | 126 |
| body..... | 522 | Forearm..... | 223 |
| Fingers..... | 139 | Fornix..... | 521 |
| Fissure of the anus..... | 238 | Fossa of bone..... | 34 |
| ethmoidal..... | 59 | glenoid..... | 62 |
| glenoid..... | 62 | hemielliptical..... | 622 |
| great longitudinal..... | 515 | hemispherical..... | 622 |
| longitudinal, of liver..... | 323 | infra-clavicular..... | 200 |
| oral..... | 274 | infra-spinous..... | 130 |
| transverse, of liver..... | 323 | intercondyloid..... | 149 |
| of the vulva..... | 492 | ischio-rectal..... | 497 |
| Flesh..... | 178 | jugular..... | 64, 193, 199 |
| Flexion..... | 47 | navicular..... | 479 |
| Flexure, sigmoid..... | 315, 316 | pterygo-maxillary..... | 89 |
| Fluoride of calcium..... | 28 | spheno-maxillary..... | 89 |
| Fluorine..... | 21 | submaxillary..... | 199 |
| Fold, alar..... | 162 | subscapular..... | 130 |
| aryteno-epiglottic..... | 445 | supra-clavicular..... | 193, 199 |
| axillary..... | 223 | supra-spinous..... | 130 |
| epigastric..... | 220 | temporal..... | 88 |
| glosso-epiglottic..... | 445 | trochanteric..... | 148 |
| recto-uterine..... | 304, 484 | Fossæ, cranial, anterior..... | 67 |
| recto-vesical..... | 304, 463 | middle..... | 68 |
| semilunar..... | 598 | posterior..... | 68 |
| utero-vesical..... | 463 | inguinal, internal..... | 220, 304 |
| vesico-uterine..... | 304, 463, 484 | external..... | 220, 304 |
| Follicular glands..... | 269 | nasal..... | 92 |
| Fontanel, anterior..... | 74 | Fourchette..... | 492 |
| lateral..... | 75 | Fræna, glosso-epiglottic..... | 280 |
| posterior..... | 75 | Frænum, inferior labial..... | 275 |
| Fontanels..... | 74 | lingual..... | 280 |
| Foot..... | 148, 157 | preputial..... | 475 |
| arch of..... | 157 | superior labial..... | 275 |
| hollow of..... | 157 | Fringes, synovial..... | 49, 265 |
| sole of..... | 157 | Frontal bone..... | 58 |
| Foramen, of bone..... | 34 | Front teeth..... | 286 |
| anterior ethmoidal..... | 92 | Fundus, of gall-bladder..... | 328 |
| anterior palatine..... | 78, 90 | of urinary bladder..... | 463 |
| condyloid..... | 51 | of uterus..... | 482 |
| coracoid..... | 130 | Furrow, naso-labial..... | 184 |
| infra-orbital..... | 77 | | |
| jugular..... | 69 | GALL-BLADDER..... | 328 |
| lacerated..... | 68 | Ganglia..... | 512 |
| obturator..... | 124 | Gangliated cord..... | 582 |
| of Winslow..... | 302 | Gangliform enlargement of the fa- | |
| optic..... | 55 | cial nerve..... | 552 |
| oval, of sphenoid bone..... | 56 | Gangliform plexus..... | 555 |
| of heart..... | 344 | Ganglion, inferior cervical..... | 584 |
| posterior ethmoidal..... | 92 | jugular..... | 555 |
| posterior palatine..... | 90 | middle cervical..... | 584 |

Ganglion, ophthalmic.....	544	Glans of the penis.....	475
otic.....	550	of the clitoris.....	493
petrous.....	554	Glenoid cavity.....	131
semilunar, of solar plexus.....	586	fissure.....	62
semilunar, of trifacial.....	543	fossa.....	62
spheno-palatine.....	546	tubercle.....	62
submaxillary.....	550	Globulin.....	27
superior cervical.....	583	Glomerule, renal.....	460
Ganglionic system of nerves.....	512	Glosso-epiglottic fræna.....	280
Gastric juice.....	309	folds.....	445
General anatomy.....	17	Glottis.....	447
Germinal eminence.....	486	Glucose.....	28
spot.....	487	Glycogen.....	27
vesicle.....	487	Grape sugar.....	28
Gimbernat's ligament.....	215, 243	Gray substance.....	505
Glabella.....	183	Grinders.....	288
Gland.....	267	Gristle.....	171
mammary.....	500	Groin.....	212, 238
parotid.....	278	Groove, bicipital.....	133
pineal.....	526	dental.....	292, 293
prostate.....	480	digastric.....	62
sublingual.....	279	labial.....	184
submaxillary.....	279	labio-mental.....	184
Glands, agminated.....	312, 313	Gubernaculum of testicle.....	469
Bartholine's.....	494	Gullet.....	297
bronchial.....	436	Gums.....	273
Brunner's.....	312	Gutters, ethmoidal.....	57
ceruminous.....	616	Guttural region.....	90
coeliac.....	439		
convoluted.....	270	HAIRS.....	636
Cowper's.....	481	Ham.....	251
deep inguinal.....	437	strings.....	251
duodenal.....	312	Hand.....	140
follicular.....	269	Handle of sternum.....	117
gastric.....	308	Hard palate.....	275
iliac, external.....	437	Head.....	183
internal.....	437	of bone.....	34
intercostal.....	436	of muscle.....	179
lachrymal.....	598	Heart.....	341
lingual.....	283	Heel.....	238
lumbar.....	438	Helicine arteries.....	478
lymphatic.....	428, 429	Helix.....	613
mediastinal, anterior.....	436	Hemispheres of the cerebellum.....	527
posterior.....	436	of the cerebrum.....	515
mesenteric.....	438	Hepatic cells.....	326
mesocolic.....	438	duct.....	324, 328
odoriferous.....	634	substance.....	324
palatine.....	275	Hernia.....	220
palpebral.....	596	femoral.....	243, 244
perspiratory.....	633	inguinal, direct.....	221
Peyer's.....	313	oblique.....	220
popliteal.....	437	Hernial sac.....	220, 244
preputial.....	476	Hilus of kidneys.....	458
pulmonary.....	436	of spleen.....	329
racemose.....	270	of supra-renal bodies.....	466
sebaceous.....	634	Hip.....	212
simple follicular.....	276	bones.....	121
solitary.....	312, 313, 318	joint.....	159
suburethral.....	481, 494	Hippocampus.....	522
superficial inguinal.....	437	Hollow of the foot.....	157
sweat.....	633	of the knee.....	238
tubular.....	269, 312, 318	Homogeneous filaments.....	18, 30

- Homogeneous granules..... 18, 29
 liquid..... 18, 29
 membrane..... 19, 30
 Horns of the lateral ventricles..... 522
 Human anatomy..... 17
 Humerus..... 132
 Humor, aqueous..... 610
 vitreous..... 611
 Humors of the eye..... 600
 Hyaloid tunic..... 612
 Hydrogen..... 21
 Hymen..... 490
 Hyoid bone..... 96
 Hypochondriac regions..... 299
 Hypogastric region..... 299

 ILEUM..... 310
 Ileo-colic valve..... 316
 Iliac regions..... 299
 Ilium..... 121
 Ilio-pectineal line..... 126
 Ilio-pubic eminence..... 124
 Incisors..... 286
 Infundibulum..... 518
 Inguinal canal..... 219
 fossæ, external..... 220
 internal..... 220, 304
 hernia, direct..... 221
 oblique..... 220
 region..... 212
 Innominate bones..... 121
 Inosit..... 28
 Instep..... 157
 Intermuscular partitions..... 182
 Interposed velum..... 524, 535
 Intervertebral disks..... 107
 foramina..... 98
 ligaments..... 107
 notches..... 98
 Intestinal juice..... 313
 Intestine..... 309
 large..... 315
 small..... 309
 Iodine..... 21
 Iris..... 607
 Iron..... 21, 26
 Irregular bones..... 34
 Ischium..... 121
 plane of..... 124
 Ivory..... 289

 JAW BONE, lower..... 83
 Jejunum..... 310
 Joints..... 46
 Jugular foramen..... 51, 69
 fossa..... 64, 193, 199

 KIDNEYS..... 458
 Knee cap..... 150, 238
 joint..... 160
 Knuckles..... 140

 LABIA, of the vulva..... 492
 Labial fræna..... 275
 Labyrinth, of ear..... 621
 membranous..... 623
 Lacerated foramen..... 68
 Lachrymal apparatus..... 598
 bone..... 80
 caruncle..... 598
 orifice..... 595, 599
 papillæ..... 595, 599
 point..... 599
 sac..... 599
 Lachrymo-nasal duct..... 80, 91
 Lacteals..... 438
 Lamina, membranous spiral..... 626
 osseous spiral..... 625
 Laminae of the cerebellum..... 527
 Larynx..... 440
 aperture of..... 445
 cartilages of..... 440
 muscles of..... 444, 445
 ventricles of..... 445
 Layer, cellular, of membranes..... 259
 fibrous, of membranes..... 262
 Ligament, anterior annular... 138, 225
 accessory of hip joint..... 159
 annular, anterior, of the wrist... 225
 of the radius..... 145
 of the ankle joint..... 241, 242
 of the ear..... 616
 of the stirrup..... 619
 posterior, of the wrist..... 225
 arcuate, external..... 218
 astragalo-scaphoid..... 164
 calcaneo-cuboid, inferior..... 165
 capsular, between radius and
 ulna..... 145
 of ankle joint..... 163
 of astragalus and scaphoid
 bone..... 164
 of calcaneum and cuboid
 bone..... 165
 of elbow joint..... 144
 of hip joint..... 159
 of knee joint..... 161
 of scapulo-clavicular ar-
 ticulation..... 142
 of shoulder joint..... 143
 of sterno-clavicular artic-
 ulation..... 141
 of tempero-maxillary ar-
 ticulation..... 87
 of wrist joint..... 146
 coraco-acromial..... 143
 coraco-clavicular..... 142
 coraco-humeral..... 143
 coracoid..... 130
 costo-clavicular..... 142
 costo-transverse, anterior..... 119
 middle and posterior..... 119
 costo-xiphoid..... 119

- Ligament, cotyloid..... 159
 dental..... 286
 denticulate..... 537
 external calcaneo-scaphoid..... 165
 lateral, of ankle joint..... 164
 of the jaw..... 87
 of elbow joint..... 145
 of knee joint..... 162
 of wrist joint..... 146
 glenoid..... 143
 great sacro-sciatic..... 126
 ilio-lumbar..... 126
 inferior calcaneo-cuboid..... 165
 calcaneo-scaphoid..... 165
 inter-articular, of rib..... 118
 inter-clavicular..... 142
 internal lateral, of ankle joint.. 164
 of elbow joint..... 145
 of knee joint..... 162
 of wrist joint..... 146
 interosseous, of tarsal bones... 164
 left lateral, of liver..... 302, 321
 long plantar..... 166
 nuchal..... 111
 of the patella..... 161, 249
 ovarian..... 485
 palmar, of fingers..... 147
 pterygo-maxillary..... 190
 radiating..... 118
 round, of hip joint..... 159
 of ulna and radius..... 145
 of uterus..... 484
 right lateral, of liver..... 302, 321
 small sacro-sciatic..... 126
 spheno-maxillary..... 195
 stylo-hyoid..... 64, 96
 stylo-maxillary..... 194
 superior calcaneo-cuboid..... 165
 supra-spinous..... 111
 sub-pubic..... 125
 suspensory, of the anvil..... 619
 of the clitoris..... 493
 of the liver..... 302, 321
 of the mallet..... 619
 of the penis..... 476
 of the spleen..... 302, 329
 thyro-epiglottic..... 443
 transverse..... 112
 triangular..... 497
 vertebral, anterior..... 109
 posterior..... 110
 Ligaments, acromio-clavicular..... 142
 anterior of the bladder..... 463
 arcuate..... 221
 atlo-axoid, anterior..... 112
 posterior..... 112
 band-like..... 48
 broad, of the uterus..... 304
 capsular..... 48
 of the costal cartilages..... 119
 of the ribs..... 118, 119
 costo-sternal..... 119
 Ligaments, crucial..... 161
 dorsal..... 147, 165
 interosseous..... 147
 of metatarsus..... 165
 of tarsus..... 165
 interspinous..... 111
 intervertebral..... 107
 lateral, of the bladder..... 463
 lateral, of phalanges..... 147
 occipito-atloid, anterior..... 111
 posterior..... 111
 odontoid..... 113
 of the ear..... 613, 619
 of the liver..... 301, 302, 321
 of the metatarso-phalangeal articulations..... 166
 of the phalangeal articulations.. 166
 of the tibio-fibular articulations..... 163
 of the uterus..... 484
 of the urinary bladder..... 463
 of the larynx..... 442
 palmar..... 147
 palpebral..... 596
 sacro-iliac..... 126
 sterno-clavicular..... 142
 thyro-hyoid..... 442
 vaginal, of fingers..... 226
 of the toes..... 242
 yellow..... 109
 Linea aspera..... 148
 alba..... 217
 Line, median, of abdomen..... 217
 semilunar, of abdomen..... 217
 Lines, transverse, of abdomen..... 217
 Lime, phosphate of..... 28
 carbonate of..... 28
 oxalate of..... 29
 Lingual frænum..... 280
 Lips..... 274
 of the uterus..... 482
 Liquid, cerebro-spinal..... 539
 Liquor sanguinis..... 340
 Liver..... 300, 321
 Lobes of a gland..... 270
 of the cerebrum..... 515
 of the liver..... 322, 323
 of the lungs..... 451
 of the prostate gland..... 480
 Lobules of glands..... 270
 of the liver..... 271, 325
 of lungs, primary..... 452
 secondary..... 452
 Loins..... 211
 Lower jaw bone..... 83
 Lumbar regions..... 211, 299
 vertebræ..... 103
 Lungs..... 450
 Lunula..... 641
 Lymph..... 430
 corpuscles..... 430
 Lymphatic system..... 428

- Lymphatic glands..... 428, 429
 anterior auricular..... 434
 axillary..... 435
 bronchial..... 436
 coeliac..... 439
 deep cervical..... 434
 deep inguinal..... 437
 external iliac..... 437
 intercostal..... 436
 internal iliac..... 437
 internal maxillary..... 434
 lumbar..... 438
 mediastinal, anterior..... 436
 posterior..... 436
 mesenteric..... 438
 mesocolic..... 438
 occipital..... 433
 popliteal..... 437
 posterior auricular..... 433
 pulmonary..... 436
 submaxillary..... 434
 superficial cervical..... 434
 inguinal..... 437
 trunk, broncho-mediastinal..... 436
 intestinal..... 439
 vessels..... 428
 anterior mediastinal..... 436
 deep cervical..... 434
 deep facial..... 434
 intercostal..... 435
 lingual..... 434
 occipital..... 433
 of the exterior of the tho-
 rax..... 435
 of the large intestines..... 438
 of the liver..... 438
 of the lower extremities... 437
 of the stomach..... 438
 of the upper extremities... 435
 pulmonary..... 436
 superficial cervical..... 434
 facial..... 434
 temporal..... 433

 MAGNESIA, phosphate of..... 28
 Magnesium..... 21, 26
 Malar bone..... 83
 Malleolus, internal..... 152
 external..... 153
 Mallet..... 618
 Malpighian corpuscles..... 460
 Mammæ..... 499
 Mammillary eminences..... 518
 Manganese..... 21
 Margarin..... 27
 Marrow..... 36, 39
 Mastoid portion of temporal bone... 62
 process..... 62
 sinuses..... 62, 620
 Matrix of nails..... 640
 Maxillary bone, inferior..... 83
 superior..... 76

 Maxillary sinus..... 76
 Meatus..... 34
 external auditory..... 63, 615
 inferior, of the nose..... 94
 internal auditory..... 63, 627
 middle, of the nose..... 57, 93
 superior, of the nose..... 57, 93
 Mediastinal cavities..... 454
 Mediastinum of the testis..... 470
 Mediastinum..... 454
 Medulla..... 36, 39
 oblongata..... 530
 Medullary cavity..... 36
 sheath..... 505
 substance of kidney..... 459
 of supra-renal bodies..... 466
 Melanin..... 27
 Membrane, arachnoid..... 539
 basement..... 262
 fenestrated..... 334
 mucous..... 266
 of the aqueous humor... .. 603, 610
 of the tympanum..... 616
 perforated..... 334
 pupillary..... 608
 serous..... 263
 synovial..... 48, 265
 thyro-hyoid..... 442
 tympanic..... 616
 vocal..... 443
 Membranous labyrinth..... 623
 portion of urethra..... 479
 semicircular canals..... 623
 Mesentery..... 301, 303
 Mesocolon, ascending.. .. 301, 303
 descending..... 301, 303
 transverse..... 301, 303
 Mesorectum..... 301, 304
 Metacarpal bones..... 138
 Metacarpus..... 138
 Metatarsal bones..... 156
 Metatarsus..... 156
 Milk..... 502
 globules..... 502
 plasma..... 502
 Mineral bodies..... 18
 Mitral valve..... 347
 Molars..... 288
 Mons veneris..... 491
 Motion, ciliary..... 261
 Mouth..... 273
 floor of the..... 278
 roof of the..... 275
 Mucus..... 267
 Mucous corpuscles..... 267
 membrane..... 266
 gastro-pulmonary..... 266
 genito-urinary..... 266
 mammary..... 266
 nasal..... 593
 Muscle, accessory flexor..... 256
 adductor, great..... 250

- | | | | |
|----------------------------------|----------|---|----------|
| Muscle, adductor, long..... | 249 | Muscle, flexor, snort, of the toes..... | 256 |
| of the great toe..... | 257 | superficial, of fingers..... | 231 |
| of the little finger..... | 237 | gastrocnemius..... | 254 |
| of the little toe..... | 258 | geminous..... | 246 |
| of the thumb..... | 236 | genio-glossal..... | 284 |
| short..... | 250 | genio-hyoid..... | 197 |
| anal elevator..... | 499 | gluteal, great..... | 244 |
| sphincter..... | 499 | middle..... | 245 |
| anconeus..... | 229 | small..... | 245 |
| arytenoid..... | 445 | gracilis..... | 248 |
| biceps flexor..... | 228 | great serrated..... | 202 |
| biceps flexor of thigh..... | 250 | pectoral..... | 201 |
| brachial..... | 229 | hyo-glossal..... | 284 |
| buccinator..... | 190 | iliac..... | 247 |
| bulbo-urethral..... | 498 | inferior oblique..... | 209 |
| ciliary..... | 187, 605 | serrated..... | 206 |
| coccygeal..... | 499 | infra-spinous..... | 226 |
| complex..... | 208 | internal pterygoid..... | 191 |
| constrictor of the pharynx, in- | | interosseous of the foot..... | 258 |
| ferior..... | 296 | ischio-cavernous..... | 498 |
| middle..... | 296 | labio-nasal depressor..... | 189 |
| superior..... | 295 | elevator..... | 188 |
| coraco brachial..... | 228 | larger straight anterior..... | 198 |
| cremaster..... | 469 | posterior..... | 209 |
| crico-arytenoid, lateral..... | 444 | larger zygomatic..... | 189 |
| posterior..... | 444 | lateral straight..... | 209 |
| crico-thyroid..... | 444 | latissimus..... | 204 |
| cruralis..... | 249 | laxator..... | 620 |
| deltoid..... | 227 | lingual..... | 284 |
| depressor of the lower lip..... | 189 | long cervical..... | 198 |
| of the oral angle..... | 190 | lumbrical..... | 232, 256 |
| digastric..... | 196 | masseter..... | 191 |
| dorsal extensor..... | 206 | multifid spinal..... | 208 |
| elevator of the lower lip..... | 190 | mylo-hyoid..... | 197 |
| of the oral angle..... | 189 | nasal compressor..... | 188 |
| of the palate..... | 277 | dilator..... | 188 |
| of the scapular angle..... | 205 | pyramidal..... | 186 |
| of the upper lip..... | 189 | oblique, external..... | 213 |
| extensor, common, of the fin- | | inferior..... | 602 |
| gers..... | 233 | internal..... | 215 |
| metacarpal, of thumb..... | 235 | superior..... | 601 |
| of the great toe..... | 253 | obturator, external..... | 246 |
| of the index finger..... | 235 | internal..... | 246 |
| of the little finger..... | 235 | occipito-frontal..... | 185 |
| of the toes, long..... | 252 | omo-hyoid..... | 196 |
| of the toes, short..... | 253 | oral orbicular..... | 188 |
| phalangeal, of thumb, first..... | 235 | palato-glossal..... | 278 |
| phalangeal, of thumb, sec- | | pharyngeal..... | 295 |
| ond..... | 235 | palmar, long..... | 230 |
| radio-carpal, longer..... | 233 | short..... | 236 |
| radio-carpal, shorter..... | 233 | palpebral elevator..... | 187 |
| ulno-carpal..... | 234 | orbicular..... | 187 |
| external pterygoid..... | 191 | pectineal..... | 249 |
| flexor, deep, of fingers..... | 232 | peroneal, anterior..... | 252 |
| long, of great toe..... | 256 | long..... | 253 |
| of little finger..... | 237 | short..... | 253 |
| of the thumb..... | 232 | plantar..... | 255 |
| of the toes..... | 255 | popliteal..... | 255 |
| metacarpal, of thumb..... | 236 | posterior tibial..... | 256 |
| of the little toe..... | 258 | psoas..... | 247 |
| short, of great toe..... | 257 | small..... | 247 |
| of the thumb..... | 236 | pyramidal..... | 217 |

- Muscle, pyriform..... 246
 quadrate femoral..... 246
 lumbar..... 218
 pronator..... 230
 quadriceps extensor..... 249
 radio-carpal flexor..... 230
 rectus..... 249
 rhomboid..... 205
 sacro-lumbar..... 207
 sartorius..... 248
 scalene, anterior..... 197
 middle..... 197
 posterior..... 198
 semi-membranous..... 251
 semispinal..... 208
 semi-tendinous..... 250
 smaller straight anterior..... 198
 straight posterior..... 209
 small pectoral..... 202
 zygomatic..... 189
 soleus..... 254
 splenius..... 207
 stapedius..... 620
 sterno-costal..... 210
 sterno-hyoid..... 195
 sterno-mastoid..... 195
 sterno-thyroid..... 196
 straight, of abdomen..... 216
 stylo-glossal..... 284
 stylo-hyoid..... 196
 stylo-pharyngeal..... 295
 subclavian..... 202
 subcutaneous cervical..... 193
 subscapular..... 226
 superciliary..... 187
 superior oblique..... 209
 serrated..... 205
 supinator, long..... 233
 short..... 235
 supra-spinous..... 226
 tarsal tensor..... 187
 temporal..... 192
 tensor of the ear..... 620
 of the femoral fascia..... 248
 of the palate..... 278
 terete, greater..... 227
 lesser..... 226
 pronator..... 230
 thyro-arytenoid..... 444
 thyro-hyoid..... 196
 tibial, anterior..... 252
 trachelo-mastoid..... 208
 transverse..... 215
 of foot..... 258
 transverse perineal..... 499
 trapezius..... 203
 triceps extensor..... 229
 sural..... 254
 ulno-carpal flexor..... 230
 uvular..... 278
 vaginal constrictor..... 498
 vastus, external..... 249
- Muscle, vastus, internal..... 249
 Muscles..... 178
 ciliary..... 605
 costal elevator..... 210
 form of..... 179
 head of..... 179
 insertion of..... 179
 intercostal..... 210
 interosseous of the hand..... 237
 inter-spinal..... 209
 inter-transverse..... 209
 of eyeball..... 601
 of the larynx..... 443
 origin of..... 179
 pectinate..... 344
 straight..... 601
 Muscular fibres..... 178
 striated..... 181
 unstriated..... 271
 fibrils..... 181
 Myolemma..... 181
 Myrtiform caruncles..... 490
- NAILS..... 640
 Nares..... 92, 184, 588
 Nasal bone..... 81
 cavities..... 92, 591
 fossæ..... 92
 meatuses..... 93, 591
 notch..... 77
 orifices..... 92
 partition..... 591
 plate..... 79
 process..... 77
 septum..... 92
 spine..... 77
 Nates..... 238
 Navel..... 212
 Navicular fossa..... 479
 Neck..... 193
 Nerve, auriculo-temporal..... 548
 capsular bodies..... 510
 cells..... 505
 circumflex..... 568
 crural..... 574
 cutaneous, external..... 566
 internal..... 566
 small..... 566
 deep auricular..... 552
 dorsal of penis..... 578
 clitoris..... 578
 external cutaneous, of lumbar
 plexus..... 574
 fibres..... 504, 508
 frontal..... 544
 genito-crural..... 573
 great auricular..... 563
 sciatic..... 578
 ilio-hypogastric..... 573
 ilio-inguinal..... 573
 inferior dental..... 549
 hæmorrhoidal..... 577

- Nerve, inferior maxillary 543, 548
 infra-orbital..... 552
 intercosto-humeral..... 572
 internal cutaneous of crural... 576
 lachrymal..... 544
 lingual..... 548
 long saphenous..... 576
 median..... 568
 middle cutaneous..... 575
 musculo-cutaneous..... 579
 musculo-spiral..... 570
 nasal..... 544, 547
 obturator..... 574
 perineal..... 578
 peroneal communicating..... 581
 phrenic..... 563
 popliteal, external..... 579
 internal..... 579
 posterior interosseal..... 570
 pterygoid..... 547
 pudendal..... 578
 pudic..... 577
 radial..... 570
 short saphenous..... 580
 small occipital..... 563
 petrosal..... 550
 sciatic..... 578
 splanchnic, great..... 585
 small..... 585
 third..... 585
 superficial cervical..... 563
 superior gluteal..... 577
 maxillary..... 545
 temporal..... 552
 temporo-malar..... 546
 tibial, anterior..... 579
 posterior..... 581
 trifacial..... 542
 tympanic..... 552, 554
 ulnar..... 568
 zygomatic..... 552
 Nerves..... 503
 abducent..... 550
 accessory..... 558
 apparent origin of..... 510
 auditory..... 553
 cochlear branch of..... 626
 vestibular branch of..... 623
 cardiac..... 557
 inferior..... 584
 middle..... 584
 superior..... 583
 cerebral..... 514, 540
 cerebro-spinal..... 507, 514
 cervical..... 561
 coccygeal..... 576
 ciliary..... 544
 cochlear..... 628
 deep origin of..... 510
 dental..... 546
 digital..... 581
 facial..... 551
 Nerves, fibres of..... 508
 ganglionic system of..... 512
 glosso-pharyngeal..... 553
 hypoglossal..... 559
 inferior gluteal..... 578
 infra-orbital..... 546
 intercostal..... 571
 laryngeal..... 557
 lumbar..... 572
 oculo-motor..... 541
 olfactory..... 540
 ophthalmic..... 543
 optic..... 541
 origin of..... 509
 palatine..... 547
 pathetic..... 542
 pharyngeal..... 557, 583
 plantar..... 581
 plexuses of..... 508
 pneumogastric..... 555
 pulmonary..... 557
 real origin of..... 510
 sacral..... 576
 spheno-palatine..... 546
 spinal..... 514, 559
 subscapular..... 566
 superficial origin of..... 510
 supra-clavicular..... 563
 termination of..... 509
 thoracic..... 565, 570
 vestibular..... 628
 Nervous system..... 503
 Neurilemma..... 505
 Nipple..... 500
 Nitrogen..... 21, 25
 Nose..... 588
 back of..... 184
 bridge of..... 184
 cartilages of..... 590, 591
 column of..... 184
 meatuses of..... 591
 root of..... 184
 sinuses of..... 591
 wings of..... 591
 Nostrils..... 184
 Notch, coracoid..... 130
 great sciatic..... 122
 lesser sciatic..... 123
 nasal..... 77
 semilunar..... 85
 Nucleolus..... 23
 Nucleus..... 23
 lenticular..... 523
 Nymphæ..... 493
 OBTURATOR FORAMEN..... 124
 membrane..... 125
 Occipital angle..... 52
 bone..... 50
 cross..... 52
 protuberances..... 52
 region..... 91

- | | | | |
|--------------------------------|----------|-------------------------------------|------------|
| Odontoid ligaments | 113 | Peduncles of pineal gland..... | 526 |
| process | 101 | Pellucid septum..... | 521 |
| Œsophageal orifice..... | 222 | Pelvis..... | 126 |
| Œsophagus | 297 | cavity of..... | 494 |
| Olecranon..... | 135 | of kidney..... | 461 |
| Olein | 27 | Penis | 475 |
| Olfactory region..... | 593 | Pepsin..... | 27, 309 |
| Olivary bodies..... | 530 | Pericardium..... | 349 |
| Omentum, gastro-colic..... | 303 | Perilymph..... | 623 |
| gastro-hepatic | 301, 302 | Perineum | 496 |
| gastro-splenic..... | 303, 329 | Periosteum..... | 39 |
| great..... | 301, 303 | Peritoneum..... | 300 |
| Optic commissure..... | 518, 541 | Permanent teeth..... | 286 |
| tract..... | 541 | Petrous portion of temporal bone... | 63 |
| Orbital entrance | 91 | Peyer's glands..... | 313 |
| plate | 77 | Phalanges of foot. | 157 |
| Orbits..... | 91 | of hand..... | 139, 140 |
| Organic cells..... | 22 | Phalanx..... | 139 |
| Organized bodies..... | 18 | Pharynx..... | 294 |
| Orifice, aortic..... | 222 | Phosphorus..... | 21 |
| auriculo-ventricular | 344 | Pia mater of brain..... | 535 |
| œsophageal..... | 222 | of spinal cord..... | 536 |
| urethral | 480 | Pimple mite..... | 636 |
| Orifices of the ureters..... | 464 | Pineal gland..... | 526 |
| Origin of nerves..... | 510 | Pit of the stomach | 200, 212 |
| Osseous tissue..... | 40 | Pituitary body..... | 518 |
| Ossification | 42 | fossa..... | 53 |
| centres of..... | 42 | Plane of the ischium..... | 124 |
| Otolites | 624 | Plate, nasal..... | 79 |
| Oval foramen, of heart..... | 344 | of malar bone..... | 83 |
| sphenoid bone..... | 56 | orbital..... | 57, 59, 77 |
| Oval window..... | 618 | palate..... | 78, 79 |
| Ovarian ligament..... | 485 | Pleura | 454 |
| Ovaries | 485 | Plexus, aortic..... | 586 |
| Oviduct | 488 | brachial | 563 |
| Ovisacs | 486 | cardiac..... | 584 |
| Ovum | 486 | carotid..... | 583 |
| Oxalate of lime..... | 29 | cavernous..... | 583 |
| Oxygen..... | 21, 25 | cervical..... | 562 |
| | | choroid..... | 523, 536 |
| PACINIAN CORPUSCLES..... | 510 | coronary | 586 |
| Palate..... | 275 | dorsi-spinal..... | 423 |
| half arches of..... | 276 | gangliform..... | 555 |
| bone | 78 | hæmorrhoidal..... | 319, 424 |
| Palatine region..... | 90 | hepatic..... | 586 |
| Palm..... | 140, 223 | hypogastric | 587 |
| Pancreas | 300, 320 | intra-spinal | 423 |
| Pancreatic juice..... | 321 | lumbar..... | 573 |
| Pancreatin..... | 27, 326 | mesenteric, inferior..... | 586 |
| Papillæ of taste..... | 282 | superior..... | 586 |
| tactile..... | 630 | œsophageal..... | 558 |
| Papillary muscles..... | 345 | pampiniform | 473 |
| Parietal bone..... | 60 | pharyngeal | 583 |
| Parotid gland..... | 278 | phrenic..... | 586 |
| Parovarium..... | 487 | prostatic | 424 |
| Partitions, intermuscular..... | 182, 239 | pulmonary | 557 |
| Patella..... | 150 | renal | 586 |
| Pavilion | 488 | reteform | 471 |
| Pectinate muscles..... | 344 | sacral | 577 |
| Pectineal line..... | 123 | solar | 585 |
| Pedicle, olfactory..... | 540 | spermatic | 586 |
| Peduncles of cerebellum..... | 528, 529 | splenic..... | 586 |

Plexus, supra-renal.....	586	Process, vermiform.....	527
uterine.....	587	Promontory.....	617
utero-vaginal.....	424	of the pelvis.....	126
vesical.....	425	Prostate gland.....	480
vesico-prostatic.....	587	Prostatic portion of urethra.....	478
vesico-vaginal.....	587	Protuberance, occipital, external....	52
Plexuses, nervous.....	508	internal.....	52
venous.....	336	mental.....	84
Pons.....	529	zygomatic.....	62, 83
Popliteal region.....	238, 251	Ptyalin.....	27
Potassa, carbonate of.....	28	Pubic symphysis.....	125
phosphate of.....	28	arch.....	127
urate of.....	29	Pubis.....	121, 123
Potassium.....	25	Pulp of cavity.....	286
chloride of.....	28	of teeth.....	286
Poupart's ligament.....	242	of the spleen.....	330
Premolars.....	287	Pulsation.....	350
Preperitoneal cavity.....	217	Pulse.....	350
Prepuce of clitoris.....	493	Pupil.....	607
of penis.....	475	Pulmonary circulation.....	350
Process, angular, external.....	58	Pyloric extremity of stomach.....	305
internal.....	58	orifice.....	305
articular, of temporal bone..	64	sphincter.....	306
auditory.....	63	valve.....	307
basilar.....	51	Pyramidal bodies.....	530
ciliary.....	605	Pyramid of the tympanum.....	618
clinoid, anterior.....	53	Pyramids, decussation of.....	531
posterior.....	53	posterior.....	531
coracoid.....	132	renal.....	459
coronoid.....	85, 135	QUADRATE FORAMEN.....	223
falciform.....	243	RADIUS.....	135
frontal.....	83	Rami of pubis.....	123
lateral, of calcaneum.....	154	Ramus of ischium.....	123
long, of the mallet.....	619	Raphé of perineum.....	496
malar.....	78	of scrotum.....	468
mastoid.....	62	of tongue.....	280
nasal.....	77	Receptacle of chyle.....	431
odontoid.....	101	Rectum.....	318
of bone.....	34	Region, guttural.....	90
olivary.....	53	occipital.....	91
orbicular.....	619	oral.....	90
orbital.....	80	palatine.....	90
pterygoid, external.....	55	Regions of the abdomen.....	299
internal.....	55	Renal glomerule.....	460
pyramidal.....	80	papillæ.....	459
short, of the mallet.....	619	pyramids.....	459
sphenoidal.....	80	Restiform bodies.....	531
spinous.....	34	Reteform plexus.....	471
of ilium, anterior.....	122	Retina.....	608
posterior.....	122	Ribs.....	114
superior.....	122	Ridge, asperous.....	148
of radius.....	136	inter-trochanteric.....	148
of sphenoid bone.....	55	molar.....	84
of temporal bone.....	63	of bone.....	34
of the tibia.....	151	superciliary.....	58
of vertebræ.....	98	temporal.....	61, 88
styloid, of ulna.....	135	Ring, external abdominal.....	213, 219
transverse, of occipital bone...	51	internal.....	219
transverse, of vertebræ.....	98	Root of lungs.....	450
turbinated, inferior.....	57	of hairs.....	636
superior.....	57		
vaginal.....	63		

- Rostrum..... 54
 Rotation..... 48
 Rotund foramen.. 56
 Round window 618


 SAC, LACHRYMAL..... 599
 Saccule, spherical 623
 elliptical 623
 Sacrum..... 104
 Saliva..... 280
 Saphenous opening 240
 Scala, tympanic 626
 vestibular..... 626
 Scalp..... 184
 Scapula 130
 Sclerotica 602
 Sclerotic coat..... 602
 Scrotum..... 468
 Sebaceous glands..... 634
 matter..... 635
 Secondary tympanic membrane..... 618
 Secretion 267
 Semen..... 474
 Semi-bulbs of the clitoris..... 493
 Semicircular band..... 524
 canals..... 622
 membranous 623
 Semilunar fibro-cartilages..... 160
 folds..... 598
 valves..... 346, 347
 Seminal liquid..... 474, 472
 vesicles..... 473
 Seminiferous tubules..... 471, 472
 Septal fibres .. 531
 Septula of testicles..... 470
 Septum, osseous nasal..... 92
 pellucid 521
 Serum..... 340
 Sexual differences of the pelvis..... 128
 Shaft of bone..... 34
 Shin 151
 Shin bone..... 150
 Shoulder blade..... 130
 Sigmoid flexure of the colon..... 315
 Sinews..... 180
 Sinus, anterior occipital..... 411
 cavernous..... 411
 circular 418
 circular, of the iris..... 601
 frontal..... 60
 inferior longitudinal..... 410
 petrosal 411
 lateral..... 409
 maxillary.. 76
 of bone..... 34
 posterior occipital..... 412
 straight..... 410
 superior longitudinal..... 410
 petrosal 411
 Sinuses, sphenoidal 54
 ethmoidal 57
 lactiferous 501
 Sinuses, mastoid..... 62, 620
 of dura mater 409, 538
 venous 336
 Soda, carbonate of..... 28
 phosphate of..... 28
 taurocholate of..... 29
 urate of..... 29
 Sodium..... 21, 25
 chloride of..... 28
 Skeleton.. 33
 Skin..... 628
 Skull..... 85, 87
 Smegma..... 476
 Soft epidermic layer..... 633
 Soft palate..... 275
 Solar plexus 585
 Sole..... 157
 Space, anterior, perforated..... 519
 posterior " 518
 Special anatomy 17
 Sperm cells..... 472
 Spermatic cones..... 471
 cord..... 469
 duct..... 471, 472
 liquid..... 472
 Spermatozooids 474, 472
 Sphenoid bone..... 52
 Sphenoidal foramen..... 55
 Spinal cord..... 513, 533
 columns of..... 534
 commissures of..... 533
 fissures of. 533
 gelatinoid substance of..... 535
 gray substance of..... 505
 horns of 534
 white substance of 504
 Spine, nasal..... 77
 of scapula 131
 palate..... 79
 Sphincter of the anus..... 319
 of the bladder..... 464
 Spinous foramen..... 56
 Spiral lamina, osseous 625
 membranous 626
 tract 628
 Spleen..... 329
 Splenic corpuscles.. 330
 Spongy body, of clitoris..... 493
 of penis 477
 portion of urethra..... 479
 Squamous portion of temporal bone. 61
 Sternum..... 117
 Stirrup 619
 Stomach 305
 pit of. 211
 position of..... 299
 Strait, inferior, of pelvis..... 127, 494
 superior " 127, 494
 Striated body..... 523
 Stroma of the ovary..... 485
 Sub-arachnoid space 539
 Sub-arachnoid tissue 264

- | | | | |
|-----------------------------------|---------------|--------------------------------|----------|
| Submaxillary gland..... | 279 | Tissue, adipose..... | 176 |
| Sub-mucous tissue..... | 266 | areolar..... | 170 |
| Sub-serous tissue..... | 264 | connective..... | 170 |
| Substance of bone..... | 36 | elastic..... | 175 |
| Superciliary ridge..... | 58 | fat..... | 176 |
| Supra-renal bodies..... | 465 | fibrous..... | 167 |
| Sutures..... | 46, 66 | sub-archnoid..... | 264 |
| dentated..... | 46 | sub-serous..... | 264 |
| of the cranium..... | 66 | Toes..... | 157 |
| of the face..... | 86, 90 | Tongue..... | 280 |
| serrated..... | 46 | Tonsils..... | 276 |
| squamous..... | 46 | Tonsils of the cerebellum..... | 528 |
| Sweat..... | 634 | Topographical anatomy..... | 17 |
| duct..... | 633 | Trabeculae of penis..... | 476 |
| glands..... | 633 | of spleen..... | 330 |
| Sylvian fissure..... | 515 | Trachea..... | 447 |
| Sympathetic system of nerves..... | 581 | Tract, spiral..... | 628 |
| Symphysis..... | 46 | Tricuspid valve..... | 345 |
| of inferior maxillary bone..... | 84 | Trochanters..... | 148 |
| pubic..... | 125 | Trunk of skeleton..... | 96 |
| sacro-iliac..... | 125 | Tubercle..... | 34 |
| Synovia..... | 49, 265 | mental..... | 84 |
| Synovial bursae..... | 183, 265 | Tuberosity..... | 34 |
| fringes..... | 49, 265 | Tunics of the eye..... | 600 |
| membranes..... | 48, 265 | Turbinated bone..... | 81 |
| Systemic circulation..... | 351 | Tympanic membrane..... | 616 |
| | | secondary..... | 618 |
| TACTILE CORPUSCLES..... | 511, 630 | Tympanum..... | 616 |
| papillae..... | 630 | ULNA..... | 134 |
| Tapetum..... | 607 | Umbilical region..... | 299 |
| Tarsal bones..... | 153 | Umbilicus..... | 212 |
| Tarsus..... | 153 | Urachus..... | 463 |
| Teeth..... | 285 | Urea..... | 29, 462 |
| bicuspid..... | 287 | Ureter..... | 461 |
| canine..... | 287 | Ureters..... | 458 |
| eruption of..... | 293 | Urethra..... | 465, 478 |
| eye..... | 287 | Urinary bladder..... | 462 |
| front..... | 286 | Urine..... | 462 |
| jaw..... | 288 | Uriniferous tubules..... | 460 |
| milk..... | 288 | Uroerythrin..... | 29 |
| permanent..... | 285, 286 | Uterus..... | 481 |
| stomach..... | 287 | Utricle..... | 474 |
| temporary..... | 285, 288 | Uvula..... | 275 |
| Temple..... | 183 | of the cerebellum..... | 528 |
| Temporal bone..... | 61 | vesicle..... | 464 |
| fossa..... | 88 | VAGINA..... | 489 |
| regions..... | 183 | Valley..... | 527 |
| Tendinous cords..... | 346 | Valve, ileo-colic..... | 316 |
| Tendon of Achilles..... | 254 | mitral..... | 347 |
| Tendons..... | 178, 180, 182 | of the brain..... | 529 |
| Tentorium..... | 538 | pyloric..... | 307 |
| Testicles..... | 468 | tricuspid..... | 345 |
| Thalami..... | 524 | Valves of veins..... | 336 |
| Thalamus..... | 524 | semilunar..... | 346, 347 |
| Thoracic aorta..... | 381 | Valvulae conniventes..... | 266, 310 |
| duct..... | 431 | Vas deferens..... | 472 |
| Thorax..... | 119 | Vein, angular..... | 414 |
| Throat..... | 193, 294 | axillary..... | 417 |
| Thymus body..... | 456 | azygos..... | 419 |
| Thyroid body..... | 455 | basilic..... | 418 |
| cartilage..... | 440 | | |
| Tibia..... | 150 | | |

- | | | | |
|------------------------------|----------|--------------------------------------|---------------|
| Vein, cardiac, anterior..... | 406 | Veins, cerebellar, superior | 412 |
| posterior..... | 406 | cerebral, inferior..... | 412 |
| cephalic | 418 | internal | 412 |
| coronary | 405, 422 | median | 412 |
| cystic | 422 | superior..... | 412 |
| dorsal lingual..... | 416 | common iliac | 423 |
| of clitoris | 425 | companion..... | 335 |
| of penis..... | 425 | diploic | 413, 423 |
| facial..... | 414 | dorsi-spinal plexus of..... | 423 |
| femoral | 426 | hæmorrhoidal plexus of..... | 424 |
| frontal..... | 414 | hemi-azygos | 419 |
| iliac, external..... | 425 | hepatic | 421 |
| internal..... | 424 | inferior palpebral..... | 414 |
| innominate, left..... | 406 | innominate | 406 |
| right..... | 406 | intercostal, left..... | 420 |
| internal maxillary..... | 415 | right | 419 |
| jugular, anterior..... | 413 | internal mammary..... | 407 |
| external | 413 | intra-spinal plexus of..... | 423 |
| internal..... | 408, 409 | jugular..... | 408 |
| posterior..... | 413 | labial..... | 414 |
| mastoid | 416 | longitudinal anterior..... | 423 |
| median basilic..... | 419 | posterior..... | 423 |
| cephalic..... | 419 | lumbar | 421 |
| mesenteric, inferior..... | 422 | masseteric | 414 |
| superior..... | 422 | median | 419 |
| middle sacral | 420 | meningeal | 413 |
| occipital..... | 416 | nasal..... | 414 |
| ophthalmic..... | 413 | œsophageal..... | 419 |
| palatine | 414 | ovarian..... | 421 |
| pharyngeal..... | 416 | parotid..... | 415 |
| popliteal..... | 426 | phrenic | 421 |
| portal | 405, 421 | prostatic plexus of..... | 424 |
| posterior auricular..... | 415 | pulmonary..... | 405, 428, 453 |
| pudic | 425 | renal..... | 421 |
| radial cutaneous..... | 418 | spermatic | 421 |
| ranine..... | 416 | submaxillary..... | 414 |
| right bronchial..... | 419 | superficial, of lower extremity..... | 426 |
| gastro-epiploic | 422 | upper extremity..... | 417 |
| saphenous, long | 426 | superior palpebral..... | 414 |
| short..... | 426 | thyroid | 416 |
| splenic..... | 422 | supra-renal..... | 421 |
| subclavian..... | 417 | ulnar cutaneous..... | 415 |
| submental | 414 | uterine | 425 |
| supra-orbital..... | 414 | utero-vaginal plexus of..... | 424 |
| supra-scapular | 413 | valves of..... | 336 |
| tempero-maxillary | 415 | vesical plexus of..... | 425 |
| temporal..... | 414 | Velum, interposed..... | 524, 535 |
| anterior | 414 | Venous plexuses..... | 336 |
| middle..... | 415 | sinuses..... | 336 |
| posterior..... | 414 | Ventricle, fifth | 521 |
| thyroid, inferior..... | 407 | fourth..... | 531 |
| transverse cervical..... | 413 | third..... | 523 |
| facial | 415 | Ventricles, lateral..... | 521 |
| vertebral..... | 407 | of the heart..... | 343 |
| Veins..... | 335, 405 | of the larynx..... | 445 |
| articular | 415 | Vermiform appendix..... | 315 |
| auricular anterior..... | 415 | process..... | 527 |
| brachial..... | 417 | Vertebræ..... | 97 |
| bronchial | 453 | cervical..... | 99 |
| buccal | 414 | dorsal..... | 102 |
| cardiac..... | 406 | false..... | 103 |
| cerebellar, inferior..... | 412 | lumbar..... | 103 |

Vertebrae, true.....	97	Vomer.....	82
Vertebral column.....	97, 113	Vulva.....	491
Vertex.....	184		
Vesical sphincter.....	464	WHITE SUBSTANCE.....	505
triangle.....	464	of the eye.....	598, 602
uvula.....	464	Windpipe.....	447
Vesicles, seminal.....	473	Window, oval.....	618
Vesico-uterine pouches.....	304	round.....	618
folds.....	304	Wings of the sphenoid bone.....	54
Vessels afferent.....	429	ethmoidal.....	56
efferent.....	429	Womb.....	481
lymphatic.....	428	Wrist.....	136
Vestibule.....	494	joint.....	146
of the ear.....	621		
of the labyrinth.....	621	YELK.....	487
Villi.....	311	Yellow ligaments.....	109
Vitelline membrane.....	487	spot.....	609
Vitreous humor.....	611		
table of bone.....	65	ZONE, ciliary.....	612
Vocal cords.....	443, 446	Zygoma.....	62
false.....	447	Zygomatic arch.....	88, 89
membrane.....	443		

104	105	106	107	108	109	110	111	112	113	114	115	116	117	118	119	120	121	122	123	124	125	126	127	128	129	130	131	132	133	134	135	136	137	138	139	140	141	142	143	144	145	146	147	148	149	150	151	152	153	154	155	156	157	158	159	160	161	162	163	164	165	166	167	168	169	170	171	172	173	174	175	176	177	178	179	180	181	182	183	184	185	186	187	188	189	190	191	192	193	194	195	196	197	198	199	200
-----	-----	-----	-----	-----	-----	-----	-----	-----	-----	-----	-----	-----	-----	-----	-----	-----	-----	-----	-----	-----	-----	-----	-----	-----	-----	-----	-----	-----	-----	-----	-----	-----	-----	-----	-----	-----	-----	-----	-----	-----	-----	-----	-----	-----	-----	-----	-----	-----	-----	-----	-----	-----	-----	-----	-----	-----	-----	-----	-----	-----	-----	-----	-----	-----	-----	-----	-----	-----	-----	-----	-----	-----	-----	-----	-----	-----	-----	-----	-----	-----	-----	-----	-----	-----	-----	-----	-----	-----	-----	-----	-----	-----	-----	-----	-----	-----



"*Libri Anatomiae corporis humani et singulorum membrorum
illius*" First perceived the Fallopian tube.
acore an English physician. translated and published Galen in 1528

11
55
25
5.00 Feb. 9. 74

