

Extirpation of a tumor of the parotid : with observations upon the pathology of that gland / by Alexander E. Hosack.

Contributors

Hosack, Alexander E. 1805-1871.
National Library of Medicine (U.S.)

Publication/Creation

[New York?] : [publisher not identified], [1844?]

Persistent URL

<https://wellcomecollection.org/works/kgkh52vp>

License and attribution

This material has been provided by This material has been provided by the National Library of Medicine (U.S.), through the Medical Heritage Library. The original may be consulted at the National Library of Medicine (U.S.) where the originals may be consulted.

This work has been identified as being free of known restrictions under copyright law, including all related and neighbouring rights and is being made available under the Creative Commons, Public Domain Mark.

You can copy, modify, distribute and perform the work, even for commercial purposes, without asking permission.



Wellcome Collection
183 Euston Road
London NW1 2BE UK
T +44 (0)20 7611 8722
E library@wellcomecollection.org
<https://wellcomecollection.org>


HOSACK (A. E.)
A Prof. Johnson

for his friend
A. H.

Dr. Hosack

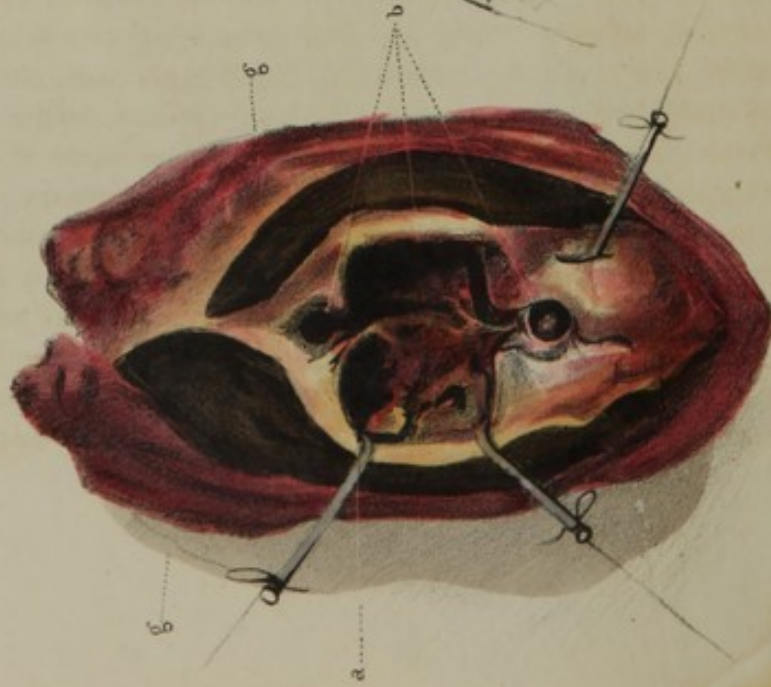


15. 2. 1864

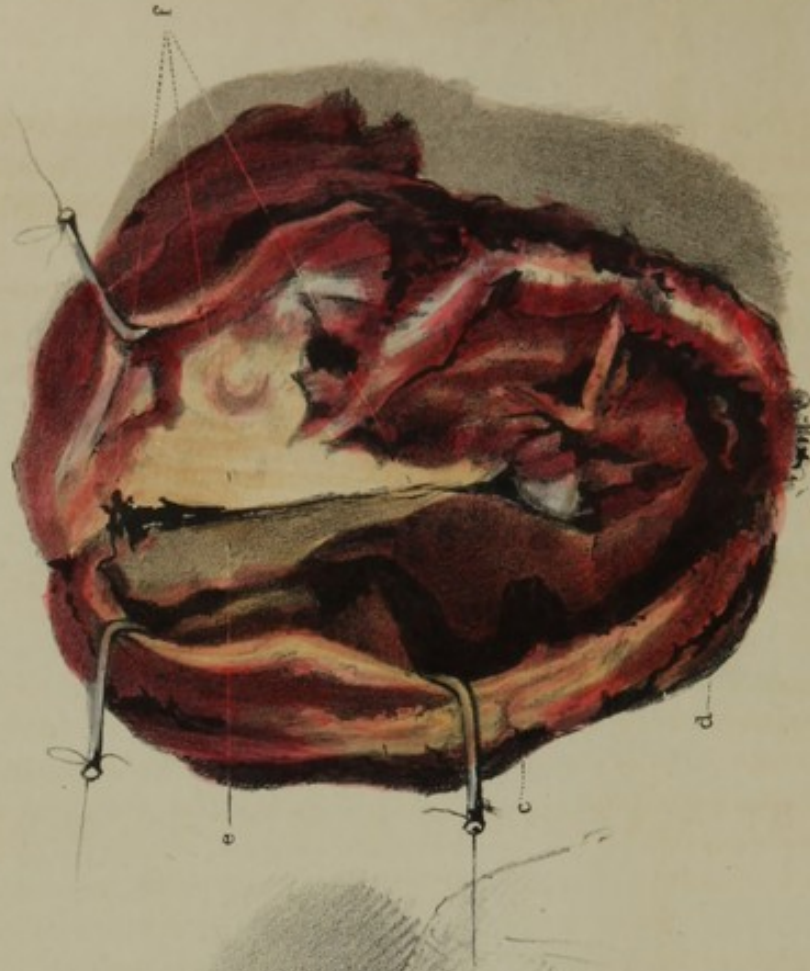


DR. HOSACK'S CASE OF TUMOR OF PAROTID GLAND.

1.



2.



a b c & d Melanotic matter.
e & f Scirrhus remains of Parotid gland.
g g Integument.

LITH OF ENDICOTT.

EXTIRPATION OF A TUMOR OF THE PAROTID;

WITH OBSERVATIONS UPON THE PATHOLOGY OF
THAT GLAND.

BY ALEXANDER E. HOSACK, M.D.,
OF NEW YORK.

EARLY in November, 1843, I was consulted by Isabella St. John, a colored woman, *et.* 38, on account of a swelling directly under the ear and behind the angle of the lower jaw, on the left side of the face. Of a robust and good constitution, she had always enjoyed excellent health. Her occupation is that of a laundress. The tumor resembled, in its noduled surface, a Nova Scotia potato, a medium-sized one of which it also rivalled in dimensions. It was quite firm and evidently contained a fluid. Although the fluctuation could not be very distinctly detected throughout, yet it was very readily to be discerned in one of the prominences. The statement she gave me of her case, was as follows: About six years since, when under the influence of an emetic and while in the act of vomiting, she felt something give way behind the angle of the jaw; and upon raising her hand to the part, she discovered a small hard lump directly under the ear. It was tender, but not painful. From that time, its growth was very gradual until it attained the size of a small pullet's egg, when it remained stationary; and as she experienced very little inconvenience from it, it was allowed to remain undisturbed. About twelve months before its removal, it began to enlarge; and it continued to grow rapidly, but was unattended with pain. There was no appearance of swelling in the fauces, nor was the jaw in the least impeded in its motion. The point at which fluctuation was most discernible, when pressed upon, readily yielded to the finger; but

upon increasing the pressure, a resisting substance was perceived, in which a small aperture existed ; and through this the fluid receded, but reappeared immediately upon the discontinuance of the pressure. The whole tumor was rendered more prominent and tense, upon opening the mouth, in consequence probably of its being pressed outwardly by the angle of the jaw. Not being able to come to a definite conclusion as to the true character of the disease, I determined to make a small valvular opening to ascertain the nature of its contents. This revealed about a table-spoonful of a thin, amber-colored fluid of the consistency of the serum of the blood. During its flow, the color was twice suddenly changed to that of dark black, and it as suddenly returned to its original hue. There was no disposition in them to unite, the two having no affinity, as both remained separate and distinct in the cup in which they were received. The black matter was much darker than the darkest blood found in the veins of bodies, that have been some time in the dissecting room—a fact that will be more fully adverted to in the sequel.

I will, therefore, proceed to describe the operation, which was done on the 16th December, about ten days after the above examination, assisted by my friends, Drs. J. K. Rodgers, Wilkes, Minturn Post, and Van Rensselaer, and in presence also of several pupils.

The patient being placed in a chair, an incision was commenced behind the conch of the ear, which was extended quite down over the tumor, terminating in the sound structure of the neck. A second incision was begun directly below the lobe of the ear, and carried over and below the tumor, where it joined the first. Upon detaching the integument on either side, and exposing the surface of the tumor, the prominence before alluded to presented a very black appearance, in all respects resembling that of melanosis. Progressing with the dissection on the side toward the face, I very soon came upon the anterior portion of the parotid gland, which, from its great vascularity and granulated structure, was immediately recognized ; but it was found to be so intimately blended with the tumor as to leave no doubt that this gland was the seat of the disease. After having detached the integument on the opposite side of the tumor, I proceeded with great caution, making my way beneath it in search of the external carotid artery, which was distinctly felt pulsating directly within the digastric muscle ; and finding this vessel to enter into, or at least to adhere to, the diseased mass, I determined to secure it at this point. I consequently placed two ligatures upon it, and divided it in the interspace. In consequence of the tumor being much reduced by the discharge of the fluid through the small opening made into it, it could readily be drawn in various directions, which greatly facilitated the remaining and most dangerous part of the operation. The diseased mass was now grasped with a double hook, and pulled downward and outward, while I dissected on, carefully advancing toward the extremity of the conical point of the inward extension of the parotid gland. It was at

this point that the carotid artery was imbedded in the substance of the tumor, but which was not to be seen or felt until the diseased part was insulated, with the exception of the extremity above alluded to. By thus cautiously advancing step by step, I was enabled to complete the dissection, leaving the part connected with the carotid artery to be severed by the last stroke of the knife; and on the detachment of which, the vessel being wounded was immediately secured. The amount of blood lost during the operation did not exceed twenty-five ounces, although there were many important vessels divided; as, for instance, the posterior auris and several branches of the temporal. The parotidian vein, from its great enlargement, was the cause of considerable embarrassment in the early part of the operation; but it was speedily secured by a ligature, and then divided. The number of vessels tied in all did not exceed fifteen. The portio dura of the seventh pair of nerves was also divided during the operation, as well as its branches, which were severed, in separating the tumor from its anterior connection with that portion of the gland resting upon the face; and which last portion, in concurrence with the gentlemen present, it was deemed not advisable to remove, as it was to all appearances perfectly sound. Upon inspecting the wound after the extirpation of the tumor, not a vestige of the gland (save the part just indicated), or of any diseased structure, could be discerned. The two orifices of the divided carotid artery with ligatures upon them, were to be seen pulsating at the bottom. The styloid muscles, as well as the anterior belly of the digastric, were exposed. The wound being cleansed, and all hemorrhage ceasing, the parts were brought together by the ordinary suture, sustained by adhesive straps. From this time, the patient continued to do well; the ligatures came away in the usual period, when the wound speedily healed. She has since perfectly recovered her strength, and she now enjoys excellent health. Immediately after the operation, I examined the removed mass, and found that the sack in front was quite firm and resisting, but of the ordinary thickness usually met with in encysted tumors about the neck. The posterior portion was very much enlarged; and upon being cut into, it presented a dense white structure of a scirrhus hardness, to the thickness of about from one half to three-quarters of an inch. This portion of the tumor had occupied the greatest depth of the wound, and it was found to be firmly adherent to the external carotid artery for a considerable extent. The internal surface of the tumor presented an unusual appearance. The different concavities of the sack seemed to be irregularly lined with a pseudo-membranous formation of a very black color. By reference to the drawing, figs. 1 and 2, it will be observed that the black structure is much darker than a tissue would be, engorged with blood, or even where blood may have been deposited upon its surface.

This black substance appeared to be distinct and unconnected with the sack, otherwise than by contact or very slight adhesions. It could

readily be scraped off, or separated by the handle of the knife ; but it was not disturbed at the time, as I was desirous of preserving the tumor with all its peculiarities. I did not, however, succeed in doing so, as this adventitious substance became broken up during the process of maceration. Upon pouring off the macerating fluid from time to time, this dark matter was found at the bottom of the vessel, resembling the finer particles of the grounds of coffee.

From these circumstances, considered in connection with the fact of the tarry-like matter being discharged alternately with the amber-colored fluid, and their not mingling when the puncture was made in exploring the disease, I am induced to conclude, that the black matter thus observed was melanosis in a semi-fluid state. The tumor may, therefore, be regarded as partaking of a three-fold character ; first, the primary disease, that of an ordinary encysted tumor, having its origin within the substance of the parotid, or in a lymphatic gland imbedded in its structure. Secondly, that of scirrhus ; and, thirdly, the adventitious formation of melanotic matter. The combination of these three distinctly marked diseases, is a circumstance I have never before met with, nor am I aware of any description of it by any surgical writers, either in this country or in Europe. Encysted tumors are never associated with scirrhus ; for they are distinct in their character, and occur under different circumstances. No mention is made by the different writers of its being concomitant with other diseases, except that of cancer. I must, therefore, conclude that the combination of these three diseases is a circumstance of very rare occurrence.

As this latter disease, melanosis, is here presented in a form different from that usually met with, I feel the necessity of offering a few observations upon it, particularly as its true character is generally but little understood. We have no knowledge of its cause, nor are we aware of any means by which it can be cured. It occurs at any period of life, and in any temperament, attacking the most robust as well as the most feeble constitutions ; and it is very generally fatal. Under these circumstances it is that every fact or peculiarity in appearance attending this disease, is deserving of special notice. The peculiar black matter has been frequently analysed by the French chemists, but nothing of importance has resulted from their investigations, further than that the dark coloring matter is carbon derived from the blood, and that it also contains fibrine, albumen, etc. According to Mérat, melanosis is divided into three classes. In the second, he describes it thus : " It is found," he says, " in very fine layers, extended over serous membranes, assuming an appearance of a glossy black color, similar to Indian ink, or to that black secretion found in the cuttle-fish." He goes on to state that he has seen it lining the whole peritoneum. MM. Andral and Brechet are quoted by Prof. John C. Warren as also having seen a liquid melanosis in the cavity of the peritoneum ; and M. Brechet further states, that he has

seen it in some of the secretions. It is spoken of also by several writers,* as occasionally found in a fluid state in the lymphatic glands, when diseased. Many more instances, were it deemed necessary, might be here adduced in illustration. For further information, the curious reader is referred to the authorities just cited.

The operation of removing the parotid gland has been so frequently performed by surgeons on both sides of the Atlantic, that a detailed account of them here is unnecessary. The parotid gland is the seat of two diseases occurring within itself, and for which extirpation has usually been resorted to. The first is a mere hypertrophy, without any change of structure, but which, according to Sabatier, subsequently may become malignant. The second is that of scirrhus. It is, however, very often removed, when it is consecutively involved in disease originating either in the lymphatic glands or adjacent cellular structure. Among the many cases published, in which the parotid has been extirpated, we find that, in most of them, the gland was secondarily affected; and from this it may be inferred that scirrhus is comparatively of rare occurrence. Scirrhus is now justly considered a species of cancer;† but it is not as malignant when it appears in the parotid gland, as in some other parts of the body. It very often remains stationary for years, and is for the most part of a local character. In its progress, it sometimes assumes the form of an encephaloid cancer, with ulceration on its surface, which ulceration differs from that usually found in cancer located in other conglomerate glands, as for instance in a cancerous mamma, where the sore extends itself in the manner of exfoliation or sloughs on different parts of the surface; while in that of the parotid gland, the parts appear to be destroyed by the process of suppuration. With this view, then, of the disease, as well as in consideration of the highly vascular endowment of this gland, the operation of tying the common carotid artery for its cure, suggested itself to me; and this I have practised in several instances with entire success.‡ The operation of placing a ligature on the carotid artery is not very painful or dangerous in itself; and if not successful in causing an atrophy of the tumor, it cannot in any way interfere with its removal afterwards by the knife. Moreover, the patient may thus be saved the danger of a very severe and uncertain operation; for when it returns after an attempt to remove it, it occupies the same position, and, unlike cancerous affections elsewhere, the viscera of the chest and abdomen never become subsequently affected, as is too frequently the

* Chomel; Dupuytren, *Anatomie Pathologique*; *Archives de Médecine*, tom. v.; *Dictionnaire de Sciences Médicales*; Laennec de *l'Auscultation Médiate*; *Dictionnaire de Médecine*, 1841; *Surgical Observations on Tumors*, by Prof. Warren.

† See Muller, Warren's Walshe, and others.

‡ See cases in *New York Lancet*, Vol. ii., p. 74.

case when the breast is the seat of the disease. Such, at least, is the result of my own observation.

The extirpation of the parotid gland is now become one of frequent occurrence, comparatively. It was performed in the United States as early as 1804, by the father of Prof. J. C. Warren, of Boston,* and in 1808 by Dr. Samuel White, of Hudson; and since then by Drs. McClellan, Randolph, and Prof. Gibson, of Philadelphia, by Drs. Mott, Parker, and Bush, of New York, and by Dr. N. R. Smith, of Baltimore.

* See page 287 of Warren's Surgical Observations on Tumors.

