

The anatomist's vade-mecum : containing the anatomy and physiology of the human body / by Robert Hooper.

Contributors

Hooper, Robert, 1773-1835.
Dana, James Freeman, 1793-1827
National Library of Medicine (U.S.)

Publication/Creation

Windsor [Vt.] : Published by Preston Merrifield ..., Farnsworth & Churchill, printers, 1809.

Persistent URL

<https://wellcomecollection.org/works/krawdku2>

License and attribution


This material has been provided by This material has been provided by the National Library of Medicine (U.S.), through the Medical Heritage Library. The original may be consulted at the National Library of Medicine (U.S.) where the originals may be consulted.

This work has been identified as being free of known restrictions under copyright law, including all related and neighbouring rights and is being made available under the Creative Commons, Public Domain Mark.

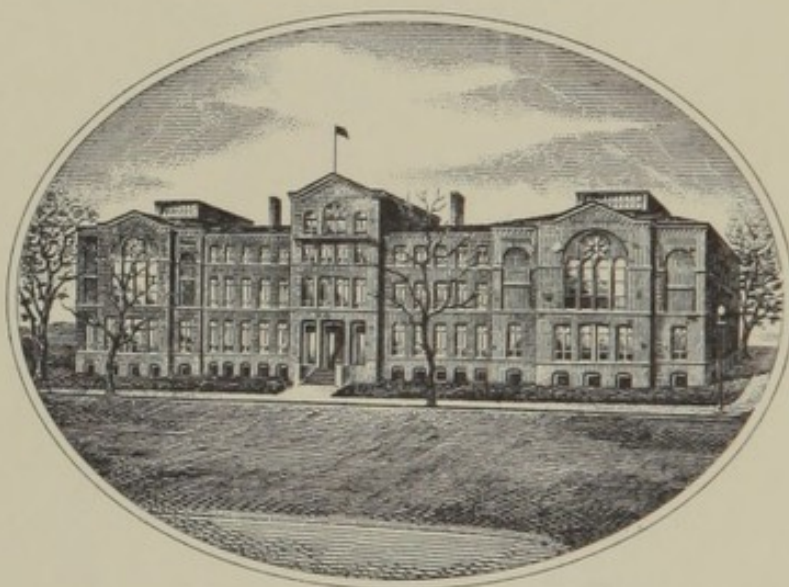
You can copy, modify, distribute and perform the work, even for commercial purposes, without asking permission.



Wellcome Collection
183 Euston Road
London NW1 2BE UK
T +44 (0)20 7611 8722
E library@wellcomecollection.org
<https://wellcomecollection.org>




NATIONAL LIBRARY OF MEDICINE
Washington





Founded 1836

U. S. Department of Health, Education, and Welfare
Public Health Service



45/209
28/2
45/209
28/2
45/209
28/2
J.F. Dana.
B.F.D. Dana





J. H. Dana
Samuel J. Dana
THE

ANATOMIST'S

VADE-MECUM:

CONTAINING THE

ANATOMY AND PHYSIOLOGY

OF THE

HUMAN BODY.

BY ROBERT HOOPER,

OF PEMBROKE COLLEGE, OXFORD, M. D. F. L. S. &c.

Nisi utile est quod facimus, stulta est gloria.

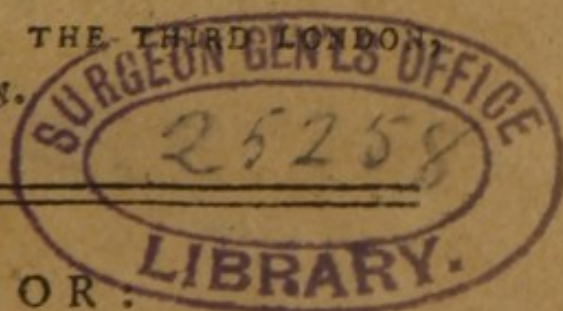SECOND AMERICAN, FROM THE THIRD LONDON
EDITION.

WINDSOR:

PUBLISHED BY PRESTON MERRIFIELD,
Sign of the Bible.

FARNSWORTH & CHURCHILL, Printers:

1809.






INTRODUCTION.

IT is the intention of the writer, in the following Compendium, to present to the student a useful anatomical conspectus, or pocket manual of anatomy and physiology ; giving a short but accurate description of the different parts of the human body and their functions ; with a glossary, or explanation of the principal terms used in that science.

The utility of such a performance will be generally acknowledged, especially when it is considered that there is no such work written upon a similar plan.

The motive that induced the author to form and collect together, in one small pocket volume, this elementary production, was his having himself experienced the want of such an assistant when applying to that branch of philosophy. He, therefore, solicits permission to recommend it to students, not as a work wherein any thing new is to be met with, but merely as their occasional companion in the prosecution of their studies.

St. MARYLEBONE INFIRMARY,
September 23, 1800.



CONTENTS.

	PAGE.
I NTRODUCTION	3
ANATOMY, <i>Division of</i>	9
OSTEOLOGY	<i>ib.</i>
<i>Table of the bones</i>	11
<i>Bones of the Cranium</i>	13
<i>Face</i>	28
<i>Cavities of the Face</i>	35
<i>Bones of the Trunk</i>	39
<i>Chest</i>	41
<i>Loins</i>	42
<i>Pelvis</i>	43
<i>upper Extremity</i>	45
<i>lower Extremity</i>	49
PERIOSTEUM	53
CARTILAGES	<i>ib.</i>
OSTEOGENY	54
CONNEXION OF BONES	57
SYNDESMOLOGY	59
MYOLOGY	66
<i>Muscles of the Cranium</i>	69
<i>Eyelids</i>	<i>ib.</i>
<i>Eyeball</i>	70
<i>Nose and Mouth</i>	<i>ib.</i>
<i>external Ear</i>	72
<i>internal Ear</i>	73
<i>lower Jaw</i>	74
<i>Muscles about the Neck</i>	75
<i>Fauces</i>	78
<i>Pharynx</i>	79
<i>Glottis</i>	80
<i>-----of the Abdomen</i>	81
<i>Male Organs</i>	82
<i>Anus</i>	83
<i>Female Organs</i>	84
<i>Thorax</i>	86
<i>upper Extremity</i>	92
<i>Muscles of the Os Humeri</i>	94
<i>on the Fore-arm</i>	95
<i>Hand</i>	98

	PAGE
<i>of the lower Extremity</i>	99
<i>on the Thigh</i>	101
<i>Muscles on the Leg</i>	103
<i>Foot</i>	105
PHYSIOLOGY AND PHENOMENA OF MUSCULAR MOTION	107
BURSALOGY	110
ANGIOLOGY	117
<i>Arteries</i>	118
<i>Action of Arteries</i>	131
<i>Veins</i>	ib.
<i>Action of Veins</i>	138
<i>Absorbents</i>	ib.
<i>Physiology of Absorption</i>	143
<i>Sanguification</i>	144
NEUROLOGY	145
<i>Nerves of the Brain</i>	146
<i>spinal Marrow</i>	152
<i>Great intercostal Nerves</i>	158
<i>Physiology of the Functions of the nervous system</i>	159
<i>Smelling</i>	160
<i>Seeing</i>	ib.
<i>Hearing</i>	161
<i>Tasting</i>	162
<i>Touching</i>	163
ADENOLOGY	164
<i>Glands of the Skin</i>	165
<i>Cranium</i>	ib.
<i>Neck</i>	167
<i>Thorax</i>	168
<i>Abdomen</i>	169
<i>Male Organs</i>	170
<i>Female Organs</i>	171
<i>Physiology of Secretion</i>	172
SPLANCHNOLOGY	173
<i>Common Integuments</i>	175
<i>Physiology of Perspiration</i>	176
<i>Viscera of the Head</i>	177
<i>Dura Mater</i>	178
<i>Membrana arachnoidea</i>	179
<i>Pia Mater</i>	ib.
<i>Brain</i>	ib.
<i>Cerebellum</i>	180

	<i>Page</i>
Medulla oblongata	181
spinalis	ib.
Action of the Cerebrum, Cerebellum, Me- dulla oblongata, and Medulla spinalis	} 182
Eye	183
Ear	185
Nose	186
Mouth	187
Physiology of Mastication	ib.
Tongue	188
Fauces	189
Pharynx	ib.
Œsophagus	190
Physiology of Deglutition	ib.
Larynx	191
Physiology of the Voice	192
Speech	ib.
Ventriloquism	193
Trachea	ib.
Breasts	194
Pleura	195
Diaphragm	ib.
Lungs	196
Physiology of Respiration	197
Pericardium	198
Heart	199
Circulation of the Blood	202
Of the Abdomen and its Viscera	204
Peritoneum	ib.
Omentum	205
Stomach	ib.
Digestion, or Chymification	207
Intestines	ib.
Chylification	210
Expulsion of the Fæces	211
Mesentery	ib.
Liver	212
Gall-Bladder	ib.
Spleen	213
Pancreas	214
Lacteals	ib.
Kidneys	215
Excretion of the Urine	ib.

	<i>PAGE</i>
Supra-renal Capsule	216
Of the Pelvis	ib.
Urinary Bladder	217
Male Organs of Generation	ib.
Penis	ib.
Testicles	219
Secretion and Excretion of the Semen	220
Vesiculæ seminales	221
Female Organs of Generation	222
Vagina	ib.
Uterus	223
Physiology of Menstruation	ib.
Physiology of Conception	224
Of the gravid Uterus	226
Placenta	ib.
Funiculus umbilicalis	ib.
Membranous Ovum of the Fœtus	227
Liquor Amnii	ib.
Fœtus	228
Peculiarities in the arterial and venal System of the Fœtus	} ib.
Circulation of the Blood in the Fœtus	229
HYGROLOGY	ib.
The Blood	230
The Lymph	231
The Vapour of the Sheaths of the Nerves	ib.
Fluids in the Cavity of the Cranium	232
Nostrils	ib.
Mouth	ib.
Fauces	233
Eyes	ib.
Ears	235
Neck	ib.
Thorax	236
Breasts	237
Abdomen	ib.
Parts of Generation in Men	239
Women	240
Articulations	241
Bones	ib.
of the common Integuments	ib.
A GLOSSARY	243

ANATOMY,

A SCIENCE which explains the structure and use of every part of the human body.

The examination of brute animals, fishes, reptiles, plants, polypi, &c. in order to illustrate more clearly, or to demonstrate by analogy the structure and functions of man, is called COMPARATIVE ANATOMY.

Anatomy is divided into nine parts—namely,

Osteology,	} or doctrine of the	{	Bones.
Syndesmology,			Ligaments.
Myology,			Muscles.
Bursalogy,			Bursæ mucosæ.
Angiology,			Vessels.
Neurology,			Nerves.
Adenology,			Glands.
Splanchnology,			Viscera.
Hygrology,			Fluids.

OSTEOLOGY,

OR

DOCTRINE OF THE BONES.

BONES are hard substances, composed of animal earth and gluten, which support and form the stature of the body, defend its viscera, and give adhesion to its muscles. SUBSTANCE. *Compact*, as in the bodies of the long bones; *spongy*, as in the extremities of the long bones; and *reticular*, called also the *cancelli* of bones, as in the cavities of bones which have marrow. COLOUR. Whitish. FIGURE. Various. DIVISION. Long and irregular shaped bones are

divided into a body and extremities; and flat bones into body and margins. Bones are variously NAMED; some from their situation, as the frontal, parietal, occipital, nasal, malar, &c.; others, from their figure, as the ethmoid bone, clavicle, os cuboides, naviculare, tibia, &c.; and some from their use, as the sphænoid bone, the maxillary bone, the femur, &c. The *processes* & *cavities* of bones are named after their figure, as the acetabulum of the os innominatum, the odontoid process of the second cervical vertebra, the coracoid process of the scapula, &c.; or from their use, as the trochanters of the thigh bone; or from their situation, as the nasal, palatine, orbital processes, &c. &c.

When the bones are deprived of their soft parts, and hung together, in their natural situation, by means of wire, the whole is termed an *artificial skeleton*: but when they are kept together by means of their ligaments, it is called a *natural skeleton*.

A Table of the Bones.

		No.		
Bones of the HEAD.	The bones of the <i>cranium or skull</i>	Os frontis	1	
		Ossa parietalia	2	
		Os Occipitis	1	
		Ossa temporalia	2	
		Os ethmoides	1	
		— sphænoides	1	
	The bones of the <i>face</i>	Ossa maxillaria sup.	2	
		— jugalia	2	
		— nasalia	2	
		— lachrymalia	2	
		— palatina	2	
		— spongiosa infer.	2	
		Os vomer	1	
		— maxillare infer.	1	
	<i>Dentes, or teeth.</i>	Incisores	8	
		Cuspidati	4	
		Bicuspides	8	
		Molares	8	
		Sapientia	4	
	Bone of the <i>tongue</i> , or	Os hyoides	1	
	Bones of the internal <i>ear</i> , situated with- in the temporal bone	Malleus	2	
		Incus	2	
		Stapes	2	
		Os orbiculare	2	
Bones of the TRUNK.	The <i>spine</i>	Vertebrae { Cervical	7	
		{ Dorsal	12	
		{ Lumbar	5	
	The <i>thorax</i>	Sacrum	1	
		Os coccygis	1	
	The <i>pelvis</i>	Sternum	1	
		Ribs	24	
		Ossa innominata	2	
				116

Bones of the Upper EXTREMITIES.

The shoulder	{ Clavicula -	2	
	{ Scapula -	2	
The arm	Os humeri -	2	10
The fore-arm	{ Ulna -	2	
	{ Radius -	2	
The hand	{ Carpus, or wrist	Os naviculare	2
		lunare	2
		cuneiforme	2
		orbiculare	2
		trapezium	2
		trapezoides	2
		magnum	2
		unciforme	2
	Metacarpus	-	10
	Phalanges	-	28

Bones of the Lower EXTREMITIES.

The thigh	Os femoris -	2	
The leg	{ Patella -	2	
	{ Tibia -	2	
	{ Fibula -	2	6
The feet	{ Tarsus	Os calcis	2
		astragalus	2
		cuboides	2
		naviculare	2
		cuneiformia	6
	Metatarsus	-	10
	Phalanges	-	28
			14

240

Sesamoid bones of the thumb and great }
toe, occasionally found } 8

Total 248

The skeleton is divided into head, trunk, and extremities.

OF THE HEAD.

The head is divided into the cranium and face.

OF THE CRANIUM, OR SKULL.

SHAPE. Various, according to the customs of different nations, the bones of the child being so tender as to be moulded into almost any form. It is COMPOSED of eight bones—viz. one os frontis, which forms the forehead; two ossa parietalia, situated at the upper part and sides of the head; two ossa temporum, placed below the parietal bones; one occipital, forming the back part of the head; one sphænoidal, placed in the middle of the basis of the cranium; and one ethmoid, situated behind the root of the nose.

Upon viewing the superior part of a skull externally, several zigzag lines are observable: that which extends from one temple across over the head to the other temple is termed the *coronal suture*; it unites the frontal bone to the two parietal: that which proceeds from behind one ear upwards across to the other is the *occipital* or *lambdoidal suture*: it unites the occipital bone to the two parietal: and the suture which

extends upon the crown of the head, from the lambdoidal to the coronal, uniting the two parietal bones, is called the *sagittal*. They are sometimes termed the *true sutures*, to distinguish them from two *spurious* or *squamous*, which are found, one on each side of the cranium, extending from the temple backwards, in the form of an arch, and uniting part of the temporal bone to the parietal. There are, sometimes, one or more triangular shaped bones observed in the course of some of the sutures ; these are called *ossicula triquetra*, *triangularia*, or *Wormiana*. Besides these sutures, there are several *prominences* upon the upper part of the cranium ; two in the frontal bone, one immediately over each eye between it and the suture ; one in the middle of each parietal bone ; and one in the middle of the occipital : these eminences point out the centre of ossification of those bones.

Upon the internal surface of the upper part of the cranium there are a number of *grooves*, in an arborescent form ; they are made by the spinous artery of the dura mater. The sutures are here seen in the form of a line, not dovetailed, and the whole surface appears more polished than the external.

The bones forming the upper part of the skull, or, as it is sometimes called, the calvaria, are composed of an *external* and an *internal table*, which are of a compact structure, and of a spongy intervening substance, called the *medullæ*, or *diploe*.

The internal surface of the basis of the cranium is divided naturally into eight considerable *depressions*, adapted to the lobes of the brain and cerebellum. the two *anterior* are immediately over the orbits, and are separated from each other by an obvious eminence, above the root of the nose, called *crista galli*. Immediately before this eminence is a small hole, called the *foramen cæcum*; and on each side of it are a number of perforations, which transmit the olfactory nerves into the nose; they are called the *foramina cribrosa*. Passing backwards, there are two round holes, near each other, one going to the bottom of each orbit; these are for the passage of the optic nerves, and are called *foramina optica*: beyond these holes there is a small cavity, which will admit the end of one's little finger, surrounded by four processes, two of which are *anterior* and two *posterior*; these are termed *clinoid processes*, and the cavity in their middle, which contains the pituitary gland,

the *sella turcica*. Under each anterior clinoid process is a considerable fissure, the *foramen lacerum orbitale superius*, which communicates with the orbit, and transmits the third, fourth, the first branch of the fifth, and the 6th pair of nerves, and the ophthalmic artery. Beyond this fissure, proceeding backwards, there is a round and then an oval hole; the first is the *foramen rotundum*, through which the second branch of the fifth pair of nerves passes; the other, the *foramen ovale*, for the passage of the third branch of the 5th pair of nerves. Contiguous to the *foramen ovale* is a small hole, the *foramen spinosum*, through which the spinous artery of the dura mater enters. Between the *foramen ovale* and the posterior clinoid process, on each side of the *sella turcia*, there is a considerable ragged aperture, the *carotid canal*, which is partly filled up with cartilage in the fresh subject, and is for the entrance of the carotid artery and the exit of the great intercostal nerve. A projecting portion of bone next presents itself, called the *petrous portion* of the temporal bone: It has upon its posterior surface an oval opening the *meatus auditorius internus*, through which the nerve for the organ of hearing, and the facial nerve, enter. Immediately below this is

an irregular oval opening, formed by the junction of the occipital with the temporal bone ; this is the *foramen lacerum in basi cranii* : through the anterior parts passes the eighth pair of nerves, and the posterior part transmits the blood from the lateral sinus of the dura mater, whose course is marked by a *deep groove* leading to the foramen lacerum, into the jugular vein. The portion of bone which proceeds backwards from the posterior clinoid processes, between the petrous portions of the temporal bone, is the *cuneiform process* of the occipital bone ; it is somewhat *hollowed* for the reception of the medulla oblongata, which lies upon it. At the bottom of this process bone is a considerable opening, called the *foramen magnum occipitale* ; it transmits the spinal marrow, the vertebral arteries, and the accessory nerves of Willis, and a process of the second vertebra of the neck lies in its anterior part. Between this opening and the foramen lacerum in basi cranii is the *foramen condyloideum anterius*, which gives passage to the lingual pair of nerves. Beyond the great occipital foramen is a *crucial eminence*, to which processes of the dura mater are attached ; the horizontal eminence sepa-

rates the two *superior occipital cavities* from the two *inferior*.

FRONTAL BONE.

SITUATED in the anterior part of the skull, forming the forehead and upper part of the orbits. FIGURE like a cockle-shell. PROCESSES. Two *frontal eminences*, which mark the centres of ossification ; two *frontal tuberosities*, which are situated over the frontal sinuses ; two *superciliary ridges* or *arches*, which give origin to the frontal muscles, and whose extremities are called the angular or orbital processes ; an *external frontal spine*, upon which the ossa nasi rest ; an *internal frontal spine*, to which the dura mater adheres ; and two *orbital plates*, which separate the orbits from the cavity of the cranium. CAVITIES. The *cerebral cavity* which contains the anterior portions of the hemispheres of the brain : a large *notch* between the orbital plates for the situation of the cribriform plate of the ethmoid bone ; two *frontal* or *pituitary sinuses* within the bone, above the root of the nose ; two *orbital cavities*, in which are two depressions for the situation of the lachrymal gland ; a *notch* in each superciliary ridge for

the trochlea of the superior oblique muscle ; a *superciliary foramen*, through which passes the frontal artery and nerve ; the *foramen cæcum*, situated below the beginning of the internal frontal spine. **CONNEXION.** The frontal bone is connected with the two parietal by means of the coronal suture ; with the two ossanasi, the two superior maxillary bones and the two lachrymal bones, by means of what is called the *transverse suture* ; with the sphænoid bone by means of harmony, called *harmonia sphænoidalis* ; with the ethmoid bone by *harmonia ethmoidalis*, and with the os jugale, by means of suture. The **USE** of the frontal bone is to constitute the forehead, pituitary sinuses, part of the orbit, and to contain and defend the anterior lobes of the brain.

PARIETAL BONES.

SITUATION. One on each side of the superior part of the cranium. **FIGURE.** Arched, and somewhat quadrangular. **DIVISION.** Into an *external* and an *internal surface* and four *angles*, viz. the *frontal*, *sphænoidal*, called also the *spinous process*, the *occipital* and *mastoid*.

CAVITIES. A *semicircular ridge*, from which the temporal muscle originates ; and the *foramen parietale*, which is near the sagittal suture, and transmits an artery and a vein of the dura mater. Upon its internal surface are the *grooves of the spinous artery* ; and when the two bones are united, there is a deep *cavity* extending along the sagittal suture, for the longitudinal sinus of the dura mater. Each parietal bone is **CONNECTED** with its fellow by means of the sagittal suture ; with the frontal bone by the coronal suture ; with the occipital by the lambdoidal suture ; and with the temporal by the squamous suture. The **USE** of these bones is, to form the superior part of the cranium—**SYNONIMS.** Ossa verticis, syncipitis, verticalia vel bregmatis.

OCCIPITAL BONE.

SITUATION. In the posterior part of the cranium. **FIGURE.** Quadrate oblong. **EXTERNAL PROCESSES.** The *occipital tubercle*, in the middle of the bone to which the ligamentum nuchæ adheres ; a *transverse spine*, proceeding from each side of the tubercle, to which the trapezius and complexus muscles are attached ; a *lesser transverse spine*, below the former, for

the insertion of the recti muscles ; a *prominent ridge* running downwards from the occipital tubercle, and forming, with the above mentioned ridges, a *crucical spine* ; the *cuneiform* or *basilary process*, situated before the great foramen ; two *condyloid processes* or *condyles*, which are united to the first vertebra of the neck.

INTERNAL PROCESSES. An *internal crucical spine* ; the superior branch gives adhesion to the longitudinal sinus of the dura mater, the two lateral, to the lateral sinuses and the inferior to the septum cerebelli. CAVITIES. The *foramen magnum occipitale*, through which the spinal marrow proceeds into the spine, and the vertebral arteries and accessory spinal nerves into the cranium ; two *anterior condyloid foramina*, for the passage of the lingual pair of nerves ; two *posterior condyloid foramina* (which are sometimes wanting,) for the passage of the occipital vein into the lateral sinus ; two *notches*, which, with two corresponding notches of the temporal bones, form the *foramina lacerata in basi cranii*, for the passage of the blood from the lateral sinuses in the jugular vein and the exit of the parvagus ; a considerable *groove* leading to the above notches, in which the lateral sinuses are situated. The internal surface has also

four considerable *depressions* formed by the *crucial spine*: the two superior contain the posterior lobes of the brain, and the two inferior, the two lobes of the cerebellum. **CONNEXION.** The occipital bone is connected by the cuneiform process to the sphænoid bone, in the adult by synostosis; hence Professor Soemmering describes them as one bone, *os occipito-sphænoidale*; but in youth by synchondrosis; with the two parietal and two temporal bones by the lambdoidal suture; with the first vertebra of the neck by ginglymus, and with the second by syndesmosis. **THE USE** of the occipital bone is to constitute the posterior and inferior part of the cranium; to contain the posterior lobes of the brain, the cerebellum and medulla oblongata, and to serve for the articulation of the head with the spine. **SYNONYMS.** *Os basilare, os memoriæ, and os nervosum.*

SPHÆNOID BONE.

SITUATED in the middle of the basis of the cranium, extending underneath from one temple across to the other. **FIGURE.** Irregular, compared to a bat with its wings extended. **EXTERNAL PROCESSES.** Two *alæ majores*,

whose anterior part forms a portion of the orbit; the inner surface has lying upon it a portion of the middle lobe of the brain, and the whole external surface is covered by the temporal muscle. Two *spinous processes*, a narrow point projecting behind each foramen spinosum. The *sphænodal spine*, or *azygous process*, upon which the basis of the vomer lies. Two *pterygoid processes*, each of which is distinguished into a root and two extended plates, or wings; one external, which gives origin on its external surface to the pterygoideus externus muscle, and on its internal surface to the pterygoideus internus muscle; and the other internal. Two *hamular* or *hook-like processes*, one on the end of the internal wing of each pterygoid process, over which the tendon of the circumflexus or tensor palati muscle turns. INTERNAL PROCESSES. Two *alæ minores*, which form the upper part of the superior orbital fissures. Four *clinoid processes*, two *anterior* and two *posterior*. EXTERNAL CAVITIES. The *sphænodal pituitary sinus*, which is in the middle of the bone, has a communication with the nostrils, and is divided by an intermediate septum. Two *pterygoid depressions*, one between each greater and lesser wing, for the reception

pter

pterygoideus

of a part of the palate bone. Two *foramina*, each leading to a canal, called the *ptergoid* or *Viduan canal*, in the root of the ptergoid process, through which the recurrent or Viduan branch of the fifth pair of nerves passes into the cranium. INTERNAL CAVITIES. The *sellaturcica*, or *ephippium*, which is surrounded by the four clinoid processes, and contains the pituitary gland. Two *foramina optica*, one before each anterior clinoid process, which transmit the optic nerves. Two *grooves*, one on each side of the sella turcica, between the anterior and posterior clinoid processes, formed by the pulsation of the carotid arteries. Two *foramina lacera orbitalia superiora*, between each greater and lesser wing, through which the third, fourth, first branch of the fifth, and the sixth pair of nerves, and the ophthalmic artery pass out of the cranium. Two *foramina rotunda*, for the passage of the second branch of the fifth pair of nerves. Two *foramina ovalia*, for the third branch of the fifth pair. Two *foramina spinosa*, through which the spinous artery of the dura mater enters the cranium. The sphænoid bone is CONNECTED with all the bones of the cranium; with the frontal, the ethmoid, the two parietal, and the two temporal by harmony,

and with the occipital by synostosis: it is also united to the two cheek bones, the two superior maxillary bones, and the two palate bones, by harmony, and to the vomer by gomphosis. Its USE is to form the basis of the cranium, to concur in forming the orbits, the pituitary sinuses of the nose, the temples, &c. and to contain the middle lobes of the brain.—SYNONIMS.—Os multiforme, os cuneiforme, os pterygoideum.

TEMPORAL BONES.

SITUATION. At the sides and inferior part of the cranium. **FIGURE.** Irregular. **DIVISION.** Into a squamous portion, which is flat, and forms the squamous suture; and a petrous portion, which is very irregular, and is situated in the basis of the skull. **PROCESSES.** The *zygomatic process*, which, with a process of the os jugale, forms the *zygoma*, yoke, or arch of the temples, underneath which the temporal muscle moves, and from whose lower edge several muscles of the face arise, particularly the masseter and zygomatic. The *mastoid* or *mammary process*, which projects from under the ear, and has inserted into its anterior part the sterno-cleido-mastoideus, muscle, and into its posterior

part the complexus, the obliquus and trachelo-mastoideus. The *styloid process*, which is long and pointed, and gives origin to a ligament of the os hyoides, also to the stylo-hyoideus, stylo-pharyngeus, and stylo-glossus muscles. The *vaginal process*, which surrounds the root of the styloid. The *auditory process*, or outer bony circle of the auditory passage, to which the membrana tympani and cartilage of the ear are fixed. CAVITIES. The *meatus auditorius externus*, which leads to the cavity of the organ of hearing. The *meatus auditorius internus*, which begins on the internal and posterior surface of the petrous portion, and transmits the seventh pair of nerves; it has immediately within it the internal opening of the aqueduct of Fallopius. Each temporal bone is CONNECTED with the parietal by the squamous suture; with the occipital by the lambdoidal suture; with the sphaenoid and jugular bones by harmony, and with the lower jaw by arthrodia. SUBSTANCE- The squamous portion consists of two tables and a diploe; the mammary process of cells which communicate with the cavity of the organ of hearing; and the petrous portion is very hard and compact. USE. To contain the middle lobes of the brain, and the organ of hearing;

and to concur in forming the temples and the basis of the cranium.

ETHMOID BONE.

SITUATION. In the anterior part of the basis of of the cranium, above the root of the nose and between the orbits. FIGURE. Cubelike. PROCESSES. A *Cerebral* or *cribriform plate*, which lies horizontally above the root of the nose within the cavity of the cranium: it is every where perforated by a number of small foramina, through which the olfactory nerves pass into the cavity of the nostrils. The *crista galli*, a process somewhat like a cock's comb, which proceeds upwards from the middle of the cribriform plate, and has attached to it the falciform process of the dura mater. Two *orbital plates*, called also *ossa plana*, and *plana papyracea*, which are very smooth externally, and form the inner side of the orbits. The *septum ethmoidale*, *nasal plate*, *azygous process*, or *perpendicular lamina*, a considerable process, descending directly under the crista galli into the cavity of the nose, and forming with the vomer the septum narium. Two *cavernous substances*, which are curled, like a piece of parchment, one on each side of the septum,

Sup. meatus. 20

called the superior turbinated, or spongy bones. CAVITIES. A number of *cribriform foraminula*, situated on each side of the crista galli. Two *foramina orbitalia nasi*, one situated in the line of union between the frontal bone and orbital plate of the ethmoid, for the passage of the nasal branch of the orbital nerve. A number of *cells*, which compose the internal part of the bone, and form the pituitary sinuses of the ethmoid bone. The ethmoid bone is CONNECTED with the os frontis, the two nasal bones, the two superior maxillary, the two palatine, the sphaenoid bone, and the vomer by harmony. USE. To form an extensive surface for the organ of smell, to constitute part of the nose, orbits, and cranium.

OF THE FACE.

The bones of the face are fourteen in number, and are DIVIDED into those of the upper and under jaw. The upper jaw is formed of thirteen bones, viz. two superior maxillary, two nasal, two palatine, two jugal, or malar, two inferior spongy, two lachrymal, and the vomer, which are united to the cranium, and with one another, by harmony. The under jaw consists of one bone.

There is an obvious *line*, beginning at the external angle of the orbit, where the frontal bone is united to the cheek bone, which leads to the inferior opening in the orbit, proceeds upwards to the nose, whose root it crosses, and then traverses the other orbit to the external angle : this is called the *transverse suture*. The other harmonies of the face are named after the bones which they unite, as the *zygomatic, nasal palatine harmonies*, &c.

SUPERIOR MAXILLARY BONES.

SITUATED in the anterior and middle part of the face. FIGURE. Irregular. PROCESSES. The nasal process, which forms the side of the nose. The *orbital process*, or *plate*, which forms part of the orbit. The *malar process*, by which it is united to the cheek bone. The *alveolar process*, in which the teeth are situated. The *palate process*, which forms the palate. A *spine*, formed by the union of each palate portion upon which the vomer rests. The *orbital margin*. CAVITIES. The *antrum maxillare*, called also, *antrum Highmori* and *sinus maxillaris pituitarius*, in the body of the bone, between the orbital and palate processes ; it has an opening

into the nostrils. The *infra-orbital canal*, which opens under the margin of the orbit, and transmits the infra-orbital nerve. The *lachrymal depression*, situated in the superior and internal part of the nasal process, for the situation of the lachrymal sac; it leads to the *canalis nasalis*, which conveys the tears into the nostrils. The *posterior palatine foramen*, near the last tooth on the inside, for the passage of the alveolar nerve. A *notch* on the anterior part of the palatine process, which with the corresponding notch of the other superior maxillary bone, forms the *foramen palatinum anticum*, or *foramen incisivum*, which transmits the anterior palatine nerve and artery. **CONNEXION.** Each superior maxillary bone is connected with its fellow, with the os frontis, one os nasi, one lachrymal bone, the ethmoid, sphænoid, one os jugale, one palatine bone, and one inferior spongy bone, by harmony, and with the vomer and teeth by gomphosis. **USE.** The use of these bones is to form part of the face, palate, nose, nostrils and orbits, and to afford a convenient situation for the organ of mastication.

JUGULAR, OR MALAR BONES.

SITUATION. At the sides of the face. FIGURE. Almost quadrate. PROCESSES. The *upper orbital process*, which forms part of the orbit and the sharp edge of the temple. The *inferior orbital process*, opposite to the former, and constituting in part the bottom of the orbit and the edge of the cheek. The *internal orbital process*, which also forms a part of the orbit. The *maxillary process*, by which it is joined to the superior maxillary bone. The *zygomatic process*, which is joined to the temporal bone, to form the zygoma. *2480* CONNEXION. The os jugale is united to the frontal, superior maxillary, sphæ-noid and temporal bone. The USE of these bones is to assist in forming the face and orbits.

OSSA NASI, OR BONES OF THE NOSE.

SITUATED in the superior and middle part of the nose. FIGURE. Quadrangular and oblong. SUBSTANCE. Compact. USE. To form the bridge and external part of the nose. Each bone is CONNECTED with its fellow, and the superior maxillary bone by harmony and with the frontal and ethmoid by the transverse suture.

LACHRYMAL BONES.

SITUATION. In the internal angle of the orbit. **FIGURE,** like the nail of the finger. **CAVITIES.** A groove, which holds the lachrymal sac. **SYNONIM.** Os unguis. **CONNEXION.** Each bone is connected with the frontal, ethmoid, superior maxillary and inferior spongy bone by harmony.

INFERIOR SPONGY BONES.

SITUATED in the side and lower part of the nostrils. **FIGURE.** Spiral, and convoluted. **USE.** To augment the surface of the organ of smelling. **CONNEXION.** Each bone is united with the superior maxillary, the palate, lachrymal and ethmoid bone by harmony. **SYNONIMS.** Ossa turbinata inferiora, conchæ inferiores.

PALATINE BONES.

SITUATED in the posterior part of the nose, from which they ascend laterally to the orbits. **FIGURE.** Irregular. **DIVISION.** Into palatine, pterygoid, nasal, and orbital portions. **PROCESS-**

ES. The *palatal plate*, which forms the posterior part of the roof of the mouth. The *pterygoid process*, which is situated behind the last grinder. The *nasal process*, which arises perpendicularly from the palate, and covers a part of the antrum of Highmore. The *orbital process*, which is situated in the orbit. **CAVITIES.** The *palatine cells*, which communicate with, and form part of the sphæmoid cells. **USE.** To form the posterior part of the palate and part of the nose and orbit. Each bone is **CONNECTED** with its fellow, with the superior maxillary bone, the sphæmoid, ethmoid, inferior spongy bone and vomer by harmony.

VOMER.

SITUATED in the middle of the cavity of the nostrils, which it divides into two parts. **FIGURE.** It resembles a ploughshare. **USE.** To sustain and divide the cavity of the nostrils. **CONNECTION.** Superiorly it is united with the sphæmoid bone by gomphosis, and with the ethmoid by harmony ; inferiorly with the superior maxillary and palatine bones by harmony ; anteriorly it is united to the cartilaginous septum of the nose.

LOWER JAW BONE.

SITUATION. In the inferior and anterior part of the face. **FIGURE,** like an horseshoe. **PROCESSES.** Two *condyloid*, or *articulatory processes*, which are received into the articulatory cavities of the temporal bones. Two *coronoid processes*, which are sharp pointed, and give adhesion to the temporal muscles. The *alveolar process*, in which the teeth are fixed. The *symphysis* of the jaw, in the middle of the chin. The *inferior margin*, whose ends form the angles of the jaw. **CAVITIES.** A *semilunar notch*, between each coronoid and condyloid process. Two *posterior maxillary foramina*, one above each angle on the inner surface of the jaw, which transmit the lower maxillary nerve and artery into a *canal* in the middle of the bone, called *canalis mentalis*, which conducts the same artery and nerve to the *anterior maxillary foramina*, upon the external surface of the bone, one on each side of the chin, from whence the artery and nerve again emerge upon the chin. **USE.** To retain the roots of the teeth in the alveolar margin; to constitute the inferior segment of the cavity of the mouth, and to af-

ford a point of adhesion to the muscles of the face, neck, larynx, and tongue. CONNEXION. The lower jaw is connected with the temporal bones by ginglymus, with the teeth by gomphosis, and with the os hyoides and other parts by syssarcosis. SYNONIMS. *Mandibula.*

OF THE CAVITIES OF THE FACE IN PARTICULAR.

ORBITS.

SITUATED under the forehead, at the root of the nose. FIGURE, canoid. The angles of the orbits are called *canthi*. CAVITIES. A *depression* for the lachrymal gland ; a *notch* of the orbital trochlea ; a *depression* for the lachrymal sac ; the *canalis nasalis* for the passage of the tears ; a *superior* and *inferior*, or *sphæno-maxillary orbital fissure*. The *superciliary foramen* ; the *infra-orbital canal* ; the *foramen nasale*, and the *optic foramen*. COMPOSED of seven bones ; the frontal maxillary, jugal, lachrymal ; ethmoid, palatine, and sphenoid. USE, to contain and defend the organ of sight and its adjacent parts.

CAVITY OF THE NOSTRILS.

SITUATED under the anterior part of the cranium, in the middle of the face. FIGURE, pyramidal. PROMINENCES. The *septum narium*; the *cavernous substance* of the ethmoid bone, improperly called the superior spongy bones; and the *inferior spongy bones*. CAVITIES. Three pair of *pituitary sinuses*, namely the frontal, sphaenoid, and maxillary; the *caverns* of the ethmoid labyrinth; the *anterior foramina* of the nostrils; the *ductus nasalis*; the *sphaenopalatine foramina*, and the *anterior palatine foramina*. COMPOSED of 14 bones, viz. the frontal; two maxillary; two nasal; two lachrymal; two inferior spongy; the sphaenoid, vomer, ethmoid, and two palatine bones. USE, to form the organ of smelling and the pituitary sinuses of the nostrils, and to serve also for speech and respiration.

CAVITY OF THE MOUTH.

SITUATED between the upper and under jaw. FIGURE, anteriorly ovate. DIVIDED into upper and under jaw. COMPOSED of five bones, viz. two superior maxillary; two palatine; the

lower jaw-bone, and 32 teeth. *Use*, for mastication, speech, and respiration.

TEETH.

SITUATED in the alveoli or sockets of the jaws. *NUMBER*, commonly 32, 16 in each jaw. *DIVIDED* into four kinds, *incisores*, or front teeth, four in each jaw; *cuspidati*, one on each side of the incisores; *bicuspides*, two on the side of each cuspidatus; and *molares*, or grinders. Each tooth is divided into a crown, neck, and root. The substance of the root and internal part of the crown is compact; the external surface is very hard, of a shining white colour, and is called the *enamel*. *Use*, for mastication, and pronunciation, of dental syllables. The teeth are *CONNECTED* with the jaws by gomphosis.

CAVITY OF THE FAUCES.

SITUATED under the basis of the cranium, within the superior bodies of the vertebræ and posterior part of the nostrils. *FIGURE*, superiorly quadrate. *COMPOSED* of 10 bones, viz. the occipital; two palatine; the vomer; the bodies of the three first vertebræ; the *os hyoides*, and the two temporal bones. *Use*, for the sit-

uation of the fauces, larynx, pharynx, and os hyoides.

OS HIOIDES.

SITUATED in the fauces, between the basis of the tongue and Larynx. FIGURE, semilunar. PROMINENCES, two *cornua majora*, and two *cornua minora*. USE, to serve for the adhesion of the tongue ; for deglutition ; and for a point of adhesion to many muscles. SYNONIM. Os linguale. CONNEXION. It is connected with the styloid process of the temporal bone, the scapulæ, lower jaw, and sternum, by various muscles, and with the larynx by ligament.

CAVITY OF HEARING.

SITUATED internally in the petrous portion of each temporal bone. DIVISION, into meatus auditorius externus ; cavity of the tympanum ; labyrinth ; and meatus auditorius internus. In the *cavity of the tympanum* are, the orifice of the Eustachian tube ; mastoid sinuosity ; the fenestra ovalis ; the fenestra rotunda, and the ossicula auditus. The *labyrinth* consists of the cochlea, vestibulum and semicircular canals. The *cochlea* has a basis, apex, modiolus, scala vestibula, scala tympani, and a spiral lamina.

The *vestibulum* has a foramen ovale, and the orifices of the semicircular canals. USE. The cavity of hearing is the organ in which hearing is performed.

OSSA CULA AUDITUS.

ossicula
SITUATED in the cavity of the tympanum. NUMBER 4, viz. malleus ; incus ; stapes, and os orbiculare. SUBSTANCE, compact. USE, for hearing.

OF THE TRUNK.

THE trunk of the skeleton is divided into the spine, chest, loins, and pelvis.

SPINE.

A long column, or pillar, which extends in the posterior part of the trunk from the occipital bone to the os sacrum. COMPOSED of 24 bones, called *vertebræ*, viz. 7 of the neck, 12 of the back, and 5 of the loins. Each *vertebræ* is DIVIDED into a *body*, and 7 *processes*, viz. the spinous, 2 superior oblique, 2 inferior oblique, and 4 transverse processes. CAVITIES. The *spinal canal*, called *specus*, or *theca vertebralis* ; and the *lateral foramina* of the *vertebræ*. CONNEXION. The first bone of the spine is connect-

ed with the occipital bone by ginglymus. The second vertebræ is united with the first by trochoides, and with the occipital bone by syndesmosis. The bodies of the vertebræ are connected with one another by peculiar intervertebral substance ; and posteriorly by a yellow elastic ligament and by their oblique processes. Use, to support the head and trunk, and to contain and defend the spinal marrow. SYNONIMS. Spina dorsi, columna spinalis, columna vertebralis.

CERVICAL VERTEBRÆ.

The first vertebræ is called atlas. PECULIARITIES. No body nor spinous processes, but forms an *arch*, which anteriorly surrounds the dentiform process of the second vertebræ. Instead of upper oblique processes, there are two *articular sinuses*. The second vertebræ is termed epistrophæus, or dentatus. PECULIARITIES. An *odontoid* or *dentiform process* at the upper part of the body. All the transverse processes of the remaining cervical vertebræ have a peculiar *foramen* for the passage of the vertebral arteries.

DORSAL VERTEBRÆ.

PECULIARITIES. At the sides of the bodies is a *depression*, and a superficial one in the points of the transverse processes, for the attachment of the great and little heads of the ribs.

LUMBAR VERTEBRÆ.

PECULIARITIES. They are much larger than the dorsal, and the transverse processes have no depressions.

OF THE CHEST, OR THORAX.

THE thorax is composed of 12 dorsal vertebræ, 24 ribs, and the sternum.

RIBS.

SITUATED obliquely from the dorsal vertebræ to the sternum. FIGURE, semicircular. NUMBER 24, twelve on each side. DIVISION, into 7 true, which are uppermost, and 5 spurious. EMINENCES. The *great head*, which is connected to the bodies of the dorsal vertebræ; the *neck*; the *lesser head*, which is joined to the transverse processes of the dorsal vertebræ; and the *angle* of the rib. CAVITIES, a longitudinal groove, for the intercostal artery. SUB-

STANCE, anterior part *cartilaginous*, rest *bony* and compact. CONNEXION. Anteriorly with the sternum, and posteriorly with the bodies and transverse processes of the dorsal vertebræ. USE, to form the thorax ; to serve for respiration ; to defend the vital viscera, and to give adhesion to muscles.

STERNUM.

SITUATED in the anterior part of the thorax, between the true ribs. FIGURE, somewhat like a dagger. CAVITIES, the *jugular sinus*, at the superior and inner part ; two *clavicular sinuses*, for the attachment of the clavicles ; and 7 *costal depressions*, to which the ribs adhere. SUBSTANCE, somewhat spongy. USE, to form the thorax, and give adhesion to the mediastinum. CONNEXION. The sternum is connected by arthrodia with the clavicle and with the seven true ribs by synchondrosis.

OF THE LOINS.

THE bones of the loins are five lumbar vertebræ

OF THE CAVITY OF THE PELVIS.

SITUATED in the lower region of the trunk. FIGURE, somewhat like a barber's bason. COMPOSED of 4 bones, viz. two ossa innominata, the os sacrum, and os coccygis. USE, to contain the organs of generation; the bladder; intestinum rectum; and to support the spine.

OSSA INNOMINATA.

SITUATED at the sides of the pelvis. FIGURE, irregular. DIVISION, each bone into three portions, viz. ilium the uppermost, ischium the lowest, and pubis the anterior. EMINENCES. The *crista* of the ilium, from which the oblique and transverse muscles of the abdomen arise---at its posterior part are two *spinous processes*, which give adhesion to ligaments.—at its anterior part are also two *spinous processes*, the *superior* gives adhesion to the sartorius, tensor vaginæ femoris, and the ligament of the thigh; the *inferior anterior spinous process*, about an inch from the former has arising from it the rectus femoris. The *external surface* of the iliac portion is covered by the glutæi muscles; the *internal* by the internal iliac. Upon the internal surface there is a *line* even with the pubis; this is call-

crista: 3 parts X. in. Pub. and nail
nail

ed *linea innominata*, or rim of the pelvis ; it divides the cavity of the abdomen from the pelvis. Upon the ischiatic portion or ischium are, the *tuberosity* of the ischium, upon which we sit ; the *spinous process* of the ischium, which projects backwards, and gives adhesion to the uppermost sacro-sciatic ligament ; the *ramus ischii*, which joins the pubis. Upon the *pubic* portion, or pubis, are the *body*, near the socket ; the *angles* and *arches* of the pubis. CAVITIES, a *notch* between the anterior spines of the ilium ; an *anterior* and *posterior ischiatic notch* ; the *acetabulum*, which receives the head of the os femoris, and the *foramen thyroideum*, or *ovale*. Each os innominatum is CONNECTED with its fellow anteriorly by symphysis, with the sacrum posteriorly by strong cartilages and ligaments, and with the head of the thigh bone by enarthrosis. USE, to form the pelvis ; to retain the gravid uterus in its situation, and to constitute the acetabulum for the thighs.

OS SACRUM.

SITUATED at the posterior part of the pelvis: FIGURE, triangular, bent forwards. EMINENCES, two *superior oblique processes* ; *appearances* of the spinous processes ; *appearances*

of the oblique and transverse processes, and the appearances of the vertebral bodies. CAVITIES, four pair of *external*, and four pair of *internal foramina*, and five *longitudinal middle canals*. USE, to constitute the pelvis, and sustain the spine. CONNEXION. Superiorly with the last lumbar vertebrae, laterally with the ossa innominata, and inferiorly with the os coccygis.

OS COCCYGIS.

SITUATED at the apex of the sacrum. FIGURE, irregular. USE, to sustain the rectum and prevent the rupture of the perinæum in parturition. It is CONNECTED to the apex of the sacrum.

OF THE SUPERIOR EXTREMITIES.

THE bones of the upper extremities are, on each side, the clavicle, scapula, humerus, radius, ulna, bones of the carpus, metacarpus, and fingers.

CLAVICLE.

SITUATED obliquely in the upper and lateral parts of the thorax. FIGURE, like the letter S. CAVITIES, a furrow, or *groove* of the subclavian vessels on the inferior surface. USE, to connect the scapula and humerus to the thorax, and to

defend the subclavian vessels. **CONNEXION.** Anteriorly it is articulated to the sternum, and posteriorly to the scapula, by arthrodia.

SCAPULA.

SITUATED in the upper and lateral part of the back. **FIGURE**, triangular. **EMINENCES.** The *spine*, which is in the middle of the external surface. Its anterior termination is called the *acromion*. The *coracoid process* which stands out opposite to the acromion. The borders of the bone are called *costæ*, and the corners *angles*. The circle below the articular cavity is called the *neck*. **CAVITIES.** The *articular* or *glenoid* cavity, which receives the head of the humerus. The scapula is **UNITED** with the clavicle by arthrodia, with ribs and os hyoides by muscle, and with the humerus by arthrodia. **USE**, to defend the back, and give articulation to the humerus. **SYNONIM.** Omoplata.

OS HUMERI, OR OS BRACHII.

SITUATED between the scapula and forearm. **FIGURE**, long. **EMINENCES**, the *head*, which is rounded on its superior part; the *neck*, which is immediately below the head; the *greater tubercle*, near the neck, which receives the *supra spinatus* muscles; and the *lesser tubercle*,

which is near the former, and has fixed to it the subscapularis. *On the inferior extremity* are three *condyles*, namely, an *external* and an *internal* condyle, which gives origin to the flexor and extensor muscles of the arm; and the trochlea of the humerus. CAVITIES, a furrow between the tubercles, for the long tendon of the biceps. *in the inferior extremity*, a *posterior fossa* for the anconoid process of the ulna, and an *anterior depression*, for the coronoid process. *Use*, to constitute the arm. CONNEXION. The humerus is connected with 3 bones; with the scapula by arthrodia, and the cubit and radius by ginglymus.

CUBIT, OR ULNA.

SITUATED in the inside of the fore-arm, towards the little finger. FIGURE, long, and thicker above than below. EMINENCES, the *olecranon*, or *anconoid process*, upon which we lean, and the *coronoid process* which is opposite to it. In the lower extremity are the *lower head*, the *neck*, and the *styloid process*, which gives a strong adhesion to the ligament which secures the wrist. CAVITIES, the sigmoid cavity, at the upper end. *Use*, to constitute the chief support of the fore-arm. CONNEXION. Superiorly

with the throchlea of the humerus by arthrodia, inferiorly with the carpus by arthrodia, and with the radius by trochoides, as in pronation and supination.

RADIUS.

SITUATED in the external side of the fore-arm, towards the thumb. FIGURE, long. EMINENCES, upper head, which is excavated; the *little head* and the *syloid* process at the inferior extremity. CAVITY, the *glenoid cavity*. USE, to assist in forming the fore-arm, and to serve for flexion, supination and pronation. The radius is CONNECTED to the humerus by ginglymus, to the cubit by an interosseous ligament and trochoides; and to the carpus by arthrodia.

CARPUS, OR WRIST.

COMPOSED of 8 bones, which lie close to each other in a double row. SITUATED between the fore-arm and the metacarpus. DIVISION, into two rows, superior and inferior. *In the superior row* are (from the thumb to the little finger), os scaphoides, or naviculare; os lunare; os cuneiforme; and os orbiculare, or sub-rotundum. *In the lower row*, os trapezium, os trapezoides, os magnum, and os unciforme.

METACARPUS.

SITUATED between the carpus and fingers. COMPOSED of 5 longitudinal bones ; one of the thumb, and four metacarpal bones of the fingers. USE, to form the middle part of the hand.

FINGERS.

SITUATED at the inferior extremity of the metacarpus. COMPOSED of a thumb and four fingers. The thumb has two bones, and each finger three, which are called phalanges. USE, to form the fingers, which are the instruments of touch, defence, and labour.

OF THE INFERIOR EXTREMITIES.

THE bones of the inferior extremity are, the femur, patella, tibia, fibula, the bones of the tarsus, metatarsus, and toes.

FEMUR.

SITUATED between the pelvis and tibia. FIGURE, long. EMINENCES, the *head*, which is received into the acetabulum of the os innominatum, and has a small *dimple* in its middle, for the attachment of the round or restraining ligament ; the *neck*, upon which the head stands, it is rough, and gives attachment to the capsu-

lar ligament ; the *great trochanter*, which is a large eminence below the neck, for the insertion of the *glutæi* muscles ; the *little trochanter*, which receives the *psoas* and *iliacus internus* ; and a rough line on the body of the bone, called *linea aspera*.

On the inferior extremity are the *external* and *internal condyle*, and between them posteriorly a deep *notch*, for the passage of the great artery, vein, and nerve of the leg. **USE**, to form part of the lower extremity. The femur is **CONNECTED** to the acetabulum of the *os innominatum* by *enarthrosis*, and to the tibia and patella by *ginglymus*. **SUBSTANCE**. Compact on its outside ; spongy in the extremities ; and cancellated internally.

TIBIA.

SITUATED in the inside of the leg, between the femur and tarsus. **FIGURE**, longitudinal. **EMINENCES**, the *upper head* of the tibia ; the *spine* of the tibia, to which the great ligament of the patella is fixed ; and the *lower head* of the tibia, which forms the outer ankle. **CAVITIES**, two *articular sinuses*, in the upper head, for the reception of the condyles of the femur ; and the *articular cavity* at the side of the head for the reception of the fibula. **USE**, to sup-

inner

port the leg, and serve for the flexion of the lower extremity. The tibia is CONNECTED to the femur and patella by ginglymus, to the fibula by syneurosis, and to the astragalus by arthrodia.

FIBULA.

SITUATED in the outer part of the leg by the side of the tibia. FIGURE, longitudinal. EMINENCES, the *head* of the fibula, at the upper part, and the *malleolus externus*, or outer ankle, at the lower end. CONNEXION. It is connected to the tibia by an interosseous ligament, and to the astragalus by arthrodia. USE, to form a fulcrum for the tibia, and assist in forming the leg.

PATELLA, ROTULA, OR KNEE-PAN.

SITUATED in the sinus between the condyles of the femur, and above the tibia. FIGURE, somewhat resembles an heart. The patella is CONNECTED to the condyles of the femur, by ginglymus. And with the tibia by syneurosis. USE, to strengthen the knee-joint, and to serve as a common pulley for the extensor muscles of the tibia.

TARSUS:

SITUATED between the leg and metatarsus. FIGURE, in the superior part, headed, and broad below. COMPOSED of seven bones, placed in a double row : *in the first row* are the astragalus and os calcis ; *in the second row*, the os naviculare ; os cubiforme ; and three cuneiform bones, which are placed close to each other. EMINENCES, head of the astragalus, and the tuberosity of the heel. USE, to form the basis of the foot, and to serve for its motion. The CONNEXION of the bones of the tarsus is with the tibia and fibula by arthrodia, and with the metatarsal bones, and also with one another, by amphiarthrosis.

METATARSUS.

SITUATED between the tarsus and toes. COMPOSED of 5 longitudinal bones. USE, to form the-back and sole of the foot.

TOES.

COMPOSITION. The great toe is composed of two small bones ; each toe, of three small bones, called phalanges.

SESAMOID BONES.

SITUATED in the joints, under the phalanges of the thumb and of the great toe.

PERIOSTEUM.

DEFINITION. A membrane which invests the external and internal surface of all the bones except the crowns of the teeth. **NAMES.** *Pericranium* on the cranium ; *periorbita* on the orbits ; *perichondrium*, when it covers cartilages ; and *peridesmium*, when it covers ligaments. **SUBSTANCE,** fibrous, furnished with arteries, veins, nerves, and absorbent vessels. **USE,** to distribute the vessels on the external and internal surfaces of the bones.

CARTILAGES.

DEFINITION. White, elastic, glistening substances, growing to the bones. **DIVISION,** into *obducent*, which cover the articulatory surfaces of bones ; *inter-articular*, which are not accreted to the bones, but adhere to the capsular ligament, and lie between the articulating extremities, as in the knee joint, &c. and *uniting* cartilages which unite bones firmly together, as the symphysis pubis, bodies of the vertebræ, &c. **USE,** to lubricate the articulation of the cartilages ; to connect some bones by an immovable

connexion ; and to facilitate the motion of some articulations.

OSTEOGENY,

OR

DOCTRINE OF THE FORMATION AND GROWTH OF BONES.

OSSIFICATION is a specific action of small arteries, by which ossific matter is separated from the blood and deposited where it is required.

The first thing observable in the embryo, where bone is to be formed, is a transparent *jelly*, which becomes gradually firmer, and is formed into *cartilage*. The cartilage gradually increases to a certain size, and when the process of ossification commences, vanishes as it advances. Cartilages previous to the ossific action are solid, and without any cavity ; but when the ossific action of the arteries is about to commence, the absorbents become very active, and form a *small cavity* in which the bony matter is deposited ; bone continues to be separated, and the absorbents model the mass into its required shape.

The process of ossification is extremely rapid in utero : it advances slowly after birth, and is not completed in the human body till about the twentieth year.

Ossification in the flat bones, as those of the skull, always begins from the *central point*, and the radiated fibres meet the radii of other ossifying points or the edges of the adjoining bone.

In long bones, as those of the arm and leg, the clavicle, metacarpal and metatarsal bones, a *central ring* is formed in the body of the bone, the head and extremities being cartilage, in the central of which ossification afterwards begins. The central ring of the body shoots its bony fibres towards the head and extremities, which extend towards the body of the bone. The head and extremities at length come so close to the body as to be merely separated by a cartilage, which becomes gradually thinner until the twentieth year.

Thick and round bones, as those of the tarsus, carpus, sternum and patella are at first all cartilage : ossification begins in the *centre* of each.

At birth the BONES OF THE FŒTUS are very imperfect. The extremities and processes

of almost all the long bones are connected to the body of the bone by cartilage. These portions of bones are called EPIPHYSES. The cranium has no sutures; its bones are connected together by a firm and almost cartilaginous membrane. On the anterior part of the cranium, between the parietal bones and the frontal, is a considerable membranous space, called the ANTERIOR FRONTANEL, and a similar but smaller one between the parietal bones and the occipital, termed the POSTERIOR FRONTANEL. The frontal bone consists of two bones, and the occipital of four. The teeth are partly formed, especially the enamel, and are placed in a double series. The external auditory foramen is surrounded by a *bony circle*, in which there is a groove for the attachment of the membrana tympani. This circle gradually elongates into the meatus auditorius. The articular cavities of all the bones are much more shallow than in the adult. The os innominatum consists of three bones, the ilium, ischium, and pubis, which are connected together by very firm cartilage. The bodies of the vertebræ and its processes are united by cartilages.

OF THE CONNEXION OF BONES.

BONES are CONNECTED with one another, so as to admit of motion, and this kind of union is termed *diarthrosis* ; or so as to admit of no motion, which is termed *synarthrosis* ; and when connected with one another by an intervening substance, the union is termed *symphysis*. *Diarthrosis*, *synarthrosis*, and *symphysis*, are to be considered as the genera only of articulations, each genus comprehending several species, which are arranged as follows.

GENERA.

SPECIES.

DIARTHROSIS, or moveable Connexion.

Enarthrosis, when the round head of one bone is received into the deep cavity of another, so as to admit of motion in every direction ; as the head of the os femoris with the acetabulum of the os innominatum.

Arthrodia, when the round head of a bone is received into a superficial cavity of another, so as to admit of motion in every direction ; as the head of the humerus with the glenoid cavity of the scapula.

Ginglymus, when the motion is only flexion and extension ; thus the tibia is articulated with the os femoris ; and the cubit and radius with the os humeri.

Trochoides, when one bone rotates upon another ; as the first cervical vertebræ upon the odontoid process of the second, and the radius upon the ulna, or cubit.

Amphiarthrosis, when there is motion, but that very obscure ; as the motion of the metacarpal and metatarsal bones.

SYNARTHROSIS, or
immoveable connexion.

Suture, when the union is by means of dentiform margins ; as in the bones of the cranium : hence the sagittal, lambdoidal, or occipital and coronal sutures.

Harmony, when the connexion is by means of rough margins, not dentiform ; as in the bones of the face.

Gomphosis, when one bone is fixed within another, like a nail in a board ; as the teeth in the alveoli of the jaws.

GENERA.

SPECIES.

SYMPHYSIS, or mediate Connexion.

Synchondrosis, when a bone is united with another by means of an intervening cartilage ; as the vertebræ and bones of the pubis.

Syffarcosis, when a bone is connected with another by means of an intervening muscle ; as the os hyoides with the sternum.

Syneurosis, when a bone is united to another by an intervening membrane ; as the bones of the head of the foetus.

Syndesmosis, when a bone is connected to another by means of an intervening ligament ; as the radius with the ulna, &c.

Synostosis, when two bones, originally separated, are united to one another by bony matter.

SYNDESMOLOGY,

OR

DOCTRINE OF THE LIGAMENTS.

LIGAMENTS are elastic and strong membranes connecting the extremities of the moveable bones. DIVISION, into *capsular*, which surround joints like a bag, and *connecting* ligaments. USE, the capsular ligaments connect

the extremities of the moveable bones, and prevent the efflux of synovia ; the external and internal connecting ligaments strengthen the extremities of the moveable bones.

LIGAMENTS OF THE LOWER JAW. The condyles of the lower jaw are connected with the articular sinuses of the temporal bone by two ligaments, the capsular and lateral ligament.

LIGAMENTS OF THE OCCIPITAL BONE, AND VERTEBRÆ OF THE NECK. The condyles of the occipital bone are united with the articular depressions of the first vertebræ by the capsular, broad, anterior, and posterior ligaments of the odontoid process, and ligamentum nuchæ.

LIGAMENTS OF THE VERTEBRÆ. The vertebræ are connected together by means of their bodies and oblique processes. The bodies by a soft cartilaginous substance, and the processes by ligaments, viz. the transverse ligament of the first vertebræ ; the anterior and posterior common ; the interspinous ; the intertransverse ; the intervertebral ligaments ; the capsular ligaments of the oblique processes ; and the ligaments of the last vertebræ of the loins with the os sacrum.

LIGAMENTS OF THE RIBS. The posterior extremity of the ribs is united with the vertebræ; the anterior with the sternum. The ligaments of the posterior extremity are, the capsular ligaments of the greater and lesser heads; the internal and external ligaments of the neck of the ribs: and a ligament peculiar to the last rib. The ligaments of the anterior extremity are, the capsular ligaments of the cartilages of the true ribs, and the ligaments of the ribs *inter se*.

LIGAMENTS OF THE STERNUM. The ligaments connecting the three portions of the sternum to the ribs are, the membrana propria of the sternum; and the ligaments of the ensiform cartilage.

LIGAMENTS OF THE PELVIS. The ligaments which connect the ossa innominata with the os sacrum are, three ligamenta ileo-sacra; two sacro-ischiatic ligaments; two transverse ligaments of the pelvis; the ligamentum obturans of the foramen ovale, and the ligamentum Poupartii, or inguinale.

LIGAMENTS OF THE OS COCCYGIS. The basis of the os coccygis is connected to the apex of the os sacrum, by the capsular and longitudinal ligaments.

LIGAMENTS OF THE CLAVICLE. The anterior extremity is connected with the sternum and first rib; and the posterior extremity with the acromion of the scapula by the interclavicular, the capsular ligament, the ligamentum rhomboideum, and in the posterior extremity, the capsular ligament.

LIGAMENTS OF THE SCAPULA. The proper ligaments which connect the scapula with the posterior extremity of the clavicle are the conoid and trapezoid ligaments.

LIGAMENTS OF THE HUMERUS. The head of the humerus is connected with the glenoid cavity of the scapula by the capsular ligament.

LIGAMENTS OF THE ARTICULATION OF THE CUBIT. The elbow joint is formed by the inferior extremity of the humerus, and superior extremities of the ulna and radius. The ligaments connecting these bones are, the capsular, the brachio-cubital, and the brachioradial ligaments.

LIGAMENTS OF THE RADIUS. The radius is affixed to the humerus, cubit, and carpus by peculiar ligaments, namely, the superior, inferior, oblique, and interosseous ligaments.

LIGAMENTS OF THE CARPUS. The ligaments which connect the eight bones of the wrist together, and with the fore-arm and metacarpus, are, the capsular ligament of the carpus ; the first and second transverse ligament ; the oblique and the capsular ligament proper to the bones of the carpus.

LIGAMENTS OF THE METACARPUS. The bones of the metacarpus are in part connected with the second row of bones of the carpus, and in part together, by the articular and interosseous ligaments.

LIGAMENTS OF THE FINGERS. The fingers and phalanges are connected together, and with the metacarpus ; and the thumb with the carpus, by the lateral ligaments of the fingers, and ligament of the thumb with the os trapezium of the carpus.

LIGAMENTS WHICH KEEP THE TENDONS OF THE MUSCLES OF THE HAND IN THEIR PROPER PLACE. The ligaments which keep the tendons of the muscles of the hand in their place, are situated partly in the palm, and partly on the back of the hand. In the back of the hand are, the external transverse ligament of the carpus, the vaginal, and the transverse ligaments of the extensor tendons. In the palm of the hand

are, the internal transverse ligament of the carpus, the vaginal or crucial ligaments of the flexor tendons of the phalanges, and the accessory ligaments of the flexor tendons.

LIGAMENTS OF THE ARTICULATION OF THE FEMUR. The head of the os femoris is strongly annexed to the acetabulum of the os innominatum, by two very strong ligaments, the capsular ligament, and ligamentum teres, or restraining ligament.

LIGAMENTS OF THE ARTICULATION OF THE KNEE. The knee joint is formed by the condyles of the os femoris, head of the tibia and the patella. The ligaments are the capsular, the posterior, the external and internal lateral ligaments, the crucial and the alar ligaments, of the semilunar cartilages, and ligaments of the patella.

LIGAMENTS OF THE FIBULA. The fibula is connected with the tibia by means of the capsular ligament of the superior extremity, the interosseous ligament, and the ligaments of the inferior extremity.

LIGAMENTS OF THE ARTICULATION OF THE TARSUS. The inferior extremity of the tibia and fibula forms the cavity into which the

astragalus of the tarsus is received. This articulation is effected by the anterior, middle, and posterior ligament of the fibula, the ligamentum tibiæ deltoides, the capsular ligament, and the ligaments proper to the bones of the tarsus.

LIGAMENTS OF THE METATARSUS. The bones of the metatarsus are connected in part together, and in part with the tarsus, by means of the capsular ligament, the articular ligaments, the transverse ligaments in the back and sole of the foot, and the interosseous ligaments of the metatarsus.

LIGAMENTS OF THE TOES. The phalanges of the toes are united partly together, and partly with the metatarsus, by the capsular and lateral ligaments.

LIGAMENTS WHICH RETAIN THE TENDONS OF THE MUSCLES OF THE FOOT IN THEIR PROPER PLACE. These ligaments are found partly in the back and partly in the sole of the foot. They are the vaginal ligament of the tibia, the transverse or crucial ligaments of the tarsus, the ligaments of the tendons of the peronei muscles, the lacinated ligament, the va-

ginal ligament of the extensor muscle and and flexor pollicis, the vaginal ligaments of the flexor tendons, the accessory ligaments of the flexor tendons, and the transverse ligaments of the extensor tendons.

MYOLOGY,

OR

DOCTRINE OF THE MUSCLES.

A MUSCLE is a fibrous body. DIVISION, into head, belly, and tail. ADHESION, the head and tail are firmly attached to the bones; the place of attachment of the former is called its *origin*; it is usually that part nearest the trunk of the body: the latter is termed the *insertion*, which is more remote from the trunk of the body, and is implanted into the part to be moved. The body adheres laxly to other parts, by means of the cellular membrane, in order that it may swell when the muscle acts. SUBSTANCE, fleshy in the belly, tendinous in the extremities. The former is composed of fleshy fibres, which are irritable and sensible; the latter of white fibres, which are neither sensible nor irritable.

When the tendinous extremity of a muscle is rounded, it is called a *tendon* ; when broad and expanded, *aponeurosis*, and sometimes *fascia*. Muscles are variously NAMED, according to the arrangement of their fibres, or from their action ; or from their origin and insertion ; or from their figure or situation : thus when the fibres go to the same direction, it is said to be a *simple* muscle ; when they are in rays, a *radiated* muscle ; when arranged like the plume of a feather, a *penniform* muscle ; and when two penniform muscles are contiguous, a *compound penniform*. Muscles sometimes surround certain cavities of the body, forming a thin lamina, as in the intestinal canal, bladder, &c. When they are situated around any opening, so as to shut or open it, they are termed *sphincters*. There are many muscles named from their action, as the flexors, extensors, depressors, levators, corrugatores supercili, &c. The muscles which receive names from their origin and insertion are very numerous ; as the sterno-cleido-mastoideus, stylo-hyoideus, stylo-glossus, &c. The deltoid, pectineus, pyramidalis, &c. are named from their figure, and the pectoralis, lingualis, temporalis, pterygoideus &c. from their situation. Muscles that concur in producing the

same action, are called *congeneres* ; but those that act contrary to each other *antagonistæ*.
VESSELS. Arteries, veins, and absorbents, abound in the fleshy part ; but very few indeed in the tendinous. NERVES of muscles are also numerous in the fleshy parts, and wanting in the tendinous. USE. Muscles are the organs of motion.

MUSCLES OF THE INTEGUMENTS OF THE CRANIUM.

Name.	<i>Arises from</i>	<i>Inserted into</i>	<i>Use.</i>
<i>Occipito-frontalis.*</i>	The upper ridge of the occipital bone; its aponeurosis covers the upper part of the head.	The skin of the eyebrows and root of the nose.	To pull the skin of the head backwards—raise the eyebrows and skin of the forehead.
<i>Corrugator supercilli.†</i>	Above the root of the nose.	The inner part of the occipito-frontalis.	To wrinkle the eyebrows.

MUSCLES OF THE EYELIDS.

<i>Orbicularis palpebrarum.</i>	Around the edge of the orbit.	The inner corner of the eyes.	To shut the eye.
<i>Levator palpebrae superioris.</i>	The bottom of the orbit near the optic foramen.	The cartilage of the tarsus of the upper eyelid.	To open the eye, by raising the upper eyelid.

† The reader will be pleased to observe, that although all the muscles (a few only excepted, which are marked thus*) are in pairs, mention is made here only of the muscles of one side.

MUSCLES OF THE EYEBALL.

Rectus superior.
Rectus inferior.
Rectus internus.
Rectus externus.
Obliquus superior
 ieu
Trochlearis.

Around the optic foramen of the sphenoid bone, at the bottom of the orbit.

Near the optic foramen, and passeth through a trochlea in the internal canthus of the eye, and is reflected to be

Obliquus inferior.

The ductus nasalis,
and is inserted

The anterior part of the tunica sclerótica, the tunica sclerótica, opposite to each other.

The posterior part of the bulb, between the rectus and the entrance of the optic nerve.

Opposite to the former.

To raise it upwards.
 To pull it downwards.
 To turn it to the nose.
 To move it outwards.

To roll the eye, and turn the pupil downwards and outwards.

To roll the eye.

MUSCLES OF THE NOSE AND MOUTH.

Levator labii superioris alaeque nasi.

*Levator labii superio-
ris proprius.*

The nasal process of the superior maxillary bone.

The upper jaw, under the orbit.

The upper lip and
ala of the nose.

The middle of the upper lip.

It raises the upper lip, and dilates the nostrils.

To pull the upper lip directly upwards.

Name.	Arises from	Inserted into	Use.
<i>Levator anguli oris</i>	The orbital foramen of the sup. max. bone.	The orbicularis, at the angle of the mouth.	To raise the corner of the mouth.
<i>Zygomaticus major.</i>	The os jugale, near the zygomatic future, and runs downwards.	The angle of the mouth, with the depressor of the lip.	To inflate the cheek and raise the angle of the mouth.
<i>Zygomaticus minor.</i>	Above the zygomaticus major.	The angle of the mouth.	To raise the angle of the mouth outwards.
<i>Buccinator.</i>	The fockets of the last molares, and the coronoid process of the lower jaw.	The angle of the mouth, and is perforated by the duct of the parotid gland.	To contract the mouth, and draw the angle of it outwards and backwards.
<i>Depressor anguli oris.</i>	The lower edge of the under jaw, near the chin.	The angle of the mouth.	To draw the corner of the mouth downwards.
<i>Depressor labii inferioris.</i>	The inferior part of the lower jaw, next the chin.	The middle of the under lip.	To draw the under lip downwards and outwards.

*Orbicularis oris.**

This muscle furrounds the lips, and is in a great measure formed by the buccinator, zygomatici, and others, which move the lip.

To shut the mouth, by contracting the lips.

Depressor labii superioris alaeque nasi.

The sockets of the upper incisor teeth.

To pull the ala nasi and upper lip down.

Constrictor nasi.

The root of one wing of the nose, and goes across to the other.

To compress the wings of the nose.

Levator menti vel labii inferioris.

The lower jaw, at the root of the incisors.

To raise the under lip and skin of the chin.

MUSCLES OF THE EXTERNAL EAR.

Superior auris, or attollens aurem.

The tendon of the occipito-frontalis above the ear.

The root of the cartilaginous tube of the ear.

To draw the ear upwards, and make it tense.

Anterior auris.

Near the back part of the zygoma.

The eminence behind the helix.

To raise this eminence forwards.

Posterior auris, or retrahens auris.

The mastoid process, by two and sometimes three fasciculi.

The septum that divides the scapha and concha.

To draw the ear back, and stretch the concha.

Name.	Arises from	Inserted into	Use.
<i>Helicis major.</i>	The upper, anterior, and acute part of the helix.	The cartilage of the helix, a little above the tragus.	To depress the upper part of the helix.
<i>Helicis minor.</i>	The inferior and anterior part of the helix.	The crus of the helix.	To contract the fissure.
<i>Tragicus.</i>	The outer and middle part of the concha, near the tragus.	The upper part of the tragus.	To depress the concha, and pull the tragus a little outwards.
<i>Antitragus.</i>	From the root of the inner part of the helix.	The upper part of the antitragus.	To dilate the mouth of the concha.
<i>Transversus auris.</i>	The upper part of the concha.	The inner part of the helix.	To draw these parts towards each other.

MUSCLES OF THE INTERNAL EAR.

<i>Latator tympani.</i>	The spinous process of the sphenoid bone.	The long process of the malleus.	To draw the malleus obliquely forwards, towards its origin.
-------------------------	---	----------------------------------	---

Tensor tympani
To pull the malleus and membrane of the tympanum towards the petrous portion.
Stapedius
To draw the stapes obliquely upwards towards the cavern.

The cartilaginous extremity of the Eustachian tube.
The handle of the malleus.
A little cavern in the petrous portion, near the cells of the mastoid process.
The posterior part of the head of the stapes.

MUSCLES OF THE LOWER JAW.

Temporalis.

The lower part of the parietal bone and os frontis; squamous part of the temporal bone; back part of the os jugale; the temporal process of the sphenoid bone, and the aponeurosis which covers it.

The coronoid process of the lower jaw, its fibres being bundled together and pressed into a small compass, so as to pass under the jugum, or zygoma.

To move the lower jaw upwards.

Name. <i>Masseter.</i>	<i>Arises from</i>	<i>Inserted into</i>	<i>Use.</i>
<i>Pterygoideus inter-</i> <i>nus,</i>	The sup. max. bone, near the os jugale; and from the anterior part of the zygoma.	The angle of the lower jaw upwards to the basis of the coronoid process.	To raise and move the jaw a little forwards and backwards.
<i>Pterygoideus exter-</i> <i>nus,</i>	The internal pterygoid process of the sphenoid bone. The external pterygoid process.	The lower jaw, on its inner side, and near its angle. The condyloid process of the lower jaw and capsular ligament.	To raise the lower jaw, and draw it a little to one side. To move the jaw, and to prevent the ligament of the jaw from being pinched.

MUSCLES WHICH APPEAR ABOUT THE ANTERIOR PART OF THE NECK.

<i>Platysma myoides.</i>	The cellular membrane covering the pectoral and deltoid muscles.	The side of the chin and integuments of the cheek.	To draw the cheeks and skin of the face downwards.
<i>Sterno-cleido-mastoides.</i>	The upper part of the sternum, and fore part of the clavicle.	The mastoid process, and as far back as the occipital future.	To move the head to one side and bend it forwards.

MUSCLES SITUATED BETWEEN THE LOWER JAW AND OS HYOIDES.

<i>Digastricus.</i>	A fossa at the root of the mastoid process.	The lower and anterior part of the chin.	To draw the lower jaw downwards.
<i>Mylo-hyoideus.</i>	The inner surface of the jaw bone.	The basis of the os hyoides.	To move the os hyoides upwards.
<i>Genio-hyoideus.</i>	The inside of the chin.	The basis of the os hyoides.	To move the os hyoides upwards.
<i>Genio-glossus.</i>	The inside of the chin.	The tongue, forming part of its substance.	To move the tongue in various directions.
<i>Hyo-glossus.</i>	The horn, basis, and cartilage of the os hyoides.	Into the tongue laterally.	To draw the tongue downwards and inwards.
<i>Lingualis.</i>	The root of the tongue laterally.	The extremity of the tongue.	To shorten and draw the tongue backwards.

MUSCLES SITUATED BETWEEN THE OS HYOIDES AND TRUNK.

<i>Sterno-hyoideus.</i>	The sternum and clavicle.	The basis of the os hyoides.	To draw the os hyoides downwards.
-------------------------	---------------------------	------------------------------	-----------------------------------

Name.	<i>Arises from</i>	<i>Inserted into</i>	<i>Use.</i>
<i>Omo-hyoideus.</i>	Near the coracoid process of the scapula.	The basis of the os hyoides.	To draw the os hyoides downwards.
<i>Sterno-thyroideus.</i>	The upper and inner part of the sternum.	The thyroid cartilage.	To pull the thyroid cartilage downwards.
<i>Thyreohyoideus,</i> or <i>Hyo-thyroideus.</i>	Part of the basis and horn of the os hyoides.	The side of the thyroid cartilage.	To raise the cartilage, and depress the bone.
<i>Cricothyroideus.</i>	The side of the cricoid cartilage.	The inferior horn of the thyroid cartilage.	To pull the thyroid cartilage towards the cricoid.

MUSCLES SITUATED BETWEEN THE LOWER JAW AND OS HYOIDES, LATERALLY.

<i>Stylo-glossus.</i>	The apex of the styloid process.	The side of the root of the tongue.	To pull the tongue backwards.
<i>Stylo-hyoideus.</i>	The basis, and about the middle of the styloid process.	The basis of the os hyoides.	To draw the os hyoides upwards.

<i>Stylo-pharyngeus.</i>	The root of the styloid process.	The edge of the pharynx, and back of the thyroid cartilage.	To dilate the pharynx, and raise the cartilage.
<i>Circumflexus, seu Tensor palati.</i>	Near the Eustachian tube, and passes through the hamulus of the pterygoid process, to be	The velum pendulum palati.	To draw the velum pendulum palati obliquely downwards, and stretch it.
<i>Levator palati mollis.</i>	The point of the ossipteroseum, the Eustachian tube, and sphenoid bone.	The velum pendulum palati, being expanded upon it.	To pull the velum pendulum backwards and upwards.

MUSCLES SITUATED ABOUT THE ENTRY OF THE FAUCES.

<i>Constrictor isbim faucium.</i>	Near the root of the tongue, on each side, and goes round to be	The middle of the velum pendulum palati, near the uvula.	To raise the tongue, and draw the velum towards it.
-----------------------------------	---	--	---

Name.

Palato-Pharyngeus.

Arises from

The middle of the soft palate, goes round the entry of the fauces, the tendon of the circumflexus palati, and velum pendulum palati, to be

The commissure of the ossa palati.

Inserted into

The upper and posterior part of the thyroid cartilage.

Use.

To contract the arch of the fauces.

*Azygos uvulae.**

The extremity of the uvula.

To shorten and raise the uvula.

MUSCLES SITUATED ON THE POSTERIOR PART OF THE PHARYNX.

Constrictor pharyngis inferior.

The cricoid and thyroid cartilages.

The middle of the pharynx.

To compress part of the pharynx.

Constrictor pharyngis medius.

The horns, and appendix of the os hyoidei.

The ambit of the pharynx.

To compress the pharynx, and draw the os hyoides upwards.

Constrictor pharyngis superior.

The ptergoid process, the lower jaw, and the cuneiform process of the os occipitis.

The middle of the pharynx.

To move the pharynx upwards and forwards, and to compress its upper part.

MUSCLES SITUATED ABOUT THE GLOTTIS.

Crico-arytaenoides posticus

The cricoid cartilage posteriorly.

To open the glottis.

Crico-arytaenoides lateralis, or obliquus.

The side of the cricoid cartilage

To open the glottis.

Thyreoid-arytaenoides.

The back of the thyroïd cartilage.

To draw the arytaenoid cartilage forward.

Arytaenoides obliquus.*

The root of one arytaenoid cartilage.

To draw them towards each other.

Arytaenoides transversus.*

One of the arytaenoid cartilages.

To shut the glottis.

Thyreoid-epiglottideus.

The thyroïd cartilage.

To pull the epiglottis obliquely downwards.

Name.	Arises from	Inserted into	Use.
<i>Arytaeno-epiglottideus.</i>	The upper part of the arytaenoid cartilage laterally.	The side of the epiglottis.	To move the epiglottis outwards.

MUSCLES SITUATED ON THE ANTERIOR PART OF THE ABDOMEN.

<i>Obliquus descendens externus.</i>	The lower edges of the eight inferior ribs near the cartilages.	The linea alba†, ossa pubis, and spine of the ilium‡.	To compress the abdomen.
<i>Obliquus ascendens internus.</i>	The spinous processes of the three last lumbar vertebræ, back of the sacrum, and spine of the ilium.	The cartilages of all the false ribs, linea alba, and pubis, and sternum, by a flat tendon.	To compress the abdomen.

† A long, but narrow, tendinous expansion, which reaches from the cartilago ensiformis of the sternum, down to the middle of the pubis.

‡ In this course it forms Poupart's ligament.

Transversalis abdominis.

The cartilages of the seven lower ribs, and the transverse processes of the four lower lumbar vertebræ and spine of the ilium.

The linea alba, throughout its whole length, and into the ensiform cartilage.

To compress the abdominal viscera.

Rectus abdominis.

The outside of the sternum and xyphoid cartilage.

The side of the symphysis of the pubis.

To compress the abdomen, and bend the trunk.

Pyramidalis.

The anterior upper part of the pubis.

The linea alba, below the umbilicus.

To assist the lower portion of the rectus.

MUSCLES ABOUT THE MALE ORGANS OF GENERATION.

Darto.*

By some said to be muscle: appears, however, to be no more than a condensation of the cellular membrane lining the scrotum, which admits of being corrugated and relaxed.

Cremaster.

The inguinal ring, and Poupart's ligament.

The tunica vaginalis of the testicle.

To draw up the testicle.

Name. <i>Erector penis.</i>	<i>Aries from</i> The tuberosity of the ischium, embraces one crus of the penis.	<i>Inserted into</i> A strong tendinous membrane, that covers the corpora cavernosa.	<i>Use.</i> To compress the urethra.
<i>Accelerator urinae</i> seu <i>Ejaculator seminis.</i>	The sphincter of the anus, and above the bulb of the urethra.	The line in the mid- dle of the bulb.	To compress the urethra.
<i>Transversus perinaei.</i>	The fatty membrane covering the tuberosity of the ischium.	The accelerator uri- nae, and sphincter ani.	To dilate the bulb of the urethra†.

| 33 |

MUSCLES OF THE ANUS.

<i>Sphincter ani.</i>	The skin and fat surrounding the anus on both sides.	The perinaeum, ac- celeratores urinæ, and transversus perinaei.	To shut the passage through the anus into the rectum.
-----------------------	--	---	---

† There is often another muscle behind this, called *Transversus perinaei alter*. It assists the former.

Levator ani.*

The internal surface of the pubis, ilium, and ischium, of both sides, in a radiated manner.

The sphincter ani, acceleratores urinæ, & os coccygis; and surrounds the rectum, neck of the bladder, &c. like a funnel.

To draw the rectum up after the defection of the fæces, and to assist in shutting it.

MUSCLES OF THE FEMALE ORGANS OF GENERATION.

Erector clitoridis.

The crus of the ischium internally.

The upper part of the crus and body of the clitoris.

To draw the clitoris downwards, and make it tense.

Sphincter vaginae.

The sphincter ani, and side of the vagina which it surrounds.

The union of the crura clitoridis.

To contract the mouth of the vagina.

MUSCLES SITUATED WITHIN THE PELVIS.

Obturator internus.

The foramen ovale obturator ligament, ilium, ischium, and pubis.

A large pit between the trochanters of the femur.

To roll the femur obliquely outwards.

Name.
Coccygeus

Arises from
The spinous process
of the ischium.

Inserted into
The extremity of the
sacrum and os coccy-
gis.

Use.
To move the coccyx
forwards and inwards.

MUSCLES SITUATED WITHIN THE CAVITY OF THE ABDOMEN.

Diaphragma.*
Quadratus lumborum.

The student will find described in SPLANCHNOLOGY
The posterior part
of the spine of the il-
ium.

The transverse apo-
physes of the loins and
last spurious rib.

To support the spine
and draw it to one
side.

Psoas parvus.

The transverse proc-
esses of the last dorsal
vertebræ.

The brim of the pel-
vis, near the place of
the acetabulum.

To bend the loins
forwards.

Psoas magnus.

The bodies and proc-
esses of the last dorsal
and all the lumbar ver-
tebræ.

The os femoris, a
little below the tro-
chanter minor.

To bend the thigh
forwards.

Iliacus internus.

The internal surface
of the spine of the il-
ium.

The femur in com-
mon with the psoas
magnus.

To assist the psoas
magnus.

MUSCLE SITUATED ON THE ANTERIOR PART OF THE THORAX.

Pectoralis major.

The clavicle, sternum and seven true ribs.

The upper and inner part of the humerus.

To draw the arm forwards, or obliquely forwards.

Subclavius.

The cartilage of the first rib.

The under surface of the clavicle.

To move the clavicle downwards.

Pectoralis minor.

The third, fourth, and fifth ribs.

The coracoid processes of the scapula.

To roll the scapula.

Serratus major anticus.

The eight superior ribs.

The basis of the scapula.

To bring the scapula forwards.

— ∞ —

MUSCLES SITUATED BETWEEN THE RIBS AND WITHIN THE THORAX.

Intercostales externi.

The lower edge of each upper rib.

The superior edge of each lower rib.

To elevate the ribs.

Intercostales interni.

Like the former, their fibres are directed from behind forwards.

Triangularis

The middle and inferior part of the sternum

The cartilages of the five last true ribs.

To depress the cartilages of the ribs.

vel

Sterno-costalis.

MUSCLES SITUATED ON THE ANTERIOR PART OF THE NECK, CLOSE TO THE VERTEBRÆ.

Name.	Arises from	Inserted into	Use.
<i>Longus colli.</i>	The bodies of the three upper dorsal and transverse processes of the four last cervical	The anterior tubercle of the dentatus.	To pull the neck to one side.
<i>Rectus internus capitis major.</i>	The transverse processes of the five last cervical vertebræ.	The cuneiform processes of the os occipitis.	To bend the head forwards.
<i>Rectus internus capitis minor.</i>	The fore part of the atlas.	The os occipitis, near the condyloid process.	To assist the former.
<i>Rectus capitis lateralis.</i>	The transverse processes of the atlas.	The os occipitis, near the mastoid process.	To move the head to one side.

MUSCLES SITUATED ON THE POSTERIOR PART OF THE TRUNK.

<i>Trapezius</i> sen	The os occipitis and the spinous processes of all the vertebræ of the neck and back.	The clavicle, part of the acromion, and the spine of the scapula.	To move the scapula, bend the neck, and pull the head backwards.
<i>Cucullaris.</i>			

Latissimus dorsi.

The spine of the ilium, spinous processes of the sacrum, lumbar and inferior dorsal vertebrae; adheres to the scapula and inferior false ribs.

The os humeri, between its two tuberosities in the edge of the groove for the tendon of the biceps muscle.

To draw the os humeri backwards, and to roll it upon its axis.

Serratus posterior.

The spinous processes of the two last dorsal and three lumbar vertebrae.

The lower edge of the three or four lowermost ribs, near their cartilages.

To draw the ribs outwards, downwards, and backwards.

Rhomboideus.

The spinous processes of the three last cervical, and four first dorsal vertebrae.

The basis of the scapula, at its upper and lower part.

To move the scapula upwards and backwards.

Splenius.

The spines of the four last cervical, and four superior dorsal vertebrae.

The two first cervical vertebrae, and the side of the os occipitis.

To move the head backwards, and also to one side.

Name.

Serratus superior. posterior.

Arises from

The spinous processes of the three last cervical, and two superior dorsal vertebrae.

Inserted into

The second, third, and fourth ribs, by three neat fleshy tongues.

Use.

To expand the thorax, by elevating the ribs.

Spinalis dorsi.

Two spinous processes of the loins, and three lower of the back.

All the spinous processes of the back, except the first.

To extend the vertebrae.

Levatores costarum,
or
Supra-costales.

The transverse processes of the last cervical and the dorsal vertebrae.

The angles of the ribs.

To lift the ribs upwards.

Sacro-lumbalis.

The sacrum, spine of the ilium, and the spinous and transverse processes of the lumbar vertebrae.

The lower edge of each rib, by a flat tendon.

To draw the ribs downwards, to move the body upon its axis, to assist the long dorsi, and to turn the neck back, or to one side.

Longissimus dorsi.

The same parts as the former, and by one common broad tendon.

The transverse processes of all the dorsal and one cervical vertebrae.

To stretch the vertebrae of the back, and keep the trunk erect.

Complexus.

The transverse processes of the four inferior cervical, and seven superior dorsal vertebrae.

The middle of the os occipitis, at its tubercle.

To draw the head backwards.

Trachelo-mastioideus.

The transverse processes of the five lower cervical and three upper dorsal vertebrae.

The os occipitis, behind the mastoid process of the temporal bone.

To draw the head backwards.

Levator scapulae.

The transverse processes of the four superior cervical vertebrae.

The upper angle of the scapula.

To move the scapula forwards and upwards.

Semi-spinalis dorsi.

The transverse processes of the 7th, 8th, 9th, and 10th dorsal vertebrae.

The spinous processes of the four superior dorsal and the last cervical vertebrae.

To extend the spine obliquely backwards.

Name.	<i>Arises from</i>	<i>Inserted into</i>	<i>Use.</i>
<i>Multifidus spinæ.</i>	The sacrum, ilium, oblique and transverse processes of the lumbar, the transverse of the dorsal, and four cervical vertebræ.	The spinous processes of the lumbar, dorsal, and cervical vertebræ, except the atlas.	To extend the back, and draw it backwards or to one side, and prevent the spine from bending too much bent forwards.
<i>Semi-spinalis colli,</i> or <i>Spinalis cervicis.</i>	The transverse processes of the six upper dorsal vertebræ.	The spinous processes of the five middle cervical.	To stretch the neck obliquely backwards.
<i>Transversalis colli.</i>	The transverse processes of the five upper dorsal vertebræ.	The transverse processes of the cervical vertebræ.	To turn the neck obliquely backwards, and to one side.
<i>Rectus capitis posterior major.</i>	The transverse processes of the second cervical vertebræ.	The lower ridge of the os occipitis.	To extend the head, and draw it backwards.
<i>Rectus capitis posterior minor.</i>	The first vertebræ of the neck.	The os occipitis at its tubercle.	To assist the <i>rectus major</i> .
<i>Obliquus capitis superior.</i>	The transverse processes of the atlas.	The end of the lower occipital ridge.	To draw the head backwards.

Obliquus capitis inferior.

The spinous process of the dentatus.

The transverse processes of the atlas.

To draw the face to one side.

Scalenus.

The upper surface of the first and second rib.

The transverse processes of the cervical vertebrae.

To move the neck forwards, or to one side.

Interspinales.

Between the spinous processes of the six inferior cervical vertebrae.

The spinous processes of the vertebrae above.

To draw the spinous processes towards each other.

Inter-transversales.

Between the transverse processes of the vertebrae.

The transverse processes of the vertebrae above.

To draw the transverse processes towards each other.

MUSCLES OF THE SUPERIOR EXTREMITIES.

Supra-spinatus.

The basis, spine, and upper end of the scapula.

A large tuberosity at the head of the os humeri.

To raise the arm.

Infra spinatus.

The cavity below the spine of the scapula.

The upper part of the same tuberosity.

To roll the os humeri outwards.

Name.	<i>Arises from</i>	<i>Inserted into</i>	<i>Use.</i>
<i>Teres minor.</i>	The inferior edge of the scapula.	The greater tuberosity of the humerus.	To assist the former.
<i>Teres major.</i>	The inferior angle and edge of the scapula.	The side of the groove for the long tendon of the biceps.	To assist in rotating the arm.
<i>Deltoides.</i>	The clavicle, and the acromion and spine of the scapula.	The anterior and middle part of the os humeri.	To raise the arm.
<i>Coraco-brachialis.</i>	The coracoid processes of the scapula.	The middle and inner side of the os humeri.	To roll the arm forwards and upwards.
<i>Subscapularis.</i>	The basis, superior and inferior edge of the scapula.	The protuberance at the head of the os humeri.	To roll the arm inwards.

MUSCLES SITUATED ON THE OS HUMERI.

Biceps flexor cubiti.

Two heads, one from the coracoid process, the other, called the long head, from the edge of the glenoid cavity of the scapula.

The tuberosity at the upper end of the radius, at its fore part, and a little below its neck.

To bend the forearm, which it does with great strength, and to assist the supinators.

Brachialis internus.

The os humeri at each side of the tendon of the deltoides.

The coronoid process of the ulna.

To assist in bending the forearm.

Triceps extensor cubiti.

The neck of the scapula, and the neck and middle of the humerus.

The upper and outer part of the olecranon.

To extend the forearm.

Anconeus.

The external condyle of the humerus.

The back part or ridge of the ulna.

To assist in extending the forearm.

MUSCLES SITUATED ON THE FORE-ARM.

Name.	Arises from	Inserted into	Use.
<i>Supinator radii longus.</i>	The external condyle of the humerus.	The radius, near the styloid process.	To assist in turning up the palm of the hand.
<i>Extensor carpi radialis longior.</i>	The external condyle of the humerus	The metacarpal bone of the fore-finger.	To extend the wrist.
<i>Extensor carpi radialis brevior.</i>	The external condyle of the humerus.	The metacarpal bone of the middle finger.	To assist the former.
<i>Extensor digitorum communis.</i>	The external condyle of the os humeri.	The back of all the bones of the fingers.	To extend the fingers.
<i>Extensor minimi digiti.</i>	The outer condyle of the humerus.	The second joint of the little finger.	To assist in extending the fingers.
<i>Extensor carpi ulnaris.</i>	The outer condyle of the os humeri.	The metacarpal bone of the little finger.	To assist in extending the wrist.
<i>Flexor carpi ulnaris.</i>	The inner condyle of the humerus and olecranon.	The os pisiforme, at its fore-part.	To assist in bending the hand.

<i>Palmaris longus.</i>	The internal condyle of the os humeri.	The annular ligament of the wrist, and there forms the aponeurosis of the hand.	To bend the hand.
<i>Flexor carpi radialis.</i>	The internal condyle of the os humeri	The metacarpal bone of the fore-finger.	To bend the hand.
<i>Pronator radii teres.</i>	The internal condyle of the humerus and coronoid process of the ulna.	The outer ridge of the radius, about the middle of its length.	To roll the hand inwards.
<i>Spinator radii brevis.</i>	The outer condyle of the humerus, and edge of the ulna.	The anterior, inner, and upper part of the radius.	To roll the radius outwards, and assist the anconeus.
<i>Extensor ossis metacarpi pollicis nanus.</i>	The middle of the ulna, interosseous ligament, and radius.	The os trapezium, and first bone of the thumb.	To stretch the first bone of the thumb outwards.
<i>Extensor primi intermodii.</i>	Near the middle of the ulna, interosseous ligament, and radius.	The convex part of the second bone of the thumb.	To extend the second bone of the thumb outwards.

Name.	Arises from	Inserted into	Use.
<i>Extensor secundi intermodii.</i>	The back of the ulna and interosseous ligament.	The third and last bone of the thumb.	To stretch the thumb obliquely backwards.
<i>Indicator.</i>	The middle of the ulna.	The metacarpal bone of the fore-finger.	To extend the fore finger.
<i>Flexor digitorum sublimis.</i>	The inner condyle of the os humeri, coronoïd process of the ulna, and upper part of the radius.	The second bone of each finger, after being perforated by the tendons of the profundus.	To bend the second joint of the fingers upon the first, and the first upon the metacarpal bones.
<i>Flexor digitorum profundus vel perforans.</i>	The upper part of the ulna, and interosseous ligament.	The fore part of the last bone of each of the fingers.	To bend the last joint of the fingers.
<i>Flexor longus pollicis.</i>	The upper and fore part of the radius.	The last joint of the thumb.	To bend the last joint of the thumb.
<i>Pronator radii quadratus.</i>	The inner and lower part of the ulna	The radius opposite to its origin.	To roll the radius inwards.

MUSCLES SITUATED CHIEFLY ON THE HAND.

Ambricales.

The tendons of the flexor profundus. The tendons of the extensor digitorum communis. To bend the first and extend the second phalanx.

Flexor brevis pollicis manus.

The os trapezoides, ligament of the wrist, and the os magnum The ossa sesamoidea and second bone of the thumb. To bend the second joint of the thumb.

Opponens pollicis.

The os scaphoides and ligament of the wrist. The first bone of the thumb. To bend the thumb.

Abductor pollicis manus.

The annular ligament, and os trapezium. The root of the first bone of the thumb. To draw the thumb from the fingers.

Abductor pollicis manus.

The metacarpal bone of the middle finger. The root of the first bone of the thumb. To pull the thumb towards the fingers.

Abductor indicis manus.

The first bone of the thumb, and os trapezium. The first bone of the fore finger posteriorly. To move the fore finger towards the thumb.

Palmaris brevis.

The annular ligament, and palmar aponeurosis. The metacarpal bone and skin of the little finger. To contract the palm of the hand.

Name.	Arises from	Inserted into	Use.
<i>Abductor minimi digiti manus.</i>	The annular ligament and os pisiforme.	The first bone of the little finger.	To draw the little finger from the rest.
<i>Abductor minimi digiti.</i>	The os cuneiforme and carpal ligament,	The metacarpal bone of the little finger.	To move that bone towards the rest.
<i>Flexor parvus minimi digiti.</i>	The annular ligament & os cuneiforme.	The first bone of the little finger.	To draw the little finger from the rest.
<i>Interossei interni, and Interossei externi.</i>	Between the metacarpal bones, to the sides of which they are attached.		To extend the fingers, and move them towards the thumb.

MUSCLES OF THE INFERIOR EXTREMITIES.

<i>Pectinalis.</i>	The anterior edge of the os pubis.	The upper part of the linea aspera of the femur.	To bend the thigh.
--------------------	------------------------------------	--	--------------------

<i>Triceps adductor femoris.</i> <i>Adductor longus</i> <i>femoris.</i> <i>Adductor brevis</i> <i>femoris.</i> <i>Adductor magnus</i> <i>femoris.</i> <i>Obturator externus.</i>	The upper and fore part of the pubis.	The middle and back part of the linea aspera.	To bend the thigh.
	The fore part and ramus of the os pubis.	The inner and upper part of the linea aspera.	To bend the thigh, and move it inwards.
	The lower and fore part of the ramus of the pubis.	The whole length of the linea aspera.	To move the thigh inwards, and assist in bending it.
<i>Gluteus maximus.</i>	The obturator ligament, and half of the thyroid hole.	The femur near the root of the great trochanter.	To pull forwards, and rotate the thigh.
	The spine of the ilium, posterior sacrospinous ligaments, and os sacrum.	The upper part of the linea aspera of the femur.	To extend the thigh, and assist in its rotatory motion.
<i>Gluteus medius.</i>	The spine and superior surface of the ilium.	The great trochanter of the os femoris.	To assist the gluteus maximus.

Name.	Arises from	Inserted into	Use.
<i>Gluteus minimus.</i>	The outer surface of the ilium and border of its great notch.	The root of the great trochanter.	To assist the two former.
<i>Pyriformis.</i>	The anterior part of the os sacrum.	A cavity at the root of the great trochanter.	To roll the thigh outwards.
<i>Gemini.</i>	The spine and tuberosity of the ischium.	The same cavity as the pyriformis.	To roll the thigh outwards.
<i>Quadratus femoris.</i>	The tuberosity of the ischium.	A ridge between the two trochanters.	To move the thigh outwards.

MUSCLES SITUATED ON THE THIGH.

<i>Facialis, or</i> <i>Tensor vaginæ femoris.</i>	The upper spinous process of the ilium.	The inner side of the membranous fascia which covers the thigh.	To stretch the fascia.
<i>Sartorius.</i>	The upper spinous process of the ilium.	The upper and inner part of the tibia.	To bend the leg inwards.
<i>Gracilis.</i>	The fore part of the ischium and pubis.	The upper and inner part of the tibia,	To bend the leg.

<i>Rectus femoris,</i> vel <i>Rectus cruris.</i>	The lower spinous process of the ilium, & edge of the acetabu- lum.	The upper and fore part of the patella.	To extend the leg.
<i>Vastus externus.</i>	The root of the great trochanter, and linea aspera.	The upper and lat- eral part of the patel- la.	To extend the leg.
<i>Vastus internus.</i>	The trochanter mi- nor, & the linea aspera.	The upper and in- ner part of the patella.	To extend the leg.
<i>Cruralis, or</i> <i>Crureus.</i>	The anterior part of the lesser trochanter.	The upper part of the patella.	To extend the leg.
<i>Semi-tendinosus.</i>	The tuberosity of the ischium.	The upper and inner part of the tibia.	To bend and draw the leg inwards.
<i>Semi-membranosus.</i>	The tuberosity of the ischium.	The back part of the head of the tibia.	To bend the leg.
<i>Biceps flexor cruris.</i>	The tuberosity of the ischium.	The upper and back part of the tibia, form- ing the <i>outer hamstring</i> .	To bend the leg.

Name.
Popliteus.

Aries from

The external condyle of the thigh bone.

Inserted into

The upper and inner part of the tibia.

Use.

To assist in bending the leg.

MUSCLES SITUATED ON THE LEG.

Gastrocnemius externus, or Gemellus.

The internal and external condyle of the femur.

The os calcis, with the tendon of the soleus.

To extend the foot.

Gastrocnemius internus, or Soleus.

The head of the fibula, and back part of the head of the tibia.

The os calcis, by a common tendon, which is called *tendo Achillis*.

To extend the foot.

Plantaris.

The outer condyle of the os femoris and capsular ligament.

The os calcis, near the tendo Achillis.

To assist in extending the foot.

Tibialis anticus.

The upper and forepart of the tibia.

The os cuneiforme internum.

To bend the foot.

Tibialis posticus.

The back part of the tibia, interosseous ligament, and adjacent part of the fibula.

The middle cuneiform bone, and upper part of the os naviculare.

To move the foot inwards,

<i>Peroneus longus.</i>	The head of the tibia, and upper and outer part of the fibula.	The metatarsal bone of the great toe.	To move the foot outwards.
<i>Peroneus brevis.</i>	The outer and fore part of the fibula.	The metatarsal bone of the little toe.	To assist the peroneous longus.
<i>Extensor longus digitorum pedis.</i>	The upper part of the tibia, interosseous ligament, and inner edge of the fibula.	The first joint of the smaller toes by four tendons.	To extend the toes, and separate them from one another.
<i>Extensor proprius pollicis pedis.</i>	The upper and fore part of the tibia.	The convex surface of the bones of the great toe.	To extend the great toe.
<i>Flexor longus digitorum pedis,† profundus, perfolians.</i>	The upper and inner part of the tibia.	The last bones of all the toes, except the great toe, by four tendons.	To bend the last joint of the toes.

† The tendons of this muscle pass through the perforations in those of the flexor digitorum brevis. There is, about the middle of the foot, a fleshy mass, which unites with this muscle, called after Jacobus Sylvius, who first described it,

Name.	Arises from	Inserted into	Use.
<i>Flexor longus pollicis pedis.</i>	A little below the head of the fibula.	The last bone of the great toe.	To bend the great toe.

MUSCLES CHIEFLY SITUATED ON THE FOOT.

<i>Extensor brevis digitorum pedis.</i>	The upper and anterior part of the os calcis.	The first bone of the great and other toes, except the little.	To extend the toes.
<i>Flexor brevis digitorum pedis, perforatus sublimis.</i>	The lower part of the os calcis.	The second phalanx of each of the small toes, by four tendons, which are perforated by those of the flex. long. dig. ped.	To bend the second joint of the toes.
<i>Lumbticales pedis.</i>	The tendons of the flexor longus digitorum pedis.	The tendinous expansion at, the upper part of the toes.	To draw the toes inwards.
<i>Flexor brevis pollicis pedis.</i>	The fore part of the os calcis, and external cuneiform bone.	The first joint of the great toe, by two tendons.	To bend the first joint of the great toe.

<i>Abductor pollicis pedis.</i>	The inner and lower part of the os calcis.	The first joint of the great toe.	To move the great toe from the rest.
<i>Abductor pollicis pedis.</i>	The ligament extended from the os calcis to the os cuboides.	The outer sesamoid bone, or first joint of the great toe.	To draw the great toe nearer to the rest, and to bend it.
<i>Abductor minimi digiti pedis.</i>	The tuber of the os calcis, and metatarsal bone of the little toe.	The first joint of the little toe externally.	To draw the little toe outwards.
<i>Flexor brevis minimi digiti pedis.</i>	The root of the metatarsal bone of the little toe.	The root of the first bone of the little toe.	To bend the little toe.
<i>Transversales pedis.</i>	The ligament connecting the bones of the tarsus.	The tendon of the adductor pollicis.	To contract the foot.
<i>Interossei pedis interni.</i>	Between the metatarsal bones.		To draw the smaller toes towards the great toe, and assist in extending the toes.
<i>Interossei pedis externi.</i>			

PHYSIOLOGY AND PHENOMENA OF MUSCULAR MOTION.

Muscular motions are of three kinds ; namely, voluntary, involuntary, and mixed. The VOLUNTARY MOTIONS of muscles are such as proceed from an immediate exertion of the active powers of the will : thus the mind directs the arm to be raised or depressed, the knee to be bent, the tongue to move, &c. The INVOLUNTARY MOTIONS of muscles are those which are performed by organs, seemingly of thier own accord, without any attention of the mind or consciousness of its active power ; as the contraction and dilatation of the heart, arteries, veins, absorbents, stomach, intestines, &c. The MIXED MOTIONS are those which are in part under the control of the will, but which ordinarily act without our being conscious of their acting ; as is perceived in the muscles of respiration, the intercostals, the abdominal muscles & the diaphragm.

When a muscle acts, it becomes shorter and thicker ; but its origin and insertion are drawn towards its middle. The sphincter muscles are always in action ; and so likewise are antagonist muscles, even when they seem at rest.

When two antagonist muscles move with equal force, the part which they are designed to move remains at rest ; but if one of the antagonist muscles remains at rest, while the other acts, the part is moved towards the centre of motion.

All the muscles of living animals are constantly endeavoring to shorten themselves.

When a muscle is divided, it contracts. If a muscle be stretched to a certain extent, it contracts, and endeavors to acquire its former dimensions, as soon as the stretching cause is removed : this takes place in the dead body ; in muscles cut out of the body, and also in parts not muscular, and is called by the immortal HALLER *vis mortua*, and by some *vis elastica*. It is greater in living than in dead bodies, and is called the *tone* of the muscles.

When a muscle is wounded, touched, or otherwise irritated, it contracts independent of the will ; this power is called IRRITABILITY, and by Haller *vis insita* ; it is a property peculiar to and inherent in the muscles. The parts of our body which possess this property are called irritable, as the heart, arteries, muscles, &c. to distinguish them from those parts which have no muscular fibres. With regard to the degree of this property peculiar to vari-

ous parts, the heart is the most irritable, then the stomach and intestines ; the diaphragm, the arteries, veins, absorbents, and at length the various muscles follow ; but the degree of irritability depends upon the age, sex, temperament, mode of living, climate, state of health, idiosyncrasy, and likewise upon the nature of the stimulus.

When a muscle is stimulated, either through the medium of the will or any foreign body, it contracts, and its contraction is greater or less in proportion as the stimulus applied is greater or less. The contraction of muscles is different according to the purpose to be served by their contraction : thus, the heart contracts with a jerk ; the urinary bladder, slowly and uniformly ; puncture a muscle, and its fibres vibrate ; and the abdominal muscles act slowly in expelling the contents of the rectum. Relaxation generally succeeds the contraction of muscles, and alternates with it.

The USE of this property is very considerable ; for upon it depends all muscular motion, and the function of every viscus, except that of the nerves.

BURSALOGY,

OR

DOCTRINE OF THE BURSÆ MUCOSÆ.

BURSÆ mucosæ are mucous bags, composed of a proper membrane, containing a kind of muscous fat, formed by the exhaling arteries of their internal surface. They are of different SIZES and FIRMNESS, and are CONNECTED here and there by cellular membrane, with the capsular ligaments of cavities, tendons, bones, or ligaments. Their *internal surface* is highly vascular, smooth, and shining. SITUATION. Various. DIVISION, into vaginal and vesicular. USE. To lubricate the muscles and tendons, which are very frequently in motion.

BURSÆ MUCOSÆ OF THE HEAD.

1. *A bursa of the superior oblique muscle of the eye situated behind its trochlea in the orbit.*
- 2 *The bursa of the digastricus, situated in the internal surface of its tendon.*
3. *A bursa of the circumflexus, or tensi palati, situated between the hooklike process of the sphænoid bone and the tendon of that muscle.*
4. *A bur-*

sa of the sterno hyoideus muscle, situated between the os hyoideus and larynx.

BURSÆ MUCOSÆ, SITUATED ABOUT THE
SHOULDER JOINT.

1. *The external acromial*, situated under the acromion, between the coracoid process, deltoid muscle, & capsular ligament. 2. *The internal acromial*, situated above the tendon of the infraspinatus and teres major : it often communicates with the former. 3. *The coracoid bursa*, situated near the root of the coracoid process : it is sometimes double, and sometimes triple. 4. *The clavicular bursa*, found where the clavicle touches the coracoid process. 5. *The subclavian bursa*, between the tendon of the subclavicularis muscle and the first rib. 6. *The coracobrachial*, placed between the common origin of this muscle and the biceps and the capsular ligament. 7. *The bursa of the pectoralis major*, situated under the head of the humerus, between the internal surface of the tendon of that muscle and another bursa placed on the long head of the biceps. 8. *An external bursa of the teres major*, under the head of the os humeri, between it and the tendon of the teres

major. 9. *An internal bursa of the teres major*, found within the muscle where the fibres of its tendon diverge. 10. *A bursa of the latissimus dorsi*, between the tendon of this muscle and the os humeri. 11. *The humero bicipital bursa*, in the vagina of the tendon of the biceps. There are other bursæ mucosæ about the humerus, but their situation is uncertain.

BURSÆ MUCOSÆ, SITUATED NEAR THE
ELBOW JOINT.

1. *The radio bicipital*, situated between the tendon of the biceps, brachialis, and anterior tubercle of the radius. 2. *The cubito-radial*, between the tendon of the biceps, supinator brevis, and the ligament common to the radius and ulna. 3. *The anconeal bursa*, between the olecranon and tendon of the anconeus muscle. 4. *The capitulo-radial bursa*, between the tendon common to the extensor carpi radialis brevis, and extensor communis digitorum and round head of the radius. There are other bursæ, but as their situation varies, they are omitted.

BURSÆ OF THE INFERIOR PART OF THE
FORE ARM AND HAND.

On the Inside of the Wrist and Hand.

1. A very large bursa, for the tendon of the flexor pollicis longus. 2. Four short bursæ on the fore part of the tendons of the flexor sublimis. 3. A large bursa behind the tendon of the flexor pollicis longus, between it and the fore part of the radius, capsular ligament of the wrist, and os trapezium. 4. A large bursa behind the tendons of the flexor digitorum profundus and on the fore part of the end of the radius, and fore part of the capsular ligament of the wrist. In some subjects it communicates with the former. 5. An oblong bursa, between the tendon of the flexor carpi radialis and os trapezium. 6. A very small bursa between the tendon of the flexor carpi ulnaris and os pisiforme.

On the back Part of the Wrist and Hand.

7. A bursa between the tendon of the abductor pollicis longus and the radius. 8. A large bursa between the two extensores carpi

radiales. 9. *Another* below it, common to the extensores carpi radiales. 10. *A bursa*, at the insertion of the tendon of the extensor carpi radialis. 11. *An oblong bursa*, for the tendon of the extensor pollicis longus, and which communicates with 9. 12. *A bursa* for the tendon of the extensor pollicis longus, between it and the metacarpal bone of the thumb. 13. *A bursa* between the tendons of the extensor of the fore, middle, and ring fingers. 14. *A bursa* for the extensors of the little finger. 15. *A bursa* between the tendon of the extensor carpi ulnaris and ligament of the wrist. There are also *bursæ mucosæ* between the muscoli lumbricales and interossei.

BURSÆ SITUATED NEAR THE HIP JOINT.

On the fore Part of the Joint.

1. The *ileo-puberal*, situated between the iliacus internus, psoas magnus, and the capsular ligament of the head of the femur. 2. The *pectineal*, between the tendon of the pectineus and the thigh-bone. 3. *A small bursa* of the gluteus medius muscle, situated between it and the great trochanter, before the insertion of the

pyriformis. 4. *A bursa* of the gluteus minimus muscle between its tendon and the great trochanter. 5. *The gluteo-fascial*, between the gluteus maximus and vastus externus.

On the posterior Part of the Hip Joint.

6. *The tubero-ischiatic bursa*, situated between the obturator internus muscle, the posterior spine of the ischium, and its tuberosity. 7. *The obturatory bursa*, which is oblong, and found between the obturator internus and gemini muscles and the capsular ligament. 8. *A bursa of the semi-membranosus*, under its origin and the long head of the biceps femoris. 9. *The gluteo trochanteral bursa*, situated between the tendon of the psoas muscle and the root of the great trochanter. 10. *Two gluteo femoral bursæ*, situated between the tendon of the gluteus maximus and os femoris. 11. *A bursa of the quadratus femoris*, situated between it and the little trochanter. 12. *The iliac bursa*, situated between the tendon of the iliacus internus and the little trochanter.

BURSÆ MUCOSÆ, SITUATED NEAR THE
KNEE JOINT.

1. *The supra-genual*, which adheres to the

tendons of the vastus and cruralis and the fore part of the thigh bone. 2. *The infra-genual bursa*, situated under the ligament of the patella, and often communicates with the above. 3. *The anterior genual*, placed between the tendon of the sartorius gracilis and semitendinosus and internal and lateral ligament of the knee. 4. *The posterior genual*, which is sometimes double, and is situated between the tendons of the semi-membranosus, the internal head of the gastrocnemius, the capsular ligament, and internal condyle. 5. *The popliteal*, conspicuous between the tendon of that muscle, the external condyle of the femur, the semilunar cartilage, and external condyle of the tibia. 6. *The bursa of the biceps cruris*, between the external part of the tendon, the biceps cruris, and the external lateral ligament of the knee.

BURSÆ MUCOSÆ, SITUATED IN THE FOOT.

On the Back, Side, and hind Part of the Foot.

1. *A bursa of the tibialis anticus*, between its tendon, the lower part of the tibia, and capsular ligament of the ankle. 2. *A bursa be-*

tween the tendon of the extensor pollicis pedis longus, the tibia and capsular ligament of the ankle. 3. *A bursa of the extensor digitorum communis*, between its tendons, the tibia and ligament of the ankle. 4. *A large bursa*, common to the tendons of the peronei muscles. 5. *A bursa of the peroneus brevis*, proper to its tendon. 6. *The calcaneal bursa*, between the tendo Achillis and os calcis.

In the Sole of the Foot.

1. *A bursa for the tendon of the peroneus longus*. 2. *A bursa common to the tendon of the flexor pollicis pedis longus, and the tendon of the flexor digitorum pedis communis longus profundus*. 3. *A bursa of the tibialis posterior*, between its tendon, the tibia, and astragalus. 4. *Five bursæ for the flexor tendons*, which begin a little above the first joint of each toe, and extend to the root of the third phalanx or insertion of the tendons.

ANGIOLOGY,

OR

DOCTRINE OF THE VESSELS.

VESSELS are long, membranous canals, which carry blood, lymph, or chyle. DIVIS-

ION, into arteries, veins and absorbents. **SITUATION.** Except the epidermis, membrana arachnoidea, and nails, every part of the body has vessels, which injections demonstrate.

OF ARTERIES.

Arteries are elastic membranous canals, which pulsate : they always become narrower as they proceed from the heart towards the extremities. **ORIGIN**, from the ventricles of the heart ; namely, the pulmonary artery from the right, and the aorta from the left, ventricle : so that there are only two arteries, of which the rest are branches. **TERMINATION**, in veins, exhaling vessels, or they anastomose with one another. **COMPOSED** of three membranes, called coats ; an external one, a middle coat, which is muscular, and an inner one, which is smooth. **USE**, to convey blood from the heart to the different parts of the body, for nutrition ; preservation of life ; generation of heat ; and the secretion of different fluids.

OF THE AORTA.

The aorta arises from the left ventricle of the heart, forms an *arch* towards the dor-

sal vertebræ, then *descends* through the opening of the diaphragm into the abdomen, in which it proceeds by the left side of the spine to the last vertebra of the loins, where it divides into the two iliac arteries. In this course it gives off, just above its origin, two *coronary* arteries to the heart, and then forms an arch.

The ARCH OF THE AORTA, gives off three branches, which supply the head, neck, and arms, with blood ; these are,

I. ARTERIA INNOMINATA, which divides into the right carotid and right subclavian arteries.

II. THE LEFT CAROTID.

III. THE LEFT SUBCLAVIAN.

THE CAROTID ARTERIES, having emerged from the chest, run up along the neck one on each side of the trachea, to the angle of the lower jaw, where they divide into external and internal.

THE EXTERNAL CAROTID gives off eight branches to the neck and face.

1. *Arteria Thyroidea*, which is very tortuous, supplies the thyroid gland, and gives off branches to several adjacent muscles.

2. *A. Lingualis*, which lies flat upon the

side of the tongue, and gives off the *ramus hyoideus*, *dorsalis linguae sublingualis*, and *ramina*.

3. *A. Labialis*, called also the *external maxillary*, the *angular*, and *facial artery* : it gives off the *palatina inferior*, the *submentalis*, and the *coronary of the lips*.

4. *A. Pharyngea inferior*, which sends a number of small twigs about the *fauces* and *basis of the cranium*.

5. *A. Occipitalis*, from which the *posterior temporal* arises.

6. *A. Posterior auris*, which furnishes the parts about the *cartilages of the ear* with blood, and transmits the *arteria tympani* and *stylo-mastoidea*.

7. *A. Maxillaris interna*, which is extremely tortuous, and gives off—the *spinous artery* to the *dura mater*—the *lower maxillary artery*, which is included in the *lower jaw*, and supplies the *teeth and face*—the *pterygoid arteries*, which nourish the *pterygoid muscles*—~~two~~ *deep temporal arteries*, which lie wider than the *temporal muscle*. The *internal maxillary* then gives off a *branch*, which almost immediately divides into the *alveolar* and *infra orbit-*

tal ; then an artery to the palate, the *superior palatine* ; the *upper pharyngeal*, which plays about the sphænoid sinus ; and, lastly, the *nasal artery*, which is transmitted through the sphæno-palatine foramen to the cavity of the nostrils.

8. *A. Temporalis*, which perforates the parotid gland, and sends off the *transversalis faciei*, which inosculates with the arteries of the face ; and several branches which go to the ear, forehead, and about the temples.

THE INTERNAL CAROTID leaves the external at the angle of the jaw, and proceeds by the par vagum and intercostal nerve to the carotid canal in the petrous portion of the temporal bone, where it is shaped like the letter *f*, and enters the cranium at the side of the sella turcica, having given off two very small twigs to the pituitary gland, & 3d, 4th, and 5th pair of nerves ; and when it has reached the anterior clinoid process, it sends off—

1. *Arteria Ophthalmica*, which is distributed on the eye.

2. *A. Anterior cerebri*, which proceeds before the sella turcica, unites with its fellow, and forms the circle of Willis, from which a

branch proceeds to the third ventricle, septum lucidum and the *arteria corporis callosi*.

3. *A. Media cerebri*, which runs between the anterior and middle lobes of the brain, gives off the *artery of the choroid plexus*, and is lost on the middle lobe of the brain.

4. *A. Communicans*, which proceeds backwards, and soon inosculates with the vertebral.

THE SUBCLAVIAN ARTERY arises on the right side from the *arteria innominata*, and on the left from the arch of the aorta. Each subclavian gives off five branches.

1. The *internal mammary*, from which arise the *A. thymica*, *A. comes phrenici*, the *pericardiac*, and the *phrenico pericardiac*.

2. The *inferior thyroid*, from which arise the *ramus thyroideus*, the *tracheal arteries*, the *ascending thyroid*, and the *transversalis humeri*.

3. *A. Vertebralis*, which proceeds into the vertebral foramina, to ascend into the cavity of the cranium, where it unites upon the cuneiform process of the occipital bone with its fellow of the other side, and forms the BASILARY ARTERY, which immediately gives off the *posterior artery of the cerebellum*; it then proceeds upon the *tuberculum annulare*, to give

off four branches, two to the right, and two to the left, which constitute the *A. anterior cerebelli*, which branch to the *crura cerebelli*, the *cerebellum*, *vermis*, *crura cerebri*, *corpora quadrigemina*, *pineal gland*, and *fourth ventricle*; and the *A. posterior cerebri*, which is joined by the *communicans*, and supply the *thalami nervorum opticorum*, the *centrum geminum*, *infundibulum*, and *crura fornicis*, and the posterior lobes of the brain, inosculating with several arteries.

4. *A. Cervicalis profunda*.

5. *A. Cervicalis superficialis*, both of which are distributed about the muscles of the neck.

6. *A. Intercostalis superior*, which lies between the two upper ribs.

7. *A. Supra scapularis*, which sometimes arises from the *A. thyroidea*, when it is called the *transversalis humeri*.

As soon as the subclavian has arrived in the axilla, it is called the **AXILLARY ARTERY**, which runs into the arm, where it is termed the **BRACHIAL**.

The **AXILLARY ARTERY** gives off,

1. The four *mammary arteries*, called *thoracica superior*; *thoracica longior*; *thoraci-*

ca humeriana, and *thoracica alaris* or *axillaris*, which supply blood to the muscles about the breast.

2. The Sub-scapularis, which supplies the lower surface of the scapula.

3. The circumflexa posterior.

4. Circumflexa anterior, which ramify about the joint.

The BRACHIAL or HUMERAL artery gives off,

1. *Many lateral vessels.*

2. *A. Profunda humeri superior.*

3. *A. Profunda humeri inferior.*

4. *Ramus anastomoticus magnus*, which anastomoses round the elbow joint.

The brachial then becomes the ulnar, and gives off the RADIAL.

The ULNAR or CUBITAL ARTERY sends off,

1. *The recurrent branches*, which anastomose with the ramus anastomoticus magnus.

2. *A. Interossea communis.* It then sends small branches to the adjacent muscles, as it proceeds down to the wrist; just before it arrives here, it gives off *A. dorsalis ulnaris*, which goes round to the back of the little fin-

ger. At the wrist it gives off *A. palmaris profunda* ; then forms a great arterial arch, called the *superficial palmar arch*, which supplies branches to the fingers.

The RADIAL gives off the *radial recurrent*, proceeds to the wrist, where the pulse is felt, and gives off the *superficialis volæ*, and then divides into the *A. dorsalis pollicis*, *A. radialis indicis*, *A. magna pollicis*, and *A. palmaris profunda*.

The DESCENDING AORTA gives off in the breast,

1. The *bronchial*, which nourish the lungs.
2. The *œsophageal*, which go to the *œsophagus*.
3. The *intercostals*, between the ribs.
4. The *inferior diaphragmatic*.

Within the abdomen, it gives off eight branches.

1. THE CÆLIAC, which divides into three branches.

1. *Arteria Hepatica*, which gives off,
 - a. *A. Duodeno-gastrica*, which sends off the right *gastro-epiploic* and the *pancreatico-duodenalis*. The latter transmits the *piloricæ inferior* and the *transverse pancreaticæ*.

b. *A. pilorica superior hepatica.*

The hepatic artery then ramifies through the liver.

2. *A. Coronaria ventriculi, or Gastrica,* which gives off the superior coronary and superior piloric arteries.

3. *A. Splenica,* from which arise the *pancreatica magna* and *pancreaticæ parvæ*, the posterior gastric arteries, the left gastro-epiploic artery, and the *vasa brevia*.

2. *The superior mesenteric, or meseraic,* of which the *colica media, colica dextra,* and the *ileo-colica* are branches.

3. *The renal arteries, or emulgers,* which are short, and divide into three or four branches in the pelvis of the kidney.

4. *The spermatic arteries,* which are very small and long, and proceed with the spermatic cord to the testicles.

5. *The inferior meseraic,* from which arises the left colic artery and the internal hæmorrhoidal.

6. *The lumbar arteries,* which nourish the muscles and vertebræ of the loins.

7. *The middle sacral artery,* which is distributed about the sacrum.

The aorta then bifurcates, and becomes the iliac arteries.

The iliacs soon divide into *internal and external*.

Each INTERNAL ILLAC or HYPOGASTRIC ARTERY gives off five branches :

1. *The lateral sacral arteries*, three or four in number.

2. *The gluteal*, which ramify upon the back of the haunch bone, and supply the gluteal muscles.

3. *The ischiatic*, which turns downwards along the hip, and gives off the *coccygeal artery*.

4. *Arteria pudica communis*, which is sometimes a branch of the sciatic artery ; it proceeds out of the pelvis, through the sciatic notch, returns into the pelvis, and runs towards the symphysis of the pubis. In this course it gives off *branches* to the vesiculæ seminales and prostrate gland ; and the *lower or external hæmorrhoidal artery* to the anus, and then forms the *A. perinei*, the *A. penis*, which proceed one on each side ; and a branch which plunges deep into the substance of the penis.

5. *The obturatory*, which passes through the

oval foramen, and is distributed on the thick muscles in the centre of the thigh.

Each EXTERNAL ILIAC gives off,

1. *The epigastric*, which is reflected from Roupart's ligament upwards, along the abdomen.

2. *A. Circumflexa iliaca*, which runs backwards along the crista ilii.

THE EXTERNAL ILIAC then passes under Roupart's ligament, becomes the FEMORAL or CRURAL ARTERY, and is continued along the thigh into the popliteal. In this course it gives off near the groin,

1. *The profunda femoris*, which gives off the *A. perforans prima*; the *A. perforans secunda magna*; the *A. perforans tertia*; the *A. perforans quarta*, which nourish the muscles of the thigh. The femoral artery then makes a spiral turn round the os femoris, and sends off small branches of no importance to adjacent muscles. About two hands breadth from the knee it gives out,

2. *The Ramus anastomoticus magnus*, which ramifies about the knee joint.

The femoral artery having reached the ham is called the POPLITEAL, which gives off several small branches about the joint, and divides

below the ham into the *tibialis antica* and *tibialis postica*.

The **TIBIALIS ANTICA** soon perforates the interosseous ligament, and passes along the tibia over the bones of the tarsus, and then inosculates with the back arteries. In this course it gives off,

1. *The recurrent*, which inosculates with the articular branches of the popliteal; it then sends off small branches to neighbouring muscles, as it passes down the leg.

2. *A. Malleolaris interna*, about the inner ankle.

3. *A. Malleolaris externa*, about the outer ankle.

4. *A. Tarsea*, which lies upon the bones of the tarsus.

5. *A. Metatarsea*, to the tendons of the peronei muscles.

6. *Dorsalis externa halucis*, which runs along the metatarsal bone of the great toe.

The **TIBIALIS POSTICA** passes along the back part of the tibia, goes round the inner ankle, and divides at the heel into the two plantar arteries. In this course it sends off,

1. *A. Nutritia tibiæ*, which gives branches

to the popliteus, soleus and tibialis anticus muscles, before it enters the bone.

2. *Many small branches*, as it passes downwards.

3. *A. Plantaris interna*, which runs along the inner edge of the sole of the foot, and sends off *four branches* about the foot.

4. *A. Plantaris interna*, which forms an arch and inosculates with the anterior tibial artery, and gives off the *digital branches* to the toes.

PULMONARY ARTERY.

The pulmonary artery arises from the right ventricle of the heart, and conveys the blood into the lungs, that is returned to the heart by the veins; not for their nutrition, but to receive from the air in the lungs a certain principle, necessary for the continuance of life, and which the arterial blood distributes to every part of the body. It soon divides into a *right* and *left*, the right going to the right lung and the left to the left lung, where they divide into innumerable ramifications, and form a beautiful *net-work*, or *plexus of vessels*, upon the air vesioles, and then terminate in the pulmonary veins.

THE ACTION OF THE ARTERIES.

The arteries, by the impulse of the blood from the ventricles of the heart, are dilated and irritated, and by means of their muscular coat contract upon the blood, and thus propel it to the glands, muscles, bones, membranes, and every part of the body for their nutrition and the various secretions, and then into the veins. This dilatation and contraction is called the PULSE, which is perceptible in the trunks and branches of the arteries, but not in the capillary vessels, except when inflammation is going on.

OF VEINS.

VEINS are membranous canals which do not pulsate : they gradually become larger as they advance towards the heart, in which they terminate, and bring back the blood from the arteries. ORIGIN. From the extremities of the arteries by anastomosis. TERMINATION of all the veins is into the auricles of the heart. DIVISION, into trunks, branches, ramuli, &c. SITUATION. They run by the sides of arte-

ries, but more superficially. COMPOSED like arteries of three membranes, but which are semi-transparent and more delicate. VALVES are thin semi-lunar membranous folds, which prevent the return of the blood in the vein.

The blood is returned from every part of the body into the right auricle :—the vena cava superior receives it from the head, neck, thorax, and superior extremities :—the vena cava inferior from the abdomen and inferior extremities ; and the coronary vein receives it from the coronary arteries of the heart.

THE VENA CAVA SUPERIOR.

This vein terminates in the superior part of the right auricle, into which it evacuates the blood, from

The right and left subclavian veins and the vena azygos.

The right and left subclavian veins receive the blood from the head and upper extremities, in the following manner.

The veins of the fingers, called *digitals*, receive their blood from the digital arteries, and empty it into,

1. The *cephalic of the thumb*, which runs on

the back of the hand along the thumb, and evacuates itself into the external radial.

2. The *salvatella*, which runs along the little finger, unites with the former, and empties its blood into the internal and external cubital veins. At the bend of the fore-arm are three veins, called the great cephalic, the basilic, and the median.

THE GREAT CEPHALIC runs along the superior part of the fore-arm, and receives the blood from the external radial.

THE BASILIC ascends on the under side, and receives the blood from the *external* and *internal cubital veins*, and some branches which accompany the brachial artery, called *venæ satellitum*.

THE MEDIAN is situated in the middle of the fore-arm, and arises from the union of several branches. These three veins all unite above the bend of the arm, and form

THE BRACHIAL VEIN, which receives all their blood, and is continued into the axilla, where it is called

THE AXILLARY VEIN. This receives also the blood from the scapula, and superior and inferior parts of the chest, by the *superior* and *in-*

ferior thoracic vein, the *vena muscularis*, and the *scapularis*.

The axillary vein then passes under the clavicle, where it is called the SUBCLAVIAN, which unites with the external and internal jugular veins, and the vertebral vein which brings the blood from the vertebral sinuses; it receives also the blood from the *mediastinal*, *pericardiac*, *diaphragmatic*, *thymic*, *internal mammary* and *laryngeal* vein, and then unites with its fellow, to form the *vena cava superior*, or, as it is sometimes called, *vena cava descendens*.

The blood from the external and internal parts of the head and face is returned in the following manner into the external and internal jugulars, which terminate in the subclavians.

The *frontal*, *angular*, *temporal*, *auricular*, *sublingual*, and *occipital* veins receive the blood from the parts after which they are named; these all converge to each side of the neck, and form a trunk, called the EXTERNAL JUGULAR VEIN.

The blood from the brain, cerebellum, medulla oblongata, and membranes of these parts, is received into the lateral sinuses, or veins of

the *dura mater*, one of which empties its blood through the *foramen lacerum in basi cranii* into the INTERNAL JUGULAR, which descends in the neck by the carotid arteries, receives the blood from the *thyroideal* and *internal maxillary veins*, and empties itself into the subclavians within the thorax.

The *vena azygos* receives the blood from the *bronchial*, *superior œsophageal*, *vertebral* and *intercostal veins*, and empties it into the superior cava.

VENA CAVA INFERIOR.

The *vena cava inferior* is the trunk of all the abdominal veins and those of the lower extremities, from which parts the blood is returned in the following manner. The veins of the toes, called the *digital veins*, receive the blood from the digital arteries, and form on the back of the foot three branches, one on the great toe called the *cephalic*, another which runs along the little toe, called the *vena saphena*, and one on the back of the foot, *vena dorsalis pedis*; and on the sole of the foot they evacuate themselves into the *plantar veins*.

The three veins on the upper part of the foot coming together above the ankle, form the an-

terior tibial ; and the plantar veins with a branch from the calf of the leg, called the *sural vein*, form the *posterior tibial* ; a branch also ascends in the direction of the fibula, called the *peroneal vein*. These three branches unite before the ham, into one branch, the *sub-popliteal vein*, which ascends through the ham, carrying all the blood from the foot : it then proceeds upon the anterior part of the thigh, where it is termed the *crural* or *femoral vein*, receives several muscular branches, and passes under Poupart's ligament into the cavity of the pelvis, where it is called the **EXTERNAL ILIAC**.

The arteries which are distributed about the pelvis evacuate their blood into the *external hæmorrhoidal veins*, the *hypogastric veins*, the *internal pudendal*, the *vena magna ipsius penis*, and *obturator veins*, all of which unite in the pelvis, and form the **INTERNAL ILIAC VEIN**.

The external iliac vein receives the blood from the external pudendal veins, and then unites with the internal iliac at the last vertebra of the loins, and form the **VENA CAVA INFERIOR**, or **ASCENDENS**, which ascends on the right side of the spine, receiving the blood from

the *sacral lumbar, right spermatic veins*, and the *vena cava hepatica* ; and having arrived at the diaphragm, it passes through the right foramen, and enters the right auricle of the heart, into which it evacuates all the blood from the abdominal viscera and lower extremities.

VENA CAVA HEPATICA.

This vein ramifies in the substance of the liver, and brings the blood into the *vena cava inferior* from the branches of the *VENA PORTÆ*, a great vein which carries the blood from the abdominal viscera into the substance of the liver. The trunk of this vein, about the fissure of the liver in which it is situated, is *divided* into the hepatic and abdominal portions. The *abdominal portion* is composed of *splenic, meseraic* and *internal hæmorrhoidal veins*. These three venous branches carry all the blood from the stomach, spleen, pancreas, omentum, mesentery, gall-bladder, and the small and large intestines, into the *sinus* of the *vena portæ*. The *hepatic portion* of the *vena portæ* enters the substance of the liver, divides into innumerable ramifications, which secrete the bile, and the superfluous blood passes into corresponding branches of the *venæ cavæ hepaticæ*.

THE ACTION OF THE VEINS.

Veins do not pulsate ; the blood which they receive from the arteries flows through them very slowly, and is conveyed to the right auricle of the heart, by the contractility of their coats, the pressure of the blood from the arteries called the *vis a tergo*, the contraction of the muscles, and respiration ; and it is prevented from going backwards in the vein by the valves, of which there are a great number,

OF THE ABSORBENTS.

ABSORBENTS are very thin and pellucid vessels, which carry the lymph from every part of the body ; substances applied to the surface of the body, and the chyle from the intestines ; into the thoracic duct. DIVISION, into *lacteals* and *lymphatics*. They are called *lacteals* in the intestines and mesentery, and *lymphatics* in every other part. FIGURE, branching, becoming broader as they proceed towards their termination. Valves, numerous, giving them a knotted appearance. SITUATION. It is supposed that they exist in every part of the body, although they have not been as yet detected in

some, as the brain, &c. **ORIGIN.** The cellular membrane, the viscera, the excretory ducts of the viscera, the external surface, and every part of the body. **TERMINATION,** in the thoracic duct, or subclavian veins. **LYMPHATIC** or **CONGLOBATE GLANDS** are situated everywhere in the course of the lymphatics. **SUBSTANCE.** They consist of tender, pellucid, strong tunics. The **USE** of *the absorbents* is to carry back the lymph from different parts ; to convey the chyle from the intestines to the thoracic duct, where they become mixed and diluted ; and to absorb substances from surfaces and parts on which they originate.

ABSORBENTS OF THE HEAD AND NECK.

Absorbents are found on the scalp and about the viscera of the neck, which unite into a considerable *branch* that accompanies the jugular vein. Absorbents have not been detected in the human brain ; yet there can be no doubt of there being such vessels : it is probable that they pass out of the cranium through the canalis caroticus and foramen lacerum in basi crani, on each side, and join the above *jugular branch*, which passes through some glands as it proceeds into the chest to the angle of the subclavian and jugular vein.

ABSORBENTS OF THE UPPER EXTREMITIES.

The absorbents of the upper extremities are divided into superficial and deep-seated. The *superficial absorbents* ascend under the skin in every direction to the wrist, from whence a *branch* proceeds upon the posterior surface of the fore-arm to the head of the radius, over the internal condyle of the humerus, up to the axilla, receiving several branches as it proceeds. Another *branch* proceeds from the wrist along the interior part of the fore-arm, and forms a *net work* with a *branch* coming over the ulna from the posterior part, and ascends on the inside of the humerus to the glands of the axilla.

The *deep-seated absorbents* accompany the larger blood-vessels, and pass through two glands about the middle of the humerus, and ascend to the glands of the axilla. The superficial and deep-seated absorbents having passed through the axillary glands, form *two trunks*, which unite into *one*, to be inserted with the jugular absorbents into the thoracic duct, at the angle formed by the union of the subclavian with the jugular vein.

ABSORBENTS OF THE INFERIOR EXTREMITIES.

These are also superficial and deep-seated. The *superficial ones* lie between the skin and muscles. Those of the toes and foot form a *branch* which ascends upon the back of the foot over the tendon of the *cruræus anticus*, forms with other branches a *plexus* above the ankles, then proceeds along the tibia over the knee, sometimes passes through a gland, and proceeds up the inside of the thigh to the subinguinal glands.

The *deep-seated* absorbents follow the course of the arteries, and accompany the femoral artery, in which course they pass through some glands in the leg and above the knee, and then proceed to some deep-seated subinguinal glands.

The absorbents from about the external parts of the pubis, as the penis, perineum, and from the external parts of the pelvis, in general proceed to the inguinal glands. The subinguinal and inguinal glands send forth several branches, which pass through the abdominal ring into the cavity of the abdomen.

ABSORBENTS OF THE ABDOMINAL AND THORACIC VISCERA.

The absorbents of the lower extremities accompany the external iliac artery, where they are joined by many branches from the *uterus*, *urinary bladder*, *spermatic chord*, and some branches accompanying the internal iliac artery: they then ascend to the sacrum, where they form a *plexus*, which proceeds over the *psoas muscles*, and meeting with the lacteals of the mesentery form the thoracic duct, or trunk of the absorbents, which is of a serpentine form, about the size of a crow-quill, and runs up the dorsal vertebree, through the posterior opening of the diaphragm, between the aorta and vena azygos, to the angle formed by the union of the subclavian and jugular veins. In this course it receives

The absorbents of the kidneys, which are superficial and deep-seated, and unite as they proceed towards the thoracic duct.

The absorbents of the spleen, which are upon its peritoneal coat, and unite with those of the pancreas.

A branch from a plexus of vessels passing above and below the duodenum, and formed by

the absorbents of the *stomach*, which come from the lesser and greater curvature, and are united about the pylorus with those of the *pancreas* and *liver*, which converge from the external surface and internal parts towards the portæ of the liver, and also by several branches from the *gall-bladder*.

PHYSIOLOGY OF ABSORPTION.

Absorption is the taking up of substances which are applied to the mouths of absorbing vessels; thus the chyle is absorbed from the intestinal tube by the lacteals, the vapour of circumscribed cavities, and of the cells of the cellular membrane by the lymphatics of those parts; and thus mercury and other substances are taken into the system, when rubbed on the skin.

The principle by which this absorption takes place is a power inherent in the mouths of absorbing vessels, a *vis insita*, dependent on the high degree of irritability of their internal membrane by which the vessels contract and propel the fluid forwards. Hence the use of this function appears to be of the utmost importance,

viz. to supply the blood with chyle; to remove the superfluous vapours of circumscribed cavities, otherwise dropsies, as hydrocephalus, hydrothorax, hydrocordis, ascites, hydrocele, &c. would constantly be taking place; to remove the superfluous vapour from the cells of the cellular membrane dispersed throughout every part of the body, that anasarca may not take place; to remove the hard and soft parts of the body; and to convey into the system medicines which are applied to the surface of the body.

SANGUIFICATION.

Sanguification appears to be nothing more than the mixing, by the action of the blood-vessels, of the chyle with the blood; for as it passes from the subclavian vein, it changes its colour, and when it has reached the heart, cannot be distinguished from the mass of circulating blood.

NEUROLOGY,

O R

DOCTRINE OF THE NERVES.

NERVES are long whitish cords, composed of bundles or fasciculi of fibres, which serve for sensation. **ORIGIN.** The cerebrum, cerebellum, medulla oblongata, and medulla spinalis. **TERMINATION.** The organs of sense; viscera; vessels; muscles; bones, &c. **FIGURE,** branched. **DIVIDED** into trunks, branches, ramuli, capillary fibres, papillæ, nervous plexuses, and ganglions, or knots. **SUBSTANCE,** pulpy. **DIVISION,** into cerebral and spinal. *Number,* thirty-nine pair; nine pair of cerebral nerves, and thirty pair of spinal. *The nine pair of cerebral nerves are,* 1. The olfactory. 2. The optic. 3. Oculorum motorii. 4. The pathetic, or trochleatores. 5. The trigemini, or divisi. 6. The abducent. 7. The auditory and facial. 8. The par vagum, or great sympathetic nerves. 9. The lingual pair. *The thirty pair of spinal nerves are divided into* eight pair of cervical, twelve pair of dorsal, five pair of lumbar, and five pair

of sacral nerves. USE, for sensation in sensible parts, for the five external senses, as touch, sight, hearing, smelling, and taste ; and for the motion of muscles.

OF THE NERVES OF THE BRAIN.

THE FIRST PAIR, or *Olfactory nerves*, arise from the corpora straita, pass forwards over the sphænoid and frontal bones, one to each side of the crista galli, where they send off a number of branches, which go through the cribriform foramina of the ethmoid bone, to be distributed on the pituitary membrane of the nose. USE, for smelling.

THE SECOND PAIR, or *Optic nerves*, arise from the thalami nervorum opticorum, decussate each other, then pass through the foramina optica, and perforate the bulb of the eye, and in it form the *retina*, which is the organ of vision.

THE THIRD PAIR, or *Oculorum motorii*, arise from the crura cerebri, near the pons Varolii, pass forward towards the top of the petrous portion of the temporal bone, where they perforate the dura mater, and proceed to the orbital fissure, to be inserted into the muscles of the bulb of the eye, which they move.

THE FOURTH PAIR, or *The Pathetic nerves*, arise from the crura of the cerebellum laterally, pass forward, and pierce the dura mater below the third pair, and proceed with them through the orbital fissure, to be inserted into the trochlearis muscle of the eye.

THE FIFTH PAIR, or *Trigemini*, arise from the anterior part of the crura of the cerebellum, and are divided within the cavity of the cranium into three branches, viz. the ophthalmic or orbital, and the superior and inferior maxillary.

The *orbital* nerve gives off a *branch*, near its origin, which unites with a branch of the sixth pair, to form the great intercostal nerve : it then divides into three branches, the *frontal*, which goes through the superciliary foramen to the muscles and integuments of the forehead ; the *lachrymal*, which goes to the lachrymal gland ; and the *nasal*, which goes forward to the inner canthus of the eye, where it gives off a branch or two, then returns into the cranium, and passes through the cribriform plate of the ethmoid bone, and is distributed on the pituitary membrane.

The *superior maxillary* nerve goes through the foramen rotundum, is divided into, 1st. the *sphæno-palatine*, which goes through the sphæ-

no-palatine foramen, sends twigs to the internal pterygoid muscle, then enters the cavity of the nostrils, and is lost on the Eustachian tube, soft palate, and pituitary sinus of the sphænoid bone; 2d. the *posterior alveolar* branch, which descends through the foramen by the last grinder, and is distributed to the molares; 3d. the *infra-orbital* nerve, which goes through the infra-orbital foramen, and is distributed on the muscles of the cheek, nose, lips, and communicates with the facial nerve.

The *inferior maxillary* goes out of the cranium, through the foramen ovale, giving branches to the muscles and glands in its course, and to the facial nerve, and divides as it passes over the pterygoid muscle, into, 1st. the *internal lingual*, which is connected with the chorda tympani, and supplies the sublingual glands and contiguous muscles, but more especially the tongue: 2d. the more proper *inferior maxillary*, which goes into the canalis mentalis of the lower jaw, and gives a branch to each tooth, and comes out again to supply the lower lip and chin.

THE SIXTH PAIR, or *Abducent nerves*, arise from the posterior part of the pons Varolii, proceed forwards, perforate the dura mater,

and send off some branches near the sella turcica, which unite with branches of the ophthalmic nerve of the fifth pair, to form the great intercostal nerve; they then accompany the third and fourth pair through the orbital fissure, and are distributed on the recti externi muscles of the bulb of the eye.

THE SEVENTH PAIR, or *Auditory nerves*, as they are commonly called, originate on each side by two branches, the *portio dura* and *portio mollis*. The *portio dura* is, in fact, a nerve of the face, and is therefore, with more propriety, called the *Facial nerve*: it arises from the fourth ventricle of the brain, passes through the petrous portion of the temporal bone, where it gives off the *chorda tympani*, proceeds through the stylo-mastoid foramen, perforates the parotid gland, and then divides into seven or eight branches, which constitute the *pes anserinus*, and supply the ear, parotid gland, and muscles of the face, and communicate with the branches of the fifth pair on the face.

The *portio mollis* arises from the medulla oblongata and the fourth ventricle, enters the internal auditory passage, and is distributed by innumerable branches on the membrane of the

cochlea, vestibulum, forming the immediate organ of hearing.

THE EIGHTH PAIR, or *Par vagum*, arise by several branches, partly from the medulla oblongata and partly from the fourth ventricle behind the pons Varolii. It is connected at its origin with the *accessory nerves of Willis*, which ascend through the great occipital foramen from the fifth cervical nerve: these nerves proceed together through the foramen lacerum in basi crani. The accessory nerves then separate from the par vagum, and vanish in the *sterno-clido mastoideus* and *cucullaris* muscles: the par vagum then gives off branches in the neck to the tongue, larynx, and thyroid gland, from which parts they acquire names, and then descends into the cavity of the thorax, where it gives off,

1st. The *right* and *left recurrent*; the former arises on the right side, near the subclavian artery, which it surrounds, and then returns upwards to the thyroid gland: the latter arises under the arch of the aorta, which it surrounds, and then ascends to the oesophagus. Both nerves are lost in the muscles of the larynx and pharynx.

2dly. *Several branches* which proceed to the

superior part of the pericardium, to form with other nerves the *cardiac plexus*, which sends branches to the heart.

3dly. The par vagum then extends on the posterior surface of the lungs, on each side, and gives off some *branches*, which, with others from the cardiac plexus and recurrent nerves, form a *right and left pulmonic plexus*, which supplies the lungs and trachea.

4thly. Both trunks of the par vagum then descend with the oesophagus, and give off many *ramifications* which form the *oesophageal plexus*, from which the oesophagus and adjoining parts are supplied.

5thly. Having passed the diaphragm with the oesophagus, they form, about the cardia, two *stomachic plexuses*: the anterior is expanded over the anterior surface of the stomach and its greater curvature; the posterior over the posterior surface and lesser curvature, and it transmits also branches to the liver, pancreas, and diaphragm.

6thly. The par vagum also sends some *branches* to unite with the great intercostal, and thus concurs in forming the *hepatic, splenic, and renal plexuses*.

THE NINTH, or *Lingual pair* of nerves, arise from the medulla oblongata, between the corpora olivaria and pyramidalia, pass out of the skull through the foramina condyloidea anteriora, and communicate with the par vagum and first pair of cervical nerves : they then proceed forwards between the jugular vein and carotid artery, to be distributed on the muscles of the tongue and os hyoides.

Thus it appears that the olfactory, opthalmic, and oculorum motorii arise from the cerebrum ; the trochleatores and trigemini from the cerebellum ; and the auditory, par vagum, and linguales, from the medulla oblongata.

OF THE NERVES OF THE MEDULLA SPINALIS.

Those nerves are called SPINAL which pass out through the lateral or intervertebral foramina of the spine.

They are divided into *cervical, dorsal, lumbar, and sacral* nerves.

CERVICAL NERVES.

The CERVICAL nerves are *eight* pairs. The

first are called the *occipital*; they arise from the beginning of the spinal marrow, pass out between the margin of the occipital foramen and atlas, form a ganglion on its transverse process, and are distributed about the occiput and neck.

The *second* pair of cervical nerves send a branch to the accessory nerve of Willis, and proceed to the parotid gland and external ear.

The *third* cervical pair supply the integuments of the scapula, cucullaris, and triangularis muscles, and send a branch to the diaphragmatic nerve.

The *fourth*, *fifth*, *sixth*, *seventh*, and *eighth* pair all converge to form the *brachial plexus*, from which arise the six following

NERVES OF THE UPPER EXTREMITIES.

1. THE AXILLARY nerve, which sometimes arises from the radial nerve. It runs backwards and outwards around the neck of the humerus, and ramifies in the muscles of the scapula.

2. THE EXTERNAL CUTANEAL, which perforates the coraco-brachialis muscle to the bend of the arm, where it accompanies the

median vein as far as the thumb, and it is lost in its integuments.

3. THE INTERNAL CUTANEAL, which descends on the inside of the arm, where it bifurcates. From the bend of the arm, the anterior branch accompanies the basilic vein, to be inserted into the skin of the palm of the hand; the posterior branch runs down the internal part of the fore-arm, to vanish in the skin of the little finger.

4. THE MEDIAN nerve, which accompanies the brachial artery to the cubit, then passes between the brachialis internus, pronator rotundus, and the perforatus and perforans, under the ligament of the wrist to the palm of the hand, where it sends off branches in every direction, to the muscles of the hand, and then supplies the digital nerves, which go to the extremities of the thumb, fore and middle fingers.

THE ULNAR nerve, which descends between the brachial artery and basilic vein, between the internal condyle of the humerus, and the olecranon, and divides in the fore-arm into an *internal* and an *external* branch. The former passes over the ligament of the wrist and sesamoid bone to the hand, where it divides into three branches, two of which go to the ring and little finger, and the third forms an arch

towards the thumb in the palm of the hand, and is lost in the contiguous muscles. The latter passes over the tendon of the extensor carpi ulnaris and back of the hand, to supply also the two last fingers.

6. THE RADIAL nerve, which sometimes gives off the axillary nerve. It passes backwards, about the os humeri, descends on the outside of the arm between the brachialis externus and internus muscles to the cubit ; then proceeds between the supinator longus and brevis to the superior extremity of the radius, giving off various branches to adjacent muscles. At this place it divides into two branches ; one goes along the radius, between the supinator longus and radialis internus to the back of the hand, and terminates in the interosseous muscles, the thumb and three first fingers :—the other passes between the supinator brevis and head of the radius, and is lost in the muscles of the fore-arm.

DORSAL NERVES.

THE DORSAL nerves are twelve pairs in number. The *first* pair gives off a branch to the brachial plexus. All the dorsal nerves are distributed to the muscles of the back, intercos-

tals, serrati, pectoral, abdominal muscles and diaphragm. The five inferior pairs go to the cartilages of the ribs, and are called *costal*.

LUMBAR NERVES.

The five pair of LUMBAR nerves are bestowed about the loins and muscles, and skin of the abdomen and loins, scrotum, ovaria, and diaphragm. The second, third, and fifth pair unite and form the *obturator nerve*, which descends over the psoas muscle into the pelvis, and passes through the foramen thyroideum to the obturator muscle, triceps, pectineus, &c.

The third and fourth, with some branches of the second pair, form the *crural nerve*, which passes under Poupart's ligament with the femoral artery, sends off branches to the adjacent parts, and descends in the direction of the sartorius muscle to the internal condyle of the femur, from whence it accompanies the saphena vein to the internal ankle, to be lost in the skin of the great toe.

The fifth pair are joined to the first pair of the sacral nerves.

SACRAL NERVES.

There are five pair of SACRAL nerves, all of which arise from the cauda equina, or termination of the medulla spinalis ; so called from the nerves resembling the tail of a horse. The four first pair give off branches to the pelvic viscera, and are afterwards united to the last lumbar, to form a large *plexus*, which gives off the *ischiatric nerve*, the largest in the body. The ischiatic nerve immediately at its origin sends off branches to the bladder, rectum, and parts of generation ; proceeds from the cavity of the pelvis through the ischiatic notch, between the tuberosity of the ischium and great trochanter, to the ham, where it is called the *popliteal nerve*. In the ham it divides into two branches. 1. The *peroneal*, which descends on the fibula, and distributes many branches to the muscles of the leg and back of the foot. 2. The *tibial*, which penetrates the *gastrocnemii* muscles to the internal ankle, passes through a notch in the *os calcis* to the sole of the foot, where it divides into an *internal* and *external plantar nerve*, which supply the muscles and aponeurosis of the foot and the toes.

OF THE GREAT INTERCOSTAL OR SYMPATHETIC NERVES.

The great intercostal nerve arises in the cavity of the cranium from the union of a branch of the sixth with a recurrent branch of the fifth pair, called the *Vidian nerve*. It passes out of the cranium through the carotid canal, and descends on the sides of the cervical, dorsal, and lumbar vertebræ and sacrum, in which course it is joined by filaments from all the spinal nerves, forming small ganglions at their junctions.

In the neck it forms only three *cervical ganglions*, from which arise the *cardiac nerves* and *pulmonic plexuses*, which send nerves to the heart and lungs. In the thorax there arise five branches from the third, fifth, seventh, eighth, and ninth ganglions, which descend in the course of the vertebræ, and pass through the diaphragm, where they unite on each side into one trunk, the *splanchnic* or *anterior intercostal nerve*, which soon unite together, and form the great SEMILUNAR GANGLION, from which nerves are given off to all the abdominal viscera, forming ten plexuses, which communicate with one another, and are named after the ad-

• jacent viscera, viz. the *cœliac plexus*, situated near the *cœliac artery*, and supplying the stomach ; the *splenic*, near the spleen ; the *hepatic*, near the portæ of the liver ; the *superior*, *middle*, and *inferior mesenteric plexus* ; two *renal* and two *spermatic plexuses*.

PHYSIOLOGY OF THE FUNCTIONS OF THE NERVOUS SYSTEM.

Nerves are the organs of our senses. Bodies applied to certain parts of our system produce changes in those parts, which changes are conveyed in an unknown manner to the brain by means of the nerves only, and SENSATION is produced ; so that sensation is a property peculiar to the nervous fibre, as irritability is to the muscular fibre : and hence all sentient parts are supplied with nerves, although they cannot be detected by the eye.

The senses are distinguished into internal and external.

THE INTERNAL SENSES are ideas which the sensorium commune, or mind, forms to itself, and may be produced from the external senses, or they may be excited spontaneously ;

such are, *memory, imagination, conscience, the passions of the mind, and reasoning*, by the superior excellence of which, man differs so eminently from the brute.

THE EXTERNAL SENSES are, smelling, seeing, hearing, tasting, and touching.

OF SMELLING.

Smelling is a sensation by which we perceive the smell of substances. The organ of smell is the nervous papillæ of the olfactory or first pair of nerves, which are distributed on every part of the pituitary membrane of the nose.

OF SEEING.

Seeing is a sensation by which we perceive bodies around us, and their visible qualities. The organ of sight is the retina, an expansion of the optic or second pair of nerves. The object of sight is the rays of light which penetrate the bulb of the eye and stimulate the retina. *Light* is a subtile and solid material, which emanates from the sun or any lucid body with a very rapid motion, in right lines, which are called *rays of light*, and penetrate to the retina in the following manner: the rays of

light fall on the pellucid and convex cornea of the eye, by whose density and convexity they are united into a focus, which passes the aqueous humour and pupil of the eye, to be more condensed by the crystalline lens. The rays of light thus concentrated, penetrate the vitreous humour, to stimulate the retina, upon which they impress the image of external objects to be represented to the mind through the medium of the optic nerves.

OF HEARING.

Hearing is a sensation by which we perceive the sound of any sonorous body.

Sound is a tremulous motion of the air excited by striking any sonorous body. Sound is conveyed to an enormous distance in the atmosphere, in straight lines, which are called sonorous rays. Soft bodies diminish or stifle sound; elastic ones increase it. The *organ* of hearing is the portio mollis of the seventh pair of nerves, whose pulp is beautifully distributed in the vestibulum, semicircular canals, and cochlea of the ear. Hearing is *performed* in the following manner: the rays of sound emanating from a sonorous body arrive at the ear, which by its

elasticity and peculiar formation, concentrates them, that they may pass along the external auditory foramen, to the membrana tympani, which they cause to vibrate. The trembling tympanum communicates its vibrations to the malleus, which is in contact with it: the malleus conveys them to the incus, the incus to the os orbiculare, and the os orbiculare to the stapes. The stapes adhering to the fenestra ovalis causes it to vibrate. The trembling fenestra ovalis communicates its vibrations to the water contained in the vestibulum and semicircular canals, and causes very gentle motions of the nervous expansion contained therein, which transmit them to the sensorium commune, where the mind is informed of the presence of sound, and judges of its difference. Gravity and acuteness of sound depend upon the number of vibrations given at the same time.

OF TASTING.

Tasting is a sensation by which we distinguish the qualities of bitter, sweet, sour, &c. substances. The nervous papillæ of the ninth or lingual pair of nerves, which are situated in the apex and margins of the tongue, are the chief organs of taste. The parts subservient to

*and from where is the organ situated
after following the tremulous motion through
the labyrinth the sound is then to be heard*

taste are—The *tongue*, which gives a convenient situation to the nervous papillæ, and by its extensive motion applies them to the substance to be tasted—The *epidermis* of the tongue, which moderates any excessive stimuli—The *saliva* and *mucus* of the mouth, which assist the organ of taste when it is necessary that the substances should be dissolved in order to be tasted, and which also keep the nervous papillæ moist.

OF TOUCHING.

Touching is a sensation by which we distinguish the qualities of hardness, softness, heat and cold, &c. of substances, and by which we perceive any substance that comes in contact with the skin, particularly at the points of the fingers. The *organs* of touch are the nervous papillæ of the skin, which are extremely numerous and sensible at the points of the fingers.

Too great a sensation is moderated by the epidermis, which also defends the papillæ from being dried by the air.

ADENOLOGY,

O R

DOCTRINE OF THE GLANDS.

A **GLAND** is a small round body, which serves for the secretion or alteration of a fluid. **DIVISION**, into folliculose, globate, glomerate, and conglomerate; they are also divided from the liquid they secrete or change, into sebaceous, muciparous, lymphatic, lachrymal, salival, bilious, lacteal, &c.

A *folliculose gland* consists of an hollow vascular membrane, having an excretory duct; as the muciparous and sebaceous glands.

A *globate gland* consists of a glomer of lymphatic vessels, connected together by cellular membrane, and has no cavity nor excretory duct, as the lymphatic glands of the lymphatic vessels.

A *glomerate gland* is formed of a glomer of sanguineous vessels; has no cavity, but is furnished with an excretory duct, as the lachrymal and mammary glands.

A *conglomerate gland* is a gland composed of many glomerate glands, whose excretory ducts unite, and form one large canal, or duct.

The pancreas and salival glands belong to this class.

The *excretory duct* of glands is a thin canal, which goes out of the gland, and excerns the secreted fluid, by the contractility of its coats.

The *nerves* and *vessels* of glands are numerous, and come from the neighboring parts.

Glands are connected with other parts by cellular membrane. They are larger in infants than in adults. *USE*, to secrete or change a fluid.

GLANDS OF THE SKIN. The *subcutaneous glands* are sebaceous, and situated under the inferior surface of the skin, which they perforate by their excretory ducts.

GLANDS IN THE CAVITY OF THE CRANIUM. 1. *Glands of the dura mater*, called also, after their discoverer, *Bacchonian*, are situated near the superior longitudinal sinus of the dura mater, in peculiar foveolæ of the os frontis and parietal bones. They appear to be globate. 2. *Glands of the choroid plexus* are globate, and situated in the choroid plexus of the lateral ventricles of the brain. 3. The *pituitary gland*, situated in a duplicature of the dura mater, in the sella turcica of the sphænoid bone. The

infundibulum of the brain terminates in this gland.

GLANDS OF THE EYES. 1. *Meibomius's glands*. These are small and numerous sebaceous glands, situated under the skin of the eyelids, near their margins. Their excretory ducts open on the margins of the tarsi, and are called *puncta ciliaria*. 2. The *lachrymal gland*, which is glomerate, and situated above the external angle of the orbit, in a peculiar depression of the os frontis. This gland has six or eight excretory canals, through which the tears are conveyed, and which open upon the internal surface of the upper eyelids. 3. The *caruncula lachrymalis*, a small and red prominence, obvious in the internal angle of the eye, between the tarsi of the eyelids. It consists of small sebaceous glands, which secrete a feculent humour.

GLANDS OF THE NOSTRILS. The pituitary membrane lining the nostrils and its sinuses, is every where furnished with *muciparous glands*, which secrete the mucus of the nose.

GLANDS OF THE EAR. The *ceruminous glands* are situated under the skin of the meatus auditorius externus, and secrete the wax of the ears.

GLANDS OF THE MOUTH. The glands of the mouth, which secrete the saliva, are called *salival*, and are, 1. The *parotid*, two large conglomerate glands, situated under the ear between the mamillary process of the temporal bones and angle of the lower jaw. The excretory canal of this gland opens in the mouth, and is called, from its discoverer, the *Stenonian* duct. 2. The *maxillary*, which are conglomerate glands, situated under the angles of the lower jaw. The excretory ducts of these glands are also called, after their discoverer, *Warthonian*. 3. The *sublingual* glands, situated under the tongue. 4. The *glands of the cheek*, situated on the internal surface of the cheeks. 5. The *labial* glands, on the internal surface of the lips, under the common membrane of the mouth. 6. The *molar* glands, situated on each side of the mouth, between the masseter and buccinator muscles, and whose excretory ducts open near the last dens molaris.

EXTERNAL GLANDS OF THE NECK. 1. The *jugular* glands, which are globate, and found under the skin of the neck about the external jugular veins: they are in general about 20 in number. 2. The *submaxillary* glands, also globate, and situated in the fat under the

Jaw. 3. The *cervical*, found under the cutis in the fat about the neck. 4. The *thyroid*, a large gland lying upon the cricoid cartilage, trachea, and horns of the thyroid cartilage. It is uncertain whether it be globate or conglomerate. Its excretory duct has never been detected, and its use is unknown.

GLANDS OF THE FAUCES. The glands situated under the membrane which lines this cavity, are muciparous, and divided, from their situation, into *palatine*, *uvular*, *tonsil*, *lingual*, *laryngeal*, and *pharyngeal*.

GLANDS OF THE BREASTS. The *mammary*, or *lacteal glands*, are situated under the fat of the breasts. Their excretory ducts are called *tubuli lactiferi*, *tubuli galactoferi*, and run from them to the nipple, in which they open.

GLANDS OF THE THORAX. 1. The *thymus*, a large gland, peculiar to the foetus, and which disappears soon after birth : it is situated in the anterior duplicature or space of the mediastinum, under the superior part of the sternum, and above the pericardium. An excretory duct has not been as yet detected, but lymphatics are seen going from this gland to the thoracic duct. 2. The *bronchial*, which are large

blackish glands near the end of the trachea, and beginning of the bronchia, and which secrete a blackish mucus. 3. The *oesophageal glands*, found under the internal membrane of the *oesophagus*, and which secrete the mucus of that canal. 4. The *dorsal glands*, situated upon the 4th or 5th vertebra of the back, between them and the posterior surface of the *oesophagus*. They have no excretory ducts.

GLANDS OF THE ABDOMEN. 1. The *gastric glands*, which are muciparous, and situated under the external membrane of the stomach. 2. The *intestinal glands*, which are also muciparous, and found under the internal membrane of the intestines, especially the large. 3. The *mesenteric glands*, situated here and there in the cellular membrane of the mesentery. The chyle from the intestines passes through these glands to the thoracic duct. 4. The *hepatic glands*, also called *acini biliosi*, which form the substance of the liver, and separate the bile into small ducts, which, at length, terminate in the *ductus hepaticus*. 5. The *cystic glands*, which are muciparous, and found under the internal membrane of the gall-bladder, especially about its neck. 6. The *pancreatic glands*,

which constitute the pancreas ; a small duct arises from each gland, which unite to form the *ductus panereaticus*. See SPLANCHNOLOGY. 7. The *epiploic* or *omental glands*, which are globate, and situated in the omentum.

GLANDS OF THE LOINS. 1. The *supra-renal glands*, situated in the adipose membrane, one above each kidney. An excretory duct has never been detected, and their use is unknown. 2. The *kidneys*. See SPLANCHNOLOGY. 3. The *lumbar glands*, which are globate, and situated about the beginning of the thoracic duct. 4. The *iliac glands*, found about the beginning of the iliac vessels. 5. The *sacral*, which are globate glands, and adhere to the os sacrum.

GLANDS OF THE ORGANS OF GENERATION OF MAN. 1. The *odoriferous glands* of the glans penis, which are sebaceous, and situated around the *corona glandis*. 2. The *mucous glands of the urethra*, situated under the internal membrane of the urethra. The mouths of their excretory ducts are called *lacunæ*. 3. *Cowper's glands* (so called from their inventor) are three large muciparous glands, two of which are situated before the prostate gland under the *acceleratores urinæ*, and the

third more forward before the bulb of the urethra. 4. The *prostate*, a very large, heart-like, firm gland, situated between the neck of the urinary bladder and bulbous part of the urethra. It secretes a lacteal fluid, which is emitted into the urethra by ten or twelve ducts near the verumontanum, during coition.

GLANDS OF THE FEMALE ORGANS OF GENERATION. 1. The *odoriferous glands* of the *labia majora* and *nymphæ*, which are sebaceous, and situated under the skin of those parts. 2. The *odoriferous glands* of the *clitoris*, which are numerous, situated about the basis of the clitoris, and are of the same nature as the former. 3. The *mucous glands* of the *urethra*, situated under the internal membrane of the female urethra. 4. The *mucous glands* of the *vagina*, situated under the internal membrane of the vagina.

GLANDS OF THE EXTREMITIES. The *glands in the groin*, or *inguinal glands*, are globate, or lymphatic, are situated in great numbers in the cellular membrane of the inguinal region, and receive the lymphatic vessels from the glans penis, and lower extremities. The *subaxillary glands* are also globate, and are situated in the cellular membrane of the

arm-pit: they are also numerous, and receive the lymphatic vessels from the breasts and superior extremities.

GLANDS OF THE JOINTS. The small fat-like masses, situated within the moveable joints, are erroneously called *synovial glands*: their structure is not glandular, they are composed of adips and an arrangement of the internal vascular membrane of the joint, which gives them a fimbriated appearance. By these little masses the synovia is separated from the blood for the easy motion of the joint.

PHYSIOLOGY OF SECRETION.

Secretion is a particular function in an animal body, by which a fluid is separated from the blood, different in its properties from the blood.

The *organs* which secrete the various humours are the glands. The *proximate* or *immediate cause* of secretion is a specific action of the arteries of the glands; for every secretion is formed from the extremities of arteries (the secretion of the bile is no exception to this law, for the vena portæ takes upon itself the func-

tion of an artery) ; thus the mucous glands secrete mucus, the salival glands saliva ; the acini of the liver, bile ; the penicelli of the kidneys, urine, &c.

The secreted fluids are the proper stimuli to the receptacles and ducts through which the secretion is to pass to its place of destination ; so that the secretions move along the excretory ducts by means of the contractility of the coats of the ducts and the assistance of neighboring moving powers.

SPLANCHNOLOGY,

O R

DOCTRINE OF THE VISCERA.

BODY, divided externally into head, trunk, and extremities. **HEAD**, divided into face, and hairy part. **HAIRY PART**, into vertex, or crown, sinciput, or the fore part, occiput, or hinder part, and sides. **FACE**, into forehead, temples, nose, eyes, mouth, cheeks, chin, and ears. **TRUNK**, divided into neck, thorax, and abdomen. **NECK**, into anterior and posterior part. **THORAX**, into anterior

and posterior part and sides. ABDOMEN, into anterior, posterior, and lateral regions. ANTERIOR REGION, subdivided into three regions, 1. the *epigastric*, which lies over the stomach, and whose sides are termed the *hypochondriacal regions*; 2. the *umbilical*, surrounding the navel, and whose sides are called the *flanks*; 3. the *hypogastric*, which lies over the urinary bladder, and whose sides are called *groins*. The PUBES is the hairy part under the abdomen, between the groins. Under the pubes are the parts of generation—in men, the scrotum and penis—in women, the labia and rima vulvæ. The space between the genitals and anus is called the *perinæum*. EXTREMITIES, divided into superior and inferior. SUPERIOR EXTREMITY, into top of the humerus, brachium, fore-arm and hand. HAND, into carpus, metacarpus, and fingers. FINGERS, into pollex, index, digitus medius, digitus annularis, digitus auricularis. INFERIOR EXTREMITY, divided into femur, or thigh; crus, or leg, and extremity of the foot. FOOT, into tarsus, metatarsus, and toes.

INTERNAL DIVISION of the body, into three cavities, viz. cavity of the cranium, thorax, and abdomen.

COMMON INTEGUMENTS.

These are so called, because they are the common coverings as it were to the body ; they consist of epidermis, rete mucosum, cutis, and membrana adiposa.

EPIDERMIS, OR SCARF SKIN.

A thin, pellucid, insensible membrane, covering the external surface of the body. CONNECTION, with the cutis, hairs, exhaling and inhaling vessels. COLOUR, white. USE, to cover the sensible cutaneous papillæ.

RETE MUCOSUM.

A mucous substance, disposed in a net-like form, between the epidermis and cutis. COLOUR, white in Europeans, black in Ethiopians, &c. &c. USE, to cover the sensible cutaneous papillæ, to connect the epidermis with the cutis, and give the colour to the body. SYNONYMS. Mucus Malpighianus.

CUTIS, OR TRUE SKIN.

A thick membrane between the rete mucosum and adipose membrane, covering the

whole body. SUBSTANCE, fibrous, vascular, and nervous. USE, for the situation of the organ of touch, exhalation, and absorption. See pages 143 and 163.

PHYSIOLOGY OF PERSPIRATION.

Perspiration is a species of secretion by which the blood is freed of a quantity of aqueous fluid by the exhalent arteries of the skin. It is divided into *insensible* and *sensible perspiration*: The former is continually going on, by which means the surface of the body is kept smooth and moist, and may be detected by placing any part of the skin near a looking-glass, which will become soiled. The latter commonly termed *sweat*, is observed only occasionally.

UNGUES, OR NAILS,

Are horny laminae, situated in the extremities of the fingers and toes. USE, to defend the nervous papillae from contusion.

PILI, OR HAIRS.

Thin, elastic, dry filaments, growing out from the skin. COLOUR and SITUATION, various. CALLED capilli on the head; supercilia, or eye brows, above the eyes; cilia,

or eye-lashes, on the margin of the eyelids; vibrissæ in the nostrils; pili auriculares in the meatus auditorius; mystax on the upper lip; barba on the lower jaw, &c. &c.

ADIPOSE AND CELLULAR MEMBRANE.

A membrane formed of small membranous cells, which are sometimes distended with fat. SITUATION, under the cutis, and in some soft parts. USE, to cover and defend the muscles; to unite the soft parts; and to render the muscular fibres flexible. When without fat, it is called *tela cellulosa*, or cellular membrane, which forms the substance of almost all the membranes, and connects various parts together.

OF THE HEAD.

The parts which form the head, are DIVIDED into external and internal. The *external parts* are the common integuments; hair; a tendinous expansion; three pair of muscles; pericranium; and cranium itself. The *internal parts* are, the dura mater; membrana arachnoidea; pia mater; cerebrum; cerebellum.

luna; medulla oblongata; nine pair of nerves; four arteries, and twenty-two venous sinuses.

DURA MATER.

A thick membrane, which strongly adheres to the internal surface of the cranium, especially about the sutures. PROCESSES. The *falciform process*, which divides the hemispheres of the brain; *tertorium cerebelli*, which separates the brain from the cerebellum; and *septum cerebelli*, which separates the two lobes of the cerebellum. COMPOSED of two strong membranous layers adhering together by fibrous texture. ARTERIES. Meningea anterior, media and posterior. VEINS are called venous sinuses; in number they are twenty-two, the principal of which are the *superior longitudinal*, *lateral*, and *inferior longitudinal*; all of which evacuate their blood through the foramen lacerum in basi cranii, into the internal jugular veins. NERVES, none. GLANDS, situated about the longitudinal sinus, are called *Bacchonian*. USE, to form the internal periosteum of the cranium, and to contain and defend the cerebrum and internal parts of the brain from compression.

Bacchonian - vide in plate

the gland

MEMBRANA ARACHNOIDEA.

A very delicate and transparent membrane, SITUATED between the dura and pia mater, surrounding the cerebrum, cerebellum, medulla oblongata, and medulla spinalis. SUBSTANCE, very thin and filamentous, and apparently without vessels and nerves. USE, not known.

PIA MATER.

A thin membrane, firmly accreted to the convolutions of the cerebrum, cerebellum, medulla oblongata and spinalis. SUBSTANCE, almost wholly vascular. USE, to distribute the vessels to, and contain the substance of, the cerebrum.

CEREBRUM, OR BRAIN.

A great viscus in the cavity of the cranium. FIGURE, oval. SIZE, larger in man, in proportion to his size, than in any other animal. SUBSTANCE, cortical and medullary. DIVIDED into two *hemispheres*, right and left. Each hemisphere subdivided on its inferior surface into three lobes, an anterior, middle, and posterior. PRINCIPAL CAVITIES, two *anterior or lateral ventricles*, in each of which are

several eminences & a loose vascular production of the pia mater, called the *plexus choroides*; a *third* and *fourth ventricle*. **PRINCIPAL PARTS**; *corpus callosum*, seen when the hemispheres are separated from each other; *septum pellucidum*, which divides the lateral ventricles; the *fornix*; the *digital processes*; *pedes hippocampi*; *corpora striata*, and *thalami nervorum opticorum*, which are found in the lateral ventricles; *valvula magna cerebri*; *commissura anterior et posterior*; *corpora quadrigemina*, i. e. *nates* and *testes*; *glandula pinealis*; *glandula pituitaria*; *eminentiæ candicantes*, and the *crura cerebri*, all of which can only be learnt upon the subject. **ARTERIES**, branches of the internal carotids and vertebrals. **NERVES**, none, but emits nine pair. **VEINS**, return from the cortex of the cerebrum, and evacuate themselves into twenty-two venous sinuses of the dura mater. **USE**. It is the organ of all the senses.

CEREBELLUM, OR LITTLE BRAIN.

A small brain situated under the tentorium in the inferior occipital depression. **FIGURE**, round. **DIVISION**, into a right and left lobe. **SUBSTANCE**, externally cortical; internally

medullary. EMINENCES, two *crura cerebelli*; an anterior and posterior *vermiform process*, and the *arbor vitæ*. CAVITIES, none. VESSELS, common with the cerebrum. USE, the same as the cerebrum.

MEDULLA OBLONGATA:

A medullary part lying upon the basillary or cuneiform process of the occipital bone, formed by the connexion of the crura of the cerebrum and cerebellum. EMINENCES, *pons varolii*; *corpora pyramidalia*; and *corpora olivaria*. USE, the same as the cerebrum.

MEDULLA SPINALIS.

A continuation of the medulla oblongata, which descends into the specus vertebralis, from the foramen magnum occipitale to the third vertebra of the loins, in which course it transmits between the vertebræ thirty pair of nerves. FIGURE, cylindrical. Terminates, in various nerves, which form the *cauda equina*. INTEGUMENTS, the dura mater; tunica arachnoidea, and pia mater. SUBSTANCE, externally medullary; internally cortical. ARTERIES, anterior spinal. USE, to admit thirty pair of nerves, called spinal.

OF THE ACTION OF THE CEREBRUM,
CEREBELLUM, MEDULLA OBLONGATA,
AND MEDULLA SPINALIS.

The most important functions of an animal body are those of the brain. In order to explain these accurately, it is necessary to mention a few experiments which have been made upon animals.

Upon dividing, compressing, or tying a nerve, the muscles to which the nerve goes become paralytic. If the nerve thus divided, compressed, or tied, had any particular sensation, that sensation no longer exists; but upon untying or removing the compression, its peculiar sense returns.

If the cerebrum, cerebellum, or medulla oblongata, be irritated, dreadful convulsions take place all over the body.

If any part of the brain be compressed, that part of the body is deprived of motion which has nerves from the compressed part.

From these phenomena, it is evident that the cause of every sensation and motion in an animal body arises from the brain and spinal marrow, and that from these parts it is conveyed to every sentient part through the medium

of the nerves. Hence it follows, that the nerves are the organs by which the various sensations are produced. The manner, however, in which the nerves exercise sense and motion ; how the will is conveyed from the brain to the different parts, and how, from the different parts sensations are conveyed to the brain, remains involved in obscurity ; several hypotheses have been deduced to explain it, but none appear to be satisfactory. See also page 159.

EYE.

The parts which form the eye are divided into external and internal. The **EXTERNAL PARTS** are the supercilia, or eyebrows ; the palpebræ, or eyelids ; the cilia, or eyelashes ; the lachrymal gland ; the lachrymal caruncle, a small fleshy substance at the inner angle of the eye ; the puncta lachrymalia, two small openings on the nasal extremity of each eyelash ; the canalis lachrymalis, formed by the union of the ducts leading from the puncta lachrymalia, which meet and constitute it at the internal angle of the eye ; the saccus lachry-

malis, a dilatation of the *canalis lachrymalis*, and which ends in the *ductus nasalis*, a continuation of the same canal; which conveys the tears into the nose; the muscles of the eyelids; the muscles of the bulb of the eye, and the fat of the orbit. The BULB OF THE EYE consists of eight membranes, two chambers, and three humours. The bulb is covered anteriorly by an exquisitely sensible and delicate membrane, which begins from the edge of the eyelash, and is reflected over the eye to the edge of the other eyelash. This membrane is the seat of inflammations of the eye, and is called the *tunica conjunctiva*. MEMBRANES. 1. The *sclerotic*, which is white, and the outermost. 2. The *choroid*, which is highly vascular, and whose vessels are called, from their direction, the *vasa vorticosa*. 3. The *retina*, which is the innermost; and, 4. The *hyaloid*, or *arachnoid*, which includes the vitreous humour. In the *anterior* part are, 5. The *cornea transparens*, which is part of the *sclerotic*. 6. The *iris*, a part of the *choroid*: it is of various colours; hence white, black, blue eyes, &c. 7. The *uvea*, which is the posterior part of the *iris*; and, 8. The *capsule of the crystalline lens*. The chambers of the eye are distinguished into *anterior* and *posterior*. The *anterior*

is the space between the transparent cornea and the fore part of the iris ; the *posterior* the space between the uvea and capsule of the crystalline lens. The *Humours* are the aqueous, the crystalline lens, & the vitreous. See *Hygrology*.
CONNEXION OF THE BULB. Anteriorly, it is connected with the membrana conjunctiva ; posteriorly, with the orbit, by means of muscles and the optic nerve. **ARTERIES**, orbitalis interna, the central, and the optic. **VEINS**, empty themselves into the external jugulars.—
NERVES. The optic, or first pair, and branches from the third, fourth, fifth, and sixth pair.
USE. It is the organ of vision. See *Physiology of Vision*, page 160.

EAR.

The soft parts which form the ear are divided into external and internal. The **EXTERNAL SOFT PARTS** are, the auricula, in which are various prominences and sinuses, as the helix, antihelix, tragus, antitragus, concha auriculæ, scapha, seu fossa navicularis, & lobulus; the meatus auditorius externus, and membrana tympani. The **INTERNAL SOFT PARTS** are the periosteum, a proper membrane, which lines every part of the internal ear & the Eustachian tube which begins by a large opening in the fauces, and gradually di-

minishes as it passes along its bony canal into the ear. ARTERIES, auditoria interna and externa. VEINS, empty themselves into the external jugular. NERVES of the external ear are, branches of the seventh pair, or nervus auditorius durus ; and those of the internal part are branches also of the seventh pair, but of the portio mollis. USE. It is the organ of hearing. See *Physiology of Hearing*, page 161.

NOSE.

A prominence of the face between the eyes and mouth. DIVISION, into root, back, apex, and alæ. SOFT PARTS. Common integuments, muscles, cartilages, periosteum, perichondrium. SOFT PARTS OF THE NOSTRILS. A pituitary membrane, which lines the internal surface of the nose and all its cavities, contains the mucous glands, and has distributed on it the olfactory nerves ; and the periosteum. ARTERIES, branches of the internal maxillary. VEINS, empty themselves into the internal jugulars. NERVES, branches of the olfactory, ophthalmic, and superior maxillary. MUCIPAROUS GLANDS, situated every where in the pituitary membrane. USE, for smelling, respiration and speech. See *Physiology of smelling*, page 160.

CAVITY OF THE MOUTH.

The parts which form this cavity are external and internal. The **EXTERNAL** are the lips, the philtrum, the chin, and the cheeks. **COMPOSITION**, common integuments and the muscles of the upper and under jaw. **ARTERIES** of the external part are branches of the infra-orbital, inferior alveolar, and facial. **VEINS**, empty themselves into the external jugular. **NERVES**, from the fifth and seventh pair. The **INTERNAL** parts of the mouth are the palate, two alveolar arches, the gums, tongue, cavity of the cheeks, and three pair of salival glands. **USE**, for mastication, speech, respiration, deglutition, suction and taste.

PHYSIOLOGY OF MASTICATION.

Mastication is the comminution of the food between the teeth, effected by the jaws, the tongue, cheeks and lips. The powers which move these parts are their various muscles, by which the lower jaw is pulled from the upper and again brought to it, whilst the tongue perpetually puts the food between the teeth, and the cheeks and lips impede it, when masticated, from falling out of the mouth. By this

process, the food is divided, lacerated, and, as it were, ground, and mixed with the saliva and mucus of the mouth and the atmospherical air, and thus rendered fit to be swallowed and digested; so that mastication is in fact an incipient digestion.

TONGUE.

A muscular body, moveable in every direction, situated in the cavity of the mouth. **DIVISION**, into basis, body, sides, apex. **CONNECTION**, with the os hyoides, bottom of the infra-lingual cavity, and lower jaw. The **NERVOUS PAPILLÆ**, which are situated at the apex of the tongue, are pyramidal, fungiform, or conoid. **SUBSTANCE**, fleshy, covered by cuticle, rete mucosum, cutis, and cellular membrane. **LINGUAL ARTERIES**, branches of the external carotid. **VEINS**, empty themselves into the external jugulars. **NERVES**, from the fifth, eighth, and ninth pair. **GLANDS** are muciparous. **USE**, for speech, mastication, deglutition, suction, and taste. See page 162.

OF THE NECK.

The parts which form the neck are divided into external and internal. The **EXTERNAL PARTS** are the common integuments ; the muscles of the neck ; eight pair of cervical nerves ; two carotid arteries ; two vertebral arteries ; two external jugular veins ; two internal jugular veins ; the jugular glands ; the thyroid gland ; the eighth pair of nerves of the cerebrum ; and the great intercostal. The **INTERNAL PARTS** are, the fauces ; pharynx ; oesophagus ; larynx, and the trachea.

FAUCES.

The cavity behind the tongue and the curtain of the palate, or velum palatinum. **SOFT PARTS**, common integuments and muciparous glands. **ARTERIES**, branches of the external carotid. **VEINS**, empty themselves into the internal jugular. **Muscles**, see *Myology*. **NERVES**, from the fifth and eighth pair. **Use**, for deglutition, respiration, speech, and hearing.

PHARYNX.

A muscular sac, like a funnel, situated be-

hind the larynx, adhering to the fauces, and terminating in the œsophagus. Connected, by means of muscles, with the cranium ; vertebrae ; and os hyoides. **USE**, to receive the masticated food, and convey it into the œsophagus.

ÆSOPHAGUS.

A membranous muscular tube, descending from the pharynx to the stomach. Composed of three membranes, viz. a common, muscular, and villous. **ARTERIES**, branches of the aorta. **VEINS**, empty themselves into the vena azygos. **NERVES**, from the eighth pair and great intercostal. Muciparous glands, every where. **USE**, for deglutition.

PHYSIOLOGY OF DEGLUTITION.

Deglutition is the conveying of the masticated food from the cavity of the mouth into the fauces, and from the fauces through the œsophagus into the stomach. This is performed by the jaws shutting, so as to prevent the food from falling out of the mouth ; the tongue is then applied to the palate, by which the food lying upon the back of the tongue is pressed into the cavity of the fauces, where it is received.

by the dilated pharynx. The pharynx then is irritated to contract, by which the food is expelled into the œsophagus, by the contraction of whose muscular fibres it is conveyed through the cardia into the stomach.

The pharynx is dilated by its dilatatory muscles, and by the root of the tongue, os hyoides, and larynx, being drawn forwards and backwards by their proper muscles.

The food is prevented during the act of swallowing from passing into the posterior opening of the nostrils, the Eustachian tube, and larynx, by the velum pendulum palati and uvula being pressed against the former, and the epiglottis being bent backwards over the glottis.

When a fluid is to be drank, the head inclines backwards, the same actions take place, and the fluid passes on each side of the epiglottis. During deglutition the food is covered with the mucus of the fauces and œsophagus.

LARYNX.

A cartilaginous cavity, situated behind the tongue in the anterior part of the fauces. Composed of five cartilages ; various muscles ; and an internal nervous membrane. **CARTILAGES**, the *epiglottis*, at the root of the

tongue; the *thyroid*, or *scutiform*, which is the largest, and two *arytaenoid* cartilages; and the *cricoid* cartilage, which is below the thyroid. A *very sensible membrane* covers their internal surface. The superior opening of the larynx, through which the air passes, is called the *glottis*. *Arteries*, branches of the external carotid. *Veins*, empty themselves into the external jugular. *Nerves*, branches of the eighth pair. *Glands*, the thyroid. *Use*. It is the organ of the voice, and serves also for respiration.

PHYSIOLOGY OF THE VOICE.

The voice is caused by the sound of the air propelled through the glottis; so that the organ of the voice is the larynx and its muscles.

The shrillness and roughness of the voice depends on the diameter of the glottis, its elasticity, mobility, and lubricity, and the force with which the air is expelled: thus when the diameter is increased, the voice is more bass, and *vice versa*.

SPEECH

Is the modification of the voice in the cavity of the mouth and nostrils.

VENTRILOQUISM

Consists in the motion of the uvula, epiglottis, and fauces, by which the sounds are modulated without the lips, teeth, or palate. The mouth being nearly shut, and the voice resounding between the larynx and cavity of the nose, the sound is returned as if emitted by some one at a distance.

TRACHEA.

A tube, composed of cartilaginous rings continued from the larynx, and situated before the œsophagus. It descends to the sternum, and there divides into two branches called *bronchia*. The bronchia, entering the substance of the lungs, divide into innumerable little branches, which terminate in the *vesiculæ pulmonales*, or air-cells. The cartilaginous rings of the trachea and bronchia are not completely cartilaginous, but fleshy on the back part. The internal surface is lined by a *very sensible membrane* continued from the larynx. **VESSELS and NERVES**, common with the larynx. **USE**, for respiration and speech.

OF THE THORAX.

The cavity situated between the neck and abdomen is called the *thorax*, or breast. The *external parts* are, the common integuments; the *mammæ*, or breasts; various muscles and bones. The *internal parts* are, the pleura; lungs; heart; thymus gland; oesophagus; thoracic duct; the arch of the aorta; branches of the vena cava; the vena azygos; the eight pair of nerves, and part of the great intercostal nerve.

MAMMÆ, OR BREASTS.

Two soft hemispheres adhering to the anterior and lateral region of the thorax, most conspicuous in females. On the middle of the external surface is the *papilla*, around which is the coloured orb or disc of the papilla, called *areola*. **SUBSTANCE**, common integuments; adipose substance; lacteal glands and vessels. **ARTERIES**, external and internal mammary. **VEINS**, empty themselves into the axillary and subclavian vein. **NERVES**, branches of the costalis superior. **LYMPHATICS**, empty themselves into the subaxillary glands. **USE**, to suckle new-born infants.

PLEURA.

A membrane lining the internal surface of the thorax, and covering its viscera. It forms a great process, called the *mediastinum*, which is a membranous septum to the cavity of the thorax, dividing it perpendicularly into two cavities, arising from the duplicature of the pleura. It is connected with the ribs, muscles, sternum, bodies of the dorsal vertebræ, pericardium, and diaphragm. SUBSTANCE, fibrous and vascular. ARTERIES, from the intercostals. VEINS, empty themselves into the intercostals. NERVES, very few. USE, to divide the thorax into two cavities, and render the surface moist by the vapor it exhales, and to give a membrane to the lungs and pericardium.

DIAPHRAGM.

A fleshy and tendinous division, separating the cavity of the thorax from the cavity of the abdomen. ADHESION, anteriorly with the sternum and ribs, posteriorly with the vertebræ. SUBSTANCE, in the centre, tendinous; in the ambit, fleshy; its superior surface is covered by the pleura; its inferior by the perito-

neum. Apertures, a *right foramen*, through which the vena cava ascendens passes to the right auricle of the heart, a *left foramen*, through which the oesophagus and the par vagum pass into the cavity of the abdomen, and a *posterior opening*, which transmits the aorta into the abdomen, and the thoracic duct and vena azygos, into the thorax. ARTERIES, from the descending aorta. VEINS, empty themselves into the vena azygos. NERVES. The diaphragmatic, or phrenic nerves, arise from the spinal nerves of the neck. USE, for respiration, situation of the heart, expulsion of faeces, and parturition.

LUNGS.

Two viscera, situated in the cavities of the thorax, by which we breathe. DIVISION, into right and left lung; the right has three lobes, the left only two. CONNEXION, with the neck and heart. SUBSTANCE, vesicular, vascular, and bronchial, connected together by a parenchymatous substance. It has an external membrane from the pleura. VESSELS, pulmonary and bronchial. NERVES, from the eighth pair and great intercostal. LYMPHATICS, are to be seen on its external

surface. GLANDS, called bronchial. USE, for respiration, sanguification, and voice.

PHYSIOLOGY OF RESPIRATION.

Respiration consists of *inspiration*, or the ingress of the air into the lungs, and *expiration*, or the egress of the air from the lungs.

During sleep, respiration is performed without our knowledge, and therefore termed *spontaneous*; but when it can be augmented or diminished according to our will, it is termed *voluntary*. The *exciting cause* of inspiration is the air rushing into the lungs and irritating its nerves, which irritation is by consent of parts communicated to the diaphragm and intercostal muscles, and compels them to contract. The contraction of the intercostal muscles and diaphragm, and the pressure of the elastic air, therefore dilate the chest. The air being deprived of its stimulus, the intercostal muscles and diaphragm become relaxed, the cartilages of the ribs and abdominal muscles, before expanded, return to their former state, and thus the air is expelled from the lungs. The small branches of the pulmonary artery form a beautiful *net work of vessels* on the inter-

nal membrane of the air vesicles. During expiration, the air-vessels are collapsed; consequently the blood-vessels become tortuous, and the blood is prevented passing. In inspiration then, the air vesicles being dilated, the tortuous vessels are elongated, and a free passage afforded to the blood: the very delicate coats of these vessels are also rendered so thin as to suffer a *chemical action* to take place between the air in the vesicles and the blood in the vessels. This constitutes the primary use of respiration; viz. the blood absorbing the oxygen from the atmospheric air, by which the nervous energy is increased, and it is generally believed, heat generated; but this subject is yet undetermined.

PERICARDIUM.

A membranous sac surrounding the heart. ADHESION, with the diaphragm, pleura, sternum, cartilages of the ribs, œsophagus, aorta descendens, and the veins and great arteries going to and from the heart. ARTERIES, branches of the internal mammary and mediastinal. VEINS, empty themselves into the internal mammary. NERVES, from the superficial cardiacs. USE, to contain the heart,

and to preserve a fluid, which may lubricate and preserve it from concretion with the pericardium.

HEART.

A muscular viscus situated in the cavity of the pericardium, which serves for the motion of the blood. DIVISION, externally into base, surfaces, and margins; internally, into auricles and ventricles. SITUATION, oblique, not transverse. The CAVITIES OF THE HEART are called auricles and ventricles. The auricles are situated upon the base of the heart, and are so named from their resemblance to dog's ears. They are composed of muscular fibres, which are very delicate, and are lined by an extremely sensible and contractile membrane. They surround the origin of the aorta and pulmonary arteries, when distended, and are separated from each other by the *septum auricularum*.

The RIGHT AURICLE has opening into it, at its upper part, the vena cava superior, at its lower part the vena cava inferior, and at one side the large coronary vein; so that its office is that of receiving the blood from every part of the body. Besides these openings, it has

one much larger, communicating with the right ventricle, from the margin of which there hangs into the right ventricle, connected with the chordæ tendineæ, a valve, called, from its shape, the *tricuspid*, or triglochine valves.

The LEFT AURICLE is composed of the same materials as the right ; it has opening into it the four pulmonary veins ; so that the blood of the pulmonary artery passes through the lungs into the left auricle. Besides the openings of the four pulmonary veins, the left auricle has a communication with the left ventricle, and from the margin of this opening there hangs into the left ventricle a valve, which, from its resemblance to a bishop's mitre, is termed the *mitral valve*. It is also connected to the chordæ tendineæ of the ventricle.

The ventricles are situated in the substance of the heart, and are divided from each other by a thick muscular septum, called *septum cordis*. The parietes of the ventricles are very thick, and composed of strong muscular fibres. In the ventricles are a number of fleshy cords, running in various directions ; these are called *carneæ columnæ*, and many of them are connected with the valves of the auricular openings by tendinous cords, termed *chordæ tendi-*

nee. The ventricles are lined by a similar membrane to that which lines the auricles.

The RIGHT VENTRICLE has a communication with the right auricle, as before mentioned, in order to receive its blood; it has also an opening into the pulmonary artery, which arises from it, and through which organ the blood is expelled from the ventricle. At the origin of the artery three large valves are placed, called, from their shape, *semilunar valves*.

The LEFT VENTRICLE is much stronger than the right: besides the opening for the entrance of the blood from the left auricle, it has also an opening through which it transmits its blood, and this is into the aorta, which arises from it, and has, like the pulmonary artery, three *semilunar valves* placed at its origin.

VESSELS are common and proper; the *common* are the aorta, pulmonary artery and veins, and the vena cava; the *proper* are the coronary arteries and veins. NERVES, branches of the eighth pair and great intercostal. USE. It is the primary organ of the motion of the blood.

CIRCULATION OF THE BLOOD

The blood is continually in motion, passing from the auricles of the heart into the ventricles ; from the ventricles into all the arteries of the body, and from the arteries into the veins, which return it again to the auricles. The blood is brought from every part of the body to the heart by the two vense cavæ (the superior bringing it from the head, upper extremities, and thorax, and the inferior from the abdomen and inferior extremities,) which terminate in the right auricle. The right auricle, when distended with blood, contracts, and empties itself into the right ventricle ; the right ventricle then contracts, and propels the blood into the pulmonary artery, the opening between the ventricle and auricle being shut by the tricuspid valves. The pulmonary artery conveys the blood by its numerous ramifications into the small branches of the air-cells of the lungs, where it undergoes a change, and passes into the veins which bring it by four trunks into the left auricle of the heart. It is prevented returning from the pulmonary artery into the right ventricle, by the three semilunar valves which are placed at its origin. The blood having thus passed

through the lungs, and become of a florid colour, distends the left auricle, which is then stimulated to contract, and pours the blood into the left ventricle. The left ventricle next contracts, and propels the blood through the aorta, to be conveyed by its branches to every part of the body. The mitral valves, which are placed at the auricular opening into the left ventricle, prevent the blood from returning, when the ventricle contracts, into the auricle: and lest the blood should be prevented by any impediment passing immediately along the aorta, the three semilunar valves placed at its origin prevent its regurgitating into the ventricle. From the numerous arteries of the aorta the blood is conveyed into the veins, where it loses its florid colour, and becomes darker, to be returned, in the way above mentioned, to the right auricle. Thus the blood of the right auricle and ventricle, and of the pulmonary arteries, is of a dark colour; and that of the pulmonary veins, left auricle, ventricle, and all the arteries (except the pulmonary) of a florid hue.

From what has been said, it is evident that the action of the heart consists in the alternate contraction and dilatation of its auricles and ventricles.

The dilatation of the heart is termed *dias-tole*, and the contraction *systole*. The excessive sensibility of the membrane which lines the auricles and ventricles disposes them to contraction, which is effected by the irritation of the stimulus of the blood, and by that of the distension of its cavities.

OF THE ABDOMEN.

A cavity situated between the thorax and pelvis. Divided into several regions, as has already been mentioned. The **EXTERNAL PARTS** are, the common integuments, five pair of abdominal muscles, and the peritoneum. The **INTERNAL PARTS, or VISCERA**, are the omentum, stomach, small and large intestines, liver, gall bladder, mesentery, lacteal vessels, spleen, pancreas, kidneys, supra-renal glands, aorta descendens, and vena cava ascendens.

PERITONEUM.

A membrane lining the internal surface of the abdomen, and covering all its viscera. **CONNECTED**, by means of cellular membrane, with the diaphragm, abdominal muscles, verte-

bræ of the loins, bones of the pelvis, urinary bladder, uterus, intestinum rectum, and all the viscera of the abdomen. **VESSELS OF THE PERITONEUM**, from the adjoining parts. **USE**, to contain and strengthen the abdominal viscera, and to exhale a vapour to lubricate them.

OMENTUM, OR EPIPLOON.

An adipose membrane, a production of the peritoneum, attached to the stomach, and lying on the anterior surface of the intestines. **DIVISION**, into *large* and *small* omentum. The *former* hangs pendulous from the great curvature of the stomach. The small omentum fills up the space between the small curvature of the stomach, liver, &c. Immediately behind the biliary ducts there is an opening which will admit the finger, called the foramen of Winslow. **ARTERIES**, branches of the cœliac. **VEINS**, empty themselves into the vena portæ. **USE**, to lubricate the intestines ; keep them warm ; and to preserve them from concretion.

STOMACH.

A membranous receptacle, which receives the ingesta from the œsophagus. **SITUATED**

in the epigastric region. **DIVIDED**, when empty, into an anterior and a posterior surface ; a great and little curvature ; the cardia, or superior opening ; and the pylorus, or inferior opening. **CONNEXION**, with the œsophagus, duodenum, omentum, and pancreas. **COMPOSED** of three membranes, or coats, viz. a common, muscular, and villous coat. **ARTERIES**, branches of the cœliac—the coronaria, which goes to the small curvature—the gastrica sinistra, which is distributed to the great and arises from the splenic artery,—gastrica dextra, which passes to the great curvature, and the pylorica, supplying the pylorus ; all of which unite with each other, and form a net-work of blood-vessels. **GASTRIC VEINS** empty themselves into the vena portæ, corresponding with the trunks of the arteries. **NERVES**, branches of the par vagum. **ABSORBENTS**, those of the small curvature terminate in thoracic duct, where the cœliac artery is given off, and those passing along the great curvature join with the absorbents of the spleen. **GLANDS**, muciparous, under the internal tunic. **USE**, to receive the ingesta from the œsophagus, and to retain, mix, digest, and expel it into the duodenum.

DIGESTION, OR CHYMIFICATION.

Digestion, or chymification, is the change which food undergoes in the stomach, by which it is converted into chyme.

The circumstances necessary to effect a healthy digestion of the food are—

1. A certain degree of heat of the stomach.
2. A free mixture of saliva with the food in the mouth.
3. A certain quantity of healthy gastric juice.
4. The natural peristaltic motion of the stomach.
5. The pressure of the contraction and relaxation of the abdominal muscles and diaphragm. From these circumstances, the particles of the food are softened, dissolved, diluted, and intimately mixed into a soft pap, called chyme, which passes through the pylorus of the stomach into the duodenum.

INTESTINES.

The membranous tube, six times longer than the body, in the cavity of the abdomen,

variously contorted from the pylorus of the stomach to the anus, is so called. **DIVISION**, into small and large. The **SMALL** are the *duodenum*, which begins at the pylorus of the stomach, and is reflected over the spine under the peritoneum. It is about twelve fingers breadth in length, and has an oblique perforation near its middle, which is the common opening to the pancreatic duct and ductus communis choledochus. The *jejunum* and *ileum* compose the remainder of the small intestines. They always hang from the mesentery into the cavity of the pelvis. There is no alteration of structure in any part of the small intestines, the termination of the one and beginning of the other is imaginary. The *jejunum* constitutes the first half from the *duodenum*, the other half is *ileum*. The small intestines have internally a number of anular folds, which augment the surface for the situation of the lacteal and other vessels ; these are called *valvulæ conniventes*. They are peculiar to the small intestines. The **LARGE** intestines are divided into the *cæcum*, colon, and *rectum*. The *cæcum* lies upon the right hip over the *iliacus internus* muscle, to which it is attached by cellular membrane : it is a large

cul de sac: the small intestine opens obliquely into it, in such a manner as to form a valve to impede the return of the *fæces*; and nearly opposite to this valve there arises from the *cæcum* a small vermiform canal, imperforated at its extremity, called the *appendicula cæci veriformis*. The intestine is now called colon; it ascends towards the liver, and is called the *ascending portion of the colon*, and having reached the liver, forms a *transverse arch* across to the other side. The colon then descends, forming what is termed its *sigmoid flexure* into the pelvis, where the gut is termed the *rectum*, which terminates in the anus. The large intestines are lobulated, have sometimes little fat portions adhering to them called *appendiculæ epiploicæ*, and also three longitudinal bands upon their external surface. COMPOSED of three membranes, or coats, one common, a muscular one, and the third villous. CONNEXION, with the mesentery, kidneys, os coccygis, and urinary bladder, and in women with the vagina. ARTERIES, branches of the superior and inferior mesenteric, duodenal, and internal hæmorrhoidal. VEINS, run into the meseraic. Their NERVES are, productions of the eighth pair and intercostals. LACTEAL

VESSELS. These arise from the small intestines, and run into the mesenteric glands. GLANDS, muciparous, under the villous coat. USE, to receive the chyme, and retain it for a time ; to mix it with the enteric juice and bile ; to separate and propel the chyle into the lacteal vessels ; and to eliminate the fæces.

CHYLIFICATION.

This is the change of the chyme in the small intestine into chyle. The chyme in the duodenum is mixed with the pancreatic juice, the bile and enteric juice ; from which mixture, effected by the continual peristaltic motion of the intestines, a milk-like fluid is separated, which is termed chyle, and is absorbed by the pendulous opening of the lacteals, and conveyed through the mesentery into the thoracic duct, to be sent into and mixed with the blood, to form new blood.

Chylification is performed quicker than chymification, and both are effected within three hours.

The excrementitious particles of the food, called the fæces, are propelled into the cæcum, through the colon, and where they ac-

quire a peculiar smell, into the rectum, to be expelled.

EXPULSION OF THE FÆCES.

The irritation of the fæces in the rectum induces it to contract, the sphincter relaxes, and the fæces are protruded through the aperture of the anus, by the pressure of the abdominal muscles, and the anus closed again by the contraction of its sphincter and levator muscles.

MESENTERY.

A membranous duplicature, formed of a production of the peritoneum, to which the intestines adhere. DIVISION, into mesentery, to which the intestines adhere, and mesocolon, to which the colon adheres. CONNEXION, with the lumbar vertebræ. ARTERIES, inferior and superior, mesenteric, branches of the aorta descendens. VEINS, empty themselves into the vena portæ. NERVES, branches of the eighth pair and intercostals. The GLANDS, which are situated in the mesentery, are called mesenteric glands. The lacteals proceed to the glands, and from them to the thoracic duct. USE, to strengthen the intestines, and afford a

situation to the lacteal vessels, glands, and nerves, blood-vessels, &c. of the intestines.

LIVER.

The largest of the abdominal viscera, placed in the right hypochondriac region, and somewhat in the epigastric. DIVISION, into three lobes; the great, small, and a less one, called the Spigelian. CONNEXION, with the diaphragm, by means of the suspensory and other ligaments. SUBSTANCE, vascular. The GLANDS which compose the substance of the liver are called *acini biliosi*. The EXCRETORY DUCTS OF THE GLANDS are termed *pori biliiari*: They arise from the acini of the liver, form larger trunks, called *ductus hepatici*, which converge together, and constitute a common canal, the *ductus hepaticus*, which unites with the cystic duct, and forms the *ductus communis choledochus*. USE, to secrete bile.

GALL-BLADDER.

An oblong membranous receptacle, situated under the liver, in the right hypochondrium. DIVISION, into bottom, body, and neck, which terminates in the ductus cysticus. The

ductus cysticus arises from the gall-bladder, proceeds to the duodenum, and unites with the *ductus hepaticus*, to form the *ductus communis choledochus*, which perforates the duodenum, and conveys the bile into the intestines. The gall-bladder is COMPOSED of three membranes, a common, fibrous, or muscular and villous. ARTERIES, branches of the hepatic. VEINS, empty themselves into the vena portæ. ABSORBENTS, very numerous. NERVES, from the eighth pair and intercostals. GLANDS, muciparous. USE, to retain the gall, which regurgitates from the hepatic duct, there to become thicker, more bitter, and acrid.

SPLEEN.

A spongy viscus, situated in the left hypochondrium, near the fundus of the stomach, under the ribs. Figure, oval. CONNEXION, with the omentum, diaphragm, pancreas, and colon. ARTERIES, the splenic artery is a branch of the cœliac. VEINS, empty themselves into the vena portæ. ABSORBENTS, very numerous. Nerves, from the par vagum and great intercostal. Use, unknown.

PANCREAS.

A glandular body, of a long figure, compared to a dog's tongue, situated in the epigastric region, under the stomach. COMPOSED of innumerable small glands, the excretory ducts of which unite and form the pancreatic duct. Its external membrane is from the mesocolon. ART. RIES, from the neighbouring parts and splenic artery. VEINS, evacuate themselves into the splenic. The *pancreatic duct* perforates the duodenum with the *ductus communis choledochus*, and conveys its secretion into the intestines. USE, to secrete a humour similar to saliva, and carry it into the duodenum.

LACTEAL VESSELS.

The absorbing vessels of the mesentery are so termed, because they convey the chyle, a milk-like fluid, from the intestines into the thoracic duct. ORIGIN, from the surface of the duodenum, jejunum, and ileum. TERMINATION, in the thoracic duct, or trunk of the absorbents, which runs near the aorta on the spine, and empties its contents into the jugular vein. As they run through the mes-

entery, they pass through a number of glands, in which the chyle is altered, and then proceed to their trunk. **USE.** To carry the chyle from the intestines into the blood. See *the Physiology of Absorption and the Absorbents*, pages 138. 143.

KIDNEYS.

Two viscera, which secrete the urine. **SITUATED** behind the sac of the peritoneum, near the bodies of the superior lumbar vertebræ. **SUBSTANCE**, of three kinds ; cortical, tubular, and papillous. **INTEGUMENTS**, or coverings, adipose membrane, and a membrana propria. The **RENAL ARTERIES**, or emulgent, are branches of the aorta descendens. The *veins* empty themselves into the cava inferior. The *nerves* of the kidneys are branches of the eighth pair and intercostal. The excretory ducts of the kidneys are called the *ureters*, canals which convey the urine from the kidneys into the bladder. **USE**, to secrete urine.

EXCRETION OF THE URINE.

The urine is separated from the blood by the extremities of the renal arteries, which

open in the substance of the kidney into the tubuli uriniferi, from whence it is received into the pelvis of the kidney, and passes along the ureter into the urinary bladder guttatum, where it usually remains a few hours, in consequence of the sphincter of the bladder being contracted. It is prevented returning into the ureters by their entrance being oblique and valvular. The urine having remained a few hours in the bladder, excites a desire to void it, by which stimulus the sphincter becomes relaxed, the muscular structure of the bladder contracts, and by the assistance of the abdominal muscles and the acceleratores urinæ the urine is propelled along the urethra.

SUPRA-RENAL GLANDS.

Two triangular flat bodies, SITUATED, one above each kidney. USE, not known.

OF THE PELVIS.

The pelvis is a cavity below the abdomen and under the pubes, containing the urinary bladder, rectum, and organs of generation.

URINARY BLADDER.

A membranous sac under the peritoneum, in the cavity of the pelvis. SITUATION, in men, between the pubes and rectum; in women, between the pubes and uterus. DIVISION, into fundus, body and neck. COMPOSED of three membranes, like the intestines. ARTERIES, branches of the hypogastric and hæmorrhoidal. VEINS, empty themselves into the hypogastric. NERVES, branches from the intercostal and sacral nerves. GLANDS, muciparous. USE, to receive, retain, and expel the urine.

THE MALE ORGANS OF GENERATION.

These are, the penis, testicles, and vesiculæ seminales.

PENIS.

Also called membrum virile, or yard, is that cylindrical part which hangs under the mons Veneris, before the scrotum. DIVISION, into root, body, and head, called *glans*. The hairy prominence, which covers the pubes, is called

mons Veneris. **SUBSTANCE.** It consists of common integuments, two corpora cavernosa; the corpus spongiosum urethræ; and the urethra. The *corpora cavernosa*, which form the chief bulk of the penis, are composed of a cellular and very elastic substance, and arise by two crura, one from each ascending ramus of the ischium. The *corpus spongiosum* begins before the prostate gland, and surrounds the urethra. At its beginning it forms the bulbous part of the urethra, and then proceeds forwards to be expanded at the extremity of the penis into a very vascular substance, called *glans penis*, which is naturally covered by a fold of the skin, called the *prepuce*. The *urethra* is a membranous canal, which proceeds from the bladder through the corpus spongiosum urethræ to the meatus or opening in the glans penis. It is endowed with a high degree of sensibility and contractility. The *verumontanum*, or *caput gallinaginis*, is a cutaneous eminence in the urethra, before the neck of the bladder. **GLANDS**, muciparous; odoriferous; Cowper's glands; and the prostate. See *Adenology*. The penis is **CONNECTED** with the urethra, pubes, and ischium. **ARTERIES** are branches of the hypogastric and ischiatic. The **DORSAL VEIN** of the penis, called *vena magna ipsius*

penis, empties itself into the vena hypogastrica. ABSORBENTS, run under the common integuments, to the inguinal glands. NERVES, branches of the sacral nerves and ischiatic. USE, for erection, coition, effusion of semen, and of urine.

TESTICLES.

Two oval bodies contained in the cavity of the scrotum. The EPIDIDYMIS is an hard vascular substance, formed of convoluted vas deferens, lying on the testicle. INTEGUMENTS of the testicle are, the scrotum; *tunica albuginea*, which is smooth, and adheres very firmly to the body of the testicle; and *tunica vaginalis*, which descends with the spermatic chord, and surrounds the testicle, as the pericardium does the heart. COMPOSED of white slender canals, which terminate in the epididymis, and form into one great canal, the vas deferens, which proceeds from the testicle into the abdomen, over the os pubis, and then descends into the pelvis, to be inserted into the vesiculæ seminales. SPERMATIC ARTERIES, are branches of the aorta. SPERMATIC VEINS, empty themselves into the vena cava, and left vena renalis. NERVES, branches of the lumbar and great in-

tercostal. **ABSORBENTS**, ascend from the testicle through the chord. The *funiculus spermaticus*, or spermatic chord, consists of the vas deferens, spermatic artery and vein, spermatic nerves, absorbent vessels, and tunica vaginalis, which the cremaster muscle surrounds. **USE.** to secrete and prepare semen.

SECRETION AND EXCRETION OF THE SEMEN.

The semen is secreted by minute branches of the spermatic arteries, that deposit it into corresponding seminal vessels, which compose the greatest part of the body of the testicle. The semen is the proper stimulus to these vessels, which are therefore stimulated to contract, and by a very slow motion convey it into the epidymis and vas deferens, by which it is carried through the inguinal ring into the pelvis, to be deposited in the vesiculæ seminales, where it excites a desire to emit it. The cells of the corpora cavernosa penis are distended with blood by the venereal stimulus ; hence the penis swells, and is inclined for coition, during which action, at the time of the *œstrum venereum*, the vesiculæ seminales contract, and the semen is thrown with an immense force, through the

ejaculatory ducts, opening into the urethra, where it is mixed with the secretion from the prostate gland, which is expelled at the same moment, and passes with it along the urethra, to be propelled by the contraction of the ejaculatory muscles into the cavity of the uterus.

VESICULÆ SEMINALES.

Two membranous receptacles, which receive and contain the semen from the vasa deferentia. They are *situated* on the back part of the bladder, above its neck. *Substance*, membranous, white, and covered with a fibrous substance. The *ejaculatory ducts* are some lines long, and enter the cavity of the urethra from each vesicle, by a peculiar orifice at the top of the verumontanum. *Vessels and Nerves*, from the neighboring parts. *Absorbent vessels*, arise from the vesiculæ seminales, and run to the lymphatic glands about the loins. *USE*, to contain, retain, inspissate, and excrete the semen into the urethra.

THE ORGANS OF GENERATION IN WOMEN.

The parts which serve for generation in women are divided into external and internal. The external parts are the mons Veneris; the *labia majora*, two cutaneous folds, situated externally; the *labia minora*, or *nymphæ*, also two cutaneous folds, like a cock's comb, placed at the sides of the vagina; the *clitoris*, a small glandiform body, like a penis in miniature, placed under the superior commissure of the nymphæ; and the *hymen*, a membrane for the most part semilunar, situated at the entrance of the virgin vagina. The internal parts are the vagina; uterus; Fallopian tubes; ovaria; broad and round ligaments of the uterus; and the urethra.

VAGINA.

An elastic canal leading from the external opening of the vulva to the uterus. Composed of three membranes; the outermost is cellular, the middle muscular, and the internal rugous. *Glands*, mucous; situated under the internal membrane. *USE*, to receive the penis, and for the passage of the child in delivery.

UTERUS, OR WOMB.

A spongy receptacle, like a flattened pear ; situated in the pelvis between the urinary bladder and rectum. *Division*, into fundus, body, neck, and orifice, called *os tinæe*. . *Substance of the uterus*, spongy, interwoven with muscular fibres. *Arteries*, the spermatic which are branches of the aorta ; and the uterine, which are from the hypogastric and hæmorrhoidal. *Uterine Veins* are without valves, and empty themselves into the spermatic, hypogastric, and external hæmorrhoidal veins. *Absorbents* run into the iliac glands. *Nerves* are branches of the sacral and ischiatic. *Glands*, mucous. *USE*, for conception, nutrition of the foetus, parturition, and menstruation.

PHYSIOLOGY OF MENSTRUATION.

By a law of nature, women menstruate in this climate from about the age of fifteen to forty-five. Menstruation is the efflux (by some thought to be a secretion) of blood from vessels opening into the cavity of the uterus. During pregnancy, the *catamenia*, or *menses*, for so the discharge is called, stop, except in some few instances, where it is supplied by the vessels of the vagina.

The nature of menstrual blood, if women be healthy, differs only from other blood in its not coagulating, which may be caused by its slow exit, and its mixture with the secretions of the uterus and vagina. It differs, however, in quantity, the period of its first appearance, its duration, and the symptoms which precede and accompany it, according to the age, temperament, habit of body, climate, season of the year, mode of living, and other circumstances.

Women are said to be most susceptible of the action of the vivifying principle of the semen during the period of menstruation.

PHYSIOLOGY OF CONCEPTION.

The congress between man and woman is called coition, which is so well known as to require no description.

During coition the nymphæ and clitoris are tumid with blood, and the fimbriæ of the Fallopian tubes, by a power inherent in them, are stretched out, and applied over the surface of an ovum in the ovarium.

The pleasure which women experience during coition is very great, and a quantity of mucus is suddenly emitted from the glands of the vagina, during the venereal orgasm, which in

former times was erroneously supposed to be the semen of the female, but now it is the opinion of physiologists that women have no semen, as anatomy cannot detect any organ by which it can be secreted.

In order that a woman *may conceive*, it is requisite that she shall have menstruated; that the ovum in the ovarium shall have arrived at a state of maturity, and that the fimbriæ of the Fallopian tube shall be stretched around the mature ovum, so as to let the cavity of the Fallopian tube come immediately over it. In this state, the male semen is emitted into the uterus, and its vivifying part, which is extremely subtle, and called the *auris seminis*, flies through the cavity of the uterus along the Fallopian tube to the mature ovum, to which it imparts a principle by which it begins to circulate its fluids and is animated. The ovum being thus vivified, enlarges and ruptures the slender tunic of the ovarium, in which it was enclosed. At the time of its rupturing, the fimbriæ of the Fallopian tube embrace it, and it is rolled, by the peristaltic motion of the latter, into the cavity of the uterus, there to be perfected, and at the expiration of nine months to be sent into the world.

OF THE GRAVID UTERUS.

The parts of the gravid uterus are, the uterine placenta, the umbilical chord, the membranous ovum of the foetus, the liquor amnii and the foetus.

UTERINE PLACENTA.

A spongy mass, like a cake, generally adhering to the fundus of the gravid uterus, composed of a net-work of very numerous vessels. *Substance*, cellular, like a sponge filled with vessels. *Absorbents* have been lately discovered. *Nerves*, nine. *Use*, to receive and prepare the blood from the uterus for the foetus, and give off branches to the umbilical vein.

FUNICULUS UMBILICALIS, OR UMBILICAL CHORD.

A chord of an intestinal form, which runs from the navel of the foetus to the centre of the placenta. *Length*, mostly about half a yard. *Composed* of a cutaneous vagina, or sheath, a cellular substance, one umbilical vein, and two umbilical arteries. *Use*. The umbilical vein of the foetus conveys the blood from the placenta.

to the foetus, and the two umbilical arteries return it from the foetus to the placenta.

MEMBRANOUS OVUM OF THE FŒTUS.

The foetus is enclosed in a membranous ovum or bag within the cavity of the uterus. The *ovum* consists of three membranes; an outer, or filamentous, called *decidua*; a middle one, called the *chorion*; and an inner one, termed the *amnion*. **USE**, to include the liquor amnii, to prevent its flowing into the uterus, and at the commencement of parturition, to assist in dilating the os uteri.

LIQUOR AMNII, OR LIQUOR OF THE AMNION.

A lymphatic liquid, enclosed in the cavity of the ovum surrounding the foetus, secreted by the exhaling arteries of the membranes of the ovum. **QUANTITY**, about the time of parturition, two or three pounds. **PROPERTY**, gelatinous, like turbid serum of milk. **USE**, to defend the foetus from the pressure of the uterus, to give it nourishment, to dilate the orifice of the uterus in labour, and to lubricate the vagina.

FÆTUS.

During the first month of pregnancy, the ovum is about the size of a pigeon's egg; the foetus swims in the middle of the liquor amnii, and represents a little cloud, which gradually enlarges, and its parts become more firm and perfect. The parts of the foetus at birth differ from the adult, in having a *foramen ovale*, a *canalis arteriosus*, and a *canalis venosus*. The lungs are black, collapsed, and sink in water. The liver is large. All the small glands are also proportionately large, and the large intestines are filled with meconium. All the canals and vessels peculiar to the foetus are obliterated after birth, and become ligaments.

PECULIARITIES IN THE ARTERIAL AND VENAL SYSTEM OF THE FÆTUS.

The foetus has—an *umbilical vein*, which goes to the liver, and two *umbilical arteries* which arise from the internal iliac—a *canalis venosus*, or vein, which proceeds from the sinus of the vena portæ into the vena cava inferior—an opening in the septum of the auricles, called the *foramen ovale*, and a *canalis arteriosus*, or artery which arises from the pulmonary artery,

and passes obliquely into the aorta. After birth these vessels gradually become impervious, and at length are removed by the absorbents.

CIRCULATION OF THE BLOOD IN THE FÆTUS.

The fœtus receives its blood from the mother through the umbilical vein of the funis, which transmits it along the ductus venosus into the vena cava, to be carried to the right auricle of the heart; from the right auricle it passes partly through the foramen ovale into the left auricle, and partly into the right ventricle. From the right ventricle it is propelled into the pulmonary artery, which sends a very small proportion through the lungs and the remainder through the canalis arteriosus into the aorta. The blood is returned from the fœtus by the two umbilical arteries, along the chord, to the mother.

HYGROLOGY,

O R

DOCTRINE OF THE FLUIDS.

The fluids of the body are divided into *crude*, as the chyle; *sanguineous*, as the blood;

lymphatic as the lymph of the lymphatic vessels ; *secreted*, or those separated from the blood ; and *excrementitious*, as urine, *fæces*, &c.

The secreted fluids are subdivided into *lacteal*, as the juice of the prostate gland ; *aqueous*, as the aqueous humour of the eye ; *mucous*, as the mucus of the nostrils ; *albuminous*, as the serum of the blood ; *oleous*, as the oil of the adipose membrane ; and *bilious*, as the bile.

Fluids are also divided, from their motion, into *circulatory*, which continually circulate in the vessels ; *commorant*, which circulate with a slow motion, as the semen, oil of the adipose membrane ; *stagnant*, which remain for a certain time in any receptacle, as cystic bile, &c.

FLUIDS COMMON TO THE WHOLE BODY.

THE BLOOD.

A red fluid, which circulates in the cavities of the heart, arteries, and veins. COLOUR, in the arteries, of a *florid* hue ; in the veins *dark-er*, except in the pulmonary veins, in which it is

of a *lighter* cast. Blood exposed to the atmosphere spontaneously *separates* by degrees into two parts, viz. the *serum* a yellow and somewhat greenish fluid ; and a *cake*, called also the *cruor*, or *crassamentum*, which resembles a red mass swimming like an island in the serum. **USE**, to stimulate the cavities of the heart and vessels to contraction ; to generate the heat of the body, and propagate it to every part ; to nourish every part ; and to supply all the secretions, they being all separated from the blood.

THE LYMPH OF THE LYMPHATIC VESSELS.

A tasteless crystalline liquid, contained in the lymphatic vessels. **ABSORBED** from the surface ; *tela cellulosa* ; viscera ; and cavities of the viscera of the whole body ; and **CONVEYED** into the thoracic duct. **USE**, to return the superfluous nutritious fluid, the vapours of cavities, and substances applied to the skin, to the thoracic duct.

THE VAPOUR OF THE SHEATHS OF THE NERVES.

The aqueous vapour contained in the *vaginæ* and between the fibrils of the nerves. **SECRE-**

TORY ORGAN, the arteries of the sheath. USE, to moisten the nervous fibrils.

FLUIDS PROPER TO EACH PART.

IN THE CAVITY OF THE CRANIUM.

THE VAPOUR IN THE VENTRICLES OF THE BRAIN. A thin vapour contained in the cavity of the ventricles of the brain, and SECRETED by the exhaling arteries of the choroid plexus. USE, to prevent the concretion of the ventricles, and keep the medulla moist.

IN THE CAVITY OF THE NOSTRILS.

THE MUCUS OF THE NOSTRILS. The mucus *secreted* by the muciparous glands of the pituitary membrane, lining the septum and conchæ of the nostrils. USE, to preserve the nervous papillæ of the olfactory nerves moist, and to moderate excessive sensibility.

IN THE CAVITY OF THE MOUTH.

THE SALIVA. A fluid secreted by the salivary glands into the mouth. *The secretory organ* is composed of the parotid; sub-maxilla-

ry; and sub-lingual glands. **USE**, to augment the taste of the food; to mix with, dissolve, and resolve the food into its principles; and to moderate thirst.

IN THE CAVITY OF THE FAUCES.

THE MUCUS OF THE FAUCES. A mucus secreted by the muciparous glands of the tonsils, pharynx, &c. **USE**, to lubricate the fauces.

IN THE EYES.

THE AQUEOUS HUMOUR OF THE EYE. The very limpid water which fills the anterior and posterior chambers of the eye. *Secretory organ*, the floating vessels of the corpus ciliare, and exhaling vessels of the iris. **USE**, to distend the cornea; retain the crystalline lens and vitreous humour in their places; and to transmit the focus of the rays of light to the crystalline lens.

THE CRYSTALLINE LENS. A lentiform, pellucid, cellular body, distended by a very limpid aqueous fluid, enclosed in a membranous capsule, and situated in a depression in the anterior surface of the vitreous humour. **USE**, to transmit and refract the focus of the rays of light to the vitreous humour.

THE VITREOUS HUMOUR. The pellucid vitriform body, which fills the whole bulb of the eye behind the crystalline lens. *Composed of* small cells distended with a limpid water. *USE,* to expand the bulb, and transmit and moderately augment the focus of the rays of light from the crystalline lens to the retina.

THE WATER IN THE CAPSULE OF THE CRYSTALLINE LENS. *SECRETED* by the pellucid branches of the artery of the crystalline lens. *USE,* to prevent the concretion of the crystalline lens with its capsule.

THE PIGMENT OF THE IRIS. The coloured mucus, which covers the anterior and posterior surface of the iris. *USE,* to reflect the rays of light.

THE PIGMENT OF THE CHOROID MEMBRANE. The black or brownish mucus, which covers the anterior surface of the choroid membrane, and the interior of the corpus ciliare.

THE TEARS. A limpid fluid secreted by the lachrymal gland, and flowing on the surface of the eye. *USE,* to moisten the surface of the eye and eyelids.

THE JUICE OF MEIBOMIUS'S GLANDS. The unctuous humour secreted by the sebaceous glands of Meibomius, and lubricating the tarsi

of the eyelids. *USE*, to lubricate the tarsi of the eyelids, and involve the saline acridity of the tears.

IN THE CAVITY OF THE EARS.

The Cerumen, or Wax of the Ears. The bitter ceraceous fluid secreted by the ceruminous glands of the meatus auditorius externus. *USE*, to lubricate the sensible membrane of that canal, and to prevent insects from entering.

The Water of the Labyrinth. An insipid water contained in the cavity of the tympanum. *USE*, to preserve the nervous fibrils of the auditory nerve soft and moist, and to moderate the tremors of sounds.

IN THE NECK.

The Juice of the Thyroid Gland. Of a yellowish white colour, especially in infants. *USE*, not known.

The Mucus of the Œsophagus. Secreted by the muciparous glands, situated in the cellular membrane. *USE*, to lubricate the cavity of the œsophagus, and prevent the concretion of its sides.

IN THE CAVITY OF THE THORAX.

The Mucus lining the internal surface of the *trachea*, *bronchia*, and *vesiculæ pulmonales*. *Secretory organ*, the muciparous glands situated under the internal membrane of those parts. *USE*, to prevent the surface of the *trachea*, *bronchia*, and *vesiculæ pulmonales* from becoming dry by the continual passing of the air.

The Vapour in the cavity of the Thorax. A vapour which exhales from the exhaling vessels of the pleura of the lungs and ribs, into the cavity of the thorax. *USE*, to preserve the pleura soft, moist, and flexile ; and to defend and prevent it from the friction of, and concretion with, the lungs.

The Vapour or Liquor Pericardii. Secreted by the arterious exhaling vessels, which open upon the external surface of the heart and internal of the pericardium. *USE*, to prevent the concretion of the heart with the pleura ; to diminish the friction ; and preserve the parts soft.

The Juice of the Thymus Gland. A milky juice secreted by the arteries opening into the cells of this gland. *USE*, not known.

IN THE BREASTS.

The Milk of the Breasts. A white, sweetish fluid, secreted by the glandular fabric of the breasts of women. USE, to be an aliment to new-born children.

IN THE ABDOMEN.

The Gastric Juice. A limpid colourless fluid, secreted by the exhaling vessels of the very numerous arteries, which bedew every part of the stomach. USE, to digest the food.

The Pancreatic Juice. The limpid juice secreted by this gland, and conveyed through its excretory duct into the duodenum. USE, to assist in the formation of chyle.

Bile. A yellowish-green bitter juice, secreted by the glandular substance of the liver, and conveyed by the biliary ducts, in part into the duodenum, and in part into the gall-bladder: hence cystic and hepatic bile. USE, to extricate the chyle from the digested mass of food; to stimulate the intestines; and to prevent the abundance of mucus and acidity in the primæ viæ.

Chyle. A white fluid, separated from the

food in the primæ viæ, and observed some hours after eating in the lacteal vessels of the mesentery, and in the thoracic duct. USE, to form the blood.

The Enteric Juice. A limpid liquor, secreted by the exhaling arteries in the whole course of the small and large intestines. USE, to assist in digestion ; and to cleanse and moisten the intestines.

The Mucus of the Primæ Viæ. Secreted by the muciparous glands situated under the villous coat of the primæ viæ. USE, to lubricate that canal.

The Vapour or Fluid in the cavity of the Abdomen. An aqueous vapour, secreted by the exhaling arteries of the peritoneum. USE, to preserve moist and prevent the coaction of the abdominal viscera.

Urine. A saline liquid, of a citrine colour, secreted in the kidneys, and dropping down from them guttatim through the ureters into the cavity of the urinary bladder. USE, to liberate the body from the superfluous water, &c.

The Mucus of the Bladder. Secreted by the muciparous glands situated under the innermost membrane. USE, to lubricate and

defend the internal and very sensible surface of the urinary bladder.

IN THE PARTS OF GENERATION IN MEN.

The Mucus of the Urethra. Secreted by the muciparous glands situated under the internal membrane. USE, to lubricate and defend the very sensible surface of the urethra against the acridity of the urine.

The Smegma of the Glans Penis. An unctuous humour, secreted by the sebaceous follicles on the surface of the glans and prepuce. USE, to lubricate and defend the sensible surface of the glans, and prevent its concretion with the prepuce.

The Vapour of the Tunica Vaginalis Testis. The aqueous vapour, which exhales from the arteries into the cavity of the tunica vaginalis testis. USE, to prevent the concretion of the testes with the tunica vaginalis, and preserve them moist.

The Liquor of the Prostrate Gland. A milky juice, separated by the arteries of the prostrate gland, and sent through its ducts, *sub coitu*, into the urethra with the semen. USE, to serve as a vehicle to the semen.

The Semen. The prolific liquor secreted in the testes, and carried through the epididymis and vas deferens into the vesiculæ seminales. *Use*, to be emitted, *sub coitu*, into the female vagina, and there, by its aura, to penetrate to, and impregnate, the ovulum in the female ovarium.

IN THE PARTS OF GENERATION IN WOMEN.

The Smegma of the Labia and Vulva. The unctuous juice secreted by the sebaceous glands, and covering the internal surface of the labia and nymphæ. *Use*, to lubricate their sensible surface, and prevent any irritation *post mictum*.

The Mucus of the Vagina. Secreted by the muciparous glands under the internal membrane. *Use*, to lubricate the vagina, lest it be pained by friction, *sub coitu*, and to prevent the concretion of its sides.

The Liquor of the Cavity of the Uterus. Secreted into it by the exhaling arterious vessels. *Consistence*, in the virgin uterus, serous and turbid; in the gravid, milky. *Use*, to moisten the cavity, and prevent its concretion.

IN THE ARTICULATIONS.

The Synovia. An unctuous fluid, secreted by the internal membrane of the capsular ligaments surrounding the articulations of the bones. *Use,* to lubricate the cartilaginous surfaces of the articulatory bones, and facilitate their motions.

The juice of the Bursæ Mucosæ. An unctuous and somewhat mucilaginous juice, secreted by the vessels of the internal membrane of the bursæ mucosæ. *Use,* to lubricate the tendons for motion.

IN THE BONES.

The Marrow of Bones. The oily substance secreted by the arteries of the internal periosteum, and contained in the medullary cavities of the long bones, and spongy substance of others.

FLUIDS OF THE COMMON INTEGUMENTS.


The Mucus of Malpighi, or rete Mucosum. The mucus situated between the epidermis and cutis of the whole body, and secreted by the ar-

terious vessels of the skin. *Use*, to conglutinate the epidermis to the cutis; to moderate the sense of touch; to moisten the nervous cutaneous papillæ; and give the external colour to the body; hence it is *white* in Europeans, *black* in *Æthiopians*, &c.

The Oil of the Adipose Membrane. Secreted by the arteries of the cellular membrane. *Use*, to facilitate muscular motion.

Sweat. The aqueous perspirable matter excreted through the exhaling arteries of the skin. *Use*, to keep the skin moist.

A.
G L O S S A R Y,
O R
E X P L A N A T I O N
O F
A N A T O M I C A L T E R M S.



A.

ABDOMEN. The cavity of the belly ;
from *abdo* to hide, as including the intestines
and other viscera.

Acetabulum. The cavity which receives the
head of the thigh bone ; from *acetum* vine-
gar : so called, because it represents the ace-
tabulum or saucer of the ancients, in which
winegar was held for the use of the table.

Acini. The glands of the liver ; from *acinus*
a grape.

Acromion. A process of the scapula ; from *ak-*
ros extremity, and *omos* the shoulder.

Adenology. The doctrine of the glands ; from
adcen a gland, and *logos* a discourse.

Amnion. A membrane that surrounds the foetus, which is soft and shaggy ; from *amnios* a lamb's skin.

Amphyarthrosis. A species of connexion of bones, which admits of an obscure motion ; from *ampho*, both, and *anthrosis* an articulation.

Anastomosis. The communication of vessels with one another ; from *ana* through, and *stoma* a mouth.

Anatomy. The dissection of the human body ; from *Ama* and *temno* to dissect.

Ancon. The elbow ; from *ankone*, from *ankazomai* to embrace, *apo*, *tou*, *ankeisthai*, *etero osteo*, *to*, *ostëon*, because the bones meeting, and being there united, are folded one into another.

Anconeus. A muscle ; so called, from *ankone* the elbow.

Anconoid. Process of the cubit ; from *ankone* the elbow, and *eidos* shape.

Angiology. The doctrine of the vessels ; from *angeion* a vessel, and *logos* a discourse.

Aorta. *Aorte* ; from *aer* air, and *tereo* to keep ; an *artery*, so called, because the ancients supposed that only air was contained in it. It may rather be derived from *aeira* to convey,

as serving to convey the blood to the rest of the body.

Aponeurosis. A tendinous expansion ; from *apo* from, and *neuron* a nerve ; from an erroneous supposition of the ancients, that it was formed by an expansion of a nerve.

Apophysis. A process of a bone ; from *apophuo* to proceed from. A synonym of process.

Arachnoides. A net-like membrane ; from *arakne* a spider, and *eidos* likeness.

Artery. From *aer* air, and *tereo* to keep ; because the ancients supposed, that only air was contained in them.

Arthrodia. A species of connexion of bones ; from *arthroo* to articulate.

Arytænoides. The name of two cartilages of the larynx ; also applied to some muscles of the larynx ; from *arutaina* a funnel, and *eidos* shape.

Astragalus. A bone of the tarsus ; so called, from its resemblance to a die, used in ancient games, from *astragalos* a cockal or die.

Atlas. The first vertebra of the neck ; so called, because it sustains the head ; from the fable of Atlas being supposed to have supported the world ; or from *atlao* to sustain, because it sustains the head.

Azygos. A term applied to parts without a fellow ; from a priv. and *Zugos* a yoke, because it has no fellow.

B.

Brachium. The arm ; hence as *brachii*, *brachialis externus*, &c. from *brakus* short, because in a well proportioned man it is shorter from the shoulder to the hands than from the hip to the feet.

Bronchia. The ramifications of the trachea, or windpipe ; from *breko* to pour, because the ancients believed, that the fluids were conveyed into the stomach by the bronchia.

Bursa. A bag ; from *bursa* : generally applied to the *bursæ mucosæ*.

Bursalogy. The doctrine of the *bursæ mucosæ* ; from *bursa* a bag, and *logos* a discourse.

C.

Calvaria. The top of the cranium ; from *calvus* bald.

Cancelli. Lattice work ; generally applied to the reticular substance in bones.

Cardia. The superior opening of the stomach ; from *kardig* the heart, because it is situated near it.

Carotid. The name of some arteries of the neck and head ; from *karoo* to cause to sleep ; for,

If tied with a ligature, the animal becomes comatose, or has the appearance of being asleep.

Carpus. *karpōs* ; the wrist.

Chorion. The external membrane of the foetus in utero. *Korion* from *korea* to escape, because it always escapes from the uterus with the foetus.

Choroid membrane and plexus ; from *korion* the chorion, and *eidos* likeness ; so called, on account of its many blood vessels resembling the chorion.

Clavicula. The clavicle, or collar bone, a diminutive of *clavis* a key ; so called, from its resemblance to an ancient key.

Clinoid. Four processes of the sella turcica of the ethmoid bone ; are so called, from *kline* a bed, and *eidos* likeness, from their supposed resemblance to a couch.

Clitoris. A part of the female pudenda, enclosed by the labia majora ; from *kleio* to enclose or hide.

Colon. The first of the large intestines ; from *kolon* quasi *koilon*, from *koilos* hollow ; it generally being found empty, and full of wind, in the dead body.

Condyle. An eminence in any of the joints ;

kondulos from *kondū* an ancient cup, shaped like a joint.

Coraco. Names compounded with this word belong to muscles, which are attached to the coracoid process of the scapula ; as *coracohyoideus*, &c.

Coracoid process of the scapula ; from *korax* a crow, and *eidos* resemblance, it being shaped like the beak of a crow.

Coronary. From *corona* a crown. The vessels of the heart, stomach, &c. are so called, because they surround the parts in the manner of a crown.

Coronoid. A process, so called, from *korune* a crow, and *eidos* likeness, from its resemblance to a crow's beak.

Cotyloid cavity of the os innominatum, which receives the head of the thigh bone ; from *kotule* the name of an old measure, and *eidos* resemblance.

Cranium. The skull ; *kranion*, quasi *karanion*, from *kara* the head.

Cremaster. A muscle, so called ; from *kremao* to suspend, because it suspends the testicle.

Cribriform, or ethmoid bone of the skull ; from *cribrum* a sieve, it being perforated like a sieve.

Cricoid. Annular, round, like a ring ; from *krikos* a ring, and *eidos* likeness.

Crura. The plural of *crus*, a leg or root ; applied to some parts of the body, from their resemblance to a leg or root, as *crura cerebelli*, &c.

Cuboides. A bone of the foot ; from *kubos* a cube, and *eidos* likeness ; because it resembles a cube.

Cuneiform. Some bones are so called ; from *cuneus* a wedge, and *forma* likeness ; being shaped like a wedge.

D.

Dartos. A muscle of the scrotum ; from *dero* to excoriate.

Deltoid. A muscle resembling the Greek letter Δ ; from Δ , and *eidos* resemblance.

Diaphragm. The muscle which separates the thorax from the abdomen ; from *diaphratto* to divide.

Diarthrosis. A moveable connexion of bones ; from *diarthroo* to articulate.

Digastric muscles, from *dis* twice, and *gaster* a belly ; having two bellies.

Diploe. The spongy substance between the two tables of the skull ; from *diploo* to double.

Duodenum. The first portion of the small intestine ; so called, because the ancients supposed, that it did not exceed the breadth of twelve fingers ; from *duodenus*, consisting of twelve.

Dura mater. The outermost membrane of the brain ; called *dura*, because it is much harder than the other membranes, and *mater*, from the ancients supposing it was the source of all the other membranes.

E.

Embryo. The child in the womb is so called before the fifth month, after which it is termed *fœtus* ; from *embruo* to bud forth.

Enarthrosis. An articulation of the bones ; from *en* in, and *arthron* a joint or articulation.

Enteric. Belonging to the intestines ; from *enteron* an entrail or intestine.

Epidermis. The scarf or outermost skin ; from *epi* upon, and *derma* the skin.

Epididymis. The small oblong body, which lies above the testicles ; from *epi* upon, and *didumos* a testicle.

Epigastric. The superior part of the abdomen ; from *epi* upon, and *gaster* the stomach.

Epiglottis. A cartilage of the larynx, so called ;

From *epi* upon, and *glottis* the aperture of the larynx, being situated upon the glottis.

Epiphysis. A portion of bone growing upon another bone, but separated from it by cartilage; from *epi* upon, and *phuo* to grow.

Epiploon. The membranous viscus of the abdomen, which covers the intestines, and hangs to the bottom of the stomach; from *epipleo* to swim upon.

Epistrophæus. The second vertebra of the neck; from *epistrophao* to turn round, because the head is turned upon it.

Ethmoid bone of the cranium; so called, from *ethmos* a sieve, and *eidos* resemblance, it being perforated like a sieve.

F.

Fascia. An expansion of a muscle, enclosing others like a band; from *phaskia* a band.

Falciform. Shaped like a scythe; from *fala* a scythe.

Fasciculus. A little bundle.

Fauces. The plural of *faux*, the top of the throat.

G.

Galactophorous ducts of the breasts of women; from *gala* milk, and *phero* to carry, because they convey the milk to the nipples.

Ganglion. *Ganglion*, a knot in the course of a nerve.

Gastrocnemius. The muscle which forms the thick of the leg; from *gaster* a belly, and *kneme* the leg.

Genia. Names compounded with this word belong to muscles which are attached to the chin; as *Genio-glossus*—*Genio-hyoideus*—*Genio-pharyngeus*, &c. from *geneion* the chin.

Genu. The knee; from *gonu para to eis gene neuein*, because by it the body is bent towards the earth.

Ginglymus. An articulation; from *ginglamos* a hinge.

Glenoid cavity; from *glene* a cavity, and *eidos* resemblance.

Glomer. A convoluted bundle of vessels; generally applied to the lymphatic glands.

Glosso. Names compounded with this word belong to muscles, from their being attached to the tongue; as *Glosso-pharyngeus*—*Glosso-staphylinus*, &c. from *glossa* the tongue.

Glottis. The superior opening of the larynx at the bottom of the tongue; from *glootta* the tongue.

Glutæus. The name of a muscle ; from *gloutos* the buttocks.

Gomphosis. *Gomphosis* inclavation, a species of immoveable connexion of bones ; from *gomphos* a nail, because one bone is fixed in another bone, like a nail in a board.

H.

Harmonia. A species of immoveable connexion of bones ; from *aro* to fit together.

Helix. The outward circle of the ear ; from *eilo* to turn about.

Hepar. The liver. *Hepar*, an abdominal viscus.

Hyaloid membrane of the eye ; from *ualos* glass, and *eidos* likeness ; so called, from its transparent and glassy appearance.

Hygrology. The doctrine of the fluids ; from *agros* a fluid, and *logos* a discourse.

Hymen. The membrane situated at the entrance of the virgin vagina ; from *umene* hymen.

Hyo. Names compounded with this word belong to muscles, which are attached to the os-hyoides ; as *hyo-glossus*—*hyo-pharyngeus*—*hyo-thyroides* ; from *uocides* the os-hyoides.

Hyoides. A bone of the tongue, so called, from its resemblance to the Greek *u* ; from *u* and *eidos* resemblance.

Hypochondrium. That part of the body, which lies under the cartilages of the spurious ribs ; from *upo* under, and *kondros* a cartilage.

Hypogastric. The lower region of the fore part of the abdomen ; from *upo* under, and *gaster* the stomach.

I.

Ileum. A portion of the small intestines ; from *eileio* to turn ; being always convoluted.

Ilium. Part of the os innominatum, so called, because it supports the *eileia* or small intestines.

Ischium. The part of the os innominatum upon which we sit ; from *iskuo* to sustain.

L.

Lacuna. The excretory duct of the glands of the urethra and vagina ; from *lacus* a channel.

Lamoidal suture ; so called, because it is shaped like the letter *l* ; from *l*, and *eidos* resemblance.

Larynx. The superior part of the windpipe ; *larunx* the larynx.

M.

Masseter. A muscle of the face, which assists in the action of chewing ; from *massaomai* to chew.

Mastoid process ; so called, from *mastos* a breast, and *eidos* likeness, being shaped like a nipple or breast.

Mediastinum. The production of the pleura, which divides the thorax into two cavities ; from *medium* the middle, *quasi in medio stare*.

Mesentery. The membranes to which the intestines are attached ; from *mesos* the middle, and *enteron* an intestine, because it is in the middle of the intestines.

Mesocolon. That part of the mesentery in the middle of the colon ; from *mesos* the middle, and *kolon* the colon.

Metacarpus. That part of the hand between the carpus and fingers ; from *meta* after, and *karpos* the wrist.

Metatarsus. That part of the foot between the tarsus and toes ; from *meta* after, and *tarsos* the tarsus.

Mylo. Names compounded with this word belong to muscles, which are attached near the grinders ; as *mylo hyoides* ; *mylo-pharyn-*

geus, &c. ; from *mule* a grinder-tooth.

Myology. The doctrine of the muscles ; from *mus* a muscle, and *logos* a discourse.

N.

Neurology. The doctrine of the nerves ; from *neuron* a nerve, and *logos* a discourse.

O.

Odontoid, or tooth-like process ; from *hodontus* a tooth, and *eidos* resemblance.

Œsophagus. The canal leading from the pharynx to the stomach ; from *oio* to carry, and *phago* to eat ; because it carries the food into the stomach.

Olecranon. The elbow or head of the ulna ; from *holene* the cubit, and *kranon* the head.

Omentum. An abdominal viscus ; so called, from *omen* a guess ; because the soothsayers prophesied from the inspection of this part.

Omo. Names compounded with this word belong to muscles which are attached to the scapula ; as *omo-hyoideus*, &c. from *homos* the shoulder.

Omoplata. The scapula, or shoulder blade ; from *homos* the shoulder, and *platuse* broad.

Orgasm. A violent salaciousness, attended with turgescence in the parts ; from *orgao* to desire vehemently.

Osteology. The doctrine of the bones ; from *osteon* a bone, and *logos* a discourse.

P.

Pancreas. A viscus of the abdomen ; so called, from its fleshy consistence ; from *pan* all, and *kreas* flesh.

Parenchyma. The substance connecting together the vessels, &c. of the lungs, is so called, from *parenkuo* to pour through.

Parotid gland ; from *para* near, and *ous* the ear ; because it is situated near the ear.

Pelyis. A bony cavity, shaped like a bason ; from *peluse* a bason.

Pericardium. The membrane which surrounds the heart ; from *peri* around, and *kardia* the heart.

Pericranium. The membrane which covers the bones of the skull ; from *peri* around, and *kranion* the cranium or head.

Periosteum. The membrane which surrounds the bones ; from *peri* around, and *osteon* a bone.

Peristaltic motion of the intestines ; from *peristello* to contract.

Peritoneum. The membrane lining the abdomen, and covering its viscera ; from *periteino* to extend around.

Phalanx. The bones of the fingers and toes are called phalanxes, from their regular situation, like a *phalanx*, or army of soldiers.

Pharynx. A membranous bag at the end of the mouth ; *apo to pherein*, because it conveys the food into the stomach.

Phrenic or diaphragmatic nerve. *Phrenes* the diaphragm ; from *phrene* the mind ; because the ancients supposed it to be the seat of the mind.

Physiology. That part of natural history which treats of the actions and functions of an animated body ; from *phusis* nature, and *logos* a discourse.

Pia mater. The innermost membrane of the brain ; so called, because it embraces the brain as a good mother folds her child.

Placenta. The after birth ; from *plakous* a cake, from its resemblance to a cake.

Platysma-myoides. A muscle of the neck ; from *platous* broad, *mus* a muscle, and *eidos* resemblance.

Pleura. The membrane lining the thorax ; *pleura* the side.

Plexus. A kind of net-work of vessels or nerves ; from *plecto* to weave together.

Præpuce, or foreskin of the penis ; from *præ-*

rupo to cut off before, because the eastern nations usually cut it off.

Psoas. A muscle, so called; from *psoa* the loin, being situated in the loins.

Pterygoid process; from *pterux* a pen, or wing, and *eidos* likeness; so called, from its likeness to a pen, or wing.

Pylorus. The lower orifice of the stomach, which opens into the intestines; from *puloo* to guard an entrance, because it guards, as it were, the entrance of the bowels.

R.

Raphe. A suture. *Raphe* from *rupo* to sew.

Reines. The kidneys, *apo tou rein*, because through them the urine flows.

Retina. The net-like expansion of the optic nerve, on the inner surface of the eye; from *rete* a net.

Rhomboides. A muscle, so called from its shape; from *rombos* a geometrical figure, whose sides are equal but not right-angled, and *eidos* a likeness.

Rotula. The knee pan; a dim. of *rota* a wheel, from its shape.

S.

Sacrum. A bone; so called, from *sacer* sa-

ered, because it was once offered in sacrifices.

Salvatella. A vein of the foot ; so called, because it was thought the opening it preserved health, and cured melancholy ; from *salvo* to preserve.

Sanguis. The blood ; *apo tou saien guia*, because it preserves the body.

Sartorius. A muscle, so called, because taylor's cross their legs with it ; from *sartor* a taylor.

Scapha. The depression of the outer ear before the antihelix ; from *skaphe* a little boat or skiff ; from *skapto* to dig, because skiffs were formerly only trees made hollow.

Scaphoides. A bone of the carpus, so called, from its resemblance to a skiff ; from *skaphe* a skiff, and *eidos* a likeness.

Sclerotic. A term applied to the outermost or hardest membrane of the eye ; from *skleroo* to make hard.

Sella Turcica. Part of the sphænoid is so called, from its supposed resemblance to a Turkish saddle.

Sesamoid bones : from *sesamee* an Indian grain, and *eidos* a likeness, from their resemblance to the semen sesami.

Sigmoid. Parts are so called, from their resem-

blance to the letter *s* ; from *s* the letter Sigma, and *eidos* likeness.

Sphaenoid bone ; from *sphene* a wedge, and *eidos* likeness, it being shaped like a wedge.

Sphincter. The name of several muscles, whose office it is to shut up the aperture around which they are placed ; from *sphingo* to shut up.

Splanchnology. The doctrine of the viscera ; from *splanknon* an entrail, and *logos* a discourse.

Symphysis. A connexion of bones ; from *sumphuo* to grow together.

Synarthrosis. A connexion of bones ; from *sun*, with, and *arthron* a joint.

Synchondrosis. A species of union of bones by means of cartilage ; from *sun* with, and *kondros* a cartilage.

Syndesmology. The doctrine of the ligaments ; from *sundesmos* a ligament, and *logos* a discourse.

Syndesmosis. A species of union of bones by means of ligament ; from *sundesmos* a ligament.

Syneurosis. A species of connexion of bones by means of membrane ; from *sun* with, and *neurou* a nerve ; because membranes, liga-

ments, and tendons, were by the ancients considered as nerves.

Syssarcosis. A species of connexion of bones by means of muscle ; from *sun* with, and *sarx* flesh.

Systole. The contractile motion of the heart and arteries ; from *sustello* to contract.

T.

Tendon. From *teino* to extend.

Theca. The spinal canal is called *theca vertebralis* ; from *theke* from *themi* to put.

Thorax. *Thorax*. The breast or chest ; from *thoreo* to leap, because in it the heart beats.

Thyro. Names compounded with this word belong to muscles, which are attached to the thyroid cartilage.

Thyroid cartilage ; from *thureos* a shield, and *eidos* likeness, because it is shaped like a shield.

Trachea. The wind pipe ; so called, from its roughness, from *trakuse* rough.

Trapezoid bones of the carpus ; from *trapezion* a four-sided figure, and *eidos* likeness.

Trochanter. A process of the thigh bone, so called, from *treko* to run, because the muscles inserted in these parts perform the office of running.

Trochlea. A kind of cartilaginous pulley, through which the tendon of one of the muscles of the eye passes; from *trekē* to run.

Trochoides. A species of articulation of bones; from *trokos* a wheel, and *eidos* likeness; because one bone moves round upon another, like a wheel upon its axle-tree.

U.

Ulna. A name for the cubit; from *olene* the cubit.

Ureter. The canal which conveys the urine from the kidney to the bladder; from *ouron* urine.

Urethra. The passage through which the urine passes from the bladder; from *ouron* the urine.

Uvea. The posterior lamina of the iris, so called, because in beasts (which the ancients chiefly dissected) it is of the colour of unripe grapes; from *uva* an unripe grape.

Uvula. The glandular substance which hangs down from the middle of the soft palate; so called, from its resemblance to a grape. A dim. of *uva* a grape.

V.

Valves. Little membranes, that prevent the

return of the blood in the veins and arteries ;
from *valvæ* folding doors.

Vertebræ. The bones of the spine are so called, from *verto* to turn.

Vomer. A bone of the nose, so called, from its resemblance to a ploughshare ; from *vomo* to turn up.


X.


Xiphoid cartilage, so called, from its resemblance to a sword ; from *xiphos*, sword, and *eidos* likeness.

Z.

Zygoma. The cavity under the zygomatic process of the temporal bone ; from *zugos* a yoke, because it transmits the tendon of the temporal muscle like unto a yoke.

~~~~~  
THE END. ~~~~~





Med. Hist.

WZ

270

H787a

1809

C.1

