

The pocket anatomist : being a summary description of the muscles : with a tabular view of the arteries and nerves.

Contributors

Harrison, Robert, 1796-1858. Dublin dissector.

Harrison, Robert, 1796-1858. Surgical anatomy of the arteries of the human body.

National Library of Medicine (U.S.)

Publication/Creation

Philadelphia : Kay, 1844.

Persistent URL

<https://wellcomecollection.org/works/mk2cjwd8>

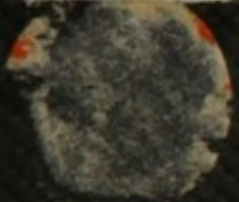
License and attribution

This material has been provided by This material has been provided by the National Library of Medicine (U.S.), through the Medical Heritage Library. The original may be consulted at the National Library of Medicine (U.S.) where the originals may be consulted.


This work has been identified as being free of known restrictions under copyright law, including all related and neighbouring rights and is being made available under the Creative Commons, Public Domain Mark.

You can copy, modify, distribute and perform the work, even for commercial purposes, without asking permission.

QS
P741
1844




THE
POCKET
ANATOMIST



The Rocket

ARMY MEDICAL LIBRARY


FOUNDED 1836



WASHINGTON, D.C.

DUE TWO WEEKS FROM LAST DATE

L SEP 10 1951



THE
POCKET ANATOMIST:

BEING A SUMMARY DESCRIPTION OF THE

MUSCLES;

WITH A TABULAR VIEW OF THE

ARTERIES AND NERVES.

CONCORDANT

WITH "THE DUBLIN DISSECTOR," AND

"HARRISON ON THE ARTERIES."

FOURTH EDITION.

Philadelphia:

JAMES KAY, JUN. & BROTHER,

179 Market Street,

1854.

QS

P741

1844

1844

ADVERTISEMENT.

AT the instance of several gentlemen, now studying Medicine in the Jefferson College and the University of Pennsylvania, the Publishers have been induced to issue the following little book. It was written in Great Britain as an accompaniment to two highly valuable and popular Medical works. "THE DUBLIN DISSECTOR," and "HARRISON ON THE ARTERIES."

"THE POCKET ANATOMIST," it is hoped, will meet with patronage from those gentlemen for whose benefit, especially in their attendance in the Lecture Room of the Anatomical Professor, it is now reprinted.

(3)

388812

APPENDIX

The following is a list of the names of the persons who have been appointed to the various offices of the State of New York, for the year 1880. The names are arranged in alphabetical order, and the offices are given in full. The names of the persons who have been appointed to the offices of the State of New York, for the year 1880, are as follows:

THE
POCKET ANATOMIST.

MUSCLES.

HEAD.

- Occipito-frontalis. Origin, two external thirds of superior transverse ridge of occipital bone, external and posterior part of mastoid process. Insertion, integuments of eye-brows.
- Superior auris, or attollens aurem. O, cranial aponeurosis. I, upper and anterior part of cartilage of ear.
- Anterior auris, or attrahens aurem. O, posterior part of zygoma, and cranial aponeurosis. I, anterior part of helix.
- Posterior auris, or retrahens aurem. O, mastoid process. I, back part of concha.
- Orbicularis palpebrarum. O, internal angular process of os frontis, and upper edge of tendo oculi. I, nasal process of superior maxilla, and inferior edge of tendo oculi.
- Tensor tarsi. O, posterior edge of os unguis. I, lachrymal ducts.
- Corrugator supercillii. O, internal angular process of os frontis. I, middle of eye-brow.

Pyramidalis nasi. *O*, proceeds from occipito-frontalis. *I*, compressor nasi.

Compressor nasi. *O*, canine fossa, in superior maxilla. *I*, dorsum of nose.

Levator labii superioris, alæque nasi. *O*, 1st, upper extremity of nasal process of superior maxilla; 2d, edge of orbit. *I*, ala nasi, upper lip, and orbicularis oris.

Zygomaticus minor. *O*, upper part of malar bone. *I*, upper lip, near commissure.

Zygomaticus major. *O*, lower part of malar bone. *I*, angle of mouth.

Levator anguli oris. *O*, canine fossa below infra orbital foramen. *I*, commissure of lips, and orbicularis oris.

Depressor labii superioris alæque nasi. *O*, alveoli of canine and incisor teeth. *I*, integuments of upper lip, and fibrocartilage of septum and ala nasi.

Depressor anguli oris. *O*, external oblique line on outer side of lower jaw, from anterior edge of masseter to mental foramen. *I*, commissure of lips.

Depressor labii inferioris. *O*, side and front of lower maxilla. *I*, half of lower lip, and orbicularis oris.

Levator labii inferioris. *O*, alveoli of incisor teeth. *I*, integuments of chin.

Orbicularis oris. Surrounds the opening of mouth.

Buccinator. *O*, 1st, two last alveoli of superior maxilla; 2d, external surface of posterior alveoli of lower maxilla; 3d, intermaxillary ligament. *I*, commissure of lips.

Masseter, anterior portion. O, superior maxilla where it joins the malar bone, and inferior edge of the latter. I, outer surface of angle of lower maxilla. **Posterior portion;** O, edge of malar bone and zygoma. I, external side of angle and ramus of jaw.

Temporalis. O, all beneath semicircular ridge on parietal bone, and temporal fossa and fascia. I, coronoid process of inferior maxilla to last malar teeth.

Pterygoideus internus. O, inner side of external pterygoid plate and pterygoid process of palate bone. I, inner side of angle of jaw and rough surface above.

Pterygoideus externus. O, outer side of external pterygoid plate, from crest on great wing of sphenoid, and back part of tuberosity of superior maxilla. I, anterior and internal part of neck of lower jaw and interarticular cartilage.

NECK.

+ **Platysma-myoides.** O, cellular membrane covering upper part of deltoid and pectoral muscles, and also from clavicle. I, 1st, chin; 2d, fascia along the side of lower jaw; 3d, fascia covering parotid.

+ **Sterno-cleido mastoideus.** O, upper and anterior part of first bone of sternum, and sternal third (sometimes half) of clavicle. I, upper part of mastoid process, and external third of superior transverse ridge of occipital bone.

^ **Sterno-hyoideus.** O, posterior surface of first

bone of sternum, cartilage of first rib, sternal end of clavicle, and sterno-clavicular capsule. I, lower border of body of os hyoides.

Sterno-thyroideus. O, posterior surface of sternum, and cartilage of second rib. I, oblique line on ala of thyroid cartilage.

Omo-hyoideus. O, superior costa of scapula behind the semilunar notch, and from ligament covering the notch; sometimes from the base of coracoid process, and occasionally from acromial end of clavicle. I, into lower border of os hyoides, at the junction of its body and cornu.

Digastricus. O, groove in temporal bone internal to mastoid process. I, rough depression on inner side of base of jaw close to symphysis.

Mylo-hyoideus. O, oblique line on inner surface of side of maxilla. I, base of os hyoides and middle tendinous line between that bone and chin.

Genio-hyoideus. O, inner side of chin, above digastric. I, base of os hyoides.

Hyo-glossus. O, cornu and body of os hyoides. I, side of tongue.

Genio-hyo-glossus. O, eminence inside of chin, beneath frænum linguæ. I, mesial line of tongue from apex to base, and body and lesser cornu of os hyoides.

Lingualis—a fasciculus of fibres on the inferior surface of tongue, running from base to apex.

Stylo-hyoideus. O, outer side of styloid process, near its base. I, cornu and body of os hyoi-

des, and fascia connecting digastric tendon to this bone.

Stylo-glossus. O, styloid process, near its point, and stylo-maxillary ligament. I, side of tongue.

Stylo-pharyngeus. O, back part of root of styloid process. I, side of pharynx, cornu of os hyoides, and thyroid cartilage.

PHARYNX.

Constrictor pharyngis inferior. O, side of cricoid cartilage, inferior cornu, and posterior part of ala of thyroid cartilage. I, mesial line on back of pharynx.

Constrictor pharyngis medius. O, cornu and appendix of os hyoides, also from stylo-hyoid and thyrohyoid ligaments. I, mesial line and cuneiform process.

Constrictor pharyngis superior. O, petrous bone, lower part of internal pterygoid plate and hamular process, also from intermaxillary ligament, posterior third of mylohyoid ridge, and side of base of tongue. I, cuneiform process and middle line on back of pharynx.

PALATE.

Levator palati. O, petrous bone in front of foramen caroticum, and behind eustachian tube. I, broad, into velum.

Tensor palati vel circumflexus palati. O, depression at root of internal pterygoid plate, from spinous process of sphenoid, and fore-

part of eustachian tube : turns round hamular process, and expands on velum.

Motor uvulæ. O, posterior extremity of spine of palate bones. I, cellular tissue of uvula.

Palato glossus vel constrictor isthmi faucium. O, inferior surface of velum. I, side of tongue.

Palato pharyngeus. O, inferior surface of palate. I, side and back of pharynx and into cornu of thyroid cartilage.

LARYNX.

Thyro-hyoideus. O, oblique ridge on ala of thyroid cartilage. I, lower edge of cornu of os hyoides.

Crico-thyroideus. O, forepart of cricoid cartilage. I, lower border of thyroid.

Thyro-arytenoideus. O, posterior surface of thyroid cartilage. I, anterior edge of arytenoid cartilage.

Crico-arytenoideus lateralis. O, upper edge of side of cricoid cartilage. I, base of arytenoid.

Crico-arytenoideus posticus. O, depression on posterior surface of cricoid. I, outside of base of arytenoid cartilage.

Arytenoideus—fills the interval between arytenoid cartilages; oblique fibres run from apex of one cartilage to the base of opposite; transverse fibres are attached to posterior surface of each cartilage.

DEEP MUSCLES OF NECK.

- ✓ Longus colli. O, bodies of three superior dorsal, and four inferior cervical vertebræ, from the intervertebral ligaments, also from the head of the first rib and anterior tubercles of transverse processes of four last cervical vertebræ. I, forepart of 1st, 2d, and 3d cervical vertebræ.
- ✓ Rectus capitis anticus major. O, anterior tubercles of transverse processes of four last cervical vertebræ. I, cuneiform process.
- ✓ Rectus capitis anticus minor. O, transverse process of atlas. I, cuneiform process.
- Rectus capitis lateralis. O, transverse process of atlas. I, semilunar ridge or jugular process of occipital bone.
- ✓ Scalenus anticus. O, anterior tubercles of transverse processes of 3d, 4th, 5th, and 6th cervical vertebræ. I, upper surface of first rib, near cartilage.
- Scalenus medius. O, posterior tubercles of transverse processes of four or five inferior cervical vertebræ. I, upper surface of 2d rib.
- Scalenus posticus. O, posterior tubercles of two or three lower cervical vertebræ. I, upper edge of 2d rib between tubercle and angle.

THORAX.

- Pectoralis major. O, sternal half of clavicle, anterior surface of sternum, cartilages of 3d, 4th, 5th and 6th true ribs, and from aponeuro-

sis common to it, and external oblique. I, anterior edge of bicipital groove and fascia of arm.

Pectoralis minor. O, external surface and upper edge of 3d, 4th, and 5th ribs, sometimes from the 2d. I, inner and upper surface of coracoid process.

Subclavius. O, cartilage of 1st rib. I, external half of inferior surface of clavicle.

Serratus magnus. O, eight or nine superior ribs. I, base of scapula.

22 Intercostales—11 external. O, inferior edge of each rib commencing at transverse processes of vertebræ. I, external lip of superior edge of the rib beneath, going on to costal extremity of cartilages. 11 internal. O, at sternum from inner lip of lower edge of each cartilage and rib, on to angle. I, inner lip of superior edge of cartilage, and rib beneath.

Levatores costarum. O, extremity of each dorsal transverse process. I, upper edge of rib beneath, between tubercle and angle.

Triangularis sterni. O, posterior surface and edge of lower part of sternum and xiphoid cartilage. I, cartilages of 4th, 5th, and 6th ribs.

BACK.

Trapezius. O, internal third of superior transverse ridge of occipital bone, ligamentum nuchæ, spinous processes of last cervical, and all the dorsal vertebræ. I, external third of

- clavicle and of acromion process, also upper edge of spine of scapula.
- Latissimus dorsi.** O, six inferior dorsal spines, and by lumbar fascia from all the lumbar spines, from back of sacrum, posterior third of crest of ilium, and from three or four last ribs. I, inner or posterior edge of bicipital groove.
- Rhomboideus minor.** O, lower part of ligamentum nuchæ, and last cervical spinous process. I, base of scapula, opposite to, and above the spine.—**Major.** O, four or five superior dorsal spines. I, base of scapula, from spine to inferior angle.
- Levator anguli scapulæ.** O, posterior tubercles of transverse processes of four or five superior cervical vertebræ. I, base of scapula, between spine and superior angle.
- Serratus posticus superior.** O, ligamentum nuchæ, and from two or three dorsal spines. I, second, third, and fourth ribs external to their angles.
- Serratus posticus inferior.** O, two last dorsal, and two upper lumbar spines. I, lower edge of four inferior ribs anterior to their angles.
- Splenius colli.** O, spines of third, fourth, fifth, and sixth dorsal vertebræ. I, transverse processes of three or four superior cervical vertebræ.—**Splenius capitis.** O, spinous processes of two superior dorsal and three inferior cervical vertebræ, and from ligamentum nuchæ. I, back part of mastoid process, and into occipital bone, below superior transverse ridge.

- Sacro-lumbalis.** O, posterior third of crest of ilium, oblique and transverse processes of sacrum, sacro iliac ligaments, and from transverse and oblique processes of lumbar vertebræ. I, all the ribs near their angles.
- Longissimus dorsi.** O, posterior surface of sacrum, transverse and oblique processes of lumbar vertebræ. I, internally into all the dorsal vertebræ, externally into all the ribs between their tubercles and angles.
- Spinalis dorsi.** O, two superior lumbar and three inferior dorsal spines. I, nine superior dorsal spines.
- Musculi accessorii.** O, superior edge of each rib. I, tendons of sacro lumbalis.
- Cervicalis descendens.** O, by 4 or 5 tendons from as many superior ribs between their tubercles and angles. I, Transverse processes of 4th, 5th, and 6th cervical vertebræ.
- Transversalis colli.** O, transverse processes of five or six superior dorsal vertebræ. I, transverse processes of three or four inferior cervical vertebræ.
- Trachelo mastoideus.** O, transverse processes of 3 or 4 superior dorsal vertebræ and as many inferior cervical. I, inner and back part of mastoid process.
- Complexus.** O, transverse and oblique processes of 3 or 4 inferior cervical, and 5 or 6 superior dorsal vertebræ. I, occipital bone between the two transverse ridges close to its fellow.
- Spinalis colli.** O, transverse processes of five or six superior dorsal vertebræ. I, by four

heads into spinous processes of second, third, fourth, and fifth cervical vertebræ.

Semispinalis dorsi. O, by five or six tendons from transverse processes of the dorsal vertebræ from the fifth to the eleventh. I, by five or six tendons into the extremity of two inferior cervical and three or four superior dorsal vertebræ.

Multifidus spinæ.—The first arises from spine of dentatus, and is inserted into transverse process of third, and so on to the last, which arises from spine of last lumbar vertebra, and is inserted into the false transverse process of sacrum.

Interspinales—are described by name. They seem double in the neck.

Inter-transversales—are attached and situated as their name implies.

Rectus capitis major. O, spinous process of second vertebra. I, inferior transverse occipital ridge.

Rectus capitis posticus minor. O, posterior part of atlas. I, occipital bone behind foramen magnum.

Obliquus capitis inferior. O, spinous process of second vertebra. I, extremity of transverse process of atlas.

Obliquus capitis superior. O, upper part of transverse process of atlas. I, occipital bone, between its transverse ridges just behind the mastoid process.

UPPER EXTREMITY.

Shoulder and Arm.

- Deltoides.** O, lower edge of spine of scapula, anterior edge of acromion and external third of clavicle. I, rough surface on outer side of humerus.
- Supraspinatus.** O, all that portion of scapula above its spine, and from fascia covering this muscle. I, upper and forepart of great tuberosity of humerus.
- Infraspinatus.** O, inferior surface of the spine of scapula and dorsum of this bone below this process (as low as the posterior ridge, on the inferior costa), also from the aponeurosis of this muscle. I, middle of external tuberosity of humerus.
- Teres minor.** O, depression between the two ridges on inferior costa of scapula, from the fascia covering it, and from ligamentous septa enclosing it. I, inferior depression in great tuberosity of humerus.
- Subscapularis.** O, all the surface and circumference of subscapular fossa. I, small tubercle of humerus.
- Teres major.** O, rough flat surface on inferior angle of scapula, below infra spinatus. I, inner or posterior edge of bicipital groove.
- Coraco-brachialis.** O, point of coracoid process, and tendon of short head of biceps. I, internal side of humerus about the middle, and ridge leading to internal condyle.

Biceps—short head. O, coracoid process. Long head, O, upper part of glenoid ligament of scapula. I, back part of tubercle of radius.

Brachialis anticus, or externus. O, centre of humerus by two fleshy slips, one on either side insertion of deltoid, from forepart of bone down to condyles, and as far as intermuscular ligaments. I, coronoid process of ulna and rough surface beneath that process.

Triceps extensor cubiti—long, or middle head. O, lower part of neck of scapula and anterior portion of inferior costa;—external, or 2d head. O, below insertion of teres minor from a ridge on the outer side of humerus, and from the bone behind this ridge, from intermuscular ligament, and from external condyle—third, or short head. O, below insertion of teres major, ridge leading to internal condyle, and internal intermuscular ligament. I, olecranon process.

Fore-arm and Hand.

Palmaris brevis. O, annular ligament and palmar fascia. I, integuments on inner side of palm of hand.

Pronator radii teres. O, anterior part of internal condyle, fascia of fore-arm, and its intermuscular septa and coronoid process of ulna. I, outer and back part of radius about its centre.

Flexor carpi radialis. O, inner condyle and intermuscular septa. I, base of metacarpal bone of index finger.

Palmaris longus. O, inner condyle, and fascia

of fore-arm. I, near root of thumb into annular ligament and palmar aponeurosis.

Flexor carpi ulnaris. O, inner condyle, inner side of olecranon process, inner edge of near whole length of ulna, and fascia of fore-arm. I, pisiform bone and base of fifth metacarpal bone.

Flexor digitorum sublimis perforatus. O, internal condyle, internal lateral ligament, coronoid process, and radius below its tubercle. I, anterior part of second phalanx.

Flexor digitorum profundus perforans. O, three superior fourths of anterior surface of ulna, internal half of interosseous ligament, sometimes from radius below tubercle. I, last phalanx of each finger.

Flexor pollicis longus. O, forepart of radius below tubercle to within two inches of carpus, sometimes from coronoid process. I, last phalanx of thumb.

Pronator quadratus. O, inferior fifth of anterior surface of ulna. I, anterior part of inferior fourth of radius.

Supinator radii longus. O, external ridge of humerus from below deltoid to within two inches of outer condyle, also from intermuscular ligament. I, rough surface on outside of radius near styloid process.

Extensor carpi radialis longus. O, ridge of humerus between supinator longus and external condyle. I, back part of carpal end of metacarpal bone of index finger.

Extensor carpi radialis brevis. O, inferior and posterior part of external condyle and external

lateral ligament. I, carpal extremity of the third metacarpal bone.

Extensor digitorum communis. O, external condyle, the fascia, and its intermuscular processes and from ulna. I, phalanges of four fingers.

Extensor carpi ulnaris. O, external condyle, fascia and intermuscular septa, also from ulna. I, carpal end of fifth metacarpal bone.

Anconæus. O, external condyle at posterior and inferior part. I, external surface of the olecranon and superior fifth of posterior surface of ulna.

Extensor minimi digiti. O, in common with the last. I, posterior part of the phalanges of little finger.

Supinator radii brevis. O, external condyle, external lateral and coronary ligaments, and ridge on outer side of ulna, which commences below its lesser sigmoid cavity. I, upper third of external and anterior surface of this bone from above its tubercle to insertion of pronator teres.

Extensor ossis metacarpi pollicis, or abductor pollicis. O, middle of posterior part of ulna below anconæus, interosseous ligament and posterior surface of radius, below supinator brevis. I, os trapezium, and upper and back part of metacarpal bone of thumb.

Extensor primi internodii pollicis, or extensor minor. O, back part of ulna below its middle, and from interosseous ligament and radius. I, posterior part of first phalanx, and often into second.

- Extensor secundi internodii pollicis, or extensor major.** O, posterior surface of ulna above its centre and interosseous membrane. I, posterior part of last phalanx.
- Extensor indicis, or indicator.** O, middle of posterior surface of ulna and interosseous membrane. I, 2d and 3d phalanges.
- Abductor pollicis.** O, anterior part of annular ligament, os naviculare and trapezium. I, outside of base of first phalanx, and by an expansion into both phalanges.
- Opponens pollicis, or flexor ossis metacarpi.** O, annular ligament and os naviculare. I, anterior extremity of metacarpal bone of thumb.
- Flexor pollicis brevis.** O, external or anterior head, from inside of annular ligament, and from trapezium and scaphoid bones. I, external sesamoid bone and base of 1st phalanx of thumb; 2d head, or internal or posterior, arises from os magnum and base of metacarpal bone of middle finger. I, internal sesamoid bone and base of first phalanx.
- Adductor pollicis.** O, three-fourths of anterior surface of third metacarpal bone. I, inner side of the root of first phalanx of thumb.
- Abductor indicis.** O, metacarpal bone of forefinger, and one half of that of thumb. I, outer side of base of first phalanx.
- Lumbricales.** O, outer side of the tendons of the flexor profundus near carpus, a little beyond annular ligament. I, middle of first phalanx into tendinous expansion covering back of each finger.
- Abductor minimi digiti.** O, annular ligament

and pisiform bone. I, ulnar side of first phalanx.

Flexor brevis minimi digiti. O, annular ligament and unciform bone. I, base of first phalanx of little finger.

Adductor, or opponens minimi digiti. O, internal to last and overlapped by it. I, all the metacarpal bone of this finger.

The four Interossei antici, or interni or palmares. O, sides of metacarpal bones. I, first phalanges and tendinous expansion covering dorsum of each finger, viz. first, or prior or externus indicis. O, radial side of second metacarpal bone. I, external side of first phalanx of forefinger—Second, or posterior, or internus or adductor indicis. O, ulnar side of second metacarpal bone. I, inner side of first phalanx of forefinger—Third, or prior or externus or adductor annularis. O, radial side of fourth metacarpal bone. I, external side of first phalanx of ring finger—Fourth, or abductor minimi digiti. O, radial side of fifth metacarpal bone. I, outside of first phalanx of little finger.

Posterior interossei. O, opposed sides of two metacarpal bones. I, base of first phalanx of each finger and posterior tendinous expansion—First, prior or externus medii. O, second and third metacarpal bones. I, outer side of the base of the first phalanx of middle finger—Second, or externus medii, situated between metacarpal bones of middle and ring finger I, inner side of first phalanx of middle finger—Third, or externus annularis, is between fourth

and fifth metacarpal bones. I, inner side of ring finger.

ABDOMEN.

Obliquus externus, or descendens. O, eight or nine inferior ribs at a little distance from their cartilages. I, ensiform cartilage, linea alba, pubis, Poupart's ligament, and two anterior thirds of crest of ilium.

Obliquus internus, or ascendens. O, fascia lumborum, all the crest of ilium, and external third or fourth of Poupart's ligament. I, cartilages of seven inferior ribs, ensiform cartilage and the whole length of linea alba, and by conjoined tendons to symphysis and upper edge of pubis, and into linea innominata.

Cremaster. O, internal surface of external third of Poupart's ligament, and from lower edge of obliquus internus, and sometimes from transversalis (frequently having a tendinous attachment to pubis). I, tunica vaginalis. A few fibres are lost in scrotum.

Transversalis. O, fascia lumborum, crest of ilium, iliac third of Poupart's ligament, seven lower ribs. I, along with obliquus internus into whole length of linea alba, upper edge of pubis and linea innominata.

Rectus. O, upper and anterior part of pubis. I, by internal fasciculus to ensiform cartilage, and costo xiphoid ligament, by the middle to cartilage of sixth rib, and by external to cartilage of fifth rib.

- Pyramidalis.** *O*, pubis. *I*, linea alba, half-way to umbilicus.
- Diaphragm**—first, superior or true diaphragm. *O*, posterior surface of xiphoid cartilage, internal surface of cartilages of last true, and all the false ribs from external or false ligamentum arcuatum, and from convex edge of true ligamentum arcuatum. *I*, cordiform or central tendon, which tendon is divided into anterior, right and left portions; the first the largest, the last the smallest. Second, Inferior portion, or appendices or cura. *O*, right crus, from forepart of bodies of four first lumbar vertebræ; left crus, from sides of two or three first lumbar vertebræ. *I*, posterior border of cordiform tendon.
- Quadratus lumborum.** *O*, posterior fourth of spine of ilium and ilio-lumbar ligament. *I*, extremity of transverse processes of four first lumbar vertebræ, and of last dorsal, also into internal surface of posterior half of last rib.
- Psoas parvus.** *O*, side of last dorsal, and first lumbar vertebra. *I*, linea ileo-pectinæa, fascia iliaca, and fascia lata, behind femoral vessels.
- Psoas magnus.** *O*, side of the body of two last dorsal, and bodies, and transverse processes of all the lumbar vertebræ, and from intervertebral ligaments. *I*, back part of lesser trochanter and ridge below that process.
- Iliacus internus.** *O*, transverse process of last lumbar vertebra, inner margin of three anterior fourths of crest of ilium, two anterior spinous processes, and intervening notch, brim of acetabulum, capsular ligament, iliac

fossa and iliac fascia. I, along with psoas magnus, or rather into it; the inferior fibres are inserted into anterior and inner surface of femur below lesser trochanter.

MALE PERINÆUM.

Sphincter ani. O, from a ligamentous substance extending from os coccygis to rectum. I, in front of rectum into raphe and superficial fascia, and common central point of perinæum.

Sphincter internus vel orbicularis—encircles lower extremity of rectum close to mucous membrane.

Erector or compressor penis. O, inner surface of tuber ischii, and from the insertion of great or inferior sacro-sciatic ligament. I, fibrous membrane of corpus cavernosum, or crus penis.

Accelerator urinæ, or ejaculator seminis. O, 1st, triangular or interosseous ligament; 2d, by a broad tendon common to opposite muscle, and which lies above urethra, between it and pubis; 3d, more anteriorly by a tendinous expansion from the side of corpus cavernosum penis. I, middle tendinous line or raphe of perinæum.

Transversalis perinæi. O, inside of tuberosity of ischium. I, central point of perinæum.

Levator ani. O, posterior part of symphysis pubis, obturator fascia, ilium above thyroid hole, inner surface of ischium, and spinous process. I, the anterior or pubic fibres into central point of perinæum, and forepart of

rectum; the middle fibres into side of rectum, the posterior into back of rectum, and tendinous raphe extending from rectum to os coccygis and into the two last bones of coccyx.

Compressor urethræ. O, by a tendon from inside of symphysis pubis, about one-eighth of an inch above lower edge of arch. I, below membranous portion of urethra, into a narrow tendinous line which becomes lost in central point of perinæum.

Coccygeus. O, inner surface of spine of ischium. I, extremity of sacrum and side of coccyx.

INFERIOR EXTREMITY.

Forepart and Sides of Thigh.

Tensor vaginæ femoris. O, anterior superior spinous process of ilium. I, duplicature of fascia lata on outer side of thigh, about three inches below the great trochanter.

Sartorius. O, anterior superior spine of ilium and notch below that process. I, upper end of tibia, below tubercle.

Rectus femoris. O, anterior inferior spinous process of ilium, superior and external border of acetabulum and capsular ligament. I, upper edge of patella, and by a few fibres into ligamentum patellæ.

Vastus externus. O, root and anterior part of great trochanter, outer edge of linea aspera, oblique ridge leading to external condyle, all the external surface of the bone, and from

fascia lata. I, external surface of tendon of rectus, side of patella, and head of tibia.

Vastus internus. O, anterior part of femur, from the intertrochanteric line, all the inner edge of *linea aspera*, and inner side of femur. I, inner edge of tendon of rectus, patella and head of tibia.

Cruræus. O, anterior and external part of femur, commencing at intertrochanteric line, and extending along three-fourths of bone as far outwards as *linea aspera*. I, upper and outer edge of patella, and synovial membrane of knee.

Gracilis. O, lower half of symphysis and inner edge of descending ramus of pubis. I, superior part of internal surface of tibia.

Pectinæus. O, *linea innominata* on horizontal ramus of pubis. I, rough ridge leading from lesser trochanter to *linea aspera*.

Triceps adductor femoris.

1. *Adductor longus.* O, anterior surface of pubis, between spine and symphysis. I, middle third of *linea aspera*.

2. *Adductor brevis.* O, anterior inferior surface of pubis, between symphysis and thyroid hole. I, superior third of internal root of *linea aspera*, extending three inches below lesser trochanter.

3. *Adductor magnus.* O, anterior surface of descending ramus of pubis, ramus of ischium, and external border of tuberosity of ischium. I, rough ridge leading from great trochanter to *linea aspera*, *linea aspera* and internal condyle of femur.

HIP.

- Glutæus maximus.** O, posterior fifth of crest of ilium, rough surface between the crest and superior semicircular ridge, posterior ilio sacral ligaments, and lumbar fascia, tubercles on posterior surface of sacrum, side of coccyx, and great sciatic ligament. I, rough edge leading from trochanter to linea aspera, upper third of that line, and fascia lata.
- Glutæus medius.** O, deep surface of fascia, extending from its anterior edge to the crest of ilium, three anterior fourths of crest of ilium, superior semicircular ridge leading from anterior spinous process of ilium to upper part of sciatic notch, and surface of ilium above and below that ridge. I, upper and outer part of great trochanter.
- Glutæus minimus.** O, inferior semicircular ridge on dorsum of ilium, rough surface between it and edge of acetabulum. I, upper and anterior part of great trochanter.
- Pyriformis.** O, anterior or concave surface of 2d, 3d, and 4th divisions of sacrum, and by a few fibres from the anterior surface of the great sciatic ligament, and from upper and back part of ilium. I, upper part of digital fossa, at the root of great trochanter.
- Gemellus superior.** O, spine of ischium. I, upper part of digital fossa of great trochanter along with obturator internus.
- Gemellus inferior.** O, upper part of tuber

ischii, and great sciatic ligament. I, digital fossa with the former.

Obturator internus. O, superior or pelvic surface of obturator or thyroid ligament, all the circumference of obturator foramen (except where the nerve and vessels pass), and from ligamentous arch beneath these, pubes internally, ischium inferiorly, and from a thin strong fascia of same name, covering and separating this muscle from levator ani. I, digital fossa of great trochanter.

Quadratus femoris. O, external surface of tuber ischii. I, inferior and posterior part of great trochanter, and posterior intertrochanteric line.

Obturator externus. O, inferior surface of obturator ligament, surrounding surface of pubis and ischium. I, lower part of digital fossa.

BACK PART OF THIGH.

Biceps flexor cruris—long head. O, outer and back part of tuber ischii;—short head, O, linea aspera from below insertion of glutæus maximus to within two inches of external condyle. I, head of fibula.

Semitendinosus. O, great tuberosity of ischium, with long head of biceps, and from tendon of biceps for three inches. I, anterior angle of tibia below tubercle.

Semimembranosus. O, upper and outer part of tuber ischii. It divides into three processes, one passing outwards, another downwards, and a third forwards. First, is inserted into

external condyle of femur, and termed posterior ligament of knee, or ligament of Winslow; second, inserted into posterior part of heads of tibia and fibula; third, into head of tibia.

LEG.

Anterior and External Part of Leg.

Tibialis anticus. *O*, outer part of two superior thirds of tibia, head of fibula, inner half of interosseous ligament, fascia of leg, and intermuscular septa. *I*, inner side of great cuneiform bone, and base of first metatarsal bone.

Extensor digitorum longus. *O*, external part of head of tibia, head of fibula, and from about 3-4ths of this bone, part of interosseous ligament, fascia of leg and intermuscular septa. *I*, last phalanx of each of four external toes.

Extensor pollicis proprius. *O*, inner edge of middle third of fibula, interosseous ligament nearly as low as angle, lower part of tibia. *I*, by two tendinous fasciculi, one into base of first, and the other into base of second phalanx of great toe.

Peronæus tertius, or anticus. *O*, anterior surface of lower half of fibula. *I*, base of fifth metatarsal bone, and frequently sends a band of fibres to join fourth tendon of extensor communis.

Extensor digitorum brevis. *O*, upper and anterior part of os calcis, cuboid bone, astragalus and annular ligament. *I*, internal tendon

into base of first phalanx of great toe, the three others join outer edge of corresponding tendons of extensor digitorum longus, to assist in forming the aponeurosis which covers the dorsum of each toe.

Outer part of Leg.

Peronæus longus. *O*, around head of fibula, adjacent surface of tibia, upper half of external angle of fibula, fascia and intermuscular septa. *I*, outer side of metatarsal bone of great toe, and adjacent sesamoid bone, also into internal cuneiform and base of 2d metatarsal bone.

Peronæus brevis. *O*, outer and back part of lower half of fibula, and from intermuscular septa. *I*, base of metatarsal bone of little toe, and into os cuboides.

Back of Leg.

Gastrocnemius. *O*, internal head from upper and back part of internal condyle of femur, and oblique ridge above it, the external from above external condyle. *I*, lower and back part of os calcis.

Plantaris. *O*, back part of femur above external condyle, and from posterior ligament of knee. *I*, posterior part of os calcis anterior to tendo-achillis.

Salæus. *O*, external head, from back part of head, and superior third of fibula, internal head, from middle third of tibia, unites with

gastrocnemius to form tendo-achillis. I, lower and back part of os calcis.

Poplitæus. *O*, depression on outer condyle. I, flat triangular surface, occupying superior fifth of posterior surface of tibia.

Flexor digitorum perforans. *O*, posterior flat surface of tibia, from below poplitæus to within three inches of ankle, from fascia and intermuscular septa. I, last phalanx of each of four lesser toes.

Tibialis posticus. *O*, posterior and internal part of fibula, upper part of tibia and almost entire length of interosseous ligament. I, tuberosity on inferior and internal part of os naviculare, internal cuneiform bone, cuboid and second and third metatarsal bones.

Flexor pollicis longus. *O*, two inferior thirds of fibula. I, last phalanx of great toe.

FOOT.

Abductor pollicis. *O*, lower and inner part of os calcis, internal annular ligament, plantar aponeurosis, and internal intermuscular septum. I, internal sesamoid bone, and internal side of base of first phalanx of great toe.

Flexor digitorum brevis perforatus. *O*, inferior and internal part of os calcis, internal annular ligament, plantar aponeurosis, and intermuscular septa. I, second phalanx of four outer toes.

Abductor minimi digiti. *O*, outer side of os calcis, strong ligament extending from this to fifth metatarsal bone, base of the latter,

plantar fascia, and its external intermuscular septum. I, outer side of base of first phalanx of little toe, and adjoining surface of metatarsal bone.

Musculus accessorius. O, inferior and internal part of os calcis. I, upper and outer part of tendon of flexor digitorum longus just before it divides.

Four Lumbricales. O, tendons of flexor digitorum longus. I, internal side of first phalanx of four lesser toes.

Flexor pollicis brevis. O, lower and anterior part of os calcis and external cuneiform bone. I, sesamoid bones beneath first phalanx of great toe.

Adductor pollicis. O, calcaneo cuboid ligament, base of second and third metatarsal bones. I, external sesamoid bone with the last.

Transversalis pedis. O, anterior extremities of four external metatarsal bones. I, external sesamoid bone of great toe.

Flexor brevis minimi digiti. O, cuboid and fifth metatarsal bone, and from the sheath of perinæus longus tendon. I, inner side of base of first phalanx of little toe.

Seven Interossei muscles. Three seen on sole; and four on dorsum of foot.

Inferior are named interossei interni, or inferiores.

1st, or adductor medii digiti, situated between second and third metatarsal bones. O, chiefly from inner side of latter bone. I, inner side of first phalanx of third or middle toe.

2d, or adductor quarti digiti. O, inner side of fourth metatarsal bone. I, inner side of first phalanx of fourth toe.

3d, Adductor minimi digiti. O, fifth metatarsal bone. I, inner side of little toe.

Superior, or interossei externi, are bicipital muscles.

1st, Adductor digiti secundi. O, internal side of second metatarsal bone, and from outer side of first. I, inner side of base of first phalanx of second toe.

2d, Abductor digiti secundi. O, opposite surfaces of second and third metatarsal bones. I, outer side of first phalanx of second toe.

3d, Abductor medii digiti. O, opposite surfaces of third and fourth metatarsal bones. I, outer side of first phalanx of third or middle toe.

4th, Abductor digiti quarti. O, opposite surfaces of fourth and fifth metatarsal bones. I, outer side of first phalanx of fourth toe.

INTERNAL EAR AND BALL OF EYE.

Tympanum.

Stapedius. O, within the pyramid. I, neck of the stapes.

Tensor tympani. O, in the canal in the petrous bone above the Eustachian tube. I, into the short process below the neck of the malleus.

Laxator tympani. O, spinous process of sphenoid bone, and from Eustachian tube. I, into

processus gracilis of malleus, or process of Raw.

Orbit.

Levator palpebræ superioris. O, upper edge of foramen opticum. I, superior border of tarsal cartilage, and into superior palpebral sinus of conjunctiva behind the palpebral ligament.

Obliquus superior. O, on the inner side of the preceding. I, sclerotic coat between the superior and external recti.

Obliquus inferior. O, orbital edge of superior maxillary bone above infraorbital foramen. I, sclerotic coat behind the transverse axis of eye, and between sclerotic coat and external rectus.

Rectus superior vel attol- lens oculi.	} O, optic foramen, the external being also attached to foramen lacerum.
Rectus inferior v. depres- sor oculi.	
Rectus internus v. adduc- tor oculi.	
Rectus externus v. abduc- tor oculi.	

I, behind cornea
about a quarter of
an inch.

ARTERIES.*

AORTA.

Arch of Aorta.

- I. Arteria coronaria dextra vel anterior.
 1. Superior branch.
 2. Inferior branch.
 3. Posterior branch.
- II. Arteria coronaria sinistra v. posterior.
 1. Superior branch.
 2. Inferior branch.
- III. Arteria innominata.
 1. Middle thyroid artery.
 2. Right common carotid artery.
 - A. External carotid artery.
 - a. Superior thyroid.
 - α . Ramus hyoideus.
 - β . Ramus superficialis.
 - γ . Ramus laryngeus.
 - δ . Ramus thyroideus.
 - b. Lingual artery.
 - α . Ramus hyoideus.
 - β . Arteria dorsalis linguæ.
 - γ . Arteria sublingualis.
 - δ . Arteria ranina.
 - c. Labial, fascial, or external maxillary.
 - α . Arteria palatina inferior.
 - β . Arteria tonsillaris.
 - γ . Arteriæ glandulares.

* As described by Harrison.

- δ. Arteria submentalis.
- ε. Arteria labialis inferior.
- ζ. Arteria coronaria inferior.
- η. Arteriæ massetericæ.
- θ. Arteria coronaria superior.
- ι. Arteria nasi lateralis.
- κ. Arteria angularis.
- d. Sterno mastoid or muscular artery.
- e. Occipital artery.
 - a. Posterior meningeal artery.
- f. Posterior auricular artery.
 - a. Muscular branches.
 - β. Branch to stylo-mastoid foramen.
 - γ. Anterior branch to cartilage of ear.
 - δ. Posterior branch to side of cranium.
- g. Ascending pharyngeal artery.
 - a. 3 or 4 Internal branches.
 - β. External branches.
 - γ. Branches to dura mater.
- h. Transverse artery of face.
 - a. Ascending branches.
 - β. Descending branches.
- i. Temporal artery.
 - a. Arteriæ anteriores auris.
 - β. Arteria capsulares.
 - γ. Arteria temporalis media.
 - δ. Arteria temporalis posterior.
 - ε. Arteria temporalis anterior.
- k. Internal maxillary artery.
 - a. Arteria meningeæ media.
 - β. Arteria dentalis vel maxillaris inferior.
 - γ. Arteriæ Pterygoideæ.
 - δ. Arteriæ temporales profundæ.
 - ε. Arteriæ massetericæ.

- ζ. Arteriæ buccales.
- η. Arteria dentalis vel maxillaris superior.
- θ. Arteria infra orbitalis.
- ι. Arteria palatina descendens.
- κ. Arteria nasalis.
- B.** Internal carotid.
 - a* & *b.* Arteriæ receptaculi.
 - c.* Arteria ophthalmica.
 - α.* Arteria lachrymalis.
 - β.* Arteria centralis retinæ.
 - γ.* Arteria supra orbitalis.
 - δ.* Arteriæ ciliares breves et longæ.
 - ε.* Rami musculares.
 - † Anterior ciliary arteries.
 - ζ. Arteria ethmoidalis.
 - η & θ. Arteria palpebralis superior and inferior.
 - ι. Arteria nasalis.
 - κ. Arteria frontalis.
 - d.* Arteria posterior communicans.
 - e.* Arteria cerebri anterior.
 - α.* Arteria communicans anterior.
 - β.* Ramus inferior.
 - γ.* Ramus superior.
 - f.* Arteria cerebri media.
 - α.* Choroid artery, &c.
 - β.* Superficial branch.
 - γ.* Deep branch.
- 3.** Right subclavian.
 - A.** Vertebral artery.
 - a.* Arteria cerebelli inferior vel posterior.
 - b* & *c.* Arteriæ medullæ spinalis posterior et anterior.
 - A.** Arteria basilaris.

- a.* Arteria cerebelli anterior vel superior.
 - a.* Branch to meatus internus.
 - b.* Arteria cerebri posterior.
- B.** Internal mammary artery.
 - a.* 5 arteriæ intercostales anteriores.
 - a* & *β.* Rami superiores and inferiores.
 - b.* Arteriæ mediastini.
 - c.* Arteria comes nervi phrenici.
 - d.* Arteria musculo phrenica.
 - a.* 6 anterior intercostal branches.
 - β.* Branches to diaphragm.
 - e.* Ramus abdominalis.
- c.** Axis thyroideus.
 - a.* Arteria thyroidea inferior vel ascendens.
 - b.* Arteria cervicalis ascendens.
 - c.* Arteria supra scapularis vel transversalis humeri.
 - a.* Arteria acromialis superior.
 - β.* Arteria supra-spinalis.
 - γ.* Arteria infra-spinalis.
 - d.* Arteria transversalis colli.
 - a.* Arteria cervicalis superficialis.
 - β.* Arteria scapularis posterior.
- D.** Arteria cervicalis profunda.
- E.** Arteria intercostalis superior.
- 3.** Axillary artery.
 - A.** Arteria thoracica acromialis.
 - a.* Pectoral branches.
 - b.* Branches to shoulder.
 - c.* Inferior acromial artery, &c.
 - B.** Arteria thoracica suprema.
 - c.** Arteria thoracica alaris.
 - D.** Arteria thoracica longa vel mammaria externa.

- E. Arteria subscapularis.
 - a. Ramus anterior.
 - b. Ramus posterior, or arteria circumflexa scapulæ.
 - α. Ramus ascendens vel arteria infra-spinata.
 - β. Ramus descendens.
- F. Arteria circumflexa posterior.
- G. Arteria circumflexa anterior.
- 3. Arteria brachialis.
 - A. Arteria profunda superior.
 - B. Arteria profunda inferior.
 - C. Arteria anastomotica magna.
 - D. Arteria nutritia humeri.
 - E. Arteria radialis.
 - a. Arteria radialis recurrens.
 - b. Arteria superficialis volæ.
 - c. Arteria anterior carpi radialis.
 - d. Arteria dorsalis carpi radialis.
 - e. Arteria dorsalis pollicis radialis.
 - f. Arteria dorsalis pollicis ulnaris.
 - a. Arteria dorsalis indicis.
 - g. Arteria magna vel princeps pollicis.
 - h. Arteria radialis indicis.
 - i. Arteria palmaris profunda.
 - F. Arteria ulnaris.
 - a & b. Arteria recurrens anterior and posterior.
 - c. Arteria interossea.
 - α. Arteriæ recurrentes anteriores.
 - β. Arteria interossea anterior.
 - † Anterior branch.
 - † Posterior branch.
 - γ. Arteria interossea posterior.

† Posterior interosseus, recurrent
or ascending.

† Descending branch.

Middle branches.

External branches.

Internal branches.

d & *e*. Arteriæ carpi ulnaris anterior et
posterior.

f. Arteria communicans vel profunda.

g. Arteria palmaris superficialis.

IV. Left common carotid.

V. Left subclavian.

Thoracic Aorta.

I. Superior bronchial arteries.

II. Inferior bronchial artery, or arteries.

III. Arteria œsophageæ.

IV. Arteriæ intercostales.

1. Posterior branches.

2. Anterior branches.

A & B. Ascending and descending branches.

C & D. Superior and inferior branches.

Abdominal Aorta.

I. & II. Arteriæ phrenicæ.

1. External branches.

2. Internal branches.

III. Arteria vel axis cœliaca.

1. Arteria gastrica vel coronaria ventriculi.

A. Ramus superior.

B. Ramus inferior.

2. Arteria hepatica.

A. Arteria pylorica superior.

- b. Arteria gastrica-duodenalis.
 - a. Arteriæ pyloricæ inferiores.
 - b. Arteria pancreatica duodenalis.
 - c. Arteria gastro-epiploica dextra.
- c. Arteria hepatica sinistra.
- d. Arteria hepatica dextra.
 - a. Arteria cystica.
 - a. To coats of gall bladder.
 - β. To gall bladder and liver.
- 3. Arteria splenica.
 - A. Arteriæ pancreaticæ parvæ.
 - B. Arteria pancreatica magna.
 - c. Vasa brevia.
 - D. Arteriæ splenicæ.
 - E. Arteria gastro-epiploica sinistra.
- IV. Arteria mesenterica superior.
 - 1. Branches to pancreas and duodenum.
 - 2. Arteria colica media.
 - A. Right branch.
 - B. Left branch.
 - 3. Arteria colica dextra.
 - A. Superior branch.
 - B. Inferior branch.
 - 4. Arteria ileo-colica.
 - A. Superior branch.
 - B. Middle branch.
 - c. Inferior branch.
 - 5. Branches to jejunum and ilium are 16 to 20.
- V. & VI. Arteriæ capsulares vel atrabiliaris.
- VII. & VIII. Arteriæ renales vel emulgentes.
- IX. & X. Arteriæ spermaticæ.
- XI. Arteriæ lumbales (5 on each side).
 - 1. Spinal branches.

2. Posterior muscular branches.
3. External or abdominal branch.
- XII. Arteria mesenterica inferior.
 1. Arteria colica sinistra.
 - A. Ascending branch.
 - B. Descending branch.
 2. Arteria sigmoidea.
 3. Arteria hæmorrhoidalis superior et interna.
- XIII. Arteria sacra media.

COMMON ILIAC ARTERY.

- I. Internal iliac artery.
 1. Ileo-lumbar artery.
 - A. Ascending branches.
 - B. Descending branches.
 - C. External branches.
 2. Sacro-lateral artery.
 3. Middle hæmorrhoidal artery.
 4. Vesical arteries.
 5. Umbilical artery.
 6. Uterine artery.
 7. Vaginal artery.
 8. Thyroid or obturator artery.
 - A. Branches within the pelvis.
 - B. Posterior or external branch.
 - C. Anterior or internal branch.
 9. Gluteal artery.
 - A. Superficial branch.
 - B. Deep branch.
 - a. Branch to substance of ileum.
 - b. Superior branches.
 - c. Middle branches.
 - d. Inferior or descending branches.

10. Sciatic artery.
 - A. Coccygeal artery.
 - B. Comes nervi ischiadici.
 - c. Muscular branches.
11. Internal pubic artery.
 - A. External hæmorrhoidal arteries.
 - B. Perinæal artery.
 - c. Transverse artery of perinæum.
 - D. Artery of the bulb vel spongiosi urethræ.
 - a. Branch to gland of Cowper.
 - b. Branch to corpus spongiosum.
 - E. Artery of corpus cavernosum.
 - F. Dorsal artery of penis.
- II. External iliac artery.
 1. Epigastric artery.
 2. Circumflex ilii artery.
- II. Femoral artery.
 1. Superficial epigastric artery.
 2. Superficial or external pubic arteries, superior and inferior.
 3. Superficial circumflex ilii artery.
 4. Arteria profunda femoris.
 - A. External circumflex artery.
 - a. Ascending branches.
 - b. Circumflex branches.
 - c. Descending branches.
 - B. Internal circumflex artery.
 - a. Branches to perinæum, &c.
 - b. Branch to acetabulum.
 - c. Superior branch to digital cavity of trochanter.
 - d. Inferior branch.
 - c. Arteria perforans prima.
 - d. Perforans secunda.

- e. Perforans tertia.
- f. Perforans quarta.
- 5. Arteria anastomotica magna.
- II. Popliteal artery.
 - 1. Rami musculares superiores.
 - 2. Arteria articularis superior externa.
 - A. Superficial branch.
 - B. Deep branch.
 - 3. Arteria articularis superior interna.
 - A. Superficial branches.
 - B. Deep branches.
 - 4. Arteria articularis media vel azyga.
 - 5. Arteria articularis inferior externa.
 - 6. Arteria articularis inferior interna.
 - 7. Rami musculares inferiores.
 - 8. Posterior tibial artery.
 - A. Peronæal artery.
 - a. Anterior peronæal artery.
 - b. Posterior peronæal artery.
 - B. Internal plantar artery.
 - C. External plantar artery.
 - a. Perforating branches.
 - b. 4 digital arteries.
 - 9. Anterior tibial artery.
 - A. Arteria recurrens.
 - B. Rami musculares.
 - C. Arteria malleolaris interna.
 - D. Arteria malleolaris externa.
 - E. Arteria tarsi.
 - F. Arteria metatarsi.
 - G. Ramus communicans.
 - H. Arteria pollicis.

NERVES.

CEREBRAL NERVES.

I. Olfactory nerves.

1. Internal branches about 10 to septum.
2. Middle branches to the roof of each nostril.
3. External branches descend on turbinated bones.

II. Optic nerves become retina, which is divisible into three tunics, viz. serous, nervous, and vascular.

III. Motores oculorum.

1. Superior branch or smaller.
 - A. Smaller division to superior rectus.
 - B. Larger division to levator palpebræ.
2. Inferior branch or larger.
 - A. A filament, which with ramus ciliaris of the nasal branch of ophthalmic division of the fifth pair, forms the
 - a. Lenticular or ophthalmic ganglion between optic nerve and external rectus.
 - α . Inferior ciliary fasciculus.
 - β . Superior ciliary fasciculus.
 - γ . Internal ciliary fasciculus.
 - B. Internal branch to internal rectus.
 - C. Middle branch to inferior rectus.
 - D. External branch to inferior oblique.

iv. Trochleator or pathetic to upper surface of superior oblique.

v. Trigemini.*

Threads to unite with great intercostal.

1. Ophthalmic division.

A. Frontal nerve.

a. Small filament to unite with infra-trochlear twig of nasal branch.

b. Supra-trochlear twig, and on passing out of orbit becomes internal frontal nerve.

c. Proper frontal.

B. Lachrymal nerve.

a. Mesial or internal twig to gland, upper eyelid, &c.

b. Exterior or temporal twig to join subcutaneous of superior maxillary.

C. Nasal nerve.

a. Threads to third pair.

b. Ramus ciliaris, contributing to lenticular ganglion.

c. Infra-trochlearis passes out of orbit.

2. Superior maxillary nerve.

A. Malar or subcutaneous of cheek.

B. Infra-orbitary nerve.

a. Posterior dental nerve.

a. Anterior branch to buccinator muscle.

β. Posterior branch to prominence behind superior maxilla, three posterior teeth, &c.

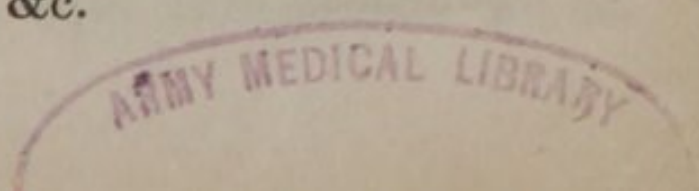
* The trigemini are according to Professor Lizar's description.

- b.* Anterior dental nerve to antrum, nose, teeth, &c.
- c.* Pterygo-palatine, forms ganglion Meckelii.
 - a.* Palatine nerve.
 - a.* External palatine to velum palati, &c.
 - β.* Superior posterior nasal nerves: a branch from each side, uniting with the termination of palatine forms ganglion naso-palatinum at foramen incisivum.
 - γ.* Inferior posterior nasal nerves.
 - δ.* Branches to pterygoid muscles and velum palati.
 - ε.* Terminates in filaments to gums and soft palate.
 - b.* Pterygoid or Vidian nerve.
 - a.* Posterior superior nasal nerves.
 - β.* Petrosal branch first sends
 - † Branches to tensor tympani, and joins fascial, afterwards is reflected and becomes
 - β.* Chorda tympani.
 - † Twig to laxator tympani major, and ultimately joins the gustatory nerve.
 - γ.* Intercostal branch, to assist in forming great intercostal with reflected twigs of abducens.
- 3. Inferior maxillary nerve.
 - A.* Superior branch.
 - a.* Masseteric twig to muscles and articulation of maxilla.

- b.* Exterior deep temporal twig.
- c.* Internal deep temporal twig.
- d.* Superficial temporal or auricular to articulation, and joins with fascial and occipital of second cervical.
- e.* Buccinator twig is largest to surrounding parts.
- f.* Pterygoid nerve.
- B.** Inferior branch.
 - a.* Mandibulo-labialis or inferior maxillary.
 - a.* Mylohyoideus branch.
 - b.* Lingual branch joined by chorda tympani.
- VI.** Abducens to ocular surface of external rectus muscle.
- VII.** Portio dura, or fascial nerve.
 1. Twigs to tensor tympani and stapedius.
 2. Posterior auricular.
 3. Stylohyoid nerve to digastric and stylohyoid muscles, and anastomosis with sympathetic and glosso-pharyngeal nerves.
 4. Submastoid nerves.
 5. Temporo-fascial communicates with auricular of inferior maxillary, and with cervico-fascial, forming with the latter the pes-anserinus.
 - A.** Temporal division.
 - B.** Malar division.
 - C.** Buccal division.
 6. Cervico-fascial nerve.
 - A.** Maxillary division unites with mental nerve and temporo-fascia.
 - B.** Submaxillary.

c. Cervical branches.

- VII. Portio mollis, or auditory nerve.
1. Anterior branch to cochlea.
 2. Posterior to vestibule and semicircular canals.
- VIII. Glosso-pharyngeal nerve, or 1st branch of 8th pair.
1. Twigs to carotid plexus in cavernous sinus.
 2. Filaments to fascial, pneumo-gastric, and sympathetic nerves.
 3. Branches to pharyngeal plexus, some descend and unite with sympathetic and cardiac nerves, others ascend to amygdala.
 4. Branches to stylo-pharyngeus, hyo-glossus, and superior and middle constrictors of pharynx, mucous membrane of fauces, &c.
 5. Branches to root of tongue.
- VIII. Pneumogastric nerve, or nervus vagus, or 2d branch of 8th pair.
1. Pharyngeal nerve, receives a twig from spinal accessory.
 - A. Branches to assist in forming pharyngeal plexus, &c.
 2. Superior laryngeal nerve.
 - A. Filament to pharyngeal plexus (which plexus sends branches to mucous membrane of pharynx and fauces).
 - B. External division to sterno and hyothyroid muscles, &c. thyroid gland, and cartilages of larynx.
 - C. Internal division perforates thyrohyoid membrane.
 - a. Branches to epiglottis and mucous membrane, &c.



- b.* Long branch to crico-thyroid muscle.
- D.* Filaments to carotid artery, sympathetic and cervical nerves.
- E.* Cardiac branches.
- 3. Inferior laryngeal nerve or recurrent.
 - A.* Cardiac branches.
 - B.* Branches to forepart of trachea and thyroid gland.
 - c.* Branches to pharynx and laryngeal muscles.
- 4. Pulmonary branches.
 - A.* Anterior branches pass in front of bronchial tubes, and form the
 - a.* Anterior pulmonary plexus.
 - α.* Filaments to pulmonary vessels, lungs and pericardium.
 - B.* Posterior branches to join posterior pulmonary plexus.
- 5. Posterior pulmonic plexus, formed by the vagus increasing at the root of each lung.
 - A.* Filaments to bronchial tubes and substance of lungs.

Œsophageal plexus, or plexus gulæ, is the union and encircling of the opposite nerves on the œsophagus.

Cardiac plexus is their union on the stomach. The left nerve is anterior on the stomach, the right posterior.

VIII. Nervus accessorius, or third branch of 8th pair.

- 1. Filaments to sternomastoid and cervical plexus.
- 2. Terminates in trapezius muscle and integuments.

ix. Lingual, or 9th pair of nerves.

1. Branches to lingualis and genioglossus muscle and tongue.
2. Descendens noni receives a filament from pneumogastric and internal descending branches of cervical plexus, forming a triangular plexus which goes to omo and sterno-hyoid and thyroid muscles, and sends some filaments to the chest.
3. Filaments to constrictors of pharynx and stylo-pharyngeus, and one to thyrohyoid muscle.
4. On hyoglossus it sends branches to surrounding muscles and gustatory branch of 5th pair.
5. Terminates in genio-hyoglossus.

SPINAL NERVES.

Eight Cervical Nerves and 1st Dorsal.

- i. Posterior branches are small, *unless* the 2d, which accompanies the occipital artery, the rest go to neighboring muscles.
- ii. Anterior branches; the first, or suboccipital, twists round atlas to anterior branch of second, and forms the Nervous loop, or arch of atlas; the four superior form the
 1. Cervical plexus, by uniting together,
 - a. Ascending branches.
 - a. Superficial branches to platisma, integuments, parotid, ear, back of head, chief branch is superficialis vel as-

condens colli, from third cervical to parotid and accompanying external jugular.

- b.* Deep branches to sterno-mastoid, digastric, splenius and adjacent muscles.
- B.** Descending branches.
 - a.* Internal branches.
 - a.* Superficial branch to join descendens noni.
 - β.* Deep branch, or phrenic nerve, or internal respiratory—chiefly from fourth cervical, often a filament from brachial plexus.
 - † Branches to inferior cava, liver, œsophagus, and stomach.
 - † Terminates on diaphragm.
 - b.* External branches.
 - a.* Superficial branches to clavicle, acromion process, pectoral and deltoid muscles and integuments.
 - β.* Deep branches descend behind clavicle and supply muscles on side of neck and those connected with scapula; the largest branch, named external respiratory, goes to serratus magnus.
- 2.** Brachial plexus, formed by the junction of anterior branches of four inferior cervical and first dorsal.
 - A.** Thoracic nerves are four or five in number, and from upper part of plexus; they divide into
 - a.* Anterior thoracic branches, which descend behind clavicle in front of axil-

- lary artery, and supply the pectoral muscles.
- b.* Posterior thoracic nerves, pass behind the vessels to serratus magnus, posterior scalenus and rhomboid muscles.
- B.** Supra scapular nerve.
- a.* A branch to supra spinatus.
- b.* Branches to infra spinatus and teres muscles.
- C.** Subscapular nerves are three or four in number, descend behind the vessels to subscapular latissimus dorsi, and teres major muscles.
- D.** Internal cutaneous nerve.
- a.* External branch descends as low as wrist.
- b.* Internal branch descends towards internal condyle, and divides into branches to inner and posterior part of forearm.
- E.** External cutaneous—musculo-cutaneous, or perforans Casserii.
- a.* Branches to coraco-brachialis, biceps and brachiaëus anticus.
- b.* Anterior branch to ball of thumb and palm of hand.
- c.* Posterior branch to dorsum of hand.
- F.** Median or brachial nerve, the largest branch.
- a.* Branches to muscles of arm and forearm, but none to the supinators.
- b.* Anterior interosseal nerve supplies the deep flexors.
- a.* Division to pronator quadratus.
- b.* To dorsum of hand.

- c. Superficial branch given off above wrist, to palm of hand.
- d. 5 Digital branches.
- g. Ulnar nerve.
 - a. Muscular branches.
 - b. Dorsalis carpi ulnaris to three inner fingers, and integuments on dorsum of hand.
 - c. Superficial palmar branch divides into
 - a. Three digital branches.
 - d. Deep palmar branch.
- h. Musculo-spiral nerve.
 - a. Branches to triceps.
 - b. Cutaneous branch goes on to thumb.
 - c. Branches to long and short supinators and extensors.
 - d. Anterior branch, or radial nerve, descends along inner side of and supplies supinator longus.
 - a. Branch to integuments of thumb.
 - β. Branch to dorsum of hand, supplying index and middle finger, and communicating with dorsalis ulnaris.
 - e. Deep branch, or posterior interosseal nerve.
 - a. Superficial branches to superficial muscles.
 - β. Deep branches to deep muscles.
 - f. Circumflex or articular nerve.
 - a. Branches to subscapular muscle, &c.
 - β. Superior branch.
 - γ. Inferior branch.

Eleven Inferior Dorsal Nerves.

- I. Posterior branches to muscles and integuments of back and loins.
 - II. Anterior or intercostal branches. The 2d and third are smaller than the first, and at angle of ribs pass between intercostal muscles, and running along the lower edge of each rib supply surrounding muscles; opposite the axilla they send off.
 1. The nerves of Wrisberg, or cutaneous nerves of arm.
 2. End in cutaneous and muscular branches to lateral and forepart of thorax.
- Last 9 are similar to the 2d and 3d in distribution, supplying intercostal and adjacent muscles; the two last go chiefly to diaphragm, and the twelfth sends a branch to join the 1st lumbar; they are all connected by one or two short branches to the ganglions of sympathetic.

Five Pairs of Lumbar Nerves.

- I. Posterior branches.
- II. Anterior branches unite in the psoas to form the Lumbar plexus.
 1. External inguino-cutaneous.
 - A. Branches to abdominal muscles.
 - B. Cutaneous branch to integuments on outer part of thigh.
 - C. External spermatic nerve.

2. Middle inguino-cutaneous to skin on outer part of thigh.
3. Internal inguino-cutaneous.
 - A. Branch to cord accompanying spermatic vessels.
 - B. Branch to integuments and glands of groin.
4. Anterior crural nerve, from four superior nerves.
 - A. Superficial fasciculus, 4 or 5 long branches, and piercing fascia lata descend to knee.
 - B. Deep fasciculus.
 - a. External muscular branches to vastus externus, rectus, iliacus internus, and tensor vaginæ femoris.
 - b. Internal muscular branches to sartorius, vastus internus, and cruræus.
 - c. Branches to femoral artery, 3 or 4 in number, going near to knee.
 - d. Internal saphenus nerve, joins saphena vein at knee on coming out between gracilis and sartorius; it goes on to inner side of foot, sending off numerous branches to integuments.
5. Obturator nerve from 3d lumbar.
 - A. Twigs to obturator internus.
 - B. Anterior branch to adductor brevis, pectinæus and vastus internus.
 - C. Posterior branch to gracilis, adductor magnus and longus.
6. Lumbo-sacral nerve from 4th and 5th lumbar.

- A. Superior gluteal to glutæus medius and minimus.
- B. Communicating branch to join first sacral nerve or sciatic plexus.

Five Pairs of Sacral Nerves.

- I. Posterior branches.
- II. Anterior branches, the 3 superior are very large, the two last much smaller, and the 5 with the branch of last lumbar, form the Sacral plexus.
 - 1. Internal or pelvic branches.
 - A. Hæmorrhoidal, vesical, uterine and vaginal.
 - 2. External branches.
 - B. Lesser sciatic nerve.
 - a. Superficial branches pass over hamstring muscles with posterior cutaneous nerve, and are lost in these muscles.
 - b. Deep branches to quadratus femoris, upper part of adductor magnus, hip joint, &c.
 - c. Inferior glutæal nerve to glutæus maximus, perinæum, and inner side of thigh.
 - d. Posterior cutaneous nerve, to thigh and leg posteriorly.
 - e. Pubic nerve.
 - a. Inferior branch to muscles of perinæum and scrotum.
 - b. Superior branch to glans penis.
 - f. Great sciatic, or posterior crural nerve.
 - a. Cutaneous and muscular branches,

the latter to ham-strings, gracilis, and adductor magnus.

b. External poplitæal or peronæal nerves.

a. External cutaneous nerves of leg, they communicate with external saphenus.

β. Musculo-cutaneous nerve.

† Internal tarsal or dorsal nerves, to integuments of first and second toes.

† External tarsal or dorsal nerves, to three outer toes.

γ. Anterior tibial nerve.

† Branches to integuments.

† Branch to extensor digitorum brevis, cutaneous, and communicating filaments.

† Terminating branches to first interosseal muscle, and communicates with plantar nerves.

Internal poplitæal or posterior tibial.

a. Posterior or external saphenus.

β. Muscular branches to gastrocnemius, soleus, plantares and deep muscles.

γ. Filaments to posterior and anterior tibial arteries.

δ. Internal plantar nerve.

† 4 Digital branches.

ε. External plantar nerve.

† Superficial branch to little toe and outer side of fourth.

† Deep branch to plantar muscles and interossei.

SYMPATHETIC OR GANGLIONIC
NERVES.

THE Sympathetic communicate with the Spinal nerves: to each Cervical, by one filament, and to the Dorsal, Lumbar, and Sacral, by two.

CERVICAL GANGLIONS.

- i. Superior cervical ganglion extending from first to third sacral vertebra.
 1. Ascending or superior branches are two ascending in carotid canal to cavernous sinus, and communicates with the 6th and Vidian branch of 5th.
 2. Descending or inferior branches are filaments to join laryngeal nerves and vagus, superior cardiac and sympathetic itself. The superior cardiac takes a long course, and, in passing to the chest, communicates with the laryngeal nerves, the vagus and middle and inferior ganglions of sympathetic. It has sometimes a small ganglion on it near inferior thyroid artery, passing behind subclavian vein and over arteria innominata, it divides into several filaments; some pass along the coats of that vessel to aorta, others join the recurrent nerve and middle and inferior cardiac nerves.
 3. Internal branches unite with pharyngeal plexus.

4. External branches join superior cervical nerves.
 5. Anterior branches unite with others from vagus and fascial, and form a plexus around carotid artery from which branches proceed along external carotid, forming branches around each principal branch, named accordingly.
- II. Middle cervical ganglion is sometimes wanting.
1. Branches to join cervical nerves and vagus.
 2. Middle cardiac nerve of right side is generally the largest of the cardiac nerves, and is sometimes wanting on the left; entering thorax anterior to subclavian artery is joined by large branches from vagus and recurrent, and passing along innominata terminates in cardiac ganglion or plexus.
- III. Inferior cervical ganglion lies between transverse process of last cervical vertebra and neck of first rib.
1. Filaments to phrenic nerve and brachial plexus, subclavian artery, and its branches.
 2. Inferior cardiac nerve or nerves; the right descends along arteria innominata to arch of aorta to its forepart, and terminates in the anterior cardiac plexus; some branches pass between aorta and pulmonary artery to cardiac ganglion. On the left side these nerves accompany the subclavian artery, and partly join the middle cardiac nerve and partly the cardiac plexus.
- Cardiac plexus, or cardiac ganglion, is situated

behind the ascending aorta near its origin in front of trachea and right pulmonary artery; it consists of a plexus of nerves formed by the cardiac from opposite sides, and branches of the eighth pair and recurrent. In the meshes of this plexus several small ganglions are inclosed, and to the aggregate of these the term cardiac ganglion is applied.

THORACIC GANGLIONS.

- I. Branches to mediastinum ramify on aorta. &c., and communicate with the pulmonary plexus.
- II. Great splanchnic nerve from sixth, seventh, eighth, ninth, and tenth ganglions, and unite on the tenth dorsal vertebra into one cord, and entering the abdomen along with the aorta, or separated from it by a fasciculus of the diaphragm, expands into the semilunar ganglion. The semilunar ganglion of each side is situated on the diaphragm, and partly on aorta on either side of celiac axis, and communicating, are termed

Solar plexus, it is situated behind the stomach, above the pancreas, in front of aorta.

1. Branches in various directions accompanying the blood-vessels forming plexuses around each, named accordingly, as hepatic, splenic and gastric, and these communicate with the eighth pair.

2. Branches descending in front of aorta, which subdivide at the renal and mesenteric arteries, accompanying them and forming plexuses, named accordingly, viz. renal, superior and inferior mesenteric, and into each of these branches of the lumbar ganglions enter
- A. Renal plexus.
 - a. Spermatic plexus.
 - B. Inferior mesenteric plexus, sends branches descending to the edge of the pelvis, unite with others from the lumbar ganglions, and form a plexus around the internal iliac artery and its branches, named hypogastric plexus. It is joined by numerous filaments from the lumbar and sacral ganglions of sympathetic, and communicates with the pelvic branches of the sacral plexus.
- III. Lesser splanchnic nerve arises by two roots from the tenth and eleventh ganglions, and uniting on the side of the last dorsal vertebra, enters the abdomen through the crus of diaphragm, and ends in the renal plexus.

LUMBAR GANGLIONS.


The Lumbar ganglions are five on each side, sometimes three or four.


- I. Branches to anterior branches of lumbar spinal nerves.
- II. Branches to assist in forming the different abdominal plexuses.

SACRAL GANGLIONS.

The Sacral ganglions, are three or four in number.

- I. Branches to sacral nerves.
- II. Filaments to hypogastric and pelvic plexuses.
- III. A small branch from the last ganglion on each side, which passes in front of coccyx, there forming ganglion impar, which sends
 1. Filaments to coccygeus, levator, and sphincter ani muscles.





15