

## **Case of amputation at the shoulder-joint / by Charles Freiott.**

### **Contributors**

Freiott, Charles.  
National Library of Medicine (U.S.)

### **Publication/Creation**

[Troy, New York?] : [publisher not identified], [1853]

### **Persistent URL**

<https://wellcomecollection.org/works/hv38ef24>

### **License and attribution**

This material has been provided by This material has been provided by the National Library of Medicine (U.S.), through the Medical Heritage Library. The original may be consulted at the National Library of Medicine (U.S.) where the originals may be consulted.

This work has been identified as being free of known restrictions under copyright law, including all related and neighbouring rights and is being made available under the Creative Commons, Public Domain Mark.

You can copy, modify, distribute and perform the work, even for commercial purposes, without asking permission.



Wellcome Collection  
183 Euston Road  
London NW1 2BE UK  
T +44 (0)20 7611 8722  
E [library@wellcomecollection.org](mailto:library@wellcomecollection.org)  
<https://wellcomecollection.org>

*Freiott (Chas)*

---

CASE OF

Amputation at the Shoulder-Joint.

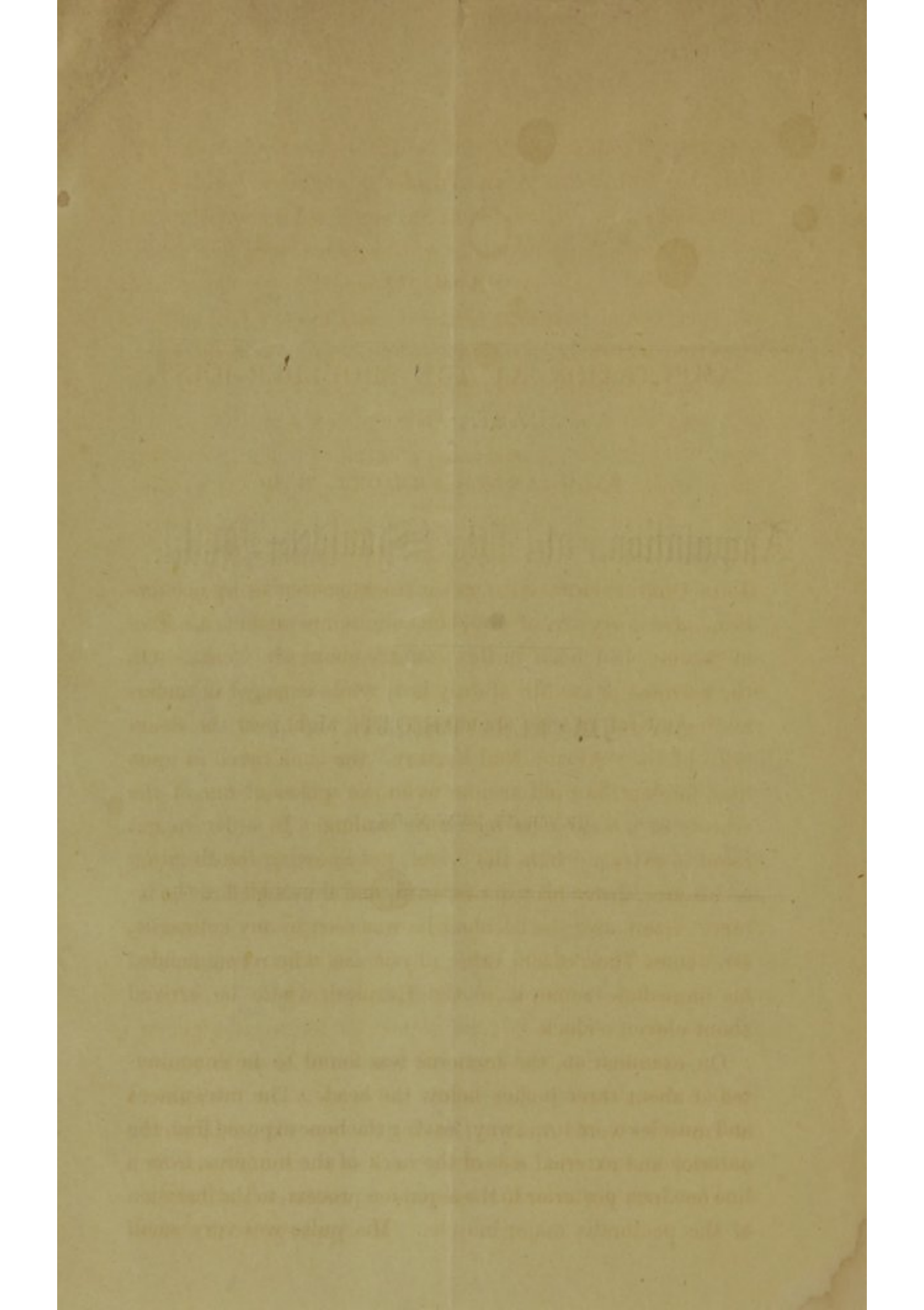
---

BY CHARLES FREIOTT, M.D.,

OF TROY, NEW-YORK.

---

24954





CASE OF

## AMPUTATION AT THE SHOULDER-JOINT.

BY CHARLES FREIOTT, M. D.

JOHN CHRISTOPHER STEVENS, a stocking-weaver by occupation, aged forty-six, of a melancholic temperament, a native of Saxony, had been in this country about six weeks. On the morning of the 5th of July last, while engaged in undermining a bank of clay about eight feet high, near the steam mills of the "Albany Nail Factory," the bank caved in upon him, forcing the right arm between the spokes of one of the wheels of a wagon he had been loading. In order to get room to extricate him, the driver, not knowing the situation of his arm, drove his team forward, and thus added to the injury. Soon after the accident he was seen by my colleague, Dr. James Thorne, and other physicians, who recommended his immediate removal to the Hospital, where he arrived about eleven o'clock.

On examination, the humerus was found to be comminuted at about three inches below the head. The integument and muscles were torn away, leaving the bone exposed from the anterior and external side of the neck of the humerus, from a line one inch posterior to the acromion process, to the insertion of the pectoralis major muscle. His pulse was very small



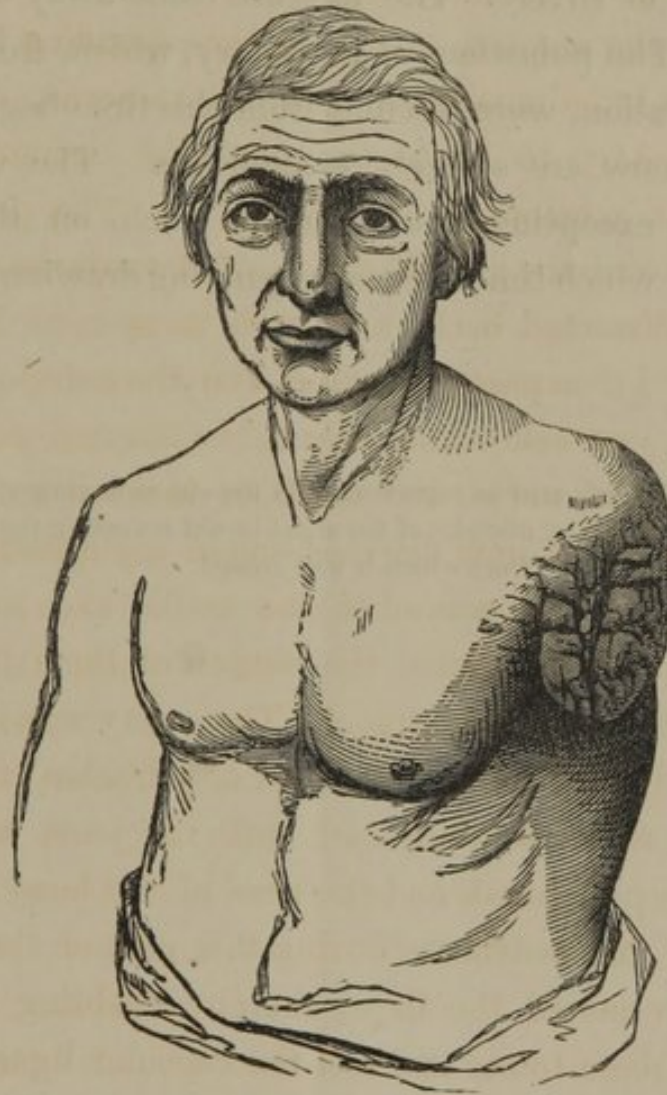and thready, and his extremities were cold. Brandy was given him very liberally, which in a short time produced slight reaction, when I commenced the operation, with the concurrence and approbation of my colleague Dr. Thorne, and several medical gentlemen of this city.

The first step of the operation consisted in removing the torn shreds of muscle on the anterior and external portion of the shoulder. I then cut through the integument and muscle to the bone, commencing an inch below the acromion process of the scapula, to a point corresponding to the insertion of the latissimus dorsi into the humerus, when it became necessary to ligate the posterior circumflex artery, which for a moment bled very freely. The posterior flap was dissected to the glenoid cavity, afterwards the anterior flap was also dissected back, and both were held back by an assistant. I then passed a scalpel from the anterior to the posterior flap, just below and close to the internal portion of the neck of the humerus, and made an incision an inch and a half in length. I now directed one of my assistants to pass his thumb into the wound in the axilla, and compress the artery while I completed the section of the axillary artery, vein, muscles, and integument. The artery was immediately seized and ligated without the loss of a drachm of blood. The dissection was now continued until the joint was exposed, which was punctured, and the head of the bone easily disarticulated. My assistants, during this part of the operation, strongly retracted the flaps, thereby enabling me to have plenty of room to see and feel the capsular ligament.

The wound, after being thoroughly sponged, was dressed by bringing the opposing flaps together, and retaining them by sutures, after which a compress of lint was laid on the wound, and retained by strips of adhesive plaster, and cold-water dressings applied.

July 6th.—Patient complains of considerable pain, and had slept very little, pulse 90 and full, tongue clean and no appetite ; ordered morphia sulph. gr.  $\frac{1}{4}$ , at night, and continue cold-water dressings.

July 7th.—Has passed a good night, little pain, pulse 80, tongue clean, has a good appetite, feels cheerful, asks permission to drink “lager-bier,” which was granted, with full diet, cold-water dressing, and morphine at night continued.



July 8th.—Rested well, pulse 72, other symptoms favorable. A slight discharge was noticed to issue from underneath the dressing, accompanied with slight odor. The dressings were removed, when several maggots were seen in the pus,



which was of a healthy appearance; creosote lotions were used, with a dressing of resin cerate, and the morphine was continued at night.

July 9th.—Symptoms still favorable, wound looks healthy, the upper and lower portions are uniting by first intention. Continue the same treatment as yesterday.

The patient now continued to improve daily, with chloride of soda and creosote lotions, and an occasional application of the nitrate of silver. The ligature came away on the 28th of July. The pulsations of the artery, which, from the time of the operation, were forcible, from this time began to diminish, and now are scarcely perceptible. The wound was cicatrized, excepting about half an inch, on the 28th of August, at which time the accompanying drawing was taken.

---

NOTE.—The *left* arm is represented in the cut as having been amputated, instead of the *right*, by mistake of the artist in not reversing the drawing made from the daguerreotype from which it was copied.

