

**The diseases of the human teeth : their natural history and structure : with the mode of applying artificial teeth, etc., etc. / by Joseph Fox and Chapin A. Harris ; with two hundred and fifty illustrations.**

### **Contributors**

Fox, Joseph, 1776-1816.

Harris, Chapin A. 1806-1860.

Fox, Joseph, 1776-1816. Natural history and diseases of the human teeth.

National Library of Medicine (U.S.)

### **Publication/Creation**

Philadelphia : Lindsay and Blakiston, 1855.

### **Persistent URL**

<https://wellcomecollection.org/works/jdgquazk>

### **License and attribution**

This material has been provided by This material has been provided by the National Library of Medicine (U.S.), through the Medical Heritage Library. The original may be consulted at the National Library of Medicine (U.S.) where the originals may be consulted.

This work has been identified as being free of known restrictions under copyright law, including all related and neighbouring rights and is being made available under the Creative Commons, Public Domain Mark.

You can copy, modify, distribute and perform the work, even for commercial purposes, without asking permission.



Wellcome Collection  
183 Euston Road  
London NW1 2BE UK  
T +44 (0)20 7611 8722  
E [library@wellcomecollection.org](mailto:library@wellcomecollection.org)  
<https://wellcomecollection.org>





ARMY MEDICAL LIBRARY  
WASHINGTON  
Founded 1836



ANNEX

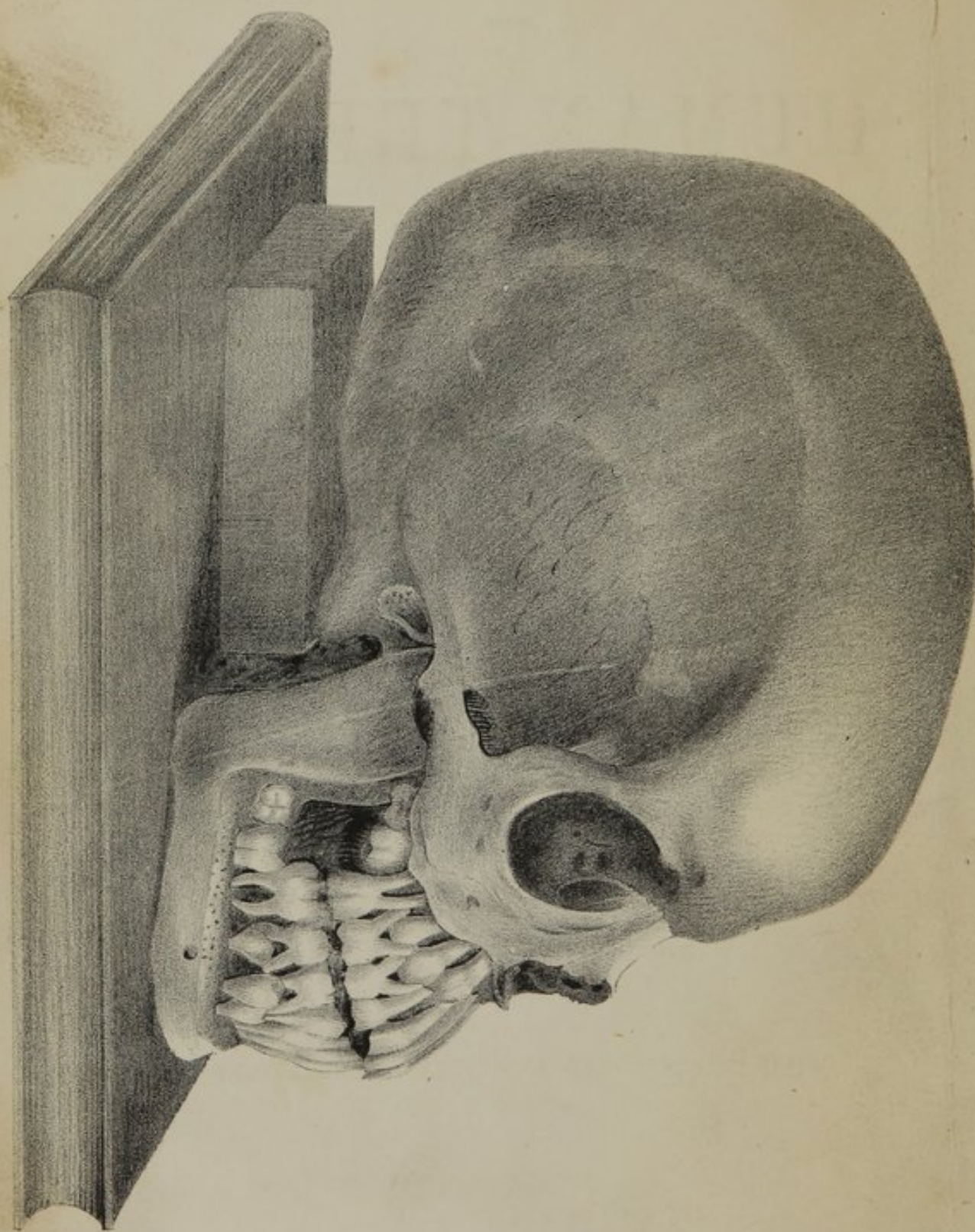
Section .....

Number 358562

DUE TWO WEEKS FROM LAST DATE

NOV 9 1964





THE  
DISEASES  
OF THE  
HUMAN TEETH:  
THEIR  
NATURAL HISTORY AND STRUCTURE,  
WITH THE  
MODE OF APPLYING ARTIFICIAL TEETH,  
ETC., ETC.

BY  
JOSEPH FOX,  
SURGEON DENTIST, LECTURER ON THE STRUCTURE AND DISEASES OF THE TEETH AT GUY'S HOSPITAL,  
ETC., ETC.

AND  
CHAPIN A. HARRIS, M.D., D.D.S.,  
PROFESSOR OF THE PRINCIPLES OF DENTAL SURGERY, IN THE BALTIMORE COLLEGE, AUTHOR OF  
PRINCIPLES AND PRACTICE OF DENTAL SURGERY, ETC., ETC.

WITH TWO HUNDRED AND FIFTY ILLUSTRATIONS.

---

PHILADELPHIA:  
LINDSAY AND BLAKISTON.  
1855.

1300



Ephe 43  
20

Anney  
WLI  
g F792n  
f 1855

5715

## P R E F A C E

### TO THE AMERICAN EDITION.

---

THE first complete edition of this Work was published in 1806; and, notwithstanding the rapid progress which Dental Surgery has made subsequently to that period, it still occupies a high place in the literature of this department of medicine. It has been more extensively quoted than any other Treatise upon the same subject, and has passed through three editions in England. The last of which was published in 1833. There is still, both in Europe and America, a steady demand for it.

The Author, during his professional career, enjoyed a high reputation as a practitioner of Dental Surgery; and for many years previously to his death was a lecturer on this branch of medicine in Guy's Hospital. Although he has passed from among the living, he has left behind him a memorial which will perpetuate his name to the latest period of time. Wherever, and so long, as this branch of Surgery shall be practiced by educated men, will the name of Fox be held in grateful remembrance.

In preparing the work for republication in this country, the editor has found it necessary to make numerous and



extensive additions, in order to adapt it to the present state of dental practice. These are designated [by brackets,] and are about equal to three-fourths of the original text. He has also added seven plates, remodeled the arrangement of the subjects, and placed over each an appropriate caption.

The English editions are divided into two parts. This has three. The last is devoted to artificial teeth, obturators and palates, and with the exception of four or five pages, consists of additions furnished by the editor.

Although it has been deemed necessary to change the arrangement of some of the subjects of the Treatise, the whole of the original text, with the exception of some ten or twelve pages, will be found in the present edition of the work. These were left out, because they related to treatment of affections of the teeth which at present is never adopted.

It will be found that the scope of the work has not been materially enlarged—the chief aim of the editor having been, to supply such details of subsequent improvements in practice, as the present state of the science and art seemed to demand. If the manner in which he has done this shall prove satisfactory to his professional brethren, his object will have been accomplished, and he will not regret having consented to assume the task.

CHAPIN A. HARRIS.

BALTIMORE, MD.

Jan. 1, 1846.

## P R E F A C E

TO THE THIRD LONDON EDITION.

---

SINCE the appearance of the Second Edition of this work, the profession have lost the personal services of its respected Author; but, notwithstanding twenty years have elapsed since he gave his last attention to the subject, it is the opinion of good authorities that neither alterations nor additions are required.

The importance of duly attending to the diseases of the teeth, and the motives which induced the Author to publish, cannot be better explained than by making the following reprint of his own preface.

“The operations of the living functions of all animal bodies having a constant tendency to consume the substance of which the general frame consists, a certain and regular provision is required for the repairs of those injuries which the body commits upon itself.

“Abundant supplies for the production of new corporeal matter exist, as articles of food, in the animal and vegetable kingdoms; and, by a bountiful Providence, are adapted to the taste and instincts of all his creatures.



But before these articles of food can become nutriment for the body, they must undergo certain processes. The first is, that whereby it is broken down into small particles, and, being mingled with the fluids of the mouth, is comminuted into a fine mass, and prepared for the action of the stomach, in the process of digestion.

“The teeth are the organs provided by nature for the mastication of food, which is an operation so essential to health, that without a due preparation of the aliments, the digestion must always be more or less deranged.

“The teeth which appear in the early part of life are adapted to the state of childhood; and at a certain period are succeeded by a second set, which are designed to continue during the remainder of life.

“The first, or temporary set of teeth, are very liable to become diseased; and in the majority of cases they do not naturally fall out in sufficient time to permit the second, or permanent, set of teeth to arrange themselves in their proper order.

“A knowledge of the changes which the teeth undergo, is a very interesting part of natural history, and is absolutely requisite to enable a practitioner in surgery to render such assistance during the progress of the second dentition, as may preserve the permanent teeth from being injured by the diseases of the temporary teeth; or, from acquiring that irregularity which always occasions so much deformity, and often destroys correct pronunciation.

“An attention to the appearance of the teeth;—a desire to preserve them in a healthy state;—and the necessity which exists of procuring relief when affected by disease, are sources of considerable occupation. In the metropolis and large towns, professional men, as dentists, are enabled to confine their practice to this department alone; but in those situations where surgeons are obliged to undertake medicine and surgery in all their branches, it is very necessary that they should be as well acquainted with the structure and diseases of the teeth, as of any other part of practice whatsoever.

“Mr. Hunter’s publication on the teeth was the first scientific book ever published upon this subject; and, as an anatomical work, must ever enjoy great celebrity; but not having practically devoted much of his attention to the operations upon the teeth, there can be no reflection upon Mr. Hunter’s merit in stating, that in many essential points he was wholly, but unavoidably, deficient; particularly in regard to the right management of the teeth during the second dentition.”

Further it appears that during the time the Author was engaged as a dresser with Mr. Cline, he found amongst the pupils of St. Thomas’ and Guy’s Hospitals a great desire to obtain particular information concerning the diseases of the teeth. Frequent conversation on these subjects, and descriptions of the modes of performing some operations, led to the delivery of a Course of Lectures on the Structure and Diseases of the Teeth. In this undertaking, much assistance was rendered by



Mr. (now Sir Astley) Cooper. The first Course was given in the Spring of 1799, after which they were continued as one of the Spring Courses of Lectures delivered at Guy's Hospital, and finally gave origin to the present work.

LONDON,  
Oct. 15, 1833.

## CONTENTS.

---

INTRODUCTION, . . . . .	21
-------------------------	----

### PART FIRST.

THE NATURAL HISTORY OF THE FORMATION AND STRUCTURE OF THE TEETH, &c. &c., . . . . .	27
--	----

#### CHAPTER FIRST.

OF THE FORMATION OF THE TEMPORARY TEETH, . . . . .	29
--	----

#### CHAPTER SECOND.

OF THE FORMATION OF THE PERMANENT TEETH, . . . . .	35
--	----

#### CHAPTER THIRD.

OF THE MANNER IN WHICH THE TEETH ARE FORMED, . . . . .	44
Manner of the formation of the Enamel, . . . . .	52
Arteries of the Teeth, . . . . .	59
Nerves of the Teeth, . . . . .	60
Absorbents of the Teeth, . . . . .	61
Articulation of the Teeth, . . . . .	62
Structure of the Teeth, . . . . .	ib.

#### CHAPTER FOURTH.

OF THE SHEDDING OF THE TEETH, . . . . .	66
---	----



## CHAPTER FIFTH.

OF THE IRREGULARITY OF THE TEETH, . . . . .	76
Accretion of the Jaws, . . . . .	78

## CHAPTER SIXTH.

OF THE TREATMENT TO PREVENT IRREGULARITY OF THE TEETH,	83
--	----

## CHAPTER SEVENTH.

OF THE TREATMENT TO REMEDY IRREGULARITY OF THE TEETH,	87
---	----

## CHAPTER EIGHTH.

OF SUPERNUMERARY TEETH, . . . . .	103
-----------------------------------	-----

## CHAPTER NINTH.

OF THE DECAY OF THE TEMPORARY TEETH, . . . . .	105
--	-----

## CHAPTER TENTH.

OF THE DISEASES WHICH ATTEND DENTITION, . . . . .	108
---	-----

## CHAPTER ELEVENTH.

THE ANALYSIS OF THE HUMAN TEETH, . . . . .	123
Analysis of the Enamel, . . . . .	125

## EXPLANATION OF PLATES TO PART FIRST.

Plate One, . . . . .	131
Plate Two, . . . . .	132
Plate Three, . . . . .	134
Plate Four, . . . . .	135
Plate Five, . . . . .	136
Plate Six, . . . . .	136
Plate Seven, . . . . .	137
Plate Eight, . . . . .	140
Plate Nine, . . . . .	141

# CONTENTS.

XV

Plate Ten, . . . . .	143
Plate Eleven, . . . . .	145
Plate Twelve, . . . . .	147
Plate Thirteen, . . . . .	148
Plate Fourteen, . . . . .	149
Plate Fifteen, . . . . .	150

## PART SECOND.

THE HISTORY AND TREATMENT OF THE DISEASES OF THE TEETH, GUMS, &c. &c., . . . . .	151
INTRODUCTION, . . . . .	153

### CHAPTER FIRST.

OF CARIES, . . . . .	157
Proximate Cause of Caries, . . . . .	160
Predisposing Cause of Caries, . . . . .	166
Prevention of Caries, . . . . .	172
Treatment of Caries, . . . . .	176

### CHAPTER SECOND.

OF FILING THE TEETH, . . . . .	179
--------------------------------	-----

### CHAPTER THIRD.

OF STOPPING THE TEETH, . . . . .	185
----------------------------------	-----

### CHAPTER FOURTH.

TOOTH-ACHE, . . . . .	197
Treatment of Tooth-Ache, . . . . .	198

### CHAPTER FIFTH.

OF THE EXTRACTION OF THE TEETH, . . . . .	209
Instruments Employed in the Operation, . . . . .	210
The Key Instrument, . . . . .	ib.



The Paces, . . . . .	212
The Perpendicular Extractor, . . . . .	213
Of the Forceps, . . . . .	ib.
Forceps for the Extraction of the Superior Incisores and Cuspidati, . . . . .	215
Forceps for the Extraction of the Superior Molares, . . . .	216
Forceps for the Extraction of the Superior Dentes Sapientiae, .	217
Forceps for the Extraction of the Bicuspidetes of both Jaws and the Inferior Cuspidati and Dentes Sapientiae, . . . .	ib.
Forceps for the Extraction of the Inferior Incisores, . . . .	218
Forceps for the Extraction of the Inferior Molares, . . . .	ib.
Manner of Extracting Teeth, . . . . .	219
Directions for the Extraction of the Incisores and Cuspidati, .	220
Directions for the Extraction of the Bicuspidetes and Molares, .	222
Directions for the Extraction of Roots of Teeth, . . . . .	229
Particular Directions for the use of the Key Instrument, . . .	233
Hemorrhage after Extraction, . . . . .	237

## CHAPTER SIXTH.

OF EXOSTOSIS OF THE FANGS OF THE TEETH, . . . . .	238
---	-----

## CHAPTER SEVENTH.

OF NECROSIS AFFECTING THE FANGS OF THE TEETH, . . . . .	245
---	-----

## CHAPTER EIGHTH.

OF THE DISEASE RESEMBLING SPINA-VENTOSA, . . . . .	247
--	-----

## CHAPTER NINTH.

OF THE REMOVAL OF THE ENAMEL BY THE DENUDING PROCESS, . . .	249
---	-----

## CHAPTER TENTH.

OF THE WEARING OF THE TEETH BY MASTICATION, . . . . .	252
---	-----

## CHAPTER ELEVENTH.

OF FRACTURES OF THE TEETH, . . . . .	254
--------------------------------------	-----

## CHAPTER TWELFTH.

OF THE DISEASES OF THE GUMS, . . . . .	260
Of the Scurvy in the Gums, . . . . .	261
Of Preternatural Growth of the Gums, . . . . .	265

## CHAPTER THIRTEENTH.

OF GUM-BOIL AND ABSCESS, . . . . .	275
------------------------------------	-----

## CHAPTER FOURTEENTH.

OF THE DISEASES OF THE ALVEOLAR PROCESSES, . . . . .	286
--	-----

## CHAPTER FIFTEENTH.

OF TARTAR (SALIVARY CALCULUS) OF THE TEETH, . . . . .	296
Analysis of the Tartar, . . . . .	302
Analysis, . . . . .	303

## CHAPTER SIXTEENTH.

OF SCALING (REMOVING THE TARTAR) OF THE TEETH, . . . . .	306
--	-----

## CHAPTER SEVENTEENTH.

OF THE EFFECTS OF MERCURY UPON THE TEETH, . . . . .	309
---	-----

## CHAPTER EIGHTEENTH.

OF THE DISEASES OF THE ANTRUM MAXILLARE, . . . . .	317
--	-----

## CHAPTER NINETEENTH.

OF LUXATION OF THE LOWER JAW, . . . . .	325
---	-----

## EXPLANATION OF PLATES TO PART SECOND.

Plate Sixteen, . . . . .	353
Plate Seventeen, . . . . .	337
Plate Eighteen, . . . . .	338
Plate Nineteen, . . . . .	339



Plate Twenty, . . . . .	340
Plate Twenty-one, . . . . .	341
Plate Twenty-two, . . . . .	342
Plate Twenty-three, . . . . .	343
Plate Twenty-four, . . . . .	344
Plate Twenty-five, . . . . .	345
Plate Twenty-six, . . . . .	346
Plate Twenty-seven, . . . . .	347
DISSECTION OF TUMOUR, . . . . .	349

## PART THIRD.

ARTIFICIAL TEETH, OBTURATORS AND PALATES, . . . .	351
---	-----

### CHAPTER FIRST.

ARTIFICIAL TEETH, . . . . .	353
-----------------------------	-----

### CHAPTER SECOND.

OF THE MANNER OF INSERTING A PIVOT TOOTH, . . . .	370
Manner of Preparing the Root, . . . . .	371
Of the Manner of Fitting and Attaching a Tooth to the Root, . . . .	376

### CHAPTER THIRD.

OF THE MANNER OF FITTING AND ADAPTING A PLATE, AND AT- TACHING CLASPS AND ARTIFICIAL TEETH TO IT, . . . .	380
Of the Manner of taking a Wax Impression, . . . . .	381
Of the Manner of obtaining a Plaster and Metallic Model and Counter Model, . . . . .	382
Of the manner of Fitting and Stamping a Plate and attaching Clasps to it, . . . . .	384
Of the manner of Fitting and Antagonizing the Teeth, at- taching them to the Plate, and finishing the work, . . . .	387

## CHAPTER FOURTH.

OF THE TEETH TO WHICH IT IS MOST PROPER TO APPLY CLASPS, AND THE MANNER OF COUNTERACTING THE INJURY LIABLE TO RESULT FROM SUCH APPLICATION, . . . . .	395
---	-----

## CHAPTER FIFTH.

OF THE CONSTRUCTION OF A DOUBLE SET OF ARTIFICIAL TEETH MOUNTED ON PLATES WITH SPIRAL SPRINGS, . . . . .	399
---	-----

## CHAPTER SIXTH.

OF THE CONSTRUCTION OF PLATES FOR ARTIFICIAL TEETH IN PARTICULAR CASES, . . . . .	404
--	-----

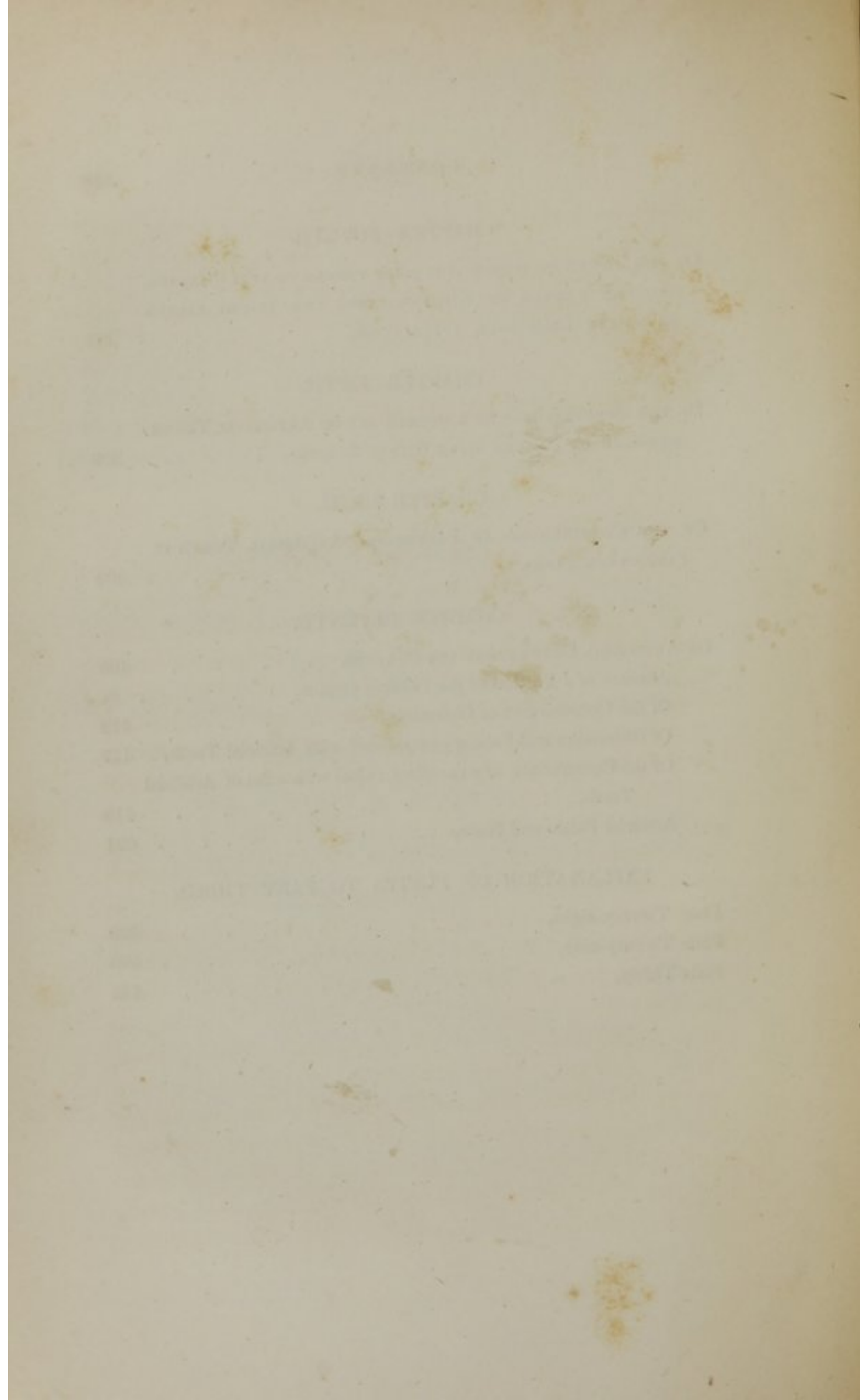
## CHAPTER SEVENTH.

OF ARTIFICIAL OBTURATORS AND PALATES, . . . . .	408
Absence of a Portion of the Palatine Organs, . . . . .	ib.
Of the Construction of Obturators, . . . . .	412
Of Obturators and Palates complicated with Artificial Teeth, . . . . .	417
Of the Construction of a complete Palate with a Set of Artificial Teeth, . . . . .	419
Artificial Palate and Nose, . . . . .	421

## EXPLANATION OF PLATES TO PART THIRD.

Plate Twenty-eight, . . . . .	429
Plate Twenty-nine, . . . . .	430
Plate Thirty, . . . . .	431





## INTRODUCTION BY THE EDITOR.

---

THE teeth are not only among the most useful and important organs of the human body, but they are also among the most ornamental. They play an important part in the animal economy, and form an essential portion of the organism of man—contributing, when sound, to the health of the whole body, and when diseased, to the impairment of many, and often of all its functional operations. Planted deeply in the alveolar border of each jaw, they are important both in an anatomical and in a physiological point of view. They sustain, through the medium of the fifth pair of nerves, an intimate relation with the brain and whole nervous system, as well as with all the parts dependent on them. They are the prime organs of mastication—an operation which constitutes the first stage of digestion, and which, if improperly performed, necessarily vitiates the whole process of assimilation. They contribute too, in an eminent degree, to distinct enunciation, and by preventing the jaws from coming together, they give rotundity and symmetry to the face. Therefore, in whatever light they may be viewed, they are of priceless importance to the well-being and comfort of every individual.



But notwithstanding the value and importance of the teeth, they, like other parts of the body, are liable to disease, and are often destroyed by it at a very early period of life. Unlike other parts of the body, however, these organs are not endowed with recuperative powers. When attacked by disease, art only can stop its progress, and repair the injury which it has inflicted; and happily her resources, when applied in time, have been found amply sufficient, both for the one and the other. Skilful, however, must be the hand, and perfect the knowledge of the operator, who deals with organs, the diseases of which can only be arrested by mechanical means; and, it is greatly to be regretted, that so few of the practitioners of dental surgery, possess these indispensable qualifications. The numerous unsuccessful operations on the teeth, daily performed, and the lasting, and often irreparable injury resulting therefrom, are all attributable to the want of a sufficiently thorough, theoretical and practical knowledge of this branch of the curative art.

But the treatment of the diseases of the teeth and the replacement of their loss with artificial substitutes, do not comprise all the duties of the surgeon dentist. The treatment of the various affections of the gums, alveolar processes, and their contiguous parts, as well as the management of second dentition, when effected in a faulty or improper manner, and the correction of irregularity in the arrangement of these organs, all come legitimately within his province. He therefore who would be a successful practitioner of the dental branch of medicine, should not only be thoroughly skilled in the various mechanical manipulations which belong to it, but he should also have a knowledge of anatomy, physiology, pathology, and the therapeutical indications of disease



generally. Without this knowledge, no one should take upon himself the responsibility of practising the profession, and to obtain it, requires much time and close and persevering application. Neither mechanical ability nor the highest medical attainments, nor both combined, without a thorough knowledge of the diseases of the dental apparatus and their treatment, can make a skilful practitioner of this branch of the healing art.

That any one, therefore, should be guilty of the egregious folly of committing the treatment of the diseases of organs so valuable as the teeth, to an individual totally destitute of all qualifications, and having no other claim to skill in their management, than the mere assumption of the name of dentist, is almost incredible; and yet it is done every day, and by persons who would not think of putting a watch, or any common jewelry for repair into the hands of a man not known to be well skilled in such matters. Such inconsistency, might seem paradoxical, if it were not constantly observed in individuals moving in the most learned and polished walks of society, and manifesting in most matters great prudence, shrewdness and judgment. But this is not so culpable in others, when medical men, eminent for erudition and skill in their profession, have been known to employ and recommend practitioners of this description. Thus encouraged they have multiplied with most astonishing rapidity, and if it were not that some men of education, talent and ingenuity are engaged in this field of practice, they would, long before now, have destroyed all confidence in the alleviatory resources of the profession. But thanks to the efforts and unwearied labour of such men, notwithstanding the multiplication of empirics, the progress of the science and art of dental surgery has been rapid; it has outstripped the most ardent flights of imagi-



nation, and has already attained a degree of excellence, which a few years ago was supposed impossible.

The importance of a higher standard of qualification for practitioners in this department is beginning to be felt every where, and it is gratifying to perceive that efforts are now making for the accomplishment of this important object. That it has not been previously done, is not at all surprising, for until recently, the practice had not assumed the importance it now possesses, nor had any public or ample private facilities been furnished for the acquisition of a thorough and comprehensive knowledge of the art. Therefore, it was only by the application of rare abilities and the most untiring efforts, that those who have attained to eminence and skill in it, were enabled to do so.

But the dawn of a brighter day has begun. Ample facilities are now furnished by the Baltimore and Cincinnati Colleges of Dental Surgery, for obtaining a thorough medico-dental education. The former was chartered by the Legislature of Maryland in 1840, and has been in successful operation five years; the latter was chartered about twelve months since, by the Legislature of Ohio, and commenced operation in November last.

The advantages of collegiate over private instruction are as great in dental surgery as they are in medicine and general surgery. Few private teachers are provided with the means and necessary facilities for imparting a thorough knowledge of the various branches that should enter into the professional education of an accomplished dentist, and most of those who commenced practice with no other information upon the subject, than that which they obtained from private instructors, did so with exceedingly limited qualifications, and soon found that they had still much to learn.

The study of dental surgery is now invested with peculiar interest. A revolution has commenced in the ranks of the profession, which must before long result in an entire change in the character of the pursuit and its relation to the liberal sciences. The number of educated men engaged in it is rapidly increasing, and they are uniting their energies to accomplish this change.

They have already done much toward effecting it, and the result of their past labours encourages, nay warrants, the belief that the day is not distant, when none but men capable of practising the art upon scientific principles, and of enriching it by the result of enlightened observation and critical research, shall be permitted to exercise its duties. Then, and not till then, will the malign influence of dental empiricism cease, and the sanitary and restorative resources of this branch of medicine be properly appreciated and acknowledged.





# PART I.

---

THE HISTORY OF THE FORMATION AND STRUCTURE OF THE  
TEETH.

THE SYMPTOMATIC DISEASES INCIDENTAL TO THE FIRST  
DENTITION.

THE CHANGES WHICH TAKE PLACE DURING THE SECOND  
DENTITION;

AND

THE TREATMENT TO PREVENT AND REMEDY IRREGULARITIES  
IN THE ARRANGEMENT OF THE TEETH.



## PART I.

THE HISTORY OF THE FORMER AND PRESENT STATE OF THE

THE FORMER AND PRESENT STATE OF THE

THE FORMER AND PRESENT STATE OF THE

THE FORMER AND PRESENT STATE OF THE

THE FORMER AND PRESENT STATE OF THE

## PART FIRST.

---

### CHAPTER FIRST.

#### OF THE FORMATION OF THE TEMPORARY SET OF TEETH.

WHEN the fœtus has advanced so far in the organization of its different parts, as to take some determinate form or figure, we may perceive a considerable progress in the preparatory steps for the formation of the teeth.

As soon as the ossific deposit commences in the cartilaginous parts of the embryo, both jaws are filled with small membranous sacs; and, in the anterior parts, we may perceive the rudiments of alveolar processes.

In a fœtus of about four months, the jaw bones are distinctly formed; but at this time they only consist of thin grooved bones, having a cavity extending through their whole length.\* In the under jaw, anteriorly, this cavity is narrower and deeper; but, posteriorly, it becomes wider and more shallow. At this time, if the membranous parts be removed, small processes of bone may be perceived shooting across from each side; which as

\*The description of what takes place in one jaw, will completely exhibit what concerns the formation of the teeth in both; therefore, in order to avoid confusion, I shall refer to the under jaw only.

the fœtus increases in growth, gradually acquire more distinctness, and at length form separate sockets for the teeth.\*

During the fœtal state, and also for some months after birth, the blood vessels and nerves belonging to the teeth, run along at the bottom of this cavity, immediately below the pulps of the teeth; but afterwards a distinct canal is formed, through which the principal vessels and nerves pass; separate filaments being sent off to the several teeth.

When the gum which covers the alveolar groove of a fœtus of the age above-mentioned, is stript off from the bone, small processes or elongations from the inner surface of the gums may be distinctly perceived; these are the first appearances of the pulps from which the teeth are formed.†

The alveolar processes soon become perfectly distinct; for, the bony partitions which divide the longitudinal cavity in the jaw, rise to the upper margin; and thus those membranous processes, now enlarged and become more evolved, begin to be contained in separate cells.‡

In a fœtus of about four months old, the rudiments of the teeth may be very distinctly seen; upon examining those substances found in the jaws, they are seen to be soft, or pulpy bodies, bearing a resemblance to the figure of the body of the tooth to be formed, and each of them is contained in a membrane proper to itself.||

For some time during the formation of the teeth, the alveoli grow much faster than the teeth themselves, which are consequently but loosely contained within them. At the time of birth, the alveolar processes have increased so much, that they almost enclose or cover the teeth; thus a firm support is given to the gums, and the infant is enabled to make considerable pressure in sucking, &c.

\* Plate I. Fig. 1.

† Plate I. Fig. 2.

‡ Plate I. Fig. 3, 5.

|| Plate I. Fig. 4.



without injury to the progress which is going on underneath.

The ossification of the teeth begins to take place very early; it is first visible upon the tips of the incisores. In a fœtus of about five or six months, ossification has commenced upon the pulps of the incisores and cuspidati, and on the points of the molares; this gradually advances and extends itself, over the pulp, down to the neck of the tooth, from the cutting edges or highest points, where it had first commenced.

At the time of birth, the bodies of ten teeth are distinctly formed in each jaw; these are the teeth designed to serve during the years of childhood, and are commonly called the temporary, shedding, or milk teeth.\*

These temporary teeth, which constitute the first set, are twenty in number, and are divided into three classes, incisores, cuspidati and molares. In each jaw there are four incisores, two cuspidati, and four molares, and the teeth on one side of the mouth correspond in figure with those of the other, so that they are situated in pairs.

Besides these twenty teeth, there are in a very early stage of their formation, the rudiments of some other teeth, which are to form part of the permanent or adult set.†

[At birth, the jaws contain the rudiments of fifty-two teeth—twenty temporary and thirty-two permanent.]

After birth, as the ossification goes on, the teeth become too long to be contained within the alveolar cavity, they therefore begin to make pressure upon those parts which cover them; this produces the process of absorption, which proceeds with the enlargement of the tooth, first removing the membranes which enveloped the teeth, and afterwards the thick gum which covered them, this

\* Plate II. Fig. 1.

† Plate II. Fig. 1. A. B.

gradually becoming thinner and thinner, till at length the teeth are suffered to pass through.

There is considerable variety as to the precise time when the teeth begin to make their appearance. This frequently seems to depend upon the health and vigour of the child: for sometimes the first tooth comes as early as four or five months, while on the contrary, in those of more delicate and weakly constitutions, no tooth makes its appearance until the child is ten or twelve months old; and it is not very uncommon for a child to be turned of fourteen months before any tooth appears.

It may be expected that the formation of the teeth will go on more rapidly in the healthy, and proceed more slowly in the weak and delicate: Yet there are exceptions to this, for often the teeth seem not to be influenced by any state of health. Those of a weakly child will sometimes arise in rapid succession, while those of one more robust will often come forward but slowly.

In general, children begin to have their teeth about the sixth, seventh, or eighth month after birth;\* those which correspond with each other generally appearing about the same time, first in the under jaw, and then in the upper.

The following is the order in which the teeth of a child

\* Sometimes a child is born having one or two teeth; these are generally the central incisores of the under jaw: In such cases the socket for the forming tooth has not been sufficiently deep, and therefore the tooth has passed through the gum prematurely. These early productions are only the upper parts or crowns of teeth, no fangs having yet been formed. And as they have only a weak attachment to the gums, they soon get loose, producing a considerable inflammation in the mouth of the child, as well as occasioning inconvenience to the mother. It is therefore advisable to extract them immediately, for they can never come to perfection.

[If teeth, which appear through the gums at birth, had as the author asserts, always a weak attachment, and soon get loose, it would be proper to adopt the practice which he recommends. But having met with cases where they were firmly articulated, and were productive of no unpleasant effects, I cannot join with him in recommending their immediate removal; this operation should only be resorted to when they give rise to irritation of the gums.]



generally appear.—The first teeth are the central incisores of the under jaw, one generally coming a few days before the other; then, in the course of a month, the two central incisores of the upper jaw. These are succeeded in a few weeks by the lateral incisores of the under jaw, and then soon after by the lateral incisores of the upper jaw. The cuspidati are generally slower in completing their growth than the molares, they are placed deeper in the jaw, and therefore are preceded by the first molares. The small molares of the under jaw usually come before those of the upper; they commonly appear about the fourteenth or sixteenth month, and are soon met by those of the upper jaw. After these, the cuspidati come through, first in the lower jaw, and then in the upper. At some time between two years and two years and half, the second molares make their appearance, and thus complete the temporary set of teeth.\*

The obtaining of the temporary teeth usually occupies a child from about the sixth or eighth month until between two or three years of age. The teeth most commonly follow the order above-mentioned; but this is not always to be expected: there are often great irregularities; sometimes the upper teeth appear before the under; now and then the lateral incisores precede the central. I once saw an instance of the first molares of the under jaw appearing before the lateral incisores; and sometimes more teeth come about the same time than ought naturally to be expected. These cases of irregular succession of the teeth are often attended with considerable derangement of health, and alarming symptoms of irritation.

[The periods for the eruption of the temporary teeth are stated by Mr. Thomas Bell, to be, for the four central incisores, from the fifth to the eighth month; for the four

\* Plate II. Fig. 2, 3, 4.

lateral, from the seventh to the tenth; for the four anterior molares, from the twelfth to the sixteenth; for the cuspidati, from the fourteenth to the twentieth; and for the posterior molares, from the eighteenth to the twentieth. I am however of the opinion, that he is somewhat in error with regard to that of the last. The second temporary molares seldom appear before the twenty-fourth month.]



## CHAPTER SECOND.

### OF THE FORMATION OF THE PERMANENT SET OF TEETH.

IN the management of the teeth of children, it is highly necessary that the surgeon should have a perfect knowledge of the order in which the teeth of the permanent set are formed, and of the time when each tooth is expected to pass through the gums.

The formation and perfection of this set of teeth, occupy a very important portion of our limited existence; no less than twenty years, and often more, being necessary for their complete evolution. Nature begins to attend to the production of these permanent instruments of mastication, even before birth, and in many instances, they are not wholly completed before the twenty-fifth, or thirtieth year.

The permanent set of teeth vary much from the temporary set, some of the teeth being much larger, and others differing much in figure; they are in number thirty-two, and therefore consist of twelve teeth more than the temporary set.

This set of teeth may be divided into two distinct classes; those which are to succeed the temporary, and those which are superadded; the formation of both these divisions begins nearly about the same time, and the progress furnishes one of the most curious changes the animal frame can exhibit.—The incisores and cuspidati of

the child are succeeded by teeth similar in form, but larger in size, and they have the same appellation; but the teeth, which take the places of the temporary molares, are much smaller, and being divided at their grinding surfaces into two points, are called bicuspidates. The molares of the adult are the teeth which are superadded, and these succeed one another as the jaws advance in growth.\*

The teeth of the adult are divided into four classes: incisores, cuspidati, bicuspidates, and molares.

The teeth differ very much in the figure of their bodies, and in the number and shape of their fangs. The cuspidati are of a middle nature between the incisores and the bicuspidates; as are the latter between the cuspidati and the molares.

The incisores, or cutting teeth, are situated in the anterior part of the jaw, and form the front of the mouth. In each jaw they are four in number, and are so placed, that the two central stand somewhat more advanced than the lateral.

The bodies of the incisores are broad, and rather flat. The anterior surface is convex, the posterior concave; they both go off from the neck of the tooth somewhat sloping: the two surfaces terminate in a cutting edge, which is placed in a direct line with the apex of the fang. When viewed in front, the cutting edge is seen to be the broadest part of the tooth, but gradually becomes smaller as we approach to the neck. When viewed laterally, the cutting edge is the thinnest, and the tooth, to the neck of it, increases in thickness. This gives to the body of the tooth the form of a wedge, which is its true office, it being used to cut or divide soft substances.

The enamel is continued farther, and is thicker on the



anterior and posterior surfaces than on the sides; it is even thicker on the fore part than on the back part of the tooth. The fangs are conical, and are shorter than those of the cuspidati.

In the upper jaw, the central incisores are much broader and larger than the lateral; in the lower jaw they are all nearly of the same size, but much smaller than those of the upper jaw.

The cuspidati are four in number, one of them being placed on the outer side of each of the lateral incisores.

The shape of the crown of a cuspidatus is like that of an incisor, with its corners rubbed off, so as to end in a point, instead of a broad edge. The fang is thicker and larger, and is more depressed at the sides, which causes it to appear considerably broader, when viewed laterally, than when seen in front. The fang, which is the largest of any of the teeth, may be felt with the finger, running up a considerable length, and projecting beyond those of the other teeth.

The cuspidati of the lower jaw very much resemble those of the upper, both in figure and in length. The enamel covers more of the lateral parts of these teeth than of the incisores: When they are first formed they are pointed, but by the friction of each upon the other in mastication, they become rounded, and sometimes acquire a flat edge.

The use of the cuspidati is not like that of the incisores, to cut and divide substances, nor like the molares for mastication; but they are similar to the canine teeth of carnivorous animals, and seem to be designed for the laying hold of and tearing of substances.

The bicuspidates are situated immediately behind the cuspidati. They were formerly called the first and second grinders, but as they do not possess the true figure

of grinders, and only have an intermediate resemblance between those teeth and the cuspidati, Mr. Hunter considered them as a particular class.

These teeth are very much like each other, and when viewed as they are situated in the mouth, are not unlike the cuspidati. They are eight in number; those belonging to the upper jaw have the body divided into two points, one external, the other internal. Their fangs appear as if compressed at the sides, and resemble two fangs united, with a depression running between them: commonly the first bicuspid has two small fangs, the second has seldom more than one; but in this they are subject to variety.

[The editor has several superior bicuspides in his anatomical cabinet; each of which has three fangs.]

The bicuspides of the under jaw are smaller than those of the upper; the points upon their surfaces are not so distinct, and they have only one fang. The enamel is distributed nearly equally around the crown, and they stand in the jaw almost perpendicularly, but have a slight inclination inwards.

The molares, or grinders, are placed behind the bicuspides; there are three on each side of the jaw, making twelve in the whole. The first and second molares are so much alike in every particular, that the description of one will convey a perfect idea of the other. The third grinder has several peculiarities, and therefore must be described separately. The molares are the largest teeth; they have a broad base, furnished with several points, which fits them for their office in grinding of food, and they have several fangs.

The molares of the under jaw have an inclination inwards, while those of the upper jaw are placed nearly perpendicularly with respect to the jaw.



The upper grinders have commonly three fangs, two situated on the outer part of the tooth, and one on the inner; the inner fang is very oblique in its direction, and is larger and rounder than the others. Those of the under jaw have two fangs, one placed forwards, the other backwards; they are rather flat, and continue broad all down their length.

Sometimes molares of the upper jaw are met with having four distinct fangs.\* I have one with five fangs, which is the only one I ever saw.† The molares of the under jaw now and then have three fangs.‡

The third molaris is called *dens sapientiæ*; it is smaller than the others, its body is rather rounder, and the fangs are not so regular and distinct: they often appear as if squeezed together, and sometimes there is but one fang. The *dentes sapientiæ* of the lower jaw often have their fangs curved, and sometimes they are so much inclined inwards, as scarcely to rise above the ridge of the coronoid process.

The incisores of the upper jaw being much broader than the same teeth in the under jaw, cause the other teeth to be placed farther back in the circle than the corresponding teeth of the lower jaw; hence in a well-formed mouth, when the teeth are shut close, the central incisores of the upper jaw come over the central and half of the lateral incisores of the lower jaw: The lateral incisor of the upper jaw covers the half of the lateral incisor, and more than half of the cuspidatus of the under jaw. The cuspidatus of the upper jaw falls between and projects a little over the cuspidatus and first bicuspid of the under jaw. The first bicuspid of the upper jaw falls partly upon the two bicuspides in the lower jaw: The second bicuspid shuts upon the second bicuspid and the first molaris:

\* Plate IX. Fig 11.

† Fig. 13.

‡ Fig. 6.



The first upper molaris covers two-thirds of the first and part of the second molaris of the under jaw: The second upper molaris shuts upon the remainder of the second and part of the third; and the third molaris of the upper jaw, being smaller than that in the under jaw, shuts even upon it.\*

From this mechanism of the teeth their power in mastication is increased, and if one tooth be extracted, the antagonist tooth does not become useless, since it can in part act upon another.

[When this is not the case, as often happens, it becomes elongated, or is gradually forced from its socket by a deposition of bony matter at the bottom of the alveolus; and from this it would seem, that when a tooth has lost its antagonist, it becomes, in some degree, obnoxious to the system, and an effort is made by the economy to expel it from the jaw. In accordance with this indication of nature, Dr. Koecker recommends the removal of such teeth. But as this tendency can in many cases, by constant attention to the cleanliness of the tooth, be measurably counteracted, the operation should be resorted to only in those cases where it is absolutely required.]

The permanent incisores and cuspidati are formed behind the temporary incisores and cuspidati; the bicuspidates underneath the temporary molares, and they are contained in sockets of their own.

The molares are, one after the other, formed in particular parts of the jaws: In the upper jaw, that posterior part called the tubercle, is the place for the formation of the upper molares; and the molares of the under jaw are formed in that part situated beneath the coronoid process, one succeeding the other, as the jaws in their growth carry the teeth forwards.

\* Plate VIII. Fig. 1.

Those teeth of the permanent set which first begin to be formed are the anterior molares, the pulps of which may be found in a fœtus a short time previous to birth, when they are situated quite at the posterior parts of the jaws. At the time of birth ossification has commenced upon their highest points; at this time also, on examining the membranes of the temporary incisores, small membranous sacs, containing a jelly-like substance, will be found attached to them at the posterior and upper part. These are the early rudiments of the permanent molares; ossification commences upon their tips soon after birth, but always first in the lower jaw.

When an infant has cut the central incisores of the upper jaw, and the four incisores of the under jaw, a considerable progress has been made in the ossification of the permanent incisores and first molares; in the under jaw it has begun on the points of the cuspidati, and in the upper jaw, pulps for cuspidati have become distinct, the ossification of which usually commences when a child is aged about sixteen months.\*

Between two and three years, when all the temporary teeth have appeared through the gums, the size of those permanent teeth already mentioned is much increased, and ossification has commenced upon the points of the bicuspidates of the under jaw.†

After this time the teeth very much alter their position: At first the permanent teeth are contained in the same sockets as the temporary; but as the formation of both sets advances, the permanent teeth, by the growth of the alveolar processes, become placed in a kind of niche; there is also a small bony process, shooting across the bottom of the common socket, which gradually increases, till at length nearly a complete separation is produced,

\* Plate II. Fig. 2 and 3.

† Plate II. Fig. 4.



and the permanent teeth are contained in sockets of their own. This may be very well observed in the head of a child of about four years of age; at this time the jaws have become deeper, in consequence of the complete formation of the temporary teeth and their alveolar processes, and the permanent set may be presented to view, upon removing the external plate of the jaws.\*

About this age the ossification of the incisores, cuspidati, first bicuspidēs, and first molares, is much advanced, some progress has been made in the formation of the second molares, and soon after, the ossification of the second bicuspidēs commences.

At about six years of age those teeth designed to succeed the temporary ones, and the first and second molares, are in considerable forwardness, and if none of the temporary teeth have yet been removed, there are at this time in the head, forty-eight teeth, twenty in situ, and within the jaws beneath the gums, in the progress of formation, twenty-eight.†

In the eighth or ninth year the formation of the third molares, or *dentes sapientiæ* begins, by this time some of the front teeth have been shed, and all the others are much advanced in growth.‡

[The rudiments of the *dentes sapientiæ* have been discovered at birth, but at this period they exist only as *mucus papillæ*.]

The permanent incisores and cuspidati, during their formation, are all situated on the inner side of the temporary teeth, consequently they are contained within the segment of a circle, smaller than that which holds the temporary teeth; they are also much larger, and therefore very much crowded and forced into irregular order. The lateral incisores are placed sometimes crossways, and

\* Plate III.

† Plate IV.

‡ Plate V.

always behind, in the space between the central incisores and cuspidati. In the upper jaw the cuspidati are placed so high as only to be just underneath the suborbital process, and in the lower jaw they are placed almost as deep as the under margin.

This description which has been given of the progressive steps taken by nature in the formation of the teeth, may not exactly agree with that given by some respectable writers. Into Mr. Hunter's treatise, for want of closer attention, many inaccuracies have been suffered to creep. Besides, descriptions of this kind are liable to disagree, because the formation of teeth in children of the same age may be in a more or less advanced state. But from various preparations and observations I have made, the above is the order in which the formation generally takes place.



## CHAPTER THIRD.

### OF THE MANNER IN WHICH THE TEETH ARE FORMED.

THE teeth are formed in a manner peculiar to themselves, differing from the mode observed in the formation of bones in general; instead of having for their basis cartilage or membranous substance, as the cylindrical and flat bones have, they are formed from a soft pulpy substance, which possesses the shape of the body of the tooth to be produced.

[The pulp of a tooth, according to Mr. Nasmyth, is of a cellular structure, having the aspect when examined under a microscope, of small vesicles—varying in size from the smallest perceptible microscopic appearance, to an eighth of an inch in diameter. These are arranged in layers “throughout the body of the pulp.” When macerated, these layers, says Mr. N. “present an irregular reticular appearance,” and are “interspersed with granules.”]

Each pulp is covered by a membrane strongly attached to the gum, and to the pulp at its base, so that the pulp at its edge is loosely contained within the membrane, which is only reflected over it; at the base the pulp is weakly connected with the alveolar cavity in the jaw.

When a jaw has been minutely injected, we find that the pulps are vascular, and also the membranes by which they are enveloped. These membranes may with care

be separated into two lamellæ, the external of which is rather of a loose and spongy texture, and possessed of vascularity; the internal lamella is more smooth, and is also vascular: the membranes derive their vessels from their gums, and the pulps receive theirs from the artery which passes through the jaw.

Some preparations, in the injection of which I have very happily succeeded, fully warrant the above statement in all its variations from those of Mr. Hunter or Dr. Blake the author of an inaugural dissertation, published in Edinburg in 1798, containing many excellent physiological remarks on the formation of the teeth. Mr. Hunter observes, that the external membrane is soft and spongy, without vessels, the other much firmer, and extremely vascular. Dr. Blake says, "they (the membranes) can easily be separated into two lamellæ, the external of which is spongy and full of vessels; the internal one is more tender and delicate, and seems to contain no vessels capable of conveying red blood." In several preparations which are minutely injected, taken from the human subject, and also from the fœtal calf, I have found both the lamellæ to be very vascular.\*

The manner in which the permanent teeth derive their origin, was never properly understood until described by Dr. Blake, and is a discovery which shews very accurate observation.

[The supposed discovery of Dr. Blake with regard to the manner of the formation of the permanent teeth, is said to have been made twenty years before, by a French dentist by the name of Herbert.]

When the rudiments of the temporary teeth are somewhat advanced, a new sac is given off at the upper and posterior part of their membranes. These sacs are at

\* Plate X. Fig. 1, 2, 3, 4.



first contained in the same socket, and are so intimately connected with the membranes of the temporary teeth, that they cannot be separated without tearing one or both.\* As the sacs of the permanent teeth advance, the sockets of the temporary ones become enlarged, and little niches are formed in the internal plate of the alveolar processes; these increase in proportion with the size of the permanent sacs, and gradually form a distinct socket round each of them.

There is however an opening left immediately under the gum, through which the membranes of both sets of teeth continue to be connected.† When the temporary teeth have risen in the socket, the membranes are much elongated, and remain attached to the gum at the neck of the tooth, small foramina being left in the jaw for them to pass through; thus they continue to derive their vessels from the gums.‡

The second and third permanent molares are in like manner formed from the first: a small process or sac is sent off posteriorly, which is at first contained in the same socket as the pulp of the first molaris; by degrees a new socket is formed in which the pulp of the second molaris becomes perfect: this then sends off another process, which forms the third molaris.||

[The recent researches of ARNOLD and GOODSIR have thrown much new and valuable light on the manner of the formation of the teeth. Their progress, almost from the moment of their appearance, as simple mucous papillæ, until the completion of both sets, has been minutely and accurately traced, by the last named gentleman, and his observations go to prove many of the views of Dr. Blake upon this subject to be incorrect.§

\* Plate X. Fig. 5.

† Fig. 10.

‡ Fig. 6.

|| Fig. 9.

§ Vide Edinburg Medical and Surgical Journal for January, 1839.



Without entering into a minute or detailed description of the result of the researches of Mr. Goodsir, it will be sufficient to state, that the formation of the temporary teeth, commences as early as the seventh week after conception. At this period, the germ of the first temporary molaris of the upper jaw, may be seen rising up from the mucous membrane lining the floor, of what he denominates the *primitive dental groove*, in the form of a "simple free granular papilla," of an "ovoidal" shape—"the long diameter of which is antero-posterior." Another papilla, of a rounded and granular form, between the "middle and anterior" curve of the jaw, on the floor of the same groove, is observable about the eighth week. This is the rudiment of the temporary cuspidatus. The germs of the incisores—the central first and then the lateral, make their appearance in the form of mucous papillæ, during the ninth week. During the tenth week, the sides of the groove before and behind the first molar papilla, gradually approach each other, sending off processes from each side, which meet, and enclose it in a follicle. A similar follicle, in the mean time, is gradually forming around the germ of the cuspidatus. The papilla of the second temporary molaris, makes its appearance during the latter part of the tenth week.

The incisor follicles are formed during the eleventh and twelfth weeks, and during the thirteenth week, a follicle is formed for the papilla of the second temporary molaris. Each papilla now begins to assume a particular shape, the incisores that of the 'future teeth,' the cuspidati that of 'simple cones,' the molares 'become flattened transversely.' About this time, the papillæ begin to grow faster than the follicles, and soon protrude from their mouths. The depth of the follicles varies to correspond with the length of the fangs of the future teeth; and their



mouths as they become more developed, are formed into opercula, which, in some measure, correspond with the crowns of the future teeth. The incisor follicles have two opercula—one anterior and one posterior—the first larger than the latter; the follicles which contain the cuspidati papillæ, have three—one external and two internal, and the molar follicles, as many as there are tubercles on the masticating surfaces of these teeth.

During the fourteenth week, the lips of the primitive dental groove meet in a valvular manner, giving to the papillæ the appearance of having receded back into the follicles, in which they are nearly hid by the closing of the opercula.


The germs and follicles of the lower teeth do not appear quite so soon as those of the upper, but in every other respect the manner of their formation and their progress are almost precisely similar.

At about the last mentioned period, provision is made for the production of the teeth of replacement, consisting in the formation of a crescent-shaped depression, immediately behind the inner opercula of each follicle—first of the central incisores, next of the lateral, then of the cuspidati, and lastly of the first and second molares. These crescent-shaped depressions, are soon formed into what Mr. Goodsir calls "*cavities of reserve*," and from which the sacs and pulps of the ten anterior permanent teeth are produced.

The primitive dental groove has by this time attained a higher level, and is now very properly denominated, by Mr. Goodsir, the secondary *dental groove*. It has now extended itself back of the second temporary molaris, and from the floor of which, about the sixteenth or seventeenth week, the papilla and follicle of the first permanent molaris begins to be developed.

As the papillæ of the temporary teeth increase in size, they gradually assume the shape of the teeth they are respectively destined to form. The pulps of the upper molares are perforated by three canals, which penetrate to their centres, and the lower by two. The primary base is divided into an equal number of secondary bases. From these, the roots of the future teeth are formed. The sacs of the teeth now grow more rapidly than the pulps, so that a space is formed between them. There is deposited in this, a gelatinous granular substance. This, at first, is small in quantity, and adheres only to the proximal surfaces of the sacs, but about the fifth month, it becomes closely and intimately attached to the whole of the interior of these organs, except for a small space of equal breadth, all around the base of the pulps, and as these become perforated by the canals just mentioned, the granular matter sends processes into them, which adhering, reserve the narrow space described above, between themselves and the secondary bases. These processes of granular matter disappear near the point of junction of the canals which enter the pulp. The granular matter does not adhere to the pulps, but is accurately moulded to all their depressions and prominences.

The cavities of reserve gradually recede and assume a position behind the temporary teeth, and about the fifth month the distal extremities of the anterior ones begin to distend, and give rise to the germs of the replacing teeth, which soon acquire the appearance of dental pulps. About a month later, bony septa are thrown across the alveolar groove, and niches formed in the posterior walls of the alveoli for the sacs of the permanent teeth. Up to the eighth, and sometimes even up to the ninth month, the sacs of the permanent molares are embedded in the





maxillary tuberosity. In the formation of the roots of the temporary incisores, "three cotemporaneous actions," says Mr. Goodsir, "are employed, viz: the lengthening of the pulp; the deposition of tooth substance upon it; and the adhesion to the latter of that portion of the inner sac which is opposite to it." The sacs of the permanent teeth continue to recede during the advance of the temporary teeth and "their sockets to their perfect state," and to "insinuate themselves" "between the sacs of the former" until "they are only connected by their proximal extremities" through the alveolo-dental canals or *itineraria dentium*, as they are termed by M. Delabarre.

From the foregoing brief summary of the result of the researches of Mr. Goodsir, as given at length by himself, it will be perceived, that the germs of the permanent teeth, although like those of the temporary, originating from mucus membrane, are nevertheless of distinct origin, and have no connection with them. Their origin and progress, however, as well as those of the temporary, will be more readily and better understood by an examination of plate VII. copied from the diagram given by the author of the paper in question.]

A tooth is composed of two substances, one of which, called the enamel, is spread over that part which is not covered by the gums. The other substance is bone; it consists of the fang and all the body of the tooth situated within the enamel. [To these may be added the pulp and *crusta petrosa*, or *cementum*.]

[The pulp is soft, gelatinous, and has a semi-transparent appearance; its surface is covered by an extremely thin and vascular membrane, designated by Raschkow, the *præformative membrane*. This membrane constitutes the bond of union between the enamel and the bone of the tooth.]

The bone of the tooth is formed from the pulp, and the enamel from the investing membrane. The bony part of the tooth is begun to be formed before the enamel. 'When the ossification of a tooth is commencing, bone is deposited from the vessels of the pulp upon its extreme points. In the incisores it begins upon their edges, and in the molares, upon the points of their grinding surfaces. The ossification usually begins in the incisores in three spots; these increase, soon unite and produce the cutting edge of the tooth: In the molares it begins in as many spots as there are grinding points, which in the lower jaw are commonly four, and in the upper, five: These soon unite and form one thin layer of bone of the upper surface of the pulp. The ossification soon extends to the sides of the pulp, and a thin shell of bone is spread over its whole surface.'

If this shell be removed, the pulp, when uncovered, will be found very vascular. This is extremely well seen in the teeth of large animals, when in a state of formation. Some time ago I had the opportunity of examining the pulps of the teeth of a young elephant, which was dissected by Mr. Astley Cooper. Upon removing the ossification which had taken place upon the pulps, I found the vessels to be exceedingly full of blood: There was also a considerable degree of force required to separate the bone from the pulp, and this strength of union between the pulp and the ossified part, I have always found to be in proportion to the size of the tooth.

In the formation of the bone of a tooth the ossific matter is deposited in strata, one within the other; thus a tooth is formed from the outer part to the inner, and this deposition of bone continues until the tooth becomes complete. When the body of the tooth is formed, the pulp elongates, and takes that form of the fang proper to



each particular tooth, and bone is deposited upon it: It then becomes gradually smaller, until it terminates in a point. If a tooth have two or more fangs, the pulp divides, and the ossification proceeds accordingly. The cavity within a tooth, as it is forming, is at first very considerable; it becomes less as the formation advances, until it arrives at a certain point, when a cavity is left in it extending nearly through the whole length, and retaining the shape of the tooth.\*

In the crown of the tooth, the cavity is of the same figure, and it divides into as many canals as there are fangs to the teeth, a canal extends through each fang connected with the cavity in the body of the tooth: Into this cavity the nerves and blood-vessels enter and ramify upon the membrane of the pulp, which remains to line the cavity after the formation of the teeth. In this manner the nerves give sensation to the teeth, and the internal parts of them are nourished.

[MANNER OF THE FORMATION OF THE ENAMEL.]

The enamel is situated upon all that part of a tooth which in the healthy state of the gums is not covered by them. This portion of the tooth is called the body, or crown. It is formed by the membrane which invests the pulp: When a shell of bone has been formed upon the pulp, this membrane secretes a fluid, from which a very white soft substance is deposited upon the bone; this at first is of a consistence not harder than chalk, for it may be scratched or scraped off by the nail; it however soon grows hard, and seems to undergo a process similar to that of crystalization, for it takes a regular and peculiar form.

\* Plate IX. Fig. 4.

The deposition of the enamel continues nearly as long as a tooth is contained within the membrane; it is always most in quantity upon those parts where its formation first began; it is thicker upon the edges and grinding surfaces of the teeth than upon the sides, and it gradually becomes thinner as it approaches the necks of the teeth. A tooth, when sawn through, shews the arrangement of the enamel; and as it requires more heat to blacken and burn this hardest part of the animal frame than the bony part of the tooth, we can, by exposing it to the effects of fire, obtain a still more distinct exhibition of it.\* By the time the enamel is completely formed, the tooth has risen so much in the socket, that by its pressure it occasions an absorption of the membrane, which completely prevents any further addition of enamel.

When perfect, the enamel of the teeth is so hard, that a file in cutting it is soon worn smooth; and when struck with it, sparks of fire will be elicited; an effect I have several times produced with human teeth, and which may be very readily seen by striking the teeth of large animals with steel, particularly those of the Hippopotamus.

The enamel, when broken, appears to be composed of a great number of small fibres, all of which are so arranged as to pass in a direction from the centre to the circumference of the tooth, or to form a sort of radii round the body of the tooth. This is the crystalized form it acquires some time after its deposit; by this disposition of its fibres, the enamel acquires a great degree of strength, and thus it is not so readily worn down in mastication, nor so easily fractured by violent action of the teeth.†

\* Plate IX. Fig. 1.

† Plate IX. Fig. 2, 3.



[The foregoing explanation of the manner of the formation of the enamel, has, until recently, been regarded by anatomists and most writers on odontology, as correct, but the recent researches of RASCHKOW and others, have very conclusively proven it to be erroneous. In fact a different theory was promulgated as early as 1819, by M. Delabarre, in his treatise on Second Dentition. This writer contends that the enamel is an integral part of the tooth, that it proceeds from the dental embryo, and is produced by an immense number of small exhalent vessels, which form a sort of imperceptible velvet. Into these, he supposes the calcareous ingredients are deposited, and in such a way as not to destroy their organic sensibility.

According to Raschkow, the gelatinous granular substance, spoken of by Goodsir, and situated between the follicle and germ of the tooth, is the organ destined for the formation of the enamel. Raschkow calls it the adamantine organ, and says it forms a 'globular nucleus' between the follicle and dental germ, at a very early period of the growth of the latter, with a bulging externally, and presenting internally a parenchymatous appearance, gradually exhibiting angular granulations, which are connected with each other, by 'filaments of cellular tissue,' resembling 'a kind of actinenchyma, such as may be seen in plants.' The editor has frequently had opportunities, in dissecting the jaws of young animals, of demonstrating the existence of this granular substance, and it was the discovery of this, that induced him to believe the generally received opinion of the manner of the formation of the enamel, to be erroneous. This granular substance is surrounded by a limpid fluid resembling the liquor amnii, and as ossification commences on the pulp of the tooth, it is gradually transformed into a membrane, attaches

itself to it, and to which it adheres with considerable tenacity.

Raschkow says, 'the dental germ, in advancing further and further into the dental follicle, makes first only a slight impression on the globular mass of the enamel organ, but this impress is rendered gradually deeper as the growth of the germ proceeds. When the germ has penetrated further into the hollow thus made, it appears narrower towards the base, and thicker under the apex, and is enclosed around on every side by the parenchyma of the enamel organ, which thus assumes the appearance of a hood, covering the dental germ when advanced in its development.' It is disconnected from the dental capsule, except at the coronal part, where it is apparently united by some loose vessels, which supplies the parenchyma of the enamel organ with the numerous capillaries that pervade it; and from this, our author assumes, that while the tooth germ originates from the extremity of the sac next the fang, the enamel organ has its origin from the opposite extremity, and thus, 'arising at opposite points' they 'approach each other, are adapted together, and both contribute' to the production of the tooth. He also describes a peculiar organ on the inner surface of this granular substance, 'consisting of short uniform fibres, placed perpendicularly' 'to the cavity, and forming as it were, a silky lining to it, which may readily be distinguished in a transverse section of the enamel organ, from the stellated parenchyma' of this substance, which he calls the pulp.

This stratum of fibres, he represents, as originating in the transformation of the enamel pulp, with which it is for a time connected, but from which it afterwards separates, so as only to adhere by a 'few filaments of cellular tissue, and becomes a genuine membrane,' which he



styles, 'the enamel membrane.' The inner surface of this membrane, he says, 'consists of hexangular, nearly uniform corpuscles, visible only through a magnifying glass, towards the centre of each of which, is a round eminence. These corpuscles are nothing more than the ends of short fibres, of which the whole membrane is composed, and which being pressed together, assume freely the hexangular form.' They are disposed in regular series, and correspond with the arrangement of the fibres of the enamel.

These corpuscles, he regards as secretory ducts, whose peculiar office is to secrete the enamel fibres which correspond to them. This process begins immediately after the commencement of the ossification of the pulp of the tooth, and while it is going on, Raschkow thinks an organic lymph is secreted from the parenchyma of the enamel membrane, which diffuses itself between the fibres, rendering the whole substance soft, but which afterwards, by means of a kind of chemico-organic process, combines with the earthy substances, and forms the animal base of the enamel.

The membrane covering the pulp of the tooth, he calls the præformative, and this, no doubt, as has been before intimated, constitutes the bond of union between the enamel and bone of the tooth.

Little is known with regard to the manner of the formation of the cementum, or fourth substance entering into the composition of the tooth. Raschkow thinks that it may be produced by the remains of the enamel pulp. I am of the opinion, however, that it is secreted by the dental periosteum, and the more so, as it cannot be detected on the crowns of the human teeth.]

While some eminent physiologists have contended, that the teeth, when they have attained their full growth,

are to be considered as extraneous bodies, and that they no longer receive nutriment, like the other bones of the body; others have supposed, that even the enamel is kept up in future life by continued deposit: but that this cannot be the case will be obvious, when it is considered, that the membrane which invested the pulp and entirely produced the enamel is destroyed before the tooth can appear. When a tooth first appears, the enamel is thicker than at any other period of life, and from that time it begins to decrease; this may be remarked in some of the permanent teeth. The incisores, when they first pass through the gum, have their edges notched; the cuspidati are sharp at their points, and the grinding surface of the molares is always irregular. This sharpness of the points of the teeth is occasioned by a larger deposit upon those parts where ossification had first commenced. By the friction of the teeth against each other, and against the food in mastication, the teeth are worn smooth, the notches upon the incisores disappear, the points of the cuspidati are rounded, or in many cases entirely removed, and the surfaces of the molares become much smoother.

The case is quite the reverse with the bony part, for when a tooth is first seen through the gum, scarcely more than two-thirds of the fangs are formed, but the ossification continues for a considerable time afterwards.

The enamel upon some teeth has a very defective formation; instead of being a hard white substance, having a smooth polished surface, it is frequently met with of a yellow colour, and having a great number of indentations upon its surfaces. This occasions the teeth to resemble the exterior of sponge, and gives them what has been termed a honey-combed appearance.

Sometimes this appearance of the enamel is only met



with on the front teeth, near the cutting edge; at others it extends nearly over half of the tooth, the remaining parts being perfect. When the roughness is near the edge, it often wears out in a few years, or at the age of maturity it may be filed out. In some, one, two, or three indented lines pass across the front of the teeth.\*

[The affection under consideration may result from the destruction of a portion of the præformative membrane or some one or more of the enamel fibres, caused by disease of the general system, and some writers are of the opinion that it is wholly referable to the occurrence of eruptive diseases during the formation of the enamel. M. Duval has given to the disease the name of *atrophy*.]

This defective formation of the enamel is usually confined to the incisores, cuspidati, and first permanent molares: it is rarely met with on the bicuspidates, or second and third molares.—No certain reason can be assigned why the membrane secreting the enamel should so often deviate from its natural action. It can only be referred to some peculiarity of constitution, occasioning an irregular action in the membranes of the pulps, during the first months; for this appearance is only met with on those teeth, the formation of which commences about the time of birth: and even upon them, in those parts only which are first formed. In a few months after, the membranes acquire a healthy action, and the teeth which are formed later, rarely have defective enamel.

It is very remarkable that this circumstance often occurs in several children of the same family; indeed there is scarcely any part in which they resemble each other more, than in the appearance and arrangement of the teeth. I have however constantly observed that these kind of teeth are not so liable to decay, as those which

\* Plate IX. Fig. 14.

have the enamel very beautiful and transparent. We here find nature, as she does in many other particulars common to humanity, making up for defects in one part of her work, by bestowing greater perfection upon another.

[The editor's observations upon this subject do not exactly accord with the opinion of Mr. Fox. He has seldom known more than one or two of the same family to have their teeth thus affected, and he has found that atrophied teeth were just as liable to decay as any other, but the parts marked by the disease are the portions least liable to be attacked by caries.]

Sometimes in the formation of the teeth two pulps unite, and upon their surfaces, appear as two distinct teeth, but upon attempting to remove one, it is discovered to be united to the next. In Plate IX. are figures of several teeth of this kind, which must be regarded as *lusus naturæ*.\*

Very often the fangs of the teeth become crooked, from some obstruction to their growth; and teeth having two or three fangs, are now and then met with, so much bent at their points as to occasion them to be very firmly placed in the jaw. When these circumstances occur, the extraction of the teeth is unavoidably an operation of the utmost difficulty.

[ARTERIES OF THE TEETH.]

The arteries which supply the teeth with blood, are called the dental; they are branches of the internal maxillary artery, which arises from the external carotid, at that part where it is covered by the parotid gland, and lies behind the middle of the upright plate of the lower

\*Plate IX. Fig. 8, 9, 10.



jaw, where it divides into the condyloid and coronoid processes. It passes first between the jaw and the external pterygoid muscle, and afterwards runs in a very winding direction towards the back part of the antrum maxillare; it here sends numerous branches to the parts belonging to both jaws, and to the teeth of the upper jaw. It then gives off one branch to the lower jaw, called by some, the inferior maxillary, and by others, the dental. This enters the jaw-bone at the posterior maxillary foramen, passes through the maxillary canal, and gives off branches to the fangs of each tooth, and also supplies the substance of the bone: This vessel having sent a branch to the incisores, passes out at the anterior maxillary foramen; it is distributed to the gums, and communicates upon the chin with branches of the facial artery.

[NERVES OF THE TEETH.]

The nerves, which are distributed to the teeth, arise from the fifth pair, the trigemini. This pair of nerves divides into three branches; the ophthalmic, the superior maxillary, and the inferior maxillary. The ophthalmic branch passes through the foramen lacerum of the orbit, and is distributed to the parts in the neighbourhood of the eye; the superior maxillary nerve goes out at the foramen rotundum of the sphenoid bone, and divides into several branches, being continued to the posterior part of the nose, the palate, velum palati, and contiguous parts. At the posterior part, small filaments of nerves, accompanying branches of arteries, enter the superior maxillary bone by foramina which lead to the molares, and also to the membrane lining the antrum maxillare: The nerve then goes into the canal under the orbit, and forms the infra orbital nerve. Whilst in the canal, it sends off

branches to the bicuspidés, cuspidati, and incisores; it afterwards passes out at the foramen infra orbitarium, and is distributed upon the cheek, under eyelid, upper lip, and side of the nose.

The inferior maxillary nerve passes through the foramen ovale of the sphenoid bone, and is distributed to the muscles of the lower jaw: it sends off a large branch, the lingual, which goes to the tongue, which is the true gustatory nerve; it then enters the maxillary canal of the lower jaw, passes through the bone under the alveoli, and gives off branches, which entering the fangs, ramify upon the membrane within the cavities of the teeth; it passes out at the anterior maxillary foramen, and is spent about the chin and lip.\*

[ABSORBENTS OF THE TEETH.]

There is another set of vessels, called absorbents, of the existence of which, in the structure of common bone, I believe there is no doubt; and on account of certain effects produced upon the teeth, we must conclude that they are not destitute of them.

During the progress of the second dentition, the fangs of the temporary teeth are absorbed; and even the permanent teeth, when diseased, often lose a considerable portion of the fangs. It may be argued, that in these cases the absorbent vessels are situated in the socket, and act upon the tooth as if it were an extraneous body. But in some cases, we find the teeth undergo the ulcerative process, and a considerable quantity of the inner part is removed, a circumstance which could not happen unless there were absorbents entering into the cavities of the teeth, and properly belonging to them.

\* Plate IX. Fig. 5.



Besides these instances, the effects of absorption in the tusks of elephants are often seen; sometimes in sawing these bodies, iron balls, spear heads, &c. are met with, which have been forced into them in attempting to kill these animals. These extraneous substances are always found loose, having a space in which they can be moved. This could never happen, unless there were some action going on, by which part of the bone could be removed, and there is no other mode in which it can be effected, but through the medium of the absorbent vessels.

[As the editor will have occasion in the chapter treating of the destruction of the roots of the temporary teeth, to make some remarks concerning the phenomenon here alluded to, it will not be necessary, in this place, to enter upon its further explanation.]

[ARTICULATION OF THE TEETH.]

The teeth are fixed in their sockets by that species of articulation called gomphosis. They are attached to the alveolar cavity by a strong periosteum, which is extended over the fangs, and which also lines the socket; it is connected to the gums at the neck of the tooth, and it is vascular, like the periosteum in other parts of the body.

[STRUCTURE OF THE TEETH.]

It is very extraordinary that Mr. Hunter should have considered the teeth as devoid of internal circulation, and destitute of the living principle. The structure of the teeth is similar to that of any other bone, and differs only in having a covering which is called enamel, for the exposed surface, and in the bony part being more dense. There are several parts of the body in which we cannot

by injections demonstrate the existence of blood-vessels, of the vascularity of which no one can entertain a doubt; and as bones in general are continually receiving nourishment from the vessels which enter into their substance, it may be justly inferred that the blood sent to the teeth affords a similar supply, especially as a considerable portion of animal matter enters into their composition.

A large quantity of blood is distributed to the teeth; this may frequently be seen in performing some operations. In cutting off the crown of a tooth, in which the caries had not spread to the fang, for the purpose of engrafting a new tooth, I have several times seen a discharge of blood from the internal cavity. This blood came from the vessels of the membrane in the cavity, which I have also several times seen injected. Blood carries with it the basis of nutrition, and is sent to those parts only where renovation is necessary. For what other reason then, but to impart some principle of nutrition, can so much blood flow into the teeth? If the teeth, after their first formation, received no supply from vessels, or did not require any nourishment, it would have been better if they had been destitute of an internal cavity, and of regular organization.

[The vascularity of the teeth is now too well established to leave any room for doubt. The editor has, in his anatomical cabinet, sections of two human teeth, in which, by the aid of a microscope, vessels injected with red blood can be distinctly traced. A microscopic view of one of these is given in the second volume of the *American Journal of Dental Science*. The existence of vessels in tooth bone has also been subsequently demonstrated by Dr. Maynard of Washington City, and Mr. Norton of New York.]

It is always observed, that as persons advance in life,



their teeth lose that whiteness which they possessed in the time of youth. This change in the appearance of the teeth seems to depend upon one which takes place in their cavities, by which the vessels entering them are gradually destroyed, and the supply of blood is proportionably diminished. In the teeth of persons advanced in years, the cavity is very frequently obliterated, in consequence of a deposit of bony matter, which entirely destroys the internal organization. When this happens, the teeth always lose their colour, and become very yellow, their texture also becomes more brittle, and they acquire a horny transparency.

When a tooth has been loosened by a blow, and has afterwards fastened in its socket, a great alteration in its colour is the consequence; it gradually loses its whiteness, and acquires a darker hue; this proceeds from the vessels which enter the teeth, being destroyed, and the teeth consequently losing their supply of blood.

The teeth being constructed like common bones, are governed by the same laws, and are liable to be affected by similar diseases; like them, they are affected by the various causes of inflammation, and have the same diseased appearances produced upon them.

[That all of the diseases of the teeth are identical with those which attack other bones, is obviously erroneous. With the exception of exostosis and necrosis, they do not bear the slightest resemblance to them. Neither are they produced by the same causes nor can they be cured by the same remedies.]

In bones, the power of resisting the effects of disease is in an inverse proportion to their density. The living principle is always less in the close textured cylindrical bones, and greater in those which are flat and spongy. The teeth being the most dense bones in the body, have

the least power of resisting disease, and, in them, the general termination of inflammation is in mortification.

The teeth do not possess the power of exfoliation, it is not necessary they should, for the system suffers no injury by the loss of a tooth: and no person would have sufficient patience to bear the pain attending upon, or wait the progress of so slow a process. Like other bones, the teeth are subject to that species of inflammation called the ossific, by which the fangs become increased in size, acquire an additional quantity of bone, and exhibit all the appearances of exostosis. They are also liable to inflammation of the membrane lining the cavity, and to its supuration, during the progress of which the inner part of the tooth is removed by the absorbents, and an appearance is produced like that disease of bones called *spina ventosa*.



## CHAPTER FOURTH.

### OF THE SHEDDING OF THE TEETH.

THE falling out of the temporary teeth, to make way for those which are to be permanent, is commonly called the shedding of the teeth. It is the consequence of one of the most curious actions of nature, and is of great importance to our comfort, since the beauty of the face, and the proper articulation of speech in a considerable degree depend upon the regularity with which this part of her work is accomplished.

The necessity of teeth for the mastication of food commences as soon as the time of support from the mother ceases, and therefore a set is provided at a very early period, which occupies but a few months in formation, and only continues a few years without falling into a state of decay. These teeth are only proportioned to the size of the mouth during childhood, and would consequently be too small and too few in number, for the extended state of the jaws in the adult; hence the formation of new teeth becomes indispensable, and according to the manner already described, a set of teeth is formed, of a magnitude and number proportioned to the mature state of the body, and intended, from their compact structure to continue through life.\*

\* The same circumstances take place in all animals: They, like the human subject, shed their teeth, and obtain a new set. But in some animals there is a variety in the mode, arising from the peculiar structure of their teeth and jaws. This is

It is during the growth of the permanent teeth that the very curious process of absorption is going on in the temporary ones, which facilitates their removal from the socket, and affords a free passage to the permanent teeth.

It has been observed, that the pulps of the new teeth are placed behind the temporary ones, and in that situation they are very much crowded, and occupy but a small space. Now it is evident that as they advance in growth, they will require an increase of room, to obtain which they must come forward, so as to form a larger circle.

This effort first produces a considerable pressure against the bony partition, placed between the temporary and permanent teeth, and then upon the posterior part of the fangs of the shedding teeth. The pressure in this instance acts precisely in the same manner as it generally does in other cases where it is applied. It induces an absorption of the parts pressed against; and as the new teeth augment, the fore part of the socket which was formed around the pulp, and separated it from the temporary tooth, is removed by the process of absorption.\* The second teeth still continuing to protrude, press against the fangs of the temporary teeth, at which place their substance begins to be taken up: The absorption goes on until the greater part, or the whole, of the fangs are removed; at the same time the new teeth come forward, underneath the temporary ones, which soon drop out, when the edges of the new teeth may generally be distinctly felt.

particularly and very curiously the case in the elephant, which animal, instead of having its new teeth formed under the temporary ones, they are formed in sockets beyond those to be shed, which in due time advance from the back to the front part of the jaw. This is very accurately described by Mr. Corse, in his paper in the Philosophical Transactions. A similar mode is observed to take place in one grinder of the *Sus Ethiopicus*, as described by Mr. Home, whose paper, with that of Mr. Corse, are in the Transactions for 1799.

\* Plate II. Fig. 1, 2, 3, 4.



The absorption gives to the fangs of the teeth an appearance of being broken, but this, when compared with a fracture, will be found to differ from it very materially. While the absorption of the fangs of the temporary teeth seems to depend so much on the pressure of the rising permanent ones, it is often found to go on without such pressure; for in some children the temporary teeth will loosen and drop out many months before new teeth appear, and in many cases the same effect takes place where a new tooth does not rise to replace the one which has been shed.

These circumstances seem to prove that the absorption of the fangs of the temporary teeth is an action of nature, sometimes independent of pressure: and it is a very singular circumstance, that at a time of life when so great a quantity of ossific matter is poured forth from all the arteries concerned in the formation of bone, in one particular part, there should thus be an absorption of this substance taking place.

In many instances, however, absorption of the fangs of the temporary teeth never takes place; and it is by no means uncommon to find one, two, or sometimes more of them, remain in their sockets for a great number of years. When this happens to be the case with several teeth, it is found that no permanent teeth had been formed: which shews that the absorption of temporary teeth, although a regular action in the animal œconomy, is very considerably influenced by the pressure of forming teeth. This defect always produces an unseemly appearance, from the small size of the old teeth, when compared with the new.

Cases of deficiency of the permanent teeth are by no means unfrequent. I have seen a young lady of about twenty years of age, who had never shed the two central

incisores of the under jaw; and in the upper jaw, all the temporary incisores remained, except one of the lateral, which had been shed.

[The editor cannot believe, that this curious and singular operation of the animal economy is the result, wholly, of the action of the absorbents. Bourdet, observing a carneous substance behind the root of the temporary tooth, ascribed to it the agency of its destruction, which he believed to be effected by means of a solvent fluid which it exhales. Laforgue gives to this substance the name of absorbing apparel, believing its function to be the removal of the root of the temporary tooth, and in this opinion M. Delabarre concurs.

Having given a brief exposition of the last named author's views upon this subject, in his Principles and Practice of Dental Surgery, accompanied by his own, he will here repeat what he there stated. 'While the crown of the tooth of replacement,' says Delabarre, 'is only in formation, the exterior membrane of the matrix is simply crossed by some blood vessels; but as soon as it is completed, the capillaries are then developed in a very peculiar manner, and form a tissue as fine as cob-web; from this tissue the internal membrane, instead of continuing to be very delicate, and of a pale-red colour, increases in thickness and assumes a redder hue. As was before said, it is at the instant in which commences the reaction of the coats of the matrix, that are conveyed from the gum to the neck of the tooth, that the plaiting of the vessels, that enter into their tissue, compose a body of a carneous appearance, whose absorbents extend their empire over all the surrounding parts; it is, therefore, the dental matrix itself, that, after being dilated to serve as a protecting envelope to the tooth, is contracted to form not only this bud-like body which we find imme-



diately below the milk tooth, at the instant in which it naturally falls out, and whose volume is necessarily augmented as odontocia gradually goes on; but also a carneous mass by which the whole is surrounded and whose thickness is the more remarkable as the organ that it envelopes is nearer its orifice.'

After giving this description he asks, 'is there a dissolving fluid that acts chemically on the surrounding parts, or do the absorbents, without any intermedial, destroy every thing that would obstruct the shooting up of the tooth?' In reply to this, he says, 'Not possessing positive proof, suitable to guide me in the decision of this question, and finding those of others of little importance, I shall not attempt to answer them.'

In pursuing the subject further, he states that the vessels of the temporary tooth often remain entire in the midst of this carneous substance, and continue to convey their fluids to the central part of the tooth, whilst the calcareous ingredients and the gelatine have been removed, and that at other times they too are destroyed. And the conclusion to which he arrives, after a careful examination of the whole subject, is, that whether the earthy and animal parts of the root are removed by the absorbents of the carneous tubercle in question, without any previous change, or whether they are decomposed by the chemical action of a fluid exhaled from it, they are ultimately carried back into the general circulating system.

In proof of the agency of the fleshy tubercle in the destruction of the roots of the temporary teeth, he mentions one fact that goes very far to establish it, and if his views be correct, will account for those cases which are occasionally met with, where one or more of the permanent teeth fail to appear. It is this: if this substance fails to be developed, or is destroyed by an injurious

operation, the tooth often remains in its socket, and never makes its appearance. Cases of this kind have fallen under the notice of almost every practitioner.

In as few words as possible, I have given the views of this ingenious writer, on the subject under consideration, and although they do not seem to have attracted much attention from English writers, and are rejected by Mr. Bell, on the ground, as he says, but which I have never known to be the case, that the destruction of the root of the temporary frequently commences on a part 'the most remote from the sac of the permanent tooth,' I am disposed to believe them, for the most part, correct. As to the existence of the fleshy tubercle, there can be no question, and that it is through the agency of these that the roots of the temporary teeth are destroyed, seems more than probable. But whether it is through the agency of their absorbent vessels or a chemical fluid exhaled for the purpose, may not, as Delabarre says, be so easy to determine.

The change that takes place in the external membrane of the dental sac, as noticed by Delabarre, is observable first on the peduncle or chord leading from it to the gum behind the temporary tooth. It here becomes thickened about the time the root of the new tooth begins to form, and assumes a fleshy appearance, and it is here that the destruction of the surrounding bone commences, enlarging the alveolo-dental canal, and gradually removing the intervening long partition, and finally the root of the temporary tooth. The agency of this thickened and fleshy condition of the exterior membrane of the dental capsules, in the removal of the roots of the temporary teeth, is rendered more conclusive by the fact, that, in those cases where the roots of the permanent teeth have become partially destroyed, the alveolo-dental periosteum



had assumed a similar appearance. In the formation too of alveolar abscess, the tubercle at the extremity of the root presents a like aspect.

It oftentimes happens, that the root of a temporary tooth fails to be destroyed, and that the crown of the replacing organ comes through the gum in a wrong place. Whenever this happens, the carneous body is developed only beneath the parts through the opening of which the new has appeared, and is not brought in contact with the bony partition between it and the root of the temporary.

The manner of the destruction of the roots of the temporary teeth has been a subject of close and critical enquiry with me for several years, and the more I have examined it, the more fully have I become convinced, that it is the result of the action of this fleshy tubercle upon them, and while its formation seems to be the result of the contraction of the dental sac and its appendage, for the purpose of effecting the eruption of the tooth, it is especially charged with the removal of every thing that would obstruct its passage.

In conclusion, it is only necessary to observe, that the temporary teeth are shed in the same order in which they at first appear. After one pair has been shed, a sufficient time usually elapses before the shedding of another, for those of the same class of the permanent set to come forward and take their place. Thus, the jaws are never deprived, unless from some other cause than the destruction of the roots of the temporary teeth, of more than two teeth in each jaw at any one time.]

It frequently happens in the upper jaw, that the permanent central incisores only are formed, the lateral ones never appearing. Many persons are deficient in one or more of the bicuspidæ. I know a gentleman who re-

sides at Bath, who has never had the incisores of the under jaw; and it is remarkable, that two other persons of his family are in the same situation. I have seen a lady who had only four teeth of the permanent set in each jaw. Mr. Taunton, Surgeon of the City Dispensary, has the preparation of a child's head, in the upper jaw of which only one incisor was forming.\* These deviations often occur in the human subject; but so far as I have observed, they are very rare in animals, yet I once saw a horse rising between eight and nine years, which still retained one of the milk incisores.

The appearance of the fangs of the teeth, when absorbed, has given rise to a popular but erroneous opinion, that the first teeth have no fangs, and this was even taught by some of the old anatomists. It has also been erroneously conceived that the temporary teeth are pushed out by the permanent: Now that this cannot take place, will be seen by observing the state of the two sets of teeth. The temporary ones are firmly placed in sockets, whilst the new teeth, during their formation, are contained in cavities larger than themselves, and can only make such pressure as their gradual growth will permit. On this account, if the absorption of the old tooth be retarded, or the formation of the new tooth proceed too quickly, the latter will take an improper direction when they come through the gums, and form a second row of teeth, from the temporary teeth still remaining. Moreover, if the old teeth were pushed out by the new, we should always find those teeth about to be displaced, forced out the line of the others, a circumstance which never occurs.

The period at which children begin to shed their teeth varies considerably. In some, the teeth become loose as

\* Plate XI. Fig. 6.



early as five or six years of age; in others, this process does not begin until the eighth year: about six or seven years of age may be taken as the standard time.

The teeth of the permanent set, which usually appear first, are the anterior molares, which being somewhat more early in their formation, generally precede the incisores; and we must always expect, soon after the cutting of one or other of these teeth, that the shedding of the temporary teeth will begin.

Soon after the first permanent molares have appeared, the two central incisores of the under jaw become loose, and when they are but slightly attached to the gum, easily come away; the permanent central incisores soon after appear, one coming a little time before the other; in about two or three months the central permanent incisores of the upper jaw become loose, and having dropt out, the permanent central incisores succeed them.

In about three or four months more, the under lateral incisores, having lost their fangs, come away, and the permanent lateral incisores succeed them. The lateral incisores of the upper jaw are the next which drop out, and the permanent ones appear shortly afterwards. In about six or twelve months more, the temporary molares begin to loosen; they generally come out before the cuspidati, the long fangs of which take a much longer time in being absorbed.

The first bicuspidates take the place of the first molares, and about the time they appear, the second temporary molares, and the temporary cuspidati, become loose, and having been shed, are succeeded by the permanent cuspidati, and the second bicuspidates.

The shedding of the teeth, commencing at six or seven years of age, is commonly completed in about five or six years, when all the temporary have come out, and those

of the permanent set as far as the second molares, have taken their stations. There yet remain, to complete the set, the third molares, or *dentes sapientiæ*, and these usually appear between eighteen and twenty-one years of age, but sometimes they do not come till much later; not before twenty-seven or thirty years; and I once was consulted by a gentleman, fifty years of age, who had great pain cutting one of these teeth.

[The periods for the eruption of the permanent teeth are, like those of the temporary, exceedingly variable. The following, however, may be regarded as very nearly correct. The first molares usually come through the gums between the fifth and sixth year; the central incisores, between the sixth and eighth; the lateral incisores, between the seventh and ninth; the first bicuspidates, between the ninth and tenth; the second, between the tenth and eleventh, or eleventh and a half; the cuspidati, between the eleventh and twelfth; the second molares, between the twelfth and fourteenth; and the *dentes sapientiæ*, between the eighteenth and twentieth.]



## CHAPTER FIFTH.

### OF THE IRREGULARITY OF THE TEETH.

DURING the shedding of the teeth there are several circumstances which prevent the permanent teeth from acquiring a regular position, and often give rise to very great irregularity in their arrangement.

The most frequent cause is a want of simultaneous action between the increase of the permanent teeth, and the decrease of the temporary ones, by the absorption of their fangs. It rarely happens that so much of the fang of a temporary tooth is absorbed as to permit its removal by the efforts of the child, before the permanent tooth is ready to pass through: on which account the new tooth takes an improper direction, and generally comes through on the inside.

Cases are very frequent in which scarcely any absorption of the fangs of the temporary teeth had taken place previous to the appearance of several of the permanent teeth; and it often happens, that upon the removal of the shedding teeth to give room for the permanent ones, that no absorption of the fangs of the temporary teeth has taken place.

Irregularity of the permanent teeth is most commonly occasioned by the resistance made by the nearest temporary teeth; this is always the case if the temporary teeth are small and close set, for as the permanent incisores are

much larger than the temporary, they require more room; but as the space left by the shedding of the temporary teeth is too small for the regular position of the permanent, they are exposed to the pressure of the next tooth, and hence are frequently turned out of their right direction.

Another cause of the irregularity of the teeth arises from the permanent teeth being too large for the space occupied by the temporary ones; those parts of the jaws not being sufficiently extended to permit a regular position of the new teeth—in this case the irregularity is considerable, and occasions great deformity in the appearance of the mouth. The incisores and cuspidati being much larger than those of the child, require more room, for want of which they are turned out of their proper positions. The central incisores overlap each other—the lateral incisores are either placed obliquely with their edges turned forwards, or they are pushed back, and stand between and behind the central incisores and the cuspidati; the cuspidati are projected, occasioning the lip to stand out with considerable prominence, and the bicuspidates are placed very irregularly.

[Malconformation of the jaws may be mentioned as another cause of irregularity. The superior alveolar arch is sometimes too narrow—having a compressed appearance, and projecting so as to prevent the upper lip from covering the front teeth. The arch at other times is too broad, giving to the roof of the mouth a flattened appearance, and causing the teeth to be separated from each other. The effect upon the appearance of the individual in either of these cases, is bad, but worse in the first than the last. The lower jaw is liable to similar faulty configurations.

The disposition to defects such as these, is observable in early childhood, and is regarded by most of those who



have treated of it, as hereditary, and more peculiar to the people of some countries than others. Some attribute it to a rickety diathesis of the general system, but this opinion is gratuitous, as is shown by the fact, that most persons labouring under this affection, have good palates and well developed jaws. It cannot, therefore, with any degree of propriety be regarded as having any agency in the production of a faulty configuration of the jaws.

There is also another species of deformity sometimes met with in the upper jaw, equally difficult of explanation. It is characterized by one or more divisions of the upper lip, alveolar border, and palatine arch, always giving rise to irregularity in the arrangement of the teeth. This description of malconfiguration is congenital.

Supernumerary teeth too, may be reckoned among the causes of irregularity. But examples of this are of comparatively rare occurrence.]

It will be proper, in this place, to observe the manner in which the jaw bones grow, (the under one being taken as the example) and to point out the difference between the temporary and permanent teeth.

#### [ACCRETION OF THE JAWS.]

After a child has obtained all the temporary teeth, the jaw in general grows very little, in the part which they occupy. In those children who are an exception to this rule, the temporary teeth become a good deal separated from each other, and these are the cases in which the shedding of the teeth is effected without any assistance of art.

When the jaw of a child is compared with that of an adult, very striking difference is observed; that of a child

forms nearly the half of a circle, while that of an adult is the half of a long ellipsis. This comparison clearly points out the part in which the jaw receives its greatest increase, to be between the second temporary molaris and the coronoid process; and this lengthened part of the jaw is destined to be the situation of the permanent molares.

By the elongation of the jaw a great change in the form of the face is produced; that of a child is round, the cheeks are plump and the chin flat; in an adult the face is more prominent, with a flatness of cheek and a considerable length of chin.

The temporary incisores and cuspidati are much smaller than the permanent, while the molares of the temporary set are larger than the bicuspides which succeed them. Hence it is, that the incisores and cuspidati are so frequently irregular, and they never could be otherwise were it not that some space were gained from the molares, in consequence of the bicuspides being much smaller.

This circumstance is rendered intelligible, by examining jaws at various ages, and observing in what particulars they differ from each other.

Until about twelve months after birth, the jaw grows uniformly in all its parts, and at that time as far as the teeth extend, it approaches nearly to a semicircle; at about three years of age, when all the temporary teeth have appeared, it begins to lose its semicircular form, and become somewhat elongated; an extension takes place between the last temporary molaris and the coronoid process; and in that part, in an advanced state of formation, the first permanent molaris will be found.

At about seven or eight years of age, the jaw is more extended, the first permanent molaris has grown up, and



the second is advancing in formation. At about eleven or twelve years of age it will be found still longer; the second molaris is ready to come through the gum, and the third molaris has begun to form.

The jaw acquires its full proportion, at about eighteen or twenty years of age, when the third molaris makes its appearance, and the teeth are seen in the figure of their arrangement to form part of an ellipsis.

The growth of the jaw being nearly confined to the part situated behind the temporary teeth, where the permanent molares are placed, the anterior part of the jaw undergoes little more than an alteration in form; it adapts itself to the permanent teeth there situated, and scarcely receives any increase of size.

The same comparison of jaws exhibits the cause of irregularity in the permanent incisores and cuspidati. When a child is about to shed its teeth, the first permanent molares come through the gums behind the temporary molares, and therefore the teeth which are situated anteriorly to the permanent molares, can obtain no additional space.

The permanent incisores occupy the space of the temporary incisores, and half of that of the cuspidati. It commonly happens that the bicuspidates are earlier in their appearance than the cuspidati; therefore, when the first temporary molares are shed, a little room is gained, as the teeth which succeed them are smaller. When the second molares are shed, still more room is gained; the two bicuspidates go back against the first permanent molares, and thereby give sufficient room for the cuspidati. Thus, by the change of the molares of the child, which are large, for the bicuspidates of the adult, which are small, room is obtained for the increased size of the permanent incisores and cuspidati.

[There exists considerable diversity of opinion with regard to the increase of that portion of the jaw occupied by the temporary teeth. Some writers contend that it continues to grow until these teeth are replaced by the permanent ones, while others assert that the increase, after the completion of first dentition, is wholly confined to the back part of the jaw, between the second molares and the coronoid processes, and that the anterior portion undergoes no increase whatever. Among the former is M. Delabarre. This writer endeavours to prove that a very considerable increase takes place in this part of the jaw, but Mr. Fox entertains a different opinion, as may be perceived from what he has said upon the subject, and he endeavours to establish the correctness of his views by the measurement of several jaws, as may be seen by reference to Plate XI. Fig. 5. But the only way to arrive at the truth of the matter is, to measure the same jaw at different ages, as proposed by Mr. Thomas Bell. For example, let that portion of the jaw of a child, containing the temporary teeth, be measured immediately after the completion of this dentition, or say the third year, and then after they are replaced with the permanent teeth. If this be done, the portion of the jaw occupied by these teeth will be found to have increased a little, but not as much as Delabarre supposes. I allude to the change which takes place in the span or extent of the circle of the arch, not to the transverse or perpendicular dimensions of the bone. These continue to augment until the sixteenth or twentieth year. The premature loss of a temporary tooth, may, by the approximation of the adjoining teeth, cause a diminution of the span of the anterior portion of the jaw. For this reason the temporary teeth should never be extracted, except when called for by urgent necessity.



The popular opinion, that inasmuch as the temporary teeth are soon to be replaced, it is of little consequence whether they be retained in the jaw until they are removed by the operations of the economy, or are lost a few years earlier, is erroneous, and has been productive of a vast amount of injury.]

This change of small teeth for larger, and of larger for smaller, points out the necessity of giving some assistance to nature in one of her processes, viz: that of throwing out the temporary teeth before the permanent teeth appear: if this be done at a proper time, the teeth will always take a regular position, and every deformity arising from irregularity be prevented.

During the progress of the second dentition, an opportunity presents itself for effecting this desirable object; but every thing depends upon a correct knowledge of the time when a tooth requires to be extracted, and also of the particular tooth; for often more injury is occasioned by the removal of a tooth too early, than if it be left a little too long; because a new tooth, which has too much room long before it is required, will sometimes take a direction more difficult to alter, than a slight irregularity occasioned by an obstruction of short duration. If an improper tooth be extracted irreparable mischief will ensue; as in the case where young permanent teeth have been removed, instead of the obstructing temporary ones, which I have several times known to have been done.

## CHAPTER SIXTH.

### OF THE TREATMENT TO PREVENT IRREGULARITY OF THE TEETH.

THE advantage which attends the removing the teeth of children, depends upon its being done at the precise time when nature is tardy in effecting the absorption of the fangs of the temporary teeth. The performance of any improper operation will be prevented by a knowledge of the progress of the formation of the teeth, combined with observations upon the appearance of the gums, which become full when a tooth is about to pass through them.

To assist the permanent teeth in acquiring their proper arrangement, the mouth should be examined from time to time, that the operation be performed at the time required; for it is not sufficient to remove an obstructing tooth, when the new one is perceived to be coming irregularly, because it always requires a considerable time to bring the latter into its proper place, and often the irregularity remains unaltered.

The shedding of the teeth commonly begins at about seven years of age: sometimes it may be earlier, and at others rather later; however, it is about this time that a child's mouth begins to require frequent inspection.

There are two circumstances, the presence of either of which always denotes that the shedding of the teeth is about to commence. The first permanent molares of the under jaw make their appearance; or one or both of the central incisores in the under jaw begin to loosen.



Sometimes the absorption of the fangs of the temporary teeth goes on so slowly, that they do not get loose previous to the passing of the new tooth through the gums behind them. If then the permanent molares have been cut for some time, and there be a fulness of the gums behind the under permanent incisores, it will be expedient that the two central incisores be extracted immediately, although not yet loose. It most commonly happens that the under central incisores, by the early absorption of their fangs, becomes loose, and are taken out by the child some time previous to the appearance of the new teeth; but it often occurs, that although they have got somewhat loose, they are not sufficiently so, to come out of themselves before the new teeth are ready to pass through. When in this state, the temporary central incisores should be removed, and this will permit the permanent central incisores to take their proper place. It will soon be seen, as the new teeth arise, whether they have sufficient room; if not, it will be necessary to remove the temporary lateral incisores.

In two or three months afterwards, or sometimes later, attention must be paid to the central incisores of the upper jaw. If they have got loose they should be taken out, or if not, and there be the least fulness of the gums behind them, they must be extracted, or else one or both of the permanent incisores will come through, and produce one of the most unseemly cases of irregularity, as well as one of the most difficult to treat.

When the permanent central incisores are passing through the gum, there is seldom sufficient room for them, and it will be proper to extract the temporary lateral incisores.

[The author seems to have overlooked the fact, that, by the time the upper permanent central incisores are

ready to come through the gums, the temporary lateral incisores have become so much loosened by the wasting of their roots, as to yield sufficiently to the pressure of the former to permit these teeth to take their proper place in the arch. But when this is not the case, the temporary lateral incisores should be extracted.]

The attention is next to be turned to the under jaw, for in three, or six months time, the lateral permanent incisores may be expected to appear, and if there be any fulness of the gum, where those teeth are to pass, the temporary cuspidati must be taken out. In two or three months more the same observations should be made upon the upper jaw, and as soon as the permanent lateral incisores exhibit signs of approach, by a fulness of the gums, the temporary cuspidati should be extracted.

When the teeth are in this state, they may often remain without farther attention for near a twelve-month, during which time the incisores will be acquiring their complete growth; and the cuspidati and the bicuspidates be ready to come through. Care must now be taken that the permanent cuspidati do not take an improper direction; the gums should be examined, and if any prominence be felt, the first temporary molares must be extracted. It frequently happens that the first temporary molares get loose previous to any appearance of the cuspidati, and that when they are removed, the bicuspidates soon appear.

[The shedding of the first, and often the second temporary molares, takes place previous to that of the temporary cuspidati, so that when it becomes necessary to procure room for the permanent cuspidati, it has to be obtained by the removal of the first or second bicuspidates, or when the first permanent molares are decayed, by the extraction of these teeth, instead of the first temporary molares



as recommended by Mr. Fox. But it is only in the fewer number of cases that the resources of art are required in the dentition of the secondary teeth. Nature in most instances, is amply sufficient to manage her own work. Irregularity of the teeth more frequently results from the premature removal of the temporary teeth, than from their retention too long in the jaws.]

After this, the treatment must be guided by circumstances. If either of the cuspidati exhibit signs of early approach, and there be scarcely room between the latter incisor and the bicuspis already in its place, it will be proper to take out the second temporary molaris, the first bicuspis will then go somewhat back and the cuspidatus will get more room.

When the second temporary molares have been removed, there remain no other obstacles in the way of the completion of the second dentition. The second bicuspidates will come properly into their places, and the molares having no obstruction, will progressively occupy their proper stations.

Though the shedding of the teeth generally requires a period of four or five years, it sometimes occupies nearly six years. In some children the changes take place quickly, and in others slowly. I have seen a child of only seven years of age more advanced in the process of dentition, than another of the same family when near eleven.

## CHAPTER SEVENTH.

### THE TREATMENT TO REMEDY IRREGULARITIES OF THE TEETH.

[THERE is no truth in surgery, more fully established, than is that of the practicability of altering the position of a tooth in the mouth, after the completion of its growth; and yet there is no branch of practice in dentistry more neglected than the treatment of irregularity in the arrangement of these organs. Notwithstanding the acknowledged importance of regularity in the arrangement of the teeth, not only to an agreeable expression of the countenance, but also to the health and durability of the whole dental apparatus—hardly one practitioner in twenty ever gives the subject a thought. Their manipulations are almost wholly confined to filing and plugging the natural teeth and the substitution of artificial ones for their loss. The attention of a few of the more scientific and skilful practitioners, however, have been directed to the treatment of irregularity, and the results of their labour in this department of physical alleviation, have been as gratifying to their own feelings as they have been beneficial to their patients.

The cases of irregularity of the teeth are so various and sometimes complicated in their nature, that the skill, patience and ingenuity of the operator are often put to the severest test. Different cases require to be treated differently. To construct the appliance best calculated



to overcome the difficulty in every case, requires no small amount of tact and inventive ingenuity. It often too, becomes necessary to vary the means employed in the same case, or to use different fixtures in different parts of the operation; and the length of time required for its accomplishment, is sometimes such as to call for a greater amount of patience and perseverance on the part of both practitioner and patient, than every one can be prevailed upon to exercise. A deviating tooth cannot always be moved to the place which it should occupy in a day or a week. Months are oftentimes required to do it, and during the whole progress of the operation, the most constant attention is necessary.]

The mode of treatment described in the preceding chapter, is not always had recourse to, at a time when every irregularity might be easily obviated. Parents most commonly wait, until, by an irregular growth of their children's teeth, a manifest deformity is produced, ere they perceive the necessity of advice.

In all cases of irregularity during the shedding of the teeth, the treatment to be observed is to remove the obstructing temporary teeth, and then to apply pressure in the most convenient manner upon the irregular tooth, in order to direct it into its proper situation.

#### [VARIETIES OF IRREGULARITIES OF THE TEETH.]

I will now describe the different states of irregularity, and to avoid confusion, take each jaw separately.

In the under jaw, when the growth of the permanent central incisors has exceeded the absorption of the temporary ones, they grow up immediately behind them, in a direction towards the tongue. These two new teeth are generally so broad as nearly to cover the inner sur-

face of the four temporary incisores. It will therefore be necessary, in order to obtain room for these teeth, that the four temporary incisores be extracted. The new teeth will then gradually come forward, in which they will naturally be assisted by the pressure of the tongue of the child, and may be occasionally helped by the finger of the parent or nurse.\*

If the temporary central incisores have loosened, and come out previous to the appearance of the permanent teeth, the space is seldom sufficiently wide, and the new teeth will either grow up with their sides turned forward, or one will be placed before the other. In this case the two lateral incisores must be taken out.†

When the permanent central incisores have completely grown up, they occupy full two-thirds of the space, which contained the four temporary incisores; therefore, when the permanent lateral incisores appear, they are placed partly behind the centrals and the temporary cuspidati; or they grow up with one corner turned forwards and the other pointing backwards. In either of these cases the temporary cuspidati must be removed to give room.‡

[This arrangement, is often, though not always, forced upon the lateral incisores by want of room between the centrals and cuspidati. The space between the last mentioned teeth is often amply sufficient for the four incisores.]

The four permanent incisores take up nearly the whole of the space of the temporary incisores and cuspidati. The permanent cuspidati are large teeth, and when they have not sufficient room, they occasion very great irregularity. Sometimes they come through on the inside, but most commonly they cut the gum on the outside, and

\* Plate XII. Fig. 1.

† Fig. 2.

‡ Fig. 3, 4.



project very much out of the circular line from the temporary incisores to the temporary molares. In this case the necessity of the removal of the first temporary molares is obvious.\*

[The author here has evidently mistaken the order of the eruption of the permanent teeth. The first temporary molares and oftentimes the second are replaced with bicuspidés before the cuspidati appear, so that if the removal of any teeth becomes necessary to make room for the last mentioned organs, it will be the first or second bicuspidés, but as these are much smaller than their predecessors, it is comparatively seldom that the sacrifice of any is called for.]

It is not very common that the bicuspidés of the lower jaw are irregular, because the temporary molares are generally removed before they appear; but when this is not the case, they always come through the gums on the inside, pointing towards the tongue, in which case the temporary molares must be removed, that the bicuspidés may rise into their proper situations.†

In the upper jaw the permanent central incisores sometimes pass through the gums behind the temporary ones; when this happens, the four temporary incisores must be extracted, [if the wrong direction taken by the former has resulted from want of room between the latter,] and frequent pressure by the thumb should be applied to the new teeth, in order to bring them forward as soon as possible, and prevent one of the cases of irregularity most difficult to be remedied.

When the temporary central incisores have come out, the space is generally too narrow for the permanent ones, and hence they are pressed into some shape of distortion. Their edges do not assume the regular curve, but stand

\* Plate XII. Fig. 5.

† Fig. 6.

obliquely, or even sometimes one before the other. Cases of this kind require the removal of the temporary lateral incisores.\*

[The practice recommended in the last paragraph, is based upon the erroneous belief that the anterior part of the jaw acquires no increase of dimensions after the dentition of the temporary teeth. But by the slight increase which takes place in this part of the alveolar border and the yielding of the temporary lateral incisores, to the pressure of the permanent centrals, the latter, in the majority of cases, acquire their proper position between the former. Therefore, it is only when they are forced to take a wrong direction in their growth, by want of room between the temporary lateral incisores, that these last should be extracted.]

The permanent central incisores are very broad; they occupy the greater part of the space of the four temporary ones, and leave scarcely any room for the permanent lateral incisores; on which account these latter teeth must grow very irregularly; they generally pass through behind, being forced considerably backwards by the resistance of the central incisores and the temporary cuspidati. Some times they pass through edgeways, and now and then they project forwards. In any of these cases the removal of the temporary cuspidati is absolutely necessary, and unless the operation be timely performed, the irregularity is with difficulty remedied.†

[As has been intimated in a preceding place, a temporary tooth should not be extracted, except to make room for a permanent one, or when called for by some other special necessity. The practice in the preceding paragraph, as that in the one noticed before it, is based upon a false theory.]

\* Plate XII. Fig. 7.

† Fig. 8, 9.



The greatest deformity is generally occasioned by the want of room for the lateral incisores and the cuspidati, and when too long neglected usually becomes permanent.

When the permanent cuspidati make their appearance, [in an improper place] they generally project very much forwards, and not only disfigure the mouth, but are very dangerous. I have known several instances, where, from the accident of a blow, the upper lip has been cut through. Whenever the cuspidati are growing thus, the first temporary molares ought to be extracted.\*

When the bicuspidates appear before the temporary molares have been [removed by the destruction of their roots or] extracted, they pierce the gums above the shedding teeth, and may be seen by raising the cheek and upper lip. The removal of the temporary molares immediately permits them to come down into their right situation.† [Irregularity in the arrangement of these teeth is, however, of comparatively rare occurrence.]

In almost all the cases of irregularity which occur in the under jaw, nothing more is necessary after the removal of the obstructing tooth, than to apply the frequent pressure of the finger, in such a manner as to direct the irregular tooth into its proper place. It will assist the natural tendency of the teeth to form a regular circle, and to take up as large a space as possible. But in the upper jaw, when the irregularity has been suffered to remain for any length of time, it cannot be obviated without having recourse to other assistance.

Irregularity is often occasioned by the teeth being much too large for the space allotted them, and then it will be necessary to remove one or more of the permanent teeth.

When the incisores are perfectly regular, and the

\* Plate XII. Fig. 10.

† Fig. 11.

bicuspidates have appeared before the cuspidati, there is so little space left, that the cuspidati are thrust forward.\*

It has been the common practice to admit the cuspidati to grow down to a certain length, and then to extract them. This operation certainly removes the deformity of projecting teeth, but it destroys the symmetry of the mouth, and takes away two teeth of great importance. The cuspidati are exceedingly strong; they form the support of the front of the mouth, and in the advanced periods of life, to those persons who have the misfortune to lose the incisores, they furnish an excellent means of fixing artificial teeth. [The practice, formerly so common, of attaching artificial teeth to the cuspidati, is, at the present time, seldom adopted, when there are other teeth in the mouth further back, to which a support for artificial ones can be attached.]

On these accounts [or more properly for the reason first stated,] they should be preserved, and therefore it will be right to extract the first bicuspid on each side. The cuspidati will then fall into the circle, and if there should be any vacant space, it will be so far back, that no defect will be perceived. This is often the case in the under jaw, as well as in the upper, and the same practice ought to be adopted.

[The better practice, in cases of this sort, is, to extract the second, instead of the first bicuspid, as recommended above, except when the space between the first and the lateral incisor, is very narrow, say not more than equal to one-third the width of the cuspidatus, and in which case the first should be removed instead of the second, for although after the extraction of the other, it might be made to take its place, and the deviating tooth brought within the circle, yet still there would be such an over-

\* Plate XII. Fig. 12.



lapping of the roots of the two within their sockets, as would occasion a considerable prominence on the anterior part of the alveolar border, which would be likely to give rise to an unhealthy action in the investing soft tissues.]

The first permanent molares often become carious soon after they appear; when this is the case, and the other teeth have not sufficient room, considerable advantage always attends their extraction. Their removal permits the bicuspidates to fall back, and gives way for the regular position of the cuspidati.

The removal of these teeth when decayed ought always to be recommended, although they may not occasion pain, or there be no irregularity in the front teeth; diseased teeth always affect others, and therefore ought never to remain in the mouths of children.

If they be extracted before the second permanent molares appear, in a short time they will not be missed, because the bicuspidates will go back, and the second and third molares will come forward, so that no space will be left.

[When there is irregularity in the front teeth, or good reason for believing there will be, or that they will be crowded unless some of the permanent teeth are removed, the extraction of the first permanent molares when decayed, is unquestionably advisable, but under any other circumstances, the decision of the practitioner, should be determined by the situation and extent of the disease. If the decay has commenced on the grinding surface of the tooth, and has not invaded a very considerable portion of the organ, the better practice would be to remove the diseased part, and fill the cavity with gold.]

The front teeth may even derive much benefit from this gain of room, as there will probably be left a small space between them, which will tend to their preserva-

tion; for it is observed, when teeth are situated so close as to press hard upon each other, they almost always fall into a state of decay.

Sometimes the upper jaw is too narrow from side to side, the teeth in the fore part are thrown forwards, and project very much over the teeth of the lower jaw: they also push out the upper lip. In this case the first bicuspid on each side should be extracted, which will permit the teeth to fall into a more regular curve. [But should they fail to do so, they should be brought back by means of ligatures attached to one or more of the molares, and so applied to them, that a constant and regular pressure shall be kept upon them in the direction they require to be moved, only one tooth, however, on each side should be moved at a time.]

When the permanent incisores of the upper jaw have cut the gum behind the temporary teeth, and have been suffered to remain until considerably advanced in growth, they always stand so much inwards, that when the mouth is shut, the incisores of the under jaw stand before them, which is always an obstacle to their acquiring regularity, and occasions a great deformity.

There are four states of this kind of irregularity. The first, when one central incisor is turned in, and the under teeth come before it, whilst the other central incisor keeps its proper place, standing before the under teeth.\*

The second is, when both the central incisores are turned in, and go behind the under teeth; but the lateral incisores stand out before the under teeth.†

The third variety is, when the central incisores are placed properly, but the lateral incisores stand very much in; and when the mouth is shut, the under teeth project before them and keep them backward.‡

\* Plate XIII. Fig. 1.

† Fig. 2.

‡ Fig. 3.



The fourth is, when all the incisores of the upper jaw are turned in, and those of the under jaw shut before them. This is sometimes occasioned by too great a length of the under jaw, in consequence of which it projects considerably more forward than the upper jaw.\* But the majority of such cases originate entirely from neglect, and may be completely remedied by early assistance.

[It is also proper to state that the cuspidati as well as the incisores sometimes come out behind the dental arch, so as at each occlusion of the jaws, to strike behind the lower teeth. But this variety of irregularity with these teeth is less frequent than with the incisores. The editor has, however, treated several cases within the last four years, and he has one case at this time under treatment. Plate XIV. Fig. 8, represents an inclined plane which he employed for the purpose of bringing a deviating cuspidatus forward to its proper place in the dental circle.]

The time to affect any material alteration in the position of the teeth, is before thirteen or fourteen years of age, and as much earlier as possible; for after that time the sockets of the teeth acquire a great degree of strength, and the teeth are so fixed that they cannot be moved without much difficulty. If the irregularity be left to a much later period, it becomes a great deal more difficult to produce any alteration, and frequently all attempts are fruitless.

[Not only is the difficulty increased by delaying to a later period, and especially after the twentieth or twenty-first year, but an increased susceptibility to morbid impressions will be induced in the sockets of the teeth, whose position has been changed, which will ever after

\* Plate XIII. Fig. 4.

remain, and render them more liable to the attacks of disease.]

To remove the kind of irregularity above mentioned, two objects must be accomplished; one, to apply a force which shall act constantly upon the irregular tooth, and bring it forward; the other, to remove that obstruction which the under teeth, by coming before the upper, always occasion.

The first of these objects may be attained by the application of an instrument adapted to the arch of the mouth, which, being attached to some strong teeth on each side, will furnish a fixed point in front, to which a ligature previously fastened on the irregular tooth may be applied, and thus, by occasionally renewing it, a constant pressure is preserved, and the tooth may be drawn forward.

The second object, that of removing the resistance of the under teeth, must be attained by placing some intervening substance between the teeth of the upper and under jaws, so as to prevent them from completely closing, and be an obstruction to the coming forwards of the irregular tooth.

The instrument may be made of gold or silver; it should be so strong as not easily to bend; if about the sixteenth of an inch in breadth, and of a proportionate thickness, it will be sufficiently firm. This bar of gold must be bent to the form of the mouth, and should be long enough to reach to the temporary [or first permanent] molares, which are the teeth to which it is to be tied. Holes are to be drilled in it at those places where ligatures are required, which will be on the parts opposed to the teeth designed to be the fixed points, and also at the parts opposite to the place where the irregular tooth or teeth are situated. Then to the bar a small square piece of ivory is to be connected, by means



of a little piece of gold, which may be fastened to the ivory and the bar by two rivets. This piece of ivory passes under the grinding surfaces of the upper teeth, is kept there fixed, and prevents the teeth from closing, and consequently takes off all obstruction in front.\*

[Gold caps are now pretty generally employed instead of blocks of ivory. These, when well adapted to the teeth over which they are placed, are far preferable, as they are less annoying to the patient, and can consequently be worn with less inconvenience. The first permanent molares are the most suitable teeth to be employed for the purpose. The second temporary molares, may, however, be used, or if they have been molted and replaced with bicuspidetes, these will answer, though less suitable than either of the others. When caps are used, it is not necessary to attach them to the gold bar passing round the front teeth.]

The bar is to be attached by a strong silk ligature to the teeth at the sides, so that if possible, it may remain tight as long as it is required; a ligature is then to be tied around the irregular tooth, and the ends, being brought through the holes in the bar, are to be tied in a firm knot. In two or three days this ligature must be removed and a new one applied; the tooth will soon be perceived to move. A fresh ligature must be used every three or four days, in order to keep up a constant pressure, sufficiently powerful to bring the tooth into a line with the others.†

The same mode of treatment is to be observed whether there be one, two, or three teeth growing in a similar manner. The teeth are usually brought forwards in about a month or five weeks, and as soon as they are so

\* Plate XIII. Fig. 5.

† Fig. 6, 7.

much advanced as to allow the under teeth to pass on the inside, the piece of ivory may be removed, and the bar only be retained for a few days, until the teeth are perfectly firm, which will prevent the accident of the teeth again receding.

[The gold bar and caps should be removed, and the teeth thoroughly cleansed, every time the ligatures are removed. This is necessary to prevent the teeth from being injured by the chemical action of the corrosive matter that forms between them and the gold bar, caps and ligatures.]

In cases where the irregularity has been suffered to continue too long, no success can be expected to follow attempts to remove it; we must content ourselves in the treatment of these cases in adults, with taking away the most irregular teeth, and thus, as much as possible, lessen the deformity.

[Various other methods have been proposed and adopted for the purpose of remedying irregularity of the teeth. M. Delabarre recommends the employment of ligatures, so applied, as to keep up a constant action upon the deviating teeth. Instead of using blocks of ivory or gold to prevent the teeth from coming together and forming a permanent obstacle to the adjustment of a tooth which has come out so far back of the dental circle, as to fall behind the lower teeth every time the mouth is closed, he employs wire caps or grates placed upon two of the lower molares. (See Plate XIV. Fig. 5.) This treatment, if it were the most efficient, would for several reasons be objectionable. In the first place, the ligatures, when applied so as to act upon a deviating tooth, acts with equal force upon the adjoining teeth, and moves them just as far from their place, as it does the other toward the place it should occupy. In the second



place, it is difficult to apply it so as to prevent it from coming in contact with and irritating the gums. Thirdly, it cannot be made to act with as much force when thus applied as when used in connection with the gold bar. The fourth and last objection, applies to the wire grates. These cannot be fixed to the teeth as readily as either the ivory blocks or gold caps, and such as could be conveniently employed for the purpose, would not interpose a barrier sufficiently thick in all cases to prevent the front teeth from coming together.

For remedying the description of irregularity under consideration, M. Catalan proposes the employment of an inclined plane, which may be made either of gold or silver, but the former is preferable, as the latter is liable to corrode in the mouth, fixed upon the lower teeth, in such a way that it shall strike behind the deviating tooth, at each occlusion of the jaws, and press it forward toward the place it should occupy. When several of the upper front teeth had come out behind the arch so as to fall behind the lower incisors, Catalan employed as many inclined planes as there were deviating teeth. See Plate XIV. Figs. 1, 2, for a copy of the engraving of his instrument, taken from the *Journal Général de Médecine, de Chirurgie et de Pharmacie*, for January, 1814, and the representation here given will supercede the necessity of any other description. When only one tooth strikes behind the circle of the lower teeth, a single inclined plane will be all that is necessary, as in the case represented in Plate XIV. Figs. 6, 7, 8.

The gold frame or case applied to the lower teeth, and to which the inclined plane is attached, should be fitted with the nicest accuracy, and made to enclose one or both of the bicuspidates on each side. The cutting edges of the incisors and points of the cuspidati need not be

covered with it. Its adaptation, when applied, should be such as to hold it firmly and securely in its place, and prevent the action of the deviating tooth upon the inclined plane from jostling or moving it in the least. It will be necessary too in adjusting the inclined planes to this frame, so that they shall act upon the right points on the deviating teeth, to have a plaster antagonizing model. The manner of obtaining this will be described in another part of this work.

When this instrument is employed, it of course is not necessary to interpose any substance between the back teeth, and it is unquestionably the most efficient and powerful agent that has ever been used for remedying this description of irregularity. But before it is applied, it should be ascertained whether there be a sufficient aperture in the dental circle for the reception of the deviating tooth, or teeth, if there be more than one, and if there is not, more room should be obtained by the removal of one of the bicuspidæ on each side, or the first molaris, if that be decayed. The tooth too, which is to be brought forward, should always be opposite the aperture it is intended it should occupy, before it is submitted to the action of the inclined plane. Therefore, when it is situated at either side, as is often the case, it should be moved with ligatures, to a point directly behind the vacuity, in which it is intended it should be forced, by the inclined plane, before that is applied.

It often happens, that one or more of the teeth, though situated in the circle, stands obliquely or transversely across it, so that its anterior and posterior surfaces, present laterally. All that is necessary in cases of this sort, is simply to turn the tooth or teeth, if there be more than one, partially round, in their sockets. To do this, M. Delabarre applies a gold cap to the twisted tooth, with



ligatures attached to each side, which he passes round the adjoining teeth and secures to the temporary molares or bicuspidés on either side, in such a manner as to make them act constantly in the direction the tooth is to be turned, upon it.\* I have found a gold ring, properly fitted to the tooth, to answer better than a cap, for the reason that it is less annoying to the patient. The object may sometimes be accomplished with ligatures alone.]

\* Plate XIV. Fig. 3, 4.

## CHAPTER EIGHTH.

### OF SUPERNUMERARY TEETH.

THE growth of more teeth than the natural number frequently occurs, and is always the cause of great irregularity of the teeth. It most commonly happens that supernumerary teeth are met with in the upper jaw, and they are chiefly placed in some part about the incisores and cuspidati. They are only rarely met at the posterior part of the mouth, and then they resemble small dentes sapientiæ, being placed on one side or other of those teeth.

The form of supernumerary is very different from that of any of the other classes of teeth; they are generally small round teeth, resembling the point of a quill,\* and sometimes they are not much unlike a broad bicuspid of the under jaw.†

When these teeth appear, they always create a considerable deformity; commonly there is only one of them, and that is placed either between the central incisores, or projecting over them, or between the central and the lateral incisores, or behind, turning towards the roof of the mouth.‡

When there are two supernumerary teeth, the fore part of the mouth is so filled as to occasion the incisores and cuspidati to be placed in a double row. I have seen

\* Plate XIII. Fig. 1.

† Fig. 2.

‡ Fig. 4, 5.



three remarkable instances of this kind: in one, there were two supernumerary teeth, of the conical kind, which were placed together, and had come behind and between the central incisores, which they had thrust forwards. The lateral incisores grew in a line even with the supernumerary teeth, behind the central incisores and cuspidati, and so formed a second row. This was the most conspicuous deformity of the teeth I ever saw, for the mouth could not be opened to speak, without completely presenting them to view.\*

In the other two cases the supernumerary teeth resembled bicuspidates of the lower jaw; they had large crowns, with depressions at their bases, and, by thrusting the other teeth into very improper situations, produced an appearance of a double row.†

[Supernumerary teeth are sometimes met with which bear so close a resemblance to the others, that it is impossible to distinguish the one from the other. I have met with several examples of this sort, both in the upper and lower jaws.]

These supernumerary teeth should always be extracted as soon as they are perceived; and if they have occasioned the other teeth to turn out of their right direction, the application of a ligature will soon bring them again into their regular situation.

\* Plate XV. Fig. 6.

† Fig. 7.

## CHAPTER NINTH.

### OF THE DECAY OF THE TEMPORARY TEETH.

THE temporary teeth are very liable to become carious, and generally cause a great deal of pain. Sometimes this disposition to decay shews itself very early, and in two or three cases I have seen every tooth in a diseased state at so early a period as three years. The little patients are generally dreadfully afflicted, and by their rest being disturbed, and their being unable to masticate food with comfort, the health is often much impaired. These circumstances render the extraction of these decayed teeth highly necessary.

Sometimes abscesses of considerable extent form about the sockets and gums of these carious teeth, and produce considerable mischief. I have seen the gums acquire a sloughy appearance, discharging a quantity of fetid matter; and sometimes so much injury is done as to occasion the death and exfoliation of portions of the jaw bones; when this happens it usually extends so far as to include the sockets containing the forming permanent teeth, which I have seen come away with the diseased temporary ones.\*

On these accounts it should always be recommended, when a child's teeth have become carious, and occasion pain, gum-boils, or abscesses, to extract them, as they not

\* Plate XVI. Fig. 12.



only very materially injure the health, but also are liable to prevent the formation of the permanent teeth.

[The preservation of the temporary, as has been stated in a preceding place, until they are removed by the operations of the economy, to give place to the secondary or permanent ones, or until the latter are about to appear, is of the utmost importance, and this, in the majority of cases, might be effected by timely and proper attention. The temporary teeth should be cleansed with a brush and waxed floss silk, three or four times every day, and if this were done from the time they make their appearance, there would not be one decayed deciduous tooth where there are now twenty. But when from neglect or any other cause, they do decay, such treatment should be instituted, as may be best calculated to arrest the progress of the disease. This, however, should be had recourse to, before the teeth have become much loosened from the wasting of their roots, for then, the use of the file upon them, and plugging, which are the proper remedies for caries, might, by shaking them in their sockets, cause injury to the new teeth beneath. But previously to this time, the treatment may be applied with impunity and it will be found as successful in the preservation of these as the permanent teeth. For arresting the progress of caries on the approximal surfaces of the temporary teeth, and especially the incisores, filing is preferable to plugging, but when the decay is in the grinding surface of the molares, the last operation is the proper remedy.

Sound teeth are as desirable and just as necessary to the comfort and health of a child as they are to an adult, and therefore they should not be permitted, from neglect of the means of their preservation, to decay, and the temporary teeth require as much care as do the perma-

nent ones, and they should never be extracted except for the relief of pain, that cannot be removed by any other means, or the cure of an alveolar abscess, or, as has been before stated, to make room for a permanent tooth. The popular opinion, that inasmuch as these teeth are to be replaced with others, it is of little importance whether they remain in the mouth until they are removed by nature to make room for their successors, or are lost a year or two earlier, is erroneous, and has been productive of much injury.]



## CHAPTER TENTH.

### OF THE DISEASES WHICH ATTEND DENTITION.

THE period of dentition in children is generally considered as one of the most critical in life. In infancy the animal frame is so delicate, that the least local irritation produces a sudden and universal sympathy throughout the whole body. Hence the excitement occasioned by the passage of the teeth through the gums often gives rise to the most alarming constitutional symptoms, which are always with difficulty alleviated, and not unfrequently terminate in death.

The mode in which the teeth pass through the gums is very much misunderstood; the prevailing opinion is, that as the teeth advance in growth, they find their way through the gums by their own mechanical pressure. The idea has given rise to the common expression of cutting the teeth, and the pain during dentition has been considered as being produced by a laceration of the membrane and gum covering the tooth.

That this is an erroneous opinion will be perceived, when the state of the teeth and gums at that time is considered. During its formation a tooth is loosely contained in the socket, and can exert no force sufficient to perforate so firm a substance as the gums. The gums also possess a certain degree of elasticity, and could by the gradual pressure of the rising teeth, be stretched so

as to become elongated with the progress of the teeth, and would continue to cover them.

A passage for the teeth is opened by the process of ulceration. By the pressure of any extraneous substance upon a sound part, or by a diseased enlargement of some part within the body, an absorption of the parts subjected to the pressure will take place. This, in a very remarkable degree, is seen in cases of aneurism, in which, by the pressure of a soft tumour, bones of the most compact structure are removed by the process of absorption, and that unattended with any secretion of pus.

[The foregoing explanation of the mechanism of dentition is too general to be very clearly or well understood. The most ingenious, and at the same time most plausible theory that has been advanced upon this subject, is given by M. Delabarre. This writer is of the opinion that the escape of a tooth from its matrix or sac, and passage through the gum is analogous, if not identical with that of the birth of a child. He regards the sac in connection with its neck or chord which passes from it to the surface of the gum, as the prime agent in this operation of the economy. It is by the retraction of this upon the neck of the tooth to which it is attached, that the tooth is raised from its socket towards the mouth or orifice of the matrix, and ultimately brought to a level with the gums. The peduncle or chord leading from the sac to the surface of the gum, is said by Goodsir to be solid, but Delabarre has demonstrated conclusively, that it is hollow, and there is reason for believing that as the tooth advances, it dilates so as to give egress to the tooth, and ultimately becomes the margin or free edge of the gum around its neck.

This is the only theory that explains upon any thing like sound philosophical principles, this most curious and



singular operation of nature. As the Editor has stated in another place, he repeats, it is difficult to imagine how the elongation of the pulp, or the moulding of the alveolar walls to it, can have any agency in raising or depressing a tooth through the gums. If the elongation of the pulp commenced before the crown of the tooth had made any progress toward the gums, it would at once come in contact with the floor of the alveolus, and in its soft and yielding condition, be caused to assume a configuration different from that presented by the root of a naturally developed tooth. The crown of the tooth must therefore make some progress toward the gums, before the elongation of its pulp can commence, and it is difficult to conceive how this can be effected, if it is not, as Delabarre supposes, by the contraction of the fibres of its sac.]

When the teeth have advanced so much in their formation as to be too long to be contained in the socket, under the gum, they press upon the membranes which enclose them; these become absorbed, and then the pressure being applied against the gum, that also is removed, and the teeth make their appearance. When the absorption of the membrane and gum takes place early, the child suffers no inconvenience during the progress of dentition. The teeth advance without any trouble, and their appearance is discovered by the mother or nurse with some degree of surprise: but when the growth of the teeth is too rapid for the absorption of the gums, dentition is often attended with much pain and derangement of the whole system. At this early period of life, as I have already observed, the constitution is so delicate, and the irritability so great, that the least cause of irritation produces an universal sympathy throughout the whole system. It is well known to many adults, that the



pain attending the protruding of the *dentes sapientiæ* is very great, and it therefore cannot excite surprise that this cause of irritation should in children produce so many distressing symptoms, and even be the cause of destroying so many.

When the formation of the tooth goes on very rapidly, and the absorption of the parts which cover it does not proceed in proportion, it becomes confined; this produces a distension of the membrane, and occasions pressure upon the pulp, nerves and vessels at the bottom of the socket. The tooth continues to grow, and the increased pressure, which is occasioned by this augmentation, produces inflammation, and a variety of symptoms of general irritation.

[If the theory advanced, just before, with regard to the mechanism of dentition be correct, and that it is, seems more than probable, the irritation produced by it cannot be caused by pressure of the tooth upon the 'pulp, nerves and vessels at the bottom of the socket,' but must result from inflammation produced by the pressure of the tooth against the sac and superincumbent gums.]

Few children obtain all their teeth without undergoing some degree of suffering: in many, the symptoms are merely local, in others they often arise to a very alarming height, and not unfrequently terminate fatally.

When the symptoms are merely local, the gums become very tender, and look redder than ordinary, the child is restless, and rather fretful: these symptoms with some children are of short duration, and always go off as soon as the tooth appears. Nature operates in a very salutary manner for their relief, by occasioning an increase in the secretion of the saliva, which generally is discharged in large quantities, and thus diminishes the action of vessels. In other cases a gentle diarrhœa takes



place, which also reduces the state of irritability. They also find relief from rubbing or pressing the gums, which is best done by themselves. The coral, though used as a common appendage to a child's dress, is a very injurious and a very improper substance: children ought to have nothing hard; they will put their fingers into the mouth and bite upon them; or they may have a soft crust of bread; this slight pressure will expedite the absorption of the gum, and consequently the passage of the tooth; while that produced by a harder substance will increase the irritation and inflammation.

When the constitution becomes affected, all the symptoms of general irritation occur, and there is scarcely any affection we do not meet with in one case or other of difficult dentition.

Fever is a frequent attendant, and it often comes on very suddenly; at first there is a heaviness about the eyes, the child then becomes hot, having the skin dry and tongue white; it gets very restless, putting the hand into the mouth, and can neither eat nor sleep. Sometimes these symptoms are so much aggravated that delirium will take place, and convulsions supervene.

In other children, the skin is more particularly affected; a little fever arises, which is soon followed by some kind of eruption. There are several appearances seen upon the skin during childhood, and which are the consequence of irritation during the time of dentition.

A very common eruption is a rash, which resembles the measles, and which appears in spots about the face and neck, sometimes extending over other parts of the body. This rash is like an aggregate of small pimples, so that when the finger is pressed over the red part, from the skin which is healthy, a small rising may be felt. This has been called the red gum, and is very common

to children during the early months. It may in general be esteemed beneficial; for the blood being carried to the skin, takes off any improper determination to important parts, and prevents more serious disease.

Sometimes postules arise in different parts of the body; they are at first transparent, from being filled with a limpid fluid, which afterwards becomes purulent, a scab forms, and the changes afford an appearance not unlike a mild small-pox.

There are other eruptions which form very unpleasant and extensive scabs; they break out upon the corners of the mouth, or on the cheek. Sometimes they begin upon the forehead, and spread over part of the scalp; they form large loose scabs, which drop off, but are soon succeeded by others. These scabs, however, leave no scar, and therefore are to be considered only as troublesome, and not dangerous.

Other children are subject to an inflammation, and a discharge from behind the ears; this may always be regarded as salutary, since from its contiguity to the teeth, it tends to divert the inflammation.

A gentle diarrhœa, during teething, is a beneficial effort of nature; it takes off the excitement from the constitution, and diminishes the febrile symptoms. But sometimes it becomes so excessive as to produce the most alarming symptoms; the discharges are of a green colour, very frequent, and attended with excessive griping; the rest is so much disturbed that no strength is gained by it; the child is continually starting, and spasms of various parts are occasionally seen; at length the whole system becomes so reduced that convulsions of the whole body take place, which continue until nature becomes completely exhausted.

In some children, the irritability of the nervous system



is so great, that convulsions supervene in a very short time after the appearance of any febrile symptom, and this is constantly the case with the cutting of every tooth. Besides these different affections, there are so many other anomalous symptoms, that it may be truly said, that every symptom of general irritation which can be mentioned, may be met with during the time of dentition. In some children the lungs are much affected, and they are troubled with difficult breathing; in others, the continual derangement of health is often the cause of scrofula, rickets, or consumption. Mr. Hunter mentions a remarkable sympathetic affection in a child, which arose from the irritation excited by teething. Formerly children were often placed under most dangerous circumstances, when they happened to be attacked with the small-pox at the same time as they suffered from dentition; but happily now, they may be defended from that dreadful malady, by the shield which has been raised by the admirable discovery of Dr. Jenner; and we have the certain prospect, that this most horrible of human maladies is about to withdraw its pestilential influence from the world for ever.

In the treatment of any affection incident to children during the progress of dentition, if the teeth are at all suspected to be concerned, the removal of the cause of irritation ought to be first attended to. This must be done by opening the gum, so as to take off the confinement from the tooth, and enable it to pass through. This operation ought always to be had recourse to in the first instance, and then other remedies should be applied according to the various symptoms which may appear.

When there is fever, the antiphlogistic regimen must be adopted. The bowels should be evacuated. The best medicine for children is calomel, which may be

combined with rhubarb or scammony; or some of the neutral salts may be exhibited.

After these, saline draughts or gentle antimonials should be administered, in order to produce a determination to the skin. If the head should be much affected, a blister to the nape of the neck would be very useful. In all cases of rash, or eruptions, the child should be kept warm, and be particularly preserved from taking cold, as great danger often follows the sudden disappearance of any affection of the skin. If this should happen, the child should be put into the warm bath, and some medicines administered to produce diaphoresis; also attention is to be paid to the bowels, that no costiveness be suffered. In general, slight eruptions are to be regarded as beneficial, and particularly those occurring behind the ears, attended with moderate discharge. In cases of difficult dentition, when no sore ear has arisen spontaneously, much benefit has followed the practice of rubbing a small quantity of blister ointment behind the ears, and thus inducing a slight discharge.

If scabs are extensive and become dry and hard, they may be washed with warm milk and water, and touched with a little oil. They also may occasionally be wetted with the *hydrargyrus muriatus, in aqua calcis*, in the proportion of 1 gr. to 1 oz.: the scabs should never be picked off, but left to separate of themselves. When they extend over the head and are moist, much trouble and pain is occasioned by the sticking of the cap; they should then be dusted with a little powder, or some fine fuller's earth, and a singed rag should be laid over them. In these cases much good has been seen to attend the use of an oiled silk cap, or a piece of oiled silk laid over the part, this prevents evaporation, and the scabs do not dry and become so troublesome.



All eruptions are to be regarded as salutary, for so great a sympathetic connection exists between the skin and the stomach, that it often happens, that the repelling of any eruption from the skin, immediately produces considerable derangement of that organ, which ought to be regarded as a sort of centre of sympathetic action. This is very strikingly seen in a variety of diseases in which the stomach sympathizes with the other parts of the body, and therefore during dentition it is of consequence not to check any mild eruption which may appear.

If a diarrhœa be only moderate, it should not be checked; it tends to diminish fever, and takes off the excitement from the constitution. As it is usually connected with acidity, a little magnesia, or some of the testaceous powders may be exhibited; but when the diarrhœa runs on for a great length of time, and seems to be causing weakness, which threatens fatal atrophy, serious endeavours must be made to subdue it.

The treatment of this complaint is attended with many difficulties, and medicines which succeed in some cases will totally fail in others. If the abdomen be much enlarged, two grains of calomel every night, purged off in the morning with ten grains of rhubarb and half the quantity of magnesia, will generally be found beneficial. This should not be persevered in more than three or four days successively, and should be succeeded by eight grains of the *pulvis cretæ comp. cum opio*, and four or five grains of columba root. The patient should be warmly clothed, especially on the abdomen and lower extremities. On some occasions the *pulv. trag. comp.* appears preferable to the *pulv. cretæ comp.*; and the *syrup.* or *decoct. althæ*, with 20 drops of paregoric elixir, have succeeded when the other usual means have failed. The warm bath may be considered as another perfect species



of warm clothing, and is attended with good effects, by relaxing the pores of the skin and relieving the bowels. If the above mentioned remedies cannot be taken by the patient, opiate frictions of the abdomen or back should be used, and the following formula will answer very conveniently. *R. Ung. hydr. fort. ʒi.—pulv. opii puri. ʒi. olei oliv. ʒiij. fiat linimentum bis terve in hebdomade infric;* but the quantity and repetition must be regulated by the judgment of the practitioner. If the patient is much distressed by tenesmus and stools streaked with blood, clysters of starch, with 20 drops of *tr. opii*, and twice that number of *tr. catechu* or *kino*, should be given every evening.

When convulsions have taken place, we must endeavour to remove what appears to be the exciting cause. If the stomach have been overloaded with improper food, or there be signs of indigestion, a gentle emetic should be given. If there is costiveness, or the bowels are affected, they should be cleansed by a clyster: when the stools are offensive, or the breathing at all affected, a few grains of calomel and scammony may be given with advantage. If those medicines do not succeed, antispasmodics should be administered. It often happens that the deglutition is much affected, then it will be right to give an enema with *asafœtida*: or if not, in a draught, a drop or two of *tinct. opii* should be given. The back may be rubbed with oil of amber, or *aqua ammoniæ*.—During the fit it is always proper to put the lower parts of the body into warm water, which by exciting a greater flow of blood to the legs, takes off too great a determination to the head; a blister should be applied to the back of the neck, and leeches may be applied to the temple.

Other symptoms which arise, must be met according to their urgency; but we ought never to lose sight of what



may appear to be the principal exciting cause, viz. the inability of some teeth to pass through the gums.

Under every circumstance of indisposition, arising from dentition, the lancing of the gums ought never to be omitted. The benefit which attends the operation is so sudden, and if performed sufficiently early, is so certain, that it ought never to be neglected. As soon as the gum is lanced and the membrane is divided, the tooth obtains an increase of room, the pressure is immediately taken off from the socket, and the cause of irritation is removed.

It is very surprising that, notwithstanding the manifest advantage which attends the lancing of the gums, in cases of painful dentition, there are persons who entertain strange prejudices against this safe and important source of relief. But the uniform experience of its good effects, and no instance of its doing harm ever having occurred, should produce an unanimous consent for adopting it. Some persons object to the operation on account of the pain which it will occasion to the child, not considering that the inflammation produced by the resistance of the gum to the tooth, is far more acute than dividing the gum with a sharp instrument. Others suppose that the formation of the teeth is injured, and that they are more liable to decay; but neither of these circumstances can occur; for at the time that the teeth is about to pass through, the enamel is completely formed, and no injury can be done to the formation of the fang, which is always continued for some time after the appearance of the crown.

When it is necessary to lance the gums some time before the teeth are quite ready to appear, they unite, and in this case the cicatrix has been said to impede the progress of the tooth, presenting a greater resistance than the gums in their natural state; but it is now certainly known that a newly formed part always gives way sooner to the

process of absorption than the surrounding parts, and hence the passage of the tooth is facilitated.

The hæmorrhage which is occasioned by the operation is never considerable, but is always beneficial; the vessels become unloaded, and the inflammation is always soon diminished.

The most convenient instrument for this purpose is a round edged gum lancet; this cuts much easier than a pointed one. It is necessary that the tooth be felt with the edge of the instrument, else the membrane may still be left upon the stretch, and no other benefit be derived than that which proceeds from the topical bleeding. In lancing the incisores it will be proper, in dividing the gum, to pass the lancet down on the anterior part of the tooth: for if it be carried deep on the posterior part of the tooth, there may be a danger of dividing the membrane which connects the pulps of the permanent teeth to those of the temporary, and the formation of the former may be injured.\* [When the incision is made directly through the summit of the gums covering the alveolar ridge, the lancet passes behind the teeth, and to prevent which it should be made about the twelfth or sixteenth part of an inch anterior to it.]

When the gums of the molares are to be lanced, a crucial incision may be made, or two semilunar incisions, the gums soon separate, and the tooth shortly makes its appearance. The symptoms which usually precede any indisposition arising from teething ought to be universally known, because then the certain remedy may be applied in time, and a great deal of suffering be spared to the child. If the nurse be attentive, she will find the child does not take the nipple with the same degree of force as ordinary, or it holds it only for a short time, and soon

\*Plate IX: Fig. 5.



lets it go; the gums feel hot, and are redder than usual; the cheeks appear flushed, the eyes look heavy, and the child is uneasy. When these symptoms appear, the mouth should be examined, and if there be any fulness of the gums, or they have the appearance of inflammation, they should be lanced at that part. The order in which the teeth appear should always be kept in mind, and then there will be little probability of mistake, as to the spot where the cause of irritation is seated.

As a child increases in strength, the symptoms arising from dentition diminish, and often become merely local; but the diseases to which infants are liable, frequently keep them in weak health, and much disposed to be affected by any exciting cause of irritation.

To delicate children there is often danger attending the cutting of the cuspidati and the first molares. These teeth advance in growth nearly at the same time, so that there are eight teeth making pressure upon the membranes and the gums at the same period. If at this time a child should be at all indisposed, one or other of these teeth may be the cause of convulsions, or some other serious disease; therefore, when any of these teeth appear to be in a state of forwardness, the gum should be lanced. This is the only method of treatment to be relied on to bring a weakly child through this period.

During the second dentition, with one exception, scarcely any pain is felt; the constitution has acquired such a degree of strength that the sympathetic action is with more difficulty excited, and the only inconvenience ever experienced is, when the permanent teeth, which are placed at the base of the temporary ones, by the increase of their growth make pressure against them; this more particularly happens when the bicuspidæ are endeavouring to come forward, and being resisted, by the continuance

of the temporary molares, a tenderness and pain are occasioned, which can only be relieved by extracting the temporary teeth, and thus giving way for the passage of the permanent.

The exception to which I have alluded with respect to pain during the second dentition, is in the *dentes sapientiæ*; very often a great deal of pain attends the progress of these teeth. When there is scarcely sufficient space for them to grow, or the gum being very thick is firmly bound over them, considerable inflammation, and sometimes swelling of the face takes place. In many cases the pain is so severe as to excite a considerable degree of fever and indisposition. I have known persons confined from this cause only, during several weeks. If the *dentes sapientiæ* of the upper jaw pass through first, it very much increases the inflammation, because whenever the mouth is closed, the gums which cover the teeth in the under jaw are bitten upon by the upper, and being continually pinched, the patient suffers extremely.

Generally it is only necessary to lance the gums with a crucial incision; there is often a good deal of hemorrhage, which is very useful in reducing the inflammation; the gum soon retracts, and the tooth gradually passes through. When the upper *dentes sapientiæ* appear first, it is sometimes necessary to cut off the piece of gum which covers the under tooth.

In many cases the gum is very thick, and will often close and unite again after the operation; this produces a necessity for repeating it; but which might always be prevented, by inserting a small piece of lint between the edges of the divided gum, which then cannot unite; they remain separated, and gradually receding, the tooth has no longer any obstruction.

Sometimes, in these cases the gum is exceedingly



swelled over the tooth, and when divided by the lancet, a considerable quantity of glairy fluid escapes; in some instances I have met with considerable quantity of matter, and in one case the gum was ulcerated to a great extent.

[But neither lancing the gums nor cutting out a piece from over the tooth, will always afford relief, the extraction of the tooth itself is often necessary, or the antagonizing one in the other jaw, which, having made its appearance first, strikes the gums covering this, at each occlusion of the mouth, causing it to inflame and swell and oftentimes to become exceedingly painful. The extraction of the second molaris will generally give relief, and when this is very much decayed, it is better to remove it, than the dens sapientiæ. So great is the irritation sometimes produced by the dentition of these teeth, that trismus has been known to result from it. Two cases of this sort have fallen under my own observation. In cases of this sort, the treatment should be addressed to the general system. Copious bleeding, warm bath and small doses of emetic tartar should be had recourse to, for the purpose of inducing a relaxation of the muscles of the jaw, and so soon as this is accomplished, the tooth should be extracted.]

## CHAPTER ELEVENTH.

BEING desirous to render this work as complete as possible, I requested the favour of my friend, Mr. Pepys, to make a chemical analysis of the teeth, and from the accuracy with which all his experiments are conducted, I flatter myself that the following observations will not a little enhance the value of the publication.

### THE ANALYSIS OF HUMAN TEETH.

BY W. H. PEPYS, JR.

Mr. Charles Hatchet, in his valuable paper on shell and bone, [Phil. Transact. for 1799] enumerated the several substances which enter into the composition of the human teeth; it is to be regretted that the nature of his subject did not render it necessary for him to ascertain the proportions in which they are respectively found, as it could not have failed to have proved highly useful, and his known accuracy would have precluded the necessity of any other person undertaking such a labour. Several good analyses of bone have been published, but I believe no accurate analysis of the teeth has yet been offered.

Bone, it has been observed, when exposed to the action of acid menstrua, becomes dissolved; that is to say, the solid or constituent substance of them is abstracted, and a gelatinous matter is left of the form of the original bone.



Nitric, muriatic, and acetic acids are capable of producing this change, which is accompanied with a liberation of an æriform fluid, that precipitates lime in lime water, changes vegetable blues red, and by its gravity is known to be carbonic acid gas. These acid solutions yield a copious precipitate with pure ammonia, which is again soluble in either of the acids. After the precipitation by pure ammonia, the solution of the carbonate of ammonia will still produce a new precipitate.

The precipitate of the first solution, by pure ammonia, as noticed above, is soluble again in the acids before mentioned; these solutions yield, with a solution of acetite of lead, a copious precipitate, proving the presence of phosphoric acid.

The precipitate obtained by the carbonate of ammonia is also soluble in either of the above acids, but with effervescence; and these solutions are not precipitated by acetite of lead; they fall, however, with oxalate of ammonia, carbonate of ammonia, or any precipitant of lime.

The great solubility of the phosphate of lime, in even the weakest of the acids, is very extraordinary. Phosphate of lime mechanically suspended in water, is speedily and completely dissolved by passing a copious stream of carbonic acid gas through it.

With these facts before me, I have ventured to examine the several specimens of the human teeth; as the enamel, the bone, or roots, the teeth of adults, and the shedding teeth of children.

Previous to an account of the analysis, it may not be uninteresting to notice the action of some of the articles of the *materia chemica* on the teeth.

Sulphuric acid, of the specific gravity 1.83, appears at first to have no action; in the course of an hour small bubbles are perceived, the roots become blackened, and

in twelve hours the enamelled part bursts, cracks, and separates, accompanied with an evident formation of selenite, by the action of the acid on the lime, which enters into the composition of the teeth.

Nitric and muriatic acids of the specific gravity of 1.12, act instantly on the tooth, accompanied with an evolution of a quantity of small air bubbles from the whole of the surface; about eight times their weight of these acids are sufficient for the solution of the solidifying principles of the teeth. The mass left undissolved has nearly the original form of the tooth, is flexible, semi-transparent, and easily divided by the nail.

The dilute acetous acid (distilled vinegar) has a very trifling action, but when concentrated, acts both on the phosphate and carbonate of lime.

Boiling nitric acid acts strongly on a tooth, with the evolution of carbonic acid, and a considerable quantity of azotic gas. The gelatine and solid substance are dissolved as the surfaces present themselves; but the operation being stopped at any part of the process, the residuum is firm and hard, but reduced in size proportioned to the time the tooth has been acted upon.

## ANALYSIS OF THE ENAMEL.

One hundred grains of the enamel of human teeth, (carefully rasped) were placed in 600 grains of nitric acid of the specific gravity of 1.12. Slight effervescence ensued, and after twelve hours 200 grains more of the acid were added. Allowing for the loss by evaporation in a corresponding vessel, after thirty-six hours it was found to have lost four grains and a half.



It was then diluted with four ounces of distilled water, precipitated by pure ammonia, and then filtered.

The precipitate obtained being dried in a water bath, at  $212^{\circ}$ , weighed 102 grains. It was then ignited, after which it was found to weigh 78 grains.

The filtered solution was then precipitated by carbonate of ammonia in solution, and filtered:

The separated precipitate being dried in a heat of  $212^{\circ}$ , weighed six grains. Enamel then consists of

Phosphate of lime,	.	.	.	78
Carbonate of lime,	.	.	.	6
				<hr/> 84
Water of composition and loss,	.			16
				<hr/> 100

A loss of 16 grains here takes place, which is easily accounted for, from the impossibility of directly ascertaining the state of dryness in which the ingredients existed originally in the enamel; for we have seen, that by drying the phosphate of lime in a heat of  $212^{\circ}$ , (after which it had the appearance of being as dry as possible) it yet contained so much moisture, as to yield a gain of 8 grains in the analysis.

On the other hand, when ignited, its state is driven to the opposite extreme, and there is a loss of 16 grains. It is impossible, however, that the materials could exist in the teeth, in a state of dryness to be compared with that produced by exposing them to such a high temperature. And it appears but reasonable to conclude, that the real quantity of moisture lies nearer to that given by the heat of  $212^{\circ}$ , than to that given by ignition, and consequently that the 16 grains lost by exposure to such a high temperature, were chiefly water.

Bone, or roots of teeth, yielded by analysis in 100 grs.,

Phosphate of lime, . . .	58
Carbonate of lime, . . .	4
Gelatine, . . . . .	28
	<hr/>
	90
Water of composition and loss, .	10
	<hr/>
	100

The teeth of adults yielded on analysis in 100 grains,

Phosphate of lime, . . .	64
Carbonate of lime, . . .	6
Gelatine, . . . . .	20
	<hr/>
	90
Water of composition and loss, .	10
	<hr/>
	100

Specific gravity of adults' teeth, . 2.2727.

The shedding, or primary teeth of children, yielded on analysis in 100 grains,

Phosphate of lime, . . .	62
Carbonate of lime, . . .	6
Gelatine, . . . . .	20
	<hr/>
	88
Water of composition and loss, .	12
	<hr/>
	100

Specific gravity of children's teeth, . 2.0833.

In these analyses, as in the former, the phosphate of lime was also exposed to a red heat, and consequently was reduced to a greater degree of dryness than that in which it existed in the tooth.

In all of them the carbonate of lime was dried in a heat of  $212^{\circ}$  (above which it would have been liable to decomposition) and the gelatine of the three last in the same temperature.



These various of earth yielded by analysis in 100 grs.

1. Magnesia, 100 grs. 100

2. Silica, 100 grs. 100

3. Alumina, 100 grs. 100

4. Iron, 100 grs. 100

5. Lime, 100 grs. 100

6. Potash, 100 grs. 100

7. Soda, 100 grs. 100

8. Magnesia, 100 grs. 100

9. Silica, 100 grs. 100

10. Alumina, 100 grs. 100

11. Iron, 100 grs. 100

12. Lime, 100 grs. 100

13. Potash, 100 grs. 100

14. Soda, 100 grs. 100

15. Magnesia, 100 grs. 100

16. Silica, 100 grs. 100

17. Alumina, 100 grs. 100

18. Iron, 100 grs. 100

19. Lime, 100 grs. 100

20. Potash, 100 grs. 100

21. Soda, 100 grs. 100

22. Magnesia, 100 grs. 100

23. Silica, 100 grs. 100

24. Alumina, 100 grs. 100

25. Iron, 100 grs. 100

26. Lime, 100 grs. 100

27. Potash, 100 grs. 100

28. Soda, 100 grs. 100

29. Magnesia, 100 grs. 100

30. Silica, 100 grs. 100

31. Alumina, 100 grs. 100

32. Iron, 100 grs. 100

33. Lime, 100 grs. 100

34. Potash, 100 grs. 100

35. Soda, 100 grs. 100

36. Magnesia, 100 grs. 100

37. Silica, 100 grs. 100

38. Alumina, 100 grs. 100

39. Iron, 100 grs. 100

40. Lime, 100 grs. 100

EXPLANATION OF PLATES


TO

PART FIRST.



EXPLANATION OF PLATES

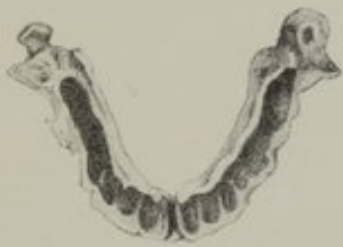PART FIRST.



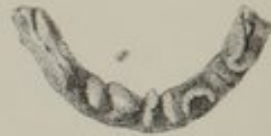

*Plate 1.*

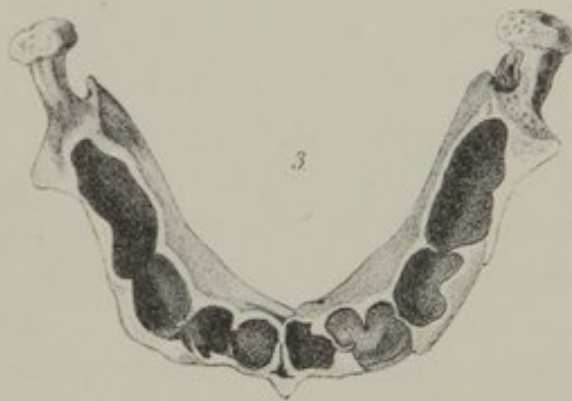*Fig. 1.*



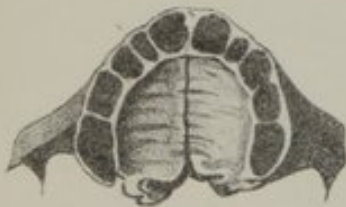2



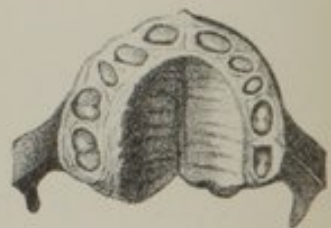3



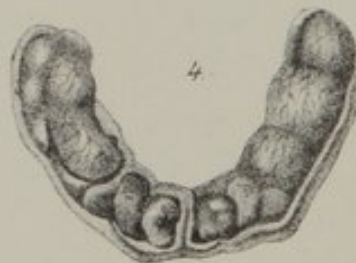5



6



4



## PLATE I.

### THE RUDIMENTS OF THE ALVEOLAR PROCESSES AND THE PULPS OF THE TEETH.

FIG. 1. The under jaw of a fœtus at three or four months. In the anterior part, processes of bone are shooting across to form the alveoli for the incisores.

FIG. 2. The gums removed from the same jaw bone, exhibiting the first appearance of the pulps, those of the incisores being the most distinct.

FIG. 3. The under jaw of a fœtus at six months, in which the alveolar processes are seen more advanced.

FIG. 4. The pulps removed from the same jaw, distinctly formed, each contained within its proper membrane.

FIG. 5, 6. The upper jaws of fœtuses of the same age, as in Fig. 1, 2; exhibiting the alveolar processes and pulps.



## PLATE II.

THE PROGRESS IN THE FORMATION OF THE TEETH FROM THE  
TIME OF BIRTH, UNTIL BETWEEN TWO AND THREE YEARS  
OF AGE.

\* \* The figures on the left side of the plate represent the teeth as naturally situated; those on the right side as taken out from the sockets; the dotted lines represent the gums.

FIG. 1. The teeth at the time of birth, when they are only shells, having the form of the crowns of teeth.

- a.* The central incisores.
- b.* The lateral incisores.
- c.* The cuspidati.
- d.* The first molares.
- e.* The second molares.

*A.* Points of ossification upon the tips of the pulps of the permanent incisores.

*B.* Points of ossification upon the points of the permanent molares.

FIG. 2. The teeth of a child about six or eight months after birth. At this time the central incisores of the upper jaw, and the central and lateral incisores of the lower jaw, have made their appearance; the other teeth are considerably advanced in growth.

Fig 1

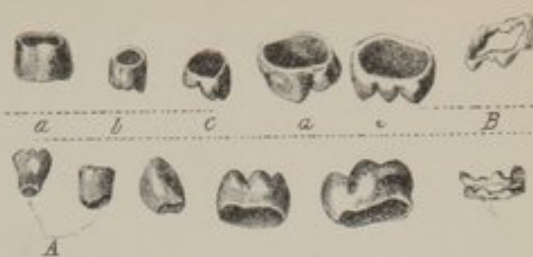
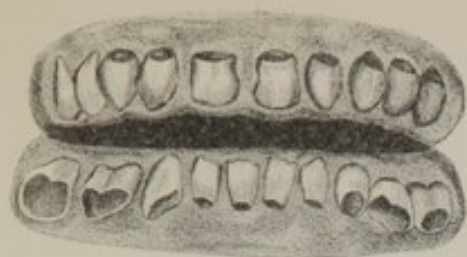
Fig 2



Fig 3

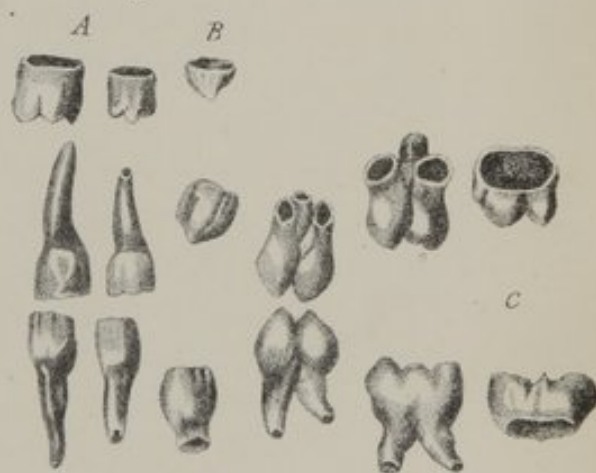
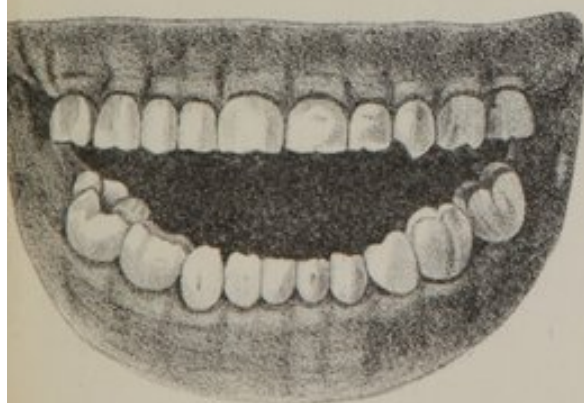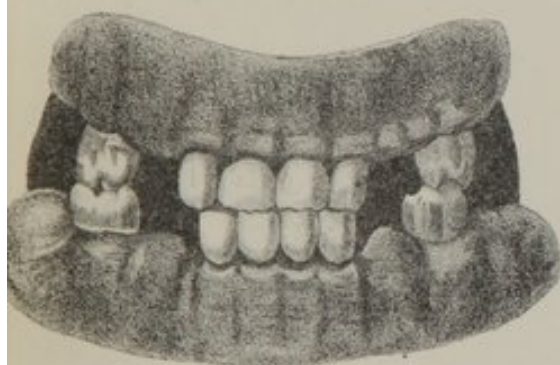
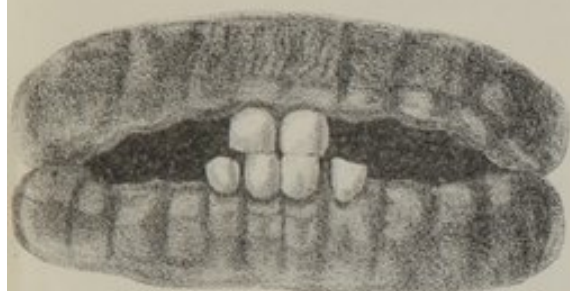
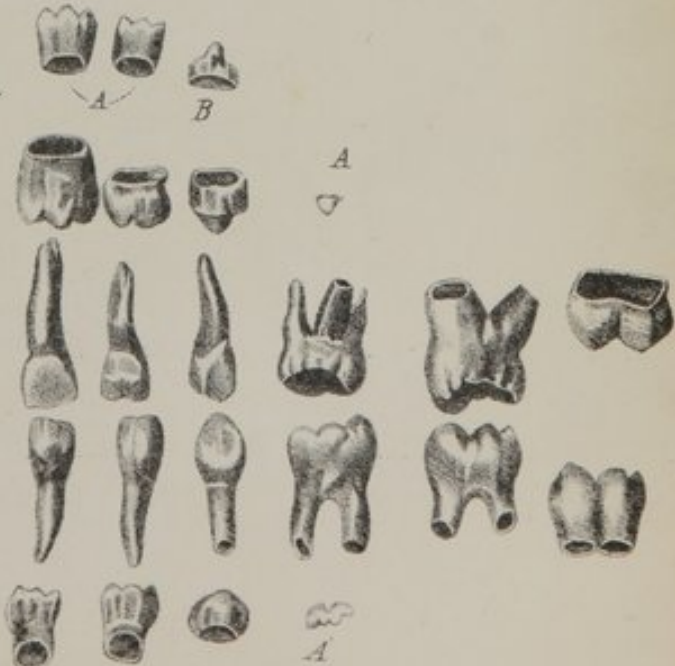



Fig 4







*a b c d e.* The temporary teeth.

*A.* The permanent central incisores.

*B.* The permanent lateral incisores.

*C.* The permanent cuspidatus of the lower jaw.

*D.* The first permanent molares.

FIG. 3. The teeth of a child at sixteen months. The incisores in each jaw, and the first molares, have passed through the gums.

*A.* The permanent incisores much increased.

*B.* The cuspidati.

*C.* The first permanent molares.

FIG. 4. The temporary set of teeth have all passed through the gums, and in addition to the permanent teeth already described are,

*A A.* The points of the first bicuspidates.



## PLATE III.\*

THE TEETH OF A CHILD BETWEEN FOUR AND FIVE YEARS  
OF AGE.

FIG. 1. A side view.      FIG. 2. A front view.

### *Of the temporary set.*

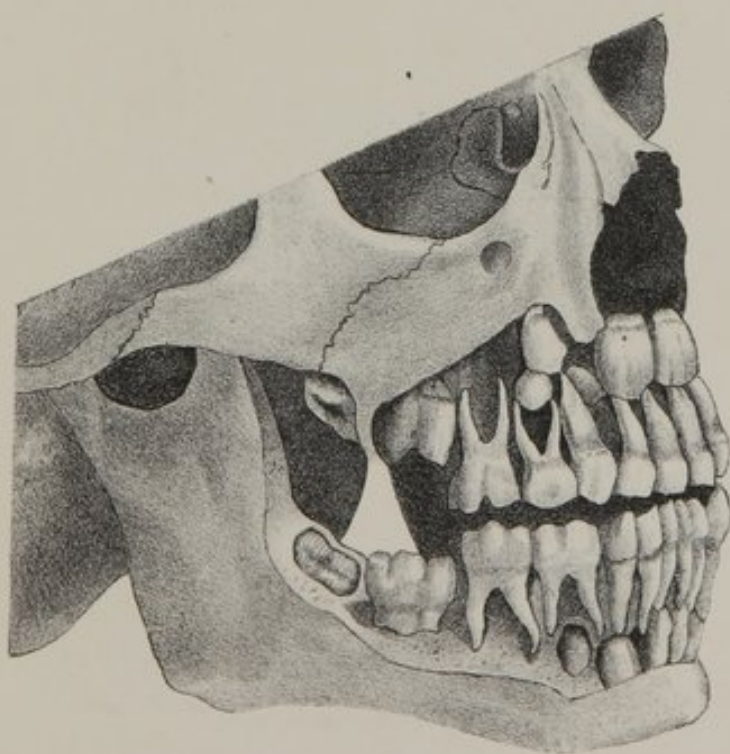
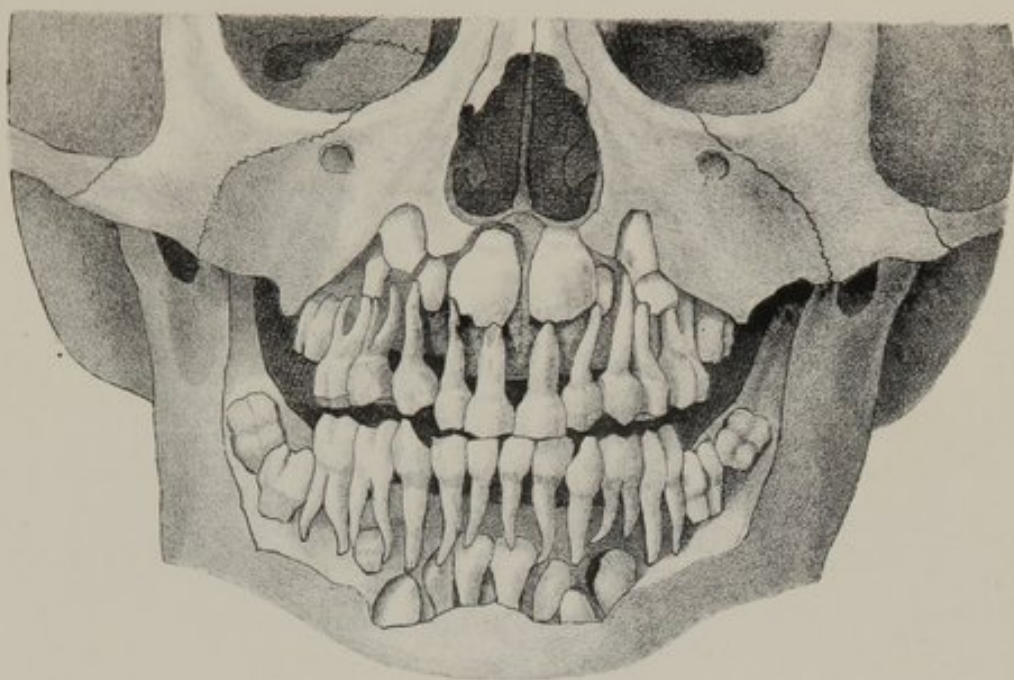
- a a a a.* The central incisores.
- b b b b.* The lateral incisores.
- c c c c.* The cuspidati.
- d d d d.* The molares.

### *Of the permanent set.*


- e e e e.* The central incisores.
- f f f f.* The lateral incisores.
- g g g g.* The cuspidati.
- h h h h.* The first bicuspidates.
- i i i i.* The first molares.
- k k.* The second molares.


The formation of the second bicuspidates has not yet commenced.

\* For the references to this Plate, and Plates IV. and V. see the outline Plate VI.

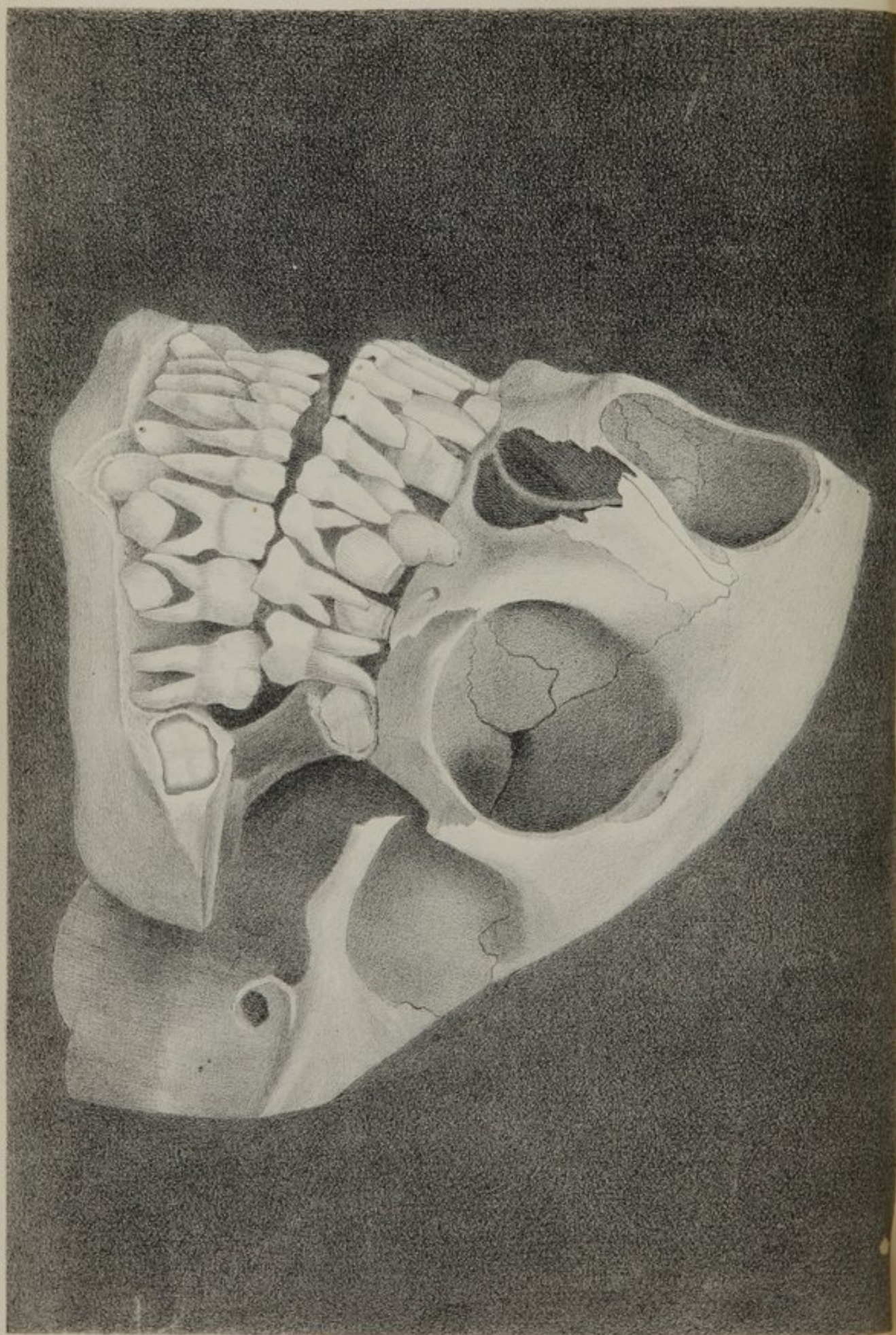












## PLATE IV.

THE TWO SETS OF TEETH AT SIX YEARS OF AGE.

FIG. 3. of Plate VI.

### *Of the temporary set.*

*a a a a.* The central incisores.

*b b b b.* The lateral incisores.

*c c c c.* The cuspidati.

*d d d d.* The molares.

### *Of the permanent set.*

*e e e e.* The central incisores.

*f f.* The lateral incisores.

*g g g g.* The cuspidati.

*h h h h.* The first and second bicuspidates.

*i i.* The first molares.

*k k.* The second molares.



## PLATE V.

THE TEETH AT EIGHT OR NINE YEARS OF AGE. THE INCISORES HAVE BEEN CHANGED, AND THE FIRST PERMANENT MOLARES HAVE APPEARED.

### FIG. 4. of Plate VI.

#### *Of the temporary set.*

*a a.* The cuspidati.

*b b b b.* The molares.

#### *Of the permanent set.*

*c c c c.* The central incisores.

*d d d d.* The lateral incisores.

*e e.* The cuspidati.

*f f f f.* The bicuspidates.

*g g.* The first molares.

*h h.* The second molares.

*i i.* The third molares, or dentes sapientiæ, beginning to form.

Fig 4.

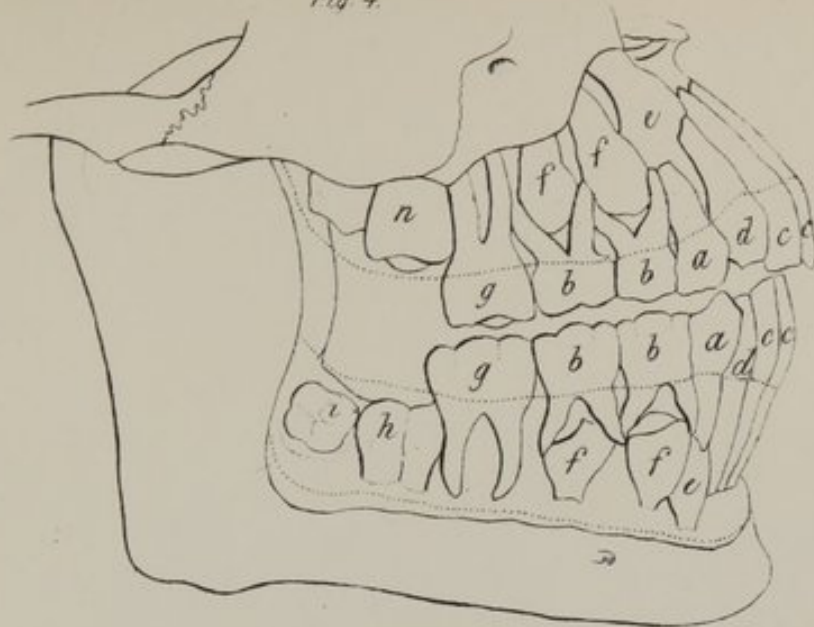


Fig 2

Fig 1

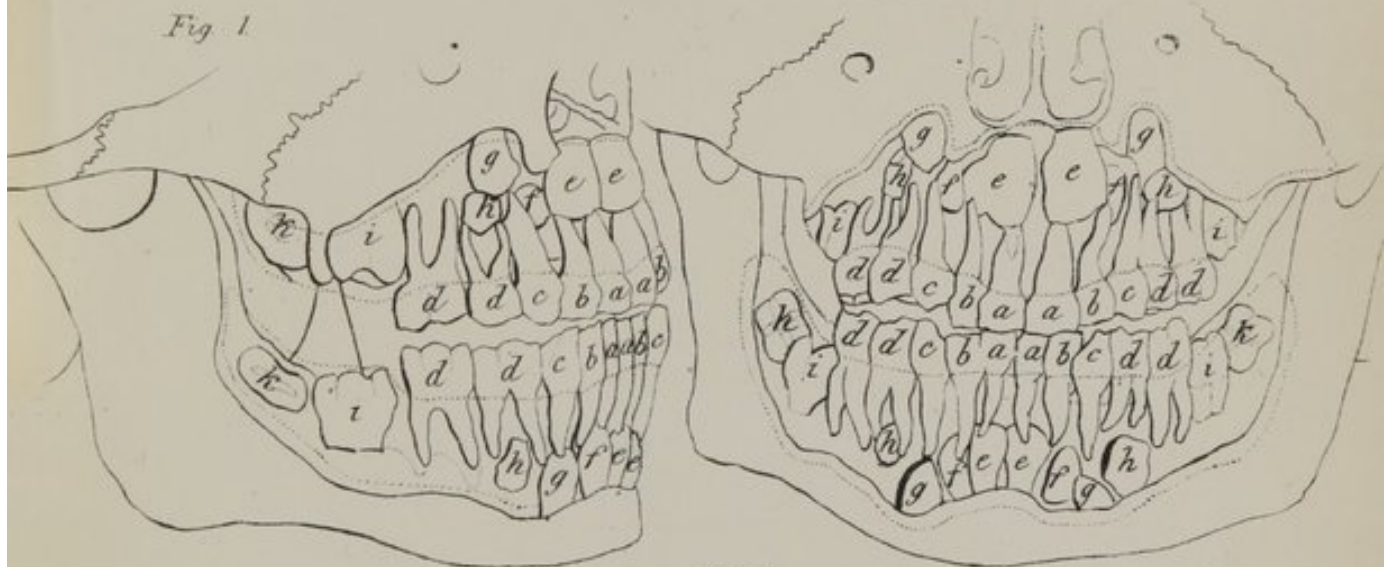
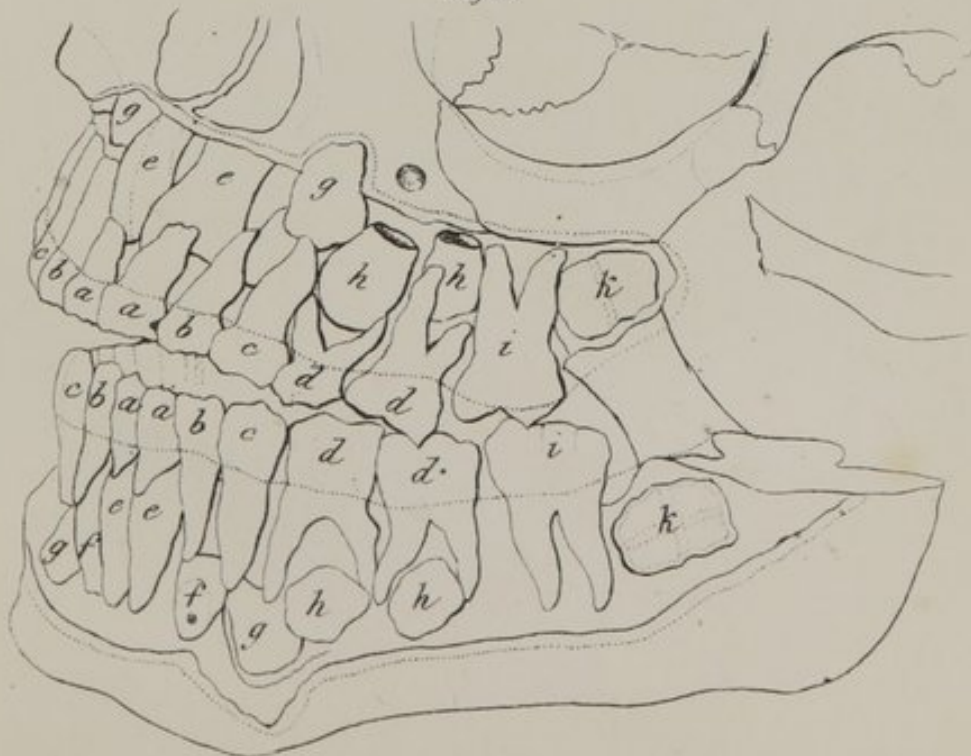




Fig 3

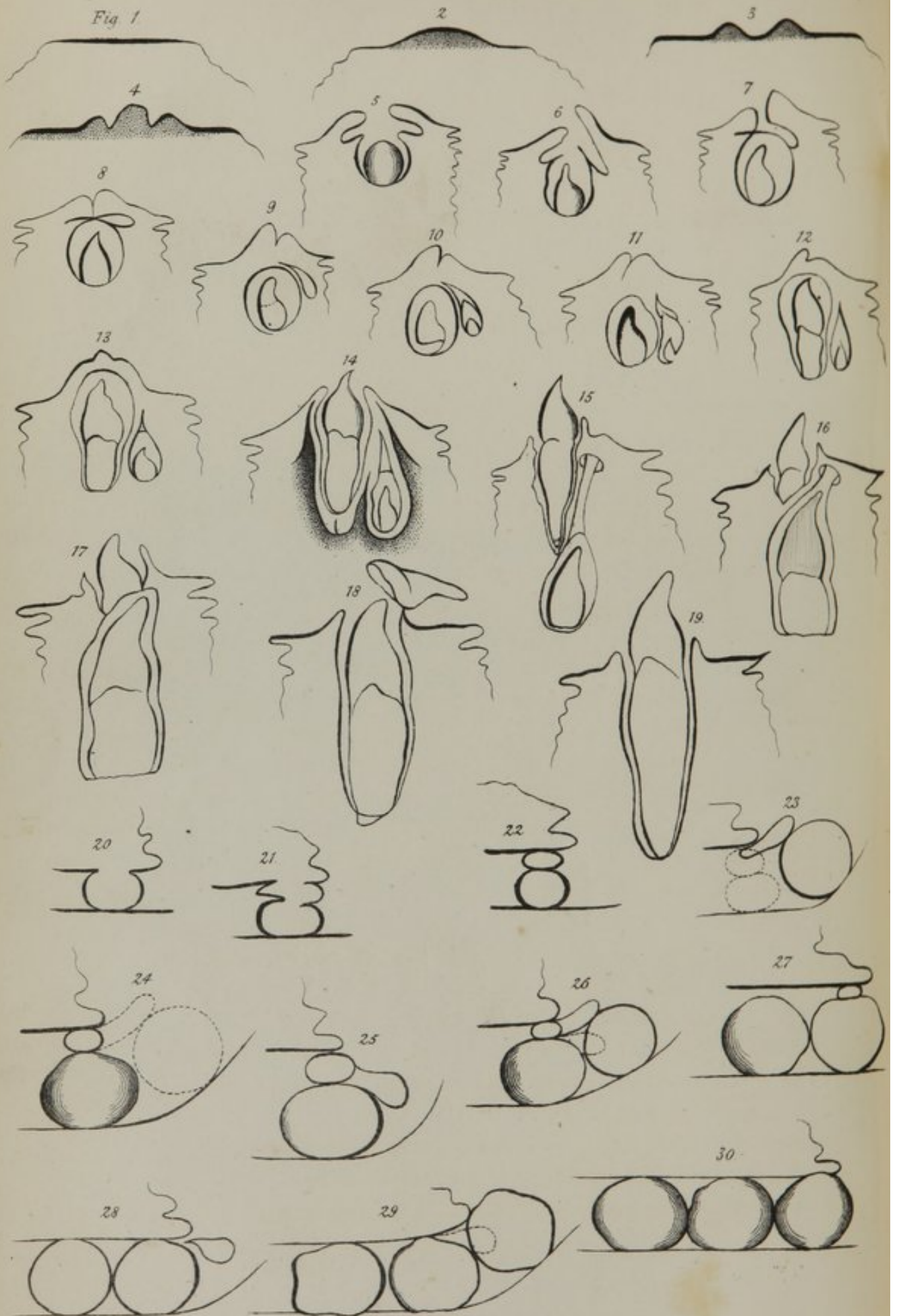












## PLATE VII.

(FROM GOODSIR.)

FIG. 1. Mucus membrane.

FIG. 2. Mucus membrane with a granular mass rising up from it.

FIG. 3. Primitive dental groove.

FIG. 4. A papilla on the floor of the groove.

FIG. 5. The papilla enclosed in a follicle, and the secondary dental groove forming.

FIG. 6. The papilla assuming the shape of a pulp, the opercula forming and a depression for a cavity of reserve behind the inner operculum.

FIG. 7. The papilla after it has become a pulp, the follicle a sac by the adhesion of the lips of the opercula, and the secondary dental groove in the act of closing.

FIG. 8. The secondary groove adherent, except behind the inner operculum, where there remains a shut cavity of reserve for the formation of the pulp and sac of the permanent tooth.

FIG. 9. The last change more complete by the deposition of the granular body, deposition of tooth-bone commencing.

FIG. 10. The cavity of reserve receding, its bottom in which the pulp is forming dilating.

FIG. 11. The cavity of reserve becoming a sac with a



pulp at its bottom, and further removed from the surface of the gum; the temporary tooth covered with a layer of bone, and the granular substance absorbed.

FIG. 12. The temporary tooth getting its fang, and approaching the surface of the gum.

FIG. 13. Root of the temporary tooth longer, and its sac touching the surface of the gum.

FIG. 14. Eruption of the temporary tooth; its sac again a follicle, and the permanent receding further from the surface of the gum.

FIG. 15. Completion of the temporary tooth; free portion of the sac become the vascular margin of the gum, and the permanent sac connected by a chord passing through the alveolo-dental canal or foramen.

FIG. 16. Lengthening of the root of the permanent tooth, the crown approaching the gum, and the root of the temporary tooth partly destroyed.

FIG. 17. The changes last described more advanced.

FIG. 18. The eruption of the permanent tooth, and the molting of the temporary.

FIG. 19. The permanent tooth perfected.

FIG. 20. The primitive dental groove in its non-adherent state.

FIG. 21. The papilla and follicle of the first molaris on the floor of the non-adherent portion of the groove, now become the secondary groove.

FIG. 22. The papilla a pulp, and the follicle a sac, and the lips of the secondary groove adhering, so that the latter has become the posterior or great cavity of reserve.

FIG. 23. The sac of the first molar increased in size, advancing into the coronoid process or maxillary

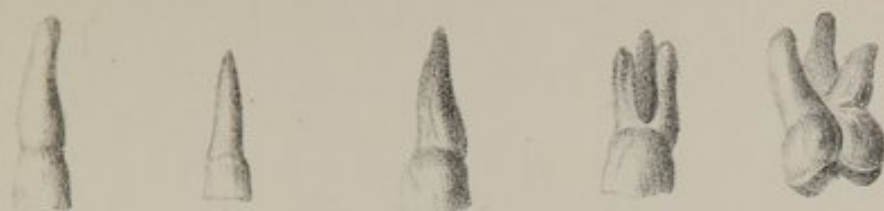tuberosity, and the cavity of reserve lengthened.

- FIG. 24. The sac of the first molaris returning by the same path to its former position, and the cavity of reserve shortening.
- FIG. 25. The cavity of reserve sending backwards the sac of the second molaris.
- FIG. 26. The sac of the second molaris passing into the coronoid process or maxillary tuberosity.
- FIG. 27. The second molar sac returned, and the cavity of reserve shortened.
- FIG. 28. The cavity of reserve sending off the sac and pulp of the wisdom tooth.
- FIG. 29. The sac of the wisdom tooth advanced into the coronoid process or maxillary tuberosity.
- FIG. 30. The sac of the wisdom tooth returned to the extremity of the dental range.

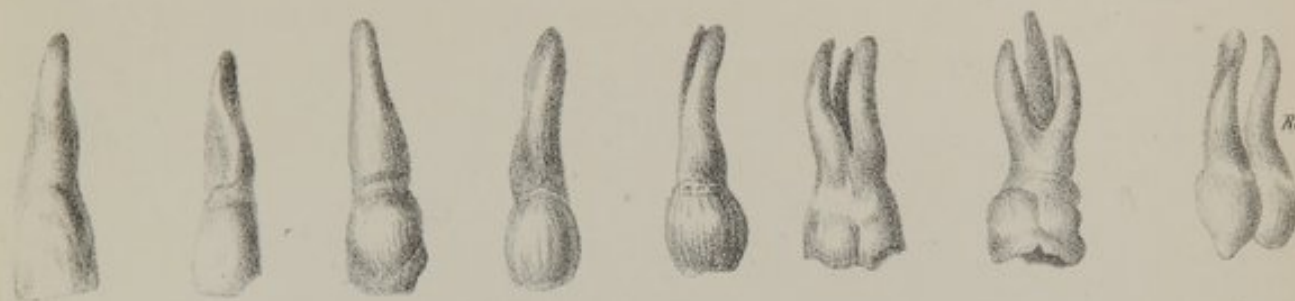

## PLATE VIII.

- FIG. 1. The permanent set of teeth complete.  
Row 1. The temporary teeth of the upper jaw.  
Row 2. The permanent teeth of the upper jaw.  
Row 3. The permanent teeth of the lower jaw.  
Row 4. The temporary teeth of the lower jaw.



Row 1.



Row 2.

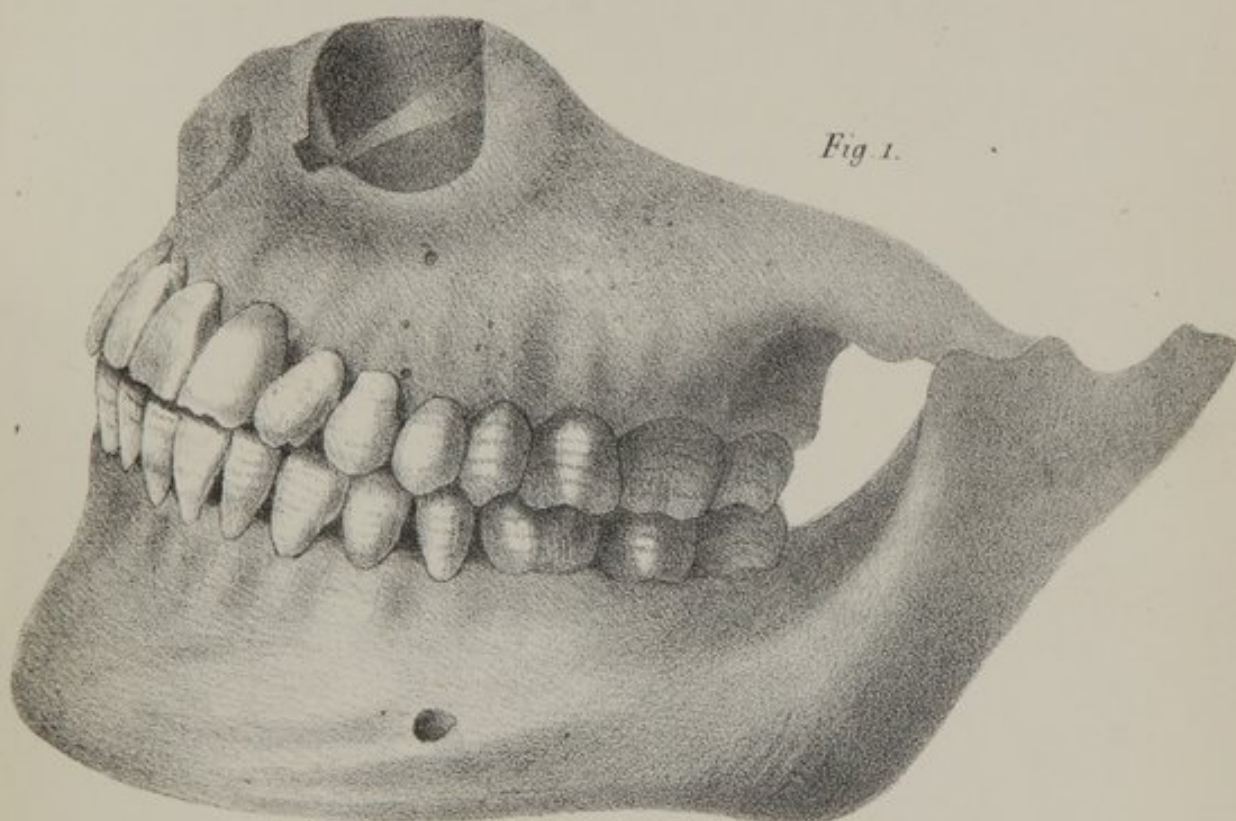
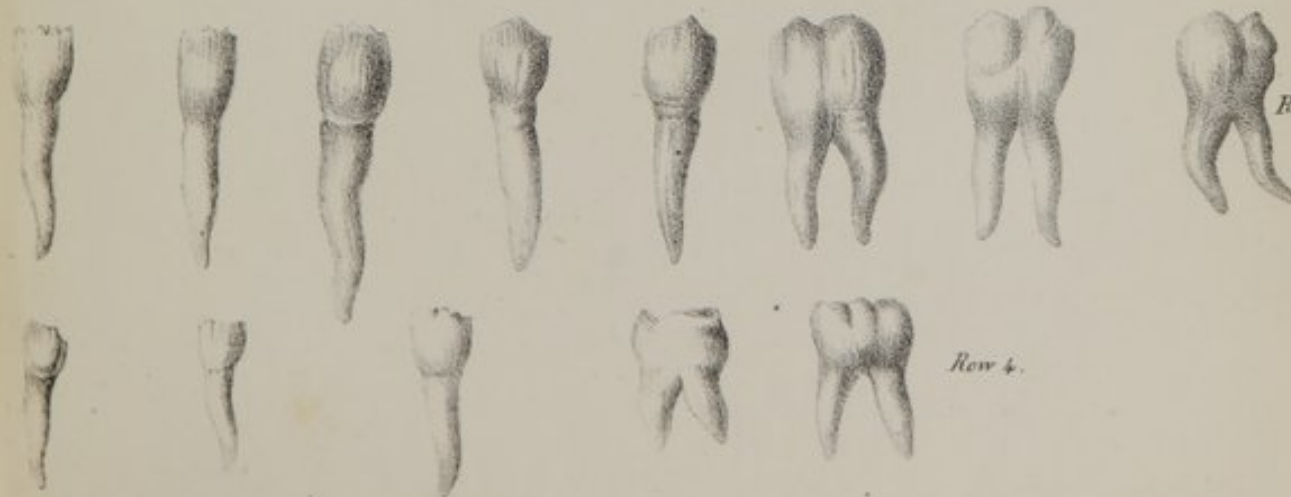

Fig. 1.




Row 3.



Row 4.






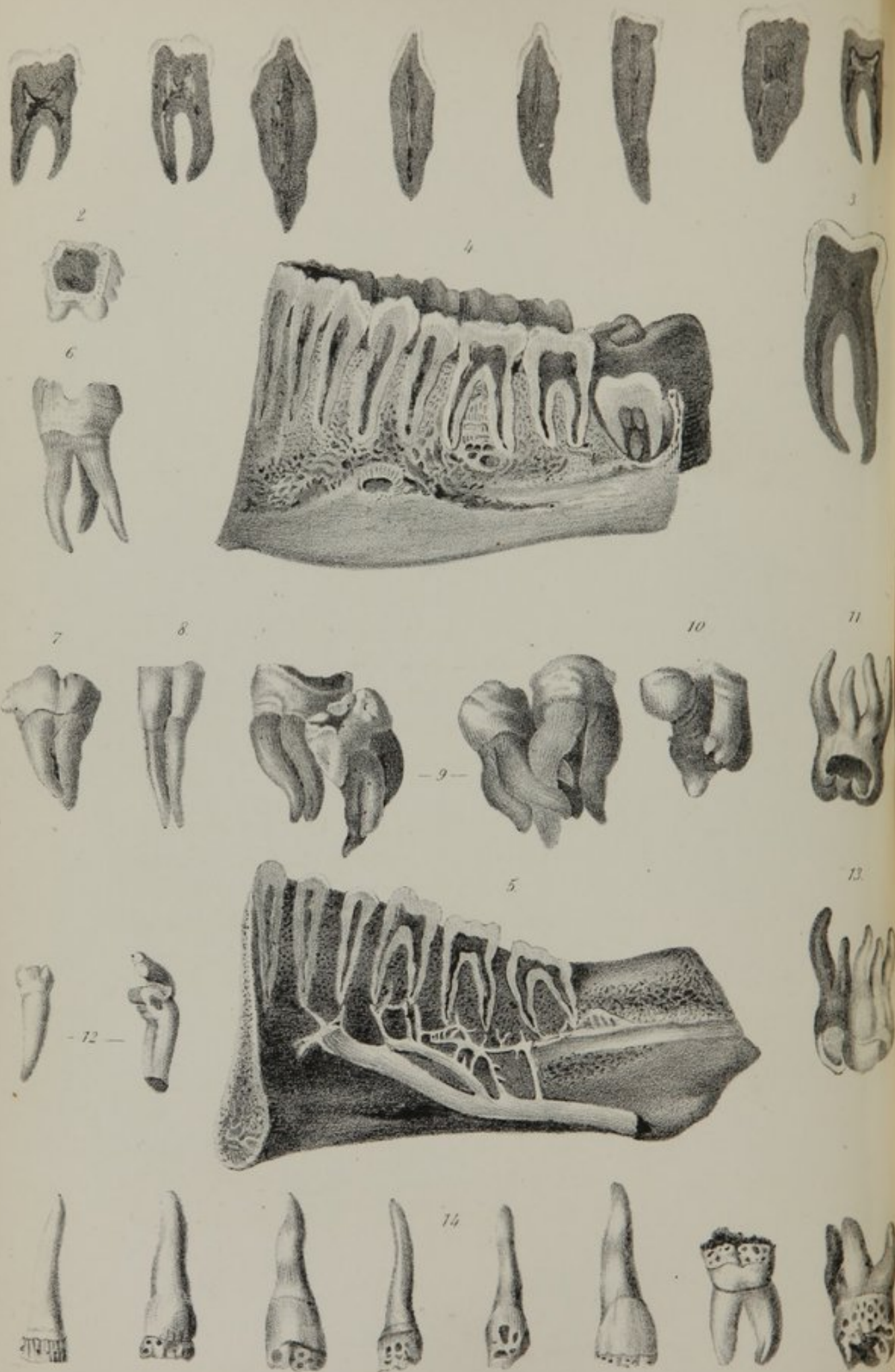




Fig. 1



## PLATE IX.

- FIG. 1. Longitudinal sections of teeth, the bony part of which has been burnt, to render the distribution of the enamel more conspicuous.
- FIG. 2. The transverse section of a molaris.
- FIG. 3. A tooth magnified, to exhibit the striated appearance of the enamel.
- FIG. 4. An under jaw, the fore part of which, and of the teeth, have been sawn away to shew the cavities in the teeth.
- FIG. 5. A section of the under jaw; the nerve is seen giving off branches which enter the cavities of the teeth.
- FIG. 6. A molaris of the under jaw, having three fangs.
- FIG. 7. A molaris having on its side a deposit of enamel like a pearl.
- FIG. 8. The central incisores of the under jaw united at the sides.
- FIG. 9. Two views of the second and third molares of the upper jaw, which are united by the inner fangs.
- FIG. 10. A molaris of the under jaw, having the crown of a bicuspid growing out of its side.
- FIG. 11. A molaris of the under jaw, having four fangs.
- FIG. 12. The permanent central incisores of the under jaw, having an exceedingly deformed appearance.

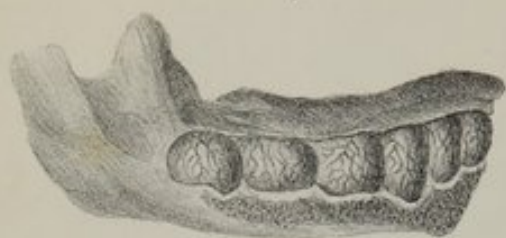

- FIG. 13. A molaris of the upper jaw, having five fangs.  
 FIG. 14. Several teeth, shewing the appearance of the enamel when defective in quantity, the surface of the teeth being covered with small indentations.

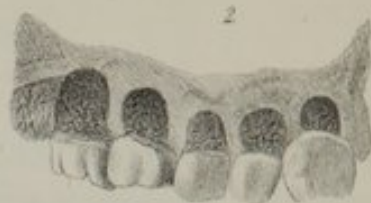




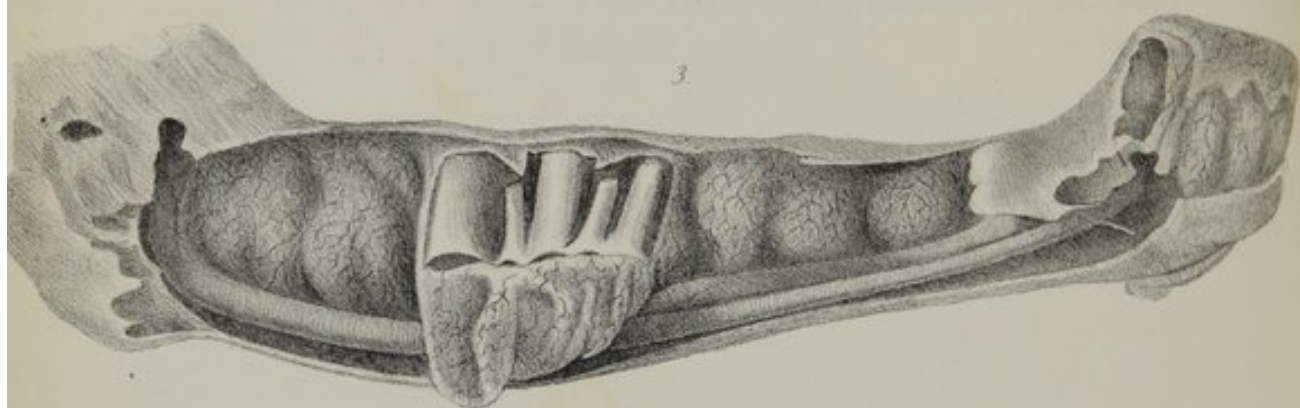
Fig 1



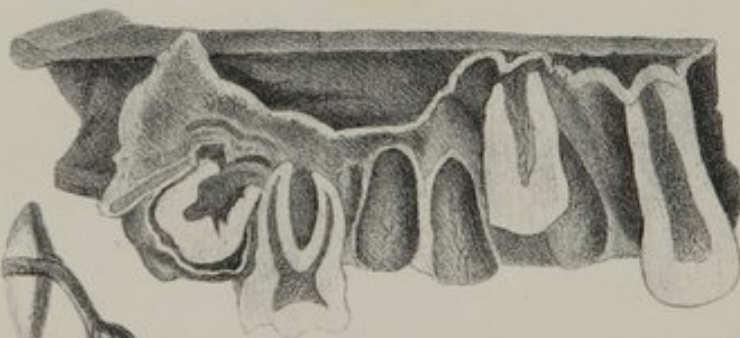
2



3



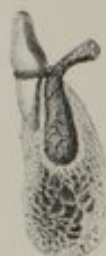4



7



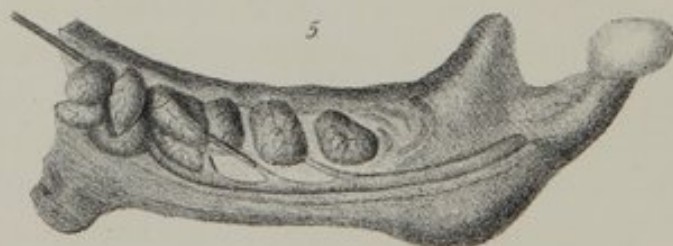8



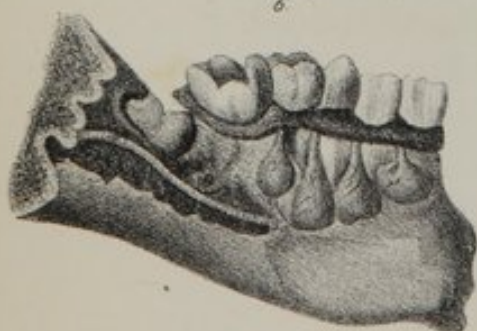
9



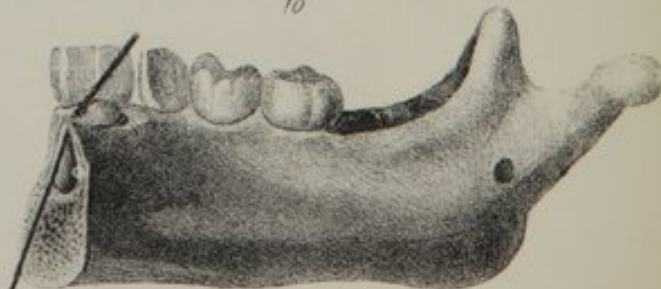5



6



10



## PLATE X.

ALL THE FIGURES OF THIS PLATE ARE FROM INJECTED PREPARATIONS.

FIG. 1. The under jaw of a child at the time of birth; the fore part has been removed, and the membranes inclosing the teeth are seen to be vascular.

FIG. 2. The teeth have been turned out of the sockets, and the inner membranes are also seen to be vascular.

FIG. 3. The lower jaw of a fœtal calf, in which the vascularity of both membranes is seen. The membrane belonging to one tooth has been turned down to exhibit the vascularity on the inner side.

FIG. 4. Half of the upper jaw of a boy about eight years of age. Part of the central incisor, the cuspidatus, the first molaris and the second molaris, (not yet completely formed) has been cut away to show the vascularity of the membrane within the cavities of the teeth. The lateral incisor and the bicuspidates are contained within the membranes.

FIGS. 5, 6, 7, 8, and 9, represent the manner in which permanent teeth are formed.

FIG. 5. Half the under jaw of a child soon after birth. The membranes of the teeth are seen, and over the bristle the membranes of the pulps of the incisores and the cuspidatus of the permanent



set, which are firmly attached to the membranes of the temporary teeth.

**FIG. 6.** Part of the jaw of a child about three years of age. The permanent teeth are placed deep in the jaw, and their membranes remain attached to the gums. The vessels of the membranes are derived from the gums. The artery which passes through the jaws sends off branches to the pulps of the teeth.

**FIG. 7.** Teeth which have been removed from the sockets to explain the attachments of the permanent to the temporary teeth.


- a.* The pulp of the temporary teeth inclosed within its membrane.
- b.* The pulp of the permanent teeth attached by its membrane to that of the temporary.
- c.* The temporary tooth completely grown.
- d.* The permanent tooth attached to the gum, the membrane being elongated into a sort of pedicle.

**FIG. 8.** A section of the lower jaw, showing the temporary tooth, with the manner of the situation and attachment of the permanent tooth.

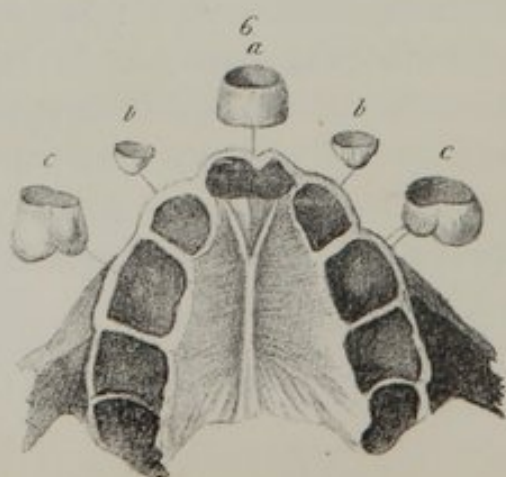
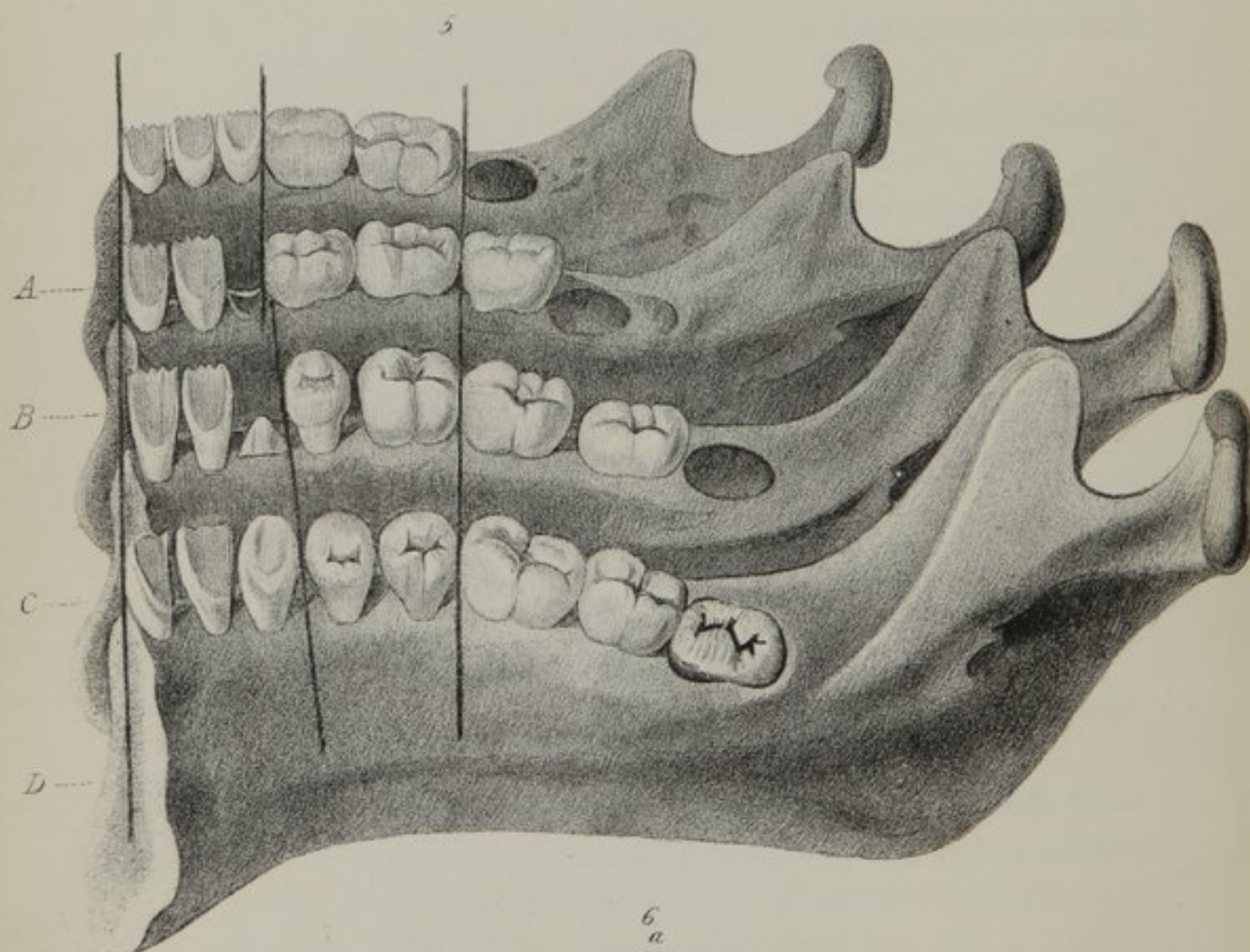
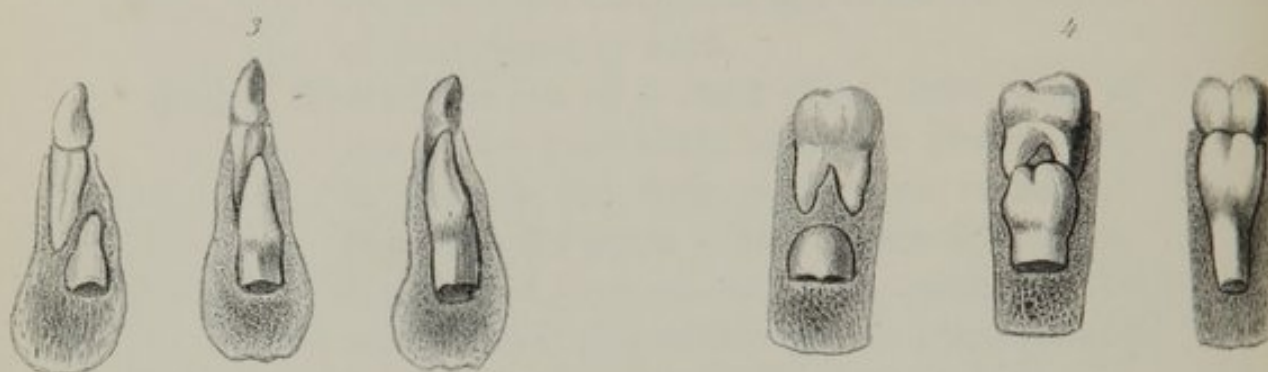
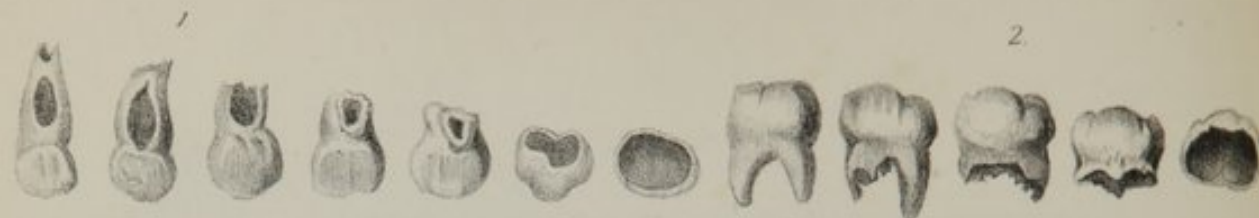**FIG. 9.** Exhibits the manner in which the pulps of the permanent molares are produced.

- a.* The first permanent molaris inclosed in its membrane.
- b.* A small membranous substance given off from the membrane of the first, and which becomes the pulp of the second permanent molaris.

**FIG. 10.** Half of a young jaw, showing the foramina through which the membranes of the permanent teeth pass, to be attached to the gums. A bristle is placed in one, and is seen going into the socket of the new tooth.







## PLATE XI.

FIG. 1. The progress of absorption in several of the temporary cuspidati.

FIG. 2. The same circumstance exemplified in several of the temporary molares.

FIGS. 3 and 4. Sections of the lower jaw exhibiting the progress in the formation of the permanent teeth, and the absorption of the fangs of the temporary teeth.

FIG. 5. Exemplifies the changes which take place in the teeth at different periods.

*A.* Part of the under jaw of a child at six years, when the temporary teeth only are visible.

*B.* Part of the jaw of a child about eight or nine years of age. The temporary incisores and cuspidatus have been removed; the permanent incisores and the first permanent molaris have grown up.

*C.* In this jaw the first temporary molaris has been removed, and is succeeded by the first bicuspis; the cuspidatus and the second permanent molaris are appearing.

*D.* Part of a jaw in the adult state. The second temporary molaris has been succeeded by the second bicuspis. The third molaris, or dens sapientiæ, has made its appearance. In this series of jaws, the change of the temporary



teeth for the permanent, and the addition of the permanent molares are clearly elucidated. The teeth which succeed the temporary incisors and cuspidati are larger, and those which succeed the temporary molares are smaller.

FIG. 6. The upper jaw of a fœtus, in which only one incisor had formed.

a. The incisor.

b. b. The cuspidati.

c. c. The first molares.






Fig 1

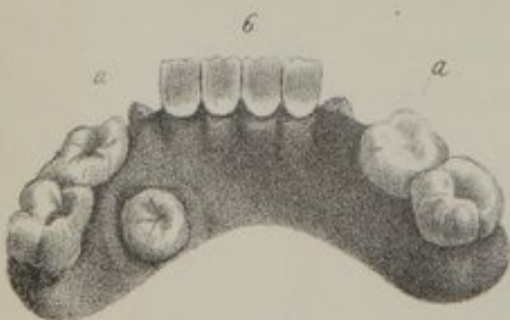
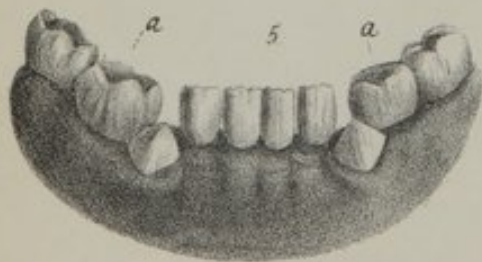
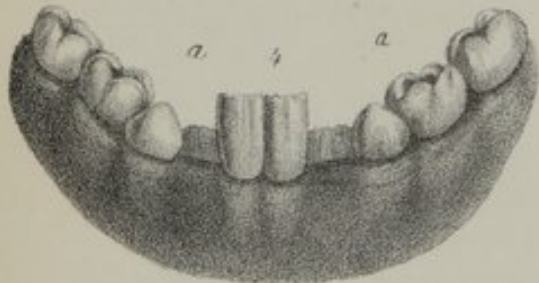
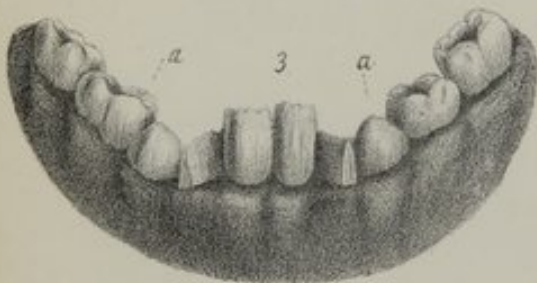
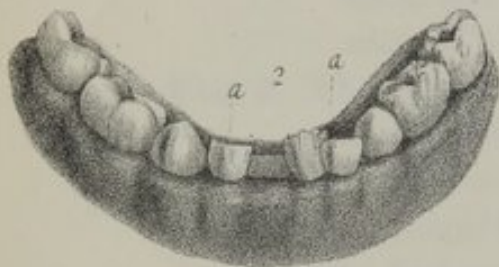
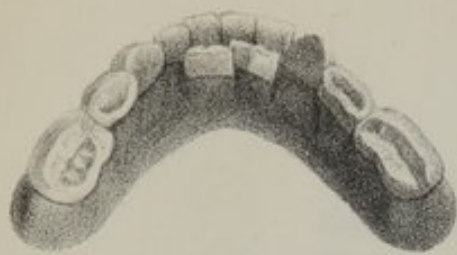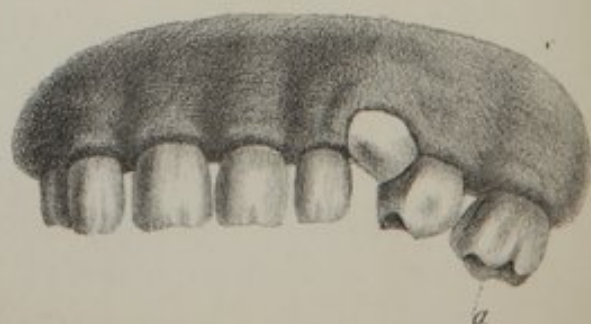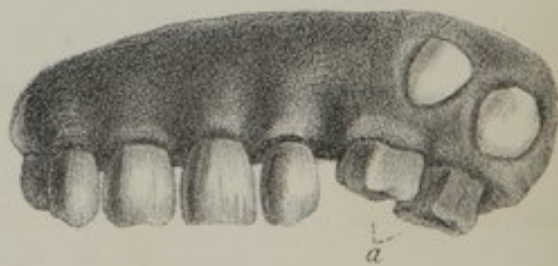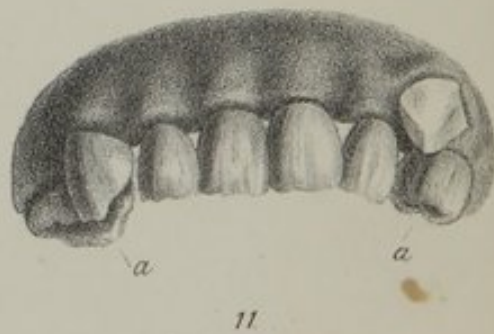
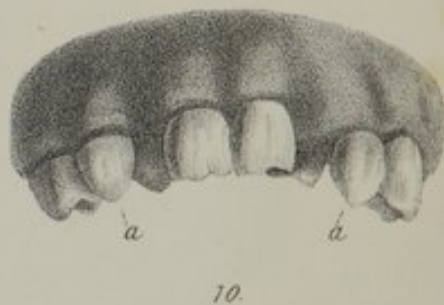


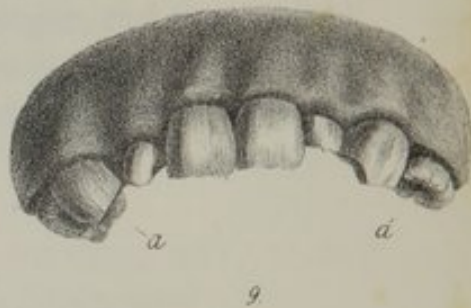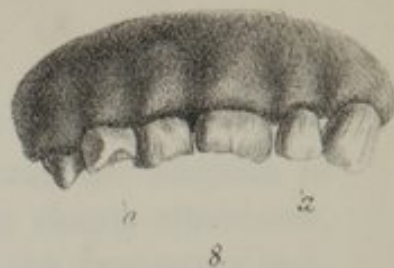Fig 7



## PLATE XII.

EXAMPLES OF IRREGULARITY SOMETIMES OCCURRING DURING  
THE SECOND DENTITION.

Those permanent teeth which are acquiring an irregular position, are sufficiently obvious. Those marked *a*, are the temporary teeth which ought to be extracted.



## PLATE XIII.

FIG. 1. One central incisor turned in, being placed when the mouth is closed, behind the under teeth.

*a a.* The temporary lateral incisores.

FIG. 2. The same circumstance occurring in both the central incisores. The lateral incisores being placed properly.

*a a.* The temporary cuspidati.

FIG. 3. The central permanent incisores rightly situated, the lateral ones turned in.

*a a.* The temporary cuspidati.

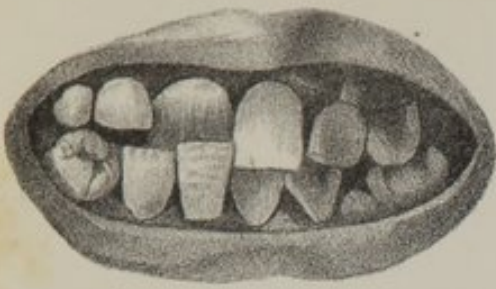
FIG. 4. The four permanent incisores, having the same improper situation.

FIG. 5. The bar to be fixed on the teeth, in order to remedy this kind of irregularity.

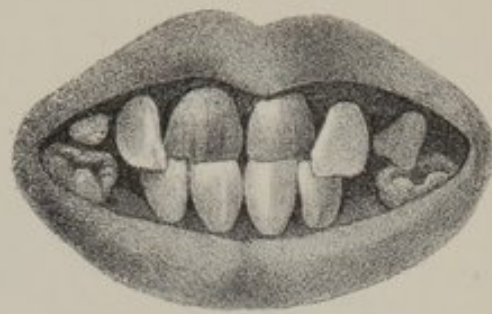
FIG. 6. Represents the bar as fixed in order to bring one of the central incisores forward.

FIG. 7. The bar fixed, with ligatures applied to the four permanent incisores, which are to be drawn forward.

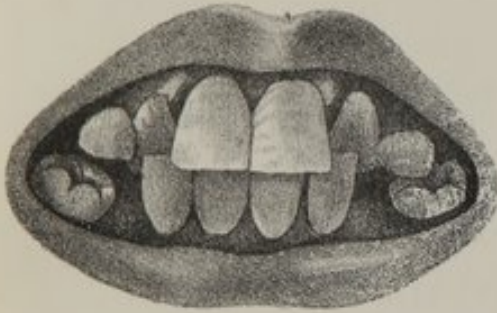
1.



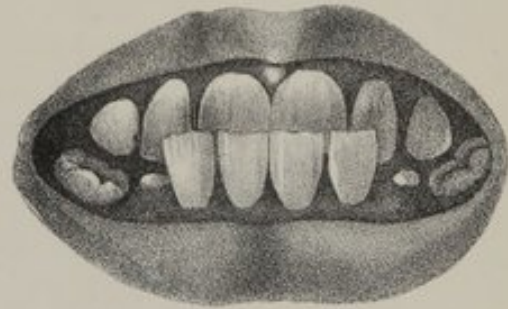
2.



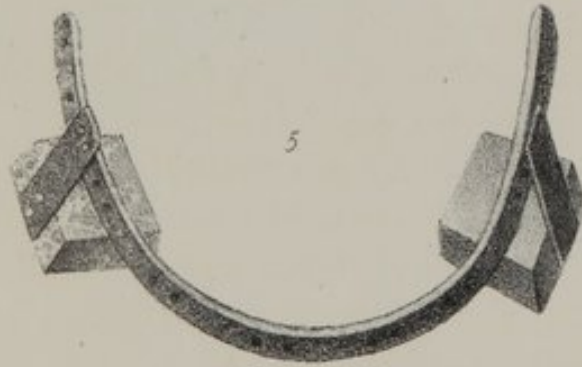
3.



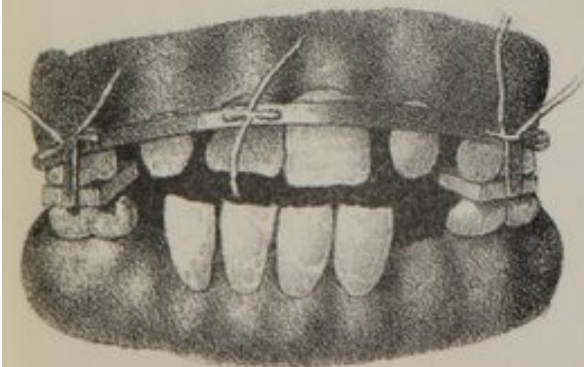
4.



5.



6.



7.

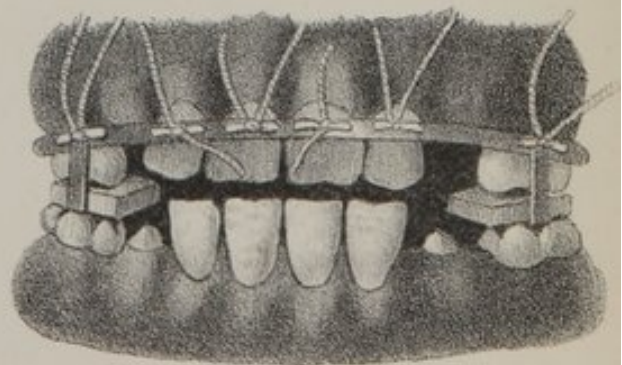




PLATE 311

Fig. 1. The dorsal view of the head of the male of the species, showing the eyes, antennae, and mouthparts.

Fig. 2. The ventral view of the head of the male of the species, showing the mouthparts and the base of the antennae.

Fig. 3. The lateral view of the head of the male of the species, showing the profile of the head and the position of the eyes.

Fig. 4. The dorsal view of the head of the female of the species, showing the eyes, antennae, and mouthparts.

Fig. 5. The ventral view of the head of the female of the species, showing the mouthparts and the base of the antennae.

Fig. 6. The lateral view of the head of the female of the species, showing the profile of the head and the position of the eyes.

Fig. 7. The dorsal view of the head of the male of the species, showing the eyes, antennae, and mouthparts.

Fig. 8. The ventral view of the head of the male of the species, showing the mouthparts and the base of the antennae.

Fig. 9. The lateral view of the head of the male of the species, showing the profile of the head and the position of the eyes.


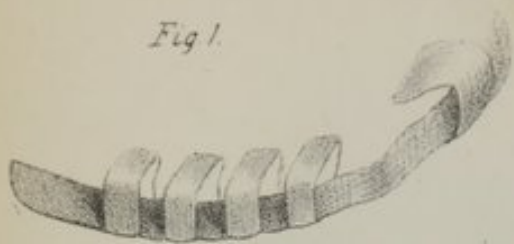
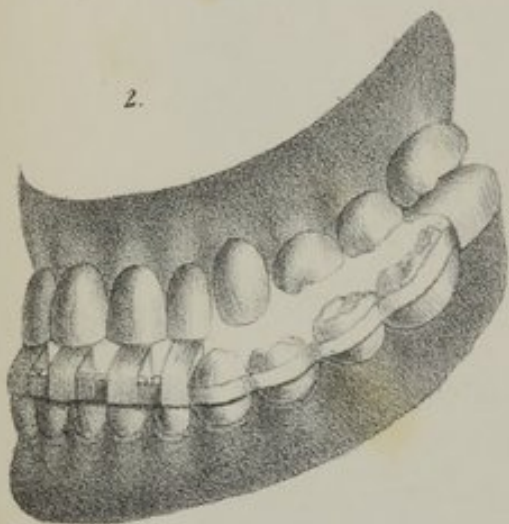




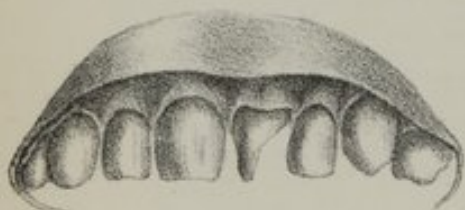
Fig 1.



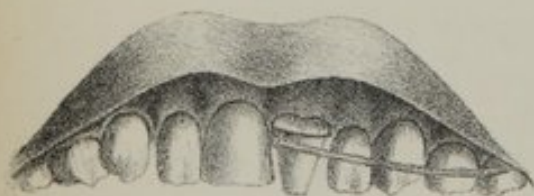2.



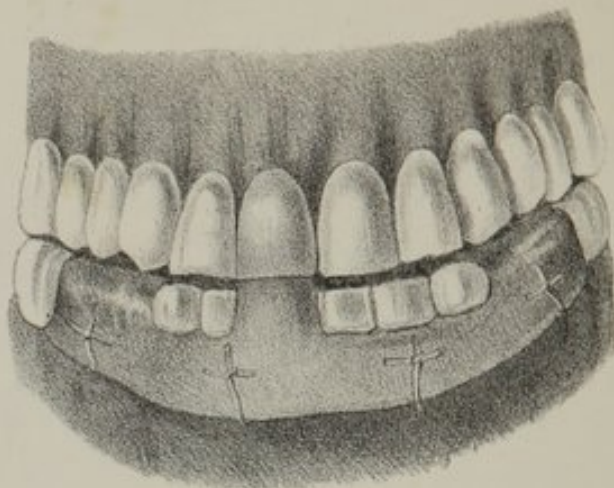
3



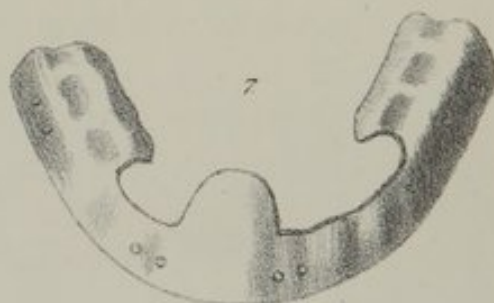
4.



6



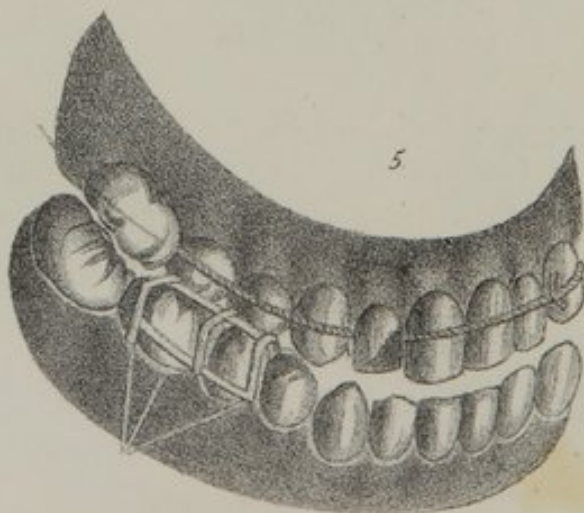
7



8



5



## PLATE XIV.

(FROM CATALAN, DELABARRE, ROBERTSON AND NATURE.)

- FIG. 1. An apparatus invented by M. Catalan to be placed upon the lower teeth, with four inclined planes fixed to it, and designed to act upon the four incisores of the upper jaw.
- FIG. 2. The apparatus applied with a view to exhibit the principle upon which it acts.
- FIG. 3. In this figure, copied from Delabarre, an incisor tooth with one of its approximal surfaces presenting anteriorly, is represented.
- FIG. 4. A cap applied to the deviating incisor with ligatures attached to it, for the purpose of turning the tooth in its socket until the front surface shall present anteriorly. This figure is also copied from M. Delabarre.
- FIG. 5. The manner of correcting irregularity of the teeth by means of ligatures and a metallic grate, as proposed by M. Delabarre.
- FIG. 6. This figure, representing an apparatus applied to the lower teeth with an inclined plane acting upon a central incisor, is copied from Mr. Robertson's Treatise on the Teeth.
- FIG. 7. The last named apparatus before being applied to the teeth.
- FIG. 8. A gold case fitted to the lower teeth with an inclined plane to act upon a deviating cuspidatus, constructed by the editor.



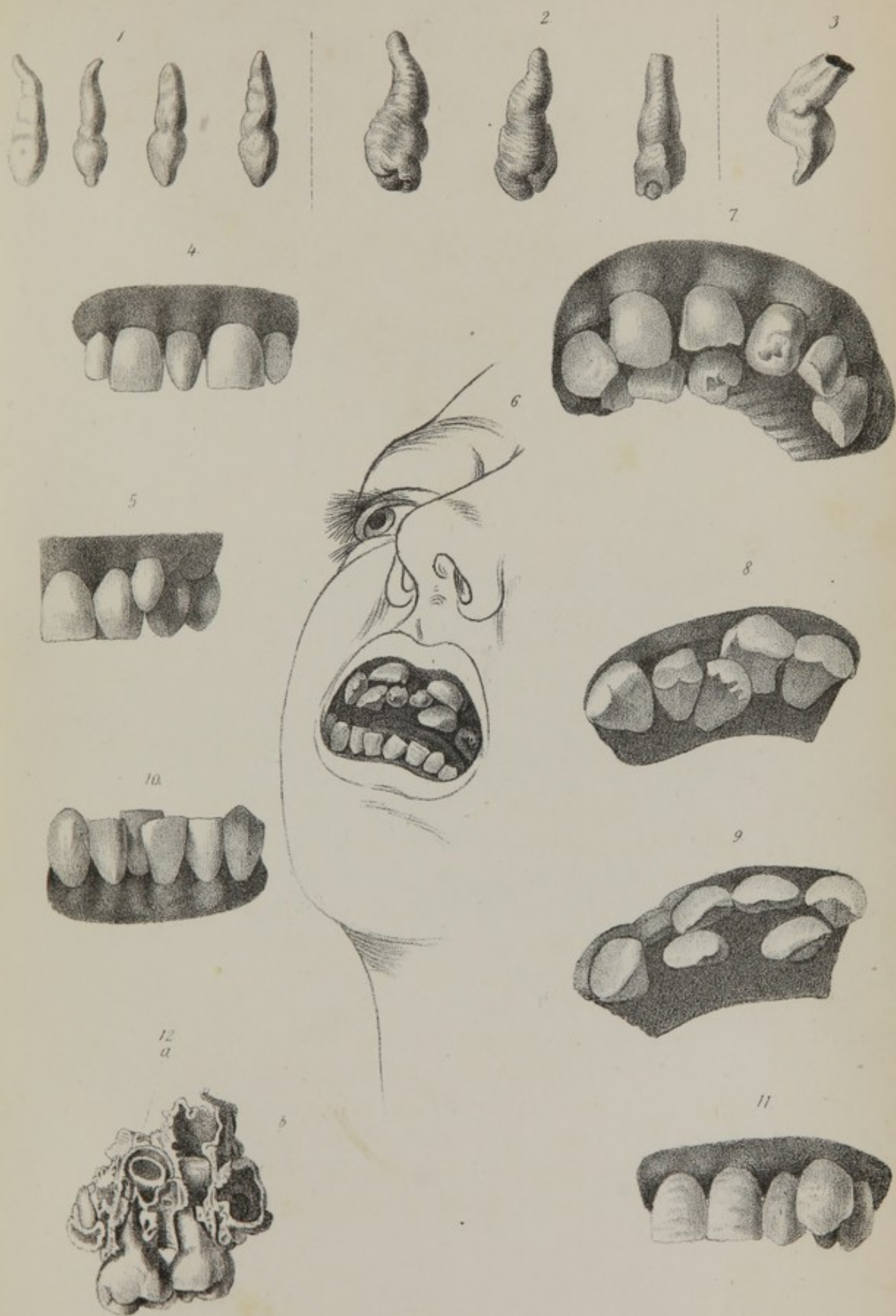
## PLATE XV.

### CASES OF IRREGULARITY FROM SUPERNUMERARY TEETH, &c.


- FIG. 1. Supernumerary teeth of the conical form.  
FIG. 2. Supernumerary teeth resembling bicuspides.  
FIG. 3. A tooth which acquired a distorted shape during its formation, from the resistance of the temporary tooth.  
FIG. 4. A supernumerary tooth placed between the central incisores.  
FIG. 5. A supernumerary tooth growing above the central and the lateral incisor.  
FIG. 6. A remarkable case of irregularity, occasioned by the growth of two supernumerary teeth.  
FIG. 7. A similar case, the supernumerary resembled bicuspides of the lower jaw.  
FIG. 8. A case of two lateral incisores on the same side.

### IRREGULARITY AT AN ADVANCED PERIOD.

- FIG. 9. The lateral permanent incisores to be extracted.  
FIG. 10. The most irregular tooth must be removed, when the others will approximate.  
FIG. 11. A cuspidatus left projecting until a late period; this being removed, the teeth will appear regular, as the lateral incisor and the first bicuspid are close to each other.  
FIG. 12. An exfoliation from the upper jaw, containing the temporary molares, and (*a a*) the bicuspides advancing in formation. *b*. The socket for the permanent cuspidatus.







## PART II.

---

THE HISTORY AND TREATMENT OF THE DISEASES OF THE  
TEETH, THE GUMS, AND THE ALVEOLAR PROCESSES,

WITH

THE OPERATIONS WHICH THEY RESPECTIVELY REQUIRE;

TO WHICH ARE ADDED

OBSERVATIONS ON OTHER DISEASES OF THE MOUTH.



PAGE 11

THE HISTORY AND TREATMENT OF THE DISEASES OF THE  
TUBER COW AND THE ALBINO HORSE

THE

THE HISTORY AND TREATMENT OF THE DISEASES OF THE  
TUBER COW AND THE ALBINO HORSE

THE

THE HISTORY AND TREATMENT OF THE DISEASES OF THE  
TUBER COW AND THE ALBINO HORSE

## INTRODUCTION.

---

IN the former part, I endeavoured to prove that the teeth are organized in a similar manner to other bones, and that, as possessing life, they are connected with, and form an integral part of, the system.

I have now the satisfaction to find that the same opinion is entertained by almost all the enlightened members of the surgical profession.

Mr. Hunter, who made many experiments, by feeding animals with madder, in order to ascertain the effect it would produce in colouring the different bones of the body, having observed that the teeth did not become tinged so speedily as the other bones, or, when tinged, that they retained their colour longer, hence concluded, that "they are to be considered as extraneous bodies, with respect to a circulation through their substance."

The consequence of having formed this opinion was, that he could not, in any satisfactory manner, assign a cause for the different diseases of the teeth. It must, however, appear extraordinary that Mr. Hunter, who was so accurate an observer of the phenomena of nature, should have published this opinion, when he immediately added, that "they (the teeth) have most certainly a



living principle, by which means they make part of the body, and are capable of uniting with any part of a living body."

The diseases which affect the mouth, and which are commonly considered as cases on which the surgeon-dentist is to be consulted, arise from affections of the teeth, the gums, and the alveolar processes.

The teeth are the organs of mastication; they are placed in sockets called alveoli, which are formed upon and make a part of the jaw bones, and are there firmly held by a periosteum, which lines the socket, and is also reflected over the fangs of the teeth. The alveolar processes are covered with a continuation of the gums, which are firm, but very vascular substances.

These parts have such an intimate connection with each other, that, when diseases originate in one, the others always become more or less affected. It is therefore absolutely necessary that an accurate knowledge should be had of all the diseases of those parts connected with the teeth; for, as the loss of the teeth is the ultimate consequence of disease in any of the contiguous parts, we can only expect to preserve instruments, so important to our comfort and welfare, by speedily applying such remedies as will restore the parts with which they are connected to healthy action.

The diseases to which the teeth are subject are similar to those which affect bones in general, and in like manner they have their origin in inflammation.\* The teeth differ only from bones in not possessing sufficient living power to effect the process of exfoliation.

These different kind of diseases affect various parts of

[\*To this error, we alluded in the first part of the work, and our reasons for rejecting this hypothesis, we shall presently state at length.]

the teeth. A death of any part of the crown of a tooth constitutes caries.

The fangs are occasionally enlarged, as in exostosis.

The membrane contained within the cavity of a tooth sometimes inflames and suppurates, and the matter, being discharged at the extremity of the fang, causes that part of the tooth to acquire an appearance of a bone affected with *spina ventosa*.

A death of the fangs of the teeth often takes place, and presents a disease resembling that which in bones is called necrosis.

Besides these diseases, there are changes produced by a removal of the enamel from the bone of the tooth, called by Mr. Hunter, decay by denudation. Also very disagreeable and painful affections resulting from accidents, such as fractures or luxations of teeth.

The gums are subject to several diseases peculiar to themselves, and to others which proceed from those of the teeth, or alveolar processes, beside other affections, which may be considered as the index of constitutional derangement.

The alveoli of the teeth have also their distinct diseases, as well as others in common with the teeth and gums, and are liable to be affected by diseases of the constitution.

In addition to these various diseased actions, there is an earthy deposit, called tartar, which, in a greater or less degree, accumulates about the teeth of most persons; this, if suffered to increase to any quantity, causes a separation of the gums from the necks of the teeth, and a consequent absorption of the alveolar processes.

There are also diseases requiring surgical aid to which the antrum maxillare is liable; and different imperfections of the palate or roof of the mouth, arising either from



natural malformation, or the consequence of disease.—When these have been considered, the mode of supplying the loss of teeth, by means of artificial ones, will be described: and the work concluded with an account of the method of performing the several operations which the diseases of the teeth require.

## PART SECOND.

---

### CHAPTER FIRST.

#### OF CARIES.

CARIES, or, as it is commonly called, decay, is the disease with which the teeth are most frequently affected. At first it has its origin in the bony part of the crown of the tooth, the structure of which is gradually destroyed, and the disease proceeds until the whole of the crown of the tooth, both the enamel and bone, is entirely removed. [The enamel, though less frequently, is nevertheless sometimes, first attacked.]

When caries has made some progress internally, a small, opaque spot appears upon the enamel, where it covers that part of the tooth which is diseased, and the bony part of the tooth situated underneath this spot will be found of a dark brown [black, light brown or white] colour: when the decay has advanced so far as to destroy the texture of part of the bone of the tooth, the enamel loses its support, then breaks away, and a cavity is discovered in the tooth.\* Thus it is that in the first instance, caries originates; and

\* Plate XVI. Fig. 1, 2.



it is by no means uncommon for a person, in a very short space of time, to discover cavities in several teeth, which had been supposed perfectly sound. In the mastication of hard substances, pieces of the enamel are broken off, on account of the texture of the bony part being destroyed by the caries, which had previously gone on internally.

[The first manifestation of the disease, is in some] in the irregularities of the grinding surfaces of the molares, and resembles a crack filled with a black substance, which at length breaks into a cavity in the centre of the tooth; in others, it commences in the side of the tooth next the cheek; and sometimes at the neck of the tooth, the decay extending into the body of the tooth underneath the enamel.

The decay very often commences on those sides of the teeth which are placed in opposition to each other; this is the worst possible situation for the disease, because it often makes considerable progress without being discovered, and is much less conveniently placed for the performance of an operation to arrest its progress.

In the incisores, the caries most commonly begins at the sides, between the teeth; in some, it appears near the neck, the cavity extending across the tooth and the disease proceeds until the tooth is nearly divided in two; in this case, whilst biting something hard, the lower part of the tooth usually breaks off, leaving the fang in the socket, and a small portion of the body of the tooth.

The molares are more subject to this disease than any of the other teeth: the incisores of the upper jaw are very frequently affected by it, whilst the incisores of the lower jaw very seldom become decayed.

When a decayed tooth is examined, the carious part appears to be disposed in strata, the external is the most decayed, is black, and so soft that it may be easily picked

away.\* The next stratum will be found of a harder texture, and not so black in colour, and as the substance of the tooth is less decayed it becomes more dense, until we arrive at the sound part. Whenever a decay has taken place in a tooth, and the enamel, by becoming opaque, begins to exhibit the appearances of this disease as having gone on underneath, if the tooth be sawn through, a brown mark will be found extending into the natural cavity of the tooth: it is in this direction the decay always proceeds, and, when the cavity is exposed, the membrane which lines it, and upon which the nerve and the blood-vessels ramify, most commonly becomes inflamed, and causes pain.

During the progress of caries in a tooth, it is the internal part of the crown which is the soonest removed, causing the tooth to appear as if the inside had been scooped out. The enamel, being much harder than the bone, remains, and only breaks away as it loses its support, from the bony part becoming dissolved and removed.†

The progress of caries seems to be retarded when it has destroyed the whole crown of a tooth; for although the decay may have gone on in the body of the tooth with great rapidity, yet the fangs will often remain for many years with scarcely any alteration, and they often continue for a considerable length of time firmly attached to the socket, without occasioning any inconvenience. Persons rarely experience the tooth-ache, properly so called, from stumps; for, when the caries has destroyed the whole of the body of the tooth, the membrane which

[\*The consistence of the carious part of a tooth is exceedingly variable,—depending upon the density of the organ. In some teeth, it is almost as hard as the tooth itself throughout every part of it; in others, it is very soft, and the colour is generally dark in proportion to the density of the affected organ.]

† Plate XVI. Fig. 4, 5.



lines the cavity is also removed, and the blood-vessels and nerves, which pass through the canal in the fangs, generally likewise perish; on which account, whenever pain proceeds from decayed stumps, it usually is the consequence of inflammation taking place in the sockets, whereby the attachment of the periosteum is destroyed, and the stump becomes an extraneous body, causing great inflammation in the socket and the gums, which often terminates in suppuration.

It very frequently happens, when a tooth has become so decayed as to leave only the stumps, that nature, as if conscious they were no longer useful, makes an effort to thrust them out; the socket gradually closes at the bottom, and thus the stumps are protruded, until they only adhere to the gum, thus they become loose, and occasion soreness and slight inflammation. The attachment being very weak, they are with great ease taken away.\*

[PROXIMATE CAUSE OF CARIES.]

The cause of caries has not been satisfactorily explained, from the structure of the teeth not having been duly considered. Mr. Hunter says, "It does not arise from external injury, or from menstua, which have a power of dissolving part of a tooth; but we may reasonably suppose that it is a disease arising originally in the tooth itself." It is surprising that, although Mr. Hunter went thus far, he gave no correct idea of the manner in which the disease can alone originate.

The proximate cause of caries appears to be an inflammation in the bone of the crown of the tooth, which, on account of its peculiar structure, terminates in mortification.

\* Plate XVI. Fig. 6, a.

[The author's opinion with regard to the cause and nature of dental caries is, as the editor has shown in another place, evidently incorrect.\* If it were the result of inflammation, as he asserts, none but living teeth would be attacked by it, but so far from this being the fact, it is well known that teeth after having been deprived of their vitality are as liable to be affected with it as the living organs. Artificial teeth too, of bone or ivory, decay as readily as the natural ones.

Caries of the teeth is the result of the action of chemical agents, and not that of any operation of the animal economy, and it consists simply in the decomposition of the calcareous molecules of the organs. The fluids of the mouth, especially the mucous, when in a vitiated condition, contain an acid, namely, the septic (nitrous,) which has a strong affinity for the earthy ingredients of these organs, and it is by the action of the former upon the latter, that the affection is produced. Inflammation may influence the progress and perhaps the appearance of the diseased part, but it cannot of itself produce it.

If inflammation were the cause of caries, the operations of filing and plugging, would tend rather to increase than arrest its progress, inasmuch as they augment, for a time at least, the susceptibility of the organs to impressions from heat and cold, and as a consequence to inflammation. They do not, however, when properly performed, give rise to the disease in question. On the contrary, they completely arrest it.

A series of experiments were instituted about three years since, by Amos Westcott, M. D. of Syracuse, N. Y. who is well known to the profession as an accomplished writer and able practitioner, for the purpose of ascertain-

\* Vide, Principles and Practice of Dental Surgery; also, Characteristics of the Teeth, &c. &c. by the Editor.



ing the effect certain aliments produced upon the teeth, after having underwent chemical decomposition, and the result proves conclusively, that caries of the teeth is produced by the action of external corrosive agents. For a detailed account of these experiments, the reader is referred to a Dissertation delivered by Dr. W. before the fourth annual meeting of the American Society of Dental Surgeons, and published in the 3d vol. Amer. Jour. Dental Science.

The term mortification, or gangrene, as used by a later writer, if at all applicable to any morbid condition of the teeth, would be more so to that of necrosis, than the affection under consideration. But to neither of which, according to its usual signification, can it with any degree of propriety be applied, it being a term used to signify the death of a soft, not that of a solid tissue. Nor does caries convey a correct idea of the true nature of the affection, yet because of its almost universal adoption, it may, perhaps, be as well to continue it.]

The membrane which is contained within the cavity of a tooth is very vascular, and possesses a high degree of nervous sensibility: an inflammation of this membrane is liable to be occasioned by any excitement which produces irregular action; and as the bone of the tooth is very dense, and possesses little living power, a death of some part of it may speedily follow an inflammation of the vessels of the membrane which are contained within the cavity.\*

\* Some time ago, I was applied to by a gentleman, who complained of an acute pain arising from one of the molares of the under jaw: as I could discover no appearance of caries in it, I advised the loss of blood from the gums, with a view to remove the inflammation in the socket, or other parts connected with the tooth. This treatment was by no means effectual, for the pain continued with scarcely any intermission: the gentleman therefore determined to have the tooth extracted. In attempting this operation, the tooth broke off at the neck, and completely exposed the internal cavity. Fortunately, this accident proved to be satisfactory, as it afforded an oppor-



If a sound tooth, that has been recently extracted, be broken, the membrane will be found to be firmly attached to the bone of the tooth, forming the inner cavity. But when this membrane becomes inflamed, it separates from the bone, and the death of the tooth is the consequence.

That this is the proximate cause of caries, appears to be highly probable, by remarking that a caries of other bones is caused by a separation of those membranes which cover them, and which are attached to them. Thus a separation of the periosteum will cause a death of part of the tibia, or that of the pericranium, a caries of some part of the bones of the head.

This opinion is also confirmed by comparing the symptoms which accompany inflammation in a bone with those which are occasionally felt by persons in their teeth, previously to any appearance of caries.

During the inflammation of a bone, there is an obtuse, rather than an acute pain; the parts which surround or cover it feel sore, and cannot bear pressure; and, when there is the opportunity of making the comparison, an inflamed bone is found to have a darker appearance than a healthy one.

Very similar to these are the symptoms which are observed by every one when their teeth have been affected by what is commonly termed a cold. At this time a dull, uneasy pain is felt extending along the jaw, the teeth are tender, and cannot be pressed together with the ordinary degree of force; and it may almost always be observed,

tunity of ascertaining the cause of the pain. The membrane lining the cavity of the tooth had become so highly inflamed, that it had proceeded to suppuration, and the cavity of the tooth was filled with pus. Immediately after the operation, the gentleman was perfectly relieved, and had no return of pain. In a similar case, instead of extracting the tooth, I should recommend the drilling a hole, at the neck of the tooth, into the cavity, in order to make an opening by which the matter might escape. [But this operation, while it will generally afford relief from pain, seldom effects a radical cure. Therefore, it is better in most instances to remove it at once.]



that the teeth thus affected have a darker appearance than those which are perfectly free from pain.

When these inflammatory symptoms subside, the pain in the teeth goes off; but as inflammation may have caused a death of some part of one or more teeth, the decomposition of the internal part of the tooth goes on, until the enamel is broken away, and a caries is discovered.

I could mention many cases in corroboration of this statement, and produce several examples of teeth with the decay extending through the internal part, whilst the enamel remained perfectly sound.

In Plate XVI. Fig. 4 *a*, is the representation of a tooth which I extracted for a lady, who complained of having suffered great pain from it for a length of time; the tooth appeared to be perfectly sound, but, on sawing it asunder, a considerable caries was discovered in the centre.

Fig. 5 *a* represents the perfect enamel of a tooth that separated from the bony part, which, by caries, had become quite soft and black.

Fig. 3 *a* shows the dark line which may be seen passing through the bone of a tooth from the external part to the cavity, in the centre, as described in page 159.

[Inflammation of the lining membrane of a tooth often terminates in suppuration and the death of the crown and inner walls of the root, or roots, if it have more than one, of the organ—gives rise, in the majority of cases, to the formation of alveolar abscess, but the only indication of caries resulting therefrom, is the softening of the inner walls of the tooth, caused by the chemical action of the matter therein contained. But examples of this sort, are comparatively rare, and between the pulp cavity and external surface of the bone of a tooth, within its substance caries never commences.

The symptoms mentioned by the author, as being an

accompaniment of inflammation, are rarely present during the progress of caries, or not until the lining membrane has become exposed. The disease, until this time, is seldom attended with pain, and it oftentimes happens, that tooth after tooth, until not a sound one remains, is destroyed by it, without giving rise to any unpleasant symptoms whatever. Again, the membranes of the teeth often become inflamed, causing pain and soreness in the teeth for weeks and even months, without being accompanied or followed by caries.

The decomposition of the internal part of a tooth, as spoken of by Mr. Fox, is caused, not by inflammation, but by the acrimonious qualities of the fluids which accumulate in the pulp cavity after the destruction of the lining membrane, and not only do they break down the solid basis of the parts of the organ with which they are in immediate contact, but they give to the whole of the crown of the tooth, a dark brown, muddy or purple appearance. If the tooth be permitted to remain in the mouth, and no outlet made for the escape of the matter, nor means used to prevent its re-accumulation, the destruction of its interior walls goes on, until ultimately, in biting some hard substance, the crown is broken in, when the ravages of the disease becomes manifest.

Caries almost always commences on the exterior surface of the tooth, beneath the enamel, and at points where this outer casing has sustained some injury, or is imperfect, as for example, within the indentations on the grinding faces of the molares and bicuspides or the approximal sides of the organs, and proceeds interiorly toward the centre.]



## [PREDISPOSING CAUSE OF CARIES.]

The chief predisposition to this disease consists in a defective formation of either the enamel or the bony part of the teeth.

The teeth of many persons are formed with a less quantity of earthy matter than of animal substance, on which account they do not acquire such a density as is necessary to make them durable, and resist those various causes of decay to which the teeth are constantly exposed. Teeth thus formed are at first very white, and have a certain transparency; but they soon begin to decay, and frequently, in a very few years, the disease extends through the greater part of them.

Sometimes the enamel does not acquire a proper degree of hardness, its attraction of cohesion being defective, in which case it has a dead yellowish tinge, and is of a chalky consistence.

When either of the above states of formation of the teeth occur, they very soon fall into a state of disease; because the enamel is not sufficiently dense to resist the force applied to the teeth, in the mastication of hard substances, without being broken; and the bone is of too soft a texture to continue long without being affected by some cause of inflammation. [The author should have said to the action of the chemical agents, to which all teeth are more or less constantly exposed.]

This original defect in the structure of the teeth must depend upon a want of healthy action in the pulps, during the time of the formation of the teeth. It is impossible to conjecture what can be the cause of this imperfection, but it is very singular, and also very certain, that the same kind of structure may be observed in the teeth of many individuals in the same family, who, in all other respects, are very healthy.

That the teeth acquire this disposition to decay from some want of healthy action, during their formation, seems to be proved by the common observation, that they become decayed in pairs; that is, those teeth which are formed at the same time being in a similar state of imperfection, have not the power to resist the causes of disease, and, therefore, nearly about the same period, they exhibit signs of decay, while those teeth which have been formed at another time, when a more healthy action has existed, have remained perfectly sound to the end of life.

Decay of the teeth is often the consequence of certain states of the constitution, in which the functions of the body are performed irregularly, inducing various dyspeptic symptoms. [Just in proportion, as any functional disturbance of the body deteriorates the healthy qualities of the fluids of the mouth, does it contribute to the decay of the teeth.]

In these cases, the caries affects many teeth at the same time, and often proceeds so quickly as, in a short period, to destroy the crowns of the teeth, leaving only the fangs. [This is more especially the case when all the teeth are equally susceptible to the action of those causes upon the presence of which, the decay of the teeth is dependent.]

It is remarkable that the caries, arising from these constitutional affections, has often a whitish appearance, and the bone of the tooth is then much softer than when it proceeds from simple inflammation. [The density of the tooth has more to do with the colour of the caries than any constitutional causes which may be concerned in its production. Generally, in proportion to the softness of a tooth is the colour of the caries light, and to its density is it dark.]

I have also often had occasion to observe that great



changes take place in the economy of the teeth, in consequence of continued fever: however sound the teeth of such persons may have been, previously to the disease, they have shortly afterwards discovered marks of caries, by which, in a few years, many of the teeth have been injured or destroyed. [This however is to be accounted for by the fact, that such diseases always vitiate the secretions of the mouth, especially the mucous, and impart to them a corrosive quality, which they do not, when in health, possess. At such times too, little or no attention is paid to keeping the teeth clean, and in consequence they become coated with clammy acidulated mucus, and which by its long contact, causes a more general and rapid decay.]

Caries has been very commonly attributed to the use of certain articles of diet, and animal food has been supposed very much to contribute to this disease. In support of this opinion, it is observed that persons in the country, who live on plain fare, and those of Indian nations, who live on vegetable food, have their teeth perfectly sound and free from disease. That these persons are very often found to possess perfect sets of teeth, is incontrovertible; but it is also to be observed that, amongst the same classes of mankind, there are great numbers whose teeth are very much diseased.

But why should animal food, more than any other kind, produce disease in the teeth? In a chemical way, it cannot act upon them; and, if in itself it had any injurious action upon the teeth, then all carnivorous animals, whose teeth are of the same structure as the human, ought equally to be liable to caries.

The various articles of our food can only produce a diseased action in the teeth, in consequence of their being taken at a temperature either much above or below the natural heat of the body.

The experience of every one teaches, by the effects, that extremes of heat or cold are injurious, because the sudden application of either, generally occasions a very unpleasant sensation in the teeth; this painful feeling arises from irregularity being produced in the circulation within the cavities of the teeth, and also the application of an unnatural degree of heat affecting the nerves of the teeth, and producing that painful sensation consequent on such application.

The reason therefore why persons, who live in a less luxurious state, have their teeth less liable to caries is, that, their food being all of a moderate temperature, they are not injured by that frequent stimulus which is produced by the use of very hot or cold substances. This statement seems to be confirmed by the observations I have been enabled to make upon the teeth of persons inhabiting different situations.

As a general rule, I think it may be asserted that the inhabitants of warm inland countries have teeth free from disease, and that those who dwell in colder regions, and also in seaports and large towns, have bad sets of teeth. For, in all warm countries, the refreshment which always accompanies the application of whatever is cool, induces persons to make use of their culinary preparations at a moderate degree of heat, and their drink consists of such articles as are proper to allay thirst, and produce but little stimulus.

In cold countries, on the contrary, where the application of heat is congenial to the feelings, the food is taken very hot; also in these regions, and likewise in seaports and places of great commercial intercourse, strong spirituous and fermented liquors are very constantly made use of, which, in addition to the injury arising from the use of the food at a high degree of temperature, keep the



mouth in constant heat, and produce all the injurious effects which arise from the accidental occurrence of fever.

[Neither the variations of temperature, nor food, nor drinks, has any agency in the production of caries, for if it had, teeth whose susceptibility to the action of heat and cold, as has been before stated, has been increased by dental operations, would be more liable to decay than others. But this is not the fact, and hence the inference is incorrect. The supposition too, that particular sorts of diet exert a more deleterious influence upon the teeth than others, is equally gratuitous. They can do this only as they prejudicially affect the health of the body and impair the healthy qualities of its fluids. The same may also be said with regard to climate. As a general rule, those who have good innate constitutions and have enjoyed good health during infancy and childhood have well-formed and regularly arranged teeth—teeth not easily acted upon by the causes that produce caries; and as their constitutions are otherwise, will their teeth be susceptible to the action of such cause.]

The destruction of a tooth, which has become carious in the manner above described, is not the extent of the mischief, for the disease is generally communicated to those teeth which are in contact with the decayed part. Cases occasionally occur which appear to militate against this opinion; as, for instance, a tooth may become decayed, and be entirely broken away without causing any disease in the neighbouring ones. Such examples, however, are rare; and it may be asserted, as a general rule, that caries in one tooth will produce disease in that which is contiguous.

When the caries is communicated by contact, it probably arises from the action of some acrimonious discharge

from the decaying tooth, which, in the first place, occasions a decomposition of the enamel, and afterwards the destruction of the tooth. But there is this peculiar difference, that, in the one, the decay proceeds from the interior to the exterior part; whilst, in the other, it commences on the surface, and extends towards the cavity. [If this cause is capable of producing it in the one case it is fair to conclude it is in the other.]

Caries is also very frequently the consequence of the teeth being crowded so much together, as to cause them to be pressed too closely against each other. This is the most common cause of the decay of the incisores in the upper jaw, on which account, in the earlier part of life, means should be made use of to give more room, which would permit the teeth to separate, and press with less force on each other.\* If the person be more advanced in years, then a small space should be made by passing a thin file between all the front teeth.

[Filing teeth to gain room for the purpose of correcting a slight irregularity is a practice which has been productive of incalculable injury. The editor has frequently in other places, expressed his disapproval of it, and he is happy to believe, that, at present, it is seldom resorted to for this purpose. For the removal of caries on the approximal surfaces of the teeth, the file, in the hands of a skilful practitioner, is one of the most valuable resources of the dental art, but in the hands of an ignorant and inexperienced operator, it is an unsafe and dangerous instrument.

When the file is employed for the above mentioned purpose, the filed surfaces soon come together, and give lodgment to the mucous secretions of the mouth and other extraneous matter, which by being retained there soon be-

\* Vide Natural History of the Teeth, page 62.



come vitiated, and act chemically upon the rough denuded sides of the teeth. Thousands of teeth have in this way been sacrificed. I will not however, in this place, dwell longer upon this subject, as I shall have occasion hereafter to advert to it more at length.]

To these various causes of decay of the teeth, may be added, want of cleanliness in the mouth, and a diseased state of the gums. When the teeth are not regularly cleansed from the tartar which constantly gathers about them, and also particles of food which may lodge between them, a putrefactive fermentation takes place, which (not to speak of the offensive fetor it produces) always injures the gums, and disposes the teeth to fall into a state of decay.

[PREVENTION OF CARIES.]

The great distress which usually accompanies, and the inconvenience which always follows, the loss of the teeth, makes the discovery of some mode of prevention of caries very desirable.

This delightful secret, although it is pretended to in the advertisements of every quack, we can only expect to acquire when the philosopher's stone and the grand panacea have been obtained. It is not in our power to alter the laws of nature, or change the natural constitution of man; we can only obviate evils by attending to the causes which produce them, and it is in this manner we can, in a very great measure, preserve the teeth from disease.

The principle means of preserving the teeth from decay consist in paying such a degree of attention to them in early life, during the period of the second dentition, as to allow the permanent teeth to acquire a proper regularity, without pressing too much upon each other; and, at

the same time, if the temporary teeth should become decayed, and be in contact with any of the new teeth, they should be removed. [The better practice, when practicable, is to remove the decayed surfaces of the temporary teeth with a file.]

When these circumstances have been observed, young persons should be urged to keep their teeth very clean, and the daily use of a tooth brush, with water only, will in most cases be quite sufficient. In addition to cleanliness, the habitual use of all kinds of food at a moderate temperature will almost certainly prevent any disease from taking place, unless there be any radical defect in the teeth themselves.

[In addition to the use of the brush, great advantage may be derived from the employment of waxed floss silk, as recommended by Dr. L. S. Parmly. This is used by passing it between the teeth or around a single tooth at a time and drawing the ends backwards and forwards some ten or a dozen times. In this way the impurities that cannot be reached with a brush, are removed from between the teeth, and which, when permitted to remain, cause their decay. If it were possible to keep the teeth thoroughly and constantly clean, they would never decay.

With regard to the influence the temperature of food exercises on the teeth, I have before alluded; it is not necessary therefore, to say more upon that subject.]

If, in persons more advanced in years, any of the teeth should have become decayed, and be in contact with sound ones, and they are not sufficiently injured to make it necessary that they should be extracted, so much of them should be filed away, as to separate them from those teeth which are sound: this will prevent the decay from being communicated.



If the teeth have become so much decayed as to leave only stumps, then they should be extracted, because they are not only liable to cause the other teeth to become diseased, but they often produce gum-boils and other diseases of the sockets. [They also exert a deleterious influence on the general health, giving rise not unfrequently to dyspepsia, neuralgia of the face and a multitude of other diseases, so that the importance of their removal cannot be too strongly impressed upon all who have such teeth in their mouth.]

The decay of the teeth, as far as I have been able to judge, does not appear to be peculiar to any age, temperament, or state of health. The teeth of children are very subject to this disease. I have frequently seen nearly all the temporary set of teeth decayed; and, in two or three instances, I have attended children who have been so constantly tormented with the tooth-ache as to make it necessary to extract almost all their teeth before they have arrived at five years of age.

The teeth of robust and healthy persons seem to be equally liable to caries as those of the delicate and less healthy. Nosologists mention, as one of the characteristic marks of predisposition to phthisis, sound teeth of a beautiful transparent whiteness. This must only be considered as an accidental circumstance, and not as a general rule; for great numbers of the persons, and especially those rather more advanced in years, who fall victims to this disease, have lost many of their teeth. The observation applies only to those delicately-formed persons who, unhappily, in our climate, so frequently fall victims to consumption. In the teeth of these persons, there is too small a quantity of earthy matter in proportion to that of the animal substance, on which account they have that fine transparent appearance.

[If the author had studied closely the physical characteristics of the teeth of different individuals, he would have discovered that temperament, and the state of the constitutional health at the time of their ossification, had much to do in determining their susceptibility to the action of the causes that produce decay, and these are influenced in a great degree, by residence in certain localities and modes of living. But for a full exposition of the editor's views upon this subject, the reader is referred to Part Second, Chapter Second, of his Principles and Practice of Dental Surgery.]

Mr. Hunter thought that teeth did not decay after a person had passed fifty years of age; but I have had many opportunities of observing that, even on this head, no certain opinion can be formed; for I have met with several persons who have not only passed fifty years without having caries in their teeth, but who have arrived at sixty without having felt the tooth-ache, and, after that period, have been obliged to have several teeth extracted on account of the extreme pain, which the inflammation arising from caries had occasioned.

[As a general rule, teeth which escape the attacks of caries until the fortieth or fiftieth year of age, rarely suffer much from this disease, except in those cases where the healthy qualities of the fluids of the mouth, from general disease, or some change in the state of the constitutional health, become impaired, and are thereby rendered corrosive.]

The early loss of teeth, however, cannot be considered, in itself, as a mark of short life, for there are many persons enjoying the most healthy old age, who have lost all their teeth before they had attained thirty or forty years of age. [This remark however, applies only to those whose general health has suffered from the presence



of diseased teeth and gums; and the improvement of health in such cases, which follows the loss of the teeth, is oftentimes very surprising.]

#### TREATMENT OF CARIES.

I shall now proceed to state the mode of treatments necessary to be adopted in the different stages of caries. In the preceding pages, I have shown that the progress of caries may be retarded, and the patient be preserved from pain by keeping the cavity of the tooth constantly and completely stopped. Beneficial as this practice really is, there are some cases in which it cannot be adopted; such are, an unfavourable situation of the decay, or its being so superficial as not to afford depth sufficient to retain the gold leaf.

When the decay is situated on that side of a tooth which is in opposition to another, so that persons say, the decay is between two teeth, it is always difficult, and frequently impossible, to retain the stopping, in which case, great inconvenience arises from the food lodging in those cavities, whence it is not easily removed; great benefit will here be derived from passing a file between the teeth, in which operation the opening should be so much enlarged as to allow a quill tooth-pick to be used with ease. If the caries has affected one tooth only, the next to it will be preserved by filing away as much of the decay as possible, and, should it not have made such progress into the body of the tooth, the remainder may be preserved for a number of years by the removal of the more carious part.

[When the decayed part cannot be removed without filing away so much of the tooth as greatly to injure its appearance, after having formed a sufficiently wide aper-

ture to enable the operator to get at the diseased portion, this should be removed and the cavity filled with gold in the manner to be hereafter described.]

The success of the operation of filing away a decayed portion of a tooth must not always be regarded as certain, the decay proceeds so rapidly, that it cannot be checked by any means, likewise the file cannot at all times be used, the position of the teeth rendering its application not only inconvenient but impracticable.

[Experience, however, has proven, that this is one of the most valuable operations in dental surgery, but in order to be successful, it is necessary that the whole of the diseased part of the tooth should be removed. In another place, the manner in which the operation should be performed will be fully described.]

In the Natural History of the Human Teeth, p. 95, I have described the ill effects which usually arise from the incisores being too closely placed against each other, and I there stated the mode of obviating them. If the teeth, in this state, have been neglected until persons have arrived to adult age, considerable advantage will be obtained from separating them by a very thin file, as it is on the sides of these teeth that the caries commences in the form of black spots. [It has been already stated, that this operation should be resorted to only in treatment of caries.]

If caries has proceeded in the manner delineated in Plate XVII. Fig. 1, a file rather thicker may be used, so as to separate the teeth as in Fig. 2. If one tooth only be injured, the file should be smooth on one side, in order that no part of the enamel of the sound one may be removed.

When the decay has considerably advanced, a small round, or half-round file may be used, and it should be carried into the mouth in an oblique direction, so as to



preserve as much as possible of the front part of the tooth; should the filing cause much pain, from the great sensibility of the tooth, the operation ought not to be continued, as it may render the patient liable to future tooth-ache, by causing an exposure of the nerve. In these cases we may file a little at a time until the decay has been nearly or quite eradicated, recommending during the intervals the application of spirits of wine to the decayed parts, which tends to harden the carious substance of the tooth and to diminish its sensibility. [A flat file should always be preferred for the front teeth, and experience has demonstrated that it is better to complete the operation at one sitting, even though the tooth be sensitive, and no advantage whatever is derived from the application of spirits of wine as recommended by the author.] Supposing the decay to have extended into the cavity of the tooth, it will be better to omit the filing altogether, and endeavour to stop it with gold leaf. [In many cases where the decay has extended thus far, neither filing nor plugging will save the tooth.]

[It will be seen from the foregoing remarks, that the treatment of caries is comprised in two operations, namely filing and plugging, and the manner of performing which will now be described.]

## CHAPTER SECOND.

### OF FILING THE TEETH.

THE application of a file to the teeth is considered by some persons, as one of the most injurious practices which can be performed; and they think that the decay of the tooth will certainly follow the removal of the least portion of enamel. These opinions have been disseminated by certain empirics, who have considered diseases of the teeth as a source of profit, and have therefore, paid no regard to the correctness of their statements, provided that they could acquire gain.

In those cases of caries where filing has been recommended to retard its progress, the most decided advantages were promised; and it is a practice defensible on the most just principles. Caries is a disease which it is not in our power entirely to arrest by any remedy whatsoever: its progress is gradual, but certain, until the destruction of the tooth is effected. The only plan that promises success, is to remove the carious part from that which is sound, with the expectation that the disease will thereby be stopped. This theory is justified by the success of the practice, whenever it is adopted before the caries have reached the internal cavity of the tooth.

The decay of a tooth is never occasioned by the loss of a part of the enamel, provided it be superficial, and not entering the cavity: this is frequently seen in those cases



where a piece of a tooth has been broken off, and caries has not been produced. In like manner, a considerable portion of a tooth may be filed away and the remainder will continue perfectly sound.

These facts may be well illustrated by stating the customs of some savage nations; these people have many customs, in which doing something to the teeth forms an essential part of the ceremony. In New Holland, the beating out one of the lateral incisores is performed by the priest, when a youth has gone through various ceremonies previous to his being introduced into the class of warriors. In one of the tribes of New Zealand, the queen is distinguished by having a piece of gold substituted for her two front teeth. Upon the effects of filing the teeth, the Abyssinian Negroes and the Malay Indians furnish striking examples. The Abyssinian Negroes have a method of cutting off the corners of the cutting edges of the incisores in both jaws, in order to make them all into pointed teeth; this operation they perform without entering any part of the cavity.\* Mr. Cline was in possession of a skull of one of these Negroes, in which, although it bore the marks of having belonged to a man who had been somewhat advanced in years, the teeth, thus filed, were not in the least rendered carious. A most convincing proof that the mere filing of a tooth does not cause it to decay. The other example in the custom of the Malay Indians, consists in filing the incisores of the upper jaw, in a direction across the upper part of the anterior surface, so as to give them the appearance of being fluted. By this mode of filing the teeth, the enamel is not only removed, but the cavities in the teeth are more or less exposed: the consequence of this is, that the teeth soon become carious. I had an opportunity,

\* Plate XXII. Fig. 5.



some time back, of examining the teeth of three of these men: they were all filed as represented in Plate XXII. Fig. 4. In those teeth which had the cavities exposed, caries had taken place, and those remained sound from which little more than the enamel had been taken off. These facts demonstrate that the teeth are not rendered carious by filing, excepting when any part of the cavity is exposed.

The incisores of the upper jaw, as I have already shown, are very liable to become carious, in consequence of being crowded, or pressed much against each other. To prevent this disease from taking place, it is advisable to make a separation between each tooth with a very thin file; and the space ought not to be wider than to allow a piece of paper, or fine linen, to be passed between the teeth. If the teeth have begun to be carious, a wider space should be made. In case one tooth should be carious, and the next to it perfectly sound, then the file should be smooth on one side, which will save the sound tooth from being injured.

Sometimes there is so much sensibility in the teeth, that filing causes pain; here it will be proper to file but a little at a time, until the decayed part is removed. If the decay appear to have entered the cavity of a tooth, it will be advisable not to touch it with the file. In that disease of the alveolar processes, where the teeth are protruded from the socket, the tooth should be made firm to the side teeth, by means of a ligature, previous to making use of the file; the projecting piece may then be filed off without causing any disagreeable jar or shaking of the tooth. In filing off the ragged points of broken teeth, no other direction is required than not to make use of a coarse file; fine Lancashire files are the most proper for all these purposes.



[It is sometimes necessary, from the peculiar nature of the decay to file away a considerable portion of the tooth, and in doing which, it is important that the symmetry of the organ, as far as practicable, should be preserved. Anteriorly, the aperture should be no wider than is necessary to admit of a sufficiently oblique motion, of a safe-sided separating file, for the removal of the caries. A third, on even more, of a tooth, may, in this way, be removed without materially injuring the appearance of the organ anteriorly.

It has been before remarked, that in filing the teeth, it should be done in such manner as to prevent the filed surfaces from coming together. To prevent which, a projection should be left on each tooth near the gum. Where the approximal sides of two incisores are decayed, an equal portion, as nearly as the circumstances of the case will permit, should be removed from each tooth.

During the operation, the file should be frequently dipped in water, lukewarm, if cold causes an unpleasant sensation. After the removal of the caries, the filed surfaces should be made smooth with a very fine half-worn file and burnisher. The edges and sharp corners should next be removed and made smooth to prevent annoyance to the tongue and lips of the patient.

The operator, in filing the front teeth and those of the right side of the mouth, should stand at the right and a little behind the patient, steadying his head with his left arm, while with the fingers of the same hand he raises and retracts his lips and properly exposes his teeth for the operation. Then with the file firmly grasped between the thumb and middle finger of the right hand, with the end of the fore-finger resting on its edge near the extremity, the operation should be commenced by moving it backwards and forwards in a straight line.

When both teeth are affected with caries, a file cut on both sides of about half a line in thickness, should first be used, and after having passed this between them, the balance of the operation should be completed with a safe-sided file of about the same thickness. If only one tooth is affected, the operation should be commenced and completed with a file of the description last named.

For the bicuspidæ, a file shaped like the pinion-file of a clock, or one that is oval on one side and flat on the other, will be found the best adapted for the operation, as the aperture to be formed should be made to resemble somewhat the letter V, except that the angle at the gum where it should terminate, should be less acute. The approximation of the teeth will be prevented by an aperture between them of this shape, and should plugging become necessary, the dentist will, without difficulty, be enabled to perform the operation in the most perfect manner.

When it becomes necessary to separate the molares, a similar shaped aperture should be formed, but as these teeth are situated farther back in the mouth, it cannot always be done with a straight file. To obviate this difficulty, operators have been in the habit of employing an instrument, with which every dentist is familiar, denominated, a file-carrier, but as this, for many reasons, is not very well suited to the purpose, the editor has used for several years files which he had made expressly for these teeth. They are in pairs, or rights and lefts, about an inch and a half in length and shaped something like the pinion-file of a clock, with a handle to each, bent so that they may be used without interfering with the corners of the mouth. These files, together with others of a somewhat similar construction, are now used by many dentists, and are highly approved.

To many, the sensation produced by the action of the



file on the teeth is exceedingly disagreeable, and to some quite painful, but the operation should never be suspended on this account. The teeth too, after having been filed, are often exceedingly susceptible to heat and cold, so much so, in fact, as to be more or less painful when any thing hot or cold is taken into the mouth. But this susceptibility soon subsides, generally in a few days, without causing any other inconvenience.

After the operation has been completed the patient should be directed to keep the filed surfaces of the teeth constantly clean. The observance of this precaution is absolutely necessary to prevent a recurrence of the disease for which it was performed.]

### CHAPTER THIRD.

#### OF STOPPING [PLUGGING] THE TEETH.

It frequently happens that persons apply to have this operation performed, with an expectation that it will relieve the tooth-ache: the error of this opinion will appear, when it is considered that tooth-ache, being a consequence of inflammation, can only be relieved by such applications as diminish increased action.

The cavity of an inflamed tooth is commonly so very sensible, that even the accidental entrance of any substance will cause the most acute pain; hence an endeavour to fill up the cavity of a tender tooth, with any material that requires pressure, would increase all those sufferings from which it is the desire of the patient to be relieved. A tooth then can only be stopped when it is perfectly free from pain or tenderness.

By stopping a tooth, it is rendered artificially sound again. The carious cavity being completely filled up, the introduction of particles of food, and that taint of the breath which arises from their becoming putrid, are prevented; the nervous membrane, in the natural cavity, is preserved from being irritated, and is rendered less susceptible of changes of temperature in the articles of food: and, if care be taken to keep the stopping in a complete state, the progress of decay is very retarded, and the tooth-ache almost prevented. I am acquainted with per-



sons who have had carious teeth for several years, but who have never felt the tooth-ache, from keeping the cavities in their teeth constantly stopped.

[The value of the operation however, depends upon its being well performed, and with an indestructable material. When thus performed, and with such material, the preservation of the tooth, unless it be attacked by caries in some other place and no means used to arrest its progress there, may be regarded, in almost every instance, as certain; but when performed by an unskillful hand, or with a bad material, it has a contrary effect—it often hastens, rather than arrests, the progress of the disease. Although to one inexperienced in this branch of manual medicine, the operation may appear very simple, yet it is the most difficult one in dental surgery. It, in fact, requires so great an amount of mechanical aptitude and practical skill, that hardly one in fifty, engaged in this department of physical alleviation, have acquired an eminent degree of excellence in it. At the time of the publication of the first edition of this work, it was but little understood, and consequently, the directions given by the author for its performance are too brief, and inexplicit to serve as a proper guide to the student. Therefore, the editor has thought it best to omit them altogether.

As a general rule, the operation should be performed before the pulp cavity of the tooth has been reached by the disease, for after the lining membrane has become exposed, its success, especially on a molaris, in at least four cases out of five is rendered hopeless. A filling may often be introduced into a cavity in the side of a bicuspid, cuspidatus or incisor, which extends in to the lining membrane, without touching it, and in such a manner as to secure the preservation of the tooth. But to do this,

much mechanical tact and practical experience is required, for if the filling touch the lining membrane, the pain and inflammation it will excite will render its removal indispensable.

It is seldom proper to plug a tooth after the destruction of its lining membrane, except it be an incisor or cuspidatus, and even then the success of the operation is very doubtful. A tooth after being deprived of the greater portion of its vitality, becomes more or less obnoxious to the periosteal tissue of its socket. It causes it to become thickened about the extremity of its root or roots, if it have more than one, and a morbid secretion, which is constantly discharged through the tooth, so long as the cavity remains open. If this be closed by a filling, the matter accumulates, and ultimately in the majority of cases, makes a passage for its escape through the alveolus and gum or into the antrum. This, however, is not so frequently the case with the incisores and cuspidati, as with the bicuspidates and molares, and probably, for the reason that the roots of the former derive a greater amount of vitality from their investing membrane than do the latter, and are hence, after the destruction of their lining membrane, productive of less irritation to the surrounding parts.

The accumulation of matter, however, secreted at the extremity of the root, may be prevented, by leaving an opening through the filling, as proposed by Dr. L. S. Parmly, which is done by introducing the foil round a small probe or wire, with one end resting on the bottom of the pulp cavity, and which, after the operation is completed, is to be withdrawn. But while the decay of the tooth immediately around the filling is thus prevented, it is constantly going on interiorly, and ultimately destroys the tooth. The practice, therefore, of filling the bicus-



pides and molares after the destruction of their lining membrane, whether by the process of inflammation and suppuration, or by arsenic or any other means, is, to say the least of it, unscientific, and should never be adopted, except when called for by some peculiar necessity. Nor should a front tooth, from the root of which fetid matter is discharged, ever be filled.

In cases of exposure and inflammation of the lining membrane, Dr. Koecker recommends the application of leaf lead, previously to the introduction of the gold, supposing the former is less irritating to the animal fibre than the latter, but the contact of any hard substance with as sensitive a tissue as is this membrane, would of necessity increase the disturbance. The practice recommended by Dr. Fitch, which consists in covering the exposed nerve with a gold plate, and in such a way that it shall not come in contact with it, is altogether preferable. The plate, however, should be so fitted to the walls of the cavity as to prevent it from touching the bottom or from becoming displaced by the introduction of the filling. But when the lining membrane is inflamed, Dr. F. recommends the application of Aleppo galls to it, for the purpose of reducing the inflammation, previously to filling the tooth. The editor, however, has seldom derived any advantage from the application of this remedy. Some benefit may occasionally be derived from the application of leeches to the gum, but neither by this nor any other treatment that has ever been adopted, can inflammation of this tissue be always reduced. In fact, it is only in the fewest number of cases that it can be.

It oftentimes happens that a tooth is very sensitive when the decay has penetrated but a short distance into its osseous structure. This, however, need never prevent the dentist from proceeding with the operation, provided

the patient can be prevailed upon to endure the pain consequent upon the removal of the diseased part, for, after he has accomplished this, it is seldom that any other inconvenience will afterwards be experienced.

From the foregoing remarks, it will be perceived, that the plugging of teeth is advisable only under certain circumstances, and to which reference should always be had in the performance of the operation. And now, having premised these few general observations on the subject, it may be well, before describing the manner of performing the operation, to say a few words concerning the materials employed for the purpose, and upon this point, we shall be brief.

Various articles and preparations have been employed for filling teeth, and hardly a month passes, that we do not hear of the discovery of some new material or nostrum, recommended by the discoverer as being superior to anything previously used for the purpose. But pure gold or platina is the only material capable, under all circumstances, of resisting the action of the secretions of the mouth, and is the only one that should ever be employed for filling teeth. Gold is softer and can be more easily introduced into the cavity of a tooth than platina, and for which reason, is altogether and by far preferable to that metal. This, when properly prepared in leaves of from four to ten or twelve grains, can be so packed in the cavity of a tooth as to exclude every particle of moisture, which is indispensable to the preservation of the organ. With this metal, the object for which the operation is performed, may with certainty be secured. It is therefore good enough; no better material is wanted, and indeed, none better can be had.

Tin is the next best material. This metal is very soft, and can be easily and compactly introduced in the cavity



of a tooth, but in consequence of its being more easily acted upon by the secretions of the mouth, it is of a less durable nature; though in the mouth of a healthy person, it will often last for many years, and sometimes through life. But inasmuch as it cannot be depended on in all cases, and under all circumstances, we are of the opinion that it should never be employed.

Silver is even more objectionable than tin. It is much harder and cannot be so firmly packed, and besides it oxydizes more readily; consequently, it is at present little used for filling teeth: Lead, a few years ago was much employed for this purpose, but in consequence of its being easily decomposed by the septic (nitrous) acid of the mouth, its use has been almost wholly abandoned. An alloy of bismuth, tin, and lead, in consequence of its fusibility at the temperature of boiling water, was at one time recommended. This, however, was never much used, as it was found, that the temperature at which it had to be used, caused inflammation in the lining membrane of the tooth, and that when it cooled, it shrunk and admitted the fluids of the mouth around it into the cavity of the organ.

The most objectionable and pernicious article that has ever been employed for filling a tooth, is an *amalgum* of *mercury* and silver, known by the various names of *lithodeon*, *mineral cement*, &c. &c. This preparation not only readily oxydizes in the mouth, but it also turns the teeth black, causes them to decay more rapidly than they would do if let alone. It moreover, exerts a hurtful influence upon the alveolo-dental periosteal tissue, gums, and in fact the whole body. A number of clearly marked cases of silivation produced by the use of this amalgum have fallen under the observation of the editor, yet it has been most extravagantly eulogized by a few unscrupulous

pulous empirics, during the last six or seven years, and thousands of teeth both in America and Europe have been destroyed by it.

Having said thus much concerning the materials employed for filling teeth, we shall now proceed to offer a few remarks on the instruments for and manner of preparing the cavity, and for this part of the operation, a variety of delicately, different shaped, and well tempered instruments are required, which are designated by the name of excavators. They should be so curved and shaped at their points as to be easily applied to any part of the tooth, and each one should have a sharp cutting edge, which may be made to act with facility upon every part of the caries and walls of the cavity, it may be necessary to form for the retention of the filling. Each may have a separate handle or be made to fit in a socket fixed to one common handle. It would be well however for every operator to be provided with a good supply of both kinds, and in case of necessity he should be able to make them himself; for without such as are exactly suited to each individual case, he will not only labour under great inconvenience, but oftentimes be unable to form the cavity in the best and most proper manner.

In addition to the foregoing instruments, cherry-headed and flat drills are oftentimes exceedingly useful in some portions of this part of the operation. They may be used either in a socket handle or drill-stock. The latter may be turned with the thumb and forefinger or a string and bow. Some practitioners, without reason, but on the alleged ground that the more rapid motion which is thus given to the instrument, causes a greater amount of irritation to the bone of the tooth, object to the latter method of using it. In the hands of a skilful operator it



may be used in this way with impunity, and frequently with great advantage, especially in opening a cavity on the grinding or outer surface of a molaris. But for this, the cherry-headed drill should be employed. The flat-drill too, in many cases is very useful. A cavity in a tooth however, can, without the aid of other instruments, seldom be properly formed with either of these. They are chiefly useful for opening and enlarging the orifice, and this done, its formation should be completed with properly shaped excavators, and in the majority of cases, the whole of this part of the operation should be performed with these instruments. When the drill is used, the precaution of dipping it frequently in water, to prevent it from becoming heated, should never be neglected.

The forming of a properly shaped cavity, preparatory to plugging a tooth, is an important part of the operation; and though generally the easiest, is nevertheless sometimes attended with difficulty. The removal of every portion of the caries, is not all that is required in the formation of the cavity—it often becomes necessary to cut away some of the sound part of the tooth, to give to it the proper shape for the retention of the gold. It should always, if possible, be as large at the bottom as at the orifice, and if there be any difference, it should be rather larger here than there, though the dimensions of the former should never greatly exceed that of the latter. The walls of the cavity too, surrounding the orifice should be strong and smooth, presenting no unequal or brittle edges. It sometimes happens however, that the extent and peculiar limits of the decay is such, as to render it impracticable to make the bottom of the cavity as large as the orifice. In this case, a firm support should be secured for the filling, by cutting several circular grooves in the walls of the cavity. This precaution, if properly attended to, will prevent the filling from becoming displaced.



It is generally much easier to form a cavity in the grinding surface of a molaris or bicuspid, than in any other part of these, or any of the other teeth. But there are cases, in which, the formation of a properly-shaped cavity, even in the grinding surface of a molaris is very difficult, especially when the caries, having attacked the centre of the tooth, follows the various indentations or depressions which leads out in various directions from it. The caries, after having attacked the tooth, spreads as it penetrates it, and it is necessary to cut away the points at least, of the intermediary converging portions of the enamel, in order to make a sufficiently large orifice, and these are often very thick and hard, requiring considerable time to do it. When the caries is situated in the approximal side of a tooth or sides, as is most frequently the case, it should first be exposed by filing a space between the organs in the manner as before described, and this should always be wide enough to enable the operator to remove with facility the caries and fill the cavity.

To fill a tooth well when the cavity is situated in its side next an adjoining tooth is often a very nice and exceedingly difficult operation. It was formerly regarded as impracticable, but its practicability is now fully established. An experienced and skilful practitioner can put in, under favourable circumstances, as substantial and durable a filling here, as in any other part of a tooth.

After the formation of the cavity is completed, it should be wiped out and freed from all loose particles of matter, before the introduction of the filling.

The next step in the operation is the introduction of the gold, and this is by far the most difficult part, requiring ordinarily more time and mechanical skill in its execution. A number of instruments are required for the



purpose. Some dentists employ more than others, and the majority of practitioners have more than is absolutely necessary. With from twelve to fifteen, properly constructed, a good operator will be able to fill any cavity in any tooth. Those generally employed, are illy suited to the purpose. Filling instruments should be made of the best of steel, have a spring temper and be strong enough to bear all the pressure the operator is capable of putting on them. Their points should be shaped so that they may be applied to any cavity in any tooth—some should be curved slightly, others to an angle of ninety degrees, and others again should be straight. Most of them should be shaped like a thin wedge, especially those that are to be used for the introduction of the foil. A few should have blunt and some oval points, and they should vary in size to suit the cavity in the tooth, and they should be securely fixed in strong octangular handles.

Being provided with a sufficient number of properly shaped instruments, the operator should cut his gold foil in strips of from half an inch to an inch in width. These should be loosely rolled or folded lengthwise, and beginning at one end, it should be introduced, with a wedge-pointed instrument, in folds, commencing on the side of the cavity, making one end of each of which, press on the bottom while the other projects a short distance out of the orifice. Thus fold after fold, and piece after piece should be introduced until it is tolerable tightly filled. This done the point of the instrument should be forced down through the centre of the filling and the gold firmly pressed out against the walls of the cavity. The opening thus made should next be filled in the manner as first described. Every part of the filling should now be tried with a tolerably sharp wedge-pointed instrument, and an opening effected similar to the first, and filled as before



described, whenever it can be made to penetrate the gold. After having put in as much foil as can possibly be introduced, the part projecting out of the cavity should be packed, if it be in any part, except the approximal surfaces of the teeth, with a blunt-pointed instrument, and if here with the side of a wedge-pointed one, with as much force as can be applied, or as the tooth will bear.

If the filling be in the grinding, labial or lingual surface of the tooth, so much of it as still protrudes should be scraped or cut away, leaving it however flush with every part of the cavity, and the surface highly polished. If the filling be on the approximal surface of the tooth the extruding portion should be removed with a very fine or half worn file, and polished as before stated.

Too much labour and pains cannot be bestowed on the introduction and finishing of the filling. The gold should be thoroughly packed, and inserted in folds as just described to prevent the liability of its crumbling. If in finishing the filling, any small particle should crumble or be displaced next the wall of the cavity, an opening should be made here, deep enough for the introduction of more gold, so that when the operation is completed, it shall present a firm, uniform, unbroken and highly polished surface.

When the lining membrane is exposed, the folds of the foil should not be carried to the bottom of the cavity, and in packing it, the instrument should be forced down at the side, instead of through the centre of the filling, as before described. It is seldom, however, that any other tooth than a bicuspid, cuspidatus or incisor can be filled under such circumstances, and even then it cannot always be done, and never, except by a very skilful operator.]

Having stated, in the preceding pages, the causes of caries, and described its progress in destroying the teeth,



it now becomes necessary to treat of the symptoms of inflammation, which usually attend this disease, and the occasional consequent affections of the contiguous parts. [As the symptoms to which the author refers, belong strictly to tooth-ache, and are comparatively seldom an accompaniment of caries, we shall head his remarks upon the subject with the name of that disease, and arrange them in a separate chapter.]

## CHAPTER FOURTH.

### [TOOTH-ACHE.]

THE pain commonly termed the tooth-ache, is one of the most excruciating to which we are liable. It is caused by an inflammation of the membrane lining the cavity.

In inflammation, one of the usual consequences is a swelling of the part, which is generally followed by a diminution of the pain, the degree of which seems to be regulated by the resistance and compression which the inflamed vessels suffer from the surrounding parts; hence we see inflammation of a part, which may be easily distended, is not so painful as that of one situated under a tense membrane, or fascia. In the former case, the symptoms of general irritation are scarcely perceptible, whilst, in the latter, the constitution always becomes considerably affected.

These remarks sufficiently demonstrate, that in consequence of the membrane of the tooth being contained within a bony cavity, which is incapable of distension, there must necessarily exist an insurmountable obstacle to the swelling of the membrane, and this it is which renders the pain so extremely acute.

In some few instances, caries will proceed without being accompanied by any painful sensations: the tooth gradually breaks away, until the whole of it is removed;



after which, the gum becomes perfectly smooth, and appears as if the tooth had been extracted. [Its appearance, however, is of a deeper red; sometimes it is almost purple, and bleeds from the slightest injury.]

Generally, no tooth-ache is experienced until the caries has made some progress. It is impossible accurately to describe an attack of tooth-ache, as persons are so variously affected by this malady. Some are suddenly seized with a pain darting from the tooth, through the head, so acute as almost to induce fainting. A few instances of this mode of attack I have witnessed where the patients have endured the pain for a short period, and, alarmed at a return, have been so importunate to have the tooth extracted, as scarcely to allow sufficient time for preparing the instrument, and, after the operation, they have exclaimed that the pain could not in the least be compared with the sufferings attendant upon the attack.

[Tooth-ache is often induced by a cold, which causes inflammation and pain in the investing and alveolar membranes; in this case the teeth are slightly raised from their sockets and exceedingly sensitive to the touch—at other times it is sympathetic, being the result of disease in some other part. Females during gestation are very subject to it.]

#### [TREATMENT OF TOOTH-ACHE]

More commonly, at first, the pain of the tooth-ache is slight, and occurs at intervals, being occasioned by exposure to cold, or the accidental pressure of some adventitious substance, such as a piece of crust, the seed of some fruit, or any thing sweet: either of these getting into a tooth, partially decayed, generally causes some uneasiness. This kind of pain may almost always be

relieved by a little *tinctura opii*, or it may subside of itself. In either case, a recurrence may generally be prevented, by filling up the cavity of the tooth with some substance sufficiently hard and durable to keep out particles of food, and not liable to be acted upon by the moisture or heat of the mouth. [But whenever they are applied, the operator should be careful not to touch the pulp of the tooth if it be exposed.]

For this purpose wax, gum mastic, &c. have been employed, but they are soon dissolved and destroyed, therefore are improper. Formerly it was very much the practice to stop teeth with lead leaf, but the use of this substance ought to be forbidden, as it becomes corroded by the saliva, and the introduction of a very small quantity of this metal into the body is found to be productive of deleterious consequences: there is indeed reason to believe that, being dissolved by the menstrua contained in the saliva, it may occasion pains in the stomach, or other uneasy sensations.

On this account, nothing ought to be used but what is insoluble, or, if soluble, innoxious. Gold leaf is the most proper substance: also pure tin, beaten into leaves, may be used with nearly equal advantage: it is not so durable as the gold, as the saliva gradually acts upon it, but it cannot do any injury to the constitution. [But the plugging of a tooth with a metallic substance after it has ached, is seldom advisable. This operation has been treated of in another place.]

By thus excluding the air, and preventing any particles of food from lodging in the cavity, the progress of decay may be greatly retarded, the pain prevented, and the teeth preserved for many years.

If no means have been used to prevent the recurrence of the tooth-ache, it usually becomes so violent and con-



stant, that rest is disturbed, and persons are incapacitated from pursuing their accustomed avocations: when this is the case, the tooth should be extracted.

There is scarcely any thing occasions so much fear as the idea of the extraction of a tooth, and this very dread is often the cause of most unpleasant consequences.

The inflammation proceeds from the tooth, and affects the contiguous parts, the gums and the integuments of the face swell, and become much inflamed. The swelling is often so great, that the mouth cannot be opened, and the eye becomes closed: in other cases, the swelling extends down the neck, and the constitution is affected with the symptoms of general irritation.

Sometimes the inflammation and swelling will subside, and resolution take place, but most frequently it terminates in suppuration. Now and then, after the matter has been discharged, the pain will cease; but, as the diseased tooth remains, the symptoms are liable to recur upon every exposure to cold. Whenever the gums are inflamed, the alveolar processes are also affected, and they are removed by the process of absorption. If a person should have had formation of matter two or three times about the fangs of a tooth, the sockets will be so much absorbed [or rather wasted] that the tooth will become loosened: in this state, it causes so much trouble, that the patient is obliged to have it extracted, and a cure is thus obtained.

The inflammation is sometimes so great as to extend to the substance of the jaw bone, and even to occasion its partial mortification.

The distress attending the process of exfoliation, and the consequent deformity, should warn all persons against exposing themselves to the hazard of such an occurrence.

The pain proceeding from the inflammation of the

membrane of a carious tooth is not of the same kind in all persons, arising probably from some peculiarities of constitution, for it not only varies in its intensity, but likewise the sensation excited.

Some describe it as a gnawing kind of pain, not amounting to acuteness, but being constant, and admitting of no continued relief, it renders them unfit for either mental or bodily exertion. In others, it comes on suddenly, occasioning an acute pain, as if an instrument had been passed through the jaw: this occurs at intervals, and the expectation of an attack often causes as much anxiety and distress as the pain itself. In others, the pain is periodical, there being an intermission of some hours. In these cases, bark has been sometimes exhibited with a degree of success; but, at length, patience being exhausted by the continuance of the pain, extraction of the tooth has been the only remedy. [When it is the result of a disordered state of the stomach an emetic or cathartic will often give relief. When it occurs during pregnancy, a dovers powder and peldilurum on going to bed has been found beneficial.]

The pain often follows the course of the nerves, being diffused all over the cheek, shooting up to the temple, and affecting the head generally.

It frequently happens, that, when either of the dentes sapientiæ of the under jaw occasions pain, the patient does not suffer so much in the tooth itself as in the ear.

I have also frequently observed that the last tooth of the upper jaw, when diseased, has occasioned many confused sensations, the pain most commonly has been referred to the first or second molares, and with the greatest difficulty could patients be persuaded to have the dens sapientiæ extracted.

These sympathetic pains, arising from carious teeth,



proceed from the intimate connection which subsists between the branches of the fifth and those of the seventh pair of nerves. The pain in the ear is therefore sympathetic, arising from disease in the dens sapientiæ; it is caused by a union of a branch of the seventh pair of nerves with the lingual branch of the fifth pair; this nervous filament enters the cavity of the tympanum, passes on the inner side of the membrana tympani, and is called the corda tympani.

From the connection which subsists between these two pairs of nerves, it happens that not only inflammation in the teeth causes a sympathetic pain in the ears, but disagreeable and unharmonious sounds produce a sympathetic effect upon the teeth, and occasion that unpleasant sensation called the teeth being set on edge.

In that disease of the nerves called tic douloureux, the teeth are generally suspected to be the seat of the pain.

In the Medical Records and Researches is a very excellent paper on this subject, by Dr. Haighton. The disease is there described as chiefly affecting the fifth and the seventh pair of nerves, and the doctor relates several cases of persons, affected with this disease, having submitted to the extraction of a great number of teeth, before the true cause of the pain had been ascertained. I have had the opportunity of observing a few of these cases, one of which I shall relate, on account of the remarkable benefit which followed the operation, as recommended by Dr. Haighton. An elderly gentleman applied to me for the purpose of having some stumps extracted from the upper jaw, stating that he suffered considerable pain from them: without further enquiry, I performed the operation. Two days afterwards, he came to me again, and expressed a wish that I would extract the teeth which were remaining on that side of the upper jaw. The teeth to which

he directed my attention were two molares, both of which appeared to be perfectly sound. I then enquired what his particular kind of pain was: he described it as a pain which had come on at intervals for nearly two or three months past; at first it was slight, but had gradually arisen to such a degree of acuteness as almost to cause fainting: whilst he sat still he was easy; but, if he spoke quickly, or ate any thing which required mastication, or walked hastily, or was shaken by riding in a carriage, the pain returned, shooting through his cheek, and affecting his teeth and all the side of his face, as if he had received an electric shock. I had the opportunity of seeing him during two or three of these painful attacks. Whilst he was relating to me the above statement, he was seized with so much pain, that he suddenly stopped, and the water streamed from his eyes. On comparing his description with what I then saw, I immediately conceived that his complaint was caused by a disease of the sub-orbital branch of the fifth pair of nerves, and offered to accompany him to Mr. Astley Cooper, in order to take his opinion. As I went with him in the coach, a sudden jolt caused another attack. Mr. Cooper, after having heard the above statement, concurred in the opinion I had given, but was more particularly confirmed in it by producing another attack, by only rubbing the hair of his beard contrary to its natural direction.

The gentleman assented to the operation, which Mr. Cooper performed immediately. The nerve was completely divided, as the power of raising that side of the lip ceased, and it remained as in a state of paralysis. The wound healed in a few days, after which the pain entirely left him, he could eat with comfort and take exercise without fear. His joy was so great at the deliverance which he had experienced from so much suffering, that



he could not afterwards speak of it without shedding tears.

Sometimes when persons suffer extremely with the tooth-ache, they find a great difficulty in fixing upon the tooth from which the pain proceeds; and it is not uncommon for them to refer it to a tooth not in the least connected with the seat of the disease: frequently they will fix upon a sound tooth, and it often happens that the pain is conceived to originate from a tooth of the upper jaw, instead of one of the under jaw, and vice versa.

Whenever any doubt is expressed, great caution should be observed previously to the extraction of the tooth. The teeth may be examined by striking them with the end of a pair of forceps, in order to discover that which is the most tender; as it usually happens that a tooth in a state of inflammation is so sensible that it will not bear to be struck without pain. If this mode of examination be not satisfactory, and there should be more than one carious tooth, they should be carefully examined by picking the hollow part with the point of a probe, or other small pointed instrument, bent in the form of a hook; by doing this the exposed nerve of the tooth, that has caused the pain may be touched, which will immediately assure the patient and the surgeon of the tooth from which the pain proceeds. [The seat of the disease may, in the majority of cases, be ascertained in this way, but not in all.]

The means which have been employed to relieve the pain arising from inflammation of the membrane of a tooth, are attended with very different success; some persons deriving benefit from one application, and others from another.

Whenever tooth-ache exists, without any sympathetic affection of the gums or socket, those medicines which

tend to diminish nervous sensibility, afford relief; opium conveyed into the tooth, either in the form of tincture, or solid opium, frequently succeeds. Camphor, the smoking of tobacco, essential oils of cloves or of thyme, the concentrated acids, &c. are also recommended, and with occasional effect.

It is most extraordinary, but not less true, that there is scarcely any pain to which the human body is subject, that is so much under the influence of the passions of fear or hope, as the tooth-ache; this is experienced by almost every patient, and as constantly observed by every surgeon, by the pain generally leaving that individual who is under the immediate expectation of having the tooth extracted.

Empirics are not wanting who take advantage of this circumstance, and pretend to cure tooth-ache by certain charms and nostrums: indeed, at the moment they often appear to be successful, from the passions of fear or hope causing a temporary suspension of pain.

The burning of the antihelix of the ear, in order to relieve this complaint, must be ranked amongst the above methods of cure; it is one not worthy of notice, had it not been formerly a very popular remedy, and lately recommended in a periodical publication. The slightest knowledge of the distribution of the nerves to the teeth must convince every one, that a division of any part of the ear cannot separate the connection which subsists between the teeth and the principal branches which go to the brain, and therefore no more benefit can be derived from this formidable operation, than may be attributed to the influence of fear.

When the carious part of a tooth is very sensitive the pain not being constant, but only excited by some cause of irritation, it is much in the same state as an irritable



ulcer, and the pain may be relieved in a similar manner, viz. by destroying its surface with caustic. This method of treatment was first mentioned to me by Mr. Abernethy, as one that he had tried with great success, and which I have also found to be very beneficial.

The cavity of the tooth is first to be wiped dry with a small piece of lint, or cotton, then some lunar caustic, in solution, may be introduced on the point of a camel's hair pencil, spreading it over the whole of the carious surface. This should be repeated two or three times, after which, if the tenderness be removed, the tooth may be stopped with gold leaf, and thus be preserved.

[The application of lunar caustic to the carious part of a tooth will sometimes, but not always, allay the sensitiveness of the diseased portion, and in consequence of the uncertainty of its effects, its employment for this purpose is, at present, seldom resorted to.]

Attempts have been sometimes made to destroy the nerve with the actual cautery, by introducing a red-hot wire; but I have scarcely ever found this plan to be effectual; and, as it always gives great pain, and sometimes produces an increase of inflammation, I think it is better never to recommend it. Indeed, all applications are very uncertain, and therefore, if relief be not speedily obtained, it is advisable to suffer pain once for all, by having the tooth extracted.

[It was ascertained by Mr. Spooner of Montreal some years ago, that the nerve of a tooth might always be destroyed in a few hours by the application of a small quantity of arsenious acid. This discovery was published to the profession shortly after by his brother Dr. S. Spooner of New York, in a popular treatise on the management of the teeth. At first the discovery promised to be of great value, but it was soon ascertained, that,

though the nerve could with certainty be destroyed by it, and the tooth afterwards plugged, alveolar abscess was almost sure to result. The use of it therefore, has been almost altogether abandoned by the more skilful and experienced of the profession.]

Some years since I attempted a mode of destroying the nerve, which at first promised to be very successful. I knew that a nerve once divided did not re-unite for a considerable length of time, and therefore concluded, that if I could separate the nerve going into the tooth from the principal branch, that the pain would be prevented, and useful teeth might be thus preserved.

The method which I adopted, was to raise the tooth, by the common operation of extraction, so high in the socket as certainly to break the nerve and vessels which enter the extremities of the fangs; then, on withdrawing the force, to press the tooth back again into its former situation. I not only recommended this operation, but also performed it upon a great number of persons, and for a short time flattered myself with very sanguine expectations; these, however, were quickly destroyed, for some of my patients, in about three or four weeks afterwards, came complaining of pain, and were anxious to have the tooth completely removed. They did not suffer the tooth-ache so acutely as before, but the tooth had become sore, and was protruded from the socket, so that, whenever the mouth was closed, the pressure of the teeth in the other jaw against the tender one occasioned great pain.

On extracting these teeth, I found the fangs covered with a considerable quantity of coagulated lymph; which circumstance led me to believe, that this operation could not be recommended with any certainty, as it only succeeded in those cases in which union of the fangs to the



socket took place, as it were, by the first intention; but if any inflammation followed, so as to produce an effusion of lymph, it caused a thickening of the periosteum, and a consequent protrusion of the tooth, which induced a necessity for its complete removal. Since that time, I have only followed this practice in cases where a tooth has been but slightly decayed, and the patient has been very desirous to suffer any experiment for its preservation. In a great number of cases it has perfectly succeeded; but I have always represented the possibility of its failure.

The incisores of the upper jaw, although very liable to become carious, do not often occasion the tooth-ache; but when this is the case, I always recommended the extraction of the tooth before any inflammation has affected the gum; the decayed part of the tooth may then be removed, or the cavity be very perfectly stopped with gold leaf, and it is then to be returned into the socket. The fangs of these teeth being straight and conical, renders this operation almost always successful; the tooth soon becomes perfectly fixed, and may remain many years useful for the articulation of sounds, as well as ornamental to the sight.

[The practice here recommended, even under the most favourable circumstances, is objectionable. A tooth being thus deprived of its vitality, is more or less obnoxious to the surrounding parts. The removal altogether of the tooth and the substitution of an artificial one is far preferable.]

## CHAPTER FIFTH.

### OF EXTRACTION OF THE TEETH.

FEW operations in the ordinary practice of medical men, are more repugnant to their own feelings, as well as to those of their patients, than the extraction of a tooth. In this operation, both surgeon and patient are frequently alike influenced, as it often happens that the former is quite as much averse from performing the operation, as the latter is from suffering it. This reluctance in the surgeon can only arise from deficiency of confidence in his own abilities, producing fear lest he should perform the operation unsuccessfully. I shall, therefore, offer a few hints, which may tend to remove distrust, and, in this way, increase the fortitude of a timid operator.

The various conditions of the teeth, which may create necessity for their extraction, produce equally great variety in the difficulty or ease with which the operation may be performed. In some, the teeth are so loose, that they may almost be taken away by the fingers; in others from the carious state of the teeth, or from the direction and strength of the fangs, it is impossible to succeed, notwithstanding the greatest care or ability. [This, no doubt was true, at the time of the publication of the first edition of this work, but it is not at present. Any tooth may now, with proper instruments, be removed, with safety, by a skilful operator.]



Extraction of the teeth is required for the following reasons: in children, to prevent or remedy irregularity in the arrangement of the permanent teeth, and on account of tooth-ache arising from caries of the molares, which is a very common circumstance. In adults, from the teeth having become loosened from an absorption of the alveolar processes; or from some other cause, as the effects of caries.

[INSTRUMENTS EMPLOYED IN THE OPERATION.]

It would be useless to mention the great variety of forms in which instruments for extracting the teeth have been made: I shall only describe such as are really useful, and make a few remarks on some that have been strongly recommended.

[THE KEY INSTRUMENT.]

The key instrument, or, as it has been commonly called, the German key, is the most useful: it has undergone several alterations in form, and has received some improvements, which, I think, have brought it as near to perfection as possible. The first material improvement in this instrument was made by Mr. Spence: it consisted in adding a projecting part at the end of the bolster, through which the screw is passed. This addition was made for the purpose of fixing a claw, in an advanced position, beyond the bolster, which was found extremely useful in the extraction of the *dentes sapientiæ*.

Mr. Savigny introduced his improved key with a round bolster, and a raised form in the stem of the instrument, which is very convenient for avoiding injury to the front teeth, when it may be required to extract a

tooth, by fixing the bolster on the inner side of the jaw. It occurred to me that another addition was still requisite to make it complete, and that was, to be able to fix a claw behind the bolster, that it might act on a principle similar to Mr. Spence's improvement, which is, to have the fulcrum of the instrument applied at a different place from the carious tooth to be extracted. In Mr. Spence's instrument, the claw is placed before the fulcrum, in mine, the fulcrum is placed before the claw. This improvement I have found of very essential service in extracting the bicuspidæ of the lower jaw, and also in cases where a large gum-boil, of extreme sensibility, happened to be situated at the part where the fulcrum of the common instrument would have been placed; a circumstance of great utility, as the pressure may be made upon an insensible, rather than upon an inflamed part. The descriptions in Plate XXII. will clearly illustrate the above statement. The alterations in this instrument, from Mr. Savigny's improved key, which had the advantage of Mr. Spence's improvement, consist in a place for fixing the claw behind the fulcrum, and in having the bolster of an oval form instead of a round one, as the latter occupies too much room in the mouth. This instrument is applicable to the extraction of the bicuspidæ and molares.

For the removal of the molares of children, a small spring key instrument is very requisite. In operating upon a child, nothing ought to be exhibited that might occasion alarm: a very small instrument may be hidden in the hand, which, by preventing terror in the child, will produce submission to the operation: this small key instrument may be accommodated to the handle of the large one.

Sometimes it happens that a molaris on each side of the mouth occasions tooth-ache at the same moment, in



which case, it is desirable to remove both of them; but there is great difficulty, after a child has felt the pain from the extraction of one tooth, to persuade it to submit to a second operation; on this account we must always endeavour to be as quick as possible. It is very easy, when the mouth is open, to extract more than one tooth, as the claw of a spring key can be turned in so short a time that the little patient scarcely knows any thing about it. Parents are too solicitous to prepare the minds of their children for undergoing the extraction of a tooth, by talking of it, and assuring them that they will not be hurt, &c. &c. but I have usually observed that attempts of this kind are often unsuccessful, and the contrary disposition is more generally excited. The best plan is not to mention to the child any intention of having its tooth extracted, but only to allow the time for performing the operation to be the moment of deliberation. Children are often tortured with the anticipation for several days together, and, when the moment arrives, they have lost all their fortitude.

## THE PACES.

For the extraction of the incisores in the adult, and the incisores and loose molares in children, an instrument is used, called the paces: this instrument is an improvement upon the crow's-bill, formerly used. The form recommended by Dr. Blake, of Dublin, is the best; they are made straight and curved. The instrument for adult teeth should be larger and stronger than that for the temporary teeth. For the extraction of a stump, the instrument commonly called a punch is employed. Besides these instruments, a pair of forceps, like the common dressing forceps, but rather stronger, are required for the purpose of removing a loosened stump, or any small splinter.

## THE PERPENDICULAR EXTRACTOR.

Some persons have very strongly recommended instruments adapted for the perpendicular extraction of teeth: much ingenuity, indeed, has been exercised in the construction of all these; but they are not applicable to general use. The principle on which they all act is this; that, after having fixed the extracting instrument on the carious tooth, a powerful action is made with it, and the tooth is removed, just on the same principle as that by which a cork is drawn from a bottle by the patent corkscrew. There are several insurmountable objections to this mode of extraction: in the first place, the instruments being of complicated structure, they cannot be used quickly, a circumstance of the greatest importance: secondly, it not unfrequently happens that the tooth to be extracted is much stronger than the tooth on which the counter pressure is to be made; here the sound tooth is much injured, and the carious one cannot be extracted: thirdly, the fangs of some teeth being very divergent, it is not possible to extract them in a perpendicular direction, any more than a piece of wood, dove-tailed in a mortise, can be removed in any other way than in a lateral direction: fourthly, there may be no teeth remaining on which the counter pressure can be made. In trying these instruments, I have met with all these various difficulties, and, therefore, think them inapplicable to general use.

## [OF THE FORCEPS.]

[It is not surprising that the author should have given a decided preference to the key instrument, for, during his time, the forceps employed for the extraction of teeth, were so awkward in their construction and illy adapted



to the operation, as to render them not only inefficient in their use, but also inconvenient in their application. But the objections to their use, that existed at that time, cannot now be urged. They have been so improved during the last twelve or fifteen years, that, at present, they are the safest, most convenient, and efficient instruments that can be employed. Any tooth that can be removed with the key, can be extracted with a properly constructed pair of forceps, and in the majority of cases with greater ease and convenience to the operator, and less pain and injury to the patient; besides, many teeth which cannot be removed with that instrument can be extracted with ease and safety with these.

In discussing the relative merits of the key instrument and forceps, the editor can speak advisedly upon the subject, having used both for many years, the former for more than eight and the latter for about twelve years. He is happy too, to believe, that in giving his preference to properly constructed forceps, he expresses the opinion of all who have given both instruments a fair trial. There may be some, who, having been accustomed to the use of the key instrument for many years,—have only occasionally employed forceps, and which perhaps were not of the best construction, still persist in giving a preference to that instrument. But this constitutes no argument whatever in its favour. To form a correct opinion of the relative merits of the two instruments, it is necessary to use each for a length of time, say three or four months, to the entire exclusion of the other. All who have done this, give a decided preference to the forceps. The author himself acknowledges that frequent injuries to the alveoli are unavoidable in the use of the key, which, with forceps properly adapted to the operation, need seldom if ever be inflicted.

But notwithstanding the great improvements which have been made in the shape and form of forceps, not one dentist in five, of those who use them, have such as are best suited to the operation. Many too, have four times as many as are really requisite, believing from their number, they will always be able to select one, adapted to the peculiarity of any case which may come up in their practice, seemingly ignorant of the fact, that efficiency of their action depends more on their shape and construction than on their multiplicity. Seven pair are all that are required for the operation. The beak of each of these should be so adapted to the necks of the teeth to which it is intended to be applied, as to secure a firm hold; the handles should be no longer than is absolutely necessary to accommodate the hand of the operator, to which, they should be accurately fitted and so bent as not to interfere with the teeth in the opposite jaw. But in describing them, it will be better to do it, under the names of the teeth, intended to be extracted by each. I will commence with those to be used on the teeth in the upper jaw.

FORCEPS FOR THE EXTRACTION OF THE SUPERIOR INCISOR  
AND CUSPIDATI.

For the extraction of the upper incisores and cuspidati, but one pair of forceps is required. These should be straight, with the nibs of their beak hollowed out on the inside so as not to press upon the crown of the tooth during the operation. The extremity of each nib, too, should be sufficiently hollowed on the inside to fit the neck of an incisor or cuspidati tooth. They should also be slightly notched to prevent them from turning on it, when a rotary motion is given to the instrument; the



handles should be broad and about five or five and a half inches in length; one should be bent near the end so as to form a hook to pass round the little finger of the hand of the operator. The extremities of the beak should be thin, in order to admit of being forced high up on the tooth under the gums. But a better idea may be formed of the instrument by an examination of Fig. 1, Plate XXIV. where it is represented. These forceps, besides being specially adapted to the extraction of the superior incisores and cuspidati, are in many cases the best that can be employed for the removal of the upper bicuspides.

#### FORCEPS FOR THE EXTRACTION OF THE SUPERIOR MOLARES.

The above named teeth, having three roots each, two outer and one inner, require for their removal two pair of forceps, one for the right and one for the left side of the mouth. The beaks of these forceps should be bent sufficiently to clear the tooth, anterior to the one on which it is to be applied without depressing the handles so much as to throw them in contact with the teeth in the lower jaw. The outer nib of the beak of each pair, should have two grooves filed in its extremity, with a fine point between them, to fit in the depression on the side of the neck of the tooth, just below the bifurcation of its outer roots. The inner nib or blade, should be grooved to fit the neck of the tooth on the palatine side. The handles should be broad and strong enough to prevent them from springing under the grasp of the hand of the operator. The handle of each instrument toward the operator, when applied to the tooth, should have a hook on the end of it to pass round the little finger, in order to prevent it from slipping in the hand when it is moist with perspiration. These forceps are represented in Figs. 2

and 3, Plate XXV. Their handles should be about the length of the incisor and cuspidati forceps.

FORCEPS FOR THE EXTRACTION OF THE SUPERIOR DENTES SAPIENTIÆ.

Although in most cases, the forceps to be hereafter described for the extraction of the bicuspidæ of both jaws and the cuspidati of the lower, are the most convenient and best instrument that can be used for the removal of the superior dentes sapientiæ: it sometimes happens, that one of a different shape is necessary, these should be bent in the beak above the joint so as to form two right angles. The object of this is to clear the second molaris, when the dens-sapientiæ is considerably shorter than this tooth. Each blade or nib of the beak of these forceps, should be grooved on the inside, to make them fit the necks of these teeth. The handles should be broad and one bent at the end in the manner as before described.

These forceps are also useful for the extraction of the root of a tooth situated close behind another tooth. Fig. 4, Plate XXIV. is an accurate representation of them.

FORCEPS FOR THE EXTRACTION OF THE BICUSPIDES OF BOTH JAWS AND THE INFERIOR CUSPIDATI AND DENTES SAPIENTIÆ.

But one pair of forceps are required for the extraction of these teeth. The handles of these should be straight and broad, without a hook on either. Each nib should be grooved on the inside, and both bent so as to form an angle of twenty-five or thirty degrees with the handles. They should also be narrow to prevent interfering with the adjoining teeth, and thin so as to admit of being slipped under the gums to the edge of the alveolus.



With a forcep of this description, a bicuspid in either jaw can readily be extracted. They are also better suited to the extraction of the inferior cuspidati and dentes sapientiæ than any other instrument. In the majority of cases too, they are the best for the removal of the upper dentes sapientiæ. These forceps are represented in Fig. 2, Plate XXIV.

#### FORCEPS FOR THE EXTRACTION OF THE INFERIOR INCISORES.

The only difference between the forceps now under consideration and those last described, is, that the beak of the latter should not be more than one-third the width of those of the former. The handles should be of the same width and length, and the beak have the same curvature. And while forceps of this description are admirably adapted to the extraction of the lower incisors, they are the most efficient instrument that can be employed for the removal of the roots of the bicuspides and molares, for it often happens that the former are so much funneled out by caries as to prevent their walls from affording a sufficiently firm support to any other forceps for their extraction. But with these a portion of the alveolus may be included between the nibs, and cut through and the root grasped and removed at once. This, therefore, may be regarded as one of the most valuable extracting instruments that has ever been employed. A view of it is exhibited in Fig. 4, Plate XXV.

#### FORCEPS FOR THE EXTRACTION OF THE INFERIOR MOLARES.

The lower molares having two roots, one anterior and one posterior, require for their removal, forceps of a different construction from any which have yet been de-

scribed. Each blade or nib of the beak should have two grooves with a point in the centre, so constructed as to fit the depression on each side, just above the bifurcation of the roots. The beak should be curved just enough to make the instrument clear the tooth immediately before the one to which the instrument is applied. Mr. Snell, the inventor of the beak of these forceps, as well as those for the extraction of the upper molares, employs two pair for the removal of the teeth in question. But by an improvement made by the editor, one pair will answer the purpose better than two. The improvement consists in having the handles bent so that the instrument may be applied with equal convenience to a tooth on either side of the mouth, while the operator always occupies the same position and has his left arm and hand to control his patient's head and lower jaw, which he can do better than any assistant. But a better idea may be formed of the shape and peculiar construction of these forceps, as improved by the editor, from an examination of Fig. 1, Plate XXV. than from any description which can be given of them. The handles it will be perceived are bent towards the operator, with a hook on the inner one, to pass round the little finger like some of the others which have been before described.

The manner of using these forceps will be described in connection with the parts of the work which treats on the extraction of the different classes of teeth.]

[MANNER OF EXTRACTING TEETH.]

I shall now state the manner of extracting the different classes of teeth, accompanied with cautions necessary to be observed under different circumstances.

Previously to the extraction of a tooth, it is very



necessary that the gum should be separated as much as possible from the neck of the tooth and the edges of the alveolar processes. This is to be done with a gum lancet, and a round edged one is to be preferred to a pointed one. The lancing the gum saves it from being torn by the raising of the tooth, and the claw of the instrument can be pushed so much under the gum as to obtain a firmer hold upon the neck of the tooth. In young children, we may dispense with the lancing of the gum, on account of their extreme timidity; beside, as their teeth are commonly not very strong in the sockets, there is very little danger of injuring the gums.

[DIRECTIONS FOR THE EXTRACTION OF THE INCISORES AND CUSPIDATI.]

The incisores and cuspidati, although very subject to caries, are not frequently affected with tooth-ache, therefore it is not often required to extract them on that account. In the loose state, they are easily removed, and the paces have commonly been used; but, when firm in the head, it has been usual to employ the key instrument. There are two or three objections, however, to this practice: it must be recollected that the fangs of these teeth are long, and the alveolar processes thin; it is, therefore, almost impossible to extract an incisor or a cuspidatus with a key instrument, without splitting up the alveolar processes. This accident, together with the unavoidable contusion of the gum, occasioned by the pressure of the instrument, leaves an unpleasant ulcer, which, being in the front of the mouth, is very perceptible, and as it is a considerable time in healing, the patient often expresses much dissatisfaction; there is also a danger of breaking the tooth in the middle of the fang,

especially in the case of the cuspidati. These accidents are avoided by making use of the paces; and, as these teeth are straight, and have conical fangs, they may be extracted in the direction of the socket, which will prevent its fracture, as well as the contusion of the gum.

The manner of using the paces is this: the tooth is to be laid hold of, upon the fang, as far as possible under the gum. The instrument is then to be grasped with a force just sufficient to hold the tooth tight, but not to pinch so hard as to crush it. The attachment of the periosteum of the fang to that of the socket is then to be separated by moving the tooth from side to side, by a gentle but steady motion of the wrist. When the tooth has thus been moved in its socket, it may be drawn straight out. Sometimes it will be requisite to use efforts for some time to loosen the tooth; for it must be remarked, that scarcely any man has sufficient strength to extract one of these teeth by direct force; but if a tooth be first loosened in the socket, by moving it from side to side, it may then be extracted successfully. The teeth of children are always removed with facility; the only impediment being the resistance induced by their fears.

[It is not to be wondered that the extraction of the incisores should have been regarded both as a difficult and rather dangerous operation, when for the want of a more suitable instrument, it often became necessary to have recourse to the key for their removal. The injuries of which the author speaks, as being, in many cases unavoidable, need never be inflicted in the extraction of these teeth. With forceps such as have been described by the editor, they can always be removed with both ease to the operator and safety to the patient.

For the extraction of an upper incisor or cuspidatus, the forceps first described and represented in Fig. 1,



Plate XXIV. should be employed. With these, after having separated the gum from the neck of the tooth, it should be grasped as high up as possible, and just tight enough to prevent the instrument from slipping. This done, it should be moved several times in quick succession, backwards and forwards, and then with a rotary motion, the tooth may be pulled from the socket. The root of an upper cuspidatus being rather more flattened than that of an incisor, will not admit of as much rotary motion, in its extraction. This, the operator should bear in mind in the removal of these teeth. It is also longer, and oftentimes requires considerable more force for its removal.

The lower incisores are generally less firmly articulated than the upper, and as might readily be supposed, are, in the majority of cases, more easily removed. The forceps represented in Fig. 4, Plate XXV. should be employed for their extraction. They should be applied as low down on the neck of the tooth as possible, and after moving it several times backwards and forwards, giving at the same time, a slight rotary movement to the instrument, it should be raised from the socket. When the tooth to be extracted is situated behind the arch, as is often the case, a rotary motion only should be given to the instrument, previously to the removal of the organ.

The inferior cuspidati may also be removed with the forceps recommended for the extraction of the lower incisores, but it is better to use a pair having wider beaks.]

[DIRECTIONS FOR THE EXTRACTION OF THE BICUSPIDES AND MOLARES.]

The bicuspides and molares should be extracted with the key instrument which must be always furnished with

three claws, adapted to the different sizes of the crowns of the teeth. The smallest claw is designed for the bicuspidæ; the next in size for the molares of the under jaw, and the dentes sapientiæ of the upper jaw; and the largest size for the first and second molares of the upper jaw. The bicuspidæ of the upper jaw may be extracted with the claw placed in the usual mode, as little difficulty attends their removal; but the bicuspidæ of the lower jaw being very long and slender, the fangs are liable to be broken off at about two-thirds of their length, leaving a piece in the socket; this circumstance arises from the pressure of the bolster of the instrument against the exterior part of the middle of the fang, and the resistance to the extraction of the fang made by the inner and lower part of the socket.

These accidents are certainly avoided by fixing the claw behind the bolster, as in Fig. 8, Plate XXII. and in Plate XXIII. Fig. 2. The instrument, in this way, acts upon the tooth only in the place where the claw is fixed, and, by the fulcrum being applied beyond the tooth, no resistance is made against the side of the alveolus; thus the tooth is usually extracted perfectly whole, and with great ease.

The molares are extracted with claws proportioned to their size, which are to be fixed even with the bolster.\*

Much diversity of opinion has existed as to the precise direction in which the teeth should be drawn: it has been recommended by some, to draw the second and third molares of the under jaw inwardly, and all the others outwardly. The reason assigned for this rule is, that those teeth naturally incline inwardly, and the alveolar processes, being thin on that side, yield with greater ease, by which the extraction of the tooth is facilitated.

\* Plate XXII. Fig. 7, and Plate XXIII. Fig. 3.



From much experience, however, I have found that this plan cannot be practised without incurring difficulty and danger; when these teeth incline much inwards, they are situated out of the perpendicular with respect to the jaw, and hang considerably over the base. When the instrument is fixed, the claw taking hold of the tooth at the outer side, the bolster presses upon the jaw in a part relative to the tooth, in a line so much out of the perpendicular, that the force applied acts upon the tooth in a diagonal line from the outer part, at the neck, to about the middle of the inner part of the fangs: hence there is great danger, if the fangs are very strong, that the tooth will be broken off, and leave a part of the fangs in the socket. There is also danger lest the extraction of the tooth should be attended with a fracture of the alveolar processes, for it is very liable to extend considerably.\*

Much soreness is likewise occasioned by the pressure of the instrument against the soft parts under the side of the tongue, which causes a swelling and a tenderness that continue for some time. Extraction, in this manner, is frequently rendered impracticable, by the caries being situated at the side where the claw should be fixed: this is very commonly the case with the *dentes sapientiæ*, which would render the removal of these teeth an impossibility, without using the instrument according to Mr. Spence's improvement.† For these reasons, a general rule may be given, that the key instrument should always be applied in such a manner, as to extract the tooth outwardly, except in those cases where the state of the decay renders it impossible.

The extraction of the *dentes sapientiæ* of the under jaw is attended with more difficulty than that of any other of the teeth. The jaw-bone begins to rise on the outer

\* Plate XXIII. Fig. 5.

† Plate XXII. Fig. 6.

side of the *dentes sapientiæ*, in order to form the coronoid process; and, in some persons, the rise of the bone is nearly as high as the tooth. Hence there is not sufficient depth for the bolster of the instrument to be applied on the outside of the tooth, and there would always be a necessity for drawing the tooth inwardly, if we did not possess a safe method of extracting it outwardly. It was with this view that the improvement of Mr. Spence was introduced. A *dens sapientiæ*, which is much decayed on the outer side, could not be drawn inwardly, because the decayed state of the tooth would prevent proper hold for the instrument. Likewise, with a common key instrument, it would not be possible to draw it outwardly, because the rise of the jaw-bone would render it impracticable. These difficulties are entirely obviated by advancing the claw beyond the bolster; a fulcrum is then conveniently obtained by applying the bolster upon the jaw at the outer side of the second molaris, and the claw being fixed on the inner side of the tooth, it may be drawn outwardly with great safety. By operating in this manner, much difficulty is obviated, and the danger of breaking away large portions of the alveolar processes is prevented.\*

[The bicuspides and molares, as has been before stated, can be extracted with more ease and less danger of injury to the alveolar processes, with forceps than with the key instrument, and as the directions given by the author upon the subject apply exclusively to the latter, the editor will add such as he deems necessary for the former. But before he does this, he will advert briefly to the directions given by the author, with regard to the manner of applying the key to the second and third inferior molares. In the application of the instrument to these teeth, he recom-

\* Plate XXIII. Fig. 1.



mends placing the bolster or fulcrum on the outside of the tooth, and the reasons which he offers for so doing should at once, determine the application of it on the other side. As these teeth incline inwardly, the direction of the force exerted by the key when the fulcrum is placed on the outside, is on a line which forms a more abrupt angle with the tooth than when it is applied on the inside, and consequently requires a much greater amount of power for its removal, and in proportion to which, is the danger of injury to the alveolus increased. When, therefore, the key instrument is used for the extraction either of the second, third, or first molaris or bicuspidates of the lower jaw, the fulcrum of the instrument should be placed on the inside of the tooth. And as a general rule, it should be placed on the inside in the extraction of the upper molares or bicuspidates.

For the extraction of the bicuspidates of either jaw, and the inferior cuspidati, the forceps represented in Fig. 2, Plate XXIV. should be used. The gum having been perfectly separated from the neck of the tooth, the forceps should be placed on it as high up or low down as it may happen to be, in the upper or lower jaw, as possible, grasping it sufficiently tight to prevent the instrument from slipping and not tight enough to fracture the tooth, it should be quickly pressed outwards and inwards until it begins to yield or give way in the socket, when it should be raised with a very slight rotary motion from the alveolus. But if the tooth above the alveolus, is so much weakened by caries as to be unable to bear the pressure of the instrument, the gum should be laid open vertically with a sharp lancet, for an eighth of an inch or more if necessary on the alveolus, and this grasped sufficiently high up, if the tooth be in the upper jaw, and low down, if it be in the lower, to reach a sound part of

the root, with the narrow-beaked forceps represented in Fig. 4, Plate XXV., which, by a little pressure, on the handles, will be cut through, when the affected organ may be easily removed.

The lower cuspidati should be extracted in nearly the same manner, when similarly circumstanced, but when their roots are not funneled out by caries, the forceps represented in Fig. 2, Plate XXIV. should be employed for their removal.

It may be as well to observe here, that it often happens, when a tooth decays on the side next to an adjoining tooth, the last, by the approximation of the two, infringes upon the first in such a manner, as to oppose a formidable obstacle to its removal—one which can only be overcome by filing away a portion of the encroaching organ. In a case of this description, no attempt should be made to extract the carious tooth, until so much of the adjoining one as has impinged upon it, has been removed with a file. If this precaution be neglected, two teeth, if no more serious injury should result, will be removed instead of one.

The directions given for the extraction of the bicuspidæ and lower cuspidati, will, in most instances, be found applicable for the removal of the dentes sapientiæ. It sometimes happens however, that when the lower dentes sapientiæ are situated far back under the coronoid processes they are somewhat difficult of removal, but with forceps, such as represented in Fig. 2, Plate XXIV. and a little tact, on the part of the dentist, they may be grasped and removed. If the crown be decayed off down to the alveolus, the narrow-beaked forceps should be used, and in their application, the upper edge of the socket should be included between the nibs of the beak of the instrument. It sometimes happens too, that the



roots of these teeth are bent in such a way as to constitute a considerable obstacle to their removal, but a little patience and management on the part of the operator will enable him to extricate them. When the crowns of the second molares in the upper jaw are very much longer than those of the *dentes sapientiæ*, the forceps represented in Fig. 4, Plate XXIV. should be employed for the removal of the last named teeth, instead of the ones last referred to.

The superior molares having three roots are generally more firmly articulated than any of the other teeth, and as a consequence, usually require more force for their removal. When therefore, one of these teeth is to be extracted, it should be firmly grasped high up under the gums, with one of the forceps represented in Figs. 2 and 3, Plate XXV. and pressed outwards and inwards, until it begins to yield in the socket, then by depressing the instrument it should be removed. The forceps for the removal of the upper molares should be strong and accurately fitted to the teeth, and when of the proper shape and construction they are the safest and best instruments that can be used for their extraction.

Although the inferior molares have but two roots, they are often very firmly articulated, and require considerable force for their removal; yet with forceps such as represented in Fig. 1, Plate XXV. in the hands of a good operator, they can usually be extracted without difficulty. The points on the ends of the nibs of the beak, should, in the application of the instrument, be forced down between the roots of the tooth, which being firmly grasped should be forced several times, outwards and inwards, and as soon as it begins to move freely in the socket, it should be raised from it. When the crown of the tooth has decayed off, a portion of the alveolus on each side

should be included between the points of the nibs of the forceps, and cut through in the manner as before described. This done, a firm hold is obtained upon the tooth, which now may easily be removed.

The position of the operator, while extracting a tooth, whether in the upper or lower jaw, or on the right or left side, should always be at the right and a little behind the patient. This position gives him an opportunity of controlling his head, and guarding the instrument more effectually than he could do were he to occupy any other position. And as a general rule, the instrument should rest upon the palm of his hand, while he is using it.]

#### DIRECTIONS FOR THE EXTRACTION OF ROOTS OF TEETH.

Stumps are often extracted with much ease; they are sometimes so much thrust out by the socket as to require very little force for their removal; but in other instances, there is great difficulty, from the depth at which they are placed in the jaw, and the very decayed state of the exposed part. Stumps can rarely be extracted with the key instrument, as a sufficient purchase for the claw can scarcely be obtained, they must therefore be extracted with the punch. The mode of using this instrument is as follows; the gum should be well separated with the lancet, that the instrument may be applied to a sound part of the stump; it is then to be pushed with a steady force, sufficient to displace the stump from the socket. As there is danger that the punch may slip, and tear some part of the mouth, care should be taken to avoid such an accident, by wrapping a cloth around the forefinger of the left hand, which, being introduced into the mouth, will receive the point of the instrument, should it slip, and prevent any injury from being inflicted.



[In addition to the punch, an elevator, hook and screw, instruments too well known by every dentist at the present day to need description, are now used in the extraction of roots of teeth. The punch, elevator and hook, are used chiefly for the extraction of the roots of the bicuspid and molares. The two former for the removal of roots on the right side of the mouth, and the latter, for the removal of roots on the left side.

In using the punch or elevator, care is necessary to prevent the instrument from slipping and inflicting injury on the soft parts of the mouth. With the hook there is not so much danger. The manner of using the elevator, is to force the instrument between two roots or one root and a sound tooth, and then by turning it, the edge against the root to be removed, and the back against the adjoining tooth or root, the root to be removed, is lifted from the socket. The hook acts upon pretty much the same principle as the punch.

The narrow-beaked forceps, however, previously described, are much better adapted for the removal of the roots of the bicuspid and molar teeth than either the punch, elevator or hook, and in the hands of those who have made trial of them, it has superceded their use almost altogether. It can be more easily used, and is a much safer and more efficient instrument.

The screw employed for the extraction of roots of teeth, is of a conical shape, somewhat like that of the roots of the incisores and cuspidati, and for the removal of which, it is especially designed. After the loss of the crown of one of these teeth, the caries oftentimes extends up the roots, funneling it out, and leaving only a thin exterior shell, which is too weak to bear the requisite amount of pressure from forceps for its removal. But after removing the softened, decomposed bone from the

interior, with a screw like the one here described, firmly introduced, it may easily be removed.

On the conical screw which has been in use for a long time, Dr. Hullihen of Wheeling, Va. has made a highly valuable improvement, consisting of a combination of this with a pair of forceps, which he designates "Compound Root Forceps." A representation of them is exhibited in Fig. 3, Plate XXIV. and the editor will here quote the description which he has given of them.

He says, "the above named forceps, were contrived some time since, for the purpose of extracting hollow roots of teeth, with more expedition and at the same time, with less pain to the patient than was possible with the instrument in general use, and as the forceps have fully answered the purpose for which they were intended, I have thought them of sufficient importance to lay them before the profession.

The compound root forceps are about nine inches in length, and like the common straight forceps with the exception that the beak is much longer, and much narrower and thinner at the point. Lengthwise, within and between the blades of the beak is a steel tube, one end of which is open; the other solid and flat and jointed in a mortise in the male part of the forcep's joint. When the forceps are opened, this joint permits the tube to fall backwards and forwards from one blade of the beak to the other, without any lateral motion. Within this tube is a spiral spring, which forces up the shaft, two-thirds of the length of the shaft is rounded and fitted neatly into the tube, the other part is a well tapered or conical screw. The shaft is retained in the tube by a small screw, that is fixed into the shaft through a notch half an inch long in one side of the tube. The shaft and tube are so fitted together, and to the beak of the forceps, that one-half of



the rounded part of the shaft projects beyond the end of the tube; so that the shaft may play up and down upon the spring, the length of the notch, and the screw part projecting beyond the point of the forceps, so that the shaft may be embraced between its blades, just behind the base of the screw. A full sided view of the beak of the forceps with its tube and shaft is well represented in the cut,—for a copy of which see Fig. 3, Plate XXIV.

The forceps are used, by first embracing the shaft between the blades. Then screwing it gently and as deeply into the root as possible, the blades are opened and pushed up upon the root, which is then seized in either of the ways as the case may require.

The screw thus combined with the forceps, prevents the root from being crushed. It acts as a powerful lever when a lateral motion is given; it is likewise of advantage when a rotary motion is made, as it prevents the forceps from slipping, or of their action being lost, should even one side of the root give way in the act of extracting it, and is used with equal advantage where one side of the root is entirely gone. In short, this combination of the screw and forceps forms an instrument which fulfils every indication that can be desired in the extraction of hollow roots.

The shaft of the compound forceps is easily changed; a number of different sized screws may therefore be used in the same pair of forceps."

In conclusion, the editor would remark, that he has tested the merits of this instrument, and can recommend it to the profession as one of great value.]

[PARTICULAR DIRECTIONS FOR THE USE OF THE KEY  
INSTRUMENT.]

In extracting a tooth, the first thing to be considered, is the choice of a claw adapted to the size of a tooth: it should neither be too large, nor too small: if it be too large, there is great danger of breaking away a large portion of the alveolar process; and, if it be too small, as it can only act upon the crown of the tooth, there will be almost a certainty of breaking it off, and leaving the fangs in the socket.

In Plate XXIII. are too examples of the dangerous consequences of attempting to use an instrument with too large a claw, Fig. 7 is the representation of all the molares of the upper jaw that were torn from the mouth of a gentleman, by an injudicious operator, in attempting to extract one of them, which was decayed.

Fig. 8, represents the dens sapientiæ of the lower jaw, of a lady, which was attempted to be extracted inwardly with too large an instrument; the consequence was, the bringing away a large piece of the jaw with the tooth, as described.

The fixing an instrument upon the tooth is a circumstance which ought particularly to be attended to, as many teeth have been broken for want of regarding this circumstance.

The key instrument, in the extraction of a tooth, acts precisely upon the principle of a lever of the first kind. It is an improvement upon the very ancient instrument called the pelican, which consisted of a claw laying hold of the tooth, a fulcrum to press upon the jaw, and a straight handle by which to exert the power. In the present form of the instrument, the claw, or hook, forms the point of the lever, the bolster the fulcrum, and the



handle, which is now placed at a right angle with respect to the claw, is the part with which to exert the power.

The point of the claw should always be fixed as far as possible on the neck of the tooth, that the power may act upon the fangs; and the bolster should be fixed on the opposite side, rather below the point of the claw. When an instrument is thus fixed, and power is applied by turning the handle, it immediately acts, by raising the tooth.\* But, if the point of the claw and the fulcrum be in direct opposition to each other, the increasing of the power only pinches the crown of the tooth, and does not act so as to raise the fangs. In this case, the crown of the tooth must be broken off, without moving the fangs, or the claw will be broken in the centre of its curve.†

When the instrument has been fixed in a proper manner, the next thing to be regarded is the best mode of using it.

There is one method of using the instrument which cannot be too strongly reprobated, as it is sometimes attended with the most mischievous consequences; this is, the attempting to extract a tooth quickly, by turning the instrument in a sudden, violent manner. I have known many accidents result from this practice, and therefore cannot but condemn it in the strongest terms. No tooth can be extracted safely, unless its attachment to the jaw be overcome by a force, which being gradually increased, will cause the parts concerned to yield with safety. For want of attending to this principle, various distressing accidents have been occasioned; commonly the teeth are broken in the socket, and sometimes part of the jaw itself; and often the alveolar processes are extensively fractured. About six years ago, I attended a lady who suffered most dreadfully, for a great

\* Plate XXII. Fig. 4.

† Fig. 6.



length of time, from having a tooth extracted in this sudden manner. The gentleman who performed the operation, removed the tooth, the second bicuspid in the lower jaw, with a very sudden jerk of the instrument; two or three days afterwards, the face became much swollen, and a considerable quantity of matter formed; this was discharged at the socket from which the tooth had been drawn. The lady was in this state when I saw her; the discharge of matter was very considerable, and the other bicuspid was somewhat loosened; it was very tender to the touch, and appeared to be a cause of irritation: it was, therefore, judged expedient to remove it. The pain and discharge of matter still continued, and small pieces of bone worked out of the gum; at length the abscess extended to the socket of the first molaris, and it became so tender as to make it necessary to extract that tooth. Shortly after this had been drawn, some very large pieces of the jaw exfoliated; but still the lady was not relieved from pain, nor did the abscess appear to be disposed to heal: in a little time afterwards, the second molaris became sore, and was affected by the abscess as the other teeth had been; and, therefore, it was determined upon, that this also should be extracted. The removal of this tooth permitted a piece of bone, more than two inches in length, to come away; soon after which the discharge of matter ceased, and the parts became perfectly healed. This is an instance in which three teeth were lost, besides the originally diseased one, with extensive exfoliation of the jaw, and six months excessive pain; all this resulting from extracting a tooth with a violent jerk.

To be able to extract a tooth well, the surgeon should act with firmness and self-possession: having these qualifications, he will not be so confused as to place the instrument upon a wrong tooth, nor act with so much precipitation as to endanger the safety of the patient.



The observation of a most distinguished anatomical lecturer, that all operations are performed sufficiently quick, which are performed well, is very applicable to the extraction of a tooth

The plan that I have always adopted, with the greatest success, is gradually to increase the power of the instrument until the tooth be moved; and then, by raising the hand, endeavour to draw the tooth in a direction as nearly perpendicular as possible.

Sometimes, although the utmost care has been taken in the extraction of a tooth, a portion of the alveolar process will be broken off: it may either come away adhering to the tooth, or it may remain loose in the socket: it is, therefore, highly proper that the gum should be cautiously examined, and, if any loose splinter be felt, it must be taken away: for this purpose it is always right to be prepared with a pair of forceps. If any splinter should be left in the gum, it will be productive of future inconvenience, as the gum remains very sore, and is kept from healing until the piece of bone has come away. This examination may always be made at the time of closing the gums, without exciting any alarm in the mind of the patient.

When the crown of a tooth is much decayed, success does not always attend an attempt to extract it; the whole, or a part of the fangs may remain: sometimes the gum will grow over such portions of the fangs, and then they can no longer be the cause of uneasiness: or the socket, by closing at the bottom, will gradually thrust them forwards, until they may readily be taken hold of, and extracted. The pain of the tooth-ache is usually removed by the destruction of part of the nervous membrane, or the hemorrhage caused by the operation; and, if the stumps should afterwards become troublesome, they may, in a few months, be easily removed.

## HEMORRHAGE AFTER EXTRACTION.

Sometimes, after the extraction of a tooth, a considerable hemorrhage continues; the artery which belonged to the tooth does not contract; or, from being of large size, a coagulum sufficiently strong to restrain the flow of blood is not formed. Hence a great quantity of blood may be lost. The best mode of stopping this hemorrhage is by the application of pressure. A piece of very fine lint, or cotton, dipped in spirits of turpentine, should be pressed into the socket, over which a large compress of lint should be laid, which may either be pressed firmly with the finger, or, in closing the mouth, by the teeth of the other jaw. In this manner, a hemorrhage may soon be restrained; little or no benefit is ever derived from washing the gums with styptic remedies, as they cannot act upon the mouth of the bleeding vessel, and therefore are ineffectual.



## CHAPTER SIXTH.

### OF EXOSTOSIS OF THE FANGS [OF THE TEETH.]

ONE of the species of exostosis in bones, is an enlargement arising from a deposit of bony matter, so compact in its structure as very much to resemble ivory. This is that kind of enlargement to which the fangs of the teeth of some persons are liable.

The cause of this disease is obscure, and the slow increase in the size of the fang is the reason why pain does not occur until a considerable augmentation of its bulk has taken place.

It is sometimes found to exist where the crowns of the teeth remain perfectly sound; in other cases, it appears to be the effect of indolent inflammation, arising from caries in the body of the tooth, and extending to the fang. This kind of disease does not produce suppuration; the gum continues quite healthy; but, whenever pain occurs, as no permanent relief can be obtained without the extraction of the tooth, it becomes necessary, when the teeth are sound, to be very attentive to distinguish this disease from mere rheumatic affections of the jaw bones.

In Plate XVI. Fig. 12, are two teeth, the first molaris of each side of the lower jaw, which I extracted from a lady, who had complained, for a considerable length of time, of pain on both sides of the face, arising from each of these teeth. She described her symptoms to be, a

constant uneasiness, like the gnawing sensation of rheumatism, which, continuing almost without intermission, exhausted her health and spirits. The teeth and gums were quite free from any diseased appearance, the pain therefore was considered as rheumatic: she had taken much medicine, and continued under the care of an eminent practitioner, for a considerable length of time, without receiving any benefit. The gums were lanced, blisters were applied behind the ears, but all means were ineffectual: she at length determined to have both of the teeth extracted. This was reluctantly performed, because they appeared to be perfectly free from disease.

When one tooth was removed, the cause of her complaint became evident, for the whole surface of the fangs was increased in size by the irregular addition of a quantity of bony matter. This induced me to comply with her wish of removing the other, which had precisely the same appearance. The cause of her pain now became certain; the increase in the size of the fangs necessarily occasioned a distention of the alveolar cavity, and kept up a constant uneasiness. The lady was immediately relieved, and recovered her health and spirits, to the great joy of her family, who were nearly deprived of her society, by reason of her excessive nervous irritability.

Where this disease has occurred in teeth already carious, the persons have not been afflicted with extreme tooth-ache, but they have had occasional uneasiness, which at length has become more uninterrupted, and the tooth has projected to a certain degree from the socket, so that in closing the mouth the tooth felt as if out of its natural situation, thus rendering mastication painful. When extracted, the fangs have been found enlarged as in the teeth represented in Fig. 13, Plate XVI.

Some persons will refer this appearance upon the fangs



of the teeth to an original mal-formation; but so different is it in appearance from the smooth structure of any ill-formed, crooked, or undiseased tooth; and when extracted, so much whiter than any other part of the fang; that it can only be referred to diseased action, occasioning a deposit of bony matter, as in other cases of exostosis.

Of this disease of the teeth, the most extraordinary case on record occurred to a young lady scarcely twenty years of age. The following letter, from the surgeon who had attended the lady, and by whom she was introduced to me, presents a full narrative of the case.

SIR,

9th Nov. 1809.

Miss — —, the young lady who will deliver this to you, has been under my care for near twelve months, with a very extraordinary complaint in her face, teeth and gums. It commenced with a deep-seated pain in the face, confined principally to one side, returning most mornings at about eleven o'clock, and continuing several hours. This had gone on for near three months, before she, or her friends, thought it sufficiently serious to call in any medical assistance. When first I saw her, she had suffered great pain all that day, from the teeth, gums, and face: on one side the gums were rather swollen and inflamed; and as one of the teeth was slightly decayed, I thought it most advisable to extract it, which gave relief till the next day, when the pain returned with still greater violence, so much so, that she was desirous of having the adjoining tooth taken out, which she fancied gave her more pain than the rest. This had the same effect as the other, only giving relief till the next day, when the pain returned with equal violence. I then tried scarifying the gums, cold lotion to the face, giving at the same time a brisk purgative, and afterwards an opiate. This was



continued for a short time without abating the pain; I then changed the plan for the more soothing one of fomentation and poultice, applying a fig to the gums, occasionally changing it for a crust of bread soaked in warm milk, taking at the same time a saline and opiate draught every four hours; but with just the same effect as the preceding remedies. In short, the pain in the teeth and face continued, the gums became partially ulcerated, and in the course of six months, I was under the necessity of extracting, at different times, all the teeth in the lower jaw, excepting the four incisores, which very soon became affected in a similar way to the rest: these her friends would not allow to be drawn; nor was I desirous of performing the operation, as the removal of the others did not appear to have given any permanent relief, excepting that the gums healed, and remained well where the teeth had been extracted. During this time almost every remedy that could be thought of was tried, such as frequent scarifying of the gums, leeches, permanent blisters to the lower jaw and behind the ears, astringent lotions, as the infusion of roses with the tincture of myrrh, decoctions of bark, oak bark, infusion of galls, solutions of alum, argentum nitratum, salt and water, lemon-juice, oxymel æruginis, borax, charcoal and soda, tepid bath, artificial sea bath, and afterwards sea bathing, seton in the neck, issue in the arm, &c. &c. with a great many other applications which it would be useless to name. Internally she has taken strong purgatives, calomel combined with antimony, and afterwards continued alone in small doses to salivation, solutio mineral. solut. calc. muriat. bark, with nitrous acid, steel, lemon-juice in large quantity, tinct. opii. to the amount of gut. 60 at bed time, and repeated in small doses during the day at short intervals, cicuta, &c. &c. prescribed by an eminent physician of this place, without



receiving little more than slight temporary relief from any one medicine prescribed. She has now all the teeth of the upper jaw affected in a similar way to the lower; the palpebræ of one eye have been closed for near two months, and, when opened, can discern objects but very imperfectly; the secretion of saliva has for some time been so copious as to flow from the mouth whenever opened. She is now come to London, purposely for advice, and I have recommended that she should call upon you.

I remain, Sir,

Your obedient servant,

T. S.

This letter not only fully describes the very afflicting case, but also shows that medicine under every form had altogether failed: of course no benefit could be expected from a repetition of any similar treatment.

At the time I saw the lady, she was only able to take fluid nutriment, for the teeth of the upper jaw were so very tender that the slightest touch caused extreme pain. As described by Mr. S. the flow of saliva was so considerable that there was a continual necessity of discharging it. The lady herself said she was assured she should never get well, unless all her teeth were extracted. It was however desired if possible to seek such relief as should prevent so painful an expedient which could only be regarded as the last resort.

Dr. Babington and Mr. Cline were consulted, who prescribed a blister on the head, to be kept open by the application of the ceratum sabinæ. This was tried without success. The pain in the mouth, the soreness of the teeth, and the general irritation on the constitution, all combined to render the extraction of the most painful

tooth advisable. This was the first molaris of the upper jaw, situated under that eye, the palpebræ of which had become closed.

The fangs of this tooth were much enlarged, and from the periosteum being greatly thickened, the fangs had the appearance of being cartilaginous. The removal of this tooth was attended with great benefit; as, in two days after the operation, the affected eyelids so much recovered, as to open simultaneously with those of the other eye. This relief unhappily was of short duration: and as the other teeth remained very sore, the lady determined to have them extracted one after the other. She submitted to this operation, every two or three days. The fangs of those teeth which had caused the most pain, were the most enlarged; but each partook of the disposition to exostosis.

The relief from pain which was experienced by the loss of the teeth was so great, that with the utmost resolution this afflicted lady persevered until every tooth was extracted. After the loss of the teeth, from time to time, portions of the alveolar processes exfoliated, which rendered it necessary to scarify the gums. I am happy to say that a material improvement has taken place in the general health, although not so perfectly as could be desired. One most important benefit resulted from the removal of the teeth, in arresting the progress of the other diseased actions: for the other eye had begun to be affected; and sometimes was so dim, as scarcely to enable the lady to guide herself about the house. In point of appearance, however, I had the satisfaction of completely restoring the lady, the teeth which had been extracted were replaced, as an artificial set; which, with the greatest comfort she has now used for more than twelve months.



[To the foregoing highly interesting and very remarkable case, the editor could add several others, but as most of them have been elsewhere noticed, he does not think it necessary to extend the limits of this work by their introduction here. With the exception of necrosis, this is the only disease of the teeth which bears the least analogy to any of the morbid affections that are met with in the other osseous structures of the body. The cause of exostosis, has never been satisfactorily explained. Some writers suppose it to be the result of inflammation of the dental periosteum, but as it often attacks the roots of sound teeth, it is most likely dependent on some peculiar constitutional idiosyncrasy.]

## CHAPTER SEVENTH.

### OF NECROSIS AFFECTING THE TEETH.

WHEN a bone, or part of a bone, has completely lost its living principle, it is precisely in the same state as soft parts when affected by gangrene: no restoration of the part can be effected, the surrounding parts become inflamed, and an action takes place, which has for its object the separation of the dead from the living part. When the fang of a tooth has lost its life, the whole of the tooth becomes, in consequence, an extraneous body; and, as in bones, the cure of necrosis depends upon the exfoliation of the dead piece; so, in the case of the tooth, the cure can alone be effected by its entire removal.

This disease usually affects teeth which are perfectly free from caries.\* And it is more particularly confined to the front teeth, the others being rarely affected in this way. When the fang of a tooth has lost its living principle, the socket becomes inflamed, the gum appears of a darkish red colour, loose in its texture, and matter begins to be discharged. In some, the discharge is from two or three orifices through the gums, opposite to the extremity, or the middle of the fang of the tooth; in other cases the matter passes out at the neck of the tooth. In all, there is an uneasy pain, and the discharge of the matter is very disagreeable.

\* Although teeth which in other respects are sound, are frequently deprived of vitality, it is by no means uncommon for carious teeth to be affected by necrosis.



During the progress of this disease, the alveolar processes are absorbed, [wasted] and the teeth are loosened, from which great inconvenience arises.

In the early stage of this disease, considerable benefit attends the scarification of the gums; the loss of blood abates the inflammation; and, as it is very unpleasant to lose a front tooth, we may, by repeatedly lancing the gums, arrest the progress of the disease for a considerable time; but, when it has proceeded so far as to loosen the tooth, it is better to extract it, especially as the whole of the uneasiness arises from the tooth being an extraneous body; the discharge then ceases, and the gum becomes perfectly healed in a short time. After extraction, the fang of the tooth is always found to be very rough; in most cases it is dark coloured, being of a deep green, brown, or black colour. In Plate XVII. are several teeth illustrative of this appearance. [The cause of this affection, as has been before stated, is inflammation and suppuration of the lining membrane.]

## CHAPTER EIGHTH.

### OF THE DISEASE RESEMBLING SPINA VENTOSA.

SPINA VENTOSA is the term usually given to that species of tumor in bone, which is originally an abscess forming in the centre: the ulcerative process removing the bone from the inside, whilst there is a correspondent increase on the outside.

This disease, according to my observation, is confined to the incisores and cuspidati of the upper jaw; it produces upon the gum and socket similar effects to the disease last described. The seat of the malady is in the cavity of the tooth; the vessels ramifying on its membrane acquire a diseased action, by which the membrane becomes thickened, absorption of some of the internal part of the tooth takes place, and the opening at the extremity of the fang also becomes enlarged. This disease of the membrane is attended with the formation of matter discharging itself at the point of the fang into the alveolar cavity, which, being rendered more porous by the process of absorption, affords an easy exit. During the progress of the disease, the gum covering the alveolar process becomes inflamed, and acquires a spongy texture; the matter passing from the socket makes its escape into the mouth by several openings through the gum, which is thus kept in a constant state of disease. The discharge, which is generally considerable, produces great fetor of



the breath, the taste is constantly affected, and the socket is gradually absorbed until the tooth becomes quite loose. [This affection simply consists of inflammation and supuration of the lining membrane of a tooth affected with exostoses, and the enlargement of the canal passing through its root by the corrosive action of the fluids therein contained.]

When the tooth has been extracted, I have usually found the membrane sprouting at the end of the fang, the internal part of which is much enlarged, and the external part has a rough, scaly appearance; also, during the progress of this disease, the body of the tooth changes in appearance, and gradually acquires a dark colour.

The only treatment which can be observed here, is to scarify the gums occasionally, and to wash the mouth frequently with an astringent lotion: for this purpose, the infusion of roses with tincture of myrrh is very beneficial. As no cure of this complaint can be expected, the extraction of the tooth should be recommended as soon as the gums have acquired a truly diseased appearance; for, if the disease be allowed to take its natural course, the gums become so extensively affected as to induce absorption of the alveolar processes belonging to the neighbouring teeth, which is followed by their consequent loss.

## CHAPTER NINTH.

### OF THE REMOVAL OF THE ENAMEL BY THE DENUDING PROCESS.

THIS is a disease producing a change in the teeth, by which they acquire an appearance unlike that of caries, but attended with a loss of substance.

The tooth does not, as in caries, become softer, nor, like that disease, does it originate in inflammation, but it consists in a removal of the enamel from the bone of the tooth, as if by solution and gradual abrasion.

It affects the incisores much more frequently than any other teeth, and, in all the cases which I have seen, its operation is limited to the exterior surface of the teeth.

The first appearance is in the enamel of one or more of the incisores becoming thinner, and appearing as if a small portion had been scooped or filed out, occasioning a slight depression. This removal of the enamel continues until so much is taken away as to leave the bone exposed: as this denuding process, according to Mr. Hunter's term, advances, the tooth changes in its colour, gradually becoming yellower, as the bony part is more exposed. When the whole of the enamel is destroyed, part of the bone is also removed: the remainder acquires a brownish hue, is very highly polished, and will often remain in this state for a number of years.

I have seen a few cases in which the teeth have been so much wasted, as to have all the anterior part removed;



but yet the natural cavity has not been exposed, for the bone has remained in a prominent line, as it were defending that particular part, and thus preventing pain.

Sometimes teeth thus affected become tender, very susceptible of cold, and are made uneasy by the use of acids.

It is difficult to make a very good engraving of this disease. Fig. 3, Plate XVII. is designed to show the common and early appearance of it. In other cases there is an appearance as if a small round file had been applied to the anterior surface of the teeth, close to the gums, removing a considerable portion of them, but leaving the surface exceedingly smooth.

Fig. 4, is intended to describe this appearance as extending across the necks of all the incisores of both jaws. In these cases the molares participate in the disease.

Fig. 5, are two cuspidati, in which are very great depressions, as if made by a round file.

I am not able to assign any cause for this loss of the enamel and part of the substance of the tooth, especially as it is confined to that portion of the teeth which could not be acted upon by the friction of one tooth against another. I have observed it both in healthy and delicate persons. As it appears to be connected with some cause which may produce a solution of the enamel, it is very possible that the saliva may have some influence, and that the friction of the lips may contribute to the removal of the enamel. [The editor is of the opinion that it is the result of the action of the mucous secretions of the mouth, which, in some persons, are found to contain more septic acid than in others.]

The only means to prevent a rapid progress of this disease, is to avoid whatever may contribute to it; there-

fore, as all acids act powerfully upon the teeth, their use as an article of diet should be forbidden: and, whenever there is any necessity for employing a medicine which contains an acid, persons should be extremely careful to rinse the mouth, and wipe the teeth immediately afterwards with a cloth. [The affection may oftentimes, after it has made some progress, be arrested by plugging the diseased part. Whenever it is possible to form a suitable cavity for the retention of the filling, this can always be done.]



## CHAPTER TENTH.

### OF THE WEARING OF THE TEETH BY MASTICATION.

THE mouths of some persons are so constructed, and the teeth so placed, that, when the jaws are closed, the incisores, not being so long as they usually are, meet each other at the cutting edges. Thus a variety is formed from the usual mode, which is for the incisores of the upper jaw, when the mouth is closed, partially to overlap those of the under jaw.

When the teeth meet in the manner above described, they all act upon each other, and the jaw has a much more extensive lateral motion. This occasions greater friction in mastication, by which the teeth gradually wear away a part of each other. In some persons they become worn down equally all around the mouth, whilst in others, who have acquired a habit of masticating their food on one side only, the teeth which have been in constant use are worn down, the others remaining quite perfect. The same circumstance also happens, if persons, by reason of caries, have lost several teeth in the early part of life: those which have remained have become very much worn away. I have seen a gentleman whose teeth were so much worn down as to have the whole of the crowns removed, leaving only the fangs in the jaws even with the edges of the gums.

It is not unfrequent for teeth in this state to become

tender; the application of cold or acids excites considerable pain, but this generally soon subsides; for, during the time that the teeth are wearing away by their action upon each other, a process goes on in the cavity, by which their sensibility is destroyed; the vessels take on a new action, and deposit ossific matter until the whole cavity is completely obliterated. This circumstance also happens very frequently in the teeth of old people, which accounts for their not being so liable to the tooth-ache.



## CHAPTER ELEVENTH.

### OF FRACTURES OF THE TEETH.

THE teeth are liable to be fractured by blows, which may be inflicted either by accidents, or from malicious intentions. The incisores of the upper jaw are the most exposed to these accidents: boys, in their various amusements, occasionally receive blows in the mouth, which not unfrequently occasion fractures of the front teeth.

In falling upon the face, the teeth are sometimes struck against a stone; in throwing of stones at each other, one may be received against the teeth; in an incautious attempt to catch a cricket ball, the force of which is not sufficiently spent, it may come with violence against the mouth: in these, and other similar ways, persons are subjected to fractures of the teeth; also, in the mastication of food, hard substances, such as splinter of bone, or a small stone, or a shot in game, may unexpectedly be bitten upon, at which time the muscles of the lower jaw, being in very strong action, exert a force sufficiently powerful to fracture a perfectly sound tooth.

The treatment of these cases will depend much upon the extent of the injury. If a small piece be broken off from the point of a tooth, nothing more will be necessary than with a fine file to make the rough edge smooth.

A tooth rarely becomes carious in consequence of an accident of this kind; for, if there be no predisposition in

a tooth to decay, the mere removal of a small portion of it will not cause caries.

A fracture of a tooth occasions inconvenience in proportion to the injury done to the cavity of the tooth. If it should extend nearly into the cavity, having left only a thin piece of bone to cover it, the person will be subject for some time to pain on exposure to cold air; this, however, is generally cured by a deposit of bone taking place within the cavity, by which the nerve is defended, and the tooth may remain during life without exciting further trouble.

If the fracture should extend into the cavity, the membrane will immediately be exposed, and inflammation will follow. In this case the treatment must be regulated by the age and peculiar circumstances of the patient. If the accident should have happened to a youth under fifteen or sixteen years of age, it would be better to extract the tooth, because the teeth on each side will gradually approach each other, so that when he is arrived at maturity the loss may never be observed.

It is to be understood that I am speaking of accidents occurring to the permanent teeth; blows received by children under five or six years of age can only injure the temporary teeth; sometimes by accidents one or more of these are beaten out: this never fails to produce alarm in the minds of the parents; but, as in a short time a removal of those teeth must have been affected by nature, or performed by art, it cannot be considered as a permanent injury.

If the case be neglected for some time, the inflammation extends to the fang and socket, and produces a considerable gum-boil, which can only be cured by the extraction of the tooth.

When an accident of this kind occurs to a person more



advanced in years, the loss is very considerable, as the appearance of the mouth and also the speech becomes thereby much affected.

In Plate XVIII. Fig. 9, is a representation of two central incisores which were broken by a fall. Fig. 10, is the posterior view of these teeth, the fracture of which will be seen extending into the cavity.

In an accident of this kind affecting either one or both teeth, if the person should apply for assistance immediately after the accident, and before any inflammation has supervened, I should recommend that the tooth or teeth be extracted with great care. When this has been done, the cavity in the tooth should be cleared out as much as possible, and some gold-leaf be introduced, so as completely to fill it up.

After the cavity has been thus stopped, the teeth are to be restored to their sockets, and there to be confined by a ligature; they will soon fix, and in a few days be as secure as ever, and may afterwards remain without inconvenience for a great number of years. [The editor has found this treatment to succeed only in the fewest number of cases. Teeth after having been removed and placed back in their sockets, are, in the majority of instances, at times, more or less troublesome.]

If the fracture of a tooth should be so great as in Fig. 11, the patient must submit to extraction: or, if he should be desirous to preserve the appearance of his mouth, he may be recommended to have the remainder of the tooth filed away, so as to make the fang even with the gums, and, in the manner hereafter to be described, have a tooth fixed to the fang by means of a pivot. [The concussion of a blow sufficiently severe to fracture a tooth, generally induces inflammation in the alveolo-dental periosteal tissue and renders the root unfit to support an artificial

crown; it should therefore be removed, and the loss of the tooth supplied with a substitute on gold plate in the manner to be hereafter described. The application of an artificial crown to such a root has been known to be productive of very hurtful consequences. The practice, to say the least of it, is unscientific, and should never be adopted, except in cases of the most absolute necessity.]

When a blow has been received upon a tooth so as to loosen it, if the person be young, it will become fast again; but it gradually loses the whiteness of its colour, and at length acquires a bluish tinge. [This is owing to the destruction of the vitality of the organ, resulting from inflammation and suppuration of the lining membranes.]

When the like accident occurs to a person rather advanced in life, a disease usually takes place about the fang, which eventually affects the socket; the tooth then becomes very loose, and must be extracted.

A young gentleman had the central incisores broken by a cricket ball, as represented in Fig. 9. The fracture did not extend into the cavity. In this case the teeth were filed so as to remove the irregular portion, and bring them as nearly as possible into a line with the other teeth.

Fig. 10 represents a posterior view of the central incisores of a young gentleman, who, falling on his face, struck his mouth against a stone. So much of the teeth were broken off as to uncover the membrane; the entrance into the cavity is described by the dark spots, *a a*. Immediately after the accident, the mere touch of the tongue passing over the exposed part of the membrane occasioned extreme pain; in a short time, inflammation extended to the socket, the lip became very much swollen, and a considerable quantity of matter was formed. The parents, being very desirous to preserve the teeth, made use of every means to abate the inflammation; but,



as the gums remained thickened, and the discharge of matter continued, they were at length obliged to consent to the extraction of the teeth: on examining the fangs, they were found covered with a considerable quantity of lymph, which is a common consequence of a neglected accident of this description.

In Fig. 11 is the representation of the teeth of a young gentleman who had the central incisores broken by a blow of a stick: being anxious to have the deformity removed in the best possible manner, he was willing to submit to any means that should be recommended. I stated to him the necessity of preserving the fangs for the purpose of fixing other teeth in a permanent manner; but, perceiving that the sensibility of the exposed membrane was very great, I concluded that he would not be able to endure the pain attendant on the common mode of destroying the nerve, therefore determined to extract the teeth partially, and return them back into the socket; after which I introduced an instrument, and passed it up to the extremities of the fangs, without occasioning the least painful sensation. Union of the fangs to the socket took place in a few days, when the remainder of the crowns of the teeth was filed away, and other teeth fixed.

If a blow be inflicted with sufficient violence to remove a tooth from its socket, it may be returned again; and, if secured to the other teeth by a ligature, it will become fast in a few days. I have known a case in which a tooth had remained out of the socket for six hours, and yet, when returned, became again perfectly united. It will be necessary when a tooth has been out of the socket for some time, to introduce a probe, and remove, the coagulated blood; the fang may then be inserted with ease, and inflammation will be avoided. But when the teeth have been loosened or beaten out by a blow, and

the alveolar processes have been injured, or fractured, the teeth will never become perfectly fast; inflammation arises, and nothing but extraction will effect the cure.

[We think it doubtful whether the replacement of a tooth, which has been forcibly thrust from its socket, is strictly proper under any circumstances, yet necessity may sometimes seem to justify it. We have never known a tooth thus replaced to become so perfectly re-united as not, occasionally, to be productive of disturbance to the surrounding parts, and ultimately to cause a thickening of the periosteum of the alveolus.]



## CHAPTER TWELFTH.

### OF THE DISEASES OF THE GUMS.

THE alveolar processes of both jaws are covered by a substance which is called the gums. They have a semi-cartilaginous hardness, are very vascular, and possess considerable contractability. Under slight inflammation, occasioned by cold, they become thickened, enlarged, and swollen, and of a loose, spongy texture.

The gums adhere to the necks of the teeth, and pass between each of them, being attached to the bony partitions of the alveolar processes, by which the inner and outer gums are connected together.

When the gums are in a healthy state, they are firmly attached to those parts of the teeth which are not contained in the sockets, and their extreme edges lie upon the enamel. The gums, which are between the teeth in the upper jaw, descend lower; and, in the under jaw, are situated higher than the other parts: hence, at the necks of the teeth, they form an arched appearance. Naturally, they do not possess much sensibility, and therefore are not injured by the friction which is unavoidably occasioned by the mastication of hard substances; but, when inflamed, they acquire such extreme sensibility, that even the pressure of the cheek causes pain.

In infancy, during the progress of dentition, should there be inflammation of the gums, the slightest touch

produces so much suffering, that children will even refuse the breast, on account of the pain attending the necessary pressure of the nipple. On the contrary, when there is no inflammation, the gums are so insensible, that they are pleased with sucking or biting a hard crust. In old age, when there are no teeth, the gums possess so little sensibility, that the biting or bruising of food is attended with no pain; and it is remarkable, that those who have lost all their teeth enjoy their food much more than those who have only a few weak ones left.

Several affections of the gums originate from diseases of the teeth, but there are others peculiar to the gums themselves: I shall first describe those diseases which arise from the teeth.

#### OF THE SCURVY IN THE GUMS.

The most common disease of the gums, is that which has been usually called scurvy in the gums, thus denominated from assuming an appearance similar to that which happens to persons afflicted with the sea-scurvy.

[But this affection is wholly unlike that, and although favoured and aggravated by a scorbutic diathesis of the general system, it often occurs in individuals, in whom there exists not the slightest tendency to that disease.]

This disease is generally marked by the gums becoming redder than ordinary, and enlarged from a turgescence of the vessels, which are made to bleed by the slightest causes, such as the use of a tooth-brush, the biting of a crust, or even by only sucking them.

If the complaint be not attended to in this stage, the gums become very soft and spongy, and shortly afterwards they are affected with considerable soreness, being so tender as scarcely to allow the mastication of food;



this is often followed by a discharge of matter at the necks of the teeth, and an exulceration may be observed on the edges of the gums between the teeth; also those parts which form the arched appearance are soon destroyed, so that the gums have a uniform straightness, and the necks of the teeth are consequently uncovered.

This disease next proceeds to the alveolar processes, the substances of which are destroyed by absorption; at length the teeth become loose, and, in a few years, drop out, one after the other, at short intervals, until the person is rendered toothless.

It is from this complaint that many persons lose their teeth at a very early period of life; indeed, most individuals are more or less subject to it, as the gums, in some part or other, although there be no disease of the teeth, are liable to become preternaturally red, enlarged, or tender: whenever, therefore, a tendency to this disease is observed, great care should be taken to apply such means as will arrest its progress. At its commencement it is very manageable, and may always be relieved by puncturing, with the point of a lancet, those parts which appear unnaturally red or distended. The loss of blood affords immediate relief; and whenever the slightest soreness, or an increased fulness of the gums is perceived, the above plan of scarifying the vessels will be found highly beneficial. Suppose the disease to have proceeded to that stage in which the gums become spongy or loose in texture the lancet should be then used with greater freedom. Essential service is always derived from the loss of blood: in some cases the use of leeches, as drawing away a larger quantity of blood, is attended with the best effects. Frequent recourse should be had to this treatment, which may be accompanied with the use of astringent lotions, such as the infusion of roses



with the tincture of myrrh, decoction of bark, solutions of alum, arquebusade water, &c. In these cases great benefit is derived from the use of sea-water, and therefore I always recommend it, whenever it can be procured; adding, that, if the gums be tender, it should be used warm. In all cases where there is a tendency to inflammation of the gums, arising from this disease, much is to be expected from the free use of a tooth-brush; at first the gums are apt to bleed a little, by which the same benefit is obtained as from the lancet: by degrees, the gums become more firm, and at length a hard brush may be used without causing any loss of blood, or giving the slightest pain.

When the gums are exceedingly tender, and have the smallest tendency to exulceration, the patient should be directed to wash the mouth very frequently with barley water sweetened with honey: in two or three days, if the soreness should be diminished, the lancet should be cautiously used, accompanied with diluted tincture of myrrh, as a wash.

If the edges of the gums do not heal under this treatment, and if they should hang loosely about the necks of the teeth, much good will be derived from the use of the argentum nitratum in solution. If the disease be only partial, the caustic should be applied with a camel's hair pencil dipped in the solution. This remedy appears to communicate a new action to the gums, and they generally get well in a short time. Indeed, whenever the gums are very full, and discharge a good deal of offensive matter, washing the mouth with a solution of lunar caustic is a very excellent remedy for rendering the mouth sweet and comfortable.

When this is applied to the sore edges of the gums with the hair pencil, it may be used as strong as in the



proportion of a drachm to an ounce of water; but, if the mouth be rinsed with it, it ought not to exceed the proportion of one grain to two ounces of water; because, if it get into the fauces, it is liable to produce an unpleasant nausea.

Persons who are subject to inflammation of the gums, should have them scarified whenever they become painful, or are more turgid than usual. By the loss of a little blood, they are instantly relieved, and the disease is thus prevented from proceeding to the extent which has been described.

In scarifying the gums, the lancet should be applied longitudinally to those parts which are situated between the teeth, because, if the gums are cut in those parts where they cover the fangs, they will, in healing, retire, and leave the necks of the teeth exposed; whereas, if they are lanced in the angles, between the teeth, they will in healing be drawn tighter, and the teeth will eventually be strengthened.

[Although favoured by certain constitutional tendencies, the immediate cause of inflammation, and sponginess of the gums, is local irritation, and the removal therefore of every thing from the mouth which can act as irritants upon this structure, constitutes the first curative indication. If there be any dead teeth in the mouth, or roots of teeth, or teeth which from their peculiar position act as irritants to the gums or alveolar periosteal tissues, they should be removed; also all loose teeth which from the partial destruction of their sockets cannot regain their lost firmness, as well as all tartar or other extraneous matter that may have collected around or on the teeth. This should constitute the first step in the treatment of spongy and inflamed gums, and in addition to which, the gums should be lanced in the manner as directed by the

author, the mouth too, should be gargled several times a day with some astringent lotion. In the mean time the most constant attention should be paid to the cleanliness of the teeth. They should be thoroughly cleansed with a good brush and waxed floss-silk, four or five times every day. The observance of this last is indispensable, and if it be neglected, no matter how appropriate the other treatment may be, it will be found inefficient and fail to accomplish a cure.

As a gargle, the editor has found nothing better than a strong decoction of the inner bark of young green white oak prepared as directed by Dr. Fitch, by taking two pounds, putting it into six quarts of water and boiling it down, until it becomes strongly impregnated with the bark, which last is then to be taken out, and the water boiled down to two quarts, strained, and put in a bottle for use. The following, recommended by Dr. Koecker, is also a very excellent gargle. Take of honey and the tincture of rhattania two ounces each, mix and dilute in the proportion of three table-spoonfuls to a pint of warm sage tea or water, to be used frequently through the day.

But should matter be discharged from between the gums and necks of the teeth, notwithstanding the use of the foregoing remedies, a solution of the nitrate of silver, as recommended by the author, should be employed. It is also sometimes necessary to have recourse to constitutional treatment, which should accord with the peculiar indications of the case.]

#### OF PRETERNATURAL GROWTH OF THE GUMS.

Decayed teeth are sometimes the cause of deranged action in the arteries of the gums, by which they become so enlarged as to form excrescences or tumours of con-



siderable size. These are frequently the consequence of carious stumps, and are produced in the following manner. The crown of a tooth having been removed by caries, and the stump remaining in the socket, even with the gums, if the socket do not close at the bottom, so as to cause a protrusion of the stump, it is so much wasted away, that the edges of the gums have a tendency to grow over it. When the gum has thus partially grown over a ragged stump, it is liable to become very sore and inflamed, from the constant irritation which the gum suffers from being pressed upon the sharp edge of the stump. Hence a diseased action is caused, and the gum very rapidly increases in size. I have seen an enlargement of this kind, surrounding some stumps in the lower jaw, equal to the size of a walnut. In these cases no cure can be expected whilst the cause is permitted to continue; the first thing, therefore, to be done is, to extract the stumps, which in general effects all that can be desired; the enlargement of the gums being of a soft, spongy, and fungous nature, is always reduced by the hemorrhage which attends this operation, after which, the cause of irritation being removed, the vessels contract, and the gums acquire their natural state.

Some time since, Mr. Cooper was applied to, by a lady who had an enlargement of the gums in the lower jaw, which nearly filled up one side of the mouth; there were several decayed stumps remaining, around which this enlargement of the gums had taken place. Mr. Cooper sent her to me for the purpose of extracting the stumps, intending, when these had been removed, to extirpate the tumour. The stumps being imbedded in the gums, the operation was unavoidably attended with laceration of the excrescence, and consequently a considerable hemorrhage. A few days afterwards the tumour

became very flaccid and dark coloured, it then sloughed away in large pieces, so that a cure was effected without any other operation.

Sometimes tumours arise from the gums without there being any diseased tooth, or any evident cause: these are of a much firmer texture than those above described, frequently being of the same consistence as the gums, when in a healthy state.

They are very vascular, and the treatment has always been considered as extremely troublesome: the usual mode adopted for removing them has been that of excision; this operation has generally been attended with a great loss of blood, to stop which, as Mr. Hunter observes, "it is often necessary to apply the actual cautery, for arteries going to increased parts are themselves increased, and also become diseased, and have not the contractile power of a sound artery." A great hemorrhage from the gums, or any part of the mouth, must always be regarded as alarming, on account of the impossibility of discovering and securing any principal branch of the artery; or, if the bleeding should be from a number of small vessels, the difficulty of applying pressure with advantage is so very great, that recourse must always be had to more powerful agents. Mr. Hunter also remarks, that these excrescences are liable to grow again, after the operation of excision; and mentions, that they have been removed six times, and have as often been reproduced; which he attributes to a cancerous disposition. On these accounts, I determined some years since, that, if any cases of this kind should ever come under my care, I would attempt their removal by means of ligatures. The first case, in which I was consulted, was a lady of about forty years of age, who had several of the teeth on the right side of the upper jaw extracted when she was a



young woman: about five years before I saw her, the gums, covering the jaw where the teeth had been situated, appeared to be thicker than before; they gradually increased in size until a very large tumour was formed: it had now become so large as to affect the speech, and in other ways was extremely troublesome.

The lady was very desirous to have it removed; to effect which, without incurring the danger of hemorrhage, I employed ligatures. The basis being very broad, I passed a needle, with two ligatures, close to the jaw bone, through the substance of the tumour, half of which was then included in each ligature. The ligatures were tied just tight enough to stop the circulation; the next day there was a great deal of inflammation, which subsided in proportion as the ligatures began to produce ulceration, which on the fourth day was very considerable: new ligatures were then applied; on the sixth day these were removed and others introduced; on the eighth, one ligature came away, leaving the tumour hanging only by a small pedicle; this being cut through with a lancet, the whole was removed; the surface was then touched with some diluted nitrous acid, and the gums have ever since continued in a perfectly healthy state.

Subsequent experience has furnished me with many opportunities of removing several excrescences of a similar nature. The basis of these are generally very broad, and therefore cannot be included in a single ligature; on this account, I have commonly passed a needle, armed with two ligatures, through the middle part of the tumour, as close to the bone as possible, and then have included half of the substance in each of the ligatures. The ulcerated process goes on here very quickly; in some cases the application of a second ligature has been quite sufficient, and in most cases it has not been necessary to make use of more than three or four ligatures.



Last summer, a lady applied to Mr. Cline, having an enlargement of the gums on one side of the upper jaw; a tumour of very large size was formed, which pressed the cheek so much out as to give the appearance of a swelled face. The teeth were still remaining, and not decayed; but the molares were so surrounded with the excrescence of the gums, that no successful attempt could be made to extirpate it until they had been removed. Mr. Cline sent the lady to me for that purpose, I extracted the farthest tooth; the hemorrhage being rather profuse, the extraction of the second was deferred; two or three weeks afterwards, I removed the second molaris; at the time the excrescence had become completely altered in form, being more dependant, and after the second tooth was extracted, it contracted at the basis and acquired a pyriform shape; this afforded a very favourable opportunity for its removal by ligature, which Mr. Cline performed.

There are other excrescences which sometimes form upon the gums, differing in appearance from either of the former; they are soft, exceedingly red, and very liable to bleed. These originate from some diseased state of the jaw bone, and can only be cured by the removal of such disease. It has most commonly happened that surgeons have not sufficiently regarded the cause of the disease; for, simply attending to the state of the gums, they have cut off these fungous excrescences with the knife, or burnt them with caustic; but having been foiled in their various attempts, by their speedy renewal, they have considered them as cancerous, and the patient has been rendered extremely unhappy by having been thus informed.

Sometimes these fungi of the gums arise from a diseased state of the fangs of a tooth, which fangs have



caused a death of part of the alveolar processes, and a consequent diseased state of the gums. In these cases, the first thing to be done is to extract the tooth more particularly connected with the disease of the gums, an opportunity is then given to examine the state of the alveolar processes; if these are found to be in any way diseased, means must be used to hasten the process of exfoliation. If, on examining with a probe, the socket should be found to be rough, or in any way denuded of its periosteum, then a dossil of lint, dipped in a weak solution of nitrous acid, should be applied two or three times a day; this will hasten the exfoliation of the bone, and produce a cure of the gums.

The strength of this lotion should be one drop of nitrous acid to an ounce of water.

A very extraordinary case of tumour arising from the lower jaw, was admitted into Guy's Hospital on the 9th of April, 1812. The patient's name Sarah Dulwich, aged 13, of a scrofulous constitution. The tumour was situated under the left cheek. It appeared first about twelve months ago as a small tumour from the gums of the lower jaw. At the time of her admission into the Hospital, the tumour was globular, and occupied the whole of the left cheek. Under the integuments it was irregular, and projected below the jaw; it extended to the cuspidatus of the right side irregularly under the tongue, which it thrust close to the right cheek. The surface was very irregular, and it felt hard in substance.

The pressure of the teeth of the upper jaw had caused a superficial ulceration, from whence there was occasionally an offensive discharge. Viewed externally it reached from the fore part of the chin, passing up by the side of the left nostril, to the edge of the left orbit, and thence round to the ear. The nose was pushed consid-



erably to the right side, thereby occasioning a great distortion of the countenance. In size it was nearly half that of the head. The skin over the whole surface had a slight blush on it, and the veins appeared to be considerably enlarged. She complained of pain at the back part of the tumour, and there was some suppuration from the right ear. Mastication had become very difficult and painful, in consequence of the pressure of the teeth on the left side of the upper jaw upon the tumour as it arose from the lower jaw. From the pressure of the tumour, the teeth of the left side of the upper jaw were pushed towards the opposite side of the mouth, as were also the teeth of the lower jaw. In other respects this poor girl was in good health, and had a good appetite.

Before the disease appeared, she was subject for some months to the tooth-ache in the two molares of the lower jaw, which were exceedingly carious, and from the gums of which teeth this tumour sprang.

When she was first received into the Hospital the jaws were separated nearly an inch from each other by reason of the projection of the tumour from the back to the fore part of the mouth. It was with difficulty the lips could be brought together, but in the common state they separated to at least an inch and a half distance.

The tumour continues to increase rapidly, and by degrees it becomes more protruded from the mouth. The ulceration on the surface becomes much more extensive. In about six months from her admission, it had become so exceedingly enlarged as to project considerably beyond the lips, which were extended to an almost incredible degree. At this time her only mode of taking nourishment is by sucking fluids through a tube, and she is gradually becoming exceedingly emaciated.

Besides these various affections of the gums, they are



subject to diseased appearances, symptomatic of constitutional disease. Children of scrofulous habits are more particularly liable to a spongy state of the gums, accompanied with great fetor of the breath; they become ulcerated so as to cause the alveolar processes and fangs of the teeth to be exposed. When this disease occurs to children, the teeth which are thus affected are only the temporary teeth, and therefore the removal of these is not attended with any permanent disadvantage. I have always considered it right, whenever any ulceration has taken place about the gums of children, to extract the teeth, and I have usually found that this plan has completely arrested the progress of the disease: at the same time the general health of the patient should not be neglected, and the appearance of the gums must only be considered as indicative of constitutional derangement.

Fig. 1, Plate XX. represents all the alveolar processes of the under jaw, which exfoliated in consequence of a neglected disease of the gums, in a child of scrofulous habit. It was given me by Mr. Goldston, surgeon, of Bath. Similar exfoliations sometimes take place in consequence of fever.

In more advanced age, the gums are also symptomatically affected: I once saw a lady, who laboured under general weakness, whose gums were so relaxed and devoid of vital energy, as to be perfectly soft, of a livid colour, and apparently quite dead. I pared off a great quantity of them, and ordered a stimulating lotion; which with attention to the general health, and change of situation, sea air, &c. effected a cure.

[The whole substance of the gums all the way round, and of both jaws, are sometimes affected with a morbid growth, by which the crowns of the teeth become completely imbedded in them. When in this condition they

are exceedingly sensitive to the touch and bleed from the slightest injury. This peculiar affection, although first excited by local irritation, is determined by a bad habit of body. Scorbutic and scrofulous dispositions are more subject to it than any other.

The proper treatment in cases of this sort, consists in removing all that portion which has grown over the crowns of the teeth, and all dead and loose teeth, roots of teeth, and teeth so badly affected with caries as to render their restoration to health impossible. The mouth should be gargled several times every day, with a decoction of oak bark, prepared as before directed; also with a solution of the chloride of soda, for the purpose of correcting the fetor of the mouth. The margins of the gums should at the same time be occasionally touched with a solution of the nitrate of silver. In addition to which, such general treatment should be adopted, as may be indicated by the state of the constitutional health.

Temporizing treatment in this form of diseased gums will never answer. To be successful, a decided impression must be made at once. The treatment must be thorough. It is not sufficient to remove all dead and loose teeth, and the roots of decayed teeth. The morbid growth of the gums which encase, as it were, the crowns of the teeth, should be removed by means of a horizontal incision on a line near the termination of the enamel; in addition to this, they should be frequently scarified with a sharp lancet. This should be passed through them between the teeth, so as to make a complete section. It is only in connection with this treatment, that gargles will prove at all beneficial.

Another important item in the local treatment of the disease, consists in cleansing the teeth frequently and thoroughly, with a soft and elastic brush. This should



be done, at least, five times a day; namely, immediately after getting up in the morning, after each meal, and at night before going to bed. If any relics of food, or extraneous matter of any sort, or clammy mucus, be permitted to collect between or around the teeth or along the margins of the gums, the cure will be retarded, if not wholly defeated.]

## CHAPTER THIRTEENTH.

### OF GUM-BOIL AND ABSCESS [ALVEOLAR ABSCESS.]

[INASMUCH as the seat of the above named disease is always within the alveolus, the gum being only secondarily affected, it would be more proper to term it, as Mr. Thomas Bell justly remarks, *alveolar abscess*, and should be treated of under the head of diseases of the alveolar process.]

Carious teeth frequently become inflamed at the root, and suppuration takes place in the socket, attended with swelling and soreness of the gums. In these cases, the same laws are observed for the exit of matter as in abscess in general, viz. ulceration takes place in some part of its surface, so as to make an outlet for the matter in the best possible situation. When matter forms at the root of a tooth, the periosteum which covers its fang thickens, and in some cases becomes detached from it; the matter is accumulated as in a bag, by the extension of which, considerable pressure is made against the sides of the socket, the consequence of which is, that that part of the alveolar process, situated on the outside, becomes absorbed, [wasted] rather than that within the mouth.\*

The ulcerative process continues until the gum bursts, nearly opposite to the place where the point of the fang is situated, and thus the matter escapes from this natural

\* Plate XVI. Fig. 10, 11.



opening: the edges of the opening are generally raised, having the appearance of a small, red fungus; sometimes, after the discharge of the matter, the inflammation will subside; but the gum-boil rarely disappears, and a small fistulous opening remains, at which, matter continues to be discharged; or, upon taking cold, persons are liable to a recurrence of inflammation, occasioning a reaccumulation of matter; but which is seldom attended with much pain. These gum-boils, being occasioned by diseased teeth, are seldom cured without their removal; but, as the operation of extraction cannot always be submitted to, means must be employed to render them as little injurious as possible.

[The matter does not always make for itself a passage through the alveolus and gum; it sometimes escapes into the maxillary sinus, but this rarely happens except the abscess has formed in the socket of a superior molaris, which is situated immediately beneath this cavity, where its floor is often very thin and sometimes even penetrated by one or more of the roots of the subjacent teeth. Diseases of the antrum of a very serious nature have been produced in this way. But the extraction of the affected tooth in this, as in the other case, is generally soon followed by a subsidence of every unpleasant symptom.]

At the first appearance of a gum-boil, that is, as soon as the gums, by their swollen condition and soft feeling, together with the sensation of throbbing pain, indicate that matter is already formed, a puncture should be made with a lancet, in order to suffer it to escape: this will relieve the pain, and prevent any extensive effusion.

Sometimes the tooth becomes very sore, and rather loose, in which case, as it will never be serviceable, it would be far better to extract it, which will prove a cure to the gum-boil.

When the inflammation occasioned by a carious tooth is very great, we should be particularly careful to guard against its effects. The formation of matter is often so considerable, as to produce an abscess of no small extent. In some cases the matter is contained within a cavity, extending through the length of one side of the jaw. The teeth which produce the most distressing symptoms are the *dentes sapientiæ* of the under jaw; when inflammation extends from either of those teeth to the contiguous parts, the swelling is speedily diffused over all the cheek, so as to close the eye, and cause a considerable hardness at the upper part of the neck, near to the angle of the jaw.

The muscles of the jaw are also affected by the adhesive inflammation, and they become so rigid that it is with great difficulty the mouth can be opened.

These cases require the utmost attention, for a large abscess is usually formed, which, if left to itself, generally points externally; the ulceration extends through the substance of the cheek, there producing a most troublesome sore, which, when healed, leaves a deforming scar. To prevent these sad consequences, when the matter is formed, a free opening should be made, on the inside of the cheek, into the softest part of the tumour. [The immediate extraction of the tooth however, would be preferable, as the matter in this case, if already formed, would escape through the alveolus into the mouth.]

A common notion exists, that it is extremely dangerous to extract a tooth at the time the gum is inflamed; but this is erroneous. Certainly, at this time, the operation is attended with rather more pain than at another; but, as the carious tooth is the cause of all disease, the removal of it is the most certain, and always the most speedy, mode of cure.



In those cases where the mouth is closed, as this practice cannot be adopted, we must wait until the inflammation be sufficiently subsided for the mouth to be opened.

When inflammation and swelling of the gums and face arise from a carious tooth, they seldom subside without going into the suppurative stage. I have frequently attempted by leeches, cold applications, &c. to prevent suppuration, but have rarely succeeded: the progress of inflammation having been by these means only retarded, not prevented; for, after a certain time, it has come on with redoubled violence, and has gone through its progress: on this account, whenever there is any considerable swelling, and the patient too timid to submit to the extraction of the tooth, or if the mouth be so much contracted that the instrument cannot be conveyed into it, I think it advisable to hasten the suppurative process by fomentations, &c. and as soon as a soft place can be felt on the inside of the cheek, to introduce a lancet, and discharge the matter. People very often continue poulticing a swelling of this kind, in order, as they term it, to bring it to a head; in so doing, they cause ulceration to take place through the substance of the cheek. If the tooth producing the abscess be situated in the upper jaw, it will discharge in the middle of the cheek; if in the lower jaw, the opening will be at the lower part of the jaw, either near the angle or at the edge of its base.

These abscesses are rarely healed; the painful symptoms may subside, but the opening remains fistulous, attended with a consequent discharge of matter.

I have known persons persist in their attempts to heal these kinds of abscesses for some months. One lady continued the application of dressings and lotions to a sore of this kind for two years, but with no benefit.

In all these cases, the fangs of the teeth become very



much diseased, and are the cause of the perpetual discharge; therefore, no cure of these abscesses can be expected without the extraction of the tooth.

In these cases, at the opening where the matter was discharged, the skin rises and acquires a sort of fungous appearance, being very red, and of a loose, spongy texture; when the tooth has been extracted, the discharge gradually diminishes, and the external opening closes; but, as the inner part of the integuments have been destroyed by the ulcerative process, in healing the skin becomes contracted, and a deep scar or pit remains.

From the situation and appearance of these scars, they are liable to be attributed, by superficial observers, to the effects of scrofula, which, to a female, or a person of nice feelings, is always a source of uneasiness.

[When the matter from the abscess has been permitted to escape, for a considerable length of time, from a fistulous opening through the cheek, or lower part of the face beneath the inferior maxillary, the removal of the tooth, though it cures the abscess, is not always followed by the closure of the opening exteriorly. A diseased action having been set up here is often continued after the cure of the primary affection. Although this rarely happens, examples are on record. Mr. Thos. Bell, in his treatise on the Anatomy, Physiology, and Diseases of the Teeth, gives a very interesting case. The plan of treatment which he instituted, and which might in like cases be adopted, was, after the extraction of the tooth, the removal of a circular portion of the parietes of the tube towards the gum, and the bringing of the integuments together as a simple wound.]

When teeth, which have caused abscesses of this kind, are extracted, the fangs are found covered with a fleshy substance, which are granulations extending to the bottom



of the socket; this being only an effort of nature to effect the healing process, and to fill up the cavity occasioned by that absorption of substance, which always attends the formation of matter.

When unfortunately the patient is so much under the influence of fear, that neither acute pain nor protracted suffering is sufficient to induce submission to the extraction of the tooth, the inflammation of the jaw bone is often so great as to terminate in the mortification of a large portion of its substance.

The process of exfoliation is necessarily a tedious one, the patient is in a continual state of uneasiness, and the mouth is constantly filled with an offensive discharge. As the process of separating the dead portion of the jaw from the living advances, the gums gradually recede from the alveolar processes; at length the dead bone begins to separate, it gradually becomes loose, and, when it is completely separated from the bony attachment, it may be taken away.

In Plate XVI. are two specimens of the mortification of portions of the jaw bone, in consequence of carious teeth.

Fig. 8 represents a portion of the superior maxillary bone, containing a central and lateral incisor, and the cuspidatus of the left side: this case occurred to a gentleman whose lateral incisor was decayed, he had pain for a day or two, when his gums and lip became swollen; in this state, instead of taking proper advice, he poulticed and fomented his face for several days in succession: a considerable quantity of matter formed, and discharged itself under the lip: in this state it continued for some time; when he applied to me, I found that not only the diseased tooth was loose, but also the one on each side. I extracted the carious tooth, but found the socket quite

rough, arising from the destruction of the periosteum. I told him I expected that the socket of this tooth would exfoliate; a short time afterwards I saw him again, when on touching the other teeth, I perceived a motion under the gums, through the extent of the three teeth.

Some weeks after, the whole became so loose, that a slight force brought it away. The parts then healed, but not without leaving an immense cavity.

Fig. 9 exhibits a similar case, which occurred to a young lady, a patient of Mr. Williams, in the Borough of Southwark.

This lady was tormented by the tooth-ache for a long period, her face swelled, and matter formed; but all the entreaties of Mr. Williams, and the dreadful consequences which he taught her to expect, could not raise in her mind sufficient courage to permit the tooth to be extracted. The consequence was, that a large piece of the jaw mortified, the bicuspidæ, in consequence of their attachment to the bone being destroyed by the ulcerative process, became loose, and, being single-fanged teeth, were easily taken away; at length the piece of bone was so completely detached, as to allow of its removal, bringing away with it the diseased tooth: at this time, the second molaris, having lost almost the whole of its support, was found to be so loose as to render it necessary to be extracted. Here is an instance where a person lost four teeth, and a large portion of the jaw, through an obstinate determination of not submitting to the extraction of the originally-diseased tooth.

I saw also a woman in Bartholomew's Hospital, who, from a similar cause, lost all the teeth with the alveolar processes of the anterior part of the lower jaw.

When abscesses form in the mouths of children, from diseases of the temporary teeth, the greatest care should



be taken, as, by an exfoliation of part of the jaw bone, the teeth may be destroyed.\*

A knowledge of the evils which may result from a carious tooth, ought to influence all persons, who may be affected with this malady, to take such early steps for their prevention as prudence shall dictate.

Sometimes an indolent kind of inflammation will exist at the bottom of the socket of a carious tooth, occasioning a hard lump, or small tumour, of the size of half a nutmeg. In this state it will continue for months, with no other alteration than being rather sore; when, in consequence of a cold, a little active inflammation may arise.

These hard swellings should always be regarded as very dangerous, because, as during their indolent existence they have caused a certain degree of absorption of the inner part of the integuments of the face, if any active inflammation occur, it very speedily runs on to suppuration; and, as the skin has already become thin, ulceration to the external part takes place so rapidly, that I have known an opening formed through the cheek in a very few days. On these accounts I always endeavour to persuade patients to have any tooth extracted, which may be accompanied with any hardness or swelling. It is also much better to submit to the extraction of any carious tooth which has produced an abscess; for it will be always a source of trouble, as well as occasion an offensive state of the breath.

[A very singular case of alveolar abscess fell under the observation of the editor about four years ago. The subject of which was a lady about thirty years of age. She had been troubled with a dripping of pus from behind the curtain of her palate for near twelve months, and becoming somewhat alarmed at its long continuance,

\* Vide Natural History of the Teeth, page 105.



called the attention of her family physician, Professor Bond, to it, who after having carefully examined the case, endeavoured to trace it to its origin. He soon came to the conclusion that it come from the socket of a diseased tooth, and after passing his finger around on the gums covering the alveolar border, discovered a protuberence over the extremity of the root of each superior central incisor, nearly the size of a hazelnut. This tended to confirm the opinion which he had formed with regard to the place whence the matter came, and he requested us to visit the lady with him, which we did, and on examining the case advised the immediate removal of the affected teeth, and the more strongly, as they were found to be in a necrosed condition.

The lady readily consented to the operation, which was performed on the following day. The discharge behind the curtain of the palate immediately ceased, and thus the patient was relieved from an affection that had proved a source of great annoyance to her. The pus from the abscess in this case, instead of passing out through the alveolus and gum, had effected a passage through the nasal plates of the superior maxilla, passed back over the roof of the mouth and escaped in the manner as described.

The following highly interesting case of alveolar abscess, described by Dr. I. I. Greenwood of New York, is quoted from the American Journal of Dental Science.\*

"Some few years past a foreign gentleman applied to me for professional aid, who had been treated by an eminent surgeon dentist for several years for a diseased dens sapientiæ. On examining the case, the malady was found to be seated in the alveolus of the tooth on the right labial side of the dracranian maxillary at the base of

\* Vide Vol. II. page 291.



the coronoid process, where it forms a conjunction and continuation of the alveoli. In the first instance it had been formed by an erosive exposure of the medulla of that organ. The patient being of a timid disposition, and the surgeon not determined in extracting the tooth, an abscess had formed, and the pus passing off from the weight of the matter aslantwise, and through the base of the alveolus of the tooth, had perforated the Levator, affecting the rotary muscles opposite the orifice, and through the anterior surface of the skin, immediately under the centre of the belly of the digastricus, where it pierces the meatus auditorius externus, forming a considerable orifice; which issue he was in the habit of probing with a silver instrument, about six inches in length, and cleansing with lint, &c. It was found that in making use of this instrument and forcing it in the whole length of the canal, which was straight and considerably indurated, the rigidity being such that the digastricus could not have its full force of expansion, and the masseter muscle of that side at its lower portion was affected as well as the pterygoideus externus in such a manner, that the patient was not enabled to open his mouth more than half an inch.

By further probing the wound the instrument was found to strike upon a hard substance at the base, which by the sound was known to be the fangs of the diseased organ. The alveolus being destroyed on that side of the diacranian opposite, and on the labial section of the surface of the tooth; from the continuous issue of matter, the tooth irritating and acting as an extraneous body, and causing this flow, it was determined at once to perform the operation of extraction. No worse result could take place when the member was removed. The cutting was carefully yet fearlessly made, and the operation performed. The patient immediately feeling relief, the sanguineous

discharge which followed was somewhat free, and considered as favourable. Yet still the indurated canal remained, and the rigidity of the parts not remedied. The patient was advised when the wound healed in a measure, to lubricate the parts externally with emollients, such as had been prescribed by his physician and were of a mercurial nature, to cause a plianthness and relaxation of the muscles. The advice was concurred in, and a restitution of the parts was the effect of the application.”]



## CHAPTER FOURTEENTH.

### DISEASES OF THE ALVEOLAR PROCESSES.

THE alveolar processes are elongations of the external and internal tables of the maxillary bones, which, being united by transverse processes, are divided into cavities called alveoli, or sockets, for containing the fangs of the teeth.

The alveolar processes are to be considered as necessarily belonging to the teeth, and not essential to the formation of the jaw bones. In the earlier part of life, they contain the rudiments of the teeth, which they accompany in their growth, and when the teeth are completely formed, they acquire a form exactly suitable to the shape of the fangs.

The alveolar cavities are lined with a vascular membrane, analogous to the periosteum in other bones; this membrane is also attached to the fangs of the teeth, and by it the teeth are fixed in their sockets: the alveoli are larger than the fangs of the teeth they are meant to contain, as may be seen by examining a skull that has been macerated; where the membranous parts being destroyed, those teeth which have single fangs drop out, whilst the others are retained by the irregular shape of their fangs. On this account it is, that the teeth have a certain degree of motion, which is of great benefit in mastication, thereby preventing that injury which might

arise from the concussion consequent on the breaking of hard substances. This motion of the teeth in their sockets, is made evident to all persons when the fangs of a tooth are inflamed; hence, many expect that the operation of extraction will be attended with little pain, and no difficulty; an error which we cannot be too careful to correct, by explaining that the looseness of the tooth is only its natural motion, now become more observable from the increased sensibility of the periosteum. This explanation leads the patient to abandon those delusive expectations, and preserves the surgeon from the imputations, of having given unnecessary pain. [Not only is the motion of a tooth more perceptible when its alveolar membranes are inflamed, but it is actually looser, and this results from its being slightly raised from its socket by the swollen and thickened condition of the periosteal tissue which surrounds its root, or roots, if it have more than one.]

The alveolar processes are always sympathetically affected by all the diseases of the teeth and gums. When inflammation affects either the teeth or gums, it shortly extends to the alveolar processes; in consequence of which, an increased action of the absorbents is induced, and the substance is removed. An absorption of the alveolar processes invariably follows a loss of the teeth, occasioned by any cause whatsoever. This may be noticed in very old persons, who have lost all their teeth; the upper jaw becomes much diminished in extent, and the roof of the mouth, instead of being arched, is rendered nearly flat; the under jaw becomes simply a thin bone covered by the gums. Thus, by the removal of the teeth and alveolar processes, a loss of substance is sustained nearly equal to an inch and a half in depth; and, when this is the case, the muscles of the lower jaw,



in the endeavour to draw it against the upper, produce those characteristic marks of old age, the shortened face, the wrinkled cheek, and the projecting chin.

The alveolar processes have certain diseases peculiar to themselves, independent of affections arising from the teeth and gums. The most common disease to which they are subject, is a gradual absorption of their substance, whereby the teeth lose their support, become weak, and at length are so loosened as to drop out. This disease usually begins to show itself in persons between forty and fifty years of age; and, from its frequent occurrence without any evident cause, it would seem to be a consequence of having passed the middle period of life.

In the majority of cases in which this disease occurs, the teeth are perfectly sound, and, from numerous observations, I think I may venture to assert, that persons who have had several of their teeth affected with caries in the early part of life, are not liable to lose, by an absorption of the sockets, those which remain sound; but where the teeth have not been affected with caries in the early part of life, persons, as they approach fifty years of age, and often much earlier, have their teeth become loose from absorption, or a wasting of the alveolar processes.

When the alveolar processes are removed by the action of the absorbents, the gums which are supported by the alveolar processes, partake also of the disease; thus, in the progress of the disease, as the absorption of the bony matter advances, the gums lose their attachment to the teeth, and recede in proportion to the wasting of the sockets. Hence when an absorption of the socket is taking place, the necks of the teeth become exposed, and the teeth appear to increase in length; which circumstance has caused many persons to imagine that they are actually extended by natural growth. In this opinion, how-

ever, they are soon undeceived; for, as the disease increases, the teeth become weak, and at length, by losing their natural support, are rendered so exceedingly loose, that, in a short time, they drop out.

Sometimes this disease proceeds without the appearance of any assignable cause, the gums retain a very healthy aspect, are quite free from pain or inflammation, and yet will gradually recede, until the teeth become very loose.

The causes which more particularly produce this affection are such as occasion any continued or considerable inflammation of the gums. These are an accumulation of the tartar about the teeth, an habitual predisposition in the gums to inflammation, as happens in that disease commonly called the scurvy in the gums, or that state of them which is produced by the action of mercury.

When this disease attacks the alveolar processes in both jaws, it is generally discovered by all the teeth appearing longer, and having larger spaces between them than formerly, accompanied also with a difficulty of masticating hard substances. Soon after a person has made these remarks, he finds some one tooth become loose, occasioning much uneasiness, by preventing the use of that side of the mouth in which it is situated, and therefore its removal is determined upon. Shortly afterwards another tooth fails, and so in succession, until, in the course of eight or ten years, most of the teeth are lost.\*

In some cases of absorption of the alveolar processes, and removal of the gums, the disease causes a very peculiar appearance; the gums are very much swelled between the teeth, the fangs are uncovered irregularly, and are also quite black.†

\*Plate XVIII. Fig. 5.

†Fig. 6.



Sometimes the alveolar processes are affected only partially, the absorption being confined to the sockets of two or three teeth only, after the loss of which there may be no appearance of the disease for a great length of time.\*

When several teeth together have become loose, as is often the case with the incisores, they may be strengthened in an artificial manner, by tying or fixing them with a silk ligature, or a fine gold wire, to those neighbouring teeth, which may happen to be firm. By this operation, the loose teeth are supported and kept steady, not only giving comfort to the patient, but also arresting the progress of the disease, by removing that irritation which is kept up in the gums and sockets by the looseness of the teeth.

[The destruction of the alveoli is not the result, as supposed by the author, of the direct action of the absorbents, but of that of the corrosive matter secreted by the gums on their inner edge and the periosteal tissue. The wasting of the alveoli is always preceded and accompanied by a diseased action in the gums, and sometimes by a morbid diathesis of the alveolo-dental membranes. And disease in these tissues, may result from the presence of diseased teeth, tartar or other extraneous matter, or a vitiated or morbid condition of the fluids of the mouth.

If the wasting of the alveolar processes were the result of a spontaneous action of the absorbents, independently of local irritation, they would all be attacked at about the same time, but inasmuch as they are not, and as some are more liable to be destroyed than others, and especially those, the teeth of which are most liable to accumulations of tartar, the inference that the author's opinion is incorrect, seems irresistible. Moreover, the matter secreted

\*Plate XVIII. Fig. 7, 8.

by the inner edge of the gums, around the necks of the teeth, is known to be possessed of corrosive qualities, and capable of breaking down the calcarious molecules of bone, and the parts of the alveoli first destroyed are their edges, which are in contact with this matter.

The affection is not a necessary consequence of old age, as the author seems to imagine. Many persons retain all their teeth firmly in their sockets to extreme old age, but that it should frequently occur, after the middle period of life, is not to be wondered, when we take into consideration the fact, that as the healthful energies of the body begin to decline, all its fluids begin gradually to deteriorate, those of the mouth as well as those of other parts of the organism, and hence the morbid action in the gums which about this period oftentimes manifests itself, and the consequent gradual wasting of the alveoli, and especially when no means are used to counteract it—such for example, as the observance of thorough and constant cleanliness of the dental apparatus.

The lower teeth are by far more liable to loosen and drop out from the destruction of their sockets than the upper. As soon as they begin to loosen, they, by their increased motion in their sockets, become a source of irritation to the gums and alveolo-dental periosteum, and hence it is, that the loss of three or four loosened teeth, often, for a time at least, arrests the progress of the disease.

The employment of an artificial support, such as ligatures or wires, for teeth which are loose, is decidedly improper, for the reason, that though it may steady the teeth for a short period, it prevents them from being properly cleansed, and affords a lodgment to extraneous matter, and will thus ultimately increase the evil.]

The treatment found to be most successful in arresting



the progress of this disease, is the removal of that which may appear to be the exciting cause. If this be tartar, it should be removed; and, if there be a tendency to an habitual deposit, the person should be careful, by frequent attention, to prevent its accumulation. In some cases, this disease is accompanied with inflammation extending along the fangs of the teeth, giving the sensation of tension, and occasioning great uneasiness; this is relieved by scarifying the gums, a practice which should always be had recourse to, as the loss of blood, by abating the inflammation, relieves the pain, and checks the progress of the disease.

Sometimes the absorption of the alveolar processes is attended with a considerable secretion of pus, which oozes out from under the gums, at the necks of the teeth. This discharge is not only very disagreeable, but often renders the patient very unhappy. Persons thus affected, from observing, when they squeeze the gums with the finger, that matter passes out at the necks of the teeth, form an opinion, that it must produce injurious effects upon the sockets of the teeth, as well as render the breath offensive; on these accounts, they frequently squeeze the edges of the gums, and wipe the teeth, in order to remove what they consider to be so offensive and injurious. This practice, however, cannot be too strongly reprobated, as it tends to promote the very effects they so much fear. By frequently squeezing the gums, a constant irritation is kept up on the secreting surface, by which the discharge is not only rendered more copious, but also more acrid.

In these cases, nothing more should be done than to use a soft tooth-brush, night and morning, and cleanse the mouth by rinsing it with some lotion, such as a decoction of Peruvian bark, the infusion of roses with tincture

of myrrh or tincture of catechu, diluted arquebusade water, &c. By attending to these rules, the discharge will be moderated, and the mouth become much more comfortable. [In addition to the foregoing, the ulcerated edges should be touched with a solution of nitrate of silver.]

An extraordinary change in the position of the teeth is sometimes produced by a slow and peculiar absorption of the alveolar processes. The teeth advance from the posterior to the anterior part of the mouth, and cause the incisores to become irregular; this irregularity sometimes increases, even to the entire projection of one tooth: and, if the projected tooth should become loose, and be extracted, the loss will not be perceived, as the tooth on each side has approached so near to each other. In this manner I have seen the cuspidati advance so much towards the symphysis of the jaw as not to leave sufficient space for more than two teeth. [The loss however of two of the front teeth, even though the space between the cuspidati be filled, gives to the teeth a disagreeable appearance.]

This alteration in the position of the teeth arises from an absorption of the transverse alveolar processes, and the irregularity from the difference which exists in the form of the fangs and the crowns of the teeth; the former being much thinner than the latter, necessarily occasion, when the fangs are approximated, a considerable irregularity in the position of the teeth. When this kind of change takes place in the teeth of the upper jaw, the incisores project so much as to be placed one over the other, and produce very great deformity.\*

There is another disease of the alveolar processes

\* Plate XVIII. Fig. 4.



frequently occurring, but which differs from the appearances already described. It rarely affects more than one tooth at the same time, and, instead of being an absorption of the socket, it is a filling up or contraction of the bottom of it, by which it becomes shortened, and the tooth consequently pushed out.

The appearance produced is an increase in the length of the tooth: the gum is not affected, but retains its natural situation. As the disease in the socket advances, the tooth continues to be protruded, until it loses so much of its support as to become loose, after which it soon drops out. The loss of the tooth is much hastened by occasionally striking against the teeth in the other jaw: a disagreeable effect is also produced in the symmetry of the mouth, by one tooth being much longer than the others. In this case, all that can be done, is to file away a portion of the lengthened tooth, so as to make it even with the others. This operation should be performed from time to time, as the tooth continues to be protruded, which will save it from being struck by the other teeth, and obviate the deformity arising from the otherwise unavoidable irregularity.\*

The alveolar processes occasionally become enlarged by exostosis. This sometimes takes place at that part formed by the union of the superior maxillary bones; the central incisors, from being closely situated together, become so much separated as to appear as if a tooth had been extracted. The same circumstance also sometimes occurs at the symphysis in the lower jaw.†

I once met with a case of considerable enlargement of the alveolar processes at the posterior part of the upper jaw, in which the molares were still remaining; great deformity was occasioned by the projection of the cheek.

\* Plate XVIII. Fig. 1, 2.

† Fig. 3.

The practice adopted was to extract the teeth with the view of producing a decrease in the size of the tumour by that absorption of the alveolar processes which always follows the removal of a tooth. This proved very successful, for the tumour was not only diminished in size, but the progress of the disease was arrested.



## CHAPTER FIFTEENTH.

### OF THE TARTAR [SALIVARY CALCULUS] OF THE TEETH.

EXCEPTING the disease of caries, nothing is so destructive of the healthy condition of the mouth, or of the duration of the teeth, as the accumulation of tartar. This is an earthy substance held in solution by the saliva, and is deposited upon the teeth, as the saliva undergoes decomposition. Almost every person is subject to a formation of it in a greater or less degree; in some, the deposit is so habitual and copious, that without unremitted attention, their teeth cannot be preserved in a decent state; whereas, in others, it is so small in quantity that the least degree of care is sufficient to keep the teeth perfectly clean.

The formation of tartar is much influenced by the state of the health; for, during the continuance of any febrile complaint, in which the secretions of the whole alimentary canal are disordered, the mouth and teeth are loaded with a thick mucus; hence there is commonly a very large accumulation: the same also is observed during confinement from any cause whatever, when there is not an opportunity of constantly cleansing the teeth: it is remarkably so in the confinement attendant on parturition. [Some temperaments too are more favourable to depositions of this substance than others, and the relative proportion of the earthy and animal constituents of

tartar varies in different dispositions, but for a description of its physical characteristics the reader is referred to Part Second of the editor's Principles and Practice of Dental Surgery.]

After sleep, the teeth are usually found covered with a viscid, yellowish mucus, which, if not entirely removed by the use of a tooth-brush and washing, adheres to the teeth in those parts not subject to friction during mastication. Through neglect, this viscid mucus gradually accumulates, depositing itself in layers until it acquires a hard consistence, and sometimes a magnitude equal to that of the teeth themselves.

When the tartar is soft, it has a yellowish [or whitish] appearance: but as it becomes harder, it changes to a dark brown, or a black colour; in this way the teeth are rendered very disgusting to the eye, and, by its effects on the gums, a very disagreeable fetor is communicated to the breath.

In the formation of tartar about the teeth, it insinuates itself under the gums, and detaches them from the necks of the teeth; the gums are thus brought into a diseased state, are subject to inflammation and pain, and at last gradually recede from the teeth. This state of the gums soon causes the alveolar processes to become affected, and absorption in them is induced; so that, in proportion to the increase and accumulation of tartar about the teeth, their natural support is destroyed, they become loose, and at length, by some accident, a large piece of tartar is broken off, when the tooth, being deprived of its artificial support, drops out. In like manner, the other teeth give way one after the other, until in a few years the greater number are entirely lost. Persons who lose teeth from this cause, complain that they came away perfectly sound, not considering it as the effect of their negligence; and it



is but too commonly the the case that nothing less than commencement of the loss of teeth induces them to pay attention either to their cleanliness or preservation.

The tartar always accumulates in greater quantity about those teeth situated near to the openings of the salivary ducts; and, in some few instances, it has been found, in no inconsiderable quantity, in the ducts themselves: hence, the inner side of the incisores in the under jaw, and the external sides of the molares in the upper jaw, are the most covered by it. If, on account of a carious tooth that may be tender, only one side of the mouth be used in eating, the teeth on the other side usually become very much incrustated; which circumstance demonstrates that the friction of the food in mastication very much tends to cleanse the teeth.

There is another kind of tartar which collects chiefly about the teeth of young persons: it is of a dark green colour, rather resembling a stain than an earthy concretion: it is very injurious in its effects upon the teeth, as it corrodes the enamel, and disposes the teeth to become carious.

In Plate XIX. are a variety of examples of accumulated tartar, showing also the manner in which it produces its injurious effects.

The deposition of tartar is an unavoidable circumstance, depending upon the effusion and decomposition of saliva; but it is in the power of most persons to keep their teeth free from an injurious accumulation, by carefully washing and brushing the teeth every morning, to remove that soft matter which is deposited during the night, and also by rinsing the mouth after meals, to cleanse them from those particles of food that may lodge about them, and which, being left in the intermediate spaces of the teeth, become changed during the night, and not only contribute



much to the formation of tartar, but also produce a tainted breath [and caries of the teeth.]

If the constant use of a tooth-brush and water be not sufficient to keep the teeth perfectly clean, a tooth-powder may be used, composed of some substance not possessing any chemical property which can act on the enamel, or of too hard a quality, by which it would grind it away. [The use of waxed-floss silk as before directed will also be found a valuable auxiliary to the brush.]

Powders for this purpose may be composed of any of the finely powdered earths, or boles, or any of the testaceous powders; charcoal, finely levigated, has been recommended and much approved by many. In the formation of a tooth-powder, no ingredient ought to be used that can have any chemical action upon the enamel of the teeth; nothing more is desirable than something which will mechanically act with the brush, in taking from the teeth that inspissated mucus which forms [or rather mixes with and agglutinates the particles of the tartar together,] nor should any acid be introduced into washes, tinctures, essences, or dentifrices, for diseases of the gums, as, by their power in decomposing the enamel, the greatest injury is done to the teeth. In cases of disease, where acid remedies are necessary, persons should be careful to wash and wipe their teeth immediately after their exhibition, to prevent future injury of the teeth; for whatever renders the enamel thinner necessarily tends to the destruction of the teeth.

[The editor is of the opinion that neither charcoal nor bark should enter into the composition of dentifrices, for the reason that it gets between the edges of the gums and necks of the teeth, where it oftentimes remains for years, giving to the margin of the former a blackish or reddish brown appearance. It moreover is a constant source of



irritation. Equal parts of prepared chalk, oris root and castile soap, finely pulverized and passed through a fine sieve, constitute a much better dentifrice, but no powder should be employed when the gums are in an inflamed and spongy condition.]

When tartar has collected about the teeth, it is to be taken off by means of instruments; this operation is called scaling of the teeth, which is one of the most useful and necessary for their preservation. Much prejudice has been excited against this operation by the very injurious practice of some dentists, who apply the muriatic or vitriolic acid for the purpose either of softening the tartar, or whitening the teeth: the effect of these agents upon the teeth, is to remove the external coat of enamel by its solution, and to give to the teeth a beautiful white appearance immediately after its application. The natural polish of the enamel being thus destroyed, the surface is left rough, and the teeth soon afterwards become dark coloured from the adhesion of the colouring matter contained in the food. But, if this practice of applying the acid be not adopted, and the tartar, as it may accumulate, from time to time, be carefully removed from all parts of the teeth, the gums will be preserved in a healthy state, and absorption of the alveolar processes be entirely prevented.

The tartar, when it has been suffered to accumulate in large quantities, should be taken off cautiously, otherwise the sudden exposure of the necks of the teeth will be a cause of tenderness and pain. In such cases, a small portion of tartar should be removed at a time, beginning at the edges of the gums, which will permit them to grow up about the necks of the teeth; by this gradual procedure, a week or fortnight intervening between each operation, a very large quantity of tartar may be removed



without occasioning the slightest inconvenience: in the interim, the gums should be frequently washed with an astringent lotion.

[It would be preferable, if it could be done, to remove the whole at one time, but from the turgid condition of the gums, this is not always possible, hence it becomes necessary to resume the operation, at intervals of two or three days, or a week, until it is completed.]

I have seen many cases of great soreness and extensive ulceration of parts of the mouth, arising from large accumulations of tartar. A lady from the country applied to me, complaining of a sore mouth, which had baffled all the attempts made by a very skilful surgeon to heal it. The inside of her cheek was in an ulcerated state, and under the tongue, at the frænum, there was a considerable thickening, with a line of ulcerated surface. She had been in this state for more than twelve months, and could only obtain temporary relief from any application. Her teeth were covered with an immense quantity of tartar, such as described in Figures 14, 15 and 16 of Plate XIX. The edges of this substance, being very ragged and sharp, were continually cutting into the soft parts, that pressed against them. Sometimes a small portion would break off, when, from the new edge being very sharp, much irritation immediately ensued. I removed the tartar at intervals, in the manner above described, the sore places healed, and since that period, by an occasional removal of newly formed tartar, her mouth has continued perfectly well.

In scaling the teeth, care should be taken to use the instruments with no greater force than is necessary to remove the tartar, lest the enamel be scratched or injured; attention is also required to distinguish an irregular-formed tooth from the distorted shape, which accumulated



tartar frequently assumes; and, in teeth that are naturally yellow, not to mistake the body of the tooth for the extraneous matter upon it, a discrimination highly important, when applied to those yellow teeth, with very rough surfaces, described in the *Natural History of the Teeth*, page 57.

## ANALYSIS OF THE TARTAR.

DEAR SIR,—The specimens of the Tartar of the Teeth, which I received from you, I have examined chemically. Previous to their analysis, I subjected a portion of them to the following experiments. I am,

Dear Sir,

*Artillery Place, Finsbury,*

truly yours,

Dec. 1, 1805.

W. H. PEPYS.

To MR. FOX.

Tartar of the teeth, of a dirty white colour, inclining to brown stained in parts yellow and green; spongy, porous texture, yet considerably hard; when it is detached in large pieces, exhibits the impression of the teeth on which it was deposited. The pieces which were examined were dry and free from smell. Specific gravity 1.5714.

Sulphuric acid 1.85 is immediately blackened, the substance becomes spongy and soft, but no complete solution takes place.

Nitric acid 1.12 acts in nearly a similar manner on this substance as on the teeth.\* A gas which has the negative properties of nitrogen, is evolved in small bubbles, and a flocculent mass, of the form of the piece immersed, is left.

\*See *Natural History of the Teeth*, page 123.

Solution of potash, boiled for some time upon it, had but little action; the tartar became whiter, the solution yellow; upon the addition of nitric acid to the separated solution, the colour nearly disappeared without any precipitate being formed: ammonia reproduced the yellow colour.

The flocculent substance left by dilute nitric acid, after washing off the acid, being boiled with solution of potash, was not wholly dissolved; the solution became yellow. Nitric acid being added, discharged the colour, which ammonia reproduced.

Water boiled for some time upon tartar gave no precipitate or turbid appearance on the addition of solution of tannin.

Tartar exposed to a red heat, in a silver crucible, smokes, accompanied with a greasy smell, is blackened in a similar manner to bone, and becomes more easily soluble in nitric acid, leaving a carbonaceous residuum.

The solutions of potash which have been boiled on tartar, being neutralized with nitric acid, gave no precipitate with solution of nitrate of barytes.

## ANALYSIS.

Fifty grains of tartar of the teeth were placed in 400 grains of nitric 1.12; nitrogen gas was slightly liberated: in twenty-four hours it was diluted with two ounces of distilled water, and then filtered.

The solution was then precipitated by ammonia, and filtered; and, upon the addition of carbonate of ammonia, remained clear; the precipitate produced, being dried at  $212^{\circ}$ , weighed 40 grains, and, when ignited, it weighed 35, which were again soluble in dilute nitric acid, giving a copious precipitate with solution of acetate of lead: this



precipitate, washed, dried, and exposed to a flame, urged by a blow-pipe, fused in a globule, accompanied with a bright phosphorescent appearance, and was therefore phosphate of lead.

The substance not soluble in nitric acid, was washed and dried at  $212^{\circ}$ , weighed 15 grains, and adhered firmly to the filter.

The 15 grains of the last experiment were boiled in a solution of potash for a quarter of an hour; being separated, washed and dried at  $212^{\circ}$ , weighed 9 grains.

The separated solution was of a yellow colour, the addition of nitric acid produced no precipitate, but lost colour, which was recovered by ammonia.

The 9 grains of residuum after treatment of the potash, were placed in boiling concentrated nitric acid, by which they were completely dissolved; and, by the test of tannin, proved the cartilage to have been gelatinized.

Tartar of the teeth consists of

Phosphate of lime,	.	.	.	35
Fibrina, or cartilage,	.	.	.	9
Animal fat, or oil,	.	.	.	3
Loss,	.	.	.	3
				<hr/> 50

[The following is the result of an analysis by Berzelius.  
One hundred parts contained,

Phosphate of lime and magnesia,	79.0
Salivary mucus and salavine,	13.5
Animal matter,	7.5
	<hr/> 100.

In an analysis made by Mr. Dwinelle, a scientific dentist of Cazenovia, N. Y. One hundred parts yielded,

Phosphate of lime, . . . .	60
Carbonate of lime, . . . .	14
Animal matter and mucus, . .	16
Water and loss, . . . .	10
	<hr/>
	100

It is probable that no two analyses could be made to give the same result for the reason as before stated, that the relative proportions of its constituents vary in different individuals.]



## CHAPTER SIXTEENTH.

### OF SCALING [REMOVING THE TARTAR FROM] THE TEETH.

By the term scaling the teeth, nothing more is meant than the removal of the tartar; though, through prejudice, a popular notion prevails, that, by scaling the teeth, a removal of the enamel is intended. The instruments for performing this operation are made of various forms, so adapted, as to be easily used on the different parts of the teeth. The most conveniently formed set of instruments consists of, one having the shape of a chisel, a straight and a curved spear-pointed instrument; one like a rugine, being three pointed, and adapted for scraping; and another form for scraping, but smooth at the back. In some sets, there may be one or more instruments of different shapes; but this depends more upon caprice than real utility, as it is not so much the form of an instrument that is of consequence, as the proper manner of using it. [The form of the instruments, however, should be such that they may be readily applied to every part of the teeth, for it is important that every particle of tartar be removed from them.]

The patient should be seated in a chair, having a high back, that the head may rest conveniently; and, by being kept steady allow the operation to be performed with convenience to the surgeon, and ease to the patient. Endeavours should be made to acquire a habit of taking

off the tartar without violence, operating with as light a hand as possible.

The chisel-formed and straight spear-pointed instruments are designed for the anterior surface of the under incisores; the curved spear-pointed and the scraping instrument with a smooth back, for the outer side of the molares and other teeth; and the three-pointed instrument, or other scraping instruments, for the posterior surfaces of the teeth. By attending to these hints, with a little practice, a habit may soon be acquired of removing the tartar without leaning heavily upon the mouth, or jarring the teeth, which are two circumstances of considerable importance.

[In the removal of the tartar from the lower front teeth, when they are loose, the thumb of the left hand of the operator should be placed on them in such a manner as to prevent them from being jarred or shaken in the operation. The patient should be directed to wash his mouth from time to time, during the operation, to free it from blood and the small particles of tartar that lodge along the edges of the gums.

For the removal of the tartar on the approximal surfaces of the teeth, a thin-bladed instrument like that of a knife should be employed, and the operator should be careful not to injure the periosteum. When the gums are very much swollen and inflamed, and the accumulation very considerable, several sittings will be required to complete the operation. After which the patient should be directed to cleanse his teeth several times a day with a soft elastic brush and waxed-floss silk, to prevent a re-accumulation. If any small particles be left upon the teeth, they will constitute nuclei for its re-accumulation, and thus, in a measure, counteract the means employed to prevent it. It is important therefore, that the operation



be thorough, that not a particle be left upon the teeth ; and as the presence of this substance, gives rise to disease in the gums, it is also important that such other treatment be instituted, as the nature of the morbid condition in this structure may seem to require. But, as this has been described in a preceding chapter, it will not be necessary to recapitulate what has been said upon the subject.

Some writers recommend for the removal of this substance from the teeth, chemical agents,—such for example, as diluted muriatic and even sulphuric acids, but the employment of either of these, or any acid, for this purpose, is highly improper. Any chemical agent which will decompose the tartar of the teeth, will act upon the teeth, therefore, mechanical, is the only means that should be employed for its removal.]

## CHAPTER SEVENTEENTH.

### THE EFFECTS OF MERCURY UPON THE TEETH.

WHEN mercury has been introduced into the system, certain circumstances occur which are usually regarded as criteria of its specific and constitutional action. The most evident of these are an increased discharge from the salivary glands, soreness of the mouth, and fetor of the breath. The gums become tumid and spongy, are very tender, and liable to bleed; the teeth also become loose, and cannot bear the pressure necessary for the mastication of hard substances: this loosened state of the teeth arises from the thickening of the periosteum which covers the fangs, and by which the teeth are held in the sockets; the soreness of the gums is probably occasioned by that fulness of the vessels which the peculiar action of the mercury induces. These affections of the teeth and gums generally subside soon after the use of mercury is discontinued, the teeth again become fast, and the gums acquire their natural firmness.

A common consequence of the use of mercury is, an increased action of the absorbent vessels, and there is no part on which this action is more evident than the alveolar processes. On examining these parts in persons who have died during the use of mercury, they will be found much less dense, and of a more porous texture than the bone ought to be in its sound or natural state. The use



of mercury is therefore no uncommon cause of premature loss of the teeth, by inducing absorption [wasting] of the alveolar processes; this injurious consequence, arising from the use of this remedy, is now greatly obviated by the improvement adopted in its exhibition; namely, by keeping up a longer but slighter action of it upon the system, rather than that violent one which accompanied the old practice of salivation.

Where the use of mercury is carried very far, the teeth, even during its exhibition, often become so loose as to drop out: in other constitutions, still greater mischief is experienced; there is a considerable inflammation of all the parts of the mouth, attended with great swelling and ulceration. This sometimes extends even to mortification of parts of the jaw-bones. It would not be difficult to collect cases of extensive mischief following an injudicious use of this valuable medicine; several striking examples of which have been presented to me by various surgeons of my acquaintance. In Plate XX. Fig. 2, is the representation of a large piece of the anterior part of the under jaw, containing the incisores and cuspidati, which exfoliated, in consequence of a long-continued salivation.

Fig. 3 represents nearly the whole of the under jaw, which mortified and exfoliated; this person also lost almost every tooth of the upper jaw, which became loose, and dropped out.

A very similar case occurred to a patient in Guy's Hospital, who applied for advice on account of great disease in his mouth, as the consequence of a late salivation. He had an exfoliation nearly similar to the last case, and it was surprising to observe how small a deformity attended the loss of so great a part of the jaw. During the progress of the exfoliation, so large a deposit of new



bone took place, around the dead portion, that it became, as it were, inclosed in a case; and, after it came away, the new bone was rounded, and the gums healed over very perfectly.

Last year I saw a most dreadful instance of the injurious consequences of an improper use of mercury, in a lady, a patient of Mr. Norris, who had just arrived from the East Indies, where she had been salivated on account of a liver complaint. She had been advised to employ so much mercury, that she was literally poisoned, her mouth became completely ulcerated, and the whole constitution was so much affected, that she lay for some time in a state of insensibility. As she recovered, the soreness of the mouth rendered the opening of it painful and difficult; and, as the ulcers healed, so much adhesion and contraction took place at the posterior part of the mouth, that it could scarcely be opened even to admit a tea-spoon; at length, the contraction increased to that degree that she completely lost the power of opening it. On this account, she was under the necessity of receiving nutriment in the form of thick milk, soups, &c. introduced into the mouth by a large syringe, the pipe of which, being curved, was passed into the mouth through an opening formed by the loss of one of the molares. In addition to these calamities, the great inflammation which had been excited, caused the mortification of nearly the whole of the alveolar processes of both jaws. On separating the lips, a most dreadful appearance presented itself, the gums had retired from the teeth, leaving the alveolar processes uncovered, and quite black. I removed several teeth which had become loose, and in two or three places exfoliation was beginning to take place.

The constant discharge of matter made a very frequent syringing of the mouth with tincture of myrrh and water



absolutely necessary, and had she not possessed a most exemplary patience and composure of mind, she must have been completely miserable.

Some time since a man became a patient in Guy's Hospital, who had been so injudiciously treated in a course of mercury as to cause a complete ulceration of the gums and the inner surface of the cheeks and lips. The consequence of which was, that, as the process of healing advanced, so much adhesion of those parts took place, that the mouth could scarcely be opened. The man could only be relieved from this distressing situation by the dissection of the lips and part of the cheeks from the gums, which was performed by Mr. Cooper, the parts were then preserved from re-uniting by the interposition of lint, until they had perfectly healed.

During the use of mercury, when the mouth becomes affected, it should be frequently washed with a mild astringent lotion: for this purpose I have usually recommended the infusion of roses with a small quantity of alum; and, if the soreness of the mouth be very considerable, some tincture of myrrh may be added. During the exhibition of mercury, there is usually a considerable deposition of tartar about the teeth; to obviate the ill effects of which, it should always be removed, as soon as the medicine is discontinued; the gum will then soon recover their healthy state, and material injury to the teeth be prevented. [If it were requisite the editor could give the particulars of several very interesting cases of the pernicious effects resulting from an imprudent use of this medicine, but he does not deem it necessary to extend the limits of this work by so doing.]

Effects similar to those arising from the injudicious use of mercury sometimes attend that dreadful disorder, the small-pox. In the excellent museum of Mr. Heaviside



are several specimens of exfoliations which have been occasioned by the deadly operation of that loathsome pestilence. The preparations which the Figures 4 and 5 of Plate XX. represent, have the following statement affixed to them. "This very curious exfoliation is from the under jaw of a little boy about four years old, from matter formed between the gums and the bone, after the small-pox. As soon as it became pretty loose, the whole was carefully removed, which shows itself to be the substance of the lower jaw, with some teeth in it. A small portion of the anterior part of the upper jaw also exfoliated with two of the incisor teeth and two secondary teeth."

A similar case has for some time past been under the care of Mr. Dorratt, of Bruton Street. A child had the small-pox about Christmas last: soon after the fever had abated, the mother found a tooth upon the child's pillow; other teeth soon afterwards became loose, and dropped out. After this, great swelling of the integuments covering the face and chin, succeeded; this inflammation soon proceeded to suppuration, a great quantity of matter was discharged from the gums, which then began to retire from the jaw bones.

A large piece of bone, with several teeth, exfoliated from the upper jaw, and another piece from the under jaw; and when Mr. Dorratt gave me the account of the case, he informed me that he expected the exfoliation of another large piece.\*

In page 114 of Part First, I could not refrain from expressing the hope that this scourge of mankind would soon be driven from the world by the mild, but powerful, influence of vaccine inoculation; a triumph for humanity, which might have been achieved in our country as well

\*Plate XX. Fig. 6, 7.



as in some of the states and cities on the continent. It is a lamentable fact, that, in the country that gave birth to this glorious discovery, there should be found persons capable of taking every method to alarm the fears and excite the prejudices of the careful, but uninformed, parent; and who instead of uniting in the benevolent effort to preserve human life, have exulted at every unfavourable circumstance; and have taken advantage of those accidents which have resulted from negligence or want of information; and have unremittingly attempted to destroy the confidence of the public in this most salutary gift of Providence.

But the attempts of these persons have only tended to confirm the success of the practice; for, while by the industrious but malignant attempt to render the small-pox epidemical, by extending its inoculation, the atmosphere of the metropolis has been for some time past impregnated with the infection, the thousands who have been satisfactorily inoculated with the vaccine have remained in perfect health, although surrounded by the most active and virulent contagion. I cannot but express the hope that the legislature will wisely interfere, and, by restricting the inoculation of the small-pox, effectually prevent these gentlemen from indulging themselves in experiments so fatal to the public welfare; but which they openly endeavour to turn to their own private emolument.

This wonderful discovery was announced in the year 1798. From our favoured isle, it was soon carried to the other nations of Europe, and to America. In Russia, by the order of the emperor, it has been diffused through his vast empire. From Vienna, it was conveyed through Persia to our possessions in the East, where it was received with enthusiasm, not only by the European



settler, but by the Hindoo, it was regarded as an immediate gift from Heaven. Through the exertions of Mr. Ring, whose zeal in this cause must render him estimable to every philanthropist, it has been successfully conveyed to our settlements in New Holland, and there is reason to believe that it has been introduced into Africa.

Thus, like the sun, has this discovery extended its benign and life-preserving influence around the globe. What gratitude to the Almighty ought to possess the mind of him, on whom has been conferred the happiness of communicating so great a blessing to man! Long may he live,—and may the name of JENNER ever be revered as one of the great benefactors of the human race!

[Mercury does not, as many suppose, exercise any direct action upon the teeth. It is only by vitiating the fluids of the mouth, inducing inflammation and sponginess of the gums and the destruction of the alveolar process, that the teeth are prejudicially affected by it. By vitiating the juices of the mouth, it increases their corrosive qualities and renders them more hurtful to these organs, and by its effects upon the gums and sockets of the teeth, it often causes them, as stated by the author, to loosen and drop out.

In the treatment of sponginess of the gums, originating from a mercurial diathesis of the general system, whether accompanied with ulceration or not, it is important that the use of this medicine be first discontinued, as no beneficial effect will be obtained during its employment. The mouth should be frequently gargled with some astringent lotion, such, for example, as a decoction of sage and honey, with a little subcarbonate of soda. For correcting the fetor of the breath, a wash of the chloruret of soda, well diluted, to prevent injury to the teeth, will be found very



serviceable. The bowels should, at the same time, be kept open with some gentle aperient.

Scarification of the gums is recommended by some practitioners, but no advantage will be derived from it during the action of the medicine, and even after it has ceased to act, its effects are much less salutary, than in sponginess of the gums which has been produced by other causes. It may however, sometimes, after the disease has assumed a chronic form, be attended with beneficial results.

Disease in the gums, produced by a mercurial action of the general system, however perfectly it may have subsided, increases their susceptibility to morbid impressions. Hence, they are ever after more liable to disease.]

## CHAPTER EIGHTEENTH.

### OF THE DISEASES OF THE ANTRUM MAXILLARE.

THE antrum maxillare is a large sinus or cavity in the superior maxillary bone. It is situated over the molares, and under the orbital plates: it is lined with a membrane, and has communication with the cavity of the nose by a small aperture in that part of the side of the sinus which is membranous, and which is placed between the superior and inferior turbinated bones.

Inflammation in the antrum is often occasioned by diseases of the teeth, but it also occurs when the teeth are quite sound. Sometimes, in examining the prepared bones of the head, one or more fangs of the large molares may be found passing into the cavity. In such a case, inflammation, excited by a diseased tooth would speedily communicate to the membrane lining the cavity, and cause suppuration. [It however more frequently causes an obliteration of the nasal opening, and a consequent engorgement of the cavity.]

Much mischief usually follows the neglect of an abscess of the antrum. The natural opening from the cavity is usually rendered impervious, hence the matter is obliged to make its exit by an ulceration through one of its sides, which most frequently is that situated under the cheek. It is common to membranes, under inflammation, to become thickened, and as the opening into the nose is



through a membranous part, it is probable that when inflammation takes place, it is in consequence of the thickening of this membrane that the opening of the antrum into the nose becomes closed.

During inflammation in the antrum, the patient at first conceives the pain to proceed from the tooth-ache; but, if the teeth should not be diseased, a more accurate observation is made upon the peculiar sensations excited. The pain usually extends towards the forehead, in the direction of the frontal sinus, and a sensation of tightness and weight, with throbbing, is felt on the side of the face. In a short time, the cheek becomes red, and appears as if swollen; it feels very hard, and, on raising the lip, a considerable fulness above the fangs of the teeth may be observed.

If the disease be not attended to in this stage, as the matter rarely passes out at that side leading into the nose, an absorption of the bone above the molares takes place, and the matter discharges itself through the gum; but this does not cure the abscess,\* the formation of matter still continues, and the ulcerative process goes on, until so great a destruction of the bone is caused as to render the disease incurable.

This case requires the same kind of treatment as abscesses in general, viz. an outlet to be made for the matter: the best mode of effecting this is by extracting one of the molares, and making a perforation into the antrum, through the socket of one of the fangs. If it should happen that either the first or second molaris be carious, it will be proper to extract it; but, when the teeth are perfectly sound, the second molaris is to be

[\* Abscess, according to the true definition of the term, rarely occurs in the maxillary sinus. Therefore, it is improper to term an altered condition of its secretions and engorgement by that name.]



preferred, as the antrum descends the most at that part, and it is desirable to have the opening in the most depending situation.

When the matter has been discharged, the object must be to restore the parts to their former condition; with this view, a solution of tincture of myrrh is to be frequently injected, with a syringe, through the opening. As the inflammation subsides, the natural opening usually becomes pervious, and the injection will pass into the nose: when this opening is restored, the discharge gradually diminishes, the gum may then be suffered to heal over the artificial opening, and a cure is effected. As there is always a disposition in the gum to close over the part from whence a tooth has been extracted, it may be kept open, where the socket has been perforated, by introducing a piece of bougie, which sticking at the upper part of the socket, and hanging just low enough to be taken hold off, may be withdrawn at the time of syringing, and then be again returned.

[The diseases of this cavity being caused in a large majority of the cases, by irritation produced by diseased teeth, it is seldom necessary to do any thing more than remove the affected teeth and provide an outlet for the escape of the matter by perforating the floor of the sinus through one of the alveoli.]

If the natural opening into the nose has become perfectly obliterated, it will be requisite to preserve an artificial one; this may be accomplished by wearing a silver tube in the perforated part, through which the mucus will constantly pass into the mouth, and future accumulations be prevented.

I have met with several cases of disease in the antrum, occasioned by carious stumps, in which a considerable enlargement, with absorption of some of the anterior part



of the bone had taken place. The extraction of these stumps has been followed by a great discharge of a glaucous fluid: from the socket the discharge continues for some time, but it gradually diminishes until the part acquires a healthy state.

The antrum is sometimes the seat of formidable diseases, but these cases are not common. That which most frequently occurs is the formation of a polypus, or fungous tumour, within the cavity. The usual progress of this malady is, that the tumour having acquired a certain size, an absorption of the bone is induced by the pressure, this absorption commences in the internal part of the cavity, which is gradually rendered thin, until the whole is completely removed. The alveolar processes and even part of the fangs of the teeth are absorbed, when the remainder of the teeth, becoming loose, irritate the gum, and must be extracted.\* The tumour continuing to increase, the cheek becomes much enlarged, and, instead of bone or fungous substance, occupies the whole side of the face; at length ulceration takes place in some part, which, as it increases, is attended with so considerable a discharge of matter, that the strength of the patient is gradually diminished, and at length the disease terminates fatally.

The antrum is sometimes most dreadfully affected with cancerous disease. Happily these cases are very rare; the only specimens that I have seen are in the possession of Mr. Heaviside and Mr. Taunton. The histories of these cases are very similar, the patients were both elderly women; at first they complained of pain in the side of the face, extending up to the forehead and the eye, and back to the ear; these symptoms continued for about four months, when a tumour formed near the ear, from

\*Plate XVII. Fig. 17.



which, shortly afterwards, there was a discharge of a very fetid, dark-coloured fluid. Ulceration then began in the cheek, over the maxillary bone, by which, after great ravages had been committed, their strength was gradually exhausted, until death terminated their sufferings. These cases were about fourteen months in their progress.

In the patient under Mr. Taunton's care, the disease, which was on the right side, occasioned the absorption of the os maxillare superius, the os palati, the os malæ, the os unguis, and the condyloid and coronoid processes of the os maxillare inferius; also there was an opening of communication from the orbit to the dura mater by an absorption of part of the os sphenoides and of the os frontis; but the dura mater was not injured.

In Mr. Heaviside's museum is the skull of a woman who had a disease of the antrum, attended with a very great enlargement: in the course of the disease, an ossification in the substance of the tumour took place. Mr. Heaviside, who very kindly favoured me with drawings from which the Plate XXI. and Fig. 1, Plate XXII. were engraved, is not in possession of any accurate history of the case. It occupied, in its progress, about five years. When it had existed about four years, matter began to form under the skin of the face, which, ulcerating, was attended with a great discharge, under which the patient finally sunk.

A few years since I had the opportunity of observing the progress of an antrum case, in a respectable gentleman, Mr. W. The disease first exhibited itself as a tumour above the molares, occasioning a slight prominence of the cheek. By the direction of Mr. Cline, about once a fortnight I made an incision with a lancet into the tumour, which being attended with a considera-



ble hemorrhage, greatly diminished the tension which arose from the fulness of the vessels.

As the tumour increased, an absorption of the maxillary bone took place, together with the fangs of the teeth,\* which becoming loose, were extracted. At length the tumour became so enlarged as nearly to fill the mouth, and by its projecting of the cheek, greatly deformed the countenance. By adhering to the occasional use of the lancet, the disease was retarded in its progress for about five years, when ulceration commenced, by the distressing effects of which the life of the sufferer was terminated in a few months.

Mr. Cooper is in possession of a remarkable case of ossification from both antra: a tumour projected from each antrum, which, by their gradual enlargement, effected such a change in the structure of the orbits, that the eyes considerably projected; at length the ossification proceeded upwards, and produced so much pressure upon the brain as to be the cause of the death of the patient.

[The character which the disease assumes is doubtless always determined by the state of the general system, but whatever may be the particular tendency of this, it would probably never manifest itself in disease here, were it not for local irritation, and there is no source of irritation to which this cavity is so much exposed as that which arises from an unhealthy condition of the teeth, gums and alveolar processes. Therefore, where a morbid condition of these organs or the parts with which they are connected, are the suspected cause of disease in this cavity, the treatment should be first directed to the mouth. If any of the teeth in the upper jaw beneath the affected sinus are carious, or in any way productive of irritation to the alveolar membranes, they

\* Plate XVII. Fig. 17.



should be removed at once, and such other treatment afterwards instituted as the nature of the case may indicate.

Disease of this cavity should never be neglected, as it is impossible to determine the character which it may assume, until it has made considerable progress, and involved to some extent, at least, the surrounding structures, when, if it has not taken on a malignant or dangerous form, its cure will be more difficult and tedious. When taken in the incipient stage, almost every form of disease to which the maxillary sinus is subject, may, in the majority of cases, be easily cured. But there are some which, if permitted to continue until the neighbouring parts have become involved, bid defiance to the skill both of the medical and surgical practitioner.

Inflammation of the pituitary or lining membrane, is the simplest and most common form of disease to which the antrum is liable, and often subsides spontaneously, but when it continues for a long time, it not unfrequently becomes chronic, giving rise to other and often more aggravated affections. Among the most common of these is a purulent condition and accumulation of its fluids, and sometimes ulceration of the lining membrane, caries of its osseous parieties, fungous and other varieties of tumour.

The symptoms indicative of inflammation of the lining membrane, is often similar to those of some forms of tooth-ache. For the most part, they consist of a fixed and deep-seated pain in the substance of the maxillary bone, under the cheek, extending from the alveolar ridge to the orbit. This is sometimes very severe and lancinating; at other times it is dull and heavy. A purulent condition of the secretions of this cavity, is sometimes indicated by the escape of offensive matter from the nostril of the affected side when the patient inclines his



head to the opposite side. Engorgement may generally be suspected from the formation of a soft tumour on the cheek accompanied by a sense of fulness, weight, redness and tumefaction of the integuments covering the antrum. The tumour generally first makes its appearance below the molar bone, this being the point which generally but not always first gives way.

The symptoms of abscess are very similar to tooth-ache, and ulceration of the lining membrane, is usually accompanied with constant pain, and when the patient inclines his head to the opposite side, an occasional escape of fetid matter through the nasal opening, which sometimes has flocculi mixed with it. These not unfrequently choke up the natural opening and cause an accumulation of the matter and a consequent distension of the walls of the cavity. If the ulcer be of a fungous nature, the matter will be mixed with blood and of a dark brown or blackish colour. If it be of a cancerous character, the pain will be sharp and lancinating and the matter serous, very offensive, and streaked with blood.

Caries and necrosis may be detected by perforating the cavity and exposing the diseased bone. When it occurs in the alveolar ridge, the gums assume a livid appearance, and separate from the alveoli and slough. Tumours of the maxillary sinus, cannot be prognosticated during their early stage. It is not until after they have attained sufficient size to distend the cheek or depress the roof of the mouth, that their existence can be ascertained.

But we will not enlarge upon the subject. For a fuller and more detailed description of the diseases of this cavity and their treatment, the reader is referred to Part Third, of the editor's "Principles and Practice of Dental Surgery."]

## CHAPTER NINETEENTH.

### OF LUXATION OF THE LOWER JAW.

WHEN I commenced the present work, I had no intention of introducing this subject, as it was then one upon which I had not had any experience; but, having since had an opportunity of attending a case, I think there is a propriety in making some remarks upon this very disagreeable accident. The object I have chiefly in view, is to take notice of a mode of reduction, which, although it has been long recommended, is not sufficiently known; but which is much more expeditious, and less painful to the patient than the one commonly adopted.

The structure of the articulation of the lower jaw, and the nature of its dislocation, have been treated with great minuteness, by several distinguished anatomists. Dr. Monro's excellent dissertation, first inserted in the Edinburgh Medical Essays, and afterwards published in the complete edition of his works, is not only comprehensive in its anatomical description, but contains the most accurate rules for the reduction.

The condyloid processes of the lower jaw are connected with those parts of the temporal bones which are situated just under the beginning of the zygomatic arch, and before the meatus auditorius externus. In this part of each of the temporal bones, there is a cavity adapted for the reception of the condyles, and a tubercle, or



eminence, which, with the cavity, forms the articulatory surface.\* The condyles of the jaw, and the cavities and eminences of the temporal bones, are covered with a smooth cartilage; there is also interposed between the condyles and the temporal bones a cartilage, which is movable, and which contributes greatly to the steadiness of the jaw in all its motions. These parts are united by a ligament, which rises from the circumference of the articulatory surface of the temporal bone, is attached to the edge of the movable cartilage, and then surrounds the condyle of the jaw, and is inserted into the neck of that bone.†

The structure of this joint is admirably adapted to the necessity which exists for a great variety of motions, combined with strength of action; it is peculiar to the human subject; all animals possess the movable cartilage, as it is of essential service in diminishing the effects of friction. Graminivorous animals, which require an apparatus suited to the grinding and minutely dividing of their food, possess considerable lateral motion of the jaw, whereby they can move it from side to side, as in chewing the cud; and they reduce their food to an impalpable mass. For this purpose the articulatory surfaces on the temporal bones are very large, and permit the condyles of the jaw to perform the necessary lateral motion. Carnivorous animals, which only tear or cut their food, and require no grinding, have their jaw confined to the simple hinge-formed joint, and therefore possess only the power of depressing and elevating the jaw.

Man, being an inhabitant of every clime, is provided with digestive organs suited to every kind of food; the articulation of his jaw, therefore partakes of the structure both of the graminivorous and carnivorous animal: it can

\* Plate XXVI. Fig. 4.

† Fig. 3.

perform lateral motion, and be confined to mere elevation and depression.

When the mouth is closed, the condyles of the jaw are placed back in the cavities; when the jaw is brought horizontally forwards, the condyles slide forward upon the eminences: this action may be performed by the condyles alternately, one being brought forward and the other held back, so that the jaw may be turned from side to side, as in the action of grinding. In opening the mouth, the condyles slide forward upon the eminences; when it is required to open it very wide, the condyles are brought forward to the extremity of the articulatory surface, and rise a little, by passing over the convexity. In all these motions of the jaw, the movable cartilage is of very great service: it is doubly concave, and, by adapting itself to the rounded head of the condyle, and that part of the articulatory surface which forms the eminence, it gives steadiness to the jaw in all its motions; without this cartilage, the jaw would have been very liable to accident. As convex surfaces can only touch at one point, the condyles would have been liable to slip back into the cavity, or too much forward and cause a dislocation.

The motion of the lower jaw is produced by five pairs of muscles; these are, the masseter, temporalis, pterygoidæus externus, pterygoidæus internus, and digastricus. The masseter, temporalis, and pterygoidæus internus, act in raising the jaw, and in bringing it back. The pterygoidæi externi act in bringing the jaw forward; when one only of these muscles acts, a lateral motion is produced, one condyle is brought forward, while the other is kept back; this alternate action of the muscles causes the jaw to be moved from side to side, and produces the



action of grinding. The digastric muscles are employed to depress the jaw.

The luxation of the jaw is commonly occasioned by an excessive opening of the mouth; as in yawning, or from a spasmodic action of the muscles affecting them at the time of opening the mouth. When the jaw is luxated, it remains wide open, and the patient cannot shut it by any muscular exertion. The nature of this accident will be made very plain, by observing that, when the jaw is luxated, the condyles are advanced so much upon the anterior part of the eminence, that they quit the proper place of their articulation; the muscles then cannot draw the jaw back on account of the posterior edges of the condyloid processes being fixed against that part of the eminence where it goes to form the zygomatic process.\*

A person, to whom this accident has once happened, is liable to a recurrence, whenever the mouth is opened very widely; a circumstance which renders the caution necessary, of supporting the jaw, in order to prevent too great an extension in yawning, &c. On this account also, those who have been subject to luxation of the jaw are in danger, if under the necessity of submitting to the extraction of a tooth, as at this time the mouth must be opened widely, and the muscles are then liable to be spasmodically affected.

The mode of reduction that has been commonly recommended is, to wrap linen about the two thumbs, which are to be introduced between the posterior molares; the base of the jaw is to be held firmly by the fingers, and the palms of the hands are to be applied to the chin. The extension is made by pressing the jaw down at the posterior part with the thumbs, when also it may be pulled a little forward by the fingers: at this time, if the

\* Plate XXVI. Fig. 2.



muscles appear to yield, the chin is to be raised by pressing it upwards with the palms, when the condyles become disengaged from the zygoma, and they slide backward into their proper situation.

Dr. Monro observes, "that when the thumbs have not force enough to make this reduction, his friend Dr. Simpson, professor of medicine at St. Andrew's, makes use of a round piece of wood, eight or nine inches long, one end of which is cut into the form of a wedge, to introduce it between the teeth of the luxated side, with the thinnest part, as far back as the posterior grinders: when, having the head secured, and raising the chin, he pushes the other end of the wood upwards, to depress the back part of the jaw with the thin end, by which the force is much greater than the thumbs can exert."

It was in attempting to extract a tooth that I had an opportunity of attending to this accident. Last summer, in passing through Dorchester, I called to see a gentleman, who, after the customary salutations, informed me there was a lady of his acquaintance who wished to have a tooth extracted, and was at that instant upon the point of going to Weymouth, to consult a dentist from London, who was on a visit there. He immediately introduced me to her. I found that this lady had several times been the subject of luxation of the jaw, and she was in fear lest that accident should again be occasioned by the operation. The tooth she wished to be extracted was one of the *dentes sapientiæ* of the lower jaw. I consented to attempt the operation, but wished that Mr. Arden, the surgeon, who had reduced her jaw two or three times before, should be present. I had scarcely fixed the instrument upon the tooth, when, by a spasmodic action of the muscles, the jaw slipt forward, and became luxated. Attempts were immediately made, first by Mr. Arden,



and then by myself, to reduce the jaw by the usual method of pressing down the back part of the jaw with the thumbs, and raising the chin with the palms of the hands: but neither of us could succeed, although very considerable efforts were made. I then happened to recollect a statement once made to me by M. de Chemant, of his having been frequently applied to by a person at Paris, who was subject to this accident, and that he always succeeded in reducing the luxation immediately, by making use of a lever of wood, as recommended by Dr. Monro. I then inquired for a piece of wood, which I could employ in this way, and was so fortunate as to be furnished with a piece of about an inch square, and ten or twelve inches long, which was used as a flat ruler. I introduced this into the mouth, so that the extremity lay upon the under molares, and then, by raising the other end with my hand, the teeth in the upper jaw became the fulcrum. The jaw on that side was then depressed at the posterior part, when the condyle immediately passed over the edge of the eminence. I then applied the lever to the other side of the jaw, and disengaged that in like manner, when the muscles instantly drew the jaw back into its proper situation.

The quickness with which the reduction was performed, by this means, gave great pleasure, as the lady had sometimes been a very long time before reduction in the common mode could be effected. Once, when at a distance from home, this accident happened to her, and she was nearly two hours submitting to attempts, before reduction could be effected.

In addition to this case, I have been informed by Mr. Heaviside, that he was lately sent for to reduce a luxation of the jaw, which had occurred to a lady, from merely opening her mouth widely, to have her teeth scaled.

To prevent this accident from happening in the extraction of a tooth, to persons who have previously been subject to a luxation of the jaw, I have contrived a bandage, which will insure the safety of the patient during the operation. This bandage consists of a piece of leather, formed so as to receive the chin, and a strong cap, that may be placed upon the top of the head, which are connected by two straps on each side: it is to be fixed when the mouth is opened to a certain degree, with the condyles as far back as possible: the cap is then to be put on the posterior part of the crown of the head, and the leather being applied to the chin, the straps are to be buckled tight, when it will not be possible, by any effort, to advance the jaw so much as to endanger its luxation, and the tooth may be extracted with safety.\*

\* Plate XXVI. Fig. 5.





EXPLANATION OF PLATES


TO

PART SECOND.

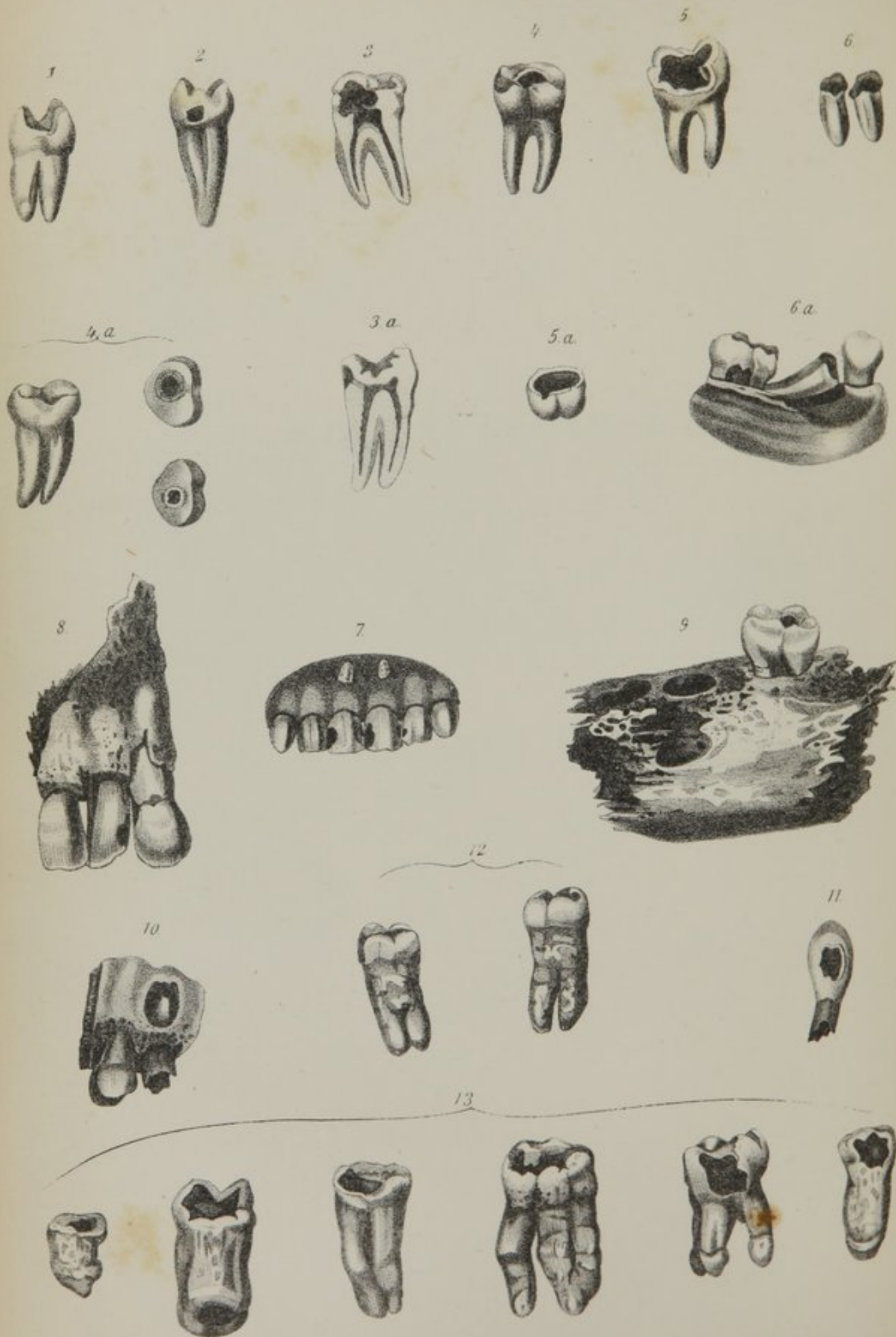


EXPLANATION OF PLATES

PART SECOND.







## PLATE XVI.

**FIGS. 1, 2, 3, 4, 5, 6.** Represent the progress of caries.

On the side of Fig. 1, is a dark appearance, resembling an opaque spot upon the enamel: in Fig. 2, the caries has produced a cavity: Fig. 3, is the section of a molaris, to show that the caries proceeds to the natural cavity in the tooth: Fig. 4, a molaris with caries in the centre: Fig. 5, the decay much increased: and Fig. 6, the whole of the crown being removed, the fangs only are left.

**FIG. 3 a.** The section of a molaris, in which there was a superficial decay; a dark mark is seen extending from the caries to the cavity in the tooth, showing the direction of the death of the bone of the tooth.

**FIG. 4 a.** A molaris apparently quite sound; but, on being sawn into, a considerable caries was formed in the body of the tooth.


**FIG. 5 a.** The enamel of a molaris which separated from the tooth, in consequence of the bony part being destroyed by caries.

**FIG. 6 a.** A stump protruded by the closing of the socket, until it was held only by the gum.

**FIG. 7.** The incisores of a child decayed, the points of the fangs ulcerated through the gums.

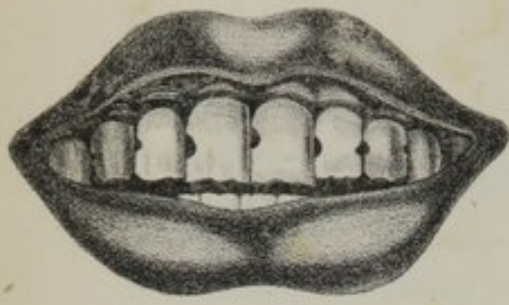


- FIG. 8. An exfoliation from the upper jaw, containing two incisores and a cuspidatus: the disease was caused by the inflammation attendant on the decay in the lateral incisor.
- FIG. 9. An exfoliation from the under jaw, from the effects of caries in a molaris.
- FIG. 10. The effects of an abscess at the point of a stump. A considerable portion of the alveolar process is absorbed.
- FIG. 11. The point of a stump with a membranous bag attached to it, in which matter was contained.
- FIG. 12. Two molares extracted on account of exostosis of the fangs.
- FIG. 13. Examples of exostosis of the fangs in several teeth.

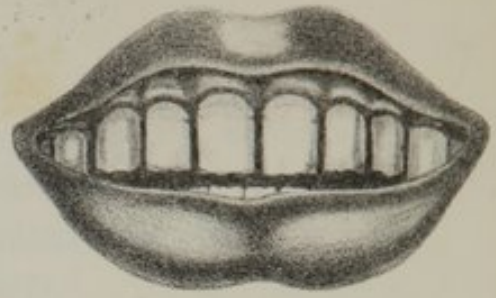




1

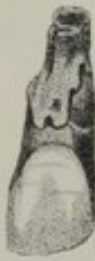

2



6

7



8



9



10



11



12



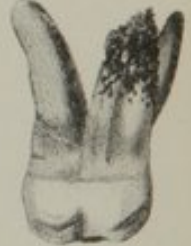13



14



15



16



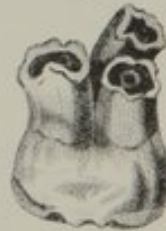17



18



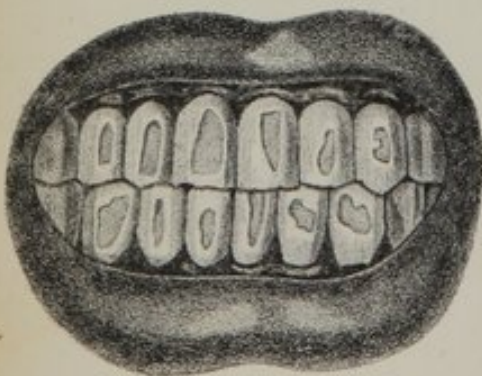
17



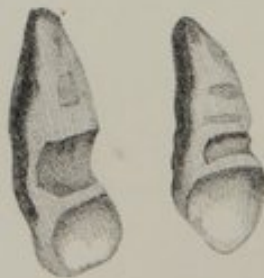19



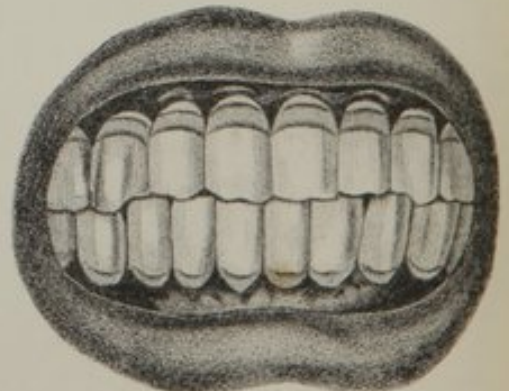
3



5



4



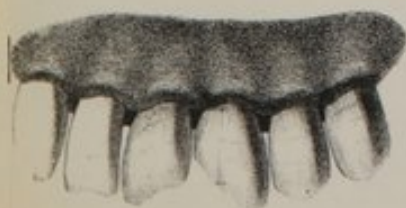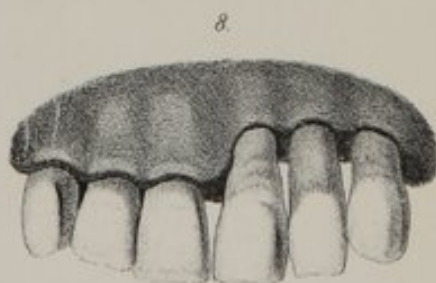
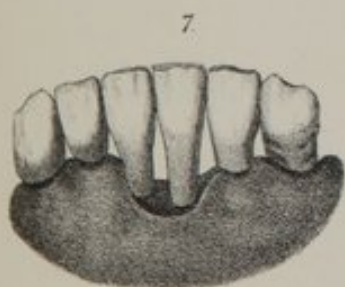
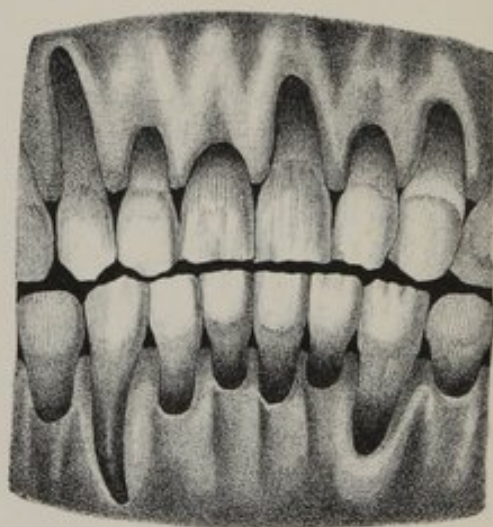
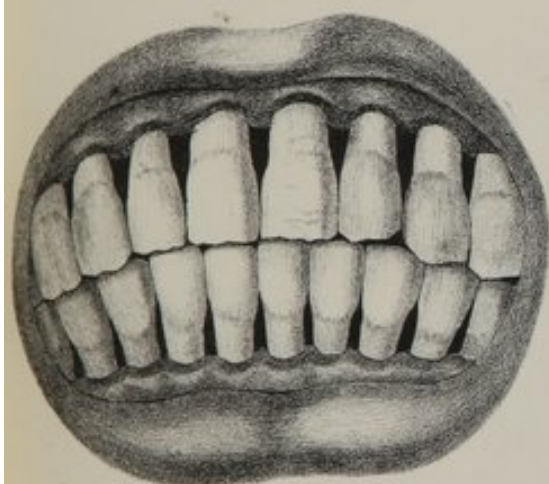
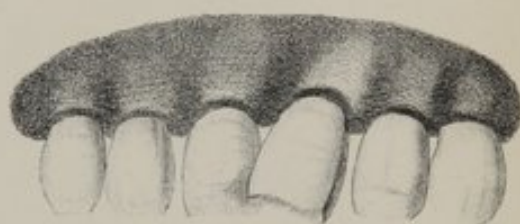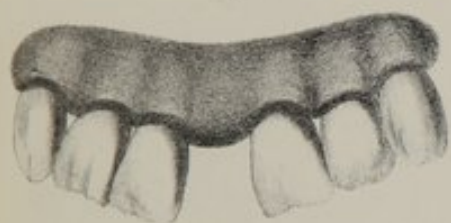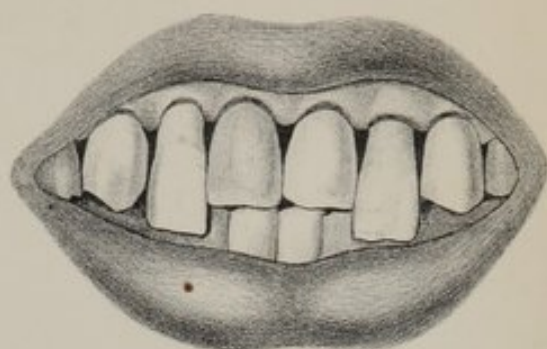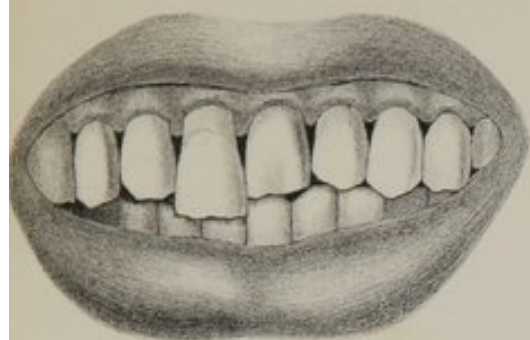
## PLATE XVII.

- FIG. 1. Caries on the sides of the incisores.
- FIG. 2. Represents the teeth with the caries filed out.
- FIG. 3. The appearance of the teeth when denuded of the enamel.
- FIG. 4. A deep notch formed at the necks of the teeth by the denuding process.
- FIG. 5. Two cuspidati, with deep notches, from the same cause.
- FIG. 6. Examples of diseases in the fang, resembling spina ventosa.
- FIGS. 7, 8, 9, 10, 11, 12, 13, 14, 15, 16. Diseases of the fang, resembling necrosis in bones.
- FIGS. 17, 17. Two molares, the fangs of which were absorbed in consequence of a tumour formed in the antrum.
- FIG. 18. A tooth which had been transplanted, the fang of which was absorbed in a most curious manner.
- FIG. 19. Two incisores of the under jaw, the fangs of which were absorbed, in consequence of disease in the socket.





## PLATE XVIII.

- FIG. 1. A central incisor protruded by the closing of the socket at the extremity of the fang.
- FIG. 2. The two lateral incisores protruded from the same cause.
- FIG. 3. A great separation of the central incisores from an exostosis of the transverse alveolar process.
- FIG. 4. Irregularity of the teeth arising from disease of the sockets.
- FIG. 5. The appearance of the teeth under absorption of the gums and alveolar processes.
- FIG. 6. Absorption of the gums and sockets, leaving the fangs of the teeth uncovered and black.
- FIG. 7. Absorption of the gums and sockets of two teeth in the under jaw.
- FIG. 8. The same disease in the gums and sockets of three teeth in the upper jaw.
- FIG. 9. Two teeth fractured at the points; the fracture not having extended into the cavities, the dotted lines show how much may be filed off to make them even.
- FIG. 10. Two teeth fractured by a blow; the cavities in each were exposed, and caused great inflammation; *a.....* points to the cavities.
- FIG. 11. Two central incisores fractured by a blow; the remainder of the crowns were filed off, and the teeth pivoted to the fangs.

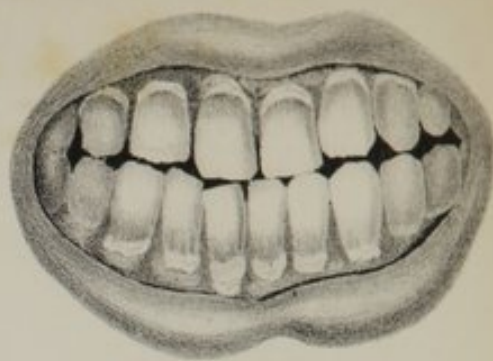

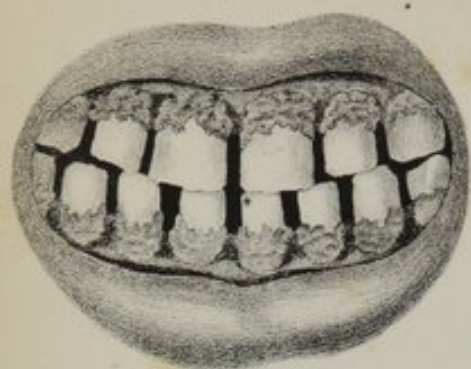





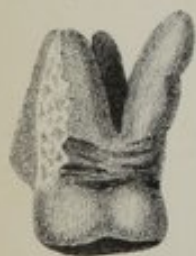






8

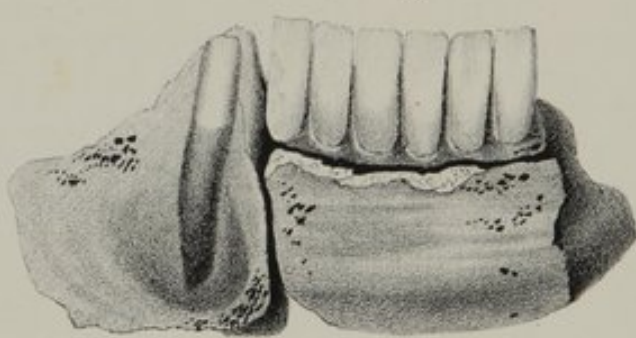
4



5



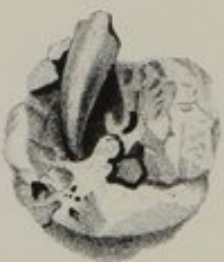6



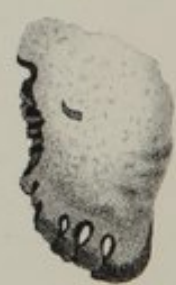7



11



12



13



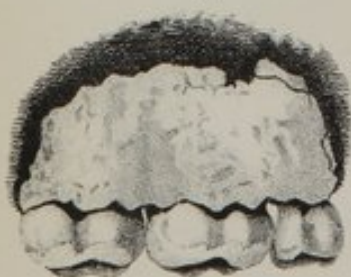9



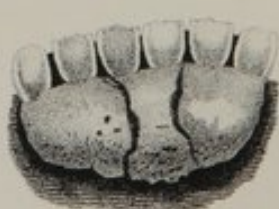10



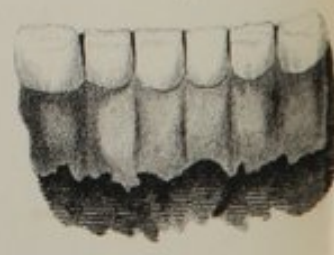
14



15



16



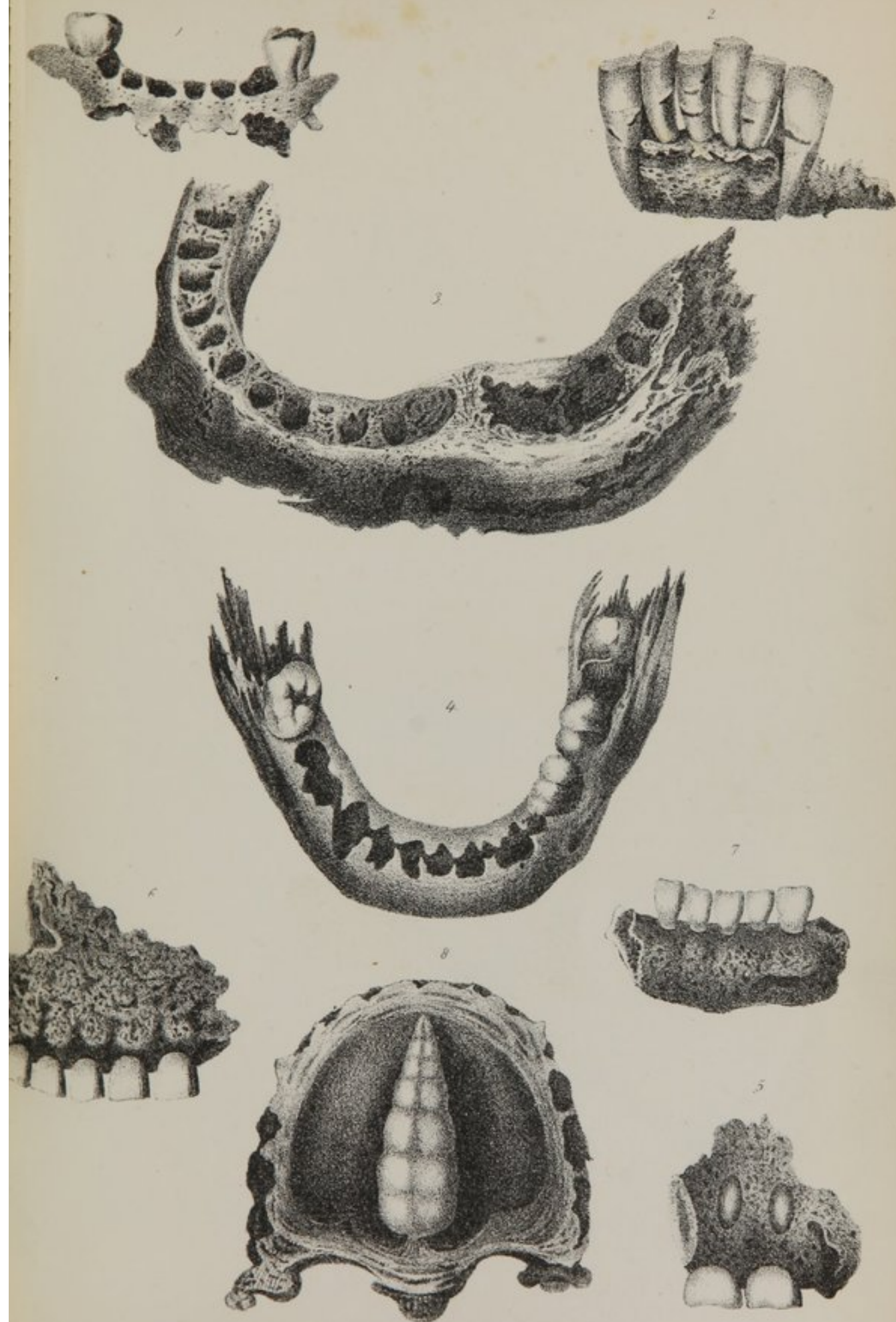
## PLATE XIX.

- FIG. 1. Black, hard tartar, collected about the necks of the teeth.
- FIG. 2. Represents the yellowish coloured tartar, and the teeth much stained.
- FIG. 3. The manner in which the progressive accumulation of tartar causes the loss of teeth.
- FIGS. 4, 5, 7, 8, 9, 10, 11, 12, 13. Examples of considerable accumulation of tartar about different teeth.
- FIG. 6. A piece containing six artificial teeth, about which a most prodigious quantity of tartar was suffered to accumulate, also a large mass about the cuspidatus; the whole, when quite dry, weighed three drachms and a half.
- FIG. 14. A large accumulation on the side of the molares.
- FIG. 15. A large quantity collected on the posterior surface of the under incisores.
- FIG. 16. A similar accumulation on the anterior surface of the incisores.

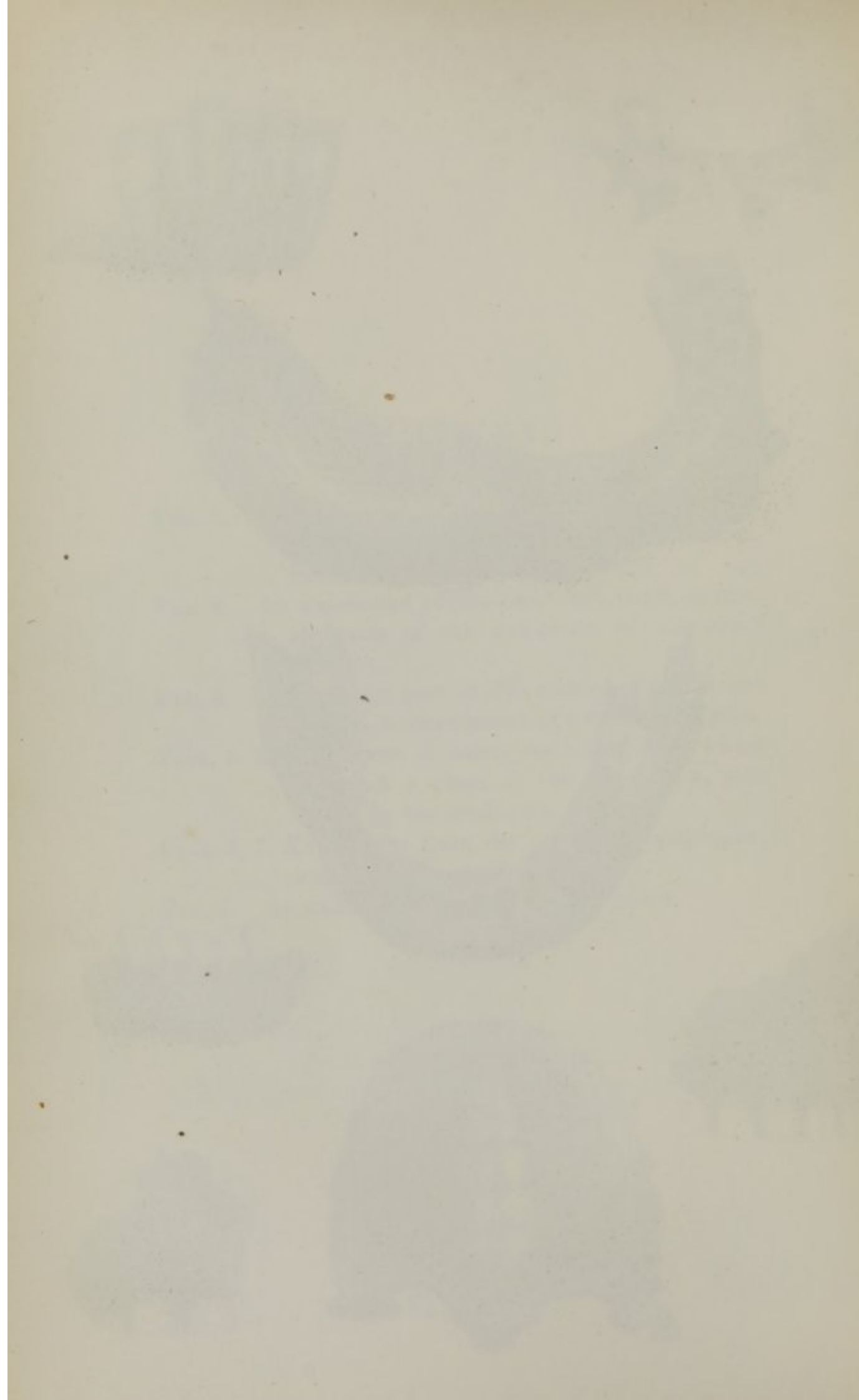



## PLATE XX.

- FIG. 1.** An exfoliation of the alveolar processes of the temporary teeth, proceeding from a scrofulous disease in the gums.
- FIG. 2.** An exfoliation of jaw-bone and teeth, in consequence of the exhibition of too much mercury.
- FIG. 3.** The greater part of the under jaw, which exfoliated in consequence of a violent salivation.
- FIGS. 4, 5.** Exfoliations of nearly the whole of the under jaw, and a piece of the upper jaw, produced by the small-pox.
- FIGS. 6, 7.** Exfoliations from the upper and under jaw, caused by the small-pox.
- FIG. 8.** An exostosis of the bones of the palate.

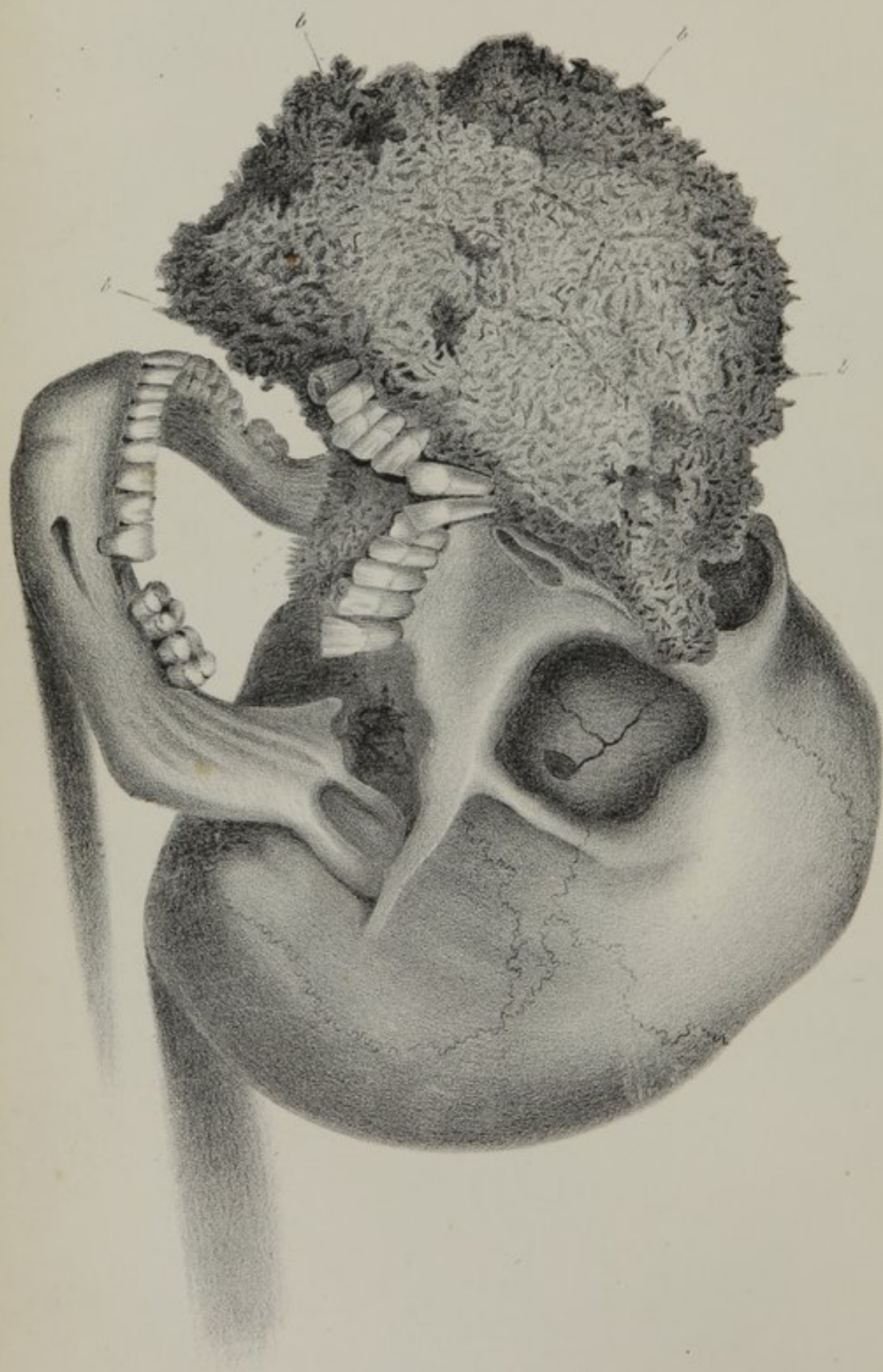












## PLATE XXI.

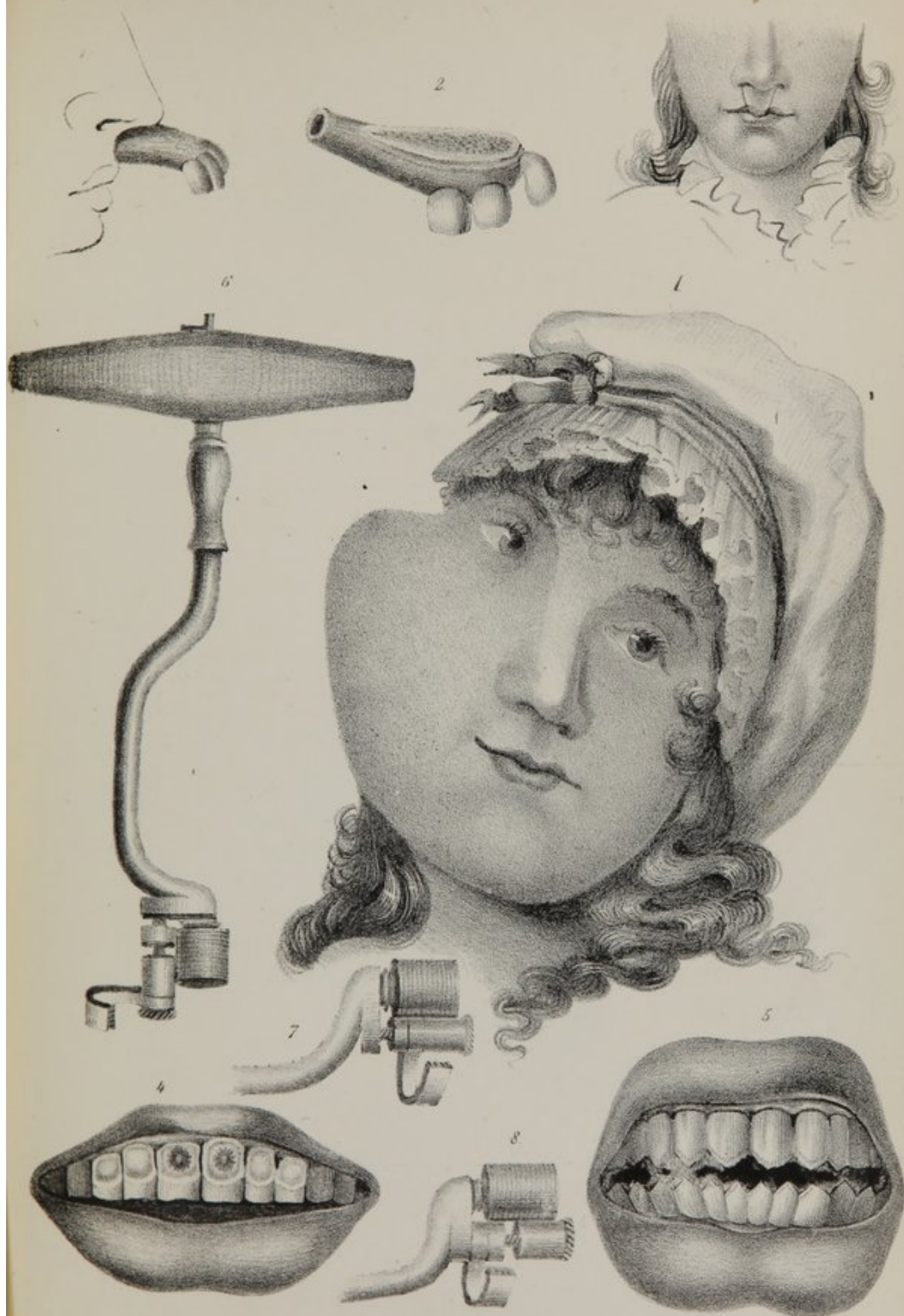
The skull of a female who had a disease of the antrum, which produced an ossific tumour, in the possession of John Heaviside, Esq.

- a.* The cartilage of the nose unaffected by the disease.
- b b b b b.* The extent of the bony tumour.
- c.* The bony matter that filled up the roof of the mouth.
- d d d d d d.* Several teeth pushed out of their proper situations; the sockets of which are greatly absorbed. The dark parts on the surface of the tumour are chasms made by the matter under the integuments.





## PLATE XXII.

- FIG. 1. The appearance of the face of the person who was the subject of the antrum case, described in Plate XXI. before any ulceration took place.
- FIG. 1. The profile of the face of a young gentleman who had a distorted growth of the upper jaw, combined with harelip.
- FIG. 2. The piece of bone, with three teeth, which was sawn off.
- FIG. 3. The appearance of the face after the operation was completed.
- FIG. 4. Represents the teeth of a Malay Indian, which are filed on the anterior surface; the central incisors were filed so nearly into the cavities, as to be the cause of caries.
- FIG. 5. Represents the teeth of an Abyssinian Negro, filed into a pointed form.
- FIG. 6. The key instrument, having three places in which the claw may be fixed: in this figure, the claw is placed beyond the bolster.
- FIG. 7. The claw is placed in the usual position.
- FIG. 8. The claw is placed before the bolster.

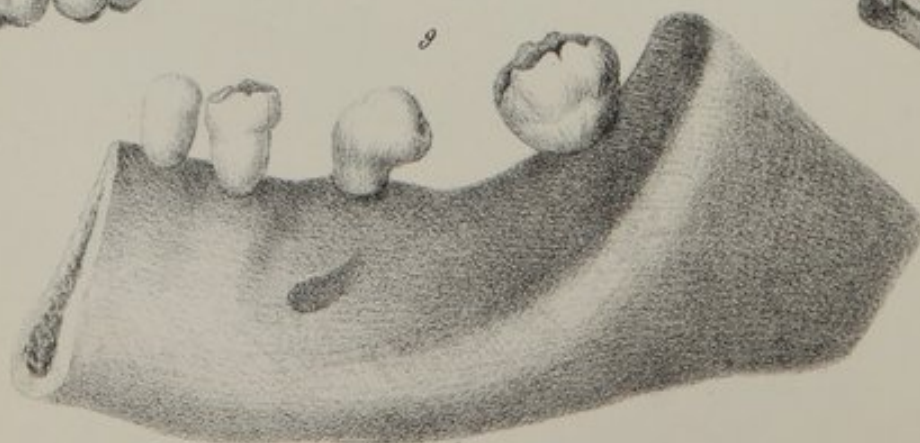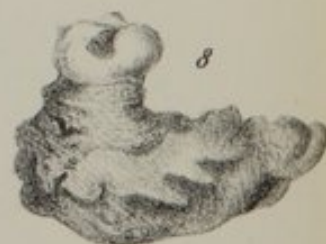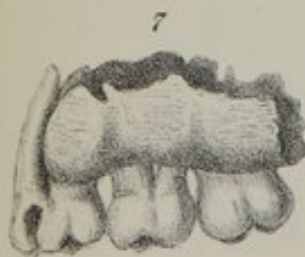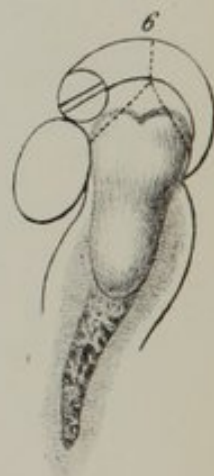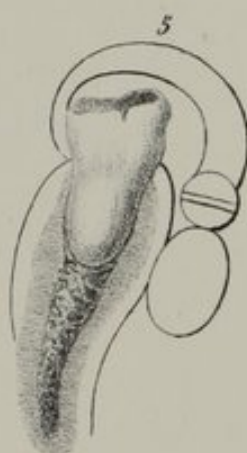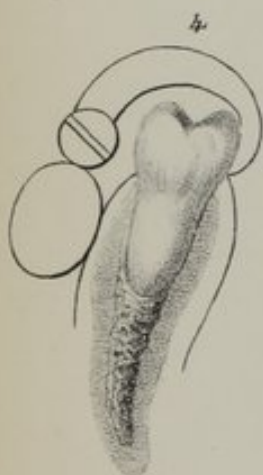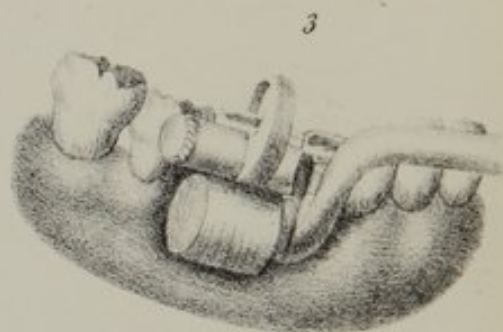
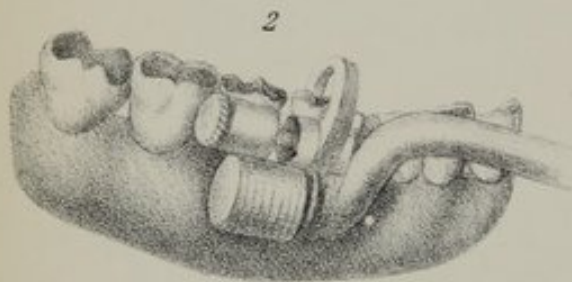






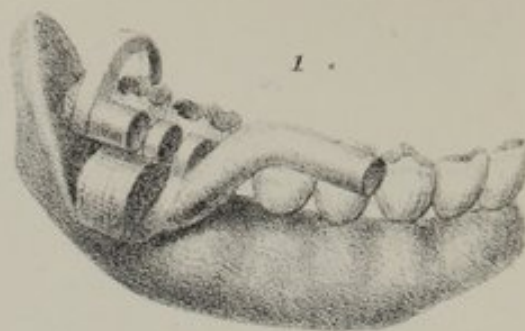





## PLATE XXIII.

- FIG. 1. The key instrument, with the claw beyond the bolster, and fixed as in the extraction of the dens sapientiæ in the lower jaw.
- FIG. 2. The key instrument, with the claw before the bolster, and fixed as in the extraction of a bicuspid in the lower jaw.
- FIG. 3. The key instrument, with the claw opposite to the bolster, and fixed as in the extraction of the molares.
- FIG. 4. The key instrument as fixed in the most proper manner.
- FIG. 5. Represents the possible consequence of using too large a claw, or of placing the bolster too low; the tooth is liable to be broken in the direction of the dotted line.
- FIG. 6. Represents the possible consequence of using too small a claw; the tooth is liable to be broken in the direction of the dotted line, across the neck of the tooth, or the claw will be broken in the centre of the curve.
- FIG. 7. The molares of the upper jaw, which were torn away by an improper mode of attempting to extract one which was decayed.
- FIG. 8. A dens sapientiæ, with a large piece of jaw-bone, broken away by an unskilful application of the instrument.
- FIG. 9. Represents the manner in which teeth incline towards each other, after an intermediate one has been extracted.

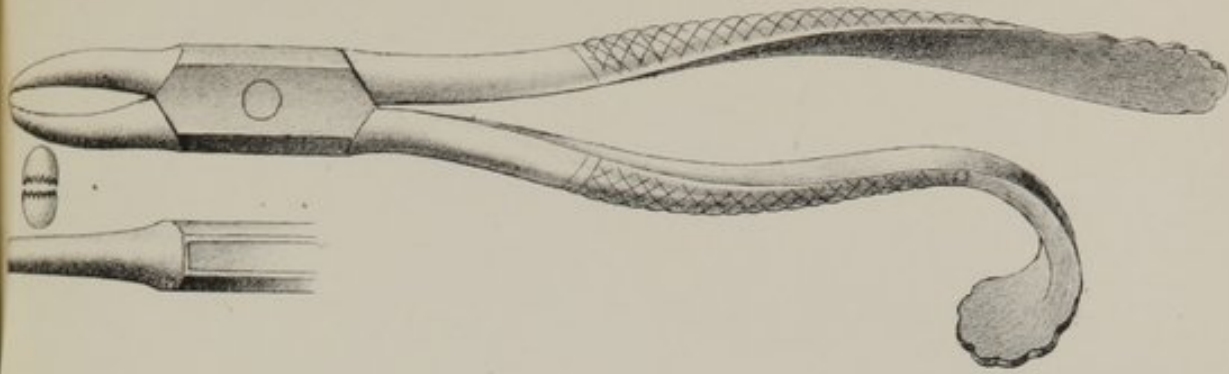


## PLATE XXIV.

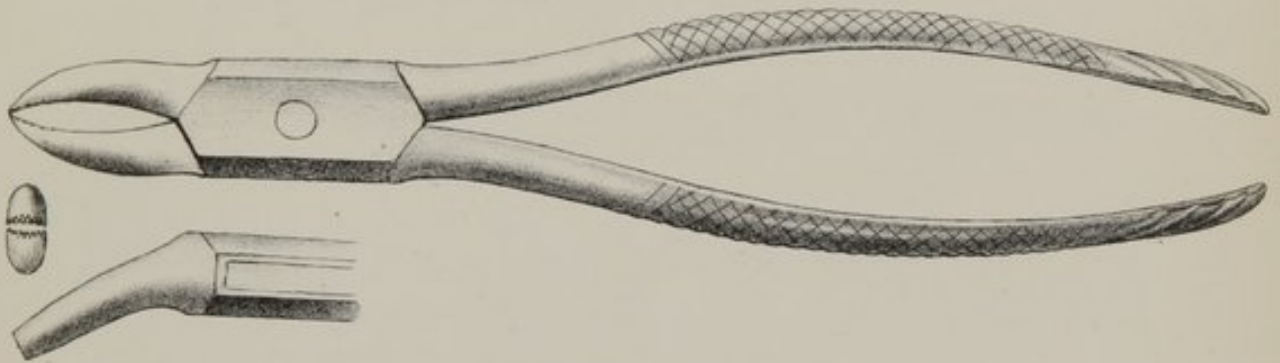
FORCEPS FOR THE EXTRACTION OF THE TEETH, AS IMPROVED  
BY THE EDITOR.

- FIG. 1. Straight forceps for the extraction of the superior incisores and cuspidati.
- FIG. 2. Forceps for the extraction of the bicuspidēs and dentes sapientiæ.
- FIG. 3. Dr. S. P. Hullihen's compound screw-forceps, for the extraction of the roots of the superior incisores and cuspidati.
- FIG. 4. Forceps for the extraction of the dentes sapientiæ of the upper jaw.

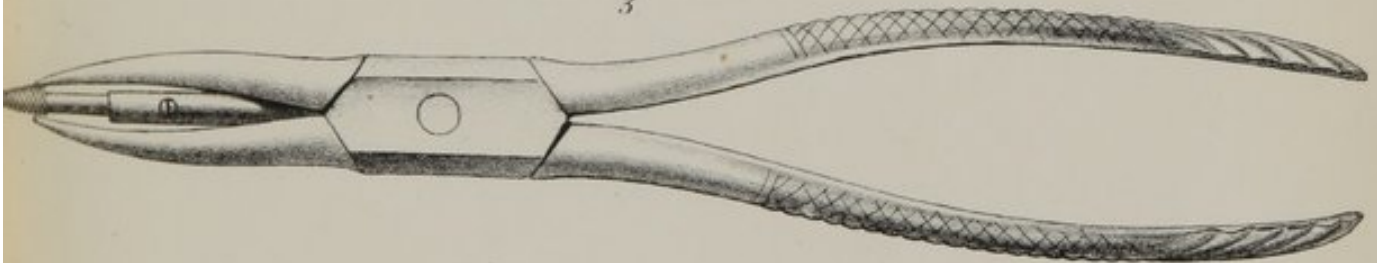
Fig. 1.



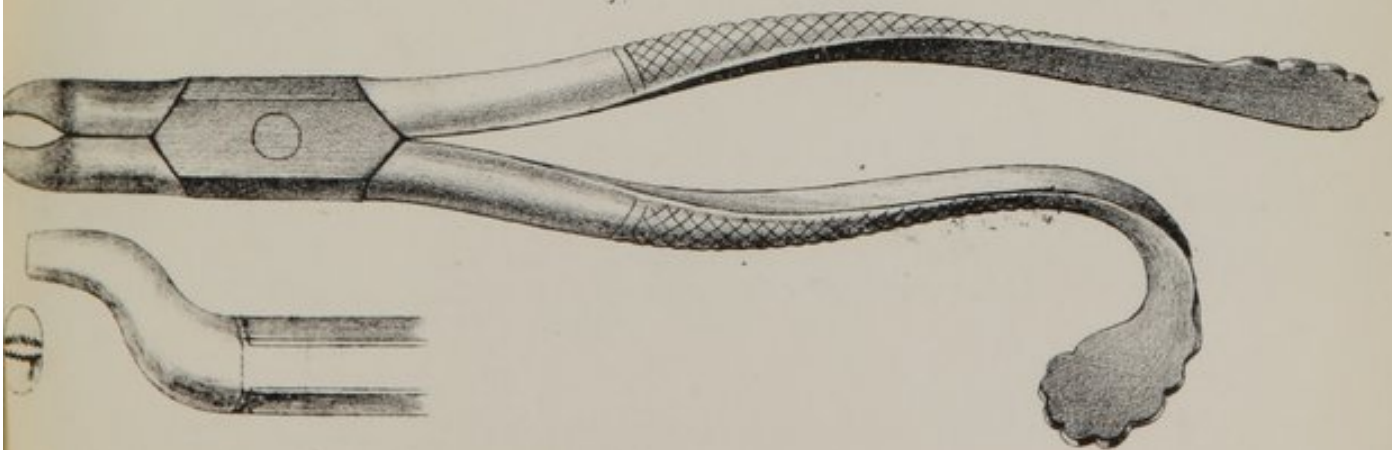
2




3



4








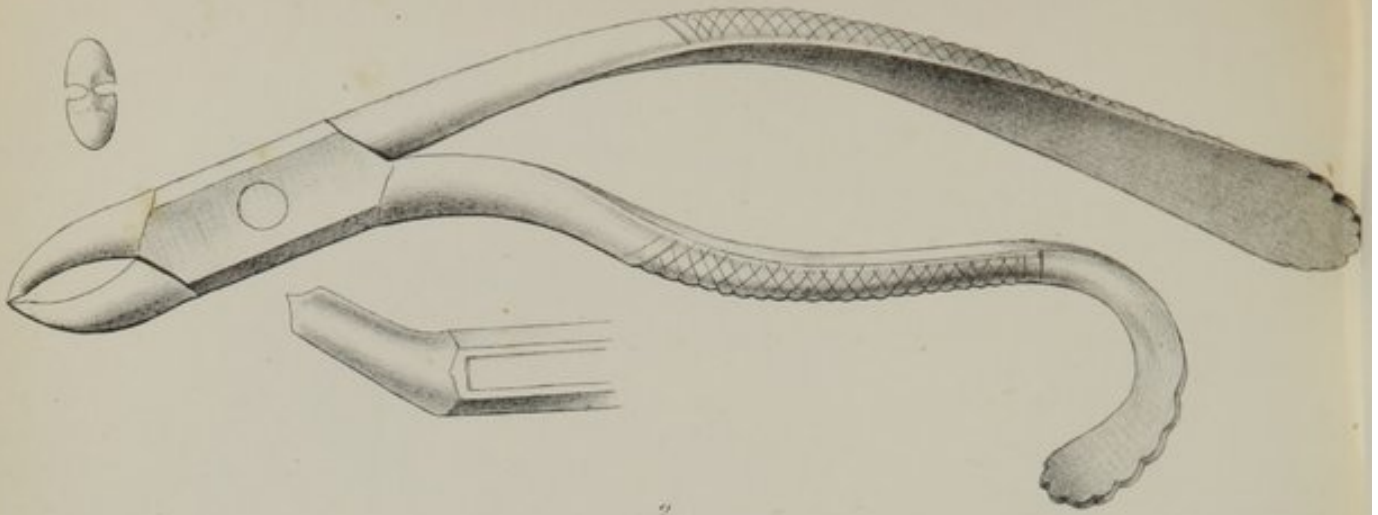
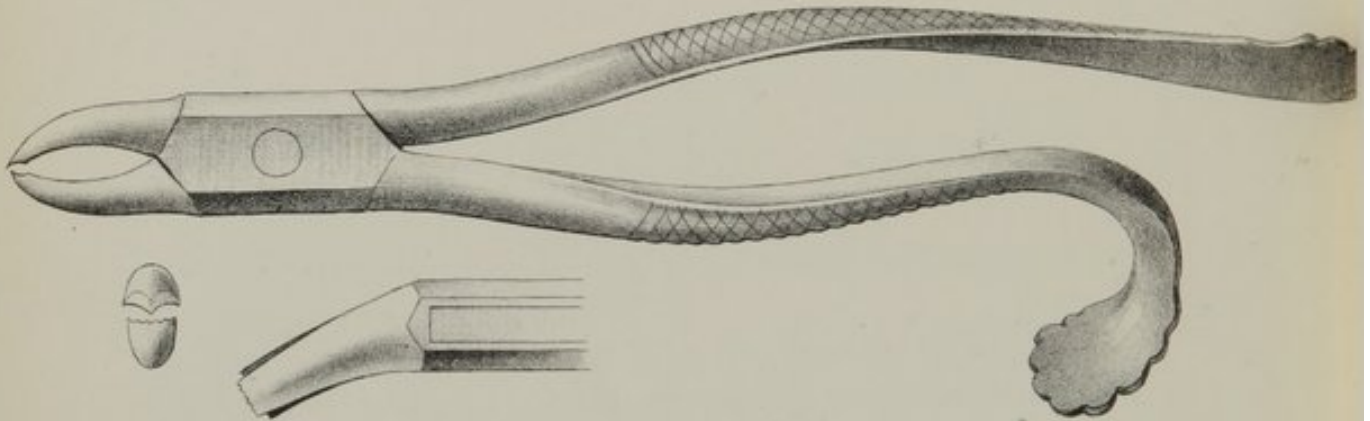




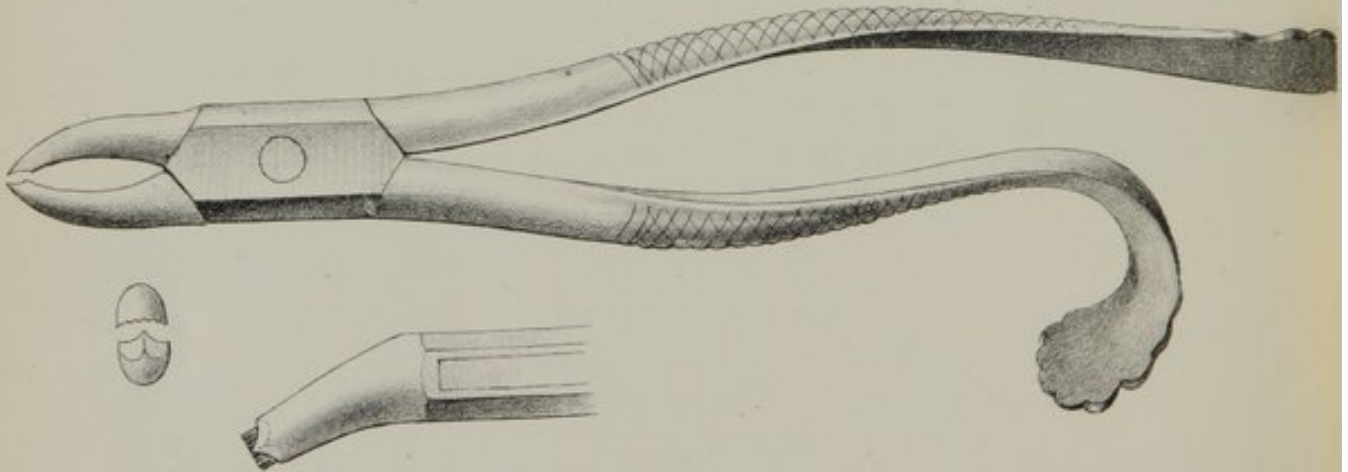
Fig. 1.



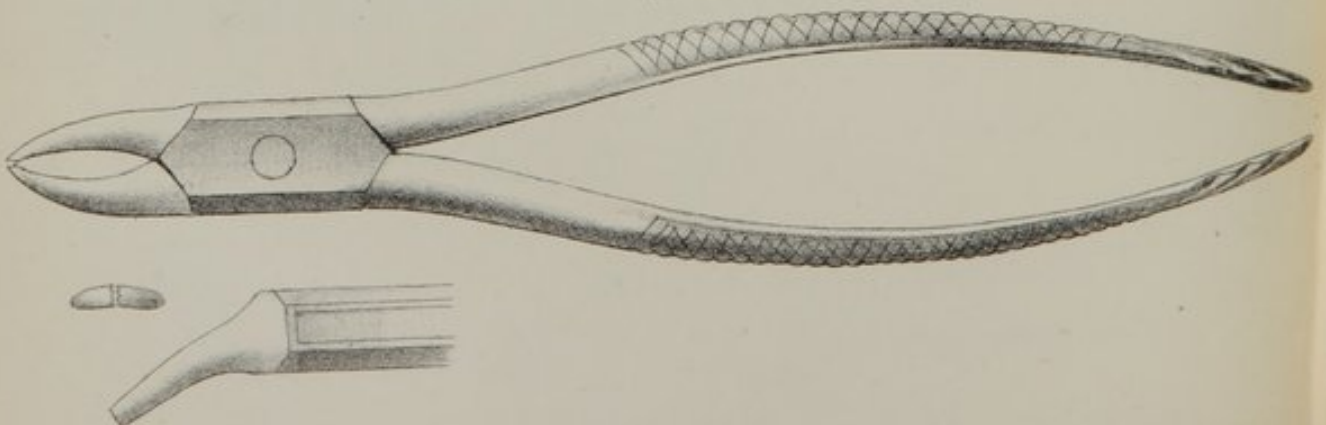
2.



3.



4.



## PLATE XXV.

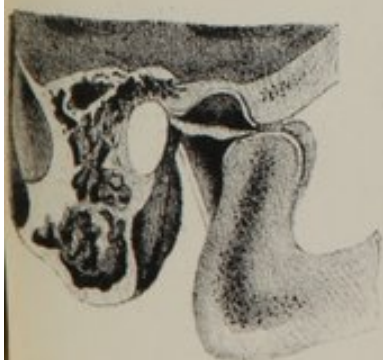
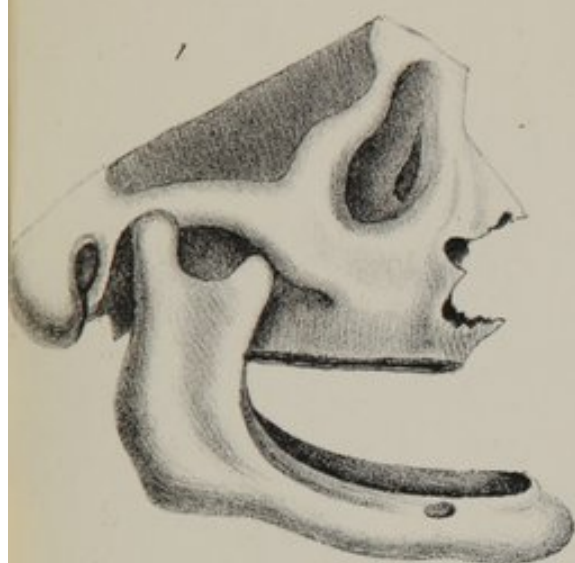
FORCEPS FOR THE EXTRACTION OF THE TEETH, AS IMPROVED  
BY THE EDITOR.

- FIG. 1.** Forceps for the extraction of the inferior molares. They will apply with equal facility to either side of the mouth.
- FIG. 2.** Forceps for the extraction of the right superior molares.
- FIG. 3.** Forceps for the extraction of the left superior molares.
- FIG. 4.** Forceps for the extraction of the roots of teeth and the lower incisores.




## PLATE XXVI.

- FIG. 1. The appearance of the jaw-bones when the whole of the alveolar processes have been absorbed.
- FIG. 2. The position of the lower jaw when luxated; the condyloid processes are advanced so much over the articulatory eminence, that it is prevented from returning, by resting against the lower part of the zygomatic arch.
- FIG. 3. A section of the temporal bone with the condyloid process of the lower jaw, representing the ligament and movable cartilage.
- FIG. 4. A section of the temporal bone and part of the lower jaw, representing the head of the condyloid process in the cavity; the articulatory eminence, or tubercle, being before the condyle.
- FIG. 5. Represents a mouth opened, and a bandage applied to keep the jaw back, and prevent luxation during the extraction of a tooth.

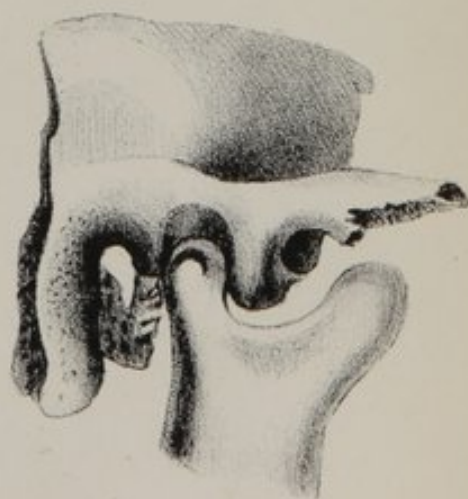

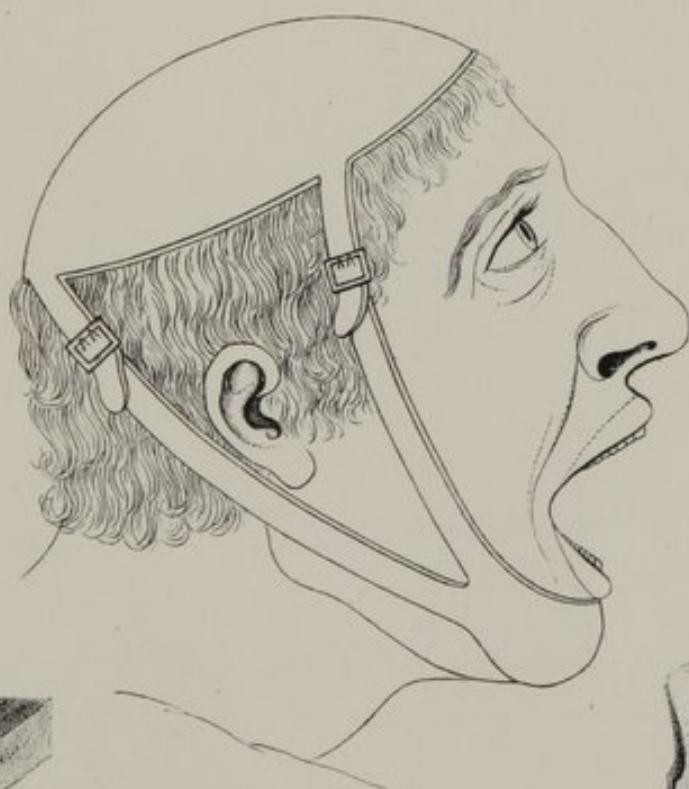
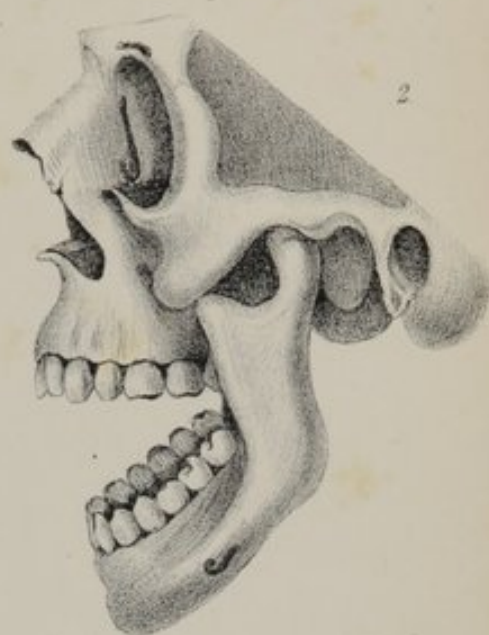







Fig. 1



Fig. 2

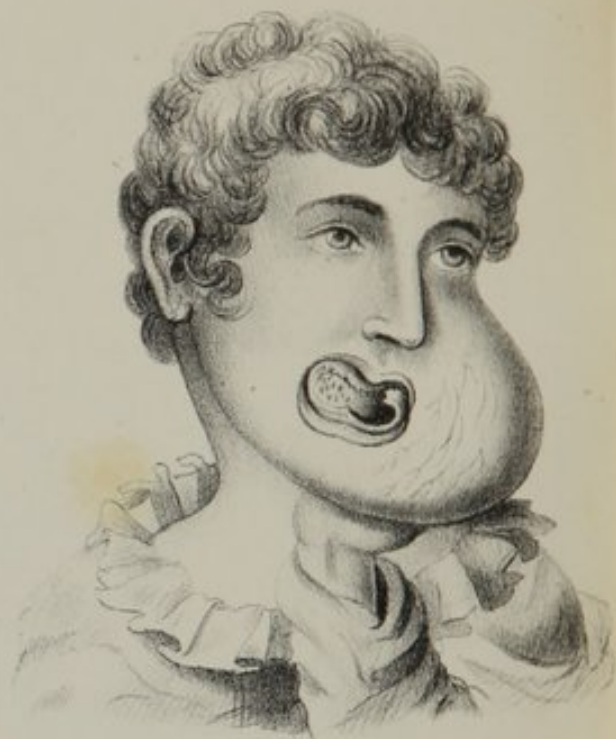

Fig. 3

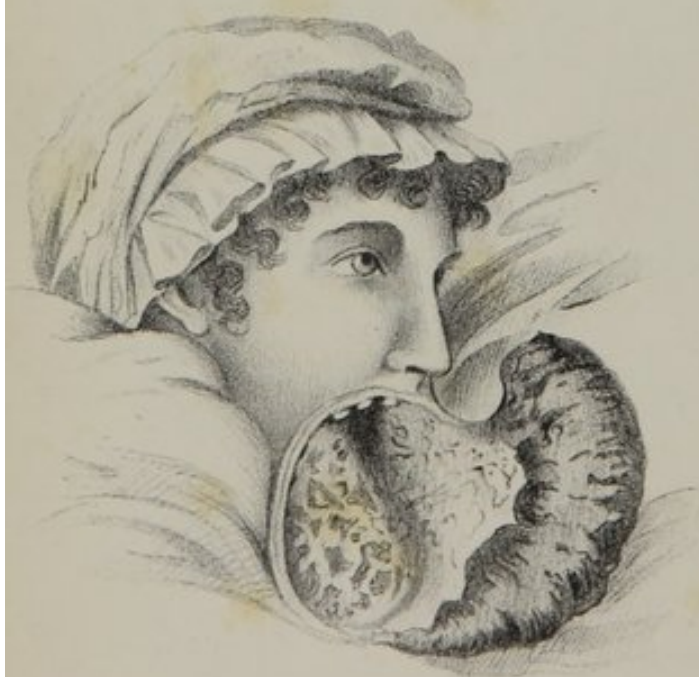
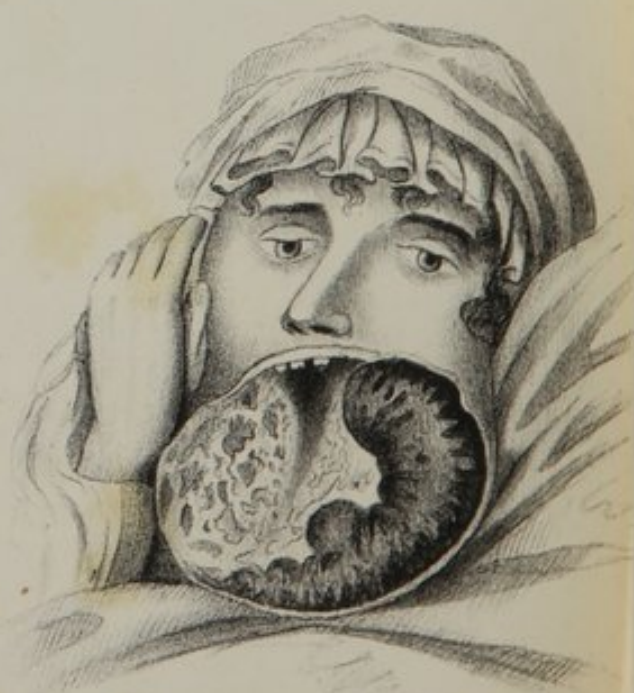
Fig. 4



## PLATE XXVII.

Represents the case of Sarah Dulwich.

FIG. 1. The appearance of her face when first admitted into Guy's Hospital.

FIG. 2. The appearance about two months after her admission, when the tumour began to protrude from the mouth, having the surface ulcerated.

FIGS. 3, 4. The appearance a short time before her decease, viewed laterally and in front.

\* \* The unfortunate sufferer was alive when the former account of her case, as before inserted, was in the press, rendering it impossible in the body of the work to detail all the particulars. The following account is taken from the notes of Mr. Astley Cooper, who possesses the preparation of this most extraordinary disease.

---

SARAH DULWICH, æt. 13, scrofulous constitution, was admitted into Guy's Hospital on April 8, 1812, with a large tumour under the left cheek, which first made its appearance twelve months previously, in the form of a small tumour of the gum upon the lower jaw, and at that time not painful.



At the time of her admission, the tumour occupied the whole of the left cheek; it was globular; it felt irregular under the integuments; it projected below the jaw, and extended from the cuspidatus of the lower jaw on the right side, irregularly under the tongue, which it had thrust close to the right cheek, and consequently rendering speech difficult and indistinct; internally its surface was irregular, hard, and unyielding; it was in a superficial state of ulceration from the pressure of the teeth of the upper jaw on the left side. For six months previously from its rising above the teeth of the lower jaw it prevented the approximation of the jaws, the lips remaining an inch and a half or two inches apart. The discharge from the ulcerated surface was sometimes bloody and offensive to the smell.

Upon viewing the tumour externally it reached from under the edge of the orbit, extending by the side, and pushing up the left nostril, and around to the ear, forming an immense extended tumour even down to the fore part of the chin; it was at least half the size of the head, the skin in some places had a slight blush on it, and here and there the veins were seen of considerable size running over its surface.

Deglutition was extremely difficult and painful in consequence of the pressure of the tumour against the teeth of the upper jaw.

Half the upper jaw, together with the teeth, from the pressure of the tumour, were pushed towards the opposite side.

The only cause she can assign for the disease is, that she was subject to constant tooth-ache in the two molar teeth of the lower jaw, for two or three months previous to the appearance of the tumour on the gum. In other respects her health is good.

The tumour continued increasing in size, and distorting the countenance. About two or three months after admission, it began to press forward and to hang out of the mouth, and about this time she began to be troubled with a constant discharge of saliva over the tumour, together with a profuse discharge of fetid bloody matter.

About five or six months after her admission the tumour and lower jaw became extremely painful, and small pieces of the jaw began to exfoliate from under the tumour, and from that time to her demise about ten or twelve pieces of bone exfoliated.

She died in about eleven months after admission.

---

### DISSECTION.

THE tumour was found to be growing from the inner and left side of the lower jaw.

It had thrust the tongue backwards and to the right side, so that its apex reached only to the cuspidatus tooth.

The upper edge of the lower jaw was thrust forwards, and the teeth, instead of being opposed to those of the upper jaw, had their points thrust forwards and outwards.

One of the molares on the left side was carried by the tumour in which it was imbedded to the right side under the apex of the tongue.

On cutting into the disease it was found white in colour, firm, and of a consistence approaching to the nature of cartilage, but not quite so firm; but under this



cartilage, and close to the jaw, the basis of the tumour was composed of large masses of bone.

The periosteum of the jaw covered the tumour.

This disease was therefore an exostosis of the lower jaw, but its surface remained cartilaginous whilst its basis was composed of bone.

ASTLEY COOPER.

October 31, 1813.

## PART III.

### ARTIFICIAL TEETH, OBTURATORS AND PALATES.





## PART THIRD.

---

### CHAPTER FIRST.

#### ARTIFICIAL TEETH.

[GREATER improvements have been made in the construction and application of artificial teeth, during the last quarter of a century, than in any other branch of dentistry. Previously to this time, and even down to a much later period, artificial teeth, for the most part, were carved from blocks of ivory and fastened in the mouth by ligatures to the adjoining teeth, or by springs constructed in the awkwardest and most bungling manner. It is true, the invention of porcelain teeth, had, at a much earlier date been made, but their manufacture had not been brought to a sufficient degree of perfection, to render them at all desirable as substitutes for the loss of the natural organs. Some idea may be formed of the state of this department of practice, at the time of the publication of this work, by the remarks of the author upon the subject, which the editor, in order to preserve the whole of the original work, will give entire.



He says] “upon this subject, I cannot attempt to do more than give a very general statement, it being impossible to teach a mechanical art, in any other way than by manual practice.

The inconvenience which attends the loss of teeth, in respect to enunciation, as well as mastication, renders the introduction of some substitute very desirable. For this purpose artificial teeth are invented, which not only remedy the effects above-mentioned, but also preserve the symmetry of the mouth.

Artificial teeth are most commonly formed from the tooth of the hippopotamus, which is the most dense osseous substance with which we are acquainted. Of late years, they have also been made of a porcelain composition, which has been introduced by M. de Chemant: this gentleman's invention merits much commendation, as it affords a more durable substance for those, who, from acidity, or some peculiar property in the fluids of the mouth, destroy artificial teeth, made of osseous substances. However, these teeth do not sufficiently resemble nature, and considerable allowance must be given to the statements of an author disposed to regard his own invention as meriting a decided preference.

The manufacture of artificial teeth require a proficiency in mechanical art which can only be acquired by much patient labour, and it is the exactness with which they are adapted to the mouth, and the ease with which they can be worn, that constitute their chief excellence. In order to be able to prepare an artificial tooth, a model of the space to be filled up must be taken in wax; from which a cast in plaster of Paris may be made. The impression of the mouth in the wax being the reverse, will cause the plaster of Paris to acquire the exact representation of the person's mouth. Having thus obtained a



model, the substance designed to be the artificial tooth must be fitted with great nicety, and be so formed as to correspond with the other teeth. The same general directions apply to the formation of more teeth than one, and so even to a complete set.

Artificial teeth are made secure by fastening them to the adjoining teeth by ligatures of silk, Indian weed, commonly called silk-worm gut, or fine gold wire. If the teeth are made to fit very correctly, a slight fastening will be sufficient; and, in all cases, persons should avoid tying ligatures very tightly, as then they are very liable to create pain, and do mischief. In other instances, they are fastened by means of gold springs.

The foregoing remarks apply only to those cases in which the teeth have been extracted, or being loose, have dropped out: but, when teeth are lost by caries, another mode of inserting artificial teeth is adopted.

The incisores and cuspidati of the upper jaw are very frequently affected with caries, and the crowns of the teeth decay, so as to leave little more than the fangs in the sockets. When the teeth are in this situation, if there be no disease in the socket, new teeth may be fixed to the fangs of the decayed ones, without any attachment to the other teeth being required. This operation is to be performed as follows: All the ragged or carious remains of the crown of the tooth are to be filed away close to the gum; the hole in the fang, which forms the natural cavity, is then to be prepared for receiving the pivot, by which the new tooth is to be fastened; this is done by passing a small instrument, called a broach, into the cavity, and drilling it into a smooth round hole.—The fang being thus prepared, the crown of a human tooth, corresponding with the one that has been filed off, is to be fitted to the fang, a hole is then to be drilled,



and a piece of gold wire screwed firmly into it; the wire being left of a length equal to the hole in the fang, and filed to the exact size, is to be introduced, and, being made tight, it may continue for many years without occasioning any trouble, or requiring any repair. In this mode, several teeth belonging to the same person may be replaced, which cannot be discerned upon the most minute inspection.

Much prejudice has been excited, without foundation, against the use of human teeth, in the manner as above described, on account of various alarming symptoms having attended the former practice of transplanting. No person can be a greater enemy to that operation than myself, but there is a most essential difference between the two modes of practice; for, in that which is recommended, we only use a piece of tooth, which may be considered precisely in the same condition as any common piece of bone. No tooth formed by art can be compared to a natural tooth, fixed in this manner; as artificial teeth must differ, in some degree, from human teeth, both in colour and form.

Natural teeth connected to a plate of gold, or a base made of the tooth of the hippopotamus, may be fixed in the same manner as artificial teeth. This is a very neat mode of supplying the loss of teeth, and cannot be detected, by any difference in their colour or form, from the natural set.

It was Mr. Hunter who introduced and recommended the practice of transplanting teeth; and, under his immediate inspection, it was carried on to a great extent. In his treatise on the diseases of the teeth, he goes into the subject at great length, and he admits it to be a difficult, uncertain, and often an unsuccessful operation.

In the course of the practice many very disagreeable



and alarming symptoms attended some of the cases. In a later work, Mr. Hunter endeavoured to diminish the disrepute into which a practice had fallen that he was naturally partial to, from its being of his own invention, by accounting for all the symptoms which occurred, on the principal of irritation exciting deranged sympathies. That the mere irritation of a foreign body, as the tooth of one person inserted into the alveolus of another, will occasion many extraordinary sympathies, independent of any infection, may readily be conceived. I have been informed by Dr. Jenner of a person who had blotches on the skin, from the irritation which followed the replacing of a tooth into the same socket from which it had been extracted.

However, the ill success and unfortunate consequences that sometimes occurred, have caused the practice to be abandoned for many years past. The other modes of supplying the loss of teeth are so unexceptionable, and invariably successful, that we have no reason to regret the failure of the practice of transplanting. I might indeed have observed, that this operation involved in it a defect of the moral principle, as one person is injured and disfigured, in order to contribute to the luxury and convenience of another.

In Plate XVII. Fig. 18, is the representation of a transplanted tooth, which was worn by a gentleman eleven years; it had never been quite fast, but, during the last two or three years, it had become very loose, at length the crown broke off, and left the fang in the gum: on extracting it I found it to have been absorbed all around in the most curious manner, and contrary to the common mode in which the absorbents act upon the fangs of teeth, which is to begin at the point, and extend towards the neck. In this way the absorbents, as if con-



scious that this tooth was an intruder, exerted their utmost power to eat it out, rather than permit its continuance."

[The materials used for and the manner of applying artificial teeth at the time this work was written, were, for many reasons, exceedingly objectionable. To be both serviceable and desirable, they should not only be applied in such a manner as not to exert an unhealthy influence upon the parts on which they rest, or be, in any way, productive of injury to the remaining natural teeth, if there be any, but they should also correspond in shape and appearance with those which they replace, and be incapable of being acted upon by the fluids of the mouth, whether in a healthy or diseased condition. When badly applied or of an improper material, they are not only both an annoyance and nuisance, but are productive of vastly more injury than benefit, and notwithstanding the high comparative state of perfection to which this department of the art has been brought, and is at present practiced by a few, nineteen-twentieths of the artificial teeth worn, are of this description, or at least, so far as it regards the manner of their application.

The demand for artificial teeth has become so general, since the improved manner of their construction and application, has so fully established their utility, that every one having the most meagre pretensions to a knowledge of dentistry, is now called upon for them, when, in reality, not more than one in twenty possesses either the judgment or skill, never having been properly instructed in the art, to construct or execute, in a proper manner, a piece of dental mechanism. Neither mechanical ability to execute nor a judgment sufficiently enlightened to design the plan most proper for the construction and application of artificial teeth in the various cases which



are constantly presenting themselves, separately, constitutes the qualifications requisite for a practitioner in this department. Both should unite in the same person, and in addition to which, a correct knowledge of the remedial indications of the various morbid conditions of the several parts and structures of the mouth, is indispensable; for, it is never strictly proper, to apply artificial teeth when the remaining teeth, gums, or alveolar processes are in a diseased condition.

And as indispensable as are these various branches of knowledge even to a mechanical dentist, there are hundreds of practitioners in the country, who have made but little, if any proficiency in either; and it is to the very limited professional acquirements of most of those engaged in the exercise of the duties of the art, that so few of the artificial teeth worn even at the present day, are not only worth nothing at all, but a source of constant annoyance and actual injury to those who wear them.

Of the various materials which have been employed for artificial teeth, the porcelain is almost the only sort, at present, used. The perfection in which these have been manufactured during the last ten years, and especially in the United States, has secured for them a decided preference over every other description of artificial teeth. They are now made to resemble so closely the natural organs, as to render their detection when placed in the mouth, exceedingly difficult. But resemblance to the natural teeth, is not their only merit. Unlike all osseous substances, they never change in colour, or not materially, nor are they liable to be acted upon by the secretions of the mouth. They can also be more neatly and firmly secured in the mouth than any other dental substitute.

Although there are many dentists engaged in the manu-



facture of porcelain teeth, it does not necessarily constitute any part of his duties. It is a distinct business, and it is one which has been carried on for the last ten or twelve years, in the United States, very extensively. During this period, one establishment, the editor has been informed, has sold annually, from ten to twenty-five thousand dollars worth.

So much more highly esteemed are the American porcelain teeth than the European, that they are now extensively used both in Great Britain and France, as well as in other foreign countries. It is but just, however, to say, that these teeth so far as it regards shape and resemblance to the natural organs, are at present manufactured in very great perfection in London. The editor has seen some very beautiful specimens manufactured by Mr. Ash, of that city.

The porcelain teeth manufactured in France, although very strong, and seldom break under the blow-pipe, approach less nearly in resemblance, so far as the editor has had an opportunity of examining them, to the natural teeth, than do those of either England or America, consequently they are not employed as much at present as formerly.

Teeth constructed from the ivory of the tusk either of the hippopotamus or elephant, are, at present, but little used, and it is a matter of astonishment that they should ever have been employed, to the extent they once were, for certainly they are more objectionable than any other description of artificial teeth ever worn, except those made from common bone. In the first place, they readily absorb the fluids of the mouth, and in consequence, in a very short time, exhale an exceedingly fetid odour, contaminating the breath, and rendering the air expired not only offensive to those who wear them, but also to others. In the second place, they are less durable than



other kinds of artificial teeth, being in the majority of cases, soon decomposed by the fluids of the mouth, which they vitiate and render unfit for the purposes for which they are designed. In the third and last place, they bear but a very slight resemblance to the natural teeth, assuming in a short time a blue or yellowish appearance, and eventually they become almost black.

But notwithstanding the foregoing objections, these were for many centuries almost the only kind of artificial teeth used. In fact, twenty-five years ago, they were more frequently inserted than any other, and there are some dentists, even at present, who use them.

Of the two descriptions of ivory, that of the teeth of the hippopotamus is preferable, and in the construction of artificial teeth from this, the enamel, after filing off the outer rough surface, is, when practicable, usually left, and the teeth cut out in such a way as that it shall cover their front or labial surfaces.

But, for a number of years, previously to the introduction of porcelain teeth in general use, the crowns of human teeth, were much employed, and next to these, they are altogether and by far preferable, to any other, as artificial substitutes for the living organs. When properly and accurately applied, their detection is rendered almost impossible. They are, however, liable to decay, and a portion of their bony structure being necessarily exposed to the action of the fluids of the mouth, they generally, after one or two years, assume a dark brown appearance.

The manner in which they are usually procured is from individuals who supply dissection rooms of medical colleges with subjects, and the demand for them among dentists, was so great, that it was difficult to supply it, although the most exorbitant price was offered for them.



The teeth of various animals have been used for artificial teeth, but those which have been found to answer the best purpose, are those of neat cattle. They are usually procured from slaughter yards, and from beeves of from seven to nine years old, after the pulp cavities of their teeth have become nearly filled with bony matter. By filing the lateral and posterior surfaces of these teeth, they may be made to resemble very nearly in shape, the human incisores, and when used as substitutes for them, oftentimes last for several years. They are only suitable, however, for engrafting to the natural roots, though they have often been attached to plate and secured in the mouth to the adjoining teeth by means of clasps. They are usually much whiter than human teeth, and have apparently a smoother and more glossy surface, which renders their detection, when used as substitutes for these, almost certain, even by the most casual observer. They are, however, preferable to artificial teeth made of ivory, though by no means equal to human teeth, and since the manufacture of the porcelain teeth has been brought to its present comparative perfection, they are seldom, if at all used.

It will be perceived from the forgoing remarks concerning the relative merits of the various kinds of artificial teeth, that the porcelain is preferable to any which have ever been employed. Having said thus much upon this branch of the subject, it will be proper to offer a few observations on the different methods of applying dental substitutes.

In the insertion of artificial teeth, it frequently becomes necessary to adopt different methods, in different cases, in order to meet the peculiarities of each. A method which is applicable, and would be most proper in one, oftentimes is not in another. But different methods have been



adopted in the same description of cases, and where one is far preferable to any other. The advantages and disadvantages of each will be noticed in the proper place.

The pivoting method of inserting artificial teeth, under certain circumstances, is the best that has ever been adopted, and under all others, is one of the worst. It consists in placing an artificial crown upon a natural root, made fast by means of a pivot or tenon fixed to the former and introduced into the latter; which, when it is in a healthy living condition, will oftentimes remain firmly and securely in its place, from five to twenty years. But from the simplicity of the operation, and the ease with which it can be performed, it has been greatly abused, having been practiced under all circumstances; and hence, the worst and most lamentable consequences have frequently resulted from it. Not only should the root be possessed of vitality and free from disease, but the parts also which surround it, should be in a healthy condition. Under any other circumstances, the application of an artificial tooth upon this principle, is not only unscientific and improper, but is always, to a greater or less extent, productive of bad effects. There are some cases, it is true, where these, to some extent, may be counteracted, and where, from some very peculiar necessity, a dentist may be justifiable in inserting an artificial crown upon the root of a tooth partially deprived of its vitality, provided the contiguous parts are in a healthy state. But under no circumstances, when these are diseased, should the operation be performed.

Thus, it will be perceived, that the pivoting method of inserting artificial teeth is applicable only in the fewest number of cases which require such substitutes. Nor is it applicable under any circumstance for the replacement of the molar or bicuspid teeth, and very seldom for that



of the inferior incisores and cuspidati. As a general rule, the roots of the superior incisores and cuspidati are the only ones capable of affording a firm and secure support to artificial teeth.

The next method, which the editor proposes to notice, consists in the application of artificial teeth on plates secured in the mouth, to one or more of the remaining teeth, by means of clasps. This method is applicable to a much greater variety of cases, and in the replacement of the bicuspidates, the first and even second molares, as well as the incisores and cuspidati, when there are not healthy sound roots to engraft these last to, if the second or even third molares are free from disease, and firmly articulated, it is the best and most proper method that can be adopted. It has this advantage too, over all others, in supplying the loss of part of the teeth in either jaw; the teeth may be removed by the patient and cleansed, as often as necessary, and replaced with perfect ease and without the slightest difficulty. This should always be done two or three times every day, and the teeth left out every night, to prevent the secretions of the mouth from remaining between the plate and the parts on which it rests until they become vitiated, and from between the clasps and the teeth round which they pass, until they become acidulated and cause the decay of the latter, which they will do, if this precaution be neglected.

Artificial teeth applied upon this principle, if done correctly, may be worn as long as the teeth lasts, to which they are attached, and they are useful in the division and mastication of food, in proportion to the number in immediate contact with each other. But this description of dental mechanism, to subserve the purposes just mentioned, as well as all others for which such apparatus is designed, and can be made capable of doing, should be



neat in its execution, perfect in its adaptation to the subjacent parts and the teeth to which it is attached, and be sufficiently strong to prevent the liability of injury from the force to be exerted upon it by the antagonizing teeth. The plate should be three-fourths of an inch in width, and sufficiently thick to give to it the necessary strength; the clasps should be as wide as the length of the teeth to which they are applied will admit of their being made, and about one-third or half thicker than the plate. They should both be made of gold, the former of from twenty to twenty-two carots fine, and the latter of from eighteen to nineteen. Gold less pure than the above-mentioned, should never be used for any purposes in the mouth, as it is liable to oxydize and turn dark. Silver is often used by a certain class of practitioners, but it is objectionable for the reason just stated.

The application of artificial teeth with spiral springs, is never called for, except, for supplying the loss of all, or the greater part of the teeth in both jaws, and when no other method for their retention in the mouth can be adopted. The springs being attached on each side to each piece, work with the jaws and hold both, when of sufficient strength and fixed in the proper manner and at the right points, firmly and securely in their place.

The lower plate should be fully double the thickness of the upper, and both should be accurately adapted to all the inequalities of the parts on which they are to rest, so as not to be productive of the least irritation. The teeth should be so antagonized that all shall come together, when the mouth is closed, at the same instant.

The difficulty which so frequently attends the insertion of double sets of teeth, or teeth applied with spiral springs, results from the thinness and want of correct adaptation of the plates, and the improper manner in



which the teeth are antagonized. Much judgment and mechanical skill is required to design and construct in a proper manner, a double set of artificial teeth, but when put up in this manner, they may be worn with ease, and in most instances, will subserve to a considerable extent, the purposes of the natural teeth.

But, it is not always necessary in the application of a double set of artificial teeth to have recourse to spiral springs for their retention in the mouth. Under favourable circumstances, they may be confined in the mouth by the pressure of the atmosphere and capillary attraction, and when the springs can be dispensed with, it is always better that they should be. The editor has succeeded, in applying them without springs, during the last two or three years, in a number of cases. When they can be made to adhere sufficiently tight, without springs, they are worn with much more comfort and satisfaction by the patient, and the want of success which has so frequently resulted from attempts to apply them upon this principle, has been owing to the want of perfect adaptation of the plates to the parts which they cover. This is indispensable, and in order to which the wax impressions of the alveolar ridges must be perfectly true and correct.

It is much easier to apply a dental substitute to the upper than to the lower jaw upon this principle, as the upper usually presents a much smoother and more prominent ridge. It is also much easier to obtain a correct impression of the upper than of the lower jaw, and besides, a wider plate, for the atmosphere to act upon, can be employed, which is a matter of no small moment in applying teeth upon this principle—yet it is not necessary to have the plate in any case more than an inch and an eighth or an inch and a quarter in width, for in pro-



portion as it is wider than this, the greater will be the difficulty of obtaining a perfect fit. A plate of the width just mentioned presents a sufficient amount of surface for the atmosphere to act upon, and if one wider than this be employed, there will, in nine cases out of ten, be some places on the back part of the ridge or palatine arch to which it will not be closely fitted, and where the air will be admitted and weaken the attachment of the whole. For a long time, the editor was unable to discover the cause of the difficulty he sometimes met with in the application of teeth upon the suction or atmospheric pressure principle, and it was only by accident that he at last did do it. Since which time he has employed narrower plates, and his success has been more uniform and perfect.

As the lower plate can never be very wide, in consequence of the narrowness of the inferior alveolar ridge, it should be extended, when it is designed to apply one upon this principle, as far back, on each side, as possible. They should be made to reach up, a short distance, on the coronoid processes. It was for a long time thought impossible, to apply a lower plate upon this principle, but the editor has demonstrated its practicability in a number of cases, and now he adopts in all, where the circumstances are at all favourable, and he has succeeded in some, where, from the great irritability of the integuments covering the alveolar ridge, the individuals were unable to bear the pressure of spiral springs. But for a fuller exposition of the merits of this principle, in the application of artificial teeth, the reader is referred to his *Principles and Practice of Dental Surgery*. He would, however, remark, before he dismisses this part of the subject, that it is seldom applicable except for a full upper or under set.

The next method which he will notice, is one which



was much in vogue during the period of the professional career of the author, and although it is now never adopted by scientific practitioners, it may nevertheless be proper to notice it. It consists in fastening artificial teeth in the mouth by ligatures, of silk or sea grass, or with gold or silver wire to the adjoining natural teeth. This affords not only a weak and insecure support, but it is productive of injury to the teeth to which the ligatures are attached. It often pulls them from their sockets, or rather by the continual pressure which they exert upon the teeth, they cause the destruction of the sockets and a gradual loosening and ultimate loss of the teeth. But this is not the only effect which results from fastening teeth in the mouth by this means. They afford a lodgement for extraneous matter around the teeth to which they are attached, which, by being retained there, soon cause them to decay. Teeth too, inserted in this way, not being easily removed by the patient, are often retained in the mouth for weeks and months, without being taken out and cleansed, imparting to the breath, the most disagreeable fetor, and so vitiate the fluids of the mouth as to render them unfit to be taken into the stomach. Fortunately, however, this method of inserting artificial teeth, is seldom resorted to at the present day.

That barbarous practice of transplanting a tooth from the mouth of one person into the socket of that of another, as practiced by that celebrated French Surgeon Ambrose Parè and recommended by John Hunter, is very justly condemned by the author. It rarely succeeded even under the most favourable circumstances, and was oftentimes instrumental in communicating to the patient disease, which in some instances proved fatal. A case of this sort given by Dr. Watson, is contained in "The Medical Transactions of the College of Physicians"



and copied by the editor in his Principles and Practice of Dental Surgery. But it is unnecessary to say more concerning this method of inserting artificial teeth, opposed as it is, both to the laws of the animal economy and to common sense. Happily, it is now never practiced.

In conclusion, it may be proper to say a few words concerning the condition of the mouth at the time of the application of artificial teeth, and especially as this is a matter which has been too little regarded by the majority of dental practitioners. Hence, in many instances, the bad effects which so frequently result from their insertion.

Every part of the mouth should be in a perfectly healthy condition at the time of their application, to ensure the advantages capable of being derived from them. If the gums are swollen or inflamed, or there be dead, loose or decayed teeth, or tartar, or any other extraneous matter on the remaining organs in the mouth, such preparatory treatment should be first instituted as may be necessary to their restoration, else, the morbid action already existing in the parts, will be aggravated by the presence of any substitute for teeth, which have been lost, that can be applied, however perfect, may be its construction. For the completion of the changes in the alveolar ridge, which follows the loss of any of the teeth, from three to nine months are oftentimes required. If artificial teeth be inserted before these have taken place, the plate to which they are fixed, will lose its adaptation to the gums, press upon them unequally, and in consequence of which, be a constant source of irritation.

To obviate the difficulty and inconvenience which some persons experience from the loss of the natural teeth, a temporary substitute may be applied and worn when absolutely necessary, until a permanent one can be inserted. The material, however, employed for this, should be as pure and incorruptible as that for the other.



## CHAPTER SECOND.

### OF THE MANNER OF INSERTING A PIVOT TOOTH.

As it regards the mere manipulations, the insertion of a pivot tooth, ordinarily, is one of the simplest and most easily performed operations in dental surgery. But cases are, nevertheless, occasionally met with, presenting difficulties which require all the judgment, tact and skill, of the operator, to overcome. For example, when the root has an oblique position in the jaw, or is situated behind the circle of the teeth, so as to render it necessary, in order to the proper position of the artificial crown to be placed upon it, to employ a crooked pivot, or a plate with a pivot or tenon and plate tooth. In either of the above cases, much difficulty is oftentimes experienced in the proper adjustment and insertion of the artificial tooth. But the manner of overcoming the peculiar difficulties presented by each, will be presently described. When the root of the tooth does not deviate from a vertical direction in the jaw, requiring merely a straight pivot, the only skill called for in the insertion of the tooth, is, to fit it accurately to the fang, except in those cases where the pivot hole in one is not in exact opposition to that in the other, or when one of the adjoining teeth impinges on the vacuity occasioned by the loss of the one which is to be replaced. The first of the last-mentioned difficulties can usually be overcome by the selection of a suitable

tooth, and the last may be obviated by filing off a portion of the side of the tooth that impinges upon the aperture, or even by grinding the artificial crown.

#### MANNER OF PREPARING THE ROOT.

In the majority of the cases in which it is proper to adopt the pivoting method for the insertion of an artificial tooth, a portion of the crown of the natural tooth that is to be replaced, is still remaining, so that the first step to be taken in the operation, is, its removal. This is done by some practitioners, at once, with a pair of strong excising forceps, while others prefer cutting it partly off, with a file, and afterwards completing the operation with that instrument. By the first method the root is oftentimes fractured and so much injured as to render it unfit to sustain a tooth, and even when this does not happen, the concussion is frequently so great as to induce violent inflammation in the alveolo-dental membranes, which not unfrequently terminates in suppuration and necrosis of the socket of the tooth. By the second method, such effects are rarely produced, and on which account, it is preferable to the other.

The process of filing should be commenced with a safe-sided separating file, which should be passed between the tooth to be removed and one of the adjoining ones, the smooth side of the file towards the latter, nearly up to the apex of the gum, where the upper edge of it should be turned to the pulp cavity, and the operation continued until it has nearly reached it. The other side of the tooth should next be filed in the same manner, and then a deep horizontal notch filed across its front surface, when it should be suddenly snapped off with a pair of excising forceps. The crown of the tooth should never,



when the nerve is alive, be entirely cut off with a file, as the pain which would be produced by the contact of the instrument with the lining membrane and pulp, would be too protracted to be endured by the patient.

After the removal of the crown of one tooth, if there be another to be taken off, the operation for the removal of the second will be greatly facilitated by the increase of room, gained, for the movement of the file, and besides, an oval or half round file may be employed instead of a flat one, which is not so liable to become choked up and stick in the tooth.

Having proceeded thus far with the operation, the next thing to be done, is the destruction of the nerve. This is effected by most French, as well as by some English and American practitioners, by passing a fine iron or steel wire, heated until it is white, suddenly up the canal of the root. The destruction of the nerve by this means, is exceedingly painful, several applications of the heated wire often being necessary, and besides, it is very apt to excite inflammation in the surrounding parts, and in some instances has been known to produce very alarming consequences. But notwithstanding, it is strongly recommended and advocated as preferable to any other method by many very respectable dentists. The editor has, in many cases, tested the relative merits of this with other modes of destroying the nerve, and so much more objectionable is this than any other which he has ever tried, that for nearly seventeen years, he has not resorted to it in a single instance.

Since the employment of arsenic was recommended for the destruction of nerves in teeth, this article has been much used for this purpose. But it is objectionable for the reason, that it not only destroys the whole of the lining membrane of the tooth, but it also induces an unhealthy



action in the investing membrane, which, generally, in the course of a few months, terminates in alveolar abscess, thereby rendering the root unfit for the support of an artificial crown as well as obnoxious to the surrounding living parts. It is important, therefore, that as much of the vitality of the root as possible, should be preserved.

The best method of destroying the nerve, is, to do it with a small iron or silver wire with the point brought to an edge and left rough, or with a small flat untempered drill or broach. Either will answer equally well. The manner of performing the operation, is to introduce the instrument into the canal of the root, about half or five-eighths of an inch, giving it at the same time a quick rotary motion, which will extirpate the nerve as far up as the drill or broach extends, leaving the remaining portion, and lining membrane to supply the inner walls of the fang with vitality and nutriment, which they will oftentimes do for years. But before a wire can be successfully used, it is necessary that the nerve cavity should be completely exposed, to prevent the operation from being too protracted. With the broach or drill, the cavity, even though it be covered with a thin layer of bone, can be readily and at once reached.

But whatever instrument the operator may determine to employ, it is necessary to use the same precaution to prevent it from being broken off in the root, by any sudden motion which the patient may give to his head. This, however, in most instances, will be prevented by informing him beforehand, that the operation will be attended with considerable pain, but which, will be of but two or three seconds duration, if he remain perfectly quiet. This is usually long enough for its completion.

This part of the operation having been completed, the operator should next proceed to file the root off, with a



round or half round file, up to the gum, and a little above its free edge, so that when the artificial tooth is fitted to it, the point of connection between the two, may be wholly concealed. The common rat-tail file was formerly used for this purpose, but files are now made expressly for the operation which may be had in most of the larger cities.

In filing the root above the free edge of the gums, the file, as it is moved backward and forward, should be held firmly against it, and made to act upon it, all the way across, to prevent wounding the latter structure, which will be done, if the instrument be used in any other manner.

Having filed the root in the manner as just described, it only remains to enlarge the canal in it, as far up as it is necessary for the pivot or tenon to extend, which may be done either with a broach or a burr or cherry-headed drill. The enlargement of the canal, when a wood or a wood-cased pivot is to be employed, should extend about three-eighths of an inch up into the root, and should be about the sixteenth or twentieth of an inch in diameter. No advantage whatever is gained by making the canal any larger, and when it is done, as it frequently is, the walls of the root are weakened, and a much larger surface presented to the action of the secretions of the mouth,—consequently its destruction is thereby greatly hastened. When a metallic pivot is to be employed, the enlargement of the canal should extend up about half an inch.

When the canal has been enlarged by caries, so as to give the root a funneled appearance, after the removal of the diseased part, it should be tightly filled with some soft wood, and red cedar is perhaps as good as any that can be employed, with a perforation through the centre,

sufficiently large for the metallic pivot. But the better practice in cases of this sort, is, to introduce a hollow gold tube, with a screw cut on so much of the upper extremity as will occupy the upper part of the canal which is of uniform dimensions. This done, the opening around the lower part of the tube, should be firmly and compactly filled with gold foil, which will not only hold it securely in its place, but will at the same time protect the inner walls of the root against the action of the secretions of the mouth. The opening in the tube, which is intended for the reception of the pivot, should be about the sixteenth of an inch in diameter.

This method of preparing a root is more troublesome, but by far preferable to any other, and as it is very seldom, when a root is so much decayed as to call for it, that there is sufficient vitality in it to prevent it from being a source of irritation to the contiguous parts, it is not often necessary to resort to it for the purpose of obtaining a hold for the pivot. After having secured it in the manner as above described, so much of it as projects below the root, together with the filling around it, should be removed with a fine oval or half round file.

The introduction of a hollow gold screw into the canal in any case, after having sufficiently enlarged it, would contribute greatly to the preservation of the root, and if dentists would provide themselves with hollow gold wire of the proper size, and a screw plate and taps, the operation would not be attended with much more trouble than is consequent upon the ordinary method of inserting a pivot tooth.

The balance of the operation consists in selecting, fitting, and attaching the artificial crown to the root, which the editor will now proceed to describe.



OF THE MANNER OF FITTING AND ATTACHING A TOOTH TO  
THE ROOT.

In the selection of the tooth, the operator should be careful to procure one of the right size and colour, so that in neither, it shall differ sufficiently from the corresponding natural tooth, to render its detection easy by a striking contrast; for in that case, the effect that would be produced on the observer, would be worse than that caused by the loss of the original organ. The base too, of the artificial tooth, should be large enough to cover the root, and the pivot-hole in it deep, and exactly in the centre, and as large at the bottom as it is at the orifice. In many of the porcelain teeth, the pivot-hole is faulty in all of these respects, and therefore, it is a matter that should never be overlooked by the dentist. If it is smaller at the bottom than at the orifice, the swelling of the pivot, if a wood one be employed, will force the tooth off from the pivot, or if it be a little to one side, or have an oblique direction, as they oftentimes have, the proper adjustment of it on the root, will be attended with great difficulty.

It is often necessary in fitting an artificial crown to the root, to alter its original shape, which is done by means of a grinding apparatus. This may consist of an emery wheel or stone fixed on an axle, and turned either with the hand or foot. The most convenient and portable kind are turned by a small crank with the hand of the operator, and the emery wheel, when properly prepared, is preferable to almost any stone which can be procured. It cuts more rapidly, and is less liable to injury from use.

After the tooth has been ground so as to fit the root accurately, it should be fixed to it with a temporary pivot, and if it deviates in the least from the exact position it

should occupy on the root, or if the teeth with which it is to antagonize, strike it in closing the mouth, such alteration should be made in the pivot or tooth, as the peculiar nature of the case may require. When the upper teeth close over the lower, it is often necessary to make the tooth very thin by grinding it away on the inside. As a general rule, the artificial tooth should not touch any of the teeth in the under jaw.

After having accurately fitted the tooth to the root, the operator should then proceed to arm it with a pivot. Wood is most commonly employed, and in most cases is preferable to any metallic substance, inasmuch as by the swelling of it in the root, it becomes very tight, and will often hold the tooth securely in its place for many years. The kind generally used, is close-grained, well seasoned young hickory. This is now prepared especially for the purpose, by being made of the right size and firmly compressed, and may be had at the principal establishments in the country for the sale of porcelain teeth. When the piece is larger than the hole in the tooth, one end should be reduced to the right size and firmly forced up into it. It should then be cut off about a fourth of an inch, or a little more, from the tooth, and the projecting part trimmed down until it will tightly fit the canal in the root, into which, after having been wiped out, it should be introduced. No more pressure will be required for this purpose than can be exerted with the thumb and forefinger of the hand of the operator. Some practitioners are in the habit of driving the pivot into the root, by striking on the tooth with a hammer, but this is wholly unnecessary, as the moisture of the mouth will cause the pivot to swell sufficiently to prevent it from loosening or coming out.

It sometimes happens that the antagonizing tooth can-



not be prevented from striking the artificial tooth, and they occasionally do it in such a way as to act with great force against the pivot, causing it as it becomes saturated with the fluids of the mouth, to bend, and the tooth to project. To prevent which, the editor some ten or twelve years ago, adopted the plan of passing a gold screw through the wood previously to reducing it to the proper size, and he has derived much benefit from it. This description of pivot, especially in cases where the lower teeth strike the artificial, is perhaps the best that can be employed. The simplest way of making one, is to drill a hole, about three-fourths of an inch long, of the size of a small knitting-needle, lengthwise into a piece of well-seasoned hickory of about an eighth of an inch in diameter. This done, a screw is cut on a piece of gold wire, large enough to fill the hole. The wood around the gold wire is then reduced to the proper size, fixed in the tooth, cut off a little more than an eighth of an inch from it and the projecting part introduced into the canal in the root, in the manner as before described.

For a metallic pivot, gold is the proper metal to be employed. It should be fully eighteen carats fine, and is prepared for use by being made into wire of about the sixteenth part of an inch in diameter. A piece of about five-eighths or three-fourths of an inch is cut off, the cavity in the tooth is filled with pulverized borax, (sub borate of soda) and water, one end of the wire inserted around which several pieces of gold solder is placed, the tooth is then fixed in a piece of charcoal, and a flame from a lamp thrown on it until the solder fuses and runs down into it around the wire. By this simple process the wire is made fast in the tooth, and after this has been done, it is made sharp at the point with a file, and several small beards cut on it, so that when it is introduced into

the canal in the root, which should be previously filled with some soft wood, pierced through the centre, it will not be liable to loosen and come out. Artificial teeth are often securely retained by this description of pivot for many years.

When an artificial tooth is engrafted to a root from which there is a fetid discharge, an outlet should be provided for the escape of the matter. This may be done by cutting a groove on the side of the pivot as recommended by Dr. L. S. Parmly, or by the employment of a tubed pivot with an opening through the crown of the tooth opposite to the pivot-hole as proposed by Dr. E. H. Elliott. Either method, by giving egress to the matter, will prevent its accumulation in the root, and the consequent formation of an alveolar abscess.

That it is unscientific to apply an artificial crown to the root of a tooth under such circumstances, every one must admit, but there are cases, in which, from some peculiar necessity, the practice may, perhaps be justifiable, and by adopting the plan just described, the hurtful effects that would otherwise inevitably result, may be measurably counteracted. But even the presence of a dead root of a tooth, or that of one from which fetid matter is constantly being discharged, must of necessity be productive of injury to the patient, and therefore, under all ordinary circumstances, a dentist would be exceedingly remiss in the discharge of his duty, if he fails to urge upon him the importance of its immediate removal.



### CHAPTER THIRD.

#### OF THE MANNER OF FITTING AND ADAPTING A PLATE, AND ATTACHING CLASPS AND ARTIFICIAL TEETH TO IT.

IN the construction of a dental substitute to be held in the mouth by means of a gold plate and clasps, fixed to some of the remaining natural teeth, it is necessary that it should be adapted with the most perfect accuracy, to the parts on which it is to rest, and that it antagonize correctly with the teeth, with which it should come in contact when the mouth is closed, or that it does not strike these before the others meet, provided there be teeth back of it in both jaws. It should be so contrived too, as to restore the symmetry of the face, which is always more or less injured by the loss of several teeth. The operation of constructing a dental substitute of the description now under consideration, may be properly divided into four parts.

The first consists in taking an impression of the parts on which the substitute is to rest, and with which it is to be connected, in wax. The second, in procuring from the wax impression, first, a plaster, and second, a metallic model and counter model. The third, in swedging up the plate and attaching clasps to it. The fourth and last, in taking an articulating model, in fitting, antagonizing, and attaching the teeth, and finishing the work.

In describing these several parts of the operation, the order just mentioned will be followed.

## OF THE MANNER OF TAKING A WAX IMPRESSION.

Although the taking of an impression of the mouth, is a very simple operation, it is nevertheless often attended with great difficulty, for if this be incorrect, it will be impossible to make a plate to fit the parts on which it is to rest and the natural teeth to which it is to be attached. Different dentists employ different preparations of wax for this purpose, but there is nothing better than the common beeswax. But whether this or any other preparation be used, it should be previously softened, until it is of about the consistence of soft putty, in warm water. It should then be placed in a semi-circular box or frame, made of tin or silver, large enough to encase or cover the whole, or so much of the alveolar ridge, as an impression from which, may be required, and leave a small space on each side. The wax thus enclosed, should be placed in the mouth, and pressed against the jaw until a deep impression is made in it by the parts to which it is intended to apply the artificial teeth, and to the adjoining natural teeth as far back as it may be necessary to extend the plate, and to which, the clasps are to be fixed. This done, the wax which has escaped from the frame, should be pressed against the alveolar ridge, all round, and on each side, by the forefinger of the hand of the operator; and after being well assured a correct impression has been made, the whole should be carefully removed from the mouth. In doing this, the greatest care is necessary to prevent the wax above the outer edges of the frame from being bent by the corners of the mouth. This is oftentimes attended with great difficulty, and sometimes it is necessary to take several impressions before a perfect one can be obtained.



The wax-holder or frame, should have a handle attached to the front part of it, of about an inch and a half or two inches in length. Every dentist should be provided with from ten to fifteen frames of this description, varying both in shape and size. Dr. Elliott of Plattsburg, N. Y. recommends that they be "formed by being swedged between a model and counter model, in the same manner that a gum plate is fitted to the mouth." This description of wax-holder, is certainly preferable to those commonly used, and in one instance the editor found it absolutely necessary to have one made, in order to obtain a correct impression. But in all cases where the mouth is of the ordinary size, the others will answer.

#### OF THE MANNER OF OBTAINING A PLASTER AND A METALLIC MODEL AND COUNTER MODEL.

Previous to filling the wax impression with plaster, every part of it should be smeared with oil. The best way of applying this, is, with a small camel's hair pencil. If there are any teeth in the jaw, a pin or short piece of small iron wire should be stuck in the bottom of the impression made by each, for the purpose of strengthening those which will be formed on the plaster model, and to prevent their liability to break.

As it will be necessary to raise the plaster above the wax impression, a rim or border of pasteboard or folded paper, an inch wide, may be passed around it and made fast by pinning. The connection of this to the wax impression should be sufficiently close to prevent the plaster from escaping.

The plaster should be of the best quality. That used for making busts is generally superior to any other that can be obtained, and when this can be had, it should be

preferred. It should be prepared by stirring it in water until a batter is formed, which should not be too thick to prevent it from descending readily into all the depressions in the wax. The plaster being thus prepared, the impression should be slowly filled, putting on a sufficient quantity of the batter, which by this time will have become much thicker, to raise the model nearly to a level with the paper border.

From two to four hours should elapse, after filling the impression, for the plaster to harden, before it is taken from the wax, which, in most instances, is easily done, but when from the number, great length, or peculiar shape of the teeth, it cannot be easily separated, the wax should be placed in warm water and allowed to remain, until it has become a little softened, when the plaster may be readily removed.

It should now be trimmed in such a manner that the metallic model which will be shaped exactly like it, may be removed without difficulty from the counter metallic model. This is sometimes neglected, and in consequence of which, the two become locked together, so that they cannot be separated.

Brass, zinc, lead, and tin, are the metals usually employed for the metallic models. The last is more easily fused than either of the others, and in the majority of cases, answers equally well. The plan which the editor, in common with many other dentists, adopts, for the procurement of a metallic model, is, to fuse some four or five pounds of lead in a strong round sheet iron box or ladle, about three inches deep, and at the bottom, about three inches in diameter, but a little larger at the top; then to immerse as much of the plaster model in it as was formed in the wax impression, and holding it there, until the metal chills around it. When the lead gets cold,



which process may be hastened by pouring cold water on it, the plaster may then be broken to pieces and taken out. The counter model thus formed should be covered with a little whiting mixed with water, put on with a camel's hair pencil, or smoked over a lamp. This done, three or four pounds of tin should be fused in another ladle, and at a temperature which will not char or discolour white paper, poured in this while still in the ladle first employed. When cold both may be taken out and separated from each other.

This is the simplest way in which a metallic model and counter model can be obtained. It is also the most perfect. Some dentists, however, are in the habit of making the model first, which is done by making an impression with the plaster cast in sand, such as is used at brass and iron foundries; then fusing the tin or brass, or zinc and lead, whichever may be employed, and pouring it into the impression thus made, and afterwards obtaining a counter model from the model thus procured. The first method is the best, for the reason that it ensures a much smoother and more perfect model. But it is necessary when taken in that way to have a duplicate plaster model, which, however, may generally be obtained from the wax impression in which the first was formed. Should this, however, be injured, in the removal of the first plaster model, it will be necessary to take a second wax impression.

#### OF THE MANNER OF FITTING AND STAMPING A PLATE AND ATTACHING CLASPS TO IT.

The plate in the first place should be got out to the proper size and shape, from a sheet lead pattern, previously obtained from the model, which should be from

three-fourths of an inch, to an inch in width. And it may be well to remark here, that the plate should be thick enough to prevent it from being easily bent or broken, and the best way to secure a uniform thickness, is to have it always got out by a gage, such as is used by watch casers, which are numbered. The plate usually used by the editor for the upper jaw, and he does not think it at all too thick, fits tightly in number twenty-six, and that which he employ for clasps, in twenty-four or five.

After having cut out a plate of the right size and shape, and fitted it as closely to the model as possible with a pair of plate forceps and a small round-faced hammer, it should be annealed, by heating it on a piece of charcoal with a lamp and blow-pipe. This done, it should be swedged up between the model and counter model, with a heavy hammer, until it fits with the most perfect accuracy, every part which it covers. And during the process, it is often necessary to take it out once or twice, and re-anneal it.

The posterior extremities of the plate should fit up closely to the teeth to which the clasps are to be applied, and if there be any anterior to these, a space of an eighth or twelfth of an inch between it and them should be left uncovered, to prevent irritating the margins and apices of the gums, which is almost certain to result from contact with the plate.

The plate should now be placed on the plaster model, and clasps accurately fitted to the teeth, one on each side, when practicable, if two be employed. But when the teeth on one side have all been lost, and there be good teeth to clasp to on the other, two may be used on that side, and which, when properly applied, may be made to support a plate with artificial substitutes for all the other



teeth. In fact, one has oftentimes been made to do this for years, without having been attended with any unpleasant effects whatever, and in the insertion of a single tooth in the front part, or two or even three on the side, of the mouth, it is seldom necessary to apply more than one clasp. But in this case, the clasp should be fixed to a bicuspid or first or second molaris.

After the clasps have been fitted to the teeth, they should be connected to the plate, while on the model, by means of two pieces of wax, softened until they are about the consistence of putty. The plate and clasps should now be taken off, without altering in the least their relative position, and placed on a piece of paper with the concave side of the plate upwards, then plaster of Paris, prepared in the manner as before described, poured over it and the clasps. As soon as this becomes hard, the piece may be lifted from the paper, and the wax taken off, when, if there be any apertures between the clasps and plates, they should be filled either with gold foil or small pieces of plate. Finely ground borax (sub borate of soda) mixed with water, until it is of the consistence of cream, should now be applied with a camel's hair pencil, to the parts to be united, and after which, several small pieces of fine gold solder. It should next be placed on a piece of charcoal and the flame of a spirit or oil lamp be thrown upon it with a blow-pipe, until the solder fuses and unites the clasps to the plate.

It is much better to solder the clasps to the plate in this manner than to do it on the plaster model, as that will be afterwards needed, and is liable to be injured by the intense heat necessary to be applied to fuse the solder.

The clasps having been soldered to the plate, the piece should be placed in diluted sulphuric acid, and allowed to remain about twenty or thirty minutes for the purpose

of decomposing the borax which remains on the part of the plate and clasps to which it was applied, and by the action of the heat has become almost as hard as glass. This done, the work should be cleansed for the reception of the teeth.

When it is necessary to supply the loss of several teeth, in different parts of the mouth, but in the same jaw, by means of one plate, the teeth on the plaster model should be cut off, before the metallic model is made, and a plate covering the whole of the alveolar ridge, or extending back as far as the teeth to which it is to be clasped, should be swedged up, and the places of the natural teeth afterwards filed out. A plate can be made to fit more perfectly in this way than by cutting out the places for these teeth before it is stamped up, as in this process, it is liable to draw off from them.

OF THE MANNER OF FITTING AND ANTAGONIZING THE TEETH,  
ATTACHING THEM TO THE PLATE, AND FINISHING THE  
WORK.

After having selected such teeth as correspond in class with those which have been lost, and in colour with the adjoining natural teeth, the operator should proceed to fit them to the plate, and in doing this, it will be necessary, in the majority of cases, to grind them more or less on the base. No apertures should be left between the teeth and plate, as they would become receptacles of extraneous matter, exceedingly difficult to clean, and to prevent which, great care is requisite, especially in those cases where the alveolar ridge is very rough and uneven.

As the teeth are selected and arranged on the plate, they should be held in their place by a rim of softened wax behind them, such as recommended to be used in



taking impressions, and it will be proper to remark in this place, that when the alveolar ridge is exposed in laughing, the plate should not cover the anterior part of it. The anterior portion of the base of the artificial teeth, in this case, should cover the edge of the plate and be accurately fitted to the gums, but when the alveolar ridge is not exposed in laughing, a much larger portion of it may be covered by the plate.

It sometimes happens that the whole of the alveolar ridge has been wasted by disease in the gums and alveolo-dental membranes, or destroyed by necrosis and exfoliation. To supply this loss of substance, it becomes necessary to make a raised or box plate, or to employ what is commonly termed gum teeth, and in some cases both can be advantageously applied. The most convenient and best manner of making a box plate, is, to fit up a plate first in the usual manner, then to put on a paste, or thick batter, made of plaster of Paris, which should be raised to the proper height and afterwards trimmed to the proper shape, leaving about an eighth of an inch of the plate on each side exposed—with this a metallic model and counter model should be obtained in the manner as before described, and between which another plate should be swedged. This last is to be filed until it fits the first, and then soldered to it. But previously to this, a small hole should be pierced for the escape of the air, which becomes expanded by the heat employed in soldering, and after the teeth have been soldered on, it should be closed by the introduction of a small gold screw, which, in finishing the piece, should be cut off close to the plate.

In arranging the teeth on the plate, it is better, in most cases, to have an antagonizing model, which may be obtained in the following manner. Place a rim of soft-



ened wax, three-fourths of an inch in width, on the convex side of the plate, after it has been fitted and the clasps attached to it; let the plate now be put in the mouth, and the patient be directed to close his jaw naturally, until his back teeth come together, or if he has none which antagonize with each other, pass a wedge of wood, of a width equal to the length required for the artificial teeth, through the wax, with one edge in contact with the plate, and then let him be directed to close his mouth until the teeth which are to antagonize with the artificial ones, come in contact with the other. The wax should now, while the jaws are thus closed, be pressed around the natural teeth; this done, the mouth may be opened, and the plate with the wax removed, using the precaution at the time, not to bend or alter the shape of the latter.

Let the concave side of the plate, and the wax which has received the impression of the teeth, be now lightly smeared with olive oil, in the manner as previously described; next place it on a piece of paper, some six or eight inches square, and fill one side with a thick batter made of plaster, letting it extend back of the wax impression, or plate, as the case may be, on the paper, about two inches, adding to it from time to time, as it becomes stiffer, until it is about an inch in thickness. As soon as the plaster has solidified sufficiently, the edges and sides may be trimmed with a sharp knife, and about half an inch of the under surface extending behind the wax and plate cut away, and two or three deep grooves formed across it, and crossing each other at right angles. These should now be oiled and the whole of the surface of the plaster on the same side, together with the wax impression or plate in front of it, if it were not done at the time the oil was applied to the side previously filled. This done,



let a batter of plaster be put on this side in the manner as directed for putting it on the other, and when it has hardened sufficiently, it may be trimmed, and the two taken apart and the wax removed.

In a model of this description, the teeth may be arranged, fitted and so antagonized that all shall meet the teeth in the other jaw at the same instant. But when only one or two teeth are to be inserted, it will not be necessary to incur the trouble consequent upon the procurement of such a model.

The teeth being fitted to the plate, and antagonized, the next thing to be done, is, to put on gold backings. For this purpose two platina rivets are fixed in the palatine or lingual surface of each, about the twelfth of an inch long. They are fixed in the teeth while they are being manufactured before they are baked. The backings are made from a strip of gold plate, a little thicker than that to which the teeth are applied. The manner of putting a backing on a tooth, is to punch a hole through the strip of gold plate near one end, with a pair of punch forceps made expressly for the purpose, to insert one of the platina rivets into it, and by moving the other end of the plate two or three times backwards and forwards, over the other rivet, to mark its distance from it, then to punch another hole through the plate at the point thus indicated, immediately below the first; afterwards to enlarge the holes on the outer side of the plate with a sharp triangular pointed instrument, called a counter sink, then put the plate on the tooth, file off the protruding ends of the platina pins nearly down to the plate, which should now be made fast by riveting. This done, the plate should be cut off close up to the tooth, which should now with its gold back be refitted to the plate it is to be attached to, the rim of wax on the inside behind it, still supporting



and keeping it in its proper place. The backing, however, should be filed and made to fit closely to the plate. It should also fit up closely to the tooth, and have its edges neatly bevelled off. It should cover the whole of the back of the tooth to within about a sixteenth of an inch of its cutting extremity.

Some dentists are in the habit of putting on a raised back, giving as a reason for so doing, that it gives to the tooth a firmer support, but the editor has never been able to perceive that any advantage whatever was derived from it. Others again, after fitting the teeth to the plate, cover their anterior surfaces and cutting edges with plaster, and take off the rim of wax from behind, before they put on the backings, believing that they can in this way fit them more closely to the plate. They may, however, be fitted to it as accurately in the manner first described, as by this method, and in one-half the time.

When the backings are all fitted to the teeth, the plate with the teeth and wax should be taken from the model and placed on a large piece of charcoal, and then covered with a batter of plaster. When this becomes hard, the wax should be removed, and if there be any openings between the backings and the plate, they should be closed with small pieces of gold plate or foil. This done, borax, prepared in the manner as before described, should be freely applied, where it is intended the solder should take effect, namely, at the points of connection between the backings and the plate and around each platina rivet. At each of these places, several small pieces of fine gold solder should be placed, except over the rivets,—one being sufficient for each of these.

The solder employed for this purpose, as well as that for uniting any description of mechanism to be worn in the mouth, should, if possible, be fine enough to resist



the action of the secretions of this cavity. The following recipe, copied from the editor's Principles and Practice of Dental Surgery, will perhaps be found as well adapted to dental purposes, as any that can be employed. It makes an excellent fine flowing solder.

2 dwt. 22 car. gold.

16 grs. fine silver.

12 grs. roset copper.

Previous to use, it should be rolled out in a thin strip, and cut into very small pieces. It fuses more readily and flows more freely when the pieces are small.

The soldering on of the teeth, is a nice and somewhat difficult part of the operation, and although greatly facilitated by a good lamp and blow-pipe, a thorough knowledge of it can only be acquired by practice. The lamps most frequently employed, and which answer very well, are similar to those used by silver and goldsmiths, and spirits of wine (alcohol) is now generally preferred to oil. It makes a clearer and purer flame, and gives out about the same quantity of heat. When this is used, the lamp should hold fully a pint, and have a spout from three to four inches in length, and three-fourths of an inch in diameter, which should be filled with wick, to prevent the flame from extending down into the lamp and causing an explosion. This has sometimes happened, when the above precaution has been neglected.

Hook's self-acting blow-pipe is thought much of by some practitioners, and as improved by Dr. Jahial Parmly of New York, is certainly very valuable for dental purposes. Dr. Elliott of Plattsburg, has also added to this blow-pipe and lamp a very important improvement, which consists in feeding the flame with atmos-



pheric air, by means of a bellows worked by the foot. But Dr. Somerby's furnace and blow-pipe is the best instrument of the kind which the editor has ever employed. An engraving of this, as well as Dr. Elliott's self-acting blow-pipe, may be seen in the editor's *Principles and Practice of Dental Surgery*, to which, for a more minute description of each, the reader is referred.

If the common blow-pipe be used, it should be from fifteen to eighteen inches in length, and have a tolerably large orifice, to enable the operator to control as much of the flame of the lamp as possible. The blow-pipes ordinarily employed by silversmiths are too short. They bring the eyes of the operator so near the flame of the lamp, that they are oftentimes injured by the intensity of the heat and light.

The work being ready for soldering, the lamp should be lit, and as much of the flame as possible, thrown with the blow-pipe, on, first, the plaster, and kept there until this has attained a red heat, then on the point of connection between the backing of one of the teeth and the plate, and as soon as the solder flows well here and around the two platina rivets, it should be passed to another and another, until the whole process is completed. After the solder has flowed freely at the first point, it will be comparatively easy to fuse it at all the others, as the temperature of the whole piece will be raised so high by this time, that little additional heat will be necessary to fuse the solder at the various other points where it is required. The flame, however, when it is directed to a single point, for the purpose of fusing the solder there, should be brought to a smaller focus, than when first thrown upon the work with a view of heating the plaster.

Should the solder flow in a wrong direction, as it often



does, when the heat is not concentrated upon the right place, the focus of the flame of the lamp, should be directed upon the point where it is desired it should take effect, when it will immediately flow in that direction. When the solder is only partially fused it is apt to run together and form a lump or small ball, which is fused with great difficulty, or to leave a rough uneven surface, and thus render the process of finishing both tedious and troublesome.

When the soldering is completed, the plaster, after it has cooled, should be removed, and the work immersed in a mixture of equal parts of sulphuric acid and water, for the purpose as before stated, of decomposing the borax and cleansing the plate. From fifteen to thirty minutes are required for this, and when it is completed, the work should be taken out, washed in water, and all rough portions carefully removed with suitable scorpers (scrapers) and a smooth neat finish given to it. This done, it is ready to be applied to the mouth, but in its insertion it is often necessary to bend and file the clasps a little to complete their adaptation to the teeth which they are intended to encircle.

## CHAPTER FOURTH.

OF THE TEETH TO WHICH IT IS MOST PROPER TO APPLY CLASPS,  
AND THE MANNER OF COUNTERACTING THE INJURY LIABLE  
TO RESULT FROM SUCH APPLICATION.

THE utility of artificial teeth applied on plate, when retained in the mouth by clasps to some of the natural teeth, depends very much upon the teeth to which they are clasped. The first molares, when sound and firmly articulated, offer a better means of support to a dental substitute than any of the other teeth, and when they can be as conveniently employed for this purpose, they should certainly be preferred. Next to these, the second molares are the best, and next to these the second bicuspidæ, then the first, and lastly the dentes sapientiæ. But no loose tooth, nor one within whose socket there is a diseased action, or which is so much affected with caries, that it cannot be restored to health, should ever, when it can be avoided, be made a means of support to artificial teeth. When none but such can be had, the proper course to pursue, is, to extract every tooth in the jaw, and replace the loss of the whole, with artificial substitutes, as the application of clasps to diseased or loose teeth, always aggravates the diseased action, and causes them to become a source of increased annoyance to the patient, as well as a cause of disease to the adjacent and contiguous parts. This, at any rate, would have to be



done, in two or three years, and it is better to do it at once, than to subject him to the increased trouble and expense consequent upon a double operation. Moreover, when the clasps are applied to loose teeth, the artificial ones not being held firmly in their place, move up and down with the motions of the lip, and thus render their detection by every observer, almost inevitable.

A plate with artificial teeth, when properly fitted and constructed, exerts but little mechanical force upon the teeth to which it is applied. Therefore, with the proper care and attention, a dental substitute of this description, may, under favourable circumstances, be worn, without being altered or replaced by another, from ten to twenty years. But it is important in every case, that the clasps be accurately adapted, and applied in such a manner as not to strain or exert any undue pressure upon the teeth to which they are fixed.

The cuspidati, being of a conical shape, and wholly unsuited to the application of clasps for the retention of artificial teeth, should never, when it can possibly be avoided, be used for that purpose. It is true, they are oftentimes fixed to them, but the practice is nevertheless objectionable. But when from peculiar necessity, it becomes absolutely requisite to use these teeth, the clasps should be adapted with great accuracy, and in such a manner as to prevent their presence from being detected, which can only be done, by making them very short and narrow. They should only reach a little more than half way round the teeth, and, applied very near to the gum.

As a means of support for artificial teeth, the incisores are worse than the cuspidati. It is almost impossible to apply clasps to these teeth so as to hold even a single artificial tooth securely and firmly in the mouth, still when others cannot be had, it is sometimes necessary to



use these, but they should only be had recourse to as a dernier resort.

Having now mentioned the teeth to which it is most proper to apply clasps, it will be proper to say a few words concerning the means necessary for the prevention of the effects liable to result from their application. It is well known, not only to practitioners of dentistry, but also to most persons who have worn artificial teeth, applied upon the principle under consideration, that the liability of the teeth to decay, to which the clasps are applied, is always increased by their application. The reason of this, has often very erroneously been ascribed, to the mechanical action of the clasps. It is a common remark, even among dentists, that when teeth, to which clasps or ligatures, have been applied, have decayed; they have been worn off; when in reality, the loss of substance which they had sustained, was wholly attributable to another cause, to the action of chemical, not to that of mechanical agents. By the retention of the secretions of the mouth and other extraneous matter, between the clasps and the teeth to which they are applied, they soon become putrid and acidulated, decomposing, first the enamel, and afterwards the bony structure of the organs.

This being the cause of the injury sustained by teeth, to which clasps are applied, the means for its prevention, must, at once, suggest themselves to every reflecting mind. They consist in the frequent removal of the artificial teeth, and the cleansing of the natural ones, to which the clasps have been applied. This should be done every morning and night, immediately after rising, and before going to bed, and after each meal. For which purpose, both a brush and waxed floss silk should be employed, and the teeth rubbed until every particle of vitiated mucus and foreign matter is removed.



By the constant and regular observance of these means, the decay of the teeth may be prevented; but if neglected, their destruction, will, in most cases, be both speedy and inevitable. Therefore, the importance of attending to them, should always be strongly impressed upon the mind of the patient, who, at the same time, should be properly instructed in the manner of removing and replacing the artificial teeth, and the plate and clasps should be so constructed, that this may be done with the most perfect ease and convenience.

But the decay of the teeth caused by the presence of corrosive agents, is not the only injury liable to be produced by the application of clasps. They are oftentimes so fitted, that when applied, they force themselves down between the necks of the teeth and gums, giving rise to inflammation in the last-mentioned structure and the alveolo-dental membranes, and ultimately to the destruction of the alveolar processes, and the gradual loosening and loss of the teeth. It is always necessary, therefore, to guard against these effects, by so adapting the clasps to the teeth as to prevent them from pressing too much upon the gums.

## CHAPTER FIFTH.

### OF THE CONSTRUCTION OF A DOUBLE SET OF ARTIFICIAL TEETH MOUNTED ON PLATES WITH SPIRAL SPRINGS.

THE mouth being in a fit condition, an impression of each alveolar ridge should be taken in wax, from which plaster and metallic models and counter models should be obtained, in the manner as before described. Between the latter, a plate for each jaw, of the thickness and width before mentioned, should be swedged and properly fitted. Having proceeded thus far, the next thing to be done, is, to make an antagonizing model, which may be obtained in the following manner. First, take a thin piece of soft wood, trim off its edges until its width shall be equal to the length it is intended the front teeth in both jaws shall be, then fix a rim of softened wax about an inch or an inch and a quarter in width, between the convex surfaces of the two plates; next pass one end of the wood through the frame part of this about on the medial line; put the whole in the mouth, adjust the plates, each to its proper place, then direct the patient to close his jaws naturally until they come in contact with the edges of the wood, when his mouth should be opened and the plates and wax removed, without, in the least, changing their relative position. The concave surfaces of the plates should now be oiled, and a batter of plaster of Paris, put first on one side and then on the other, in



the manner as directed for obtaining an antagonizing model when a dental substitute is required for only one of the jaws.

When the plaster has become sufficiently hard, the two pieces may be separated, and the wax removed. This done, let a narrow rim of wax be put around the convex surface of each plate, which is supposed to be still connected with its own part of the model. The two parts of the model may now be put together, and the teeth selected and arranged on the wax, beginning with the superior central incisores, then with the inferior, and so on; first, with two in the upper and then with two in the lower jaw, until all are selected and arranged.

As a general rule, the upper incisores and cuspidati should overlap the lower, and the superior centrals should cover the inferior centrals and about one-half of the laterals. The upper lateral incisores should cover the lower laterals, and about one-half of the inferior cuspidati, and the superior cuspidati should cover the remaining half of the lower and about one-half of the first inferior bicuspidates. The first superior bicuspidates should cover the remaining half of the first inferior and about one-half of the second, and the second superior bicuspidates should cover the remaining half of the second inferior and about one-third of the first molares. The first upper molares should cover the remaining two-thirds of the first lower and about one-third of the second; and lastly, the second superior molares should cover the remaining two-thirds of the second inferior. The third molares, or *dentes sapientiæ*, are usually dispensed with in a set of artificial teeth.

The foregoing arrangement being about that of the natural teeth, should always be observed in the construction of an artificial set, for the reason, that it adds to



their strength as well as to the beauty of their appearance.

In fitting, arranging, and antagonizing a double, as well as a part of a set of artificial teeth, it is almost always necessary to alter the shape of their base or the part which is to be fitted to the plate, and this can only be done by means of an emery wheel or grind stone.

The teeth being all properly adjusted and antagonized, the operator should next proceed to make suitable supports for the springs. These are differently constructed by different dentists, but the simplest, and if not the best, that have ever been employed, consist of strips of gold about an eighth of an inch in width, the sixteenth or twentieth of an inch in thickness, and about a fourth or three-eighths of an inch in length, with a shallow open socket on the outside of the end towards the coronal extremities of the teeth, for the head of the eyelet, perforated in the centre for the reception of a screw, or simply with a very narrow strip of gold, a little thicker than the head of the eyelet, soldered, transversely across, a little below the perforation for the screw, to prevent the spring from coming in contact with the gums. The other extremities of these supports are soldered to the plate, one on each side on the outside of the teeth, at a proper point between the medial line and the posterior extremities, which, in most, if not in all cases, will be found to be between the second bicuspid and first molars. The screw-heads should be a little larger than the heads of the eyelets, which last should be about a twelfth of an inch in diameter. The screws need not be larger than a small knitting-needle. The object of having large heads to them is to prevent the springs from coming in contact with the walls of the cheek.

The arm of the eyelet or the part intended to enter the



spring should be about half an inch long, and the size of the spindle or wire around which the spring is wound.

The springs should be made from eighteen carot gold wire, which should be no larger than is necessary to give to them a sufficient degree of power. Their diameter should not exceed a tenth or at most an eighth of an inch. Their length should be varied from an inch and a half to two inches, according to the distance of the jaws from each other when the mouth is opened to its greatest extent.

The manner of winding the wire is very simple. It is sometimes done by means of a small crank, but the simplest way of doing it is to grasp it between two blocks of wood in a small bench-vice. This done, let the upper end be grasped with the wire or spindle on which it is to be wound, which should not exceed, in size, a small knitting-needle, by a pair of sliding tongs or a small hand-vice. This then, with the end of the spindle resting on the blocks of wood, should be made to revolve by turning it in the hand, until a coil of sufficient length shall have been firmly and closely wound on the spindle.

But the construction, both of the springs and supports, will be better understood by the student, by an examination of Plate XXIX. Fig. 8, where they are represented, than by any description which can be given.

It is often necessary to employ spiral springs for the support of an upper and part of a lower set of artificial teeth; as for example, where only three or four teeth are required on each side of the back part of the inferior maxillary—six or eight of the natural teeth in the front part of the mouth being present and firmly articulated. The lower plate, in a case of this sort, should pass behind the natural teeth which remain, and cover the alveolar ridge posteriorly where they are wanting. But the part

of the plate which passes behind the natural teeth should be thickened, by soldering another piece over it, to give it the necessary degree of stiffness and prevent it from bending. It is seldom, however, that a set of teeth constructed in this manner, is worn with as much comfort and satisfaction as a full set, and where only five or six teeth remain, it would be better to extract them and insert a complete set at once; or if there be eight good teeth, or even six, in the front part of the mouth in the lower jaw, to dispense with a substitute for the others, and apply only an upper set.



## CHAPTER SIXTH.

### OF THE CONSTRUCTION OF PLATES FOR ARTIFICIAL TEETH IN PARTICULAR CASES.

As the stability of artificial teeth, applied on plate, greatly depends on the construction of the plate, it may be well to describe the shape that should be given to it, in a few different cases. But the reader will be able to form a more correct idea of their shape and the manner of their application, from the representations given in Plates XXVIII. and XXIX., than from any description which can be given. To these, therefore, he is referred.

It is seldom necessary, in the application of a single incisor to attach to the plate more than one clasp. If this be applied to a suitable tooth, it will give to the plate and artificial organ sufficient stability for all the purposes to which a substitute for a single tooth can be made subservient. The plate should be about a quarter of an inch in width and carried back on the palatine side of the alveolar ridge, to the second bicuspid or first molares, of the same side, if either of these are remaining, and are in a suitable condition to be employed for its support. But when these teeth are wanting, and no other suitable tooth on this side of the mouth can be had, the plate should be carried across to a bicuspid or molaris on the other side, to which it should be clasped. In either case, however, the plate should not be fitted up close to the

teeth by which it passes. A space of a twelfth or an eighth of an inch should be left between it and them, so that it may not become a cause of irritation to the apices and margin of the gums. The anterior edge of the plate should not ordinarily come so far forward over the alveolar ridge, as to prevent the anterior part of the base of the tooth from covering it.

But when from any peculiarity in the shape of the bicuspidés and molares, one cannot be found capable of affording a sufficiently firm support for a clasp, or that will not admit of the application of one sufficiently wide to do this, then the plate should be extended back on each side, to the second bicuspidés or first molares, or to the teeth which it is to be clasped.

The foregoing general directions with regard to the construction of a plate for an artificial incisor, will, in most instances, serve as a sufficient guide to the student or young practitioner, yet cases will occasionally present themselves, in which his judgment alone, will have to suggest the description of plate that it will be most proper to employ.

When two or more incisores of the superior maxillary are to be replaced with artificial teeth applied on a metallic base, the part of the plate to which the teeth are to be attached should be from three-fourths of an inch to an inch in width, and extend back on each side of the alveolar ridge to the second bicuspidés, or first or second molares, or whichever may afford the best means of support to the artificial piece to be placed in the mouth. And, as in the case of the plate for a single tooth, it should come as far forward over the alveolar ridge, as the anterior portion of the base of the artificial teeth will admit. This part of the plate, except in those cases in which the gums are never exposed in laughing, should



be covered by the artificial teeth to prevent its presence from being detected.

A plate of this description, when firmly secured by a clasp to a bicuspid or molaris on each side of the mouth, will afford a secure support to substitutes for all of the incisores and even the cuspidati; and artificial teeth thus applied, may be made to subserve to a very great extent, all the purposes of the natural organs whose loss they supply.

In constructing a metallic base for the incisores, cuspidati and bicuspidates, the plate should be shaped very much like the one last described, except that it should be about the same width all the way round. It should be accurately fitted to the teeth to which the clasps are to be applied, and be fully one inch in width. The loss of all the teeth in the upper jaw as far back even as the *dentes sapientiæ*, may be replaced with artificial teeth attached to a plate of this description. But when it is to be clasped to the second molares, if the third be wanting or have been removed, it should be extended back to the maxillary tuberosity on each side, to prevent its weight, together with that of the artificial teeth, from acting unequally and prejudicially on the organs that sustain it.

It frequently becomes necessary to supply the loss of one or more upper incisores as well as the bicuspidates and sometimes one or two molares on one side of the mouth, by means of a plate secured by clasps to teeth on the other side. In cases of this sort, the plate should be made to cover such parts of the alveolar ridge as are to be supplied with artificial teeth, and to fit up closely to the teeth to which it is to be applied, and when practicable, the second bicuspid and second molaris should be selected for this purpose. By attaching clasps to the plate at points a little distant from each other, greater stability will be secured to the piece.

It is seldom necessary, in the application of substitutes for one or two bicuspidés on each side of the mouth, to extend a plate across from one side to the other. Two separate plates may be employed, and each made fast to a molaris. When thus applied, they are worn with more comfort and satisfaction by the patient, than when the plate is extended all the way across the mouth, however accurately it may be fitted.

In constructing a plate for artificial substitutes to supply the place of all the natural teeth in the upper jaw, except a single molaris, it should be about one inch in width, and made to cover as much of the alveolar ridge as possible, and to all the inequalities of which, it should be accurately fitted. It should extend back of the remaining natural tooth to the tuberosity of the bone, which it should cover. The clasp should be wide and applied in such a manner as to keep the plate in its proper place. A single molaris may oftentimes be made the means of support to a plate with twelve or thirteen artificial teeth for a number of years, but as a general rule, when there is only a single tooth remaining, it is better to extract it and apply a whole upper set upon the atmospheric pressure or suction principle; for the reason, that the operation can be made more perfect and durable.

Most dentists are in the habit, in the application of artificial teeth upon the last-mentioned principle, to make the plate wide enough to cover the whole of the roof of the mouth, but in doing this, it is impossible to fit it with as much accuracy to the various inequalities of the parts as can be done, when a narrower one is employed. A plate, an inch or an inch and a fourth in width can, for this reason, be made to adhere more firmly than a much wider one.



## CHAPTER SEVENTH.

### OF ARTIFICIAL OBTURATIONS AND PALATES.

BEFORE giving a description of the mechanical contrivances most proper to be employed for remedying the various defects met with in the palatine organs, it will be proper to offer a few general remarks concerning the nature and extent of the injury to which these parts are liable.

#### ABSENCE OF A PORTION OF THE PALATINE ORGANS.

Imperfections in the palatine arch, involving a loss of substance, always interferes, in proportion to their nature and extent, with the functions of mastication and deglutition, and this difficulty is greatly aggravated, when the defects here, are accompanied by malformation of the jaws. But notwithstanding the inconvenience to which an individual, labouring under an affection so distressing as that of the absence of the whole of the palatine arch, and even a portion of the anterior part of the alveolar border, together with a fissure of the upper lip, they do, nevertheless, manage to perform these functions; and it is curious to see how readily an infant, thus affected, draws from the breast of its mother or nurse, the aliment which it requires for its sustenance and growth. The plan which it adopts to effect this process, is very curious.

The nipple, instead of being taken upon the top of the tongue, is carried beneath it, and this organ, as is observed by M. Delabarre, is thus made to perform the office of an obturator, by being applied to the roof of the mouth and closing the opening through it. It now, by the contraction of its lips and depression of its tongue, draws the milk from the breast.

Unconscious of the imperfection in its palate, it does not perceive, as is observed by the author just mentioned, until the period approaches, when it should begin to make its wants known by words, the great importance of a distinct articulate voice. This function, in consequence of which, is little cultivated. Every word being badly articulated, it "makes no effort to render itself intelligible. All the sounds are nasal, and resemble a dull murmur, difficult to understand, and disagreeable." Nor can age enable the unfortunate individual to give a much more distinct utterance to words.

Imperfections of the palatine arch are sometimes congenital; at other times they are the result of disease, or of mechanical violence. The former are seldom unaccompanied by a fissure of the upper lip, and sometimes two, and the division or perforation of the palate, is always along the median line. This description of defective formation, extends both to the bones and soft parts, causing the cavities of the nose to communicate with that of the mouth.] There is much variety in them, in some, there is deficiency of the *velum pendulum palati*, or soft palate; in others, there is a fissure extending through the whole roof of the mouth, both the bony and soft parts being divided.

[There is sometimes too, a complete division of the alveolar border, oftentimes accompanied, by great distortion of the jaw-bone. Mr. Fox, describes a most extraordi-



nary case, which came under the care of Mr. Heaviside.\* He says.] It was in a young gentleman born with a double harelip; the upper jaw bone projected considerably under the nose. When the time of dentition arrived, three teeth came in this projecting piece, and the appearance of the mouth was as in Plate XXII. Fig. 1. At the time that Mr. Heaviside was first consulted, he advised that no operation should be attempted until the young gentleman had arrived at an age when the success of the operation would have no chance of defeat from childish resistance. When he was about six years of age, Mr. Heaviside began to perform the operation; at that time he dissected from the bone a piece of skin which grew upon the upper surface; he then sawed off the projecting piece, with three teeth in it, Fig. 2. Twelve months afterwards, he performed the operation for harelip on one side. He then left his patient for another year, when he performed the like operation on the other side. The piece of skin that had been attached to the upper surface of the bone, formed the central portion of the lip; and when the cure was completed, the face appeared as in Fig. 3, having a most perfect symmetry, and free from any deformity.

[It is to be regretted, that the extent of the imperfection in the palatine arch in the foregoing case, is not described. Nor does it appear from the history which the author has given of it, that any surgical operation was performed, or mechanical contrivance applied to remedy this part of the defect. But when recourse is had to mechanical means as a substitute for the absence of any portion of the roof of the mouth, or palate, it should not be, until after the completion of the growth of the jaws, and it may be, that the employment of means for remedying the defect in

\* Vide Plate XXII.

these parts, was for this reason deferred to a later period of life, which may not have been until after the publication of this work.

M. Delabarre, who in his work on mechanical dentistry, treats of the subject in question at some length, divides accidental leisons of the palatine organs, into three species. The first is circumscribed by the osseous substance. The second consists of a perforation of the velum of the palate only; and the third, in the destruction of the entire vault of the palate, or at least, a great part of it; and to these ravages, is sometimes added, says the author just named, the loss of the inferior portion of the vomer and the cornets.

"The two first," says Delabarre, "are most frequently situated on the side of the palatine raphe, thus penetrating only a single nostril." He then adds, that, whatever be the extent, form and position of these accidental leisons the victims of them have not the advantage of the young infant; for having acquired the habit of eating by placing their food on the tongue, they always force a certain quantity of it up into the nose. The natural tone of the voice is destroyed, articulation of words, in some cases, where the loss of substance is very considerable, is wholly prevented. They also affect deglutition as well as the voice. The case of a young man, is mentioned by the above named writer, who, suffering from a division of the velum palati, could swallow no fluids, "without a part of them being returned by the nose." He however managed to remedy to some extent, this difficulty, by throwing his head back, and letting them run into the œsophagus. Similar examples of effects resulting from a loss of a portion of the palatine organs have fallen under the observation of the editor.

In the destruction of the solid tissues which enter into



the formation of the roof of the mouth, the soft parts participate. Nor does the injury always stop here. It frequently extends to the nose, lips and cheeks; the greater portion of which, are sometimes destroyed, giving to the unhappy sufferer, the most hideous and frightful appearance, but as it constitutes no part of the design of the editor to treat of the means employed for remedying defects in these parts, although the aid of art is often invoked, and has in many instances supplied the loss with useful and ingenious mechanical contrivances, he will not in this place, attempt to give a minute description of them.

Imperfections of the palate may oftentimes be remedied by surgical means—by an operation, denominated staphyloraphy, said to have been first instituted by a French dentist by the name of La Monnier, and who first performed it about the year 1764. M. Roux, a French surgeon, is the author of an excellent memoir on this operation, which was published in 1825. It is also minutely described by Dr. Hullihen of Wheeling, Va. in a well written paper in the fifth volume of the American Journal of Dental Science. But with the surgical treatment of leisons of the palatine organs, the editor at present, has nothing to do; his object being merely to describe the mechanical means employed for remedying them.

#### OF THE CONSTRUCTION OF OBTURATORS.

The employment of obturators to supply the abscence or replace the loss of a portion of the palatine arch, was resorted to, many centuries ago, but their construction, for a long time, was exceedingly faulty, and as a consequence, the wearing of them was not only attended with

inconvenience, but was also productive of actual injury. They were retained by means of a piece of sponge. This instrument, according to Guillemean, was applied by the Greek physicians, who called it *hiperari*. But as the disease to which the destruction of the palatine organs were supposed to be only attributable, was not known at so early a period, some have questioned the correctness of the above statement. On the other hand, it has been shown, that dental abscesses have been known to give rise to necrosis and exfoliation of the bones of the palate, and that hence it is rendered very probable.

The celebrated French surgeon, Ambrose Parè, gives an engraving of an obturator which he had constructed in 1585, which consisted of a plate, probably of gold or silver, applied to the opening in the palatine arch, and retained by means of a piece of sponge, secured with a screw to an upright attached to the upper surface of the plate. The sponge, by absorbing the moisture in the nostrils, swelled sufficiently to prevent the plate from falling. But this description of obturator is the most objectionable of any that has ever been employed. By the stagnation of the fluid in the sponge, we are told, and as any one might readily suppose, it soon becomes so insufferably offensive, as to render the approach of an individual almost impossible. Besides, the sponge not only counteracts the efforts made by nature to effect a cure, but it has been found, that it gradually enlarges the opening. The following case, quoted from Lefoulon, and by this author, from a memoir upon obturators, by M. Baillif, a dentist of Berlin, is in point.

"The 1st of November, 1824," he says, "Dr. Siedmogrodzki presented himself to me with M. de \*\*\*, who had had the misfortune to lose his nose, and part of the



vault of the palate, by a siphilitic malady, in the years 1807, 1808.

The hole formed in the anterior of the palate was ten millimetres long and eight wide.

To remedy these accidents, an artificial nose had been made for him, and an obturator formed of a plate of fine silver, furnished with a sponge, such as recommended by Ambrose Parè, Gariot and other practitioners of our days. The compression which the sponge of the said obturator had caused upon the maxillary and palatine bones, during the period extending between the years 1808 and 1824, has so dilated the parts, that all the maxillary and palatine vault is consumed entirely, without any sign of disease, and in an imperceptible manner, leaving nothing but the velum and uvula at the posterior part. The anterior part of the maxillary bones is so thin that they are separated at their suture, in such a way that the obturator could no longer be applied.

In short, the opening, which was only twelve millimetres long and fourteen broad, to day presents the enormous extent of ten inches long and an inch and a half broad. Such was the deplorable situation of this patient, who could not articulate a single syllable. All the sounds that she could utter by any effort, amounted to no more than a kind of bellowing.

This fact proves incontestibly, that we should banish from use, obturators sustained upon the lateral parts by the compression of sponges; also, those with wings, plates and flat springs, because they dilate and destroy every part which they touch either by compression or friction."

In speaking of the application of any appliance which may interfere with the curative efforts of the economy, Bourdet, thus judiciously remarks. "Before considering



the cicatrized perforations of the palate as being of a nature incapable of diminishing in diameter, practitioners should satisfy themselves properly and beyond doubt that such is the case. I do not think so, for positive facts attest the contrary, and as holes made in the cranium with the trepan, close almost entirely, in like manner, those of the palate constantly diminish." The *juxtaposed obturator* proposed by Bourdet, and as improved by Delabarre, is free from the objections of those fastened with sponge, or lateral wings or slides, which, for a long time, were employed. The obturator contrived by Bourdet consists of a metallic plate, large enough to cover the opening in the palate, accurately fitted, with two lateral prolongations extending to the teeth and to which they were fastened by means of ligatures. But as the ligatures were productive of irritation to the gums, and did not hold the plate sufficiently tight to prevent it from moving, it found but little favour among dentists. Both of these objections, however, were obviated by the improvement made by Delabarre, which consisted in the employment of clasps, attached to the lateral branches of the plate, instead of ligatures, for fastening it to the teeth. And to prevent these from slipping, he attached to each a small metallic spur, which, descending between the teeth, was bent below over its grinding surface. To this improvement he made another equally valuable, not only for the purpose for which he applied it in a case he relates, in connection with the description he gives of it, viz. to supply the loss of substance and prevent an accumulation of mucus in the cul de sac, resulting from the wound being closed only on the side of the mouth, but also, to prevent fluids in swallowing, from passing between the obturator and soft parts, through the opening into the nostrils, which by the contraction of the muscles of the palate are sometimes slightly raised.



This last improvement consists in the application of a drum to the top of the plate, which, to use the author's own words, "resembles a man's hat, the crown of which is very low and enters the opening." It is fastened to the plate by means of two screws. He supplied his patient with several of these, gradually diminishing in size, so that as the opening closes, a smaller one may be put on.

A copy of the engraving of the obturator just described, as given by M. Delabarre in his *Treatise on Mechanical Dentistry*, may be seen in Plate XXX. Fig. 5.

The manner of constructing an obturator after the above plan is very simple. First, let an impression be taken in wax of the palatine vault, and alveolar ridge, then procure a plaster and metallic model and counter model, in the manner as before described. Between the last, let a gold plate be stamped, large enough to cover the opening in the palate, with an arm on each side extending to a bicuspid or molar tooth to which a broad clasp should be soldered. Second, let an impression of the opening be now taken, and from this another plaster and metallic model and counter model obtained, and a plate smaller than the first stamped—to the upper surface of which, it should be fitted and made fast by soldering. But the drum should never be so large as to press against the walls of the opening. But this last, should never be applied, except absolutely required, to prevent the passage of fluids into the nostrils.

Every part of the mechanism should fit with the most perfect accuracy, and in such a manner as not to be productive of the slightest irritation to the soft parts, and as in the case of the insertion of artificial teeth, the health of the natural teeth and their relative and contiguous parts should be previously secured. This should never

be lost sight of, as the success and durability of the operation will greatly depend on it. The obturator too, should be removed and thoroughly cleansed two or three times every day, as also the teeth to which the clasps are applied.

A plate of gold replacing nearly the whole of the loss of the entire palate, may be applied in the manner as just described.

#### OF OBTURATORS AND PALATES COMPLICATED WITH ARTIFICIAL TEETH.

The loss of one or more teeth oftentimes accompanies the destruction of the palate, and when this happens, the substitute for the latter should be connected with that for the former, and the idea of complicating the two with each other, was first suggested by Fouchard. When there are healthy and firmly articulated natural teeth remaining in the upper jaw, such substitutes may be advantageously connected, but the mechanism, as intimated by Delabarre, would be too heavy to be sustained by lateral wings.

"But we find," says the author just mentioned, "in vol. 50, page 386, of the *Journal of General Medicine*, the description of a dental obturator, presented to the Society of Medicine, by M. Touchard, surgeon dentist, of Paris, similar to the one he had applied for a man who had lost the two medial incisores, the lateral incisores, the canine and the first bicuspid of the right side, and all the part of the maxillary bone, in which these teeth were situated, as well as a portion of the ascending apophysis of the same side, and finally nearly the anterior half of the bony plate which forms the palatine arch. Notwithstanding the loss of osseous substance, the opening which



formed the accidental communication between the nose and the mouth, was only an inch in diameter, and round. M. Touchard thought that in perfecting the obturator described by M. Fouchard, he might apply it advantageously in the case in question. Consequently, he made it of two distinct parts, one of which was an obturator of gold, the lower side concave, and the upper presented a round elevation, destined to be inserted in the opening of the palatine arch. The other was a piece of hippopotamus, to which he gave the form of the missing portion destroyed by the disease, and into this human teeth were inserted.

The obturator and teeth were firmly united by means of a metallic staff, dove-tailed, in the posterior part of the latter. Two elastic plates of gold proceeding from the sides of the instrument and pierced with holes, passed behind the remaining teeth on each, and by their tendency to separate from one another, served to maintain the apparatus in its place."

After giving the foregoing description, M. Delabarre remarks, "the learned dentist entrusted with the report of this obturator, has judiciously observed, that the prolonged action of the elastic plates, would result in the loosening and displacement of the supporting teeth. Not only am I of this opinion, but I have had occasion to test that machines, however wanting in elasticity, always operated to the detriment of the organs against which they acted."

Again, he says, "M. de Chamant has engraved in his opusculi on mineral paste teeth, a dental obturator, which occupied the place of the incisores, the coronoids and the four bicuspidés; and he has shown me another mode after the same plan, and supported by lateral ligatures. We perceive all the advantage resulting from the employ-

ment of porcelain, whenever there is occasion to replace the loss of substance when it is as considerable as in the case just mentioned. Finally, as it is essential to take care of the supports, it is not proper to make use of the elastic plates advised by M. Touchard, nor the ligatures used by Fouchard and M. de Chemant, but the elastic compressors (clasps) may be applied with more advantage."

When the loss of substance is very great, instead of having recourse to porcelain block teeth, the better plan is, to make a raised or box plate, as the latter would be much lighter, and as a matter of course much less cumbersome than the former. The plate should be made of twenty-one or two carot gold, and be no thicker than is absolutely necessary. Plate XXX. Figs. 3 and 4 represents an obturator and plate complicated with artificial teeth.

But in the construction of a dental obturator, the dentist will always have to be governed by the circumstances of the case, and therefore, no rules can be laid down from which it will not be necessary occasionally to deviate. By reference, however, to the illustrations given in Plate XXX. the reader will be able to obtain such general knowledge of the subject, as will enable him to give the proper construction to the mechanism for any case in which his aid may be sought.

#### OF THE CONSTRUCTION OF A COMPLETE PALATE WITH A SET OF ARTIFICIAL TEETH.

The following is a description of a most ingenious contrivance planned by M. Delabarre for replacing the loss of the palate, together with most of the teeth in the su-



perior maxillary. He says "the most serious case which can be presented is that which I am about to relate. An individual had lost, in consequence of siphilis, all the bony and membranous arch of the mouth, and also the greater part of the upper teeth, among which were the lateral ones, which would have been the most favourable to be embraced by the hooks, (clasps.) I thought of constructing a mineral set of teeth, surmounted by an arch and velum of platinum, bearing upon sides of the cavities a circle surrounding the parts to be supplied. Inside of this circle was encased a very light box, though representing the thickness and figure of the nasopalatine floor, so that by this means, I restored to each of the cavities the form it had before. This being done, I supported the obturator by springs which took their insertion upon a metallic case which enclosed the lower dental arch.

The machine subserved a part of the object; that is to say, the nose and the mouth were separated by it; the patient however still spoke through his nose, because the soft portion of the palate was wanting. It was then necessary to replace this. I could have constructed a cover and a movable plate in metal, as the goldsmith Cadot, of whom Cullerier speaks, has done. But I preferred gum elastic. I wished to employ the mechanism of deglutition for my purposes, which were that the artificial cover should raise and fall every time the passage of food, and even that of saliva, should be effected from the mouth into the pharynx. Consequently the tongue became the means of putting the mechanism in motion, and this latter was disposed of to this effect, in the following manner.

I made an oval window in the fore part of the plate; I then placed a valve which clasped itself hermetically and which was held in place by means of an axis and a small



very soft spring. To this plate was soldered a lever which passing backward, rested on another which was held in a see-saw position by an axis. This last lever was enough to reach the extremity of the principal plate, and it was flattened, so as to fasten to the movable velum, which itself was attached to the pharyngeal border of the instrument.

During deglutition, the point of the tongue, applying itself, pressed upon the valve, which transmitted to all the other parts the movement impressed upon it. Thus the velum was raised, and from a vertical, assumed nearly a horizontal position; in such a way that neither solid food nor drinks could escape into the nasal cavities. This plate, complicated with the artificial teeth, was yet by no means heavy, for the plates were of very thin platina, soldered with fine gold. The patient derived great advantage from it, both in mastication and deglutition, and in the articulation of words."

It is possible that a piece of mechanism, such as the one just described, might be made to answer, to some extent, the purposes for which that was designed, but happily, cases seldom occur which call for so complicated an apparatus. A copy of the engraving which the author has given of it may be seen in Plate XXX. Fig. 6.

Although constituting no part of the design of the editor, to treat, in this place, of the prosthesis of any other organs than the palatine and maxillary, he will, in conclusion, subjoin the following description of an artificial palate complicated with an artificial nose, as well as with artificial teeth, furnished at his request, by his brother Dr. John Harris, formerly of Georgetown, Ky. The subject of



which, a young lady, the editor had an opportunity of seeing about twelve months since, and so neatly was the mechanism constructed and applied, that none but a very close and critical observer, would suspect it to be the work of art.

ANNAPOLIS, *July 28, 1845.*

*Dear Brother,*—Your letter of this morning requesting me to send you by return of mail a description of the artificial nose and palate which I made for the young lady of Scott County, Kentucky, is now before me, but received too late to enable me to comply with your request, but I will endeavour to do so by the next succeeding mail.

I very much regret, from the novelty and importance of the case, that you had not allowed me more time, but I will endeavour to do the best I can.

The subject of the affliction requiring the artificial ap-purtenances referred to, is, Miss A. C., now about twenty years of age, of high personal and family respectability.

When but little past infancy, she lost her nose and the central portion of the soft and bony palate, about three-fourths of an inch in length and three-eighths in width, commencing about five-eighths of an inch in rear of the front teeth and extending backwards.

I have no knowledge of the cause that led to the affliction, only that it was preceded by inflammation, ulceration, and general constitutional derangement.

When about twelve years of age she submitted herself to be operated on for an artificial nose, in Cincinnati, Ohio, by Dr. M. The design of which was to supply the defect by the transfer of integument from the arm, over the deltoid muscle, called the rhynoplastic or telecopeon operation.

To say nothing of the expense, pain and suffering consequent upon the operation, and the jeopardy her life

was placed in, as soon as her health would admit, she returned to her home, in a much worse condition than when she left it.

To add to her misfortune, before she left the city, or had fairly recovered from the effects of the first operation, mortified with her now aggravated condition, as a last alternative, she had a nose manufactured of wood by a Mr. Rostang, resident dentist of the same city, and confined in its position by means of spectacles, and an artificial palate, to which the nose was connected by intermediate fixtures, passing through the palatine fissure.

As might have been expected, the subsequent development of the maxilla and other parts soon rendered the whole apparatus useless, though not until it had destroyed the three teeth, which had been selected as a support to the palate, by means of as many rough, badly constructed and arranged clasps.

About four years ago, at which time I was consulted in her case, her teeth and relative parts exhibited the following appearance, viz. several of her teeth besides the three irrecoverably injured by the clasps, were more or less decayed: some of which quite loose; the gums and adjacent soft parts much inflamed, tumefied and spongy, the dental arch and general dimensions of the mouth, (whatever it might ever have been) was evidently very much collapsed or contracted, say to nearly one-half of the usual size, as was evidenced by the position of the superior cuspidati, now standing parallel to each other and nearly in contact, between which there had been the usual number of incisores and of the ordinary dimensions, and which were lost when she was about ten or eleven years of age.

Although the design and plan of the apparatus was a good one, for the accomplishment of the purpose for



which it was intended, its premature application was unquestionably productive of the worst of consequences, and to which the contraction of the mouth may principally be ascribed.

Her timidity arising, no doubt, from the recollection of her previous suffering, gave me no little trouble in obtaining her consent, to the course of practice which I recommended, but after explaining what must soon be her condition, she reluctantly yielded her assent and permitted me the full exercise of my judgment in the management of her case.

The removal of the three teeth previously referred to, was immediately effected, as also all deposits of salivary calculus.

In about eight weeks, with the usual treatment, the soft parts of her mouth were restored to health. The local maladies of her teeth were next attended to, and in some four weeks, thirteen carious places, after the usual preparatory treatment, were filled with gold foil.

With the mouth thus restored to health, but one question could arise as to the propriety of supplying my patient with another palate, &c., that was, if the maxillary organs have not attained their full development, the same destructive consequences might be produced, as was from the other palate.

From the circumstance of her advanced age, I did not much fear this would be the case, though, had I been governed entirely by my own inclination, I should have deferred all further proceedings to some more remote period, but in this I was overruled, by not only my fair patient herself, but by all her family connections, and as yet, I have not had cause to regret the course I took.

I therefore constructed a palate of fine gold upon the usual plan, with only two clasps, made broad and heavy,

one on the left and one on the right margins of the palate, embracing two of the soundest and most suitable teeth.

To the convex or superior surface of the palate one end of a piece of gold wire three-fourths of an inch long, was soldered at a point corresponding with the fissure—from front to rear, and on a line extending between the two teeth embraced by the clasps, describing the centre of action; the wire or upright was then bent forward and upwards so as to pass through the fissure and present the upper end parallel with, and at a convenient distance from, the anterior opening of the naries,—this place of attachment I found necessary, that no unequal or undue pressure might result from the weight and action of the superincumbent parts upon the palate.

A screw was now cut on a platina wire, for one-half inch, made to fit in a corresponding one, made through the upper end of the upright wire, on a level with the external opening of the nose; upon the other or anterior extremity of the horizontal platina wire, a hook or catch was made as a support to the nose by means of a gold loop attached to the septum of the artificial nose, the tightness of the nose to be regulated by screwing the horizontal wire in or out, and its position by bending the upright backwards or forwards.

The length of the horizontal wire is one inch, the size or strength needs no further description.

It is now about four years since the operation was completed, and thus far, I have heard no complaint.

Yours, affectionately,

JOHN HARRIS.

The dentist, although seldom called upon to replace the loss of the nose with an artificial substitute, yet the manner of doing it should be understood by him.]





EXPLANATION OF PLATES

TO

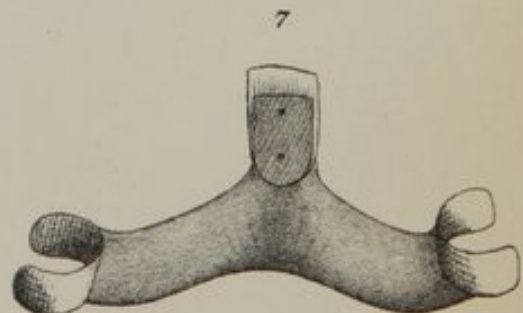
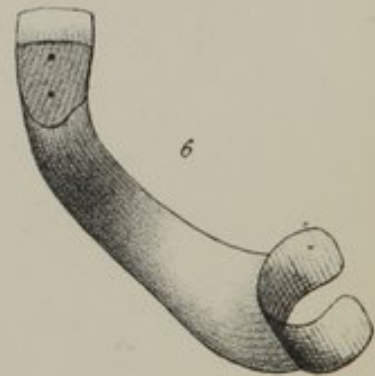
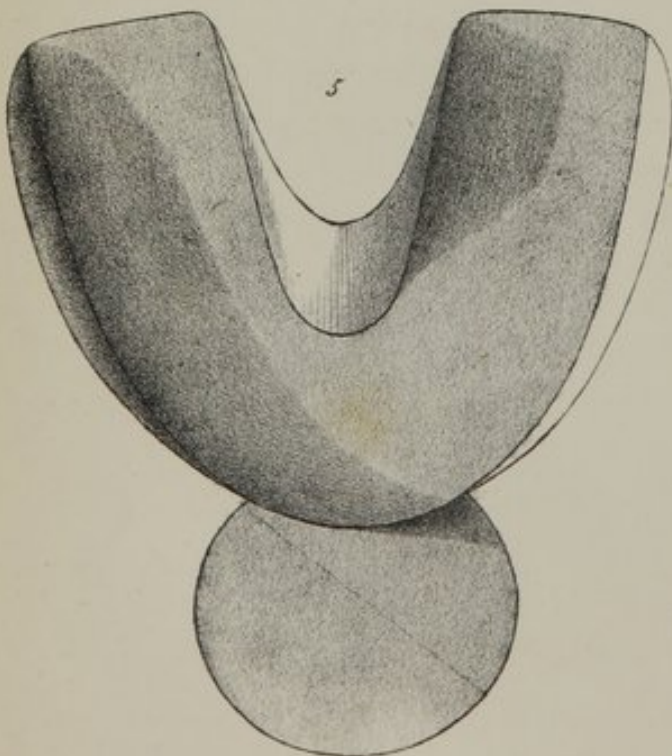
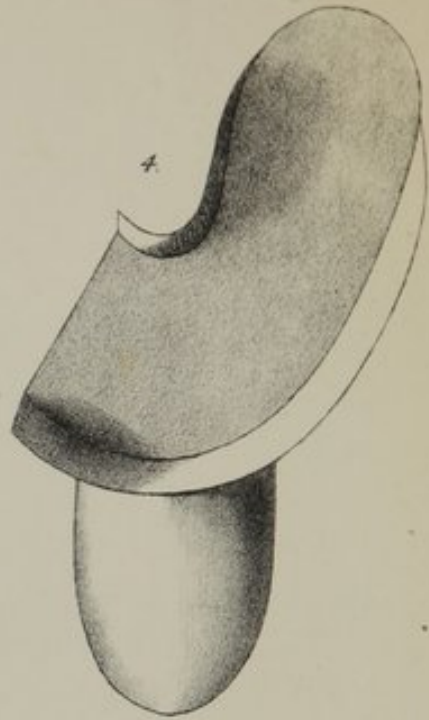
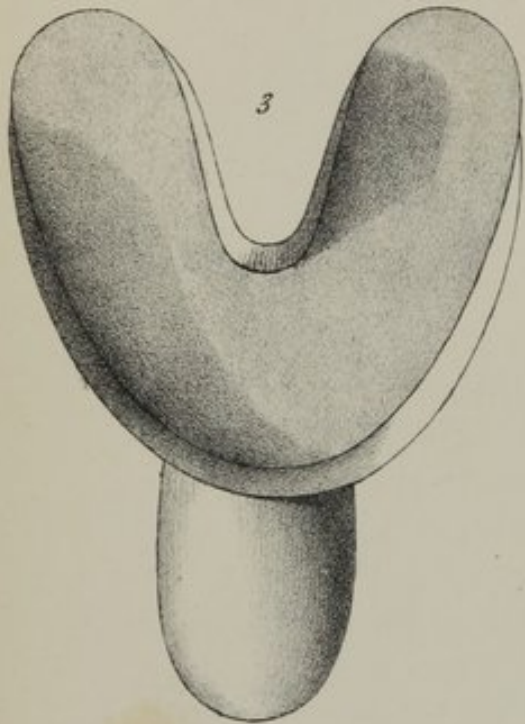
PART THIRD.



Fig. 1.

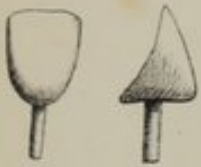

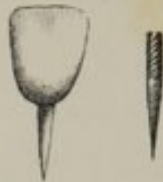Fig. 2.



## PLATE XXVIII.

FROM SUBJECTS FURNISHED BY THE EDITOR.

- FIG. 1. A front and side view of a porcelain tooth with a wood pivot or tenon, for the replacement of the crown of a superior central incisor.
- FIG. 2. A front view of a porcelain tooth with a metallic pivot for the replacement of the crown of a superior central incisor, with a representation of the pivot before it is fixed in the tooth.
- FIG. 3. A wax holder made of tin for taking an impression of the upper jaw.
- FIG. 4. A wax holder for taking an impression of the front and right side of the upper jaw. A similar one should be employed for taking an impression of the front and left side.
- FIG. 5. A wax holder for taking an impression of the lower jaw.
- FIG. 6. A porcelain substitute for the left central incisor of the upper jaw, mounted on plate, to be clasped to the first molaris of same side.
- FIG. 7. A porcelain substitute for the left central incisor of the upper jaw, mounted on plate, to be clasped to the first molaris on each side.



## PLATE XXIX.

FROM SUBJECTS FURNISHED BY THE EDITOR.

FIG. 1. Porcelain substitutes for the two central incisores of the upper jaw, mounted on plate, to be clasped to the second bicuspid.

FIG. 2. Porcelain substitutes for the upper incisores and cuspidati, mounted on plate, to be clasped to the first molares.

FIG. 3. Porcelain substitutes for the upper incisores, cuspidati and the left bicuspid, and first molaris, mounted on plate, to be clasped to the first bicuspid and first molaris on the right side.

FIG. 4. Porcelain substitutes for the upper incisores, cuspidati and bicuspid, mounted on plate, to be clasped to the first molares.

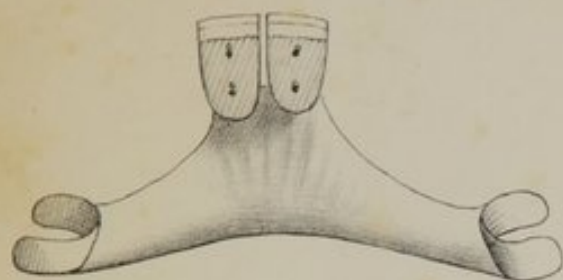
FIG. 5. Porcelain substitutes for the upper incisores, cuspidati, bicuspid and first and second left molaris, mounted on plate, to be clasped to the first right molaris.

FIG. 6. Porcelain substitutes for all the upper teeth, except the dentes sapientiæ, which are generally omitted in an artificial set, mounted on plate, to be applied upon the atmospheric pressure and suction principle.

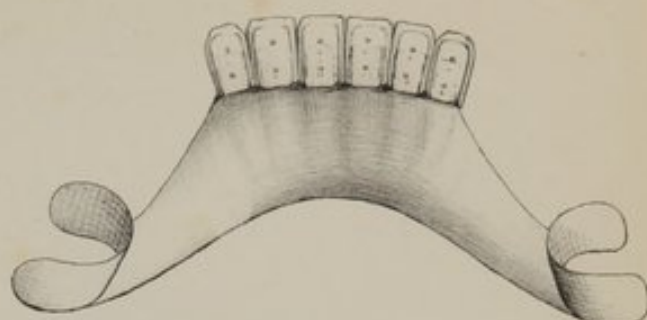
FIG. 7. Porcelain substitutes for all the teeth of both jaws, except the dentes sapientiæ, which are omitted, mounted on plates with spiral springs.

FIG. 8. A spiral spring, with its attachments, before being fixed to the plates.

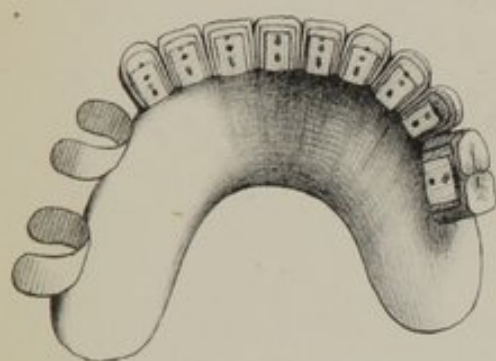
Fig. 1.



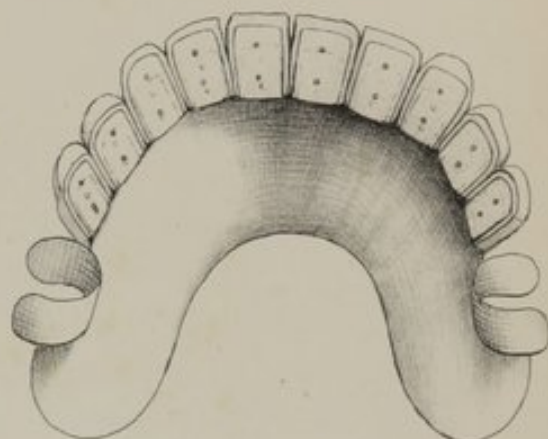
2



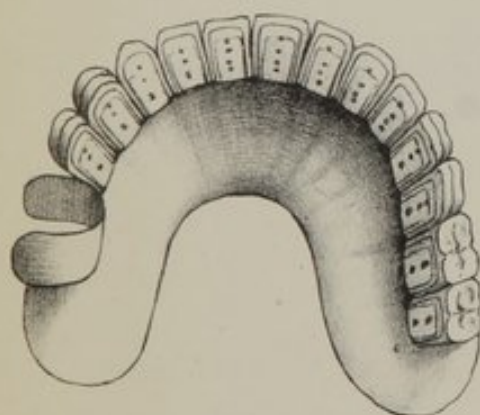
3



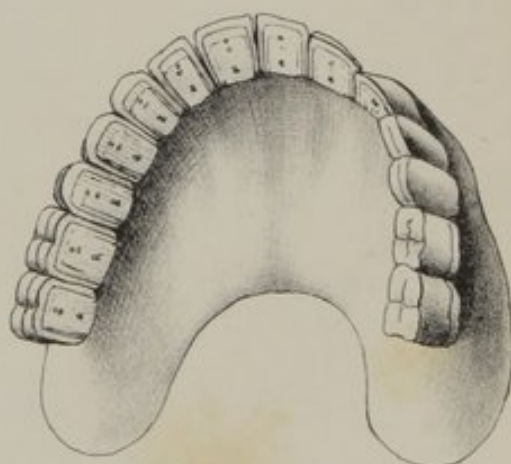
4



5



6




7

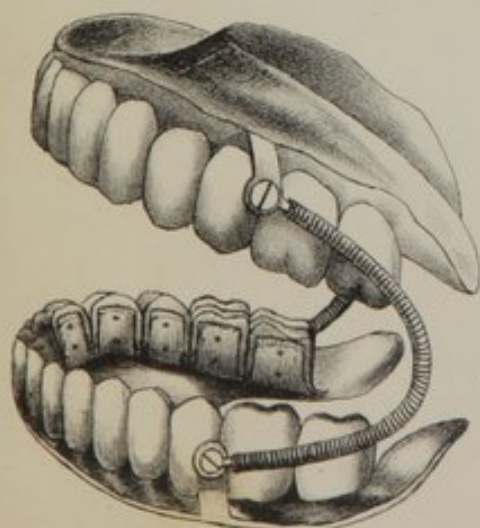



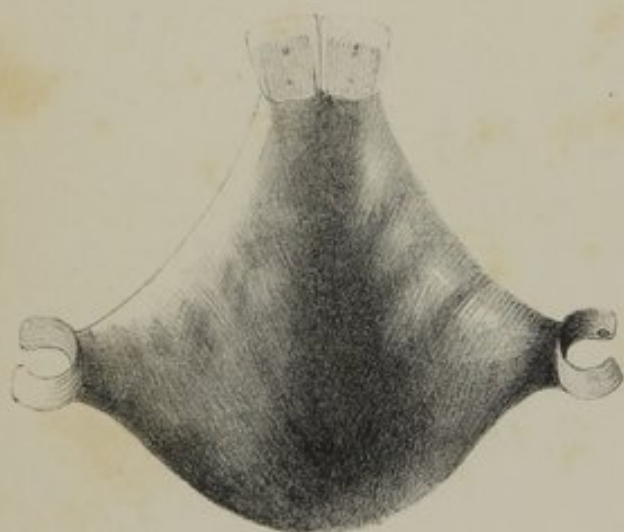
Fig. 1.



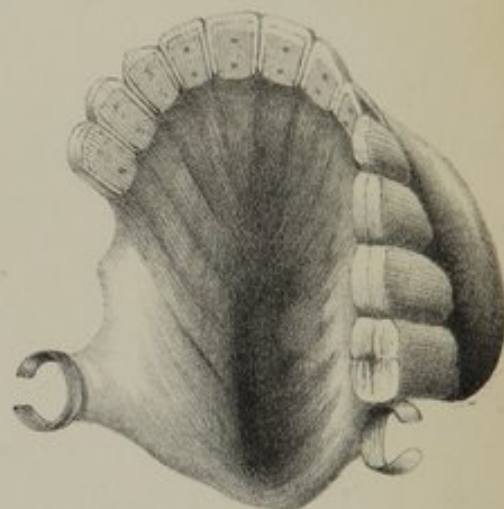
2



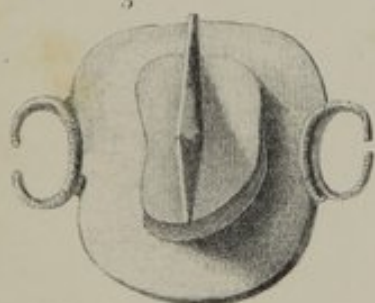
3



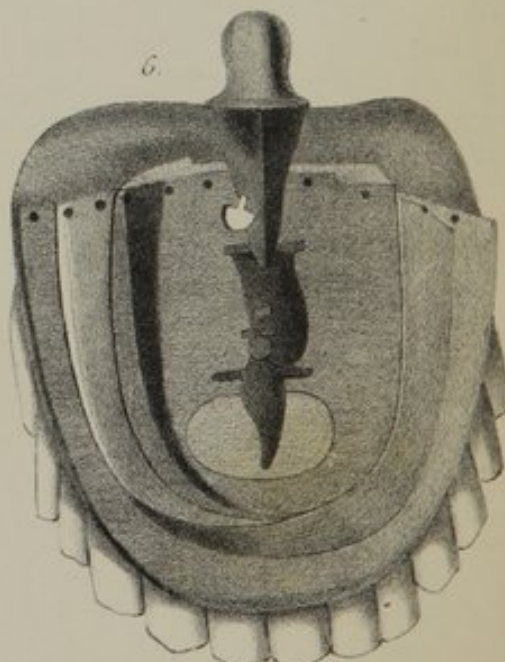
4



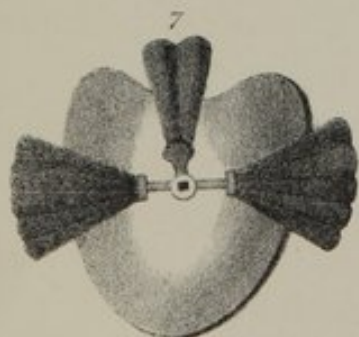
5



6



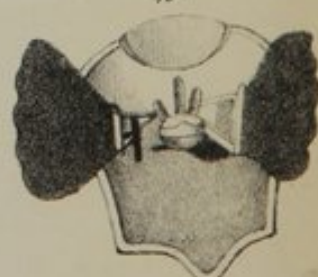
7



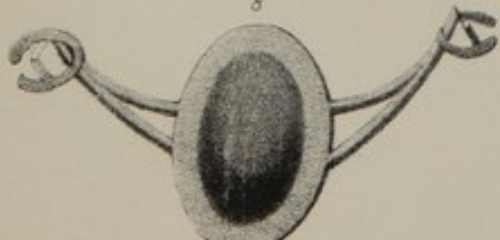9



10



8



## PLATE XXX.

FIGURES 1, 2, 3, and 4, are from original subjects, furnished by the editor, the others are copied from Fouchard and Delabarre.

FIG. 1. An obturator, for an opening of about half an inch in diameter through the palatine arch, to be clasped to the first molares.

FIG. 2. An obturator similar to the last, but for covering a much larger opening.

FIG. 3. An obturator complicated with the two central incisores.

FIG. 4. An obturator complicated with the incisores, cuspidati, bicuspides, and the first and second molares of the left side of the mouth, clasped to the dentes sapientiæ, which were sound and firmly articulated. The original of this was constructed after the plan adopted by Dr. Koecker, for restoring a similar defect. On the left side of the mouth, the alveolar border had been destroyed, and there was a large opening into the antrum as well as through the roof of the mouth.

FIG. 5. A representation of an obturator constructed by Delabarre with a drum on its upper surface.

FIG. 6. A representation of a complete palate, with fourteen teeth, constructed by M. Delabarre.



FIG. 7. A representation of a palate obturator with the uvula, to be held up by wings, copied from M. Delabarre's Mechanical Dentistry, but constructed by Cadet.

FIG. 8. Represents an obturator constructed by M. Delabarre, to be retained in the mouth by elastic compressors. This instrument is an improvement on one invented by Bourdet, which was held up by means of ligatures applied to a tooth on each side of the mouth.

FIG. 9. Represents a winged obturator, invented by Fouchard, the wings turning on a pivot. This obturator is inserted by placing one wing above the other, and when put in place, the wings are turned by means of a key in opposite directions, which prevents it from falling.

FIG. 10. Represents another winged obturator invented by Fouchard and applied by means of a key. It is held in its place, by means of a piece of sponge in connection with the wings.

## INDEX.

---

### A.

- ABRASION of the teeth, mechanical, 252.
- Abscess, alveolar, remarks on, 275.  
    fomentations to cheek, for the relief of, 278.  
    remarkable cases of, 282, 283.  
    seldom cured, except by removal of tooth, 276.  
    treatment of, extraction when the gums are inflamed recommended, 277.  
    when produced by dentes sapientiæ most painful, 277.
- Abscesses, formation of, 105.
- Acids, their deleterious effects on the teeth, 300.  
    used in analysis of the teeth, 124.
- Adhesion of the lips and cheeks from excessive use of mercury, 312.
- Adjustment and adaptation of artificial teeth to gold plate, 388.
- Alveoli, description of, 286.  
    absorption of, not independent of local irritation, 290.  
    diseases of, 288.  
    growth of, 30.
- Anatomists, former views of, on the destruction of temporary roots, 73.
- Antrum maxillary, description of, 317.  
    diseases of, 318.  
    effects of diseased teeth on, 319.  
    polypus in, and cancerous affections of, 320.  
    treatment of, 322.
- Apparatus for grinding artificial teeth, 376.
- Arch, palatine, imperfections of, 408.
- Arnold's view of dental germs, 47.
- Arteries, dental, 59.  
    distribution of, 60.
- Atrophy of the teeth, 58.

### B.

- Backings for artificial teeth, 390.



## C.

- Calculus, salivary, description of, 296.  
    formation of, and pathological condition of the general system, favourable to its production, 296.  
    its effects, 297.  
    means necessary to prevent its accumulation, 298, 299.
- Canal, dental, formation of, 30.  
    preparation of, for reception of pivot, 374.
- Care necessary on the part of those who wear artificial teeth, 398.
- Caries, dental, arresting progress of, in temporary teeth, 106.  
    agency of diet in its production, considered, 168.  
    constitutional causes, 167.  
    dependent on hereditary predisposition, 170.  
    first manifestation of, 158.  
    frequently caused from defective formation of the teeth only, 166.  
    internal, doctrines of, refuted, 165.  
    of permanent teeth, 157.  
    predisposing causes of, 166.  
    prevention of, 172.  
    produced by pressure, 171.  
    progress of, 157.  
    proximate cause of, 160.  
    results from chemical agents, 161.  
    treatment of, 176.
- Cementum of the teeth, and formation of, 56.
- Clasps for holding artificial teeth, their construction, 365.
- Climate, its influence in producing caries of the teeth, considered, 169.
- Constitutional effects of dentition, 112.
- Convulsions, causes of, in children, 113.
- Cooper's, Mr. Astley, observations on vascularity of dental pulps, 51.
- Crowns of teeth, manner of excising, 371.

## D.

- Decay of temporary teeth, 105.
- Dentes sapientiæ, formation of, 42.
- Dentifrices, description of, for the prevention of tartar, 299.
- Dentition, diseases of, 108.  
    erroneous notions of, 108.  
    mechanism of, by M. Delabarre, 109.  
    symptoms of, 110.
- Diarrhœa, causes of, in children, 113.  
    treatment of, 114, 115.

## E.

- Effects of clasps on the teeth considered, 397.  
Enamel, analysis of, 125.  
    removal of, by denuding process, 249.  
    defective formation of, 57.  
    formation, hardness, and composition of, 52, 53.  
Eruption, cutaneous from dentition, 112.  
Excavating caries, its importance, and the difficulty attending it, 192.  
Excavators, dental, description of, 191.  
Excrescences of the gums, removal of, by ligatures, 268.  
Exostosis of the teeth, 238.  
    case of, 242.  
    probable causes of, 244.  
    symptoms of, 239.  
Experiments with chemical agents, their effects on the teeth, 162.  
Extraction of teeth, remarks on, 209.  
    directions for those of the incisores and cuspidati, 220.  
    manner of, 219.  
    objects of, and reasons for, 210.  
    of bicuspidæ and molares, 222.  
    of roots of teeth, 229.

## F.

- Fangs of teeth, formation of, 39.  
    ossification of, 57.  
    temporary, absorption of, 61, 67.  
Files for teeth, best shape of, &c., best manner of using them, 183.  
Filing, its bad effects in the regulation of teeth, 171.  
    custom of savage nations in relation to, 180.  
    for removal of caries, highly beneficial, 171.  
    manner of, in order to prevent reapproximation of teeth, 182.  
    root of tooth for the reception of artificial crown, 374.  
Foil for filling teeth, proper manner of introducing it into, 194.  
Fomentations to face, when necessary, 278.  
Forceps for extraction of teeth, remarks on their superiority, 214.  
    for extraction of bicuspidæ of both jaws, inferior cuspidati, and  
        inferior dentes sapientiæ, 217.  
    for inferior incisores, 218.  
    for inferior molares, 218.  
    for superior dentes sapientiæ, 217.  
    for superior incisores and cuspidati, 215.  
    for superior molares, 216.



- Forceps, number requisite, 215.  
    their formation described, 215, 218.  
    compound root, description of, 231.

## G.

- Goodsir's views of the formation of dental germs, 47.  
Gumboils, produced by decayed stumps, 174.  
    influence on the general health, 174.  
Gums, diseases of, 260.  
    preternatural growth of, and treatment, 265, 266.  
    lancing of, in difficult dentition, 118.

## H.

- Hemorrhage after extraction of teeth, 237.  
    mode of arresting it, 237.  
Hunter's, John, views on structure of the teeth, 62.

## I.

- Impressions of the mouth, how taken, 354, 381.  
Incisores, ossification of, 50.  
Inflammation of membrane in nervous cavity, 162.  
Instruments for extraction of roots of teeth, directions for the use of the  
    elevator, hook and screw, 230.  
Irregularity of teeth, the treatments necessary to remedy, 87, 93.  
    caused by cuspidati, 93.  
    construction of appliances for the remedying of, 88.  
    four states of, 95.  
    time most suitable for its correction, 96.  
    varieties of, 88.  
Irritation, consequent upon dentition, 111.

## J.

- Jaw-bone, exfoliation of, caused by diseased tooth, 280.  
    exfoliation of, caused by use of mercury and by small-pox, 312.  
    articulation of, 326.  
    its movements resembling that, both of the graminivorous and  
        carnivorous animals, 326.  
Jaw, inferior, alveoli of, more liable to absorption than superior, 292.  
    its motion produced by five pair of muscles, 327.  
Jaws, mal-conformation of, 77.  
    accretion of, 78.  
    diversity of opinion concerning their increase, 81.

## K.

- Key instrument, remarks on, 210.  
directions for the use of, 233.

## L.

- Lancing the gums, benefits of, in dentition, 118.  
Lancet, gum, description of, and the parts necessary to be lanced, 120.  
Luxation of lower jaw, reduction of, 325.  
how produced, and liability of its recurrence, 328.  
manner of relieving, various means spoken of, 330.  
prevention of, 331.

## M.

- Matrix, dental, transformation of, 69.  
Maxilla, foetal, development of, 29.  
Membrane, dental, preformative, 56.  
destruction of, 58.  
Membranes, dental, vascularity of, 45.  
Mercury, its effects on the teeth, 309.  
deleterious, and fatal effects of, as exhibited in the case of a patient in Guy's Hospital, 311.  
its influence on the gums; renders them more susceptible to future morbid affections, 316.  
produces no direct effect on the teeth, 315.  
symptoms of its presence; manifested by looseness of teeth and soreness of the gums, 309.  
Models, metallic, how obtained, and metals necessary for, 382, 383.  
antagonizing, how obtained, 388, 399.  
Molares, first, their liability to decay, 94.  
permanent, anterior, formation of, 41.  
ossification of, 41, 51.  
Mouth, its healthy condition necessary for reception of artificial teeth, 369.

## N.

- Nasal and palatine apparatus, constructed by Dr. John Harris, 422, 425.  
Necrosis, dental, remarks on, 245.  
causes of, 246.  
confined particularly to the front teeth, 245.  
treatment in the early stages of, 246.  
Nerves, dental, distribution of, 60.  
method of destroying, 207, 208, 373.



## O.

Obturator, artificial, 408.

- complicated with artificial teeth, 417, 418.
- construction of, their former imperfection and consequences, 412—415.
- improvements on, by M. Delabarre, 416.

## P.

Paces, its use in the extraction of teeth, 212.

Palates, artificial, 408.

- with sets of artificial teeth, 419.

Peduncle of dental sac, observations on, 109.

Perpendicular extractor, 213.

Phthisis pulmonalis, indicated by transparency of the teeth, 174.

Pivoting method of inserting artificial teeth, manner of, 356.

Pivot teeth, manner of inserting, 370.

Pivots, suitable materials for, and manner of preparing them, 377.

- tubed, for escape of pus, with holes in artificial crown, 379.

- with gold in centre, 378.

- with groove on side for egress of matter, 379.

Plate, gold, for artificial teeth, its thickness and purity, 365.

- box, recommended, in some cases, 388.

- confined by atmospheric pressure, 366.

- manner of stamping, fitting and attaching clasps to, 384.

Plates, construction of, in particular cases, 404—407.

Plugging the teeth, when indicated, 186.

- as recommended in case of exposed nerve, 188.

- in such way as to admit the escape of pus, 188.

- so as to prevent pressure on exposed nerve, 188.

- suitable instrument for, 191, 194.

- the difficulties of, 193.

- the proper material for, 189.

- when improper, 187.

Porcelain, its use in the manufacture of teeth, 359.

Processes, alveolar, description of, 286.

- absorption of, not independent of local irritation, 290.

- diseases of, 288 293.

Pulps, dental, first appearance of, 30.

- elongation of, 52.

- union of, 59.

- vascularity of, 44—51.

- Processes, alveolar, rudiments of, 29.  
Punch for the removal of roots of teeth, 212.  
Pustules, formation of, during dentition, 113.

## R.

- Raschow and others, researches of, on the formation of the teeth, 54.  
Roots of teeth, temporary, destruction of, 72.  
    manner of attaching an artificial crown to, 376.  
    manner of preparation of, for artificial teeth, 371.  
    temporary, non-absorption of, 68.  
    the condition necessary for the reception of artificial  
    crowns, 363.

## S.

- Sacs, dental, their appearance when given off, 45.  
Scaling the teeth, manner of applying the instruments, 306.  
    description of instruments necessary for its performance, 307.  
Scrofulous habits in children, and their consequent liability to tumours  
    and excrescences of the gums, 272.  
Scurvy of the gums, 261.  
    how marked, 261.  
    treatment of, in the more advanced stages, 263.  
    treatment of, in the incipient stages, 262.  
Sockets of teeth, inflammation of, indolent kind, 282.  
    formation of, 41.  
Soldering teeth to plate, preparation for and manner of, 391.  
    apparatus necessary for, 392.  
Spina Ventosa, confined to the incisores and cuspidati of upper jaw, 247.  
    what it consists of, its effects and treatment, 248.  
Springs, spiral, when used, 365.  
Stumps of teeth, generally cause inflammation, 160.  
Substance, granular, transformation of, 54.  
    carneous, remarks on, 70.  
Substitutes, dental, temporary, 369.  
Symptoms of dentition, 111.

## T.

- Teeth, temporary, ossification, number and division of, 31.  
    articulation of, 39.  
    composition of, 50.  
    description of, 36.  
    discoloration of, 64.  
    eruption and completion of, 32, 33, 34.



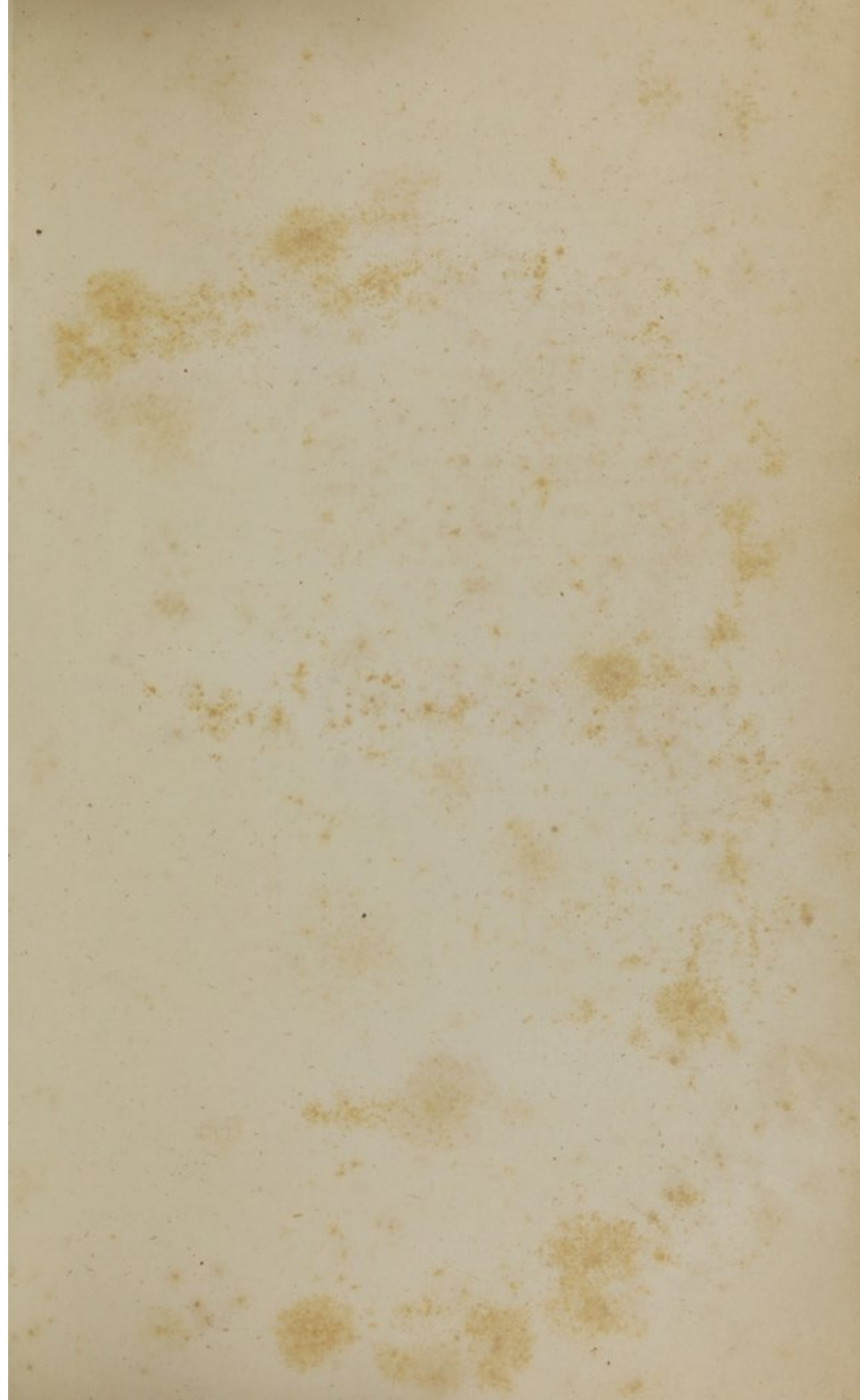
- Teeth, fractures of, and treatment for, 254.  
    human, analysis of, 123.  
    irregularity of, causes of, 76, 78.  
    irregularity of, prevention of, 83.  
    most suitable for the attachment of clasps, 395.  
    permanent, formation of, 35.  
    permanent, irregularity of, 76.  
    supernumerary, 103.  
    temporary, importance of their removal at a proper time, 82.  
    temporary, shedding of, 66, 74.  
    temporary, shedding of, time required for, 84, 86.  
    temporary, time and manner of replacement, 74.  
    artificial, arrangement of, and how antagonized, 400.  
        demand for, 357.  
        great improvement in their manufacture, 353.  
        insertion of, 362.  
        insertion of, on plate, and secured by clasps, 364.  
        manner of confinement in the mouth, 355.
- Tic douloureux, description of, 202.  
    case of, recorded by Dr. Haighton, 202, 203.
- Tooth-ache, arising from sympathetic affections of gums or sockets, 204.  
    remarks on, 197, 198.  
    its frequent results, 202.  
    remedies for, 201.  
    treatment of, 199, 200.
- Tooth, carious, removal of sensitiveness for purpose of filling, 205.
- Transplanting teeth, former practice of, 356.  
    immoral tendency, and baneful effects of, 357.
- Treatment of first dentition, 104.
- Trismus produced by dentition of molar teeth, 122.
- Tube, gold, for pivoting when it is necessary, 375.
- Tubercle, carneous, proofs of, 70.  
    first appearance of, 71.

## V.


- Vaccination, its importance, and happy influence in the prevention of  
    small-pox, 314, 315.
- Vascularity of the teeth, 63.

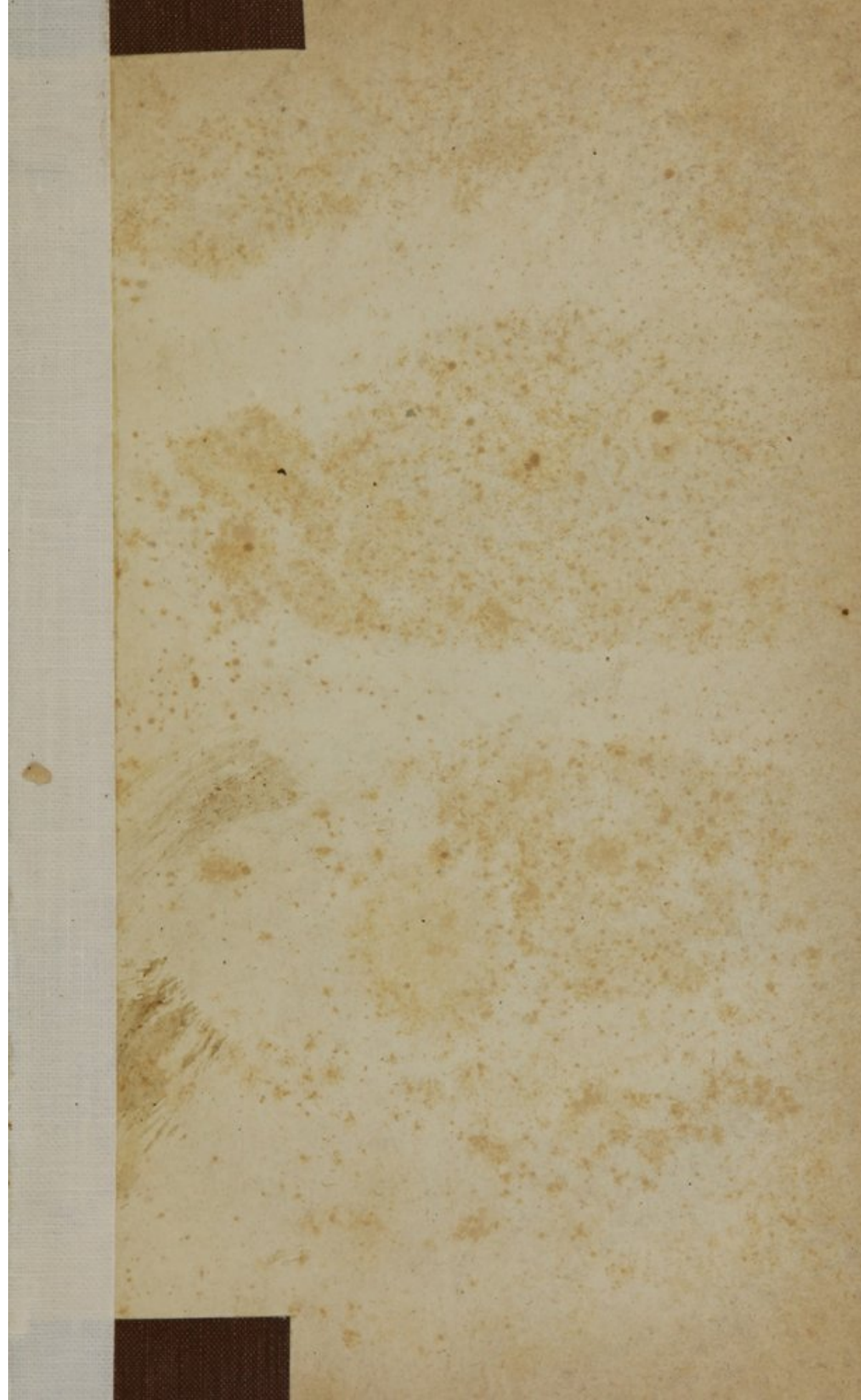
## W.

- Wax-holder, description of, 382.











NATIONAL LIBRARY OF MEDICINE



NLM 03289251 4