

**Surgical observations on tumours : with cases and operations / by John C. Warren.**

**Contributors**

Warren, John Collins, 1778-1856.  
Francis A. Countway Library of Medicine

**Publication/Creation**

Boston : Ticknor, 1848, ©1837.

**Persistent URL**

<https://wellcomecollection.org/works/fr6eggn7>

**License and attribution**

This material has been provided by This material has been provided by the Francis A. Countway Library of Medicine, through the Medical Heritage Library. The original may be consulted at the Francis A. Countway Library of Medicine, Harvard Medical School. where the originals may be consulted. This work has been identified as being free of known restrictions under copyright law, including all related and neighbouring rights and is being made available under the Creative Commons, Public Domain Mark.

You can copy, modify, distribute and perform the work, even for commercial purposes, without asking permission.



Wellcome Collection  
183 Euston Road  
London NW1 2BE UK  
T +44 (0)20 7611 8722  
E [library@wellcomecollection.org](mailto:library@wellcomecollection.org)  
<https://wellcomecollection.org>





10  
To The Library  
of the  
Massachusetts General Hospital  
from  
John C. Warren

Feb. 1<sup>st</sup> 1847

A. 37

MASSACHUSETTS GENERAL HOSPITAL

Treadwell Library.

23

K

10



MEDICAL LIBRARY.


1848.











Digitized by the Internet Archive  
in 2011 with funding from  
Open Knowledge Commons and Harvard Medical School





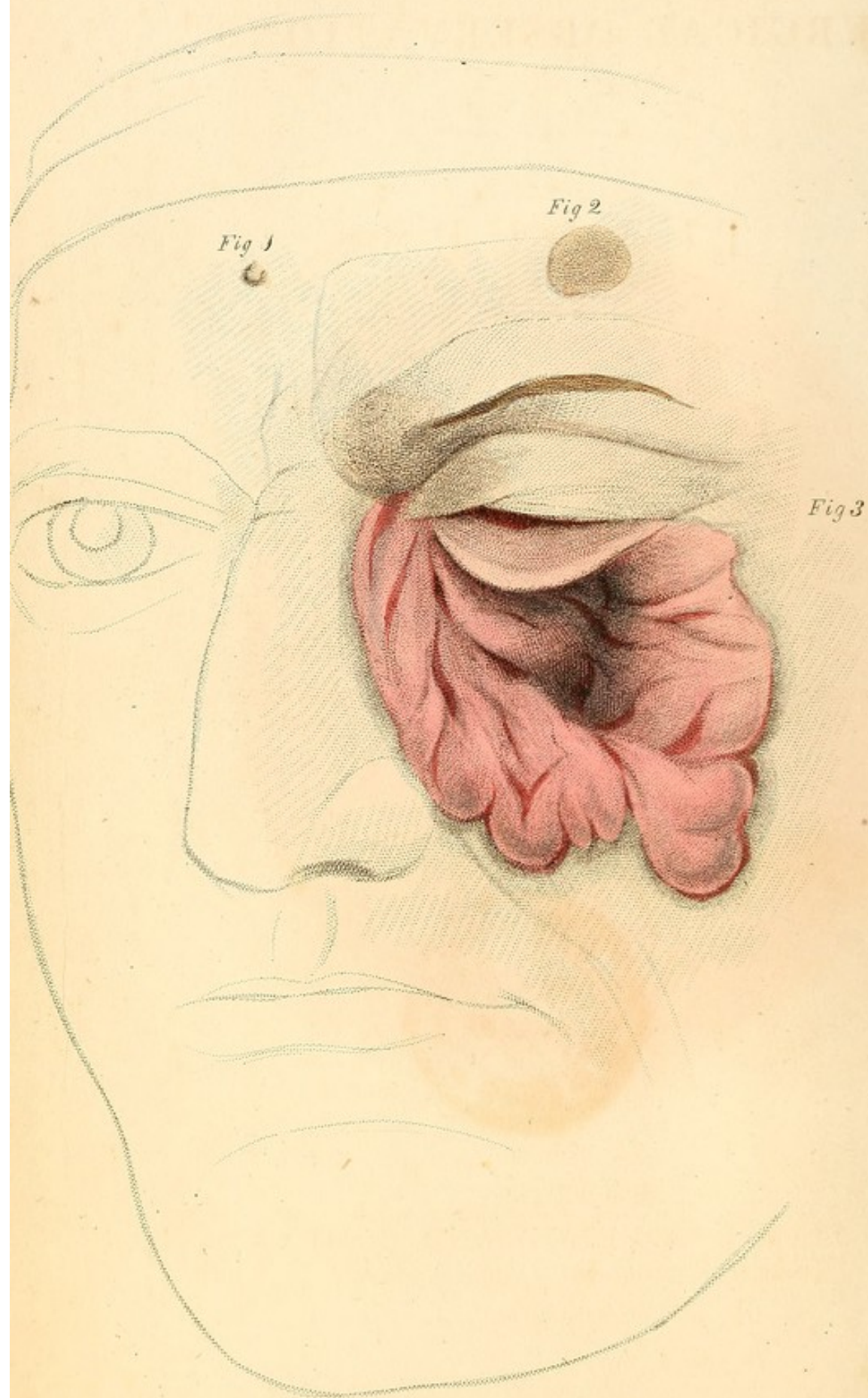


232 10

Treadwell







*Lepoides*

# SURGICAL OBSERVATIONS

ON

## TUMOURS,


WITH

CASES AND OPERATIONS.

BY

JOHN C. WARREN, M. D.

PROFESSOR OF ANATOMY AND SURGERY IN HARVARD UNIVERSITY,  
AND SURGEON OF THE MASSACHUSETTS GENERAL HOSPITAL.



BOSTON:  
WILLIAM D. TICKNOR AND COMPANY.

CORNER OF WASHINGTON AND SCHOOL STREETS.

M DCCC XLVIII.



23K  
(2)

Entered according to Act of Congress in the year 1837,  
BY JOHN C. WARREN,  
In the Clerk's Office of the District Court of Massachusetts.



BOSTON:  
WILLIAM D. TICKNOR AND COMPANY,  
Printers, 11 CORNHILL.



TO

SIR ASTLEY COOPER, K. B.

---

MY DEAR SIR,

The lapse of nearly forty years has not effaced the grateful recollection of the sound and able instructions received from you in the earliest period of my medical studies. I wish it were in my power to offer you some token of respect satisfactory to my feelings, and worthy of your great name. The discoveries and improvements

you have made in science, the freedom with which you have communicated them, the noble works by which you have enriched the healing art, demand of its cultivators all the consideration they can pay. Unable to present to you any adequate expression of respect, I must ask the privilege of prefixing your name to these sheets, not as an honour to you, but as an ornament to them.

With the highest respect,

I remain your grateful friend,

JOHN C. WARREN.



## P R E F A C E .

HAVING been in the habit of examining and preserving the tumours presented by surgical operations, and having thus made a considerable collection of these objects, I was naturally led to add some lectures, on this branch of surgical science, to my usual course. After doing this, it occurred to me that it might be useful to my profession in this country to commit these lectures to writing, for public use. My plan was to have given place in them to the facts I had collected, and to these only ; on the ground that the generalities, which naturally made a part of a surgical course, would be found more thoroughly elaborated and better displayed in works already published. Discovering some material objections

to this plan, I have been led to introduce such general remarks as were necessary to connect together the histories of particular cases, and I have added to them a concise account of the treatment applicable to each disease. It will be understood then that this is not to be considered as a treatise comprehending all that is known on the subject, but rather as a collection of cases intended to illustrate the distinctions between different tumours.

While I have not intended to make a compilation from books, neither have I designedly omitted to avail myself of the labours of the able and distinguished men who have done so much for the advancement of this branch of science. The writings of John Hunter, Desault, Bell, Callisen, Abernethy, Alibert, Laennec, Andral, Lisfranc, Louis, Velpeau, Wardrop, Carson, Hope, Lawrence, Liston, Travers, Hodgkin, and Sir Astley Cooper, have been occasionally consulted, (perhaps too imperfectly;) and to the three last-named authors I have been indebted for important considerations.



One of the most useful works in surgery, which I can imagine, would be a collection of representations of all known tumours. The inadequacy of language to convey to the mind the appearance of these diseases, renders an appeal to the senses desirable, whenever it can be employed; and when the objects themselves cannot be presented, the best substitute for them is to be found in casts and engravings. Mr. John Bell and Sir Astley Cooper have done much to supply this desideratum, and I should have felt proud to have effected something that might be considered an addition to their labours. To accomplish this would have required more time and better opportunities than it has been my privilege to enjoy. But as I could not abandon the attempt to be useful to those who have not access to more perfect works, I have procured such representations of tumours as could conveniently be obtained.

Practical men in this country, called as they are to every kind of medical duty, possessing no time they can devote to study, but what is robbed

from hours which the wearied faculties require for repose, can estimate the obstacles to any literary labour among us. To the common embarrassments of my profession, I think myself bound to state one of an accidental nature. At the period of preparing this work, important considerations made it necessary for me to suspend my professional pursuits in order to undertake a voyage across the Atlantic. Compelled to accomplish this publication, under an unusual pressure of affairs, or to defer it to an uncertain period, I thought it right to relinquish the attempt at an elaborate and finished production, to clothe the facts collected in the best dress that circumstances permitted me to give them, and to content myself with the expectation that the errors which may have escaped me now, will be readily discovered hereafter, both by myself and others.



## CONTENTS.

---

DEDICATION, - - - - -	iii
PREFACE, - - - - -	v
INTRODUCTION, - - - - -	1

### SECTION I.

EPIDERMOID TUMOURS, - - - - -	15
Verruca, - - - - -	15
Clavus, - - - - -	16
Ichthyosis, cornea, - - - - -	19

### SECTION II.

DERMOID TUMOURS, - - - - -	22
Definition of Malignant Tumour, - - - - -	22
Lepoides, - - - - -	27
Keloides, - - - - -	40
White Elevation, - - - - -	41
Red Pimple, - - - - -	43
Malignant, - - - - -	44

Eiloides, - - - - -	48
Anomalous Dermoid Tumours, - - - -	49
Molluscum, - - - - -	50
Accidental Tumour, - - - - -	52

## SECTION III.

TUMOURS OF THE CELLULAR MEMBRANE, - - -	55
Steatoma, - - - - -	55
Simple Cellular Tumour, - - - - -	58
Painful Sub-cutaneous Tubercle, - - -	59

## SECTION IV.

MUSCULAR TUMOURS, - - - - -	64
Encysted Muscular Melanosis, - - - -	65
Scirrhus Muscular Tumour, - - - - -	66
Malignant Melanosis, - - - - -	71
Fungoides, - - - - -	73
Anomalous, - - - - -	83
Tumours of the Fibrous Texture of the Tendons,	90
Simple Fibrous Tumour, - - - - -	90
Fungus Non-Hæmatodes, - - - - -	95

## SECTION V.

PERIOSTEAL TUMOURS, - - - - -	100
-------------------------------	-----



## SECTION VI.

OSSEOUS TUMOURS, - - - - -	111
Periosteal Exostosis, - - - - -	111
Os Maxillare Inferius, - - - - -	111
Os Hyoides, - - - - -	117
Spine, - - - - -	117
Os Femoris, - - - - -	117
Medullary Exostosis, - - - - -	119
Maxillary Exostosis of the Spongy Texture, -	127
Osteo-sarcoma, - - - - -	136
Lower Jaw, - - - - -	144
Clavicle, - - - - -	146
Ribs, - - - - -	152
Clavicle and Sternum, - - - - -	158

## SECTION VII.

TUMOURS OF THE GLANDS, - - - - -	162
Tumours of Lymphatic Glands, - - - - -	162
Scrofulous, - - - - -	162
Scirrhus, - - - - -	164
Non-malignant, - - - - -	164
Malignant, - - - - -	168
Groin, - - - - -	169
Axilla, - - - - -	172
Neck, - - - - -	173

Fungoid, - - - - -	184
Thigh, - - - - -	189
Neck, - - - - -	195
General, - - - - -	199

## SECTION VIII.

TUMOURS OF THE SECRETING GLANDS, - - -	203
Tumours of the Breast, - - - - -	204
Non-malignant, - - - - -	204
Hydatidal, - - - - -	205
Incipient Hydatidal, - - - - -	207
Chronic Mammary, - - - - -	210
Cartilaginous and Osseous, - - - - -	213
Scrofulous, - - - - -	214
Irritable, - - - - -	226
Adipose, - - - - -	228
Malignant, - - - - -	230
Fungoides, - - - - -	230
Carcinoma, - - - - -	234
Sloughing Scirrhus, - - - - -	274
Cancer of the Breast in the Male, - - -	282
Tumours of the Salivary Glands, - - - - -	285
Parotid, - - - - -	285
Sub-maxillary, - - - - -	291
Sublingual, - - - - -	295
Tumours of the Thyroid Gland, - - - - -	302
Goitre, - - - - -	302
Scirrhus, - - - - -	303



## SECTION IX.

TUMOURS OF THE TESTIS, - - - - -	309
Epididymis, - - - - -	309
Body of the Testicle, - - - - -	314
Non-malignant, - - - - -	314
Common Inflammation, - - - - -	314
Syphilitic, - - - - -	316
Scrofulous, - - - - -	317
Hydatidal, - - - - -	322
Chronic Enlargement, - - - - -	324
Malignant, - - - - -	328
Cancer of the Scrotum, - - - - -	328
Fungoid Testis, - - - - -	329
Scirrhus Testis, - - - - -	338

## SECTION X.

TUMOURS OF THE MUCOUS GLANDS, - - - - -	339
Cancer of the Lip, - - - - -	341
Tumours of the Tongue, - - - - -	343
Cancer of the Tongue, - - - - -	345
Tumours of the Soft Palate and Pharynx, - - - - -	353
Tumours of the Tonsils, - - - - -	355
Common Induration of the Tonsils, - - - - -	359
Scirrhus of the Mucous Glands of the Cardiac	
Orifice of the Stomach, - - - - -	363
Scirrhus of the Mucous Glands of the Pyloric Ori-	
fice of the Stomach, - - - - -	365

Scirrhus of the Mucous Glands of the Intestines,	365
Tumour of the Mucous Glands of the Rectum, -	369
Tumours of the Mucous Glands of the Vagina,	371
Tumours of the Uterus, - - - - -	375
Fungoid Tumour of the Bladder, - - - -	393
Cancer of the Penis, - - - - -	395

## SECTION XI.

TUMOURS OF THE VASCULAR TEXTURE, - - -	398
Tumours of the Arteries, - - - -	398
Accidental Aneurism by Anastomosis, - -	398
Spontaneous, - - - - -	400
From Wounds, - - - - -	409
Spongy Tumour of the Gums, - - -	411
Congenital Aneurism by Anastomosis, - -	413
Tumours of the Veins, - - - - -	427
Congenital, - - - - -	427
Accidental, - - - - -	432
Tumours of the Spermatic Veins, - - -	437
Tumours of the Nerves, - - - - -	449

## SECTION XII.

TUMOURS OF THE MEMBRANOUS TEXTURES, - -	452
Tumours of the Mucous Membranes, - - -	452
Rectum, - - - - -	453
Nostrils, - - - - -	468



# CONTENTS.

XV

Polypus, - - - - -	468
Membranous, - - - - -	468
Fibrous, - - - - -	476
Vascular, - - - - -	479
Antrum, - - - - -	480
Fibrous, - - - - -	480
Fungous, - - - - -	482
Uterus, - - - - -	487
Mild Fungus, - - - - -	487
Malignant Fungus, - - - - -	490
Tumours of the Serous Membranes, - - - - -	494
Peritoneum, - - - - -	494
Tunica Vaginalis Testis, - - - - -	495
Spermatic Cord, - - - - -	502
Tumours of the Synovial Membranes, - - - - -	503
Tumours of the Fibrous Membranes, - - - - -	509
Tumours of the Eye, - - - - -	513
Fungoides, - - - - -	513
Scirrhus, - - - - -	516
Melanosis, - - - - -	518
Petrous Tumour, - - - - -	521
Cancer of the Eyelids, - - - - -	523

## SECTION XIII.

ENCYSTED TUMOURS, - - - - -	526
Eyelids, - - - - -	527
Back, - - - - -	528
Scalp, - - - - -	533

Neck, - - - - -	535
Sanguineous, - - - - -	555

## SECTION XIV.

ABDOMINAL TUMOURS, - - - - -	557
Lymphatic Glands, - - - - -	558
Mesenteric Glands, - - - - -	564
Tumours of the Stomach, - - - - -	573
“     “   Liver, - - - - -	575
“     “   Spleen, - - - - -	580
“     “   Pancreas, - - - - -	581
“     “   Omentum, - - - - -	583
“     “   Kidney, - - - - -	585
“     “   Ovarium, - - - - -	588
Scirrhus, - - - - -	588
Dropsy, - - - - -	591
“     “   Uterus, - - - - -	594

## DISTINGUISHING CHARACTERS OF THE MOST COMMON

TUMOURS, - - - - -	603
--------------------	-----



## EXPLANATION OF THE PLATES.

	Page.
Plate I.....Lepoides, - - - - -	1
Fig. 1. Open cancer of the face.	
Fig. 2. The scale extended, and occasionally ulcerating.	
Fig. 3. The incipient scale.	
Plate II.....Cutaneous cancer of the knee, - -	38
Fig. 1. Situation of the disease.	
Fig. 2. Appearance of the tumour.	
Plate III.....Keloides of the skin of the shoulder, -	45
Plate IV.....Eiloides of the neck in a negro girl, -	48
Plate V.....Muscular tumour on the lower part of the thorax, - - - - -	67
Fig. 1. Appearance of the tumour before the operation.	
Fig. 2. Shows its situation.	
Fig. 3. The tumour after being dissected out. The left edge shows the muscular layers entering into the tumour.	



# EXPLANATION OF PLATES.

	Page.
Plate VI.....Fungus hæmatodes of the leg,* - -	76
Fig. 1. Shows its situation.	
Fig. 2. The appearance of the fungus after it had broken through the skin.	
Plate VII.....Exostosis of the lower jaw, - -	113
Plate VIII.....Osteo-sarcoma of the clavicle, - -	148
Plate IX.....Scirrhus tumour of the lymphatic glands, not malignant, - - - -	166
Plate X.....Malignant scirrhus of the lymphatic glands, - - - -	179
Fig. 1. Situation of the tumour on the right side of the neck.	
Fig. 2. Appearances of the tumour be- fore the operation.	
Plate XI.....Cancer of the tongue, - - -	347
Plate XII.....Vascular tumour of the gums, - -	411
Plate XIII.....Congenital aneurism by anastomosis in the lip, face, and eye, - -	421
Plate XIV.....Congenital venous tumour in the neck of a child, - - - -	428
Plate XV.....Fungus hæmatodes of the antrum max- illare, - - - -	485
Plate XVI.....Encysted tumour of the oleaginous glands of the neck, - - - -	529
Fig. 1. Appearance of the tumour.	
Fig. 2. Shows its situation.	

---

\* For the drawing of this tumour I am indebted to Dr. A. Gould, who sketched it while he was house surgeon of the hospital.







## INTRODUCTION.

AN exact discrimination between different kinds of tumours is very important to the practitioner of surgery. His attention is continually called to these affections, and he is obliged to decide, whether they may involve the life of the patient, or are quite trivial and free from danger. Whether they are to be subjected to a medical treatment; or to require, what every one views with terror, a painful operation. The opinion he may offer in such cases will soon be put to a severe and public test; for the course of these diseases lies open to the view of the patient and his friends, and the result must be known to them.

Desirable as it may be to distinguish different tumours from each other, it is not easy to do so.

The difficulties arise from a number of causes : from the great variety of these diseases, which is such that the most experienced surgeon is frequently meeting with species he has never before seen ; from the resemblance in external appearance between tumours whose character is quite different ; from the want of an arrangement which may enable him to view them in groups, instead of being compelled to consider them, as often happens, merely as individuals.

These difficulties, in the actual state of our data, are insuperable. The last has been frequently the subject of the labours of ingenious and experienced men. Attempts have been made at arrangement and classification ; but with so little success, that even the authors of these attempts have risen from their labours with disappointment and despair.

The difficulties of diagnosis are not the greatest which attend this subject. We are in ignorance of the causes of these morbid changes ; of their intimate texture and organization ; and in many instances of their diversity from or identity with that of the textures in which they are situated. More facts are wanted. More histories of the origin, course and results of such affections. More



observations on their intimate structure at the different periods of their existence.

You will not therefore expect a complete and satisfactory account of these affections. What you may principally hope for is, a collection of a considerable number of objects, which being brought as it were into a single view, may by means of a comparison of their appearances and symptoms enable you to acquire some general notions in regard to them, and form some arrangement, which, however imperfect, is better than the confusion of an indiscriminate grouping.

What is a tumour? This, at first view, seems an easy question to answer; but on a little investigation you will find some difficulty in it. The most simple idea of it is, *an unnatural enlargement in some part of the human body*. But is this enlargement an increase of a natural part, or a new formation. If the former, we might expect it to consist of a texture similar to that in which it originates. If the latter, how can we explain that the vessels of a part should generate a substance different from that part? Mr. JOHN HUNTER gave this definition: "A tumour is a circumscribed substance produced by disease, and different in its nature and consistence from the surrounding



parts." This perhaps is the best that can be given. But even this is not perfect; and the inherent difficulty of the subject is shown by this fact, that even the powerful mind of HUNTER was unable to surmount the obstacle presented at the first step towards a knowledge of these diseases. For it might be asked, in reference to this definition, for example, in what does a steatoma differ from the cellular texture in which it is developed? and if it be replied, it differs in density; it might then be asked, in what does an exostosis differ from the bone in which it originates? You will see that it is easy to start objections to any definition, but not so easy to offer a satisfactory substitute.

What is the CAUSE of tumours? An individual making a violent effort of some muscle, has a tumour formed afterwards in the muscle, and we say the tumour is caused by the strain. That is, the strain changes the healthy action of the capillary exhalants of the part, so that instead of their usual deposit they form a morbid substance. Or, he may receive a blow on the testicle, and a disease succeeding, we say the blow is the cause. A female has a mammary abscess, which leaves a chronic induration, and when she reaches a particular period of life, this, assuming the character of a



schirrhous, we say the induration is the cause. But is it not notorious, that similar accidents occur constantly and are not usually followed by such results. Of course, it is impossible that those injuries are the simple causes of the morbid action generated in such cases. We must look for accessory causes, such as some peculiarity in the accident, or in the individual. The former is inconceivable, and we are therefore compelled to suppose a peculiarity in the constitution of the individual. Such peculiarity may sometimes be fairly suspected, as in the case of a female, one of whose parents had been cancerous; or in a man who had abused his health by the use of ardent spirits. But how many instances remain where no such cause can be seen; and how many cases are there where no cause either predisposing or exciting comes within the cognisance of our observation?

Mr. HUNTER suggested the notion that a drop of blood being accidentally effused became organized, and assumed a growth independent of the system, and continued to grow till it was limited by some obstacle opposed to it. The objection already instanced has been offered to this opinion, namely, that effusions of blood take place con-



tinually without any such consequence. How far will the following case, which will be more fully stated hereafter, be considered as a fact in favour of Mr. Hunter's opinion? A lady 52 years old, in running across a field to escape from a cow, fell and struck her breast; a swelling arose, which after some months assumed the form of a schirrhous. I removed it, and in the centre of the schirrhous lump found the remains of effused blood in the interior of a tumour with a thin cyst. She has remained four years without any re-appearance of disease.

Effusion of lymph, or coagulable lymph, from the capillary vessels has been considered as a possible cause of the origin of tumours. The lymphatic effusion must of course become organized and thus constitute a new formed substance. Such effusions are common after accidents and during diseases. We notice them in the cellular texture, in the muscles, in the serous cavities. In the two first of these textures they more rarely become organized, but are soon taken up by the absorbent vessels, and disappear. In the last, organization occurs in a great number of instances, but does not produce a tumour. The effusion of lymph therefore is not necessarily followed by



tumour, even when it becomes organized. Yet that some tumours are generated in this way, I have no doubt.

A third supposable mode of the production of tumours is by chronic inflammation of a natural texture. A blow, or the constant irritation of a foreign body may derange the action of the capillary vessels, and thus bring on a new deposition. A case will be related hereafter of a person, who, while holding a shoe, on which he was at work, against the chest, allowing it to slip, received a smart stroke on the cartilages of the ribs, attended with considerable pain. On the following day he perceived a hardness, which increased, and at the end of two years was a formidable tumour.

This chronic inflammation happens most frequently in parts disposed to inflame, as the cellular texture. Steatomatous tumours are caused in females in the cellular texture on the upper part of the deltoid muscle by the pressure of their dress, with a frequency which is notable. The greater number of tumours being formed without any such accidents, so far as we know, this from chronic inflammation, if admitted to be a cause, is only a partial or occasional one.



On the whole therefore, it must be understood, that we have but a very imperfect knowledge of the predisposing and exciting causes of these derangements of organization.

Under the disadvantages from a want of information on a number of important points, we are limited in our means of distinguishing the various tumours from each other, with a satisfactory degree of confidence. To accomplish our diagnosis, as far as practicable, we should begin the investigation with the acquirement of a history of the origin and progress of the tumour, its influence on the part where it is situated, and on the whole system. After having obtained this history, a physical examination should be conducted with great care, and if there be any obscurity in the case, should be repeated frequently, and under different circumstances. With the exception of steatomatous and simple glandular tumours, how few of these diseases appear on dissection, as the imagination of the surgeon had depicted them? Such misconceptions do not prove either a want of attention or of skill. They prove only the uncertainties of the best studied investigations, and the necessity of bringing to our aid all the methods of elucidation which time, reflection and care may



furnish. Therefore we should never advise nor undertake any decisive measure, at first view, in any but the plainest cases. To be called to operate on a chronic tumour at first sight, is an impropriety which no prudent surgeon should submit to.

The physical qualities of tumours, like those of other bodies are primary and secondary. Each of these, as far as may be, should be successively studied. The *figure* is the quality, which first strikes our senses, and should be well considered. Certain species of tumour affect particular forms; the steatoma for example, is commonly rounded, and encysted tumours always have this form. Bony tumours and those of the complicated glands are irregular. *Extension* is an important quality, as it involves the connexion with surrounding parts. This is more difficult to understand, because we have access to a part only of the object inspected, the rest being concealed by organs attached to it. The extent of the part beyond the reach of the senses of touch and vision, is that which may implicate the most important structures, and cause the greatest embarrassment. The *solidity* will decide whether the tumour consists of bone as an exostosis: or of bone and soft substance combined,



as an osteo-sarcoma : or of fluid as in the encysted tumour. Of the secondary qualities, that of *colour* has a great influence on our judgment in these cases. When the natural colour of the skin over a tumour is changed to red, our first impression leads to the suspicion of a malignant action, which may be confirmed or confuted by further examination. If this change appeared in a chronic affection of the breast the suspicion would probably be well founded ; if on one in the back, the appearance would, most likely, prove to be accidental. We are perhaps ready to attribute too much importance to this quality, considering its variableness, and the different lights in which it appears to different persons. A lady came to me from the country with a very tumid breast, the skin of which was of a bright red color, giving it a formidable and very malignant aspect. On the following day the colour was less, and gradually diminished, till the part had the usual appearance of healthy skin, and the disease proved not to be malignant.

Besides these qualities there are others which may be called accidental, such as *pulsation*, *vibration*, *undulation*. These may exist in the tumour itself, or in a part connected with it, and may indicate aneurism, aneurism by anastomosis, a fluid



contained in a cyst; or the proximity of such diseases to the part inspected.

A mental comparison of the qualities of the object under examination, with those of other tumours, is a process which every one naturally institutes; of course, the greater the number and variety of these objects, the more full will be the investigation, and the more certain the decision. In order to give you the means of making this comparison, it would be desirable to present the different kinds of tumours with their natural appearances; but as this is not practicable, the best substitute I can offer is a collection of these objects, in as natural a state as possible. These should be accompanied with descriptions and with histories of their course, so far as these seem adapted to enable us to take the views above mentioned, and to afford useful practical information.

The order in which this should be done, is a matter for serious consideration. In other branches of natural history the acquisition of knowledge is wonderfully aided by exact classification. In this, the want of information of the origin, causes, tendencies, and distinctions of tumours render it impossible to make a scientific division and ar-



rangement; and it is no disparagement to the abilities of those who have attempted it, to say, that every such attempt has failed to receive the support of publick opinion. Of course we shall not propose a scientific arrangement; but as some kind of method must be pursued, shall follow that which seems most convenient, and most useful for practical objects. The plan proposed is to present the different tumours under the head of the different textures of the body, so far as may be done. In many cases this indeed will be impossible, either in consequence of our utter ignorance of the texture of the tumour, or because it is composed of a variety of textures, neither of which predominates, and neither of which we can certainly say gave it origin. In such difficulties we shall not deem it necessary to discuss the reasons for placing it under one head or another, unless a practical use is to result from such discussion.

There are I am aware many objections to this plan. One has just been alluded to, that we are often ignorant what texture gives origin to the disease. Another is that it may be situated in a texture different from that in which it took its birth. This happens for example, in the skin, where the diseases of the cuticle have their origin



in the cutis. In regard to such difficulties as these we would wish to have it understood, that though some pains have been taken to examine the structure of tumours, yet considering that the knowledge we possess on this point, is not sufficient for the basis of an exact arrangement, we have not felt anxious to conform rigidly to any.

There is another and more weighty objection to the plan preferred. In various instances it comprises, under the same head, malignant and non-malignant tumours. However important it may be to establish a strongly marked line of distinction between the two, it does not seem possible to do it, until we know exactly what tumours in the different textures are malignant, and what are not. Perhaps the nature of disease will forever render it difficult. Many tumours, not originally malignant, become so by accident; others by the lapse of time. I have known a tumour remain free from the least mark of malignity for thirty years, and then to become so, without any assignable or conceivable cause, in a perfectly healthy subject, in the vigour of life. More than one such instance will be related to you. Such are some of the objections which may be urged against the arrangement to be pursued; but as we can devise



none more satisfactory, this must answer our purpose.

Instead of beginning with the general textures, we shall consider it convenient to speak first of those which are most superficial, most easy of inspection, and whose affections are most simple. Beginning then with the textures of the skin, we take next those of the cellular membrane; then the muscular; the fibrous, and the osseous. After these most obvious and extensive textures, we shall place the numerous tumours of the glandular texture; next those of the vascular; and then those of the membranous textures, mucous, serous, fibrous, and synovial. Finally, tumours composed of different textures and not found exclusively in any, the encysted tumours. Some remarks will further be made with a view to direct your attention to the diagnosis of tumours in the cavity of the abdomen.

## SECTION I.

### EPIDERMOID TUMOURS.

THE epidermis or cuticle being an unorganized part, derives its growth and diseases from the cutis. The tumours it bears might therefore be referred to the dermoid texture, were it not that they differ in their tendency from such of the dermoid as they resemble in appearance. Epidermoid tumours are unorganized in their origin and course.

Excluding the affections which fall under the head of cutaneous diseases, we shall speak of three kinds of epidermoid tumours, VERRUCA, CLAVUS, and ICTHYOSIS CORNEA.

VERRUCA. A wart is an excrescence of the cuticle, of a conical form, of small extent, hard, insensible, in colour usually darker than the sur-



face around it. In structure it appears radiated. Being unorganized, it has no principle of growth in itself, and derives its nourishment from the cutis on which it lies. The situations in which it is most commonly found, are the hands and the face, though it is not rare in other parts of the body. It is inoffensive, excepting from its pressure on neighbouring parts, when it is so situated as to interfere with them, as between the fingers and toes. Young people are more subject to it than old.

A multitude of remedies have been proposed for the cure of warts; and it is curious to notice how often they disappear under the use of trivial applications, while such as have real power in other cases, have no influence on them. The most effectual remedy is excision with the portion of cutis which supports them. They may be removed in a slower way by touching them daily with a hair pencil dipt in sulphuric acid.

**CLAVUS.** A corn, is a hard, insensible, colourless substance, found most commonly in the foot, sometimes in the hand, rarely in other parts of the body. Its texture is more firm in the central part than the exterior. The form and size are various: usually the form is rounded, and the size



that of a pea. Sometimes it forms an expanded plate of indurated substance. Its cause is pressure, commonly that of a shoe or some other covering. And the first joint of the great toe being a prominent part, is its most frequent seat. In this situation its hardness and pressure sometimes produce ulceration of the synovial membrane, and a consequent opening into the joint. The synovial fluid makes its way out, and establishes a fistulous sore, in some cases, very troublesome to the patient. A lady sent for me not long since for an inflammation of the foot; supposed by her to be brought on by taking cold from wetting her feet; after visiting her once or twice, a small aperture was seen on the upper part of the first joint of the great toe, and a fluid issued from it, which seemed to be a mixture of pus and synovia. The skin was indurated and thickened. It appeared that this induration had existed a long time, that lately there had been a glairy discharge, and that the inflammation had immediately followed upon a long walk. The whole foot being swollen and a degree of fever existing, a free use of leeches was employed. This, aided by mild poultices, relieved the inflammatory symptoms; and by a confinement of the foot in the horizontal posture



for three months, with occasional touches of nitrate of silver, the fistula healed, and the joint became tolerably sound.

Other situations in which these excrescences are particularly inconvenient, are between the toes and fingers; and on the tendons, especially the flexor tendons in the palm of the hand, in working people. The thickening in all these cases arises from the vessels of the part being irritated by pressure, and throwing out coagulable lymph in successive layers on the surface of the cutis. Corns are more common in females than males, and more common in the rich than the poor. There seems to be a constitutional tendency to them in some families; for we notice that a very moderate pressure is sufficient to cause this complaint in such instances.

In order to accomplish the cure, the patient must be directed in the first instance to remove the cause. If the foot be the part affected, the shoe must be made perfectly easy and pliable. The foot is a part extremely abused in civilized countries. There are few adult individuals, especially females, who have not undergone some alteration in the natural form of this part, in consequence of compression. Not only do we find



the cuticle thickened in various parts, but even the bones are materially changed in their form and direction. This sacrifice to fashion is followed by an unsteadiness in the support and motions of the body, from a want of regularity in the supporting part, and from the impracticability of expanding the foot to the extent nature designed.

Corns may be softened by frequent immersion of the part in warm water with soap; by wearing a covering of gummed silk or soap plaster, which retains the moisture of the skin. Some persons are in the habit of filing them down in a gradual way. They may be removed by cutting out carefully if the patient is willing to be quiet until the wound heals; otherwise this is not safe, particularly in bad habits. When the corn is situated under a nail, there is no short and effectual remedy but extirpation of the nail.

**ICTHYOSIS CORNEA.** This rare disease consists in the production of horny tumours or excrescences from various parts of the body. They are found on the parts most prominent, as the extremities of the fingers and toes; the projections of the heel and elbow, and the protuberant parts of the forehead. Specimens of these productions are here exhibited to you. Some of those from the



extremities of the fingers are an inch in length; in form they much resemble the terminal phalanx of the fingers; but are more porous in consistence, appearing to the eye to have the texture of cork, yet being in fact nearly as hard as the bone on which they were situated. The tumours from the back part of the heel are more than one inch long. Those from the forehead are broader and shorter.

This disease is described by Dr. Willan and by Alibert. The former states that he had never seen an instance of it, and extracts two cases from the *Philosophical Transactions*. In these cases there was a stiffness of the skin over the whole body, so that the limbs could not be flexed, and the patient was unable to move. In a patient under my care some years since, the skin was generally soft, and not changed from its natural state excepting at the parts where the excrescences existed. This patient was a respectable woman from the country, thirty five years old. Her health had been bad for some years, and she suffered particularly from disorders of the digestive organs. She had been married, had children, and never had been affected with any syphilitic disease. The tumours she exhibited were of various sizes, from that of a pea, to that of a body an inch

in length, and three quarters of an inch in breadth. She had two or three on the forehead very large, and some small. They appeared like conical horns forcing their way through the skin, surrounded by circles of a red colour, while the rest of the skin was pale and delicate. The horns were constantly falling off, and regenerating in the same places, while new ones also appeared in other places. She was feeble, and kept to her bed rather from weakness than stiffness of the limbs. After residing here some weeks, she went into the country, and died in a short time. The specimens I have shown you were taken from another person ; a girl fourteen years old, a patient of the late Dr. Haskell, of Lunenburg. Her symptoms were very similar to those of the case just mentioned.

This disease is, so far as we know incurable. The treatment adopted in the case of my patient consisted in a careful attention to cleanliness, good food, and the use of tonic medicines.



## SECTION II.

### DERMOID TUMOURS.

UNDER this head we shall describe three kinds of tumours of the true skin, LEPOIDES, KELOIDES and EILOIDES. Some of these are malignant and others not ; but on the whole, the disposition to malignant tumour in the cutis is well marked.

Here it may be asked, what is meant by a malignant tumour? Experienced surgeons, when they speak on this subject, understand or believe they understand, what is intended by this expression ; but if asked to give a general notion of such a disease, for the information of those who have not the same experience, find it difficult to make a reply satisfactory to themselves. If we were to borrow the style of Mr. Hunter, and I am not certain he has not employed the very terms, we

should say that a "Malignant disease was one in which the destructive action overbalanced the restorative." This would be a true definition, but not a perfect one. It would be true because in malignant diseases, the natural power of the system or *vis medicatrix* is not sufficient to overcome the morbid actions and cause a restoration to health. But it would not be perfect, because there are many diseases not malignant, in which the destructive actions overbalance the restorative, as in phthisis pulmonalis.

The most striking and important feature in a malignant tumour, is its tendency to affect the whole system either primarily or secondarily. Primarily through the sanguiferous vessels, or secondarily, through the absorbent vessels. Whether the first mode is admissible, may be a question. The second is common. A carcinoma of the breast, for example, propagates a morbid action to the lymphatic glands, to the mesentery, the liver, uterus, stomach, lungs; and the disorder of some or all of these parts produces death. In such cases, the sanguiferous actions are ultimately disturbed; not from any virus imbibed from the original tumour, but from an interruption of the functions of important organs.



We will mention two species of malignant disease, as being well known and accurately distinguished from each other, CARCINOMA and FUNGOIDES. The former is found in the skin, in the female breast, and other parts; in some characterized by its hardness; in others by its tendency to destructive ulceration. This is called also by the name of *scirrhus* and *cancer*. FUNGOIDES, a term established by Sir Astley Cooper, is seen in the testicle, the muscles, and other organs, and is known also by the various names of *encephaloid disease*, *fungus hæmatodes*, *fungoid disease*, *soft cancer*, *cerebriform disease*, and *medullary sarcoma*.

To give a satisfactory idea of the distinctions between the two classes of malignant disease would require a history of all their symptoms. It is not my intention to endeavour to make you acquainted with them by general and abstract statements, but rather by the relation of facts, and the exhibition of specimens of disease. At present, I will only repeat, that there are two classes of malignant diseases CARCINOMA and FUNGOIDES. That the most striking features in CARCINOMA are *hardness* and *ulceration*. While FUNGOIDES is distinguished by *softness* and *bleeding*.



Other classes of malignant diseases have been spoken of, and will no doubt be well known as distinct forms hereafter; but I have preferred to lay before you only those which are well established, well distinguished, and of frequent occurrence. The recent labours of Mr. Travers, of Laennec, and of Dr. Hodgkin, throw much light on these affections and the expected publication of Sir Astley Cooper's work on malignant diseases of the breast, will give us further aids and illustrations.

Having stated that there are two well established classes of malignant tumours; I will now mention another, which by able writers has been considered as a third class under the name of MELANOSIS. This is derived from their black colour.\* Contrasted with the tumours constituting the two others, these are excessively rare, and still more rarely are they malignant. Such at least is the result of my experience; but this has no doubt been small compared with that of the distinguished authors who have written on this subject; and I would therefore be considered as speaking with reserve, but with the plainness that truth demands.

---

\* Μελας black.



Melanosis is a black coloured tumour, which may be developed in most of the textures. I have seen it in the muscles, the eye, the skin, the breast, the lungs, the liver, and the cellular membrane; sometimes in the form of a solid, sometimes encysted. Most commonly it is a solid, black tumour, covered, as most tumours are, by a formation of cellular membrane; not usually painful nor malignant; becoming pernicious by its size only. Sometimes it is actually a malignant disease, and then has more of the character of carcinoma than many other species belonging to that division of malignant tumours.

The black deposit often seen in the lungs, and so generally found in the bronchial lymphatic glands, which Fourcroy considered as a carbonaceous deposit from the blood, is a kind of melanosis.

We shall have occasion to mention some instances of this disease, under the heads of the tumours in which it has been noticed, and which will be exhibited to you.\*

---

\* Laennec states that melanosis appears in four different forms. 1. In that of masses enclosed in cysts. 2. In that of masses not encysted. 3. In that of matter infiltrated in the texture of an organ. 4. In that of matter deposited on the surface of an organ. M. Andral has seen a *liquid* melanosis in the cavity of the peritoneum, in chronic peritonitis, and M. Breschet has noticed it in some of the secretions.



We shall now proceed with the consideration of tumours of the true skin.

LEPOIDES.\* This is the best term we can devise to express the scaly crust, or bark-like roughness of the skin, it is intended to designate. The scale of the cutis is most commonly seen in the face, especially of aged persons. It is an irregular, rough crust, of a brown colour, which might be mistaken for a wart. Crusts are very common in the face, in those advanced in life, and sometimes spread over a considerable surface, forming a rough brown coloured plate; but the true lepoides, represented in Plate I. is a circumscribed crust, which at first appears like a discoloured speck or a piece of earth. This falls off, and is renovated in the same form, for many successive years. When the crust separates spontaneously, it sometimes leaves a new cuticle behind, which gradually thickens. In other cases the cutis, being exposed, presents a spicular surface of unfavourable aspect. This surface throws out an ill conditioned pus, which dries in the form of irregular scales. At length, owing to accidental irritation or a change in the constitution, from age or other

---

\* Λεπρος, bark.



cause, the cutis ulcerates slowly, and forms an incurable sore, or cancer of the face, represented in Plate I. The tendency of this disease is to advance very gradually without much pain, and without contaminating any parts, but those in contact with it; so that the patient may live a number of years before he is worn out by it.

The proper remedy for this disease is extirpation. This should be effected before ulceration begins, if practicable. A question here arises in what cases is this necessary? The mere existence of a scale on the face, even of a patient advanced in life would not call for an operation. We should say, that this should be resorted to when the following conditions are combined; a crust of small size, with a decided elevation and well defined red edge; with pain or shooting; and any surrounding induration. These appearances would derive additional importance from old age. Should ulceration actually exist, the proper course will be more distinct; and this may be followed with a hope of success, even when ulceration is much extended, because the morbid action is limited to parts in immediate contact with the ulcerous affection.

The modes of extirpation are two, the knife and caustic. The former is to be preferred. The



crust, with an edge of skin about it, is seized with the small pointed forceps, and removed with a stroke of the knife, lancet, or scissors. Allowing the bleeding to subside, the wound is covered with minute portions of scraped lint, which forms a crust with the blood, precludes the necessity of a plaster, and the wound heals without a second dressing.

When the patient dreads an incision, and we are called on to employ a caustic, we may choose between the arsenical paste, sulphuric acid, powdered nitrate of silver, potass with lime, and pure caustic potass. The best of these is the potassa cum calce. This is effectual and manageable. One or two pieces of adhesive plaster, double the diameter of the crust, with each a hole of the exact size of this crust, are applied so as to receive it in their aperture. The caustic paste is then put into the aperture, to the thickness of the twelfth of an inch, and covered with another piece of adhesive plaster. The plasters and caustic may be removed the next day, and the eschar will separate in five or six days, without requiring any thing further.

A gentleman, about fifty years old, came to me with an ulcer on the side of the nose, near the eye, about half an inch in diameter. The edge



was red and a little elevated. No surrounding hardness existed. The surface of the ulcer had a glossy red colour, some scattered risings or granulations, and a hole in the centre which might admit the head of a large pin. Twenty-five years before, he received a blow from a piece of ice thrown at him, which caused an excoriation. On this a crust formed, which was occasionally thrown off and renewed. Lately he noticed a discharge from the part, and an extension of the scab or crust. Although there was no hardness nor pain in the sore, and although its progress was very slow, I was satisfied from the long continuance of the disease, and from its situation, setting aside its aspect, that no remedy could bring on a restorative action. He was therefore informed it was a cancer, and that extirpation was the only means of eradicating it. The removal was immediately performed, and with the sore a portion of sound skin nearly a line in width was removed with its circumference. On examining the surface beneath, it appeared healthy. The internal face of the sore had a number of round, white coloured bodies, connected together by a dense white texture. These are the appearances observed in a considerable number of the varieties of malignant tumours.



Alexander Nichols, Æt. 66. Farmer.—Eight years since observed a small scaly patch on left temple. Scale desquamated, leaving skin underneath of bright red colour, but without ulceration. This scale was renewed and cast off several times, but gradually began to assume the appearance of a scab, leaving, when off, a slight appearance of ulceration. Ulcer increased in size, till at expiration of four years it was as large as a cent, circular, surface smooth, ungranulating, ulcer not extending deeper than skin. At this time an operation was performed, and the part removed was by report cartilaginous. Incision soon healed. Six months afterwards ulceration formed anew, and has continued ever since. Ulcer now nearly an inch in diameter between external angle of orbit and upper part of ear. Circular, smooth, ungranulating, bleeding easily. Has never given him much pain, has not increased in size for some months. Had a diseased spot on right anterior part of vertex one year since, which commenced in the same manner as present disease, which soon yielded to topical applications.—(*Hospital Record.*)

Operation Oct. 13, 1830.—Two curved incisions were made through the skin, beginning above and a little behind diseased parts, and meeting



each other below and before, near external angle of orbit. The portion included within these incisions was then dissected from the temporal fascia, two arteries tied, skin approximated by adhesive straps, covered with lint and compress and secured by bandages. The wound healed favourably, and the patient was discharged well in fifteen days.

The case which next follows had a less favourable result. The plate which represents the appearances in an advanced stage of the disease, shows also its incipient form on another part of the face. This last has been pursuing the course described, so long as we have observed it; that is, the scales are often separating, leaving sometimes a cuticle and sometimes a raw surface, both becoming ultimately covered with a new crust.

Nathaniel Stearns, *Æt.* 54. Farmer. Entered M. G. Hospital, May, 1836.—Noticed a small scale or scab on cheek, just below left eye, about twelve years since, for the first time. Upon removing this, it was soon followed by another of the same kind. Was in the habit of picking these off from time to time as they formed. This sometimes caused a little bleeding, but he had no other trouble or inconvenience from it for many years.



A few years since a small sore formed at this place and continued to grow worse till two years since, when he applied to a cancer doctor, and remained under his care several months. Had various applications made, which gave intense pain. Thinks potash was applied several times. After this, sore became worse and extended rapidly. Omitted all remedies for several months. Sore remained in rather an indolent state. Has been using an ointment lately, which he obtained from said cancer doctor. Thinks that sore has been getting deeper within a few weeks. General health tolerably good. Now a foul irregular ulcer, about two inches in diameter, on left cheek, just below eye—edges thick and ragged—integuments about ulcer red and indurated—profuse serous discharge. No pain and very little sensibility about ulcer. Eyelids of left eye much swollen. On right temple there are two small scabs which resemble those which first appeared on left cheek, by report of patient. p. and t. natural—appetite good—bowels regular.—(*Hosp. Rec.*)

This patient remained in the hospital long enough to make trial of all known remedies. Caustic potass, sulphuric acid, kreosote, and other applications were employed without effect. The



disease made a regular though slow advance. The periosteum of the surrounding bones became diseased. The maxillary bone ulcerated into the antrum. The eye became irritated and swelled. A consultation being called, it was made a question whether the maxillary bone could be removed with a prospect of favourable result. This was decided in the negative, and the patient discharged as incurable.

The history contained in the following letter is interesting from its long continuance, its practical utility, and from its occurrence in the sex commonly exempted from it.

Navy-Yard, Charlestown, January 14, 1836.

DEAR SIR,—In compliance with your request, I here communicate to you such particulars of the case of Miss E. B. as I have been able to ascertain.

About fifteen years ago, Miss B. discovered, over the upper and anterior edge of the temporal bone of the right side, a slight roughness of the skin, occupying a space not more than the fourth of an inch in diameter, and which she supposed was occasioned by her comb. In the course of the five following years, no other change took place



than a gradual extension of the roughness. At the end of this period, however, the affected surface was not more than half an inch in diameter. There was occasionally a slight itching in the part, but no pain or heat; nor had there been, at the end of the five years, any discharge.

But about this time there began to be a slight discharge, which formed a hard brown scab, that would sometimes remain for months, and then fall off, leaving a superficial and healthy looking sore. Until this time it had attracted very little attention, and nothing had been done for it; but now a plaster of some kind was applied by the direction of a physician, which seemed rather to increase the discharge, and accelerate the progress of the disease. It now became an open ulcer, and from this time onwards, until the operation was performed, its progress, though extremely slow, was not materially interrupted by the various means that were employed to arrest it. Until within the last year or two, only the external surface of the skin was affected, but during this period its whole thickness has been involved in the ulceration.

I saw the case, for the first time, at least I noticed it particularly for the first time, about four years ago, at which time the ulcer was about



three-fourths of an inch in diameter. It presented then a healthy appearance, and was attended with no other uneasiness than a slight itching. The general health of the patient has been, with a few slight interruptions, perfectly good. From the period just referred to, an interval of nearly three years elapsed before I saw Miss B. again, which was in the summer of 1834; and I found that during this time the disease had advanced more rapidly than at any time before, and that it also penetrated deeper. Still there was no pain or heat in the ulcer, and the discharge was of a healthy appearance. The bottom of the ulcer had now become somewhat uneven, and the edges were also more irregular. Its dimensions now were an inch and a half by three-fourths of an inch. The ulceration had extended mostly towards the temple and eye, and had attacked the upper part of the eye-brow. Dr. White, of Hudson, N. Y., now had charge of the case, and was employing a lotion of chloride of soda and an unguent, the composition of which I do not know.

The next time I saw Miss B. was last August, when you was consulted and recommended an operation. At this time the ulcer was about two inches in length, and rather more than an inch in



breadth. It had extended to the edge of the orbit, and a tumour had formed under the eyebrow nearly as large as a hazle nut. The ulcer exhibited now a more unhealthy appearance than it ever had done before, the bottom of it being more uneven, and its edges more irregular and inflamed. But even now there was so little pain as to cause no uneasiness. The operation was performed by yourself on the 24th of August, and the whole of the diseased structure was removed. The dressings were removed on the 4th day, and appearances were favourable. After this the dressings were renewed daily. For some time appearances continued favourable, and the dressings consisted at first of fine linen and dry lint, and afterwards of ung. comp.. It was not long, however, before the whole surface of the wound began to exhibit a fungous appearance, and the repeated application of escharotics, together with compression, became necessary. The ung. lap. calam was used for some time, but was exchanged for one composed of tereb. venet. oxid. plumb. ol. oliv. sperm. ceti. and cer. alb. which answered much better than any other dressing that has been used. The cure now advanced without interruption, and was completed on the 28th of December, since which she has



been perfectly well. It ought to be noted, that from the time of the operation, the patient has been restricted almost entirely to a vegetable diet, as you advised.

I am very respectfully Sir, your ob't. servant,

B. TICKNOR, *Surgeon U. S. Navy.*

The temple is a situation very apt to be the seat of this disease. It arises here from the pressure of the covering of the head in male and female. A gentleman now living in Boston was operated on three years ago; when the disease had attained the size of a dollar. It was on the right temple, and was by the patient always attributed to irritation from his hat. This though large differed from other cases in being perfectly dry. It extended to the outer angle of the eye, and had a great thickening and hardness which gave it a bad appearance. Being thoroughly removed, it has never re-appeared, although the gentleman is advanced in life.

I shall here notice a remarkable tumour from a different part, which is before you, and represented in Plate II. It is of a circular form, three inches in diameter, and one inch in thickness. The surface is variously coloured with

Pl II

Fig 2

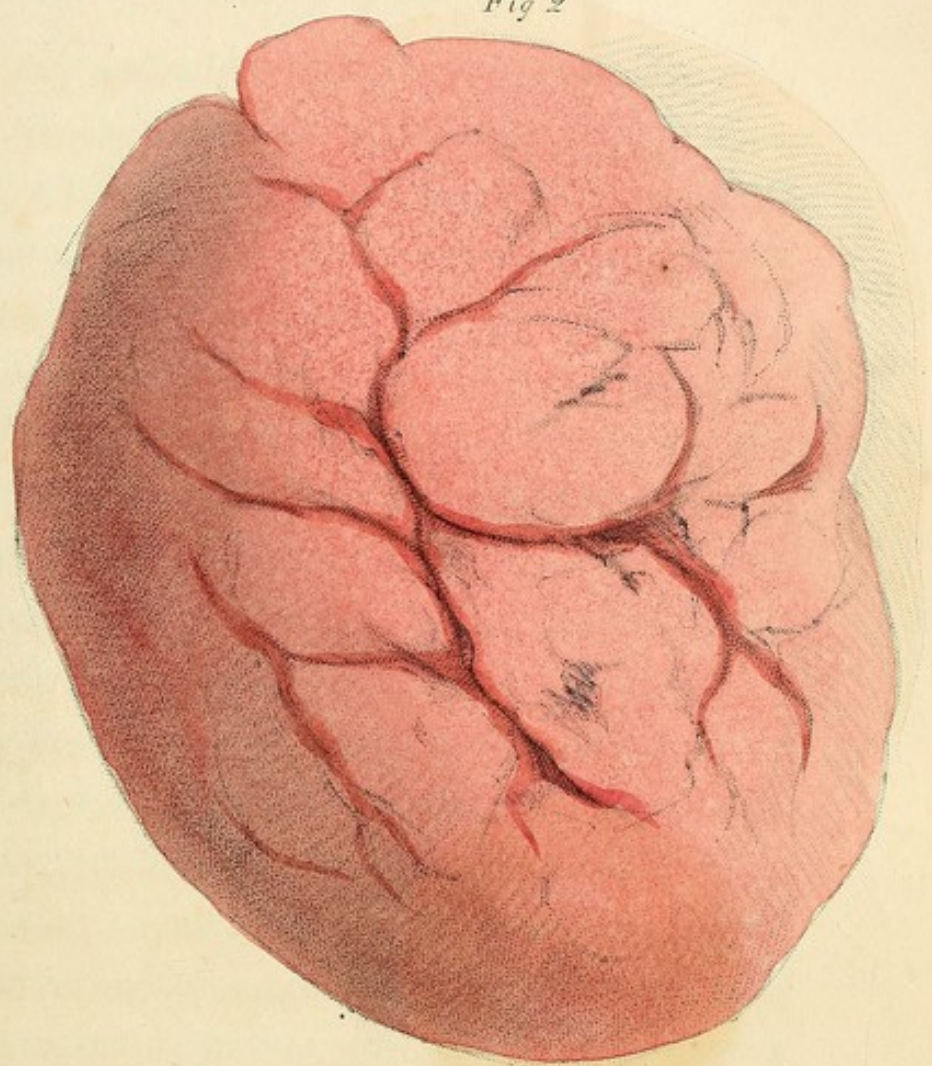
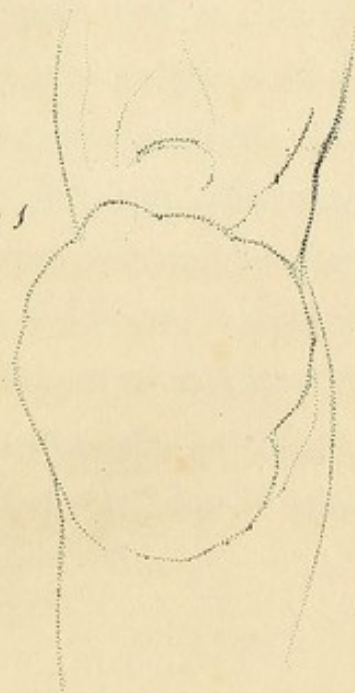


Fig 1



*Cutaneous cancer of the knee*





purple, red and white. It is composed of a collection of excrescences larger than the granulations of a common ulcer ; surrounded by a border of sound skin, which is regularly connected with the granulations and not everted nor inverted. The history of the case is this. A farmer about thirty years old, received a slight injury on the knee below the patella, which produced inflammation, and a small ulceration, not sufficient to confine him. After some time the sore extended, interfered with motion, and became somewhat painful. The applications which were made, produced no favourable change, and it continued to increase in size, till it attained the extent you may see. On his applying to me, it had the appearance of an ulcer, with uncommonly large red granulations ; was sometimes painful ; discharged a moderate quantity of pus, and regularly increased in size, even after he was confined to a horizontal posture. No bleeding ever occurred. The constitution was occasionally, but not constantly disturbed by it. After observing its course for between two and three weeks, I became satisfied it was incurable, and advised amputation above the knee. The patient would not agree to this, and insisting on the extirpation of the tumour, I reluctantly removed it;



with the conviction, that the removal of such a mass from the vicinity of the knee joint, would produce a dangerous and even fatal inflammation, of which he was repeatedly and fully apprised.

The operation was performed, without cutting into the joint. A violent inflammation followed, and terminated fatally on the eleventh day. Examination being made of the parts connected with it, no disease was found in the bone, ligaments or synovial membranes, excepting what arose from recent acute inflammation.

This disease, though at first view it may be thought to resemble, is very different from fungus hæmatodes; not only as to the fact of its not bleeding, but in other important points. The most remarkable of these is, that it was entirely a local affection; the constitution of the patient being no further disordered, than it would be from sympathetic action. It began in the skin, and of course may properly be placed under the head of dermoid tumours.

**KELOIDES.** This name was adopted by Alibert, from the red vascular processes, extending from the tumour, and giving it the appearance of crabs claws. Though I have followed a high authority for this term, there are some objections



to the use of it. First, the same idea has given origin to the name of a very different and very common disease, *cancer*. Second, in one kind of affection, which must be referred to this head, there are no such processes, and they do not always exist in the others.

Under the head of keloides, we shall place three varieties. 1. A white permanent elevation of the skin. 2. The spider like pimple of the face. 3. The keloides of Alibert.

The first variety is a rising of the true skin in the form of the cicatrix of a burn. It is a white elevation of the skin, without discolouration, or with a very slightly coloured margin; not sensible nor painful; but differing from the cicatrix of a burn in its disposition to grow, and in the difficulty of eradicating it. No ulceration occurs, nor does it terminate in a malignant disease. As it resembles the scar of a burn, so it sometimes originates in such a scar. It is seen to occur in disordered habits, after operations for the removal of small tumours, such as common warts, small encysted tumours &c.

A young lady showed me a wart-like tumour on the right shoulder, which she had noticed two years before, in size about a quarter of an inch,



and raised from the surface one sixteenth of an inch. It was cut out, the wound healed slowly. In about four weeks it began to rise and shortly attained a diameter of three quarters of an inch, with less elevation than at first. Caustic potass was then applied. The eschar separated and the wound was subjected to frequent touches of the nitrate of silver. After it healed, the raised cicatrix was again seen. I removed it once more by the knife, including a quarter of an inch of sound skin around, and a layer of cellular membrane from beneath. This time it healed well, and there was no return of the tumour.

A young lady wished me to remove a large mole from the left scapula, which was done with a single cut of the knife. Some months after, she requested me to look at the scar, and I discovered a raised cicatrix about half an inch in diameter, producing a considerable deformity, when the shoulders were uncovered, as in a fashionable dress. The excrescence was carefully dissected out with the knife. Every thing went on well for a time; till on the expiration of some weeks, there was found to be an indisposition of the wound to heal. Plasters, ointments, powders and poultices were applied. The arm was confined in



a sling; a blister placed on it; perfect quiet enjoined; a sparing vegetable regimen; laxative medicines, and change of air were employed without good effect. The sore continued for a year; and I began to fear it might assume a malignant character. At this time it occurred to me that the patient formerly had a slight cutaneous affection, which had disappeared. I advised her to take the common solution of oxymuriate of quicksilver. After taking it for six days, she complained of tender gums, and on examining the wound, it was found to be in a healing state. The medicine was continued for two or three weeks, during which the wound cicatrised; and though once or twice it took on a threatening aspect, at length became sound, and has continued so ever since, a space of four years.

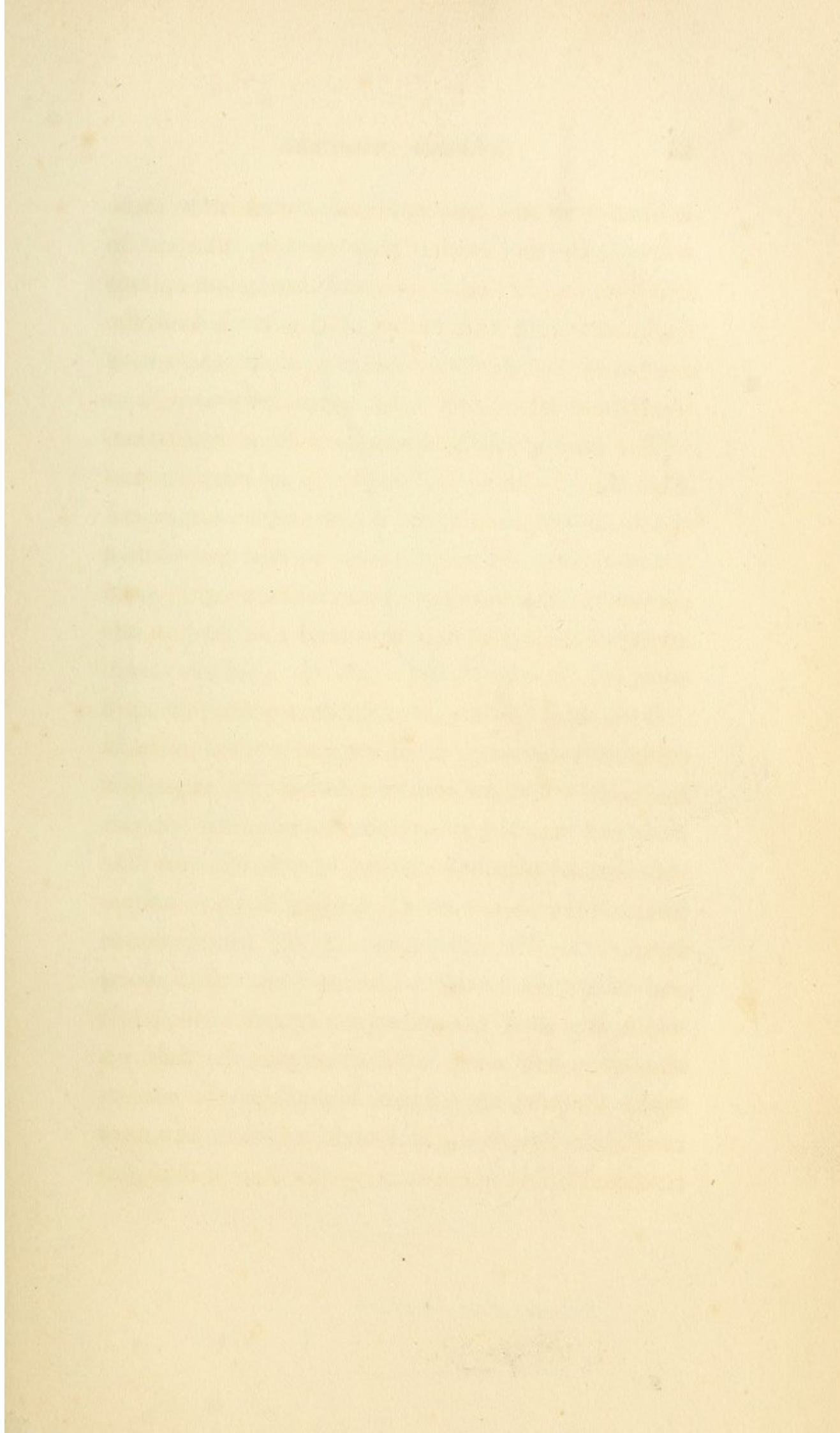
The second variety is the small red pimple appearing most commonly on the face; radiating red processes into the surrounding skin. The size of the body of this tumour is usually about the eighth of an inch; the rays sometimes extend half an inch around it. For a long time after its existence, there is no pain nor any uneasy sensation. After having continued for years, it assumes a prickling and finally a burning pain; increases



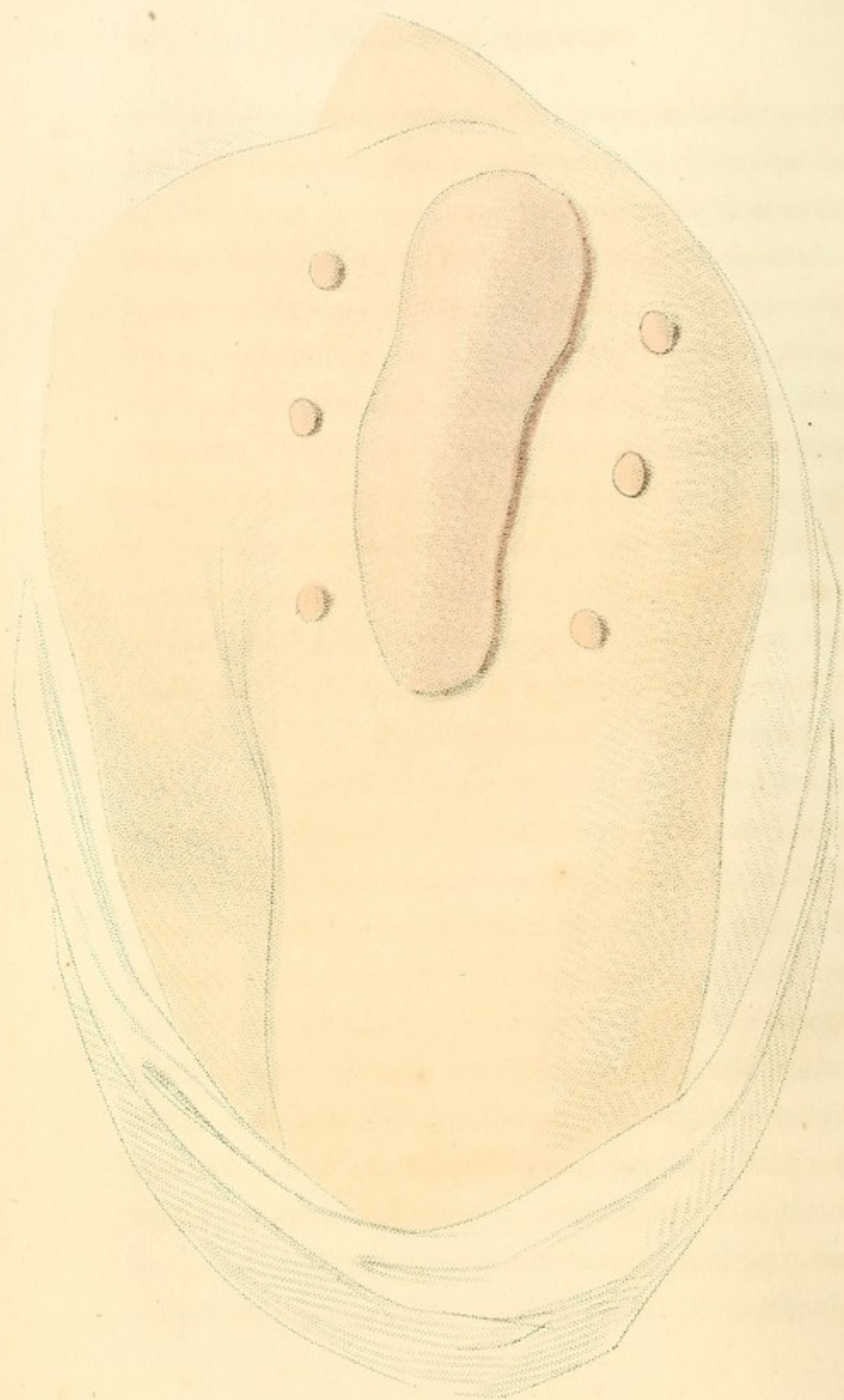
in size, ulcerates, and assumes a cancerous character. In the earlier part of life, that is in children, and in young adults, I have never seen it degenerate into a cancerous affection. It is in the decline of life, and especially in persons who live freely, and take much wine, that it ulcerates.

The cure is easily accomplished by extirpation. This may be done by the knife or caustic; and should be proposed early, if the patient has passed his meridian. If not, it may be delayed, with a caution to the patient to watch its progress, and attend to it on the first appearance of pain or ulceration.

The third variety is a more troublesome and dangerous disease. Like the first, it resembles, in the early stage, the scar of a burn. In colour it is more red than the surrounding skin, and shoots out red vascular processes, which give it the crab-like form. The elevation is not great in the common form of the disease. It is sensible to the touch, and is attended with a burning pain. The parts which are most frequently its seat, are the back, shoulders, and neck. On dissection it exhibits a white fibrinous appearance, much like the scirrhus-cancerous deposit in the female breast. The most remarkable fact about it is the disposition to regen-







*Keloides of the shoulder*

erate after removal. This may happen a number of times; and eventually it may ulcerate and become a malignant sore.

The following is a case of true keloides. Miss B——, of Worcester, six years since perceived a small rising of the skin on the left shoulder, accompanied with a stinging, burning pain. This tumour increasing gradually, she had it cut out. As soon as the wound healed, the rising of the membrane showed that the disease was regenerating. After some time it was again removed, and the edges of the wound brought together by three stitches. When it again healed, the same disposition to a rising showed itself. The tumour, when I first saw it after the second operation, was about two inches long and half an inch wide; of a slightly red colour; raised from the surrounding skin like the scar of a burn, and a small red projection extending from its edge. A burning and shooting was felt in the parts. At each of the points where the needle was passed through, there was a little rising, similar to the first, and about the size of a pea's head, and quite red. So that instead of one tumour there were seven. These are represented in Plate III.



Explaining to the patient the uncertain effect of any operation, I offered to remove it for her : but she has not yet felt encouraged to repeat the trial of what has twice failed to relieve her. In such a case, it would be proper to include a considerable portion of sound skin with the excised tumour. The extirpation of the sub-cutaneous cellular texture with the skin should also be accomplished.

We have stated that keloides is not always attended with the red processes or radiated lines which led to affix to the disease the name of keloides. The following is a genuine case of this affection, though much less threatening than common in its beginning, and more rapid and violent in its subsequent course.

A short time since, Dr. Jeffries desired me to see a patient of his, who was affected with a tumour of the nose, which he had twice cut out. It occupied the right ala of the nose, extending from the edge upwards half an inch, and involving the cartilage of the ala, though its seat was originally in the skin. The surface was but little raised and the colour not decidedly varied from that of the skin, though perhaps a little more deeply reddened. There were no red processes shooting out of it. The patient experienced some uneasy sen-



sations. He removed it a third time in such a manner that it could not, I believed, be regenerated. When removed, it was about half an inch in diameter, quite firm: consisted of a white fibrinous matter, perfectly distinguishable from the skin and cartilage around.

Between two and three months after the operation, I was requested by Dr. Jeffries to see the patient again. The wound had healed and remained perfectly sound. A considerable tumour appeared on the face, and another under the jaw. The latter especially is quite large and hard. The patient's appearance is greatly altered, and her health much impaired. She is a married person, of twenty-two years of age. She was formerly very good looking, and I believe healthy. When it is recollected that this formidable disease sprang from a small white rising in the wing of the nostril, the course it has taken is certainly extraordinary. It affords a good example of the worst variety of keloides.

March 23, 1837.—I saw the patient this day, after an intervention of a fortnight. A tumour is now seen extending from the right eye and side of the nose to the cheek, where there is a frightful enlargement including all the textures of the face and the gums. There is also a large tumour under



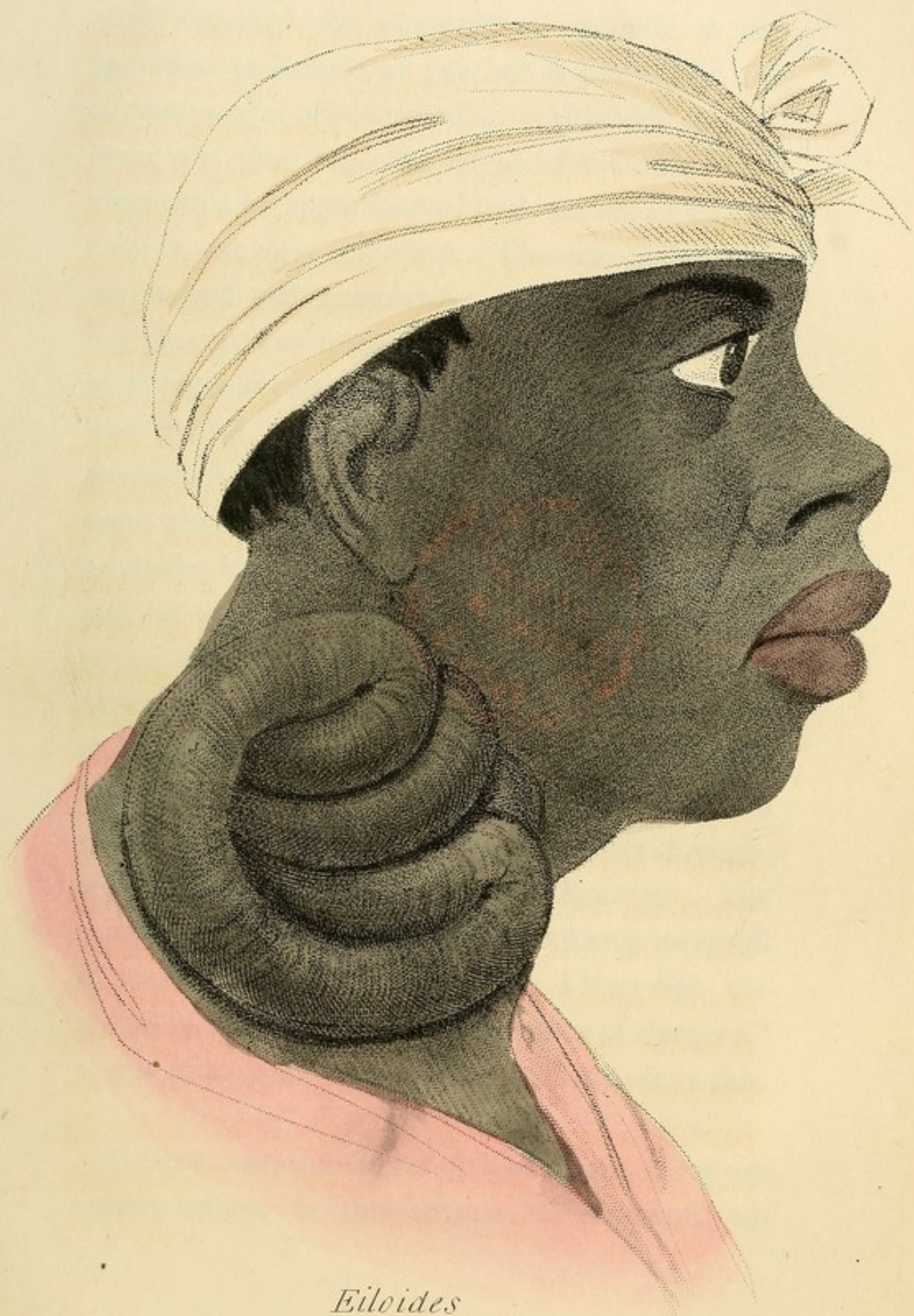
the jaw, and a chain of indurated glands running down the neck to the clavicle.

*EILOIDES*.\* The name we have given to this tumour is derived from the rolls and coils it forms. It is a very rare disease, and I have seen but one instance of it. This a true production of the cutis and continues so throughout its growth, although it may become very large. The first appearance of it is an elevation of the skin, similar to that from a burn ; without pain, redness, heat or ulceration, it increases to a great size ; and ultimately affects the patients health. If removed, it is reproduced. No cause is known, but a scrophulous habit seems to predispose to it. The specimen I present to you is of this description of disease. It appears like a triple coil of inflated intestine, each roll being four inches long, growing by a narrow base from the side of the neck. The patient as you perceive by the colour of the skin was a negress. She was about fifteen years old when she first applied to me ; I was astonished at the view of this remarkable production, hanging from the side of the neck. See Plate IV. She had not been perfectly healthy ; nor was she apparently much disordered. I proposed, and soon

---


\* *Eilo* to coil.





*Eiloides*





after executed the removal; taking care in the operation to include as you see a portion of the circumference of sound skin. Although the tumour was thus large, the edges of the skin could afterwards be approximated and united, in a great part, by the first intention. The non-united part suppurated and granulated; and during the healing process was frequently subjected to the action of astringent caustics. In four weeks, the wound was healed perfectly smooth. About eighteen months after, she came to me with a tumour in the same place, not so large as the first, but occupying a broader base. She wished to have it removed; and on my declining, applied to another practitioner, who operated on it. Soon after it regenerated; grew rapidly; the patient's health failed, and she died dropsical. On examination of the body, the lymphatic glands in the abdomen were greatly increased, forming large tumours throughout the cavity. The liver was diseased. The serous cavities and the cellular membrane were full of water.—The case of Eleanor Fitzgerald, depicted in Mr. John Bell's "Principles of Surgery," seems to have been of the same character as this.

BESIDES the tumours described above, there are various others in this texture, of comparatively



rare occurrence, and which, in the actual state of our information, must be considered anomalous. Among these is the MOLLUSCUM, represented in Dr. Willan's plates, and described by Dr. Bateman. I have met with only two or three instances of this affection. One of these was a patient who came to the hospital for admission; but I discouraged his entrance, on the ground that nothing could be done for him. The other is described in the following letter.

DEAR SIR,—I am very desirous of your advice in the case of a patient of mine—a Capt. M. of Kennebunk Port, about thirty-five years of age. About a year ago, I was consulted for a hard tubercle under the skin, below the clavicle, but adherent to the skin, with a perceptible purplish discolouration of the skin, the size of a hazle nut, which had been noticed some months, but gave no trouble from soreness or pain, except when irritated by the clothing. I advised excision, and removed it. A few months after, he noticed some small tumours in the neck, of the same side, and similar external character, excepting that the skin retained its natural colour—one on the opposite side of the chest, and a number on the scalp, the size of peas, excepting one large one, the size of a large nut-



meg, that had been noticed for some time before that one was removed from the chest, but was presumed to be a wen.

All these tumours have been gradually increasing in size on the head, while many more have sprouted out. The old ones have become projecting and excrescent.

Some of the excrescences have grown out three-quarters of an inch. Their surface was the colour of the skin, before any applications were made to them. They are all of soft consistence, not painful, and the patient's health is perfectly good.

Will you have the goodness to forward me your advice on the case, and whether there is any thing that will promise a cure.

He has used an ointment of ioduret of mercury externally, solution of lunar caustic, tincture of iodine externally and internally, Fowler's solution and pills of red oxide of mercury internally. All these have been used in succession, but of none do I think he has made a satisfactory trial.

The only perceptible effect has been a flattening of some of the tumours, and rendering others stationary in their growth.

Yours very respectfully,

BURLEIGH SMART.



THE CASE which follows was not one of circumscribed tumour of the skin. As the principal part of the patient's sufferings arose from a thickening of this texture, it may be useful to state the case here.

Dr. Channing requested me to see a patient of his, who was very much reduced by excessive pain in evacuating the bowels. For some months she had not had a solid evacuation, in consequence of the distress occasioned by an effort at stool; so that after waiting as many days as she could, medicine was taken and liquid stools produced. There was much pain in passing water, and a bearing down sensation in the vagina; but the most distressing symptom was a pain darting through the hips and into the bowels, which came on after evacuation, and continued throughout that day with great severity.

On investigating the case, it appeared that six months before, she was confined without any notable occurrence, but after the birth of her child she never had an easy evacuation, and the suffering had been constantly increasing. She said the distress was at times so great, that to have a solid evacuation would prove fatal to her. On examining the perineum, it was found to be exquisitely



sensitive. An involuntary scream followed the least touch. The skin between the anus and vagina formed a solid tumour, was red, hard, and tender. The vagina very sensitive to the touch, but when I attempted to pass the finger into the rectum, the pain was insupportable, from pressure on the tumour. However, I succeeded in detecting a small rising, inside the rectum, as large as a pea, and running upwards from this lump, a fissure in the mucous membrane, an inch long. Here was the seat of the principal suffering. I was at once satisfied that this fissure was the cause of the trouble, and advised an operation, which was assented to, and performed on the following day.

The patient being placed on the edge of the bed, the feet on the floor, was directed to bend forwards on the bed. The parts were separated as much as possible by assistants. A round bladed knife was then introduced, and the sphincter on the side towards the os coccygis was divided throughout as fairly as possible. A small piece of lint was interposed to prevent immediate adhesion.

On the day following, the patient took a dose of medicine, and had the first comfortable evacuation for six months. After that time, she recovered



rapidly, and is now perfectly well. The tumour gradually disappeared.

In this case the incision was made through the tumour and the fissure. In cases where the fissure has been in the side of the rectum, I have not divided the fissure, but made the incision towards the os coccygis, from its greater facility. The object being to take off the tension of the sphincter, and thus give the fissure an opportunity of healing, it is not important where the incision is made, provided there be a sufficient division of the sphincter.

The sympathetic affections caused by this lesion are very extensive. Not only the organs of the pelvis, but those in the cavity of the abdomen are much disturbed. I operated on a patient with fissure, who had severe paroxysms of pain in the right hypochondriac region. After dividing the sphincter, these pains were relieved.

The practical lesson derived from this case will, I trust, be an excuse for its introduction in this place, connected as it is with a common and obscure affection, *the fissure of the anus*.

### SECTION III.

#### TUMOURS OF THE CELLULAR MEMBRANE.

THE cellular texture is the seat of many kinds of tumour. That which is most frequent and belongs particularly to this texture is the common wen, or steatoma.

STEATOMA. This varies in size, from a few grains to many pounds. I show you one taken from the back of the neck by Dr. Miller, of Providence, which weighs over twenty pounds. In external appearance, it is distinguished by its smoothness and regularity. In consistence it is usually firm. There is no change of the natural colour of the skin; no sensibility, nor painfulness. Most commonly it is moveable under the skin, and on the surface of the muscles to which it is attached. On exposing its surface, it presents, as you



see in these preparations, a yellowish white colour externally. There is always a distinct coat investing it, composed of transparent cellular texture. Processes of cellular texture, penetrate and divide its substance into lobules of various sizes.

There is a kind of steatoma now and then met with, which is soft, and has the appearance of containing a fluid. This soft wen I have seen, most frequently in the neck, and on the shoulder. It may be distinguished from an encysted tumour which it much resembles in external appearance, or an abscess, by the want of an undulating movement, or vibration of its parts. Practical men cannot fail to have noticed that they are sometimes deceived by an appearance of undulations or fluctuations in parts, wholly composed of solids. If we strike the fleshy part of the thigh, with one hand, an appearance of undulation will be communicated to the other placed within two or three inches distance. This is simply the vibration of solid parts. When a fluid tumour is treated in the same manner, an undulatory movement is perceived. A delicate test of the existence of a fluid, is obtained by placing the thumb and forefinger of the same hand on the tumour. A very



light tap of the fore finger will communicate an impression to the thumb, if there be a fluid within; if a solid, not.—These soft wens are less regular in form than the hard; sending out processes or prolongations of the main body, which insinuate themselves between the muscles.

When a common steatoma lies, as it usually does, in the subcutaneous cellular texture, its nature is readily ascertained. When it is situated under the muscles, there is more difficulty in obtaining a satisfactory notion of its character.

Mr. N. a gentleman thirty years of age, very corpulent, presented himself at the M. G. Hospital, with a tumour at the angle of the ribs, on the right side; occupying a space, apparently about five inches in diameter; not distinctly circumscribed; becoming flat on raising the arm, so as to excite a doubt whether it was any thing more than the accumulation of common adipose substance, or whether it might not be a fluid. It had been discovered about three weeks before I saw it. An incision being made through the skin, the adipose substance was dissected through, without any appearance of tumour. The latissimus dorsi muscle being exposed, was divided; yet no tumour discovered in, nor under it. I



began to apprehend that I had been mistaken ; and some degree of excitement was experienced by those who witnessed the operation, at the difficulty. The serratus major muscle having been brought into view, was in its turn divided, and under this, the tumour was found, buried in a mass of fat. A very firm adhesion to the ribs and intercostals rendered it difficult to raise it from its attachment. When removed, it was found to be about an inch thick, and three inches diameter, composed of adipose substance, excepting in the middle, where was found a small cellular sac, containing a curdy fluid. The patient had a slight pleuritic attack three days after the operation, this being relieved by two bleedings, he did well afterwards.

In the medico-chirurgical transactions, Mr. Lawrence has mentioned a tumour of the cellular membrane, wholly free from fat, a purely cellular tumour. The case described by him, is very remarkable, and unlike any I remember to have seen.

THE CELLULAR MEMBRANE is subject to the formation of a tumour, having a fibrous arrangement, and being composed of layers of condensed cellular texture. This is much firmer than the adipose tumour ; not so regular, being flattened, apparently



by the action of muscles between or under which it is situated. It is not painful; causes much lameness, when in the extremities; and is apt to be regenerated, probably from prolongations, which escape detection at the time of operation. The colour is whitish; consistence firm, and texture laminated. A case of this nature occurred to me in July 1834. This tumour was about four inches in diameter; of a flattened form; was situated under the hamstring muscles, where the tendons separate. The dissection was deep and difficult, from the irregular processes running under the muscles; but the whole of it was removed apparently; the wound healed by the first intention and the patient left town in a week from the operation. About a year after, that is in the summer 1835, she returned with a tumour not quite so large; nearly in the same situation, which I again removed. She soon recovered, and went home, and I have not heard from her since.

#### PAINFUL SUB-CUTANEOUS TUBERCLE.

This tumour has been described as a swelling of a nerve; and some have represented it as a tumour situated on a nerve. These opinions have been



founded on the painful nature of the disease. It is in fact developed in the sub-cutaneous cellular texture, and, consists probably of this texture. It is hard, and in size may be about a quarter of an inch in diameter. Ordinarily it does not cause an external tumour, or any rising of the skin; unless situated on a superficial bone, as the superficial part of the tibia. There is no discolouration. The pain is great, though fluctuating, and varies in kind as well as duration; for it is sometimes an aching, and sometimes a sharp, burning, lancinating pain. The lower extremities are more frequently its seat. After lasting some time it may inflame, the skin over it ulcerate, and a foul, acrid discharge issue in small quantities. Then the lymphatic glands between it and the trunk become swollen. A constitutional affection manifests itself. The pulse quickens, appetite fails, the tongue is furred, and when allowed to reach this stage, it proves fatal. Such is the malignant form of the disease. But it does not generally follow this course, especially when the subject is young.

Mr. W. aged sixty-two, a baker of good constitution, applied to me in the year 1835. He had a sore on the right leg, three inches below the knee, on the superficial part of the tibia; in



diameter about an inch; of a livid colour, very offensive. The skin about it, was of a dark red colour, for some distance around. The periosteum and all the textures near it were swollen, so as to give the appearance of a diseased bone. He informed me that seven years before, a small hard tumour appeared under the skin of that spot, accompanied with much pain. He made some applications, which had the effect of changing the colour of the skin, and increasing the pain. It continued to be a small, hard, troublesome tumour for four years, during which, it was excessively painful, but not discoloured, and showed no disposition to ulcerate, till he afterwards applied caustics. It did not ulcerate till the fourth year. He then began to use active caustics, and once, after these applications when the slough had separated, it healed. In two or three months it broke out anew, and slowly increased in size. At the time I first saw him, he was confined to his chamber; had a quick pulse; foul tongue; no appetite; constant diarrhoea; pains in the bowels, and a considerable cough, with purulent expectoration; yet was not much emaciated. His pains were severe, and with small remissions. After examining his case twice, I came to the conclusion that



nothing would save him but amputation. I had much question, whether it was not too late for this ; but the want of emaciation gave me some hope ; and the pains were so great that amputation would probably mitigate his sufferings. The operation was assented to, and performed a few days after, above the knee. The wound united in part. The inferior angle of the wound kept open after the second week, and began to discharge very copiously an excessively foul pus. In the third week, a large slough presented itself, and was drawn out. At the end of six weeks, a suppuration formed high up the limb, in the course of the artery, and a considerable bleeding took place, which was arrested by compression. In the mean time the cough, diarrhoea, and pains in the bowels continued, the stomach was pained and distressed by all food, and the case presented a hopeless aspect. Soon after this, however, the sore put on a better appearance. The patient began to have appetite ; the other bad symptoms disappeared. The wound healed in three months from the operation. It is now two years since its performance, and he remains well. Ever since the operation he has been free from the pains which tormented him ; excepting at the time the abscesses formed.



A young man of sixteen came to me in July, 1836, for relief from a tumour on the right thigh, below the great trochanter. He had perceived it three months before, from the pain it gave him. Since then he had been greatly annoyed; had applied blisters and frictions without benefit. On examination by the eye, I could discover nothing. Placing the finger on the part I felt a tumour of the size of a small bean. Somewhat moveable; tender; quite hard; not discoloured. He was advised to have it cut out, but has not yet brought his mind to submit to the knife.

Miss B. forty years old, has for two years been afflicted with very distressing pains in the right side, below the edge of the right breast. Six months since, she discovered a lump there as large as a common bean; which has not increased. This tumour is sensitive, hard, quite moveable, does not show itself to the eye, but is very distinct to the touch. She considered it a cancer of the breast. I was able to relieve her of this apprehension; and advised the removal of the tumour.



## SECTION IV.

### MUSCULAR TUMOURS.

THESE are formed in the substance of the muscles. They are not very common. On external examination they are less distinctly defined than steatomatous tumours, and less moveable. When the muscles, in which they are situated, are perfectly relaxed, they possess a considerable mobility; when these are firmly contracted, the tumour is quite fixed, and these circumstances constitute their most remarkable character. The diseased part is not very easily distinguished from the healthy; so that in operation it is necessary to trench deeply into the surrounding muscle. They are more frequently accompanied with pain than cellular tumours; and more disposed to degenerate into malignant affections. Their origin is often

traceable to accidental injury—a blow, strain, or continued pressure. After removal they are apt to re-appear.

ENCYSTED MUSCULAR MELANOSIS. The first case of muscular tumour to be mentioned, is of a rare kind. In the autumn of 1835, a young woman belonging to Weymouth, came to me with a tumour on the anterior part of the thigh, about the size of a hen's egg. It had existed five or six months, and no cause for it had been discovered. When the muscles were relaxed, it was freely moveable in a lateral direction; when they were contracted, it was perfectly fixed. It was free from pain or tenderness. Soon after, I removed this tumour. An incision being made over the rectus muscle, its tendinous fibres were exposed below the middle of the thigh. These being separated, the tumour was found buried in the midst of the rectus, from which it was removed with considerable pain and hemorrhage. The wound united in part by the first intention; but a small sinus remained open about four weeks, after which she recovered, and has had no return.

On examination of this tumour, it proved to be a melanosis. It was seen to be composed principally of hard dark-coloured muscular substance;



but its nucleus consisted of an osseous shell, an inch in diameter, containing a dark-coloured fluid, and lined by a black crust. This curious specimen you here see. Probably it took its origin in this way. The patient received a blow on the part, which ruptured some vessels. A coagulum was formed, and gradually covered with an osseous crust. The injured muscular substance might become indurated either before or after the formation of the crust, and partook of the melanotic action. The case was certainly not malignant, as the patient has been well for two years.

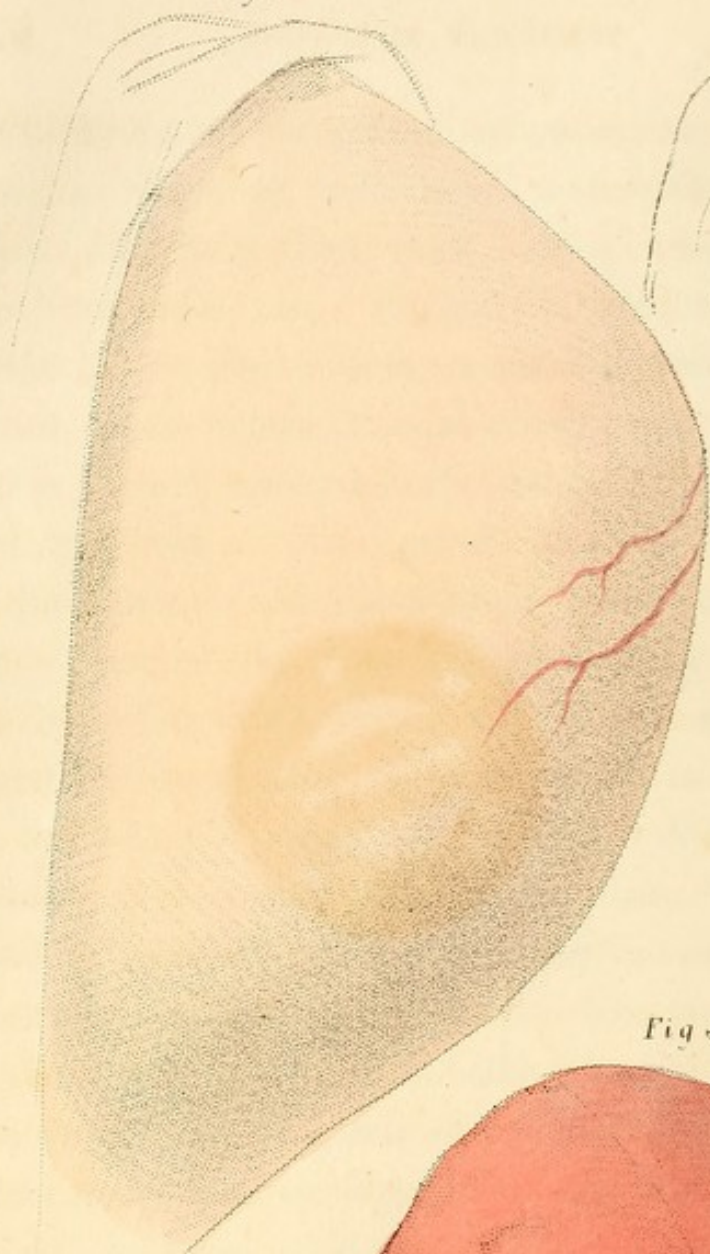
SCIRRHOUS MUSCULAR TUMOUR. W. M., formerly a shoemaker, now a trader, came to see me in the spring of 1836, with a hard tumour on the cartilages of the left ribs. His history was this. Two years before, while holding a shoe, on which he was at work, against the breast, the shoe slipped under the pressure, and hurt him over the cartilage of the sixth rib. Next day he perceived a slight swelling on the spot. This gradually increased and was three inches long when I first saw it. The patient is of small stature, compactly made, and has good health.

An operation was advised. To the necessity of this he assented ; but having some affairs to trans-

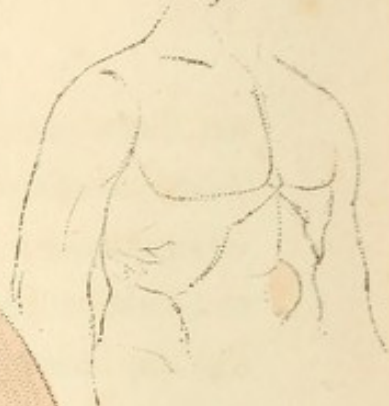




*Fig 1*



*Fig 2*



*Fig 3*



*Muscular scirrhus*

act, he went home, and did not appear again till a year had elapsed.

In March, 1837, he came to the hospital, with his tumour much increased in size. Beginning at the upper edge of the cartilage of the fifth rib, it extended to the lower edge of that of the eighth, and required the breadth of six fingers to cover it vertically, and of four to cover it transversely. Its breadth lay from the median line to the left, beginning from the linea alba. In colour, the skin was not changed, excepting that it exhibited numerous enlarged veins. In consistence, it had the hardness of a periosteal tumour, that is, something less than that of bone. A degree of sensibility existed on the edge of the cartilage of the fifth rib, and at some other points. It was slightly moveable in a lateral direction, but not in the vertical, and its movement did not appear to affect the ribs. There was a sensible pulsation, without any vibration. See Plate V.

The patient wished to know whether an operation for his relief could be safely performed. The first question was, what is the nature of this tumour? To the eye it had the aspect of osteosarcoma—to the touch, it wanted the hardness of that disease. Was it a disease of the mus-



cles or of the perichondrium? Might it not be a projection caused by internal aneurism? Did it lie on the outside of the ribs, or might it not extend inwards, as well as outwards?—for there was an obvious dip of the tumour below the edges of the cartilages into the epigastre.

My opinion was that it was a scirrhus tumour of the rectus muscle. This was derived from the first examination, when it was smaller and less hard than it afterwards became. Its extreme hardness led me to doubt afterwards whether this opinion was correct; but on the whole it was the most satisfactory.

As it extended over the edges of the cartilages, it might pass under them for some distance. This led to the question, whether these cartilages could be removed, if necessary. An examination satisfied me that the internal oblique and transversalis might be separated from their edges and internal face, and that the diaphragm might also be dissected sufficiently without cutting into the pericardium pleura or peritoneum.

On the 9th of March, 1837, the operation was performed in the following manner. The patient being placed on a table, an incision, seven inches long, was made from the fourth rib downwards,



and the anterior face of the tumour was exposed by dissecting away the integuments. Its face being laid bare, exhibited a blueish colour, and was of a scirrhus hardness. Every stroke of the knife around it, was followed by a copious flow of blood. When the circumference of the tumour was uncovered, its edges were found to be quite undefined and concealed by the muscular connections. These being cut through, I was able to discover an ill defined edge and proceeded with the knife under this edge, and soon found I could detach the tumour from the faces of the cartilages; pursuing the dissection altogether by the touch, as the streams of blood and the hardness of the tumour prevented an inspection of the parts beneath. The operation proceeded favourably, till the tumour turned down over the cartilages into the epigastric region. Here it was obvious that if it involved the internal oblique and transversalis to the extent it did the external oblique and rectus, the incisions would penetrate the cavity of the peritoneum, especially if this membrane adhered to the inner face of the tumour. Such was found to be the fact. The two inner muscles formed part of the disease; the peritoneum adhered to it for about an inch, and not having the advantage of ocular



inspection, it was of course difficult by feeling to make a nice dissection of the adherent membrane. This was, however, accomplished, and the whole disease was removed in one mass. Four large arteries, and many smaller ones, required ligatures. The patient suffered much when the tumour was raised, from its drawing the peritoneum outwards. This part of the operation was short, and as soon as it was concluded, he ceased to suffer severely. The wound was closed, leaving an outlet for the sanguineous oozing.

The patient had a smart fever after the operation, and a slight degree of peritoneal inflammation which was relieved by two or three bleedings. His symptoms afterwards were perfectly favourable, and the wound healed in the third week.

On examining the tumour, it presented a cartilaginous hardness. Its surface on all sides, was composed of the muscles between which it lay. Its substance consisted of a brownish texture, in which a multitude of granulations, the sixteenth of an inch in size presented, with intermixture of a fibrous arrangement. At one point there was a softening, as if suppuration were about to begin. At another a dark red spot was seen. The internal or epigastric part was equally hard with the



rest of the tumour. The surface of the cartilages was deeply depressed where the tumour had lain.

The obscurities of this case were not removed till after a careful examination of the tumour, and a consideration of the circumstances connected with it. The shining appearances of the external oblique muscle in a perfectly healthy state, though intimately connected with the tumour, showed that this was not the original seat of disease. The cartilages of the ribs were indented, but healthy. The internal oblique and transversalis were closely connected with the inner face, but quite apart from the tumour at its origin. The rectus muscle, on the other hand, was in the situation of the first prominence caused by the injury. The texture of this muscle was wholly absorbed in the tumour, and no vestiges of it remained. The tumour itself consisted of a mixture of granulated and fibrous organization, such as is seen in scirrhus tumours of various organs.

**MALIGNANT MELANOSIS.** A gentleman applied in the year 1832, for a tumour on the back between the posterior edge or base of the scapula and the spine. Three years before, in making a great effort with the right arm, he felt something yield or break. Sometime after, perceiving a



lameness and pain at the part, he examined it, and found a tumour there. The pain increasing, he had an operation performed by a surgeon in the country, and the wound healed well. When he came to me, I found a considerable tumour of irregular form, lying at the edge of the scapula, about four inches long, but not so wide; not tender nor discoloured; the skin of the cicatrix of the first operation drawn in, and adherent to the substance of the tumour. It was slightly moveable; but if he was desired to elevate the arm, became entirely fixed. When I saw it, he suffered great pain.—Soon after, he was operated on in the hospital. An incision in the direction of the base of the scapula of an oval form was carried round the cicatrix; and at right angles with this another towards the spine, over the surface of the tumour. The trapezius muscle was with some difficulty distinguished, in consequence of its diseased state, and the former wound. This muscle being cut all round the tumour, the rhomboideus was exposed, found involved in the disease, and cut through. Then through the bleeding and contracting muscles, the whole tumour was raised and removed. On examination, it was found to consist of the two muscles above named, the trapezius and rhom-



boideus. The centre of the tumour was hard; and its whole interior black as ink; as you may perceive by the preparation now presented to you. The irregular fringed edge is formed by the sound muscles. There is a portion of hardened cellular membrane interwoven with the muscular matter. The wound adhered partially. An erythematous affection followed, with so severe constitutional derangement, as to threaten life. After some time he recovered, and went home apparently well. In about six months after the operation, the disease reappeared, with the symptoms of a cancerous affection, and proved fatal. This is a fair example of melanosis in the muscular tissue, which was of a malignant character. Whether any different mode of operating would have saved the patient, as for instance, a more extensive removal of the surrounding parts, is a question worthy of consideration. In both operations, I have reason to believe that the whole of the visible disease was extirpated.

FUNGOIDES. Fungus hæmatodes appears in the muscles, as it does in many other textures. Whether in any case it begins in this texture, or is at any time confined to it, we know not. The mus-



cular texture is however extensively affected when the disease exists in the limbs or trunk.

As already stated, this disease is remarkable for its softness and disposition to bleed. In its early stage, it forms a soft projection, with some pain. The swelling becomes discoloured, points like an abscess, opens, and throws out a soft fungous excrescence. All the textures become involved in a soft uniform mass, which bleeds readily from its whole surface, and sometimes freely. The lymphatic glands, and the great organs, ultimately become diseased. This affection proves fatal, unless extirpated in an early stage.

The first case of Fungus hæmatodes I ever saw occurred in 1805, before the disease was well known and distinguished. The patient Mr. T. of this place was moving a large roll of sheet lead which slipping from his hands fell against the middle of the right thigh. No great inconvenience followed immediately. After a few weeks he began to have pain in the thigh; and at the end of the fifth month, an irregular swelling appeared a little above the middle on the inside. This continued to increase until it pointed; and having every appearance of containing a fluid, was punctured, and a free discharge of blood appeared, but



no pus. From time to time it continued to bleed, and at length threw out an exuberant dark red coloured fungus, three or four inches in diameter, and an inch above the skin. Much pain and frequent hæmorrhages attended. Not being then acquainted with the character of the disease, I extirpated it with the knife, and on its returning, with caustic, neither of which being effectual, amputation was advised; he declined this, and put himself in the hands of an empiric, who hastened his exit by acrid applications.

A farmer twenty-three years old, of good constitution, belonging to Andover, in this state; without any observable cause perceived a swelling on the upper part of the left arm. The skin was not discoloured, and for some time he felt no apprehension from it. Becoming painful, he applied to the late Dr. Kittredge, who extirpated it by the knife, and on its re-appearing, by caustic. On its occurring the third time, he came to me, and exhibited the tumour I now show you. It is situated on the upper part of the radius and ulna—is about three inches diameter,—the dark coloured part was an external bleeding fungus. You see it attached to the periosteum of these bones which does not distinctly exhibit any diseased appear-



ance. The bones are perfectly free from disease. The superior articulating extremity of the radius you see is smooth, bright, and free from any morbid change. All the other textures from the periosteum to the skin, are involved in a confused mass of disease. On seeing this tumour, I advised amputation of the upper arm. This was performed, and after it, there was no recurrence of disease. The tumour has been successfully injected, which gives it as you may perceive a brilliant red colour.

The following case of a hospital patient, is a good specimen of the common course of this disease. See Plate VI.

Abigail Day, Æt. 50. Widow. Andover. March 4, 1829.—Little more than a year since bruised her leg against the wheel of a wagon. The part was considerably discoloured. The patient went lame for three or four weeks; often struck the part while carrying a bucket of water, and thus kept up an irritation for the time. Made no application, and as lameness subsided, thought all was well. About two months from the time she was hurt, while accidentally passing the hand over the part, perceived a tumour as large as an acorn. It was hard, not tender to the touch. Skin white and shining. She showed it to a physician

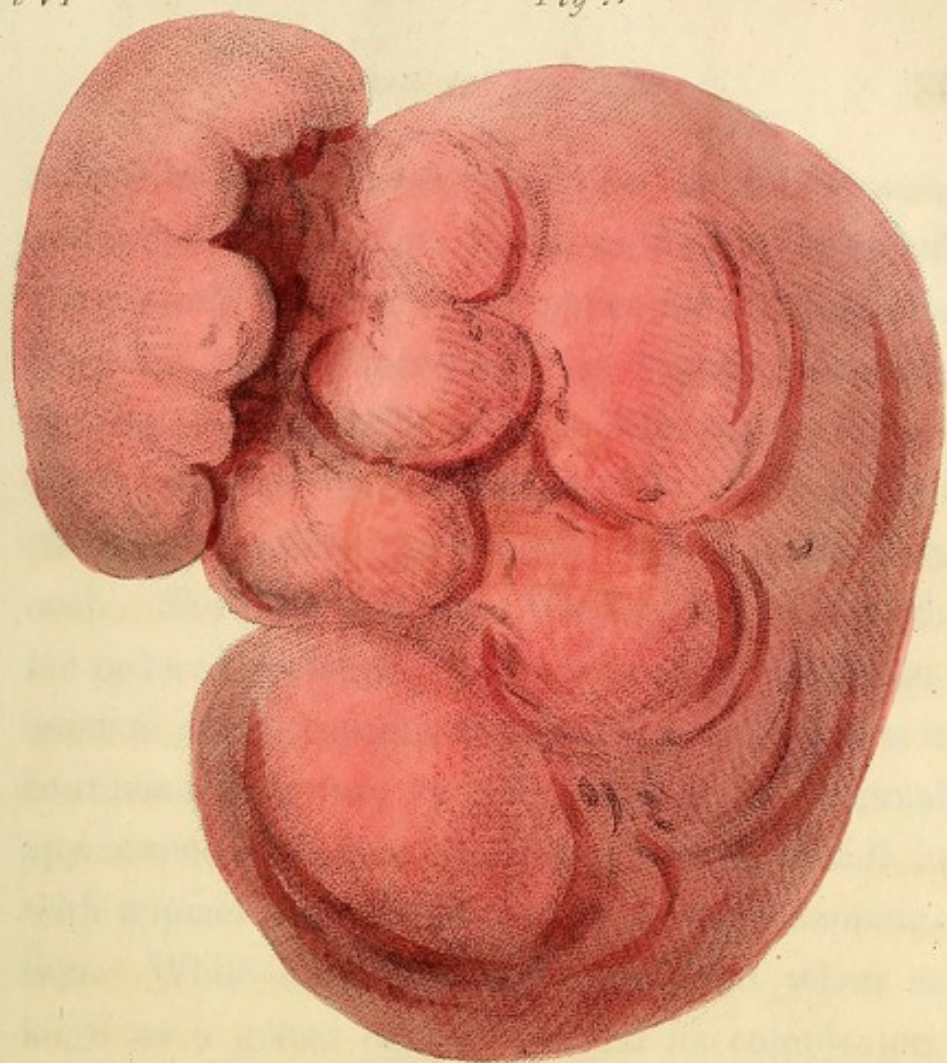
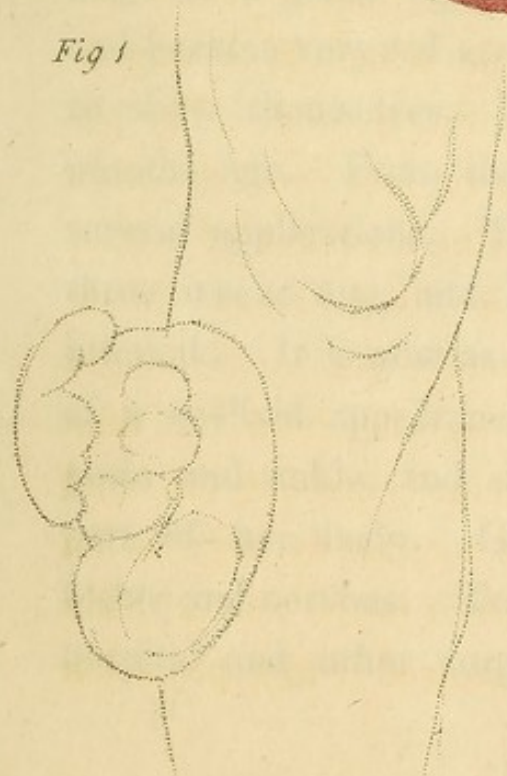


Fig 1



*Fungus hæmatodes of the Leg*





a few days after, who called it a scrofulous wen, and proposed to remove it, but as the patient would not consent, he made some application. From this time the tumour increased very rapidly, retaining the same aspect. She saw Dr. Kittredge. He ordered salt water bath, ointment, &c. This had no effect in retarding the growth, but kept the part cool. She then saw Dr. Whiting, of Haverhill. He ordered showering, and perfect quiet to the tumour in other respects, but notwithstanding this it continued to grow, retaining the same external appearance. At this time she chanced to fall in with a quack, who attempted to produce suppuration. While under his treatment, and when as large as a goose egg, it changed its complexion, and became very red and hot; blood vessels began to show themselves. This happened about five months ago. From that time to this has made several applications. The tumour began to bleed three weeks ago, and has continued with short intervals. It is now as large as an infant's head, of a sublivid appearance, pains shoot from it to groin and ankle, and she thinks it affects every part of her body. General health not good; feeble and nervous. To-day a consultation of the hospital and other surgeons was held. It was



unanimously decided that an amputation of the leg promised the only ground of hope to the patient. The patient was accordingly removed to the theatre, and the operation performed above the knee. Three arteries were secured—no after hemorrhage. Wound was dressed in three hours after the operation with adhesive straps and lint.

The patient at first appeared to be doing well after the operation. The wound soon healed. In about three weeks, a tumour appeared in the groin, which increased rapidly. The abdomen began to swell. Wishing to go home, she was discharged, and died in a few weeks after.

Perhaps I have not insisted sufficiently on the obscurity which exists in the early part of this disease. Its slow progress, in some instances, also is a point proper to be kept in view. In a number of cases, its first symptom is a deep-seated pain, which may be mistaken for rheumatism, or some local disease to which the part affected may be liable. This may go on even for years before it is followed by an external tumour. When the latter begins to appear, it is so ill-defined that we are not at once able to decide what the real nature of the disease may be. So, in the interesting case which follows; the disease was long supposed to



be lumbar abscess, and treated as such. Nor can it be considered as extraordinary that the most experienced surgeons were unable to form a right opinion of a disease involved in so great obscurity.

DEAR SIR,—It appears from recollection, fortified by a recurrence to letters, that my unfortunate son, whose death has filled us with grief, and whose last sickness you attended, made a voyage to Calcutta in the years 1816 and 1817, during which period he enjoyed his health. Early in the year 1818, he sailed again for Calcutta, and upon his arrival there, wrote to us that he had had the rheumatism severely ever since he left home, and added that, “since coming on shore, I have been in constant pain, and slept very little, till finding myself falling away daily, and my pain almost insufferable, I asked the assistance of Dr. Russell, a very skilful man, who told me my rheumatism was of a dangerous and uncommon kind, &c. I am confined to my chair, and forbidden to walk.

“I have for three days been entirely free from pain, by the application of leeches to my hip, which has been badly swollen and inflamed, and the danger appears to be a suppuration, which



Dr. R. is now taking effectual measures to prevent."

With Dr. Russell's assistance, he was so far relieved as to be able to embark for home, and I only find one jocose allusion to his rheumatism in his whole journal of his passage ; nor did we hear much of his complaint on his return home, in Dec. 1818. In the spring of 1819, he had several threatening symptoms of a return of his disorder, and a small swelling appeared, which was submitted to your examination ; when, if you recollect, you intimated to me an opinion that lumbar abscess was to be apprehended. He however soon regained his health, spent some time at Saratoga, and continued free from disease ; so that I had drawn the conclusion that your profession even was not exempt from error of opinion, and that you had been under a mistake in the one you gave of his case. His health thus became so re-established, that I consented to his going to Manilla with his brother, and they sailed the 9th of last June. On the passage, off the Isle of France, on the 22d of Sept. he had a return of his complaint, which has always been denominated rheumatic, and which reduced him very much. The heat of the cabin being excessive, and being



unable to go on shore at Manilla, where a dangerous insurrection existed at the time, he proceeded to Canton for advice, having for the thirty days previous, had an attack which was excessively violent, with a swelling of the hip and thigh bone, and great pain in the groin, knee and ankle joint, with such severity as to leave his legs literally a skeleton, and hip so weak as to be prevented, except by crawling, from going on deck. At Canton he was under the care of Dr. Pearson, and the swelling on the hip had extended under the bone, with an enlargement of the groin. A seton under the thigh was resorted to; and I learnt from him that he had, altogether, used blisters on the swelling twenty-seven different times. He has since been unable to move, except by the aid of a crutch. He arrived at New-York twenty-five days ago, when Drs. Hosack and McLane saw him, and talked of lancing the swelling, but decided that it was best to get him home first. A tedious passage of twelve days brought him here, when you were immediately consulted. This brief history of his case, with your examination of him before and since his death, may and I hope will be of some future utility. How far his excessively rapid growth, which began at the age



of fourteen, after a voyage to Europe for the relief of the asthma, from which he then suffered, may have been the cause of his fatal complaint, must be left to conjecture.

Yours with esteem.

J. T.

On examination of the patient at this time, I found a large diffused tumour on the right side of the spine, in the lumbar region. This was attended with an appearance of fluctuation, throughout a space about six inches square, that is, the region between the crista of the ilium and inferior ribs. The skin was not discoloured, and the part not tender. The patient was emaciated throughout, and suffering excruciating pain.

Doubtful whether the disease was fungus hæmotos or lumbar abscess, I considered that the patient's sufferings might possibly be mitigated by opening the tumour, and accordingly made a puncture. No pus appeared. Nothing followed but a little blood. No alleviation was of course produced.

In a week after his arrival, the patient died, and I was allowed to examine the body.

On laying open the tumour, it presented an enormous fungous mass, occupying the space of the lumbar muscles, all which had quite disappeared, leaving only a fibrous covering to the tumour. The tumour reached the spine, which was not diseased. The cavity of the abdomen was distended by a mass of enlarged glands in the fungoid state, that is, softened almost to a paste. The liver was enlarged, and contained many soft tubercles in its substance. The thoracic glands were not diseased.

The following is a very rare and interesting case. Whether the tumour was originally muscular or cellular, I know not. It terminated in involving all the surrounding textures, and in this resembles fungus hæmatodes; while in some points it is quite dissimilar.—In the year 1827, a lady, who had been for many years my patient, requested my advice in regard to a tumour on the outer and upper part of the left thigh, below the trochanter major. Her age was between thirty and forty. She had borne four or five children, and occasionally suffered much in consequence. Sometime before this tumour appeared, she had a



very bad attack of jaundice, and her health never seemed well established afterwards. The tumour had been discovered some months before I saw it; but being without pain, had not excited alarm, till its extension, with the urgent request of her husband, induced her to submit to an examination. I found an irregular hardness, without much rising, at the part indicated, for about the extent of my hand; presenting much the feeling of the swelling in œdematous erythema; but not discoloured, and something harder than the swelling mentioned. It was not tender to the touch, and not painful. The general health somewhat impaired. I advised rest, a careful regimen, and the application of leeches. While she continued under my care, no material change occurred. It soon after became necessary that her family should go to the south for the winter. She reached New-York; though not without suffering from the latter part of the journey to that city. On her arrival there, she became worse, and was immediately put under the care of my friend Dr. Perkins. The letters which follow, will show the melancholy sequel of the case.

(Letter from Dr. Perkins's son.)

Dr. Perkins desires me to say, that by the journey here, performed mostly by land, and in very inclement weather, Mrs. — suffered much from fatigue, and all her previous symptoms became much aggravated.—She walks with great difficulty and is not able to be much out of bed. The tumour, as you will remember, is not well defined on either of its margins, but is gradually lost in, and apparently incorporated with the natural parts—Of the hardness of ordinary scirrhus tumours—and evincing little sensibility on pressure—though there is considerable irritation and soreness immediately above and below. There is a point of the tumour which has been gradually becoming more prominent, and over which the skin is already tense and discoloured—yet the hardness there is scarcely less than when Mrs. — first arrived here. The pain in the back, hip, and down the limb would be oftentimes intolerable, but for the recurrence to strong anodynes; indeed Mrs. — has rarely a comfortable hour without their aid. Above and below the tumour there is considerable swelling—sometimes more, and sometimes less—and within a few days, œdema about the lower



part of the spine and sacrum. When Mrs. — arrived here, one of the inguinal glands, on the side affected, was much enlarged, prominent and very hard. This has been increasing, so as now to project more than an inch—but shows no disposition to suppuration.

Dr. Post has been attending in conjunction with Dr. Perkins—and the case has been treated by leeching and soothing anodyne poultices. At present leeching is discontinued, and iodine is employed internally and externally—poultices and anodyne liniments continued. The general health is considerably impaired, though perhaps less than might be apprehended in a case so protracted and attended with so much general irritation.

(Letter from Dr. Perkins.)

New York,

MY DEAR SIR,—I should have written you before on the subject of Mrs. —'s case, but that I hoped you might have been so situated as to make us a visit. We still consider the case as essentially different from a common vascular sarcoma. Dr. Post and Dr. Hosack as they inform me, have never before met with a tumour of this description. I have written to Dr. Physick, giving him as full

and minute an account of its history and symptoms as I could; which I exhibited to Drs. Post and Hosack, before forwarding it, that it might be improved by such suggestions as they could make.

I have received Dr. Physick's reply, in which he states, that the only case like this which has ever come under his observation, was in the year 1790 or 91. It occurred in a patient of Mr. John Hunter, and was situated in the back part of the thigh, extending nearly to the tuberosity of the ischium. Mr. H. came to the determination to amputate the limb, as high as he could, and then to dissect out the upper part of the tumour. But the patient died suddenly, and unexpectedly before the operation was performed.

There has been no essential change in the appearance of this tumour since Mrs. — has been in New York, that is—it is as hard and insensible on pressure, as ever. It has increased somewhat in size, and is more pointed. The skin over the centre, where it has become thin and discoloured, is of course tender, and I think will very soon give way. The œdematous swelling about the back has increased since I wrote you. There is perhaps rather more numbness in the limb, and she is



not so able to move it the last two days, but there is less pain; all which changes may be accounted for, by an increased pressure of the tumour on the nerve. Her pulse has become more frequent, (rising one hundred); and her strength has rather diminished though her appetite is tolerable, and her perspirations which have sometimes been profuse during sleep, have been considerably checked. Her respiration has been somewhat difficult for some days, but not constantly so. She has some cough—her voice is enfeebled, and she can speak but little without fatigue. Two grains of opium combined with assafoetida and camphor, is the minimum dose which gives her a comfortable night, and which is less than she required a week ago. Some slight pain and uneasiness was complained of this morning in the abdomen, and on passing my hand over it, I discovered a very extensive and hard tumour, no doubt an enlargement of the lymphatic glands, and which must have been forming for some time. Dr. P. has not yet examined this.

I have been thus particular, knowing how deep an interest you must feel in this case. One in which I know from the beginning, you felt the pov-



erty of art. The prospect fills me with anxiety and affliction.

Very respectfully and truly yours,

CYRUS PERKINS.

P. S. Both Mr. and Mrs. — are very anxious to see you, and I hope, if possible, you will so arrange your business, as to come. C. P.

Soon after the last letter was received, there was a rapid advance of the symptoms. The pains became excessive; the skin ulcerated, and a serous discharge in small quantity issued; the strength failed, and the patient soon sunk under the severity of her sufferings. On examination after death, the glands of the abdomen were found extensively diseased. The liver was indurated, and the other abdominal organs presented the derangements which accompany a scirrhus affection. This affection must therefore be considered of a scirrhus character; but we cannot trace its origin, nor discover the texture in which it was primarily situated. The occurrence of this disease, must be very uncommon, since it had so rarely come within the experience of the distinguished practitioners mentioned above.



TUMOURS OF THE FIBROUS TEXTURE OF THE  
TENDONS.

As the periosteum has been considered to have a fibrous organization, similar in nature to that of the tendons; affections of these parts might have been placed under the head of tumours of the periosteum. The fibrous texture of the tendons however differs so much in its physiological and pathological phenomena from those of the periosteum, that it seems proper to place them under a different head.

The tendinous texture, having a low degree of excitability, is rarely enlarged into the form of a tumour. It may be produced however, by rheumatism or syphilis; but is more commonly the consequence of excessive efforts of the muscles, with which the diseased tendons are connected. Tumours of the tendons are hard, not sensible, not commonly painful when confined to the fibrous texture; and they are difficult to remove. They are productive of loss of power in the limb, where they are situated. The following case will serve to illustrate their course.

The patient was a clerk or writer, eighteen years old, possessed of great muscular power. In



the summer of 1834, he undertook to raise himself from the ground, while sitting with his lower extremities extended; and this was to be done without using his hands. This feat he succeeded in accomplishing. No immediate inconvenience was recollected. Two or three weeks after this act, he perceived a weakness about the knees, and examining, found a slight hardness along the tendons of the flexor muscles. He continued to move about, but found the tumours and lameness regularly increasing. It was three months after the effort spoken of, before he applied to me. On examining him, there was felt along the tendons of the biceps muscles, in both limbs a hardness of about four inches in length, and near an inch in thickness, principally seated on the inner edge of the tendon, and partly on its posterior face. When the muscles were contracted by an effort to raise the leg, the patient lying on his face, the tumour became of a stony hardness. When the muscles were relaxed, it was less obvious. No distinct uneasiness was caused by compressing the part. At this period he was unable to walk more than a few steps. After considering his case, I told him, it was of a difficult and protracted nature; and that most patients became tired of



the treatment necessary in such a case, and applied to bone and sinew doctors, which course, if he had a disposition to adopt, he had better do it at once, without giving himself or me the trouble of beginning a treatment, he would probably not carry through. He then informed me he had already made a trial of the practice mentioned, and finding himself growing worse; and being now seriously apprehensive of being crippled for life, he was ready to submit to the requisite treatment. He was then informed that he must prepare himself for a confinement of at least a year, possibly of two years or more. He was directed to keep in a horizontal posture on a bed; the knees to be slightly flexed, and supported in this posture, and never to be moved, excepting passively. Twelve to eighteen leeches every fifth day for the first six weeks. Occasionally a purgative. No animal food, and the quantity of food limited.—I heard no more from him for five months. He then sent for me. I found him pale and emaciated. He had severe pains in the bowels, and frequent bleedings at the nose. He had followed the course directed in every particular. I expressed my surprise that he should have undertaken to proceed so long a time,



without giving me an opportunity of accommodating the treatment to circumstances. He apologised by intimating that being compelled to relinquish his occupation, he was without means of defraying more than the expenses of subsistence. From this time, I attended him regularly. I should have mentioned that the tumours were sensibly diminished. He was now directed to take a little meat twice a day—to drink from four to six ounces of wine, and forty drops of tincture of sulphate of quinine every two hours. Whenever the abdominal pains were urgent, to take thirty drops of tincture of opium. Under this management, he recruited slowly ; and at the end of four weeks the wine gave him head ache, and was discontinued. Animal food was continued a month longer, and then, seeming to disagree with him, was omitted. He now resumed the original course, with the exception of substituting injections for purgatives, and sometimes taking a little meat. After eight months confinement, he was directed to use frictions of a stimulating liniment, and to have the limbs bathed twice a day in hot water and soap. Finding the tumour lessening regularly, when he had been confined a year, I directed him to bandage the whole limb ; and to



get out of bed once a day. This was followed, after two or three weeks trial, with a thickening of the cellular substance between the hamstring muscles; in consequence of which he was put on the bed for a month longer, and then advised to get up and walk the room once a day. At the end of fifteen months, he was able to walk a quarter of an hour at once. I now urged him to walk out; but his apprehension of re-producing the disease was so strong that it was sometime before this could be effected. At last he got out, and increasing his walks very gradually, in three months he was able to walk to my house; and I had the satisfaction to find that all remains of the swellings were wholly dispersed. Since then he has recovered his strength, and is now perfectly well.

Nothing short of the extraordinary perseverance and power of endurance possessed by the patient could have brought his case to a favorable termination. This young man, between eighteen and twenty years of age, devoted a year and a half of confinement and solitude to the cure of his disease; and by this means was saved from being a cripple for life. I took occasion to express my



admiration of his conduct, and the abundant compensation received by the pleasure of his recovery.

Some persons may have doubts as to the nature of the tumour in this case; and, especially, whether it consisted of a fibrous texture. This may be a very reasonable doubt, on account of the unalterableness of the fibrous substance. There is, however, no doubt in my mind as to this point. I have often seen the substance of the tendons about the knee inflamed, thickened, and quite changed in texture, from continued inflammation. The same fact, also, I have noticed in the continuity of limbs during necrosis. The slow production of this disease, its slower cure, and its effect on the muscular action of the limbs, agree with the pathology of no other texture, but the fibrous.

FUNGUS NON HÆMATODES. This is a rare tumour. In consistence, it is soft; in extent, variable; in colour it is white. Its situation is usually deep among tendons and muscles, and therefore it has no immediate influence on, or connection with the skin over it, whose colour, texture, and sensibility remain unchanged. The texture of this tumour is fungoid, breaking in pieces under a very moderate force. In its early



stage it is not painful; nor do I know that it becomes so, otherwise than by compressing surrounding organs. This is a malignant disease; returning after extirpation, and ultimately proving fatal.

Mrs. F., a married lady from the country, applied to me in the summer of 1834, for a tumour above the right knee, extending from the superior edge of the patella upwards, about three inches. In form it was rounded and prominent; had no great sensibility, no pain, and gave her no trouble, but from the lameness it caused, which was very great, it being situated exactly at the place of the insertion of the extensor tendons. She had perceived it to arise six months before, without any cause. Her health was pretty good.

Finding there a deep-seated tumour, not discoloured, I was quite at a loss to determine what it was. One thing was clear, that it must be removed. The operation was performed in June, 1834. After making a free incision of the skin and cellular texture, I sought for the tumour. Instead of it, I found the extensor tendon of the muscles of the thigh expanded over the surface, and no way was discovered of getting under it. Of course, I divided the tendon longitudinally,



and then came in contact with a white fungus more firm than fungus hæmatodes, but breaking in pieces when handled, and showing no disposition to bleed. Continuing the dissection, I found this fungus intermixed with fair looking fasciculi of tendinous substance, much interwoven with it, but of a totally different aspect from the tumour. Having followed its irregularities into the interstices of the neighboring muscles, by a laborious dissection, I at length got out the whole.

The most absolute rest being enjoined after the operation, the patient recovered without very severe symptoms, obtained the use of the limb, and went home apparently well.

In the autumn of 1835, she came to pay me another visit, and I was sorry to find the tumour had returned, was growing rapidly, and that it had attained nearly its original size. Now it was clear that nothing would save her life but amputation. Her health not being affected, and the rest of the limb appearing well, she could not submit to this, preferring to die with her limb, and desiring that the tumour might be again removed. It was removed accordingly. The appearances were very similar to those in the first operation, with the ex-



ception that fewer of tendinous fibres were seen, and the disease was more purely a fungus.

The consequences of this operation were severe. Inflammation extended from the wound to the articulation of the knee ; and through the following winter she remained constantly under my care, vibrating between life and death. In the spring of 1836, she at length recovered, got out, and with the exception of some stiffness of the knee, though without the least swelling or hardness, she appeared quite well and went home.

In the autumn of 1836, a message was sent to me that her thigh began to swell above the place of the tumour. Soon after, a swelling in the groin was discovered ; then a hard tumour in the abdomen ; and finally an effusion of water into this cavity. Her strength is now failing ; but I have not heard that the disease has yet proved fatal, which, of course, it must do shortly.

For a long time, I was uncertain in what light to consider this tumour, as to its origin and character. The name affixed to it expresses my view of the latter ; but as to the former, I am still in doubt. The bone and the periosteum were certainly not implicated. It had nothing of the

aspect of a common muscular tumour. We must suppose then, it took its origin either from the common cellular texture or the fibrous; or from the cellular texture of the latter; and the intermixture of fibrous and fungous substance seems to sanction the last supposition. These considerations have led me to place it under this head.



## SECTION V.

### PERIOSTEAL TUMOURS.

THICKENING of the periosteum is a frequent consequence of blows, and rheumatism, and syphilis. This is not what we intend by periosteal tumour.

Excreescences of a permanent nature are seen growing from the condyles of the os femoris and os humeri; and from almost every superficial and exposed bone, and seem to be composed of bony substance. Take for example that which grows like exostosis from the condyles of the os femoris, and of which you here see a specimen. You may satisfy yourselves by the section of this tumour that it is not bony; for it is semi-transparent, admits the instrument to penetrate readily, and has

the aspect of cartilage. This, although not a quarter of an inch thick, formed a considerable tumour in appearance, while covered by the integuments. It is wholly free from osseous matter, but such is not always the case; and an earthy deposit is sometimes intermixed with the thickened periosteum. On external examination it appears as hard as bone; and of course is not readily distinguished from a bony tumour. As the natural tendency of irritated periosteum is to produce bone, it might be made a question whether the periosteal tumour should be considered as a distinct disease. The appearance and course of this kind of tumour will be explained by the following cases.

Some years ago, a medical gentleman now dead, called me to visit a patient of his, whose limb, he thought, would require amputation. I found a swelling of the internal condyle of the left os femoris, apparently an inch in thickness and forming a considerable tumour; without discolouration, tenderness or pain. The patient, a young lady of eighteen, knew no cause for it. She perceived it six months before. Since then it had increased, and now caused a lameness. I advised her not to disturb it. After the lapse of eight or



nine years, it has ceased to cause any inconvenience; does not grow, being as she tells me of the size it was when I first saw it. The lameness has subsided. A few weeks since you saw in the hospital a tumour of this kind, occupying the external condyle of the left os femoris. Its base was at least three inches long and two wide. The skin was not discoloured. This tumour was slightly tender, sometimes painful, and caused so much lameness, that the patient, a farmer, was obliged to give up his labours and come to the hospital for relief. By means of rest and leeches, the pains and lameness were removed, and the swelling a little diminished. The patient being able to resume his occupations, was then discharged.

These tumours are frequently seen on the upper surface of the foot, from pressure. In one instance, a tumour of this kind was so troublesome, that the patient wished to have it removed. This was accomplished by exposing and cutting it off with a strong knife from one of the cuneiform bones.

In some cases of necrosis, the periosteum assumes an extraordinary growth, and presents itself in the form of a tumour, the true character of which is not always easy of detection. The following case will exemplify this.



In the summer of 1835, a master of a vessel came to me from a distance for advice in regard to a tumour on his face. This was situated on the right side, extending from the edge of the lower jaw to the zygomatic arch, and had somewhat the form, and nearly the size of a lemon. It had existed a year; came on without any known cause; was colourless; quite hard; not attended with much pain, and made a formidable appearance. The patient's health was perfectly good. The disease had been suspected to be exostosis; osteosarcoma; fungus of the antrum. Its situation satisfied me it was not the last named affection; and that it was neither of the two former, appeared from the irregularity of the tumour and the regular form of the condyloid process, which was distinguishable. The breath being offensive, I examined the mouth, and at length discovered a small aperture leading to the lower jaw. Introducing a probe, I struck a rough bone, and was at once satisfied of the nature of the case. I made a perpendicular incision about three inches long, and laid bare the masseter; after dissecting through this muscle a semi-cartilaginous substance appeared; the knife with difficulty penetrated this, and being forced to some depth did not reach any



thing of a different character. I then proceeded to excise this hard substance ; and neglecting the circumference, cut out a mass an inch and a half square and an inch thick, from its centre. This being removed, a probe was passed, and struck a diseased bone. The aperture was then enlarged, a strong forceps introduced, and with some difficulty a dead piece of the lower jaw was extracted, about two inches long, and comprising the whole mass of the lower jaw bone for that extent. The wound healed favourably, though slowly ; the relicks of the hard substance gradually disappeared, and the patient was discharged in three weeks after the operation. The extraordinary thickening, in this instance, was caused by the effort of nature to supply the deficiency of the dead bone, connect together the separated parts of the jaw, and keep up its motions, which were never suspended, though much limited. In this case, as well as others of periosteal tumour, an extraordinary sensibility exists in the thickened periosteum. This symptom was remarked in most of the cases mentioned ; and in necrosis, where it has been necessary to remove portions of thickened periosteum to expose a dead bone, the patient has always seemed to suffer excessive pain from cutting this part.



In the case which I shall next relate the periosteal growth was more considerable than in the former, though less regular. A gentleman of this city, a patient of Dr. Bigelow, forty years old, had an abscess form on the right side of the chest, at the junction of the bone, and cartilage of the sixth rib, in consequence of a typhus fever, which occurred in the summer of 1834. When I first saw the patient in the spring of 1835, there was an aperture about an inch deep at the part indicated; surrounded by an irregular hard substance for two or three inches. The probe after passing down an inch struck on a firm but not osseous substance, and could not be made to proceed deeper, by altering its direction. The discharge of pus from the wound was small. In the succeeding winter the pain about the ribs gradually increased; at the union of the ribs with the spine, it was very severe. At times he was seized with a troublesome hiccough, indicating that the diaphragm was involved in the disease. Finding himself unable to pursue his business, wasting in flesh and strength, and suffering constant pain, he resolved to undergo an operation, the nature and dangers of which were fully explained to him.



The aperture through which the probe passed, was opposite the junction of the cartilage of the sixth rib, with its bone. It was about the sixth of an inch in diameter, and surrounded by a firm substance, which I at first supposed to be thickened and hardened cellular membrane. The plan which I formed for the operation was this. To make an incision four inches long, over the sixth rib, passing across the aperture. To cross each extremity of this wound with another, two inches long, at right angles to it. To dissect up the two flaps, expose the ribs, divide the intercostal muscles, and fascia, separate the pleura and diaphragm from the inner face of the ribs, and saw or cut through them. As happens in most operations, the execution varied considerably from the plan. An incision was made four inches long over the bone and cartilage of the sixth rib, and one at each extremity of the first, about two inches long. Proceeding to raise the flaps as proposed, I here met an obstacle. The skin adhered to a hard substance under it, so closely, that it was extremely difficult to raise the integuments, without cutting them in pieces. This being at length accomplished, the hard substance presented itself, covering the ribs and cartilages, and confounding the appearance of the bones,



and cartilages in a mass of semi ossified fibro cartilage ; so that I was at a loss how to prosecute the operation, in order to discover the seat of the diseased bone or cartilage. I proceeded in the following manner—The semi ossified matter was shaved off in successive layers, till it became so thin as to allow a strong director to be pushed in under this substance, and under the rib with which it was cemented ; and passing it from within outwards, and from above downwards, for about two inches, between the pleura and the ribs, with this director for a guide, other portions of the hard matter were removed, till the diseased ribs and cartilages were sufficiently uncovered. About three inches of the bone and cartilage of the seventh rib, and somewhat less of the sixth were carefully separated from the pleura, and diaphragm, and cut out by the chain saw, and cutting forceps. No artery of any importance was wounded. The whole length of the external wound at the end of the operation, was six inches, and its width four. It was brought together. On the second day after the operation, the patient had a smart attack of pleuritic inflammation. This yielded to a copious bleeding ; and he recovered so rapidly as to be able to walk in the course of



the second week. Exerting himself too much, an erythematous affection occurred below the wound, over the crest of the os ilii. This terminated in a partial suppuration; and left behind it an extensive induration.

From the consequences of the erythematous affection, the patient recovered slowly. The fistulous opening continued for some weeks. Occasionally he was troubled with severe pain, extending along the course of the wounded ribs, to the back, and I began to fear an extension of disease. In the summer he left town, and did not return till autumn. When he returned, his pains had gone off, his wounds were healed, and his strength increasing. It is now ten months since the operation. A few days since, I met him in the street, and had the pleasure of hearing that he was perfectly well, and quite rugged and strong.

This operation was painful to the patient, and laborious to the surgeon. The irregular effusion of semi-ossified cartilage, obscured the situation of the diseased bones; the diaphragm at the lower edge of the wound, and the pleura above, made it necessary to proceed with great caution; and the suffering from cutting the newly formed cartilage increased the embarrassment. It was not till an



inch in thickness had been removed, that any definite notion could be obtained of the place and condition of the diseased bones. When this was accomplished, the pleura was separated without difficulty, and the essential part of the operation was effected with great ease, that is, the excision of the diseased parts. The intercostal arteries must have been obliterated, either partially or wholly. The parts removed are here presented for your inspection.

The tendency of the periosteum to thicken from accidental irritation, will be farther illustrated by the following case. In 1835, I amputated the thigh of a girl of a scrophulous habit, fourteen years old, for a disease of the spongy texture of the condyles, which had grown to a large size. The stump was well covered with skin and muscle, which adhered over its extremity. After a few days the adhesion gave way. The soft parts gradually retracted, although daily brought down; the end of the bone became exposed, and covered by a tumour; and after waiting some weeks, with the hope of the skin uniting to the bony granulations, I removed an inch of the bone. This bone is surrounded by an osseous exudation, which makes its diameter double that of its origi-



nal cylinder; and at its extremity, also, you see an osseous formation an inch long. After the removal of this bone, the same disposition continued. A bony growth is daily forming; and although resisted by caustics, it is seen to increase. The patient in the mean time improves in strength and flesh. What is to be the termination of this case? What is the law which influences these productions in some cases, and does not operate in others apparently similar? These questions I am not able to answer.\*

---

\* This patient recovered under the daily application of caustics, and left the hospital, after a few weeks, perfectly well.

## SECTION VI.

### OSSEOUS TUMOURS.

ALL the bones are subject to increased growths when inflamed. Those which present themselves in the form of regular tumours, are known by the name of exostosis; divided by Sir Astley Cooper into periosteal and medullary. The first originate on the surface of bone, the latter in the spongy texture of its interior. Periosteal exostosis is characterised by its hardness, regularity, slow growth and want of sensibility. The attachment, or base, is commonly more narrow than the body, so as to form something of a neck to the tumour. The fine specimen I present you, situated on the lower jaw, is about two inches in diameter, has a narrow neck, and is situated on the right side of the jaw, anteriorly. It is a perfect bone; solid, like

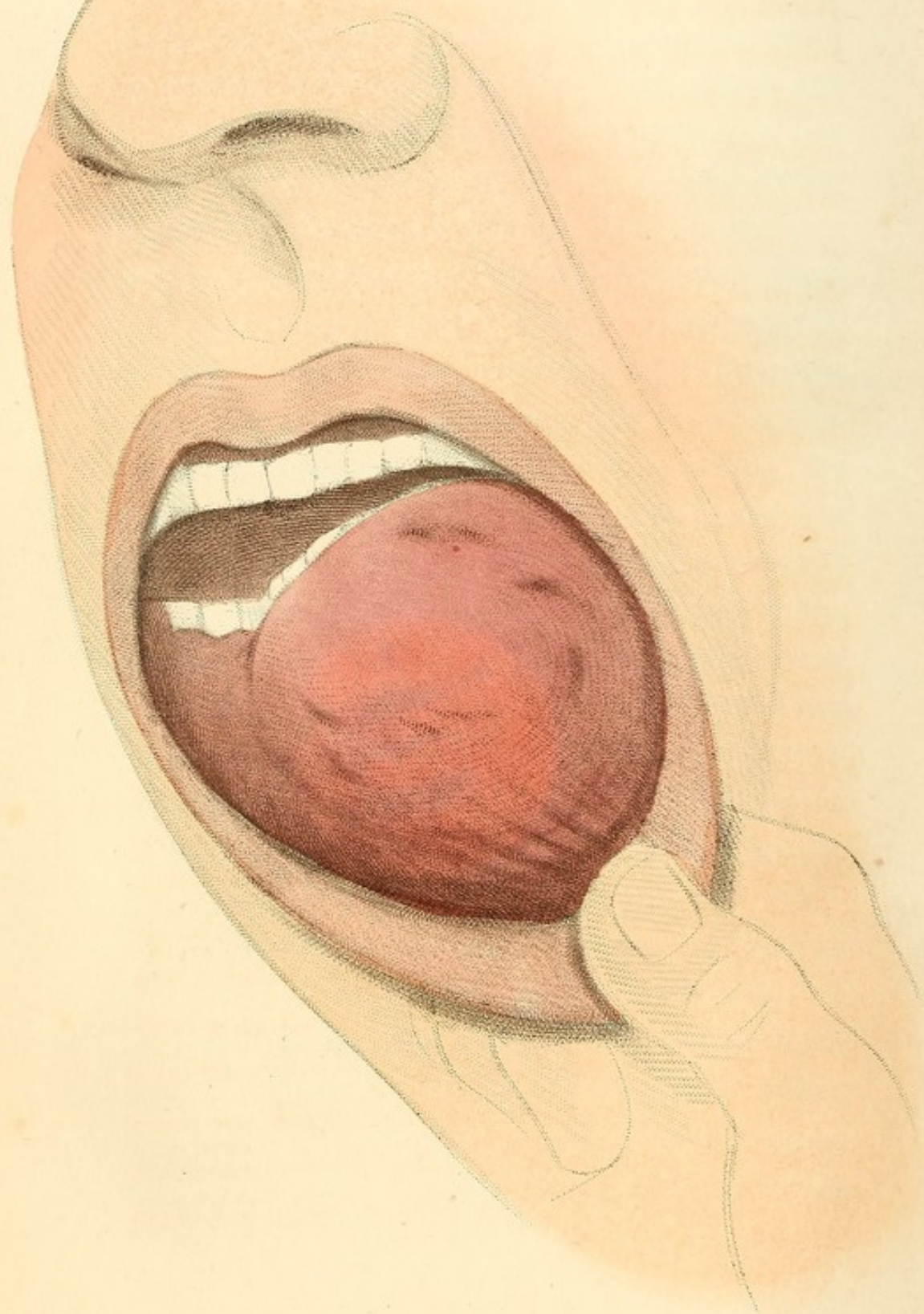


the body of the jaw. On its surface, you notice slight indentations, which distinguish it from healthy bone. The teeth above it are sound, and the inner face of the bone is not swollen. The patient died of another disease; and never having experienced much inconvenience from it, was unwilling to undergo an operation.—Sometime since, while travelling, I accidentally saw a farmer with a tumour exactly in the situation of this, and about the same size, exteriorly. He had undergone one operation; but when I saw him, the tumour was as large as this exteriorly, and had extended to the interior of the bone, so as to press the tongue back. He told me he was going to the surgeon who had operated before, to have a second operation. I afterwards learnt that this was not more successful than the first, and that sometime after it, he died of the disease. At the period when I saw him, the extirpation of the jaw on that side, would have saved him.

Mrs. A. has for ten years had a tumour growing on the lower jaw, principally on the left side. It extends from the first bicuspid tooth on the right side to the branch of the jaw on the left, including four incisors, the cuspidati, two bicuspides, and two molar teeth. On the outside of the jaw it is







*Exostosis of the Lower Jaw.*



prominent like an egg, and extends through the substance of the bone to its inside. The tumour is of a bony hardness—is painful occasionally; interferes with speech and mastication. Of late it has increased rapidly. See Plate VII.

The patient is of a thin habit and delicate constitution, is very reluctant to an operation, though convinced of its necessity.

On seeing the tumour, I was led to the belief that the jaw must be cut below the condyle on the left side, or disarticulated; but a second examination showed there was room between the tumour and the left branch to saw in front of the last named part. The facial artery ascended on the outer edge of the tumour. This led me to believe it possible to raise it with the muscles and skin, without cutting the artery.

The operation was performed Oct. 6, 1836, in the following manner. The patient was placed in a common chair, with the head on the breast of an assistant. The lower lip being made tense, was divided at the median line, and the incision continued as low as the edge of the thyroid cartilage of the larynx. A shorter incision would not have allowed the dissection of the flap far enough back to have uncovered the jaw near its branch. The



right flap was then raised sufficiently to expose the jaw under the first bi-cuspid tooth. The left flap was next dissected from the tumour and from the digastric region of the neck; including the muscles in the facial part of the flap; and in the digastric part, the skin, cellular membrane, and platysma muscle. The dissection was continued to the left as far as the edge of the masseter muscle; the facial artery was included in the flap, and was not divided. The stump of the dens sapientiæ and also the first bi-cuspid tooth of the right side, were then removed. This being done, a narrow bladed knife was passed behind the bone, corresponding with these two teeth, and the soft parts carefully separated from the jaw. Then the bone was sawed through.\*

---

\* The saw employed was constructed for the purpose, and had the following dimensions: Length, two inches; breadth, two lines; thickness, one-fourth of a line; handle, four inches long, rough and thick; end of the saw rounded. This is the best kind of saw that can be employed for this and similar operations. The chain saw and the bow saw cut more rapidly, but catch and cause delay and embarrassment. Heys' saw is slow and laborious in operation. The rotatory saws are unmanageable. I think a saw half an inch longer, that is, two and a half inches long, might have been better. The great difficulty in the use of the saw, in these cases, has led me to describe this simple instrument minutely, with the hope that it may be as useful to others as it has been to me. It is proper to have two or three of these saws, varying a little in dimensions.



The bone having been divided, appeared quite loose. I therefore seized it with the left hand, and proceeded rapidly with the separation of the tumour from the parts connected with its internal face, and here divided the left submental artery, the only one which required a ligature. About to sever the lowest remaining muscles, I perceived the tongue drawn back into the pharynx, and the patient in a state of suffocation. Immediately seizing the tongue with the left hand, I drew it out of the pharynx, and confiding it to a friend, completed the section, and prepared a large needle and ligature to transfix and secure the tongue. This happily was not necessary. After waiting five minutes, the spasmodic action ceased, and did not return. The parts were then brought together and secured by six sutures, two of them being on the surface of the lip, one without, the other within. An aperture at the lower edge of the wound was left to drain the mouth and wound; and some adhesive plasters and a light bandage, with but little pressure, completed the dressing.

The patient, though a delicate person, supported the operation perfectly well. A faintness and failure of resolution occurred for a moment, but directly passed off. She was able to swallow a



little water in the afternoon and evening, and had no subsequent difficulty in this respect. The pulse scarcely exceeded eighty during the following week. The wound united perfectly by the adhesive inflammation, excepting the lower angle, which had been designedly left open. On the eighth day from the operation, the patient appearing perfectly well, I noticed an acceleration of the pulse, with intermission of every fourth beat. This symptom I did not mention, but visited the patient a few hours after, to see what followed, and discovered a slight erythematous affection of the face. The bandages and dressings were directly removed, and only a light, dry linen fold applied to the wound; and a mild laxative medicine was given. The erythema terminated in two or three very small abscesses, which having discharged themselves, the patient rapidly recovered and attained a state of health and comfort she had not experienced for ten years.

The relick of jaw on the right side was quite moveable, and possessed a comfortable degree of masticating power. The wound on the face left a scar hardly visible, and the general aspect of the face was not greatly altered, and exhibited no deformity. The tumour, as you may observe, had



a bony hardness, and was so situated as to cause great inconvenience. The section of bone on each side is perfectly healthy, an appearance which gives us confidence there will be no return of disease.

A man came to my late father with an exostosis of the right cornu of the os hyoides, of a sugar-loaf form, about three inches in height. My father dissected the tumour to the os hyoides; exposed this bone; sawed it off near its base; and thus succeeded in curing the patient speedily and effectually.

A few months since, many of you saw an operation of this kind, in the hospital. It was for an exostosis, springing from the transverse process of the seventh dorsal vertebra. I uncovered the tumour to its base; sawed through the transverse process with a narrow saw, and removed the remainder of the process with cutting pliers.

The specimen we have here, is a spicular exostosis of the body of the os femoris, taken from the patient after death. It may be three inches in diameter and an inch thick, from above downward. The most striking thing about this is, its being loosened from the shaft of the os femoris. As soon as the periosteum became dry, the exos-



tosis separated, so that it may be revolved on the bone. That it actually belongs to this bone, you may see from the furrow on the outside of the cylinder of the os femoris, where the diseased periosteum was attached.

Patients affected with periosteal exostosis, are generally healthy in other respects. The specimen we have here, was taken from a patient who was an exception to this rule. It is a large exostosis of the os femoris, just above the condyles, belonging to a person whose limb was amputated by my colleague, Dr. Hayward. The patient was a young woman of a scrophulous habit, and ultimately died of phthisis.

From the cases related above, you will infer that I should recommend the excision of the bone, which has given origin to this disease, whenever it is practicable. But if this excision should involve the sacrifice of the limb, it would be better to try the experiment of removing the exostosis first. This was done by Sir Astley Cooper, in a case of exostosis on the upper part of the tibia, of a young woman in Guy's hospital. This case is related in the "Surgical Essays," and I happened to see it, for at the time it occurred, I was dresser to that most distinguished surgeon; and having

this patient under my particular charge, I well recollect that the case was considered hopeless by other surgeons. The woman was not so reduced as to justify amputation, for she was able to walk; yet the extirpation of the tumour was thought useless, on account of the probability of its re-appearance. Sir Astley determined to try the experiment. He removed the exostosis carefully, by sawing. The wound healed favourably, and the disease did not return.

The periosteal exostosis you will not confound with periosteal tumour. The latter, I must repeat, is a thickening of the periosteum; the former is an exudation of bone. Periosteal tumour is a diffused, irregular, moderately hard swelling. Periosteal exostosis is a regular, circumscribed tumour, of bony hardness. Periosteal tumour may diminish and disappear. This is not the case in periosteal exostosis.

#### MEDULLARY EXOSTOSIS.

THIS originates in the spongy texture of the bones, especially in the extremities of the oblong bones. Commonly it occurs in scrophulous con-



stitutions. The first sign of the disease when it appears in the lower extremities, is some lameness. This is followed by a uniform swelling of the affected part, which increases with more rapidity than other enlargements of the bones. When it attains a considerable size, it presents the following appearances. The skin retains its usual colour, excepting where it is traversed by veins, the enlargement of which is conspicuous. The surface of the tumour, on a superficial examination, seems hard; but on a careful investigation, a number of soft spots, of greater or less extent, may be discovered. After attaining a considerable size, ulceration takes place, and a quantity of watery pus, mixed with flocculent substance, is discharged. Unless the part can be removed, the patient gradually sinks under the constitutional affection, consequent on so extensive a source of irritation.

A young man nineteen years old, of rather delicate constitution, a farmer by occupation, entered the hospital for a supposed disease of the left hip joint. On the outside of the os femoris, about and below the great trochanter, appeared a swelling nine or ten inches long. On the outer part it was quite hard; towards the fore part of the thigh



softer, without fluctuation. He had some pain three or four months before, attributed to a severe blow. The bone was moveable in its socket, without much pain. The limb was not shortened nor turned out; so that I was soon satisfied the disease was not a common hip case. After two or three weeks the tumour extended down the outside of the thigh; manifested a softness, and fluctuation; and eventually pointed about the middle of the thigh. The constitution in the mean time, had become much affected. He had frequent chills, quick pulse, loss of appetite, and strength. The tumour was opened by a small incision, and discharged two quarts of watery flocculent pus, not offensive. On introducing a sound ten inches long, it passed its whole length upwards. On passing the finger, the excavation was found to be filled with membranous partitions, forming large cells, containing a fluid like that spoken of above. In a short time after, the patient died; and you see here the morbid parts taken from him. The upper part of the os femoris excepting its head, is dilated into a large shell, composed of a bony network; the parts of which are connected together in some places by a half formed cartilage, in others, by a fibrous mem-



brane ; which is the original periosteum expanded. In the cavity, we see the vestiges of bony cells, which were continuous with the membranous cells mentioned before. The head and the inferior extremity of the bone, are healthy. Could the patient have supported an operation of extirpation of the os femoris, he might have recovered ; as the acetabulum was perfectly sound.

The fine specimen I now show you was taken from a girl thirteen years old, of a delicate constitution, who in running, struck her right knee against a plank, so as to cause temporary lameness. In June, 1835, this knee began to enlarge, and when she came to the hospital in December, 1835, was as large as her head. The tumour occupied the lower part of the os femoris. The skin was not discoloured, excepting where large veins passed over it. To the touch, it appeared quite hard at first ; but on a careful examination, two or three soft spots of small extent were discoverable. She had no great pain, and her health was not much impaired. The disease had been supposed to be a white swelling. You may recollect that as soon as I saw it, I remarked to you that it was quite a different disease, though of a scrophulous nature, and that it required immediate



amputation. The operation was accordingly performed. This tumour you have seen in different stages of its dissection. On injecting the limb, the skin being removed, a shining fibrous membrane appeared, which was composed of the extended tendons of the anterior muscles. This did not cover the whole surface; some dark coloured spots were seen, which seemed to be composed of semi-cartilaginous substance, forming a thin coat, and this being opened, a quantity of venous blood was discharged. The cavity thus opened, was filled with blood and effused injection, poured out from the arteries. Many fragments of bone in the form of scales were intermixed. The shaft of the bone above was not in the least enlarged. A small portion of one of the condyles with its investing cartilage, was seen below, and the articular surface of the tibia was perfectly healthy.

Some years ago I saw a case of this nature amputated by my late father, in an adult female. The tumour was so large, that when removed, it just filled a common water pail. The bony basket work, that formed its parietes, was so delicate, that the tumour could not be preserved whole, but soon broke in pieces, and was destroyed.



Here is another specimen of this affection, in which the disease has reached the lower bone. This limb was amputated some years since. The tumour is about eight inches long, and four across. Above it you see the os femoris perfectly unaltered. The upper part of it is composed by the enlarged condyles of the os femoris. Within their cavity, we see at the back part, the spongy texture of the bone expanded into cells larger than their natural size. On the sides is a network of a fibrous texture, something like the fleshy lining of the right ventricle of the heart in form; and on the fore part is a large insulated plate of bone appearing as if broken off, but really separated by the expansion of the condyles. The head of the tibia exhibits similar appearances. Behind the joint we see a very large bony tumour, perfectly solid; forming a real exostosis, and apparently springing from the back of one of the condyles.

The following is an instance of affection of the upper extremity of the tibia, in a hospital patient.

March 25, 1829. Sarah Wingate, *Æt.* 32. Eleven months since first felt at times a sharp pain in the right knee joint. It soon commenced swelling around the fore part of leg, just below patella. At this time, and some months after the



commencement of the disease, there was a throbbing in the swelling perceptible to the eye, or hand, when laid on it. This swelling has continued to increase slowly to the present period, without much pain, excepting at times a sharp and darting one. Now the joint is enormously swollen, measuring in circumference, eighteen and a half inches. On the fore part, about two inches below patella, the swelling is prominent, and pointing. She has lost much flesh, countenance pale, feels weak. Appearance scrofulous, and has had scrofulous ulcers at different times in her life. Does not know that she has ever strained or otherwise injured the part affected.

April 1. Tumour being very painful and appearing to point, was opened. No pus was discharged, but some blood and portions of a fungous substance. 10. Her health is failing. 19. Died. Appearance of the diseased part on dissection, as follows :

The opening in the knee joint was enlarged, and all the blood and purulent matter clearly washed away. The soft parts surrounding the joint, especially below the patella, muscles, cellular membrane, and ligaments, were in a diseased state, appearing to be changed principally into a



soft fungous and vascular substance. The enlargement of the joint observed before death, was produced by a morbid growth of bony matter. The upper part of the tibia, for three inches or more, had been absorbed. The upper end of the remaining portion of bone was rough, thin almost to an edge, and very dark coloured, nearly black. The rest of the bone appeared to be healthy. The fibula and the femur were not diseased. The semi-lunar cartilages were ossified and rough. The muscles above and below the joint, wherever divided, had nothing of their usual colour, but were of a very pale red.

In all these cases, inflammation begins in the interior of the bone. Fluids are effused, sometimes of pure blood, sometimes of parts of it. Pressure on the interior of the bone causes its absorption within; and nature, to prevent the bone from breaking, deposits bony matter on the outside, where she can supply it; and where she cannot, a cartilaginous or a fibrinous substance; and thus the tumour increases to a great size, unless the parietes ulcerate and discharge its contents; in which case there is no further increase. These affections are not malignant; and



if removed by amputation, before the constitution is much altered, the patient recovers.

#### MAXILLARY EXOSTOSIS OF THE SPONGY TEXTURE.

THE spongy texture of the jaws, especially of the upper, is subject to inflammation and exostosis. Tumours of this kind are without much difficulty distinguished from periosteal exostosis of the jaws by this; that they are swellings of the *substance* of the bone, and not of its *surface*. The last is most commonly seen on the lower jaw; the first on the upper. Exostosis of the spongy texture of the jaw, is a hard tumour, of a rounded form; appearing on the external surface of the bone; producing a prominence of the gum, and if it attains a considerable size, of the cheek. It is not discoloured, nor painful. Enlarges rapidly at first in young subjects. This disease often begins in the bottom of an alveolus. A diseased action arises in the membrane, is propagated to the bone, which swells in the outward or peripheral direction, commonly in the earlier stage of the disease, though it happens sometimes that the internal plate of the jaw becomes involved ultimately. This kind of tu-



mour is to be distinguished from the vascular tumour of the alveolus, which will be spoken of hereafter.

Mary J. Pomeroy, *Æt.* 10. Bristol, Me. May 11th, 1831.—This girl has a hard swelling on the left side of the superior maxillary bone, which first began about two years since at the root of the left canine tooth. This tooth being a little decayed, was extracted, but the tumour continued to enlarge, involving the sockets of the two bicuspides and two molares, which have been sucessively extracted. Tumour is very hard, bony, and projecting outwards towards the cheek, and inwards towards the cavity of the mouth. At the commencement of the disease, the gums were cut and bled freely. Tumour now bleeds once a week a gill at a time. Has never had any pain. Health good. The surface from which the tumour bleeds is soft and fungous.

24th. Extract third molar tooth, and left lateral incisor, the only remaining teeth on left side of upper jaw.

26th. Operation.—The lip and cheek were first dissected from the bone to a small extent, that all the diseased portion might be effectually removed. A perpendicular section of the bone was then made



between the sockets of the central and left lateral incisors, extending upwards to the meeting of the divided edge of the lip and bone. This was done with a pair of bone-forceps, prepared expressly for this operation. A pair of cutting forceps, of the common shape, was then employed to divide the bone in a transverse direction, and the alveolar processes were removed through their whole extent, from the first and perpendicular section to their termination, backwards. The hemorrhage was not very copious, and did not require any applications to arrest it. The patient recovered rapidly, and had no return of disease.

In the summer of 1833, a gentleman brought me his son, fourteen years old, with a disease of the right side of the upper jaw, apparently in the gums. It was seated above the superior cuspidatus, included this tooth, the bi-cuspid behind it, and the incisor before it. All these teeth were somewhat loosened. The tumour was hard, red, not ulcerated, not painful, nor tender; and had existed five months, without any known cause. The father being called on to leave town, the boy was obliged to undergo the necessary operation without the presence of any friend; and it was



done as follows. First, the three teeth were removed. Second, a knife was carried on each side the tumour, within and without, and the lateral incisions were united before and behind the bone, by transverse incisions an inch above the edge of the alveoli. Next, the bone was divided on each side, by two perpendicular cuts of the cutting forceps, and the operation was finished by horizontal forceps, removing the bone between the perpendicular cuts. The boy supported the operation perfectly well, and went home on the fifth day. Six months after, he came to me with an apprehension that the disease was returning. On examining, I found the vacant space well filled with bone, having its surface covered with a purple coloured gum. The bone, however, appeared to me sound ; so that I could relieve the apprehensions of father and son, by an assurance that there would be no further trouble from the complaint ; and so it proved, for he has been perfectly well since that time.

In 1834, a young gentleman, an only son, fourteen years of age, was brought to me for a tumour on the left side of the upper jaw, as large as a hen's egg. It began six months before, without any obvious cause. The parents, after



many questions put to them, had an indistinct recollection of a painful tooth having been removed from that side of the jaw, a year before. The tumour arose above the molar teeth, made a considerable projection in the cheek, and a slight prominence on the inside of the upper jaw. It was neither tender nor painful. The practicability of reaching it through the mouth having been considered, I decided against it, on account of the difficulty of managing an operation on the inside of the cheek, and the subsequent embarrassment from hæmorrhage.—Three teeth were extracted. An incision, about two inches long was made through the cheek, down to the tumour, and the membrane of the mouth dissected from its surface. Then by means of the cutting forceps, invented by Dr. Flagg, who assisted in the operation, I divided the jaw in a vertical direction, by two or three successive cuts through the bone. The transverse section was accomplished by two cuttings of a forceps, differently formed; the wound was closed, and a speedy adhesion followed.

On examining the disease, it was found to be composed externally of a thin layer of compact bone, including a spongy osseous substance, in the centre of which was a cavity about the size of a



hazel nut, lined by a membrane. This appearance led to the belief that the disease originated from the bottom of the alveolus.

Some years since, I was desired to see a young man, for a large sugar loaf shaped tumour of the cheek, of some months growth, perfectly hard and insensible. On cutting into it, a tooth was discovered in the maxillary cavity; after the removal of which, the bony tumour soon disappeared, and the cheek resumed its natural form.

In the year 1828, I was called to see a young lady, eight years old, who had a considerable tumour on the left side of the face. It was noticed three months before; had since increased much. It was very hard; not painful nor tender. No blow had been received on the part, and no cause was known for its existence. The tumour being in the situation of the maxillary cavity, and the process of dentition being at that time in activity, I suspected a tooth had slipped into the cavity, and advised not to do any thing at the time; and after watching the tumour for some months, seeing no increase, and nothing that could lead to the suspicion of malignity, I ceased to attend her, and heard no more of the matter until May, 1836. Her mother then informed me, that



four weeks previous, a tooth had appeared on the inside of the upper jaw, within the other teeth; and as soon as this happened, the tumour in the face began to lessen. The tooth was extracted; since which the relicks of the swelling had been rapidly disappearing. The patient being now a fine handsome young lady of sixteen, felt very grateful to me for having spared her a bad scar, by cutting open the antrum.

The last case of this affection of the upper jaw which I shall mention, is that of Mary Rice, a young lady of 28 years of age, not of very good health and of a nervous and scrophulous constitution. Two years since she had the cuspidatus tooth of the right upper jaw filled. About three months after, she had a severe pain in this and the bicuspid tooth behind it, which has continued ever since, with occasional remissions. In the month of April, 1836, she first applied to me. When I examined the jaw, I found the cuspidatus tooth slightly loosened; the last incisor, next to it, very loose; a red tumour extending over the alveoli of these two teeth, and in a slight degree over that of the next incisor. No swelling within the alveoli. The surface of the gum presented an unhealthy ulceration, which ex-



tended to the membrane of the cheek. Believing it possible that the whole disease might depend on constitutional derangement, I advised a careful regimen, occasional laxatives, and the powder of cinchona, as a local application. This course was followed for a month, when she visited me a second time, quite worn down with pain and anxiety. The ulceration had a little increased. Although I believed that this was not a malignant disease, I was now satisfied it would proceed to a carious state of the bone, and advised an operation, which was performed the next day. First, I removed the cuspidatus and the incisor teeth. Next, surrounded the ulcerated part with an incision. Then with perpendicular cutting forceps, divided the bone on each side, and by a horizontal forceps connected the two incisors and removed the diseased bone. The whole operation was accomplished in three or four minutes.

In December, 1836, the patient paid me a visit. Her jaw was in a perfectly sound state. The lost teeth had been replaced by a dentist, with others. Her health was quite good.

In the early periods of my practice, I removed the bone in these cases with the saw and chisel, and the operation was tedious and painful. In



the year 1831, I first employed the cutting forceps, by which this operation was greatly facilitated. Since then, the ingenuity of my friend, Dr. Flagg, to which I have often been indebted, has greatly improved this instrument, in its application to the jaws. As the straight forceps are with difficulty brought to bear uniformly on the inside and outside of the jaw, he gave to these instruments the hawk's bill form. One of these is made to cut vertically, and another horizontally; by which the two kinds of incisions are rapidly and perfectly made; and the patient suffers but little pain. The introduction of the cutting forceps into the surgery of the jaws, is a great practical improvement. Instead of the long and painful operations with the saw, they give us the power of removing a bony tumour from these parts in a few minutes. When the tumour is of some extent, they have not sufficient power. This defect may be remedied by a compound forceps, which bring in the aid of an additional lever.

---

NOTE. Since the above was written, I have seen a pair of cutting forceps, from France, which cut at right angles from their shaft, and must be very useful, when the tumour lies far back in the mouth.



## OSTEO-SARCOMA.

MR. TRAVERS has given the name of osteo-medullary tumour, to what is generally known by the title of osteo-sarcoma. As this disease sometimes has a fungoid character, the new term appeared to me appropriate, and I had determined to adopt it; but on reflection, perceiving that its nature was not so fully settled as it may be hereafter, I have retained, for the present, the common appellation.

This is a hard tumour, taking its origin from periosteum or bone. In external appearance, it has usually a firm consistence, a rounded form, extends over and appears to involve and bury the bone, from which it is derived. In colour, it is like the skin commonly, though sometimes reddened, and exhibiting enlarged veins, like many other tumours of similar consistence.

Although hard in its early stage, as it increases in size, it acquires more or less elasticity, and of course softens as it grows. The consistence is, in fact, variable from day to day; at least in some instances. Whether this accidental change is caused by the different quantities of blood it may



contain, or by a change in the amount of the fluids deposited in its cavity, I am unable to say. The size also has appeared to be slightly variable; but that such fluctuations do actually exist, seems questionable. A variation in the colour of the integument is not surprising; as the prominence of the part exposes it to friction, and the temporary increase of morbid action in the interior, would affect the external covering.

The pain is not acute. A sense of aching is a common, though not invariable attendant.

A characteristic symptom of osteo-sarcoma, is a tuberculated surface. The inequalities which cause this appearance are not produced by an intervention of plates of bony and cartilaginous substance. They are the masses of the unequally thickened periosteum, which form the covering of the tumour. In osteo-sarcoma I have never seen bony plates excepting at the points where the tumour is connected with the bone. If, for example, the bone be cylindrical, bony fragments may be noticed at those parts where the extremities of the bone enter the tumour. At other points I have not seen them.

Osteo-sarcoma is generally believed to arise from the reticulated texture of bone; and certainly



the disappearance in many instances of a part of the affected bone, the occasional enlargement of its extremities, where it enters the tumour, and the supposed existence of bony plates in the parietes, would seem to authorize this opinion. There is however, reason to believe that such is not the fact.

In all the instances of osteo-sarcoma, which have occurred in my experience, and these of course are few in number, compared with those which happen to experienced surgeons in Europe, this tumour has appeared to have its origin in the periosteum, and not in the bone. The constituents of the tumour are three. 1. The bone on which the tumour is placed. 2. The periosteum, and 3. The medullary fungus, contained in the periosteum. To these we must add a fluid of varying consistence, found in cells, in the interior of the periosteal cavity.

First ; the bone in most of these cases, appears as if a part of it had been broken out, and the fractured ends are enlarged, or else the thickened periosteum gives them the appearance of enlargement. But this appearance is not universal. You may see in the case of Corey, the third case mentioned, that the rib, from which the tumour origi-



nated, was entire. Its surface only, showed the origin of the tumour. Consequently, the tumour in this case must have had its origin in the surface; and this fact cannot be considered as a mere exception to a general law; it breaks up such a law; for if a true osteo-medullary tumour can be traced to a periosteal origin in one instance, we may believe it to have such an origin in others, unless the contrary is proved. Second; the periosteum in these tumours exhibits an extraordinary activity of growth. It is quite vascular, and forming the surface of the tumour, is thickened in some parts to the extent of half an inch, and forms the protuberances characteristic of the tumour, as you may verify in this tumour of the clavicle and that of the rib. Third; the fungoid formation which constitutes the mass of the tumour, appears, so far as we are able to discover, to arise from the periosteum nearest the bone, whence it shoots in a pedunculated or arborescent form into the large periosteal cavity. So much for this short survey of the anatomical structure. Let us now ask how far the history of the cases to be mentioned, may support this.

In the first and second cases, the disease was brought on by a blow. Cook received a violent blow on the left side of the lower jaw; and a



tumour appeared in the part, where the blow was received. Let me ask whether such an external violence is most likely to produce inflammation of the periosteum, or of the reticulated texture of the jaw. Certainly the former. In the same case the bone was enlarged; that is, the periosteum was thickened quite beyond the tumour, over the condyloid process.

The case of Smith is more strikingly in favour of this opinion. This man, while lifting a heavy piece of timber, felt a very severe pain about his collar bone; a pain and tumour appeared directly, and never left him. We cannot believe that the application of violence, in such a mode, could operate on the cancelli of the interior of the bone, unless it fractured it. But it is easy to conceive that the action of the pectoral muscle might have injured the periosteum, and produced the phenomena mentioned, namely, the giving way of something in the part, the pain, and the tumour which followed.

In Corey's case no violence was known to have been inflicted. But in him, the substance of the rib, not having been enlarged, nor absorbed, though the disease had run on for six years, it seems highly



probable, that the disease took its origin in the periosteum.

Setting aside particular facts, and placing the subject on the ground of general reasoning, which is most probable, I would ask, whether such tumours as we speak of, should take their origin from the reticulated texture of bones as solid as the lower jaw, clavicle and rib; or from the periosteum, covering these bones? Evidently analogy is in favour of the latter.

The mass of reticulated texture in the extremities of the long bones, is very well adapted, from its vascularity, to become the seat of inflammation, and extraordinary growths. Hence we find the head of the os humeri, the lower extremity of the os femoris, and the upper extremity of the tibia to become the seats of enormous tumours, with real bone for their parietes. Cases of this kind have been mentioned under the head of medullary exostosis. To give you an opportunity of contrasting them with the cases mentioned below, I will state the following: In the summer of 1836, a gentleman came to consult me, from the British provinces, for a tumour of the knee. He was much out of health. He had a cough; was emaciated; the lymphatic glands in every part of



the body and limbs were enlarged, to the number of more than a hundred. His knee presented a very hard irregular basket-like tumour, covered with distended veins. A considerable part of the surface was bone; but there were various soft spots scattered over it.—I advised him to return home, as his disease must speedily prove fatal. This disease began with a uniform enlargement of the lower extremity of the os femoris, without external injury.

From the facts and considerations stated above, it would seem that this is in truth a periosteal medullary formation.

Is this disease malignant? Fungoid diseases being generally disposed to affect the system, or to originate from constitutional causes, we should apprehend such a tendency in this. In some cases, however, the affection is so purely local that we cannot lay it down as a general law. In the first and third cases related here, there was not the least appearance of constitutional taint. In the second and fourth, we might suspect a diseased state of the system; but in neither of these does there appear to have been any important derangement, which might not result from the local cause. In reply to the question then, we should say, that



when the patient's health is not disturbed ; when there is no secondary local affection ; and especially when the disease can be traced to an accidental violence, we may consider the constitution secure, and proceed accordingly. In any case where a secondary affection has not appeared, it seems right to give the patient a possibility of recovery, by extirpation of the tumour.

When allowed to go through its course without interference from art, it terminates in a sloughing of the integuments, followed by an extensive foul sore, which would ultimately exhaust the patient, if he should not previously be destroyed by secondary affections in important organs. The lymphatic glands in the great cavities fall into a fungoid degeneration ; the liver, spleen, kidneys, stomach, and lungs, in different cases, come under the morbid influence.

How may this be distinguished from other tumours ? From exostosis it may be known by wanting the hardness of the latter. From common periosteal tumour, by its greater size and more regular form. From scirrhus, situated on a bone, by being more closely connected with the bone. From medullary exostosis, in wanting the basket-like surface, caused by mixture of layers of



bone and membrane. The history of its growth will aid in illustrating the distinctions: yet, after all, there are cases in which it is impossible to ascertain with certainty what its nature is.

OSTEO-SARCOMA OF THE LOWER JAW. James Cook, Blockmaker, *Æt.* 17.—Sixteen months since he received a violent blow on the left side of the lower jaw. Four months afterwards, he perceived an enlargement of the bone on that side, which for ten months was slow, but for the last month has been rapid in its increase. The tumour now produces a most unsightly projection of the face on the left side. At first view, it appears to be seated on the front of the bone, but on examination is ascertained to extend inwards to the mouth, as well as outwards. The whole of the left side of the jaw is found to be in an enlarged state, from the chin to the ear; the condyloid process enlarged; and the projection in front of the bone is of the size of a large egg.

Operation, February, 1825.—An incision was begun close to the fore part of the ear, and carried downwards to the angle of the jaw, thence forward in a semi-circular form to the chin, pursuing the line of the lower edge of the jaw. The skin and muscles were dissected upwards so as



to uncover the jaw and tumour. The dissection was then carried under and within the jaw, to separate it from the mouth. Next, the two front teeth of the left side were removed; then the bone was sawn through by Heys' saw; in doing which it was necessary to have the bone supported by an assistant, on account of its unsteadiness under the saw. In this way the bone being divided, the anterior part of it was drawn forwards, and the knife carried on its inside, to complete the division of the flesh within up to the joint. The bone being found to be enlarged quite into the socket, it was necessary to disarticulate it. In order to accomplish this, the attachment of the temporal muscle to the coronoid process was separated, and with less difficulty than was expected. After this, the ligaments of the joint being cut, the bone was removed from the socket.

The facial artery was divided; and the internal maxillary artery being in contact with the tumour, was necessarily cut off. Both bled furiously, but were readily stopped by compressing the carotid artery firmly while they were secured by ligature. The patient did not lose much blood; nor did he complain very much of the operation.



The skin was brought together and secured by plasters ; and the large excavation, formed by taking out the bone, was filled by sponges on the outside of the dressings, and well secured by bandages.

On the evening of the operation, the patient, after appearing well, was excessively faint ; not from loss of blood, but from constitutional sympathy, and great fears were felt for his life. By the use of cordials and external warmth, he revived, and had no further bad symptoms.

Great part of the wound was found united on the first dressing, and the rest healed well. So that in a month he was sufficiently recovered to quit the hospital.

Notwithstanding the loss of half the lower jaw, he was able to bite and chew very comfortably. Before he left the hospital, some one asking him if he could use his jaw, he answered, " Give me a cracker, and I will show you."

OSTEO-SARCOMA OF THE CLAVICLE. Daniel Smith, *Æt.* 24, farmer ; of Wayne co. Maine. Admitted into the M. G. Hospital, for a tumour of the right clavicle, Nov. 1st, 1832.—One year ago, in attempting to roll a heavy stick of timber over, placed both arms under it, bringing his chest firmly against it.



Immediately after accomplishing his object, felt a severe pain and an enlargement near the junction of the right clavicle with the sternum. After finishing his work, he applied to a physician for advice. The physician did not understand the case, but the swelling was lessened by warm bitter fomentations.—Continued to work, though his arm was quite weak, till the month of August last, when he quitted his labour, thinking he had “sprained the other collar bone.”

The following month, October, the swelling began to increase rapidly, and became hard. At times he felt, as he thought, a “rubbing of the bones.” Now he has a tumour measuring seven inches from sternal end of the right clavicle, in a line with this bone to the scapular end; from its upper boundary, viz. the clavicle, towards the nipple, five inches. Thinks it varies in size, being sometimes larger than at others. At times feels it pressing on the wind-pipe; it feels hard; there is no evident fluctuation; a pulsation is slightly perceived in it by stethoscope; some pains most of time; increased by using arm, or by coughing; pulse eighty-four; no sensible difference in the pulsation at wrists; general health not materially



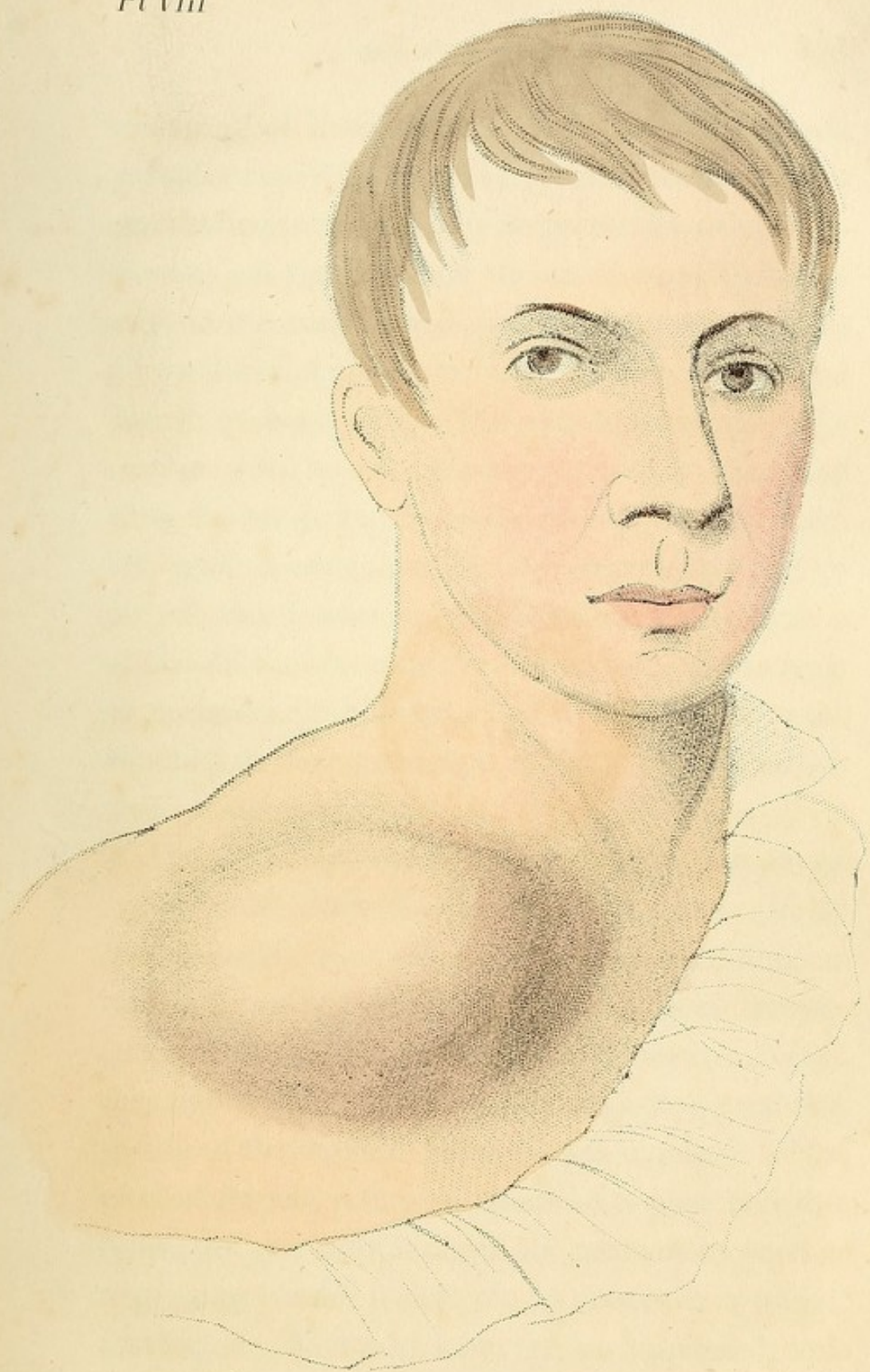
impaired, but constitution scrophulous and irritable. See Plate VII.

9th. Some enlargement of tumour, extending to right shoulder.

The preceding history is extracted from the hospital record.

10th. Operation.—The patient being placed on a table, the shoulders elevated, an incision was made from the acromial extremity of the clavicle to the sternal extremity of the clavicle of the opposite side. This was crossed by an incision at right angles with it, beginning just below the middle of the sterno-mastoid muscle, and extending to the face of the pectoralis muscle below the middle of the clavicle. The four flaps were then dissected from the surface of the tumour. Next, the outer extremity of the clavicle was laid bare, by dissecting the deltoid muscle from its anterior edge, and the trapezius from its posterior edge, and by the division of the coraco-clavicular ligaments. An eyed probe, armed with a ligature, was then passed under the clavicle, and the ligature being attached to a chain saw, this was drawn under, and the clavicle sawed through.

The separation of the tumour now began. A strong ligature being passed around the outer



*Osteo Sarcoma of the Clavicle*





extremity of the divided clavicle, the tumour was partially raised by it, so as to give tension to the surrounding soft parts. The pectoralis major muscle was cut through, and dissected from the lower edge of the tumour, and drawn so as to expose the pectoralis minor and the cephalic vein. Now the dissection extending under the tumour, the subclavian muscle was distinguished and dissected from the tumour at its outer part, but at the sternal part it was lost in the tumour, where, of course, the dissection proceeded, over the surface of the subclavian vein. An adhesion of the tumour to the second rib, in which it was imbedded, prevented a perfect separation of this part until at the close of the operation.

The next step was to divide the attachments of the upper or cervical edge of the tumour. First, the posterior external jugular vein was divided and tied. It was filled below with a dense lymph, and discharged some red blood from above. Next, the sterno-mastoid muscle was cut across, and the sheath of the cervical blood vessels exposed. The internal jugular vein was perceived to pass from the neck into the substance of the tumour, in such a way as to render it difficult to dissect it without dividing it. This was, however, accomplished, and



the carotid artery and par-vagum nerve presented themselves. On reaching the internal extremity of the tumour, the anterior external jugular vein was found bedded in it. This was filled with solid lymph, and was tied, as it would not have been safe to have left it without a ligature. Nothing now remained to be done, but to separate the sternal end of the tumour from the corresponding part of the jugular and subclavian veins. By great caution this was safely accomplished, and the tumour removed. When this was effected, the whole extent of the subclavian, the lower part of the jugular vein and par-vagum nerve were exposed.

These being put in motion by the pulsation of the subclavian and the carotid arteries, presented a formidable appearance.

Little blood was lost in the operation. Only one or two arteries were tied, and the veins specified above. The flaps were brought over and retained by three sutures and adhesive plasters, so as to cover the wound perfectly.

The patient's appearance, after the operation, was good; and by a recurrence to the surgical diary, it appears his symptoms were most favourable to the thirteenth day. He was then able to



sit up; had appetite; took small quantities of solid food, and had every promise of a favourable termination of his case.

The wound healed to a considerable extent, by the first intention, and the un-united part went on favourably. On the thirteenth day he was affected with chills, pain in the epigastric region, and his pulse rose from 80 to 112. These symptoms were followed by a nervous agitated state, and eventually by a slight delirium, with no other local phenomena than those above mentioned.

On some days he appeared better, and in a fair way to recover; and this hope was not abandoned till the day before his death, which occurred on the 8th of December, in the fourth week from the operation.

On examination of the body after death, a slight adhesion appeared at the point where the pleura corresponded with the wound; but this membrane, in the vicinity of the wound, was sound, and the lung not inflamed at that part. The inferior edge of the right lung was fringed with lymph. The lung of the other side had a more considerable effusion of lymph, externally; and in its substance two or three spots of effused lymph, near an inch in diameter. A quantity of sanguin-



eous fluid was discharged into the left cavity. The heart and pericardium were unchanged. The brain presented nothing remarkable. The viscera of the cavity of the abdomen were healthy, excepting a slight blush where the intestines were in contact, and an enlargement of the right kidney. The subclavian vein, the upper part of the axillary, and the cephalic veins, each contained a coagulum, which was of long standing and adhered closely to the coats of the vessels.

Three years after the death of this man, I met a patient who was in the hospital at the same time with Smith. This was a respectable lady, who occupied a room on the opposite side of the entry. She expressed her regret at his death, after the trouble we had with him; and informed me, it was a fact well known to her and some others, that he got his chill by leaving his room to pay her a visit, while his nurse was absent. This was never made known to me before; and may serve as an instance of the deceptions our profession is liable to.

OSTEO-SARCOMA OF THE RIBS. Mr. Hiram Corey, of Stanbridge, Upper Canada, aged 30, stout and healthy, a surveyor. Six years ago he perceived a small tumour on the left side



of the chest, beginning, as he thinks, about the ninth, or tenth rib, without any hurt or injury. At first it was very hard. As it has increased in size it has increased in softness, or rather the hardness is not so great, for it is not soft at any point. In size it measures from one edge of the tumour, across its summit, to the opposite part, seven inches each way, and of course is circular in form. Its projection above the surrounding surface, is from one to two inches. Four ribs are covered by it; the seventh, eighth, ninth, and tenth. Its internal or anterior edge corresponds with the cartilages of these ribs. The tumour is not discoloured, tender nor painful. When moved, it raises the ninth rib more sensibly than the others. The eighth also is affected by its motion.

As the tumour increases rapidly, and must, if permitted to grow, soon attain a great size, an operation was at once recommended, and agreed to. The plan proposed for the operation is the following.

The patient is to be placed on a table, with his chest raised considerably, so as to prevent a retention of the blood of the wound. All the instruments that can possibly be required should be at hand,—particularly saws, cutting forceps, strong



scissors, chisels, gouges, besides the common instruments and dressings.

An incision is to be carried from above, downwards, so as to extend an inch both above and below the tumour. This is to be crossed at right angles by a similar incision. The flaps, consisting of skin, cellular membrane, and the external oblique muscle, are to be dissected from the surface of the tumour, and from its circumference, so far as to expose the ribs, particularly the eighth and ninth; to one or both of which the tumour adheres. The bleeding being arrested, proceed next to examine the connections of the tumour with the ribs. If it adheres inseparably to more ribs than one, the tumour should be cut off by strong cutting forceps, and the rib, from which it took its origin, is to be removed afterwards, and such others as seem to be involved in the disease; or, if they cannot all be removed, they must be cauterized. If the tumour seems to be connected with only one rib, this rib may be removed. In order to accomplish this, the face of the rib must be perfectly exposed near the tumour. Then carefully dissect from its edge, first the external, then the internal intercostals; beginning with the upper edge of the rib. In dissecting the intercostals from the lower



edge, the artery, vein, and nerve should be dissected, if possible, from the rib, and left on the surface of the pleura. Then, the rib being drawn outwards, or raised, a blunt instrument is to be insinuated between the rib and pleura, to separate the latter from the former. A director, or small piece of cloth, should be then passed under the rib, which may be divided by the cutting forceps applied to its upper and lower edges. The fragment of rib is then to be raised, and the intercostals and pleura dissected from it, to the point where the internal oblique, transversalis and diaphragm adhere; which adhesions are also to be separated. If the intercostal artery should be wounded before the rib is divided, the artery may be secured by dissecting it out from its groove, in the direction of the spine. This may require the previous elevation of the serratus muscle.

The operation was performed on the 27th of March, 1837, nearly in the manner proposed. Instead of a crucial incision, after the longitudinal cut, another was made on the right edge of the wound, that proposed on the left edge not being necessary. The external oblique being fairly dissected off, some obstacle was presented to laying bare the circumference of the tumour, by the



strong contractions of this muscle. At the outer, or left edge, a still greater was produced by the contractions of the latissimus dorsi, even after the edge was fairly divided. The patient suffered severely, whenever the muscles were cut. The next step of the operation was to examine the connection of the tumour with the ribs. For this purpose, I uncovered a small portion of the ninth and tenth ribs, and soon ascertained that the tumour originated in the ninth and was adherent to the seventh, eighth and tenth. The knife was insinuated between the tumour and these three ribs, with some caution, on account of the danger of penetrating the intercostals; and now the tumour being separated from these, was perceived connected with the ninth only. A question arose, whether it was best to divide the rib first, or to take off the tumour. Ascertaining that by removing the tumour I could save an inch of the rib, by dividing it under the tumour, I cut off the tumour with an inch of the cartilage of the rib, and then having the morbid origin of the tumour in full view, proceeded to remove the rib. The intercostals, above and below the rib, were carefully divided with the knife. The intercostal artery vein and nerve were separated with the pleura. A



small director was then insinuated between the pleura and bone; and on the director the rib was cut with the cutting forceps, applied to the edges of the rib. The diseased portion was then dissected from the pleura and diaphragm, with a portion of the cartilage of the rib. The exposed diaphragm rose into the aperture of the wound, forming a sort of hernia. The hæmorrhage was not great.

The wound was brought together by a suture and adhesive plasters, and the patient carried to bed, quite comfortable and happy.

My expectation certainly was to have found some degree of thickening of the pleura and diaphragm, and to have derived a security from this, in separating the rib. Nothing of the kind, however, existed. These parts, as well as the inner face of the rib, were perfectly natural. However, the principal difficulty in the operation arose not in the separation of the rib, but in the active muscular contractions of the external oblique and latissimus. Had the first incisions been less ample, this would have caused great embarrassment. But as it had been foreseen and guarded against, it was soon surmounted, and the operation completed in a very short time.



I would not, however, be willing to have it understood, that the raising of a rib from the pleura or diaphragm, is a light and easy operation. It is one of great danger both in the execution and the consequence, if the pleura retain its healthy state; but if it be thickened, the danger and difficulty are much diminished.

On the day after the operation, a considerable degree of fever appeared; and for ten days the pulse was 120, without distinct symptoms of inflammation of the pleura or diaphragm.

April 14. The pulse has now become natural; the patient has appetite, sits up, and the wound is nearly healed.

The case next to be mentioned, will show the course of this disease when left to itself. The patient I visited with Dr. Wellington, of West Cambridge, in 1833. She was a healthy looking female, about fifty years old. When I first saw her, an operation appeared feasible, but the patient would not agree to it. The symptoms of the disease I cannot state better than they are done in the following account, which Dr. Wellington had the goodness to send me.



West Cambridge, April 2, 1837.

MY DEAR SIR,—I this morning received your note, and will cheerfully give you the information requested. Sometime in the summer of 1833, Mrs. Cutter mentioned to me that she had a troublesome rheumatic pain in her shoulder, for which I recommended the application of sinapisms to the part, and heard nothing more about it until October, when she showed me her collar bone, where there was evidently some enlargement. The tumour was immoveable, without discolouration, and attended with little pain from handling. I then recommended a mercurial plaster, applied to the part, and my attention was not again called to the disease, until Feb. 17, 1834. At this time, the tumour had increased to the size of half an egg, was on the end of the clavicle next the sternum, immoveable and without change of colour. She complained, to use her expression, of a “dullering pain” in it, and said she had suffered much during the winter. It was now, for the first time, that I suspected the tumour to be malignant; and I advised her to consult Dr. Walker immediately, which she did on the same day. In answer to a note which I sent by her, Dr. W. said that he feared the tumour was malig-



nant ; and if so, he saw no prospect of cure, but in the removal of a portion of the bone. At a subsequent examination, some weeks after, he expressed the same opinion, and mentioned the operation to her, to which she was decidedly opposed. Dr. Walker, at this time, expressed his doubts to me whether an operation would be successful. The tumour continued to enlarge, until you saw it, which, I believe, was in June ; it was then, as near as I can recollect, the size of a large apple. The colour had now changed, and become livid ; the blood vessels over the surface were very distinct, and the tumour, as it advanced, became elastic to the touch, and an obscure fluctuation could be felt. In January, 1835, it was as large as a child's head, and pressed so forcibly on the œsophagus and trachea, that food could be swallowed in minute portions only at a time, and the respiration was often so difficult as to threaten suffocation.

During all this time, her general health had suffered but little ; her appetite was generally good, and there was but little emaciation. About the last of March the tumour burst, and discharged at least a quart of fluid, in colour and consistence much resembling tea made from the slippery



elm bark, with an odour rather unpleasant and sickening than foetid. Immediately after the bursting of the tumour, the parts became gangrenous, the discharge extremely offensive, the constitution very rapidly affected, and she sunk and died about the 10th of April. The appearances after death you saw, and accordingly they need not be described.

Yours, respectfully,

T. WELLINGTON.

In company with Dr. Wellington, Dr. Walker, and other gentlemen, I examined the body. A large sloughing surface appeared over the tumour on the right side of the neck. The neck, upper part of the chest, including the sternum, right clavicle and a part of the left, were involved in a mass of disease which obscured all the textures, excepting some spiculi of bone belonging to the sternum. A portion of clavicle, on the right side, was with difficulty discovered. The morbid mass appeared to consist principally of a soft substance, in which filaments of various textures were confusedly mixed.



## SECTION VII.

### TUMOURS OF THE GLANDS.

GLANDULAR tumours may be divided into three kinds. First, TUMOURS OF LYMPHATIC GLANDS; second, of SECRETING GLANDS; third, of MUCOUS GLANDS. Perhaps we might add a fourth division, tumours of OLEAGINOUS and SEBACEOUS GLANDS.

1. TUMOURS OF LYMPHATIC GLANDS. These I shall divide into three species,—*scrofulous*, *scirrhou*s, and *fungoid*.

SCROFULOUS GLANDULAR TUMOURS are simple enlargements of lymphatic glands, and present themselves most frequently in the neck, groin, and armpit. They are usually of ovoidal form; firm to the touch, but not hard; covered by a fair skin, without adhering to it; and are especially distinguished from other tumours, by presenting them-

selves in clusters, or rather in chains, as you see in the preparation before you. They are not attended with pain, unless the process of suppuration occurs. Then they redden, become painful, and finally open and discharge a flocculent matter, and sometimes continue to discharge for a long time.

A medicine has been introduced of late years, which has acquired much reputation in this and other forms of scrofulous disease. It is not surprising that physicians should with avidity take up any remedy which may promise to relieve so common and inveterate a disease as scrofula; especially one analogous in its character to those of which experience has most approved. I must say, that after many years trial of the preparations of iodine, in various forms of scrofulous affection, I have rarely seen any very distinct advantages from it. I have employed it in large and small doses, in hospital practice and private, externally and internally. Nor in truth ought we to allow ourselves to expect the results which have been promised. Scrofula is a constitutional, and commonly an hereditary disease. If there be any remedy for such a disease, it must be found in agents which influence the intimate structure of



the body more generally and intimately than iodine, or any medicinal substance can do. Such agents are food; a healthy state of the excretory apparatus; a pure atmosphere; and an exercise of the muscular system, suited to the constitution of the patient. I do not wish to dissuade from the use of so convenient a medicine as iodine; but would advise it to be employed in such a way as not to disturb the functions which remain healthy; and that it never should be used to the exclusion of those restorative means, to which reason and experience have given their sanction.

2. SCIRRHOUS LYMPHATIC GLANDS. These may be divided into two kinds, non-malignant and malignant.

#### NON-MALIGNANT SCIRRHUS OF THE LYMPHATIC GLANDS.

THE NON-MALIGNANT SCIRRHOUS GLAND is of a globular form; quite hard; not discoloured nor painful. It is distinguished from the simple scrofulous tumour by its permanent hardness and steady increase in size. Sometimes it is insulated; more frequently double; and not rarely clustered, as in this specimen taken from the



axilla, in which you see from fifteen to twenty tumours, suspended from a pedicle of lymphatic vessels. This was dissected from the axilla of a negro boy about eighteen years old. It involved the axillary vein and some of the axillary nerves. The operation was safely terminated, and the patient recovered from it.

When dissected out, this kind of tumour is found to be covered with one or more coats, formed by a condensation of the surrounding cellular texture, and constituting a cyst. On cutting it open, a white substance is seen near its central part, from which issue rays of the same matter to its exterior. Between these rays there is a pale reddish substance, something like the healthy appearance of the lymphatic glands.

The application of the term *scirrhus* to a non-malignant tumour, is objectionable ; but there does not appear to be another word to express the hardened lymphatic gland covered by a cyst, and forming a permanent tumour.

A question is constantly presenting itself to the surgical practitioner, whether these tumours should be extirpated by the knife when they are not malignant. To this it may be answered, that, when the tumour has continued a year or more, when it

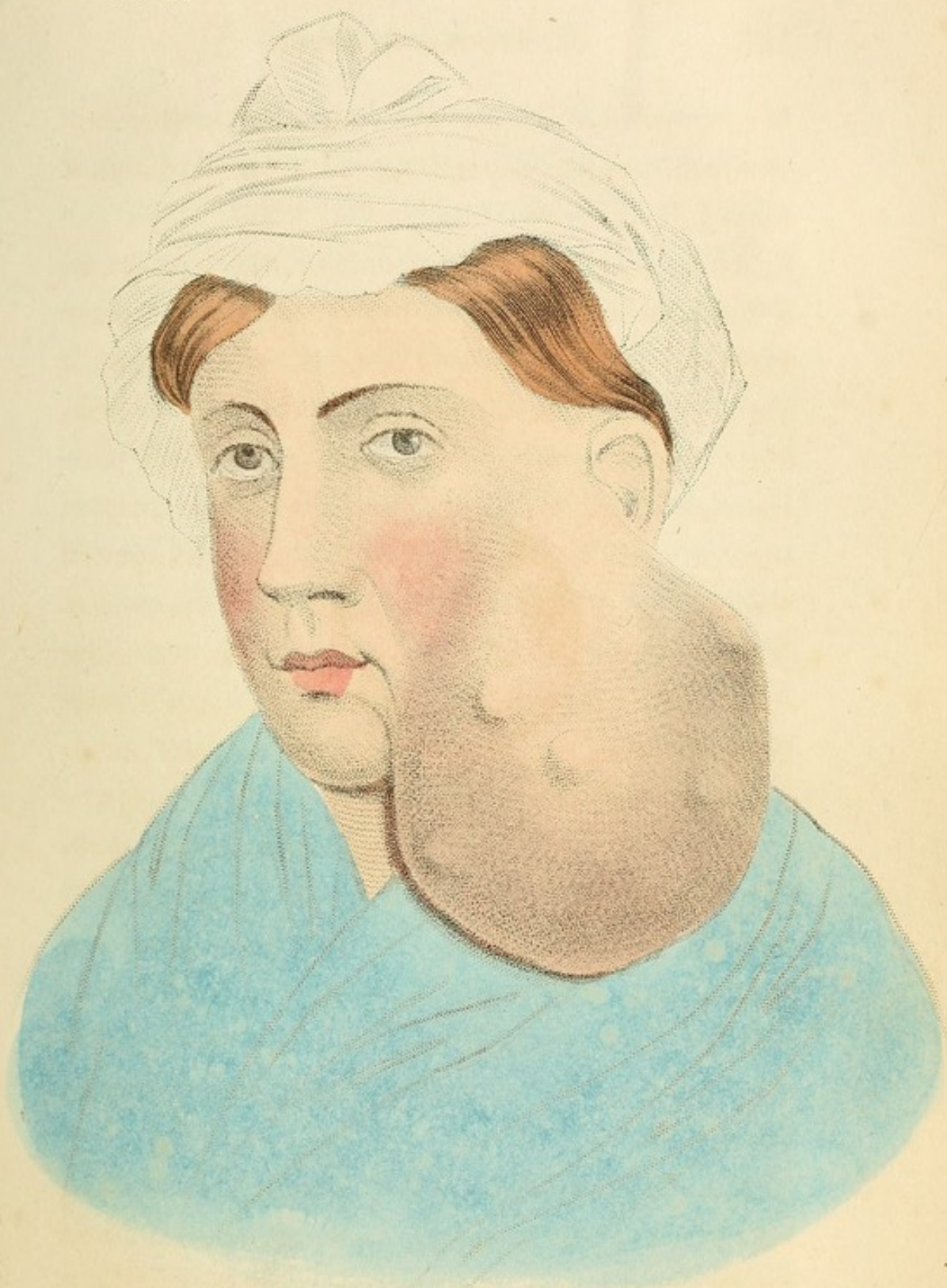

is so situated as to press on important parts; and when it increases regularly in size and hardness, it must be removed.

As an instance of the simple glandular scirrhus, I will mention the following. A short time since I removed a scirrhus tumour of the size of a pigeon's egg from the neck of a child three years old. The par-vagus nerve lay on its fore part, the carotid artery on its inside, and the internal jugular vein on its outside. The child supported this operation surprisingly, and soon recovered. The tumour you see is quite hard, has a regular cyst, and is large. It had existed nearly a year. Now this would never I think have become malignant.

Here follows an account of one of greater magnitude, published in the papers of the Massachusetts Medical Society, and represented in plate IX. The tumour, large and formidable in appearance, was superficial, and not malignant. This may be contrasted with the malignant scirrhus, shown in plate X.

Mary Litchfield, aged forty years, has a tumour on the right cheek, which began to appear about twenty years ago, and increased gradually till it arrived to about two thirds its present size, when



*Scirrhus of the lymphatic glands not malignant*





it remained stationary, till the last ten months. It began just above the angle of the jaw, in front of the ear. From the zygomatic arch, it passes under the ear, which is raised by it to within a short distance of the mastoid process, thence along the jaw to the chin, and thence upwards to the alar nasi, measuring around the base sixteen and a half inches, and from the ear over the tumour to the jaw, nine and a half inches. It is quite loose and moveable, and has three or four prominences of considerable size, which are very soft and elastic, and seem to contain fluid. It is not painful nor tender to the touch.

Operation, Nov. 14, 1828.—An incision was begun in front of the ear, about an inch above the base of the tumour, and carried down about an inch, then continued round the tumour about the same distance from the base to its lowest point; then another incision on the other side, meeting the first; the tumour was then dissected from its connections with the subjacent muscles. It was not connected with the zygoma, nor the os maxillæ inferioris by the periosteum. Several considerable arteries were cut, the temporal, aural and facial, which ran under it; but they were all stopped by compression, till the operation was



finished. A considerable hemorrhage however occurred; and the patient was in a state of syncope, during most of the dressing.

The tumour was composed of numerous enlarged glands, conglomerated, and the eminences upon it were globular masses of fatty matter.

No remarkable occurrence followed the operation, and she was discharged well on the 12th of December.

#### MALIGNANT TUMOURS OF THE LYMPHATIC GLANDS.

By malignant tumour, I mean a disease in which destructive action overbalances restorative, and thus produces an incurable disease. A malignant tumour is not necessarily attended with ulceration. It may be so, or otherwise.

There are two kinds of malignant tumour of the lymphatic glands, the SCIRRHOUS MALIGNANT and the FUNGOID.

The disposition of lymphatic glands to assume a malignant affection, was not so generally admitted some years back, as it is at present. The secreting glands were supposed to be more inclined to come into this state, than the lymphatic. It is however certain that the latter are often the seat of these derangements, without a preceding disorder



of the other. The scrofulous habit, which disposes to the simple lymphatic enlargements, is also more frequently the seat of the malignant tumour. The latter like the other is found in those parts where the glands are numerous.

It begins with a simple glandular induration, not at first attended with soreness or pain, but exhibiting much hardness in an early stage. After some months a darting pain is perceived; other glands in the vicinity, partake of the disease; the patient begins to lose flesh and strength; the glands between the tumour and thoracic duct are enlarged; the pain becomes great, and particularly affects the back, when the tumour is seated in the groin. Watery effusions occur in the thorax, abdomen, and in the extremities; and the patient wastes away under a general disease of the lymphatic apparatus. Not unfrequently the original tumour ulcerates, and produces a disgusting sore attended with great pain.

In the year 1830, a lady sixty years old, of fine constitution, informed me she had a small tumour in the left groin, about the size of a filbert, very hard, but not tender. I suggested it might be a rupture, or a disease of the glands, and proposed examination. She was averse to this, and deter-



mined to go on without doing any thing, unless she had more trouble. After a few weeks she visited me again, and stated that she began to feel pain, and that there was an additional tumour formed. I enforced the importance of an examination; intimating that it might be a most serious disease, and declining any prescription till I was satisfied of the nature of the swelling. Two or three months were allowed to pass over; the tumour extended; the pain increased, and the examination was submitted to. The result was the discovery of a hard tumour of about three inches superficial extent, and of considerable depth; knotted as if composed of many glands; and a little tender. I examined the abdomen above, and found a fulness and tenderness in the left inguinal region; convincing proof that the abdominal glands were diseased.

It was obviously no case for a surgical operation, nor for medical treatment. But notwithstanding the former pertinacity of the patient in refusing to submit to a proper examination, I felt unwilling to notify her that she was under sentence of death. Some palliative medicines were prescribed, she passed a few months without severe suffering, when she was attacked with a



congestive inflammation of the lungs, which proved fatal in five days.

On examination of the body, the left lung was found hepatized and covered with coagulated lymph. The pleura contained about thirty ounces of water. There was also much water in the abdominal cavity. The mesenteric glands on the left side, formed a large tumour, of which you see here a portion about four inches thick. The glands of the groins are seen in a separate jar, and are covered with a triangular piece of skin of the groin, to which they closely adhered. These glands are hard and white at their circumference, soft and of a dark red in their centre. The peritoneum was studded over with tubercles. Both of the lower extremities were œdematous, particularly the left.

The lymphatic system was, it seems, extensively diseased. Did this disease take its origin externally or internally, in the groin or in the abdomen?

While the last case was in progress, I was requested to see a gentleman about thirty years old, of a scrofulous habit, for a large knotted tumour in the left groin. It began a year before, had been extirpated once, and when I saw it, was



larger than before the operation. I advised not to meddle with it further. No long time after, it was removed. The wound never healed, but spread extensively, became very painful, and the patient died four months after the last operation, in a state of great suffering.

The following case will show the extent to which an internal glandular affection may proceed without any considerable appearances in external parts. A lady, under forty, apparently of good constitution, showed me a hard tumour in the armpit, composed of a cluster of lymphatic glands. It had existed about three years and was increasing. There was no tenderness, pain, nor redness. She informed me that she had some years before experienced a cutaneous eruption of very limited extent, which she was anxious to get rid of; and after using remedies of an active nature, succeeded. Not long after this, the tumour began to show itself. Her health was impaired in a degree out of proportion to the apparent disease; and after watching the case, I became satisfied it was not a subject for surgical operation; but rather of general treatment. Soon after, a distressing pain occurred in the back, principally in the lumbar region, ultimately affected one thigh, and was



followed by an œdematous state of that limb and a contraction of its muscles. The pains and emaciation advanced; the pulse became permanently quickened; the appetite failed; and about five months after I saw the tumour, hard knots were discovered in the abdomen, and a tumour of some size in the right iliac region. About a month after the discovery of the abdominal tumours, she expired in a state of great emaciation.

The body was not examined.

Where this kind of tumour consists of many glands, intermixed with the blood vessels and nerves of the neck, axilla, or groin, it forms a most difficult case for operation. For when this occurs, the diseased glands contract adhesions with the nerves and vessels, and the separate dissection of all these vessels and nerves is difficult, and sometimes impossible. In the last case, the operator must remove what he can, and break up the texture of those glands which he is compelled to leave.

In the year 1827, a farmer, sixty years old, of weak constitution, came to me with one of these scirrhus glandular tumours in the neck. It had existed over a year, and occupied the whole of the left side of the neck, from the ear to the clav-



icle, and from the trachea to the spine. The mastoid muscle, all the arteries, veins and nerves of the neck, were included in its substance. A process extended under the jaw into the pharynx, and filled the left half of this cavity with a red tumour, and greatly impeded deglutition. The external tumour was very hard, knotted, not discoloured and not tender. The growth had been rapid. The patient's health was failing, and his suffering from the act of swallowing, quite distressing.

What was to be done in this case? My first impression was not favourable to a surgical operation. The swelling in the pharynx could not be removed without a wide opening into that cavity. Portions of the tumour must adhere closely to the various nerves, and the separation would require a dissection longer than the patient could support; therefore some of these portions must be left, and thus a root to regenerate the disease would remain.

On the other hand appeared the prospect of a lingering and inevitable death.

The patient, finding an increase in his sufferings, became more desirous of an operation. I then agreed to submit the case to a consultation



of the surgeons of the Hospital, and if they should determine that an operation was proper, I would not shrink from performing it. Accordingly a consultation was held, the case was fully considered, and the result was, that the patient should be made acquainted with the danger and uncertainty of a surgical operation, and that, if after a view of these, he desired it to be done, it was right to undertake it. The patient, after a consultation with his friends, determined to go through it, and it was performed at the Hospital in the following manner.

An incision was made from behind the ear to the anterior third of the clavicle; the surface of the tumour uncovered, the mastoid muscle was sought for, but was partly absorbed, and partly buried in the tumour. After clearing the tumour from the ear, the jaw, larynx, and dorsal muscles, an attempt was made to get under the tumour, just above the clavicle; and now the difficulties of the operation appeared. The carotid artery, internal jugular vein, and par-vagus nerve, were covered by and connected with processes of the tumour, in such a manner as to render it difficult to distinguish them. This was at last accomplished by breaking down the lower part of the



tumour, till these parts were made out. The vein was obliterated, the artery diminished in size, but pervious. A ligature was applied on the latter, and the par-vagum nerve was separated as carefully as possible, though not wholly cleared of the tumour. The separation from the nerves at the upper part of the neck, was next attempted successfully, with the exception of the sublingual, which so barred access to the pharyngeal part of the tumour, that I determined to divide it; and then followed the disease into the pharynx, as far as could be done without cutting open its cavity; the operation was finished by breaking down such parts of the tumour as could not be separated from the nerves. There was but little hæmorrhage, as is common in large and hard tumours. The parts were brought together, and the patient removed to his bed. He was faint twice, but otherwise supported the operation well.

On the following days, he had great difficulty in swallowing. At the end of a week this subsided; the wound united by the first intention, excepting the inferior part, which was kept open, and in twenty-two days he left the hospital, and went to his home in the country. A portion of the tumour adhering to the parietes of the pharynx, which I



could not remove by the knife, was attacked by the actual cautery, after he had recovered from the operation, a few days before he left the hospital, and I would have repeated its application had the patient been willing to submit; and might possibly have succeeded in wholly eradicating the disease. After an interval of some months, the throat began to ulcerate, and this ulceration gradually extending, produced a difficulty in swallowing, and, wearing him down, proved fatal in about a year from the operation, as nearly as I can recollect, no minutes of the case having been obtained after he left the hospital.

The case just related is sufficiently formidable, and perhaps it may appear unnecessary to introduce here another more so. An account of such cases is, however, the best substitute I can present for actual experience; and hoping it may be useful, I shall beg leave to make a statement of it.

Mr. S. H., a respectable farmer of Lincoln, was brought to me by Dr. Russell, about the first of March, 1837. He had a large tumour on the neck, extending from the spinous processes of the cervical vertebræ to the lower jaw, pharynx, œsophagus, and larynx, running upwards behind the ear, and downwards near to the clavicle. The



patient, who was a healthy, good looking man, fifty-two years of age, told me the tumour had existed for thirty years. Within the last year it had increased rapidly; and of late had pushed his head to the opposite side; impeded the motions of the head and neck; caused dizziness, head-ache, and dyspnœa. On examination, I found it of a cartilaginous hardness, and quite fixed in its situation. The hardest portion extended from the origin of the sterno-mastoid muscle directly downwards, and there the patient said the tumour first appeared.

After examining and considering the case, I conceived the following state of things to exist. Taking its origin in the lymphatic glands, behind the posterior edge of the sterno-mastoid muscle, it had extended backwards under the trapezius to the spine, and forwards under the mastoid to the pharynx. That it adhered to the splenius and complexus and trachelo-mastoideus, and involved the digastricus and all the styloid muscles. Of the blood vessels, that it involved the external carotid artery, with its eight branches, excepting possibly the superior thyroid. Of the veins, the internal jugular, all the external jugulars, and the accompanying branches of the arteries. Of the





Fig 2

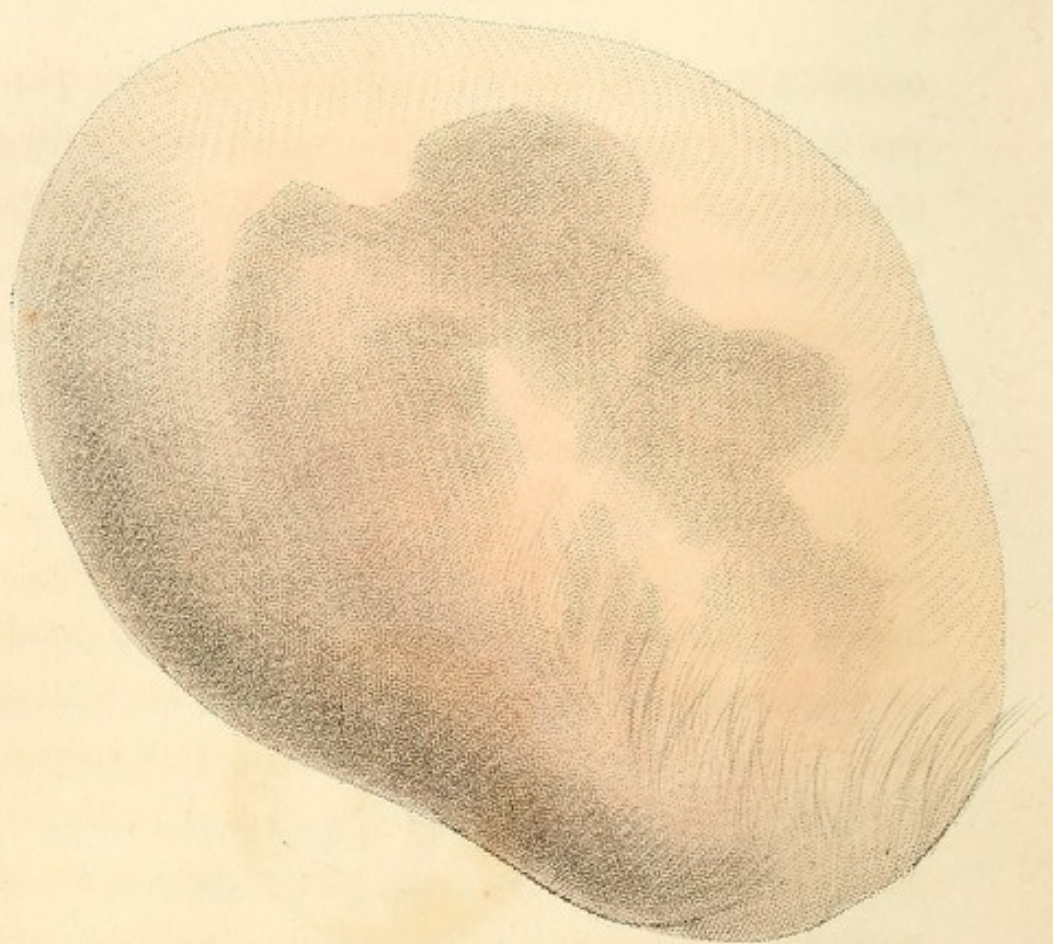

Fig 1



*Malignant Scirrhus of Lymphatic Glands*

nerves, the three or four superior cervical, the par-vagus, sublingual and its descending branch, the glosso-pharyngeal, laryngeal, and probably the gustatory, and great sympathetic. Of the glands, the parotid and submaxillary. Of the canals and passages, the larynx, pharynx, the auditory passage, and possibly the œsophagus. See Plate X.

To extirpate with safety a tumour thus situated, had it been loose and moveable, would not have appeared impossible. To extricate a cartilaginous mass from delicate nerves and blood vessels, was quite a different affair. Dr. Lewis, Dr. Inches, and Dr. Mason Warren being present, I requested them to examine the tumour, and after consulting with them, I stated to the patient the great dangers of the operation, the impracticability of disengaging the whole of the tumour, and left it to his decision to decline or agree to it. He replied that having considered the subject a long time, he had made up his mind to have an operation done, if it could be done without danger of his expiring at the time. On this point, I could only assure him, that if, in attempting it, any obstacle presented, which could not be surmounted without fatal consequences, I should cease to prosecute it.

The patient, having heard this, determined on



an operation. On the 7th of March, I went to Lincoln for the purpose, and performed it in presence of Dr. Russell, of Lincoln, Dr. Bartlett, of Concord, Drs. Otis and Mason Warren, of Boston, and a number of other medical gentlemen.

The patient was placed in a chair, with his head duly supported. My wish was to have secured the carotid artery first ; but perceiving the depth of this vessel from the rising of the hard tumour on the outside, and the trachea on the inner side, an incision was made from the spine to the angle of the jaw, to meet another incision from this last point downwards, in the direction of the anterior line of the sterno-mastoid muscle. The last incision extending down the neck near to the clavicle. The flap thus formed, was elevated by a dissection, laborious from the close adhesion of the integuments to the tumour. This flap being turned down, exposed the posterior half of the tumour, a hard, knotted, bloody surface, extending from the spine near to the trachea, and showing the mastoid muscle firmly imbedded in the scirrhus substance.

Next, having dissected the mastoid from its inferior adhesion to the scirrhus, the carotid artery was exposed and tied.



The superiour flap of integuments was then raised, and I attempted to disengage the mastoid muscle from the furrow it occupied in the tumour, in order to pursue the dissection under it. This was found impossible. The alternative then presented of cutting across this muscle and dividing with it the accessory nerve,—the consequence of which last, I was unacquainted with,—or else dividing the tumour through its middle part, behind the mastoid. The latter course was adopted. The scirrhus mass was cloven in two. The posterior half was dissected out, and it then remained to separate and disengage the anterior part from the posterior face of the sterno-mastoid from the digastric, the nerves and bones; including the parotid and submaxillary glands. The mass of the tumour was then happily removed from the parts just mentioned. Some portions adhering to the fore part of the bodies of the vertabræ and to their transverse processes, could not be wholly dissected without exhausting the patient's strength.—The operation was therefore concluded by the application of the actual cautery to the last mentioned parts, with very little complaint from the patient.



In the latter part of the operation, the patient was seized occasionally with a spasmodic cough, produced, apparently, by the division of some of the inferior branches of the accessory nerve. The internal jugular vein was buried in the tumour, and in order to raise the lower edge of the mass, it was necessary to divide and tie this vessel. To accomplish this with safety, it was compressed between the tumour and the clavicle, then divided and tied. A few bubbles of air entered the open mouth of this vessel, but were arrested by the finger below, and forced back again.

The principal branches of the first and second cervical nerves, were seen and divided. Others, running through the substance of the tumour, were also divided, as it appeared by the sensations of the patient, without being seen.

The integuments were laid down on the face of the wound and moderately secured, so as to protect it, without too much confining the parts destroyed by the cautery.

The patient walked to his bed, assisted in undressing himself, and talked freely of the operation.

What will be the result of this case is uncertain. The long continuance of the disease



without ulceration, or constitutional affection, afford some ground for encouragement that it may be favourable. The ligature of the carotid, depriving the morbid parts of nutriment, increases this encouragement. The patient is certainly relieved of a formidable mass of disease, and after surmounting the immediate effects of the operation, must be comparatively comfortable, whatever be the ultimate result.

An inspection of this tumour presented the following appearances. The interior appeared to be composed of small white granulations, imbedded in a fibrinous matrix. Membranous septa, of different degrees of distinctness, could be discovered in various parts, consisting, no doubt, of the coverings of lymphatic glands, of which the disease was originally composed. Various nerves were noticed in its substance; but the blood vessels were generally effaced; so that a section did not discolour the knife.\*

---

\* The patient's symptoms, after the operation, are stated in the following letter.

DEAR SIR,—I take the liberty of giving you a history of the symptoms of Mr. H., since the operation. I was called to him at 3 o'clock, on the morning after the operation, in consequence of the severity of the re-action. I found him labouring under extreme restlessness, difficulty of



## FUNGOIDES OF THE LYMPHATIC GLANDS.

You will recollect the distinction we have made of two kinds of malignant tumours, carcino-

---

respiration and deglutition, pulse 110, but not full. There had been considerable hæmorrhage, and the dressings were very uncomfortable. Some delirium. He spoke with great difficulty. I had, when I left him, in the previous afternoon, enjoined that he should be kept quiet, and not allowed to get out of bed; but when I visited him in the night, I found him so uncomfortable, that I allowed him to get out of bed, which gave him much relief. Five o'clock, P. M., same day, symptoms as in the morning, excepting that they had increased in an alarming degree. Pulse 110, very feeble, especially on the *left* side, with not exactly paralysis, but great difficulty in moving the *left* arm and leg. He could carry his hand to the head, but it was with great difficulty, very like a person after an injury of the shoulder joint. The difficulty of respiration was so great, the dressings so exceedingly uncomfortable, and the countenance indicative of such extreme suffering, that I was under the necessity of removing a part of the dressing. I removed the bandage and the compress which lay over the trachea, as they were very hard. This gave him instantaneous relief. He could breathe much easier and his countenance changed for the better. His swallowing continues very difficult. When he attempts to swallow, it produces a cough, and what he is attempting to swallow is thrown off. The pulse fell to 86, full but soft.

Thursday 9th, 9 o'clock. Symptoms much as yesterday, except considerably mitigated in severity. Breathing easier, pulse 96, rather full on the right side, feeble on the *left*, difficulty of moving, as yesterday; very restless, slept but little last night, some delirium; desirous of having the neck dressed.



matous and fungoid. Both of these are found to exist in the lymphatic glands, the latter perhaps more rarely than the other.

---

Five o'clock, P. M. same day. Symptoms much as in the morning.

10th, Friday, 4 o'clock, A. M. Has not slept, great restlessness, some delirium, dressings very uncomfortable, considerable discharge from the wound, pulse 96. Dressings removed, wound looks well, a portion of the skin below the horizontal incision looks flaccid, has lost its vitality. After the dressing he was more comfortable, slept one hour very well. Gave an enema, he having no discharge from the bowels since Wednesday. His respiration is easier, swallows easier. Temperature of the right side of the head lower than the left, (this has been the case since Wednesday.) Diet, gruel, crast water, sol. sup. tart. potass. 5 o'clock, P. M. Symptoms as in the morning, pulse 100.

11th, Saturday, 3 1-2 o'clock, A. M. Symptoms as yesterday, excepting that there is no delirium, pulse 86. Deglutition much easier, takes more food, wound looks well, skin begins to slough. The line between live, and dead skin very distinct. Has slept pretty well, appears to be doing well. 5 o'clock, P. M. As in the morning, swallows easy, speaks distinctly. Gave an enema as yesterday.

12th, 9 1-2 o'clock. Comfortable. Pulse 86. Has been rather restless through the night. Has suffered little from pain since the operation. sits up an hour at a time, without inconvenience.

13th, 4 o'clock, A. M. Has passed an uncomfortable night. Pulse 100. I was called on account of his desire of having the neck dressed. On removing the dressings, I found an *erythematous inflammation* commencing behind the right ear, which was involved in it. Pulse 86, soft and rather full. Gave him sulph. mag. one ounce, allowed him gruel, lemonade, molasses and water, &c. The dead skin has separated, the edges of the wound looks healthy. 5 o'clock, P. M. Erythema extended over the right side of the face, affecting the temple, but *not* the forehead or *scalp*. Applied solut. acet. plumbi. Wound



Fungoides of the lymphatic glands, is an insidious, deceitful tumour. When first discovered in

---

dressed looks well. I would remark here, that I have been under the necessity of dressing the wound twice a day. There is so much discharge, and it is so offensive to the patient, that he is very desirous of having it dressed as often as I am willing to do it. I would remark too, that the difficulty of swallowing is very much removed, and he breathes about as easy as in health. His appetite is tolerably good.

14th, 9 o'clock, A. M. Erythema extended across the nose, and a part of the left cheek. Right side less swollen. Pulse 80, soft and not very full. Tongue coated, but not more than it has been since the operation. Neck looks well; healthy granulations springing up in different places; sterno mastoid muscle looks healthy. Slough has not all come away. After the dressing, considerable hemorrhage from the opening for the securing the carotid. Constitutional symptoms much as yesterday, had rested pretty well. Sudden death, at 12 o'clock this morning, of an aunt, who lived next door, had agitated him some. I applied argent. nit. over the inflamed surface of the face. 6 o'clock, P. M. Pulse 94, rather full. Inflammation in face rather less, incipient coma, loss of sensation and motion in the left arm. Much hemorrhage to day. Symptoms generally more unfavourable. Gave at 7 o'clock, P. opii grss. repeated at 1 o'clock, A. M.

15th, 9 o'clock, A. M. Symptoms decidedly better. Pulse 78, soft. More animation in the countenance. Inflammation in face subsided. Argent. nit. had desicated a little in several places. Sensation and motion in arm returned. Neck looks well. One very good evacuation from the bowels during the night. Has rested better than since the operation.

I have thus given you an outline of the most prominent symptoms, and hope my management of the case thus far will meet your approbation. Any suggestions you may be pleased to make, will be most gratefully acknowledged. Would it be proper to confine the head in an erect



the groin, thigh, or neck, it is small; its consistence soft; its connections confused and not precisely limited. Without colour at first, it sometimes ultimately becomes of a livid red, and when of considerable size, that for example of a lemon, it has a livid red colour; so that it much resembles an abscess, and if you had not known the history, you would say it contained a fluid. You puncture it, nothing is discharged but a bloody water or blood. You extirpate it, thoroughly as you think, after some months it appears again in the cicatrix. Do what you will, it proceeds onwards, though with extreme slowness and little pain, and in a course of years gradually affects the lymphatic glands and great organs in the cavities.

---

position by means of appropriate bandages, as it is much inclined to the left side? Is it probable the patient will require diffusible stimuli? or cinchona? He has a desire for wine.

Yours, with much esteem,

GEORGE RUSSELL.

*Lincoln, March 15th, 1837.*

P. S. The bleeding was not as I expected, but came from the side and back part of the head.

Some time after receiving the above letter, I learnt that the bad symptoms had disappeared, and that the patient was recovering.



The number of lymphatic glands which become disordered, both internal and external, is very great in some cases. They may amount to hundreds. The external glands, which are secondarily affected, are not ordinarily discoloured. It is usually the primary disease, which becomes of a livid red colour.

The duration also varies. Some of these cases going through their course much more rapidly than others. You will see a considerable difference in this respect, between the first and second I shall mention. The second having proved fatal in three years from the operation; while the first, at the end of six years, still appears distantly removed from that event.

Among such varieties of phenomena and progress, it is, I am aware, difficult to give a satisfactory idea of the peculiar characters of the fungoid lymphatic disease, and especially of the marks which distinguish it from a general scirrhus affection.

The fungoid disease of the lymphatic glands is discriminated, we should say, by the *softness* of the tumour, its tendency to *discolouration*, its *early* influence on the constitution, and the *extent* to which it affects the lymphatic system.



A lady of lymphatic temperament, the mother of many children, and not very healthy, had a tumour about the size of an egg, in the middle of the thigh; perfectly smooth; not painful; without discolouration of the skin. She had it more than a year before I saw it. As soon as the case was made known to me, an operation was recommended; and immediately performed. The tumour had the aspect of a softened gland; and as often happens, was not so regular under the skin as it appeared on the outside. It was carefully removed, the skin brought together, and the wound, which, in common cases would have united by the first intention, did not heal sooner than in a month's time. She was well for more than a year, when a small tumour was seen at the lower extremity of the cicatrix, involving the skin, as well as the parts under. It had attained about the size of the first tumour; was attended with pain, and occasional swelling of the limb below. An operation was immediately performed; every trace of disease carefully removed, and the wound healed slowly as at first.

Thus far nothing malignant could be suspected. The first tumour was obviously a diseased gland. The second I supposed to have been a gland



below the first, whose organization had become impaired by the necessary division of the absorbent vessels proceeding from it. There was nothing suspicious about it, but the adhesion to the skin.

Two years after this operation, I was desired to visit the patient again. At the seat of the old cicatrix, I found a tumour as large as a lemon; of a purplish red colour, like the appearance on a cancerous breast before ulceration. The subcutaneous cellular texture was indurated to the extent of half an inch around the tumour. The central part was soft, and might be supposed to contain pus. It was not tender; occasionally painful, and did not much impede motion. The patient's health was as good as it had been for some years.

What course was to be pursued in this case? Would extirpation be more likely to succeed, than in the two former operations? Was amputation of the limb to be relied on, where there was reason to fear a constitutional disease, and affections of the abdominal glands? Or was it best to leave the disease to nature? The course I pursued was to state the difficulties and uncertainties fully to the friends of the patient, and leave the decision to them. They came to the conclusion

to adopt no active measures at present ; and after the expiration of some months, the patient continues much the same in health, the tumour slowly increasing.

In 1835, I was requested to visit a patient affected with this disease, at New Bedford, with Dr. Reed, who has had the goodness to give me the following statement of the history of this case, and the appearances after death.

New Bedford, Aug. 8, 1836.

DEAR SIR,—Your letter was not received immediately after due, as I was out of town, and unavoidable circumstances have prevented my answering it until the present time. I shall not now be able to give you so minute a history of the case referred to as I could wish, some time having elapsed since the termination of the case, and having but few notes to assist the memory in furnishing a description.

Mr. K. had been from early life a very regular, temperate and industrious man. Previously to the last three or four years, he had been accustomed to great fatigue and labour in his business as an agriculturalist. He was predisposed to pleuritic attacks on taking cold, and often suffered severely



from this cause. He was likewise subject to severe inflammation about the neck of the bladder, attended with so much difficulty in voiding urine as to require the use of the catheter. These diseases, however, did not affect him the last years of his life. About three years before his death, I removed by the knife, a cancerous ulcer from his face, which had resisted all other remedies. The cure was perfect, no appearance of the disease having ever returned. Soon after this period his health began gradually to decline. There were no very marked symptoms of disease local or general, but a want of usual energy and an inability to perform his accustomed labours. About this time he consulted me concerning a small sub-cutaneous tumour, which he discovered on the right side of the chest, about an inch from the nipple. It was of the size of a large bean, a little tender to the touch and slightly inflamed. I directed some application, which removed the inflammation, but had no effect in diminishing the tumour. This was followed in a few weeks by the appearance of another of a similar character towards the axilla. Nearly at the same period, other tumours appeared in the inguinal region, and these were followed by others in different



parts of the abdomen, breast, and about the right shoulder. These tumours enlarged very gradually, were quite hard and unyielding, free from pain, and never showed any disposition to suppurate. Symptoms of functional derangement of the stomach and bowels began to appear, attended with loss of appetite, constipation, flatulence, &c. There was yet no pain in the abdomen, and the bowels were relieved by the mildest laxatives. About the 2d of February, 1834, I was called suddenly, and found him labouring under severe pain in the umbilical region extending to the back and loins. Leeching, succeeded by warm fomentations, and the use of pulv. ipec. comp. relieved the urgent symptoms, but the paroxysms of pain returned more or less frequently until the fatal termination. The tumours now increased in number and size, but were never painful and only slightly tender. The digestive organs began to fail in the performance of their functions, and loss of strength and emaciation followed rapidly.

About this time the abdomen became somewhat distended, was painful on pressure, and felt as if embracing parts more dense and unyielding than its natural contents. Local bleedings, and the cautious administration of mild, unirritating laxa-



tives, followed by gentle anodynes, were the means which afforded the most relief; but this was only partial and temporary. In the early stage of the disease, the pil. hydrargyri, conium, the solution mur. hyd. with the syrup. pyrol. comp, &c. were tried, and followed by the preparations of iodine. The last medicine produced no apparent effect. The hardness of the abdomen continued to increase until death, which took place about the third of May. The last days of life were attended with frequent paroxysms of intense suffering, which were but partially relieved by large doses of opium.

A post mortem examination was made in presence of Drs. Whiting, Mackie, and West. On opening the abdomen, scarcely a vestige of any thing natural presented. The abdominal viscera were completely covered with a diseased mass, having little or no resemblance to the omentum from which it originated. Some portions of it were two or three inches in thickness, and of different degrees of consistence. Some parts were quite soft, and others of a scirrhus hardness. The mesentery, pancreas, kidneys, and spleen, were so involved in a mass of tumours, that they could scarcely be separated or recognised. The



liver was nearly or quite natural in its appearance. The stomach was somewhat involved by its vicinity to this general mass of abdominal disease. The lungs were slightly adherent on one side, and had some small tumours on their external surface. The heart likewise had several tumours on its surface, similar to those found in other parts of the system. In fact, every organ seemed to partake more or less of the disease, except the liver.

I am, &c.

ALEXANDER READ.

Three weeks since, a gentleman from the country applied to me for advice in regard to a tumour on the neck. He was a stout, well-looking person, between fifty and sixty years old, and had till recently enjoyed good health. Three months since he perceived a tumour on the left side of the neck. It had a soft elastic feeling, like an abscess. Soon after, other similar tumours appeared in its vicinity, and now the whole of the lower part of the neck is filled with a mass of soft lumps extending to and under the clavicle. On the right side a similar cluster is beginning to form. There is an uneasiness in the chest, some cough and



fever. The tumours are all of a soft consistence, and are increasing rapidly.

In the case which is stated in the following letter, the symptoms of this disease were developed in a striking manner.

Upper Middletown, Oct. 29, 1833.

SIR,—I take the liberty of stating to you a case, which to me is a novel one, for the purpose of obtaining your opinion of its nature, and the proper method of treating it.

The Rev. T. L. W. of this place, some time in December last, discovered a small tumour on the left side of the neck, a little above the clavicle, and between the trapezius and mastoid muscles. It made its appearance soon after speaking in a warm, confined room, and subsequent exposure to a cold air. Fomentations were the only remedies applied, with the use of which it soon disappeared, and it appears that no more was thought of it until the latter part of July, when it re-appeared in the same situation. But on reflection, Mr. W. is convinced that for several months he has experienced an unusual debility of the left arm, with some pain about the shoulder. I first saw the tumour in August, when it was



nearly of the size of a pullet's egg, of a knotty hardness, circumscribed, descending deep between the muscles, and rising somewhat above the adjacent parts. It was not painful nor tender to the touch. A fortnight afterwards, the appearance was similar, but rather enlarged. In another fortnight, other tumours, of the size of filberts, were felt, appearing to adhere to the original one. These increased and amalgamated with the first, while on its edges others have appeared, and in the same manner disappeared, in the general enlargement of the main tumour. The small ones are tender to the touch, while the body of the tumour is quite insensible. The tumour now extends over the shoulder, dipping down under the clavicle, forwards nearly to the trachea, and up on the neck. A small detachment has lately appeared under the angle of the jaw, and one of considerable size is to be felt in the axilla. The body of the tumour is so confined by the platysma and other muscles, that, on viewing the shoulder, a general enlargement or fulness only is perceptible ; excepting that when it first made its appearance, it was of the size and shape of a small watch chrystal, with a soft feeling, as though it contained a drachm or two of synovial fluid. There has never



been any discolouration of the skin. The system did not appear to suffer from the disease, till the middle of September, when the shoulder became very painful, and loss of appetite, profuse sweats, and great muscular debility rapidly succeeded. The pain was exclusively of a dull, heavy, or aching kind, and appeared to be the principal cause of the sweating. The pain was soon very much mitigated by moderate doses of opium, viz. one grain three times per day; and is now only occasionally troublesome, and is chiefly of a lancinating kind, down the side and arm. The arm and fore-arm have been for a few days past considerably swelled and œdematous. The pulse usually ranges from 90 to 100, but is sometimes 115. He is obliged to use considerable caution in moving, as the pain is much increased in the arm and side. The treatment of the case commenced with a stimulating and anodyne liniment, iodine internally in tincture, and externally in ointment. The iodine was continued for some time in doses of twenty min. four times per day. Before he discontinued the iodine, he commenced with ext. conium and red ox. iron sufficient to form a pill. The dose was increased till twenty grains were taken daily, in three doses, when slight dizziness was



produced, and the dose has been slowly increased since to forty grains per day, without any specific effect. The conium is of the best English kind. Three or four pills, of one grain each of opium, are taken in the course of each day. The decoction of sarsaparilla, with one-eighth grain corrosive sublimate, in four doses, is taken each day. Under this treatment, the appetite is generally good, much better than it has been—with strength so that he sits up most of the time. The sweats are only occasional, and not very profuse; sleeps quietly, and feels pretty comfortable.

I am very respectfully yours,

RICHARD WARNER.

The termination of this case, and the morbid appearances, if a post mortem examination took place, I could not obtain an account of, as the patient lived at a considerable distance.

About two years since, the late Dr. Robbins requested me to see a young lady, a patient of his, whose case was attended with some obscurity. She was an only daughter, of a delicate habit, and had frequently been ill. Six months before, she began to be affected with shortness of breath, accompanied with great weakness and loss of appe-



tite. About the same time, a small glandular tumour appeared on the right side of the neck. Her pulse became quick, and she began to have head aches of an irregular character.—These symptoms continued without remarkable aggravation to the time I saw her. The tumour of the neck then had the size of an orange. The respiration was frequent and short. The headaches had terminated in drowsiness, with occasional delirium; so that at the time I saw her, she was with difficulty aroused sufficiently to answer questions. The thorax on percussion gave a flat sound on the anterior right side, and in the sternal region. On the left side, in front, the chest resounded well, and the respiration was loud. The dorsal region could not be examined, because the patient was sitting up dressed, and was moved with difficulty. There was no cough nor expectoration.—The case had some obscurity, which might perhaps have been removed by a full investigation of the physical phenomena, had this been practicable. The best notion I could form of the character of her disease, was, that there was either a great induration of the right lung, a collection of fluid, or a great tumour; and that a



physical derangement of the brain existed, consisting in an effusion of water or a tumour.

About fourteen days after this she died, and an examination was allowed. In the thorax a tumour was found, composed of diseased glands in a fungoid state, filling the middle and right lateral region. The right lung was very much compressed; and its summit filled with tubercles. The left lung was sound. Some water in the pleural cavities. In the brain, on the right side, was a fungoid tumour, nearly three inches in diameter, which you see here. When recent, it was soft, and of a red colour, as if bloody. The glands in the cavity of the abdomen were indurated, but not much enlarged.

This case and some of those preceding, show a great extent of internal glandular disease, with comparatively slight external. They render it improbable that the internal affection is always a consequence of the external; and consequently tend to show that a surgical operation would not be applicable to all such cases. In saying this, I would not have you understand that a surgical operation is not to be performed in any cases of malignant scirrhus of the lymphatic glands. When the disease is distinctly limited to an exter-



nal part, and no signs exist of a constitutional affection, an early operation is proper and necessary. Even when there is a bare probability of constitutional disease, an operation may sometimes be proper. Under these circumstances, the patient must be made to understand the nature of his case, and called on to decide for himself. But when there are distinct abdominal tumours, it is trifling with the patient, and an abuse of the influence of the practitioner, to propose or even to allow the performance of a painful and useless operation.

## SECTION VIII.

### TUMOURS OF THE COMPLICATED OR SECRETING GLANDS.

THE complex organization of these parts, and the activity of their functions, render them liable to disorder. The breast, the testis, the salivary glands, are among the parts which most frequently become the subject of surgical treatment and surgical operations. The forms of disease in these different organs are much varied by the texture of each organ. The most common malignant affections of the breast differ from those, which most commonly occur in the testis. Carcinoma, the most frequent disease of the breast, is rare in the testis; while the fungoid disease is rare in the former and frequent in the latter. It follows that we cannot describe the diseases of these different



organs under the same head ; they must be noticed separately, each having its peculiar tendencies.

#### TUMOURS OF THE BREAST.

ALL tumours of this organ are in danger of being considered to be cancers, and treated accordingly. But perhaps it would be safe to say that the greater number of them are not cancerous. Yet it must be allowed that every tumour in the breast must be esteemed suspicious, and worthy of careful attention. The kinds of tumours in this organ are so many, that I despair of laying before you such rules for distinguishing them, as may be satisfactory. The knowledge of these affections has been greatly elucidated by Sir Astley Cooper's work on diseases of this organ, and by the treatise of Mr. Travers on malignant affections, in the *Medico-chirurgical Transactions*.

Sir Astley Cooper divides the diseases of the breast into malignant and non-malignant. Of the former, he has already treated—the latter he reserves for a future work. The species of tumours he describes are the following. 1. The hydatid disease of the breast. 2. The chronic mammary

tumour. 3. The cartilaginous and osseous tumour. 4. The adipose tumour. 5. The large pendulous breast. 6. The scrofulous swelling. 7. The irritable tumour. I shall speak of these affections so far as they have come within my cognizance.

1. HYDATID TUMOUR OF THE BREAST. Three distinct kinds have been noticed by Sir Astley Cooper. That which is most common occurs in females of middle age. It begins with a hardness in one part of the breast, and increases sometimes slowly, but often with great rapidity, till it attains a large size. The cases I have seen were not accompanied with great pain; and were troublesome principally from the excessive distention of the part. As it increases in size, it assumes a knotted appearance and feeling, as if it were composed of a number of separate bodies, which in fact it is. This tumour sometimes suppurates, discharges and shrinks; but the general tendency is to attain a great size. Although not of a malignant character, it is only to be cured by extirpation; and when all the hydatids are removed, the disease does not re-appear.

In June, 1835, I was requested by Dr. Jeffries, to see a patient of his, who had applied to him



about six months before. The lady had enjoyed perfect health, and discovered a tumour in the breast accidentally, and without being led to it by pain. It had the size of an egg when first noticed, but soon increased considerably. By the application of leeches, its size was so much diminished, that he thought it unnecessary to visit the patient longer; and having requested her to inform him if it increased, he left her with directions how to manage. After an interval of four months, he was again consulted, and found the disease so much increased, that he immediately desired me to examine the case. On visiting the patient, I found her looking well in health. The tumour being exposed, was found to be of enormous size; not painful; not discoloured. It occupied the whole breast, and appeared to be composed of a collection of globular bodies, giving a knotted, very irregular appearance to the organ. None of the lumps were tender. Some of them had a soft elastic feeling, as if containing a fluid. The whole breast was moveable and pendulous. The axillary glands not enlarged.—Being satisfied the tumour was composed of hydatids, I advised an operation, and assured the patient of its being successful in the eradication of the disease. This assurance gave



her great comfort, as she had apprehended a different result. The operation was performed immediately. An oval portion of the skin was included, and the whole tumour dissected out in a few minutes, leaving a layer of cellular texture to protect the pectoral muscle. The bleeding was considerable for a short time, but not long enough to require ligatures. The skin being brought over, united by the first intention; the patient recovered speedily, and has been in perfect health since.

You here see this tumour. On the suggestion of Dr. Jeffries, it was weighed after the operation; and was found to have between twelve and thirteen pounds weight. It consists of globular hydatids and a connecting medium of coagulated lymph. Some of the large globes contain a glairy fluid. They are of various sizes, from two inches diameter down to the size of a small shot. The cysts are of unequal thickness, some being composed of a single layer, others of two or three. The solid matter in the cyst has a considerable degree of firmness.

INCIPIENT HYDATIDAL TUMOUR OF THE BREAST.  
Miss ———, in good health, accidentally discovered a small induration in the left breast, in May 1836. It increased considerably from that



time to August, when I saw it. The breast was small and flat; and at the first examination scarcely seemed altered from the natural state, but on comparing it with the other was found to be decidedly hardened and somewhat enlarged. A month after I saw it again. It had increased considerably at one part, without pain, although she had a slight uneasiness. There was no adhesion to the skin; no discolouration, nor other change in the integuments, excepting that the nipple was somewhat enlarged and the surrounding parts seemed to rise around it, giving the aspect of its being drawn in, although in fact it was of greater dimensions than natural. The patient being of an age at which the scirrhus-cancerous tumour might appear, I should have considered it as this disease, but for the total absence of pain and the rapidity of increase. It could not be a chronic mammary tumour, because it was not moveable, occupied the whole breast and had increased faster than that affection usually does. There was no reason to consider it scrofulous. What might it be? I was unable to decide. A practical view of the case was not so obscure. It might prove a carcinoma, therefore it was necessary to remove it. The patient herself felt



satisfied of this, and it was removed without delay. The whole of the gland was amputated, leaving a covering of cellular texture over the pectoral muscle. The wound healed by the first intention and the patient was well in a few days.

On handling the tumour after its extirpation it was found much firmer than the natural gland: but not scirrhus. The anterior surface presenting nothing remarkable at first view, I turned to the posterior face, and then perceived the soft tumour, whose cavity you here notice, about the size of a nutmeg, and filled with a reddish water. Near to this, were smaller cysts, some of them with opaque, but many with transparent sacs of a yellowish colour and containing a yellow fluid, which gave them this appearance. Other little eminences were seen covering the whole posterior surface, most of them not larger than the head of a pin and not containing a visible fluid. Again examining the anterior face, I perceived on a slight section that the gland was filled with these little bodies, not larger than a pin's head. The glandular texture appeared to be buried in an adventitious white substance, which obscured its natural aspect and seemed to be a deposit be-



tween its lobes, filled with the small bodies above mentioned.

The tumour then was constituted by the species of hydatid, called by Sir Astley Cooper, cellulous hydatid, mostly in an incipient state. The sudden increase of swelling was caused by the formation of fluid in the large cyst, which constituted a considerable part of the tumour. Had the disease been left to itself, it would soon have attained a great size.

2. CHRONIC MAMMARY TUMOUR. Sir Astley Cooper gives it this name on account of the length of time it continues, and its disposition to remain in a stationary condition. This kind of tumour is of a rounded form; moveable under the skin; not penetrating the substance of the breast; not tender; and generally not painful. There is no adhesion to the skin: no redness nor appearance of a disposition to ulceration. The most remarkable circumstance regarding it is, that it occurs in young and healthy females.

The preparation you see here is a specimen of this disease. It possesses, as you notice, the lobulated appearance described by Sir Astley Cooper. This is about an inch and a half in



diameter; but they are often found larger. It was taken from a young lady of twenty, remarkable for her beauty and vigorous health. She noticed it accidentally a year before I saw it. Since then it had increased but little, was rarely painful, and had no tenderness. She expected and wished to have it removed; but knowing it was not malignant, I was at first unwilling to operate on it. Considering, however, that she had come from a distance, that of consequence I should not be able to observe its progress; and noticing the anxiety she felt about it, I determined to remove it. This was readily effected by an incision through the skin, and the dissection of a firm membranous substance, which connected it with the surrounding parts. The wound united by the first intention. Four years after, I had the pleasure of seeing this lady, and was informed that she was married, had an infant which she nursed from this breast as well as the other, and that there was no trace of remaining disease.

Miss N., thirty-five years old, dyspeptic. Four years ago, noticed a lump in the right breast, which has increased slowly and regularly. The tumour is very moveable, neither tender nor painful, though it affects the motions of the arm. It



is about the size of an egg. Has an irregular and knotted appearance, and is not very hard. The skin is healthy, and glides over the tumour; and the axillary glands are sound.

The tumour being large in proportion to the breast, it was necessary to remove the whole gland. The operation was performed by Dr. Mason Warren, on the 30th of Sept. 1836. The wound healed in a great measure by the first intention, and the patient soon went home, in excellent spirits and good health.

This tumour, which is before you, is the most beautiful specimen of chronic mammary tumour I have seen. On cutting the skin of the breast, a white fibrous sac appeared. This being opened, displayed a perfectly white body, having exactly the appearance of a small cauliflower. The sac readily peeled off from the surface and sides of the tumour, and showed it to have a posterior attachment by a pedicle, which penetrated the sac and connected itself with the substance of the breast. This specimen affords a fine example of the pedunculated and encysted structure so well described by Dr. Hodgkin. You may see a regular sac or cyst, perforated as it were at one point, where the tumour is connected with the substance



of the breast; entering the cyst at this point, it expands itself in this beautiful white cauliflower excrescence. The gland itself seems healthy and small; its nourishment has gone to supply the new growth.

The moveableness which characterises this tumour, is, you see, readily explained by the looseness of the connection between the skin and sac; and the independence which this latter part gives it, from the substance of the breast.

A tumour of the kind you see here, although it has no malignity, and could not terminate in a cancerous affection, must be, as this has been, a source of great anxiety to the patient. It might attain a large size, and being in some degree insulated, could not be absorbed.

3. CARTILAGINOUS AND OSSEOUS TUMOUR OF THE BREAST. This form of mammary disease has not come within my observation as a distinct disease; but I have seen two or three instances of cartilaginous formation, and one of calcareous effusion in the scirrhus breast. That which I show you, was taken from a patient forty-five years of age. She had perceived a swelling in the breast two years before, which had slowly increased; without much pain, and without external inflam-



mation. I took it to be a scirrhus of uncommon hardness; advised its removal; and on examining the tumour, there appeared three separate nuclei of calcareous matter, each about the size of a hazle nut, lodged in the midst of a scirrhus mass. The patient recovered, and I did not hear of her afterwards.

4. SCROFULOUS TUMOUR OF THE BREAST.—Scrofulous swelling of the breast has been thought to be a common disease. Sir Astley Cooper, whose opportunities for determining this point, probably exceed those of any living individual, informs us he has rarely met with it. The disease presents itself in young females, of slender shape and weak constitution. In form it is flattened rather than rounded; smooth on the surface, but irregular at the edges. It is free from tenderness, and also from pain, unless it suppurates. The skin is not discoloured, and does not adhere to the tumour. It is of slow growth; and if the patient has good health, and is able to keep up her exercise, it disappears after some time. In other cases, it comes on suddenly, inflames, suppurates, and forms a protracted abscess. This not unfrequently terminates in a fistulous passage extending deeply into the gland; and I have known



it penetrate through the intercostal muscles, pleura and lungs, and form a communication with the air tubes, without great inconvenience to the patient.

The scrofulous tumour of the breast is not a subject for surgical operation. It depends on the state of the constitution, and is to be treated principally by constitutional remedies. The open air, regular exercise, sea-water bathing, careful regimen, and attention to all the necessary evacuations, compose the constitutional treatment. The local applications are leeches, sparingly used, warm sea-weed poultice, a warm plaster, such as the plaster of the red oxide of iron, with some aromatic. Preparations of iodine I have not seen distinctly successful.

The following cases will give a more satisfactory view of the history and treatment of this affection, than a general description. Abigail Baker, aged 17, of pale complexion, thin skin, came to me in July, 1833, from Maine, for the purpose of having a tumour of the breast removed. She had perceived it about seven months before, during which it had increased to the size of about three inches diameter. It was flat, smooth on its surface, not well defined at the edges, not tender, nor discoloured. Her health had been good,



though she was not robust.—On the first examination I was uncertain whether the tumour would prove to be of a scrofulous character, or a chronic mammary tumour. It wanted the rounded form and moveableness of the latter, and I therefore was inclined to consider it scrofulous. I advised against an operation, and recommended her going to the Massachusetts General Hospital, where she could be watched and carefully treated.

She accordingly entered on the 30th of July, 1833; and was put on a moderate regimen, took small doses of sulphate of magnesia on alternate days, and had leeches applied to the tumour occasionally. After she had been there a short time, she exhibited a disposition to febrile attacks, at first slight, gradually increasing in severity, and accompanied with some pain in the breast. At length this organ began to inflame; the pain, heat, redness and swelling became considerable. She had severe chills, finally a distinct softening, and on the 27th of August an abscess opened and discharged most copiously. She now fell into a state of great weakness, so that I had some apprehensions she might sink under it. During the month of September the suppuration diminished, her appetite and strength improved till the 10th of



October, when a new abscess formed with the same symptoms as at first. This being opened, she was greatly relieved; and recovered so rapidly as to request her discharge from the Hospital on the 26th of October. During the latter part of her time, the constitutional treatment consisted in the regulation of the digestive organs; the local, in warm, moist applications, and stimulating ointment.

In April, 1835, that is, six months after her discharge, this patient came to the Hospital again, for a tumour in the right breast, similar to that she had before had in the left. It appeared soon after the discharge from the left breast ceased. It occupied the inner and upper part of the breast; was perfectly smooth and without any tuberculated appearance; was tender to the touch and often painful. After entering the Hospital she had frequent attacks of fever, accompanied with a general swelling of the breast and threatening of suppuration. No suppuration took place however. In the latter part of May she slipped on the floor of the apartment and hurt her ankle. This was followed by a severe and threatening inflammation. After three weeks this subsided and she left the Hospital well on the 30th of June. The tumour



in the right breast was dissipated; the left was sound; and the ankle well.

During her last residence in the Hospital, she took a small dose of sulphate of magnesia every other day. For five or six weeks the tincture of iodine, in doses of from fifteen to fifty drops, three times a day. This last dose brought on nausea and was reduced to thirty, which she continued fifteen days. When the breast was attacked with acute inflammation, leeches were used, the part was bathed with tepid sea-water, and sea-water poultices were applied.

The history of this case shows it to be a truly scrofulous affection. The constitution of the patient; the suppuration of the left breast; the subsequent induration of the right; the sudden and severe affection of the ankle, from a slight injury; and finally the disappearance of the disease, serve to prove the existence of a scrofulous inflammation. How far any single remedy might have influenced the cure, I should not be ready to say. Probably the sulphate of magnesia deserves the credit of having done more than the others. During the greater part of her residence in the Hospital, she was not in a state to bear the salt water bath.



The following case will give a view of the course of fistulous cavities so common in these diseases. A young lady who had previously enjoyed excellent health, though some members of her family were decidedly scrofulous, discovered a tumour on the inside of the left breast, about the size of a small egg. At first it was not painful; but after the lapse of three months, it inflamed and suppurated. The pus did not make its way through the skin, but began to be absorbed, so as to take off the tension of the skin. The skin was then punctured, and a considerable discharge of thick flocculent pus followed. This continued for a number of weeks; and the larger cavity contracting, formed a fistulous tube between two and three inches long. I then began the use of sponge tent, introduced daily to dilate the external part of the wound; and injections of nitrate of silver, giving internally the sulphate of quinine. The fistula showing no disposition to heal, after two or three months, I dilated the external part of the tube by the knife, but finding the internal extremity running quite through the breast into the cellular substance between it and the pectoral muscle, I could not with propriety reach the bottom of the fistula. The patient, in the mean



while, retained all the healthy functions ; was not confined to the house ; but used much exercise, and regularly followed the sea-water bath. Owing to some imprudent exposure she was seized with chills, pains in all the limbs, and fever ; when these symptoms subsided she discovered a tumour in the bend of the elbow, under the biceps muscle. This was the size of an olive, quite firm, not tender. It caused a remarkable disability of the use of the arm, from its adhesion to the biceps muscle.

The treatment pursued was the following :  
1. Entire rest of the limb. 2. Laxative solution of salts every third day. 3. Thirty drops of tinct. sulphate of quinine, three times a day. 4. A vegetable regimen. The solid food not to exceed twelve ounces a day ; and the liquid equally restricted. 5. To the affected part apply three leeches every third day for six weeks ; afterwards a blister of two and a half inches near the tumour. This course was continued for six months. At one period a threatening cough appeared. At length, however, the cough subsided. The tumour was absorbed. The fistulous opening healed, and the remains of the mammary tumour also disappeared. The arm was stiff for a long time ;



but by a residence of some months on the sea coast, with dry frictions to the part, every symptom of local and general weakness was removed, and the patient's health entirely confirmed.

This case continued a long time; sometimes had an unfavourable and even alarming aspect; was discouraging to the patient and her friends and very troublesome to me. I had to contend with the outcries of ruining her health by confinement and dieting, in a very uncomfortable way; and had I not felt much interest in the patient, and a perfect confidence that no other course would succeed, should have quitted her.

In regard to this case, I have given details which may seem minute, but which I hope you will find to be of practical use.

A young lady, nineteen years of age, of the fairest possible skin and sandy hair, consulted me for an irregular tumour of the breast, which it was expected would be removed. Her mother informed me she had been a great invalid, having an unusual susceptibility of colds, frequent long continued coughs, and occasional swellings of the lymphatic glands in the neck. Their minds were much relieved by the information, that it would not be necessary to operate on this tumour. The



patient was recommended to ride on horseback, keep in the open air, use sea-water bathing, rub the skin with a coarse cloth twice a day, apply two leeches weekly to the tumour. This treatment has been continued seven months. The patient's health is greatly improved and the tumour entirely dissipated.

An interesting case of scrofulous tumour in the vicinity of the breast, with fistulous opening into the lungs, in a patient of Dr. Pierson's, will be best introduced here.

Salem, Oct. 3, 1836.

MY DEAR SIR,—After so long a delay in replying to your inquiries, I am enabled to state to you the particulars of Miss ——'s case. She applied to me first in 1831, September 1st, with a somewhat painful rising on the sternum, just beneath the articulation of the clavicle, which had been several weeks in reaching its size, about two inches in length by one in breadth. The application of leeches, poultices, &c., had no effect to disperse it, and on the 1st of October, the tumour having become softened, was opened, and a moderate quantity of thin pus, with some curdy shreds was discharged. There was a relief of the painful and inflammatory symptoms after the dis-



charge, but the interior of the cavity did not heal and a fistulous opening was established. On the 17th of January, 1832, I dilated the opening in two directions as the sinus was found to be bifurcated at the top. The lower portion of the sinus healed, while the upper continued to discharge. In this state she visited you on the 7th of February, 1832. It was at this time she commenced using injections of hydriodate of potass, and after they had been thrown into the sinus three or four times, she found that an effort to cough was occasioned, and a portion of the fluid was ejected from the larynx. In order to be perfectly satisfied of this fact I directed her to use an injection of wormwood, the taste of which she instantly perceived on coughing it up.—There was a gradual diminution of the discharge till the sinus appeared to be very narrow, but still there was constantly a degree of moisture exuding from a minute opening, through which a probe would pass till it was stopped against the cartilage of the second rib on the right side. This continued to be the condition of it till the month of August, after which I was absent from the country, but the same treatment was continued for several months. During a portion of the treatment the external orifice of



the sinus was dilated with sponge, by which means a more complete application of the hydriodate of potass was effected. During this period the sinus completely healed. Her general health was at times impaired, and some pulmonary symptoms caused a degree of anxiety, but nothing of a very serious nature occurred, and the only remedies used, were a proper attention to diet, exercise, and the functions of the alimentary canal.

You inquire about the present condition of the part. I saw Miss — yesterday, which is the first opportunity I have had, since I received your letter, of examining the cicatrix. The skin is perfectly healed, and not in the least tender or painful. At the upper part it has grown firmly to the sternum, in one small point, as if a stitch had been passed through and drawn down to the bone. She occasionally feels some sensations of stricture within the chest.

I once saw a remarkable case, in which there was a communication existing between a sinus over the sternum and the air passages. I have given an account of the pathological appearances of this subject, in the Medical Magazine, in the first number of the third volume, page 28.

A. L. PIERSON.



The above cases have been taken without special selection from a great number of those I consider to be instances of scrofulous breast. Perhaps some of them may be thought to be cases of chronic mammary abscess. They occurred, however, in scrofulous constitutions, and had the lingering progress of scrofulous affections. Some of them were connected with derangement of the periodical evacuation, others not. I will now mention another, of more brief duration, which may be called either scrofulous tumour or mammary abscess. The patient was nineteen years old, with a thin, white, freckled skin, sandy hair and blue eyes, unmarried. I saw her in March, 1837. Six weeks before that time, she perceived a tumour in the left breast, without any local injury. At the time, she had not been regular for two months, and being a nursery maid, she might have received a slight shock, or might have wet her clothes in doing some kind of washing. The tumour was of an irregular form, occupying about half the substance of the breast. Soon after its appearance she was seized with chills, headache, and other marks of fever, and the breast swelled, became red and painful, with a lameness in the corresponding arm. The swelling suppura-



ted after about three weeks, and opened at two points below the nipple. The discharge of course relieved her. She remained under my observation five weeks after suppuration, during which time the remains of the tumour were dissipated.

It is scarcely necessary perhaps to mention to you that, during the inflammatory stage, leeches and warm moist applications were made to the part, and a proper attention was paid to evacuation of the alimentary canal. When the inflammatory symptoms subsided, she took iodine, and had iodine ointment applied to the breast, of the strength of one scruple of iodine to an ounce of simple ointment.

5. IRRITABLE TUMOUR OF THE BREAST. This is a small, hard, sometimes knotted tumour of adult females, both married and unmarried. Its distinguishing characters are, its tenderness and disposition to inflame and become painful at intervals, which are sometimes regular.

The course of this complaint may be explained by the following case. A young married lady, with a child seven months old, came to me from the country, with a tumour in the right breast, which she had been advised to have removed. She was a delicate person, twenty-two years of



age ; had formerly been under my care for two or three years, for an affection of the retina, which deprived her of the use of her eyes ; but from this she had wholly recovered. At the end of a month after her confinement, she had severe inflammation of the breast, without suppuration, which terminated in leaving a small, hard, tender tumour. At the time I saw her, the whole breast was swelled and very painful ; with quite a severe constitutional disturbance ; quick pulse ; great heat ; pain in the head ; nausea ; loss of appetite. Leeches, with warm fomentations and purgatives being applied, the swelling of the breast disappeared on the fifth day, and left the small hard tumour as before. She informed me that these paroxysms occurred about once a month, though not regularly.—The course advised was to employ leeches and warm fomentations of stramonium in the paroxysms, and in the intervals, to take the sulphate of iron, not exceeding a grain three times a day, and to continue nursing her child. In two months after these directions were given, she sent me word from the country, that she had only one paroxysm after I saw her ; that the tumour had disappeared, and both she and her child were in excellent health.



In this preparation you have an opportunity of observing the anatomical structure in this disease. The tumour is of an oblong form, about two inches in length and an inch and a half through. On cutting it open, you see it exhibits a remarkable redness, almost as much as if it had been injected; while the surrounding cellular texture is colourless. The tumour seems to be composed of cellular texture in a condensed state, containing many small blood vessels. It was taken from a young lady, about twenty years old, who perfectly recovered from the operation, and has remained well since.

6. ADIPOSE TUMOUR OF THE BREAST. This consists in an increased growth of the fatty substance which naturally constitutes a part of the breast. The size it attains is sometimes very great. Sir Astley Cooper mentions one which weighed fourteen pounds. This complaint is not attended with pain, and is only to be considered the subject of an operation when its size becomes great.

A lady belonging to Worcester in this State, consulted me, in the summer of 1834, for an enlargement of the left breast. She was about twenty-eight years old; married. Had noticed



the disease a few months before ; and it had grown rapidly. There was no acute pain in it. On examining the breast, I found it very much enlarged ; smooth and regular on the surface ; not tender ; no affection of the lymphatic glands. The skin covering it was, at the time I saw it, very red and hot ; and the general circulation was quickened. She informed me that she had occasional paroxysms of inflammation, accompanied with fever. Otherwise her health was good.

Never having seen a case like this, I was at a loss how to proceed with it ; but considering its disposition to increase, and its angry appearance when I saw it, I thought the proper way of proceeding would be to have it removed. She returned home ; had the proposed operation performed by Drs. Green and Heywood, of Worcester ; and on cutting into the tumour after removal, it was found that there was no change in its organization ; but only an increased growth of the adipose substance. The tumour weighed eight pounds. There has been no return in that breast, but Dr. Green informs me there is a tendency to a similar enlargement in the other. This may perhaps be checked by pressure and an abstemious regimen.



## MALIGNANT DISEASES OF THE BREAST.

Sir Astley Cooper has promised us a second part of his work on diseases of the breast, to contain an account of its malignant affections. In the Medico-chirurgical Transactions, we find a number of valuable papers by Mr. Travers, on malignant diseases, in which are contained an account of malignant tumours of the breast, to which I would refer you for the essential characters of these affections, their pathology and anatomy. My principal object is to give you some aid in distinguishing these from other diseases.

The malignant diseases of the breast are of two kinds; the FUNGOID and the CARCINOMATOUS. The former is a rare affection of this organ, the latter, as is well known, a very frequent one.

FUNGOIDES, FUNGUS HÆMATODES, CEREBRAL OR ENCEPHALOID TUMOUR, OR SOFT CANCER, is a disease which may appear in various parts of the body; the testis, the eye, the maxillary cavity, are particularly liable to its attacks. Wherever it may occur, it is usually dependent on a constitutional cause, and is a local symptom of constitutional disease.



In the mamma it is not often seen. It is a disease of early life, and of a scrofulous habit. It begins with a soft elastic tumour, which increases rapidly; approaches the surface of the breast; seems to point like an abscess; but on being opened discharges a thin, bloody fluid. A fungus shoots out from the wound, which sometimes bleeds. The patient's health becomes impaired; signs of affection of the lungs appear; sometimes the abdomen swells; the limbs become œdematous, and the patient dies with a general dropsy. The disease is constitutional and malignant; of course it is incurable in any stage.

The disease with which the fungoid tumour of the breast is most likely to be confounded is the hydatidal tumour. Mr. Travers informs us how to distinguish them. The fungoid tumour is often preceded and always attended with constitutional disturbance. In which, as we have before seen, it differs from the hydatidal tumour. The fungoid tumour appears to be composed of two or three large masses, more or less rounded. The hydatidal presents a number of pretty regular eminences of a globular form. In the former, the superficial veins are conspicuously enlarged, in the latter not. The fungoid tumour adheres to the pectoral



muscle, the hydatidal is unattached and pendulous.

In April, 1823, a young woman, 16 years of age, whose parents were English emigrants, came to me with a tumour in the left breast, between two and three inches in diameter. She discovered it two months before, and since then it had increased considerably. To the touch it was elastic. It had some tenderness, and was occasionally painful. The skin was not discoloured. The patient had black eyes and dark hair; a good colour; and the appearance of health. She had experienced however some glandular swellings, and was considered by her mother to be a weak, delicate person. I was struck with the quickness of her pulse, and attributed it to mental disturbance. On repeated observations, however, this symptom presented itself uniformly. At first, I advised only constitutional remedies, and for a short time carefully watched the developement of the disease. This was not slow in occurring. The tumour increased, and assumed an irregular appearance. The cutaneous veins became conspicuous. A soft and a somewhat prominent spot appeared in the skin.—Believing that if any thing in the way of cure was to be effected, it must be by a surgical



operation, speedily performed, I advised this course; at the same time giving notice to the mother that its success was uncertain. The operation was agreed to. A tentative incision was made at the prominent part, and evacuated a large quantity of bloody serum. The whole tumour was then extirpated; though not without difficulty, from its being confounded with the parts about it. The bleeding was considerable, but not alarming. On examining the morbid mass, it was found to consist of a red, soft, frangible matter, containing a sac in the midst of the large original tumour, and smaller sacs in the recently formed substance. The skin being brought together, united in a great measure by the adhesive inflammation. Yet there was no healthy pus formed; but a red coloured ichor was discharged from the wound. In three months after this operation, a fungous substance began to protrude from the wound. The patient was affected with difficult respiration, cough and fever. The abdomen became tumid. Under a constant and rapid increase of these symptoms, she died between four and five months after the operation.

On examining the body, the thorax was found to be half filled with a tumour, similar in its texture



to the diseased breast. Another very large fungoid tumour was found in the upper part of the abdominal cavity. Both of them were ascertained to consist of diseased glands. The first of the bronchial, and the latter of the mesenteric.

CARCINOMA, OR SCIRRHOUS CANCER OF THE  
BREAST.

Carcinoma and cancer, one derived from the Greek, and the other from the Latin language, mean the same thing. They are both taken from a supposed resemblance in the external appearance of the cutaneous blood vessels in this disease to the claws of a crab. The adjective scirrhus, has been added by some authors to cancer, on account of the hardened state of the breast, which state is not a necessary accompaniment of cancer generally.

Carcinoma, or scirrhus cancer of the breast, usually occurs between the ages of forty and fifty, the period when a change is produced in the system, by the cessation of the monthly evacuation. But I have seen it often, at the age of thirty-five, and sometimes it has appeared after sixty.

Besides the pre-disposing causes just alluded to, we find in a number of instances that some of the patient's relations of the first or second preceding generation have been affected with carcinoma. The kind of constitution which disposes to it is not well known. Whether it appears most frequently in fat or thin persons, in those who have lived sparingly or freely, I am not able to say decisively. My impression is that I have seen a greater number of occurrences in persons who have lived luxuriously than in those of abstemious habits. Among the poorest class, the number is, in my experience, small.

The disease may often be traced to a blow, as the exciting cause. The induration remaining from a mammary abscess during lactation, and also from a concretion brought on by inability to nurse from one breast, seems sometimes to give it origin.

In most cases, the discovery of the tumour is accidental. It may exist a long time without pain; although this symptom does occasionally call the attention of the patient to it, at an early period. The tumour, first perceived, is a hard, irregular lump, varying in size, from that of a nut, to a mass involving the whole organ. Its



limits are not nicely defined. Buried as it is in the cellular texture of the organ, which is to some extent indurated in the vicinity of the tumour, we cannot expect to define its limits very exactly.

In its early stage the tumour is in some degree moveable; that is, it moves with the portion of the gland in which it is situated, but does not move in that portion, like the chronic mammary tumour. As the disease increases, it contracts adhesions with the pectoral muscle under it, and with the skin on its surface, and then becomes fixed. These adhesions produced a wrinkling or puckering of the skin, characteristic of carcinomatous breast. The adhesions to the lactiferous ducts, produce a drawing in, and sometimes a distortion of the nipple.

In its early stage, it is not sensitive to the touch, nor is it always painful. In some instances, there are indeed darting and burning pains; but these are not of invariable occurrence, so that we cannot, from their absence, infer that the disease is not malignant. As the diseased growth increases and presses on the surrounding parts, the pain increases and may become severe; though I am inclined to believe it is not so urgent and distressing as seems to be expected from these cases. Certainly I have



seen many instances of extensive disease without violent pain. In such, the scirrhus substance compresses, and interrupts the function of the nerves, in the interior of the tumour. The pain is greater when the skin has become affected by the cancerous inflammation.

Before external ulceration takes place, the glands in the axilla commonly enlarge, from the extension of the diseased action along the absorbent vessels, or along the cellular processes which shoot from the scirrhus into the arm-pit.

Ulceration of the skin is preceded by an elevation of perhaps an inch in diameter, with a softening, like that from a contained fluid. In fact, it is constituted by a cyst containing a bloody ichor, but no pus. This should never be opened by the lancet, as the pain is greater afterwards.

The elevated and softened part undergoes a change from the natural colour of the skin to a livid red.

When ulceration has taken place, a badly formed, offensive pus is discharged, the edges of the ulcer are of a livid red, peculiarly hard, and are turned out. Ulceration proceeds very slowly; and when the disease has extended its ravages to the great internal organs, the ulcer is often ar-



rested, and makes no further progress, secretes but little of its peculiar pus, and seems as if it had partially lost its vitality.

In the mean time, the organs in the cavities of the thorax and abdomen are attacked. When one or both lungs are affected, the patient has cough from inflammation of the mucous membrane. She has pains in the chest and side, from inflammation of the pleura, and the formation of tubercles in this membrane; and difficult respiration, from effusion of water, and from a spasmodic action of the muscular fibres of the bronchial tubes.

In the abdomen, the pains occur from the participation of the arteries in the morbid action; from the formation of tubercles in the mesentery, and compression of the nervous plexuses in their vicinity; from scirrhus of the liver, and tubercles in and upon this organ; from scirrhus of the stomach; and finally, from the pressure of water copiously effused into this cavity. These symptoms constitute the most distressing effects of the disease, and far overbalance those from the local ulcer.

To describe all the consequences of this affection, would require more time than I can here with propriety devote to the description. The hectic



fever, the loss of appetite and dyspeptic troubles, the fragility of the bones, I can barely name.

Examination of the scirrhus tumour, after being taken from the breast, presents different appearances in different subjects and different stages. When I have examined a specimen of small growth, and at an early period of its existence, proceeding from the surface inwards, and scraping away the fat of the breast, a number of white processes are seen radiated from the central nucleus. These at first seem to be mere cords, but on observing further, they proved to be membranous prolongations from the central nucleus to various parts of the breast. Coming to the nucleus itself, this is found to be hard and irregular, and requiring an incision. Cutting through this hard body, we find it grows more firm as we approach its central point, where its hardness is very great. On examining the section thus made, we find the circumference of the nucleus constituted by a membrane or cyst, which has different degrees of distinctness, and disappears at one part where its scirrhus substance is continuous with that of the breast. The substance within the cyst is composed of granulated bodies intermixed with a white mass, of a fibrous aspect



and radiated direction. In some instances, the colour of the contents of the cyst is dark. The hard nucleus after a time softens gradually to the consistence of a paste. An absorption of a part of it takes place, and in the cavity thus formed there is a fluid of variable colour, either reddish, purple, or black. The nucleus itself I have seen of a black colour, and forming a melanosis.

Such are the most common and distinctly marked appearances presented in the early stage. There are various other morbid phenomena in this disease. It is not rare to find the whole breast involved in a scirrhus mass ; the natural aspect of the gland, and even of the cellular texture, being lost and buried in a white scirrhus substance. This is not merely an advanced stage ; it occurs at an early period in particular instances, as in the case of Elkins, to be described hereafter.

Dr. Hodgkin has traced certain forms of tubercle to a cyst, which generates within itself other cysts, and so on till a mass is formed ; and he seems disposed to consider carcinoma of the breast as originating in this way. In most cases we can in fact detect a cyst, or the remains of a cyst, open at one part, through which opening a pedunculated structure grows out from the cyst into the



substance of the breast. This will give you some idea of his views, though I should not wish to be thought to have done them justice in so few words.

Mr. Carmichael, of Dublin, is of opinion that carcinoma is an entozoary formation. It consists of three parts: first, a cyst; second, a softened substance within the cyst—and these two constitute a parasitical animal; third, the scirrhous or cartilaginous formation, which is a barrier thrown up by nature against the further progress of the parasite.

Tubercle and fungoides he also considers to be entozoa, or parasitical animals. Tubercle in the lungs is not, he thinks, pernicious, while it retains its vitality; but when it dies, it becomes a foreign body, and causes irritation and ulceration.

According to this doctrine, there are four species of entozoa. 1. Tubercle in the lungs. 2. Tubercle in the abdominal organs. 3. Fungoides. 4. Cancer.

The limited condition of the disease in its early stage, is a fact which affords some encouragement to hope success from extirpation at that period; and may serve in a measure to balance the many unfavourable circumstances, both pathological and practical, which weigh on the other side.



Many successful operations, in cases of undoubted cancer, I have certainly witnessed. Numbers of my patients, operated on ten, fifteen, and twenty years ago, are still living in health, to give their testimony to this statement.

The marks by which carcinoma may be distinguished from other mammary affections, will be noticed after presenting to your attention such facts as are fitted to give practical notions of the disease. Before mentioning these, I will state that Mr. Travers has distinguished two species; one he calls *granulated*, the other *spicular*. The granulated tumour is most common in fat women. It is of a rounded form, moderately hard, occupies the axillary part of the breast, and is not commonly attended with enlargement of the lymphatic glands. The spicular tumour occurs in thin subjects, is of stony hardness, occupies a principal part of the breast, is seated in or among the milk ducts, and is more malignant in its character, and more rapid in its course than the other.

You see here a considerable number and variety of preparations, illustrative of the different appearances of this affection. The first I present to you includes the whole breast, which was removed from a lady forty-two years of age, of good health,



the mother of a number of children. Three months before the operation, she discovered a lump in the axillary half of the breast, touching its circumference. In that space of time it had increased to the size of a common egg. She had not felt much pain or tenderness in it. At the time of the operation, the appearance was such as you see in this preparation, which includes the mammary gland and an oval portion of skin with the nipple. The nipple is fair and not drawn in. The skin is also free from discolouration, and moveable on the surface of the breast, excepting at the axillary portion, where it adheres to the tumour within it, and is not moveable. The tumour is inordinately hard, and of a rounded form. Turning the preparation, so as to view the breast on the internal or pectoral surface, you notice the intermixture of the soft yellow adipose substance with the firm white texture of the gland. On scraping away the adipose matter covering the hard lump, you are gradually and insensibly introduced into the substance of the scirrhus. As the adipose matter is thus removed, you perceive it to be contained in white membranous prolongations, springing from the lump and extending in every direction. Some of the



membranous productions are long, to the extent of two or three inches. The nucleus of the tumour is quite hard, of a white colour and of a granulated texture. At some distance from the hard part, about the centre of the breast, under the nipple, in the midst of the milk ducts, you see a cylindrical cavity, an inch long, and a line in diameter, which contained a black fluid when I first examined the part. This was evacuated on opening the tube. This tube is formed by a cyst; and although not surrounded by any hard matter, was probably an incipient state of disease in this part, and led me to rejoice in having removed the whole breast, instead of taking only the scirrhus portion.

The patient recovered favourably, and continues well, at the end of a year.

The following case presents a history of the course of this disease, and of the appearances after death.

Sept. 1833. Mrs. —, a lady forty-two years of age, discovered a tumour in the right breast, six months since. She is rather fat and florid, with a clear, healthy looking skin; is married; has no children; regular in the catamenial evacuation till within a year. In this time it became at first



irregular, and afterwards ceased. She was healthy to the age of twenty-six; then had a continued fever, since which she has been subject to pulmonary inflammation from slight exposures. Her health is now good. The tumour occupies a considerable part of the breast; is moderately hard; does not adhere closely to the skin, which is perfectly healthy. There is a knot of enlarged glands of some size in the axilla.

When I informed her that the tumour was of a scirrhus-cancerous nature, and that an operation was the only resource for its relief, she was shocked and distressed. In a few days, however, she agreed to the operation, and the breast, together with the enlarged glands, was removed. The skin was brought together and united speedily. From this period till the following summer, July, 1834, her health was good, and there was no appearance of disease. At the expiration of this time, she desired me to examine the cicatrix, which I found scarcely visible; but at one part of it there was a hardness of the skin an inch long and half an inch wide. This appearance of course alarmed me; but finding my patient perfectly tranquil, and being certain it would be useless to remove the induration, I assured her



nothing more was to be done ; recommended to her to dismiss the subject from her thoughts, and to be attentive to her general health. She was satisfied with this advice, and never made complaint of her breast again.

Shortly after, she began to be affected with occasional attacks of pain in the right side, accompanied with fever, and the phenomena of pleuritic inflammation. These paroxysms were usually relieved in seven days, by a small bleeding and purgatives. They recurred with increasing frequency till the latter part of the summer of 1835, when I noticed that after the pain was relieved, the pulse did not, as formerly, lose its quickness and return to the healthy state. In September, 1835, the pains ceased to occur in the right side, and appeared in the left ; and after the severe paroxysm was over, left her with a sense of constriction extending from the left side to the middle of the body, about the epigastric region. This symptom, together with the permanent increase of quickness of the pulse, led me to apprehend the approaching storm, though unable to judge on what organ it would fall. Certainly I thought it most likely to attack the lungs or pleura. About this time the lower extremities became œdematous,



and soon after the abdomen gave signs of a collection of fluid. This collection gradually increased, and eventually produced great distress, by the excessive distension of the abdominal parietes. On passing the hand over the abdomen, I perceived at the upper part, inclining to the left side, a hard tumour, of considerable size. It was exactly in the place of the stricture complained of, and undoubtedly had been the cause of that sensation by pressure on the diaphragm and abdominal muscles. As the abdominal collection of water increased, this local constriction diminished, and gave place to the general distress caused by the pressure of water.

At the latter part of January, 1836, the patient was evidently sinking. A consultation with Dr. James Jackson was held at this time ; the patient presenting the following symptoms. The body much emaciated, skin and conjunctiva yellow, abdomen much enlarged by water, tumour at the upper part hard. Tongue white. Appetite small. Great thirst. Bowels obstinately costive, fæces of a natural yellow colour. Urine very dark yellow. Pulse 120. Respiration somewhat labour-ed. Intellect a little obscured.



Physical signs in the thoracic region: the patient sitting up, much bent forwards and supported. Right back, respiration not audible. Percussion produced sufficient resonance. Left back, respiration above scapula supplementary; below, not sensible. Breast examined with difficulty. Resonance on percussion sufficiently good at the upper part on both sides. Respiration audible, at the upper part, most so on the left side. Lower part of the chest in front not examined, on account of the state of the patient.

The question principally agitated in the consultation was, whether it would be expedient to draw off the water from the abdomen. This was settled in the negative, on these grounds. 1. The patient might sink under the operation. 2. The relief, if any, would be of short duration. 3. The thought of any operation would be distressing to her.

The suffering from abdominal distension, and at one period, from pressure on, and ulceration of the back, was so great as to require frequent doses of morphine. From this period she gradually failed, and after a protracted suffering, died on the 14th of February, 1836. For two days before death, there was a suppression of the urinary secretion.



On the day after death, the body was examined. Externally it presented a yellow colour, and great emaciation. The abdomen being evacuated by a trochar, two gallons of water were drawn off. The cicatrix formed by the operation on the right breast, was linear; indurated for a small extent, as it had appeared at the examination which took place between one and two years before death, and without ulceration. There was no enlargement of the axillary glands. The lungs were sound, with the exception of some very limited white appearances, of an anomalous texture, under the pleura. These were perhaps four in number, about a quarter of an inch long, and the eighth of an inch thick. They could not be called tubercles, having neither their form, texture, nor situation. In all other respects the texture, colour and consistence of both lungs was natural. In the left pleural cavity, there was twenty-four ounces of water. Heart and pericardium sound.

On opening the abdominal cavity, a brilliant show of tubercles was seen covering the surface of every visible organ. So thickly were the organs studded, and so bright their appearance, as to suggest a comparison with the chrystals of the dog-tooth spar. The liver was very large, prominent,



and of a semi-cartilaginous hardness. An incision exposed a marbled appearance of red and white, occupying the whole organ, and leaving no spot of healthy structure. There was a pale coloured bile in the gall bladder. The edges of the stomach and intestines exhibited a fringe formed by the tubercles which covered them. A portion of the intestine you here see. The tumours about it, are of various forms and sizes, many of them as large as a filbert. These tumours, which we have called tubercles, perhaps improperly, have an exterior coat, thick, and of a semi-cartilaginous hardness, at the intestinal connexion. There you see many blood vessels. The coat covering the apex is thin. The interior of the tubercles has somewhat the appearance of fat, or rather what has been called the encephaloid tumour. The other organs were in a healthy state. A strong urinary effluvia issued from the kidneys.

This case has been stated with some degree of minuteness, in order to give you an idea of the history and the morbid appearances of a case of cancer. There are, however, some important variations, which it is necessary for me to advert to. The lungs were not in the state they are



often seen to exhibit. In some cases, they are filled with a grey deposition, and are much indurated, and often covered with tubercles adherent to the pleura of the ribs. This you have an opportunity of verifying in the specimen I now exhibit to you. Here are the whole of both lungs of another patient, much indurated, converted, I may say, into a solid organ. Their pleura are covered with small tubercles. The adhesion to the pleura was extensive; yet the pleural cavities contained water, which was the immediate cause of dissolution. This specimen was taken from a subject in whom both breasts were diseased; both operated on; yet at the time of the patient's death, the external disease was slight; the ulceration in the breast very small.

The recent specimen we have now before us, is one you saw amputated, about a month since, by Dr. Hayward. It has some peculiarities. The scirrhus texture involves every part of the breast. The glandular structure, and the intervening cellular texture is lost in the new formed granulated white scirrhus effusion. It is remarkably hard. Yet this disease had not been long in coming to the state you see. The patient was a well formed woman of 35—rather delicate in ap-



pearance, and had never been robust. About a year since she discovered a lump in the right breast, which at first was not painful, but had become so lately, and she had sometimes required opiates at night. The monthly evacuation had been regular to the time she entered the Hospital. Two of her father's sisters had been affected with cancer of the breast, and had undergone operations. The disease, so far as she knew, did not return in them; as one died of consumption twenty years after operation, and the other is still living.

This patient, Ann Elkins, went through the operation well, and the following week passed without any unfavourable symptom, excepting some degree of difficult breathing. In eight or ten days this difficulty increased, the pulse became very quick, the abdomen tumid and painful; and after three or four days suffering, she died unexpectedly.

A termination so sudden and unlooked for, led to a careful examination of the body after death, and the following appearances were noticed.

External appearance of the body natural, excepting some tumefaction of the abdomen. On opening the cavity of the thorax, the lungs were adherent to the parietes very closely on the right



side, and slightly on the left. The non-adherent surfaces were reddened and uniformly covered with a thin fresh layer of lymph. The surface of the pleura exhibited some irregularities, as if there were tubercles within. This appearance was found to be caused by a thickening of the cellular texture under the pleura.

The interior of the right lung was in a state of hyperemia, the upper lobe to a great extent; the two others less so, but not natural. The left lung was in a slight degree affected in the same way.

The mucous membrane of both lungs, and of the trachea, was very much reddened and somewhat thickened. The longitudinal fibres were strongly marked in all the large bronchial tubes, as in persons affected with chronic bronchial inflammation. Emphysematous appearances were visible in the lower part of the lungs. The cavities of the heart were quite empty. The foramen ovale was so far open as readily to allow an instrument to pass from the right to the left auricle, through an aperture a quarter of an inch long.

In the cavity of the abdomen, the intestines were excessively distended with flatus. The whole peritoneal surface, both lining and investing,



was covered with a layer of coagulated lymph; and the capillary vessels injected with red blood. The liver, of a lighter colour than common, was of a crisp consistence, and its coat opaque. The uterus was enlarged, thickened, and very hard. Its fundus was covered with a tumour as large as a walnut, excessively hard, so as to be cut open with difficulty. The cut surface presented an arborescent appearance of white striæ, branching from the pedicle which connected it with the body of the organ, exhibiting the pedunculated growth described by Dr. Hodgkin. The right ovarium was increased in size, hard, and contained a number of enlarged ova, some of the size of a pea, with thickened, hard, white coats. The left ovarium was double its common size; soft, and presenting a number of large flaccid sacs. Near the ovaria were seen two or three membranous strings, from one to three inches long, with a cyst at the extremity of each, lying unattached in the cavity of the abdomen. An incision into the substance of the uterus exhibited two or three hard, white nodules, like small pebbles of quartz.

The membranes of the brain were not inflamed, and nothing morbid was seen in its substance.

The lymphatic glands in the axilla were rather



large. One of them had three times the usual size. This gland being divided, was found much reddened within, and contained two kinds of structure—an external, of a deep red, and an internal, composed of white rays. Two or three absorbent vessels, running into this gland, were considerably enlarged from their natural size. The cellular texture, surrounding and enveloping these glands, was intermixed with striæ of white fibres.

This patient was unmarried, of excellent character; of a constitution not vigorous, but rather inclining to scrofula. No cause was known for the disease. The immediate consequences of the operation were in every respect favorable. The wound was in a healing state when she was seized with fever.

The existence of erythema erysipelatoum in the hospital at the time, gives us reason to believe that this patient was affected and died with an erysipelalous inflammation of the internal organs. No cause we are acquainted with can so well explain this sudden and unexpected termination. Nor is such an occurrence new to me. I have seen numbers of patients perish a few days after



operations, at the time that erysipelas prevailed in the hospital, without the slightest external erythema. In such instances, I have been in the habit of stating to you that these patients died of erysipelas, as truly as if they had been covered with an erythematous eruption. The disease is constitutional. It may affect the skin, and generally does so. It may affect the internal organs, without affecting the skin; and in such instances is most dangerous.

It is true that patients sometimes die suddenly from constitutional sympathy, after operation for cancerous breast; but I think the explanation I have given, to be most satisfactory in this case.

The appearances of malignant disease were less than might have been expected. The heart, lungs, and the abdominal organs exhibited no traces of this affection, with the exception of the uterus. The sympathy between this and the breast, no doubt influenced the production of disease in one of these organs. From the comparative appearances, we might suspect that the uterus was the original seat of disease, and that the affection of the breast was secondary. The disease in the two parts was very similar in character; in both exhibiting an almost stony hardness,



and a tendency to involve in the disease every texture about it. In the breast there was scarcely a remaining vestige of original structure; and the same was true of the uterus.

The organs of a cancerous patient have just been brought to me by Dr. John B. S. Jackson, from a case he had just examined. The stomach is, as you see, contracted to a very small size, and is in a scirrhus state in its whole extent. The scirrhus change is found in the muscular and cellular coats, especially the former, which you see to be hard, thick, and strongly marked. The serous coat is smooth, without tubercles, and exhibits at its edges, a number of very large lymphatics. The mucous coat is corrugated and dark coloured. The peritoneum was covered with small white tubercles, about a line in diameter. The uterus and ovaries are in a scirrhus state. The abdominal cavity contained six gallons of water. The lungs had no tubercles, were œdematous and had a calcareous deposit in the bronchial glands. About half a pint of serum in the left pleural cavity. The auricles communicated by three small apertures under the foramen ovale. The lymphatic glands in the groin were inflamed, and their lymphatic vessels much en-



larged. One of the ossa femoris had been fractured and united by a large round ball of bony matter, like an exostosis.

The patient from whom these parts were taken, was fifty years old. She had a tumour of the breast ten years ago, which she would not allow to be removed till within a few months. The wound healed, and she had no further trouble from it, and died of the ascites.

I should have mentioned that the kidneys had white spots on their surfaces, which extended into their substance.

The appearance of the inguinal glands is interesting. These bodies are inflamed; their absorbent vessels enlarged; and the cellular texture which imbeds them is the seat of white fibrous prolongations of considerable length, similar to those found in the early stage of scirrhus breast.

Having stated cases to illustrate the history and morbid changes of this disease, I feel bound to introduce here a case of amputation of the breast, which occurred to me some years since, and was attended with the fatal accident of the introduction of air into the vascular system, through the sub-scapular vein. An accident most unexpected, and to me incredible previously; although



it had been mentioned to me by my distinguished friends, Dr. Mott and Dr. Stevens, of New-York, as having occurred within their knowledge, and had been publicly stated by M. Dupuytren. This case was prepared for publication at the request of Dr. Hays, and inserted in his valuable *Cyclopædia of practical medicine*.

Nancy Barker, of Trenton, in Maine, married, her age thirty-three. Three years since, she noticed an induration in the right breast, which increased till it involved the whole gland in a tumour, very hard, moveable, yet connected with the pectoral muscle by a morbid adhesion. The nipple drawn in. The axilla is occupied by a considerable tumour, of a globular form, and quite hard. An operation was performed on the 24th of December, 1831.

The patient sat in a chair. The right arm was extended, raised above a horizontal line, in order to give tension to the skin, and permit access to the arm-pit, and was supported in the position by an assistant. The skin on the surface of the breast, with the diseased nipple, were included in an oval incision. The breast was dissected from the pectoral muscle, and left connected with the axillary glands, while the extirpation of these



glands was effected. As they adhered to the great axillary vessels, they were cautiously detached by dissection, and by insinuating the finger where the cellular substance was loose, between the tumour and the great vein, this separation was nearly effected—only a slight connection still existing at either extremity of the tumour. Proceeding to separate it, at the outer part of the axilla, a vein was divided, and a small quantity of venous blood discharged. Scarcely was this done, when the patient struggled, her complexion changed to a livid colour, and at the same instant, a bubbling or gurgling noise, which had not been noticed before, was heard, though indistinctly ; but the place from which it issued was not visible, the surrounding skin and fat lying over it. On this, the axilla was immediately compressed. The patient became insensible, breathing as in apoplexy. The tumour was at once separated. The posture of the patient was changed, and she was supported by those around. Some brandy was poured down the throat, and ammonia introduced into the nostrils. The pulse, however, became less distinct every instant. Cloths dipped in hot water, were thrown over the extremities. Strong frictions were applied to the chest, and



to all parts of the body. Considerable quantities of brandy were again poured down the throat. At this moment, the livid colour of the cheeks gave place to a suffusion of vermillion red—and no glow on the cheek of a youthful beauty ever gave one so much pleasure, as that flush. But the flush soon passed off; the lividness re-appeared; the respiration became more feeble; pulse at the wrist scarcely perceptible; and notwithstanding the redoubled applications of external heat and moisture, the extremities and the whole body cooled rapidly, and presently the respiration ceased. As a last effort, the larynx was opened, and the inflation of the lungs, by a bellows, was put in operation in a speedy and perfect manner, imitating the movements of inspiration and expiration, with great exactness—continuing at the same time the general application of heat and friction to the whole surface.

These measures were employed for about twenty minutes longer. At the end of this time, there was no remaining hope of the restoration of the patient to life. The friends being anxious to take advantage of a vessel then sailing for their home, the body was soon after removed, and no opportunity afforded for examination.



The fact of the introduction of air into the veins, during surgical operations, may be viewed as being established by abundant evidence. It must, therefore, be a matter of importance to surgery, to prevent and to remedy so formidable an occurrence. To throw some light upon the subject, we shall consider, first, the manner in which air gains admission into the veins, in surgical operations; second, the mode in which it influences the functions and causes death; third, the means of prevention; fourth, the remedies to be applied when the accident has occurred.

1. The manner in which air gains admission into the veins.

In order to understand this, two things are to be considered; the state of the heart, and that of the affected vein. First, the heart. This organ has a dilating, as well as a contracting power. The auricles, after contracting, dilate by an active motion, and suck the blood from the neighbouring veins. By this suction of the right auricle, it is that air may be drawn in at the opening in the wounded vein. Second, the condition of the vein is to be regarded. The coats of the veins are flaccid; and in their ordinary state, an attempt to suck in air at any aperture, would be followed by



a collapse of the walls of the vein; and the introduction of air in this mode would be impossible. But if the coats of the vein are prevented from collapsing, by an adhesion to an unyielding substance, air might be sucked into and through it, without any difficulty. If a suction-hose were composed of a thin skin, water could not be drawn through it; but if it were covered with metal to which it adhered, there could be no obstacle to the suction process. In order that air may be sucked into a vein, in the living body, its coats must be prevented from collapsing, and this may be done by different causes. First, by position. If the arm, for example, be extended to the utmost degree, the axillary vein will, at the time, be in a state of tension; and should an aperture be made in it, in that situation, the vein could not collapse, and air might be drawn in. Second, if the vein passed through, and adhered on the outside, to a firm tumour, the vessel could not collapse. Third, the same result would be produced by an attachment to surrounding fascia, which is again attached to bone. Other causes might produce the same effect; as, the situation of a short vein between two others, with each of which it is connected—the situation, for example, of the transverse jugular



veins, which pass across from the anterior to the middle jugular. When such conditions of the veins near the heart are taken into view, together with the suction power of the right auricle, there seems to be no difficulty in explaining the entrance of the air into the vein and heart.

2. The mode in which air introduced into the circulating system, causes a derangement of the vital functions, is not so satisfactorily explained.

The organs whose functions have been supposed to be especially deranged, are the lungs, the brain, and the heart. The *lungs* have been found to contain air in their sanguiferous vessels; and as the phenomena bear a resemblance to those of asphyxia, this organ has been supposed to be the primary seat of derangement. The livid appearance of the skin, also, and the gurgling noise in the chest, seem to indicate an affection of the lungs; but the latter symptom arises merely from the passage of air through the blood of the heart and of the lungs; the former, from the imperfect state of the circulation. The *brain*, by others, is believed to be affected by the introduction of air into its blood vessels. Bichat produced appearances in animals, similar to those from this accident, by injecting air into the carotid artery; and



in our own cases the privation of sensibility, the slowness of the pulse, and the heavy respiration, appeared to indicate pressure on the brain. It has been said that the time is not sufficient for the imbibed air to reach the brain; but there is a sensible interval between the entrance of the air and occurrence of the phenomena—an interval quite sufficient for the air to pass through the right side of the heart, the lungs, the left side of the heart, and the carotid arteries, to the brain.

In examinations of the bodies of some of the victims of this accident, air has been found in the right auricle of the *heart*. This fact, taken in connection with the slowness or total failure of the pulse, has been thought to prove that the great organ of the circulation is the principal seat of disorder. The experiments of Nysten favour this explanation, and seem to show that the distension of the heart by air, is sufficient to account for the fatal effects of the introduction of that fluid into the veins.

### 3. Means of prevention.

The veins most likely to be the seat of the accident, are those near to the heart, viz: the anterior, middle, and posterior external jugular veins; the internal jugular, subclavian, axillary, and their col-



lateral veins. The external iliac; and even the saphæna, when in an enlarged and indurated state, may also become so. When surgical operations are performed in the vicinity of these vessels, or when they are to be wounded necessarily, the operator must bear in mind the danger, and adopt the following cautions. 1. He will avoid implicating the veins named above, until the latest period of his operation, in order that he may have a better opportunity of compressing them. 2. He will, if possible, cause such veins to be compressed between his incisions and the heart. 3. When he sees a stream of black blood issuing under his knife, he must suspend his operation till he has ascertained whether air is drawn in. 4. The instant he perceives the peculiar sound of air passing through a narrow aperture, he makes compression on the wounded part, and abandons the operation unless he is able to compress the vein between the wound and the heart. 5. In dissecting near those veins, he must avoid that posture which gives strong tension to the vein. In the axilla, for example, if the axillary vein happens to be wounded while the arm is extended and elevated, air may be drawn in; but if the vein is wounded when not in a state of tension, air will not enter. 6. When



the operator is compelled to divide any of those veins, he desires the patient to make a full inspiration before his incision.

#### 4. Treatment.

If, during an operation, the patient faint, the surgeon must carefully attend to his condition, and, comparing his symptoms with those of ordinary syncope, make himself certain of the nature of the affection; for the air may have been admitted without his notice. When he has satisfied himself on the subject, he proceeds as follows.

If the pulse is slow and suffocated, the patient not having lost much blood, the temporal artery is to be opened, and blood abstracted, varying in quantity according to the effect of the abstraction. On the other hand, if much blood has been lost, and the pulse is very low, stimulants must be employed. Cold water is to be dashed in the face, and ammonia applied to the nostrils; and if the patient can swallow, this medicine is to be taken into the stomach; if not, it must be thrown in by a syringe. Frictions must be applied to the extremities; and blankets, wrung out of hot water to every part of the body. Should these means fail of success, artificial respiration must be resorted to, by introducing a tube into the glottis, or



through an aperture between the thyroid and the cricoid cartilages. When no better instrument is at hand, common bellows may be used. The efforts should be continued long and steadily—say from half an hour to an hour. An attempt to pump the imbibed air from the heart, through the internal jugular vein, by means of a syringe, is an operation that cannot be recommended, since it appears more likely to allow the entrance of a further quantity of air, than to abstract that already admitted. A proposal, which at first view, may seem scarcely more plausible than that mentioned, might be made with some hope of advantage. The introduction of a liquid into the veins, has been often attended by the revival of the patient, in cases of cholera, though rarely with ultimate success. In this accident, the vital powers not having received that lesion which is the result of an exhausting disease, it may be hoped that a successful revival might sometimes be effected, by the injection of the saline solution into the veins.

The other specimens here presented, show various appearances of schirro-cancerous breast. Let me direct your attention to this small tumour, as an example of what Mr. Travers has called spicular cancer. Externally you see an oval portion of skin



including the nipple. The nipple is drawn in ; and by its side you notice a deep, narrow ulcer, as if the part had been eaten into by a worm. On the pectoral face of the tumour, is a lobulated appearance arising from enlargements of different portions of the gland. The adipose cellular texture, so abundant in some of the specimens, is here wanting. On cutting into the tumour on this posterior face, we find it hard externally ; then a marbled surface, gradually becoming softer as we approach the centre of the tumour. Here we find it not much firmer than a thick pus, and finally we open into a number of cavities, each about the size of a hazle nut ; six or eight in number, and apparently communicating with each other. The cavities are filled with a dark ichor, which discolours their parietes. A portion of the pectoral muscle adheres to the tumour, and shows that this muscle had become diseased and consolidated with it.

The following case, of a similar character, gives additional evidence in favour of the connection between the uterus and the breast, in scirrhus-cancerous affections ; and further, shows that the scirrhus affection of the uterus may precede that of the breast. The patient was the daughter of a mechanic, who, not being wil-



ling to depend on her father, undertook sewing for her support. She was forty years old, of rather delicate constitution, and of excellent character. For the last three years has been affected with abdominal pains, and an enlargement in the lower part of the cavity, with irregularity in the catamenial discharge. She applied to a medical practitioner for advice in regard to this swelling, and was told to take ergot freely, which she did for some time, with apparent diminution in the abdominal tumour.

In the beginning of Feb. 1837, she came to me with a tumour in the left breast, which she said she had discovered nearly a year before. It was perfectly hard, knotted, moderately moveable on the muscle, the skin passing over it freely, with no discolouration, no change in the nipple, and no enlargement in the axillary glands. About one-third part of the breast was involved in the tumour. Her health was as good as usual, and she had continued her occupations to the time she came to me.

Being informed that she had a cancerous disease, which no medicine could cure, she determined to have an operation performed; and this was done on the 22d of Feb. The operation pre-



sented nothing remarkable. The whole breast, which was small, was removed; and, contrary to my expectation, there was at one point an adhesion to the pectoral muscle, and a scirrhusity of a small part of the muscle, requiring its removal. She was quite comfortable afterwards. The wound being dressed on the fifth day, was found to have adhered throughout.

On examining the tumour, it was ascertained to be composed of a scirrhus nodule, of a pale red colour, about the size of a hen's egg, contained in a thin cyst, or what seemed to have been a cyst; for three-quarters of its exterior, on the sternal side of the nodule, extended confusedly, and was lost in the substance of the breast. There was a very dark spot at its superficial part, but neither softening nor cavity. Fibrous prolongations were visible on the median portion of the breast.

At four in the morning of the first of March, she was suddenly attacked with acute pain in the right side of the abdomen, below the ribs; and I found her, on my visit, with symptoms of peritonitis. These continued, without mitigation, till she died, which was on the morning of the 6th of March.



The appearances on examination, were these. The abdomen was tumid with flatus. The wound on the breast had lost its adhesion, and gaped as after the operation. When the thoracic cavity was opened, a drop of pus started from the sternum, on its right upper part, far distant from the wound. The lungs adhered extensively to the pleura on both sides, most on the right. These adhesions were old; and where there were no adhesions, there was a layer of recently effused lymph. The lungs presented the cicatrix of a former ulcer at the apex of the upper lobe on the right side, and there were some calcareous deposits in their substance. Otherwise there was nothing morbid. The heart contained blood in the right and left cavities. In the cavity of the abdomen, the intestines were much distended with air. The liver was covered with a layer of lymph; its surface was pale; substance indurated, and contained the cicatrix of a former ulcer. The peritoneum near and below the liver was covered with lymph. Spleen of moderate size and very soft. Kidnies thick, and of a pale colour, with a slight induration at the pelvis of the right. Mesenteric glands somewhat indurated and enlarged. At the lowest part of the cavity, was seen a tumour of



the size of the uterus at the fifth month of pregnancy. On each side of the tumour the ovaries were distinguished in a somewhat enlarged state. The tumour was an enormous scirrhus of the uterus. The exterior of this organ appeared highly vascular. On incision, the parietes were found to be not more than a quarter of an inch thick. To their inner face adhered the tumour composed of a whitish coloured, elastic substance, of a fibrous organization, quite uniform throughout. The os uteri was tumid, rounded, not hard, and not pervious. The vagina was studded with enlarged mucous glands; its substance otherwise natural.

The tumour of the uterus was what has been called a fibrous tumour. The fibrous organization was strongly marked, and the muscular fibres of the uterus itself were developed in a remarkable manner.

The cause of the peritoneal inflammation was satisfactorily ascertained to have been an imprudent and extraordinary exposure to which she subjected herself on the fifth day after the operation.

What her fate would have been, had she escaped the peritonitis, we may surmise. The



removal of the mammary irritation would probably have been followed by an increased developement of the uterine disease, which, in a course of years, would have proved fatal.

I ought to state that she concealed this affection of the uterus from me, and that I learnt it from one of her friends after the operation.

SLoughing scirrhus. In the autumn of 1836, Dr. George Bartlett requested me to visit with him a patient affected with a peculiar disease of the breast. She was a married woman, thirty-nine years old, of strong constitution, had borne one or two children many years before. A few months previous to the time I saw her, she was attacked with severe pains in her left breast, followed by a considerable swelling and some fever. The swelling increased, notwithstanding the judicious treatment she was under, till the whole breast became involved in a stony tumour, of large size. This when I saw it, was tender and painful, not discoloured. She had fever and loss of appetite. Dr. B. made a question of extirpation of the tumour; but I told him I could not at present venture to recommend it, and we agreed on other applications. In a short time I saw her again, and found the breast as before, and two or three lym-



phatic tumours in the limbs. Now, I was clearly satisfied that no operation should be performed; and did not see the patient again till the following spring, March, 1837, when I visited her with Dr. Lewis. I found that she had suffered much in the winter; that the lymphatic tumours had not increased, and that three weeks before, the breast showed marks of gangrene. At the period of my visit, a large part of the breast was involved in the gangrenous mass, and was in a fair way to slough off. The patient had been much prostrated, was now better, having recovered some degree of appetite, so that she has a hope of a favorable termination of this unusual attack. It is now about a year since the beginning of her indisposition, which she informed me took place without any known cause; as she lived very comfortably, regularly, and was in no way exposed.

The sloughing in this case might be attributed to compression of the vessels supplying the tumour, by the growth of indurated substance. Hence the tumour would lose its vitality, and slough. According to Dr. Hodgkin's views, a different explanation would be made. In the pedunculated structures, the fresh growth of peduncles compres-



ses and interrupts the circulation at their necks, and brings on the softening of scirrhus-cancer.

A consideration of the cases above-mentioned, and the morbid appearances after death, presents a striking, and it may be said, unexpected fact—the great amount of internal disease, compared with those external appearances, which are believed to be the original roots of the whole. In some instances, where the breast had been removed, there were in fact no remains of external disease, while of the internal organs scarcely one seemed to have escaped its ravages.

Such appearances naturally lead us to question the probability of the transmission of morbid influence from the breast to other parts. How can such a transmission take place? There are two possible modes: First, the absorbent vessels may convey the poison. Second, it may transmit its influence by exciting sympathetic actions. In support of the first, we have the fact that the lymphatic glands, in the course of the absorbent vessels, are often diseased. The secondary affection of these glands is readily explained by this hypothesis. But the derangements of the great organs in the abdominal cavity is not so easily traced to this source. To explain these affections



we must believe something more, viz. that a tumour sometimes small and not ulcerated, is capable of yielding a poison sufficient to contaminate a number of organs, while it leaves intact others more near.—If we adopt the second hypothesis, that of sympathy, we should expect to find the uterus always diseased in scirrho-cancer of the breast; also that the thoracic viscera would be more frequently diseased than the abdominal; which last is not the fact.

Not having any favourite doctrine to support, I present these considerations for discussion. The truth must be come at, by inferences from numerous observations. Among the inquiries in relation to this subject, one would be, whether the uterus is not the organ primarily affected in scirrho-cancer of the breast? It is perhaps more likely to be disturbed by physical and moral causes than the breast; and though disease in the latter organ seems to be excited by local injury in some instances, there are a much greater number where injury of this part does not produce scirrho-cancer. Considering the greater frequency of disease in the uterus than in the breast, is it not probable that where an injury produces disease in this part, the uterus, being previously disordered, may influence



the developement of scirrhus-cancer, by that sympathy which exists between the two organs?

If this question should be decided in the affirmative, the amputation of the breast would be less frequently performed than it is now. Until then, we must continue to operate in cases where the affection is not so far advanced as to preclude any hope of interrupting the course of internal disease.

Experience has satisfied me that many cases may be cured by operation. According to the best of my information, I should say that one case in three had been cured without relapse. When, therefore, the tumour is not large, has not been of long standing, is not ulcerated, and there are no signs of constitutional affection, it is best to try an experiment, which, notwithstanding its painfulness, is generally desirable and satisfactory to the patient. I wish I could say anything more definite on so important a point, but I am not at present able to do so.

It would be useless for me to give a more particular account of the manner of doing this operation, than what has been already given in the relation of the cases. There is one remark I would make, on a point which experience has taught me; that, it should be a general rule in



a case of scirrho-cancerous breast, to remove the whole organ. You have seen that a partial operation is almost certain to leave behind it some of those membranous productions which are generated by the disease. How far these possess the power of communicating a malignant influence, we cannot tell. It is best not to try an experiment so dangerous as that of leaving any of them. There is another reason for removing the whole breast. When not large it is less painful in its performance and its consequences, than the partial operation.

Is it possible to distinguish the different kinds of tumours, of the female breast, from each other?

An affirmative answer to this question cannot be given without qualification; but I shall briefly state the more striking facts adapted to illustrate the distinctions between these tumours.

1. Scrofulous tumour. This occurs in early life, usually before the age of twenty-four. It is connected with constitutional appearances of scrofula. The tumour is large, irregular, indistinct, not painful, varies in size, at different times increasing and then diminishing.

2. Chronic mammary tumour. This occurs before the age of thirty-five. It is seen in healthy and in feeble constitutions. The tumour is cir-



cumscribed, of a rounded form, quite moveable, not tender nor painful, increases slowly, and remains stationary for a long time. It is not malignant.

3. Irritable mammary tumour. This occurs before the middle age, in delicate and irritable habits. The tumour is not large, not well defined, is tender, painful, sometimes accompanied with general swelling of the breast and fever, which subside and leave the original tumour. This is not malignant.

4. Hydatidal tumour. This commonly appears before the middle age. It is with difficulty distinguished in its early stage from the scrofulous and from the scirrhus tumour. It is harder than the former, and not so hard as the latter. The tumour is irregular, occupies the whole breast, is not tender, painful, nor discoloured: increases rapidly, and finally attains a great size. In this last condition it is readily distinguished by the globular bodies which form its surface; at well as by its magnitude and freedom from pain.

5. Adipose tumour. This occurs in fleshy and healthy females. Its great size, elasticity, freedom from sharp pain, and regular surface, well distinguish it from the hydatidal and scirrhus breast.



6. Cartilaginous and osseous. These are rare, and are known by their extreme hardness.

7. Scirrhus-cancer. The period of life at which this occurs, is most commonly between the ages of forty and fifty. Frequently some of the relatives of the affected person are cancerous.\* The tumour is at first of a small size, increasing with variable rapidity, is found more frequently in the axillary part of the breast, is very hard, moveable at first, afterwards less so, is accompanied with lancinating pains, sometimes but not always severe, increases gradually, contracts adhesions with the skin, produces distortion and drawing in of the nipple, ultimately causes a redness of the skin, followed by ulceration and discharge of a foetid matter; the

---

\* The following instances of hereditary cancer have occurred within my knowledge, to a family in this vicinity. The grandfather died of a cancer of the lip; whether others of his generation were affected, I know not. The son had a cancer of the breast, and, at the age of sixty, was operated on by my late father, but died of cancer some years after. Two of his sisters had cancer of the breast, were operated on, and ultimately died of the disease. A daughter of one of the ladies had a cancer of the breast, which I removed at an early period; she recovered, but died some years after of disease of the uterus. A daughter of the gentleman has a cancer of the breast, but declines any operation. I have reason to believe that other members of the family are affected, and conceal the existence of the disease.



edges of the ulcer turn out, bleedings occur, sometimes profuse, from the ulceration of vessels. It is accompanied with enlargements of the axillary glands, swelling of the arm, difficulty of breathing, cough, abdominal pains, dropsy of the abdomen and thorax, and fragility of the bones. The patient dies, not from the cancer in the breast, but from disease of internal organs.

8. Fungus hæmatodes, medullary cancer. This is rare. It occurs in young subjects. The tumour is large, soft, consists of two or more globular bodies, increases rapidly, causes ulceration of the skin, and an external fungus, which bleeds from the whole surface. The constitution soon becomes affected, and most of the functions disordered. The bleedings are severe and dangerous, but the patient generally dies of internal disease.

CANCER OF THE BREAST IN THE MALE. This disease is rare; I do not recollect more than two cases of it. One occurred twelve years since in a gentleman of this place, about thirty years old. He had not enjoyed good health for three years, being dyspeptic. He had also frequent pains in the chest. These pains at last concentrated in the right side, near the nipple. Passing his hand over this part, he discovered a



small tumour. The pains increased and became very severe within six months from the discovery of the tumour. The hardness extended around, involved and drew in the skin, giving it a puckered appearance. The skin ulcerated near the nipple, and discharged a foul matter. I excised the whole scirrhus mass, comprehending the skin with the nipple, and the cellular substance to the pectoral muscle, about four inches in length and two in breadth. The wound of course was long in healing, but has since remained perfectly sound. A few months since I saw him, and ascertained that he was free from pain or trouble at the affected part, and in perfect health.

Tumours about the nipple frequently occur in boys, and are sometimes of long duration. In such instances, the application of a few leeches has been followed by the disappearance of the tumour. A similar tumour is often seen in young infants. This is very transient, and disappears without applications.

Treatment of scirrho-cancerous breast.

When the disease has been decided to be cancer, and the patient declines an operation, and wishes for advice how to proceed without it, we are called on to propose remedies to satisfy the



patient, and smooth the fatal path there is no means of avoiding.

Pressure has been recommended to produce absorption of the tumour. This is applied by first surrounding the breast with scraped lint or other soft substance, and applying a bandage over it with a pressure gradually increased.

Leeches are thought to lessen the pains in some cases.

Hemlock is an ancient and standing medicine, when nothing effectual can be done.

Iodine is a later and more fashionable application.

Arsenic and strong caustics have been used. They are painful and useless.

When the disease has assumed the ulcerated form, perfect cleanliness must be attended to. This may be attained by the use of soap and water, sprinkling with prepared carbon, and by a very diluted wash of chloride of soda. The mildest applications are the best. Something is necessary to prevent adhesion of the coverings to the wound. A perfectly pure mutton suet, or hog's fat, commonly answers better than compound ointment. The diet need not be restricted, unless the patient suffers great pain. In this case, wine and animal food should be avoided.

For the relief of pain, fomentations of the leaves of stramonium sometimes have a good effect. The most severe pains are not commonly in the diseased breast, but in the back, side, and abdomen. The fomentations should be applied to the seat of the pain. In most cases we are compelled sooner or later to resort to the use of opium in some form. That which deranges the stomach least, is the sulphate of morphine in doses from an eighth of a grain upwards, till relief is obtained.

#### TUMOURS OF THE SALIVARY GLANDS.

The parotid, sub-maxillary, and sub-lingual glands are subject to enlargement. The sub-maxillary I have found to be frequently affected in this way; the parotid rarely, and the sub-lingual most rarely.

**TUMOUR OF THE PAROTID.** The parotid gland is the seat of two species of induration; one in the lymphatic glands situated about it, which is common; the other a genuine induration of the parotid itself, which is quite rare. The lymphatic tumour of the parotid shows itself in the form of a globular enlargement below the lobe of the ear.



This increases pretty rapidly, but does not usually attain a large size. I have not often seen it larger than a nutmeg, though it does sometimes attain a more considerable bulk; and is then liable to be mistaken for a disease of the parotid itself. This tumour may be distinguished ordinarily from an affection of the gland itself, by its smoothness, roundness, want of hardness, and freedom from pain. Not unfrequently it terminates in suppuration. When it does not take this course, but remains long in an enlarged state, it may be necessary to extirpate it.

The induration or scirrhus of the parotid gland begins deeply in the space between the branch of the jaw and the mastoid process. Its confined situation renders it painful at an early period. Being confined on three sides by bone, it extends outwards and downwards, assuming a conical form in all the cases I have seen. This tumour is of a scirrhus hardness. It is attended with much pain, with difficulty in mastication and swallowing, with head-ache and vertigo. Ulceration does not take place under a long series of years, but it may and does sometimes prove fatal by compressing the internal jugular vein, and causing apoplexy.



The facial part of the gland is commonly unaffected. There is some reason to believe also that the deep portion which gives passage to the carotid artery, is not always indurated, even in an advanced state of the disease. What leads to this suspicion is the fact, that the external carotid artery does not always bleed in cases of the extirpation of the gland. I must say, however, that there is another way of accounting for this, which appears to be more satisfactory. In various tumours of the neck I have known the great veins and even the arteries, to be obliterated by the compression they had undergone. We may therefore suspect this obliteration to occur in those cases of undoubted extirpation of the gland, in which the artery does not appear to be wounded.

The scirrhus state of the parotid being incurable by remedies, a surgical operation is the only resource, an operation requiring some degree of skill, coolness and knowledge of anatomy.

The first operation of this kind I recollect to have witnessed was performed by my late father, in the year 1804. The patient was a lawyer from Maine, thirty years old, of good constitution and altogether a favorable subject. The tumour was large, hard, painful, and of a conical form. It was



removed without the division of the carotid artery. The facial nerve was divided and the muscles of the face partially paralysed for some years. This paralysis gradually diminished and I believe had quite disappeared before the death of the patient, which took place about fifteen years after the operation from some cause not connected with the disease nor operation.

The only instance of this operation in which I am certain to have cut off the external carotid artery, was that of a lady of this city, sixteen years ago. The tumour, then removed, you have here an opportunity of seeing; and from its form and granulated structure you perceive it to be the parotid and nothing besides. The circumstances were these. The patient was a widow lady, about thirty years old. She had perceived the tumour two years before, from which time it increased regularly, till it formed a very considerable conical projection from the side of the neck, extending from above downwards so as to involve the ear and cover the angle of the jaw. The pain and other sufferings from it were such that she anxiously sought for an operation.

An incision three inches long was carried from behind the ear to below the angle of the jaw in a



slightly oblique direction from behind forwards. This not affording room, a transverse incision an inch and a half long was carried from the anterior lip of the wound in the direction of the lower edge of the jaw, and just below this bone. The tumour was then dissected from the face, ear, and mastoid muscle. The facial or external maxillary artery was cut and immediately tied. The tumour being disengaged, as much as possible, from the parts above mentioned, was seized with a double hook at the inferior part and drawn outwards. The dissection under its lower edge was carried on cautiously, until it became deep and the pulsations of the carotid were quite visible, though the vessel itself could not be discovered, so as to secure it. Now being sensible of the probability of involving the external carotid artery, I requested an assistant to compress the common carotid and then began to pursue the deep dissection. In an instant the assistants, the operator, and the ceiling of the room were covered with a torrent of blood. The common carotid was at once compressed effectually. The blood being sponged off, I sought for the divided artery; but soon found it had retreated below and within



the digastric and stylo-hyoid muscles. These muscles were dissected, the artery brought into view and tied, the operation continued and concluded.

For three days after, the patient suffered alarmingly from difficulty in breathing. She was obliged to sit up in bed constantly and could not swallow without spasm, the face swelled and was painful. After the first dressing she became quiet and had no other bad symptoms. The wound soon healed, with the exception of a small salivary fistula from the facial part of the gland. This continued for two years, and ultimately disappeared under the application of the nitrate of silver.

The paralysis of the face was for two or three years remarkable. It gradually diminished; so that in five or six years she was married a second time. She has now no remains of paralysis I believe, nor any vestige of the disease or operation, excepting the cicatrix of the wound.

The removal of the body of the parotid is certainly a serious operation. It should be undertaken with a full view of its difficulties and a perfect arrangement to meet them, and may then be practicable and safe.



## TUMOUR OF THE SUB-MAXILLARY GLAND.—

This is much more common than that of the parotid. This gland is often enlarged from colds, sore throat, measles, and from scrofula. These enlargements are generally transient. Their dissipation is sometimes aided by leeches and a protecting plaster. The permanent enlargement, or scirrhus is distinguished from these by its size, its hardness, the pain attending it, interference with swallowing, and by its regular increase. This tumour is usually invested with a sac more or less thick, which excludes it to a certain extent from the action of the absorbent vessels. Every tumour covered by a sac is less likely to be removed by the natural powers than those without a sac. The capillaries continue to nourish, while the absorbents are too few to remove it.

When the tumour assumes a permanent hardness it is proper to remove it. This gland is favourably situated for an operation. Its only coverings are the skin, the platysma muscle, and a thin fascia. Below it is the digastric muscle, the sublingual nerve which it sometimes covers, the sublingual artery, and still lower the os hyoides. Above, and extending a little over the



gland, is the lower jaw. At its posterior extremity, at the angle of the jaws, it is connected with the parotid gland. Its anterior extremity is also connected by a small glandular process with the sublingual gland. The most important point in the anatomy of this part is its relation to the facial artery. This vessel crosses its external third, passes through the substance of the gland, and thence rises on the lower jaw, exactly at the edge of the masseter. As it passes through this gland it gives off a large artery, the submental. It is of course impossible to remove the gland, without cutting off the facial artery, which is readily secured.

The preparation I have here, shows the gland in its enlarged state. This was removed from the neck of a young woman two years ago. The facial artery when divided bled very freely, and was immediately secured.

Some of you present may recollect to have seen the removal of this gland, for a painful affection, and when not indurated, in the summer of 1836. The patient, a schoolmaster, had been affected with pain in both the sub-maxillary glands for three years, and was desirous to have both of them removed. I advised him to apply leeches,



and a stramonium fomentation, before trying an operation. As these applications gave no relief, I agreed to extirpate one of them. The distinguished surgeon Dr. Rhea Barton, of Philadelphia, assisted in the operation. An incision two inches long was made transversely. in the direction of the lower jaw. The gland was exposed, the facial artery brought into view below the gland, and secured before dividing. The operation was almost bloodless. The patient soon recovered, and was so well satisfied with the effect of the operation, as to relinquish the design of getting rid of the other gland.

Many years ago, I saw this operation performed in a way, which made a strong impression on me, and which for your instruction I may venture to speak of, as all the parties concerned have been long dead. The operator held a very responsible situation. He was a bold surgeon, but a bad anatomist. The first incisions were handsomely performed ; presently he struck the facial artery, apparently much to his surprise ; for instead of suspending the operation to secure it, he accelerated his incisions, in the midst of a torrent of blood, and soon after wounded the sublingual artery. Sponges were now thrown on in abundance. Attempts



were made to secure the vessels ; but before this could be accomplished the patient lost so much blood, that he expired within twenty-four hours.

The following case of a cure of scirrhus sub-maxillary has been mentioned in my former lectures, as an instance of the power of the imagination on the physical frame. Whether it will be considered as the effect of mental action, or as an accidental coincidence, I know not. I have seen many cases of the influence of imagination which have been, in my view, not less remarkable.

Some time since, a female presented herself to me, with a tumour of the sub-maxillary gland, which had become troublesome and alarming to her. It was about the size of an egg, had lasted two years, and was so very hard that I considered any attempt to dissipate it by medicine to be vain, and advised its removal by an operation. To this the patient could not bring her mind ; therefore, to satisfy her wish, I directed some applications of considerable activity to be made to the part ; and these she pursued a number of weeks, without any change. After this she called on me, and with some hesitation begged to know whether an application recommended to her would in my opinion be safe. This consisted in



applying the hand of a dead man three times to the diseased part. One of her neighbors now lay dead, and she had an opportunity of trying the experiment, if thought not dangerous. At first I was disposed to divert her from it; but recollecting the power of the imagination, I gravely assured her she might make the trial without apprehension of serious consequences. A while after, she presented herself once more, and, with a smiling countenance, informed me she had used this remedy and no other, since I saw her; and on examining for the tumour, I found it had disappeared.

TUMOUR OF THE SUBLINGUAL GLAND. Only two or three instances of a scirrhus state of the sublingual have occurred in my practice; and although I doubt not it has been removed, I have found no account of such an operation. The cases I have seen were attended with great soreness at the root of the tongue, with acute pain and much uneasiness in swallowing. The position of this gland is such, that its enlargement is not readily discovered. It lies under the lateral parts of the tongue. Its edge forms a projection at the floor of the mouth, and there produces an oblong eminence of a red colour, which contains its little ducts, and also the duct of the sub-maxillary.



Being about two inches long, it extends from the inner face of the anterior part of the jaw backwards to the root of the tongue. Its internal face is in contact with the genio-hyo-glossus muscle ; its external with the lower jaw. Below, lies the mylo-hyoideus muscle. By its posterior extremity it is connected with the sub-maxillary gland. The submental artery enters it, and the sublingual artery takes its course to the tongue beneath it, in company with the sublingual nerve, which runs close to its lower edge. The posterior extremity of this gland is so connected with the lingual branch of the fifth pair of nerves, that it seems almost impossible to extirpate the whole gland without cutting this nerve.

The mode of removing this gland, when required to be done, will be seen in the relation of the following case. A lady from the country applied to me three years ago, on account of a pain and soreness in the mouth, from which she had been suffering for more than two years. Examining her mouth, I could see nothing unusual, and advised her going to the hospital, where, by repeated investigations, I hoped to be able to discover the nature of her difficulty. She accordingly went there, and I questioned her daily as to



the seat of her pain, and found it referred to different parts of the lower portion of the mouth, and most commonly to the inferior and posterior part of the tongue. After many observations, I was at last able to discover a tumour, by placing the fore finger on the gland within the mouth, and the thumb of the same hand under the jaw, so as to embrace the sublingual gland. Being now satisfied that the gland was indurated, its extirpation was advised, and performed as follows.

The patient being seated in a chair, the mouth kept open by a wedge, the gland was griped by a double pointed forceps, and an incision the length of the gland made from behind forwards on each side. The knife then passed behind the posterior extremity of the gland would have brought it out at the next incision, but the patient made a violent effort to throw out the blood, which compelled me to stop. Then, laying down the knife, the excision was completed by a stroke of the scissors. The bleeding was less than was expected. No arteries were tied. The wound healed in about two weeks, and she went home, quite relieved. About a year and a half after the operation, I saw her, and was informed she had some return of pain. I advised her, if it continued, to come in



town for a few days, that I might ascertain the cause of this pain. As I have not heard from her since, I have hopes that the pain did not continue.

The following case involved the parotid, sub-maxillary, and the lower part of the sublingual glands. It was also attended with that formidable accident, the introduction of air into the veins, and has been published under that head, in Dr. Hayes' Cyclopædia.

William Burrill, of Salem, Æt. 60, was admitted into the M. G. Hospital on the 16th of October, 1830. He had a cancerous affection on the left side of the face and neck, of the extent of three or four inches diameter. It was hard at the edges, of a livid red colour, ulcerated in the centre, very offensive, very painful, and had made an impression on the general health. The parotid gland, the sub-maxillary, the sublingual, and all the textures, excepting the bone, were involved in the complaint. The lower jaw was thought to be diseased, at first, but it afterwards appeared not to be so. In so bad a state of things, there seemed to be little hope of eradicating the disease, and the operation would not have been attempted, had not the patient solicited it.



Considering the extent of the disease ; that important blood-vessels would be divided, namely, the facial and sublingual arteries, probably the temporal, and possibly the external carotid ; it was thought best to secure the carotid trunk. An incision, for this purpose, was begun opposite the thyroid cartilage ; and carried two inches downwards. The platysma muscle was divided ; the edge of the mastoid exposed and dissected. Thus far, only a few drops of blood were discharged. The face of the sheath of the great vessels was a little uncovered, when a small effusion of venous blood appeared under the knife, and checked the operation. At that instant a very distinct sound was heard, like the passage of air through water. A few bubbles were seen in the venous blood, the flow of which was immediately arrested by applying a finger on the part. The patient exclaimed, "I am faint." On regarding his countenance, it was not pale, but livid, almost black, and the muscles agitated by a convulsive motion. The respiration became deep, laboured, and stertorous, like that of apoplexy. The pulse being examined at the wrist, was found distinct, but very slow.—The wound not bleeding, and very little blood having been lost, the temporal artery was opened,



and the blood flowed from it with great freedom. As it flowed, the respiration became more frequent and less laborious—the pulse at the wrist more natural. The leaden colour in the cheeks assumed a reddish tinge, and the alarming character of the symptoms was evidently diminished. About twenty minutes elapsed during these changes. At the end of half an hour, it was thought safe to remove the patient to his bed, where he lay in a state of insensibility for two hours, at the expiration of which, he awaked as from sleep, still breathing like an apoplectic. The night was passed without any accident, and on the following morning he was as well as usual, with the exception of a moderate soreness over the thorax, and a head-ache.

In seven days after the accident described above, the operation was performed without tying the carotid artery.

The diseased parts were surrounded in an elliptical incision, extending from the lobe of the ear to the upper part of the neck, and including the sub-maxillary, the sublingual and parotid glands—all of them in a morbid and disorganized state, and they were all entirely removed. The hæmorrhage was copious, but readily arrested, with the

exception of that from the facial vein, which, from its depth, under the jaw, could not be distinguished so as to admit the application of a ligature, and was therefore compressed by a sponge. The veins below the wound were compressed during this operation. The patient experienced a slight faintness, which soon passed off. He had no bad symptoms; and on the 10th of December, the wound being nearly healed, he requested his discharge, which was granted.

The vein wounded was a small vein which crosses the artery from one of the thyroid veins to the internal jugular. I have noticed it in almost every operation on the carotid since the above, and presume it has often been divided in this operation without any bad consequence. It should, however be avoided, not only on account of the danger of the introduction of air, but because it causes a flow of blood from the upper part of the wound, and thus interferes with the dissection of the carotid artery.



## TUMOURS OF THE THYROID GLAND.

The thyroid gland is subject to two kinds of enlargement. One of a temporary nature, known by the name of goitre; the other a permanent scirrhus.

The goitre is a smooth, soft tumour, not discoloured, not tender nor painful, not interfering with swallowing or breathing, and causing little inconvenience, excepting from its size. It is a disease of inland countries, and of territories situated on the banks of large rivers. In this country, it is frequently seen on the banks of the Ohio and the Mississippi. It is not unfrequent in the mountains of Vermont, of Virginia, and probably of other regions of this country.

Many persons coming from the interior to the sea coast, obtain relief from the swelling. It is, however, liable to return, and they are compelled to have recourse to the same remedy again. The goitre is not unknown as a native of the sea coast. The cases are less numerous, and the tumours do not attain so large a size.

The ancient remedy for this affection was burnt sponge, taken internally. The disease being con-

sidered to be of a scrofulous character, the saline impregnation of the sponge was viewed as its proper remedy. At present, the internal and external use of iodine is thought to be the specific treatment adapted to goitre. To this is added, with more distinct and certain effect, the application of leeches to the part; and the practice of sea-water bathing. Not an inconsiderable number of cases resist every mode of treatment, and the patient, most commonly a female, is obliged to submit to carry the trouble through life, and wear a covering on the neck to conceal it.

**SCIRRHOUS THYROID.** This is a hard tumour, on one or both sides of the middle region of the neck below the thyroid cartilage. It grows very slowly and does not prove troublesome for many years. Increasing in size and in hardness, it becomes painful, compresses the trachea, esophagus, and blood vessels of the neck, causes dizziness, head-ache, and difficult respiration. In some cases, it ulcerates, presents all the phenomena of a scirrho-cancerous affection, and proves fatal.

This disease being wholly intractable by medicine, has become the subject of a surgical operation, which is one of the most dangerous. The scirrhus thyroid involves the trachea, larynx,



carotid artery and a greater or less number of its branches, the jugular veins, the nerves of the neck, par vagum, descendens noni, and others, and the esophagus. Moreover when it is extirpated its arteries are divided so near the carotid, that the course of blood in the latter artery prevents the formation and adhesion of a coagulum in the thyroid; and as soon as the ligature ulcerates through, a secondary hemorrhage appears, and ultimately proves fatal.

When therefore the scirrhus thyroid is to be removed, the carotid artery of one side must be tied. If both lobes were diseased, it would not be safe to tie both carotids at the same time, but it might be effected by two operations, in a case where urgency justified a measure so hazardous, as was successfully done by Dr. Mussey a few years since.—In the following case the operation was safely done on the left lobe.

Eunice Young, *Æt.* 45, married, entered the M. G. Hospital, Sept. 14, 1836.—Two years ago, she perceived a tumour growing on the left side of the neck, slowly at first, but rapidly of late. It is about three inches long and two broad, and situated on the left side of the trachea and larynx, is so intimately connected with these parts,



that every motion of swallowing gives a correspondent movement of the tumour. The sterno-mastoid muscle lies over it. It has no pulsatory motion. She experiences an increasing difficulty in swallowing, amounting to what she calls choking.

The patient being in the upright posture, an incision nearly four inches long was carried along the anterior edge of the sterno-mastoid muscle. This exposed the platysma, which being incised, the edge of the sterno-mastoid muscle presented. On turning this aside, the sterno-hyoid and sterno-thyroid muscles were perceived to cover the tumour in such a way that it was necessary to separate these muscles from each other and dissect between them. The surface of the tumour being brought into view, was fully exposed by dissection. Then by the handle of the knife it was separated from the sheath of the carotid artery, and there was appearance of its coming out without difficulty; but on getting under it, a solid adhesion was found to the trachea for one or two inches, and also to the œsophagus for a small extent. These adhesions required the knife. The dissection then being pursued upwards and backwards to extract the superior cornu of the gland,



the superior thyroid artery was divided in so deep a situation, that it was impossible to draw it from between the muscles. The carotid artery having its sheath already exposed for some extent, was tied. The inferior thyroid artery either did not exist, or did not bleed.

The patient had a sense of sinking at the epigastrium, in the afternoon, and, in the following day, a pain in this part, which continued forty-eight hours. As she had bled freely from the thyroid artery, it was not thought expedient to bleed from the arm; although the symptoms arose probably from a change in the course of the circulation, in consequence of the ligature of the carotid artery. By the use of injections, and of hot applications to the part, she obtained relief, and had no other bad symptom till the fifth day. On the day preceding that, she was clamorous for food, and not being allowed it, she left her bed when unobserved, in the evening, and got a biscuit which she had secretly treasured up. Not satisfied with this imprudence, after the nurse had retired, she arose, and with naked feet crossed the floor of the apartment to blow out the lamp, which was set for the night. In consequence of these acts, she was seized with a bad chill, pain in the stomach, and



subsequent fever, which kept her down some time. The ligature separated from the carotid on the thirteenth day.

The wound healed soon after, and she left the hospital in about a month from the operation.

The tumour, on being examined, was found to be covered with a firm fibrous sheath, and to consist of a spongy texture, in which appeared a considerable number of cells, some of them of large size, containing a bloody fluid. In colour it resembled the usual appearance of the thyroid gland. Its consistence was firm, but not scirrhus, excepting at its upper horn, which had begun to assume a scirrhus texture in consistence and had a white colour.

The fact of there being no bleeding from the inferior thyroid is remarkable, and I was at a loss to understand it, till, in the subject which I used in my lectures to demonstrate the arteries, this artery, as you may recollect, was wanting. In that case, no inferior thyroid proceeded to the thyroid gland on the right side; but the right inferior thyroid, arising further outwards than usual towards the shoulder, instead of going to the gland, entered the vertebral cavity between the fifth and sixth cervical vertebræ. This peculiarity led me



to preserve the head and upper part of the trunk of the subject, which has been dissected and dried, and you may now see the whole system of arteries, from the subclavian, exhibiting this peculiarity, and another, which consists in the entrance of the right vertebral into the spine, two vertebræ higher than usual.

At this time, I have under treatment the case of a young lady, of this vicinity, who has a tumour situated precisely like that I have described, and of the same form and appearance, though not so large. I have not yet advised its removal, believing it proper to try every expedient for its cure, before resorting to operation.

## SECTION IX.

### TUMOURS OF THE TESTIS.

THE structure and diseases of this organ have been clearly and fully described by Sir Astley Cooper, in his admirable work; and to this I would refer you for a full acquaintance with the subject.—The epididymis being often diseased independently of the testicle, I shall first call your attention to tumours of this part.

### TUMOUR OF THE EPIDIDYMIS.

The extremities of the epididymis, and even its whole substance, are frequently indurated, while the body of the testicle remains sound. The superior extremity, or globus major, is, in my



experience, much more frequently enlarged than the inferior, or globus minor. This induration occurs without pain, and is usually discovered by accident. It is a small, hard tumour, at the upper and back part of the testis; not tender nor painful; not usually increasing; but remaining stationary a long time, without any obvious ill consequence. Whether the function of the testicle is affected by it, would be difficult to decide; because the other testicle may continue its secretion. We should certainly expect that so hard a tumour would impede the transmission of the seminal fluid through the vasa efferentia, and cause much inconvenience. This is certainly not the fact ordinarily; but that it may sometimes be so, will appear probable from the following case.

A married gentleman, thirty years old, applied to me for advice in regard to a most painful and obstinate colic, as he called it. He was of a spare frame, yet powerful muscular strength, and very active and laborious in his habits. Notwithstanding these qualities and habits, I had known him in the earlier part of his life as a subject of severe scrofulous affection of the lymphatic glands of the neck.



For three years back, he informed me, he had been subject to violent attacks of pain once in three months, beginning in the anus, shooting thence into the scrotum, and increasing to an insupportable degree. Soon after these pains began, the left testicle swelled suddenly to a large size; but he was not quite certain that the swelling and pain did not begin at the same time. These pains lasted from twelve to twenty-four hours. They then very suddenly shot up into the cavity of the abdomen, accompanied with a sudden sense of heat through this cavity. The pains now assumed the character of colic, and after continuing one or two days, under the operation of powerful remedies gradually subsided. The paroxysm required about three days for its completion, and left the patient feeble, yet able to resume his pursuits after a day's interval.

The form of this attack, and its obstinate resistance to remedies, embarrassed me. I inquired if there were hæmorrhoids, or any other derangement in the rectum. The answer was negative. I asked him if there were any change in the state of the testicles. The reply was doubtful, and I requested to examine. On compressing the left testicle, I found the upper extremity of the epidid-



dymis very hard and considerably enlarged. The enigma was now solved; or at least I considered it so. When, from causes of occasional or periodical occurrence, there was an unusual congestion in the testicle and epididymis, the seminal secretion was unable to pass through, and being accumulated in the vasa recta, produced distention, a consequent sympathetic pain in the rectum, and sympathetic swelling of the testicular coverings. In this way the attack of pain in the rectum may be explained. The sudden transfer of pain from these parts to the cavity of the abdomen, is more difficult to account for. Perhaps it might be a sympathetic affection; or possibly it might have arisen from the secretion having at length forced its way through the obstructed epididymis into the vas deferens, and by its quantity and sudden irruption into the abdominal part of the vas deferens, have caused the severe abdominal pains. The patient, it may be remarked, expressed himself as suffering less from the latter than the former.

The first object of treatment in this case was the removal of the obstruction in the epididymis. This I knew would be a matter of difficulty, and so apprized the patient. He was recommended to put on three leeches every fifth day, to take five



grains pilula hydrargyri every night, and wear a suspensory bandage. At the same time to give up animal food, and eat sparingly, and take care to keep the bowels open. In case of the attack, to evacuate the bowels directly by an injection; and follow this with an enema of a gill of water and two drachms of tincture of opium, and apply a dozen leeches to the scrotum and lower part of the abdomen.

It is about ten months since this course has been pursued pretty constantly. He has had only two paroxysms since; one did not require medical aid. In the other, he was attended by Dr. Mason Warren; and under his direction the force of the paroxysm was broken by the opiate enema, composed as above directed.

The induration of the epididymis is much diminished by the course of treatment. Whether it will wholly disappear is doubtful; for, as has been already stated, this affection is apt to be permanent.

The extremities of the epididymis are often the seat of a cartilaginous excrescence, which is loosely attached, and might be dissected off; but this is rarely necessary.



## TUMOURS OF THE TESTICLE.

The testicle is subject to a number of tumours, not very easy to discriminate from each other. Some of them are of a malignant character; others are not malignant. The latter are the TUMOUR FROM COMMON INFLAMMATION, from SYPHYLTIC and from SCROFULOUS INFLAMMATION; the HYDATIDAL TESTIS and the CHRONIC ENLARGEMENT of the testis. The malignant tumours are the FUNGOID TESTIS, the SCIRRHOUS TESTIS, and we must place with these the CANCER OF THE SCROTUM.

ACUTE INFLAMMATION of the testis may be brought on by cold and by injuries. It may be distinguished by its arising suddenly; and generally from an assignable cause. The part becomes enlarged, hard, painful, hot, and red. It is usually tender to the touch. The constitution sympathises. There is increased circulation, headache, pain in the back and in the abdomen.—These symptoms subside in a few days, together with the swelling. Frequently, however, after the constitutional affection has disappeared, the



swelling of the testicle continues, and constitutes chronic inflammation of the part.

The following case, which you have seen, will serve to exemplify these forms of inflammation. J. B. Adams, a seaman, thirty-one years of age, entered the M. G. Hospital in July, 1836. Five weeks before, while riding in a stage-coach, he bruised the testis from a sudden jolt. He was exposed to cold that night, and the next day the testicle began to be painful, to swell, and became red and hot. His journey being continued on horseback, the swelling and pain increased, and became severe, and he was attacked with fever. In a few days the fever went off; but the swelling of the part continued, and it is now four times larger than natural. At present he has no great pain, but some degree of tenderness. The skin is not now red nor hot.—He was directed to be confined to the horizontal posture; apply three leeches to the scrotum every three days; take a purgative solution every other day; and adopt a sparing vegetable regimen. The derangement not yielding to this treatment, he was ordered five grains of *pilula hydrargyri* every night, blisters on the thighs, and warm fomentations. A continuance of this treatment for four weeks, reduced the part



to its natural size, or nearly so, and he then left the hospital.

Inflammation of the testis, arising during a VENEREAL INFLAMMATION, is not necessarily a venereal affection, especially if it occur during gonorrhœa. If it appear at the time of a confirmed lues, it is more likely to be of a syphilitic nature; but even in this case it is often produced by a sympathy with inflamed inguinal glands, or with inflamed urethra.

The following case may have been syphilitic, or not. Different opinions will be entertained on the subject. The fact of the patient having recovered under the use of mercury, will be considered by some as proof of the existence of lues; but if there had been no such affection, would not the mercury have had a similar effect?

J. S. having contracted a severe gonorrhœa, applied to an empirical doctor, and obtained from him a strong astringent injection, which soon checked the flow from the urethra, and was immediately followed by a swelling of the testicle. He was admitted into the M. G. Hospital in April, 1836. He was directed to be confined to his bed, and adopt a severe regimen. A bougie, covered with mercurial ointment, was passed into the

urethra twice a day, and caused a slight return of discharge from the urethra, and a sensible diminution of the swelling. Instead of the mercurial ointment, balsam copaiba was applied to the bougie, and, as he did not feel this, a mixture of three-quarters olive oil, and one of spirits of turpentine was introduced on the bougie. He made no complaint of this application, and it was followed by a sensible diminution of the swelling, which was now very much reduced, and he was evidently convalescent. Finding, however, that he recovered very slowly, I directed some mercurial remedies; and under these, and the stimulating applications to the urethra, he soon got well.

The real venereal tumour presents nothing in its aspect by which you can distinguish it from a common inflammatory enlargement. By the history of the case, the nature of the affection must be determined.

SCROFULOUS TUMOUR OF THE TESTIS. The collection of symptoms which constitute a scrofulous habit, have been alluded to, on another occasion, and are therefore not to be described at this time. A tumour of the testis, arising from what we call scrofulous inflammation, is perhaps



the most frequent of the permanent tumours of the part.

The scrofulous tumour occurs in the scrofulous constitution, or *strumous diathesis*, as it has been denominated, between the ages of twenty and thirty. The predisposition is commonly aided by an abuse of the generative apparatus. An exciting cause is not always discoverable, but it is not unfrequently traced to a slight blow, and sometimes to the consequence of a continued fever. It comes on slowly, without pain or vascular excitement. The tumour is at first uniform on its surface, and does not include the epididymis. After a time it involves its appendages, the epididymis and the spermatic cord. It is not tender to the touch. The integuments are not discoloured. At length it becomes irregular, and presents a protuberance at one point. As this increases, it gets to be painful, and is occasionally attended with contraction and lameness of the corresponding limb. At length it opens and discharges a bloody serum, mixed with flocculent matter, which may be the secretion of the gland, or an ill-formed pus. The wound becomes fistulous, and the discharge continues a long time, perhaps for years. The testicle, if



not wholly disorganised before the opening takes place becomes so afterwards, and never can be restored to a healthy state. If the patient's health is sufficient the wound may heal, leaving the relics of a testicle.

Here I will state a case which may give an idea of the origin and course of this disease ; and of the morbid appearances it exhibits.

Dr. Ware, of Milton, in this vicinity, requested me to see a patient of his, afflicted with disease of the right testicle. On visiting the patient, I found him confined to his bed with a painful affection and stiffness of the right thigh and leg, consequent on the disease. He was a gold-beater by trade ; twenty-one years old ; of a slender frame ; thin sandy hair ; thin skin ; had never enjoyed perfect health. At ten years of age, he received a blow on the right testicle ; after which it was frequently painful ; but did not swell. In the spring of 1836, he had an attack of continued fever, which lasted about five weeks and when it subsided, left him with a swelling of this gland, and an enlargement of the lymphatic glands on both sides of the neck. He was however able to resume his business and continued it through the summer. In the autumn the swelling and pain in-



creased ; he had a febrile attack, consequent on it, and was compelled to keep his bed. The pain in the diseased part was so great as to require very large doses of opium to procure sleep. Examining the part, I found it of the size of a hen's egg ; hard quite to the abdominal ring ; tender to the touch ; and on the lower part, a considerable soft projection, indicating the existence of a fluid. The skin was not diseased.—Considering the severity of his sufferings and the certainty that the part would not regain a healthy condition, I advised its immediate removal. This was done the next day. I elevated the skin and with a cut of the knife divided the integuments ; separated them on each side ; seized the cord with a pointed forceps and divided it. The spermatic, external pudic and deferential arteries required ligatures which were cut close ; and the skin was brought together with three sutures.

On dissection of the part the appearances were these. The section of the cord showed a thickening of the cellular substance without an essential change in its organization. The external tunica vaginalis was thickened, and adhered to the close tunic through half its extent. The tunica albuginea was perforated at the lower part by the ulcer-



ative process and on cutting into the small projection formed at this ulceration there was a discharge of bloody serum and a little blood; and also a flocculent white liquid, which came from the interior of the gland. The body of the testicle presented no distinct remains of its natural texture; and the vasa recta could not be unravelled. Many cells were scattered through the morbid mass, which contained a white glutinous fluid. At the back of the testicle, corresponding in situation with the mediastinum, a yellow membrane was seen, forming a sac as large as a hazel nut, within which was a dark coloured soft mass, with little appearance of organization. The epididymis had a cavity in the globus major and a larger in the globus minor; and the terminations of the vasa efferentia, as well as the beginning of the vas deferens were thickened and hardened. A number of yellowish hydatids were seated in the spermatic cord.—This should be considered as an uncommonly severe instance of scrofulous testicle; though certainly of this character. Usually the constitutional and local symptoms are much less violent.

The removal of the testicle will give the patient great relief. It is doubtful whether he may recover a good state of health. His constitution, origin-



ally scrofulous, has been broken by the continued fever; and the state of weakness, induced by it, has favoured the developement of the scrofulous action in the testis and lymphatic glands.

In the incipient stage of scrofulous tumour, the disease may be arrested, by a regimen restricted as to the quantity of food; by keeping the patient quiet; and applying a blister to the thighs alternately. Preparations of iodine have not been efficacious in these cases, so far as I have used them. The tincture of iodine has been given to the amount of forty five drops three times a day. This quantity was sufficient to produce diarrhœa; but after a long use had no effect on the tumour. The same must be said of the hydriodates of soda and potass, which I have frequently given in this and other scrofulous cases in the dose of seven grains three or four times a day, till it irritated the stomach and bowels without influencing the cure.

**HYDATIDAL TUMOUR OF THE TESTIS.**—Hydatids are frequently found in the tunica vaginalis testis and in the spermatic cord. When they grow large in these situations, they produce symptoms of hydrocele of the tunica vaginalis or of the cord.—The hydatid tumour of the testis differs essentially from these, being situated within the tunica



albuginea, in the substance of the testis. It is a rare disease, not malignant; and is analogous in these and other points to the hydatid tumour of the mamma. The most remarkable facts relating to it are its rapid growth and great size. In form it is oval and much resembles hydrocele; but is less regular.

J. B. came to the M. G. hospital with a tumour in the scrotum as large as the head of a child three years old. He says that about fifteen months since he felt a pain near the right crista ilii and soon after, some uneasiness in the spermatic cord, which was followed by an enlargement of the testicle without much pain. Since then it has increased irregularly and lately with great rapidity, so that he has found it extremely inconvenient to move about. The scrotum is not discoloured. The tumour is of an ovoidal shape, flattened at the sides. It is not tender to the touch, exhibits no sign of fluctuation and is not diaphonous. The patient is well in other respects; has had no disease and received no injury which can have brought on the complaint.—An incision was made through the scrotum and tunica vaginalis which discharged from the latter cavity a quantity of red coloured fluid, thicker than serum. The tunica albuginea being



then opened, was found to contain a number of cells filled with a semi-transparent gelatinous fluid. These cells were of different sizes and occupied a principal part of the cavity of the albuginea, leaving but little appearance of solid substance in any part of this cavity. The diseased mass with a portion of the scrotum was then excised. The patient recovered rapidly and I have not learned that he has since experienced any trouble in the part.

CHRONIC ENLARGEMENT OF THE TESTICLE.—

This is one of the most common tumours of the organ. Not unfrequently it arises from common inflammation. The testicle, having been swollen by cold or from injury, the swelling does not wholly subside, but assumes a chronic form, and continues in a state of enlargement for years. In some cases the enlargement becomes considerable. This kind of tumour is not attended with much pain. There is no discolouration of the skin, and no great tenderness. The surface of the testicle is somewhat irregular, and its substance firm, without being positively hard. The epididymis is sometimes, not always, enlarged. The spermatic cord is rarely affected.—Hydrocele is frequently connected with chronic enlargement. The fluid is sometimes found above and sometimes below



the testicle. This state of things produces an embarrassment to the operator. The tumour presents the undulatory movement of a fluid, with the firmness of a solid ; but by habit and careful examination, you may learn to distinguish the hard inelastic feeling of the testis from the yielding, undulating hydrocele. Sometimes, however, it is impossible to decide that the testis is enlarged, until the fluid is drawn off. This, of course, must be done with peculiar care to avoid wounding the testis. When the water cannot safely be drawn off by the trochar, the tumour may be cautiously punctured with a lancet ; and sometimes it may be necessary to make a careful dissection with the scalpel ; cutting through the skin, cellular membrane, and tunica vaginalis, by successive incisions, until the fluid is reached.

In the chronic enlargement, the disorganization of the testicle does not occur to the same extent as you will see it in some other affections of the part. In this specimen, you may observe that though the gland is much enlarged, the septa are perfectly visible, and even the vasa recta may be discerned, though bound together by effusion of lymph.



The treatment of the chronic enlargement consists in the application of leeches every fourth day; blistering the thighs successively; purgatives; sometimes a course of mercurials; the horizontal posture, if practicable; and, if not, a suspensory bandage.

Mr. —, of Maine, applied to me in 1833, for a considerable enlargement of both testicles. He is a married man, of thirty-five, very strong and fleshy, and a good liver. His swellings have been coming on for three years back. Fifteen years ago, before his marriage, he had a gonorrhœa, but no disturbance in the testicles. Three years since, in riding on horseback, the horse started, and bruised the left testicle. The pain was great at the time, yet was not immediately followed by swelling. Some weeks after, he felt a hardness in the part, which increased gradually to its present size. When the left began to swell, he does not know, having believed till lately that the right testicle only was enlarged. He has had no pains of any importance. Both the testicles are very large, and appear hard. On a careful examination, I found that a quantity of fluid was contained in both sacs, and proposed to discharge it. The water was accordingly drawn off, and the testicle being



left without fluid, was found to be about three times the natural size, hard, and irregular, the cord sound. At a subsequent period, the water was drawn from the other side. The operation has been since repeated, sometimes annually, sometimes once in six months. The tumours continue to be of their original size, neither increasing nor diminishing.—In 1835, he committed some imprudence, after the tapping, and brought on an acute inflammation with fever, which confined him for three weeks, but eventually left him as at first.

A few days since, a gentleman of this town, sixty years old, married, of vigorous constitution, applied, on account of a rupture he was unable to manage. On examining his case, I found an irreducible hernia of the omentum on the right side, below this, a chronic enlargement of the testicle of the existence of which he was ignorant, and a reducible hernia on the left side. It appeared, from his account that the rupture on the right side had existed for twenty years; but whether in a reducible or irreducible state, it was impossible to ascertain, as he had an enlargement existing there, which he believed to be connected with his rupture, and of course took no means to remove it. The chronic enlargement of the testicle was no



doubt a consequence of the pressure of the truss on the spermatic cord. He was advised to leave off the truss from the right side, and wear a suspensory, continuing his truss on the left. He complained to me afterwards that the suspensory and the truss interfered, and the testicle being quite large, he could not manage either of his complaints so as to be comfortable. I told him there was no remedy I could devise for this, but the removal of the testicle.

#### MALIGNANT DISEASES OF THE TESTIS.

We shall advert first, to those affecting the integuments; second, to those of the body of the testis.

**CANCER OF THE SCROTUM.** This is a true cancer. It is called in England, *chimney sweep-er's cancer*. I have never seen it in chimney sweepers in this country, but have met with a few instances in persons not of that business. The disease begins with a warty excrescence on the scrotum. This, as it increases, becomes sore and ulcerates. The ulcerated surface is elevated. The cellular substance gets diseased, the glands in

the groin swell, and the complaint, if left to itself, terminates fatally.

T. B., thirty-five years of age, applied to me, in the year 1825, for a sore on the scrotum. He said he discovered a wart there six months before. This, as it increased, got rubbed off, and a new crust formed. At last, it became so large that a crust no longer formed, and it continued an open sore. It was, when I first saw it, about the size of half a dollar, and of an oval shape. It had a bright red colour; was somewhat thickened at the edges; very sensitive; and had sometimes a burning pain.

This tumour was cut out; healed well, and the patient has been in perfect health to this time.

**MALIGNANT TUMOUR OF THE TESTIS.**—This disease was formerly called scirrhus testis and cancerous testis. Sir Astley Cooper, and other authors, have shown that a true scirrhous of the testicle is very rare, and that the common malignant disease of the part is not a true cancer, but a fungoid disease.

**FUNGOID TESTIS.**—This is what is commonly called scirrhus and cancerous testis. It is of



frequent occurrence, as you see by the various specimens placed before you. Most commonly it is seen in persons of unhealthy constitution, sometimes arising spontaneously, and sometimes from violence. The patient is led, by sense of uneasiness, to examine the part, and finds it enlarged and somewhat irregular. Pains shoot up the cord, and into the small of the back. The tumour increases, and becomes more painful. The constitution shows signs of disturbance. In some cases, the tumour opens through the scrotum, shoots out abundance of unhealthy granulations, and discharges a fœtid matter. Instead of granulations, we see, as in the specimen, a fungoid appearance, like the unravelled seminal duct. The glands in the groin enlarge. The patient has a febrile affection, with loss of appetite and emaciation. The abdomen swells. The lungs show marks of disease, and the patient wastes with pain and derangement of the functions of the great organs.

This disease is disposed to terminate fatally, and will generally do so unless it be arrested by an early operation. In some of the cases from which the specimens exhibited were taken, the



wounds healed, and the patients recovered, and continued well, so far as we know. Three cases terminated fatally, and these, as the more instructive, will be related. In only one of the three was the disease in a state of open fungus, at the time of operation. In the two others, there were remarkable affections of the great organs: in one, of the brain and lungs—in the other, of the viscera of the thorax and abdomen.

James Colby, a farmer, 47 years old, admitted into the hospital Dec., 1832.—When seventeen years old, fell on a fence, and bruised the testicles. The right testicle swelled, became painful, and has continued to do so occasionally since. Four months ago the swelling became permanent, and accompanied with great pain. A plaster was applied. The integuments opened, and a foul, offensive fungus shot out, which you see here. The severity of the pain, and the rapid increase of the disease, brought him to the hospital. The testicle was extirpated. The symptoms were perfectly favourable till the fourteenth day, when the pulse quickened, and the countenance became ghastly, although the patient made no complaint, and would not admit himself to be very ill. On



the seventeenth day he died. Examination of the body was not permitted. The abdominal organs were no doubt diseased in this case ; but the suddenness of the termination I am disposed to attribute to internal erysipelatous inflammation.

W. Colton became a patient in the hospital in October, 1833. He was twenty-seven years of age ; a comb-maker by trade ; appeared feeble and emaciated. He said that seven years previous he felt a darting pain in the left testicle, without any known cause. The testicle swelled, and after a short time subsided ; and subsequently, when he took cold, this swelling and pain recurred. Two years since, he slipped down, and felt something give way in the left groin. The swelling returned, and from that time became permanent. In the day, it was always greatest ; in the night, it diminished.—At this period, both epididymis and testis are much swollen, yet can be distinguished from each other. The pains are severe ; his health is much affected ; pulse quick ; tongue furred ; little appetite ; much acidity and flatulence. Oct. 11th.—The testicle was extirpated. The symptoms immediately afterwards were not unfavourable. On the 31st, the patient expressed himself as feeling very comfortable, and the wound



was nearly healed. On the next day, Nov. 1st, he said he had been troubled with pain in the head. This symptom increased daily. The temporal artery was opened. Leeches were applied daily. He became delirious on the 11th, and on the 14th died. On examination of the body, the membranes of the brain were found to be covered with an effusion of lymph. The ventricles contained three ounces of water. The substance of the lungs was inflamed, and presented many tubercles, and the pleura adhered to the parietes of the chest. Abdominal viscera not diseased. The testicle exhibits a great enlargement, as you see, and internally presents the appearance of the medullary substance of the brain. It is, you observe, of a uniform appearance, without cavities. The coats are thickened.

The third specimen of fungoid testis to which I would direct your attention, is, as you see, of large size, and altogether remarkable. The coats are thickened, and compacted together. The epididymis is not distinguishable from the body of the gland. A section of the tumour presents the same formidable aspect it had when first removed. You notice a sanguineous colour, intermixed with yellow, pervading the mass. This



mass is broken up into numerous cells, which contain a bloody fluid, and some of them a curdy matter. These cells would lead you, perhaps, to consider this to be an hydatidal testis. The encephaloid appearance of the intervening mass, and the comparatively small size of the cells, together with the thickening of the cord, will correct this opinion. The peculiar texture of the disease, with the nicer shades of distinction, have disappeared. This specimen was taken from an individual thirty years old, a farmer, who noticed the incipient symptoms three years before. They began with pains in the groin and testis, succeeded by a hardness, which increased pretty regularly to the time he entered the hospital, in October, 1833. His health was then very much affected; the cord enlarged at the ring; but the coats not perforated by disease. The operation of excision was directly performed, and the patient went on without any bad symptoms for three weeks, excepting that the wound showed no disposition to heal, the two lips of it lying in contact without forming the least union, and having an unhealthy, glossy appearance. His appetite became worse. He had some fever, and a sense of fulness of the abdomen. Thus he went on from the third to the seventh week, when,



without exposure, he was seized with pleurisy, and died in five days.

On examination, the body was greatly emaciated. The cavity of the abdomen contained water. A knot of scirrhus glands extended from the groin to the aorta, which was buried in a mass of these enlarged and softened glands. The right cavity of the thorax contained a quart of bloody serum, and was lined with flakes of lymph. The right lung was highly tuberculous, and indurated. The left lung was partially affected in the same way. The brain was not examined.

The statement of these cases will give you an idea of the disposition there is to constitutional disease in the fungoid testis. Whether this constitutional derangement precedes or is consequent on the local malignity, we cannot certainly determine, because we cannot examine the internal organs in an early stage. The common opinion is that the evil begins in the local affection. Until this point shall be decided in a way contrary to this opinion, it must be considered a matter of the greatest consequence to extirpate the testicle at an early period. But how are we to know whether the disease is of a malignant character, before malignant symptoms arise? Simple chro-



nic inflammation, scrofulous and venereal inflammation, may produce appearances similar to the early stage of the fungoid disease. How then are we to discriminate the fatal disorganization in season to arrest its transmission to the great organs?

It must be admitted that this discrimination is often impossible in the early stage. We must be careful to study the history of the case, and satisfy ourselves that there is not a scrofulous, syphilitic, nor sympathetic action going on in the part. We must inquire if the patient has suffered much pain; whether the functions of the digestive and pulmonary organs are disturbed; we must notice whether the tumour is irregular and comparatively hard. In the case where these symptoms show themselves, we are not to wait. Better is it to remove a number of testicles, without absolute necessity, than to allow one to proceed beyond the reach of art. The scrofulous, and even the venereal inflammation, when they have continued long, produce a disorganization, from which it is impossible to recover. The organ, in such instances, is of no use; it is but a name; and though men are naturally tenacious of preserving it, even in this unsubstantial state, they would not desire



to extend the experiment long enough to endanger life. When they are thus determined, it is better that the patient should take this responsibility on himself; and therefore, without exciting unnecessary fears, I should fairly state to him the dangers he has to encounter, and let him decide the question.

Even the scrofulous testis, in an ulcerated condition, is better removed. For, although the healing of such ulceration is often accomplished, the texture of the part is broken down, as already stated, and its function lost, in most cases. The cure is long, and causes much pain and embarrassment.

I have known, and have at this time in my care, a number of patients, who have had chronic enlargement of the testicle for many years. I do not propose to remove such tumours, for the following reasons: because the patient suffers no pain; because his health is unimpaired; because the disease does not advance; and because I can trace the origin of these tumours to some satisfactory cause, not connected with the character of malignity.

The discrimination of the fungoid disease from hydrocele, varicocele, and hernia, will be made



easily in most cases, if you are properly informed of the symptoms of these derangements.

A true scirrhus of the testis has been stated by Sir Astley Cooper, to be very rare. It has been common to call every confirmed induration of this organ by the name of scirrhus. But if you compare the many preparations laid before you, both those in jars, and those you have an opportunity of examining and touching, you must see that there is nothing in all these like the real scirrhus of the breast, of the lymphatic glands, and of other parts. Here is a single instance of this disease, which I have possessed many years, but never cut open until this day, which you see has this character. The tumour is not large. Its external part is as hard as cartilage, and even grits under the knife. In the center is a cavity lined by a dark coloured membrane, and containing a dark fluid; appearances precisely such as we meet in the scirrhus breast. I am sorry to say that I know nothing of its history; for at the time it was removed, I had no knowledge of the distinction between this and the fungoid disease, and neglected to open it when first removed.

## SECTION X.

### THIRD DIVISION OF GLANDULAR TUMOURS.



#### TUMOURS OF MUCOUS GLANDS.

UNDER this head will be placed the morbid enlargements in the mucous membrane, which seem to have their origin in the muciparous glands.

Many of the tumours situated on the mucous membrane, originate in the glands scattered through their course. Perhaps all the cancerous diseases of this texture take their origin in these parts. The early stage of such affections exhibits a white fibrinous\* substance, either intermixed

---

\* By fibrinous substance, I mean a texture formed of, and resembling the fibrin of the blood. Fibrous substance I understand to mean the white, insensible, inelastic texture of tendons and aponeuroses.



with muciparous glands, or lying on their surface ; and the glands themselves are much enlarged in the vicinity of the tumour. Even we can discern, by the microscope, spiculi, of whitish substance, extending from them, and running into the fibrous induration, or from the indurated texture to the glands. There is therefore, it seems, a deposit of new substance from the disordered glands, which forms the beginning of these tumours. This deposit goes on to a limited extent ; and in a longer or shorter time, ulceration begins, commonly at the most superficial part. Then an ill looking excrescence is protruded ; and thus ulceration and deposition go on together, in a slow manner. We can easily conceive of the progress of increased deposition from some local irritation, as tobacco, applied to a part covered by a thin cuticle. But what brings on this process of ulceration, is not so easy to explain.

The early stage of this disease is not accompanied with pain. When ulceration begins, there is a burning and shooting sensation. After the disease has continued for some time, the lymphatic glands, in the course of the absorbent vessels, become swollen, and the disease may then be considered as incurable.



## CANCER OF THE LIP.

The *lower* lip is the seat of this disease. This happens from its dependent situation, in consequence of which, irritating substances fall on it from the mouth, as tobacco juice, fat, ardent spirits, which are among the most common causes of the local irritation. Various are the forms under which this affection presents itself in the early stage. Sometimes we see a cuticular crust, which, being frequently broken off, and leaving a raw surface of the true skin, at length terminates in a thickening of this skin. Sometimes the diseased growth is first discovered in the true skin itself, and sometimes in the sub-cutaneous glands. The first of these forms progresses slowly; the others, more rapidly. The cuticular crust will continue to be regenerated for years before it assumes a malignant character. This is apt to be confounded with psoriasis labialis,—a non-malignant affection, yet not always a manageable one.—Although each form is susceptible of cure in the early stage, yet, when it does not soon yield to a careful regimen, and the removal of causes of irritation, it is best to resort at once to the knife,



—a short and certain remedy. If the disease has made such advances as to thicken the surrounding parts to a great extent, to present an ulcerated surface and a fœtid discharge, and the lymphatic glands under the jaw are enlarged, you may cut out the tumour, because the patient must otherwise die ; but you cannot promise him a recovery.

The following case is an early and favourable instance of this disease, and one not produced by tobacco.

Mr. R. applied for advice in November, 1830, in regard to a thickness of the lip, about three quarters of an inch in extent, with a small ulceration in the centre. He is twenty-two years old ; temperate ; has rarely used tobacco, and that only in the way of smoking. Two years ago, he perceived a small pustule on the lower lip. This burst, and left a scab. Then the lip thickened, and became somewhat painful, and has gradually increased to its present size. He has made many applications, with no good effect.—The tumour was removed. On examination of the indurated parts, there appeared at its base very large mucous glands. Thence there shot out a whiter substance, which ran into a pure fibrinous indura-

tion in the skin of the lip. The result of the operation was perfectly successful.

## TUMOURS OF THE TONGUE.

There is an enlargement of the mucous glands of the tongue, formidable in appearance, but not malignant. These glands become quite prominent ; of a strong red colour ; are seen most commonly in the lateral parts of the organ, and present an appearance which might be mistaken for that of a fungous tumour. On examination, it will be found, in these cases, that, the patient having been out of health, some local cause, as a broken tooth, has irritated the tongue, and produced the appearance mentioned. The part is sensitive ; not painful ; there is no real ulceration nor thickening of the tongue : by which circumstances the disease is distinguished from cancer.

Mrs. —, after being affected with fever, perceived a tenderness in the left side of the tongue in August, 1835. A tooth which irritated the part having been removed, the tenderness subsided, and did not return for some weeks. It then recurred, and she came into the hospital in the



summer of 1836. At this time, there was seen on the left side of the tongue, for the extent of an inch and a half, a cluster of red eminences, having the aspect of a fungous tumour. There was no ulceration, and no discharge of pus; but the mouth was offensive, and the part very sensitive to the touch, so that for a long time she had been quite unable to eat solid food.—The teeth on the side were removed, with relief to the sensitiveness. But the swollen glands did not return to their natural state, and therefore caustic potass was twice applied; and then the surface was brushed daily with a saturated solution of nitrate of silver. The disease amended slowly. She was able to eat with great comfort. But finding that the cure would still require a long time, she was discharged, with directions how to proceed. The patient having been under my eye for six months, and during that time all the symptoms having diminished, I felt myself justified in concluding that the disease was not cancerous.

The large mucous glands on the surface of the tongue, near its root, are sometimes swollen from a derangement of the stomach. This condition may continue for months, but at length gives way to a proper regulation of the stomach and bowels.



It is sometimes useful to make a local application of solution of nitrate of silver.

The glands at the back part of the pharynx, behind the fauces, and also those lower down behind the larynx, are subject to a similar affection. Those in the last situation, being seated in the contracted part of the pharynx, cause much inconvenience, and are least tractable. Neither of these affections are of a scirrhus nature.—The same course of treatment is proper in both. When the nitrate of silver is applied in the last situation, it may be done by the sponge of a probang, dipt in the solution.

The tongue, and the lips, and the mucous membrane of the mouth, are subject to a small blue coloured rising, which is constituted by a cyst, containing a transparent, glairy fluid. This often subsides of itself; sometimes is cured by a puncture, to discharge its contents; and sometimes requires excision.

#### CANCER OF THE TONGUE.

Cancerous diseases of the tongue present themselves in three forms. First, in that of a small

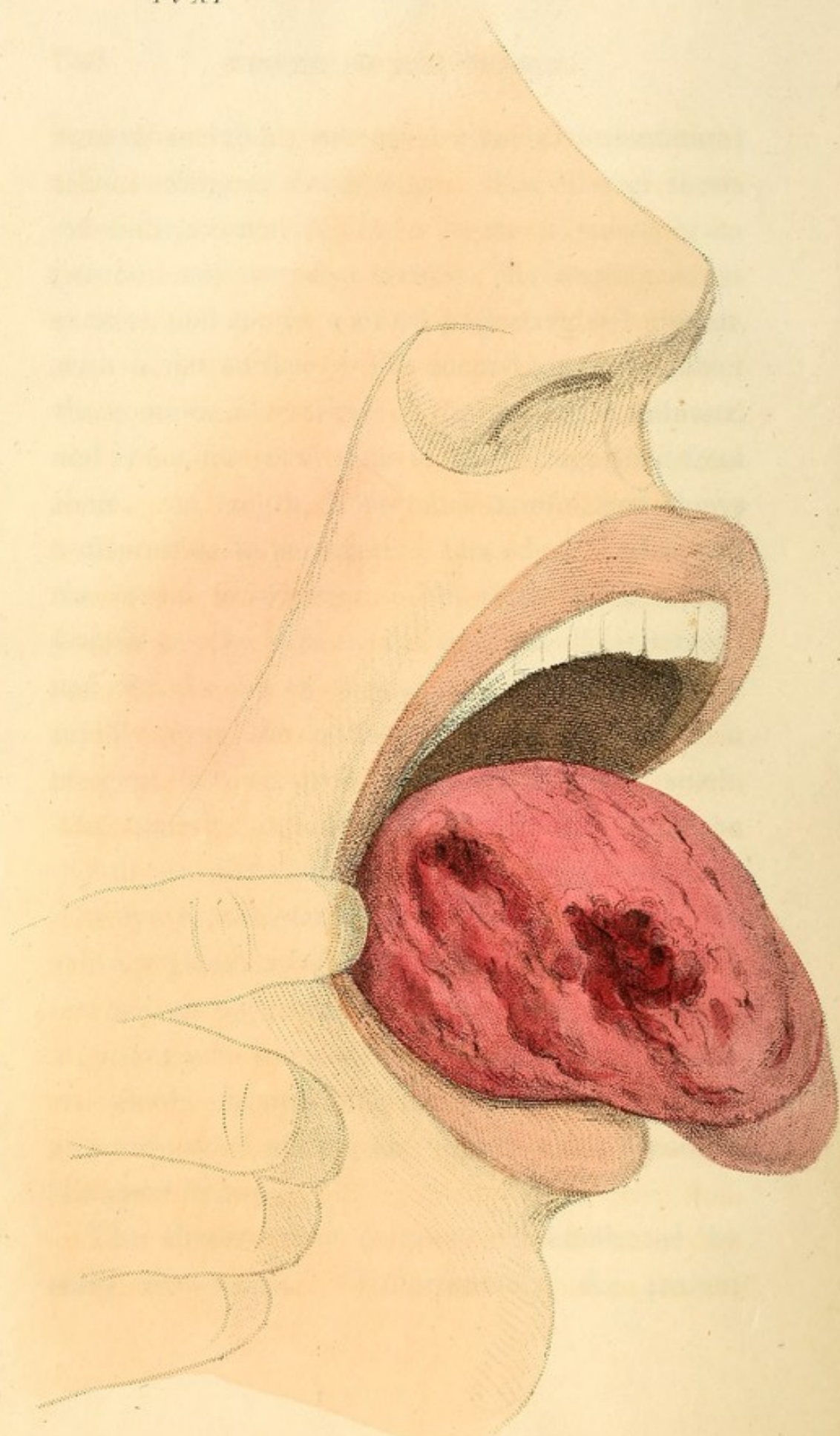


tumour or lump ; second, a superficial ulceration ; third, a fungous excrescence. The first of these, when discovered, may have the size of a pea ; is not painful ; and increases slowly. Eventually, it ulcerates, and shows a broad projecting red tumour, with a flat surface.—The second much resembles the common ulcerations of the mucous membrane, and is not for some time to be distinguished from them. At length, it becomes painful, and shows a disposition to penetrate. The edges harden, and the mouth is offensive.—The third begins with a pimple on the side of the tongue. This breaks, and throws out a fungus, which extends itself rapidly over the surface ; is attended with a pungent burning pain, and very offensive smell. The appetite is lost. Aliments taken into the mouth are distressing, instead of being agreeable. The lymphatic glands in the neck, and also the salivary glands swell and become painful.—I have not had an opportunity of examining the body of a patient who had died of this disease. Probably we should discover enlargement of the thoracic and abdominal glands, and disordered structure in the great organs.

This disease may certainly be eradicated by early extirpation. Unfortunately, the patient







*Cancer on the tongue*



often protracts his consent to this remedy until the disease is past cure. There are three modes of removing them,—the knife, ligature, and actual cautery. The first is most to be relied on; and the only objection to it is, the hemorrhage from dividing the lingual artery. In these cases, however, I have not found any difficulty in applying a ligature to this vessel.—When we adopt the second mode, a needle, much curved, is armed with a double thread. The tongue is transfixed behind the middle of the tumour, and the thread tied on each side, so as to include the whole.—The third, or cautery by the red-hot iron, is much used in some countries. We only employ it as auxiliary to others, either to destroy what could not be removed, or to arrest a subsequent hemorrhage.

Jabez Wood, Jr., seaman, of Maine, was admitted into the M. G. Hospital, Nov. 8, 1836. He has a large fungous sore, occupying the right side of the tongue for nearly two inches in length, and covering half the breadth of the organ. Its appearance is that of a foul mushroom fungus, of a dark red colour, ulcerated deeply in the middle, and rising above the surface of the tongue a quarter of an inch. See Plate XI. The mouth is



very offensive, and the teeth are blackened by the foul discharge. The disease is not constantly painful. At times, he has a sharp pain darting from the tongue into the ears. It is rarely sufficient to keep him from sleeping in the night. It appears, that eleven weeks since, he noticed a small hard lump on the right edge of the tongue. This shortly became painful, and, bursting, discharged a fluid, and the aperture ulcerated, and formed a sore. Of late, this has increased rapidly. About three weeks since, a lymphatic gland on the right side of the neck swelled, and continues so. The patient has been, for a great many years, a free consumer of tobacco, and the disease originated on the part of the tongue which lay in contact with the tobacco while in his mouth.

At the first view of this case, I felt very little disposition to meddle with it. On further examination, I found it would be possible to remove every part of the primary disease. Considering its short duration, the want of hardness in the gland affected secondarily, and the impossibility of his escape without an operation, it was concluded, at his earnest request, to make an effort in his favour. The ligature suggested itself first: that is, to pass a crooked needle, with a double thread,



through the middle of the tongue, and tie on each side, so as to include the whole tumour. To effect this perfectly would be a matter of difficulty, as the ligature could not be pushed down towards the root of the tongue, so as with certainty to embrace the whole tumour in that direction. The knife, on the other hand, involved the danger of hæmorrhage from the lingual artery. On the whole, I concluded that course to be best, which promised to be most effectual, whatever might be its dangers.

The operation was done as follows. The patient, having his head resting against a support connected with his chair, I desired him to put his tongue out. As soon as he did this, I attempted to seize it with a double pointed forceps. The instant he felt the forceps, he drew the tongue back. I then thrust the forceps into his mouth, caught the tumour and a portion of the sound tongue on each side of it, in their gripe; drew the tongue out of the mouth, and in two or three seconds removed the tumour, including a portion of sound substance all around and under it. The lingual artery bled copiously. This artery was soon seized, and a ligature applied. Then, for greater security, I passed a red hot iron over the



surface of the wound. In the afternoon, the patient had some hæmorrhage, which was checked by ice. The following day he was quite comfortable.

On examination of the tumour, I found that all the diseased portion was surrounded by healthy substance, excepting at its base, where the internal surface of the scirrhus part, presented itself, covered by a cyst, which perfectly insulated it from the substance of the tongue, and is here shown to you. Cutting into the scirrhus, it was found to consist of a white substance, intermixed with small white globular bodies, like mucous glands. From the white substance, spiculi, of a reddish white colour, a quarter of an inch long, shot into the superficial fungous part of the tumour.

The origin of the disease in this case may be traced pretty satisfactorily. The habitual application of the poisonous tobacco gradually perverted the action of the parts it touched, the result of which was the deposit of white morbid matter. You ask, how can tobacco produce cancer? How can a vegetable narcotic produce a specific disease? Cancer is not a specific disease. It has a variety of forms, of causes, and of habitudes of action. It is one thing in the tongue, another in the skin,



another in the breast. There is nothing specific in it, unless you call its incurable disposition specific; but this it has in common with other diseases. Besides, cancer, though rarely cured, is not universally incurable. We see it disappear, in various parts of the body, without excision; though most rarely.—But again you ask, why do not all tobacco-chewers have cancers of the tongue or lip? I answer, because they are not predisposed. You smile; but there is something in this predisposition. Its co-operation is necessary. Where has the predisposition arisen in this case? The patient's parents and ancestors had no cancers, so far back as he knows.—I take it for fact, that the predisposition in this case was generated by the long use of ardent spirits—that this agent had gradually disordered his system, and laid it open to the inroads of morbid irritation from any quarter.—There is nothing specific in the action of tobacco. If he had kept a leaf of stramonium in his mouth for some years, the consequence would have been the same. A mineral, or even a mechanical irritant would, I doubt not, have brought on the disease in this man, had either of them been applied for so great a length of time. Yet we know that tobacco is a common cause



of cancer in the tongue and in the lip. For many years back I have questioned those affected with these diseases, as to their use of tobacco, and you have had opportunities of witnessing that they have generally answered in the affirmative. Every man who chews tobacco, may, I think, consider himself particularly exposed to the danger of having a cancer in his lip or tongue.

This patient recovered from the operation. The wound healed in three weeks. The tumour in the neck continued. His previous sufferings were removed, and he expressed himself highly delighted with the comfort he enjoyed, and in that condition went home. About a month after, he appeared again. The tongue had ulcerated in the cicatrix. He was anxious to have an operation performed again. I declined it. He pressed the matter on the ground that if an operation did not cure him, the alleviation he expected would render it desirable. However, I could not feel justified in doing any thing further, and with difficulty prevailed on him to abandon the hope he still cherished, and to go home, and "set his house in order."



## TUMOURS OF THE SOFT PALATE AND PHARYNX.

The mucous glands of the soft palate and of the parietes of the pharynx, are often the seats of a true scirrhus. An induration is discovered sometimes in the base of the uvula, sometimes in one of the arches. It is attended with but little pain; and the inconvenience it causes is difficulty in swallowing. The tumour increases slowly, in every stage interfering much with the act of deglutition, especially when it becomes large. Yet it rarely runs into the ulcerous state.—Many years since, I saw a tumour of this description removed by my late father. It lay in the middle of the soft palate, was about the size of a hazel-nut, and involved the uvula. He seized it with a hook and cut it out with curved scissors, leaving a considerable fissure, from retraction on each side. He then took a needle, very much bent, and securing it in a common dressing forceps, passed the needle with a ligature, brought the sides of the wound together, and produced a good union, so that the utterance of the patient was not impaired. This operation made a strong impression on my mind, and led me, many years after, when called to



operate for connate fissure, before this operation had been much practised, to contrive an instrument, with a moveable eye, which answered my purpose for that operation.

In the summer of 1835, a lady came to me with a scirrhus affection of the palate, occupying three quarters of its width, and running into the two columna and the tonsil of the right side. It was hard, red, sensitive, caused great difficulty in swallowing, and a deafness in the right ear. The patient was a married woman, thirty years old, of a delicate habit. She informed me that the disease had been in progress six months. The affection of the right side of the fauces and pharynx, led me to doubt that it could be eradicated, and so I told the patient. However, she was anxious to have something done, and I therefore attempted the cure in the following manner. The patient being properly seated, the jaws were separated by a speculum oris; then a four-pronged hook, with two sliding points, was passed behind the middle of the tumour, the two inferior prongs were drawn outwards into the tumour, and the two superior points were slipped inwards, so as to meet the others, and thus hold the palate securely. Then a knife, bent in the direction of its flat part, was



entered through the sound portion on the left, and swept round from left to right, removing the whole of the diseased palate, and as much of the columna as possible. A few seconds were sufficient for this. A conductor was then placed on the tongue, and the actual cautery applied to the right columna and pharynx. I wished to have repeated this application, but the patient refused, and thus defeated the success of the operation, which would otherwise, I believe, have been perfect. In the summer of 1836, she came to me with a distinctly moveable tumour on the right side; so moveable that I thought it might be cut out; but the patient utterly refused, and contented herself with daily applications of caustic potass, which I believe will be of no service.

## TUMOURS OF THE TONSILS.

The tonsils are constituted by a collection of mucous sacs, and mucous glands opening into these, connected into one organ by a dense cellular texture, and covered and lined by the mucous membrane of the mouth. Of course the description of their diseases may be considered in this



place.—Chalk concretions occur in the muciparous sacs; and sometimes extensive calcareous and osseous depositions are found occupying a large part of the organ. Scirrhus affections of the tonsils are not very rare. Like those of the palate, they are slow of growth, not painful, and not much disposed to assume the cancerous ulceration. This disease is difficult to eradicate, as it runs into the substance of the pharynx. The operation of excision must be aided by the actual and potential cautery. It is a bloody and dangerous operation.—The ligature is still more objectionable; for if the tumour be large, its effects are distressing and alarming. I once applied the ligature on a scirrhus tonsil, which occupied a large part of the pharynx. A wire was twisted till the tumour was strangulated. The patient suffered atrociously from difficult swallowing, salivation, and dyspnoea; and at the end of five days, symptoms of tetanus appeared, when I was glad to remove the ligature without delay. However, the tumour was destroyed, and sloughed away.

In the month of June, 1835, my attention was called to a disease of this kind by Dr. Shattuck. A patient of his, Mrs. Aves, sixty years old, had



been labouring under a scirrhus tumour, on the left side of the pharynx, for some years. When I saw it, the fauces were nearly filled, respiration was impeded, and deglutition difficult. Her pulse was quick, tongue furred, appetite poor, and she had the aspect of a person sinking under the pressure of disease. I was disposed to decline any operation, from the little hope of a radical cure, and the great danger of immediate death. Dr. Shattuck urged that she must die with the disease, and that, if the removal of the tumour did not effect eradication, it yet might give some relief from the distressing state in which she was. These reasons influenced me to perform the operation immediately. The jaws being fixed, the hard tumour was seized with a pointed forceps, and, with a round-edged knife, I removed the mass by two strokes of the instrument. An enormous gush of blood followed. Passing the finger in, I felt another mass in the pharynx, below the first, which was seized, and cut out by a curved probe-pointed bistery. When the hæmorrhage had a little subsided, a red-hot iron was passed, on a conductor, to the diseased spot twice. No further hæmorrhage occurred. The next day, I left town, and consigned the charge of the patient to my son



for some weeks. On my return, I found the patient, contrary to my expectation, in a convalescent state. The quickness of pulse had subsided. Appetite had returned. No difficulty in swallowing remained. I was informed that some applications of caustic potass had been required, and an exfoliation of a small piece of the superior maxillary bone followed. After this, she wholly recovered her health.—The tumour, it should have been stated, was partly of a cartilaginous consistence, and contained also calcareous matter.\*

Such operations as this are attended with very great danger. A hæmorrhage might present itself from the deep parts involved therein, which no art could suppress.

The lower part of the pharynx, behind the larynx, we stated to be the seat of a common enlargement of the mucous glands. It is also the seat of a true scirrhus tumour, characterized by great difficulty in swallowing, and attended with

---

\* In the winter of 1836, this lady was, from a sudden exposure, attacked with a fatal peritonitis. The body being examined after death, was found to exhibit an extraordinary mal-position of the thoracic and abdominal organs, which has been described by Dr. Mason Warren, in the American Journal of Medical Science.

sharp pains.—A young lady, of twenty-three, was sent to me, a short time since, by Dr. Graves, of Lowell, with this disease. She first perceived uneasiness in swallowing, then pain, and, on inspection by her physician, a tumour was discovered. On looking into the pharynx, while depressing the tongue, I could, on repeated attempts, see nothing. She then stated, that, when she had a cold, as at the time, the tumour was not to be seen. Requesting her to open the mouth, I introduced the finger, and passed it down low enough to circumscribe the epiglottis, without feeling any tumour. On a second attempt, she was made sick. The pharynx was elevated, and I then perceived a hard spicular tumour, perhaps half an inch long and wide, but not thick. I proposed, that, at some time, when the tumour was visible, an operation should be done by introducing a long curved pointed forceps to seize the excrescence, and to cut it out with a long curved scissors.

#### COMMON INDURATION OF THE TONSILS.

This is an affection very frequent and very well known. It occurs mostly in children of a scrofu-



lous habit, and is very often accompanied with deformity of the thorax and spine. The symptoms are, a difficult, loud respiration soon after going to sleep, with sudden starts, and other appearances of troubled breathing—violent perspirations, and consequent wasting of the flesh. The voice is thick and indistinct, and the sense of hearing is often impaired.—On looking through the mouth, you discover two lumps, like cherries, placed one on each side of the fauces. Pressing the fingers down on the exterior of the neck, you feel, just within the sub-maxillary glands, the hard tumours of the enlarged tonsils.

The treatment applied for indurated tonsils, has varied with the fashion of the time. Thirty years since, I began to employ the ligature, according to the plan of Desault. This is not only difficult to apply, but this and every form of ligature is very distressing to the patient. Salivation, difficult deglutition, disgusting foetor, inability to sleep, are some of the consequences.—The tonsil scissors cannot be satisfactorily applied when the tumour is small.—The knife, aided by pointed forceps, is preferable, but may be followed by alarming hæmorrhage.—The actual cautery is a formidable application, and cannot be used with children.—Caustic potass and



sulphuric acid are inadequate to the reduction of the tumour.—Some years since, the instrument I show was invented by the distinguished Dr. Physick, and here is one from Dr. Coxe, of New York. A very ingenious instrument was shown me by Dr. Alex. H. Stevens, which, you may observe, is of complicated structure. The last instrument I have often used with satisfaction, but not always ; and having had occasion to employ it without complete success for the son of an ingenious gentleman, of this place, some conversation took place between us, which led to the conclusion that an instrument cutting by a convex edge, was more perfect than one cutting by a concave edge, and that one which cut on entering, was more perfect than one which cut in retreating. These views led to the construction of the instrument I exhibit to you, which I generally use, and believe to be, on the whole, the best. It is something like a guillotine in miniature,—a convex knife, sliding in a grooved ring of a diameter proportioned to the size of the tumour, from an inch downwards.\* This is an effectual instrument, and, so far as my experience

---

\* This instrument is very much like that of Dr. Physick, though we did not know it at the time it was contrived.



goes, safe from the danger of producing hæmorrhage. Being passed into the mouth, it compresses the tongue; the ring is slipped over the tonsil; the knife is pushed down, and cuts it off. The whole tonsil is not removed in this operation. This is impracticable and unnecessary.—It is proper to have at hand the means of applying the actual cautery, should the severity of hæmorrhage require it.

This operation is resorted to when the tonsils are free from inflammation. I have employed it, also, with great relief, when they were in a state of high inflammation. A lady, in whom I felt a strong interest, had been subject from infancy to indurated tonsils, frequently accompanied with inflammation. Having received a very unfavourable impression of their removal, by noticing the effect of ligature in a friend, she uniformly objected to this operation. In the winter of 1835, she was attacked with a severe inflammation, and having remained some hours scarcely able to breathe, and not able to swallow, and there being no symptoms of suppuration, I proposed excision. Though fainting with exhaustion, she immediately assented, and being placed in a chair, the tonsils were removed. The hemorrhage was slighter than in ordinary



cases. In an hour, she was entirely relieved, and has had no return of the affection.—In two or three weeks, her son, a young gentleman of twenty, was attacked with the same inflammation, underwent the removal, and was as speedily and effectually relieved. Since then, I have not hesitated to propose the operation in cases of inflamed tonsils, and the result has been as favourable, and never unpleasant.

When we reflect on the frequency of this inflammation, its distressing and sometimes dangerous consequences, I feel a hope that this procedure may be adopted with relief in a great number of instances. In cases of malignant cyananche, it would not be applicable generally. But even in these, when the disorder was epidemic, and fatal, as sometimes happens, to a number of individuals of the same family, I should be disposed to a resort to it.

SCIRRHUS OF THE MUCOUS GLANDS OF THE CARDIAC ORIFICE OF THE STOMACH.

A scirrhus tumour of the cardiac orifice of the stomach, is attended with difficulty and pain in



swallowing, with an immediate rejection of food, with pain in the epigastric region, and, after the disease has made much progress, with a tenderness and a sensible tumour in this region.—The preparation you have here, was taken from a lady who died of this disease. It is seated in that part where the mucous glands of the cardiac orifice are abundant. The parietes are much thickened; but this thickening is irregular, and, at one place, the tunics are thin, and have the appearance of ulceration. The patient had dyspeptic symptoms three years before she died. Then followed rejection of food, and distressing pains in the pit of the stomach. At length, a tumour was discovered below the ensiform cartilage of the sternum, and the cartilages of the ribs on the left side.—Before death, the pain was most violent, and required very large doses of opium.

SCIRRHUS OF THE PYLORIC ORIFICE OF THE  
STOMACH.

This is distinguished from the former by the want of difficulty in swallowing; by the less frequent rejection of the aliment, and its rejection in

greater quantity ; by the dark colour of the substances thrown up ; by the existence of a tumour larger, lower, and more on the right side of the abdomen.—This disease is more frequent than that of the cardiac orifice. You notice a number of specimens. This preparation of the whole stomach exhibits a considerable tumour, corresponding in situation with the valve of the pylorus. In this case the enlargement appears regular ; but during life it is frequently very irregular, from an affection of the neighboring glands. The symptoms, with the exceptions just mentioned, much resemble those of disease of the cardiac orifice. To the discriminating symptoms may be added the fact, that the tumour at the pylorus is earlier discoverable than the other.

#### SCIRRHUS OF MUCOUS GLANDS OF THE INTESTINES.

These tumours form in the small intestines more frequently than the large. They are usually of small size, and of a rounded form. The symptoms caused by them exist long before the disease is discovered or suspected. These symp-



toms are costiveness, a derangement of the gastric functions, oppression from food, acidity, flatulence, occasional vomiting.—The specimen you see here was taken from the body of a medical gentleman of this town, Dr. Coffin. For some years before death, he was subject to violent attacks of colic, accompanied with constipation, and followed by much prostration. He had a strong appetite, with constant indigestion and occasional vomiting.—After continuing in a bad state of health for some time, a tumour was discovered in the right iliac region. After this, he gave up business, went into the country, and in a few months died from exhaustion, caused by inability to bear food enough to support him. On examination of the body after death, a tumour was found in the lower part of the intestine ilium, so situated as to compress the intestine and prevent the passage through it of the alimentary mass. One of his last requests was that this tumour should be taken out after his death, and sent here for public instruction.

At this time I have in charge a lady who came to visit me from a distance, under the existence of a supposed dyspepsia. She is about sixty years old ; was formerly very fleshy. Four years since she began to have signs of indigestion, which she



attributed to want of exercise. These signs were costiveness, requiring the regular use of purgatives; attacks of what was called *bilious colic*; oppression from food, even when taken in small quantities and carefully selected; acidity; flatulence; emaciation.—On hearing her story, it seemed to me improbable that so long continued and variable a train of symptoms could exist without diseased organization. I suspected a scirrhus of the pyloric orifice. This suspicion was abandoned when I learnt that the food was not constantly thrown up; and that when it was thrown up, it was not materially changed in appearance; which seemed to shew a sympathetic rather than a primary affection of this organ.—On examination of the abdomen, I found a considerable number of hard bodies scattered about the small intestines. Pressing and rubbing these caused a distinct contraction of the intestine, and a movement of these lumps. A brisk purgative, followed by injection, being taken, the lumps disappeared on the following day. Another examination being then made, I detected a tumour in the middle of the abdominal cavity, behind the umbilicus. This tumour was quite hard, but slightly moveable, of a round form, and about two inches in diameter.



This lady remained under my care ten or twelve days. When she lived on liquid food, taking a gill of gruel once in three hours, the stomach was quiet. If she took four or five ounces of solid food, she was distressed by it, and in the evening vomited. The bowels did not move without medicine, and in an irregular and uncertain manner. The evacuations were natural in appearance. The tumour did not vary in place or size; but I noticed that when she turned on her right side, the contents of the abdomen seemed to be poured out of their cavity, and lay on the bed. This I attributed to the looseness of the skin, from her having been very fat formerly, and now much emaciated. While under my care, she was, for the most part, free from much suffering, and went home in a comfortable state. The sequel of this case will be stated hereafter.

It must be admitted there is a great obscurity about tumours in the cavity of the abdomen, and the best informed are sometimes deceived in their diagnosis. This subject I will take into special consideration at a future time, and shall therefore make no further remarks on it at present.

## TUMOUR OF THE MUCOUS GLANDS OF THE RECTUM.

Stricture of the rectum, produced by scirrhus parietes of the canal, very probably resides or begins in the mucous glands; but I shall not speak of it here; and direct your attention to the scirrhus cancer of this part. This is a disease of rare occurrence, compared with the scirrhus stricture. It is seated most frequently at the back part of the cavity, towards the os sacrum. It begins with a roughness of the intestine, like a cluster of enlarged mucous glands. It soon makes itself known by a pain in evacuation, which increases with the growth of the tumour, and at last becomes excessive. In the early stage there is no discharge but of blood. After it has attained a considerable size, a discharge of mucus and occasionally of a little pus appears. The pain becoming constant, and very distressing on evacuations, the patient is obliged to resort to full doses of opium. The disease is always fatal.

A medical gentleman, forty years old, who had lived well and enjoyed fine health, applied to me for what he believed to be internal piles. For



more than a year he had experienced considerable pain when the bowels were evacuated, and the evacuations were commonly accompanied by a little blood. On introducing the finger, I perceived, at the back part of the rectum, about an inch and a half from the anus, an irregular projection, of the size of half a nutmeg, very tender to the touch, and very painful after examination. I informed him it was a cancerous disease, and advised its immediate removal. He could not be satisfied of the practicability of such an operation, and, after hesitating some time, returned to the country. In about three months he made me another visit. His pains had greatly increased. He had a mucous discharge, sometimes mixed with pus. His evacuations were very distressing. He had begun to use opium freely, and sometimes took large quantities of gin, with temporary relief of pain, and permanent increase of disease. The tumour had grown to the size of an English walnut.—The advice given at first was impressed on him anew ; yet without success. He could not bring his mind to bear the thought of an operation. After this, he lived about nine months in a state of great suffering, and died, worn out with pain.



TUMOURS OF THE MUCOUS GLANDS OF THE  
VAGINA.

Enlargements of the mucous glands of the vagina occur most frequently in females of delicate and scrofulous habit. They appear scattered through the parietes of the canal, in the form of papillary eminences, of various size, from that of a millet seed to that of a pea. When very small, no distinct symptoms indicate their existence, excepting there is an actual examination by touch. When of large size, an uneasiness exists in the passage; a slight discharge; paroxysms of strangury; and a distinct tenderness on touching them.

A married lady, twenty-two years old, who had not had children, complained to me of an uneasiness in the urethra, with a bearing down, frequent attacks of strangury, a constant sense of heat in the vagina, and a mucous discharge, sometimes tinged with blood. Apprehending a prolapsus, or a scirrhus of the os uteri, I proposed examination.—On introducing the finger, and touching the os uteri, I found this part not prolapsed, nor enlarged. On examining the parietes of the vagina, they were studded with enlarged



glands, of various sizes. When pressed, these were painfully affected, the larger more than the small. Her health was tolerably good otherwise. The menstrual evacuations were regular.—She was advised to assume the horizontal posture, use a warm injection of soap and water twice a day, apply six leeches to the perineum every five days, and avoid the use of animal food. This treatment was continued many weeks, without change in the symptoms. At the end of four months, the burning diminished. It was not till after seven months' steady pursuit of the course, that the strangury and heat in the affected part ceased. A discharge continued two or three weeks longer. The examination at the end of this time was without any uneasy sensations; the tumours had disappeared; and she has recovered perfect health, and retained it for some years.

A married female, twenty-four years old, without children, became affected with a sense of bearing down, with occasional attacks of strangury—her health having been good previously. These symptoms she bore for four or five weeks, before she made any application for advice.—On a careful consideration of the case, without examination, I could not satisfy myself of the existence of pro-



lapsus, of scirrhus, or of any organic affection of the urinary passage ; and being thus entirely at a loss, proposed a manual examination. This, as I expected, was not assented to. I was therefore obliged to proceed in darkness, and administer such powerful remedies as seemed likely to remove the disease ; and as no relief was obtained, a great variety were employed.

At last, I was suddenly sent for, and found the patient labouring under an excessive pain in the bowels, and strangury—greatly alarmed, and apprehending a fatal issue to her sufferings. I seized the occasion to propose the proper mode of investigating the complaint. This was at once agreed to. The os uteri, and the body of the uterus, were found to be perfectly healthy. At the posterior part of the vagina, towards the rectum, there was a little tumour, hard and tender, about the size of a hazle-nut, and no other perceptible change of organization. Believing that this might be the cause of the trouble, I recommended the application of leeches to the part, and they were used some time without relief. Finding the difficulties increasing, I proposed the excision of the tumour, and this was agreed to. When the operation was performed, I found much difficulty



in reaching, and afterwards dissecting the tumour out, without cutting into the rectum. This was, however, accomplished. I passed a hook into the tumour, and gave it to an assistant, who held a speculum in the other hand. Then, introducing the fore finger of my left hand into the rectum, I pushed the tumour to the vagina, and thus succeeded in dissecting it out without injury to the rectum. The patient recovered speedily from the operation, and was entirely cured by it. I would not have believed, had I not seen the fact, that so small a tumour, thus situated, would have produced so much suffering, and that its removal could be so perfectly and permanently effectual towards a cure.

It is certainly remarkable that a small tumour, in the back part of the vagina, should so severely affect the urinary organs. That this sympathy is thus excited, is manifest from these cases, and others I could adduce, and thus shows the indispensable necessity of resorting to the touch in affections of these parts.

The following case terminated less favourably. It occurred in a lady of good constitution and sanguine temperament, forty-eight years old. She felt an uneasiness in the vagina, with strangury,

and a slight mucous discharge. She bore the disease a number of months before asking medical aid. When requested to examine her, I found the whole vagina studded with small hard tubercles, not very tender. The os uteri was perfectly healthy. Examination by the rectum gave the sensation of an osseous cylinder in front of it. The uterus was not diseased.—The patient lived four years with this complaint, and was at last exhausted by pain, without hemorrhage, and a very moderate muco-purulent discharge.

## TUMOURS OF THE UTERUS.

The uterus is very subject to organic derangement. In one case out of four, of females over forty, its healthy structure has been said to be disturbed either in its body, mouth, or appendages. I can only allude to these diseases, and refer to the works of Madame Boivin, of Lisfranc, and of Duparque, lately translated by Dr. Warrington, in Philadelphia, for a full account of them.

The mucous glands of the os uteri are the seat of various kinds of induration and tumefaction,



vesicular, papular, and scirrhus, arising from scrofulous, venereal, and cancerous affections.

The SCIRRHO-CANCER of this part begins in an induration of one of the labia of the os uteri, consisting in a number of irregularities, which may be enlargement of the mucous glands, although we rarely have opportunity of observing the disease in its incipient state.—The disease is generally first known in the state of ulceration, when the offensive bloody discharge, accompanied with shooting pain, gives the alarm to the patient. Examined in this stage, we find the whole of the os uteri enlarged, very hard, and presenting great irregularities and scirrhus tubercles, of various forms and sizes; and some of these tubercles are in a state of ulceration. The fetid discharge, the hemorrhage, and pain increase, till, by their combined action on the stomach and intestines, the patient is worn out after the lapse of one or more years.

The cauliflower scirrhus of the os uteri is a tumour which, after a time, fills the vagina, and is accompanied by nearly the same symptoms. The ulcerous disposition, in this case, is less, and the enlargement greater. This should not be confounded with the fungous polypus. This last,



which will be noticed hereafter, takes its origin from the interior of the uterus ; fills the vagina with a bleeding fungous tumour ; produces, in some cases, ulceration in the rectum ; and is especially distinguished from the cauliflower excrescence of the os uteri, by a pedicle, which can be traced into the cavity of the uterus.\*

The FLESHY TUBERCLE OF THE UTERUS is a very different disease from those which have been mentioned. Whatever texture it may originate in, it grows to a large size, sometimes forming a single protuberance, sometimes two, or more. Without giving acute pain, it occasionally becomes so large as to be felt in the cavity of the abdomen. In this state it may continue a great number of years, without materially affecting the patient's health. This tumour generally occurs in scrofulous habits. In examinations for the purpose of ascertaining its existence, it is more readily and fully discovered through the rectum than the vagina.

---

\* M. Lisfranc, in his lectures on diseases of the uterus, distinguishes six varieties of cancer of this organ :—1. Scirrhus cancer proper ; 2. Hard scirrhus cancer ; 3. Fungous cancer ; 4. Encephaloid cancer ; 5. Cancer hæmatodes ; 6. Mixt cancer.



I shall illustrate the most frequent and distinct affections of this organ, by cases in which they occurred.

INCIPIENT SCIRRHUS OF THE OS UTERI.—A lady, thirty-five years of age, who had one child, and had ceased to live with her husband for some years on account of the irregularity of his habits, complained of occasional pains in the vagina, with slight and infrequent discharge of blood. Catamenia regular. Appetite good. She had lately lost flesh and strength. The first uneasiness had been perceived three or four months since.—On examination, I found the os uteri larger and less regular than natural. Around it there appeared to the touch a row of small, hard substances. In the midst of the posterior labium, one tumour was perceived to project more than the others. Its length might be the sixth of an inch. The os uteri was unnaturally tender when compressed.—She assured me there had been no other discharge besides the slight sanguineous appearance already noticed.—The danger of her case was represented to her, and she was advised to an abstemious vegetable regimen, frequent application of leeches, and the horizontal posture.



Some months after the above was written, the patient called to inform me that she had pursued the advice, and had the satisfaction to say that she was entirely relieved of all the symptoms, and felt assured that every morbid appearance had subsided.

SCIRRHO-CANCER OF THE OS UTERI.—The subject of the case now to be stated, was a lady, forty years of age, who had borne a number of children, and met with frequent miscarriages. In the year 1820, she noticed some slight and irregular discharges of blood from the vagina. In the beginning of 1821, these appearances increased, and were preceded with pain; and she had also a white coloured discharge, of an offensive nature. She now submitted to an examination, which had been repeatedly refused before. The result of this examination was as follows. The os uteri is low and enlarged or tumid. Its opening is of an irregularly oblong form. The anterior labium uneven; and the posterior sensibly ragged, from a number of irregular protuberances. The part is tender, and stains the finger with blood.—The operation of excision was proposed as the only probable remedy; but this was at once rejected. The horizontal posture, leeches, a sparing regimen,



mild injections, and the free use of conium, were then ordered. An examination, two months from the first, presented a considerable increase of the ragged protuberant state of the os uteri; and when the finger was passed into the rectum, the lower part of the body of the uterus was found considerably enlarged. After this, the hemorrhages became more considerable, and the yellowish white discharge more offensive. She had strangury, costiveness, bearing down pains, also a pain in the left hip, extending thence into the left thigh. Here I may remark that, in this disease, the left hip is much more frequently affected than the right. At this time, the patient had sensibly emaciated, and had a sallow, unhealthy aspect; was excessively troubled with watchfulness and nervous feelings, especially when she indulged her appetite, which was often the case. When she lived sparingly, and had the bowels evacuated regularly, by cathartics or enemas, she was comparatively quiet and comfortable.

At this period, a cancer doctor, highly recommended, was sent for. This man pronounced her disease not to be cancer; and recommended the use of cajeput oil internally; astringent injections, and the use of animal food. Under this treatment



she was persuaded to believe she improved daily. At the end of three months, I was requested to attend her again. This I wished to decline, but as a matter of humanity, ultimately consented to.—I have mentioned this occurrence, as an instance of the numerous delusions we are compelled to witness in the practice of medicine and surgery.

The patient now became anxious for a surgical operation; but I declined it, as improper and hopeless; for now the scirrhus excrescences had shot out so much, as at times to push between the labia. I would have wished to avoid any active treatment. The leeches were suspended, and the conium intermitted. As something was imperiously demanded, I assented to her taking the hydriodate of soda; and afterwards, resuming the conium, which was employed long and freely, without any good effect. The pains increasing and becoming severe, it was necessary to use different preparations of opium, sometimes very largely. As the disease advanced, the hemorrhage became less frequent; and when it did occur, was always followed by remission of symptoms. At the expiration of a year from the discovery of the disease, she was still able to ride.



But for the last two or three months any motion was distressing, and finally insupportable. The strength of the patient was exhausted by pain, indigestion, and the free use of opium; and she died a year and a half from the time the disease distinctly manifested itself.

In the species of disease, of which this case is intended to be the representative, a yellowish white discharge, with occasional tinge of blood, and sometimes darting pains, especially if accompanied with a change of complexion, should be regarded with suspicion. An immediate examination should be required; and if this corroborates the above symptoms, the hope of saving the patient rests on an immediate resort to repose, abstinence, local bleedings, or extirpation.

**CAULIFLOWER EXCRESCENCE.**—The last patient I saw with this form of disease, was a delicate lady, thirty-eight years old. A fungous vegetation filled the vagina. On touching it, a copious bleeding followed. The urgency of the patient led to a trial of the most powerful caustics without effect. The hemorrhage was so violent as sometimes to require plugging the vagina, and she died from the immediate effect of one of these attacks.



FLESHY TUBERCLE OF THE UTERUS.—More than fifteen years ago, a married lady, thirty-two years of age, who had never had children, applied to me for the treatment of this affection. She had a bearing down, some degree of leucorrhœa; uneasiness in the alvine evacuations. The catamenia had been interrupted for a few months. On examination by the vagina, the os uteri was ascertained to be healthy. On passing the finger behind the posterior labium, an indistinct, hard body was felt. Examining by the rectum, the body of the uterus was perceived to be of a large size, extremely hard, and presenting to the touch three protuberances.—The patient was recommended to rest three months, apply leeches once a week, take extract of conium, and restrict herself to vegetable food. At the end of the time stated, I examined, and found the tumour smaller. The symptoms had subsided in a great measure, and the catamenial evacuation had appeared sparingly. She was advised to use remedies no longer, and has since had pretty good health. I saw her two weeks since, moving about and looking well.



FLESHY TUBERCLE OF THE UTERUS, BEGINNING IN THE OS UTERI.—Aug. 10, 1836. This case is attended with rare and peculiar circumstances, which lead me to give a minute relation of it.—Dr. L. L. Miller, of Providence, requested my attention to a lady, who had been under his care a short time. The lady accordingly visited Boston, and I examined her case in company with Dr. Miller and his father, well known as an able surgeon.

The following history was obtained from the patient, a very intelligent and amiable lady of thirty. Three years since, she was confined with her first child, after some years of matrimony. The process of parturition continued about six hours. The child was living, and continued to live six weeks, and then wasted away without any distinct disease.

The placenta did not come off spontaneously: and therefore considerable efforts were made by the father and brother of the lady, both medical men, to remove it. These not being successful, it was thought best to await the arrival of another practitioner, which took place about six hours after. Then the efforts were renewed, and with great difficulty portions of the placenta were



removed. The patient was much exhausted, and afterwards so ill, that she cannot recollect distinctly the course of events in the following weeks. There was, she thinks, the usual discharges after delivery. There was no swelling of the abdomen; and no secretion of milk. About three weeks after confinement, a considerable mass was discharged from the vagina, which was thought to be the relicks of the placenta. She does not recollect any further discharge till nine weeks from her confinement; at which time there took place a gush of a gill of whitish gelatinous matter, of a very offensive odour. From that time to the present, she has had no discharge from the vagina of any kind, either healthy or morbid. For five months she remained quite ill, and for the most part confined to bed. At the expiration of this time she got out, and had a tolerable degree of strength, though she still carried the marks of a constitution which had been powerfully assailed by disease, and still had occasional pains in the abdomen.

Within the last year, these pains increased so much as to lead her to seek the assistance of Dr. Miller and Dr. Parsons, of Providence, and afterwards of Dr. Miller, the elder, of Franklin. These



gentlemen, considering her case to be very important and interesting, advised her to come to Boston, where the consultation of Drs. Miller and myself took place.

The patient being in a reclined posture, I placed my hand on the cavity of the abdomen, and soon discovered a hard tumour in the lower part of the cavity, which, at the first moment, struck me to be a diseased ovarium. Passing the hand around it, I perceived it had not the globular shape generally assumed by this organ. In size, it was about four inches from right to left, and something more than half that in thickness, with a surface irregular and knotted. The consistence was very firm. From the region of the pubes, it descended into the cavity of the pelvis, as far as the touch could trace it. A tenderness existed, sufficient to cause the patient to shrink. This examination satisfied me that the diseased organ was the uterus; and the examination per vaginam confirmed this opinion; for, on the introduction of the finger, a tumour was perceived near the os externum, occupying the anterior part of the vagina, and swelling out above, so as to fill a large part of the cavity of the pelvis. Tracing it upwards as far as possible, there appeared to be a contraction at the



upper part of the pelvis; and on pushing the tumour upwards with the left hand, the right hand, placed on the exterior of the abdomen, was sensible of a distinct movement of the portion above the pubis. No pain was caused by pressure from below. But the most remarkable circumstance discovered here, was the absence of any trace of os internum or of the labia of this orifice. Nor was any appearance of these parts visible on examining by the speculum, although the interior of the canal was brought fairly into view. The vagina was in fact much shorter than common, which I at first attributed to the pressure downwards of the tumour, but was afterwards satisfied arose from a different cause. From the posterior part of the tumour, a septum passed backwards to the posterior part of the vagina, forming a partial division of the canal into a right and left cavity. No softness nor elasticity was any where discoverable. There was no interference with the urinary or alvine evacuations.

Considering the appearances, the hypothesis which presented itself to me was, that the disease began in an induration of the anterior labium of the os uteri, which had extended downwards to the external parts, and upwards to the fundus of



the uterus and cavity of the abdomen. This, however, did not explain the disappearance of the os uteri; for although the labia might be effaced by, and buried in the tumour, some appearance of orifice would be discoverable to the touch or sight. Connecting the fact of this non-appearance with that of the total absence of any uterine evacuation for three years, it seemed probable that the tumour must be complicated with an adhesion and obliteration of the upper part of the vagina. To this it seemed necessary to add an obliteration of the cavity of the uterus, or there must have occurred a collection of fluid in this cavity, which would have produced symptoms of abdominal distension. This consideration, involving a practical point of great consequence—that is, the question whether a puncture should be made into the tumour, to evacuate a supposed collection—was the subject of particular attention and discussion. But while there was strong reason to believe the existence of a vaginal adhesion, there being reason to suspect also the existence of a uterine obliteration; and there being a total absence of softness, elasticity, or fluctuation; the propriety of such an operation could not be admitted.—With great regret, therefore, we were compelled to



decide that the case was not susceptible of operation, nor of any important treatment.—The peculiarities of this case were, 1. The great extension of a disease beginning in the os uteri; 2. The disappearance of this part; 3. The obliteration of the uterine and upper part of the vaginal cavity.

FIBROUS TUMOUR OF THE UTERUS.—This disease consists in the formation of an organized mass in the cavity of the uterus. The newly formed substance is of a whitish colour, elastic consistence, and exhibits a perfectly distinct appearance of fibres, running through and forming its texture. The size of this substance is various. The largest I have seen filled a small water pail. This was shown me by Dr. J. B. S. Jackson, who informed me it was taken from a patient who died of pneumonia. A large tumour of this description, which you see, was found in a patient who had been operated upon for cancer of the breast, and who died of peritoneal inflammation.

These tumours are quite distinct from the substance of the uterus, with which they are loosely connected by vessels and fibrous texture. The muscular structure of the uterus is very much developed about them, and perhaps gives origin to



the real so abundantly interspersed in their substance.

The fibrous tumour forms without any great pain. There is a suspension of the catamenia—a sense of fulness and weight, often mistaken for signs of pregnancy, especially if it happens, as it sometimes does, that the breasts are affected in the same manner as in pregnant women.

This disease is subject to great changes. After reaching a considerable size, it often diminishes, and, we have reason to believe, sometimes disappears. Of course, it is not of a malignant character.

The treatment consists in the frequent application of leeches to the vulva, with a proper regulation of food, and of the alvine evacuations.

For practical uses, I have thought it best to direct your attention to four only of the many diseases of the uterus accompanied with tumour—two of them malignant, and two non-malignant. The preparations laid before you exhibit not only these, but various other forms of uterine affection. The apprehension of producing confusion and uncertainty in your minds, prevents my describing other varieties.

## OPERATION OF EXCISION OF THE OS UTERI.—

In the operations of surgery, I have described and performed before you the excision of the os uteri for scirrhus of the part.—This operation was introduced to notice, by professor Osiander, some years since. The instruments employed by the professor you have seen, and can judge of their adaptation to the object for which they are destined. The excision of the os uteri, and of the body of the uterus, and even of the whole organ, has, it is said, been successfully performed. The first of these may be safely and properly done in certain cases. The extirpation of the body of the organ I cannot recommend. I have, indeed, performed it once, but should not do it again. The size of the uterine vessels, their inaccessible situation, the existence of circumstances favourable for maintaining hemorrhage, and the injury to the peritoneum, are facts which seem to me to place this disease beyond the hope of a successful operation.—The excision of the os uteri is proper when the scirrhus affection is confined to this part, so that it may be performed without cutting through the parietes of the vagina.—The manner in which the operation should be performed is this:—The patient being placed on her back,



with the pelvis at the edge of a table, the limbs supported by assistants, the strong curved four-pointed forceps are introduced, on the fore and middle fingers of the left hand, till the instrument touches the os uteri. The forceps being opened, the whole substance of the os uteri is transfixed and held by them. Then the operator proceeds to draw on the os uteri, and thus to extend the neck of the organ, until it is brought down to the external aperture, if possible. The forceps being now confided to an assistant, the fore and middle finger of the left hand of the operator are introduced into the vagina behind the knife. A round-bladed scalpel is then employed to divide the neck of the uterus.

In some cases, a ligature might be preferred to excision. For example : when there is no apprehension of disease of the neck of the uterus, and the labia are sufficiently enlarged to retain the ligature. Both of these operations I have performed, and should give a preference to excision. The mode of passing a ligature is the same as that employed for polypus of the uterus, which disease will be noticed hereafter.



## FUNGOID TUMOUR OF THE BLADDER.

A discharge of blood with the urine is the first sign of this disease. The quantity is small at first, scarcely tinging the urine, but gradually increasing till it becomes a formidable and exhausting symptom. There is but little pain attending it; and it must be understood that this symptom varies in different cases, both of fungoides and scirrhus, some cases of each of them going through their course with a very moderate degree of pain. A constant desire to pass urine is one of the most distressing consequences; and this is accompanied with a sympathetic irritation of the rectum, and inclination to stool. The disease comes to a fatal issue from the consequent derangement of the stomach and intestines, rather than from pain or hemorrhage.

A lady applied to me, in the spring of 1836, for what she thought a strangury, with discharges of blood in the urine. She was fifty years old, and of a delicate constitution. The symptoms mentioned had been troubling her for six months. I made an examination, and found, at the anterior part of the vagina, a tenderness, and the indistinct



impression of a soft tumour in the bladder, about an inch and a half in diameter. The passage of a catheter into the bladder made this tumour appear more sensibly to the finger in the vagina, and caused pain and a discharge of blood from the urethra.

After thinking of the matter, I told her I could find no precedent for an operation such as her case required, but that such an operation might be done. I proposed one of two modes—first, to make an incision through the vagina, and cut away the diseased portion of the bladder, or, second, to cut open the urethra on its side, and, introducing a finger, to examine the tumour, seize it with a hook, draw it out as much as possible, and excise it. In the first case, I thought she might have an incurable fistula; in the second, an effusion of urine into the cellular membrane about the bladder. The prospect of these evils prevented my urging the operation, and her consent to it. She lingered about eight months; and dying in the country, I had no opportunity of examining the body.

## CANCER OF THE PENIS.

The tumour formed by this disease may be very considerable, when, as in the preparation presented to you, the disease is allowed to reach an advanced stage. A warty excrescence on the glans or prepuce is the first appearance of this malignant affection. The wart may be distinguished from the venereal wart, in being more fleshy, and being accompanied with a stinging pain. The crust being broken off, the sore does not heal, but extends itself into the surrounding parts, and produces a formidable fungous excrescence, covering the glans, as you see in the preparation exhibited. The glands in the groin soon become enlarged. They soften and produce an imperfect abscess, which, being opened, discharges a sanious fluid without relief to the patient. The constitution sympathizes, as is seen by a foul tongue, loss of appetite, quick pulse, and emaciation of the body. The countenance assumes the sickly sallow hue which belongs to cancerous patients. The severity of pain increases, and, notwithstanding the necessary employment of anodynes, soon exhausts the vital power.



You have lately seen, in the M. G. Hospital, an instance of this disease. The man was a farmer from the country, thirty years old, who had enjoyed good health. He entered in March, 1836, and stated that, in the June preceding, he noticed a sore on the glans, which increased fast, and was attended with a burning pain. The complaint advanced so rapidly, that, in October, he underwent an amputation. A few weeks after, he had a swelling of the inguinal glands.—In this state, he appeared at the hospital in March, 1836. The wound of the penis was healed, and a considerable tumour existed in the groin, which he expected would be removed by operation. Various powerful substances were employed without the least mitigation of suffering. Unwilling to pronounce to him his fatal sentence, I advised him to leave the hospital, and go home to his native place. He did so. In May, he returned, still impressed with the expectation of a recovery by operation. The tumour in the groin enlarged, reddened, and softened, and the pain became so great that I put a lancet into the cavity. Nothing was discharged but blood, and the pain was not relieved. He now put to me very definite questions as to the tendency of his disease, and I felt bound to

answer him definitely, and to advise him to return to his family. From the severity of pain, loss of appetite, quickness of pulse, and great emaciation, I presume he did not live long afterwards, so that the whole duration of his complaint would be little more than a year.

The only remedy for this disease is an early extirpation. The cancerous wart must therefore be early discriminated from the insensible, elongated, scattered, venereal warts; and if there be a doubt as to the character of the excrescence, it is best to extirpate it.

The specimen I have shown you was taken from a person who had allowed the disease to make great progress before he applied for surgical aid. Amputation was performed. The disease soon appeared in the groin, and, advancing much in the way related in the preceding case, he died a few months after the amputation.



## SECTION XI.

### TUMOURS OF THE VASCULAR TEXTURE.

—

#### ERECTILE TUMOURS.

UNDER this head we shall speak of TUMOURS OF THE ARTERIES, and TUMOURS OF THE VEINS.

ARTERIAL TUMOURS are ACCIDENTAL and CONGENITAL.

ACCIDENTAL are ANEURISM and ANEURISM BY ANASTOMOSIS.

ANEURISMAL TUMOURS, being treated of in connection with operations of surgery, will not be described here; and, for the same reason, we omit the description of aneurismal varix. These tumours form a most interesting class of diseases in operative surgery. Their essential character is a

pulsation communicated to them by the action of the heart.

ACCIDENTAL ANEURISM FROM ANASTOMOSIS, may arise from wounds, contusions, and other accidents. Sometimes it occurs without an obvious cause. It has received its name from the very free communications between each other of the arteries which compose it.

Aneurism by anastomosis is a pulsatory tumour, composed of small arterial branches. Those parts which are most vascular are most likely to be its seats; as the angle of the eye, the face, and the scalp. The tumour is soft and compressible, so that by pressure it may be emptied of its contents, and then it immediately fills again. Sometimes the trunks of arteries, which supply it, may be ascertained and compressed; and then, during the compression, the pulsatory character is suspended, and the tumour, if evacuated, does not fill at once. The skin, in these tumours, commonly retains its usual colour. There is a slight heat in it. The most notable symptom is pulsation, and a consequent vibration or thrill which is communicated to all the arteries near; not only of the same but sometimes also of the opposite side. An aneurism in the face may communicate the vibratory motion



and the saw-mill sound to the carotid artery of its side, and also to that of the opposite side. The pulsations produced even by a small tumour are, therefore, sometimes very distressing.

The following case of accidental aneurism will, perhaps, give a distinct notion of the disease. It is to be noticed that, though called accidental, no injury was inflicted, and that it arose spontaneously, the term being used in opposition to congenital. The patient was a very fat, comely girl, eighteen years old, belonging to Dracutt, in this State. She entered the M. G. Hospital, May 4, 1829. Little more than a year before, she began to experience a strange feeling in the internal angle of the right eye, at the anastomosis of the facial, ophthalmic, and frontal arteries. This sensation she described as a crowding feeling in the eye. It soon extended to the head, and was accompanied with a pain so severe, that though otherwise in perfect health, she was obliged to give up her work, that of a house-servant, and had remained idle for some months before she entered the hospital.

At this time, there was a small tumour at the internal angle of the right eye, just above the lacrymal sac, as large as a hazel nut. It had an



active pulsation, which extended into the surrounding arteries. The pulsations of the facial were very strong; and by compressing it, the vibrations of the tumour were much lessened. Compression of the temporal artery produced no change. The skin over the tumour was slightly reddened, and there was a sensible increase of heat. The carotid artery had an increased pulsation. Pressure on this artery suspended the pulse of the tumour. The stethoscope, applied to the carotid and facial arteries, gave the saw-mill sound.

Having observed the case for a few days, I performed the following operation on the 11th of October. A small incision was made between the tumour and the cavity of the orbit. The pulsation of the anastomosing branch of the ophthalmic was discovered, and a ligature passed round this branch. Next, an incision was made across the facial artery, below the tumour, and after allowing it to bleed about eighteen ounces, a compress was applied, to include the artery and sac. On the division of the facial, the pulsation ceased, and the patient was relieved from her bad feelings. On removing the compression, three days after, a slight pulsation was perceived. The wounds



healed immediately, and the patient finding herself very comfortable, was discharged on the first of June, although the pulsation had not wholly ceased. This was done at her request ; and I was disposed to believe that the cutting off the supply from these two vessels, must be followed by a disappearance of the tumour. The frontal branch was not divided at this time, because there was no pulsation in it.

My expectations were disappointed. In the latter part of October, of the same year, she entered the hospital again. A very slight pulsation was discernible in the tumour. The internal angle of the other eye had a pulsation somewhat stronger than that in the right eye. The arteries leading into it, had strong pulsations. The carotids on both sides, especially on the right, throbbed violently ; so that she sometimes said she felt as if "the top of her head was flying off." The upper part of the face and forehead were red and swollen ; and, on the whole, there was a great aggravation of disease. I was at a loss how to proceed under these circumstances, as the disease now appeared equally on the left and on the right side, and extended apparently to the whole arterial system of both. It seemed therefore proper



to begin with trying the effect of general remedies. The patient was ordered to be kept perfectly quiet; to live as low as possible; to have blood taken from the arm, and leeches applied frequently to the head; and she also took the tincture of digitalis. These measures were followed by no favourable effect. I therefore laid bare and penetrated the temporal artery of the right side, allowed it to bleed freely, and then divided it. No permanent mitigation of symptoms followed. The vibrations and their distressing consequences remained unmitigated.—There seemed but one course remaining—that of tying both carotids; or rather, of tying one, and, if this did not answer, the other.—On the 2d of January, 1830, I tied the right carotid. The pulsations of the right side were immediately relieved. Those of the left side continued for a time, then slowly subsided, and on the 3d of March, she was discharged perfectly well.

There are two important pathological facts brought into view by this case. The first is the sympathy of the arterial system of one side of the head with that of the other. The vibratory action of the vessels of the right side, produced corresponding vibrations in those of the left. Hence arose



some embarrassment in the treatment of the case ; since it seemed probable that the cure of the original affection would leave behind it a disease equal in amount to itself ; and it never could be determined whether this would be the fact, but by actual experiment. In the period of disease which succeeded the operations on the facial, opthalmic, and temporal arteries, the phenomena were in truth more conspicuous on the left than on the side originally deranged. So very striking were they, that I was entirely at a loss whether the ligature of the right or left carotid would be most likely to be useful. The perfect success, from tying the right carotid, showed that the affection of the left side was altogether sympathetic ; yet certainly it is remarkable that two great arteries like the carotids, should seem to be so much under the influence of the nerves, as to take on this sympathetic action ; unless we deny the doctrine that the pulsations of the great arteries are dependent principally on the action of the heart, and allow that they act from their own power.

But here I must state (what has not been mentioned before, and which seems to obviate this difficulty without a denial of the power of the heart on the pulsations of the arteries) that, in this



young woman, the actions of the heart were really disturbed, and, in some degree, partook of the tumultuous movements of the carotid arteries. As a result from this fact, we might expect to find the pulsations of the arteries of the trunk and extremities to be more or less disturbed. This was not the case. The arteries of the superior and inferior extremities presented nothing remarkable in their action. How shall we explain so extensive a disturbance without any disorganization of the principal parts concerned in it?—The explanation which occurs to me is this:—The vibrations of the original aneurism in the angle of the eye were propagated backwards, something in the way that the inverted peristaltic action is propagated from one part of the intestinal tube to others. These vibrations on the right side increased in extent with the duration of the disease, till the carotid artery of the side was drawn into this morbid action. On the left side, the angular arteries were first disturbed by sympathy; their disorder then extended to the carotid on the left side, as it had done on the right; and finally the combined vibrations of the two carotids were sufficiently powerful to influence the heart. It might be asked why the tumultuous action of the left



ventricle did not operate on the subclavian and the descending aorta. To this I can only answer, that it was not sufficient. Had the disease been left to itself, it is probable, and nearly certain, that ultimately they would have become so; and thus the whole arterial system would have been convulsed by an agitation beginning in the angular vessels of the right eye.

To these speculations you can attach such importance as you please. I shall next advert to a second pathological fact in this case, which has a more practical bearing than the one just spoken of.—The point to which I would now direct your attention is the comparative effect of intercepting the circulation in the arteries which immediately supply the tumour, and that from interrupting the course of the great trunk from which these arteries arise. It would seem from this case, that, as the interruption of the current through the small arteries (the facial and opthalmic) was not successful in checking the disease—that, as it was ultimately cured by ligature of the carotid—that, therefore, in this and similar cases, it should be the carotid that must be secured, and not the immediate arteries of the tumour. This, however, is not the inference I should make, nor



the practice I would recommend. I would not recommend the ligature of the carotid artery in such a case, in the first instance, because I should expect that vessels so small as those connected with the tumour, so distinct from the great artery, and of so free connection with vessels of the other side, would be immediately supplied with blood from anastomosing arteries to a sufficient degree to keep up the circulation and maintain the morbid action in the tumour. These opinions are not merely theoretical. They are supported by facts. In the same year, for example, at a period previous to the first operation on this girl, I operated for a similar affection in a woman in the hospital. This woman had fallen down stairs, and struck the inner angle of the right eye. A pulsating tumour arose there, which affected the vision of that eye. It extended into the orbit, so that I could not reach the ophthalmic branch within the tumour. I therefore tied the carotid artery, and without an alleviation of the disease. I would then have attempted the angular arteries ; but the patient refused, left the hospital, and I lost sight of her.— In other cases where I have tied the great trunk in the extremities, on account of some difficulty in securing the divided branches, I have generally had



occasion to regret this course when the injured vessels were at a distance from the trunk so tied. A gentleman divided the ulnar artery, three inches above the wrist, with a penknife. I did not see him till a week after the accident, in which time he had three great bleedings. The cellular substance of the arm was so thoroughly injected with blood, that, when I came to tie the ulnar artery, I could discover no difference between muscle, artery, vein, nerve, and even tendon, and felt it necessary to tie the brachial at the bend of the elbow. In exactly twenty-four hours after, the ulnar began to bleed anew, and I was compelled to open the wound, to raise the whole mass of flesh, and gradually to separate the different parts, till the vessel from which the blood seemed to issue was alone retained ; and this being tied, there was no more bleeding, and the patient got well.—With these and other such occurrences in mind, I would spare no pains to come at the vessels nearest to the diseased or injured part, and, when this was practicable, not meddle with the great trunks.

The success which followed the tying of the carotid artery does not prove that, if the same operation had been done at first, it would have produced the same result. I feel satisfied that it



would not have accomplished the cure, for reasons stated already. The facial, temporal, and ophthalmic (the vessels directly supplying the disease) had been already cut off, and the disease had felt the impression of these measures. True, there still continued a morbid action of minuter vessels than these just mentioned, and this action, it seems, was sufficient to cause a sympathetic action on the other side. Still it is obvious that the immediate sources of supply were cut off, and the strong impulsions they had produced were deadened; and, in this state of weakened action, the suspension of the current from the carotid, coming in aid of the curative means already employed, was sufficient to exhaust the sources of the disease. In cases like this, therefore, our first object is to interrupt the vessels which afford immediate supply; and if the disease still goes on, the next thing is to attack the more remote auxiliaries to the morbid action.

ANEURISM BY ANASTOMOSIS FROM WOUNDS.—

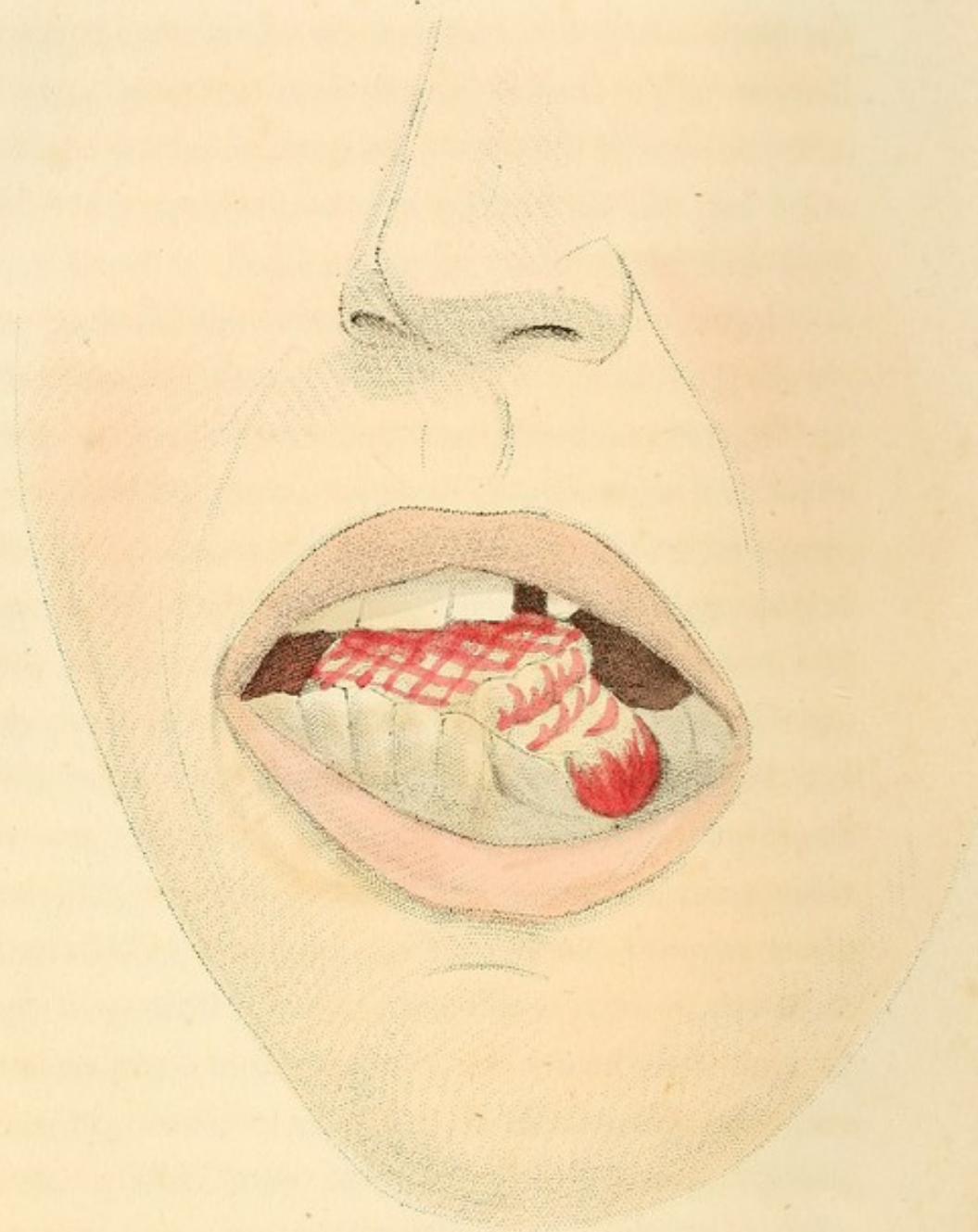
The small vessels sometimes become strangely affected from a common wound, without our being able to discover why they are so in one case rather than in a hundred other apparently similar.—In 1834, a son of Mr. F——, of this place, received



a cut from a stone on the right side of the occipital region, not far from the right ear. The wound being contused, healed slowly. Three months after the accident, I was desired to see the boy, and found a small pulsating tumour, the size of a nutmeg, in the part described. The vibrations of the tumour affected the head, by producing dizziness whenever the boy ran about or engaged in his common plays. Strong compression had been made for some time, without sensible improvement. I therefore shaved the hair, and cut round the tumour in the sound skin, and dissected out the whole disease as well as I could judge. Three arteries required ligatures in this little tumour, and a number of small vessels continued bleeding so as to demand the compression of a methodical bandage. The healing process went on very well; but I soon discovered a pulsation in one edge of the wound. I immediately applied caustic potass to the part as thoroughly as I was able. This was followed by bleeding, which required strong compression to stop it. The caustic potass was again applied after three days. Still I noticed a disposition to regeneration of the disease; and finding it impracticable to make the frequent applications the case required, I directed







*Vascular tumour of the gums*

the boy's mother to pour on the aneurismal part of the sore six grains of the sulphate of copper daily. This course, pursued for two weeks, destroyed the pulsating vessels, and the wound soon after healed well and sound.

SPONGY TUMOUR OF THE GUMS.—This is a red, soft, elastic tumour, springing sometimes from the surface of the gum, sometimes from the socket of a tooth. It is not painful, and does not bleed readily.—This is quite a different kind of tumour from those we have described under the head of arterial tumours, for it is peculiar to the gums, and is characterized by their texture.—I have thought of placing this species under the head of tumour of the capillary vessels; but as there are some objections to this, I propose to let it remain here, until a proper place can be allotted to it.

There are two kinds of this tumour, malignant and non-malignant. The last is a cancer of the gums, and is known by its ulcerating, sending out a foul discharge, and proving obstinate and intractable. The non-malignant tumour is represented in Plate XII.

The cure of the malignant disease of the gums requires a perfect excision of all the soft parts



affected, and this can rarely be accomplished without the removal of the bone on which it lies. The manner of doing this will be mentioned in speaking of the other species.

The non-malignant tumour may be cured, in some instances, by cutting it close to the bone. When it arises from a socket, it is proper to remove the bone from which it springs. In the latter case, if it be merely cut, though treated afterwards with caustic, the disease is refractory. The bone itself must be removed. In the case of which we have here a representation (see Plate XII,) the patient perceived a small excrescence springing from between the cuspidatus and last incisor of the lower jaw, on the left side. The tumour continued to grow, assumed an oblong form, and became pendulous, sometimes protruding on the outside of the teeth, sometimes getting on the tongue, and being bitten. It had been twice cut off close to the gum, and cauterized.—I removed the cuspidatus and the third incisor, applied the vertical forceps on each side the diseased socket, from which the tooth had already been expelled, and then, with a transverse forceps, the tumour and socket were removed together, and you here observe them—the tumour dependent, and the pieces



of bone from which it originated. The patient recovered rapidly, and had no return of disease.

In what instances it is proper to cut through the bone, and in what to satisfy ourselves with the mere excision of the soft tumour, it is sometimes difficult to decide. Whenever the tumour can be traced into the socket of a tooth, and when it grows over the socket of a tooth which has been removed, the bone should be excised. If it grows from the external or internal face of the gum, it may with propriety be cut down, and if it returns, a step further must be taken.

You will of course distinguish this soft spongy tumour from the hard excrescence constituted by a swelling of the reticulated texture of the bone, which has been described under the head of diseases of that texture.

CONGENITAL ANEURISM BY ANASTOMOSIS.—The *nævi materni*, or natural marks, have been considered as arterial tumours, composed of small anastomosing vessels. They are not exclusively arterial. On the contrary, some are composed principally of veins. A *nævus*, which seems at first to consist only of arteries, after a time begins to exhibit veins under and around it, which may ultimately compose the larger part of the tumour.



Congenital aneurism by anastomosis, is a red spot, of various size and form, most common on the face, scalp, and neck ; and seen occasionally on other parts. It does not pulsate ; but often swells out, particularly when the child cries, and then it is much more conspicuous than ordinary. These tumours generally increase, and sometimes attain a considerable size ; and when they are situated on a vascular part, as the neck, the veins which return their blood, assume the morbid action, and increase in size. Although they have a disposition to grow to a certain extent, they rarely become widely spread. Their growth seems to be limited by some law, and they at last cease to extend themselves. At least this is generally true, though there are exceptions. When the tumour has reached its utmost limits, it begins to fade, and become of a less vivid colour ; and the vessels seem to shrink, and the tumour is less prominent.—Another course often occurs, particularly on the trunk of the body. Having reached their utmost growth, they seem unable to maintain their vitality ; they die and slough away ; or sometimes, instead of disappearing in this mode, nature attacks them by ulceration of the edges of the surrounding skin ; in consequence of which



they are gradually insulated and cast off.—They are sometimes seen to pursue a different course. After remaining quiet for many years, from some injury they suppurate, discharge an unhealthy matter, a fungous shoots out, and they take on the character of a malignant fungus, or cutaneous cancer.

A lady, forty-five years old, sent for me in the summer of 1836, for a supposed cancer of the hip. She had a small congenital mark, a little behind the trochanter major, which had increased within four or five years, and in the preceding summer had become chafed and irritated, for she was very fat; an ulceration had taken place over the whole surface, and continued to spread slowly, and at the time of my examination, was about two inches in diameter, with hardened and red edges, considerably elevated above the surrounding skin, presenting a fungous aspect, without a propensity to bleed. The pain she had from it was slight, but the inconvenience very great, and besides, it was evidently in a fair way to become a permanent and perhaps malignant ulcer.

Extirpation was proposed, agreed to, and in a few days accomplished. The cellular membrane under it was found fair and healthy; and



I took care to remove a good portion of skin around ; so that I believe she will have no further trouble from it. The wound healed in about six weeks.

The tumour, you see, has a threatening aspect. It somewhat resembles the malignant tumour of the leg, already spoken of, under the head of cancer of the skin, and is more formidable in appearance than some of the worst specimens of cancer of the face you have seen.

It is certainly an extraordinary piece of neglect to allow a disease of this kind to run on in an ulcerated state for months, and even for years. When a *nævus* ulcerates, and the ulceration runs into its substance, and continues for a long time, it ought to be removed.

The treatment of this tumour will vary according to its situation and size. If on the face, scalp, or neck, it is best to remove it by excision, as soon as discovered ; especially if it be near to the mouth, eyes, nose, or other natural apertures. When situated on the trunk, or extremities, I should commonly be willing to wait the action of the natural powers, until some circumstance render its removal necessary.



If it has been allowed to attain a large size in the parts, from which it should have been early removed, it may be difficult to extirpate. Perhaps it will have reached the lips, the eyelids, or mouth. Or, in the neck, it may have attained so great a size as to involve the danger of an alarming hemorrhage. In these unpleasant cases, we may sometimes remove the tumour by the knife, and bring the sides of the wounds together by sutures, so as to make a strong compression. This practice I have pursued in regard to the lips. But when the danger of hemorrhage is great, the ligature must be employed.—Vaccination of the tumour has been often tried, and generally without success. When the the tumour is small, this course merits an experiment, because it is perfectly safe. In adopting it, we must recollect that the chance of success depends on exciting inflammation sufficient to cause an effusion of lymph, in order to compress and obliterate the vessels. The punctures should therefore be numerous.

There are various ways of applying a ligature. The most simple consists in passing a curved needle, armed with a double ligature, under the tumour, entering at one edge, and issuing at the opposite edge; then passing another double lig-



ature at right angles with the first. The base of the tumour is to be tied by quarters; so as to include the base of the whole in the eight threads. They should be drawn as tightly as possible. The tumour immediately assumes a purple colour; on the third day it begins to dry, and from the sixth to the ninth separates in the form of a crust. The child suffers severely for two or three hours; but I have not known dangerous symptoms to arise under these circumstances. It should be recollected that the more closely the ligature is tied, the sooner will the patient cease to suffer.

Another mode of producing inflammation, and obliterating the vessels of the tumour, is by the actual cautery. Dr. Bushe, of New-York, informs me that he has often pursued this practice with success. A number of long sewing-needles are heated to a white heat. These are pushed across the tumour in different directions, so as to cauterize every part of it. If the needles are of a white heat, the pain caused by them is not excessive.

When the tumour is too large to be well embraced by the cross ligatures, in the way I have described before, the practice of Dr. Rhea Barton may be resorted to. This consists in passing two



needles, at right angles with each other, across the base of the tumour, and then carrying a ligature under them. The object of the needles is to confine the ligature about the attachment of the tumour. This ligature, being tightly drawn, perfectly strangulates the part.

When the tumour is too large to be safely attacked at once by any of the modes mentioned, it may be destroyed in detail, by including portions of it in a ligature successively. This has been practiced by Dr. Physick.


Whatever plan is adopted, it is not to be considered as accomplished, unless every portion of the diseased vessels is removed; for, if any part be left, the disease will be liable to be regenerated, perhaps very slowly, yet surely; and a second operation will be required to arrest its growth.

OPERATION BY EXCISION.—Dr. Channing called my attention to a child two years old, with a *nævus* on the top of the head, about an inch in diameter; of a red colour; little elevated above the surface of the skin, excepting when the child cried; then it became much distended, and of a brighter colour.—I made an incision around the tumour, in the sound skin, at the distance of one-

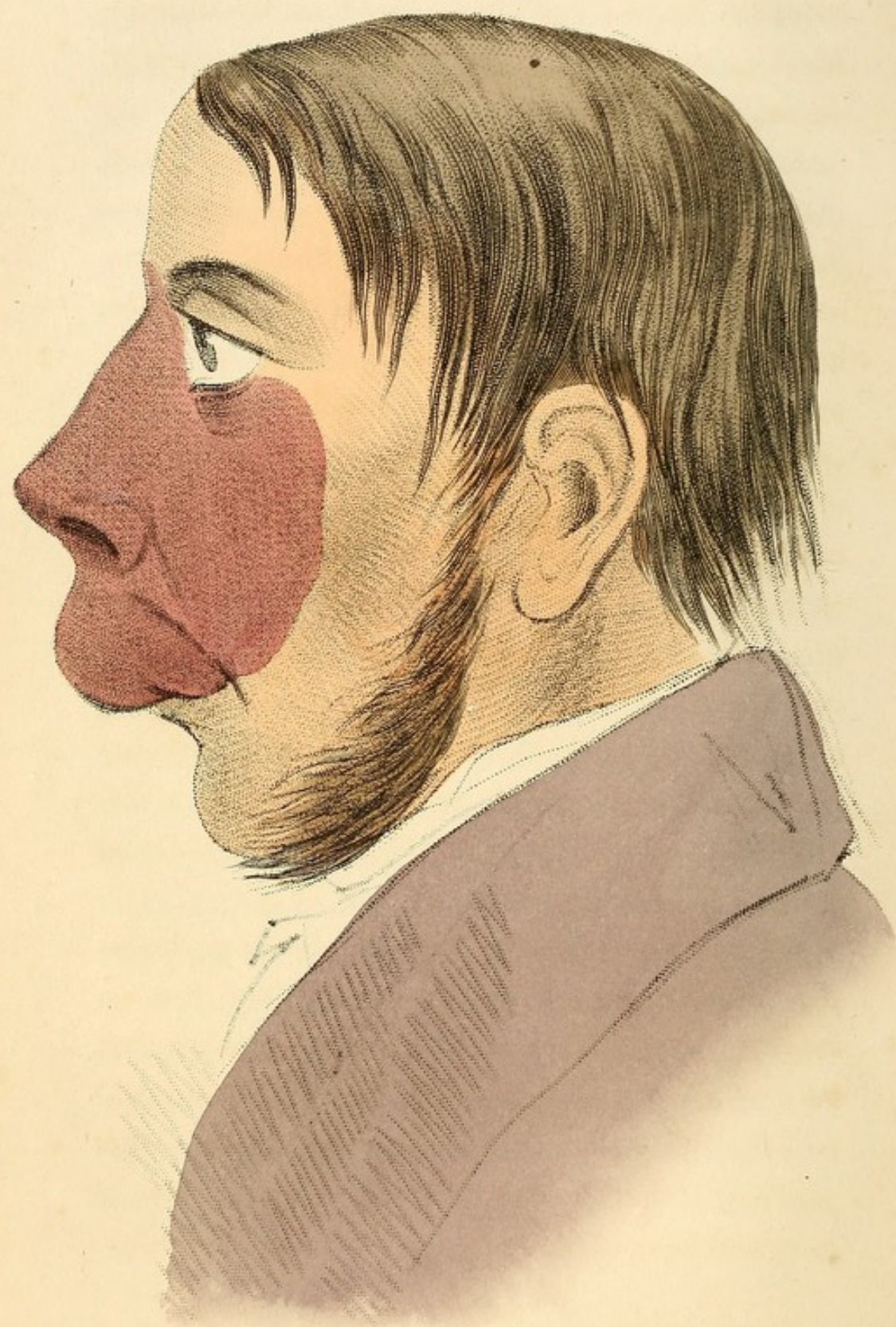

sixteenth of an inch, and dissected it off carefully, avoiding as much as possible an interference with the pericranium. I noticed, however, that at one part the membrane was a little elevated; it being impossible, in the midst of the gushing blood, to make the dissection perfectly accurate. The wound bled copiously; but by pressing on a sponge this bleeding was soon checked. The wound healing slowly, I was requested, in ten days after the operation, to examine the child. I saw, by the glossy appearance of the surface, that there would be exfoliation; and, in a short time after, a scale of bone separated, and the healing took place. This accident I have occasionally met with; nor does it appear possible always to avoid it, so great is the bleeding, and so loose the attachment of the pericranium in these young subjects.

At the same time with this operation, I removed one from the forehead of a child three years old, in the same manner. The bleeding was great, but soon subsided. The wound was of oval form, and the edges were drawn to each other by adhesive plasters, and the wound healed in fifteen days.







*Congenital aneurism by anastomosis*



The following case illustrates well the erectile tumour, as described by Dupuytren, supervening on congenital nævus.

W. B., painter. This person has borne from his birth a large red mark, usually called nævus maternus, affecting the skin of nearly half the face. —The coloured portion commences just over the left eyelid, extends to the conjunctiva both of the eyeball and lid, and over the cheek, lips, and left side of the nose. During his childhood, the lip of that side began to increase in size, and this increase has gone on rapidly of late years, so that, at present, the swelling forms quite a prominent tumour, extending both outwards and downwards over the under lip. See Plate XIII. The gums, also, have assumed somewhat of a spongy appearance, bleeding frequently on the slightest accident. His health is pretty good. He is in the habitual use of tobacco and ardent spirits.

A careful examination of the lip being made, no perceptible hardness was to be discovered in its substance. On seizing it between the fingers, and making a strong compression, the blood could be entirely driven out, leaving the integuments pale and shrunken. On relaxing the pressure, it soon resumed its former size; not at once, how-



ever, but by repeated jerks, synchronous with the pulsations of the heart. From the nature of the disease, its liability of extending to the surrounding parts, and added to this the deformity produced by it, it was thought best that it should at once be extirpated. This, at present, seemed practicable from its being sufficiently circumscribed. The operation was done by Dr. Mason Warren, whose patient he was.

The lip being held by an assistant, an incision, two inches and a half in length, was commenced at the angle of the mouth, and carried to within an inch of the nose. This was joined by another incision, having its origin at the middle of the upper lip. By these incisions, a triangular portion of the lip was removed. Three or four arteries which were cut, bled freely, one of which it was necessary to secure by a ligature before the wound could be dressed. The hemorrhage was much less than had been expected, and at no point was there a bleeding from the whole surface, as is the case when the erectile tissue is cut into. The edges of the wound were brought together by two pins, and two points of the interrupted suture, one of the sutures being made through the lower edge of the lip, so that the prostomion should be accu-



rately adjusted. The wound united by the first intention, except its upper angle, from which there was, once or twice, in the space of a week, a very slight hemorrhage. Notwithstanding the large portions of lip removed, owing to the great extensibility of the parts, little or no deformity remained after the operation.

*Appearance of the morbid texture.*—The posterior part, formed by the mucous membrane of the mouth, exhibited a layer of mucous glands, so large as readily to be separated from each other. The portion next the skin was intimately connected with it, and was composed of a tough, spongy texture, of a whitish colour, in the section of which appeared cells, formed by the division of the blood vessels. These vessels, however, did not bleed. The part was rather more free from blood after its removal, than the section of a healthy lip.

OPERATION BY LIGATURE.—In the summer of 1834, Mr. C., of Virginia, brought me his child, two years old, very fat and healthy. A nævus occupied the left side of the neck, from the chin to the clavicle. It was of a red colour, with a cluster of purple-coloured vessels at its base and under it. This tumour, at birth, was little larger



than the head of a pin. Of late, it had increased rapidly, and has sometimes bled. From the upper edge of the tumour, a little process extended towards the chin.—The tumour was too large, too deeply placed, and in a part too vascular, to allow me to think of excision.—The effectual application of a ligature was difficult, in consequence of the rising of the tumour on the chin, and especially of the process spoken of.—The passing of straight needles through the base of the tumour would also have been difficult, if not impossible, from the concavity and irregularity of the surface. Crooked needles could be passed; but I saw no mode of preventing their extremities from irritating and ulcerating into the neck.—The red-hot needles would, I feared, not be effectual in this case; and I was also apprehensive of injurious effects in this part from their penetrating too deeply. Considering these things, I resolved to employ the cross ligature, which, with the assistance of Drs. Channing and Brown, was performed as follows:—A long, curved needle, carrying a double ligature of two strong silk threads, was entered at the top of the tumour, above the little process; and the tumour being pinched up and drawn outwards with the thumb and fore finger, with some little diffi-



culty the needle was brought out near the clavicle. Another needle and ligature was passed across the neck, at right angles with the first. Then I took a thread of the first and second ligature, and tied them, so as to include a quarter of the tumour, the opposite ends of these ligatures being held by an assistant, to prevent drawing them out. The first ligature was made without difficulty. When I came to tie the others, the unevenness of the neck caused them to slip on the tumour. To prevent this, I seized the tumour with a double curve-pointed forceps, and, drawing it outwards, confided it to an assistant. The remaining quarters were then tied as tightly as possible. Finding, however, that the small process eluded the thread, before removing the forceps, a circular ligature was passed under the others, with a view to include the process.—The tumour immediately lost its red colour, and became livid, and in the evening cold. The child cried violently for two hours; then a leech was applied near the tumour, after which the child ceased to suffer. On the third day, the ligatures were cut through. The tumour dried, became hard, and came off on the seventh, and the wound soon healed.—The year following, I saw the patient and found that



the little process still existed in the form of a small purple spot, which was thought to be increasing. This was cut off with a lancet, which completed the cure.

OPERATION BY NEEDLES AND LIGATURE.—In the spring of 1836, I operated on a child three years old, with a *nævus*, two inches in diameter, on the right shoulder. Two needles were passed under the tumour, at right angles with each other, and a ligature carried under them and tied as tightly as possible about its base. The needles were removed on the third day, and the tumour being separated, the child was allowed to go home to the country on the seventh.

The cases stated will give you an idea of the way of doing those operations which are most likely to be required.

Another mode of treating large *nævi* has been proposed recently by an English surgeon, Mr. Lloyd. This consists in injecting the *nævus* with a stimulating liquid. A small syringe is introduced through the sound skin, near the circumference of the tumour, and the liquid is forced into its cellular texture. This is repeated at the same or different operations, until the whole has been injected. Pressure should be applied around, so



as to prevent the injection from penetrating the cellular texture in the vicinity of the tumour.—The injections employed consisted of aromatic spirits of ammonia, or of a mixture of one part of strong nitric acid, with ten or fifteen parts of spirits of nitrous ether. The fluid should be retained from five to ten minutes.

CONGENITAL TUMOURS OF THE VEINS.—That these tumours, which consist principally of, and receive their peculiar character from, the veins, do consist exclusively of veins, I would not be understood to say. Some of them, which present the character of venous tumours in a marked degree, contain, also, a spongy erectile texture of arteries, intermixed with that of the veins. I shall have occasion to advert to this subject hereafter, and will therefore only add, at present, that I mean to include in this division the tumours which present enlarged veins as the most striking external appearance. These are distinguished from the arterial tumours by the absence of discolouration of the skin. The tumour formed by diseased veins is under, and not in, the skin. Another character by which this kind of tumour is known is the corded feeling of the vessels; that is, the sensation



of a cord communicated to the finger of the examiner. When of any size, this swelling feels as if it were composed of a number of little cords, folded side by side. This peculiar state is produced by blood accumulated in the veins, and by thickening of their coats; for these veins, being unnaturally large and out of the common healthy circulation, transmit the blood with more difficulty than healthy vessels.—The congenital varix is often larger at birth than any arterial nævus is ever seen to be, but has not the same disposition to increase as the other. I have, however, sometimes seen it enlarge rapidly, and attain a great size.

The case of which you here see a drawing is that of a child still living, with this enormous tumour of the neck. See Plate XIV. The child is now twelve months old. I first saw it six months since, and it was then nearly of the size you see it represented. It filled the whole neck, and projected beyond the chin. To the eye, the purple colour of the veins was very conspicuous through the skin; and a knotted appearance was also sensible. To the touch, the tumour appeared like a coil of vessels, folded in every direction on each other, or like a bundle of round worms. Sometimes it was hard to the touch almost as



*Congenital tumour of the veins*

*D.C. Johnston sc.*





cartilage, particularly on the left side. At others, this hardness was less considerable. When the child cried, the tumour was much enlarged. It appeared at birth, and was then the size of a nutmeg. The growth was, of course, rapid. Besides the external part of it seen represented in the drawing, it projected into the mouth, and is seen under the tongue, pressing up this organ, and impeding its use. This part of the tumour within the mouth varies more than the external.—When I first saw it, I thought of attempting to cure it in detail. By raising and cutting the skin, I expected to be able to pass ligatures so as to include portions of the veins, and, by successive operations, to master the whole. But as I could not promise the mother that the child would survive the effects of the operation, she preferred to trust it to nature.—The child has had frequent attacks of illness, apparently in the lungs, and often seems to suffer a great uneasiness, probably from the pressure on the tongue. Whenever it is unwell, the swelling is larger.

A gentleman brought to me his infant, about a year old, with a tumour on the left side of the neck, of the size of a pigeon's egg. It was situated directly below the parotid gland. The skin was



not discoloured, but the purple colour of veins was seen through it. To the touch, the tumour presented irregularities, like a folded cord. Not seeing any thing important, to be done with safety, I advised to wait, and make compression on the tumour. This compression did not appear to have any effect at first; yet, after a few months, the tumour diminished, and at last wholly disappeared without an operation.

The following case was undoubtedly congenital, though reported otherwise by the father of the patient. This was a boy ten years old, who came to the M. G. Hospital in December, 1833. He had a tumour on the back part of the head, covering most of the os occipitis, especially on the right side. It was an irregular, knotted, flaccid tumour, composed of very hard cords; so hard that it seemed impossible they could be veins; yet there shot out from this tumour, purple-coloured vessels to the right side of the head, as far as the forehead, and also over the summit of the head. In the centre of the swelling was quite a solid knot, like a filbert.—The father's story was, that he first saw a small tumour on the back of the head, when the boy was two years old, and that it had gradually increased since. The father was a German emi-



grant, and had been absent from the child most of the time since he had been in this country, which was about nine years. The boy was subject to the head-ache, and had been frequently ill, and had a sickly complexion.—A question being made as to the expediency of the removal of the tumour, or rather of that part of the tumour on the os occipitis, I had some doubts as to the effect of the operation, from its being impracticable to remove the ramifying veins from the upper part of the scalp. If, however, these veins were supplied from those in the tumour, or if, on the other hand, they returned their blood through the tumour, the interruption caused by the removal of the latter, might result in a successful termination.—An operation being therefore decided on, I made a crucial incision on the surface of the tumour, dissected up the scalp, and exposed this large knot of vessels buried in a mass of connecting substance. Then, seeking for the base of the tumour, I could find no place distinctly marked as such, because the venous net-work extended itself gradually and insensibly into the surrounding substance. I therefore carried the knife round the body of the tumour, cut through numerous large, hard veins, which poured out



a torrent of blood, and removed the mass down to the pericranium. The bleeding veins had no disposition to contract, and were tied. In tracing some of them, as far as they could be distinguished, they seemed to penetrate the cavity of the cranium—an appearance which gave me some uneasiness lest I should not be able to secure them, and lest the contents of the cranium might be disturbed by the inflammatory process consequent on the operation. By ligature and compression the bleeding was stopped. The wound was brought together and the skin united. Part of the wound did not heal at once. Two weeks after, the boy had a slight attack of erysipelatous inflammation. He recovered wholly, and was discharged in about six weeks from the operation. The veins on the scalp gradually diminished, and when he went off, seemed in a fair way to shrink up. The boy's health was perfectly good.

ACCIDENTAL TUMOURS OF VEINS.—The term accidental is employed, it will be recollected, in opposition to congenital.—The veins, from the weakness of their coats, are very apt to become enlarged, distended, and are then said to be in a varicose state. The causes of distention may be



a sudden violence, or the slow application of debilitating agents.

The appearances and the effects of these tumours are various, according to the veins diseased. There are some appearances common to all of them. A purplish colour, a soft consistence, and a yielding substance is generally seen. The corded and knotted feeling is also common. The veins most frequently the seat of this complaint, are the saphena veins of the lower extremity. You have lately seen three of these cases in the hospital at the same time. One was a labouring man, who had the leg very much enlarged from the distention of these veins, and the consequent effusion into the cellular texture of the limb. You recollect the general redness of the limb, with a mixture of purple from the knotted and enlarged veins; the cluster of these vessels below the knee, and the ulcer at the inferior part of the limb, through which the vein had lately burst, and caused such a hemorrhage that he was nigh bleeding to death at the instant.—To cure this affection, I divided the vein below the knee in the following manner: A bandage was applied above the knee, to prevent the entrance of air when the vein was incised; then, pinching up the skin and vein to-



gether, I divided them both at a cut. This I think a better plan than introducing a small knife so as to divide the vein only; because the blood may enter the cellular texture, and because you cannot certainly know that the whole vein is divided, so as to allow its retraction; and if this is not done, the vein may re-unite.—In the case alluded to, there was no inflammation of the vein, although the patient was a rum-drinker. The wound healed soon. The ulcer cicatrised. The man was relieved from pain, and left the hospital in a month.—In order to have completed the cure, the patient should have been kept in a horizontal posture three months after the operation, with the limb bandaged; and the bandage, or a laced stocking, continued so long as there was any appearance of enlargement.—On the day that this operation was done, a similar one was performed by Dr. Hayward, on a man with varicose veins in both legs. You may recollect that in this case the legs preserved their white colour, excepting at the lower part, where one was ulcerated. This man had been troubled with the disease for many years. His legs were weak and very painful. The operation appeared to relieve him, and he left the hospital in an im-



proved state.—The third case was that of a fat washer-woman, who had been compelled to give up her business by the state of her leg. The veins had been varicose for many years. The leg was greatly swollen, very red, and covered with ulcers. We put this woman on a more abstemious diet than she had followed; kept her limb in a horizontal posture, and applied leeches on alternate days for three weeks; then dressed the whole limb with strips of adhesive plaster; and she recovered rapidly: that is, all the sores healed, and the leg looked and felt well. How long this is to last, will depend on the pursuits and habits of the patient.—A laced stocking, cold affusion, and frictions have been very successful in the early period of the complaint; even without the preservation of the horizontal posture.—It is surprising to see patients in good circumstances, neglect a seasonable attention to this difficulty. A few days ago, a young gentleman, of good family, came to show me his leg, covered with clusters of varicose veins, with a general redness of the skin, and a foul ulcer at the lower part of the leg. He had no suspicion of the obstinate nature of his complaint; and I was obliged to tell him he might lose his life in a few minutes, by a sudden rupture of the vein, to bring



him to feel the necessity of taking measures for arresting the disease. A confinement through the winter, in a horizontal posture, relieved him.

Besides the means of remedying this evil, already suggested, it has been sometimes practised to cut out a part of the vein, to prevent its re-union. This is quite unnecessary, if the vein and the hardened cellular texture about it are divided, so as to allow retraction of the vein. In this case a small compress, being well placed and bandaged on the part, the whole leg and thigh being also bandaged, there is no danger of re-union of the vein; nor have I ever seen any other bad consequences in the many cases in which I have operated, by division of the vein.—Certainly the operation is not always successful in the perfect cure of the disease. This arises from a want of due confinement afterwards. It is also sometimes the consequence of an enlargement of the two saphena trunks below the knee. When both are enlarged, I would divide both; or divide the trunk formed by their union above the knee. This I have sometimes done.—There is another way of operating on the varicose saphena, which consists in placing a ligature on the vein below the knee. This has been thought to bring on



fatal inflammation of the vein sometimes, and is now rarely practised.—Should a favorable case present, I should divide the veins at the lower part of the leg. The principal objection to this would be the number of enlarged veins commonly existing at this part, and the objection is valid. It is only when the enlargement is confined to one or two branches, that this method would be practicable.

TUMOUR OF THE SPERMATIC VEINS.—Varicocele is nearly as common as varix of the saphena veins, though we do not hear of it so often. The patient, feeling a little uneasiness, and applying his hand to the scrotum, discovers a fulness, and the appearance of one or more cords. As the derangement increases, the scrotum becomes relaxed and elongated, and causes increased uneasiness. This goes on until a positive pain is felt in the part first affected, and afterwards in the abdominal cavity. In many cases, the patient does not attach importance to the complaint, till the occurrence of the aching pain in the abdomen compels his attention to it, and often interrupts his common pursuits.—Examined in this state, the tumour presents that corded and knotted feeling which is peculiar to varicose veins. By this is it easily distinguished



from other tumours in the scrotum. When the patient lies down, it slowly disappears, and slowly returns after he has risen. These symptoms lead patients and ignorant truss-makers to consider the disease to be a hernia, apply a truss, and thus aggravate the affection.—When the enlargement is considerable, the testicle wastes, and loses its power of forming a healthy seminal secretion. This tumour occurs more frequently on the left, than on the right side, and not rarely on both, though they are not equally affected.—The causes of varicocele are, 1st. The abuses to which the organs are exposed in early life. 2d. It is often traced to a sudden effort. The patient, in lifting a heavy weight, feels something give way. A pain is felt, and the spermatic veins are found to be considerably swelled. 3d. The use of tobacco relaxes the spermatic veins, and, if it does not alone cause varicocele, co-operates with other causes in producing it.

The treatment in the early stage consists of immersion of the scrotum in iced water until a sense of pain is brought on; and this is to be repeated three times a day—the scrotum to be kept as cool as possible, and always supported by a suspensory bandage.



When it becomes distressingly painful, an operation must be performed. There are four modes of operating—1st. Compression; 2d. Ligature of the spermatic artery; 3d. Ligature of the spermatic veins; 4th. Excision of these veins.

1st. *Compression.*—This has been proposed and practised by M. Breschet, of Paris. It is executed by a small instrument, which receives the veins between two flat pieces of iron, half an inch square, which, being brought together by a screw, pinch the veins, and bring on inflammation and obliteration of their cavities. I have not been able to prevail with patients to keep on the screw long enough to effect the object wished for. The last to whom it was applied took off the screw a short time after its application, walked out of the hospital, and has not been heard of since. 2d. *The ligature of the spermatic artery* has been frequently performed by an able surgeon in this country. One patient who had been operated on in this way, came to me afterwards, having experienced no benefit. I excised the veins, and he recovered perfectly in ten days, and has remained well ever since. 3d. *Ligature of the spermatic veins.*—Whether the ligature of the spermatic veins has been performed by others, I know not. In one



instance, I have done it successfully, and will state the case. S. A., carpenter, entered the M. G. Hospital, May 9, 1824.—Says the left side of the scrotum has been larger than the right as long as he can remember. Within a few months back, has had a pain in the swelling, which led him to apply to a physician in the country, who put on a truss, and he wore it some weeks—of course, without relief. He is subject to nocturnal emissions, is dyspeptic, weak, low-spirited, and suffers severe abdominal pains, which disable him from business.—On examination, it seems that the spermatic veins on the left side are moderately enlarged. On the 22d May, an operation was done as follows:—An assistant held the vas deferens and spermatic artery between his thumb and fore finger to protect them. A curved needle, armed with a thick ligature, was passed so as to include the veins and exclude the vas deferens. The two ends of the ligature were then tied on the convex part of a cork, divided lengthwise, and applied by its flat surface to the veins. The ligature was drawn moderately tight. The patient experienced but little pain or swelling from the application, and went on quietly for a week, when the ligature, being loose, was tight-



ened. After this, considerable pain, swelling, and heat occurred, followed by a formation of pus. The ligature was loosened. In two or three days it was made tighter, and was wholly removed on the 11th of June. The patient recovered, and left the hospital entirely cured on the 6th of July. A year after, he came to the hospital, and said that he continued well.

4. *Excision of the spermatic veins.*—This operation I have been in the practice of doing for a number of years. I have operated on many cases, and found the operation give great relief. In no instance has it been necessary to repeat it.—The manner in which I have done it has been this :—The patient is placed on a table, the external parts being previously shaved. An assistant holds the vas deferens firmly and carefully between his thumb and fore finger. An incision is made over the swelled veins two inches long. They burst through the aperture of the skin, are seized by the operator, and divided first at the upper angle of the wound, then at the lower. In the first division, it is necessary to avoid pulling down the veins, because the bleeding orifices, being drawn upwards into the sheath of the cord, are more difficult to discover. If they continue to bleed



after a few minutes, ligatures are applied to as many orifices as require them. After waiting till the bleeding has wholly ceased, a stitch is to be made in the middle of the wound, and the rest closed with adhesive plaster. The wound often heals by the first intention.

J. L., manufacturer, twenty-six years old, was admitted to the M. G. Hospital, July 14, 1825. —Has a considerable enlargement of the left spermatic veins, which has existed for some years. He attributes it to a strain while lifting a heavy body, as he felt something give way in the scrotum at the time. He has been lately affected with distressing pains in the lower part of the abdomen, and is so much weakened by them as to be desirous of undergoing any operation that promises relief.—The excision of the veins was performed on the 16th of July. An incision two inches long was made over the veins, which immediately appeared. A needle and ligature was passed, through the cellular membrane, under them at the upper part of the wound, by which the veins were secured from retraction. They were then divided above and below. The hemorrhage was considerable at first, and required two ligatures. No bad symptoms followed, and



the patient left the hospital well on the 5th of August.

Having heard the description of the different ways of treating severe cases of this complaint, you will ask which is to be preferred.—In regard to compression by a screw, I apprehend there are few patients who would submit long enough to the pressure to effect the object of the operation. Then the danger of a sloughing, more extensive than could be desired, is worthy of consideration. This method, I think, should be applied only in cases where the dread of the knife is so great as to induce the patient to submit to a more painful and lingering course to avoid it.—Secondly, the ligature of the artery has the following objections: 1st. The operation of discovering so small a vessel is difficult and tedious; 2d. The operation sometimes fails to remedy the distension of the veins, as in a case already alluded to, in which it was necessary to tie the veins a year after the artery; 3d. There are sometimes two spermatic arteries, in which case, the ligature of one only would be useless; and the ligature in this case would be doubly difficult from the smallness of the vessels; 4th. We consider the expediency of tying the veins, without making an incision. This operation succeeded



in the case stated above ; but I have not experience enough in regard to it, to be able to recommend it for common use. We might expect, from such an application, that the consecutive symptoms would be severe, although they were not so in the case mentioned. The plan adopted in that instance was such as to enable me to remove the cause of irritation as soon as bad symptoms arose. Perhaps, however, the removal of the cause would not always arrest them. With these views, I shall leave this mode of treating the disease for future experience before recommending it.—Lastly, we are to consider the advantage of excision. This operation I have done, as already stated, many times with success, and never with any unpleasant consequences, excepting in a single instance. In that case, after doing the operation, I left the patient in charge of an intelligent medical friend, with a request that he would inform me if the patient had a bleeding. In four hours after the operation, he sent for me ; and going immediately, I found the scrotum enormously enlarged with extravasated blood, and the blood still flowing. I perceived, at once, that the patient must have an extensive sloughing of the cellular membrane from the injected blood. The bleeding vessel was



secured, though with much difficulty, from its being buried in the injected cellular membrane. The wound was left open. The consequent symptoms of inflammation were not severe; but the cellular membrane sloughed and came away, and with it the testicle; after which the patient recovered. He was, you may believe, not well pleased with the loss of the part, nor was I. For although the organ was wasted and useless, the idea of its possession is of value. This occurrence was a warning to me, and I wish it may be to others, to have the case carefully watched after the operation is done. You have perhaps heard of the fate of professor Delpech, of Montpellier, who was assassinated by a man who had lost the testicle from excision of the spermatic veins. Such an occurrence would almost prevent our doing an operation, in which there is danger of consequences insupportable to the pride of the patient. The proper course would be to let the patient know that the testicle is probably useless before the operation, and that after it, the organ may wither and even shrink away. I mean to say that it may wither up; not that it necessarily will do so. We must then leave to the patient the decision of the question whether he will continue to support the



disease, or take the consequences of the operation. On the whole, I consider excision of the veins as the only sure mode; and that it is generally free from any bad consequences, which may not be obviated, excepting only the wasting of the testicle.

Veins in other parts occasionally become varicose from disease and from accidental injury. The brachial veins are particularly liable to be the seat of this swelling. A short time since, I was called to see a boy, eight years old, for a swelling on the left arm, a little above the elbow, as large as an olive. It had been thought to be an aneurism. I could discover no pulsation in it; and its purple colour and very soft consistence satisfied me it was an enlargement of the veins. He said, that in throwing a stone, he perceived something give way in his arm, which then felt very weak; but he did not discover, or did not show the swelling to his mother for some days. I bandaged the whole arm, and made compression on the tumour. A pursuance of this course for ten weeks was necessary to effect the cure.—A year after, the vein was again swollen from a similar accident, and cured by a similar treatment.



About the time of the above occurrence, a gentleman came to me, with a tumour in the middle of the upper arm, at the inner edge of the biceps muscle. It was an inch long, and half an inch thick, of a blue colour, and was very compressible. It followed a fever in the West Indies. I told him it was an enlargement of the veins; and, as he felt a weakness of the arm, and uneasiness at the part, that he might have the tumour cut out and the vein compressed. He said he would submit to the operation, but that he had one in the other arm also. He then showed me a tumour exactly like the first, in the corresponding place in the left arm, which had appeared a considerable time after the other. Could this be the effect of sympathy? As he was to be absent some time, he declined doing any thing then; but said he should visit me on his return to this country.

In treating this subject, my first plan was to have made three divisions of vascular tumours. First, those consisting of arteries; second, of veins; third, those consisting both of arteries and veins. In the last, or third division, it was intended to place the accidental and congenital tumours, consisting principally of veins, but exhibiting a



distinctly erectile character, which they must be thought to derive from arteries. This third division, however, seemed rather fitted to obscure than elucidate the subject, and has therefore been omitted.

That small arteries do exist in some of the venous tumours, both accidental and congenital, there is no doubt ; because though obviously composed in a principal degree of veins, they exhibit a distinct pulsation, and other characters of arterial action. The following accidental case will illustrate the nature of this combination of vascular disease. C. M., aged eighteen, entered the M. G. Hospital, in March, 1837. He had a bad ulcer on each ankle of the right leg. Connected with these ulcers, was seen a mass of varicose veins, covering the whole leg, and forming a continuous spongy texture throughout the leg, and even through a large part of the internal face of the thigh. This vascular organization was quite elastic, disappearing on pressure, and returning when the compression was removed. But the most remarkable symptom was a powerful thrill or vibration in the tumour, similar to that of aneurism by anastomosis, with a distinct pulsation in every part, sufficient to move the finger. Yet to

the eye the tumour seemed to consist of veins, which were very conspicuous.—The history of the case was this. Seven years before, he struck a knife into the outside of the thigh, and wounded the femoral artery. This vessel was tied soon after. The limb swelled, a sloughy disposition appeared in various parts of it, which terminated in the loss of half the foot and part of the flesh of the leg and thigh. During this process he came into the hospital, in the year 1831, where I saw him. He did not remain there long, but went out during the sloughing, and I heard no more of him till March, 1837. He said that the venous tumour appeared soon after the wounds healed, and had continued, with considerable alternations, from that time. As the artery was tied, what could have caused this remarkable enlargement of the veins? Could the cicatrix have included the saphena vein in the thigh?

## TUMOURS OF THE NERVES.

The nervous texture seems less disposed than any other to organic diseases. That the nerves



are capable of inflammation, we know from their being susceptible of re-union after division. But inflammation of nerves, whether common or scrofulous, or venereal or cancerous, rarely produces a change of organization, with tumour. It has been said that the nerves are swollen, in advanced cases of cancerous affection. I show you here a preparation of the heart and lungs, from a patient who died of cancer. You notice that the lungs are covered by cancerous tubercles. Their substance is indurated from protracted cancerous inflammation. On the back part of the bronchiæ, you see the par vagum and its plexus carefully dissected; and these nerves appear large indeed, but not tumified. After a careful examination of them, in this and other instances, I cannot say that I am satisfied of the existence of an unnatural enlargement; and certainly I have not been able to detect any such change of texture as might be expected in a diseased nerve.—The nerves, at the extremities of amputated stumps, being exposed to pressure against the bone, sometimes enlarge, become painful, and require excision.—So, also, pressure on a nerve, from a substance accidentally lodged in or near it, produces an enlargement. In the

excision of portions of nerves of the extremities, which had been long the seat of painful affections, we have thought the nerve larger than natural. On the whole, however, we must say, that we do not happen to have met with any such enlargements as would constitute a *tumour* of the nerves, in the sense we attach to this term.



## SECTION XII.

### TUMOURS OF THE MEMBRANOUS TEXTURES.

UNDER this head we are to place tumours of the MUCOUS, SEROUS, SYNOVIAL, and FIBROUS membranes.

### TUMOURS OF THE MUCOUS TEXTURE.

In speaking of glandular tumours, we have endeavoured to show a distinction between tumours of the mucous glands and those of the mucous membrane. Whether this distinction can be supported by facts, we leave to the decision of others. At present we shall adhere to it; and having already spoken of tumours of the mucous glands, shall now give some account of those of the mucous membrane.

The TUMOURS OF THE MUCOUS MEMBRANE differ from those of the mucous glands, in their soft, spongy, and sometimes flocculent texture. Their most frequent situations are those parts of the mucous passages which approach the external apertures, as the nostrils, rectum, vagina.

The mucous membrane of the rectum is remarkably the seat of such enlargements, which pass by the name of hemorrhoids, and prolapsus ani. —There are three forms in which this affection presents itself. 1st. An internal tumour; 2nd. A tumour occasionally appearing without the anus; and, 3d. A tumour permanently external. The two first are arterial tumours of the mucous membrane, and differ only in degree. The third is an enlargement of the veins of the rectum, with an intermixture of small arterial vessels.

The internal tumour is often formed long before its existence is known. The first evidence of it is a moderate discharge of blood with the evacuations, and without pain. On examining by the finger, in the early stage, it is difficult to detect an alteration from the ordinary state. By the speculum, we discover an unusual redness, with an appearance of a vertical fold of the membrane.



If the disease continues, the mucous membrane becomes swollen and elongated, protrudes beyond the anus when the rectum is evacuated, and forms a red tumour—usually retiring, in a short time, into the cavity of the rectum, especially after a discharge of blood, which relieves the swelling. In this way is generated the second form of the disease, which is much more troublesome than the first ; for the tumour is, at length, difficult to return, and while it remains out, being pinched by the sphincter muscle, gives great pain, and uneasiness in sitting and in moving. The vascular organization of the rectum, and the loose cellular connection between the mucous and sub-mucous coat, allow the extension of the tumour to the circumference of the rectum ; and, at length, a circular portion of the membrane is protruded, and constitutes prolapsus ani. This state of the complaint is formidable. The difficulty of returning the swelling is greater, the consequent pain is now more distressing, and the hemorrhage considerable. The blood is thrown out at the time of evacuation in a gush, sometimes to the amount of a gill or more at one time.—The patient becomes much reduced by this constant discharge of blood, and, if it continues, may at length sink under it.



This result, however, rarely occurs, unless he has neglected the proper means of relief.—The tumour formed in prolapsus, in many persons, becomes indurated after a time. Then the copious discharge of blood is prevented by the pressure on the vessels, made by the indurated substance. But in this case, an evil arises scarcely less annoying. The tumour descends in the common movements of the body, so that the patient is unable to walk without bringing it down; and the consequence is, that he is obliged to wear a bandage, acting like a truss, to retain the swelling in its place.

The third and most common form is the external tumour known by the name of piles. This is originally a swelling of the hemorrhoidal veins, covered by the extreme verge of the mucous membrane, and by the skin connected with it. It is, at first, a soft, compressible tumour. By time, it becomes hard, and forms one or more nipple-like eminences about the anus. In its early stage, it is of a blue colour, like other venous tumours. As the skin over it thickens, and the veins harden, their cavity is diminished, the blue colour disappears, and they assume the colour of the skin of the part.



The causes of these different forms of affection are of the same nature. They are either such as, by compressing the hemorrhoidal veins, prevent a free return of blood from them, or such as, by over-exciting the vessels of the rectum, produce accumulations of blood in the small arteries. Among the former are costiveness and pregnancy ; and of the latter, dysentery, and the continued use of strong cathartic medicines.

The remedies for these complaints vary according to the form of disease. The internal swelling of the hemorrhoidal arteries, accompanied with a discharge of blood, is frequently a salutary operation of nature. It occurs as such in amenorrhœa, in organic affections of the heart, and in incipient disease of the lungs, and should then be rather encouraged than suppressed; for no artificial evacuation can be substituted for one of these natural arrangements of the animal economy, and an injudicious suppression in the cases mentioned above, would be followed by an aggravation of a constitutional disorder, or the confirmation of a disease which might have passed away.

When the complaint is purely local, it may usually be removed, or rendered inoffensive, by a careful regulation of the state of the bowels, so as



to avoid costiveness. This is one of the difficulties most frequently calling for medical advice in this country. In the cities especially, it prevails very extensively from the free use of fine bread, and other articles of food prepared with fine wheat flour,—a substance positively constipating to the bowels. For the last twelve or fourteen years, I have been in the habit of recommending to patients troubled in this way, the use of bread made of unbolted wheat flour; and I have ascertained that, with many persons, the quantity sufficient to produce a regulation of the bowels is eight ounces, or half a pound, in a day. If the difficulty be of an obstinate nature, a larger quantity must be employed. What led me to think favourably of this article, was the knowledge of the good effects of wheat bran in some cases of dyspepsia. When taken moderately, it had a decisive and immediate influence on the peristaltic movement. Some persons, indeed, without medical advice, have used this bran so freely as wholly to stop and plug up the intestines. Not being a digestible substance itself, but acting merely as a stimulus to the stomach and intestines, intermixed in too large a proportion with other food, it will at last accumulate, and produce mischievous consequences. In



one or two instances, I have been called on to give surgical aid to deliver the patient of an enormous mass formed by this bran in the rectum. I have never known this accident from the use of the bread made of unbolted flour. On the contrary, it has proved a valuable and extensive remedy.

When the mucous membrane projects externally, bleeds freely, and becomes painful, other methods are required to give relief; yet the recommendation of means to avoid costiveness must make a part of the treatment of every form of this complaint. This being enjoined, we should further advise the following course. 1. Before every evacuation, the patient should throw up a gill of cold water into the rectum, and retain it a few minutes. 2. After evacuation, the part should be bathed in very cold water, and, when convenient, ice should be employed. 3. The part should be kept anointed with an unctuous substance at all times. Should these applications not prove effectual, let him inject half a gill of rose water, with thirty grains of sulphate of zinc, every night, and retain this through the night. In some cases, I have employed a rectum bougie, introduced on going to bed, and retained as long as could be



done without uneasiness.—If the disease has reached a state not to be affected by these remedies, the patient may be relieved by an operation.

In the earlier part of my practice, I was in the habit of applying a ligature to the projecting tumour of the mucous membrane. Finding the patient to be sometimes affected with severe abdominal pains from this application, I was induced to substitute excision for ligature, and continued this operation for fifteen years. During this time, the number of operations I have performed has been very considerable, and without any fatal instance, and rarely with symptoms which gave me any uneasiness, although some of them involved an extensive excision. In a few of these, there has been a considerable bleeding, such as to cause faintness, large stools of blood, and much alarm to the patient and his friends. The occasional appearance of such accidents has led me, of late years, to recur to the ligature in a partial degree, and to combine its use with that of the knife.

The patient should be purged the day before the operation, and should live sparingly for two or three days. On the morning of the operation, a simple enema should be used.—At the operation, the patient is to be directed to bend forwards, and



place his head and chest on the bed, his feet being on the floor, and the nates forcibly separated by two assistants. He is then to strain so as to force out the tumours, or, if he cannot do it in this posture, he may sit a few minutes on the close-stool-pan. The parts, being sufficiently protruded, are to be seized by a double-pointed forceps, drawn down sufficiently to give tension to the membrane, and then, with one or two strokes of a round-edged dissecting knife, the tumour removed. If there are tumours on both sides, as commonly there are, the same is to be done on the opposite side ; and the co-existing external piles are to be excised in the same way. It is necessary to avoid taking off a circular piece of the anus, as this is apt to be followed by a contraction, which may require another operation. The patient should be carefully watched for three or four hours ; and if he has an inclination to stool, let him indulge it, and he will probably discharge a large quantity of blood, showing that an internal hemorrhage has been going on. Fainting at the distance of half an hour or more after the operation, indicates bleeding. In both of these cases, the introduction of sponge will be required. For this purpose, take a piece of sponge, of cylindrical form, two inches



long, and an inch in diameter. Pass a thread through one end of it, and then introduce it so far that it shall scarcely appear externally. This I have never known to fail of checking the hemorrhage. When there is no dangerous bleeding, so that the sponge is not necessary, a piece of oiled lint should be introduced to separate the opposite parts of the anus.

The patient should be kept in the horizontal posture a longer or shorter time, according to the degree of disease under which he has laboured; for although no confinement is required by the operation itself, it is proper to aid it by giving the affected vessels time to contract. In none of these cases are all the disordered parts excised, so that we must trust much to the salutary operation of nature to finish the cure, and must allow opportunity to perform her work unembarrassed by the movements of the body.—The most annoying symptom after this operation, arises from the effort of the intestines to expel their flatus. When the impulse thus given reaches the wounded part, it brings on a spasmodic contraction of the sphincter, which is excessively painful. The flatus is resisted, and driven back into the colon, and accumulates to a distressing amount. The



interposition of the oiled lint commonly allows the flatus to pass down. When it fails to do so, the patient must submit to the use of a mild injection, which, however painful to the wounded part, soon affords relief. Sometimes it becomes necessary to remove these contractions by the use of opium.—On the third day a cathartic of castor-oil is administered ; and this, with bathing the part daily with warm water, and applying some unctuous substance, is all the treatment required.

Prolapsus ani is a greater degree of the affection we have been speaking of. The repeated descent of the mucous membrane drags down an increasing portion of intestine, until a circular fold is protruded with the natural evacuations, and often from the common movements of the body in walking.—In my former practice, I was in the habit of removing the protruded circular portion of mucous membrane. This, as already intimated, I found to be followed with troublesome consequences. I once operated in this way on a gentleman who had prolapsus for nine or ten years. He was recovering very well ; when I found him at one of my visits unable to discharge the contents of the rectum. By the use of oily injections, he with difficulty got relieved. The obstruction recurred in a



day or two, with increasing severity, and I directed him to use bougies and retain them. This, however was not sufficient to cure the evil; nor could he get comfortable till I made a free incision on the posterior part of the sphincter towards the os sacrum, and employed bougies during the healing of the cut. It is now many years since he has been quite well.—In another case of a young lady, with whom I proceeded very cautiously, and did not remove a circular portion, but was compelled, from the extent of the affection, to cut in three places, the contraction took place, and twice I was called on to relieve the consequent accumulation by a scoop. Keeping the bowels very open, and using a small injection of oil and warm water three times a day, she was cured of this trouble without incision or bougie.

A gentleman who had been affected with prolapsus for more than thirty years, and had worn a truss for the purpose of retaining it, having heard of the relief afforded by some operations on similar cases, applied for my opinion on the expediency of adopting it. He was more than sixty years old, of rather a delicate constitution, and of sedentary habits. His complaint was very troublesome, he said, or he should not have thought of applying so



late in life. To have an evacuation from the bowels, was the principal consideration of the day ; and required about an hour of attention in bathing, soliciting, and re-adjusting the parts affected. He had great pain in the bowels after an evacuation, and sometimes at other periods of the day. Examining his tumour, I found it enormously large, and hard. The common cuticle covered the greater part of it below ; the upper part was of a pale red colour ; thus showing a difference between the most exposed and the least exposed part of the tumour.—The age of the patient, his bad constitution, and the long duration of the complaint, were reasons for declining an operation. He was, however, resolutely decided on it ; and when I considered that the hardness of the tumour, and its want of redness, indicated an absence of irritability and vascularity, I thought the operation might be done. It was accordingly performed. I seized the upper red portion on each side, and removed it with a knife. Then the lower whiter and harder mass was removed by an incision on each side.—The bleeding was slight. I kept him at home three weeks. He recovered entirely, and lived in good health to be more than seventy years old ; and finally died of hydrothorax. The last eight



years was the only comfortable period he had experienced since the earlier part of his life.

Although no alarming accident has occurred, in a very great number of instances of excision of the mucous membrane of the rectum, the desire to avoid a possible danger, has led me, for a few years back, to make use of ligature in certain cases. As the bleeding from tumours, external to the anus, is never great, and could be easily suppressed, a ligature would be misapplied to them. The internal tumours are more vascular, of course bleed more freely, and the hemorrhage is more difficult to discover and to control. The latter are then the proper subjects of ligature, when it is to be used.—The mode of applying it is this: The patient is placed as directed for excision; is desired to force out the internal tumour by straining. A crooked needle, armed with two ligatures, each consisting of three threads, is passed through the middle of the tumour on one side of the rectum. The threads are then tied on each half; one ligature including the one, another the opposite half. The threads are to be drawn as tightly as possible. The same is done on the opposite side of the anus. Then the external tumours are removed with knife or scissors. The



pain of the ligature is great at first ; but if tightly drawn, the sensibility is soon destroyed, and the pain ceases. The tumour lessens after being tied, from the oozing out of its blood. If it has much thickness, its separation will be slow. But I have not found it necessary to apply a second ligature, although this, I doubt not, may be required sometimes. The ligature comes away in four or five days. If it remain longer, the relicks of the tumour may safely be cut off, without danger of bleeding. When the pain caused by the ligature is very great, it may be removed after a few hours, without much endangering the success of the operation.

The last patient I operated on in this way was a literary gentleman, who for fifteen or twenty years, had been highly dyspeptic. He kept himself alive by continued exercise. A number of years since, he was attacked with bleeding hemorrhoids, which increased till it brought on prolapsus. His exercise was now checked, and his health became worse, from indigestion, loss of blood, and pain ; when he accidentally heard of some one who had been relieved, by an operation, under similar circumstances. At once he resolved to undergo it.—When I examined him, the tumours



taken together were near the size of a hen's egg. After a cathartic medicine, I operated on him. A ligature was applied on each side of the rectum, about an inch above the anus, including in each ligature a substance as large as a filbert. The portions of tumour without the anus were cut off. He had no great suffering at the time nor afterwards. The ligatures separated, one in three days; the other I cut off, with the remains of the tumour, in five days, without bleeding. I kept him quiet till the tenth day, when, from his impatience, he was discharged. He has been perfectly relieved, and able to resume his accustomed exercise.

On the whole, I can say, that there are no operations I have performed with so great relief, as from these. I will here add, for example, the case of a lady, who lived at a distance, and was so feeble from enormous discharges of blood, that, for some time, she was not able to be brought to Boston. The death of her mother, from a neglected complaint of the same kind, roused her to an extraordinary effort, and she succeeded in getting here. The daily discharge of blood, she thought was not less than a pint. Certainly it was very great; for she was in appearance as bloodless as a corpse.—



The tumours were removed ; and it is now fifteen years she has had perfect health.

TUMOURS OF THE MUCOUS MEMBRANE OF THE  
NOSTRILS.

The tumours to be referred to this head are the excrescences called polypi, found in the mucous membrane of the superior portions of the aerial passages. It might be made a question whether all the tumours known under this name are productions of the mucous membrane ; as some of them possess a tenacity which does not belong to this texture.

The polypi of the nostrils, I have had occasion to notice, are of three kinds, which may be called membranous, fibrous, and vascular.

THE MEMBRANOUS POLYPUS is a tumour of a pear-shaped form, such as you see here. Most commonly it has a contracted portion or neck, by which it adheres to the upper and back part of the nostrils, and a bulbous part dependent in the anterior part of the nostril. This form is not universal. The polypus is frequently of the same thickness throughout, and sometimes its attached

extremity is broader than the other. In colour, it is whitish, with more or less transparency. Its consistency is almost gelatinous. It yields and breaks under the pressure of the forceps. It is composed of a coat of about the thickness and strength of the mucous membrane, from which it originates, and an internal cellular texture—the cells containing a watery fluid. In most cases, instead of there being a single tumour, two or more are found to arise from a common base ; and in other instances, a number spring up near each other from separate bases. Examined through the external aperture of the nostril, by the aid of the sun's rays, directed into the cavity, we notice a shining substance, filling the nostril, and often presenting a red appearance from the reflection of the red colour of the nasal cavity. The patient being directed to blow his nose, the tumour is brought down, and is then discovered to have a whitish colour, as already mentioned. By the aid of a speculum, the form and size of the tumour is more fully seen. A common dressing forceps is a substitute for a speculum.—On touching the tumour, it is found destitute of sensibility, and more or less moveable.—The nature of the affection will be further elucidated by the symp-



toms of the patient. The nostril being obstructed, there is difficulty in breathing when the other nostril is stopped. The voice is more flat than natural. When both nostrils are affected, these symptoms are more remarkable, and the sufferings of the patient are greater.—The discovery of the tumour is usually preceded by repeated bleedings from the nostrils.

It might be thought that a disease like this would be easily discriminated. In fact, when a polypus exists, practitioners find no difficulty in ascertaining it. There are, however, other appearances in the nostrils, which are quite often mistaken for polypi. Few weeks elapse without my seeing a patient who has been thought to have polypus, when in reality there was nothing of the kind. There are three derangements of the nostrils which are mistaken for polypi :—1st. An unusual size of the lower turbinated bone ; 2d. An inclination of the septum of the nostrils to one side ; 3d. A thickening of the mucous membrane of these cavities.—1st. The unusual size of the turbinated bone is the most common of these three cases. The patient, finding some difficulty in breathing through one of the nostrils, passes his finger into the cavity, and discovering something



he had not before noticed, applies to his medical attendant. On looking into the cavity, the practitioner sees a shining projection, and concludes at once it must be polypus. He attempts to seize the prominent part with a polypus forceps, and employs many manœuvres to remove it. The patient, suffering severely from the operation, compels the practitioner to desist, after he has succeeded, perhaps, in crushing and bringing off a portion of the obnoxious bone. 2d. The prominence of the septum is not an unfrequent occurrence. In few subjects is the septum perfectly vertical in its direction. In some persons, the inclination to one side is so great as to obstruct the free passage of air; and on looking into the nostril, the appearance of a shining projection is noticed, like that of the turbinated bone already mentioned, excepting that the projecting septum appears on the inner side of the nostril, and that of the turbinated bone on the outer. The forceps, if applied in this case, are not so mischievous as in the other, because nothing can be embraced by them. 3d. The thickening of the membrane is more rare, and more difficult to make out. There is no projection in this case. The sufferings of the patient arise from an obstruction to the course of air



through the nasal passage.—A short time since, a person came to me from the country to be operated on for polypus,—an operation which had been twice attempted without any result. On desiring him to close the left nostril, and force air through the right, he was able to do it in a very slight degree. Listening to the inspiration in its natural state, it was obvious, by the whistling sound, that there was an obstruction to the free passage of air. Nothing unnatural was discoverable in the nostrils or throat. It was thought possible there might be a polypus in the back part of the cavity. To ascertain whether this was the fact, I passed a moderate-sized bougie along the floor of the nostrils, keeping the point towards the septum. It went through the passage without difficulty, and was arrested only at the back part of the pharynx. I then carried my fore finger through the mouth and pharynx to the posterior aperture of the nostril, and found it perfectly free. The membrane of the nose was redder than usual, and I concluded that the narrow passage between the turbinated bones and the septum was obstructed by the thickening of the mucous membrane.

The membranous polypus is commonly removed by the curved forceps made for the purpose. The



operation is rarely effectual in eradicating the disease,—a fact not surprising when it is considered that, from the weakness of the polypus, the membrane from which spring its nutrient vessels can rarely be torn out. The operation must therefore be repeated as often as the disease is regenerated. —The best kind of forceps are those with twisted handles and straight blades. Occupying less room than the others, they can be more widely opened, and the tumour more perfectly embraced. A smaller forceps than that commonly used is more manageable, gives the patient less pain, and, for the reason just stated, being more widely opened, takes a better hold of the polypus.—The common mode of using the instrument is, after introducing it, to open the blades and insinuate them deeply into the cavity. Then, closing the handles to seize the tumour, the instrument is twisted once or twice to unroot it from its attachment. With the small, straight forceps, we can, if necessary, open the blades in a vertical, instead of a horizontal direction, and, in this way, sometimes get a better hold of the polypus. The tumour, when once caught, rarely slips from the instrument, but breaks off.



After the operation, the patient is directed to introduce a piece of lint, wet with a saturated solution of sulphate of zinc. This is to be carried down to the roots of the tumour, and to be frequently renewed, so as to keep the part continually moistened. This remedy has been lately recommended by an English surgeon, and is often effectual in preventing a return of the disease. Under its use, the mucous membrane, after a few days, becomes white, loses its vitality, and sloughs off. The same solution may be employed with good effect, when no operation is performed.

When the tumour is so considerable as to make its way backwards into the pharynx, it cannot always be drawn out through the nostrils. Commonly, when very large, it may be torn off in the nostril, and then, falling into the patient's throat, is quickly ejected.—However, I lately operated on a young woman who had quite a large polypus, which was seen hanging in the pharynx. Seizing the tumour in the nose, it was detached, and working very gradually, it was drawn through the nostril, though not without dilating the part so much as to threaten its bursting open. A practitioner in this vicinity informs us that, when the polypus is very large, he slits open the nostril with



a knife, has then no difficulty in unrooting the tumour, and finishes the operation by sewing up the nose.

There are cases of this kind of polypus which are not to be managed in any of these modes, and require a ligature, as practised on the large fibrous polypus.

The following case will show the action of the sulphate of zinc, as alluded to above. April 7th, 1835. George Wales, *Æt.* 15, entering the M. G. Hospital, reports that, four months since, he began to be troubled with bleeding from the left nostril. After this had continued to appear every five or six days, for six weeks, he perceived a tumour in the nostril, which obstructed his breathing through it. The bleedings still continued. Otherwise, his health is perfectly good.—April 8th. Make a solution of sulphate of zinc, (one drachm to one ounce of water,) dip a piece of lint in it, and apply deeply in the nostrils, so as to cover the tumour. 10th. Polypus has a white appearance, and is much contracted in size. Use a saturated solution of sulphate of zinc. 14th. A portion of the polypus, one third of an inch thick, came away. The nose is swollen, sore, and painful. Omit the solution till the soreness is better. 20th. Re-



apply the saturated solution. 30th. A number of portions of polypus came away. Nostril very sore. Omit the solution, and syringe three times a day with warm chamomile tea.—May 8th. No polypus visible. The crusts on the side of the nostril, caused by the action of the zinc, have not wholly separated. In other respects, well. Discharged cured.

FIBROUS POLYPUS OF THE NOSTRILS.—This we call *fibrous* polypus from its tenacity. Whether there be actually any fibrous texture in it, I know not. In two or three cases, I have thought there was a striated appearance, like that of the aponeurotic expansions. Fibrous polypus is not to be distinguished from membranous by its appearance in the nostrils. Its distinguishing quality resides in its strength of cohesion. When drawn out by the forceps, it resists, and requires an effort of strength to remove it, whether it be in part or whole. These tumours are sometimes smaller and more numerous than the membranous species.—There is a gentleman living in this vicinity, who has a polypous affection of both nostrils, which has existed for some years, and causes great inconvenience. Astringent and escharotic applications have no influence upon his



disease. About once a year, he is obliged to resort to an operation; and as the tumours are situated in the upper part of the nasal cavities, he has a rending pain in the head from extracting them. They are very small; one or two are removed at each introduction of the forceps; and this operation is continued as long as his strength permits; but I never knew the whole of them to be removed at one operation. The force required is as great as can be readily employed.—Sometime since we had a clergyman in the hospital, on whom I operated a number of times for this kind of polypus; and finding no end to the operations, I obtained for him a small polypus forceps, taught him how to use it, and advised him to employ it when necessary, which he succeeded in doing with great adroitness.

The relation of successful cases alone, is not sufficient to convey instruction. Those which are not successful are often most useful in leading to a knowledge of the difficulties which may occur. For this purpose I will relate the following case. A boy, fourteen years old, came to the M. G. Hospital in June, 1835. He had a large polypus filling the right nostril, and hanging in the pharynx, so as to be just visible below the soft



palate.—Divers attempts had been made to remove it without success. It was therefore thought best to make a trial of the sulphate of zinc. This and a solution of nitrate of silver were applied for some time without producing any change in the tumour.—This point being settled, it was thought best to try a ligature. A canula, with a strong silk ligature, was passed through the nose; the ligature was seized and expanded in the mouth; but it was found impossible to include the polypus in the noose.—A silver wire, of the strongest and best fabric, was next employed. A noose being formed, was passed through the nostril, seized in the pharynx, and brought into the mouth; the noose expanded, and the wire carried over the polypus and drawn up into the nostril, and there twisted as tightly as possible. On the third day it was found that the tumour was discoloured. The wire was twisted anew. After this, some portions of the tumour came off. It appeared, however, on waiting five or six days longer, that the body of the polypus remained sound; the wire being at the time twisted as closely as possible. The following operation was then performed: Two very strong hooks were passed through the mouth, and engaged in each side the tumour in



the pharynx. Then by lateral movements, efforts were made to pull out the tumour. As it did not yield, the power was gradually increased, till the boy and the assistant who supported him, were dragged forwards two or three feet from his chair, and about a third of the tumour was removed, the rest holding firmly to its adhesion. A probe-pointed bistoury was then introduced to cut the neck of the polypus in the nostrils; but the neck could not be attained in consequence of the lateral pressure of the tumour on the parietes.—The efforts were then relinquished. The boy remained two or three weeks longer, during which time some further portions separated. Being unwilling to have any thing more done, he was then discharged, the wire being allowed to remain, with the hope it might at last ulcerate through the tumour.

VASCULAR POLYPUS OF THE NOSTRIL.—This affection is rare, compared with the other species. I have most commonly found it in young persons, and rarely of a malignant character; although its appearance would lead to the apprehension of such a character. It is of a red colour, bleeds from a very slight cause, and from every part of its surface.—I have eradicated it commonly by the for-



ceps; and in some instances an astringent injection alone has effected the cure, without relapse.

#### FIBROUS TUMOUR OF THE ANTRUM.

This is of rare occurrence, compared with the fungoid tumour of the antrum. It is of slow growth, begins without pain, and does not become painful till it makes pressure on the surrounding parts. The bones of the face are not pushed out by it as in the fungoid disease; for it seems to creep along the periosteum, sometimes in the direction of the nose, or that of the eye or face. Its consistence is so firm, that it is not readily torn. Its colour is a brownish white; showing a moderate vascularity; but it does not bleed freely.

A man entered the hospital in the year 1836, with a small tumour under the right eye. He was fifty-one years old, a farmer, somewhat given to the use of ardent spirits. A few months before, he felt some uneasiness in the right eye, which fell into a state of inflammation, and became watery. Soon after, he perceived a tumour an inch below the orbit, and about an inch in length,

extending transversely under the eye. This was somewhat painful ; but his greatest trouble continued to be in the eye.

I made an incision over the surface of this tumour, and having with difficulty raised the integuments from it, endeavored to insulate it. Finding this not easily done, I dissected the lower part of the orbit, and perceived it to extend half an inch in that direction. Then following it down on the side of the face, on looking for the basis formed by the maxillary bone, an aperture was discovered in this bone, and a ragged edge about the tumour. A probe, passed through this aperture, went to the bottom of the antrum, which was filled with a tumour like that on the side of the face. The external tumour was then cut off, and found to be of a very firm fibrous texture, of a whitish colour, with no disposition to bleed.—Being satisfied by examination, that the disease could not be cured but by removing the whole bone, the wound was dressed. The patient was informed of his situation, and of what was necessary to relieve him. He soon after left the hospital, with the intention of returning ; but probably will not return, till the time for relief has passed over.



While he remained, he suffered much from his eye, which was constantly in an inflamed and watery condition, arising from the pressure on the lower part of the orbit.

The character of this disease was, in many respects, very different from that of fungus hæmatodes of the antrum, especially in wanting the soft consistence and bleeding disposition of that fungus. Nor did it in any way resemble an osteo-sarcoma of the antrum, if there be any such disease, of which I have doubts. Osteo-sarcoma of the face I have seen; but never that of the antrum. Probably the tumours supposed to be osteo-sarcoma, have been those fungoid cases, which are covered with a hard shell, apparently of bony consistence.

#### FUNGOID TUMOUR OF THE ANTRUM.

This is a malignant and distressing affection. It begins with an uneasiness in the nose. After a time, the nostril of the diseased side is obstructed, and the patient thinks he has a polypus. A red tumour is seen in the nostril, which, if grasped by the forceps, gives out a copious discharge of blood. The obstruction increases, and is accompanied



with pain. The nostril frequently bleeds without provocation. An offensive ichorous discharge issues from the anterior and posterior apertures of the nostrils. The face swells. The portion of maxillary bone, which covers the antrum, protrudes and produces a horrible deformity. Sometimes the first protrusion of bone will be perceived in the mouth, from a depression of the palatine plate, pushed downwards by the enlarging antrum. The molar teeth drop out, and are followed by a discharge of blood, which, for the time, gives some relief. As the tumour grows large, the nostril of the opposite side becomes obstructed from the pressure of the septum into it. The external swelling of the maxillary bone assumes a sugar-loaf form, and seems to be composed of bone and cartilage intermixed. Fistulous openings appear. The throat becomes obstructed from a posterior extension of the disease. The eye is sometimes protruded, and sometimes buried in the tumour.—This disease is always fatal. I have proposed to those affected with it, the extirpation of the superior maxillary bone, a formidable but valuable expedient, where no other ground for hope remains.—Twenty years ago, a patient applied to me to have the antrum opened, though he

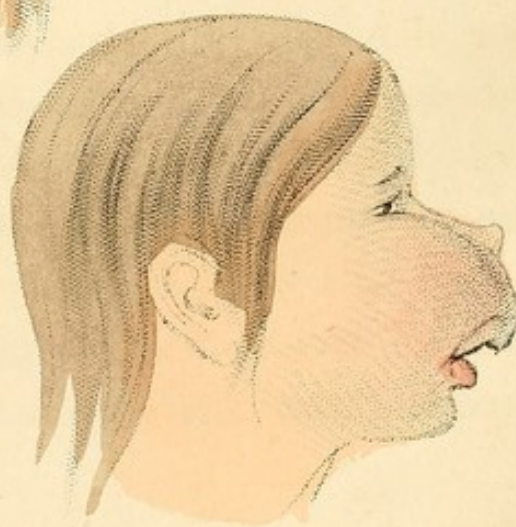
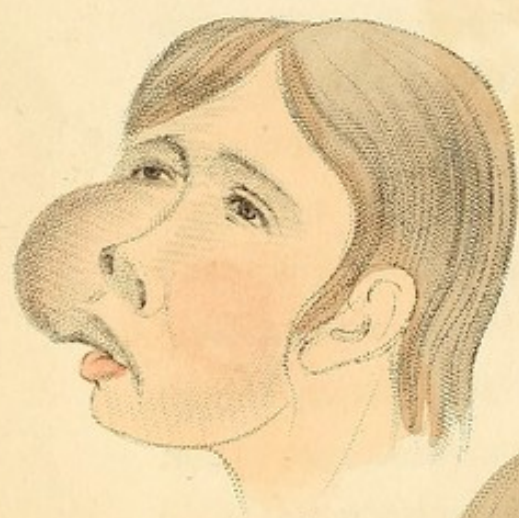
had been informed that such an operation would not probably be effectual. In his case the disease extended first into the nose, then into the mouth, causing a projection like the convexity of the bowl of a spoon. The disease was too far advanced, but at the patient's desire I operated. The bone being softened, was readily removed by a gouge. The antrum was extensively opened, and all the visible part of the tumour removed. Then its interior was thoroughly and repeatedly cauterized with caustic potass.—The patient was relieved for a short time; but the disease soon re-appeared and extended into the throat, causing great pain and difficulty in swallowing. His distress was mitigated by the constant use of opium.—The operation of extirpating the superior maxillary bone, viewed in relation to this disease, must be considered a valuable discovery, and will no doubt be frequently performed, even though it may rarely succeed.

A few weeks since, a case presented which, for some time, excited a painful interest in my mind. Dr. Green, of this place, brought to me a poor child, twelve years old, with a frightful swelling of the right side of the face. After careful examination, I ascertained that this appearance arose







*Fungus hæmatodes of the Antrum*



from a tumour of the antrum, either an osteo sarcoma or a fungus hæmatodes. It began on the side of the face not three months before, extended downwards into the mouth, and latterly filled the right nostril. There was no bleeding, no pain, and no discolouration of the skin. See Plate XV. Having considered the case for some time, I came to the conclusion that the whole disease might be eradicated. There was room in the sound parts to divide the malar bone, the nasal process of the maxillary bone, the palatine plate of the maxillary, and thus to extract the os maxillare superius, and comprehend the whole of the disease. It seemed to me, that, if the disease were fungoid, yet the period of life was favourable to its eradication; for it is well known that malignant disease is not so liable to regenerate at the early part of life. It appeared probable, also, that the operation would not be excessively painful, and, considering the youth of the subject, might be accomplished in a short time. Having formed this opinion, I requested Dr. Flagg, who is very conversant with diseases of the parts affected in this case, to consult with Dr. Green and myself. After a careful examination, they agreed with me that an operation might and ought to be done.—



There being no apartment where the child resided which was convenient for the purpose, I advised her going to the hospital. After her arrival there, I requested the opinion of a considerable number of gentlemen of the profession. They were unanimously of opinion that an operation in this case promised so little, that they could not recommend it.—Having invited the opinion of gentlemen whose judgment I was in the habit of respecting, I did not feel justified in operating contrary to that opinion. The child still lives, and will probably continue to live for some time ; and the disease is constantly increasing.—The idea of abandoning every case of fungus hæmatodes of the antrum as incurable, after having for some time enjoyed the hope that a mode of eradicating the disease had been discovered, is scarcely to be tolerated. I am not satisfied that, where the disease is confined to the antrum, its extirpation may not sometimes be successful; yet I can never expect to see a case more likely than this mentioned to come to a favourable result.



## FUNGOID TUMOUR OF THE UTERUS.

This disease is to be distinguished from the cauliflower excrescence of the uterus. The latter most commonly begins in the os uteri, and is accompanied with more pain. The fungous tumours have the polypous form, and begin in the cavity of the organ. Examination enables us to distinguish them with ease. The fungous tumour may, perhaps, fill the vagina; but on passing the finger to the os uteri, its labia are found to be healthy, and the tumour is traceable, with more or less ease, into the cavity of the uterus. This tumour has an irregular surface, bleeds on examination, and at other times is accompanied with an offensive discharge. There are two species—one malignant, the other not; yet the symptoms and appearances are so much alike in both, that it is not easy to distinguish them but by the results.—Perhaps the two following cases, one of each kind, will throw some light on the discriminating points.

The first is a case of the MILD FUNGUS. Mrs. —, a lady thirty-five years old, who has had a number of children, was affected with a sense of bearing down, and an aching pain in the lower



part of the abdomen. After this had continued for some weeks, she perceived a watery discharge, slightly offensive, and occasionally tinged with red. This was soon after succeeded by a flow of blood, appearing occasionally, and becoming more frequent as it continued, and at last constant. She became very much enfeebled, and was thought to be sinking with incurable affection of the uterus. When I saw her, a tumour was perceived filling the vagina, and extending to the os uteri and its aperture, so that, at first, it was thought to spring from the labia. On passing a probe along the finger, it entered the uterus about an inch, and could not be forced further. The tumour could be seen by separating the external labia. It was of a red colour, soft consistence, excepting at its neck, and bled on being handled. A ligature was applied to it in the following manner:—Two silver canulæ, each ten inches long, and a little curved at the upper extremity, were threaded with one very strong silk ligature, two feet long. The canulæ, being separated to the distance of an inch from each other, were passed up the vagina behind the tumour. Then they were brought round its neck, so as to encircle it with the ligature. Two rings connected



together, and about half an inch long, were placed on the external ends of the two canulæ, and slipped to their extremities, so as to draw them together. Two other rings were fixed on the external extremities of the canulæ, having an ear on each side to receive and fasten the ligature. The ends of the ligature were now drawn through the outer extremities of the canulæ, and secured there. The instrument projected about three inches below the os externum.

The patient had no bad symptoms after the operation. On the day following, the ligature was tightened. On the evening of the next day, the instrument dropped out, without any accompanying tumour. Diligent search was made for some appearance of tumour; but nothing could be discovered, excepting some small coagula. The natural inference was, that the ligature had slipped from the tumour, or else that it had never included it. The last, I knew to be impossible, and the former, nearly so. An examination of the patient was then made, and the vagina was found perfectly free from disease, and the os uteri in good order. What, then, had become of the tumour? At first, I was at a loss to answer this question. On a little reflection, however, there



was no difficulty in explaining the matter. Vascular tumours shrink surprisingly after their supply of blood has been cut off. The tumour, diminished in size from this cause, had come away with the canulæ, or before, and in so reduced a state as not to be noticed in the evacuations. The patient soon recovered her health, and, when I last heard from her, continued quite free from disease.

MALIGNANT FUNGOUS POLYPUS.—Mehitable Gomer, a servant, unmarried, *Æt.* 32, entered the M. G. Hospital, Nov., 1827. About ten months since, she discovered a tumour in the vagina, which sometimes descended through the os externum. She began to have pain about the time the tumour was discovered; has had a foetid, sanguinolent discharge, and sometimes copious bleeding from the vagina; is sometimes unable to pass her water without the aid of a catheter, and has pain in evacuating the intestines; knows no cause for the disease, and had good health before it appeared.—On making examination, she complained of excessive pain. A bleeding tumour was found filling the vagina so entirely, that with difficulty could the finger be insinuated. The finger being at length passed in, the os uteri could not be reached in consequence of the uterus having been



pushed up by the tumour. By bending the thighs close to the body, and making a powerful effort, the os uteri was touched, and a large probe, ten inches long, was passed into the cavity of the uterus about three inches.—The surface of the tumour was very irregular, cauliflower-like, and bled copiously on examination. The discharge was pungently offensive.

On the 10th of January, 1828, the application of ligature was made in the operating theatre. The patient was placed on the edge of a table, on her back, her knees separated, and firmly secured by assistants. The double canulæ were passed as in the last case, but with much more difficulty. The resistance to the introduction of the instrument was great, and to the encircling the neck of the tumour still greater. This was accomplished, and the cat-gut ligature, which had been selected for the purpose with great care, was drawn tight, and, at the moment the operation appeared to be finished, snapped short. The patient was carried to bed, and was not in a condition to have the operation repeated till the 7th February. It was then effected without any additional difficulty.

Great pain followed the operation, and symptoms of peritoneal inflammation occurred, and kept



her in a doubtful state to the 25th of February. The abdominal pains had been constant till that time, and seemed to be increasing, so that I thought it best to cut the ligature, although no part of the tumour had separated. The instrument was allowed to remain three days longer, and was then taken away. The symptoms of peritoneal inflammation did not subside at once; but during the month of March, considerable portions of the tumour successively separated, and she became more easy. In the latter part of the month, she began to be affected with diarrhœa. The discharge from the vagina continued in great quantity, and, though not bloody, was so offensive as to require her being kept in a room by herself. —In the beginning of April, she was more comfortable, with the exception of a cough, and some shortness of breath. In the latter part of this month, she was better, and recovered appetite. On the 7th of May, after eating pretty well, she failed suddenly, and died in fifteen minutes.

On examination of the body, the cavities of the thorax were found to contain a large quantity of water. Water was found in the abdomen, and marks of previous inflammation of the peritoneum. Remains of the tumour were seen attached to the



anterior wall of the uterus, as you see in the preparation of the parts which is here presented. There is also, you may notice, an ulceration through the vagina into the rectum, at least an inch in diameter. This was produced by the pressure of the tumour on those parts; and the diarrhoea was probably caused by this affection of the rectum. The difficulty, it may be said even impossibility, of the ligature cutting off the neck of the tumour, arose from the scirrhus hardness of that part of it.

The termination of these two cases is widely different; but the symptoms in the early stage varied little from each other. Had the last been attended to as early as the first, possibly the similarity of symptoms would have been continued.—In this operation there is difficulty in carrying the instrument round the tumour. A canula of steel, with the internal extremity a little swelled, would be an improvement on the instrument employed in this case; and the material for ligature should be dentist's twist of six threads, which is better than catgut or wire.



## TUMOURS OF THE SEROUS MEMBRANE.

We find, in the peritoneum, and in the pleura, that, in scrofulous and cancerous affections, particularly the latter, small tumours, under the name of tubercles, are developed on the internal surfaces of these membranes. Calcareous and even petrous tumours are also found in them. You see here a stone of the size of a musket bullet, attached to a piece of peritoneum, which was taken from a dead body.—The most remarkable tumour of this kind is the one now exhibited, which is as large as the head of a fetus at birth. This was sent me by the late Dr. Bradstreet, of Newburyport, who thought it much resembled the head of a child; but you see it is perfectly solid, composed probably of a calcareous substance, covered by a thin membrane. Whether this covering was peritoneum, or cellular membrane, is not known, as the tumour came in a dried state.—The history of the case is this. The subject was a maiden lady, who died at the age of seventy. Her health had not been good for some years. This tumour had been discovered in the lower part of the abdomen, on the left side, twelve years before death. She felt some incon-

venience from it, but it did not seem to have a connection with the cause of her death. It was attached to the peritoneum of the left inferior part of the cavity, by an adhesion of about an inch diameter. The length of the tumour is four inches, and its thickness three. Whether it was a production of the peritoneum, or a degeneration of the ovarium, could not be determined. Some of the gentlemen who attended the examination of the body, viewing the matter in a mysterious light, could see nothing in it but the head of a fetus, which had got there they knew not how.—When we compare it with other hard concretions of the membrane, there does not appear any thing mysterious about it; though its size must be acknowledged to be extraordinary.

#### TUMOUR OF THE SEROUS MEMBRANE OF THE TESTIS.

The tunica vaginalis testis is the seat of a dropsical collection, under the name of hydrocele. This tumour is known by its smooth, regular surface; by its undulating movement when struck; and by its diaphanous appearance, or transmission



of rays of light, when a lighted candle is placed on one side of it in a dark room, the edge of the hand of the observer being placed on the tumour so as to intercept the rays of light from his eye. This diaphanous appearance does not exist when the tunica vaginalis is much thickened, as often happens in an old hydrocele. When it is partial, the testicle is probably enlarged, and the collection of water is limited to a part of the serous sac. This tumour may be distinguished from varicocele by its smoothness, the latter having a knotted form, and by its permanency, while the varicocele lessens in the horizontal posture : from hernia, by the history of the case ; the hernia beginning at the upper part of the scrotum, hydrocele from the lower ; also by the want of that impulse given to hernia by coughing : from enlargement of the testicle, by wanting the irregular form of the latter : and from all these by the diaphanous appearance, when it exists. When it does not exist, there will be some difficulty in distinguishing it with certainty from the last disease, the enlargement of the testis ; and the surgeon must proceed with great caution in making out his diagnosis, and founding his practice thereon. If he wishes to evacuate the supposed collection of water, he must



not at once puncture an opaque hydrocele. The skin should be opened with a scalpel, and a dissection made to the tunica vaginalis. If found to contain water, an incision half or three-quarters of an inch long, will discharge it without costing the patient much pain. When the tumour is partially diaphanous, the trochar may be plunged into the diaphanous part, care being taken to avoid the testicle. In pure hydrocele, the situation of the testis may commonly be felt through the water. When the disease is a complication of enlarged testicle and water, this is not so easy, and the caution of the operator must be proportioned to his uncertainty. Probably there are more mistakes made by experienced surgeons, in puncturing for hydrocele, than in any other case.

The treatment of hydrocele is not well settled. The palliative treatment is most commonly adopted. The water is discharged by trochar and canula, with the expectation of its being formed again, and the operation being required to be repeated at a period varying from three months to two years. Those who have not ready access to a surgeon, look for a radical cure. Among the many methods proposed, two are principally adopted in practice, for the accomplishment of



this end, injection and incision. Injection is performed by first evacuating the fluid by trochar and canula, and injecting a stimulating liquid into the tunica vaginalis. The liquid usually consists of equal parts of port wine and warm water, employed in quantity sufficient to distend the tunica vaginalis not quite so much as before the evacuation. Great care is to be taken not to inject the cellular membrane of the scrotum. This is an accident very liable to happen, from the slipping of the canula out of the tunica vaginalis. The operator should retain the canula in his left hand so long as it remains in the scrotum, and the edge of the hand should rest constantly on the scrotum. The period during which the injection should continue in the cavity, is decided by the degree of pain the patient feels. This should always be considerable, in order to bring on inflammation. The tunica vaginalis and its coverings afterwards inflame, swell, and an adhesion takes place between it and the testicle. This object is rarely accomplished in the common mode of operating; especially if the hydrocele be of long standing. There is usually some inflammation effected, but not sufficient to produce a general adhesion. The patient thus loses his time, experiences great dis-



appointment, and is discouraged from repeating the operation. Its repetition is in truth often difficult; for a partial adhesion between the testicle and outer tunic taking place, it is impossible afterwards to puncture with safety. To render the operation more certain of success, the injection should be repeated with a more stimulating article, immediately on the evacuation of the first; provided the pain induced is not as great as the patient can support.—A gentleman belonging to Para, on the river Amazon, in South America, applied to me for a hydrocele, under the following circumstances. He had been affected for ten years, and the fluid had been evacuated only two or three times. He determined to make a voyage to England, for the purpose of undergoing a radical operation. While in England, he was so situated as to be unable to go through the operation, and left England for Boston, to have it effected here.—When he arrived, his hydrocele was large enough to hold a quart of water; too hard to distinguish the testicle, and perfectly opaque. The undulation of water could be perceived. He had been told that injection was the proper mode of operating, and he wished me to practice it, which I therefore did. The fluid of



the hydrocele being discharged by trochar and canula, near a quart of port wine and water was injected, without exciting pain. This being evacuated, as much port wine, with a quarter part brandy, was used. No pain being brought on, a pint and a half of brandy, with two drachms of sulphate of zinc, was injected. This caused a little pain; and the injection having been thrice practised, I would not proceed further with it; though satisfied it would not be followed with sufficient inflammation. The next day, however, the scrotum swelled, and he had a little fever. On the third day, the swelling was rapidly abating, and so continued the next two days, without pain. Convinced that adhesion would not be effected, and perceiving the great inconvenience he would suffer from waiting the result two or three weeks longer, I prevailed on him to submit to incision. The operation was directly performed by laying open the whole length of the vaginal sac. As soon as this was done, a little water issued. The tunica vaginalis was, in hardness, almost cartilaginous. On looking into the sac, I saw a most delicate net-work of lymph, filling the space between the testicle and tunic. This lymphatic exudation formed large cells, containing abundance of water.



With the finger and a probe, I broke away all this lymph, cleared out the water, and placed a piece of lint in contact with the testicle the full length of the wound. In this way, the requisite irritation was produced. In seven days, the lint was drawn away; and in three weeks from the incision, he was perfectly well.

Had the lymphatic exudation been more solid than it was, yet the cure would not have been accomplished. The thickness of the vaginal coat preventing its contraction, a large space existed between it and the testicle, which could not be filled with lymph; and if it had been so filled, it would have formed a more inconvenient tumour than the hydrocele, since probably it never would have been absorbed.

The want of excitability in the tunica vaginalis is very remarkable in some persons, even when the hydrocele is not old. A medical student requested me to inject a hydrocele, moderate in size, and of two year's standing. The following year, he came to me to say he was not cured, and wished the operation of incision. This was done not without difficulty and danger to the testicle, which, in consequence of the injection, had some adhesions. A week after the operation,



there being but little appearance of inflammation, the inside of the wound was rubbed with nitrate of silver. Even this was not sufficient, and finally he was advised to pour into the wound a quantity of powdered sulphate of copper daily. Under the use of this article, the cavity slowly filled up.

When the patient is healthy, and is not so situated as to permit the palliative operation by a regular evacuation of the fluid, incision is proper. This operation consists in laying open the tunica vaginalis for its whole length, and interposing lint to prevent adhesion of the sides of the incision. Dangerous results from this operation are spoken of. Although I have not seen any such, I admit their having existed, and advise not to adopt this method in delicate or sickly persons, and not ordinarily when the testicle is diseased.

#### HYDROCELE OF THE CELLULAR MEMBRANE OF THE SPERMATIC CORD.

This has less fluctuation, less transparency, and is less regular, than the hydrocele of the tunica vaginalis. It is larger above than below. The testicle is more distinctly felt. On opening this

tumour, the water is discharged in a stream at first, but soon ceases to flow in consequence of being contained in a number of cells, the whole of which it is impossible to evacuate at once. When a small puncture has been made, membranous, transparent sacs may be forced into the aperture, and may be cut out partially.

This disease cannot be essentially relieved by a puncture. An injection will not penetrate the cells. The best mode of treatment is to make a free incision, and keep the wound open till the cellular organization is destroyed by inflammation.

#### TUMOURS OF THE SYNOVIAL MEMBRANE.

Synovial tumours are various in size, from that of a pea to some inches in diameter. Their consistence is soft, though less so than that of a common abscess. The colour is not different from the usual colour of the skin. When of considerable size, they have some degree of fluctuation. They are not sensitive on pressure, and not painful. Their most remarkable property is that of weakening the muscular action of the part in which they are placed. A small synovial tumour



on the hand sometimes causes great weakness in the wrist and fore arm.—These affections are brought on by contusions, and still more frequently by strong muscular efforts. We see the effect of contusion in a blow on the elbow or knee, which now and then produces a synovial swelling on the olecranon or patella. A strong exertion of the muscles of the fore arm sometimes causes a sense of snapping, and the patient discovers a tumour on one of the extensor tendons on the back of the hand.

The bad effects of the synovial tumour will be in proportion to its size and the complexity of the part it is connected with. The enlargement of the synovial sac on the patella will give more trouble than that on the olecranon.—The synovial enlargement on the external surface of the patella is very common. It is found most frequently in maid servants who are compelled to be much on their knees, and appears in the form of a soft tumour, corresponding in its circumference with that of the patella, and extending forwards perhaps an inch. There is not much pain nor lameness from it. Still it is inconvenient to the patient, and she is anxious to get rid of it. The cure may sometimes be effected by the com-



pression of a bandage. When it does not yield readily, I have been in the habit of puncturing the tumour, provided the patient could be kept in the horizontal posture during the healing of the wound; and then it is rare to see any bad symptoms follow the puncture. If the patient imprudently uses the limb, or is exposed to the cold, a degree of inflammation may arise, which will give anxiety to the surgeon. No one, I suppose, would mistake this tumour on the patella for an enlargement of the synovial sac of the knee joint, the tumour of which occurs on each side of the patella, below and above. A puncture in the latter might be productive of the loss of the limb, or even the life of the patient. The tumour of the sac on the olecranon process is caused by blows, and by leaning on the elbow heavily for some time. It is rarely attended with inconvenience, often is discovered by accident only, and is cured spontaneously.—The ganglion on the back of the hand, being connected with the tendon, causes more distinct and troublesome symptoms than those mentioned. The immediate consequence is, a weakness of the extensor muscles. Some surgeons are in the habit of rupturing these sacs by a smart blow. This may be done, or the sac



opened by a lancet, the contents discharged, and the wound healed by the first intention. This rarely fails of effecting the cure, and is not productive of bad symptoms. In an obstinate case, the sac is to be dissected out. The tendon it involves must, of course, be left untouched, and the hand must be kept quiet and protected till the wound heals.

The sheath which invests the tendons of the common flexors of the fingers above the wrist, is the seat of a synovial enlargement. The tumour makes its appearance above the edge of the annular ligament between the lower extremities of the radius and ulna. The projection it causes is slight, and about an inch in length; soft and yielding when the muscles are relaxed; firm and prominent when they are contracted. Great weakness of the limb attends this tumour, and of course the patient is anxious to be relieved from it. Leeches, blisters, and pressure have very little effect on it. I have sometimes ventured to make an opening in it. Some years ago, a young lady, eighteen years old, came to me from the country with this affection. I punctured it, and discharged its synovial contents. Very slight marks of inflammation appeared, and she recovered in fourteen



days. Three years since, this same operation was performed on a patient in the hospital. A quantity of synovia was discharged, and eighteen or twenty cartilages, each about the size of a pea, were pressed out. Believing there were more of these than could be extracted, I interposed a piece of lint to keep the wound open. A protracted inflammation came on; a train of abscesses followed, and the patient came near losing the limb. Of course, I should not recommend any thing more than simple puncture, a delicate treatment of the wound, and perfect rest till it healed.

The synovial sac between the deltoid muscle and the head of the os humeri, is liable to be swollen from injury, and from scrofulous and rheumatic inflammation. The tumour, lying under a thick muscle, is but faintly circumscribed. It raises the whole muscle. The fluctuation and comparative depth will serve to distinguish it from a common steatomatous tumour, and from an induration of the muscle. When the steatomatous tumour is of the soft kind, it is not so easy to discriminate it from a fluid. The occurrence of the former is much more frequent than that of the latter, and, of course, when it is impossible to make out the case satisfactorily, it must be considered that



probability is in favor of the steatoma. The inflammation which causes an increased flow of the natural exhalation of the sac by which the tumour is produced, is sometimes violent enough to bring on suppuration. The constitution becomes affected in this case. The symptoms are severe, and even fatal. It is justifiable and necessary, in the case of suppuration, to make an opening to discharge the contents of the sac. In the first instance, it should be small. At a subsequent time, it may be proper to enlarge it. This, like most parts of the body, may learn to bear irritation. Thus, operations on the eye, at first very irritating, almost cease to be so from habit. The first time of cutting the conjunctiva for an opacity is painful and irritating. On frequent repetition, the impression is so much diminished that I have known a patient to separate the eyelids with his fingers while the conjunctiva was excised. The same happens in the operation of cataract for absorption or depression. Operations are often borne by an organ with a tranquillity proportioned to the frequency of repetition. We notice this on the application of caustic to the eye and other parts. So it is that the sudden evacuation of a large abscess, especially from the cavity of a syno-

vial membrane, is some times dangerously irritating. By making a small aperture, and evacuating at successive periods, no severe shock is given to the nerves of the part.

The sac lying between the trochanter major of the os femoris and the tendon of the gluteus maximus, is not unfrequently the seat of a swelling. Commonly it may be relieved by external irritation of the skin covering the part.

#### TUMOURS OF THE FIBROUS MEMBRANES.

The fibrous texture, possessing a low degree of irritability, is not often the seat of morbid growths. There is an exception to this law in relation to the periosteum. This part we have spoken of, in connection with bony tumours, as frequently the seat of enlargements.—The saccular fibrous membranes are rarely thickened. The fibrous coat of the pericardium is scarcely ever tumified by inflammation, so far as I have noticed. The albuginea of the testis, sclerotica of the eye, and the dura mater of the brain, are sometimes, though not very often, the seat of tumours.



TUMOUR OF THE DURA MATER.—Mrs. B—— was admitted into the M. G. Hospital in 1828, with a tumour on the right temple, two inches in diameter, and an inch above the surrounding surface. It had a pulsation; was very hard; not discoloured. The base was particularly firm, appeared a little raised, and within it was something like a depression; appearances common in tumours of the scalp. A pulsating pain in the head existed constantly, and led her to seek relief. Otherwise her health was good. She walked about, ate, and talked as usual, and had good spirits. She was about thirty-five years old.—What the nature of this tumour was, I was unable to determine. It had none of the characters of a cancerous affection, nor of a common wen. On the whole, the most probable opinion seemed to be that it was a disease of the periosteum; or it might possibly be an aneurism by anastomosis. An operation seemed necessary, though it would be proper to pursue it cautiously. An incision being made through the integuments, they were carefully raised. Under them appeared a firm substance, almost bony at some points, but very irregularly constituted. On dissecting through this hard substance, a spongy fungous mass presented, bleeding



freely, and now and then throwing out a jet of arterial blood. This being removed, a bony edge was perceived surrounding the base of the tumour, and it was now obvious we were within the cavity of the cranium. However, I proceeded in the separation of the whole of the diseased mass within the cavity, and left the wound in a tolerably good looking condition. The skin was brought over and principally healed at once. In four weeks she was apparently well, with the exception of a slight discharge which continued to ooze from the diseased part. No extraordinary affection of the head, or other part, manifested itself, and she left the hospital with the confident expectation of perfect recovery.—After a few months the tumour re-appeared, her health gradually declined, she had attacks of convulsions, and died about two years subsequent to the operation.—On examination of the body, the dura mater and the bone covering it had disappeared in a space whose diameter was about two inches. The brain was in a fungoid state, opposite the aperture, to the extent of two inches.

The specimen of tumour of the sclerotic coat of the eye, you see here, was extirpated from a patient in the hospital four years ago. The globe



of the eye was enlarged and projected, the eyelids swollen, and the aspect of the case much resembled a cancerous disease. After the eye was extirpated, the patient had no bad symptoms. The wound healed favourably, and there is reason to believe that no return of the disease has occurred.

## TUMOURS OF THE EYE.

THE globe of the eye is subject to three kinds of tumours, FUNGOIDES, SCIRRHUS, and MELANOSIS. The two former are of a malignant character; the last is occasionally so, but not always.

### FUNGOID TUMOUR OF THE EYE.

FUNGOIDES FUNGUS HÆMATODES, or SOFT CANCER, is the most frequent of these three, and is commonly supposed to be a real cancer of the eye. The distinction we have before made between fungoides and scirrhus, the bloody tumour and true cancer, will, we suppose, present the diagnosis between the two in its proper light.

The fungoid tumour takes its name from the exuberant fungus it throws out in its advanced



stage. The earlier periods of the disease present nothing of the kind. It begins with a slight defect of vision, and an enlargement of the pupil. On looking into the back part of the eye, what has been called a metallic appearance, is seen. This gradually advances to the fore part ; involves the vitreous and chrystalline humours, the iris and the cornea. The cornea loses its transparency and thickens. Near its circumference, the sclerotica begins to enlarge, and one or more tumours are seen rising in it, which have a leaden colour. The surrounding parts become indurated. A hardness and elevation is seen at the angles of the eye. The cornea bursts, and throws out a red bleeding fungus.—In the latter periods of the disease, pain, at first slight, comes on ; and this, with frequent hemorrhages, exhausts the patient's strength.

This disease is most common in children and infants, though not rare in adults. It is slow in progress, and generally fatal : though it is possible that the extirpation of the eye, in the first stage, might be successful in arresting it.

For many years I have ceased to extirpate the eye in cases of fungoid tumour. The last I operated on, was in the case of a gentleman from the country, who had felt symptoms of the ap-



proaching disease for four years. He was of a weak, scrofulous constitution. He informed me that he had been subject to pain in the head, which at last centered in the eye, but was not very severe. He soon perceived a loss of distinct vision, which increasing, had, when I saw him, deprived him wholly of sight. The globe was enlarged, and a slight tumour formed in the sclerotica. The conjunctiva was red and swelled, the cornea opaque. As there was no organic change in the accessory organs, I removed the globe. The disease appeared again in a few months, and in about a year he died.

In this case, the conjunctiva and sclerotica were much thickened. The choroides also, and the membrane between it and the retina, were opaque and thickened. The chamber of the vitreous humour was occupied by a fungus, which adhered to the back part of the eye, and made compression on the crystalline, iris, and cornea. The optic nerve was enlarged.

The fungoid tumour has been thought to be a disease of the optic nerve. Mr. Travers has shown that it may spring from any of the textures of the eye.



## SCIRRHOUS TUMOUR OF THE EYE.

This is a disease of the later periods of life. It begins with a deep-seated, aching pain, which increases in severity, till it has the cancerous symptoms of burning and lancinating. The eye discharges an acrid water. The conjunctiva becomes red and thick, and the cornea loses its transparency. The globe enlarges somewhat, but not to the degree it does in the fungoid affection. The appendages are discoloured, thickened, and acquire a positive hardness, and the lymphatic glands under the jaw and neck become tumid.

The morbid appearances of the dissected eye are very different from those in the fungoid disease, as you perceive by the preparation presented to you. First; you will notice the very distorted aspect of the coats of the organ. A section exhibits the form of a triangular rather than a globular object. Second; on examining the section closely, you notice that the membranes are all thickened. The cornea is ten times its healthy thickness. The sclerotica, four or five times. The iris and choroides so much enlarged, that, at



first view of the section, I took the disease to be melanosis, from which disease, however, it is found, on inspection, to differ essentially. The iris is more thickened than the choroides, and adheres to the cornea, showing the place of the pupil, and nothing more. The humours are in a state of disorganization. The crystalline is quite distinct, and in its proper situation, with the exception of being pushed a little forwards. It is very much enlarged. The optic nerve (or its coat, strictly speaking) is thicker than it should be.

This eye was taken from a gentleman sixty years old. He had been troubled with it for more than ten years. For a long time, he had a pain in the back of the orbit. The eye became sore and weeping, the conjunctiva red, and the whole globe swelled. The vision was lost about three years before the eye was removed. The appendages were not indurated, and it was thought fair to extirpate it. I never heard that the disease returned.

The prospect of success in this operation is better than in the fungoid disease of the eye, as the latter, like those affections generally, is likely to be constitutional, while the scirrhus is local for



a time. We cannot be sanguine in the expectation of a cure in any of these cases, however favourable they may appear.

#### MELANOSIS OF THE EYE.

Melanosis is a rare affection of the eye. There are two kinds,—one malignant, the other not. I have never seen the former, and presume it has the characters of a black fungoides.

The melanosis I have seen is a black tumour, presenting itself at some part of the shell of the eye, usually in the sclerotica, near the cornea. At first view, it might be mistaken for the tumour in the sclerotic coat produced by the fungoid disease. But the latter is noticed to have a bluish or leaden colour: the melanosis is decidedly black.

A black speck arises without accident, and goes on without pain. Its course is very slow. Vision is not disturbed by it for a long time. The external coats, the conjunctiva, cornea, and sclerotica are but little affected at first. The portions not near the tumour do not thicken, but remain healthy till it reaches them. As it increases, it gradually involves them; and, of course, if it

becomes large, they are largely implicated, as it adheres to the globe of the eye by a broad base. The conjunctive coat on the surface of the tumour has its vessels enlarged so as to admit more of the blood than common. The disease is not painful, excepting on pressure.

When the melanotic eye has been removed from the socket, it exhibits the appearances you may notice here. The natural globe is scarcely distinguishable. You see a white globular body, rather larger than the natural globe, buried in an irregular black mass. This mass, you notice, lies, or did originally lie, on the outer part of the globe. Now, it extends from the outer part, upwards, downwards, and backwards, so as to leave a very small portion of the sclerotica visible at the inferior internal part; but at the back of the eye, you discover as much as a third of the sclerotic coat. The tumour, rising in front of the cornea, partly covers it, and extends forwards half an inch beyond it.

On opening the globe, behind the tumour, the sclerotica is observed to be of its natural thickness; but on looking into its cavity, the inner face is seen to be puckered at the part corresponding with the adhesion of the tumour. The iris and choroides connected are in a perfectly natural state



—as is the retina. The optic nerve is larger than usual.

On making a section of the tumour, you may see it is blacker within than without. It is perfectly solid, almost to scirrhusity. Its texture is fibrous. We see an intermixture of white fibres with the black mass. It is covered on the outside by the cornea, and on the inside by the sclerotica.

At the first view of this tumour, I certainly was led to believe, from its colour, that it must be a production of the choroid coat. This proved not to be the fact. The choroides is not in the least degree connected with it. The tumour undoubtedly arose from the sclerotica, and has the fibrous organization of that membrane. Whence it derives the black colour, I cannot tell.

The patient from whom this tumour was taken came to Boston in the month of June, 1819. The tumour was then about double the size of a pea. Its first appearance was twenty years before, some time after which period, it was removed by Dr. Miller, of Franklin. Nothing more was seen of it for thirteen years, when it returned, and he had it removed a second time.—Being about to leave town when the patient arrived, he was referred to Dr. Hayward. He entered the hospital,

and had the tumour removed. Three years after, he came again with a new growth, about the size before mentioned, and it was again removed. In two or three years more, he returned with the disease you here notice. Although he felt no acute pain, and the sense of vision was not destroyed, yet, as the size of the tumour made it troublesome, and as it was perfectly obvious that nothing would cure it but extirpation, the eye was removed by Dr. Hayward. He soon recovered, and, as I have not heard from him since, I presume he continues well.

The disease had nothing of the fungoid character. If it had been a malignant scirrhus, the surrounding textures, during the long space of time that this tumour existed, would probably have been affected by it, and have become disorganized.

## PETROUS TUMOUR OF THE EYE.

Stony and calcareous formations in the globe of the eye, bring on a chronic inflammation, and sometimes an enlargement of the globe, liable to be mistaken for fungus or scirrhus. The same



deep pain, the same weeping, the same appearance of swelling and redness, accompany both diseases. When the petrous substance is in the anterior part of the organ, (for instance, a petrification of the crystalline,) the symptoms are similar to those caused by displacement of the crystalline. Pressure on the iris causes, first, a fixed dilatation of the pupil, and then brings on inflammation, ending in this disorganization. An occurrence of this kind first led me to notice an accident I have frequently seen since, and of which I gave an account in the *New England Journal of Medicine* for 1806. A patient of my late father being affected with severe inflammation of the eye, on examining him, I found the crystalline pressing on the iris, extracted it, and have had occasion to do the operation for this accident many times since. It is an accident occurring principally to those advanced in life, sometimes from violence, as a fall or blow, and sometimes spontaneously. The dilated and fixed state of the pupil, with impairment of vision and chronic inflammation, will usually enable us to detect the transposition of the lens, and the operation of extraction will relieve the patient, though the sight is rarely preserved.



A stony formation in the vitreous humour is not so easily ascertained. The symptoms are not to be distinguished from those of a scirrhus formation.—The case from which the eye we have before us was taken, is a proof of what I have said. You see a human eye, enlarged to the size of that of an ox. It was extirpated from a man who had the signs of a scirrhus affection, and was operated on for that disease. On examination, you perceive that all the coats of the eye are much thickened, and the optic nerve enlarged. The vitreous humour is converted into a thickish substance, in the centre of which is a stony body, of the size and form of a hazle-nut, and of nearly the same colour. I do not know that it would be possible to discover the existence of a body thus situated without removing the organ from its socket.

## CANCER OF THE EYELID.

This disease is to be distinguished from cancer of the globe. The latter is a true scirrhus: that we now speak of is not a scirrhus, but a cancerous ulcer. Scirrhus and cancer, you will recollect, are



different species of carcinoma. This is, in fact, the cancer of the face already spoken of. It begins, like that, with a small scab, crust, or wart, which the patient picks off; and then it is renewed many times during a series of years. It appears most frequently at the inner part of the eyelid. At length, the scab increases in size, and, when it falls off, is imperfectly renewed. A foul discharge occurs. The surrounding skin looks red and angry, becomes a little elevated and sometimes painful. Gradually the disease involves the upper, and afterwards the lower eyelid. They become thickened, hardened, and of a red colour, and the globe of the eye is at length affected. The conjunctiva is red, swollen, and discharges an increased quantity of mucus.—The disease is very slow in its course, and is not uniformly painful; but there is sometimes the lancinating pain of cancer. It is a disease of the aged, and is more frequent in those who have used ardent spirits.

Peter Loring, a farmer, sixty-four years old, entered the hospital in September, 1833. Eight years before, he discovered a small ulcer, as he called it, on the upper eyelid, near the nose. He paid little attention to it for some time; but about three years since, finding it increase in size,



he began to try remedies.—The ulcer now extends from the inner angle of the eye into the upper eyelid, about half of which has been destroyed. The lower eyelid is hard, thick, red, and ulcerous partially. The ulceration has extended deeply into the cavity of the socket.

An oblique incision was made across the forehead to the internal angle of the eye; another from the external angle to the nose; and these were united by a perpendicular cut down the middle of the nose. The globe of the eye and the whole of the indurated parts were dissected out; and the periosteum and other suspicious points had the actual cautery applied.

In a month after the operation, the wound had cicatrized over about half its surface. The patient felt much relieved, and desired his discharge from the hospital.—However satisfactory to him the result of this operation may have been, we cannot expect it will accomplish eradication of the disease.



### SECTION XIII.

#### ENCYSTED TUMOURS.

ENCYSTED TUMOURS are so called because surrounded by a sac. This character, however, is not sufficient to constitute them as a distinct class; for steatomatous, glandular, and other tumours usually have cysts. A very large portion of non-malignant tumours possess a coat, which separates them from the surrounding parts.

The existence of a sac, then, does not constitute an encysted tumour. The contents must be of a different texture from the sac, and not of a solid consistence. These contents must vary in consistence, from that of a thin liquid to that of soft cheese. Hence the old designations of atheroma and meliceris; the former meaning an encysted tumour, with a thick pap-like

substance; the latter, one containing a fluid as thick as honey, or honey and wax mixed.

Encysted tumours may exist in various textures. They may also be composed of various textures. Of course they cannot be referred to a single one, as the other tumours spoken of have been. A cyst may be constituted of two or more. The cellular, fibrous, and muscular are not unfrequently combined in the formation of a sac.

An encysted tumour, then, it appears, is an organized sac, containing an unorganized soft substance of variable consistence.

These tumours vary exceedingly in form, size, and organization, from the little cyst in the eyelids, to the large sacs sometimes seen in the neck. —The encysted tumour of the eyelid seems to be an enlargement of the duct of a sebaceous gland; owing probably to an obstruction in its aperture, in consequence of which the secretion is retained, enlarges the little tube, and produces a globular tumour. This increases slowly and irregularly; in some cases becomes permanent; in others disappears by the absorption of the wax-like substance, or by its evacuation through the natural aperture. The best application for dissipating it is the frequent bathing of the eyelid



with tepid water. When the tumour becomes permanent, if of a size sufficient to cause inconvenience, it must be excised. The mode of doing this is to make a little incision across the fibres of the orbicular muscle; and having exposed the cyst, to seize it with the small pointed forceps, and dissect it from the tarsal cartilage. Sometimes it adheres so firmly to the latter, that a portion of it is necessarily cut out. This accident should be avoided, if possible. An incision in the direction of the fibres of the orbicularis will be closed by the contraction of these fibres, and render the dissection difficult.

The black specks, often seen on the face, are the orifices of ducts of oleaginous glands. The concreted oil being pressed out, the spot disappears.

Encysted tumours of the back and of the scalp are of a similar nature. Their contents are a substance like soft white wax, of a peculiar, offensive odour. The cyst is generally of a soft texture, readily tearing. Its colour internally is white; and from its smoothness, it reflects the light strongly. The following case and specimen will give you a notion of this species of tumour.





Fig 1

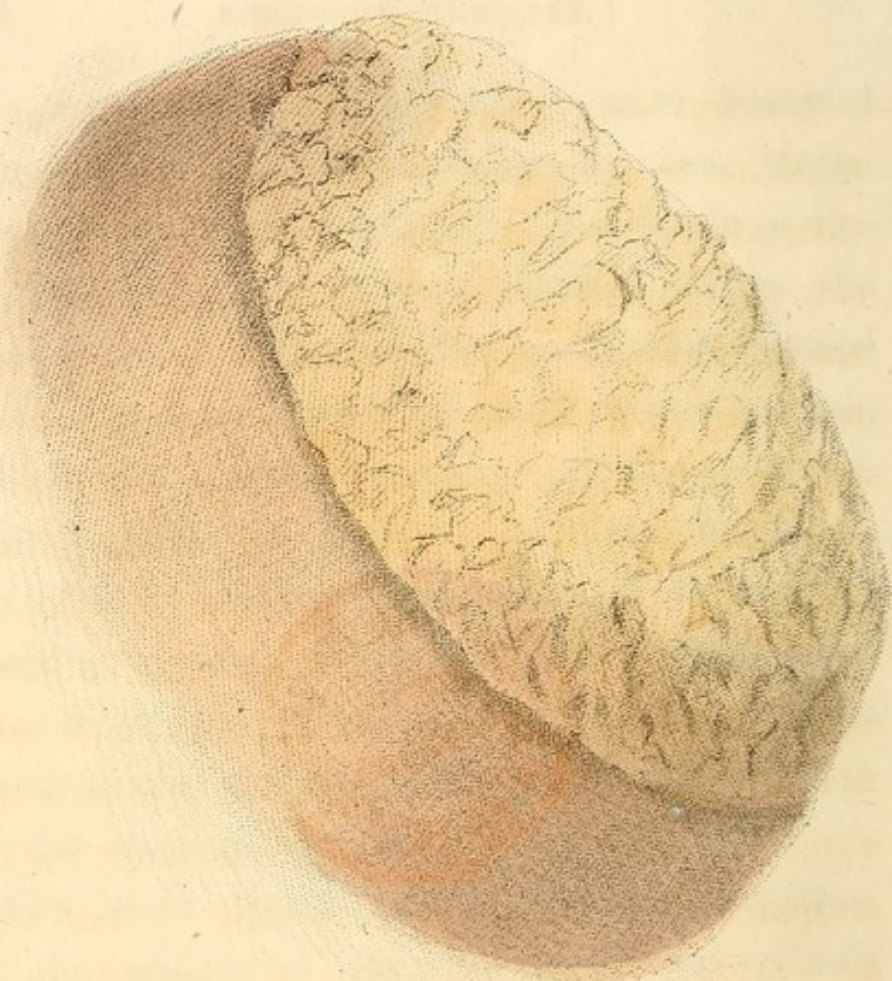



Fig 2



Cyst on the back

On the 30th November, 1836, Dr. Fisher desired me to see a patient of his, a gentleman about thirty-five years old, who had a tumour on the left side of the pelvis, above and in front of the great trochanter. When it was uncovered, I saw a tumour, which might be compared to a tea-cup, filled and overflowing with foaming ale. The cup was composed of the common skin, surmounted by a red edge, and the surrounding skin was very red. In the interior of the cup was a mass of curdy substance, like half formed cheese. See Plate XVI. The smell was very offensive. At first sight it seemed to be a red, malignant, fungous tumour. A little examination showed that it had no hardness at its base, and was moveable on the cellular texture under it. The patient's account of it was, that a small tumour had existed for twenty years; that it had gradually increased in size, and a scab or crust had formed on its summit, which, during the past summer, he had occasionally removed. Within fourteen days an inflammation had occurred on the surface, from scratching it, as he thought. The skin had in consequence sloughed, separated, and left the open cup filled with a white substance. He had no pain; but had experienced some constitutional



disturbance for the last ten days.—I proceeded to remove the tumour; surrounded it with an elliptical incision at a little distance from its base; dissected it up and found the cellular texture under it in a healthy condition.—This tumour and the drawing which represents it, you now see. Its aspect is certainly extraordinary, and at first view would lead us to believe it to be a dangerous affection. On dissecting away the surrounding part, I found a regular cyst, not very thick, composed of the texture usually found in these cysts on the back; and filled with offensive cheese-like substance, which I had a difficulty in retaining in connexion with the cyst. The patient had no bad symptoms after the operation. The wound healed in a month.

When our attention is called to these tumours, they commonly are of a small size, say that of a hazle-nut. There is often an aperture, through which, on compression, the offensive cheese-like substance may be made to ooze. Not unfrequently the patient neglects the tumour till it becomes inflamed, either from its own distension, or from some external cause. Seen in this state it presents a bad aspect; but the history of the case will commonly remove any alarming appre-



hensions as to the character of the complaint. When it has existed a long time without any inconvenience or any discolouration of the skin, and has suddenly become red and painful, we may conclude that the disease is not malignant. The inflammation arises from a process instituted by nature to get rid of the tumour. Sloughing or suppuration will probably follow, and the disease be removed without the aid of the knife. If it is thought expedient or necessary to cut it out, this may be done during the state of inflammation without ill consequences. The inflammation however causes an adhesion of the sac to the skin, which renders the separation of this part from the surface of the tumour more troublesome than in the common state.

A gentleman, of this place, showed me an encysted tumour on the back, as large as a walnut. He was advised to have it removed, but, being of a timorous character, declined an operation. Some years after, I was sent for to visit him. I found him in a febrile state, with a considerable inflammation on the back, and the tumour presenting the appearance of a carbuncle. It was proposed to open it. This was declined, and a suppuration in the cyst took place, in consequence of



which he suffered so much that at last he was glad to have it opened. The sac sloughed out, and the wound required seven or eight weeks to heal.

The operation in these cases is, first, an incision of the skin over the sac. Then the dissection of each of the lips of the incision from the tumour. Then, seizing the tumour with the pointed forceps, it is drawn outwards and disengaged by the knife from surrounding parts.—When the tumour is small Sir Astley Cooper advises to cut it in halves, with a stroke of the scalpel ; to seize the halves successively with a hook, and dissect out with one or two incisions.

Sometimes the situation of these cysts is such as to render it difficult to get out the whole of the sac. The operator must be careful to avoid this omission, by sponging the bottom of the wound, and examining for the remains of the white, shining cyst.—That leaving a small part of the membrane will regenerate it, is by no means certain, especially if its inner face has been hacked in the operation. Yet it is obvious, that, if any considerable portion be left, this polished surface may not adhere to the contiguous parts, and must, of course, perform its natural secretion, and reproduce a tumour.—This accident, I must say, has not occurred



to me. Whether from caution in removing the whole of the cyst, or from any other cause, I know not ; but I have no recollection of being called to operate in such a case a second time.

The small cysts in the scalp are removed with ease, in the way advised by Sir Astley Cooper. There is a little preparation not to be omitted,—that of shaving the hair from the surface of the tumour and its vicinity. When the cyst on the head is large, as may happen from long growth, an operation becomes more important ; for in this confined situation, the tumour contracts adhesions, both to the skin which covers it, and the periosteum on which it lies. No long time since, I removed one of the size of an orange from the head of a lady. The tumour you see. It is inverted, and has a quantity of hair adhering to its inner smooth surface. The patient was forty years old. She had it in her childhood, and allowed it to grow till its pressure brought on a chronic headache, and threatened to impair her health seriously. After shaving the hair from the tumour and the surrounding scalp, I made an elliptical incision in the skin, and dissected the integuments from the side of the sac. On coming to the lower part of the tumour, it was found to adhere closely to



the pericranium, so as to cause a difficulty in getting out the sac without this membrane. This part of the sac was in a cartilaginous state,—an appearance that puzzled me till it was recollected that the periosteum might throw out a cartilaginous substance from being irritated. The whole cyst was removed with care, and then there appeared a deep excavation in the bone, corresponding with its internal part. This was caused by an absorption of the bone from pressure. It explained the headaches to which she had been subject; for it is probable, that, as the bone was absorbed on the outside of the skull, a deposit took place on the inside, as usually happens under such circumstances. This internal deposit must have compressed the brain, and would have brought on the most serious consequences, but for the slowness of the change, and the time given to the brain to accommodate itself to that change. The sac, as I have mentioned, contained a quantity of hair.\* Some of the bulbs of the hair must have been involved in the sac by the close union of the two,

---

\* It is well known that cysts, in the great cavities, sometimes contain hair,—a fact of which we shall hereafter see an instance.

and these bulbs had given roots to the hair discovered. Besides hair, there was a cheese-like substance, which probably constituted the contents of the tumour originally ; and, moreover, the curds and hair were intermixed with a thick, glutinous fluid.—The wound healed slowly, and the patient has recovered a perfect state of health, after many years of indisposition and occasional illness.

ENCYSTED TUMOURS OF THE NECK.

Encysted tumours of the neck are of various sizes, shapes, and situations. They for the most part have one common circumstance,—a difficulty in distinguishing their character before cutting into them. This may lead to an operation, based on a wrong view of the disease, and, of course, an operation not likely to be as easily or safely executed as if the nature of the tumour were known before it. This peculiar difficulty of knowing the structure of these tumours is not confined to the neck, though it exists most frequently in this part. The causes of the uncertainty are two. First, the tumours may lie under muscles, which, being



expanded on the surface, keep them in a tense and apparently hard state like a solid body. Second, the sac, in these cases, is commonly distended to its utmost degree ; for the collection, at first small, gradually increases, and keeps the sac perfectly filled. Now, unless there is a yielding of some part of the sac, there can be no sensible movement of its fluid, and, of course, no undulation,—the diagnostic symptom of this species of tumour. The perfectly smooth exterior might seem to present sufficient means of distinguishing a tumour with fluid contents. But this smoothness is not discoverable, for the reason already mentioned,—the existence of a muscular covering. Moreover, these tumours have not always the smooth surface alluded to. In their growth, they contract adhesions with various organs about them, and these, on external examination, seem to be a part of the enlargement.

There is another fact peculiar to encysted tumours of the neck : their exterior often presents a prominence very inviting to the surgeon. He feels confident that his knowledge of anatomy will safely and readily carry him through the extirpation. But if he could see the posterior face of the tumour, he would find a very different aspect.



There he would see this tumour sending its processes and little sacs about different arteries, and veins, and small nerves, and covering those parts so as to render their dissection most difficult and dangerous.

Before beginning an operation for tumour of the neck, the surgeon must proceed in the following manner :—First, having seen the tumour, he must learn the history of its appearance and growth with perfect accuracy. Second, he must study all its connections—its relation to the skin; sternomastoid, digastric and hyoideal muscles; the trachea, larynx, os hyoides, and jaw; the thyroid, sub-maxillary, and parotid glands; and, so far as he is able, the great artery and principal veins, the jugular, facial, and thyroid. Third, he must get the opinion of other surgeons. Even those who have not so much experience as himself may afford him excellent hints, and strike out from his own mind thoughts which, without this collision, would not have been elicited. Fourth, he should examine the tumour at different times before operation, for he will find, on each view, something new; and after he has made his plan of operation, he should re-examine with a view to this plan.



An operator should not be satisfied with tracing a plan in his mind only. It should be fairly written out; and he should imagine all the possible difficulties and embarrassments, and put them in writing. Let him imagine all he can, he will find, in practice, a number which his imagination had not suggested to him.—It seems hardly necessary to intimate that a perfect knowledge of the anatomy of the complicated structure of the neck is indispensable, considering there are so many vital parts concerned.

The cysts on the neck which are least agreeable to an operator are those situated on its lowest part, before the trachea, and within the sternothyroid muscles. They are liable to run under the sternum, to form processes and contract adhesions, we know not where, because they are out of sight. The carotid arteries are on each side, the lungs below, and the thyroid veins either before or behind the tumour. These veins are of considerable size, and, being near to the heart, may suck in air, and destroy the patient at once.

The cyst here is commonly irregular, and also of a soft consistence, so as to break under the effort of the operator to draw it forwards or upwards. Some years since, while engaged in



an operation on one of these tumours, (the patient being a young woman of eighteen, who was under the care of Dr. Ware,) at the moment of dissecting the part concealed under the sternum, a bubbling was seen in the wound, and the patient immediately fainted. After compressing the wound two or three minutes, finding the pulse returning, and no difficulty in respiration, I proceeded with the operation, got out the whole of the tumour, and the patient never had any trouble afterwards. What the phenomenon was owing to I cannot say. At the moment, I believed the pleura to be perforated, and that the bubbles were caused by air passing through the bloody wound into the cavity of the pleura. On reflection, however, it seemed, from the course of the incisions, to be more probable that the air was pushed out of the wound, by a strong effort of inspiration, previous to fainting, the pleura not being punctured. Another suspicion has since occurred to me, that it might have been caused by a small portion of air drawn into the thyroid veins. But if this had been the case, the consequent symptoms would probably have been more alarming.

The admission of air into the cavity of the pleura may occur in consequence of the extirpa-



tion of tumours about the thorax ; also from the excision of ribs, as well as from accidental wounds ; and as it has been mentioned, it may be proper to say a few words about it. The admission of any quantity of air into the cavity of the pleura produces a collapse of the lung, and severe consecutive symptoms. If the lung itself is wounded, these symptoms will be most violent and dangerous. The wound of the vessels of the lungs, the bleeding in the cavity of the pleura, and the consequent inflammation, make an impression on the system which sometimes overpowers it. This formidable injury is not, however, certainly fatal. We see recoveries from wounds of the lungs from broken ribs. In this case, the rib, not penetrating deeply, does not wound the large blood vessels. A moderate plunge of a knife or a sword into these organs is not necessarily fatal. The following may serve as a case to support this position. A lad, fifteen years old, was wounded by a jackknife, in a quarrel with another, to the depth of three inches. Immediate distress in breathing came on. The wound discharged large quantities of blood, and continued to do so for four days. Then appeared signs of pulmonary inflammation, violent cough, with bloody expectoration, great difficulty



in breathing, and excessively quick pulse. Signs of watery and lymphatic effusion followed. The boy was ill for three months. After this time, he recovered his health, and resumed his occupations. In this case, we may suppose an adhesion of the lungs to the parieties of the chest, and a gradual exclusion of air through the wound. It is possible, also, that the air in the pleura might be absorbed.

The admission of air into the pleura, even when complicated with a wound of the lungs, is not, it appears, an accident necessarily fatal. Still less is the admission of air into the cavity of the pleura, without a wound of the lungs, to be considered fatal, especially if the quantity be not sufficient to cause a total collapse. Several years since, I was operating in the hospital on a patient with a large scirrhus breast extending over the axillary edge of the pectoral on the serratus muscle. At the moment I was separating the portion on the serratus, where the parietes are most thin, the patient made an extraordinary movement of the chest forwards, throwing herself on the knife. A bubbling of air through the wound satisfied me that the pleura was wounded. Those who attended, heard the sound produced by the passage of air, but had no suspicion of the cause ;



nor did I think it was necessary to explain it at the moment. As soon as the accident was perceived, I pressed my fingers on the wound, and found I could check the entrance of air. Then, asking for a curved needle, I included a portion of the serratus in a circular suture; finished the operation, and dressed the patient carefully with adhesive plaster. At the moment of the accident, the patient had some distress in breathing, though her conduct in the operation was so extraordinary as to render it impossible to decide exactly how great the difficulty was. In the afternoon, and on the two days following, her respiration was quicker than it should be. The pulse 120, and a sense of uneasiness in the left side of the thorax, the seat of the wound. On the second day she was bled. The bad appearances went off by the fourth day; after which nothing more than common occurred. The wound united in a great measure at once. The suture in the muscle came away, and she was discharged well in four weeks.

The favourable termination of such cases would not justify us in taking any unnecessary risk of wounding the pleura. On the other hand, when the life of the patient is dependent on an operation in which the pleura is involved, we should



not abandon the case from a too high estimate of the dangers of wounding this membrane. I have stated cases of periosteal tumour and necrosis of the ribs, in which an extensive uncovering of the pleura took place. Such operations we should not venture on, were the opening of the pleura believed to be fatal.

The removal of large encysted tumours from the neck, is among the most dangerous of surgical operations, in consequence of the irregular prolongations of the cyst among the blood vessels and nerves. The two following cases will give some idea of the course of such operations.

J. Watson, of Tamworth, N. H., aged thirty, applied to me in June, 1834. He has a tumour which occupies the whole of the right side of the neck; extending from the lobe of the ear to the clavicle, and filling the space between the larynx and the trapezius muscle. The mastoid muscle presents itself in the form of a round cord on the middle of the tumour. Anteriorly the tumour adheres to the larynx, and superiorly to the parotid gland. Below it can be lifted from the clavicle. The surface is smooth and regular, excepting at the upper part. On compression it presents different degrees of consistence, as if it were



composed of solid and fluid parts. There is no fluctuation, and no pain but from the distention of the parts about the tumour. It has existed a number of years, and lately has much increased.

An operation being decided on, the following plan was written down on the evening previous to its performance :

1. Make an oval incision of the skin, an inch wide, at the middle of the neck, and extended from the ear to the clavicle.

2. Dissect the skin from the lateral parts of the tumour, as far as its adhesion to the deeper points of the neck. Make a small puncture in its fore part to discharge the fluid contents.

3. Separate the tumour from the omo- and sterno-hyoid muscles on the laryngeal side of the wound, and from the inner face of the sterno-mastoid.

4. Clear the tumour of its connection with the ear above, and the clavicle below ; then separate it on each of these extremities above and below from all the most accessible attachments.

5. Next, raise the tumour from its deeper adhesions. Begin near the clavicle to dissect from the face of the hyoideal muscles ; or, if it lie under these muscles, from the sheath of the carotid



artery and internal jugular vein. Pursue the dissection regularly upwards, as far as possible, till you come to the superior connexions; then,

6. Dissect away the adhesions to the parotid and sub-maxillary glands, and to the digastric muscle, avoiding the facial artery and the external carotid. The lingual and superior thyroid will probably not be involved. If the tumour is found to insinuate itself between the carotid artery and internal jugular vein, the anterior part of it must be cut away, and the posterior part left, detaching however as much as possible. Wounded arteries must be tied as they bleed. Wounded veins must be immediately compressed below the wound and tied. The internal jugular, if wounded, must be compressed both above and below.

Operation, June 19.—The patient sitting in a chair, I proceeded as follows:

An oval incision was made from the lobe of the ear to the clavicle. The skin being raised at the outer incision, exposed the external jugular vein, which was dissected up a little at the lower part of the wound, and then cut across, the inferior portion being compressed till it appeared there was no disposition in it to imbibe air. The upper part did not bleed much, from being compressed by the



tumour. Then the dissection of the skin being prosecuted a little on each side, there appeared a covering of muscle, which was thought at first to be the platysma, and afterwards the sterno-mastoid, although the latter had appeared to be at the spinal edge of the tumour. Eventually this muscular covering was found to consist of the omo-hyoid, sterno-hyoid, and sterno-thyroid muscles. Of course the tumour, it appeared, must have had its origin under these muscles, in or near the sheath of the carotid artery.

The connexion of the muscles with the larynx and trachea obscured the laryngeal edge of the tumour; so that for some time I was obliged to grope along through the thickened muscles, without any guide but the indistinct hardness under them. At length the surface was freed at one point from this muscular covering. Then the dissection went on rapidly, till the face of the tumour was well exposed, and the larynx was seen bounding one edge, and the sterno-mastoid muscle the other. The larynx and trachea were separated, also the sterno-mastoid; then the parotid and sub-maxillary glands; a portion of the former, adhering so closely as to make a part of the tumour, was removed with it. An attempt was now made



to raise the tumour from its clavicular connexions. Here it appeared obscured and confounded in parts between it and the clavicle, which from its prominence over them could not be distinctly made out. Then it was thought best to puncture the sac. A quantity of glairy fluid, intermixed with flocculi, spouted from the aperture. The diminution of the enlargement now enabled us to see that the obscure connexions with the lower part of the tumour were with the internal jugular vein and the carotid artery, which ran through the posterior part of the sac. The blue colour of the vein making it sufficiently distinct, I dissected a little way into the tumour, found it was inseparably connected with it, and that the tumour or vein must be cut through. Believing the vein to be partially or wholly obliterated above, I divided the vein, and placed a ligature on the lower orifice, which bled freely till tied. Then the sac was dissected from the carotid artery to the upper part of the neck. The larynx, trachea, and digastric muscle were dissected; the par vagum nerve was removed out of the way, not without some convulsive heaving of the chest; the lingual nerve and its descending branch were exposed and guarded; the various processes of the sac dissected out;



and the whole sac itself was separated, as you here see. The necessary evacuation of the sac effaced the line of demarkation between the tumour and its adhesions, and greatly increased the difficulty of separating them. Only one artery required tying; a branch of the inferior thyroid. The ligature on this and the internal jugular vein were all that were necessary.

The wound was brought together and united by the first intention. In a week the patient was entirely well, excepting that the aperture of the ligature remained. He then left Boston for New-Hampshire, where he resided.

The course of the operation was nearly what had been proposed. The tumour lay on the inside of the hyoideal muscles, instead of the outside as its appearance had indicated. This, of course, increased the dangers of the operation. There was no solid part of the tumour, as the external appearance had led us to believe. The apparent variation in the density of different parts, arose from the compression made by the hyoideal muscles. The plan of evacuating the sac might have been a good one, if a part of the tumour had been solid; but as this was not the fact, it increased the difficulty of discriminating between the texture



of the tumour and that of its attachments,—a most important difficulty in this and similar operations.

The tumour I now exhibit to you. Its length is five inches : breadth, three inches. Now it appears rounded and regular—different from the state in which it actually was in the body. On the anterior face of it, you see the oval piece of skin, extending the whole length of the tumour. At the upper part, is a portion of the parotid gland, adhering to the sac. On each side of the skin, is a layer of muscular fibres of the hyoideal muscles. Under this, where it is raised, we see a fibrous or tendinous expansion, covering the external hemisphere of the tumour. The internal seems to be composed of cellular texture. The interior of the sac is glossy, and is pretty generally studded with shining, red eminences. What these are, I know not. They may have been lymphatic glands, that had become interwoven with the sac in the early stage of its formation, or perhaps the ova of new sacs.

Another encysted tumour, which you now see, and which is not so large as that of which the history has been given, was still more formidable in operation. It lay in the upper part of the neck,



under the jaw and the parotid gland, and involved the greater part of the most important nerves of the neck,—the par vagum, sublingual, accessory, and the descending branch of the sublingual; also the internal carotid artery, and the highest part of the internal jugular vein. The operation was performed on the 3d of October, 1834, in presence of Drs. Hayward, J. B. Flint, and other gentlemen.

The patient was a seaman, about thirty, of good habits. The tumour was situated at the upper part of the neck, extending from the thyroid cartilage of the larynx backwards, running under the highest part of the sterno-mastoid muscle, and showing itself beyond the posterior edge of this muscle. It filled the hollow about the angle of the jaw, extending some distance below, and reaching the base of the cranium above. The flattened form of the tumour, and the practicability of pressing it from behind the mastoid muscle forwards, led to the opinion that it contained a fluid. On the other hand, a total absence of undulation threw a doubt on this opinion. Directly over the sub-maxillary gland, appeared a cicatrix, two inches long,—the consequence of an attempt, made two years before, to remove the tumour, which had been effected but partially on account of its depth



and dangerous situation.—It had been first discovered four years previous to the present operation.

An incision, three inches long, was extended from the insertion of the sterno-mastoid muscle downwards, along the middle of the muscle. Another incision was carried an inch and a half inwards, at right angles with the first. The platysma being divided, the surface of the sterno-mastoid was exposed, and dissected to its inner edge. The tumour was now sought through layers of cellular and fibrous membrane, but for some time did not appear. The inner edge of the sterno-mastoid was cut through, and, after some further dissection, the fibrous surface of the tumour began to show itself. When it was more fully exposed, the accessory nerve appeared half buried in the tumour, and presently the descendens noni, passing over its anterior surface. Both of these were dissected off, and also the sublingual nerve from the anterior part. On striking the tumour at its outer edge, a distinct undulation was perceived, and the tumour decided to be encysted. Prosecuting the dissection behind the digastric muscle, the tumour was traced inwards, between the internal carotid artery and



internal jugular vein. Thence it took its course across, to get behind the sterno-mastoid muscle. The internal carotid artery was found to be imbedded in a groove in its posterior face. A question now arose, whether it was practicable to follow the dissection behind the great vessels, through so deep and narrow a wound, and whether, if the vein was cut, it was possible to tie it in so high a situation. The last was obviously impracticable on account of the proximity of the base of the skull.

I determined, however, if possible, not to disappoint the patient in his hopes of a cure on this second operation, and proceeded as follows.

First, the external wound was enlarged in a direction downwards, by a free cut of the integuments.

Second, the tumour was seized with a pointed hook, and its contents partially discharged to make room for discovering the vessels, without allowing so great a discharge as to obscure the distinction between the tumour and surrounding parts. The internal jugular vein was carefully dissected from the tumour. Then the latter was drawn upwards to admit the dissection of the artery, and at length extricated from its deep bed, and taken out entire,



leaving the internal carotid artery and the jugular vein standing insulated in the middle of the wound. One artery only was tied, and this a sub-cutaneous one.

On the following day, the patient was found dressed, and sitting in a chair, smoking a cigar. He complained of a little soreness of the throat, but had a good appetite.

The wound healed by the first intention. The patient went out of the house a few days after the operation ; and in ten days, returned to his home, at Cape Cod.

The sac appears to have a more simple organization than that previously shown. We distinguish on its anterior surface a fibrous texture. The rest seems to be composed of cellular membrane. Its interior is perfectly smooth, and its contents are a glairy fluid, intermixed with white flocculi.

The origin of these tumours is obscure. They begin, probably, in the vicinity of the great artery, and thence extend towards the surface, covering themselves with such parts as they encounter in their progress. Whether the primary seat of the affection lay in a lymphatic gland, or in the cellular texture about the artery, is uncertain. The contents of the sac would lead to the suspicion of



its forming in the first of these ; while the structure of the cyst seems to point out the latter as its original nucleus, and this I think the probable seat of its origin in this instance.

We cannot look back on operations like these without shuddering at the dangers we have escaped. The slightest oversight or deviation, in the midst of a deep and obscure dissection, might have prostrated the patient on the spot. A grave question here arises, whether a surgeon is justified in undertaking these operations in which, notwithstanding the greatest caution, he might destroy his patient, and involve his own reputation. Some have proposed to substitute for these hazardous dissections an excision of such parts of the sac as might be extricated without danger, leaving the remainder, and taking the risk of a regeneration of the disease. This had been actually tried in the last case ; but the experiment had entirely failed. Perhaps a cauterization of the interior of the sac might have brought on inflammation sufficient to cause adhesion to the surrounding parts. Whether this was attempted, I know not. I must say, however, that I have never yet felt willing to trust the patient to so doubtful an expedient, especially when he was so situated as to be able to

devote only a limited time to the trial for relief. When the operator does not feel a perfect confidence in his own experience, he would, I think, do rightly to adopt the plan least hazardous to his patient's life, although the probability of cure might be greatly diminished.

#### ENCYSTED TUMOUR OF BLOOD.

Collections of blood from accident become enveloped with a thin cyst after some time, and may thus continue in the form of a sanguineous tumour. They are not painful nor troublesome when in the body or limbs. In the head, they are inconvenient, and, therefore, instead of leaving them to the slow action of the absorbent vessels, it is best to open them, and clear out the coagula.

A sanguineous tumour is seen to arise spontaneously from the rupture of vessels, without external violence. This may put on the appearance of a regular encysted tumour. The skin is not discoloured; there is no pain nor tenderness; there is a sensible fluctuation; and sometimes the tumour increases.



A young lady came to the hospital for advice in regard to a tumour in the neck she had discovered two years before, without any cause she knew of. It was situated under the left sterno-mastoid muscle, and was about the size of an orange. There was some irregularity in its form, and a very decided fluctuation. It was free from tenderness or pain. Dr. Hayward first examined her, and referred her to me. After seeing the tumour two or three times, I made a puncture on the outer edge of the sterno-mastoid muscle, and this was followed by a discharge of a gill of thin, venous blood. I passed my finger into the cavity, and discovered a very thin cyst, covering the irregularities of the neck,—the muscles, larynx, and blood vessels. A piece of lint was interposed to prevent the immediate adhesion of the wound. The patient was faint after the operation, but comfortable in the afternoon, although a sanguineous oozing continued. In the following days, she had pain and other marks of inflammation in the sac, accompanied with some degree of constitutional disturbance, which has now subsided, and left her without uneasiness, while the wound continues open, and exhibits a fistulous disposition.

## SECTION XIV.

### ABDOMINAL TUMOURS.

IN the investigation of ABDOMINAL TUMOURS, we lose the benefit of the organs of vision, and are compelled to rely on the sense of touch partially applied, and on the history of the case. This history may elucidate the nature of the disease perfectly in some instances ; in others it sheds but a doubtful light upon it.

As a preparatory knowledge to the investigation of these affections, the practitioner should acquaint himself with the ordinary state of the abdominal organs, as they present themselves to the touch. In doing this he will keep in mind the difference of the condition of the intestines in their full and empty state.



In examination of the abdomen, the patient should be placed in a horizontal posture, so as most perfectly to relax the abdominal muscles. The examination should begin with the lower part and gradually ascend to the upper. Commonly it is best to employ both hands, one placed on each side of the linea alba. If a tumour be discovered, we notice its exact situation ; its size ; its form ; its connexions ; its consistence ; its sensibility ; its mobility. To aid these explanatory means, percussion may be brought in, and, in some instances, auscultation. The posture of the patient should be shifted from the back to each side, and sometimes to the opposite position, on the hands and knees.

The organs which are the subjects of enlargement in the cavity of the abdomen, are the following : the LYMPHATIC and MESENTERIC GLANDS, the OVARIUM, the UTERUS, the SPLEEN, the LIVER, the PANCREAS, the STOMACH and INTESTINES, the OMENTUM, and the KIDNEY.

The LYMPHATIC and the MESENTERIC GLANDS are the seats of tumours of quite different characters. The tumour of the lymphatic glands is commonly seated at the lower part of the abdomen in the inguinal regions. It is an irregular,



knotted tumour ; sensible to the touch ; often very painful ; frequently following fever, and tending to suppuration. It is a fixed tumour.

The tumour of the MESENTERIC GLANDS is more commonly perceived in the iliac regions, and most frequently occurs in scrofulous patients. It is deeply seated, moveable, not sensible nor painful ; does not tend to suppuration ; is commonly discovered by accident rather than by any severe pain ; and continues for months and even years without greatly affecting the functions of any organ.

The cases which next follow will serve to illustrate the enlargements of the lymphatic glands in the lower part of the abdominal cavity.

A married gentleman, about thirty years old, of excellent constitution, had an attack of fever, which lasted ten days. As the fever left him, he felt a stiffness in the right thigh, and placing the hand on the lower part of the abdomen, a tumour was found above Paupart's ligament, four inches in diameter, quite hard, of irregular surface, tender and painful. For a few days it increased. Then it began to diminish, and disappeared in six weeks from the time it was discovered.



Mr. B., machinist, was admitted into the hospital in March, 1836. He had a large hard tumour in the right iliac fossa, extending down into the thigh, very tender and painful; so that he could neither stand nor walk. The tumour appeared three months before, subsequently to a slight febrile attack. Previous to this attack he had made severe muscular efforts. His constitution is delicate; age, twenty-eight. His pulse is quicker than natural; tongue furred; he has no appetite. The pains have increased so much lately as to prevent sleeping, without large doses of opium. The size and hardness of the tumour, and the severe local and constitutional affections, gave an unfavourable aspect to the case.—Leeches, hot fomentations, with a careful treatment of his system, were followed for some weeks. The tumour suppurated, was opened, and discharged copiously for fifteen days. The swelling dissipated, and he left the hospital quite well in two and a half months from the time he entered.

The next instance of this affection is a specimen of a great number of cases of deep sinus consequent on glandular inflammation and suppuration. Capt. — became a patient in the M. G. hospital, in Sept. 1835. Some months before,



while in a foreign country, he had a severe fever ; and, when convalescent, perceived a large tumour in the right inguinal region, extending backwards towards the iliac fossa and the right lumbar region, and downwards into the thigh. After some weeks suppuration took place. More than a pint of pus was discharged, and his sufferings relieved. When he entered the hospital, a fistulous aperture was seen below the crural arch, into which a bougie being introduced, passed its whole length in the direction of the right lumbar region, through the iliac fossa. The discharge was still very considerable. The patient's appetite good ; but he had no locomotive power, being confined to his bed by the lameness of the right limb. I endeavoured to make a sufficient impulse by a bougie on the integuments of the side, to lead to a safe counter opening in the lumbar region ; but could not accomplish it. The fistulous opening was then dilated as high as the crural arch ; and stimulating injections of the nitrate of silver were employed daily. Under this treatment, with occasional changes in the kind of injection, the deep sinus gradually filled, and he was discharged well in three months from the time of his entrance.



When it has been practicable to make a counter opening in these cases, the cure has been more rapid; but usually the time required for the treatment is so long that the greater number have gone home with but little alteration, though with a prospect of ultimate recovery.

Many of these cases assume a more chronic character than those mentioned above, and may be considered as scrofulous. The following is an instance of this. The Rev. Mr. — applied to me in the year 1829, labouring under a severe affection in the right side of the abdomen. He was of a delicate habit and of sedentary life. Some months before, he had noticed a swelling in the right inguinal region, which gradually enlarged till it occupied an area of five inches above the crural arch. As it increased, it became painful; and at length the pains were as severe as those of neuralgia. The slightest movement of the limb gave great distress. He was of course unable to walk. His appetite was poor, bowels costive, and pulse quick. The application of leeches, fomentations, sea-water bathing, and various internal remedies, produced no change. The hard, irregular, sensitive tumour resisted every remedy; and



the patient seemed to be doomed to a slow cachectic death. When he had been in this state two years, the pains began to lessen, the tumour to disappear, and the other unfavourable symptoms to subside. He at length, after four years of great suffering, recovered his health, and now continues perfectly well.

Every fact relating to a subject so obscure as that of abdominal tumours, is of some interest, and I will therefore relate the following case.

In the year 1834, my advice was asked for Mrs. C., the wife of a farmer in a distant part of the country. She was thirty-eight years old, had borne eight children, the last during the winter before her application to me. Two weeks after her confinement, she made a visit in a sleigh to a neighbour, at about six miles distance. On returning, she was seized with chills, followed by a febrile attack of eight or ten days' duration; and, on recovering from this, perceived a tumour in the lower part of the abdomen, on the right side. This, when I saw it, was a very distinct cluster of enlarged lymphatic glands, three or four inches long, situated one or two inches above the crural arch. To the touch it was quite tender. It interfered with motion so much as to keep the



patient on the bed a great part of the time. She was emaciated and enfeebled, though she still continued to nurse her child. Her pulse was usually about 100. A person, bearing the name of physician, had advised her to eat beef-steaks and drink brandy and water; which course she was diligently pursuing, and daily growing worse. My advice to her was to give up animal food and spirits; to lie on her bed constantly; to apply leeches every fourth day, and continue nursing her child. I did not hear of her again till a year after; when it appeared that by following the course directed during four months, she recovered a perfect state of health, and the tumour was dissipated.

TUMOUR OF THE MESENTERIC GLANDS is situated higher in the cavity than the last described. It is placed most frequently between the lower edge of the ribs and the crest of the ilium. The depth at which it lies prevents its being easily discovered or exactly defined. The surface is irregular, knotted, and passes off indistinctly into the surrounding parts. Its sensibility is slight, so that it is doubtful to the patient, when it is pressed, whether he feels more than from pressure on a healthy part. Usually it is not attended with



pain, especially in its early stage, whence it happens that its discovery is accidental. The increase is very slow, and the tumour does not always attain a size sufficient to interfere with the functions of the neighbouring organs. The direction of the enlargement may be such as to compress the intestines. This will, of course, interfere with their functions, and involve important consequences.

The tuberculated state of the mesenteric glands has been already noticed under the head of effects of cancer of the breast. The tumour formed in these cases is extensive, and is sometimes spread out through the cavity of the abdomen. At the same time, it is so frequently accompanied with dropsy as to render it impossible to distinguish it. We shall now attempt to illustrate, by facts, the tumours of the mesenteric glands considered as scrofulous.

A gentleman, between forty and fifty years old, applied to me in the summer of 1834, on account of a glandular tumour on the right side of the neck. Though not a strong man, he had enjoyed good health until this swelling appeared, a few weeks before the time at which I saw him.—The swelling occupied the inferior part of the neck,



was not painful, had no discolouration, and presented five or six knots included in one tumour.—The discovery of iodine affords a happy resource for the treatment of diseases considered as scrofulous. Iodine he took, applied leeches, and used sea-water bathing, without any great change. In 1835, he began to be affected with occasional discharges of blood from the urethra, sometimes attended with pain, and generally with strangury. The pain was most commonly on the left side of the abdomen, near the spine. The paroxysm occurred at irregular intervals of three or four weeks. When these symptoms were mentioned to me by his attending physician, I was led to propose an examination of the abdomen, with the view of ascertaining whether any discoverable enlargement existed. This examination took place. On passing the hand over the middle region of the abdomen, a large tumour was found a little above and to the right of the umbilicus, occupying the space between the lower edge of the ribs and the crest of the ilium. It was hard, knotted, indistinct, slightly moveable, not tender, and, as he had not suspected its existence, of course not painful. He had a good appetite, and regular state of bowels. Has had one or two paroxysms of febrile action,



indicated by increased frequency in the pulse. The tumour on the neck continues.—He was advised to take from twenty to forty grains of hydriodate of soda in a day, beginning with the first-named dose, and gradually increasing to the last; friction of iodine ointment to the part affected; two drachms of sulphate of magnesia every three days; warm sea-water bath twice a week; to walk moderately and daily; and take his usual food. This course he has pursued seven or eight months. His health and flesh have improved. The tumour remains unchanged. During the time mentioned, he has had three or four paroxysms of discharging bloody urine, each continuing for about three days, with frequent inclination to pass water, and sometimes an inability to pass any for some hours.—With exception of the strangury, he has rarely had pain; but has an increase of sensibility on the left side during the paroxysm. Had this symptom occurred on the right side, we should have been disposed to connect it with the tumour, and have believed that the pressure of the tumour on the right kidney caused the sanguineous discharge. But its occurrence on the left not favouring this opinion, we are led to the belief that there is an affection of one or both kidneys,



dependent on the cause which has generated the tumours of the neck and abdomen.

March 20, 1835. During the winter, the patient has had frequent attacks of bloody discharges from the bladder, and they still continue. This appearance has sometimes been accompanied with pain in the left side of the abdomen, and over the region of the kidney. The quantity of blood discharged is sometimes a pint at a time, and the discharge continues usually for a few hours. It is preceded with an irritation in the urethra, which always denotes that blood has passed into the bladder; and it continues till the whole of the coagula are thrown off, thus evidently arising from their presence in the bladder.—The abdominal tumour has diminished since these copious evacuations of blood. The patient's appetite is good, and his strength moderate.—The hydriodate was discontinued some months since.

Mrs. —, a lady who has had four children, has a tumour in the right iliac region, about three inches in diameter; very hard and prominent; not moveable; slightly tender; sometimes painful.—She perceived it eleven weeks since. Her looks do not indicate disease. She suffers from indigestion and costiveness, without any severe symptoms,



such as colicky pains or vomiting. Appetite not very good ; pulse a little accelerated. Her treatment, during seven months she has been under my care, has been to take a blue pill once in three days, and apply leeches and frictions of the ointment of tartrate of antimony to the region of the tumour. Her food, both solid and liquid, is restricted. When it is necessary, she takes small doses of epsom salts. After she got under the influence of this course, the dyspeptic symptoms were relieved. The tumour remains as it was.

The mesenteric tumour, arising from a constitutional cause, is less likely to be influenced by medical treatment than that of the lymphatic glands ; but its slow growth allows time for the system to become accustomed to it, so that it sometimes continues many years without important consequences. On the other hand, the mesenteric enlargement may be rapid, especially in young subjects, and may then make a strong and dangerous impression on the abdominal organs.

A delicate girl, fifteen years old, entered the hospital in April, 1837, on account of a disease of the left foot. In December of the preceding year, after walking out, she perceived a lameness and pain in the metatarso-phalangean articulation of



the great toe. These symptoms had increased, and were accompanied with tenderness and swelling, so that she was unable to walk. Her pulse was 120, appetite little, tongue furred, and breath slightly offensive.

The quick pulse led me to suspect some lesion more important than that in the foot; but as she reported herself free from any bad feeling independent of the local disease, I was diverted from this suspicion, and proceeded to treat the affection as a scrofulous inflammation of the tarsal bones. After a few days, it was discovered that she had occasional pains in the abdomen, slight diarrhœa, sickness of the stomach, and increasing failure of appetite. These symptoms led me to examine the abdomen, and I was not greatly surprised to find a tumour in the region of the umbilicus, full three inches in diameter, with an irregularly flat surface, and a knotted circumference, throwing out on its left border a process about an inch long. The tumour was prominent, but not definitely separated from the neighbouring organs; not tender, nor painful, and but slightly moveable. It was obvious that this was the affection which had so much disturbed her system, and that the tarsal inflammation was of secondary importance.



On investigating her domestic history, it appeared that her father was healthy, and still living ; that her mother had died of phthisis five years before ; and that she herself had always been sickly. Her skin was delicate and freckled ; hair, light-coloured ; eyes blue, with dilated pupils ; her limbs long, and slightly framed. The catamenial evacuation appeared at the age of thirteen, and had continued until the last term, when it did not occur.

The first object in the treatment of this case was to regulate the action of the intestines ; but this was found impracticable. Alternations of costiveness, diarrhoea, and vomiting, such as generally attend mechanical obstructions in the alimentary canal, rendered it impossible, by any accommodation of remedies, to produce regular evacuations. Vomiting was not frequent, but sometimes severe, and produced an evacuation of thick green mucus, like chopped grass. The faecal discharges had nothing morbid.

Desirous of doing something to check the progress of the disease, and relieve the sufferings of the patient, I directed external irritation, and the internal use of solutions of muriate of lime, of baryta, and muriatic acid in mixture and in pills,



successively. The acid she bore well. The other medicines were mischievous by bringing on pain, diarrhœa, and sickness. On the whole, I came to the conclusion that she was best when she took no medicinal article, except occasional enemata.

In the course of three weeks, the tumour increased from a diameter of three inches to an extent occupying a large part of the abdominal surface, leaving around it just space sufficient to separate it from the borders of the cavity. Its anterior face continued irregular, moderately hard, not tender, and no longer moveable.—The pulse is, less frequent, the tongue cleaner, and she has more appetite. Her cough continues, with slight expectoration; but no physical signs of thoracic disease can be detected. The patient is emaciated, and evidently failing in strength.

It is obvious, I think, that this tumour resides in the mesenteric glands. Its original seat and subsequent progress enable us to distinguish it from an enlargement of the liver, spleen, pancreas, kidneys, ovaria, and uterus. Moreover, the signs of pressure on the intestines are not such as would arise from enlargement of any of these organs; and they are such as would be caused by a tumour closely connected with the intestinal canal. I



think there is little reason to doubt that it is an enlargement of these glands, with a growth unusually rapid and extensive.

#### TUMOURS OF THE STOMACH.

The tumour formed by a scirrhus of the muciparous glands of the cardiac and pyloric orifices of the stomach, has been already adverted to, in speaking of tumours of those glands. At present it is necessary to allude to them only for the purpose of distinguishing them from other abdominal tumours.

The tumour of the CARDIAC ORIFICE is difficult to discover, on account of the deep situation of this orifice. In an early period of the affection, it is not possible to perceive it. It must be discovered by the history of the case. After a time, however, we are able to add to the evidence of functional affection the tangible proof afforded by the existence of a tumour. The scirrhus-cancerous disease of the mucous glands of the cardiac orifice is felt very high in the epigastric region, just under the ensiform cartilage of the sternum; thence extending towards the left, under the cartilages of



the ribs. Being but indistinctly felt it appears to be a large, hard, irregular tumour, not well defined, tender to the touch, and not causing any external prominence of the skin.

The tumour formed by the PYLORIC ORIFICE, in a scirrhus state, is much more distinct than that of the cardiac ; yet more likely, from its situation, to be confounded with other diseases, were it not that the gastric derangement is so remarkable as to remove any obscurity. It is perceived in the right hypochondriac region, below the edge of the right ribs. There is usually one principal tumour, of an inch or two in diameter, very hard, quite prominent, sensitive to the touch, moveable, and varying in its situation to a small extent. The principal tumour is usually connected with one or more smaller knots.—The situation will readily distinguish it from the tumour of the cardiac ; the form from enlargement of the liver ; the hardness from that of the mesenteric glands. Tumours of the intestines, omentum, and gall bladder, being comparatively rare, are not likely to be confounded with it.

## TUMOURS OF THE LIVER.

The enlargement of the liver, when of a sufficient size to become noticeable, is not difficult to distinguish. In the horizontal posture, the healthy liver does not descend so low as the edges of the ribs. When enlarged, it appears lower than the ribs, forming quite an extensive surface on the right side, and corresponding in its course with the lower edge of the thoracic walls. No other organ is very liable to form a tumour which could be mistaken for this in the adult. In the young infant the liver is sometimes so much enlarged as to occupy a great part of the cavity of the abdomen. At the same period of life we sometimes see a great enlargement of the spleen, which may extend to the right side, and be mistaken for enlargement of the liver. The right kidney may be so much enlarged in the adult, as to occupy the whole right part of the abdomen, extend upwards to the ribs, and assume the appearance of a very large liver; but this is a rare occurrence. The symptoms of the case will help us to determine whether the kidney or liver be the seat of disease.



When the liver is much diseased, suppurations take place in the substance of the organ, and occasionally discharge either externally through the parietes of the abdomen, or internally into the intestines.—In the former case an external tumour is formed. This is situated below the edges of the right ribs, and occupies a space of four or five inches in diameter. This tumour is quite hard, immoveable, not distinctly defined, not tender to the touch in its early stage. Eventually it becomes tender and red, then softens and opens. This happened to a patient of mine in the years 1831 and 1832. He was a young man of a scrofulous habit, eighteen years old; perfectly temperate. He became dyspeptic; lost his appetite; was sometimes constipated and sometimes relaxed in the bowels. At length his skin assumed a dark yellow. An enlargement of the liver was discovered in the right side, extending as much as three inches below the ribs. He was now unable to go out. After this enlargement had existed for three months, the side, which before had been the seat of a slight uneasiness, became painful. On examination, a hard tumour was found below the edge of the ribs. This, after a few weeks, altered to a red colour, pointed in the middle, and exhib-



ited a distinct fluctuation. It was allowed to remain in this state for ten days. Then it was opened, and a very large quantity of pus discharged. The opening continued for a year, and then closed. He was about three years longer in recovering his health, and is now well.

The following case belongs rather to legal medicine than to surgery. Its importance will perhaps justify the introduction of it here.

A young gentleman of this place, being employed as supercargo of a ship, had a dispute with a seaman, which led him in a moment of irritation to project a coffee-mill towards the offender. The blow was received in the right side, in the region of the liver. The seaman was knocked down by the violence of the blow, and carried by his comrades to his berth, from which he did not rise during the remainder of the voyage.—In fifteen days after the injury the ship arrived in Boston. The seaman was taken ashore, and remained in his lodgings fourteen days, when he died. It being believed that his death was caused by the blow from the coffee-mill, an examination was ordered, with a view to ascertain whether the appearances in the dead body would support this charge.



On the right side of the body, below the ribs, a considerable tumour appeared, obviously arising from an enlarged state of the liver. Above this tumour, corresponding with the eighth and ninth rib, was an enlargement, apparently proceeding from the ribs. Two ribs, it appeared, had been fractured, the eighth and ninth. In the liver, near the right side, a large abscess was discovered, and another near to it.

These appearances were thought sufficient to justify a charge of manslaughter, and perhaps of murder. The young gentleman was arrested and thrown into prison.

The counsel employed to defend the accused, George Sullivan, Esq., now of New-York, happened to be a gentleman well acquainted with anatomy. On investigation of the case, he was led to suspect there might be some mistake; and having communicated to me his suspicions, he was advised to obtain permission of the police to have the body exhumed and re-examined. The body was accordingly, after a week's interment, dug up and brought to the medical college, and a careful investigation made of every part.—The organs which had been previously examined, had been cut in pieces and lay promiscuously in the cavity



of the abdomen.—My first object was to replace the parts in their natural situation. This with much difficulty was accomplished satisfactorily. Then it appeared, First, that the abscess in the liver did not correspond with the fracture of the ribs. They were distant some inches from each other. This abscess was quite large, but not the only large one in the liver. The organ was excessively diseased throughout, and contained ten or twelve abscesses of considerable size. No part of its texture was healthy.—Second; the ribs, as stated, had been fractured. They were, however, perfectly united, and all the exuberant ossified matter had been absorbed, so as to give the fracture a smooth and uniform appearance, such as must have required the agency of the absorbent vessels for a long time. Third; the cavities of the abdomen, thorax, and cranium were full of water, which happily had been retained during the first examination.—Fourth; all the arteries in the body were in a state of disorganization; their coats were much thickened, and many of them were ossified in different degrees.—On these appearances were grounded the opinions, First; that none of the morbid changes were caused by the blow on the side.



Second ; that these changes were, all of them, the effect of an excessive and inveterate use of ardent spirits.—On the following day these opinions, with the facts on which they were founded, were stated in a court held for the purpose by the chief justice Parker ; and thereon he ordered the accused to be admitted to bail.—In a few days the matter being brought before the grand jury, no bill was found, and the accused was fully discharged.—The dead man, it seemed, had been in the habit of using ardent spirits so freely as to have brought on incurable disorders. He availed himself of the injury to keep to his berth ; and finally died of extensive organic derangements produced by his bad habits.

#### ENLARGEMENT OF THE SPLEEN.

The spleen it is well known varies in size at different times during the state of health. In fever it also varies. In typhus, it often assumes a considerable size, and afterwards returns to its ordinary state. The enlargement which takes place during intermittent fever, is apt to continue. This organ may assume the cartilaginous and even the osseous transformation.

Tumour of the spleen is known by its situation in the left hypochondriac region, below the ribs of the left side, extending downwards between the umbilicus and the crest of the ilium. The surface is quite smooth and uniform ; consistence, firm, not amounting to hardness ; size, variable ; sensibility not remarkable.

#### TUMOUR OF THE PANCREAS.

The pancreas is not unfrequently found in an indurated state after death, but is rarely so much enlarged as to form an external protuberance during life. When it is much enlarged, it will be found below the ribs of the right side, and so nearly in the situation of a scirrhus of the pyloric orifice as not to be distinguishable from it by physical signs. The tumour is quite hard, and not very tender. The right part, including the small pancreas, is most enlarged, and making pressure on the duodenum interferes with the functions of this part, and causes pain, symptoms of indigestion, diarrhœa, and consequent emaciation. The following case will give an idea of the functional disorder brought on by this affection.



A gentleman, forty-five years old, applying to me, stated he had been subject to colick pains for some years back. Lately, they had increased to a most painful degree, and required large doses of opium to give relief. When not under this pain, he had strong dyspeptic symptoms. Acidity and flatulence were the most remarkable. He was very costive, and regularly took medicine to open the bowels. Lately, he had become quite unfitted for business, and seldom went out. Examining the abdomen, I found a very hard tumour, deeply situated in the right hypochondriac region, near the pyloric orifice of stomach. It appeared to be three inches long in a transverse direction, and two broad. There was some tenderness on pressure.—The complaint might have been thought to be a scirrhus of the pyloric orifice, but that the patient did not frequently vomit, nor ever, excepting when he had pain. After a long series of sufferings, he died. On examination, I found the pancreas of a scirrhus hardness, especially at its right extremity. There it pressed on the duodenum, and partially interrupted the passage through this intestine.—The colicks were the effect of this interruption, rather than of the scirrhus condition of the gland.



## TUMOUR OF THE OMENTUM.

There are three kinds of tumour of the omentum which have fallen under my notice. The first is that which is connected with scirrhus-cancer of the breast, an instance of which has been mentioned under that head. This tumour is hard, irregular, not tender; varying in size, sometimes very large; varying in situation, sometimes extending through the abdominal cavity.—The second is an exuberant deposit of fat in the laminae of the omentum. This occurs in persons who are generally charged with adipose matter; but when it constitutes a disease, is deposited in the form of masses, lumps, or nodules. I attended a gentleman, in consultation with the late Dr. Dixwell, under symptoms of colick. He had been out of health for some months, owing to great indulgence in eating. The last attack consisted of vomiting and pain in the bowels. It continued three days only and proved fatal. On examining the body, we found the omentum containing a number of fatty tumours, one of which, of a rounded form, about three inches in diameter, pressed upon the caput coli, and caused a total obstruction of



the canal, and was the cause of the fatal termination.—Third, the umbilical hernia of the omentum occasionally forms an adhesion to the umbilical ring, and produces a hard, regular, rounded tumour, without sensibility or pain, but troublesome from its situation and hardness. In cases where there is a certainty of adhesion to the ring, and full evidence that there is no intestine included, this tumour may be removed by the knife.—A lady, thirty-five years old, applied to me for a tumour of this description, of the size of an orange—perfectly smooth, hard, without sensibility. It had existed for twelve years. Lately, she thought it had increased, and had become more inconvenient from its hardness, as it interfered with her dress, and kept her in an uncomfortable state. The tumour, with an oval piece of skin, was removed, together with the peritoneal sac covering it, and which had become consolidated with the omentum. After dissecting the skin from the tumour, it was separated from the omentum at the umbilical adhesion. No peritoneal inflammation, nor any mark of constitutional disturbance followed, and the patient soon recovered.—An internal hernia of the omentum in the peritoneal

cellular tissue is related at page 367, under the head of tumours of the stomach and intestines.

## TUMOUR OF THE KIDNEY.

The depth of the place of the kidney from the fore part of the abdomen, and its bony protection on the back part, render it most difficult to ascertain the condition of this organ when moderately enlarged. When, however, it attains so great a size as to form a projection on the fore part of the abdomen, it is sufficiently conspicuous, but not always easy to discriminate from enlargements of the liver and of the spleen. The local and physical signs, in truth, present no discriminating facts. It is by the derangement of the functions we are to be guided in this case.—The two following instances will show how easy it is to be deceived, and how far it is practicable to discriminate, in regard to the tumour of this organ. An unmarried lady, fifty years old, of bad constitution, came to me with a very large abdominal tumour on the left side. On examining it, I traced it up under the ribs of the left side, where



it disappeared in the direction of the spleen. Downwards, it extended below the crest of the ilium in front, leaving but a small space below not occupied by it. The tumour was hard, smooth, not sensible—had existed about three years. No derangement of the urinary secretion had been noticed by the patient. Her health was but little impaired; appetite good; no fever. The tumour had the appearance of an enlarged spleen. The patient received instructions how to proceed, and I did not hear from her for a number of months. Then I was called to see her in the country. I found the tumour increased in size; the whole abdomen tense from a dropsical effusion; severe abdominal pains, which required the use of opium; and, at times, she had paucity of urine, and a frequent inclination to pass it. Attributing this symptom to the dropsical effusion, I did not attach the importance to it which perhaps it deserved. She lingered a few weeks more, and the body being examined after death, the tumour was found to be a monstrous enlargement of the left kidney.

Mr. B——, a respectable rigger and sail-maker, of Boston, sent for me in the winter of 1832. He was sixty-five years old, of very full habit, and healthy till he was affected with the existing dis-



ease. In the former part of his life, his business had called him to considerable efforts and frequent exposure in wet clothes, which he had not been careful to remove. His symptoms he considered to be dyspeptic. His food troubled him. He had alternations of costiveness and diarrhœa. His appetite was good. With some difficulty, it was discovered that he had frequent attacks of strangury, and that he had a swelling in the abdomen. Having prevailed on him to allow an examination, a rounded tumour, about five inches in diameter, was perceived on the left side, below the anterior edge of the left ribs—not extending under the ribs, not moveable, nor tender. This had been known to him a few weeks only. After this time, I attended him regularly. By restricting his food, he was kept easy and comparatively comfortable, so as rarely to require the use of opium. The strangury was frequent, though not distressing. The urine, charged with mucus, was of a dirty yellow colour. The local and general remedies had no effect in retarding the growth of the tumour. This increased till it occupied the left half of the cavity of the abdomen. He died in July, 1832. I was absent from town at the time of his death, and no examination was made. There can



be no reasonable doubt, I think, that his disease was seated in the left kidney.

#### TUMOUR OF THE OVARIUM.

The enlargement of the ovarium is perhaps the most common of abdominal tumours. This is the more observable, because this organ is not exposed to the operation of external agents, and must be affected secondarily and sympathetically in the greater number of cases.

Two kinds of ovarian enlargement principally attract our notice: first, the scirrhus, and, second, the dropsical affection of this part. **SCIRRHOUS OVARIUM** begins with a hard tumour in one of the lateral regions of the inferior part of the abdomen. It is not attended with pain in the early stage. As it increases in size, it occupies the middle region, so that it is not easy to determine, at this period, on which side it took its origin. This is, however, a fact important in enabling us to decide as to the nature of the tumour. This tumour is distinguishable by the place of its origin; by its regular growth; by its hardness; its smooth surface, with occasional projections; its moveable-

ness, which is considerable, though various ; its freedom from pain, excepting what it causes by distension of the abdominal parietes, and by pressure on the surrounding organs, when it has attained a great size. It contains no fluid, and of course has no fluctuation. To get a distinct notion of it, the patient should be examined while lying on the back, on each side, and also in the upright posture. This disease admits of no remedy but a surgical operation, and this would probably prove fatal.

Catherine Wait, a single woman, aged forty, was admitted into the M. G. Hospital, Oct. 28th, 1830. Four years previous to this time, she perceived a tumour as large as a goose-egg, below and to the right of the umbilicus ; hard, moveable, not painful nor sensitive. Examination per vaginum does not detect the tumour. It has lately increased very much, fills the cavity of the abdomen, being fourteen inches in length, and extending across the cavity. Catamenia profuse. After she entered the hospital she was much troubled with pains in the sides. Her appetite failed. She had considerable cough. Finding that the disease was advancing, and that its issue must certainly be fatal ; and influenced by the accounts



published of favourable operations, the extirpation of the tumour was proposed to her, and she readily consented to it. The tumour was accordingly removed, and you here see it. The weight is about twenty-five pounds. It is of almost cartilaginous hardness, and, as you see by the incision, it has no cavity and contains no fluid.

The operation was performed in November, 1830. Preparatory to it, the operating theatre was warmed to between seventy and eighty degrees. Warm soft water and soft cloths were ready to cover the intestines. These and all other necessary arrangements having been carefully made, an incision was carried from above downwards through the linea alba, the length of twelve inches. The abdomen being opened, the tumour was felt with a broad adhesion at the lower part of the cavity. This adhesion was encircled by a thick ligature. Below the ligature a needle with double thread was carried through the adhesion and tied on each side. The adhesion was then cut and the tumour removed. Owing to the shortness of the pedicle, the ligature partially slipped off as soon as the scirrhus was taken away, and though the vessels were secured as fast as possible, they were so numerous and



large, that the patient in a short time sunk from loss of blood.

The event of this case has led me to decline repeating the operation ; and I should advise others to decline it, unless there were some peculiar insulation of the tumour, as when it formed a hernia, or when it had a very long and narrow pedicle, if this could be known before the operation, so that its connexions might surely be attained, and the blood vessels speedily and certainly secured.

DROPSICAL OVARIUM is distinguished from scirrhous by its smoothness, elasticity, and fluctuation ; by its more rapid increase, and occasional diminution ; by the great size it may attain ; and finally by the length of its duration. I know many individuals, who have been affected with ovarian dropsy for eight or ten years, whose health is as good now as when I first saw them.

When this tumour reaches so great a size as to compress the surrounding organs and interrupt their functions, it may be necessary to evacuate the fluid. This should be deferred as long as possible. First ; because the fluid will soon collect anew. Second ; it is often of a gelatinous, ropy consistence, which prevents its being readily evacuated. This difficulty will be still greater when



the cavity of the ovarium is filled with hydatids, as often occurs.—One of the most distressing cases of this disease, in which dropsy and scirrhus were combined, I saw five years ago. A lady in the prime of life, and of great personal beauty, after having a number of children, was attacked with ovarian dropsy. Methods were employed to check its progress. Still it went on, and in the space of two years after I first saw her, filled the abdominal cavity, and gave her great distress. The water was partially evacuated by puncture, but soon regenerated and interfered with all the abdominal and thoracic functions. Pain from distension, dyspnœa, costiveness, strangury, vomiting, and finally a protrusion of the uterus and vagina, successively followed. She was tapped a second and a third time. After the third operation, she died. The body was examined. The cyst was a quarter of an inch thick and filled with hydatids. All the organs were strongly compressed, and many of them displaced, so as with difficulty to be distinguished. The whole cavity presented a mass of disease and decomposition, such as had rarely been witnessed.—This is not the usual course of ovarian dropsy, unless complicated with scirrhus. Twelve years ago, I was requested by my la-



mented friend, Dr. Gorham, to see a lady affected with an ovarian tumour about the size of the head of an adult person. She had perceived this tumour some years before; had not had much inconvenience from it, except occasional attacks of pain in the side. Lately there had been a watery effusion into the cavity of the abdomen, which caused some uneasiness. The ovarian tumour was a perfectly regular oval; smooth and uniform, without knots or protuberances; and exhibited a distinct fluctuation.—We agreed to adopt an active course of purgatives for a short time. This produced absorption of the water, and lessened the tumour. Since then she has frequently had recourse to the same remedies with similar effects. In other respects she retains her health, pursues her avocations, and intermixes with gay society, as if free from disease.

Fifteen years ago, a young lady, whose health had always been good, applied to me for a tumour in the breast, which increasing in size, and being of a doubtful aspect, I removed. She got well through the operation and its effects, and the next year had an ovarian dropsy. This was tapped a number of times. She eventually recovered from it, and now has perfect health, and is even



more active than most persons of her age. I have frequently quoted this case to encourage patients labouring under this disease, with the hope of restoration to health.

#### TUMOUR OF THE UTERUS.

This has been adverted to under another head. Here we have only to notice its appearance as a tumour discoverable through the parietes of the abdomen. Although often diseased and enlarged, the uterus does not very frequently increase to a size sufficient to make a protuberance which can be felt by external examination. In tuberculous and carcinomatous affections, it is rarely perceived above the pubes. When, as in a case mentioned under the head of tumours of mucous glands, it rises above the pelvis, it may be felt as a hard, moveable, not sensible tumour. The best mode of ascertaining its existence and seat is to pass the finger of one hand into the vagina, and place the other on the lower part of the abdomen. In this way an enlargement will be ascertained by the communication of an impulse from one hand to the other.



## ANOMALOUS TUMOURS OF THE ABDOMEN.

The tumour which is now exhibited to you was presented to me by Dr. E. Hale. The minutes of the case, as taken from his note-book, are as follows :

ENCYSTED TUMOUR IN THE ABDOMEN.—Helen Stevenson, aged three years.—For a long time, perhaps from infancy, this little girl's abdomen had been very prominent. Last summer she had a severe diarrhœa, which was treated by the mother, and continued up to the time of my visit. She then had two or three watery stools in a day, without much fæcal matter. Her appetite had been good until recently. Her abdomen was prominent, tense, and very tender on pressure. She took calomel and rhubarb in small doses, and in two or three weeks seemed nearly to have recovered. On the 23d instant, she was at play in her father's shop, without exposure to cold, when she suddenly complained of pain. She was taken into the house, and soon began to vomit ; and although every remedy was exhibited, the vomiting continued with one or two intermissions of ten or twelve hours, until her death, which took place



on the morning of the 28th. Previously to this attack the bowels were freely open; but after the vomiting began, no discharge could be obtained, except what was obviously merely the contents of the lower intestines, discharged by enemata. Calomel in repeated doses, castor-oil, and a variety of other cathartics, were exhibited; rubefacients and a blister to the abdomen; the warm bath and frictions,—all without effect.

*Examination twelve hours after death.*—Externally, the prominence of the abdomen had subsided, leaving an irregular projection a little to the left of the umbilicus. On opening the cavity, this projection was found to be occasioned by a large tumour. Over it lay the omentum, which adhered to the surface of the tumour, and also to the peritoneum, forming a sort of anterior coat; and the two folds of the omentum adhered together, so that the tumour was firmly attached to the anterior portion of the peritoneum, by the intervention of the adhering omentum. This adhesion covered a spot of several inches in extent, but did not, however, appear to have been the origin of the tumour. Behind, it was attached, by a sort of pedicle, nearly two inches in length, to the left side of the spinal column, a little below the kid-



ney. This pedicle was made up of a peculiar cellular structure, firm and tenacious, with very large cells, containing a transparent fluid. At its base, it extended to the left extremity of the kidney and the left extremity of the pancreas, and was involved in the cellular membrane around each of these organs. By these two attachments, the tumour was confined between the spinal column behind and the abdominal muscles in front. The intestines lay about it chiefly on the right side; but a portion of the jejunum (about one third of its distance from the stomach to the cœcum) was compressed firmly between the tumour and the spine, so as wholly to close its cavity, and prevent any thing passing through it. The whole intestines below it were empty and contracted, while above it they were full and distended. The tumour was dissected out, opened, and found to contain half a pint of dirty greenish fluid.

The tumour is inverted, so that we have a view of its internal surface. This is perfectly smooth, and resembles the inner coat of those encysted tumours already spoken of.

MOVEABLE TUMOUR IN THE ABDOMEN.—J. W., aged twenty-three, sail-maker and preacher, was



admitted into the M. G. Hospital, 1836. Was unmarried. Has good health, excepting the inconvenience he experiences from a tumour on the left side of the cavity of the abdomen. It is situated between the ribs of the left side and a line drawn from the umbilicus to the crest of the ilium. The patient, when standing, can cause it to descend as low as the umbilicus. By the least movement of the body, it is suddenly drawn up under the ribs, so as to be felt but indistinctly; whereas, when it is down, its anterior surface can be fully perceived, and the tumour almost grasped in the hand. This surface is about four inches in diameter, of a rounded form, quite hard, and not more sensible than other parts of the abdomen. He suffers no pain from it when at rest; but, in walking, experiences much uneasiness, and is obliged to stop frequently. In consequence of this, he is unable to pursue his usual occupations. He first noticed it twelve years ago, as a small, hard body in the left hypochondriac region. Gradually it has increased in size, but has caused no inconvenience till within four years past. He cannot lie on the right side, on account of the pressure it makes on the bowels. He feels uncomfortable after eating, as if he had taken a very



heavy meal. This lasts about half an hour. The tumour disappears in the horizontal posture.—The patient being desirous to have the tumour removed, a consultation was requested with a view to decide, first, what the nature of the tumour might be, and, second, whether it should be removed. To the first question it was answered, that the tumour might be an enlargement of the omentum; a disease of the mesenteric glands; a loose spleen; a second spleen; an encysted tumour; a solid, adventitious tumour. As the functions were not deranged, no light could be thrown on the case by the disordered state of any abdominal organ. The supposition most probable seemed to be, that it was a tumour of the omentum, which admitted of being drawn down, from the looseness of this membrane, and was suddenly raised by its attachment to the stomach and colon. To the second question it was replied, that, as the case was quite obscure, the consultation would not recommend an operation on any ground but the wish of the patient. — This being stated to the patient, he referred the decision to me. I advised him to postpone an operation until he should perceive his health to be decidedly affected by the disease. On this, he quitted the hospital in March, and I



did not see him again until December. In the mean time, the tumour had increased in size, and the inconvenience in walking was much greater. His health not impaired. He said he was now determined to have the tumour removed at any risk.—For the purpose of more fully observing it, I recommended his being admitted again to the hospital. For some reason, he was not admitted, and is, at present, living in the country.

An operation for the removal of this tumour would undoubtedly be dangerous, and it was with a sensation of relief, I learnt that this patient had returned home.—If, however, he should apply again, with an earnest desire for the operation; and if it appeared that his health was impaired, and his usefulness interrupted by it, I should not feel at liberty to refuse to operate.—In this case, I should make an incision of about four inches through the muscular parietes of the abdomen; should examine the tumour at first through the peritoneum; and perhaps find reason to abandon the operation in this stage. If not then the peritoneum should be opened, the intestines carefully guarded, and kept in the peritoneum; the tumour brought to the aperture, and fully examined before proceeding further. Next,



its pedicle should be secured by one or more ligatures, passed through it to surround its nutritious vessels in such a way that they could not possibly escape the ligatures. In doing this, it might be necessary to enlarge the wound upwards so as to obtain a perfect security on this head. Then the dissection from the adhesions or attachments should be prosecuted and completed.

Great as the hazards of such an operation would be, they do not appear to me to approach those of an extraction of the ovarium; and if there were no alternative but death, the responsibility ought not to be evaded, however painful and burdensome it might be. But, on the other hand, we should never allow ourselves to recommend, or to perform, such an operation in a case which does not give a reasonable hope of a favourable result.

---

At page 366 is stated the case of a lady then under treatment, who was affected with tumour of the abdomen. She returned home, and after a few weeks died. An examination was made by her physician, Dr. Tobey, who had the goodness to send me an account of the appearances.



“The stomach, near its cardiac orifice, had two ulcerated spots, each about four lines in diameter, penetrating apparently through the two inner coats of the organ. These, I should judge, were recent in their formation. In other respects, the internal surface of the organ presented a natural appearance. Its size was inordinately large. Duodenum natural. Jejunum, within two inches of its connection with the duodenum, presented what resembled a hernia of the intestine, about the size of a hickory nut; another, of the same size, about an inch below the first; and three inches below this, a third, of the size of a hickory nut. Upon examining these singular protrusions, we found the villous, cellular, and muscular coat destroyed, the peritoneal coat only remaining, and distended to the size I have mentioned. The margins of these openings through the coats of the intestine were circular and hardened.” “The tumour that attracted your attention appeared to be an omental hernia, situated in the cellular substance covering the abdomen. The peritoneal sac was perfect, and was filled with a portion of omentum strongly adherent to the sac.”



SOME OF THE DISTINGUISHING CHARACTERISTICS OF  
THE MOST COMMON TUMOURS.

**VERRUCA** ; a brownish, rough, conical excrescence of the cuticle.

**CLAVUS** ; a hard, irregular, sometimes conical, thickening of the cuticle.

**ICTHYOSIS CORNEA** ; a hard, horn-like, pointed, insensible, deciduous projection of the cuticle.

**LEPOIDES** ; a scale or crust of the cuticle of the face, falling off, frequently renewed, and terminating in ulceration of the cutis.

**KELOIDES** ; a flat, slightly reddened, firm projection of the cutis, like the cicatrix of a burn.

**EILOIDES** ; a morbid growth of the cutis, coiled or folded.

**STEATOMA** ; a tumour of fat in the cells of the cellular membrane—smooth, moveable, colourless, not sensible, painful, nor malignant.

**SIMPLE CELLULAR TUMOUR** ; without fat, irregular in growth, not painful, not malignant.

**MUSCULAR TUMOUR** ; irregular, hard, hardness increased by muscular contraction, painful, malignant.

**FUNGUS HÆMATODES** ; soft, not moveable, colourless, painful, bleeding, involving different textures, malignant.



FIBROUS TUMOUR; according to many pathologists, a tumour exhibiting a fibrous arrangement. It may exist in various textures.

FIBROUS TUMOUR OF THE TENDONS; insensible, inelastic, hard, hardness increased by muscular contraction.

PERIOSTEAL TUMOUR; irregular, diffused, sensible, painful, variable in size, not malignant, accompanying necrosed bone.

EXOSTOSIS, PERIOSTEAL; a hard, insensible, regular tumour of bone, not malignant.

EXOSTOSIS, MEDULLARY; irregular, moderately hard, with admixture of softer material, sometimes malignant.

OSTEO-SARCOMA; tuberculated, irregular, moderately hard, somewhat variable in size, connected with bone, sometimes malignant.

SCROFULOUS LYMPHATIC GLAND; not hard, nor tender, nor painful, lying in chains or clusters, sometimes suppurating.

SCIRRHOUS LYMPHATIC GLAND; non-malignant, smooth, regular, moderately hard, moveable, not painful, colourless.

MALIGNANT SCIRRHOUS LYMPHATIC GLAND; of cartilaginous hardness, painful, aggregated.

FUNGOID LYMPHATIC GLAND; soft, painful, red, not suppurating, malignant, connected with abdominal disease.

SCROFULOUS MAMMA; superficies smooth, circumference irregular, not discoloured, sensible nor painful, occurring in early life.

CHRONIC MAMMARY TUMOUR; hard, moveable, regular, of small size, not painful, nor malignant, occurs in early life.

ADIPOSE BREAST; a luxuriant growth of the cellular and adipose substance, not malignant.



**FUNGOID BREAST**; soft, diffused, painful, of rapid growth, ulcerates and bleeds, occurs in young persons, malignant.

**SCIRRHO-CANCEROUS BREAST**; hard, at first moveable, afterwards less so, burning, lancinating, red, ulcerating, affecting various organs, malignant.

**SCIRRHOUS PAROTID**; knotted, hard, irregular, painful.

**GOITRE**; a soft tumour of the thyroid gland, occupies the anterior middle region of the neck, not painful, discoloured, nor malignant.

**SCIRRHOUS THYROID**; a hard, painful, malignant tumour, attaining a considerable size.

**CANCER OF THE SCROTUM**; a warty excrescence, followed by cancerous ulceration of the skin.

**HYDROCELE**; a rounded, smooth, undulating, translucent tumour within the scrotum and tunica vaginalis testis.

**HEMATOCELE**; a tumour composed of blood, within the tunica vaginalis testis, or tunica albuginea.

**CHRONIC ENLARGEMENT OF THE TESTICLE**; a hard, irregular swelling, without pain, affection of the cord, or constitutional disease.

**SCROFULOUS TESTICLE**; an enlargement connected with a scrofulous habit, not commonly painful, often suppurating, and forming a fistulous ulcer.

**FUNGOID TESTICLE**; a painful tumour, of irregular form, not hard, affecting the spermatic cord, throwing out a luxuriant, bleeding fungus, malignant.

**SCIRRHOUS TESTICLE**; a rare and malignant disease, attended with great hardness.

**CANCER OF THE LIP**; a cuticular crust, with a thickened cutis, afterwards ulceration and induration of lymphatic glands of the neck, malignant.



**PSORIASIS LABIALIS** ; a very thick crust of the lip, often separating and regenerating, not malignant.

**CANCER OF THE TONGUE** ; a foul, irregular, raised ulcer, beginning with a pimple or an induration.

**CANCER OF THE EYELIDS** ; a malignant ulceration, beginning with a scale or crust extending to the globe of the eye.

**SCIRRHUS OF THE EYE** ; a hard, painful, malignant thickening of the membranes.

**FUNGOIDES OF THE EYE** ; soft, painful, affecting the humours and coats, throwing out a bleeding fungus, involving the surrounding parts and the constitution.

**MELANOSIS** ; a black, firm, fibrous excrescence, malignant and non-malignant.

**ERECTILE TUMOUR** ; consists of small blood vessels, susceptible of extraordinary distension.

**ARTERIAL NÆVUS** ; a congenital, erectile tumour, composed mostly of small arteries, accompanied with a discolouration of the skin.

**VENAL NÆVUS** ; a congenital, erectile tumour, consisting principally of veins, which are seen through the skin, without discolouration.

**ANEURISM** ; a dilatation of an artery, produced by blood, and attended with a pulsation.

**ANEURISM BY ANASTOMOSIS** ; a tumour composed of minute arteries, accompanied with a vibratory sensation or thrill to the finger.

**VARIX** ; a tumour composed by an enlarged vein.

**VARICOCELE** ; an enlargement of the spermatic veins, having the feeling of a folded cord.

**ANEURISMAL VARIX** ; a dilatation of a vein, from the blood of an artery thrown into it, attended with a pulsation.

**CYST** ; a sac of various consistence, covering a solid, or containing a fluid.

**HYDATID** ; a cyst containing water.

**ACEPHALO-CYST** ; a hydatid possessing vitality, constituting an entozoary animal.

**ENCYSTED TUMOUR** ; a membranous sac containing a fluid, or semi-fluid, either caseous, gelatinous, flocculent, sanguineous, or aqueous, commonly distinguishable by its undulatory movement.

**MEMBRANOUS POLYPUS** ; a tumour of the mucous membrane, covered by a white shining coat, and composed of a fluid in small cells.

**FIBROUS POLYPUS** ; a striated tumour of the mucous membrane, of great tenacity.

**FUNGOUS POLYPUS** ; a red tumour of the mucous membrane, bleeding readily, malignant and non-malignant.

















