

**An investigation into the microscopic anatomy of interstitial nephritis :
being a gold medal thesis for the degree of M.D. in the University of
Edinburgh / by Bryan Charles Waller.**

Contributors

Waller, Bryan Charles.
Francis A. Countway Library of Medicine

Publication/Creation

Edinburgh : E. & S. Livingstone, [1878?]

Persistent URL

<https://wellcomecollection.org/works/hfpy46x5>

License and attribution

This material has been provided by This material has been provided by the Francis A. Countway Library of Medicine, through the Medical Heritage Library. The original may be consulted at the Francis A. Countway Library of Medicine, Harvard Medical School. where the originals may be consulted. This work has been identified as being free of known restrictions under copyright law, including all related and neighbouring rights and is being made available under the Creative Commons, Public Domain Mark.

You can copy, modify, distribute and perform the work, even for commercial purposes, without asking permission.


**wellcome
collection**

Wellcome Collection
183 Euston Road
London NW1 2BE UK
T +44 (0)20 7611 8722
E library@wellcomecollection.org
<https://wellcomecollection.org>


INTERSTITIAL NEPHRITIS





BRYAN CHARLES WALLER




561 - 574









With The Author's Compliments


AN INVESTIGATION
INTO THE
MICROSCOPIC ANATOMY
OF
INTERSTITIAL NEPHRITIS;

BEING
A Gold Medal Thesis
FOR THE DEGREE OF M.D. IN THE UNIVERSITY
OF EDINBURGH,

BY
BRYAN CHARLES WALLER, M.D., F.R.C.S. (Ed.)
LECTURER ON PATHOLOGY IN THE SCHOOL OF MEDICINE, EDINBURGH.

Αἴλινον αἴλινον εἶπὲ τὸ δ' εὖ νικάτω.
ÆSCH.: *Agam.*, 121, 159.

EDINBURGH: E. & S. LIVINGSTONE
57 SOUTH BRIDGE AND 15 TEVIOT PLACE



25143 Bi

Printed by Porteous and Denholm

for

E. & S. LIVINGSTONE, EDINBURGH

LONDON } SIMPKIN, MARSHALL, AND CO., BAILLIERE,
 (TINDALL, AND COX, AND DAVID BOGUE

DUBLIN FANNIN AND CO.

17 E. 277.

PREFACE.

THE following monograph comprises the substance of a Thesis presented to the Medical Faculty of the University of Edinburgh for the degree of M.D., which was fortunate enough to be deemed worthy of the award of a Gold Medal. It is therefore with the greater confidence that the Author now submits it to a more extended audience of his professional brethren.

The original Thesis was illustrated by a large number of water-colour drawings, and by more than two hundred and fifty microscopical preparations, derived from twenty-five distinct cases of interstitial nephritis. The Author has since examined specimens from fifteen additional cases, which have further served to confirm the results he had previously arrived at. It will thus be seen that the views now advocated are based on the evidence afforded by about forty specimens of interstitial nephritis, comprising every stage of the lesion, from the most incipient to the most advanced. Specimens from three cases of glomerulo-nephritis were submitted with the Thesis, and two more have been examined subsequently; these cases being found not only interesting in themselves, but valuable also from the important side-light which they cast on the histogeny of the ordinary varieties of interstitial nephritis.

The Author's thanks are due to his friend Mr James Rodger, M.B., Pathologist to the Aberdeen Infirmary, for

many fine specimens, and much welcome courtesy ; to Mr A. B. Stirling, Sub-Curator of the Anatomical Museum of the University of Edinburgh, for one or two valuable hints on histological technique, and for a reference on the subject of the anatomical structure of the glomeruli ; to Mr D. J. Hamilton, for several good specimens of granulation tissue, and for a receipt for logwood staining fluid ; to Mr Charles A. Doyle for the transference of two drawings to the wood ; to his late class assistant, Mr James Ryan, for two drawings ; and to Miss E. P. Burton of Morton House, for care and pains in the faithful execution of the engravings.

In concluding his Preface, the Author would venture to recall to the minds of friendly critics a certain saying of old Dan Chaucer's, applicable alike to the works of the disciples of the Apollo Iatros, as to those of the votaries of his more brilliant alter ego, the Musagetes :—


“ For every word men may not chide or pleine,
For in this world certain ne wight there is
That he ne doth or sayth sometime amis.”

TO THE MEMORY
OF
THOMAS LOVELL BEDDOES, M.D.
POET AND PHYSIOLOGIST,
PROFESSOR-ELECT OF THE UNIVERSITY OF ZURICH
AND
AUTHOR OF "THE BRIDE'S TRAGEDY,"
THIS WORK
IS AFFECTIONATELY AND REGRETFULLY DEDICATED
BY
HIS YOUNGER BROTHER IN MEDICINE AND SONG
THE AUTHOR.

—o—

Ἄρχετε Σικελικαὶ τῷ πένθεος, ἀρχετε Μοῖσαι.
αἰ αἰ ταὶ μαλάχαι μὲν ἐπὰν κατὰ κᾶπον ὄλωνται,
ἢ τὰ χλωρὰ σέλινα, τό τ' εὐθαλὲς οὖλον ἀνηθον
ὑστερον αὖ ζῶντι, καὶ εἰς ἔτος ἄλλο φύοντι·
ἄμμες δ' οἱ μεγάλοι καὶ καρτεροὶ ἢ σοφοὶ ἄνδρες,
ὁππότε πρῶτα θάνωμες, ἀνάκοι 'ν χθονὶ κοίλα
εὐδομες εὖ μάλα μακρὸν ἀτέρμονα νήγρετον ὕπνον.

MOSCHUS: *Elegy on Bion.*





INTERSTITIAL NEPHRITIS

CHAPTER I.

INTRODUCTORY.

MANY and various have been the views which, from the days of Dr Bright down to our own time, have been broached respecting the morbid anatomy of the small red granular, or contracted kidney. Theories "near the mark, or farther from the mark, or even altogether far away from any mark," of these, as Carlyle says, "there have been enough." The literature of the subject is extensive, and includes papers of all degrees of merit, some of them chiefly noticeable on account of the daring and poetic imagination evinced by their authors, who with the eye of faith behold appearances otherwise invisible to mortal ken; some, on the other hand, rich in observation and research, and bearing that unmistakable imprint which long and careful study never fails to bestow. Other writers, again, probably with a view to the conservation of energy, have adopted at second hand one or another of the plentiful stock of ready-made theories, dressing and bedizening the changeling in accordance with their several tastes, without troubling themselves in the least with superfluous inquiries into the legitimacy of its parentage. These, in too many cases, are blind men led by the blind; and it is to be feared that the ditch is but too often their ultimate, and perhaps not uncongenial, resting-place. Thus it is not to be wondered at, if a large percentage of the dissertations on the nature of the contracted kidney are worth precisely the paper they are printed on, and are valuable chiefly to the butterman as envelopes for his unctuous wares. Well would it be, if being worthless, they were also harmless; but such is not the case, for the bewildered learner or busy practitioner

with no opportunities for actual observation, is swept away by contending currents of opinion into a whirlpool of conflicting authorities, and there abandoned, like a ship without a rudder, tossed about by every wind of doctrine. For the student, too, there is yet another danger — there are the sunken rocks of examinations; and as examiners are but men, and for the most part each one strives, pilot-like, to steer the medical aspirant into their own pet harbour of theory, 'tis oftentimes more by good luck than good guidance if the victim's ribs and keel are not grazed in the process by some theoretical reef, capable of working very practical damage. Fully aware, therefore, of the harm done to the cause of science by those who add to its literature without just cause, due thought, and assiduous labour; who build upon its foundations a superstructure of wood, hay, and stubble, when gold, silver, and precious stones lie ready to their hands, it has been the author's earnest endeavour, throughout the present investigation, to form no crude opinions, to promulgate no groundless theories, and to rush into no hasty and ill-digested generalisations. How far he has succeeded must now be determined by the arbitrament of others, to whose judgment the author, hopefully, yet somewhat diffidently, commits the results of the constant labour of about two years. One thing, however, he can confidently aver—that, whatever be the value of his conclusions, they have, at least, been arrived at independently; for, though not overweeningly confident in the light of his own lantern, he has, at any rate, the satisfaction of knowing, that in following its guidance, he has been pursuing no will-o'-the-wisp. Throughout the whole research he has striven to think for himself, and to divest his mind of any previously acquired predilections in favour of one theory or another; and though necessarily obliged to cultivate an acquaintance with the works of others, he has never, consciously, adopted their views, save when in accordance with the testimony of his own experience and the evidence of his own eyesight. It has been his object to take nothing upon trust, and to adopt as his own the motto of erudite and cultivated Horace, who preferred to manufacture his ideas at home, and to be "*Nullius addictus jurare ad verba magistri,*" rather than save himself the trouble of independent reflection, by accepting those so assiduously, yet so fruitlessly, instilled into him by the worthy "*plagosus Orbilius.*"

The chief microscopical powers employed in the course of this investigation have been Hartnack's objectives, 3 and 7, and his oculars, 3 and 4; Baker's 1-inch, $\frac{2}{3}$ -inch, and $\frac{1}{4}$ -inch objectives, with oculars A and B; and for very high magnifying powers, Hartnack's objectives 8 and 9, and Ross's $\frac{1}{8}$ -inch. Two stands have been used—a full-sized one of Ross's pattern, and a small and extremely convenient one by Bryson of Edinburgh, after a design by Swift. A word or two seems advisable on the subject of the accompanying drawings. Accuracy rather than artistic merit has been the author's aim, and this, he believes, he has attained. Great pains have been taken to ensure their being as nearly as possible *fac-similes* of the objects as seen through the microscope.* Most of the microscopic sections which furnished the materials for this Thesis were cut with the freezing microtome, and are, in some instances, of a size which may well be termed enormous, often including the whole of the kidney substance, from capsule to papilla. The continuity thus obtainable will be easily seen to be of immense advantage to the histologist, in that it enables him to direct his attention to a large connected area, and thus more accurately to appreciate the distribution of the pathological changes over different portions of the organ under examination. In addition to this, sections so cut, though of such a size as to look like tracts of country under a high power, are surprisingly uniform in thickness, thus affording a flat field instead of one full of hills and hollows, as is the case with even the best sections cut by other means. The introduction of the freezing microtome has created a revolution in histology; and the present author is more fortunate than many of his predecessors in having been able to avail himself of its aid. How in any other way could sections be cut measuring an inch and a-half across, and of mathematically regulated thickness—sections, in fact, absolutely perfect for the purposes for which they are designed? And yet the author has quite recently seen a book or paper—he forgets which—in which the freezer was condemned as useless! May one be pardoned the thought, that the fault

* This Thesis was originally illustrated by about sixty coloured drawings; but owing to the great expense of engraving, the Author has only been able to reproduce a small selection from them. It is hoped, however, that enough are included to render the text of the Thesis intelligible. The whole of the original drawings have been deposited in the Library of the University of Edinburgh.

lay, perhaps, not so much with the tool as with the workman? Like most other things worth doing, section-cutting cannot be learned by the light of nature; but a little practice will soon render any one not intolerably clumsy an adept in the art.

CHAPTER II.

ON THE METHODS OF PRESERVATION, PREPARATION, STAINING, AND MOUNTING OF SPECIMENS.

As certain methods of preparation, and the use of various reagents have been sometimes not unreasonably credited with the production of pseudo-pathological appearances, the author proposes in the present chapter to give a short account of the different processes to which his preparations were subjected, in order to eliminate as far as possible all chance of error in this direction.

In most cases the fresh specimen was cut into pieces, and hardened, first for a fortnight or so in Müller's fluid, and next transferred to a $\frac{1}{4}$ per cent. solution of chromic acid, where it has been suffered to remain until properly hardened. Better results are thus obtained than by placing the specimen directly in chromic acid, which does not penetrate so well as the bichromate, and is apt, especially if the pieces are large, to cause hardening at the circumference, while the centre remains nearly unaffected. This untoward result is obviated by the previous use of Müller's fluid, which saturates the tissues completely, and acts as a pioneer for the chromic acid. On the other hand, it is not advisable to trust to Müller's fluid alone, as kidney so prepared is scarcely ever sufficiently hardened, and almost always cuts badly, the epithelium being disturbed in the tubules, and the microscopic appearances thus rendered untrustworthy.

Chromic acid specimens often evince a great tendency to resist the effects of carmine staining. Though left for an hour or upwards in strong carmine solution, it will generally be found that almost all the dye comes off on washing. This, were there no means of obviating it, would be of itself an

almost fatal objection to the employment of chromic acid as a hardening agent; for experience has convinced the author that preparations containing carmine are the most suitable pigments for staining kidney substance. Fortunately, the remedy is easy and effectual. The water in which the sections are washed after staining, should be slightly acidulated with a few drops of 1 to 8 solution of acetic acid. This admixture prevents the washing off of too much carmine, and at the same time brightens the colour, and renders it more agreeable to the eye. But while avoiding the Scylla of washing off too much of the dye, we must be careful not to fall into the Charybdis of acidulating the water too strongly, as in that case the sections will be far too deeply and coarsely coloured to admit of examination under high powers. Diffuse colouring is to be avoided: the carmine should stain only the nuclear tissues (protoplasts), leaving the general stroma comparatively untinged. Under low powers delicately stained sections do not look, perhaps, so distinctive as those which have retained more of the colouring matter; but with a power of 300 diameters or upwards (such as Hart. oc. 3, obj. 7), these specimens come out beautifully, whereas the heavily coloured ones are well-nigh entirely useless.

The principal staining reagents employed during this research were carmine, picro-carmine, logwood solution, and one-half per cent. osmic acid solution. We shall say a word or two on each of these.

Osmic acid, besides blackening fat, is also a general staining reagent of great delicacy. It tinges the outlines of cells, and defines the boundaries between different structures. When he first began to work on the kidney, the author was accustomed to use it alone; but afterwards, seeing how admirably sections thus stained bore further colouring with carmine, he has latterly had recourse largely to this method of double staining. The sections are left for an hour in one-half per cent osmic acid solution, then taken out and washed, floated upon a slide, and covered with strong carmine solution, in which they are likewise allowed to remain an hour. They are then washed in acidulated water, again placed on a slide, and mounted. If more acid is mixed with the water, they will stain sufficiently with carmine in from fifteen to twenty minutes.

It has been said that osmic acid will only stain fresh specimens; but this is a mistake, for it acts with great beauty

and certainty even on specimens hardened in chromic acid. The staining, slight at first, deepens and improves on mounting and exposure to light.

Strong carmine and logwood solutions have been used throughout this investigation. The author has had some experience of weaker fluids, but has not been compensated by any appreciably more satisfactory results for the extra expenditure of time and labour entailed by their employment.

The following is the formula of the carmine solution:—

Carmine, purest	ʒi.
Strong ammonia	ʒi.
Water	ʒiv.

Make the ammonia and the carmine into a paste in a mortar, and then add the water.

This fluid stains most tissues in from five to twenty minutes, but chromic acid preparations often require longer. If the pigment tends to precipitate, the fluid should be filtered.

Logwood staining is especially useful for low powers, but is usually inferior in delicacy to carmine; though sometimes from some unknown cause, the colouring is very delicate and beautiful, and shows well under a power of 300 diameters or upwards.

The chief difficulty with logwood is to procure a good solution. Martindale of London manufactures a satisfactory one; but the following receipt, for which the author is indebted to Mr D. J. Hamilton, Pathologist to the Royal Infirmary, Edinburgh, is perhaps the best he has ever worked with. Much, however, depends on the quality of the extract used in its preparation:—

Formula.—Finest Extr. Hæmatox. (in cake) ʒii.

Alum Sulphate grs. xx.

Dissolve in 20 oz. of water, letting the mixture stand for a week, and shaking every day. Then filter, add 10 oz. of glycerine, and evaporate away one fourth of the liquid: if the colour precipitates, add a few grains more alum. While hot, add ʒi. of pure refined carbolic acid.

This solution stains in from three to seven minutes; but a better result is obtained by allowing the tissue to remain in the fluid for fifteen minutes or so, and then removing the excess of colouring matter with glacial acetic acid, which washes out diffuse staining, leaving only protoplasts affected

by the colouring matter. After being dyed, the section should be washed in water, floated out quite flat on a slide, and covered with glacial acetic acid by means of a glass rod. When its deep purple colour changes to a sort of dirty brown, it should again be thoroughly washed, and then mounted. If the logwood fluid be weak, or of inferior quality, dilute acetic acid (1 to 8) should be used instead of glacial, as the strong acid may in that case remove the colour entirely.

Picro-carmin, when well prepared, after Ranvier's receipt, is a very valuable reagent. It may be used either alone or with osmic acid. Picro-carmin is especially useful in determining the *quæstio vexata* as to which coat of the renal arteries is hypertrophied in interstitial nephritis.

Most of the preparations were mounted in thick Farrant's solution, though Rimmington's glycerine jelly was used in a few instances. Dammar was sometimes employed for mounting injected preparations; but it is not suitable for the general demonstration of kidney, as it renders the tubules too transparent. But one section was mounted in pure glycerine, and this only with a view of showing how misleading are the effects produced by this preservative. Indeed, the author believes, as will be stated in an ensuing chapter, that had Sir William Gull and Dr Sutton used Farrant's solution instead of glycerine and camphor water in the mounting of those preparations which gave rise to the formation of their well-known "Arterio-Capillary Fibrotic" theory, a serious modification, not to say radical change, might have been effected in their views.

Every specimen was stained and mounted with the author's own hands,* the utmost care being taken not to tear or otherwise alter the appearance of the section by rough and careless usage.

A few sections of injected cat's kidney, illustrative of certain points in the normal anatomy, were made by hand with a long sharp thin-bladed knife. The kidney from which they were cut had been kept for a long time in spirit, and was so brittle as to cut badly in the freezer, though the author has since been able to freeze and cut kidneys so over-

* Some few of the preparations were hardened when they came into the Author's possession, and several were actually ready cut; but the Author is able to state that the method of hardening was in every case identical with that detailed above.

hardened, with extreme ease, by soaking them for several days in strong gum water. The best pattern of hand section knife much resembles the so-called "Brain Knife" in an ordinary *post-mortem* case. Such an instrument is far preferable to the clumsy razor still in general use, the blade of which is too short and unwieldy for such delicate work. The blade of the section knife should be well wetted with alcohol, and the tissues to be cut embedded in some suitable substance, such as waxy liver. If, however, this not omnipresent substance is not forthcoming, a mixture of paraffin and oil of cloves, or, in default, a piece of common carrot, will yield an available substitute. The carrot should not be stringy, or the knife will suffer. Hand section knives should be made of special temper, very thin in the edge, and flat on both sides of the blade, which should be of sufficient length, perfectly straight, and rather more than half-an-inch broad. Special care should be bestowed on their setting, as, if blunt, they not only waste the tissue to be cut, but seriously damage the good temper of the operator. They are favourites with surgical instrument makers, for they cost a small fortune to keep in order. What is sharpness in any other knife, is bluntness in them; they are necessary evils, as the Dean of St Patrick's said of servants. But necessary they are, and will be, for all the more delicate and friable tissues, until Time, Chance, or Ingenuity, discover some new and improved method of hardening.

CHAPTER III.

ON CERTAIN POINTS RELATING TO THE HISTOLOGY OF THE NORMAL KIDNEY.

It would serve no useful purpose to devote much space in the present dissertation to the consideration of the histology of the normal kidney, as the subject has been already amply and ably treated by many competent authorities, whose writings are easily accessible. Among these the author may mention the following works, which he has himself had occasion to consult :—

1. "Quain's Anatomy," 8th edit.
2. Bowman, Phil. Trans., 1842.
3. Beer, Die Binde-substanz der menschlichen Niere.
4. Rindfleisch, Path. Hist., Syd. Soc's. Trans., vol. ii.
5. Stricker's Histology, Syd. Soc's. Trans., Art. Kidney.
6. Klebs, Handbuch der Path. Anat., Lief. iii.
7. Chrzonszczewsky, Virch. Archiv., 1864.
8. Southey, Barth. Hosp. Reports, 1865.
9. Henle, Zur Anat. der Nieren, Gott., 1862.
10. Henle, Handbuch ———.
11. Heidenhain, Arch. fur Mikrosk, Anat., 1874.
12. Ludwig and Zawarykin, Weiner Acad. Sitzungsbericht, vol. 48.
13. Schweigger-Seidel, Die Nieren des Menschen und der Säugethiere.

There are, however, one or two points of special interest to the morbid anatomist which seem to demand some little notice at this stage of our inquiry, as ignorance or disregard of them has proved a fruitful source of all kinds of errors in the study of pathological conditions, in that some writers have been thereby betrayed into the mistake of attributing strictly normal appearances to the results of disease. And here it may not be thought out of place to bestow a word of condemnation on the practice which is, we fear, but too prevalent, of attempting to study the pathology of an organ without any precise acquaintance with its healthy structure. A practitioner who is the fortunate owner of a large and expensive microscope, fitted up with costly lenses, and apparatus procured regardless of expense, is but too apt to think that the mere possession of such an instrument is of itself sufficient to render him an accomplished histologist. One might as well suppose that the difference between an artist and a dauber lay in the completeness and excellence of their respective pictorial armamentaria. A long apprenticeship of careful observation is imperatively required of the histologist who would do work worth the performance. With heart and mind, with strength and purpose, he must address himself to his task; the normal anatomy of an organ must be mastered before proceeding to the pathological;—the eye as well as the mind must be trained to observe and discriminate. No amount of simple reading and listening to lectures will make a pathologist who, when made, will repay the cost of manu-

facture. Actual contact with facts is the one and only means of appreciating their significance. For well says the trite old adage:—

“*Segnius irritant animos demissa per aures
Quam quæ sunt oculis subjecta fidelibus.*”

There is no royal road to histological proficiency; we must be normal anatomists first, and pathological anatomists afterwards; the scientific fledgeling cannot, chicken-like, run almost ere his beak has chipped the shell; he must crawl first, and crawl very slowly sometimes. Nor does it at all follow that because a man is an excellent physician, he is also a competent pathologist. He may be so, and indeed ought to be so; but proficiency in the one branch cannot be taken as evidence of corresponding attainments in the other. But to resume.

We shall glance very briefly at a few facts connected with—(1.) The Renal Tubules; (2.) The Renal Connective Tissue; (3.) The Renal Vessels.

1. THE TUBULES.

IN almost every drawing the author has seen, the calibre of the tubules, especially the convoluted ones, has been represented as far too wide. Normally, it is but narrow, and is often apparent only as a kind of three-cornered star on the end of a seemingly solid cylinder. (See Turner's Anatomy, engraving, page 789.) By far the greater portion of the interior of the tubules is occupied by epithelium; and if their lumen appears wide, it is owing to the partial falling out of the epithelium during the preparation of the section. Almost any good preparation of normal kidney will serve to demonstrate this fact; and it is indeed generally admitted, but almost as generally, we fear, ignored. Some little time ago this narrowness of the calibre of the uriniferous tubes formed the topic of a conversation between the author and a clever pathologist who cultivates a somewhat rude and dogmatic style of assertion. “Pooh,” said this gentleman, “it's a well-known fact.” “True,” replied the author, “but why then is it not a well-remembered fact?” If we consider for a moment the issues which depend upon it, we shall not be disposed to underrate its importance. It vitally affects Dr Johnson's theory, which we shall frequently have occasion to allude to in the ensuing pages, and it has continually led to mistaken ideas as to the blocking up of healthy tubules. We

would also call attention to another normal appearance of no less moment, namely, the natural granularity of healthy renal epithelium.

2. THE RENAL CONNECTIVE TISSUE.

THE existence of connective tissue in the kidney, which was first described by Bowman and Goodsir, has been denied by some writers, but is now universally recognised by all the best authorities. (See Beer, Rindfleisch, Klebs, and *Art. Kidney* in Stricker's *Histology*.) The renal connective tissue is distributed along with the vessels in the same manner as in the liver. It contains cell-elements, fibres, and, according to Ludwig, lacunar spaces in connection with the lymphatic system. Rindowski also mentions lymphatics with complete endothelial walls (*Centralblatt* 69, sec. 145). Delicate connective tissue processes pass inwards from the capsule into the substance of the cortex, which become much enlarged on the supervention of interstitial changes. Connective tissue is likewise present in the glomerulus, binding together the capillary loops, as first noticed by Axel Key. In proof of the existence of this connective tissue, may be cited the fact mentioned, the author believes, by Hyrtl, that the glomerulus, on being picked out from the surrounding tissues, does not collapse, but retains its pristine form. Among the connective tissue of the glomerulus are a number of rounded cell-elements, situated between the vascular loops, which cellular bodies become greatly increased in number in that post-scarlatinal affection of the kidney to which Klebs has given the name of Glomerulo-Nephritis. These bodies are not merely cells from the epithelial covering of the glomerulus, but true connective tissue corpuscles, as proved by the fact that they are found lying, not only on the circumference of the glomerulus, but also in its substance, between the individual capillary loops. A demonstration of their anatomical site can be obtained by placing an injected glomerulus on a slide with a drop of water, and then squeezing it out by pressure under a rather thick cover-glass. Logwood stains them a deep violet.

3. THE RENAL VESSELS.

As before stated, the arteries of the kidney are accompanied by processes of connective tissue, distributed in a

manner similar to that observed in the liver. A kind of spurious adventitia is thus formed, immediately external to the adventitia proper, which is very thin. (See paper by Dr Ringrose Atkins, *Brit. Med. Jour.*, April 3, 1875.) On picking out a normal renal arteriole from its surroundings, this spurious adventitia adheres to it as a shreddy, ragged investment. It is this spurious adventitia, and not, as supposed by some, the real outer coat of the arteries, which is primarily enlarged on the occurrence of interstitial changes. This point will be fully dealt with hereafter, and need not therefore be further discussed at this stage of our inquiry. In the normal kidney, the glomerulus never entirely fills the space inside Bowman's capsule.

Preparations of injected cat's kidney are useful, as affording a general idea of the normal structure of the renal vessels, especially if mounted in dammar, which renders the tubules transparent, and thus brings the injected vessels into greater prominence. The author has made many attempts to use the far more delicate silver injection, but never hitherto with much success. Thinking the failure might be due to the action of the urine salts, especially the chlorides, upon the silver fluid, he, in several instances, carefully washed out the vessels with distilled water, and with distilled water acidulated with nitric acid, previously to the introduction of the silver injection. This, however, did not answer the desired purpose, and although he has not abandoned the idea, he has not, up to this time, been able to accomplish it successfully. Perhaps this failure may have been partly owing to the animals (chiefly cats) having been killed before injecting the silver salt; for although the injection was always performed with the utmost expedition, and with every precaution, such as the immersion of the body in warm water, there may have been time for the loss of some of that textural vitality, in the absence of which experience has shown that attempts at injection with silver are invariably futile. Were he free to follow his own ideas, the author would be inclined to try again on the living animal; but considering the present state of the law in this country, it is not likely that the opportunity will be afforded him for some time to come. It is true that by flight into Germany and France, distressed seekers after forbidden knowledge may find countenance and refuge at the price of temporary expatriation; but, unfortunately, now,

as of old, it is equally true that, "Non cuivis homini contingit adire Corinthium." A little rest, a little slumber, a little folding of the hands to sleep, this is the destiny to which English Science is now consigned. So, to alter Longfellow's lines, her votaries must learn to wait, since they are not allowed to labour. Probably they may have ample leisure to cultivate the virtue of patience. Charles Lamb has shown, in his delightful Essay on Roast Pig, how many hundreds of years elapsed before the pig-tailed celestials became convinced that a general domiciliary conflagration was not absolutely essential to the proper culinary preparation of that savoury animal, the form and fashion of whose caudal extremity they have so industriously copied in their own persons since the days of Confucius; how much longer, then, will it take, before the elimination of the perennial porcine and asinine elements from our British Houses of Parliament is at last successfully accomplished? We will leave the reader to muse on this distant contingency.

CHAPTER IV.

HISTORICAL RÉSUMÉ.

THE compilation of a complete bibliographical record of all the descriptions and theories, good, bad, and indifferent, which, since the days of Bright, have been given to the much-enduring medical world on the subject of Interstitial Nephritis, would be a task alike beyond the range of the author's reading, and the limits within which he would fain confine the proportions of the present treatise.

It has, however, occurred to him that a short exposition of the views of a few of the leading British and Continental authorities might not only prove interesting from a historical point of view, but instructive also, as evidencing the very different conclusions drawn by various observers from the same facts. These theories are all, of course, more or less coloured by the different pathological systems predominant

at the time of their first promulgation; but many of the older ideas have displayed a curious vitality, and, at the present day, still continue to be firmly held, notwithstanding the manifold changes which later discoveries have wrought in the complexion of pathological science. The new light thrown of late years upon the process of inflammation has, however, induced many to adopt explanations of the morbid appearances, very different from those which would have been considered tenable before the researches of Virchow, Lister, Cohnheim, Stricker, Recklinghausen, Ludwig, Klein, and many other modern investigators. We shall omit all mention of those authors who, without committing themselves to any particular theory, confine themselves to a mere enumeration of microscopical appearances, as the differences between their several descriptions are so slight and unimportant, as not in any way to affect the question of the true nature of the morbid process. For instance, some authorities describe the colour as red, others as pale, whereas, in point of fact, like the disputants who quarrelled over the colour of the chameleon, both are right, and both wrong, the colour being a matter simply dependent on the presence or absence of mechanical hyperæmia. The essential pathological conditions become visible only by the aid of the microscope, which alone reveals those minute structural alterations of the kidney substance wherein they consist. Upon these alterations two distinct interpretations have been put, and it is possible, therefore, to make a primary sub-division of the theorists into two classes — firstly, those who hold that the primary and essential lesion has its seat *inside* the uriniferous tubules; and secondly, those who consider that the primary alterations are to be referred rather to the interstitial tissues, all intratubular changes being secondary to, and consequent on, certain primary interstitial changes. Among those who hold the former opinion, may be mentioned Johnson, Simon, Frerichs, Niemeyer, Todd, and Lebert; whilst of those who advocate the latter, Rindfleisch, Beer, Klebs, Dickinson, Grainger Stewart, Green, and Jones and Sieveking (in the latest edition of their work, edited by Payne), are the most conspicuous.

Besides these two very distinctly opposed schools, there is another and smaller one, the members of which are disposed to consider the diseased state as originating in the renal vessels. Sir William Gull and Dr Sutton on the one hand,

and MM. Cornil and Ranvier on the other, may, though differing much among themselves, be grouped together under this last head.

DR GEORGE JOHNSON'S VIEWS.

DR JOHNSON maintains that the primary changes, which lead to the formation of the "small red granular kidney" (which, by the way, is oftener pale than red, and in the early stages is enlarged, instead of diminished in size), consist in destructive alterations of the epithelium of the uriniferous tubules, due to the circulation in the blood of various morbid products. See *Med. Chir. Trans.*, Vols. XXX., XXXIII., LVI.; *Trans. Path. Soc.*, 1877: *On Diseases of the Kidneys*, 1852; *Lectures on Bright's Disease*, etc.

We quote his own words as taken from the *Pathological Society's Trans.*, 1877, p. 390:—"The primary and essential structural change in the granular kidney consists in disintegration and destruction of the glandular epithelium of the convoluted tubes; the products of this disintegrating process appearing in the urine during life in the form of granular casts of the tubes, and the result is that when sections of the kidney are examined microscopically, while some tubes retain the normal lining of epithelium, others are filled and rendered opaque by epithelium in various stages of disintegration, and others are more or less completely denuded of epithelium, a few granular particles only adhering to the inner surface of the basement membrane. Then, as a result of this destruction of their gland cells, many tubes are seen in different stages of atrophy and contraction, and between these contracting tubes are seen wide spaces, more or less hyaline or fibrous, which are mainly occupied by the atrophied remains of other wasted tubes and capillaries. In some tubes the normal epithelium is replaced by a lining of delicate transparent rounded cells, each with a single nucleus; again, other tubes may be seen in various stages of dilatation into cysts. This process of dilatation goes on until cysts more or less numerous may be seen by the naked eye. The explanation of this cyst formation is probably to be found in the fact that some tubes continue to secrete an aqueous fluid, while their lower portions are plugged by an epithelial débris, and thus they become distended by their own secretion."

He further says that though there may be a little increase of the fibrous stroma, he agrees with Drs Wilks and Moxon in saying that it is "not much." This, though culled from one of his latest utterances, is substantially the opinion first held by Dr Johnson in 1847, in a paper read before the Royal Med. Chir. Society. On the same evening, his then colleague, Mr Simon, read an independent paper on the same subject, the result of his investigations leading him to adopt substantially the same opinions, though Mr Simon "believes the transparent portions of the kidney to be microscopic cysts," while Dr Johnson "interpreted them to be denuded tubes, as they are now generally admitted to be."

As we propose presently to consider Dr Johnson's views at more length, we shall pass them by for the present without further comment.

IEWS OF FRERICHS, NIEMEYER, ETC.

FRERICHS (*Die Brightsche Nierenkrankheit*, 1851) considers the small red granular kidney to be merely the last stage of parenchymatous nephritis, which, he says, passes through the three stages of (1.) Hyperæmia and incipient exudation; (2.) Changes in the exudation; and (3.) Atrophy. Niemeyer (*Text-Book of Practical Medicine*, Humphreys and Hackley's Trans.) agrees practically with Frerichs, though he allows that there is a secondary or concomitant proliferation of the interstitial tissue. He also mentions a primary interstitial nephritis, leading to increase in the fibrous stroma, but this he dismisses in few words as apparently of rare occurrence, and comparatively unimportant. Lebert (*Traité d'Anatomie Pathologique*, vol. ii, page 336), though a general follower of Frerichs, seems to be in doubt whether the atrophied and contracted kidney is not rather a separate form of Bright's disease than a subsequent stage of the parenchymatous variety. He says—"Nous avons surtout confirmé les doctrines que professe Frerichs sur ce sujet." His description of the atrophic form is as follows:—"Dans la troisième forme les canaux et les capsules s'affaissent, le tissu cellulaire de nouvelle formation autour des canaux se contracte et devient cicatriciel, tout l'organe diminue notablement de volume et de poids, la capsule est adhérente, la surface est irrégulière, lobulée, creusée de sillons, les granulations sont nombreuses.

La consistance devient coriace, la substance corticale est surtout notablement réduite de volume, les granulations se montrent aussi dans les pyramides. . . . Les canaux urinifères renferment des épithéliums granulo-graisseux, des grumeaux de graisse, et des granules; les cylindres sont également infiltrés de graisse. Les contours des canaux sont irréguliers, plissés, fibreux; les capsules de malphigi sont remplies de gouttelettes de graisse; beaucoup de capillaires dans les glomérules ont disparu. La substance est pâle, anémique; on trouve quelquefois beaucoup d'éléments fibroplastiques autour des capsules, mêlés de fibres, qui leur donnent un aspect concentrique; le tissu fibreux est parsemé de gouttelettes de graisse." Even in the second form, he allows some increase in the connective tissue stroma;— "Dans la seconde (forme) l'exsudation se trouve dans les capsules, dans le parenchyme, dans les épithéliums, sous forme de granules mêlés de graisse. Une partie des matières exsudées s'organise en tissu cellulaire." See also Lebert's Plates, 140, 141, and 142.

Todd (Clinical Lectures on Diseases of the Urinary Organs, 1857) is more or less a disciple of Johnson, "though the evidence of an inflammatory process having any share in the production of this state of kidney," appears to him "to be very unsatisfactory." He considers that certain abnormal materials contained in the blood are conveyed to the kidney for elimination, and that "in their passage through these glands, the poisonous elements create a highly disturbed state of their nutrition, a state possibly in some degree inflammatory, but chiefly atrophic, the tendency of which is to cause the organs to waste and shrink."

VIEWES OF DICKINSON, RINDFLEISCH, KLEBS, ETC.

DICKINSON (On Albuminuria, 2d edition); BEER (Die Bindesubstanz der menschlichen Niere); RINDFLEISCH (Path. Histology, Syd. Soc. Trans.); KLEBS (Handbuch der Pathologischen Anatomie, Dritte Lief.); GREEN (An Introduction to Pathology and Morbid Anatomy); JONES and SIEVEKING (Pathology, 2d edit., by Payne); and AITKEN (Pract. Med., vol. 2), though differing on some minor points, are all at one as to the essential nature of the morbid process, which they refer to an Interstitial Nephritis, or inflammation of the con-

nective tissue stroma, leading to increase of the intertubular tissue, owing to the presence of a small-cell growth, analogous to granulation tissue, which growth presently undergoes a more or less complete transformation into fibrous tissue. This newly-formed fibrous tissue next proceeds to shrink, and by its contraction compresses the secreting structures, thereby leading to secondary changes in them. Dr GRAINGER STEWART (A Practical Treatise on Bright's Disease of the Kidneys, 2d edition, 1871) while maintaining that the changes are due to increase in the amount of the fibrous stroma, is of opinion that there is no proof of the inflammatory origin of this fibrous increase, and considers it rather in the light of a connective tissue hyperplasia, unconnected with inflammation both as regards origin and course. Dr Stewart distinguishes between this primary interstitial overgrowth, and that secondary hypertrophy of the stroma, consequent on Parenchymatous Nephritis. This last he considers to have its origin, as stated by Johnson, Frerichs, and Niemeyer; while in the case of the true primary interstitial kidney, which he denominates "Cirrhotic," he believes, in accordance with others of his school, that the intratubular changes are secondary to the intertubular overgrowth. The theory of Drs GULL and SUTTON we shall presently discuss in a separate chapter: it is, however, shortly this;—namely, that the kidney changes are but part and parcel of a general morbid state, consisting in the deposit of a "hyalin," or "hyalin-fibroid" material in the adventitia of the arterioles, and of a "hyalin-granular" change in the walls of the capillaries.

MM. CORNIL and RANVIER attribute the change to a chronic arteritis.

There is thus, as we have seen, no lack either of theories or of investigators. On the question of the small red granular kidney it is almost a case of "tot hominum quot sententiæ;" and, besides these prominent leaders of opinion, there is a host of followers on either side. Some of these we shall now very briefly indicate.

Dr Tanner (Practice of Medicine, 6th edit.) appears to endorse the opinion of Dr Johnson; as does also Sir T. Watson in the latest edition of his elegant and classical work.

Dr Bristowe (Practice of Medicine) does not commit himself to any distinct opinion as to the essential pathology, though he allows the reality of the connective tissue hyper-

trophy, and further remarks that the origin is distinctly inflammatory in certain cases.

Drs Wilks and Moxon also give forth an uncertain sound. They say (Pathology, page 510)—“The term chronic desquamative nephritis rests on a supposition as to the origin of the disease, of which there is no sufficient proof. The pathological nature of the change is probably analogous to cirrhosis of the liver, or sclerosis of the nervous centres. Some regard the epithelium as the special seat of the disease; others, the interstitial tissue, which is supposed to increase and compress the tubes; but no sufficient evidence of this is given. From having been often able to trace the shrivelled tubes up to wasted malpighian corpuscles, we are inclined to believe that closure of these corpuscles may be the starting-point of the disease. But all that can be certainly said is that the tubes waste in the manner above described.” Respecting the occurrence of a third or atrophic stage of the parenchymatous variety, they say that though there is no proof of its existence, they do not absolutely deny its possibility. These gentlemen also inform us that the consistence of the interstitial kidney is not tough! Had they the misfortune to be fed on meat of the same consistence for a fortnight or so, they might find cause to alter their opinion; unless, indeed, some beneficent fairy, compassionating their sad plight, were to endow them with a strength of jaw equal to that of Old Father William in Lewis Carroll’s racy piece of nonsense, “Alice in Wonderland.”

Dr F. T. Roberts (Practice of Medicine, page 855) says:—“Most English writers are of opinion that the true cirrhotic kidney is the result of chronic interstitial nephritis, attended with proliferation of the intertubular connective tissue, which becomes much increased, and compresses surrounding structures.” He does not, however, express any positive leaning towards one side or the other, and ends by remarking that “the whole question is at present in a state of great uncertainty.”

Dr Ringrose Atkins (see British Med. Jour., April 3, 1875) and Dr T. J. Maclagan of Dundee, in a paper read before the Medico-Chirurgical Society of Edinburgh (see British Med. Jour., June 26, 1875), uphold Dr Johnson’s conclusions; while in Virchow’s Archiv. for 1877 are two excellent papers, the one by Thoma and the other by Ewald, in which the opposite theory is advocated.

In the midst of such a cloud of conflicting witnesses, it is perhaps no easy matter for the independent observer to keep his head cool, to preserve a judicial frame of mind, and to form and maintain an unbiassed opinion; for the eye is very prone to see what it is led to expect, and the mind is often apt to be unduly influenced by the spirit of partisanship, or by one or another fashionable pathological idea. As some sort of safeguard against this possible untoward influence of precept, the author consulted his specimens first, and the voluminous literature of the subject afterwards. Not till he had carefully examined many dozens of sections, and had begun, as he thought, to see in his own mind the dawn of a well-grounded conviction, did he seek in the works of others either strictures upon, or facts and arguments in support of the conclusions at which he had thus, in a manner independently, arrived. From that time forward, however, he has made constant reference to a great mass of writings; and he trusts that while, on the one hand, he has endeavoured to see and think for himself, yet that, on the other, he has not been heedless or unmindful of those rich stores of information so lavishly garnered up at the expense of the labours of others.

CHAPTER V.

ON GRANULATION TISSUE, WITH REFERENCE TO THE NUCLEAR TISSUE OF INTERSTITIAL NEPHRITIS.

As has been stated in the preceding chapter, Dr George Johnson, and those who agree with him, attribute the appearances seen in the small red granular kidney to the breaking down and disintegration of the uriniferous tubules and their epithelium, which are, in his opinion, alone and entirely responsible for the appearances met with in what is commonly known in this country as Interstitial, Cirrhotic, or Contracted Kidney. Drs Wilks and Moxon also lend a partial sanction to this view (*Path. Anat.*, page 509), stating that there is very little fibrous increase, except in the neighbourhood of the vessels. As Dr Johnson's theory is considered

at some length in Chapter VII. *infra*, we shall content ourselves meanwhile with endeavouring to show the absolute identity of the so-called "nuclear tissue" of interstitial kidney, with that known as "embryonic," "indifferent," or "granulation" tissue, and seen, for example, in the first stage of new formations, in healing ulcers, and in the reparative process in wounds. If Plate i., which represents a portion of granulation tissue taken from a healing ulcer in the human subject, be compared with Plate ii., which represents the "nuclear tissue" from a well-marked example of early interstitial change, the resemblance between the small-cell growths in both instances will at once arrest attention. We shall now proceed to consider whether we can adduce sufficient evidence to warrant the conclusion that both are substantially of the same nature.

On page 11 we made passing mention of the lymphatic spaces and vessels discovered by Ludwig and Rindowski in the connective tissue of the kidney. In this, as in all connective tissue, there are two kinds of cells, stable, and mobile; the mobile being, in all likelihood, leucocytes which have migrated through the vascular wall, passing through the stigmata, and entering the lacunar system of lymphatics. As these lymphatic spaces and vessels play a conspicuous part in interstitial inflammations, it may be well, before proceeding further, to recapitulate shortly a few facts relative to the anatomy of the lymphatic system which bear upon the point at issue.

Note on the Lymphatic System.

Lymph-canals are of two kinds—lymph vessels proper, with a regular endothelial wall, and irregular-shaped lacunar spaces in connection with them, called plasma-canals, or lymph-canalicular systems. They are easily demonstrable by means of nitrate of silver, in the cornea, and in the pencilled diaphragms of young rabbits, cats, and guinea-pigs. In the plasma-canals lie the permanent branched connective-tissue corpuscles of the part, which may be rendered visible by means of Chloride of Gold; but, besides these, the plasma-canals contain a number of mobile or wandering corpuscles, like leucocytes, which are, in fact, white blood-corpuscles which have found their way into the lymph-canalicular system by means of openings in the walls of the blood-vessels and

lymphatics, presently to be described. On the occurrence of inflammation, their number becomes greatly increased. The lymphatic spaces, demonstrated in the kidney by the injections of Ludwig, are simply the plasma-canals of its connective tissue, which here, as elsewhere, contain the stable and mobile corpuscles just mentioned.

On the surface of serous sacs, and in the walls of the lymphatic vessels, are certain openings called stomata. Corresponding openings also exist in the walls of the blood-vessels. They are called stigmata, and are in connection with the lymph-canalicular or plasma-canal system, as are also the stomata of the lymphatics. Thus an indirect communication exists between the blood and lymph-vascular systems proper, by the medium of the plasma-canals, into which open the stomata of the lymphatics and the stigmata of the vessels. Whether lymphatics and blood-vessels ever directly communicate in the tissues without the intervention of a system of plasma-canals, is a point not as yet settled.

The plasma-canals follow the course of the blood-vessels; and when leucocytes pass through the vascular wall, they enter the lacunar system, and become, as before stated, the so-called mobile cells of connective tissue. When the number of these migratory cells is increased by inflammation, they occupy first those lacunar spaces in the immediate neighbourhood of the vessels; and this fact, together with the normally greater amount of connective tissue around the renal vessels, and consequent preponderance of plasma-canals in its substance, serve to elucidate the occurrence of fibrous increase around the vascular walls in Interstitial Nephritis, to a greater extent than in the general stroma.

When interstitial inflammation supervenes in the kidney, an abundant emigration of leucocytes takes place from the vessels into the lacunar system of Ludwig. The inflammation being of a formative character, these leucocytes give rise (either alone, or more probably in conjunction with the fixed corpuscles, which by their division may take some part in the process) to embryonic, indifferent, or granulation cells, which after a time assume the type of more or less fibrillated connective tissue. The nucleus becomes oval, the cell elongates, takes on a lanceolate or fusiform shape, and presently fibrillation occurs, leading to the development of a greater or less amount of wavy fibrous tissue. This fibrillation can be

traced from stage to stage, and is identical with the transformation of the round cells of cicatricial tissue,—so identical, indeed, that the nature of the round-cell tissue in the kidney is matter, not of conjecture, but of almost absolute inferential certainty.

Dr George Johnson has never given any satisfactory explanation of the above facts. A simple negation can hardly be accepted as argument, nor will it, we think, in many cases, suffice to make those of the adverse party distrust the results of their own observation. In typical specimens of the latest stages of the interstitial process, coarse, wavy, fibrous tissue may be found in abundance,—in far greater quantity than can be accounted for by the shrinking together and approximation of that normally present, which is altogether so little as to have led some writers into the error of affirming its entire absence. It should be further remembered, that the normal connective tissue is in great part cellular; though, without doubt, there is an admixture of fibres. Perhaps Dr Johnson may be inclined to admit the fibrillar transformation of the cellular connective tissue present in the normal organ (see *Path. Soc.'s Trans.*, 1877, page 391); but even this concession would be very far from sufficient: for were the appearance of fibrous increase in reality due to contraction consequent on the destruction of the tubular and other secreting structures, the diminution in size of the interstitial kidney,—great though it be in extreme cases,—would, nevertheless, be inadequate to account for the large tracts of fibrous tissue, so evident in many portions of the atrophied organ.

If, then, the fibrous increase be real and not merely apparent, how, according to Dr Johnson's theory, can this increase be accounted for? Dr Johnson avers that there is no fibrous increase, but the testimony of the author's preparations is entirely against him.

Again, it may be argued that the round cells of interstitial kidney are smaller than those of granulation tissue. This objection, however, is not worth much. Granulation cells exhibit great differences in relative size, the largest (excluding giant cells) measuring from about the $\frac{1}{1800}$ th to the $\frac{1}{1800}$ th of an inch in diameter, while the smallest are not more than the $\frac{1}{2500}$ th of an inch, or even less. Their size will differ greatly, according to the amount of fluid present in the tissue containing them; and in the kidney, owing, *firstly*, to the chronic or subacute nature of the interstitial process;

secondly, to the density of the kidney substance ; and *thirdly*, to the drain afforded by the uriniferous tubules, fluid in any appreciable quantity is never met with. Nothing but the nuclei of disintegrated epithelium could in any other way account for the round-cells in question ; and if we take into consideration the fact, presently to be mentioned, that in the first stage of the interstitial process there are positively no intratubular changes observable (see Dickinson On Albuminuria), there is, in the author's opinion, no way of escape from the inevitable conclusion, in favour of which so many valid arguments are forthcoming, while those against it are, for the most part, found on rigid examination to possess no solid basis of probability.

The following is a list of the principal arguments in favour of the interstitial theory. Those which we have not already discussed will be hereafter somewhat fully considered :—

- i. In the first stage of Interstitial Nephritis the kidney is enlarged. Had the process been simply one of wasting and disintegration of the secreting structures, we should expect diminution rather than increase in size.
- ii. In the earlier stages, the intertubular septa are greatly increased in width by the presence of a small-cell infiltration, precisely resembling granulation tissue, which in many parts forms large tracts, very conspicuous even under low powers.
- iii. In the early stages, the tubules, if not actually perfectly normal, in that they are sometimes compressed, are, at all events, easily recognisable ; so that there is little fear of confounding the products of intra-tubular disintegration with those of intertubular cell-infiltration.
- iv. The round cells of the new tissue may be seen elongating into spindles, and differentiating into fibres. They are, therefore, in a condition of growth, not of decay.
- v. Owing to this differentiation, an abundant fibrous increase may be seen in the later stages of marked specimens,—this increase being far greater than could be accounted for by the approximation of the small amount of fibrous tissue normally present in the healthy kidney.

CHAPTER VI.

AUTHOR'S OWN VIEWS.

FROM what has been said in the previous chapter, it will by this time be pretty evident to the reader, that the views of the author are in accordance with those of that school of pathologists which ascribes the appearances constituting the "small red granular," or "interstitial" kidney, to the results of a subacute or chronic inflammatory process, chiefly affecting the cortical substance, and attended with increase of the interstitial tissue. This is the opinion of Klebs, Rindfleisch, Dickinson, and many others; and the results of the author's investigations agree substantially with the conclusions expressed in the works of these authorities.

Briefly, then, he believes that the origin of the morbid process is to be referred to an inflammation, causing an emigration of leucocytes through the walls of the vessels; which leucocytes, either alone, or more probably aided in some degree by the proliferation of the connective tissue corpuscles, give rise to a small-cell formation of the nature of granulation tissue, the cells of which, being at first round, become subsequently spindle-shaped, and are finally converted into fibrous tissue. This process is strictly an Interstitial Nephritis, and by this name he prefers to designate it. For descriptive purposes it will be convenient to divide the interstitial changes into two stages; though it must be understood that all sorts of intermediate appearances are, as a rule, met with in the same specimen, thereby, indeed, affording a necessary proof of the connection existing between those constituting the two ends of the chain. These two stages are—

- (1.) *Stage of Cell-Infiltration :*
or Formation of Granulation Tissue.
- (2.) *Stage of Cell-Transformation :*
or Fibrous Metamorphosis of the Granulation Tissue.

We shall first describe these two stages somewhat shortly, and afterwards consider in detail those points which possess special features of instruction and interest.

I. STAGE OF CELL-INFILTRATION.

(See Plate ii.)

(a.) *Naked Eye Examination.*—Kidney generally heavier than normal; enlarged, sometimes very appreciably; colour pale-whitish; surface smooth; capsule easily detached, congested veins being often noticeable on the surface; consistence soft and doughy, nearly resembling that of the parenchymatous kidney. On section, the cortex is seen to be enlarged, its consistence is doughy, and its colour yellowish-white, and bloodless. (Some observers affirm, on the contrary, that there is no yellowish tinge;—but see Rindfleisch. The colour is, of course, not due to fat.) It has sometimes been described as resembling a section of raw turnip. The Malpighian bodies are red and prominent. The medulla is congested, otherwise unaltered.

Modifications.—According as the process has been more or less chronic, the new tissue is more or less fibrous, and the kidney may be either enlarged or lessened in bulk. The capsule also may be to some extent adherent, and the surface slightly granular. Some specimens are red, owing to passive congestion.

This stage closely resembles the first stage of cirrhosis of the liver, in which the organ is frequently enlarged;—Smooth Interstitial Hepatitis.

(b.) *Microscopic Appearances.*—The capsule of the kidney is seen to be thickened, and is often more firmly adherent than in the normal organ, though sometimes separable with great ease. Stretching inwards from the capsule into the substance of the cortex, are bands of new material consisting of small-celled or granulation tissue. These bands are due to an enormous thickening of the delicate connective tissue processes which normally pass from the capsule into the substance of the kidney.

Tubules and vessels are included in the new tissue, which embraces and constricts them. On examining this nuclear tissue with a high power, it is seen to contain multitudes of round cellular bodies of the nature of leucocytes, in which, under a very powerful lens, a nucleus is sometimes discernable. These cells may also be seen in process of conversion into spindles, and the spindles again undergoing transformation into fibrous tissue. The round cells are

sometimes rather ill-defined ; but in most specimens they are extremely conspicuous. The connective tissue along the path of the renal vessels is increased by a similar formation. These changes are not uniform, some parts of the kidney being much more affected than others. The adventitia of the renal arterioles is in the first instance perfectly normal and unthickened, although the connective tissue following the path of the vessels is, as has been said, increased in amount. The middle or muscular coat of the arteries already presents an appearance of thickening ; while the tunica intima is also affected with that condition described by Heubner under the name of *Arteriitis Obliterans*, which consists in a proliferation of the inner coat, leading to ultimate occlusion of the vessels affected. Wilks, Bristowe, Hughlings-Jackson, and some others, have made passing mention of this lesion ; but to Heubner is due the credit of first investigating it, and bringing it prominently under the notice of the profession.

The tubules are normal, with the exception of those constricted by the new material, which forms a ring around them, lessening their calibre, and leading to subsequent obliteration. Colloid matter is often present in the tubules ; and the glomeruli also are not unfrequently similarly degenerated. Some authorities speak of the colloid material as being of a waxy nature. This, however, is not the case, for it is stained neither by iodine nor by methyl-aniline ; while, on the contrary, it stains with carmine in precisely the same manner as colloid found elsewhere. It is derived from the renal epithelium which after a time degenerates, owing to the pressure exercised on the tubules by the new material. Globules of colloid form inside the epithelial cells, which presently burst, setting free the colloid in the interior of the tubes. The epithelial nuclei appear, as a rule, to resist the colloid change, for they are often seen arranged round the inside wall of a tubule filled with colloid, adhering more or less closely to the basement membrane, and contrasting markedly with the colloid, which takes the dye much more faintly. In the same manner, and from the same cause, the glomeruli become converted into colloid masses. Bowman's capsule is much thickened, and new material is generally especially abundant in the neighbourhood of the Malpighian bodies. (See Klebs, Virchow, and Traube.) The glomeruli consequently become compressed, and their vessels are presently rendered impervious ; degeneration then ensues, and, after a time,

nothing but a mass of colloid is left in the place of the capillary loops. (See Plate viii.) The medullary portion of the kidney is little affected.

This stage is identical with that described by Beer as "corpuscular over-growth." The new material, which is at first composed of lymphoid cells resembling those of granulation tissue, presently undergoes that fibrous transformation which constitutes the second stage of the interstitial process; but even at this early period, especially if the progress of the change has been slow and chronic, fibrillation more or less advanced may be here and there apparent, a fact which conclusively establishes the connection between the enlarged kidney of this stage and the shrunken, atrophied, and granular one of the second. Rindfleisch, to be sure, makes the remarkable statement (see *Syd. Soc. Trans.*, vol. II., page 151) that, "even in extreme cases of contracted kidney, no appearance of delicate striæ, or of fibrillation can ever be detected in the encroaching connective tissue." This assertion is the more inexplicable, as even in the earliest stages observed by the author, some amount of fibrillation has, as a rule, been recognisable.

II. STAGE OF CELL-TRANSFORMATION.

(See Plate iii.)

This stage corresponds to the "small red granular," "cirrhotic," "contracted," or "gouty" kidney of other authors.

The granulation tissue, the formation of which constitutes the first stage, becomes in this stage differentiated into more or less completely formed fibrous tissue, which shrinks, and by its compression causes atrophy of the other renal structures, with great diminution in the size of the organ.

(a.) *Naked Eye Examination.*—Weight diminished, often excessively; size visibly smaller, sometimes very much atrophied and shrunken; contour altered, irregular; surface rough, uneven, granular, or hobnailed; capsule thickened, opaque, and very adherent, — so much so that, on forcible tearing off, portions of the kidney substance come along with it; colour pale, unless red from passive congestion, the granular projections being light-coloured, "like parched peas" (Dickinson), while the depressions between them are red

from the presence of the superficial vessels, which run in these valliculæ. (See Coloured Plate, *Dickinson on Albuminuria*; see also *Bright's Reports of Medical Cases*, 1827, vol. i., Plates i.-iii.) Cysts are often seen on the surface. The consistence is tough and leathery, somewhat like caoutchouc. On section, the cortex is observed to be tough and diminished in size, being in extreme cases reduced to not more than two or three lines in thickness; its colour is pale yellowish, uniform or mottled with red. The convoluted tubules and Malpighian capsules are frequently dilated into cysts. (See Plate vii.) These are sometimes very numerous, some being visible to the naked eye, while others are microscopic. The Malpighian bodies are small and atrophied, and so approximated by the general shrinking as to appear abnormally numerous. The medullary substance is generally but little altered, though occasionally cystic; the pyramids are sometimes hyperæmic, sometimes pale yellowish like the cortex.

(b.) *Microscopic Appearances.*—The cell-infiltration of the preceding stage is now in process of differentiation into fibrous tissue. Many of the cells are seen elongating and assuming a spindle shape; and the spindles, in their turn, are here and there undergoing metamorphosis into fully-formed fibrous tissue. True wavy fibrous tissue is most abundant in the spurious adventitia of the vessels, and around the Malpighian capsules and convoluted tubules; that is to say, the increase is most marked in those situations where fibrous tissue normally exists. The Malpighian capsules are greatly thickened, leading to compression of the vessels of the glomerulus. In this stage, the small-cell formation is very distinct. Its elongation into spindles is perhaps best seen in logwood preparations, as this reagent stains the cells more deeply than carmine; and while inferior for general purposes, affords a somewhat readier demonstration of this particular fact. The importance of the fusiform change in the shape of the infiltrated round-cells is very great, as it affords one of the strongest arguments against Dr Johnson's theory of their origin from epithelial *débris*. The dispute as to the nature of the new tissue is to all intents and purposes settled by the fact of the cells assuming this fusiform shape; for it is thus seen that they are in a stage, not of regression, but of growth; not of disintegration and decay, but of progression and differentiation.

The arterioles of the kidney also present many noteworthy

pathological appearances. Many of them are obliterated by the pressure of the new material. The increase of the connective tissue which accompanies them in their distribution is now very evident. (See Plate ix.)

The adventitia proper does not at first share in the thickening, but in many cases the process involves it secondarily, and it becomes blended with the surrounding new formation, making, as it were, common cause with the general fibrous increase. It is, however, often distinguishable as a separate structure, even in very advanced specimens of interstitial change. Nor is there *ever*, according to the author's now not small experience, any material of a "hyalin-fibroid" nature to be found in connection with it. When thickened, its thickening is secondary, and consequent on an extension of the general interstitial change.

The tunica media is unquestionably hypertrophied. (See Plates iv. and v.) Of this there can be no doubt; for in well-stained specimens, there is little fear of even a comparative tyro mistaking one coat for another. On this point the author cordially agrees with Dr Johnson, whose claims to be the first to call attention to this hypertrophy have been hitherto too generally ignored. The hypertrophy appears to be a true one, the multiplied nuclei of the contractile cells being rendered very visible by the addition of acetic acid.

The tunica intima is frequently affected with Endoarteritis Obliterans. (See Plates v. and vi.) The presence of this condition, which passed unnoticed and almost unknown until the publication of Heubner's monograph On Syphilitic Diseases of the Arteries of the Brain, may formerly have given rise to mistakes as to which of the three arterial coats was hypertrophied. Now, however, it need no longer prove a source of fallacy. It is well marked in kidneys taken from syphilitic subjects, but is by no means confined to these, since almost all interstitial kidneys exhibit it more or less.

Endoarteritis Obliterans may, therefore, be considered as a common, though, perhaps, not invariable factor in the interstitial process.

Extensive changes consequent on the pressure of the new material are now evident in the uriniferous tubules. The epithelial cells become detached, and the tubes denuded of their lining. In some cases the pressure leads to distortion of the epithelial cells, as figured by Dr Dickinson; more rarely, to fatty change; and again, very frequently to the

formation of colloid. It must not, however, be supposed that all the empty tubules in a mounted section are stripped of their epithelium solely as the result of the morbid changes. Especially in thin sections, much epithelium will fall out during preparation, in spite of every precaution. In determining, therefore, how much has been destroyed as the result of disease alone, it is advisable to examine some of the thicker sections, in which it is more readily retained.

Many tubules are entirely obliterated by pressure. Their basement membrane appears, like the adventitia of the vessels, to take a secondary share in the interstitial process. It becomes thickened and fibrous, and is ultimately blended with the new formation.

Owing to the unequal pressure exercised on the tubules at different points of their course, cysts and dilatations are very common. (See Plate vii.) Colloid degeneration of the epithelium may also lead to the formation of cysts. Thus a tubule may be constricted at two places; the epithelium between these two constricted points next undergoes colloid degeneration; the colloid is then carried away through the very narrow yet still pervious opening, and escapes in the urine as hyaline material, a cyst remaining behind. Again, cysts may be formed by the *vis a tergo* of the urine acting upon a constricted point in the lumen of a tubule; and as many points in the same tubule are sometimes simultaneously narrowed, a tubule so compressed is often found to present a series of moniliform dilatations. Perhaps also the contraction of the new material may to some small extent further the cystic change, by drawing asunder the walls of the tubes; as is supposed to be the case in Bronchiectasis.

The thickening of Bowman's capsule leads to obliteration and colloid degeneration of the contained glomerulus (see Plate viii.); and on the disappearance of the capillary loops, the interior of the capsule may be dilated into a cyst. Those glomeruli which have not yet undergone the colloid change are diminished in size, and much compressed; while the general shrinking greatly diminishes the distance between them. The pressure often leads to rupture of the capillary loops, and small hæmorrhages are consequently not unfrequent. The processes of new material, which have been before alluded to as passing inwards from the capsule into the substance of the cortex, may now be seen to arise opposite the depressions between the hobnail projections visible to the naked eye on

the kidney surface,—these depressions being caused by the shrinking of the new tissue, while the hobnail protuberances are due to the bulging of portions of kidney substance, surrounded and strangled by its tightening grip.

The interstitial changes and shrinking above described, are for the most part confined to the cortex. As a rule, the medullary portions of the kidney are but slightly altered, even in advanced stages. In certain exceptional cases, however, the cortical changes may involve the medulla also. The intertubular tissue is increased, colloid matter is seen in the straight tubules, extending almost as far down as the papilla, and the epithelium in many tubules is changed and granular.

It should be noticed that those cases are very few and far between in which the whole, or nearly the whole, of the small-cell formation takes on a truly fibrous type. In most granular kidneys, even in the very last stages of shrinking and atrophy, round cells and spindles are still visible over large areas of the new formation. (See Plate iii.)

Having thus given an account, as succinct as possible, of the various morbid appearances met with in the two stages of Interstitial Nephritis, we shall now proceed to carry out our plan of considering in a little more detail some of the results at which we have arrived. Firstly, then, there occurs the question, Is the interstitial cell-infiltration to be referred to a nephritis, or is it simply the consequence of a hypertrophy of the normal connective tissue, altogether apart from inflammation? Dr Grainger Stewart, in his work on Bright's Diseases of the Kidney, argues in favour of the latter mode of origin, and quotes Dr Handfield Jones in support of his position. On page 184 of the latest edition of his work he states that the evidence in favour of the inflammatory nature of the interstitial changes appears to him to be defective. (See also article by Dr Stewart, *Brit. Med. Jour.*, Nov. 15th, 1873; and Report of Discussion before British Medical Association, Sept. 6, 1873, *Brit. Med. Jour.*) He further says:—"I know of no observation which warrants the assertion that in the earliest stage free exudation is to be found among the elements of the stroma; and, as we shall presently see, there is much reason to think that there is no such exudation. In the absence of direct evidence, this view (as to the inflammatory origin) appears to rest upon two con-

siderations: 1st, That the formation of connective tissue is a common result of inflammation; and, 2d, That the analogous disease of the liver is supposed to result from inflammatory action." From this statement it is warrantable to conclude that the presence or absence of "exudation" conclusively settles, according to Dr Stewart's opinion, the question as to the presence or absence of inflammation, or at least throws such a weight into the wavering balance that the unfortunate nephritic theory is obliged then and there to kick the beam.

But is "exudation" necessary to inflammation? This will depend largely upon what the word is taken to signify. If understood to mean merely the liquor sanguinis, the phenomena observed in non-vascular structures at once negative the conclusion that its presence is a *sine quâ non* of the inflammatory process. If, on the contrary, the emigration of white blood corpuscles be included in the term, there is abundant evidence of the outpouring of a vast number of these in the first stage of nephritic cell-infiltration. We shall assume, however, that it is the liquid exudation, the absence of which inclines Dr Stewart to reject the inflammatory theory. And here, before going further, the author is anxious to call attention to the fact that the liquid exudation in a formative inflammation like the interstitial, is always at a minimum; while even in exudative inflammation proper, the liquid exudation is at times very insignificant in quantity, as, for instance, in the dry varieties of Pericarditis. But, taking into consideration the structure of the kidney, we should, far from wondering at its absence, be rather at a loss to account for its outpouring in quantity, or long-continued presence. In the first place, the interstitial inflammation is chronic or subacute, and in an inflammation of this character fluid exudation is always inconspicuous or absent. Further, for aught we know, some slight fluid exudation may be present in the earliest stages; but these are rarely seen in the *post-mortem* room, for the simple reason that they are seldom attended with any fatal result. Moreover, the density of the kidney substance, and the drain afforded by the uriniferous tubules, militate strongly against the effusion or long persistence of any fluid exudation. Green (*Pathology*, 2d edit., page 191) well remarks: "In dense organs, as the liver and kidney, owing to the compactness of the structure, a large amount of effusion is impossible, and what there is, is

so intermingled with the structural elements of the organ that it does not appear as an independent material." Again, in those rare cases in which a kidney comes under the observation of the pathologist in the very earliest stages of the interstitial process, it is actually enlarged, soft, and doughy; the capsule is thickened and juicy, and the general appearances present a remarkable resemblance to those induced by parenchymatous inflammation. Surely this is a strange state of matters if due to other causes than inflammation. Further, be it remembered that the abundant small-cell infiltration is not, in the first instance fibrous, or even of the nature of differentiated connective tissue, but consists of cells precisely identical with leucocytes, the emigration of which in such numbers seems to point conclusively to inflammation as a cause. Dr Handfield Jones, whose authority Dr Grainger Stewart quotes, describes the occurrence of fibrous patches in serous membranes, such as the arachnoid, pericardium, pleuræ, peritoneum, cardiac valves, etc., in the mucous and submucous tissues of the stomach, and in the substance of organs, such as the liver, lungs, testicles, and uterus. These, he rightly argues, are not all due to inflammation. But, further, he says, as quoted by Dr Stewart, "that the hypertrophy causing the increase and thickening of fibrous tissues goes on and on, as a substantially independent process totally unassociated with any trace of inflammation, even though it may by possibility have originated in it." Now, this last is a rather *naïve* admission, and seems, in fact, equivalent to a total abandonment of the position previously gained at the cost of so much argument. If a fibrous increase is originated by an inflammatory process, and due to the migration of lymphoid elements consequent on inflammation, then the overgrowth is unquestionably inflammatory, even though it proceed after the subsidence of the inflammation. The cicatricial tissue of wounds is generally acknowledged to be inflammatory, though we do not expect to meet with the phenomena of inflammation in a scar a year old. The inflammation simply supplies the material, which is afterwards utilised at leisure. It is the waggoner who conveys the blocks of stone to the site of the future building,—not the mason who, with mallet and chisel, hews them into shape. If, then, inflammation is, in the first instance, the provocative agent of a fibrous hyperplasia, providing the round-cells which are presently to be differentiated into fibres, the fibrous

overgrowth, when complete, is assuredly inflammatory, even though the inflammation has long ago disappeared.

We must not be understood as wishing to refer all fibrous increase to the result of antecedent inflammation. The "simple overgrowth," described by Beer, in the kidney, milk spots on the pericardium, and many other fibrotic changes, are, it may be, not only carried on, but initiated totally apart from any inflammatory action. But so-called "Irritative Hypertrophies" trench so often upon the province of inflammation, that in many cases, such as those where the tissue elements are numerically increased, the author believes the distinction to be one without a difference, and dependent rather upon the degree than upon the nature of the changes included under the term. The "corpuscular overgrowth" of Beer corresponds to Interstitial Nephritis; and thus he is in accord with the present writer in attributing it to the results of inflammation. It is a common fallacy to say that where there is no lymph and exudation, there is, or has been, no inflammation. The lymph and exudation may have vanished, whereas the consequences of the inflammation may remain.

One can understand that a fibrous increase, such as that constituting a "milk-spot," may take place somewhat after this manner:—Owing to some cause or another—from friction, in the present instance—the normal subserous connective tissue is excited to increased activity of growth. It enlarges, and after a time, like the cuckoo in the hedge-sparrow's nest, not finding its quarters sufficiently spacious for its increased requirements, provides itself with elbow-room at the expense of its next-door neighbours. But it is the same connective tissue after all; it has grown larger, and become a bully; but its textural elements have received no numerical additions. In short, its elements are enlarged, but their number remains unaltered. Such a fibrous increase need not, perhaps, be accounted inflammatory; but if the connective tissue elements are increased numerically, this increase is traceable, in the vast majority of instances, to the results of an antecedent inflammation. It may be thought, that according to this view, too great a prominence is assigned to inflammation as a cause of connective tissue hyperplasia; but yet how universal a process inflammation is! The labourer would, perhaps, be not a little surprised, if told that his horny hands had been provided with their pachydermatous covering by the aid of this so-much-dreaded condition! Yet such is the case. A little

more of the exciting cause, and not an epidermal increase, but a blister would be the consequence. It is perfect nonsense to ascribe such an epidermal thickening to "Irritative Hypertrophy." Inflammation, and inflammation alone, is responsible for it, as amply evidenced by the redness and heat of a delicate hand, when subjected to some unaccustomed attrition. To be sure, the inflammation goes no further than congestion; but though slight in degree, its nature admits of no question. If the connective-tissue elements of a part are increased, the new elements must have originated from some pre-existing ones; and whether they arise from migrated leucocytes, or from division of the permanent connective tissue corpuscles, both these processes are, according to the present state of our knowledge, alike characteristic of inflammation. Of course, the transformation of already existing cellular into fibrous tissue does not of necessity involve the presence of inflammation; and thus some appearance of numerical hypertrophy may sometimes be caused; but if the increase be greater than can be accounted for in this way, it appears to the author that the inflammatory theory can alone sufficiently account for the presence of the new elements. The advocates of "Irritative Hypertrophy" may say that this view is merely theoretical, and incapable of proof. True, it is theoretical; but so is their own, and the *onus probandi* lies with them, not with us; for before proceeding to separate "Irritative Hypertrophies" from inflammation proper, it is but reasonable that something more than mere supposition should be alleged in favour of such a divorce.

"Irritative" numerical hypertrophy, then, unless used as the equivalent of "nascent inflammation" (to borrow a term from Chemistry), is a name likely to mislead, and expressive of a purely hypothetical condition.

The case, therefore, as to the inflammatory or non-inflammatory nature of the interstitial cell-infiltration may be shortly tabulated as follows:—

DR STEWART, *con.*

I. There is no free exudation.

II. There is no direct evidence of its inflammatory nature.

III. Fibrous increase is often met with totally apart from inflammation.

THE AUTHOR, *pro.*

I. Free exudation is not to be looked for, because—

(1.) The inflammation is chronic and formative.

(2.) The density of the kidney substance prevents its effusion.

(3.) The uriniferous tubules drain it off as fast as it is poured out. Against this it may be argued that the urine contains little or no albumen in the earlier stages. But, as shown by 1 and 2, there is little or no albuminous exudation poured out, so that its absence in the urine is not to be wondered at.

(4.) In the very earliest stages, a small amount of free exudation may, for aught we know, be present (*Klebs*).

II. There is direct evidence, as follows:—

(1.) The enlarged, soft, doughy, and juicy condition of the kidney in the earliest stages.

(2.) The abundant infiltration with lymphoid cells.

III. Increase in the size of the original elements is often so met with; but increase in their number is very seldom, perhaps never, so met with.

In conclusion, it occurs to the author that Dr Stewart's reasons for rejecting the inflammatory theory, may perhaps have been due to his still holding, at the time of the publication of the last edition of his work, some of the older ideas as to the nature of the inflammatory process. In this case we may look for some alteration of his views in subsequent editions.

Dr Stewart's conclusions are generally marked by such care and accuracy, and are in the main so consonant with the results of the author's observations, that he has thought fit to

discuss at some length this, their almost only point of material difference.

So far as one may judge from the last edition of *Jones and Sieveking's Pathology* by Payne, Dr Handfield Jones seems to have modified his opinions as to the pathology of contracted kidney; for in this reprint of the conjoint work, the origin of the disease is clearly ascribed to a nephritis.

*THE NEW TISSUE, AND THE CHANGES CONSEQUENT
ON ITS PRESENCE.*

ONE of the most noticeable changes in the interstitial kidney is the thickening and adhesion of the capsule. This thickening is of a densely fibrous character, with here and there a few fibrillating spindles, and occasional round-cells; small vessels and lymphatic spaces also, are to be seen in its substance. The normal delicate bands of connective tissue passing between it and the cortex are enormously increased, and penetrate far into the cortical substance. So firm is the adhesion caused by the thickening of these processes, that in advanced stages large portions of the cortical substance are torn off on forcible evulsion of the capsule. The author has never seen a specimen sufficiently early to exhibit typically the stage of small-cell infiltration, which doubtless occurs here as in the substance of the kidney proper; though in Glomerulo-Nephritis it appears to be comparatively but little affected. Interstitial kidneys are seldom long allowed to retain their capsular investment. The difficulty experienced in separating the capsule, seems to be provocative of attempts to do so; and these are generally so unfortunately successful that by the time the specimen reaches the hands of the histologist, there is seldom any capsule left to separate. Of course if we make our own *post-mortems*, it is within our power to exercise some restraint over our evulsory propensities; but *post-mortems* in private practice are rare.

In order to determine whether or not the apparent new tissue is in reality a something superadded to the normal elements of the kidney substance, or simply an appearance produced by the destruction of the tubules and epithelium, we should examine rather those specimens which exemplify

the early stages, than those later ones in which there has been great destruction of the secreting structures. Although the tubular epithelium is often but little changed even at later periods, yet by thus directing our attention to specimens in which, save for the results of compression, it is to all intents and purposes normal, we do much to eliminate sources of confusion and fallacy. At the outset, however, we have to confront the difficulty caused by the extreme rarity of such early specimens. In this dilemma we derive valuable aid from the examination of the interstitial tissue in cases of Glomerulo-Nephritis, such as that represented in Plate ii. In these the round-cell infiltration is abundant, while, owing to the comparative integrity of the tubules, its nature is unmistakeable. Glomerulo-Nephritis is, in fact, simply an Interstitial Nephritis, differing only from the common variety in its anatomical site of greatest intensity, —*i.e.*, attacking not merely the general interstitial tissue, but also that which binds together the vascular loops of the glomeruli. In consequence of this peculiar anatomical situation, it is a dangerous and fatal disorder; and such cases afford perhaps the most typical examples of early interstitial change which ever find their way into the hands of the pathologist.

The normal connective-tissue septa are much increased in width, and as the tubules are generally pretty normal, and even when compressed are still recognisable, there is the less danger of mistaking connective-tissue increase for disintegrated tubules and epithelium. Indeed, there is but slight fear of a practised observer falling into this error. It may be argued that the epithelial nuclei stain with reagents in precisely the same manner as the lymphoid cells of the new tissue. Granted; but for all this there are ways and means of appreciating a difference considerably greater than that between tweedledum and tweedledee. The epithelial nuclei are sharply defined, round in shape, never fusiform or clavate, though they may be oval, and larger and more opaque than the lymphoid cells. Then, again, they lie in relation to portions of compressed tubules, which afford a ready means of identifying them. As to the tubules themselves, it is the author's belief that their basement membrane never becomes disintegrated. It enters into the process going on around it, and undergoes fibrillation with even greater readiness than the new material itself. If warrant for this assertion be demanded, the author would

direct attention to the constricting ring generally seen around an atrophied tubule, which ring is formed of the thickened basement membrane, which (as in the case of Bowman's capsules) is distinctly more fibrillated than the surrounding small-cell tissue. (See *Niemeyer; Humphreys and Hackley's Trans.*, 1876, vol. II., page 23; also *Wilks and Moxon's Pathology*, page 509). In these constricting rings, and in the thickened Bowman's capsules, spindles are often very apparent; and in these two situations, as also in the increased connective tissue around the vessels, the process of transformation of the round-cells first into spindles, and subsequently into fibres, may be very satisfactorily observed. Not that it is at all difficult to recognise it elsewhere; but in these places it is often very plainly and beautifully exemplified. Later on, the same thing occurs in the adventitia proper of the renal arterioles, which becomes thickened, and is presently blended with the surrounding new material. (See Plate ix.) It should, however, be distinctly understood that this is a secondary change. The fibrotic process, far from beginning in the adventitia of the arterioles, involves it only when the changes elsewhere have become very evident.

Picro-carminé in one per cent. solution (Ranvier's receipt) gives a very good demonstration of the coats of the arterioles. The adventitia and intima are stained yellow, while the muscular coat is coloured red. The newly formed tissue around the adventitia is coloured red, if not advanced in fibrillation; if fibrous, it is yellow also; but the adventitia, being denser, is easily distinguishable by its deeper colouration. Double staining with carminé and osmic acid answers the same purpose extremely well, and the importance of the aid afforded by these reagents in enabling us to recognise and distinguish the several coats, can scarcely be over-estimated. All dubiety, all uncertainty vanish with their use. Dr Galabin (*On the Connection of Bright's Disease with Changes in the Vascular System*, page 14,) says:—"It is somewhat difficult in a transverse section to distinguish between the circular muscular fibres and the fibrous tissue outside them." This difficult matter becomes an easy one with the assistance of picro-carminé. Of course, a whole regiment of bottles full of staining fluids will not make a competent histologist out of a neophyte; for microscopic reagents require to be used as Opie mixed his colours—with brains; but in the hands of a practised observer and dainty manipulator,

they are capable of affording the most absolute evidence as to which is which in the matter of the arterial coats.

The middle or muscular coat is, as has been already stated, hypertrophied. (See Plates iv. and v.) This hypertrophy is noticeable at a comparatively early period in the history of the interstitial changes; indeed, the author has scarcely ever seen an undoubted example of the ordinary variety of interstitial kidney, the arteries of which did not show it in a greater or less degree. He is therefore led to consider it as a practically constant appearance; though all parts of an artery are not equally affected by it, as is easily seen in longitudinal sections embracing any appreciable length of the vascular coats. The hypertrophy appears to be a true one; that is to say, the enlargement is probably due to increase in the number of the non-striped muscular elements. In these the author has seldom observed any notable structural alterations; according to his experience they colour normally with carmine and other reagents; (Gull and Sutton say that the nuclei do not absorb carmine so readily as in healthy vessels); the nuclei are normal in shape, nor has he ever seen them fattily degenerated. Dr Dickinson (*On Albuminuria*, 2d Edit.), while admitting the existence of the muscular hypertrophy, says that degenerative changes also occur in the middle coat of the vessels. His illustrations are taken from the arteries of the *pia mater*. Traube and Ludwig also hold similar views. The author has pretty frequently met with this apparent atrophy. At times it appears to him to be not so much atrophy as an absence of hypertrophy, those parts of the muscular coat which still retain their normal thickness appearing wasted, by contrast with the adjoining greatly hypertrophied portions. At other times, he must confess, it looks very like atrophy proper. The muscular coat appears more homogeneous than natural, and is in some places unquestionably reduced in thickness. This condition of the tunica media is almost invariably accompanied by considerable obliterative thickening of the intima. The occasional muscular atrophy is, however, no argument against the co-existence of the abundantly evident hypertrophy. (See Johnson, *Trans. Path. Soc.*, 1877, page 385.)

The occurrence of thickening of the middle coat in the early stages of interstitial kidney, may be taken as an argument against the true muscular character of the increase, since muscular hypertrophy is a slow and gradual process.

But, as has been often before mentioned in the present treatise, the very early stages of Interstitial Nephritis rarely come under clinical, far less under pathological, observation. What, therefore, the morbid anatomist recognises as an early stage of interstitial change, may in reality be the product of a morbid process which has lasted for months. Interstitial Nephritis is essentially chronic, or at most subacute; the fatality of its initial stages is almost *nil*; and a sufficient time, consequently, elapses between its supervention and its recognition at the autopsy, to allow of even the tardy development of muscle cells. The absence of hypertrophy of the muscular coat in the author's speedily fatal cases of Glomerulo-Nephritis, further tends to strengthen these conclusions.

In a monograph like the present, which deals solely with the Morbid Anatomy of interstitial kidney, it would be out of place to propound or endorse any theory as to the cause of this muscular hyperplasia; suffice it to say, that the author is convinced of its existence. (See Plate iv.) The hypertrophy is far too great to admit of its being explained away on the ground of *post-mortem* contraction, analogous to the so-called "concentric hypertrophy" of the heart. The muscular coat is frequently two or three times as thick as in normal arteries, and no possible amount of mere contraction could give rise to such an appearance of increase. Confirmatory evidence in favour of its true muscular character is given by Dr Grainger Stewart (*Brit. Med. Jour.*, Sept. 6, and Nov. 15, 1873); by Dr Atkins (*Brit. Med. Jour.*, April 3, 1875); by Dr T. J. Maclagan (see *Report of Trans. of Med. Chir. Soc., Edin., Brit. Med. Jour.*, June 5, 1875); rather hesitatingly by Dr Galabin (*On the Connection of Bright's Disease with Changes in the Vascular System*); and in the 2d edition of *Jones and Sieveking's Pathology*, by Payne. Again, on examining the arterial coats in longitudinal section, the muscular nuclei are seen in greater numbers than in unaffected vessels; which not only proves the true nature of the hypertrophy, but at the same time negatives the theory of *post-mortem* contraction. Sir W. Gull and Dr Sutton say the muscular layer varies in thickness, and that it is difficult to say what are or are not its normal dimensions. Well, so do men vary in stature; yet if we meet with a man eight feet high, we call him a giant. How much more Brobdignagian, then, should we consider him if he towered above our diminished heads to the height of twelve or eighteen? Yet

this disproportion is no more than actually exists between the muscular coat of healthy arteries, and that of the hypertrophied vessels of Interstitial Nephritis.

We subjoin a few measurements, showing the relative thickness of the muscular coat as compared with that of the whole arterial wall. It will be seen from this table, that interstitial arteries, as compared with normal ones, show thickening of the media and intima, whereas the adventitia is but little increased.

NORMAL.			INTERSTITIAL.		
ADVENTITIA.	MEDIA.	INTIMA.	ADVENTITIA.	MEDIA.	INTIMA.
$\frac{3}{4}$	1	$\frac{1}{8}$	$1\frac{1}{2}$	8	5
$1\frac{1}{2}$	2	$\frac{1}{4}$	2	$4\frac{1}{2}$	4
$1\frac{1}{2}$	2	$\frac{1}{4}$	$2\frac{3}{4}$	$6\frac{1}{4}$	5
2	$3\frac{1}{2}$	$\frac{1}{2}$	2	16	$7\frac{1}{2}$ } same
1	2	$\frac{3}{8}$	About 3	7	$2\frac{1}{2}$ } artery
2	2	$\frac{1}{2}$	3	$4\frac{1}{2}$	5
$1\frac{1}{2}$	$1\frac{1}{2}$	$\frac{1}{4}$	2	4	4
2	$2\frac{3}{4}$	$\frac{1}{4}$	About 1	3	3
2	2	$\frac{3}{8}$	3	$7\frac{1}{4}$	$3\frac{3}{4}$
3	3	$\frac{3}{4}$	About 2	7	$3\frac{1}{4}$
About 3	$4\frac{1}{4}$	$\frac{1}{4}$	2	5	About 5
Disorganised	5	$\frac{1}{2}$	About 2	6	$4\frac{1}{2}$
2	3	$\frac{1}{2}$	2	5	4
$1\frac{1}{4}$	2	$\frac{1}{4}$	3	7	4
1	2	$\frac{1}{4}$	About 2	7	$3\frac{1}{2}$
2	2	$\frac{1}{4}$	„ 2	4	Nearly $\frac{1}{2}$
1	1	$\frac{1}{8}$	„ 3	6	4
1	$1\frac{1}{2}$	$\frac{1}{8}$	} Blended with the surrounding fibrous tissue. }		
$2\frac{1}{8}$	$3\frac{3}{4}$	$\frac{1}{8}$	2	5	3
Nearly 3	4	About $\frac{1}{2}$	2	9	2
4	$5\frac{1}{2}$	1	Blended	4	$1\frac{1}{2}$
3	$3\frac{1}{2}$	Nearly 1	2	$5\frac{3}{4}$	Nearly 2
$2\frac{1}{2}$	3	Much wrinkled	$\frac{1}{2}$	$7\frac{1}{2}$	$\frac{1}{2}$
2	2	$\frac{1}{4}$	1	7	$1\frac{1}{4}$
2	$2\frac{1}{2}$	$\frac{1}{2}$	1	4	$\frac{1}{2}$
About 3	$4\frac{1}{2}$	Nearly $\frac{1}{2}$	1	6	1
$3\frac{1}{2}$	$4\frac{1}{4}$	„ $\frac{1}{2}$	$2\frac{1}{2}$	6	2 } same
2	3	„ $\frac{1}{8}$	2	7	2 } artery
$1\frac{1}{2}$	About 2	$\frac{1}{8}$	2	7	1 }
$2\frac{1}{4}$	$2\frac{3}{4}$	Nearly $\frac{1}{2}$	2	$6\frac{1}{2}$	$1\frac{1}{2}$
2	2	„ $\frac{1}{8}$	About 3	8	Nearly 2
About 2	2	„ $\frac{1}{8}$	2	4	„ 3
5	8	$\frac{1}{8}$	Blended	5	4
			} In another portion, this coat is only 2; no hypertrophy }		

From these measurements it is evident that the intima, as well as the media, is very generally thickened by the "Arteriitis Obliterans" of Heubner. For the awkward and cacophonous word "Arteriitis," we prefer to substitute the term "Endoarteritis," which is sufficiently euphonious to merit exemption from the category of

"Words which should only be said on holidays,
When one has nothing else to do."

Atheroma is already known by the term Endo-arteritis Deformans, and there appears to be no valid reason, save the German nationality of its discoverer, for the introduction of an extra "i" into the name of the unfortunate Heubnerian lesion, whereby its back is broken for all purposes of utterance.

The inner coat may be anatomically divided into three layers, exhibiting distinct structural differences. The inner surface of the tube is lined by a layer of irregularly lanceolate epithelioid cells. Preparations of frog's rectum and bladder injected with nitrate of silver afford a very beautiful demonstration of this epithelium.

Immediately underneath this epitheloid layer is one of greater pathological importance, consisting of connective tissue, with branched corpuscles lying in lacunar spaces, similar to those in the cornea, etc. The corpuscles are demonstrable by chloride of gold, which, though a somewhat uncertain reagent, gives occasionally very beautiful results; while the lacunæ in which these cells lie, are rendered visible by the action of nitrate of silver, which stains the ground substance of a dark colour, leaving the lacunæ visible as irregular patches of a lighter hue. The ground substance is for the most part homogeneous, though it may sometimes present an appearance of striation, or even of fibrillation. A longitudinal elastic network is sometimes said to be present in this layer. The last and thickest portion of the inner coat consists of elastic layers which are superimposed on one another as a varying number of longitudinal fibrous networks, which not unfrequently assume a membranous form with perforations, constituting the "fenestrated membrane of Henle."

Having thus glanced briefly at the normal structure of the inner coat, we shall be in a position to appreciate the morbid alterations induced by the obliterative changes above referred to. These are probably initiated, and have their chief seat

in the middle or connective-tissue layer of the inner coat. The microscopic appearances are, shortly, as follows:—The inner coat becomes thickened, and assumes a sort of fibrous character, the sides of the lumen of the vessel being, in the advanced stages, rough, ragged, and splintery, like coarse cocoa-nut matting. (See Plate vi.) The fibrous filaments have a concentric arrangement around the axis of the vessel, and obscure spindles are often noticeable among them, together with large roundish, oval, or irregularly spheroidal bodies of the nature of connective-tissue corpuscles. No trace of epithelial lining is in most instances discoverable. In the earliest stages, the sides of the narrowed lumen are still smooth, but present no appearance of epithelium, unless some irregular cells close to the inner edge may be considered as such. (See Plate v.) The elastic coat of the intima appears to be separated more or less completely into its component layers. Small vessels are sometimes seen in the proliferated intima. These require high powers for their satisfactory demonstration (such as Hart. oc. 3, \times obj. 9, wide angle, tube out). The thickening of the intima goes on until at last the affected arterioles are completely occluded by a fluffy, ragged material, which, when the artery is altogether obliterated, becomes denser and more fibrous, and assumes the appearance of more or less perfect concentric fibrillated rings. Sir W. Gull and Dr Sutton have noticed this occlusion (*Med. Chir. Trans.*, vol. lv., page 275). Dr Grainger Stewart also makes mention of a thickening of the intima in the arterioles of the *pia mater*, but says he has never seen evidence of diminution of the lumen (*Brit. Med. Jour.*, Nov. 15, 1873).

The author has never seen the proliferated elements arranged in distinct layers of different morphological type, as represented in syphilitic arteries by Dr Greenfield (*Path. Soc. Trans.*, 1877, plate xiii.); the appearances as seen by him being more comparable to Dr Barlow's drawing (plate xv., fig. 1, *ibid*); though in the author's specimens, spheroidal cells were more abundant than spindles; fibres more abundant than either; and epithelium rarely and doubtfully present. Something, however, may be due to the size of the arteries examined; for those in the author's specimens were much smaller, and necessitated the use of far higher powers.

The process seems to consist essentially in a proliferation of the connective-tissue corpuscles of the middle layer of the

inner coat, with subsequent fibrillation of the connective tissue. Such a theory is in accordance with the behaviour of connective tissue elsewhere, under like inflammatory conditions, and is in the author's opinion a satisfactory explanation of the nature of this interesting lesion. (See also Thoma, *Virchow's Archiv.*, Band 71, Heft ii.)

It is evident that this narrowing and obliteration of arteries must materially contribute towards the causation of secondary intratubular changes; for owing to the direct obstacle thus offered to the blood supply, the nutrition of the tubules and their epithelial contents must be interfered with almost as seriously as by the presence and pressure of the increased interstitial tissue. The intratubular cell-infiltration might even, if very abundant, give rise in the first place to the formation of new vessels for its nutrition; but the obstacle occasioned by the blocking up of the normal ones, admits of no such extenuating circumstances. Intratubular nutrition is, therefore, impaired by two causes; *firstly*, by the presence and pressure of the new material, which presently shrinks, and obliterates not only any vessels which may have been formed for its nutrition, but many of the normal ones as well; and *secondly*, by the blocking up of the normal arteries by obliterative changes in their intima. Remembering, then, these two factors of interference with blood supply, it is no wonder if, after a time, intratubular changes follow in the wake of the intertubular increase.* The tubules themselves are compressed, and their nutriment is cut off; and, accordingly, we find the secreting structures undergoing various forms of secondary alteration. The epithelium is loosened from the basement membrane of the constricted tubules; sometimes it breaks up into a finely granular mass; sometimes it undergoes colloid degeneration; less frequently it becomes fatty; in other cases a few epithelial cells appear to have vanished *en masse*, their remaining neighbours being nearly normal, though this may be partially due to the falling out of the absentees during the preparation of the specimen. The author has noticed that the protoplasm of the epithelial cells occasionally stains with carmine and other reagents in an apparently capricious manner. This is probably due to com-

* Klebs thinks that the interference with blood-supply has even more to do with the atrophy of the kidney than the shrinking of the new tissue.

mencing degenerative change. He has also in a few instances remarked a similar deep colouration of the connective-tissue corpuscles in the substance of the glomeruli, which he regards as the herald of impending colloid degeneration. Sometimes, also, from some unknown cause, the lymphoid cells of the nuclear tissue are stained with a clearness perfectly diagrammatic. The nuclei of the epithelial cells often vary in the extent to which they absorb the colouring matter; but this inconsistency cannot be looked upon as an indication of actual abnormality, as the same thing occurs in normal specimens, and is very likely due to unimportant chemical changes. The epithelial nuclei are the most persistent of all the intratubular elements; and a tubule is often seen in transverse section, with the nuclei still clinging to its inner wall, from which all trace of the cells themselves has disappeared.

Altogether, considering the immense interference with function which the presence and shrinking of the new material cannot fail to induce, the intratubular changes, though great, are not more than might be expected from a like cause. In the later stages some epithelium is fatty; much is entirely destroyed, and much also converted into colloid; many tubules are dilated and cystic (see Plate vii.); the denuded basement membrane is thickened, fibrous, and blended with the new material; the glomeruli become impervious, and finally degenerate into colloid masses (see Plate viii.); Bowman's capsules are thickened and fibrous like the basement membrane of the tubules; many tubules are compressed and atrophied, and others are entirely obliterated. But while fully recognising the importance of these intratubular alterations, we cannot agree with Dr Johnson in regarding them as the primary or essential part of the morbid process. They occur as a consequence and not as a cause; and are subsequent, not antecedent, to the primary small-cell increase of the kidney stroma.

Before closing this chapter, it will be necessary to say a few words on a form of renal disease closely resembling true primary Interstitial Nephritis, namely, that increase in the fibrous stroma sometimes seen in the later stages of chronic parenchymatous inflammation, and consequent on a secondary irritation of the connective tissue occasioned by the primary intratubular affection. The clinical history of such cases, and more especially the marked appearances of intratubular change, together with the much less evident granularity of

the kidney surface, the less firm adhesion of the capsule, and the much smaller amount of fibrous increase, alike concur to separate this condition from that consequent on true primary interstitial inflammation. This secondary fibrosis has been well described by Dr Grainger Stewart in his treatise on Bright's Disease (*Op: cit: 2nd Ed., p. 16*), and great credit is due to him for clearly establishing the distinction between it and the true primary one; for while, on the one hand, Johnson and his school have fallen into the manifest error of regarding all intertubular alterations as subordinate and secondary to intratubular changes, we must be careful to guard against rushing into the opposite extreme, by ascribing all intratubular changes to primary intertubular increase. In the present treatise we shall not enter into a detailed account of this secondary form, which belongs rather to the domain of the parenchymatous inflammation upon which it is consequent; but shall refer our readers meantime to Dr Stewart's description in the second edition of his work; also to a discussion on Bright's Disease, held during the forty-first annual meeting of the Brit. Med. Assoc. (see *Brit. Med. Jour.* Sept. 6, 1873), in which Dr Grainger Stewart again affirms and expounds his views on this subject.

We may shortly summarise the contents of the preceding chapter as follows:—

1. The "small red granular," "cirrhotic," "interstitial," or "gouty" kidney, is the result of a true interstitial inflammation, attended with increase of the normal stroma, owing to the formation of a tissue composed of indifferent or embryonic cells, which new tissue is presently transformed into more or less completely developed fibrous tissue.
2. For descriptive purposes, two stages may be distinguished in the history of the morbid process—*i.e.* (1.) a stage of Cell-Infiltration; and (2.) a stage of Cell-Transformation.
3. The original lesion is essentially intertubular, and all subsequent intratubular changes are secondary to, and consequent on, the primary intertubular change.
4. The adventitia of the renal arterioles is not at first hypertrophied, but may subsequently become so by an extension to it of the hyperplastic process affecting the connective tissue, which normally

accompanies, and is distributed with, the vessels.
(See Plate ix.)

5. The tunica media of the renal arteries is hypertrophied, sometimes greatly; the hypertrophy being probably due to true muscular increase. Sometimes, however, this coat is atrophied.
6. The tunica intima of the arterioles is frequently thickened and proliferated, the increase being of the same nature as that described by Heubner under the name of "Arteriitis Obliterans," and by Thoma as Fibrous Endarteriitis.
7. The already familiar designation, "Interstitial Nephritis," is pathologically correct, and fulfils all the requirements of an accurate and scientific terminology.

CHAPTER VII.

DR GEORGE JOHNSON'S VIEWS.

"I FIND myself once more called upon," remarks Dr Johnson in a paper published in the *Pathological Society's Transactions*, 1877, page 389, "to maintain that the small red granular kidney is not the result primarily and essentially of an interstitial nephritis, or of an arterio-capillary, or any other form of fibrosis, as Sir W. Gull and others believe. . . . I still maintain the view that the primary and essential changes in this form of renal degeneration are intratubular, and consist of degeneration and disintegration of the granular epithelium." . . . He quotes Drs Wilks and Moxon, who say (see *Op: cit: page 509*): "Some authors, especially Dr Dickinson, describe an increase of fibrous tissue. We think there is a little increase round the vessels, but not much. The patches, apparently of fibrous tissue, figured in Dr Dickinson's excellent drawings we have always seen, but high powers resolve these patches into the remains of tubes, as indeed would probably follow from consideration of the drawings themselves. . . . We have found that a fibrillated condition prevails in the tube walls, which become coarse looking; but all large patches of apparent fibre we have always found to be chiefly made up of apparently wasted tubes."

Dr Johnson goes on to state that this is the opinion which he maintained in 1847 (see *Med. Chir. Trans.*, vol. xxx., *On the Inflammatory Diseases of the Kidney*; see also paper by Mr Simon, in the same volume), and which he has subsequently seen no reason to alter, save that in his paper in the 33rd vol. *Med. Chir. Trans.*, he made mention for the first time of the fact of the muscular hypertrophy of the arterioles. We have quoted Dr Johnson's own words as given in the report of the *Pathological Society's Transactions*, in order to avoid all chance of misrepresenting or overcolouring his ideas.

In our former Chapter on Granulation Tissue we noticed the identity of the interstitial process with that which provides for the repair and healing of wounds. This we shall not again discuss. When Drs Wilks and Moxon admit that there is a little increase of fibrous tissue around the vessels, they admit a fact glaring and patent; for the increase is oftentimes not a little, but goes as far as the formation of patches or oases of coarse unmistakeable fibres. (See Plate ix.) But let us not be misunderstood;—by this admission we afford no support to Sir W. Gull and Dr Sutton's theory of Arterio-Capillary Fibrosis; for it is not the adventitia of the arterioles, but the connective tissue distributed with them, which is thus hypertrophied. (See Thoma, *Virch. Arch.*, Band 71, Heft i.)* In three situations, as before mentioned, fibrillation is most conspicuous; namely, around the vessels, external to their adventitia,—in Bowman's capsules, and around wasted tubules (Klebs, Traube, Virchow, Thoma, and Dr Ringrose Atkins, *Brit. Med. Jour.*, April 3, 1875); but it is not absent elsewhere—far from it. Neither is the fibrous appearance due merely to the shrinking of the connective tissue normally present, for reasons which we have already discussed.

On page 390 of the *Pathological Society's Transactions*, 1877, Dr Johnson gives a detailed account of his interpretation of the appearances met with in the small red granular kidney. To that account, as the latest exposition of his views, the author will now refer. In it he affirms that “the primary and essential change consists in disintegration and destruction of the glandular epithelium of the convoluted tubules.” Here again we arrive at a direct conflict of evidence, and who

* Thoma says—“Es liegt somit offenbar eine pathologische Bindegewebsneubildung vor, welche zuerst weich und zellreich, später derb und narbig wird, und sich im Ganzen der Gefässverzweigung anschliesst.

shall decide? We shall not convince Dr Johnson, neither will Dr Johnson, with the evidence on which he at present relies, succeed in convincing us. As to the state of the epithelium in the early stages, the present writer is entirely at one with Dr Dickinson. (Thoma also, *Virchow Arch.*, Band 71, Heft ii., page 47, says,—“Nirgends zeigen die Epithelbekleidungen in uncomplicirten Fällen selbständige Erkrankung, weder im Bereiche der bindgewebigen Wucherungen, noch auch in den relativ intact gebliebenen Abschnitten der Rinde.”) Dr Johnson says the tubes are filled and rendered opaque. (See also page 219, *Johnson on Kidney Diseases*, 1st ed.) This is precisely what they are normally. If they present much appearance of lumen, it is owing to falling out of the epithelium. Cut a small section of fresh normal kidney, not too thin; place it directly on a slide without washing it, and examine with Hartnack oc. 3 × obj. 7; or, in spite of its having been washed, take any characteristic normal specimen (not too thin a one, as these part with their epithelium more readily,) and examine it with the same power. This will show what is, or is not, the typical appearance of healthy convoluted tubules. The kidney which furnished one of the author's Normal Series was in all respects typically healthy, being that of a strong male adult killed by accident, and in this kidney the opacity of the tubules was constant. The tubules of the kidneys of healthy cats are also uniformly opaque. “Other tubes,” says Dr Johnson, “are more or less completely denuded of epithelium, a few granular particles only adhering to the inner surface of the basement membrane.” Perfectly correct; but this is a secondary change, consequent on the presence and pressure of the increased interstitial tissue. “In some tubes,” pursues Dr Johnson, “the normal epithelium is replaced by a lining of delicate transparent rounded cells, each with a single nucleus.” (See also *Brit. Med. Jour.*, Feb. 15, 1873.) The author has observed these “cells,” but he has seldom observed the fact of their nucleation. If nucleated, as they are sometimes, though rarely, they are lymphoid cells which have escaped into the tubules *viâ* the capillary loops of the glomeruli. Such are more frequently seen inside the tubules, in that variety of Interstitial Nephritis which more especially affects the glomeruli. (See Chapter on *Glomerulo-Nephritis*. See also Art. by Dr Klein, *Pathological Society's Transactions*, 1877, page 436.) The

presence in quantity of these lymphoid cells in the tubules would be very likely to give rise to secondary intratubular changes, such as compression, loosening, and shedding of epithelium. Dr Johnson may, of course, state in return that their presence is due to a primary intratubular epithelial change; but in that case we should expect to find the epithelium in much the same condition as in parenchymatous nephritis. Dr Johnson may, perhaps, maintain that it is so; but we cannot give in our adhesion to such a doctrine. More frequently these "cells" are, in reality, not cells at all, being nothing more nor less than the nuclei of the cells of the tubular epithelium, which, being more persistent than the other cell-constituents, remain after the secondary intratubular changes have caused the disappearance of the epithelial cell-wall and protoplasm.

Again; Why is it that cysts are so frequent in the small red granular kidney, and so infrequent as a consequence of Parenchymatous Nephritis, either acute or chronic, where the intratubular changes are undoubted? Why should one form more than another of intratubular change lead to cystic formation and dilatation of the tubules? On the hypothesis of intertubular increase the presence of these cysts is easily accounted for; but how does Dr Johnson account for it? Let us see what his paper says:—"The explanation of the cyst formation is probably to be found in the fact that some tubes continue to secrete an aqueous fluid while their lower portions are plugged by accumulated epithelial *débris*, and thus they become distended by their own secretion" (*Pathological Society's Transactions*, 1877, p. 399). According to this explanation, cystic formation should be at least as common in the parenchymatous, as in the interstitial form of inflammation. But is it so? The answer is not far to seek. Except in cases where chronic intratubular changes have induced a secondary interstitial nephritis, examples of cystic change in the tubules are merely accidental.

Dr Johnson says that the phenomena, as described by him, are caused by the irritation of the renal structures, owing to the circulation through them of some blood poison, such as those of gout, rheumatism, alcoholism, lead-poisoning, and chronic dyspepsia (to which the present author, in accordance with Dr Bristowe, would add syphilis). This irritation, he says, soon destroys the delicate epithelium, while

the basement membrane of the tubules, the capillaries, etc., remain much longer, in accordance with the law of "the survival of the toughest." The author agrees with Dr Johnson as to the blood poison (that is, in cases of bi-lateral Interstitial Nephritis), but differs from him altogether as to its effects on the kidney structures. The irritation being chronic, and not very intense, is just as likely to give rise to interstitial as to intratubular change. The nature of the irritation, then, affords no argument for Dr Johnson's theory, though it may, perhaps, by its chronic character, furnish a slight presumption against it. "In some parts," pursues Dr Johnson, "the basement membrane and the Malpighian capsules appear to be thickened, and assume a fibrous texture, so that an examination of the granular kidney without reference to the normal structure, and especially to the appearance of the fibrous network which is seen on examination of a normal kidney after washing away the gland cells, might lead to the belief that the tubes are surrounded by an abnormal fibrous tissue." Of course, after the gland cells are washed away, there remains a "fibrous network" in the normal organ; but a large proportion of this network consists in the natural condition of vessels only, as is seen on examination of carefully injected specimens. It is well known that Dr Johnson's "fibrous network"—that is to say, speaking roughly, one-tenth part fibre and nine-tenths vessels, exists between the tubules of the normal kidney; but now comes the question, If this fibro-vascular stroma be found in the small red granular kidney, as it very commonly is, increased to four or five times its natural dimensions, where is the argument in favour of Dr Johnson's conclusion afforded by its existence in normal quantity in the normal organ? Dr Johnson ought not to be content with washing the gland cells from a section of healthy kidney; let him take also an advanced shrunken and granular kidney in the second stage of Interstitial Nephritis, and wash them out of this also, and then put the specimens side by side under two microscopes; when, in spite of the superior vascularity of the former, he will find the "fibrous network" far more abundant in the nephritic. As to the basement membrane and Malpighian capsules "appearing" to be thickened, they "appear" to be so much in the same manner as the sun appears to shine, or as day and night appear to an unprejudiced and minute observer to succeed

each other. Dr Johnson proceeds — “The remarkable changes within the uriniferous tubes receive no explanation from the theory in question (*i.e.*, the theory of an Interstitial Nephritis). They are, therefore, left unheeded, and, of course unaccounted for.” The author trusts that, should the present essay ever come under the eyes of Dr Johnson, that renowned pathologist will have no cause to complain of the question of intratubular changes being shirked or slurred over; for, according to the best of his ability, he has not left these changes either unheeded or unaccounted for, but has striven to show that they are explicable in a more easy and consistent manner, on the theory of increase of the fibrous stroma, than on that of primary intratubular inflammation.

Dr Johnson now proceeds to point out a “few amongst the insuperable objections to the theory of interstitial fibrosis, which is so confidently maintained by some pathologists.” The first of these is the red colour of the granular kidney. This is held to be “quite inconsistent with the doctrine of intertubular deposit, which must inevitably obliterate the capillaries, and render the cortex more or less pale and anæmic.” To tell the truth, this does not sound very insuperable; for the contracted kidney of Interstitial Nephritis is oftener pale and red. Thoma, *Virch. Arch.*, Band 71, Heft 1, says:—“Die Farbe des Organes schwankt je nach dem verschiedenen Blutgehalte von einem schmutzigen Weissgrau, bis zu blassrothen und matt dunkelrothen Schattirungen.” If red, the colour is due to passive congestion; but so frequently is it pale and anæmic, that in the description in Chapter VI., paleness has been stated as the rule, and redness as the exception. But Dr Johnson assumes that an intertubular deposit must have an obliterating influence on the intertubular capillaries, vastly in excess of that which the author is disposed to allow or ascribe to it. He compares the anæmia which would result from such a deposit, to that “visible over a circumscribed spot, when arteries and capillaries are obstructed by embolic patches of fibrin.” But surely it is one thing to plug up an artery completely, and another to exercise pressure upon its outside, —pressure which it is quite unwarrantable to assume to be severe enough to cause immediate and total occlusion. Such anæmia, he says, is visible in the large white kidney. Surely not. Otherwise, if at all comparable to that induced over a limited tract by an embolism, it would, by affecting

the whole kidney, produce not anæmia, but gangrene. Again, he says that we should expect fatty transformation of the epithelium, consequent on the pressure of the intertubular deposit. Why fatty and not colloid? Degeneration of some kind we should both expect, and do actually meet with; but the author quite fails to see why it must of necessity be fatty. He agrees with Dr Johnson in saying that fatty intratubular change, consequent on Interstitial Nephritis, is comparatively rare, but he accepts in its stead the extensive colloid transformation, which Dr Johnson has "left unheeded, and, of course, unaccounted for." There are also changes of a disintegrative nature, which point to a loosening of the attachment of the epithelium to the basement membrane, and compression of the cells one against another in the narrowed tubules; and presently we find a stage in which the tubules are in parts altogether denuded of their lining. There is no need to go over again in this place the history of changes which we have before minutely particularised; suffice it to say, that these changes are quite consistent with the hypothesis of interstitial increase.

The next "insuperable objection" is the following:—"On examining a section of the kidney, the characteristic intratubular changes may often be seen in various stages of progress, while the intertubular capillaries surrounding these morbidly changed tubes are injected with blood, and evidently quite normal." Here again Dr Johnson is assuming complete circulatory arrest as a consequence of intertubular deposit. The consequence, we repeat, of such complete arrest would be gangrene. Indeed, the author does not believe in the complete stoppage of the circulation, even in the very small capillaries, during the first stage of cell-infiltration. He could even conceive, as he has before hinted, the formation at first of new vessels for the nourishment of the exuded mass of lymphoid cells. The process of vascular obliteration takes place in the stage of cell-transformation and shrinking of the kidney, not in that of cell-infiltration and enlargement. But we have yet to account for the fact of the intratubular changes being seen "in various stages of progress, while the intertubular capillaries surrounding these morbidly changed tubes, are injected with blood, and evidently quite normal." First of all, then, the author differs from Dr Johnson on the question of facts. Where the intertubular changes are most

marked, there he has likewise remarked the consequent intratubular alterations: but where the intertubular changes have been insignificant or absent, there, he has, he may say invariably, found the intratubular structures normal also. But even granting Dr Johnson's statement, is there no way of accounting for intratubular change as consequent upon interstitial inflammation, even though the parts in the immediate neighbourhood of the tubule may be comparatively normal? Already in this chapter we have mentioned the occasional presence of leucocytes in the tubules. May not their presence be sufficient to account for the occasional occurrence of this phenomenon? The escape of blood into a tubule from actual rupture of the capillaries of a glomerulus connected with it, might also produce the appearance, or even the reality, of intratubular change.

The fact that interstitial changes may be induced in a kidney by obstruction of its ureter, appears to the author to be a fact of no significance either way, though mentioned by Dr Johnson in the above-quoted article in support of his own theory. Subacute or chronic irritation from any cause may induce interstitial inflammation; and to the author it seems a matter of little moment whether this irritation arise from a blood poison or from a local cause.

While entirely agreeing with Dr Johnson, as to the hypertrophy of the muscular coat of the arterioles, the author differs from him on an anatomical point respecting the structure of this coat. On page 114 *Med. Chir. Trans.*, vol. xxxiii.; on pp. 149, 150, *Med. Chir. Trans.*, vol. lvi.; and on page 384 *Path. Soc.'s Trans.*, 1877, in criticising a drawing of Sir William Gull and Dr Sutton's (*Med. Chir. Trans.*, vol. lv., plate vi., fig. 7), he avers that the muscular coat consists of two layers, an inner longitudinal, and an outer circular. This statement is at variance with all modern anatomical teaching, and contrary to the results of the present author's investigations. Of the curious drawing criticised by Dr Johnson we shall have occasion to speak in the ensuing chapter, so that we shall pass it by for the present. But the author believes, in common with all accepted anatomical authorities, that the muscular coat of the arterioles is arranged in but one direction, and that a circular one (See Klein, *Path. Soc.'s Trans.*, 1877, pages 433-4); and of the hypertrophy of this circular layer there is, in his opinion, ample and

convincing evidence. What Dr Johnson terms the inner longitudinal muscular layer, is probably nothing more than the intima thickened by Endoarteritis Obliterans. Such, at any rate, must have been the case in the arteriole figured on page 114 *Med. Chir. Trans.*, vol. xxxiii.

The author has seen the appearance of hypertrophy of the muscular coat in arterioles taken from the tongue of a cat; but he is quite ignorant of the state of this animal's kidneys.

With regard to the view that the muscular hypertrophy is simply the result of *post mortem* contraction of the muscle cells, while perfectly convinced in his own mind that no amount of contraction could produce so marked an appearance of thickening, it was the author's intention to perform a series of experiments which he was in hopes would conclusively settle the question. It was his purpose to ascertain the amount of apparent thickening, if any, of the tunica media in the arteries of animals poisoned both by a single large dose, and by a succession of small doses of some drug causing contraction of the arterioles, such, for instance, as ergot. Unfortunately, however, for the completeness of his researches, they had not reached this stage before the passing of the recent prohibitory enactments, so that he was presently compelled to apply to the Home Secretary for a licence authorising him to proceed. This was curtly and peremptorily refused, without the assignment of the smallest reason. If, however, it be a consolation to have companions in misfortune, the author was soon able to avail himself of this sorry crumb of comfort; for he speedily learnt that he was but one out of many sufferers from a piece of legislation, which if it continue to be enforced, will have the effect of so retarding the flood of scientific progress in this country, that in the course of a decade or so, our legislators may proudly reflect upon the fact that during that period the world has been preserved from some hundreds of useful discoveries, and the march of intellect in these islands retarded not a little by the ingenious disposition of a very formidable and effectual stumbling-block, planted in the way of the pioneers of knowledge and humanity by a Government which, despite its pretended oligarchical tendencies, has proved itself but too ready to hand over the control of the educated few to the ignorant many, and to purchase evanescent popularity at the price of lasting folly. Truly, if the intellect of the nation is to be thus hedged

about with contumelious restrictions, we shall come at last to echo the dreary dictum of Sophocles—

ἐν τῷ φρονεῖν γὰρ μηδὲν ἡδιστος βίος

Ajax. 554.

'Tis a happy thing to be a numskull.

Metaphorically speaking, a dose of Curara has been given to British Science, and its limbs, formerly so active, now hang paralysed and useless. Better paralyse the legs of a frog than the brains of a nation. But we digress somewhat.

On page 107, *Med. Chir. Trans.*, vol. xxxiii., Dr Johnson makes the curious statement that, as a consequence of the destruction of the gland cells and arrest of the process of secretion, *oil globules collect in the interior of those blood-vessels* in which the circulation has ceased. Such a collection of oil globules the author has never seen, nor is he without grave doubts as to its even occasional existence; for, in spite of the constant use of osmic acid, he has in no single instance detected any sign of intravascular fatty change. The condition has, however, been mentioned by other authors. Dr Galabin (*On the Connection of Bright's Disease with Changes in the Vascular System*) says (page 14), "As to the state of the capillaries or minutest arterioles, I have found a granular or apparently fatty condition common in cases of granular kidney." He does not say in what situation, whether inside the lumen, or in the coats; and the present writer thinks it not improbable that the numerically increased muscular nuclei of the tunica media may have been mistaken by Dr Galabin for fatty granules,—an error not quite so impossible as might at first sight appear. Sir W. Gull and Dr Sutton (*Med. Chir. Trans.*, vol. lv., page 281) describe groups of fat granules aggregated together in the walls of the smaller arterioles of the pia mater. Todd also (*Clin. Lect. on Diseases of the Urinary Organs*, 1857, Lect. 4, page 109,) says that the canals of the minute afferent arteries of the Malpighian bodies are sometimes blocked with oil. Nevertheless, we suspect that with the improved methods of microscopical observation now becoming general, the discovery of oil in the vessels of interstitial kidneys will become less frequent day by day.

CHAPTER VIII.

VIEWS OF SIR WILLIAM GULL AND DR SUTTON.

IN the fifty-fifth volume of the *Medico-Chirurgical Transactions*, Sir W. Gull and Dr Sutton first published their now well-known paper, on "Arterio-Capillary Fibrosis," a supposed general morbid state of the vascular system, of which, as they maintain, the lesions, occurring in Interstitial Nephritis are but part and parcel. We quote *verbatim* from this paper the following summary of the results of their investigations. (*Med. Chir. Trans.*, vol. lv., page 283.)

- "(1) That the arterioles throughout the body, in that condition usually called Chronic Bright's Disease with contracted kidney, are more or less altered.
- "(2) That this alteration is due to a 'hyalin-fibroid' formation in the walls of the minute arteries, and 'a hyalin-granular' change in the corresponding capillaries.
- "(3) That this change occurs chiefly outside the muscular layer, but also in the tunica intima of some arterioles.
- "(4) That the degree in which the affected vessels are altered, and the extent to which the morbid change is diffused over the vascular system in different organs, varies much in different cases.
- "(5) That the muscular layer of the affected vessels is often atrophied in a variable degree.

"These facts show that there is a morbid state in which the kidneys are contracted, the heart hypertrophied, and the minute arteries and capillaries altered by a hyalin-fibroid formation. Further, that the kidney changes are often, but not always, a part and parcel of this morbid state. The absence of such lesions of the kidneys proves that they do not constitute an essential and indispensable part of the general process." (Page 286.)

We will further allow Drs Gull and Sutton to describe the "hyalin-fibroid" substance in their own words. "A fine hyalin or hyalin-fibroid substance was seen between the convoluted tubules, which made the tubules appear wider apart than normal. In some parts this substance had a homogeneous appearance; in others it had a striated or fibroid

appearance, like a network, and contained minute indistinct nuclei (?); and in others it had a coarser and more defined fibre-like character. This substance was seen in considerable quantity round the Malpighian bodies, and in still greater amount in and around the walls of the minute arteries." (Page 274.)

In the first place we would ask attention to the fact that the foregoing description of hyalin-fibroid substance answers almost equally well for granulation tissue: and, in point of fact it is simply and solely the granulation-tissue deposit between the convoluted tubules, to which Drs Gull and Sutton apply the term of "hyalin-fibroid" substance. It is but an alteration in name, and that for the worse; since such terms as "nuclear tissue," "granulation" or "embryonic tissue," "small-cell infiltration," "infiltration with lymphoid cells," and the like, convey a correct notion of the pathology of the new formation, whereas the appellation, "hyalin-fibroid substance," points to an etiology which, as we shall presently see, is but slightly corroborated by facts. Further, this "hyalin-fibroid" alteration is said to be seen in the walls of the minute arteries, outside the muscular layer, and also in the tunica intima of some arterioles. In the earlier stages of granular contraction, Sir W. Gull and Dr Sutton say (page 275), "In the walls of some of the minute arteries, and also outside and around them, there appears to be an excess of fibroid tissue, and the arteries, in consequence, seem thicker than normal. In making this observation, we are well aware that there is normally more or less of areolar tissue around the minute renal arteries, therefore it is difficult with any degree of certainty to appreciate any slight increase in such tissue, but after careful observation, it seemed to us that the outer coats of the arterioles, even at this early stage, were thickened by increase of fibroid tissue. The muscular tissue did not appear increased." According to the present author's experience, the "areolar tissue around the minute renal arteries" is the seat of small-cell infiltration at an early period in the history of Interstitial Nephritis, as might be expected from the presence of the lymphatic spaces before alluded to as demonstrated by the injections of Ludwig. But as to the adventitia proper, it is far otherwise. In a great number of instances it remains normal and unthickened, even in very advanced stages of granular contraction; and if thickened at all, this thickening is due to a secondary extension of the process of

hypertrophy going on in the connective tissue surrounding it. This connective tissue is both early increased and early fibrillated, and on casual observation might, perhaps, convey the idea of thickening of the adventitia, though that coat is distinctly visible as a narrow, dense, finely-fibrillated ring, quite normal, and but loosely connected with its hypertrophied surroundings, as may be proved by picking it out with needles. In the author's specimens, thickening of the adventitia proper is only seen in a very few of the most advanced; and in these it is simply due, as just stated, to an extension of the processes going on around. Primary or early thickening of the adventitia, whether hyalin or fibroid, the author has absolutely *never* seen; hyalin changes in the adventitia he has also never seen, if we except that thickened and translucent appearance sometimes observed in the loops of the glomerulus, which is probably the harbinger of impending colloid change. Fibroid thickening of the adventitia he has only seen late in the disease, and as a secondary consequence. He does not, however, in the least impugn the absolute correctness of the description given by Sir W. Gull and Dr Sutton of the appearances seen by them in their own specimens; though he is persuaded that if such a state of matters as that described by them is visible in their preparations, it is simply owing, as stated by Dr Johnson (*Med. Chir. Trans.*, vol. lvi.), to the methods of manipulation and mounting to which they were subjected. Sir W. Gull and Dr Sutton admit that their specimens were not mounted by themselves, but by an assistant; and they could therefore have had no opportunities of observing any changes which might ensue in consequence of the use of reagents and mounting fluids. Now, certain mounting media, especially glycerine, are very prone to alter specimens preserved in them. Dr Galabin (*On the Connection of Bright's Disease with Changes in the Vascular System*, pages 13 and 14), and also, to some extent, Dr Grainger Stewart (*Brit. Med. Jour.*, Nov. 15, 1873) confirm Dr Johnson's statements as to its untrustworthy character, especially if acidulated. These allegations the author has verified, and he thoroughly concurs in the condemnation of pure glycerine as a mounting medium. Well-made Farrant's solution, and Rimmington's glycerine jelly, though both containing glycerine in some form or other, are free from these objections. Arteries of the *pia mater*, mounted in glycerine alone, or in glycerine and

camphor water (the fluids used for the preparation of Drs Gull and Sutton's specimens), rapidly present appearances of hyalin change, and still more so if acetic acid be added. With care and pains also, "hyalin-fibroid substance" may be largely manufactured in the kidney; that is to say, if the specimen has not been hardened in chromic acid, which seems inimical to its development. Fresh kidney, mounted in acetic acid and glycerine, readily assumes this guise; kidney hardened in bichromate solution or Müller's fluid less readily, though the author has had some success, even with specimens so treated.

Plate x. represents an instance of these factitious changes. The vessel there figured was taken from a normal kidney hardened in Müller's fluid, and was itself normal before undergoing the following treatment. First of all it was stained late in the afternoon in $\frac{1}{2}$ per cent. solution of osmic acid, and then allowed to remain all night in a bowl of clean water. On examination in the morning it appeared quite natural, under both low and high powers. It was then spread out upon a slide, and covered with glycerine acidulated with a drop or two of 1 to 8 solution of acetic acid. After remaining thus for about two hours, a cover glass was placed on it, when, upon renewed examination, it presented the remarkable appearances given in the woodcut. From this it will be seen that no distinct muscular coat and no intima are distinguishable. The wall, whose thickness is very irregular, is apparently composed of "hyalin-fibroid" material, surrounded by a somewhat denser ring representing the adventitia proper. Around this is some connective-tissue, pretty normal in general appearance, though rather "hyaline," and swollen to nearly twice its original proportions. Curiously enough, close to this strangely metamorphosed artery was another and smaller one much less altered; for though its wall appeared nearly homogeneous from blending together of its coats, it was not swelled out like that of its neighbour, thus affording a striking example of the capriciousness of these spurious appearances. On comparing Plate x. with two of Sir W. Gull and Dr Sutton's drawings (Figs. 6 and 4, plate vi. *Med. Chir. Trans.*, vol. lv.) a close resemblance will be observed, more especially in the case of Fig. 6, which represents an arteriole from the muscular tissue of the heart greatly thickened by fibroid material. In Fig. 4, the globular bodies inside the

arterioles are puzzling, though they may possibly merely represent swellings of the intima caused by the glycerine.

The author has never seen anything exactly like the arteriole in Fig. 7 of the same Plate, though three more or less feasible conjectures might be hazarded as to its nature. Thus, it might either represent an artery with thickened media and intima, the adventitia from some cause being left unfigured; or, an artery with thickened intima, the outer and middle coats being confused by the glycerine; or, lastly, the glycerine may have confused the middle and inner coats, while greatly swelling out and distending the external one. However this may be, it is at least certain that glycerine tends to render the three arterial tunics separately indistinguishable.

Were it permitted us, we should recommend future observers to harden their specimens of kidney in chromic acid of the strength of 1 part to 400, letting them remain in this fluid at least four weeks; a preliminary sojourn in Müller's fluid of about three weeks' duration being advisable, especially if the pieces of tissue are large. Let them then be cut in the freezing microtome, a strong solution of gum being used for imbedding. Before cutting, they should remain for a night in plenty of clean water, to allow the chromic acid to soak out. After cutting, let them be mounted, not in glycerine, but in thick Farrant, prepared with strong gum solution, or in good glycerine jelly, such as Rimington's. They will then pass through the ordeal unchanged, and give their testimony in a trustworthy manner. Should Drs Gull and Sutton thus treat their next series, we venture to predict that it will not prove rich in "hyalin-fibroid" material.

Mr D. J. Hamilton, Pathologist to the Royal Infirmary, Edinburgh, who had an opportunity of inspecting Drs Gull and Sutton's specimens, once told the present author that there appeared to be nearly as much "hyalin-fibroid" material in the healthy as in the abnormal ones. Of this we have no doubt; for normal arteries mounted in glycerine often present very much the same appearances as diseased ones.

Plate v., fig. 1, vol. lv., *Med. Chir. Trans.*, represents some Malpighian bodies, as seen by Sir W. Gull and Dr Sutton. Bowman's capsule is with perfect correctness represented as thickened and fibrous; but in place of the glomerulus, a number of "fat and other granules" are figured in the

drawing. The author has never seen such an appearance in any specimen examined by him. Some of the "fat granules" remind him somewhat of the nuclei visible in the same situation in Glomerulo-Nephritis; but altogether this drawing is nearly as puzzling as that of the arteriole.

Lebert (*Traité d'Anat. Path.*) says, referring to the atrophic form of Bright's Disease, "les capsules de malpighi sont remplies de gouttelettes de graisse" (vol. ii., p. 336), but it is probable that his description refers to the atrophic or third stage of parenchymatous inflammation. (See Dr Grainger Stewart's work already cited, 2d. ed., page 16.) The author would not say that a glomerulus never becomes fatty in ordinary uncomplicated Interstitial Nephritis; but he can affirm unhesitatingly that among hundreds of specimens he has never seen one so changed. Was there any parenchymatous nephritis in the kidney which furnished the drawing? We conclude not, as Drs Gull and Sutton make no mention of it. The kidney was from the body of a girl nine years old, an unusual, though not unprecedentedly early age for interstitial changes; for Dr Barlow (*Lancet*, Aug. 1st and 8th, 1874) records a case of granular kidneys, with hypertrophied heart, in a child five years and eleven months old. On the contrary, out of 79 cases collected by Dr Galabin from the *post mortem* records of Guy's Hospital during the four years 1869-72, there was none younger than ten years. Perhaps the case may be one of those secondary fibrotic ones described by Dr Stewart. Or, again, the irrepressible glycerine may be responsible for the "fat granules;" for the appearance of the glomeruli, in sections mounted in glycerine, especially if the vascular loops contain blood cells, is often not a little curious.

On page 177 (*op. jam. cit.*) Sir W. Gull and Dr Sutton attribute the granularity of normal renal epithelium to mechanical congestion, and consider it as a sort of *post-mortem* phenomenon. It is, however, equally evident in the kidneys of cats rapidly bled to death by cutting the throat, or by complete decapitation; though in such specimens *post-mortem* or directly *ante-mortem* congestion is, from the manner of death, impossible. The conclusion, therefore, appears inevitable, that granularity is the natural and typical condition, though it may, of course, be indefinitely exaggerated as the result of disease. Still the normal granular appearance should always be remembered in estimating the

normal or abnormal nature of the granularity of epithelium in any given kidney.

In the present monograph, the author is not prepared to follow Drs Gull and Sutton into their elaborate paper on "Arterio-Capillary Fibrosis" in the spinal cord. (*Path. Soc's. Trans.*, 1877.) Should he have the opportunity, he will gladly do so at some future period; nor is he altogether unprepared to begin the prosecution of such investigations; though, up to this time, material to work upon has been entirely wanting. Yet, though diseased spinal cords have found their way but very sparingly into the author's hands; though those which he has hitherto possessed have been as few and far between as angels' visits, or as the currants in a confectioner's bun, there are a few observations which, from his acquaintance with the normal structure of the cord, he may perhaps not unwarrantably venture to make. Firstly, then, he begs to congratulate Drs Gull and Sutton upon their enforced abstinence during this investigation from the use of the staff of that broken reed — glycerine. Canada balsam is an excellent mounting medium for nervous tissues, and only second, perhaps, to well-prepared Dammar fluid. In either of these fluids, specimens may be mounted, with ordinary care, without the least fear of adventitious change. Secondly, he would allude to the fact that in the cord, as in the kidney, more or less connective tissue is distributed with the vessels, which connective tissue cannot in any sense be said to constitute their adventitia. In interstitial inflammations, it may be taken as a rule that the greatest increase of connective tissue will be met with in those parts which contain the most normally; and, as a consequence, it is not surprising, if as mentioned by Rindfleisch (*Path. Hist., Syd. Soc's. Trans.*, vol. ii.), the foci of fibrous thickening in Inflammatory Induration of the cord present a red spot or line in their centre, which is, in fact, a distended blood vessel. But a connective-tissue inflammation cannot be said to be an "Arterio-Capillary Fibrosis," simply because the distribution of connective tissue in any given organ follows the path of the blood vessels.

Rindfleisch, however, in speaking of Inflammatory Induration of the cord, says that the adventitia of the vessels is made up of concentric layers of round cells (*op. cit.*, p. 350); and he further states that the vessels are in a state which he

would not scruple elsewhere to call one of chronic inflammation. Drs Gull and Sutton (*Path. Trans.*, 1877, p. 377) quote this passage in support of their conclusions, for Rindfleisch's Inflammatory Induration is, in their opinion, simply "Arterio-Capillary Fibrosis," as seen in the cord. The statements of so accurate an authority as Rindfleisch must always have great weight, especially when corroborated by the results embodied by Drs Gull and Sutton in their careful and beautifully illustrated paper. We will not, therefore, attempt to deny that the arteries, as also the capillaries of the cord, which last have, as Stricker believes, a continuous layer of protoplasm on their outer surface, are really involved in the process of Inflammatory Induration. What, however, we entirely fail to see is, that this state of matters in the cord has anything more than an incidental connection with the very dissimilar kidney lesions. There is no condition of the renal vessels analogous to this in Interstitial Nephritis. The two pathological states appear to us to be quite different. Assuming, with Rindfleisch, that the first anatomical element of Inflammatory Induration, or, as Drs Gull and Sutton would doubtless prefer to call it, "Arterio-Capillary Fibrosis" of the cord, is to be recognised in alterations of "individual vascular tufts," the present author can testify with a clear conscience to the fact of no such alterations being visible in any of his specimens of interstitial kidney. Never, under any circumstances, has he seen the adventitia of the renal arterioles "made up of concentric layers of round cells, often five deep." Thickening of the adventitia he has seen, but it was not the first anatomical element of the disease,—no, nor the second, nor the third, but a very late and entirely secondary one. As to the influence of reagents in inducing an appearance of thickening of the outer coat in the case of vessels from the *pia mater*, Dr Grainger Stewart says (*Brit. Med. Jour.*, Nov. 15, 1873), "The conditions which I have observed are . . . first, a more or less marked thickening of the coats of the small arteries. This is in some cases so distinct as to attract attention by its wavy fibrous appearance and the sinuous outline of the vessel where no reagent has been applied. But these appearances become much more distinct when the specimens are placed for a short time in water or in glycerine, or when a little dilute acetic acid is added. In many cases the application of these reagents produced an appearance of thickening, certainly of increased prominence of the external coat, even when the

vessel without reagent appeared natural. But the appearance thus artificially produced differed from that of the true thickening in that it was never wavy or fibrous looking. I found no evidence of free exudation or of the presence of any solid material in connection with the outer coat. The condition thus described corresponds exactly to the appearances of the specimens of so-called hyalin fibroid disease which I examined." He also found evidence of thickening of the tunica media, and in some cases of the intima. The tunica media was never atrophied, nor was the lumen of the vessels diminished. No thickening or exudation was seen in the walls of the capillaries. These facts were gathered from the examination of a series of twenty-three cases, in twelve of which the vessels were normal. But here ends all that is favourable in Dr Stewart's evidence to the theory of Arterio-Capillary Fibrosis; for-out of ten cases in which the outer coat was thickened, there was no Bright's Disease whatever in six. Dr Stewart is, nevertheless, clearly of opinion that some of his cases presented a thickening of the outer coat of the arterioles, not traceable to the use of reagents. But Sir W. Gull and Dr Sutton are not much advantaged by this admission; for Dr Stewart's statistics go to prove that the thickening was altogether unconnected with Bright's Disease, either as effect, or as necessary concomitant. In the walls of some of the vessels were small aneurisms, due probably, as we may conjecture, to that diseased state known as Chronic Peri-arteritis, which might quite satisfactorily account for the thickening; unless, indeed, Drs Gull and Sutton would include this also in their "Arterio-Capillary Fibrosis," in spite of the entire absence of connection between it and Nephritis of any kind. Now, the author has seen plenty of Chronic Peri-arteritis; but he has never seen any thing of the nature of "Arterio-Capillary Fibrosis" in the vessels of the *pia mater*, or elsewhere, except as a consequence of the use of reagents. Not that he would aver that the adventitia is never thickened;—it may be so from many causes; but what he states is simply this, that so far as he knows, there is not a grain, or the ghost of a grain, of evidence to connect this thickening with Interstitial Nephritis; while, on the contrary, there is strong proof in favour of a relation subsisting between thickening of the tunica media and this variety of renal lesion. Such evidence is afforded in the course of Dr Stewart's paper above-mentioned, as well as by many other authorities already quoted.

The thanks of pathologists are due to Sir W. Gull and Dr Sutton, not only for the careful manner in which they have sought to collate facts in support of an ingenious theory, but also for having, by their example, afforded a powerful incentive to others to prosecute researches in the same direction, thereby conducing greatly to the wider and more thorough ventilation of the whole question. But while sensible of the benefit they have thus rendered to the profession, the author is unable to accept their principal conclusions, his own investigations having led him to believe that they have fallen into certain errors already stated, which may be epitomised under the following heads :—

- (1.) In the interstitial kidney, Sir W. Gull and Dr Sutton have probably, in many instances, mistaken the middle for the outer coat of the arterioles, and have thus been misled by a factitious appearance of thickening of the latter. Their use of glycerine as a mounting fluid has probably done much to further this confusion.
- (2.) In other instances, though “well aware that there is normally more or less of areolar tissue around the minute renal arteries,” they have fallen into the error of confounding this with the adventitia proper, a mistake also, perhaps, traceable to the use of glycerine.
- (3.) In the pia mater, brain, spinal cord, and other organs, they have observed a state of matters partly real, partly factitious, which, in consequence of their ideas as to the nature of the kidney lesions, they have been led to consider anatomically identical with those lesions, whereas material differences exist between them.

In conclusion, then, there appears at present to be no conclusive evidence of the existence of a general morbid state characterised by “Arterio-Capillary Fibrosis” and “hyalin-fibroid” changes; for such a state of matters does not exist in the kidney, and there are grave reasons for doubting its existence elsewhere.

NOTE ON GLOMERULO-NEPHRITIS.

The materials of the following note have been gathered from an examination of the kidneys in three cases of post-scarlatinal nephritis.

Klebs (*Handbuch der Path. Anat.*, Lief: iii., pp., 644-647) was the first to direct special attention to a post-scarlatinal change in the glomeruli, to which he gave the name of Glomerulo-Nephritis. A. Beer, Dr Bristowe (*Path. Soc's. Trans.*, vol. viii., p. 235,) and Dr Wilks (*ibid.*, vol. vi., p. 264) had previously remarked conditions more or less similar; but to Klebs belongs the credit of first accurately describing the microscopic anatomy, and of clearly distinguishing this variety from others previously recognised. Until recently, post-scarlatinal nephritis was generally considered to be of the Parenchymatous variety, though Biermer, Coats, Wagner, and Cayley have described cases in which the changes were interstitial. We shall first give a translation of Klebs' description, and then proceed to a consideration of the appearances as seen by ourselves:—

“On *post-mortem* examination, the kidneys are seen to be slightly or not at all enlarged, firm to the touch, the capsule easily separable, the surface smooth, and the parenchyma hyperæmic. On careful inspection, the glomeruli appear pale, like small whitish spots. The uriniferous tubes are often unaffected, though occasionally the convoluted tubules are somewhat cloudy. On microscopic examination, we find neither interstitial changes, nor that proliferation of epithelium known as Renal Catarrh, a state of matters often supposed to exist in default of other perceptible derangements; so that with the exception of the condition of the glomeruli, there seems to be nothing beyond the congested state of the kidney to account for the symptoms (anuria, uræmia, and acute dropsy). This, however, is palpably insufficient, since complete retention of urine and acute uræmia have never been observed either in active or passive hyperæmias of equal intensity, such, for example, as those consequent on poisoning by carbonic oxide, or on mechanical congestion. If a thin section of the fresh kidney be made with a Valentin's knife, the anæmic condition of the glomeruli becomes still more evident; and if the sections be washed in water, the glomeruli stand out in

their substance as objects darker and denser (trüber) than the uriniferous tubules, while in direct light they are visible to the naked eye as white spots. On microscopic examination, the whole interior of the capsule is seen to be filled with somewhat small angular nuclei lying embedded in a finely granular mass; while on the inner surface of the capsule the epithelial lining is seen in profile as a row of flat, knobby projections. The vessels of the glomerulus are almost entirely obscured by the nuclear mass. It is somewhat difficult to ascertain accurately the real anatomical situation of the manifest nuclear increase; and this can only be done by careful isolation of the glomerulus"—and picking it to pieces with fine needles—"whereby one learns that the epithelial lining of the glomerulus is still visible, and is, indeed, as a general rule, even more closely adherent than normally. The epithelial cells are for the most part polygonal or clavate, with large, oval, bladder-shaped (bläschenförmigen) nuclei, and very often adherent by one corner to the surface of the glomerulus; in certain cases I have seen them fattily degenerated, but as a general rule, their substance has a clearer and denser (heller und fester) appearance than under normal conditions. By carefully separating these epithelial cells, we recognise in the fragment of glomerulus, around and between the unchanged and empty capillary loops, the same small angular nuclei, already so conspicuous on a general view of the glomerulus. The difference of these elements from those of the epithelium, both in respect of form and situation, shows quite clearly that their origin is due to a multiplication of the connective tissue corpuscles of the glomerulus, owing to the presence of which the vascular loops are subjected to compression." (Klebs, op: cit: Lief. iii., pp. 645-6.)

On the question of naked eye appearances, the author is entirely at one with Klebs, so that there is no occasion for a reiterated description. We shall therefore proceed at once to an enumeration of the microscopical appearances observed in the three specimens already alluded to. These respectively afforded examples of the early, intermediate, and later stages of the lesion.

On examination with a low power (Hart. oc. 3, \times obj. 7), the attention is principally arrested by the dense appearance of the glomeruli, which occupy almost the whole of the interior of Bowman's capsules. Even with this power, especially if the tube of the microscope be drawn out, small

bodies like grains of sand can be seen covering the loops of the glomeruli. These small bodies can also be seen in scattered foci among the general intertubular stroma, and especially around the vessels. (*See Plate xii.*) Most of the uriniferous tubes are unchanged, save here and there in the immediate neighbourhood of the Malpighian bodies, where some few may be seen whose epithelium is granular, cloudy, or more frequently fatty. The capsule of the kidney is slightly thickened, and the interstitial tissue appears more abundant and distinct than in the normal organ.

On examination with a high power (Hart. oc. 3, \times obj. 7), a most interesting series of lesions becomes visible. The Malpighian bodies are the parts principally affected. Bowman's capsules are thickened and infiltrated with round cells. These round cells are also aggregated outside the capsules, their numbers varying with the intensity of the process, and the stage at which it comes under observation. The unaltered epithelial lining on the inside of Bowman's capsules can be recognised without difficulty. Inside the capsules, on and between the capillary loops of the glomeruli, are great numbers of small roundish, oval or angular bodies like leucocytes, which correspond to Klebs' 'nuclei.' (*See Plate xi.*) As mentioned on page 11, a certain number of corpuscular bodies are normally found in this situation; but in Glomerulo-Nephritis their number is very largely increased. Speaking roughly, there may be perhaps six or eight times the normal number in the earlier examples, while in extreme cases Bowman's capsules are often completely filled with them. They are probably derived both from migratory leucocytes, and from proliferative increase of the normal corpuscles. A number of the Malpighian bodies may be entirely obscured by dense corpuscular aggregations, situated anatomically both within and around Bowman's capsules.

These abundant cell-accumulations must evidently exercise great compression on the vascular tufts, and thus present a serious obstacle to renal circulation and excretion. The compressed and empty capillaries of the glomeruli are not infrequently converted into more or less dense fibrous masses, wholly impervious, and continuous here and there, if not entirely, with the inner circumference of their thickened capsules. (*See Klein, Trans. Path. Soc. 1877, pl. 33, fig. 7.*) The number of corpuscular bodies on the surface and in the substance of these fibrous glomeruli is invariably greatly

diminished. The fibrous glomeruli stain but faintly with carmine and logwood, thus contrasting markedly with their capsules, which continue to absorb the colouring matter readily.

These processes of cell-aggregation, in and around the Malpighian bodies, constitute the characteristic features of the disease, and those upon which the clinical symptoms of anuria, uræmia and dropsy appear to be mainly, if not entirely, dependent. But the present writer cannot corroborate Klebs in asserting the complete absence of other anatomical lesions; for in his specimens, as in Dr Klein's, there were abundant evidences of ordinary Interstitial Nephritis, as well as of minor intratubular changes. Dr Klein, in the paper above referred to, endeavours to account for the interstitial changes on embolic grounds. Having encountered emboli in the arteries of a kidney from a case of thirteen days' duration, accompanied by very intense interstitial inflammation, he thinks it not impossible that embolism may always stand "in a causal relation to the interstitial inflammation." He states no grounds for this conjecture, which appears rather hasty, considering that emboli were only seen in one case out of his series of twenty-three. As the author has observed but one doubtful embolus in a single artery, he is unable to concur with Dr Klein in ascribing the interstitial changes to this curious and apparently very unusual cause. The interstitial affection is eminently characteristic. The intertubular cell-infiltration is so abundant and evident, that, in our humble opinion, such specimens might serve to convince even Dr Johnson as to the reality of an interstitial cell-infiltration. In these cases the round cells cannot possibly be confounded with epithelial *débris*; and their intertubular situation is thus placed entirely beyond doubt. Glomerulo-Nephritis is, in fact, nothing but an interstitial nephritis, specially affecting the glomeruli, and in consequence of this special anatomical site, proving fatal in the early stages with a rapidity and constancy fully equal to the rarity of a like result in the initial stages of the ordinary variety.

Around the arterioles there are large accumulations of migrated leucocytes. (See Plate xii.: also Klein, *Path. Trans.*, 1877, pl. 32, fig. 4.) The intertubular capillaries are much dilated, and contain great numbers of white blood-corpuscles. Sometimes the leucocytes accumulated outside a vessel have

the appearance of lying in a sort of adenoid reticulum, as noticed by Klein; but this appearance the author is disposed to attribute to underlying capillaries, the walls of which are more or less visible through the superincumbent mass of lymphoid cells. The author has not seen any germination of the nuclei of the middle coat of the arteries such as that mentioned by Klein, neither has he observed any hyaline degeneration of the intima, as stated by the same authority. In his specimens all the arterial coats were perfectly normal.

Small interstitial hæmorrhages, evidenced by the presence of red blood corpuscles, and hæmorrhages into Bowman's capsules from rupture of the glomerular loops, are by no means infrequent phenomena.

Intratubular changes are present to a greater or less degree. These changes are not uniform, but sporadic, a few tubules here and there being affected, while others in their neighbourhood remain perfectly normal. On the whole, the tubules thus altered are few in number, compared with those which remain unchanged. The convoluted tubules are more frequently affected than the straight. Those tubules in the immediate neighbourhood of the Malpighian bodies seem especially liable to undergo alteration of their contents. The alterations consist of cloudy swelling and granular degeneration of the epithelium, the cells breaking up into a mass of small, dark granules, which occasion more or less blocking up of the lumen of the tubules. Fatty degeneration also is a change of still more frequent occurrence. It often appears to begin in the nucleus of the epithelial cells, and is rendered very evident by staining with osmic acid. Red blood-corpuscles and leucocytes are frequently seen inside the tubules. Their presence may have something to do with the intratubular alterations, which are secondary to the interstitial changes, and may be accounted for both by the entry of blood cells into the tubules, and also on the score of deficient blood supply, due to the pressure exercised by the small-cell tissue, both on the glomeruli, and also on the intertubular arterioles and capillaries. Dr Klein also regards the intratubular alterations as secondary, for he says—"This (*i.e.*, the parenchymatous change), becomes distinct after the interstitial changes have reached a certain degree, and they (*sic*) are quite insignificant before this degree of interstitial nephritis is attained." And again:—The "more intensive (*sic*) the degree of interstitial change, the more marked is the enlarge-

ment of the kidney, and the more distinct is also the parenchymatous nephritis, the number of urinary tubes, which either contain casts, or are in process of destruction by being flooded with the inflammatory products (especially cells), increasing gradually. . . . It follows from this that the intensity of the parenchymatous change, is dependent upon the degree of the interstitial nephritis." In the author's cases, he has never seen any deposit of lime in the epithelium or lumen of the urinary tubules (Klein).

The changes just enumerated are most conspicuous and widespread in the cortical portion of the kidney, though the medulla is by no means exempt.

Dr Klein ascribes the corpuscular increase on the surface of the glomeruli to a proliferation of epithelial nuclei; but as mentioned by Klebs, the nuclear bodies differ from epithelial cells or nuclei, alike in form and in anatomical site. They are situated between the vascular loops as well as on their surface, a fact which is alone sufficient to negative the supposition of their epithelial nature. Dr Klein also states that in the course of his investigations, he has never seen any accumulation of these nuclear bodies within the Malpighian capsules, in numbers sufficient to be likely to cause compression of the vessels of the glomeruli, and consequent interference with the circulation. He admits, however, that his cases were probably different from those described by Klebs. Of this there can be no doubt, for a very cursory inspection of the author's specimens would suffice to confirm the accuracy of Klebs' description, and to demonstrate beyond doubt the immense obstacle which the excessive nuclear proliferation must of necessity occasion to the free passage of blood through the capillary loops. Indeed, a more favourable condition for the development of anuria, uræmia, and acute dropsy could scarcely be imagined.

The principal changes just described, may be thus briefly recapitulated:—

SUMMARY.

A. SPECIAL CHANGES.

- (1) Increase of nuclear bodies, probably leucocytes and proliferated connective-tissue corpuscles, inside Bowman's capsules, on the surface and between the loops

of the glomeruli, in such quantity as to occasion serious circulatory obstruction from pressure on the vascular loops.

- (2) Thickening and nuclear infiltration of the substance of Bowman's capsules, with great accumulation of nuclear bodies in the immediate neighbourhood of their outer surfaces.
- (3) Fibrous degeneration of the glomeruli, consequent on pressure and obstructed circulation.

B. GENERAL INTERSTITIAL CHANGES, ETC.

- (1) Appearances consequent on general Interstitial Nephritis, namely, dilatation of capillaries, with accumulation of leucocytes in their interior, migration of leucocytes through the walls of the vessels, and connective-tissue increase from small-cell infiltration.
- (2) Small hæmorrhages, interstitial, and into the interior of Bowman's capsules.
- (3) Embolism (?) of an artery, in a single instance.

C. SECONDARY INTRATUBULAR CHANGES.

- (1) Sporadic parenchymatous nephritis affecting principally those tubules immediately adjacent to the Malpighian bodies, and characterised by (*a*) cloudy swelling; (*b*) granular degeneration; and (*c*) fatty degeneration of the tubular epithelium.
- (2) Presence of leucocytes and red blood corpuscles in the interior of the uriniferous tubules.

BIBLIOGRAPHY

- AITKEN, *Practice of Medicine*, vol. 2.
AITKINS, RINGROSE, *Brit. Med. Journ.*, April 1875.
BARLOW, *Trans. Path. Soc.*, 1877.
,, *Lancet*, August 1874.
BARTELS, *Die allgemeine Symptomatologie der Nierenkrankheiten, und die diffusen Krankheiten der Nieren:—von Ziemmsen's Handbuch der speciellen Pathologie und Therapie*, Band ix., Erste Hälfte.
,, *Volkmann's Klinische Vorträge*, No. 25, 1871.
BEER, ARNOLD, *Die Bindesubstanz der menschlichen Niere*, 1859.
BILLROTH, *Surgical Pathology*, *Syd. Soc's. Transl.*
BOWMAN, *Phil. Trans.*, 1842.
BRIGHT, *Reports of Medical Cases*, 1827.
BRISTOWE, I. S., *Practice of Medicine*.
,, *Trans. Path. Soc.*, vols. 8 and 9.
CAYLEY, *Trans. Path. Soc.*, vol. 21.
CHRZONSCZEWSKY, *Virch. Arch.*, 1864.
CORNIL and RANVIER, *Manuel d'histologie pathologique*.
DICKINSON, *On Albuminuria*, Second Edition.
EWALD, *Virch. Arch.*, 1877.
FRERICHS, *Die Brightsche Nierenkrankheit und deren Behandlung*, 1851.
GALABIN, *On the Connection of Bright's Disease with Changes in the Vascular System*.
GREENFIELD, *Trans. Path. Soc.*, 1877.
GREEN, *Pathology*.
GULL and SUTTON, *Med. Chir. Trans.*, vol. 55.
,, ,, *Trans. Path. Soc.*, 1877.
,, ,, *Brit. Med. Journ.*, June 1872.
HENLE, *Zur Anat. der Nieren*. Gött., 1862.
,, *Handbuch*.
HEIDENHAIN, *Arch. für mikros. Anat.*, 1874.
HEUBNER, *Monograph on Syphilitic Diseases of the Arteries of the Brain*.
JOHNSON, *Med. Chir. Trans.*, vols. 30, 33, 56.
,, *Trans. Path. Soc.*, 1877.
,, *Diseases of the Kidneys*, 1852.
,, *Lectures on Bright's Disease*.
,, *Brit. Med. Journ.*, June 1875.
JONES and SIEVEKING, *Pathology*, Second Edition, by Payne.
JONES, HANDFIELD, *Brit. For. Med. Chir. Rev.*, vols. 13 and 14.

- KEY, AXEL., *Hygiea*, XXII, 1862.
 KLEBS, *Handb. der Path. Anat. Lief.* iii.
 KLEIN, *On the Lymphatic System.*
 „ *Trans. Path. Soc.*, 1877.
 LIEBERMEISTER, *Beiträge zur path. Anat., und Klinik der Leberkrankheiten.* Tübingen, 1864.
 LEBERT, *Traté d'Anat. path.*, vol. 2.
 LUDWIG and ZAWARYKIN, *Weiner Acad. Sitzungsab.*, vol. 48.
 MACLAGAN, T. J., *Paper read before Med. Chir. Soc., Edin.*; see *Brit. Med. Journ.*, June 26, 1875.
 NIEMEYER, *Text Book of Practical Medicine, Humphrey's and Hackley's Trans.*, vol. 2.
 PAGET, *Surgical Pathology, by Turner.*
 QUAIN'S *Anatomy*, Eight Edition.
 RAYER, *Mals des Reins.*
 RINDFLEISCH, *Path. Hist. Syd. Soc's. Transl.*
 RINDOWSKI, *Centralb.*, 69 S. 145.
 ROBERTS, F. A., *Practice of Medicine.*
 SCHWEIGGER-SEIDEL, *Die Nieren des Menschen und der Säugethiere.*
 SIMON, *Med. Chir. Trans.*, vol. 30.
 SOUTHEY, *Barth. Hosp. Rep.*, 1865.
 „ *Report of Med. Chir. Trans., Lancet*, April 13, 1878.
 STEWART, T. GRAINGER, *A Practical Treatise on Bright's Disease of the Kidneys*, Second Edition.
 „ *Brit. Med. Journ.*, Sept. 6, 1873. *Report of Debate.*
 „ *Brit. Med. Journ.*, Sept. 6 and Nov. 15, 1873.
 STRICKER'S *Histology, Syd. Soc's. Transl.*
 RECKLINGHAUSEN, *On the Lymphatics in Relation to Connective Tissue.* Berlin, 1862.
 TANNER, T. H., *Practice of Medicine.*
 THOMA, *Virch. Arch.*, 1877.
 TODD, R. B., *Clin. Lect. on Dis. of the Urinary Organs*, 1857.
 TURNER, W., *Anatomy.*
 VIRCHOW, *Cellular Pathology, by Chance.*
 WATSON, Sir T., *Practice of Medicine.*
 WILKS and MOXON, *Pathology.*
 WILKS, *Trans. Path. Soc.*, vol. 6.

MS. Graduation Thesis by Dr Robert Saundby, for Degree of M.D. in the University of Edinburgh, "The Participation by the Walls of the Blood-vessels in the Morbid Changes of the Connective Tissue," 1877. In the Library of the University of Edinburgh.

DESCRIPTION OF PLATES

PLATE I.—Hart. oc. 3, obj. 7. Typical granulation tissue, from a healing ulcer in the human subject.

PLATE II.—Hart. oc. 3, obj. 7. Patch of interstitial cell-infiltration (ordinary interstitial nephritis in the first stage), from a case of glomerulo-nephritis. Most of the tubules are normal, though a few are somewhat compressed: others are empty, from falling out of their epithelium during the preparation of the section. The new tissue bears a close resemblance to that of the healing ulcer (Plate I).

PLATE III.—Hart. oc. 3, obj. 7, tube out. Second stage of interstitial change, or that of cell-transformation. The round cells of the interstitial tissue are seen in process of conversion into spindles and fibres. The basement membrane of the tubules is thickened and fibrous: but the tubules themselves, though somewhat compressed are but little altered. Two of them however contain colloid cylinders. The nuclei of the cells of the tubular epithelium are very apparent, owing to the specimen having been treated with Acetic Acid.

PLATE IV.—Hart. oc. 3, obj. 7, tube out. Wall of an artery in longitudinal section. *a*, intima somewhat thickened and fibrous: *b*, muscular coat, hypertrophied, with numerical increase of muscle nuclei: *c*, adventitia, normal and unthickened: *e, e, e*, compressed tubules; the lowest one is empty save for the epithelial nuclei which remain adherent to the thickened and fibrous wall: *d*, interstitial tissue in a stage of advanced fibrillation: *f*, tubule containing colloid.

PLATE V.—Hart. oc. 3, obj. 9. Portion of the coat of an artery in transverse section. *a*, adventitia, normal and unthickened: *b*, muscular coat, moderately hypertrophied: *c*, tunica intima exhibiting an early and interesting stage of endo-arteritis obliterans. *d, d, d*, cells of the epithelial lining of the lumen (?), or perhaps identical with *g*: *f, f, f*, elastic layer of the tunica intima split up into its component layers: *g, g, g*, rounded cellular bodies, probably proliferated connective tissue corpuscles from the middle layer of the intima.

PLATE VI.—Hart. oc. 3, obj. 9, tube out. Transverse section of an artery in an advanced stage of endo-arteritis obliterans. *a*, intima thickened by a fluffy, ragged, fibrous material, like cocoa-nut matting: *b, b*, roundish corpuscular bodies, probably identical with those marked *g*, in Plate V: *c*, fenestrated membrane or elastic layer of intima split up: *d*, muscular coat, fairly normal: *f*, lumen, much narrowed by the obliterative thickening; its walls are ragged and destitute of epithelium.

PLATE VII.—Baker oc. A, obj. 1 inch. Cystic Kidney. Shrivelled and denuded tubules, and arterioles with hypertrophied media are seen among the increased interstitial tissue. Four large cysts formed from dilated tubules, and several tubules in various stages of cystic dilatation are represented in the engraving. The large cysts were plainly visible with the naked eye.

PLATE VIII.—Hart. oc. 3, obj. 7, tube out. A glomerulus transformed into a colloid mass. Bowman's capsule is thickened and fibrous, and appears continuous with the surrounding interstitial increase. A few compressed tubules are imbedded in the increased interstitial tissue.

PLATE IX.—Hart. oc. 3, obj. 3, tube out. A moderate sized arteriole from the kidney. The tunica media is somewhat hypertrophied, and the intima appears thrown into

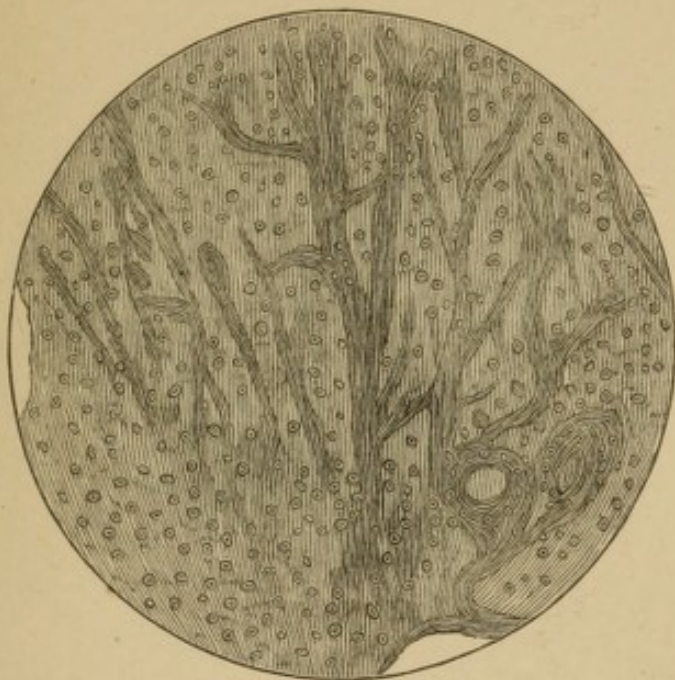
folds, but the coats are otherwise pretty normal. The connective tissue distributed with the vessel is much increased: immediately around the tunica adventitia this increase is of a densely fibrous character; but at the circumference of the field of view it is less completely fibrillated, and contains round cells. Denuded and dilated tubules are seen near the vessel lying in the midst of the fibrous increase, and altogether outside the adventitia of the vessel, which is plainly visible as a dense dark ring.

PLATE X.—Baker oc. A, obj. $\frac{1}{4}$ inch. Artificial “hyalin-fibroid” substance, in the coats of an arteriole. This curious factitious specimen is described on Page 62 of the Text.

PLATE XI.—Hart. oc. 3, obj. 7. A glomerulus with its adjacent tubules, from an advanced case of glomerulonephritis. The capillary loops of the glomerulus are entirely concealed by a dense congeries of “nuclear bodies.” Bowman’s capsule is much thickened, and around it are seen numbers of nuclear bodies similar to those obscuring the capillary loops. The uriniferous tubules contain leucocytes and granular matter, and some of them appear empty, and denuded of a portion of their epithelial lining. The contents of one tubule (represented by the darker shading), have become fatty, and were stained black with Osmic Acid.

PLATE XII.—Hart. oc. 3, obj. 7, tube out. An arteriole in transverse section, with its surrounding meshwork of capillaries, from a lightly pencilled preparation of glomerulonephritis. The coats of the arteriole are normal, but numbers of leucocytes are seen collected immediately outside the adventitia. The capillaries communicating with the arteriole are crammed with leucocytes. At the bottom of the drawing a dense congeries of cells marks the site of a Malpighian body.

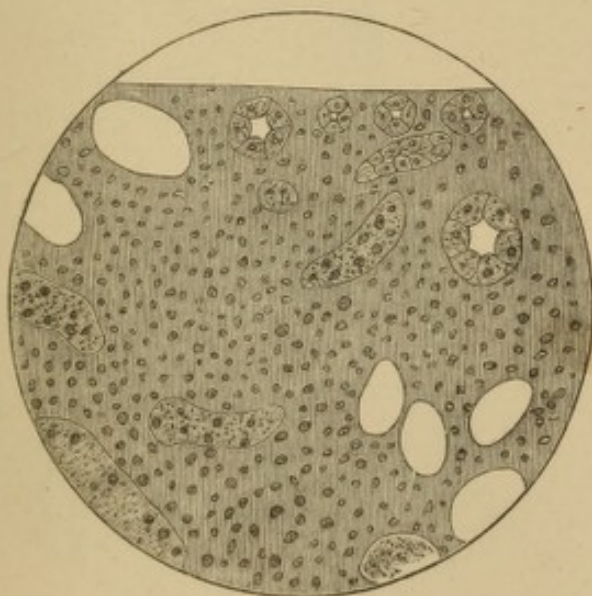
PLATE I.



B. C. W., *delt.*

E. P. B., *sculp.*

PLATE II.



B. C. W., *delt.*

E. P. B., *sculp.*


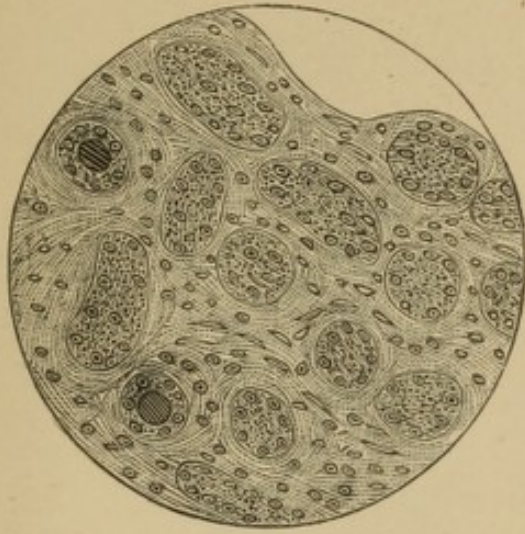


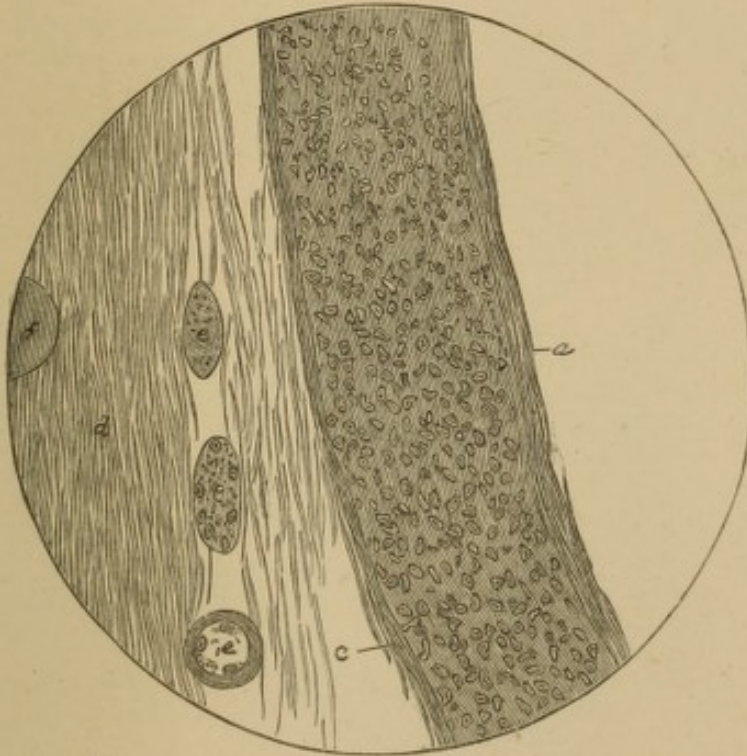
PLATE III.



B. C. W., *delt.*

E. P. B., *sculp.*

PLATE IV.



B. C. W., *delt.*

E. P. B., *sculp.*


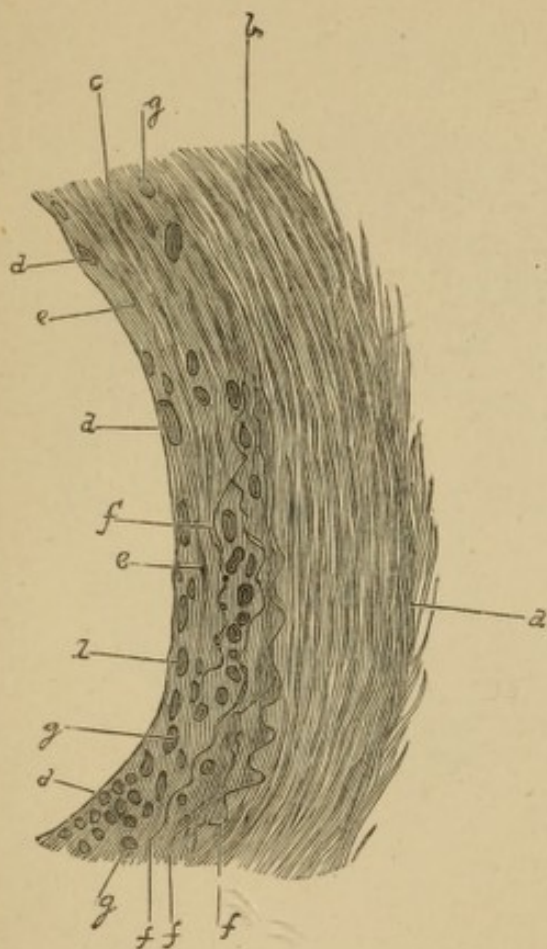


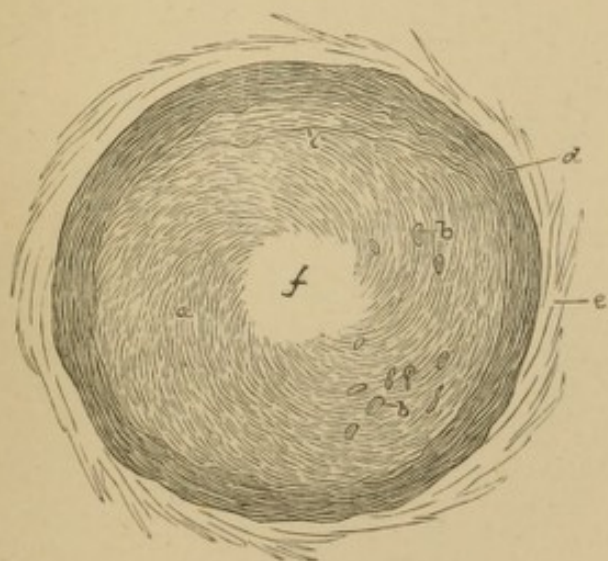
PLATE V.



B. C. W., *delt.*

E. P. B., *sculp.*

PLATE VI.



B. C. W., *delt.*

E. P. B., *sculp.*


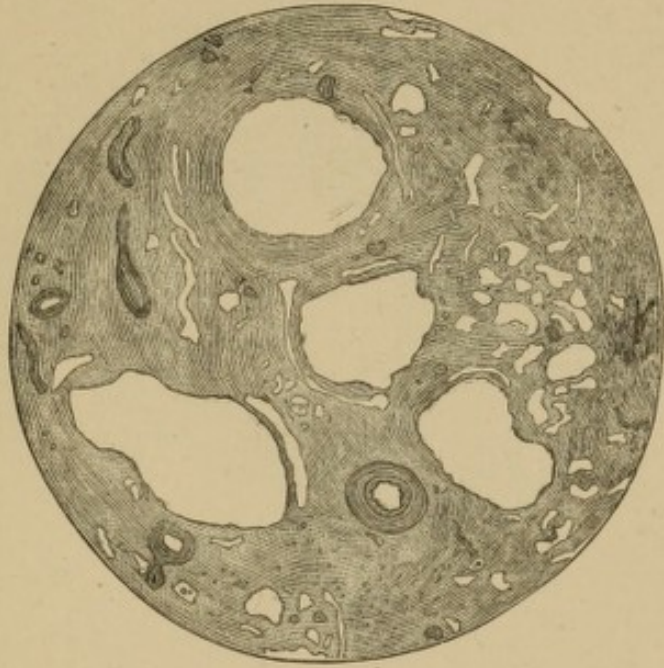


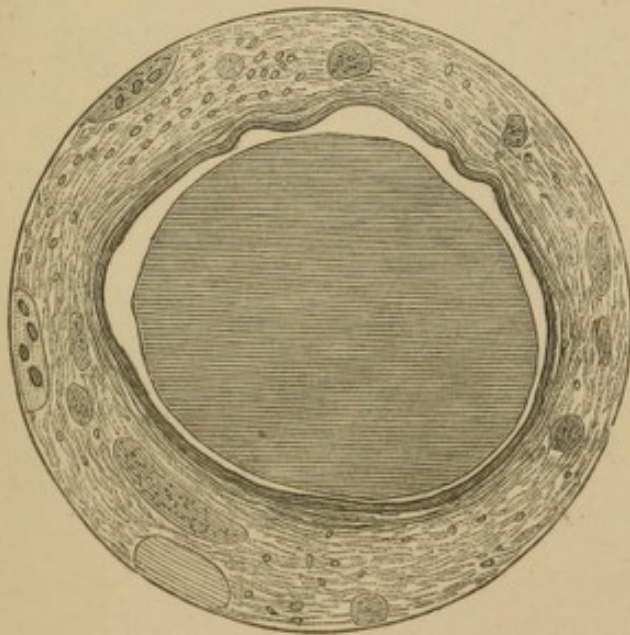
PLATE VII.



J. P. E. R., *delt.*

E. P. B., *sculp.*

PLATE VIII.



B C. W., *delt.*

E. P. B., *sculp.*


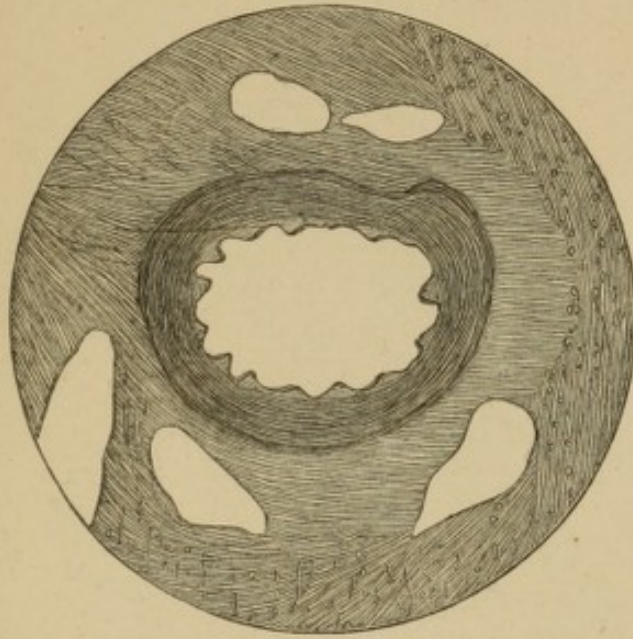


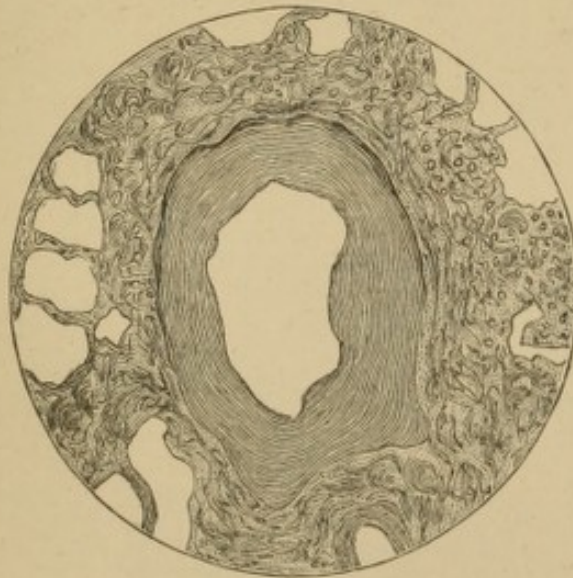
PLATE IX.



B C. W., *delt.*

E. P. B., *sculp.*

PLATE X.

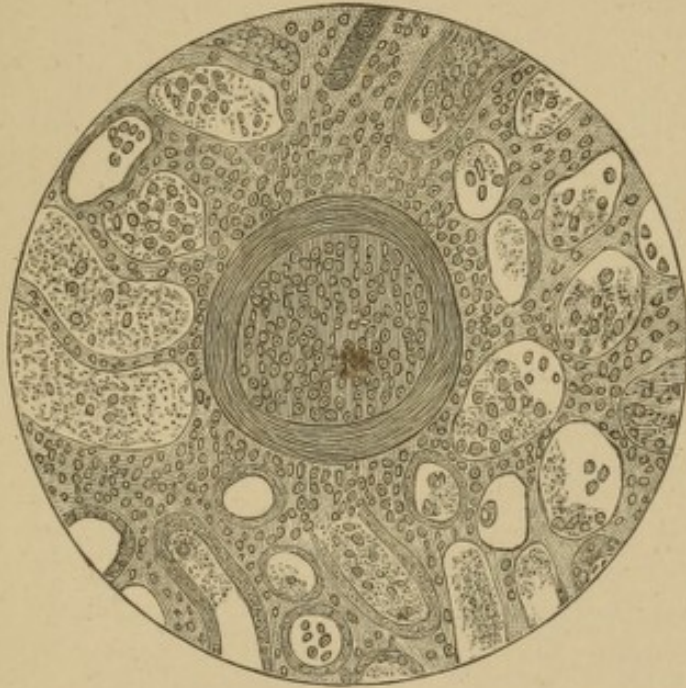

J. P. E. R., *delt.*

E. P. B., *sculp.*




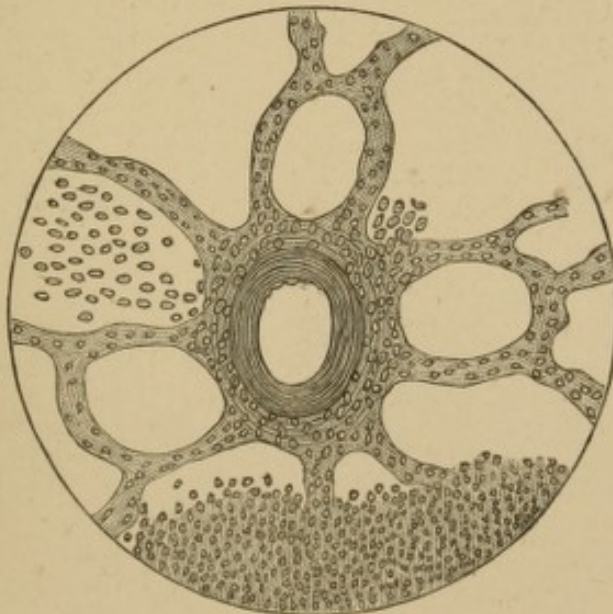
PLATE XI.



B. C. W., *delt.*

E. P. B., *sculp.*

PLATE XII.



B. C. W., *delt.*

E. P. B., *sculp.*

