

**Surgical emergencies : together with the emergencies attendant on parturition and the treatment of poisoning : a manual for the use of general practitioners / by William Paul Swain.**

**Contributors**

Swain, William Paul.  
Francis A. Countway Library of Medicine

**Publication/Creation**

London : Churchill, 1874.

**Persistent URL**


<https://wellcomecollection.org/works/qng3vs3r>

**License and attribution**

This material has been provided by This material has been provided by the Francis A. Countway Library of Medicine, through the Medical Heritage Library. The original may be consulted at the Francis A. Countway Library of Medicine, Harvard Medical School. where the originals may be consulted. This work has been identified as being free of known restrictions under copyright law, including all related and neighbouring rights and is being made available under the Creative Commons, Public Domain Mark.

You can copy, modify, distribute and perform the work, even for commercial purposes, without asking permission.







23 26.1



F. HOLDEN  
48 CHURCH ST.  
LIVERPOOL  
BOOKSELLER  
FISHER & STATION





6/-



**SURGICAL EMERGENCIES**

*By the same Author.*

INJURIES AND DISEASES OF THE KNEE-JOINT, and  
their Treatment by Amputation and Excision Contrasted. Jacksonian Prize  
Essay of the Royal College of Surgeons. With Wood Engravings. 8vo. 9s.

---

PRELIMINARY MEDICAL EDUCATION AT PROVINCIAL  
HOSPITALS. Second Edition. Sixpence.



*Benjamin Cushing*

# SURGICAL EMERGENCIES

TOGETHER WITH THE

EMERGENCIES ATTENDANT ON PARTURITION

AND THE TREATMENT OF POISONING


A MANUAL

FOR THE USE OF GENERAL PRACTITIONERS

BY

WILLIAM PAUL SWAIN, F.R.C.S.


SURGEON TO THE ROYAL ALBERT HOSPITAL, DEVONPORT



LONDON

J. & A. CHURCHILL, NEW BURLINGTON STREET

1874



2188



TO

CHRISTOPHER HEATH, Esq., F.R.C.S.

SURGEON TO UNIVERSITY COLLEGE HOSPITAL,

ETC. ETC.

*This Book is Dedicated*

AS A TRIBUTE OF SINCERE PERSONAL REGARD,

AND IN REMEMBRANCE OF MANY KINDNESSES RECEIVED,

BY

THE AUTHOR.

TO

CHRISTOPHER LEATH, Esq., M.D.

Author of "The History of the

of the

of the

of the

of the

BY

THE AUTHOR



## PREFACE.

---

THIS Manual pretends to be little more than a compilation from the best and most recent works on Surgery. It is intended to supply what the Author believes is a widespread want—viz., a small book containing directions for the immediate treatment of all those various emergencies with which the general practitioner may be called upon to deal at any moment. The aim has been throughout to condense as much as possible, without sacrificing precision and clearness in details. A chapter on the various emergencies attending Parturition, and also one on the treatment of Poisoning, have been introduced as affording information upon conditions particularly liable to arise at any moment, and requiring precise and immediate treatment. The chapter on Antiseptic Treatment has been kindly written by Dr. Bishop, at the request of Professor Lister, and embodies the most

recent and exact directions for the effectual carrying out of this method.

I have sincerely to thank the various gentlemen who have permitted me to use their woodcuts for the purposes of this Manual, particularly Sir William Fergusson, Mr. Bryant, and Mr. Christopher Heath. I must also acknowledge, with thanks, the kind assistance rendered to me by Mr. G. Lawson in the compilation of the chapter on "Injuries to the Eye;" and by Dr. Alfred Meadows, for similar help in the chapter on "Emergencies connected with Parturition."

WILLIAM PAUL SWAIN.

DEVONPORT, *May*, 1874.



# CONTENTS.

---

## CHAPTER I.

### INJURIES TO THE HEAD.

Wounds of the Scalp—Fractures of the Skull—Trephining—  
Injuries to the Face—Fracture of the Nasal Bones—Foreign  
Bodies in the Ear and Nostril—Epistaxis—Fractures and  
Dislocations of the Jaw—Injuries to the Spine . pp. 1—15

## CHAPTER II.

### INJURIES TO THE EYE.

Injuries of the Conjunctiva, Cornea, and Sclerotic—The Iris—The  
Lens—The Choroid—Injuries from Chemicals—Foreign  
Bodies within the Eyeball—Excision of the Eyeball—Injuries  
to the Orbit . . . . . pp. 16—25

## CHAPTER III.

### INJURIES TO THE MOUTH, PHARYNX, ŒSOPHAGUS, AND LARYNX.

Wounds of Tongue—Foreign bodies in Pharynx and Œsophagus  
—Foreign Bodies in Windpipe—Scald of Larynx—Laryn-  
gotomy—Laryngo-tracheotomy—Tracheotomy—Cut-throat  
—Stabs in the Throat—Ligature of Common Carotid—  
Drowning—Hanging—Artificial Respiration . pp. 26—39

## CHAPTER IV.

### THE CHEST.

Fracture of the Ribs—Wounds of the Chest—Hernia of the Lung  
—Wounds of the Lung—Emphysema—Pneumothorax—  
Hæmothorax—Paracentesis Thoracis—Wounds of the Heart  
—Gunshot Wounds of the Chest . . . . . pp. 40—45

## CHAPTER V.

## THE UPPER EXTREMITY.

Wounds at Wrist-joint—Wounds of Palmar Arch—Needle in the Hand—Fracture and Dislocation of the Clavicle; of the Scapula; of the Humerus—Compound Injuries to the Shoulder-joint—Resection of Shoulder-joint—Amputation at Shoulder-joint—Fractures and Dislocations of the Radius; the Ulna; the Bones of the Hand—Compound Injuries to the Elbow-joint—Excision of Elbow—Compound Injuries to Wrist-joint—Amputation of the Thumb and Fingers  
pp. 46—79

## CHAPTER VI.

## THE ABDOMEN.

Rupture of Muscles—Rupture of the Peritoneum—Rupture of the Viscera—Non-penetrating Wounds—Penetrating Wounds—Protruded Viscera, Constriction, Distension with Flatus, Gangrene, Wounds—Protruded Omentum—Sutures in Wounded Parietes—Foreign Bodies—Obstructed, Inflamed, and Strangulated Hernia—Umbilical, Inguinal, Femoral, and Obturator Hernia . . . . . pp. 80—94

## CHAPTER VII.

## THE PELVIS.

Fractures and Dislocations—Injuries to the Bladder—Foreign Bodies in the Urethra and Bladder—Dilating the Female Urethra—Injuries to the Urethra—Retention of Urine—Use of Catheter—Puncture of the Bladder per Rectum; by Aspiration; above Pubes—Cock's Operation for Perineal Section—Retention from Enlarged Prostate—Extravasation of Urine—Injuries to the Penis—Paraphimosis—Phimosis—Injuries to the Scrotum; Testicle—Rupture of Vas Deferens—Injuries to the Pregnant Uterus; to the Vagina—Foreign Bodies in the Rectum—Hæmorrhage from the Rectum  
pp. 95—111



## CHAPTER VIII.

## THE LOWER EXTREMITY.

Contusions—Rupture of Muscles—Sprains—Wounds of the Knee-joint—Ligature of Superficial Femoral ; of Posterior Tibial ; of Anterior Tibial—Fractures and Dislocations of the Femur—Compound Injuries to the Shaft of the Femur and Knee-joint—Excision of Knee-joint—Amputation of Thigh—Fractures and Dislocations of Patella ; of Tibia ; of Fibula ; of both Bones—Compound Comminuted Fractures—Compound Dislocation of Ankle-joint—Fractures and Dislocations of Tarsal Bones ; of Metatarsal ; of Phalanges—Amputation of Leg—Chopart's Amputation—Hey's Amputation—Amputation of Toe . . . . . pp. 112—153

## CHAPTER IX.

## EMERGENCIES CONNECTED WITH PARTURITION.

Accidental Hæmorrhage—Placenta Prævia—Retained Placenta—Flooding—Induction of Premature Labour—Cæsarean Section—Craniotomy—Embryulcia—Decapitation—Mal-presentations—Turning—Prolapse of the Cord—Puerperal Convulsions—Rupture of the Uterus ; of the Bladder ; of the Perineum—Inversion of the Uterus . . . . . pp. 154—167

## CHAPTER X.

## POISONING.

Poisoning by Sulphuric Acid—Nitric Acid—Oxalic Acid—Salt of Sorrel—Hartshorn—Phosphorus—Arsenic—Scheele's Green—Orpiment—Sugar of Lead—Blue Vitriol—Tartar Emetic—Chloride of Zinc—Cantharides—Mussels—Opium—Godfrey's Cordial—Dalby's Carminative—Paregoric Elixir—Prussic Acid—Cyanide of Potassium—Essential Oil of Bitter Almonds—Chloroform—Tobacco—Strychnia—Hemlock—Water-Hemlock—Monkshood—Deadly Nightshade—The Use of the Stomach-Pump . . . . . pp. 168—179

## CHAPTER XI.

## ANTISEPTIC TREATMENT.

General Remarks—Carbolic Acid—Antiseptic Gauze—Gauze Bandage—Antiseptic Atmosphere—Steam Spray Apparatus—Boracic Acid—Chloride of Zinc—Protective Oil-Silk—Drainage Tube—Catgut Ligature—Carbolized Silk Sutures—Abscesses—Precautions before and during an Operation—Dressing after Operations—Compound Fractures—Dressing in Compound Fractures—Operations on parts affected with Sinuses—Abscess by the side of Rectum . . pp. 180—193

## CHAPTER XII.

## APPARATUS AND DRESSINGS.

Pasteboard Splints—Plaster-of-Paris Bandage—Gutta-percha Splints—Extension by Weight—The Use of the Aspirator—Transfusion of Blood—Hutchinson's India-rubber Catheter—Esmarch's Bloodless Operation—Deep seated Abscesses  
pp. 194—207



## LIST OF ILLUSTRATIONS.

---

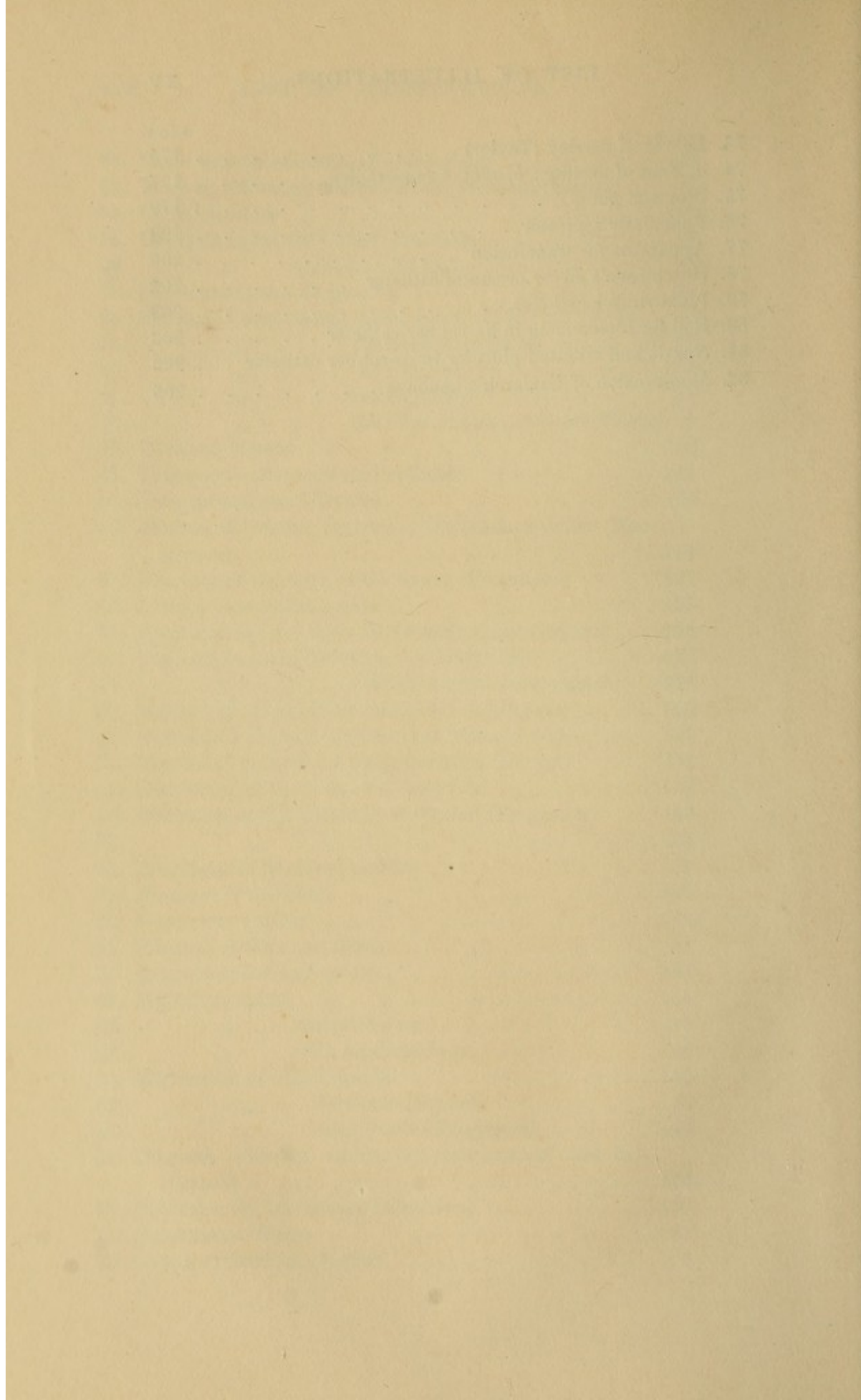
|  | PAGE |
|--|------|
| 1. The operation of trephining (Bryant) . . . . .                      | 3    |
| 2. Elevator . . . . .  | 4    |
| 3. Hey's saw . . . . .   | 4    |
| 4. Needle-holder . . . . .   | 6    |
| 5. Syphon-tube (Heath) . . . . .                                       | 7    |
| 6. Ear forceps . . . . .   | 8    |
| 7. Plugging posterior nares (Fergusson) . . . . .                      | 8    |
| 8. Instrument for plugging posterior nares . . . . .                   | 9    |
| 9. Bandage for fracture of the lower jaw (Bryant) . . . . .            | 12   |
| 10. Instrument for removing foreign bodies from the eye . . . . .      | 17   |
| 11. Eye speculum (Lawson) . . . . .                                    | 17   |
| 12. Broad needle . . . . .   | 18   |
| 13. Fine needle . . . . .  | 18   |
| 14. Liebreich's eye bandage (Lawson) . . . . .                         | 19   |
| 15. Scissors for extirpation of eyeball (Lawson) . . . . .             | 24   |
| 16. Horse-hair probang (Bryant) . . . . .                              | 27   |
| 17. Money probang . . . . .  | 28   |
| 18. Tracheotomy canula . . . . .                                       | 32   |
| 19. Pilot trocar . . . . .   | 32   |
| 20. Tracheotomy tube . . . . .   | 33   |
| 21. Sylvester's method (Heath) . . . . .                               | 37   |
| 22. . . . .  | 38   |
| 23. Strapping for fractured ribs (Bryant) . . . . .                    | 41   |
| 24. Gordon's apparatus for fractured clavicle . . . . .                | 48   |
| 25. Splint for fracture of the neck of humerus (Heath) . . . . .       | 53   |
| 26. Method of treating fracture of the shaft (Bryant) . . . . .        | 56   |
| 27. Aitkin's Crimean splints . . . . .                                 | 56   |
| 28. Sub-glenoid dislocation of humerus . . . . .                       | 58   |
| 29. Sub-coracoid dislocation of humerus . . . . .                      | 59   |
| 30. Reduction of dislocated humerus by manipulation (Bryant) . . . . . | 60   |
| 31. . . . .  | 60   |



|  | PAGE |
|--|------|
| 32. Small saw for resection of elbow-joint . . . . .                       | 62   |
| 33. Method of treating fracture of the fore-arm (Heath) . . . . .          | 65   |
| 34. Colles' fracture . . . . .   | 67   |
| 35. Gordon's splint for Colles' Fracture . . . . .                         | 68   |
| 36.        "        applied to the arm . . . . .                           | 69   |
| 37. The clove-hitch (Fergusson) . . . . .                                  | 74   |
| 38. Method of amputating phalanges of the thumb (Ferg.)                    | 77   |
| 39.        "        the metacarpal bone        " . . . . .                 | 77   |
| 40.        "        the forefinger        " . . . . .                      | 78   |
| 41.        "        the ringfinger        " . . . . .                      | 78   |
| 42.        "        the third phalanx of finger (Heath)                    | 79   |
| 43. Urethral forceps . . . . .   | 98   |
| 44. Thompson's probe-pointed catheter . . . . .                            | 101  |
| 45. Perineal catheter (Bryant). . . . .                                    | 105  |
| 46. Method of treating rupture of the tendo-Achillis (Fergusson) . . . . . | 114  |
| 47. Fracture of the neck of the femur (Fergusson) . . . . .                | 121  |
| 48. Liston's long splint applied        " . . . . .                        | 125  |
| 49. Fractured leg put up in M'Intyre's splint (Bryant) . . . . .           | 126  |
| 50. Dislocation of the femur on the dorsum ilii . . . . .                  | 127  |
| 51.        "        into the great sciatic notch . . . . .                 | 128  |
| 52. Method of reduction by manipulation (Bryant) . . . . .                 | 130  |
| 53. Dislocation of the femur into the foramen ovale . . . . .              | 131  |
| 54. Method of reduction by manipulation (Bryant) . . . . .                 | 132  |
| 55. Dislocation of the femur on the pubis . . . . .                        | 132  |
| 56. Reduction of dislocation by extension (Fergusson) . . . . .            | 133  |
| 57.        "        "        " . . . . .                                   | 134  |
| 58. Treatment of fractured patella        " . . . . .                      | 139  |
| 59. Fracture of the fibula . . . . .                                       | 141  |
| 60. Dupuytren's splint . . . . .   | 142  |
| 61. Fracture of tibia and fibula . . . . .                                 | 143  |
| 62. Arnold's splint and cradle . . . . .                                   | 144  |
| 63. McNalty's splint . . . . .   | 145  |
| 64.        "        opened for use . . . . .                               | 146  |
| 65.        "        with leg fixed in it. . . . .                          | 146  |
| 66. Dislocation of tibia inwards . . . . .                                 | 148  |
| 67.        "        forwards (Bryant) . . . . .                            | 148  |
| 68.        "        backwards (Fergusson) . . . . .                        | 149  |
| 69. Diagram showing various amputations of the foot<br>(Bryant) . . . . .  | 152  |
| 70. Perforator for craniotomy (Meadows) . . . . .                          | 160  |
| 71. Craniotomy forceps        " . . . . .                                  | 161  |
| 72. Leaves of hemlock (Taylor) . . . . .                                   | 175  |



|   | PAGE |
|---|------|
| 73. Leaves of parsley (Taylor) . . . . .                                  | 175  |
| 74. <i>a</i> , Root of aconite ; <i>b</i> , root of horseradish . . . . . | 177  |
| 75. Stomach pump . . . . .  | 179  |
| 76. Pneumatic aspirator . . . . .   | 198  |
| 77. Apparatus for transfusion . . . . .                                   | 200  |
| 78. Hutchinson's silver prostatic catheter . . . . .                      | 202  |
| 79. India-rubber catheter . . . . .                                       | 203  |
| 80. Rod for introducing india-rubber catheter . . . . .                   | 203  |
| 81. Nozzle and stiletted plug for india-rubber catheter . . . . .         | 203  |
| 82. Modification of Esmarch's bandage . . . . .                           | 205  |





# SURGICAL EMERGENCIES.

## CHAPTER I.

### INJURIES TO THE HEAD.

*Wounds of the Scalp—Fractures of the Skull—Trepining—Injuries to the Face—Fracture of the Nasal Bones—Foreign Bodies in the Ear and Nostril—Epistaxis—Fractures and Dislocations of the Jaw—Injuries to the Spine.*

WOUNDS of the scalp are generally flap-wounds, and however extensive, the flap should be thoroughly cleansed, replaced, and kept in position by silver-wire sutures and strapping. Care must be taken not to include any part of the occipito-frontalis muscle in the sutures. The same treatment will be pursued if the bones of the skull are exposed. As a rule, these wounds are not followed by erysipelas. Punctured wounds are sometimes followed by diffuse inflammation, and if suppuration takes place, very free incisions down to the bone must be made.

Wounds of the scalp.

Fractures of the skull may occur in the vault or at the base. In the vault, fractures are generally the result of direct violence. The external

Fractures of the vault.



table alone may be driven in, especially over the frontal sinuses, or a very slight injury to the external table may be accompanied by extensive fracture of the inner table. Very extensive depressions of bone may exist, especially under the temporal muscles, without the possibility of discovery, whilst extravasations of blood under the scalp may be mistaken for depressed fractures. If there be a wound down to the bone, care must be taken not to confound the cranial sutures with fissured fracture. The distinguishing point is, that a fissure presents a red line along the course of the fracture.

When not to  
trephine.

Simple fractures with depression, and comminuted fractures unaccompanied with a wound of the scalp, without brain symptoms, are not to be interfered with. Neither should an operation be proposed if the symptoms are slight, as they may arise from mere concussion. If, on the other hand, the nature of the accident and the severity of the symptoms indicate severe compression and contusion to the brain, trephining for the local injury is worse than useless. In children, compound depressed fractures, if no brain symptoms are present, should be let alone.

When to  
trephine.

In compound comminuted fractures, with depression, the bone should be at once elevated, without waiting for symptoms, and if needful the trephine should be used. Any spicula of bone penetrating the substance of the brain should be

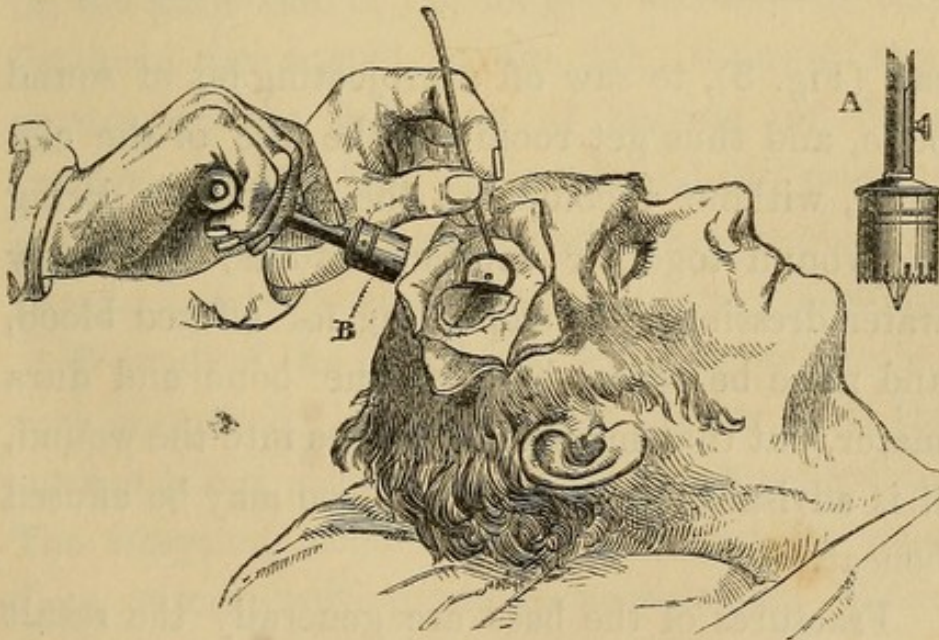


removed, if this can be accomplished without damage to the brain tissue. In local injuries to the skull, especially in those arising from blows with sharp instruments, if symptoms of compression ensue, the depressed bone should be elevated. If the injury be such as to make it probable that the middle meningeal artery is wounded, the trephine may be used near the anterior inferior angle of the parietal bone, for the purpose of letting out the effused blood.

The instruments required for the operation of trephining are—1. Scalpel ; 2. Trephine ; 3. Hey's Saw ; 4. Elevator ; 5. Bone forceps ; 6. Probe, with flattened or pointed extremity.

How to  
trephine.

FIG. 1.



The patient's head having been shaved, make a free crucial incision down to the bone over the site of the fracture, and dissect back the flaps. Place the central pin of the trephine, fixed as at A, on



the edge of the sound bone, and cut into the outer table by a semi-rotatory movement; when a sufficient groove is made in the bone, withdraw the pin of the trephine, as at B, and complete the section of the outer table; cut through the inner table with great caution. The bits of bone being removed, raise the depressed portion with the elevator (Fig. 2). It may be possible by the use of Hey's

FIG. 2.

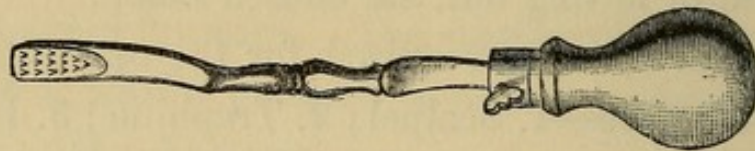
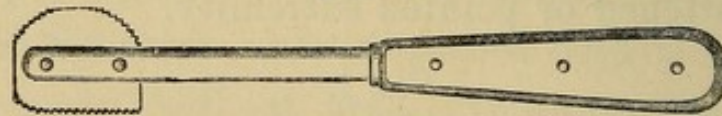


FIG. 3.



saw (Fig. 3), to saw off a projecting bit of sound bone, and thus get room for the use of the elevator, without recourse to the trephine. Bring the wound together without sutures, and apply water-dressing. If trephining for effused blood, and none be found between the bone and dura mater, but that membrane bulges into the wound, it is advisable to open it, as blood may be effused beneath it.

Fractures of  
the base.

Fractures of the base are generally the result of indirect violence, except in the nostrils and orbit, through which foreign bodies are sometimes thrust into the brain. In fractures through the orbital plate of the frontal, blood appears *first*



beneath the ocular conjunctiva, then it spreads to the eyelids, the lower one being generally the first affected. Bleeding from the nose and mouth, *if continuous*, indicates fracture through the ethmoid, body of the sphenoid, or basilar process. Large and continuous bleeding from the ears points to fracture through the petrous portion of the temporal. So, too, the profuse discharge of cerebro-spinal fluid indicates rupture of the cerebral membranes. In fractures of the base the following symptoms indicate injury to nerves :—Loss of smell and sight indicate injury to the 1st or 2nd pair ; ptosis and dilated pupil to the 3rd ; paralysis of the face and loss of sensation on the injured side, loss of taste and sensation on the same side of the tongue, and loss of sensation in the nostril, to the 5th ; internal strabismus, to the 6th ; loss of hearing and facial paralysis, to the 7th. The 8th and 9th pair are seldom injured ; but when they are, aphonia, dysphagia, and dyspnœa are the prominent symptoms.

Wounds of the face should be brought together very accurately, if possible with plaster only, the surface being painted over with flexile collodion. The strapping should not be removed for some days, unless swelling and redness appear. When the wound cannot be kept in apposition with plaster alone, serrefines will be found useful, as avoiding the cicatrix left by a suture. For sewing wounds about the eyelids a very fine curved needle is

Injuries to  
cerebral  
nerves.


Injuries to  
the face.  
Wounds.



Wounds of  
the eyelids.

the best, and the operation is much facilitated by the use of a needle-holder such as that shown

FIG. 4.



in Fig. 4. In wounds of the eyelids the fine ophthalmic silk will be found sufficient when the skin only is involved. If the tarsal cartilage is cut through by a clean incision, a very fine needle should be inserted close to the tarsal edge, and the edges drawn together with a twisted suture of fine silk. If the cut through the cartilage is jagged, it is better to pare the edges with a small scalpel, and then bring them together as above. In the eyebrow care should be taken to preserve the line. In wounds of the ears and nose the greatest care should be taken to replace the parts and fix them with sutures. This should be done under the most unpromising circumstances.

Wounds of  
the lips.

Wounds through the thickness of the lips should be brought together with hare-lip pins, care being taken to keep the exact red-line of the lips; in order to effect this the first pin introduced should be at the margin of the lips.

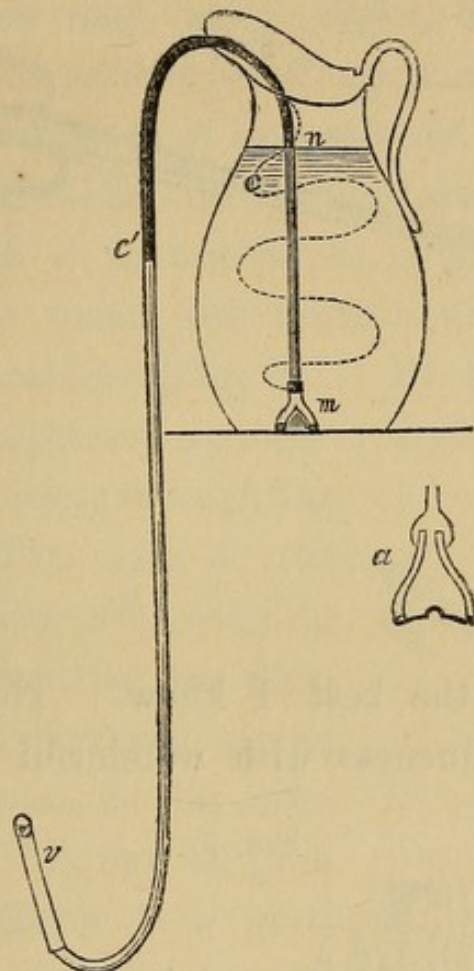
Foreign bodies  
in nose and  
ears.

Foreign bodies may be removed from the nose with ordinary polypus forceps, or by those figured below (Fig. 6). Or a current of water may be injected up the opposite nostril, when if the patient is directed to keep the mouth open, it will return



behind the foreign body and eject it. For this and other like purposes the syphon-tube (Fig. 5)

FIG. 5.



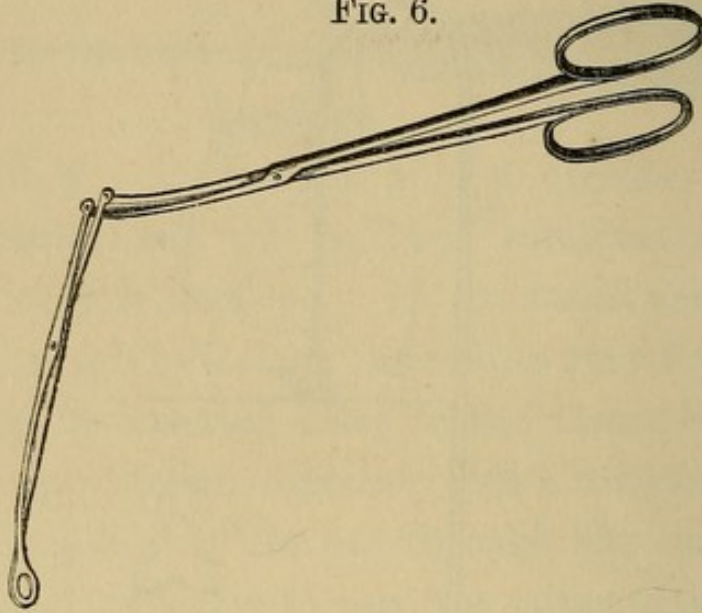
will be found very useful, the force of the current being regulated by the height at which the jug containing the water is placed.\* For removing

---

\* The perforated weight, *a*, is placed at *m* in the bottom of the jug. The india-rubber tube is then curled up under the water, and left for a couple of minutes. Then raise the jug to the required height, and pinching the tube at *c* between the forefinger and thumb, draw it out over the brim of the jug to *c'*, when, being converted into a syphon, water will run continuously through the nozzle *v*. For injecting the nostrils salt and water should always be used, water alone being very painful.

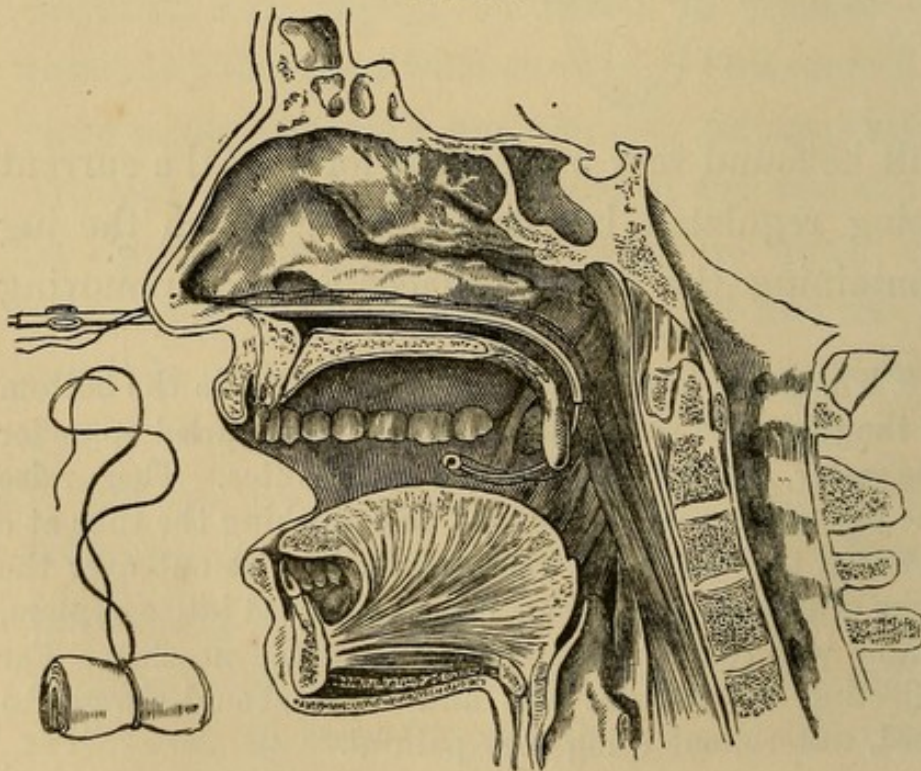
foreign bodies from the ear a current of water will very frequently suffice, but if this fails then the forceps (Fig. 6) made by Meyer and

FIG. 6.



Meltzer are the best I know. They combine very great fineness with wonderful power and

FIG. 7.





strength. In young and timid children it is better to administer chloroform, if any difficulty occurs in removing the foreign body.

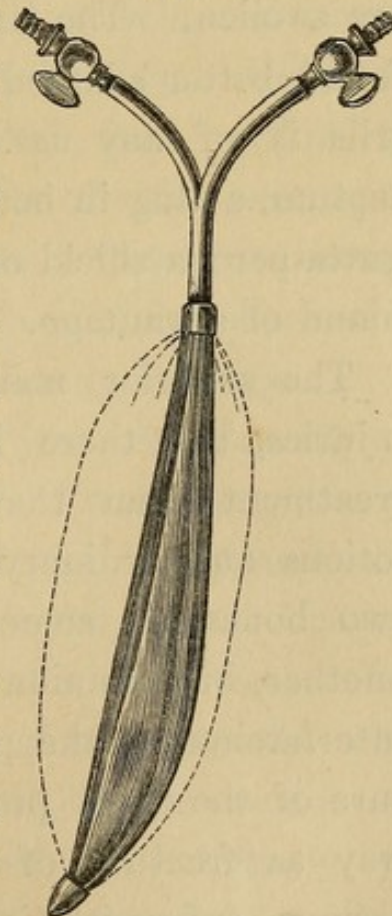
Epistaxis may, when slight, be arrested by making the patient snuff up tannic acid, or by injecting a current of iced salt and water through the nostril with the syphon-tube, as described above. If it be needful to plug the posterior nares, the usual instrument recommended is Bellocq's canula (Fig. 7). By this a plug of lint or compressed sponge is drawn up into the

Epistaxis.

Plugging posterior nares.

posterior nares, through the mouth. The ends of the string being left hanging from the nostrils, are separated, and tied over a plug of lint placed in the anterior nares. A flexible gum elastic catheter is a good substitute for the canula, the silk or whipcord being passed down through the eye of the catheter. An ingenious instrument, made by Meyer and Meltzer, is here figured (Fig. 8). In its collapsed condition it is introduced along the floor

FIG. 8.

Meyer's  
instrument.

of the nostril. The thin india-rubber bag may then be blown up, thus exercising pressure on



the whole interior of the cavity; or it may be distended with iced water, a constant current being sent through it, passing in at the upper tube and out at the lower one. Before plugging care should be taken to syringe out all clots, which are often the cause of the hæmorrhage being kept up.

Fractures of  
the nasal  
bones.

In fractures of the nasal bones with displacement, all that can be done is to replace the bones as accurately as possible, by pressure from within the nostril. A female catheter is the instrument usually recommended to effect this, but its point is too large, especially when the parts are swollen. The end of a small sound will be found better adapted. No plugging of the nostrils is of any use. In displacement of the septum, a plug in both nostrils with a well-fitting gutta-percha shield on the nose, outside, will be found of advantage.

Fractures of  
the upper  
jaw.

The superior maxillæ are subject to various injuries, but there is seldom room for more treatment than that afforded by evaporating lotions and ordinary retentive bandages. The two bones are sometimes separated from one another, but reunion takes place without much interference on the part of the surgeon. Fracture of the nasal process is treated in the same way as fracture of the nasal bones. A very serious deformity is caused by depression of the malar bone and fracture of the antrum. The deformity may be remedied by making an open-

Fracture of  
the antrum  
and depression  
of malar bone.



ing into the antrum through the alveolar process, and then pressing up the malar bone with a sound, or, as recommended by Hamilton, making a small incision through the cheek at the anterior margin of the masseter muscle, and then introducing a hook under the zygoma, and thus lifting it up. Before having recourse to these severe measures, an attempt should be made to replace the bone by pressing with the thumb, through the mouth, against the zygoma. Fractures of the zygoma are only of consequence when the fragments, projecting inwards, enter the tendon of the temporal muscle and impede the movements of the lower jaw. Reduction should then be attempted from within the mouth. In fractures of the alveolar process the teeth in the broken fragment should be secured to a firm tooth, if there is one, by silver wire; or a mould of gutta-percha may be fitted.

Fractures of  
the zygoma.

Fractures of the lower jaw are generally the result of much violence. Fractures are more frequent in the body of the bone, and they generally happen at or near the mental foramen. If it be a single fracture it is easily detected by pressing the posterior fragment inwards, when mobility and crepitus will be discovered. If the fracture—as is not unfrequently the case—be double, then it is discovered by taking the central fragment between the finger and thumb and moving it. Fractures at the angle

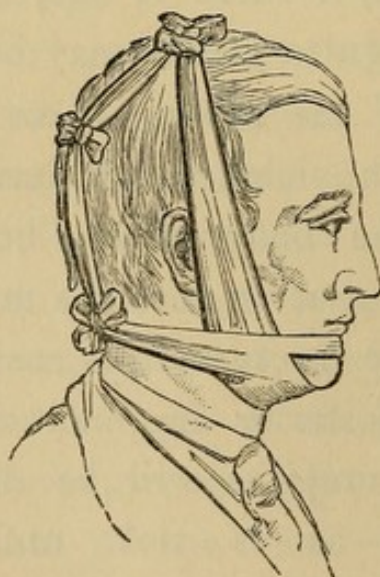
Fractures of  
the lower jaw.



and ascending ramus present the same features as those of the body, only there is less displacement and mobility. Fractures of the coronoid are rarely met with, but a severe blow on the chin will sometimes fracture the neck of one or both condyles. This may be discovered by the pain at the seat of fracture, on moving the jaw, and by crepitus, which the patient can himself generally feel and hear. The chin is also turned towards the affected side, which will distinguish it from dislocation. In the treatment of fracture of the jaw, all teeth that are very much loosened from their sockets should be removed. If there is much displacement, and the teeth contiguous to the fracture are sound, they should be tied together either with silver wire or thick silk ;

Treatment of  
fractures of  
the lower jaw.

FIG. 9.



but this should be avoided if possible. The simplest and most efficacious form of bandage



is the one figured (Fig. 9). It is made with a piece of bandage or muslin, a yard long, and four inches wide. A slit four inches long is made longitudinally in the centre, and the ends of the bandage are torn down to within three or four inches of this slit. The chin is then placed in the slit, the anterior tails are tied behind the nape of the neck, the posterior ones over the top of the head, and the two connected together.

The lower jaw may be dislocated in one or both sides. In both the displacement is forwards. The double dislocation is the most frequent. The condyles are drawn upwards and forward by the action of the pterygoid and temporal muscles, and the coronoid processes rest on the back of the superior maxillæ. The symptoms are—widely open mouth, and immobility of the jaw, with considerable pain, loss of power of deglutition and articulation. The dislocation may be reduced in two ways. Place the patient on the floor with the head between your knees. Then put two pieces of cork as far back as possible between the molars on either side. Press the point of the chin steadily and directly upwards. Or, standing in front of the patient, place your two thumbs well guarded with a towel between the last molars. Grasp the jaw firmly with the hands. Press downwards and backwards with the thumbs, and at the same time elevate the chin.

Dislocations of  
the lower jaw.

Reduction.



Injuries to the  
spine.  
Sprains.

Sprains of the spine are found principally in the cervical and lumbar regions. In the neck they are accompanied with intense pain, and partial loss of power in the arms and legs, with numbness and pricking throughout the body. In the lumbar region there is general pain across the loins, with considerable swelling, and frequently hæmaturia. But the line of spinous processes is found level, and the pain on pressure cannot be limited to any particular spot. Perfect rest and hot fomentations are alone required.

Fractures and  
dislocations.

Fractures of the spine above the level of the fourth cervical vertebra cause, as a rule, instant death. In the cervico-dorsal region fracture frequently takes place. All below the point of fracture is paralysed, but there is sensation as low as the nipples. Breathing is entirely carried on by the diaphragm and the serratus magnus. In the dorsal region, between the fourth and the tenth vertebræ, there is generally complete paralysis of the lower extremities, of the abdominal muscles, and of the bladder and rectum. Respiration is imperfectly performed by the diaphragm and upper part of the thorax.

In the lumbar region there may be an absence of paralysis, or if it is present in the erect position, when the patient is placed on his back the fractured parts are replaced, and he recovers the use of his lower extremities.



All motion of the spine should be guarded Treatment.  
against during the removal of the patient, by  
placing him on a door, or board. If the fracture  
be cervical, the head should be surrounded with  
a sack filled with sand, to prevent all motion.  
The clothes should be cut off, to avoid dis-  
turbance. If much displacement is apparent,  
gentle stretching may be employed, but all  
violent pulling avoided. Bleeding should not  
be resorted to. A catheter should at the  
earliest moment be introduced, and the urine  
drawn off.

## CHAPTER II.

### INJURIES TO THE EYE.

*Injuries of the Conjunctiva, Cornea, and Sclerotic—The Iris—The Lens—The Choroid—Injuries from Chemicals—Foreign Bodies within the Eyeball—Excision of the Eyeball—Injuries to the Orbit.*

- Injuries of the conjunctiva. Effusion of blood. **SUDDEN** effusions of blood sometimes take place beneath the conjunctiva, following a sneeze, or some other violent exertion. They produce considerable alarm, but call for no treatment.
- Lacerations. Lacerations of the conjunctiva produce much swelling, but it is seldom needful to do more than keep the eye closed, and apply some evaporating lotion. If a large flap is torn, it may be sometimes necessary to put in a suture or two of fine ophthalmic silk. Very small curved needles are the best for the purpose, used with the needle-holders, figured above (Fig. 4, p. 6).
- Foreign bodies in the cornea. Very minute portions, generally of iron, become imbedded in the epithelium of the cornea. They cause great pain, lachrymation, and intolerance of light. To remove them, seat the patient in a chair, and standing behind him, draw up the upper lid, and steady the globe of the eye with the fore and middle finger of one hand,
- Method of removal.



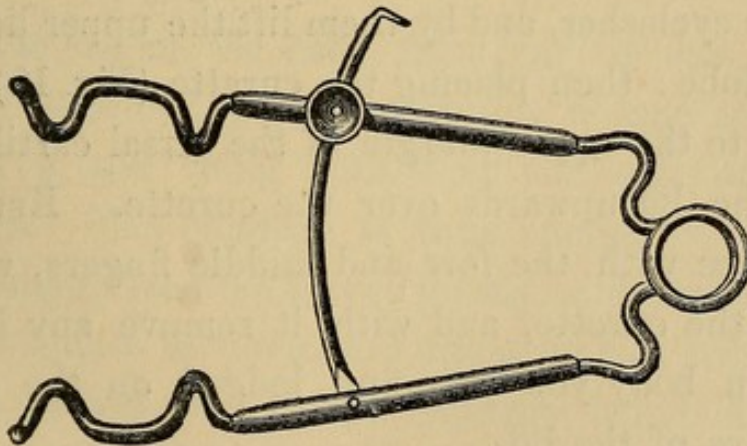
whilst with the other pick out the foreign body with a small spud or chisel (Fig. 10). This

FIG. 10.



little instrument for the pocket contains on one side a curette, which is very useful for everting the lids, and other purposes, whilst on the other side is the spud. Care must be taken, if the foreign body is deeply fixed, not to press it into the anterior chamber; and if there be danger of this, a broad needle must be passed into the anterior chamber from the corneal edge, and pressed against the cornea immediately behind the foreign body, which can then be picked out with another needle. For this operation there will be required a spring speculum (Fig. 11), a broad needle

FIG. 11.



(Fig. 12), a fine needle (Fig. 13), and conjunctival forceps to steady the eye with. After this operation a little castor-oil dropped into the eye is very soothing.



Abrasions of  
the cornea.

Abrasions of the cornea cause considerable pain, intolerance of light, and lachrymation.

FIG. 12.



FIG. 13.



They appear as little facets where the cornea has been abraded. The application of castor-oil, and the closure of both eyes, affords very great relief.

Foreign bodies  
beneath the  
eyelid.

Foreign bodies very frequently become lodged beneath the upper lid, and abrade the cornea. They cause much distress, and are frequently overlooked, the inflammation of the eye caused by their presence being put down to cold, &c. It is wise always to evert the upper lid when there is the least suspicion of a foreign body being present. To do this, seat the patient on a chair, and standing behind him, take hold firmly of the eyelashes, and by them lift the upper lid off the globe: then placing the curette (Fig. 10) parallel to the upper margin of the tarsal cartilage, tilt the lid upwards over the curette. Keep it in place with the fore and middle fingers, withdraw the curette, and with it remove any little foreign body you may find lodged on the conjunctiva of the lid.

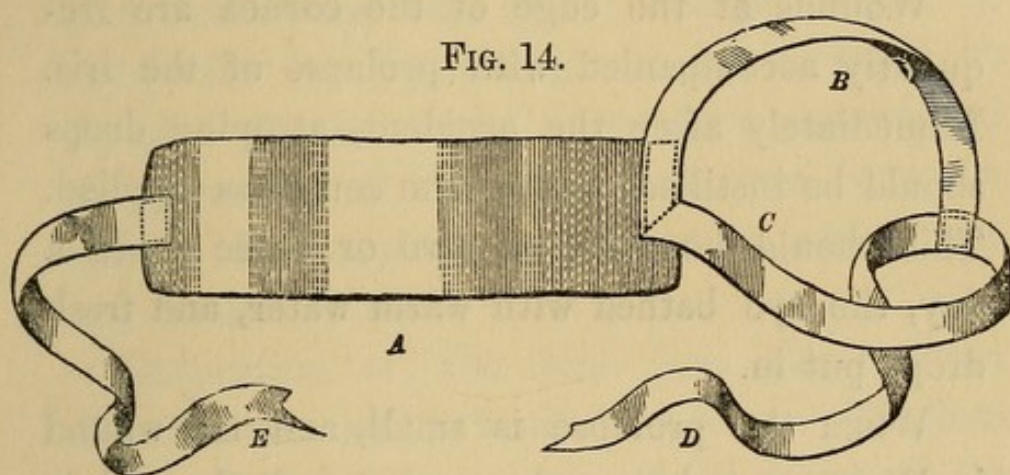
Wounds of the  
cornea and  
sclerotic.

Wounds of the cornea, if simple, heal rapidly, the eye being kept closed with a pad of cotton wool and a bandage. Wounds accompanied with much contusion, especially those involving



the sclerotic, are very dangerous, and perfect rest should be at once enjoined, both eyes being closed, and three or four leeches applied to the temples.

For closing the eye, in this and other cases requiring such treatment, "Liebreich's Eye Bandage" (Fig. 14), will be found the most useful. It consists of a knitted band, *A*, ten inches long, and two and a half inches broad. The tape *B*, twelve inches long, passes



over the top of the head, from ear to ear; the second tape *C D*, passing through a loop at the end of *B*, and tying with *E* at the side of the temples. The bandage is thus applied:—Make the patient close both eyes gently, and over each place a square of linen, and again on this a round pad of cotton-wool. The bandage being fitted to the head, is drawn across the eyes, and fastened on the temple opposite to the injured eye.

The iris is sometimes injured by sharp blows, as from a soda-water cork, &c. The immediate

Injury to the  
iris.



Hæmorrhage  
into anterior  
chamber.

result may be hæmorrhage into the anterior chamber, from rupture of some of the vessels of the iris. As a rule, the blood is rapidly absorbed, rest and an evaporating lotion being the treatment. Another effect of a blow may be the

Detachment  
of iris.

separation of the iris from its ciliary border. This is accompanied by considerable hæmorrhage into the anterior chamber, but if uncomplicated by other damage generally does well.

Prolapse of  
iris.

Wounds at the edge of the cornea are frequently accompanied with prolapse of the iris. Immediately after the accident, atropine drops should be instilled, and a firm compress applied. This should be removed two or three times a day, the eye bathed with warm water, and fresh drops put in.

When the prolapse is small, and the wound in the cornea clean and not contused, the nodule of iris may be cut off with a pair of scissors. If the prolapse is large, and the corneal wound inclined to gape, the nodule should be frequently punctured with a needle.

Injury to the  
lens.

The lens is frequently wounded, in company with the cornea and iris. When this is the case the lens tissue rapidly swells and becomes opaque. The iris should be kept fully dilated with atropine to prevent the swollen lens pressing upon it.

Traumatic  
glaucoma.

Should symptoms of "traumatic glaucoma" come on, indicated by increased pain, hardness of the globe, diminution of the anterior chamber, and



pink tinge of the sclerotic, the lens should be at once removed. As it is generally soft, the suction operation will be applicable, or the entire lens may be removed through a small corneal wound, by the simple introduction of the curette, accompanied with slight pressure on the cornea.

If urgent symptoms, however, do not manifest themselves, atropine drops, belladonna lotion (ext. belladonnæ ℥ij, aquæ destillat. fl. oz. 8), and perfect rest by closing both eyes, should be the plan of treatment. It must be remembered that opacities of the lens sometimes come on after a blow on the eye, unaccompanied with any external wound.

Dislocation of the lens into the anterior chamber may be the result of a blow. The lens appears "like a large drop of oil lying at the back of the cornea, the margin exhibiting a brilliant yellow reflex." The iris is pushed backwards, and widely dilated. Great pain and inflammation attend this accident, as a rule. It is advisable at once to remove the lens, linear extraction being the operation most suitable. When the lens is dislocated into the vitreous, the symptoms are, a falling backwards and dilatation of the iris, which also becomes tremulous. If great pain and irritation come on, it is better to endeavour at once to remove the lens—the traction operation being in this case the best.

Dislocation of the lens into the anterior chamber ;

into the vitreous.



Partial  
dislocations.

Partial dislocations of the lens are the result of severe blows, and generally terminate in cataract. There is also sometimes a glaucomatous state produced, which intermits, but is highly dangerous to sight, and the lens should be removed by the traction operation, with a large iridectomy. In all these cases the operation is sure to be accompanied with loss of vitreous.

Injuries to the  
choroid.

A severe blow on the eye will frequently cause hæmorrhage to take place between the choroid and the retina. If the hæmorrhage is severe all useful vision is lost, but if slight, recovery may be looked for with a blind spot corresponding to the detached portion of retina. The treatment should consist of a couple of leeches to the temple, ice over the eye, atropine drops, and perfect rest to both eyes.

Injuries to the  
eye from  
chemicals, &c.:  
lime.

Injury to the eye by lime or mortar, if *seen immediately* should be treated by washing out with a tepid solution of vinegar (ʒj ad aq. ʒij). The upper lid should be everted, and all portions remaining in the eye carefully removed; a drop of castor-oil may then be put in, and the eye closed with a pledget of wet lint.

Strong acids.

When the eye is injured by strong acid it should be syringed out with an alkaline solution (sodæ bicarb. gr. v, aq. ʒj), the after treatment being the same as that above described. If the lids are injured with the acid they should be dressed with the following liniment:—



Olei lini,

Liq. calcis, āā fl. oz. iv.

Cretæ preparatæ oz. ij.

Lint dipped in this liniment should be applied over the eye, and a pad of cotton-wool placed over it, with a bandage.

When the eye is injured by an explosion of Gunpowder, all the loose powder should be carefully removed with a syringe and tepid water. The cornea should also be carefully searched, and all particles embedded in it removed with the spud. Castor-oil should then be dropped in, and belladonna lotion applied.

The fragments caused by the explosion of Foreign bodies percussion-caps, and small shot, very frequently penetrate the eyeball. If the foreign body can be seen, an attempt should be made to remove it. If its presence is only suspected great watchfulness must be exercised. The following symptoms indicate the presence of a foreign body within the eye:—

1. Continuation of primary inflammation.
2. Subacute choro-iritis, after the subsidence of the primary inflammation.
3. Non-union of the corneal wound.
4. Severe and continued pain in the eye.

The continuance of these symptoms should lead to excision of the eyeball. But if at the time of the accident sight is destroyed, and no doubt exists as to the presence of a foreign



body within the eye, the eyeball should be at once extirpated.

Extirpation of  
the eyeball.

The instruments required for this operation are—1, a spring speculum; 2, conjunctival forceps; 3, a blunt-pointed pair of scissors, curved on the flat (Fig. 15): and 4, a strabismus-

FIG. 15.



hook. The patient being placed under the influence of chloroform, the spring speculum is introduced between the eyelids. A fold of conjunctiva is then nipped up with the forceps close to the corneal edge. One blade of the scissors being introduced into this opening, they are run round the edge of the cornea, snipping as they go, and thus dividing the conjunctiva completely. The forceps are then laid aside, and the recti muscles are taken up on the squint-hook in succession, and divided with the scissors, close to the globe. By pressing the speculum backwards into the orbit the globe is now made to protrude from the socket. The remaining oblique muscles and the fascia are then divided. The closed scissors are next passed backwards along the inner side of the eyeball, and, on being opened, are made to include the optic nerve, which is divided, and the entire globe lifted from the orbit. Brisk hæmorrhage



ensues from the central artery, which is easily controlled by a stream of cold water. If it continues to bleed, the best plan is to leave the speculum between the lids, and press a small dry sponge into the orbit, retaining it there firmly with a bandage for an hour or two.

Foreign bodies are sometimes impacted in the orbit. To remove them, the outer canthus should be slit with a pair of scissors or a scalpel. If the body be in the upper part of the orbit, the upper lid must be turned up, and the fold of mucous membrane reflected from the globe, divided. The foreign body being felt, may then be removed with a pair of forceps. If it is in the lower part of the orbit, the lower lid must be drawn down, and the conjunctiva divided. Should the foreign body be small and metallic, anything like prolonged search is to be deprecated, as frequently little or no harm comes from its presence in the orbit, and considerable mischief may follow the attempt to remove it.

Injuries to the orbit.



## CHAPTER III.

### INJURIES TO THE MOUTH, PHARYNX, ŒSOPHAGUS, AND LARYNX.

*Wounds of Tongue—Foreign Bodies in Pharynx and Œsophagus—Foreign Bodies in Windpipe—Scald of Larynx—Laryngotomy—Laryngo-tracheotomy—Tracheotomy—Cut Throat—Stabs in the Throat—Ligature of Common Carotid—Drowning—Hanging—Artificial Respiration.*

Wounds of  
tongue.

WOUNDS of the tongue, if the parts gape, must be drawn together with fine silk. The suture should be placed deeply, with a curved needle set in a handle. In young children it is better to give chloroform, the mouth being opened with a screw gag, and the tongue drawn well forward by seizing it at the tip with a pair of hooked forceps. Ice, or the application of perchloride of iron, will generally stop all bleeding; but if it persists, a ligature may be passed with a curved needle round the bleeding point, enclosing the muscular tissue.

Foreign bodies  
in the  
pharynx:

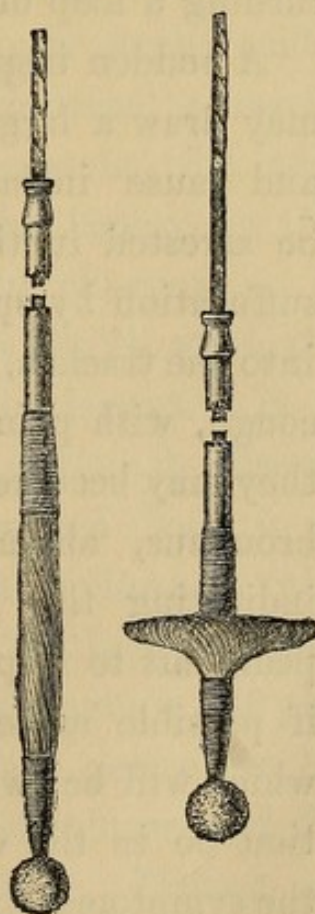
Small sharp bodies, such as bristles, fish bones, or pins, are generally found sticking between the pillars of the fauces and the tonsils. The laryngoscopic mirror is a great aid in finding them; and a pair of fine urethral forceps are the



best with which to remove them. Larger substances, such as pieces of meat, coins, or false teeth, are generally arrested at the junction of the pharynx with the œsophagus, or between the base of the tongue and the epiglottis. If the foreign body can be reached with the fingers, it may be hooked up, or it may be seized with a pair of curved forceps. It should never be pushed down. If suffocation is impending, laryngotomy should be immediately performed (see below), and then further attempts made to remove the obstruction. If the body is rough or angular, a blunt hook will often catch it. A common skewer, heated in the fire, and the point turned, has served for this purpose.

Foreign bodies stick in the œsophagus generally, either opposite the cricoid cartilage, or just above the diaphragm. If they are soft, and not likely to damage the stomach, they may be pushed on with an ordinary sponge probang, or stomach tube. Sharp bodies, like pins, should not be pushed on, but an endeavour should be made to catch them with the "horse-hair probang" (Fig. 16). This being pushed gently, unex-

FIG. 16.

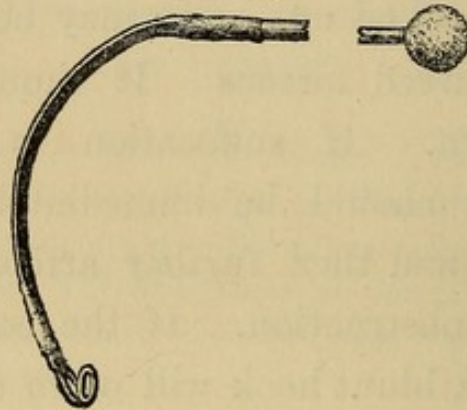


In the  
œsophagus.



panded, beyond the point where the pin or bone is stuck, is expanded by pulling up the handle, and then withdrawn with a slightly rotatory motion. If a coin is impacted, a "money probang" (Fig. 17) may succeed in

FIG. 17.



catching it. This may be easily improvised by turning a loop of stout wire sharply on itself.

In the larynx. A sudden inspiration, when the mouth is full, may draw a large piece of food into the larynx and cause instant death. Smaller bodies may be arrested in the cavity of the larynx, causing suffocation by spasm; or they may pass onwards

In the trachea. into the trachea, the symptoms being intermittent cough, with pain at the point of impaction; or they may become impacted, generally in the right bronchus, absence of respiration in the lung indicating this fact. To be sure that the impediment to respiration is not in the œsophagus, if possible make the patient drink some water, which will be swallowed with ease if the obstruction be in the windpipe. The sudden onset of the symptoms, the intermission of the paroxysms, and the dyspnœa during *expiration*, distinguish



the symptoms due to the presence of a foreign body from croup or laryngitis.

In scalds of the larynx the respiration is affected two or three hours after the injury, the voice becoming hoarse, and the inspiration croupy. Sometimes fatal spasm occurs. A hot sponge should be applied at once to the throat, warm vapour inhaled, and if swallowing be possible, two or three grains of calomel should be given every hour. The œdematous tissue about the fauces should be freely scarified with an ordinary tenaculum. Should the respiration become rapidly worse tracheotomy must be performed (see below), and the earlier the better, before the lungs become involved. The same treatment is applicable to injury by strong acids. When taken suicidally, the windpipe is rarely injured, but when taken by mistake, the acid frequently finds its way into the larynx, in the efforts made to expel it from the pharynx.

Scald of  
larynx.

Strong acids.

Laryngotomy is applicable in adults, when the foreign body is above or in the larynx. It is not to be recommended in children, in disease of the larynx, or when the foreign body is in the trachea or bronchus. The following rules apply to the three operations of Laryngotomy, Laryngo-tracheotomy, and Tracheotomy. If possible give chloroform. Place the patient on his back, with a pillow under his shoulders, and the head thrown back over the pillow. Place a pad under the neck, to increase the anterior convexity

Laryngotomy.

Position of  
patient.



of the cervical spine. Elevate the chin, and depress the shoulders. The head being held perfectly straight, a line drawn through the middle point of the lower jaw, and the notch in the upper border of the thyroid, down to the upper border of the sternum will give the direction for the incision. The instruments required are—1, a scalpel; 2, dissecting forceps; 3, retractors; 4, blunt hooks (for which bent probes answer the purpose); 5, sharp hook; 6, tracheotomy tube; 7, wires armed with cotton-wool.

Laryngotomy. Laryngotomy may be performed, in great emergency, by the simple thrust of a penknife horizontally through the skin and crico-thyroid membrane, at a point just an inch (in the adult) below the pomum Adami, the wound being then enlarged laterally. When the operation is performed more deliberately, an incision is made through the skin perpendicularly in the middle line, an inch and a half long, extending from the middle of the thyroid cartilage, to the base of the cricoid. The sterno-hyoid muscles are then separated, and held aside by retractors, and the crico-thyroid membrane exposed. The knife is thrust well through the mucous membrane into the larynx, air, blood, and mucus being expelled. The opening is enlarged transversely, and an oval canula, curved on the flat, introduced. If time allows, bleeding vessels should be ligatured before the larynx is opened,



some branches of the superior thyroid (the cricothyroid arteries) being the only vessels likely to be wounded. The canula must be secured by tapes passing round the neck, and may be repeatedly cleared with the wires armed with cotton-wool, or with a camel's-hair brush. A flannel, wrung out of hot water, should be placed over the throat, and the patient, if possible, kept in an atmosphere impregnated with steam.

The first steps of the operation for Laryngo-tracheotomy are the same as laryngotomy, except that the external incision must be a little lower. The incision in the windpipe is prolonged through the cricoid cartilage, and the first ring of the trachea. This latter incision must be made from below upwards, to avoid wounding the thyroid body. The operation is useful in children, when the obstruction to respiration is either in or above the larynx, and is more rapidly performed in great emergencies than tracheotomy. It should be avoided, if possible, in the adult.

Laryngo-tracheotomy.

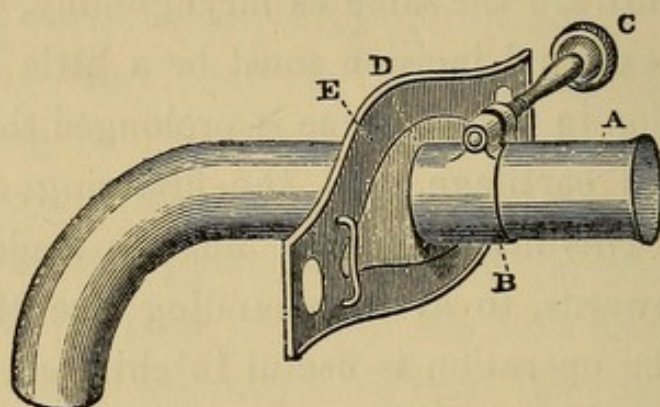
In Tracheotomy the steps of the operation are as follows:—Standing on the right side of the patient, make—1st. A free external incision in the median line, from just above the cricoid cartilage to the upper edge of sternum. 2ndly. Clear away fat and cellular tissue, and making out the division between the sterno-hyoid muscles, separate them with the handle of the knife, and let them be gently held aside by retractors. If needful

Tracheotomy.



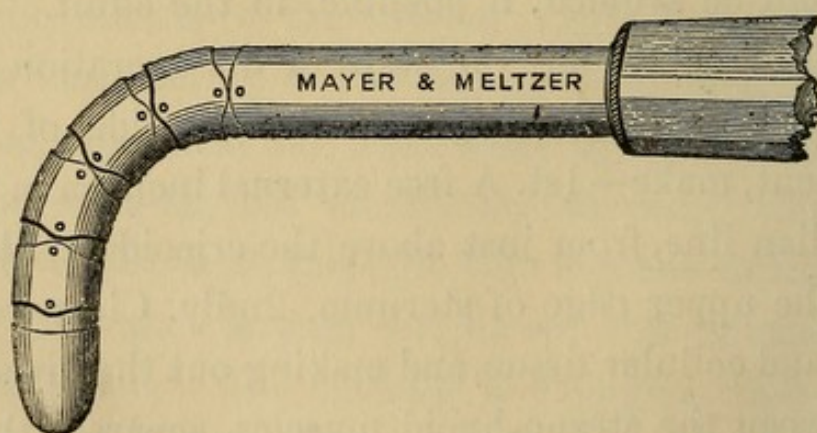
secure bleeding arteries, and let large veins be hooked aside with bent probes. 3rdly. On getting the rings of the trachea in view pass a sharp hook into the upper part of it to steady it and pull it well forward. 4thly. Turning the edge of the knife upwards, puncture the trachea in the lower part, being careful not to plunge the knife too far in, and incise it freely upwards. 5thly. Introduce the canula (Fig. 18) fitted on

FIG. 18.



the "pilot trocar" (Fig. 19), and withdrawing the trocar, introduce the inner tube (Fig. 20):

FIG. 19.




tie the canula in with tapes passing to the back of the neck. This canula is constructed so as to lengthen or shorten the straight portion, by



changing the position of the collar, which is fixed by the screw shown in the figure. The introduction of the tube is necessary when the obstruction

FIG. 20.



is *above* the opening in the trachea. When it is below, the edges of the incision in the trachea should be kept widely open, a spring speculum used for separating the eyelids being a good form of instrument for the purpose. An attempt may be made to catch the foreign body with a pair of tracheal forceps, but it should not be persevered in. Better to keep the tracheal wound open and wait for the subsidence of the spasm, and then renew the attempt.

If during the operation respiration should cease, the tube must be introduced as rapidly as possible, and artificial respiration immediately commenced, and persevered with for a considerable time, until natural respiration is restored. If any blood gets into the canula and obstructs the entrance of air, it must be sucked out with the mouth, if it cannot otherwise be disposed of.

In cut throat the first thing to be done is to Cut throat.



search for all bleeding vessels, veins as well as arteries, and either twist or ligature them. If hæmorrhage is severe, and the bleeding point cannot at once be seen, compress the common carotid against the transverse process of the fifth or sixth cervical vertebra, and then continue the search. If it is impossible to arrest the hæmorrhage, put a ligature on the common carotid. (See below.) In the next place, all coagula should be cleared from the wound. If the wound is inflicted above the hyoid bone, it is possible that the tongue may fall backward, and cause suffocation. A ligature should be passed through the tip, and secured to the cheek by sticking plaster. If the wound is just above the thyroid cartilage, a portion of the epiglottis may be divided, and obstruct respiration. It should be either cut off altogether, or else secured in its place with a suture. If the trachea is entirely divided, the divided edges may be kept together by some sutures. *On no account apply sutures to the external wound, except at the angles, where the wound is superficial.* Place the patient in bed, with the shoulders well raised, and the head thrown forward on the chest, and secured there by tapes passing from a nightcap to a roller round the chest. If the pharynx or œsophagus is wounded, the patient must be fed with the stomach-pump tube passed through the mouth, and if needful



guided down the gullet with the finger placed in the wound. Should the patient be much depressed beef-tea and brandy must at once be administered in this way.

In stabs and punctured wounds of the throat, the general treatment is the same as for cut throat. If the trachea is wounded, emphysema may ensue. A pad of dry lint, firmly applied, will suffice. When any large vessel is wounded, the wound must be enlarged, if needful, and the bleeding vessel secured. If this cannot be done the common carotid must be ligatured, generally below the omo-hyoid. For this operation the following instruments are required.—1. Scalpel; 2. Dissecting forceps; 3. Blunt hooks and retractors; 4. Grooved director; 5. Aneurism needle; 6. Ligatures.

Stabs in the throat.

Ligature of common carotid below the omo-hyoid.

Place the patient on his back, with raised shoulders, the head being thrown back and turned to the opposite side. 1st. Make an incision through the skin, platysma, and superficial fascia, extending along the anterior border of the sterno-mastoid, from a point opposite the thyroid cartilage, to the sternum.

2ndly. Relax the sterno-mastoid, by turning the head slightly, and pull this muscle outwards, the sterno-hyoid and thyroid being drawn inwards, with blunt hooks. Look for the anterior belly of the omo-hyoid, in the upper part of the wound, its fibres being seen passing downwards and outwards.



3rdly. Divide the dense fascia attaching this muscle to the sheath on the director. The descendens noni will then be seen on the sheath, and must be drawn to the inner side.

4thly. Pinch up the sheath with forceps, and divide it with the knife, cutting on the flat. Enlarge the opening on the director.

5thly. Insert the aneurism-needle, armed with the ligature, from without inwards, between the vein and artery; care being taken to keep close to the under surface of the artery, so as to avoid the vagus.

6thly. Disengage the ligature from the needle, and tie, taking care not to raise the artery from its sheath. The wound is then to be brought together with sutures, and dressed. During the operation, all veins should, if possible, be held aside with bent probes, to avoid wounding them.

Drowning. In cases of suspended animation from drowning, the following rules should be observed:—

1st. Remove from the mouth all dirt, saliva, &c, and, pulling the tongue well forward, cause it to be retained in that position either with a pair of hooked forceps, or by passing an elastic band over it and under the chin.

2ndly. Remove from the body all clothing that may constrict the chest, and lay the body on its back, with the shoulders raised on a firm cushion, placed under the shoulder-blades.

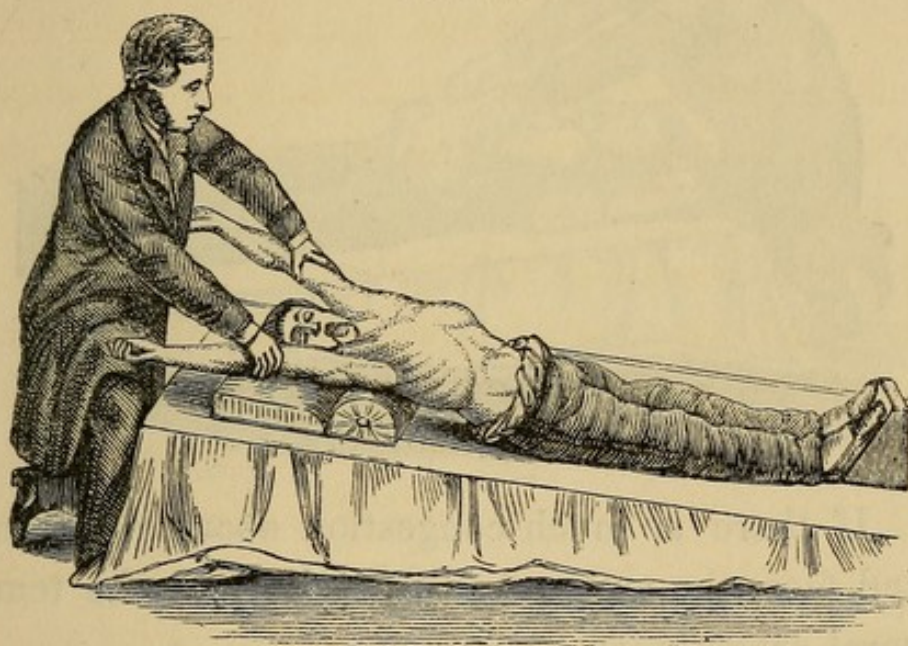


3rdly. Adopt Sylvester's method to restore respiration :—

Artificial  
respiration.

(a) Standing, or kneeling behind the patient, grasp the arms above the elbows, and draw the arms steadily upwards above the head, and keep them so stretched for a couple of seconds (Fig. 21).

FIG. 21.



(β) Turn the arms down, and press them firmly for a couple of seconds against the sides of the chest (Fig. 22).

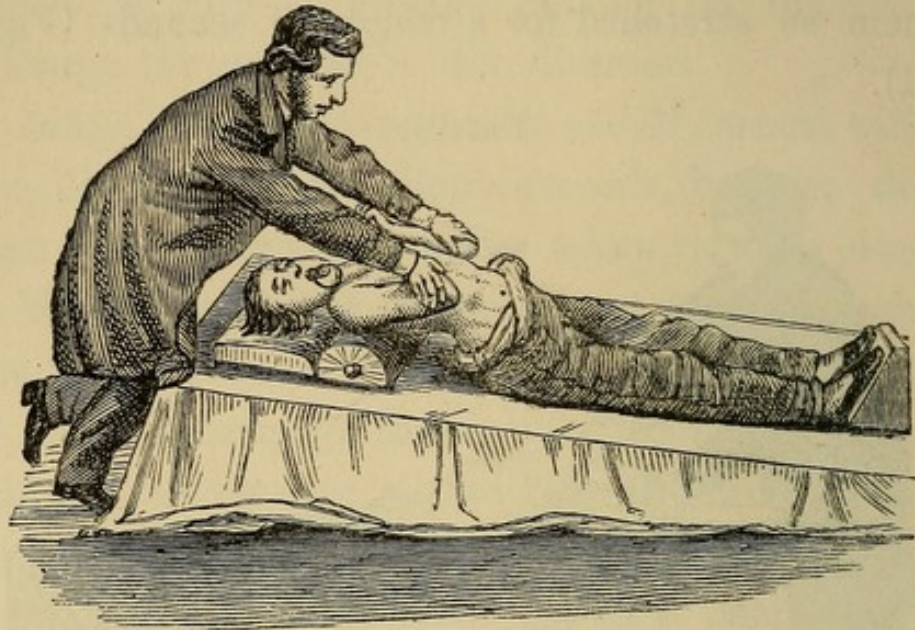
Repeat these movements from fifteen to twenty times in a minute, and persevere in them, if needful, for one or even two hours. The expiratory act is much aided by an assistant pressing on the lower border of the ribs and the diaphragm.

4thly. During these efforts, have the wet clothes removed from the body, and let the limbs be rubbed in an upward direction with hot flan-



nels. Dash hot and cold water alternately on the chest. If a warm bath is procurable, the body may be immersed in it for five minutes, Sylvester's method being still pursued.

FIG. 22.



If there is much congestion about the head and face, the external jugular vein, or the temporal artery, may be opened.

5thly. As soon as natural respiration is established, the patient should be removed to a warm bed, the room being kept thoroughly well ventilated, and free from all crowding. An enema of brandy and beef-tea may be administered. If any fluid is given by the mouth, it must be in very small quantities, and with considerable care, lest suffocation should ensue.

Hanging.

In cases of suffocation from hanging, the treatment is substantially the same as is adopted in case of drowning. The body should be in-



stantly cut down, the ligature removed from the throat, and Sylvester's method commenced. Bleeding from the external jugular may also be useful, and a galvanic current may be passed from the nape of the neck to the pit of the stomach to excite the diaphragm.



## CHAPTER IV.

### THE CHEST.

*Fracture of the Ribs—Wounds of the Chest—Hernia of the Lung—Wounds of the Lung—Emphysema—Pneumothorax — Hæmothorax — Paracentesis Thoracis—Wounds of the Heart—Gunshot Wounds of the Chest.*

Fracture of  
the ribs.

**FRACTURE** of the ribs may be from direct violence, the ends being driven inwards ; or it may be from indirect violence, as from a squeeze against a wall, when the rib gives way at its most convex part, and the ends are driven outwards. The symptoms are—1. Pain at the seat of injury ; 2. Increased pain on taking a deep inspiration ; 3. Arrest of the movements of the ribs in breathing ; 4. Crepitus, which may be detected by pressing one hand over the seat of the injury, and the other on the opposite side of the chest. Crepitus is also detected on deep inspiration, or the stethoscope may reveal it, when it cannot in any other way be discovered.

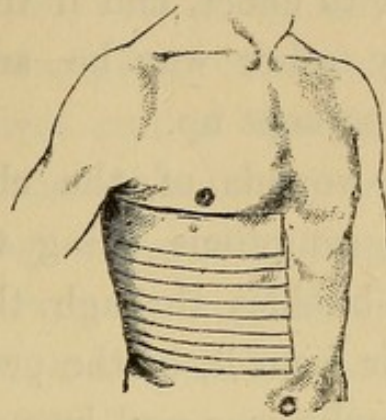
Treatment of  
fractured ribs.

In simple fracture, the best plan is to apply strips of plaster two inches broad, stretching from the spine behind, to the sternum in front, and extending some inches above and below the site



of the fracture (Fig. 23). By this means, the ribs are kept perfectly at rest on the injured side.

FIG. 23.



The occurrence of crackling under the skin, and of hæmoptysis, are indications that the lung has been wounded by the point of the broken rib. The immediate treatment will not vary from that for ordinary fracture of the ribs.

In wounds which do not penetrate the chest cavity, but involve the muscular tissue in front, the edges should be approximated with sutures, and the arm brought forward in front of the chest, and secured there with a bandage. In extensive wounds posteriorly, the elbows should be as much as possible approximated behind.

In wounds of the intercostal arteries, the application of ice and a compress should first be tried. To apply this compress, lay a large piece of linen over the wound, and press the central portion into the wound with the finger. Into this depression insert pieces of sponge, until firm pressure is made. Thus all fear of the compress slipping

Non-  
penetrating  
wounds of the  
chest.

Wounds of  
intercostal  
arteries.



into the cavity of the chest is avoided. If this plan fails, the wound must be enlarged, and if possible the divided ends of the vessel secured. This is difficult to effect, and if the hæmorrhage cannot in any other way be arrested, digital pressure must be kept up.

Penetrating  
wounds of the  
chest.

Penetrating wounds of the chest are easily diagnosed, the symptoms being the passage of blood and air-bubbles through the wound, the expulsion of air from it, or the protrusion of the lung itself. Emphysema and hæmoptysis are also pretty sure signs of a wounded lung. In deep punctured wounds, when these prominent signs are not present, it is impossible to say for certain whether the wound is a penetrating one or not. No attempt must be made to ascertain this, either by introducing the finger or a probe. A careful search for a foreign body must, however, be made, and its removal effected, if present. Hæmorrhage must be stopped, and the external wound closed. The parts should then be kept perfectly at rest with strapping or a rib bandage.

Hernia of the  
lung.

The lung may protrude through a wound, forming a round tumour covered with pleura. It should be returned by gentle manipulation, and if there is much constriction at the neck, the wound may be cautiously enlarged with a blunt-pointed bistoury. If symptoms of gangrene are present, the protruded lung should not be returned, but ligatured and cut off.



The symptoms of wounded lung are—1. Pas-  
 sage of air and blood through the wound. 2. Ex-  
 pectoration of bright red, frothy mucus. 3. Deep  
 pain in the chest, with cough and dyspnœa. There  
 is generally also great collapse. The treatment  
 must be perfect rest of the parts, by strips of  
 plaster from the spine to the sternum, arrest of  
 all hæmorrhage externally, immediate closure of  
 the external wound, application of ice to the  
 chest externally, and exhibition of it internally.  
 Stimulants should not be administered in the  
 collapse stage, unless under very urgent circum-  
 stances.

Wound of the  
lung.

In emphysema, resulting from wounded lung,  
 either by a punctured wound or fractured rib, if  
 the pressure of the hand relieves the patient, a  
 bandage should be applied. If, however, pressure  
 increases the dyspnœa, no application should be  
 made. In penetrating wounds it is better to  
 close the external wound at once, and if possible  
 make pressure. If the emphysema should be-  
 come so extensive as to encumber the patient's  
 breathing, incisions through the skin may be  
 made with a scalpel, or scarificators, and cupping-  
 glasses applied to various parts over the inci-  
 sions. Antimony and ipecacuanha should be  
 given in full and repeated doses.

Emphysema.

Pneumothorax only calls for immediate treat-  
 ment when it occasions great compression of the  
 lung, and consequent dyspnœa. The original

Pneumo-  
thorax.



wound may then be enlarged, or the air may be drawn off with a small trocar and canula, or by the aspirator. (For use of aspirator, see chap. xii.)

Hæmo-  
thorax.

Hæmothorax may be diagnosed by the presence of the symptoms of excessive hæmorrhage, together with dulness on percussion, absence of respiratory murmur, and immobility of the ribs on the affected side. If the symptoms become urgent, paracentesis must be performed. Owing to the coagulation of the blood, it is difficult to remove the accumulation through a canula; therefore it is better to enlarge the wound, or make counter-openings in a dependent position.

Paracentesis  
thoracis.

The operation of paracentesis is best performed with the pneumatic aspirator. But if this is not to be had, an ordinary trocar and canula will serve. The spot to be selected should be the sixth or seventh intercostal space, midway between the sternum and the spine. An incision should be made with a scalpel through the skin close to the lower rib, and the trocar or needle thrust in. If a canula is inserted, care must be taken to exclude the entrance of air, as the fluid ceases to flow; and an assistant should firmly compress the ribs whilst the canula is being withdrawn. The opening is then to be closed with a pledget of lint and a strap of plaster.

Wounds of the  
heart.

Where wounds of the heart are not immediately fatal, the symptoms are those of internal



hæmorrhage, with small intermitting pulse. Absolute repose, ice externally, and early venesection must be employed, with the administration of belladonna and digitalis internally.

In penetrating gunshot wounds of the chest, arrest external hæmorrhage, remove foreign bodies and spicula of bone. If there is only one wound, place the patient on the wounded side. If there is a wound of exit as well, let the upper wound be closed, and the other left for drainage.

Gunshot  
wounds.



## CHAPTER V.

### THE UPPER EXTREMITY.

*Wounds at Wrist-Joint—Wound of Palmar Arch—Needle in the Hand—Fracture and Dislocation of the Clavicle; of the Scapula; of the Humerus—Compound Injuries to the Shoulder-Joint—Resection of Shoulder-Joint—Amputation at Shoulder-Joint—Fractures and Dislocations of the Radius; the Ulna; the Bones of the Hand—Compound Injuries to the Elbow-Joint—Excision of Elbow—Compound Injuries to Wrist-Joint—Amputation of the Thumb and Fingers.*

Wounds. IN wounds near the wrist joint, the ulnar or radial arteries are frequently divided. If possible, both ends of the bleeding vessel should be secured, and the hand and arm placed on a long splint, to secure perfect rest. In incised wounds of the palmar arch, the vessels can generally be secured. In punctured wounds it is not advisable to enlarge the wound, in order to secure the vessel, but a compress must be applied to the wound, and a hard ball being placed in the palm, the fingers must be firmly bandaged over it. This failing, extreme flexion of the forearm on the arm, with a pad at the bend of the elbow, will effectually compress the brachial, and prevent further hæmorrhage.

Wounds of the  
palmar arch.



Needles, or portions of them, are frequently run into the hand. The ordinary practice of cutting down on the needle, is a troublesome, and frequently a useless proceeding, as the needle recedes before the knife. A plan, which will rarely fail, is to pass the point of a long curved bistoury under the needle, and cut out a flap. The needle will generally be found lying in the flap, and may be removed with a pair of forceps. The flap is then replaced and secured with a strip of plaster and a bandage.

Needle in the hand.

The clavicle is generally fractured by indirect violence, such as a fall on the point of the shoulder. The fracture is usually found near the outer side of the middle third. Symptoms: 1, the patient leans toward the injured side; 2, the shoulder falls downwards, forwards, and inwards; 3, the sternal fragment is tilted upwards, and can be distinctly felt; 4, pain when the arm is raised towards a right angle with the body; 5, crepitus, when the shoulders are forcibly drawn backwards. Sometimes the fracture takes place at the acromial extremity, when the external deformity is wanting. In fractures from direct violence the bone is often comminuted, and the intervening fragments sometimes fall out of the line of the bone, and are difficult to restore.

Fracture of the clavicle.

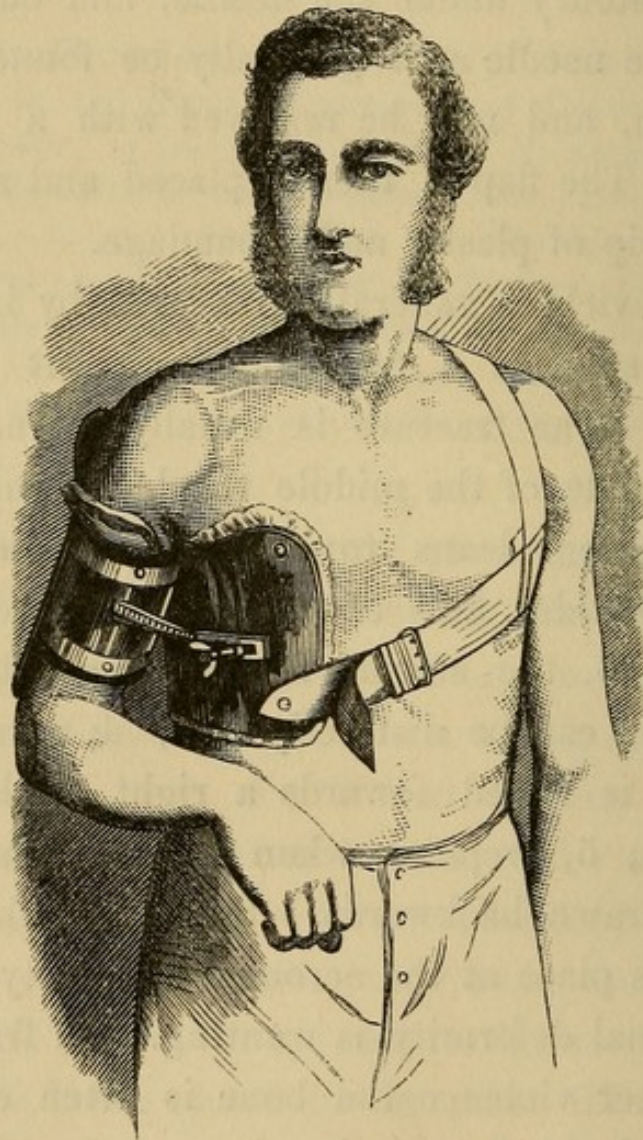
The usual treatment with the pad in the axilla and the figure-of-eight bandage, is quite

Treatment of fractured clavicle.



inadequate to keep the fragments in place; and, if no other means are at hand, bandaging the arm to the side, and supporting the forearm in a sling, is sufficient. The apparatus (Fig. 24) devised by Professor Gordon, appears to be a most

FIG. 24.



efficient means of treatment, and is thus described by him:—

“The indications fulfilled by the clavicular apparatus are, by means of an artificial clavicle,



placed lower than the natural one, to keep the shoulder outwards and backwards. An iron plate, well padded, and resting upon the fore, back, and outer surface of the chest, constitutes the body of the apparatus; to the fore part of which, by means of a screw and slide, the inner end of this artificial clavicle is fixed. The front arm-splint is attached to the outer end of the artificial clavicle, and the back-splint, by means of two slips of iron, is attached to the anterior border of the front splint.

“The apparatus is reversible, so that it will fit either side. Along the posterior border are two knobs, a superior and an inferior. To the superior is fixed the strap which passes upwards, over in front, and beneath the shoulder of the sound side, and is buckled to the inferior knob behind. To the front of the body is attached, by means of another knob, a second strap, which is fixed to the strap coming in front of the shoulder; these two straps hold the apparatus immovably, in a position inclining backwards and upwards. Having made a thick, wedge-shaped pad, it is applied upon the front arm-splint, so high as to protect the lower border of the axilla from being pressed upon by the upper margin of the splint. The pad of the back splint is laid on, and both are secured by means of two small straps. As the front pad is wedge-shaped, and its base above,



it may be seen that an interspace exists between the lower end of the front splint and the arm. When we tighten the lower strap we approximate the arm to the lower end of the front splint, and the shoulder is carried well outwards and backwards; and thus very often, the deformity from the over-riding of the fragments of the broken clavicle disappears."

Dislocation of  
the clavicle.

Dislocation of the sternal end of the clavicle forwards is the most common displacement. Symptoms:—1, The head of the bone can be felt on the sternum; 2, the shoulder falls a little back; 3, the clavicular portion of the sternomastoid is very prominent; 4, placing the knee against the spine, and drawing the shoulders back, the deformity may be reduced.

It has been mistaken for a tumour of bone, and fractures of the sternal end sometimes very much resemble it.

Dislocation upwards is rare. Symptoms:—1, Depression of the shoulder; 2, elevation of the sternal end.

Dislocation backwards is still more rare. Symptoms:—1, Disappearance of the head of the bone behind the sternum; 2, difficulty in respiration.

Treatment of  
dislocations of  
the clavicle.

The reduction of these dislocations is very simple—viz., by placing the knee against the spine, and drawing back the shoulders. But in the first two varieties it is almost impossible to retain the bone in position. In dislocation



backward, the bone may be retained in position, by placing the patient on his back, with a thick pillow placed between the shoulders, or by bandaging the shoulders to a splint placed across behind, with a thick pad intervening between it and the spine.

Fractures of the scapula are the result, generally, of direct violence, and are difficult to diagnose on account of the accompanying contusion. Fractures through the spine are easily felt on passing the finger over the ridge. Fracture of the posterior angle is best discovered, by placing the hand of the affected side on the opposite shoulder. In examining for fractures below the spine, the forearm must be laid across the back.

Fractures of  
the scapula.

Crepitus may be detected, by placing the hand on the scapula, and moving the arm in various directions. A fracture of the neck through the supra-scapular notch is rare. The symptoms are described in column 2, p. 54.

Fractures of the body of the scapula are treated by bandaging firmly to the trunk. Fractures of the neck require the shoulder to be raised by a sling round the elbow, and to be kept out from the side by a pad in the axilla, the arm being confined to the side by a bandage.

Treatment of  
fractures of  
the scapula.

The scapula is sometimes dislocated from its acromial attachment to the clavicle. The displacement is usually downwards. Symptoms:—

Dislocations of  
the scapula.



1, Falling of the shoulder; 2, prominence of acromial end of clavicle. The treatment is to raise the shoulder, and depress the clavicle, by a belt passing round the elbow, and over the clavicle.

Injuries at the shoulder-joint.

Injuries about the shoulder-joint are frequently difficult to diagnose. The tables, from "Hamilton on Fractures and Dislocations" (pages 54, 55), present the points of similarity and difference between the various injuries.

Fracture of the anatomical neck of the humerus.

Fracture of the humerus at the anatomical neck is rare, and the result of direct violence. It may happen that the head of the bone is thrust through the capsular ligament into the axilla. If it remains in the glenoid cavity there is little displacement of the fragments, and little deformity. Pain at the seat of fracture and crepitus, with the absence of the signs of other injury, are the chief indications. Sometimes impaction occurs, and then the humerus is shortened, the acromion projects more than is natural, and the globular head of the bone is not distinctly felt. This accident is usually accompanied with fracture of the tuberosity, so that crepitus is felt on firmly grasping the head of the bone and rotating the arm.

For symptoms of fracture at the epiphysis and surgical neck, see columns 3 and 4, p. 55.

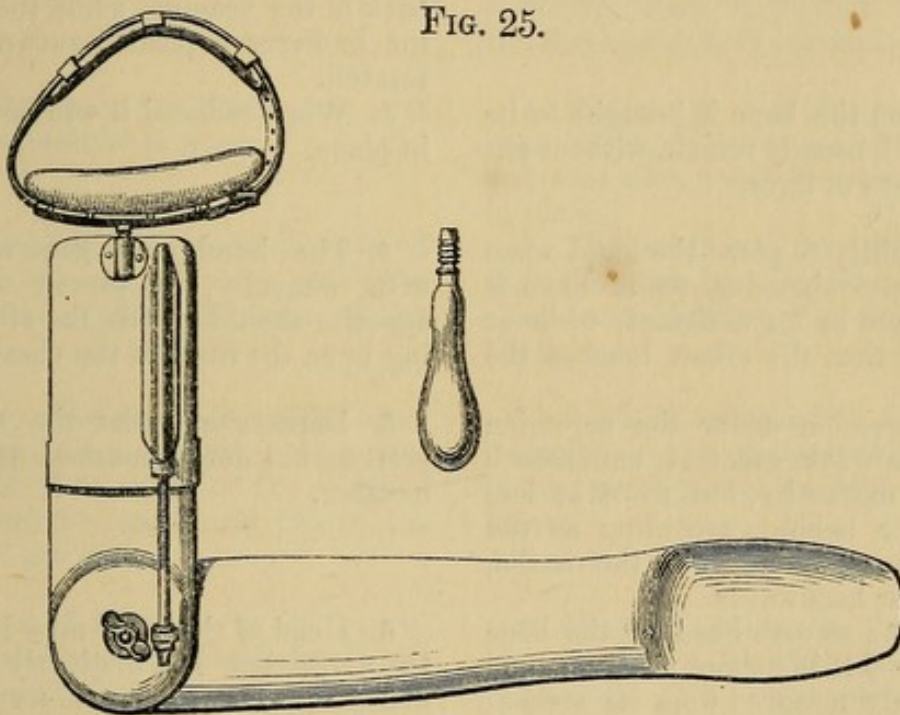
Fractures of the anatomical neck, without displacement, and impacted fractures, may



be treated in the simplest manner, by bandaging the arm to the side, and securing perfect rest. Great care should be taken, when the fracture is impacted, not to displace the fragments by forcible manipulations. In fracture at the epiphysis, and at the surgical neck, when there is displacement, the splint (Fig. 25) is useful. The crutch

Treatment of fractures of the upper extremity of humerus.

FIG. 25.



is placed in the axilla, the strap and pad passing over the shoulder. The arm and forearm are then bandaged to the splint, and extension made with the key. Care must be taken, in making extension, not to press too firmly on the axillary vessels. A more simple plan is to mould a firm gutta-percha splint to the outer side of the arm, taking care to make it fit as a cap, well over the shoulder. The arm is then bandaged to this splint, and the upper turns of the



*Hamilton's Differential Diagnosis.*

## COLUMN I.

*Signs of a dislocation. (Cause, a fall upon the elbow, or sometimes a direct blow.)*

1. Preternatural immobility.

2. Absence of crepitus.

3. When the bone is brought to its place it will usually remain without the employment of force.

4. Inability to place the hand upon the opposite shoulder, or to have it placed there by an assistant, while at the same time the elbow touches the breast.

5. Depression under the acromion process; always greatest underneath the outer extremity, but more or less in front or behind, according as the dislocation may be into the axilla, forwards or backwards.

6. Round smooth head of the bone sometimes felt in its new situation, and very plainly removed from its socket; moving with the shaft. Absence of the head of the bone from the socket.

7. Elbow carried outwards, and in certain cases forwards or backwards, and not easily pressed to the side of the body.

8. Arm shortened in the dislocation forwards, and slightly lengthened, or its length not changed when in the axilla.

## COLUMN II.

*Signs of a fracture of the neck of the scapula. (Cause, generally a direct blow.)*

1. Preternatural mobility.

2. Crepitus, generally detected by placing the finger on the coracoid process, and the opposite hand upon the back of the scapula, while the head of the humerus is pushed outwards and rotated.

3. When reduced it will not remain in place.

4. The hand may generally, but with difficulty, be placed upon the opposite shoulder with the elbow resting upon the front of the chest.

5. Depression under the acromion process, but not so marked as in dislocation.

6. Head of the bone may be felt in the axilla, but less distinctly than in dislocation; never much forwards or backwards; head of the bone moves with the shaft. Head of the bone not to be felt under the acromion process, although it has not left its socket.

7. Elbow carried a little outwards, but not so much as in dislocation. Easily brought against the side of the body.

8. Arm lengthened.

9. The coracoid process carried a little toward the sternum and downwards.

10. Pressing upon the coracoid process, it is found to be moveable, and it is also observed that it obeys the motions of the arm.



*Hamilton's Differential Diagnosis.*

COLUMN III.

*Signs of separation of the epiphysis.*  
(Cause, direct blows.)

1. Preternatural immobility.
2. Feeble crepitus; less rough than the crepitus produced when broken bones are rubbed against each other.
3. Fragments replaced are not easily maintained in place.
4. The hand can be easily placed upon the opposite shoulder, while the elbow rests against the front of the chest.
5. The depression is not immediately under the acromion, yet higher than in most fractures of the surgical neck, perhaps one inch below the acromion process.
6. Head of the bone in its socket, and not moving with the shaft. Upper end of lower fragment projecting in front when displacement exists, and feeling less sharp and angular than in case of a broken bone; indeed, being slightly convex and rather smooth, it may easily be mistaken for the head of the bone.
7. Elbow hanging against the side, when the fragments are not displaced, but away from the side when displacement exists.
8. Length of arm not changed unless the fragments are overlapped, or both fragments are tilted upon each other. When the fragments are overlapped the arm is shortened.

COLUMN IV.

*Signs of fracture through the surgical neck.* (Cause, generally direct blows, but in aged people frequently caused by falling on the elbow.)

1. Preternatural mobility often, but not constantly present
2. Crepitus produced easily when there is no impaction, or when the displacement is not complete, but with difficulty when impaction exists, or the displacement is complete.
3. When once the fragments have been displaced it is exceedingly difficult ever afterwards to maintain them in place.
4. The hand can be easily placed upon the opposite shoulder, while the elbow rests against the front of the chest.
5. A slight depression below the acromion, not immediately underneath its extremity, but an inch or more below.
6. Head of bone in the socket, and moving with the shaft when impacted. The upper end of the lower fragment being often felt distinctly pressing upwards toward the coracoid process, its broken extremity being easily distinguished by its irregularity from the head of the bone.
7. Elbow hanging against the side when the fragments are not displaced, but away from the side when displacement exists.
8. Length of arm unchanged, unless the fragments are impacted or overlapped, or both fragments are much tilted inwards. If the fragments are completely displaced the arm is shortened.



bandage passing over the shoulders and pressing against the acromion, draw the lower fragment outwards. The arm is then placed in a sling.

Fractures of  
the shaft.

Fractures of the shaft of the humerus are usually the result of direct violence, sometimes of muscular action. If, as is usual, the fracture is transverse, there is little displacement; when oblique, the fragments over-ride. If the fracture is above the insertion of the deltoid, the upper fragment inclines inwards, and the lower one outwards; if below the insertion, the reverse effect is observed. An angular splint should be applied on the inner side, extending from the axilla to the hand, with short splints from the shoulder to the elbow externally, and posteriorly, if needful (Fig. 26). The ribbed "Crimean arm

Treatment.

FIG. 26.

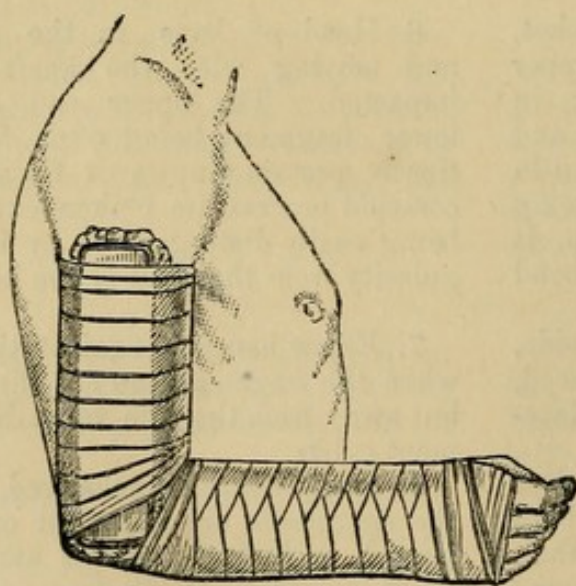



FIG. 27.



splints," made by Aitkin, of York, are admirably suited for this purpose (Fig. 27).



The lower extremity of the humerus is fractured above the condyles, by falls upon the bent elbow. In young subjects, the lower epiphysis is separated in the same way. In consequence of the great and rapid swelling, considerable difficulty sometimes arises in diagnosing between fracture of the humerus and dislocation of the radius and ulna backwards. The former injury is always caused by falls on the elbow, the latter never so, but by falls on the palm of the hand. Symptoms:—1, Preternatural mobility, which, however, ceases after a few hours; 2, crepitus, discovered on extending the forearm; 3, reduction on extension, but immediate return of the deformity on flexion; 4, shortening on measurement from the internal condyle to the tip of the acromion; 5, detection of the ends of the fragments, particularly the lower one, beneath the triceps; 6, unnatural relations between the condyles and the olecranon.

These fractures are best treated with gutta-percha splints. The bones being placed in position, the elbow is bent at right angles, and a firm gutta-percha splint moulded to the back part of the arm, as far down as the wrist. The arm and forearm are firmly bandaged to the splint, care being taken to put plenty of cotton-wool at the bend of the elbow, and to protect all the prominent points of bone with thick padding. If considerable swelling exists, and fracture into the

Fractures of the lower extremity of the humerus.

Treatment of fractures at the elbow-joint.

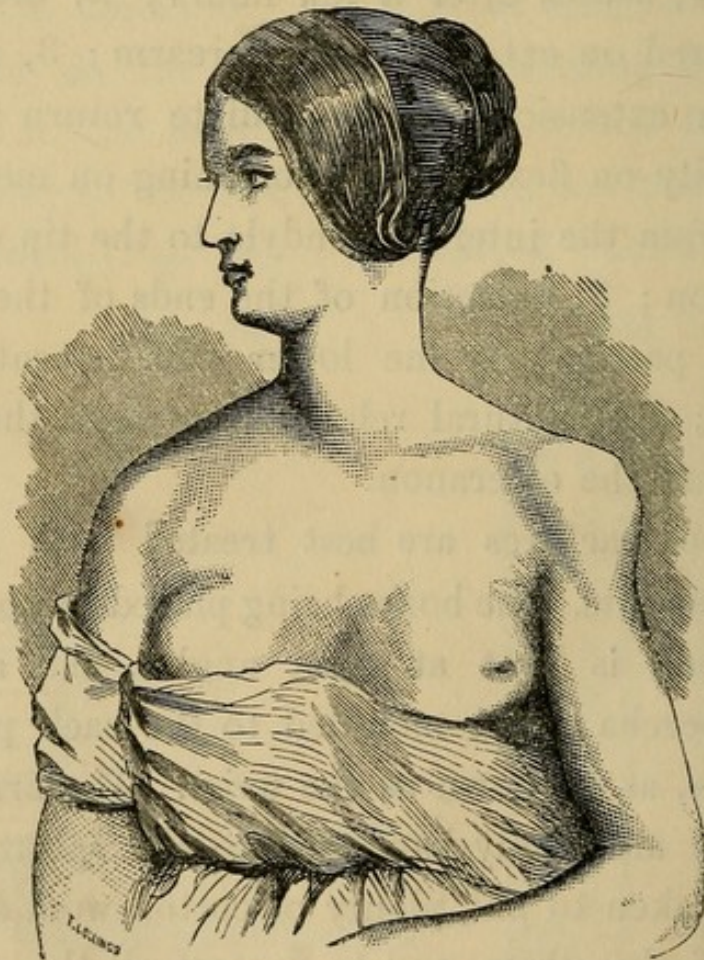

joint is suspected, the arm should be placed in a semi-flexed position on a pillow, and evaporating lotions applied, to reduce the swelling.

Dislocations of  
the humerus.  
Downwards, or  
sub-glenoid.

Dislocations of the humerus downwards into the axilla, are caused by direct blows upon the upper part of the humerus, or by violent leverage carrying the elbow away from the side. Symptoms:—1, A depression immediately under the acromion; 2, the elbow carried outwards from the side and a little backwards; 3, the head of

FIG. 28.



the humerus felt in the axilla; 4, numbness of the arm, and pain; 5, the elbow being placed

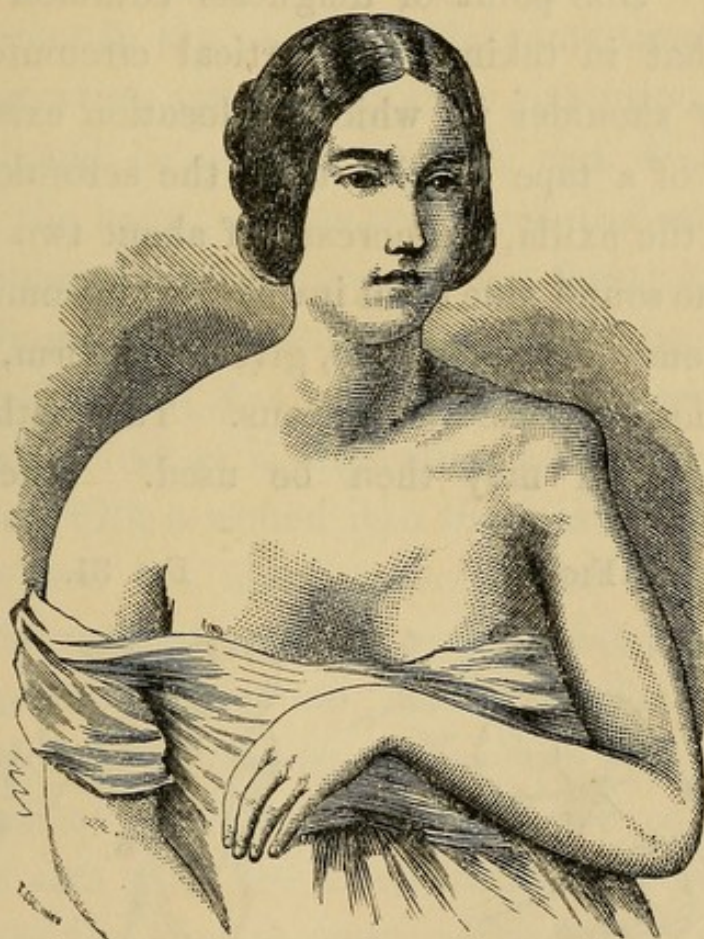


against the side, it is impossible to place the hand on the opposite shoulder (common to all); 6, lengthening of the arm, from half an inch to an inch (Fig. 28).

Dislocations forward arise from the same causes, except that the force is generally from behind, as, for example, from a fall on the elbow,

Forwards, or  
sub-coracoid.

FIG. 29.



when the axis of the limb is directed backwards. Symptoms:—1 and 2, same as above; 3, axis of the limb directed towards the middle of the clavicle; 4, fulness underneath the clavicle on the sternal side of the coracoid process (Fig. 29).



Backwards, or  
sub-spinous.

Dislocations backwards are rare. They arise from falling forwards on the extended arm, or from pushing violently with the arm elevated. Symptoms :—1, Projection under the spine of the scapula ; 2, wide space between the head of the bone, and the coracoid process ; 3, forearm carried across the chest ; 4, axis of humerus upwards and outwards, to a point posterior to the glenoid cavity. One point of diagnosis common to all is, "That in taking the vertical circumference of any shoulder in which dislocation exists, by means of a tape carried over the acromion and under the axilla, an increase of about two inches over the sound side is an invariable concomitant."

Treatment.

Whenever it is possible, give chloroform, in the reduction of these dislocations. The method by manipulation may then be used. When the

FIG. 30.

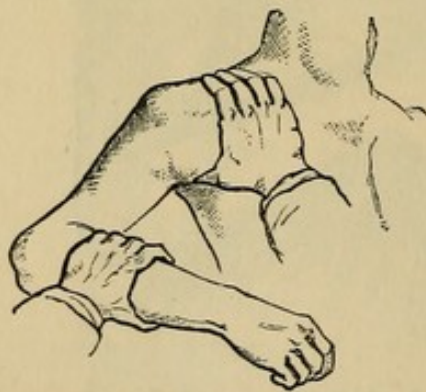
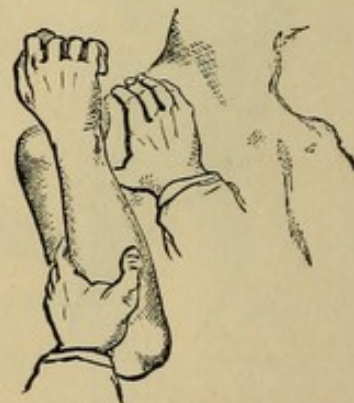


FIG. 31.



Reduction by  
manipulation.

patient is fully under the influence of chloroform, grasp the arm below the elbow with one hand, and carry it well out from the side. Place the other hand on the shoulder, pressing with the



thumb upon the head of the bone (Fig. 30). Next, firmly extending the limb, make it describe a semicircle towards the sternum, at the same time pressing the head of the bone towards the glenoid cavity. Then suddenly bring the arm down to the side (Fig 31).

When chloroform is not given, the reduction is accomplished as follows:—The patient being placed on his back, the surgeon places the heel of his foot in the axilla, at the same time grasping the wrist, and making firm extension. The arm should be slightly rotated, and drawn towards the body. After reduction, the arm is to be bandaged to the side, and the forearm placed in a sling. Evaporating lotion should be applied to the shoulder, if much swelling is present.

Reduction by extension.

When there is a dislocation of the shoulder, together with a wound into the joint, if the soft tissues are not much injured, the dislocation must be reduced, and the wound treated antiseptically (see chapter on Antiseptic Treatment). A bag of ice should be *continuously* applied, and the patient kept under the influence of opium. If the soft parts are much involved, it is better to resect the joint at once. (See below, p. 62.)

Compound injuries to the shoulder-joint.

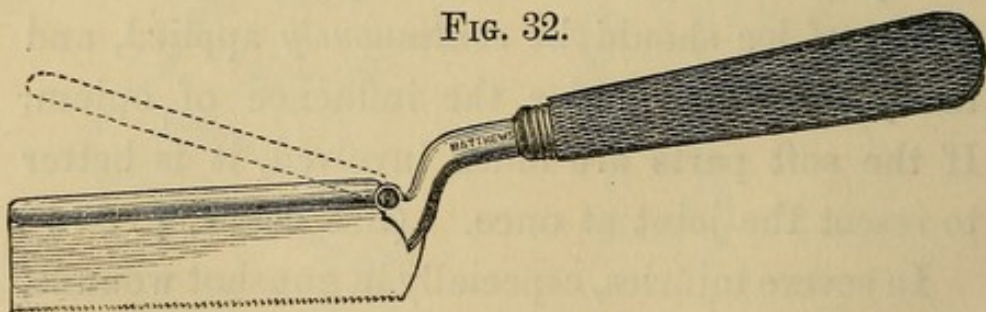
In severe injuries, especially in gunshot wounds, where the bone is very much comminuted, the soft parts lacerated, or the main vessels involved, amputation at the shoulder-joint may be required. (See below, p. 63).



Resection of  
shoulder-joint.

In resection of the shoulder-joint for compound injuries, the instruments required are: 1, large bistoury; 2, retractors; 3, lion-forceps; 4, saw; 5, bone forceps. The operation is thus performed:—1st. Enlarge the original wound, in a direction which must accord with the condition of the soft parts. A line from the tip of the acromion, to the insertion of the deltoid, is the usual direction. 2ndly. The arm being carried across the chest, rotate it first inwards, and then outwards, to allow of the division of the scapular muscles attached to the tuberosities. 3rdly. Open the capsule of the joint, the long head of the biceps being, if possible, slipped aside. 4thly. Carry the elbow backwards, and thrust the head of the bone out through the wound. 5thly. The head of the bone being held firmly with the lion-forceps, remove it with the saw, cutting through the tuberosities. The saw best adapted for this, and many other purposes, is one made by Matthews, of

FIG. 32.



Portugal Street, with a bent shaft, and a moveable back (Fig. 32). The wound being dressed, the arm is abducted and laid on a pillow.



In amputation at the shoulder-joint, the instruments required are: 1, a long stout bistoury, 2, a catlin, nine inches long; 3, lion-forceps. The operation is thus performed:—1st. The artery being compressed by an assistant on the first rib, form an anterior, or antero-posterior flap, according to circumstances, by cutting from without inwards with the bistoury, and dissecting the deltoid upwards. 2ndly. Open the capsule with the heel of the knife. 3rdly. As in these cases, the bone is generally much shattered, and leverage is impossible, grasp the head of the bone with the lion-forceps, and divide, in succession, the scapular muscles attached to the tuberosities. 4thly. Change the bistoury for the catlin, and, still holding the head of the bone with the lion-forceps, slip the knife behind it and cut close to the bone. 5thly. Let an assistant follow the knife, with his thumb feel for the artery, and grasp it between the thumb, in the wound, and the fingers outside the flap. 6thly. Cut outwards, dividing the artery, and completing the flap. 7thly. At once secure the axillary artery.

Amputation at the shoulder-joint.

Amputations at lower points of the arm, are best performed by the ordinary flap operation—by transfixion. In making the anterior flap, the brachial artery should be avoided, so as not to cut it until the last sweep of the knife in the formation of the posterior flap.

Amputation of the arm.

Fractures of the lower end of the humerus, Injuries to the elbow-joint.



involving the elbow-joint, have been noticed at p. 57.

Fracture of  
the olecranon.

Fracture of the olecranon is caused by falls on the elbow, or direct blows upon the part. Symptoms:—1, Crepitus when the fragments are not separated, or when they are brought together by extension of the forearm; 2, depression between the fragments; 3, semi-flexion of the forearm, and inability to straighten it. Before the age of fifteen, this fracture seldom or never happens. Great swelling soon follows the injury, and obscures the diagnosis. If suspected, the arm should be kept in the straight position, and evaporating lotions applied. Treatment:—The arm must be placed on a straight splint, extending from near the upper part of the humerus to the wrist-joint, and placed on the front of the arm. It should be fixed in position with strips of adhesive plaster, and then a bandage should be carried upwards from the hand, which, on reaching the elbow, must be made to embrace the upper fragment in a figure of eight, and thus draw it down into position.

Fracture of  
the coronoid  
process.

Fracture of the coronoid process is very rare. Symptoms:—1, Luxation backwards of the ulna, or the ulna and radius; 2, probable crepitus; 3, the fragment felt in front of the trochlea. Treatment:—The arm must be placed at right angles, and so secured on a rectangular splint.

Fracture of the neck of the radius is rare.



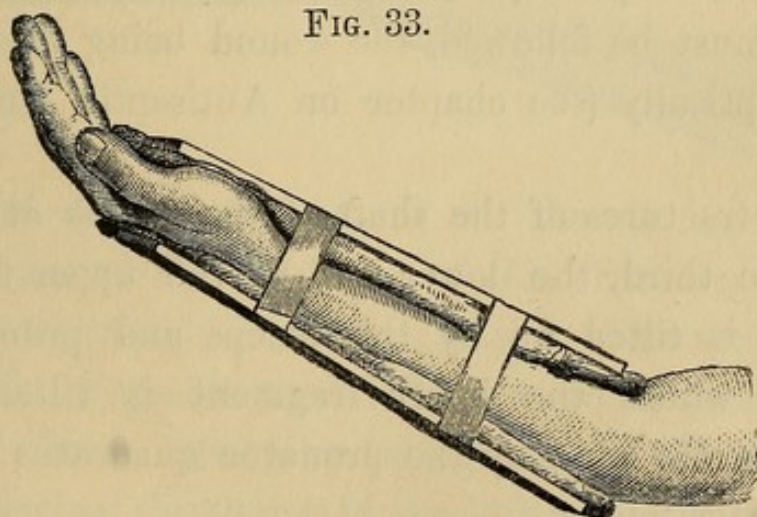
Symptoms :—1, The upper end of the lower fragment is carried forward by the action of the biceps; 2, the displacement is increased on extension; 3, pronation, and inability to supinate. Treatment :—The forearm must be flexed on the arm, and supported by a single dorsal splint, whilst a compress must be placed over the upper end of the lower fragment, and secured with a bandage.

Fracture of  
the neck of  
the radius.

Fracture of the shaft of the ulna alone is generally the result of direct violence. It is frequently found in conjunction with other serious injuries—*e.g.*, dislocation of the head of the radius, or dislocation of both bones backwards. Symptoms :—Crepitus and mobility, discovered by seizing the bone above and below the point of contusion, and moving it in opposite directions. The direction taken by the fragments is uncertain. When outwards towards

Fracture of  
the shaft of the  
ulna.

FIG. 33.



the radius, there is slight projection of the styloid process. When accompanied with dis-



location of the head of the radius, there is shortening of the forearm. Treatment:--If the fragments fall towards the radius, the finger must be forcibly pressed between the bones in order to restore the fragments; whilst at the same time extension is made, and the hand is supinated. If they press forwards or backwards, direct force must be used to their extremities in order to reduce the deformity. The arm is then to be put up in splints, as in Fig. 33.

With  
dislocation of  
the head of  
the radius.

If dislocation of the head of the radius is also present, this must, if possible, be reduced. Let an assistant seize the humerus, not in front, but by the condyles, and at the same time flex the forearm, and extend it. Then push the head of the radius towards its socket. Fix the arm to an angular splint, placed upon the palmar surface. Should the fracture be compound, as it not unfrequently is, with dislocation, the same plan must be followed, the wound being dressed antiseptically (see chapter on Antiseptic Treatment).

Fracture of  
the shaft of  
the radius.

In fractures of the shaft of the radius at the middle third, the lower end of the upper fragment is tilted up by the biceps and pronator teres, whilst the lower fragment is tilted in against the ulna by the pronator quadratus and supinator longus.

In fractures of the lower third, the ends of the fragments are generally tilted in towards the

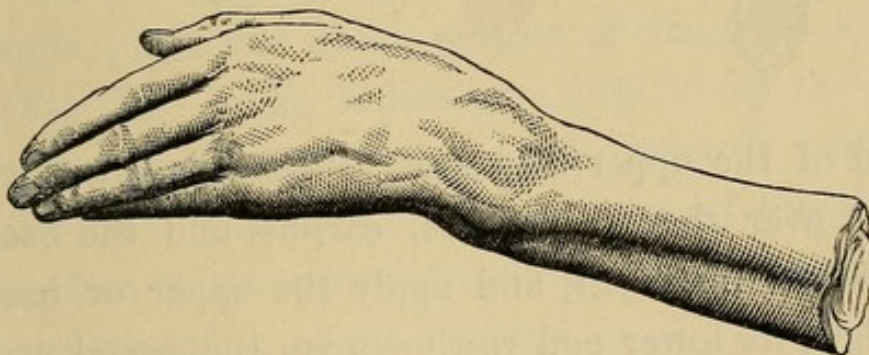


ulna. The treatment of these fractures is the same as that indicated above for fractures of the shaft of the ulna.

Colles' fracture takes place an inch above the carpal end of the bone, and is generally caused by falls on the palm of the hand. Symptoms:— 1, The patient cannot pronate or supinate, except with great pain; 2, the hand is turned backwards, and to the radial side; 3, the styloid process of the ulna is very prominent; 4, prominence on the dorsum of the wrist, and a corresponding depression in front; 5, crepitus on powerful extension. Fig. 34, from a cast in King's

Colles'  
fracture.

FIG. 34.



College, shows one aspect of this deformity. Treatment:—The reduction of this fracture, and its treatment by Gordon's splint, is thus accomplished. Supposing the left radius to be broken, reduce the deformity by laying hold of the forearm, placing the thumb of the left hand upon the lower end of the upper fragment, and the thumb of the right hand upon the upper end of the lower fragment, as much to the inner side as

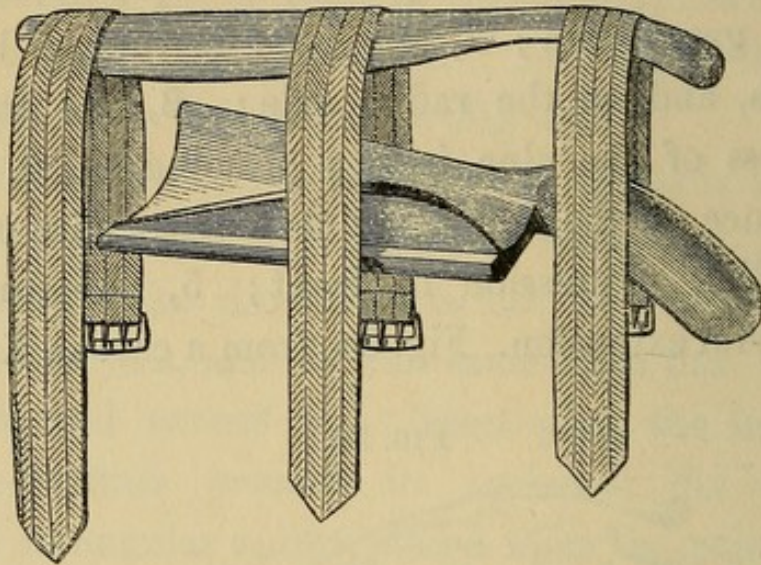
Gordon's  
splint.



possible. Both fragments are thus pushed backwards and outwards, the hand being at the same time strongly adducted.

Apply the bevelled portion of the under splint (Fig. 35) previously padded, against the lower

FIG. 35.



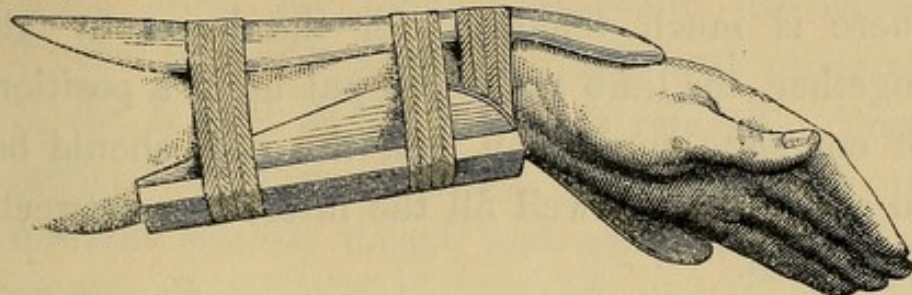
end of the upper fragment. Then place a thick pad over the metacarpus, carpus, and the back of lower fragment, and apply the upper or back splint, its lower end resting upon the dorsal pad.

Both splints are now held in their position by three straps with buckles attached, the upper strap being placed as high as possible, and the second strap low down, almost at the end of the body of the splint (Fig. 36). This strap serves the double purpose of pressing the bevelled portion of the splint against the lower end of the upper fragment, pushing it backwards, whilst at the same time, acting upon the back splint, the



carpus and the carpal fragment are pushed forwards, restoring and maintaining the natural form of the radius.

FIG. 36.



As the main displacement of the lower fragment is backwards and outwards, it is necessary that the hand should be maintained in a state of abduction: therefore place a moderately thick pad over the outer margin of the carpus, the third strap being applied encircling the dorsal splint, and the ulnar portion of the front splint (Fig. 36). The indications fulfilled by the last strap are, to force the carpus inwards towards the ulna, and remove the pressure of the upper surface of the carpus from the outer part of the carpal surface of the radius.\*

Both bones of the forearm are sometimes fractured together. The cause is, generally, direct violence, or, more rarely, a fall on the palm of the hand. Symptoms:—1, Crepitus and mobility; 2, pain and loss of power; 3, visible bend in the limb.

Fracture of  
radius and  
ulna.

\* The above description of the application of the splint is from the pen of Dr. Gordon, Professor of Surgery at Queen's College, Belfast.



Treatment :—If there is but little displacement the limb must be put up in the ordinary manner (Fig. 33, p. 65). If the fracture is oblique and there is shortening, extension must be made. If there is much tendency for the bones to fall together, the limb should be put up in a position of complete supination, and the pads should be so adjusted as to well fill the interstices between the bones.

Fracture of  
the carpal and  
metacarpal  
bones.

Fractures of the carpal bones are generally compound. When it is a simple fracture, little or no treatment is required beyond rest. Fractures of the metacarpal bones are the result of direct violence, or of blows upon the clenched fist. Crepitus may be detected, and in some cases an angular projection on the dorsum. Treatment :—A ball or a roller is placed in the palm, and the fingers firmly fixed over it, either with a bandage or adhesive plaster. If the fragments are much displaced, traction on the fingers of the broken metacarpal bones will bring them into place, and they may be retained there by a gutta-percha splint, moulded either to the back or palm of the hand, and well padded. Care must be taken to make the splint project on either side of the hand, in order to keep off the pressure of the bandage from the lateral metacarpal bones.

Dislocation of  
the head of  
the radius.

Dislocation of the head of the radius forwards, is caused by falls on the elbow, or on the extended forearm when pronated. It may be



caused also in young children, by lifting them up by the arm. Symptoms:—1, The head of the bone can be felt in its new position, and its absence from its natural situation discovered; 2, the arm is inclined outwards and pronated; 3, the tendon of the biceps is relaxed. Treatment:—Extension should be made with the forearm slightly flexed, and whilst this is kept up the elbow must be grasped, and the head of the radius forcibly pushed back into its position. No attempt to straighten the forearm should be made, but it should at once be put up flexed at right angles, and placed in a sling.

Dislocation backward is generally the result of a direct blow on the front and upper part of the bone. It is rare without accompanying fracture. Symptoms:—1, The head of the bone is felt rotating behind the condyle; 2, the forearm is slightly flexed and pronated; 3, supination cannot be performed. Treatment:—Extension being made, the forearm is forcibly supinated, the head of the bone being at the same time pressed forward into its place.

Dislocation of both bones of the forearm is an accident to which youth is particularly liable. Dislocation backwards is caused by a fall on the hand, or inner side of the ulna; or by a violent twist, or a direct blow on the front and upper part of the forearm. Symptoms:—1, The forearm is slightly flexed; 2, the lower end of the humerus can be felt in front of the elbow; the

Dislocation of  
the radius  
and ulna  
backwards.



olecranon projects behind the head of the radius, becoming more prominent on flexion and less so on extension (just the reverse of what occurs in fractures of the humerus above the condyles); 3, the olecranon instead of being below the internal condyle, is carried about an inch above it; 4, the forearm is shortened, on measurement from the internal condyle to the styloid process of the ulna; 5, there is no shortening from the acromion to the internal condyle. Treatment:—Seat the patient sideways on a chair. Place your foot on the chair, and your knee in the bend of the elbow. Take firm hold of the wrist, and pressing the knee firmly against the radius and ulna, forcibly, but slowly, bend the forearm. Thus the coronoid process is brought forward in front of the elbow, and is pulled by the muscles into its place. When reduction is supposed to have taken place, the joint should be flexed and extended, and if this can be done with ease, it is evident that the bones are in place.

Dislocation  
outwards.

Dislocation outwards is usually incomplete. Symptoms:—1, Great prominence on the inner side of the internal condyle, with a deep depression below; 2, prominence on the outer side of the cup of the head of the radius. Treatment:—Extension and counter-extension being kept up, lateral pressure must be made on the radial side.

Dislocation  
inwards.

Dislocation inwards is a rare accident. Symp-



toms :—1, The olecranon is felt projecting on the inner side, and the head of the radius indistinctly in the bend of the arm ; 2, the external condyle is very prominent ; 3, the forearm is flexed and the hand pronated. Treatment :—As above, by extension, counter-extension, and pressure in the direction of the natural position of the bones.

Dislocation forwards is very rare. Symptoms :—1, The forearm flexed at right angles, immovable and supinated ; 2, absence of the olecranon from its natural position ; 3, head of radius in the coronoid fossa. Treatment :—Flexion on the knee, as described above. The ulna may be reduced without the radius, which must then be pressed into its position, as before described.

Dislocation forwards.

Dislocations at the wrist are rare, fracture of the lower end of the radius being generally the accident mistaken for it. Dislocation backwards may be caused by falls on the palm, or on the back of the hand. Symptoms :—1, A very abrupt angle caused by the projection of the carpus ; 2, absence of crepitus ; 3, easy reduction. Treatment :—Simple extension will generally be sufficient.

Dislocation of the carpal bones backwards.

Dislocation of the carpus forwards may be the result of a fall on the palm. The radius and ulna are felt projecting posteriorly, whilst the carpus forms a tumour anteriorly. It can be reduced by extension.

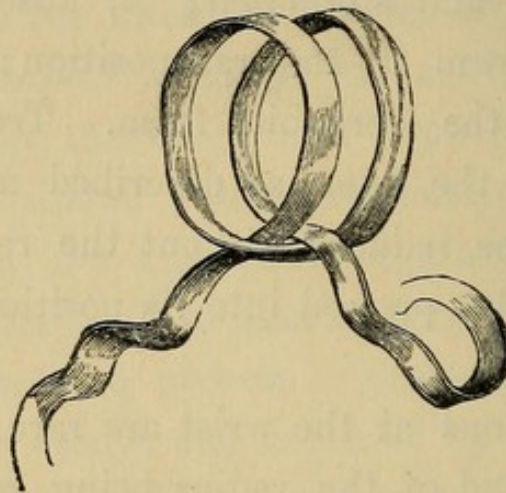
Dislocation forwards.



Dislocation of  
the thumb.

The most usual dislocation of the thumb is that of the first phalanx backward on the metacarpal bone. Symptoms:—1, The end of the metacarpal bone projects in the palm; 2, the proximal end of the first phalanx is found on the dorsum of the metacarpal. Treatment:—The thumb being protected with lint, a clove-hitch (Fig. 37) is fixed on it, and extension

FIG. 37.



made; or reduction may be secured by bending the phalanx forcibly backwards, at the same time pressing the base towards the articulation. Dislocation forwards may be reduced by bending the phalanx forwards towards the palm.

Compound  
injury to  
elbow-joint.

When the elbow-joint is laid open without further injury, it must be treated antiseptically (see chapter on Antiseptic Treatment). The limb should be placed on an angular splint, and, if possible, ice kept constantly applied. When the bones are severely injured, as in gunshot wounds or crushes, if the vessels are not damaged, pri-



mary excision of the joint should be performed.

For this operation the following instruments are required:—1, Scalpel; 2, blunt hooks and retractors; 3, lion-forceps; 4, saw; 5, bone-forceps. The original wound may be enlarged, if placed conveniently, or a straight incision may be made at the back of the joint, about five inches long. If possible, the triceps should not be divided, but it should be separated with the fascia from the olecranon, and held aside with a retractor. The olecranon process should then be cut off with bone-forceps. The end of the humerus is then cleared, the ulna nerve being slipped forwards over the internal condyle, and held aside with a blunt hook. It must be remembered, that in injuries to the elbow-joint the nerve is sometimes displaced, so that great care must be taken to avoid it, from the very first. The entire condyloid surface of the humerus is then removed with the saw, and the end of the ulna, including the sigmoid cavity with the head of the radius. The section of the bones must be modified, according to the injury they have sustained; the usual mistake is the removal of too small a portion. Hæmorrhage being arrested, the wound is brought together, and the arm extended on a straight splint placed in front of the arm.

Excision of  
elbow-joint.

If the injury to the soft parts, and the vessels



Amputation  
at the elbow-  
joint and in  
the forearm.

is so great that amputation is needful, it may be performed at, or in close proximity to the joint. The best form of operation, both here and in the forearm, is the "mixed method" of skin flap, with circular division of the muscles. The instruments required are:—1, Long bistoury; 2, saw; 3, lion and bone-forceps. An oval flap of skin, large enough to cover in the end of the stump, is marked out with the bistoury, either in front, behind, or laterally, as the case demands; or two short flaps are cut, to meet over the end of the stump, one being sometimes longer than the other, in order to remove the cicatrix from the face of the stump. A circular sweep is then made through the muscles, about an inch below the base of the skin flaps. The muscles are cleared upwards from the bone, and the section through the bones completed with the saw. If the amputation is at the joint, the bones are disarticulated previous to the section of the muscles.

Compound  
injury to the  
wrist-joint.

In compound injury to the wrist-joint, the joint must be treated in the same manner as the elbow or shoulder-joint, the forearm and hand being placed on a straight splint. If the bones of the forearm protrude, and the tendons and blood-vessels are injured, amputation must be performed, the one just described being applicable.

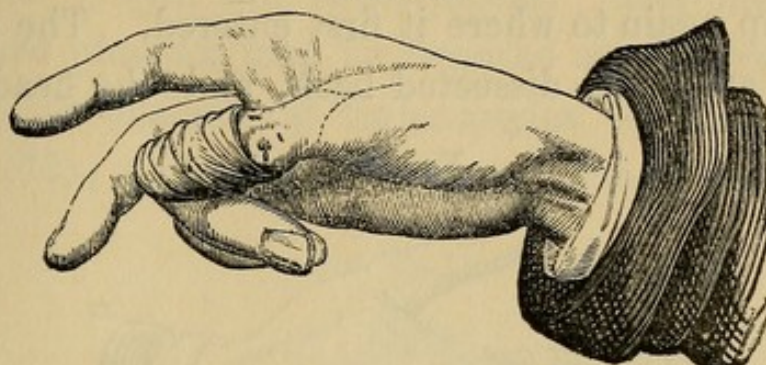
Amputation of  
the thumb.

Every attempt should be made to save any portion of the phalanges or metacarpal bone of the thumb. But if the injury renders this im-



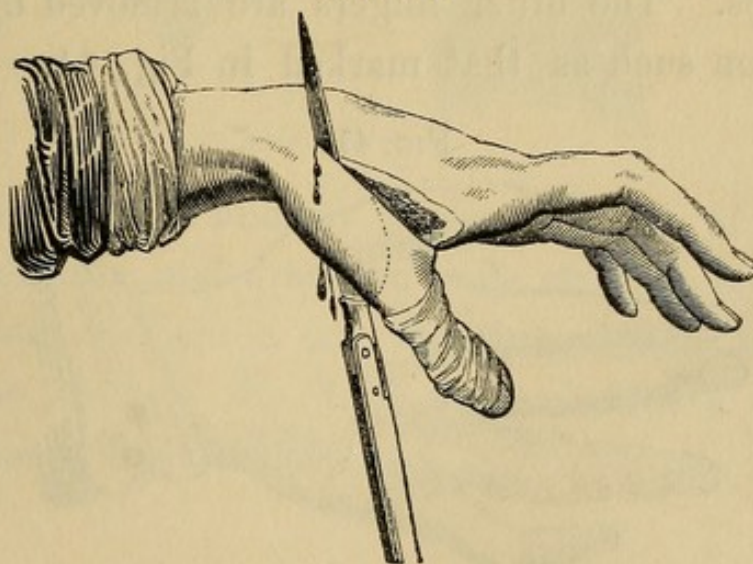
possible, the phalanges may be removed by the incisions shown in Fig. 38, or the metacarpal bone

FIG. 38.



by the incision marked in Fig. 39. A long narrow-bladed bistoury is carried through the soft parts, between the metacarpal bone of the thumb and index finger, up to the trapezium ; it

FIG. 39.



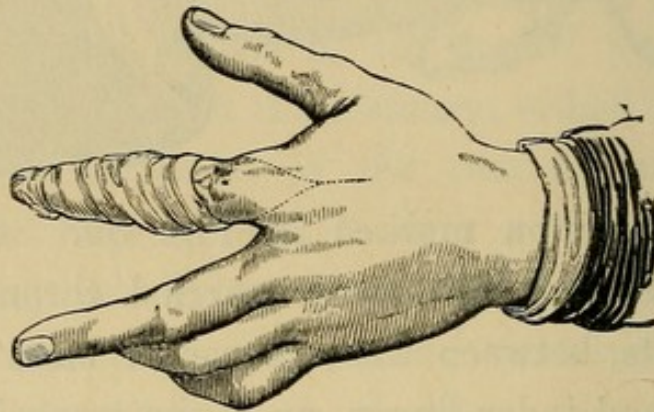
is then turned outwards, and the joint cut through, the incision being completed in the direction of the dotted line.

The index and little fingers may be removed by incisions corresponding to the dotted line Amputation of the fingers.



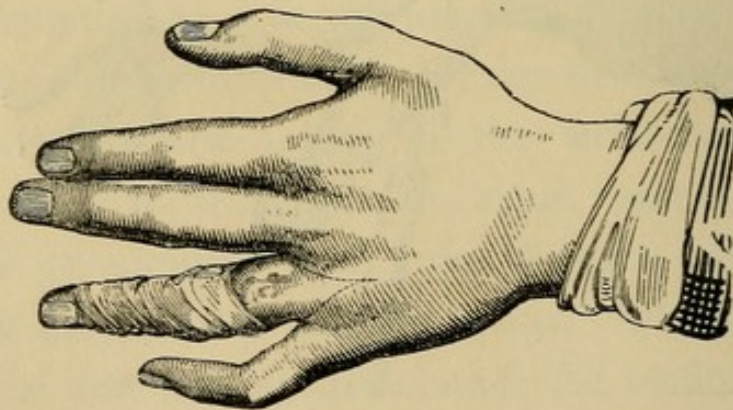
in Fig. 40. The point of the knife is entered on the back of the metacarpal bone, and carried by the side, and underneath the finger, and up again to where it first entered. The soft parts are then dissected back, and the head of

FIG. 40.



the metacarpal bone divided with the bone-forceps. The other fingers are removed by an incision such as that marked in Fig. 41. The

FIG. 41.

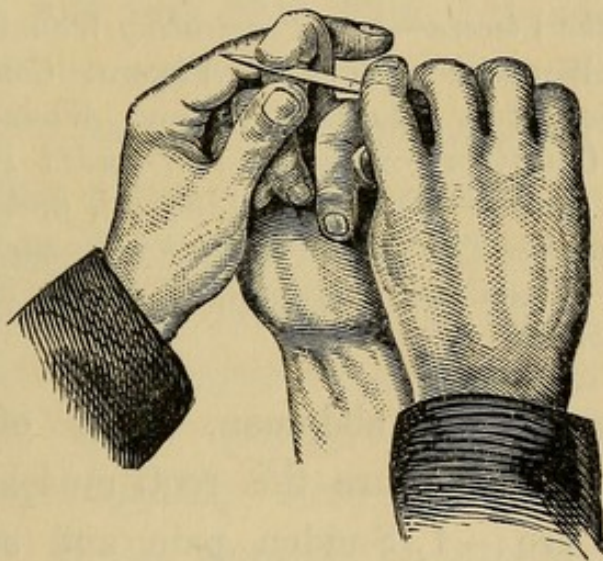


adjoining fingers being held aside by an assistant, grasp the finger firmly, and place the heel of the knife on the web of the finger. It is then carried upwards to the joint, through which it passes, and is brought out on the other



side, cutting a flap similar to the one first made. If the possessor of the hand is a labourer, leave the head of the metacarpal bone, else remove it with the bone-forceps. The second or third phalanx may be removed as follows:— Bend the phalanx at right angles to the next (Fig. 42); place the heel of a bistoury at the

FIG. 42.



side of the joint midway in the thickness of the next phalanx, and draw the knife straight across the joint; straighten out the fingers, and turning the edge of the knife forwards, cut a flap from the palmar surface.



## CHAPTER VI.

### THE ABDOMEN.

*Rupture of Muscles—Rupture of the Peritoneum—Rupture of the Viscera—Non-Penetrating Wounds—Penetrating Wounds—Protruded Viscera, Constriction, Distension with Flatus, Gangrene, Wounds—Protruded Omentum—Sutures in Wounded Parietes—Foreign Bodies—Obstructed, Inflamed, and Strangulated Hernia—The Taxis—Operation for Strangulated Hernia—Umbilical, Inguinal, Femoral, and Obturator Hernia.*

Rupture of muscles from blows.

BLOWS upon the abdomen, even of slight character, may rupture the recti muscles. The symptoms are:—1, Sudden pain and swelling; 2, sometimes a palpable sulcus between the torn ends; 3, increased pain on movement. The treatment is—rest, in a position to relax the muscles, with the shoulders raised, and the thighs bent on the abdomen. A large pad should be placed over the site of rupture, and retained by a broad roller.

Rupture of the peritoneum.

The peritoneum may be ruptured by blows on the abdomen. The symptoms are:—1, Extreme collapse; 2, excessive pain, especially on movement, and pressure; 3, thoracic respiration; 4, tense contraction of the abdominal muscles. If



the peritoneum attached to the pregnant uterus, to the mesentery, or omentum be torn, considerable hæmorrhage may occur, when all the symptoms of great loss of blood will present themselves. The treatment is perfect rest in the recumbent position, leeches to the abdomen, linseed-meal poultices, sprinkled over with laudanum, and opium internally. All purgatives must be avoided, and very light fluid diet administered. Ice must be applied to the abdomen, and the collapse of hæmorrhage counteracted by stimulants freely given. In all cases of severe blows, or crushing force applied to the abdominal wall, where collapse is present and injury to any of the viscera is suspected, perfect rest must be enforced, opium administered, poultices with laudanum applied, and purgation strictly avoided. If the stomach, or intestines are probably ruptured, no food of any kind must be given by the mouth, but nutritive enemata, in small quantities, administered by the rectum, every four or six hours. It is also advisable to empty the bladder with a catheter, especially if damage to the kidneys is suspected.

Rupture of the viscera.

In non-penetrating wounds of the parietes, especial care must be taken to search for foreign bodies, and remove them. If there is much hæmorrhage, and the vessel cannot be seen, the wound must be enlarged, and the vessel secured; but if in punctured wounds the bleeding is not

Non-penetrating wounds of the parietes.



severe, it may be left, but the mouth of the wound must not be closed. In incised wounds of the epigastric region sutures must be inserted, as there is considerable tendency to gape.

Penetrating  
wounds.

Penetrating wounds of the abdomen, especially punctured wounds, should be treated from the commencement with perfect rest and opium, even, although at the moment, no serious symptoms are present. If any of the viscera are wounded, the symptoms will be:—1, Collapse; 2, severe local pain, which soon becomes radiating; 3, vomiting, sometimes of blood.

Protruding  
viscera.

The various viscera are sometimes protruded through wounds in the parietes—"the small intestines most frequently, next the large, then the stomach, and lastly, the cæcum. Of the solid viscera the omentum is by far the most common, and is often associated with that of the viscera." (Poland.) When protruded through small wounds, they are likely to be strangulated. If the protrusion be intestine, and it is uninjured, it must be thoroughly cleaned with a stream of tepid water and returned, care being taken to press it directly backwards, in order to avoid pushing it between the peritoneum and the muscles. If any

Constriction.

constriction exists, the external wound must be enlarged, and the fibres of the muscle or fascia divided; but if possible the peritoneum should not be interfered with. If the bowel is so distended

Distension  
with flatus.

with flatus as to prevent its return, it may be



punctured in three or four places with a grooved needle, and the air allowed to escape. If the intestine be gangrenous it must be opened, its contents allowed to escape, and then it must be fixed, with one or two sutures, to the edge of the wound. If the intestine has sustained a small punctured wound, the lips of the wound may be held together with a pair of forceps, and a fine silk or catgut ligature tied firmly round the orifice. The ends are then cut off close, and the intestine returned. Incised wounds must be closed with the continuous suture either of silk or catgut, all the coats being included in the suture, and care taken to secure perfect coaptation of the edges. The intestine is then returned. When a large portion of the circumference of the bowel is divided, particularly if the wound is lacerated, it is better to fix the divided portions by silk sutures to the edge of the external wound.

Gangrene.

Wounds.

If omentum is protruded through the wound, it should be carefully examined to ascertain that no intestine is enclosed in its folds. If it is quite healthy, and free from laceration, it may be at once returned. But if it is dirty or lacerated, or great difficulty is found in returning it, a double ligature should be passed through the base, tied firmly, and the protruding portion cut off. The ligature may be cut short and returned with the omentum.

Protruded  
omentum.



Sutures to  
wounds of  
parietes.

When there is an incised wound opening the abdominal cavity, it must be closed with interrupted sutures. The edge of the peritoneum should be included in the deep sutures, and superficial ones should be placed between them, including the skin only. The deep sutures are best inserted by transfixing the edges of the wound with a needle set in a handle, then threading the needle and withdrawing it, pulling the suture back with the needle. Wire is best for the deep, and silk for the superficial sutures.

Foreign  
bodies.

When foreign bodies have passed from the œsophagus into the stomach, purgative treatment should be studiously avoided, and the diet should consist of as much solid material as can be conveniently taken, in order that the foreign body may be, if possible, embedded in solid fœcal matter, and thus extruded per anum.

Obstructed  
hernia.

A patient with a hernial protrusion is liable to certain accidents other than strangulation of the bowel. An accumulation of gas and fœcal matter may become pent up in the protruded bowel, and prevent its return. The symptoms are:—1, Pain; 2, distension of the tumour; 3, gurgling on manipulation; 4, generally constipation; 5, vomiting; 6, absence of the severe constitutional symptoms which indicate strangulation. The treatment consists of warm applications to the tumour, and a stimulating enema of castor-oil, turpentine, and



gruel. If the vomiting is not very severe, purgatives may be given by the mouth. Manipulation of the tumour should be avoided as much as possible.

The previous condition may pass on into one of inflammation, or this may be set up by a blow on the tumour, the pressure of a badly fitting truss, or by the extension of a similar condition in the rest of the alimentary canal. The symptoms are:—1, Pain; 2, enlargement of the tumour; 3, if it be omental, increased hardness; if intestinal, increased elasticity, or fluctuation, from the presence of fluid in the sac. The treatment consists of rest, purgative enemata, and the application of ice to the tumour.

Inflamed  
hernia.

Usually the earliest symptom of a strangulated hernia is vomiting, first of the food contained in the stomach, then of yellow and green bile, and lastly of brown offensive stercoraecous matter. At the same time the hernial tumour, if not recent, becomes tense, painful, and irreducible. The bowels are confined, and there is a feeling of dragging between the hernia and the bowel. Great prostration comes on, with quick respiration and feeble pulse; the surface is cold, and the countenance anxious. All these symptoms may exist when the intestine is inflamed, but not strangulated.

Strangulated  
hernia.

The rule is, that when the intestine is inflamed but not strangulated, the local symptoms



Difference  
between  
inflamed and  
strangulated  
hernia.

first supervene; but when strangulation comes first, and inflammation as a secondary result, the remote and constitutional symptoms are the first to appear, and the local ones afterwards.

When the local symptoms are urgent, and come on after the remote symptoms, it is a strong argument for immediate operation. When the remote symptoms are present, but no hernia is observable, the strictest search should be made for one. If a hernia exists in which no local signs are present, but which cannot be reduced, an operation should be performed: or it should be performed at the site of any tumour which might contain a hernia; or in the case of double irreducible herniæ, both should be operated on, if, in the first, no obstruction is found.

The taxis.

The attempt to reduce a strangulated hernia by the taxis, must be made with great gentleness. The following rules should be observed:—1. It should be very sparingly tried without chloroform, and chloroform should be administered if the first attempt fails. 2. When chloroform has been administered, the manipulation must be very gentle. If gentle manipulations fail, more forcible ones will only damage the bowel, without reducing the hernia. 3. The attempt, in a small hernia, should not extend over two minutes, and in larger ones not over ten minutes, at the outside. 4. It should not be made by more than one person. 5. It should not be repeated,



if it can be ascertained that it has been previously tried. 6. It is quite inadmissible, if the strangulation has been for some hours, and if the constitutional symptoms, such as vomiting, collapse, and tender abdomen are present; or if it can be ascertained that the hernia has been habitually irreducible. If the symptoms are not very urgent, a grain of opium may be given, and the patient placed in a very hot bath, the taxis being attempted in the bath. If the hernia be not reduced, but no bad symptoms—such as severe pain, vomiting, or abdominal tenderness are present—the patient may be placed in bed, and kept under the influence of opium, a strict watch being kept for the onset of any bad symptom. The rule of waiting is, however, a very exceptional one, and the condition of the patient must be very favourable to permit delay.

The use of the aspirator, as an aid to taxis, has been introduced, with considerable success, by Dr. Dieulafoy. The aspirator being exhausted, one of the smallest needles is introduced into the hernial tumour. The cock connecting the needle with the vacuum is then turned, and the needle passed on slowly through the tissues. The first fluid met with will probably be in the sac; but it is not until fæcal matter, mixed with bubbles of gas, passes that we can be sure the gut is punctured. When the

Use of the  
aspirator in  
taxis.



aspiration of fæces and gas is complete, the attempt to reduce the hernia may be made.

The operation  
for strangulated  
hernia.

The description of the operation for strangulated hernia applies, with little modification, to the various forms of hernia met with. The instruments required are:—1. Scalpel. 2. Dissecting forceps. 3. Straight director. 4. Curved hernia-director. 5. Hernia knife. 6. Retractors. An incision, the direction of which varies with the particular hernia, is made through the skin, and the superficial structures are divided, if needful, on the straight director, until the sac is exposed. The forefinger of the left hand is then passed up to the neck of the sac, and the nail insinuated beneath the stricture, if it be external to the sac. The hernia knife is next guided along the left forefinger and passed on the flat, by the side of the nail, beneath the stricture. The edge is then turned directly forwards, and the stricture divided for about a quarter of an inch by a slight sawing movement. If the nail cannot be inserted beneath the stricture the hernia director must be used and the knife passed up in the groove of the director.

Reduction  
without  
opening the  
sac.

The stricture being divided, an attempt must be made to return the bowel by very gentle manipulation. If the whole contents return with the characteristic gurgle, the surgeon may be satisfied that the stricture is relieved. If, however, reduction does not take place, or some



portion remains behind, then the sac must be opened. In order to do this a small portion of the sac must be taken up with the forceps, and nicked through with the scalpel, cutting sideways. A small opening being made, the straight director is passed in, and the sac divided on it for a very small distance. The left forefinger is then inserted and the stricture sought for at the neck, and divided as above directed. If a director is used, great care must be taken not to pass it too far up, as it might perforate the intestine above the stricture. On using the knife, the intestine must be gently pressed back with the left forefinger, to prevent its bulging over the edge of the knife and being wounded. In doing this, however, great gentleness must be used, especially if the intestine is in a bad condition, as very little pressure will rupture it.

Opening the  
sac.

On opening the sac the contents must be carefully examined. If the intestine is quite dead, it must be left in the open wound, the stricture above being divided, and all the tissues freely laid open. If it is dark, mottled, and studded with lymph, or if there is a doubt as to its condition, it is better to return it to the abdominal cavity, especially if it is elastic and glistening. If there is a small rupture or perforation, it may be pinched up with the forceps and tied with a catgut ligature. If there are recent adhesions, they may be separated; old

Examination  
and treatment  
of the  
intestine.



ones must be left without interference. If the bulk of the intestine is so large from distension with flatus as to impede reduction, it may be punctured with a grooved needle and the flatus allowed to escape. If omentum is present in a recent hernia, and is non-adherent, it should be returned with the intestine; if it is very adherent, it may be left in the sac. If there is much of it, and it is in a bad condition, it may be ligatured and cut off. The greatest care must be taken to examine omental protrusions, in order to discover if they contain, as they frequently do, especially in femoral herniæ, knuckles of intestine. Intestine so found, must be carefully examined to find out if any omental bands are constricting it.

Umbilical  
hernia.

In umbilical strangulated hernia, the incision must be made in the median line, commencing two or three inches above the neck of the sac, and continued as far downwards as may be needful. Every endeavour should be made to relieve the stricture without opening the sac, which is a most fatal proceeding in this hernia. It should be remembered that this hernia often becomes obstructed, with very severe constitutional disturbance, and that aperient enemata frequently rectify this, without recourse to an operation.

Inguinal  
hernia.

Inguinal hernia protrudes from the abdomen above Poupart's ligament, the spinous process of



the pubes being external to the neck of the tumour. In attempting the taxis, the patient should be placed with the pelvis raised, and the thighs close together, pressure being made upwards and outwards. The operation for the relief of strangulated inguinal hernia is performed as follows. 1st. An incision, from four to five inches long, is made through the integuments, in the axis of the tumour commencing about two inches above the centre of the external abdominal ring. 2ndly. The margins of the external abdominal ring are exposed. 3rdly. The remaining tissues are divided down to the sac, which may be recognised by its blue translucent appearance. 4thly. The tip of the forefinger is gently insinuated beneath the external ring, but if this is impossible, a director must be passed, and the ring incised with the hernia knife. The finger is then passed on and any constriction divided, when possibly the hernia may be returned. 5thly. If this cannot be done the sac must be opened, as directed above, and the forefinger carried up to the constriction, which is then divided, if needful, on the hernia director. All the incisions for the relief of constrictions, must be made in a line parallel to the linea alba, thereby avoiding the internal epigastric artery.

The taxis

The operation.

The above rules apply equally to direct inguinal hernia. It must, however, be remembered that the spermatic cord in the male is

Direct  
inguinal  
hernia.



more prominent in direct than in oblique hernia, and that the deeper coverings are often much thinner, and therefore require greater care in their division.

In the female. The only differences between inguinal hernia in the female and in the male are, that the round ligament is substituted for the spermatic cord, and that the hernial protrusion is found in the labium.

Femoral  
hernia.

In femoral hernia the protrusion is found below Poupart's ligament, the spinous process of the pubes being internal to the neck of the tumour. The abdominal ring will also be found unoccupied by any tumour. The symptoms of strangulated femoral hernia are generally much more severe than in inguinal. For the taxis, the patient must be placed on his back, the thighs flexed towards the abdomen, and the thigh of the affected side rotated inwards, and crossed over its fellow. The tumour must be pressed first downwards, then backwards and upwards. The

The taxis.

The operation. operation for strangulated inguinal hernia is as follows:—1st. An incision three or four inches long is made through the integuments, on the pubic side of the neck of the tumour, commencing an inch above Poupart's ligament. 2ndly. Poupart's ligament should be clearly defined, and Gimbernat's ligament felt on the pubic side. This may be slightly incised upwards, when, if the hernia is recent, an attempt should be made



to reduce the hernia. This failing, the fascia propria must be divided on a director; upon which a layer of fat will be exposed, which must not be mistaken for omentum. On clearing this, the sac is exposed and opened; the finger must then be pushed up to Gimbernat's ligament, and that ligament divided in a line parallel to the linea alba. The incision must be very sparing. The obturator artery, as it comes off from the internal epigastric or femoral, lies close to the neck of the sac, and may be wounded. It should be felt for and avoided.

Obturator hernia appears in the thigh, in front of the capsule of the hip-joint, and below the horizontal ramus of the pubis. In front of it is the pectineus muscle, on the outer side, the femoral artery and vein, and to the inner side the tendon of the adductor longus muscle. If well marked symptoms of strangulated bowel exist, and a tumour is felt in this region, the supposition would be that it was a strangulated obturator hernia. But it frequently happens that no tumour can be felt; then, if no hernia can be found at any of the other outlets, and pain is referred to the course of the cutaneous branches of the obturator and internal cutaneous nerves, also on rotation of the hip-joint outwards, and on pressure at the site of the obturator foramen, an exploratory operation is justifiable. The operation is performed by—1st. Making an

Obturator  
hernia.



incision through the integuments, commencing a little above Poupart's ligament, midway between the spine of the pubes and the femoral artery, and parallel with it. 2ndly. The fascia over the pectineus muscle being exposed and divided, the fibres of the muscle are separated, and the fat over the obturator externus exposed. 3rdly. If the tumour be not then found, the fibres of the obturator must be separated, and the tumour searched for with the finger at the obturator canal. If the hernia is discovered, the tissues round the neck are divided, and if not then reducible, the sac must be opened, and the constriction sought for and incised. Care must be taken to avoid the obturator nerve.



## CHAPTER VII.

### THE PELVIS.

*Fractures and Dislocations—Injury to the Bladder—Foreign Bodies in the Urethra and Bladder—Dilating the Female Urethra—Injuries to the Urethra—Retention of Urine—Use of Catheters—Puncture of the Bladder per Rectum; by Aspiration; above Pubes—Cock's Operation for Perineal Section—Retention from Enlarged Prostate—Extravasation of Urine—Injuries to the Penis—Paraphimosis—Phimosis—Injuries to the Scrotum; Testicle—Rupture of the Vas Deferens—Injuries to the Pregnant Uterus; to the Vagina—Foreign Bodies in the Rectum—Hæmorrhage from the Rectum.*

THE pelvic bones are fractured or displaced, generally, by crushing violence. A crush may cause separation at the symphysis pubis without fracture, a sulcus being felt externally. Pressure on the ilium, or any attempt to stand or walk, is attended with considerable pain. The urine passed is generally bloody. Such displacement is, however, generally accompanied by fracture of the rami, and also of the ilium. In fractures of the ischium, the injury may be discovered by passing the finger into the rectum, or the vagina in the female, or the tuber ischii being grasped

Fractures and dislocations of pelvic bones.



Of the  
acetabulum.

and moved laterally, crepitus may be felt. Fractures of the floor of the acetabulum are caused, generally, by falls on the trochanter major, the head of the femur being sometimes thrust through the cavity in the acetabulum. The diagnosis is very obscure. The trochanter is driven in towards the pelvis, and pressure on it causes deep-seated pain. Crepitus is specially felt during the extension of the limb and its subsequent drawing up, and not on flexion and rotation. Symptoms of injury to the pelvic viscera are also usually present. The brim of the acetabulum is sometimes broken by the same force which causes dislocation of the femur on to the dorsum ilii. Added to the symptoms of the dislocation there is obscure crepitus, and inability to retain the head of the bone in the socket after reduction. In all cases of injury to the pelvis one of the first things to be done is to pass a catheter and empty the bladder; if the urethra or bladder is lacerated, the catheter must be retained. The patient should then be placed on his back, the knees bent, and supported on pillows.

Treatment:—In separation of the symphysis, or fracture of the ilium, the parts may be drawn together and kept in position by a pelvic band firmly buckled round the pelvis. If portions of bone are detached, as portions of the brim, or the anterior superior spine, they may be kept in position with a pad and strapping.



Fractures of the sacrum may occur from falls on it, or by crushing violence. Simple fractures are rare, and may be detected through the rectum, the lower portion of the sacrum being carried forward. The symptoms are, pain at the seat of injury, especially in the attempt to defecate. The principal treatment is rest on the back, with a firm cushion under the upper fragment to take off pressure from the lower one; and opium to confine the bowels. If the displacement forwards is very great, it may be reduced by the finger in the rectum, and a tube having been passed up to provide for the escape of flatus, the rectum must be plugged round it.

Fracture of the  
sacrum.

The bladder may be ruptured by falls, or by blows upon it when distended. The rupture is generally found posteriorly, and urine is extravasated into the peritoneal cavity. Intense abdominal pain, rapid collapse, and urgent desire to micturate, without the ability to pass a drop of urine, are the prominent symptoms. Death generally ensues at an early period. Should the patient survive, the immediate treatment must be directed to keeping the bladder in a state of collapse, by not allowing urine to accumulate in it. For this purpose a large flexible catheter should be passed, great care being taken not to introduce it beyond the neck of the bladder, to avoid passing it through the rent, into the peritoneal cavity. The best form of

Injury to the  
bladder.

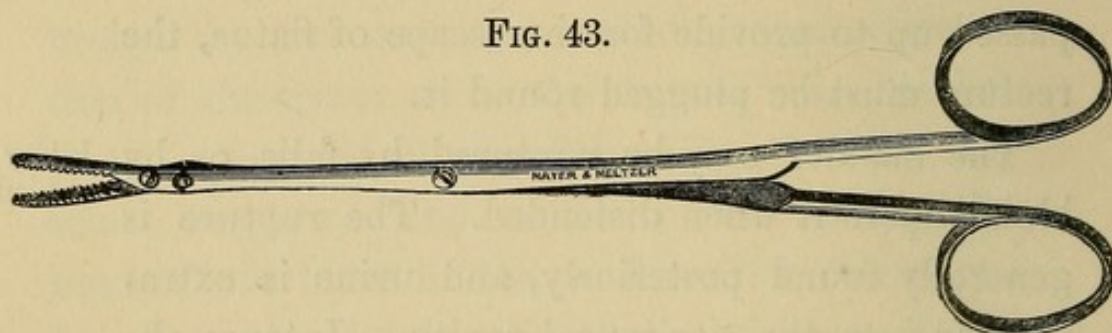


instrument is a flexible india-rubber catheter (see chap. xii.), which may be retained in the urethra, as there described. Wounds of the bladder are inflicted through the abdomen, rectum, or urethra, and must be treated as above directed.

Foreign bodies  
in the urethra.

Foreign bodies are frequently impacted in the male urethra. Slate-pencils, penholders, &c., may be pushed down the urethra; when an endeavour should be made to seize and extract the substance with a pair of urethra forceps, such as those made by Meyer and Meltzer (Fig. 43).

FIG. 43.



These forceps are constructed with a double joint, so that they open widely at the points, without largely distending the anterior portion of the urethra. A hair-pin, with the bent end foremost, has been passed down the urethra, and the ends springing apart, have become imbedded in the urethra. To extract it, a tube should be passed down the urethra, and the points of the pin pressed together and placed in the tube, where they become fixed, when the tube and pin may be withdrawn together. Fragments of a calculus, or a small calculus, especially in children, may become im-



pacted in the urethra; they may be removed by the forceps, or else pushed back into the bladder with a catheter. If a body is impacted in the urethra, in front of the scrotum, and it cannot be removed by other means, the urethra must be incised. The incision should be made parallel with the long axis of the urethra, and must be longer externally than through the mucous membrane. There is no occasion for the use of sutures, nor for the retention of a catheter during the healing of the wound. Foreign bodies introduced into the female urethra, quickly pass into the bladder. If they cannot easily be seized with forceps and withdrawn, the urethra may be dilated, by introducing the blades of a long narrow pair of forceps, and slowly opening them. In a few moments the urethra becomes dilated sufficiently to admit the point of the little finger, which should be gently, but firmly passed in; then the index finger may be introduced in the same way, and the interior of the bladder explored. A pair of forceps should then be passed by the side of the finger, the foreign body seized in a favourable position, and withdrawn.

Foreign bodies  
in the  
female  
bladder.

Dilating the  
female  
urethra.

Incised wounds of the urethra heal readily, when inflicted in its long axis. The principal danger arises from extravasation of urine. If, therefore, the wound is in the deeper portions of the urethra, it is better to enlarge the

Injuries to the  
urethra.  
Incised  
wounds.



external wound freely, in order to give plenty of vent for the urine.

Lacerated  
wounds.

The urethra is frequently lacerated, especially in youth, by such accidents as a fall on the perinæum, astride a rail. The immediate external signs are generally very slight: the chief symptoms are—bleeding from the urethra, retention of urine, pain at the point of injury, and extravasation of blood into the perineum. An attempt should at once be made to pass a catheter into the bladder. It should be a flexible one, either such as that referred to at p. 98, or one of the French probe-pointed flexible catheters. If it can be introduced, and the water drawn off, it must be retained in the bladder. If, however, the catheter cannot be passed, it is better at once to incise the perineum through the median raphé. It may then be possible to discover the divided ends of the urethra, and to bring them together with a suture, after which a catheter may be passed into the bladder. If much hæmorrhage occurs after the incision in the perineum, the wound must not be plugged, but the bleeding must be controlled by digital pressure, provided the ends of the vessels cannot be secured.

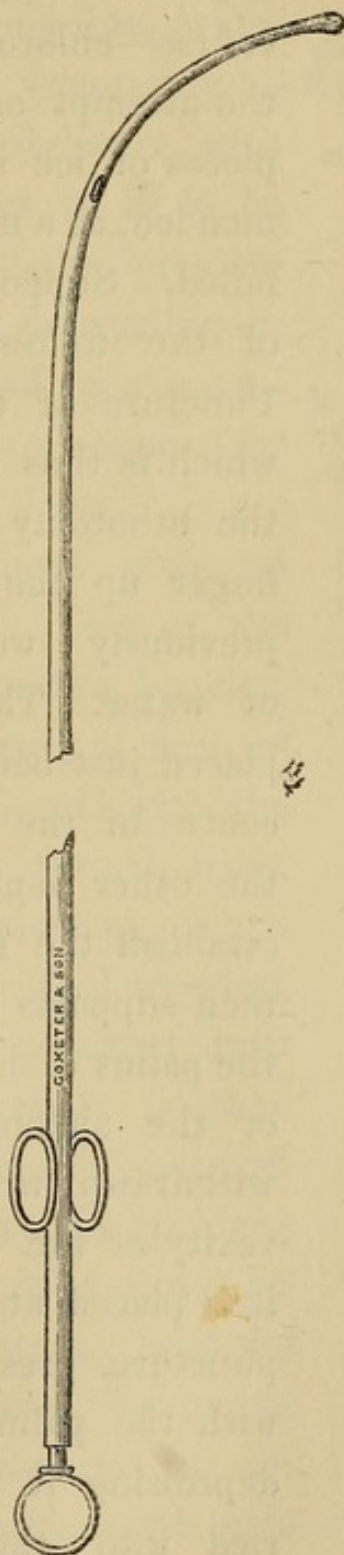
Retention of  
urine.

When a patient is suffering from retention of urine, it is needful, as far as possible, to determine the cause of the obstruction. It may be (1) inflammatory, when there will be a history of purulent discharge from the urethra, which has



probably suddenly ceased ; or (2) it may be the result of organic stricture ; or (3) of enlarged prostate gland. Whatever may be the cause, an attempt should be made at once to pass an instrument into the bladder. As a rule, the flexible probe-pointed French catheter is the instrument which will be the most easily introduced—certainly it is the one which produces the least pain in its use, and which is likely to inflict the least injury. It is essentially useful in strictures of the inflammatory type, and in enlarged prostate. In old organic strictures, it will generally be found needful to employ a metallic instrument. A probe-pointed catheter, invented by Sir Henry Thompson, and made by Coxeter, is a very useful instrument (Fig. 44). If the retention arises from enlarged prostate, and the French catheter fails, the usual prostatic catheter must be used, or a full-sized gum elastic, which should be kept for the purpose on an over-curved stilette (see p. 106). If the

FIG. 44.





first attempt to introduce an instrument fails, recourse must then be had to the hot-bath, and a full dose of opium ; or else—and this is the better course—chloroform should be administered, and the attempt again made. The introduction of pieces of ice into the rectum has been recommended, as a means of relief, when all others have failed. Supposing failure again takes place, one of the following plans may be adopted:—

Puncture of  
the bladder  
per rectum.

Puncture of the bladder through the rectum, which is thus performed:—Place the patient in the lithotomy position ; then pass the left forefinger up the rectum, which must have been previously well cleared out by an enema of water. The point of the finger must be placed just behind the prostate, and as near the centre of the trigone as possible. A tap with the other hand on the hypogastric region will establish the fact of fluctuation. An assistant then supports the bladder externally, by placing the palms of his hands firmly on the lower part of the abdomen ; then pass the rectum trocar, withdrawn within the canula, along the convexity of the forefinger in the rectum. When it is placed at the point where you intend to puncture, press home the handle of the trocar with the palm of the hand, at the same time depressing it. Thus the point will be carried into the bladder, the direction being towards the umbilicus. Then withdraw the



trocar, and fix the canula in with tapes attached to the shield, and carried, two in front and two behind, and tied to a bandage round the loins. Puncture by the rectum is not admissible, when fluctuation cannot be felt, as will frequently be the case in old standing cases of stricture, with greatly thickened bladder; neither is it to be used in very great enlargement of the prostate gland. It is also a questionable proceeding in cases where the circumstances lead to the conclusion that the canula will have to remain for a longer period than two or three days.

When  
puncture by  
the rectum is  
not  
admissible.

The bladder may be punctured with an aspirating needle above the pubes. One of the finest needles must be passed into the bladder, just above the symphysis; and when a drop of urine appears, the needle is connected with the exhausted aspirator and the tap turned, when the urine will flow into the receiver. When this is full, it is emptied by the discharge-tap, again exhausted, and the process repeated until the bladder is empty. The needle is then withdrawn. The plan is admirably adapted for the immediate relief of a distended bladder; but unless there is a prospect of getting an instrument through the stricture, as may be frequently accomplished after the bladder is emptied, it is better to have recourse to an operation which will secure a permanent exit for the urine. This may be secured by punc-

Aspiration  
above the  
pubes.



Puncture  
above the  
pubes.

turing the bladder above the pubes with a trocar. The operation is thus performed:—The pubes being shaved, place the patient in a semi-recumbent position; make a vertical incision two inches long through the integuments directly above the symphysis; dissect down through the fat, until the top of the forefinger can be placed upon the distended bladder; puncture the bladder with a straight, or slightly curved trocar, the direction being a little downwards; withdraw the trocar, and pass in through the canula either a gum elastic catheter, or else one of the india-rubber ones, which must be secured by tapes round the loins. In all cases where it is probable that the puncture will be made the exit for the urine for some period, this operation is the preferable one. It cannot, however, be performed in cases of greatly thickened bladder, as the bladder does not rise sufficiently above the pubes to permit of its being punctured with safety.

Opening the  
urethra  
through the  
perineum.


Cock's  
operation.

When none of the above proceedings are admissible, it is needful to open the bladder through the perineum; and for this purpose Cock's operation is the easiest, and safest. It is devised in order to open the urethra behind the point of stricture. The instruments required are:—1. A broad double-edged knife. 2. A large silver probe-pointed director with a handle (Brodie's flexible one, used for fistula in ano, will



answer the purpose). 3. A perineal catheter (Fig. 45). The operation is thus performed :— Place the patient in the lithotomy position, taking care to keep the pelvis perfectly even. Introduce

FIG. 45.



the left forefinger into the rectum, and place the tip on the apex of the prostate. Plunge the knife into the median line of the perineum, and carry it forward steadily, *without any withdrawal*, towards the tip of the left forefinger in the rectum; at the same time, by an upward and downward sawing motion, enlarge the external wound vertically in the median line. When the point of the knife is clearly felt by the left forefinger to be in close proximity to the apex of the prostate, carry it forward with a slightly oblique movement into the urethra. Withdraw the knife, and introduce the probe-pointed director, guiding it with the left forefinger still in the rectum, into the bladder. Remove the forefinger from the rectum, and holding the director with the left hand, introduce the perineal catheter along the groove, and secure it with tapes in the ordinary way. A flexible catheter may be used instead of the metal one.

When the bladder is distended from enlarged



Retention of  
urine from  
enlarged  
prostate.

prostate, instruments specially adapted for use in such cases must be employed. A large-sized French probe-pointed catheter; the ordinary silver prostatic catheter, from twelve to fourteen inches long, and about No. 10; a gum-elastic catheter, kept for the purpose on an over-curved stilette, or a gum-elastic curved at the beak, like a sound for stone, are all instruments which will be found useful in their turn. The first attempt should be made with the French probe-pointed catheter, which in a vast number of cases will succeed, and which is by far the easiest to pass. To pass the silver instrument, place the patient on his back, and standing on his left side introduce the point of the catheter into the urethra, the shaft being held parallel to the left groin. Carry the instrument on as far as it will go without elevating the handle, then bring it gently to the median line of the body, and at the same time raise it a little. By degrees bring it to the perpendicular, and then depress it between the patient's thighs, keeping the beak well against the roof of the urethra. If the point fails to enter the bladder, withdraw it a few inches, and then incline first to one side, and then to the other. If a silver catheter cannot be passed, the overcurved gum-elastic must be tried. Withdraw the stilette, and do not warm the catheter. Pass it over the left groin, pulling the penis well down over the



groin, and proceed to pass it in the same direction as the silver instrument. This failing, try the gum-elastic curved at the beak. To obtain this curve, put the point of the catheter into warm water, curve it to the desired extent, and then plunge it into cold water, which will fix the curve. In all these attempts, the left forefinger in the rectum will be found a great adjunct in tilting up the point of the instrument over the prostatic enlargement, and thus enabling it to enter the bladder.

A change in the position of the patient will sometimes enable you to pass an instrument: thus if your endeavours have failed with the patient recumbent, it is possible that you may succeed with him in the erect posture, or *vice versâ*.

Extravasation of urine generally shows itself first in the tissues of the scrotum, then on the penis, pubes, and abdomen. Free incisions must be at once made, especially in the scrotum, on either side of the middle line, and the patient should be well supported with alcohol, ammonia, and bark. The perineum ought to be carefully examined, for extravasation sometimes takes place between the layers of the deep perineal fascia. A deep-seated, obscure, brawny swelling may be detected, which must be at once very freely incised in the median line.

Incised wounds of the penis gape considerably, and must be drawn together with sutures.

Extravasation  
of urine.

Injuries to the  
penis.



Effusions of blood from blows may cause prolonged priapism. They must be treated by rest and evaporating lotions. Children have a trick of tying a string round the penis. This causes great swelling, and at a later period ulceration. A careful search must be made for the ligature, which will be found sometimes deeply imbedded in the tissues. The removal of the ligature, and water-dressing soon brings about a cure.

**Paraphimosis.** Paraphimosis, both in adults and children, should be reduced without delay. The best way is to grasp the penis firmly in the palm of the left hand, whilst with the fingers and thumb of the right hand you steadily compress the glans penis, previously well oiled. The prepuce should be pushed forwards with the left hand, and the glans penis pressed backward with the right at the same time. Steady and prolonged pressure in this manner will seldom fail. In children, chloroform should be given. If the attempt fails, the constricting band must be freely divided with a sharp-pointed curved bistoury, when reduction will be accomplished.

**Phimosis.** Phimosis, when acute, must be remedied at once. If, after a short fomentation and syringing out with warm water, the prepuce cannot be drawn back, the following plan will enable you to do so:—Take a blunt-pointed tenotomy knife, pass it down on the flat between the glans penis and the prepuce, then turning the edge towards the



prepuce freely incise the mucous membrane. Do this in three places, and you will then be able to draw back the prepuce. This is not to be a substitute for circumcision at some future period, should it be needful.

Incised or lacerated wounds of the scrotum are sometimes attended with extrusion of the testicle. Warm fomentations must be applied for a time to relax the tissues, and the wound must then be carefully brought together with sutures, over the testicle. A cold lotion should then be applied, the patient kept perfectly at rest on his back, and the scrotum raised on a small pillow or sandbag.

Injuries to the  
scrotum.

A blow or a squeeze will frequently cause the testicle to swell, and give excessive pain, both in the testicle itself, and in the inguinal region. Rest, leeches, hot fomentations, and opiates are the remedies. In some cases, if there is much fever, active purgatives, with small doses of tartar emetic, will be found useful.

Injuries to the  
testicle.

A violent straining exertion will occasionally cause rupture of the vas deferens. The symptoms are:—1, A sense of something giving way in the groin, and great pain; 2, swelling of the testicle on the same side; 3, discharge of arterial blood from the penis; 4, clear and bloodless urine on use of catheter. The treatment consists of rest, leeching the testis and lower part of the abdomen, and opiates.

Rupture of the  
vas deferens.



Injuries to the  
pregnant  
uterus.

In wounds involving the pregnant uterus, if the foetus has escaped, an endeavour should be made to bring it through the os uteri. If, however, it presents at the wound, it should be removed and the placenta also. (See Cæsarean Section.) If a limb only protrudes, replace it in the uterus, dilate the os uteri, and deliver as soon as possible.

Injuries to the  
vagina.

Falls on broken crockery may cause severe hæmorrhage from wounds in the vagina. The internal pudic is the most likely source of hæmorrhage, and the cut ends of the vessel must be secured if possible, else digital pressure must be employed.

Foreign bodies  
in the  
rectum.

Foreign bodies, such as fish-bones, or the husks of apple-pips, cause considerable pain by sticking within the verge of the anus. Frequently, by getting the patient to strain well down, the offending body may be seen, and extracted with a pair of dressing forceps; remembering that in the case of bones or other sharp bodies descending from above, the traction should be made in an upward direction.

Hæmorrhage  
from the  
rectum.

Severe hæmorrhage from the rectum sometimes occurs after the operation for piles, just when the ligatures are separating. The following is Allingham's plan for plugging the rectum:—Take a bell-shaped sponge of fair size. Pass a strong silk ligature up through the apex and back again. Having wetted the sponge and



wrung it dry, cover it with powdered alum or persulphate of iron, and pass it five inches up the rectum, apex first, with a penholder or bougie. Fill up the cavity with cotton-wool impregnated with alum or iron. Then, pressing up the wool with one hand, pull down the apex of the sponge by the silk ligature, with the other hand. This inverts the sponge, and fixes it in position. Introduce a catheter, or tube by the side to allow flatus to escape. This plug may remain in a week or more.



## CHAPTER VIII.

### THE LOWER EXTREMITY.

*Contusions—Rupture of Muscles—Sprains—Wounds of the Knee-Joint—Ligature of Superficial Femoral; of Posterior Tibial; of Anterior Tibial—Fractures and Dislocations of the Femur—Compound Injuries to the Shaft of the Femur and Knee-Joint—Excision of Knee-Joint—Amputation of Thigh—Fractures and Dislocations of Patella; of Tibia; of Fibula; of both Bones—Compound Comminuted Fractures—Compound Dislocation of Ankle-Joint—Fractures and Dislocations of Tarsal Bones; of Metatarsal; of Phalanges—Amputation of Leg—Chopart's Amputation—Hey's Amputation—Amputation of Toes.*

Contusions. CONTUSIONS about the hip-joint sometimes simulate impacted fractures of the neck of the femur. In a doubtful case, it is better to treat it from the first as a fracture, with Liston's splint. This will provide the perfect rest necessary for the case, if it be only a contusion.

Rupture of muscles.

Certain muscles of the lower extremity are subject to rupture, generally by a sudden and violent attempt to recover a lost step, or by some unexpected force being suddenly applied to a certain muscle. The symptoms are:—1, Sudden pain, like a sharp blow from a whip, and some-



times a distinct sound like snapping; 2, loss of motion in the part, or motion accompanied by very severe pain and spasm; 3, if the muscle is superficial, a distinct sulcus between the ruptured ends. The ligamentum patellæ, biceps, gastrocnemius, plantaris, and tendo Achillis, are the most frequent sites of rupture.

In rupture of the ligamentum patellæ, which is caused by such movements as an attempt to prevent falling backwards, the patella is drawn up some inches. It must be treated in the same manner as fractured patella (see below), and the effusion of blood dispersed by evaporating lotions. Rupture of the biceps may be caused by severe wrenches, or attempts to lift heavy weights from the ground. The symptoms are severe pain on the outer and posterior part of the thigh, and inability to bear weight on the thigh. If the tendon is ruptured near its insertion, a depression will be felt near the head of the fibula. The treatment is to flex the leg on the thigh and fix it to an outside splint. If flexion cannot be accomplished, a straight Liston's splint must be substituted. The fibres of the gastrocnemius are sometimes ruptured, causing severe pain at the moment and swelling. The plantaris is ruptured in the act of raising the heel from the ground, especially when a heavy burthen is being carried on the back. The tendon sometimes snaps audibly. One of the principal symptoms is dragging and eversion of the foot.

Of  
ligamentum  
patellæ.

Of the biceps.

Of the  
gastrocnemius  
and plantaris.

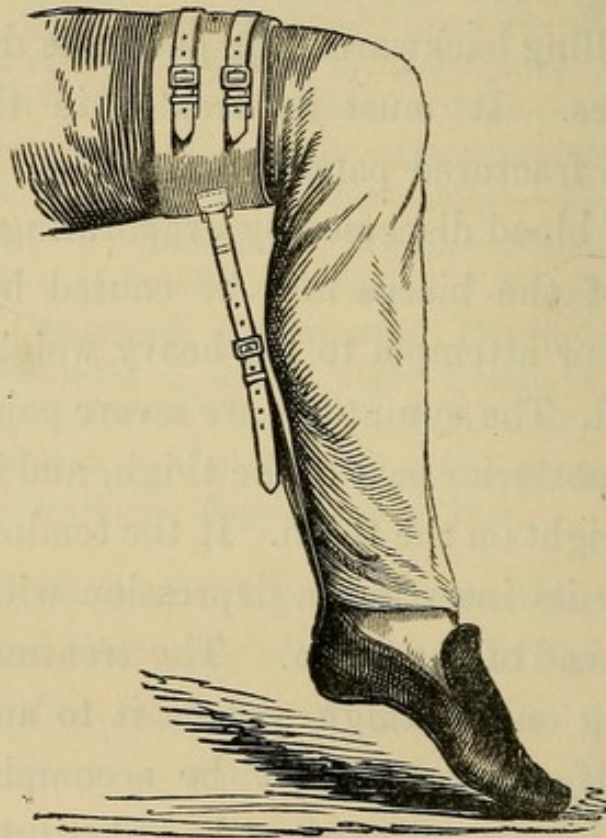

The heel must be raised and the knee bent, the treatment being the same as for rupture of the tendo Achillis.

Of the tendo-  
Achillis.

The tendo Achillis is ruptured in the same manner as the plantaris. The treatment is to flex the knee and draw the heel up by attaching a strap to the heel of a slipper, as in Fig. 46.

FIG. 46.



Sprains of the  
ankle-joint.

Sprains of the ankle-joint are of very frequent occurrence, and arise from "turning the foot over." Severe pain and rapid swelling supervene, and it is very difficult to decide in many cases whether the fibula is not broken. In cases of doubt, it is better to act as if it were. In simple sprain of the ankle the best treatment, if you



see the case early, is at once to put on a dozen leeches, and let the bites bleed into a hot bran poultice for an hour or two. Then strap the joint firmly with soap plaster, and bandage it. The next day remove the strapping, replace it more firmly, and make the patient move about on the foot. If the ankle is too painful to bear this treatment, cold evaporating lotions must be used, or hot fomentations if more agreeable to the patient.

The knee-joint is peculiarly liable to incised and punctured wounds. The symptom of wound into the joint is the flow of synovia. The synovia, if rubbed between the finger and thumb, feels oily and sticky. If any doubt exists as to the joint being opened, the treatment should be the same as if it were wounded; but no probing of the wound should be attempted where no doubt exists.

Wounds of the  
knee-joint.

The treatment consists in syringing out the joint with carbolic oil (1 part to 6). This must be squeezed out, and the lips of the wound, if it be incised, accurately brought together with catgut sutures and covered over with lint steeped in carbolic oil. The limb must then be placed on a MacIntyre splint and swung in a Salter's swing. A bag of ice should be kept constantly applied.

The femoral artery, from its superficial position, is not unfrequently wounded. It is better

Of the femoral  
artery.



Application  
of tourniquet.

at once to apply a tourniquet. The usual method of placing the pad of the tourniquet in Scarpa's triangle is a bad one. The proper place to compress the femoral artery is at the spot where it passes over the pubes, and the best instrument for the purpose is Signoroni's horse-shoe tourniquet. The lower pad of the tourniquet is placed on the tuberosity of the ischium, while the upper one is screwed down upon the artery. In making digital pressure, the best plan is to lay the three middle fingers of the left hand over the artery, and then, with the right hand, to press down on them a large door-key with the handle well padded with lint or cotton-wool. In this way pressure may be kept up for a considerable time without tiring the fingers.

Digital  
pressure.

Enlarge  
the wound in  
search for cut  
ends.

The immediate hæmorrhage being restrained, the wound must, if needful, be enlarged, and the wounded ends tied or twisted. The more freely the wound is enlarged, the greater will be the facility with which the vessel will be secured.

Ligature of  
superficial  
femoral.

Supposing all other means fail to arrest the hæmorrhage, the artery must be tied, and Scarpa's triangle will be the most probable spot for the operation. For instruments required, see p. 35. The operation is thus performed:—The patient must be laid on his back, with the thigh slightly abducted and rotated outwards, and the knee bent and resting on a pillow. A line from the middle of Poupart's ligament to the inner side of the knee indicates the position



of the vessel. 1st. Make an incision through the skin four inches long, commencing two or three inches below Poupart's ligament, and carried obliquely across the line of the artery from within outwards. 2ndly. Divide the fascia lata to the same extent, avoiding the saphena vein, which may appear on the inner side. 3rdly. With the handle of the scalpel, or better with the two forefingers, define the edge of the sartorius, an assistant drawing it outwards with a retractor. 4thly. Take up a bit of the sheath of the artery which now appears, with the forceps, and nick it with the scalpel, cutting on the flat. 5thly. Still holding the sheath with the forceps, and making it tense, insert the aneurism needle into the opening, and pass it round the vessel from within outwards, making the point emerge at the same aperture in the sheath; or, if any tissue appears on the point of the needle as it turns forwards, scratch it through with the nail of the forefinger, or gently nick it with the knife. 6thly. Pass the ligature through the eye of the needle, and withdrawing the needle pull the ligature back with it. 7thly. First ascertain, by gently pulling up the ligature and pressing with your forefinger on the vessel, that you have the artery between your finger and the ligature, and then tie in the usual manner. If the catgut ligature be used, the ends are cut short. If the ordinary hempen ligature, one end is cut short, and the other



drawn out through the most dependent part of the wound. 8thly. Bring the edges of the wound together with several sutures, and apply a pad of lint and a bandage.

In wounds of the leg, especially when inflicted by thin sharp instruments, like a chisel, and between the tibia and fibula, it is sometimes impossible to secure the bleeding vessel. Ligature of the posterior or anterior tibial then becomes needful.

Ligature of  
posterior  
tibial.

The operation on the posterior tibial is thus performed:—The patient must be placed on his back, the limb being laid on its outer side, with the knee bent and the heel raised. A line from the centre of the popliteal space to midway between the internal malleolus and the tendo Achillis indicates the course of the artery. 1st. Make an incision through the skin four inches long, one inch from the inner edge of the tibia and parallel with it, commencing two inches above the junction of the upper and middle third of the leg. 2ndly. Divide the deep fascia, and having exposed the edge of the gastrocnemius, let an assistant draw it aside with a retractor. 3rdly. The soleus being thus exposed, divide its tibial origin along the whole length of the wound on a director. The glistening anterior surface of the muscle must not be mistaken for the fascia between the superficial and deep layers of muscles which must be, 4thly, now divided, thus exposing



the artery lying on the tibialis posticus. It will be found with its two veins, one on either side, and the nerve somewhat superficial and to the outer side. It is to be secured in the usual way.

The course of the anterior tibial is indicated by a line drawn from the head of the fibula to the base of the great toe.

The operation for ligaturing the vessel in the upper part of the leg, is as follows:—1st. Make an incision four inches long through the skin, midway between the spine of the tibia and fibula, commencing two inches above the junction of the upper and middle third of the leg. 2ndly. The deep fascia being thus exposed, a white line external to the tibia will indicate the septum between the tibialis anticus and the extensor longus digitorum; these muscles must be separated. 3rdly. The anterior tibial nerve will now be seen in front of the artery, which lies on the interosseous membrane between its two veins, and may here be ligatured.

Fractures of the neck of the femur are either intra-capsular, extra-capsular, or extra-capsular impacted. The table on the following page, from Mr. Holthouse's paper in Holmes' "System of Surgery," gives the differential diagnosis in each case. Fig. 47 shows the usual appearance of this injury.

There are some conditions likely to be mistaken for fractures of the neck of the femur.

Ligature of  
anterior  
tibial.

Fracture of  
the femur at  
the neck.

Conditions  
likely to be  
mistaken for  
fracture of the  
neck.



TABLE to assist in the Diagnosis of *Intra- and Extra-capsular Fractures of the Femur.*

|                             | INTRA-CAPSULAR FRACTURE.  | EXTRA-CAPSULAR FRACTURE.  | EXTRA-CAPSULAR IMPACTED FRACTURE.   |
|-----------------------------|---|---|---|
| 1. Cause:—                  | Often slight or indirect.   | Falls on the trochanter with great force.                             | Falls on the trochanter with moderate force.  |
| 2. Age:—                    | Rare before fifty.  | Not peculiar to, though more common in the aged.                      | Ditto.  |
| 3. Sex:—                    | More frequent in females.   | Relative frequency in males and females not determined.               | Ditto.  |
| 4. Shortening:—             | Not exceeding an inch. Can be removed by moderate extension, but recurs when this is remitted.    | An inch and a half to two and a half. Ditto.                          | Not exceeding an inch. Cannot be overcome without using great force.                  |
| 5. Position of the limb:—   | It rests on its outer side.   | Ditto.  | Inclination outwards less.  |
| 6. Position of trochanter:— | Nearer the iliac crest than normal; moves in a small arc; head of the bone does not move with it. | Nearer the iliac crest; often detached; does not move with the shaft. | Nearer the iliac crest; moves with the shaft, and the head of the bone moves with it. |
| 7. Crepitus:—               | Difficult to detect.  | Crepitus readily detected.  | None.   |
| 8. Helplessness:—           | Great.  | Ditto.  | Limb less helpless.   |
| 9. Pain:—                   | Generally moderate.   | Often severe.   | Generally slight.   |
| 10. Bruising:—              | Generally none.   | Frequently evident.   | Not generally evident.  |

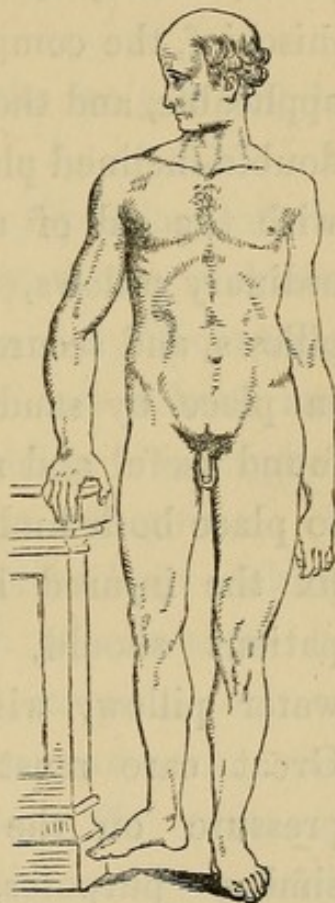


1. Fractures of the pelvis (see p. 96). 2. Dislocation of the head of the bone on to the pubes (see p. 132). 3. Contusion of hip, where you may have every symptom of fractured neck, with the exception of shortening and crepitus; and as in some cases of fracture there is hardly any appreciable shortening and no crepitus, the difficulty of diagnosis is very great.

Chronic rheumatic arthritis will give rise to symptoms of fractured neck. After a fall on the hip the limb may be found shortened, and pain on movement very great. Further examination will show that extension does not remove the shortening, nor can crepitus be produced. A previous history of rheumatic arthritis will also be elicited.

In all cases of injury about the hip-joint, the greatest gentleness must be exercised in making the examination. All violent attempts to procure crepitus are most injurious. For if the fracture is impacted, such attempts will probably disengage the fragments from one another; or if it be intra-capsular, the capsule will very likely be torn across, and the fragments sepa-

FIG. 47.



Treatment.



rated. If there are sufficient signs present to make you even suspect fracture, it is better to act on the supposition that one exists. The treatment will vary with the condition of the patient. If the patient is very advanced in years, infirm, and has any tendency to bronchitic mischief, the complete recumbent posture is not applicable, and the limb had better be put up on a double-inclined plane. This can be easily formed with the aid of a round sofa-cushion and some ordinary pillows, the knee being bent over the pillows, and secured by strips of bandage, or kept in place by sand bags. Frequently it will be found useful and more comfortable to the patient to place both limbs on the double-incline, and to fix the injured limb to the sound one. The patient should, if possible, be placed on a water pillow, with the shoulders well raised. Great care must be taken to prevent any pressure on the heel. For this, and any similar purposes, the felt-plaster, made by Ewen, of Jermyn Street, is admirably adapted. Or a small circular air-cushion, made of india-rubber, with a hole in the middle to receive the point of the heel, will be found serviceable.

If the patient will bear complete recumbency, then Liston's long splint may be used; and if it is a case of non-impacted fracture, extension should be made. If it is an impacted fracture, exten-



sion must not be used. Sometimes a weight and pulley will be found a useful substitute for the long splint. When required for extension, the weight must be increased; when only to steady the limb, it must be just sufficient for that purpose, sand bags being placed on either side of the thigh and the leg.

The method of applying the weight will be described in a future page.

Fractures of the femur in any portions of the shaft are generally caused by direct violence. The following are the symptoms:—1, Shortening from half an inch to an inch and a half, and deformity; 2, eversion; 3, mobility; 4, crepitus on rotation; 5, pain and loss of power. If crepitus is produced on rotation without making extension, the fracture may be presumed to be oblique; if, on the contrary, crepitus cannot be produced without previous extension, the fracture is probably transverse. The ordinary treatment for fractures of the shaft is with Liston's long splint, and the perineal bandage. The method of application is as follows:—The patient must be placed on a firm mattress, resting, if possible, on a small iron bedstead. A set of fracture-boards intervening between the mattress and the bedstead are a great adjunct to successful treatment. Each fracture-board should be about four or five inches broad, and long enough to reach from side to side of the

Fractures of  
the shaft of the  
femur.

Treatment.



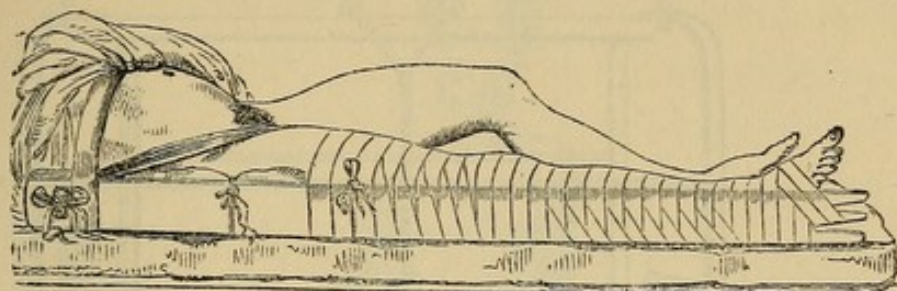
bed. There must be a sufficient number of them to reach from the foot of the bed to within a few inches of the head. The outer and inner ankles and the tendo Achillis should then be guarded with felt-plaster (p. 122), and the foot and ankle bandaged with a few turns of the roller. The splint, well padded, is then to be applied to the outer aspect of the limb, and must extend from a point opposite the nipple to four inches below the foot, care being taken to make the outer ankle fit into the oval hole provided for it. The roller is then carried round the foot and splint, passing through the notches at the extremity of the splint, and being carried up a little above the knee. The perineal band should be made of a piece of bandaging sewn into a long narrow bag, and stuffed with cotton-wool. It should reach from the middle of the groin to a corresponding point behind, and terminate in long tapes. The padded portion rests on the perineum, and the tapes are passed from within outwards through the two holes at the upper end of the splint. This being adjusted, extension is made until the length of the limb is ascertained to equal its fellow, when the perineal band is to be tightened, and the tapes tied in a bow on the outside of the splint; the upper part of the splint is then confined to the side by a few turns of a broad roller (Fig. 48). In fractures of the lower third, Sir William

Perineal band.



Fergusson recommends the following ready method:—A long outer splint, and a shorter one for the inner side, rolled up on each side of

FIG. 48.



a double tablecloth until there is just space enough in the middle to contain the limb. The bones being placed in apposition, the limb is then laid between the splints, and retained there by broad tapes, or straps.

Fractures of the shaft of the femur in children are best treated with the extension apparatus, described hereafter. Children are very intolerant of the long splint, and the perineal bandage, being continually wetted, is sure sooner or later to cause excoriation.

Fractures of  
the shaft in  
children.

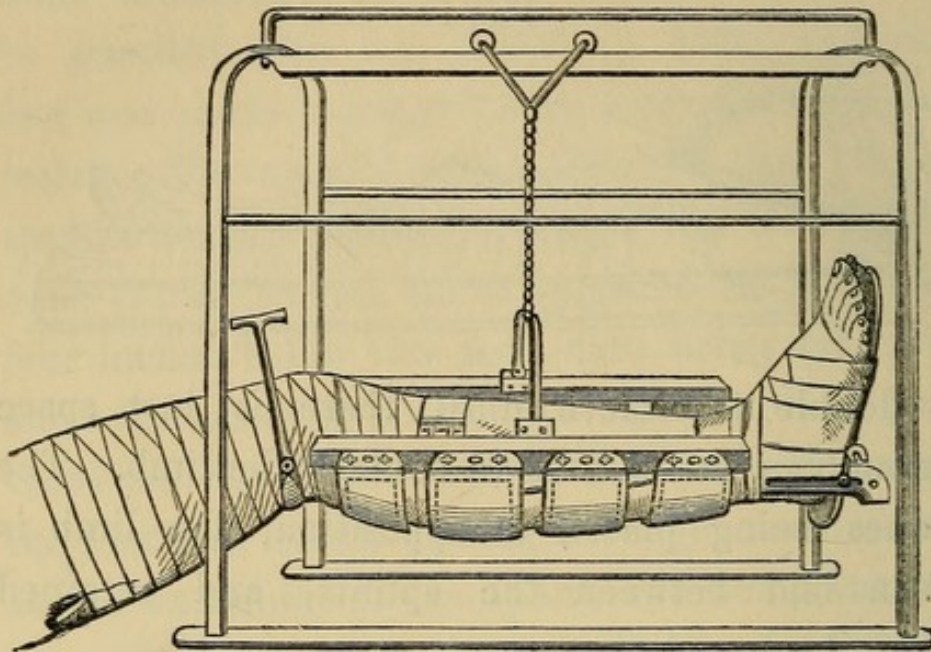
Fractures of the condyles of the femur or of the head of the tibia necessarily involve the knee-joint. They are attended with considerable effusion into the joint, and unless the case is seen immediately after the accident, the swollen joint must be treated by evaporating lotions, ice, and leeching if pain and swelling are very great. The limb should be laid on a pillow, and kept in place with sand-bags. If the case is seen early, and

Fractures into  
the knee-joint.



there is little swelling, it had better be put up in a MacIntyre splint and swung in a Salter's swing (Fig. 49).

FIG. 49.



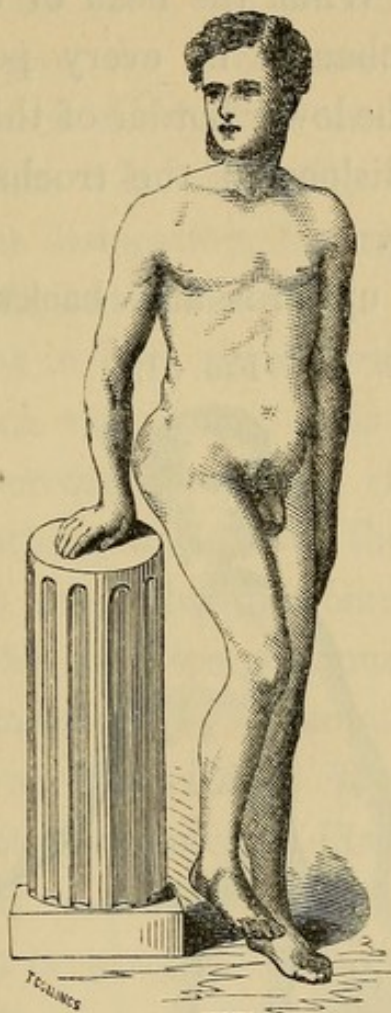
Dislocation of  
the femur on  
the dorsum  
ilii.

Dislocation of the head of the femur upwards and backwards on the dorsum ilii is caused by extreme violence, such as a fall from a height upon the outer side of the knee, a fall on the foot or knee when the thigh is adducted, or the fall of a weight on the pelvis when the body is bent forward. Symptoms:—1, Shortening from one inch and a half to three inches; 2, adduction, rotation inwards, and slight flexion of the thigh, the great toe of the dislocated limb resting on the instep of the opposite foot; 3, approximation of the great trochanter to the anterior superior spine; 4, inability to abduct the limb; 5, in thin subjects the discovery of the head of the bone in its new



position, where it may be felt moving in flexion and extension (Fig. 50). The following table

FIG. 50.



shows the points of difference between this injury and fracture of the neck of the femur :—

| <i>Fracture of the Neck of Femur.</i> | <i>Dislocation on Dorsum Ilii.</i>           |
|---------------------------------------|--|
| 1. Crepitus generally felt.           | 1. No crepitus.                              |
| 2. Limb mobile.                       | 2. Limb fixed.                               |
| 3. Toes everted.                      | 3. Toes inverted.                            |
| 4. Limb slightly shortened.           | 4. Limb shortened, $1\frac{1}{2}$ to 3 ins.  |
| 5. Ability to walk on the limb.       | 5. Inability to bear any weight on the limb. |



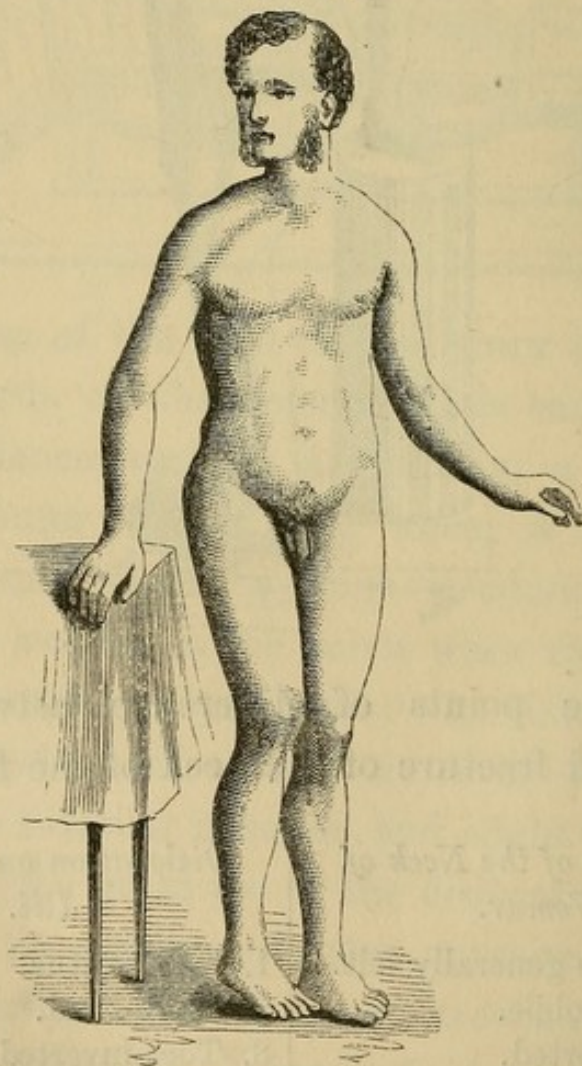
A test of  
dislocation.

The following test applies to all dislocations of the thigh:—Draw a line from the anterior superior spine to the most prominent part of the tuber ischii. When the head of the bone is in place, the trochanter in every position of the limb touches the lower border of this line. When the thigh is dislocated the trochanter is found above this line.

Dislocation  
into great  
sciatic notch.

Dislocation upwards and backwards into the

FIG. 51.



great sciatic notch is caused in a similar manner to the last, only the limb at the time of the



accident is more nearly at a right angle with the body. The symptoms are very similar to dislocation on the dorsum, but the shortening is not more than half an inch, the flexion is generally less, and the tip of the great toe of the dislocated limb touches the ball of the great toe of the opposite side. In Fig. 51, showing the deformity in this dislocation, the right great toe is not drawn sufficiently forward.

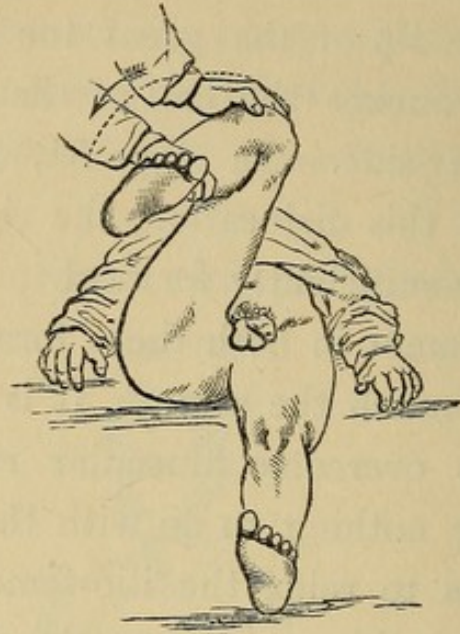The treatment in both these forms of dislocation is very much the same. It is directed, not so much to overcome muscular rigidity, which has little or nothing to do with the difficulty in reduction, as to relax the ilio-femoral ligament. To accomplish this an attempt should be made to reduce the dislocation by manipulation. This should be tried at first without chloroform. The operation is thus performed:—Place the patient on his back on a mattress laid on the floor. Supposing it to be a right limb, grasp the ankle with the right hand and the knee with the left, flex the leg on the thigh, and the thigh on the pelvis in a direction towards the umbilicus. The flexion of the thigh on the pelvis should cease as soon as resistance is felt. Then move the knee outwards, at the same time rotating the limb slightly outwards, and when the thigh is brought nearly at right angles with the body, bring it down suddenly to its natural position in a straight line with the body (Fig. 52). Should

Treatment.



the first attempt fail it may be renewed under chloroform. Occasionally the head of the bone

FIG. 52.



ruptures the ilio-femoral ligament and passes through a slit like a button-hole in the ligament. The bone being grasped in this slit the reduction is prevented. To overcome this, before the manipulations above described are commenced the limb should be freely circumducted, by which means the rent in the capsule is enlarged, and the head of the bone permitted to return through it. In dislocations into the sciatic notch the extent of the circuit outwards must be diminished, as it sometimes happens that the head of the bone may be tilted into the foramen ovale instead of into the acetabulum. Should this happen the reverse movement must be made, as directed at p. 132. After



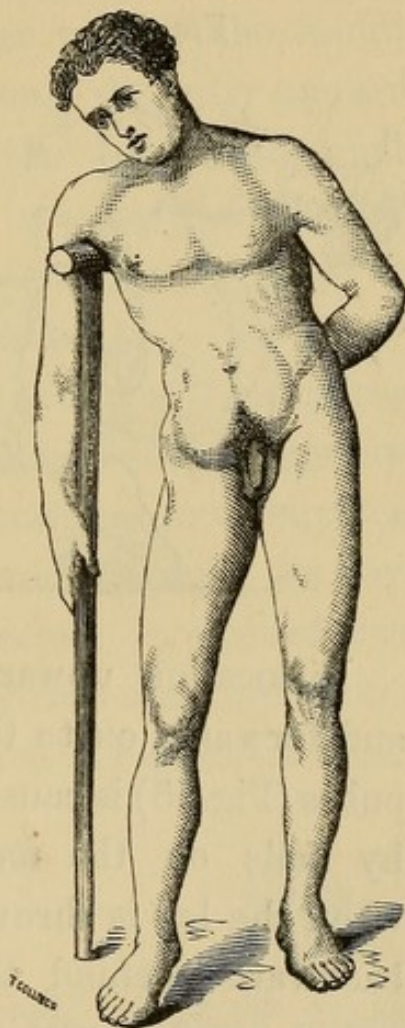
reduction has been accomplished the two limbs must be tied together, no splints being required.

Dislocation downwards and forwards into the foramen ovale (Fig. 53) is caused by such violence

Dislocation into the foramen ovale.

as the fall of a weight on the back of the pelvis, the thigh being at the moment abducted and the body bent. Symptoms:—  
1, Lengthening of the limb by from one to two inches;  
2, bending forward of the body on the thigh;  
3, advance of the dislocated limb in front of its fellow, the toes pointing directly forwards;  
4, flattening of the hip, and approximation of the trochanter towards the mesial line;  
5, tension of the adductors, the head of the bone being sometimes felt beneath them.

FIG. 53.



The treatment by manipulation is thus performed:—Grasping the limb as before described, the knee is carried upwards towards the abdomen until resistance is felt. The limb must then be made to describe an arc inwards and be suddenly brought down to the straight position (Fig. 54). When the knee is just opposite the

Treatment.



pubes the thigh should be gently rotated inwards, which helps to tilt the head of the bone into the acetabulum. It may further be assisted into its place by a band placed round the upper part of thigh and pulled on by an assistant.

FIG. 54.

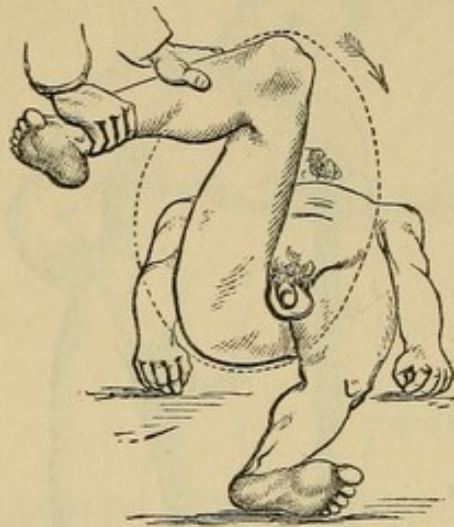
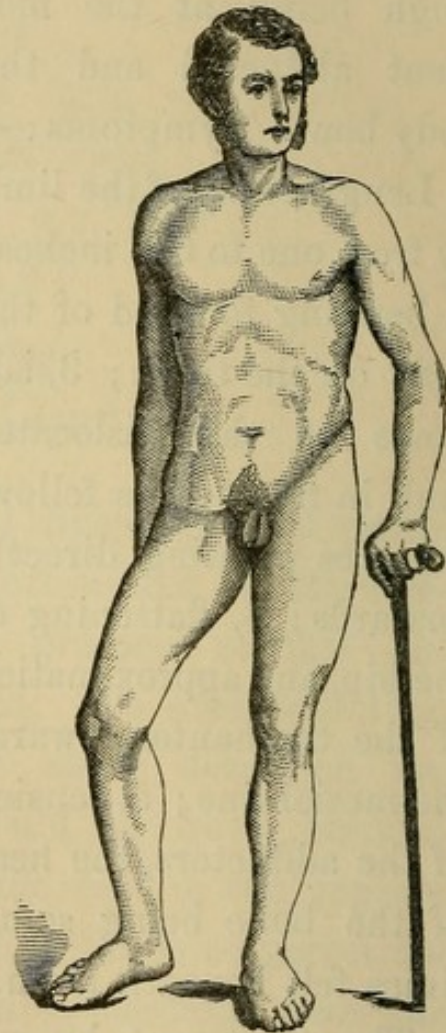


FIG. 55.



Dislocation on  
to the pubes.

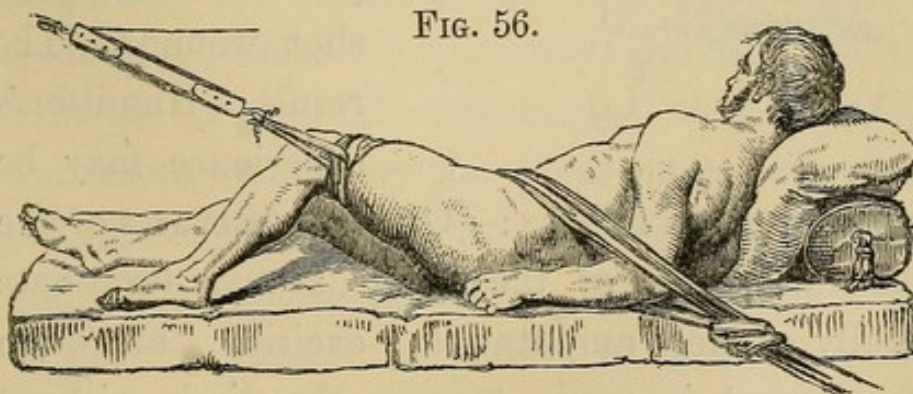
Dislocation upwards and forwards on to the pubes (Fig. 55) is caused by falls on the foot, when the leg is thrown backwards behind the centre of gravity. Symptoms:—1, Shortening, abduction, slight flexion and rotation outwards of the thigh; 2, rotation inwards of the trochanter and flattening at its usual situation; 3, the discovery of the head of the bone in its abnormal position. The treatment by manipulation is as follows:—Seize



the limb by the foot and knee, and rotate the thigh well outwards. Flex the leg on the thigh and bend the knee well over the opposite knee, keeping the heel elevated and the knee firmly pressed down. Continue the motion by carrying the thigh over the sound one as far up as the upper part of the middle third. Then carry the limb directly upwards by elevating the knee, the foot being held firmly, at the same time making gentle oscillations with the knee, when the head of the bone will drop into its socket.

Should manipulation fail in any of these cases, it will then be needful to have recourse to the pulleys. The patient being laid on a mattress, must be placed under the influence of chloroform, and the parts likely to be galled well protected. In cases of dislocation on to the dorsum or into the sciatic notch, the pulleys will be arranged as in Fig. 56, care being

Reduction by  
extension.

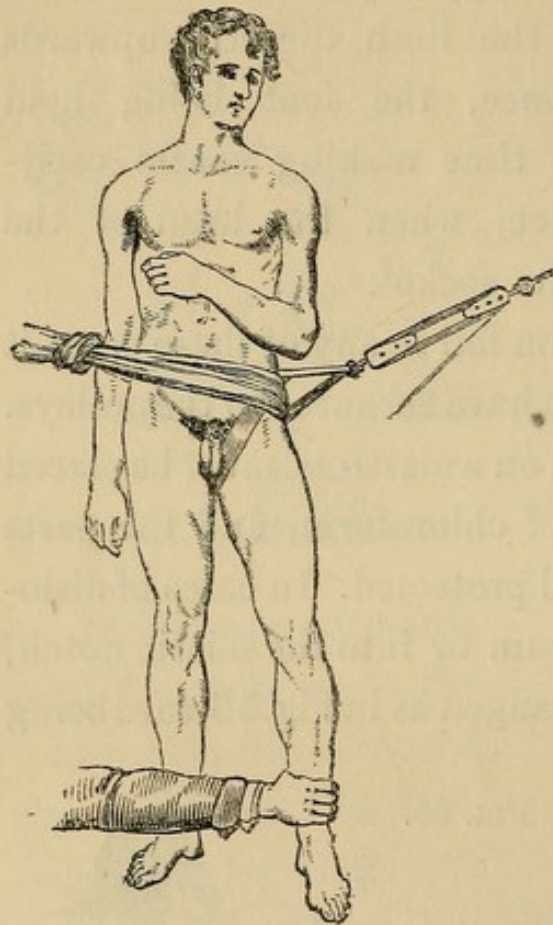


taken to pad the perineum well and to bandage the lower part of the thigh above the knee. The traction must be very gradual, and the trochanter



must be watched as it descends. Reduction may be assisted by traction with a long towel placed round the upper part of the thigh in a transverse direction. In dislocation into the foramen ovale, the pulleys must be arranged as in Fig. 57. Less

FIG. 57.



Compound  
injuries to  
shaft of  
femur.

force is required, and the reduction is facilitated by drawing the foot of the dislocated limb towards its fellow, using the strap of the pulley as a fulcrum on which to lever the bone into its socket.

Compound fractures of the thigh are the frequent accompaniments of gunshot wounds. The result of Hamilton's experience may be

summed up as follows:—Gunshot fractures of the head and neck of the femur always terminate fatally under amputation, excision, or when an attempt is made to save the limb without recourse to the knife. In the upper third the results are nearly the same, but if the main artery and the principal nerves are un-



injured, there is a slight balance in favour of attempting to save the limb. In the middle third the chances between amputation and the endeavour to save the limb are equal. In the lower third the chances are in favour of amputation. If an attempt is made to save the limb, the following rules should be observed:—

1. Remove all projecting pieces of bone which cannot be replaced, with the bone-forceps or saw. The lion-forceps and the small saw figured at p. 62 will facilitate this. Remove also all detached portions of bone and all foreign bodies.
2. All portions of muscle or fascia and tendon blocking the wound must be freely divided.
3. Every possible facility must be given for free drainage by counter openings and the insertion of drainage tubes if necessary.
4. The limb should be put up on an extension apparatus.

Compound injuries of the knee-joint are frequently the result of gunshot wounds. The treatment must be entirely guided by the damage to the soft tissues, by the extent of the fracture, and by the presence or otherwise of injuries to other parts. If the soft parts are not much lacerated, and the fracture is confined to the joint ends, the patient being of fit age, it is quite admissible to excise the joint (see below). But if the soft tissues are much lacerated, and the fracture extends up into the shaft of the femur, amputation must be performed (see below).

Compound  
injuries to  
knee-joint.



Operation for  
excision of the  
knee-joint.

In performing the operation of excision of the knee-joint the following instruments and appliances are required:—1, A long, strong bistoury; 2, a saw, with a blade at least three and a half inches broad; 3, lion-forceps; 4, retractors; 5, stout scissors, cutting on the flat; 6, an excision splint; 7, a Salter's swing; 8, four strips of adhesive plaster, three inches broad, and long enough to go twice round the limb and splint. The operation is thus performed:—Make an incision with the bistoury across the joint, which must be modified according to the condition of the integuments, but must be carried through the ligamentum patellæ into the joint; the joint being well flexed divide the lateral and crucial ligaments. Having cleared the end of the femur, lower the thigh on to the table, the leg hanging over the edge, and being supported by an assistant, and proceed to remove the condyles of the femur with the saw, another assistant steadying the bone with the lion-forceps. The section through the bone must be modified by the direction of the fracture; thus if one condyle alone is involved, remove it by an oblique section, sawing off only the articular surface of the other. The thigh must then be raised from the table, and the head of the tibia thrust well upwards, cleared with the knife, and a section removed with the saw. The patella must then be dissected out, the vessels secured, and the



limb adjusted on the splint, and retained there by straps of plaster and bandages. The wound is then closed with sutures.

When amputation of the thigh becomes need-  
ful it should be performed as low as possible. Amputation of  
the thigh.  
It is better to risk making a poor stump, than for the sake of getting perfectly sound tissue for flaps to amputate higher up in the thigh.

For amputation at the hip-joint the following Amputation at  
the hip-joint.  
instruments are required:—1, A Lister's abdominal tourniquet; 2, a long straight bistoury; 3, an amputating knife, twelve inches in the blade; 4, lion-forceps; 5, tenacula. The operation is thus performed:—Place the patient with the buttocks well over the edge of the table, and compress the abdominal aorta with Lister's tourniquet. 1st. Make an external semicircular skin flap, commencing the incision with the bistoury at the centre of the groin just external to the femoral vessels, and carrying it down in a circular direction about four inches below the great trochanter, and up to the tuberosity of the ischium; retract this flap, and expose the joint. 2ndly. The limb being, if possible, forcibly adducted by an assistant, open and disarticulate the joint. When, as is usually the case in traumatic amputations, the bone is shattered very high up, the neck of the femur must be firmly laid hold of with the lion-forceps, and pulled inwards. 3rdly. Lay aside the bistoury, and make



the internal flap by transfixing with the amputating knife, entering the point in front at the upper angle of the external flap, and bringing it out at the lower angle in front of the tuberosity of the ischium. Cut out through the adductors, and thus form the internal flap; with a few touches of the knife divide any tissues remaining uncut, and secure the vessels as rapidly as possible.

Amputation in  
the upper and  
lower third.

In amputation of the thigh in the upper third, anterior and posterior skin-flaps, with a circular sweep through the muscles, form the best amputation. In the lower third a long anterior skin-flap and a short posterior are best.

Amputation at  
the knee-joint.

In some cases of severe injury of the leg, amputation at the knee-joint, or through the condyles, is useful. The operation is thus performed:—The instruments required are, 1, a bistoury; 2, a catlin, or amputating-knife; 3, an excision saw; 4, lion-forceps; 5, tenacula. Standing on the right of the limb to be amputated (supposing it to be a right limb), 1st, enter the point of the bistoury at the inner side of the knee-joint just below the internal condyle of the femur, and bring it round through skin and fat in a circular direction below the tuberosity of the tibia, to a corresponding point at the outer side of the joint below the external condyle; 2ndly, dissect up the skin-flap, taking as much cellular tissue as possible; 3rdly, flex the knee,

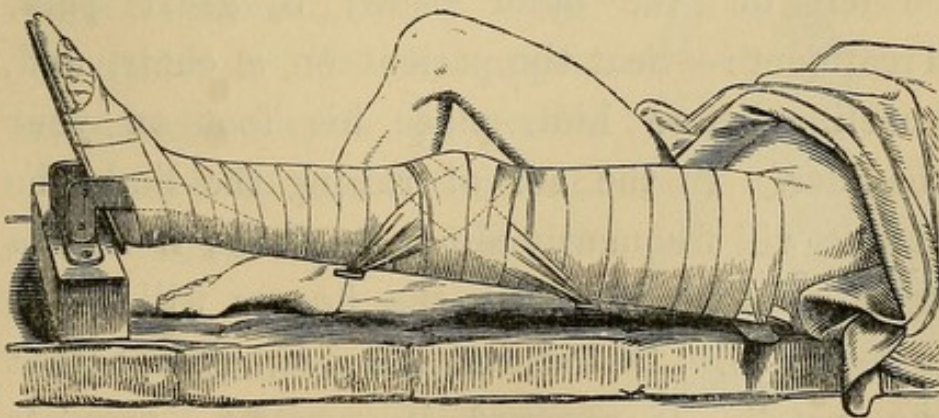


and open the joint ; 4thly, lay aside the bistoury, and with the long knife cut a short posterior flap, passing the blade of the knife close behind the head of the tibia, and cutting outwards through all the tissues ; secure the popliteal and other vessels. If it is needful to amputate a little higher, the condyles of the femur may be removed with the saw, an assistant steadying the bone with the lion-forceps. In either case the patella need not be removed.

Fractures of the patella are caused either by muscular action or by direct blows. Symptoms :—  
 1, Inability to stand or extend the leg on the thigh ; 2, in transverse fractures, which are the most usual, separation of the fragments ; 3, rapid effusion into the knee-joint. Blows on the patella frequently cause longitudinal or comminuted fractures. The immediate treatment of fractured patella must be guided by

Fracture of  
patella.

FIG. 58.



circumstances. If the effusion is very great the limb must simply be placed in the horizontal



position, and leeches, ice, or hot fomentations applied. If, however, effusion has not taken place, the limb may be immediately placed on Wood's splint (Fig. 58). The fragments are approximated by a figure of eight bandage carried round the hooks on the under surface of the splint, and the entire limb carefully bandaged from the toes upwards. A bag of ice may be kept constantly applied to the joint. Compound fractures should be treated in a similar manner.

Dislocations of  
patella.

Dislocations of the patella are caused by muscular action, and occur especially in knock-kneed persons and in women, by twisting the thigh inwards, the foot being fixed. Sometimes the accident is caused by direct violence.

Dislocation  
outwards.

Dislocation outwards is the most common form. Symptoms:—1, Limb slightly bent, but immovable; 2, breadth of knee increased; 3, projection of internal condyle; 4, patella can be felt on the outer side; 5, great pain. Treatment:—Seat the patient on a chair, and, kneeling before him, place his foot on your shoulder. In the act of raising the limb the patella will frequently slip into place; if not, a little manipulation with the fingers will cause it to do so.

Dislocation  
inwards.

Dislocation inwards, except that the patella is reversed in position, presents similar symptoms, and requires the same treatment.



Dislocation of the patella on to its edge is rare; the projecting edge of the bone is sufficient to show the nature of the injury. Treatment:—If the above plan does not answer, forcible flexion and extension must be tried, with rotation of the tibia on the femur. At the moment of extension the lower edge of the bone should be pressed on with the handle of a door-key, well protected with lint, by which means the bone is tilted back into its place.

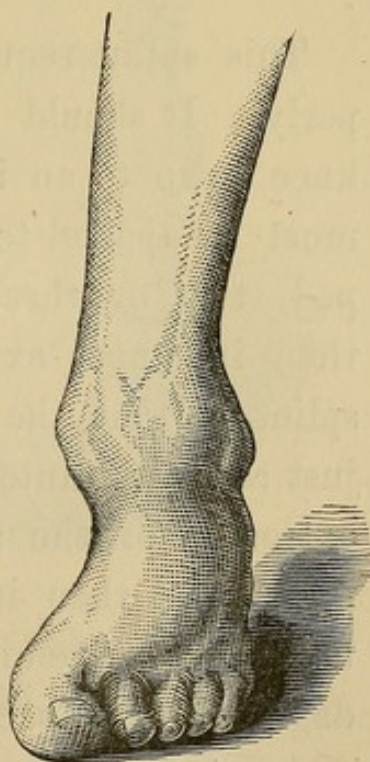
Dislocation of the patella on its edge.

Fractures of the tibia alone are generally the result of direct violence. The nearer the joint the more transverse is the fracture. The tendency to displacement is very slight, and the treatment simple. A plaster-of-Paris bandage is perhaps the most effective (see p. 195).

Fracture of the tibia.

Fractures of the fibula alone are caused either by direct violence, or by turns of the foot. In the upper two-thirds it is generally fractured by direct violence, in the lower third by indirect violence. Fracture in the lower third is usually accompanied with eversion of the foot, and dislocation inwards of the tibia. Fig. 59, taken from a cast in King's College

FIG. 59.



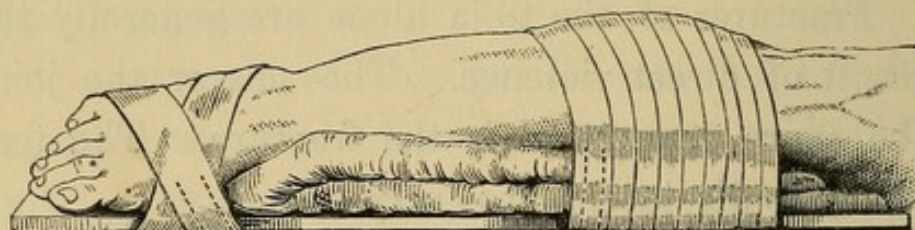
Fracture of the fibula.



Museum shows the deformity. Treatment:—If the external malleolus is alone fractured, or if the fracture is in the middle or upper third, simple rest on a pillow, or a plaster-of-Paris bandage will suffice. If, however, the foot is twisted, with displacement of the tibia, indicative of fracture in the lower third, the case had better be treated with Dupuytren's splint (Fig. 60).

Dupuytren's  
splint.

FIG. 60.



This splint requires some care to adjust properly. It should reach from a little above the knee down to an inch or so below the toes, and must be applied to the inner side of the leg. A pad, two or three inches thicker at its lower than its upper extremity, must be fitted to the splint, so that the lower end rests on the tibia just above the internal malleolus. Fix the upper extremity of the splint with a few turns of a roller, and then inverting the foot secure it to the lower extremity with a figure-of-eight bandage, taking especial care not to carry the bandage above the external malleolus. Bend the knee, and lay the leg on its outer side on a pillow.



Fractures of both bones of the leg are generally the result of direct violence. Muscular action and falls on the feet will also cause fracture of both bones. The lower third is the most frequent site for fracture of the tibia, the fibula being fractured at the same time frequently somewhat higher. The fractures are almost invariably more or less oblique, the upper fragment of the tibia riding in front of the lower, and more upon the inner than the outer side.

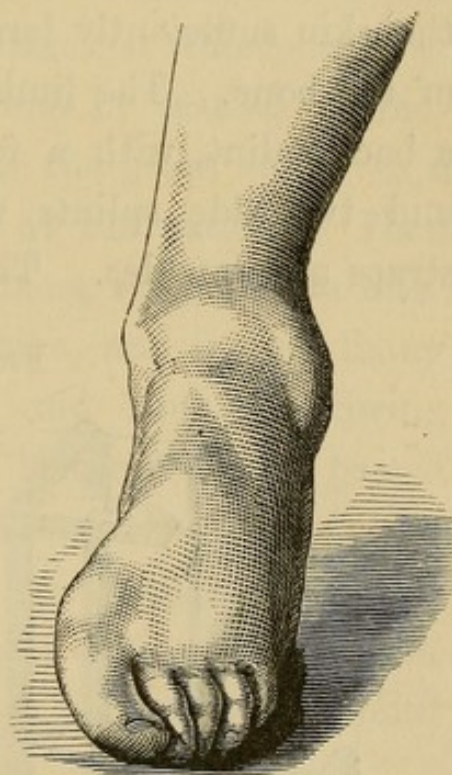
When the fracture is just above the ankle, it presents the appearance in Fig. 61 (taken from a cast in King's College Museum).

Treatment:—If there is not much displacement, a MacIntyre splint will be of use. The foot should first be bandaged to the foot-piece, which should then be drawn down a little, and fixed

with the screw in order to make slight extension. The upper part of the leg and the thigh may then be fixed, and the limb swung in a Salter's swing. In oblique fractures with much displacement, good apposition may be secured

Fracture of  
tibia and  
fibula.

FIG. 61.



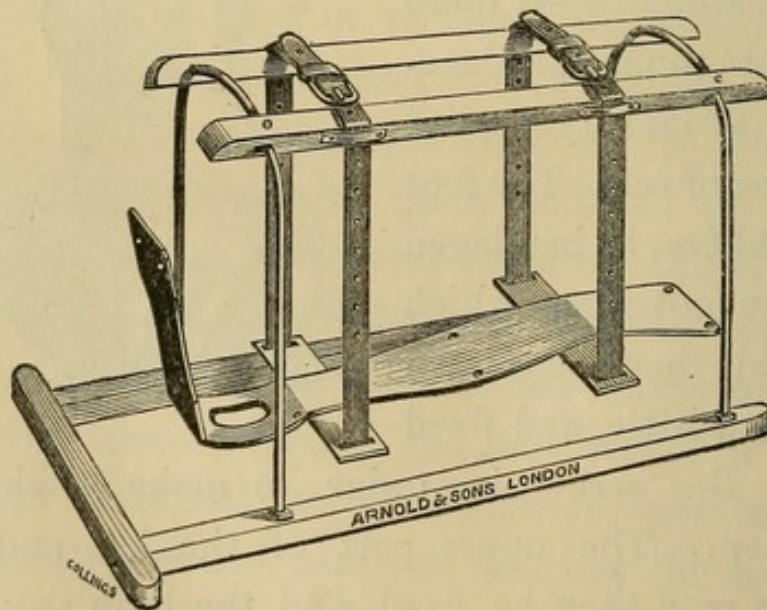


by flexing the leg at right angles to the thigh, and keeping it in that position by a light wooden angular splint applied on the outer side, and extending some inches above the knee. The limb must then be laid on its outer side on a pillow, and the patient's body inclined to that side.

Compound  
fracture.

In cases of compound fracture, if there is difficulty in returning the point of bone beneath the skin, endeavour, with a probe, to raise the inverted edges of the skin; and if the bone cannot then be returned, make an incision through the skin sufficiently large to admit of the return of the bone. The limb had better be put up in a back splint, with a foot-piece at right angles, and two side splints, which can be secured by straps and buckles. The splint made by Messrs.

FIG. 62.

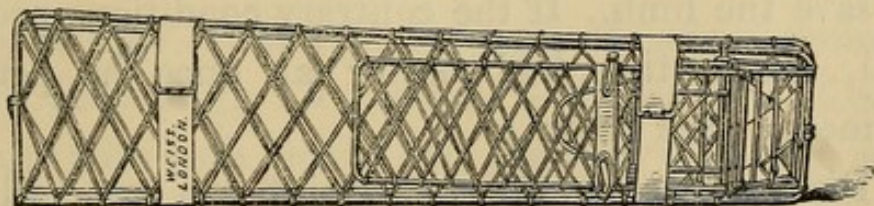


Arnold (Fig. 62), and used at St. Bartholomew's, is a very useful one. It is thus ap-



plied :—Place the leg on the back splint of iron, which must be well padded, carefully fitting the heel into the opening made for it. Secure the foot to the footpiece with a thick piece of gutta-percha moulded to the dorsum, coming round the edges of the footpiece, and fastened with tapes passed through holes bored in the gutta-percha. Some flannel should be placed between the foot and the gutta-percha, and the latter should be punched with a number of holes for ventilation. Take care that the ball of the heel and the ball of the great toe are well against the footpiece; and, as in all other methods of setting a fractured leg, that the ball of the great toe is in a line with the inner border of the patella. Then apply the side splints, securing them to the knee with a mould of gutta-percha, and further fixing them in place with straps and buckles. Swing the limb to a cradle with leathern straps passed through the two cross-bars of the back splint. The wire splint, invented by Surgeon McNalty, will be found useful, especially in country practice, as it is very portable. Fig. 63 shows this splint

FIG. 63.

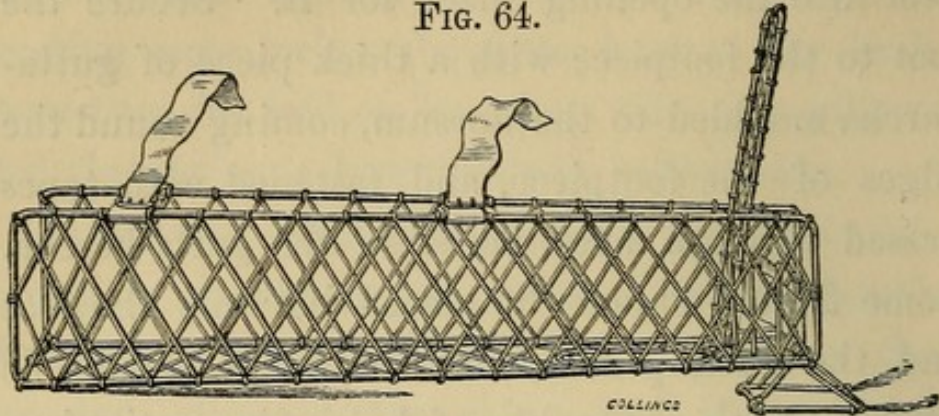


folded up; Fig. 64 shows it open; and Fig. 65 represents the limb placed in it.



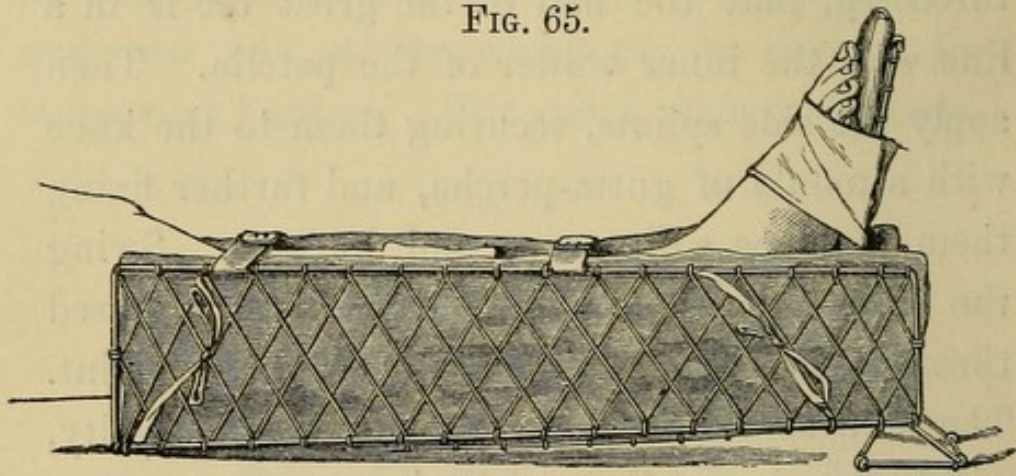
In comminuted fractures remove all detached pieces of bone, but any fragments firmly adhe-

FIG. 64.



rent to periosteum, and covered with it, should if possible be preserved. (For antiseptic treatment of compound fractures, see chap. xi.) As a

FIG. 65.



general rule, if the temperature and sensation of the foot are natural, an attempt should be made to save the limb. If the contrary conditions prevail, amputation had better at once be performed. (See below.)

Dislocations of  
the tibia at  
the knee-joint.

Dislocations at the knee-joint are generally the result of severe violence. The symptoms are so pronounced as to require no description. The



reduction is accomplished by forced flexion and extension, combined with a rocking motion of the joint. Sometimes it may be needful to apply extension by pulleys, and to make firm pressure on the prominent dislocated bone.

Displacement of the semilunar cartilages of the knee-joint may be caused by catching the point of the toe in a stone during walking, and thus wrenching the knee-joint; or by a patient turning in bed, the weight of the bedclothes on the toes twisting the knee. Symptoms:—1, Sudden severe pain; 2, the joint fixed in the semiflexed position; 3, sometimes the patient falls suddenly to the ground. Treatment:—Flex the leg as much as possible, and then suddenly extend it. If the first attempt fails, repeat it with a rocking motion of the joint. Reduction is attended by immediate cessation of pain and return of free motion to the joint.

Dislocations of the semilunar cartilages.

Dislocation of the tibia at the ankle-joint inwards, combined with fracture of the fibula, has been described at p. 141. Dislocation outwards is frequently associated with fracture of the internal malleolus. Fig. 66, taken from a cast in King's College Museum, shows this deformity. Treatment:—Grasp the foot firmly with both hands, and draw on it gently, at the same time rotating the foot outwards.

Dislocations at the ankle-joint.

Outwards.

Dislocation forwards (Fig. 67) is caused by violent extension of the foot. The fibula is fre-

Forwards.



quently fractured. Treatment:—Flex the leg on the thigh; and whilst an assistant makes

FIG. 66.

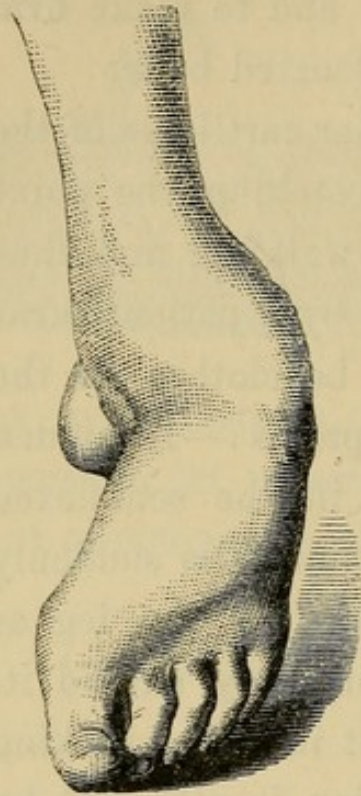
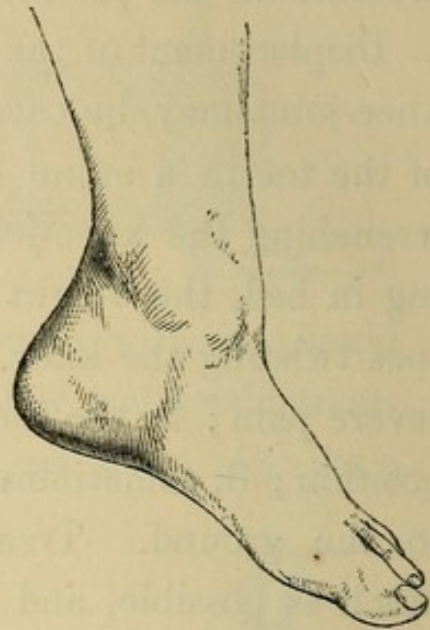


FIG. 67.



extension from the foot, press the tibia backwards and the heel forwards. As the bones begin to slide into place, forcibly flex the foot on the leg. Great difficulty is found in keeping the bones in place, and it may be needful to divide the tendo-Achillis, after which the limb should be fixed to an outside splint and laid on its side on a pillow, in the semiflexed position.

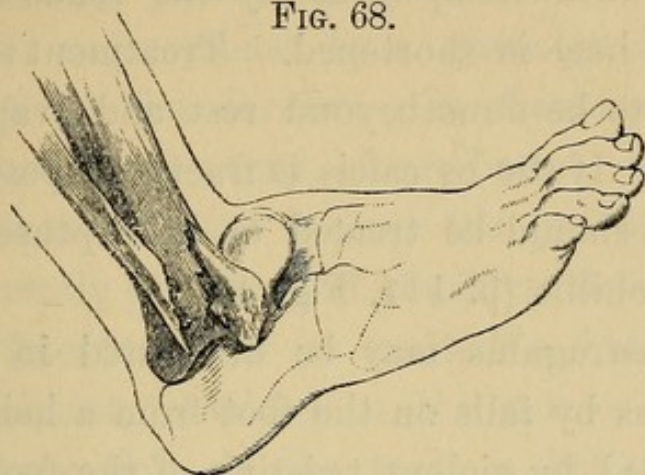
Dislocation  
backwards.

Dislocation backwards is very rare (Fig. 68). It is usually accompanied by fracture of one or both malleoli. It is caused by any force which produces extreme flexion of the foot. Treatment:—The tendo-Achillis will probably have



to be divided before reduction can be accomplished. Steady extension, with alternate flexion

FIG. 68.



and extension of the foot on the leg, must be employed.

In compound injuries to the ankle-joint every attempt should be made to save the limb, and unless the soft parts are very severely damaged, amputation should not be performed. If the protruding ends of the bone cannot be replaced, they should be removed, the extremities being firmly held with the lion-forceps, and the section made with the small saw figured at p. 62. For the antiseptic treatment see chap. xi.

Compound dislocations of the ankle-joint.

The astragalus and os calcis are sometimes broken by falls on the feet, and occasionally the latter is broken by muscular action, as in jumping on the toes, the posterior portion of the bone being separated by the tendo-Achillis. The other bones of the tarsus are generally broken by crushing violence. Symptoms:—The only prominent symptom in fracture of the tarsal bones is crepitus,

Fractures of the tarsal bones.



and this is not always present. When the posterior part of the os calcis is separated, the fragment is drawn upwards by the tendo-Achillis, and the heel is shortened. Treatment:—There is little to be done beyond rest and evaporating lotions. If the os calcis is fractured posteriorly, the case should be treated as in rupture of the tendo-Achillis (p. 114, Fig. 46).

Dislocations of  
the tarsal  
bones.

The astragalus may be dislocated in various directions by falls on the foot from a height, accompanied by violent twisting of the foot; or it may be dislocated by a direct blow. Symptoms:—1, Great prominence of the bone in the direction of the dislocation; 2, lateral deviation of the foot; 3, shortening of the leg; 4, in the backward dislocation the position of the foot is not much changed, but its dorsal aspect is shortened. So great is the force needful to dislocate this bone that it is frequently a compound injury. Treatment:—In simple luxation place the patient under the influence of chloroform, and firm extension being made, endeavour to press back the bone into its place. This failing, divide the tendo-Achillis, when reduction may be accomplished. Should it, however, be still impossible, it is better at once to divide the skin over the bone and remove it. In compound dislocation this latter course is invariably the best.

Displacement of the other tarsal bones may be easily reduced by simple pressure.



In fractures of the metatarsal bones the usual displacement of the fragments is upwards. They must, if possible, be pressed backwards into position, and retained by a gutta-percha splint, moulded to the dorsum. In fractures of the phalanges it is very often better to amputate, as the attempt to save the end of the toe is frequently the cause of considerable irritation. If the fracture is to be treated, a broad gutta-percha splint, moulded to the sole of the foot, and supporting all the toes, is better than a narrow one for the broken toe alone.

Fractures of the metatarsal bones and phalanges.

One or more or the entire row of metatarsal bones may be dislocated from the tarsus. The direction is generally upwards and backwards. Treatment:—To reduce a single bone pressure on the head is the most effectual method; but if the whole row be displaced, extension must then be made, in addition to pressure on their heads.

Dislocations of metatarsal bones.

The phalanges are generally displaced backwards. The reduction may be accomplished by combined extension and pressure on the head of the bone.

Dislocations of the phalanges.

In amputation of the leg the best operation is by lateral skin-flaps, with a circular amputation through the muscles. Make two lateral flaps of skin sufficiently long to cover the end of the stump, retract the flaps, and divide the muscles one inch below their base by a circular sweep down

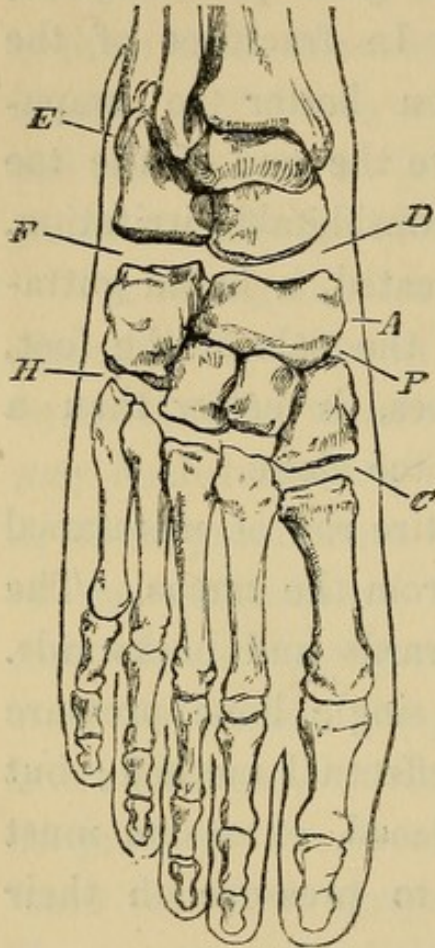
Amputation of the leg.



to the bone ; make the section of the bones with the saw on a level with the base of the skin-flaps.

Amputation  
of the foot.

FIG. 69.



Chopart's  
amputation.

The various amputations through the foot are indicated in the adjoining diagram (Fig. 69), from Bryant's "Surgery," which will be referred to in the following descriptions.

Chopart's amputation is thus performed on the right foot:—Grasp the fore part of the foot with the left hand, placing the forefinger on a point one inch behind H, the prominence of the metatarsal bone of the little toe, and the thumb on A, the tu-

bercle of the scaphoid. Make a curved incision between these two points through the skin, and a second incision through the tendons down to the bone ; forcibly bend down the foot, and open the articulations between the os calcis and the cuboid and between the astragalus and scaphoid. Keeping the knife close to the bones, cut the plantar flap as far down as the roots of the toes.

Hey's  
amputation.

When all the toes require removal, Hey's amputation must be performed. Operation on



right foot :—Grasp the foot with the left hand ; commence the incision on the dorsum, half an inch in front of the point H, the projection of the metatarsal bone of the little toe, and carry it with the convexity downwards to a point half an inch in front of c, the base of the metacarpal bone of the great toe ; make the plantar flap by two lateral incisions, carried from the base of the dorsal flap along the metatarsal bones, and joined by a curved incision a little beyond the ball of the great toe ; reflect this flap, and with a saw divide the metatarsal bones just in front of their articulations with the tarsus.

The rules for amputation of the toes are precisely similar to those given for the fingers at pp. 77–79. The head of the metatarsal bone should never be removed if it can be saved.

Amputation  
of toes.



## CHAPTER IX.

### EMERGENCIES CONNECTED WITH PARTURITION.

*Accidental Hæmorrhage—Placenta Prævia—Retained Placenta—Flooding—Induction of Premature Labour—Cæsarean Section—Craniotomy—Embryulcia—Decapitation—Mal-presentations—Turning—Prolapse of the Cord—Puerperal Convulsions—Rupture of the Uterus; of the Bladder; of the Perineum—Inversion of the Uterus.*

Accidental hæmorrhage.

ACCIDENTAL hæmorrhage may occur before delivery from detachment of a portion of the placenta. It is caused generally by falls, blows, violent mental emotions, jars in driving over a rough road, or by railway travelling. The symptoms are pain at the seat of injury, sense of distension, feeble pulse, fainting, and all the ordinary signs of loss of blood. It is possible that no blood may escape externally, but often the quantity which escapes is enormous. If labour is in progress, the flow will be arrested during a pain, or when faintness comes on. The following are the distinguishing points between accidental hæmorrhage and placenta prævia :—



| <i>Accidental Hæmorrhage.</i>                              | <i>Placenta Prævia.</i>                                |
|--|--|
| 1. Discharge arrested by labour-pain.                      | 1. Discharge increased by labour-pain.                 |
| 2. Membranes felt, with a portion of the child presenting. | 2. The placenta felt as a soft substance.              |
| 3. The os thin.  | 3. The os very thick and pulsating.                    |
| 4. History of injury.                                      | 4. No history of injury; bleeding coming on of itself. |

Treatment:—If slight rest and astringents, such as the Acetate of Lead two grains, with half a drachm of dilute acetic acid in water every four or six hours, fails, plug the vagina with soft linen, tow, or cotton wool, introduced gradually, and forced well up to the os, a firm binder being applied externally. If the hæmorrhage is very excessive, delivery must be expedited. Puncture the membranes, and give ergot. If needful, turn, or apply the forceps. If the patient is apparently dying from loss of blood attempt transfusion (see below).

Plugging the vagina.

In placenta prævia hæmorrhage generally comes on about the seventh or eighth month. It is a sudden discharge, and stops suddenly, to be repeated again probably in a week or fortnight. The other symptoms are given above. Treatment:—If the hæmorrhage is slight, keep the patient cool and in the recumbent posture; give the acetate of lead, and opiates, if there be uterine action. If the hæmorrhage is severe, the

Placenta prævia.



sooner labour is commenced and terminated the better. If the os is not dilated, plug the vagina and wait for uterine action. If this is tardy remove the plug, puncture the membranes with a stilet, and plug again if hæmorrhage continues. If the os does not dilate, the dilating india-rubber bags may be employed (see below), and when the os is sufficiently dilated either turn or apply the forceps. If the patient is too exhausted to bear turning or the forceps, pass the fingers into the uterus, completely separating the placenta, and leave the case to nature.

Retained  
placenta from  
adhesion to  
the womb.

Retained placenta from adhesions to the uterine walls may be diagnosed by the fact that uterine action continues after the birth of the child, without expelling the placenta, the uterine contractions being generally accompanied by gushes of blood. On digital examination the placenta will be found closely adherent to the walls of the uterus. Treatment:—Introduce the hand into the cavity of the womb, the other being placed on the fundus ; feel along the cord for the centre, and thence for the edge of the placenta, and gently peel it off. If it is impossible to remove some portions without the risk of damage to the womb, it is better to leave them.

Retained  
placenta from  
uterine atony.

When the placenta is retained from uterine atony give ergot, apply pressure with the hand on the fundus, and dash cold water on the vulva and abdomen. In cases of hour-glass contraction, introduce the fingers, cone-shaped, into

Retained  
placenta from  
hour-glass  
contraction.



the womb, and endeavour to dilate the contraction; then grasping the placenta, gently withdraw it. Chloroform is of great assistance.

Hæmorrhage into the cavity of the womb after the expulsion of the placenta is the result of uterine atony. Treatment:—Place the patient on her back, and give stimulants freely; grasp the uterus with one hand externally, and with the other in the cavity of the womb clear out all clots; pour cold water on the abdomen from a height, and, if at hand, introduce ice into the cavity of the womb. If these means fail, inject four ounces of *Liquor Ferri Perchloridi Fortior* (B. P.), diluted with twelve ounces of water. A Higginson's syringe, with a uterine tube attached, may be used; and the injection must be gently sent well up to the fundus, great care being taken to inject no air. As a last resource, transfusion may be had recourse to.

Flooding.

The induction of premature labour is required as an emergency, in cases of placenta prævia, of pulmonary or cardiac disease, or of convulsions. The best plan is to introduce one of Barnes's india-rubber bags. They are of various sizes, the smallest the size of the finger, with a constriction in the middle, by which it is grasped by the os and kept in situ. Being well oiled, the bag is passed through the cervix as far as the constriction; it is then distended with air or water through the elastic tube attached to the lower

Induction of  
premature  
labour.

Dilating bags.



end. If the bag be not at hand, an elastic male catheter with the top cut off must be passed through the os, and the membranes ruptured by passing the wire stilet through the catheter. Labour will come on after the lapse of several hours.

Cæsarean  
section.

Cæsarean section may be called for as an immediate proceeding in cases of sudden death of the mother, provided it can be ascertained that the child is viable, and the stethoscope determines that it is living. If the mother has died of hæmorrhage or asphyxia, it is probable that the child too is dead. Ten minutes after the mother's death is the longest period that can elapse with the chance of saving the child. In opening the uterus care must be taken not to wound the child, and in removing the child it should be grasped so as to bring out the head or the breech first. When Cæsarean section is performed with a view of saving the mother's life as well as that of the child, the following are the directions for the operation. The instruments required are:—1, Large, strong bistoury; 2, director; 3, retractors; 4, dissecting forceps; 5, large curved needle set in a handle; 6, silver wire sutures; 7, catgut ligatures. The rectum and bladder being emptied, place the patient on her back with the shoulders raised and the pelvis elevated. Do not give chloroform except under very exceptional circumstances, such as high nervous excitement or

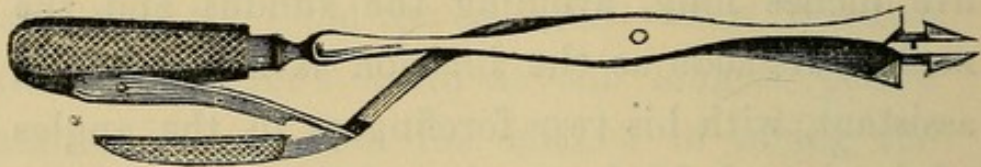


fear of the operation. Use the ether spray for the first incision, which should extend for six or eight inches from the umbilicus to within a short distance of the pubes. Make the incision exactly in the linea alba. Dissect down to the peritoneum and divide that upon the director. The parts being held aside with retractors, the uterus is now exposed. Feel on its surface with your hand for the thrill indicative of the position of the placenta, and if possible avoid that spot. Make an incision into the body of the uterus, five inches long, avoiding the fundus and the neck. As soon as the incision is made, let an assistant, with his two forefingers in the angles of the wound, hook up the uterus towards the external wound. Should the placenta be met with, thrust it aside, extract the child, and after it the membranes and placenta. If the uterus does not contract, press it with the hand, or insert a lump of ice into its cavity, or apply galvanism. Clear out all clots, and see that the os is perfectly free. Do not apply sutures to the uterine wound. Bring the parietal wound together with silver sutures passed with the curved needle, and including the cut edges of the peritoneum. During all the proceedings keep hot flannels on the abdomen and over the intestines, should they protrude. Apply broad straps of plaster across the abdomen, put on a large wad of cotton wool, and a binder or flannel roller.



Craniotomy.      Craniotomy may be required immediately, in convulsions, rupture of the uterus, or hæmorrhage, when the forceps cannot be used, or when they have failed to deliver. As little delay as possible should be made. The operation is thus performed:—Empty the bladder and rectum, and place the patient in the usual obstetric position. An assistant pressing on the fundus, pass two fingers of the left hand up to the head, and upon them guide the perforator (Fig. 70).

FIG. 70.



Do not perforate through a suture, or fontanelle, but placing the point of the instrument perpendicularly to the bone at the most dependent point of the head, push it by a gentle semi-rotating movement, through up to the shoulder or cutting notch. Open the blades to the full extent, thus cutting an opening in the skull. Repeat this proceeding in the opposite direction, thus making a crucial opening. Thrust in the perforator, and break up the brain. Wait to see if uterine action will expel the head. If it does not, then apply the craniotomy forceps (Fig. 71), one blade being placed within the skull and the other external to it.

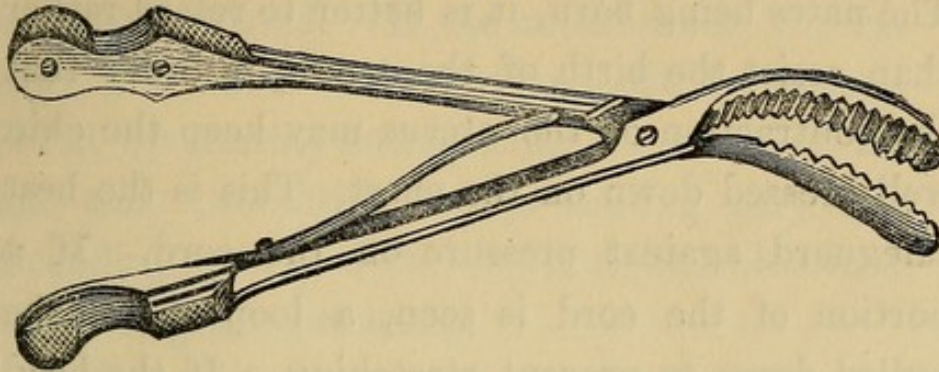
In cases of arm presentation, the liquor amnii having escaped, and the child being jammed down into the pelvis, so that turning is im-



possible, the operation of embryulcia may be used. This consists in thrusting the perforator

Embryulcia

FIG. 71.



through an intercostal space, and cutting through the ribs, if needful, with a pair of long-pointed scissors. The contents of the thorax are then evacuated. Decapitation is best performed with a long pair of sharp-pointed scissors. These are thrust into the neck, and the spinal column divided. The head being separated from the trunk, the latter is brought down, the former being afterwards extracted with the forceps.

Decapitation.

Face presentations may be mistaken for the breech. The distinctive mark is the bridge of the nose. The malar bone and the eye may also be felt. The treatment required is not special, except that in some cases of delay it may be needful to apply the forceps.

Mal-presentations. Face.

A breech presentation is diagnosed by the plump, round feel of the buttocks, the anal aperture, and the sharp point of the coccyx. The tuberosities of the ischium may be mistaken for the malar bones, but the absence of the bridge of

Breech.



Treatment.      the nose will correct this error. The presence of meconium is no sure test, as it may occur in head presentations. The treatment is simple. The nates being born, it is better to retard rather than assist the birth of the trunk, in order that the contraction of the uterus may keep the chin well pressed down on the chest. This is the best safeguard against pressure on the cord. If a portion of the cord is seen, a loop should be pulled down to prevent stretching. If the head remains unborn, and pulsation in the cord ceases, place two fingers of the left hand on the upper jaw on either side of the nose, and press the head down, at the same time making traction on the shoulders with the fingers of the right hand. If this fail, apply the forceps without delay.

Shoulder.      A shoulder presentation has the following peculiarities:—1, The membranes project in a conical form; 2, the shoulder feels smaller and softer than the head, but larger than the elbow, and it has not the two prominences with the groove between, characteristic of the knee; 3, the scapula with its spine, the neck, and the ribs may be felt. The shoulder is generally the first presenting part of the upper extremity, but it may be succeeded by the arm and hand. The hand is distinguished from the foot by the greater length of the fingers, the irregularity of their length, the distance the thumb may be stretched

Arm and hand.



away from the fingers, the being able to close them on the palm, and the absence of the heel. The treatment is to turn as soon as the os is sufficiently dilated. If the membranes rupture before the os is dilated, this must be accomplished by steadily introducing the hand, at the same time preventing the presenting part from descending. When the os is rigid, chloroform will be of great assistance.

Hands and feet, and with them the cord, sometimes present during the progress of labour. The presentation will become one either of hands or feet alone. If possible draw down the feet, and terminate the labour as in a breech.

Hands and feet.

When the hand and head present, an attempt should be made to return the hand. If there is then delay in the descent of the head, the forceps must be applied, or turning or craniotomy resorted to.

Hand and head.

The operation of turning is thus performed :— If the right hand and arm present, pass up the right hand on the left of the pelvis, along the right side of the child, until the fundus is reached. Then, if the membranes are not previously ruptured, break through them with the finger, and search for a foot. Be sure and make no mistake between a foot and a hand (see above). Seize the foot, and by gentle traction bring it down, when the arm will recede within the os. During the whole of this process, steady the

Turning.



uterus with the other hand on the fundus. If the left arm presents, introduce the left hand on the right side of the pelvis. The feet must be brought down over the abdomen, and not over the back. Protect the cord from pressure by pushing it aside to one or other sacro-iliac synchondrosis. If the head is long in being born, apply the forceps.

Prolapse of  
the cord.

Prolapse of the cord requires either its immediate replacement within the uterus, or the delivery of the child. The first may be accomplished by raising the patient's hips very high on pillows, the waist being on a much lower level. The cord may then by the force of gravity slip back into the uterus, and a pain will force down the head, and prevent the re-prolapse. If this does not succeed, either turning or the forceps must be used. No steps need be taken if the pulsation in the cord has ceased, and the stethoscope still further confirms the death of the child.

Puerperal  
convulsions.

Puerperal convulsions present all the ordinary features of epileptic convulsions. The treatment is:—1, Evacuate the contents of the bowels freely with scammony and jalap; 2, shave the head, and apply ice or evaporating lotions; 3, empty the bladder, or at any rate pass a catheter to be sure that it is empty; 4, wait until the os is sufficiently dilated, and then apply the forceps and deliver the child as soon as possible. Chloroform should be given, both to allay the violence



of the convulsions, and also to facilitate the delivery; 5, give chloral hydrate in thirty-grain doses. If the patient is unable to swallow, administer it by the rectum. If the uterus is rigid, and the labour does not advance, the convulsions being constant, perform craniotomy.

The symptoms of rupture of the uterus are:—  
 1, Violent and continued uterine action without corresponding descent of the child; 2, sudden agonizing pain of a crampy character; 3, a sensation of something having given way; 4, cessation of all uterine action; 5, sickness, clammy sweats, small pulse, and anxious expression; 6, recession of the child beyond the reach of the hand, its limbs being felt through the abdominal walls; 7, hæmorrhage from the vagina; 8, vomiting of a coffee-ground appearance. The treatment is at once to deliver the child. If the head can be reached, the forceps may be applied; if not, the hand and arm being passed up into the uterine cavity, an attempt to turn must be made. If this cannot be done, it is better at once to perform the Cæsarean section as the best chance of saving the life of the child. Very free administration of stimulants throughout is needful.

Rupture of the bladder presents many of the symptoms of rupture of the uterus; but, 1, There is no hæmorrhage from the vagina; 2, no recession of the child, or indication of its presence

Rupture of the  
uterus.

Treatment.

Rupture of the  
bladder.



Treatment. in the abdomen; 3, uterine action is not arrested. The belly, however, becomes rapidly swollen and tender. The treatment is, first of all, as rapidly as possible to deliver the child by the forceps or turning. A gum-elastic catheter must then be introduced into the bladder, and retained. One of the soft india-rubber catheters would be the best if at hand. The patient must be placed under the influence of opium as rapidly as possible, and turpentine stupes applied to the abdomen.

Rupture of the perineum. Rupture of the perineum is often the result of too speedy delivery, especially when the forceps are used. It is of little consequence, unless the sphincter ani is torn through. If this be the case, the better plan is at once to bring the parts together with interrupted sutures. It is not needful to use the quilled suture. Pass three or four sutures of thick silk through the deep parts with a curved needle set in a handle, and some superficial ones of finer silk, with an ordinary needle, should be inserted between. The patient should be kept on her side, with the thighs tied together. The water must be drawn off with a catheter, and the bowels confined for a few days.

Inversion of the uterus. Inversion of the uterus is sometimes the result of precipitate labour, and sometimes it is spontaneous, occurring after labour, or as the result of violent coughing, or straining of any kind. The symptoms are:—1, Great pain, of a dragging,



bearing-down character, with a sense of nausea and sinking ; 2, a round, hard tumour is felt per vaginam, whilst on examining the abdomen, the uterus cannot be felt. The treatment is to Treatment.  
return the womb to its proper position as soon as possible. To accomplish this, firmly grasp the uterus so as to empty it of blood, at the same time pressing firmly on the fundus with the palm of the hand. As the organ returns, follow it with the hand, which should not be withdrawn until the uterus firmly contracts upon it. If the placenta is attached, it must be removed before reduction is attempted.



## CHAPTER X.

### POISONING.

*Poisoning by Sulphuric Acid—Nitric Acid—Oxalic Acid—Salt of Sorrel—Hartshorn—Phosphorus—Arsenic—Scheele's Green—Orpiment—Sugar of Lead—Blue Vitriol—Tartar Emetic—Chloride of Zinc—Cantharides—Mussels—Opium—Godfrey's Cordial—Dalby's Carminative—Paregoric Elixir—Prussic Acid—Cyanide of Potassium—Essential Oil of Bitter Almonds—Chloroform—Tobacco—Strychnia—Hemlock—Water-Hemlock—Monkshood—Deadly Nightshade—The Use of the Stomach-Pump.*

**Sulphuric acid.** POISONING by strong sulphuric acid is accompanied by intense burning pain in the throat, gullet, and stomach, vomiting of coffee-grounds, mixed with shreds of mucus and blood. Treatment:—The administration of any alkali at hand, such as lime or magnesia, and of demulcent drinks.

**Nitric acid.** The symptoms of poisoning by nitric acid are the same as those above, and the remedies are also the same.

**Oxalic acid.** Oxalic acid is sometimes taken in mistake for Epsom salts. The symptoms are, burning sensation in the throat, great collapse, and vomiting of dark green matter. Treatment:—The adminis-



tration of copious draughts of warm water, and of chalk or magnesia, made into a creamy paste. The stomach-pump should be applied as early as possible. Salt of Sorrel, or essential salt of lemons, is used for bleaching straw and removing ink stains ; it consists of acid oxalate of potash, and, if taken, produces all the symptoms of oxalic acid poisoning, and must be treated in the same way. Salt of sorrel.

Poisoning by "hartshorn and oil" is not uncommon. The symptoms are, intense burning sensation in the throat, gullet, and stomach, and, when vomiting occurs, which is not always present, the vomited matter is mixed with blood of a dark brown colour. The immediate remedy is to give vinegar, lemon-juice, and demulcents. Ammonia, or hartshorn.

Phosphorus paste is sometimes taken as a poison. The symptoms of phosphorus poisoning are those of an irritant poison. There is intense thirst, nausea, severe pain, and an odour of garlic in the breath and vomited matter. The treatment is to administer emetics, and give magnesia. Phosphorus.

Various powders for the destruction of vermin, &c., contain arsenic, and are frequent sources of poisoning. The symptoms come on about half an hour after the dose has been taken, and are—nausea and burning pain in the stomach, violent vomiting, intense thirst, purg- Arsenic.



ing, and pain in the epigastrium on pressure. The treatment is, to excite vomiting as much as possible by the administration of a scruple of Sulphate of Zinc and Ipecacuanha and plenty of warm water, and to apply the stomach-pump as soon as possible. The Hydrated Sesquioxide of Iron, given in large quantities, is also useful; and a mixture of linseed-meal, castor-oil, and water, made to the consistency of treacle, may also be given to protect the stomach.

Scheele's  
Green.

Scheele's Green, or arsenite of copper, is met with in a variety of pigments and paper-hangings. Symptoms of poisoning by it are those of arsenical poisoning, and must be treated in the same way.

Orpiment.

Orpiment, or sulphide of arsenic, is also employed in the arts as a yellow colouring, and may produce arsenical poisoning.

Corrosive  
sublimate.

Corrosive sublimate, or Perchloride of Mercury, when taken in poisonous doses, produces a metallic taste in the mouth, pain, vomiting of white matter, and profuse diarrhœa. Treatment:—Give white of eggs, followed by infusion of galls or catechu, and use the stomach-pump as soon as possible.

Sugar of lead.

Sugar of Lead, or Acetate of Lead, is frequently taken as a poison, although it is seldom fatal except when given in very large doses. The symptoms are:—Pricking sensation in the throat, dryness, thirst, vomiting, and colic. Treatment:—



Emetics of Sulphate of Zinc, diluents, and Sulphate of Soda and Magnesia, and Phosphate of Soda.

Blue vitriol, or Sulphate of Copper, when taken, causes such severe vomiting as to be an antidote to itself. When this is not effectual, the symptoms are, headache, abdominal pain, purging, and sometimes convulsions. Treatment:—Encourage vomiting with warm water, and give milk, flour and water, and coffee; white of egg also is useful.

Blue vitriol.

Tartar emetic has been taken in mistake for Epsom salts. The symptoms are collapse, with livid countenance, violent pain in the stomach, spasmodic contraction of the muscles, particularly of the arms and abdomen, violent vomiting, and purging. Treatment:—Excite vomiting, and use the stomach-pump; give infusions of gall-nuts or cinchona, or strong tea.

Tartar emetic.

“Sir W. Burnett’s Fluid,” which is a solution of chloride of zinc, is not unfrequently the cause of poisoning. The symptoms are, immediate pain and vomiting, burning pain in the gullet, and collapse. Diluents must be freely given, and milk, white of egg, and Sulphate of Soda and Magnesia. The fatal effects are generally of a secondary character.

Chloride of zinc.

Cantharides, either in powder or tincture, is sometimes administered in poisonous doses for criminal purposes; one or two drachms of the

Cantharides.



powder will cause burning in the throat, pain in the abdomen, vomiting of bloody mucus, incessant desire to pass water. The treatment must consist of emetics and demulcents.

Mussels. Poisonous mussels produce uneasiness and weight in the stomach, numbness in the extremities, dryness in the throat, cramps in the limbs, swelling of the eyelids, and eruption of nettle-rash, with great exhaustion. Emetics must be freely given, and diffusible stimulants, with opiates to allay pain.

Opium. In poisoning by opium the symptoms are:—Stupor, from which the patient may be roused, but at once relapses; pulse small and irregular; skin warm and livid; pupils contracted in the early stage, but dilated at a later period; occasionally the odour of opium in the breath. The symptoms usually commence about half an hour after the poison has been taken. Treatment:—Immediate use of the stomach-pump, Zinc emetics, animal charcoal, infusion of galls or Tannic Acid, cold affusion to the head, and strong coffee. The patient must be kept in continual motion, the surface of the body being flapped with wet towels. Lastly, when all else fails, artificial respiration should be kept up for a considerable time.

Godfrey's  
Cordial.

Godfrey's Cordial is made of infusion of Sassafras, Treacle, and Tincture of Opium. It



contains about one drachm of the latter in six ounces, or half a grain of Opium in an ounce. Half a teaspoonful has been known to cause the death of an infant.

Dalby's Carminative is composed of essential oils, aromatic tinctures, Carbonate of Magnesia, and Tincture of Opium. It contains one-eighth of a grain of Opium in every ounce. Forty drops have been known to kill an infant.

Dalby's  
Carminative.

Paregoric Elixir is a preparation of alcohol, Opium, Benzoic Acid, and Oil of Anise and Camphor. It contains one grain of Opium in every half ounce. Half a teaspoonful has been fatal to an infant.

Paregoric  
Elixirs.

Prussic acid, when taken in a large dose, is generally immediately fatal. In smaller doses (about thirty minims of the weak acid) the symptoms are weight and pain in the head, giddiness, nausea, quick pulse, loss of muscular power, foaming at the mouth, strong odour of bitter almonds. Treatment:—Cold affusion to the head and spine, Carbonate of Ammonia internally, inhalation of chlorine gas, or small doses of Chloride of Lime or Soda. The chemical antidote, if there is time for its administration, is the moist Peroxide of Iron.

Prussic acid.

Cyanide of potassium, much used by photographers, when taken produces all the symptoms of poisoning by prussic acid; and the treatment

Cyanide of  
potassium and  
essential oil of  
bitter almonds.



is the same. So also the essential oil of bitter almonds, used as a flavouring, has been known to destroy life in a dose of seventeen drops.

Alcohol.

The symptoms of poisoning from alcohol come on in the course of a few minutes, and soon proceed to coma. Insensibility may, however, not come on for some time, and then suddenly. Intoxication, concussion of the brain, and poisoning by Opium are likely to be confounded. Usually in intoxication the smell of the breath is decisive. If this is absent it may be presumed that the case is not one of intoxication. In alcoholic poisoning the face is generally flushed and the pupils dilated; in opium poisoning the face is pale and the pupils generally contracted. The contents of the stomach will usually reveal the true state of affairs. Treatment:—Immediate use of the stomach-pump, cold affusions to the head, and artificial respiration, if the breathing is affected.

Chloroform.

In threatened death from Chloroform, the tongue should be immediately pulled forwards with hooked forceps, and the epigastrium forcibly pressed up; artificial respiration by Sylvester's method (see p. 37) should be resorted to without delay, and galvanism; the patient should be placed in a current of cold air, and the chest and extremities flapped with a wet towel. The head, if the face is pale, should be lowered; if turgid, should be raised. Artificial respiration should



be kept up for a long period, even after all appearance of life has ceased.

The symptoms of poisoning with Tobacco are faintness, vomiting, giddiness, delirium, coldness of the surface, and convulsions. The treatment is the administration of stimulants, strong coffee, and the application of warmth to the surface. Tobacco.

Poisoning with Strychnia shows itself at variable periods after the dose has been taken. The sixteenth of a grain has been known to kill a child, and half a grain an adult. The symptoms are, twitchings of the head and limbs, tetanic convulsions, opisthotonos, livid face, with complete retention of the intellectual faculties. The patient either dies or recovers within two hours of the commencement of the attack. The treatment is to inject into the stomach large quantities of powdered charcoal suspended in water. If the spasms have set in, chloroform should be given, or large doses of chloral. Strychnia.

Hemlock, or Conium Maculatum, has been taken in mistake for parsley. The symptoms are, loss of power in the upper and lower extremities and of deglutition, partial paralysis of sensation, and fixed pupils. The two plates, Figs. 72, 73, exhibit the difference between the leaves of hemlock and parsley. Hemlock.

The water-hemlock has given rise to fatal accidents, its roots having been mistaken for parsnips. The symptoms are, dimness of sight, Water-hemlock.

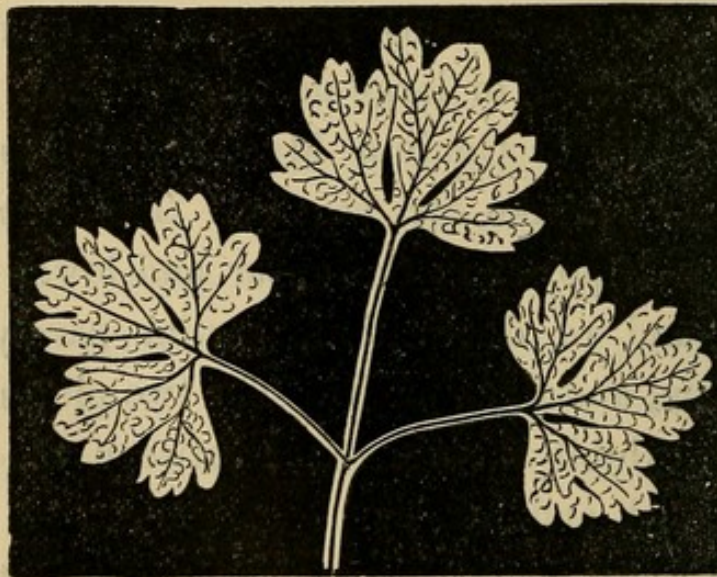


difficulty of breathing, burning pain in the stomach, vomiting, and convulsions.

FIG. 72.

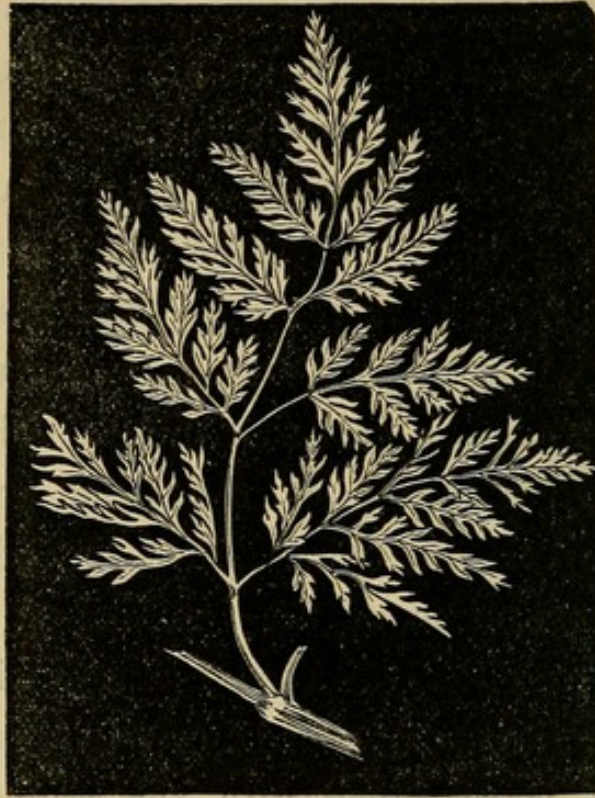

FIG. 73.

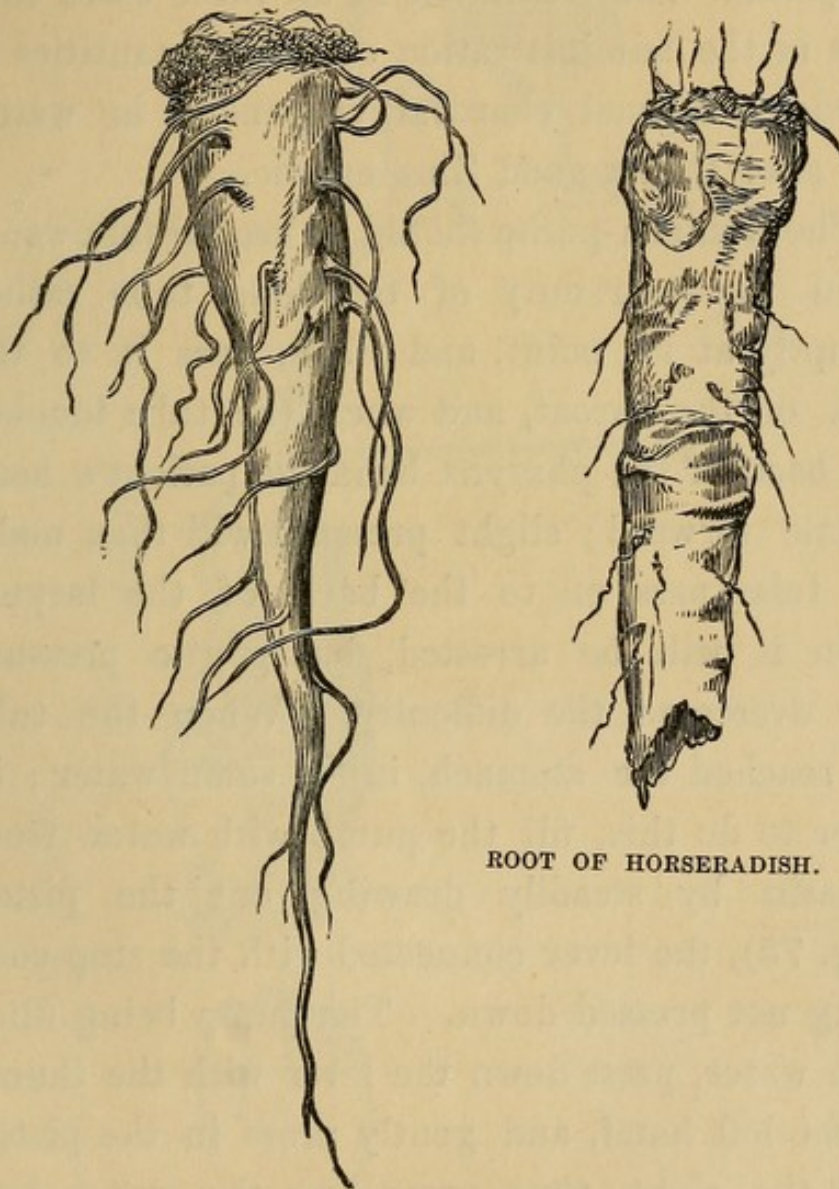


Monkshood. Monkshood, or *Aconitum Napellus*, has frequently been the cause of poisoning, the root



being mistaken for horseradish. Fig. 74 shows the difference between the two roots. The symptoms of poisoning are tingling and numbness

FIG. 74.



ROOT OF HORSERADISH.

ROOT OF ACONITE.

in the throat and limbs, frothing at the mouth, severe pain in the stomach, vomiting and purging, dimness of sight, dilated pupils, and livid skin.

Death has sometimes been caused by par-

Deadly  
Nightshade.



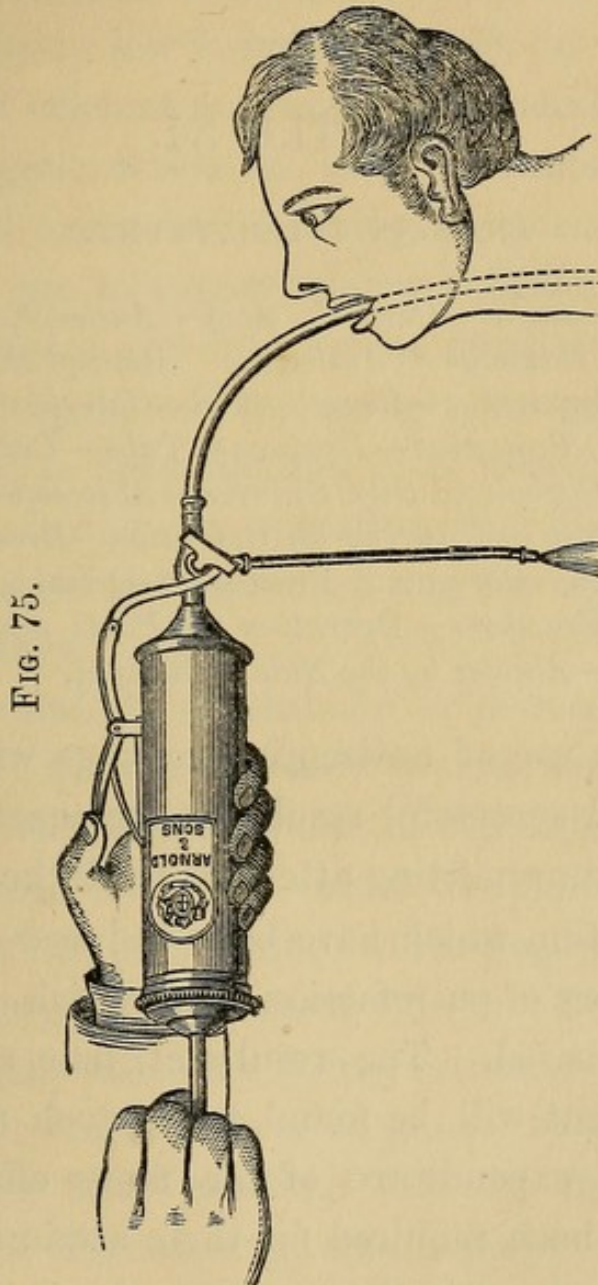
taking of the berries or the leaves of Deadly Nightshade, or *Atropa Belladonna*. The symptoms are, hot and dry throat, flushed face, dilated pupils, staggering gait, loss of hearing and power of speech. The treatment in all these cases consists in the administration of large quantities of powdered animal charcoal, suspended in water, and after that a good Zinc emetic.

The use of the  
stomach-  
pump.

The stomach-pump should be used as follows:— Bend the extremity of the long tube rather abruptly at its point, and oil it; pass it to the back of the throat, and when the tube touches the back of the pharynx bend the patient's head a little forward; slight pressure will then make the tube pass on to the back of the larynx, when it will be arrested, but gentle pressure will overcome the difficulty. When the tube has reached the stomach, inject some water; in order to do this, fill the pump with water from a basin by steadily drawing out the piston (Fig. 75), the lever connected with the stop-cock being not pressed down. The pump being filled with water, press down the lever with the thumb of the left hand, and gently press in the piston with the right, thus propelling the water into the stomach. When enough has been injected reverse the action. If the tube becomes blocked, again reverse, and so eject the fragment blocking the eye of the tube. If the patient is unconscious or unruly, the mouth must be



opened with a screw-gag, and kept open with a wooden gag supplied for the purpose with the



stomach-pump. If a stomach-pump is not at hand an ordinary Higginson's syringe, fitted to a gum-elastic catheter, may be used on the emergency.



## CHAPTER XI.

### ANTISEPTIC TREATMENT.

*General Remarks—Carbolic Acid—Antiseptic Gauze—Gauze Bandage—Antiseptic Atmosphere—Steam Spray Apparatus—Boracic Acid—Chloride of Zinc—Oil-Silk Protective—Drainage Tube—Catgut Ligatures—Carbolized Silk Sutures—Abscesses—Precautions before and during an Operation—Dressing after Operation—Compound Fractures—Dressing in Compound Fractures—Operation on Parts affected with Sinuses—Abscess by the Side of Rectum.*

General remarks on antiseptic treatment.

THE mere use of antiseptic dressings will not of itself yield successful results to the surgeon. He must give unremitting attention to all the minutiae of application which have been deduced from the germ-theory of putrefaction, upon which the treatment is based. The results of true antiseptic management will be found to be such as would repay the expenditure of far more effort than will have been required for their attainment; to say nothing as to the average saving of time, and the relief derived from diminished anxiety.

The following is a short account of the antiseptic treatment employed by Prof. Lister, of Edinburgh, in May, 1874:—

The three antiseptics which have been found



most useful are Carbolic Acid, Boracic Acid, and Chloride of Zinc.

Pure carbolic acid—remarkable for its power of destroying low forms of life—is, on the whole, the most efficient antiseptic for general purposes. Its energetic action on the epidermis makes it the best agent for cleansing purposes. In the form of one to twenty watery solution it is used for purifying the integument of the part to be operated upon, and the sponges, instruments, &c. As a one to forty solution it is used for washing sponges during an operation, for the hands of the operator and assistants, and for the changing of dressings.

The volatility of carbolic acid renders it invaluable for dressing hollow wounds and abscesses. It is the active constituent of the ordinary dressing—antiseptic gauze—which is applied, in eight layers, of size proportioned to the expected amount of discharge. A piece of thin mackintosh cloth (technically called hat lining) is interposed beneath the outer (eighth) layer of gauze, to prevent the discharge from soaking directly through the centre of the dressing, washing out the portion of acid there stored up, and thus giving putrefactive organisms direct access to the cavity. Further, as carbolic acid is given off very slowly by the gauze at the ordinary temperature of the air, it is quite possible that septic organisms, accidentally adherent, might be conveyed to the

Carbolic acid.

Antiseptic gauze.



Gauze  
bandage.

wound by the surface of the dressing itself. To guard against this mishap, that portion of the inner layer of gauze which will lie opposite to the wound is damped with the promptly acting one to forty solution, or else a small portion of gauze wrung out of the same solution is applied before the ordinary eight-fold dressing. The antiseptic gauze is convenient in the form of bandage, which not only applies itself, and retains its position better than a calico bandage, but is often a valuable addition to the antiseptic quality of the dressing. In the case of stumps in which there is a tendency to retraction of the soft parts, the antiseptic bandage enables the surgeon to overcome what would otherwise be a considerable difficulty in the treatment of the case.

Antiseptic  
atmosphere.

It is not sufficient to have a reliable dressing, and to be able to purify the skin and the instruments employed. There must also be an antiseptic state of the atmosphere, which cannot fail to gain access to the wound, or abscess, during the operation, or changing of dressings. This is provided in the form of a spray of one to forty carbolic acid solution, for which the most easily managed and efficient instrument will probably be found to be a steam spray apparatus, manufactured for Mr. Lister by Mr. J. Gardner, 45, South Bridge, Edinburgh.\*

Steam spray  
apparatus.

---

\* Of whom may be obtained all the materials required for the antiseptic treatment.



When the spray is suspended during an operation, or the changing of a dressing, the wound should be covered with a piece of sound calico moistened with one to forty carbolic solution, which for convenience is termed the guard. Of course, neither spray nor guard is required for superficial sores.

Boracic acid is a powerful antiseptic, but its non-volatility prevents its being used for the dressing of hollow wounds, and for the spray. It is bland and unirritating as compared with carbolic acid, and is therefore particularly useful as a dressing in all superficial wounds and sores. It is employed in the form of a saturated watery solution, and as boracic lint, which contains about half its weight of the crystals of boracic acid. The mode of using these preparations is given in the sequel.

Boracic acid.

Chloride of zinc has the remarkable peculiarity among antiseptics of producing such an effect upon the tissues of a recent wound, when applied in a watery solution of about forty grains to the ounce, that, as the result of a single application, the cut surface, though not presenting any visible slough, is rendered incapable of putrefaction for two or three days, though exposed to the influence of septic material. The patient is thus tided over the dangerous period preceding granulation, during which the divided tissues are most prone to inflammation and the absorption of septic products. Hence this salt, though very

Chloride of  
zinc.



irritating and non-volatile, and therefore not adapted for general use, is of the highest value in circumstances which render it impossible to exclude septic organisms in the after-treatment; as, for example, after the removal of tumours of the jaws, or operations about the anus, and amputations or excisions in parts affected with putrid sinuses. The solution is freely applied to all textures, including bones, by means of a piece of lint held in dressing-forceps. Sinuses are injected at the conclusion of the operation by means of an ordinary brass syringe.

In order to obtain the best results from the antiseptic treatment, it is desirable to protect the healing parts from the irritating influence of the antiseptic itself, which, in the case of carbolic acid, would often prevent cicatrization altogether, and which even with the much blander boracic acid is better avoided. This is done by interposing a protective layer, consisting of some material unirritating in itself, and as far as possible impervious to the antiseptic agent.

Oil-silk  
Protective.

The protective commonly used is composed of thin oil-silk, varnished with copal, and then coated with a layer of dextrine. The dextrine allows the oil-silk to become uniformly wetted by the antiseptic solution, into which it is dipped at the moment of application. It is obvious that the antiseptic dressing proper must extend a considerable distance beyond the protective, or



putrefaction may spread under the latter, in spite of the dressing which is above it.

The application of antiseptics to the raw surfaces of a wound causes a certain amount of irritation, and leads to an unusually abundant discharge of serum; so, in order that this may not be pent up, and occasion inflammation from tension, a very free outlet must be provided. This is effected by means of Chassaig-nac's drainage tubing, of which four sizes are used, having an external diameter of  $\frac{1}{3}$ ,  $\frac{1}{4}$ ,  $\frac{1}{5}$ , and  $\frac{1}{8}$  inch respectively. Large holes are cut in the walls, so as to allow the discharge to reach the lumen of the tubes; and two loops of silk thread, knotted at the ends, are attached to opposite sides of the margin of the outer extremity of the tube to prevent displacement. The outer end is to be cut either transversely or obliquely, according to the direction of the cavity, so that the orifice of the tube may be flush with the integument.

Drainage  
tube.

When abscesses are opened, a drainage tube should be used, of a length equal to the depth of the cavity, and of a calibre proportioned to the quantity and thickness of the pus discharged. The tube should be shortened from time to time as the cavity becomes smaller.

For arresting arterial hæmorrhage, the prepared catgut used antiseptically combines the security and universal applicability of the ligature with the practical absence of any foreign

Catgut  
ligature.



body from the wound. The vessel is tied in the usual way, but the ends of the catgut are cut off near the knot.

The catgut may be conveniently carried in the pocket case in one of Mr. Lister's catgut-holders. As the right preparation of the catgut is a matter of very great importance, it is best to obtain it ready prepared along with the other antiseptic materials.

Carbolized  
silk sutures.

As metallic sutures are liable to catch in the dressings, carbolized silk sutures are used with advantage. They are prepared by passing ordinary ligature silk through melted beeswax, containing ten per cent. of carbolic acid. The superfluous wax is wiped off from the warm thread as it is drawn out from the mixture. The antiseptic property of the silk is conveniently retained by keeping it wrapped in antiseptic gauze.

Directions for special cases :—

Abscess.

I. *Abscess.*

This is the simplest case for antiseptic treatment, the antiseptic not being applied at all to the affected tissues, but merely used to prevent the access of septic mischief from without.

Carefully select the spot for incision with special attention to its distance from a source of putrefaction,\* so that the dressing may extend

---

\* So important is this that it might lead to the refusal to operate—*e.g.* in a case of spinal abscess pointing near the anus.



freely beyond the incision in every direction. The skin, the knife, and the operator's fingers having been cleansed with one to twenty carbolic solution, after shaving off hairs from the integument if necessary, let the spray play effectively on the part, then make an incision in the selected position, and of such a size as will easily admit the drainage tube; press out the pus; insert the drainage tube, and extend the loops of silk in opposite directions; apply over the incision a small bit of gauze wetted with carbolic solution, cover this with a large dressing consisting of eight folds of gauze and the enclosed piece of mackintosh, as above described; and lastly, secure this with a well-adjusted gauze bandage, and with safety-pins, which must not penetrate the centre of the mackintosh, or its efficiency will be destroyed. If it is desirable to explore the abscess cavity with the finger, special care must be taken that the latter be well cleansed about the nail and elsewhere with the solution immediately before introduction.

Next day let a hand be placed so as to keep the dressing in position whilst the pins are being removed and the bandage is being cut. Direct the spray towards one side of the dressing, which must then be cautiously raised, so that the spray may pass into the angle between the dressing and the skin. Remove the drainage tube under the spray; cover the incision with a guard; wash the drainage tube and the skin

Changing dressings.



with one to forty solution; again direct the spray to the incision, remove the guard, insert the tube, and dress as above described.

Chronic  
abscess.

As the discharge diminishes dress the case every two, three, four, five, or six days as required. Give the same amount of care to every dressing until cicatrization is complete; this being the only trustworthy evidence that the sinus is closed. In cases of chronic abscess due to caries of vertebræ, or to morbus coxæ, keep the patient in bed six weeks after the abscess is closed. In the latter cases keep on the long splint during the whole period.

II. *Operations on parts where the skin is unbroken.*

Precautions  
before  
operating.

These cases come next in the order of simplicity of treatment, the essential object being, as in abscesses, to prevent the introduction of septic organisms during the operation; although the divided tissues are necessarily more or less exposed to the influence of the antiseptic in the spray and the sponges &c.

Prepare the skin, the hands of the operator and the instruments as above; conduct the operation as usual, but keep the spray at work until the dressing has been applied—of course, using the guard if the spray be suspended.

When an instrument has been laid aside during the performance of an operation, it is an essential point, very apt to be overlooked, that before being reintroduced into the wound it



should be again thoroughly cleansed with the carbolic solution.

After securing the vessels, adjust a drainage tube, and stitch up the wound with carbolized silk. In some cases intermediate stitches of horsehair (which has been dipped into the carbolic solution) may be employed; then dip a piece of protective, large enough just to cover the incision, into the solution, and lay it over the wound; over this apply a piece of gauze wetted with the solution, and the usual well overlapping dry gauze dressing. Change the dressing next day, and then afterwards dress more or less frequently according to the amount of the discharge.

Dressing after operation.

In amputations apply a gauze dressing large enough to wrap round the limb, and to turn up over the face of the stump, like the wrapping at the end of a parcel.

In primary amputations, and in amputations through limbs above the seat of putrid discharge, cover the contused or putrid parts with a towel wrung out of one to twenty carbolic solution, so that the sound parts may not become contaminated during the operation.

III. *Accidental wounds, including compound fractures and dislocations which do not require amputation.\**

Compound fractures.

Here opportunity having been afforded for

---

\* Experience will soon teach the surgeon that he may save, under the antiseptic treatment, many cases that would require amputation without it.



the entrance of septic material before the case is seen by the surgeon, whether in the infliction of the injury or subsequently, the antiseptic must be introduced into all the recesses of the wound, in order to counteract the mischief so introduced. For this purpose a strong antiseptic solution must be used, but while it must be introduced among the blood-clots in the recesses of the wound, it is very undesirable that it should pass unnecessarily into the cellular tissue. In ordinary circumstances the one to twenty carbolic solution is employed, but instead of forcing it into the wound generally, by means of a syringe, it is better to apply it to the various irregularities of the injured part by a flexible catheter adapted to the syringe with caoutchouc tubing. When several hours have passed after the infliction of the injury, Mr. Lister has of late used a still more powerful solution—viz., one part of carbolic acid to five parts of methylated spirit.

These operations are conducted under the spray after cleansing the skin with the one to twenty solution. If a fragment or an end of a bone is projecting, it is well washed with the same solution and returned, in some cases after sawing off its extremity; but reduction is never effected until the depths of the wound have been injected—loose fragments and foreign bodies being, of course, extracted.

It is difficult to assign the precise limit of



time when antiseptic treatment must be regarded as hopeless in such injuries. Success has sometimes been obtained as late as thirty-six hours after the accident.

The introduction of stitches should always be avoided in this class of injuries, and in some cases a drainage tube should be inserted; and if the wound is very small, it should be enlarged to prevent tension from accumulating serum.

The dressing is then applied, as in the last class of cases; the folded gauze being made to envelop the limb for a considerable extent above and below the injured part, in accordance with the large amount of bloody and serous discharge to be anticipated. A gauze padding for the splints in the vicinity of the injury is also often valuable as an additional precaution.

Dressing in  
compound  
fracture.

The dressing should always be changed on the following day; but afterwards, if all proceeds satisfactorily, the intervals between the dressings are increased as the discharge diminishes. It must, however, be borne in mind, that from the very nature of these cases—as some organisms in the recesses of the wound may occasionally elude the action of the antiseptic—success cannot be reckoned on with the same certainty as in the two former classes.

IV. *Operations through parts affected with putrid sinuses.*

Operations  
on parts  
affected with  
sinuses.

These cases present the greatest degree of complexity in the antiseptic treatment. It is



hardly to be expected that the putrefaction which exists in the recesses of the sinuses can be completely eradicated; but in a certain proportion of cases this is effected by the practice adopted in such circumstances, of injecting the tracks of the sinuses with the solution of chloride of zinc at the conclusion of the operation.\* The chloride is at the same time applied to the cut surfaces, and by this means the patient is saved a great deal of pain and danger, as above alluded to—even should putrefaction ultimately show itself.

The usual external antiseptic dressing is employed in the hope of an aseptic result, while it also protects the atmosphere of a hospital ward from foul emanations in case of putrefaction occurring.

It is hardly necessary to say that the spray is not required in operations on this class of cases; it is, however, employed in the changing of the dressings so long as an aseptic result is hoped for.

Abscess by  
side of rectum.

#### V. *Abscess threatening fistula in ano.*

This particular case of abscess is of such importance as to deserve special notice here. In

---

\* At one time Mr. Lister recommended the injection of the sinuses before the operation was commenced; but though this is the most effective mode of introducing the solution, it has been abandoned for some time past in consequence of inconveniences having in some cases followed from the solution becoming diffused into the cellular tissue of the part.



consequence of the vicinity of the anus preventing the overlapping of the skin around the wound by the dressing to a sufficient extent to insure absence of putrefaction, the gauze cannot be employed. But the difficulty may be overcome by applying to the anal orifice and surrounding parts a mass of lint soaked with a solution of carbolic acid in ten parts of olive oil, and retained in position by a T-bandage; the patient being directed to draw the pad of lint slightly towards the affected side before defecation, so that the evacuation may be effected without exposing the wound, and to cleanse the anal outlet with the oily solution before re-adjusting the pad. The oiled lint is changed about every four hours during the first day; but when the discharge becomes very slight, every twelve hours is sufficiently often. The abscess is opened under the spray as usual, after washing well with the one to twenty watery solution; and instead of a drainage tube, a bit of lint soaked in the carbolic oil is inserted to prevent primary union. Fœtor of the pus on evacuation of the abscess must not discourage the surgeon from continuing the antiseptic measures; experience having shown that in such circumstances, as well as where the pus is odourless, the usual results of the antiseptic system applied to abscesses may be attained, all further suppuration ceasing, and fistula being averted.



## CHAPTER XII.

### APPARATUS AND DRESSINGS.

*Pasteboard Splints—Plaster of Paris Bandage—Gutta-percha Splints—Extension by Weight—The Use of the Aspirator—Transfusion of Blood—Hutchinson's India-rubber Catheter—Esmarch's Bloodless Operation—Method of Opening Deep-seated Abscesses.*

Pasteboard  
splints.

IN treating a fracture with pasteboard, plaster of Paris, or gutta-percha splints, it must be remembered that it is necessary to secure the immobility of the joints above and below the fracture. For instance, in a fracture of the upper part of the humerus the shoulder and elbow must be secured, or in a fracture of the thigh the hip and knee. For pasteboard splints rough unglazed millboard, one-eighth of an inch thick, is to be used. It should not be cut, but bent over the edge of a table, and then torn, by which a soft edge is obtained. After the splint is properly shaped it should be soaked for a few minutes in boiling water. The limb to be encased must be carefully covered with cotton wool, and the pasteboard moulded so as to fit accurately to the wool, and secured with a



bandage, which should be smeared with starch a little thicker than that ordinarily used in the laundry. An interval of a quarter of an inch to an inch should intervene between the edges of the splint.

The plaster of Paris bandage is best applied as follows:—Pour a small quantity of water into a basin, and sprinkle into it perfectly fresh and dry plaster of Paris until a thin paste is formed. Take an ordinary unbleached calico bandage of the required breadth, previously saturated with water, and unroll and re-roll it under the paste, so as to impregnate the whole bandage with the plaster paste. The bandage must then be rapidly applied to the limb, which should be first covered with a flannel bandage. If possible, no turns should be made in the bandage, and some of the paste may be laid on with the hand between the layers. If the plaster is fresh and dry the bandage will set in five minutes, when it may be painted over with white of egg, to prevent its crumbling.

Plaster of  
Paris.

Gutta-percha splints are made, as a rule, about one-eighth of an inch in thickness. The gutta-percha is obtained in sheets, and the best method for cutting out the splint is to trace the outline with the point of a knife. Then bending the gutta-percha, and drawing the point of the knife successively along the original line, the gutta-percha will give before it, and a clean cut

Gutta-percha  
splints.



will be effected in the exact direction required. It is then to be placed flat in a tub of boiling water, and retained long enough to make it quite soft. The limb must be well oiled, and the gutta-percha being moulded to it should be retained in place for a few minutes by a bandage. When it is sufficiently hard it may be removed, and the inside covered with flannel stuck on with paste. The splint must then be well perforated with small holes made with a punch, and the edges paired and bevelled off. If the splint requires strengthening at any point, this may be accomplished by putting on strips of gutta-percha, softened in boiling water, to the parts requiring extra support.

Extension by  
weight.

The method of applying extension to the lower extremities by weight is as follows:—A strip of adhesive plaster, two inches wide, is cut long enough to reach from the knee down one side of the leg, and up the other side to the knee again, leaving a loop about six inches long below the sole of the foot. This being applied, it is further fixed by strips of plaster, one inch wide, encircling the limb from just above the ankle to the tubercle of the tibia, the whole being kept in place by a bandage firmly applied from the toes upwards. To the loop is attached a cord, with a weight at the other end, the cord passing over a pulley at the foot of the bed. A piece of stick should be placed transversely across



the loop, to take off all pressure from the ankles, and the bed should be raised at the foot, to prevent the patient being pulled down by the weight. The amount of weight must vary with the age of the patient, it being estimated that a pound should be allowed for every year up to twenty.

The use of the aspirator has been alluded to in the previous pages. The following description of the aspirator, and its method of use, is published by Messrs. Weiss, whose aspirator is here figured (Fig. 76) :—

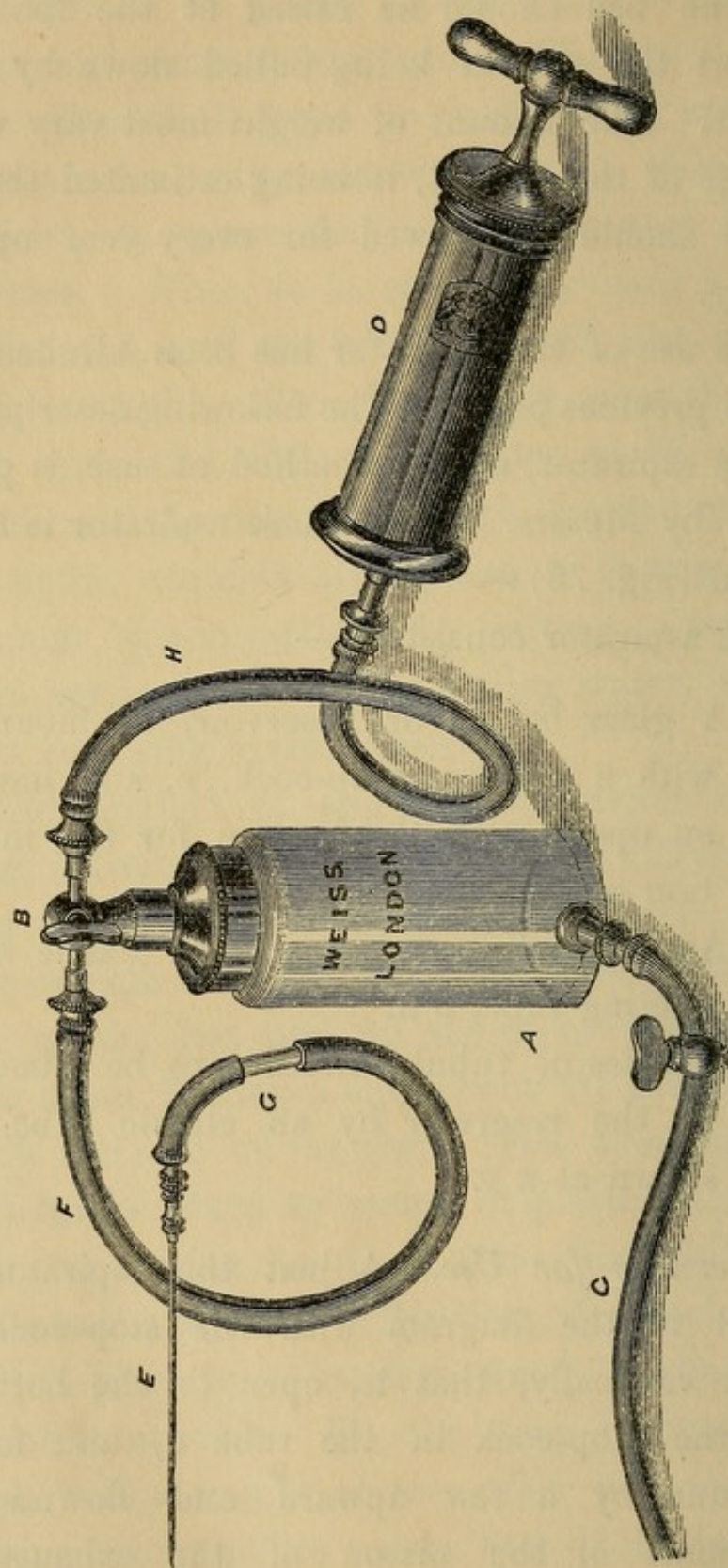
The aspirator consists of—

1. A glass bottle or reservoir, A, mounted with a two-way stop-cock, B, and having an opening at the bottom for the insertion of the tube c.
2. An exhausting syringe with elastic connecting tube, D H.
3. A series of tubular needles to be attached to the reservoir by an elastic tube, as shown at E F.

*Directions for Use.*—Adjust the aspirator as figured in the diagram with the stop-cock B turned vertically, that is, open to the bottle; close the stop-cock in the tube c, and form a vacuum by a few upward and downward movements of the piston of the exhausting syringe D.



FIG. 76.





Insert one of the needles beyond the two eyes, attach tube F to it, turn the stop-cock B towards the needle—namely, horizontally, and continue the insertion of the needle until fluid is seen to flow through the short glass tube G into the reservoir.

To empty the latter turn stop-cock B vertically, detach the syringe tube, and open the stop-cock in tube C.

The presence of fluid having been established by the use of one of the fine needles, it is recommended for more quickly emptying the cyst to use one of the larger needles or trocars.

The introduction of the needle into the tissues requires some precautions. In place of endeavouring to penetrate by pressure, as with an ordinary trocar, it is preferable to combine pressure with rotation, by taking the needle in the forefinger and thumb, and rolling it between them. Such a manœuvre is rendered necessary by the extreme fineness of the needle, which would be liable to bend or twist if driven in by direct pressure. Before using a needle it is well to be assured of its permeability.

In cases requiring transfusion of blood, the best method is that described by Dr. Aveling. His instrument, made by Messrs. Krohne and Sesemann, is here figured (Fig. 77), and the mode of operating is thus described:—

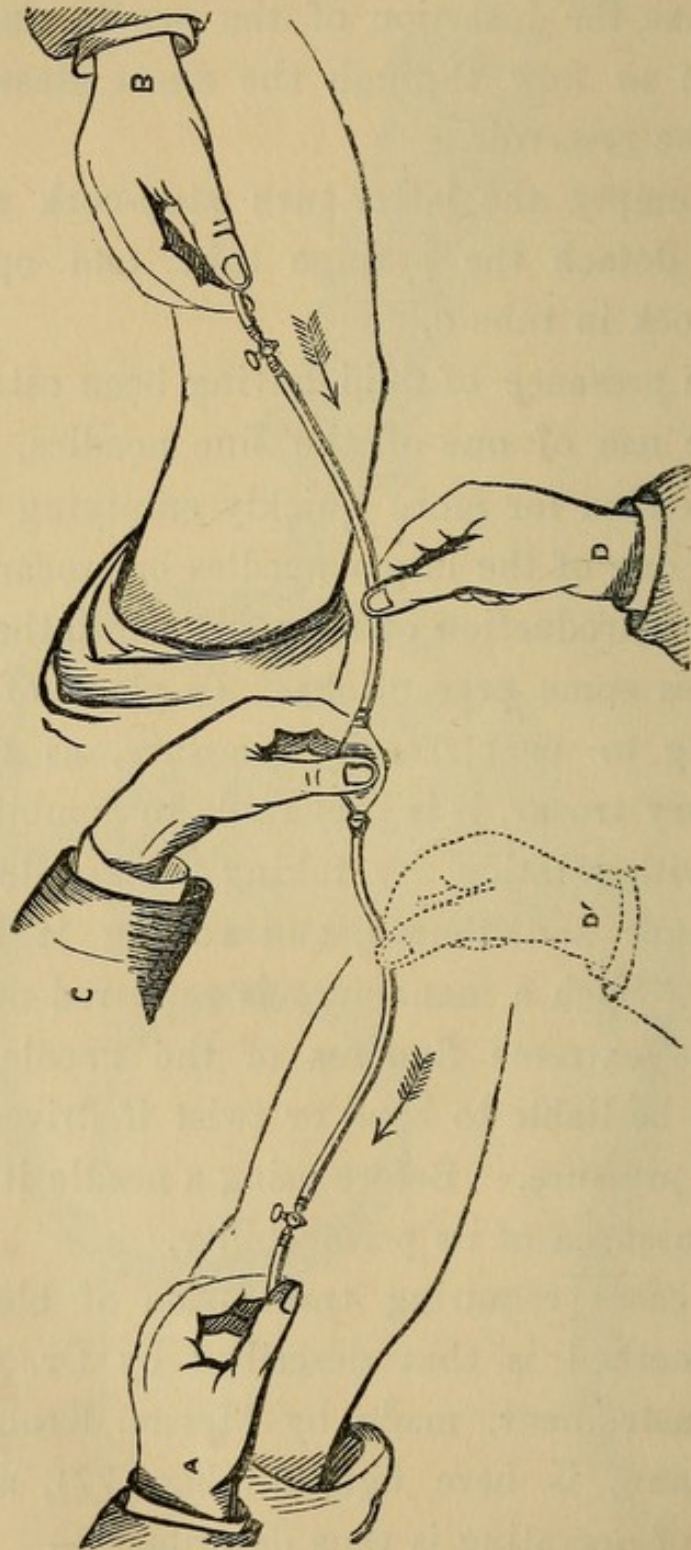
Transfusion.

First place the apparatus in a basin of tepid



water, and while completely under the water, to fill it and insure its cleanliness, compress the bulb until all the air is expelled.

FIG. 77.



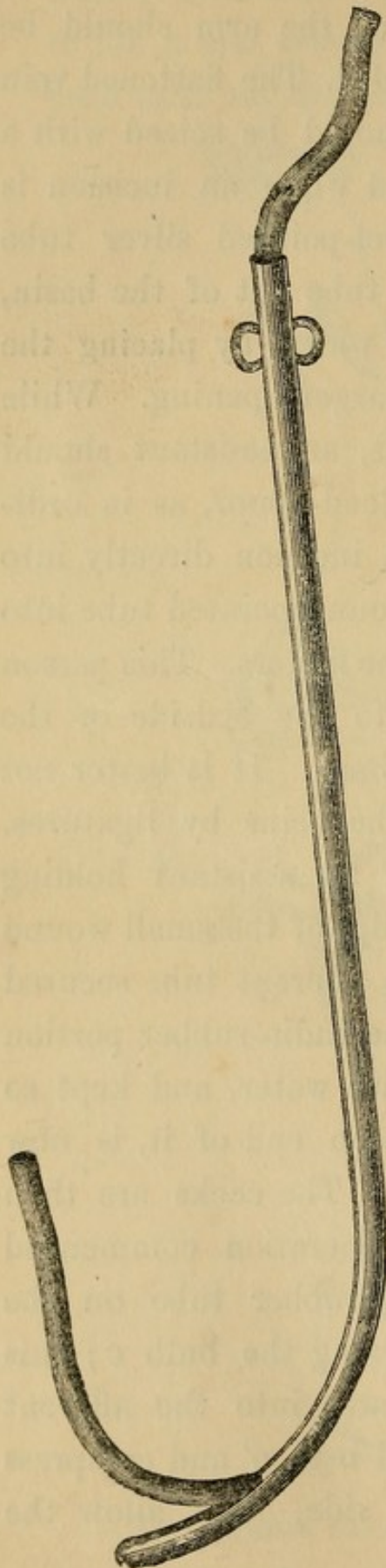
The patient having been brought to the side



of the bed, and the arm bared, a fold of skin over a vein at the bend of the arm should be raised, transfixed, and divided. The flattened vein now brought into view, should be seized with a pair of fine forceps, raised while an incision is made in it, and the bevel-pointed silver tube inserted. In taking this tube out of the basin, it should be kept full of water, by placing the tip of the thumb over its larger opening. While the operator is doing this, an assistant should prepare the arm of the blood-donor, as in ordinary bleeding, making an incision directly into the vein, and passing the round-pointed tube into it, with its point towards the fingers. This person should then be brought to the bedside of the patient, and seated in a chair. It is better not to secure the tubes in the veins by ligatures. B represents the hand of an assistant holding the efferent tube and the lips of the small wound together, and A shows the afferent tube secured in the same manner. The india-rubber portion of the apparatus, filled with water, and kept so by turning the cock at each end of it, is now fitted into the two tubes. The cocks are then turned straight, and the operation commenced by compressing the india-rubber tube on the efferent side D, and squeezing the bulb C; this forces two drachms of water into the afferent vein. Next shift the hand D to D' and compress the tube on the afferent side, then allow the



FIG. 78.



Hutchinson's  
india-rubber  
catheter.

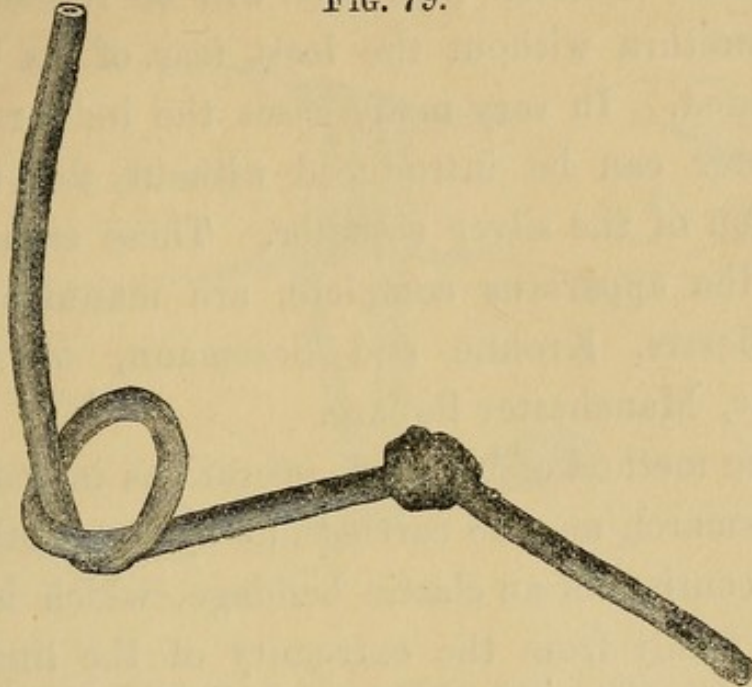
bulb to expand slowly, when blood will be drawn into it from the efferent vein. By repeating this process any quantity of blood can, at any rate, be transmitted, the amount being measured by counting the number of times the bulb is emptied.

Hutchinson's flexible catheter has been already referred to. Its method of use is here explained. Fig. 78 represents a silver prostatic catheter, with this peculiarity—that instead of having two eyes, one on either side, there is only one, placed in front. This catheter having been passed into the bladder, a flexible india-rubber catheter or tube, represented in Fig. 79 (it is represented as tied in knots in order to show its perfect flexibility), is passed through the silver



catheter, its point emerging through the eye. Then as the silver catheter is withdrawn, the

FIG. 79.



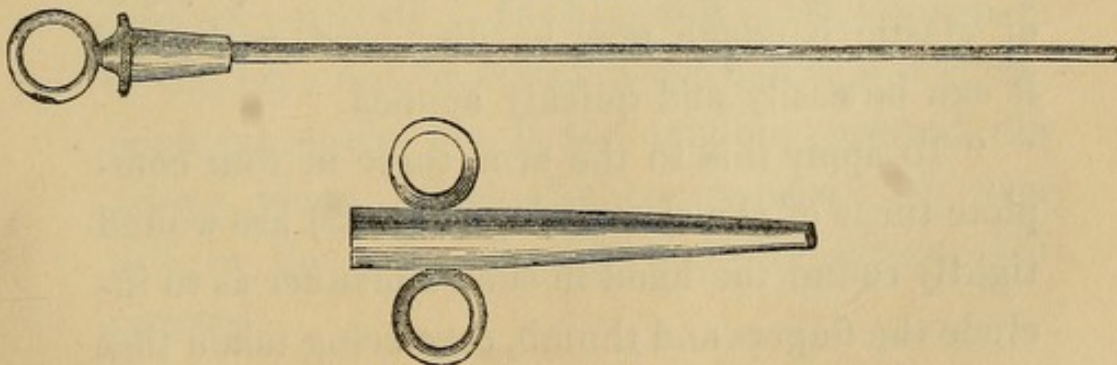
india-rubber one is pushed down the tube with the rod (Fig. 80), and thus it is prevented from

FIG. 80.



being withdrawn with the silver catheter. In order to retain the india-rubber catheter in the bladder, the metal nozzle with two rings (Fig. 81) is introduced, and fastened to the penis

FIG. 81.





by tapes and plaster. The stiletted plug (Fig. 81) is then placed in the nozzle. It is found that a flexible catheter thus fixed will be retained in the urethra without the least fear of its being extruded. In very many cases the india-rubber catheter can be introduced without the intervention of the silver catheter. These catheters, and the apparatus complete, are manufactured by Messrs. Krohne and Sesemann, of Duke Street, Manchester Square.

Esmarch's  
bloodless  
operation.

The method of bloodless operations introduced by Esmarch may be carried out by two methods. One consists of an elastic bandage, which is applied firmly from the extremity of the limb to be operated on to a point above the site of the operation. A thick india-rubber cord is then wound very tightly round the limb just above the edge of the elastic bandage, which is then removed. The limb below the india-rubber cord will then be found perfectly blanched and empty of blood. A second method is described by Mr. Cripps in the *Lancet* of October 11th, 1873:—

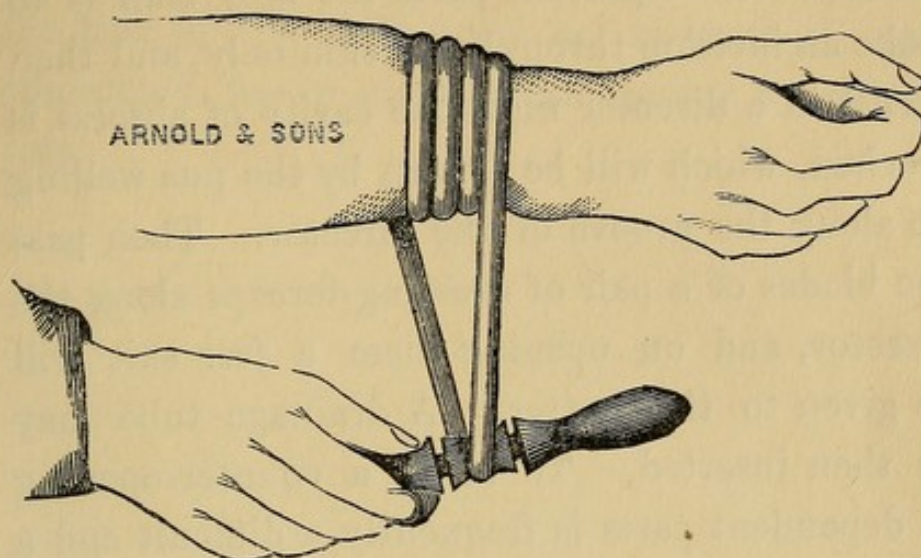
“The following is a simple modification of Esmarch's arrangement, by which many yards of elastic bandage may be dispensed with, and it can be easily and quickly applied.

“To apply this to the arm, three or four complete turns of the elastic ring (Fig. 82) are wound tightly round the hand in such a manner as to include the fingers and thumb, care being taken that



the turns lie even and do not cross one another. The reel is then put up under the free portion of

FIG. 82.



the ring connecting the upper and lower coil. The reel is passed round and round the limb in an upward direction: thus each coil is unwound from below as another is added above. In this way four tight coils of india-rubber are carried up the limb to any distance required. The degree of tightness can be regulated with the greatest nicety by the distance the reel is drawn from the limb by the bandager.

“This method of driving blood from the limb answers perfectly in the arm and in the lower part of the leg; but in carrying the bandage over the popliteal space the flexor tendons prevent the artery being effectually compressed. A firm pad in the space would probably answer the purpose.



“ It may be unrolled by reversing the action of the wheel to remove the bandage.”

Opening  
deep-seated  
abscesses.

In opening a deep-seated abscess in the neighbourhood of important parts the best plan is to make an incision through the skin only, and then thrust in a director until the cavity of abscess is reached, which will be known by the pus welling up along the groove of the director. Then pass the blades of a pair of dressing-forceps along the director, and on opening them a free exit will be given to the matter. A drainage tube may be then inserted. To make a counter-opening in dependent parts is frequently a difficult and a dangerous proceeding. I have found great help from the use of a rectum trocar and canula. Pass the canula, with the trocar withdrawn within it, down to the point where the counter-opening is desired; make it project underneath the skin, and then rapidly push the trocar through; withdraw the trocar, and pass a drainage tube through the canula, or, if desirable, enlarge the counter-opening by passing a blunt-pointed bistoury down by the side of the projecting end of the canula. (To open an abscess by the antiseptic method, *see* p. 186.)

Counter-  
opening.

Dressing for  
burns and  
scalds.

By far the best local application for burns is collodion, the flexile of the Pharmacopœia. This should be painted on smoothly with a large brush. It will frequently prevent vesication, if it has not already taken place. If there are



vesications the serum should be let out through small openings, and the surface painted over with the collodion. In extensive burns, which are generally accompanied by considerable shock, the heat of the body must be maintained, and stimulants freely given, with opiates to relieve pain.



...the ... of the ...  
...the ... of the ...  
...the ... of the ...  
...the ... of the ...  
...the ... of the ...

...the ... of the ...

...the ... of the ...

...the ... of the ...

...the ... of the ...

...the ... of the ...

...the ... of the ...

...the ... of the ...

...the ... of the ...

...the ... of the ...

...the ... of the ...

...the ... of the ...

...the ... of the ...

...the ... of the ...

...the ... of the ...



## I N D E X.

---

- A**BDOMEN, injuries to, 80  
Abscesses, opening, under carbolic acid, 186  
    "    "    deep-seated, 206  
Accidental hæmorrhage in parturition, 154  
Acetabulum, fracture of, 96  
Acids, injury of the eye by, 22  
    "    "    larynx by, 29  
Aconitum Napellus, poisoning by, 176  
Aitkins' Crimean arm splints, 56  
Alcohol, poisoning by, 174  
Amputation of arm, 63  
    "    "    at elbow-joint, 75  
    "    fingers, 77  
    "    fore-arm, 76  
    "    foot, 152  
    "    at knee-joint, 138  
    "    of leg, 151  
    "    at shoulder-joint, 63  
    "    at the hip-joint, 137  
    "    of thigh in upper and lower third, 138  
    "    of thumb, 76  
    "    of toes, 153  
Anterior chamber, effusion of blood into, 20  
Anterior tibial artery, ligature of, 119  
Antiseptic atmosphere, 182  
    "    gauze, 181  
    "    "    bandage, 182  
    "    treatment, 180  
Antrum, fractures of, 11  
Ankle-joint, dislocation of, 147  
    "    sprains of, 114  
Arm and hand presentation, 162



Arnold's splint, 144  
 Arsenic, poisoning by, 169  
 Artificial respiration, 37  
 Aspirator, description of, 197  
 „ use of, in hernia, 87  
 „ „ retention of urine, 103  
 Atropa belladonna, poisoning by, 177

**B**ANDAGE for fracture of lower jaw, 12  
 Bladder, foreign bodies in the female, 99  
 „ injury to, 97  
 „ puncture of, by rectum, 100  
 „ rupture of, 165  
 Blue vitriol, poisoning by, 171  
 Breech presentation, 161  
 Boracic acid in dressings, 183  
 Burns, 206

**C**ÆSAREAN section, 158  
 Carbolic acid, 181  
 „ dressing, 189  
 Carbolized silk sutures, 186  
 Carpal bones, dislocation of, 73  
 „ fracture of, 70  
 Canula for tracheotomy, 32  
 Catgut ligature, 185  
 Catheter, india-rubber, 203  
 „ probe-pointed, 101  
 „ prostatic, 203  
 Cantharides, poisoning by, 171  
 Chloride of zinc dressing, 183  
 „ „ poisoning by, 171  
 Chloroform, death from, 174  
 Choroid, injuries to, 22  
 Clavicle, dislocation of, 50  
 „ fracture of, 49  
 Clove-hitch, 74  
 Coins in the throat, 28  
 Colles' fracture of radius, 67  
 Common carotid, ligature of, 35  
 Compound fractures, treatment by carbolic acid, 189  
 „ „ of the leg, 144



- Conjunctiva, effusion of blood under, 16  
     ,, lacerations of, 16  
 Cord, prolapse of, 164  
 Cornea, abrasions of, 18  
     ,, foreign bodies in, 16  
     ,,         ,, instrument for removal of, 17  
     ,, wounds of, 18  
 Coronoid process, fracture of, 64  
 Corrosive sublimate, poisoning by, 170  
 Counter openings, 206  
 Cock's operation for retention of urine, 104  
 Craniotomy 160  
     ,, forceps, 161  
 Cut-throat, 33  
 Cyanide of potassium, poisoning by, 173
- D**ALBY'S carminative, poisoning by, 173  
 Decapitation of foetus, 161  
 Detachment of iris, 20  
 Dilating bags, 157  
 Dislocation of ankle-joint, 147  
     ,, clavicle, 50  
     ,, femur on to the pubes, 132  
     ,,         ,, on dorsum ilii, 126  
     ,,         ,, into foramen ovale, 131  
     ,,         ,, sciatic notch, 128  
     ,,         ,, reduction of, by extension, 133, 134  
     ,,         ,,         ,, manipulation, 130, 132  
     ,, humerus, sub-coracoid, 59  
     ,,         ,, sub-glenoid, 58  
     ,,         ,, sub-spinous, 60  
     ,,         ,, reduction of, by extension, 61  
     ,,         ,,         ,, manipulation, 60  
     ,, lens, 21  
     ,, lower jaw, 13  
     ,, metatarsal bones, 151  
     ,, patella, 140  
     ,, radius, 70  
     ,,         ,, and ulna, 71  
     ,, scapula, 51  
     ,, semilunar cartilages, 147  
     ,, spine, 15  
     ,, tarsal bones, 150



Dislocation of thumb, 74  
 „ tibia, 146  
 Drainage tube, 185  
 Drowning, 36  
 Dupuytren's splint, 142

**E**ARS, foreign bodies in, 6  
 „ forceps for, 8  
 Elbow-joint, amputation at, 75  
 „ compound injuries to, 74  
 „ excision of, 75  
 „ injuries to, 63  
 Elevator, 4  
 Embryulcia, 161  
 Emphysema, 43  
 Epistaxis, 9  
 Esmarch's bloodless operations, 204  
 Essential oil of bitter almonds, poisoning by, 173  
 Extension by weight, 196  
 Extirpation of eyeball, 24  
 Eye, extirpation of, 24  
 „ bandage, 19  
 „ foreign bodies within, 23  
 „ „ under lid, 18  
 „ injuries to, from chemicals, 22  
 „ „ gunpowder, 23  
 „ needles for operations on the, 17  
 „ speculum, 17  
 „ lids, wounds of, 6

**F**ACE, injuries to, 5  
 „ presentation, 161  
 Female bladder, foreign bodies in, 99  
 Femoral hernia, 92  
 Femoral artery, application of tourniquet to, 115  
 „ digital pressure on, 115  
 „ ligature of, 116  
 „ wounds of, 115  
 Femur, compound injuries of, 134  
 Fingers, amputation of, 77  
 Fish bones in the throat, 26  
 Flooding, 157



- Foot, amputations of, 152  
 Forceps for the ear, 8  
 Foreign bodies in œsophagus, 27  
   "      cornea, 16  
   "      ear, 23  
   "      under eyelid, 18  
   "      in the larynx, 28  
   "      "      nose, 6  
   "      "      pharynx, 26  
   "      "      rectum, 110  
   "      "      trachea, 28  
   "      "      urethra, 98  
 Fracture of antrum, 10  
   "      base of skull, 4  
   "      carpal and metacarpal bones, 70  
   "      clavicle, 47  
   "      coronoid process of ulna, 64  
   "      at elbow-joint, 57  
   "      the femur, neck of  
   "          "      table of diagnosis in, 120  
   "          "      shaft of, 123  
   "          "      "      in children, 125  
   "      fibula, 141  
   "      humerus, neck of, 52  
   "          "      shaft of, 56  
   "          "      lower extremity of, 57  
   "      into the knee-joint, 125  
   "      lower jaw, 11  
   "      metatarsal bones and phalanges, 151  
   "      nasal bones, 10  
   "      olecranon, 64  
   "      patella, 139  
   "      pelvis, 95  
   "      radius, neck of, 65  
   "          "      shaft of, 66  
   "          "      and ulna, 69  
   "      ribs, 40  
   "      sacrum, 97  
   "      scapula, 51  
   "      skull, 1  
   "      spine, 14  
   "      tarsal bones, 149  
   "      tibia, 141



- Fracture of tibia and fibula, 143  
 „ ulna, shaft of, 65  
 „ upper jaw, 10  
 „ zygoma, 11

- G**ASTROCNEMIUS, rupture of, 113  
 Gauze bandage, 182  
 Glaucoma, traumatic, 20  
 Godfrey's cordial, poisoning by, 172  
 Gordon's apparatus for fractured clavicle, 48  
 „ splint for Colles' fracture, 67  
 Gunpowder, injuries of the eye from, 23  
 Gunshot wound of chest, 45  
 Gutta-percha splints, 195

**H**ÆMOTHORAX, 44

- Hamilton's tables of injuries to the shoulder, 54  
 Hands and feet presentation, 163  
 „ head „ 163  
 Hanging, 38  
 Hartshorn and oil, poisoning by, 169  
 Hemlock, poisoning by, 175  
 Hernia, the aspirator in, 47  
 „ femoral, 92  
 „ inflamed, 85  
 „ inguinal, 90  
 „ obstructed, 84  
 „ obturator, 93  
 „ operation for, 88  
 „ strangulated, 85  
 „ the taxis in, 86  
 „ umbilical, 90  
 „ of lung, 42  
 Hey's saw, 4  
 Hip-joint, contusion of, 112  
 „ amputation at, 137  
 Horsehair probang, 27  
 Humerus, dislocation of, 58, 61  
 „ fracture of, 52, 57

- I**NDUCTION of premature labour, 157  
 Inguinal hernia, 90



- Injuries to cerebral nerves, 5  
 Instrument for plugging nose, 9  
 „ removing foreign bodies from cornea, 17  
 Intestines, constriction of, 82  
 „ foreign bodies in, 84  
 „ gangrene of, 83  
 „ protrusion of, 82  
 „ wounds of, 83  
 Iris, injury to, 19  
 „ detachment of, 20  
 „ prolapse of, 20  
 Iron in cornea, 16

- K**NEE-JOINT, amputation at, 138  
 „ compound injuries to, 135  
 „ excision of, 136  
 „ fractures into, 125  
 „ wounds of, 115

**L**ARYNGO-TRACHEOTOMY, 31

- Laryngotomy, 29  
 Larynx, foreign bodies in, 28  
 „ injury by acids, 29  
 „ scalds of, 29  
 Leg, amputation of the, 151  
 Lens, dislocation of, 21  
 „ injury to, 20  
 Liebreich's eye bandage, 19  
 Ligamentum patellæ, rupture of, 113  
 Lime, injury of the eye by, 22  
 Lips, wounds of, 6  
 Lower jaw, dislocations of, 13  
 „ fractures of, 11  
 Lung, hernia of, 42  
 „ wound of, 42

- M**ACINTYRE'S splint, 126  
 McNalty's splint for fracture of leg, 145  
 Malar bone, fracture of, 10  
 Mal-presentations, 161  
 Metacarpal bones, fracture of, 70



Money probang, 28  
 Muscles, rupture of abdominal, 80  
 „ „ of lower extremity, 112  
 Mussels, poisoning by, 172

**N**ASAL bones, fracture of, 10  
 Needle-holder, 6  
 „ in the hand, 47  
 Nitric acid, poisoning by, 168  
 Nose, bleeding from, 9  
 „ foreign bodies in, 6  
 „ plugging the, 9

**O**BTURATOR hernia, 93  
 Œsophagus, foreign bodies in, 27  
 Olecranon, fracture of, 64  
 Omentum, protrusion of, 83  
 Opium, poisoning by, 172  
 Orbit, injuries to, 25  
 Orpiment, poisoning by, 170  
 Oxalic acid, poisoning by, 168

**P**ALMAR arch, wounds of, 46  
 Paracentesis thoracis, 44  
 Paregoric elixir, poisoning by, 173  
 Paraphimosis, 108  
 Parturition, accidental hæmorrhage in, 154  
 „ emergencies of, 154  
 Pasteboard splints, 194  
 Patella, dislocation of, 140  
 „ fracture of, 139  
 Pelvis, fracture of bones of the, 95  
 Penis, injuries to, 107  
 Perforator, 160  
 Perineal catheter, 105  
 Perineum, rupture of, 166  
 Peritoneum, rupture of the, 80  
 Pharynx, foreign bodies in, 26  
 Phosphorus, poisoning by, 169  
 Phimosis, 108  
 Pins in the throat, 26  
 Placenta prævia, 155



- Placenta, retained, 156  
 Plantaris, rupture of, 113  
 Plaster of Paris bandage, 195  
 Plugging posterior nares, 9  
 Pneumothorax, 43  
 Poisoning by alcohol, 174  
   " arsenic, 169  
   " blue vitriol, 171  
   " cantharides, 170  
   " chloroform, 174  
   " chloride of zinc, 171  
   " corrosive sublimate, 170  
   " cyanide of potassium, 173  
   " Dalby's carminative, 173  
   " Deadly Nightshade, 177  
   " essential oil of bitter almonds, 173  
   " Godfrey's cordial, 172  
   " hartshorn and oil, 169  
   " hemlock, 175  
   " monkshood, 176  
   " mussels, 172  
   " nitric acid, 168  
   " opium, 172  
   " orpiment, 170  
   " oxalic acid, 168  
   " paregoric elixir, 173  
   " phosphorus, 169  
   " prussic acid, 173  
   " salt of sorrel, 169  
   " Scheele's green, 170  
   " strychnia, 175  
   " sugar of lead, 170  
   " sulphuric acid, 168  
   " tartar emetic, 171  
   " tobacco, 175  
 Posterior tibial artery, ligature of, 113  
 Premature labour, induction of, 157  
 Prolapse of cord, 164  
   " iris, 20  
 Prostate, enlarged, 106  
 Protective oil-silk, 184  
 Prussic acid, poisoning by, 173  
 Puerperal convulsions, 164



Puncture of bladder by rectum, 102  
 Punctured wounds of scalp, 1

**R**ADIUS, dislocation of, 70  
 „ fracture of the neck of, 65  
 „ „ „ shaft of, 66  
 Rectum, foreign bodies in, 110  
 „ hæmorrhage from, 110  
 Retained placenta, 156  
 Retention of urine, 100  
 „ „ probe-pointed catheter for, 101  
 „ „ from enlarged prostate, 106  
 Ribs, fracture of, 40

**S**ACRUM, fracture of, 97  
 Salt of sorrel, poisoning by, 169  
 Saw for resection of shoulder-joint, 62  
 Scalds, 206  
 Scapula, dislocations of, 51  
 „ fractures of, 51  
 Scheele's green, poisoning by, 170  
 Scissors for extirpation of eyeball, 24  
 Sclerotic, wounds of, 18  
 Scrotum, injuries of, 109  
 Semilunar cartilages, dislocation of, 147  
 Shoulder-joint, amputation at, 63  
 „ „ compound injuries to, 61  
 „ „ injuries to, 52  
 „ „ resection of, 62  
 „ presentation, 162  
 Speculum for eye, 17  
 Spine, injury to, 14  
 Splint for fractures of the neck of humerus, 53  
 Sprains of ankle-joint, 114  
 Steam spray apparatus, 182  
 Stomach-pump, use of, 178  
 Strapping in fractured ribs, 41  
 Strychnia, poisoning by, 174  
 Sugar of lead, poisoning by, 170  
 Sulphuric acid, poisoning by, 168



Sylvester's method of artificial respiration, 37  
 Syphon tube, 7

**T**ARSAL bones, dislocation of, 150  
 „ „ fracture of, 149  
 Tartar emetic, poisoning by, 171  
 Tendo-Achillis, rupture of, 114  
 Testicle, injuries to, 109  
 Thigh, amputation of, 137  
 Throat, stabs in, 35  
 Thumb, amputation of, 76  
 „ dislocation of, 74  
 Tibia, fracture of, 141  
 Tobacco, poisoning by, 175  
 Toes, amputation of, 173  
 Tongue, wounds of, 26  
 Trachea, foreign bodies in, 28  
 Tracheotomy, 31  
 Transfusion, 199  
 Trephining the skull, 2  
 Turning, 163

**U**LNA, dislocation of, 71  
 „ fracture of the shaft of, 65  
 Umbilical hernia, 90  
 Upper jaw, fracture of, 10  
 Urethra, forceps for, 98  
 „ foreign bodies in, 98  
 „ wounds of, 99  
 Urine, extravasation of, 107  
 „ retention of, 100  
 Uterus, injuries to pregnant, 110  
 „ inversion of, 166  
 „ rupture of, 165

**V**AGINA, injuries to, 110  
 „ plugging the, 155  
 Vas deferens, rupture of, 109  
 Viscera, injury to abdominal, 81  
 „ protrusion of, 82



- W**OUNDS of abdominal parietes, 81  
,, chest, 41  
,, cornea, 18  
,, eyelids, 6  
,, face, 5  
,, heart, 44  
,, intercostal arteries, 41  
,, intestines, 83  
,, lips, 6  
,, lungs, 42  
,, palmar arch, 46  
,, scalp, 1  
,, sclerotic, 18  
,, tongue, 26  
,, urethra, 99  
,, near wrist-joint, 46  
Wrist-joint, compound injury to, 76

**Z**YGOMA, fracture of, 11

THE END.



## ILLUSTRATED GIFT BOOKS.

---

**MEDICAL ANATOMY.** By FRANCIS SIBSON, M.D., F.R.C.P., F.R.S. Imperial Folio. 21 Coloured Plates. Cloth, £2 2s.; half-morocco, £2 10s.

**SURGICAL ANATOMY.** A series of Dissections, illustrating the Principal Regions of the Human Body. By JOSEPH MACLISE, F.R.C.S. *Second Edition.* Folio. 52 Plates, Cloth, £3 12s.; half-morocco, £4 4s.

**ON DISLOCATIONS AND FRACTURES.** By JOSEPH MACLISE, F.R.C.S. This Work is uniform with "Surgical Anatomy." Folio. 36 Plates. Cloth, £2 10s.; half-morocco, £2 17s.

**MEDICINAL PLANTS.** By ROBERT BENTLEY, F.L.S., and HENRY TRIMEN, M.B., F.L.S. This work will include full Botanical descriptions and an account of the properties and uses of the principal plants employed in Medicine. Each Species will be illustrated by a Coloured Plate drawn from nature. The work will be published in monthly parts and, when completed, will form a very handsome addition to the Library of every Medical man.

**PORTRAITS OF DISEASES OF THE SKIN.** By ERASMUS WILSON, F.R.C.S., F.R.S. Folio. 48 Coloured Plates, life size. Half-morocco, £13.

**THE THANATOPHIDIA OF INDIA;** being a Description of the Venomous Snakes of the Indian Peninsula; with an Account of the Influence of their Poison on Life, and a Series of Experiments. By J. FAYRER, M.D., F.R.C.S., C.S.I. *Second Edition.* Folio. 31 Plates (28 Coloured). £7 7s.

---

J. & A. CHURCHILL, NEW BURLINGTON STREET.



## STUDENTS' BOOKS.

---

- A MEDICAL VOCABULARY**; or an Explanation of all Names, Synonymes, Terms, and Phrases used in Medicine. By R. G. MAYNE, M.D., LL.D. *Third Edition.* Fcap. 8vo, 8s. 6d.
- PRINCIPLES OF HUMAN PHYSIOLOGY.** By W. B. CARPENTER, M.D., F.R.S. With nearly 300 Illustrations on Steel and Wood. *Seventh Edition.* Edited by Mr. HENRY POWER. 8vo, 28s.
- THE SURGEON'S VADE-MECUM.** By ROBERT DRUITT. With numerous Engravings. *Tenth Edition.* Fcap. 8vo, 12s. 6d.
- INTRODUCTION TO INORGANIC CHEMISTRY.** By WM. G. VALENTIN, F.C.S. With 82 Engravings. 8vo, 6s. 6d.
- NOTES ON COMPARATIVE ANATOMY**: A Syllabus of a Course of Lectures. By WM. MILLER ORD, M.B. Crown 8vo, 5s.
- PRACTICAL CHEMISTRY**, including Analysis. By JOHN E. BOWMAN and C. L. BLOXAM. With numerous Illustrations on Wood. *Sixth Edition.* Fcap. 8vo, 6s. 6d.
- LECTURES ON THE DISEASES OF WOMEN.** By CHARLES WEST, M.D., F.R.C.P. *Third Edition.* 8vo, 16s.
- A TOXICOLOGICAL CHART**, exhibiting at one view the Symptoms, Treatment, and mode of Detecting the various Poisons. By WM. STOWE. *Thirteenth Edition.* On Sheet, 2s.; mounted on Roller, 5s.
- A PRACTICAL MANUAL OF THE DISEASES OF CHILDREN.** By EDWARD ELLIS, M.D. *Second Edition.* Crown 8vo, 7s.
- THE COMPARATIVE ANATOMY OF THE DOMESTICATED ANIMALS.** By A. CHAUVEAU and G. FLEMING. With 450 Engravings. 8vo, 31s. 6d.
- DISEASES AND INJURIES OF THE EAR.** By W. B. DALBY, F.R.C.S. With Engravings. Fcap. 8vo, 6s. 6d.
- PRINCIPLES AND PRACTICE OF SURGERY.** By WILLIAM PIRRIE, M.D., F.R.S.E. With 490 Engravings. *Third Edition.* 8vo, 28s.
- NOTES ON NATURAL PHILOSOPHY.** By G. F. RODWELL, F.R.A.S. With 48 Engravings. Fcap. 8vo, 5s.
- HANDBOOK FOR THE PHYSIOLOGICAL LABORATORY.** By J. B. SANDERSON, M.D., F.R.S., E. KLEIN, M.D., M. FOSTER, M.D., F.R.S., and T. L. BRUNTON, M.D., D.Sc. Two vols., with 123 Plates. 8vo, 24s.
- A MANUAL OF MIDWIFERY.** By Dr. KARL SCHROEDER. Translated by CHARLES H. CARTER, M.D. With Engravings. 8vo, 12s. 6d.



## STUDENTS' BOOKS.

---

**A SYSTEM OF PRACTICAL SURGERY.** By Sir WILLIAM FERGUSSON, Bart., F.R.S. With 463 Engravings. *Fifth Edition.* 8vo, 21s.

**OUTLINES OF SURGERY AND SURGICAL PATHOLOGY.** By F. LE GROS CLARK, F.R.C.S., and W. W. WAGSTAFFE, F.R.C.S. *Second Edition.* 8vo, 10s. 6d.

**DIAGRAMS OF THE NERVES OF THE HUMAN BODY.** Six Plates, with Explanatory Text. By W. H. FLOWER, F.R.S. *Second Edition.* Royal 4to, 12s.

**A MANUAL OF THE ANATOMY OF VERTEBRATED ANIMALS.** By Professor HUXLEY, LL.D., F.R.S. With 110 Engravings. Fcap. 8vo, 12s.

**INTRODUCTION TO THE CLASSIFICATION OF ANIMALS.** By Professor HUXLEY, F.R.S. With 47 Engravings. 8vo, 6s.

**A MANUAL OF MINOR SURGERY AND BANDAGING.** By CHRISTOPHER HEATH, F.R.C.S. With Engravings. *Fourth Edition.* Fcap. 8vo, 5s. 6d.

**NOTES FOR STUDENTS IN CHEMISTRY: A Syllabus.** By ALBERT J. BERNAYS. *Fifth Edition.* Fcap. 8vo, 3s. 6d.

**TABLES OF ZOOLOGY FOR STUDENTS, LECTURERS, AND OTHERS.** By J. REAY GREENE, M.D. Three large sheets, 7s. 6d.; mounted with roller, 18s.

**THE PRINCIPLES AND PRACTICE OF OBSTETRIC MEDICINE AND SURGERY.** By F. H. RAMSBOTHAM, M.D., F.R.C.P. With 94 Plates. *Fifth Edition.* 8vo, 22s.

**THE ANATOMICAL REMEMBRANCER; or, COMPLETE POCKET ANATOMIST.** *Seventh Edition.* 32mo, 3s. 6d.

**A MANUAL OF MEDICAL DIAGNOSIS: being an Analysis of the Signs and Symptoms of Disease.** By A. W. BARCLAY, M.D., F.R.C.P. *Third Edition.* Fcap. 8vo, 10s. 6d.

**THE STUDENT'S GUIDE TO MEDICAL DIAGNOSIS.** By SAMUEL FENWICK, M.D., F.R.C.P. With 87 Engravings. *Third Edition.* Fcap. 8vo, 6s. 6d.

**THE STUDENT'S GUIDE TO SURGICAL ANATOMY.** By E. BELLAMY, F.R.C.S. With 50 Engravings. Fcap. 8vo, 6s. 6d.

**THE STUDENT'S GUIDE TO MATERIA MEDICA.** By J. C. THOROWGOOD, M.D. With Engravings. Fcap. 8vo, 6s. 6d.

**THE STUDENT'S GUIDE TO ZOOLOGY.** A Manual of the Principles of Zoological Science. By ANDREW WILSON. With Engravings. Fcap. 8vo, 6s. 6d.

---

J. & A. CHURCHILL, NEW BURLINGTON STREET.



## CHURCHILL'S SERIES OF MANUALS.

---

- ANATOMY.** With 371 Engravings. By ERASMUS WILSON, F.R.S., and G. BUCHANAN, M.D. *Ninth Edition.* 14s.
- BOTANY.** With 1138 Engravings. By ROBERT BENTLEY, F.L.S. *Third Edition.* 14s.
- CHEMISTRY.** With 164 Engravings. By GEORGE FOWNES, F.R.S. Edited by HENRY WATTS, B.A., F.R.S. *Eleventh Edition.* 15s.
- DENTAL SURGERY.** With 263 Engravings. By JOHN TOMES, F.R.S., and C. S. TOMES. *Second Edition.* 14s.
- EYE, DISEASES OF.** With 7 Coloured Plates and 53 Wood Engravings. By C. MACNAMARA. *Second Edition,* 12s. 6d.
- MATERIA MEDICA.** With 110 Engravings. By J. FORBES ROYLE, M.D., F.R.S., and FREDERICK W. HEADLAND, M.D., F.R.C.P. *Fifth Edition.* 12s. 6d.
- MEDICAL JURISPRUDENCE.** With 55 Engravings. By ALFRED SWAINE TAYLOR, M.D., F.R.S. *Ninth Edition.* 14s.
- MEDICINE, PRACTICE OF.** By G. HILARO BARLOW, M.D. *Second Edition.* 12s. 6d.
- MICROSCOPE AND ITS REVELATIONS.** With 500 Engravings. By W. B. CARPENTER, M.D., F.R.S. *Fifth Edition.*
- NATURAL PHILOSOPHY.** With 700 Engravings. By CHARLES BROOKE, M.A., F.R.S. Based on the work of the late Dr. Golding Bird. *Sixth Edition.* 12s. 6d.
- OPHTHALMIC MEDICINE AND SURGERY.** With Coloured Plates and 173 Wood Engravings. By T. WHARTON JONES, F.R.S. *Third Edition.* 12s. 6d.
- PATHOLOGICAL ANATOMY.** With 167 Engravings. By Dr. HANDFIELD JONES and Dr. SIEVEKING. 12s. 6d.
- PHYSIOLOGY.** With 250 Engravings. By WILLIAM B. CARPENTER, M.D., F.R.S. *Fourth Edition.* 12s. 6d.
- POISONS.** By ALFRED SWAINE TAYLOR, M.D., F.R.S. *Third Edition.*
- PRACTICAL ANATOMY.** With 226 Engravings. By CHRISTOPHER HEATH, F.R.C.S. *Third Edition.* 12s. 6d.
- SURGERY, PRACTICE OF.** With 507 Engravings. By THOMAS BRYANT, F.R.C.S. 21s.
- THERAPEUTICS.** By E. J. WARING, M.D., F.R.C.P. *Third Edition.* 12s. 6d.



