M. Wyman
April 26 1848

M. Wynnan

A

TREATISE ON FRACTURES

IN

THE VICINITY OF JOINTS,

AND

ON CERTAIN FORMS

OF

ACCIDENTAL AND CONGENITAL

DISLOCATIONS.

BY

ROBERT WILLIAM SMITH, M.D., M.R.I.A.,

FELLOW OF THE ROYAL COLLEGE OF SURGEONS IN IRELAND;
LECTURER ON SURGERY AT THE RICHMOND HOSPITAL SCHOOL OF MEDICINE; SURGEON TO THE TALBOT DISPENSARY, AND TO THE LUNATIC ASYLUM, ISLAND-BRIDGE;
SECRETARY TO THE PATHOLOGICAL SOCIETY OF DUBLIN; FELLOW OF THE ROYAL MEDICO-CHIRURGICAL SOCIETY OF LONDON.

DUBLIN:
HODGES AND SMITH, GRAFTON-STREET.
1847.

DUBLIN:
PRINTED AT THE UNIVERSITY PRESS,
BY M. H. GILL.

PREFACE.

"On ne saurrait assez insister sur le diagnostic des fractures et des luxations, car on rencontre à chaque instant dans les hôpitaux beaucoup des cas qui ont échappé à la sagacité et à l'observation des grands maîtres. C'est ainsi que les affections de l'articulation coxo-fémorale, les luxations scapulo-humérales, les fractures de l'extrémité inférieur du radius, et en general toutes les solutions de continuité au voisinage des articles, sont les sources de nombreuses erreurs."

DUPUYTREN, *Leçons Orales*, t. iii. p. 393.

THE object which I have had in view in submitting the following pages to the consideration of the Profession, has not been to present a systematic treatise upon the extensive subject of fractures and dislocations (which the valuable work of Sir Astley Cooper renders unnecessary), but to direct attention to that most difficult portion of it—fractures in the vicinity of joints; and even here I have, for the present, limited myself to the consideration of those of which I had most experience, the differential diagnosis of which I found to be attended with the greatest difficulty, and whose anatomical characters I have had the most frequent opportunities of investigating.

The elaborate researches of Breschet, Dupuytren, Bouvier, Guerin, and others, have done much towards elucidating the subject of congenital luxations; it must still, however, be considered as being in its infancy, and,

therefore, any addition to our knowledge of it cannot be deemed unimportant, the more especially as congenital and accidental luxations are frequently confounded.

It has been my endeavour to make the style of the work as familiar and perspicuous as possible. Whatever deficiencies may exist in the descriptions of the various injuries alluded to, will, I trust, be found amply compensated for by the illustrations, for the accuracy of which I pledge myself. They have, with the exception of a few copied from other works, been drawn from nature under my own immediate inspection, by that distinguished artist, Mr. Connolly, whose name is a sufficient guarantee for their fidelity. They have been, with the exception of those contained in the fourth, seventh, and eighth chapters, engraved by Mr. George Hanlon, whose abilities are too well known to require any eulogium upon my part.

To the Publishers, Messrs. Hodges and Smith, my best thanks are due, for the readiness with which they acceded to all my wishes with regard to the work.

DUBLIN, 63, ECCLES-SREET,

April, 1847.

CONTENTS.

CHAPTER I.

PAGE.

On the Diagnosis and Pathology of Fractures of the Neck of the Femur, ... 1

CHAPTER II.

On Chronic Rheumatic Arthritis of the Hip-joint, ... 113

CHAPTER III.

On Fractures of the Bones of the Fore-arm, in the vicinity of the Wrist-joint, ... 129

CHAPTER IV.

On Fractures of the Humerus, in the vicinity of the Shoulder-joint, ... 176

CHAPTER V.

On Fractures of the Acromial Extremity of the Clavicle, . . . 209

CHAPTER VI.

On Dislocations of the Bones of the Foot, ... 224

CHAPTER VII.

PAGE.
On congenital Luxations of the Wrist-joint, ... 238

CHAPTER VIII.

On congenital Dislocations of the Shoulder, ... 256

CHAPTER IX.

On Dislocations of the Lower Jaw, ... 273

CHAPTER X.

Additional Observations on Fractures of the Radius, Dislocations of the Bones of the Foot, and congenital Luxation of the Wrist-joint, ... 294

ANALYTICAL INDEX.

CHAPTER I.

DIAGNOSIS AND PATHOLOGY OF FRACTURES OF THE NECK OF THE FEMUR.

PAGE.

General symptoms of fracture of the neck of the femur, ... 2
Appearances of limb, when the patient is supported in the erect position, . 4
Fracture without the previous occurrence of a fall upon the hip, ... 5
Diagnosis of the injury frequently very obscure, ... 5
Contradictory statements respecting the amount of shortening in fractures within and external to the capsule, ... 6
Cervical ligament of the femur—"retinacula" of Weitbrecht, ... 7
Circumstances which influence the amount of shortening of the limb, . . 8
Different periods after the accident at which shortening may occur, . . 11
Sudden occurrence of shortening, some time after the receipt of the injury, 12
Erroneously ascribed by Dupuytren to the yielding of the provisional callus, 13
Opinion of Rodet as to its value, as a diagnostic sign of the seat of fracture, 14
Opinion of Rodet as to amount of shortening, in each variety of fracture, 15
Extracapsular fractures accompanied by fracture of the trochanters, . . 16
Causes from which the second lesion of the bone results, ... 17
Rodet's diagnostic sign of the seat of fracture with respect to the capsule, 20
General position of the foot in each variety of fracture, ... 22
Opinions entertained respecting the cause of inversion of the foot, . . . 23
Mr. Guthrie's explanation inapplicable to cases of intracapsular fractures, 23
Dupuytren's opinion incorrectly stated by the editors of his lectures, . . 26
Symptoms of impacted fractures of the neck of the femur, ... 28
Difficulties which attend the diagnosis in these cases, ... 29
Impacted fracture and contusion of the hip frequently confounded, . . . 30
Contusion in cases of chronic rheumatic arthritis, mistaken for fracture, 31
Usual anatomical characters of intracapsular impacted fractures, . . . 33
Anatomical characters of extracapsular impacted fractures, ... 34
Rare variety of extracapsular impacted fracture, ... 35

PAGE.
Osseous deposits about the trochanters in extracapsular fractures, . . 36
Erroneous opinions generally entertained as to their use, ... 37
Object for the attainment of which they are formed, ... 40
Hæmorrhage in cases of extracapsular fractures sometimes fatal, . . . 41
Anatomical characters of fractures within the capsular ligament, . . . 41
Partial fracture of the neck of the femur external to the capsular ligament, 44
Mr. Adams's opinions as to the mode of occurrence of partial fracture, . 46
Objections to the doctrine of partial fracture of the neck of the femur, . . 48
Mr. Colles's cases of partial fracture within the capsular ligament, . . . 50
Question of osseous union in intracapsular fractures briefly considered, . 52
Prognosis in cases of fracture within and external to the capsule, . . . 64
Causes of death in cases of fracture of the neck of the femur, ... 65
Changes in the head and neck of the femur, consequent upon old age, . . 66
Illustrative cases, ... 69
General conclusions, ... 110

CHAPTER II.

CHRONIC RHEUMATIC ARTHRITIS OF THE HIP-JOINT.

Authors who have particularly noticed the disease, ... 114
Causes and symptoms of the affection, ... 114
Difficulty of flexing the hip-joint, ... 115
External characters of the disease, ... 115
Case by Mr. Adams, ... 116
Case of the late Doctor Percival, ... 119
Anatomical characters of the disease, ... 119
Condition of the synovial membrane and ligaments, ... 120
Alterations in the acetubulum, ... 120
Alterations in the head of the femur, ... 122
Alterations in the neck of the femur, ... 124
Treatment of the disease, ... 127

CHAPTER III.

FRACTURES OF THE BONES OF THE FORE-ARM, IN THE VICINITY OF THE WRIST-JOINT.

Mr. Colles's description of fracture of the lower end of the radius, . . . 130
Causes and symptoms of the injury, ... 134
Position in which the hand is supported by the patient, ... 134
Difficulty of supinating the hand, ... 135
Alteration in the form of the lower extremity of the fore-arm, ... 136
Projection of the lower extremity of the ulna, ... 137
Usual situation of the fracture, ... 137

PAGE.
Diday's opinion respecting the direction of the fracture, ... 137
Shortening of the posterior surface of the radius, ... 138
State of the internal lateral ligament of the carpus, ... 138
Peculiar appearance of the wrist, ... 139
Sequelæ of the injury, ... 139, 170
Anatomical characters of the injury, ... 140
Nature of the displacement of the lower fragment, ... 140
Overlapping of the fragments seldom occurs, ... 141
Direction of the fracture generally transverse, ... 142
Voillemier's doctrine of impaction, ... 143
Cases illustrative of the pathology of fractures of the lower end of the radius, 146
Voillemier's theory considered, ... 156
Fracture with displacement of the lower fragment forwards, ... 162
Differential diagnosis, ... 163
Fracture of the radius and ulna, close to the wrist-joint, ... 164
Differential diagnosis, ... 164
Treatment of fracture of the lower end of the radius, ... 167
General conclusions, ... 171

CHAPTER IV.

FRACTURES OF THE HUMERUS IN THE VICINITY OF THE SHOULDER-JOINT.

Fractures of the greater tuberosity of the humerus, ... 176
External characters of the injury, ... 177
Anatomical characters, ... 178
Cases recorded by Mr. Guthrie, ... 181
Difficulty of maintaining the fragments in apposition, ... 183
Ligamentous union between the fragments, ... 183
Impacted fractures of the neck of the humerus, external to the capsule, . 185
Diagnosis obscure, ... 186
Anatomical characters, ... 187
Intracapsular variety generally combined with fracture of the tubercles, 188
Differential diagnosis, ... 188
Osseous union of the intracapsular variety, ... 189
Permanent deformity, ... 191
Anatomical characters, ... 192, 194
Alterations in the aspect of the head of the bone, ... 194, 196
Separation of the superior epiphysis of the humerus, ... 199
Projection beneath the coracoid process, ... 200
Deformity likely to be permanent, ... 202
Osseous union, ... 202
Error of Vidal respecting the anatomy of the epiphysis, ... 202
Sir Astley Cooper's description of the injury, ... 204
General conclusions, ... 206

CHAPTER V.

FRACTURES OF THE ACROMIAL EXTREMITY OF THE CLAVICLE.

PAGE.
Opinions of authors respecting the displacement of the fragments, . . . 209
Anatomical characters of fractures external to the conoid ligament, 210, 218
Fractures between the conoid and trapezoid ligaments, ... 215
Fractures external to the trapezoid ligament, ... 215
Nature and causes of the displacement, ... 216
Diagnostic signs of fracture between the coraco-clavicular ligaments, . . 217
Symptoms of fracture external to the trapezoid ligament, ... 218
General conclusions, ... 222

CHAPTER VI.

DISLOCATIONS OF THE BONES OF THE FOOT.

Sources of security of the bones of the foot against displacement, . . . 224
Symptoms of luxation of the metatarsus and internal cuneiform bone, . . 225
Rotation of the foot upon its long axis, ... 225
Alteration in the form of the sole of the foot, ... 226
Anatomical relations of the displaced bones, ... 227, 231
Anatomical characters, when the luxation remains unreduced, . . 228, 232
Mode in which the injury is produced, ... 233
Internal cuneiform bone generally remains with the metatarsus, . . . 233
Sanson's account of Dupuytren's cases, ... 234
Case of luxation of the metatarsus recorded by Mazet, ... 235
Cases of luxation of the tarsal bones, by Mr. Liston and Sir A. Cooper, . 236
Importance of early reduction, ... 236

CHAPTER VII.

CONGENITAL LUXATIONS OF THE WRIST-JOINT.

Case recorded by Cruveilhier as an unreduced luxation, ... 238
Opinion of Dupuytren respecting it, ... 240
Congenital luxation of the right carpus forwards, ... 241
Congenital luxation of the left carpus backwards, ... 245
Anatomical characters compared with those described by Cruveilhier, . . 250
Case of congenital luxation of the carpus forwards, ... 251
Proofs that the deformity was congenital, ... 253
Dislocation of the carpus from injury, ... 254

CHAPTER VIII.

CONGENITAL DISLOCATIONS OF THE SHOULDER.

PAGE.

Condition of the shoulder which may be mistaken for congenital luxation, 257
Congenital luxations frequently escape observation in the infant, . . . 257
Varieties of congenital luxation of the shoulder observed by Guerin, . . 258
Cases of congenital sub-coracoid luxations, ... 258–265
Sub-acromial congenital luxations, ... 266
Opinions as to the causes of congenital luxations, ... 271

CHAPTER IX.

DISLOCATIONS OF THE LOWER JAW.

Case of congenital luxation of one condyle, ... 273
Appearances of the face, ... 274
Condition of the temporo-maxillary articulation, ... 279, 280
Opinion of Ribes respecting the development of the glenoid cavity, . . 283
Glenoid cavity formed by the growth of the articular eminence, . . . 285
Symptoms of luxation of both condyles from accident, ... 286
Appearances when the luxation is left unreduced, ... 287
Ribes's description of the changes which take place, ... 287
Symptoms of luxation of one condyle from accident, ... 289
Deformity produced by chronic rheumatic arthritis of the jaw, ... 290
Anatomical characters of the disease, ... 291
Differential diagnosis of the congenital luxation, ... 292

CHAPTER X.

ADDITIONAL OBSERVATIONS ON FRACTURES OF THE RADIUS, DISLOCATIONS OF THE BONES OF THE FOOT, AND CONGENITAL LUXATION OF THE WRIST-JOINT.

Cases of fracture of the lower end of the radius, ... 294
Gangrene from tight bandaging, in cases of fracture of the radius, . . 295
Fracture of the lower extremity of each radius, ... 297
Dupuytren's cases of luxation of the metatarsus, incorrectly described by Sanson, ... 298
Translation of Dupuytren's Memoir upon the subject, ... 298
Analysis of Cruveilhier's case of luxation of the wrist, by Dupuytren, . 303

A

TREATISE ON FRACTURES,

&c. &c.

CHAPTER I.

ON THE DIAGNOSIS AND PATHOLOGY OF FRACTURES OF THE NECK OF THE FEMUR.

"La science du diagnostic tient le premier range entre toutes les parties de l'art et en est la plus utile et la plus difficile; sans un diagnostic exact et précis, la theorie est presque toujours en defaut et la pratique souvent infidele."—*Mem. de l'Academ. Roy. de Chirurg.*, t. v.

THE words of the celebrated Louis, which I have prefixed to this memoir, although written with reference to the diagnosis of fungous tumours of the dura mater, apply with propriety to the subject of which I am about to treat in the following pages. Many and valuable additions, it is true, have of late years been made to our knowledge of the subject of fractures of the neck of the femur, but there are still many points connected with its history which are involved in obscurity, and some upon which there still exists much variety of opinion. If I shall succeed in removing any of this uncertainty, if I shall be able to place the diagnosis of the various forms of fracture of the neck of the femur in a clearer light than has hitherto been done, I shall have accomplished fully the object which I proposed to myself, in bringing forward a subject upon which so much that is valuable has already been written, but the difficulties attendant upon which every practical surgeon will, I am sure, freely admit, and the importance of

which is sufficiently attested by the number of the memoirs that have been devoted to its consideration.

In the majority of cases of fracture of the neck of the femur, the nature of the injury is announced by symptoms sufficiently striking, and equally remarkable, whether we examine the limb while the patient is in a recumbent posture, lying upon a horizontal plane, or while he is supported in the erect position, resting the weight of his body upon the uninjured limb. When we make the examination as the patient lies in bed, we observe that the injured limb is shortened; that the heel corresponds to some part of the region between the tendo Achillis and the internal malleolus of the sound side; that the foot is everted, and that the entire limb rests upon its external surface; the knee-joint is slightly flexed; an unnatural fulness is seen in the inguinal region, and the upper and outer part of the thigh presents an unusual convexity, and a certain amount of tension; the patient complains of pain throughout the whole of the region of the hip-joint, and in the vicinity of the insertion of the psoas muscle: the pain in the latter situation is generally aggravated when the surgeon inverts the limb and flexes the thigh upon the pelvis; the trochanter major does not stand out from the pelvis as prominently as upon the sound side; it is approximated to the crest of the ilium, and the glutæal region is flattened. When an extending force is applied to the foot, and continued sufficiently long to overcome the contraction of the muscles which draw the lower fragment of the broken bone upwards, the limb is restored to its natural length, and most of the external signs of the fracture disappear; but if, while the extending force still continues in action, the surgeon communicate to the limb a movement of rotation, a grating of the fragments upon each other becomes manifest, the crepitus can be felt by the hand placed upon the trochanter major, and is frequently communicated to the hand of the assistant who is extending the limb from the foot: when, however, the extending force ceases to operate, this characteristic sign of the fracture disappears, and the limb, once more abandoned to the uncontrolled power of the muscles, is again shortened, and the foot becomes again everted. By rotating the limb we also ascertain that the trochanter major moves in the segment of a smaller circle than

natural, or revolves upon its own axis. If the patient be desired to raise the extended limb from the horizontal plane upon which it rests, he at once, and without even making the effort, expresses

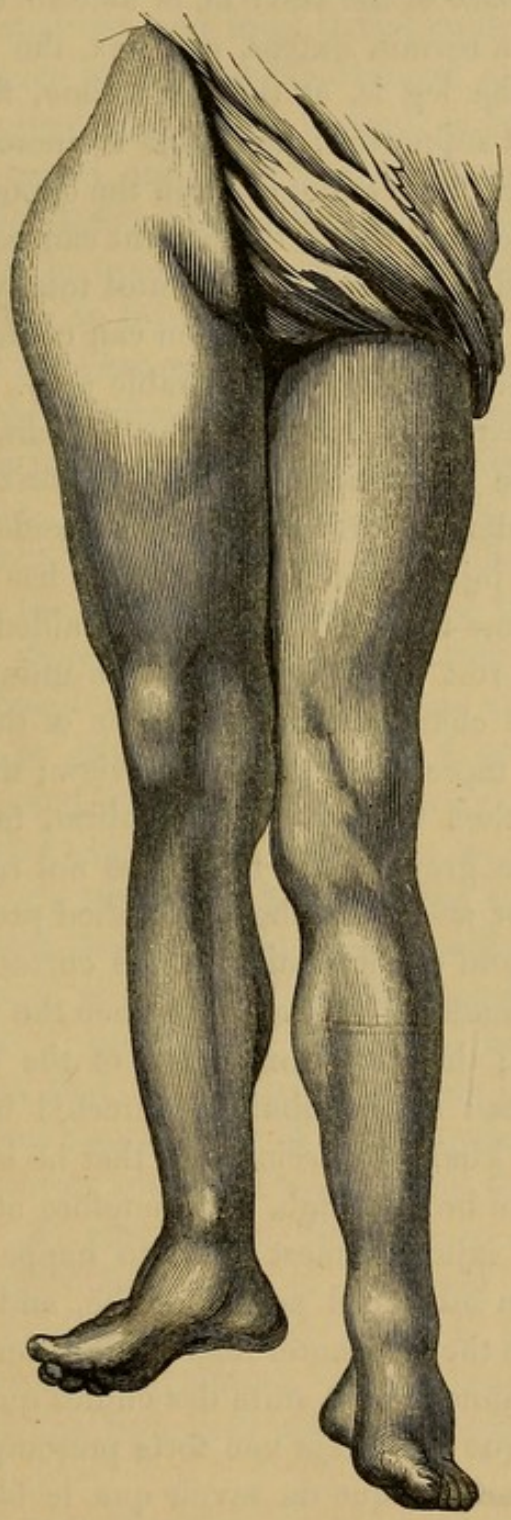

his total inability to do so: if urged to make the trial, he attempts it by placing the toes of the uninjured limb behind the heel of the other, and thus contrives to raise the latter a little; or else he

places his hands behind the broken femur, and by their assistance flexes the thigh slowly and with caution upon the pelvis, bends the knee-joint, and draws up the foot, but without raising the latter from the surface of the bed: he is able to extend the limb perfectly, and, to a certain extent, can flex the thigh upon the pelvis, provided the leg is, at the same time, flexed upon the thigh, and the foot supported: he is able to increase the rotation outwards of the foot, but cannot perform the opposite motion: the motions, such as flexion, which the patient can perform only in a limited degree, and that which he is almost totally unable to execute, viz., rotation inwards, the surgeon can communicate to the limb, but not without causing considerable pain.

Having now carefully examined the appearances which the limb presents while the patient lies upon a horizontal plane, let the surgeon, in order to form a still more decided opinion as to the nature of the injury which the hip-joint has suffered, direct the patient to assume the erect posture, and, aided by the support of an assistant, to rest his weight upon the uninjured limb; he will then have the characteristic symptoms of the accident presented to him in a more striking point of view; the shortening of the broken limb then becomes very manifest, for although the toes may touch the ground, the heel does not rest upon it; the eversion of the foot and knee, the diminished prominence of the trochanter major, and the flattening of the corresponding side of the nates, are also rendered very evident when the patient assumes the erect position; the posterior region of the thigh looks inwards, and the head of the fibula is directed backwards; the patient possesses a kind of consciousness that he is unable to bear his weight upon the broken limb, and therefore attempts nothing of the kind. The injury is most likely to happen to those who have arrived at an advanced period of life, and is usually the result of a fall upon the trochanter major. Sabatier has remarked: "Elle est si communement la suite des chutes qui se font sur le grand trochanter, que c'est deja une forte presomption pour l'existence de cette fracture, que de savoir que le blessè est tombe sur cette partie." I believe, however, with Sir Astley Cooper, that, under many circumstances, the fall is the result and not the cause of the fracture; and in several instances which I have

seen, the neck of the femur has been broken, although the individual has not fallen at all, having supported himself by laying hold on some convenient object; and it should ever be remembered that the slightest and most trivial causes are sufficient to produce the injury in persons of advanced age; the foot being caught by some inequality in the ground, or becoming entangled in a hole in the carpet, are by no means uncommon sources of the fracture; and Sir Astley Cooper has done well in cautioning the young surgeon to be upon his guard, as he might otherwise imagine that so serious an injury as fracture of the neck of the femur could not result from causes so trivial, and without the occurrence of a fall upon the trochanter. Such is a general outline of the symptoms which indicate the existence of a fracture of the neck of the thigh bone. These symptoms are each, however, liable to so many important varieties, and are so modified by the situation of the fracture, the relative position of the fragments, and the extent of injury done to the soft parts entering into the composition of the articulation, or in its immediate vicinity, that it becomes necessary to examine somewhat in detail the more important symptoms, and to consider attentively the circumstances which, in any given case, may modify the signs and obscure the nature of the injury which the hip-joint has suffered. The surgeon who supposes that the difficulties attending the diagnosis of fracture of the neck of the femur are slight, and easily overcome, can have had but a very limited experience indeed of such injuries; and I think that, in the course of this inquiry, it will become manifest that the majority of the symptoms of fracture may be present in cases in which the neck of the femur is uninjured; and that, upon the other hand, the fracture may be unaccompanied by the more important of the usual diagnostic signs.* We cannot, in investigating these injuries, form our opinion, guided by any particular symptom, for there is not one which, separately considered, can be looked upon as unequivocally indicating

* "Le diagnostic du fractures du col (du femur) n'est pas sans d'assez grandes difficultés, et plus d'une fois des practiciens exercés ont eté incertains sur le jugement qu'ils devaient porter. L'on voit, par exemple, des invidus qui présentent les signes rationnels de cette lésion sans être atteints, et d'autres, au contraire, qui n'en offrent aucun quoiqu'elle existe réellement."—*Leçons Orales*, t. ii. p. 95.

the existence of a fracture of the neck of the femur; it is by the union of all that we can alone hope to arrive at a correct diagnosis.

There is no feature in the history of fractures of the neck of the thigh bone, which at first sight appears more extraordinary than the difference of opinion which has existed, and indeed still continues, as to the amount of shortening of the limb which occurs in the two varieties of this important lesion. Upon this question the most eminent surgeons of modern times are directly opposed to one another. Sir Astley Cooper, Amesbury, Chassaignàc, Vidal (De Cassis), and others, maintain that the shortening is greater in the intracapsular fracture than in the extracapsular. Upon the other hand, Desault, Boyer, Dupuytren, Cloquet, Earle, Stanley, &c., have stated, that the greatest amount of shortening accompanies the fracture external to the capsule. How are such conflicting statements to be reconciled? Are we to agree with Rodet, who says: "Cette opposition formelle entre les opinions de ces grands chirurgiens vient sans doute de ce qu'il n'y a rien de constant dans le degré du raccourcissement, qui accompagne de ces deux espèces des fractures?" I do not think so, and I feel satisfied that the degree of shortening of the limb may, *with certain precautions,* be considered as diagnostic of the seat of the fracture, and that it is greater when the lesion of the bone is external to, than when it is within the capsular ligament. In discussing this question, I wish it to be understood, that I allude to the retraction of the limb which *immediately* succeeds the receipt of the injury; this is the period at which it is most important to form a correct diagnosis; for the surgeon is expected not only to give a decided opinion, almost at sight, as to the nature of the injury, but also to state his prognosis, and as this must be materially influenced by the diagnosis which he may form, the importance of being able to ascertain exactly the seat of the injury with respect to the capsule is apparent. The chief circumstances according to which the degree of shortening varies in cases of intracapsular fractures are, the direction of the fracture and relative position of the fragments, and the amount of laceration suffered by the fibrous covering of the neck of the bone. With regard to the former, when the line of fracture is perpendicular to the axis of the neck of the bone, or when it has passed from the superior

part of the corona of the head obliquely downwards and inwards, there is nothing in either of these cases, so far as the relative position of the fragments is concerned, to prevent the inferior fragment from being drawn upwards; but when the fracture runs from the inferior part of the corona of the head obliquely downwards and outwards towards the summit of the trochanter major, then, provided there be no displacement as regards the diameter of the bone, the ascent of the lower or external fragment is opposed by the superior, and the amount of shortening is less than in either of the other cases which I have supposed. This is only in accordance with an obvious and general principle, viz., that the direction of a fracture regulates to a certain extent the nature and amount of the displacement consequent upon the lesion, but I do not see that the knowledge of this general principle is of much use, when we endeavour to apply it to the case before us, for, notwithstanding what has lately been asserted to the contrary by Rodet, I am inclined to agree with Dupuytren, who has said: "Il n'y a aucun moyen de reconnaitre dans quel sens a lieu cette obliquite." I shall, however, allude hereafter more particularly to the opinions of Rodet upon this point, and pass on at present to consider how far the shortening of the limb is influenced by the condition of the fibrous membrane which encircles the neck of the bone: this important investment constitutes a cylindrical sheath of great strength, extending from the inferior attachment of the capsular ligament to the circumference of the cartilage of the head of the femur; it is derived from the deep fibres of the capsule, and here and there appears to be thrown into longitudinal folds or bands, which Weitbrecht has termed "retinacula;"* it is covered upon its external surface by synovial membrane, and numerous vessels pass along it to the head of the bone. It may, for convenience sake, and from the function which it fulfils in many cases of fracture within the capsule, be termed the "cervical ligament of the femur." If the force which acts upon the neck of the femur be inconsiderable, and, as it were, exhausted, after producing the fracture, this ligament may escape uninjured, or nearly so. In such a case, the retraction of the limb will be very

* Syndesmologia, 1742.

slight, and will be at its minimum when the fracture has traversed the bone obliquely from the inferior part of the head of the femur downwards and outwards. When the cervical ligament remains nearly entire, it not only limits the retraction of the limb, but it likewise becomes the sole medium through which a vascular communication is maintained between the fragments; it is, therefore, very important to observe the utmost caution in examining the limb; and if the existence of fracture of the neck of the femur is rendered evident by the presence of the other symptoms which characterize this lesion, we should, I think, abstain from instituting such an examination as is necessary to produce crepitus. In doubtful and obscure cases, this examination should of course be cautiously made, but I perfectly coincide with the opinion of Boyer, that, in the majority of cases of fracture of the neck of the femur within the capsule, the nature of the injury is sufficiently indicated by other symptoms.* Mr. Stanley observes, that in several instances of recent fracture of the neck of the femur within the capsule, he has found a considerable portion of the synovial and fibrous covering of the bone entire, and the extent of its laceration has obviously influenced the degree of displacement in the limb. This covering, remaining entire on either side of the neck of the bone, must counteract the shortening of the limb. Should it be preserved entire on the anterior side, the eversion may be wholly prevented; and when, as in the following instance, the membrane is uninjured, the fractured surfaces in such case may be kept firmly together, and the limb secured from any change in its length or position. A man, aged sixty, was knocked down in the street, and on his admission into

* "Un assez grand nombre d'autres phénomènes la caractérisent suffisament, sans avoir recours a celui-là, que la situation profonde des fragmens et la grande epaisseur des parties molles qui les entourent, doivent rendre au moins très-difficile à distinguer; et quand bien même ce signe serait facile a reconnaître, les mouvemens propres à le mettre en évidence seraient-ils exempts de danger? Nous ne parleront point de l'irritation des parties environantes, que nous croyons bien moins facile a produire et moins dangereuse qu'on ne l'a pensé; mais est il indifferent de s'exposer à rompre complétement le prolongement fibreux de la capsule que s'etend sur le col du femur, et qui lui sert de périoste? Les mouvemens de rotation communiques au fragment inferieur ne sont-ils pas le moyen le plus propre a produire cet effet pernicieux?"—*Boyer: Traite des Maladies Chirurgicales*, t. iii. pp. 268–9.

St. Bartholomew's Hospital, shortly after the injury, he complained of pain in the hip, but there was neither shortening nor eversion of the limb, and its several motions could be executed with freedom and power. In this absence of all the usual indications a fracture was not suspected ; the patient, therefore, was merely confined to his bed. At the end of a fortnight he had an attack of inflammation in the intestines, from which he recovered, but suffered a relapse, and died in the fifth week from the date of the accident. On examining the body, no trace of injury was found in the parts around the hip-joint, but, on opening the capsule, small effusions of blood, apparently not recent, were discovered beneath the synovial and fibrous membrane, covering the neck of the femur, also beneath the synovial membrane, covering the ligamentum teres. The head and neck of the bone were sawed through the middle, and in each portion a dark line, evidently occasioned by the effusion of blood, was seen extending through the bone at the basis of the neck. A fracture was discovered extending along this line, but the broken surfaces were in contact, and the synovial and fibrous membrane covering the neck of the bone was uninjured. In this case, Mr. Stanley remarks, if an attempt had been made to walk at the end of two or three weeks from the accident, a separation of the fractured surfaces, and consequent shortening of the limb, would have been the result. Hence, in cases where the nature of the injury is doubtful, we may infer the obvious propriety of imposing on the patient a strict confinement to his bed for as great a length of time as if the fracture had been ascertained.* Cruveilhier likewise has alluded to the injurious consequences which may result from an over-anxiety upon the part of the surgeon to elicit crepitus. This distinguished pathologist remarks: " On conçoit combien il est peu rationel de vouloir a tout prix par des mouvemens de rotation imprimés aux membres, obtenir le bruit de crepitation, comme moyen de diagnostic ; il n'est pas besoin de dire que ces mouvemens peuvent avoir le grave inconvenient de completer la rupture du repli fibro-synovial, respecte in quelque sorte par la cause fracturante."†

* Medico-Chirurgical Transactions, vol. xiii.

† Anatomie Pathologique, livraison xxvi.

Among the causes which limit the retraction of the limb in cases of intracapsular fractures, we must not omit to mention the powerful capsular ligament, which so closely embraces the articulation. Sir Astley Cooper states that, when the bone is broken within the capsule, the leg becomes from one to two inches shorter than the other. So great a degree of shortening I have never witnessed as an *immediate* result of the fracture, nor do I think the capsule would admit of such an amount of displacement, unless it were extensively lacerated, an occurrence which is very rare indeed. "With respect to the shortening of the limb," says Mr. Earle, "to the extent of two inches, as I have never witnessed such an occurrence, I cannot but conceive that there must be some inaccuracy in the statement, more especially when the great strength and unyielding nature of the capsular ligament are considered." Boyer likewise expresses the same opinion; he says: "Quand la fracture a lieu dans l'un des points de la longueur du col du femur qui correspondent à l'interieur de l'articulation, le ligament orbiculaire qui n'est jamais rompu, contre-balance les causes de displacement, et en resistant en haut et en bas à l'impulsion des deux fragmens, il borne quelquefois la raccourcissement du membre à quelque lignes."* But when the fracture is external to the capsule, and not impacted, there is but little to prevent the full force of muscular action upon the lower fragment of the bone, while, at the same time, the upper is depressed by the weight of the body, so that, from these two causes, a degree of shortening may be produced equal to, or even greater than the entire length of the neck of the bone. In confirmation of his opinion of there being a comparatively slight degree of shortening in extracapsular fractures, Sir Astley Cooper describes the case of a man who died in a fortnight after having sustained this injury. In the account of the post-mortem examination he mentions that all the limbs were rigid from the fixed contraction of the muscles, yet the broken limb was found to be not quite three-quarters of an inch shorter than the other; the fracture was external to the capsule, and the neck of the bone was forced into the cancelli of the trochanter major. "Before writing this statement," Sir Astley

* Traite des Maladies Chirurgicales, t. iii. p. 262.

observes, "I again inquired of Mr. Key (with whom he had attended the case) the degree of diminution in the length of the limb, and his answer was: "If you mention three-quarters of an inch, you will state rather more than its degree of retraction, even when all the muscles were contracted to their utmost rigidity." Sir Astley Cooper has here, however, entirely overlooked the influence which the circumstance of the fracture having been impacted exerted upon the shortening of the limb. In almost all such cases (as I shall afterwards endeavour to prove), the shortening is less than in the more ordinary form of extracapsular fracture, in which the neck of the bone does not remain implanted in the cancellated tissue between the trochanters. Between these two varieties of the extracapsular fracture, it appears to me, that, as respects the shortening of the limb, this distinguished surgeon has not made the necessary distinction; had he done so, I do not think he would have maintained the opinion, that the greater amount of shortening accompanied the intracapsular fracture. It seems probable, that the difference of opinion which exists upon this point is also in some measure to be ascribed to a proper distinction not having been made between the shortening which occurs immediately after the occurrence of the fracture, and that which is noticed at a later period. Indeed, the period at which shortening occurs is subject to much variety; it may manifest itself instantaneously upon the receipt of the injury, and that to a considerable degree. In such cases the injury will generally be found to be a comminuted fracture external to the capsule, a fracture which has lacerated the whole of the fibrous structures which invest the trochanteric region of the femur.

Again, we meet with cases in which the shortening of the limb is not by any means decided or evident for several days after the receipt of the injury: in such instances it usually happens that the muscles have been, to a certain extent, paralyzed by contusion; but according as, under the influence of rest, &c., they regain their power of contracting, the limb becomes slowly and gradually shortened, and this independent of any process of absorption. A third class of cases occur, in which the retraction of the limb, having been at first scarcely perceptible, at the expiration of a few weeks becomes very considerable, owing to the

rapid absorption of the neck of the bone. In the case of Margaret Myler (No. IX.), the amount of shortening was at first only a quarter of an inch, but at the end of six weeks amounted to one inch and a half. Lastly, examples are sometimes seen in which the limb retains nearly its natural length for many weeks after the receipt of the injury, and then a very decided and, comparatively speaking, considerable degree of shortening occurs, not gradually, but suddenly. In these cases the diagnosis is somewhat obscure; the cause which has produced the fracture is comparatively slight, and the patient has not made any attempt to use the limb after the receipt of the injury; the eversion of the foot is by no means so well marked as when the retraction has occurred early; the patient is, it is true, unable to raise the limb *en masse*, but this may be owing to the effects of contusion upon the muscles; in fact, in cases such as those to which I allude, there may be at first neither shortening of the limb to any appreciable extent, eversion of the foot, nor any change in the position of the trochanter; and therefore, unless we can ascertain crepitus, it is most difficult to decide whether the neck of the bone be broken or not; and if we fail to elicit crepitus, the more prudent course is to withhold our opinion until time shall more fully develope the nature of the injury. In these cases the surgeon is apt to allow greater freedom to the patient than is advisable, or, it may be that, in his anxiety to establish the nature of the injury by producing crepitation, he employs too much force in rotating the femur; in either case it is highly probable that the sudden occurrence of shortening of the limb will establish the nature of the lesion which the joint has suffered; the eversion of the foot now becomes decided, and the trochanter altered in position. These phenomena may take place long after the occurrence of the accident. In these instances it is most probable that, at the time of the receipt of the injury, the cervical ligament, having escaped laceration, prevented the retraction of the limb, but that subsequently it was torn, either in consequence of some imprudent exertion upon the part of the patient, or too eager a desire upon that of the surgeon to produce crepitus by forcible extension and rotation of the limb; the retraction then takes place as the immediate result of the laceration of this important membrane.

This subject has been fully considered by Amesbury, and the Baron Dupuytren, in the second volume of his Oral Lectures, remarks: "C'est ainsi que le deplacement des fragmens ne s'est fait qu'au bout de quelque heures, de deux, trois, cinque, dix, et meme trent jours, par suite de quelque mouvemens du malade, ou bien pendant que l'on faisait des recherches pour s'assurer de la nature de la maladie." I am of opinion, however, that this celebrated surgeon has not given the correct explanation of a phenomenon with which it is obvious he was familiar. He says: "Au bout de deux ou trois mois, *le cal provisoire cede* au poids du membre sur lequel les malades se soutiennent, et les fragmens cessant d'etre en rapport, une difformite a lieu, un raccourcissement se produit." Now, if the opinion be correct, as I believe it to be, that the *sudden* occurrence of shortening, at a period more or less remote from the receipt of the injury, is diagnostic of the presence of a fracture within the capsular ligament, I think I am justified in ascribing it to the more or less complete laceration of the cervical ligament, consequent upon some imprudence upon the part either of the surgeon or of the patient, and that it is in no instance to be referred to the yielding of the callus, when the patient attempts to bear the weight of his body upon the injured limb. It is, I conceive, highly probable that the shortening noticed by Dupuytren, at so distant a period as four months after the occurrence of the accident, did not take place *suddenly*, but was owing to the gradual process of absorption going on in the neck of the bone, though it may have escaped observation as long as the patient remained in bed, with the limb enclosed in an apparatus destined to maintain extension. Furthermore, if there be any one fact in surgical pathology more certain than another, it is this, that in cases of fracture of the neck of the femur within the capsular ligament, there is scarcely any callus ever effused; it certainly is never formed in such quantity as to be at all capable of counteracting the causes which produce shortening of the limb: in extracapsular fractures, osseous matter is poured out in many cases most copiously, but when the lesion of the bone is entirely within the capsule, the absence of callus, either provisional or final (if there be any truth in such a distinction), is most remarkable, even in those cases in which osseous union has occurred

between the fragments. If the plates representing the union by bone of the fracture within the capsule, which are appended to the cases published by Messrs. Langstaff, Adams, and Jones, be compared, the resemblance which they bear to each other will be found to be very striking: in all union has taken place without the deposition of osseous matter around the fragments; in all consolidation has been effected by the direct union of the two bony surfaces which were confronted to each other, and not by the effusion of callus. The opinion, therefore, which ascribes the phenomenon in question to the yielding of the callus, when the weight of the body is thrown upon the limb, must, I fear, be rejected as erroneous, although supported by the high authority of so distinguished a surgeon as the late chief of the Hotel Dieu.

It has lately been asserted that the opinion which maintains that the sudden occurrence of shortening of the limb, some time after the receipt of the injury, is diagnostic of a fracture within the capsule, is incorrect, and Monsieur Rodet believes it to be equally characteristic of an extracapsular fracture: he correctly describes the whole of the trochanteric region of the femur as being invested with a dense fibrous covering, derived from the tendinous structures attached to the trochanter; he believes that this fibrous expansion may escape uninjured at the time of the occurrence of the fracture, that it may be subsequently lacerated, either by forcible rotation of the limb, or premature exertion on the patient's part, and that, under such circumstances, consecutive displacement will occur. I do not by any means wish to deny the possibility of such an occurrence in extracapsular fractures, but I certainly cannot admit the assertion of Rodet, that it is as frequent in the one variety of the fracture as in the other. I have never witnessed consecutive displacement in cases of fracture external to the capsule, nor have I ever seen an instance of this fracture, in which there was not shortening of the limb from the very moment of the occurrence of the accident. When, moreover, I consider that the extracapsular fracture is always accompanied (as I shall afterwards endeavour to prove) by a fracture of one or both trochanters, and that this second lesion of the bone is the result of the impaction of the upper fragment into the cancellated tissue of the trochanter, I think I am justified in main-

taining that there is, in every instance of fracture of the neck of the femur, external to the capsule, a primary and immediate shortening of the limb, and that the so-called consecutive displacement is merely an increase in the amount of shortening already existing.* It has been shewn that, in fractures within the capsule, the degree of shortening consequent upon the injury depends chiefly upon the condition of the cervical ligament; and it is maintained by Rodet that the state of the fibrous structures which invest the trochanteric region will regulate the amount of retraction of the limb, when the lesion of the bone is external to the capsule; and that, when these tissues remain uninjured, and the trochanter unbroken, there will be no shortening of the limb: but I shall quote the words of the author. "*Si la fracture est extracapsulaire*, les tissus fibreux de la region trochanterienne pourront aussi dechirés a des degres differens, et le raccourcissement qui l'accompagne devra varier dans la meme proportion. Il y a cependant ici une autre condition dont il faut tenir compte, c'est l'etat dans lequel se trouve le grand trochanter. S'il est intact, ainsi que les tissus fibreux qui l'entourent, le raccourcissement est nul." "Mais si le grand trochanter est brisé en plusieurs fragments, ces fragments s'écartent les uns des autres, et alors le raccourcissement se produit sous de faibles efforts, quoique les tissus fibreux ne soient pas déchirés. Si le nombre de ces fragmens est considerable, ou si les tissus fibreux sont largement divisés, le raccourcissement ne reconnait presque plus de limite, et peut etre porté jusqu'a 3, 4, 5 centimetres et au delâ. De tout ce qui precède il est permis de conclure:

"1. *Que le raccourcissement peut etre nul dans les fractures intra-articulaires et extra-articulaires.*

"2. *Que lorsqu'il ne dépasse par* 18 *ou* 20 *millimètres, il peut appartenir également aux deux espèces des fractures, et n'a par consequent rien de différentiel.*

"3. *Enfin, que lorsqu'il dépasse d'une manière notable ce degre de* 20 *millimètres, il est à peu pres certain que la fracture est extràarticulaire.*"†

* "Le déplacement est rarement ainsi consecutif; il s'opere presque toujours immediatement, *surtout si la fracture est extra-capsulaire.*"—*Sanson.*

† L'Experience, 14 Mars, 1844.

Now there is, in my opinion, one important objection to the first conclusion, i. e. it supposes a condition which I believe never exists. M. Rodet says, that in extracapsular fractures there will be no shortening of the limb if the trochanter remains unbroken, and its fibrous coverings uninjured; but, I would ask, does it ever happen that the neck of the femur is broken external to the capsule, without injury to the trochanter? My own experience leads me to believe that it does not. I believe, as I have already stated, that all extracapsular fractures are, in the first instance, also impacted fractures, and that all impacted fractures are necessarily accompanied by a fracture traversing some part of the trochanteric region. I have omitted no opportunity of investigating this point, and have now examined here and elsewhere upwards of one hundred specimens of the extracapsular fracture, and have found in all, without a single exception, a second fracture, traversing some portion of the intertrochanteric space: this space is somewhat of a semilunar shape, bounded above by the summit of the trochanter major, below by that of the trochanter minor; its concavity corresponds to the posterior intertrochanteric ridge, and its convexity to a line drawn from the base of one trochanter to the other. Cruveilhier has alluded to this second lesion of the bone; this accurate observer remarks: "Il est excessivement rare de voir une fracture extracapsulaire du col du femur parfaitement simple."* The second fracture usually begins near the centre of the summit of the trochanter major,† passes from thence downwards and inwards, following in general the convexity of the space I have mentioned, and either terminates before it reaches the lesser trochanter (Case No. LII.), or else it is continued through the centre (Case No. XLIV.), or below the base of that process (Case No. XXXV.). Sometimes it is a fissure, which splits either one or both trochanters (Case No. XLV.) without detaching any portion of either. Chaissaignac has alluded to a case of this description; he observes: "Le grand trochanter offrait une fracture oblique incomplete, beanté a la partie superieure, et s'effacant peu a peu

* Livraison xxii.

† "Cette eminence (le grand trochanter) se brise, presque toujours en meme temps que la base du col, et la lieu de la brisure est generalement le point de re-union des deux tiers posterieurs avec le tiers anterieure."—*Cruveilhier, loc. cit.*

vers la partie inferieure, ou l'on voyait enfin cesse toute trace la solution de continuite." This second lesion of the bone is the necessary result of the forcible impaction of the broken cervix into the shaft of the femur, and it is, probably, the second fracture in order of time. What occurs appears in fact to be this: the neck of the femur is, in the first instance, broken by the fall upon the hip, and then driven into the cancellated tissue, between the trochanters, by the weight of the body, and the prolonged action of the first shock; but as soon as the neck of the bone is broken, the femur is rotated outwards, even before the action of the first impulse has ceased; thus the posterior inter-trochanteric ridge being thrown forwards is forcibly driven against the back of the neck of the femur; two forces, therefore, combine to produce the fracture through the inter-trochanteric space, one of which consists in the impaction of the cervix into the shaft, while the other is found in the collision which takes place between the broken neck of the bone and the posterior inter-trochanteric ridge. The impaction of the superior fragment is of itself, however, not only capable of producing the second lesion of the bone, but is the chief cause of it, especially in those cases in which the neck of the bone is driven into the cancellated tissue between the trochanters, leaving the greater part of the inferior fragment in front (Case No. XLVI.); for in such cases the broken cervix is driven directly against the ridge connecting the trochanters posteriorly, which it breaks off by its wedge-like action alone, and moreover, this second fracture is as constantly present in cases attended with rotation of the foot inwards.

It depends principally upon the violence with which the injury has been inflicted, whether the neck of the bone shall remain implanted between the trochanters, or whether these processes shall be so completely separated from the shaft of the femur as to allow of the escape of the cervix from the cavity which it had formed in the reticular tissue of the lower fragment; if the force has not been very great, the neck of the femur remains wedged in between the trochanters, and one or both of these processes are split off from the shaft; but if the fibrous structures before alluded to have not been injured, these broken portions of the trochanters are still held firmly in their places, and the impacted cervix

does not become loosened; but if the force has been considerable, the impulse prolonged, the bone in a state of senile atrophy, or if, as frequently happens, the patient, in endeavouring to rise, falls a second time, then, under these circumstances, the trochanters are not only broken from the shaft of the femur, but are so far displaced and separated from their connexion with the soft parts, that the cavity, or socket, as it were, into which the superior fragment has been received, is destroyed, the impacted cervix, thus set free, no longer opposes the ascent of the inferior fragment, and the case then presents the characters of the ordinary extracapsular fracture, with great shortening of the limb.

It appears to me that no other adequate explanation can be furnished to account for the constant and uniform occurrence of the second fracture, than that which has been suggested, namely, that in all cases of extracapsular fracture of the neck of the femur, the superior is driven into the inferior fragment; if it were simply the result or consequence of the fall upon the trochanter, surely we should meet with it frequently in cases of fracture within the capsular ligament; but it does not occur in such cases, and must therefore be the result of a force which operates in the extracapsular, but not in the intracapsular fracture, and that force seems to be the impaction of the upper into the lower fragment, for although in fractures within the capsule we occasionally find impaction, it is always to a trifling extent, can never influence the condition of the trochanter, and presents altogether phenomena totally different from those which accompany it when the neck of the bone is broken external to the capsule. From the opinion, therefore, of Rodet, that there may be no shortening of the limb in certain cases of fracture external to the capsule, I must altogether dissent; I can *imagine* a case of fracture within the capsule, without shortening of the limb, though it is difficult to be conceived, and rarely met; and it is very probable that in the recorded cases of the absence of shortening of the limb, there has been inaccuracy of measurement; we cannot always be sure that we have measured from *exactly* corresponding points in the crests of the ilia, and cannot therefore employ that degree of accuracy which it would be necessary to do, before the fact of the *complete* absence of shortening in any given case could be established. Still I am

not prepared to deny the possibility of the occurrence of fracture within the capsule, without shortening of the limb. But with respect to extracapsular fractures, the case is very different; for in all such injuries there is impaction, and if so there must inevitably be shortening of the limb, even though there may be no loss of obliquity in the neck of the femur, no separation or displacement of the fractured trochanter, no laceration of the fibrous structures.

The second conclusion which M. Rodet has arrived at is the following: "Que lorsqu'il ne depassé pas 18 ou 20 millimetres, il peut appartenir egalement aux deux especes de fracture, et n'a pas rien differentiel." If we limit this conclusion to cases of intracapsular fractures and extracapsular *impacted* fractures, we must acknowledge it to be correct; but it cannot be extended to those cases of extracapsular fractures (and they constitute the majority) in which, in consequence of the displacement of the broken trochanter, the neck of the femur does not remain impacted. In the impacted fracture it is true that the amount of shortening is frequently not greater than that consequent upon fracture within the capsule, so that from this symptom alone we cannot form a diagnosis as to the seat of the injury; but when to the other symptoms which attend the impacted fracture we add the circumstance of there being a comparatively slight degree of shortening, the latter then becomes an important element in the differential diagnosis. With respect to the ordinary extracapsular fracture, with fracture and displacement of the trochanter, the shortening is always greater than in cases of recent fracture within the capsule; I am not, therefore, disposed to agree with the opinion which maintains that the shortening of the limb is a symptom destitute of value, in determining the seat of the injury with respect to the capsule; cases, it is true, frequently occur in which this symptom is not of itself sufficient to determine the question, but the well-informed and experienced surgeon does not ground his diagnosis of these obscure injuries either upon this or upon any other symptom *separately* considered, for he knows that the union of all can alone lead to the formation of a correct opinion. Suppose he meets with a case in which the shortening of the limb amounts to only half an inch, he knows that this may indicate a fracture either within or without the capsule, but will he there-

fore reject the consideration of this symptom? Surely not, for he learns from it that if the fracture be external to the capsule, it is, in all probability, an impacted fracture; he then examines further, and if he finds it impossible, or extremely difficult to restore the limb to its natural length by extension, that he cannot elicit crepitus, that the loss of power is not as complete or absolute as in cases of fracture within the capsule, he at once connects these symptoms with the slight degree of shortening, and from their union he forms the diagnosis of extracapsular impacted fracture of the neck of the femur.

Having rejected the amount of shortening, as diagnostic of the seat of fracture with respect to the capsule, M. Rodet then endeavours to prove that the direction in which the force has acted furnishes the only certain diagnostic sign, and that the fracture will be intra or extracapsular, oblique or transverse, according as the force has acted in a vertical, lateral, or transverse direction; he maintains that when the force has been applied vertically, as in a fall upon the feet or knees, the fracture will be oblique and within the capsule; and that if the anterior part of the trochanter strikes the ground, the fracture will be intracapsular and transverse; that it will be mixed, or partly internal and partly external to the capsule, when the force acts chiefly upon the back of the trochanter; but that in a directly lateral fall, the fracture will be completely external to the capsule. The statement may be arranged thus:

FORCE ACTING.	FRACTURE.
Vertically,	Oblique and Intracapsular.
Antero-laterally,	Transverse and Intracapsular.
Postero-laterally,	Mixed.
Transversely,	Extracapsular.

Now, in rejecting the amount of shortening, and substituting the direction of the force as a means of arriving at a differential diagnosis, the author has not thrown much light upon the subject; on the contrary, it appears to me that he has abandoned the aid of a symptom which, if the proper precautions are taken, is not likely to lead to the formation of an incorrect opinion; for if the surgeon is familiar with the causes which modify the shortening of

the limb, he will know the exact amount of value that he is justified in attaching to this symptom; and if he connects it properly with the other symptoms present, he will find that it furnishes not only one of the most important indications as to the seat of the fracture, but also one that is available in the generality of cases.

With respect to Rodet's diagnostic sign, it will, of course, be admitted as a general principle, that the mode of application of the force, and the direction in which it acts, will determine the situation and direction of a fracture; but I contend that it is seldom available in practice in determining the seat of a fracture of the neck of the femur with respect to the capsule, for it would be extremely difficult, if not impossible, in the generality of cases, to obtain from patients a description of the direction in which the force was applied, as accurate as would be necessary before we could avail ourselves of it as a means of diagnosis; it is not probable that a person of advanced age, who had just suffered so severe an injury as fracture of the neck of the thigh bone, would be able to inform us whether the shock was sustained by the external surface of the trochanter, or whether there was a deviation, either anteriorly or posteriorly, from a directly lateral fall. Rodet seems to have been aware of this difficulty, for he observes that the direction in which the force acted is to be ascertained, not only from the account given by the patient, but also by examining the hip, and ascertaining the precise situation of any contusion that may exist; but in many cases, though there may be considerable swelling, there is no external ecchymosis, and in others, both contusion and tumefaction are so considerable and so extensive, that they lose all value as indications of the precise spot to which the force was applied, or of the direction in which it acted. In Case No. LIX. there was a distinct abrasion of the skin over the most prominent and external part of the trochanter, shewing that the force was applied transversely, the direction which, it is maintained, indicates an extracapsular fracture, and yet dissection proved that the fracture was completely within the capsular ligament. I could adduce other similar cases, but think it useless to do so, for even though we were to admit the correctness of the theory, we could not avail ourselves in practice of the proposed diagnostic sign.

The position of the foot, in cases of fracture of the neck of the femur, is not subject to as much variety as the shortening of the limb; in general it is turned outwards. The degree of eversion, however, varies in different cases: sometimes the foot, as the patient lies in bed, rests upon the heel, and the toes merely incline outwards, while in other instances the eversion is complete, both of the foot and of the entire limb, the patella being directed outwards, and the head of the fibula backwards. This complete eversion may be present either in the intra or the extracapsular fracture, but in general is less marked in cases of impacted fracture: the patient is seldom able to invert the foot in the slightest degree, and when the motion of rotation inwards is communicated to it by the surgeon, severe pain is complained of. The number and strength of the muscles which rotate the limb outwards, and the natural tendency to eversion which exists in the foot, account for the limb assuming this position in almost all cases of fracture of the neck of the femur, but it is extremely difficult to offer a satisfactory explanation of those comparatively rare cases in which inversion is the posture which the foot assumes. I do not here speak of those instances in which the posture varies at different times, under the influence of external and accidental circumstances, or of those in which the foot will remain turned either inwards or outwards, according as it may have been placed. Those examples of the injury are now alluded to in which the position of inversion is decided and permanent, the patient being unable to alter it, and where the surgeon, though employing much force, and causing considerable pain, can only communicate to the limb the motion of rotation outwards to a very limited extent.

My own experience would lead me to say that inversion of the foot is most frequently seen in cases of extracapsular fractures. I have seen seven examples in which the foot was turned inwards, in five of which the fracture was external to the capsular ligament. Such cases merit the closest attention, for they are especially liable to be confounded with luxations. I have seen this mistake committed more than once, and the patient submitted to a painful and injurious extension of the limb. Mr. Stanley has justly observed that, among the more complicated injuries to which the hip-joint is liable, that of frac-

ture of the trochanter major combined with fracture of the neck of the femur has, under certain circumstances, a strong resemblance to dislocation of the head of the bone. Whenever the fractured portions of the trochanter can be brought into contact, a crepitus can be produced, which may enable the surgeon to ascertain the precise nature of the injury. But when, from the direction of the fracture, one portion of the trochanter has been drawn by the action of the muscles towards the great ischiatic notch, no crepitus may then be discoverable; a direct source of mistake will then arise, from the positive resemblance of the fractured portion of the trochanter to the head of the femur, the former occupying the same place which the latter would do in dislocation; and if with these circumstances there should happen to be inversion of the injured limb, the difficulty of the diagnosis must be considerably increased. The case of Patrick Murphy (No. XXIX.) furnishes a good illustration of the truth of the preceding observations, and several others of a similar nature might be adduced. They should teach us not to ground our diagnosis upon the presence or absence of one symptom merely, in cases of fracture of the neck of the femur.

But what are the circumstances which prevent eversion of the foot, or what are the causes of its being occasionally turned inwards? Mr. Guthrie is of opinion that when the fracture has taken place in such a manner as to be external to the insertion of the rotators outwards, yet sufficiently within the insertion of the glutæus medius and minimus, so as not to deprive them of their due action, the toe will be turned inwards, or else remain without any change of position. This explanation is not satisfactory, for it only applies to cases of fracture external to the capsule, and affords no solution of the occurrence of inversion of the foot in cases of intracapsular fracture;* and, moreover, even though in any given case the fracture took the precise course which Mr. Guthrie has supposed, it does not follow that inversion of the foot should necessarily result; for the adductor muscles and the pectinæus should still be more than sufcient to counteract the tendency of the anterior portion of the glutæus medius and of the tensor vaginæ femoris to in-

* Mr. Guthrie states that inversion of the foot does not occur in the intracapsular fracture. This is manifestly an error.

vert the foot. It may also be observed, that Mr. Guthrie's explanation fails to account for the occurrence of inversion of the foot in those cases of extracapsular impacted fractures in which the trochanter, though split, is not displaced—in which it still remains connected by its fibrous coverings to the shaft of the bone, every motion of which it follows; in such cases, the attachments of the rotators outwards are not destroyed, and yet we occasionally find the foot inverted.

Without, therefore, rejecting Mr. Guthrie's explanation of the cause of this deviation from the usual symptoms of fracture of the neck of the femur, some other solution must be sought for, that will admit of more general application—one that will have reference to fractures within the capsule, as well as to those external to it, whether the latter are impacted or otherwise. The inversion of the foot has been attributed by Ekl to the circumstance of the neck of the bone being driven obliquely into the lower fragment.* This explanation, even though it were founded upon fact, only applies to one variety of the fracture; it is, however, merely an hypothesis. In fractures external to the capsule, with comminuted fracture and displacement of the trochanters, the position of the foot is not subject to much variety. In the great majority of cases there is complete eversion, in consequence of the action of the adductor muscles, and the weight of the limb, naturally preponderating in this direction; and I am of opinion that we should ascribe the occasional occurrence of inversion, in such instances, to the relative position of the shaft and of the neck of the femur, rather than to the action of the muscles which rotate inwards; for those rotators outwards, whose influence the fracture does not affect, still preponderate over their antagonists. At all events, in the cases to which I am alluding, the presence of inversion of the foot should never be permitted to embarrass our diagnosis: the facility with which the limb can be brought down to its natural length by extension, and the shortening removed, the recurrence of this shortening when the extending force ceases to act, and the possibility of flexing the thigh upon the abdomen, should be sufficient to enable

* Ergebnisse in dem Klinikum zu Landshut. 1826.

us to form the diagnosis of fracture external to the capsule, with fracture and displacement of one or both trochanters.

There is one remarkable circumstance which appears to have escaped the observation of those who have described injuries such as those now alluded to, accompanied by inversion of the foot, and which appears to support the opinion that this symptom is to be ascribed to the relative position of the fragments, rather than to the influence of muscular action. I have observed it several times, and it is this: the deformity having been removed, and the limb restored to its natural length by extension, as soon as the extending force ceases to act, though the limb is again shortened, the foot will be found to remain everted. Why should this be so, if muscular action had been the sole, or even the chief cause of the inversion in the first instance? In other fractures, accompanied by deformity, the result of muscular action, if deformity recurs after having been removed by extension, it will be found to present the same features, or nearly so, as those which, in the first instance, characterized the injury. I know of no instance in which, under such circumstances, it will not only not present similar features, but exhibit actually opposite characters. Muscular action, therefore, is not of itself sufficient to explain the occurrence of inversion of the foot, in cases of fracture of the neck of the femur, no matter where situated; and it has been justly observed by Cruveilhier, in reference to this subject, "deviation du pied devrait etre toujour la meme, si elle tenait a une cause identique, l'action musculaire."

Inversion of the foot may accompany fractures within the capsule, as well as those external to it; of this I have myself seen two examples, and Stanley, Cruveilhier, &c., have mentioned similar cases. A middle-aged man fell in the street, and his hip struck the curb-stone. The immediate consequences were that the limb was inverted, and shortened to the extent of an inch, and no crepitus could be discovered. It was presumed that a dislocation had occurred, and accordingly an extension of the limb was made. The constitutional irritation occasioned by repeated trials to reduce the supposed dislocation was such, that the man died five months from the time of the occurrence of the accident. In the dissection of the hip, a fracture was found, ex-

tending obliquely through the middle of the neck of the femur, but entirely within the capsule. A portion of the fibrous and synovial membrane, on the anterior side of the neck of the bone, had escaped laceration.* With reference to this case, Mr. Amesbury observes: "The causes which gave rise to the inversion of the limb in this instance are evident." This is certainly a simple method of disposing of the question, but it would have been more satisfactory had he specified the causes for the information of others. I suppose he alludes to the fact of the cervical ligament having been uninjured on the anterior side of the neck of the bone; but, as Mr. Stanley has justly observed, this circumstance might, *probably*, prevent the limb from being turned outwards, but it affords no explanation of the occurrence of inversion.

In every case of fracture of the neck of the femur, accompanied by inversion of the foot, which I have had an opportunity of examining after death, the inferior has been placed in front of the superior fragment; it was, therefore, with much surprise that I read the following passage in the Leçons Orales: "Si le fragment interne se porte en arriere, et l'externe en avant, il y a alors deviation en dehors, si au contraire la fracture est oblique en sens inverse, la déviation aura lieu en dedans."† These remarks were so directly opposed to the result of my own observations, that I could only explain them upon the supposition that the opinion of Dupuytren had been incorrectly stated; and a confirmation of this conjecture occurs in the memoir of Mercier upon fractures of the neck of the femur, published in 1835, in the Gazette Medicale. In a note appended to this memoir it is asserted that, in the passage which has been quoted from the Leçons, the opinions of Dupuytren have been erroneously stated by the editors of the Lectures; that, in fact, the words "en dehors" and "en dedans" should be transposed: and in the article upon fractures, published in the Dictionnaire de Medicine et de Chirurgie Pratiques, Sanson states it to have been the opinion of Dupuytren that inversion of the foot occurred when the lower fragment was placed in front of the superior. Cruveilhier also has recorded a case of fracture with inversion, in which, after death, this relative position of the frag-

* Medico-Chirurgical Transactions, vol. xiii.

† Tome ii p. 109.

ments was found.* The difficulty, however, still remains to be solved, viz. how does the circumstance of the lower fragment being placed in front of the superior, favour the occurrence of inversion of the foot? The rotation inwards, in such cases, is probably to be ascribed to the change in the direction of the fibres of certain muscles, and consequent alteration in their action, resulting from the displacement forwards of the lower fragment. This position of the lower fragment would, probably, render the pectinæus and superior portion of the adductor magnus rotators inwards, while, at the same time, the position of the superior fragment behind the inferior presents a mechanical obstacle to rotation outwards, the tendency to which is further prevented by the diminution in the power of the small rotator muscles of the hip, consequent upon the fracture of the trochanter. If the lower fragment be so far displaced forwards as to bring the insertion of the pectinæus and upper portions of the adductors in front of their origin, these muscles would, probably, become rotators inwards, or, at all events, their power of rotating outwards would be lessened.

Whether this conjecture (for it is nothing more) be correct or otherwise, it still appears to me that the influence of the muscles, in producing inversion of the foot, is but secondary; and that the lower fragment must first be thrown, by the violence which produced the fracture, into a position favourable to their action as rotators inwards. I am conscious, however, of the insufficiency of these observations to explain the occurrence of the phenomenon in question, in cases of intracapsular fractures; for in such it is difficult to conceive how the lower fragment could be thrown so far forwards as to affect the action of the muscles, by altering the direction of their fibres. The question is still open to investigation.

There has been already mentioned a remarkable species of fracture of the neck of the femur, termed the impacted fracture, which is characterized by symptoms very different from those which accompany any other form of this lesion, and with which it is most important that the practical surgeon should be well acquainted. In many cases these symptoms are so obscure,

* Livraison xxvi.

and so much at variance with those with which we are familiar, as denoting the existence of the more common forms of fracture of the neck of the thigh bone, that more than ordinary caution is requisite to enable us to avoid committing an error in diagnosis, and pronouncing that the injury which the joint has suffered is merely a severe contusion, which will not be followed by any serious impairment of the functions of the limb; whereas the truth is, that shortening and lameness are the inevitable and permanent results of even the slightest degree of impaction of the broken cervix into the shaft of the femur.

This peculiar form of fracture is the only one, the diagnosis of which is attended with difficulty, for it rarely happens that the limb is shortened to the same extent as in the ordinary examples of extracapsular fractures; in general the amount of retraction is nearly the same as in cases of fracture within the capsule. Between these two forms of injury, therefore, the shortening of the limb is not available as a means of differential diagnosis; upon further examination, however, it will generally be found that crepitus cannot be elicited upon rotating the limb, because upon the one part the neck of the femur is so firmly wedged into the cancellated tissue of the shaft, that the fractured surfaces cannot be moved upon each other; and upon the other the integrity of the strong fibrous and tendinous structure which invests the whole of the region traversed by the second fracture, which has been already alluded to as being always present, is such that the detached portion of the trochanter, whether large or otherwise, in general moves with the shaft of the bone, and it is only by submitting the patient to an examination unjustifiably severe, that we are occasionally enabled to produce this characteristic evidence of fracture. When we endeavour to extend the limb, we usually find that no force which it is safe to employ will restore it to its normal length, and in general the dislocated head of the femur will return into its socket more readily than the impacted cervix will leave the cavity between the trochanters, into which it has been driven.

More remarkable deviations than these, from the ordinary symptoms of fracture of the neck of the femur, sometimes attend this particular lesion; and cases have occurred in which the patient

has not only raised himself from the ground after the fall which caused the fracture, but has even walked a considerable distance, bearing his weight upon the injured limb.*

In ordinary cases of fracture of the neck of the femur, when the limb is viewed as the patient lies upon his back, the appearances are such that the surgeon has no difficulty in ascertaining the nature of the injury which the joint has suffered; but in that particular form of fracture now alluded to, in which the broken cervix remains firmly implanted in the cancellated tissue between the trochanters, the whole expression of the limb is well calculated to deceive us: it does not present that completely powerless aspect which we notice in other cases of fracture of the neck of the thigh bone; the patient has more command over its motions, and I have seen cases, in which, after the lapse of a few days, he has been able to raise the extended limb by the unaided efforts of its own muscles: there is frequently no greater degree of shortening than a very slight inclination of the pelvis would account for; and although the limb is usually turned outwards, it does not lie everted in that prostrate, powerless state, which in its whole expression announces the ordinary fracture of the neck of the femur; indeed in many instances the patient is seen to maintain the limb resting fairly on the heel, turned neither inwards nor outwards, and is able without much pain to flex the leg on the thigh, and the latter on the abdomen: the trochanter major, being still supported by the neck of the femur, firmly implanted in the lower fragment, does not fall back towards the ischium as it does in those cases in which there is no impaction; on the contrary, it frequently seems to stand out even more prominently upon the injured than upon the sound side, and when the patient is supported in the erect posture, the prominent position of the injured hip becomes very apparent: add to these the impossibility of eliciting crepitus, and

* "Nous avons vu un homme qui a peu marcher pendant plusieurs jours, avec le secours d'un bâton, avant qui les fragmens d'une fracture du col du femur se fussent déplacés. On ne peut concevoir un fait aussi extraordinaire qu'en considérant que la cassure de cette partie du fémur est ordinairement inégale; que l'engrenure des inegalités des deux fragmens peut les soutenir; que leur separation est moins facile quand l'une d'eux est taillé en forme de coin, et engagé dans une echancrure proportionnée de l'autre."—*Boyer*, t. iii.

we have a group of symptoms by no means characteristic of fracture of the neck of the femur, but such as would rather induce us to arrive at the conclusion that the injury was merely a severe contusion, from which, under the influence of rest and treatment, the patient would recover, without any impairment of the functions of the limb.

These are truly embarrassing cases, for we are expected to pronounce at once our opinion as to whether the bone is broken or not; the recollection of every surgeon will furnish him with instances in which he has experienced the utmost difficulty in coming to a conclusion in his own mind, under the circumstances which have been described; and it is certain, that not only have cases of impacted fracture of the neck of the femur been often mistaken for contusion of the hip, but also that numerous instances of the latter injury have been recorded as examples of fracture of the cervix femoris cured without lameness or deformity resulting. In the Gazette des Hopitaux* it is recorded that a woman, æt 64, was treated for an intracapsular fracture of the neck of the femur, and that she was discharged from hospital at the expiration of *one month*, "*parfaitement guerie et sans claudication.*" It would indeed require a more than ordinary share of credulity to enable us to believe that in this case there had been a fracture of any part of the neck of the femur, much less an intracapsular fracture. The truth is, that when the muscles around the hip-joint have suffered a violent contusion, in consequence of a heavy fall upon the trochanter, and all the component parts of the joint have received a severe shock, when we examine the limb as the patient lies in bed, there is much in the appearances and symptoms calculated to mislead us; the patient is, in general, unable to raise, by one voluntary effort, the extended limb from the bed; the inclination of the pelvis produces an apparent shortening, and the foot lies everted; there is swelling around the joint, and every motion is attended with pain.

These cases of contusion of the hip-joint, the result of a fall upon the trochanter, are not unfrequently followed (especially in old people), at a period remote from the receipt of the injury, by

* Tome ix.

a real shortening of the limb and eversion of the foot, circumstances well calculated to confirm the belief of a fracture of the neck of the femur having been the original injury, whereas the fact is, these subsequent changes are the result of a vital process, a slow and mild inflammatory action, excited by the contusion in the cancellated tissue of the head and neck of the femur: the delicate vascular structure of the interior of the bone suffers, as it were, a kind of concussion, by which the vessels are excited to increased action, and interstitial absorption of the neck of the bone results; the limb becomes shortened, the foot everted, and not unfrequently we will find in such cases all the symptoms of chronic rheumatic arthritis established.*

We are, in general, enabled to ascertain the real nature of the injury by observing the relation which the trochanter major bears to the anterior superior iliac spine; this relation, being the same upon each side, is usually sufficient evidence of there being no other injury than contusion; but it is to be remembered that the normal relation of these two processes being altered does not always imply the existence of a fracture of the neck of the femur, and I can suppose a case in which the position of the trochanter major with respect to the iliac spine will not serve as a diagnostic mark between a contusion of the hip and the impacted fracture of the neck of the femur. For instance, a man of advanced age, who has long suffered from the effects of chronic rheumatic arthritis of the hip-joint, falls upon the trochanter and receives a severe contusion,—how are we to distinguish this case from one of impacted fracture of the neck of the femur? In both there is shortening of the limb, eversion of the foot, and a change in the position and bearings of the trochanter major; in neither can we elicit crepitus, or elongate the shortened limb; in neither can the patient raise the limb *en masse*, or it may be, that in each he has supported his weight upon it, or even walked a little after the receipt of the injury. If we find, upon questioning the patient (and in such

* "Enfin je soupçonne que dans certains cas ou on a observe le raccourcissement chronique du membre, dans ces circonstances ou les signes de la fracture avaient ete equivoques, il n'y point eu fracture du col, mais que la col a subi une violence qui y a determine des alterations organiques de nature diverse par suite desquelles s'est operée une resorption ulterieure."—*Chassaignac.*

cases we should never omit to institute this inquiry), that he has been long subject to pain and stiffness in the joint, that he walked lame in consequence of a gradually increasing shortening of the limb,—if, in short, we find that he has been suffering from the symptoms of chronic rheumatism of the hip-joint, and if the powerless state induced by the recent injury wears off, under treatment, in a short time, we have, of course, grounds for believing that there is no fracture of the neck of the femur; and upon the other hand, we are justified in supposing that some more serious injury than contusion has taken place, if after long confinement to the horizontal posture, the patient still remains incapable of using the limb.

But although the previous history and the progress of the case may elucidate the nature of the lesion which the joint has suffered, the means of distinguishing between these two forms of injury of the hip *at the time of their occurrence* still remain to be supplied. The evidence of the existence of an impacted fracture of the cervix femoris is of a negative rather than of a positive character, and may be thus briefly stated. 1. Slight shortening of the limb. 2. Slight eversion of the foot. 3. Absence of crepitus. 4. Great difficulty in all cases, and in the majority of instances an impossibility, of removing the shortening of the limb by extension; and lastly, less loss of power than in other forms of fracture of the neck of the femur.

With respect to the anatomical characters of the impacted fracture, we usually find that when the neck of the bone is broken transversely with respect to the direction of its axis, the superior fragment is simply implanted in the cancellated tissue of the inferior, without any interlocking of the broken surfaces; but occasionally we meet with cases in which the irregularity of the line of fracture is such, that the fragments become interlocked, or, as it were, dovetailed together, as in Case No. XLI. The latter form of impaction may occur in cases both of extracapsular and of intracapsular fractures, but the former can only happen when the fracture is external to the capsule; for the relative size of the fragments in the intracapsular fracture is such, that the one could not be received into the other: hence, in these cases we find a dovetailing together of the fragments rather than impaction, the

broken surface of each fragment presenting eminences and depressions which mutually accommodate one another.*

In all the examples of impacted fractures of the neck of the femur within the capsule, which I have had opportunities of examining, the anatomical characters of the injury, and the relative position of the fragments, have been strikingly similar; the head of the bone sunk below its natural level; its superior surface lying nearly in the same horizontal plane with the summit of the trochanter major; the inferior or internal portion of the upper overlapping the lower fragment; and the superior or external part of the latter rising above the level of the corona of the head of the bone, and frequently overlapping its cartilaginous surface (see case No. LVIII.) When a vertical section is made through the head and neck of the bone, and through the trochanters, the line of fracture is seen taking an undulating course, the broken surface of the upper fragment presenting, near its centre, a kind of dentiform process, which buries itself, as it were, in the cancelli of the lower fragment, while the compact tissue of the arch of the latter penetrates the reticular structure of the head of the bone.† I had an opportunity of examining, in the "Musee Dupuytren," the specimen illustrated by the annexed wood cut, but could not learn the history connected with it. It was an example of fracture within the capsule, at the line of junction of the head

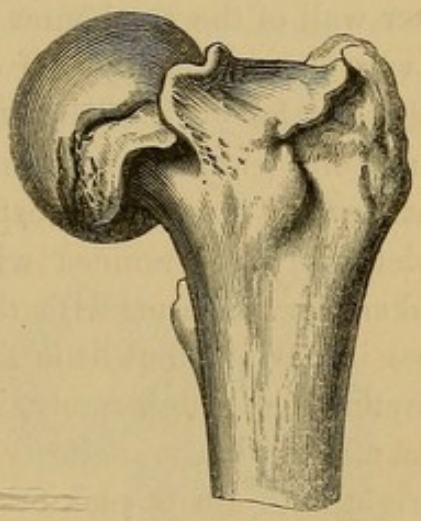

* "L'engrènement des fragmens s'observe moins souvent peut-être dans la fracture intra-capsulaire, que dans la fracture extra-capsulaire. Cependant je l'ai observé plusieurs fois; dans un cas de fracture intra-capsulaire du col, observé sur un adulte très vigoreux, j'ai trouvé un engrènement rèciproque formé ainsi qu'il suite: le fragment supérieure et le fragment inférieure présentaient chacune une cavité et une avance osseuse: la cavité de l'un recevait l'avance de l'autre et réciproquement; l'engrènement était tel qu'il y avait immobilité complète."—*Cruveilhier*, Liv. xxvi.

† Par suite de ce mouvement de descente de la tête, la partie inférieur de sa surface fracturée a cessé de correspondre au col du femur; et réciproquement la partie supérieure de la surface fracturée du col, abandonnée par la tête, est libre, et se présente à nu aux regards de l'observateur."—*Musée Dupuytren: publié au Nom de la Faculté.* Tome premier.

with the neck of the femur. The head of the bone had sunk below its natural level, its upper surface being in the same horizontal plane with the summit of the trochanter major; the line of fracture was undulating; inferiorly the compact tissue of the lower fragment had penetrated the cancellated structure of the head of the bone, while, at the upper part, the lower fragment overlapped the superior. The fragments thus mutually supported each other. They were closely united by an exceedingly dense, fibrous tissue.

The distance to which the superior fragment, in cases of extracapsular fractures, is driven into the cancelli of the shaft, varies considerably. In some cases (No. LII.) it does not exceed a few lines, while in other instances the broken surface of the upper fragment is in contact with the compact structure of the outer wall of the trochanter (No. XLVII.); and if the force applied be very great, this layer of compact tissue may itself be broken, and then the neck of the bone is found in contact with the tendon of the glutæus maximus, or with the bursa which separates that muscle from the great trochanter (No. XLVI.) The same variety is to be noticed with respect to the angle which the broken cervix forms with the shaft of the femur. In some few cases it deviates but little from the natural angle (No. LI.), and sometimes, although rarely, it forms an acute angle with the shaft (No. L.); but in the majority of instances the fragments are placed at right angles with each other (No. XLVII.) This deviation from the natural angle is not, however, the only displacement which the neck of the bone suffers in cases of impacted fractures; for in numerous examples of this injury the neck forms with the shaft of the femur, an angle salient in front, the axis of the broken cervix being directed backwards instead of forwards: in some cases this displacement is carried to such an extent that the anterior surface of the neck of the bone, together with the anterior portion of its broken surface, is placed in front of the shaft, the posterior part of the fractured surface alone being imbedded in the cancellated tissue between the trochanters; the back of the neck of the bone, in such cases, is found resting against the posterior intertrochanteric ridge. This alteration in the axis of the neck depends principally upon the direction in which the force

which has produced the fracture has been applied; and in such instances the eversion of the foot will be greater than is usual in cases of impacted fracture; while, upon the other hand, when the cotyloid fragment is implanted in the shaft in such a manner as to leave the greater part of the inferior fragment in front of it, the eversion of the foot will not only be less than usual, but may even be altogether absent, and inversion is the usual position of the foot in such cases.*

There is a very remarkable variety of the impacted fracture external to the capsule, of which I have seen but one example: in this the lower fragment penetrates a short distance into the cancellated tissue of the superior, the reverse of what generally happens. The shaft of the bone being drawn upwards when the fracture occurs, and the neck of the femur being driven downwards, the angle formed where the inferior extremity of the broken surface of the lower fragment meets the internal margin of the shaft, penetrates the lower portion of the reticular tissue of

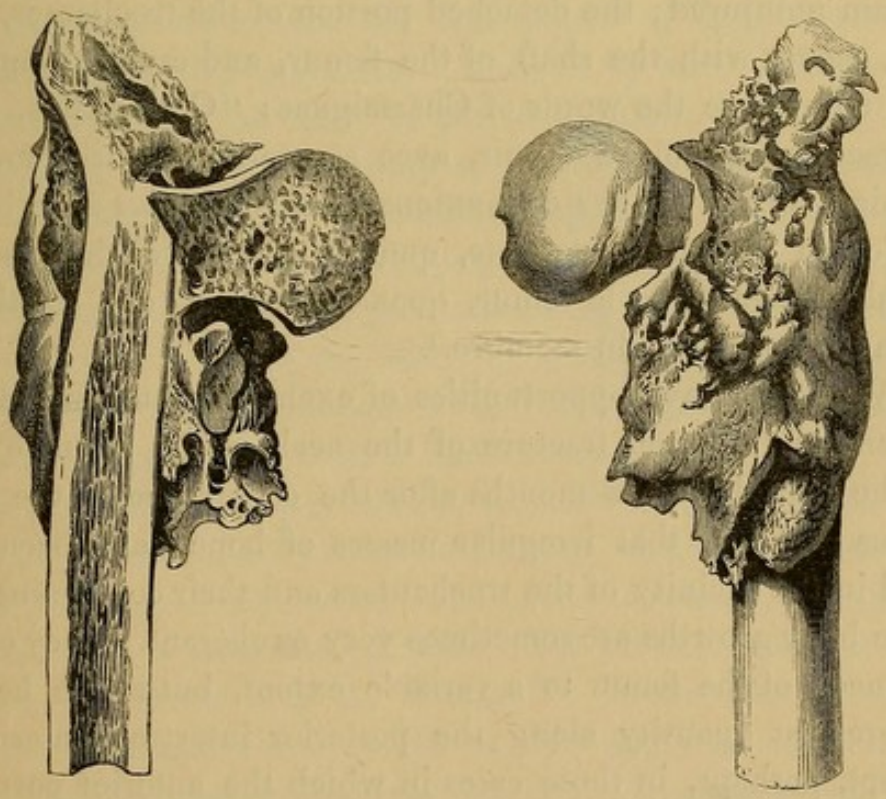

the upper fragment: this tissue is thus brought into contact with the external or superficial surface of the compact structure of the

* See case XLVI.

inner wall of the shaft of the femur, while the upper part of the broken surface of the cervix rests upon the lower portion of the surface of the lower fragment. An example of this singular form of impacted fracture has been delineated by Mr. King.* Its occurrence must depend upon the direction in which the force which broke the bone was applied, but, unfortunately, I am not in possession of the history of the specimen represented in the preceding wood-cuts. The fracture, in this instance, has been wholly united by bone, and a profusion of osseous matter has been deposited around the fragments.

In alluding to the history of the extracapsular fracture of the neck of the femur, accompanied with invagination of the superior fragment, it has been already mentioned that a second fracture traverses the posterior intertrochanteric space: in general, the existence of this second lesion of the bone is only revealed by post mortem examination, for the tendinous and fibrous structures which invest the whole of the trochanteric region usually remain uninjured; the detached portion of the trochanter, therefore, moves with the shaft of the femur, and crepitus cannot be elicited: to use the words of Chassaignac: "Quelquefois, malgre la fracture du col du femur, avec separation du trochanter, ce dernier, conservant des connexions asses resistantes avec le corps de l'os au moyen du perioste, que n'a pas été dechire, se meut simultanement avec le femur, quand on exerce une traction sur la partie inferieure du membre."

When we have opportunities of examining anatomically specimens of impacted fracture of the neck of the femur external to the capsule, some months after the occurrence of the injury, we usually find that irregular masses of bone have been deposited in the vicinity of the trochanters and their connecting lines: these bony growths are sometimes very exuberant. They encircle the neck of the femur to a variable extent, but are to be found in greatest quantity along the posterior intertrochanteric line, except, perhaps, in those cases in which the anterior part of the broken surface of the neck of the bone projects in front of the shaft, or when, as sometimes happens, the anterior part of the

* Cyclopædia of Surgery, article "Fractures."

lower fragment has been broken off from the shaft; the bony material is then deposited freely along the anterior line.

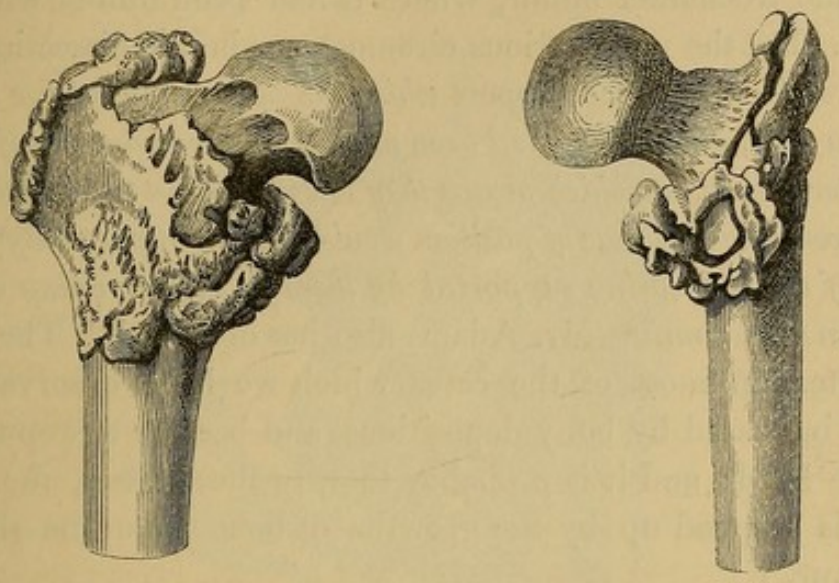

These exostotic growths have not escaped the attention of pathologists, but it has appeared to me that the purpose which they are intended to serve, and the true object of their formation, have been altogether mistaken. They have been described as being simply additions made to the trochanters, and their connecting lines, by which a species of socket is formed to receive the neck of the bone, the acetabulum supported, and the individual enabled to bear his weight upon the injured limb: they have been supposed to be merely provisions adopted by nature for the support of the weight of the body. "Quelquefois la nature dispose avec une sorte d'intelligence ces ossifications, de manière à les rendre propres a consolider l'articulation accidentelle. Tels sont les cas où des anneaux osseux completes ou incompletes, provenant de la base du col ou des trochanters, ou formant un sourcil avancé à la partie superieure de la cavité cotyloïde, invaginent pour ainsi dire la fausse articulation. Tel est encore ce cas communiqué par Powel a S. A. Cooper."* These observations of Vidal are, perhaps, correct, as far as they apply to cases of fracture within the capsular ligament; but in the instance to which he has referred, as recorded by Sir Astley Cooper, the fracture was external to the capsule and impacted. "The neck of the femur

* Traité de Pathologie Externe. Par Aug. Vidal (De Cassis), t. ii.

had been broken at its junction with the body of the bone, and had been forced into the cancellated structure between the trochanter major and trochanter minor, where it had been united with the cancelli. But the most curious circumstance in this dissection was, that, *in order to give the support which the body required for a limb in such a state, an addition had been made to the trochanter major and trochanter minor, by which means they rested against the acetabulum, and in every slight change of position would give an opportunity for the weight of the body being supported by these processes resting against the os innominatum.*"* Mr. Adams also has observed, " The lesser trochanter, in most of the cases which we have observed, was greatly increased by bony depositions, and became a prop to support the head; and it is probable that, in these cases, the acetabulum is propped up by the growths of bone from the shaft of the femur."†

After an attentive consideration of this subject, and a careful examination of a great number of specimens of the impacted extracapsular fracture, with a view to ascertain the truth or fallacy of this doctrine, it appears to me that the mechanical support of the head and neck of the femur, and of the acetabulum, is neither the sole, nor even the principal object intended to be accomplished by the deposition of these irregular masses of bone; in general they are less copiously deposited below the neck of the bone than elsewhere; they are most luxuriant about the back of the trochanters and the posterior intertrochanteric space, and are usually proportionate in amount to the extent of the lesion which the trochanters have suffered: when the trochanter major is merely, as it were, split, or fissured, its fibrous coverings remaining entire, and the broken surfaces directly confronted to each other, the quantity of new bone is exceedingly small, while, upon the other hand, it is abundant when a large portion of the trochanter is broken off and displaced, in consequence of the laceration of the fibrous tissues which invest this region; and finally, these osseous depositions are most exuberant when the trochanters are comminuted, and the fragments displaced both from the

* Sir A. Cooper on Dislocations, &c., page 150, plate ii. fig. 1.

† Todd's Cyclopædia, page 810.

shaft and from each other. If to afford mechanical support to the pelvis were the true object of their formation, surely we

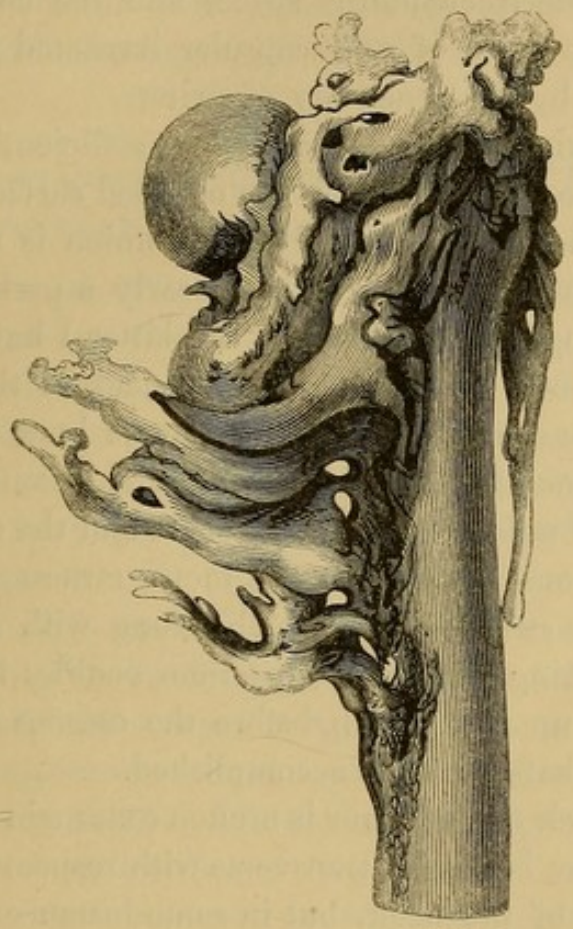

should expect to find them more frequently than we do in cases of fracture within the capsule, for it is in such cases that this mode of support is most necessary; but although it is no doubt true that in many of these cases they are present, it is equally true that in the great majority of intracapsular fractures they are never formed, whereas in almost all cases of intracapsular impacted fractures, where the patient survives the accident a sufficient length of time, bony matter is deposited in greater or less quantity; and yet, in these cases, the circumstance of the neck of the bone being impacted in the shaft, renders less necessary the mechanical support which these adventitious growths have been supposed to afford; and although I am willing to admit, that when very exuberant they may afford support to the neck of the bone

* Sandifort, Museum Anatomicum, vol. iv.

and to the pelvis, yet I feel convinced that such is not the object for the attainment of which they are deposited; the final cause of their formation is the union of the fracture already described as traversing the intertrochanteric space, and the constant existence of which, in cases of extracapsular impacted fractures, has been overlooked by the generality of writers.

When the patient survives the accident sufficiently long, bony consolidation takes place between the opposed surfaces of the impacted cervix and of the shaft, but this union is never accomplished with so much facility, or at so early a period, as that of the fracture through the trochanter; the latter I have frequently found united firmly by bone, while the neck of the femur has, upon being left for some time in water, become loose in the cavity which it had formed for itself between the trochanters: in these cases the bond of union between the cervix and the shaft is generally a cartilaginous, or fibro-cartilaginous, structure of extreme density and great strength, and which, along with the mechanical support resulting from the impaction, enables the patient to bear his weight upon the limb before the osseous union of the cervix with the shaft has been accomplished.

When the neck of the femur is broken external to the capsule, the line of fracture is usually transverse with respect to the direction of the axis of the neck, but in some instances the fracture passes downwards and outwards so obliquely that a portion of the great trochanter remains connected with the upper fragment, while in other cases the obliquity is in the reverse direction; and Vidal mentions his having seen one instance in which the obliquity downwards and inwards was such, that the trochanter minor remained with the superior fragment; such cases are, however, correctly speaking, examples of fracture through the trochanter, rather than of the neck of the bone. The extracapsular fracture is frequently accompanied by extensive ecchymosis, and upon post mortem examination we occasionally find that the effused blood has separated from each other the muscles of the thigh, even as low as the knee-joint; the surfaces of the fracture bleed freely, and in recent cases we find clots of blood occupying the space or cavity circumscribed by the fragments of the shattered bone. The hæmorrhage from the lacerated vessels of the cancel-

lated tissue is sometimes very profuse, causing great tumefaction and excessive pain; and Cruveilhier has recorded an instance in which the patient sunk upon the fifth day after the receipt of the injury, apparently in consequence of the profuse bleeding which took place, from the source just alluded to.

ANATOMICAL CHARACTERS OF FRACTURES OF THE NECK OF THE FEMUR, WITHIN THE CAPSULAR LIGAMENT.

In recent cases of intracapsular fractures of the neck of the femur, there are but few phenomena worthy of notice revealed by the anatomical examination of the joint; indeed the only one which deserves more than a passing notice has reference to the condition of the cervical ligament, but this subject has already been alluded to at sufficient length. There is generally observed a preternatural amount of vascularity of the synovial membrane, and in some cases a small quantity of blood is found within the capsule, and sometimes coagulable lymph is seen adherent to the internal surface of the capsular ligament; the surfaces of the fracture are themselves sometimes covered by a layer of lymph, which can be drawn out into delicate bands by gently separating the fragments from one another.

In those cases, however, in which the injury has happened many years before the death of the patient, the morbid appearances are as remarkable as they are varied. The capsular ligament is usually greatly increased in thickness, and occasionally osseous matter is deposited in its structure. I have seen only one example in which it was extensively lacerated, but in several instances of oblique fracture have found it perforated by the sharp extremity of the upper fragment; and the late Mr. Colles has recorded a case in which a sharp projecting splinter, belonging to the upper fragment, pierced the front of the capsule and the bursa, which is here placed, connected with the psoas muscle, the tendon of which appeared as if unravelled in its texture, or split into a number of softened tendinous threads. The synovial membrane also is usually thicker than in the normal state, and lymph is deposited upon its surface, not only where it lines the interior of the capsule, but also where it is reflected upon

the neck of the femur; in some cases the lymph, although formed into an organized membrane, does not constitute the medium of any adhesion, but hangs in fimbriated masses (No. XIII.), similar to those seen in this articulation in cases of chronic rheumatic arthritis; but in numerous examples it forms adhesions of great strength between the opposed synovial structures, and also between these and the broken structure of the upper fragment, and sometimes both fragments are thus connected to the capsule and to each other (No. XXIII.).

The synovial membrane sometimes presents the anatomical characters of acute inflammation, but in general the lymph which we find effused is the product of chronic rather than acute synovitis; nevertheless, it occasionally happens that not only the fibrous and synovial structures, which enter into the composition of the joint, become the seat of acute inflammation, but even acute osteitis is established, and the capsule rapidly becomes distended with lymph and purulent matter. These generally fatal consequences are most likely to ensue, however, while the injury is recent, and their occurrence is most to be dreaded in those individuals whose constitution, either from intemperance or any other cause, is at the time favourable to the production of diffuse inflammation. In general the head of the femur preserves its globular form, and is moveable in its socket, but sometimes it becomes adherent to the acetabulum, and the opposed cartilaginous surfaces are found invested with a false membrane, which constitutes the bond of union, and beneath which the cartilage of the head of the bone is found differing but little from its normal state; or else (in very old cases) the layer of cartilage being removed, the osseous surfaces of the head of the femur and of the acetabulum become closely joined to each other by a dense fibrous structure, and a false anchylosis is established; in some rare cases, an organized membrane covers the head of the femur, and also the acetabulum, and yet no union takes place between the two opposed vascular surfaces. The ligamentum teres generally remains unaltered in its texture, but sometimes it appears, as it were, unravelled, and resembles a cellular more than a ligamentous structure.

The superior fragment of the broken cervix usually disappears

to the level of the brim of the acetabulum, either in consequence of the action of the absorbent vessels, or by the friction of the broken surfaces, or perhaps it is due to a combination of both these causes. The absorption, however, sometimes extends much further; I have seen half of the globular head of the bone thus removed, and a case has been recorded in which the head of the bone was completely absorbed. In some cases its lower surface becomes uniformly concave, and a shallow socket, as it were, is formed, into which the upper end of the lower fragment is received; or the upper fragment may present both a concavity and a convexity, which are adapted to a corresponding eminence and depression upon the surface of the lower fragment, and the relative position of which depends upon the original direction of the fracture. In a few rare examples the lower surface of the cotyloid fragment presents an uniform convexity, which is received into a very superficial and shallow socket, formed in the condensed cancellated structure between the trochanters, the femoral fragment having been absorbed. The case of Patrick Doolan (No. XI.) affords a good example of this condition of the fragments, the superior of which was united by membranous anchylosis to the acetabulun, while the lower surface of this fragment represented the half of a sphere; the neck of the bone had entirely disappeared, and a shallow cup was hollowed out in the space between the trochanters, to receive the convex surface of the upper fragment: both these surfaces possessed the hardness of ivory and the polish of enamel.

In old cases the femoral fragment is likewise absorbed to a greater or less extent; sometimes it disappears entirely to its base, and the portion of the shaft, from which, in the normal state, it springs, presents a smooth and even surface, limited by the trochanters and their connecting lines (Nos. XIX. and XX.) In general the two portions of the bone move freely upon each other, but in not a few instances they are united by a ligamentous or fibrous structure, the result of the deposition of lymph: this dense tissue is sometimes formed over the entire surface of each fragment, maintaining them in close apposition, and preventing effectually the free motion of one upon the other; but very frequently we find that the material of this union has been formed only at one

or two points; in such cases the lower fragment enjoys a considerable extent of motion, and the uniting medium becomes elongated into bands an inch or more in length. Occasionally the lower fragment suffers but little from absorption (although the fracture may have occurred many years before the death of the patient), its extremity merely becoming rounded, and presenting a smooth surface more or less convex. Portions of the compact structure along the posterior margin of one of the fragments, are frequently laid down upon the fractured surface and united to it; it is comparatively rare to witness this phenomenon along the anterior margin of either fragment, and I believe that it takes place at the moment of the occurrence of the fracture, and that it is to be ascribed to the collision between the posterior margin of each fragment, consequent upon the rotation outwards of the inferior.

The absorption of the lower fragment is sometimes effected with extraordinary rapidity; in case No. IX. the shortening of the limb, which immediately followed the receipt of the injury, was only a quarter of an inch, but after the expiration of six weeks it amounted to one inch and a half; and in case No. XII. the removal of the greater part of the neck of the bone was accomplished in less than a month. According as the absorption proceeds, the shortening of course increases, and the trochanters are gradually approximated to the level of the acetabulum. We usually find that the broken surfaces, and all the structures which compose the false articulation, are lubricated by a viscous synovial fluid, in which flocculi of lymph are often seen, either free or attached to the synovial lining of the capsule, or of the neck of the bone: sometimes, but not frequently, we find what are usually termed foreign bodies, either free in the interior of the joint, or attached; they are analogous to the foreign bodies found in the articulations in cases of chronic rheumatic arthritis.

PARTIAL FRACTURE OF THE NECK OF THE FEMUR.

A peculiar form of injury of the neck of the femur, termed "Partial Fracture," has been described by the late Mr. Colles, and also by Mr. Adams. The former author has spoken of its

occurrence in cases of fracture within the capsular ligament, and the latter has described the symptoms and the morbid appearances supposed to characterize it in extracapsular fractures. In the article upon the "Abnormal Conditions of the Hip-joint," published in the Cyclopædia of Anatomy, Mr. Adams, when speaking of the impacted fracture, remarks: "In general the fracture is complete of the compact and reticular tissue of the neck of the bone, and the upper fragment is wedged into the lower, as is the fang of a tooth into its alveolus; but cases, we believe, have occurred, in which the fracture of the cervix femoris was incomplete, and had engaged merely the under stratum of the compact tissue of the neck of the femur. To comprehend well what occurs in the partial, as well as in the impacted fracture, we should attend a little to the normal anatomy of the interior of the cervix femoris, and the disposition of the compact and reticular tissue. Let us make a vertical section through the neck of

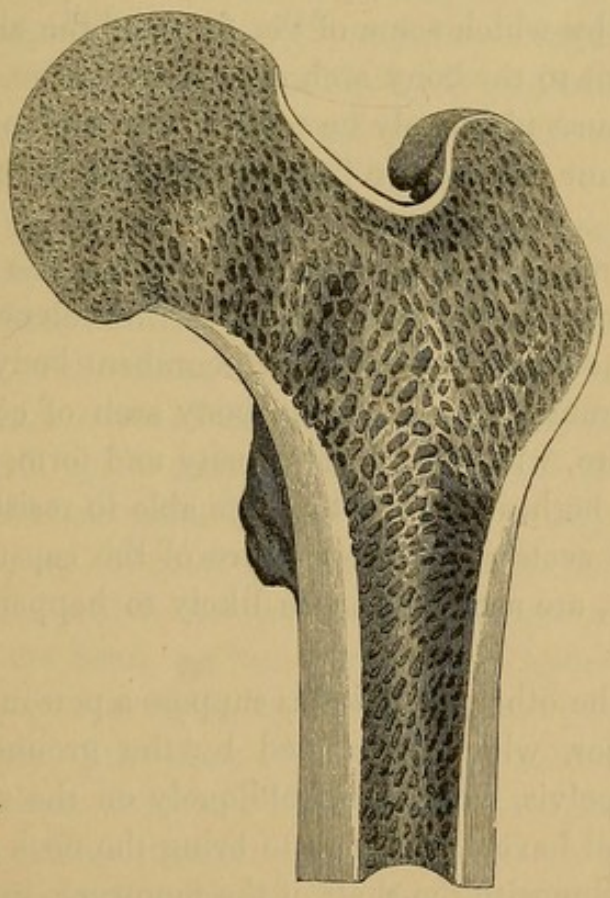

a healthy femur, in the direction of its long axis, and continue it down through the shaft of the dry bone, the section leaving

one-half of the femur in front, and the other behind with the lesser trochanter, as has been done in the healthy femur of a well-formed adult man, from which the adjoining figure has been taken.

"This simple view shews us that the principal strength of the neck resides in the arch of compact tissue, which begins small where the globular head joins the under part of the neck, but which gradually enlarges downwards towards the lesser trochanter, and even so low as the middle of the femur, where it will be found to be nearly twice the breadth of the opposite wall of the shaft of the bone; the compact structure which, scarcely thicker than a wafer, invests the entire head of the upper part of the neck and trochanter, seems to have little reference to any design of imparting strength or resistance to this part of the bone.

"When we fall, or leap from a height, on the feet or knees, the thin upper stratum of the neck, and the whole of the reticular tissue of the neck, will first receive, and probably yield somewhat to the weight, by which some of the force of the shock may be decomposed, but to the bony arch of compact tissue, to which we have alluded, must ultimately be referred any violence which the neck of the femur can receive from any impulse transmitted from above.

"We seldom hear of a fracture of the neck of the femur occurring to a healthy adult, when he falls with violence on his feet or knees, for the weight of the superincumbent body is thrown in the most favourable manner on the bony arch of compact tissue before alluded to, which, from its density and form, and strength derivable from both, it is almost always able to resist; and even a fracture of the acetabulum, or rupture of the capsular ligament and dislocation, are accidents more likely to happen under such circumstances.

"But, on the other hand, let us suppose a person to fall on the trochanter major, which is resisted by the ground, while the weight of the pelvis, &c., acting obliquely on the under surface of the neck, will have a tendency to bring the neck of the femur into a straight line with the shaft of the femur, or, in other words, to efface its obliquity, hence the compact tissue, so often alluded to, cracks across, and if no more happens for the present, we have

the simplest form of partial fracture of the neck of the femur. The possibility of such an accident occurring implies that there is toughness and tenacity enough of the material composing the reticular part of the neck of the femur to yield without breaking, of which there can be now no doubt entertained.

"While circumstances are in this state, we can conceive the possibility of a patient being able to stand after such an accident, or even to walk for some distance; and when examined by the surgeon, we can understand how the latter, as it has often happened, might be deceived into the opinion that there was really no fracture.

"Again, we can easily imagine how, under such circumstances, an awkward movement or a fall may render the fracture complete, or how, from a severe secondary injury, or even the continued action of the first impulse, somewhat varied in its direction, the broken neck of the femur could be wedged into the cancelli of the shaft. When we remove the femur, which has been the subject of this partial fracture of its neck, and examine it, we shall uniformly find that its natural obliquity is lost, and that the head and neck of the bone are directed simply horizontally inwards, at right angles with the shaft.

"Viewed posteriorly, the intertrochanteric line, in all the cases I have examined, seemed to have been the seat of osseous depositions, and the interval between this and the head, which constitutes the back part of the neck, was diminished one-third. When we make a vertical section of the femur we observe that the compact structure at the upper part of the cervix, and the whole of the reticular tissue shew not a trace of fracture, or any alteration except that of loss of obliquity; but if we examine the compact arch of bony material which stretches from the lesser trochanter to the under part of the head, we find that this has been the seat of fracture, and that by a gradual, or sudden effort, it has been driven into the cancelli of the shaft of the femur, and with the compact tissue of the latter, forms a T-like disposition of these structures."

In the preceding observations it appears to me that the author has furnished us with a concise, but, as far as it extends, accurate description of the anatomical characters of those cases of impacted fracture of the neck of the femur, in which osseous union has

taken place; but however ingenious the remarks may be considered, they certainly afford no evidence of the occurrence of such an accident as partial fracture of the cervix femoris.

It would, in my opinion, be impossible to establish the doctrine in question, except by the examination of *recent* specimens; for in the ordinary impacted fracture, when a vertical section is made through the head, neck, and upper part of the shaft of the femur, after bony union has been accomplished, the appearances are certainly well calculated to mislead the judgment. The compact tissue of the concavity of the cervix forms, it is true, generally a right angle with that of the shaft; but beyond this, as far as the interior of the bone is concerned, there is usually but little evidence of the upper portion of the bone having ever been the seat of fracture; no line of callus indicates where the fracture traversed the reticular tissue, nor does the compact structure which lines the upper part of the cervix exhibit any trace of fracture. But it is to be recollected that, in the impacted fracture, bony consolidation (when it does occur) takes place, not by the formation of callus, but by the direct union of the two osseous surfaces which are confronted to each other. It is, therefore, not to be wondered at that the reticular tissue, in such cases, should exhibit no trace of fracture, when the parts are examined after osseous union has been for some time accomplished; and it is still less surprising that no evidence of injury is to be found in the compact tissue of the upper part of the neck of the bone, for the fracture in these cases is extracapsular, *and altogether external to the commencement of the line of compact structure in question;* it traverses the bone exactly where the neck springs from the shaft of the femur.

But what appears to me to constitute incontestable proof that the cases upon which this eminent surgeon has founded his ingenious theory should be looked upon as examples of the impacted and complete, rather than of the partial fracture of the neck of the femur, is to be found in the following passage: "*Viewed posteriorly, the intertrochanteric line, in all the cases I have examined, seemed to have been the seat of osseous depositions.*" Now, I think sufficient evidence has been already adduced to prove that these ossific deposits indicate that a fracture had traversed the posterior intertrochanteric space, and that such lesion is the

necessary result of an impacted fracture of the neck of the femur: of what use would these osseous depositions be in such a situation, if nothing but the *concavity* of the cervix had been broken? Or is it probable that the fracture through the trochanter (which the osseous deposits prove to have existed, which is the second fracture in order of time, and which is the result of the impaction of the neck of the femur into the shaft), is it likely that this second fracture would result, when the force applied was not sufficiently great even to break the neck of the bone entirely through?

It may also be remarked, that partial fracture is a form of injury to be looked for in the young subject, and most unlikely to occur at that period of life at which fracture of the neck of the femur takes place, and of all parts of the skeleton, the neck of the thigh bone appears to me the least liable to such an injury. That the case of Sherlock (No. XLVIII.) has been considered as an example of partial fracture, may be inferred from the following description given of it by Mr. Adams, in the paper already alluded to: "Alicia Sherlock, æt. 64. Section of the head and neck of the femur, shewing fracture external to the capsule. The neck of the bone has sunk nearly to a right angle with the shaft. *The compact structure which lines the concavity of the cervix has been broken, while the very thin stratum which invests the upper surface has yielded to the force without breaking;* but the cervix has sunk into the cancellated texture of the shaft at a right angle, and is now supported upon the lesser trochanter. There is no motion whatever between the broken surfaces, *nor the slightest trace of fracture at the central part of the neck of the bone. Exuberant growths of bone surrounded the seat of fracture,* and contributed to form a kind of socket which received the superior fragment."

Having recently examined this specimen with much care, and left the bone for about two hours in boiling water, I found that it separated into three distinct portions, the shaft, the cervix, and the trochanter; the fracture of the cervix was complete, and, as usual, a second fracture had detached the trochanter; for the union of this second lesion of the bone, the osseous matter alluded to had been deposited, but perfect bony union had not taken

place, although the patient survived the accident for fifteen weeks.

When it is considered that fracture of the neck of the femur occurs at a period of life when the bones are not likely to bend without breaking, and that in all the cases of supposed partial fracture, external to the capsule, there has been unequivocal testimony of the existence of a fracture of the trochanter; bearing in recollection, also, the fallacy of adducing, in support of the theory, the circumstance of there being no solution of continuity in the compact tissue of the upper portion of the neck of the femur; and having found by actual examination of the specimens, in some of the cases adduced, that the fracture of the cervix was complete, and the trochanter likewise broken, we cannot avoid arriving at the conclusion, that the doctrine of partial fracture of the cervix femoris has not been established.

In the cases described as examples of partial fracture, by the late Mr. Colles, the injury, as already mentioned, was within the capsular ligament.* In case No. VII. the fracture was transverse, and close to the head of the femur. The fracture was incomplete, for the external bony coating of the neck of the femur remained unbroken for nearly half the circumference of the bone at its posterior part, and was reduced to the softness and whiteness of cartilage. To the internal surface of this unbroken portion adhered many bony fragments of different sizes, which by the violence of the fracture appeared to have been torn away from the reticular substance of the bone. In case No. VIII. the fracture was also transverse, and close to the head of the bone, but towards the posterior part of the neck the two pieces of bone remained connected with each other by a broad band of the external coating of the neck, which was unbroken; this band was not less than an inch in breadth; it was palbably a continuation of the external coating of the bone; its internal surface was as rough as a piece of coarse sand-paper, in consequence of small particles of the cancellated tissue of the bone remaining attached to it.

I have never seen an example of fracture of the neck of the femur, the anatomical characters of which exactly corresponded

* Dublin Hospital Reports, vol. ii.

with those described by Mr. Colles. I have, it is true, frequently found a considerable portion of the compact tissue which invests the posterior surface of the cervix torn from the cancellated structure, and remaining adherent to the cervical ligament, which usually remains uninjured posteriorly, being, as already mentioned, relaxed by the rotation outwards of the limb; but in the majority of such cases, this lamina of compact tissue is itself broken into two or more fragments, in consequence also of the rotation outwards of the limb, for this motion, while it divaricates the anterior margins of the fracture, crushes, as it were, the fragments together posteriorly, and hence it is that we so often find the intracapsular fracture, although simple in front, comminuted behind.

It would be very difficult to account satisfactorily either for the shortening of the limb or the rotation of the foot outwards, as long as we suppose the posterior part of the neck of the bone unbroken; in my opinion, the presence of shortening necessarily implies, that if there be any fracture of the neck of the bone it must be complete: no one, surely, would be disposed to maintain that the thin stratum of compact tissue which covers the posterior part of the cervix femoris is likely to bend, and thus to yield without breaking, in an old person, to a force which fractures the remainder of the neck of the bone; and yet it is obvious that it must either bend or break, before retraction of the limb can occur. I have not been able to find in the Museum of the Royal College of Surgeons, the specimens which Mr. Colles has described as examples of partial fracture, nor is there any mention made of them in the printed Catalogue of the Museum, so that I cannot speak with confidence upon the subject; but from having myself repeatedly seen appearances very similar to those which he has described, in cases in which the fracture was undoubtedly complete, I am disposed to believe that some mistake has been committed, the exact nature of which it is now, of course, impossible to ascertain.

It has been already mentioned that, in the great majority of cases of intracapsular fracture, the posterior portion of the cervical ligament remains uninjured, and that large fragments of the compact tissue of the corresponding part of the neck of the bone are fre-

quently found adhering to it. In old cases, such as those described by Mr. Colles, this unbroken portion of the ligament acquires a great degree of strength, density, and thickness. In some cases it presents the characters rather of cartilage than of membrane; and were it not for the high reputation of the author, and the general accuracy of his observations, I would almost be inclined to suppose that the structure or substance which he has described as bone "*reduced to the softness and whiteness of cartilage*," was merely the thickened, semi-cartilaginous, and unbroken portion of the cervical ligament, with fragments of the compact tissue of the bone adhering to it. Be this as it may, the theory of partial fracture of the neck of the femur is one that is interesting both to the pathologist and to the practical surgeon, and it is of some importance that its truth or fallacy should be established. For my own part, although I may have failed to convince the judgment of others, I am satisfied that the doctrine has not yet been proved to be correct; nor have I arrived at this conclusion hastily, but after having given to the subject that degree of consideration which is due to the opinions of the distinguished authors referred to, as the supporters of the theory.*

Does osseous union ever take place in cases of fracture of the neck of the femur within the capsular ligament? It is not my intention to enter at any considerable length into the investigation of this long agitated question, which, in my opinion, has been satisfactorily replied to in the affirmative. We may, perhaps, for convenience sake, arrange the opinions at present held upon the subject as follows: some maintain that the reparation by bone of the intracapsular fracture, although of very rare occurrence, yet has actu-

* There is no portion of the neck of the femur which has not been described as having been the seat of partial fracture. In Mr. Colles' cases the *posterior* surface is said to have remained uninjured; in Mr. Adams', the *superior*. Mr. King, in Guy's Hospital Reports, October, 1844, describes a case in which less than one-third of the shell of the bone is said to have remained entire *superiorly and anteriorly;* and in the *Archives Generales de Medicine*, third series, second volume, Mons. Tournel has published a case in which the *inferior* surface of the neck of the bone remained entire. The patient was a man æt. 85; he survived the occurrence of the accident three months and a half; the preparation is stated to be preserved in the museum of the Military Hospital at Ajaccio.

ally happened in several instances; others, without denying the possibility of such an event, are of opinion that its actual occurrence has not been demonstrated; and, lastly, it has been asserted in the strongest possible language, not only that osseous union is altogether impossible, but that there are, in the hip-joint, "*in old people, certain provisions for the prevention of such union, as if to avoid the ill consequences which, at this part of the body, would necessarily arise from the usual mode of ossific reparation.*"

In the third volume of Guy's Hospital Reports (New Series), there is a paper by Mr. Bransby Cooper upon the causes of the non-union of these fractures, in which he dwells at some length upon the evil which he supposes would result, if osseous union were to occur: he remarks, "*What would have been the result if such union were admitted? That the provisional callus itself would have filled up the acetabulum, and in every way have so interfered with the structure of the joint as in itself to have proved destructive to the performance of every natural function of the limb. My object has been throughout to maintain, that it is ordained by nature that fracture of the neck of the femur, within the capsular ligament, is not to unite by ossific deposition.*"

Before making any observations upon the preceding statements, it will be more convenient to allude briefly to the opinion of Cruveilhier. This distinguished pathologist believes that the bony union of the intracapsular fracture is impossible, because the fragments are not surrounded by any tissues capable of forming and depositing callus; and he is of opinion that the ends of the broken bone, no matter how confronted to each other, never are directly united.

Now I believe that both the authors just alluded to are in error, in supposing that the effusion of callus around the fragments is necessary for the union of this fracture; and must altogether dissent from the opinion which maintains that the ends of the broken bone take no part in accomplishing osseous union. How is bony union effected in cases of extracapsular impacted fracture? Surely it must be by the direct union of the two bony surfaces which are confronted to each other: the surrounding soft parts cannot be in any way concerned in the process; the osseous matter which we find effused along the pos-

terior intertrochanteric space being intended for the union, not of the broken cervix, but of the fracture through the trochanter, as has been already explained; and I believe that, whenever reparation by bone occurs in the intracapsular fracture, it is owing to the direct union of the broken surfaces, and that the effusion of callus around the fragments is by no means essential to the process.

This will become obvious to any unprejudiced person, who examines the plates representing the bony union of this fracture, which are appended to the memoirs of Langstaff, Adams, Jones, &c. All these cases have been examples of one or other form of impacted fracture; either a portion of the lower fragment has penetrated the cancellated tissue of the head of the bone, or else the broken surfaces presented a series of convexities and concavities which mutually accommodated each other, and, in consequence of which, the fragments remained, as it were, dovetailed together; and, moreover, in such cases, the injury which the cervical ligament sustains is comparatively slight, so that the broken surfaces remain confronted to each other, and consolidation takes place by the direct union of the surfaces of the fracture. It is highly probable that, in the cases which have hitherto been published as undoubted specimens of the bony consolidation of the intracapsular fracture, there has been a mutual interlocking of the fragments, whereby they have been maintained in apposition: at all events, it is under such circumstances that a firm bony union is most likely to occur; for, as remarked by Desault, "it is a principle that will not admit of controversion, that, to effect consolidation, nature demands the fractured portions to be approximated, and, at the same time, to be in a state of absolute rest."

With respect to the statements and opinions of Mr. Bransby Cooper, which have been quoted, it is difficult to conceive how the provisional callus (supposing that it were formed) could "*fill up the acetabulum*," already occupied by the head of the femur; and it is equally difficult to imagine how it could impair the structure of the joint, or prove more completely destructive to the natural functions of the limb than the fracture of the neck of the bone has already done. For my own part, were I so unfortunate as to meet with this accident in my own person, I would

prefer running the risk of all the evils which Mr. Bransby Cooper supposes would arise from the union of the fracture by bone, to the necessity of carrying about with me, during the remainder of my days, so dangling and so useless an appendage as the limb usually is, in cases of disunited fracture of the neck of the femur within the capsular ligament.

In another place,* the same author remarks that callus is not formed in those situations where its presence would interfere with the motions of a joint; and he asks, "what would be the effects of a mass of callus protruding on the inner surface of a fractured skull? What degree of useful motion would remain in the knee or elbow, if both surfaces of a fractured patella or olecranon threw out a projecting callus?"

Now it is, of course, obvious enough, that such a mode of union would be injurious in the situations to which the author has referred, and, therefore, nature does not adopt it, but has recourse to another mode, from which no consequences detrimental to the functions of the part can result. It is true that a mass of callus is not formed around the fragments in fractures of the skull or of the patella, but still the fracture of the cranium readily unites by bone, and so does that of the patella, when its direction is longitudinal. If, then, the effusion of callus is not necessary in these instances, why should it be considered as indispensable that the fragments should be surrounded by it in cases of fracture of the neck of the femur within the capsular ligament? Nature is not limited to one and the same method of accomplishing her object in all cases; and if the union of a fracture by external callus is either impossible, or likely to prove injurious in any given case, bony consolidation, when it does happen, is effected by the direct union of the broken surfaces confronted to each other

After reflecting upon the cases that have been published as examples of osseous union of intracapsular fractures, I cannot by any means agree in the statement "*that it is ordained by nature that fracture of the neck of the femur within the capsular ligament is not to unite by ossific deposition,*" for there is now certainly abun-

* Sir A. Cooper on Dislocations, edited by Mr. Bransby Cooper. Note by the Editor, page 144.

dant evidence to prove the actual occurrence of osseous union: those who deny its possibility must disbelieve the recorded facts, and what grounds have they for so doing, or how are we to form a judgment of the correctness or incorrectness of any statement? Surely we must, to a certain extent, be influenced by the character of the author of the statement, and his competence to form an opinion upon the subject, whatever it may be. "In the acquisition of facts," as has been well remarked by that distinguished and enlightened physician, the late Dr. Abercrombie, "we depend partly upon our own observation, and partly upon the testimony of others. The former source is necessarily limited in extent, but it is that in which we have the greatest confidence; for, in receiving facts upon the testimony of others, we require to be satisfied not only of the veracity of the narrators, but also of their habits as philosophical observers, and of the opportunities they have had of ascertaining the facts. In the degree of evidence which we require for new facts, we are also influenced by their probability, or their accordance with facts previously known to us; and for facts which appear to us improbable, we require a higher amount of testimony than for those in accordance with our previous knowledge. *This necessary caution, however, while it preserves us from credulity, should not, on the other hand, be allowed to engender scepticism; for both these extremes are equally unworthy of a mind that devotes itself with candour to the discovery of truth.*"

If, then, we are satisfied of the veracity of the authors who have published examples of the osseous union of the intracapsular fracture of the neck of the femur, if we believe them to have been competent judges, that they have had opportunities of acquiring correct information, and that they have not been superficial observers, we must either believe their statements, or expose ourselves to the charge of scepticism, and render it obvious that our judgment has been so warped by theory and preconceived ideas, that no amount of evidence would be sufficient to alter our opinions.

It is not my intention to trespass upon the patience of my readers by entering into a consideration of all the causes which have been assigned to explain the infrequency of osseous union, nor would any advantage result from a tedious detail of the arguments that

have been adduced in support of each side of this long-disputed question; I shall, therefore, terminate this part of my subject with a concise summary of the cases which constitute the evidence by which the possibility of the occurrence of osseous union of the intracapsular fracture of the neck of the femur has, in my opinion, been established.

No. I.—*Mr. Langstaff's Case.* In this case the patient was a female, aged 50, when the fracture happened. She was confined

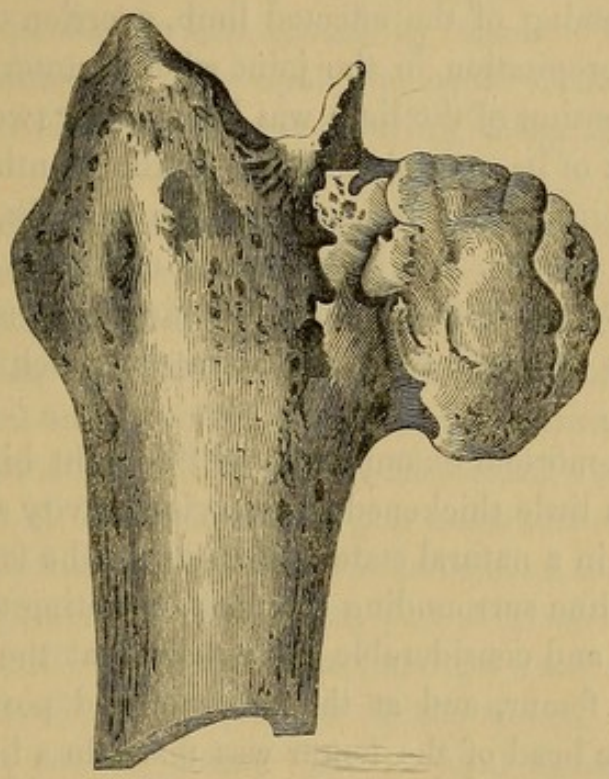

to bed for nearly twelve months after the occurrence of the accident; and during the remainder of her life, a period of ten years, walked with crutches. On dissection, it was found that the principal part of the neck of the bone was absorbed; the head and remaining portion of the neck were united, principally by bone, and partly by a cartilaginous substance. On making a section of the bone, it was evident that there had been a fracture of the neck within the capsular ligament, and that union had taken place by osseous and cartilaginous media. With a view of ascertaining whether there was real osseous union, the bone was boiled many hours, which, by destroying all the animal matter, satisfactorily proved the extent and firmness of the osseous connexion,

and exhibited the spaces which had been occupied by cartilaginous matter.*

No. II.—*Dr. Brulatour's Case.*—Dr. James, an English physician (residing at Bourdeaux), æt. 47, was thrown from his horse on the 29th of March, 1826 ; he fell directly upon the great trochanter, but got up and walked a step or two, which occasioned such acute pain in the hip-joint, that he instantly fell again. On examination immediately after the accident, Dr. Brulatour observed the principal signs of fracture of the neck of the femur, such as shortening of the affected limb, eversion of the foot, and a feeling of crepitation in the joint when counter extension was made. Extension of the limb was kept up for two months, so as to preserve it of its natural length. Three months after the receipt of the injury Dr. James was able to walk, with only the assistance of a cane, and subsequently recovered the full use of the limb. On the 20th of December, nine months after the accident, he was attacked with hæmatemesis, which proved fatal in two days.

The post-mortem examination of the right hip-joint shewed the capsule a little thickened, the cotyloid cavity and interarticular ligament in a natural state ; the neck of the femur shortened, an irregular line surrounding the neck, denoting the direction of the fracture, and considerable bony deposit at the bottom of the head of the femur, and at the external and posterior part. A section of the head of the femur was made in a line drawn from its centre to the bottom of the great trochanter, so as perfectly to expose the callus. The line of union indicated by the callus was smooth, and polished as ivory. The line of callus denoted also that the bottom of the head of the femur had been broken at its superior and posterior part.†

No. III.—*Mr. Stanley's Case.*—A young man, æt. 18, fell from the top of a loaded cart upon his right hip, the injury of which was attended with the following symptoms: he was wholly unable to move the limb, the thigh was bent to a right angle with the pelvis, and could not be extended; abduction was difficult; the limb was

* Medico-Chirurgical Transactions, vol. xiii. 1827.

† Medico-Chirurgical Transactions, vol. xiii. 1827.

everted, but there was no shortening, nor could crepitus be felt in any motion of the limb. This patient died of what was supposed to be small-pox, about three months after the occurrence of the accident. In the examination of the joint after death, the capsule was found thickened, the round ligament uninjured; a line of fracture extended obliquely through the neck of the femur, and entirely within the capsule; the neck of the bone was shortened, and its head approximated to the trochanter major. The fractured surfaces were in the closest apposition, and firmly united nearly in their whole extent by bone. There was an irregular deposition of bone upon the neck of the femur, beneath its synovial and periosteal covering, along the line of the fracture.*

No. IV.—*Mr. Swan's Case.*—Mrs. Powel, above eighty years of age, fell down, November 14, 1824. Sir Astley Cooper, who saw her soon after, believed that there was a fracture of the neck of the femur, although there was no appreciable shortening of the limb, and only a slight inclination of the toes outwards; crepitus could not be perceived. The patient died about five weeks after the occurrence of the accident. Upon examination of the joint after death, the fracture was found to have been entirely within the capsular ligament, aud the greater part of it was firmly united. A section was made through the fractured part, and a faint white line was perceived in one portion of the union, but the rest appeared to be entirely bone. The cervical ligament had not been injured.†

No. V.—*Mr. Adams' Case.*—"Owen Curran, æt. 70, was for the last five years an inmate of the pauper department of the House of Industry; he was very infirm on his limbs, and his mind was in a state of dotage. On the first of August, 1837, while walking across his ward, he fell on his right side; he was unable to rise, and complained of pain in his right hip: he was carried to bed and immediately visited by the late Mr. William Johnstone (who was then acting for me as clinical pupil), who found the limb everted, and only half an inch shorter than the other. Mr. John-

* Medico-Chirurgical Transactions, vol. xviii.

† Swan on Diseases of the Nerves, p. 304.

stone considered the case a fracture of the cervix femoris, which required no other surgical treatment than that of placing and preserving the limb in a semiflexed position over pillows. The old man suffered but little pain in the injured part: at all events he did not complain of it. In about five weeks after the accident he was raised out of his bed, and when placed standing he was able to put the heel of the injured limb to the ground. On the 30th of September, that is, about eight weeks after the accident, my friend, Mr. Smith, entered in his note-book the following memorandum of this case: 'As the patient lies in bed he can elevate the injured limb by the unaided efforts of its own muscles. The eversion is slight, and the degree of shortening amounts to one inch; no force can bring the limb down to the length of the other. From the history and symptoms, this seems to have been a case of impacted fracture.'

"This man survived the accident one year and nearly ten months, during which time he was contented to remain most of his time in his bed, but when placed on his feet could stand very well, and was able, but unwilling, to walk. On Tuesday, the 20th of May, 1839, he got an attack of bronchitis, which, the following Friday, terminated fatally. At twelve o'clock on Saturday, the 25th of May, assisted by Mr. Brabazon and some of the pupils of the hospital, I made an examination of the body.

"The right leg and thigh were much everted; the trochanter major was elevated and projected much outwards; the degree of shortening just amounted to one inch; the muscles presented a healthy appearance; the capsular ligament was of a yellowish colour, and somewhat thickened. The femur was removed from the acetabulum; this latter cavity presented a healthy appearance, except towards the margin of it, here the cartilage was softened. The round ligament was sound.

"The head and neck of the bone had lost their normal obliquity, and were directed nearly horizontally inwards; the cervix presented, both anteriorly and posteriorly, evidence of a transverse intracapsular fracture having occurred; the globular shaped head of the femur was closely approximated behind and below to the posterior inter-trochanteric line, and to the lesser trochanter, so that the neck seemed altogether lost, except anteriorly, where a

very well-marked ridge of bone shewed the seat of the displacement, and of the union of the fragments. This ridge is evidently the upper extremity of the lower fragment of the cervix. The fracture of the neck posteriorly was found to have been closer to the corona of the head than anteriorly, and the fibro-synovial fold in the former situation was unbroken. A section has been made of the bone through the head, neck, and trochanter; one portion has been subjected to maceration, and to boiling, and the bony union has been unaffected by these tests. Scarcely any portion of the neck can be said to have been left. The section shews the compact line which denotes the union of the fragments; the head and shaft seem to be mutually impacted into each other, and almost the whole of the cervix has been absorbed; the line of union is serrated, solid, and immoveable, and the cells of the head, and substance of the shaft seem to communicate freely in all places, except where the thin line of compact tissue here and there points out the seat of the welding together of the remaining portions of the head and neck of the femur.

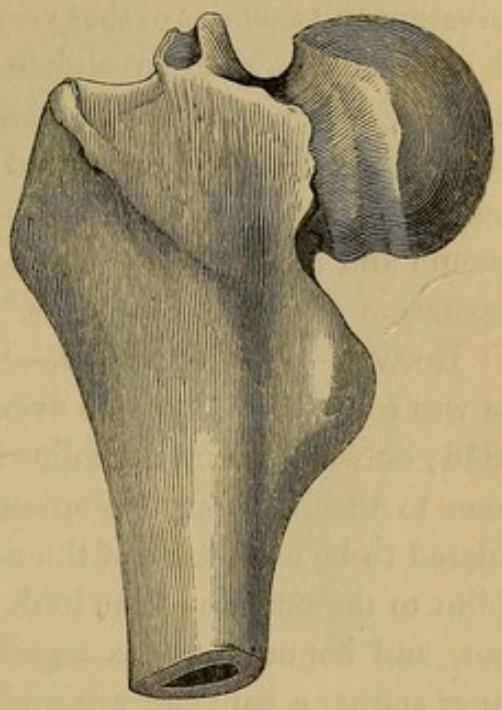

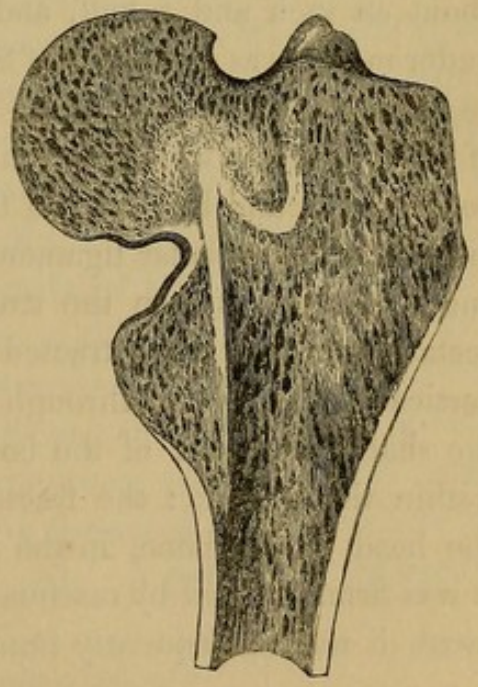

"The bone was, in its recent state, on the 25th of May, 1839, laid before a meeting of the Pathological Society. It seemed to be the universal opinion of the members present that it was a

decided specimen of the intracapsular fracture of the cervix femoris, which had been solidly united by bony callus."

This case may be adduced in formal contradiction to the observation and theories of that very eminent pathologist, Cruvelhier. It cannot be said to invalidate the more guarded opinion of Sir Astley Cooper, who, in his observations upon this subject, distinctly states, that "he would not be understood to deny the possibility of union, when the bone was broken, without its periosteum and reflected ligament being torn, or when there was no separation of its fractured ends."*

No. VI.—*Mr. Jones' Case.*—"Jenkins Thomas slipped down as he was returning home one evening about the middle of October, 1838; he was seen on the following day by Mr. Cole, House Surgeon to the Infirmary (Worcester), who detected what he considered to be a fracture of the neck of the femur. He applied a splint to the outside of the limb, extending from the pelvis to the foot, and bound the legs together, making use of the left as an inner splint; a bandage was applied around the pelvis. In about eight weeks the splints and bandages were removed, and he was allowed to get up soon afterwards.

"During the following spring and summer he was able to move about with the assistance of a stick, but with the limb shortened about an inch and a half, and considerably everted. He came under my care as an inmate of St. Oswald's Hospital, 13th January, 1840, and died on the 20th of April following, of chronic disease of the lungs. At the time of the accident he was more than eighty years of age, and he survived the injury one year and a half. On dissection the capsular ligament was found very much thickened, and the space between the trochanter major and the edge of the acetabulum greatly contracted; the bone was macerated, and a vertical section made through the head, neck, and upper part of the shaft; the neck of the bone was found to have been broken within the capsule: the fracture extended through the basis of the head of the bone, in the line of its junction with the neck; it was firmly united by osseous matter. The bone was first macerated, it was subsequently immersed for several days in a strong

* Todd's Cyclopædia, p. 813.

solution of carbonate of potash, and one half of it was boiled in water for three hours without the slightest yielding perceptible in the line of fracture."* This specimen, which is preserved in the Museum of St. Bartholomew's Hospital, was sent to Sir Astley Cooper for examination. Sir Astley was of opinion that the fracture was "in part within, and in part external to the capsular ligament; in part united, and in part not, and the neck of the thigh bone absorbed."†

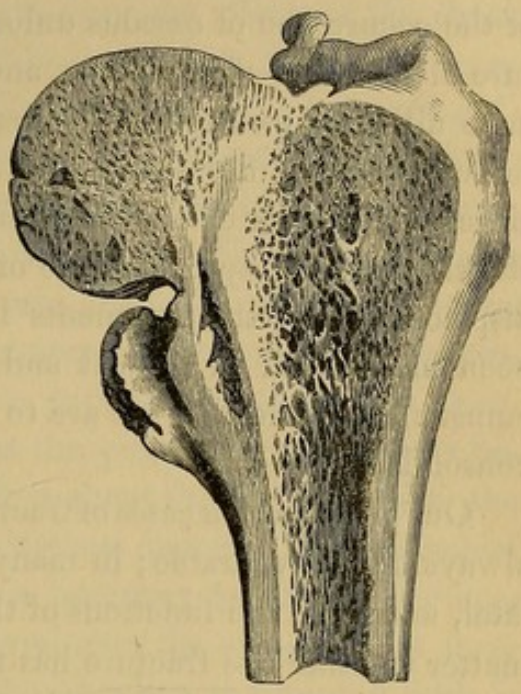

No. VII.—*Mr. Chorley's Case.* Mr. K., æt. 72, fell against the curb-stone, and was at once rendered unable to move in consequence of an injury of the hip. Upon examination the limb was found shortened and the foot everted. This patient, at the expiration of seven months, walked so well that some surgeons thought that no such injury as fracture of the neck of the femur had taken place. He died twelve months after the accident, from an attack of acute pneumonia, and on examining the hip it was found that the neck of the bone had been fractured obliquely within the capsule; the fracture commenced above, close to the margin of the cartilage of the head of the bone, and extended downwards and outwards, terminating at a point in the lower surface of the neck, one inch from the cartilaginous covering of the head of the bone.

On making a longitudinal section of the head and neck of the bone, the line of fracture was distinctly marked by the callus, which now united the opposed surfaces; the pelvic portion had been excavated, and had received the lower portion of the neck of the bone, near the middle of its fractured surface, where it was firmly united by an osseous deposit. A portion of the upper

* Medico-Chirurgical Transactions, vol. xxiv.

† Provincial Medical and Surgical Journal. 1841.

fragment extended in one situation a little external to the capsule; this portion was not united.*

The preceding cases furnish ample evidence of the possibility of the occurrence of osseous union in cases of intracapsular fracture of the neck of the femur, and it is highly probable that they have all been examples of impacted fractures: certainly in all those, of which delineations have been given, there has been either penetration of one fragment by a portion of the other, or else the irregularity of the line of fracture has been such that the displacement of the fragments has been prevented; they have been maintained in contact and at rest, and it is under such circumstances alone that we are to hope for the occurrence of bony consolidation.

Our prognosis, in cases of fracture of the neck of the femur, must always be unfavourable; in many instances the injury soon proves fatal, and in all the functions of the limb are for ever impaired; no matter whether the fracture has taken place within or external to the capsule, whether it has united by ligament or bone, shortening of the limb and lameness are the inevitable results. In forming our prognosis, we must take into account principally the age of the patient, and the situation and nature of the fracture. The results of my own experience would lead me to say, that the form of fracture which is most rapidly and most frequently fatal, is the extracapsular fracture, when it is accompanied by a comminuted fracture with displacement of the trochanters; but as regards the functions and utility of the limb during the remainder of the patient's life, the intracapsular fracture is the more serious accident, for, independent of the difference which exists between these two varieties of the fracture, as regards the possibility of the occurrence of osseous union, there is likewise a remarkable difference with respect to the *ultimate* shortening of the limb; for in the extracapsular fracture the amount of shortening which took place when the injury occurred seldom subsequently undergoes any very material increase, but when the fracture is seated within the capsule, absorption of the neck of the bone slowly but steadily proceeds, and an amount of shortening of the limb is thus ulti-

* Amesbury on Fractures, vol. i.

mately produced, equal to, or, in many cases, even greater than the entire length of the neck of the femur.

In fatal cases death may be owing to a variety of causes: sometimes the patient dies in a few days from the effects of the shock upon a system already enfeebled by age; very frequently bronchitis sets in, and terminates fatally before ten days have elapsed; in other cases the accident is followed by a severe irritative fever, the tongue becomes furred, the bowels constipated, the pulse quick and feeble, and the patient restless and thirsty; he is unable to sleep, and complains much of pain about the joint; the tongue soon becomes more loaded, the countenance dejected, and expressive of distress and anxiety; the patient begins to talk incoherently, and raves at night, then the pulse fails, the tongue becomes dry and brown, sordes collect about the lips and teeth, the anxiety of countenance and restlessness increase, the bronchial tubes become filled with mucus, a tendency to stupor, or coma, manifests itself, and then death terminates the scene. This form of fever is especially apt to be induced when the injured limb is kept firmly secured in splints and bandages, and maintained in a state of forcible extension.

In other instances a different, but equally fatal, form of fever is established: in these cases the swelling and tension about the joint and upper part of the thigh are considerable, and the pain, almost from the commencement, is of the most acute description: the patient is tortured by the slightest motion of the limb, and will not permit any examination of it to be made; the constitutional symptoms at first resemble those of traumatic fever, but very soon their whole expression is altered, and the characters which they now present are those of a typhoid fever, analogous to those which accompany diffuse inflammation; severe rigors, accompanied and followed by an increase of local suffering, set in early; all the structures which enter into the composition of the joint become the seat of an acute suppurative inflammation, and as the case draws near to its termination, pneumonia sometimes sets in, and the patient sinks under the combined effects of acute local inflammation and typhoid exhaustion.

Sometimes, as in the instance detailed by Cruveilhier, elsewhere alluded to, death is to be ascribed to the occurrence of pro-

fuse hæmorrhage into the substance of the limb; in such cases the fracture is always external to the capsule, and accompanied by a comminuted fracture of the trochanter; the blood is poured

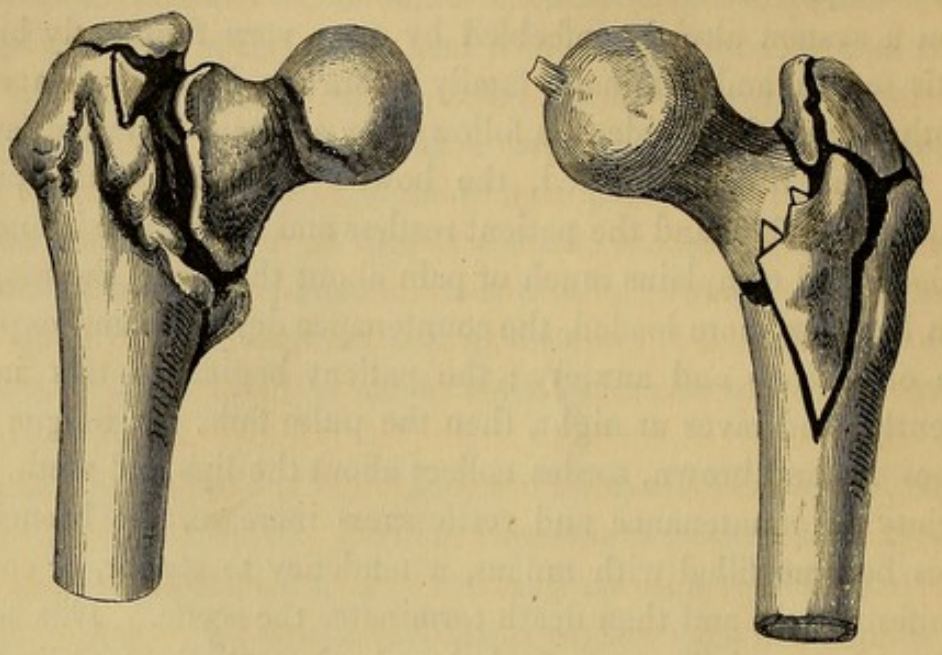

out from the torn vessels of the cancellated structure, and occasionally also from some arterial branch of considerable size, that has been lacerated, or punctured, by a spicula of the broken bone: finally, in patients of very advanced age, and where proper precautions have not been adopted, sloughing of the integuments of the nates and trochanteric region occurs, and very soon places the patient beyond the possibility of recovery.

Among all the striking and varied changes which the human system suffers under the influence of that inevitable decline of organization, which is the attendant upon advanced age, there are few more remarkable than those which affect the osseous system. These strange modifications of structure are supposed to affect the skeleton of the aged female much more frequently than that of the male, and, along with the greater breadth of the pelvis, and projection of the trochanter major, to afford an explanation of the more frequent occurrence of fracture of the neck of the femur in the elderly female than in man. It is more especially in the bodies of those who have been bed-ridden for years before their death, that we notice these alterations, and they will generally be found even in the adult who has been, from any cause, for years

confined to bed; for long disuse produces atrophy and degeneration of the osseous system, without much respect to age, and the head and neck of the femur manifest more clearly, perhaps, than any other parts of the skeleton, the consequences of this remarkable lesion of nutrition: such is frequently the incapability of resistance, that the structure of the bone can be crushed by the slightest pressure of the finger.

This condition is owing not merely to the interstitial absorption of the osseous fibres, but is also to be in part ascribed to the presence of a quantity of oil, which accumulates in, and becomes infiltrated throughout the entire of the tissue of the bone, the compact structure being, in many cases, reduced to a delicate lamina of bone, so thin as to be almost translucent, and the bony partitions, which separate from each other the areolæ of the reticular tissue, are here and there removed, in consequence of which large cavities are formed in the interior of the head and neck of the femur, and the strength of the bone, and its power of resisting external violence, are thus materially diminished. I have seen an instance in which a cavity capable of containing a moderate-sized marble was formed in the head of the femur. The cells of the reticular tissue thus enlarged, are filled, partly with oil and partly with a semifluid medullary matter, presenting great variety of colour, being in some places of a pale yellow, in others of a yellowish-grey; and again, here and there are found patches of crimson of various shades, apparently produced by the admixture of effused blood with the morbid medullary matter; the medulla in such cases becomes rapidly decomposed after death, and I have often found it presenting the green colour resulting from putrefaction, in less than twelve hours after the decease of the patient.

We also find that the arch of compact tissue which lines the concavity of the neck of the femur, and upon which the strength of this portion of the bone is mainly dependent, is in most instances reduced in thickness, and atrophied, in the aged subject; and although an example of fracture of the neck of the femur may occasionally be met with, in which this arch possesses its natural thickness (as in the case detailed by Mr. Porter*), yet this does

* Dublin Medical Journal, vol. x.

not by any means invalidate the general truth of the assertion, that the atrophy of this arch, to a greater or less degree, is of common occurrence in the advanced periods of life, and to be looked for in almost every instance of intracapsular fracture of the neck of the thigh bone: in a few instances I have found it reduced to such a degree of tenuity, and so totally altered in structure, as to permit of a section of the head and neck of the femur being made with a scissors.

The attenuation of the compact structure of the arch of the neck of the bone, the absorption of the partitions between the cells of the reticular tissue, and the consequent enlargement of these cells, together with the infiltration of the osseous structure with oil,—such are the chief local morbid changes which predispose the neck of the thigh bone to fracture from the most trivial causes; under such circumstances, as has been justly observed by Mr. Adams, the fracture should, in many instances, be looked upon more as a stage of morbid alteration, from which no amendment is to be expected, than as an accidental lesion, which the efforts of nature and the aid of surgery can be deemed adequate to repair.

These remarkable local alterations have, however, a constitutional origin; they are the effects of that decline of the vital powers which marks the approach, and attends the progress, of old age; a decline, the effects of which are not confined to the osseous system, but are likewise to be seen in the muscles both of voluntary motion and of organic life. The fatty and atrophied condition of the heart, the analogous state of the voluntary muscles, and the oily degeneration of the bones, must be looked upon as indicating enfeebled powers of assimilation, and a diminution in the energy of the circulation; the arterial blood circulates slowly, is imperfectly oxygenated, and contains an undue quantity of carbon; venous blood preponderates in the system, and to this latter circumstance especially we are to ascribe the morbid alterations in the muscles and the bones to which I have alluded. It would, however, be out of place to discuss this question, however interesting it may be to the physiologist,* I shall, therefore, terminate this memoir with a brief ac-

* For a further consideration of the subject, see Dublin Journal, vol. ix. p. 411.

count of the preparations contained in the Museums of the Richmond Hospital, and Richmond School of Medicine, accompanying the description with a concise history of the symptoms which each case presented during the life of the individual: the reader will then be able to judge how far they warrant the conclusions which have been deduced from them.

Case I.—Laurence Maguire, æt. 40.—Fracture of the neck of the femur within the capsular ligament, traversing the bone obliquely from above downwards and forwards; posteriorly the fracture has passed through the investing cartilage of the head of the bone; the anterior portion alone of the cervical ligament has been lacerated; the synovial membrane of the articulation was extremely vascular, but the joint contained scarcely any synovial fluid. A large abscess existed between the bladder and the rectum, and the mucous membrane of the former organ was inflamed.

In this case the patient had been violently thrown to the ground, and fell directly upon the external surface of the trochanter. The foot was everted, and the limb shortened half an inch. Ten days after the occurrence of the accident severe febrile symptoms set in, and soon assumed a typhoid character: the tongue became dry and brown, the pulse feeble and rapid, and severe and frequent rigors, with retention of urine, and excessive irritability about the neck of the bladder indicated the formation of matter in the vicinity of that organ. The patient died upon the fourteenth day after the occurrence of the accident.

Case II.—William Collins, æt. 36.—Fracture of the neck of the femur within the capsule, passing through the cervix transversely with respect to the direction of its axis; the cervical ligament had been torn throughout its whole extent anteriorly, but posteriorly remained perfect; the articulation contained only a small quantity of synovia, and its lining membrane was preternaturally vascular. The injury was caused by a fall upon the tro-

chanter four days before the man was admitted into the hospital. The foot was everted, and the shortening of the limb amounted to three-quarters of an inch. In this case, firm pressure was made by means of a truss applied round the pelvis, and the pad of which was adapted to the trochanter: after two days, however, the patient complained of so much pain, that it was necessary to remove the instrument: irritative fever, nevertheless, set in; the tongue became dry and coated with a brown fur; there was thirst and insomnia, and the patient gradually became comatose, and died upon the seventeenth day after the receipt of the injury.

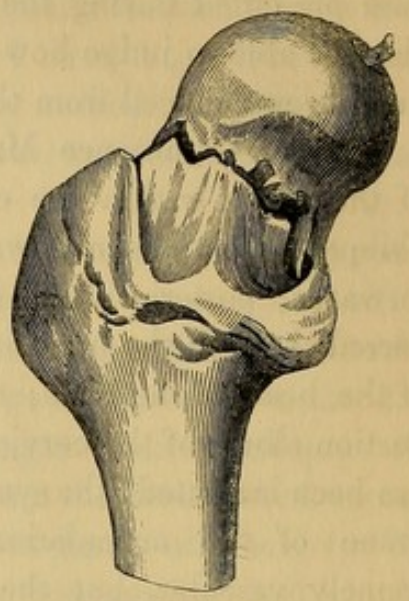

Case III.—Thomas Maguire, æt. 84.—Fracture of the neck of the femur close to its junction with the head of the bone, a small portion of the compact structure of which has been broken off in front; the cervical ligament has been torn in front, but internally and posteriorly is perfect, and holds the fragments in apposition; blood was effused between the fragments, from the ruptured vessels of the cancellated tissue. The fracture was caused by the patient's having tripped over some slight obstacle while walking across his room: he did not fall to the ground. The foot was everted, and the limb shortened exactly half an inch. The patient died of irritative fever a fortnight after the occurrence of the accident. Throughout the whole progress of the case the patient complained of severe pain in and around the articulation: there was complete insomnia. This case affords a good illustration of the occurrence of fracture of the neck of the femur from a cause the most trivial.

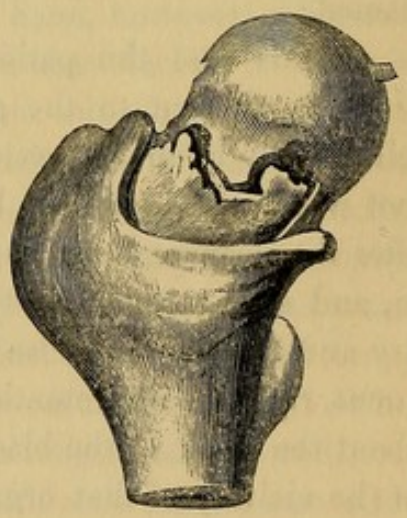

CASE IV.—Dorah Campbell, æt. 75.—Fracture of the neck of the femur within the capsule, encroaching a little upon the head of the bone; the edges of the lower fragment have been rounded off, and its surface has become nodulated; the cervical ligament has been every where lacerated, except internally, corresponding to the concavity of the neck of the femur; lymph was effused upon the fractured surfaces, and there was a little blood in the acetabulum. The injury resulted from a fall upon the hip; the foot was everted, and the limb shortened one inch. The woman died of suffocative catarrh two months after the occurrence of the fracture.

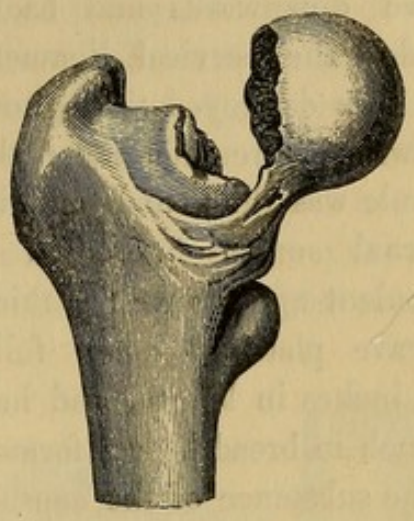

CASE V.—Mary Gill, æt. 80.—Fracture of the neck of the femur within the capsular ligament, close to the head of the bone. The broken surface of the superior fragment is deeply excavated; the cervical ligament has been ruptured throughout the whole extent of its anterior and superior surfaces, but is perfect internally and behind. The foot was everted, and the limb shortened half an inch.

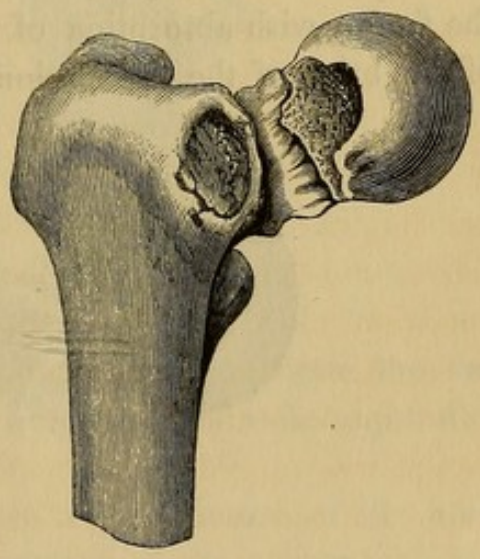

CASE VI.—Esther Christie, æt. 60.—Fracture of the neck of the femur within the capsule. The upper fragment has been absorbed as far as the level of the acetabulum, and its surface has become smooth and dense, presenting a concavity anteriorly, and a convexity posteriorly; the surface of the lower fragment is extremely irregular, and covered with a fibrous structure; a small portion of the compact tissue of the upper surface of the neck of the bone has been laid down upon the broken surface of the lower

fragment, and has been united to it by the fibrous tissue already mentioned. The direction of the fracture was oblique from above downwards and backwards; the cervical ligament has been destroyed throughout its whole circumference; the capsule was thickened, and its internal surface presented a flocculent appearance; a thick concave plate of bone, fully two inches in length, and half an inch in breadth, was formed in the substance of the capsule anteriorly. The ligamentum teres was the sole remaining attachment of the head of the bone. The limb was shortened one inch and a half.

Case VII.—Mary Lamb, æt. 80.—Fracture of the neck of the femur, with absorption of the superior fragment to the level of the brim of the acetabulum: the lower fragment was nearly

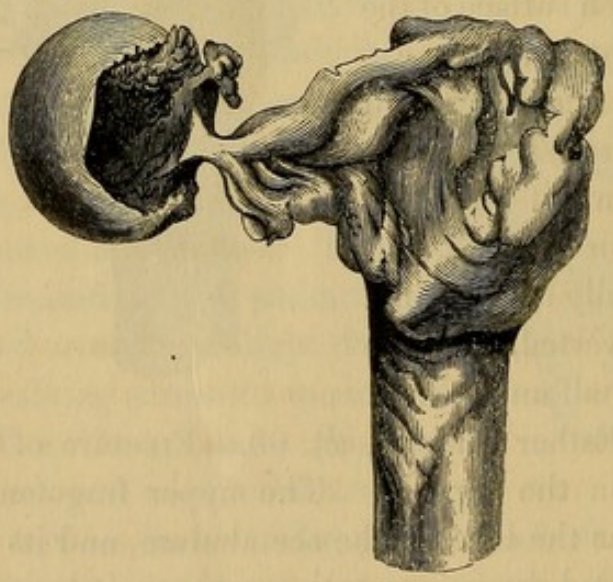

altogether absorbed, and the surface of the bone from which, in the natural state, the neck of the femur springs, was formed into an expanded, shallow cavity, covered throughout the greater part of

its extent by a fibrous structure; ligamentous bands passed from the internal surface of the capsule to both the superior and inferior fragments. The capsule, every where thickened, was in some places semi-cartilaginous. The fracture was the result of a fall upon the trochanter, and the limb was shortened three-quarters of an inch. The patient died of bronchitis and anasarca twelve months after the accident, and at the period of her death the limb was two inches shorter than the other.

Case VIII.—Margaret Burke, æt. 90.—Fracture of the neck of the femur within the capsule; the under surface of the superior fragment is slightly excavated, the lower fragment comminuted, and the cervical ligament lacerated nearly throughout its whole circumference; its attachments are perfect only along the concavity of the cervix, and here it has been perforated by a spicula of bone connected with the lower fragment; a large quantity of blood was poured out between the fragments. The shortening of the limb amounted to half an inch. The patient died of sloughing of the nates upon the day following her admission into the hospital, and a fortnight after the occurrence of the accident.

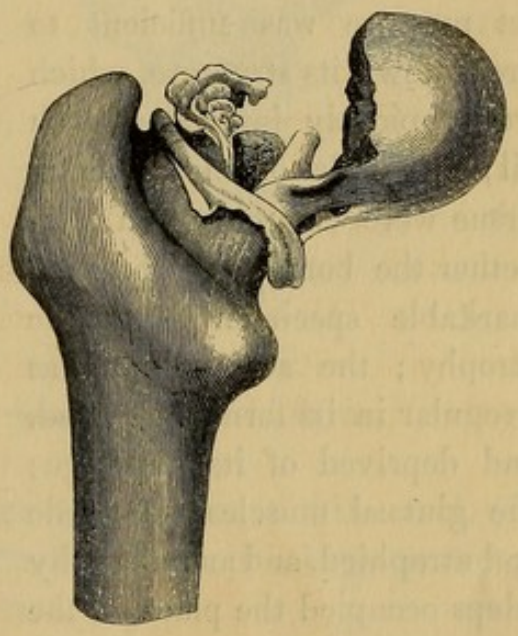

Case IX.—Margaret Myler, æt. 78.—Fracture of the neck of the femur close to the line of junction of the cervix with the head of the bone. A thin layer of the compact tissue hangs down from the margin of the fracture, the under surface of the cotyloid fragment is excavated, and dense in its structure; the greater part of the femoral fragment has been absorbed, and several portions of its compact tissue seem to have been turned in upon the fractured surface and united to it: the cervical ligament was entire only along the concavity of the neck of the bone. The amount of retraction of the limb, which followed immediately upon

the receipt of the injury, was only a quarter of an inch. The patient died two months after the occurrence of the accident, the prominent symptoms during the progress of the case having been insomnia, prostration of strength, and occasional delirium. The integuments covering the sacrum sloughed, and for some time before death purulent matter was voided with the urine.

Case X.—A female, æt. 65.—Fracture of the neck of the femur within the capsule, with absorption of the cervix; the head of the bone had lost its globular form, and was extremely irregular upon its surface; the slightest pressure was sufficient to break down its structure, which was copiously infiltrated with oil; the cells of the reticular tissue were enlarged, and altogether the bone presented a remarkable specimen of senile atrophy; the acetabulum was irregular in its form, deepened, and deprived of its cartilage; the glutæal muscles were pale and atrophied, and an unhealthy adeps occupied the place of the muscular fibres in many situations. The limb was shortened one inch, and the foot everted. The patient had been bedridden for several years before her death.

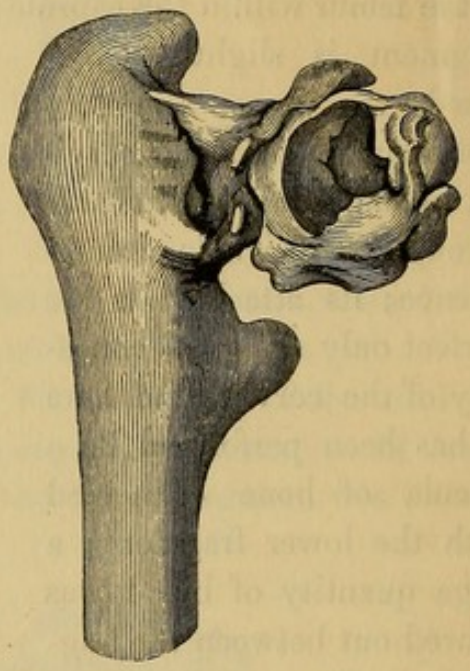

Case XI.—Patrick Doolan, æt. 60.—Fracture of the neck of the femur within the capsular ligament. The head of the bone was intimately united to the acetabulum by an exceedingly dense fibrous tissue; the lower surface of the cotyloid fragment was convex, the neck of the bone completely absorbed, and a large socket, as it were, was formed in the widely expanded surface of the lower fragment, to receive the convex surface of the superior. Both these surfaces were smooth and polished, and possessed the hardness and density of enamel. The capsule was exceedingly thick; there was complete eversion of the foot, and at the time of the patient's death (seven years after the occurrence of the accident)

the shortening amounted to two inches. This man died of aneurism of the thoracic aorta, which proved fatal without rupture of

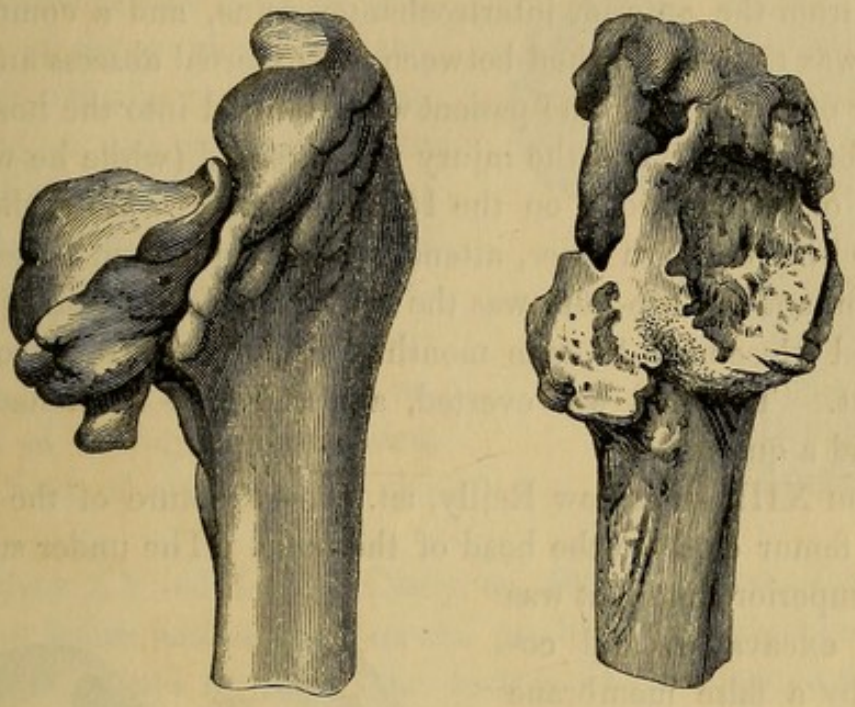

the sac; it sprung from the first portion of the arch, and was as large as an orange.

Case XII.—Michael Curry, æt. 40.—Fracture of the neck of the femur within the capsule, with absorption of a large portion of each fragment, and complete destruction of the cervical ligament; the round ligament was the only remaining attachment of the head of the bone; all the tissues entering into the composition of the joint had been the seat of acute inflammation. The upper portion of the shaft of the bone, for about two inches below the cervix, presented evidence of having been the seat of acute osteitis; the periosteum was detached, and the osseous tissue highly vascular, and the surface of the bone presented a corroded appearance, owing to the removal of the compact structure, and the exposure of the cancellated tissue.

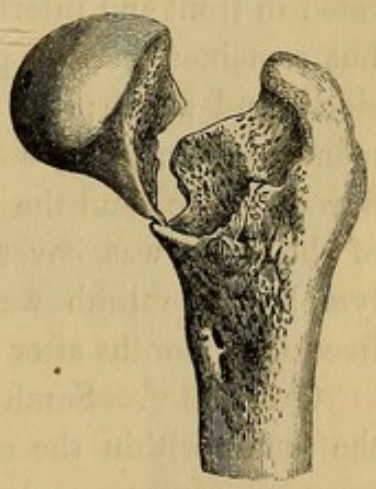

Purulent matter was found between the periosteum and the bone, and an enormous abscess surrounded the articulation, which was itself filled with pus and flakes of lymph; the capsule was detached from the anterior intertrochanteric line, and a communication was thus established between the external abscess and the interior of the joint. The patient was admitted into the hospital, December 5, 1837, and the injury was received (while he was in a state of intoxication) on the 15th November. When he was admitted he had high fever, attended with rigors and occasional delirium, and the hip-joint was the seat of most excruciating pain. He died December 16, one month after the occurrence of the accident. The foot was everted, and the limb shortened one inch and a quarter.

Case XIII.—Mathew Reilly, æt. 46.—Fracture of the neck of the femur close to the head of the bone. The under surface of the superior fragment was deeply excavated, and covered by a false membrane of considerable thickness; a small part of the lower fragment was absorbed, and its surface was covered by a fibro-cartilaginous tissue; the cervical ligament was lacerated in front and internally, but remained perfect posteriorly and above; the fragments were united by a dense fibrous tissue, and the neck of the bone was covered by a thick and fimbriated layer of lymph. The limb was shortened half an inch. The patient lived four months after the receipt of the injury.

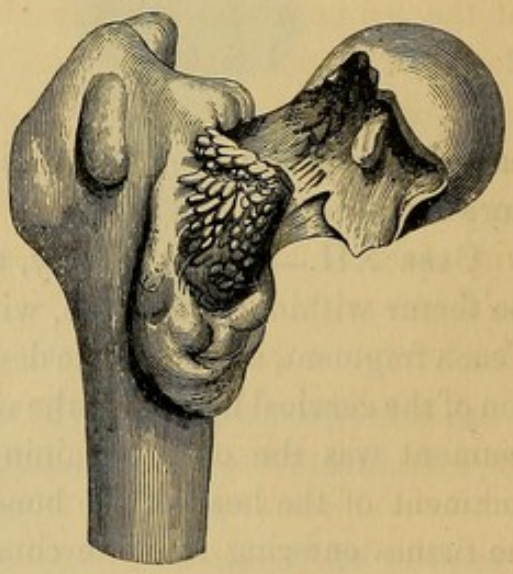

Case XIV.—Sarah Ashton, æt. 65.—Fracture of the neck of the femur within the capsule: the surface of the superior fragment was concave, and as polished as ivory; the greater part of the neck of the bone was absorbed, and the surface of the lower fragment covered partly with a fibrous tissue and partly with a structure resembling porcelain; an organized layer of lymph invested the

cartilage of the head of the bone; a considerable portion of the neck of the femur was absorbed; the fragments were connected to each other by portions of the cervical ligament, which remained entire along the upper and under surface of the neck of the bone; the joint contained a large quantity of synovia; the limb was shortened one inch and a quarter. The patient survived the receipt of the injury nine years, and died of erysipelas of the leg.

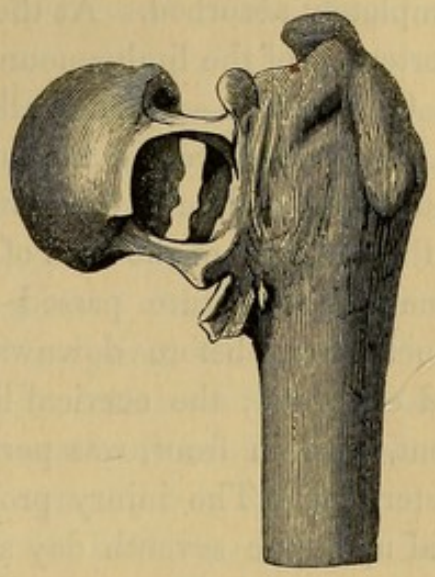

Case XV.—Elizabeth Casey, æt. 50.—Fracture of the neck of the femur within the capsule, passing obliquely from above downwards and forwards; the surface of the cotyloid fragment had become concave, and was covered with a fibro-cartilaginous structure; the lower fragment had suffered very little from absorption; the cervical ligament was perfect only along the concavity of the neck of the bone. The shortening of the limb amounted to three-quarters of an inch. The patient lived several years after the receipt of the injury.

Case XVI.—Robert Robinson, æt. 50.—Fracture of the neck of the femur within the capsule: the head of the bone was in many places destitute of cartilage, and covered with a false membrane; the surface of the upper fragment was covered by a dense fibrous tissue throughout the greater part of its extent; where this structure was deficient the surface was dense, and as smooth as ivory. The lower fragment presented similar appearances. The fracture had oc-

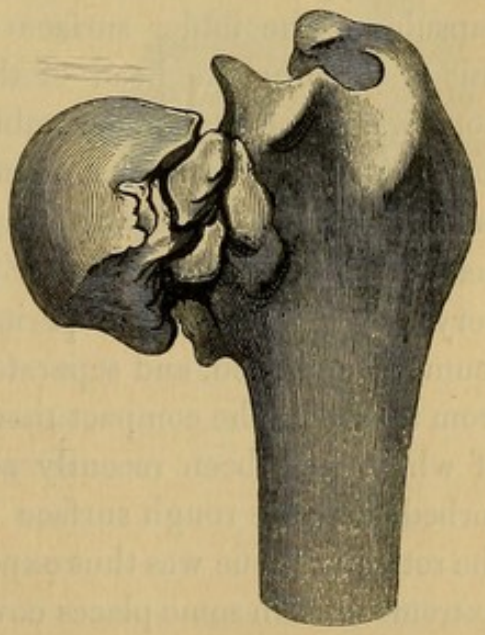

curred several years before the death of the patient, and was caused by a fall upon the trochanter; the neck of the bone was completely absorbed. At the period of the patient's decease, the shortening of the limb amounted to two inches.

Case XVII.—Ellen Walker, æt. 70.—Fracture of the neck of the femur, close to the margin of the cartilage of the head of the bone; the fracture passed obliquely from before downwards and outwards; the cervical ligament, torn in front, was perfect posteriorly. The injury proved fatal upon the seventh day after its occurrence, from the supervention of irritative fever. The limb was shortened half an inch.

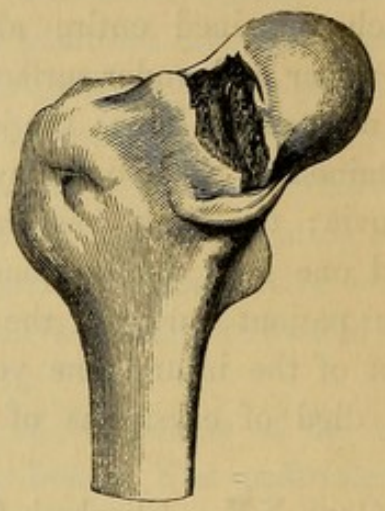

Case XVIII.—Laurence Reilly, æt. 56.—Fracture of the neck of the femur within the capsular ligament, with absorption of the entire of the cervix; the upper fragment had disappeared to the level of the cotyloid ligament; a ligamentous band of great strength extended from the capsule to the under surface of this fragment; the head of the bone was joined to the acetabulum by a very vascular membrane; the lower fragment appeared to have been the seat of very acute osteitis; the periosteum was inflamed, and separated from the bone, the compact tissue of which had been recently absorbed, and the rough surface of the reticular tissue was thus exposed: this tissue was vascular in the extreme, and in some places covered with lymph, flakes of which, mixed with pus, were contained in the cavity of the joint, and a

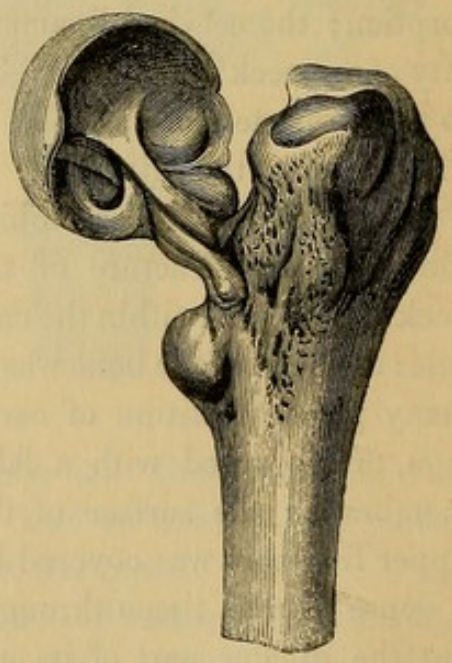

large collection of dark and fœtid purulent matter surrounded the articulation. In this case the sternum was broken at the junction of the first with the second bone; and in the situation of this fracture was another abscess, the matter of which presented the same unhealthy character as that already mentioned as existing in the vicinity of the hip-joint; the lower lobe of each lung presented the anatomical characters of the first stage of pneumonia.

The patient, a miserable-looking man, exhausted apparently by poverty and distress of every description, was admitted into the hospital, December 31, 1839; he had been knocked down by a cart loaded with hay, and it was stated that the vehicle had passed over his body. The usual symptoms of fracture of the neck of the femur were present; the limb was shortened two inches. It was at first supposed that the lesion of the neck of the femur had been the result of the recent accident, but it was afterwards ascertained to have been of several years' duration. The patient survived the receipt of the recent injury only one week. The symptoms which preceded death were analogous to those of diffuse inflammation.

Case XIX.—Joseph Seaton, æt. 90.—Fracture of the neck of the femur within the capsule. Almost the entire of the cervix had been absorbed; a false membrane which, in the recent state, was covered with minute arborescent vessels, invested the head of the bone; a similar membrane covered the acetabulum, but these layers were not adherent to each other. The bone presented a remarkable example of that peculiar atrophy which affects the osseous system of the aged; it extended throughout the whole of the shaft, which in many places yielded to a very moderate degree of pressure; the medullary canal and the cells of the areolar tissue were enlarged, and filled with a substance more resembling oil than medulla, and an unhealthy fatty deposition separated from each

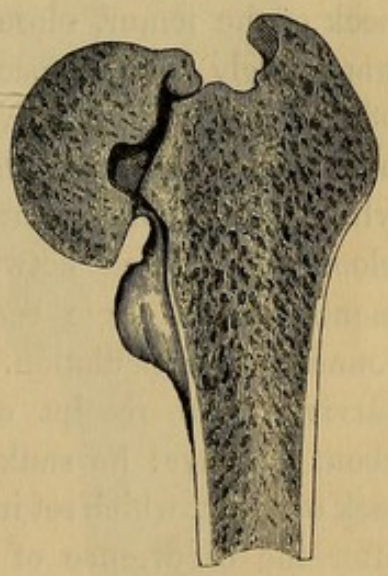

other the pale and atrophied fibres of the muscles around the joint. The fracture had occurred seven years before the patient's death, during the whole of which period he had been bed-ridden. The limb was shortened one inch and a quarter at the time of his decease.

Case XX.—A female, æt. 65.—Fracture of the neck of the femur within the capsule, with complete absorption of the cervix. The shaft of the femur, where, in the normal state, it joined the neck of the bone, presented a smooth flat surface; the head of the femur and the acetabulum were smaller upon this side than upon the opposite. The patient had sustained the injury several years before her death, and was bed-ridden from the time of the occurrence of the accident up to the period of her decease, at which time the shortening of the limb amounted to two inches and a half; the limb was likewise much reduced in size as compared with the opposite one.

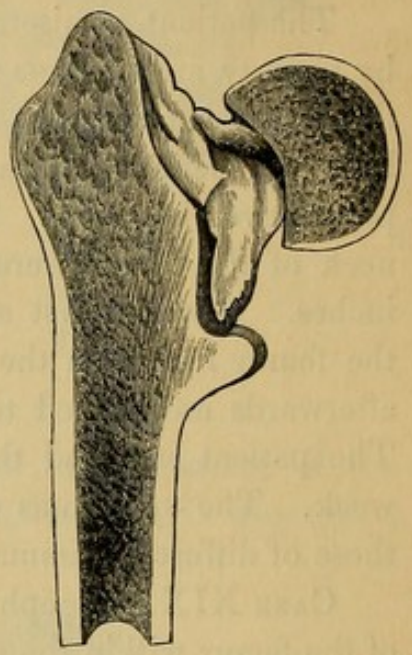

Case XXI.—Thomas Connolly, æt. 50.—Fracture of the neck of the femur, close to the head of the bone, and directed transversely with respect to the axis of the cervix; the cervical ligament had been torn nearly throughout the whole extent of its anterior surface; blood was effused between the fragments, and a large ecchymosis surrounded the articulation. The patient survived the receipt of the injury about ten days: he sunk under an attack of fever, which set in immediately after the occurrence of the accident, and which was occompanied with delirium. There was complete eversion of the foot, and the limb was shortened three-quarters of an inch.

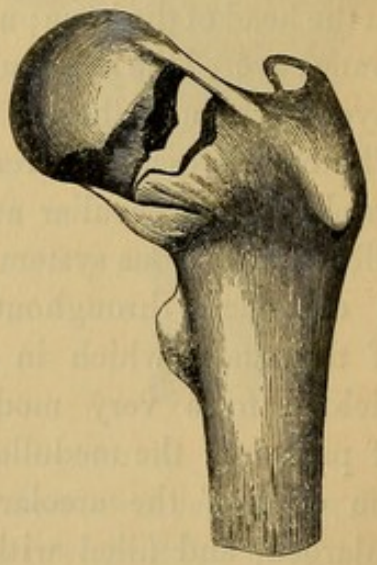

CASE XXII.—Bridget Misset, æt. 72.—Fracture of the neck of the femur within the capsule, passing obliquely from before backwards and outwards; the cervical ligament was almost everywhere torn; a small portion, a few lines in breadth, at the concavity of the arch of the neck of the bone, alone prevented the complete separation of the fragments. In this case the eversion of the foot was very remarkable. The shortening amounted to an inch. The patient lived ten weeks after the occurrence of the fracture.

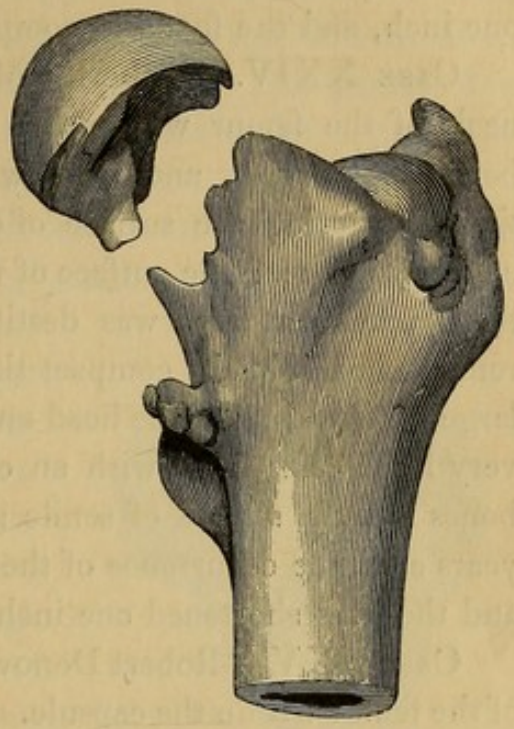

CASE XXIII.—A female, æt. 50.—Fracture of the neck of the femur within the capsule, with absorption of the entire of each fragment of the cervix: the surface, from which the neck of the bone springs in the normal state, was intimately united to the under surface of the head of the bone by an exceedingly dense ligamentous structure, arranged in bands about one-eighth of an inch in length; the entire of each surface was thus covered, and from the interior of the capsule several strong and thick ligamentous productions passed, to be inserted into the margin of the head of the bone, the cartilaginous surface of which was covered with a thin, organized membrane. The patient survived the accident several years, and en-

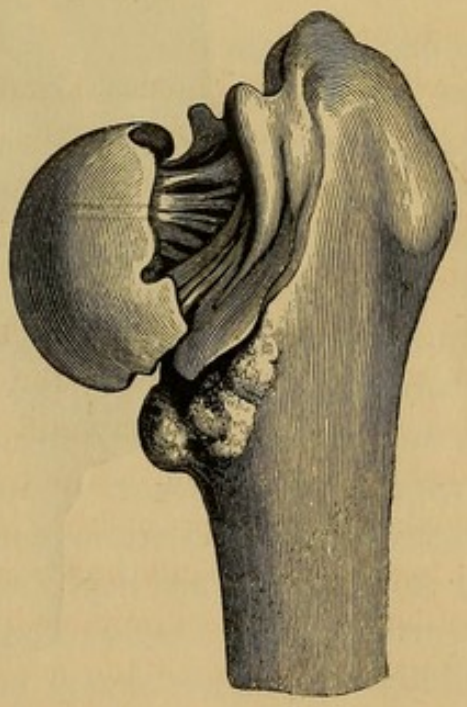

joyed very considerable motion of the limb, being able to walk well with the assistance of a stick. The shortening amounted to one inch, and the foot was completely everted.

Case XXIV.—Catherine Mooney, æt. 60.—Fracture of the neck of the femur within the capsule, passing obliquely from before backwards, and from within outwards; a dense fibrous tissue, covering the surface of each fragment, had united them closely together; the surface of the head of the bone surrounding the ligamentum teres was destitute of cartilage; the bone was remarkably light, its compact tissue thin, and its medullary canal large; the interior of the head and of the cervix contained several very large cells, filled with an oily medulla; several of the long bones were in a state of senile atrophy. This woman lived five years after the occurrence of the fracture. The foot was everted, and the limb shortened one inch.

Case XXV.—Robert Donovan, æt. 80.—Fracture of the neck of the femur within the capsule. The surface of the superior frag-

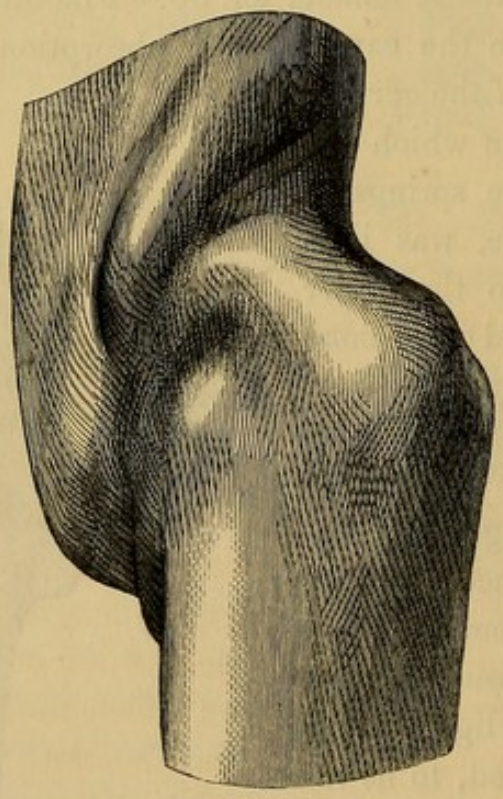

ment was concave, smooth, and polished; the neck of the bone absorbed, and the cartilage of the head atrophied, and in some places totally removed; the capsule was unusually thickened, and

organized lymph adhered to its internal surface. There was no union of any description between the two portions of the bone; the trochanter was drawn upwards towards the dorsum of the ilium, where it formed a remarkable tumour. The patient lived two years after the receipt of the injury, and at the period of his death the limb was shortened one inch and a half.

Case XXVI.—Mary Woods, æt. 70.—Fracture of the neck of the femur within the capsule, passing obliquely from above and without downwards and inwards: the superior and anterior portions of the cervical ligament were torn, but the portions corresponding to the inferior and posterior surfaces of the neck of the bone were entire; several fragments of the posterior surface of the cervix adhered to this unbroken portion of the cervical ligament, from several parts of which delicate bands of organized lymph passed, to be inserted into the surface of the superior fragment. The head of the bone had sunk below the level of the summit of the trochanter major, and a sharp spicula, connected with the inferior surface of the upper fragment, had penetrated the adjoining portion of the capsular ligament, and rested upon the upper surface of the trochanter minor. The foot was everted, and the shortening of the limb amounted to one inch. Throughout the whole progress of the case the patient complained of severe pain in and around the articulation. She had a considerable degree of fever, and occasionally a rigor. A large abscess at length formed among the muscles of the glutæal and superior portion of the femoral regions, from the constitutional effects of which the patient died, three months after the occurrence of the accident. Upon examination after death, purulent matter and lymph were found within the capsular ligament; the synovial membrane was everywhere inflamed, and the bone itself presented evidence of having been the seat of increased vascular action.

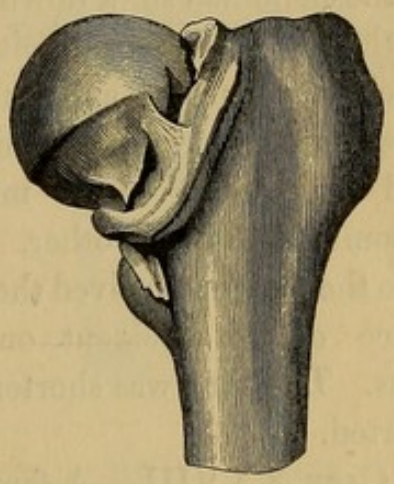

Case XXVII.—Bridget Harper, æt. 70.—Fracture of the neck of the femur within the capsule. The cervical ligament was lacerated superiorly, but the portions investing the anterior, posterior, and inferior surfaces of the neck of the bone were entire; thin and delicate bands of lymph passed from its inner surface to the superior fragment. The head of the bone had sunk down nearly to the level of the summit of the trochanter major, and the fractured surfaces presented eminences and depressions which mutually accommodated each other. In this case the patient survived the occurrence of the accident only ten days. The limb was shortened half an inch, and the foot slightly everted.

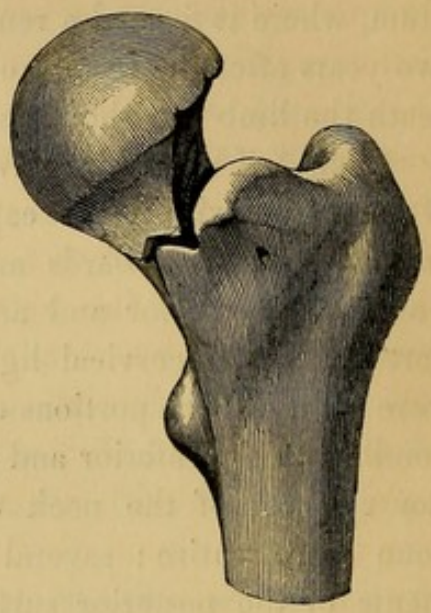

Case XXVIII.—A female, æt. 55.—Fracture of the neck of the femur within the capsule: the greater part of the neck of the bone has been absorbed, and the opposed surfaces of the fracture have become united, throughout the greater part of their extent, by a strong fibrous tissue; anteriorly, several ligamentous bands passed from the capsular ligament to the upper fragment; the fragments were in close apposition, and a ridge of bone was formed along the anterior margin of the inferior, corresponding in direction to the anterior intertrochanteric line; portions of organized lymph, attached to the capsule, were spread out over the surface of the head of the bone, but did not adhere to it. The limb was shortened

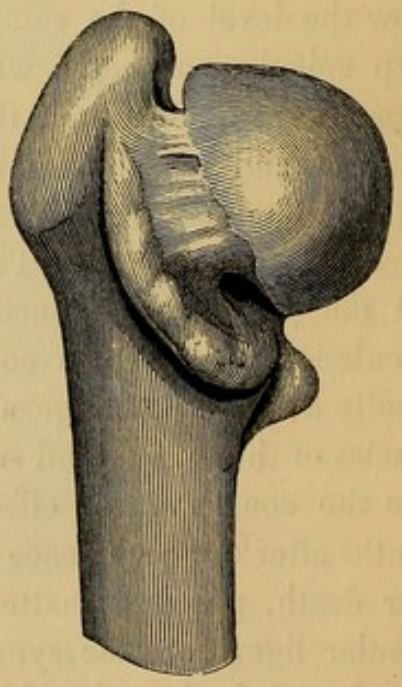

one inch and a quarter. The woman survived the receipt of the injury several years.

CASE XXIX.—Patrick Murphy, æt. 80.—Transverse serrated fracture of the neck of the femur external to the capsule, at the line of junction of the cervix with the shaft of the bone: a second fracture detached the trochanter major, which was drawn upwards and backwards, carrying with it the insertions of the pyriformis, gemelli, and obturator muscles. The trochanter minor was likewise separated from the shaft of the femur, and, along with it, the insertion of the psoas and iliacus internus; a large quantity of blood was poured out between the fragments, and among the muscles around the joint. The limb was shortened two inches, the foot *inverted*, and the entire limb in a state of adduction; the trochanter major could be felt upon the dorsum of the ilium, a little above the situation of the sciatic notch. This case was at first supposed to have been an example of luxation upon the dorsum of the ilium. The patient died upon the fourteenth day after the accident.

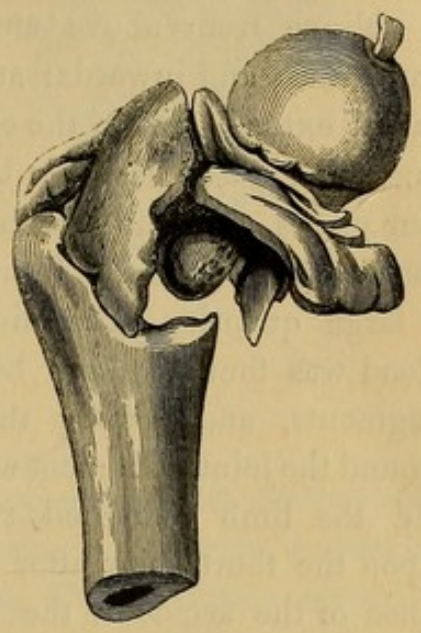

CASE XXX.—Alicia Harris, æt. 70.—Fracture of the neck of the femur external to the capsule: the greater and lesser trochanter have both been separated from the shaft of the bone, and the former broken into two portions; the posterior surface of the femur, between the two roots of the linea aspera, was also detached. Five days before her admission into the hospital, this woman had been thrown down with great violence, and having with much difficulty arisen,

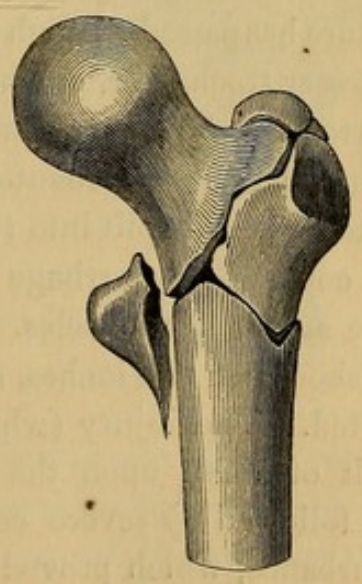

fell a second time; the parts around the joint were swollen, tense, and painful, and the limb shortened one inch and a half. She died of bronchitis ten days after the accident.

CASE XXXI.—James Stanford, æt. 67.—Comminuted fracture of the neck of the femur, external to the capsule. The fracture is oblique from above and without, downwards and inwards: at its upper part it extends within the capsule; the trochanter major has been broken into four pieces, and the trochanter minor has also been separated from the shaft; a large quantity of semi-coagulated blood was found effused between the fragments, and among the muscles around the joint. The foot was everted, and the limb shortened two inches. Upon the fourth day after the occurrence of the accident, the patient became exceedingly restless, and endeavoured to get out of bed. He died of traumatic delirium upon the eighth day from the receipt of the injury. He had been a man of most intemperate habits.

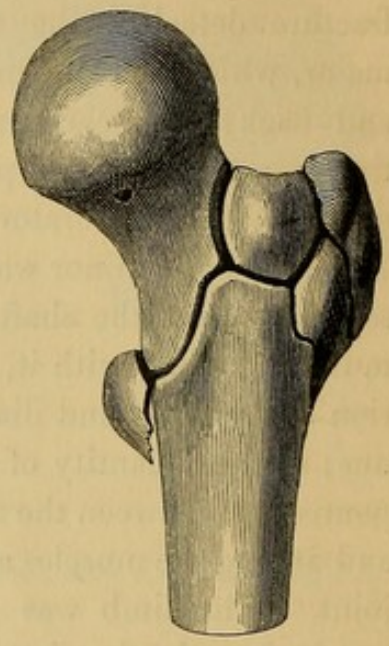

CASE XXXII.—A man, æt. 50.—Fracture of the neck of the femur, external to the capsular ligament. The fracture has passed through the centre of the lesser trochanter, one half of which thus remained connected with the shaft of the bone; the trochanter major was broken off, and split into two portions, and copious hæmorrhage had taken place among the muscles. The limb was shortened two inches, and the foot everted. The injury (which was the result of a fall upon the trochanter) was followed by severe constitutional disturbance, which proved fatal upon the fourteenth day after the occurrence of the accident. There had been delirium at night.

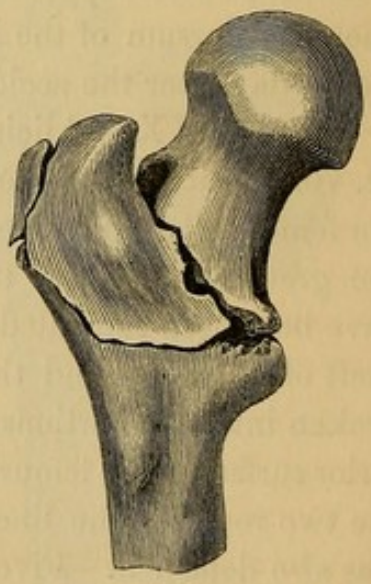

CASE XXXIII.—Mary Kelly, æt. 56.—Fracture of the neck of the femur external to the capsule: in front, a triangular portion of bone has been separated both from the shaft and from the neck of the femur; the trochanter was broken into four distinct pieces. The limb was shortened one inch and a quarter, and the foot was everted. The patient survived the occurrence of the accident only eleven days, her death being apparently owing to the severe shock caused by the injury. There was a large quantity of blood effused among the muscles around the articulation, and between the fragments of the comminuted trochanter, the fibrous structures covering which were lacerated.

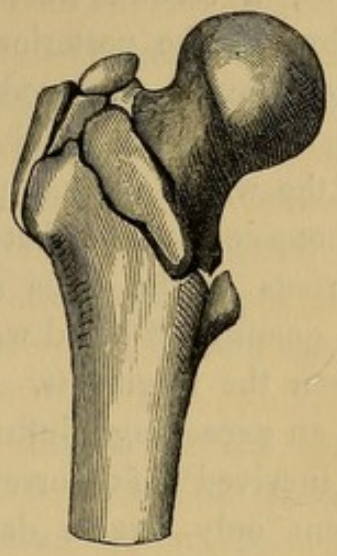

CASE XXXIV.—Ellen Bryan, æt. 65.—Fracture traversing the neck of the femur, external to the capsular ligament, at its line of junction with the shaft of the bone; a second fracture, commencing near the summit of the trochanter major, terminates at the trochanter minor, detaching the posterior half of each of these processes, together with the intervening portion of the bone, and the centre of this detached portion is traversed by a third fracture. The superior extremity of the lower fragment was deeply excavated, in consequence of the neck of the bone having been forcibly driven into its cancellated texture; the cavity thus formed was filled with blood, which was also effused between the muscles. The patient died of bronchitis five days after the receipt of the injury. There was no appreciable eversion of the foot; the shortening of the limb amounted to one inch and a half.

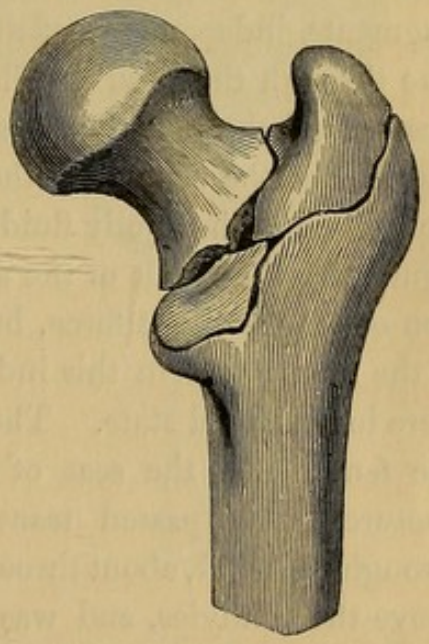

Case XXXV.—Margaret Connolly, æt. 89.—Fracture of the neck of the femur, external to the capsule; a second fracture, passing through the posterior intertrochanteric space, separated both trochanters from the shaft, together with the whole of that portion of the bone comprised between the two roots of the linea aspera; a large quantity of blood was effused between the fragments. The patient, an exceedingly infirm old woman, survived the occurrence of the accident only twelve days. The limb was shortened one inch and a half, and the foot everted.

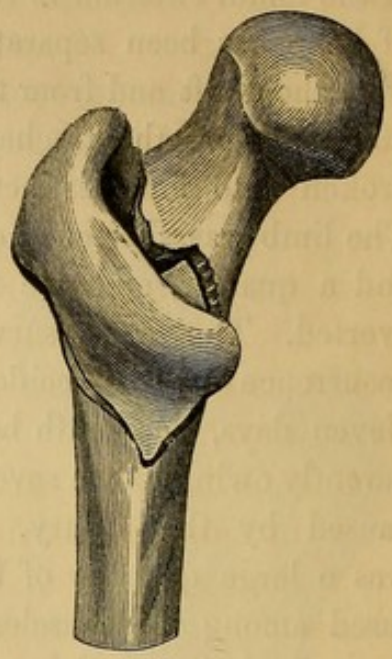

Case XXXVI.—Thomas Murphy, æt. 41.—Fracture of the neck of the femur, external to the capsule, with comminuted fracture of the trochanter major. The bone was broken into six distinct fragments, independent of the fracture through the cervix. The muscles around the joint were pale and flaccid, and the cancelli of the femur were filled with an oily fluid. The injury was the result of the application of a very slight force, but most of the long bones in this individual were in a morbid state. The opposite femur was the seat of several fractures; one passed transversely through the shaft, about three inches above the condyles, and was united with but little deformity; a second traversed the bone obliquely near its centre; this was also united, but the lower fragment overlapped the upper to the extent of four inches; a third fracture, which had separated both trochanters from the shaft, was united by a ligamentous tissue. There also

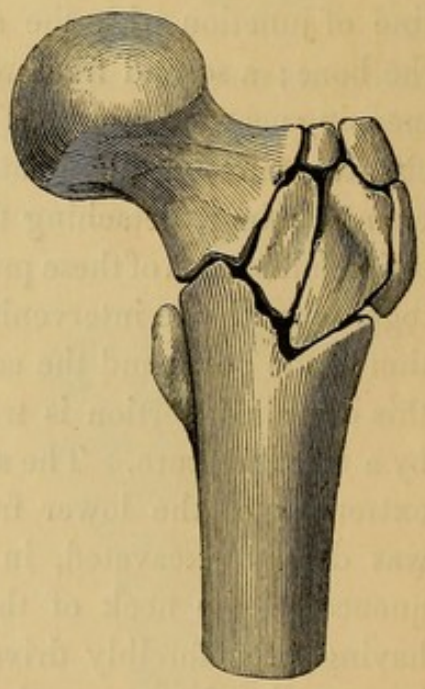

existed, upon this side, an intracapsular fracture, with complete absorption of the neck of the bone. An enormous quantity of osseous matter, of an extremely porous texture, and highly vascular, was deposited throughout the entire extent of the femur; the muscles were wasted, and contained between their fibres a pale, unhealthy adeps, and the bony tissue was infiltrated with oil. The patient had been bed-ridden for ten years preceding his death, and during the latter part of his life he suffered great agony; he at length died of diarrhœa. The olecranon process was broken during an effort of the patient to raise himself upon his elbow in bed.

Case XXXVII.—A male, æt. 60.—Fracture of the neck of the femur, external to the capsule. The neck of the bone was broken transversely at its base; it had been driven into the cancellated tissue between the trochanters, in an oblique direction,

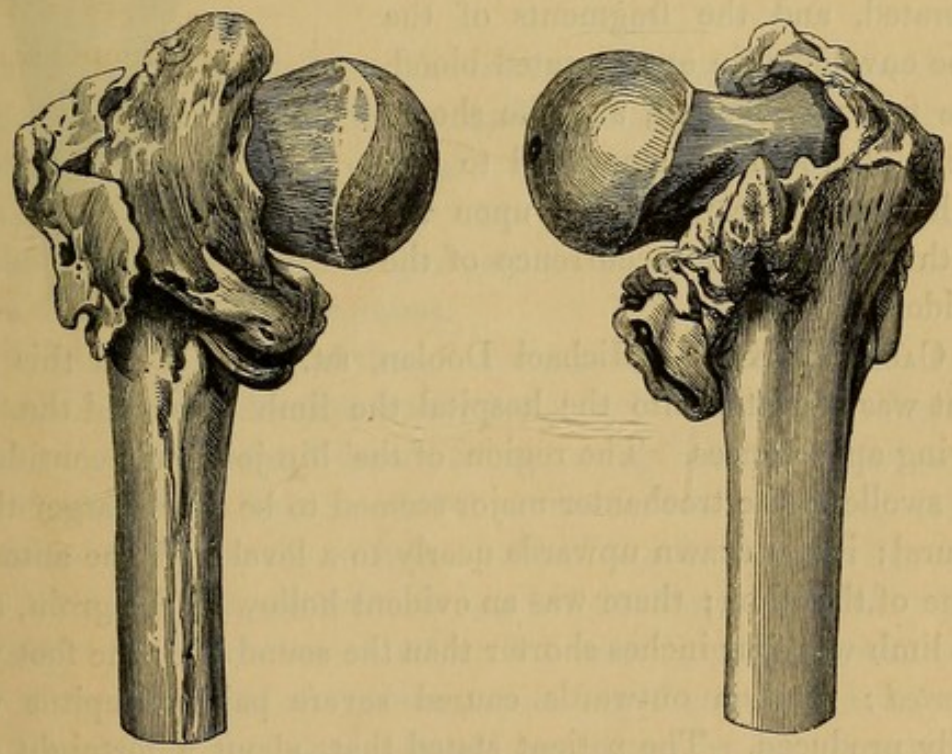

so that the broken extremity of the cervix was forcibly impelled against the trochanter major. The whole of that portion of the bone which constitutes the intertrochanteric space, together with the lesser trochanter, was completely detached from the shaft, comminuted, and displaced. The neck of the femur formed a

right angle with the shaft, which was drawn upwards in front of the anterior surface of the cervix. The fracture of the trochanter was firmly united by osseous matter, deposited copiously along the line of the solution of continuity in the bone, but the lesion of the neck of the femur itself had been repaired only by a ligamentous structure. In this case the limb was shortened two inches, the foot was *inverted*, and the injury was supposed to have been a dislocation upon the dorsum of the ilium. The patient died about six months after the occurrence of the accident.

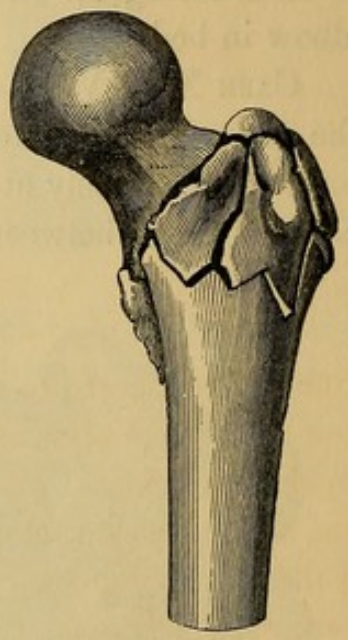

Case XXXVIII.—A male, æt. 65.—Fracture of the neck of the femur, external to the capsule, with comminuted fracture of the trochanter major, which was broken into six pieces. The fibrous coverings of the trochanteric region were everywhere lacerated, and the fragments of the bone enveloped in extravasated blood. The foot was everted, and the shortening of the limb amounted to two inches. The patient died upon the tenth day after the occurrence of the accident.

Case XXXIX.—Michael Doolan, æt. 75.—When this patient was admitted into the hospital the limb presented the following appearances. The region of the hip-joint was considerably swollen; the trochanter major seemed to be much larger than natural; it was drawn upwards nearly to a level with the anterior spine of the ilium; there was an evident hollow in the groin, and the limb was four inches shorter than the sound one; the foot was *inverted;* rotation outwards caused severe pain; crepitus was easily produced. The patient stated that, about a fortnight before his admission into the hospital, he had fallen upon a heap of stones upon the left hip; that he was at once rendered incapable of rising, and was carried to the hospital. He further stated that, many years ago, he had noticed a stiffness in the hip-joint, which was the seat of the recent injury; that by very slow degrees the limb became shortened; that he walked lame, but was never con-

fined to bed in consequence of the affection. He died one month after the occurrence of the accident. Upon examination of the joint after death, it was found that the neck of the femur was fractured at its base; the trochanter major was broken obliquely

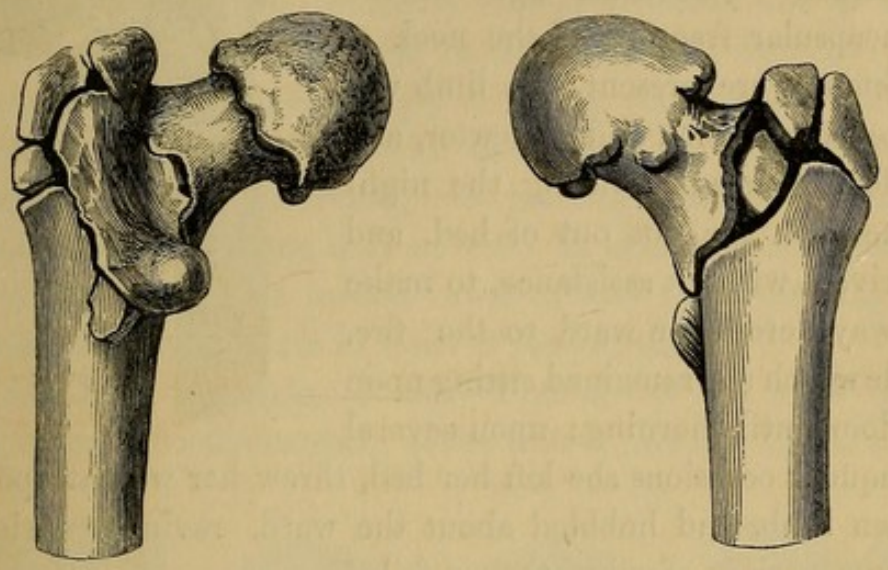

from the shaft of the bone, the fracture running in such a direction as to leave attached to the trochanter the pyriformis, gemelli, quadratus femoris, and obturator muscles; the trochanter minor was also separated, along with nearly two inches of that portion of the shaft from which it springs; the psoas and iliacus muscles were attached to this fragment.

When the interior of the joint was laid open, the state of the parts here disclosed satisfactorily accounted for the train of symptoms which the patient described as having occurred previous to the receipt of the injury. Osseous matter was deposited at the junction of the cervix with the head of the femur; the ligamentum teres had disappeared; the head of the femur was destitute of cartilage, for which was substituted a smooth, polished substance like ivory; the head of the bone was enlarged and altered in form; the acetabulum was also enlarged, and lined by the same ivory-like material as that covering the head of the femur. When the fractured portions were restored to their proper relative position, it was found that the neck of the bone was quite horizontal, and that the trochanter major was situated above the level of the head of the femur. A considerable degree of shortening (the result of chronic rheumatic arthritis) had thus existed before the occurrence of the fracture.

Case XL.—Eliza M'Cabe, æt. 80.—This woman was admitted into the hospital upon the 13th of December, 1845; she had just been violently thrown down in the street. The usual signs of the extracapsular fracture of the neck of the femur were present, the limb was shortened one inch and a quarter, and the foot everted. During the night of the 17th she got out of bed, and contrived, without assistance, to make her way across the ward to the fire, beside which she remained sitting upon the floor until morning; upon several subsequent occasions she left her bed, threw her weight upon the broken limb, and hobbled about the ward, raving occasionally and unconscious of pain. Opium failed to tranquillize her; in fact she manifested most of the symptoms of traumatic delirium. When the limb was examined after several of these attempts to walk, it was found that the shortening of the limb had reached two inches, and that there was a decided tendency to inversion of the foot. Two exceedingly sharp spiculæ of bone, belonging to the lower fragment, threatened to perforate the integuments close to Poupart's ligament, and a bony tumour could be felt towards the dorsum of the ilium. Upon the 8th of January, 1846, she was attacked with diarrhœa, and died upon the 30th, about six weeks after the occurrence of the accident.

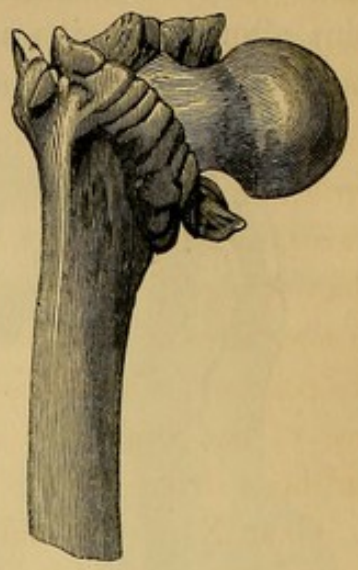



Upon examination of the joint after death, the neck of the femur was found fractured external to the capsule; it had been driven into the cancellated tissue of the lower fragment,

breaking off the entire of the trochanter major; the neck of the bone and the trochanter formed a right angle with the shaft; the former had suffered a very singular rotation, in consequence of which its anterior surface was directed upwards, and its posterior surface downwards; its concavity looked forwards, and its upper surface backwards. The head of the bone was directed backwards, and the broken extremity of the cervix forwards; the trochanter was displaced along with the neck of the bone; the anterior surface of the lower fragment presented two sharp spiculæ, the points of which were only covered by skin; the anterior surface of the femur was turned inwards, and the lower fragment had been driven upwards in front of the superior.

Case XLI.—A male, æt. 55.—Fracture of the neck of the femur external to the capsule, at the line of junction of the cervix

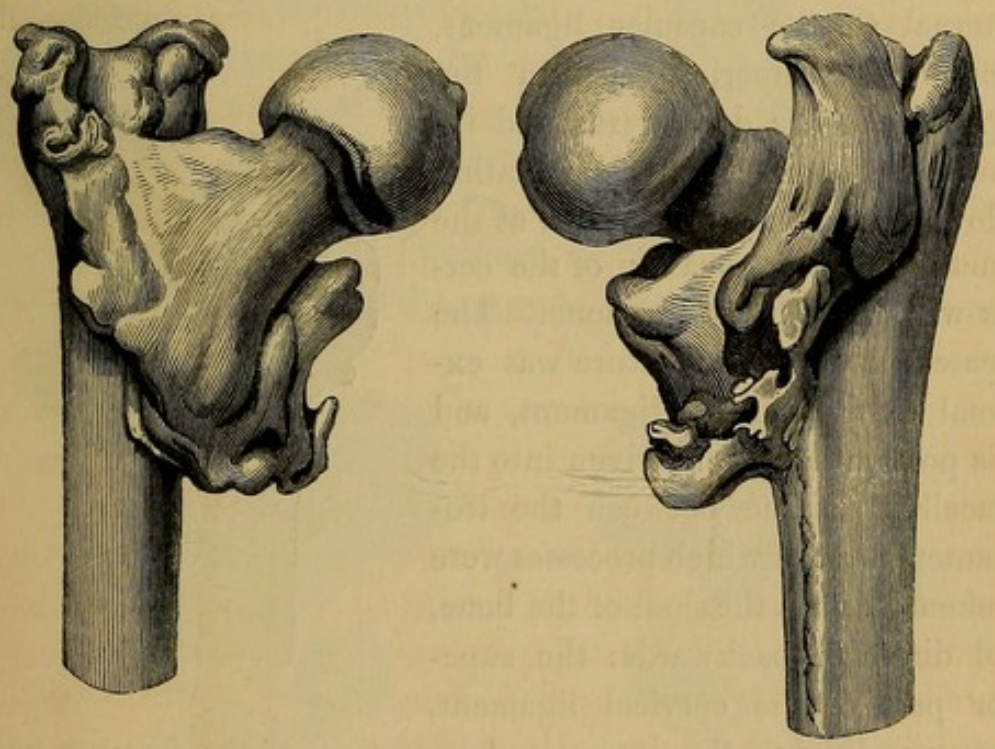

with the shaft of the bone. A second fracture, commencing near the centre of the summit of the trochanter major, passed obliquely downwards, along the inferior boundary of the intertrochanteric space, and terminated below the lesser trochanter; the large portion of bone which was thus separated from the shaft was traversed near its centre by a third fracture; the shaft of the bone was drawn upwards and backwards, and the broken extremity of

the superior fragment overlapped it in front; bony matter had been deposited along the lines of fracture, throughout the whole extent of which osseous union had taken place. In this case the limb was shortened two inches and a half, and there was complete eversion of the foot. The summit of the trochanter major was above the level of the head of the femur. In this instance osseous matter was freely deposited along the anterior, as well as along the posterior intertrochanteric line. For the opportunity of examining the specimen I am indebted to Doctor Shannon, Surgeon to the Hospital of the South Union Workhouse. The patient survived the receipt of the injury for several years, and by wearing a high-heeled shoe, was able to walk tolerably well.

Case XLII.—A female, æt. 60.—Fracture of the neck of the femur, partly internal and partly external to the capsular ligament, commencing superiorly within the capsule, passing downwards and inwards very obliquely, and terminating below, external to the capsule, at the junction of the concavity of the cervix with the shaft of the bone. The greater part of the fracture was external to the capsular ligament, and this portion had been driven into the cancellated tissue between the trochanters, both of which processes were broken off from the shaft of the bone, and displaced backwards: the superior part of the cervical ligament, corresponding to the intracapsular portion of the fracture, was lacerated. The limb, in this case, was shortened one inch and a half, and the foot everted. The patient had been knocked down with great violence; she survived the occurrence of the accident only one month. Coagulable lymph had been copiously deposited upon the broken surfaces of the neck of the bone, and osseous matter along the whole extent of the fracture through the trochanters, but consolidation had not been accomplished.

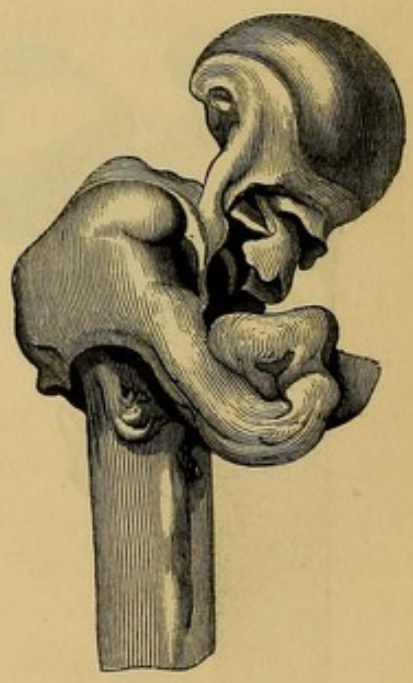

CASE XLIII.—Patrick Grant, æt. 70.—Fracture traversing the trochanter major, and inferior part of the neck of the femur. The line of fracture is slightly oblique downwards and outwards; its highest point, which corresponds to the concavity of the neck of the bone, is within the capsular ligament. In the recent state the bone presented evidence of having been the seat of acute inflammation; the periosteum was separated from it, in the vicinity of the fracture, by purulent matter, and the compact tissue of the bone was here and there absorbed; the surface of each fragment was covered with coagulable lymph. The foot was everted, and the limb shortened one inch and a half. The patient died, after suffering severe pain, upon the fifth day from the time of the receipt of the injury.

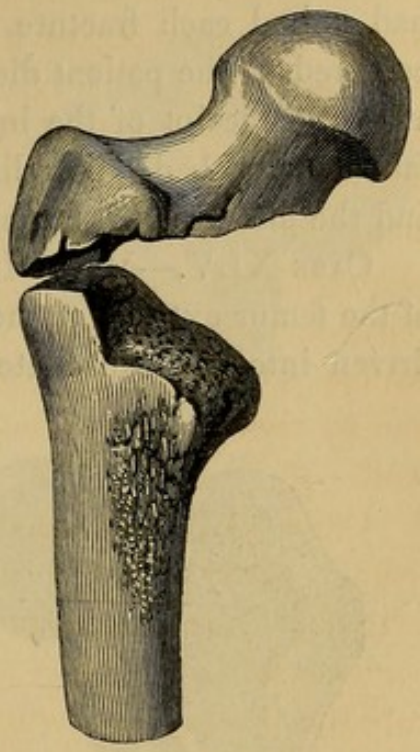

CASE XLIV.—John Summers, æt. 74.—Fracture of the neck of the femur, external to the capsule, with impaction of the superior fragment into the cancellated tissue between the trochanters; a second fracture, passing downwards and inwards towards the trochanter minor, had separated the trochanter major from the

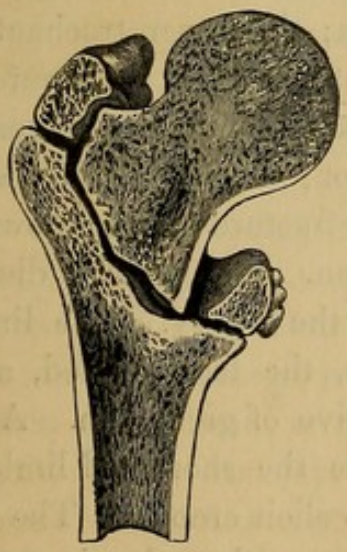

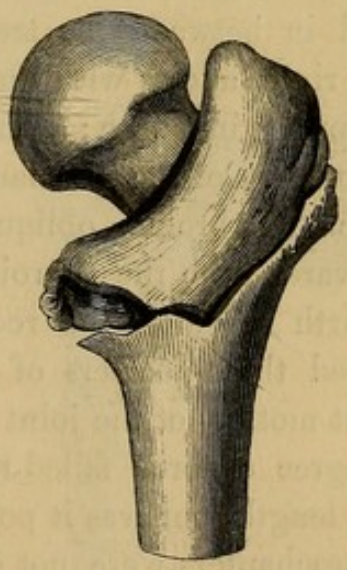

shaft, along with the whole of that portion of the bone which constitutes the posterior intertrochanteric space; the fibrous investments of this region were uninjured. An organized fibrous tissue had united each fracture, but bony union had not any where occurred. The patient died of sloughing of the nates two months after the receipt of the injury, which was caused by his having fallen out of bed. The limb was shortened one inch and a half, and the foot everted, but crepitus was not perceptible.

Case XLV.—Mary M'Kenna, æt. 52.—Fracture of the neck of the femur external to the capsule. The superior fragment was driven into the cancellated texture of the inferior, and firmly

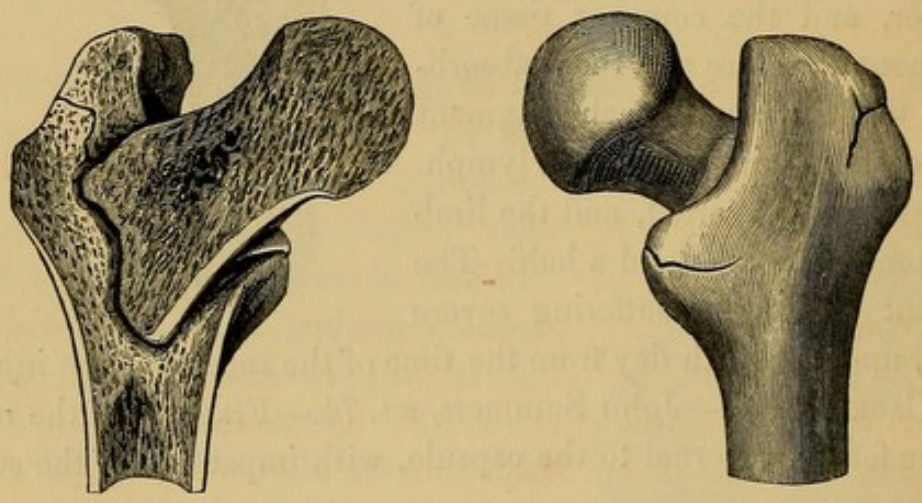

wedged in between the trochanters; the lesser trochanter was split at right angles with the shaft of the bone, the fissure being about an inch in length; a similar, but shorter fissure, traversed the posterior part of the trochanter major; the descending ramus of the pubis was broken obliquely, the fracture passing downwards and inwards from the thyroid foramen. The patient died upon the fourth day after the receipt of the injury. The limb was shortened three-quarters of an inch, the foot everted, and the slightest motion of the joint productive of great pain. A moderate degree of force failed to restore the shortened limb to its natural length, nor was it possible to elicit crepitus. The fissures of the trochanters were not continuous with each other, nor was there any laceration of the fibrous structures which invest the trochanteric region; the neck of the bone was driven into the shaft, preserving very nearly its natural obliquity.

CASE XLVI.—Catherine Egan, æt. 60.—Fracture of the neck of the femur external to the capsule. The neck of the bone has been driven into the cancellated tissue of the trochanter, and forms a right angle with the shaft of the bone: a second fracture separated the lesser trochanter and posterior half of the greater from the shaft, between which and the fragment thus detached, the broken end of the cervix appeared; in the recent state it was in naked contact with the bursa, situated under the glutæus maximus muscle; the lower fragment lay principally in front of the superior. The patient died of diarrhœa one month after the occurrence of the accident. The limb was shortened one inch and a quarter, and the foot was *inverted;* it admitted of being slightly everted, but remained throughout the progress of the case in the inverted position.

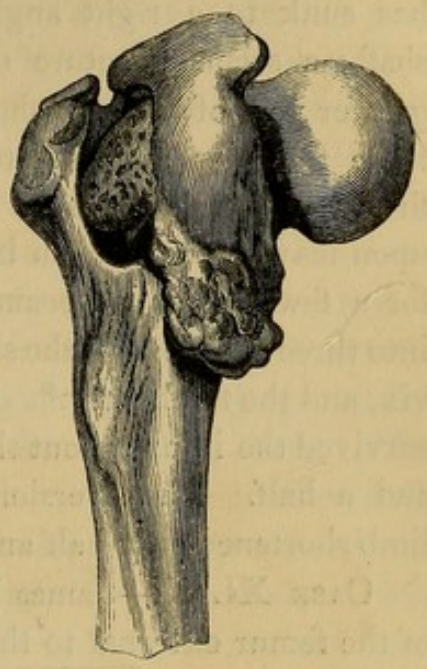

CASE XLVII.—Sarah Denny, æt. 70.—Fracture of the neck of the femur external to the capsule: the cervix has been driven in between the trochanters so far, that its broken surface is in contact with the external wall of the shaft; a second fracture, passing along the inferior boundary of the posterior intertrochanteric space, has separated both trochanters from the shaft, along with the intervening portion of the bone; a quantity of bony matter was deposited along the line of this fracture. The patient survived the injury one month. The foot was everted, and the limb shortened one inch. It was found impossible to elongate it, or to produce crepitus.

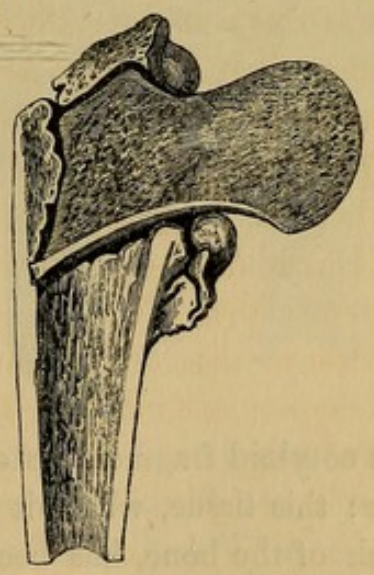

Case XLVIII.—Alicia Sherlock, æt. 64.—Extracapsular fracture of the neck of the femur, with impaction of the superior into the inferior fragment: the neck has sunk to a right angle with the shaft; a second fracture detached the greater part of both trochanters; both these fractures appeared to have been firmly united by osseous matter, but upon leaving the bone in boiling water for a few hours, it became separated into three fragments—the shaft, the cervix, and the trochanter.* The patient survived the injury about three months and a half. The eversion of the foot was very slight, and the limb shortened only half an inch: crepitus could not be produced.

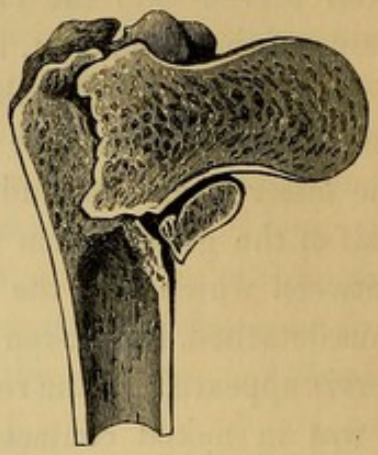

Case XLIX.—James Power, æt. 54.—Fracture of the neck of the femur external to the capsular ligament, with impaction of

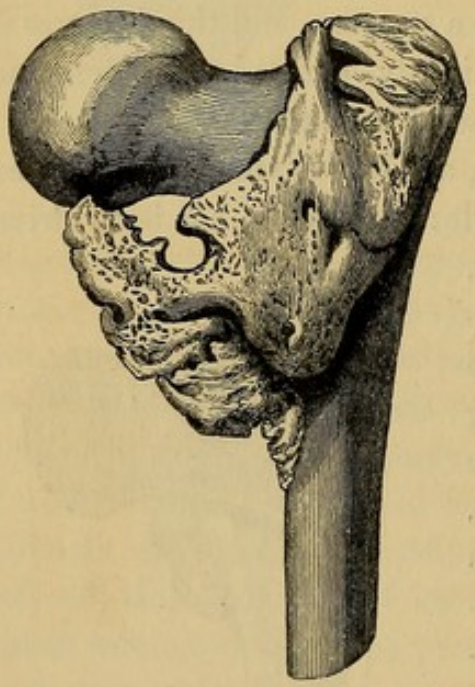

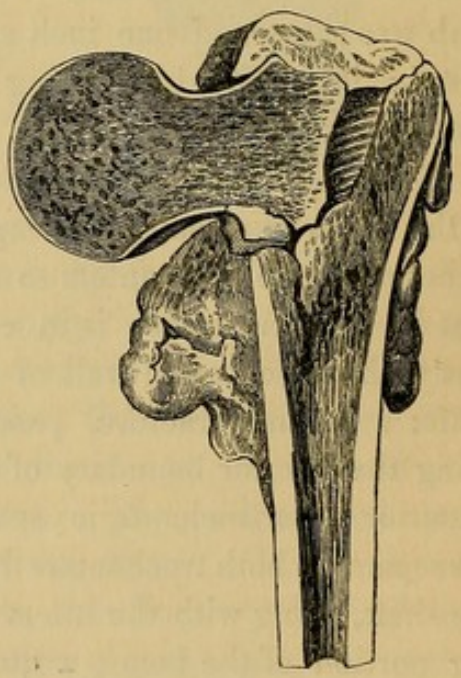

the cotyloid fragment into the cancellated structure of the inferior: this tissue, where it is opposed to the broken surface of the neck of the bone, has become exceedingly dense and firm, and

* See page 49.

here the fragments are united by short ligamentous bands, but the two portions of the fractured bone are still capable of being moved upon each other; the cervix forms a right angle with the shaft, and the anterior inferior angle of its broken extremity projects nearly half an inch in front of the lower fragment, in such a manner, that the axis of the neck is directed backwards: a second fracture, passing downwards and inwards through the posterior intertrochanteric space, has detached both trochanters from the shaft of the femur; this fracture has been united by bone, a most exuberant growth of which, very irregular in form, and of a porous, spongy texture, has sprung from the intertrochanteric line, and encircled the neck of the bone. The injury was the result of a fall upon the trochanter, January 3rd, 1839. The limb was shortened one inch and a half, and the foot everted. At the end of seven weeks the patient left the hospital, and was able to walk with the assistance of crutches. He had, at this time, disease of the bladder, for which he was readmitted June 3rd, and of which he died June 11th.

Case L.—A female, æt. 70.—Extracapsular impacted fracture of the neck of the femur, with fracture through the posterior part of the trochanter major. The neck of the bone forms an acute angle with the shaft; both fractures have been perfectly united by bone; the cancellated tissue (the cells of which were enlarged) was filled with an oleaginous medulla, and a slight degree of pressure was sufficient to crush the structure of the head of the bone; the compact tissue of the arch of the neck of the femur was atrophied, and the portion of it which had been driven into the shaft was becoming indistinct, and, as it were, resolved into cancellated tissue. The bone was remarkable for its extreme lightness. The injury was received several years before the death of the patient, who had been bedridden during the whole of the intervening time. I was unable to ascertain the amount of shortening in this case.

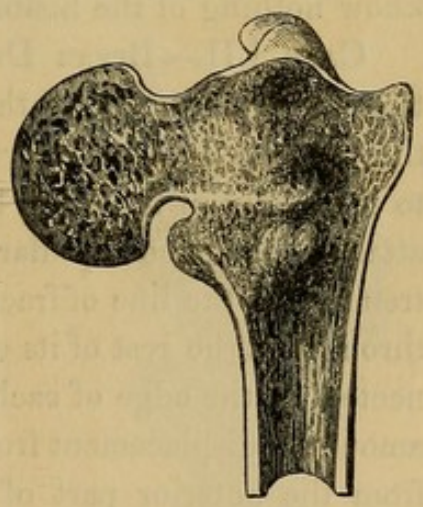

Case LI.—Fracture of the neck of the femur external to the capsular ligament, with impaction of the superior into the inferior fragment: the angle which the neck of the bone forms with the shaft in the normal state has been, in this instance, nearly preserved, but the direction of its axis is slightly altered; it forms with the shaft an angle salient in front; there is a mutual interlocking of the fragments; the centre of the broken surface of the lower fragment forming a remarkable convexity,* which is received into a corresponding concavity in the cotyloid fragment; there is no union between the fragments; a second fracture had detached the greater part of the trochanter major, but here solid bony union had occurred. The neck of the femur, although perfectly moveable, could not be extricated from the cavity between the trochanters into which it had been received, in consequence of the manner in which the fragments were dovetailed together. I know nothing of the history connected with this preparation.

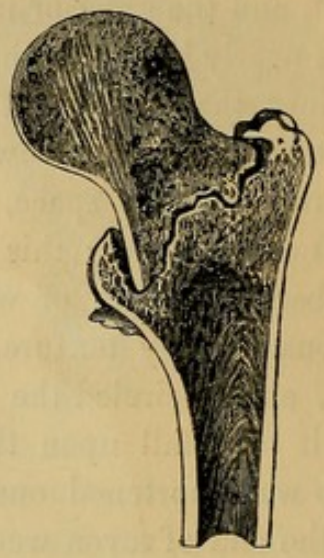

Case LII.—Bryan Dunn, æt. 60.—Extracapsular impacted fracture of the neck of the femur. The line of fracture passes through the anterior intertrochanteric line, so as to be external to the cavity of the joint, but, at the same time, concealed by the attachment of the capsular ligament; at the upper and lower extremities of the line of fracture, this attachment was lacerated, but throughout the rest of its extent it was uninjured, and, being connected to the edge of each fragment, prevented any considerable amount of displacement from occurring. A second fracture passed from the anterior part of the summit of the trochanter major, downwards and inwards, towards the lesser trochanter, degenerating into a hair-like fissure as it approached that process; a third fracture, running downwards and outwards from the posterior

* "Il est excessivement rare de voir de saille en forme de clou appartenir au fragment inferieur. Je ne l'ai vu qu'une fois."—*Cruveilhier*, liv. xxiii.

intertrochanteric ridge, met the line of the second nearly at a right angle, and thus completed the separation from the rest of the bone of that portion of the great trochanter which gives insertion

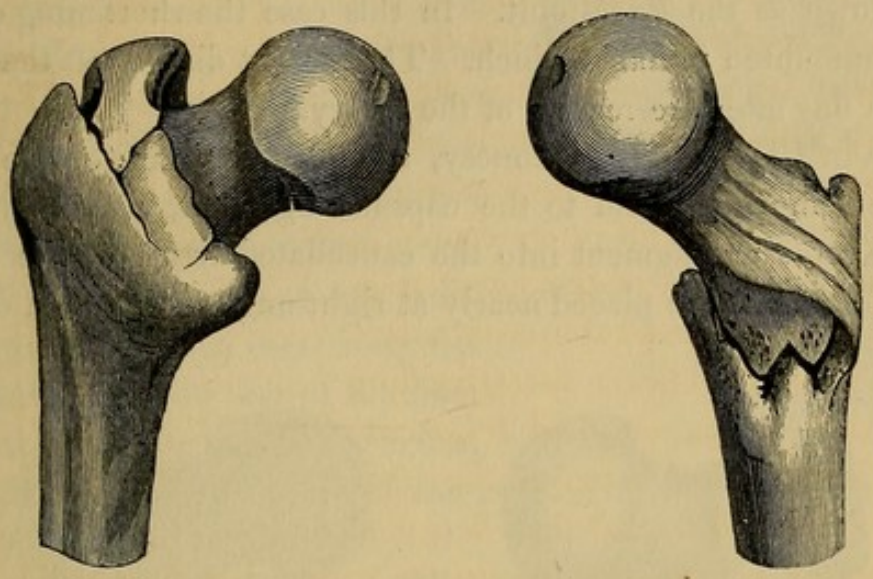

to the glutæus medius and quadratus femoris; another fissure passed downwards at right angles with the lesser trochanter, but was not continuous with the fissures already described. The fibrous investment of the trochanteric region was uninjured.

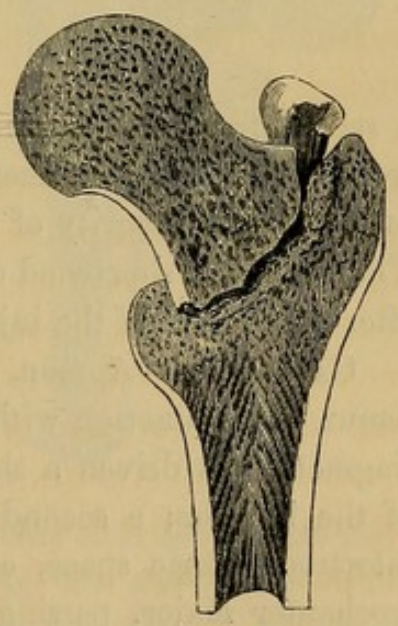

The neck of the femur had lost somewhat of its natural obliquity, and its axis, instead of being directed upwards and forwards, as in the normal state, passed upwards and backwards; it thus formed with the shaft an angle salient in front. A section of the head and neck of the bone shewed that the superior fragment had been driven into the cancellated texture of the inferior, but (owing to the obliquity of the cervix, its axis being directed backwards and its lower extremity thrown forwards) the posterior half alone of the broken surface of the upper fragment had been impacted, and that to a very slight degree. A sharp point of bone, projecting from

the anterior margin of the upper fragment, where the attachment of the capsule had been penetrated, had pierced a branch of the external circumflex artery, and the blood poured forth from the wounded vessel had separated the muscles from each other as low down as the knee-joint. In this case the shortening of the limb amounted to half an inch. The patient died upon the fourteenth day after the receipt of the injury.*

Case LIII.—Mary Hennesy, æt. 80.—Fracture of the neck of the femur, external to the capsular ligament, with impaction of the superior fragment into the cancellated tissue of the shaft. The fragments are placed nearly at right angles with each other;

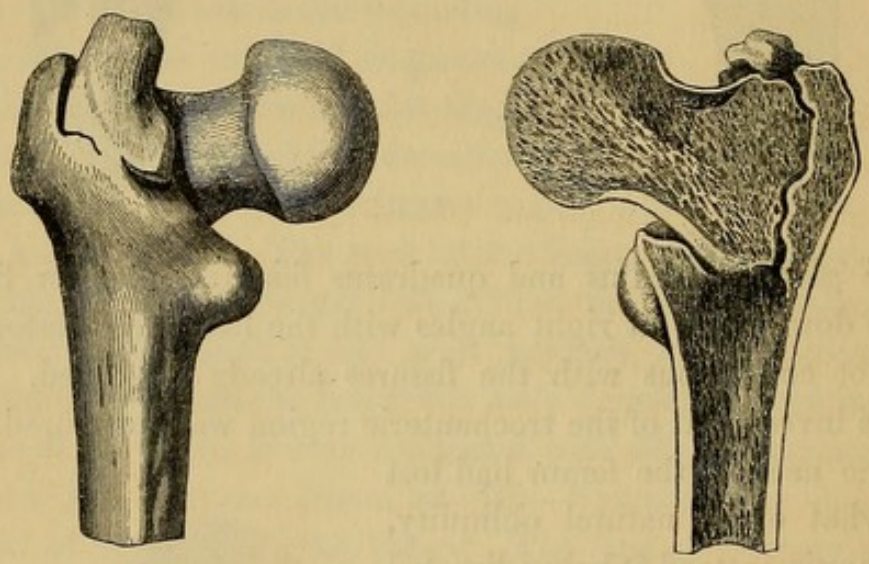

a second fracture has split off the posterior superior part of the trochanter major, but there is no displacement of the fragment, owing to the integrity of the fibrous coverings of the trochanter. The limb was shortened one inch. The patient died one month after the receipt of the injury.

Case LIV.—A man, æt. 58.—Fracture of the neck of the femur, at its junction with the shaft of the bone. The superior fragment was driven a short distance into the cancellated tissue of the inferior; a second fracture passed through the posterior intertrochanteric space, commencing behind the summit of the trochanter major, passing from thence downwards and inwards,

* A case exceedingly similar to this has been published by Mr. King, as an example of partial fracture of the neck of the femur.—See Lancet, 1844.

and terminating below the lesser trochanter, thus separating from the shaft a portion of the former, and the entire of the latter process. The neck of the bone formed a right angle with the shaft; complete and solid osseous union had taken place throughout the entire extent of each fracture. The patient survived the receipt of the injury several years. The foot was everted, and the limb was shortened three-quarters of an inch. Osseous matter had been freely deposited along the line of the fracture through the trochanter major, and the reticular structure of the neck of the bone communicated freely with that of the shaft.

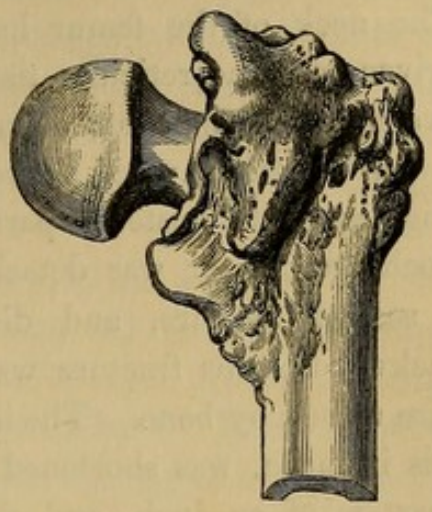

Case LV.—A man, æt. 67.—Fracture of the neck of the femur, external to the capsule, with impaction of the superior fragment into the cancellated tissue of the inferior. Perfect osseous consolidation has taken place along the whole line of the fracture; a second fracture commenced at the junction of the anterior with the middle third of the trochanter major, and terminated at the lesser trochanter; this was likewise united by bony matter, deposited freely along the line of fracture; the head and neck of the bone were placed at right angles with the shaft. The limb, in this case, was shortened half an inch, and the foot was everted. The patient lived several years after the occurrence of the accident. He was of course lame, but was able to walk a considerable distance without uneasiness or fatigue, and seldom even had recourse to the assistance of a stick; he complained, however, of pain in the hip during cold or damp weather.

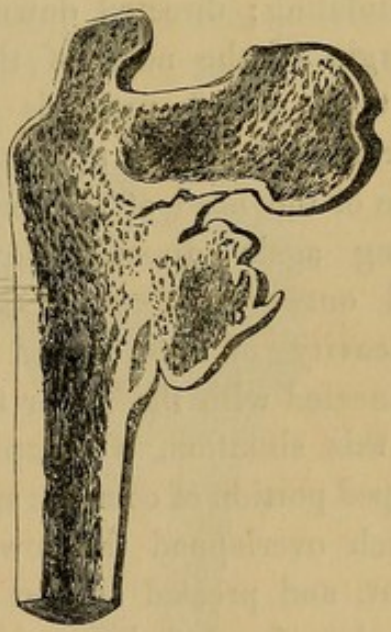

Case LVI.—A female, æt. 60.—Fracture of the neck of the femur, external to the capsular ligament, at the junction of the cervix with the shaft of the bone. The neck of the femur has been driven into the reticular tissue between the trochanters; a firm bony union has taken place between the fragments; the posterior part of the trochanter major was detached by a second fracture, and displaced backwards; this fracture was likewise united by bone. The limb, in this instance, was shortened three-quarters of an inch, and the foot was everted. The patient lived five years after the receipt of the injury.

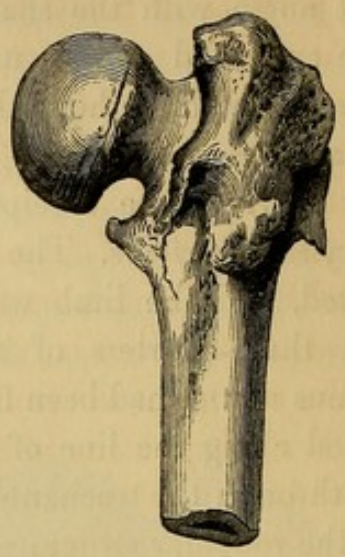

Case LVII.—Patrick M'Dermott, æt. 66.—Fracture of the neck of the femur within the capsule, with mutual impaction of the fragments. The line of fracture is exceedingly irregular and undulating; directed downwards and outwards at the superior margin of the neck of the bone, it then passed upwards and inwards, encroaching upon the cartilage of the head of the femur, and being again directed downwards and outwards, terminated at the concavity of the cervix, leaving connected with the upper fragment in this situation, a sharp wedge-shaped portion of compact structure, which overlapped the lower fragment, and pressed against the internal surface of the capsule; the surface of the superior fragment presented two concavities, separated by a convexity; the latter corresponded to a concavity in the reticular tissue of the lower fragment, while the former received portions of the compact structure of the lower fragment:

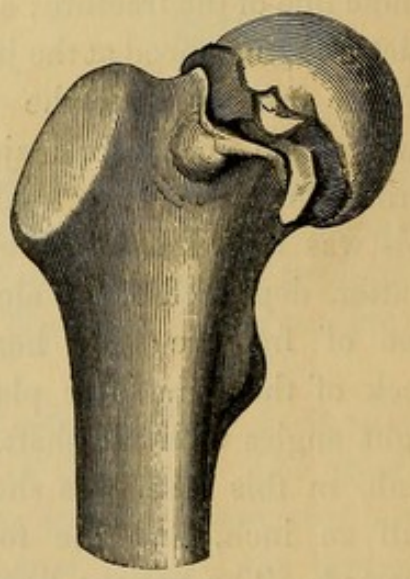

the two portions of the bone thus mutually supported each other. The cervical ligament was torn throughout the whole of its anterior portion, but posteriorly it remained perfect. In the latter situation small portions of bone, broken from the upper fragment close to the margin of the cartilage, remained adherent to the cervical ligament. The foot was slightly everted, and the limb shortened half an inch. The patient died upon the sixteenth day after the receipt of the injury.

Case LVIII.—The subject of this case was a female, æt. 80, who, while walking across her bed-room, fell upon her left hip, and was at once rendered incapable of rising. About an hour after the receipt of the injury she was seen by Dr. Fleming, who found her complaining of severe pain in the region of the joint; she had lost all power over the motions of the limb; the foot was slightly *inverted*, and any attempt to evert it caused great pain; the left limb was longer than the right, but, upon inquiry, it was ascertained that the latter had, about twenty years previously, been broken a little above the knee-joint; this fracture had been permitted to unite with much deformity, the limb being shortened and the foot everted. The case was treated by Dr. Fleming as one of intracapsular fracture of the neck of the femur; some irritative

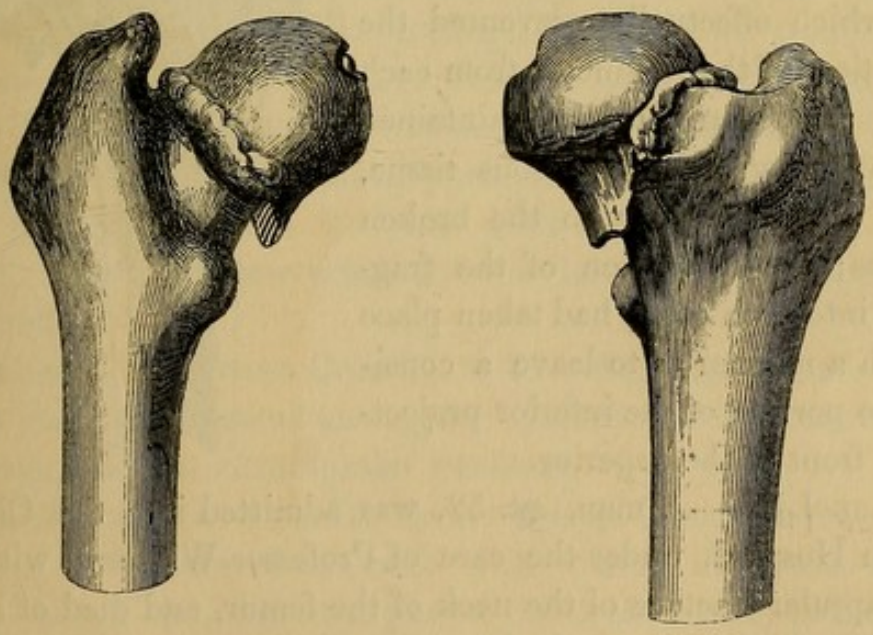

fever supervened, but gradually subsided, and, at the expiration of six weeks, the patient had regained considerable command

over the motions of the limb, and, in the seventh week, was able to leave her bed. Shortly afterwards, however, she was attacked with influenza, and died eight weeks after the receipt of the injury. The foot remained inverted throughout the whole progress of the case.

Upon examination after death, the neck of the bone was found to have been broken within the capsule; superiorly, the fracture was close to the head of the bone; from thence it passed somewhat obliquely downwards and inwards, leaving a portion, about half an inch in length, of the concavity of the neck of the bone attached to the superior fragment; the head of the bone was driven downwards, so that its upper surface was on a level with the summit of the trochanter major; internally and inferiorly, the upper fragment overlapped the lower, the compact tissue of which had, in this situation, penetrated the reticular structure of the head of the bone; while, superiorly and externally, the inferior overlapped the superior fragment to such an extent as to conceal a portion of its cartilaginous surface, and here the broken surface of the upper fragment had sunk into the cancellated tissue of the lower; from this relative disposition of the fragments resulted a mutual impaction, which effectually prevented the separation of the fragments from each other; they were further maintained in contact by a dense fibrous tissue, which adhered closely to the broken surfaces; the impaction of the fragments into each other had taken place in such a manner as to leave a considerable portion of the inferior projecting in front of the superior.

Case LIX.—A man, æt. 52, was admitted into the City of Dublin Hospital, under the care of Professor Williams, with an intracapsular fracture of the neck of the femur, and died of bronchitis upon the sixteenth day after the receipt of the injury. Upon laying open the hip-joint, very little synovia was found in its interior, but a layer of coagulable lymph covered the entire

of the internal surface of the capsule; this lymph was firm, closely adherent to the capsule, and vascular throughout; at several points it adhered to the neck and head of the femur.

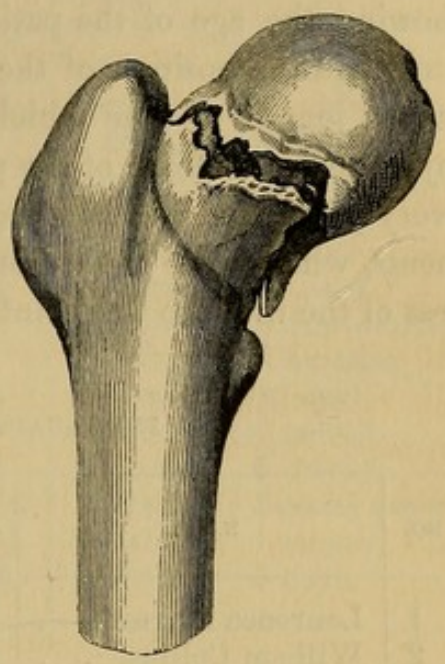

The fracture, which was entirely within the capsule, passed in a tortuous direction from above downwards, and from within outwards, until it arrived at the compact tissue of the neck of the femur inferiorly, where it ran very obliquely downwards and outwards, thus leaving connected with the upper fragment in this situation a sharp, wedge-shaped portion of the compact tissue of the bone, which overlapped the lower fragment; the cervical ligament, torn in front, was perfect posteriorly and inferiorly; the surface of each fragment was highly vascular, and several shreds of lymph passed between them, perpendicular to, and adherent to, both surfaces; in fact, a thin layer of lymph was effused between the opposed surfaces of the fracture, on separating which, it was drawn out into the thin and delicate bands above mentioned. The fracture in this case was caused by a fall directly on the most prominent and external part of the trochanter major, and the patient walked a few yards after the occurrence of the injury. The foot was everted, and the limb shortened exactly half an inch.

Case LX.—Owen Curran, æt. 70.—See page 59, where this case has been inserted among the examples of the occurrence of osseous union in intracapsular fractures.

The Museum of the Richmond Hospital contains several specimens of fracture of the neck of the femur, the result of fragilitas ossium, and also examples of the same lesion, produced by the deposition of cancerous tubercles in the reticular structure of the cervix; to these, however, it would be foreign to my purpose to allude at present.

I have now given as concise an account as possible of the preparations, the examination and history of which warrant, in my opinion, the inferences appended to this memoir, and, for the sake of more convenient reference, the following table is subjoined, shewing the age of the patient, the degree of shortening of the limb, and the position of the foot in the preceding cases, as well as the length of time which elapsed between the receipt of the injury and the death of the patient. It is right to mention, that every precaution was adopted to ensure accuracy in the measurements, which were made from the anterior superior spinous process of the ilium to the point of the internal malleolus.

INTRACAPSULAR FRACTURES.

NO.	NAME.	AGE.	SHORTENING.	POSITION OF THE FOOT.	PERIOD OF SURVIVAL.
			Inches.		
1	Laurence Maguire, .	40	$\frac{1}{2}$	Eversion,	14 days.
2	William Collins, . .	36	$\frac{3}{4}$	ditto,	17 days.
3	Thomas Maguire, . .	84	$\frac{1}{2}$	ditto,	14 days.
4	Dorah Campbell, . .	75	1	ditto,	2 months.
5	Mary Gill, ...	80	$\frac{1}{2}$	ditto,	Not known.
6	Esther Christie, . .	60	$1\frac{1}{2}$	ditto,	Not known.
7	Mary Lamb, . . .	80	$\frac{3}{4}$	ditto,	1 year.
8	Margaret Bourke, . .	90	$\frac{1}{2}$	ditto,	14 days.
9	Margaret Myler, . .	78	$\frac{1}{4}$	ditto,	2 months.
10	A female, ...	65	1	ditto,	Several years.
11	Patrick Doolan, . .	60	2	ditto,	7 years.
12	Michael Curry, . .	40	$1\frac{1}{4}$	ditto,	1 month.
13	Matthew Reilly, . .	46	$\frac{1}{2}$	ditto,	4 months.
14	Sarah Ashton, . . .	65	$1\frac{1}{4}$	ditto,	9 years.
15	Elizabeth Casey, . .	50	$\frac{3}{4}$	Inversion,	Several years.
16	Robert Robinson, . .	50	2	Eversion,	Several years.
17	Ellen Walker, . . .	70	$\frac{1}{2}$	ditto,	7 days.
18	Laurence Reilly, . .	56	2	ditto,	Several years.
19	Joseph Seaton, . . .	90	$1\frac{1}{4}$	ditto,	7 years.
20	A female, ...	65	$2\frac{1}{2}$	ditto,	Several years.
21	Thomas Connolly, .	50	$\frac{3}{4}$	ditto,	10 days.
22	Bridget Missett, . .	72	1	ditto,	10 weeks.
23	A female, ...	50	1	ditto,	Several years.
24	Catherine Mooney, .	60	1	ditto,	5 years.
25	Robert Donovan, . .	80	$1\frac{1}{2}$	ditto,	2 years.
26	Mary Woods, . . .	70	1	ditto,	3 months.
27	Bridget Harper, . .	70	$\frac{1}{2}$	ditto,	10 days.
28	A female, ...	55	$1\frac{1}{4}$	ditto,	Several years.

EXTRACAPSULAR FRACTURES.

NO.	NAME.	AGE.	SHORTENING.	POSITION OF THE FOOT.	PERIOD OF SURVIVAL.
			Inches.		
29	Patrick Murphy, . .	80	2	Inversion,	14 days.
30	Alicia Harris, . . .	70	$1\frac{1}{2}$	Eversion,	10 days.
31	James Stanford, . .	67	2	ditto,	8 days.
32	A male, ...	50	2	ditto,	14 days.
33	Mary Kelly, . . .	56	$1\frac{1}{4}$	ditto,	11 days.
34	Ellen Bryan, . . .	65	$1\frac{1}{2}$	ditto,	5 days.
35	Margaret Connolly, .	89	$1\frac{1}{2}$	ditto,	12 days.
36	Thomas Murphy,* .	41		ditto,	A few weeks.
37	A male, ...	60	2	Inversion,	6 months.
38	A male, ...	65	2	Eversion,	10 days.
39	Michael Doolan, . .	75	4	Inversion,	1 month.
40	Eliza M'Cabe, . . .	80	$1\frac{1}{4}$	Eversion,	6 weeks.
41	A male, ...	55	$2\frac{1}{2}$	ditto,	Several years.
42	A female, ...	60	$1\frac{1}{2}$	ditto,	1 month.
43	Patrick Grant, . . .	70	$1\frac{1}{2}$	ditto,	5 days.

EXTRACAPSULAR IMPACTED FRACTURES.

NO.	NAME.	AGE.	SHORTENING.	POSITION OF THE FOOT.	PERIOD OF SURVIVAL.
			Inches.		
44	John Summers, . .	74	$1\frac{1}{2}$	Eversion,	2 months.
45	Mary M'Kenna, . .	52	$\frac{3}{4}$	ditto,	4 days.
46	Catherine Egan, . .	60	$1\frac{1}{4}$	Inversion,	1 month.
47	Sarah Denny, . . .	70	1	Eversion,	1 month.
48	Alicia Sherlock, . .	64	$\frac{1}{2}$	ditto,	$3\frac{1}{2}$ months.
49	James Power, . . .	54	$1\frac{1}{2}$	ditto,	5 months.
50	A female, ...	70	not known	ditto,	Not known.
51	A male, ...	62	,,	ditto,	Not known.
52	Bryan Dunn, . . .	60	$\frac{1}{2}$	ditto,	14 days.
53	Mary Hennessy, . .	80	1	ditto,	1 month.
54	A male, ...	58	$\frac{3}{4}$	ditto,	Several years.
55	A male, ...	67	$\frac{1}{2}$	ditto,	Several years.
56	A female, ...	60	$\frac{3}{4}$	ditto,	5 years.

* The opposite femur, in this patient, had been broken in several places, and the fractures had united with great deformity; the limb was consequently much shortened, so that it was impossible to ascertain the amount of retraction consequent upon the recent fracture of the neck of the femur described at page 38.

INTRACAPSULAR IMPACTED FRACTURES.

NO.	NAME.	AGE.	SHORTENING.	POSITION OF THE FOOT.	PERIOD OF SURVIVAL.
			Inches.		
57	Patrick M'Dermott, .	66	½	Eversion,	16 days.
58	A female, ...	80	not known.	Inversion,	8 weeks.
59	A male, ...	52	½	Eversion,	16 days.
60	Owen Curran, . . .	70	½	ditto,	22 months.

The subjoined table gives the aggregate of the specimens of fracture of the neck of the femur, which are contained in the principal museums of morbid anatomy in Dublin, and shews the proportion which the examples of osseous union bear to the total number.

MUSEUM.	INTRA-CAPSULAR.	OSSEOUS UNION.	EXTRA-CAPSULAR.	OSSEOUS UNION.	TOTAL.
Richmond Hospital,	29	1	27	3	56
Royal College of Surgeons,	19	0	15	5	34
Richmond Hospital School,	10	0	6	3	16
Trinity College ditto.	8	0	1	0	9
Park-st. School of Medicine,	3	0	8	3	11
Peter-street ditto.	2	0	3	2	5
Original Peter-st. ditto,	4	0	0	0	4
South Union Hospital,	4	0	1	1	5
	79	1	61	17	140

From all that has been stated in the preceding pages, and from the evidence afforded by the numerous *post mortem* examinations which I have had opportunities of making, the following conclusions appear to be legitimately deduced:

1. A slight degree of shortening, removeable by a moderate extension of the limb, indicates a fracture within the capsule.

2. The amount of *immediate* shortening, when the fracture is within the capsule, varies from a quarter of an inch to one inch.

3. The degree of shortening, when the fracture is within the capsule, varies chiefly according to the extent of laceration of the cervical ligament.

4. It also varies according as the fracture is impacted or otherwise.

5. In some cases of intracapsular fractures, the injury is not immediately followed by shortening of the limb.

6. This is generally to be ascribed to the integrity of the cervical ligament.

7. In such cases, shortening may occur suddenly, at a period more or less remote from the receipt of the injury.

8. This sudden shortening of the limb is in general to be ascribed to the accidental laceration of the cervical ligament, previously entire, and is indicative of a fracture within the capsule.

9. The deposition of callus around the fragments is not necessary for the union of the intracapsular fracture.

10. When osseous consolidation occurs in the intracapsular fracture, it is effected by the direct union of the broken surfaces, which are confronted to each other.

11. The osseous union of the intracapsular fracture is most likely to occur when the fracture is of the variety termed "impacted."

12. In the intracapsular fracture, the mode of impaction is different from that which obtains in the extracapsular.

13. The degree of shortening, when the fracture is external to the capsule, and does not remain impacted, varies from one inch to two inches and a half.

14. When a great degree of shortening occurs immediately after the receipt of the injury, we usually find a comminuted fracture external to the capsule.

15. The extracapsular fracture is accompanied by fracture with displacement of one or both trochanters.

16. The extracapsular *impacted* fracture is accompanied by fracture without displacement of one or both trochanters.

17. In such cases, the fracture of the trochanters unites more readily than that of the neck of the bone.

18. The degree of shortening, in the extracapsular impacted fracture, varies from a quarter of an inch to an inch and a half.

19. The exuberant growths of bone met with in these cases have been erroneously considered to be merely for the purpose of supporting the acetabulum and the neck of the femur.

20. The final cause of their formation is the union of the fracture through the posterior intertrochanteric space.

21. The difficulty of producing crepitus, and of restoring the limb to its normal length, are the chief diagnostic signs of the impacted fracture.

22. The position of the foot is influenced principally by the obliquity of the fracture, and the relative position of the fragments.

23. Inversion of the foot may occur in any of the varieties of fracture of the neck of the femur.

24. When the foot is inverted, we usually find that either a portion or the entire of the extremity of the lower is placed in front of the superior fragment.

25. In cases of comminuted extracapsular fractures, with fracture and displacement of the trochanters, the foot will generally remain in whatever position it has been accidentally placed; it may be turned either inwards or outwards, or there may be inversion at one time and eversion at another.

26. Severe contusion of the hip-joint, causing paralysis of the muscles which surround the articulation, is liable to be confounded with fracture of the neck of the femur.

27. Severe contusion of the hip-joint may be followed, at a remote period, by shortening of the limb and eversion of the foot.

28. The presence of chronic rheumatic arthritis may not only lead us to suppose that a fracture exists when the bone is entire, but also, when there is no doubt as to the existence of fracture, may render the diagnosis difficult, as to the seat of the injury with respect to the capsule.

29. Severe contusion of the hip-joint, previously the seat of chronic rheumatic arthritis, and the impacted fracture of the neck of the femur, are the two cases most likely to be confounded with each other.

30. Each particular symptom of fracture of the neck of the femur, separately considered, must be looked upon as equivocal; the union of all can alone lead to the formation of a correct opinion as to the nature and seat of the injury.

CHAPTER II.

CHRONIC RHEUMATIC ARTHRITIS OF THE HIP-JOINT.

In the preceding chapter frequent allusion has been made to a remarkable disease termed "Chronic Rheumatic Arthritis," to which the hip-joint, in common with all the other articulations, is liable, more especially in the advanced periods of life, and the presence of which is eminently calculated to obscure the symptoms, and embarrass the diagnosis of the injuries to which the joint is liable.

A woman of advanced age was admitted into the Richmond Hospital, having sustained an injury of the hip from a fall upon the trochanter: on examination (the patient having been placed in the horizontal posture) the affected limb was found to be one inch shorter than the sound one; the foot was everted; flexing the thigh upon the abdomen caused considerable pain; and the patient was unable to raise the heel from the bed. From these symptoms it was suspected that the neck of the femur had been broken; upon further examination, however, it was found impossible to produce crepitus, or to restore the limb to its natural length by extension; hence it became evident that the case was one either of impacted fracture of the neck of the femur, or of contusion of a joint previously the seat of chronic rheumatism.

Upon being questioned, the woman stated that she had, for a long period, suffered from pain and stiffness in the hip-joint; that the pain was more distressing in wet weather and towards evening, but was relieved by a night's rest; that she had gradually become lame, and had been for some time obliged to make use of a stick when walking. The case was, therefore, supposed to be

one of contusion of the hip-joint, combined with chronic rheumatism, and the event proved the correctness of the diagnosis.

In the sixth volume of the Dublin Journal of Medical Science, I published a brief account of this remarkable affection, under the name of "Morbus Coxæ Senilis;" it has since been more fully described by Mr. Adams, under the title of "Chronic Rheumatic Arthritis."* Mr. Benjamin Bell has noticed it under the head of "Interstitial Absorption of the Neck of the Thigh-bone."† Sandifort has delineated the alterations which the head and neck of the femur and the acetabulum undergo in this disease;‡ and the late Mr. Colles was for many years in the habit of describing it in his lectures, but was of opinion that it did not partake of the nature of rheumatism. Its causes are involved in some degree of obscurity: it occasionally appears to be the result of an attack of acute rheumatism, and its origin is sometimes ascribed to falls upon the great trochanter; but in the majority of instances of this disease which have fallen under my observation, it seemed to have been of spontaneous origin, and the patients affected with it were unable to ascribe its commencement to any satisfactory or precise cause. It is occasionally met with among the higher classes of society, but is chiefly seen among the labouring poor, and in constitutions otherwise healthy. It is of much more frequent occurrence in males than in females, and is seldom seen before the age of fifty years, although a few examples of it, in individuals under thirty years of age, are occasionally met with.

It commences with stiffness in the hip-joint, and a dull, heavy pain, which sometimes extends down the front of the thigh; the stiffness is most troublesome in the morning, but, after the patient has walked some distance, it, to a certain extent, wears off, and the motions of the joint become more free; towards evening the uneasiness and pain increase, but are relieved by a night's rest. When the weight of the body is thrown upon the affected joint, the sufferings of the patient are increased; but, as Mr. Adams has remarked, let the surgeon press on the great trochanter, or strike the heel and sole of the foot, or adopt any other expedient, so as

* Cyclopædia of Anatomy, p. 798. † Bell on Diseases of the Bones, p. 78.
‡ Museum Anatomicum, vol. ii. tab. lxix. ad lxxiii.

to push the head of the bone even rudely against the acetabulum, these manœuvres are the sources of no uneasiness whatever to the patient.

In the generality of cases, the state of the weather exerts a remarkable influence over the patient's sufferings: during wet or even very damp weather, the pain increases, and in some cases the patient can accurately foretel the approach of rain. The motions of the joint become gradually more and more limited, especially those of rotation and flexion; the latter motion becomes, as the disease advances, so confined, that the patient cannot stoop so far as to enable him to put on his shoes, nor can he sit without uneasiness upon a low chair; he always prefers a high seat, and, from the difficulty which he finds in flexing the hip-joint, he is obliged to place himself forwards on the edge of the seat, the thigh upon the affected side remaining nearly in the same line as the axis of the trunk.

The patient affected with this disease finds difficulty in standing erect; the body is bent forwards, but, as Bell has remarked, the stoop does not form a regular curve; for, on examination, it will be found that the curvature is more or less acute at the hip-joint, and slight, comparatively speaking, in the back and loins. In fact, there is superadded to the bending forwards of the vertebral column a permanent semiflexion of the pelvis upon the femur. Gradually the limb becomes shortened and the foot everted; the apparent shortening is, however, always greater than the true, for the lumbar vertebræ become curved towards the opposite side, the pelvis oblique with respect to the spine, and elevated upon the affected side; the real shortening of the limb is, however, considerable, and frequently amounts to an inch.

Patients suffering from this disease in its more advanced stages walk very lame, can only take short steps, and are obliged to rest at very frequent intervals. A case in which both hip-joints were affected lately came under my observation, in which the power of flexing the thighs upon the pelvis was so limited, that the old man having, with much difficulty, advanced one limb six or eight inches, was then compelled to stop until the other was brought forward the same distance.

The lumbar vertebræ acquire a great degree of mobility; the

buttock of the affected side loses its natural prominence, and the glutæal fold disappears; the muscles of the hip and thigh become somewhat wasted, but remain nearly as firm to the feel as in health; it is, however, remarkable that the calf of the leg of the affected limb retains not only its firmness, but also its natural size. The trochanter major is more prominent, and *feels* larger than natural, and depositions of bone can sometimes be felt in the neighbourhood of the articulation.

When the patient is placed in the horizontal posture, and the surgeon tries to rotate or flex the thigh, not only is much pain complained of, but, in many cases, crepitation can be distinctly felt in the articulation; the patient goes up stairs with difficulty and pain; he is obliged to make use either of one or two sticks in walking, but in general, when he moves, he can place the whole sole of the foot flat upon the ground. In some instances, the disease attacks both hip-joints in the same person, but when once established in the hip, seldom engages other articulations; it does not endanger, nor even shorten life, nor does it exert any prejudicial influence upon the general health; the external signs of inflammation are seldom present, nor have I ever known this affection to be attended with suppuration, or to result in true anchylosis.

The following well-marked example of chronic rheumatic arthritis of the hip-joint I had frequent opportunities of witnessing, along with Mr. Adams, who has described the case in the paper already alluded to:

"Patrick Macken, now aged seventy-seven years, was brought up as a postilion and groom, but for the last seventeen years has been quite unfit for service, in consequence of his having been afflicted with a very severe pain in his right hip, from the first attack of which he became lame, and ever since the lameness has been slowly but gradually increasing. In every other respect his health is excellent, except that he has some wandering rheumatic pains in other joints, particularly in his right shoulder. He walks with great labour and pain, and now requires the assistance of a stick in each hand; in the morning his movements are stiff and confined, but they become freer on exercise; in the evening of a day he has walked much the pain and stiffness are

worse, and increased in proportion to the excess of exercise and labour he had undergone in the day. While he remains in bed he rests on the affected hip, and suffers no pain whatever, except he suddenly turns himself incautiously. As soon as he gets up, and throws his entire weight on the diseased hip-joint, the pain

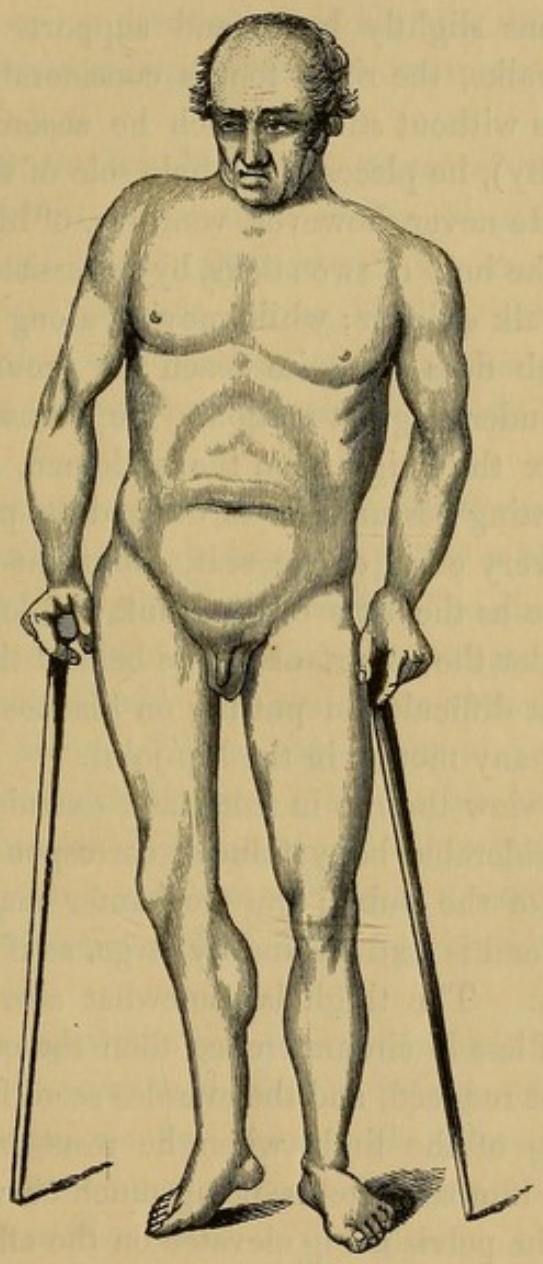

commences. If asked in what particular part of the joint he feels most suffering, he points to the back part of the great trochanter, and to a point which corresponds to the situation of the lesser trochanter: he says the pain shoots from these points down the front of the thigh to the knee. These pains are sometimes more

severe and sometimes less, without his being able to ascertain any cause for these alterations, and he cannot observe that the state of the weather has any influence on them whatever.

"As he stands at rest, he throws the weight of his body on the left or unaffected limb, while the right hangs in front and slightly across the left, and seems to be, at least, three inches shorter; he leans slightly back, and supports himself on two sticks; as he walks, the right foot is considerably everted; and when he moves without sticks (which he accomplishes with the greatest difficulty), he places the whole sole of the foot flat upon the ground. He never, however, ventures, of his own accord, to move without the help of two sticks, by the assistance of which he is enabled to walk quicker; while moving along thus, the heel of the affected limb does not quite reach the ground, and the lumbar vertebræ undergo great motion. He cannot, under any circumstances, flex the thigh upon the abdomen, so that when he assumes the sitting posture, he is obliged to place himself forwards on the very edge of the seat, the right thigh remaining in the same line as the axis of the trunk, the leg usually flexed, and placed under the chair, or across behind the other, and he finds the utmost difficulty in putting on his stockings and shoes: he has scarcely any motion in the hip-joint.

"When we view the hip in front, and examine it, we see, and can feel a considerable bony fulness, corresponding to the horizontal branch of the pubis; the trochanter major seems placed very high up, and is extraordinarily large, as if surrounded with ossific deposits. The thigh is somewhat atrophied, being an inch and a half less in circumference than the other, but the calf of the leg is not reduced, and the muscles seem firm. The apparent shortening of the limb, when he rests on the sound one, arises from the lumbar vertebræ being much curved to the opposite side, and the pelvis being elevated on the affected side, while the real shortening, ascertained by accurate measurement, amounts only to half an inch.

"If we place the patient horizontally, and attempt to communicate to the hip-joint any movement, as of rotation, flexion, abduction, a well-marked crepitus is elicited, and the range of motions is found to be very limited indeed; a little abduction is admitted;

rotation and flexion seem just to a sufficient degree, to shew that no anchylosis exists. The movements give some pain to the patient, but we can press the trochanter firmly, so as to direct the head of the bone deep against the fundus of the acetabulum, and we can even strike the heel and sole of the foot with violence without giving the patient the slightest sensation of pain." This patient died since the preceding description of his case was written, but circumstances rendered it impossible to procure a *post mortem* examination.

In March, 1839, the late Mr. Colles presented to the Pathological Society of Dublin an example of this disease in both hip-joints of the same individual; they were taken from the body of the late Dr. Percival, who, in giving his last directions to his family, requested that any portions of his remains which might be made available to the cause of science should be laid before the Society.

About the latter end of the year 1820, Dr. Percival first began to complain of pain in his right hip; he applied a blister over the trochanter, and remained quiet for a fortnight. The disease, however, soon became more troublesome, and when he attempted, on one occasion, to walk without the aid of his crutch, at a levee at the Castle, during the visit of George IV. to this country, he appeared so much distressed that His Majesty held out his hand to support him. He went through his professional duties for several years after the disease commenced, but with great discomfort, from the agony produced by motion. The left hip-joint was not affected until the year 1834.*

When we have opportunities of examining the state of the hip-joint in those who have died while suffering under this disease in its advanced stage, we find remarkable alterations in every structure entering into its composition. The muscles are in general pale, and less firm than those of the opposite hip. The capsular ligament is always much increased in thickness, and in many

* When the British Association met in Dublin in 1836, a specimen of this remarkable disease, taken from the body of Mr. Mathews, the celebrated comedian, was laid before the Medical Section by Mr. Snow Harris, as an example of fracture of the neck of the femur within the capsule, which had been united by bone. For the particulars of this case the reader is referred to Mr. Adams' paper, already mentioned, Cyclopædia of Anatomy, p. 799.

instances its internal surface is preternaturally vascular, and lined with organized lymph, and sometimes plates of osseous matter are deposited in its tissue. The cotyloid ligament disappears, and the ligaments which complete the notch of the acetabulum are usually converted into bone, but the aperture through which the blood-vessels are transmitted to the interior of the joint, is, in almost all cases, preserved; indeed I have as yet seen only one example in which it was obliterated.

In the advanced stage of the disease the ligamentum teres disappears, and the cartilage of incrustation is removed both from the head of the femur and from the acetabulum; the joint in general contains but little synovia, and what remains of the synovial membrane is usually of a bright-red colour: in several instances the neck of the bone is found surrounded by an intensely vascular fringe, consisting of fimbriated productions of the synovial membrane, of a conical form, and varying from a quarter to half an inch in length; in such cases the corona of the head of the bone is absorbed in different points, and the excavations are filled by these vascular fimbriæ. Cruveilhier has delineated them in the knee-joint of a patient who died while labouring under this disease affecting that articulation.*

These remarkable processes are a newly organized and superadded structure of a highly vascular character, and capable of absorbing the contiguous osseous texture; they are analogous to the vascular synovial fringes which Aston Key has described as performing so remarkable a function in the ulcerative process in joints;† they are frequently seen in the knee, elbow, and shoulder-joints, in cases of chronic rheumatic arthritis of these articulations.

The acetabulum undergoes various alterations of form and size; in some cases, without becoming deeper than natural, it is found increased to more than double its normal size, and measuring from ten to sixteen inches in circumference; in such cases it is usually of an oval shape: sometimes it forms a very deep and circular socket, while at the same time its margin is so much contracted, and embraces the neck of the bone so closely, that the head of the femur cannot be disarticulated: the increase of depth

* Liv. ix. pl. vi.

† Med.-Chirurgical Transactions, vol. xviii.

is accomplished chiefly by the deposition of bone around its margin, for the pelvic surface of the fundus of the acetabulum very seldom presents any prominence or irregularity. There is, however, in the Museum of the Royal College of Surgeons, a remarkable preparation, which forms an exception to this statement; it is marked in the catalogue E. b. 780, and consists of the pelvis and thigh bones of a female, æt. 60; the heads of the femora are much smaller than natural, and, as it were, drilled with an infinite number of small foramina, many of which penetrate to a considerable depth, and conduct into large cells in the interior of the bones.

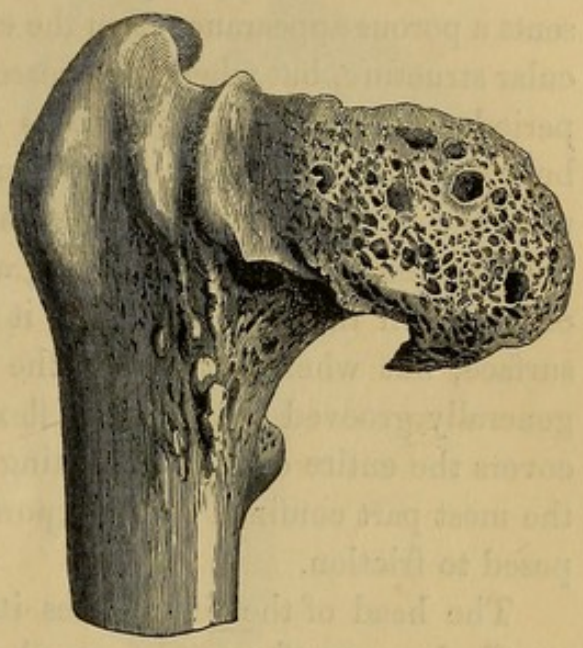

The acetabula are equally porous, and out of all proportion larger than the heads of the thigh bones: they are much deeper than natural; the increase in depth is effected, partly by osseous additions to their free margins, and partly by a protrusion of their inner walls into the cavity of the pelvis, where they form two hemispherical bulgings, which diminish the transverse measurement of that cavity by at least an inch.

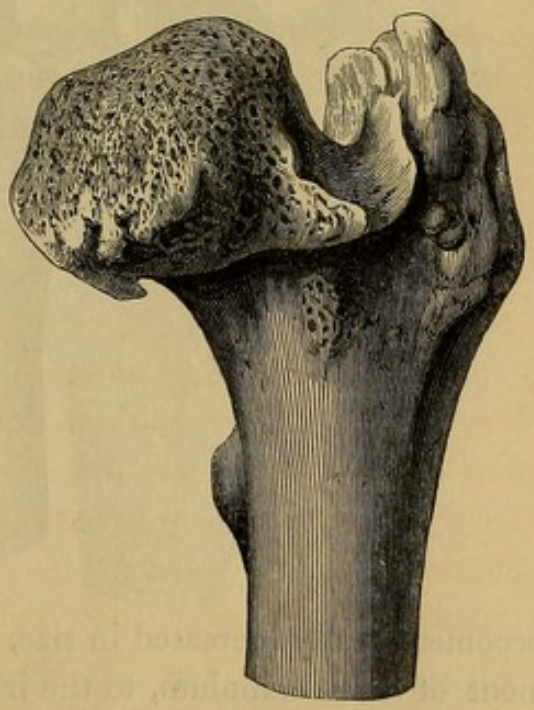

The substance termed "Haversian gland" is removed, and the depression which accommodates it in the natural state is obliterated; the interior of the acetabulum, in

consequence of the removal of its cartilage, presents a rough and porous surface, with here and there enamelled patches, possessing the hardness and smoothness of ivory. The cartilage of the head of the femur is likewise removed, and the surface of the bone presents a porous appearance from the exposure of the cells of the reticular structure, but when the disease has existed for a considerable period, and the opposed surfaces of the femur and of the acetabulum have been subjected to much pressure and friction, we usually find deposited upon the head of the femur a hard, dense, unorganized substance, possessing all the smoothness and polish of ivory: in the orbicular joints it presents an uniformly smooth surface, but when met with in the ginglymoid articulations it is generally grooved in the line of flexion and extension; it seldom covers the entire of the articulating surface of the bone, being for the most part confined to those portions of it, which are most exposed to friction.

The head of the femur loses its natural spherical form, and usually becomes flattened from above downwards; sometimes it

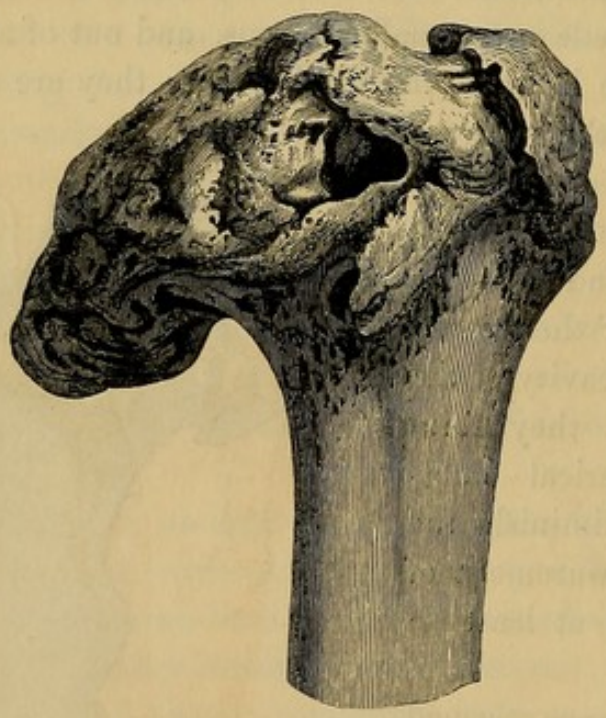

becomes greatly increased in size, keeping pace with the enlargement of the acetabulum, to the irregular form of which it is also adapted; it is sometimes so much enlarged that the lower part of its circumference approaches the lesser trochanter: as Mr. Bell

has observed, "it looks as if the head of the bone were forced downwards by the action of some great pressure, and I have seen cases in which the interstitial absorption had proceeded so far, that the head of the thigh bone rested upon the upper part of the trochanter minor."*

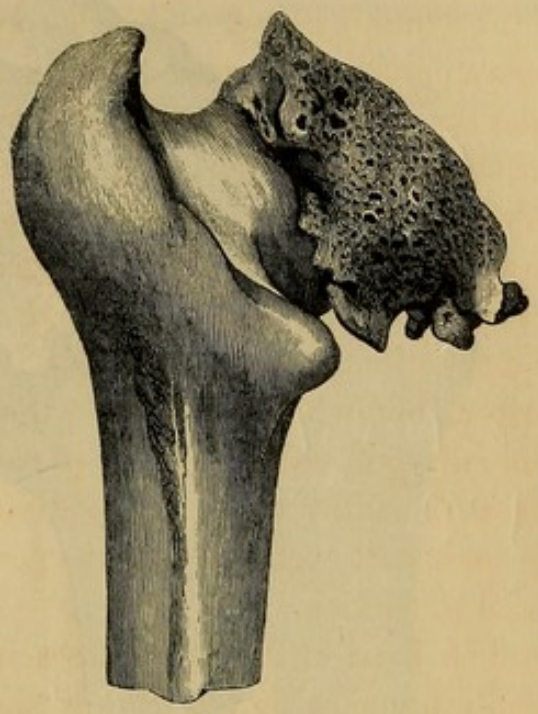

In some cases the head of the bone, without being much enlarged, sinks to a right angle with the shaft, and presents an elongated form from within outwards, its superior and anterior surfaces being, at the same time, excavated more or less deeply, so as to present a concavity directed from within outwards; this concave surface is usually smooth and polished. In other instances the head of the bone is flattened superiorly, and the line of the corona surrounded by a collar of osseous matter, very irregular in form, and highly vascular in the recent state.

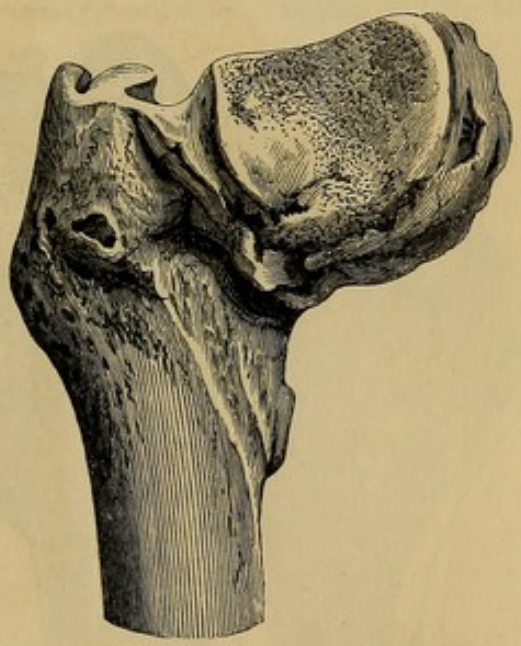

In general, the neck of the femur suffers either partial or total absorption; the head of the bone appears to spring directly from the shaft, and the posterior surface of the neck of the bone is so far diminished as not to measure more than half an inch: indeed, in some instances, its length does not exceed a quarter

* Loc. cit. p. 93.

of an inch; and it is remarkable that this shortening of the posterior surface of the cervix may occur without the anterior suffer-

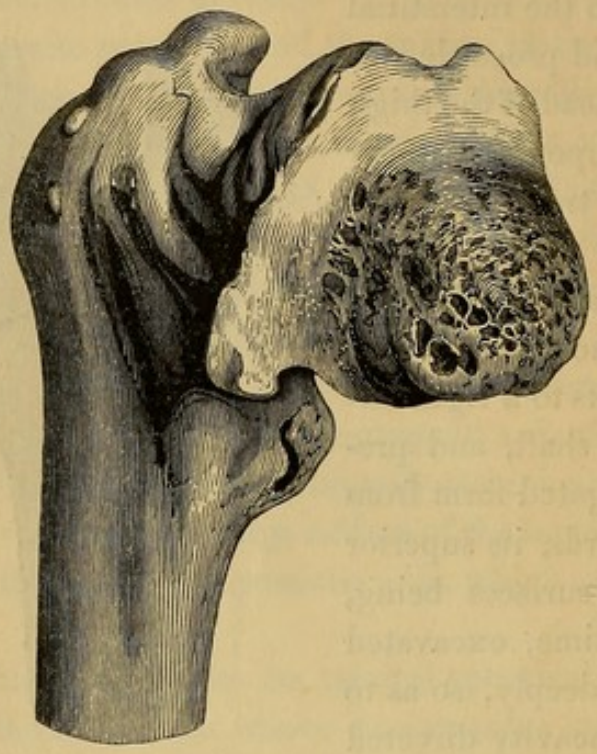

ing a corresponding diminution in length. In such cases, the eversion of the foot is usually very great.

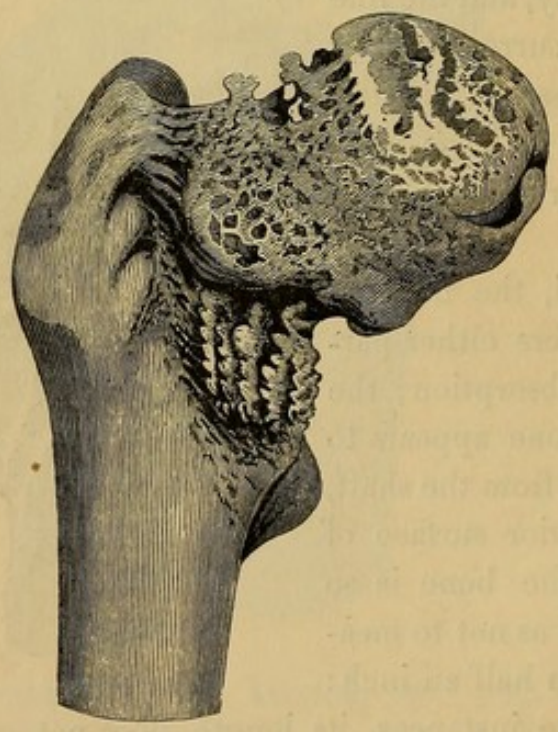

I have but seldom seen any osseous depositions upon the neck of the bone posteriorly, but its anterior surface is very fre-

quently the seat of exuberant growths of bone, which present every variety of form, distend and stretch the front of the capsular ligament, and add materially to the patient's sufferings, causing severe shooting pains along the course of the branches of the anterior crural nerve.

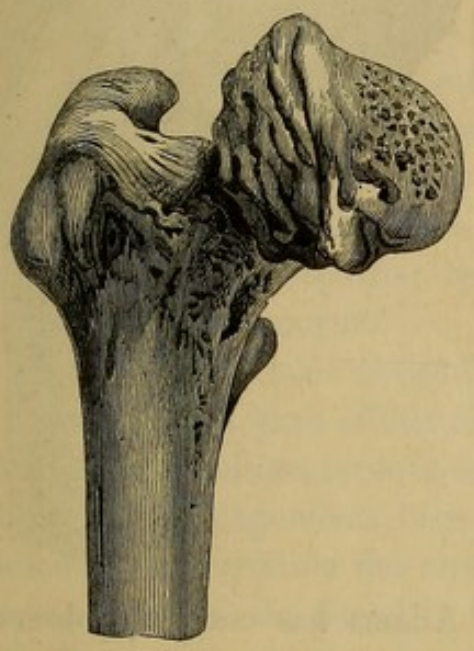

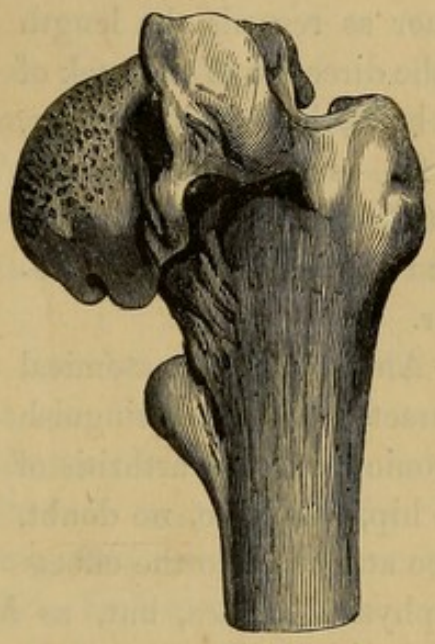

Sometimes the neck of the femur retains nearly its natural length, and yet only a small portion of it is visible when the capsule is removed, owing to the prolongation, as it were, outwards, of the margin of the head of the bone, to such an extent in some cases, as to conceal more than half of the cervix, between which and the elongated corona a deep fissure is thus left, which is frequently filled by the fimbriated productions from the vascular synovial membrane already referred to.

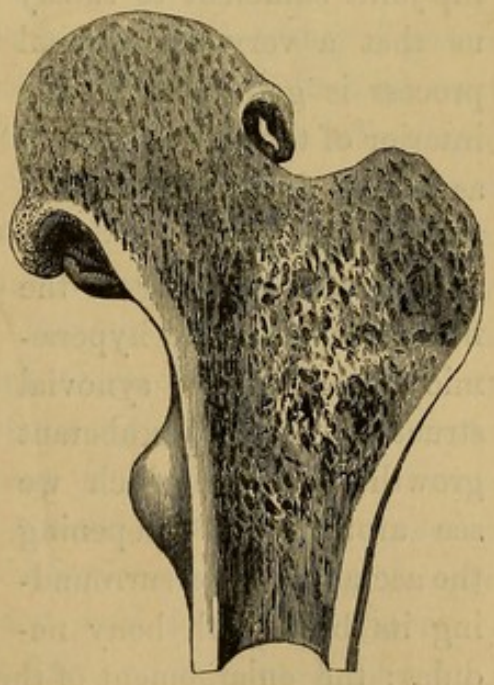

The neck of the bone, in such cases, appears, as Mr. Bell has remarked, "as if it were encased in a sheath of osseous

matter, which is sometimes of a spongy texture, and sometimes of a dense structure, and presenting an irregular stalactitic surface."*

In some few examples there is but little alteration, either as regards the length or the direction of the neck of the bone, the morbid changes, as far as the bone is concerned, being principally confined to the head of the femur.

Among the anatomical characters which distinguish chronic rheumatic arthritis of the hip, some are, no doubt, to be attributed to the effects of physical causes, but, as Mr. Adams has correctly observed, "there is, in the contemplation of the morbid results of this chronic disease of the hip-joint sufficient to satisfy us that a very active vital process is going on in the interior of the bones, as well as in all the tissues around the diseased joint.

"The thickening of the fibrous capsule, and hyperæmic state of the synovial structures, the exuberant growth of bone which we see around and deepening the acetabulum, or surrounding its brim with bony nodules; the enlargement of the head of the femur, so as to make

* Loc. cit. p. 95.

this head assume an oval convex surface, measuring in some cases, nearly a foot in circumference; all these are sufficient proofs, that, besides the interstitial absorption going on in the interior of the cervix femoris in these cases, a very active condition of the minute arteries exists externally, giving birth to those exostotic deposits which encircle the head and intertrochanteric lines of the femur.

"It has been remarked, and, we think, with much truth, that those specimens which have been frequently produced and mistaken for united fractures of the neck of the femur, have been examples of interstitial absorption of the neck of this bone, combined with external exostotic deposits; but these mistakes, we trust, are not hereafter likely to occur."

The reviewer who noticed in the Gazette Medicale the brief account which I gave of this disease in 1835, speaks of it as "une affection particulière, presque entièrement inconnue de nos chirurgiens, et que cependant bien plus que tout autre lésion de la hanche, peut entraîner des erreurs graves dans le diagnostic des fractures du col du fémur." It is to be hoped that this remarkable disease is now better known to our continental brethren, and that in future its presence will not be permitted to obscure the differential diagnosis of the injuries of the hip-joint to such an extent as it has hitherto done.

It is an affection amenable to treatment in a very slight degree, and although its anatomical characters would lead us to suppose that it depended upon chronic inflammation affecting all the tissues entering into the composition of the joint, yet it is not found that antiphlogistic treatment produces any material alleviation of pain, nor is any permanent benefit derived from local bleeding or counter-irritation. Patients labouring under this affection not unfrequently present themselves at hospitals and dispensaries, in whom the entire of the region of the hip is covered with the marks of leeches, cupping, moxa, &c., but the disease has, notwithstanding, steadily progressed, totally uninfluenced by such treatment. Rest, anodyne embrocations, keeping the joint protected by new flannel or carded wool from the influence of cold and damp, together with the free and long-continued use of hydriodate of potass, combined with the compound decoction of

sarsaparilla, and small doses of colchicum, constitute the mode of treatment from which I have seen most benefit derived. It is scarcely necessary to mention, that the action of the bowels should be maintained with great regularity; but it is to be remarked, that the particular affection under consideration is attended with much less disturbance of the digestive and assimilating functions than we usually observe where the rheumatic diathesis is present. The "Chelsea Pensioner" electuary answers remarkably well as a purgative in these cases.* Where the circumstances of the patient permit of it, residence in a warm and dry climate, not subject to vicissitudes of temperature, should be recommended, as well as a trial of the thermal springs either of Aix-la-Chapelle, Weisbaden or Bagneres, and Barèges. Such measures, however, are more likely to be useful in cases simply of the rheumatic diathesis, for when chronic rheumatic arthritis has once established itself, either in the hip or in any other articulation, and has produced alterations of structure, it is to be feared that mitigation of symptoms, and alleviation of pain, are the utmost advantages that we can expect from treatment.

* I usually prescribe this medicine according to the following formula:

R. Pulv. Guaiaci, ℥ss.	Carbonat. Potassæ, ʒi.
—— Rhei, ʒi.	Pulv. Zingiberis, ʒss.
Flor. Sulphuris.	—— Nucis Moschatæ, ʒii.
Supertart. Potassæ, aa ℥i	Mel. optimi, q. s. ut fiat Electuarium.

Sumat cochl. parva duo pro re natâ.

CHAPTER III.

FRACTURES OF THE BONES OF THE FORE-ARM, IN THE VICINITY OF THE WRIST-JOINT.

THE number and elaborate character of the essays that have of late years been published upon the subject of fractures of the lower end of the radius, sufficiently attest the importance which attaches to these injuries, and the obscurity which not unfrequently attends their diagnosis: that difficulties attend their treatment we may infer from the variety of modes which have been proposed to counteract the peculiar deformity which occurs when the lower end of the radius is broken.

In by far the most common form of this fracture, the lower fragment is displaced backwards. In this country, the name of an eminent surgeon, lately deceased, has been associated with this injury; we know it here as "Colles's Fracture of the Radius." Mr. Colles's short but accurate description of it was published in April, 1814, in the 10th volume of the Edinburgh Medical and Surgical Journal, and, with the exception of the observations of Petit and Pouteau upon the subject, I am not aware of any earlier account worth referring to. Subsequent authors have repeated what Mr. Colles had said upwards of thirty years since, but no writer (as far as I have been able to ascertain), not even the distinguished author of the Surgical Dictionary, has alluded to his account of the injury; and yet it is, I conceive, the duty of every person who undertakes to write upon a given subject, to make himself, as far as possible, acquainted with, and also to acknowledge the labours of those who may have preceded him in the same field of inquiry.

The following is Mr. Colles's description of the symptoms of fracture of the carpal extremity of the radius: "The injury to which I wish to direct the attention of surgeons has not, as far as I know, been described by any author; indeed the form of the carpal extremity of the radius would rather incline us to question its being liable to fracture. The absence of crepitus and of the other common symptoms of fracture, together with the swelling which instantly arises in this, as in most other injuries of the wrist, render the difficulty of ascertaining the real nature of the case very considerable.

"This fracture takes place at about an inch and a half above the carpal extremity of the radius, and exhibits the following appearances: the posterior surface of the limb presents a considerable deformity, for a depression is seen in the fore-arm, about an inch and a half above the end of the bone, whilst a considerable swelling occupies the wrist and metacarpus; indeed the carpus and base of metacarpus appear to be thrown backward so much as on first view to excite a suspicion that the radius has been dislocated forwards. On viewing the anterior surface of the limb we observe a considerable fulness, as if caused by the flexor tendons being thrown forwards; this fulness extends upwards to about one-third of the length of the fore-arm, and terminates below at the upper edge of the annular ligament of the wrist. The extremity of the ulna is seen projecting towards the palm and inner edge of the limb; the degree, however, in which this projection take place is different in different instances.

"If the surgeon proceeds to investigate the nature of this injury, he will find that the end of the ulna admits of being readily moved backwards and forwards: on the posterior surface he will discover, by the touch, that the swelling on the wrist and metacarpus is not caused entirely by an effusion among the softer parts; he will perceive that the ends of the metacarpal, and second row of carpal bones, form no small part of it. This, strengthening the suspicion which the first view of the case had excited, leads him to examine, in a more particular manner, the anterior part of the joint, but the want of that solid resistance, which a dislocation of the carpus (radius?) forwards must occasion, forces him to abandon this notion, and leaves him in a perplexing state of

uncertainty as to the real nature of the injury; he will, therefore, endeavour to gain some information, by examining the bones of the fore-arm.

"The facility with which (as was before noticed) the ulna can be moved backwards and forwards does not furnish him with any useful hint. When he moves his fingers along the anterior surface of the radius, he finds it more full and prominent than is natural; a similar examination of the posterior surface of this bone induces him to think that a depression is felt about an inch and a half above its carpal extremity. He now expects to find satisfactory proofs of a fracture of the radius at this spot; for this purpose he attempts to move the broken pieces of the bone in opposite directions, but, although the patient is, by this examination, subjected to considerable pain, yet neither crepitus, nor a yielding of the bone at the seat of fracture, nor any other positive evidence of the existence of such an injury, is thereby obtained.

"The patient complains of severe pain as often as an attempt is made to give to the limb the motions of pronation and supination. If the surgeon lock his hand in that of the patient, and make extension, even with moderate force, he restores the limb to its natural form, but the distortion of the limb instantly returns on the extension being removed.

"Should the facility with which a moderate force restores the limb to its form induce the practitioner to treat this as a case of sprain, he will find, after a lapse of time, sufficient for the removal of similar swellings, the deformity is undiminished; or should he mistake the case for a dislocation of the wrist, and attempt to retain the parts in *sitû* by tight bandages and splints, the pain caused by the pressure on the back of the wrist will force him to unbind them in a few hours; and if they be applied more loosely, he will find, at the expiration of a few weeks, that the deformity still exists in its fullest extent, and that it is now no longer to be removed by making extension of the limb. By such mistakes the patient is doomed to endure, for many months, considerable stiffness and lameness of the limb, accompanied by severe pains on attempting to bend the hand and fingers; one consolation only remains, that the limb will, at some future period, again enjoy perfect freedom in all its motions, and be completely ex-

empt from pain; the deformity, however, will remain undiminished through life.

"The unfavourable results of some of the first cases of this description which came under my care, forced me to investigate, with peculiar anxiety, the nature of the injury. But while the absence of crepitus, and the other usual symptoms of fracture, rendered the diagnosis extremely difficult, a recollection of the superior strength and thickness of this part of the radius* inclined me to question the possibility of a fracture taking place at this part of the bone. At last, after many unsuccessful trials, I hit upon the following simple method of examination, by which I was enabled to ascertain that the symptoms above enumerated actually arose from a fracture seated about an inch and a half above the carpal extremity of the radius:† let the surgeon apply the fingers of one hand to the seat of the suspected fracture, and, locking the other hand in that of the patient, make a moderate extension, until he observes the limb restored to its natural form; so soon as this is effected, let him move the patient's hand backward and forward, and he will, at every such attempt, be sensible of a yielding of the fractured ends of the bone, and this to such a degree as must remove all doubt from his mind.

"The nature of the injury once ascertained, it will be a very easy matter to explain the phenomena attendant on it, and to point out a method of treatment which will prove completely successful. The hard swelling which appears on the back of the hand is caused by the carpal surface of the radius being directed slightly backwards, instead of looking directly downwards.‡ The carpus and metacarpus, retaining their connexions with this bone, must follow it in its derangements, and cause the convexity above alluded to. This change of direction in the articulating surface of the radius is caused by the tendons of the extensor muscles of

* This is an anatomical error; the lower end of the radius being one of the weakest parts of the bone, in consequence of the compact tissue being remarkably thin, both anteriorly and posteriorly.

† The situation of the fracture is not so high as Mr. Colles states it to be; I have never seen it more than an inch above the carpal end of the bone; in the majority of cases it is not so much.

‡ The carpal surface of the radius does not look directly downwards, its aspect is downwards, forwards, and very slightly inwards.

the thumb, which pass along the posterior surface of the radius in sheaths firmly connected with the inferior extremity of this bone. The broken extremity of the radius being thus drawn backwards, causes the ulna to appear prominent towards the palmar surface, while it is possibly thrown more towards the inner, or ulnar side of the limb, by the upper end of the fragment of the radius pressing against it in that direction. The separation of these two bones from each other is facilitated by a previous rupture of their capsular ligament, an event which may readily be occasioned by the violence of the injury. An effusion into the sheath of the flexor tendons will account for that swelling which occupies the limb anteriorly."

After a few remarks upon the treatment of this injury, Mr. Colles says: "I cannot conclude these observations without remarking, that were my opinion to be drawn from those cases only which have occurred to me, I should consider this as by far the most common injury to which the wrist or carpal extremity of the radius and ulna are exposed. During the last three years I have not met with a single instance of Dessault's dislocation of the inferior end of the radius, while I have had opportunities of seeing a vast number of the fracture of the lower end of the radius."

In the preceding description, the most important of the diagnostic signs are correctly given, and when we recollect, that at the time the account was published, the author had had no opportunity of investigating, *post mortem*, the nature of the accident, it must, I think, be admitted that its anatomical characters have been conjectured with tolerable accuracy. Sir Astley Cooper says: "I have seen this accident frequently, and at first did not understand the nature of the injury; indeed, dissection alone taught me its real character;" and yet, although furnished with the information derived from *post mortem* examination, he observes (when describing the symptoms of the ordinary fracture of the lower end of the radius, which I am at present considering), "that there is an evident projection of the radius and ulna on the dorsal surface, and of the carpus on the palmar surface of the fore-arm."* Surely dissection could not have taught him this,

* Treatise on Dislocations and Fractures, edited by Mr. Bransby Cooper, p. 494.

for the carpus is displaced backwards with the lower fragment of the radius, and the inferior extremity of the ulna projects in front and internally.

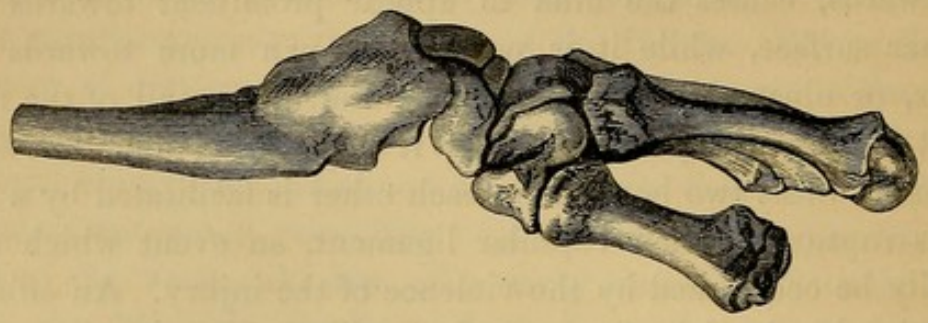

The fracture is usually the result of a fall upon the palm of the hand, and is liable to happen whenever a person, in the act of falling forwards, throws out before him his arms and hands in a state of extension, which he does, as it were, instinctively, to save the head and face from injury. Under these circumstances (if luxation of the bones of the fore-arm, at the elbow-joint, does not occur), from the influence, upon the one part, of the weight of the body and impulse of the fall, and upon the other, of the resistance given to the hand by the ground, the radius, which receives almost the whole force of the shock, breaks at its weakest part, that is, its lower extremity, for it is here that the cellular structure is most abundant, and the compact tissue thinnest: the carpus escapes uninjured, owing to the number of its articulations, which, as it were, divide and decompose the shock, and it is further protected by the palmar fascia, and by the numerous tendons which traverse the front of the carpus.

Severe pain is immediately felt at the seat of the fracture; the patient is sensible of having sustained some severe injury, and is in general conscious of something having given way in the limb; he finds that the hand is powerless, that he cannot, without material aggravation of suffering, allow it to hang unsupported; and therefore the limb is usually presented to us, for examination, resting, by its ulnar margin, on the palm of the other hand, and usually in a middle state between pronation and supination. If we desire the patient to supinate the hand, he attempts to do so, and generally succeeds in the effort, but if we

watch closely the manœuvre by which he accomplishes the movement, we will find that the motion takes place, not in any part of the fore-arm, but in the shoulder-joint; the patient rolls the head of the humerus outwards, and frequently is obliged to incline the entire shoulder towards the side of the injured limb, before he can accomplish such an amount of rotation as will be sufficient to supinate the hand. He finds it extremely difficult and painful to maintain the fore-arm and hand in the horizontal posture by the unaided efforts of the muscles; the fingers are usually flexed, and the neighbourhood of the wrist presents a singularly distorted appearance; the lower fragment of the radius and the carpus incline to the side of supination, while the shaft of the radius tends to the side of pronation: one fragment, the

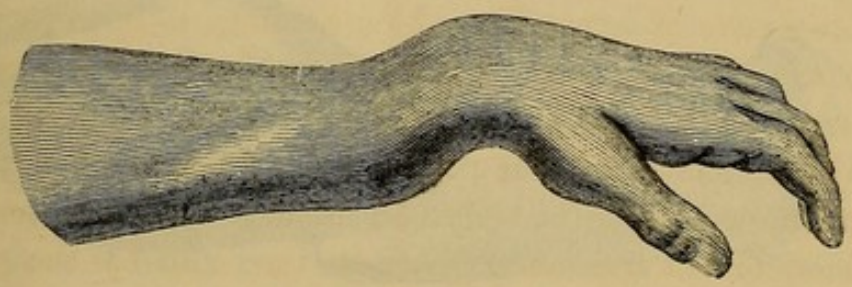

superior, is slightly drawn forwards, while the lower undergoes a considerable displacement backwards, and causes a remarkable prominence upon the dorsal surface of the fore-arm; immediately above this projection is seen a well-marked sulcus, the direction of which is generally somewhat oblique from above, downwards and inwards, towards the lower end of the ulna.

This obliquity is seen even in cases in which the line of fracture is accurately transverse, and is owing to the double displacement which the lower fragment undergoes, and which I shall presently consider.

The dorsal prominence extends across the entire breadth of the fore-arm, but, as might be expected, is most striking towards its radial border, and gradually sinks as it approaches the ulnar margin of the fore-arm. Upon the palmar surface of the limb there is likewise seen a tumour, which is less prominent than that upon the dorsal aspect, but more extensive, reaching up a considerable distance along the fore-arm; it ceases below at the annular ligament of the carpus, where a deep and narrow trans-

verse sulcus is seen, and which remains evident, even though a considerable amount of swelling has set in; these two prominences are not placed upon the same level, and, generally speaking, the dorsal is more evident and striking than the palmar, for in the latter direction the swelling is usually greater, and the form of the tumour not so circumscribed. This want of correspondence between the anterior and posterior projections is one cause of the appearance of obliquity which so many of these cases present.

The lower extremity of the fore-arm assumes a rounded form; its antero-posterior diameter is increased, but though there may be some, there is by no means a corresponding diminution in its transverse measurement; the alteration in the latter direction is

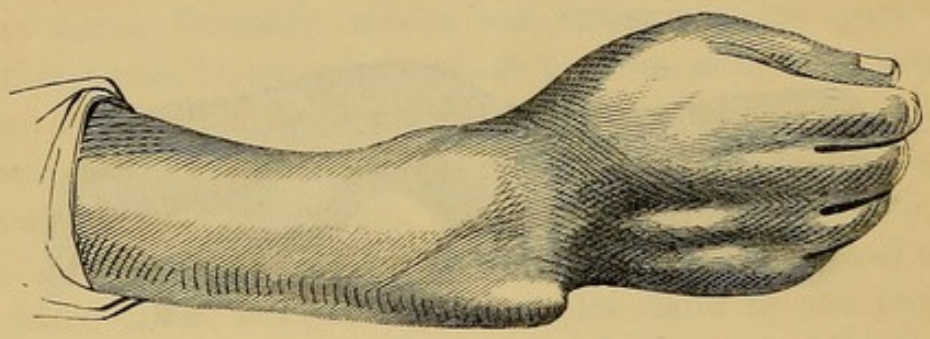

much more marked when the fracture engages the body of the bone about two or three inches above its lower extremity; it

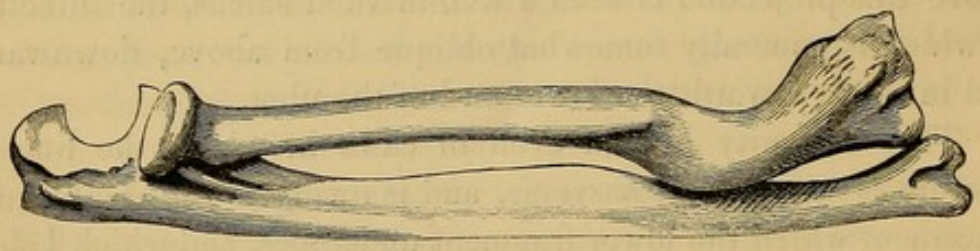

depends upon the displacement, towards the ulna, of the upper end of the lower fragment, the fracture being in general above the pronator quadratus muscle, the influence of which is then, of course, exerted upon the inferior fragment alone. The inter-osseous interval, however, in the situation of Colles's fracture, is so narrow, that the deformity arising from this cause is very slight, and the diminution in the transverse diameter of the fore-arm scarcely perceptible.

The convexity of the ulnar edge of the fore-arm is slightly increased, but when the eye is cast along the radial margin of the limb, the latter is observed to present a double concavity, one (supposing the arm to hang by the side) directed forwards, the other outwards: the head of the ulna is thrown forwards, and projects at the ulnar border of the carpus.

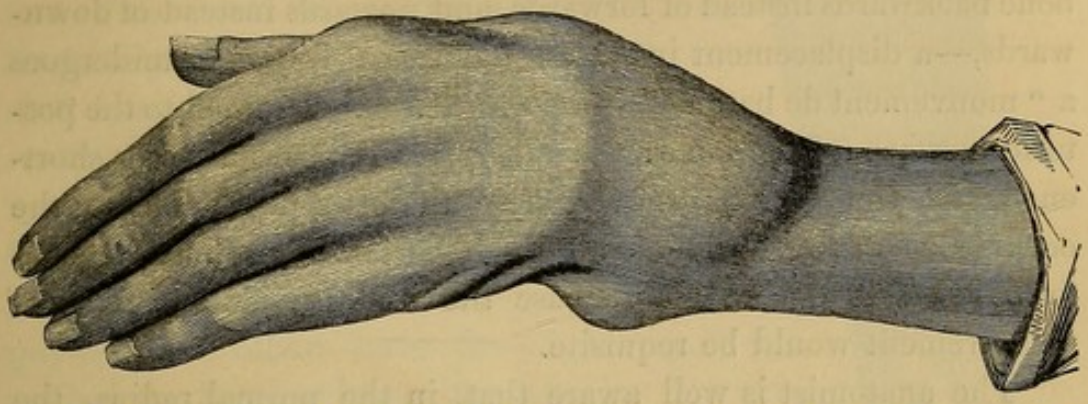

The most usual seat of the fracture is from three-quarters of an inch to one inch above the radio-carpal articulation; sometimes it is only a quarter of an inch above the joint, but I have never seen it higher than one inch: it always *appears* to be higher than it really is; but should the lesion of the bone take place at two inches or two inches and a half above the radio-carpal articulation, the injury no longer presents the peculiar and remarkable characters which distinguish Colles's fracture of the radius.

It has been lately asserted that, in cases of fracture of the carpal end of the radius, there is a palpable shortening of the bone. Monsieur Diday has maintained that, in these cases, the fracture traverses the bone obliquely from above downwards and forwards, so that the lower fragment being carried backwards, overlaps the superior, and that thus shortening of the entire bone is produced.* This opinion is correct only to a certain extent; the fracture is very rarely, indeed, so oblique as to admit of one fragment riding upon the other; indeed, in the great majority of cases, the lesion of the bone is transverse: even were it otherwise, it is difficult to conceive how such an amount of overlapping of the fragments as would produce an appreciable shortening of the bone could occur, as long as the ulna and the inferior radio-ulnar ligaments remained entire.

* Archives Generales de Medecine.—*Fevrier*, 1837.

But although I believe that the overlapping of the fragments in consequence of the obliquity of the fracture remains to be proved, I admit that there is generally shortening of the radius, even in cases where the fracture is directly transverse; but in consequence of the peculiar mode of displacement of the lower fragment,—a displacement which directs the carpal surface of the bone backwards instead of forwards, and upwards instead of downwards,—a displacement in which the carpal fragment undergoes a "mouvement de bascule,"—the shortening is confined to the posterior surface of the bone: the anterior, so far from being shortened, sometimes measures even more than it did previous to the occurrence of the accident, although certainly, it must be confessed, that to detect this increase the utmost possible nicety of measurement would be requisite.

The anatomist is well aware that, in the normal radius, the posterior surface of the bone is longer than the anterior; either the reverse is the case, when the radius is the seat of Colles's fracture, or else the surfaces are found to be of equal length. In a healthy radius which now lies before me, the posterior surface measures nine inches and a half, the anterior nine inches and a quarter, while in two specimens of the fracture which are also before me, the posterior surface of the bone, in one, measures eight inches, and the anterior eight inches and a half, and in the other the surfaces are each eight inches in length.

When pressure is made immediately below the head of the ulna, considerable pain is produced, for the internal lateral ligament is put upon the stretch by the displacement of the carpus and lower fragment of the radius. The patient fears to move the wrist, and has altogether lost the power of pronating and supinating the hand. If the surgeon, grasping the hand, imparts the motion of rotation to the radius, previous to his having reduced the deformity, he may possibly find that the head of the radius (strange as it may appear) revolves upon the ulna, and he certainly will generally fail in eliciting crepitus, and may be thus led to make an incorrect diagnosis; but if a degree of extension, sufficient to restore the fragments to their proper relative position, be first employed, and the hand then rotated, the grating of the broken surfaces upon each other will be felt, and the head of the radius will be found to remain motionless.

The hand is in general slightly flexed, and the lower fragment of the radius, along with the carpus, besides being displaced backwards, are also drawn towards the side of supination, and this twofold displacement causes the wrist to assume a singularly twisted appearance, such as might be supposed to result, were it possible to supinate the hand and wrist, the fore-arm being at the time fixed in a state of pronation. Dupuytren and others have described the hand as being in a state of abduction, but this statement is not strictly correct, for the hand is displaced outwards, along with the carpus and lower fragment of the radius, "par un mouvement de totalité." Severe pain is experienced by the patient when pressure is made in the situation of the fracture, and if tumefaction has not yet set in, the finger can in general detect an inequality in the bone.

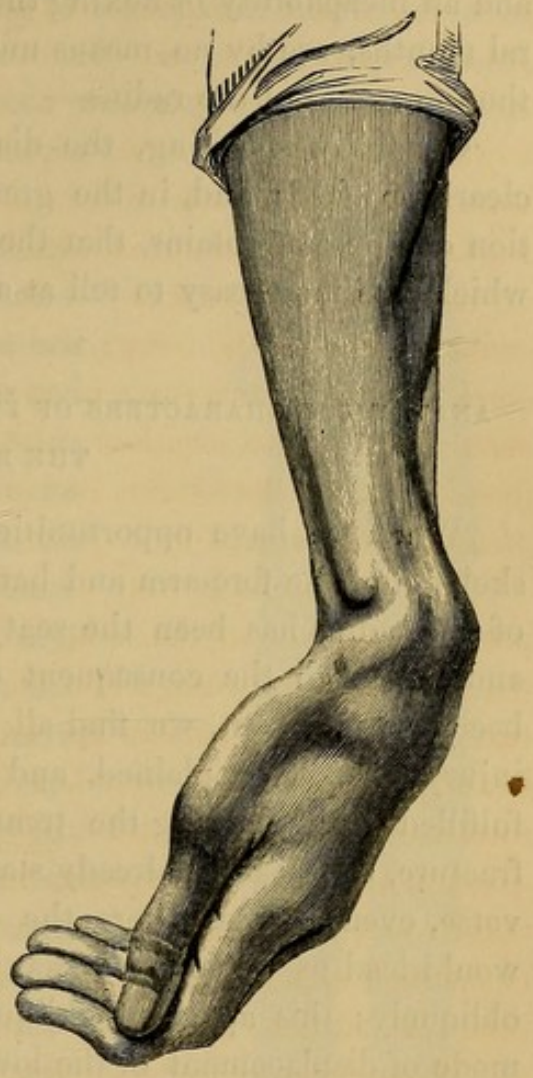

This fracture is quickly followed by a considerable amount of swelling; effusion occurs rapidly among the tendons which cross the front of the wrist-joint, obscuring the characteristic features of the injury, and rendering the diagnosis difficult in proportion. Three weeks usually elapse before the bone is united, but a much longer period must pass over before the motions of the hand and fingers are perfectly restored, and this happens even in cases which have been skilfully treated, and where no deformity remains. This sequela of the injury is a source of great inconvenience to the patient and of annoyance to the surgeon, who is often unjustly blamed for its occurrence: the practitioner

will, therefore, act with prudence in warning his patient, at the commencement of the attendance, that stiffness of the wrist-joint and an incapability of flexing the fingers during a period of several months, are by no means unfrequent results of a fracture of the lower end of the radius

Generally speaking, the diagnostic signs of this injury are clearly marked; and, in the great majority of cases, the observation of Pouteau obtains, that there is no fracture the existence of which it is more easy to tell at a single "coup d'œil."

ANATOMICAL CHARACTERS OF FRACTURE OF THE LOWER END OF THE RADIUS.

When we have opportunities of examining, *post mortem*, the skeleton of the fore-arm and hand, in cases where the carpal end of the radius has been the seat of the fracture above described, and in which the consequent deformity has been permitted to become permanent, we find all the characteristic features of the injury perfectly explained, and the indications necessary to be fulfilled in conducting the treatment clearly pointed out. The fracture, as has been already stated, is usually found to be transverse, even in cases where the external characters of the injury would lead us to suppose that the bone had been broken very obliquely; this apparent obliquity is, however, the result of the mode of displacement of the lower fragment, which is drawn obliquely backwards in such a manner that the carpal surface of the radius, instead of having its normal direction downwards, forwards, and inwards, now looks upwards, backwards, and outwards, its anterior descending below its posterior margin, and the styloid process being raised, and drawn backwards towards the side of supination.

This twofold displacement is the result of the action of the supinator longus upon the one part, and of the long extensors of the thumb upon the other; the latter, as soon as the resistance of the carpus is removed by the occurrence of the fracture, draw the lower fragment of the radius, with the carpus, towards the side of extension, thus directing the articulating surface of the radius upwards and backwards, while the former muscle, viz., the

supinator longus, besides supinating the lower fragment, also elevates the styloid process, giving the carpal surface an inclination outwards. The annexed drawing of a preparation, preserved in the Musée Dupuytren, illustrates very well the displacement upwards and outwards of the styloid process of the radius, and the oblique direction given to the carpal surface of the bone.

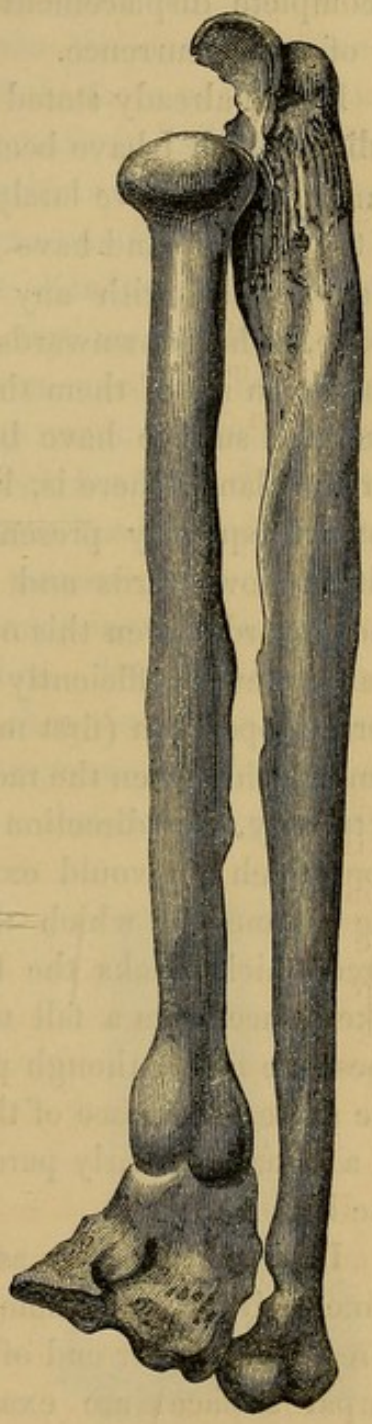

These conditions, of course, presuppose the integrity of the lower extremity of the ulna, and of the ligaments which connect this bone to the lower end of the radius; for if either of these were broken, the lower end of the radius in the one case, or the extremities of both the radius and the ulna in the other, would be displaced directly backwards, and the limb would then, to a certain extent, present the characters which have been assigned to dislocation of the carpus backwards: but as long as the inferior radio-ulnar ligaments remain unbroken, and the lower end of the ulna entire, it is obvious that the inferior fragment of the radius must be displaced *obliquely;* that, in fact, the styloid process (when being drawn upwards and backwards) must move through a portion of the circumference of a circle, and thus the upper end of the lower fragment is thrown towards the ulna. The pronator quadratus acts nearly altogether upon the superior fragment, for at least two-thirds of it are above the line of the fracture, and in some cases the solution of continuity in the bone is close to the inferior margin of the muscle.

The displacement of the lower fragment backwards is very seldom carried to such an extent as to enable it to clear the infe-

rior surface of the upper fragment: this, I conceive, would be most likely to happen in cases where the ligaments were ruptured, or the ulna broken; in such cases the deformity would be very great, and the limb would present none of the peculiar features of Colles's fracture; but when the breadth of the lower end of the radius is considered, it is obvious that, even in the supposed cases, a complete displacement of the lower fragment backwards must be of rare occurrence.

I have already stated that the fracture of the lower end of the radius, which I have been considering, is, in almost all instances, transverse. I have lately examined upwards of twenty specimens of the injury, and have not found one in which the bone had been broken with any considerable degree of obliquity from above, either downwards and backwards, or downwards and forwards; in all of them the anterior and posterior margins of the fractured surface have been nearly upon the same level and the surface plane; there is, however, an obliquity which the fracture not unfrequently presents, and which is directed either from within downwards and outwards, or from without downwards and inwards; even this obliquity, however, is always trifling, and scarcely ever sufficiently great to invalidate the truth of the general proposition (first maintained, I believe, by Monsieur Voillemier), that when the radius is broken within an inch of its lower extremity, the direction of the fracture is transverse, the direction which we would expect it to follow, from reflecting upon the manner in which the accident happens, and in which the force which breaks the bone is applied; for, when the fracture takes place from a fall upon the palm of the hand, as it usually does, the force, though principally and ultimately transmitted to the posterior surface of the lower end of the radius, yet is applied in a direction nearly parallel to the plane of the carpal surface of the bone.

It has been of late asserted,* and the opinion has been maintained with considerable ingenuity by Voillemier, that all fractures of the lower end of the radius (that is, within an inch of its carpal surface) are examples of impacted fractures. Having pointed out certain peculiarities in the structure of the lower end

* Archives Generales de Medecine, Mars, 1842.

of the radius, in explanation of its great liability to fracture, Monsieur Voillemier proceeds to describe the relative position of the fragments, which, according to this intelligent surgeon, is such, in every instance, that he has been induced to term these injuries "*Fractures par pénétration.*"

The following extracts include the substance of his opinions upon this interesting question: "In a fall upon the palm of the hand (where the radius rests chiefly upon the dorsal surface of the upper range of carpal bones), the whole force of the shock is transmitted to the radius, tending to approximate its extremities; it breaks, therefore, at its weakest part, which is a short distance above the wrist-joint, where the compact structure of the shaft is thinnest, and the cancellated tissue most abundant; the compact tissue of the upper portion is, by the continuance of the force after the fracture has taken place, driven into the cancellated tissue of the lower fragment. This may occur in several ways: if the end of the bone is large, if the shock has been transmitted in the direction of its axis, and if the bone has yielded throughout its whole circumference at the same moment, then the whole extremity of the upper fragment penetrates into the lower, and thus the two fragments are locked together. But if the force of the shock has been very considerable, then the upper fragment continues to descend, and the lower, compressed between it and the carpus, is split into several pieces; the styloid process is broken off, and the lower end of the bone crushed. Dupuytren has alluded to cases of this description, and has termed them 'Fractures par ecrasement.' This mode of penetration is, however, as might be supposed, very rare.

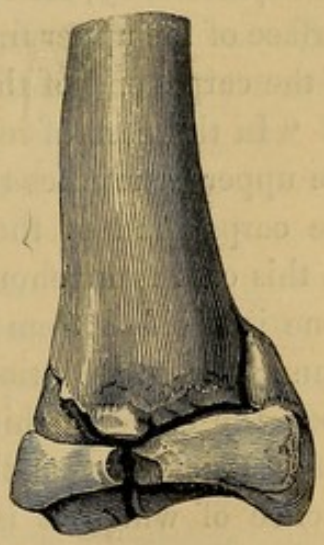

"But there is another mode of penetration, and the more common; it also happens from a fall upon the hand, the force of the shock coming obliquely upon the radius, so that the posterior surface of the bone has to support the greater part of it; the lower fragment is, at the same time, carried backwards, and thus the posterior wall of the com-

pact tissue of the upper fragment begins to penetrate into the spongy structure of the bone, while the anterior wall glides upon the palmar aspect of the carpal fragment.

"In all the specimens of fracture of the lower end of the radius, examined long after the occurrence of the accident which broke the bone, a line of compact tissue is found, covered over with cancellated structure, directed vertically, and descending to within a greater or less distance of the articular surface of the radius, as the case may be. Free below, it is manifestly continuous above with the body of the bone, the compact wall of which becomes all at once thicker where it is joined by this line. This line is never double; it is continuous with the posterior wall of the bone when the fracture is attended with displacement of the lower fragment backwards, and with the anterior, when the inferior fragment is thrown forwards.

"The explanation of this fact, not hitherto noticed, becomes sufficiently simple if we admit the doctrine of fracture by penetration. Let us take, for example, a case of fracture with displacement of the lower fragment backwards, the more common species: in consequence of the peculiar nature of the displacement (*renversement*), the penetration can only happen posteriorly, for in front '*ce véritable mouvement de bascule*' will tend rather to separate the two anterior edges of the fracture, or will leave them merely in contact. Thus the line of compact tissue can only exist posteriorly, for it is only the compact tissue of the posterior surface of the upper fragment that penetrates the cancellated tissue of the carpal end of the bone.

"In the case of reciprocal penetration, the posterior border of the upper penetrates the lower fragment, and the anterior wall of the carpal end of the bone ascends into the superior fragment. In this case there should be two lines of compact tissue, when the bone is divided from before backwards; one only, however, is found; the explanation of this fact offers itself when we reflect upon the extreme thinness and delicacy of the layer of compact tissue which invests the front of the lower fragment, in consequence of which it is broken and destroyed at the moment of penetration into the upper fragment, but posteriorly it is the thick resisting compact structure of the shaft, that penetrates the carpal fragment. We cannot judge of the extent to which

this penetration has taken place by the length of the line of compact tissue, for this always appears longer than it really is, for the periosteum in passing from one fragment to the other fills up in part the depression produced at the level of the fracture; there is also a remarkable thickness of the compact structure of the lower end of the bone, in old fractures, of which it is difficult to give an explanation." Mons. Voillemier further supposes that the circumstance of the fracture being impacted, explains the difficulty of detecting crepitus in cases of fracture of the lower end of the radius.*

This theory is, no doubt, ingenious, and the appearances are correctly described, for in every instance of the ordinary fracture of the carpal extremity of the radius, which I have had an opportunity of examining long after the occurrence of the injury, I have found, upon making a section of the bone from before backwards, a line of compact tissue continuous with the posterior wall of the shaft, extending to a greater or less distance into the reticular structure of the lower fragment.

But the question is, do the appearances above described warrant us in concluding that these injuries are examples of fracture with penetration? It appears to me, after having attentively considered the subject, that Voillemier has failed to give the true explanation of phenomena, correctly described as far as they have reference to examples of old fractures, and in which the fragments have been permitted to unite with more or less of deformity; he has not given any example of *recent* fracture, in which these appearances were noticed, and yet this is obviously a most important condition to be fulfilled, before his doctrine can be securely established. If dissections of recent specimens can be adduced, in which the phenomena in question were not present, it is clear that the theory of impaction cannot admit of general application, and some other explanation must be sought out, to account for the presence of this line of compact structure, so uniformly seen in cases of old fractures, and which, certainly at first

* Nelaton has adopted the theory of Voillemier; Elemens de Pathologie Chirurgicale, t. i. p. 742.

sight, would appear to be owing to the impaction of the superior into the inferior fragment.

It is due to Voillemier to state, that had it not been for the publication of his interesting memoir, my attention would, in all probability, never have been directed to the subject, for I had long previously had, in my possession, numerous specimens of fracture of the lower end of the radius, but had never made sections of the bones; I was, therefore, ignorant of the pathological condition upon which he has founded his ingenious theory. Since the publication, however, of his memoir in 1842, I have omitted no opportunity of investigating the subject, and have now carefully examined, post-mortem, upwards of twenty examples of the injury: in one of these the fracture had happened shortly before the death of the patient.

The result of these examinations has induced me to conclude, that the theory which supposes the fracture to be attended with impaction of the upper into the lower fragment is fallacious, and that its author, in interpreting phenomena carefully observed, has reasoned incorrectly.* I shall now give as concise a description as is consistent with my present object, of the specimens of fracture of the lower end of the radius, which I have had opportunities of making; the reader will thus be enabled to judge how far the results militate against the opinion of Voillemier, and to what extent they support the views which I entertain upon the subject.

Case I.—An elderly female having fallen from a window, received a fracture of the skull, and of the radius about half an inch above its carpal surface. The consequences of the injury of the head proved fatal in a fortnight after the occurrence of the accident. The appearances dependent upon the fracture of the skull, it is unnecessary to detail. The radius was found to have been broken about half an inch above its lower extremity; the line of fracture was irregular, but its direction nearly transverse; a por-

* In the descriptive catalogue of the Pathological Museum of St. Bartholomew's Hospital, published in 1846, the same error, as it appears to me, has been committed. See No. 78, p. 133, and No. 94, p. 136.

tion of the compact structure of the posterior wall of the shaft was detached from both fragments, bent forwards, and laid down between the fractured surfaces. The lower fragment was displaced backwards, the superior projecting one-eighth of an inch in front of it. *There was no impaction whatever in this recent specimen of either fragment into the other*, nor any line of compact structure penetrating the reticular tissue of the lower fragment. The fragments were connected by a slender fibrous structure, but there was no deposition of callus in any situation. The patient had been under the care of Mr. Cusack, and the preparation is preserved in the Museum of the Royal College of Surgeons; it is marked in the catalogue, E. a. 695.

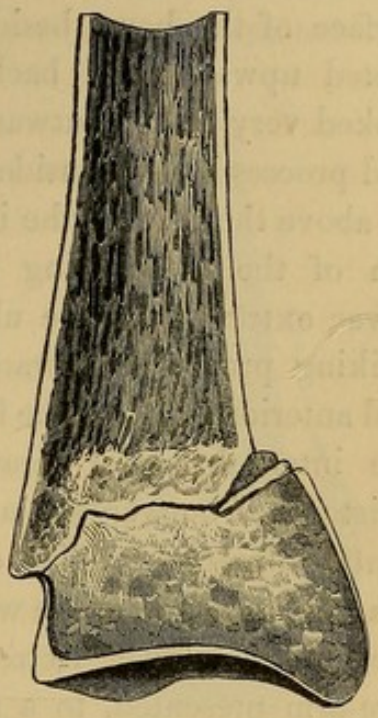

Case II.—Fracture of the left radius, rather more than half an inch above the edge of its carpal surface. The fracture is nearly transverse, but is a little higher in front than behind. The lower fragment is displaced backwards, and the carpal surface directed upwards and backwards. The lower end of the bone is much enlarged, and a thick irregular deposition of osseous matter covers its lateral and posterior surfaces, and extends three-quarters of an inch above the line of the fracture. A section of the bone, made from before backwards, shews the compact tissue of the posterior wall of the shaft, covered by cancellated structure upon both its surfaces. The length of the portion of

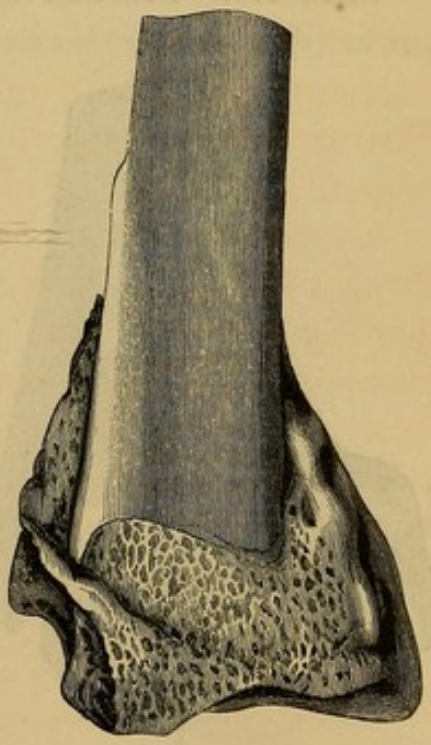

compact tissue thus enveloped is rather more than an inch, nearly double the distance of the anterior margin of the fracture above the articulation. The carpal surface of the bone, besides being directed upwards and backwards, also looked very much outwards, the styloid process being considerably elevated above the level of the internal margin of the articulating surface: the lower extremity of the ulna formed a striking projection towards the inner and anterior aspect of the fore-arm, and the internal lateral ligament of the wrist passed outwards in a nearly horizontal direction. The deformity of the limb in this instance was considerable, and the lower extremity of the fore-arm presented, to a remarkable degree, the peculiar twisted appearance which characterizes this injury.—*Museum: Park-street School of Medicine.*

Case III.—Fracture of the lower extremity of the radius,

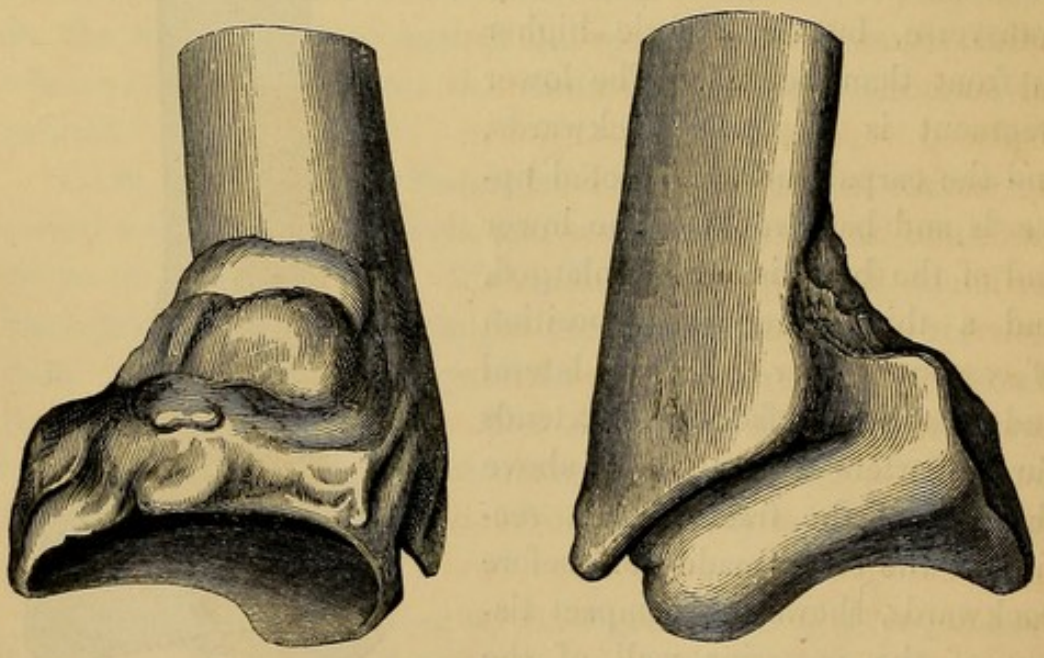

situated half an inch above the articulating surface. The fracture possesses a slight degree of obliquity, directed from without

downwards and inwards, but is transverse with respect to the antero-posterior diameter of the bone; the lower fragment is displaced backwards, slightly supinated, and elevated towards the styloid process, so that the articulating surface is directed upwards, backwards, and outwards; the lower end of the bone is considerably enlarged, irregular upon the surface, and has acquired a quadrilateral form. The section shews the posterior wall of the shaft enveloped in cancellated tissue, and at its lower extremity is seen a small detached portion of the compact tissue lying transversely. Including this isolated fragment, the length of the apparently impacted portion of the posterior wall of the shaft is one inch, the distance between the line of fracture and the edge of the carpal surface of the bone being, as I have already stated, only half an inch.—*Museum: Richmond Hospital School of Medicine.*

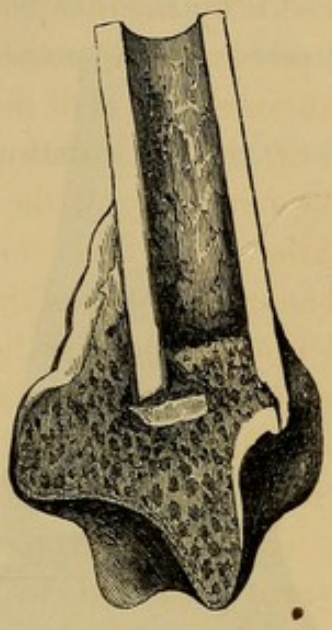

Case IV.—Transverse fracture of the lower extremity of the radius, situated one inch above its carpal surface. The lower fragment is displaced backwards, and its articulating surface is directed very much upwards and backwards. The enveloped portion of the compact structure of the posterior wall of the shaft (three-fourths of an inch in length), exposed by the section of the bone, is not more than the thirty-second part of an inch in thickness; the bone was extremely light, the medullary canal large, and the compact tissue not more than one-sixteenth of an inch in thickness in any part of the shaft. All the long bones in this case presented examples of fragilitas ossium. The

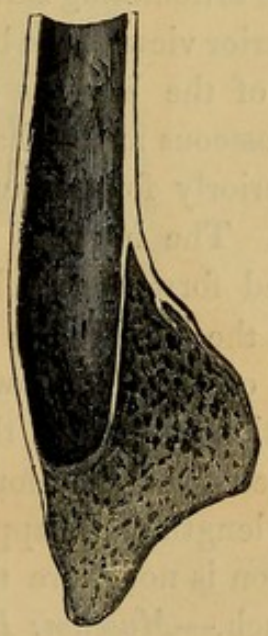

neck of the femur upon one side was fractured. The fracture of the radius was firmly united, but with great deformity.—*Museum: Richmond Hospital.*

CASE V.—Fracture of the radius half an inch above its lower extremity; the fracture is transverse, and the carpal surface of the

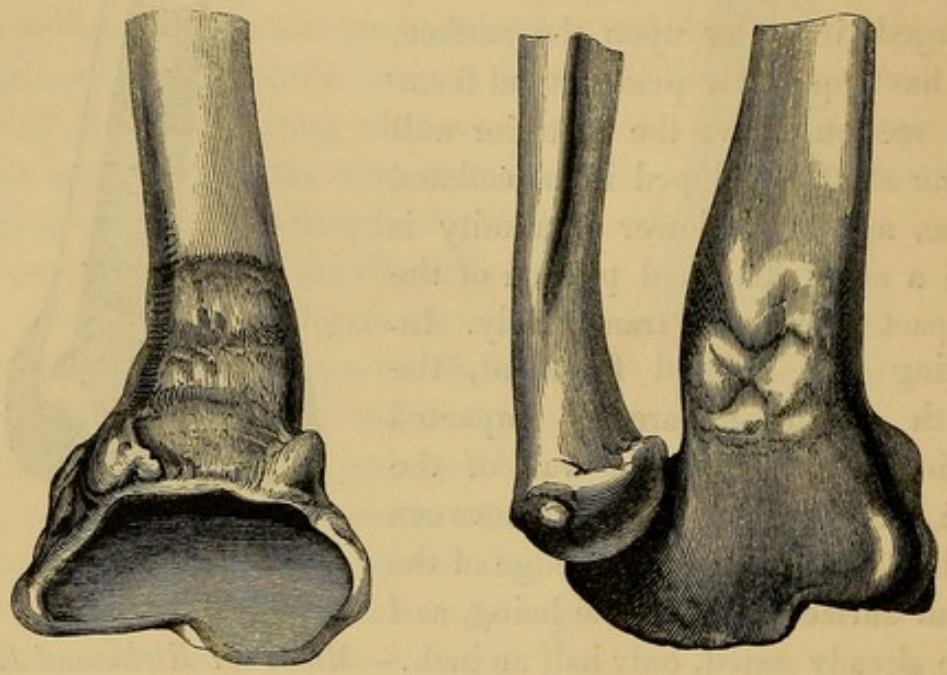

bone is thrown backwards considerably, so much so that its posterior margin is nearly half an inch above its anterior, and the entire of the articulating surface is seen in the posterior view of the bone. The lower end of the bone is much deformed, and osseous matter has been deposited posteriorly for the union of the fracture. The head of the ulna is displaced forwards. The section shews well the thickening of the posterior wall of the shaft, owing to the incorporation with it of the new bone deposited for the union of the fracture. The length of the apparently impacted portion is not more than a quarter of an inch.—*Museum: Peter-street School.*

CASE VI.—Fracture of the radius three-quarters of an inch above its carpal extremity. The fracture is directly transverse,

and the lower end of the bone is enlarged. The displacement of the inferior fragment backwards is very slight, the articulating surface looking downwards, and the anterior surface of the lower extremity of the radius being flat, instead of presenting a concavity directed forwards. When a section of the bone was made, the usual line of compact tissue, covered by cancellated structure, was visible, though much less distinct than usual. *Museum : Richmond Hospital School of Medicine.*

CASE VII.—Transverse fracture of the carpal extremity of the

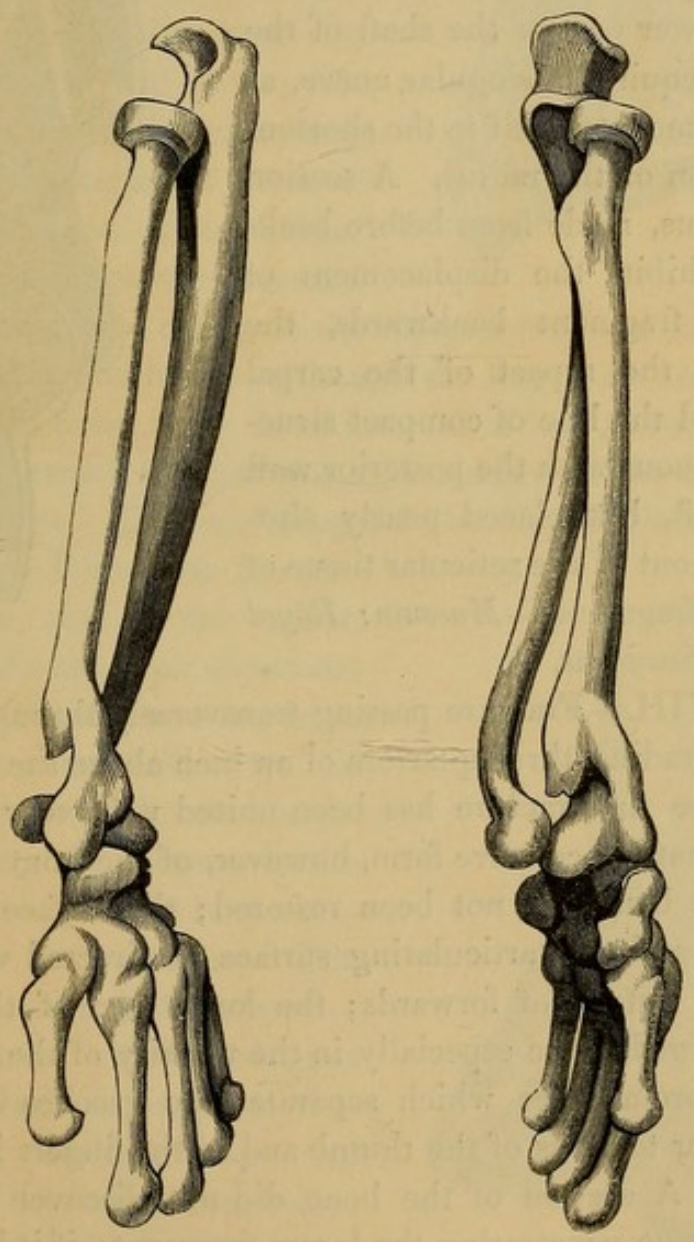

radius, three-quarters of an inch above the articulating surface: the lower fragment is displaced backwards much further than

usual; it has very nearly cleared the extremity of the upper fragment, which projects forwards, and is also slightly displaced inwards towards the ulna; the articulating surface is directed backwards, and the hand, wrist, and lower fragment of the radius are drawn towards the side of supination. The lower extremity of the ulna is displaced forwards, forming a remarkable projection towards the palmar surface of the wrist, and the lower part of the shaft of the ulna has acquired a singular curve, as if to accommodate itself to the shortened condition of the radius. A section of the radius, made from before backwards, exhibits the displacement of the lower fragment backwards, the change in the aspect of the carpal surface, and the line of compact structure continuous with the posterior wall of the shaft, but placed nearly altogether in front of the reticular tissue of the lower fragment.—*Museum: Royal College of Surgeons.*

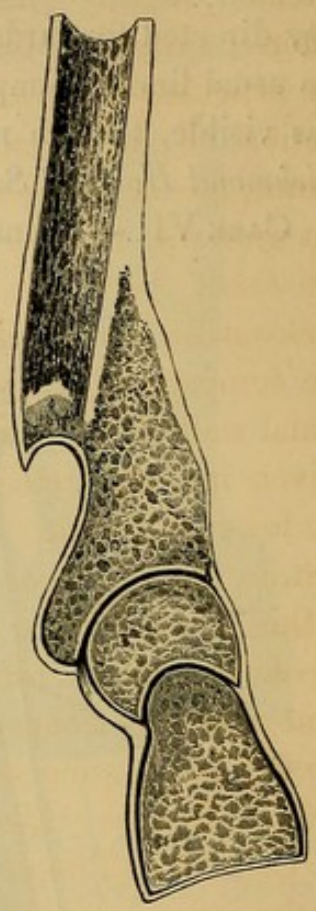

Case VIII.—Fracture passing transversely through the lower end of the radius, three-quarters of an inch above the articulation. In this case the fracture has been united with very little deformity; the natural concave form, however, of the front of the lower end of the bone has not been restored; the surface is here perfectly flat, and the articulating surface is directed very slightly backwards instead of forwards; the lower end of the radius is much enlarged, more especially in the vicinity of the styloid process; the prominence which separates the grooves which lodge the extensor tendons of the thumb and of the fingers is also much enlarged. A section of the bone did not discover any line of compact tissue penetrating the lower fragment; if it had ever existed, it had become resolved into cancellated structure.—*Museum: Richmond Hospital School of Medicine.*

CASE IX.—Transverse fracture of the lower end of the radius, three-quarters of an inch above the articulating surface, hich is directed slightly backwards; the anterior surface of the bone above the articulation is nearly flat. The section of the bone, in this instance, has been made from without inwards, instead of, as in all the other specimens, from before backwards; it exhibits, however, the compact structure of the external wall of the shaft, *apparently* driven into the reticular tissue of the lower fragment. It is obvious that, in this instance, the presence of this line cannot be owing to the superior fragment having been driven into the inferior, for, although the fragments are upon the same plane in front, there is an interval of half an inch between the line in question and the posterior surface of the lower fragment.—*Museum: Richmond Hospital School of Medicine.*

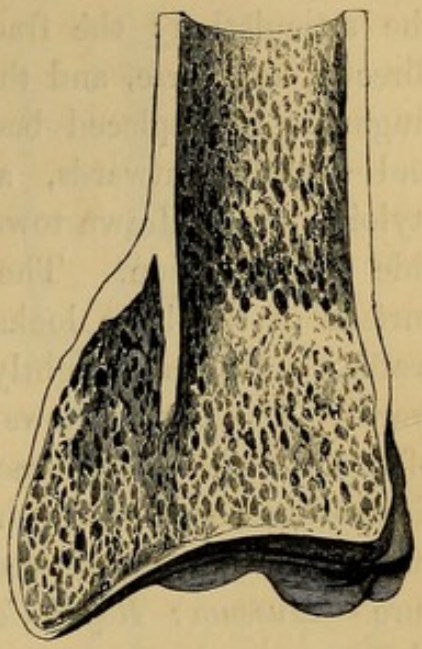

CASE X.—Transverse fracture of the lower end of the radius, situated nearly one inch above the articulation: the fracture has been united with great deformity, the carpal surface being directed backwards and very much upwards, the entire of it being visible in the posterior aspect of the radius. The head of the ulna had suffered a slight displacement forwards, but formed a considerable projection at the ulnar border of the wrist. A section of the radius from before backwards exhibited, though indistinctly, the line of compact tissue continuous with the posterior wall of the shaft.—*Museum: Richmond Hospital School of Medicine.*

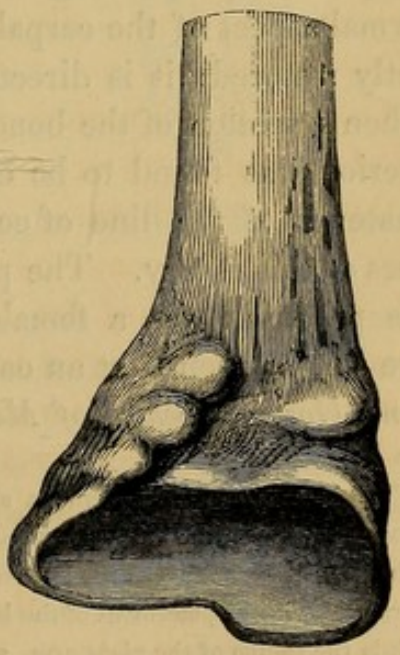

CASE XI.—Fracture of the carpal extremity of the radius, three quarters of an inch above the articulation: the fracture is directly transverse, and the lower fragment is displaced backwards and slightly outwards, and the styloid process drawn towards the side of supination. The carpal surface of the bone looks downwards, and very slightly backwards. The section shews the line of compact tissue continuous with the posterior wall of the shaft, and surrounded by cancellated structure.—*Museum: Royal College of Surgeons.*

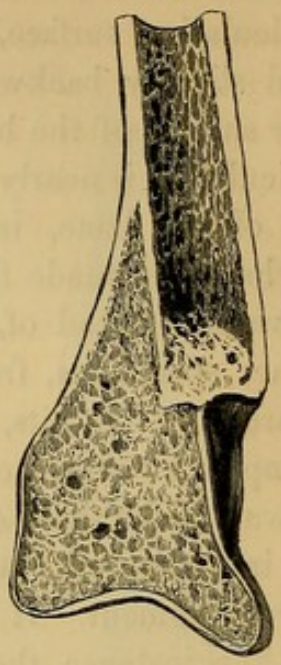

CASE XII.—Fracture of the lower extremity of the radius, about three-quarters of an inch above the articulating surface of the bone: the direction of the fracture is transverse in the antero-posterior direction, but slightly oblique from above and within downwards and outwards. The fragments have been united with, comparatively speaking, a slight degree of deformity, but the normal aspect of the carpal surface of the bone has not been perfectly restored; it is directed downwards and slightly outwards. When a section of the bone was made from before backwards, its interior was found to be entirely cellular; there was no vestige whatever of the line of compact structure, so usually present in cases of this injury. The patient from whose body the specimen was procured was a female of very advanced age, and the fracture had happened at an early period of her life.—*Museum: Richmond Hospital School of Medicine.*

* This engraving represents a section of a radius preserved in the Museum of the Royal College of Surgeons; the preparation is marked E. a. 693, and has been described in the printed catalogue as the *left radius* and ulna, shewing fracture of the lower end of the radius, with displacement of the lower fragment *forwards;* this, however, is an error, for it is the radius of the *right* arm, and the lower fragment has been displaced in the usual direction, viz., backwards. The mistake in the description has arisen from the circumstance of the radius of the right side having been inadvertently articulated with the ulna of the left.

CASE XIII.—Fracture of the radius three-quarters of an inch above the radio-carpal articulation; the lower end of the bone is enlarged and of a quadrilateral form; the inferior fragment is displaced backwards, and drawn towards the side of supination, and the head of the ulna projects at the inner edge of the wrist. The internal lateral ligament was stretched, and directed outwards. The annexed engraving illustrates remarkably well the displacement which the hand undergoes in this injury, and exhibits it, not in a state of abduction, but carried outwards, "par un mouvement de totalite," along with the carpus and inferior fragment of the radius. The usual line of compact structure, continuous with that of the back of the shaft, and enveloped in the cancellated tissue of the inferior fragment, was disclosed when a section of the bone was made in the antero-posterior direction. The deformity in this case was very considerable.—*Museum: Peter-street School of Medicine.*

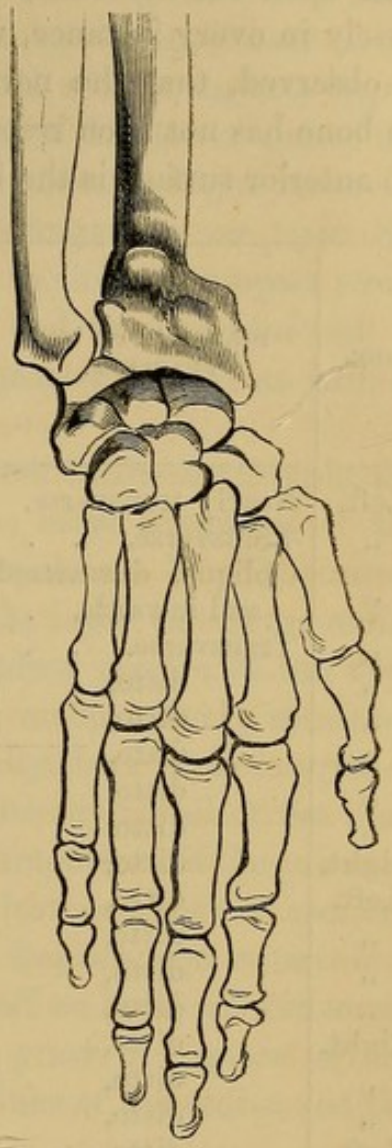

I have thought it unnecessary to give a detailed account of the other specimens of this injury which are in my possession, as they present anatomical characters closely resembling those already described in the preceding pages; I shall, therefore, proceed to the consideration of the theory of Voillemier; having first, however, arranged in a tabular form certain features presented by the specimens which I have had opportunities of examining, the greater number of which are necessary to be recollected in discussing the doctrine of impaction.

It will be seen from the following table, that out of twenty

cases of fracture of the lower end of the radius, fourteen have been upon the left side, and that the bone was broken transversely in every instance, with the exception of two; it will also be observed, that the normal length of the posterior surface of the bone has not been restored in any of the specimens, for in all the anterior surface is the longer.

SIDE.	DIRECTION OF THE FRACTURE.	DISTANCE OF THE FRACTURE ABOVE THE WRIST-JOINT.	LENGTH OF THE LINE OF COMPACT TISSUE.	LENGTH OF THE ANTERIOR SURFACE OF THE BONE.	LENGTH OF THE POSTERIOR SURFACE OF THE BONE.
Left,	Nearly transverse, .	$\frac{1}{2}$ inch.	1 inch,	$8\frac{1}{2}$ inches,	8 inches.
,,	Transverse, . . .	$\frac{5}{8}$,,	1 ,,	$8\frac{1}{4}$,,	8 ,,
,,	Oblique, downwards and inwards, . .	1 ,,	$\frac{1}{2}$,,	$8\frac{1}{2}$,,	8 ,,
,,	Transverse, . . .	$\frac{3}{4}$,,	$\frac{3}{4}$,,	$7\frac{1}{2}$,,	7 ,,
,,	ditto,	$\frac{1}{4}$,,	$\frac{3}{4}$,,	8 ,,	8 ,,
,,	ditto,	$\frac{3}{4}$,,	$\frac{1}{2}$,,	9 ,,	$8\frac{1}{2}$,,
,,	ditto,	$\frac{1}{2}$,,	$\frac{1}{2}$,,	$7\frac{3}{4}$,,	$7\frac{1}{2}$,,
,,	ditto,	$\frac{3}{4}$,,	$\frac{1}{2}$,,	$7\frac{3}{4}$,,	$7\frac{1}{2}$,,
,,	ditto,	$\frac{5}{8}$,,	$\frac{3}{4}$,,	9 ,,	9 ,,
Right,	ditto,	$\frac{3}{4}$,,	$\frac{1}{4}$,,	$7\frac{3}{4}$,,	$7\frac{1}{2}$,,
Left.	ditto,	1 ,,	$\frac{1}{2}$,,	8 ,,	$7\frac{1}{2}$,,
,,	ditto,	$\frac{3}{4}$,,	. . . .	9 ,,	$8\frac{3}{4}$,,
,,	ditto,	1 ,,	. . . .	$8\frac{1}{2}$,,	$8\frac{1}{4}$,,
,,	ditto,	$\frac{3}{4}$,,	$\frac{3}{4}$,,	$7\frac{3}{4}$,,	$7\frac{1}{2}$,,
Right,	ditto,	$\frac{3}{4}$,,	. . . .	$8\frac{1}{4}$,,	8 ,,
,,	ditto,	1 ,,	$\frac{3}{4}$,,	$7\frac{1}{2}$,,	7 ,,
,,	ditto,	$\frac{3}{4}$,,	$\frac{1}{2}$,,	$8\frac{1}{2}$,,	8 ,,
Left,	ditto,	$\frac{3}{4}$,,	$\frac{3}{4}$,,	$10\frac{1}{2}$,,	$9\frac{3}{4}$,,
Right,	ditto,	$\frac{1}{4}$,,	. . . .	$8\frac{1}{2}$,,	$8\frac{1}{2}$,,
,,	ditto,	$\frac{3}{4}$,,	$\frac{3}{4}$,,	$8\frac{1}{4}$,,	$8\frac{1}{4}$,,

From a careful consideration of the pathological characters disclosed by making sections of the bones in the preceding specimens, I am inclined to believe that the doctrine "of fracture with penetration" is untenable, and that the true, yet simple, explanation of the almost constant presence of the line of compact tissue has not been given. Let us for a moment suppose the theory to be true; it would then, in the first place, obviously follow, that the distance between the line of compact tissue which is supposed to have penetrated, and the posterior wall

of the lower fragment, should always be the measure of the extent of displacement backwards of that fragment, but there is no such correspondence. In several of the specimens in my possession, the fracture has been united with so slight a degree of displacement, that the natural form of the lower end of the radius has been so far restored as to present a slight concavity directed forwards, while in others the fragments are upon the same plane in front, but in all of them the line of compact structure exists with an interval between it and the posterior wall of the lower fragment, varying from a quarter to half an inch in breadth.

If, instead of dividing the bone from before backwards, the section be made from side to side, the same objections to the theory of impaction will be found to maintain. The illustration which accompanies Case IX. represents the lower end of the radius divided from without inwards; at the ulnar margin of the bone the lower fragment deviates but little, comparatively speaking, from its natural direction; but externally there is an interval of half an inch between the lower end of the outer wall of the shaft and the external surface of the inferior fragment: if the presence of the line of compact structure, in this instance, is to be ascribed to impaction, there must have been a displacement outwards of the lower fragment to the extent of half an inch, an occurrence which would be impossible without a previous rupture of the connections between the lower extremities of the radius and the ulna.

If the doctrine of impaction were true, the shortening of the radius in cases of fracture of its lower extremity should be much greater than it ever is, for there is a second cause of shortening in operation, *i. e.* the alteration in the direction of the articulating surface, in consequence of which the posterior surface of the radius (naturally longer than the anterior) becomes the shorter of the two; if to the extent of shortening produced by this cause we add that arising from impaction, we would have an amount of shortening much greater than ever occurs in cases of Colles's fracture.

Again, if we suppose the theory of Voillemier to be correct, it would follow that there should be (to a certain extent, at all

events) a correspondence between the length of the line of impaction and the shortening of the back of the radius, but a reference to the preceding table will shew that they are not at all proportionate; in some cases the length of the supposed line of impaction is double the amount of shortening, while in others the latter is much greater than the former; and lastly, in some, though the bone is shortened posteriorly, there is no trace whatever of impaction having ever occured.

In the first case mentioned in the table, the line of compact tissue is one inch in length, while the seat of fracture is only half an inch above the articulation; here, therefore, it is obvious that if impaction had taken place, if the upper had been driven into the lower fragment to the extent of an inch, it would necessarily have penetrated the entire of the lower fragment, and passed into the first row of carpal bones. Were it possible to separate the united fragments, and draw down the inferior so far as to extricate it from the supposed impaction, and bring its upper and posterior edge into contact with the lower and posterior margin of the superior fragment; such a manœuvre (were the theory of penetration true) would elongate the radius, in many cases, to an unnatural degree, and render its lower extremity altogether deformed. How different would be the results in cases of impacted fracture either of the neck of the femur or of that of the humerus; in these injuries, if we extricate the fragments from each other, and bring their edges into contact, we at once restore the bone to its normal length and form. Voillemier would appear to have been sensible that his theory was liable to this objection, when he remarks that we cannot judge of the extent to which the penetration has taken place, by the length of the line of impaction, for this always appears longer than it really is; the author has, however, in my opinion, failed to solve the difficulty which he has himself suggested.

But the question naturally arises, under the circumstances in which the radius is placed in the fore-arm, is impaction to any appreciable extent physically possible in cases of Colles's fracture? The radius is firmly connected to the humerus, and to the ulna above by the external lateral, coronary, and oblique ligaments, to the shaft of the ulna by the inter-osseous membrane, and to its

lower extremity by the triangular cartilage, and by strong fasciculi of ligamentous fibres passing from one bone to the other, both in front and behind the radio-ulnar articulation. I should think, therefore, that as long as the ulna remains unbroken, and the ligamentous connexions between the two bones uninjured, it is scarcely possible for either fragment to penetrate the other even to the extent of half an inch.

It has already been shewn that, in many cases, the extent of the supposed penetration is greater than the distance between the seat of the fracture and the radio-carpal articulation; surely in such cases the carpal surface of the radius should have been split; and when we consider that the line of compact tissue is almost uniformly present, if it indicated the forcible impaction of the upper into the lower fragment, we should expect to find the latter frequently split into two or more pieces; but this form of fracture of the lower end of the radius is comparatively rare. In the instance which I have given (Case No. IV.) of the occurrence of Colles's Fracture in a case of fragilitas ossium, where the line of compact tissue was not thicker than an egg-shell and equally fragile, it is difficult to conceive the possibility of its penetrating unbroken into the lower fragment to the extent of three-quarters of an inch.

But it is impossible to establish the theory of impaction unless it can be shewn to maintain in cases of recent fracture; opportunities, however, of examining such are rare, as these injuries involve no danger to life. I have as yet had but one opportunity of examining this fracture, shortly after the occurrence of the accident (Case No. I.); in this instance there was not the slightest penetration of either fragment into the other; but had the individual who was the subject of the accident lived sufficiently long to permit of osseous union, and had an opportunity occurred of examining the state of the parts long after bony consolidation had been completed, I am convinced that the appearance of impaction would have been as distinct as in any of the other cases which I have detailed.

Until, therefore, the result of the examination of recent specimens can be adduced in support of the theory, I shall be inclined to believe that the impaction is only apparent, and that the com-

pact tissue of the shaft is not found enveloped in bone, from its having penetrated the lower fragment at the time of the occurrence of the injury, but because it becomes subsequently incased in osseous matter during the process by which the bony union of the fracture is accomplished.

When the lower end of the radius is broken and displaced backwards, there is produced at the level of the fracture, posteriorly, an inequality or depression proportional to the amount of displacement: if the fragments be permitted to unite, still holding this relative position, the depression alluded to is filled up by osseous matter (not by periosteum, as stated by Voillemier), which is deposited, not in this situation alone, but upon the surface of each fragment, to a variable distance above and below the seat of fracture, and the higher it extends upon the superior fragment, the greater will be the length of that portion of the compact tissue which appears to have been impacted, but which has, in reality, only been incased, as it were, in osseous matter, formed for the union of the fracture.

Let the reader refer to the illustration which accompanies Case No. I., and let him suppose the hollow which is seen posteriorly at the seat of the fracture filled up with bony matter, and the appearance of impaction will be at once produced. In the wood-cut which illustrates the external appearances of the bone in Case No. II., the osseous deposition around the fragments is remarkably well seen, producing considerable deformity and thickening of the lower part of the radius. Voillemier has remarked, "*that in old fractures there is a considerable thickening of the compact structure of the lower end of the bone, which it is difficult to explain.*" Had what appears to me to be the true explanation of the apparent impaction suggested itself to his mind, he would have found no difficulty in explaining this phenomenon, as it would at once have become obvious, that the thickening to which he refers was the result of the deposition of new osseous matter.

In a recent fracture there is no deposition of bone, and, therefore, no appearance of impaction; when the bone is examined shortly after the completion of osseous union, the appearance is very indistinct, and we generally find in such cases great thick-

ening of the lower end of the posterior part of the bone, the whole of the thickened part being as yet compact. The annexed engraving shews the appearances which a section of the radius presents at a comparatively early period after the osseous union of the fracture has been completed: the posterior surface of the bone is greatly thickened by the deposition of osseous matter at the seat of fracture, and for a considerable distance above it; the whole of the new deposition being as yet solid, there is no appearance of impaction; but at a more distant period, the interior of the new deposit becomes cellular, and in proportion as it does so, the compact structure of the shaft becomes distinct, and the appearance of impaction is established: at a still more remote period the enveloped portion of compact structure is frequently removed by absorption; it becomes, as it were, resolved into cancellated structure, the appearance of penetration is effaced, and the whole interior of the bone presents a cellular aspect.

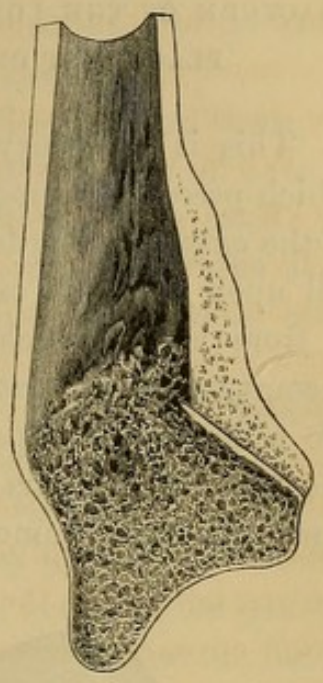

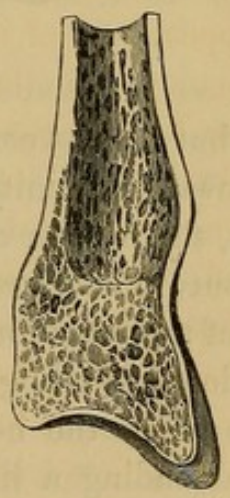

In four examples of very old fractures of the lower end of the radius, contained in the museum of the Richmond Hospital School of Medicine, although the usual deformity exists to the fullest extent, there is no trace whatever of any line of compact tissue penetrating the lower fragment, the whole interior of the lower end of the bone presenting, in each specimen, a reticular structure.

FRACTURE OF THE LOWER EXTREMITY OF THE RADIUS, WITH DISPLACEMENT OF THE LOWER FRAGMENT FORWARDS.

This is an injury of exceedingly rare occurrence, and one which presents characters closely resembling those of dislocation of the carpus forwards. It generally occurs in consequence of a fall upon the back of the hand, and the situation of the fracture is from half an inch to an inch above the articulation; it is accompanied by great deformity, the principal features of which are a dorsal and a palmar tumour, and a striking projection of the head of the ulna at the posterior and inner part of the fore-arm; the dorsal tumour occupies the entire breadth of the fore-

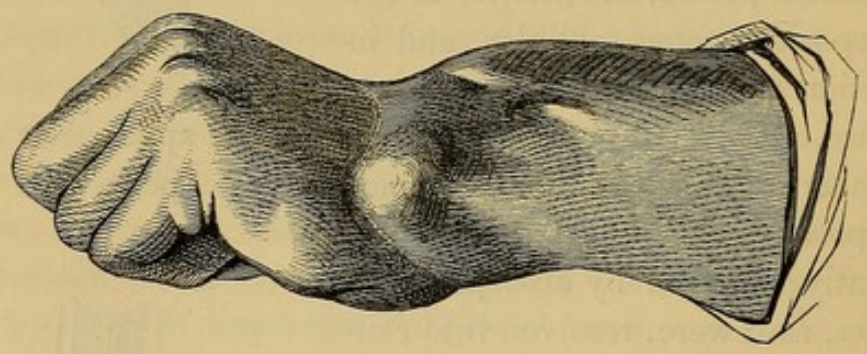

arm, but is most conspicuous internally, where it is constituted by the lower extremity of the ulna displaced backwards; from this point, the inferior outline of the tumour passes obliquely upwards and outwards, corresponding in the latter direction to the lower end of the superior fragment of the radius. Immediately below the dorsal swelling there is a well-marked sulcus, deepest internally below the head of the ulna, directed nearly transversely, but ascending a little as it approaches the radial border of the fore-arm.

The palmar is less remarkable than the dorsal tumour; formed principally by the lower fragment of the radius, it is obscured by the thick mass of flexor tendons which cross the front of the carpus, but towards the ulnar border of the limb there is a considerable projection, which marks the situation of the pisiform bone, passing down to its attachment into which, can be seen the

tendon of the flexor carpi ulnaris thrown forwards in strong relief. The transverse diameter of the fore-arm is not much altered, but the antero-posterior is considerably increased, and the radial border of the limb becomes concave at its lower part.

In the case from which the preceding drawing was made, the patient, in endeavouring to save himself from being run over by a car, fell with great violence upon the back of the hand; the lower end of the radius was broken and driven forwards along with the carpus, and the head of the ulna was displaced backwards.

I cannot speak with accuracy as to the anatomical characters of the injury, having never had an opportunity of examining after death the skeleton of the fore-arm, in those who had during life met with this accident; nor is there any preparation shewing the exact relative position of the fragments, in any of the pathological collections in Dublin;* but still I feel satisfied that the injury, the external characters of which have been just described, is a fracture of the lower end of the radius, with displacement of the lower fragment along with the carpus forwards, and of the head of the ulna backwards, and that it has not unfrequently been mistaken for dislocation of the carpus forwards and of the bones of the fore-arm backwards.

The facility, however, with which the deformity can be removed, its liability to recur when the extending force ceases to act, the production of crepitus when the limb is extended, and a motion of rotation given to the hand, and our being able to feel the irregular margin of the upper fragment of the radius posteriorly, are sufficient to enable us to distinguish this accident from luxation of the bones of the wrist forwards.

I should not omit to mention, that in the injury under consideration, the dorsal tumour exhibits a totally different character from that which it presents in cases of luxation of the bones of the fore-arm backwards at the wrist-joint; in the former the inferior outline of the tumour is directed obliquely from within outwards and upwards, being constituted internally by the lower end of the ulna, and externally by the extremity of the superior

* See page 154.

fragment of the radius; but in the latter accident, viz., luxation of the bones of the fore-arm backwards at the wrist, or, in other words, of the carpus forwards, the outline of the tumour is directed transversely, the lower ends of the radius and ulna (by which it is formed) being upon the same horizontal level.

SEPARATION OF THE INFERIOR EPIPHYSIS OF THE RADIUS, WITH FRACTURE OF THE LOWER EXTREMITY OF THE ULNA.

The lower extremities of the bones of the fore-arm are liable to another variety of fracture, which I have more than once seen mistaken for dislocation of the carpus backwards; it is the occasional result of a fall upon the palm of the hand, and a greater amount of force than usual is required for its production. When the limb is viewed posteriorly it is found to present two planes, one extending from the elbow to the seat of fracture, *i. e.* from half to three-quarters of an inch above the wrist-joint; the other, which is placed more posteriorly, begins at the situation of the fracture, and reaches to the fingers; where these two planes join, there is a deep and abrupt depression, succeeded by a solid tumour placed above the carpus, but on a level with the dorsum of the hand; the latter presents an elongated appearance.

Viewed anteriorly, the fore-arm presents an unnatural convexity, commencing immediately above the annular ligament of the carpus, and fading gradually as it ascends; the tendons of the extensors of the thumb, where they cross the hollow above the posterior tumour, are elevated, and thrown into relief, and the antero-posterior diameter of the fore-arm is considerably increased at the seat of the injury: crepitus can be readily produced, and a very moderate force is sufficient to remove the deformity. The injury consists in a fracture, usually transverse, of the lower extremities of both the radius and the ulna, close to the wrist-joint, or through the line of their epiphyses; the lower fragments are displaced directly backwards, and the superior, consequently, project in front.

In the case from which the annexed engravings were executed, the patient, a young man, fell from a scaffold, and in addition to the fracture of the fore-arm, received other injuries, of which he

died in a few hours. No attempt was made to reduce the displacement consequent upon the fracture. When the limb was examined after death, the radius was found fractured transversely

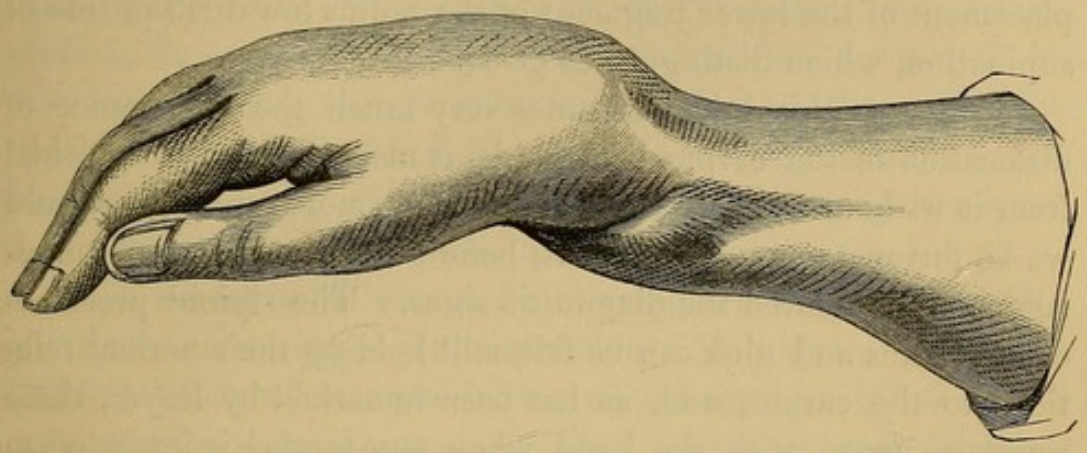

through the line of its inferior epiphysis, and the lower fragment displaced directly backwards, so far as to have very nearly cleared the extremity of the upper fragment; the lower extremity of the

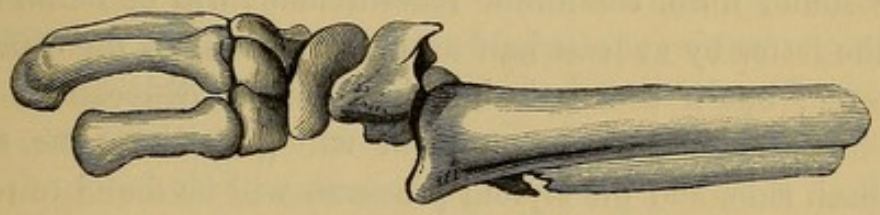

ulna was broken a short distance above the line of junction with its epiphysis; this fracture was oblique from above and before downwards and backwards; the extremities of the two fragments

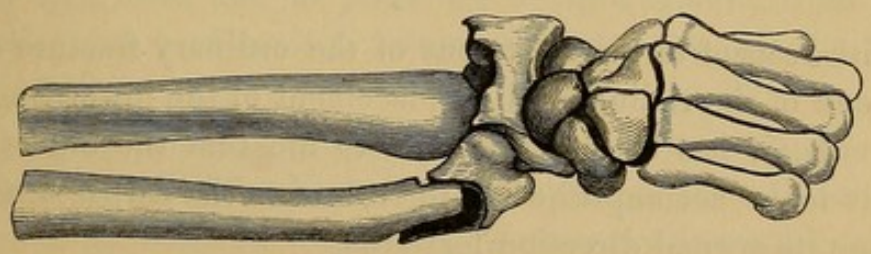

formed with each other an angle salient in front; the radio-carpal articulation was uninjured, and the carpus accompanied the lower fragment of the radius in its displacement backwards.

This accident is very liable to be mistaken for dislocation of the wrist backwards, but cannot be confounded with the ordinary fracture of the radius; the dorsal tumour is transverse, and the limb presents none of the peculiar deformity arising from the displacement of the lower fragment of the radius towards the side of supination, which distinguishes Colles's Fracture.

Although this injury assumes very much the appearance of dislocation of the carpus backwards, it may yet be distinguished from it without any considerable difficulty, more especially should we be fortunate enough to see it, before the occurrence of tumefaction has obscured the diagnostic signs. The styloid processes of the radius and ulna can be felt, still holding their normal relations to the carpus, and, as has been remarked by Boyer, these processes move with the hand when any motion is imparted to the latter. If the distance between the superior margin of the dorsal tumour, and the extremity of the middle finger of the injured limb, be measured and compared with that between the corresponding point of the hand and the upper edge of the carpus of the sound limb, the former measurement will be found to exceed the latter by at least half an inch; sometimes the difference is greater; but if the case should be one of dislocation of the wrist backwards, this measurement will give the same results upon each side, and the styloid processes will be found to remain at rest when the hand is moved; if we add crepitation, the easy reduction of the deformity by extension, and its liability to recur when the extending power is removed, we are at once furnished with a group of symptoms, quite sufficient to enable us to distinguish this injury from that very rare accident, luxation of the wrist.

With respect to the treatment of the ordinary fracture of the lower end of the radius, with displacement of the lower fragment backwards, it has always appeared to me that the object most difficult to be accomplished is to restore to the carpal surface of the bone its normal direction forwards.

It has been already mentioned that in this fracture the articulating surface becomes directed backwards, upwards, and a little outwards; the diplacement in the two latter directions can be counteracted, and the interosseous interval preserved with com-

parative facility by the means recommended by Dupuytren, but these are not calculated to restore to the anterior surface of the lower end of the radius its natural concavity, nor to direct the articulating surface forwards. In not one of the twenty specimens, which I have lately examined, has this object been accomplished; in some it has been so far effected that the carpal surface looks directly downwards, but in none of them does the posterior surface exceed the anterior in length; in those which present the nearest approach to the natural form of the bone, these surfaces are of equal length.

This objection to the mode of treatment employed by Dupuytren has not escaped the observation of Malgaigne,* Goyrand,† Diday,‡ Nélaton,‖ &c., who have modified considerably the apparatus employed by Dupuytren. The following mode of treatment, which does not differ materially from that adopted by Nélaton, I have found to answer remarkably well, and to fulfil all the more important indications.

The deformity having been, as far as possible, removed by extension and counter-extension, and the hand moderately adducted, a cushion is to be placed upon the posterior surface of the limb, of sufficient length to extend from the elbow to the fingers; the portion of this cushion which corresponds to the lower fragment of the radius and to the carpus should be thicker than any other other part, and from its ulnar to its radial border, should gradually increase in thickness. A transverse section of this portion of the cushion would represent an isosceles triangle, the base of which would correspond to the radial border of the limb. The objects proposed to be attained by constructing the pad of this form are, to press the lower fragment of the radius forwards, and to direct its external border towards the side of pronation.

A second cushion, thicker below than above, is to be placed upon the front of the limb, but should not descend below the margin of the superior fragment, for otherwise it would, to a cer-

* Gazette Médicale. 1832.

† Gazette Médicale, 1832, and Journal Hebdomadaire, 1836.

‡ Archives Generales de Medecine. Fevrier. 1837.

‖ Elemens de Pathologie Chirurgicale. 1844.

tain extent, counteract the influence of the dorsal cushion, and would tend to maintain the displacement backwards of the inferior fragment. An anterior and a posterior splint are then applied, each of which should be at least an inch broader than the fore-arm; the posterior should extend from the elbow to the fingers, and should be curved from the wrist downwards, to receive the adducted hand;* the anterior need not descend below the palm of the hand: a roller is then to be carried around the splints in the ordinary manner.

By constructing and placing the cushions in the manner above described, the two fragments are pressed in opposite directions, and the carpal surface of the inferior is directed forwards, while the curved splint, by maintaining the hand moderately adducted, tends to restore to the articulating surface its natural direction inwards, quite as effectually as the ulnar splint of Dupuytren, and with much less uneasiness to the patient. It is scarcely necessary to mention, that the form which I have recommended can be readily given to that portion of the dorsal cushion which corresponds to the lower fragment, by the employment of graduated compresses.

The apparatus recommended by Nélaton is very similar to that which I have described, and is identical with it in principle;† the use of the curved dorsal splint, instead of the ulnar splint of Dupuytren, constitutes the only difference of any importance.

* This form of splint, many years ago recommended and employed by Blandin, is far preferable to the "attelle cubitale" of Dupuytren, the effectual application of which frequently causes so much pain as to render its early removal necessary.

† "J'applique sur la face dorsale du carpe et sur le fragment inférieur du radius deux ou trois compresses graduées, placées transversalement. D'autres compresses graduées sont appliquées à la face palmaire de l'avant-bras, parallélement à l'axe du membre; ces compresses sont repliées à leur extrémité inferieure, de manière à représenter un bord assez épais, qui doit être placé à un centimètre environ au-dessus de la saillie transversale que forme le fragment supérieure. Les compresses ainsi disposées, je place deux attelles, que je fixe à l'aide d'une bande roulée. Il est facile de comprendre que les choses étant ainsi disposées, l'attelle dorsale ne touche l'avant-bras que supérieurement; en bas elle appuie sur les compresses graduées qui recouvrent le fragment inférieure, et, immédiatement au-dessus de ces compresses, il existe un vide. Quant a l'attelle palmaire, elle repose sur les compresses graduées qui recouvrent l'espace inter-osseux; mais comme ces compresses ne descendent pas jusqu' á la main, il existe encore vide entre cette attelle et l'extrémité inférieure de l'avant-bras. L'action de cette appareil est des plus faciles à com-

The mode of treatment adopted by Dupuytren is not well calculated to restore to the articulating surface of the radius the threefold obliquity which it possesses in the normal state; for, although the use of the ulnar splint tends, it is true, to draw the styloid process downwards, and thus to direct the carpal surface of the bone inwards, yet, as it appears to me, the apparatus employed by this celebrated surgeon is not capable of counteracting effectually that displacement of the lower fragment, in consequence of which the aspect of its articulating surface becomes directed backwards.

During the application of the apparatus, as well as during the subsequent treatment, the fore-arm should be maintained in a position intermediate between pronation and supination, for it is in this position that the co-aptation of the fragments can be most easily and most perfectly accomplished, in consequence of the relaxation of the pronator and supinator muscles.

Whatever mode of treatment be employed, we should be careful that the fore-arm suffers no circular compression, the effect of which would be to diminish the breadth of the interosseous space, which, for obvious reasons, it is important to preserve. It is, no doubt, true, that the interosseous interval, in the situation of Colles's fracture, is so narrow, that no very important diminution of it can occur as the consequence of treatment: this observation, however, holds good, principally as regards the lower fragment of the radius; for the superior, under the influence of external pressure, will admit of such an amount of displacement inwards towards the ulna, as most materially to interfere with the motions of pronation and supination, should the fragments be permitted to unite in this relative position.*

The splints should be allowed to remain upon the limb "for

prendre; les deux attelles, en se rapprochant par le fait de la constriction que la bande roulée exerce sur elles, doivent tendre à pousser les deux fragmens en sens inverse, en les refoulant vers l'espace vide laissé entre la surface du membre et les attelles.

"Lorsque le déplacement des fragmens est très prononcé, et que l'extrémité du cubitus forme une saillie très marquée au coté interne du poignet, j'ajoute, a l'appareil précédemment décrit, l'attelle cubitale de Dupuytren."—*Pathologie Chirurgicale*, tome premier.

* Si les fragmens de la fracture se réunissent dans cet état, les mouvemens de pronation et de supination sont très-difficiles, et quelquefois même impossibles."—*Boyer*, tome iii.

three weeks in young persons, and for four or five in the aged, before passive motion be attempted. The recovery in these cases is slow, and six months will sometimes elapse before the motion of the fingers is completely restored."*

If, however, upon the one hand, it is true, that evil consequences may result from our permitting passive motion to be commenced too early, it is, upon the other, equally certain that permanent impairment of the functions of the limb may ensue, if we maintain the parts at rest for too long a period; it is not alone the rotatory motions of the radius that suffer, for in some cases the fingers remain extended, and the patient never regains the power of flexing them perfectly, while in other instances they become permanently retracted.†

In cases where the fracture has been produced by considerable violence, and has been set immediately after the occurrence of the accident, the surgeon should never permit twelve hours to elapse without again visiting his patient, and satisfying himself as to the propriety of slackening the bandage, or removing the apparatus altogether: for in this injury, as has been already mentioned, very considerable swelling is apt to occur early, in consequence of which the pressure of the splints and bandage is rendered greater than it is safe to permit: from a neglect of this precaution, gangrene of the limb has, in several instances, resulted.

A boy, æt. 18, was admitted into the Richmond Hospital, upon Wednesday, the 2nd of September, 1840. Upon the previous Sunday he had been thrown from a horse with great force; the lower extremity of the left radius was broken, and he sustained a concussion of the brain, under the influence of which he remained insensible for three-quarters of an hour.

The accident occurred in the country, but before an hour had elapsed the boy was visited by a surgeon, who, having forcibly extended the limb, applied *a narrow roller tightly around the wrist;* upon the following day (Monday) the patient complained of intense pain in the limb, the hand was cold, and its dorsal region discoloured; the roller was not removed, nor even slack-

* Sir Astley Cooper on Dislocations.

† Goyrand: Journal Hebdomadaire. 1836.

ened. Upon Tuesday dark-coloured vesicles formed along the ulnar side of the fore-arm; the lividity of the hand had extended as far as the wrist, and before evening the boy was attacked with vomiting and delirium.

When he was admitted into the hospital upon Wednesday, the limb, as far as the elbow, was enormously swollen and tense; gangrene had reached the fore-arm; a thick fur covered the tongue; he was parched with an ardent thirst; his pulse was 150 and feeble, his countenance anxious, his cheek flushed, and his eyes dull. During the 4th and 5th the gangrene continued to spread along the outer and posterior part of the fore-arm, nor did it cease until it had arrived within two inches of the elbow-joint; a line of separation began to form upon the 6th, and upon the 26th the bones were sawn through, after which everything proceeded favourably. The radius was broken through the line of the epiphysis. Similar cases have been recorded in the Gazette Médicale.

The substance of the preceding observations may be summed up in the following general corollaries:

1. Fracture of the lower extremity of the radius, close to the wrist-joint, with displacement of the lower fragment backwards, may, with propriety, be termed "Colles's Fracture."

2. Colles's Fracture may be the result of a fall either upon the palmar or dorsal surface of the hand.

3. In Colles's Fracture the carpus does not project towards the palmar surface of the limb, as has been stated by Sir Astley Cooper.

4. In this injury the head of the ulna projects at the inner border of the carpus, in consequence of the hand being carried in the opposite direction, "par une mouvement de totalite."

5. In consequence of this displacement outwards of the hand, the internal lateral ligament of the wrist-joint is stretched, and severe pain is felt below the head of the ulna.

6. The distortion which characterizes Colles's Fracture is the result of the combined action of the supinator longus, the extensors of the thumb, and the radial extensors of the carpus.

7. The presence of this deformity pre-supposes the integrity of the lower extremity of the ulna, and of the inferior radio-ulnar connexions.

8. In this injury there is scarcely any diminution in the transverse diameter of the fore-arm, the cylindrical form which the limb acquires being owing partly to effusion among the flexor tendons, but principally to the increase in the antero-posterior diameter of the fore-arm at the seat of the fracture, consequent upon the displacement backwards of the lower fragment.

9. In Colles's Fracture the radius is usually broken from half to three-quarters of an inch above its carpal surface.

10. In Colles's Fracture the radius is generally broken transversely, with respect to the antero-posterior diameter of the bone, but the fracture may be oblique from above downwards and inwards, or downwards and outwards.

11. The external deformity would lead us to suppose, that the radius had been broken very obliquely, even in those cases in which the fracture is accurately transverse, with respect to both diameters of the bone.

12. This apparent obliquity is owing to the three-fold displacement which the inferior fragment undergoes, in consequence of which the aspect of its articulating surface becomes directed upwards, backwards, and outwards.

13. The opinion of Diday, that there is in this fracture an overlapping of the fragments, does not appear to be correct; such an event has not been demonstrated in recent specimens of the injury, and in old cases the appearances are deceptive; but even in the latter, when the bone is divided from before backwards, the fracture is usually found to have been transverse; in such cases overlapping could not happen, and the possibility of its occurrence is difficult to be conceived, even in oblique fractures, as long as the ulna and the radio-ulnar ligaments remain uninjured.

14. In Colles's Fracture the posterior surface of the limb is shortened, but the anterior *may* be increased in length, in consequence of the divarication of the fragments in front.

15. The amount of this increase will depend upon the amount

of displacement, upwards and backwards, of the carpal surface of the lower fragment.

16. To account for the shortening of the posterior surface of the bone, it is not necessary to suppose that there exists overlapping of the fragments. The shortening is to be ascribed to the alteration in the aspect of the carpal surface of the bone.

17. In Colles's Fracture the pronator quadratus acts principally upon the lower extremity of the superior fragment.

18. The theory of Voillemier, which supposes that the superior is driven into the inferior fragment, appears to me to be liable to the following objections.

a. The distance between the line of compact tissue and the posterior wall of the lower fragment is not the measure of the amount of displacement backwards of that fragment.

b. This interspace is considerable, even in those cases in which the fragments are found to be upon the same plane in front.

c. Were the theory correct, the amount of shortening of the posterior surface of the bone should be much greater than it ever is in cases of Colles's Fracture.

d. There is no correspondence between the length of the line of compact tissue and the amount of shortening of the back of the radius.

e. The possibility of either fragment being driven into the other is difficult to be conceived as long as the ulna remains entire, and the ligaments which connect it to the radius, uninjured.

f. The appearances disclosed by the examination of recent specimens, are opposed to the doctrine of Voillemier.

g. Were it possible to separate the united fragments, and draw down the inferior so far as to extricate it from the apparent impaction, we would not succeed thereby in restoring the normal form of the lower end of the radius.

19. The compact structure of the shaft of the radius appears to have penetrated the lower fragment, in consequence of its having become incased in osseous matter, deposited for the union of the fracture.

20. The extent of this deposit regulates the length of the line of compact tissue, which appears to have been impacted.

21. In the treatment of Colles's Fracture the object most difficult to be accomplished is, to restore to the carpal surface of the radius its natural direction *forwards*, and thus render the posterior surface of the bone longer than the anterior, as it is in the natural state.

22. The upper and lower fragments of the radius should be pressed in opposite directions, the former backwards and the latter forwards, but the principal amount of pressure should be exerted upon the inferior fragment.

23. The use of a curved splint, which preserves the hand in a moderate state of adduction, supersedes the necessity of employing the ulnar splint of Dupuytren.

24. The object proposed to be attained by keeping the hand in this position, is to restore to the carpal surface of the radius its normal direction inwards.

25. Fracture of the lower extremity of the radius, with displacement of the lower fragment forwards, is generally the result of a fall upon the back of the hand.

26. This injury is liable to be mistaken for dislocation of the carpus forwards.

27. The principal diagnostic signs of the nature of the accident are, the facility with which the deformity can be removed and crepitus produced, and the obliquity of the outline of the dorsal tumour, its external portion (or that constituted by the extremity of the superior fragment of the radius) being placed higher up than its internal portion, which is formed by the head of the ulna.

28. Fracture through the lower extremities of the radius and ulna is very liable to be mistaken for dislocation of the carpus backwards.

29. The chief diagnostic signs of the fracture are the following:

a. The styloid processes of the radius and ulna maintain their normal relations to the carpus, and move with the hand.

b. The distance between the margin of the dorsal tumour and the ends of the fingers, is greater than that between the upper edge of the carpus and the extremities of the fingers of the uninjured limb.

c. A very moderate degree of extension is sufficient to restore the fragments to their proper relative position, but when the extending power is removed, the original deformity is exceedingly liable to recur.

d. When the deformity has been reduced by extension and counter-extension, the carpus can be readily moved backwards and forwards, and during these motions a crepitus is distinctly felt.

CHAPTER IV.

FRACTURES OF THE HUMERUS, IN THE VICINITY OF THE SHOULDER-JOINT.

It has been justly remarked by Dupuytren, that all solutions of continuity of bones in the vicinity of joints, give rise to numerous errors in diagnosis, and the observation applies with peculiar force to the injuries which occur in the immediate neighbourhood of the scapulo-humeral articulation.

Much, it is true, has been already done, both in this country and abroad, towards elucidating their nature, but every experienced surgeon can recall to his recollection cases of injuries of the shoulder, in which he has felt the utmost difficulty in arriving at a conclusion as to the nature of the accident. It is to the rarer and more obscure injuries of the upper extremity of the humerus that I am anxious now to direct attention, in the hope of being able to succeed in removing some, at least, of that obscurity which has so often proved embarrassing to the surgeon.

The cases, therefore, which I propose to consider in the following pages are, 1st, Fractures of the Greater Tuberosity of the Humerus; 2nd, Impacted Fractures of the Neck of the Bone; and 3rd, Separation of the Epiphysis from the Shaft; for these have been the injuries in which I have seen the greatest difficulty experienced, both as regarded their diagnosis and their treatment.

FRACTURES OF THE GREATER TUBEROSITY OF THE HUMERUS.

When a person falls with violence upon the anterior part of the shoulder, it not unfrequently happens that the greater tubercle of

the humerus is separated from the remainder of the bone. The symptoms which characterize this injury are such as render it liable to be confounded with dislocation of the head of the humerus, either into the axilla, or forwards beneath the pectoral muscle, and it is probable that instances of it have been from time to time recorded as examples of partial luxation beneath the coracoid process. It resembles dislocations in the prominence of the acromion, the alteration in the contour of the shoulder, the impairment of the motions of the limb, and, in some instances, the absence of crepitus and the separation of the arm from the side; but, generally speaking, when an accurate examination of the joint is made, there is no great difficulty experienced in establishing the differential diagnosis.

One of the most striking features of this injury, and which at once attracts the notice of the surgeon, is a remarkable increase in the breadth of the articulation; in some instances the injured joint, when compared with that of the opposite side, appears to be nearly twice as broad as natural; the acromion process projects, but is never as prominent as in cases of luxation; the rounded form which the shoulder naturally presents is altered, and the deltoid muscle is somewhat flattened, but the finger cannot be sunk into the glenoid cavity; the arm is in general separated from the side, but can be approximated to it without difficulty; the under motions of the limb can be performed, but the patient cannot raise it beyond a horizontal line, and seldom, indeed, can elevate it so far; if urged to proceed in the effort to do so, he endeavours to accomplish it by inclining the upper part of the body towards the opposite side, and during the entire manœuvre he supports the injured arm with the opposite hand.

Upon examining the articulation more closely, two osseous tumours are felt: one is placed externally beneath the acromion, the other, and larger, lies beneath and a little internal to the coracoid process. The latter presents to the touch the rounded form of the head of the bone, and follows every motion imparted to the arm; between these two osseous prominences a sulcus (the depth and distinctness of which vary in different cases) can be felt, corresponding to the situation of the bicipital groove. I have, as yet, had but one opportunity of ascertaining, by *post mortem* exami-

nation, the anatomical characters of the injury in question, although numerous examples of it in the living have fallen under my observation.

Case I.—In July, 1844, I was requested to examine the body of Julia Darby, æt. 80, who had died of chronic pulmonary disease. Upon entering the room the appearances of the left shoulder-joint at once attracted my attention, and struck me as being different from those which attend the more common injuries of this articulation.

The shoulder had lost, to a certain extent, its natural rounded form; the acromion process, although unusually prominent, did not project as much as in cases of dislocation of the head of the humerus. The breadth of the articulation was greatly increased, and upon pressing beneath the acromion, an osseous tumour could be distinctly felt, occupying the greater part of the glenoid cavity; it formed a prominence which was perceptible through the soft parts; it moved along with the shaft of the humerus, but was manifestly not the head of the bone.

A second and larger tumour, presenting the rounded form of the head of the humerus lay beneath the level of, and internal to, the coracoid process, and between the two the finger could be sunk into a deep sulcus, placed immediately below the coracoid process. The elbow could be brought into contact with the side, and there was no appreciable alteration in the length of the arm.

Upon removing the soft parts the head of the bone presented itself, lying partly beneath and partly internal to the coracoid process. The greater tuberosity, together with a very small portion of the outer part of the head of the bone had been completely separated from the shaft of the humerus. This portion of the bone occupied the glenoid cavity, the head of the humerus having been drawn inwards so as to project upon the inner side of the coracoid process; it was still, however, contained within the capsular ligament.

The fracture traversed the upper part of the bicipital groove, which, in consequence of the displacement which the head of the bone had suffered, was situated exactly below the summit of the coracoid process. A new and shallow socket had been formed upon the costal surface of the neck of the scapula, below the root

of the coracoid process, and the inner edge of the glenoid cavity corresponded to the posterior part of the sulcus, which separated the head of the bone from the detached tuberosity. The latter was united to the shaft only by ligament.

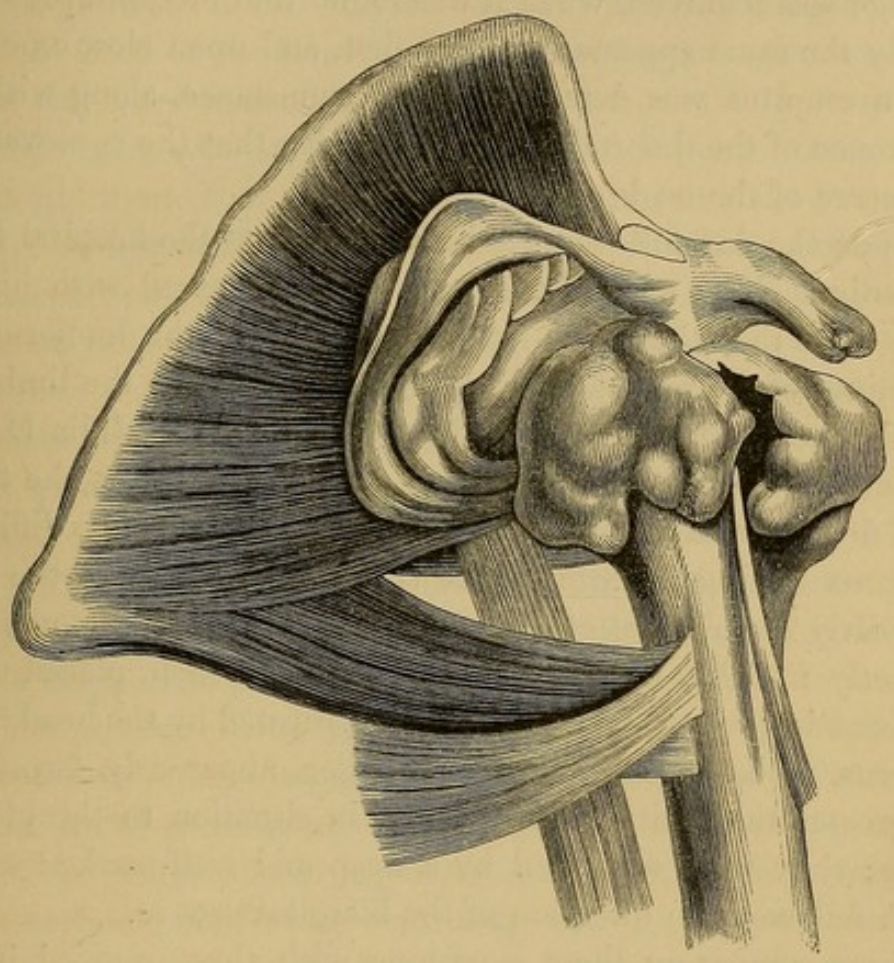

The capsule had not been injured, but was thickened and enlarged, and bone had been deposited in its tissue. The injury had evidently occurred many years before the death of the patient, but the history connected with it could not be precisely ascertained.

Case II.—A man, æt. 30, fell from a house three stories high, and received a severe injury of the left shoulder-joint. Upon his being conveyed to the Richmond Hospital, the pupil in attendance, finding the head of the bone placed more forwards than natural, the acromion process more prominent, the deltoid muscle somewhat flattened, and the elbow separated from the side, con-

ceived that the case was one of dislocation of the head of the humerus. The mode of reduction by the knee in the axilla was had recourse to, and the deformity was supposed to have been removed; the arm was then bandaged to the side. However, after a short time, as the patient complained of severe pain, the bandage was removed, when it was found that the joint presented exactly the same appearances as at first, and upon close examination, a crepitus was detected; this circumstance, along with the recurrence of the deformity, led to the idea that the case was one of fracture of the neck of the scapula.

Upon the day following his admission into the hospital I saw this patient along with Mr. Adams, and concurred with him in the opinion that there was neither luxation of the humerus nor any injury of the scapula. The appearances which the limb presented were similar to those noticed in the case of Julia Darby; the acromion was more prominent than natural, but the finger could not be sunk into the glenoid cavity; there was no difficulty in approximating the arm to the side; the breadth of the joint was nearly double that of the opposite one, and two tumours were distinctly noticed, the inner, and larger of which, placed under the coracoid process, was evidently constituted by the head of the humerus, while the external, and smaller, apparently formed by the greater tuberosity, corresponded in situation to the glenoid cavity: they were separated by a deep and well-marked sulcus, which followed the direction of the bicipital groove.

From comparing these symptoms with those noticed in the preceding case, we arrived at the conclusion that the injury was a fracture through the upper part of the bicipital groove, detaching the greater tubercle of the humerus; it could not have been a fracture of the neck of the scapula, for in this case the arm is lengthened, and the deformity is easily removed by pushing the elbow upwards, but re-appears when the limb is allowed to hang unsupported, whereas, in the case under consideration, there was no lengthening of the arm, nor could the deformity be *completely* removed by any means whatever.

At first sight the appearances, no doubt, resembled those of dislocation of the head of the humerus forwards, but the facility with which the elbow could be brought into contact with the

side, and the great increase in the breadth of the joint, were sufficient to establish the differential diagnosis.

When a fracture detaches the greater tubercle, the action upon the humerus, of the supra-spinatus, infra-spinatus, and teres minor, is annulled; the folds of the axilla, the subscapularis, and the anterior portion of the deltoid then act almost unopposed, and draw the head of the bone forcibly inwards against the inner part of the capsular ligament, while the tuberosity will move upwards and outwards, obeying the action of the muscles inserted into it. Thus there is a considerable displacement according to the breadth or thickness of the bone, and to this will be added a displacement, according to its length, if the head of the bone should be drawn inwards so far as to enable it to clear the coracoid process, for it will then be drawn upwards by the coraco-brachialis, and other muscles, whose direction is nearly parallel to the axis of the humerus.

In November, 1833, a lecture was delivered by Mr. Guthrie, on a peculiar injury of the shoulder-joint,* attended by symptoms so very similar to those which I have described in the preceding pages, that I am inclined to think the lesion of the bone was also similar. The first case mentioned by Mr. Guthrie is that of Louisa Chapman, æt. 11, who had fallen upon the shoulder; a considerable prominence was noticed at the inner and anterior part of the joint, which might have been mistaken for the head of the humerus dislocated, were it not that the whole of it did not project internally, but, on the contrary, the greater part could be felt in the glenoid cavity.

"If," says Mr. Guthrie, "the thumb or fore-finger of the left hand be placed upon the internal protuberance of bone, whilst the elbow is rotated by the right, the protuberant portion of the humerus will be found to obey the motions given to the elbow, in the clearest possible manner. If the fore-finger be carried outwards, and placed upon that part of the joint in which the external part of the head of the humerus ought to be placed, in its normal state, it will be found there, and moving most distinctly when the elbow is rotated; the arm can be elevated, and the

* London Medical and Surgical Journal.

hand placed upon the top of the head; there is no peculiar sensation communicated to the finger when pressed into the axilla, and the elbow can be pressed close to the side, although it tends a little backwards; if the point of the fore-finger be placed immediately below the middle of the acromion process, it sinks into a hollow between the protuberant point of the bone and the articulating part of the humerus, which moves in the glenoid cavity, and if the two shoulders are compared, the greater breadth of the injured one is apparent. What is the nature of the injury? Dissection has not yet explained it, but I believe that it is a longitudinal split of the humerus; the accident always happens in consequence of a fall upon the point of the shoulder, in which the head of the humerus first meets the ground, and receives the shock. I believe the split separates the small tuberosity with more or less of the head, and extends in the direction of the bicipital groove."

Mr. Guthrie adduces three other instances of the accident, in all of which the symptoms were nearly alike. The fourth case was that of a gentleman, æt. 18, who fell upon the point of the shoulder, and was supposed to have dislocated the head of the humerus; the bone, when reduced, did not, however, remain in its situation. At the end of three weeks Mr. Guthrie first saw the patient; he found that the elbow was carried very far backwards, and the head of the os humeri proportionably forwards, and apparently dislocated in that direction, but the prominence was not round like the head of the bone. In the attempts which were afterwards made to reduce the bone, this prominence could not be entirely removed: the outer portion of the humerus appeared to be in the glenoid cavity, but the greater part was internal to it.

Now if we compare the appearances in the instances which I have detailed, with those described in Mr. Guthrie's cases, they will be found to resemble each other so closely as to justify us in supposing that the nature of the injury was similar in all. The situation of the fracture may not be precisely the same in all cases, but I am inclined to think that some part of the greater tubercle, with more or less of the adjoining portion of the head of the bone, is, in general, its seat, and not the lesser tubercle, as supposed by Mr. Guthrie. The former, from its greater size and more exter-

nal situation, is more exposed to injury than the latter, and when a person falls upon the shoulder, the scapular muscles (three of which are inserted into the greater tubercle) are thrown into a state of powerful and spasmodic contraction, and must materially assist in detaching the process of bone into which they are inserted, at the moment the external violence is applied.

The symptoms of the injury will vary considerably according as the fracture has detached more or less of the greater tubercle. If a small portion only has been separated, the abnormal appearances of the joint will be but trivial, and the true nature of the injury will most probably escape detection; but if the entire of the tuberosity has been broken off from the shaft of the bone, considerable deformity will result, and great difficulty will be experienced in conducting the treatment, so as to prevent a certain amount of this deformity from being permanent, for the head of the bone will have a constant tendency to pass inwards, under the influence of the action of the muscles which constitute the folds of the axilla, while the tuberosity will be drawn in an opposite direction; hence it is extremely difficult to keep the fragments in contact by any mechanical contrivance, or by any amount of pressure which the patient can endure. Under such circumstances, the fracture, as happened in the case of Darby, will be much more likely to unite by ligament than by bone.

The following case of fracture of the greater tubercle of the humerus, was communicated to the editor of Sir Astley Cooper's work on Dislocations, by Mr. Herbert Mayo: "A gentleman, æt. 60, in going up a flight of stairs fell, and in the attempt to recover himself fell again; when he was lifted up the left arm was useless, and the shoulder in pain. On examining it within an hour after the accident, my first impression was that it was a dislocation of the shoulder. The acromion projected as in dislocation, and the deltoid was flat below it; however, the elbow did not project from the side, and though the motion of the shoulder was painful, yet it could be moved more easily than is usually the case in dislocation. The neck of the humerus was certainly not broken. When the arm was raised to a right angle with the scapula, and pulled outwards, the head of the bone seemed to be restored to its place. On lowering the elbow again, the appear-

ance of the shoulder was the same as at first. On carefully examining the outside of the head of the humerus, I found the injury to consist in fracture and separation of the greater tubercle. A figure of 8 bandage was applied to fix the scapula and steady the shoulder, and a sling to support the arm, with a lath splint on the outside of the humerus, the upper part of which was made to bear upon the separated bone by uniting the top of a circular roller to the figure of 8 bandage. The fracture united favourably, but for a long time the patient had some difficulty in carrying the arm backwards.

IMPACTED FRACTURES OF THE NECK OF THE HUMERUS.

The neck of the humerus is not unfrequently the seat of a fracture analogous, in many respects, to the impacted fracture of the cervix femoris. Of this form of injury I have seen two varieties, in one of which the upper extremity of the lower fragment, or a portion of it, penetrates the reticular tissue of the head of the bone; this is an extracapsular fracture, and occupies the situation which, in the young subject, marks the junction of the epiphysis with the shaft; in the other, the superior fragment is forced downwards into the cancellated structure between the tubercles, the greater of which processes is, in almost every such instance, split off from the shaft of the humerus; in this case the fracture is intracapsular, and occurs through the anatomical neck of the bone.

The descriptions which have been given of fracture through the anatomical neck of the humerus are not without a certain degree of obscurity, for in many instances authors appear to have confounded this injury with fracture through the tubercles, or through the line of junction of the epiphysis with the shaft.

When the anatomist speaks of the anatomical neck of the humerus, he designates by this name that portion of the bone into which the capsular ligament is inserted, and which, throughout more than half of its extent, is constituted by a narrow sulcus, placed *above* the tubercles; practical writers, however, have in many cases used the term indiscriminately, and have designated, as the anatomical neck, all that portion of the bone which is

comprised between its head and the inferior outline of its epiphysis.

Sir Astley Cooper, for instance, has described fracture through the tubercles, and through the anatomical neck of the humerus, as one and the same form of injury,* and the author of the Surgical Dictionary remarks: "Indisputable facts prove the possibility of the anatomical neck of the bone being fractured, and C. Larbaud showed Bichat the humerus of a young man, æt. 17, the head of which bone was *accurately* detached from its body, by a fracture which had passed obliquely *through the upper part of the tuberosities.*"†

The anatomist, however, is aware that the tubercles do not constitute any part of the anatomical neck of the humerus, a fracture through which, as already stated, is intracapsular, and is characterized by symptoms totally different from those which attend fractures through the tuberosities, or through the line of junction of the epiphysis with the shaft of the bone. In the latter, the deformity is considerable, in consequence of the lower fragment being drawn inwards by the muscles which constitute the folds of the axilla; but in the former there is scarcely any displacement of the inferior fragment, the influence of these muscles being counteracted by the supra-spinatus, infra-spinatus, and teres minor, attached to the greater tubercle; the bone being thus placed between two opposing forces, suffers very little displacement, and the deformity is slight in proportion; hence the diagnosis of fracture of the anatomical neck of the humerus is, comparatively speaking, obscure. The impairment of the motions of the joint and crepitus are, in fact, almost the only symptoms upon which we can depend, in forming our opinion as to the nature of the injury which the bone has sustained.

The diagnostic signs of fracture of the neck of the humerus, accompanied by penetration of the superior by the inferior fragment, are remarkably obscure, and the true nature of the injury is exceedingly liable to escape detection: there is but little devia-

* Treatise on Dislocations, &c., edited by Bransby Cooper, page 497.

† Dictionary of Practical Surgery, page 591. The age of the individual in this case renders it probable that the fracture was through the line of the epiphysis.

tion from the natural form of the shoulder, nor is there any *appreciable* alteration in the length of the limb; when the surgeon places one hand upon the shoulder, and with the other rotates the elbow, the head of the bone will be felt moving with the shaft; no satisfactory information is obtained by examining through the axilla, for although, perhaps, a slight irregularity may be felt near the junction of the neck with the head of the bone, it is usually so inconsiderable, that it cannot be looked upon as affording positive evidence of the existence of a fracture in this situation.

When, however, a person falls upon the upper and outer part of the shoulder, and at once loses the power of executing the motions natural to the articulation, when none of the characters of luxation, or of the ordinary fracture of the neck of the humerus are present, and where, at the same time, there is a certain degree of deformity, which, though slight, it is by no means easy to remove, and an unusual difficulty in detecting crepitus, we have grounds for suspecting the existence of an impacted fracture of the neck of the bone. It is not easy to say in what the deformity consists, but when the surgeon compares the two shoulders with each other, it at once becomes obvious that there is a difference in their external conformation, that which has sustained the injury appearing to be somewhat fuller and larger than its fellow.

In order, however, to form a more decided opinion as to the nature of the lesion which the bone has suffered, let the surgeon, with both hands, grasp the head of the bone with firmness, sufficient to maintain it as nearly as possible in a fixed position, while an assistant rotates the elbow; by this method crepitus can be produced in the great majority of cases.

In the ordinary fracture of the neck of the humerus, which is unattended by impaction, it is sufficient, in order to detect this characteristic sign of fracture, that the surgeon place one hand upon the shoulder, and with the other rotate the arm. In cases, however, of impacted fractures, we would derive no information from such a mode of examination; but we will seldom fail in our efforts to produce crepitus, if we adopt the method which I have mentioned, for the impaction is never by any means as firm in these cases as in the analogous injuries of the neck of the femur,

inasmuch as it rarely happens that the entire of of the lower fragment penetrates the head of the bone.

The annexed engraving shews the relative position of the fragments in the majority of cases of this form of impacted fracture. It represents a vertical section carried from before backwards, through the upper extremity of the left humerus. The direction of the fracture is transverse, and its situation nearly corresponds to the line of junction of the epiphysis with the shaft. The inner and posterior portion of the head of the humerus has

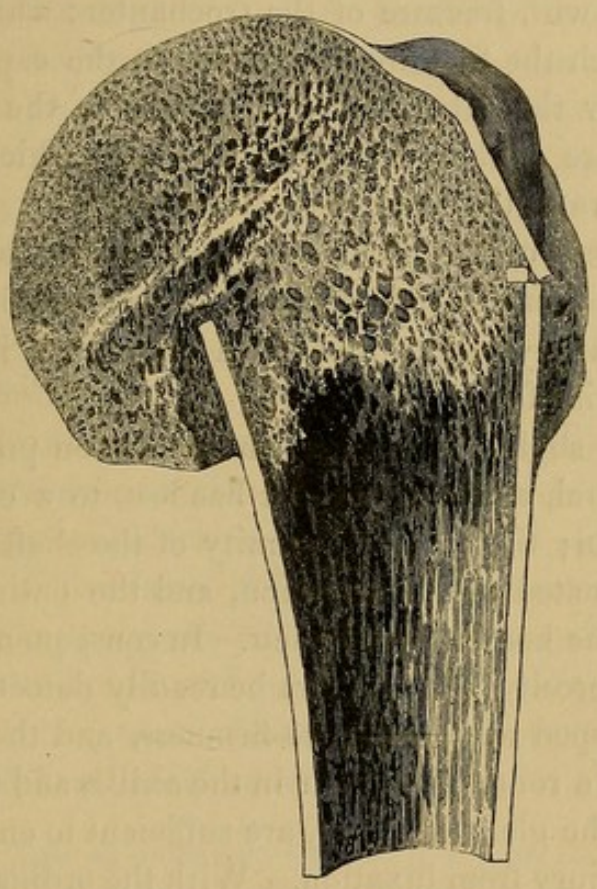

been driven downwards, and the compact tissue lining the concavity of the neck of the bone has penetrated the reticular structure of the head to the distance of half an inch,* and here consolidation has taken place by the direct union of the surfaces opposed to one another, while in front, where there is no impaction,

* In the Ninth Number of Guy's Hospital Reports, Sir Astley Cooper has delineated a somewhat similar specimen, but he does not speak of it as an example of impacted fracture.

the fracture is united by the deposition of bone in the ordinary manner.

In the second form of this remarkable injury, the fracture is situated higher up, and traverses the anatomical neck of the bone, *within* the inferior attachment, or base of the capsular ligament. It is a true intracapsular fracture of the neck of the humerus, in which the head of the bone, or superior and smaller fragment, is driven into the inferior, or larger, between the tubercles, one or other of which processes are usually broken off from the shaft. It is thus analogous to the *extracapsular* impacted fracture of the cervix femoris, with fracture of the trochanter; while the former variety, in which the fracture is external to the capsule, and immediately below the tubercles, is analogous to the *intracapsular* impacted fracture of the neck of the femur, in which the inferior fragment penetrates the head of the bone.

The diagnosis of this, the *intracapsular* impacted fracture of the neck of the humerus, is simple as compared with that of the *extracapsular* variety of the injury, in which the inferior penetrates the superior fragment.

The arm is slightly shortened, the acromion process projects more than natural, and the shoulder has lost, to a certain extent, its rounded form; the upper extremity of the shaft of the humerus is approximated to the acromion, and the entire of the globular head of the bone cannot be felt. In consequence of the fracture of the tuberosity, crepitus can be readily detected, when the shoulder is grasped with moderate firmness, and the arm rotated. The absence of a rounded tumour in the axilla, and the impossibility of feeling the glenoid cavity, are sufficient to enable us to distinguish this injury from luxation. With the ordinary fracture of the surgical neck of the humerus it would be scarcely possible to confound it, for in this injury the elbow is separated from the side, an evident depression exists two or three inches below the acromion process, the upper end of the lower fragment projects towards the axilla, and the axis of the arm becomes oblique from above and within, downwards and outwards.

Both forms of impacted fracture, to which I have alluded, unite by bone; were it not, however, for the circumstance of the impaction, we could scarcely hope for osseous consolidation in

the intracapsular variety.* In fact, were it not for this fortunate circumstance, the neck of the humerus would be in a more unfavourable predicament, as regards the occurrence of osseous union, even than the neck of the femur when broken within the capsular ligament.† In the latter case, the superior fragment continues to be supplied with blood in quantity sufficient, not only to preserve its vitality, but also sufficient, in many cases, for the accomplishment, at all events, of ligamentous union; but in the former the superior fragment is cut off from all connexion with surrounding tissues, it has no round ligament to conduct vessels into it from above, it becomes, truly, a foreign body in the articulation, and would be likely to perish from want of nutrition, were it not, by the impaction, brought and maintained in contact with living structures and highly organized tissues, capable of forming and depositing osseous matter, by which the fracture is repaired.‡

Notwithstanding, however, the unfavourable circumstances in which the head of the humerus is placed as regards bony union, when a fracture has traversed the anatomical neck of the bone, and there is no impaction, there is abundant evidence to prove that osseous consolidation may still be accomplished. But it is highly probable that in the case in which this fortunate result has occurred, although the fracture has passed through the anatomical neck of the bone, the vascular communication between the fragments has not been entirely cut off, and that the margins of the fragments have remained here and there connected to each other by the attachment of the capsular ligament, the vascular supply derived from which, proves adequate to the preservation

* "Si la tête seule est entièrement detachée, je ne pense pas que la consolidation puisse avoir lieu par la cal ordinaire."—*Vidal*, tome second, p. 113.

† "Lorsque la fracture du col de l'humérus est située au-dessous de l'insertion des muscles sus-épineux, sous-épineux et petit ronde, sa consolidation n'eprouve aucune difficulté et la malade guerit aussi promptement et aussi facilement que si la maladie avait son siège a la partie moyenne de l'os. Mais lorsqu' elle est située au-dessus des tuberosites, précisément dans la ligne qui sépare ces éminences de la tête de l'os, peut on espérer une guérison aussi facile et aussi prompte? La consolidation de cette fracture ne doit-elle pas éprouver les mémes difficultes que celle de la fracture du col du fémur qui a lieu près de sa tête?"—*Boyer*, *Traite des Maladies Chirurgicales*, t. iii.

‡ "La tête, frappée de nécrose, peut agïr sur l'articulation á la manière d'un corps étranger, et provoquer des accidents dont on prevoit la nature."—*Vidal*, tome second, page 114.

of the vitality of the head of the bone, although it may not be sufficient to enable it to take a very active part in the process of osseous union.

The reparation of the injury is accomplished principally by the lower fragment, which throws out bony matter in great profusion, and frequently gives rise to irregular stalactiform productions, which, as it were, incase the superior fragment. Sir Astley Cooper remarks, "a great quantity of ossific matter is thrown out from the periosteum and fractured neck of the shaft of the bone, but very little from the broken head. A cup of bone is formed upon the fractured neck of the shaft, in one of my preparations, which supports the head of the bone, so as to prevent the neck separating from it. A slight union is produced by the cancellated structure, the principal callus being formed upon the outer surface, and it incases the bone."*

In one case of fracture through the anatomical neck of the humerus, which I have lately had an opportunity of examining after death, I found more than three-fourths of the head of the bone enveloped in osseous matter deposited from the inferior fragment.†

Nélaton, in speaking of this injury, observes: "Ici un des fragmens est complétement isolé des parties vivantes, ou n'y tient plus que par quelques débris membraneux, contenant trop peu de vaisseaux pour permettre à ce fragment de concourir à la formation d'un cal régulier. Quelquefois il ne se forme entre les deux fragmens qu'une union fibreuse on ligamenteuse; d'autres fois, la tête de l'humerus se trouve emboitée dans des prolongemens osseux qui viennent du fragment inférieur. Assez souvent, on l'a vue pour ainsi dire usée, excavée à sa face inférieure, de manière à représenter une sorte de calotte qui coiffait ce fragment. Ces divers modes de consolidation paraîtraient, d'apres le silence que les auteurs gardent sur ce point, ne point altérer sensiblement les fonctions du membre. Dans quelque cas, heureusement très rare,

* Treatise on Dislocations, page 428.

† "Si la consolidation n'est pas constant, elle s'observe quelquefois, soit que les deux fragments y prennent part, soit que le fragment inférieur seul en fasse les frais, en poussant des prolongemens osseux stalactiformes que retiennent le fragment supérieur."—*Roche et Sanson*, t. iv.

on a vu la tête de l'humerus sortir de l'articulation et être éliminée, après une longue suppuration, comme un véritable corps étranger."*

Cloquet, in his article upon Fractures, published in the Dictionnaire de Médecine, has likewise alluded to this subject; he remarks: "On a révoqué en doute la consolidation de la fracture du col anatomique de l'humérus, de celle qui existe dans la rainure étroite qui sépare la tête de l'os de ses deux tubérosités. Il est possible que cette consolidation n'ait pas lieu dans certains cas, comme on le voit aussi pour les fractures du col du femur; cependant elle peut se faire; j'ai fait connaître, il y a quelques années, l'observation d'une semblable fracture parfaitement consolidée. Reichel avait déjà publié un fait analogue. Quelquefois la consolidation paraît être effectuée principalement par le fragment inférieur, sur lequel se développent des prolongemens osseux stalactiformes qui entourent et retiennent le fragment supérieur. On a également des observations dans lesquelles la consolidation n'avait point eu lieu; la tête de l'os avait été creusée par le fragment inférieur, de manière à representer une sorte de calotte articulaire, et était devenue le siége d'une fausse articulation."

The impacted fracture of the neck of the humerus always unites with a certain amount of deformity, which, indeed, from the very nature of the lesion, it is impossible to obviate, and as regards the intracapsular variety, it would be imprudent to restore to the joint its natural form, even were it in our power to accomplish it, for we would thus materially diminish the chance of the occurrence of osseous consolidation. It is, therefore, sufficient in the treatment of such cases, to bandage the arm to the side, and to support the fore-arm in a sling; but the prudent surgeon will never omit to announce to the patient that a certain degree of impairment of the motions of the joint will be a permanent result of the injury.

The following case afforded me the first opportunity of ascertaining, by *post mortem* examination, the exact nature of the injury under consideration. A female, æt. 47, was admitted into

* Elemens de Pathologie Chirurgicale, t. i.

the Richmond Hospital under the care of the late Doctor M'Dowell, for an injury of the humerus, the result of a fall upon the shoulder. It is greatly to be regretted that the appearances

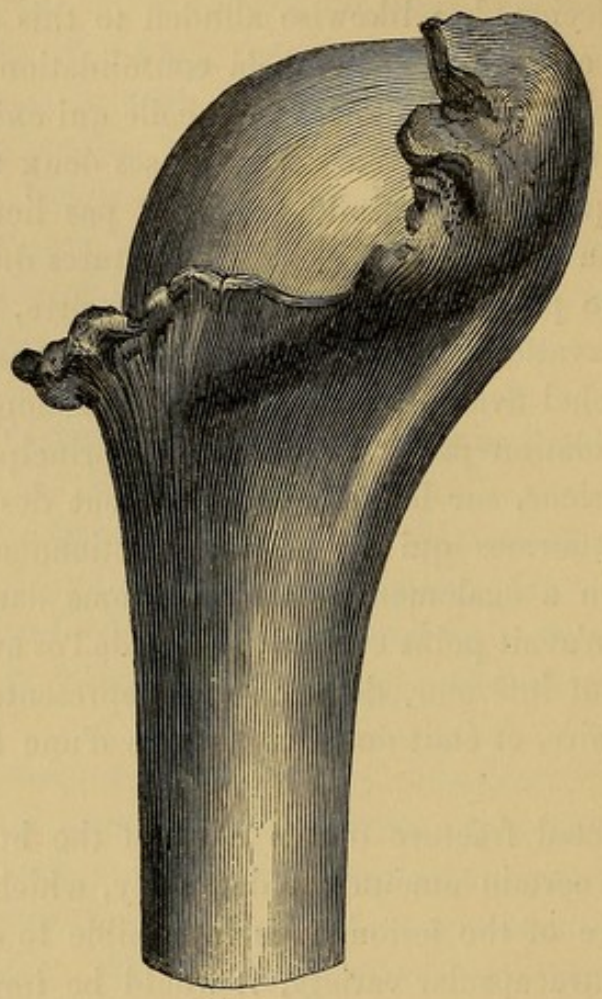

which the limb presented at the time of the occurrence of the accident have not been recorded: the case has been merely entered in the hospital case-book as "Fracture of the Humerus."

Five years afterwards the woman was again admitted, under the care of Mr. Adams, with an extracapsular impacted fracture of the neck of the femur, one month after the occurrence of which she died, in consequence of an attack of diarrhœa.

The shoulder was of course carefully examined: the arm was slightly shortened, the contour of the shoulder was not as full or round as that of its fellow, and the acromion process was more prominent than natural. Upon opening the capsular ligament, the head of the humerus was found to have been driven into the

cancellated tissue of the shaft, between the tuberosities, so deeply as to be below the level of the summit of the greater tubercle; this process had been split off and displaced outwards; it formed

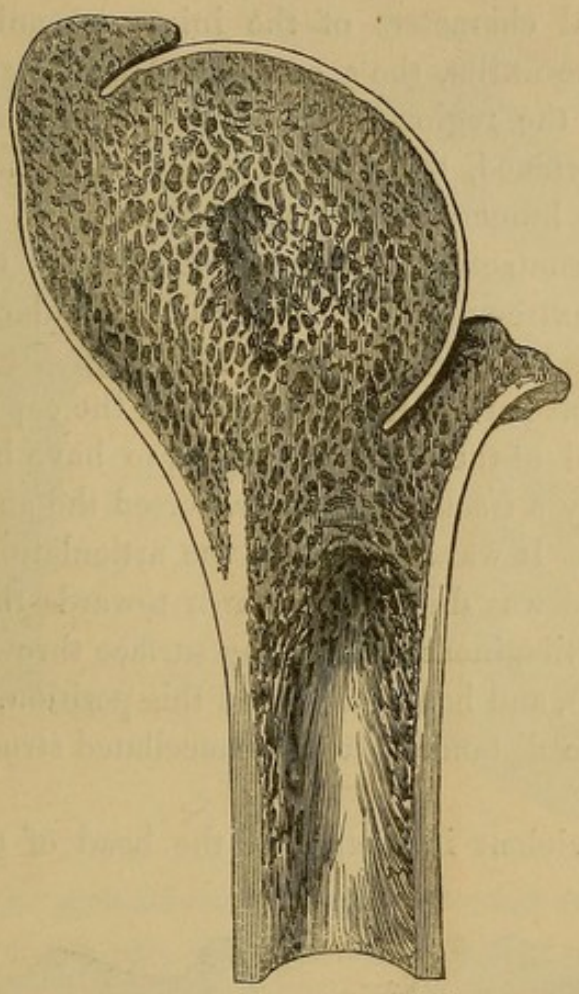

an obtuse angle with the outer surface of the shaft of the bone. The distance to which the superior fragment has penetrated into the shaft is well seen in the preceding engraving of a section of the bone; it is distinctly marked by the line of cartilage which invests the head of the humerus; osseous union had taken place along the line of each fracture.

In the year 1843, I laid before the Pathological Society of Dublin a very remarkable specimen of impacted fracture of the neck of the humerus, accompanied by fracture of both tubercles. It was removed from the body of a woman, aged 40, who, many years previous to her death, had fallen down a flight of stairs, and struck her shoulder with great violence against the edge of one of the steps, but it could not be ascertained whether she

had applied for surgical assistance or not, at the time of the occurrence of the accident. For the opportunity of examining the specimen I am indebted to Doctor Kirkpatrick, surgeon to the North Union Workhouse in this city.

The external characters of the injury resembled those of luxation into the axilla, the acromion process being unnaturally prominent, and the region of the deltoid muscle flattened; but the arm was shortened, the glenoid cavity could not be felt, and the shaft of the humerus was drawn upwards and inwards, so as to be almost in contact with the coracoid process; the motions of the joint were extremely limited, and the scapular muscles atrophied.

When the soft parts were removed, and the capsular ligament opened, the head of the bone was found to have been separated from the shaft by a fracture, which traversed the anatomical neck of the humerus. It was reversed in the articulation, so that the fractured surface was directed upwards towards the glenoid cavity, and the cartilaginous articulating surface thrown downwards towards the shaft, and having assumed this position, it was driven to a considerable distance into the cancellated structure between the tubercles.

From this violent impaction of the head of the bone into

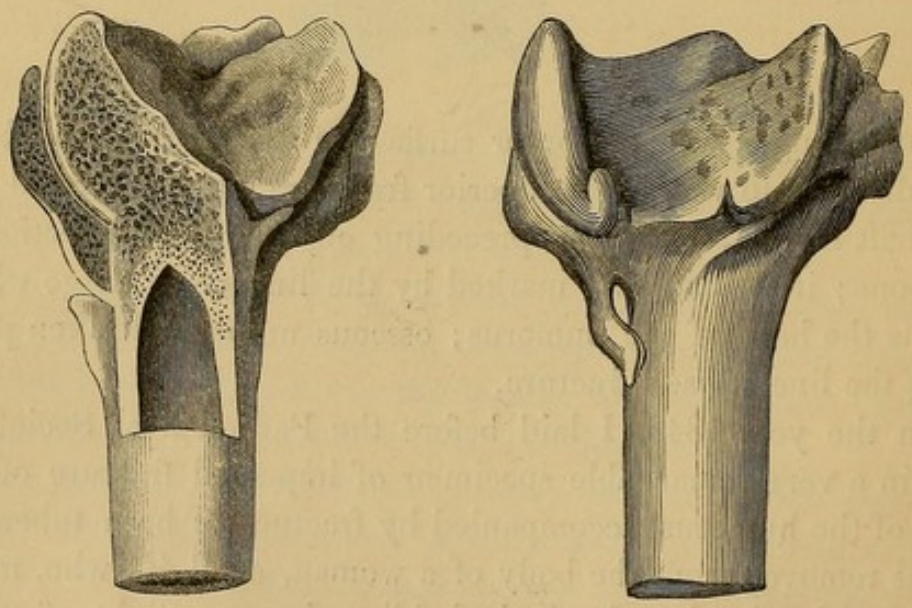

the lower fragment, a second fracture resulted, which split off the lesser tubercle, along with about two-thirds of the greater, and a

small portion of the shaft of the humerus, corresponding to the upper part of the bicipital groove. The broken surface of the upper fragment (which had become the superior surface) was in

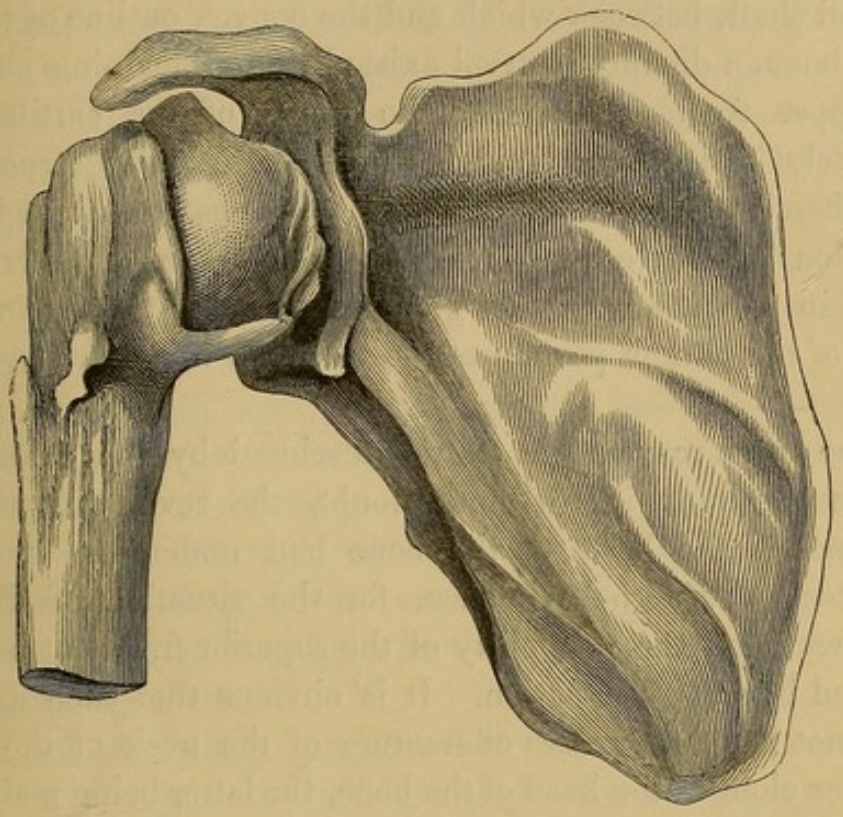

contact with the glenoid cavity, and presented an oval form (the long axis of which was directed transversely) and a very deep concavity, the outer half of which corresponded to the glenoid cavity, while the inner was applied against a new articulating surface, of a convex form, developed upon the axillary surface of the scapula, immediately internal and posterior to the glenoid cavity, and below the root of the coracoid process.

It thus appears that the head of the humerus had been displaced inwards, though it was still contained within the natural capsule of the joint. The shaft was drawn upwards close to the coracoid process, and from this twofold displacement resulted the flattening of the shoulder, the prominence of the acromion process, and the shortening of the arm.

The entire of the cartilaginous surface of the head of the bone was not buried in the cancellated tissue of the shaft; the inner part of it was free, and was directed downwards, forwards, and

inwards. The outer half was impacted to a depth of nearly an inch, and here was manifested, in a striking manner, the unwillingness of cartilage to unite with bone. The cartilage remained perfect, but was not united to the cancellated tissue of the tubercles and shaft, between which and the convex outline of the head of the bone, a distinct interval existed. The remaining portion of the upper fragment, beyond the limits of the cartilage, was intimately and firmly united with the reticular structure of the tubercles, the greater of which processes contributed to the formation of the concave surface, which I have described as being in contact with the glenoid cavity of the scapula; the union of the broken portion of the tubercles themselves was complete.

The most remarkable feature disclosed by the examination of this specimen is, without doubt, the revolution upon its axis, which the head of the bone had undergone under the influence of external violence, for the situation of the fracture precluded the possibility of the superior fragment being influenced by muscular action. It is obvious that such an event could not happen in cases of fracture of the neck of the femur, however close to the head of the bone, the latter being maintained in its place by the ligamentum teres, and being protected by the depth of the acetabulum; but when a fracture has traversed the anatomical neck of the humerus within the capsule, the head of the bone is not restrained by any such ligamentary apparatus; it becomes, as it were, a foreign body in the articulation, free within a large and loose capsule, and ready to obey any impulse that may be communicated to it from without.

Nélaton has alluded to similar cases: he observes, "J'ai vu, sur une pièce que possédait M. le docteur Dubled, la calotte qui forme la tête de l'humerus presque complétement retournée, de sorte que la surface de la solution de continuité qu'elle présentait, regardait en haut et en dedans, tandis que sa partie articulaire était en contact avec le fragment inférieure. La consolidation s'etait faite malgré ce déplacement: le fragment supérieur était enveloppé sur les bords par des prolongemens osseux, qui naissaient du fragment inférieur. M. Malgaigne a montré dernièrement à l'Académie de Médecine une pièce anatomique, où l'on voyait le

fragment supérieure déplacé, de telle sorte que la surface de la fracture regardait directement en-dehors."*

In the Museum of the Royal College of Surgeons, there is a specimen of an injury of the shoulder, which is, in my opinion, very similar to that just described. It was taken from the body of an old man who died in Cork-street Fever Hospital, and who stated that a great many years ago he had fallen upon his left shoulder; that the injury sustained was supposed to have been a dislocation, to reduce which repeated, but ineffectual, efforts were made at the time of the occurrence of the accident. He had subsequently been in several hospitals, but never regained the use of the joint.

When the limb was examined, shortly before his death, the deformity was found to resemble that which accompanies the dislocation of the head of the humerus forwards; the acromion process projected considerably, the shoulder was flattened, and what seemed to be the head of the bone, could be felt lying partly beneath the clavicle and partly below the coracoid process; the scapular muscles were wasted.

The following is an accurate description of the preparation, which was presented to the Museum of the College, by Surgeon Trant; it is marked in the Catalogue, E. b. 913.

The head of the humerus has nearly altogether abandoned the glenoid cavity, and lies partly beneath, but principally internal to the coracoid process; it forms an obtuse angle with the shaft, and is placed rather below the level of the summit of the greater tubercle; it is rotated on its axis in such a manner, as to be directed forwards, and to such an amount, that scarcely any of its cartilaginous surface is to be seen posteriorly. An irregular deposition of new bone, which has passed upwards, so as to be applied against the inner side of the coracoid process, covers the anterior, and nearly the entire of its superior surface.

This remarkable displacement of the head of the humerus appears to have been the result of a fracture traversing its anatomical neck, and having been thus detached, the head of the bone seems to have been driven forcibly against the broken surface of the

* Élémens de Pathologie Chirurgicale, tome premier, p. 730.

lower fragment, and against the tubercles, for there is unequivocal evidence of a second fracture implicating these processes. This second lesion passed obliquely downwards and inwards, from the summit of the greater tubercle, through the upper part of the bicipital groove, and continuing its course below the lesser tubercle, terminated at the inner surface of the shaft, about two inches below the head of the bone.

The shaft of the humerus (with which the greater tubercle was continuous) was drawn upwards considerably, and the glenoid cavity was occupied by this tubercle, and by the outer and posterior part of the broken neck of the bone. Those portions of the scapula and of the humerus which were in contact, were exceedingly rough, and destitute of cartilage, with the exception of the upper part of the glenoid cavity, which was in contact with the remains of the deformed greater tubercle. The superior fragment (which included the lesser tubercle) was displaced inwards, most probably by the action of the subscapularis muscle.

The tendon of the biceps ceased where the fracture traversed the bicipital groove; the capsular ligament had not been torn, but it was thickened, and had contracted abnormal adhesions to the bone.

A vertical section has been made through the humerus, from without inwards, which shews remarkably well the new osseous deposit upon the articulating surface of the head of the bone, but, as in the case last described, it has only here and there united with the cartilage. The compact structure of the inner wall of the shaft, in the situation where I have described the second fracture as terminating, is more than twice as thick as the corresponding part of the outer wall, in consequence of the deposition of osseous matter upon its surface. This thickened portion is bifurcated superiorly, exactly in the manner represented at page 193, one branch of the bifurcation being the continuation in its normal direction of the original compact tissue of the lower fragment, while the other belongs to the new ossific deposit upon the surface of the bone.

Any person who refers to the printed catalogue of the Pathological Museum of the College, will find that this specimen has not been there described as one of fracture, but has been supposed

to be an example either of an unreduced partial luxation, or of chronic disease of the joint, because the section discovers no traces of an old fracture, either about the head, neck, or shaft.

It is no doubt true, that, with the exceptions above mentioned, the interior of the bone furnishes but little evidence of a fracture having existed; but this will not seem surprising, when we recollect the length of time which elapsed between the receipt of the injury and the death of the individual, for the whole line of callus, or compact tissue, which, for a variable period after the union of a fracture, marks the seat of the welding together of the fragments, disappears in the progress of time, and the continuity of the cells of the reticular structure is restored, instances of which have already been mentioned in the former chapters.

After repeated examinations of the specimen, I feel satisfied that, upon any other supposition than that of fracture having occurred, no rational explanation of the phenomena can be given; and I am the more confirmed in this opinion from observing the resemblance which the preparation bears to that which has been described at page 194,—a resemblance so striking in all its leading and essential characters, that I have thought it unnecessary to annex any illustration of the bones in the case in question.

SEPARATION OF THE SUPERIOR EPIPHYSIS FROM THE SHAFT OF THE HUMERUS.

Fracture of the humerus through the line of its superior epiphysis, is an accident which not unfrequently occurs in early life. It is attended by a considerable degree of deformity, but of so striking a nature, that there is no great difficulty in recognising the true nature of the injury.

The axis of the arm is directed from above, within, and before, downwards, outwards, and backwards; the elbow, however, projects but little from the side, and can be brought into contact with it with facility;* the head of the bone can be distinctly felt in the glenoid cavity; a slight depression is seen beneath it, and it remains motionless, when the shaft of the humerus is rotated.

* Sir Astley Cooper states that the elbow is with difficulty removed from the side. See page 205.

The most remarkable feature, however, of this injury, is a striking and abrupt projection, situated beneath the coracoid process, and caused by the upper extremity of the lower fragment or shaft of the bone, drawn inwards by the muscles which constitute the folds of the axilla: there is but little displacement as regards the length of the bone, for the extremity of the inferior fragment is seldom drawn so far inwards as to enable it to clear

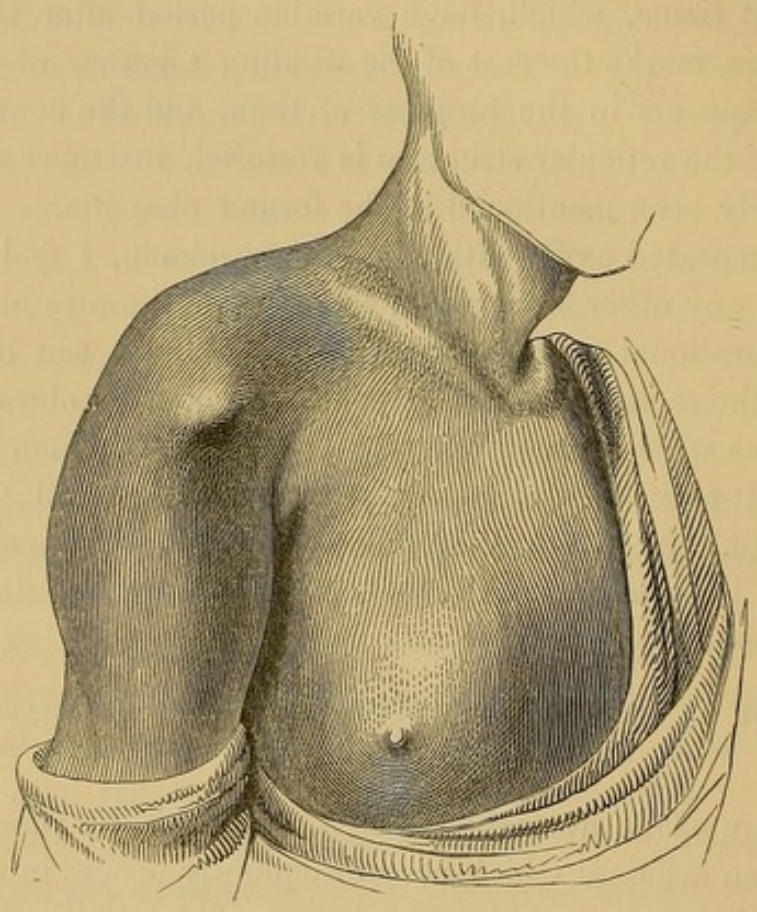

completely the surface of the superior. Were this to occur, the humerus would, of course, be drawn upwards by the muscles passing from the shoulder to the arm, in a direction parallel, or nearly so, to the axis of the humerus, and a corresponding diminution in the length of the limb would result.

This remarkable and abrupt projection does not present the sharp, irregular margin of an ordinary fracture; on the contrary, it feels rounded, and its superior surface is smooth and slightly convex. The latter can be felt as plainly as the cup-like cavity of the head of the radius, in cases of luxation of that bone back-

wards at the elbow-joint. By pressing the upper end of the lower fragment outwards, and directing the elbow inwards, during extension and counter-extension, crepitus can be perceived, and the deformity removed without much difficulty; but the moment the parts are abandoned to the uncontrolled action of the muscles, the deformity recurs.

During the early part of last year, a boy, eight years of age, was admitted into the Richmond Hospital, under the care of Doctor MacDonnell. About a week previous to his admission he had fallen upon the shoulder, and at once lost the power of using his arm.

It was at first sight evident that there did not exist any luxation of the head of the humerus, and it was equally obvious that the case was not an example of any of the ordinary fractures, to which the neck of the bone is liable. There was no diminution of the natural rotundity of the shoulder, nor any unusual prominence of the acromion process; the head of the bone could be distinctly felt in the glenoid cavity, and it remained motionless when the arm was rotated; there was very little separation of the elbow from the side, but it was directed slightly backwards.

About three-quarters of an inch below the coracoid process, there existed a remarkable and abrupt projection, manifestly formed by the upper extremity of the shaft of the humerus, every motion imparted to which it followed. Its superior surface, which could be distinctly felt, was slightly convex, and its margin had nothing of the sharpness which the edge of a recently broken bone presents in ordinary fractures.

When this projecting portion of the bone was pushed outwards, so as to bring it into contact with the under surface of the head of the humerus (previously fixed as far as it was possible to do so), a crepitus was produced by rotating the shaft of the bone. It did not, however, resemble the ordinary crepitus of fracture, but it would be extremely difficult, by any description, to convey a clear idea of what the difference consisted in.

From a careful consideration of the symptoms and appearances above mentioned (taking into account also the age of the patient), the diagnosis was formed, that the injury consisted in a separation of the superior epiphysis of the humerus from the shaft

of the bone. Various mechanical contrivances were employed in this case, but all proved ineffectual in maintaining the fragments in their proper relative position.

It is not to be imagined that any moderately well-informed surgeon will be likely to confound this injury with any other incidental to the upper extremity of the humerus; but I am sure that, however experienced the practitioner may be, he will find the treatment of the case embarrassing, and that it will require the exercise of all his ingenuity and skill to prevent a certain amount of displacement from being permanent, and to counteract the influence of the muscles, which unceasingly act upon the lower fragment. The consolation, however, remains, that, notwithstanding the deformity, the patient will ultimately regain the almost unimpaired use of the limb.

It has been a matter of surprise to some practical writers upon surgery, that, in cases of separation of the superior epiphysis of the humerus, osseous union should occur, the head of the bone being, according to their statement, detached from all connexion with living structures, and being placed in a position which precludes the possibility of its receiving any vascular supply.

It is to be regretted that so distinguished an author as Vidal (De Cassis) should have committed so flagrant an anatomical error, as that involved in the following passage. "Il est même difficile de concevoir la vie de la tête de l'humérus complètement séparée. Cependant avant tout, il faut se soumettre aux faits. M. Gueretin, dans la *Presse Médicale*, fait mention de huit cas de décollement de deux épiphyses, et il y a cinque réunions; *ces réunions seraient plus faciles à concevoir si la tête detachée faisait encore corps avec les tuberosites.*"* In another passage the same error is to be traced: "Si la tête de l'humerus est detachée par une fracture *ou un decollement d'epiphyse, le fragment inférieur peut être entrâine un peu en haut et en dehors par les muscles deltoïde, sus et sous-epineux.*"†

Had M. Vidal examined in the young subject the situation of the line of the epiphysis, he could not have formed these erroneous opinions: he would have learned the simple anatomical

* Traité de Pathologie externe, &c., tome ii. p. 114.

† Loc. cit. p. 113.

fact, that, in the injury under consideration, the tubercles of the humerus formed a portion of the superior fragment.

The annexed engravings accurately represent a posterior and an anterior view of the epiphysis, and the situation of its junction with the shaft of the humerus. It is, hence, apparent that the epiphysis comprises not only the head of the bone, but likewise the entire of both tubercles, with that portion of the bicipital groove which is situated between these processes. Internally, it corresponds exactly to the termination of the cartilaginous surface of the head of the humerus; but, in front, externally, and behind,

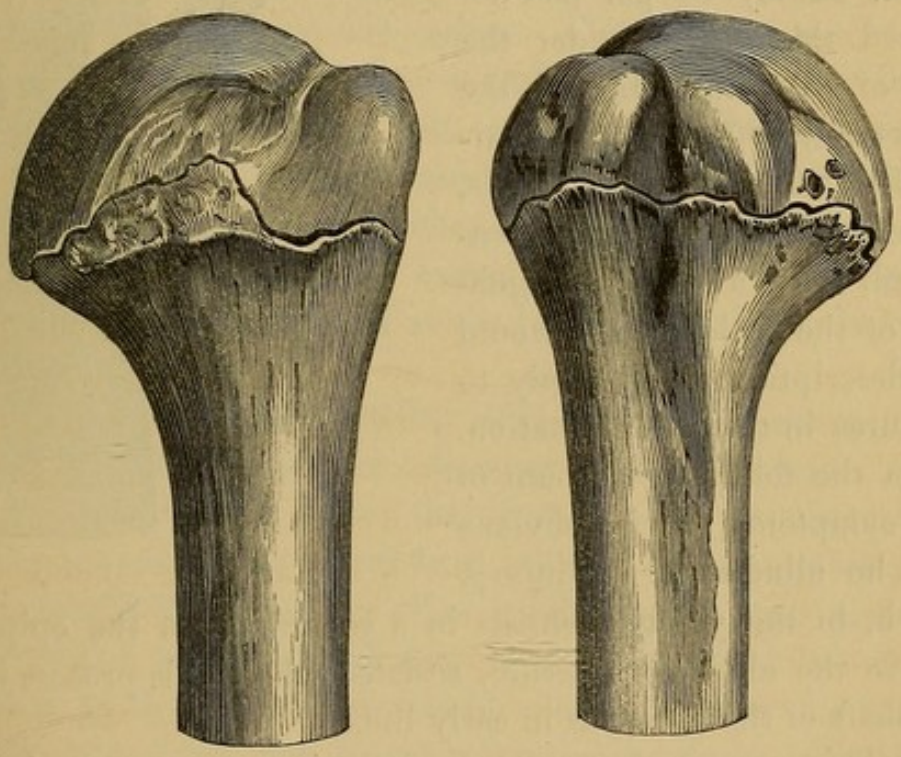

its line of junction with the shaft passes below the tuberosities. The supra-spinatus and infra-spinatus muscles, therefore, are not attached to the lower fragment, as implied in the second passage which I have quoted from the work of Vidal, nor is there any difficulty in comprehending the occurrence of osseous union, for the head of the bone forms one body with the tuberosities, is still connected to living tissues, and is amply supplied with blood.

The following engraving represents an example of fracture through the line of the epiphysis, united by bone, and exhibits very well the displacement which the upper end of the

lower fragment usually suffers, under the influence of the action of the muscles which constitute the folds of the axilla. It has been drawn inwards, but not so far as to enable it to clear the under surface of the superior fragment. So great a degree of displacement as this would imply, must, indeed, necessarily be of very rare occurrence, and could scarcely happen without rendering the fracture compound.

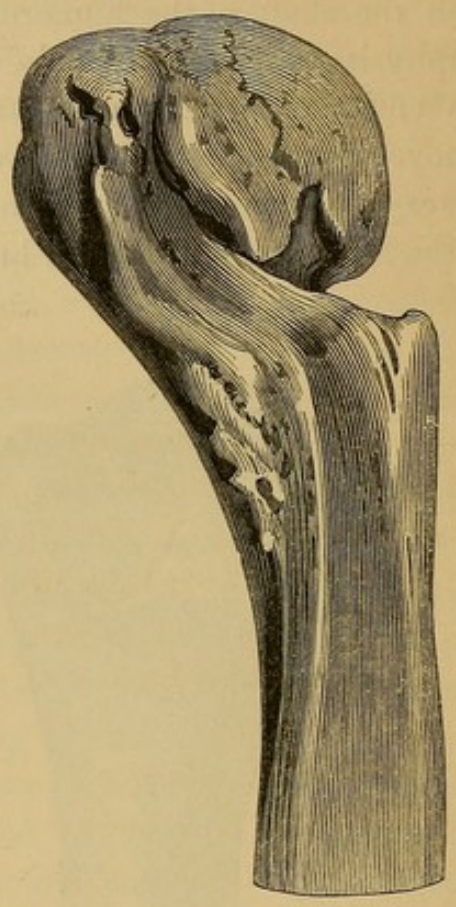

Sir Astley Cooper has described this injury under the title of "Fracture through the Tubercles, or at the Anatomical Neck of the Humerus." This, however, as I have already mentioned, is not a correct designation of the accident, nor would his description at all apply to fractures in the latter situation. From the following account of the symptoms, it is obvious that he alludes to an injury, which, in the young, consists in a separation of the epiphysis, and in the old, in a fracture, situated where this process joined the shaft of the humerus in early life.

"This is a very frequent occurrence in young people; it sometimes, though more rarely, happens in the old; in middle age it seldom occurs.

"In children it is the result of falls upon the shoulder, or it happens from a sudden or unexpected push of the arm, which it is unprepared to resist.

"I have seen it complicated with fracture of the clavicle, but this makes no difference in the treatment. The signs of this accident are as follow:

"The head of the bone remains in the glenoid cavity of the scapula, so that the shoulder is not sunken, as in dislocation.

"When the shoulder is examined, a projection of bone is perceived upon the point of the coracoid process, and when the elbow is raised and brought forwards, this projection is rendered particularly conspicuous.

"By drawing down the arm the projection is removed, but it immediately reappears upon giving up the extension, and the natural contour of the shoulder is lost.

"The motion of the shoulder is painful, and the patient cannot raise the arm but with his other hand; the elbow is with difficulty removed from the side, and the arm is obliged to be supported.

"The diagnosis of this injury is not difficult, yet I have known the accident mistaken for dislocation. The point of the broken bone is felt at the coracoid process, and this is supposed to be the head of the os humeri; but with care the head of the bone can be felt still filling the glenoid cavity. When the elbow is rolled, the head of the bone does not obey its motion.

"Upon dissection of these cases in the young, the head of the os humeri is found broken off at the tubercles, but it remains in the glenoid cavity.

"A child was brought to Guy's Hospital some years ago with this accident, and I made the following notes of the case:

"Its age was ten years; the symptoms of the injury were, inability of moving the elbow from the side, or of supporting the arm, unless by the aid of the other hand, without great pain; the tension which succeeded filled up the hollow which was at first produced by the fall of the deltoid muscle. When the head of the bone was fixed, the fractured extremity of the body of the humerus could be tilted under the deltoid muscle so as to be felt, and even shown, by raising the arm at the elbow. Crepitus could be perceived, not by rotating the arm, but by raising the bone and pushing it outwards. The cause of the fracture was a fall upon the shoulder into a sawpit of the depth of eight feet."*

With regard to the treatment of this injury, Sir Astley Cooper

* Treatise on Fractures and Dislocations, edited by Bransby Cooper, p. 427. Guy's Hospital Reports, No. IX.

recommends applying a splint on the fore and back part of the arm, placing a pad in the axilla, and using a clavicular bandage; supporting the hand, but not the elbow, in a sling, as, if the elbow be raised, the broken end of the bone projects forwards.

In one case Mr. Tyrrell found the proper relative position of the fragments best maintained by raising and supporting the arm at a right angle with the side, by a rectangular splint, a part of which rested against the side, whilst the arm reposed upon the other part.

The following conclusions may, I think, be legitimately drawn from what has been stated in the preceding pages:

1. The most valuable diagnostic signs of fracture detaching the greater tubercle of the humerus, are an increase in the breadth of the shoulder, and a vertical sulcus, corresponding to the upper part of the bicipital groove.

2. When there is much displacement of the tubercle, in consequence of the rupture of the fibrous and tendinous structures which invest it, ligamentous union is more likely to be the result than osseous.

3. Independent of fracture through the greater or lesser tuberosity, the upper extremity of the humerus is liable to be broken in three situations, viz. through the surgical neck, through the line of the epiphysis, and through the anatomical neck, or narrow line, which separates the head of the bone from the tubercles.

4. There are two varieties of the impacted fracture of the upper end of the humerus, one situated external to, and the other within, the capsular ligament: the former may pass either through the tubercles or through the line which, in the young subject, marks the junction of the epiphysis with the shaft; the latter traverses the anatomical neck of the bone.

5. In the former, it is generally the inferior fragment which penetrates the superior, while, in the latter, the head of the bone is driven into the lower fragment.

6. In the former, crepitus is not elicited without the application of considerable force; in the latter, it can be produced with comparative facility.

7. The intracapsular impacted fracture is generally accompa-

nied by a fracture of one or other, or of both tubercles, and is so far analogous to the extracapsular impacted fracture of the neck of the femur, with fracture of one or other, or of both trochanters.

8. Each variety is capable of uniting by bone.

9. In the intracapsular variety, the circumstance of the fracture being accompanied by impaction, materially increases the probability of the occurrence of osseous consolidation.

10. When osseous union occurs in this variety of fracture, the process of reparation is accomplished by the lower fragment principally.

11. In the intracapsular fracture, without impaction, the head of the humerus may perish from want of nutrition.

12. In such cases, disorganization of the joint may ensue, as the result of the processes, by which the elimination of the dead bone is accomplished.

13. In the intracapsular fracture, the head of the bone may become reversed in the articulation, and its cartilaginous surface be brought into contact with the broken surface of the lower fragment.

14. When this happens, the cartilage unites very imperfectly with the cancellated tissue of the inferior fragment.

15. In the intracapsular impacted fracture, the deformity is greater than in the extracapsular.

16. The diagnosis of the extracapsular impacted fracture is most difficult: the evidence of its existence is chiefly of a negative character.

17. The most important diagnostic signs of the intracapsular impacted fracture are, shortening of the limb, approximation of the upper end of the shaft or tubercles to the acromion process, flattening of the shoulder, crepitus, and an impossibility of feeling the entire of the globular head of the bone.

18. Each variety of the impacted fracture unites with deformity.

19. In the intracapsular impacted fracture, the removal of the deformity would diminish the probability of the occurrence of osseous consolidation.

20. The chief diagnostic signs of the separation of the supe-

rior epiphysis of the humerus are, an abrupt projection beneath the coracoid process, caused by the upper end of the lower fragment, and the immediate recurrence of the deformity when the means employed for its reduction cease to be in operation.

21. There is no fracture incidental to the upper end of the humerus, in which it is more difficult to maintain the fragments in their proper relative position.

22. The supposition that, in this injury, the tubercles form a portion of the lower fragment, involves an anatomical error, the line of junction of the epiphysis with the shaft being below these processes.

CHAPTER V.

FRACTURES OF THE ACROMIAL EXTREMITY OF THE CLAVICLE.

THAT a comparatively slight degree of deformity results from fractures of that portion of the clavicle which intervenes between the coracoid process and the acromion, is familiarly known to every surgeon. Many writers have stated, that in these cases there is no displacement of either fragment of the bone, the external being maintained in its natural position by its articulation with the acromion, and the internal by its connexion to the coracoid process, by means of the coraco-clavicular, or conoid and trapezoid ligaments, while the trapezius muscle above, and the deltoid below, oppose displacement, by neutralizing the action of each other.*

Upon the other hand, there are some who, while they admit the occurrence of displacement, as regards the thickness of the bone, have maintained that there is none in the direction of its length. Vidal (De Cassis) remarks, "s'il opére un léger déplacément, il n'a lieu que suivant une partie de l'epaisseur de l'os, jamais suivant sa longueur."† Boyer has expressed a similar opinion.‡

* "Si cet os vient à se fracturer dans un point quelconque de cette portion, le trapèze et le deltoïde, qui s'attachent en haut et en bas, s'opposent à tout déplacement des fragmens."—*Ribes, Mémoires de la Societé Médicale d'Emulation*, tome ix.

"Les fractures qui occupent l'extrémité acromienne ne presentent ordinairement aucun déplacement sensible, le fragment externe nècessairement très court étant placé entre deux puissances musculaires, le trapèze et le deltoïde, qui se neutralisent, et le fragment interne étant uni avec l'apophyse coracoïde de manière à ne pouvoir s'en écarter."—*Nélaton*, tome premier, p. 715.

† Traité de Pathologie Externe, tome second, p. 98.

‡ "Il n'y a point de dèplacement, on du moins il n'est pas de toute l'épaisseur de

The results of my own experience do not entirely accord with the observations of the authors to whom I have referred, and who, in the formation of their opinions upon this subject, appear to have been too much influenced by reasoning upon the anatomy of the parts concerned, and not to have devoted sufficient attention to the phenomena disclosed by the post mortem examination of the injury under consideration.

In the museum of the Richmond Hospital School of Medicine, there are contained eight examples of fracture of the outer extremity of the clavicle. In five of these the bone had been broken between the trapezoid ligament and the acromion process, while, in the remaining three, the fracture was situated between the conoid and trapezoid ligaments.

I shall first describe these preparations as concisely as possible, and then offer such observations as the series appear to me to suggest.

No. I.—Transverse fracture of the left clavicle, situated three-quarters of an inch from the acromion. The fragments have united nearly at a right angle with each other, the external being placed in front and slightly below the level of the internal, its broken

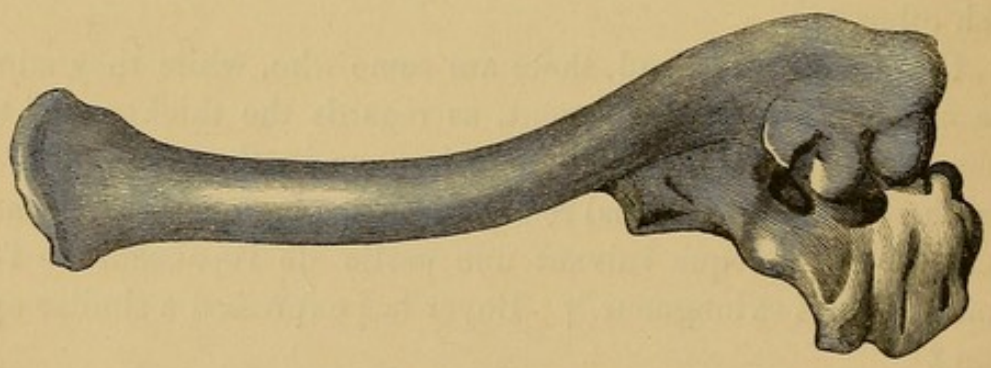

surface being directed obliquely upwards and backwards. A great quantity of osseous matter has been deposited upon the under surface of each fragment. The bone was shortened half an inch.

No. II.—Transverse fracture of the left clavicle, close to the

cette portion de l'os, qui est fort mince; et les deux fragmens étant assujettis, l'un sur l'apophyse acromion, l'autre sur le coracoïde, il ne peut pas y avoir de déplacement selon la longueur de la clavicule."—Tome iii. p. 175.

inner part of the trapezoid ligament. There is very little displacement in this instance, as regards the thickness of the bone, the fragments being nearly upon the same level superiorly; but with respect to its length and direction, the deformity of the clavicle is very great.

The fragments form a right angle with each other, the broken surface of the external being united to the anterior surface of the internal. There is no portion of the fractured surface of either fragment, in contact with the fractured surface of the other.



The acromial extremity of the external fragment was thrown forwards to such an extent, that the posterior portion alone of its articulating surface, was in contact with that of the acromion. There was no deposition of bone upon either fragment superiorly, but large and irregular osseous growths covered their inferior surfaces, in the vicinity of the fracture.

No. III.—Fracture of the right clavicle, distant three-quarters of an inch from the acromio-clavicular articulation. The fragments form nearly a right angle with each other, the articulating surface of the external being directed downwards and outwards, and its broken extremity drawn upwards and inwards. The entire of this portion of the bone was, moreover, displaced, inwards and forwards, in such a manner that its broken surface was in contact with the anterior surface of the inner fragment. There was no displacement, according to the thickness of the bone, the two fragments being upon the same plane superiorly. Osseous matter was deposited at the seat of the fracture inferiorly.

No. IV.—Transverse fracture of the left clavicle, distant one inch and a quarter from the acromion process, and traversing the bone between the conoid and trapezoid ligaments. There is

scarcely any deformity of the bone in this specimen, the only displacement being a slight deviation from its natural direction at the seat of the fracture, in consequence of which this portion of the clavicle is more convex superiorly than natural.

A section of the bone, however, showed that this increased convexity was not entirely owing to displacement of the fragments, but was in part to be ascribed to the deposition of osseous matter at the seat of the fracture.

From the tuberosity, which gives attachment to the conoid ligament, an osseous growth passed downwards towards the coracoid process; it appeared to be deposited in the substance of the ligament; its anterior inferior part was deeply concave, and rested upon the root of the coracoid process; it was of smaller size, but in every other respect similar to that mentioned in the description of the eighth specimen. The articulating surface of the external fragment was directed forwards more than natural, and had become exceedingly irregular; osseous matter had been copiously deposited upon the inferior surfaces of the fragments.

No. V.—Fracture of the right clavicle, between the conoid and trapezoid ligaments, united without deformity. The situation of the conoid ligament was occupied by a bony process, similar to that described as existing in the preceding specimen, its lower extremity, which rested upon the coracoid process, being deeply notched.

No. VI.—Fracture of the left clavicle, one inch from the acromion process, and immediately internal to the outer extremity of the trapezoid ligament. The external fragment has sunk a little below the level of the internal. This is the only displacement exhibited in this specimen. A large quantity of osseous matter has been deposited upon the under surfaces of the fragments.

No. VII.—Fracture of the left clavicle, within three-quarters of an inch of the acromion, united with considerable deformity. The broken extremity of each fragment has been drawn upwards and backwards. The entire of the external half of the bone, with the exception of its superior surface, was covered by enormous osseous depositions, which increased to two inches, the breadth of the antero-posterior diameter of its outer extremity.

The clavicle, although not in contact with, was anchylosed to

the posterior part of the coracoid process, by the intervention of an immense osseous buttress, which was united to the root of that process, close to the notch of the scapula. It gradually increased in breadth and thickness as it ascended, externally extending nearly to the acromion process, and reaching internally beyond the centre of the clavicle. There did not exist any trace of the conoid

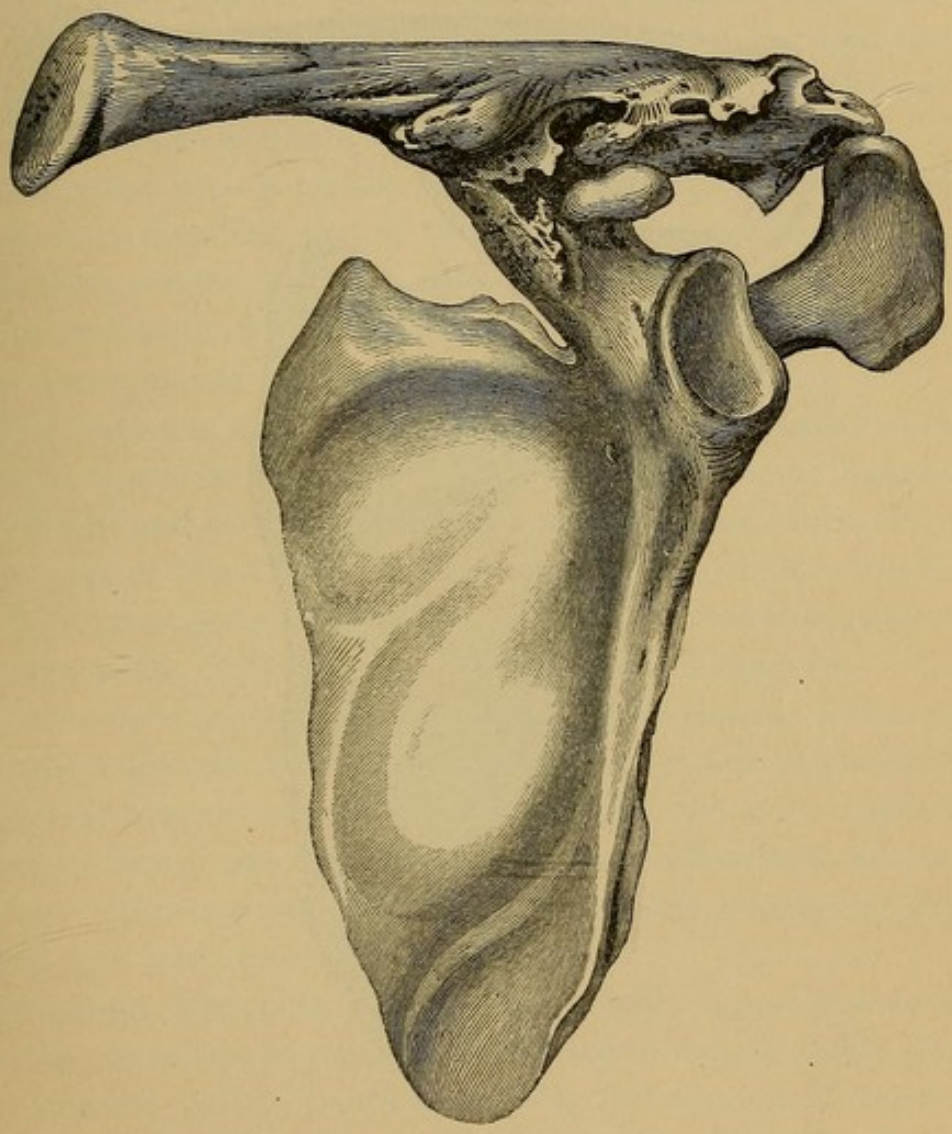

or trapezoid ligaments; their place was occupied by bone. The inner fragment was placed above the level of the outer, to which it was united nearly at a right angle. It appeared to have been pushed upwards by the immense mass of bone which intervened between it and the coracoid process; the distance between the

summit of the notch of the scapula and the under surface of the clavicle, amounting nearly to an inch and a half.

Posteriorly, this remarkable osseous growth presented a smooth, convex surface, but in front it was irregular and bifurcated, the anterior part of the coracoid process corresponding to the interval between its branches.

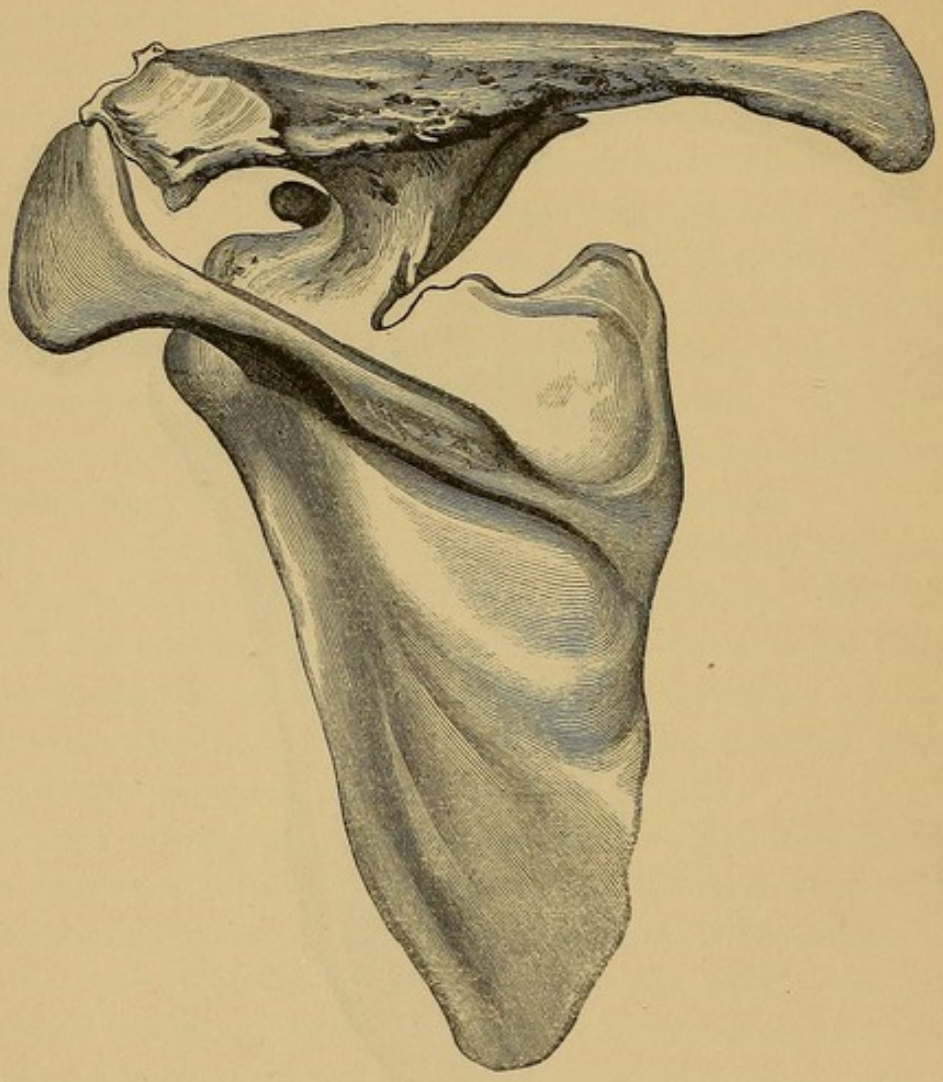

The new bony matter was joined, not to the inferior, but to the anterior and posterior surfaces of the clavicle; it thus formed three sides of an osseous canal, the fourth being constituted by the under surface of the clavicle.

This canal was nearly three inches in length, and lodged the subclavian muscle. The preparation was taken from the body of a lunatic, who had been for many years subject to violent epileptic

convulsions; the fracture was the result of a fall received during one of these attacks. The bone was exactly three-quarters of an inch shorter than that of the opposite side.

From the examination of these preparations, we learn that the outer extremity of the clavicle may be broken, either between the coraco-clavicular ligaments, or between the trapezoid ligament and the acromion; and that fracture in the former situation is of comparatively rare occurrence, and attended with scarcely any displacement of either fragment of the bone; but that in the latter, contrary to what is usually stated, there is generally a considerable amount of displacement.

When the bone is broken between the coraco-clavicular ligaments, it is manifest, that if these structures have not been injured, there can be but little displacement of the fragments, according to the thickness of the bone, although there may be a slight derangement as regards its direction.

The trapezius muscle will tend to draw the extremity of each fragment upwards, as far as the conoid and trapezoid ligaments will permit, and thus to increase the natural curve of the clavicle at the seat of the fracture. The convex form of this portion of the bone, superiorly, assists the trapezius in counteracting the tendency of the deltoid muscle to depress the fragments.

The weight of the arm may cause a slight sinking of the outer fragment below the level of the inner; but as this displacement, for obvious reasons, can seldom be carried so far, as to enable the broken surface of one fragment to clear that of the other, the overlapping of the two portions of the bone must necessarily be an exceedingly rare occurrence.

Although, therefore, it may not be pathologically accurate, yet, as far as relates to practice, the assertion may be safely made, that when the clavicle is broken between the conoid and trapezoid ligaments, there is scarcely any displacement of either fragment,—none, certainly, that can cause any embarrassment, or difficulty in the treatment of the injury.

But the case is very different when the bone is broken external to the trapezoid ligament. Here the coraco-clavicular ligaments can have no direct influence upon the outer fragment,

which is displaced, partly by muscular action, and partly in consequence of an alteration in the position of the shoulder.

The scapula, it is true, being still supported by the ligaments attached to the coracoid process, cannot be influenced, to any great extent, by the weight of the arm, and can, therefore, but seldom suffer such a displacement as would permit of any considerable overlapping of the fragments. But from the examination of the specimens, described in the preceding pages, it would appear, that the shoulder is generally drawn somewhat forwards and inwards, while, at the same time, the outer fragment of the clavicle is acted upon by the trapezius muscle, the influence of which is no longer opposed by the trapezoid ligament, as in the case of fracture between this ligament and the conoid. The scapular fragment being thus placed between two forces, acting in opposite directions, is displaced obliquely, its inner extremity passing upwards and outwards, and its articulating surface being directed proportionably downwards and inwards.

When this displacement is carried to the utmost, the two fragments, as in several of the specimens which have been described, form a right angle with each other, the outer being placed in front of the inner, and a small portion only of the articulating surface of the former remaining in contact with that of the acromion.

The alteration in the position and aspect of the shoulder is not, however, to be altogether ascribed to the causes above assigned, but must in part be attributed to a revolution of the scapula upon its axis.

When the clavicle is broken near its centre, the shoulder, having lost the support derived from the coraco-clavicular ligaments, is depressed by the weight of the arm to such an extent, that overlapping of the fragments is permitted to occur. But in the cases under consideration at present, these ligaments prevent the direct depression of the scapula; this bone, however, turns upon its axis, the weight of the arm tending to remove the superior angle from the spine, while the inferior angle is approximated to it, by the action of the rhomboid muscles, and thus the glenoid cavity and the acromion process are depressed.

The effect, upon the broken clavicle, of this mode of depression of the shoulder, or in other words, of this revolution of the scapula upon its axis, is to draw the outer fragment forwards.

It is probable, that in every fracture of the clavicle, the scapula turns upon its axis in the manner described; it, however, appears to me to occur especially, in those cases in which the weight of the arm is prevented from acting upon the shoulder, in a direction perpendicular to the axis of the clavicle.

When the clavicle is broken between the conoid and trapezoid ligaments, there is, in general, so little external deformity, that it is sometimes difficult to detect the true nature of the injury.

The motions of the arm and shoulder are, it is true, productive of pain, but can, nevertheless, be executed with a freedom* which is well calculated to deceive us, and which strikingly contrasts with the impairment of the functions of the limb, consequent upon fracture internal to the conoid ligament.

Let the surgeon, however, pass his finger along the line of the bone, making pressure upon each portion of it in succession, and he will find that the patient will wince, the moment he presses upon the spot where the bone has been broken. Let him now grasp the clavicle upon either side of this painful spot, and endeavour to move the two portions of the bone in opposite directions, and he will, during this manœuvre, become sensible of a grating of the fragments upon each other.

Generally speaking, crepitus can be more easily produced by adopting this method of examination, than by alternately elevating and depressing the shoulder, in the manner recommended by some surgeons.†

When the situation of the fracture is external to the trapezoid ligament, the diagnosis is attended with less difficulty, the defor-

* "Les mouvemens ne sont que très-peu gênés par la douleur."—*Boyer*, t. iii.

"Tous les mouvemens du membre sont conservés."—*Vidal*, t. ii.

† "La mobilité anormale est très difficile à constater; il en est de même de la crépitation; les fonctions du membre ne sont point gênées. La lesion peut donc alors passer inaperçue et être confondue avec une contusion. On parvient quelquefois cependant à produire une légère crépitation, soit en pressant au niveau du point ou l'on suppose la fracture, soit en imprimant quelques mouvemens à l'omoplate, à l'aide de l'humérus, que l'on élève et que l'on abaisse d'une main, tandis que de l'autre on fixe le corps de la clavicule."—*Nélaton*, t. i.

mity, for reasons which have been already assigned, being greater than in cases of fracture between the coraco-clavicular ligaments.

When a careful examination of the neighbourhood of the shoulder is made, the outer fragment, in the majority of cases, will be found to be slightly depressed below the level of the inner, and when the finger, passed along the bone, reaches the abrupt termination of the sternal fragment, the scapular fragment can be felt, forming with it an angle salient above,—the margin, which, in the natural state, is directed upwards, now lying nearly parallel with the superior edge of the acromion process.

The anterior part of the shoulder appears to be approximated to the middle line of the body, and when the distance between the sterno-clavicular and acromio-clavicular articulations, upon the injured side, is compared with that between the corresponding parts upon the opposite side, the latter will be found to exceed the former, the amount of this excess varying from a quarter to three-quarters of an inch.

The motions of the arm and shoulder are productive of more pain, and are more imperfectly performed, than when the bone is broken between the trapezoid and conoid ligaments.

When the surgeon places one hand upon the outer end of the clavicle, and with the other alternately elevates and depresses the shoulder, crepitus can in general be produced. This method of examination is more applicable here, than in cases where the lesion of the bone is internal to the trapezoid ligament.

It has been already mentioned, that in the injury at present under consideration, the internal fragment is seldom displaced, being maintained in its natural position by the coraco-clavicular ligaments. I have, however, seen one example of the accident, in which the derangement of the sternal portion of the bone occurred to an exaggerated degree.

No. VIII.—The annexed engraving, executed from a cast taken after the death of the individual, who had been (many years previously) the subject of the injury, accurately represents the external characters of the deformity. The two portions of the bone are seen forming nearly a right angle with each other, the broken extremity of each being drawn upwards. From this angle, salient

superiorly, the shortened fibres of the trapezius muscle passed upwards, standing out in strong relief.

The supra-clavicular space was diminished in a remarkable manner, by the elevation of the sternal portion of the bone, which formed a very acute angle with the posterior border of the sterno-mastoid muscle.

The shoulder was drawn forwards and inwards, the distance

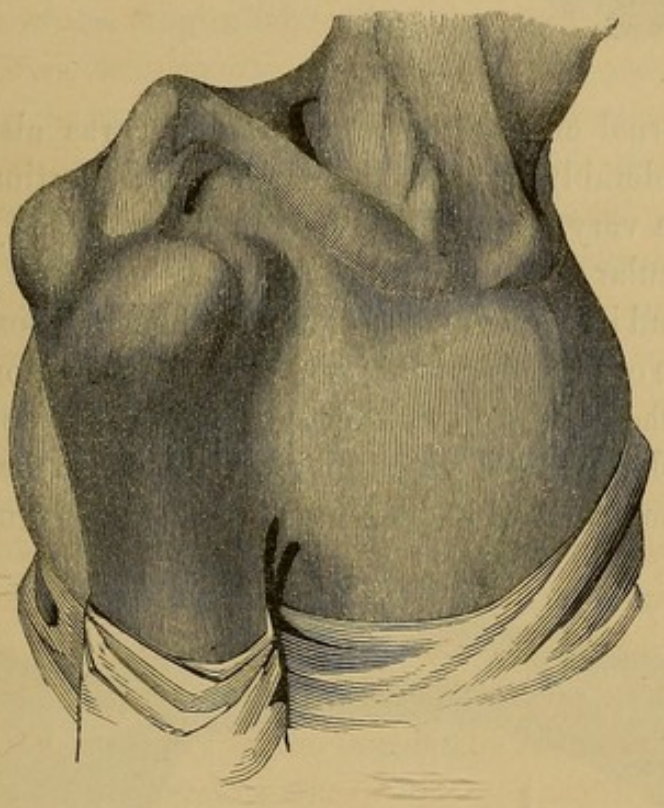

between the sterno-clavicular articulation, and the extremity of the acromion being nearly an inch less than upon the opposite side.

Upon dissection, the bone was found to have been broken about three-quarters of an inch from the acromion process. The outer fragment formed nearly a right angle with the inner; its broken extremity was directed upwards, and its articulating surface downwards. The entire of this portion of the bone was, moreover, displaced forwards and inwards, in such a manner that its broken extremity had become united to the anterior edge of the inner fragment. In consequence of this relative position of

the fragments, the outer extremity of the clavicle measured two inches from before backwards.

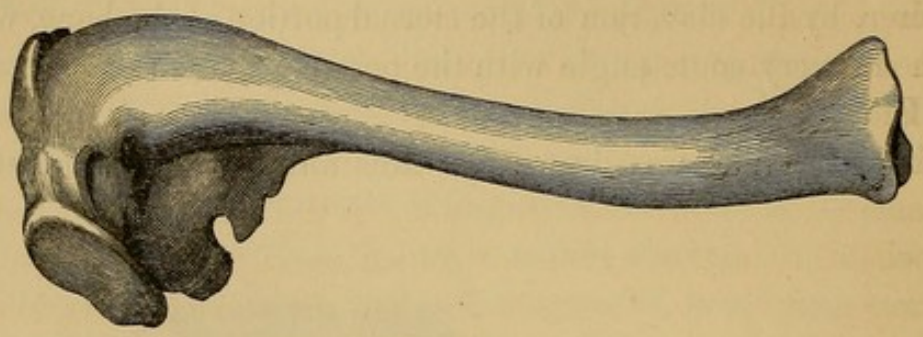

The sternal end of the inner fragment was also drawn upwards considerably, causing the entire of this portion of the bone to assume a very oblique position, in consequence of which the supra-clavicular space was diminished.

Large and irregular masses of bone had been deposited upon the deep surface of each fragment; and from the posterior margin, and inferior surface of the clavicle, exactly in the situation of the tuberosity and oblique line, which give attachment to the coraco-clavicular ligaments, there had sprung a remarkable process of bone,

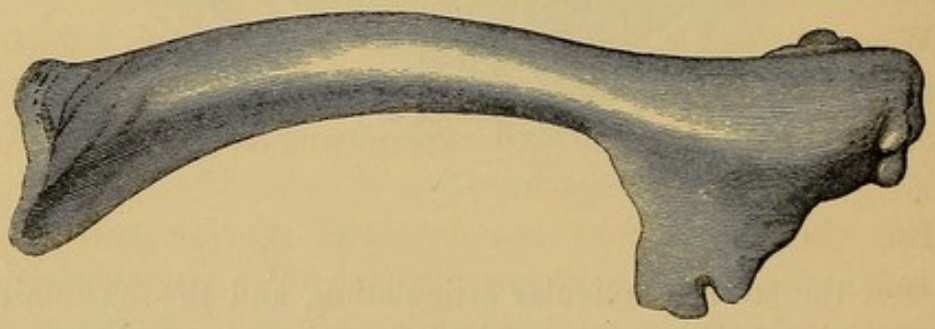

similar to that mentioned in the description of No. IV. It passed downwards in a nearly vertical direction, and was an inch and a quarter in length, and three-quarters of an inch in breadth; its lower extremity, which was slightly bifurcated, and concave in front, was applied against the most posterior part of the root of the coracoid process, where the latter appears to spring from the notch of the scapula. It constituted an osseous buttress, which effectually supported the clavicle.

There did not exist any trace of the coraco-clavicular liga-

ments; they must either have been ruptured at the time of the occurrence of the accident, or else they had subsequently become so involved in the osseous deposits alluded to, as to be no longer distinguishable. The clavicle was nearly three-quarters of an inch shorter than that of the opposite side.

From a consideration of the specimens described in the preceding pages, as well as from the examination of numerous instances of the injury in question, in the living, I am induced to believe that the statements which maintain that there is no derangement of the fragments,* when the clavicle is broken external to the coraco-clavicular ligaments, are erroneous.

Pathology shows that, in such cases, the outer fragment is displaced, often to a very considerable degree; that it usually forms nearly a right angle with, and sinks somewhat below the level of the inner portion of the bone, the displacement being not unfrequently carried so far, as to bring the broken surface of the external fragment into contact with the anterior margin of the internal, as in cases No. II. and VIII.

It is, however, to be observed, that this derangement is not, in general, accompanied by a corresponding amount of external deformity, and, perhaps, this is one circumstance to which we are to ascribe the statements of authors already alluded to.

When the clavicle is broken internal to the coraco-clavicular ligaments, the deformity which results is considerable, in consequence of the overlapping of the fragments, and the projection of the sternal portion of the bone.

But when the fracture is external to the ligaments, there is but seldom any appreciable overlapping of the fragments; they preserve very nearly their natural level with regard to each other, and the displacement consists principally in an alteration of direction. The external deformity is, therefore, comparatively slight, and is the less observable, in proportion as the seat of the fracture is nearer to to the acromio-clavicular articulation.

When the bone is broken between the conoid and trapezoid

* "Si la clavicule est rompue à son extrémité externe, entre l'articulation acromio-claviculaire et l'insertion du ligament coraco-claviculaire, ce dernier ligament soutient l'omoplate, et il n'y a pas de deplacement entre les fragmens."—*Cloquet. Art.* "*Fracture,*" *Dictionnaire de Médecine*, t. ix.

ligaments, the injury requires no other treatment, than supporting the elbow during the process of union, and keeping the limb at rest; but when the fracture is external to the trapezoid ligament, a pad should be placed in the axilla, and the management of the case conducted upon the same principles as fractures internal to the coraco-clavicular ligaments.

The consideration of the anatomical characters present, in the specimens described in the preceding pages, warrants me, I think, in deducing the following conclusions:

1. When the clavicle is broken between the coraco-clavicular ligaments, there is seldom any displacement of either fragment, and always much less than in fracture of any other portion of the bone.

2. When displacement does occur, it is usually limited to a slight alteration in the direction of the bone, by which the natural convexity of this portion of the clavicle is increased.

3. In cases of fracture between the trapezoid ligament and the acromio-clavicular articulation, the displacement of the outer fragment is, in general, considerable, its inner extremity being drawn upwards.

4. This displacement is frequently carried to such an extent, that the fragments form a right angle with each other; and it is principally due to the action of the clavicular portion of the trapezius muscle.

5. The entire of the outer fragment is also generally drawn forwards and inwards, sometimes to such a degree, as to bring the broken surface of the external, into contact with the anterior margin of the internal fragment. The reticular structure of the former unites, in these cases, with the compact tissue of the latter.

6. The displacement of the outer fragment forwards and inwards, is owing to the revolution of the scapula upon its axis, and to the action of the muscles passing from the chest to the arm.

7. The derangement, as regards the thickness of the bone, is very slight, so that there can scarcely ever be any overlapping of the fragments.

8. In consequence of the displacement, as regards the direction of the bone, the clavicle is shortened in this injury.

9. In cases of fracture external to the conoid ligament, osseous matter is freely formed upon the under surface of each fragment, but there is seldom any deposited upon the upper surface of either.

10. These osseous growths, occupying the situation of the coraco-clavicular ligaments, frequently assume a determinate form, and constitute a prop or buttress, which rests upon the root of the coracoid process. It is usually convex posteriorly, concave in front, and slightly notched inferiorly; in some cases it reaches down to the notch of the scapula.

11. In some rare instances, these osseous formations unite with the coracoid process, and anchylosis is thus established between the scapula and the clavicle.

12. In cases of fracture external to the trapezoid ligament, the amount of external deformity is seldom proportionate to the extent of the displacement of the outer fragment of the bone.

CHAPTER VI.

DISLOCATIONS OF THE BONES OF THE FOOT.

THE mechanism by which the bones of the foot are secured against the effects of external violence, is so complete and powerful, that we seldom have opportunities of witnessing luxations of the bones of the tarsus from one another, or their displacement from the metatarsal range. Some, indeed, and these the most distinguished among practical surgeons, have doubted the possibility of the occurrence of the latter form of injury; nor has the long experience either of Boyer or of Sir Astley Cooper furnished us with a single example of such an accident. The latter distinguished writer has observed, " The metatarsal bones I have never known luxated; their union with each other, and irregular connexion with the tarsus, prevent it; and if it ever happens, it must be a very rare occurrence."*

When we reflect upon the admirable mechanism of the foot, when we consider the beautiful construction of its arches, the peculiar forms of the tarsal bones, the extent of their articulating surfaces, and their mode of adaptation to each other; when we also take into account the number and strength of the ligaments which bind them together, the arrangement of the muscles, tendons, and tendinous expansions in the plantar region, and the very slight degree of motion which is permitted to the bones;—when we reflect upon all these conditions, we find, that in the mechanism of this solid, but, at the same time, highly elastic fabric, nature has adopted every provision calculated to ensure strength, and immunity from the effects of external violence.

* Treatise on Fractures, &c., edited by Bransby Cooper, p. 339.

Notwithstanding, however, these numerous and varied sources of security, the bones of the foot occasionally suffer displacement, when subjected to the influence of great external force.

The double luxation of the astragalus from the bones of the leg upon the one part, and from the os calcis and os naviculare upon the other, is an injury of comparatively frequent occurrence. Dr. MacDonnell has recorded in the fourteenth volume of the Dublin Medical Journal, an example of simple and complete luxation of the astragalus from the os calcis and os naviculare, without disturbance of the relations between the tibia, fibula, and astragalus: various luxations of the different bones of the tarsus have been described in the work of Sir Astley Cooper; and two cases which occurred in the practice of Dupuytren have been recorded by Sanson, as examples of dislocations of the metatarsus upon the tarsus.

The instances of luxations of the bones of the foot, about to be described, are, however, different from any that have been yet recorded, and are, therefore, worthy of a place in the annals of surgery, more especially as I have twice had an opportunity of ascertaining by *post mortem* examination, the precise nature of the accident, the luxation having remained unreduced in both instances.

The injury to which I wish to direct the attention of practical surgeons consists in a dislocation of the metatarsus and internal cuneiform bone, upwards and backwards upon the tarsus; its external characters are very striking, and clearly indicate the nature of the accident.

The foot is greatly deformed, but it is at first sight obvious, that the relations which the bones composing the ankle-joint bear to each other, are undisturbed. There is, it is true, a remarkable fore-shortening of the foot, but we are not likely, on this account, to confound the accident with displacement of the tibia forwards, for there is no corresponding elongation of the heel; the foot, in front of the ankle-joint, is shortened to the extent of an inch or more, but the heel preserves its natural relations to the bones of the leg.

The foot likewise appears to be rotated upon its long axis, in such a manner that the aspect of the dorsal region is directed

outwards, and that of the plantar inwards; the inner edge of the foot is elevated and the outer depressed. These alterations resemble those which are the results of the dislocation of the tibia outwards; but in the latter accident, the outer edge of the foot is applied to the ground throughout its whole length, whereas in the injury under consideration, it is only the central third of the external margin of the foot, which is presented to the ground in walking.

The next remarkable symptom which attracts observation, is the alteration which the form of the sole of the foot undergoes. Instead of presenting its natural concavity, the plantar region becomes convex, both in its antero-posterior and transverse diameters; and hence it is, that in standing or walking, the central third alone, or nearly so, of the outer margin of the foot, is presented to the ground, as has been already mentioned.

In describing the luxation of the metatarsus upon the tarsus, it appears to me to be an error upon the part of Sanson, to say that the concavity of the sole of the foot is replaced by a plane surface; for the depression of the tarsal bones renders the sole of the foot convex.

The dorsal region of the foot presents a transverse prominence, situated about an inch below, and in front of the ankle-joint; commencing almost imperceptibly at the external margin of the foot, it gradually becomes more evident, till it terminates in a very distinct projection at the inner edge of the tarsus. Between this prominence and the ankle-joint there is a superficial sulcus. The line of the transverse convexity in the plantar region, is opposite to the ridge upon the dorsum of the foot, but its most prominent part is at the outer edge of the tarsus.

Such are the principal diagnostic signs of this remarkable dislocation, the anatomical characters of which will be best explained, by a description of the specimens which I have had opportunities of examining.

The individual who was the subject of the first case had met with the accident many years before his death. He had been thrown from his horse while hunting, but circumstances rendered it impossible to ascertain, whether any attempt was ever made to reduce the luxation.

Upon examining the skeleton of the foot, I found the metatarsal bones, along with the internal cuneiform, luxated upwards and backwards upon the tarsus.

The fifth and fourth metatarsal rested upon the upper surface of the cuboid bone, the third upon the external cuneiform, and the second upon the middle cuneiform.

The internal cuneiform, still connected to the first metatarsal, lay upon the upper surface of the navicular bone; it was fractured nearly through its centre, but there was no displacement of

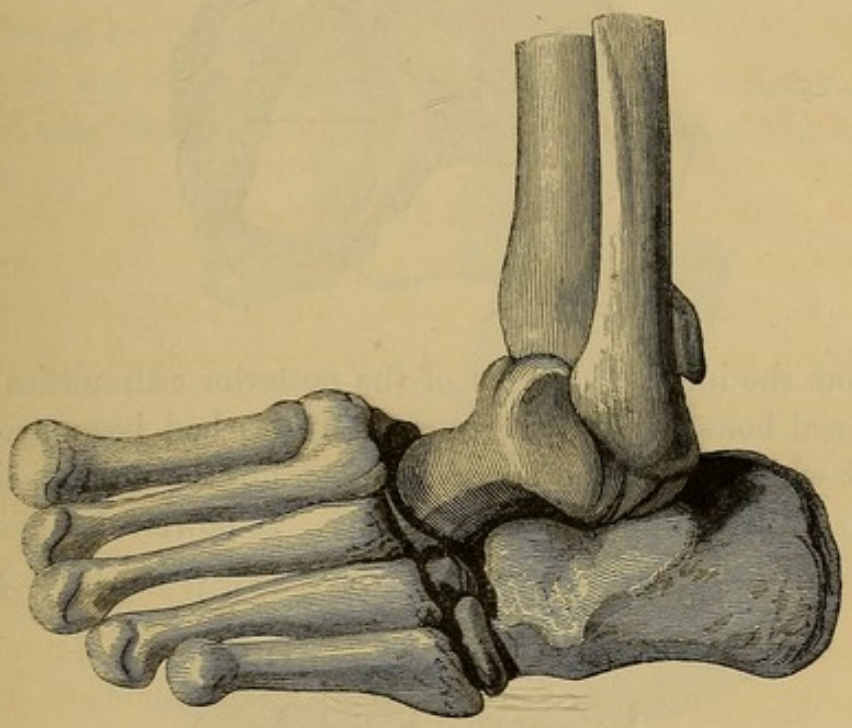

either portion from the metatarsal bone. There was only a ligamentous union between the fragments, but the superior was anchylosed to the second metatarsal bone.

The superior surface of the cuboid bone was deeply excavated anteriorly, where the fourth and fifth metatarsal bones rested upon it; but posteriorly a large irregular process of bone had sprung up, forming a buttress, against which were applied the posterior extremities of the two metatarsal bones above-mentioned.

The superior surface of the navicular bone presented a simi-

lar, but smaller bony growth, which supported the posterior surface of the internal cuneiform bone.

The displaced bones were closely joined to these osseous buttresses by an exceedingly dense, fibrous structure. A similar tissue united them to the upper surfaces of the navicular and cuboid bones, upon which they thus rested securely.

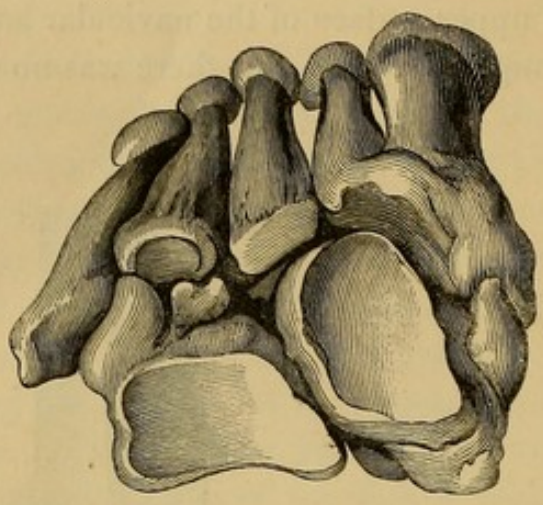

From the inferior surfaces of the posterior extremities of the metatarsal bones, similar osseous buttresses had been produced, against which rested the anterior surfaces of the cuboid, the external and the middle cuneiform bones. A powerful support was thus given to the foot, the tarsus being prevented from passing

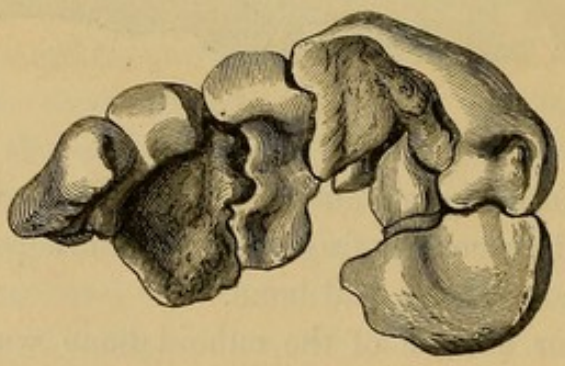

still further forwards, while the osseous productions already mentioned, as belonging to the cuboid and navicular bones, restrained the tendency to further displacement backwards of the metatarsus and internal cuneiform bone.

The natural concavity of the sole of the foot was replaced by

a convexity, formed by the tarsal bones driven downwards. The most prominent part of this convexity corresponded to the cuboid bone. The foot was shortened upwards of one inch, but there was very little rotation upon its axis.

The subject of the second case died in the Richmond Hospital of malignant disease in the abdomen, but the deformity of the foot was not discovered until after the patient's death. He was not observed to be lame in walking, and as he never directed attention to the condition of the foot, the opportunity was thus lost of ascertaining the history of the accident, which, from the *post mortem* examination, it was evident must have occurred many years before his death.

There was no elongation of the heel, but the anterior part of the foot was shortened an inch and a half, and rotated upon its

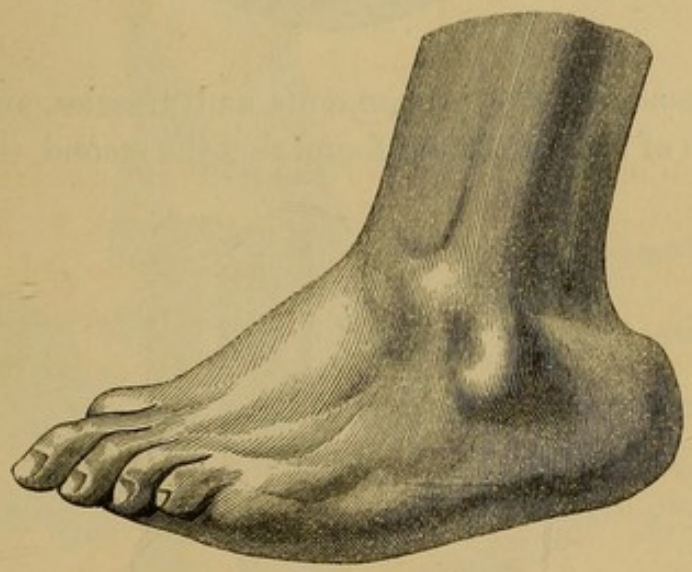

axis in such a manner, that the dorsal region looked outwards and the plantar inwards, the outer edge being depressed and the inner elevated. The skin covering the external margin of the sole of the foot was of an exceedingly thick and horny structure, but throughout all the rest of the plantar region, was as thin and fine as that upon the dorsum of the foot, showing, that during progression the outer border alone rested upon the ground. The dorsal region presented a transverse prominence in front of the ankle-joint, and the sole of the foot was convex in every direction.

The annexed engraving, which represents the foot viewed by its inner surface, shows remarkably well the convexity of the plantar region, and the rotation of the foot upon its axis.

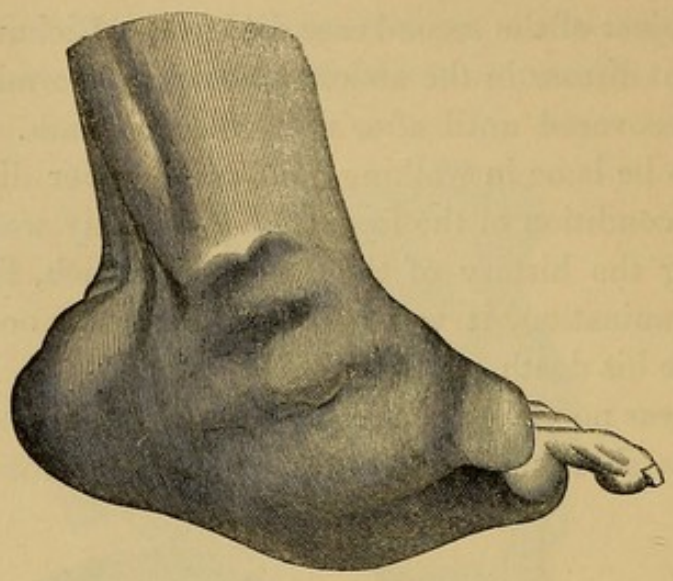

Upon removing the integuments and muscles, and exposing the skeleton of the foot, it was found that the second, third, fourth,

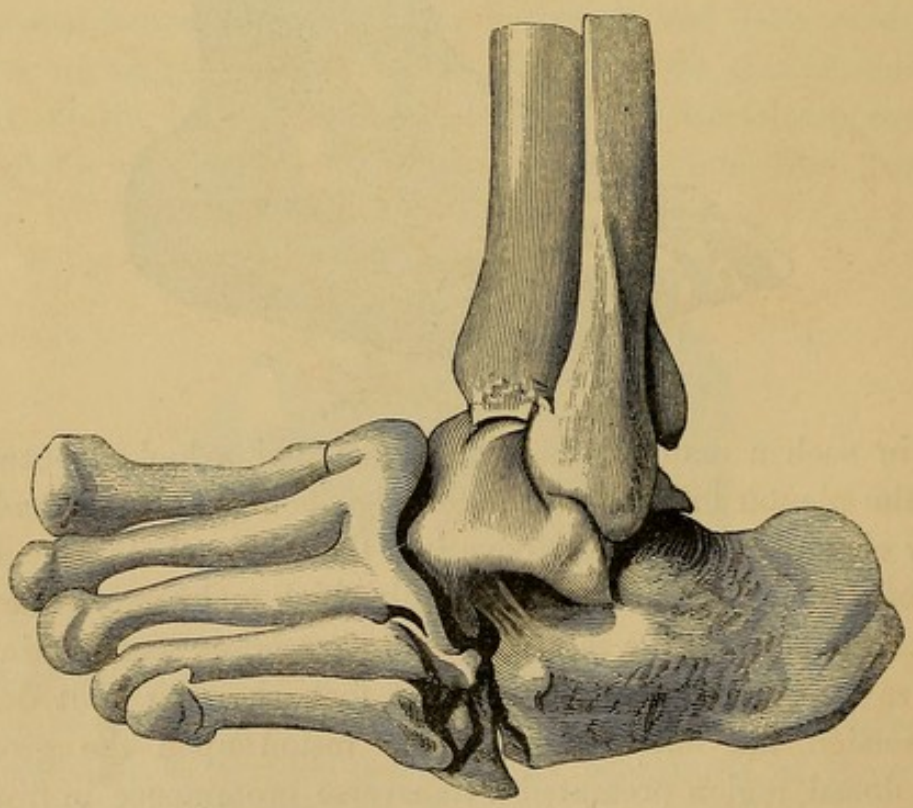

and fifth metatarsal bones, together with the internal cuneiform bone, were dislocated upwards and backwards upon the tarsus;

but the displacement had been carried to a much greater extent in this case than in the preceding, in which the internal cuneiform bone rested upon the upper surface of the navicular. In the case which I am now describing, the posterior superior edge of the cuneiform bone rested upon the neck of the astragalus, immediately in front of the articulating surface, which enters into the composition of the ankle-joint, while, by its anterior inferior margin, it corresponded to the posterior edge of the navicular bone, and with which it was anchylosed.

The second metatarsal bone also rested above the neck of the astragalus; the third was nearly upon the same level, while

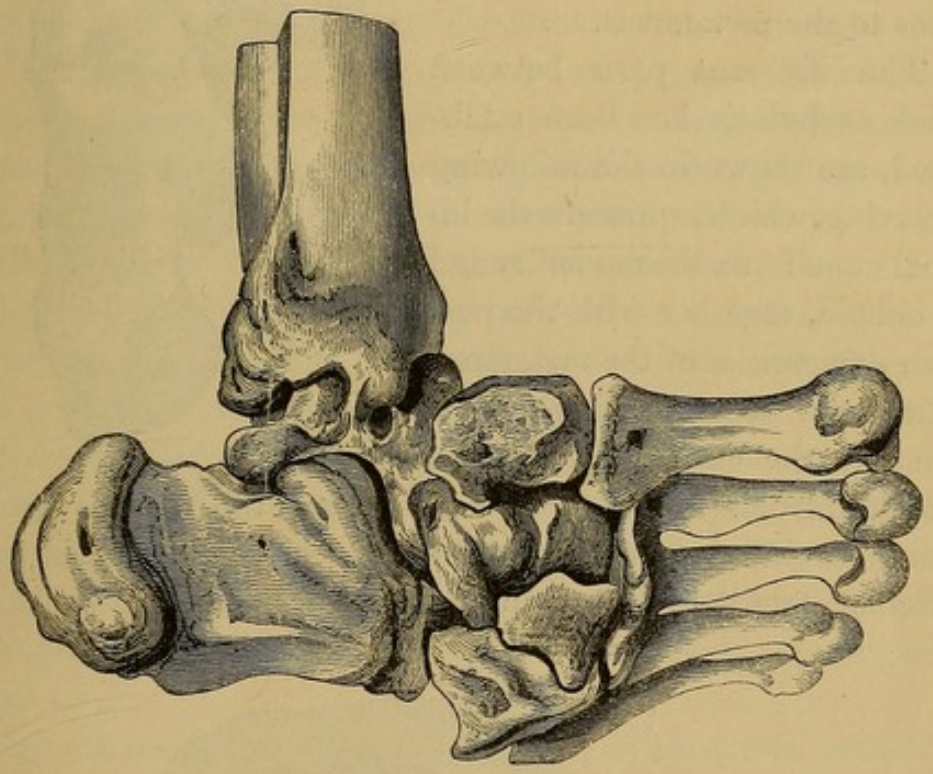

the fourth and fifth lay upon the cuboid bone. The displacement of the anterior part of the foot had thus taken place in an oblique direction, and the amount of rotation upon its axis was such, that the inner surface of the internal cuneiform bone was now directed upwards, and the under surfaces of the metatarsal bones had nearly the same aspect as the internal surface of the tibia.

The convex form which the centre of the sole of the foot had assumed, was produced by the depression of the cuboid,

navicular, external, and middle cuneiform bones. The two latter were anchylosed to the navicular, and also to the under surfaces of the second and third metatarsal bones. The navicular was also joined by bone to the lower edge of the internal cuneiform. Osseous buttresses, similar to those noticed in the case first detailed, had sprung from the inferior surfaces of the second, third, and fourth metatarsal bones, and contributed to complete the anchylosis of the tarsus to the metatarsus.

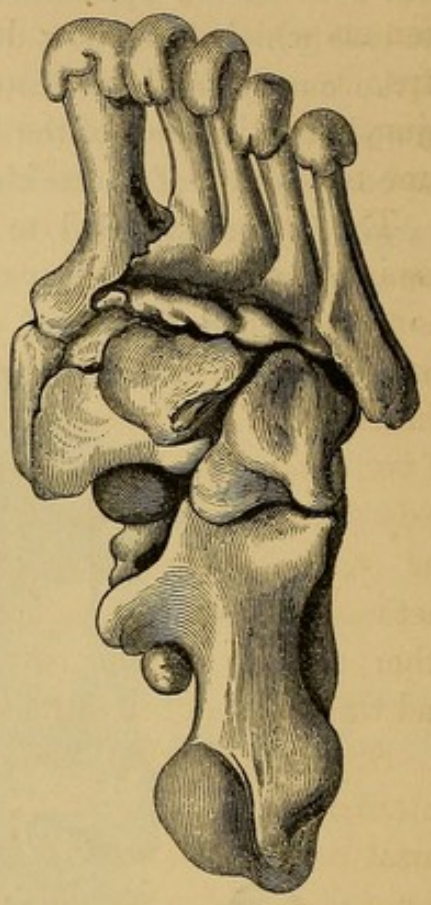

The different parts between which anchylosis had been established, are shown in the following engraving, which represents the internal cuneiform, the navicular and the cuboid, together with the posterior extremities of the metatarsal bones, the second of which is joined to the cuneiform, and the second, third, and fourth to each other; the osseous growths from their inferior surfaces are also seen, passing down to the navicular, middle, and external cuneiform bones.

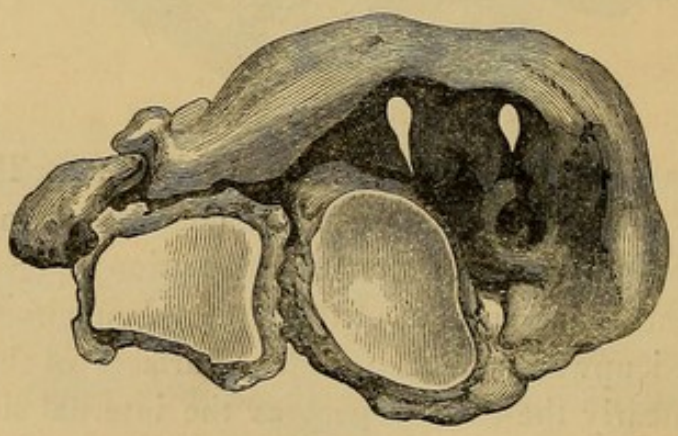

Although unacquainted with the history of the accident in this case, I am inclined to believe that the force which produced

the injury was unusually great, and I rest this opinion partly upon the great amount of displacement backwards of the metatarsus, and partly upon the circumstance of the great toe having been amputated at its metatarso-phalangeal articulation; for, perhaps, it is not stretching hypothesis too far, to suppose that the injury which rendered this measure necessary, occurred at the same time as the luxation which I have described.

This remarkable and rare dislocation may be produced by the passage of a heavy body over the dorsum of the foot, but is much more liable to occur when a person, in falling or leaping from a considerable height, alights upon the anterior part of the foot. Under these circumstances, the limb is submitted to the operation of two forces acting in opposite directions; one, the weight of the body and impulse of the fall, tending to depress the tarsal bones, the other, the resistance of the ground, tending to displace the metatarsus upwards; the articulating surfaces thus glide past each other, and the anterior part of the foot is then drawn backwards, and the aspects of its surfaces altered by muscular action.

Strictly speaking, the injury consists in a luxation of the internal cuneiform with the second, third, fourth, and fifth metatarsal bones upwards and backwards upon the tarsus, for the first is not displaced from any of its normal connexions.

I am inclined to believe that, when a luxation of the bones of the metatarsus is the consequence of a fall from a height, the individual alighting upon the anterior part of the foot, it is, in general, that which has been described in the preceding pages.

From a consideration of the anatomy of the parts concerned, it would appear that, when a force is applied to the front of the foot, capable of luxating the metatarsal bones, the internal cuneiform will be more likely to remain connected with the first metatarsal than with the navicular bone. I do not allude to the great extent of its anterior articulating surface, as compared with its posterior, but to the strong connexion maintained between it and the first metatarsal bone, by means of the tendons of the peronæus longus and tibialis anticus. Each of these tendons having an attachment to each of the bones in question, must constitute a powerful means of preventing their separation from one

another by external violence, which, in the first case which has been described, was sufficient to fracture the cuneiform bone through its centre.

Sanson has recorded two cases as having occurred in the practice of Dupuytren, as examples of dislocation of the metatarsus upon the tarsus,* both of which are remarkable: the one as having been produced chiefly by muscular action, and the other as presenting an example of the occurrence of the displacement upon each side, by the same accident.

The subject of the first case was a female, who "chargée d'un pesant fardeau, tomba en avant de telle sorte, que son pied supporta tout le poids du corps; c'est a l'instant ou, pour prévenir la chute, elle ramena le corps en avant sur le pied, que survint le déplacèment. Dans cette circonstance la jambe était fléchie, le talon fortement relevé et maintenu fixe par la contraction des muscles jumeaux et solaires, le pied dut n' appuyer sur le sol que par sa moitié antérieur. La deuxième observation est celle d'un jeune homme de 25 ans qui, dans un état d'ivresse, sauta dans un fossè du 12 pieds de profondeur et tomba sur la *pointe des pieds;* la luxation eut lieu des deux côtés."

The latter patient was admitted into the Hotel-Dieu three weeks after the occurrence of the accident, but the attempts then made to reduce the luxation failed. When he left the hospital, however, he was able to walk remarkably well, notwithstanding the double deformity.

The question here naturally suggests itself, were these cases examples of dislocation of the metatarsus, or of the injury which I have described? and it is one which may be entertained without the slightest disparagement to the judgment of the late justly celebrated chief of the Hotel Dieu. Here are four examples of an injury, all characterized by the same symptoms:† in two of these the precise nature of the injury has been demonstrated by dissection: is it not, therefore, probable that the others, which pre-

* Dict. de Med. et de Chirurgie Pratiques, en 15 vol., Art. "Luxation."

† "1st. Raccourcissement du pied de plusieurs lignes, lequel est dû, soit au chevauchement des os, soit à l'obliquité des orteils et du métatarse; 2nd. Sur le face dorsale, saillie de plus d'une demi-pouce de hauteur, dirigée en travers, et formée par l'extremité postérieure des metatarsiens, plus prononcée en dedans qu'en dehors, et sur laquelle on

sented the same external signs, also possessed the same anatomical characters?

Let me not, however, be understood, as denying the occurrence of luxation of the metatarsus; I only wish to express my opinion, founded upon anatomical reasons, that when luxation of the bones of the metatarsus results from violence applied to the anterior part of the foot in the manner described, the internal cuneiform will be most likely to preserve its connexions with the first metatarsal bone.

A case of displacement of the bones of the metatarsus has been recorded by M. Mazet,* but it is by no means satisfactory, as bearing upon the question under consideration. The preparation is preserved in the Musée Dupuytren, where I have had an opportunity of examining it.

The subject of the case was a young man, and the injury was caused by the passage of the wheel of a heavily-laden cart over the front of his foot; he fell backwards, while the foot was fixed by the wheel; the metatarsal bones were displaced and broken, and the soft parts extensively lacerated. The injury very soon proved fatal.

Upon examination, the metatarsal bones were found luxated from the tarsus, but they were not all displaced in the same direction. The first was thrown inwards, and rested against the inner surface of the internal cuneiform bone; the second, third, and fourth were luxated upwards and backwards, while the fifth was driven downwards and backwards beneath the cuboid bone; it was also fractured at its posterior extremity.

Vidal has remarked of this case, "C'est la l'observation la plus authentique, puisque la dissection a constaté le déplacement; mais on remarquera que c'était plutôt un écrasement du pied, que tout autre chose, car outre les dégâts (havock) considerables des parties molles, il y avait une fracture d'un des métatarsiens."†

peut reconnaitre les longueurs différents de chacun de ces os; 3rd. Derriere elle enfoncement très-prononcé qui peut aisément loger un doigt placé en travers; 4th. Disparition de la concavite du pied, qui est remplacée par une surface plane, due à l'abaissement des os du tarse."—*Sanson.* Loc. cit.

* Bulletin de la Société Anatomique, October, 1837.

† Pathologie Externe, tome second.

While the dislocation is recent, its reduction offers no very serious difficulty; but the second case recorded by Sanson, shows that it may become impossible to replace the bones after a comparatively short period of time, for at the end of three weeks the attempts failed, even in the hands of Dupuytren. The patient, however, when the dislocation is left unreduced, gradually regains the use of the foot, and is ultimately enabled to walk with a very trivial amount of lameness.

Mr. Liston observes, that partial dislocation of the anterior bones of the tarsus occurs occasionally from falls from a considerable height, the patient alighting on the points of the toes; and that, although little can be done to reduce the dislocated bones, the patient will be enabled, after some time, to use his foot as well as ever.

He mentions the case of a boy, æt. 14, who fell from a height of forty feet, and alighted on the extremity of the right foot. The scaphoid and cuboid bones were dislocated upwards. The foot was half an inch shorter than the other.*

No attempt was made to reduce the bones in this case, and the patient left the hospital in three weeks, able to stand on the foot.

Sir Astley Cooper has recorded a remarkable instance of displacement of the five anterior bones of the tarsus, from the os calcis and astragalus.†

"A man working at the Southwark Bridge had the misfortune to have a stone of great weight slide gradually on his foot: he was almost immediately brought to Guy's Hospital, and the following were the appearances of the foot. The os calcis and the astralagus remained in their natural situations, but the forepart of the foot was turned inwards upon these bones. When examined by the students, the appearance was so precisely like that of a *club foot*, that they could not at first believe that it was not a natural defect of that kind; but upon the assurance of the man that, previously to the accident, his foot was not distorted, an extension was made by fixing the leg and the heel; the forepart of the foot was then drawn outwards, and thus the reduction

* Practical Surgery, p. 140. † Loc. cit. p. 336.

was effected. This person was discharged from the hospital in five weeks, having the complete use of his foot."

Another example of the displacement of the anterior part of the foot from the os calcis and astragalus has been recorded by Petit; and Mr. South mentions a case of luxation of the fourth and fifth metatarsal bones upwards and backwards upon the cuboid. The patient was under the care of Mr. Green, who experienced considerable difficulty in the reduction.

CHAPTER VII.

CONGENITAL LUXATIONS OF THE WRIST-JOINT.

"Un des vices fondamentaux du plus grand nombre des traités dogmatiques, c'est de parler de la même manière et en termes aussi positifs des points litigieux de la science que des points bien constatés. Pourquoi craindre de montrer à tous les yeux les vides de la science? Au moins, l'attention de tous serait éveillée sur ces lacunes, et des travaux arriveraient en foule pour les combler."—*Cruveilhier*, *Anatomie Pathologique*, liv. ix.

THERE is no dislocation in the wide range which these accidents embrace, upon which surgeons and pathologists have expressed more contradictory, and, at the same time, more positive opinions, than luxation of the carpus, some having described four forms of this injury, while others have maintained that it is not possible for such an accident to occur, as dislocation of the wrist without fracture.

Dupuytren remarks, "que l'art, malgré tant de descriptions, ne possède pas une seul observation bien convaincante de cette lésion;"* Marjolin maintained the same opinion; while, upon the other hand, Cruveilhier has minutely detailed the morbid appearances, in a case which he conceives to have been an example of luxation of the carpus forwards, or, as he has termed it, of the fore-arm backwards upon the hand.

The following is an abstract of this remarkable case. The subject of the observation was an adult female, of whose history no record had been preserved. The accompanying figure represents the elbow, the fore-arm, and the hand viewed in profile by the radial border of the limb. The fore-arm, much shorter than natural, formed a right-angle with the hand, and the latter was

* Clin. Chir. t. iv. p. 162.

inclined towards the radial margin of the former, and could be brought into contact with it; the hand could not be extended, but admitted of flexion being carried beyond a right angle. The inferior extremities of the radius and of the ulna formed remark-

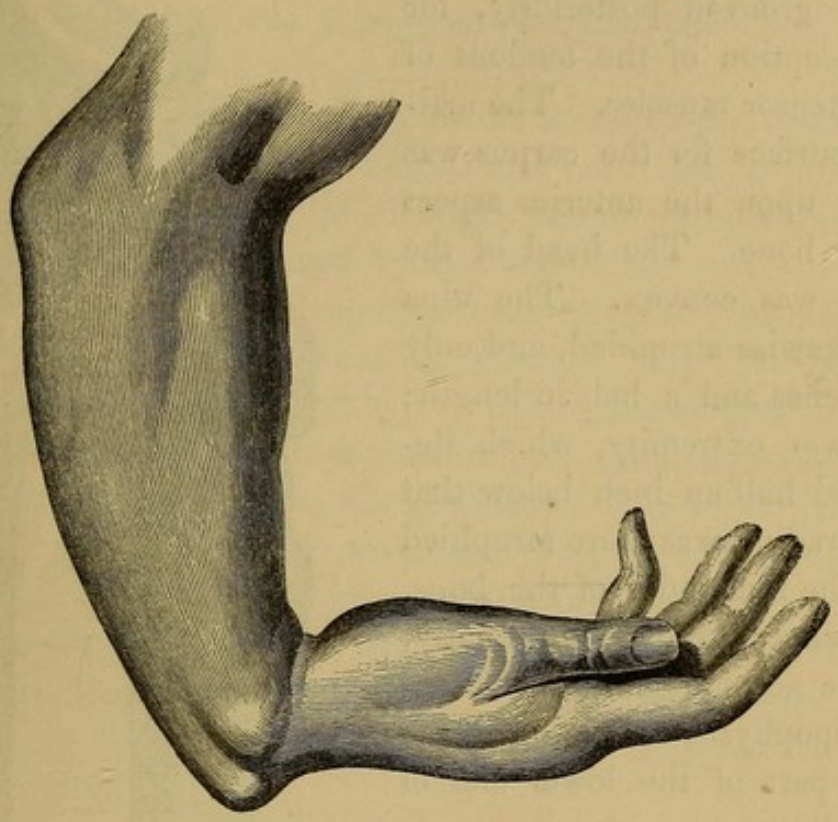

able prominences beneath the skin; that constituted by the ulna being most striking, and descending considerably lower than that which marked the end of the radius.*

The upper end of the carpus was placed upon a plane, superior and anterior to that of the lower extremities of the bones of the fore-arm. The radial and ulnar extensors of the carpus, as well as the pronators and supinators, were atrophied. The first row of carpal bones existed merely in a rudimentary state, being scarcely half their natural size; the pisiform bone alone preserved its normal form and volume. The bones of the second range were likewise deformed and diminished in size; the portions of the trapezium and trapezoid, which corresponded to the semilunar bone, were atrophied, and there was scarcely any trace of the head of the os magnum.

* Anatomie Pathologique, liv. ix.

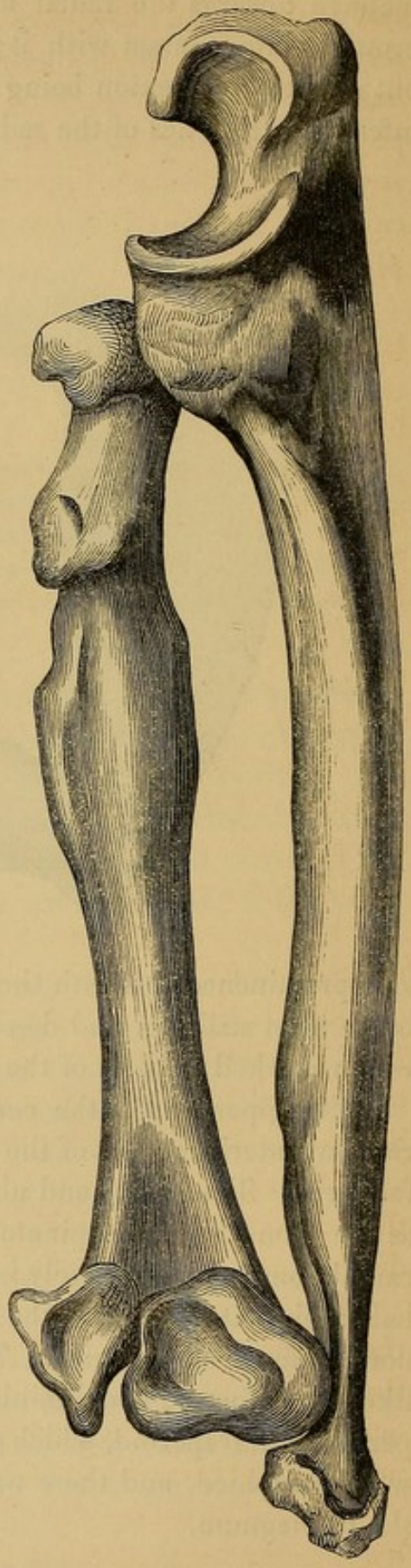

The radius, shortened and deformed, scarcely measured five inches in length. The deformity affected principally its lower extremity, which was large, and deeply grooved posteriorly, for the reception of the tendons of the extensor muscles. The articular surface for the carpus was placed upon the anterior aspect of the bone. The head of the radius was convex. The ulna was likewise atrophied, and only six inches and a half in length; its lower extremity, which descended half an inch below that of the radius, was more atrophied than the remainder of the bone, and deeply grooved externally, for the accommodation of a salient apophysis, belonging to the inner part of the lower end of the radius.

The preceding case has been considered by Cruveilhier, as affording an indisputable example of luxation of the carpus without fracture of the radius. But let us now see to what conclusion the Baron Dupuytren arrived, after maturely reflecting upon and deliberately analysing all the phenomena, disclosed by the *post mortem* examination of the specimen in question. The opinion which this distinguished surgeon formed was, that the case had been one of luxation of the ulna backwards, with fracture and displacement forwards of the lower

end of the radius; that, from the atrophy of the carpal bones, the accident had probably taken place during infancy, and that the fracture had occurred through the line of junction of the epiphysis with the shaft of the bone; and he believed that, upon any other supposition than that of fracture, the remarkable shortening of the radius was a phenomenon that could not be explained.

Now I think it will not be difficult to satisfy the reader, that both these eminent men have fallen into error, and to prove that the case in question was an example neither of fracture nor of luxation, whether produced by accident or disease, but of displacement, the result of congenital malformation. At all events, it will be rendered manifest that, whatever may have been the nature of the case recorded by the distinguished pathologist of France, it was identical with that which I am about to describe.

The subject of the case was a female lunatic, æt. 36 (Deborah O'Neil). She had been for seventeen years under observation in the House of Industry, Dublin, and during the four years preceding her death, was under my care in the Government Lunatic Asylum at Island Bridge. She had been for many years subject to epileptic convulsions, which at length terminated in a fatal apoplectic seizure.

Both upper extremities were deformed from birth. Casts of the malformed limbs were laid before the Pathological Society of Dublin, by Mr. Adams, in December, 1838; and, upon the 16th December, 1843, I exhibited before the Society, the skeletons of the limbs, together with a series of casts and drawings illustrative of the deformities.

The right extremity exhibited an example of luxation of the carpus forwards, while in the left was afforded an instance of displacement of the carpus backwards.

The patient enjoyed a considerable degree of motion in these strangely malformed joints, and was accustomed to spend the greater portion of her time in making lace and in cutting out fancy watch-papers, which she was able to do with surprising neatness and dexterity.

Right Extremity.—The hand and fore-arm were of equal length; the carpus was articulated with the anterior aspect of

the radius, which bone was only four inches and a half in length.

The ulna, six inches in length, was prolonged below the radius nearly half an inch; its lower extremity was destitute of the rounded

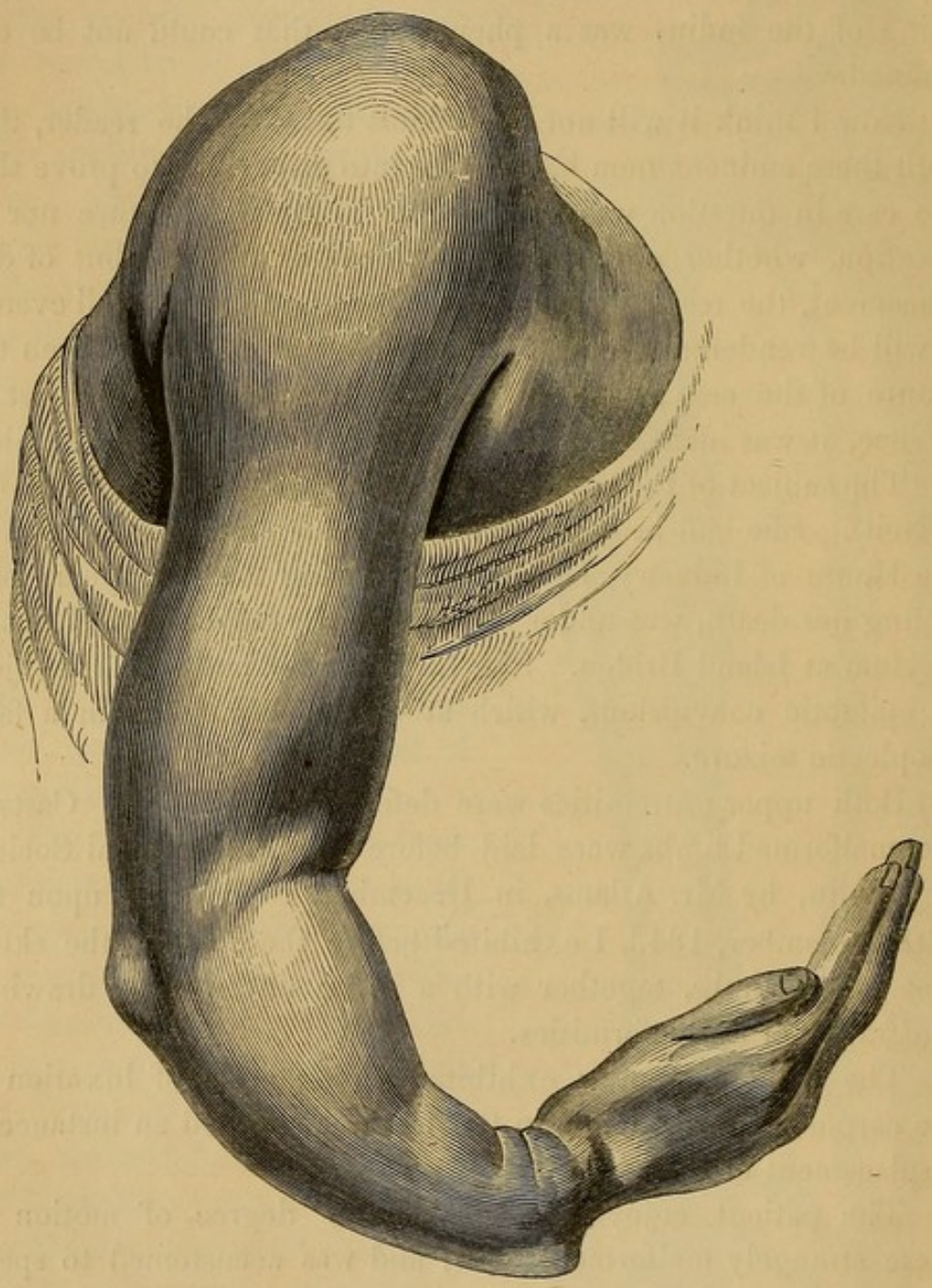

head, which, in the normal state, is received into the concavity of the radius, and was curved forwards, outwards, and upwards; it resembled somewhat the coracoid process of the scapula, and about half an inch above its termination, was in contact with the

radius, by a very small surface, which was destitute of cartilage. An anterior and a posterior ligament connected the two bones in this situation, and permitted a very slight degree of motion between them.

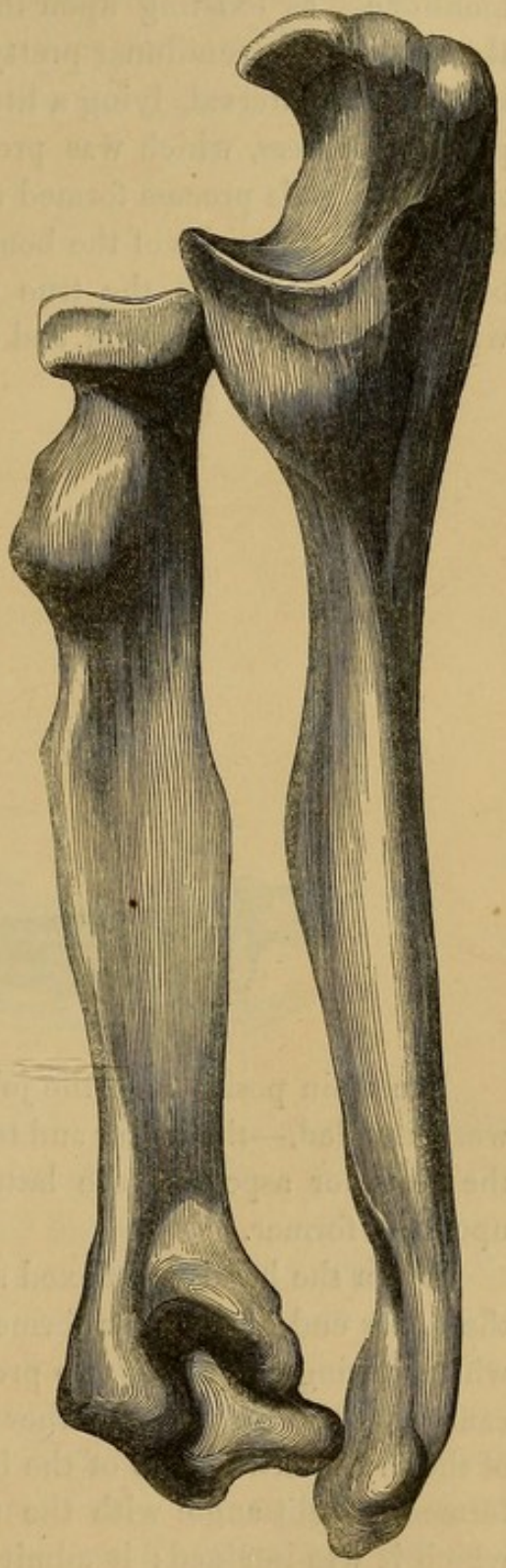

The lower extremity of the radius was totally destitute of articulating surface, and was represented by a rounded and blunt margin.

The surface, for articulation with the carpus, was placed altogether upon the anterior aspect of the bone. It consisted of a deep excavation, of an oblong form, its long diameter being directed from above and without downwards and inwards, towards the lower extremity of the ulna. It was tolerably smooth, although not invested by cartilage.

The radius and ulna were not only remarkably short, but likewise atrophied both as to breadth and thickness: they are represented of the natural size in the accompanying engraving. Their superior extremities (with the exception of being unusually small) presented no abnormal appearance.

The bones of the first row of the carpus were atrophied to a remarkable degree, especially the semilunar bone, which in size and shape exactly resembled a split pea, the flat surface being in contact with the

head of the os magnum, which was likewise atrophied; the scaphoid bone was received into the excavation or socket already mentioned, as existing upon the anterior surface of the radius; the diminutive semilunar pretty accurately corresponded to the interosseous interval, lying a little, however, upon a small, nipple-like process, which was prolonged from the radius towards the ulna. This process formed the only point of contact between the lower extremities of the bones of the fore-arm; the cuneiform bone, excluded from the true radio-carpal joint, was in contact with the front of the lower end of the ulna.

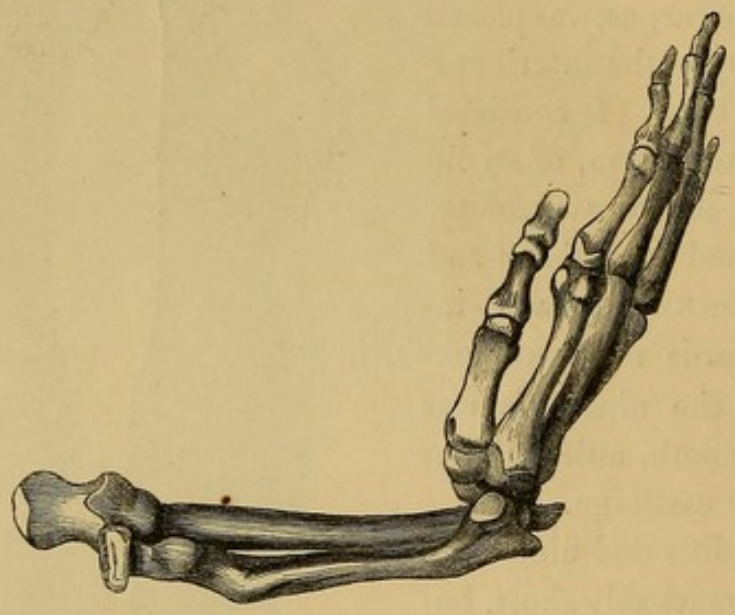

In certain positions of the joint,—for instance, when the hand was extended,—the radius and trapezoid bone were in contact, and the posterior aspect of the latter was flattened, where it moved upon the former.

When the hand was flexed at a right angle with the fore-arm, the lower end of the ulna formed a most conspicuous projection; while, during extension, two prominences were seen, one in front, caused by the carpus, the other posteriorly, marking the position of the lower extremities of the bones of the fore-arm. The hand formed a right angle with the fore-arm, to the radial border of which it was inclined; it admitted, however, of being flexed beyond a right angle, and could be extended perfectly.

The extensor tendons formed right angles in their passage

from the fore-arm to the hand; those of the extensor communis and extensor indicis being lodged in a deep and narrow groove or channel upon the posterior surface of the radius, the inner part

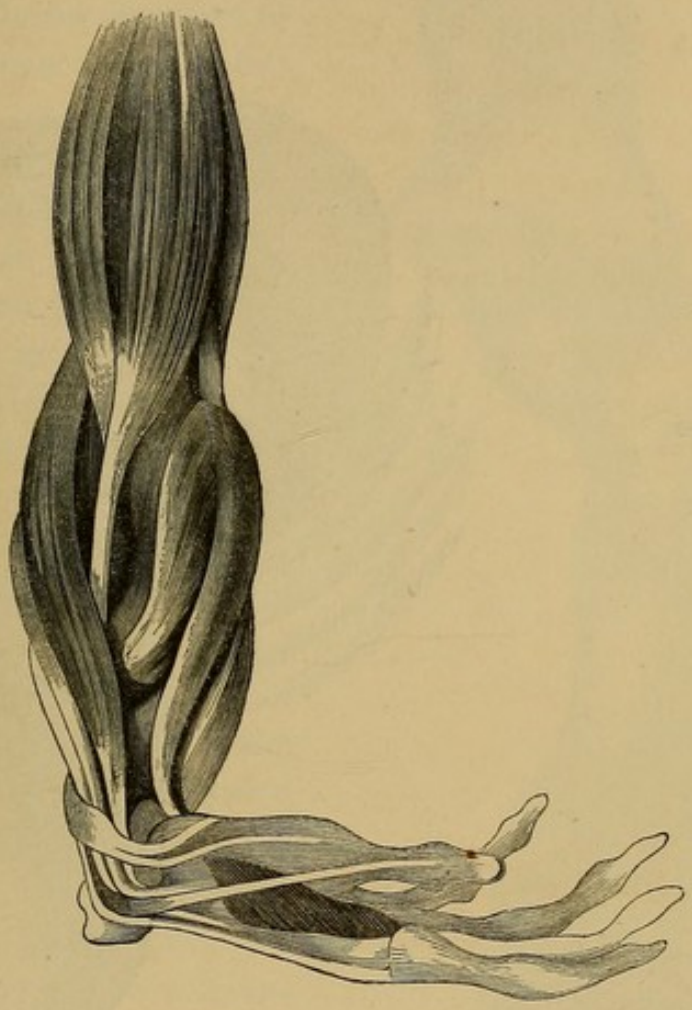

of the groove being prolonged into the nipple-like process already mentioned, as forming the only point of contact between the lower extremities of the radius and the ulna.

Left Extremity.—Upon this side the deformity was equally remarkable, although the reverse of that noticed upon the right side. The fore-arm and the hand were here also of equal length, their measurements being as nearly as possible the same as upon the opposite side, but the lower extremities of the radius and ulna were upon the same horizontal level. The upper end of the radius terminated in an exceedingly small, atrophied, and malformed head, which did not articulate with the humerus, the latter bone possessing scarcely any trace of a capitulum; the two

bones were here connected merely by a few indistinct ligamentous fibres. The bicipital tubercle, neck, and head of the radius bore a considerable resemblance in outline and relative direction to the trochanter, neck, and head of the femur. The radius (the

surface of the head of which was convex) was directed obliquely across the ulna, being pronated to the utmost, the lower end of the bone lying altogether to the inner side of the ulna, while, superiorly, the head and a portion of the neck projected outwards

and backwards far beyond the external margin of the shaft of the ulna. Upon this side, both the radius and the ulna contributed to the formation of the socket, which received the atrophied carpus; the bones were not in contact at their lower extremities; but, at a height of about an inch, two spur-like processes projected, one from each bone, and met each other, thus obliterating the interosseous interval in this situation. These processes entered into the composition of the articular surface destined for the reception of the carpus, and were joined to one another by ligaments, which permitted of a slight degree of motion of the radius upon the ulna; the socket thus formed was placed upon the dorsal aspect of the bones, and presented somewhat of a glenoid shape, the longer diameter of which was directed obliquely downwards and inwards.

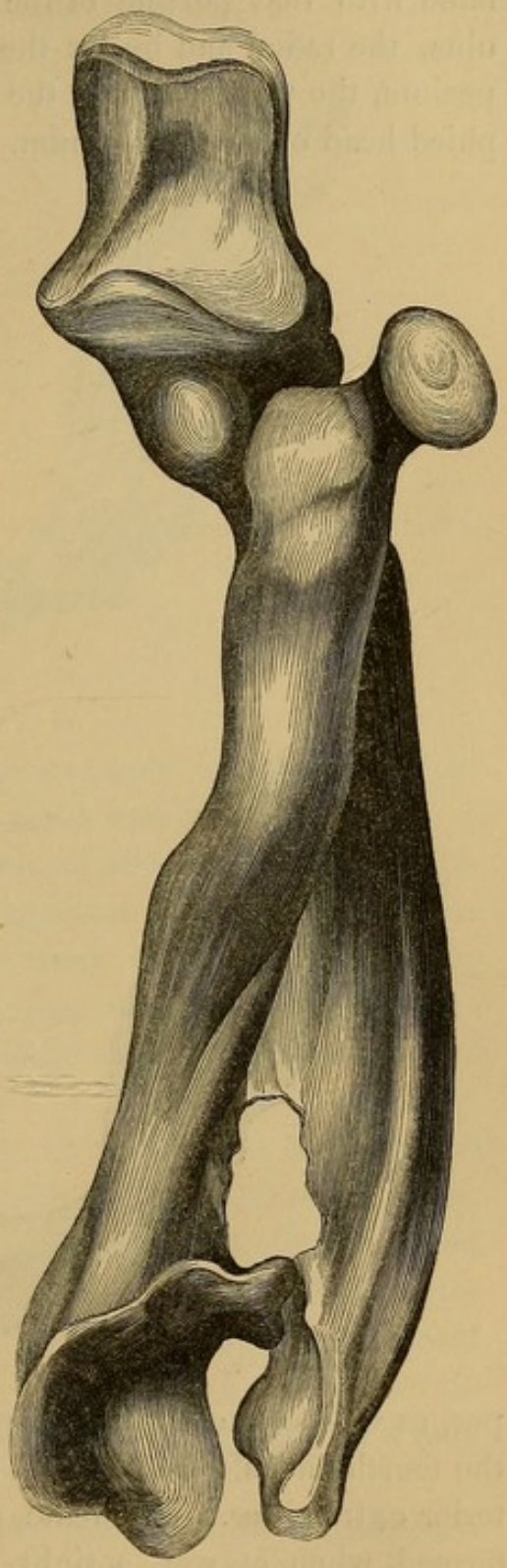

The superior extremity of the ulna presented no trace whatever of the lesser sigmoid cavity, nor were the radius and ulna in contact above.

There was neither an external lateral, nor a coronary ligament at the elbow. In short, there did not exist, in this strangely malformed limb, either a radio-humeral, or a superior radio-ulnar articulation. The humerus joined the ulna alone.

With regard to the carpus, there was in the first row of bones neither a semilunar nor a scaphoid; the cuneiform bone articulated with that portion of the socket which was formed by the ulna, the radial and by far the larger portion receiving the trapezium, the trapezoid, and the upper and outer part of the atrophied head of the os magnum. The remaining bones of the car-

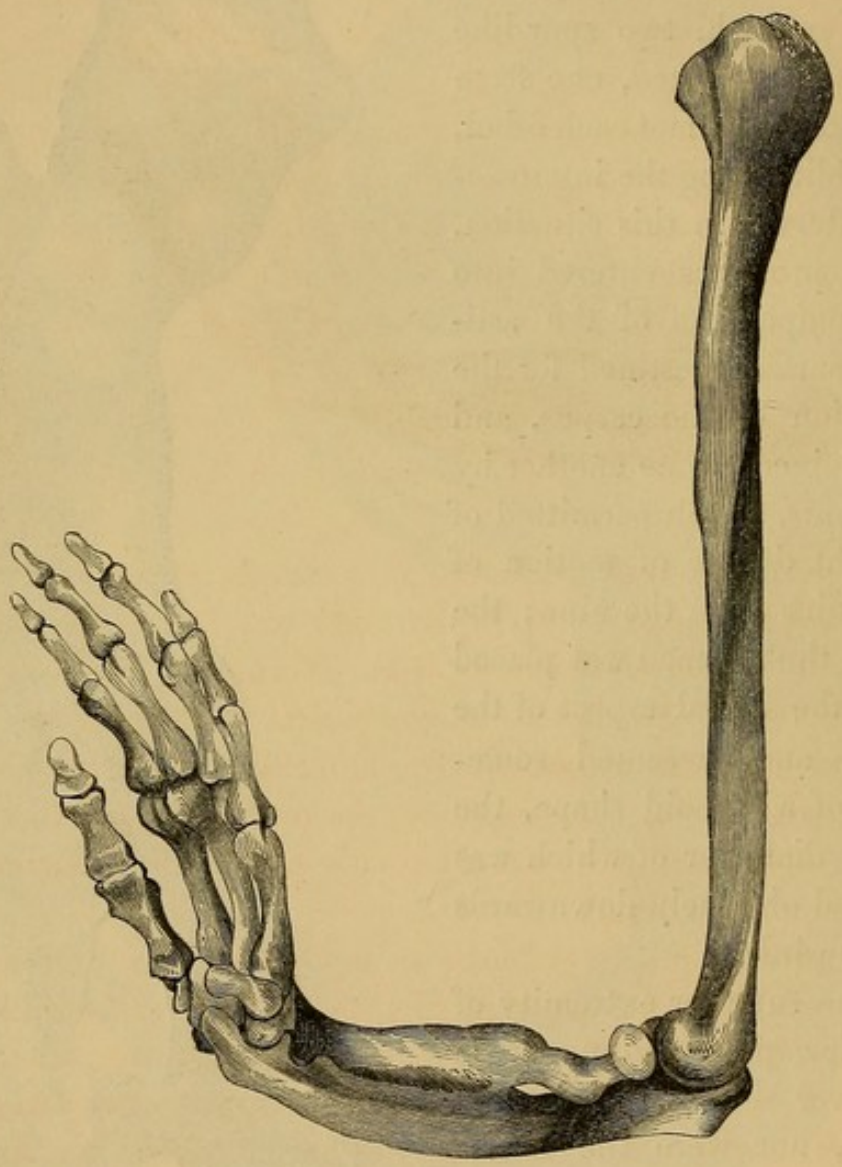

pus, as well as those of the hand, were smaller than natural, and the fourth and fifth metacarpal formed but one bone at their posterior extremities. The hand, placed upon the side of extension, formed, when at rest, a right angle with the fore-arm; but the patient had the power of bringing it into a right line with the latter, in which position two prominences were seen, but, con-

trary to what was observed upon the opposite side, the dorsal projection was here formed by the carpus, the extremities of the radius and ulna constituting the palmar eminence.

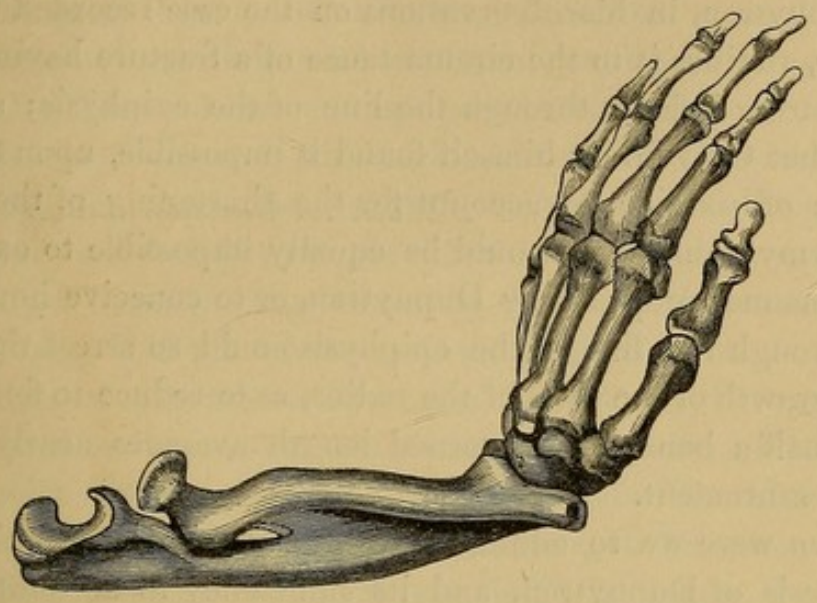

The left side thus presented an example of luxation of the carpus backwards, while upon the right was seen a specimen of luxation of the carpus forwards, both of which were, in my opinion, the result of original or congenital malformation. The hands and fore-arms presented very much the appearance of the anterior extremities of the seal and other marine mammalia. The humerus upon each side was unusually small; the remainder of the skeleton was normal.

The preceding case affords, in my opinion, a well-marked example of congenital luxation of each radio-carpal articulation. The individual from whose body the specimens were taken had been, as I have already stated, under surgical observation for more than twenty years; the history of her childhood was known, and it was ascertained beyond the possibility of doubt that no accident had ever occurred to either of the limbs, and that they had never been the seat of disease.

Upon any other supposition than that of original malformation, it would be, I conceive, utterly impossible to offer any rational explanation of the remarkable diminution in the length of the bones of the fore-arm upon each side. I know of no pro-

cess which could take place in these bones, after luxation of the carpus, fracture of the lower end of the radius, or separation of its epiphysis, which could possibly account for this singular phenomenon.

Dupuytren, in his observations on the case recorded by Cruveilhier, ascribes it to the circumstance of a fracture having taken place during infancy through the line of the epiphysis; and it is stated that Cruveilhier himself found it impossible, upon the supposition of luxation, to account for the shortening of the radius. But, in my opinion, it would be equally impossible to explain it in the manner proposed by Dupuytren, or to conceive how a fracture through the line of the epiphysis could so arrest the subsequent growth of the shaft of the radius, as to reduce to four inches and a half a bone, whose normal length averages nearly double that measurement.

Even were we to admit, for argument sake, the truth of the hypothesis of Dupuytren, and its sufficiency to account for the phenomenon, the question would still remain,—to what are we to ascribe the corresponding diminution in the length of the ulna? Neither of the authors referred to have alluded to this equally remarkable feature of the case; and yet it is obvious that the atrophy of the two bones is to be ascribed to the operation of the same cause; and as the ulna is not even supposed to have been the seat of fracture, we are compelled to consider this remarkable arrest of development (for it is not, properly speaking, atrophy) as the result of causes operating during the period of intra-uterine life.

It now only remains to consider how far the case of the woman O'Neil resembles that recorded by Cruveilhier, and it will, I think, be found that, as regards the right upper extremity, the analogy is perfect. The two specimens are identical, as regards the dimensions of the bones of the fore-arm; the equality, in length, of the hand and fore-arm; the prominence upon the posterior aspect of the limb, produced by the lower ends of the radius and ulna; the descent of the ulna half an inch below the radius; the position of the carpus upon a plane superior and anterior to that of the lower end of the bones of the fore-arm; the existence of a deep, irregular excavation upon the front of the lower end of the radius for

the lodgment of the carpus; the total absence of an articular surface upon the inferior extremity of the bone; and finally, the atrophy of the first row of carpal bones.

It is not necessary to allude to the condition of the left extremity further than has already been done, for, upon this side, the evidence of the congenital nature of the displacement was, if possible, still more decisive than upon the right.

It does not appear to me that, in the detail of the case given by Cruveilhier, nor in the elaborate analysis of it by Dupuytren, there is any satisfactory evidence that fracture or luxation, whether the result of accident or produced by disease, had ever occurred; and believing that the phenomena are explicable only upon the supposition of original malformation, I am compelled to arrive at the conclusion that that eminent pathologist, Cruveilhier, and that equally celebrated surgeon, the late chief of the Hotel-Dieu, were both in error with respect to the remarkable case recorded in the ninth livraison of the "Anatomie Pathologique."*

I have, as yet, had an opportunity of examining only one other instance of congenital dislocation of the wrist-joint. The preparation which illustrates it was taken from the body of a young woman, who, many years ago, died of phthisis in the Richmond Hospital. The right wrist presented most of the external characters which authors have assigned to luxation of the carpus forwards from injury.

The lower extremities of the radius and ulna formed a remarkable tumour posteriorly, and the carpus could be felt projecting in front. The hand, which was a little inclined towards the radial border of the limb, could be extended so far as to form a right line with the fore-arm, but the range of flexion was more limited than in the case of O'Neill.

The patient had no remembrance of having ever met with an injury, and the case was supposed to be one of displacement of the bones of the fore-arm, consequent upon caries of the wrist, occurring in early life; for the woman stated that the present

* In 1836, I saw in the museum of the Bristol Infirmary, a cast of a congenital luxation of the wrist: the characters of the deformity were precisely similar to those delineated in the preceding pages.

condition of the joint had existed as long as she could recollect.

From the following account of the *post mortem* examination of the limb, I think it will appear that neither disease nor accident had any share in producing the deformity above described, and that the phenomena, disclosed by dissection, cannot be explained upon any other supposition than that of congenital malformation of the bones composing the radio-carpal articulation.

There was no vestige whatever of the natural carpal surface of the radius having ever existed; the anterior and posterior surfaces of the bone meeting in a blunt or rounded margin, which was directed obliquely downwards and outwards. Its lowest part, which corresponded to the styloid process, was three-quarters of an inch below the level of the head of the ulna, for the reception of which the radius presented no articular surface.

About three-quarters of an inch above the margin which terminated the surfaces of the radius, there existed upon the anterior aspect of the bone a deep cavity of an oblong form, which received one of the first row of carpal bones. It was limited above by a salient apophysis, which stretched across the interosseous space towards the ulna. Immediately below this fossa there was a perfectly smooth surface, thinly covered with cartilage, and slightly concave, which, in the extended position of the hand, rested upon the posterior and internal part of the scaphoid bone.

There were five bones in the first range of the carpus, the semilunar consisting of two perfectly distinct portions, an anterior and a posterior. The latter appeared to be the supernumerary bone: it was prolonged upwards a little beyond the level of the former, and was that which articulated with the cavity already mentioned as existing on the front of the radius.

It presented five articulating surfaces: an external, which joined the scaphoid, and an internal, which articulated with the cuneiform bone; an inferior (exceedingly small), which rested upon the posterior part of the os magnum; an anterior, which was convex, and articulated with the posterior surface of the normal semilunar bone; and, lastly, a posterior or dorsal sur-

face, which was slightly concave, and was adapted to the cavity upon the front of the radius.

All these facets were perfectly smooth, and covered with cartilage; but there was no articular surface upon the superior aspect either of this or of the natural semilunar bone.

When the hand was extended as far as possible, the radius, besides resting upon this supernumerary bone, was in contact with the dorsal surfaces of the scaphoid and trapezoid, and the head of the ulna reposed upon the back of the cuneiform bone. There was no trace either of caries or of any other disease having ever existed; the investing cartilage of the carpal bones was every where perfect.

From the preceding description it is, I think, obvious that this case cannot be considered as an example of old luxation, produced by accident or disease.

To suppose that caries of the wrist-joint could be carried to such an extent, as to destroy completely the articulating surface of the radius, without implicating even the investing cartilages of the first range of carpal bones, would be altogether inconsistent with the received history of this disease.

Even were it to be admitted that the absence of the carpal surface of the radius was owing to disease, or that (supposing the case to have been originally one of accidental luxation) it became gradually effaced, when the carpus was no longer in contact with it, the presence of an additional bone in the first range of the carpus still remains to be accounted for.

Were it, for argument sake, to be further conceded that this was merely the consequence of a fracture of the semilunar bone, there is still to be explained the remarkable fact of the elongation of the radius. Neither disease nor accident will account for it; but it is a phenomenon frequently witnessed in cases of congenital luxations. In all the examples which have been recorded of congenital dislocation of the upper extremity of the radius, the neck of this bone has been found so much elongated, that its head was placed upon the same level as the summit of the olecranon process. A similar elongation of the neck of the femur has been observed in cases of congenital luxations of the hip-joint.

The condition of the first row of carpal bones, the absence of the carpal surface of the radius, the absence of an articulating surface for the head of the ulna, and the elongation of the radius, constitute, in my opinion, an amount of evidence sufficient to prove that, in this instance, the deformity was not the result of accident or of disease, but was entirely owing to an original malformation. The commemorative circumstances of the case support this opinion.

The only example of dislocation of the carpus from accident that I am acquainted with, in which dissection established the exact nature of the injury, is that which has been recorded by M. Voillemier, in the Gazette Médicale, April, 1840. The following is an abstract of this important case.

Louis Levillain, aged 27, was admitted into the Clinical Hospital, September 28th, 1832, having fallen from the third story of a house into a court-yard. He was immediately carried to the hospital in a state of insensibility, with loss of the power of voluntary motion, fixed and dilated pupils, and stertorous respiration. He had a comminuted fracture of the left humerus, and the left wrist-joint presented the appearances usually ascribed to luxation of the carpus backwards. As the patient was evidently dying, the reduction of the bones was not attempted. Death took place four hours after the occurrence of the accident.

The fore-arm was semiflexed, the hand slightly inclined to the side of flexion, and the osseous plane, represented by the metacarpus and the carpus, was nearly parallel to that of the fore-arm; the thumb was extended and abducted, and the fingers (themselves in a state of extension) were flexed upon the metacarpus. The hand was not abducted, but was completely displaced towards the inner border of the fore-arm.

At the posterior inferior part of the fore-arm there existed a prominence, apparently formed by the carpus, upon a level with the back of the hand, but elevated about eight lines above the posterior plane of the fore-arm; it was rounded, and presented to the touch no bony ridge; neither did the skin form a transverse fold at its base, in consequence of the inclined plane, which the extensor tendons, separated from the body of the radius, formed in their passage from the fore-arm to the back of the hand. The

distance from the summit of this projection to the posterior extremity of the middle finger, exactly corresponded with the length of the carpus and metacarpus of the right hand.

At the anterior inferior part of the fore-arm, there also existed a transverse eminence, situated eight lines below that which was noticed behind; it was most remarkable at the outer side. Below this, the skin formed a distinct transverse fold; for here there was no inclined plane, as the flexor tendons, which now covered the lower extremity of the radius, formed nearly a right angle with the palm of the hand.

At the outer angle of this transverse prominence, the styloid process of the radius was recognised, and both it and the styloid process of the ulna appeared to preserve their normal relations to the bones of the fore-arm.

The anatomical examination of the joint removed all uncertainty as to the nature of the injury. It was a true luxation of the wrist. The external lateral and posterior ligaments of the articulation were broken; the anterior was torn from the edge of the radius; the internal lateral ligament alone was unbroken, but the styloid process was detached from the ulna. There was no other fracture either of this bone or of the radius. The carpal bones were uninjured, with the exception of the scaphoid, a very superficial layer of which was removed close to the attachment of the posterior radio-carpal ligament. The lower extremities of the radius and ulna lay in front of the first range of carpal bones.

To the abnormal conditions of the wrist-joint, which are liable to be mistaken for dislocations of the carpus, there must now be added congenital malformations, but the history of the case will, in every instance, be sufficient to establish the differential diagnosis.

CHAPTER VIII.

CONGENITAL DISLOCATIONS OF THE SHOULDER.

"Toutefois c'est moins le triste avantage d'ajouter une infirmité nouvelle au catalogue, déjà trop nombreux, des infirmités humaines, qui me porte à donner une courte description de ce déplacement, que le désir d'éviter aux gens de l'art de graves erreurs de jugement, et aux malades des traitemens aussi inutiles qu'ils sont rigoreux.—*Dupuytren.*"

Among the numerous contributions with which the subject of the injuries and affections of the bones constituting the shoulder-joint has been of late years enriched, scarcely any have been devoted to the consideration of the congenital luxations of the head of the humerus.

In the year 1839, I published a short memoir upon this subject,* and am not aware of any detailed description of the symptoms and anatomical characters of this remarkable malformation of the bones of the shoulder-joint having been published by any other author.

Cases have been, it is true, from time to time recorded, of the reduction and permanent cure of congenital luxations of the shoulder; but we have no evidence enabling us to determine whether the deformity depended upon an original malformation of the glenoid cavity or not. Indeed, the mere fact of the permanent reduction of the dislocation appears to constitute sufficient proof, that such cases did not possess the anatomical characters which distinguish the true congenital dislocation; and that there could not have been any malformation of the glenoid cavity.

* Dublin Medical Journal, vol. xv.

I have lately had opportunities of ascertaining, by *post mortem* examination, the exact state of the parts in several cases which, during life, were supposed to have been examples of congenital luxations of the shoulder, and which presented most of the external signs of this deformity, but in which there was no malformation, either of the glenoid cavity or of the head of the humerus. Every surgeon is familiar with such cases; the patients usually ascribe the deformity to injury received during childhood, for there is a natural unwillingness to admit any original defect of organization; but, in most instances, the paralysis, upon which the deformity depends, will be found to have existed at birth.

In the instances to which I allude, the shoulder is flattened, the deltoid and scapular muscles are atrophied, and the capsular ligament is elongated. The head of the humerus can be easily pushed either inwards or outwards, so as to permit of the glenoid cavity being felt; the whole joint is, as it were, loose; the shoulder droops, and the elongated limb may be said to dangle rather than to hang by the side.

When the head of the humerus is pushed upwards, the appearance of luxation is removed, and the rounded form of the shoulder is, to a certain extent, restored, although, in consequence of the atrophied state of the muscles, it does not recover its natural fulness. In the true congenital luxation, however, there is superadded to the atrophy of the muscles, a malformation of the bones composing the shoulder-joint.

It has been demonstrated by Dupuytren, that the congenital dislocation of the head of the femur frequently escapes observation in the infant, or, if noticed, is ascribed to a cause different from the true one. But when the pelvis begins to increase in breadth, and the child is subjected to longer and more fatiguing exertions, then the diagnostic signs of the original malformation become apparent; and, when the pelvis becomes fully developed, and all parts have completed their growth, and are called into action, the nature of the affection can no longer be doubted or mistaken.

The same remarks may be applied to the analogous condition of the shoulder-joint. In early life, before the bones have reached

their full development, before the muscles which act upon the articulation are called to their full exertion, the outward signs of the deformity may escape observation; but when the bones of the shoulder have reached maturity, when the osseous prominences which overhang the joint stand out in relief, then it is that the characteristic features of the original luxation become strikingly apparent.

Guerin states that he has observed three varieties of congenital dislocation of the shoulder,* but he has not described the symptoms which accompanied them, nor furnished us with any anatomical details.

I have myself as yet ascertained, by *post mortem* examination, the existence of only two varieties of this malformation. In one of these, the head of the humerus is placed beneath the coracoid process; while in the other and more rare variety, it is lodged in an abnormal socket, formed upon the dorsum of the scapula, below the outer and posterior part of the acromion.

They may be termed the sub-coracoid and sub-acromial congenital luxations, and may exist either upon one side only or upon both. Of the latter species I have seen only one example, but several instances of the former have come under my observation within the last few years.

Case I.—*Congenital sub-coracoid Luxation.*—The first case of original luxation of the head of the humerus which came under my notice was that of Alexander Steele, æt. 20, for many years an inmate of the House of Industry, Dublin. His left shoulder presented an example of congenital displacement beneath the

* "A. *Directement en bas*, la tête de l'humérus étant située à 2 centimètres au-dessous du rebord inférieur de la cavité glenoïde, chez un jeune homme de 10 ans, dont voici le plâtre. Cette luxation s'est effectuée à la suite d'une paralysie complète du deltoïde et de la plupart des autres muscles scapulo-huméraux et d'un allongement de la capsule, par le seul poids du membre. L'épaule gauche du même sujet présentait la même difformité à un degré beaucoup moins prononcé.

"B. *Luxation de l'humérus en dedans et en bas, complète d'un côté et incomplète de l'autre, sur le même individu.* La tête de l'humérus était appliquée contre les côtes, et les bras maintenus dans une abduction presque horizontale, sous l'influence de la rétraction des muscles deltoïdes. (Le même cas a été constaté par M. Roux.)

"C. *Sub-luxation en haut et en dehors*, caractérisée par un glissement de la tête de l'humerus dans le sens indiqué."—*Guerin, Recherches sur les Luxations Congénitales.* Paris, 1841.

coracoid process, and his left foot, a specimen of that variety of club-foot termed *pes equinus*. He does not remember having ever met with any injury of the shoulder, the present condition of the joint having existed from the earliest period of his recollection.

The muscles of the shoulder and arm are wasted to a remarkable degree, the circumference of the centre of the arm being three inches and a half less than that of the opposite side. The atrophy has also extended to the muscles which pass from the side of the chest to the humerus and scapula; so much so, that the left side of the thorax, measured from the centre of the sternum to a corresponding point posteriorly, is one inch and a half less in circumference than the opposite side of the chest.

The trapezius muscle, though not so fully developed as its fellow, still is not wasted to such a degree as the other muscles of the limb. It is the principal muscle which moves the scapula; indeed it appears to be the only one capable of acting upon that bone. The left humerus is nearly half an inch shorter than the right.

The motions of the arm are extremely limited: as it hangs by his side, he can merely swing it backwards and forwards, and even in this motion the scapula largely participates. He cannot abduct it in the least, or elevate it, neither can it be abducted for him, so far as to bring it to the horizontal line. In the scapula, however, there is evidently a compensatory motion; indeed, so great is its mobility, and so relaxed are its muscles (with the exception of the trapezius), that when both elbows are pressed upwards and with equal force, the left shoulder can be made to rise between three and four inches above the right.

Although the muscles of the fore-arm are not wasted to such a degree as those of the arm, still great difficulty (owing, apparently, to the unusual mobility of the scapula, and the atrophied condition of the biceps) is experienced in flexing the elbow-joint, so as to bring the fore-arm even to a right angle with the arm. The elevation is not performed gradually, but with a sudden jerk, in which the scapula is also raised considerably, and the arm closely applied to the side. The body is also inclined to

the opposite side during the effort, and the elbow supported upon the crest of the ilium.

The head of the humerus can easily be pressed inwards, so as to allow of the finger being placed in the outer part of the glenoid cavity; and when the bone is pressed outwards towards the acromion, the remainder of the socket can be felt, situated, apparently, upon a plane posterior to the outer portion. The head of the humerus presents nearly its natural form, as far as can be ascertained by an external examination. The left acromio-clavicular articulation enjoys an unusual degree of motion.

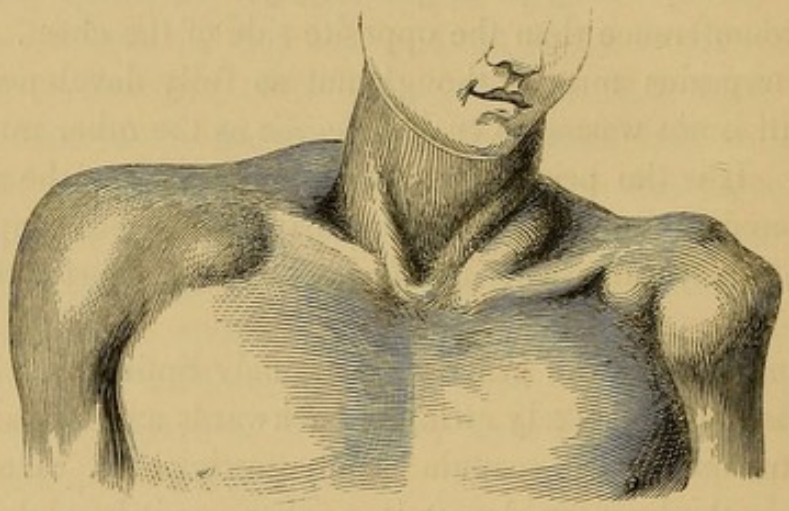

The shoulder does not possess its natural rounded form, yet still does not present the flattened appearance observed in cases of dislocation resulting from accident.

The acromion process is prominent, and when the arm hangs by the side, the head of the humerus is so far removed from the under surface of the acromion, that the thumb can with ease be placed between them. By raising the elbow, the natural form of the joint is, to a certain extent, restored; it still, however, wants the rotundity and plumpness derived from a proper development of its muscles.

Case II.—*Congenital sub-coracoid Luxation.*—In the month of April, 1839, I visited Mr. H——, æt. 20, whose left shoulder presented an example of congenital luxation beneath the coracoid

process, so closely resembling that described in the preceding pages, as to render a full description of it unnecessary.

The axis of the humerus was directed downwards and backwards; the head of the bone, as the arm hung by the side, lying beneath the coracoid process; the external part of the glenoid cavity could be felt beneath the prominent acromion.

When the elbow was drawn forwards across the chest, the head of the humerus passed outwards towards the acromion, allowing the abnormal portion of the glenoid cavity to be felt beneath the coracoid process.

The muscles of the shoulder and of the arm were wasted, but, as in the case of Steele, the trapezius appeared to be nearly as well developed as its fellow on the opposite side. The patient could neither raise nor abduct the arm, and the scapula participated in all the under motions of the limb. The deformity had existed from his birth, but became much more obvious and striking as he increased in age and stature.

Case III.—*Congenital sub-coracoid Luxation.*—A boy, æt. 9, was sent to me by Doctor Croker. The aunt of the child stated that his right arm was paralyzed, but the peculiar and characteristic manner in which the limb hung by his side induced me to suspect the existence of an original malformation of the shoulder-joint.

It was stated that he had nearly attained the age of one year before the condition of the limb attracted attention, which was then excited, not by the deformity of the shoulder, but by the atrophied condition of the muscles of the arm, when contrasted with those of the opposite side. The child had not met with any accident, nor did he ever complain of pain or of any other symptom indicative of disease of the articulation.

The case had been treated as one of simple paralysis; blisters and other severe measures were had recourse to for upwards of two years, but without being productive of any beneficial effect. Various mechanical contrivances were subsequently, but ineffectually, employed, with a view to retain the head of the bone in its proper position.

I inquired particularly whether the deformity of the shoulder had increased since it had first been observed, and learned that

several years had elapsed before the full development of the appearances which the joint now presented.

The characters of the deformity accurately resembled those which have been already mentioned, in the description of the case of Steele. There was the same prominence of the acromion process and wasting of the muscles; the same mobility of the scapula; and the glenoid cavity, imperfectly developed, could be felt with equal facility and distinctness. The trapezius muscle was as well developed as that of the opposite side.

Case IV.—*Symmetrical sub-coracoid Luxations, congenital.*—A female, æt. 29, who had been for many years a patient in the lunatic department of the House of Industry, died of chronic inflammation of the membranes of the brain, and I was called upon to make the *post mortem* examination.

Upon entering the room, my attention was attracted by the appearances which the shoulder-joints presented; the deviations from the normal state were most remarkable upon the left side.

The muscles of the shoulder and arm were atrophied; the acromion process projected considerably, and the head of the humerus could be perceived lying immediately beneath the coracoid process, the apex of which was in a line with the bicipital groove of the humerus. The natural roundness of the shoulder had disappeared, and the elbow projected from the side, but could be readily brought into contact with it.

The right shoulder presented similar appearances, but in a slighter degree; the head of the humerus was not placed so directly beneath the coracoid process, but the flattened form of the shoulder, the atrophied muscles, and the projection of the acromion, all indicated that the condition of the joint was similar to that of the opposite side.

Although from the external characters, it was sufficiently evident that the deviations from the normal state of the articulation were not the result of accidental violence, yet it was difficult to pronounce as to the exact nature of the alterations, to which the appearances above described should be attributed. But, from the circumstance of both joints being similarly affected, and from the absence of any external sign of disease, I arrived at the conclusion that the deformities were the result of an original or conge-

nital malformation. The anatomical examination of the joints confirmed this opinion.

Upon the left side there existed scarcely any trace of an articulating surface, in the situation which the glenoid cavity occupies in the normal state; but there had been formed upon the costal surface of the scapula, a socket of a glenoid shape, measuring about an inch and a half in its vertical direction, and an inch and a quarter transversely. It reached upwards to the under surface of the coracoid process, from which the head of the

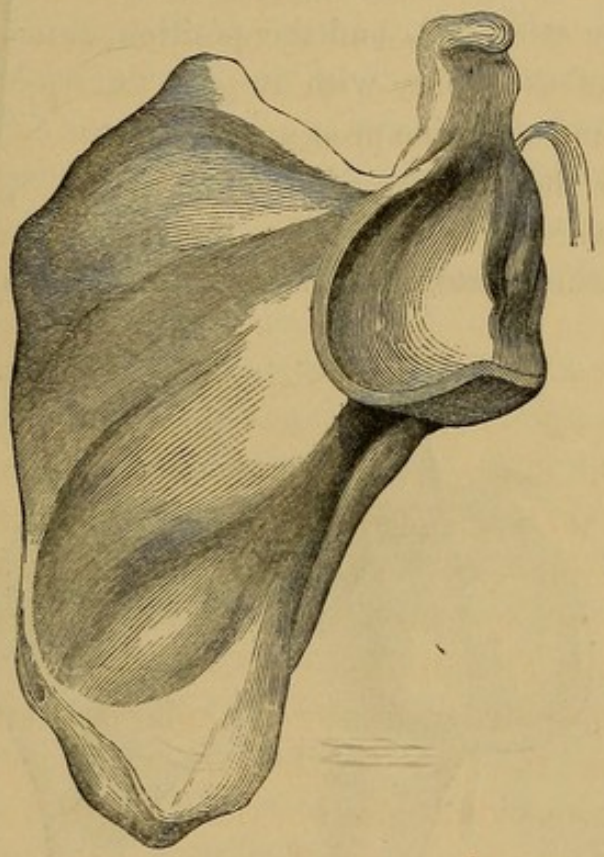

humerus was merely separated by the capsular ligament, there being no interval between the summit of the abnormal socket and the coracoid process.

Around this socket the glenoid ligament, perfect in every respect, was continued from the margin of that small portion of the natural articulating surface, which existed upon the axillary margin of the bone, and to the apex of which the tendon of the biceps was attached. The capsular ligament was perfect.

The head of the humerus did not present its natural spherical

form; it was of an oval shape, its long axis corresponding with the shaft of the bone. The oval form was principally due to the deficiency of its posterior part, and there existed between the greater tubercle and the margin of the head of the bone, where the investing cartilage terminated, a broad, shallow depression, corresponding to the edge which separated the normal from the abnormal portion of the glenoid cavity.

LEFT HUMERUS.

The shaft of the humerus was small and seemingly atrophied, and the position of the head of the bone, with respect to the coracoid and acromion processes, varied according as the motion of rotation inwards or outwards was imparted to the arm.

In the natural state, these motions produce but little change

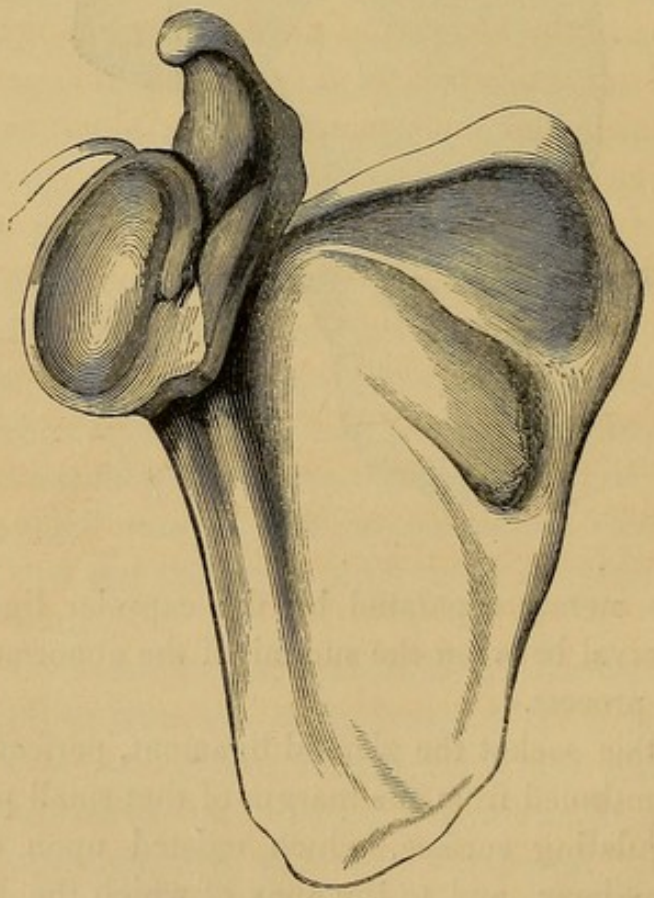

in the relative situation of the head of the humerus; but in the instance under consideration, during rotation outwards, the head

of the bone passed towards the acromion process, and occupied the small portion that existed of the natural glenoid cavity, while rotation inwards brought it altogether beneath the coracoid process, so that the finger could be easily sunk into the outer portion of the socket.

Upon the right side, although the condition of the bones was somewhat different, the characteristic features of the deformity were similar.

The malformation of the glenoid cavity (limited to its inner third) consisted in a deficiency of its internal border. At the junction of the middle with the inner portion, the surface of the socket began to slope inwards and backwards, thus presenting an inclined plane, the inner margin of which was constituted by a ridge of bone, extending from the posterior inferior part of the root of the coracoid process downwards and forwards to the lower extremity of the glenoid cavity, the surface of which was thus rendered convex from side to side.

The tendon of the biceps and the capsular ligament were perfect, but the latter was attached to the osseous ridge already mentioned, as forming the inner margin of the abnormal portion of the glenoid cavity.

The head of the humerus was of an oval form, its long diameter being placed vertically. Its posterior and external portion was deficient, the head of the bone appearing as if a section had been made of it from above downwards. Its anterior part presented an irregular osseous ridge, which corresponded to the abnormal portion of the glenoid cavity. The oval shape of the head of the humerus, and the deficiency of its posterior portion, were much more remarkable than upon the opposite side. In this case it was ascertained beyond the possibility of doubt that there had been no disease of either scapulo-humeral articulation, at any period of the patient's life, nor had they ever been the seat of injury of any description.

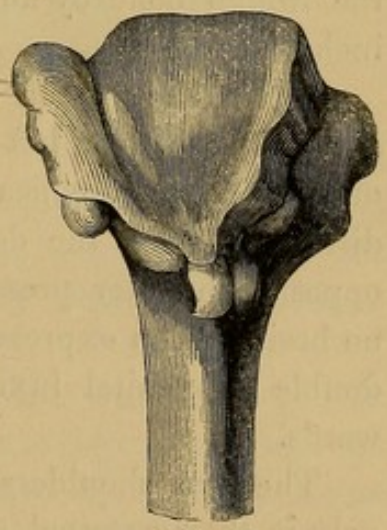

RIGHT HUMERUS.

The preceding cases furnish, in my opinion, well-marked instances of original sub-coracoid luxations of the head of the humerus. From the similarity of their history, and their close resemblance to each other, as regards the external characters of the deformity, and the period of its duration, it is obvious that they all belong to the same category; while the fourth case furnishes sufficient anatomical evidence of their having all been examples of congenital dislocations.

The position of the glenoid cavity, the remarkable form of the head of the humerus, the presence of a perfect glenoid ligament, the absence of any trace of disease, and the existence of the deformity upon each side, all indicate the original nature of the malformation.

Case V.—*Symmetrical sub-acromial Luxations, congenital.*—A woman, named Judith Tracy Doyle, æt. 42, a lunatic, died upon the 8th of February, 1839, in the House of Industry, Dublin. She had been a patient in the lunatic department of the institution for fifteen years, and was subject to severe epileptic convulsions, which ultimately proved fatal.

Upon the day subsequent to her death, I made an examination of the body. The brain presented the appearances so frequently observed in idiots; the convolutions of the cerebrum were small and atrophied, and the anterior lobes separated from the frontal bone by an interval of, at least, three-quarters of an inch.*

While engaged in the examination of the brain, an unusual appearance of the left shoulder-joint accidentally attracted my observation. The head of the humerus appeared to have been dislocated upon the dorsum of the scapula. Finding that the opposite shoulder presented precisely similar appearances, I had no hesitation in expressing my opinion, that the case was one of double congenital luxation of the head of the humerus backwards.

The two shoulders resembled each other so perfectly, not only in their external conformation, but likewise in their anatomical characters, that a detailed description of one will be sufficient.

* See Cruveilhier, livraison v. and viii.

The coracoid process, owing to the removal of the head of the humerus from its vicinity, formed a most remarkable projection, and (the subject being emaciated) the coraco-brachialis and the short head of the biceps could be seen passing very obliquely downwards and outwards, and the anterior margin of the coraco-acromial ligament stood out in strong relief. The acromion process was unusually prominent, although it did not project as much as in any of the accidental dislocations of the shoulder.

The glenoid cavity could not be felt, although the head of the humerus was far removed from its natural position; the shoulder appeared higher than natural, and was flattened anteriorly; but posteriorly a round, solid tumour plainly indicated the

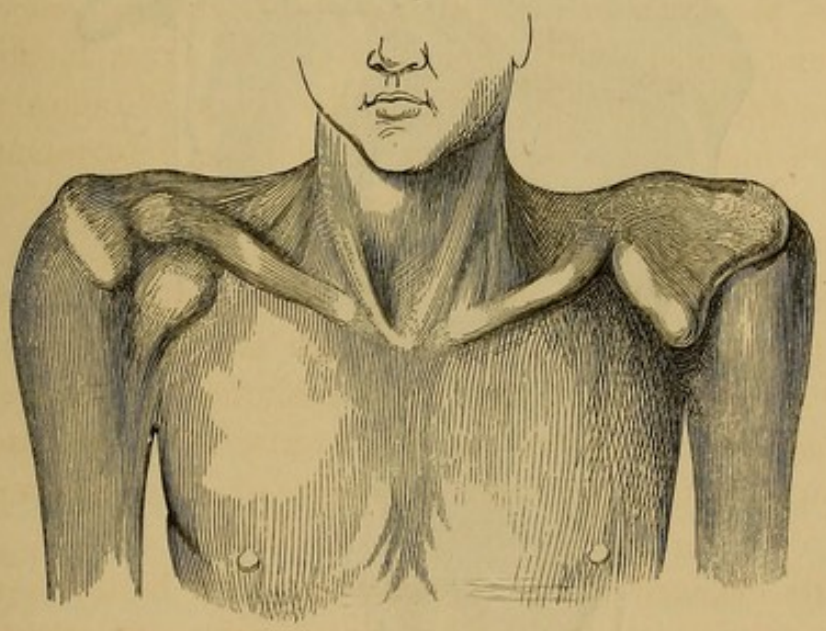

situation of the head of the bone. It accompanied every motion imparted to the shaft of the humerus, and was placed upon the dorsal surface of the scapula immediately below the acromion process.

The transverse diameter of the shoulder was much greater than natural, the distance between the coracoid process and the external surface of the head of the humerus being three inches and a half. The arm was directed obliquely downwards and inwards; the elbow was in contact with the side, and the hand and fore-arm in a state of pronation.

Upon removing the muscles, and exposing the interior of the

joint, I found that there was no trace of a glenoid cavity in the natural situation; but upon the external surface of the neck of the scapula there was a well-formed socket, which received the head of the humerus.

It was an inch and three-quarters in length, and an inch in breadth; it was a little broader above than below, and its summit was less than a quarter of an inch from the under surface of the acromion process. It was directed outwards and forwards, was covered with cartilage, and surrounded by a perfect glenoid liga-

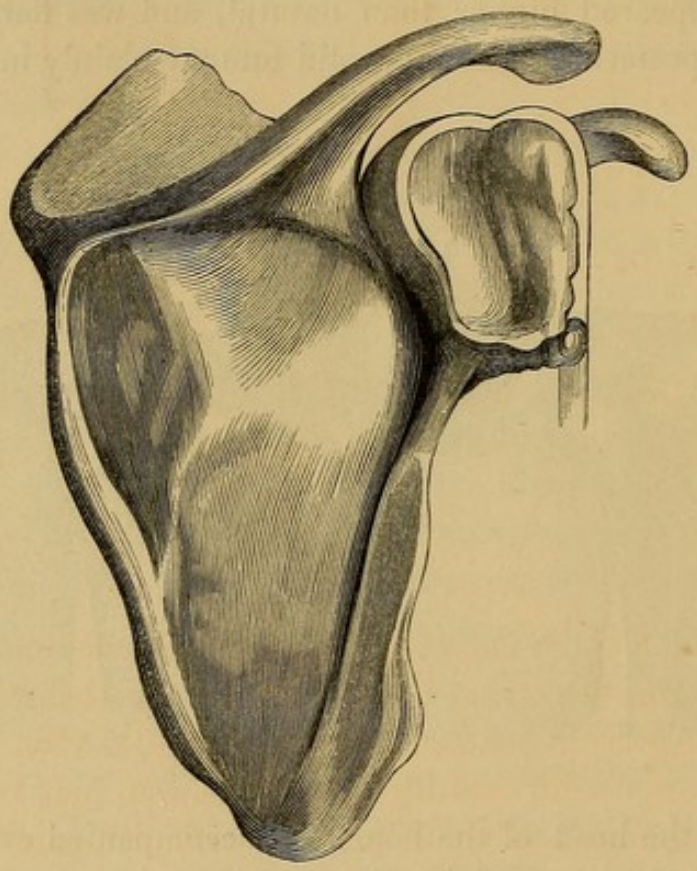

ment. The tendon of the biceps muscle arose from the most internal part of its superior extremity, from whence it passed downwards and outwards very obliquely, in order to reach the bicipital groove of the humerus. The axillary margin of the scapula, if prolonged upwards, would have passed nearly altogether internal to this abnormal socket.

The surfaces of the acromion process, instead of being directed, as in the natural state, the one upwards and outwards, and the other downwards and inwards, looked directly upwards and

downwards. The capsular ligament was perfect. The scapula was smaller than natural, and its muscles badly developed.

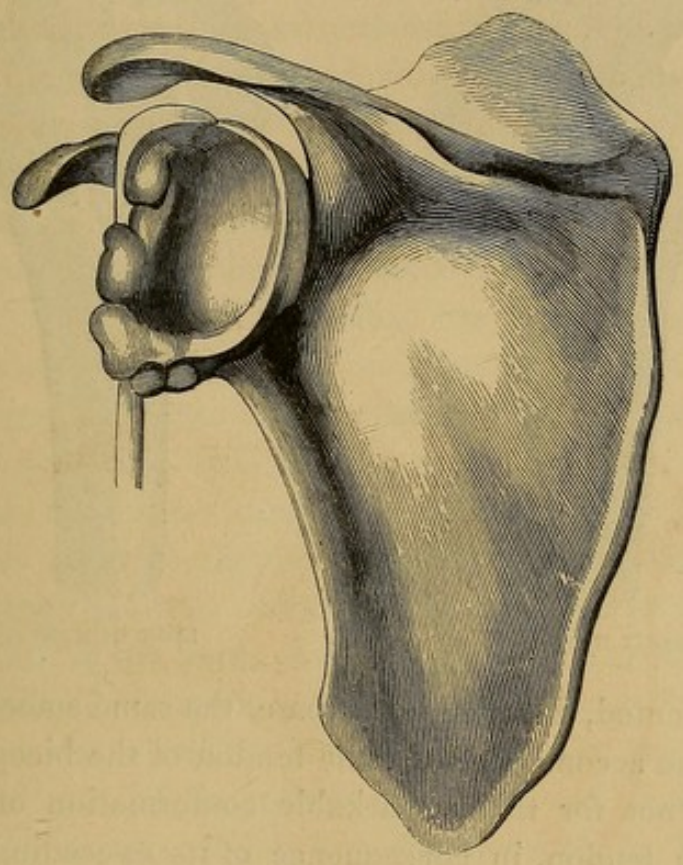

The head of the humerus, upon the right side, was of an oval or oblong form, somewhat broader above than below; its anterior half alone was in contact with the glenoid cavity. This portion was covered with cartilage, the remaining half being rough and scabrous, and totally destitute of articular cartilage. The inner edge of the humerus, if prolonged upwards, would have passed between these two portions of the head of the bone.

The greater tubercle was natural, but the lesser was elongated and curved, forming a most remarkable process: it was an inch in length, and bore some resemblance to the coracoid process of the scapula. At its root it presented a smooth, convex, pulley-shaped surface, round which passed the tendon of the biceps muscle. The arrangement reminded me of the passage of the posterior fibres of the temporal muscle over the pulley of the zygoma.

Upon the left side, the head of the humerus presented almost

precisely similar appearances,—the only difference, in fact, being that the lesser tuberosity was not as large as upon the opposite

RIGHT HUMERUS.

LEFT HUMERUS.

side. It presented, however, at its base, the same smooth, convex surface for the accomodation of the tendon of the biceps.

Were it not for this remarkable conformation of the lesser tubercle, the tendon, in consequence of its exceedingly oblique course, would have been in danger of slipping from the bicipital groove. The contraction of the biceps, tending to bring it into a right line with the muscular fibres, would, probably, have ultimately displaced it from the shallow groove which the normal bone presents. The hypertrophy of the tuberosity, therefore, appears to have been the result of a subsequent process, established in order to counteract the danger to which the very oblique course of the tendon, with regard to the muscular fibres, exposed it.

That the phenomena noticed in this remarkable case originated neither in disease nor accident is, I think, sufficiently obvious. The complete absence of a glenoid cavity in the natural situation; the existence of the deformity upon each side; the perfect resemblance between the abnormal sockets, in form, size, and position; the integrity of the tendon of the biceps and of the capsular and glenoid ligaments; and the peculiar form of the

head of the humerus upon each side;—all support the opinion that the dislocations must have existed at birth.

In the present state of our knowledge, however, and in the absence of a more extended series of observations, it is, as Chelius has remarked, impossible to determine with certainty whether the cause of the luxation should always be sought for in an original deficient formation of the articular surfaces; or whether such dislocations may not be produced by the peculiar position of the fœtus in the womb, the particular changes subsequently found depending on the long continuance of the displacement.

Indeed, notwithstanding all that has been written upon the subject of congenital luxations, our knowledge of it is still very imperfect, and opinions of the most opposite nature are maintained with regard to their causes.

Breschet, Dupuytren, and, indeed, most other writers, have looked upon them as the result of arrested development of the bones and their sockets. Chelius and Cruveilhier ascribe them to the position of the fœtus in the womb. Guerin considers them as the product of an active or primary retraction of the muscles, the remote cause of which is to be sought in the affection of some central part of the nervous system; and that they result from the same causes as club-foot, wry-neck, &c.* Chelius, as I have already mentioned, believes that the position of the fœtus in the womb is the principal cause of congenital luxation, which it produces either directly, or by preventing the development of the component parts of the joint, and, therefore, that the latter is not to be considered as a primary cause, but only as a consequence.

This opinion is, probably, to a certain extent, correct; but pathologists appear to me to have erred in ascribing the origin of these dislocations to one cause, operating in all cases. Some may be owing to the position of the fœtus; others to an arrest of development, and a lesion of some of the nervous centres may be, perhaps, the remote cause of the deformity in some instances. This opinion is supported by the frequent occurrence of conge-

* "Ces luxations s'enchaînent donc à la même théorie générale que les déviations de l'épine, le pied-bot, le torticolis."—*Recherches sur les Luxations Congénitales.* Paris, 1841.

nital luxations in idiots, and also by the fact of their being so often symmetrical; but it is difficult to believe in the possibility of effecting a permanent cure of the deformity, if we are to recognise a lesion of some of the nervous centres as its source in all instances.

It is not, however, my intention to discuss this difficult subject, for I am wholly unprepared to offer any satisfactory explanation of the causes of original luxations; nor can any sufficient solution of the phenomena be arrived at, except by the examination of the fœtus at the earliest periods of intra-uterine life. The hypotheses hitherto promulgated have reference only to that form of displacement observed at birth; but I believe, with Dupuytren, that there is another form which is original, and coeval with the earliest organization of the parts.

In his memoir upon congenital dislocations of the hip-joint, this distinguished surgeon has remarked, that "Whatever some physiologists may have said, there are certain vices of conformation which are altogether original, and are referable to a defect in the organization of the germs. May not the deformity of which we have been speaking appertain to this class? In adopting this hypothesis, a ready explanation of the simultaneous dislocation of (in most instances) both thigh-bones is afforded; and the perfect health at birth of the subjects of this affection, together with the entire absence of any evidence or symptom of disease, past or present, in or around the articulation, would serve to confirm the probability of this suggestion."

CHAPTER IX.

DISLOCATIONS OF THE LOWER JAW.

"Il semble, au premier coup d'œil, que tout ce qui est relatif à l'articulation de la mâchoire inférieure et à ses mouvements est généralement connu, ou que le peu qui resterait à dire sur cette partie de la science n'est pas d'une assez grande importance pour qu'on doive s'en occuper; cependant rien n'est à dédaigner lorsqu'il s'agit de la connaissance des fonctions et des maladies."—*Ribes.*

THE following remarkable instance of congenital luxation of the inferior maxilla came under my observation in the year 1840, and is worthy of being recorded, inasmuch as it tends to complete the series of what have been termed congenital dislocations.

I am not aware of any other example of this singular malformation having been described, the following brief notice by Guerin, being the only allusion to the subject which I have been able to discover: "LUXATION COMPLETE DE LA MACHOIRE DANS LES FOSSES ZYGOMATIQUES. Je l'ai observée sur un fœtus dérencéphale que voici; la tension et le raccourcissement des muscles abaisseurs et des ptérygoïdiens externes contrastent avec l'allongement et l'amincissement des temporaux et des masséters."*

In the month of April, 1840, Edward Lacy, æt. 38, an idiot from his infancy, was transferred from the Lunatic Asylum at Island Bridge, to the Hardwicke Hospital, in consequence of an attack of bronchitis complicated with diarrhœa. After a short period he so far recovered that he was removed into the convalescent ward of the hospital; but, upon the 2nd of May, he was again attacked with cough, followed by violent hæmoptysis, and expectorated a large quantity of blood, partly fluid and in part

* Recherches sur les Luxations Congénitales, &c., Paris, 1841.

coagulated. The hæmorrhage continued to recur at intervals during the 3rd and 4th; his breath became extremely fœtid, and his strength was observed to be failing rapidly. He died upon the night of the 5th.

It is unnecessary to describe at length the morbid appearances which the lungs presented; suffice it to say, that there existed in the lower lobe of the right lung a gangrenous cavity, containing several ounces of decomposed blood, and that the left

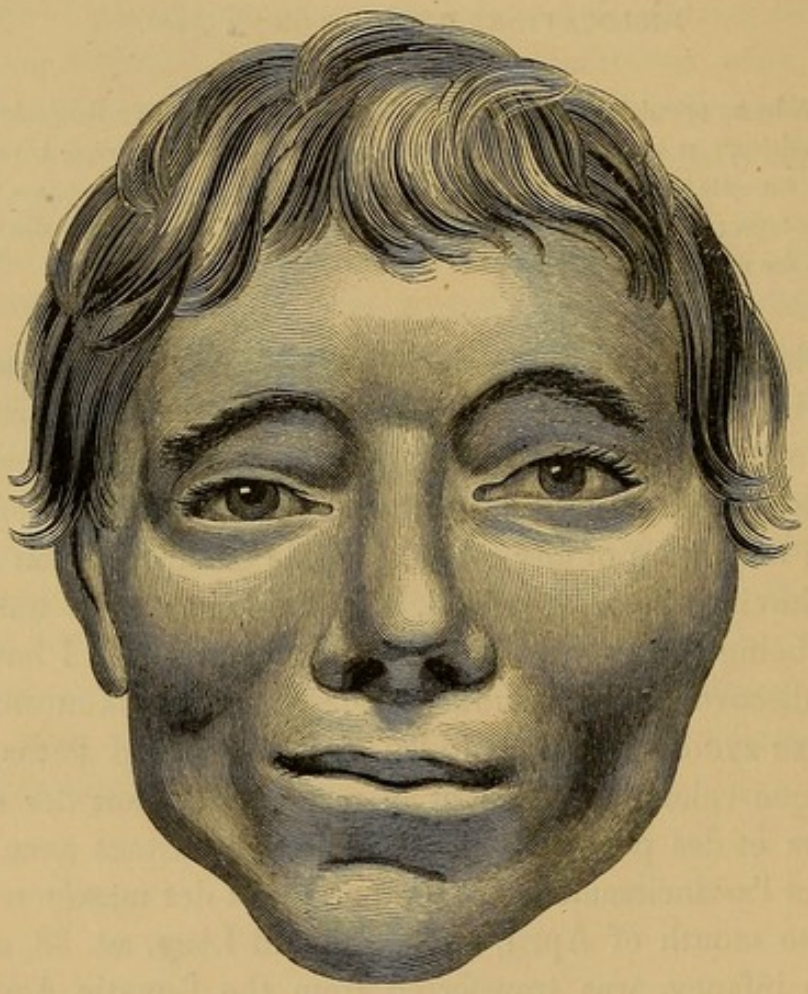

lung was similarly affected. The right side of the brain was smaller than the left; there was opacity of the membranes, and subarachnoid effusion.

While engaged in examining the head, a singular deformity of the countenance, which is accurately represented in the accompanying figure, attracted my observation. The right and left sides of the face seemed as though they did not belong to the same in-

dividual, the left being in every respect larger and more fully developed. Upon this side the prominence of the malar bone and of the arch of the zygoma, the development of the masseter muscle, and the fulness of the parotid space, all in a remarkable manner contrasted with the atrophy of the opposite half of the countenance, which, in the situation of the zygoma, presented a concavity in place of a convexity, and in the parotid space a very distinct depression. The countenance was, moreover, crooked

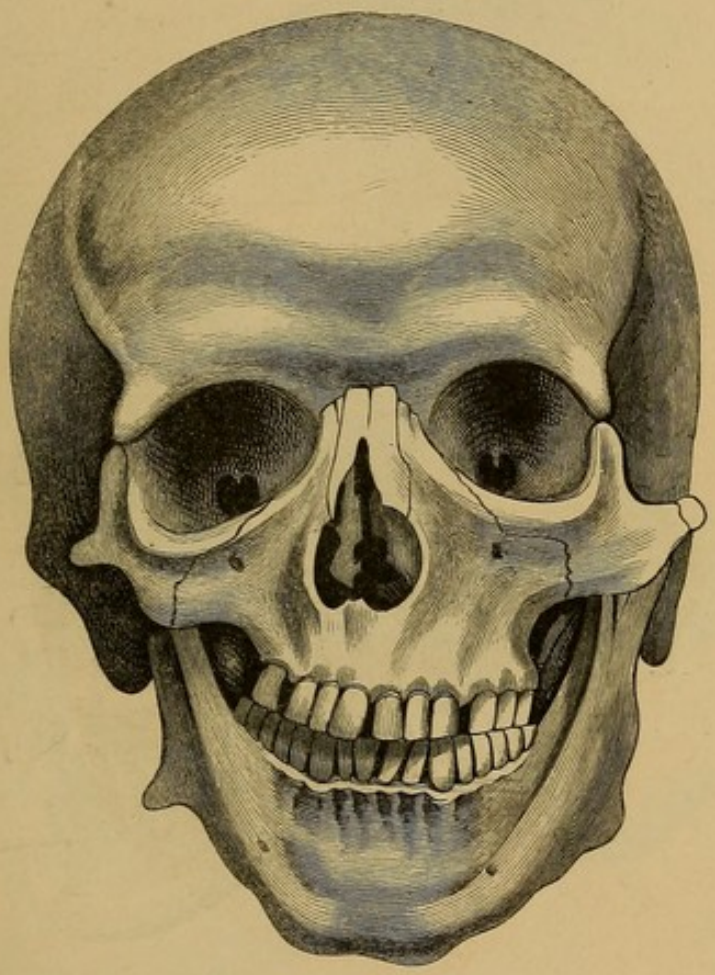

in almost every feature. Upon the right side the angle of the mouth was higher than upon the left, while upon the left the orbit was placed a little higher than upon the right; the superciliary arch was much more projecting, and the eye more prominent.

The right side of the face appeared as it were sunk in, and the extremity of the finger could be placed between the paro-

tideal margin of the jaw and the front of the external auditory canal.

In the preceding and two following views of the skeleton of the head and face, most of the characters above described can be distinctly seen.

Upon elevating the integuments, and contrasting the dissected muscles of either side, those of the right were found to be much

smaller than their fellows of the left side. The masseter, in particular, was atrophied both in length, breadth, and thickness; the temporal and pterygoid muscles also appeared small when compared with those of the opposite side, but as regarded colour and consistence, the muscular fibre did not deviate from the normal condition, nor was there any appreciable difference between the nerves of either side.

The muscles having been removed, and the bones and ligaments exposed, the condition of the right temporo-maxillary articulation was carefully examined.

When the mouth was closed, and the teeth maintained in apposition, as exact as the abnormal state of the parts admitted of, the external lateral ligament of the lower jaw, instead of being directed backwards, was seen descending obliquely forwards, to

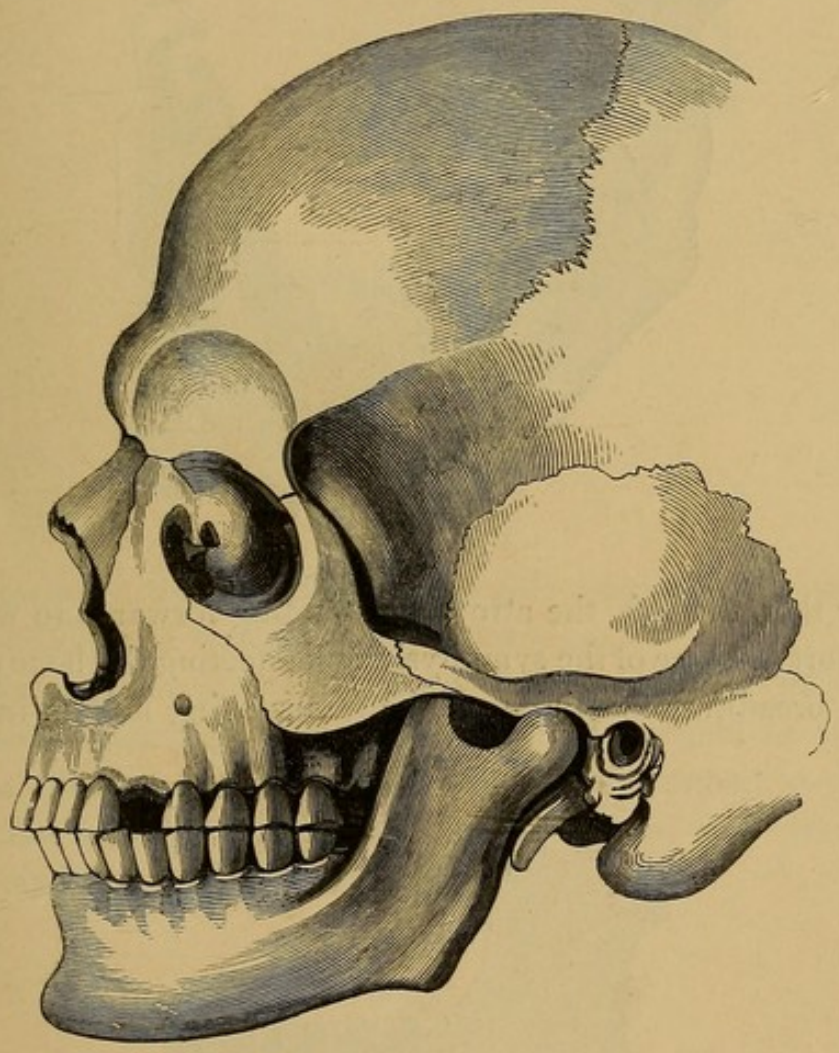

be attached to a very imperfectly developed condyle, which was not in contact with that portion of the temporal bone, which, in the natural state, corresponds to the glenoid cavity, being separated from it by an interval of at least a quarter of an inch.

There was neither an interarticular cartilage nor cartilage of incrustation, the osseous surfaces of the joint being invested by a thick periosteum alone. There was no distinct capsular ligament.

The skeleton of the cranium and face presented most interesting and remarkable appearances.

INFERIOR MAXILLARY BONE.

The right side of the inferior maxillary bone was considerably

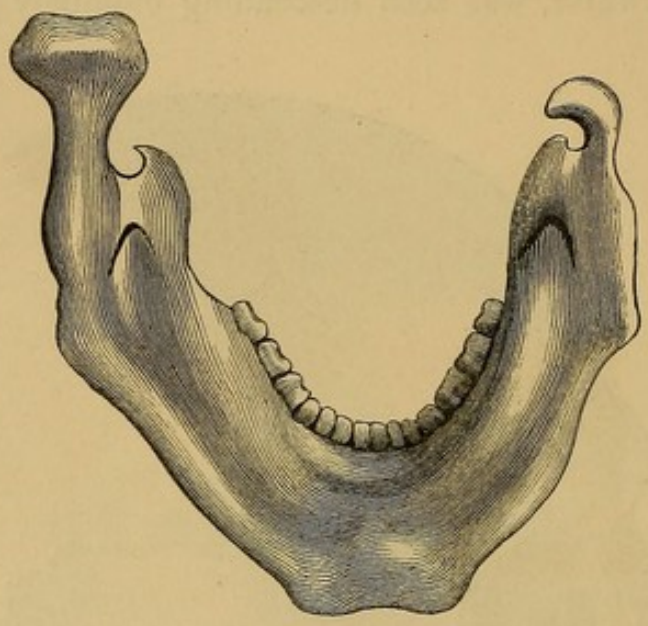

smaller than the left, the atrophy extending forwards to within a very short distance of the symphysis, and affecting the bone as to its length, breadth, and thickness, the ramus being half an inch less

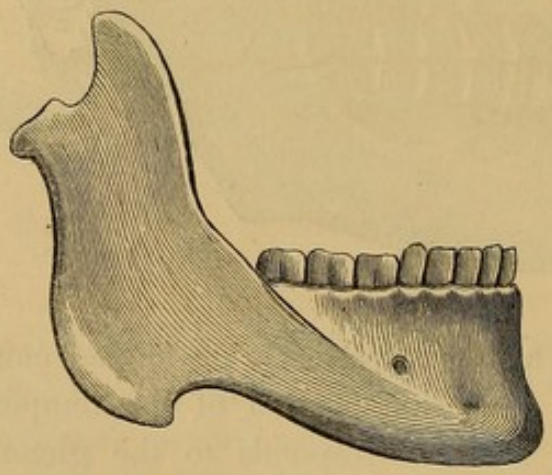

in its transverse diameter, and its parotideal margin half an inch shorter than upon the opposite side.

The lower edge of the bone presented a deep concavity at

its posterior part, and the angle was remarkably prominent and curved outwards; the parotideal margin, thin, concave at its upper part, and forming nearly a right angle with the body of the bone, terminated above in a small curved process, directed nearly horizontally inwards, its superior surface being directed slightly outwards, and its inferior slightly inwards.

This process, which in form somewhat resembled the cora-

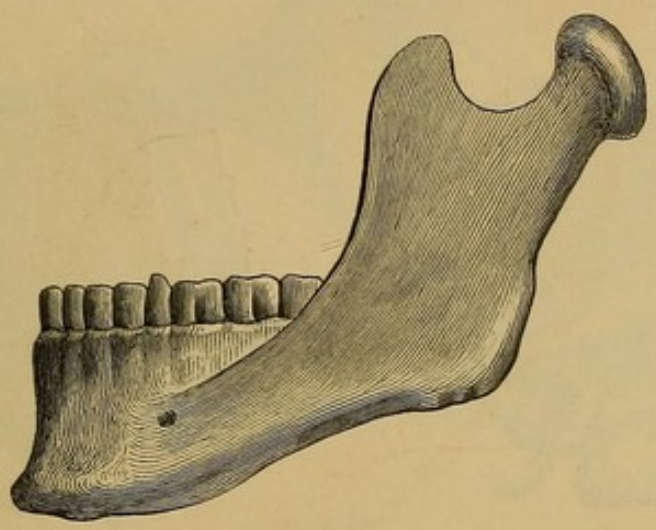

coid process of the scapula, was the only vestige of the existence of a condyle, and was destitute of cartilage.

The external pterygoid muscle was attached to its anterior and inner part, and the external lateral ligament to its outer surface; there was a complete arrest of development in the condyle; the coronoid process was small and thin, and the sigmoid notch could scarcely be said to exist.

TEMPORAL BONE.

The deformity noticed in this bone consisted in an arrest of development of the zygomatic process. The superior or longitudinal root existed, but the transverse root or articular eminence was absent, there being in its place merely a flat surface destitute of cartilage. At the point where the two roots meet in the normal state, or, in other words, at the tubercle of the zygoma, the temporal was joined to the malar bone, the suture which connected them being distant only half an inch from the circum-

ference of the external auditory canal, while upon the opposite side the interval was one inch and a half.

The transverse root of the zygoma not having been developed, there consequently did not exist any glenoid cavity. There was in its place merely a quadrilateral-shaped surface, nearly flat, the inner portion alone of which was concerned in the motions of the jaw upon this side, and here it presented a shallow sulcus, directed from before backwards, nearly parallel to the posterior part of the

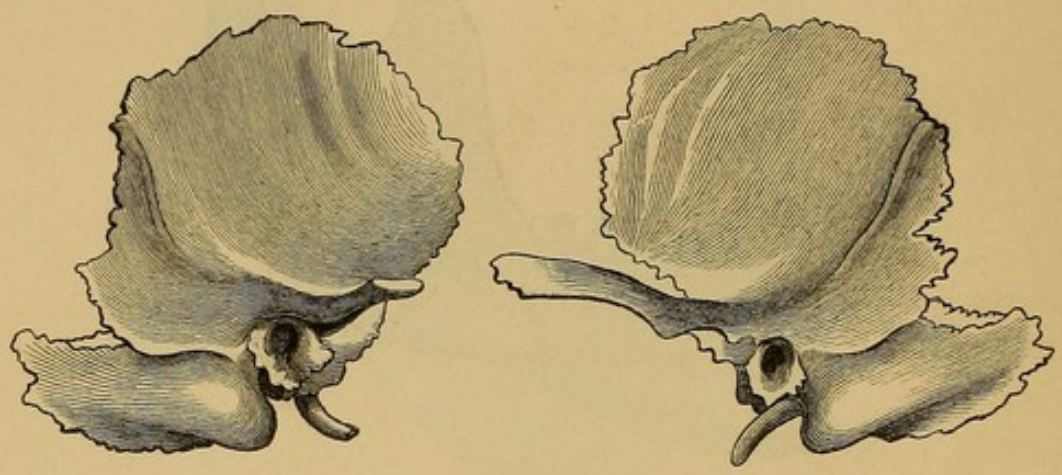

spheno-temporal suture. This sulcus formed a segment of a large circle, in which moved the curved and atrophied process, representing the condyle of the jaw. There was no deformity whatever of the non-articulating portion of the bone, posterior to the Glasserian fissure.

The entire bone was somewhat smaller than that of the opposite side. The cerebral surface of its mastoid portion presented no channel or groove whatever for the accommodation of the great lateral sinus; and the jugular foramen upon this side was scarcely half as large as upon the opposite.

MALAR BONE.

The malar bone, in size and shape, formed a very remarkable contrast with its fellow. It was small and thin, its facial surface concave and its zygomatic process, of extraordinary length, extended as far back as the situation which the tubercle of the zygoma occupies in the normal state, thus forming the entire of

the zygomatic arch, which was concave externally, and convex towards the zygomatic fossa, the transverse breadth of which was

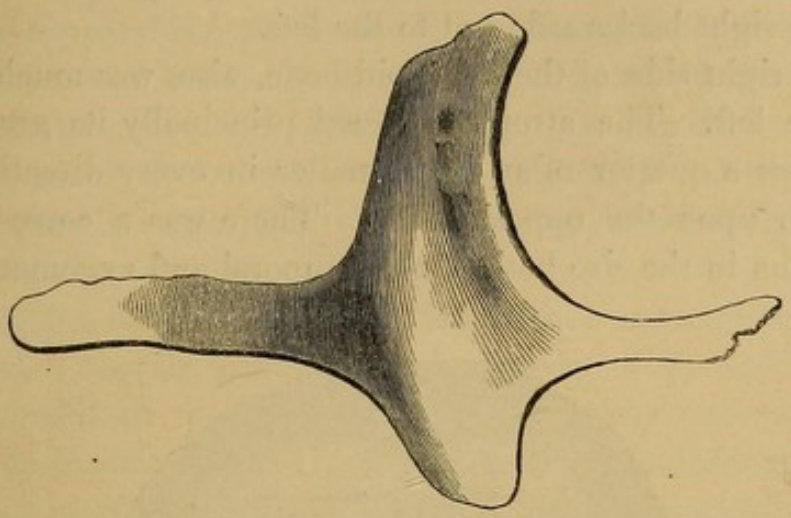

diminished by a quarter of an inch. The suture, by which it was joined to the temporal bone, was only apparent inferiorly.

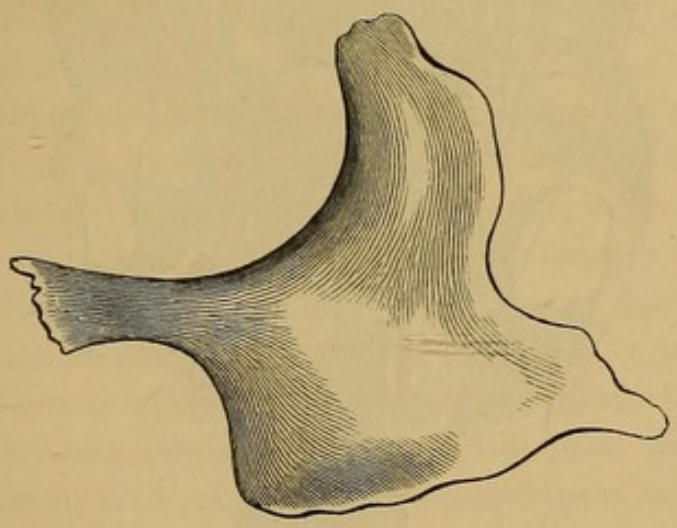

The process itself entered into the composition of the pulley-shaped surface, over which pass the posterior fibres of the temporal muscle.

SUPERIOR MAXILLARY BONE.

This bone was also much smaller than natural; its alveolar border did not descend as low as that of the opposite bone, nor

did the suture by which it was united to its fellow occupy the median line, so that the palate did not consist of two symmetrical portions, the suture being directed obliquely from before and from the right backwards and to the left.

The right side of the sphenoid bone, also, was much smaller than the left. The atrophy affected principally its great wing, which was a quarter of an inch smaller in every direction upon this than upon the opposite side. There was a corresponding diminution in the size both of the temporal and zygomatic fossæ.

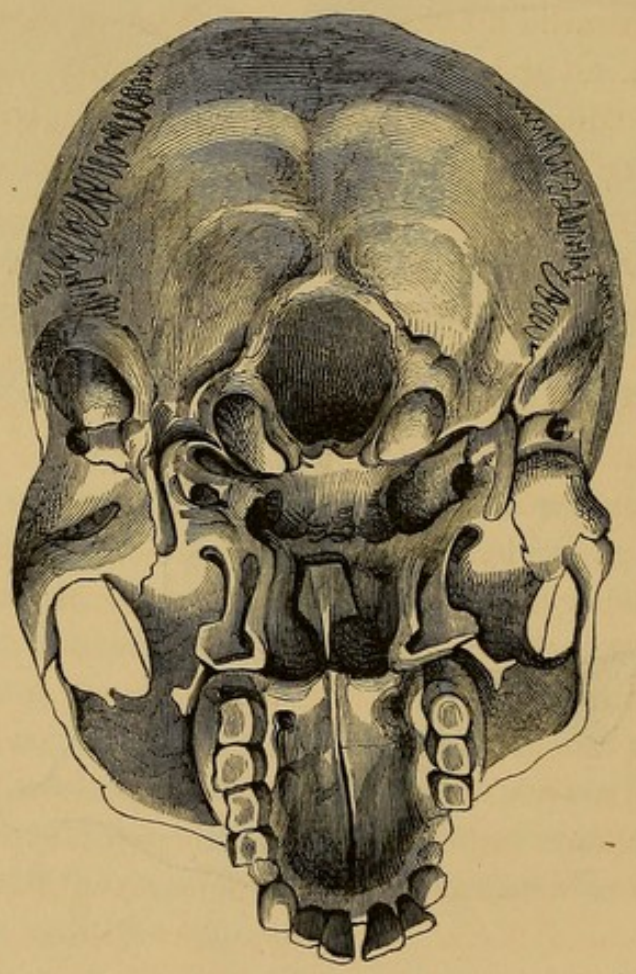

In consequence of the atrophy of the superior maxillary, malar, and sphenoid bones, the right orbit was somewhat smaller than the left; and the outer portion of its circumference retired so much, as to justify us in supposing that there must have been a much greater range of lateral vision upon this side than upon the opposite.

The motions of which the lower jaw was capable in this case

were more extensive than those which it enjoys in the normal state, especially lateral motion, or, more correctly speaking, a movement by which the right ramus was drawn backwards and forwards, approaching the auditory canal and the posterior surface of the malar bone alternately; while upon the left side the condyle underwent a species of rotation upon its axis, and during life the patient was observed to be constantly performing this motion, and the right side of the face was continually affected with spasmodic twitches.

When the mouth was closed, the incisor and canine teeth of the superior maxilla projected beyond those of the inferior, and when opened, all the features of the deformity were increased, and the crookedness of the mouth became particularly apparent.

It has been maintained by Ribes, that the formation of the glenoid cavity is consequent upon the growth of the condyle, and that, were this process not formed, there would not exist either a glenoid cavity or an articular eminence.

The opinions upon this subject, of the distinguished writer to whom I have alluded, are expressed in the following extracts from his memoir upon the articulation of the lower jaw:

"Les deux parties du temporal (glenoid cavity and articular eminence) dont je viens de parler n'existent point dans le fœtus. Jusqu'au septième mois de la grossesse, on ne trouve qu'une surface plane, et nulle trace d'apophyse transverse: vers le neuvième, on distingue à peine le commencement de la cavite glénoïdale; mais bientot l'une et l'autre partie se forment, et sont le produit de la pression que le condyle exerce sur le temporal.

"La mâchoire inférieure, par sa disposition presque droite dans les enfants, a le centre de ses mouvements, comme il sera dit plus loin, dans l'axe d'une ligne qui passerait transversalement d'un condyle à l'autre, ce qui fait que ces éminences ne changent point de place: la pression constant qu'elles exercent contre le temporal s'oppose à son développement dans ce point, et la cavité s'y forme.

"Mais comme à cet âge presque tous les mouvements sont bornés à l'abaissement et à l'elevation, le condyle qui frottait d'abord légèrement sur le rebord intérieur de la cavité, appuye par la suite sur une portion plus considérable de ce rebord.

"Ainsi toute l'étendue de cette élévation s'encroûte insensiblement de cartilage, et prend une forme analogue à celle du condyle recouvert par le ligament inter-articulaire. Cette apophyse reste toujours plus saillante que la cavité, parce que celle-ci est constamment pressée par le condyle qui s'oppose à son développement, tandis que l'autre n'est rencontrée qu'à des intervalles de temps assez éloignés pour qu'elle n'empêche son accroissement que jusqu' à un certain point.

"Le condyle porte aussi ses effets sur la partie postérieure de la cavité, et principalement sur la partie antérieure du conduit auriculaire, qui serait parfaitement cylindrique sans la pression du condyle qui l'aplatit un peu antérieurement.

"D'après ce que je viens de dire, la cavité glenoïdale et l'apophyse transverse sont le produit de la pression inégale qu' exerce le condyle sur les deux points du temporal où elles se trouvent placées; *sans la présence de cette éminence, il n'existerait aucune trace de cavité ni d'apophyse transverse et ces parties du temporal seraient au même niveau.*"*

Although the preceding description appears to be supported by the case of Lacy, I am by no means willing to admit that the formation of the glenoid cavity is the result of a process so purely mechanical as that implied in the theory of Ribes.

It is true that the development of the condyle precedes that of the glenoid cavity; but it by no means follows from thence, that the formation of the latter is the result of the pressure of the former. Were the nearly plane surface of the fœtal temporal bone, with which the condyle is in contact, deepened into a glenoid cavity, by the pressure of that condyle, it would be natural to expect that this increased depth would be indicated by a corresponding convexity of the cerebral surface of the roof of the cavity. This, however, is not the case, nor does the growth of the condyle appear to exert, as stated by Ribes, any influence upon the form of the osseous portion of the external auditory canal; for, in the case which I have described, in which it is obvious that a condyle had never existed, the meatus, both in form and size, was identical with that of the opposite side.

* Collection des Thèses de Médecine.

It appears to me that the formation of the glenoid cavity is due, not to the pressure of the condyle, but to the growth of the articular eminence, previous to the development of which, there merely exists an almost plane surface, which would readily admit of the occurrence of luxation, were it not for those peculiarities of conformation which characterize the inferior maxillary bone of the infant, and which render almost impossible the occurrence of dislocation at this period of life.

But according as the transverse root of the zygoma becomes developed, the depth of the glenoid cavity increases, and an obstacle is thus opposed to the occurrence of luxation, an accident which the form of the jaw in the adult favours, in a manner which strikingly contrasts with the immunity from such an injury enjoyed by the temporo-maxillary articulation in early life.

In the case of Lacy, the fœtal condition of the temporal portion of the joint remained throughout life, there being neither glenoid cavity nor articular eminence. The zygomatic portion of the temporal bone was, in fact, never formed, and hence the elongation of the zygomatic process of the malar bone, which, of itself, formed the entire of the arch.

This circumstance is, of itself, sufficient to prove that the abnormal state of the joint was a congenital malformation, and not the result of disease or of accident, neither of which could have produced the singular deviation from the normal position of the suture which joined the zygomatic process of the malar to the temporal bone.

The deviations from the normal state of the temporo-maxillary articulation, which it is necessary to distinguish from congenital luxation, are, accidental dislocations and chronic rheumatic arthritis.

The differential diagnosis between the congenital and the accidental luxation of the lower jaw is sufficiently simple, as will appear from the following brief description of the latter. When both condyles are luxated, the characters of the resulting deformity are so remarkable, that were there not recorded cases to the contrary, we could scarcely suppose it possible that the true nature of the accident could be overlooked.

The mouth remains widely opened, and the individual is

unable to close it; the incisor teeth of the lower project beyond those of the upper jaw; the saliva flows from the mouth involuntarily and profusely; speech is difficult, and the pronunciation of labial consonants impossible; deglutition cannot be performed, and the motions of the tongue are limited.

The masseteric regions of the cheeks are flattened, a depression is observed in front of the auditory canal, immediately below the horizontal root of the zygoma, and the finger can be sunk into the parotid space. The coronoid process forms below

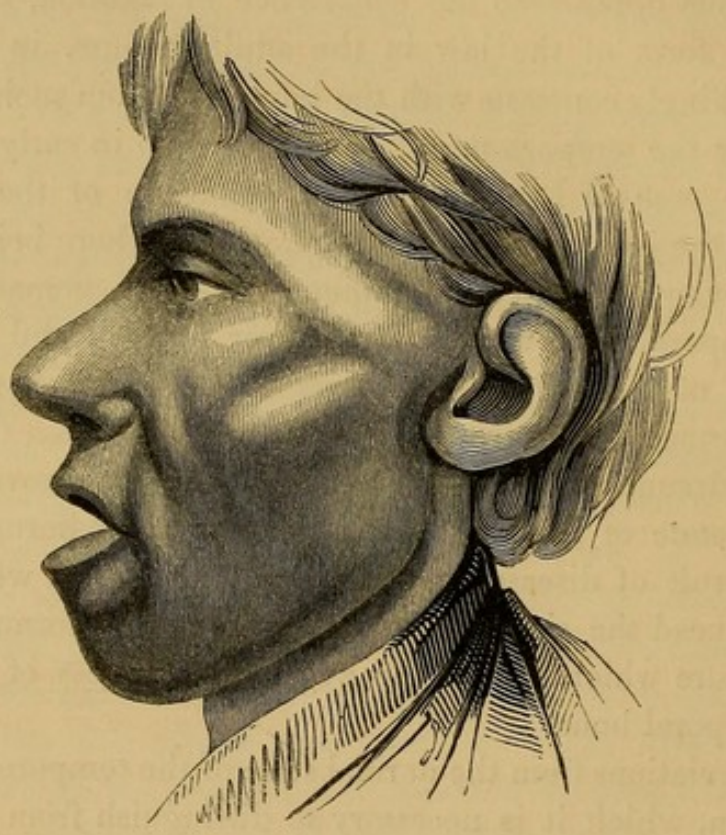

the malar bone, a prominence which is very visible externally, but which is most distinctly felt through the mouth.

There is likewise an evident fulness in the temporal fossa, between the eyebrow and the ear, immediately above the zygoma. This prominence (which does not seem to have been noticed by any writer except Mr. Adams*) appears to be thus produced. As soon as the condyle has cleared the articular emi-

* Dublin Quarterly Journal of Medical Science, New Series, vol. i.

nence, it at once becomes placed upon a higher level than the apex of the coronoid process; it is elevated in the same proportion as the coronoid process is depressed. It thus comes into contact with and pushes upwards the posterior fibres of the temporal muscle, which pass horizontally, or nearly so, over the pulley-shaped surface of the zygoma. To the displacement and stretching of these fibres over the upper surface of the condyle, the prominence alluded to is, I conceive, to be ascribed.

The preceding illustration of the external signs of luxation of the jaw was drawn from a cast of the face of a woman, who had dislocated both condyles while eating a large potato.

She applied at Jervis-street Hospital, where the pupils made several ineffectual attempts at reduction, before she was seen by Mr. Adams. She at first objected to his proceeding with another attempt, and some delay being thus incurred, he availed himself of the opportunity to have a cast made of the face. When the reduction was proceeded with, the condyles were replaced separately.

There was profuse salivation while the luxation continued: all the other symptoms are well displayed in the engraving,—the widely-open mouth, the advanced chin, and the prominence between the eyebrow and the ear in the temporal fossa.

When the luxation of the condyles is left unreduced, the chin gradually becomes elevated, the patient is enabled to close the mouth, the involuntary flow of saliva ceases, the faculty of speech is regained, and most of the characteristic signs of the nature of the injury disappear; but the projection of the chin, and the advance of the lower incisor teeth still remain, and are sufficient to distinguish the deformity from that produced by congenital malformation.

The alterations which take place when the dislocation is abandoned to nature, are thus described by Ribes:*

"Voici les changements qui surviennent. La mâchoire est élevé peu á peu; les condyles arcboutent devant les apophyses transverses, exécutent un petit mouvement de rotation d'avant en arrière dans le sens de leur axe transversal, de manière que la

* Loc. cit.

partie la plus élevée du condyle devient postérieure, et la partie antérieure devient supérieure.

"Ce premier changement favorise l'élévation de la mâchoire, et cet os est susceptible alors d'un petit abaissement. Ces premiers mouvements sont accompagnés de douleurs produites par la pression des nerfs massétérins et temporaux profonds; mais elles diminuent parce que les condyles reculent et que les nerfs sont poussés en avant.

"Il reste par la suite un espace suffisant pour que les condyles se logent devant les éminences transverses, sans que les nerfs soient exposés à aucune pression de la part du condyle. La tension douleureuse qu' éprouvent les nerfs dentaires doit cesser, parce que leur allongement devient moins grand.

"Les dents des deux mâchoires se touchent, d'abord les molaires, et les autres successivement: cependant les incisives inférieures restent un peu éloignées des supérieurs et les dépassent.

"Le menton est plus saillant, et la mâchoire inférieur, élevée insensiblement peut à la longue être presque entièrement rapprochée de la supérieure."

I have never had an opportunity of ascertaining, by *post mortem* examination, the exact situation which the condyles occupy when the lower jaw is dislocated; nor have I been able to find, in the writings of any author, a description of the anatomical characters of unreduced luxations of this bone.

It is stated by Ribes that L'Héritier exhibited before the Academy of Surgery a specimen of dislocation of one condyle, which had occurred long before the death of the individual,* but he has not detailed the particulars of the dissection.

The case represented in the annexed illustration was that of a female who was admitted into one of the metropolitan hospitals for an extensive burn received during an epileptic convulsion; she had another fit in the hospital, during which the dislocation occurred. It was not noticed by the surgeon, and remained ever after unreduced. The woman, at the time the drawing was exe-

* "L'Héritier a présenté aussi á l'Académie de Chirurgie un crâne, dans lequel il y avait luxation d'un condyle seulment; mais la disposition de cette eminence et de la cavité glénoïdale était tellement changée qu'on ne pouvait douter que la maladie n'existait depuis long-temps avant la mort."—*Ribes, loc. cit.*

cuted (a year after the occurrence of the accident) could close the lips perfectly, but was able to open the mouth only to a limited

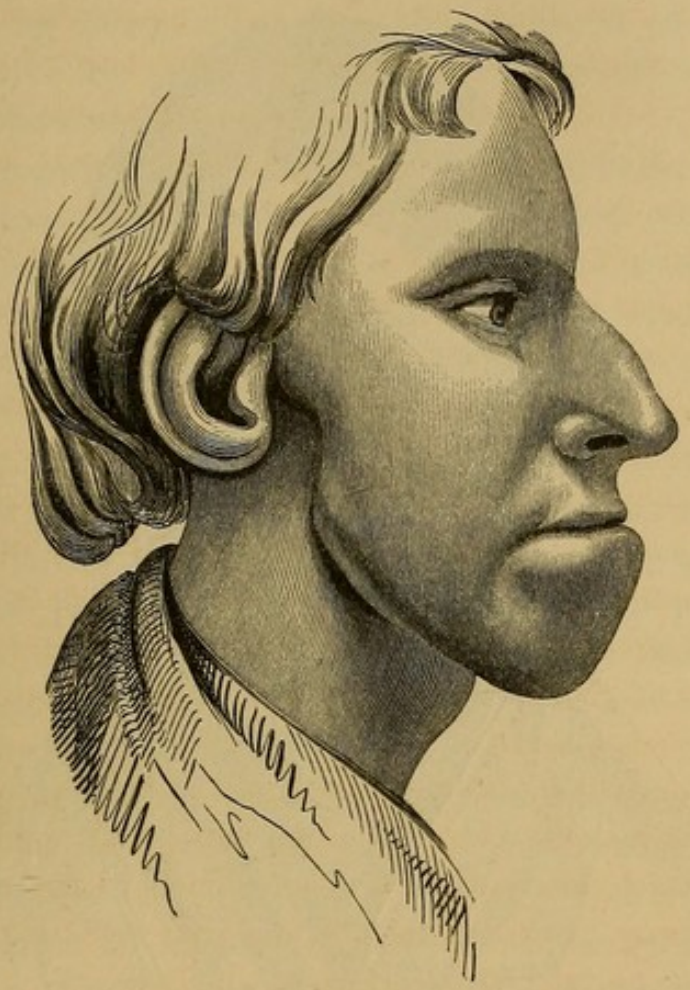

extent; the teeth of the lower jaw remained advanced, but the involuntary flow of saliva had ceased, and the faculty of speech had been regained.

When only one condyle is luxated, the mouth is half open and cannot be closed; the filtrum becomes oblique, the chin is carried towards the side opposite to that on which the luxation exists, and the teeth of the lower jaw undergo a corresponding displacement; the incisor teeth, as remarked by Sir Astley Cooper, are not only advanced upon the upper jaw, but are no longer in a line with the axis of the face. The prominence caused by the coronoid process is perhaps more striking than in the case of luxation of both condyles; the fulness of the cheek thus produced forms a remarkable contrast with the sinking in of the side of the face, in the instance of congenital dislocation which I have described.

The appearances which characterize the luxation of one condyle are well represented in the accompanying engraving. The

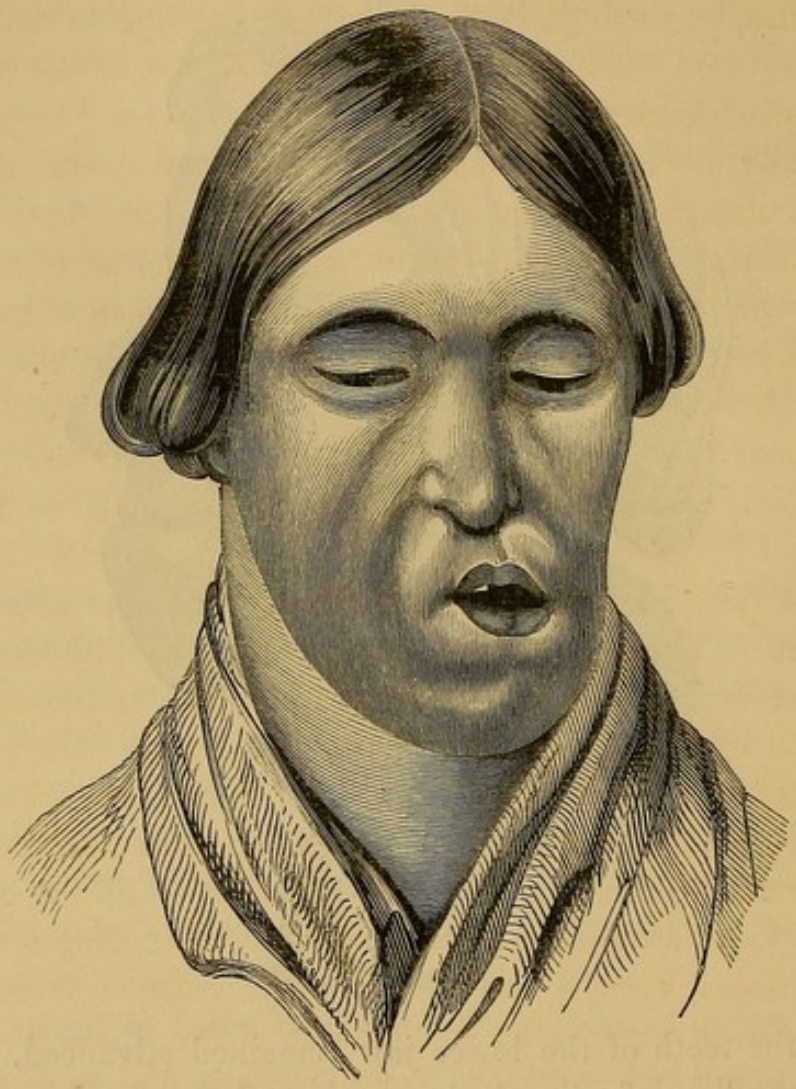

accident occurred in this instance by yawning widely, but there had been a previous dislocation during an epileptic convulsion.

Mr. Hey has observed that it is not always easy to recognise the dislocation of one condyle. "One would expect," he says, "from a consideration of the structure of the parts, and from the description given in systems of surgery, that the chin should be evidently turned towards the opposite side; but I have repeatedly seen the disease, when I could discover no alteration in the position of the chin. The symptom which I have found to be the best guide, in this case, is a small hollow which can be felt behind the condyle that is dislocated, which does not subsist on the sound side."

I have myself seen, in a case of luxation of the right condyle, the efforts at reduction applied to the left.

The deformity which accompanies the congenital luxation should also be distinguished from the distortion of the countenance produced by chronic rheumatic arthritis of the temporo-maxillary articulation.

In the majority of instances, this remarkable disease attacks those of advanced age, and is symmetrical: but occasionally it occurs during the period of adult life. In the latter case, it is generally more rapid in its progress, is accompanied by greater pain, and is more liable to implicate the neck of the condyle and the ramus of the jaw.

In some cases, a bony tumour, constituted by the enlarged condyle, can be felt distinctly beneath the zygoma, immediately in front of the external meatus. The lymphatic glands on the surface of the parotid and behind the ear, are also prone to enlargement. The pain which accompanies the disease is not usually severe, but is more or less constant, and is generally influenced by the state of the weather.

The nature of the distortion which attends this remarkable affection, varies according as one or both articulations are engaged in the disease. When it is confined to that of one side, and has existed for a considerable period, the mouth becomes crooked, the affected side of the jaw being drawn forwards and towards the opposite side, so that the teeth of the lower jaw, upon the sound side, project beyond those of the superior maxilla; but when the disease is symmetrical, the entire of the lower jaw is drawn forwards, and the chin projects just as it does (although from a different cause) in the edentulous subject.

The glenoid cavity, when the disease has been of long duration, becomes increased as to its circumference, this enlargement being accomplished at the expense of the horizontal and transverse roots of the zygoma, more especially of the latter, which in all cases is to a greater or less extent absorbed.

It is upon the destruction of this transverse root, or articular eminence, that the distortion of the countenance depends, for when the removal by absorption of this process is, to a certain

extent, accomplished, the external pterygoid muscle then draws the jaw forwards and to the opposite side, where but one articulation is diseased, and the muscles of each side act in displacing it directly forwards, when the destruction of the articular eminence is symmetrical.

The extension of the disease inwards, towards the middle line of the base of the skull, is limited by the spine of the sphenoid bone, and the spheno-temporal suture; and posteriorly it ceases at the Glasserian fissure, the non-articulating portion of the glenoid cavity never being implicated in the morbid action. The alterations of the condyle correspond pretty accurately to those of the glenoid cavity; sometimes it is enormously hypertrophied, its upper surface being flattened, and enlarged in all its diameters; while, in other cases, it assumes a conical form, and is always rough and destitute of cartilage.

The inter-articular cartilage disappears, but I have never yet found foreign bodies in the joint, and in only one instance, anything like the ivory-deposit, which forms so remarkable a feature in the pathology of this disease in the hip and other articulations.*

To enter more fully into the consideration of the symptoms and anatomical characters of this disease would be foreign to my purpose, which is merely to establish the differential diagnosis between the three abnormal states of the articulation of the lower jaw, to which I have alluded; and in the following enumeration of the distinctive characters, it is to be recollected that I only speak of the deformity as existing upon one side, for I have never seen an instance of double congenital luxation of the jaw.

1. In the congenital luxation the mouth can be freely opened and closed; in chronic rheumatism these motions can be performed, but not without uneasiness to the patient, an uneasiness which sometimes amounts to severe pain; in luxation from accident the mouth cannot be closed.

2. An involuntary flow of saliva accompanies the accidental luxation alone, although in some cases of chronic rheumatism there is an increased secretion of that fluid.

* See Dublin Medical Journal, vol. xxiii. p. 157.

3. In congenital luxation, the teeth of the upper jaw project beyond those of the lower; the reverse is observed in accidental luxation and in chronic rheumatism.

4. In congenital luxation there is no fulness in the cheek, such as the coronoid process produces in cases of accidental luxation, and the enlarged condyle in some instances of chronic rheumatic arthritis.

CHAPTER X.

ADDITIONAL OBSERVATIONS ON FRACTURES OF THE RADIUS, DISLOCATIONS OF THE BONES OF THE FOOT, AND CONGENITAL LUXATION OF THE WRIST-JOINT.

WITHIN a few weeks after the chapter upon fractures of the bones of the fore-arm in the vicinity of the wrist-joint, had been printed, I obtained three specimens of fracture of the lower extremity of the radius, in all of which the deformity was considerable.

CASE XIV.—Transverse fracture of the radius, situated one inch above the carpal surface of the bone. The lower fragment has suffered a considerable displacement backwards, its anterior surface being upon a plane a quarter of an inch behind that of the superior fragment. The carpal surface looked downwards and slightly backwards. The posterior surface of the bone was thickened for some distance above the situation of the fracture, but there was no appearance of penetration in the interior, which every where presented a cellular aspect.—*Museum : Richmond Hospital School of Medicine.*

CASE XV.—Transverse fracture of the radius, situated half an inch above the carpal surface, with displacement of the inferior fragment backwards. The styloid process is elevated, and the aspect of the carpal surface directed downwards and backwards. The concavity which the front of the lower end of the radius presents in the normal state has disappeared, being replaced by a perfectly flat surface. When a section of the bone was made from before backwards, the compact structure of the posterior wall of the shaft was seen covered with cancellated tissue, to the extent of three-quarters of an inch above the level of the fracture.—*Museum : Richmond Hospital School of Medicine.*

CASE XVI.—Transverse fracture of the lower end of the radius, three-quarters of an inch above the articulating surface, with great displacement backwards of the lower fragment. The entire of the carpal surface is seen posteriorly; the front of the lower extremity of the bone has become convex from above downwards, and the posterior surface concave in the same direction. A section of the bone did not disclose any line of compact tissue penetrating the lower fragment, but there was great thickening at the seat of the fracture posteriorly, owing to the deposition of new bone. The anterior surface of the radius was longer than the posterior.—*Museum : Richmond Hospital School of Medicine.*

The preceding cases, arranged as those at page 156, give the following results:

SIDE.	DIRECTION OF THE FRACTURE.	DISTANCE OF THE FRACTURE ABOVE THE WRIST-JOINT.	LENGTH OF THE LINE OF COMPACT TISSUE.	LENGTH OF THE ANTERIOR SURFACE OF THE BONE.	LENGTH OF THE POSTERIOR SURFACE OF THE BONE.
Right,	Transverse, . . .	1 inch.		$7\frac{3}{4}$ inches,	$7\frac{1}{2}$ inches.
Left.	ditto,	$\frac{1}{2}$,,	$\frac{3}{4}$ inch,	$7\frac{3}{4}$,,	$7\frac{1}{2}$,,
,,	ditto,	$\frac{3}{4}$,,		$7\frac{1}{2}$,,	7 ,,

The following cases, which have been recorded by Dupuytren, illustrate the importance of the precepts inculcated at page 170:

"*Fracture of the radius; apparatus applied too tightly, and consequent gangrene; amputation, and cure.*—Antoine Rilard, aged 44, fractured his right radius whilst going down into a cellar, in February, 1828, and went at once to the Hospital of La Charité. When the fracture was reduced (it was near the base of the bone), an apparatus was applied, but fastened too tightly; and, notwithstanding the great swelling, and the acute pain which the patient endured, it was not removed until the fourth day, when the hand was cold and œdematous, and the fore-arm red, painful, and covered with vesications. Leeches, poultices, and fomentations were applied, and followed by some alleviation of the local symptoms, though there was much constitutional disturbance. At the close of a fortnight from the accident, the palmar surface of the

fore-arm presented a point where fluctuation was supposed to exist; but when a bistoury was plunged into it no matter followed. Portions of the flexor muscles afterwards sloughed and the skin subsequently mortified. The only resource was amputation, which was performed above the elbow six weeks after his admission; and he afterwards recovered without the occurrence of any further untoward accident.

"*Fracture of the lower extremity of the radius; gangrene of the fore-arm, produced by applying an apparatus too tightly; amputation and death.*—R., aged 36, a bricklayer's labourer, was at work boring an Artesian well, 1832, when he was struck by a part of the machinery on the right fore-arm: he was instantly knocked down, and thrown violently on his right thigh. A surgeon, who was sent for, detected a fracture of the radius, and applied the usual apparatus, consisting of pads and splints, confined by a roller extending from the extremities of the fingers to the elbow, which compressed the arm so tightly as to give rise to very great suffering. The fingers, hand, and fore-arm were numbed almost to insensibility, and yet the surgeon in attendance did not think proper to loosen the apparatus. Such was the condition of the patient until he came to the Hôtel-Dieu four days after the accident: the fingers were then black, cold, and insensible, and when I removed the splints I found the hand likewise black, especially on its palmar surface. The lower part of the fore-arm was a shade less livid, but equally cold and insensible; and several vesicles filled with pink-coloured serum were apparent on both its surfaces, where the splints had pressed: the upper part of the fore-arm was inflamed, swollen, and very painful. He was bled, and leeches were applied to the inflamed part of the arm: camphorated spirit was applied to the fingers.

"On the following day heat was restored as low as the wrist, but the hand remained for the most part livid and cold, and the radial artery did not pulsate. Seventy leeches were applied to the fore-arm, and the local application was continued. On the second day after admission, warmth and sensibility were recovered on the dorsal surface of the fingers, but their palmar surface was unchanged; and the heat and tension of the fore-arm called for the application of thirty more leeches: the patient was

allowed some broth. On the fourth day the hand had further recovered itself so far as to encourage some hope of its being saved; but this was again blighted on the sixth day by the entire loss of heat and sensibility in the part, and increased pain and swelling in the fore-arm, to which the gangrene subsequently extended. On the twelfth day amputation was performed at the elbow-joint; but the patient did not survive the operation more than ten days, the immediate cause of death being acute pleurisy. There was a considerable quantity of purulent serosity poured out on the right side of the chest; and abscesses were found in the lungs and liver. On examining the arm, there was found to be a simple fracture of the radius about its centre.

"The above case presents a painful illustration of the neglect to which I have alluded. In nearly every instance the swelling of the limb requires that careful attention should be paid to the bandage or straps by which the apparatus is confined. Similar accidents are likely to result from the employment of an immoveable apparatus, of which an example occurred in the practice of M. Thiéry, one of my pupils. He was summoned to visit a young girl, on whom such an apparatus had been applied for a supposed fracture of the radius. After suffering excruciating torment, the fore-arm mortified, and amputation was the only resource. On examining the limb, no trace of fracture could be discovered! Had a simple apparatus been here employed, and properly watched, this patient's limb would not have been sacrificed."

Fracture of the lower extremity of the radius upon each side, is an accident of very rare occurrence; I have, however, seen one example of it in a man who fell with great force upon the palms of his hands. The lower extremity of each radius was broken about three-quarters of an inch above the wrist-joint. The inferior fragments were displaced backwards, and the deformity presented precisely the same features upon each side.

DISLOCATIONS OF THE BONES OF THE FOOT.

The chapter upon dislocations of the bones of the foot had just passed through the press, when the translation of the writings

of Dupuytren, upon the injuries and diseases of bones, was published by the Sydenham Society. In this volume is contained the memoir upon dislocations of the metatarsus, which originally appeared in the Révue Médicale, December, 1822. Being unable to procure this work, and as there is no account of the injury in the Leçons Orales,* I was obliged to remain satisfied with the very brief and, as it appears, inaccurate description given by Sanson, in which no mention whatever is made of the internal cuneiform bone. The remarkable cases which occurred in the practice of Dupuytren have been described by Sanson, and all subsequent writers who have alluded to the subject, simply as dislocations of the metatarsus upon the tarsus.

At page 233, *et seq.*, I endeavoured to show that, when a force capable of luxating the metatarsal bones is applied to the foot, the internal cuneiform will be more likely to remain connected with the first metatarsal than with the navicular bone; and I expressed my opinion that the cases recorded by Dupuytren were most probably analogous to those which came under my own observation. I was gratified, therefore, at finding, in the volume published by the Sydenham Society, a confirmation of this opinion, at least, as far as regards one of the cases described by Dupuytren. I subjoin the translation of the memoir without abridgment or alteration.

"It has been generally affirmed by authors, that the arthrodial articulations are not suceptible of displacement; an opinion which, doubtless, originated in the contemplation of their anatomical arrangement. Indeed, the plane surfaces of these articulations are so closely adapted to each other, so much strengthened by surrounding ligaments, and so protected against external violence, that one can scarcely conceive how dislocation could be produced without the employment of prodigious force, and without being accompanied by great displacement. In addition to the above considerations, it must be also remembered that these joints allow of no appreciable motion beyond a limited gliding movement, in which the relation of the articulating surfaces is scarcely changed.

* Edition 1822, four volumes.

"Boyer was struck with these facts, and positively denied the possibility of the metatarsal bones being dislocated: so, likewise, Desault, Petit, and all other authors who have written on the subject of diseases of bone, say nothing whatever respecting this injury. I therefore assume that the cases I am about to relate are unique, or at any rate the first which have been observed; they were witnessed by a large number of pupils, and the greater part of the Royal Academy of Medicine.

"*Dislocation of all the metatarsal bones on the corresponding bones of the tarsus.*—Françoise Voichot, aged 30, of excellent constitution, was brought to the Hôtel-Dieu in 1822. She stated that, in descending from the bridge of St. Michel with a burden of two hundred-weight, she fell in such a way that the whole weight of the body was received on the right foot; and that at the moment she made an effort to check herself in falling, she experienced extremely severe pain in this part, and heard a very distinct snap: she was unable to raise herself from the ground.

"On examining the two feet, one was found to be healthy, small, and perfectly well-formed; the other, on the contrary, presented a remarkable lesion; for the arch, which is prominent in well-made feet, had given place to a plane surface, much more marked than in individuals affected with the deformity known by the title of *flat-foot.* At first this appearance led me to believe that the metatarsal bones were fractured; but being unable to detect either crepitus or mobility, I abandoned this idea. *Then, the first metatarsal bone seeming to be longer than the others, whereas it is really the shortest, was also a little puzzling at first; but I soon perceived that it had maintained its relation with the inner cuneiform bone, and carried that with it, which accounted for the apparent anomaly;* and there was no doubt about the other metatarsal bones being dislocated on the corresponding bones of the tarsus.

"The short interval which had elapsed since the accident, and the entire absence of swelling, permitted of a ready verification of this anomalous condition of the parts. The following was the state of the foot:—Its length, as compared with the opposite foot, was diminished by nearly half an inch; and this was evi-

dently dependent on the riding of the dislocated bones. Extending across its dorsal surface there was a transverse elevation quite half an inch in height, formed entirely by the posterior extremity of the metatarsal bones, *and the inner cuneiform bone;* but this was much more prominent internally than externally, so as almost to lead to the deceptive impression that the dislocation was not complete in the latter situation. Immediately behind this line of elevation was a corresponding depression, deep enough to allow of a finger being lodged in it, when laid across the foot. The concavity of the foot was quite obliterated by the sinking of the tarsal bones. Lastly, the extensor tendons stood out in strong relief, and raised the toes; which, together with the other parts concerned, were immoveable: the integuments were uninjured.

"There was no difficulty in determining, under these circumstances, what was the proper course to pursue; and, considering the amount of laceration the ligaments must have sustained, I did not anticipate much resistance in effecting the reduction; but as I was anxious to make the case as public as possible, I deferred the attempt until the following day. At the time appointed, the patient was conveniently placed on a bed, and the leg being flexed and bound with a folded cloth, was firmly fixed by assistants. Extension was then made with a bandage suitably fastened to the foot; and I experienced very little difficulty, by pressing firmly on the dislocated bones, in accomplishing the reduction, which was accompanied by a loud snap, similar to that which the patient had heard when the dislocation took place. The deformity immediately disappeared, and the patient was in a great measure relieved of the acute pain she had suffered since the accident; indeed, with the exception of some trifling swelling, the affected foot had assumed the same appearance as the other: but an abnormal amount of mobility was present at the line of articulation between the tarsus and metatarsus, which was doubtless referable to rupture of the ligaments. The foot was afterwards carefully bandaged, and the limb placed, semiflexed, on a pillow. When this treatment had been persevered in for a month, all pain and swelling had disappeared, and the patient was permitted to get up; in the course of another fortnight she

was able to leave the hospital. When seen some time afterwards, the only remaining effect of this singular injury was a little lameness.

"In reviewing the mode in which this accident was produced, we find that the patient slipped whilst carrying a heavy burden, and, in the instinctive effort to save herself, threw the whole superincumbent weight on the right foot. Now, under these circumstances, the leg being flexed, and the heel raised and firmly fixed by the contraction of the gastrocnemius and soleus muscles, the foot was forced to take its purchase on the ground by its anterior half only, whilst the tarsus was pressed on by the weight from above: the effect of these contending forces was, as we have seen, to produce a rupture of the ligaments, and dislocation of the metatarsus from the tarsus. The action of the peronei and tibialis anticus I regard as quite of secondary importance in the production of this effect. It seems probable that both the dorsal and plantar connecting ligaments were ruptured. In conclusion, I may remark that this case derives its chief interest from its clearly establishing the possibility of such an accident as that detailed; and, moreover, that its occurrence is not necessarily complicated by any other serious mischief. It also demonstrates the simplicity of the diagnosis, as well as the facility of the reduction: and, lastly, we learn the importance of speedily restoring the dislocated bones to their normal position, before the attempt is rendered abortive by inflammation and its effects.

"*Dislocation of the metatarsus on the tarsus, affecting both feet at once.*—Paul Eudes, aged 24, a hosier, fell, whilst drunk, into a ditch six feet deep, and alighted on the soles of his feet. This accident was succeeded by great swelling and ecchymosis over the whole of each foot, in consequence of which the patient was obliged to keep his bed for three weeks, and applied camphorated spirits to the affected parts; at the end of that time he found he could only walk with great difficulty and pain, and accordingly came to the Hôtel-Dieu. This occurred in 1825.

"On admission, the natural convexity of the dorsum of each foot was augmented, but more remarkably so on the left side; and in conjunction with this, there was a corresponding diminu-

tion in the length of the feet. These conditions the patient had perceived, as he had been obliged to slit up that part of the shoe which corresponds to the instep; and he had also observed that his toes did not extend so far, by one inch, towards the extremities of his shoes as they did before the accident. In walking he experienced pain at the middle part of the inner border of the foot; and he was obliged, in order to relieve himself, to bring the heel to the ground first: he also found it much more difficult to go down stairs than up; but when in bed he was free from pain.

"About the centre of the dorsal aspect of the feet, a slightly curved line was very perceptible, the convexity of which faced forwards, whilst its direction was oblique from within outwards. This was due to the prominence of the metatarsus; for, on measuring the distance between the inner extremity of this prominence and the first metatarso-phalangeal articulation, it was found to correspond in length to the first metatarsal bone in the skeleton; and further, the outer extremity of the ridge in question abutted on the tuberosity of the fifth metatarsal bone, and its regularity was interrupted opposite the base of the long metatarsal bone of the second toe. As I have already remarked, the displacement was much more marked on the left than on the right side; indeed, so great was it in the former, that there was sufficient room to lodge the index finger behind the third and fourth metatarsal bones: but this could not be effected, even by pressure, with the first and second, whence I concluded that the dislocation was incomplete at these points; and the displacement was very trivial indeed between the fifth metatarsal bone and the cuboid. The flexor tendons of the toes were rendered a little tense.

"After the patient was admitted into the Hôtel-Dieu, several fruitless attempts were made to accomplish the reduction: I therefore substituted a permanent compress on the displaced bones, employing a thick leather sole which exactly fitted the plantar surface of the foot, except at a line opposite the posterior border of the metatarsus, where it was hollowed transversely. Some graduated compresses were also applied on the prominence of the metatarsus above, and the whole confined by a bandage. The sensible diminution of the deformity from this treatment was very

trifling, and the patient consequently left the hospital at the end of a fortnight.

"In summing up the principal signs characterizing dislocation of the metatarsus, we find them to be the following. The foot is shortened; the bases of the metatarsal bones present a prominent ridge along the dorsum of the foot, and behind this there is a corresponding depression: lastly, the concave arch of the foot is rendered flat by the presence of the tarsal bones, which are thrown beneath the metatarsus. The explanation which I have already given of the mode in which the dislocation was produced in the first case, will suffice also to account for the direction in which the metatarsus was forced, in both instances, from its normal position. The latter case, likewise, illustrates the importance of an early reduction, especially as contrasted with the former. It is unnecessary that I should repeat the instructions for effecting the reduction; but I may impress upon my readers the great importance of perfect repose, and for a lengthened period, to allow the distended and ruptured ligaments the opportunity of recovering fresh attachments and a healthy condition."

CONGENITAL LUXATION OF THE WRIST-JOINT.

The following analysis, by Dupuytren, of the case recorded by Cruveilhier, as an instance of unreduced luxation of the carpus, furnishes a remarkable example of the ingenuity occasionally displayed in maintaining a preconceived idea, and in explaining every thing that militates against a favourite theory:

"This case, recorded by M. Cruveilhier, as an example of luxation of the carpus forwards, furnishes us with many important considerations; and in the first place, in attentively examining the drawing, it is perceived that the antero-posterior diameter of the fore-arm is very great. The articular surface of the radius appears to be divided into two by a deep fissure; the external portion is continuous with the shaft of the bone, and presents, at its carpal end, a conical projection, not unlike the styloid process; but externally and above there is another conical projection, to which there is nothing analogous in the natural bone. The other larger and broader portion of the radius is not continuous with the

body of the bone, but is supported upon an oblong process, separated from the shaft by a kind of neck. On the hypothesis that there had been fracture, we can account for these two prominences; the superior external projection is the styloid process, and the inferior represents very well the spine which separates posteriorly the grooves which accommodate the tendons.

"On the supposition of dislocation having existed, it is impossible to account for several of the other appearances. Thus, for instance, in all dislocations the displacement of a bone on one side of an articulation, always involves the inclination, in a contrary direction, of the lever which it represents; yet here the hand is in front. But, to continue, why is the articular surface found upon a process above the joint? Why is the radius so much shortened, while the ulna, displaced with it, is half an inch longer below?

"It is easy to explain and connect the phenomena, on the supposition of fracture or separation of the epiphysis having originally occurred. It is probable that the accident happened during infancy, and hence the atrophy of the carpal bones; it is also likely that it resulted from a fall upon the back of the hand, by which the carpus was thrown forwards with the lower fragment.

"In this way we may conceive that the extensor muscles would have been but little stretched, for if the fragments were separated in respect of thickness, they were approximated as to length. But had there been luxation, the amount of tension would have corresponded to the breadth of the carpal surface of the radius.

"The detachment of the epiphysis accounts for the singular process which supports the new articulation, and the displaced ulna is, as it ought to be, longer than the broken radius.

"The case is, therefore, to be considered as one of luxation of the ulna backwards, with fracture of the radius, and displacement of the lower fragment forwards,—a case very remarkable, without doubt, but one which leaves untouched the discussion upon dislocations of the wrist."

REFERENCES

TO WORKS QUOTED IN THIS VOLUME.

PAGE.

Sabatier, Mémoires de l'Academie de Chirurgie, t. iv., ... 4
Sir Astley Cooper, on Dislocations and Fractures of the Joints, 1842, p. 136, 4
Dupuytren, Leçons Orales de Clinique Chirurgicale, 1832, t. ii., p. 95, . . 5
M. Rodet, L'Expérience, Journal de Médecine et de Chirurgie, 1844, . . . 6
Weitbrecht, Syndesmologia, 1742, ... 7
Boyer, Traité des Maladies Chirurgicales, 1822, t. iii., pp. 268-9, ... 8
Mr. Stanley, Medico-Chirurgical Transactions, vol. xiii., p. 510, ... 8
Cruveilhier, Anatomie Pathologique, livraison xxvi., ... 9
Sir Astley Cooper, on Dislocations and Fractures of the Joints, p. 128, . . 10
Mr. Earle, Practical Observations in Surgery, 1823, p. 27, ... 10
Boyer, Traité des Maladies Chirurgicales, t. iii., p. 262, ... 10
Sir Astley Cooper, on Dislocations and Fractures of the Joints, p. 171, . . 10
Mr. Amesbury, Remarks on the Nature and Treatment of Fractures, p. 102, 13
Dupuytren, Leçons Orales de Clinique Chirurgicale, t. ii., p. 96, ... 13
M. Rodet, L'Expérience, Journal de Médecine et de Chirurgie, 1844, . . . 14
Roche et Sanson, Nouveaux Elémens de Pathologie Chirurgicale, t. iv., p. 375, 15
Cruveilhier, Anatomie Pathologique, livraison xxii., ... 16
Mr. Stanley, Medico-Chirurgical Transactions, vol. xiii., p. 112, ... 22
Mr. Guthrie, Medico-Chirurgical Transactions, vol. xiii., p. 112, ... 23
Ekl, Ergebnisse in dem Klinikum zu Landshut, 1826, ... 24
Cruveilhier, Anatomie Pathologique, livraison xxiii., ... 25
Dupuytren, Leçons Orales de Clinique Chirurgicale, t. ii., p. 109, ... 26
M. Mercier, Gazette Médicale, 1835, t. iii., ... 26
Sanson, Dictionnaire de Médecine et de Chirurgie, Art.—"Fracture," . . 26
Cruveilhier, Anatomie Pathologique, livraison xxvi., ... 27
Boyer, Traité des Maladies Chirurgicales, t. iii., p. 261, ... 29
Velpeau, Gazette des Hopitaux, t. ix., ... 30
Chaissaignac, Thèse de la Fracture du col du femur, 1835, ... 31
Cruveilhier, Anatomie Pathologique, livraison xxvi., ... 33
Musée Dupuytren, publie au Nom de la Faculte, t. i. p. 220, ... 33
Mr. King, Cyclopædia of Surgery, Art.—"Fractures," 36

PAGE.

M. Vidal (De Cassis), Traité de Pathologie Externe, t. ii., p. 157, ... 37
Sir Astley Cooper on Dislocations and Fractures of the Joints, p. 150, . . 38
Mr. Adams, Cyclopædia of Anatomy, p. 810, ... 38
Sandifort, Museum Anatomicum, vol. iv., ... 39
M. Vidal (De Cassis), Traité de Pathologie Externe, t. ii., p. 154, ... 40
Cruveilhier, Anatomie Pathologique, livraison xxiii., ... 41
Mr. Adams, Cyclopædia of Anatomy, p. 806, ... 45
Mr. Colles, Dublin Hospital Reports, vol. ii., p. 345, ... 50
M. Tournel, Archives Générales de Médecine, vol. ii., 3e série, ... 52
Mr. King, Guy's Hospital Reports, October, 1844, ... 52
Mr. Bransby Cooper, Guy's Hospital Reports, vol. iii., new series, ... 53
Cruveilhier, Anatomie Pathologique, livraison xxiii., ... 53
Dr. Abercrombie, on the Intellectual Powers, 1835, p. 409, ... 56
Mr. Langstaff, Medico-Chirurgical Transactions, vol. xiii., ... 57
Dr. Brulatour, Medico-Chirurgical Transactions, vol. xiii., ... 58
Mr. Stanley, Medico-Chirurgical Transactions, vol. xviii., ... 58
Mr. Swan on Diseases of the Nerves, p. 304, ... 59
Mr. Adams, Cyclopædia of Anatomy, p. 798, ... 59
Mr. Jones, Medico-Chirurgical Transactions, vol. xxiv., ... 62
Mr. Chorley, quoted in Amesbury on Fractures, vol. i., ... 63
Mr. Porter, Dublin Journal of Medical Science, vol. x., p. 243, ... 67
Mr. Adams, Cyclopædia of Anatomy, p. 798, ... 114
Mr. B. Bell, on Diseases of the Bones, p. 78, ... 114
Sandifort, Museum Anatomicum, vol. ii., ... 114
Cruveilhier, Anatomie Pathologique, livraison ix., ... 120
Mr. Aston Key, Medico-Chirurgical Transactions, vol. xviii., ... 120
Mr. Colles, Edinburgh Medical and Surgical Journal, vol. x., ... 129
M. Diday, Archives Générales de Médecine, 1837, ... 137
M. Voillemier, Archives Générales de Médecine, 1842, ... 142
M. Malgaigne, Gazette Médicale, 1832, ... 167
M. Goyrand, Gazette Médicale and Journal Hebdomadaire, 1836, ... 167
M. Diday, Archives Générales de Médecine, 1837, ... 167
M. Nélaton, Elémens de Pathologie Chirurgicale, 1844, ... 167
Mr. Guthrie, London Medical and Surgical Journal, 1833, ... 181
Sir Astley Cooper, on Dislocations and Fractures of the Joints, p. 497, . . 185
Mr. Samuel Cooper, Dictionary of Practical Surgery, p. 591, ... 185
Sir Astley Cooper, Guy's Hospital Reports, No. ix., ... 187
M. Vidal (De Cassis), Traité de Pathologie Externe, t. ii., p. 113, ... 189
Boyer, Traité des Maladies Chirurgicales, t. iii., p. 198, ... 189
Roche et Sanson, Nouveaux Elémens de Pathologie Chirurgicale, t. iv., . 190
M. Nélaton, Elémens de Pathologie Chirurgicale, t. i., p. 731, ... 190
M. Cloquet, Dictionnaire de Médicine, Art.—"Fracture," 191
M. Nélaton, Elémens de Pathologie Chirurgicale, t. i., p. 730, ... 196
Dr. Houston, Catalogue of the Museum of the Royal College of Surgeons in Ireland, vol. ii., p. 401, ... 197
M. Vidal (De Cassis), Traité de Pathologie Externe, t. ii., p. 113, ... 202
Sir Astley Cooper, Guy's Hospital Reports, No. ix., ... 204

PAGE.
M. Ribes, Mémoires de la Societé Médicale d'Emulation, t. ix., ... 209
M. Nélaton, Elémens de Pathologie Chirurgicale, t. i., p. 715, ... 209
M. Vidal (De Cassis), Traité de Pathologie Externe, t. ii., p. 98, ... 209
Boyer, Traité de Maladies Chirurgicales, t. iii., p. 175, ... 210
M. Cloquet, Dictionnaire de Médecine, Art.—"Fractures," 221
Sir Astley Cooper on Dislocations and Fractures of the Joints, p. 339, . . 224
Dr. MacDonnell, Dublin Journal of Medical Science, vol. xiv., ... 225
M. Sanson, Dictionnaire de Médecine et de Chirurgie, Art.—"Luxation," . 234
M. Mazet, Bulletin de la Société Anatomique, 1837, ... 235
Mr. Liston, Practical Surgery, p. 140, ... 236
Sir Astley Cooper, on Dislocations and Fractures of the Joints, p. 336, . . 236
Cruveilhier, Anatomie Pathologique, livraison ix., ... 238
Dupuytren, Leçon Orales de Clinique Chirurgicale, t. iv., p. 162, ... 240
M. Voillemier, Gazette Médicale, 1840, ... 254
Dupuytren, Répertoire d'Anatomie, &c., t. ii., p. 826, ... 257
M. Guerin, Recherches sur les Luxations Congénitales, 1841, p. 30, . . . 258
Chelius, System of Surgery, translated by South, p. 770, ... 271
M. Ribes, Collection de Thèses de Médecine, 1803, ... 283
Mr. Adams, Dublin Quarterly Journal of Medical Science, vol. i., ... 286
M. Ribes, Collection des Thèses de Médecine, 1803, ... 287
Mr. Hey, Practical Observations in Surgery, p. 325, ... 290
Dupuytren, on Injuries and Diseases of Bones, Sydenham Society, p. 327, . 298
Dupuytren, Leçons Orales de Clinique Chirurgicale, t. iv., p. 200, ... 303

To those who are familiar with the literature of impacted fractures of the neck of the femur, it may, perhaps, appear strange that no reference has been made in the text to the memoir of M. Robert upon the subject, a report upon which was published in the Bulletin de l'Académie Royale de Médecine, 1844–5. It was unnecessary to allude to it, inasmuch as, in all that relates to the symptoms, diagnosis, and anatomical characters of the injury, the memoir of Robert is merely a translation of that which I published upon the subject in 1840, in the Dublin Medical Journal.

GENERAL INDEX.

Absorption of neck of femur, consequent upon fracture within the capsule, 42.
——— consequent upon chronic rheumatic arthritis, 123.
Acetabulum, alterations produced in the, by chronic rheumatic arthritis, 120.
Adams's, Mr., theory of partial fracture of the neck of the femur, 45.
——— case of osseous union of fracture of neck of femur within the capsule, 59.
Anatomical characters of impacted fractures of the neck of the femur, 32.
——— of intracapsular fractures of the neck of the femur, 41.
——— of chronic rheumatic arthritis of the hip-joint, 119.
——— of fracture of the lower end of the radius, 140.
Anchylosis between the clavicle and coracoid process after fracture, 212.

Brulatour's, Dr., case of osseous union of fracture of the neck of the femur within the capsule, 58.

Capsule of hip limits amount of shortening in intracapsular fractures, 10.
Callus, absence of, in intracapsular fractures of the neck of the femur, 13.
Cervical ligament of the femur, 7.
——— its influence in modifying the symptoms of fracture, 8.
——— importance of its preservation, 9.
——— its posterior portion seldom injured, 51.
Chelius's opinion as to the causes of congenital luxations, 271.
Chelsea Pensioner electuary, 128.
Chorley's, Mr., case of osseous union of fracture of the neck of the femur within the capsule, 63.
Chronic rheumatic arthritis of the hip-joint, causes and symptoms of, 114.
——— anatomical characters of, 119.
——— treatment of, 127.
——— of the lower jaw, 291.
Clavicle, fractures of the acromial extremity of the, 209.
——— between the coracoid and trapezoid ligaments, 215.
——— external to the trapezoid ligament, 215.
Colles's, Mr., cases of partial fracture of the neck of the femur, 50.
——— description of fracture of the lower end of the radius, 130.

Compact tissue of the neck of the femur, arrangement of the, 46.
Congenital luxations of the carpus forwards, 238, 241, 251.
——— of the carpus backwards, 245.
——— of the shoulder, sub-coracoid, 258.
——— of the shoulder, sub-acromial, 266.
——— of the lower jaw, 273.
——— supposed causes of, 271.
Contusion of the hip liable to be mistaken for fracture of neck of the femur, 30.
——— with chronic rheumatic arthritis, most liable to be mistaken for impacted fracture of the neck of the femur, 31.
Cooper's, Mr. Bransby, statement as to the possibility of the occurrence of osseous union in fractures of neck of the femur within the capsule considered, 54.
Corollaries respecting fractures of the neck of the femur, 110.
——— of the lower extremity of the radius, 171.
——— of the upper extremity of the humerus, 206.
——— of the acromial extremity of the clavicle, 222.
Crepitus, danger of lacerating the cervical ligament by attempts to produce, in cases of fracture of the neck of the femur, 8.
Cruveilhier's case of supposed unreduced luxation of the carpus, 238.
——— opinion as to the possibility of the occurrence of osseous union, in cases of intracapsular fractures of the neck of the femur, 53.

Death, causes of, in cases of fracture of the neck of the femur, 65.
Diday's opinion, that the radius is shortened in cases of Colles's fracture, 137.
Dislocation of the metatarsus and internal cuneiform bone, 225, 234, 299.
——— of the metatarsus, 234, 235, 301.
——— of the scaphoid and cuboid bones, 236.
——— of the five anterior bones of the tarsus, 236.
——— of the fourth and fifth metatarsal bones, 237.
——— of the carpus forwards, congenital, 238, 241, 251.
——— of the carpus backwards, congenital, 245.
——— of the carpus from accident, 254.
——— of the shoulder, sub-coracoid, congenital, 258.
——— of the shoulder, sub-acromial, congenital, 266.
——— of the lower jaw, congenital, 273.
——— of both condyles of the jaw, from accident, 285.
——— of the lower jaw, unreduced, 287.
——— of one condyle of the jaw, from accident, 289.
Dupuytren's opinion as to the cause of inversion of the foot, in cases of fracture of the neck of the femur, 26.
——— case of dislocation of the metatarsus, 234, 301.
——— of the metatarsus and internal cuneiform bone, 234, 299.

Epiphysis, separation of the lower, of the radius, with fracture of the ulna, 164.
——— differential diagnosis of, 166.
——— of the superior, of the humerus, symptoms of, 199.
——— of the superior, of the humerus, Sir A. Cooper's description of, 204.

FEMUR, symptoms of fracture of the neck of the, 2.
——— cervical ligament of the, 7.
——— alterations in the head and neck of the, consequent upon old age, 67.
——— consequent upon chronic rheumatic arthritis, 122-3.
Fever, different forms of, consequent upon fractures of the neck of the femur, 65.
Foot, position of the, in cases of fracture of the neck of the femur, 22.
——— inversion of the, in cases of fracture of the neck of the femur, 22.
——— dislocations of the bones of the, 224.
Fracture of the neck of the femur, symptoms of, 2.
——— of trochanters, in extracapsular fractures of the neck of the femur, 16.
——— impacted, of the neck of the femur, 27.
——— impacted, of the neck of the femur, anatomical characters of, 32.
——— intracapsular impacted, of the neck of the femur, 41.
——— partial, of the neck of the femur, 44.
——— of the neck of the femur, prognosis in cases of, 64.
——— of the radius, in the vicinity of the wrist-joint, 129.
——— of the lower end of the radius, Mr. Colles's description of, 130.
——— causes and symptoms of, 134.
——— anatomical characters of, 140.
——— treatment of, 166.
——— gangrene supervening upon, 170, 295.
——— of the lower end of the radius upon each side, 297.
——— of lower end of radius, with displacement of lower fragment forwards, 162.
——— of the humerus in the vicinity of the shoulder-joint, 176.
——— of the greater tuberosity of the humerus, 176.
——— of the neck of the humerus, impacted, 184.
——— of the acromial extremity of the clavicle, 209.
——— of the clavicle, between the conoid and trapezoid ligaments, 215.
——— of the clavicle, external to the trapezoid ligament, 215.

GANGRENE supervening upon fractures of the lower end of the radius, 170, 295.
Glenoid cavity of the temporal bone, development of the, 285.
——— alterations produced in the, by chronic rheumatic arthritis, 291.
Guerin, varieties of congenital luxations of the shoulder observed by, 258.
Guthrie's, Mr., opinion as to the cause of inversion of the foot, in cases of fracture of the neck of the femur, 23.
——— cases of fracture of the tubercles of the humerus, 181.

HÆMORRHAGE in cases of extracapsular fractures of the neck of the femur, 40.
Hip-joint, contusion of, liable to be mistaken for fracture of neck of femur, 30.
——— chronic rheumatic arthritis of the, symptoms of, 114.
——— anatomical characters of, 119.
Humerus, fractures of the greater tuberosity of the, 176.
——— impacted fractures of the neck of the, 184.
——— extracapsular impacted fractures of the neck of the, 185.
——— intracapsular impacted fractures of the neck of the, 188.
——— separation of the superior epiphysis of the, 199.

IMPACTED fractures of the neck of the femur, symptoms of, 27.
——— liable to be mistaken for contusion of the hip, 30.
——— of neck of femur within the capsule, anatomical characters of, 33.
——— of neck of femur external to the capsule, anatomical characters of, 34.
——— of the neck of the humerus, 184.
——— of the neck of the humerus external to the capsule, 185.
——— of the neck of the humerus within the capsule, 188.
Impaction, Voillemier's theory of, in fracture of lower end of radius, 142.
——— objections to, 156.
Interosseous space, diminution of, in cases of fracture of lower end of radius, 136.
Intracapsular fractures of the neck of the femur, anatomical characters of, 41.
——— osseous union in cases of, 52.
Inversion of the foot, in cases of fracture of the neck of the femur, 22.
——— Mr. Guthrie's opinion as to the cause of, 23.
——— Dupuytren's opinion as to the cause of, 26.

JAW, congenital dislocations of the lower, 273.
——— dislocations of the condyles of the, from accident, 285.
——— unreduced dislocations of the lower, 287.
——— dislocations of one condyle of the, from accident, 289.
——— chronic rheumatic arthritis of the, 291.
Jones's, Mr., case of osseous union of intracapsular fracture of neck of femur, 62.

LANGSTAFF'S, Mr., case of osseous union of fracture of the neck of the femur within the capsule, 57.
Liston's, Mr., case of luxation of the scaphoid and cuboid bones, 236.

MAZET'S, M., case of dislocation of the metatarsus, 235.
Metatarsal bones, dislocation of the fourth and fifth, 237.
Metatarsus and internal cuneiform bone, dislocations of the, 225, 234, 299.
——— dislocations of the, 234, 235, 301.

OSSEOUS depositions in extracapsular fractures of the neck of the femur, 36.
——— union, in extracapsular impacted fractures of the neck of the femur, 40.
——— in intracapsular fractures of the neck of the femur, question of, 52.
——— in intracapsular fractures of the neck of the femur, cases of, 57.

PARTIAL fracture of the neck of the femur, 44.
——— objections to the theory of, 48.
Position of the foot in cases of fracture of the neck of the femur, 22.
——— how far influenced by muscular action, 25.
Prognosis in cases of fracture of the neck of the femur, 64.

RADIUS, fracture of the lower end of the, Mr. Colles's account of, 130.
——— causes and symptoms of, 134.
——— shortening of the bone, in cases of, 138.
——— anatomical characters of, 140.

Radius, nature and causes of the displacement in, 140.
——— Voillemier's theory of impaction in, 142.
——— cases illustrative of the pathology of, 146.
——— objections to the theory of impaction in, 156.
——— treatment of, 156.
——— of lower end of, with displacement of lower fragment forwards, 162.
——— gangrene supervening upon, 170, 295.
——— fracture of, upon each side, 297.
——— differential diagnosis of, 163, 174.
——— separation of the inferior epiphysis of, with fracture of the ulna, 164.
——— differential diagnosis of, 163, 174.
Ribes's opinion respecting the development of the glenoid cavity of the temporal bone, 283.
Rodet's opinion with regard to the shortening of the limb in fractures of the neck of the femur, 14.
——— that the direction of the force is diagnostic of the seat of the fracture with respect to the capsule, 20.

Shortening consequent upon fractures of the neck of the femur, statements of authors respecting, 6.
——— different periods at which it may occur, 11.
——— sudden occurrence of, at a remote period, 12.
——— always present in extracapsular fractures of the neck of the femur, 18.
——— consequent upon contusion of the hip-joint, 30.
——— comparative amount of, in fractures of the neck of the femur, within and external to the capsule, 10.
——— amount of, in cases of impacted fractures of the neck of the femur, 28.
——— of the radius, in cases of fractures of its lower extremity, 138.
Shoulder, congenital dislocations of the, 256.
——— sub-coracoid, 258.
——— sub-acromial, 266.
Stanley's, Mr., case of fracture of the neck of the femur, without laceration of the cervical ligament, 8.
——— of fracture of the neck of the femur, within the capsule, with inversion of foot, 25.
——— of intracapsular fracture of the neck of the femur, united by bone, 58.
Swan's, Mr., case, 59.
Synovial membrane, condition of the, in chronic rheumatic arthritis of the hip-joint, 120.
Synovitis, acute, consequent upon fracture of the neck of the femur within the capsule, 42.

Tarsus, luxation of the five anterior bones of the, from the os calcis and astragalus, 236.
Trochanters, fracture of, in cases of extracapsular fractures of neck of femur, 16.
Tuberosity of the humerus, fracture of the greater, 176.

ULNA, projection of the, in cases of fracture of the lower end of the radius, 137, 162.
——— fracture of lower end of, with separation of inferior epiphysis of radius, 164.
Union by bone in extracapsular fractures of the neck of the femur, 40.
——— in intracapsular fractures of the neck of the femur, 52.

VOILLEMIER'S theory of impaction, in cases of fracture of the lower end of the radius, 142.
——— objections to, 156, 173.
——— case of dislocation of the wrist-joint from accident, 254.

WRIST-JOINT, congenital luxations of the, 238.
——— Voillemier's case of dislocation of the, from accident, 254.

THE END.