

The pathology and surgical treatment of tumors / by N. Senn.

Contributors

Senn, Nicholas, 1844-1908.
Francis A. Countway Library of Medicine

Publication/Creation

Philadelphia : Saunders, 1900.

Persistent URL

<https://wellcomecollection.org/works/x5z6s57u>

License and attribution


This material has been provided by This material has been provided by the Francis A. Countway Library of Medicine, through the Medical Heritage Library. The original may be consulted at the Francis A. Countway Library of Medicine, Harvard Medical School. where the originals may be consulted. This work has been identified as being free of known restrictions under copyright law, including all related and neighbouring rights and is being made available under the Creative Commons, Public Domain Mark.

You can copy, modify, distribute and perform the work, even for commercial purposes, without asking permission.



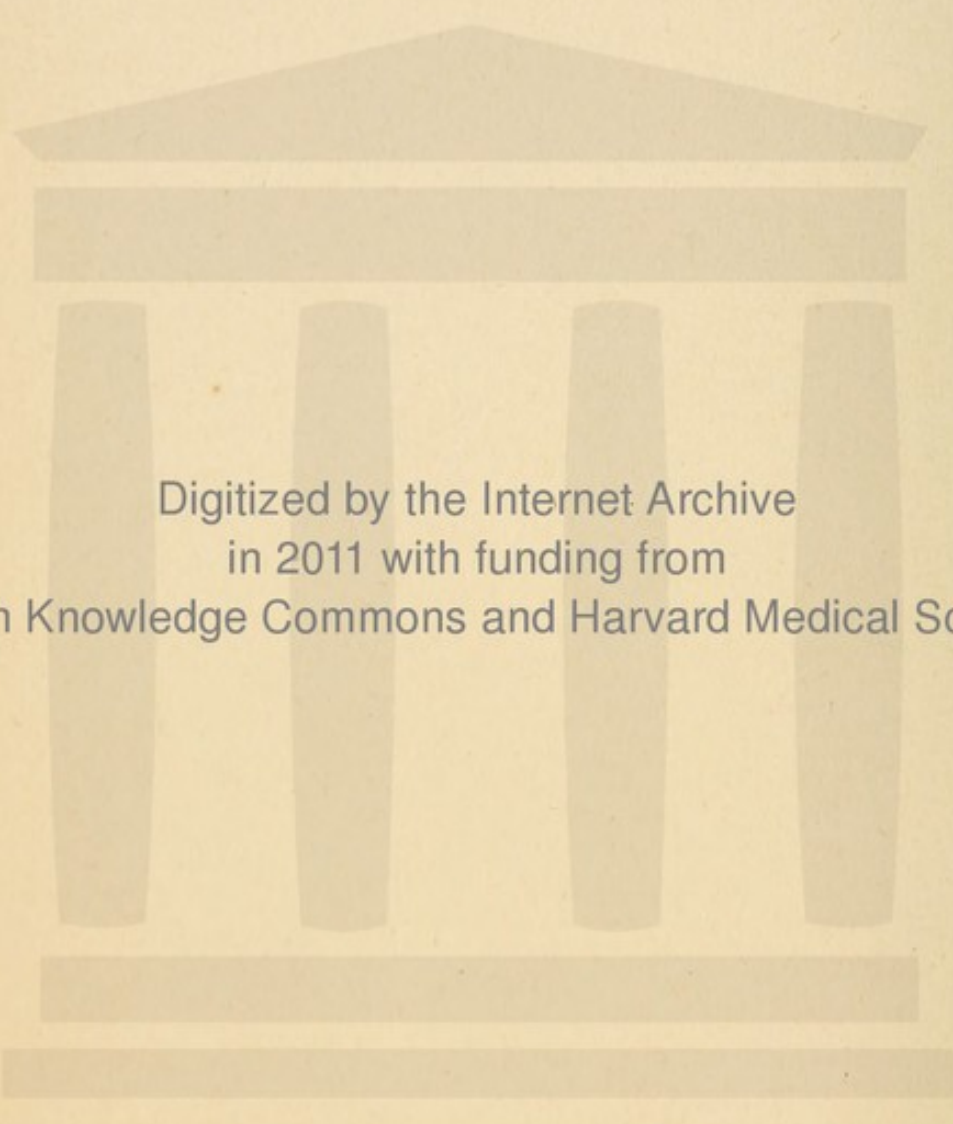
Wellcome Collection
183 Euston Road
London NW1 2BE UK
T +44 (0)20 7611 8722
E library@wellcomecollection.org
<https://wellcomecollection.org>





Property of
Timothy Leary

**TUFTS COLLEGE MEDICAL SCHOOL
PATHOLOGICAL DEPT., BOSTON, MASS.**



Digitized by the Internet Archive
in 2011 with funding from
Open Knowledge Commons and Harvard Medical School

THE
PATHOLOGY
AND
SURGICAL TREATMENT
OF
TUMORS

BY

N. SENN, M.D., PH.D., LL.D.

PROFESSOR OF SURGERY, RUSH MEDICAL COLLEGE, IN AFFILIATION WITH THE UNIVERSITY OF CHICAGO; PROFESSOR OF SURGERY, CHICAGO POLYCLINIC; ATTENDING SURGEON TO PRESBYTERIAN HOSPITAL; SURGEON-IN-CHIEF, ST. JOSEPH'S HOSPITAL, CHICAGO.

SECOND EDITION, REVISED

ILLUSTRATED BY 478 ENGRAVINGS, AND 12 FULL-PAGE
PLATES IN COLORS

BOSTON MEDICAL LIBRARY
IN THE
FRANCIS A. COUNTWAY
LIBRARY OF MEDICINE
PHILADELPHIA

W. B. SAUNDERS

925 WALNUT STREET

1900

COPYRIGHT, 1900
By W. B. SAUNDERS

ELECTROTYPED BY
WESTCOTT & THOMSON, PHILADA.

PRESS OF
W. B. SAUNDERS, PHILADA.


TO THE MEMORY
OF
SAMUEL DAVID GROSS

A MASTER IN SURGERY; A PIONEER IN PATHOLOGICAL ANATOMY; A SURGEON
HONORED AND REVERED WHEREVER HIPPOCRATIC MEDICINE IS TAUGHT
OR PRACTISED; A MAN WHOSE EMINENT PROFESSIONAL
REPUTATION WAS CROWNED BY THE PURITY
OF HIS PRIVATE CHARACTER,

THIS WORK IS

REVERENTLY AND AFFECTIONATELY INSCRIBED BY HIS FRIEND

THE AUTHOR.



PREFACE TO THE SECOND EDITION.

DURING the time that has elapsed since the appearance of the first edition of this work, no great discoveries or advancements have been made concerning the nature and treatment of tumors. The parasitic origin of malignant tumors continues to attract the attention of pathologists and surgeons, but we have made very little progress in establishing this theory by actual facts. In the proper place will be found an account of recent work done in this direction, notably by Roncali, of Rome. The text has been carefully revised and many additions have been made. A new section has been added on Sarcoma of the Decidua. Many of the old illustrations have been eliminated, and are replaced by others intended to explain more satisfactorily the subjects they represent. Most of the new illustrations are original. The publisher has again placed the author under many obligations for his liberality in inserting so many new illustrations.

N. SENN.

PREFACE.

THE appearance of a treatise on "THE PATHOLOGY AND SURGICAL TREATMENT OF TUMORS" at this time needs no apology. Books specially devoted to this subject are few, and in our text-books and systems of surgery this part of surgical pathology is usually condensed to a degree incompatible with its scientific and clinical importance. Again, the attention and energies of pathologists and surgeons during the last quarter of a century have been directed more toward the foundation and development of the new science of bacteriology and the advancement and improvement of operative technique than to a more thorough investigation of the equally important though less inviting subject relating to the origin, nature, structure, clinical aspects, and treatment of tumors.

Every teacher of pathology and surgery knows how difficult it is to impart to the student a knowledge of the structure and clinical tendencies of the different kinds of tumors sufficiently accurate to enable him to make a reliable diagnosis at the bedside. The general practitioner often remains painfully conscious of this defect in his early training, and the surgeon is frequently in doubt when to apply his art or when to pursue a conservative or palliative course when applied to for treatment by patients suffering from obscure tumors or tumors presenting one or more of the numerous complications to which they are subject.

The author has spent many years in collecting the material for this work, and has taken great pains to present it in a manner that should prove useful as a text-book for the student, a work of reference for the busy practitioner, and a reliable, safe guide for the surgeon. For the purpose of simplifying diagnosis a special effort has been made to trace every tumor to its proper anatomical starting-point and histo-

genetic source, and to make a sharp histological and clinical distinction between true tumors, inflammatory swellings, and retention-cysts.

The increase in volume caused by a tumor is due entirely to erratic cell-growth from a matrix of embryonal cells of congenital or post-natal origin; the enlargement of a part or an organ caused by chronic inflammation which so often simulates a tumor is due to proliferation of pre-existing mature cells acted upon by pathogenic micro-organisms or their toxines, and to the vascular changes and cell-migration characteristic of inflammation; while a retention-cyst essentially consists of an accumulation of a physiological secretion in a pre-formed glandular space, the result of a mechanical obstruction.

The classification of tumors in this work is in accord with this theory of the origin of tumors. The microbic origin of tumors is briefly disposed of, as it has not been established by any convincing experimental investigations or clinical observations. Should future research demonstrate a direct causative relationship between certain as yet unknown bacteria and the growth of some of the tumors, such tumors would have to be eliminated from this group of pathological products and be classified with the granulomata.

The first part of this treatise is devoted to a general consideration of tumors, and it is this part which is intended more especially for the use of students. Following the section on Classification, each class of tumors is considered separately, beginning with benign epithelial tumors and terminating with sarcoma, to which is appended a section on Retention-cysts. It will be observed that by following this course each tumor is brought to the notice of the reader three different times. Repetitions like these cannot fail in permanently impressing the subject upon the memory of the reader. It has been deemed advisable to discuss benign tumors first, as they do not deviate so far from the normal type of tissue-growth as do malignant tumors of the same germinal layer.

Retention-cysts are not true tumors, but they are discussed in the last section of the volume, as their differentiation from tumors is often exceedingly difficult, and in their structure and clinical course they resemble more closely tumor-formation than the products of inflammation. A description of each class of tumors is followed by a con-

sideration of the topographical distribution of that particular kind of tumor in the different regions and organs of the body, with a description of the different operative procedures for their removal.

The intention of the author in illustrating the text so profusely was to keep constantly before the reader's eye the microscopical picture of the tumor, which in many places is contrasted with the normal structure of the tissues corresponding with the anatomical location of the tumor. The more difficult operations are fully described and illustrated. More than *one hundred* of the illustrations are original, while the remainder were selected from books and medical journals not readily accessible to the student and the general practitioner.

The author desires to acknowledge his indebtedness to Mr. W. B. Saunders, who has spared no expense in presenting this book to the profession, and to Mr. John Vansant and Mr. Thomas Dagney of his publication rooms, for valuable assistance in supervising the details of the preparation of the work; also to Drs. Lecount and Mellish for a number of well-executed original drawings.

N. SENN.

CONTENTS.

	PAGE
I. ORIGIN AND NATURE OF TUMORS	17
Definition, 19. Histological and Clinical Differences between a Tumor and an Inflammatory Swelling, 20. Histogenesis, 23.	
II. MORPHOLOGY AND MULTIPLICATION OF TUMOR-CELLS	28
Morphology, 28. Karyokinesis, 30.	
III. ANATOMY AND BIOLOGY OF TUMORS	34
Blood-vessels, 35. Lymphatic Vessels, 35. Nerves, 36. Biology, 37. Relation of Tumors to Adjacent Tissues, 40.	
IV. PATHOLOGY OF TUMORS	42
Fatty Degeneration, 43. Mucoid Degeneration, 44. Colloid Degeneration, 44. Amyloid Degeneration, 45. Hyaline Degeneration, 45. Caseation, 46. Calcification or Cretefaction, 47. Ossification, 47. Interstitial Hemorrhage and Thrombosis, 47. Capsule of Tumor, 51. Lymphatic Glands, 51. Inflammation, 51. Ulceration, 52. Grafting of a Malignant upon a Benign Tumor, 53.	
V. TUMORS IN PLANTS AND ANIMALS	55
Tumors in Plants, 55. Tumors in Animals, 57.	
VI. ETIOLOGY OF TUMORS	60
Congenital Tumors, 60. Heredity, 61. Race, 64. Climate, 65. Age, 65. Sex, 67. Traumatism, 68. Irritation, 69. Inflammation, 69. Contagion, 70.	
VII. CLINICAL ASPECTS OF BENIGN AND MALIGNANT TUMORS	71
Relative Frequency with which Different Organs are Affected by Tumors, 71. Benign Tumors, 72. Malignant Tumors, 74. Local Infection, 75. Regional Infection, 75. General Infection, 76. Frequency of Recurrence after Extirpation, 78. Intrinsic Tendency of the Tumor to Destroy Life, 79.	

	PAGE
VIII. TRANSFORMATION OF BENIGN TUMORS AND POST-NATAL EMBRYONIC TISSUE INTO MALIGNANT TUMORS	80
Transformation of Benign into Malignant Tumors, 80. Transformation of Embryonic Tissue of Post-natal Origin into Malignant Tumors, 84.	
IX. DIAGNOSIS OF TUMORS	88
Clinical History, 88. Length of Time Tumor has Existed, 89. Location of Tumor, 89. Rapidity of Growth of Tumor, 89. Pain, 90. Tenderness, 90. Examination of the Patient, 91. Examination of the Tumor, 94. Tactile Examination, 96. Connection of Tumor with the Mother-soil, 97. Resistance and Consistence, 98. Pulsation, 101. Tenderness, 101. Crepitation, 102. Auscultation and Percussion, 102. Röntgen Ray, 102. The Value of the Microscope as an Aid in the Diagnosis of Tumors, 103.	
X. PROGNOSIS OF TUMORS	108
XI. TREATMENT OF TUMORS	113
Medical Treatment, 113. Radical Operation, 115; Ligation of the Principal Blood-vessels Nourishing the Tumor, 116; Galvanopuncture, 116; Parenchymatous Injections, 117; Injection of Erysipelas Toxines, 118; Cauterization, 119; Ligature, 123; Galvano-caustic Wire, 124; Écrasement Lineaire, 125; Avulsion, 126; Extirpation, 126. Palliative Treatment, 129.	
XII. CLASSIFICATION OF TUMORS	131
Virchow's Classification, 131. Cohnheim's Classification, 132. Williams's Classification, 133. Senn's Classification, 136.	
XIII. PAPILLOMA AND ONYCHOMA	137
PAPILLOMA, 137. Histology and Pathology, 137. Transformation into Malignant Tumors, 140. Topography, 141: Skin, 141; Cornu Cutaneum, 142; Respiratory Organs, 144; Digestive Tract, 144; Urinary Organs, 145; Female Organs of Generation, 146; Brain, 149. Diagnosis, 149. Prognosis, 149. Treatment, 150. ONYCHOMA, 150.	
XIV. ADENOMA	152
Histology and Pathology, 153. Etiology, 155. Topography, 156: Skin, 157; Adenoma Sebaceum, 157; Adenoma Sudoriparum, 157; Digestive Tract, 157; Nasal Cavities, 159; Uterus and its Appendages, 159; Thyroid Gland, 162; Mammary Gland, 167; Prostate Gland, 171; Lachrymal Gland, 172; Parotid Gland, 172; Testicle, 172; Liver, 173; Kidney, 175. Diagnosis, 175. Prognosis, 176. Treatment, 176.	

	PAGE
XV. CYSTOMA	178
Etiology, 180. Diagnosis, 180. Prognosis, 181. Topography, 181 : Traumatic Epithelial Cyst, 181 ; Deep-seated Atheroma, 183 ; Mucous Cysts, 185 ; Mesoblastic Cysts, 186 ; Thyroid Gland, 187 ; Mammary Gland, 188 ; Ovary, 189 ; Vagina, 198 ; Testicle, 198 ; Eye, 199 ; Cysts of the Vitello-intestinal Duct, 199 ; Allantoic (Urachus) Cysts, 200 ; Bone, 200.	
XVI. CARCINOMA	203
Definition, 203. Views Past and Present regarding the Origin and Nature of Carcinoma, 204 : Histogenesis, 208. Histology, 212 : Squamous-celled Carcinoma, 213 ; Cylindrical-celled Carcinoma, 214 ; Glandular Carcinoma, 215. Malignancy, 215 : Local Infec- tion, 216 ; Regional Infection, 220 ; General Infection, 225. Eti- ology, 231 : Heredity, 232 ; Traumatism, 233 ; Age, 234 ; Diet, 235 ; Climate, 236 ; Mental Depression, 236 ; Tuberculosis, 236 ; Prolonged Irritation and Inflammation, 236 ; Microbes, 239. Pathology, 242. Histological Varieties of Carcinoma, 250 : Squamous-celled Carcinoma, 250 ; Cylindrical-celled Carcinoma, 252 ; Glandular Carcinoma, 253. Diagnosis, 256. Prognosis, 264. Treatment, 266 : Palliative Operations, 269 ; Radical Oper- ations, 271. Topography, 273 : Skin, 275 ; Lip, 280 ; Face, 282 ; Mouth, 289 ; Tonsil, 291 ; Tongue, 292 ; Parotid, 298 ; Thyroid, 300 ; Mammary Gland, 303 ; Œsophagus, 323 ; Stomach, 326 ; Intestines, 335 ; Rectum, 339 ; Testicle, 346 ; Penis, 347 ; Ovary, 350 ; Uterus, 353 ; External Female Generative Organs, 370 ; Eye, 372 ; Bladder, 372 ; Kidney, 374.	
XVII. FIBROMA	378
Definition, 379. Histogenesis and Histology, 379. Retrograde Meta- morphoses, 382. Etiology, 383. Symptoms and Diagnosis, 383. Prognosis, 384. Treatment, 385. Topography, 385 : Skin, 385 ; Mucous Surfaces, 389 ; Subcutaneous Connective Tissue, 390 ; Abdominal Wall, 391 ; Nose, 391 ; Mammary Gland, 396 ; Uterus, 397 ; Ovary, 397 ; Vulva, 398 ; Gums, 399 ; Periosteum and Bone, 400, Serous Surfaces, 401. Cholesteatoma, 401.	
XVIII. LIPOMA	404
Definition, 404. Histology, 404. Regressive Metamorphoses, 405. Anatomical Varieties, 405. Symptoms and Diagnosis, 406. Prog- nosis, 407. Treatment, 408. Topography, 408 : Subcutaneous Adipose Tissue, 408 ; Eyelids, 411 ; Subserous Lipoma, 411 ; Submucous Lipoma, 412 ; Meninges of the Brain and Spinal Cord, 413 ; Intermuscular Lipoma, 413 ; Periosteum, 413 ; Joints, 413 ; Tendon-sheaths, 414 ; Eye, 414 ; Broad Ligament, 414 ; Vulva, 414 ; Scrotum, 414.	

	PAGE
XIX. MYXOMA	415
Definition, 415. Histology, 416. Etiology, 417. Symptoms and Diagnosis, 417. Prognosis, 417. Treatment, 418. Topography, 418: Skin, 418; Intermuscular Spaces, 418; Nose, 419; Middle Ear, 420; Nerve-sheaths, 420; Glands, 421.	
XX. CHONDROMA	422
Definition, 422. Origin, 422. Histology, 424. Retrogressive Meta- morphoses, 425. Etiology, 426. Symptoms and Diagnosis, 427. Prognosis, 427. Treatment, 428. Topography, 428: Cartilage, 428; Bone and Periosteum, 429; Joints, 430; Salivary Glands, 431; Testicle, 432; Ovary, 432; Connective Tissue, 432. Chon- droma Branchiogenes, 432.	
XXI. OSTEOMA	434
Definition, 434. Histogenesis, 435. Histology, 435. Anatomical Varieties, 437. Symptoms and Diagnosis, 437. Prognosis, 437. Treatment, 437. Topography, 438: Cranial Bones, 438; Frontal Sinus, 440; External Meatus, 441; Jaws, 441; Brain, 441; Epiph- yses of the Long Bones, 442; Muscles and Tendons, 442; Seat of Fracture, 443; Orbit, 443; Eye, 444; Subungual Osteoma, 444.	
XXII. ODONTOMA	445
Definition, 445. Classification, 445. Epithelial Odontomes, 445. Follicular Odontomes, 445. Fibrous Odontomes, 446. Cemen- tomes, 446. Compound Follicular Odontomes, 446. Radicular Odontomes, 446. Composite Odontomes, 447.	
XXIII. ANGIOMA	447
Definition, 447. Histogenesis, 449. Histology, 449. Complica- tions, 451. Anatomical Varieties, 452. Symptoms and Diag- nosis, 456. Prognosis, 456. Treatment, 456. Topography, 458: Skin and Mucous Membranes, 458; Deep Connective Tissue, 459; Bones, 461; Intracranial Angiomata, 462; Liver, 462; Mammary Gland, 463; Tongue, 463; Muscles, 463; Larynx, 464.	
XXIV. LYMPHANGIOMA	465
Definition, 465. Anatomical Varieties, 465. Histology and Histo- genesis, 465. Regressive Metamorphoses, 471. Symptoms and Diagnosis, 472. Prognosis, 473. Treatment, 474. Topography, 474: Tongue, 474; Lips, 474; Neck, 475; Subcutaneous and Submucous Connective Tissue, 477; Uterus, 477.	
XXV. LYMPHOMA	478
Definition, 478. Histology and Histogenesis, 480. Retrograde Metamorphoses, 480. Symptoms and Diagnosis, 481. Treat- ment, 484.	

	PAGE
XXVI. MYOMA	485
Definition, 485. Embryology, 485. Rhabdomyoma, 486. Leiomyoma, 487. Histology and Histogenesis, 487. Regressive Metamorphoses, 491. Symptoms and Diagnosis, 491. Prognosis, 492. Treatment, 492. Topography, 493: Uterus, 493; Broad Ligament, 519; Fallopian Tube, 520; Round Ligament, 521; Alimentary Canal, 521; Pharynx, 521; Œsophagus, 521; Stomach, 521; Small Intestines, 521; Rectum, 522; Bladder, 522.	
XXVII. NEUROMA	524
Definition, 524. Embryology, 524. Histology and Histogenesis, 524. Regressive Metamorphoses, 530. Etiology, 530. Symptoms and Diagnosis, 530. Prognosis, 531. Treatment, 531. Topography, 532: Multiple Neurofibromata, 532; Cranial Nerves, 533; Spinal Nerves, 533; Upper Extremity, 533; Lower Extremity, 533; Plexiform Neuroma, 534; Vulva, 535; Prepuce, 535.	
XXVIII. SARCOMA	536
Definition, 536. Histology and Histogenesis, 537. Morphology of Sarcoma-cells, 541. Histological Varieties, 542. Regressive Metamorphoses, 558. Local and General Infection, 561. Metastasis, 564. Etiology, 566. Symptoms and Diagnosis, 568. Prognosis, 571. Treatment, 571. Topography, 574: Skin, 574; Submucous Connective Tissue, 576; Fascial Sarcoma, 578; Lymphatic Glands, 580; Bones, 582; Histological Varieties, 583; Mammary Gland, 601; Thymus Gland, 604; Salivary Glands, 604; Tongue, 606; Tonsil, 606; Intestinal Canal, 606; Omentum, 607; Kidney, 607; Uterus, 610; Deciduoma Malignum, 612; Ovary, 613; Vagina, 614; Vulva, 615; Testicle, 615; Brain and its Envelopes, 616; Eye, 616; Bladder, 616; Prostate, 617.	
XXIX. TERATOMA	618
Definition, 618. Origin, 618. Endogenous Teratomata, 620. Ectogenous Teratomata, 620. BRANCHIAL CYSTS, 623. Embryology and Anatomy, 624. History, 625. Classification, 626. Mucous Branchial Cysts, 628. Atheromatous Branchial Cysts, 628. Serous Branchial Cysts, 629. Hemato-cysts of Branchial Clefts, 629. Etiology, 630. Diagnosis, 631. Prognosis, 631. Treatment, 632. DERMOID CYSTS, 635. Definition, 636. Histology, 637. Regressive Metamorphoses, 639. Diagnosis, 640.	

	PAGE
Prognosis, 641. Treatment, 641. Topography, 641 : Trunk, 641 ; Thorax, 642 ; Face, 644 ; Palate and Pharynx, 645 ; Scalp and Dura Mater, 646 ; Eye, 647 ; Tongue, 647 ; Rectum, 649 ; Auricle, 650 ; Ovary, 651 ; Scrotum, 655.	
XXX. RETENTION-CYSTS	657
Definition, 657. Histology, 658. Etiology, 660. Symptoms and Diagnosis, 661. Prognosis, 664. Treatment, 664. Topography, 665 : Thyroid Gland, 665 ; Ovary, 665 ; Skin, 666 ; Mucous Membrane, 668 ; Hydrokolpos, 671 ; Hydrometra, 671 ; Hydrosalpinx, 672 ; Trachea and Bronchial Tubes, 674 ; Appendix Vermiformis, 674 ; Bile-ducts, 675 ; Pancreas, 678 ; Kidney, 699 ; Testicle, 704 ; Mammary Gland, 706 ; Salivary Glands, 707.	
<hr/>	
INDEX	711

PATHOLOGY
AND
SURGICAL TREATMENT
OF
TUMORS.



THE PATHOLOGY AND SURGICAL TREATMENT OF TUMORS.

I. ORIGIN AND NATURE OF TUMORS.

THE subject of tumors is one of the much-neglected departments of surgical pathology. Laboratory investigation, experimental research, and clinical observations have revolutionized the etiology and pathology of inflammatory diseases during the last decade. During that time the attention of pathologists has been occupied largely in the etiological and pathological elucidation of infective diseases, while surgeons have expended their energies in enlarging the scope of operative surgery by an increased knowledge thus gained, and by the diminution of the immediate and remote risks to life of operative procedures attending the general adoption of antiseptic and aseptic precautions. The benefit to humanity in the saving of life and the lessening of suffering derived from these investigations and from improved practice is incalculable. The great work initiated by Pasteur, Lister, and Koch has inaugurated a new era in the study and treatment of disease, and must serve as a permanent foundation for all future investigations. When we realize the amount of suffering and the number of deaths resulting from tumors, it appears somewhat strange that this vast department of pathology has received so little attention on the part of modern investigators. It is true that recently a great deal of work has been done to establish the microbic origin of malignant tumors, but no positive results have been obtained so far, and we must confess that but little additional light has been shed on the etiology and pathology of tumors since the epoch-making labors of Virchow and Cohnheim.

History.—The old authors regarded tumors as something entirely foreign grafted upon the organism. John Hunter taught that a drop of blood, being accidentally extravasated, became organized and assumed a growth independent of the adjacent tissues, and continued to grow till it was limited by some obstacle opposed to it. Effusion of

lymph has been considered as a possible cause. It was suggested that in the development of the tumors the lymph played the same rôle claimed by Hunter for the extra-vascular blood. Chronic inflammation was regarded for a long time as the essential etiological factor. These and many other vague theories advanced in regard to the origin and nature of tumors prior to the time they were recognized as a part of the body they inhabited, the result of proliferation of pre-existing cells, do not merit an extended discussion in a modern text-book. Schleiden established the cell theory which inaugurated the science of biology; Schwann showed from a cellular basis the analogy of the structure of plants and of animals.

The study of tumors in plants and in the lower animals has done much in adding to our knowledge of the etiology and pathology of tumors. Pathological processes in plants are much simpler than in animals, owing to the absence in the former of many complicating factors, such as nerves and blood-vessels; at the same time, the plants are constructed upon a much simpler embryological plan. Both animal and vegetable cells have in common the nitrogenous carbon compound called "protoplasm." Johannes Müller applied the cell theory to the study of tumors. Virchow elaborated this doctrine in establishing by his immortal researches the motto of his great work on cellular pathology, *Omnis cellula e cellula*. Cohnheim imparted a new stimulus to the study of tumors by advancing a novel theory in reference to their origin. It appears recently that Durante of Rome was the real originator of the theory of the embryonic origin of tumors, as his publication on this subject antedates that of Cohnheim by one year. Virchow taught that an epithelial tumor could develop from connective tissue. Cohnheim referred every tumor to its proper embryonic layer, and claimed that a tumor never had its origin from mature tissue, but always developed from a matrix of embryonic tissue. This essential tumor-matrix he traced back to its embryological source. He believed that during the process of cell-differentiation in the embryo groups of cells not utilized in the growth of the embryo, or displaced, were arrested in their further development, and remained in a latent condition until their activity was awakened later, when the product of their proliferation resulted in the formation of a tumor. This theory found many supporters, but at the present time only a few authors uphold it in its entirety. As we shall see further on, it has much to recommend it, but it does not satisfactorily explain the origin of all tumors. In the absence of better proof of the origin of tumors, the writer will adhere to the doctrine advanced by Cohnheim, and in addition to it will claim that *the essential tumor-matrix may be composed*

of embryonic cells, the offspring of mature cells which for some reason have failed to undergo transformation into tissue of a higher type, and which may remain in a latent, immature state for an indefinite period of time, to become, under the influence of either hereditary or acquired exciting causes, the essential starting-point of a tumor.

It has been the good fortune of Roux to discover isolated colonies of cells in the middle, more rarely in the inner embryonal layer of frog embryos, sometimes in large numbers—once as many as thirteen—scattered among the other cells. Barfurth, in his experiments in the regeneration of the embryonal layers, observed that by puncturing and turning inward the ectoderm of the gastrulæ that a growth of cells very like a dermoid took place. Grawitz traced some of the tumors of the kidney to islets of separated and displaced suprarenal tissue. These experiments and observations have a very important bearing upon the development of tumors from displaced embryonal cells.

Definition.—So long as our ideas in reference to the origin and nature of tumors rest exclusively on a theoretical basis, it is evident that no satisfactory definition can be given. The definition of each author must necessarily vary according to his views on the subject. A few definitions will be given to corroborate the correctness of this statement. John Hunter thus defines a tumor: "A tumor is a circumscribed substance produced by disease, and different in its nature and consistence from the surrounding parts." "Neoplasm is a new growth characterized by histological diversity from the matrix in which it grows," is the description of a tumor given by J. Bland Sutton. Bär regards the characteristic feature of a tumor as an "active multiplication of cells which takes place independently of inflammatory processes." The process which leads to the formation of tumors he calls "a monstrosity in the development of cells." Lücke wrote on the subject of tumors from the standpoint that a tumor is "an increase of volume by the production of new tissue without a corresponding physiological function." Cohnheim, in consonance with his definite ideas concerning the origin of tumors from embryonic tissue, and the difference between the character of the tissues of which they are composed and the structure of the tissues in their immediate vicinity, describes a tumor as "a circumscribed, atypical production of tissue from a matrix of superabundant or erratic deposit of embryonic elements." From these definitions it becomes apparent how difficult it is to give even an approximately correct definition of a tumor. "Many pathologists have regarded tumors as a localized form of hypertrophy, but upon making a closer comparison we find that, to whatever extent the adapted hypertrophy may develop, the overgrown part maintains itself in the normal

type of shape and structure, while a tumor is essentially a deviation from the normal type of the body in which it grows, and, as a rule, the longer it exists the more marked becomes the deviation" (Williams). One of the greatest difficulties in the way of a proper appreciation of what is meant by a tumor is a failure on the part of authors and teachers to draw a dividing-line between tumors and inflammatory swellings. *That tumors should have been confounded with inflammatory swellings before the essential causes of the latter were discovered and understood is not strange, but that these entirely different pathological processes should not be separated sharply at the present time is inexcusable.*

It has been the writer's custom for ten years, in his lectures, didactic and clinical, to make a sharp distinction between a tumor, an inflammatory swelling, and retention-cysts. In writing this book this distinction will be maintained by eliminating from discussion all affections of which the microbic origin has been established, as well as swellings caused by retention of a physiological secretion, the latter of which will be discussed in a separate part of the book, and the definition of a tumor will therefore be framed upon a more limited basis. The definition of a tumor should explain its origin, its histological characteristics, and its behavior toward its immediate environment. *A tumor is a localized increase of tissue, the product of tissue-proliferation of embryonic cells of congenital or post-natal origin, produced independently of microbic causes.* This definition refers all tumors histogenetically to embryonic cells, which, according to Cohnheim, may be of congenital origin, or which, according to the writer's views, may also be of post-natal origin, being derived from pre-existing mature tissue in consequence of injury or disease, and, failing to undergo the normal transformation, may give rise to tumor-formation in the same manner as embryonic cells of fetal origin. This definition also excludes mature tissue and pathogenic microbes as etiological factors in the production of tumors, thus establishing a well-defined line between a true tumor and an inflammatory swelling. It is not necessary to include absence of function in the definition, as this applies equally, if not more forcibly, to swellings of an inflammatory origin. The writer does not claim that this definition is above criticism, but it will convey to the student what is so essential in teaching—a correct idea concerning the histogenesis and the essential pathological features of tumors, which knowledge will enable him, later, at the bedside to make a correct differential diagnosis between a true tumor and an infective swelling.

Histological and Clinical Differences between a Tumor and an Inflammatory Swelling.—According to our definition, the most important histological difference between a tumor and a swelling caused

by infection consists in the fact that in the former *the localized increase of tissue is the result of proliferation of embryonic cells (of pre- or post-natal origin) which are not utilized in the growth and development of the body or in the repair of injured or diseased parts, constituting thus a process entirely distinct and independent of the tissues in its immediate vicinity; while an inflammatory swelling results from tissue-proliferation provoked by the action of pathogenic microbes or their toxines upon pre-existing mature tissue-cells.* The incipient pathological product is therefore always more localized and better defined in tumor-formation than in inflammatory affections. A benign tumor always remains local, tissue-growth being limited to the fixed primary matrix. *A malignant tumor has a similar local origin, but it gives rise to dissemination by migration of cells into the adjacent tissues or by their transportation to distant parts through the lymphatic or general circulation.* In the production of an inflammatory swelling the fixed tissue-cells which have been exposed to pathogenic microbes or to their toxines participate; the new cells produced mingle with the corpuscular elements of the blood, reaching the inflamed area through damaged capillary walls caused by the same agents, and constituting with the transudation the inflammatory product. Inflammatory affections lack from the very beginning the localized character of a true tumor. Progressive and often very speedy extension by continuity and contiguity of structure is one of the most conspicuous clinical features of inflammatory diseases as compared with tumor-formation, and the existence or absence of such manifestations is often of great importance to the surgeon in making a correct differential diagnosis between a tumor and an inflammatory swelling. Another important point in the early differentiation between a tumor and a swelling of infective origin is the durability of the new tissue-product. The tissue of which a tumor is composed is permanent. While in cases of progressive marasmus the subcutaneous fat disappears ultimately almost completely, a fatty tumor in such an individual remains unaffected, showing its independence from the general laws of nutrition and waste that govern the body. *A tumor never disappears except by removal or destruction.* There is no authenticated record of spontaneous disappearance of a tumor or of disappearance of a tumor under any kind of internal medication. In all cases in which such a termination is said to have taken place we have instances in which an infective swelling was mistaken for a tumor. The growth of a tumor is usually progressive. Some of the benign tumors, such as neuroma and osteoma, reach a certain size, when further growth is spontaneously arrested. The nearer the tumor-elements resemble normal tissue, the greater the probability of spontaneous cessation of

growth. The inflammatory product, whether the result of an acute or of a chronic process, is composed of tissue which is destined to succumb sooner or later to the microbic influences which produced the inflammation. The blood-corpuscles and the embryonic cells, the product of the fixed tissue-cells, are destroyed by the primary cause of the inflammation, either quickly or slowly according to the type and intensity of the inflammatory process. One kind of swelling which has been, and still is, erroneously designated as a tumor is the *struma miasmatica*. According to our views, a struma due to miasmatic causes is not a tumor, because the early use of proper therapeutic agents, such as the internal and external use of iodine, by removing or rendering harmless the primary, as yet unknown microbic cause, succeeds in effecting a cure. Under the influence of iodine fatty degeneration, disintegration, and absorption of the cells of a parenchymatous struma are effected and a restitution *ad integrum* takes place. The swelling or pseudo-tumor disappears because the remedy administered has succeeded in removing or in neutralizing the primary cause. A hyperplasia of tissue due to an infective cause is amenable to absorption or removal on removal of the primary cause, but no such termination can be expected in the case of a tumor, whatever its structure and character may be. *We must therefore regard permanency of the new tissue as one of the evidences in favor of a doubtful enlargement being a true tumor; while early, and especially acute, degenerative changes would indicate an inflammatory origin.* The general symptoms are also to be taken into consideration in the differential diagnosis between a tumor and an inflammatory swelling. Acute suppurative inflammation is attended by such violent local and general symptoms that it is seldom mistaken for malignant disease. Chronic inflammatory affections, such as tuberculosis, gumma, and actinomycosis, are often mistaken for tumor, and *vice versâ*. Local and general increase of temperature is usually absent in all benign tumors, and is either absent or only slightly increased in malignant tumors. In chronic inflammatory affections a slight rise in the local and general temperature is often observed. The use of the clinical thermometer is therefore indicated in obscure cases in making a differential diagnosis between a tumor and an inflammatory affection. The exclusion of the granulomata (granulation-swelling) produced by the bacillus of tuberculosis, the actinomyces, the unknown microbe of syphilis, and the bacillus of glanders from the list of tumors has greatly narrowed the field of this part of pathology, and it is possible that further restriction will take place when convincing proof can be furnished of the microbic origin of one or of both varieties of malignant tumors. As soon as it can satisfactorily be shown that carcinoma and

sarcoma are caused by microbes, they must be classified with infective swellings, and not with tumors. From the present standpoint of pathological and bacteriological investigations we are forced to include these affections among the non-infective neoplasms. Enlargement of the superficial veins and œdema, such common symptoms of inflammatory lesions, are occasionally present in rapidly-growing malignant tumors; in fact, it may be stated that *the nearer a malignant tumor resembles inflammation, the greater is its malignancy.*

Histogenesis.—*A tumor never originates de novo, but is always an integral part of the organism, the product of tissue-proliferation from a matrix of embryonic cells.* Tumor-formation consists in the growth and development of pre-existing immature tissue-elements. *The structure and character of a tumor depend upon the stage of the arrested cell-growth and the embryonic layer from which the matrix is derived.* For instance, a matrix of epithelial cells from the epiblast in which cell-growth was arrested near the completion of the process of differentiation will in all probability become the starting-point of a benign epithelial tumor; on the other hand, if the development of the same cells was arrested at an earlier stage, the proliferation will result in tissue of a lower type, and the resulting tumor will be a carcinoma. The same holds true of mesoblastic tumors: the more imperfect the differentiation, the greater the tendency to the production of a sarcoma than to that of a fibroma. *The tumor-cells always correspond in type to the embryonic cells from which they are derived.* In cases of dermoid cysts in man we never find heterologous structures; we always look for the products of tissue-proliferation representing the normal tissues from the epiblast. While we expect to find in such instances in the interior of the tumor hair or other products of epithelial proliferation and degeneration, we never find feathers nor any other heterologous tissues; while in birds, when dermoid cysts occur, we find no hair, but invariably feathers. *So the products of a displaced epiblastic matrix always represent normal tissue-elements in an abnormal place.* Tumors of the connective-tissue type are invariably derived from a matrix of mesoblastic tissue, and all epithelial tumors are connected with the epiblast or hypoblast or spring from a displaced matrix from either of these embryonic layers. As in the majority of cases the tumor-matrix is composed of immature cells of fetal origin, it will be necessary to discuss in detail the

Differentiation of Tissue in the Embryo and the Origin and Disposition of the Germinal Layers.—During the earliest stages of development the embryo is composed of a mass of indifferent cells. At this time it would be impossible to make a distinction under the microscope.

Segmentation of the eggs of the frog was first described in 1836 by Prévost and Dumas. Pander in 1847 distinguished in the embryo of the chick three layers: the external, the serosa; the internal, the mucosa; and the middle, the muscular layer. This classification of the germinal layers corresponds to the more modern into epiblast, hypoblast, and mesoblast. Bär, the pupil of Pander, called the germinal layer *stratum proligerum*, and divided the embryonic tissue into two principal layers, (1) animal and (2) vegetative. Each of these layers he subdivided into two layers, the first (1) skin and (2) muscles, the second (1) vascular and (2) mucous. More recently His divides the unspecialized tissue of the embryo into two layers, (1) archiblast and (2) parablast. The archiblast includes all the tissues which are later

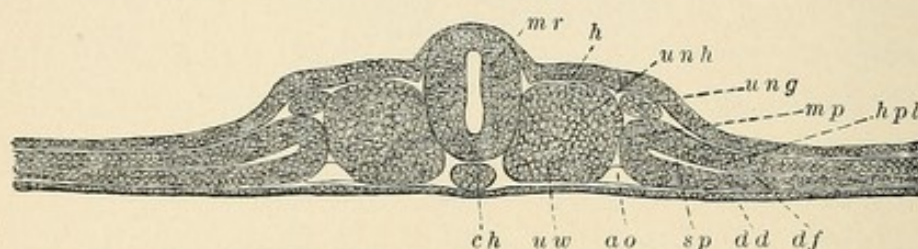


FIG. 1.—Transverse section through embryo of chick two days old; $\times 100$ (after Kölliker): *dd*, hypoblast; *ch*, cord; *uw*, primitive vertebra; *unh*, primitive vertebral canal; *ao*, primitive aorta; *ung*, primitive urinary channel; *sp*, cleft in lateral plates (first indication of pleuro-peritoneal cavity), which through the same is lost in the *hpl* and intestinal connective-tissue plates *df*, which are connected through the mesoblast *mp*; *mr*, medullary tube; *h*, epiblast thickened at some points. The embryo at this time is composed of two epithelial layers, the outer the epiblast, the inner the hypoblast, connected by the middle, the mesoblast.

transformed into epithelial cells, and it is equivalent to the epiblast and the hypoblast. The most active tissue-changes occur during early embryonic life. It is during this time that specialization of the indifferent cells takes place, upon which specialization depends the formation of different tissues and organs according to the demands of the individual or the adaptation of cells to their immediate environments. The division of embryonic tissue into epiblast, hypoblast, and mesoblast will be retained in this book, in preference to including the epiblast and hypoblast under the one term "archiblast," since in the discussion of epithelial tumors the student will more readily comprehend the location of the tumor, as well as the structure of the epithelial cells, by separating the epidermal (epiblastic) from the mucous (hypoblastic). Based upon the researches of Remak, Reichert, and Kölliker, embryologists trace all the tissues and organs of vertebrate animals, including man, to these three germinal layers which are found in embryos a few days old. In the embryo of the chick two days old (Fig. 1) these germinal layers can plainly be distinguished, and the complicated arrangement between the outer and inner layers and the mesoblast can be traced distinctly.

A few words concerning the disposition of these germinal layers during the differentiation of their cells. From the epiblast are developed all the tissues and organs composed of epidermis, the skin, the hair, the nails, all cutaneous glands, including those terminating in the mouth, also the lens of the eye and the epithelial lining of the cavity of the mouth, the nasal passages, and the labyrinth of the ear. Reichert was the first to prove that the medullary plate, the primitive central nervous system, is formed by the epiblast, and consequently that the brain and the spinal cord are epiblastic structures—a discovery which was later corroborated by the investigations of Remak and Kölliker.

The epiblast at the stage of development we are now considering is arranged in the shape of a double tube—namely, first the covering of the whole body (epidermis), and secondly, its central part, the medullary tube—while the hypoblast constitutes a single tube, the gastrointestinal canal with its glandular appendages. The hypoblast furnishes the whole epithelial lining of the digestive tract and the urinary organs, and from it are also developed the glands of the mucous lining and the glandular elements of the pancreas, the liver, the lungs, the thyroid, and the kidneys. The middle germinal layer, the mesoblast, forms the framework of the body, the bones, the connective tissue, the nerves, the muscles, the serous membranes, the vascular organs, including the lymphatics and the ductless glands, the thymus, and the spleen. The differentiation of the cells that takes place in the embryo limits their function to the part or organ to which they belong. *No transition from one type to another takes place.* The law of the specific genetic nature of the tissues as now generally recognized is observed in the embryo everywhere, and it remains in force during the entire life of the individual. In the growth of tumors the same law applies. One of the most convincing proofs that the specific nature of imperfectly differentiated cells is permanently retained is the familiar clinical fact that a displaced matrix of embryonic epithelial cells, isolated from the epiblast or hypoblast and buried in the mesoblast, when it becomes the starting-point of a tumor invariably results in the formation of an epithelial growth. Such an embryological *enkatarrhophy* is most prone to take place where the most complicated tissue-changes occur in the embryo, as about the orbit, the genital organs, and the muco-cutaneous junctions. Some of the cells remain in a state of incomplete differentiation for a long time even in man, as shown by the development of the teeth, the thymus, the mammary gland, the organs of generation, the bones, etc. These and many other facts prove the possibility of tissues remaining in a dormant condition for variable periods, and then

assuming, under the influence of an increased physiological or pathological stimulus, renewed activity, growth, and development. During a certain time of the life of the individual, or in consequence of acquired pathological conditions, cells may arise where they have no legitimate existence, or at a time when they ought not to be produced, or to an extent beyond the physiological limits. In this manner monstrosities and malformations are produced in the embryo, and later tumors are formed from such latent imperfectly specialized tissue under the same conditions. We know that certain organs up to the time of puberty remain to a certain extent in a dormant condition, not keeping pace with the general growth of the body; but when the period of puberty arrives, the genital organs, the mammary gland in the female, the skin and its appendages, are suddenly stimulated by a physiological impetus which results in increased tissue-growth. In pathology the proof of the correctness of this assertion is based on the fact that during this period are prone to appear certain epithelial tumors which are seldom met with before the age of puberty or late in life. *There is no fact better established in pathology than that during this time of life, characterized by the highest degree of post-natal tissue-activity, the intrinsic capacity of cell-production in an epiblastic matrix of cells is suddenly aroused, and the new tissue thus produced results in the formation of an epithelial tumor.* It is during this time of life that we most frequently meet with dermoid cysts in their favorite localities, branchial cysts, and adenoma of the breast. *We have reason to believe that many persons the possessors of the essential tumor-matrix of congenital or post-natal origin fail to become the subjects of a tumor either from an insufficient intrinsic capacity of cell-growth and reproduction on the part of the latent cells composing the matrix, or owing to an inadequate degree of local or general stimulation. Under such circumstances the cells of the matrix remain permanently in a latent condition.*

A general excess of embryonic tissue under favorable post-natal conditions gives rise to general giant growth. Localized excess representing the different tissues of a part or an organ results in local giant growth. Friedberg observed a case where, in a female child at the time of birth, the right leg was considerably larger than the left; after birth symmetrical development failed to take place, and the larger limb assumed giant growth, which fact induced Friedberg to assert that giant growth is not only congenital, but progressive. If an excessive amount of embryonic tissue is present at the time of birth, giant growth may take place at any subsequent period during life, awaiting a favorable opportunity until an increased afflux of blood to the part results in increased tissue-proliferation, the asymmetrical growth being due essen-

tially to the amount of embryonic tissue originally stored up in the part.

Abnormal additional centres of embryonic tissue in the embryo result in all kinds of monstrosities, parasitic fetuses, supernumerary fingers and toes, accessory glands, etc. A defective amount of building material in the embryo is responsible for many of the fetal defects, such as hare-lip, cleft palate, absence of or defective limbs, etc. Another familiar instance substantiating the correctness of the theory of the origin of tumors from a matrix of embryonic cells is furnished by the pregnant uterus. As a rule, hypertrophy of tissue is attended and produced by increased physiological function. In the gravid uterus there is an increase of muscular tissue attending simply an increased physiological growth of an organ, unattended by a corresponding increase of function, but preparatory to a sudden emergency requiring great functional activity. During pregnancy the muscular fibres remain in a condition of rest during the intervals between slight muscular contractions first observed and described by Braxton Hicks. The uterus receives an unusual blood-supply. We can explain the attending muscular hyperplasia only by assuming the presence of a superabundant deposit of embryonic cells awaiting a favorable opportunity to develop into mature, functionally-active muscular tissue.

The origin of a tumor from post-natal embryonic tissue is susceptible of a satisfactory explanation. Every surgeon can recall instances of the development of tumors from inflammatory products—scar-tissue and immature callus. We must take it for granted that in such tissue cells or groups of cells have failed to undergo transformation into mature tissue, and that they perform in the production of tumors the same rôle as the congenital matrix of embryonic cells of Cohnheim. In the absence of a more plausible theory, the writer is forced to conclude that *every tumor is the product of tissue-proliferation of a congenital or post-natal matrix of embryonic cells, aroused into activity by a general or local physiological stimulation or by congenital or acquired abnormal conditions in its immediate environment.*

II. MORPHOLOGY AND MULTIPLICATION OF TUMOR-CELLS.

Morphology.—The shape of a tumor-cell corresponds very closely to that of the cells of the organ or part in which the tumor originated. In the growth of a tumor the cells retain their original type. The development of the cells of benign tumors ultimately reaches the highest degree of perfection, so that under the microscope it is difficult if not impossible to distinguish between tumor-tissue and the tissue to which it belongs or which it represents. The macroscopical and microscopical resemblance between a lipoma and normal fatty tissue and

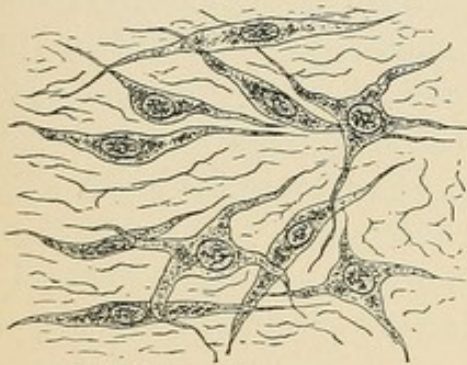


FIG. 2.—Embryonal connective tissue: the intercellular substance is only slightly differentiated (after Piersol).

an adenoma and normal glandular tissue is often almost perfect. The cells of which malignant tumors are composed do not attain maturity; consequently they resemble more closely the fixed tissue-cells in their juvenile state. From the illustration showing the shape of young connective-tissue cells (Fig. 2) and sarcoma-cells, it will be seen that their morphology is more nearly identical than would be expected from the difference in their source and the accomplishment of the ultimate object of their existence. The most striking difference between a sarcoma-cell and an immature connective-tissue cell under the microscope is the size and number of the nuclei. The nucleus of the sarcoma-cell is large and often multiple, showing greater vegetative activity as compared with the mononucleated connective-tissue cell. Absence of uniformity of size in the sarcoma-cells is another distinguishing criterion.

Most of the older text-books on pathology contain elaborate descriptions of a morphologically specific cancer-cell. The application of this teaching in practice resulted in many mistakes in diagnosis by placing too much reliance upon the morphological appearances of cells under the microscope. It is stated above that the structure of the cells of benign tumors is so closely akin to that of the normal cells of the part which the tumor represents that the microscope alone cannot be relied upon in distinguishing between the pathological product and the

normal tissue. This assertion will be strengthened by illustrations representing a non-malignant epiblastic tumor and the middle strata of the epidermis.

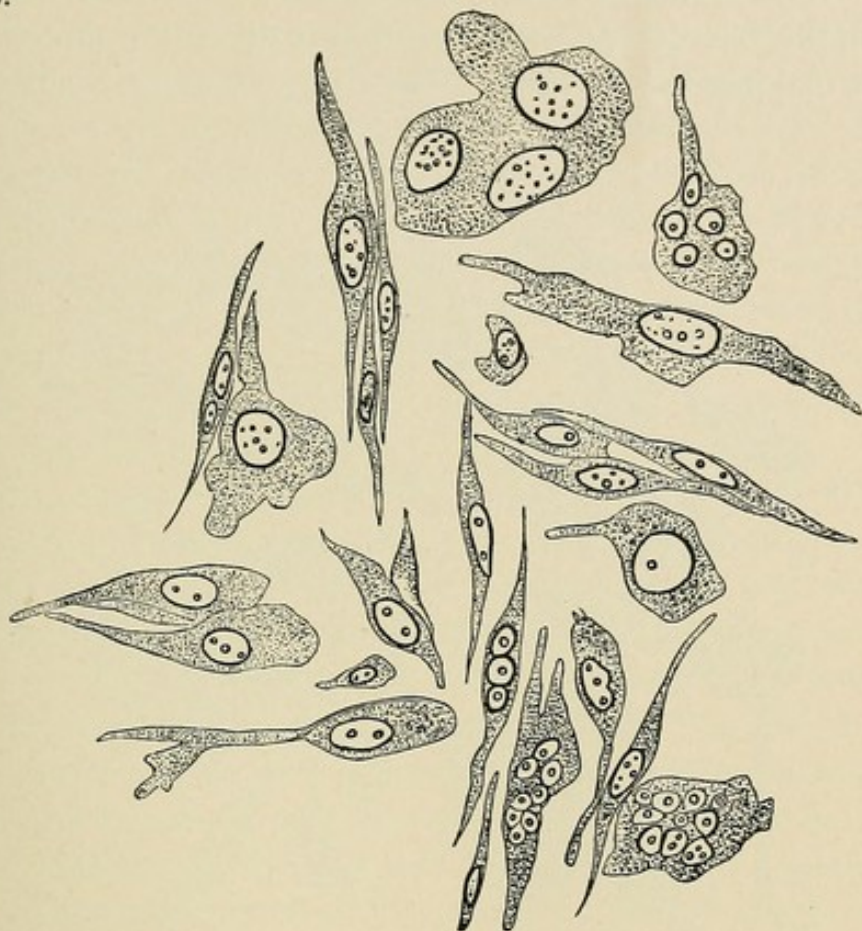


FIG. 3.—Cells from a spindle-celled sarcoma treated fresh in a solution of sodic chloride; $\times 250$ (after Perls).

In carcinoma, the malignant tumor of the epiblast and hypoblast, the cells again bear a great resemblance to the cells which compose the respective germinal layers. Like sarcoma-cells, they do not attain maturity; consequently they present in their structure more the type



FIG. 4.—Prickle-cells from papilloma of skin; $\times 250$ (after Ziesing).

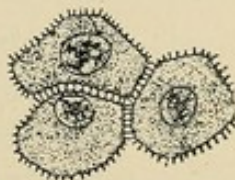


FIG. 5.—Prickle-cells from middle strata of the epidermis (after Piersol).

of embryonic than mature epithelial cells. In contradistinction to the normal epithelial cells, we find that many of the carcinoma-cells are polynucleated. The caudate prolongation of many of the cells is not a characteristic feature of a malignant epithelial cell, as was formerly supposed, but is one of the results of rapid cell-growth and pressure

from without. The polymorphism of the cells of malignant tumors is largely due to the combined effect of these two factors in modifying cell-form. The student should remember also that the contour of a cell under the microscope will depend greatly on the direction of the cutting in making the sections. Thus if, in case of a spindle-celled

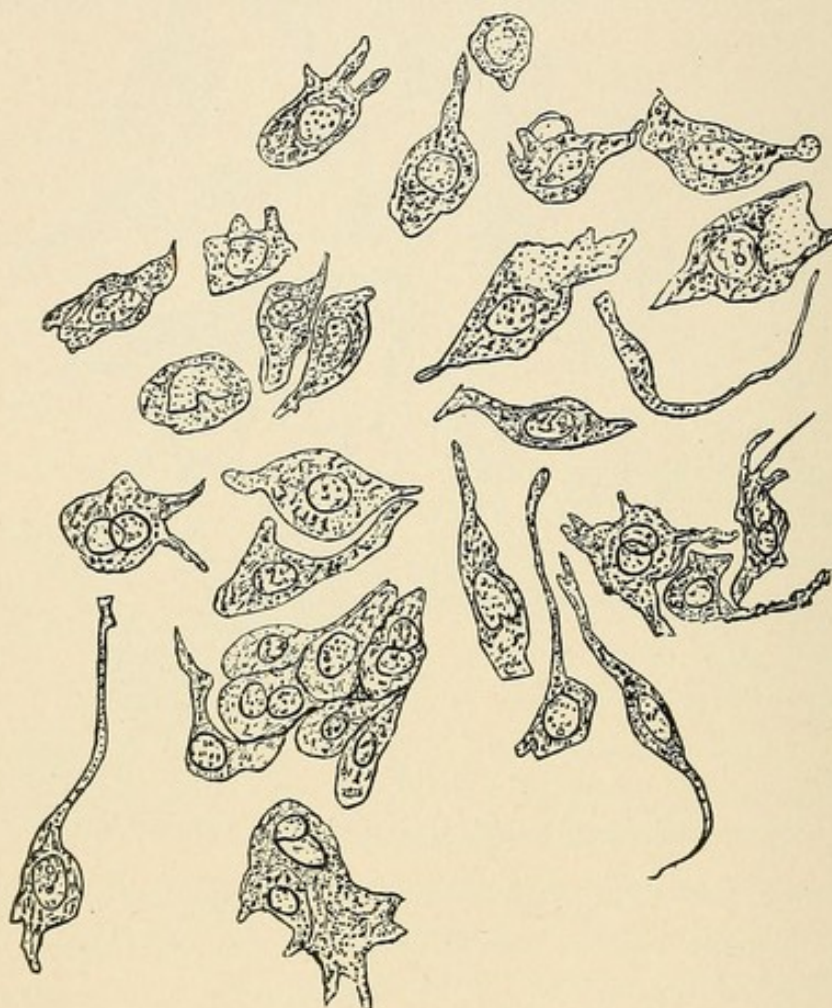

FIG. 6.—Cells from an epithelial carcinoma of the bladder; $\times 250$ (after Perls).

sarcoma, the section is made in the direction of the long axis of the cell, the cell will present a spindle-shaped appearance; on the other hand, if the cell is cut transversely, it will present an oval outline or will appear round, as in cases of round-celled sarcoma. In conclusion, it must be said that while polymorphism and multiple large nuclei strongly point toward the malignant character of cells, these conditions cannot be relied upon in making a positive distinction between normal and benign and malignant tumor-cells.

Karyokinesis.—It is now generally conceded that every pathological process has its physiological prototype. Cell-multiplication in disease may arise at a place where it is not needed, or at the wrong time, or to an extent beyond the limits of local normal requirement. Tumor-cells multiply, like most of the normal tissue-cells, by indirect

division, a process called *karyokinesis*. This is the method of reproduction of nearly all the fixed tissue-cells of a higher type in the body. This method of cell-segmentation was first described and carefully studied by Flemming, who termed the process *karyomitosis*. The essential constituents of a cell are the protoplasm and the nucleus. There is a strong tendency at the present time to refer all kinetic changes in the cell-contents to the agency of the nucleus, and to ascribe to the protoplasm the passive rôle of a nutritive substance. In the impregnated ovum influences of nuclear changes have been described, but at the same time it was shown that the protoplasm is capable of automatic as well as responsive action. Pflüger thought that gravitation is the sole guiding factor in segmentation. According to Born, Hertwig, Weismann, and Kölliker, the protoplasm alone is isotropic, but Whitman thinks that this is far from the truth. Others, like Pflüger, believe that the protoplasm contains physiological molecules from which organs are developed. Polarity of the protoplasm and the nucleus exists independently, and is not reciprocal. Contractions in the unfertilized eggs have been observed. The protoplasm is an active rather than a passive structure. M. Nussbaum was the first to establish the important fact that enucleate pieces of an infusorium are incapable of regenerating lost parts, while nucleate fragments soon regain the specific form. From this observation it will be seen that the nucleus is indispensable to the preservation of the formative energy of the cell, while the protoplasm performs an important but less essential rôle in the reproduction of cells. Nussbaum very correctly asserts that both the protoplasm and the nucleus are necessary in a cell to enable it to perform its specific function and to reproduce its own kind. The nucleus does not change its form except when it is the seat of active kinetic changes, while the form of the cell is changeable and is greatly influenced by its environments.

The researches of Flemming, Strassburger, Bütschli, and others have demonstrated the great importance of the nucleus in the reproduction of cells. The protoplasm under the highest powers of the microscope is seen to consist of a fine reticulum of protoplasmic strings, the meshes of which contain a homogeneous fluid. The mature cell is enveloped by a separate cell-wall. The meshes of a similar network in the nucleus are filled with a granular fluid. According to Carnoy and Mayzel, the nucleus contains, besides, a distinctive substance called "nuclein," or, from its intrinsic capacity to receive and to hold coloring material, "chromatin." The nucleoli in mature cells are globular masses of chromatin, one or several in number. It is the chromatin which, when properly stained, outlines the figures observed during the different

stages of the kinetic process. The kinetic process is divided into stages differently. Thus, Klebs makes four, while Strassburger describes the process as consisting of three stages: (1) Prophase; (2) metaphase; and (3) anaphase. During the first stage the nuclear chromatin arranges itself in the form of an oval mass. The metaphase is the stage of the equatorial crown when the nuclear spindle has an equatorial accumulation of chromatin fragments. During the last stage the nucleus and the protoplasm of the cell are divided into two symmetrical halves and complete the segmentation. Karyokinesis of the nucleus without division of the protoplasm of the cell results in multinucleated and

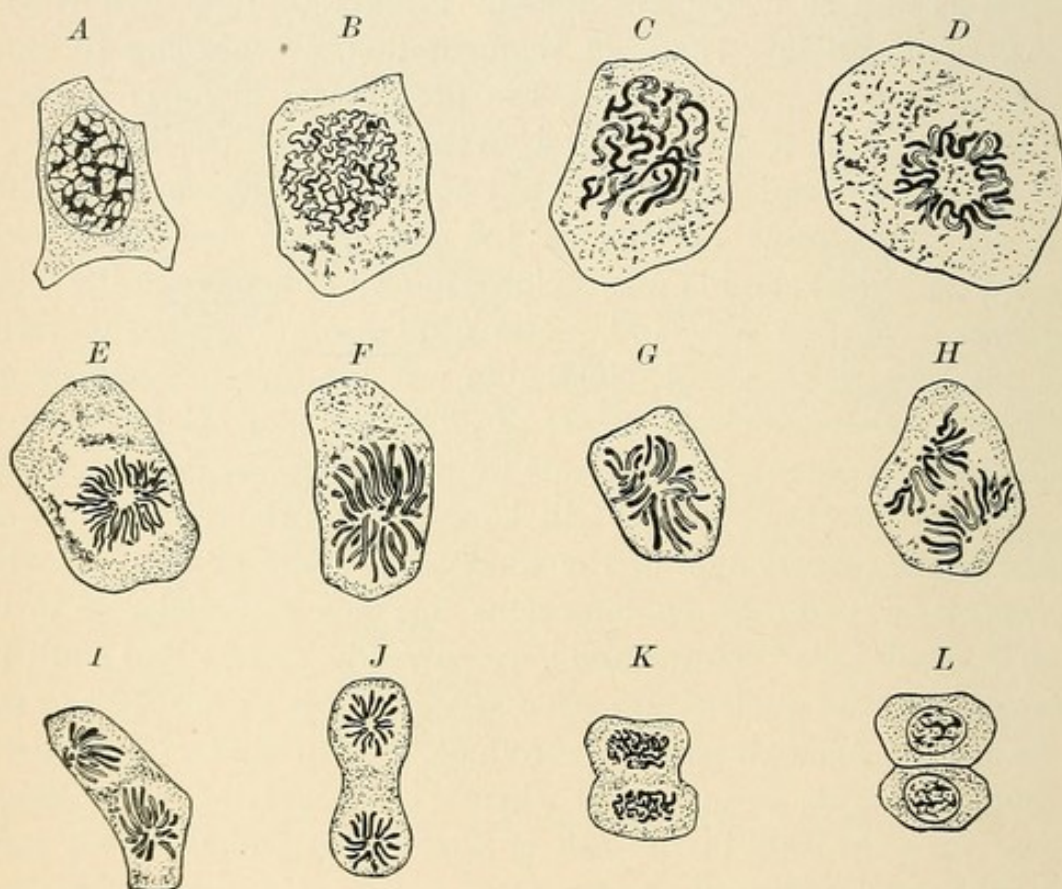


FIG. 7.—Cells from the epidermis of very young larva of newt (after Piersol): *A*, resting nucleus; *B*, close skein; *C*, loose skein; *D* and *E*, mother-stars, seen from the polar field and appearing as the wreath stage; *F*, mother-star from the side; *G*, migration of segments; *H*, daughter-stars; *I* and *J*, segments grouped about new polar fields (in *J* this protoplasm exhibits constriction); *K*, daughter-skeins (division of nucleus complete, with slight constriction of cell-body); *L*, completed division of nucleus and protoplasm.

giant cells. This incomplete karyokinesis frequently occurs in the cells of malignant tumors. The different karyokinetic figures are well shown in Figure 7. Cell-division by karyokinesis is called by Williams *agamogenesis*, in contradistinction to sexual reproduction, which he terms *gamogenesis*. In slowly-growing benign tumors new cells are added to the growth by karyokinesis; in stationary tumors the cells lost by degeneration are replaced by the same process; while in malignant tumors the karyokinetic process assumes great activity, resulting

in rapid growth and imperfect development of the cells. Karyokinesis in malignant tumors has received the careful attention of pathologists, and passes through the same phases as in the reproduction of normal tissue. In the centre of Figure 8 is seen a nucleus in which segmentation is nearly completed, while other nuclei represent incipient kinetic

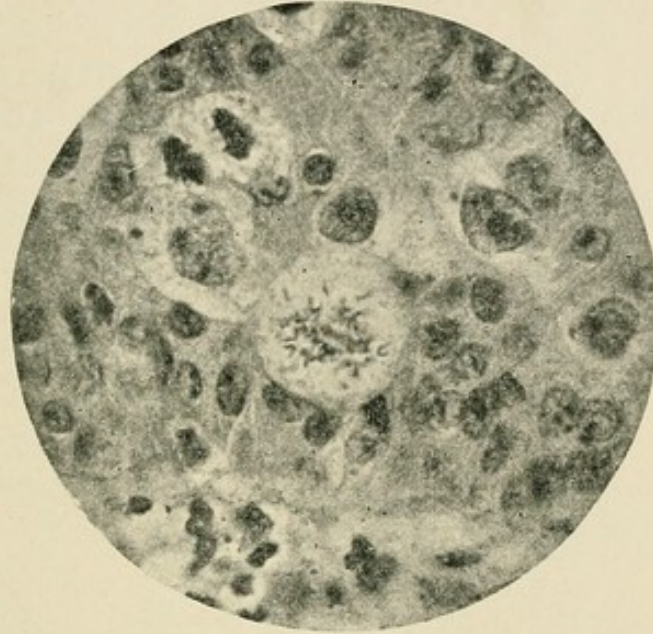


FIG. 8.—Nuclear division in the epithelial cells of the skin in Paget's disease of the nipple; $\times 800$ (after Karg and Schmorl). The deepest section of the picture represents, in the form of a small segment, the cutis infiltrated with leucocytes. After this follows the epidermis with its basal layer of cylindrical cells. The epithelial cells show different stages of nuclear division. Large nuclei are seen in the incipient stage of segmentation, surrounded by a light zone. In the centre of the field is a mass of chromatin threads in the stage of star-formation. Several chromatin loops have been separated from the dividing nuclear mass. The neighboring cells have been pushed sidewise. To the left and above, daughter-star with beginning constriction of the nuclear body. The threads of the achromatic figure are indicated. (Fixation and hardening in sublimate and alcohol; hæmatoxylin staining.)

changes. It is natural to suppose that such speedy and frequently imperfect karyokinesis would give rise to rapidly-growing, planless growths characterized by their early invasion of adjacent tissue, general dissemination, and an intrinsic tendency to destroy the life of the patient.

III. ANATOMY AND BIOLOGY OF TUMORS.

THE life-history of tumors is of great interest to the pathologist and of the utmost practical importance to the surgeon. The student must become familiar with the influences which favor and retard tumor-growth before he can formulate a correct clinical distinction between the different varieties and outline a rational course of treatment. In the preceding sections we have studied the origin and growth of the parenchyma of tumors. We traced the tumor-cells to their original

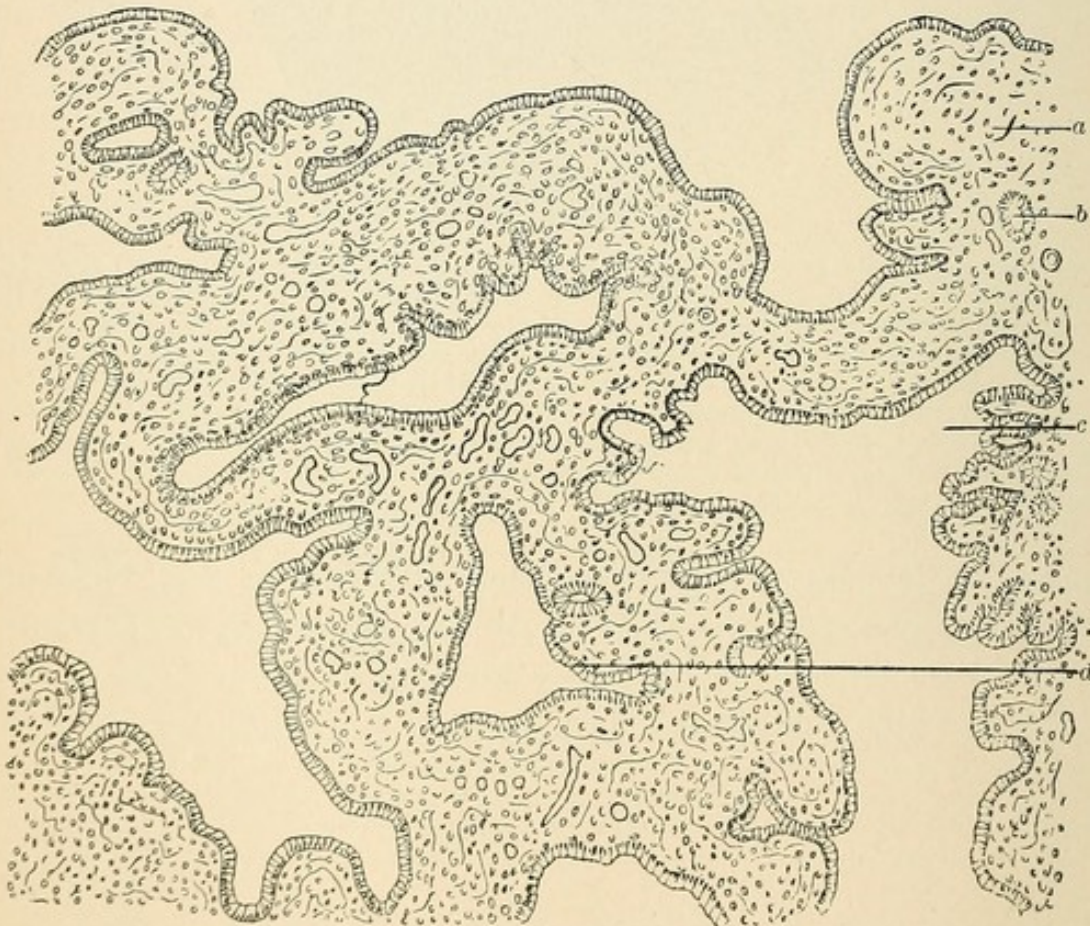


FIG. 9.—Channel polypus of cervix uteri; $\times 50$ (after D. J. Hamilton): *a*, fibro-cellular stroma of tumor; *b*, a gland of uterine mucous membrane; *c*, a channel; *d*, lining of columnar epithelium.

source and showed their manner of reproduction in the body. Before considering the biology of tumors it will be necessary to discuss a few of the more important points in their anatomy. The essential part of a tumor is its parenchyma; it is this which imparts to a tumor its anatomical characteristic and its clinical significance. The cells of a tumor are always limited by or imbedded in a stroma of connective tissue.

In Figure 9 is shown an adenoma of the cervical canal of the uterus in which the essential tumor-elements, columnar epithelial cells, are attached to and limited by a powerful stroma of connective tissue. This picture affords a good illustration of the relation of the tumor-cells to the stroma in benign tumors of the epiblast and hypoblast. In malignant and mesoblastic tumors the parenchyma appears as an interstitial product, the cells being enclosed on all sides by the stroma. The stroma or reticulum of a tumor is always derived from the mesoblast, and consists of some form of connective tissue in greater or lesser abundance (Fig. 10). In epiblastic and hypoblastic tumors the tissue reaches the tumor from the base; in mesoblastic tumors it furnishes a framework for the tumor on all sides.

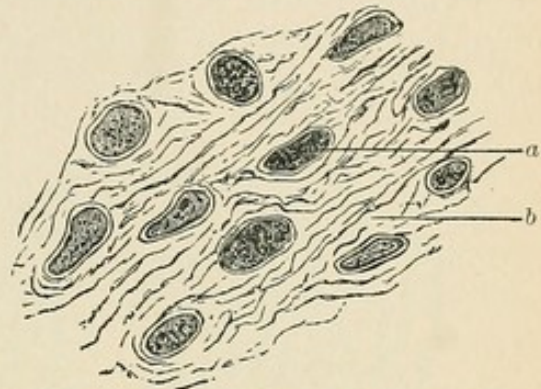


FIG. 10.—Fibro-chondroma from capsule of knee; $\times 400$ (after D. J. Hamilton): *a*, cartilage-cells; *b*, the matrix.

Blood-vessels.—A tumor is nourished by the blood-vessels which supply the part or organ in which the tumor is located (Fig. 11). The blood-vessels constitute an important part in the structure, character, and life-history of a tumor. The vascularization of a tumor usually takes place by the formation of new blood-vessels from pre-existing vessels in its immediate vicinity by a process of budding. A more atypical blood-supply is sometimes procured by canalization of cells and the entrance of blood into pre-existing hollow spaces or into connective-tissue channels entering into communication with neighboring blood-vessels. Most of the tumors contain a complete vascular system; that is, one or a number of arteries enter it from the periphery and divide into smaller branches, which terminate in a network of capillaries from which the blood is returned to the general circulation through veins. The blood-vessels follow the connective tissue of the stroma, and in very soft and cellular tumors they often come in direct contact with its parenchyma (sarcoma). The structure of the walls of blood-vessels is often very defective, especially in soft and rapidly-growing sarcoma. Great vascularity of a tumor usually indicates rapid growth and imperfect development of the parenchyma-cells of the tumor. Perforation of the walls of the blood-vessels by the tumor-tissue, especially the veins, is often observed in malignant tumors, and leads to thrombosis or embolism, or both of these complications may occur in rapid succession.

Lymphatic Vessels.—The existence of lymphatic vessels in tumors

was first discovered by Van der Kolk, who, as well as Krause, found them in carcinoma (Fig. 12). Lücke and Klebs attempted to inject the lymphatics of carcinoma of the lip before the extirpation of the tumor, but did not succeed in accomplishing the desired object. The benign growths are scantily, if at all, supplied with lymphatics. In carcinoma they are undoubtedly always present—a fact which explains on an

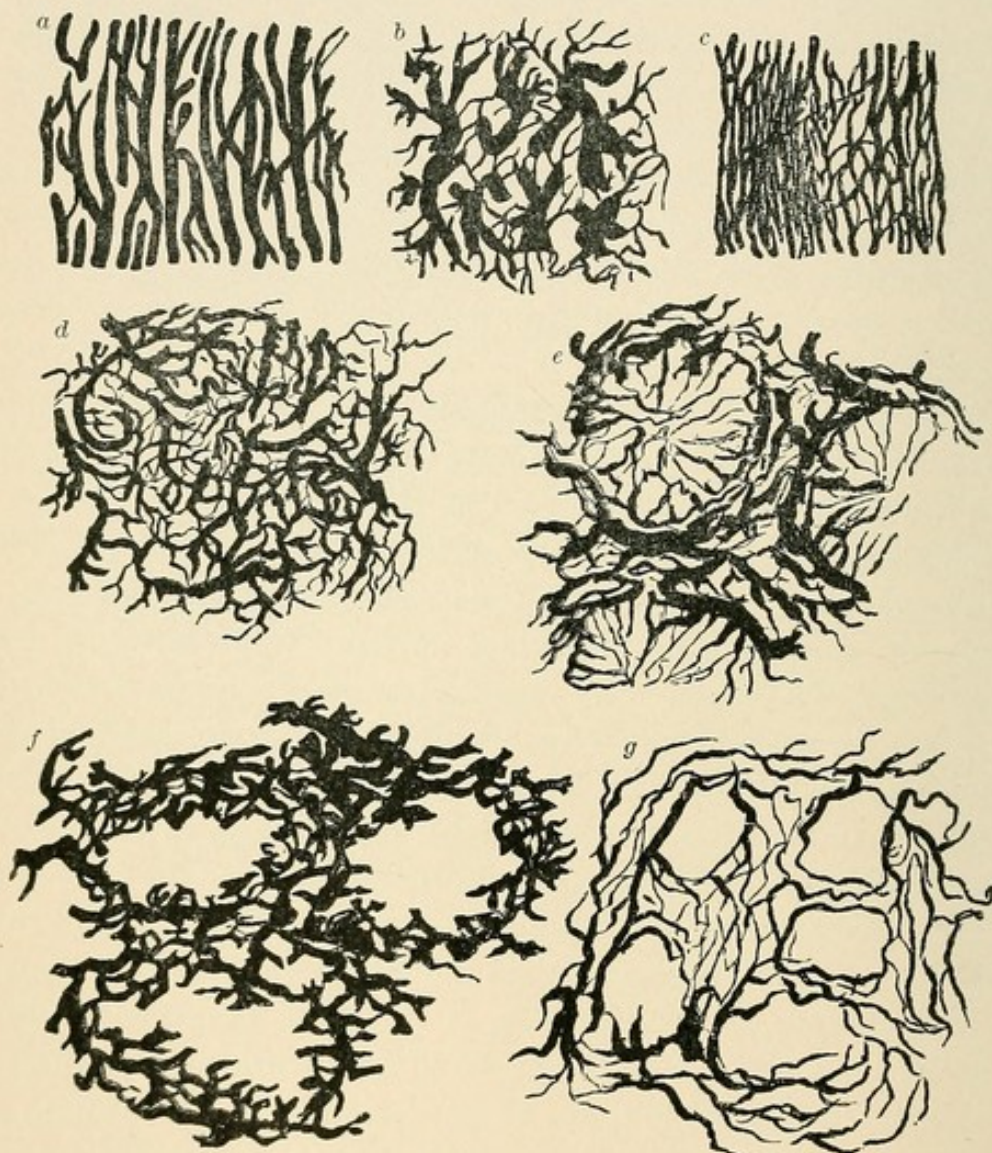


FIG. 11.—Blood-vessels of tumors (after Lücke): *a*, vascular injection in an osteoid chondroma; *b*, reticulum of veins from a sarcoma of the parotid; *c*, capillary network from a fibroma of the abdominal wall; *d*, same from a very vascular myeloid sarcoma of the lower jaw; *e*, vascular network from a carcinoma of the tonsil; *f*, alveolar vascular network from a carcinoma of the breast; *g*, injected preparation from a carcinoma of the lip.

anatomical basis the manner of regional dissemination which is so constantly observed during the clinical course of this tumor, irrespective of its anatomical location.

Nerves.—But little is known concerning the innervation of tumors. In the myelinic variety of neuroma the production of new nerve-fibres has been demonstrated. The tenderness and the spontaneous pain

which belong to certain varieties of other tumors would suggest the presence of new nerve-fibres, and should induce pathologists to make additional researches relative to the nerve-supply of tumors. The want of proper innervation undoubtedly determines largely the planless growth of tumors.

Biology.—*The life-history of a tumor is greatly influenced by the inherent formative capacity of its cells as well as by the general condition of the patient. Cells endowed with maximum reproductive power are always found in rapidly-growing malignant tumors, and the same type of tumor grows with variable speed and attains unequal size in different individuals during the same length of time.* In certain individuals of

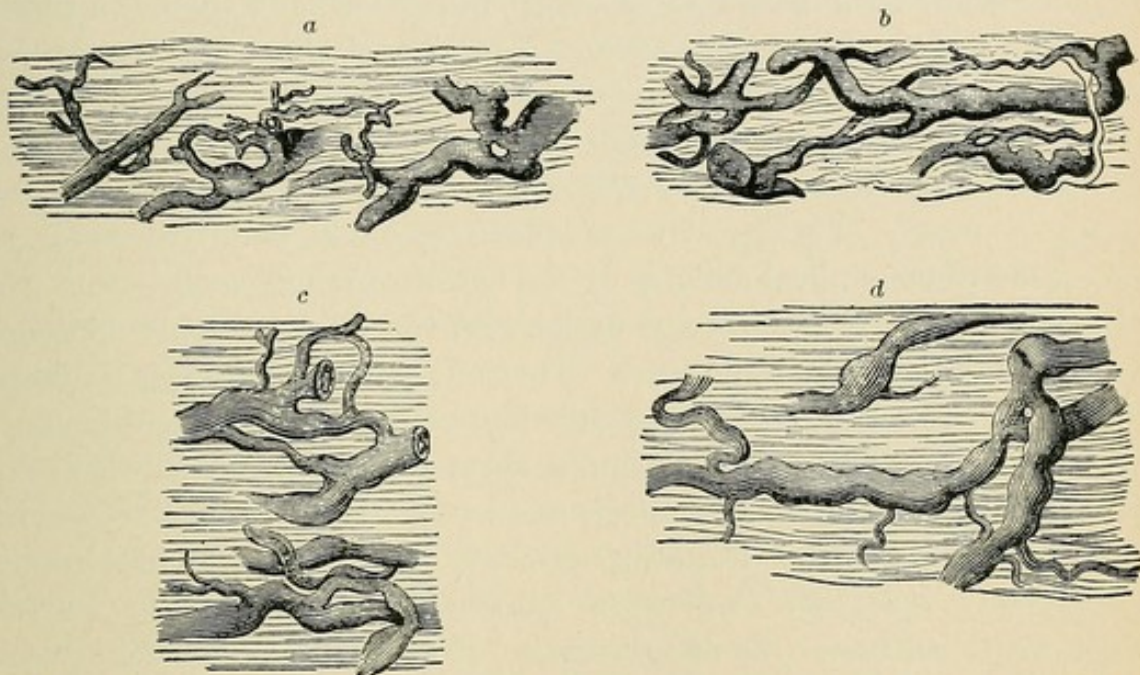


FIG. 12.—Lymphatic vessels from a fungous carcinoma of the region of the hip-joint of a young man (after W. Krause): *a*, lymphatic vessels of subcutaneous tissue which was attached to the stroma of the carcinoma; *b-d*, lymphatic vessels from the stroma of the carcinoma itself, which communicated with the vessels of the subcutaneous tissue; at *b* a lymphatic vessel projects beyond the level of the section.

the same age, living under apparently similar conditions, a fatty tumor may not exceed the size of a walnut after a lapse of twenty years, while in another person it may reach colossal dimensions in a much shorter time. This difference in the rapidity of growth of benign tumors cannot be explained upon any known physiological or pathological laws. Some of the benign tumors grow to a certain size, and then remain stationary permanently or for an indefinite period of time, when, under certain local or general acquired causes, there again takes place active tissue-proliferation, which often assumes a much more active phase than during the first stage of tumor-growth. It has been observed by Lücke and others that pregnancy plays an important rôle in the etiology and growth of tumors. This influence is particularly well marked in

tumors of the uterus and its appendages and in tumors of the breast—that is to say, tumors in organs the seat of prolonged and irregular congestions during pregnancy and lactation. Age influences the type and location of tumors. Benign tumors occur most frequently in young persons, while carcinoma attacks in preference persons past middle age. Sarcoma manifests no such predilection for senile tissue. Benign tumors grow more rapidly in the young than in the aged, and malignant tumors manifest a greater degree of malignancy in children and young adults than in persons advanced in years. Clinical experience has shown that acute infective diseases exert a retarding influence upon the growth of tumors. A tumor composed almost exclusively of parenchyma-cells is more prone to undergo early degenerative changes than is a tumor in which the stroma predominates. *The growth of all tumors requires an adequate quantitative and qualitative blood-supply.* The importance of this requirement in furthering the growth of a tumor is well shown by the tumors so frequently met with during the age of puberty—dermoid cysts. The growth of these cysts is determined by an increased physiological activity of the entire organism—and more particularly of the skin, its appendages, and the organs of generation—which is initiated at that time. The increased physiological blood-supply to special organs during this time of life explains the frequency with which we meet with dermoid cysts of the ovary, the face, the base of the tongue, and the neck in young adults. To determine the growth of a tumor it is not only necessary to have an adequate blood-supply, *but the blood itself must contain the nutritive and chemical ingredients necessary for the formation of the different kinds of tumor-tissue.* In the development of an osteoma it is not only necessary to have present an embryonal matrix of indifferent bone-cells, but the blood must also bring to the part during the growth of the tumor the proper constituent elements (the earthy salts) which enter into the formation of bone. So, likewise, in a case of lipoma it is not only essential to have present an adequate quantitative blood-supply, but the quality of the blood brought to the tumor must be such as to produce fat instead of connective tissue or bone.

An increase of blood-supply favors tissue-growth, and we can trace this increased vascularization in connection with tumor-growth either to a physiological increase or as one of the consequences of antecedent pathological conditions. The increased physiological blood-supply is either general or local. The general increase gives rise to giant growth, which consists in hyper-production of normal histological elements throughout the entire body; local increase of physiological blood-supply leads to local hyperplasia, localized giant growth, which may

implicate an entire organ or limb. Anything which in the organism will determine an increased physiological blood-supply to a pre-existing tumor-matrix favors tumor-growth—an assumption well established in cases of tumors of the breast commencing during pregnancy or lactation, at a time when the organ receives a largely increased supply of blood, which increase cannot fail in exerting a potent influence in stimulating cell-proliferation from a latent matrix. So, in cases of uterine tumors, the periodical recurrences of congestion in the affected parts during menstruation create a condition which accelerates tissue-growth. Consequently, myofibroma of the uterus almost without exception makes its appearance during the childbearing period of life, and its further growth is usually arrested with the cessation of menstruation. Surgeons have utilized this clinical fact, and have adopted a therapeutic resource which aims at diminishing the increased physiological blood-supply to this organ by suspending artificially this periodical function by the removal of the ovaries and the Fallopian tubes in the treatment of some forms of myofibroma of the uterus.

A tumor frequently presents to the naked eye an appearance of abnormal vascularization characterized by an increased circulation, either arterial, venous, or capillary, as the case may be, according to its anatomical location or the peculiarity of the structure of the new blood-vessels in the tumor-matrix or its immediate vicinity. The most striking example of atypical vascularization is furnished by tumors which present pulsation as one of their most conspicuous clinical features. By a pulsating tumor we understand, clinically, a tumor in which to the usual evidences of tumor-formation are added the pathognomonic symptoms of aneurysm. In such instances many of the larger new blood-vessels are either entirely devoid of a proper vessel-wall, or, when this is present, it is defective, forming irregular cavities or spaces into which the blood enters from some adjoining vessel, returning either in the same direction or emptying into another channel. This peculiar structure and arrangement of vessels in many sarcomatous tumors would explain the frequency with which pulsation can be felt in examining them, more especially if they have their starting-point in the interior of a bone. Such tumors are noted for their rapid growth, and have repeatedly been mistaken for aneurysms.

Local irritation increases tumor-growth. Tumors located upon the surface of the body or in other parts exposed to irritating influences grow, as a rule, more rapidly than tumors occupying more protected localities. The application of irritants, such as iodine, blisters, and stimulating ointments, liniments, and plasters, produces the same effect. The same can be said of exploratory punctures and parenchymatous

injections. The incomplete destruction of a malignant tumor by caustics is invariably followed by more rapid growth of the tumor-remnants, extensive regional infection, and early general dissemination.

Relation of Tumors to Adjacent Tissues.—*The tumor-tissue is produced exclusively from the matrix of embryonic cells from which it started; the adjacent tissues take no active part in the growth of tumors.* The adjacent tissues are acted upon by the tumor, but take no part in its development. *The benign tumors push the tissues aside or apart to make room for themselves; the malignant tumors, particularly carcinoma, infiltrate the surrounding connective tissue and include it as a temporary passive constituent of the tumor-mass.* The pre-existing connective tissue under such circumstances is subsequently destroyed and removed by the tumor-tissue. Sarcoma follows connective tissue, nerve-sheaths, and blood-vessels; carcinoma invades the lymphatics, and it is through them that regional dissemination takes place. A tumor always enlarges in the direction offering the least resistance. One of the constant effects of tumor-pressure is atrophy of the tissues exposed to pressure. Pressure-atrophy of the adjacent tissues is most certain to occur, and is most marked if the tumor is anatomically so located that its increasing size meets with great resistance. An ordinary sebaceous cyst of the scalp or a dermoid cyst above the orbit, although of slow growth, often produces by atrophy a cup-shaped depression in the underlying bone. A lipoma of great size occupying the panniculus adiposus produces little if any pressure-atrophy, because the tumor meets with little or no resistance to its outward growth. The pressure of a tumor upon a nerve often causes intense pain, and may eventually destroy its function. Prolonged compression of a large artery may result in the formation of a thrombus and the complete obliteration of a vessel. A carcinoma or a sarcoma may destroy the wall of a large artery, such an occurrence becoming often the immediate cause of death from hemorrhage. At other times a false aneurysm is established in the same manner.

Perforation of a vein by malignant tumors, preceded or followed by thrombosis, will be alluded to farther on as one of the many complications of carcinoma and sarcoma. Serious and often fatal complications may arise from the compression of an important internal organ by a tumor. Thoracic and mediastinal tumors frequently destroy life by causing compression of the heart, the lungs, or the large blood-vessels. Abdominal tumors of large size often result in death from marasmus by interfering with digestion. Tumors impacted in the pelvis may cause retention of urine, compression of the ureters, and intestinal obstruction.

Benign tumors frequently appear multiple primarily or in slow succession ; malignant tumors, while primarily multiple only in exceptional cases, give rise to secondary tumors in the same region or in distant parts. It can therefore be asserted, as a rule, that primary multiplicity would indicate a benign character of the tumors, while secondary multiplicity is almost an infallible evidence of the malignant nature of the primary tumor.

IV. PATHOLOGY OF TUMORS.

THE form of a tumor depends largely upon its location and on the structure of the tissues in its immediate neighborhood. A tumor developing from a surface and projecting beyond it, with a wide base, is said to be "sessile." If the tumor becomes more prominent and the base narrows, a pedicle forms, when it is called a "pedunculated" tumor. Such tumors attached to a mucous membrane are usually described under the term "polypus." If a tumor originates from a part surrounded by tissues offering the same degree of resistance, it usually assumes a globular or an oval shape. If it occupies a locality covered in by a broad resisting structure, it becomes flattened out, as is the case with intra-articular lipoma, called *lipoma arborescens*. Unequal resistance over the surface of the tumor moulds it in all imaginable shapes. The surface of the tumor may be smooth, lobulated, or nodular. Benign tumors are usually smooth; lipoma is often lobulated; sarcoma is either smooth or lobulated; carcinoma is nodular. The density of a tumor depends on its structure, the character of the tissues in its immediate vicinity, and the degenerative changes that have taken place. A tumor composed largely of parenchyma-cells is usually soft; tumors supplied with a well-developed stroma are hard; a tumor composed almost exclusively of blood-vessels (angioma) is greatly reduced in size under pressure; a tumor with liquid contents (cyst) ordinarily presents fluctuation; a solid but soft tumor (lipoma and sarcoma) is often mistaken for a cyst or an abscess, because on palpation a sense of fluctuation can be felt (pseudo-fluctuation). The color of tumor-tissue is greatly influenced by its vascularity, the character of the cells of which it is composed, and the extent and nature of the degenerative changes which have taken place. Most of the benign mesoblastic tumors present a whitish appearance. Sarcoma, as its name indicates, resembles on section flesh. The cut surface of a firm carcinoma is very similar in appearance and density to a raw turnip. Fatty degeneration of the contents of the alveoli imparts to the cut surface of the tumor a yellowish tinge. Hemorrhage into the substance of a tumor produces pigmentation of various degrees, from almost black to a yellow tinge. The black color of melano-sarcoma and melano-carcinoma is a distinguishing feature of these forms of malignant tumors.

Tumor-tissue, stroma and cells, is subject to the same pathological changes as the normal tissues of the body. Among the more important of these changes are the regressive metamorphoses of the cellular elements.

Fatty Degeneration.—Fatty degeneration of the parenchyma-cells of a tumor is one of the most frequent secondary pathological changes observed in tumors. The immediate cause of this form of degeneration is a defective blood-supply; hence it occurs most frequently in old benign tumors and in malignant tumors in which vascularization does not keep pace with the increase of tissue. It is a constant occurrence in slowly-growing carcinoma of the lip and the breast. In ulcerating surface epithelioma the fatty material can be squeezed out from the alveoli in yellowish-white masses resembling the contents of a small retention-cyst of the sebaceous glands. In glandular carcinoma the alveoli which have undergone this change present themselves on the cut surface as yellow areas of variable size, from which the same kind of material escapes under pressure. If this material is examined under the micro-

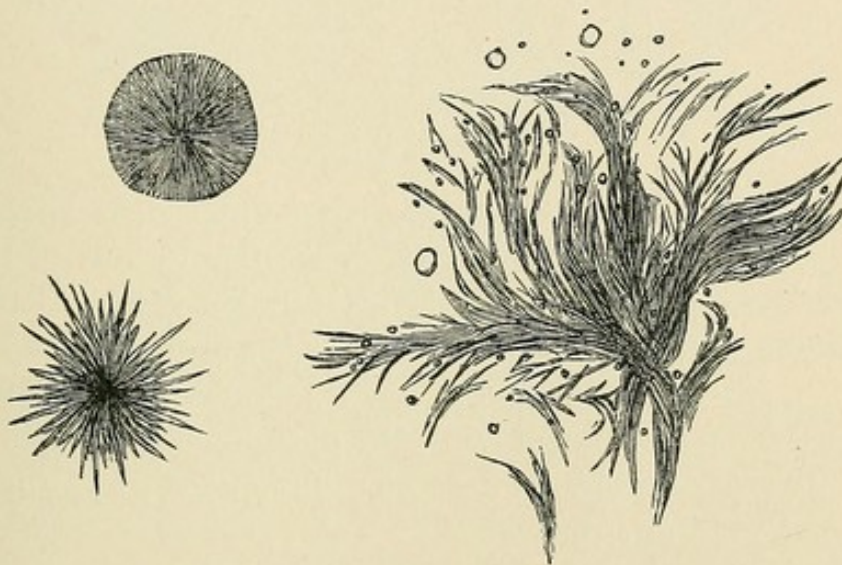


FIG. 13.—Fat-crystals; $\times 250$ (after Perls).

scope, nothing but a granular detritus can be seen, with here and there a fat-crystal (Fig. 13) or a cholesterin-plate (Fig. 14). The fatty change commences as an infiltration of the cells, this infiltration finally resulting in the breaking up of the cells into granular matter. The distinction of cells by this or by any other form of regressive metamorphosis retards tumor-growth; but while the growth has become stationary at one place it continues in other places, so that a tumor is seldom entirely removed by degenerative changes. Degeneration commences either in the oldest part of the tumor or in parts of it which by accident have been deprived suddenly or gradually of an adequate blood-supply. It is upon this well-known and thoroughly established pathological fact that surgeons

have made an attempt to imitate and anticipate the natural forces which tend to limit or to arrest tumor-growth by cutting off the blood-supply from the part, as suggested by Wölfler in the treatment of

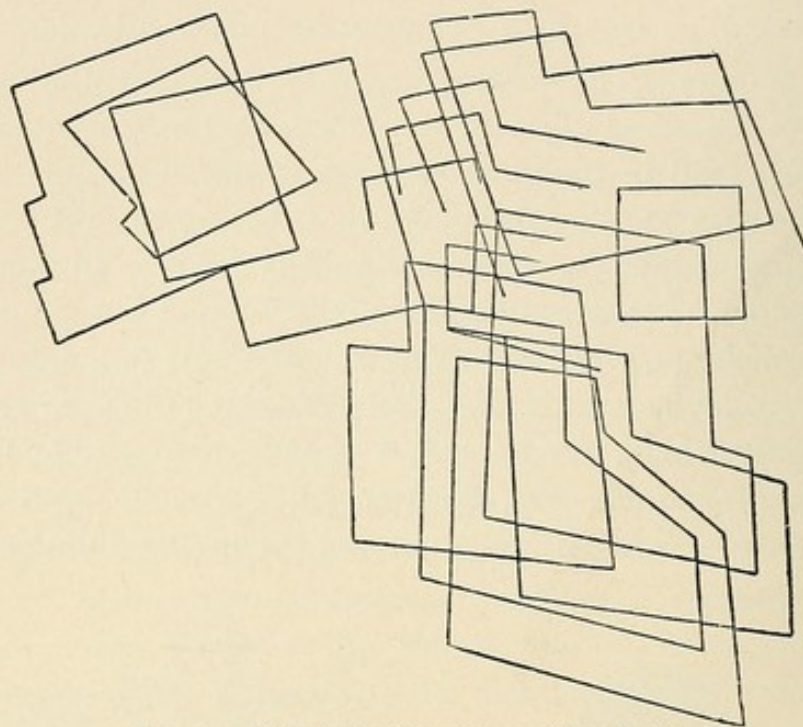


FIG. 14.—Cholesterin-plates; $\times 250$ (after Perls).

tumors of the thyroid gland, and by gynecologists in ligation of the uterine arteries in the treatment of non-malignant tumors of the uterus.

Mucoid Degeneration.—The transformation of active tumor-cells into a harmless, innocent mucoid substance has been observed in tumors

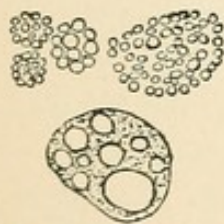
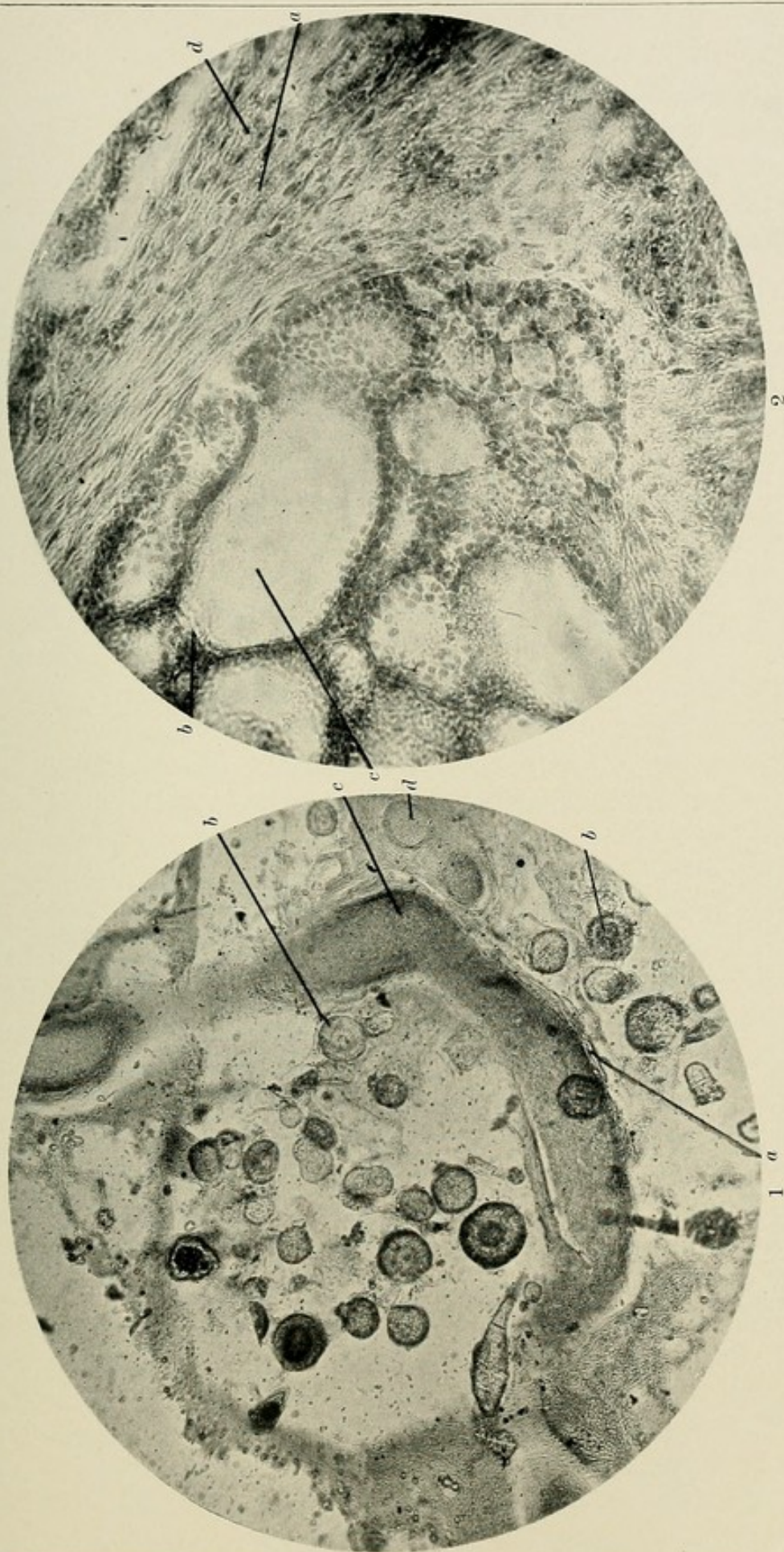



FIG. 15.—Colloid degeneration of the epithelial cells of a cancerous tumor of the mamma; $\times 400$ (after D. J. Hamilton).

belonging to the connective-tissue type, fibroma and chondroma, and also occasionally in adenoma. The part of a tumor which undergoes this form of degeneration becomes cystic.

Colloid Degeneration.—The exact chemical composition of colloid material has not been determined. Scherer regards it as an albuminous substance in combination with a carbohydrate analogous to mucin and metalbumin. Colloid material is a jelly-like, structureless substance derived by a degenerative process from the parenchyma-cells or the stroma of a tumor. This form of degeneration takes place in both benign and malignant tumors, but is observed most frequently in tumors of the thyroid gland, of the ovary, and of the gastro-intestinal canal. If the parenchyma-cells undergo this change, the colloid material appears in the protoplasm of the cell at one or different points, and the process continues until the cell-walls give way, when the colloid material is liberated (Fig. 15).



1. Corpora amylacea, cyst of choroid plexus; $\times 85$ (laboratory of Rush Medical College, Chicago): *a*, connective tissue capsule; *b*, *b*, corpora amylacea; *c*, longitudinal section of blood-vessel; *d*, transverse section of blood-vessel. 2. Malignant tumor of orbit: *a*, connective-tissue capsule; *b*, number of embryonic cells; *c*, hyaline substance; *d*, embryonic cells in capsule.



Colloid cysts of the ovary often attain a colossal size, and abdominal surgeons are well aware of the fact that such cysts are prone to return even after what seemed a thorough removal of the tumor.

Amyloid Degeneration.—The transformation of tumor-cells into a starchy substance takes place most frequently in the cells of malignant epiblastic tumors, also in secondary carcinoma of the lymphatic glands. We have no positive knowledge concerning the true nature of the *corpora amylacea* found in certain tumors as one of the many degenerative changes, and in other pathological products. It is undoubtedly an albuminate, as its micro-chemical actions correspond with those given by other albuminates. This substance has never been detected in the blood; it is therefore reasonable to suppose that it is formed in the places in which it has been found. In a specimen of cyst of the choroid plexus in the museum of Rush Medical College numerous corpora amylacea were found in close proximity to a large blood-vessel (Pl. I, Fig. 1). The degeneration of an adenoma into a colloid substance imparts to the tumor an entirely new aspect, transforming it from a solid into a cystic tumor.

Hyaline Degeneration.—The product of hyaline degeneration differs from the amyloid substance in that it does not give the reactions to iodine. The hyaline substance in tumors appears either alone, when the entire tumor has undergone degeneration, or in circumscribed places surrounded by the cells or stroma of the tumor. It is found in benign and malignant tumors of all germinal layers. Tumors in which this change was marked have been called by different names—*tumeurs hétéradéniques* (Robin); *Schlauchknorpel-geschwulst* (V. Meckel); *cylindroma* (Billroth); *Schleim-cancroid* (Förster); *Schlauch-sarcom* (Friedreich); *siphonoma* (Henle). Thiersch insisted that such tumors do not represent a special clinical or anatomical variety, but are tumors in which parts have undergone regressive metamorphosis. Hyaline degeneration in other pathological products attacks in preference the small blood-vessels, and it is more than probable that when it occurs in tumors it begins in the same place and extends from the blood-vessels to the stroma or the parenchyma-cells. Hyaline degeneration most frequently attacks endothelial structures, but it extends into the connective-tissue spaces where the hyaline substance is deposited, as is shown on Plate 2, (Fig. 1). A very interesting tumor of the orbit, which tumor in all probability started from the internal angle of the eye, examined in the laboratory of Rush Medical College, showed very extensive hyaline degeneration (Pl. I, Fig. 2). If hyaline degeneration commences at the same time in several parts of the tumor, by coalescence large spaces are formed in which no tumor-elements can be found.

Caseation.—Local anemia is a recognized cause of caseation, but it remains an open question whether this form of degeneration can occur independently of the bacillus of tuberculosis, so that when this kind of metamorphosis is found in a tumor it is well to inquire into the pres-

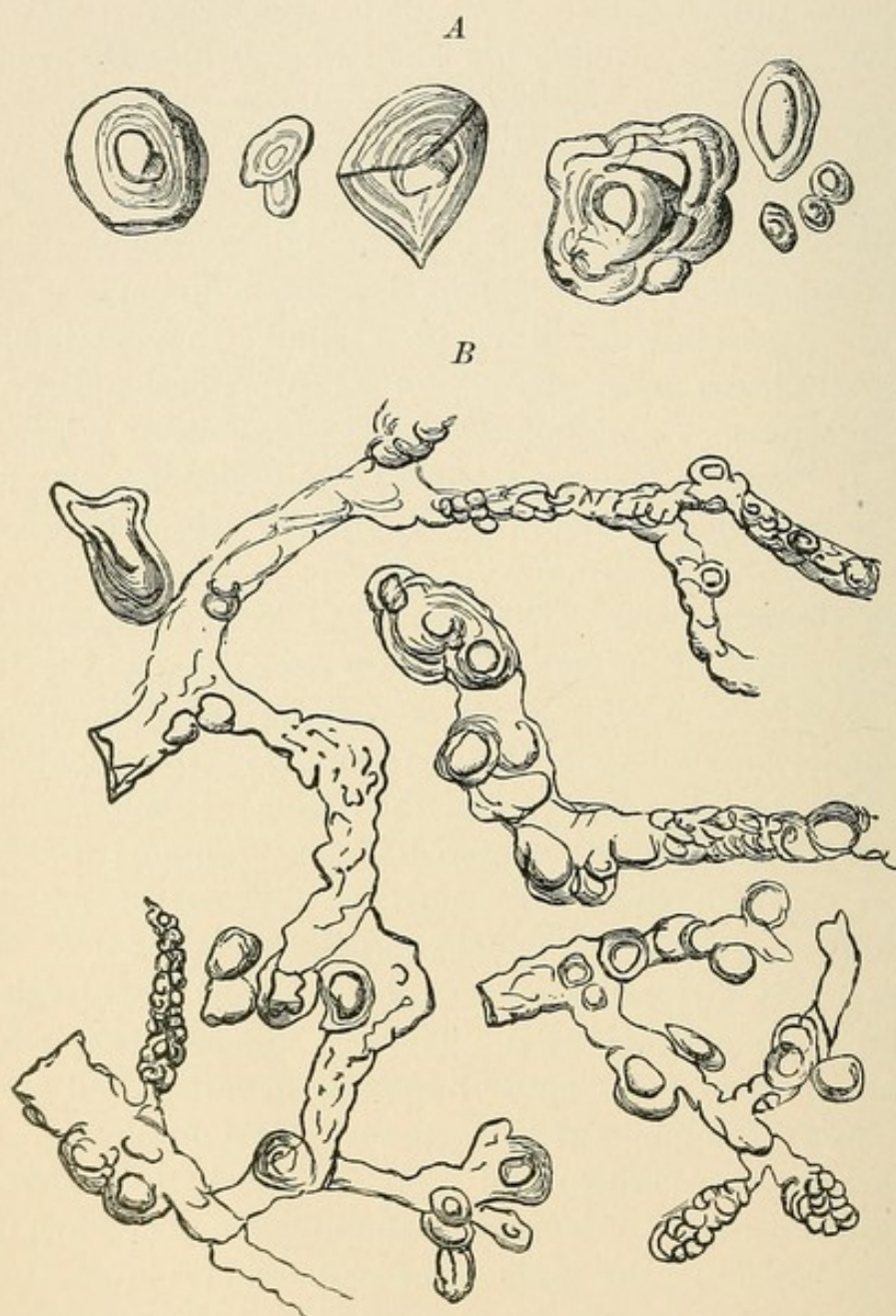


FIG. 16.—Petrification of a glioma (psammoma) of the brain; $\times 250$ (after Perls): *A*, large laminated concretions; *B*, calcification of capillaries; deposition of the lime-salts in the form of homogeneous masses.

ence of the specific influence which is known to produce tyrosis. A tumor may become the seat of infection with the bacillus of tuberculosis, and the presence of this specific cause will determine the character of the regressive metamorphosis. It is only reasonable to assume that the atypical vascularization of tumors furnishes a condition favorable

to localization of floating germs, and consequently constitutes one of the causes of auto-infection.

Calcification or Cretefaction.—This degenerative process has been seen in all kinds of tumors and in all the cellular elements, parenchyma-cells and stroma. By this process a chalky substance is substituted for the tumor-tissue. It is usually preceded by fatty degeneration; at other times it prepares the way for ossification of the tumor. It occurs frequently as a marantic change in the arteries and cartilage of the aged. The chalky material is deposited in the form of small granules in the tissues, taking the place of pre-existing degenerated cells. In a normal condition the lime-salts are kept in solution in the tissues by organic acids and by free carbonic acid. Deposition under abnormal conditions is caused by diminution in the quantity of organic acids and free carbonic acid, by the existence of insoluble in place of soluble lime-salts, or by an abnormal increase of lime-salts reaching the affected part, resulting in direct infiltration of the tissues. In some instances the entire tumor eventually is petrified, the inorganic substitute retaining the shape of the original tumor.

The so-called *lime-metastasis* described by Virchow has been observed in cases of extensive disease of the bones, and is caused by the return into the circulation of the liberated lime-salts, which become deposited in distant organs, notably the kidneys and lungs. Petrification was noted in a sarcoma of the soft tissues of the arm by Lücke. Maceration of this part of the specimen in an acid, examined under the microscope, revealed spindle-shaped cells. Calcification frequently occurs in benign epiblastic tumors and in adenomatous tumors, particularly of the thyroid gland and ovary.

Ossification.—Calcification in a tumor has frequently been mistaken for ossification. We can speak of ossification only if, after the removal of the tumor, the specimen decalcifies and the remaining part exhibits under the microscope the structure of bone. Ossification of the tumor-cells always takes place in osteoma. It occurs also in chondroma and in dermoid cysts. Periosteal sarcoma is noted for its bone-producing capacity. In periosteal sarcoma of the cranial, pelvic, and long bones we find an irregular framework of long, delicate spiculæ of bone, the spaces filled in with sarcomatous tissue. In some cartilaginous and sarcomatous tumors immature bone (osteoid tissue) is formed in place of true bone.

Interstitial Hemorrhage and Thrombosis.—The great vascularity of some tumors and the imperfect structure of the walls of blood-vessels frequently result in spontaneous hemorrhage, or hemorrhage under such circumstances is produced by a slight trauma, such as a contu-

sion, a palpation of the tumor, or an exploratory puncture. The blood escapes into pre-existing spaces (cysts) or is diffused through the stroma of the tumor or between the cells. If the hemorrhage is considerable, the tumor increases suddenly in size and becomes more tense. The tension thus produced is also the cause of a sudden appearance or increase of pain. The extravasation, if limited in quantity, is usually removed by absorption; if this does not occur, it either leads to the formation of a cyst or determines infection of the tumor by pathogenic microbes. Hemorrhage always causes a change in the appearance of the tumor-tissue from the presence of the coloring material of the extravasated blood which is imbibed by the tissues.

If the hemorrhage is profuse, the presence of extravasated blood in the tumor is often indicated on the surface, a few days after the accident, by the appearance of ecchymosis. The atypical vascularization of a tumor renders the blood-vessels peculiarly amenable to implication during the degenerative changes of the tumor-tissue. For instance, if, according to the views taught by Rokitansky, new blood-corpuscles form from the endothelial lining of a new closed blood-space by gradual growth and dilatation, this space is brought in contact with a vein-wall within or outside the tumor, and by a process of pressure-atrophy a communication is established between the pre-existing vein and a new blood-channel. Such an occurrence determines atypical vascularization of a high degree and imparts to the tumor important clinical and pathological features. The blood entering such spaces from adjacent vessels, and not meeting with normal resistance on account of a defective vascular wall, produces pulsation, and in many instances, if such abnormal vascularization exists on a large scale, there can be heard on auscultation a marked *bruit* caused by irregular distribution of the blood in the atypical vessels. These are the cases described by the older surgeons and pathologists as "bone-aneurysm," when the disease affects the bone. A simple hemorrhagic cyst resembles one of these new blood-spaces, with or without a communication with adjacent vessels. The new vessels in a tumor, when imperfect in structure and largely dilated, often become the seat of mural thrombosis, the irregular surface of the defective intima presenting projecting points upon which, by conglutination, the third corpuscles of the blood become arrested and implanted, constituting in the course of time a white thrombus, which, when it encroaches upon the lumen of the vessel or blocks it completely, gives rise to coagulation-necrosis in the impeded blood-current on the distal side or upon the surface of the white thrombus, furnishing the necessary conditions for the formation of a red thrombus, which then completely

obstructs the circulation in the corresponding part of the vessel. Another form of thrombosis and obliteration of a vessel is met with as the result of perforation of the vessel-wall by a tumor, usually of a ma-

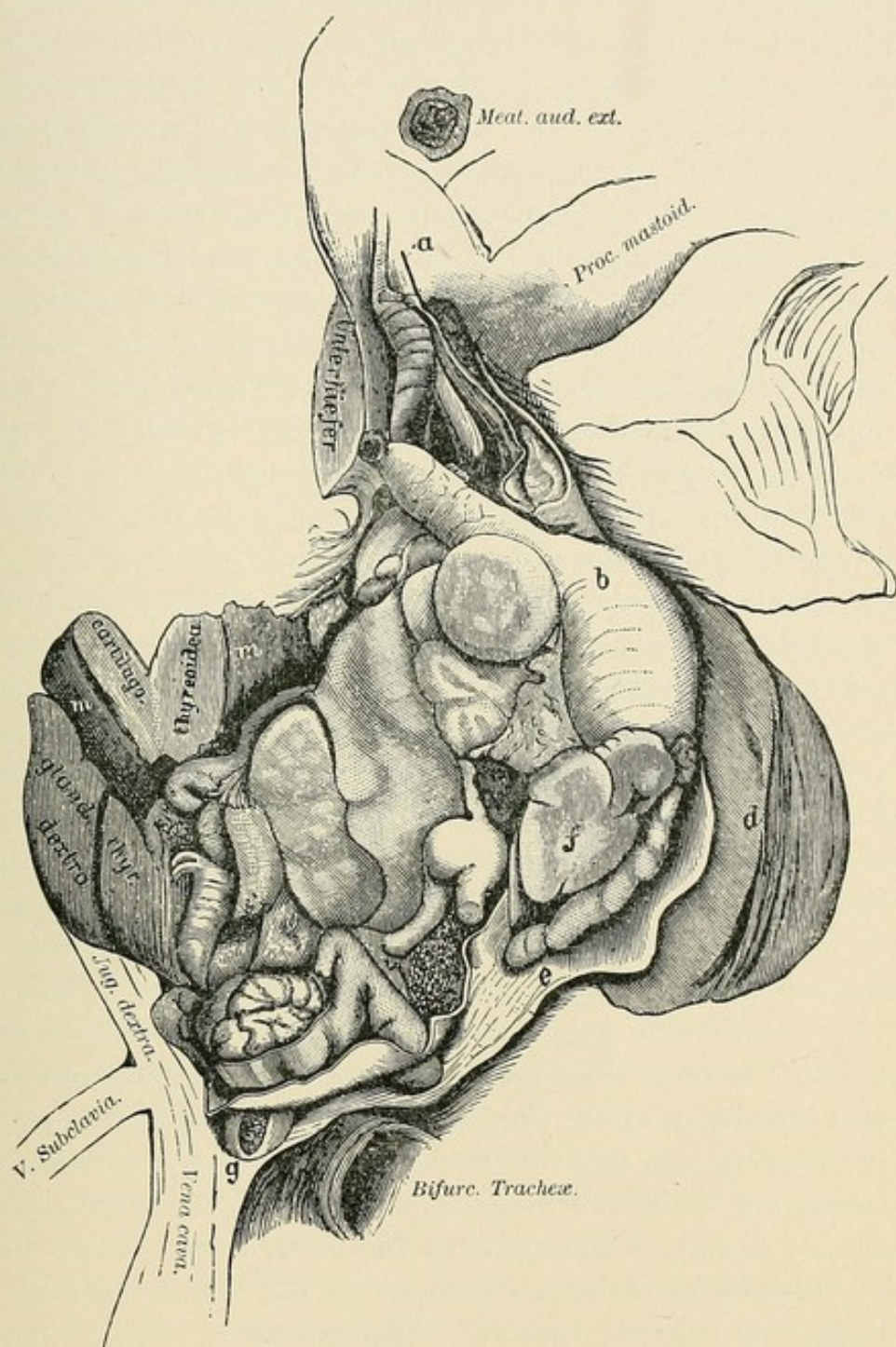


FIG. 17.—Thrombosing carcinoma-proliferation in the left jugular vein in carcinoma at the base of the brain (after Ziesing): *m*, hyo-thyroid muscle; *g*, proximal termination of inferior thyroid vein, with projecting plug of tumor-tissue; *e* and *b*, internal jugular vein; *e*, cut open, showing intravascular part of tumor; *f*; *b*, part of vein not laid open, and terminal part of facial vein; *a*, probe in jugular foramen; *d*, carcinomatous infiltration of cervical glands.

lignant type. This accident is one of the most interesting conditions in the pathology and clinical history of a malignant tumor. If, for instance, a carcinoma attacks a vein-wall, destroying pre-existing struc-

tures by infiltration, retrograde metamorphosis, and pressure-atrophy, until by perforation the tumor projects into the vein, forming a neoplastic thrombus composed of tumor-tissue, when the axial blood-current comes in contact with abnormal tissue, that tissue being devoid of the physiological properties required for a normal circulation, the thrombus increases in size by conglutination of the third corpuscle upon the most prominent part of the projecting tumor-mass, the neoplastic thrombus serving as a foreign body in the vessel; mural stasis of the white corpuscles also takes place, the conglutinated and aggregated corpuscular elements of the blood furnishing a most favorable soil for further cell-proliferation from the intravascular part of the tumor, which necessarily soon terminates in complete obstruction of the affected vessel. The writer has seen the internal jugular vein obstructed in its entire length in cases of secondary glandular carcinoma of the neck (Fig. 17). The neoplastic thrombus always manifests a tendency to increase in size by infiltration of the temporary obstructing thrombus, the blood-coagulum with tumor-cells, and when loose fragments become detached they are carried along with the blood-current, and, arriving at a point where the vessel is too narrow for their passage, become arrested and give rise to embolic metastasis. In some cases embolism takes place by the projection of the proximal end of the thrombus into the lumen of a larger vein; isolated cells and small fragments, becoming detached, are washed away by the blood-current: embolism in such cases establishes independent centres of tumor-growth wherever such tumor-infarcts occur, the products of tissue-proliferation at the distant points corresponding in every respect with that of the primary matrix. As in cases of septicemia and pyemia the emboli produce at distant points the same characteristic tissue-changes that are typical of the primary thrombus, so in cases of thrombosis and embolism in malignant growths the distant secondary tumor produced by an embolus from a neoplastic thrombus corresponds in structure and type with the primary tumor. Thrombosis and embolism in such instances effect a transplantation, as it were, of a part of the primary tumor to some distant part, the secondary tumors of embolic origin being the direct offsprings from the maternal or primary tumor. *Dissemination of benign tumors by thrombosis and embolism is unknown.*

The existence of thrombosis of many veins or of a large vein within, or in the immediate vicinity of, a malignant growth should be suspected by the presence of œdema and enlargement of the subcutaneous veins in the region from which the blood is returned through the obstructed veins. In one case of complete obstruction of the entire lumen of the internal jugular vein which occurred as a complication of carcinoma of the

lower jaw with extensive glandular infection, the œdema extended to the face on the same side and to the temporal region, and all the superficial veins were greatly distended.

Capsule of Tumor.—All benign tumors are encapsulated; that is, a well-defined connective-tissue partition is interposed between the tumor and the adjacent tissue, beyond which partition the tumor never extends. Malignant tumors are devoid of such a limiting boundary-line between tumor and surrounding tissues. In sarcoma a capsule is often found, but pathologically it is absent, because it is infiltrated with tumor-cells and the cells permeate it and infect the adjacent tissues. In carcinoma there is never even an attempt at the formation of a capsule.

Lymphatic Glands.—Enlargement of the lymphatic glands in the region occupied by the tumor indicates one of two things: 1. The introduction into the lymphatic channels of pathogenic microbes through an ulcerating inflamed benign tumor; 2. The transportation from a primary malignant tumor of tumor-cells through the lymphatic channels into the lymphatic glands. Enlargement of lymphatic glands in connection with benign tumors never occurs unless the tumor by a loss of continuity on the surface furnishes an infection-atrium for the entrance of pathogenic microbes from without. The termination of the complicating lymphadenitis under these circumstances will depend upon the number and kind of microbes that have reached the lymphatic glands. *Sarcoma seldom gives rise to glandular infection. Carcinoma, superficial and deep, almost invariably is complicated sooner or later by regional infection through the lymphatic vessels and glands.* This subject will be discussed more exhaustively in the sections on malignant tumors.

Inflammation.—If inflammation occurs in a tumor, it is an unmistakable proof that the tumor-tissue has become infected with pathogenic microbes. Infection may occur with and without a tangible infection-atrium. In the former case the tumor-tissue is exposed directly to infection by an abrasion, a cut, a puncture, or an ulcer, and through such defects pyogenic and other pathogenic microbes reach the tumor-tissue, and produce there, as elsewhere, their specific pathogenic effect. In the absence of such a direct port of entrance we must explain the occurrence of inflammation by floating microbes which reach the tumor with the circulating blood, and after localization has taken place incite inflammation in the same manner and to the same extent as when infection takes place through a more direct route. *Tumor-tissue possesses a lower resisting power to inflammation than does normal tissue; hence inflammation often results in extensive suppuration*

and gangrene, which in the case of benign tumors may result in a spontaneous and permanent cure. Malignant tumors are often the seat of infection and inflammation, but there is not a single authenticated case on record in which a spontaneous and permanent cure was effected in this manner. Inflammation, as a rule, increases the malignancy of malignant tumors, and the effects produced by it increase the suffering and hasten death. Inflammation in a tumor is often unintentionally produced by making an exploratory puncture without the necessary aseptic precautions and by making subcutaneous or parenchymatous injections.

Ulceration.—Ulceration of a tumor is either the result of accident or it follows causes inherent in the tumor itself. In the great majority of cases ulceration takes place when the tumor implicates the overlying skin or mucous membrane—when, either in consequence of pressure-atrophy or of the destruction of the skin by the tumor, a surface defect is produced and the tumor-tissue is exposed to direct infection. Sometimes, when the skin has become greatly attenuated by pressure from beneath, a small abrasion serves as a point of entrance, and the destruction of skin is hastened by an infective inflammation. The superficial ulcer in such cases is often the forerunner of a deep phlegmonous inflammation of the tumor, followed by more or less extensive sloughing. Suppurative inflammation and abscess-formation not infrequently are the direct causes of the superficial ulceration.

Accidental ulceration is often produced by friction on the part of the clothing, by contusions and wounds, by the application of irritating substances, and also by incomplete operations. The clinical behavior of an accidental ulcer varies according to its size and the character of the tumor. An ulcerated surface communicating with a suppurating cyst by a fistulous tract will not heal until the epithelial structures lining the cyst-wall are destroyed by the suppurative inflammation or are removed with the knife or destroyed by caustics. Defects of benign growths caused by inflammation, by caustics, or by incomplete operations heal, as a rule, in the same manner as do wounds of normal soft parts—by granulation, cicatrization, and epidermization.

Spontaneous ulcers—that is, ulcers caused by conditions inherent in the tumor—are constantly seen on the surface of carcinoma of the skin. The initial defect always occurs about the centre of the growth, covered by a crust which, when removed, leaves a raw and often bleeding surface. A spontaneous ulcer, as a rule, never heals: its tendency is to enlarge. The margins and the base present the firm induration so characteristic of this form of carcinoma.

Ulceration of glandular carcinoma is frequently followed by sloughing, suppuration, and putrefaction from the action of putrefactive bacilli upon dead tissue. The sloughing and suppuration of such a carcinoma usually give rise to a deep excavation in the centre of the tumor, in which excavation the secretions stagnate and putrefy, becoming the source of a sickening odor. In ulcerating sarcoma the tumor-tissue often projects far beyond the surface of the ulcer in the form of a fungous mass, the *fungus hæmatodes* of the old authors.

Grafting of a Malignant upon a Benign Tumor.—By the grafting of a malignant upon a benign tumor is meant, not the transformation

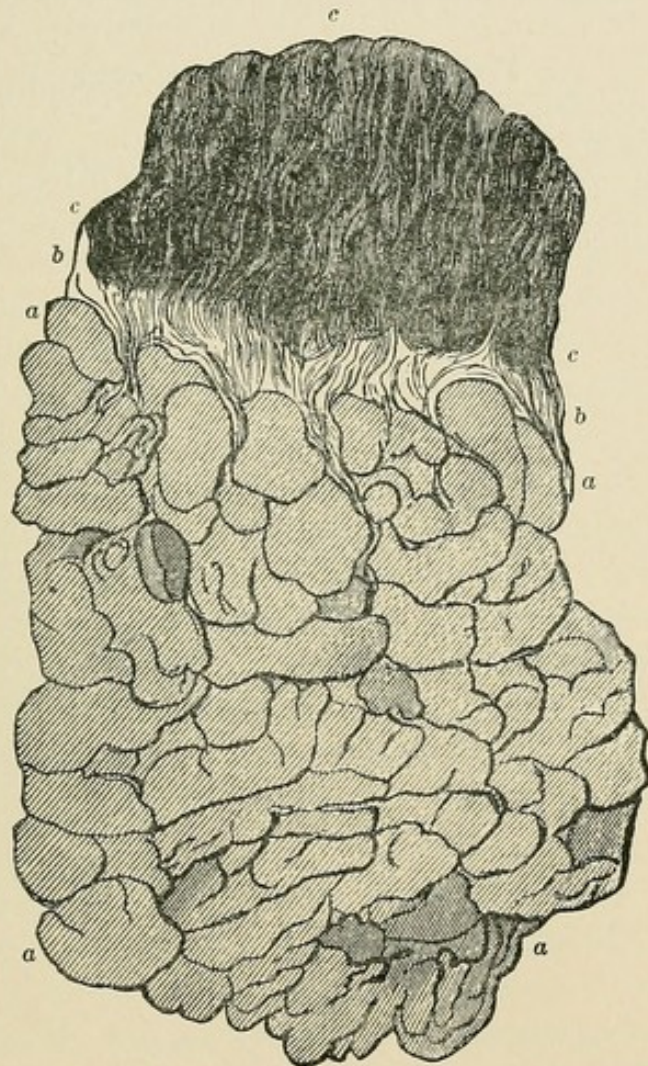


FIG. 18.—Lipoma with a sarcoma grafted upon it (Lücke): *a*, fatty tissue; *b*, connective tissue; *c*, sarcoma.

of a benign into a malignant tumor, but the appearance of a malignant tumor in the immediate vicinity of a benign tumor. Such an intimate connection between a malignant and a benign tumor is shown in Figure 18. The occurrence of the malignant tumor in such cases appears purely accidental, and yet from an embryological standpoint a more intimate relationship in the etiology of the two entirely different tumors can be shown. For instance, in the specimen shown in

Figure 18 it is evident that the lipoma sprang from a matrix of embryonic cells in the panniculus adiposus, while the sarcoma had its origin from a similar matrix in the connective tissue of the skin. It is more than probable that the embryonic cells composing the sarcoma-matrix were arrested in their development at an earlier stage than were the embryonic cells in the adjoining fatty tissue ; consequently, the matrix in the skin gave rise to tumor-tissue of an embryonic type, while the matrix in the fatty tissues produced tumor-cells which possessed the intrinsic property to develop into mature tissue. From the illustration it can readily be seen that the sarcoma would eventually invade the lipoma, the tissue of which would yield to it in the same manner as would normal adipose tissue.

In concluding this section it is proper to recapitulate that *tumor-tissue is subject to the same degenerative changes as normal tissue altered by accident or by disease, and that it constitutes a locus minoris resistentiæ in the event of direct or indirect infection with pathogenic microbes.*

V. TUMORS IN PLANTS AND ANIMALS.

BEFORE considering the etiological factors concerned in provoking tumor-growth it will be of interest to learn something of tumors in the lower animals and plants, for the purpose of showing that tumors occur in frequency in proportion to the complexity of the organism they inhabit; that is to say, they are least frequent in plants and animals of a low degree of development, and most frequent in man.

Tumors in Plants.—For the remarks on this subject the writer is largely indebted to the work of Mr. Williams on *Cancer- and Tumor-formation*. The resemblance of tumors of the higher animal organisms and those of plants was pointed out by Virchow years ago. In tumor-formation we find kindred processes throughout the organic world. Each cell leads to a certain extent a parasitic existence. If it were not for the restraining and modifying influence exerted by the whole organism, each cell might develop into the form of the parental organism. In proportion as the cells are highly specialized their primitive reproductive function is either greatly diminished or altogether lost. In the higher organism certain cells remain unspecialized. Under favorable conditions certain unspecialized or indifferent cells may grow and develop without regard to the requirements of the adjoining tissues and of the organism as a whole. Tumors can be studied to better advantage in plants than in animals. Buds may remain in a latent condition for years, and yet under favorable conditions their activity may revive. Buds may arise on any part of the plant; in fact, wherever there is an excess of nutritive materials capable of being utilized for growth by the cells of the part, there buds arise. Under such circumstances buds may be formed wherever undifferentiated cells are present. Vegetable tumors are produced by abnormal bud-evolution. Mr. Williams classifies plant-tumors into three main groups. The first group is represented by the discontinuous or circumscribed growths (Fig. 19), to which the vaguely-used term of *knaurs* should be restricted, and includes all those nodules so often met with in the bark of the beech, elm, oak, birch, holly, cedar, and other trees. These tumors correspond with the benign epiblastic tumors in man. The older nodules are generally found lying completely isolated in the bark, enclosed in

a distinct capsule. A narrow fibro-vascular pedicle may sometimes be seen connecting the younger nodules with the woody tissues of the trunk or stem. These tumors have been traced to abnormal growths of adventitious or latent buds. The writer examined the branch of a cedar tree which had evidently been injured, and found a tumor which apparently belonged to the second group. From the tumor sprang a tuft of flowering branchlets entirely different from the remaining branches. It is apparent that in this instance the injury excited tissue-proliferation from two distinct matrices, one resulting in the formation of the tumor, the other resulting in the production of branchlets bearing the generative organs.

The second group, comprising the continuous tumors—to which the term *exostosis* should be restricted—

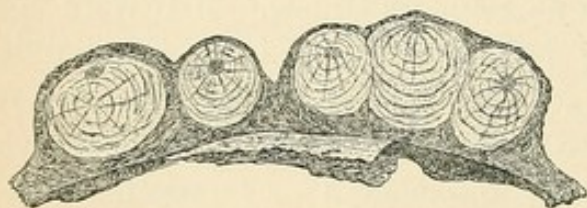


FIG. 19.—Five circumscribed tumors in the bark of a holly tree; natural size (after Williams).

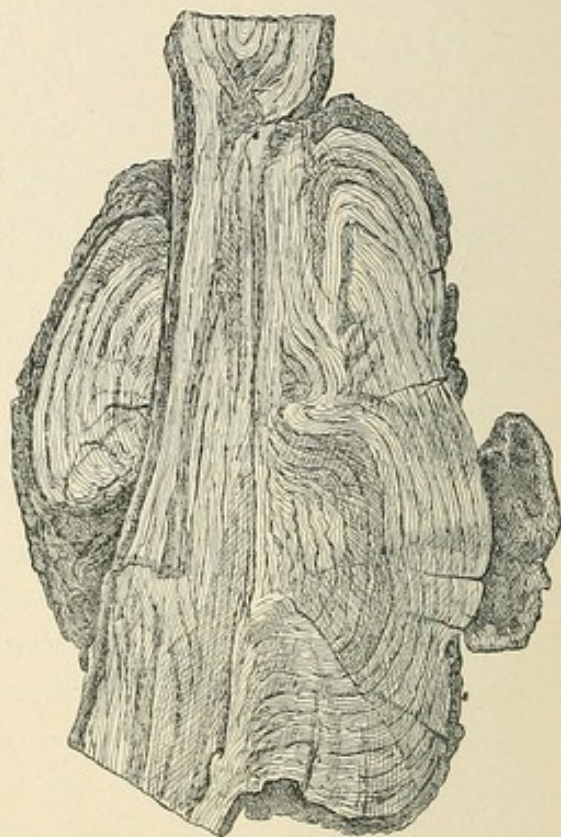


FIG. 20.—A continuous tumor (exostosis) from an elm tree, in longitudinal section (after Williams).

present themselves as nodose outgrowths of the trunk or branches (Fig. 20). The stem and branches of a tree bear a great resemblance in structure to the long bones. The centre or medulla corresponds to the medullary canal, the wood to the bone-tissue, and the cambium to the periosteum.

Tumors belonging to this group often attain great size. Dutrochet attributes these growths to an excessive local cell-proliferation of the cambium layer, but their connection with the woody tissue of the stem exists from the beginning and is never lost. Mr. Williams regards them as abnormally-developed branches.

The third group is represented by growths which present a surface thickly studded with shoots and stunted branches, constituting a combination of exostosis with diffuse bud-formations. The tumor of the cedar branch alluded to represented both the second and third groups of plant tumors. The production by these growths of large quantities of proliferating, lowly-organized cellular tissue which subsequently

undergoes imperfect evolution constitutes the nearest approach in vegetable pathology to the malignant tumors of animals. Every gardener knows that injury to plants is one of the most common ways by which latent buds in plants can be made to develop, and he makes use of this knowledge in the propagation of some of the plants in which latent buds are most constantly found.

Tumors in Animals.—J. Bland Sutton has done more than any other living author in adding to our knowledge concerning tumors in animals, and the writer can do no better than to quote freely from the chapter on this subject in his excellent book, *Tumors, Innocent and Malignant*, recently issued from the press.

Lipomata.—Fatty tumors are rare in animals. They are found most frequently in the subserous adipose tissue in horses, oxen, and sheep. In stall-fed oxen excessive accumulation of fat is common in the subperitoneal tissue, especially in the omentum; but such formations accompany general obesity, and do not come into the category of tumors.

Osteomata.—These are very generalized tumors; they have been met with in several species of fish. The bony outgrowths to which the term "exostosis" is applicable are of fairly common occurrence in mammals, and their frequency on the bones of horses can be appreciated only after a visit to a veterinary museum.

Odontomes are more frequent in animals than in man. The animals in which they are found most frequently are the marmot, agouti, porcupine, goat, sheep, bear, kangaroo, horse, and elephant.

Myomata.—Uterine myomata are almost unknown in mammals. The only specimen which came under the observation of Mr. Sutton occurred in a female baboon, and was rather a general enlargement of the uterus than an actual tumor.

Sarcomata have the widest zoological distribution. They occur with very great frequency, especially the round-celled and spindle-celled species; they are met with in fish, birds, rats, mice, horses, sheep, dogs, cats, goats, oxen, monkeys, bears, marsupials—indeed, in all the orders of mammals and in snakes.

Epithelial tumors in animals, wild or domesticated, form a subject of great interest in its bearings on cancer and its allies. Unfortunately, few reliable observations pertaining to this subject are available. For instance, a cursory review of veterinary periodical literature would indicate that epithelioma of the penis is a common disease in bulls and horses, but a critical examination of the cases reported shows clearly enough that many supposed examples of epithelioma are, as a matter of fact, instances of penile warts, and all competent histologists

who have investigated this subject are unanimous in asserting that epithelioma of the penis in horses and bulls is exceedingly rare. A specimen of secondary glandular carcinoma of the neck in a chicken has recently come into the writer's possession. The histological

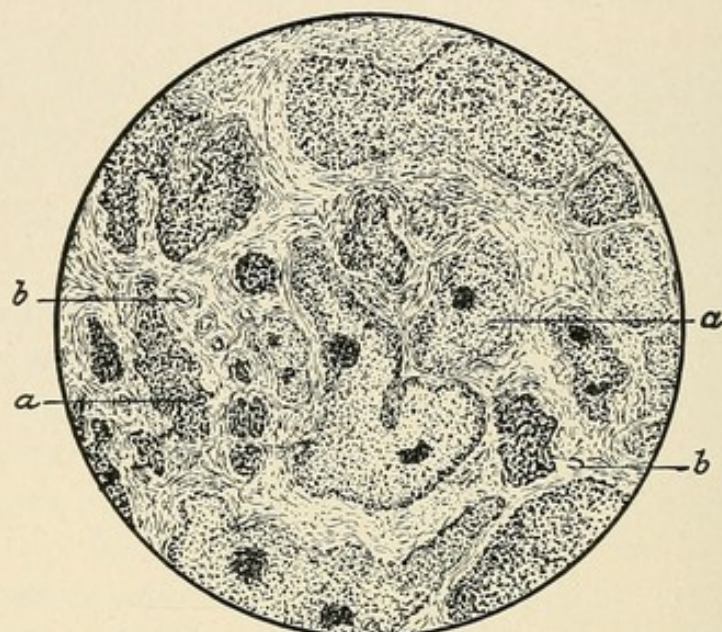


FIG. 21.—Secondary glandular carcinoma of the neck of a chicken, $\times 200$: *a*, epithelial nests; *b*, vessels.

structure of the tumor, as shown in Fig. 21, is very similar as in the same organ in man. Wild animals in a state of nature and those living in confinement appear to be absolutely free from cancer.

Adenomata occur in domestic mammals. The bitch is especially liable to tumors of the mammary gland that are analogous to the large

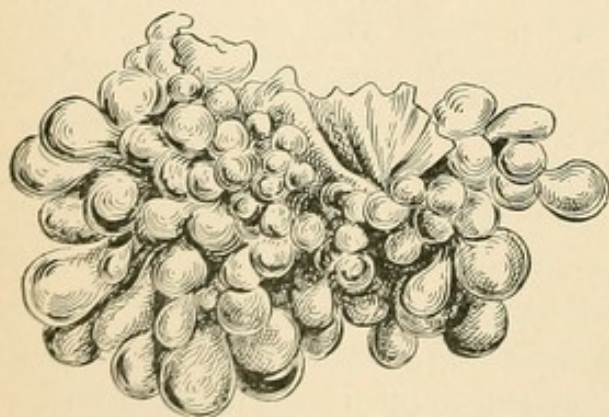


FIG. 22.—Carcinoma of the ovary of a chicken.

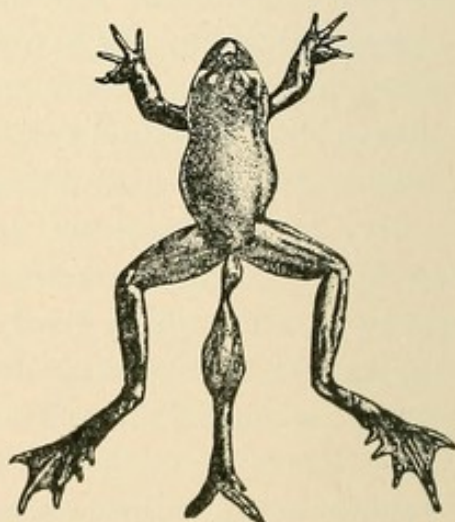

FIG. 23.—Frog with a supernumerary hind leg (after Tuckerman).

cystic adenomata of women. These tumors often attain an enormous size. Large cystic adenomata with intracystic processes are occasionally seen in the udders of cows. The mammary glands of cats are

liable to a disease histologically identical with mammary cancer in women, but cancer such as attacks the human mamma is unknown in cows, mares, ewes, goats, or bitches. Dogs are subject to ulcerating sebaceous adenoma in the skin around the anus, the tumor being prone to return after extirpation.

Teratomata are common enough among domestic animals, and many examples have been described in fish, frogs and other batrachians, lizards, snakes, birds, rabbits, etc.

Cystic Tumors.—The frequency of these tumors in vertebrata generally forms a striking contrast to the infrequency of connective-tissue and epithelial tumors. While true cystic tumors are rare, cystic tumors resulting from retention of a physiological secretion are frequently met with. Such conditions as hydronephrosis, congenital cystic kidney, and dilatations of the vitello-intestinal duct have been observed. Hydrocele of the tunica vaginalis is rare, because the funicular pouch in mammals retains its connection with the general peritoneal cavity throughout life. Cysts arising in connection with the central nervous system have been observed in foals, pigs, and calves. Hydrocephalus is fairly frequent, but spina bifida is rare. Œsophageal diverticulæ are often seen in horses, and the same animal is exceedingly liable to synovial cysts and ganglia.

VI. ETIOLOGY OF TUMORS.

IN the first section the writer made an attempt to prove, so far as present knowledge of this subject will permit, that all tumors, benign and malignant, have their origin from a matrix of embryonic cells of a congenital or post-natal origin. It remains to discuss here the influences which enable the latent cells to assume active tissue-proliferation, upon which depends the production of tumor-tissue. *We regard the matrix of embryonic cells as the essential cause of tumor-formation, without which all intrinsic and external exciting causes are inadequate to produce a true tumor. On the contrary, we must admit that such a matrix will remain harmless in the absence of congenital or post-natal exciting causes.* Certain cells never become specialized to a high degree, and consequently retain their original inherent power of proliferation. Before discussing the influence of heredity and post-natal exciting causes reference will be made very briefly to congenital tumors.

Congenital Tumors.—In a certain sense the majority of tumors are congenital in so far as the essential matrix of embryonic cells is concerned. *It is only in cases in which a tumor develops from a matrix of embryonic cells of post-natal origin that the essential tumor-matrix is not congenital.* When we speak of a congenital tumor, however, we mean a tumor which is present at the time of birth. In such cases the tumor-matrix is acted upon during intra-uterine life by influences which determine tumor-formation, and the resulting product behaves clinically after birth in the same manner as do tumors of post-natal origin. We must therefore make a distinction between a true tumor and localized hypertrophy or giant growth at the time of birth. There are in children cases of "partial obesity"—cases in which the adipose tissue of a certain region of the body is greatly in excess of the adipose tissue generally, and yet the characters of a tumor are wanting. Of such a nature is the case related by Lebert, of a female aged nineteen, the left side of whose abdomen was the seat of an enormous increase of fat. This growth began at the age of six months, and was thought to have been congenital; it grew in proportion to the rest of the body, and ceased to grow when the girl attained puberty. Lebert calls this a "lipoma diffusum." *In giant growth the tissues are under the influence of, and are controlled by, the same physiological laws which govern the growth and development of the remaining tissues of the body, while a congenital tumor recognizes and obeys no such governing influences.* Angiomata are nearly always congenital. The tumors, although pres-

ent at birth, are often overlooked, owing to their small size. Next in frequency as congenital tumors are the lipomata and cysts. Nearly all benign tumors may have a congenital origin. Only in very rare instances have malignant tumors been found and recognized as such at the time of birth. Cases of sarcoma in the cutis of the newly-born have been reported by Jacobi, Karewski, Ramdohr, Mundillon, L. W. Marshall, K. King, Senftleben Weinlechner, and several others. Ramdohr has reported a case of congenital multiple angio-sarcoma. The body of the child, which died shortly after birth, showed a large angio-sarcoma in the region of the chin, and twenty-one secondary superficial tumors; also sixteen metastatic tumors of the various internal organs. Ahlfeld reports a case of congenital fibro-sarcoma of the genital organs in a child three and a half years of age, and a case of congenital carcinoma in the distal end of an atresic rectum in a new-born infant. It is a significant fact that many tumors arise from rudimentary organs, vestiges (Sutton), or accessory organs—"rests" (Sutton) which remain functionless in the body until the time of puberty, when they become the starting-point of a tumor. Tumors from such structures seldom form during intra-uterine life, but appear later. Different forms of retention-cysts have been found in infants at the time of birth. The mechanical obstruction causing the retention is more often the result of a faulty development of the ducts of secreting organs than of other intra-uterine pathological conditions.

Heredity.—Heredity in the etiology of tumors is a subject upon which much has been said and written. We no longer speak of a "tumor-dyscrasia," but we cannot ignore the influence of heredity in the origin and growth of tumors. The laws of heredity depend upon the persistence of impressions (unconscious memory) in protoplasm (Williams); hence every living thing produces new ones, each after its own kind. It is by virtue of this property that, in the words of Sir James Paget, "a mark once made in a particle of blood or tissue is not for years effaced from its successors." All are willing to admit that there is a difference in the susceptibility to disease among different individuals placed under the same conditions. Every military surgeon knows that if a body of troops is quartered in a cold, damp garrison, some will be attacked by catarrhal affections of different organs, others will suffer from rheumatism, while the greater number will retain their health after having been exposed to the same morbid influences. We must admit that a similar inherent susceptibility to tumor-formation exists among different persons, and that such individual predisposition is often the result of hereditary influences. Benign tumors are hereditary in the same sense as monstrosities—*per excessum*. Supernumerary toes

and fingers have appeared through several generations in the same family. The same can be said of most of the non-malignant tumors, particularly angioma and lipoma. Very frequently such tumors were not only hereditary, but also occupied the same localities. Paget found carcinoma of the uterus in three generations—grandmother, mother, and daughter. The writer has repeatedly met with carcinoma of the breast in two successive generations. Sibley relates an instance of carcinoma of the uterus affecting a mother and her five daughters. Warren observed a cancer of the lip in the father; in one son and two daughters cancer of the breast; and in two grandchildren cancer of the breast. The most interesting instance of hereditary predisposition to carcinoma is reported by Broca:

First generation: Madame Z. died of cancer of the breast in 1788, aged 60.

Second generation: four married daughters:

- A. Cancer of the liver, 62 years old, 1820.
- B. Cancer of the liver, 43 " " 1805.
- C. Cancer of the breast, 51 " " 1814.
- D. Cancer of the breast, 54 " " 1827.

Third generation: Madame B., five daughters and two sons:

First son died during infancy.

Second son, cancer of the stomach, 64 years old.

First daughter, cancer of the breast, 35 " "

Second " " " "

Third " " " " } 35-40 years old.

Fourth " " " liver, }

The fifth daughter escaped the disease.

Madame C. had five daughters and two sons:

The sons remained free from cancer.

The first daughter died of cancer of the breast in 1837, 37 years old.

Of her five children, one daughter died in 1854, of cancer of the breast, at the age of 49.

The second daughter died in 1822, 40 years old, of cancer of the breast.

The third " " 1837, 47 " " " " uterus.

The fourth " " 1848, 55 " " " " breast.

The fifth " " 1856, 61 " " " " liver.

From these and other reliable observations it is evident that a predisposition to cancer may be derived by inheritance. Paget collected the histories of 322 cancerous patients with special reference to this point. Of this number, there were seventy-eight, or nearly one-fourth, who were aware of cancer in other members of their families. The proportion is much larger than could be due to chance, and its import is corroborated by the fact of many members of the same family being in some instances affected. It is evident that where a tumor is inherited the two essential causes are transmitted from parent to child: 1. A matrix of embryonic cells; 2. A lack of resistance on the part of the whole

organism or of the tissues in the immediate vicinity of the matrix to retard tumor-growth. For the growth of a tumor it is not only essential to have present the necessary matrix of embryonic cells, but it is equally essential that the environment of the matrix should not exert upon the cells an inhibitory influence which would interfere with their assuming active tissue-proliferation. If the controlling or inhibitory influence of the tissues in the vicinity of embryonic cells set apart in the organism is diminished or completely abolished, such cells regain their primitive reproductive activity and assume an individuality alone. Under such circumstances there is established a new centre of tissue-formation which has no laws to obey and no orders to observe. In such a new centre of growth there is a departure from the definite order, limitations, regular stages, and fixed periods of the normal growth. Little is known in regard to the force which holds in check permanently or for an indefinite period of time the tissue-proliferation from such a matrix. For want of a better knowledge this force has been called *physiological resistance*. Heredity implies, therefore, in connection with the subject now under consideration, two things: 1. A matrix of embryonic cells; 2. Suspended or diminished physiological resistance in the tissues of the entire body or in the immediate vicinity of the tumor-matrix. The existence of such a force has been demonstrated by experiments. Cohnheim and Maas introduced into the jugular veins of animals small pieces of young periosteum, with the expectation that they would become arrested in the smaller branches of the pulmonary artery as emboli. The animals were killed in a few weeks or months later, and the specimens examined to determine the extent of tissue-growth from the periosteal grafts. The results were uniform. The periosteum retained its bone-producing properties and produced bone, but the new product was always limited in size to the lumen of the vessel in which the periosteal embolus had become impacted. When this size was reached further growth became arrested, and the new bone in the course of time underwent complete removal by absorption. It is apparent that the intrinsic force (physiological resistance) in the adjacent tissues exerted a positive influence in limiting the production of bone from the periosteal graft to the lumen of the vessel. The same investigators have also shown that transplantation of grafts of embryonal tissue is more successful than that of mature tissue. Leopold, under the direction of Cohnheim, studied the fate of mature tissue transplanted into the anterior chamber of the eye and the peritoneal cavity in rabbits. He found that all tissue that had reached maturity was invariably removed by absorption in a short time, while embryonic tissue taken from animals before they were born retained its

vitality and continued to proliferate tissue to an astonishing extent. Grafts of fetal cartilage increased to from two hundred to three hundred times their original size, giving rise to a temporary chondroma of several months' duration. Zahn repeated these experiments with the same results. In the growth of an osteoma tissue-proliferation takes place from a matrix of osteogenetic cells, and we must assume that in the immediate vicinity of the matrix a diminution of the physiological resistance of the tissues had taken place. In the transplantations of malignant tissue, that have almost without exception been followed by negative results, we can explain the failures only by taking it for granted that the tissues in which the graft was imbedded presented an adequate physiological resistance which prevented the growth and infiltration of the transplanted cells, and that the graft acted the part of an absorbable foreign body, and was subsequently removed by the wall of granulations thrown out by the injured tissues around the graft. The physiological resistance in the adjacent tissues permits grafts from benign tumors only to grow to a limited extent if at all, after which they are removed like any other aseptic absorbable substance, while the same resistance offers an effective barrier to infiltration by cells from grafts taken from malignant tumors. From what has been said it follows that there are two essential factors present wherever a tumor grows—namely: 1. *An embryonal matrix, or at least a matrix composed of embryonic cells*; 2. *A suspension or diminution of the physiological resistance in the tissues in the immediate vicinity of the matrix. The absence of the former precludes entirely the possibility of the formation of a tumor, and only the presence of the latter negative condition enables the matrix to proliferate tumor-tissue.* Future research must determine what conditions produce diminution of physiological resistance. We have reason to believe that this predisposition to tumor-formation is often hereditary, and that it can be produced artificially by acquired pathological conditions which weaken the tissues, such as irritation and inflammation. That the chemico-vital changes which take place in inflamed tissue diminish physiological resistance has been demonstrated unmistakably by the experiments of Friedländer. It is therefore reasonable to suppose that a person born with the essential tumor-germs is more likely to become the subject of tumor-formation when the part in which they are located becomes the seat of accidental pathological conditions which result in diminution of the physiological resistance in the tissues surrounding the matrix; while persons born with a similar matrix not thus affected may escape tumor-formation, the matrix-cells remaining in a latent condition throughout life.

Race.—Race-influence plays an important part in the etiology of

tumors. Certain races are predisposed to special tumors. Negroes suffer more frequently from the different forms of fibroma than does any other race. Keloid, fibroma of the skin, and myofibroma of the uterus in women are exceedingly common among the negroes in the South. Lipoma is very prevalent among the Hottentots. The uncivilized nations, in proportion to the population, furnish a smaller percentage of malignant tumors than do the inhabitants of Europe and America.

Climate.—It is said that the inhabitants of southern countries are more predisposed to tumor-formation than are the inhabitants of the North; this applies particularly to carcinoma and sarcoma. Tumors of the thyroid gland appear as endemic affections in certain parts of Europe and in other countries. There is no doubt that malignant tumors are unequally distributed over the world, being more prevalent in some localities than in others. Heredity unquestionably plays an important part in imparting to these tumors in some localities an endemic character. The accumulation of many generations in particular localities would naturally increase the number of the victims.

Age.—Age has already been alluded to as an important determining cause. It is a familiar clinical fact that certain benign tumors from embryonic fetal remnants are likely to appear at the age of puberty, at the time of post-natal life when the whole organism, and particularly the organs of generation and the mammary gland in the female, are in a state of the highest physiological activity. It is during this time of life that we most frequently meet with branchial and dermoid cysts, cysts of the ovary and parovarian cysts, and adenoma of the mammary gland. In adult life fibroma, osteoma, chondroma, and other mesoblastic tumors are more prevalent. Carcinoma manifests a predilection for the conditions incident to senile marasmus, occurring most frequently in persons between fifty and seventy years of age. It is in individuals past middle life that we most frequently see transformation of benign growths, such as moles, papilloma, and warts, into malignant tumors. The conditions which determine such a change and which favor the formation of carcinomatous tumors are not well understood. There is anatomically such a thing as a non-malignant stage of cancer. In the early stage of epithelioma we find simply a superficial increase in the thickness of the epidermic layer—that is, the stage when carcinoma still remains as a non-malignant growth; but just as soon as the physiological boundary-line between the epithelial layer and the subjacent connective tissue is destroyed or is rendered permeable to migrating cells—in other words, just as soon as epithelial elements are found in places where they have no legitimate existence—we have to deal with a carcinoma.

A glance at Plate 2, Figures 2 and 3, and at Figures 24 and 25 will show the difference in the relation of epithelial cells in normal tis-

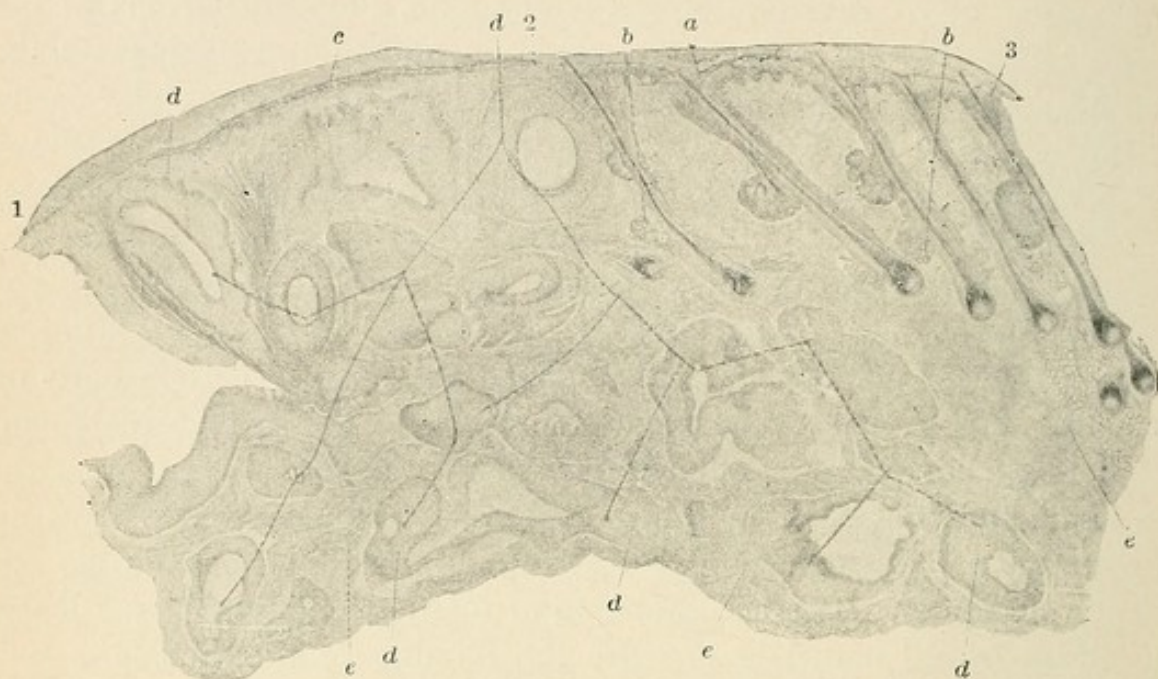


FIG. 24.—Epithelioma of skin (after Thiersch): 1-2, ulcerated surface; 2-3, adjacent skin; *a*, hair-follicles with sebaceous glands made oblique by pressure from beneath; *b*, sweat-glands; *c*, epidermis, horny layer, which extends for some distance over ulcerated surface; *d*, avascular cell-masses of an epithelial nature, formed into irregular tubes by softening, only slightly attached to the stroma in which they are lodged, or separated from the walls of the alveoli during the hardening process in alcohol; *e*, connective-tissue stroma.

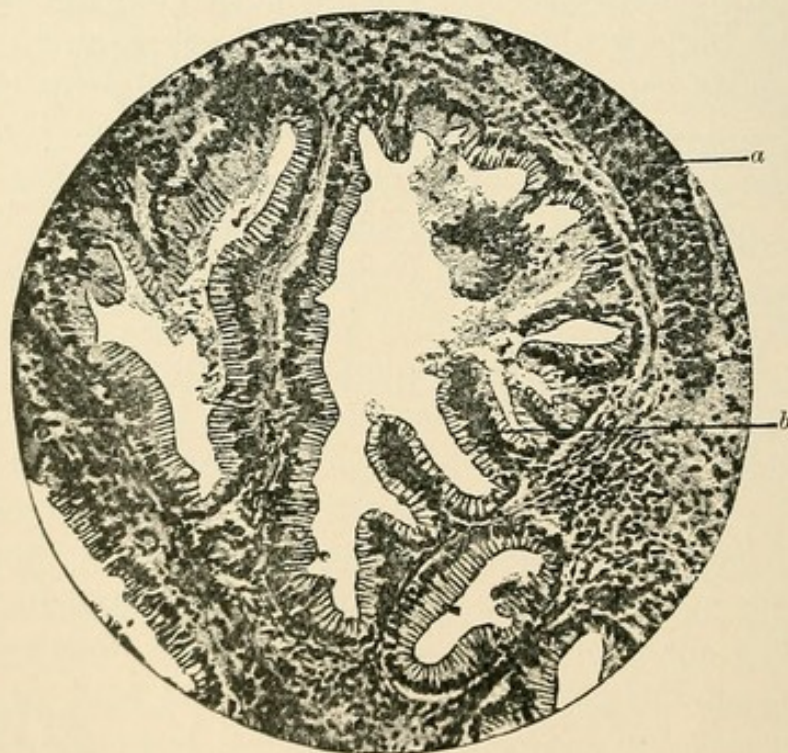
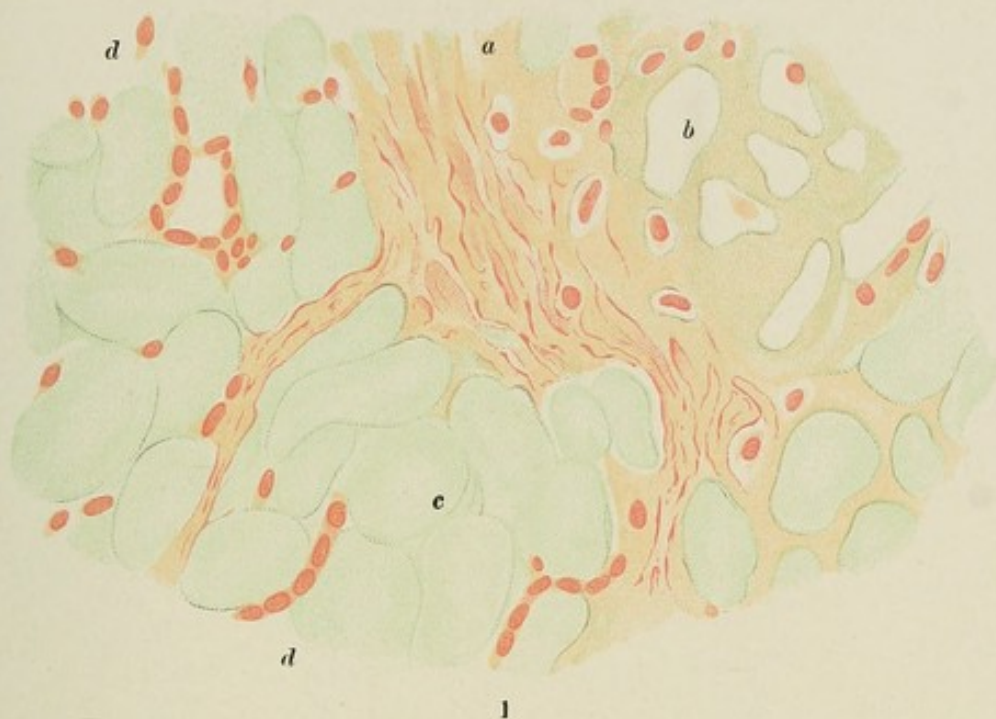
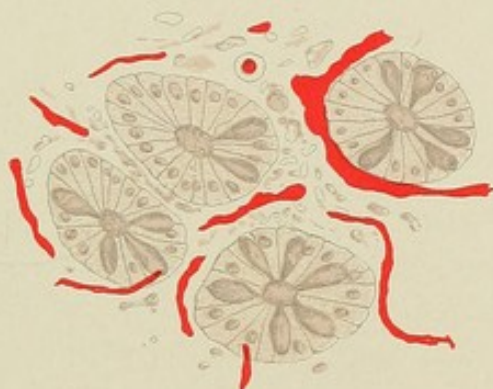
FIG. 25.—Columnar epithelioma of rectum (after Boyce): *a*, an epithelial process from skin of anus; *b*, a papillomatous gland-crypt. (Obj. $\frac{1}{4}$ without eye-piece; logwood staining.)

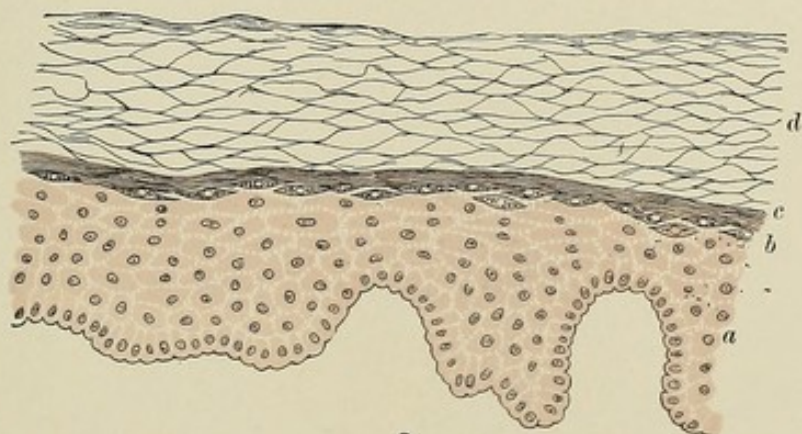
sue and in carcinoma. In the former instance the epithelial cells are in an avascular district outside of the limiting membrane, *membrana pro-*



1



2



3

1. Endothelioma hyalinum from capsule of submaxillary gland (after Klebs): *a*, stroma; *b*, smaller part of stroma; *c*, hyaline substance; *d*, cells. 2. Mucous membrane of large intestine of pig; $\times 350$ (after Klein). The capillary blood-vessels cut in different directions surrounding the crypts are injected with carmine gelatin. 3. A vertical section through the epidermis covering the skin—epidermis; $\times 350$ (after Klein): *a*, rete Malpighii, or rete mucosum; *b*, granular layer (Langerhans); *c*, stratum lucidum (Schrön); *d*, stratum corneum.



pria; in the latter instance they have found their way through the limiting membrane and have reached the underlying vascular mesoblastic tissues, where they have no legitimate physiological existence, and where they must be regarded pathologically as invaders. It appears that in the subepithelial tissues a change takes place coincident with the senile changes in the tissues of persons advanced in life. Thiersch advanced the ingenious hypothesis that this change consists in a disturbance of the normal relations between the skin and the underlying tissues, this disturbance being caused by senile changes and resulting in a loss of resistance to the proliferating epithelial cells. *There can be no doubt that in the aged some such alteration of tissue takes place, permitting embryonic epithelial cells to part with their normal anchorage and to find their way by migration into the subjacent altered tissue, where they are no longer subject to the physiological laws which govern the reproduction and growth of normal epithelial cells, and where, in consequence of such aberration and lawless conduct, they produce a planless, functionless growth which invades all tissues, regardless of their anatomical structure.*

Sex.—Statistics show on the whole that the male sex is more predisposed to tumor-formation than is the female. This difference may be accounted for in part by the male sex leading a more active life, and being subjected more to the exciting causes which later in life become such a prominent feature in the etiology of tumors. Heredity affects both sexes equally, and the difference in the frequency with which tumors occur must therefore depend largely on occupation and habits of life. Of 1145 cases of tumor treated at the clinic of Berne during a period of twenty-five years, the males furnished 58.51 per cent. and the females 41.49 per cent. C. O. Weber gives the proportion of males to females as 64:36. The proportion varies with the different forms of tumors. Carcinoma of the skin is much more frequent in the male than in the female, while in glandular carcinoma the reverse is the case. Moore in 1861 found in England one carcinoma patient to every 5846 men, and one female patient to every 2461 women. In women tumors are more prone to occur during the childbearing period of life than before and after. Carcinoma of the lip is common in men, but extremely rare in women. Of 696 cases of carcinoma of the lip collected by Lortet, 527 were men and 69 were women, the proportion of men to women being 7.6:1. According to the writer's own observations, carcinoma of the stomach and the rectum is more frequently met with in males than in females. In the female, carcinoma of the breast and the uterus occurs probably more frequently than do malignant tumors of all the remaining organs.

Social Status.—It has generally been claimed that the laboring classes furnish the largest contingent to the whole number of patients suffering from carcinoma. The statistics from which this statement was drawn were collected almost exclusively from the practice of hospital physicians. A more careful inquiry into the actual facts shows that the reverse comes nearer the truth. M. d'Epine found, in examining the mortality statistics of malignant tumors of the city of Geneva, that among the well-to-do classes came 106 deaths from this cause to every thousand inhabitants, while the poor furnished only 72 to every thousand. Walshe found that of a million of people in London in ten of the unhealthiest districts, 127 died of malignant tumors; in ten healthier districts, 183; and in ten of the healthiest, 199. From similar statistics gathered in England and Wales, Moore came to the conclusion that cancer becomes more frequent with the increasing prosperity of the people. In the United States carcinoma has been on a gradual increase with the progress of civilization. The mortality from this cause in 1850 was 9 for 100,000 inhabitants; in 1860 it was 11.79; in 1870, 16; in 1880, 26; in 1890, 33.5.

Traumatism.—The influence of a trauma in exciting tumor-growth can no longer be denied. The different forms of sarcoma frequently follow an injury. Numerous cases are on record in which sarcoma followed a fracture of the long bones. The statistics of Boll, collected with a view to prove the traumatic origin of cancer, show that of a large number of cases only about 12 or 14 per cent. were traceable to traumatism. Ziegler studied the influence of trauma in the etiology of malignant tumors in 282 cases, 180 men and 102 women. He came to the conclusion that in 18 per cent. of the cases a single trauma was the apparent cause of tumor-formation, while repeated injuries and prolonged irritation were noted in 25 per cent. He regards trauma and chronic irritations as potent factors in the causation of malignant tumors. *Traumatism alone can no more produce a tumor than can inflammation occur without the presence of pathogenic microbes. The trauma can act only as an exciting cause in stimulating a pre-existing matrix of embryonic tissue into active tissue-proliferation, or in furnishing by its remote effects on the tissue a post-natal matrix of embryonic cells.* In animals sarcomata are seen most frequently in parts most exposed to injury—in fishes in the tail and fins, in frogs in the limbs, and in birds in the neck and wings. The writer believes that in a fracture of a bone which later becomes the seat of a sarcoma the cells which are destined to furnish the bony callus fail to undergo the typical transformation from embryonic into mature tissue in consequence of some local or general cause, and that from these cells the sarcoma

takes its origin. Influenced by a preconceived idea, it is not difficult to trace many of the local affections, including tumors, to a traumatic origin. How long have we been in the habit of assigning to traumatism the first position in the causation of suppurative inflammation? Recent investigations have demonstrated that no amount of traumatism can produce inflammation and suppuration unless the injured tissues become infected with the essential cause of inflammation—pyogenic microbes. Trauma in exceptional cases may and does act as an exciting cause in the growth of a tumor, by diminishing the physiological resistance of the injured tissues or by causing irritation or inflammation in the immediate vicinity of a pre-existing tumor-matrix; or in more exceptional cases it furnishes both essential conditions for tumor-growth—a post-natal matrix of embryonic cells and a diminution of physiological resistance in the immediate vicinity of the new matrix.

Irritation.—Prolonged irritation—microbic, mechanical, chemical, and thermal—is a recognized exciting cause of tumor-growth. If we examine the topography of carcinoma, we find that it attacks parts and organs that are most frequently the seat of prolonged and repeated irritation. The clay pipe in smokers, the coal-dust in chimney-sweeps, foreign bodies in the tissues or in hollow organs, carious teeth, and other local irritants have for a long time been regarded as important causes in the production of tumors, more especially of carcinoma and sarcoma. The influence of alcoholic drinks in the production of carcinoma of the œsophagus and stomach should be mentioned here. A similar chronic local irritation is the chronic catarrh of the mucous membrane of the nose which so often precedes the formation of myxomatous tumors in this locality. Virchow very correctly mentions the frequent occurrence of cancer of the testicle where the organ remains in the inguinal canal and is subjected repeatedly to pressure and traction. The ovary is equally liable to carcinoma if it constitutes a part of the contents of a hernia. We shall assign to irritation and inflammation an influence in the production of tumors similar to that assigned to traumatism.

Inflammation.—Inflammation is never the sole cause of tumor-formation. That it is an important factor in stimulating pre-existing embryonic cells into a state of active tissue-proliferation few would deny. Friedländer has shown that embryonic epithelial cells, by virtue of their ameboid movement, can penetrate a subjacent inflamed surface. It has been shown that cancer-cells possess the same ameboid movement, which is a potent factor in the process of infiltration. Inflammation always hastens tumor-growth: this statement applies with particular force to malignant tumors. If a tumor-matrix is within

the limits of an inflamed area, it receives suddenly an increased blood-supply, which alone may be sufficient to arouse it from its dormant condition into active tissue-proliferation; at the same time the inflammation will result in diminution of the physiological resistance of the tissues around the matrix, thus still further favoring tumor-growth.

Contagion.—Under this heading of the etiology of tumors it is only necessary to mention the malignant varieties, carcinoma and sarcoma. The popular fear of the contagiousness of these growths lacks foundation. *There is not a single well-authenticated case on record in which the disease was transmitted from man to man or from animal to animal by contagion.* The cases in which the disease was reproduced in the same individual at a point opposite the primary tumor (by contact) or by bringing an ulcerating carcinoma frequently in contact with a distant part, as by rubbing (Kaufmann), are few, and the auto-inoculation was undoubtedly preceded by pathological conditions which in themselves might have furnished the essential conditions for tumor-growth, or which, at any rate, created a favorable soil for the implantation of tumor-cells. The negative results which have followed thousands of attempts to reproduce carcinoma and sarcoma by implantation of fragments of tumor-tissue in different animals furnish the most convincing proof of the non-contagious and non-parasitic character of malignant tumors.

VII. CLINICAL ASPECTS OF BENIGN AND MALIGNANT TUMORS.

THE clinical behavior of a tumor is determined by the nature of the primitive matrix, the anatomical structure and physiological importance of the part or organ affected, and the relations of the tumor to the adjacent tissues. A tumor-matrix composed of embryonic cells of the lowest degree of development is more likely to result in the formation of a malignant tumor than is a matrix representing embryonic cells capable of development into tissue of the highest physiological type. Again, the type of a tumor will depend upon the germinal layer from which the matrix is derived. A matrix from the middle germinal layer will produce a tumor of the connective-tissue type—either a benign mesoblastic tumor or a sarcoma. A matrix of embryonic cells from the epiblast or hypoblast will give rise to either a benign epithelial tumor or a carcinoma according to the intrinsic capacity of the cells to produce embryonic or mature cells, and the resisting power of adjacent tissues. A tumor of an important organ, such as the brain, heart, lungs, or digestive tract, may destroy life by its presence producing mechanical conditions incompatible with an essential function. Large tumors of less important organs may by compression of an important organ produce the same result. Malignant tumors affecting important organs not only give rise to functional disturbances by their mere presence, but they also destroy the tissues of the part or organ affected, thus greatly increasing the danger to life. A benign tumor remains limited to the part or organ primarily affected; malignant tumors, on the contrary, ignore all boundary-lines and affect adjacent tissues irrespective of their anatomical structure.

Relative Frequency with which Different Organs are Affected by Tumors.—Every clinician knows that certain tumors show a predilection for certain tissues and organs. Fatty tumors occur most frequently in the panniculus adiposus, enchondroma in the long bones; sarcoma affects most frequently the connective tissue, the glands, and the bones, while the muco-cutaneous orifices and the mammary gland are the most frequent seat of carcinoma. C. O. Weber arranged the following table of organs and parts to show their predilection for tumor-formation:

	No. of Cases.
Organs of mouth, with maxillary bones	217
Glands	174
Bones, excluding maxillary bones	161
Skin	93
Genital glands	86
Lungs	64
Nose, pharynx, antrum of Highmore	56
Subcutaneous and intermuscular connective tissue, muscles, and nerves	51
Eyes and orbits	41
Genitals, including uterus	31
Intestines and anus	13
Urinary organs	13
Brain	13

That the relative frequency with which different tissues and organs are affected is inaccurately represented by this table follows from the fact that it undoubtedly includes many chronic infective swellings which were formerly classified with tumors, and which even now are often mistaken for tumors; but the table is valuable in giving at least an approximately correct idea of the topographical distribution of tumors.

Benign Tumors.—A benign tumor always grows slowly. Myofibroma of the uterus under favorable circumstances may attain great size in the course of a few years (Fig. 26). Fibromata in other localities grow

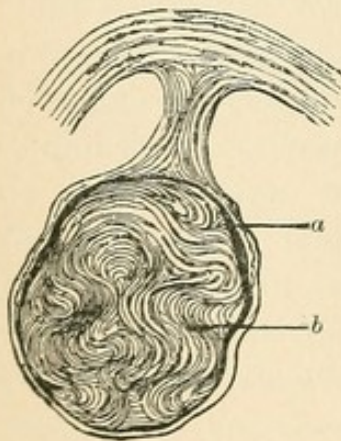
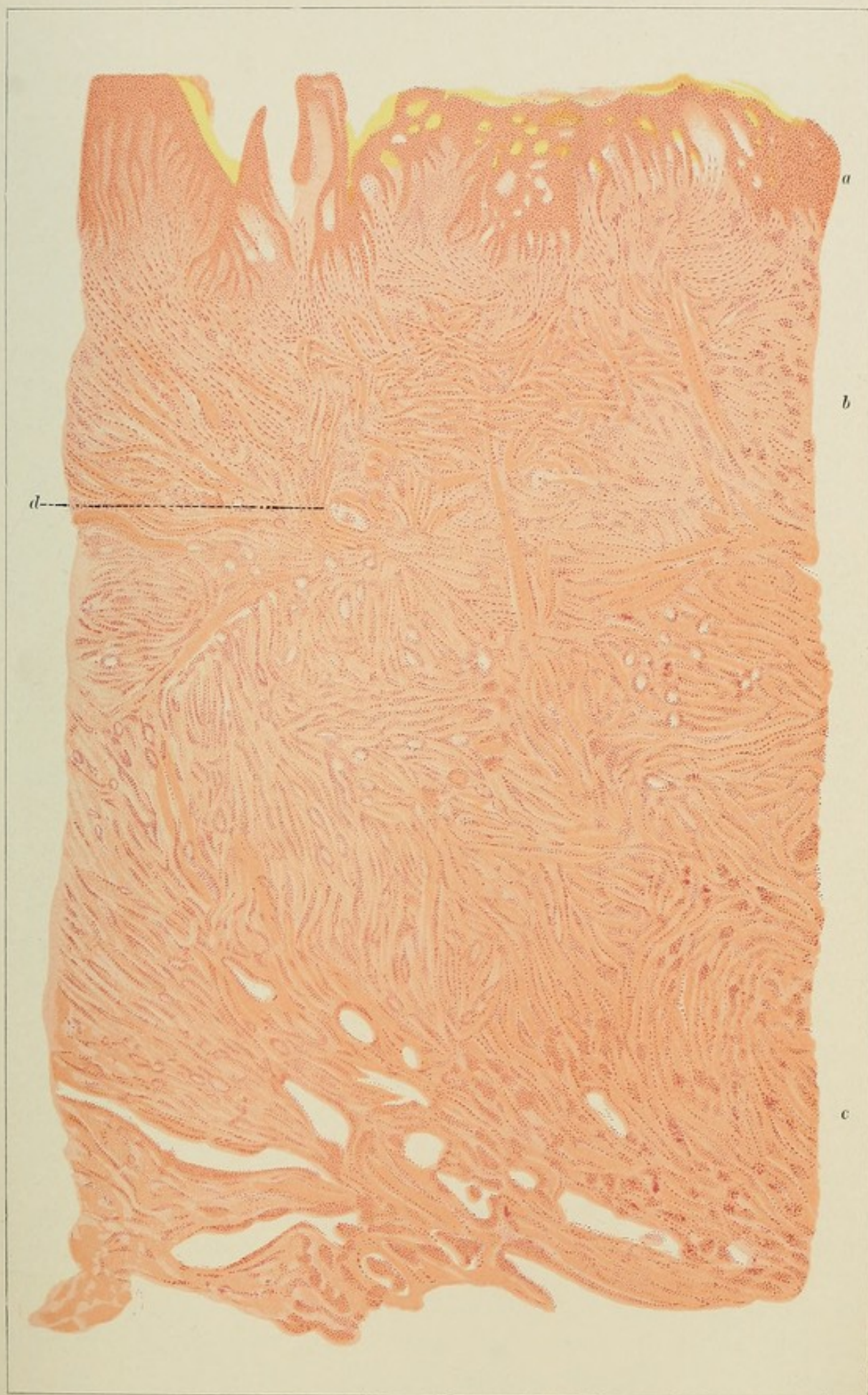

FIG. 26.—Submucous pedunculated myofibroma of the uterus (after Paget): *a*, capsule; *b*, tumor.

less rapidly. Among the tumors of slow growth, which, however, eventually often attain great size, are the cystic adenomata and chondromata. Slowness of growth must therefore be looked upon as an important clinical feature of a benign tumor. *Every benign growth is surrounded by a limiting capsule, which separates it from the adjacent tissues, and beyond which it never extends. This isolation from the surrounding tissues is the most distinctive anatomical feature of benign as compared with malignant tumors.* The existence of this connective-tissue capsule enables

the surgeon in the majority of cases to remove benign tumors by enucleation. If the capsule of a benign tumor, owing to anatomical peculiarities of the surroundings, sends prolongations into the adjacent tissues, as is sometimes the case in lipoma and fibroma, parts of the tumor may be overlooked by the surgeon, and from them takes place a local recurrence later. We are therefore prepared to appreciate the force of the statement that *incomplete removal of a benign tumor is always followed by recurrence unless the remaining part of the tumor*



Glandular carcinoma of the breast (after Klebs): *a*, epithelial layer of skin with long proliferating projections; *b*, carcinoma-tissue of epithelial cells and connective tissue; *c*, the same with predominance of epithelial cells; *d*, milk-ducts.



is subsequently destroyed by suppurative inflammation or by degenerative changes.

Encapsulation of a tumor imparts to it another clinical feature of great importance—*mobility*. This mobility, however, may be diminished or entirely prevented by the tumor being tied down by overlying firm structures, such as fascia, skin, and muscles. If the tumor is attached to the bone, as is the case in chondroma and osteoma, it is from the beginning immovable, and so remains. The question of mobility of a tumor is a valuable point in differential diagnosis, and is of special importance in the case of tumors of the breast. An adenoma of the mammary gland always remains movable, while in carcinoma of this organ the tumor almost from the beginning is so intimately connected with the surrounding tissues that the palpating finger receives an impression as though the tumor were grasped and firmly held in place by the surrounding tissues. Some of the benign tumors—myxoma, chondroma, and some forms of fibroma—have received the reputation of being *semi-malignant* on account of their occasional recurrence after extirpation. *A tumor is either benign or malignant: there is no connecting-link between them.* The recurrence of a tumor after extirpation may be explained as follows: 1. The tumor was incompletely removed; 2. The primary tumor removed was malignant from the beginning; 3. A new tumor may develop in the scar of the operation-wound or in its immediate vicinity. Local recurrence after the removal of a benign tumor has been observed most frequently in cases of chondroma, myxoma, and fibroma—tumors which, from their clinical behavior as well as from the fact that their extirpation is sometimes followed by recurrence, have been regarded by many surgeons as suspicious or semi-malignant growths. We have reason to believe that in most cases local recurrence was due to imperfect removal. These tumors have a structure which renders their complete removal uncertain. Fibroma, for instance, is often surrounded by minute nodules, not large enough to be recognized by the naked eye, which are in histogenetic connection with the main tumor, and which, if the main tumor is removed by enucleation, remain in the tissues; from these nodules a recurrence takes place later. *Such minute daughter-tumors are no evidence of the malignant nature of the primary tumor, as their histogenetic connection with the primary tumor can be demonstrated.* The jelly-like structure of a myxoma renders the outline of the tumor irregular. Projections of the tumor between muscles and connective tissue are often overlooked, and if left in the bed of the tumor they certainly would give rise to local recurrence. Virchow years ago showed that chondroma originates not from the surface of a bone, but

in its interior. Surgeons seldom extend the operation far enough to include every vestige of the tumor, hence the frequency with which an enchondroma returns. If a tumor is removed *completely* and local recurrence takes place, it is more than probable that the primary tumor was of a malignant character, and that the relapse is the result of tissue-proliferation from malignant cells left in the tissues. *The clinical course of the tumor in such cases makes a more positive and reliable diagnosis than the surgeon and pathologist. Finally, a new tumor may grow from an additional congenital matrix of embryonic cells or from latent unutilized embryonic cells in the scar or in its immediate vicinity.*

Malignant Tumors.—To the surgeon the most important clinical aspects of a malignant tumor are—1. Rapid growth; 2. Absence of limitation of the growth; 3. Local infection; 4. Regional infection; 5. General infection; 6. Frequency of recurrence after extirpation; 7. The intrinsic tendency of the tumor to destroy life. Rapidity of growth, as compared with that of benign tumors, belongs to malignant tumors as one of their salient clinical features. Some malignant tumors, particularly epithelioma of the skin, may remain in a latent stage for years before manifesting their true nature by rapid growth; these are, however, exceptional cases.

Absence of a limiting capsule is common to all malignant tumors. In some forms of sarcoma, to the naked eye such a capsule exists, but examination of the tissues adjacent to it under the microscope shows that tumor-cells have passed through and beyond the capsule into the connective tissue. The apparent capsule in such cases has been a source of deception to the surgeon who enucleates such a tumor under the belief that it is non-malignant. The absence of a proper limiting capsule brings the tumor-tissue in direct contact with the surrounding tissues, giving rise to local infection. The word "infection" as applied to the process of dissemination of malignant tumors has a different significance than when the same term is applied to the origin and extension of acute and chronic infective diseases. In the latter case infection signifies the presence in the tissues of pathogenic microbes which exert their specific pathogenic effect upon pre-existing tissues. *The word infection used to indicate the local, regional, and general dissemination of malignant tumors means the separation from the primary tumor of cells which migrate into the surrounding connective tissue, giving rise to local infection, or which are transported through the lymphatics of the region occupied by the tumor, causing regional infection; or, lastly, the malignant cells find their way directly or indirectly into the general circulation and become arrested in some distant part or organ as tumor-emboli, resulting in general infection or general dissemination.*

Local Infection.—Local infection of a malignant tumor is caused by the migration of tumor-cells from the place in which they were produced—that is, from the primary tumor—into the connective-tissue spaces in the immediate vicinity of the tumor. This migration of cells in all directions around the tumor results in a zone of tissue-infiltration by malignant cells, each cell establishing in its new location an independent centre of tumor-growth. *As soon as a malignant cell has left its birthplace, it leads an independent existence and loses all histogenetic connections with the mother-tumor. It is the establishment of innumerable independent centres of tissue-proliferation in the zone of infiltration surrounding a malignant tumor that determines its rapid growth. Infection from a malignant tumor implies, therefore, only the invasion of adjacent or distant tissues by malignant cells; it is an infection by cells instead of by microbes, as is the case in the production of infective diseases.* Another great difference in the two kinds of infection is this: in infective diseases the microbes act upon and alter pre-existing tissue-cells, while in tumor-growth the pre-existing tissue remains passive, the tissues of the tumor being derived exclusively from the tumor-cells. As a rule, local infection is much more pronounced and rapid in sarcoma than in carcinoma, hence greater rapidity of growth and larger size of the tumor.

Regional Infection.—Regional infection consists in the transportation of tumor-cells through the lymphatic channels some distance from the tumor to the lymphatic glands in the region occupied by the tumor. Familiar instances of regional infection are secondary carcinoma of the submental, submaxillary, and cervical glands in advanced carcinoma of the lip, and secondary carcinoma of the axillary glands in glandular carcinoma of the mammary gland. *The regional dissemination of carcinoma is accomplished almost exclusively through the medium of the lymphatics.* The carcinoma-cells, after finding their way into a lymphatic channel within or near the tumor, are transported by the lymph-current, and are arrested usually in the first lymphatic gland, which acts the part of a filter. The cell or cells establish here a new centre of growth, from which the tissues of the ensuing secondary carcinoma of the lymphatic gland are derived exclusively, the lymphoid cells taking no active part in the production of the tumor. From a gland thus infected tumor-cells again reach the lymphatic channel on the opposite side of the gland, and are taken up by the lymph-current and transported to the next lymphatic gland, where an additional centre of tumor-growth is established. By this progressive regional extension of the tumor the whole chain of glands between the primary tumor and the proximal termination of the lymphatic system becomes in-

volved. The lymphatic glands serve as filters and contribute much toward retarding general dissemination. General infection is likely to occur at an early date if the lymphatic glands do not participate in the regional extension of the tumor. The malignant cell after it has become detached from the mother-tumor retains all the qualities inherited from it at birth, and consequently produces the same kind of tissue, whether it remain in the vicinity of the tumor in the same region or whether it is transported to the most distant organs. *The secondary tumors resemble the primary tumor histologically and clinically* (Fig. 27). Regional dissemination of a sarcoma takes place by a continuous growth of the tumor, usually in the direction of fascia, blood-vessels, or nerve-sheaths: it is a local infection on a large scale. Occasionally

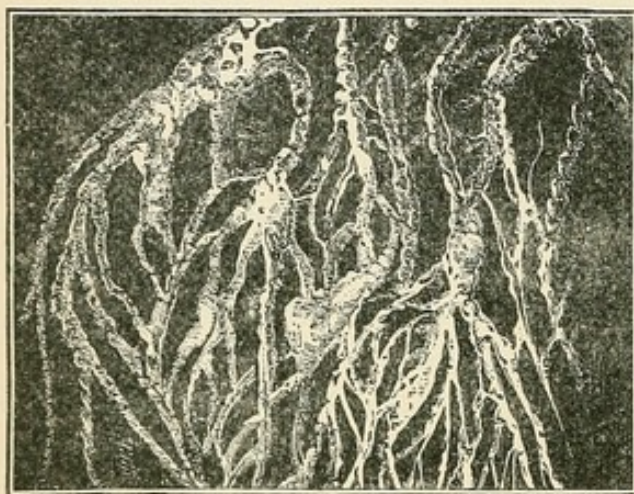


FIG. 27.—Secondary sarcoma of lymphatic vessels of omentum in the course of a medullary sarcoma (after Lücke).

a sarcoma gives rise to regional infection in the same manner and through the same channel as carcinoma.

Another method of regional infection takes place by the diffusion of particles of tumor-tissue or free tumor-cells over serous surfaces—in the abdominal cavity by the peristaltic movements of the intestines and the stomach, and in the pleural cavity by the movements of the lung during respiration. This

manner of regional infection is witnessed most frequently in sarcoma of the peritoneum and the pleura, and in carcinoma of any of the abdominal organs or of the lung after the tumor has reached the serous cavity.

General Infection.—General infection during the growth of a malignant tumor is called *metastasis*—that is, the reappearance of the same disease in a distant organ. When this stage is initiated the tumor is no longer local: the disease has become general. No modern pathologist regards—as was formerly and quite recently done—a primary malignant tumor as a local manifestation of a general disease or dyscrasia. A careful study of the pathology and histology of malignant tumors, as well as the results of accurate clinical observation, has demonstrated that malignant tumors are primarily purely local affections, amenable to successful surgical treatment, and that they become general only by the dissemination of tumor-cells through the systemic circulation. Metastasis may occur in one of three ways: 1. Tumor-

cells reach the venous circulation directly by their entrance from the primary tumor or the regional glandular tumors into a vein; 2. By progressive extension of the disease through the lymphatic channels until the last filter, the last lymphatic gland, is passed, when the tumor-cells reach the general circulation; 3. By the passage of tumor-cells through the chain of lymphatic glands into the pulmonary or systemic circulation without implicating the lymphatic glands. It is strange that the tumor-emboli are not more constantly arrested in the finer branches of the pulmonary artery. The result of post-mortem examinations of persons who died of malignant tumors would tend to show that such emboli readily pass the pulmonary filter, and may become arrested in any of the more distant vascular organs. *The exemption of non-vascular tissues from metastatic carcinoma is one of the many proofs that malignant tumors are generalized by cellular elements, and not through the agency of a virus or of microbes. Metastasis always takes place through the arteries.* Usually the emboli are small (Fig. 28). In some cases perhaps a single cell becomes implanted upon the wall of an arteriole, and later a thrombus is formed by tissue-proliferation from this cell. In other instances a vessel of considerable size is obstructed by a malignant thrombus. Metastatic tumors frequently

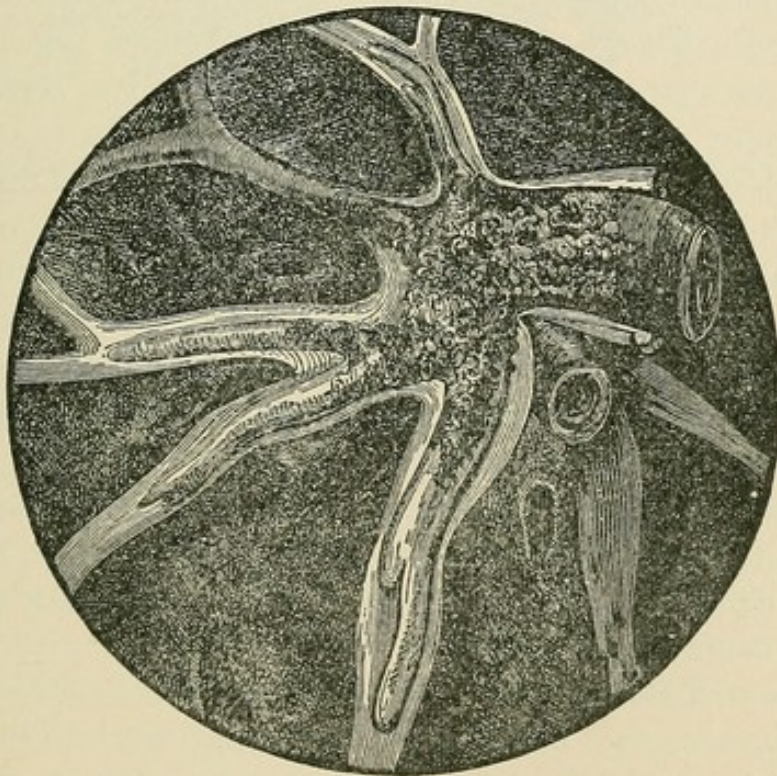


FIG. 28.—Embolism of the right pulmonary artery from a pigmented sarcoma of the thigh (after Lücke).

extend in the direction of a blood-vessel of considerable size, the multiple tumors with the blood-vessels and its branches presenting the appearance of a bunch of grapes (Fig. 29).

The number of emboli varies greatly, from a single metastatic tumor to thousands of nodules. In some very malignant forms of carcinoma and sarcoma the nodules are so numerous that the appearance of the

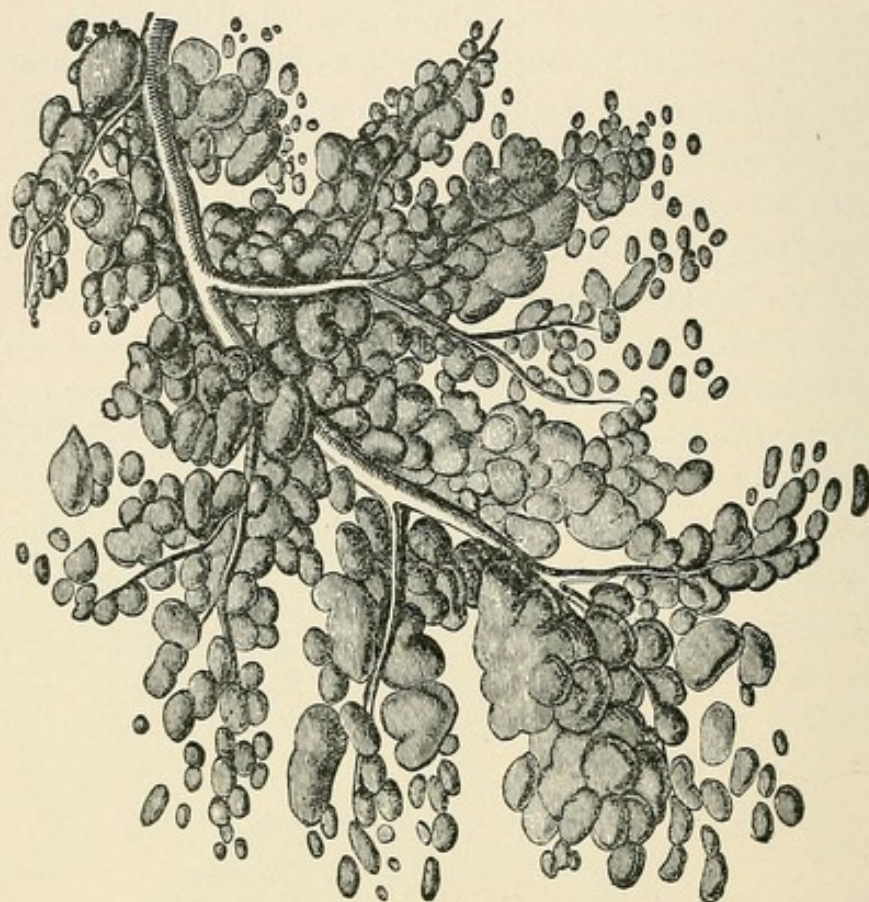


FIG. 29.—Medullary nodules in the course of an artery of the great omentum following a primary carcinoma of the right tonsil (after Lücke).

internal organs resembles very closely that of miliary tuberculosis. Metastasis occasionally takes place in the aged who have been the subjects of latent carcinoma for years. In some instances the patients were not aware of the existence of the primary tumor until the presence of a large and destructive metastatic tumor gave occasion to consult a physician. Sarcoma gives rise to general infection more constantly and at an earlier date than does carcinoma. Small-celled sarcoma is more frequently followed by early and diffuse general dissemination than are large-celled tumors.

Frequency of Recurrence after Extirpation.—It has been shown that the recurrence of a benign tumor is always local, and is invariably the result of incomplete removal of the tumor. The recurrence after the removal of a malignant tumor is either local or metastatic—in the former instance caused by incomplete removal of the primary tumor, and in the latter instance a sad reminder that the operation was not performed early enough to protect the patient against general infection.

The most competent surgeons are willing to admit that so far the best results of operations for malignant disease have not yielded more than about 15 to 25 per cent. of permanent recoveries. If we recollect how a malignant tumor reaches out in all directions into tissue which to the naked eye presents every indication of being normal, we can readily understand why local relapse should follow so frequently even after what seemed a thorough operation. Again, every surgeon has reason to regret that in most cases he is called upon to operate for malignant tumors after the disease has advanced beyond the limits of a successful radical operation. In some instances no local recurrence takes place, but the operation was performed too late, and the patient succumbs sooner or later to metastatic carcinoma or sarcoma. In such cases general infection had taken place when the operation was performed. A local recurrence may take place from three to seven years after the operation for carcinoma of the breast, as happened in a number of the writer's cases, and it may be postponed, according to Billroth, twenty years from the time of operation in cases of sarcoma. Sarcoma usually returns in the scar; carcinoma, either in the scar or in the adjoining lymphatic glands.

Intrinsic Tendency of the Tumor to Destroy Life.—If we reflect upon the fact that with the best efforts of the surgeon only 15, and at best only 25, per cent. of all persons suffering from malignant tumors escape a painful and lingering death from their immediate and remote effects, we must admit that *the intrinsic tendency of a malignant tumor is to destroy life*. The average duration of life of all persons suffering from malignant tumors of all kinds and of all parts and organs of the body, without surgical intervention, is about three years. It is a source of satisfaction to the surgeon to know that life is prolonged by radical attempts to remove malignant tumors, and that in a fair proportion of cases the disease never returns. Life is destroyed by regional or general dissemination involving important organs, by the primary tumor interfering with the function of an important organ, by hemorrhage, or, lastly, by a progressive chronic sepsis or septico-pyæmia caused by an open ulcerating carcinoma or sarcoma. The so-called "cachexia" which appears so constantly some time before the fatal termination is the result of impaired nutrition and of the introduction into the circulation from the tumor of toxic substances.

VIII. TRANSFORMATION OF BENIGN TUMORS AND POST-NATAL EMBRYONIC TISSUE INTO MALIGNANT TUMORS.

THE possibility of the transformation of a benign into a malignant tumor has been asserted by a few and denied by most of the older writers on surgical pathology. The subject is of great interest to the pathologist, and of equal practical importance to the surgeon. Accumulated clinical observations, since the diagnosis of tumors has been made more accurate by increased knowledge of their pathology and by a more frequent resort to the use of the microscope in the examination of tissue removed for diagnostic purposes and of fresh specimens after operation, have brought more convincing proof of the possibility of such an occurrence. As the result of his own observations the writer is convinced not only that such a transformation is possible, but also that it takes place much more frequently than has heretofore been supposed. *The writer is equally certain that malignant tumors not infrequently originate from embryonic tissue of post-natal origin.*

Transformation of Benign into Malignant Tumors.—*The transformation of a benign into a malignant tumor implies a change in the histological structure of the cells of the benign tumor as well as a change in its environments.* We have seen that the cells of which benign tumors are composed resemble the normal cells of the part or organ in which the tumor is located. In a myofibroma of the uterus the cells resemble the connective tissue and the unstriated muscle-cells in the uterine wall in which the tumor is located. The epithelial cells in an adenoma of the breast cannot be distinguished from the epithelium of the acini and tubules of the mammary gland. The transformation depends, therefore, upon influences which accomplish such a change from mature into embryonic cells. At the same time, and probably from the same causes, the physiological resistance of the adjoining tissues is diminished.

The liability of benign tumors to become malignant is of interest not only as a subject of pathological study, but also in relation to an opinion which is often made an argument for operations—namely, that if a tumor of any kind is left to pursue its own course, it is not unlikely to become malignant. This belief, which is entertained by the general

mass of the people, is a strong inducement for patients suffering from benign tumors to submit themselves to a timely operation. This popular belief should be strengthened, not undermined, by the medical profession, as by doing so the patient's mind is relieved and all liability to malignant disease from malignant tumors is removed, and this information and consolation should be imparted to the patient. Lebert states that he has twice met with tumors which were first benign, but afterward became cancerous.

Pirogoff relates three cases in which the removal of angioma was followed by sarcoma at or near the seat of operation.

Benjamin Brodie relates a case in which he removed a tumor the general mass of which appeared to be fatty substance somewhat more condensed than usual, but "here and there was another kind of morbid growth, apparently belonging to the class of medullary or fungoid disease."

Lebert and Benjamin Brodie reported each a case of unquestionable transformation of a benign into a malignant tumor. A few other isolated cases are recorded, but such serious doubt was entertained concerning this matter that at the time Sir James Paget published his *Lectures on Surgical Pathology* (1870) he expressed himself in a very guarded way on this subject: "It need not be denied that cancerous growths may occur in tumors that were previously of an innocent kind, but I feel quite sure that these may be regarded as events of the greatest rarity." He believes that such transitional tumors were malignant from the very beginning, and that the benignant stage simply indicated latency of a carcinomatous growth. The occurrence of a carcinoma in a scar following an operation for the removal of a benign growth he attributes to the trauma acting on the tissues and furnishing the necessary stimulus to the development of a carcinoma in persons so predisposed by heredity.

Since Paget wrote on this subject numerous cases have been recorded in which at the operation such mixed tumors were found, and in which cases there could have been no doubt of the benign nature of the primary tumor. An interesting case of this kind came under the writer's observation. The patient was a married woman fifty-two years of age, the mother of several children. For at least ten years she suffered from a pelvic difficulty which six years ago was diagnosed as myofibroma of the uterus. Since that time she has suffered from profuse menstruation. Examination disclosed a smooth tumor occupying the middle of the lower part of the abdominal cavity and reaching as far as the umbilicus. On vaginal examination the lower segment of the uterus was found high up and was affected by the movements of

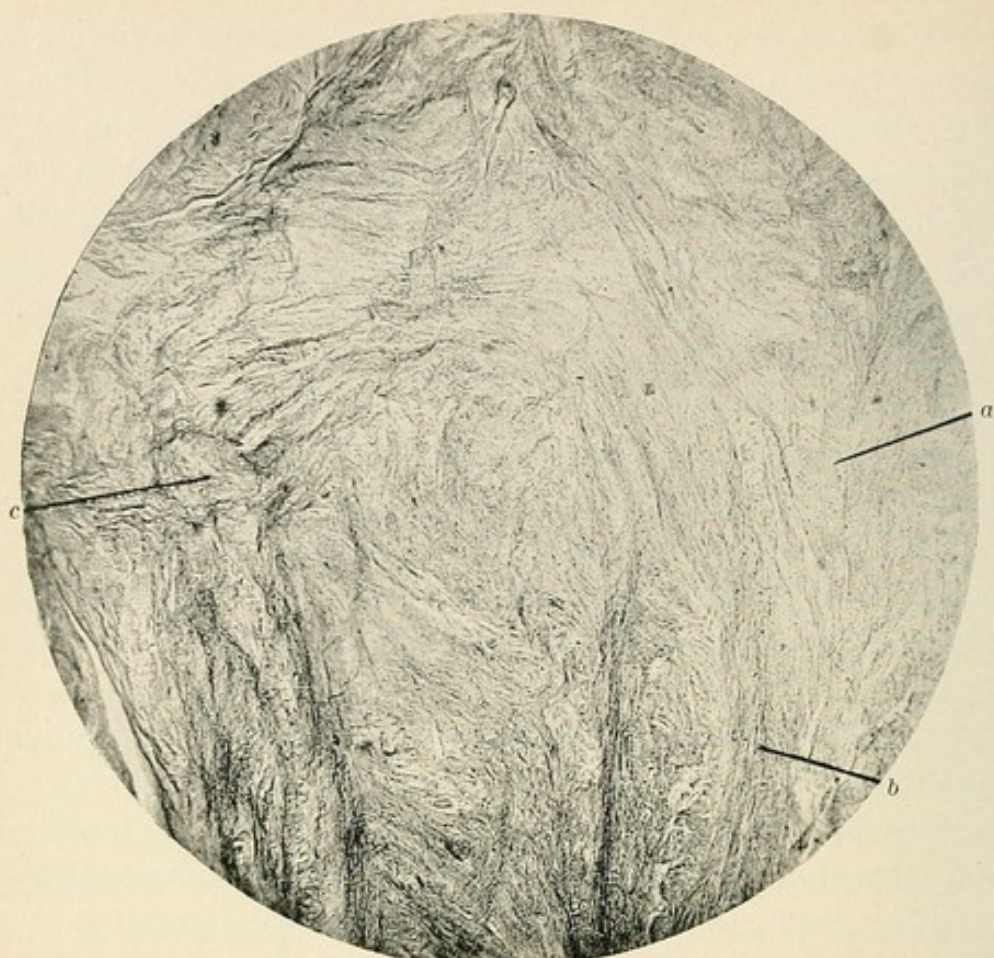


FIG. 30.—Myofibroma uteri; $\times 150$.

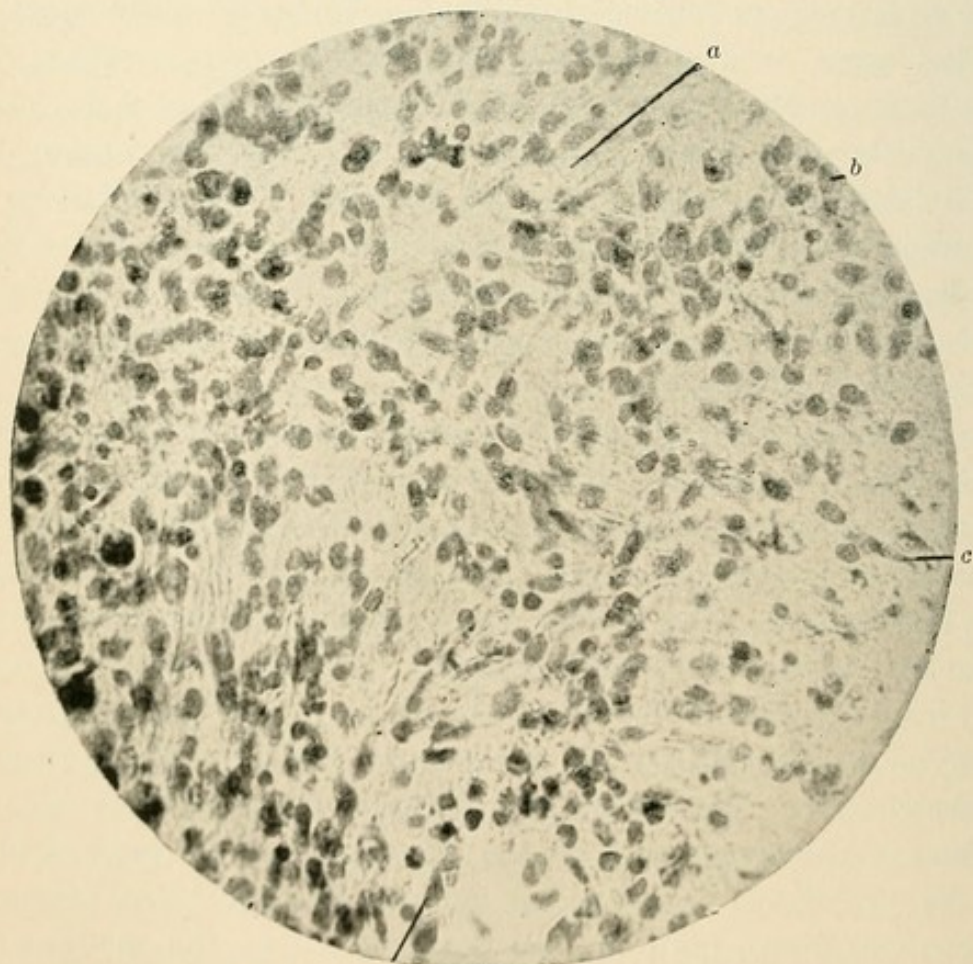


FIG. 31.—Sarcoma which started in a myofibroma uteri: transformation of a myofibroma into sarcoma; $\times 485$.

the tumor. The absence of metrorrhagia and the clinical history spoke in favor of the diagnosis previously made. On opening the abdomen there was found what appeared to be a large myofibroma of the uterus springing from the fundus between the cornua. The immobility of the pelvic part of the tumor induced the writer to make a more thorough examination, which revealed extension of the tumor-mass from the uterus to the broad ligament on the right side. The operation proved to be a very difficult one. The entire uterus, with the pelvic mass on the right side, was removed. An examination of the specimen showed an interstitial myofibroma, the lower segment soft and continuous with the extra-uterine part of the tumor. Microscopic examination of the upper, dense part of the tumor showed the characteristic structure of a myofibroma (Fig. 30), while sections from the lower part of the tumor, the infiltrated uterine wall, and the extra-uterine part of the tumor presented the typical picture of round-celled and spindle-celled sarcoma (Fig. 31). There could be no doubt in this case that the myofibroma had existed for at least ten years, and, as the sarcoma constituted a part of the tumor, it was evident that it occupied that part of the tumor which had undergone transformation from a benign into a malignant tumor. The sarcomatous degeneration did not remain limited to the tumor in which it had its origin, but extended to the uterus, and from here to the tissues outside of it, but in connection with it. The writer has seen in the aged a number of instances in which papilloma assumed active growth after having been in existence for twenty or more years, and manifest clinical evidences of their transition from benign into malignant tumors; he has also witnessed the development of the most malignant form of sarcoma in a small fibroma of the skin that had existed as a benign tumor for years. The origin of sarcoma from pigmented moles is of common occurrence and is generally recognized. In other cases the *nævus pigmentosus* is transformed into carcinoma. If the mole undergoes this transition, the principal seat of the carcinoma is in the superficial layer of the cutis and the rete mucosum, the altered cell-proliferation being limited to the epiblastic structures of the mole.

The exciting causes in effecting a transition of a benign into a malignant tumor are such local and general influences as transform mature cells into embryonic cells, and which at the same time render the surrounding tissues more passive to cell-infiltration. Among the local causes may be enumerated injury, prolonged or repeated irritation, and incomplete removal of the benign tumor by excision or by cauterization. The writer regards the incomplete removal of a benign growth by the application of caustics as one of the most fruitful sources in the transformation of a benign into a malignant tumor. Papilloma and fibroma

of the skin in localities exposed to friction by the clothing, the suspenders, etc. are liable to undergo such a transition. The incomplete removal of a myxoma of the nasal cavities by *écraseur*, forceps, or parenchymatous injections, if these procedures are frequently repeated, is very liable to give rise to sarcomatous degeneration of the growth. The senile state appears to exert a general influence which favors the change of an innocent into a malignant tumor. Malignant tumors starting from a benign tumor are met with most frequently in persons advanced in years who were the subjects of benign tumors for from ten to thirty years, and the clinical history usually points to agencies enumerated above which have brought about this transition.

Transformation of Embryonic Tissue of Post-natal Origin into Malignant Tumors.—Cohnheim's theory of the origin of tumors is not applicable to tumors originating in the products of a chronic inflammation or in scar-tissue. The writer has for years maintained that embryonic tissue of post-natal origin may in the production of tumors serve the same purpose as Cohnheim's congenital matrix. It is not difficult to understand that embryonic cells, during the process of regeneration after inflammation or in the healing of a wound or a fracture, may fail to undergo evolution into so complete a state of perfection as the maternal cells which produced them, and that such cells are set aside, and remain in the tissues in a latent condition in a manner similar to that claimed by Cohnheim for his congenital matrix of embryonic cells. The exciting causes which stimulate such a matrix to tissue-proliferation are of the same nature as those described in the section on the Etiology of Tumors. The kind of tumor produced by such a matrix will correspond to the type of tissue from which the matrix was derived. Epithelial cells buried in a scar will produce an epithelioma. In the healing of a burn some of the new epithelial cells which are derived from the epiblast and which are not utilized in the process of epidermization become buried in the scar-tissue, remain in an immature state, and not infrequently become later the starting-point of an epithelioma. Every surgeon knows that carcinoma not infrequently develops in scar-tissue. Such an origin of carcinoma is not limited to the surface of the body. Gynecologists have claimed for many years that carcinoma of the cervix of the uterus is very prone to develop in the scar-tissue produced by extensive laceration of the cervix during labor. The embryonic cells upon which depends callus-production, when for some reason, local or general, they fail to develop into mature tissue, not infrequently constitute the matrix of tumor-formation, and instead of a normal callus a sarcoma is produced. Not long ago the writer observed an interesting case of this

kind: A man fifty years of age, apparently in perfect health, riding on horseback through a woods, struck his right shoulder against a tree. He was unable to use his arm after the injury. The physician who examined the case pronounced the injury a fracture of the surgical neck of the humerus. The fracture was treated in the customary manner. Three months later, another physician gave it as his opinion that the original injury consisted of a dislocation of the shoulder-joint forward and fracture of the upper part of the humerus. Six months after the injury the patient entered St. Joseph's Hospital, Chicago. The patient was unable to use the arm. The upper part of the humerus was surrounded by a swelling which in the subcoracoid region presented on palpation distinct fluctuation. About the centre of the swelling an additional point of motion indicated that the fracture had not united. Exploratory puncture of the tumor at a point corresponding to the fluctuating area yielded blood and a few minute fragments of tissue resembling in their naked-eye appearances granulation-tissue. The patient complained of a great deal of pain in the tumor, extending in the direction of the shaft of the humerus. As the pain was greatly aggravated during the night, the patient was placed on gram doses of potassic iodide with mercurial inunctions over the swelling. This treatment was continued for nearly two months without making any impression on the subjective symptoms or on the size of the tumor. Amputation through the shoulder-joint was made. The upper five inches of the humerus was found almost completely destroyed by a central myeloid sarcoma which had evidently started at the seat of the fracture. The cartilage of the humerus was completely detached by the tumor-mass, and the disease had reached the capsule of the joint, which was carefully dissected away. The patient does not recollect having suffered any pain or impairment of function of the arm prior to the injury; hence it is safe to assume that the sarcoma developed, in consequence of the injury, from the embryonic tissue, which was arrested in its development into mature tissue by unknown local or general influences.

Maas illustrates the influence of traumatism in effecting transition from a benign into a malignant tumor by reporting the case of a medical student who had at the inner termination of the eyebrow an ordinary small congenital angioma which was injured by a sabre-cut in a duel. Within two years a racemose aneurysm developed in the scar. Maas concludes that trauma can result in the formation of a tumor if the essential embryonal matrix is present at the site of injury. We have seen that a trauma acts as an exciting cause in provoking active tissue-proliferation from a latent matrix of congenital embryonic cells, but

the case of Maas just quoted admits of another and more satisfactory explanation. In the repair of the vessel-wounds inflicted by the sabre-cut the angioblasts must necessarily have taken an active part. In the event of the new cells failing to undergo the necessary developmental stages requisite in the ideal healing of an injured part, they would, according to our position, become available as tumor-forming elements, and their histogenetic origin would determine the production of a vascular tumor of more active tendencies than the primary tumor. The writer therefore believes that the trauma, instead of acting only as an exciting cause, in this case furnished also the necessary tumor-matrix. The relationship of irritation to tumor-formation has recently increased in prominence. As is well known, the psoriasis lingualis, laryngis, nasalis, and præputialis, and the seborrhœa senilis of Richard Volkmann, have engaged, and still engage, very considerable attention. Schuchardt in 1885, Rudolph Volkmann in 1889, and others have brought together a very considerable number of surface tumors which were preceded by long-standing sources of irritation and inflammation, such as, for example, those originating from soot-sifting, tar- and paraffin-working, chronic sinuses, and lupoid and syphilitic ulceration. Cases in which there existed a combination between syphilis and carcinoma have been reported by Lang and Doutrelepon. In 1859, O. Weber showed the etiological relations of lupus to carcinoma, and cases substantiating the correctness of his observations were reported later by von Esmarch, Hebra, Lang, and others. Neisser reminds us that "one ought not to forget that complications of carcinoma and lupus occur, and in these cases, owing to lack of resistance, in part, of the lupus tissue against the encroaching cancer papillæ, it is advisable to adopt early therapeutic measures." Lesser commits himself on this subject as follows: "Occasionally pathological changes in tissue are the seat of epithelial carcinomata which are in no way directly responsible for the origin of tumors, such as ulcers of the leg, syphilitic ulcerations, lupus, etc." E. Friend of Chicago, under the tutorship of Kaposi made a very careful study of the microscopic picture of tissue representing a combination of lupus and carcinoma. Friend saw three cases of lupus vulgaris of the face complicated by carcinoma in Kaposi's clinic (Fig. 32). *The probabilities are that the atypical proliferation of the epithelial cells in the inflamed tissues, and the diminished physiological resistance of the tissues in their immediate vicinity, are the important factors in the production of carcinoma in lupoid tissue as well as in other pathological conditions representing embryonic epithelial cells with a similar environment.* The writer has seen a number of instances in which a carcinoma developed on the surface of a chronic ulcer of the leg. In such cases the islets of embryonic

epithelial cells become the starting-point of a carcinoma when the causes which maintain the ulceration have succeeded in diminishing the physiological resistance of the tissues in their vicinity sufficiently to permit the

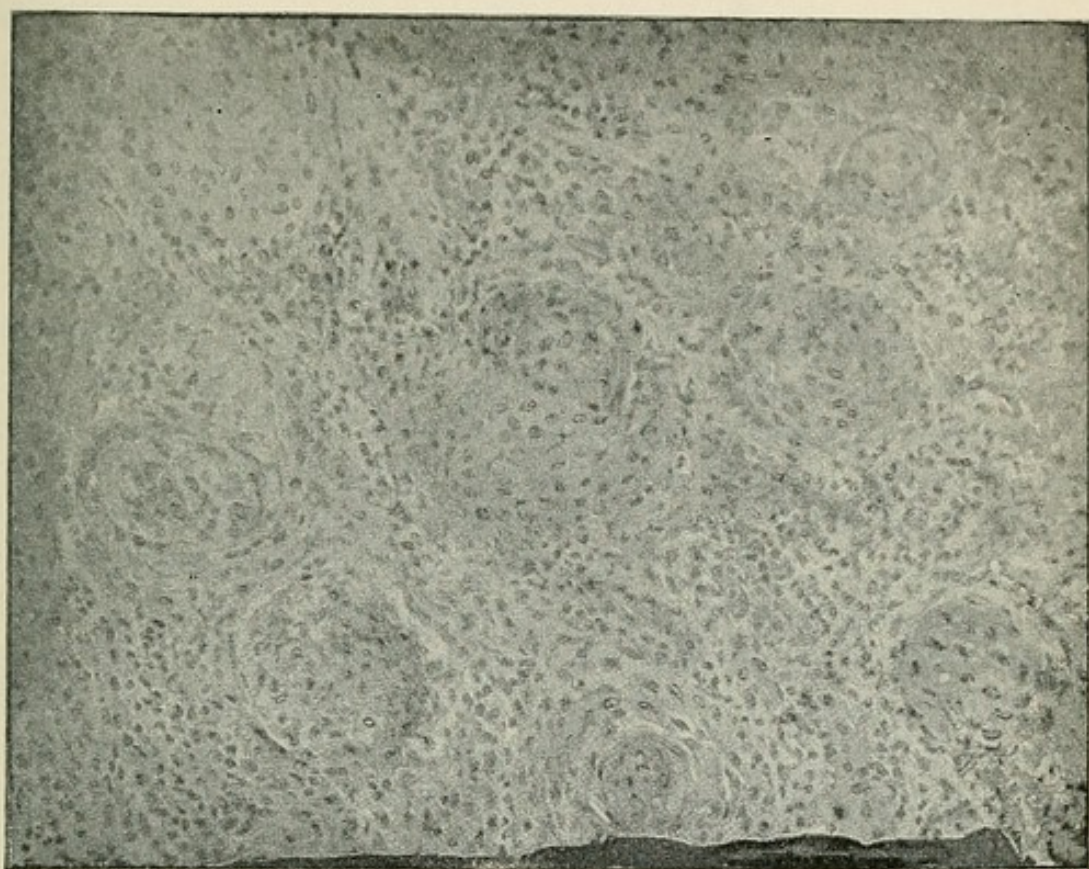


FIG. 32.—Carcinoma in lupoid tissue (after Friend). Isolated tissue-masses, called by Leloir "lupoma," lie irregularly and at different depths in the corium. Upper and papillary layer and rete Malpighii appear normal. Below and interspersed in these nodules are round and elliptical bodies with nests of epithelial cells. Section from lupus vulgaris of face complicated by carcinoma. (Zeiss, A., ocular No. 3.)

embryonic epithelial cells to migrate into the surrounding tissues. *We must therefore admit that the transformation of a benign growth and of a matrix of embryonic cells of post-natal origin into a malignant tumor is not only possible but probable when the embryonic cells, under the influences of local or general causes, assume active tissue-proliferation, and their migration is permitted by a diminished physiological resistance on the part of the adjacent tissues.*

IX. DIAGNOSIS OF TUMORS.

THE diagnosis of tumors is a science and an art—a science, because the accurate anatomical localization of a tumor and the correct appreciation of its character and tendencies presuppose a thorough knowledge of anatomy, physiology, and pathology; an art, because the determination of the exact location and character of a tumor often requires delicate manipulation and the most intelligent application of all known diagnostic resources. The accurate eye and the trained sense of touch, the *tactus cruditus*, are always at hand, and, as a rule, can be more relied upon than can the use of complicated instruments in ascertaining the location, extent, and pathological characteristics of a tumor. Practical instruction at the bedside and examination of patients under supervision of the teacher will accomplish more in rendering the student familiar with the means of diagnosis than will the most painstaking didactic teaching. An abundance of clinical material and thorough and systematic examination by the students of the cases presented are absolutely necessary in acquiring the necessary diagnostic skill. The writer knows of no department of surgery more difficult to teach and to comprehend. The interest of the student can be awakened and his senses be trained properly only by bringing him in contact with patients and by encouraging him in making thorough and systematic examinations. Oncology is usually imperfectly taught in our medical colleges; this fact will go far in explaining the lack of interest of our students in this, to them, perplexing subject.

Clinical History.—In each case of suspected tumor the clinical history should be investigated carefully. A failure to carry out properly this, the initial, part of the diagnostic work has led many a distinguished surgeon astray in making a distinction between an inflammatory swelling and a tumor. Every surgeon inquires almost instinctively into heredity as a possible factor in the production of a tumor. It is not only necessary to ascertain the existence of an hereditary influence in the parents, but the investigation must be carried farther back, as we have seen that this element may not assert itself in the offspring, but may appear again in the second, third, or fourth generation. It is also necessary to determine the existence of heredity in more distant members of the family—uncles, aunts, cousins, and nephews—as heredity

does not descend on all members of a family in the same degree, as is shown by the statistics quoted on this subject. The existence of tumors in different members of the family and in related families of two or more generations should be noted in estimating heredity as a possible etiological factor.

Length of Time Tumor has Existed.—This part of the clinical history is often indefinite and misleading. *A tumor has often existed for years before being accidentally discovered by the patient or the physician.* Patients generally fix as the date when the tumor appeared the time when it was accidentally discovered. By relying on the patient's statement in regard to the time the tumor commenced the surgeon is liable to mistake a benign tumor for a malignant tumor or an inflammatory affection. Due allowance must therefore be made in reference to the statements made by patients or their friends as to the length of time a tumor has existed.

Location of Tumor.—In eliciting from the patient the clinical history it is very important to ascertain from him, so far as possible, the exact location of the tumor when it was first noticed. The student should be made to appreciate the importance of the questions put to the patient to elicit this part of the clinical history. In investigating the probable starting-point of a large abdominal tumor it is quite important for us to ascertain from the patient whether the tumor was first noticed above the pelvis or about the pelvic brim, and on which side. In a rapidly-growing ulcerating tumor of the neck the patient's statements will often render material aid in making a differential diagnosis between secondary glandular carcinoma and lympho-sarcoma. In the absence of an appreciable source of carcinomatous infection the patient, upon questioning him properly, will probably make the statement that the first thing he noticed was a movable, painless tumor *under* the skin. This information alone from an intelligent patient will exclude a surface carcinoma. An epiblastic surface tumor commences *in* the skin, and the patient's statement will often impart valuable information in differentiating between an ulcerating malignant tumor of the epiblast and one of the mesoblast. *The relation of the skin or the mucous membrane to the tumor in its early stages must be ascertained from the patient for the purpose of enabling the surgeon to connect the tumor with its matrix, derived from the different germinal layers, in all cases in which any doubt remains as to the histogenetic source of the tumor.*

Rapidity of Growth of Tumor.—The rapidity with which a tumor has increased in size should be taken carefully into account in the differential diagnosis between a tumor and an inflammatory swelling and between a benign and a malignant tumor. We know how unreliable

the statements of patients are in ascertaining the previous clinical course of a tumor. The patient must be requested to compare the size of the tumor when first discovered with objects familiar to him, such as a hempseed, a pea, a bean, a hazelnut, a walnut, a hen's egg, a plum, an apple, an orange, a cocoanut, a child's head, an adult's head, etc. *By comparing the size of the tumor when first discovered with its present size and estimating the time that has elapsed we are in possession of facts which enable us to judge, at least in an approximately correct way, the rapidity of growth of the tumor. As a rule, a benign tumor grows slowly, a malignant tumor rapidly; the clinical behavior of a tumor is therefore very important in making a differential diagnosis between benign and malignant growths.*

Pain.—Spontaneous pain was regarded for a long time as one of the most distinctive clinical witnesses of carcinoma as compared with benign growths. The idea that carcinoma is an exceedingly painful, torturing disease is deeply rooted among the people of all nations. A peculiar lancinating, paroxysmal pain with nocturnal exacerbations has been described since the time of Hippocrates as characteristic of carcinoma. *Physicians and surgeons have placed too much stress upon the diagnostic value of this symptom.* A lancinating pain at variable intervals and only of a moment's duration is described by many patients suffering from carcinoma of the breast and epithelioma of the lip, but is by no means a constant symptom. The writer is sure that clinical observations will bear him out in making the statement that *adenoma of the breast causes more suffering than does carcinoma of the same organ and of the same size.* He has known of numerous cases of carcinoma of internal organs in which the disease was *painless* from the beginning to the end. Sarcoma, as a rule, causes less pain than carcinoma. Benign tumors, with the exception of tumors of the nerves or of their sheaths, produce pain only when, from their location or their size, they cause compression of a sensitive nerve. A small osteoma in the bony canal through which pass certain sensitive nerves will occasion excruciating pain, while a lipoma in the panniculus adiposus, of immense size and meeting with no resistance to its outward growth, will remain a painless affection throughout life.

Tenderness.—The pain produced by pressure results from compression of a sensitive nerve subjected to the pressure. Tumors of the nerves or of the nerve-sheaths most frequently give rise to pain on pressure. The subcutaneous painful tubercle is well known as the most sensitive tumor. Tumors of the nerve-sheaths of the terminal nerves in the subcutaneous tissue, described by Recklinghausen, are not painful on pressure, owing to the looseness of the structures in

their immediate vicinity. Tenderness in carcinoma and sarcoma depends either on some unusual relation of the tumor to sensitive nerves or to the existence of complications, as pain is absent in the majority of cases of uncomplicated malignant tumors. *Tenderness is an exceedingly important symptom in differentiating between a tumor and an inflammatory swelling, being usually absent in the former, and almost invariably present to a greater or less extent in the latter.*

Examination of the Patient.—*The surgeon who limits his examination to the tumor does not do his duty to his patient, and is very liable to commit mistakes in diagnosis, prognosis, and treatment.* A correct diagnosis implies more than a mere classification of the tumor for which the patient seeks relief: it includes a careful inquiry into the condition of every important organ, the elucidation of the exact pathological conditions in the tumor itself, and a careful investigation of its environment. A correct diagnosis should furnish all the clinical and pathological data required to guide the surgeon in rendering a reliable prognosis and in adopting a safe and judicious course of treatment. Specialists in surgery are very apt to overlook the importance of a thorough and unprejudiced examination of the patient as the first step in seeking reliable evidence upon which to build a correct diagnosis. A careful examination of the clinical history of the case in reference to the possibility of the existence of syphilitic infection should never be neglected. Sarcoma and syphiloma have often been confounded, to the great detriment of the patients and almost chagrin of the attending physician. If there is any doubt as to the differential diagnosis between a tumor and a gumma, the patient should be given the benefit of the doubt by subjecting him to a vigorous antisyphilitic treatment for several weeks. Von Esmarch made recently the statement that more than forty cases of supposed sarcomatous tumors were sent to him for operative treatment, which yielded to the inunction treatment and the internal use of potassic iodide. In the case shown in Fig. 33 five operations were performed, with

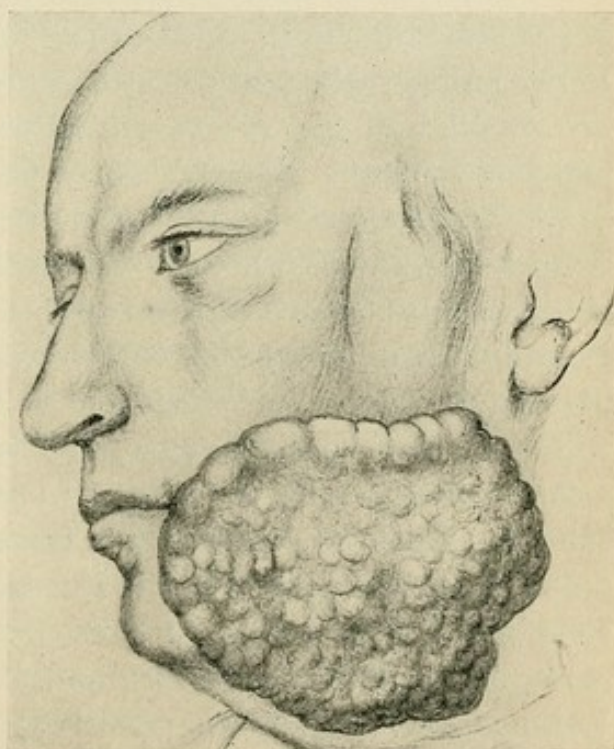


FIG. 33.—Syphiloma (after von Esmarch).

speedy relapse after each. Sprinkling the ulcerated surface daily with potassic iodide resulted in marked improvement, and later a permanent cure was effected by mercurial inunctions. The age of the patient is of some importance in determining the probable character of the tumor, as it has been shown that benign tumors are met with most frequently in persons not past middle life, while malignant tumors, on the whole, attack persons advanced in years. In this respect sarcoma constitutes frequently an exception, as it exempts no age, being sometimes found in children less than ten years of age, as well as in persons far advanced in years. It must not be forgotten, however, that carcinoma occasionally is met with in young persons. The writer has seen carcinoma of the rectum in a boy eighteen years of age, carcinoma of the stomach in a man twenty-seven years old, carcinoma of the breast in a female aged thirty, and carcinoma of the lip in a man thirty-five years old. Sex, as we have seen, predisposes to tumors, both benign and malignant, of special organs. This can also be said of certain occupations. The general appearance of the patient often enables the experienced surgeon at first sight to make a probable diagnosis between a benign and a malignant tumor. The wasting of the subcutaneous adipose tissue and the sallow complexion of the face are familiar to the surgeon as indicating far-advanced malignant disease. Œdema about the ankles and over the sternum is an indication pointing in the same direction. Occasional hemorrhages from different organs, as the kidneys, the bladder, the vagina, and the rectum, frequently call the attention of the surgeon to these organs as the probable seat of a malignant tumor. Mechanical obstruction in the different hollow viscera in persons past middle life is caused more frequently by malignant tumors than by all other causes combined. Functional disturbances of all kinds must be investigated carefully and traced to the primary cause. Neuralgic pain caused by tumor-pressure will often lead to the detection of the tumor. Obstruction to the venous circulation, if studied with the same object in view, will frequently reward the surgeon with a similar result. To show the importance of a careful and painstaking examination of the patient before venturing a diagnosis based upon a few probably unimportant local evidences, attention will be called to a few conditions which frequently present themselves to the surgeon. Let us suppose a patient presents himself suffering from a sarcoma of the intermuscular fascia of the forearm. The tumor has attained the size of a cocoanut, is movable, and has no connection with the overlying skin. The patient's general health is not materially impaired. The rapidity of the growth of the tumor, its shape, and its consistence render the diagnosis of sarcoma more than probable. The surgeon

has determined in his own mind that an amputation affords the only chance to effect a radical operation with a view of preventing a recurrence in the future. Before informing the patient of his intentions he takes the necessary pains to look for contraindications. On further examination he finds a slight convergent strabismus, the liver enlarged and nodular, and traces of albumen in the urine. The result of this additional examination has satisfied him that operative interference of any kind is positively contraindicated, as general dissemination has already taken place, important organs being implicated. The examination into the condition of the important organs has been the means of saving the patient the pain, anxiety, and risks to life incident to a useless operation, and has prevented the infliction of additional reproach upon modern surgery.

Let us suppose another case: A patient advanced in years presents himself with a lipoma over the shoulder which has given him but little inconvenience, but which he is anxious to have removed. As the patient's general health, upon superficial examination, does not appear to be impaired, the surgeon responds to the request of the patient. The patient is anesthetized and the tumor is removed. Suppression of urine follows the operation. The patient is seized with uremic convulsions and dies comatose. A post-mortem examination reveals the existence of a chronic interstitial nephritis. A careful examination of the urine would have furnished a positive contraindication to an operation, and would have been the means of preventing a premature death from the immediate effects of the anesthetic.

In calling special attention to the importance of searching for contraindications to radical operations for carcinoma another hypothetical case will be alluded to: A woman about middle life presents herself for the removal of a carcinomatous breast. The disease in the organ primarily affected has advanced to such an extent that the breast is firmly attached to the chest-wall; infiltration of the axillary glands is moderate; the patient's general health is not much impaired. She is in the hands of a careful, conscientious surgeon. The breathing attracts his attention; it is short and frequent. He makes a careful physical examination of the chest, and finds a copious effusion in the pleural cavity on the side corresponding with the diseased breast. If he had any intention whatever to advise operative interference, this will soon be abandoned, as he has satisfied himself that the disease is beyond the reach of an operation, as shown by the existence of a hydrothorax caused by extension of the disease through the chest-wall to the parietal pleura.

The hypothetical cases cited do not represent imaginary complica-

tions, but illustrate many similar cases which the surgeon is called upon to examine and treat, and they speak for themselves in showing the importance of subjecting tumor-patients to a thorough examination.

Examination of the Tumor.—The examination of a tumor should be made in a systematic manner. Much information can be gained by the intelligent use of the sense of sight. Ocular examination is extended by the use of the ophthalmoscope, the otoscope, the rhinoscope, the laryngoscope, the urethroscope, the cystoscope, and by the employment of different specula in the examination of tumors in localities inaccessible to inspection without the aid of these instruments. Inspection enables the surgeon in the examination to gain information concerning (1) color, (2) size, (3) form and structure of surface, (4) location, and (5) transmission of light.

Color.—The color alone often distinguishes the character and structure of the tumor. In angioma of surfaces accessible to inspection the color of the tumor will enable the surgeon to distinguish between the venous and the arterial variety. The venous angioma resembles in its color venous blood; the arterial angioma, that of arterial blood. The pigmentation of a sarcoma or a carcinoma distinguishes these most malignant of all tumors from the other varieties of malignant tumors. Discoloration of the surface of a tumor is also caused by interstitial hemorrhage and by inflammation.

Size.—The size of a tumor is significant to the surgeon, because certain tumors never exceed a definite size. Neuromata and osteomata never reach large size. They grow slowly, and when they attain the maximum size they remain stationary throughout life. *Very important from a diagnostic standpoint is a sudden variation in size.* This is observed in vascular tumors, which under the influence of certain agencies that cause intravascular tension increase in size and become firmer. A nævus in a child becomes more prominent and tense during the act of crying. The volume of a large venous tumor is often materially affected by respiration, the size increasing during expiration and diminishing during inspiration. In following the clinical history of a tumor careful measurements should be taken and recorded from time to time. The eye should not be relied upon in ascertaining the increase in size of a tumor. Fixed anatomical landmarks are readily available guides in following the extension of a tumor toward its vicinity—by recording at fixed intervals the measured distance between them and the margin of the tumor. When the measurements are taken the patient and the part to be examined should always be placed in the same position.

Form and Structure of Surface.—The shape of a tumor can often

be outlined by inspection, and if the tumor is sufficiently near the surface, any irregularities in its contour can be recognized at the same time. The shape of the tumor is determined largely by the structure of the mother-soil, the anatomical locality, and the resistance offered by the surrounding structures to the extension of the growth. Equal resistance on all sides determines a globular shape; later, pressure results in elongation of the tumor; absence of resistance on one side gives rise to a growth in that direction, followed by constriction at the base of the tumor and by pedunculation. Central tumors of bone usually assume the shape of a spindle. A nodular surface is often presented by carcinoma, but it is also found in all tumors which have perforated organs and tissues and grow free in all directions. The most malignant forms of carcinoma and sarcoma have a smooth surface, owing to the predominance of their cellular elements over the stroma. Nodular projections in carcinoma as well as in other tumors are produced by contraction of the stroma as well as by unequal resistance offered by the surrounding tissues. Ulceration on the surface of a tumor represents from an etiological standpoint different things: Superficial excoriations are usually the outcome of purely local accidental causes, such as trauma or the application of irritating remedies, and commonly heal upon the removal of the cause; ulcerated surfaces occupied by a fungous mass indicate the existence of a rapidly-growing tumor; extensive ulceration devoid of massive fungous granulations point to the existence of a less rapidly-growing tumor; while deep, and especially crater-like, excavations are indicative of speedy destruction of the central mass of the tumor. Of special pathological interest is the character of the floor of the ulcer—whether it is clean or ragged, red, gray, dirty, or gangrenous; frequently, characteristic parts of the tumor are exposed on the surface of the ulcer. The secretion of the ulcer is of diagnostic value in determining the stage of malignant degeneration and the character of the microbic infection which followed the exposure of the tumor-tissue to the atmospheric air. Suppuration indicates infection with pyogenic microbes; putrefaction of the secretions points to the presence of putrefactive bacilli in the dead tissue attached to the surface of the ulcer. Capillary bleeding from the surface of the ulcer is an indication of the destruction of granulations by the tumor-tissue, by pathogenic microbes, or by an injury; more profuse hemorrhage results from erosion of the wall of blood-vessels of considerable size.

Location.—Ocular inspection often reveals the primary location of the tumor. A unilateral exophthalmos denotes the presence of a retrobulbar tumor; an unusual prominence of one of the cheeks and the presence of a projecting tumor of the nose on the same side point

to the existence of a tumor of the antrum of Highmore. Inspection is also useful in some cases in determining the character of the tumor—as, for instance, in the case of tumors of the lower lip, which tumors, with few exceptions, are epithelial cancers.

Transmission of Light.—A tumor with clear liquid contents and tumors composed largely of a colorless intercellular substance transmit light to a greater or lesser extent, rendering them translucent or transparent—as, for example, hydrocele of the neck, myxoma of the nasal cavities, etc.

Tactile Examination.—Tactile examination is more important than ocular inspection in the examination of a tumor. The value of ocular examination has been overestimated greatly in the past. In ascertaining the exact location and extent of a tumor much more diagnostic information is gained by the employment of the sense of touch than by inspection with the aid of specula, if the tumor is accessible to digital examination. The mania on the part of surgeons and instrument-makers to invent new specula for the exploration of channels and cavities accessible to digital exploration has about subsided, and in its place efforts are being made to instruct students more efficiently in the use of the finger in the examination of tumors. The acquirement of the *tactus eruditus* requires long and careful training. The student should be given an opportunity to handle and examine tumors of all kinds, in order to familiarize himself with their structure and physical characteristics by the sense of touch. Instruction of this kind will impart a thorough knowledge of the nature and extent of the degenerative changes which occur in the parenchyma and stroma of tumors. The careful digital palpation of the different normal tissues and organs is an exceedingly useful exercise in acquiring a delicate sense of touch. Fluctuation can be studied advantageously by palpating a bladder or a rubber bulb distended by water. In the examination of tumors in the living subject the teacher should inform the student what he is expected to find and to feel before he proceeds to make the digital examination. If the tumor is large, manual examination takes the place of the digital. In bimanual examination both hands are employed. Bidigital examination means the use of one finger of each hand in the exploration of a tumor or other pathological product. The information gained by manual and digital examination is often used to corroborate or to render more accurate what has been learned from inspection. The tactile sense is relied upon in deciding diagnostic points of the greatest practical import to the surgeon, the most important being—1. Connection of the tumor with the mother-soil; 2. Resistance and consistence; 3. Pulsation; 4. Tenderness; 5. Crepitation.

Connection of Tumor with the Mother-soil.—The kind and extent of the connection of a tumor with the mother-soil have an important bearing on the nature of the tumor and on the selection of appropriate operative measures. The degree of mobility of a tumor and the ease with which it can be displaced are determined largely by the nature of its connection with the surrounding tissues. The wider the base of a tumor and the more projections it sends out into the surrounding tissues, the more pronounced becomes its immobility and the more limited the extent to which it can be displaced. If the tumor is attached only by a pedicle, it is freely movable and can readily be displaced. Such tumors in the abdominal cavity often become displaced in an axial direction, resulting in twisting of the pedicle. If a tumor is surrounded on all sides by resisting tissue, it is held firmly in place and cannot be displaced. The immobility of a carcinoma is due to the many prolongations which the tumor sends out into the surrounding tissues. A carcinoma is movable if it involves a movable organ before the organ becomes attached by the extension of the tumor beyond the limits of the organ primarily affected. Tumors freely movable often become firmly attached to the surrounding tissues by inflammatory adhesions following inflammation of the tumor resulting from direct infection through an ulcerated surface, from auto-infection, or from infection caused by exploratory puncture or by ineffective treatment. A branchial cyst is usually attached loosely to the surrounding tissues, and can readily be enucleated, but after ineffectual attempts at radical cure by irritating injections or after incomplete removal by enucleation the whole or a part of the cyst-wall is found firmly attached to important structures, rendering enucleation impossible and the removal by excision a difficult and dangerous procedure. In determining the mobility of a tumor its base should be grasped firmly, when by moving it in different directions the degree of mobility and the extent of its connection with the mother-soil can be determined. If the tumor is immediately under the skin or under the abdominal wall, the existence of attachments to the skin can be ascertained by gliding the superimposed structures over the surface of the tumor; adhesions between an abdominal tumor and the anterior abdominal wall can be ascertained by observing the respiratory movements of the abdominal wall, or, if the tumor is not too large, by displacing it by changing the position of the patient or by moving it with the hands. The absence of inflammatory adhesions or of neoplastic attachments of a struma to tissues other than the underlying trachea is demonstrated by the movements imparted to the tumor by the trachea during deglutition. The extent and location of attachments of tumors in some of the cavities—for

instance, the uterine cavity and the nasal passages—can often be determined only by a careful use of probes and sounds. It can be laid down as a rule that the more limited are the attachments of a tumor with the surrounding tissues, the more favorable is the prognosis and the better are the results following its operative removal. In the absence of inflammatory processes, attachment of the tumor to the underlying skin indicates that the tumor is malignant. The lymphatic glands in the region occupied by a tumor should always be subjected to a careful examination. Enlargement of the lymphatic glands in the vicinity of a tumor must always be regarded with suspicion. A consensual hyperplasia of the lymphatic glands may occur in consequence of the introduction into the lymphatic channels of pathogenic microbes through the ulcerated surface of a benign tumor. In the absence of a tangible infection-atrism implication of the regional lymphatic glands, with few exceptions, points to a malignant nature of the tumor. As lymphatic infection seldom accompanies sarcoma, when this condition exists independently of microbic infection the primary tumor in the great majority of cases is a carcinoma.

Resistance and Consistence.—Resistance and consistence are variable qualities of tumors. We seek to ascertain the density of a tumor by fixing its base, and then ascertain its resistance to finger-pressure at different points. To ascertain the density of a deeply-situated tumor or of different parts of the same tumor, Middeldorpf advised the use of acupuncture needles (Fig. 34), and he applied to this diagnostic aid the term *akidopeirasty*. The writer has found this diagnostic resource of great value in the differential diagnosis of deeply-seated tumors of bone. If the tumor is an osteoma, the needle will be arrested when it reaches the surface of the tumor; if it is a periosteal sarcoma, the needle will penetrate the soft parts of the tumor, and with its point plates or spiculæ of bone can usually be detected. If it is a central osteo-




FIG. 34.—Acupuncture needles used in exploring tumors by akidopeirastic.

ments through the atrophic compact layer of the bone encasing the tumor, after which it can be forced through the soft tumor-mass

until the opposite side of the bone is reached without meeting with any appreciable resistance. Exploratory puncture for this and other purposes should be done under strictest antiseptic precautions, otherwise puncturing may become the direct cause of infection. The needle, before being used, should be sterilized by boiling or by heating it for a sufficient length of time in the flame of an alcohol lamp, and the

surface where the puncture is to be made should be rendered aseptic by thorough washing with warm water and soap, followed by washing with a strong antiseptic solution. After the removal of the needle the puncture should be sealed hermetically with iodoform collodion. The existence of cysts in solid tumors can often be determined by the same method of exploration. Osteoma and chondroma are the benign tumors noted for their density. Fibroma varies greatly in this respect, often being nearly as hard as cartilage, in other instances being as soft as a myxoma. Uterine fibroids present both extremes as to density. A soft fibroma of the uterus usually contains muscle-fibres as the predominating histological element, and is generally much more vascular than the firm variety, in which we find more fibrous tissue and a less copious blood-supply. The density of a malignant tumor is in proportion to its benign tendencies. In soft malignant tumors the parenchyma-cells predominate, the stroma is scanty, and the vascular supply is abundant. The softness of a malignant tumor is in proportion to its malignancy. The stroma in such cases is scanty, and the cells are numerous and are endowed with a maximum capacity of tissue-proliferation; the new cells find ready access into the surrounding tissues, hence early and extensive infiltration determines rapid growth and early regional and general dissemination. Elastic softness is manifested by many fibrous, fatty, and sarcomatous tumors. Owing to the softness of the tumor-tissue in many cases of very malignant carcinoma and sarcoma, these tumors present on palpation a sense of fluctuation which is exceedingly deceptive, and which in many instances has led the surgeon to puncture or incise such tumors under the belief that the swelling contained the products of an inflammation. Pseudo-fluctuation is often elicited in the examination by palpation of benign tumors, notably myxoma and lipoma. Fluctuation is frequently absent in dense cysts, particularly if the cyst-wall is of unusual thickness.

The existence of a cystic tumor or swelling and the occurrence of cystic degeneration in solid tumors can often be determined only by the use of an exploratory needle (Fig. 35) or a trocar. The ordinary hypo-




FIG. 35.—Exploratory needle.

dermic needle answers an excellent purpose in ascertaining the presence of liquid contents in a cyst. Syringes are, however, very liable to get out of order, and this is more particularly the case on occasions when they

are most needed. Another objection to the use of the hypodermic and the exploratory syringe is the difficulty experienced in securing and maintaining them in an aseptic condition ; and, lastly, it is difficult, if not

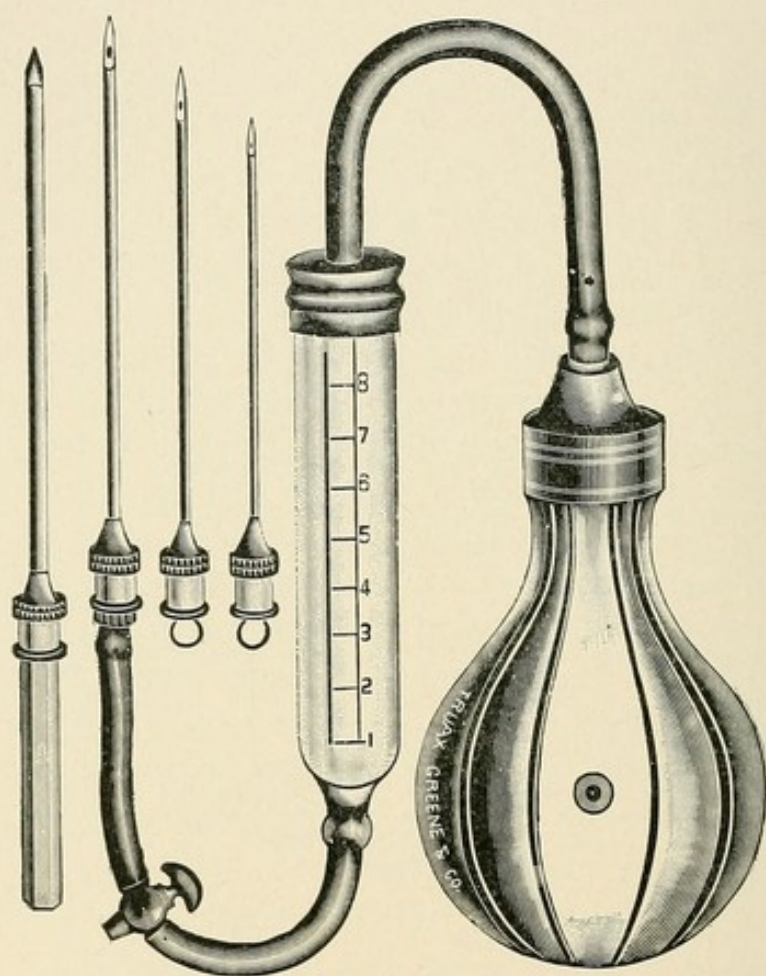


FIG. 36.—Senn's exploratory syringe.

impossible, to hold the needle perfectly steady while the piston is withdrawn in aspirating the contents of the cyst. These objections to the use of the ordinary syringe in withdrawing the contents of tumors or of swellings apply with special force to exploration of the brain, the pericardium, and the pleural cavity. The writer, who has for a long time been anxious to do away with the piston as a means of aspiration and in making intra-articular and parenchymatous injections, has succeeded at last in devising an instrument possessing all the merits of the ordinary syringe, minus the objections to the piston. This instrument is also used exclusively in making intra-articular and parenchymatous injections. The fluid is withdrawn by aspiration performed by a strong rubber bulb in place of a piston, and in making injections the fluid is propelled by a column of elastic air. The remaining part of this syringe can readily be understood from Figure 36. Some care is necessary in preventing serious complications arising from the employment

of this exceedingly useful diagnostic aid. The usual strictly antiseptic precautions should never be neglected, as tumor-tissue is very susceptible to infection, and in a great many cases the use of the exploring-needle in the hands of careless practitioners has resulted in serious and fatal complications. The puncture should be made after the skin has been withdrawn to one side, so that after the withdrawal of the needle the puncture in the deep parts will be subcutaneous. Injury to important vessels and nerves should be avoided. In puncturing abdominal tumors and swellings the needle should be inserted, if possible, extra-peritoneally; if this cannot be done, the puncture in the cyst-wall should be oblique, so that upon the removal of the needle there will be less liability of the contents escaping into the peritoneal cavity through the puncture. In such cases the needle used should be small. The removal of a considerable portion of cyst-contents will diminish tension, and thus prevent leakage through the puncture. The exploring-needle can also be used to ascertain the degree of density of the tissues which it penetrates (akidopeirastic). If the contents of a suspected cyst fail to escape on making aspiration, the point of the needle is further advanced or withdrawn while aspiration is frequently made until the point of the needle is within the cyst. It may also become necessary to remove the needle and to insert it through the same external puncture in different directions before the cyst is reached. The character of the fluid withdrawn will throw much light upon the nature of the tumor. If no fluid is withdrawn, we often find in the lumen of the needle fragments of tissue, which, when examined under the microscope, will furnish valuable information in reference to the nature of the tumor. *The exploratory syringe is a most valuable, and often an indispensable, instrument in the differentiation between a tumor and an inflammatory swelling.*

Pulsation.—Pulsation is felt in certain tumors by placing the palmar surface of the hand against the tumor. *Not all pulsating tumors are vascular tumors.* A solid tumor resting against a large artery receives the impulse from the artery. *In such cases the pulsation can be felt only in one direction, away from the artery.* A pulsating tumor, angioma, vascular myeloid sarcoma, diminishes in size under pressure, and the pulsations are not limited to one direction.

Tenderness.—The causation of pain by finger-pressure over the tumor has already been alluded to as an evidence in the diagnosis of a tumor. *Tenderness indicates either that the tumor is intimately connected with a sensitive nerve or that the tumor has become infected and is the seat of an inflammation. Under ordinary circumstances pressure over a tumor does not cause pain.*

Crepitation.—Palpation of a tumor occasionally elicits a sense of crepitation. If the crepitation is caused by the presence of chalky masses or bone, it is rough; if the plates of bone are thin, it is softer, resembling the crepitation produced by the bending of parchment. The "parchment" crepitation is produced by making pressure upon a myeloid sarcoma in which the compact layer of the bone has been reduced to thin plates or scales by pressure from within outward, and in chondroma surrounded by a thin, yielding shell of bone.

Auscultation and Percussion.—The ear, aided or unaided by the use of the stethoscope, can be utilized in the diagnosis of certain tumors. Percussion is useful in the differential diagnosis of hernia and of tumors occupying localities the most frequent seat of hernia. Percussion is also useful in outlining a tumor in the chest and in the abdominal cavity.

Auscultation is resorted to in the examination of pulsating tumors, in which usually, a distinct *bruit* can be heard, and in the differential diagnosis of aneurysm and of tumors located in close proximity to a large artery. It must be remembered that a blowing, rasping sound is often produced by the narrowing of the lumen of a large artery from outward pressure caused by a tumor.

The diagnostic resources which have been described so far are ample, if carefully and thoughtfully applied, to enable the surgeon in the majority of cases to make a correct diagnosis. In obscure cases it is advisable to repeat the examination at intervals of a few days, weeks, or months, and at the same time to observe carefully the clinical course of the tumor. *A hasty diagnosis in obscure cases is justifiable only in urgent cases demanding prompt surgical interference. Whenever permissible, the surgeon should take sufficient time and, if necessary, make repeated examinations, and exhaust all diagnostic resources before he commits himself concerning the nature of the tumor.*

Röntgen Ray.—During the year 1896 the diagnostic resources as applied to tumors were increased by the discovery of the *x*-ray by Röntgen. As bone-tissue is impermeable to this ray, the shadow-pictures obtained by its use show clearly the outlines of bones and pathological formations containing bone. The Röntgen ray will be of great value in locating osteomata and in showing their relations to adjacent joints and other structures; in ascertaining the existence of bone in mixed tumors; and in demonstrating the early existence, exact location, and size of myeloid and bone-producing periosteal sarcoma.

It remains to discuss—

The Value of the Microscope as an Aid in the Diagnosis of Tumors.—There is no doubt in the mind of the writer that the value of the microscope as an aid in the diagnosis of tumors has been greatly over-estimated. The greatest blunders in diagnosis and treatment have been committed by surgeons of eminence through placing too great reliance on the microscopic examinations of fragments of tumor-tissue obtained either before operation or from the specimens removed. The late Emperor Frederic of Germany is a case corroborating the truth of this assertion. His attending surgeon, Von Bergmann, made a correct diagnosis, basing his opinion upon the clinical aspects of the case. A part of the tumor was removed and examined by the most distinguished pathologist the world has ever seen. His diagnosis was based upon what he could see under the microscope. In the section examined he could detect nowhere any evidences of malignancy. The epithelial cells, greatly increased in number, retained their normal relation to the underlying tissues. All the pictures under the microscope represented a benign papilloma. The disease, however, pursued its relentless course, notwithstanding the favorable prognosis made, and in a few months destroyed the life of the illustrious patient. The unprejudiced surgeon will readily understand the source of fallacy in the diagnosis made by the pathologist. The part removed and examined represented only one part of the tumor. The attached deep portion contained the carcinoma-cells, and it was from this part that the




FIG. 37.—Warren's harpoon for the removal of tissue from solid tumors for microscopic examination.

disease extended from one tissue to another. The case is an extremely valuable one in showing the importance of examining different parts of a tumor if the microscope is to be relied upon in making a final diagnosis. The examination under the microscope of isolated cells is not to be relied upon, as all the varieties of tumor-cells have their counterpart somewhere in the normal tissues of the body. Instruments constructed upon the plan of a trocar have been devised by Wintrich, Bouisson, Bruns, Middeldorpf, and J. Collins Warren (Fig. 37), for the purpose of removing particles of tumor-tissue for microscopic examination. The objection to this method of obtaining tissue for examination is that by taking the tissue from only one part of the tumor the part removed

may not represent tumor-tissue, and may consequently lead to error in diagnosis; and multiple punctures are objectionable, as they are likely to give rise to considerable hemorrhage and to stimulate tumor-growth. This method of procedure is, however, advisable when all other diagnostic resources have failed and it is essential for the welfare of the patient that a correct diagnosis should be made before an opera-

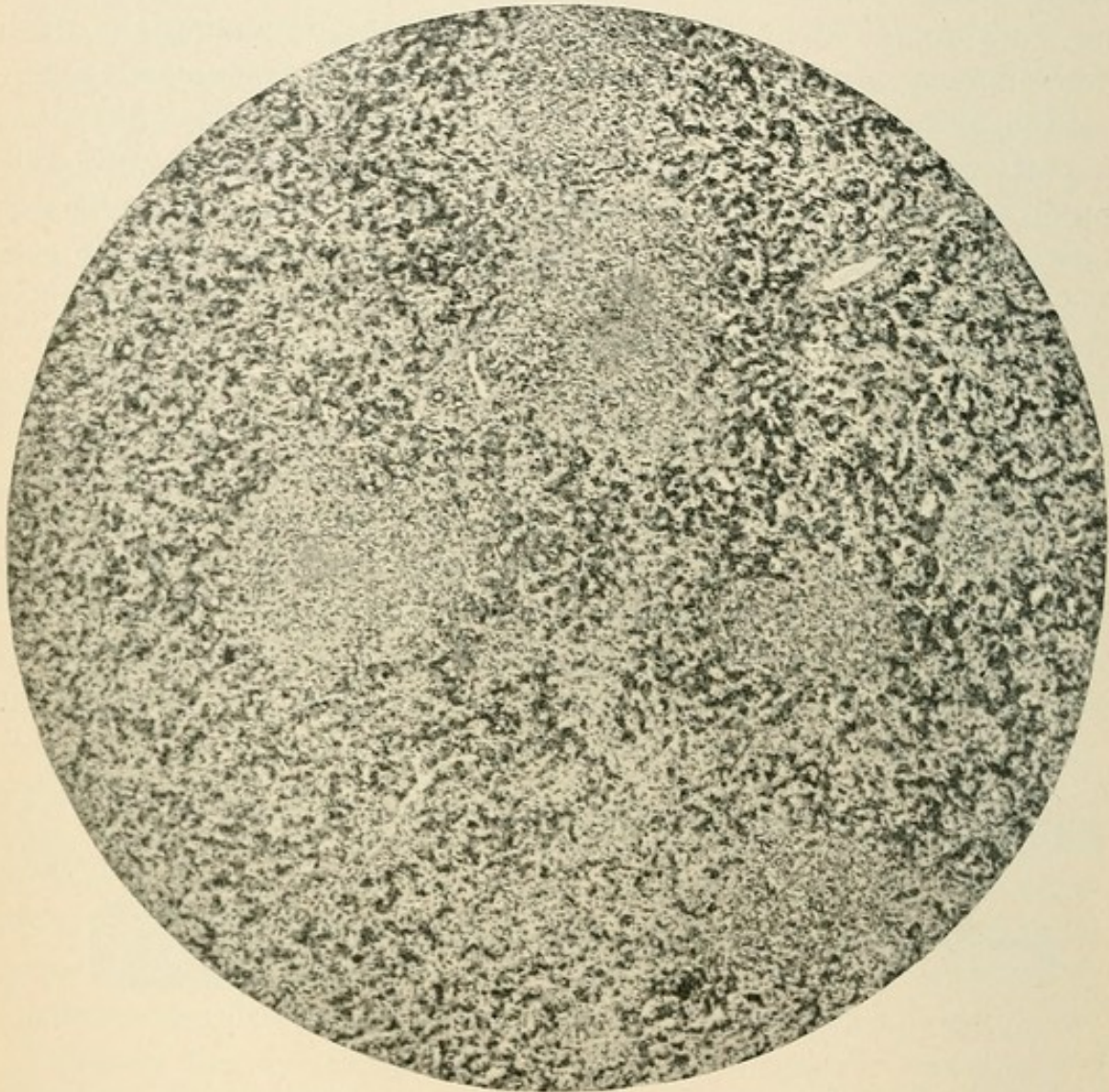


FIG. 38.—Gumma of the liver (after Karg and Schmorl). In the centre of the field circumscribed foci, miliary gummata: the same are composed of young granulation-tissue, and show in their centre evidences of degeneration. The parenchyma-cells are seen as grayish-black stripes, and are separated from each other by narrower stripes of cellular connective tissue.

tion is undertaken. Preparations of teased tissue are of but little value for diagnostic purposes. The fragment should be prepared properly, and from it sections should be taken for microscopic examination. *Only specimens which represent both cells and stroma in their proper relations enable the microscopist to interpret the character of the tumor.* How difficult it is to distinguish the tissue of some tumors from the granulomata by the aid of the microscope can readily be seen by a

FIG. 40.

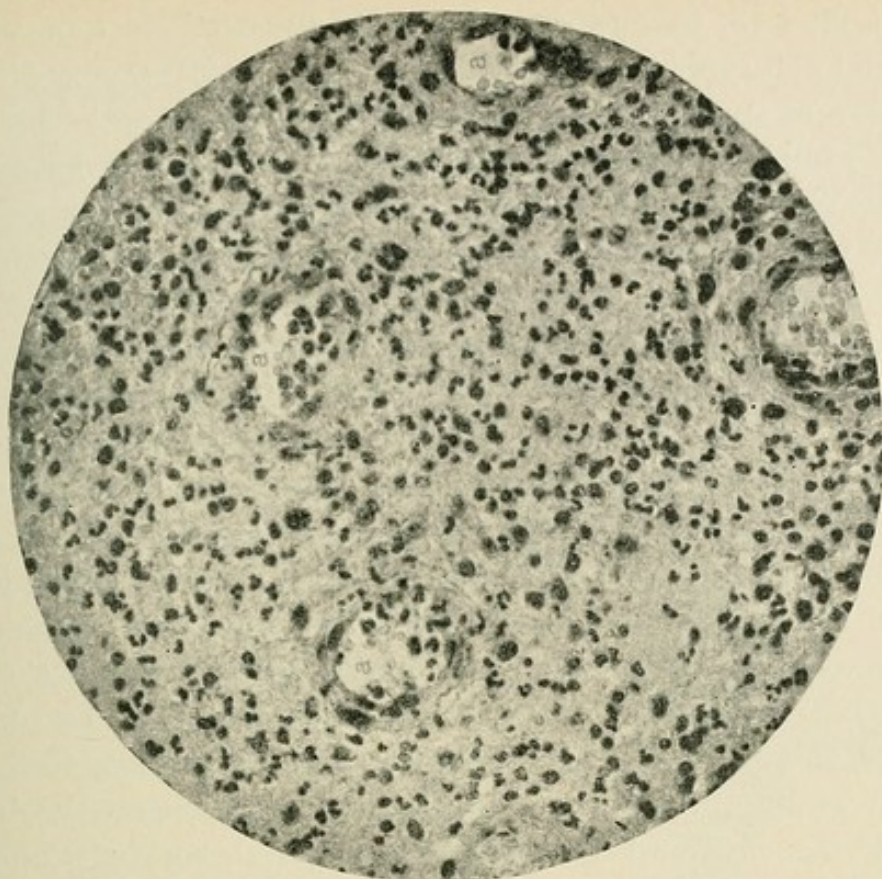


FIG. 39.

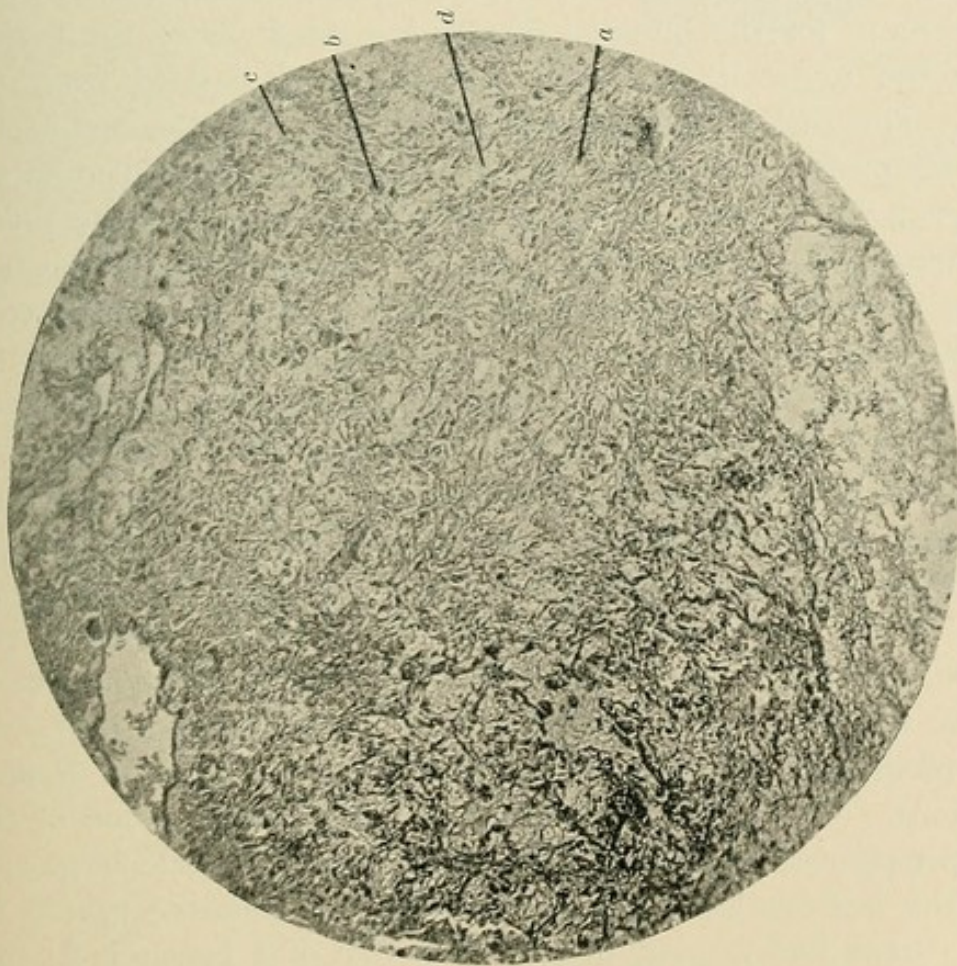


FIG. 39.—Myeloid sarcoma of tibia; $\times 85$ (from specimen in Rush Medical College, Chicago): *a*, embryonic connective-tissue cells, with mature cells in their vicinity; *b*, large round sarcoma-cell; *c*, small round sarcoma-cells; *d*, irregular periosteal cells.

FIG. 40.—Young granulation-tissue; $\times 270$ (after Karg and Schmorl): *a*, transverse section through young blood-vessels with exceedingly thin walls. Lumen of blood-vessels contains blood. Leucocytes in contact with intima, some of them on their way through the wall of the vessels. The ground-substance between the vessels shows a reticulated appearance. In the meshes of this network are seen leucocytes and granules and larger nucleated cells—the fibroblasts.

glance at Figures 38, 39, and 40. All these illustrations represent in the foreground embryonic connective tissue with a very scanty stroma. Without knowing anything about the clinical aspects, it will readily be seen that it would be exceedingly difficult to distinguish between a small round-celled sarcoma, young granulation-tissue, and a gumma. It is in just such cases that we seek additional light from a microscopic examination.

To illustrate still further the danger which may follow the use of the microscope as an exclusive and only means of diagnosis, the writer will relate a case which recently came under his observation. During the World's Fair held in Chicago he was consulted by a Russian gentleman concerning several tumors which had developed in the scar of an operation-wound. He gave the following history: Age, forty; married; the father of several healthy children; merchant by occupation. In 1890 he noticed a swelling in the skin at a point corresponding to the supraspinatus fossa of the right scapula. The tumor was movable and painless, but increased quite rapidly in size. He consulted his family physician in Russia, who pronounced the tumor a sarcoma of the skin and sent him to one of the most prominent surgeons in Berlin for operation. The Berlin surgeon made a diagnosis of gumma, placed the patient on specific treatment, and removed the tumor, more for the purpose of allaying the fears of the patient than with the expectation of any benefit being derived from the operation. The patient followed the treatment faithfully, but in the course of six months a tumor returned in the scar. He consulted the same surgeon, who at the patient's special request removed the tumor a second time, still claiming that it was not malignant. It was now decided to leave the diagnosis in the hands of the most competent pathologists. The surgeon sent a part of the tumor to an eminent Berlin pathologist, and the patient sent the balance to the foremost Paris pathologist. The specimens were subjected to microscopic examination, and each pathologist sent in a written report to the effect that the tumor was a gumma, and not a sarcoma. The patient was now placed on vigorous antisyphilitic treatment, including mercurial inunctions, baths, and the internal use of corrosive sublimate and potassic iodide in large doses. The wound after both operations healed by primary intention. The patient is not aware that he ever contracted syphilis, and never showed evidences of secondary or tertiary manifestations. When the writer examined the patient none of the remote consequences of syphilis were discovered. The pale, large scar following the last operation was occupied by four tumors, covered by intact scar-tissue and varying in size from that of a hazelnut to that

of a walnut, all of them perfectly movable, and with no attachments to the scapula. If ever a case of sarcoma of the skin was seen, this was one. Under the circumstances it was deemed prudent to advise the patient to return to his surgeon for a third operation. The writer does not wish to under-estimate the value of the microscope as an aid in the diagnosis of doubtful tumors, but he must insist that it cannot be relied upon in differentiating between a small round-celled sarcoma and some of the granulomata under circumstances such as those detailed above. In doubtful tumors of accessible surfaces tumor-tissue can be selected and removed

for microscopic examination. Sections of such specimens are better adapted for diagnosis by means of the microscope than fragments taken from the depths of tumors through the skin with the different forms of harpoons. Another course is sometimes necessary when the surgeon has decided to remove the growth and is in doubt as to its nature. Here the microscope is employed during the operation as an aid in diagnosis. As soon as the

tumor is reached, when doubt still remains as to its character, a piece is removed and sections are made with a freezing microtome (Fig. 41) for microscopic examination. The freezing microtome can be purchased at a small expense, and should have a place in the operating-room of every hospital. The result of such an examination frequently settles all doubt as to the nature of the tumor, and serves as a valuable guide to the surgeon in the performance of the operation. *The microscope is an invaluable aid in the diagnosis of tumors, but the conclusions based upon the results of the examination are not infallible; hence the importance of a careful study of the clinical aspects of the tumor, followed by a thorough examination of the patient, of the tumor, and of its environments.*

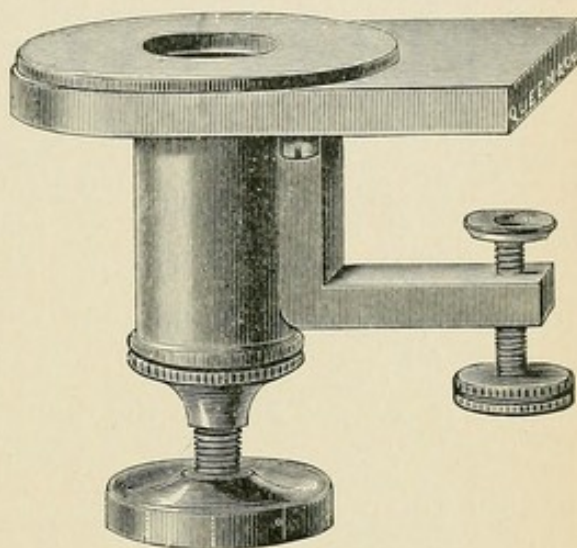


FIG. 41.—Freezing microtome.

X. PROGNOSIS OF TUMORS.

A RELIABLE prognosis presupposes a correct diagnosis. To predict correctly the probable termination of a tumor requires an accurate knowledge of its life-history and of its relations to its neighborhood and to the entire organism. The prognosis must therefore rest largely upon a careful study of the clinical history of the tumor, its anatomical location, its influence upon the adjacent tissues, and the general condition of the patient. It is when we are called upon to foretell the future behavior of a tumor that we realize most keenly the necessity of making a searching examination of the patient as well as of the tumor. From a prognostic standpoint it is absolutely necessary to divide all tumors into the two great clinical divisions (1) benign and (2) malignant. If we are able in the diagnosis to exclude inflammatory swellings, the next duty that presents itself is to differentiate between benign and malignant tumors. This task is easy in some cases, difficult or impossible in others. A carcinoma that has advanced to the stage of ulceration with regional glandular infection is recognized at sight; a rapidly-growing tumor in bone or in periosteum in localities predisposed to sarcoma is readily identified as such. Under other less obvious circumstances the question as to whether the tumor is benign or is malignant is not so easily decided. Carcinoma of some of the internal organs is often diagnosed only in the post-mortem room. Carcinoma and sarcoma of accessible organs are frequently recognized as such only after their clinical behavior has given unmistakable evidence of their malignant character. It is evident that the surgeon who regards his own reputation and the welfare of his patient must be cautious in rendering his verdict as to the probable course the tumor will pursue in the future and the ultimate fate of his patient. The prognosis should be postponed until repeated examinations—and, if necessary, the microscopic examination of tissue from the tumor—have furnished conclusive evidence of the nature of the tumor. It is most humiliating to a surgeon to make a diagnosis of malignant disease, and to render a prognosis in accordance with his views of the nature of the tumor, and to find later, by its clinical course, that it was either a benign tumor or an inflammatory swelling. It is a disregard of a duty imposed upon a surgeon to pronounce a malignant tumor non-malignant.

nant upon a superficial, hasty examination, as the loss of time may weigh heavily in the balance of failure of a too-long-postponed radical operation. *It must be apparent to the student that an intelligent, reliable prognosis must necessarily rest on a correct diagnosis, and that a prognosis should consequently be withheld from the patient and his friends until the nature of the tumor has been ascertained by conclusive evidence.*

A correct diagnosis having been made, the next question that presents itself to the conscientious surgeon is, To what extent should the knowledge gained as to the nature of the tumor be communicated to the patient and his friends? The prognosis in cases of benign tumors should be freely and candidly expressed to the patient, including the possible risks of an operation and its probable result. A different course should be pursued if the tumor is malignant. Under ordinary circumstances the writer regards it in the light of a cruelty to inform a patient directly that he is suffering from a malignant tumor. The public appreciates our shortcomings in the treatment of malignant tumors, and with few exceptions an intelligent patient regards such a diagnosis as his death-sentence. The mental depression following such a declaration not only destroys all happiness on the part of the patient, but has a disastrous effect on the disease, and is an important factor in detracting from the immediate and remote results of an operation. The surgeon is often placed in a very unenviable position when importuned by the patient in reference to the nature of the growth. The question, "Have I a cancer?" is often squarely put to him, and the reply will either inspire hope or cause a despondency from which the patient will never recover completely. It has been an invariable rule with the writer to inform the relatives as to the true nature of the tumor, and to discuss with them the propriety of an operation as well as its probable immediate and remote results. The patient is informed that he is suffering from a tumor, and this statement will prove satisfactory in the majority of cases. If asked as to the possibility of a recurrence, the facts are placed as gently as possible before the patient. If "ignorance is bliss," this adage has a special significance in the case of a patient suffering from a malignant tumor. If the patient is not aware that he is suffering from what is regarded almost universally as a fatal malady, an operation inspires hope, and, in place of the despondency often bordering on desperation that attends a knowledge of the true nature of the tumor, the patient looks forward to a complete and permanent recovery. *The surgeon should communicate to the patient's nearest relatives or friends the true nature of the tumor and the probable results of an operation, but such information should be withheld from the patient himself under ordinary*

circumstances. There are exceptions to every rule, and circumstances may arise which make it imperative on the part of the surgeon to tell the patient the whole truth.

From an anatomical standpoint every tumor is benign in proportion to its degree of isolation from the adjacent tissues and from the organism. Benign tumors, as a rule, are encapsulated; consequently they remain permanently as local affections having no connection whatever with the organism. The encapsulation of some forms of sarcoma is more apparent than real, as the capsule does not afford protection to the surrounding tissues against invasion by tumor-cells; yet when a capsule is present it imparts to the tumor a certain degree of benignancy which is not observed in malignant tumors entirely devoid of a capsule, as is the case in carcinoma and in the most malignant varieties of sarcoma. For reasons that have been explained, the soft, vascular tumors belonging to the malignant type of tumors manifest the greatest degree of malignancy. In tumors of this kind the stroma, which always acts more or less as a barrier to local and general dissemination, is always scanty and sometimes is nearly wanting. The cells remain in their embryonic state, possess ameboid movements, and are reproduced with great rapidity. Such tumors resemble inflammation very closely, and the surgeon is familiar with the well-known clinical

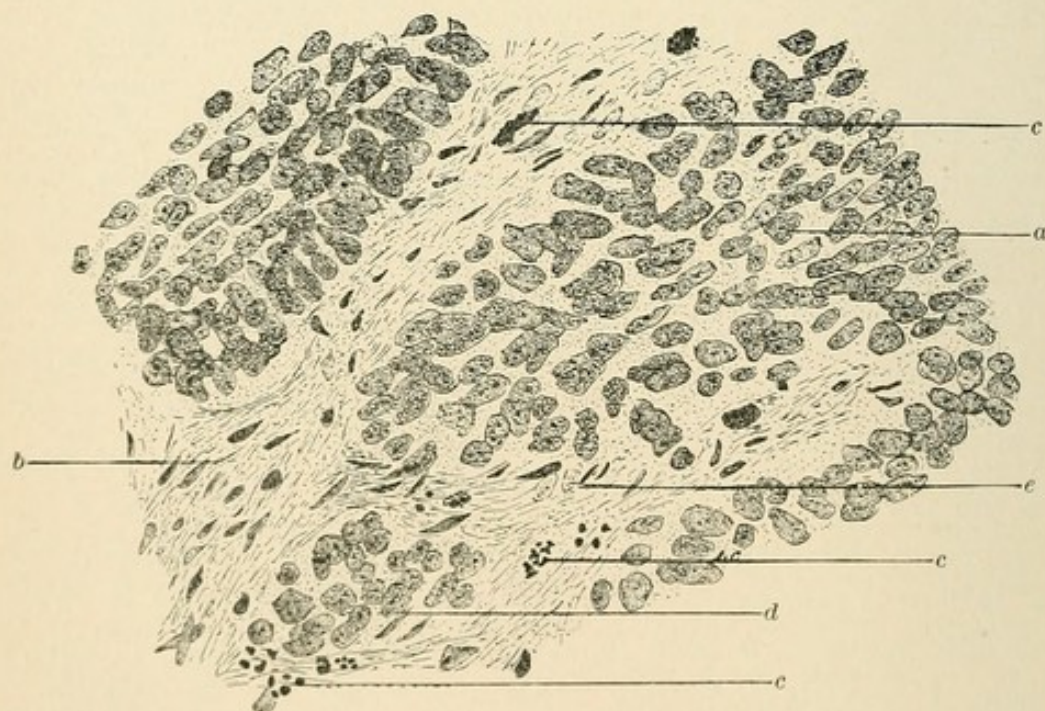

FIG. 42.—Carcinoma of mammary gland, showing numerous leucocytes between tumor-cells and along the course of blood-vessels (Surgical Clinic, Rush Medical College): *a*, carcinoma-cells; *b*, stroma; *c*, brownish granules of blood-pigment; *d*, area of new proliferation; *e*, leucocytes.

fact that *the nearer the anatomical and clinical aspects of a tumor correspond with inflammation, the greater its malignancy.* In rapidly-

growing malignant tumors we find between the tumor-cells and in the course of blood-vessels a picture closely resembling inflammation (Fig. 42).

The immigration of blood-corpuscles into the parenchyma of a tumor is caused by the imperfect development of the wall of the new blood-vessels and by the favorable local conditions in the interior of the blood-vessel for mural implantation. The imperfect wall of the blood-vessels in the tissues of malignant tumors corresponds to the damaged capillary walls in inflamed tissue, and permits the escape of numerous leucocytes, and in some cases of red corpuscles. Rhexis is of frequent occurrence in rapidly-growing carcinoma and sarcoma. The new cells in soft vascular malignant tumors possess ameboid movements in the highest degree, and encounter few obstacles on their way from the tumor into the surrounding tissues with greatly impaired physiological resistance. Cells originating under such circumstances are very liable to lose their connection with the mother-soil and to wander away into the surrounding tissues or to enter the lymphatic vessels or the blood-vessels, thus giving rise to early regional and general dissemination. *The intrinsic danger of a tumor consists in its capacity to implicate the adjacent tissues and the organism—that is, in its giving rise to regional and general infection. This capacity is possessed to the highest degree by the soft vascular carcinomata and sarcomata—tumors that are in contact with the surrounding tissues from the beginning, without any attempt at the formation of a barrier between abnormal and normal tissue.*

In carcinomatous tumors location plays an important part in determining the degree of malignancy of a tumor. For years it has been believed and taught by authors and teachers that for some unknown reason epithelioma was a less malignant affection than glandular carcinoma, the so-called "scirrhus." For a long time epithelioma was described as a tumor separate from carcinoma proper. It was also asserted that epithelioma remained as a purely local affection—that it did not give rise to regional and general dissemination. A more extended and accurate clinical observation of this form of carcinoma has convinced pathologists and surgeons that an epithelioma eventually becomes diffuse by regional and general dissemination, and destroys life in the same manner as a deep-seated carcinoma. The writer has for years claimed that the greater benignancy of a surface carcinoma as compared with a deep-seated carcinoma depends entirely upon its location. In epithelioma of the lip, as well as in the case of any other carcinoma of a free surface, the tumor can grow only in *one direction*, while a similar tumor located in an organ surrounded by tissues on all sides grows from the very beginning in *all directions*. The field for local

infection of a surface carcinoma is therefore limited as compared with that of a glandular carcinoma. *The increased area of tissue in contact with a glandular carcinoma as compared with that of a surface carcinoma will readily account for the more constant and earlier occurrence of regional infection.* Another important element determining earlier and more constant regional infection in glandular carcinoma is *pressure* caused by the tissues encroached upon by the tumor. In surface carcinoma this element in the diffusion of the tumor is absent, and consequently migration of carcinoma-cells into the surrounding tissues is retarded.

The location of a tumor is also an important factor in estimating the danger to life in the case of all benign growths. An osteoma on the external surface of the skull always remains as a harmless affection, while a similar tumor on the side of the cranial cavity may produce distressing symptoms, and may finally result in death from cerebral compression. A papilloma on the surface of the skin produces no symptoms, while the same kind of tumor in the larynx may destroy life by suffocation. A subserous fibroma of the uterus becomes a source of danger only from its size, while a small submucous tumor is a frequent cause of profuse and even dangerous hemorrhage. In connection with the location, the size of a tumor must also be taken into consideration in estimating its danger to life. Large tumors are prone to undergo various kinds of degenerations which in themselves may become a source of danger. A tumor that has undergone extensive degeneration is also more likely to become infected with pathogenic microbes. Large tumors of the ovary and the uterus by displacing abdominal and pelvic organs may cause fatal complications by pressure. A similar source of danger attends tumors occupying the cranial cavity and the thorax. Large tumors of the thyroid gland and malignant tumors of the lymphatic glands of the neck become dangerous to life from compression of the trachea.

A few words in reference to what may be expected from operative interference in the treatment of tumors: *Complete removal of a benign tumor is never followed by recurrence. The same favorable result will follow a thorough removal of a sarcoma or a carcinoma if the operation is performed before regional infection has taken place. The removal of a carcinoma or a sarcoma after regional dissemination has taken place is followed sooner or later by recurrence in the great majority of cases. Nothing but palliation can be expected from the removal of the primary tumor in all cases in which the disease has become general by metastasis.*

The partial removal of a malignant tumor with extensive regional dissemination is often followed by aggravation of the local conditions and hastens the fatal termination.

XI. TREATMENT OF TUMORS.

THE treatment of a tumor must necessarily vary according to its nature, structure, and location. The removal of malignant tumors is indicated if this can be done before the disease has passed beyond the reach of a radical operation. The operation in such instances meets an *indicatio vitalis*, because the intrinsic tendency of a malignant tumor is to destroy life. The removal of a benign tumor for a similar indication is called for only if the tumor occupies a locality where by its presence it produces mechanical conditions incompatible with the function of an important organ. In other cases benign tumors are removed for the purpose of correcting functional disturbances, for cosmetic reasons, and with a view of protecting the patient against the risks of a possible transition into a malignant tumor. The treatment of tumors divides itself into (1) medical, (2) surgical, and (3) palliative.

It is superfluous in this connection to make the assertion that a rational treatment must be based on a correct diagnosis. It is the recognition of the nature, location, and clinical tendencies of tumors that distinguishes the honest and competent surgeon from the charlatan. The cancer-quack calls every swelling a tumor, and his influence among the people is not due to the success he scores in the treatment of carcinoma, but is gained by subjecting benign tumors, retention-cysts, and inflammatory swellings to a similar barbarous treatment, and claiming the results thus obtained as so many victories over cancer. We have reason to believe that many of the alleged permanent results following operations for malignant disease were cases of mistaken diagnosis. Many a gumma and tuberculous ulcer has been removed by honest, able surgeons under the belief that they were operating for carcinoma. Gummata of bone have frequently been mistaken for sarcoma. The number of permanent results claimed for radical operations for malignant disease would be greatly decreased if we could eliminate all cases of mistaken diagnosis. Professor von Esmarch years ago called attention to the frequency with which tubercular ulcers and gumma are mistaken for carcinoma.

MEDICAL TREATMENT.

Since we have learned to distinguish between true tumors and infective swellings the indications for medical treatment have almost disap-

peared. *No kind of internal medication has any influence whatever in limiting tumor-growth, much less in causing the disappearance of a tumor.* It is interesting for the student to know what has been done in the past in the way of internal administration of medicines in the treatment of tumors. Mercury was recommended by Boerhaave, and the effects of its different preparations were praised by Gama, Akenside, Mariot, Gooch, Gmelin, Buchner, Tauchnow, and many others. Rust and his pupils had great faith in the use of Zittmann's decoction. Arsenic was introduced in 1775 by Lefebure in the form of arsenious acid. Fowler's solution found many admirers, among them Desault, Klein, Rust, Wenzel, Hill, Walshe, Thomson, and more recently Washington Atlee. The last-quoted authority had great faith in the internal use of arsenic after operations for carcinoma, as he believed the drug had a positive influence in retarding, if not preventing, a recurrence. He invariably administered this drug after an operation for cancer, and gradually increased the dose until it produced slight intoxication, when the use of the drug was not suspended, but the dose was diminished. He insisted that if patients could not take a drop of Fowler's solution they should be given a fraction of a drop; that is, that the use of the drug should be continued under all circumstances and for a long time. Preparations of gold were used by Duportail and Duparcque; the salts of copper, by Gauret, Gêrbier, Solier, and De la Romillais; chloride of barium, by Crawford and Mittag. Mineral waters, especially those containing preparations of iodine, enjoyed a good reputation for a long time, and were recommended in the highest terms by such men as Wagner, Travers, Walshe, Flinsch, Klaproth, Ullmann, Littré, Friese, Copland, and Demme. Preparations of iron were regarded with favor by Carmichael and Daniel Brainard. Animal charcoal was recommended by Weise in 1829. The highest praise was conferred upon conium maculatum in its day in the treatment of carcinoma. It was used first for this purpose in 1761 by Störk; after him it was recommended in terms of the highest praise by Récamier, Neuber, Günther, Camper, Baudelocque, Trousseau, and Solon, and it is extensively prescribed even at the present day by N. S. Davis of Chicago, De Haen, Andrée, Fothergill, and Alibert. Almost all the narcotics have had their advocates in the treatment of carcinoma. The fame of condurango was of short duration. Introduced by Bliss of Washington, it soon reached great popularity among both laymen and the members of the medical profession. Men like Andrews of Chicago and Eichhorst of Zurich extolled its merits. Like all other famous cancer remedies, it soon fell into well-deserved "innocuous desuetude." Some of the surgeons of fifty and a hundred years ago resorted to rigid antiphlogistic treatment.

Valsalva, Broussais, Brechet, Poteau, Dzondi, and Lisfranc claimed that they could eliminate the cancerous material by copious and frequently-repeated venesection. Local abstraction of blood was recommended by Velpeau. More recently, surgeons aimed to remove the virus of cancer by derivatives. After operative removal of the growth setons were inserted at different parts of the body. Other surgeons used the moxa and blisters to meet the same indication.

As a matter of historical interest, it should be known that Auzias Turenne suggested syphilization to counteract the carcinoma virus. We can readily understand why the different mercurial preparations commanded the attention and received the approbation of the most influential members of the profession for the longest time. Gummata diagnosed as carcinoma disappeared under this treatment, and the results thus obtained gave the remedy its great reputation. We have no authenticated proof that mercury or any of its preparations has ever been instrumental in retarding the growth of a tumor. The same can be said of all other internal remedies. The internal administration of medicines at the present time receives consideration only in the treatment of some of the complications that may arise and in improving the general health of the patient.

RADICAL OPERATION.

The complete removal of a benign tumor furnishes the best illustration of what is meant by a radical operation. A radical operation for the removal of a tumor has for its object the complete removal of tumor-tissue. If this object is attained, the tumor, whether benign or malignant, will not return. The removal of a benign tumor generally constitutes a radical operation, owing to the structure of the tumor and to its complete isolation from the adjacent tissues by a limiting capsule. Incomplete removal of a benign tumor is followed by recurrence, in which event the operation does not deserve to be called radical, because it failed to accomplish what is understood by the term *radical*. A radical operation undertaken for the removal of a carcinoma is radical in the estimation of the surgeon who in dealing with the tumor has made every effort to comply with the meaning of the word; but in the majority of cases he has been deceived, as is subsequently shown by a local recurrence. The term radical means more and more to the surgeon as he becomes more familiar with the pathways and the extent of local and regional infection of malignant tumors.

Radical operations include—1. Ligation of the principal blood-vessels nourishing the tumor; 2. Galvano-puncture; 3. Parenchymatous injections; 4. Injection of erysipelas toxines; 5. Cauterization;

6. Ligation; 7. Galvano-caustic wire; 8. Écrasement linéaire; 9. Avulsion; 10. Extirpation. Most of the modern surgeons resort almost exclusively to the use of the knife in undertaking the radical operation in the removal of tumors both benign and malignant. The bloodless procedures are seldom resorted to, but they deserve a brief description, as cases not adapted to extirpation may present themselves, or patients may positively object to the use of the knife, and under such circumstances it is wisdom on the part of the surgeon to yield to their request rather than to give them an opportunity to seek the services of charlatans as devoid of a moral sense of responsibility as of a knowledge of the science and art of surgery.

Ligation of the Principal Blood-vessels Nourishing the Tumor.

—It has been stated in the section on the Etiology of Tumors that a tumor can grow only if it receives an adequate quantitative and qualitative blood-supply. Sudden or progressive anemia of a tumor determines degeneration of the tumor-tissue. Surgeons have made a practical application of this knowledge, and have resorted to measures calculated to deprive the tumor of the necessary blood-supply by ligating the principal arteries nourishing the tumor. This method of treatment was first introduced in 1651 by Harvey. It has been most frequently resorted to in the treatment of tumors of the thyroid gland.

Wölfler has recently revived and improved the operation. It has been shown that ligation of the superior and inferior thyroid arteries on both sides has a curative effect in the treatment of non-malignant tumors of the thyroid gland.

In inoperable cases of malignant tumors of the pharynx and the upper part of the neck the primitive carotid artery has been tied repeatedly without even temporary benefit.

Ligation of the uterine arteries has recently been proposed as a conservative operation in the treatment of bleeding fibroids of the uterus. The results so far obtained are not conclusive as to the merits of the operation. It is possible that in the future benign tumors of other organs will be treated successfully upon the same principles. Ligation of the principal arteries nourishing a tumor is occasionally resorted to advantageously as an operation preliminary to a subsequent extirpation.

Galvano-puncture.—Electricity was used in the treatment of tumors by De Haen. Galvanism came next in use. In a case of a large sarcoma of the neck in which Lücke resorted to galvanism the tumors appeared to become smaller and more movable under its use, but careful observation showed that the reduction in size and the temporary

improvement followed the subsidence of an accompanying inflammation, and that the treatment had no effect whatever on the tumor. This has been the uniform experience of surgeons in the external application of electricity in the treatment of tumors. Electro-puncture and galvano-puncture have found special application in the treatment of cystic tumors. At the International Medical Congress held in Philadelphia in 1876, Semeleder of Mexico read a paper on this subject, from which it appeared that electricity was destined to supplement the knife in the treatment of ovarian cysts. Apostoli made similar claims for this agent in the treatment of myofibroma of the uterus at the International Congress held in the city of Washington. It is now generally conceded that electro-puncture and galvano-puncture occasionally bring about improvement, but the results have not been such as to entitle this therapeutic resource to be included among the radical measures in the treatment of tumors. The application of the electrolytic action of the galvanic current was first made use of by Nélaton. As the electrolytic action is attended by gas-formation, Billroth did not resort to electrolysis in the treatment of vascular tumors, as he feared that the gas evolved might enter the blood-vessels and produce dangerous if not fatal gas-embolism. Electrolysis has a limited sphere of application in the treatment of superficial nævi.

Parenchymatous Injections.—Injections of solutions of perchloride of iron have had an extensive application in the treatment of vascular tumors. The use of coagulating substances as injections into a vascular tumor is attended by great risks, and should entirely be abandoned. Fatal embolism has attended this procedure by the separation of a fragment of the blood-clot, with the result of causing sudden death. In other instances the injection was followed by suppuration, thrombo-phlebitis, and pyemia. Thiersch injected into carcinomatous growths a solution of nitrate of silver, with the object of bringing about speedy degenerative changes. This treatment proved a complete failure. Broadbent used for the same purpose dilute acetic acid, with similar negative results. Carbolic acid and other antiseptic substances have been used in the treatment of malignant tumors, but none of them have answered the expectations of those surgeons who regard with favor the microbic origin of malignant tumors. The use of aniline dyes, introduced by Mosetig von Moorhof, has had an extended trial, but so far no positive results have been realized. The employment of parenchymatous injections in the treatment of inoperable tumors should be encouraged, as it is within the range of possibility that there may be found a substance which, when brought in contact with the tumor-tissue, may prove beneficial either by its destructive

effects on the new cells or by effecting a change in the type of tissue-proliferation.

Injection of Erysipelas Toxines.—It has been known for a long time that an intercurrent attack of erysipelas frequently retarded the growth of a sarcoma, and in exceptional cases resulted in a permanent cure. Billroth and others have reported such cases. Since the discovery of the microbe of erysipelas by Fehleisen patients suffering from inoperable malignant tumors have been inoculated with pure cultures of the streptococcus of erysipelas. Some of the cases subjected to this treatment improved, others received no benefit, and in some the symptoms were aggravated and the treatment hastened the fatal termination. Coley and Bull have recently made use of sterilized cultures of the erysipelas microbe, and have obtained equally good, if not better, results than were obtained with the active cultures. This treatment is certainly preferable to the employment of active cultures, as it is not attended by the risks incident to an attack of erysipelas. These authors have found that the employment of the sterilized cultures was followed by better results in the treatment of sarcoma than in that of carcinoma. It has also been ascertained that the culture made of the streptococcus of erysipelas and the bacillus prodigiosus is more effective than the culture of the streptococcus alone. As in the case of Koch's lymph, the injections are followed by a rise in the temperature. The diluted sterilized culture as sold in the shops is used in doses of from 5 to 30 minims. The treatment should be commenced by injecting 5 minims every alternate day, increasing the dose gradually. Koch's syringe (Fig. 43) should be employed for this purpose. The writer has given this treatment a fair trial in twelve cases, but so far no permanent beneficial results have been obtained.

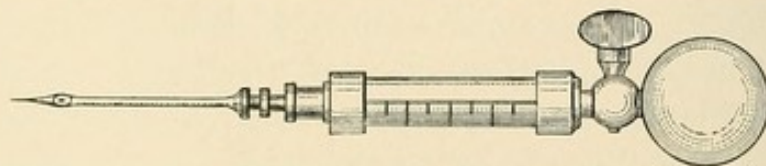


FIG. 43.—Koch syringe.

The author has given this treatment an extensive trial, with invariably negative results; and Drs. L. A. Stimson, A. G. Gerster, and B. F. Curtis, at a recent meeting of the New York Surgical Society, submitted the following report upon the use of erysipelas toxins in the treatment of malignant disease: "We believe that in the instances of apparent cure or marked improvement the correctness of the diagnosis is open to doubt. We therefore submit: 1. That the danger to the patient from this treatment is great. 2. Moreover, that the alleged successes are so few and doubtful in character that the most that can

be fairly alleged for the treatment by toxins is that it may offer a very slight chance of amelioration. 3. That valuable time has often been lost in operable cases by postponing operation for the sake of giving the method of treatment a trial. 4. Finally, and most important, that if the method is to be resorted to at all, it should be confined to the absolutely inoperable cases."

Cauterization.—The destruction of tumors by caustics and by the actual cautery is one of the most ancient resources of the surgeon in the bloodless removal of tumors. The actual cautery was preferred by the surgeons of ancient times, because it not only destroyed the tumor quickly, but at the same time also acted as a hemostatic. The use of the actual cautery has had an extended application also as a supplement to the knife in effecting the destruction of remnants of tumor-tissue and in arresting hemorrhage. The actual cautery is occasionally used now in the removal of small surface carcinomata in patients who show an unconquerable objection to the use of the knife, and in the palliative treatment of inoperable ulcerating malignant tumors. The instrument employed almost universally for this purpose is Pacquelin's cautery (Fig. 44). The bulb- or knife-point is used most frequently in the treatment of malignant tumors, while the needle-point is used almost exclusively in the treatment of angiomatous tumors. The employment of the potential cautery—chemical caustics in different forms—has found a more varied and extended application than that of the actual cautery. It is to be regretted that this method of treatment has fallen almost entirely into the hands of charlatans. The ignoramus fears blood; the public always has had, and always will have, faith in bloodless procedures; hence the great popularity which chemical caustics have enjoyed in the treatment of tumors. The war between caustics and the knife has been a long and bitter one, and it is by no means ended. The cause of caustics is defended by a great army of ignorant, irresponsible, money-loving quacks, supported and cheered by an admiring misled public. On the side of the knife stands the honest surgeon who holds out only guarded promises, confronted by patients suspicious of his skill

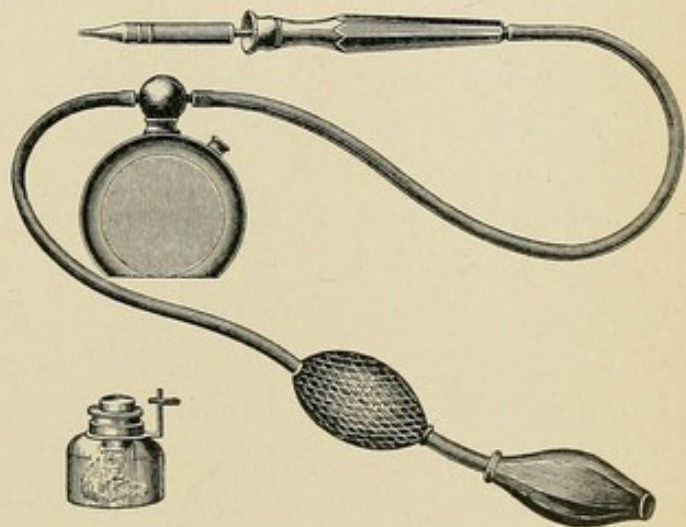


FIG. 44.—Pacquelin cautery.

and in great dread of a bloody operation. The ultimate victory of the knife must rest on earlier and more thorough operations. The quack has been educating the people to the effect that the caustic he uses destroys only cancer-tissue, and he takes special pains to point out to his patient that the remedy has not only succeeded in removing the cancer, but has also followed its roots. The patient, with the specimen carefully preserved in alcohol, returns to his home happy and hopeful, and exhibits the specimen cancer, roots and all, with satisfaction and a certain feeling of pride as a signal triumph of quackery over regular medicine. In the face of such a state of things it is no wonder that the surgeon who has regard for his own reputation is slow in substituting caustics for the knife. Chemical caustics have had an extensive trial at the hands of the regular profession. Their merits and disadvantages have been studied by competent and honest surgeons. They occupy at the present time a limited and special field in the treatment of tumors.

The value of different caustics depends on the manner of their action: the more potent its action, the less the liability to hemorrhage; the less the pain it inflicts, the more useful it is. The treatment of small benign tumors by the application of caustics often results in a permanent cure. In the treatment of carcinoma this is seldom the case. The difficulty encountered in this method of treatment is that one application is seldom sufficient to destroy all the tumor-tissue, and that repeated applications cause so much suffering and distress that few patients will endure them long enough to effect a radical cure. Some of the caustics which have been used may become absorbed in amount sufficient to produce poisoning, and on this account should never be used: this is the case with arsenical preparations. When fluid caustics are employed the surrounding tissues should be protected carefully against their action. If the caustic is to be repeated, the second application is postponed until the eschar has separated. Pain is to be subdued by the application of cold and by hypodermic injections of morphine. In the selection of the caustic we must be guided by the depth to which it is desirable to penetrate, as well as by the location to which liquid caustics are adapted.

Caustic Potash.—Caustic potash is a very energetic caustic. The rapid liquefaction which it undergoes when applied to the tissues detracts somewhat from its advantages, and it must be watched carefully and the tissues beyond its desired range of action must be protected thoroughly. It cannot be employed safely in the treatment of tumors located in cavities. Its hemostatic action is not reliable. This substance is often mixed with caustic lime, the mixture constituting

the famous Vienna paste, which is not much inferior to the caustic potash as a caustic.

Chloride of Zinc.—This article, in the form of a paste known as Canquoin's paste, has been used quite extensively as a caustic. To increase its action in paste form it is necessary that it should receive a certain amount of moisture, and it must therefore be applied under the skin. If the skin over the tumor is intact, it should be made permeable to the caustic by macerating it for some time with a dilute solution of caustic potash or by making multiple superficial incisions. It is a reliable hemostatic, which fact is an additional recommendation for its employment in the removal of vascular tumors. The eschar it produces is very dry and corresponds in size to the cubic volume of the mass of paste inserted. In a few days the eschar can readily be removed with the knife, when the cauterization is repeated. The caustic arrows of Maisonneuve are composed of a paste of flour and chloride of zinc in the proportion of 3:1. Landolfi, a famous Italian cancer-doctor, used a mixture of chloride of zinc, chloride of gold, and chloride of bromium.

Arsenic.—The arsenical preparations, especially the paste of Frère Côme, were popular for a long time, and proved useful in the removal of small epiblastic carcinomata about the face and the lip. Arsenic is an energetic caustic, but its action is slow. Intoxication from the absorption of arsenic has repeatedly been observed. For some time arsenic was regarded as a specific in the treatment of carcinoma, but this delusion no longer prevails, as it has been found that its beneficial action when applied as a caustic depends entirely upon the depth to which tissue is destroyed, as is the case with all other caustics.

Chromic Acid.—This acid inflicts less pain than any other liquid caustic, and has proved successful as a superficial caustic. It is used in the form of crystals or as a concentrated solution.

Nitric Acid.—Of all the acids, nitric acid has been used most frequently as a caustic in the treatment of tumors. The eschar is of a yellowish color, and the resulting scar is small. Nitric acid is also a good hemostatic.

Instead of resorting to cauterization from without, French surgeons devised a method by which caustics are inserted into the tissues of the tumor through punctures from different points, which method they termed "linear cauterization." The first attempts in this direction were made in 1700 by Deshaies Gendrou. His method consisted in introducing pieces of caustic paste under the base of the tumor, with the expectation that the deep cauterization from different points would eventually separate the tumor from the tissues, when it would be cast

off as a whole with the eschar. Under the name of "cautérisation en flèches" Maisonneuve in 1857 developed this procedure. He in-

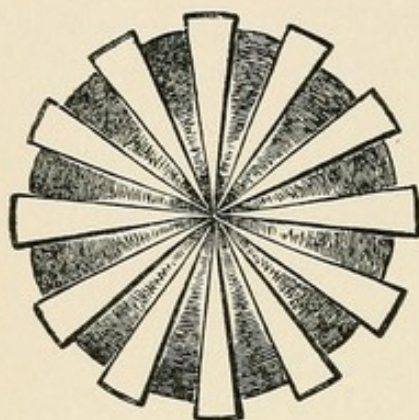


FIG. 45.—Cautérisation en rayons (after Maisonneuve).

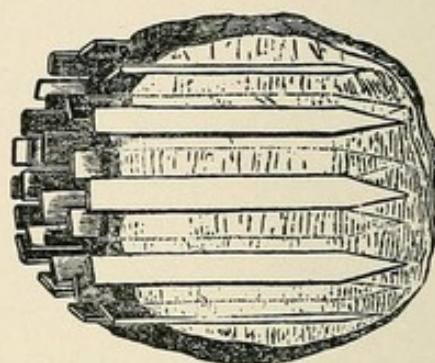


FIG. 46.—Cautérisation en faisceaux (after Maisonneuve).

sented arrow-shaped pieces of chloride-of-zinc paste into the substance of the tumor after puncturing it at different points with a bistoury. He described three methods of procedure: First, the arrows are introduced on the same level in such a way that their points meet in the centre of the tumor (Fig. 45); second, the arrows are inserted from the surface like posts driven in the ground (Fig. 46); third, an arrow was inserted into the centre of the tumor, so that cauterization should proceed from the centre toward the periphery—"cautérisation centrale" (Fig. 47).

In the removal of tumors of small size surface cauterization must be resorted to. If the tumor is large, Maisonneuve's procedures are preferable. They are, however, not devoid of danger. It has happened in the practice of Maisonneuve that the caustic destroyed the

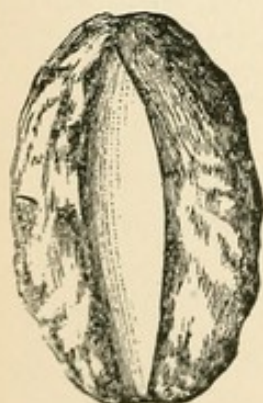

FIG. 47.—Cautérisation centrale (after Maisonneuve).

walls of large blood-vessels, and upon the separation of the eschar troublesome and even fatal hemorrhage occurred. The writer recollects a case of carcinoma in the parotid region that was treated by a charlatan by caustics. Before the patient left the institution profuse hemorrhage occurred after separation of the last eschar. The patient was informed that the cure was completed, and was advised to return to his home. Soon after he left the institution there occurred another hemorrhage, which nearly proved fatal. Greatly debilitated and almost exsanguinated, he was brought to the Presbyterian Hospital, Chicago. The

dressings were saturated with blood. An anesthetic was administered, the dressings were removed, the neck was disinfected, and the common carotid artery was tied. Upon examination of the large surface partly

covered by granulations and partly by fungous carcinoma-tissue, a large opening in the external carotid artery was found near the bifurcation of the common carotid. The surface was disinfected and the opening in the vessel was tamponed with iodoform gauze. The hemorrhage did not return, and the patient left the hospital in the course of a week.

Immediate and complete removal of a tumor is accomplished by the employment of the ligature, the *écraseur*, the galvano-caustic wire, and the knife. The complete removal of a tumor is effected in the safest manner and most expeditiously by the use of the knife, but, as all the procedures enumerated above are still endorsed by eminent surgeons, and as all of them are occasionally resorted to, they merit a brief description.

Ligature.—The ligature is an ancient surgical resource in the treat-

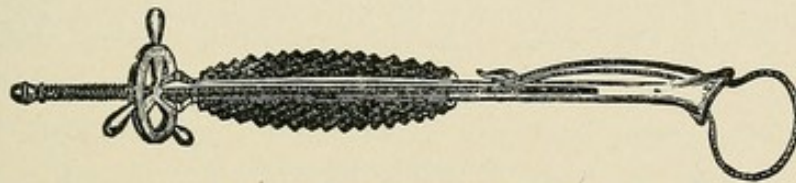


FIG. 48.—Maisonneuve's constrictor.

ment of tumors. Ambrosius Paré and De Saliceto removed with it polypoid growths from the nasal cavities and from the cervix of the uterus. Mayor described this procedure, under the name of *ligature en masse*, as a new discovery, improved the technique, and extended its use to different parts of the body. The ligature was used in two ways: 1. It was tied so firmly that it strangulated all blood-vessels, producing rapid necrosis of the tumor; 2. It was tightened from time to time, in order to cut its way more slowly through the tissues. The single ligature was used in tying off pedunculated growths. Its use was extended to the removal of tumors with a wide base, with the introduction of the double and multiple ligatures. The ligatures were either tied on the surface of the skin or inserted with needles around and under the base of the tumor. Whenever possible a pedicle was made artificially by making traction upon the tumor before inserting and tying the ligatures, or by dissecting off the skin around the base of the tumor. The percutaneous ligature has been employed

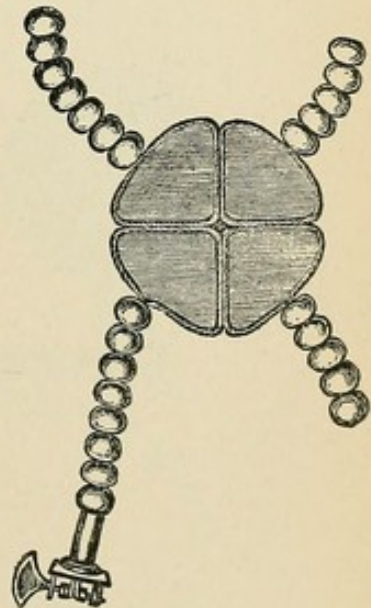


FIG. 49.—Koderik's rosary instrument.

extensively in the treatment of angioma. Recently absorbable ligatures of catgut and kangaroo tendon have been substituted for the silk and metallic ligatures in the subcutaneous ligation of vascular growths. Various instruments have been devised for the progressive constriction of the base of the tumor by the ligature. Maisonneuve's (Fig. 48) is constructed upon the same plan as Chassaignac's *écraseur*. In Koderik's instrument (Fig. 49) the ligature is tightened at intervals over a row of perforated shot. Manec contributed largely toward the perfection of the technique of the subcutaneous ligature. He devised a needle for this special purpose, the manner of use of which is well shown in Figure 50. Fergusson's method (Fig. 51) is simpler and does not require a needle of special construction. The great objections to the use of the ligature are the pain it causes and the liability to infection that attends its use. The ligature is used at the present time only in exceptional cases of angioma. The aseptic ligature should be used, attended by all necessary antiseptic precautions.

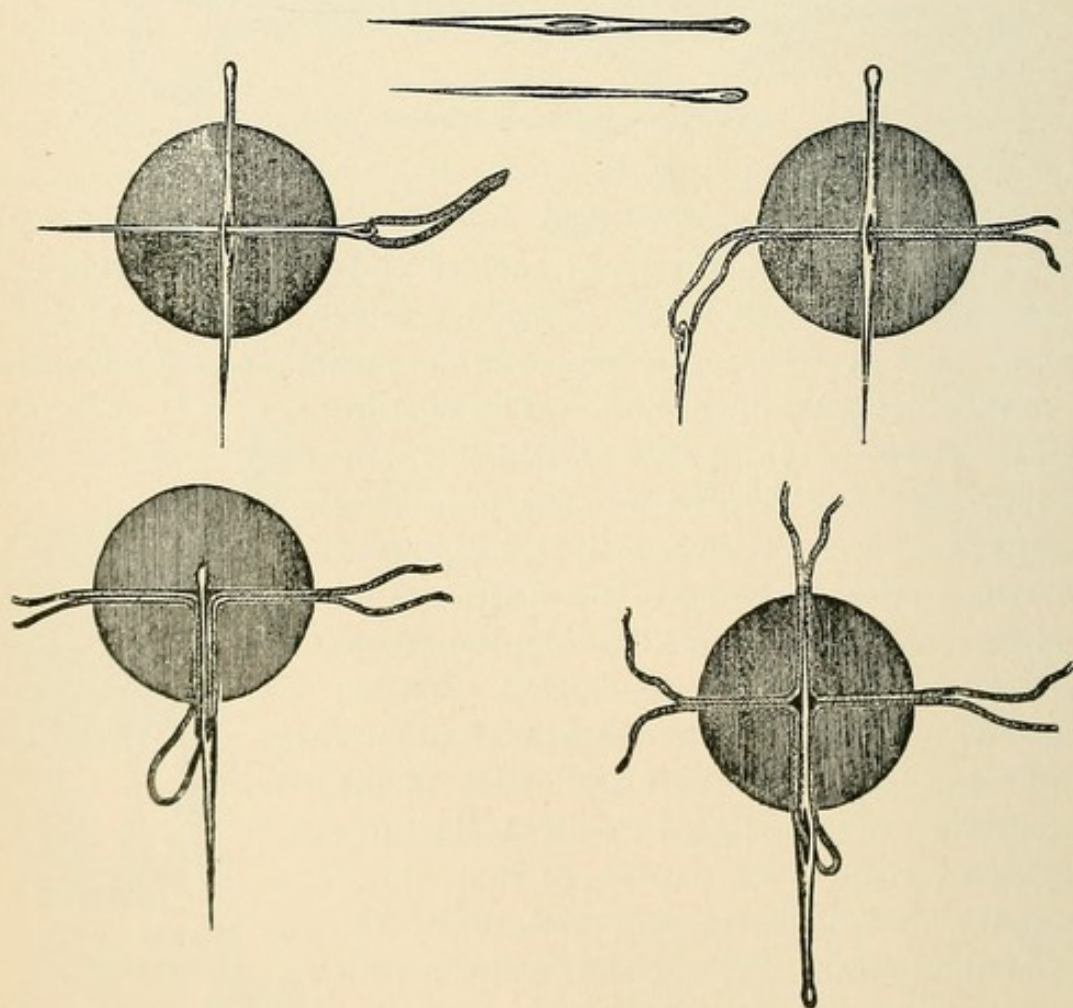


FIG. 50.—Manec's method of percutaneous ligation of a tumor (after Manec).

Galvano-caustic Wire.—Recognizing the disadvantages of the silk and metallic ligatures in the removal of tumors, Middeldorpf in 1852

substituted for ligation the galvano-caustic wire. Like the ligature, it has been used in severing the tumor from the body by cutting its way

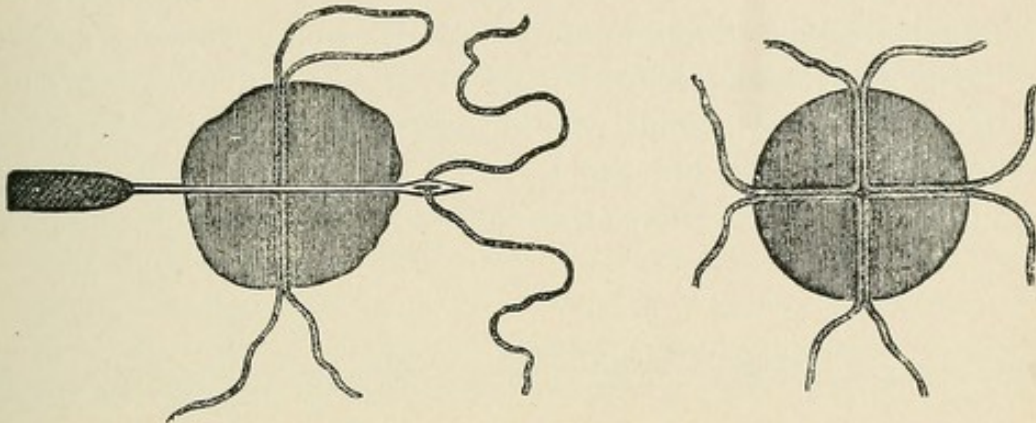


FIG. 51.—Fergusson's percutaneous ligature (after Fergusson).

from the surface and by destroying the tumor-tissue subcutaneously. The latter method of application has proved very useful in the treatment of subcutaneous angioma, as the overlying skin is protected against cauterization by insulating the platinum wire at the points of entrance and exit. The galvano-caustic wire has been a great improvement over the ligature, as it completes its work almost as quickly as the knife and leaves a wound much less liable to infection. One great objection to the use of the galvano-cautery is the well-known fact that the apparatus is very liable to get out of order, often necessitating a resort to other measures. With few exceptions it has been superseded by the needle-point of the Pacquelin cautery.

Écrasement Lineaire.—The removal of tumors by linear crushing was devised by Chassaignac. The parts included in the chain or wire of the *écraseur* are divided slowly and, if no large vessels are present, bloodlessly. Chassaignac was an enthusiast in the use of his *écraseur*

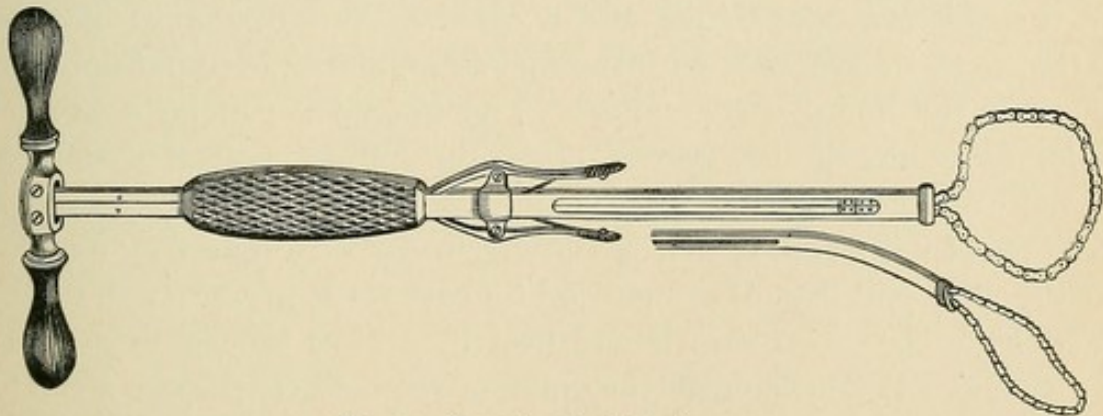


FIG. 52.—Chassaignac's chain *écraseur*.

(Fig. 52). In his practice it almost displaced the knife. According to Chassaignac's own directions, the tissues should be divided very slowly,

for the purpose of guarding more efficiently against hemorrhage. That hemorrhage is not always prevented even by exercising the greatest caution is well known. The writer has seen profuse hemorrhage from both lingual arteries after amputation of the tongue by the *écraseur*. Rhinologists and laryngologists have invented minute *écraseurs* upon which they rely almost exclusively in the removal of polypoid growths from the nasal cavities and the larynx. The general surgeon at the present time seldom resorts to the *écraseur*. Mr. Hutchinson prefers



FIG. 53.—Wire *écraseur*.

it to the knife or the scissors in removing the tongue, but few surgeons could be induced to follow his example.

Avulsion.—The removal of a pedunculated tumor by torsion is accomplished by grasping the pedicle, as close to its attachment as possible, with a pair of strong forceps and twisting it around its axis until the tumor is torn from its bed. This has been a favorite method of removing polypoid growths of the nose and the uterus. If the tumor is soft, the removal is often incomplete, and a return of the growth is the rule; if the pedicle is large and firm, unnecessary damage is often inflicted upon the organ to which the tumor is attached. Avulsion should give way to the galvano-caustic wire, to the *écraseur*, or to enucleation.

Extirpation.—The general surgeon, with few exceptions, removes all tumors by extirpation. This method of eradicating tumors has precision. The knife can be made to include any tissue that may present a suspicious appearance, and it enables the surgeon to examine the tissues as he proceeds with the operation, and thus to outline more accurately the limits of the tumor. The operation can be performed painlessly by placing the patient under the influence of an anesthetic, and the wound can be made to heal by primary intention. The contrast between the speedy and painless removal of a tumor by excision and the slow and painful destruction by caustics is great. The wound left after the use of caustics has to heal by a slow process of granulation, and, as so often happens, incomplete removal transforms a subcutaneous into an open ulcerating cancer, with all the risks and inconveniences incident to such a condition. Incomplete removal by caustics invariably results in aggravation of all the local conditions, as the inflammation which follows cauterization imparts a new stimulus to

tumor-growth. The risks of hemorrhage and infection are much greater after cauterization than after excision. The removal of benign tumors, carcinoma, and sarcoma by extirpation should be made the rule, and the use of caustics be reserved for exceptional cases of carcinoma.

The idea that the results after extirpation of malignant tumors are better if the wound suppurates and heals by granulation is wrong both in theory and in practice. Inflammation is one of the most influential factors in effecting a speedy recurrence if the tumor has not been removed completely. *In extirpation of tumors it should be the aim of the surgeon to secure healing of the wound by primary intention. If the margins of the wound cannot be brought into apposition by suturing, owing to the removal of an extensive area of skin with the tumor, the margins should be approximated as far as possible by tension-sutures, and the remaining surface be covered with a Wolfe skin-graft or with a mosaic of Thiersch skin-grafts. For the purpose of preventing wound-complications, and with the view of securing speedy healing of the wound and of obtaining an ideal functional and cosmetic result, it is absolutely necessary to resort to the strictest antiseptic precautions in the extirpation of a tumor, irrespective of its size or its location.*

The instruments should be sterilized by boiling for at least ten minutes in a 1 per cent. solution of carbonate of soda. Sterile ligatures, sutures, and gauze sponges should be used. The field of operation and the hands of the operator and of his assistants should be disinfected thoroughly by scrubbing with warm water and potash soap for at least five minutes, followed by washing in a 1 : 1000 solution of corrosive sublimate. If the tumor occupies any of the large cavities, the patient must be prepared thoroughly for the operation by preliminary treatment continued for several days. The external incision should be amply large, to facilitate deep dissection. The danger of a wound is no longer estimated by its size. The attempt to remove tumors through small incisions is attended by greater risks of injury to important structures than when the parts we wish to avoid are well exposed by a large incision. The incision should be made in a location and direction which will render the tumor most accessible and which will not implicate important structures. It must be remembered that tumors often displace important vessels and nerves, and on this account special care is necessary to avoid these structures when displaced. In operating upon the extremities the incision should be made parallel with muscles. In extirpating tumors of the neck an incision in the direction of the sterno-cleido-mastoid muscle is usually made. A transverse incision is preferred by some operators in the removal of tumors of the thyroid gland. Submaxillary growths should

be approached through a slightly-curved incision below the border of the lower jaw. In amputations of the breast the incision is prolonged behind the border of the pectoralis major muscle to the apex of the axilla. Tumors of the groin are laid bare by making an incision parallel with and a little below Poupart's ligament, and joining it by a vertical incision over the femoral vessels extended to the apex of Scarpa's space. A slightly-curved incision affords more room than a straight one. If the skin or the mucous membrane over the tumor is implicated, it is included between two elliptical incisions and is removed with the tumor. After a benign tumor has been reached, cutting instruments are laid aside and the tumor is removed by enucleation, using for this purpose the finger, Kocher's director, or blunt-pointed scissors. Extirpation of osteoma and chondroma requires the use of the chisel or the saw. Some cysts have such firm attachments that enucleation is impracticable, in which event their removal is effected by careful dissection. If the extirpation of a tumor requires a preliminary myotomy, the muscle should be united by buried absorbable sutures before the external wound is closed. If a nerve or a tendon is accidentally or intentionally cut, it is united in a similar manner. If an important fascia has been divided, it is separately sutured. As benign growths are aseptic pathological conditions, the external wound can be closed throughout by sutures and sealed. The after-treatment should include rest of the part operated upon, which can be secured by rest in bed, bandages, splints, etc. Operations for carcinoma and sarcoma are attended by great difficulties, as with the tumors the surgeon must include a zone of tissue surrounding them, and must usually extend the operation far into apparently healthy tissue to reach and remove the products of regional infection. Two great difficulties confront the surgeon during the course of the operation. In the absence of any limiting structures he is often in doubt concerning the amount of tissue he should include with the tumor, and, again, to what extent he should invade the vicinity in his attempts to eradicate the disease. No definite rules can be laid down to guide the surgeon in deciding these most important points of the operation. He must take pathological anatomy as his guide. It is well known that sarcoma follows connective tissue, blood-vessels, nerve-sheaths, and muscles. The surgeon must therefore include as much tissue in the direction of these pathways as is permissible with the importance of the structure involved. The amount of tissue to be included must necessarily vary with the character of the tumor, its location, and the importance of the structures in its vicinity. The farther the tumor is away from important vessels and nerves, and the more tissue can be included, the better will be the

results. As a rough estimate the writer would say that the incisions should be made at least an inch away from the periphery of the tumor. Sarcoma of bone usually demands amputation, although recently successful local operations have been made in cases of circumscribed myeloid sarcoma. If amputation is performed, the entire bone should be removed; that is, amputation should be made through or above the proximal joint. *In the removal of a malignant tumor enucleation must never be attempted: the tumor must be excised. Extirpation here means the removal not only of the tumor, but also of all infected tissues in its vicinity or in the same region. The knife or the scissors must be used from the beginning to the end of the operation. The extirpation of a carcinoma, unless the tumor involves a free surface and is recent and localized, must be followed by excision of the lymphatic glands of the same region, whether enlarged or not enlarged. The tumor and the string of lymphatic glands should be removed in one continuous piece by thorough and clean excision. It has been shown that carcinoma frequently selects the connective tissue as pathways for local infection; hence as much of the connective tissue as possible in the vicinity of the tumor should be included in the excision. Muscles are often divided or removed in operations for malignant tumors. Partial removal for malignant disease of organs not essential to life is bad surgery. In operating for malignant disease parts and tissues must be removed regardless of the cosmetic result. The surgeon who operates with a view of securing a good cosmetic result is very liable to perform an incomplete operation. The primary indication in the extirpation of a malignant tumor is to remove all infected tissues; the cosmetic result is of secondary consideration, and can be improved immediately or later by plastic operation. After operation it is advisable to watch the patient carefully, and in case of recurrence to repeat the operation. By following this course there is no doubt that the patient is made more comfortable and life is prolonged, and occasionally a radical cure is effected by repeated operations for local recurrence.*

Contraindications to radical operations for malignant disease are—
1. Metastasis; 2. Extreme old age; 3. Regional infection beyond the reach of complete removal of diseased tissue without imminent danger to life; 4. Very extensive local infection, as in cases of diffuse *cancer en cuirasse*.

PALLIATIVE TREATMENT.

Palliative treatment is indicated in cases of inoperable malignant tumors. It consists in protecting the tumor against irritation, and, in open ulcerating tumors, in partial removal, antiseptic applications, and

the use of anodynes to subdue pain. If the tumor is on the surface, it should be protected against friction by the clothing by a compress of aseptic absorbent cotton held in place by a bandage or by strips of adhesive plaster. As soon as indications of ulceration appear, the surface should be disinfected thoroughly and be protected by an antiseptic dressing, so that when the tumor-tissue is exposed the ulcerated surface will be protected against infection. If the ulcer or fungous mass has become infected, it is necessary to correct the fetor by the employment of strong antiseptic applications. Chlorine-water, solution of permanganate of potash, saturated solution of acetate of aluminum, and solution of chlorinated soda (Labarraque's solution) are most efficient in correcting the putrefactive processes. A 10 per cent. solution of chloride of zinc, carefully applied with a camel's-hair brush to the dried surface of the ulcer, is one of the best disinfectants. The writer has found a solution of hydrate of chloral (2:100) not only a good antiseptic, but also a local anodyne. The stronger antiseptics, creosote, carbolic acid, and corrosive sublimate, must be used with caution, as the prolonged use of even a weak solution might result in intoxication. Vegetable charcoal has been popular for a long time as a deodorizer. Great benefit often follows the removal of fungous granulations with a sharp spoon, followed by an energetic use of the actual cautery. This treatment is frequently resorted to with decided temporary improvement, so far as the local conditions are concerned, in the palliative treatment of inoperable carcinoma of the uterus. Bleeding from the ulcerated surface, commonly of capillary origin, is best controlled by applying a few layers of gauze saturated with liquor. ferri sesquichlorati, over which an antiseptic tampon is applied, and the whole kept in place with the dressing applied to the ulcer by broad strips of adhesive plaster. If a large vessel is the source of hemorrhage, and can be tied neither *in loco* nor at a distance, the antiseptic tampon will have to be relied upon. Very little is to be expected in the way of alleviating pain from local anodynes; of these, cocaine has proved the most useful. A strong solution (10 per cent.) of cocaine applied to ulcerating carcinomata of the cavity of the mouth has done much to relieve pain and dysphagia. Arnott derived great benefit from cold applications. The cold coil or the ice-bag deserves a trial as a local anesthetic. Subcutaneous injections of morphia have to be relied upon to allay pain and to procure sleep. The smallest dose possible should be commenced with; the dose must be increased rapidly as the pain increases in severity and the patient becomes habituated to the use of the drug.

XII. CLASSIFICATION OF TUMORS.

A RATIONAL, systematic classification of tumors is to the surgeon what the analytical key is to the botanist. A uniform system of classification of tumors is one of the great wants of modern pathology, and all attempts in this direction have proved failures. New classifications are being introduced from time to time, but each of them invariably represents the individual author's own views regarding the origin and nature of tumors. A classification which will be intelligible to the student and of practical utility to the surgeon must be based on the histogenesis and the clinical aspects of tumors. As the histologist traces the normal tissue to its embryonic origin, so the pathologist must follow the tumor-cells to the embryonic matrix which produced them, in order to trace tumors to their primary histogenetic origin and to classify them upon a histological basis. The botanist includes in the same class wholesome and poisonous plants from their morphological resemblance, and the pathologist groups together tumors which have a common embryonic origin; but in making a classification he must make a subdivision according to their clinical aspects, which means their relation to the surrounding tissues and the organism. To Virchow belongs the honor of having attempted the first systematic classification of tumors on a histological basis.

VIRCHOW'S CLASSIFICATION.

1. Histioid;
2. Organoid;
3. Granulomata;
4. Teratoid;
5. Combination tumors;
6. Extravasation- and exudation-tumors;
7. Retention-cysts.

Among the histioid tumors he included all tumors composed of one kind of cells.

The class of organoid tumors he made to include all tumors composed of several kinds of tissue-elements with a definite typical arrangement of the component parts.

Among the infective swellings he included carcinoma and sarcoma, calling this group "granulomata." "Teratoma" was the term applied to tumors composed of a system of organs arranged in an imperfect manner, of course, and representing different parts of the body, and sometimes a perfect body, such as dermoid cysts and *fœtus in fœtu*.

"Combination tumors," as the term implies, are tumors composed of different kinds of tumor-tissue representing two or more histioid tumors, such as adeno-chondroma, myofibroma, etc.

The extravasation- and exudation-tumors include swellings containing blood, serum, or inflammatory products.

A pure histioid tumor, according to Klebs, could be found only in a very small epithelioma and a small sarcoma. In large tumors it is represented by angioma.

The term "organoid" as applied to tumors is incorrect and misleading, because even the most perfectly-developed adenoma, as well as all the rest of the tumors, lacks physiological function.

Compound tumors occur in consequence of degenerative changes or of change in the type of tissue-growth in a primary simple tumor.

The granulomata and the extravasation- and exudation-swellings, which should no longer be classified with tumors, will be eliminated from our classification.

Retention-cysts are not tumors, but have so much in common with tumors, and occupy such a conspicuous place in the differential diagnosis, and require so frequently the same treatment as tumors, that they will be treated under a separate head in this book.

COHNHEIM'S CLASSIFICATION.

- | | | |
|----------------------------|---|--|
| 1. Connective-tissue type. | { | Fibroma;
Lipoma;
Myxoma;
Chondroma;
Osteoma;
Angioma;
Lymphangioma;
Lymphoma;
Sarcoma. |
| 2. Epithelial type. | { | Epithelioma;
Onychoma;
Struma;
Cystoma;
Adenoma;
Carcinoma. |

- 3. Myomata. { Myoma lævi-cellulare;
Myoma stri-cellulare.
- 4. Neuromata. { Neuroma;
Glioma (Klebs).
- 5. Teratomata. { (Virchow).

The classification of tumors as prepared by a committee of the College of Physicians and Surgeons of London is very defective, as among tumors it includes swellings the product of other pathological conditions.

WILLIAMS'S CLASSIFICATION.

- | | | | |
|----------------------------|---|---|---|
| 1. Archiblastic neoplasms. | { | 1. Lowly organized: | |
| | | Epithelioma. | { Squamous;
Cylindrical;
Glandular. |
| 2. Parablastic neoplasms. | { | 2. Highly organized: | |
| | | Adenoma;
Cystoma (neoplastic);
Papilloma. | |
| | { | 1. Lowly organized: | |
| | | Sarcoma;
Myxoma. | |
| | { | 2. Highly organized: | |
| | | Fibroma;
Lipoma;
Chondroma;
Osteoma. | |

Williams and Klebs classify tumors into archiblastic and parablastic, in accordance with the division by His of tissue in the embryo. For the sake of simplifying the location of tumors anatomically in the diagnosis, as well as in pointing out the differences of structure and function of the cells of the epiblast and hypoblast, we shall retain the distinction between epiblastic and hypoblastic tumors.

Virchow from a practical standpoint divided all tumors again into—
1. Homologous; 2. Heterologous—terms which have been used wrongly as synonymous with the designation “benign” and “malignant.” *All malignant tumors are heterologous, but not all heterologous tumors are malignant.* According to Virchow, a heterologous growth is a tumor which in its histological structure deviates from the type of tissue from which it grows, while a homologous tumor is one which reproduces the type of tissue of the part or organ in which the tumor is located. The innocent tumors histologically very closely resemble normal tissue;

no such resemblance can be seen in the malignant tumors. The former are homologous, the latter heterologous; but there are instances where an innocent tumor is heterologous (chondroma), and malignant tumors present a homologous appearance during the earliest stages of their development. A familiar illustration of what is meant by the term "homologous" is furnished by a myofibroma of the uterus, because it contains all the tissue-elements of that part of the uterine wall with which it is in contact. A chondroma in any of the glands—as the parotid, mammary, and testicle—represents a benign heterologous tumor, because cartilage is not a normal histological constituent of these glands. According to Cohnheim, all chondromata are heterologous tumors, as they never spring from cartilage where it normally exists, but occur in bone and soft tissues where cartilage has no legitimate physiological existence. Using the term "heterologous" in a strictly practical sense, the only tumors that are destructive are those which are heterologous in their origin and location. The homologous tumors may become destructive only by accident. Heterotopic tumors are heterologous tumors. "Heteroplasty" is another term introduced by Virchow, and in its strictest sense it takes in the malignant tumors. According to the views of this author as to the origin of malignant tumors, in cases of sarcoma and carcinoma during the earliest stages we meet with indifferent cells which, according to the nature of the initiative, assume an epithelial or connective-tissue type. It must be remembered that Virchow entertained the belief that carcinoma and sarcoma have a common origin in connective tissue, and that during a later stage the new products differ as their cellular elements reach various degrees of development.

Robin and Waldeyer showed conclusively that epithelial tumors are never developed from a connective-tissue matrix. Lancereaux, Klebs, and others have excluded from the mesoblastic tumors endothelioma, as being a separate type closely resembling epiblastic and hypoblastic tumors. Lancereaux described endothelial tumors of the lymphatics of the peritoneum; Robin, of the arachnoid and peritoneum; Gaucher, of the spleen from the endothelia of blood-vessels and lymphatic glands; Monod and Arthraud, of the retina from the vascular endothelia.

Sutton claims that the same relation exists between sarcoma and endothelioma as between carcinoma and epithelioma. We shall include endothelioma among the malignant mesoblastic tumors, and thus adhere strictly to the classification made in accordance with the division of embryonic tissue into the three germinal layers. We shall also endeavor to show that the endothelial cells are capable of being trans-

formed into ordinary connective tissue, and *vice versa*, and that their close histological and pathological relationship to the connective-tissue tumors would, *a priori*, tend to prove that they are subject to tumor-formation of the same type as the common connective tissue of similar histogenetic origin. From a practical standpoint, the division of tumors according to their clinical aspects manifested by their relations to the adjacent tissues and to the organism has always been, and always will be, of the greatest importance to the surgeon. Clinically, tumors have been divided into—1. Benign; 2. Malignant; 3. Suspicious. We have explained elsewhere why the third class should be abolished. *A tumor is either benign or malignant.* The tumors classified heretofore as suspicious are tumors which from their structure or location present conditions not favorable for thorough removal by the usual operations made for the removal of benign tumors. Such tumors as chondroma and myxoma, about which there has always lingered a suspicion as to their benign nature, from a practical standpoint have been regarded as innocent growths, and incomplete removal is responsible for many relapses after operation. *The sudden change in the clinical behavior of tumors which have been pursuing a benign course for perhaps a long time is no evidence of a semi-malignant nature of the tumor, but is an evidence that a benign tumor has undergone transition into a malignant stage, or that the tumor was malignant from its incipency, and has passed from a latent into an active condition. All the embryonic germinal layers furnish matrices for benign and for malignant tumors. The clinical type of the tumor depends upon the stage of arrest of development of the cells composing the matrix derived from the embryo or from embryonic cells of post-natal origin.*

The cells composing the tumor-matrix produce a tumor that is either benign or malignant. We shall speak of benign and malignant tumors of the epiblast and hypoblast and the mesoblast. A benign tumor is one which never extends beyond the germinal layer in which it had its origin, while a malignant tumor extends to and involves tissues derived from germinal layers other than the one from which it had its origin. *The extension of a tumor to adjacent tissues irrespective of their structure or their embryonic origin has been regarded for a long time as the most reliable clinical proof of the malignant nature of the tumor.*

We shall classify tumors with special reference to their origin from the different germinal layers—the epiblast, the hypoblast, and the mesoblast—and to the stage of arrest of development of the cells composing the tumor-matrix. The lowly-organized tumor-tissue will represent the malignant tumors, and tumors composed of highly-organized cells will include all benign growths. In the description of the different varieties

of tumors the benign tumors will be considered first, as the tissues of which they are composed bear a closer resemblance to normal tissue than do the tissues of malignant tumors, and hence the deviation from the laws governing normal growth and nutrition is less marked.

AUTHOR'S CLASSIFICATION.

- | | | |
|--|---|--|
| 1. Epiblastic and hypoblastic tumors. | { | Papilloma;
Adenoma;
Cystoma;
Carcinoma. |
| 2. Mesoblastic tumors. | { | Fibroma;
Lipoma;
Myxoma;
Chondroma;
Osteoma;
Angioma;
Lymphangioma;
Lymphoma;
Myomata, { Lævi-cellulare;
{ Stri-cellulare;
Neuromata, { Neuroma, { Myelinic;
{ Glioma (Klebs); { Amyelinic;
Sarcoma. |
| 3. Epiblastic, hypoblastic, and mesoblastic tumors. | { | Teratomata. |
| 4. Swellings caused by retention of physiological secretion. | { | Retention-cysts. |

XIII. PAPILLOMA AND ONYCHOMA.

PAPILLOMA.

A PAPILLOMA is a non-malignant epithelial tumor of the cutaneous or mucous surface. The essential part of the tumor is composed of epithelial cells; the framework is furnished by the connective tissue underneath the epithelial proliferation. The tumor-tissue proper is outside the limits of the vascular area, being separated from it by the *membrana propria*. The tissues of the epiblast and the hypoblast possess no independent organ-producing power, as their blood-supply is derived from the mesoblast. Epithelial cells in the normal mesoblast have no power to proliferate, hence in cases in which we find them multiplying here the mesoblast has undergone changes. The epithelial cells receive their nourishment from the blood-plasma and the leucocytes. As the stroma of an epithelial tumor is derived from the mesoblast, an epithelioma is a mixed tumor, in which, however, in accordance with the law of the legitimate succession of cells, the epithelial cells are derived from the epiblast or the hypoblast, and the connective tissue from the mesoblast. The development of new tissue from these sources is usually unequal: sometimes the product of one, and sometimes that of the other, predominates. The unequal representation of the two different tissue-elements, epithelial cells and connective tissue, in this form of tumor has given rise to a great deal of confusion in classification. As papillary formations are found in many tumors not belonging to this variety, and as in many specimens fibrous tissue predominates, Virchow objected to papilloma as a separate variety of tumors. Rokitsansky also treated papilloma as a variety of fibroma. Virchow proposed the name *fibroma papillare*. However, in most tumors which deserve the designation "papilloma" the epithelial elements predominate and impart character to the tumor—the reticulum, if it predominates, being an accidental product. It is the intention of the writer to show, as far as possible, in connection with every variety of tumors, the counterpart in the normal tissues of the body. A papilloma of the skin under low power presents in a hypertrophic condition all the tissues of which the skin is composed.

Histology and Pathology.—Papilloma of the skin, as shown in Figures 54 and 55, represents the same papillary structure as the skin,

the number of papillæ depending on the size of the tumor. In papilloma of the hypoblast the villi correspond with the papillæ of the epiblastic papilloma. The connective tissue and the vessels occupy the centre of the papillæ (Fig. 55, *a*), and present, on vertical section of the tumor, finger-like projections conical in shape, the base corresponding with the base of the tumor, and the apex with the summit of each papilla. The epiblastic papilloma is covered by stratified layers of squamous epithelial cells. The new cells are produced near the vascular territory (Fig. 55, *b*). As the cells become older they lose the liquid part of their contents by exposure on the surface and by more

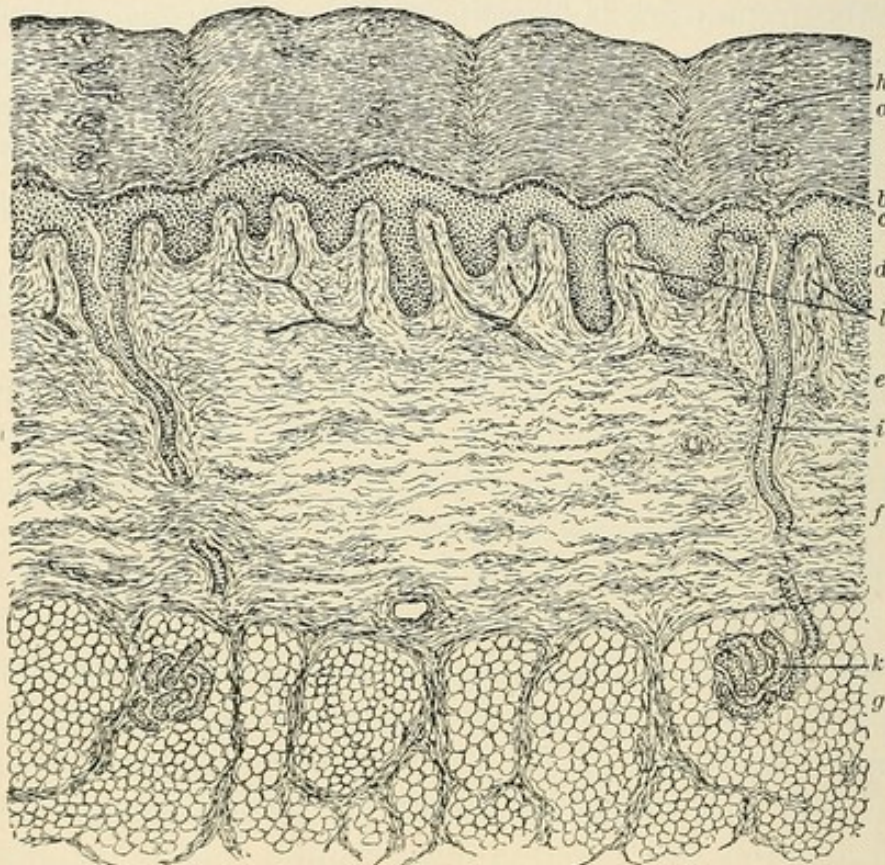


FIG. 54.—Section of human skin (after Piersol): *a*, stratum corneum; *b*, stratum lucidum; *c*, stratum granulosum; *d*, stratum Malpighii; *e*, *f*, papillary and reticular layers of corium; *g*, stratum of adipose tissue; *h*, *i*, spiral and straight portions of duct of sweat-gland; *k*, coiled portion of sweat-gland; *l*, vascular loops occupying papillæ of corium.

distant removal from the vascular supply, forming the horny layer of the papilloma (Fig. 55, *c*). The papilloma of the hypoblast is composed of a connective-tissue stroma, usually softer and more vascular than that of epiblastic papilloma, and of cells corresponding in type to the cells of the mucous membrane in which the tumor is located. The pavements of cells which constitute the essential part of the tumor are made up of cylindrical cells. As hypoblastic tumors are constantly exposed to maceration by the contents of the hollow organs in which they are located, the epithelial cells become œdematous and are very liable to undergo myxomatous degeneration. Even by excluding the papillo-

mata of inflammatory origin, we have, so far as the texture of the tumor is concerned, two varieties—(1) hard and (2) soft. The density of a papilloma depends on the amount and character of the stroma and the location of the tumor. If the stroma is abundant and compact,

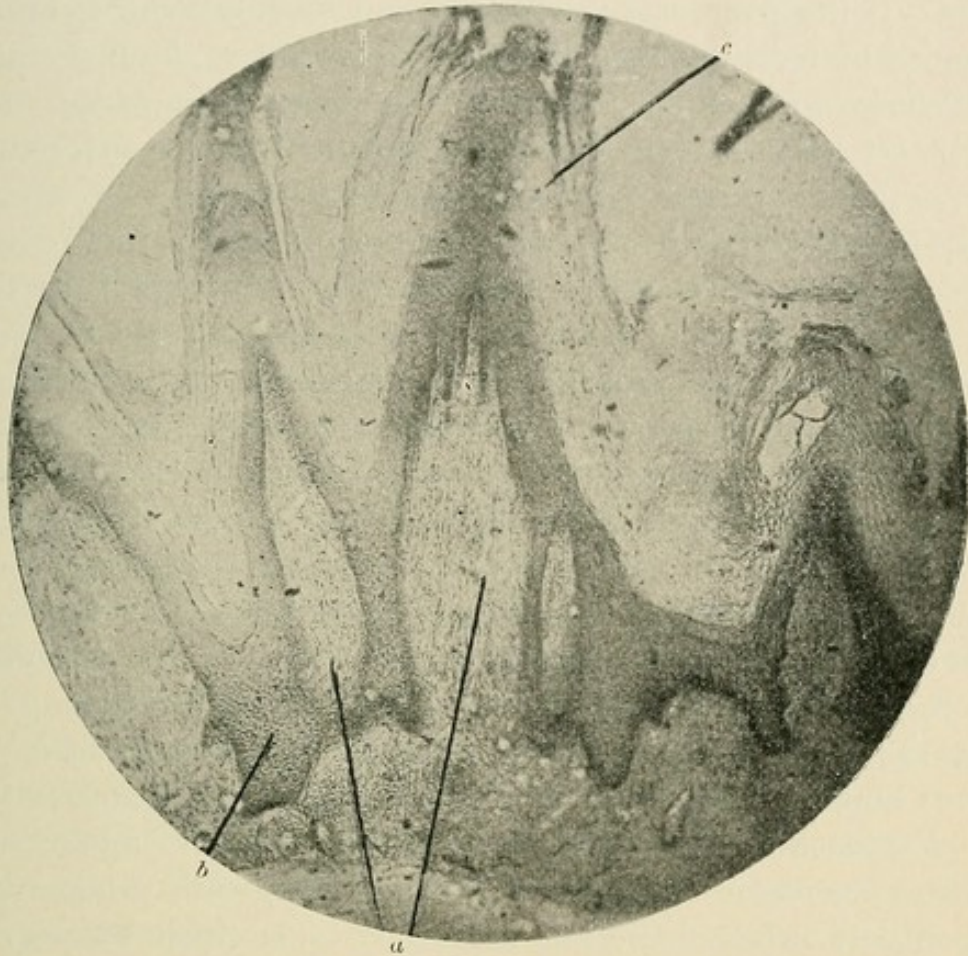


FIG. 55.—Papilloma of skin; $\times 50$ (Surgical Clinic, Rush Medical College, Chicago): *a*, connective tissue; *b*, embryonic epithelial cells; *c*, old squamous epithelial cells.

and if the tumor is not exposed to maceration by constant moisture, the tumor is firm; on the contrary, if the stroma is scanty, if the connective-tissue fibres are loosely arranged and vascular, and if the epithelial cells, by constantly imbibing moisture from their environment, become oedematous, the tumor is soft. The former conditions are most frequently presented by tumors of the skin and of mucous membranes derived from the epiblast, and the latter condition by tumors of mucous membranes lining hollow viscera and paved with columnar epithelium. In some instances a papilloma is covered by columnar epithelia if the tumor occupies a location surrounded by squamous epithelia. Hard papillomata are found most frequently in the skin and in the mucous membrane of the lip, mouth, soft palate, nose, larynx, urethra, vagina, and cervix uteri. The soft variety is found most frequently in the mucous membrane of the intestinal canal and of the bladder. If a number of papillomatous tumors develop simultaneously

or in succession in the same neighborhood, they form tumor-masses of greater or less circumference with a mushroom-like surface. The papillary excrescences are often branched, producing the so-called "dendritic vegetations." This condition is often found upon mucous surfaces. If the papilloma is not subjected to injury and is otherwise surrounded by favorable conditions for rapid growth, it often elongates into a delicate filamentous tumor, as is frequently seen in the bladder. The connective-tissue core conveys vessels and nerves to each papillary growth, the vessels forming loops as in the papillæ of normal skin and in the villi of the intestinal mucous membrane. In papillary growths in joints the vessels are absent. In benign epithelial tumors of the skin we often find epithelial cells in concentric layers arranged in pearl-like masses, a proof of the independent proliferation of the epithelial cells. A papilloma never attains great size, large tumors of this kind being met with only as a result of the confluence of a number of tumors. By the aggregation of numerous tumors, masses the size of a fist are observed in the rectum and upon the prepuce and the labia majora. An individual tumor seldom exceeds the size of a cherry. The growth of a true papilloma is always very slow, papilloma manifesting in this respect much less activity than infective papillomatous growths. Among the degenerative processes which most frequently affect papillomatous tumors are cretification, myxomatous degeneration, and ulceration. Cretification often arrests the further growth of a papilloma of the skin. Myxomatous degeneration most frequently attacks tumors of hypoblastic origin. Ulceration is the result either of mechanical irritation or of infection with pathogenic microbes through an abrasion or a fissure of the surface of the tumor. If in a pedunculated papilloma the principal artery becomes thrombosed, either in consequence of an injury, such as twisting of the pedicle or traction, or as one of the results of an accidental inflammation, gangrene of the tumor is produced, usually resulting in a permanent cure. Psammoma is very prone to undergo calcification which limits tumor-growth—a fortunate occurrence, considering the importance of the locality occupied by such tumors.

Transformation into Malignant Tumors.—Of all tumors, papillomata are most liable to undergo malignant transformation. The irritation to which such tumors are frequently exposed by their location upon a surface will account satisfactorily for this well-established clinical fact. This transition is observed most frequently in tumors which occupy localities most exposed to irritation. We seldom hear of a papilloma of the cavity of the mouth undergoing such a transformation, while carcinoma frequently originates in a papilloma of the lip. Papilloma constitutes

a more frequent starting-point of a carcinoma than of a sarcoma. The deepest stratum of epithelial cells is composed of young cells which are in touch with the membrana propria, which, so long as the tumor remains benign, constitutes an impermeable partition between the essential tumor-elements and its stroma, the subcutaneous or submucous connective tissue. If, in consequence of prolonged irritation or other exciting causes, this partition is damaged, the embryonic cells have access to the vascular part of the tumor, and, once there, the transformation from a papilloma into a carcinoma takes place. If, on the contrary, fetal "rests" or post-natal embryonic cells in the connective-tissue part of the tumor become environed by causes favoring tumor-growth, the papilloma is transformed into a sarcoma. Such a transformation was observed by Simon in a papillary growth of a joint. Sarcoma of the skin has occasionally a similar origin.

Topography.—Papilloma is met with in various parts of the body, but some parts are more predisposed to it than others. It is most frequent in localities most exposed to irritation. We shall not include papilloma of an infective origin—as warts, condylomata, and molluscum contagiosum, all of which are inflammatory swellings and not true tumors—in the discussion of the topographical distribution of papilloma. Warts (verruca) come and disappear mysteriously. They increase in size much more rapidly than papilloma, and they often disappear spontaneously. Condyloma, another papillomatous inflammatory swelling resembling in its structure papilloma, almost always appears multiple in places where skin and mucous membrane meet and are bathed with infective discharges, usually of a gonorrheal origin. The vulva, the prepuce, and the anal region are the parts most frequently affected by condyloma. The removal of the primary causes usually results in a speedy cure. Molluscum (Bateman) or epithelioma contagiosum (Virchow) is now generally recognized as an inflammatory swelling. Its contagiousness is the best possible evidence that it is not a tumor. Haab succeeded in producing it artificially in animals by inoculation. Austrian and English dermatologists have traced its starting-point to sebaceous glands. The papillary growths of non-infective origin, the true benign epithelial tumors, do not disappear spontaneously; their growth is limited by an inherent limitation of tissue-proliferation or by degenerative changes. These tumors have a very wide distribution, and the more important localities inhabited by them, and the different clinical varieties, will now be discussed.

Skin.—Papilloma of the skin occurs in two principal forms: 1. Cornu cutaneum; 2. Fibrous papilloma. In the former variety the tumor is composed almost exclusively of epiblastic tissue; in the latter

the connective tissue derived from the mesoblast is present in varying proportions.

Cornu Cutaneum.—The cutaneous horn represents a form of papilloma in which the tumor is composed almost exclusively of desiccated epithelial cells corresponding with the horny layer of the skin. The old cells, instead of becoming desquamated, remain attached to the tumor-matrix, forming projections varying in length from half an inch to twelve or more inches. Such horns are found most frequently on the scalp, temple, forehead, eyelid, nose, lip, cheek, shoulder, arm, elbow, thigh, leg, knee, toe, axilla, thorax, buttock, loin, penis (Fig. 56),

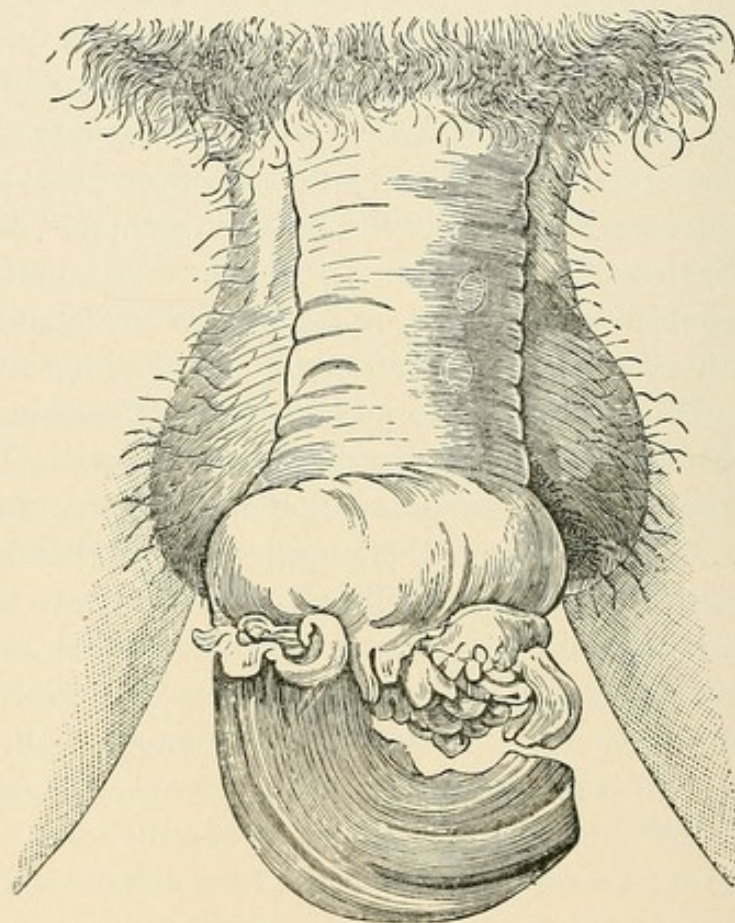


FIG. 56.—Cornu cutaneum of penis (after Pick).

and scrotum. The matrix of such tumors is very vascular. Horny tumors of the skin can readily be enucleated, and they seldom return after removal. A post-natal matrix for cutaneous horns is furnished most frequently by scars. Cruveilhier described a specimen of cornu cutaneum which originated from a scar following a burn of the forearm, the tumor reaching such an enormous size that amputation became necessary (Fig. 57). The tumors in this case were multiple.

That desiccation is not the sole cause in the production and fixation of such an enormous mass of epithelial cells is shown by the fact that papillomata of a similar structure are occasionally found in dermoid

and sebaceous cysts. The matrix of a cutaneous horn undoubtedly not only possesses the inherent capacity of producing epithelial cells very rapidly, but also furnishes the cement-substance which fixes the old epithelial cells, thus preventing their removal by desquamation.

There is no reason why papillomata should not develop as secondary formations in epithelial tumors of either a benign or a malignant type.

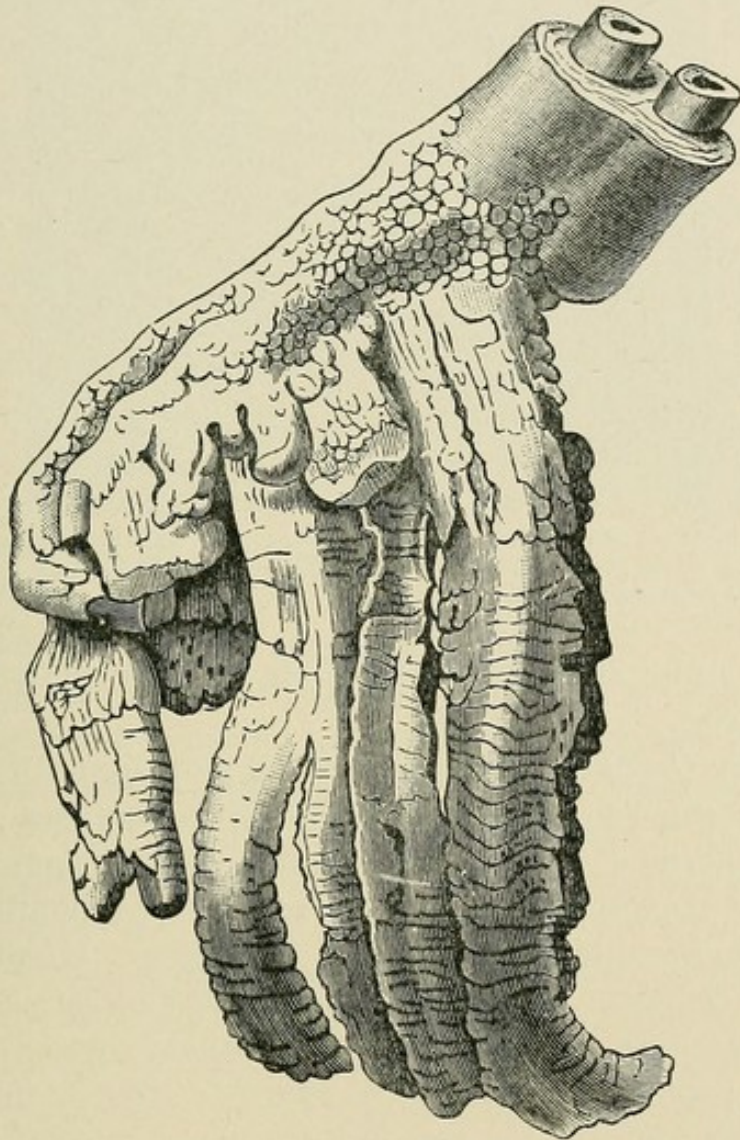


FIG. 57.—Cornua cutanea from the scar of a burn (after Cruveilhier).

Not infrequently we find in the interior of an adenoma, a cystoma, or a carcinoma papillary growths which resemble in every respect the surface papillomata, and which impart to the tumor additional pathological and clinical characteristics. Papillomatous cysts of the ovary (Fig. 58) are regarded with special interest by the surgeon. A semi-malignant nature was assigned to them long ago. There can be no doubt that in many instances such tumors are malignant from the beginning, but in other instances the papillomata are benign and remain so. The desquamated epithelial cells furnish here a part of the contents of the

cysts (Fig. 58, *d*). As in surface tumors, the epithelial cells are stratified. Tumors of large size are formed by the aggregation and coalescence of numerous smaller tumors.

The *fibrous papillomata* of the skin occupy most frequently the region

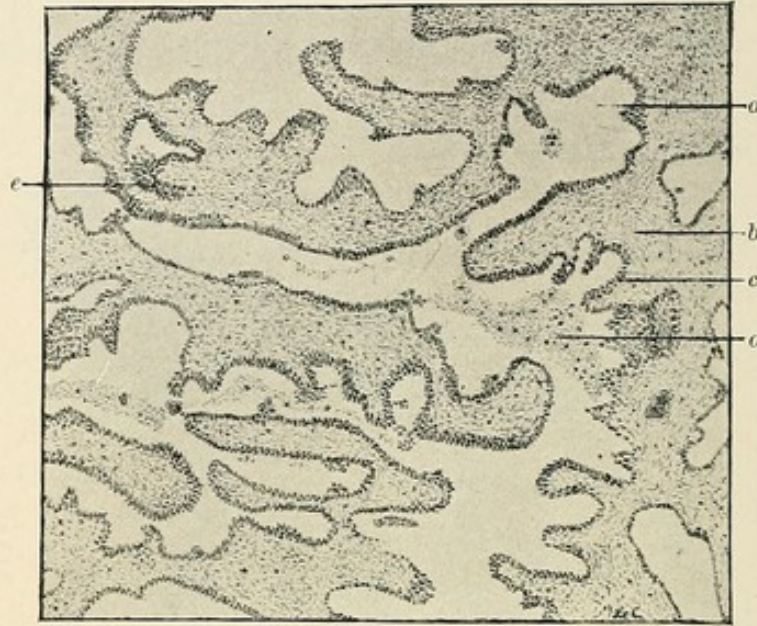

FIG. 58.—Papillomatous cyst of ovary; $\times 110$ (Surgical Clinic, Rush Medical College, Chicago): *a*, interpapillary space; *b*, stroma; *c*, epithelial lining; *d*, amorphous, non-staining detritus with a few detached epithelial cells; *e*, proliferating areas.

of the face, scalp, and hands; they are of slow growth and never attain large size.

Respiratory Organs.—The larynx is the most frequent seat of papillomata. Morgagni's pockets are their favorite locations. They appear as isolated affections or as multiple tumors closely aggregated, giving to the mass a cauliflower-like appearance. The symptoms will vary according to the size and the location of the tumor. Hoarseness, cough harassing in character, and difficult breathing alternating with temporary attacks of dyspnea, are some of the leading clinical features. Not infrequently, papilloma of the larynx undergoes transformation into carcinoma, as was probably the case in the instance referred to in the section treating of the Transformation of Benign into Malignant Tumors.

Digestive Tract.—The mucous membrane of the cavity of the mouth is derived from the epiblast and is frequently the seat of papilloma. The favorite localities are the mucous membrane of the cheek, the prolabium of the lip, the tongue, the soft palate, and the pharynx. The naso-pharyngeal space is frequently studded with papillomatous vegetations. The stomach is almost exempt from this affection. The frequency with which the mucous membrane of the intestinal canal is affected increases in a downward direction. Papillomata are rare in the intestines, while in the rectum they are most frequent, and are either

sessile or pedunculated, constituting a frequent form of polypus of this organ. The writer has repeatedly seen the mucous membrane of the lower part of the rectum studded with papillary tumors varying in size from a hempseed to a cherry (Fig. 59). The symptoms which attend this affection of the rectum are hemorrhage, usually slight, tenesmus, and a glairy discharge.

Urinary Organs.—The urinary tract is very often the seat of papilloma, and no part of it is exempt. Papillomata are frequently located in the urethra, and especially around the margin of the meatus in the female. In this locality they are often multiple, and they are a source of great distress to the patient. The tumors are very vascular, are extremely sensitive to touch, and are the source of great pain during micturition. Papillomata of the male urethra are more frequent than was formerly supposed, and their presence can now be ascertained and their removal be facilitated by the use of the urethroscope. They simulate, and have usually been mistaken for, stricture.

Papilloma of the bladder is a frequent affection of this organ. The connective tissue is usually abundant and carries with it one or more vessels of considerable size. The main stem of the tumor usually gives off branches which in turn again become branched, giving to the tumor an arborescent structure (Fig. 60). As the connective-tissue core of the tumor is often covered by only one layer of epithelial cells, and the ultimate branches are often exceedingly delicate, it is easy to understand that such tumors frequently give rise to hemorrhage. If the principal artery of such a tumor is eroded or torn, the hemorrhage may become alarming and even fatal. Sometimes small fragments of such a tumor are voided with the urine or are removed in the eye of the catheter, affording the surgeon an opportunity to make a correct diagnosis, by the aid of the microscope, in what was before an obscure case. The cystoscope renders valuable assistance in ascertaining not only the existence, but also the exact location and character, of the tumor. The liability of such growths to become transformed into malignant tumors is well known and generally recognized. A very interesting case of papillomatous tumors of the pelvis of the kidney is reported by Murchison

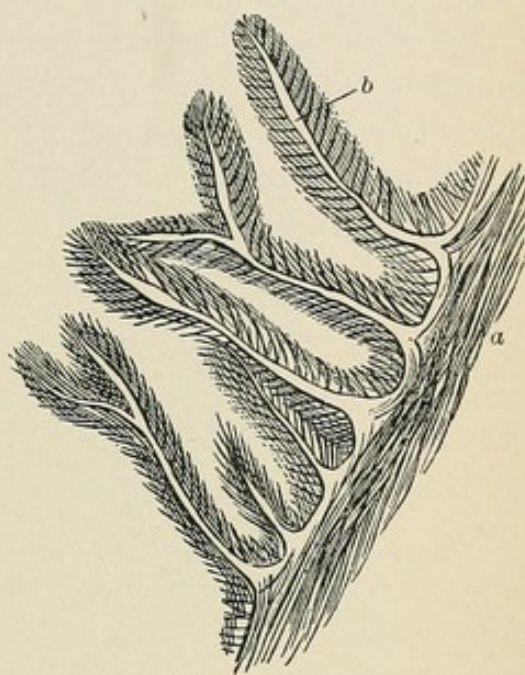


FIG. 59.—Papilloma of the rectum (after Lücke): *a*, submucous connective tissue; *b*, papillæ, some of them branching, covered by columnar epithelia.

and quoted by Sutton. The pelves of both kidneys were similarly affected, and the bladder contained two similar tumors, one on each side near the ureteral orifice. Sutton believes that in this case the tumors in the bladder were secondary, and were caused by the implantation of tumor-cells from the primary tumors upon the mucous membrane of the bladder. While this mode of origin is possible, it is more likely that the tumors developed from so many different tumor-matrices independently of one another. Multiple papilloma of the same surface or organ is not of rare occurrence.

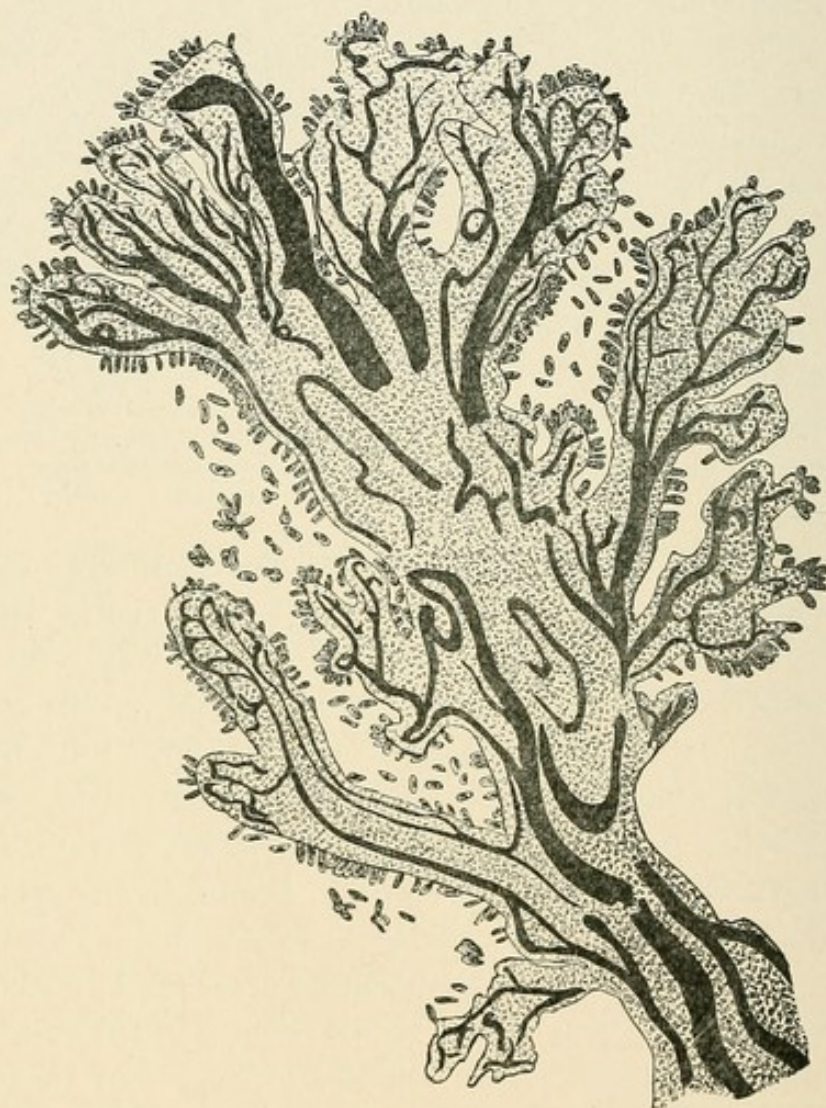

FIG. 60.—Papilloma of the bladder (after Perls).

Female Organs of Generation.—The external genitals, the uterus, and all its appendages represent conditions favorable to the origin and development of papillomatous tumors. We shall, of course, exclude infective papillary swellings, which are of such frequent occurrence upon the external genitals of gonorrheal patients and syphilitics. The labia (Figs. 61, 62) and the fringes of the hymen are frequently the starting-points of such growths. The tumors may be either single

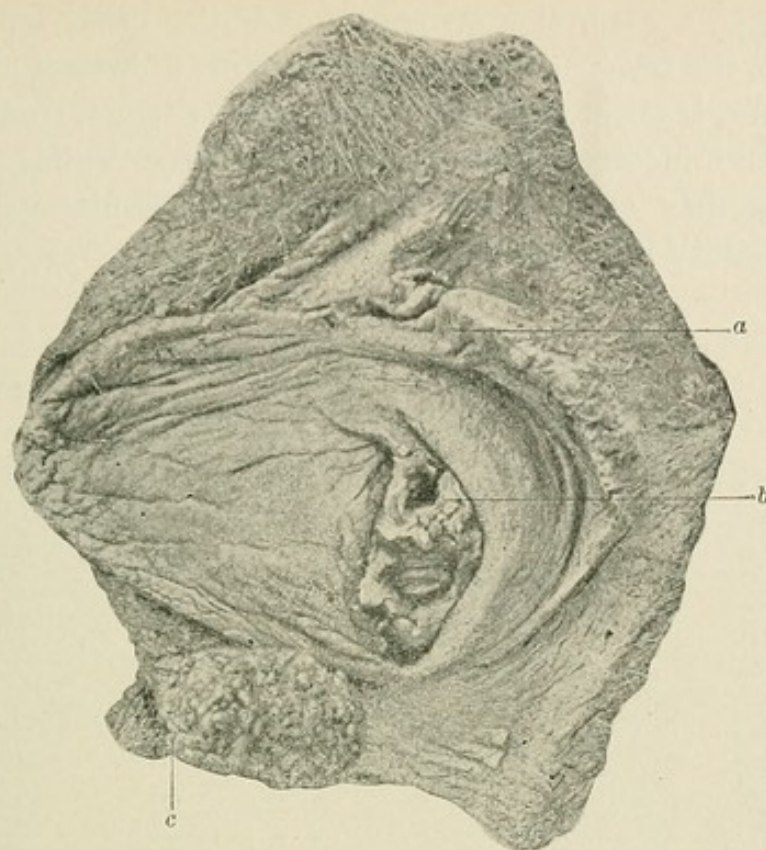


FIG. 61.—Papilloma of right greater labium (after Winckel): *a*, minor labium; *b*, dilated meatus of the urethra; *c*, papilloma.

or multiple, sessile or pedunculated. In the absence of irritating discharges they occasion but little inconvenience, and they are usually accidentally discovered in examinations for other affections.

The so-called "erosions" of the mucous membrane of the cervix uteri present under low power the typical structure of a papilloma. Many of the small polypoid growths of the cervical canal are papillary tumors. The uterine mucous membrane is often the seat of multiple papillary tumors which may produce profuse menstruation and other symptoms simulating chronic endometritis or malignant disease (Fig. 63). Papilloma of the Fallopian tubes has been described by Hennig in 1876. Doran first described a true papilloma of the tube in 1879, whilst Sutton is of the opinion that this tumor is an adenoma. Landau, Kaltenbach, and Eberth, however, support the papilloma theory, as they find that in its earliest stage the growth is a papillary elevation or

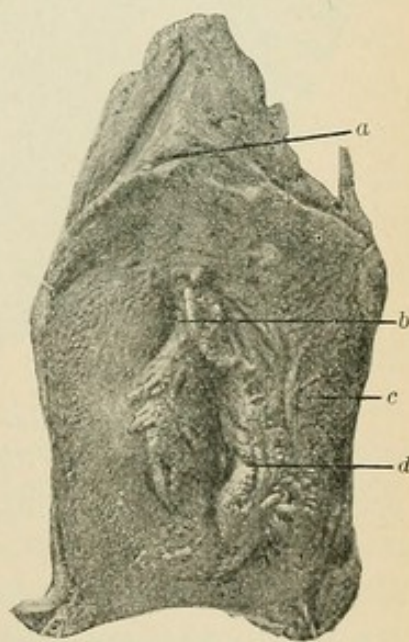


FIG. 62.—Papillomata of lesser labium (after Winckel): *a*, clitoris; *b*, orifice of urethra; *c*, papillomata; *d*, fimbriated hymen.

villus, and not a glandular structure. On the other hand, it is quite possible that the tumor described by Sutton is a distinct affection from papilloma, and is developed, if his theory be correct, from his normal tubal glands; if incorrect, from Recklinghausen's Wolffian relics. The same theory may explain the occurrence of tubular cells found by Doran in primary tubal carcinoma.

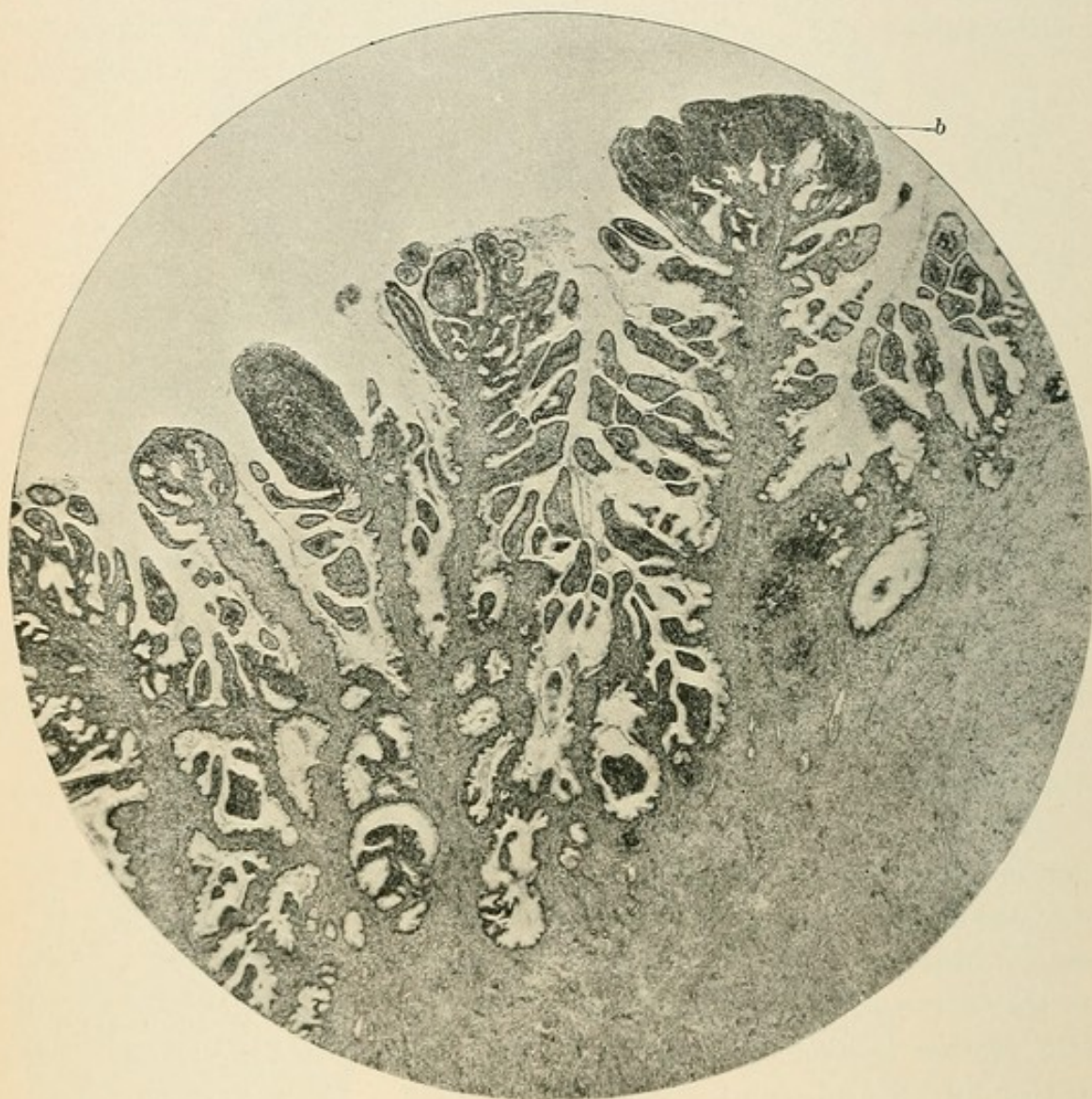

FIG. 63.—Papillary excrescences of the mucous membrane of the cervix uteri, vertical section; $\times 22$ (after Karg and Schmorl). The papillæ, as well as the remnants of glandular tissue, are covered by cylindrical epithelia. This section was taken some distance from a carcinoma, and two of the papillæ at *b* are infiltrated with epithelial cells, indicating the beginning of carcinomatous degeneration.

Papillomata may develop upon the surface of the ovary, but more frequently from the wall of glandular cysts (Fig. 58). Papillary tumors upon the surface of the ovary have been observed by Gusserow, Klebs, Birch-Hirschfeld, and Winckel. The intraglandular papilloma of the ovary will be described more fully in connection with proliferating papillary cysts of the ovary.

Brain.—The brain is developed from the epiblast, but papillary tumors of this organ are exceedingly rare. The choroid plexuses are fringed with tufts of epithelium-covered villi which occasionally become the seat of papillary tumors. Douty describes a case of this kind in which the tumor attained the size of a bantam's egg. The patient was a boy seventeen years old, and the tumor produced focal symptoms which enabled the medical attendant to localize the tumor accurately during life. Sutton is of the opinion that psammoma is an epithelial tumor, but the majority of pathologists assign to it an endothelial origin, and it will be discussed more fully in connection with epiblastic tumors.

Diagnosis.—The greatest difficulty encountered in the diagnosis of papilloma is to differentiate from it inflammatory papillary swellings and carcinoma. Inflammatory swellings usually grow rapidly and appear as a multiple affection. The microbic cause can often be ascertained. The swellings frequently present signs and symptoms of inflammation which are lacking in papilloma. The difficulty would be greatly increased if a papilloma were at the same time in a condition of inflammation. Inflammatory papillary swellings may occur at any time of life, the only essential cause being the presence of pathogenic microbes in quantity sufficient to produce either a subacute or a chronic inflammatory process. Papilloma is most frequent in adults and in persons past middle life. Age is an important factor in the differential diagnosis between papilloma and carcinoma. Carcinoma affects most frequently persons past middle life. A papillary carcinoma almost without exception is indurated at its base—a condition absent in papilloma. In doubtful cases the microscope will decide the diagnosis. The part of the tumor that it is most important to subject to microscopic examination is the base. If sections from this part of the tumor show no epithelial cells on the vascular side of the membrana propria, the tumor is benign; the presence of even a limited number of epithelial cells in the subcutaneous or submucous connective tissue is a positive evidence of malignancy. Papillomata of the meninges of the brain and of other inaccessible organs which produce no symptoms cannot, of course, be recognized during life; if they produce symptoms, these must be studied carefully and be referred, if possible, to their proper source. Papillomata of the larynx, urethra, bladder, uterus, and rectum must be seen before they can be recognized, and for this purpose the different instruments that render them accessible to sight must be employed.

Prognosis.—Papillomata never attain a large size, consequently they only become a source of danger to life if, by causing compression of an important organ or by blocking an important passage, the function of

an organ is impaired or abolished. A papillary tumor at the base of the brain may result in fatal cerebral compression. A papilloma of the larynx may be caught in the rima glottidis, and produce death from suffocation. Another element of danger is hemorrhage. A papilloma of the bladder has often been the source of serious and even fatal hemorrhage. The liability of a papilloma to undergo transformation into a malignant tumor must also be taken into consideration, and should be regarded as a forcible argument in favor of early operative treatment.

Treatment.—The only treatment of a papilloma is a radical operation. The tumors being usually small, they can be destroyed by the energetic use of the needle or the knife-point of the Pacquelin cautery, or be removed by excision. The cauterization or excision should include the entire tumor-matrix; if this is not done, a recurrence will almost surely follow the operation. Incomplete removal of a papilloma will also favor transformation of the balance of tumor-tissue into a malignant tumor. Laryngeal papillomata can be removed with a snare, aided by the use of the laryngoscope, or by laryngotomy. Laryngo-fissure is the preferable method if there is any question concerning the benign nature of the tumor. Small papillomata of the uterine cavity and the cervical canal can be removed with a sharp spoon followed by the use of the Pacquelin cautery (cervix) or of a safe caustic (uterine canal). Papillomata of the urethra require in their removal the urethroscope. When the tumor has been thoroughly exposed to sight it can be removed by torsion or by linear crushing. Papillomata of the bladder can be rendered sufficiently accessible to operative removal only by a suprapubic incision. The Trendelenburg posture will greatly facilitate the operation. The tumor is removed either by torsion, by the wire *écraseur*, or, if broad and flat, by scraping it away with a sharp spoon or a finger-nail. If the bed of the tumor can be exposed sufficiently well to sight and touch, it should be cauterized lightly with the actual cautery for the purpose of arresting hemorrhage as well as to destroy remnants of the tumor, which, if left, would give rise to a speedy recurrence.

ONYCHOMA.

Virchow described a papillary tumor of the matrix of nails under the name of *onychogryphosis* (Fig. 64), and distinguished it from an inflammatory hyperplasia occupying the same locality, which he called *onychomycosis*. A papillary tumor of that part of the cutaneous surface occupied by the nails resembles in structure and in physical appearance the cornu cutaneum. Such a tumor is composed almost exclusively of the

product of epithelial proliferation, and it has a vascular base. A true nail-horn usually appears clinically as a single tumor, while the inflammatory swelling, onychogryphosis, is a multiple affection attacking at the same time or in succession a number or all of the nails of both hands.

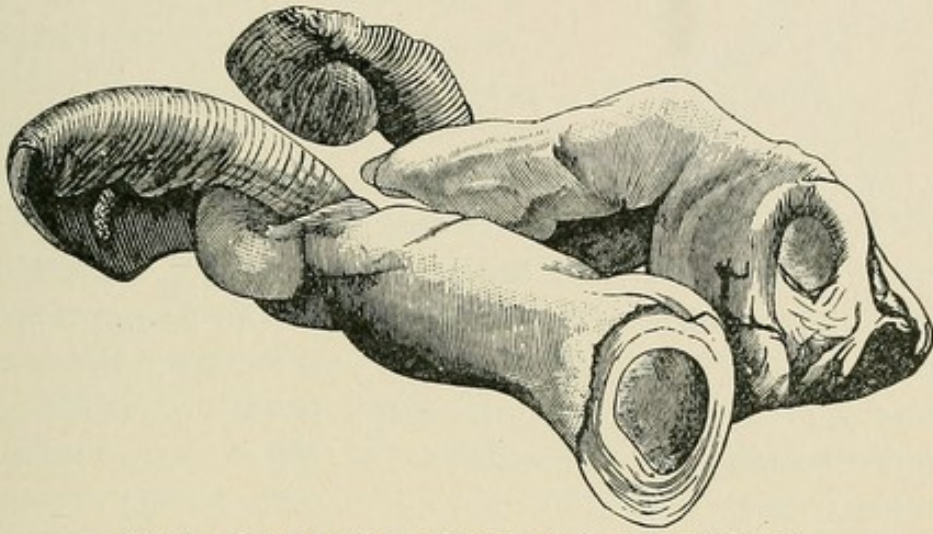


FIG. 64.—Onychogryphosis of toes; natural size (after Ziesing).

The inflammatory form of onychoma is extremely common in the toes of bedridden patients, especially old women and those who are filthy. The true onychoma occurs in persons in perfect health and under the best sanitary and hygienic conditions. The nail often reaches several inches in length and becomes curved, resembling a ram's horn. The writer removed a nail of this kind which was three inches in length. A recurrence of the tumor can be prevented with certainty only by extirpation of the whole matrix of the nail.

XIV. ADENOMA.

ADENOMA is a benign epithelial tumor which in structure resembles the glandular tissue of the organ in which the tumor is located. Adenoma is the second variety of benign tumors of the epiblast and the hypoblast. The relation of the epithelial cells to the basement membrane is the reverse of that of papilloma; that is, the basement membrane is on the outside of the parenchyma of the tumor, instead of on the inside, as is the case in papilloma. In papilloma of the cutaneous and mucous surfaces the cellular elements of the tumor often become detached and permanently lose their connection with the tumor; in adenoma the cells are confined in hollow spaces bounded by the basement membrane, and they or the unabsorbable products of their regressive metamorphoses remain permanently as a part of the tumor. These differences in the anatomical structure of the tumor will go far to explain why a papilloma never attains a large size, and why the size to which a rapidly-proliferating adenoma may attain is unlimited. In reference to the relation of the tumor-cells to the subcutaneous or submucous connective tissue, there exists a great analogy between papilloma, epithelioma, adenoma, and glandular carcinoma. An adenoma, as its name implies, is a glandular tumor. Broca included under the term "adenoma" all circumscribed glandular swellings. Cornil and Ranvier embraced in this class only glandular tumors composed of new glandular tissue. In the strictest etiological and pathological sense the term should be limited to glandular tumors containing adenomatous tissue produced from a tumor-matrix independently of the pre-existing glandular tissue. As adenoma is present in all the glandular organs, the cells of which it is composed resemble the type of cells of the gland or duct in which the tumor is located. Glandular tumors, however, are found in localities where glands do not normally exist. In such instances the tumor develops either from a matrix of embryonic cells displaced and isolated during fetal life—the so-called "rests"—or from a matrix of embryonic cells in a supernumerary or accessory gland. Such accessory glands are found in the vicinity of nearly all the glandular organs, notably the thyroid, pancreas, spleen, liver, kidneys, and mammary gland. Adenomata are found quite often in the

axillary space unconnected with the mammary gland. A fetal matrix in the vicinity of the umbilicus, derived from the intestinal tract, may give rise to adenomata representing intestinal glands. Tumors of this kind were observed by Küstner and Heukelem, and were freely supplied with unstriped muscular fibres. Glandular tumors springing from a post-natal matrix of embryonic cells are necessarily confined to normal or accessory glands.

The histological similarity between an adenoma and the normal tissues in which such a tumor may be located is well shown in Figures 65 and 66. The difference between an adenoma and normal gland-tissue, from a physiological standpoint, is best shown by tumors of glands in continuous physiological activity, such as the liver and the kidneys, from the absence of gland-ducts and the presence of an atypical in place of a typical circulation.

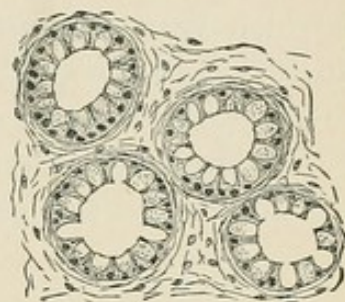


FIG. 65.—Transverse section of follicles of large intestine of dog; the individual tubules are separated by the fibrous stroma of the mucosa (after Piersol).

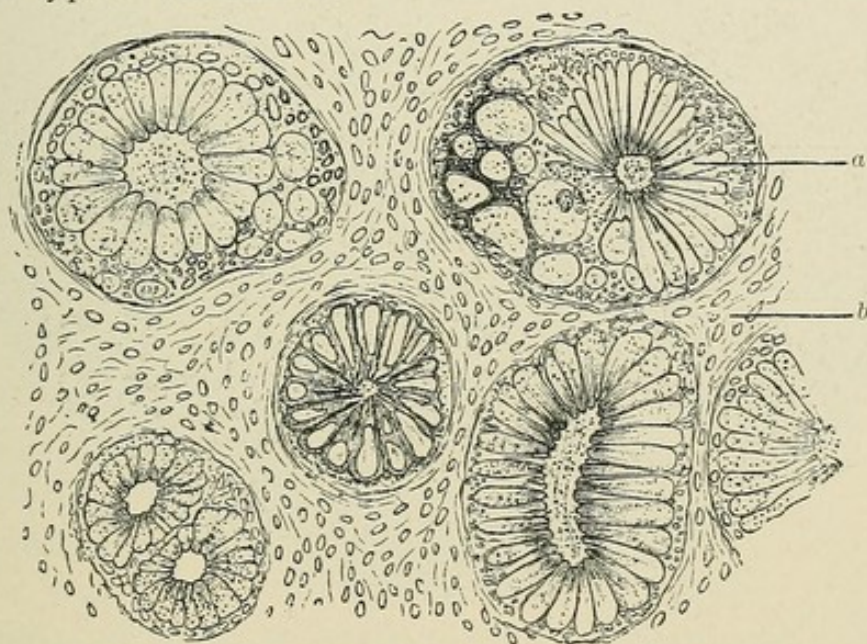


FIG. 66.—Polypus (adenoma) of rectum, showing the glands of the tumor; $\times 350$ (after D. J. Hamilton): *a*, gland lined by columnar epithelium; *b*, stroma of the tumor.

Histology and Pathology.—The histogenesis of adenoma has been referred either to a congenital matrix of embryonic cells in glandular organs, accessory glands, or displaced islets of embryonic cells (heterotopic), or to embryonic cells of post-natal origin in glands and accessory glands. Like the papilloma, it receives its stroma and its blood-supply from the mesoblast. The glandular part of a tumor remains in an adenoma permanently. The most important distinctive feature between a localized or diffuse hyperplasia of a gland and an adenoma

is the absence of function in the latter in common with all other tumors. The absence of ducts prevents the escape of the products of cell-proliferation, frequently resulting in the formation of cysts the contents of which vary according to the nature of the degenerative processes which occur in the cells of the parenchyma of the tumor. Tumors in the interior of internal organs, as a rule, attain greater size than tumors of the cutaneous or the mucous surfaces. Adenoma of the breast seldom exceeds the size of a walnut. The essential structure of an

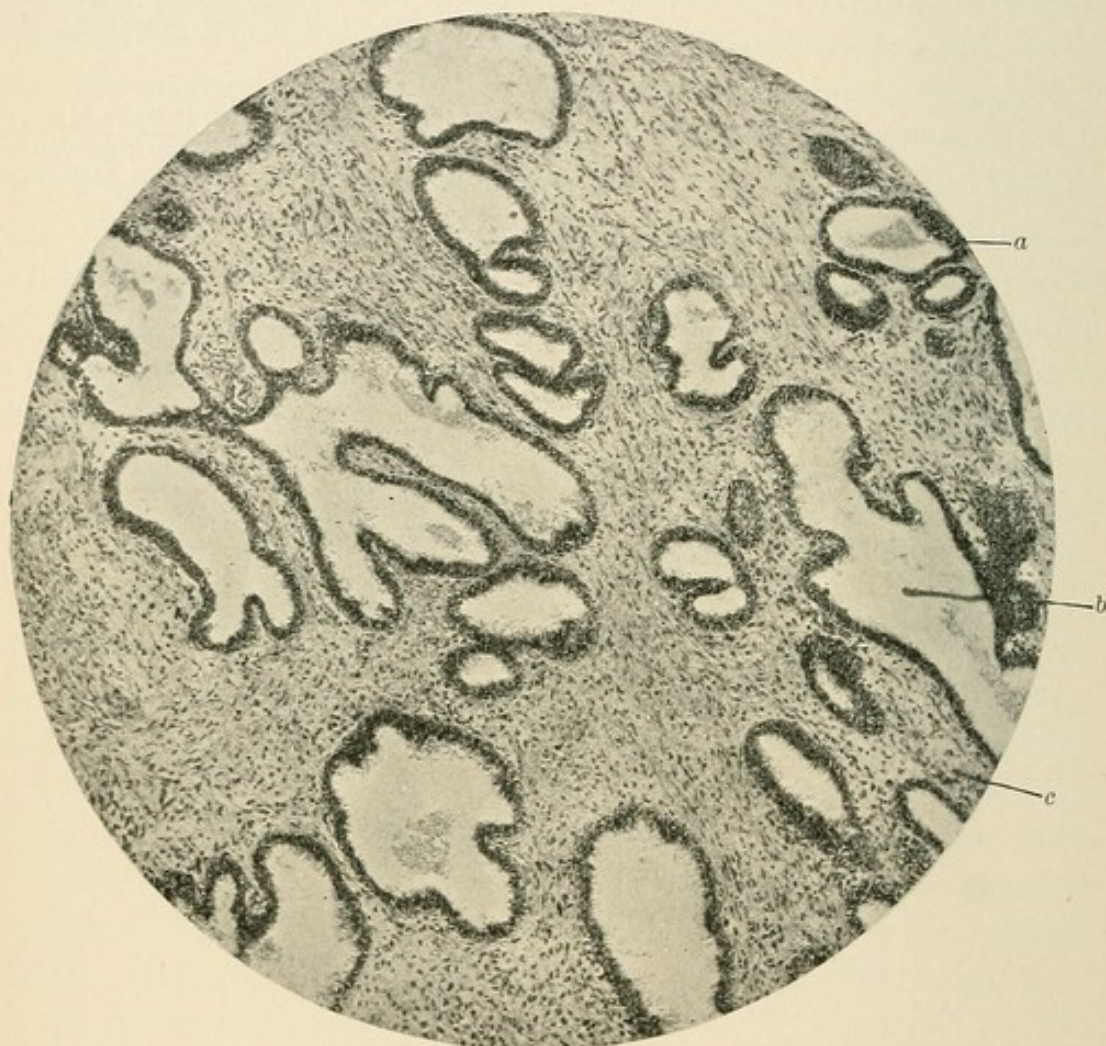


FIG. 67.—Adenoma of mammary gland; $\times 50$ (after Karg and Schmorl): *a*, epithelial cells lining gland-space; *b*, glandular space; *c*, stroma.

adenoma is the stroma of fibrous or myxomatous connective tissue containing newly-formed glands of either the acinous or the tubular variety. A central space between the epithelial cells can invariably be found, representing the glandular spaces in normal glands.

Most of the myxomatous polypoid growths are glandular tumors. Adenoma containing tubular glands presents on section under the microscope the appearance of tubular glands. The cells are arranged in a single layer or in stratified layers; the centre of each tubule shows a space toward which the unattached parts of the cells converge.

Adenoma composed of acinous glandular tissue shows on section under the microscope spaces lined by flat epithelial cells (Fig. 67). The stroma varies in amount: if abundant, the tumor is hard; if scanty, soft. The blood-vessels follow the stroma and supply each tubule or acinus of the tumor with an irregular network of capillary vessels. The cells of an adenoma are subject to fatty, mucoid, and colloid degeneration. The stroma frequently undergoes myxomatous degeneration. The progressive accumulation of the degenerated products of cell-proliferation leads to cyst-formation. Such cysts vary in size from microscopical spaces to cavities which contain many quarts of fluid. The largest cysts are found in, or in the vicinity of, the ovary. The fetal remains of ducts in the vicinity of the ovary give rise to the formation of adenoma containing tubular structures the vegetative power of which is much greater than that of the Graafian follicles. The liability of an adenoma to become transformed into a glandular carcinoma is perhaps greater than that of papilloma. In fact, according to D. J. Hamilton, carcinoma is preceded by an adenomatous stage (Fig. 68), an opinion advanced years ago by Gouley of New York. The earliest evidences that such an occurrence has taken place are a more active multiplication of epithelial cells and their migration through the basement membrane into the connective tissue outside the limits of the tumor (Fig. 68, *b*).

Etiology.—The essential cause, the matrix of embryonic cells, has been referred to in the introductory remarks of this section. Of the exciting causes, trauma, irritation, and inflammation are the most influential. Adenomata are found most frequently in organs the seat of periodical congestion, such as the mammary and prostate glands, the uterus, and the ovaries. They are common also in mucous passages the seat of catarrhal affections, such as the nasal cavities and the rectum. Adenoma is met

with most frequently in the young and in persons not beyond middle life. The greater frequency of adenoma of the ovary as compared

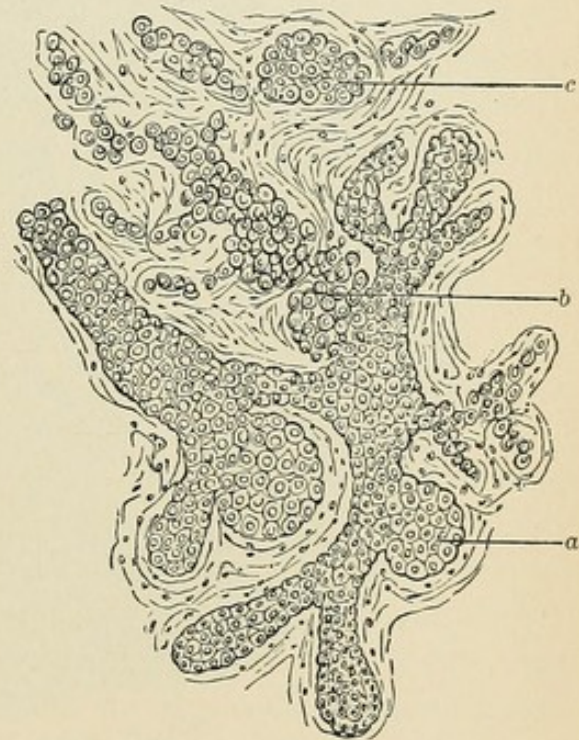


FIG. 68.—Development of a cancer of the mamma: a set of adenomatous acini becoming cancerous; $\times 350$ (after D. J. Hamilton): *a*, an adenomatous swelling of an acinus; *b*, the cells of a similar swelling which have broken out and are invading the surrounding stroma; *c*, part which is cancerous.

with that of the testicle is explained by Klebs upon the ground that in the testicle the structures retain their fetal arrangements, while in the

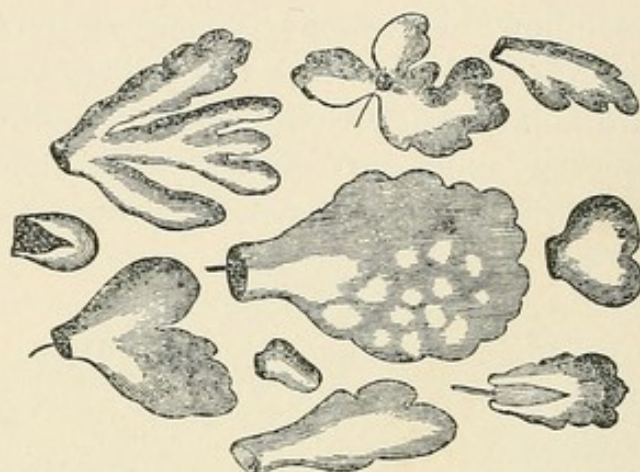


FIG. 69.—Isolated sebaceous adenomata (after Demme).

ovary they are transformed into isolated structures, the Graafian follicles. During the rearrangement of the structures of the ovary in the

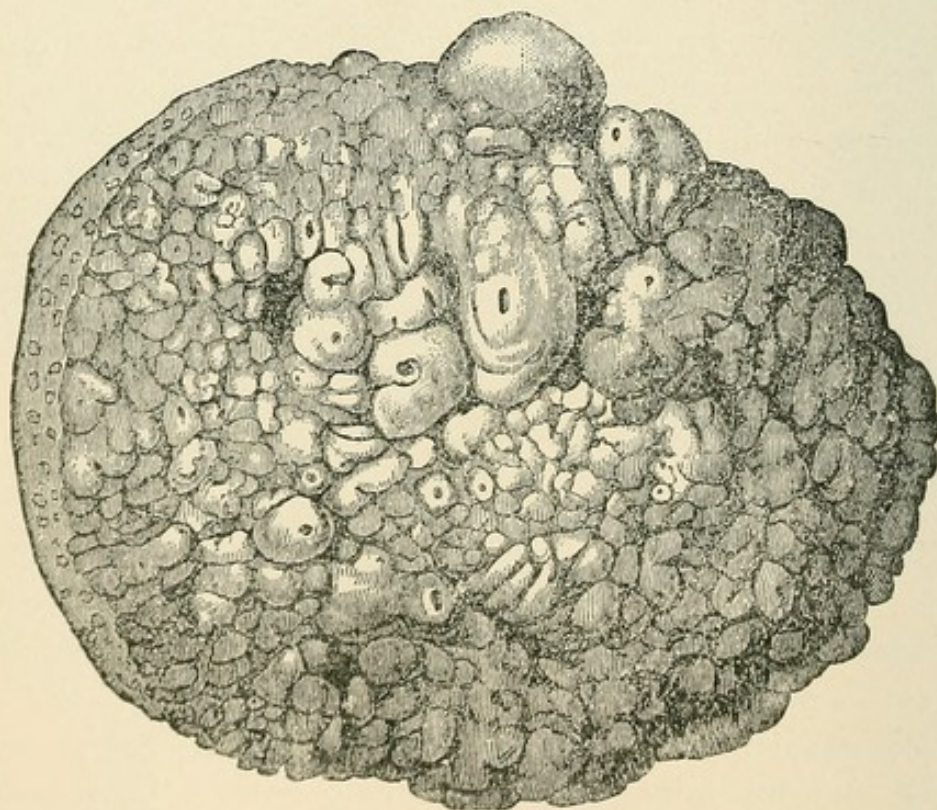


FIG. 70.—Sebaceous adenoma from the skin of the left side of the neck : upon the summit of the separate nodules the dilated outlets of the ducts can be seen (after Demme).

embryo tubular remnants not utilized in the formation of the Graafian follicles are set aside, and remain as fetal rests, from which later the large adenomatous cysts take their origin.

Topography.—The topographical distribution of adenomata furnishes an interesting proof of the importance of exciting causes in the

production of tumor-growth. We shall find that benign glandular tumors frequent localities and organs the seat of prolonged vascular fluxions and exposed to intercurrent affections which are calculated to diminish the physiological resistance of the tissues.

Skin.—Adenoma of the skin is represented by the two kinds of glands found in this structure, the sebaceous and the sudoriparous glands. Retention-cysts of these glands are, of course, excluded from present consideration. True adenomata of the skin are very rare.

Adenoma Sebaceum.—Sebaceous glands found in other tumors, such as dermoid cysts, are not tumors, but hyperplastic glands. Lücke removed an ulcerating sebaceous tumor from the nose of a man eighty years old. He suspected that the tumor was a carcinoma, but microscopic examination showed only convolutions of sebaceous glands and interglandular connective tissue—no trace of carcinoma. The tumors when small assume the shape of sebaceous glands. In larger tumors the glandular tubules form a convoluted mass. Demme described a large sebaceous adenoma of the skin of the scrotum. The few cases of sebaceous adenoma that have been reported appear to show that this tumor is found almost exclusively in the aged, and that the face and the scrotum are its favorite localities. Anatomically, this tumor is distinguished from a retention-cyst by the presence of numerous tubules instead of one cavity, as is the case in retention-cysts (Figs. 69, 70).

Adenoma Sudoriparum.—Sudoriparous adenoma was first described by Verneuil. Virchow's doubts regarding the existence of such a tumor have not been confirmed by later investigations. Lotzbeck observed a case in which the tumor was congenital. In Thierfelder's case the tumor occupied the diploë, but communicated with the skin, in which it undoubtedly had its origin. The growth of the tumor takes place from the deeper part of the tubule, which elongates and becomes more convoluted than normal sweat-glands (Fig. 71). According to Verneuil and Demarquay, these tumors may reach the size of a fist, and may manifest a great tendency to ulceration; they have been mistaken for angioma. The growth of the tumor is slow. Sweat-gland adenomata have been observed most frequently upon the skin of the face. Demarquay saw such a tumor the size of an egg in the axillary space; Verneuil, one upon the sternum and one upon the back.

Digestive Tract.—Adenomata of the cavity of the mouth are rare. In the stomach adenoma occupies most frequently the pyloric part, and may attain the size of a hen's egg and cause pyloric obstruction. It is more frequent in the intestinal mucous membrane, and is often the direct cause of invagination. The mucous membrane of the rectum is more frequently affected by adenoma than is the remaining part of the

whole intestinal tract. The majority of cases of polypus in this locality have an adenomatous structure. Port has recently collected 13 cases of multiple adenoma of the intestinal tract which terminated in carcinoma. The patients ranged in age from 10 to 30 years. In a number of the cases more than one member of the family was similarly affected. The prognosis is grave, even in the event an operation is performed, as out of the 13 cases 9 died. Only in 4 cases did the

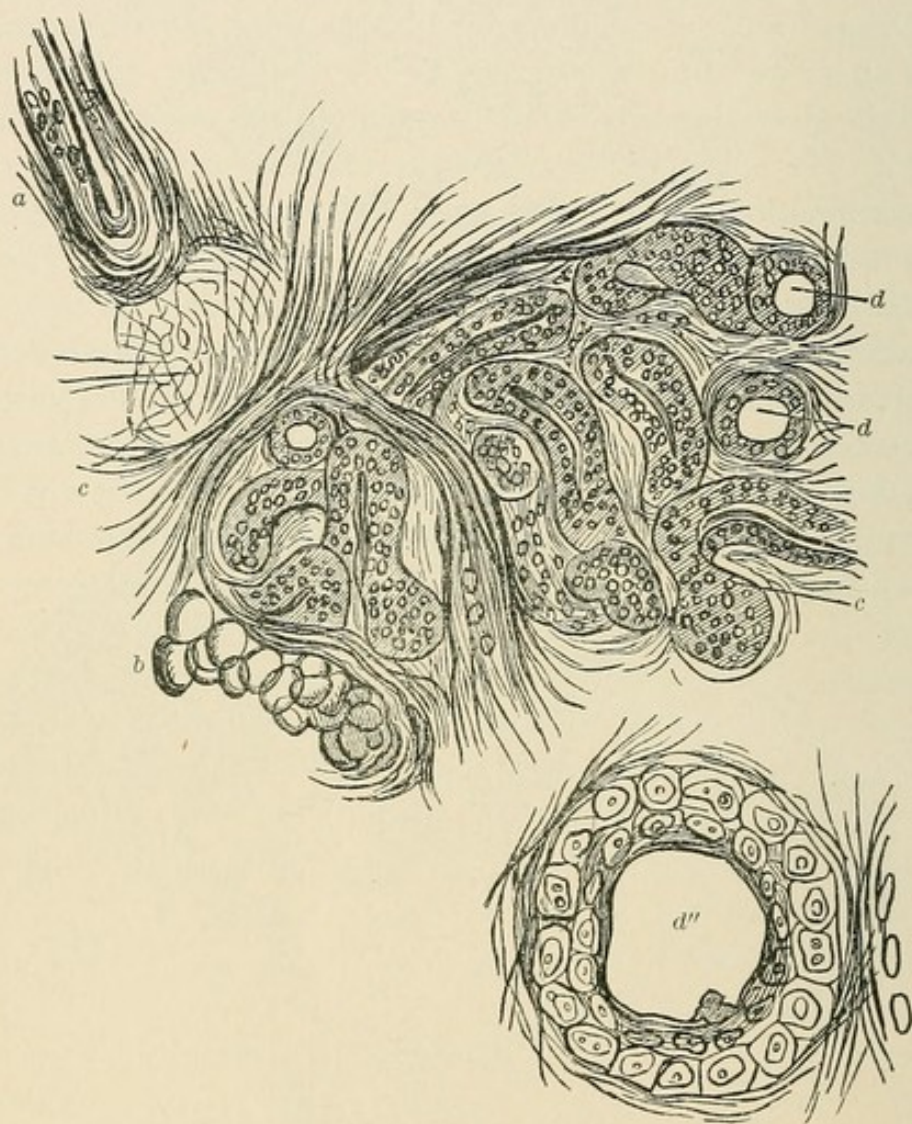


FIG. 71.—Sudoriparous adenoma from skin of frontal region of a woman; transverse section of tubule, $\times 650$ (after Lücke): *a*, hair-follicle; *b*, adipose tissue; *c*, sweat-glands in longitudinal section; *d*, *d''*, the same in transverse section.

operation result in relief for a considerable length of time. In Helfferich's case the pyloric end of the stomach was the seat of a similar affection, and the disease led to extensive glandular metastasis. Nearly all the adenomata of the mucous membrane lining the gastro-intestinal canal present in section under the microscope a tubulated appearance. Adenoma of the rectum (Fig. 72) is more frequent in children than in adults. The tumor increases slowly in size, and in the course of time

becomes pedunculated. Adenomata in this locality usually vary in size from that of a cherry to that of a walnut. At the base of the tumor or pedicle the mucous membrane of the tumor is continuous with that of the rectum. The symptoms are the same as in papilloma.

Nasal Cavities.—Many of the polypoid growths of the nasal cavities are adenomata. Billroth was the first to discover gland-follicles

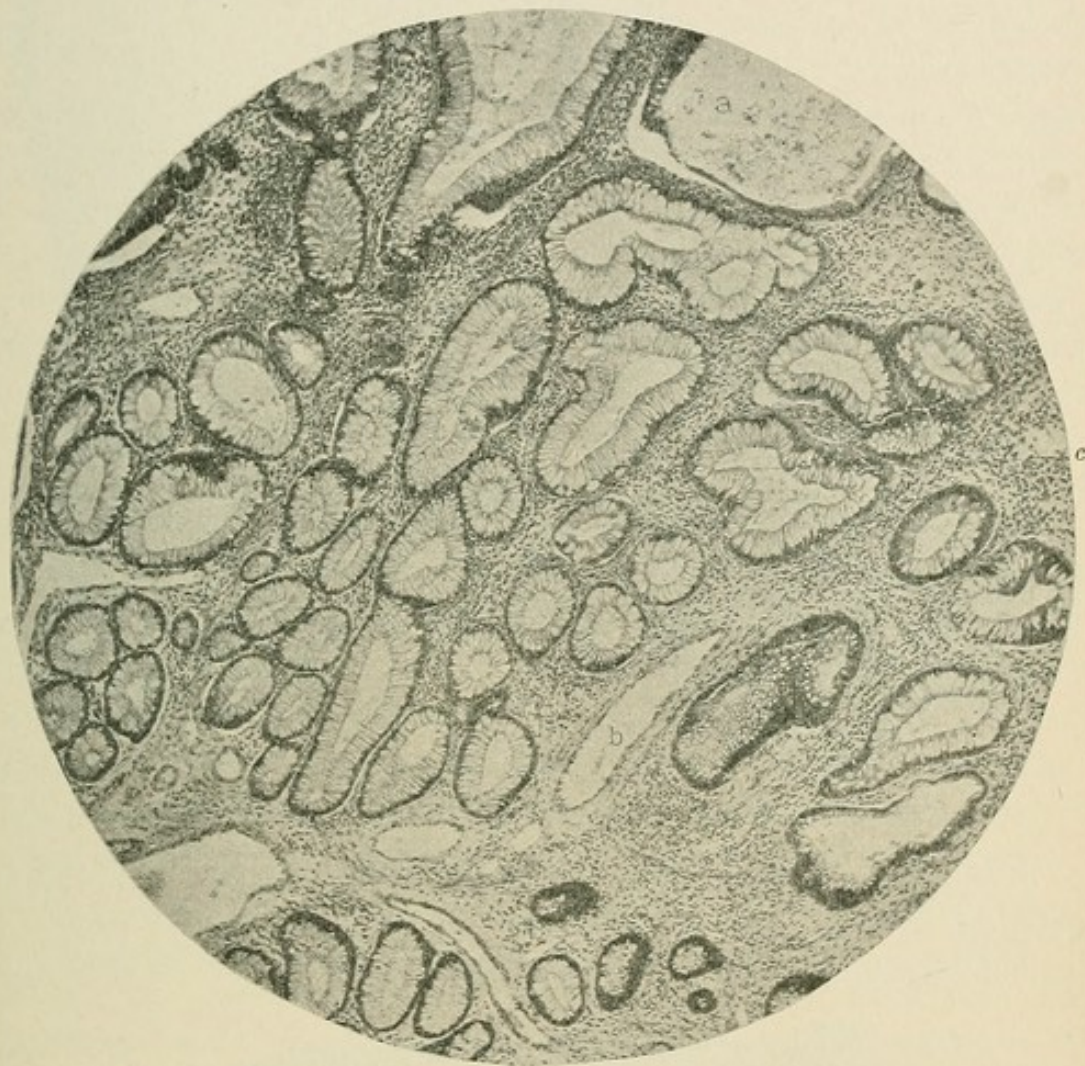


FIG. 72.—Adenoma of the rectum; $\times 48$ (after Karg and Schmorl). The tumor is composed of glandular spaces and, between them, a stroma infiltrated by small cells. The structure of the tubules corresponds with that of the normal glands of the rectum. The glandular spaces are lined with columnar cells with basal nuclei surrounded by the membrana propria. Between the columnar cells here and there can be seen goblet-cells (*c*). Some of the glands are enlarged and are supplied with lateral buds; others are transformed into larger hollow spaces (*a*). At *b* dilated blood-vessels are seen in the stroma.

in the myxomatous polypus of the nose. The connective tissue surrounding the adenomatous growth and the epithelial cells of the mucous membrane covering the tumors are in a hyperplastic condition, caused by an increased blood-supply. Adenoma of the nasal mucous membrane often appears as a multiple affection. Catarrhal inflammation often precedes, and frequently attends, adenoma of the nose.

Uterus and its Appendages.—The uterus is the organ most frequently

affected by adenoma. The development of the tumors in this locality is usually preceded by catarrhal inflammation. The inflammation evidently acts as an exciting cause in diminishing the physiological resist-

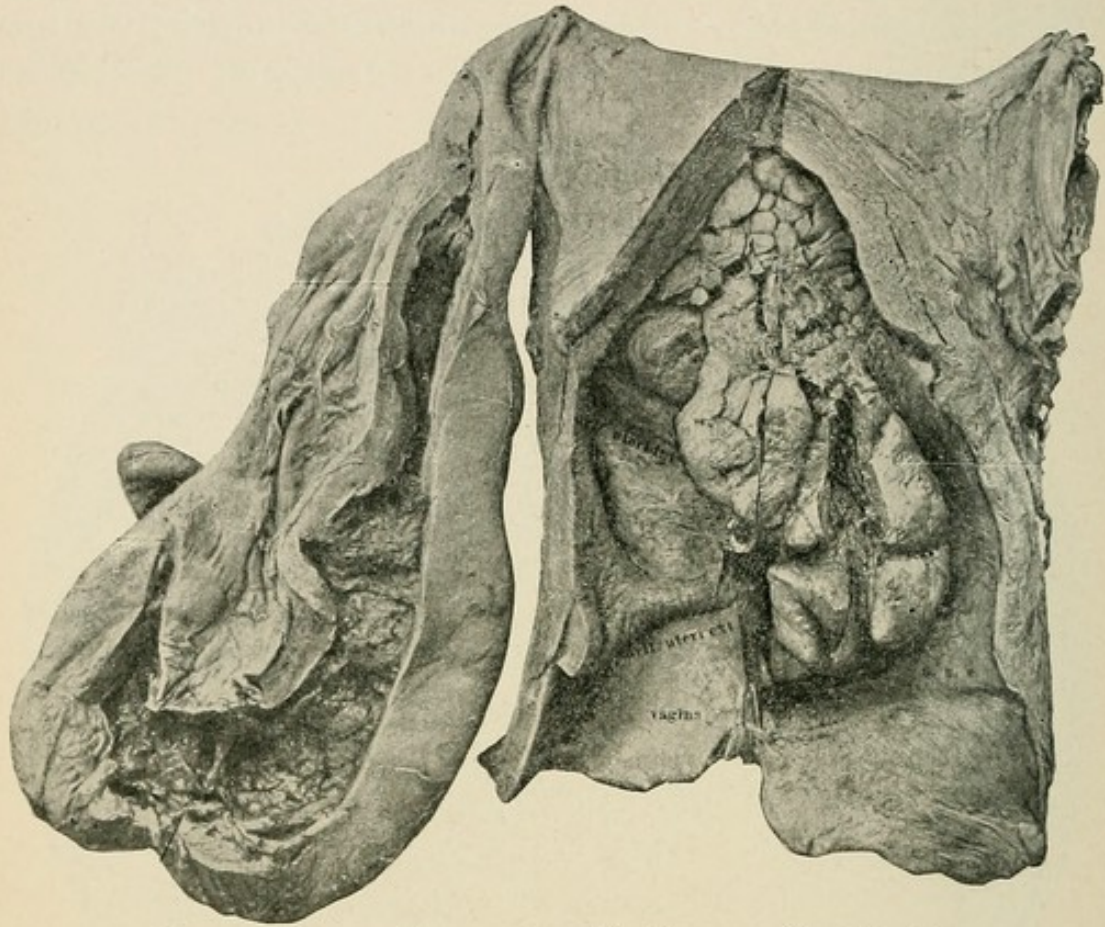


FIG. 73.—Adenoma of the posterior wall of the uterus (after Winckel).

ance of the tissue in the vicinity of the embryonic matrix. The fungous vegetations which so often cover the cervix uteri and its canal—the so-called “erosions”—are either papillomata (see Fig. 63) or adenomata.

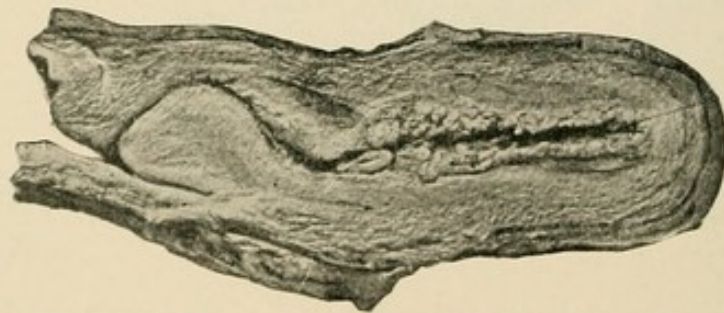


FIG. 74.—Uterine cavity entirely filled with adenomatous vegetations (after Winckel).

In the uterine cavity adenoma is found as a single tumor or in the form of diffuse vegetations covering the entire surface. Adenoma of the uterine cavity (Figs. 73, 74) or of the cervix seldom increases beyond the size of a walnut. The tumor appears first as a small nodule, pushes the mucous membrane before it, and, if it increases to the

size of a cherry, becomes pedunculated. Multiple adenomata of the uterine mucous membrane usually remain sessile. Menorrhagia, a profuse glairy discharge, and dysmenorrhea are some of the most prominent symptoms which point to the existence of adenomata of the mucous membrane lining the uterus.

Adenoma of the Fallopian tubes is a very rare affection. Ascites is sometimes produced by tumors in this locality, as the increased secretion provoked by the tumor escapes into the peritoneal cavity.

Adenoma of the ovary, according to Waldeyer, Thierfelder, and Klebs, does not originate from the Graafian follicles so frequently as was formerly believed. In the majority of cases the tumor starts from an embryonic tubular matrix, a remnant of Pflüger's ducts. Glandular tumors of the ovary appear as globular, nodular tumors of widely different form and size. Some of these tumors become so large that they exceed the weight of the patient. They develop beneath the columnar epithelial cells of the surface of the ovary, within a strong layer of connective tissue in which are imbedded the blood-vessels. In the centre of this vascular connective-tissue layer a small space lined with cylindrical cells marks the beginning of the adenoma and the incipient formation of a cyst. Waldeyer claimed that the glandular spaces are lined by only one layer of epithelial cells, while Rindfleisch, Böttcher, and others found several layers. Into a space thus formed other tubules project and open, forming secondary cysts. If the walls of the secondary cysts, by distention and growth, come in contact, the joint septum formed breaks down and a communication between the cysts is established. Coalescence of many cysts in this manner may result in the formation of enormous spaces. Cruveilhier and Virchow found in the jelly-like, structureless contents of such cysts blood-vessels, the remnants of the broken-down septa. For this kind of glandular cysts Waldeyer proposed the name "myxomatous cysts." In typical adenoma of the ovary the cysts do not reach such great size. Constant friction on the surface of the tumor destroys the epithelial layer and leads to adhesions, which in cases of glandular cysts are often very extensive and firm. From the cyst-wall form buds covered by cylindrical epithelium, projecting into the cyst and presenting the appearance of placental villi (see Fig. 58). These papillary intracystic growths carry with them large vessels and take a very active part in the proliferation of tumor-tissue. By perforation of the cyst-wall these papillary excrescences reach the peritoneal cavity, and undoubtedly have much to do with the production of ascites, which so often attends this form of ovarian tumor. The small cysts contain a jelly-like, homogeneous substance. The larger the cyst the more liquid its contents.

Waldeyer and Spiegelberg found in all cysts of the ovary paralbumin.

Thyroid Gland.—The thyroid is one of the ductless glands. It is only recently that its physiological importance has been ascertained definitely. Clinical observation and experimental research have demonstrated that the complete destruction of the gland by disease or its removal by extirpation results in myxedema and cretinism. It is a compound tubular gland, whose excretory duct, the thyro-glossal duct, in the early stages of the organ connects the tubules with the mucous surface, where its opening corresponds to the foramen cæcum. It is along this tract that remnants of the gland are occasionally found, as well as accessory glands in the vicinity of the organ, which may become the seat of adenomata resembling the structure of the thyroid gland. This gland in its normal condition contains the product of one of the retrograde tissue-metamorphoses—colloid material. It would appear

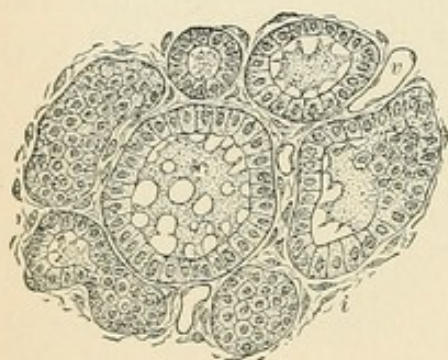


FIG. 75.—Section of thyroid body exhibiting detail of acini, which are cut in various directions (after Piersol): *c*, colloid material distending the larger acini; *i*, interacinous connective tissue; *v*, blood-vessels.

that this tendency of the cells to degeneration into colloid material in a normal condition would naturally predispose adenomata of this organ to the formation of cysts. Virchow divided the benign tumors of the thyroid gland into—(1) Struma hyperplastica; (2) struma gelatinosa; (3) struma cystica. This classification is no longer tenable, as the gelatinous and cystic varieties represent only an advanced stage of adenoma.

The ordinary bronchocele, miasmatic struma, is not a true tumor, but an infective swelling caused by an unknown microbe. Enlargement of the gland from this cause is an endemic affection. The true glandular tumor of the thyroid is produced, like other tumors, from a matrix of embryonic cells. It is in this gland that the essential cause of tumor-formation has been actually demonstrated. Wölfler has found, in the substance of the gland, cell aggregations which did not appear to belong to the gland-structure and which he regarded as remnants of embryonic tissue. From these develop the adenomata. He formulates adenomata as “epithelial new formations which develop from embryonal gland-matrices with atypical vascularization.” Wölfler has shown that the true benign tumor of the thyroid gland is an adenoma. The greater prevalence of adenomata in districts inhabited by miasmatic struma is an important proof of the part taken by the surrounding

tissues in tumor-formation. The physiological resistance of the tissues is diminished by the infective process, and matrices of embryonic cells which have remained in a latent state until then assume active tissue-proliferation and produce a true glandular tumor.

The difference between an infective swelling of the thyroid gland and a true tumor has already been pointed out. A miasmatic swelling yields to the internal and external use of iodine preparations; a true tumor is not affected by this treatment. *Early treatment of a miasmatic struma is a prophylactic measure against tumor-formation, as it restores the physiological resistance impaired by the microbes which produced the struma.* The glandular tumors are always imbedded in the substance of the gland or in the miasmatic struma, and are encapsulated. Frequently they are multiple. Small recent cysts always contain a colloid substance. Multilocular cysts are formed in the same manner as in cystic adenoma of the ovary, by coalescence of two or more cysts. In

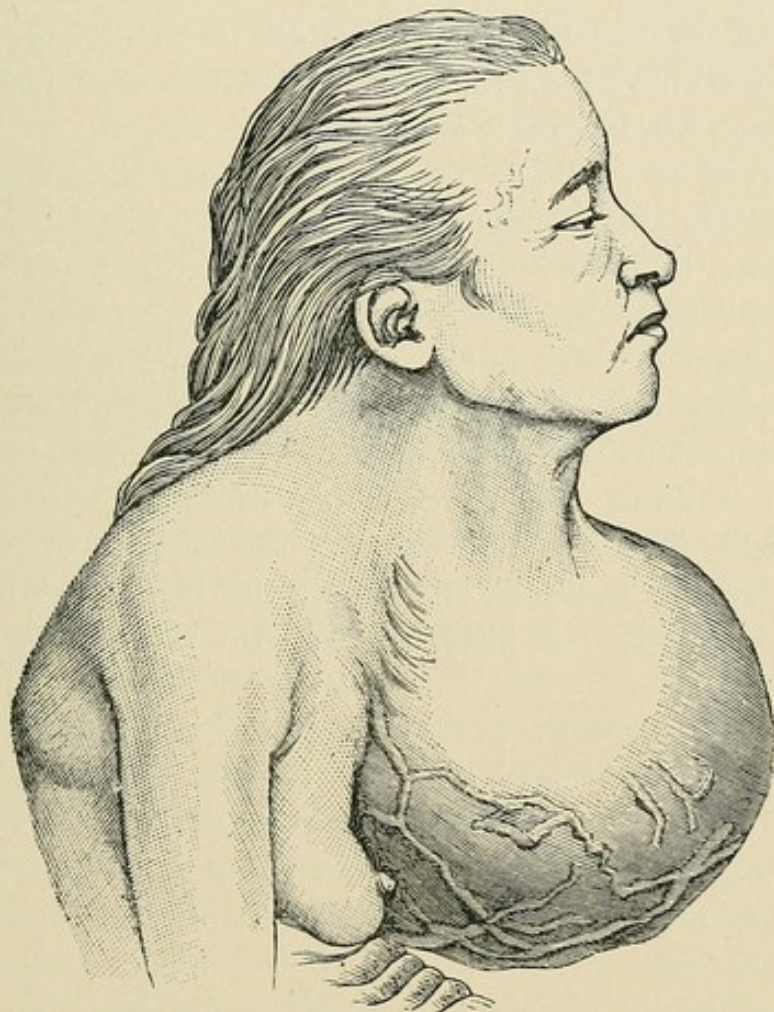


FIG. 76.—Enormous tumor of the thyroid gland (after Bruns).

old cysts the contents become more liquid, and are often changed otherwise by hemorrhage into the cyst and by the formation of numerous cholesterin-crystals. Other forms of regressive metamorphosis are

amyloid, cheesy, and fatty degeneration and calcification. The tumors often attain great size. Rose has shown that death from sudden suffocation is caused by atrophy and softening of the tracheal rings resulting from pressure of the tumor. The trachea in such cases has been found flattened, resembling a sabre-sheath. Pressure-atrophy and flattening of the trachea do not take place in proportion to the size of the tumor. A small tumor, not larger than a hen's egg, of the middle lobe of the gland will do more damage to the trachea than will a large tumor, such as that shown in Figure 76. When a tumor has attained this size pressure-symptoms are often relieved by the weight of the tumor making traction away from the trachea. Retro-sternal tumors give rise to the most distressing symptoms, as the outward growth of the tumor is opposed by the unyielding sternum. Retro-tracheal tumors or tumors encircling the trachea are also the source of great suffering, and demand operative treatment. It is generally known that adenoma of the thyroid gland shows no tendency to increase in size after the patient has reached his fiftieth year. Numerous cases of congenital tumors of the thyroid gland have been recorded. They are most likely to occur in localities where bronchocele is endemic.

If, in a person past middle life, a struma that has been stationary for years suddenly and without any special provocation commences to increase in size, it is very probable that the tumor has undergone transformation into a carcinoma or a sarcoma. Malignant disease of the thyroid gland is more likely to originate in a pre-existing tumor than in a normal gland. Tumors of the thyroid gland always receive a rich blood-supply. The gland is so abundantly supplied with blood from the four thyroid arteries that excessive vascularization of the tumor invariably occurs. The veins of the capsule of the gland, if the tumor is large or multiple, often attain the size of the little finger; the superficial veins in such instances are also enormously dilated (see Fig. 76).

The differential diagnosis in tumors of the thyroid gland has for its object to distinguish between infective swelling, adenoma, cyst, carcinoma, and sarcoma. A miasmatic bronchocele presents itself as a smooth swelling involving usually the entire gland. It is endemic in certain districts in some countries (Switzerland and Austria), and it appears usually during childhood or at the age of puberty. A few weeks' treatment with preparations of iodine will make an impression on the swelling. Adenoma commences as a small nodule in the substance of the gland, and follows the movements of the gland during deglutition. Adenoma is often multiple from the beginning, or additional nodules appear in different parts of the gland in succession.

Sarcoma and carcinoma develop in preference in a gland affected previously by infective swelling or by adenoma, and occur, as a rule, in adults and in persons of advanced age. The malignant tumors grow rapidly in size, and soon render the tumor immovable by extension to the surrounding tissues. Cysts frequently mark an advanced stage of an adenoma. Unless the cyst-wall is very tense, fluctuation can be elicited without difficulty. If any doubt exists, an exploratory puncture will furnish the desired information. A miasmatic swelling or an adenoma of the thyroid gland is prone to become the seat of microbic infection during an intercurrent infective disease. Tavel studied this subject very exhaustively from a bacteriological aspect, and reported a number of cases of strumitis in which he found in the inflamed tumors microbes similar to those which caused the general infective disease, notably typhoid fever.

Treatment.—Owing to the importance of the operative treatment of tumors of the thyroid gland, this subject will be discussed separately. The most efficient treatment of miasmatic bronchocele is by the internal and external use of iodine. The parenchymatous injections of iodine so extensively used by Lücke are no longer popular. It has been followed by disastrous results in a number of instances. Paralysis of the recurrent laryngeal nerve, great swelling, and suppuration are some of the immediate complications occasionally caused by this method of treatment. The late Professor Gunn used parenchymatous injections of a 5 per cent. solution of carbolic acid, repeated once or twice a week, with great success, and this method has remained in constant use in the clinic of Rush Medical College, and is yielding excellent results. It is perfectly safe, almost painless, and the carbolic acid appears to neutralize the primary microbic cause. The iodine treatment is employed at the same time. The injection should be made into different parts of the tumor, and should be repeated at least twice a week.

Extirpation of the thyroid gland for tumor is a comparatively recent operation. J. Collins Warren of Boston extirpated one lobe of the thyroid gland, after preliminary ligation of the common carotid artery on the same side. He believed that the operation was impracticable without resorting first to tying of the common carotid artery. Green practised rapid removal of the tumor, and ligated the bleeding vessels later. Rose tied each vessel before cutting, proceeding very slowly. The writer in 1878 witnessed one of his operations, which lasted for four hours. The operative technique of strumectomy has been perfected chiefly by the teachers of surgery in the universities of Switzerland—Billroth, Lücke, Julliard, Reverdin, Socin, and Kocher—men who were frequently called upon by patients from localities in which

bronchocele prevailed as an endemic affection. Kocher was the first to call the attention of the profession to the evil results following complete removal of the thyroid gland. He observed, in a number of cases in which he removed with the tumor the entire gland, a condition which he termed *cachexia strumipriva*, which resembled what was later discovered to be myxedema. This subject then received careful experimental investigations which corroborated Kocher's observations. Zesas found in his experiments on dogs that if only a part of the gland is extirpated the remaining part undergoes compensatory hypertrophy, and that complete removal of the gland resulted sooner or later in the death of the animal. Similar experiments with the same results were made by Bardeleben and Horsley. *The experiments have taught surgeons that complete extirpation of the thyroid gland except for malignant disease is an unjustifiable operation.* A part of the gland must be allowed to remain in order to prevent the probable occurrence of serious remote complications.

Partial extirpation of the thyroid gland is still in use in the removal of benign growths, and complete strumectomy is absolutely necessary in the extirpation of malignant tumors. The external incisions selected for this purpose must be made in accordance with the size and location of the tumor. An incision along the margin of the sterno-cleido-mastoid muscle will secure good access for the removal of tumors or for extirpation of the lateral lobes. A median incision will reach tumors of the isthmus most directly. In large tumors or in tumors involving both lobes a transverse incision over the most prominent part of the tumor, with the concavity directed upward, is preferable. So far as possible, the vessels should be ligated or be secured with pressure-forceps before being cut. This ligation is especially necessary when the thyroid arteries are reached. The isthmus of the gland is included in a ligature *en masse*. The operation should be performed slowly and carefully, and all tissues should be identified before being cut, to avoid injury to the recurrent branch of the pneumogastric nerve. Accidental section of this nerve is followed by paralysis of the vocal cords on the same side, which paralysis will in all probability remain as a permanent disability.

Extirpation of parts of the thyroid gland has largely given way to enucleation, an operation devised by Socin and strongly endorsed by Julliard. It is the ideal operation, as it leaves the gland-tissue intact. This operation is not limited to the removal of small growths, as the enormous tumor depicted in Figure 76 was successfully removed by the same procedure. *All glandular and cystic tumors of the thyroid gland are enclosed by a thick connective-tissue capsule which can be separated from the surrounding tissues with ease and without much hemor-*

rhage. The great secret in the successful removal of glandular and cystic tumors of the thyroid gland is to find the exact place, between capsule and tissues, at which to commence the enucleation. The dissection down to the capsule must be made with the utmost care, and no attempts at enucleation should be made until the proper place is found. As soon as the capsule is reached the knife must be laid aside and the tumor be enucleated by the use of the finger or of blunt instruments. The parenchymatous hemorrhage generally yields to pressure and hot water, or, in case it is not controlled in this way, to the aseptic tampon. If the aseptic tampon is not used, the mantle of thyroid tissue which was cut in exposing the tumor should be sutured with absorbable material separately before closing the external wound. If the tampon is employed, it is removed at the end of the first day and the wound is closed by secondary sutures. If more than one tumor is found, all the tumors can be removed through the same external incision by approaching them through separate incisions through the capsule or veil of gland-tissue which invariably covers them. The great advantages of enucleation over extirpation are greater ease of operation, less liability to troublesome hemorrhage, less deformity, and, lastly, that it does not deprive the patient of any normal gland-tissue, which has been found of such enormous importance in the preservation of health.

Wölfler revived the operation of ligating the thyroid arteries in the treatment of tumors of the thyroid gland. This operation, of course, can attain what is claimed for it only in parenchymatous tumors. Cysts should invariably be enucleated unless calcification of the capsule has so far advanced as to render this procedure impracticable. Adenomata should be dealt with in the same manner unless the capsule of the tumor has become firmly attached to its surrounding tissues by an antecedent inflammation. Extirpation should be limited to tumors that cannot be enucleated, and it should never include the entire gland except in the removal of malignant tumors.

Mammary Gland.—The benign tumor most frequently met with in the mammary gland is the adenoma. Until quite recently it was generally conceded that the firm tumors of the mammary gland were in the majority of cases fibromata. Careful study under the microscope of sections from such tumors has shown that glandular elements are absent only in exceptional cases, and consequently that most of the benign tumors of the gland are not fibromata, but adenomata. Schimmelbusch has shown that the tumors of the breast heretofore designated as fibromata are in reality tumors in which the adenomatous structures predominate—an opinion strongly supported by Haeckel. *In order to realize the true nature and structure of such*

tumors it is absolutely necessary to examine sections from different parts of the tumor. Some sections from the same specimen will often show epithelial cells almost exclusively, while other sections exhibit only fibrous tissue. The presence of epithelial cells in different parts of the tumor, however, leaves the impression that they take the essential part in the production of the tumor. Billroth denied that epithelial cells took any part in the origin and growth of tumors of the breast, which he designated as fibroid tumors. The adenoid structure is well marked in the tissues of young tumors, while in old tumors the epithelial cells are found arranged in an irregular manner in the

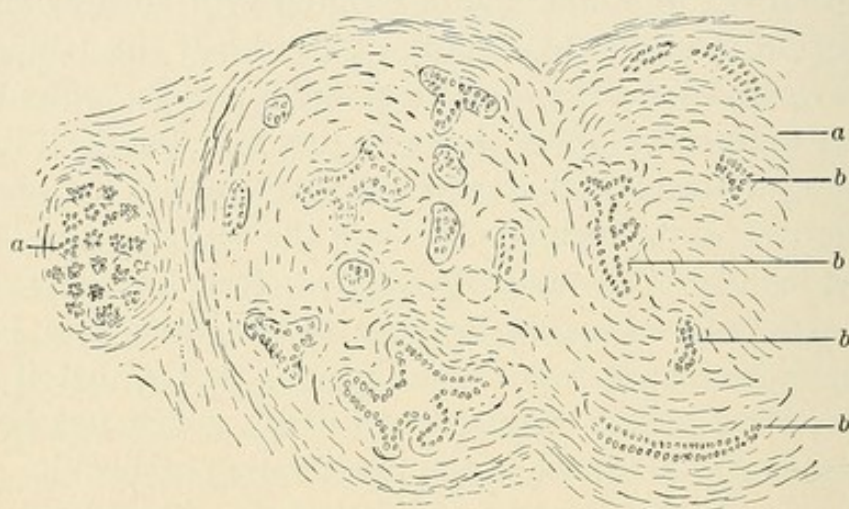


FIG. 77.—Adenoma of mamma (after Haeckel): *a*, fibrous tissue; *b*, epithelial cells. (Zeiss, Obj. A., Oc. 2.)

connective-tissue spaces. Figure 77 shows that the connective tissue has separated the acini, but the glandular appearance is well preserved. The fibrous tissue is increased by active proliferation of the interacinous connective tissue, and the new elements impart to the tissues a grayish-red or yellowish color instead of the pearly-white color of old connective tissue. At some points in the older portions of the tumor the fibrous tissue is pale and firm, at others oedematous or myxomatous.

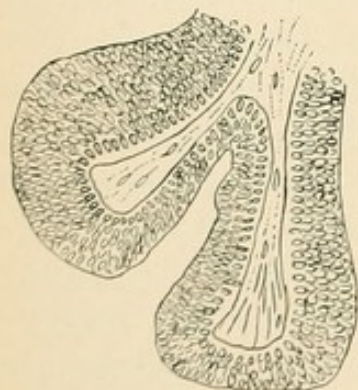


FIG. 78.—Pure adenoma of the mammary gland (after Haeckel). (Zeiss, Obj. D., Oc. 2.)

It is a question whether pure fibromata ever occur in the mammary gland. Unmixed adenomata are also exceedingly rare. Haeckel had an opportunity to remove and examine a pure adenoma of the breast, and he gives the accompanying illustration (Fig. 78) to explain its histological structure. The tubules were lined by at least twenty strata of epithelial cells.

The writer removed a tumor the size of a hazelnut from the breast of a young lady, and from its firmness

was led to believe the tumor to be a fibroma. The macroscopical appearance of a section of the tumor showed wavy bundles of connective tissue, thus confirming the opinion formed. Under the microscope the tumor revealed itself as a genuine adenoma. The microscopic appearance of the tumor-tissue and the relative proportion of glandular and connective tissue are shown in the accompanying illustration (Fig. 79). It will be seen from this illustration that, although the tumor had existed for several years, the tubules are lined by a number of layers of epithelial cells and that the glandular spaces are small. We have

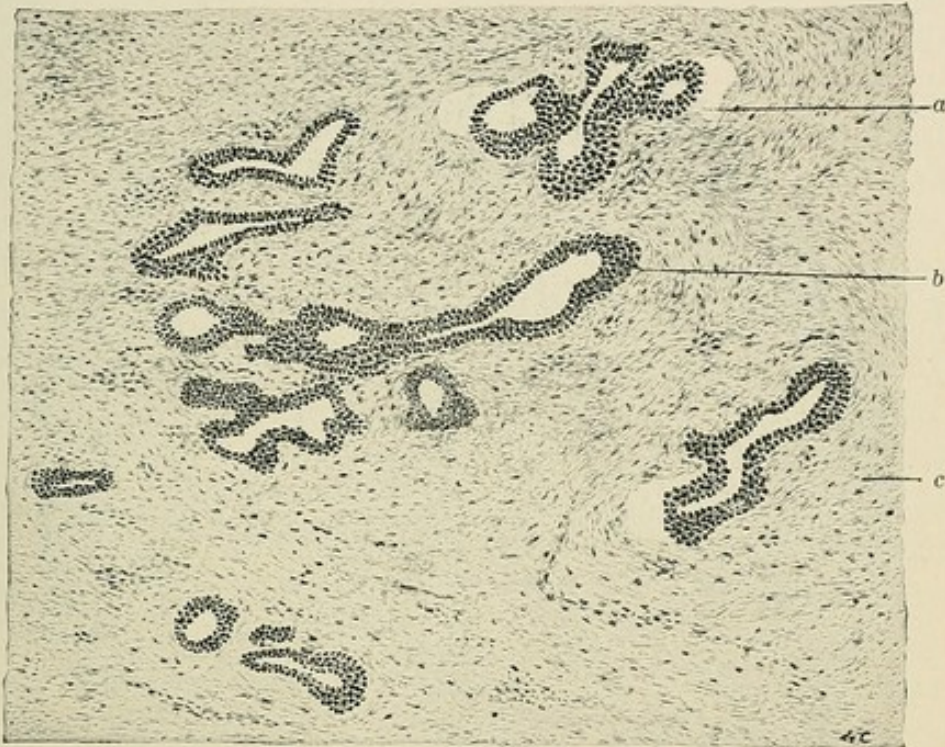


FIG. 79.—Adenoma of breast; $\times 115$, reduced one-fifth (Surgical Clinic, Rush Medical College, Chicago): *a*, shrinkage due to hardening; *b*, proliferating ducts; *c*, fibrous tissue.

reason to believe that during the future growth of such a tumor the stroma would increase more than the parenchyma, and so render the fibrous structure more apparent. Adenomata without cyst-formation never attain a large size. Usually they range in size from that of a pea to that of a walnut; 99 per cent. of them occur in females. Adenomata occupy more frequently the superficial and peripheral than the deep and central parts of the gland. They are often multiple in one breast, seldom in both breasts. They often cause great pain and are quite tender on pressure. These symptoms are much less prominent in the early history of carcinoma of the breast. Adenoma of the breast (Fig. 80) is always well encapsulated. Adhesion to the skin and retraction are

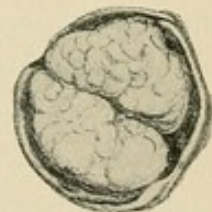


FIG. 80.—Adenoma of the breast, showing capsule (after Astley Cooper).

therefore never observed. The existence of a well-defined capsule is of great assistance to the surgeon in doubtful cases after he has exposed the tumor to make a positive diagnosis of its non-malignant nature. A section of the tumor (Fig. 81), if the fibrous tissue predominates, very much resembles in its naked-eye appearances fibroma of the uterus. The surface of the section appears as though the tumor were composed of separate parts, each of which indicates a different centre of growth. Cystic adenoma often attains great size. The contents of the cysts are variable. Colloid degeneration seldom takes place. The serous fluid is

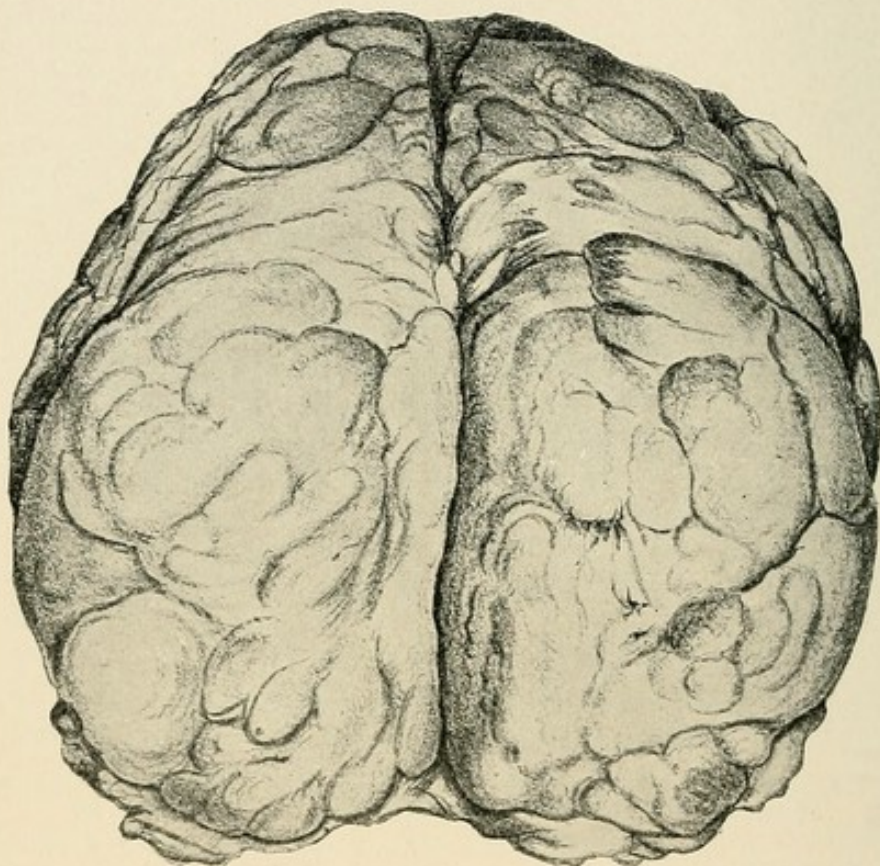


FIG. 81.—Large adenoma of breast, cut surface resembling fibroma of the uterus (after Astley Cooper).

often stained a dark color, owing to the presence of blood and cholesterin-crystals. The writer has found cystic degeneration most frequent in women advanced in years. In the diagnosis it is important to remember that carcinoma seldom, if ever, occurs in the breast as a multiple affection, while this is frequently the case in adenoma. Retraction of the nipple and the skin may follow inflammatory affections of the breast, but is never present in uncomplicated adenoma, and is of frequent occurrence in carcinoma. Adenoma resembles more closely sarcoma than carcinoma. Sarcoma, however, grows much more rapidly than carcinoma, and is usually attended by dilatation of the superficial veins. Adenoma and sarcoma occur frequently in young adults, while carcinoma is seldom met with in women less than thirty-five years

of age. The prognosis must always be guarded, as adenoma of the breast undergoes transformation into malignant tumors—carcinoma and sarcoma—perhaps more frequently than any other benign tumor. Early operative removal should be recommended, as an operation brings mental as well as physical relief, and protects the patient against the possibility of the occurrence of malignant disease caused by the transition of a benign into a malignant tumor.

Prostate Gland.—The prostate is a glandular organ and part of the genital apparatus. It was until recently supposed that the enlargement of this gland in men past fifty years of age was a tumor resembling myofibroma of the uterus. This idea, in the light of recent investigations, has been abandoned, and the enlargement is now regarded as a glandular swelling or tumor. White of Philadelphia ascertained by his experiments on dogs that castration resulted almost uniformly in great diminution in the size of the prostate. Surgeons have made use of the knowledge thus gained, and in a few instances have resorted to castration for the relief of enlargement of the prostate gland. Ramm of Christiana reports two cases in which this operation afforded permanent relief and was followed by progressive diminution in the size of the gland. Harrison of London reports a case of hypertrophy of the prostate greatly benefited by subcutaneous section of the spermatic cord on both sides. The patient begged to have castration performed, and as a compromise Harrison made subcutaneous section of both cords. Should future operations produce similar results, they would prove that in the majority of cases enlargement of the senile prostate is not a tumor, but a swelling. The writer is firmly convinced that in most instances this is the case. There is, however, a tumor of the prostate that is glandular in structure and that appears as a single or a multiple affection involving any or all of the lobes of the gland. The general enlargement of the gland consists of a hyperplasia of the glandular and connective-tissue part of the gland; the isolated nodules are adenomata. Adenomata are found almost exclusively in hyperplastic glands, in this respect bearing a strong resemblance to adenomata of the thyroid gland. The hyperplasia of the organ occurs as one of the many pathological conditions incident to old age, in the production of true tumors taking the same part as the miasmatic struma. The prostate, like the uterus and the thyroid gland, is an organ in which and around which complicated developmental changes take place; consequently there is here, as in the other organs mentioned, great liability of the deposition of unutilized embryonic cells which later become the essential tumor-matrix. So long as the physiological resistance of the tissues around the matrices remains unimpaired, tumor-growth does not

take place, but when this resistance becomes diminished by senile debility, and particularly by the changes which the prostate undergoes during advanced age, the embryonic cells assume active tissue-proliferation which results in the formation of a tumor. Billroth asserted that he never observed an adenoma in the prostate gland, and he attributed the senile enlargement to dilatation of the acini and hyperplasia of the epithelial cells. It took a long time for pathologists to make a distinction between hyperplasia of the thyroid gland and the adenomata, and the same confusion has prevailed in regard to the two entirely different kinds of enlargement of the prostate gland. The extirpation of the hyperplastic prostate *in toto* has not yielded encouraging results, and will never become a feasible surgical procedure; on the contrary, enucleation of adenomata of this organ from the perineum through Zuckerkandl's incision or through the bladder above the pubes has a promising future.

Lachrymal Gland.—Adenoma of the lachrymal gland has been studied by P. Becker and others. It appears as a lobulated, nodular tumor of moderate size, and it is very liable to undergo hyaline degeneration. The tumor increases in size very slowly, and the formation of small cysts is of frequent occurrence. Enucleation of the tumor should be done in preference to extirpation of the whole gland.

Parotid Gland.—According to C. O. Weber, the parotid gland is very rarely the seat of adenoma. Billroth maintained that adenoma of this organ, when it does exist, is only a part of a compound tumor. It cannot be denied that compound tumors of the parotid gland, such as adeno-chondroma, adeno-cystoma, and adeno-carcinoma and adeno-sarcoma, are frequently met with in the examination of tumors of this organ. Pure adenoma of the parotid gland has, however, been found, and it resembles in structure similar tumors of the thyroid gland. Glandular tumors occur most frequently in young adults. Cystic degeneration often takes place at different points, large cavities being formed by the coalescence of smaller cysts. The cyst-wall, lined by epithelial cells, often projects into the cysts at different points in the form of papillary excrescences. The tumor is well encapsulated, and it can be enucleated very readily without serious damage to the gland. The incision should be made with special reference to the location and direction of Stenson's duct and the branches of the facial nerve. A thin veil of gland-tissue has to be divided before the capsule of the tumor is reached, and the operation occasionally results in the formation of a temporary salivary fistula.

Testicle.—The relative proportion of true tumors of the testicle to inflammatory swellings is unusually small. Adenoma of the testicle

has only recently been described. Lücke called attention to its existence in connection with cystic disease of the testicle. Eve has examined a large number of cysts, including adeno-cystoma, sarcomata, myxomata, and carcinomata; they were lined with columnar, stratified, or ciliated epithelium; some were papillomatous, and cartilage and unstriated muscular fibres were occasionally present in the stroma. The adeno-myxomata were characterized by slit-like tubes or solid rods of gland-tissue surrounded by a zone of transparent tissue. Eve and Sutton believe that the majority of glandular tumors of the testicle originate in the remnant of the Wolffian body lying between the globus major of the epididymis and the testicle proper. This remnant of the Wolffian body is known as the "paradidymis."

Adenoma of the testicle is characterized by the existence of numerous small cysts. The cyst-spaces are lined with columnar or stratified epithelium. If the tumor attains large size, it causes atrophy of the testicle by pressure. The tumors are encapsulated, but in the few cases that have come under the observation of the writer their enucleation has been found quite difficult. The tumors varied in size from a hickory-nut to a walnut, and on section presented a honeycomb appearance, owing to the presence of numerous cysts, the largest of which did not exceed the size of a hempseed.

The differential diagnosis of adenoma of the testicle must take into consideration tuberculosis, gumma, carcinoma, sarcoma, and circumscribed hydrocele of the tunica vaginalis. In the removal by enucleation great care is required in preventing injury to the cord and the testicle.

Liver.—Adenoma of the liver during the last year or two has become a more interesting topic to the surgeon from the fact that in several cases tumors of this kind have been removed successfully by excision. Keen and Von Bergmann have each reported a successful case. The earliest communications on adenoma of the liver were made by Hoffmann and Lancereaux. Gruber, Wagner, and others have found detached portions of liver-tissue, often very numerous, in the peritoneal folds supporting the liver and in the portal fissure; these fragments may be a possible source of cysts and tumors. Friedreich found in the liver itself groups of cells which did not appear to form part of the parenchyma, as they were isolated from it by a capsule. These embryonic remnants are undoubtedly the matrices from which adenomata originate. Isolated tumors may be no larger than a marble; larger tumors are formed by a collection of multiple tumors. In some parts of the tumor the seat of active proliferation, metaplastic conditions of the parenchyma-cells are developed, as in a case reported by

Rindfleisch-Griesinger: the nodules in the acini of this specimen were

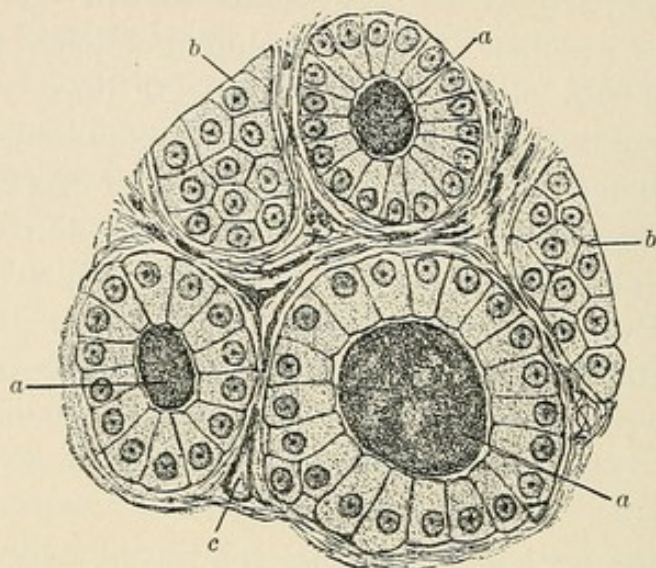


FIG. 82.—Adenoma of the liver (after Paul): *a*, section of blind duct filled with green fluid; *b*, liver-cells; *c*, connective tissue.

made up of columnar epithelial cells. Small adenomata, consisting of cylinders lined by columnar epithelium and imbedded in fibrous tissue,

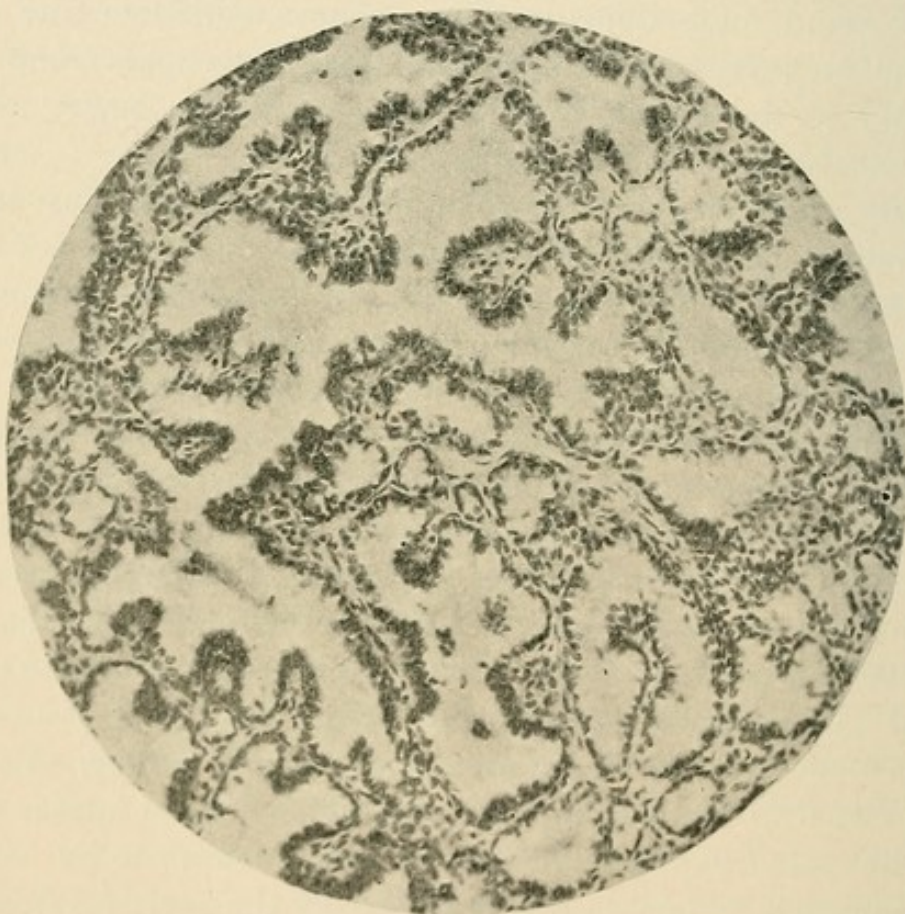


FIG. 83.—Papillary adenoma of kidney; $\times 250$ (after Karg and Schmorl): hollow spaces lined by cylindrical cells; stroma scanty and moderately cellular; papillary proliferations project into the glandular spaces.

occur (Fig. 82). The acini may be solid and hard, or they may consist of large cells and may resemble the acini of the pancreas. A slow-

growing tumor in the substance of the liver in a non-syphilitic subject would indicate the necessity of making a careful investigation with a view of determining the propriety of an abdominal section to make a positive diagnosis, and, if the tumor is found to be an adenoma, to attempt its removal. In the cases thus far operated upon a positive diagnosis was made only after the tumor was rendered accessible to direct examination by abdominal section.

Kidney.—The frequency with which the kidney is now subjected to operative treatment adds renewed interest to everything pertaining to the pathology of the numerous affections of this organ that have recently been brought within the reach of successful surgery. Very little is known of benign tumors of this organ. Occasionally small cystic adenomata are found, some of which are undoubtedly derived from retention-cysts, but it is also probable that Wolffian-body rests may be a cause. Shattock maintains, with good reason, that remnants from the mesonephros (Wolffian body) and the metanephros (true kidney) often serve as matrices for tumor-formation. The papillomatous projections into the cysts of renal adenomata as well as the cyst-wall are covered with columnar epithelium which bears no resemblance to the epithelial cells lining the uriniferous tubules (Fig. 83).

Adenomatous tumors of the kidney sometimes reach a considerable size in case the cysts are large and numerous, as in Mr. Edmunds' case (Fig. 84). The kidney represented in Figure 84 was successfully removed by Mr. Edmunds from a girl eighteen years old. Such a tumor might easily be mistaken for a sarcoma.

Diagnosis.—The differential diagnosis between adenoma and other glandular affections is of great practical importance, often is exceedingly difficult owing to the location of the organ affected, and is frequently rendered more perplexing by misleading statements on the part of the patient.

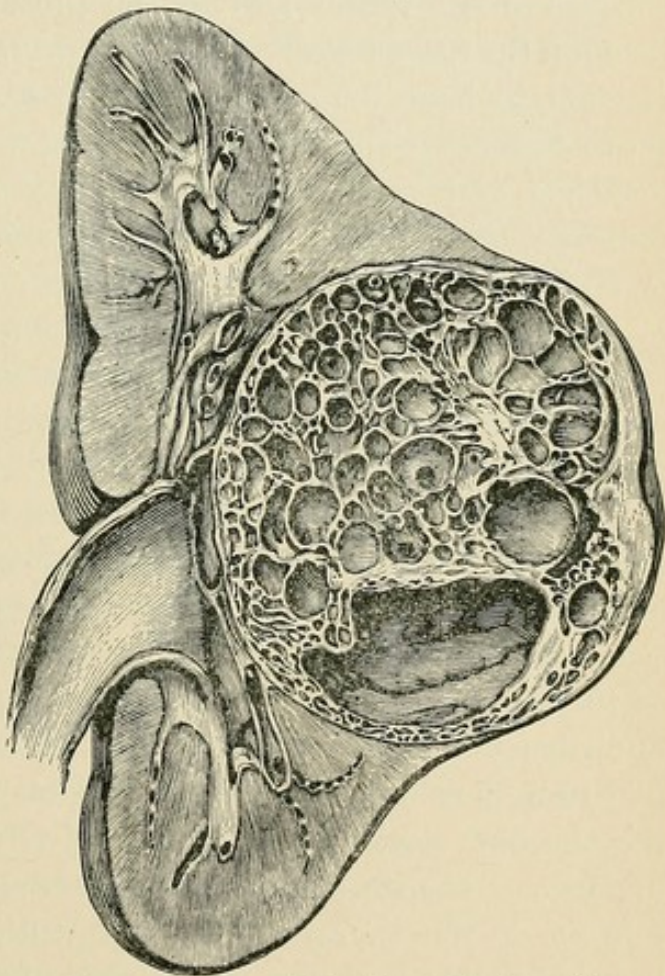


FIG. 84.—Adenoma of the kidney (after Edmunds).

Chronic infective swellings, tuberculosis, and gumma are most likely to be mistaken for adenoma. Mistakes of this kind have sometimes been made by careful and competent surgeons. Search for additional evidences of the primary cause of infection will frequently furnish valuable information. In gumma of the testicle the presence of other less apparent tertiary lesions and the existence of tuberculosis in other organs are points upon which the surgeon often rests his diagnosis in differentiating between an adenoma and an infective swelling. The central part of an infective swelling frequently degenerates and liquefies, still further complicating the diagnosis between a cystic adenoma and an infective swelling. An exploratory puncture is often of great value in ascertaining the character of the contents of a doubtful swelling. Primary tuberculosis does not often attack the organs which are the favorite seat of adenoma. Tuberculosis of the mammary, thyroid, and prostate glands is a comparatively rare affection. Carcinoma of a gland differs from adenoma by the absence of any attempts at encapsulation of the tumor and by the presence of regional dissemination through the lymphatics. *Metastasis never attends adenoma.* Cohnheim claimed to have found metastasis in a case of adeno-myxoma of the thyroid gland. The tumor perforated a vein-wall, and fragments were detached and reached the pulmonary vessels, where the secondary tumors were found. It is more than probable that in this case, the only one of the kind on record, the tumor was malignant, the strongest proof of this being the manner in which the tumor reached the lumen of the vein. Sarcoma in its earlier stages resembles adenoma, but its more rapid growth and the local and often general infection are the most important points upon which to base a correct diagnosis.

Prognosis.—Adenoma without cyst-formation never grows beyond certain limits, so that it seldom interferes with important functions by its presence. Adeno-cystoma of the ovary often reaches an immense size. Adenoma of the middle lobe of the prostate and of the isthmus of the thyroid gland of moderate size gives rise to serious symptoms of obstruction. With the exception of adenoma of the prostate, glandular tumors seldom originate in persons advanced in years, and usually they become stationary at the age of fifty. Adenoma not infrequently undergoes transformation into carcinoma or sarcoma. Malignant tumors of the thyroid gland frequently have such an origin. The transition into carcinoma is observed oftener than a resulting sarcoma.

Treatment.—Most of the adenomata can be removed successfully by enucleation. In adenoma of the breast the surgeon is often in doubt as to whether the tumor is benign or malignant when the operation is undertaken. A positive diagnosis can be made after the tumor has

been reached. If the tumor is an adenoma, it is supplied with a perfect capsule, and can be shelled out from its bed without any difficulty; if it is a carcinoma, all evidences at limitation of the growth are absent, the tumor infiltrates the surrounding tissues, and the operation is incomplete unless the entire breast and all of the axillary glands are removed. If any doubt exists in the mind of the operator in cases of glandular tumors of the breast, the patient should be informed beforehand that conditions might be revealed by the operation which would necessitate removal of the entire breast. In the enucleation of benign tumors of the breast the incision should be made in the direction of the milk-ducts, and the capsule of the gland should be sutured separately after the removal of the tumor.

Adenomata of the uterus and cervix are usually removed by the use of the sharp curette. Preliminary rapid dilatation of the cervical canal and thorough disinfection of the parts are essential in effecting complete removal of the diseased tissue and in preventing septic infection. Tamponade of the uterine cavity with iodoform gauze and rest in bed for at least a week will add to the beneficial effects of the operation and will minimize the liability to complications.

Cystic adenoma of the kidney does not justify nephrectomy, as the opposite organ is frequently found similarly affected. If the kidney has been exposed by a lumbar incision and the nature of the tumor has been determined, enucleation or partial nephrectomy is preferable to complete removal of the organ.

Adenoma of the liver may become an object of operative treatment if the abdomen has been opened for the purpose of determining the nature of an obscure tumor of that organ. The hemorrhage after removal of the tumor by enucleation or excision should be arrested by the employment of the aseptic tampon, which is brought out at the upper angle of the wound, by the application of the actual cautery, or by suturing Glisson's capsule, as advised by Von Bergmann.

XV. CYSTOMA.

THE term "cystoma" in this book will be used in the most restricted histogenetic sense, and will be applied only to those cysts in which both cyst-wall and contents are formed anew and independently of pre-existing gland-structures. A sharp etiological distinction must be made between a cyst, in the ordinary sense in which this word has been used, and a cystic tumor or cystoma. The word "cyst" has been used very indiscriminately to indicate the existence in a closed cavity of various solid and liquid contents. It has been, and is still, used to designate the existence of the products of extravasation, inflammation, and retained secretions in a closed cavity. We shall limit the term "cystoma," cystic tumor, to cystic formations in which *the cyst-wall is produced from a matrix of embryonic cells, and the contents are the products of tissue-proliferation of the cells lining the cyst-wall*. Used in such a limited sense, a cystic tumor is a hollow tumor, the interior of the cyst-wall being lined by epithelial or endothelial cells. The cells lining the cyst-wall are the essential tumor-cells. Retention-cysts and cysts caused by extravasation or inflammation will be excluded from this section. The epithelial lining of the cyst-wall is derived either from the epiblast or the hypoblast or is composed of endothelial cells. We have already described adeno-cystoma and proliferating adeno-cystoma in the section on Adenoma. In adeno-cystoma the glandular structure of the tumor predominates, the cystic part being accidental and usually limited. Proliferating cysts may attain great size, but the glandular part predominates permanently. The epithelial cells correspond in shape and structure to that part of the epiblast or the hypoblast from which the matrix is derived. In cysts representing mucous membrane and ducts the cells are usually columnar; in cysts of epiblastic origin the cells are flat, corresponding to the pavement epithelium of the skin (Fig. 85). Cysts composed exclusively of mesoblastic tissue are lined by endothelial cells. *Heterotopic* cysts are cysts lined with epithelial cells and entirely disconnected with tissues or organs of epiblastic or hypoblastic origin. *Mesoblastic* cysts are never heterotopic, as connective tissue can be transformed into endothelial cells and endothelial cells into connective tissue, and connective tissue is present in the body everywhere.

Sterile cysts are cysts in which the epithelial or endothelial lining has disappeared by degeneration of its cells (Fig. 85, *d*).

Growth of a cyst will continue so long as the cells lining the interior of the cyst-wall continue to proliferate. When the cells are destroyed by degeneration or otherwise the contents of the cyst cease to increase, and the cyst remains stationary or diminishes in size. In Figure 85 the cystic spaces at *b* and *c*, being lined by proliferating epithelial cells,

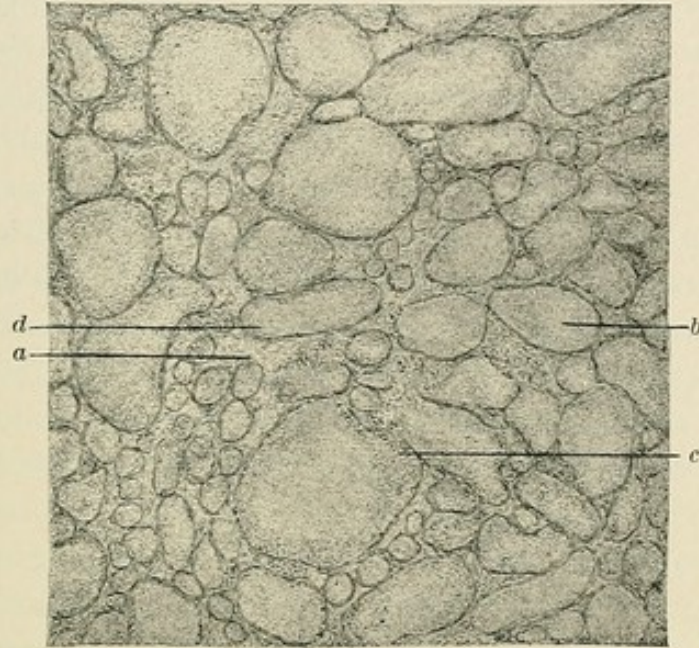


FIG. 85.—Adeno-cystoma of thyroid gland; $\times 50$, reduced one-third (Surgical Clinic, Rush Medical College, Chicago): *a*, stroma; *b*, acinus filled with colloid material and lined by epithelial cells; *c*, epithelial lining; *d*, acinus from which all epithelial cells have disappeared, constituting a sterile cyst.

would increase in size by the addition of new colloid material to the contents of the cyst, while the space at *d* would remain stationary in size, because all the epithelial cells have been destroyed by degeneration, and with the destruction of the epithelial cells the cyst has been deprived of any further source of colloid material. The framework of the cyst-wall to which the epithelial or endothelial cells are attached is composed of connective tissue. The connective tissue in a true cystoma is derived from the pre-existing connective tissue, which at first is condensed by compression caused by the gradual enlargement of the cyst, and later becomes increased in thickness by the production of new connective tissue. The cyst-wall may be exceedingly thin and delicate if it contains only a small amount of connective tissue, or in the course of time it may become enormously thickened by the production of new connective tissue. If the cyst is surrounded by tissue on all sides, this tissue gradually becomes more and more isolated from the external surface of the cyst-wall, so that finally only the vascular connections remain—a condition exceedingly favorable for the removal of the cyst by enucleation. The cyst-wall may also become

firmly attached to the surrounding structures by inflammatory adhesions, as is so often the case in ovarian cysts and in cysts in other parts of the body subjected to partial extirpation or to other inadequate methods of treatment.

The cyst-contents will vary according to the type of the cells which produced them. Cysts lined by epiblastic epithelial cells usually contain the products of fatty degeneration, an atheromatous material, or, if the fatty degeneration has progressed still further, pure oil. Cysts lined by columnar epithelial cells analogous to those found in the gastro-intestinal canal usually contain mucus. Cysts of the thyroid gland contain most frequently colloid material, or, if the colloid material has disappeared by liquefaction, a serous fluid. Mesoblastic cysts generally contain a serous fluid. The cyst-contents are modified by hemorrhage into the cyst and by the addition of cholesterolin-crystals—a frequent occurrence, especially in cysts of an epiblastic origin. A simple, single cyst is called a monolocular cyst. A cyst in which we find different compartments from the beginning, or produced later by coalescence of several cyst-walls or by proliferation from the cyst-wall, is called a multilocular cyst. The cyst-wall often undergoes calcareous degeneration, and sometimes ossification, particularly in cases in which the epithelial lining has been destroyed by degeneration.

Etiology.—Cystoma very frequently appears as a congenital affection. The tumor-matrix proliferates during intra-uterine life, and at the time of birth the activity of proliferation can be calculated by the amount of contents of the cyst. Congenital cystic tumors of the neck are of frequent occurrence. Although cystic tumors may occur at any time after birth, they are met with most frequently at the age of puberty. Sublingual epiblastic tumors make their appearance most frequently at this time of life. The great physiological activity of the organs derived from the epiblast plays an important part in stimulating a latent matrix to active tissue-proliferation, and if this matrix is of such a structure or nature that its product is not arranged in glandular form, cystic dilatation of its primary central space will follow. The growth of the cyst will depend on the amount of essential tumor-elements and the activity of their proliferation. Other exciting causes are trauma and prolonged irritation and inflammation in the immediate vicinity of the tumor-matrix.

Diagnosis.—A cystic tumor usually grows more rapidly and attains a larger size than a papilloma or an adenoma. A central hollow space is present from the very beginning, and does not appear later, as is the case in adeno-cystoma. If the cyst-wall is not too tense or thick, fluctuation can be elicited by careful palpation. If the cyst-wall is thin

and near the surface, the tumor is translucent if it contains clear serum. In uncomplicated cases of hydrocele of the neck the tumor is translucent. An exploratory puncture will often prove of great value, not only in showing the cystic nature of the tumor, but also in demonstrating the nature of its contents. This diagnostic resource must be employed with caution in the examination of abdominal tumors if the free peritoneal cavity cannot be avoided. Exploratory puncture through the free peritoneal cavity is ordinarily attended by more danger than an exploratory incision. In locating the tumor an effort should be made to ascertain its primary anatomical starting-point and to bring it in connection with the organ in which it originated. If the cyst occupies the pelvis, it should be ascertained whether it is connected with the ovary, the Fallopian tube, or the uterus. If it occupies the abdominal cavity and is not connected with the pelvic viscera, the relation of the tumor to the different abdominal organs must be studied with care to determine the organ with which the tumor is connected or to which it has become attached. Inflation of the stomach and the intestinal canal will often prove an invaluable diagnostic aid in such cases.

Prognosis.—Cystoma is a benign tumor. A proliferating cyst of the ovary may perforate the cyst-wall and invade the peritoneal cavity, but aside from this a cystic tumor does not extend beyond the limits of the organ primarily affected. Cystoma, if in close contact with important organs, may give rise to dangerous complications by causing harmful pressure. Cysts of the neck and of the pelvis may become a source of danger from pressure. Large cysts of the abdominal cavity ultimately interfere with digestion and respiration and become a source of danger from their size. Adhesions between pelvic and abdominal tumors and the surrounding organs may become a cause of intestinal obstruction. Infection of a cystic tumor with pyogenic microbes may result in suppuration and sepsis. Torsion of the pedicle of a cystic tumor of the pelvis or of the abdomen has often resulted in gangrene, septic peritonitis, and death. Malignant transformation is not as often observed in cystoma as in papilloma and adenoma.

Topography.—Cystic tumors are met with most frequently in organs and parts of the body in which during intra-uterine life the most complicated tissue-changes occur. The favorite localities are the ovaries, the base of the tongue, the neck, and the region of the orbits.

Traumatic Epithelial Cysts.—The accidental or intentional displacement of a small island of skin into the mesoblastic tissues brings about a condition closely resembling the relations of an epiblastic tumor-matrix to the surrounding tissues. A few cases have been reported in which epithelial cysts had such an origin. The difference between such

an artificial matrix and a genuine tumor-matrix is the limited product of the epithelial proliferation. Kaufmann studied the behavior of attached buried epithelial cells by resorting to a procedure which he terms *enkatarrhophy*. He selected for this purpose the cock's comb. By two elliptical incisions an island of skin was circumscribed; it was then buried by suturing over it the margins of the wound. In some of the successful cases the result was followed until the 210th day. Examination of the specimens obtained at variable periods after the operation showed that at the margins of the buried skin the epithelial cells proliferated, resulting in the formation of a cyst-wall lined throughout by epithelial cells. The cysts formed in this manner contained a material which resembled the contents of an atheromatous

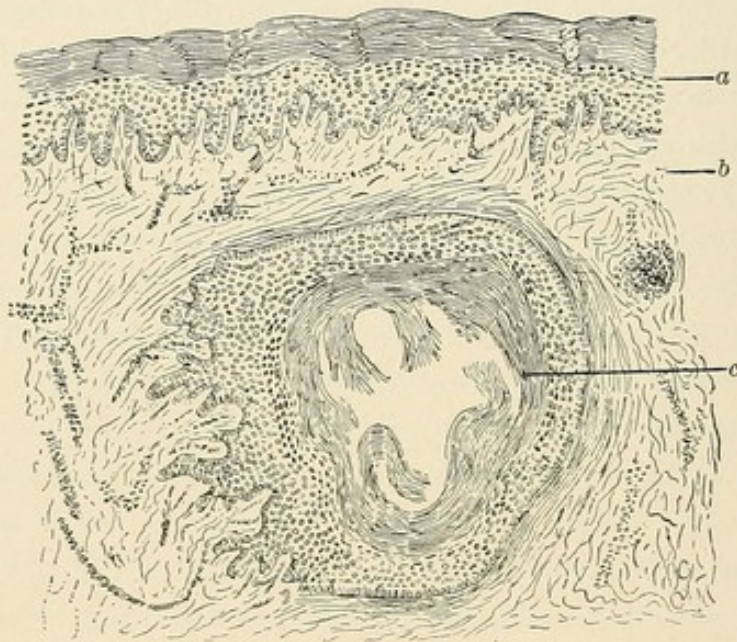


FIG. 86 —Traumatic epithelial cyst of finger (after Garré): *a*, skin; *b*, subcutaneous tissue; *c*, epithelial cyst.

cyst. The growth of the cysts continued until they reached a certain limited size, when it ceased and the cysts remained stationary.

Garré recently reported two cases of traumatic epithelial cysts of the fingers. In both cases the injury which preceded the cyst-formation was a punctured wound. The cyst developed soon after the injury. In one case the cyst was 12 millimeters in length and 7 to 8 millimeters in width. A section through the centre of the tumor showed a central cavity (Fig. 86). The implanted fragment of skin could readily be identified by its characteristic anatomical structure. The epithelial cells at the margins produced new cells which converted the piece of skin into a globular mass well supplied with blood-vessels. The cyst contained exclusively epidermic cells arranged in wavy stratified layers. In the other case the cyst had reached the size of a hempseed and showed a similar structure. The opinion of Chavasse that such cysts

are produced by the sweat-glands contained in the implanted skin is contradicted by Garrè. The process of cyst-formation as explained by Garrè can readily be understood by a glance at Figures 87, 88, and 89. He did not find any evidences of the formation of a cyst-wall as described by Kaufmann.

Reverdin believes that epithelial cysts can originate from the displacement of detached mature epithelial cells into the mesoblastic tissues. Garrè's second case was one in point. In this case only cells were forced into the subcutaneous tissue before the point of a needle, and from them a globular mass of epithelial cells developed, but no trace of a cyst-wall could be found. Rizet reported a case in which the epithelial cells that originated from a displaced fragment of skin became the seat of a calcareous degeneration. In other instances the cells have frequently been eliminated by suppurative inflammation.

Tatum observed on the scar of a scalp wound an atheroma-cyst which undoubtedly was caused by a dislocated particle of skin. A conclusion of the greatest etiological moment that can be drawn from the experiments of Kaufmann and the clinical observations of Garrè and others

is this, *that a dislocated fragment of skin does not possess the same intrinsic capacity of continued progressive tissue-proliferation as an epiblastic tumor-matrix*. Epithelial cysts of a similar origin are found more frequently in the scars following burns than after trauma. Epithelial pearls in scar-tissue, the product of buried epithelial cells, are not of rare occurrence. Traumatic epithelial cysts must be removed by thorough extirpation, otherwise a recurrence will almost surely take place.

Deep-seated Atheroma.—A retention-cyst of the sebaceous glands resembles a true atheroma so perfectly in the structure of the cyst-wall

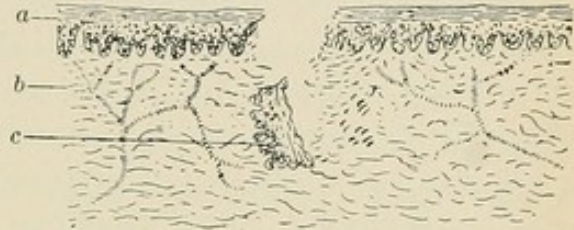


FIG. 87.—Manner of production of traumatic epithelial cyst (after Garrè): *a*, skin; *b*, subcutaneous tissue; *c*, dislocated fragment of skin.

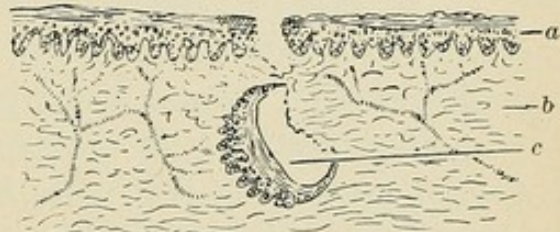


FIG. 88.—Beginning of healing of the skin-defect and commencing proliferation from the margins of the implanted skin (after Garrè).

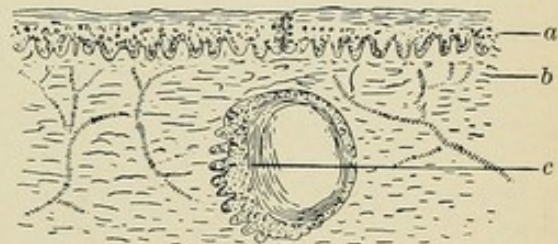


FIG. 89.—Wound entirely healed, and the buried skin-graft enlarged by proliferation from the surface and margins of the graft (after Garrè).

and in its contents that we must distinguish between them etiologically and clinically according to their location. Retention-cysts of the sebaceous glands result from obstruction to the escape of the secretions, and always retain their relations with the skin. They are superficial, being covered only by the skin. *The deep-seated atheroma has no connection with the glandular apparatus of the skin, and it always originates from a displaced matrix of embryonic epiblastic cells.* It should be distinguished from a dermoid cyst by the character of its contents. An atheroma contains only epithelial cells as its characteristic morphological cellular element, while the cyst-wall of a dermoid cyst represents skin with its appendages in the simplest cases, and in more complicated cases systems of organs in various degrees of perfection. *The displacement of the matrix of an atheroma occurred at a time prior to the differentiation of the epiblastic cells into the organs representing the appendages of the skin, while the matrix of a dermoid cyst points to a later displacement of the matrix.* Atheroma is met with most frequently in the ovaries, in the region of the orbits, especially the superciliary arch, and at the base of the tongue. In all these localities it is most frequent at the age of puberty. In the superciliary region it occurs occasionally as a congenital affection. In this locality it seldom exceeds the size of a walnut, while tumors at the base of the tongue the size of a cocoanut are not uncommon. Superciliary atheromata frequently

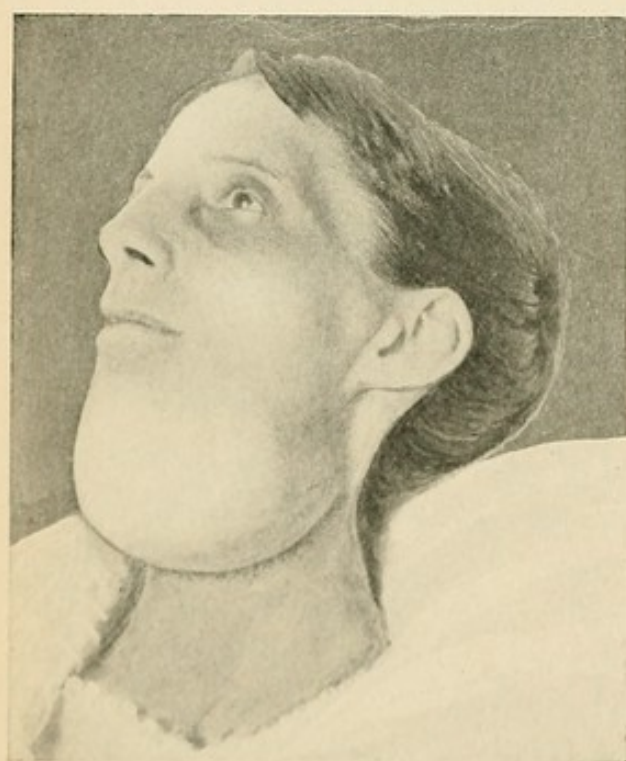

FIG. 90.—Sublingual dermoid cystoma.

contain pure oil which will ignite and burn like ordinary lamp-oil. When this stage of degeneration is reached further growth is generally arrested. In the majority of cases the tumor contains a substance resembling in every respect the contents of a retention-cyst of the sebaceous glands. The granular detritus is composed of epithelial cells which have undergone fatty degeneration suspended in a serous fluid in varying proportions. Cholesterin-crystals are often very abundant in old cysts. Cysts at the base of the tongue project toward the cavity of the

mouth, and when they have reached a certain size they form a swelling in the submaxillary region, causing great disfigurement, and by press-

ure against the tongue interfering with speech and often also with deglutition (Fig. 90). The differential diagnosis between such a tumor and a branchial cyst is often difficult, and sometimes can be made only by resorting to an exploratory puncture. A branchial cyst usually contains either mucus or a serous fluid; an atheroma contains the product of fatty degeneration of epithelial cells.

An atheroma may occur in almost any part of the body, and in the differential diagnosis of cysts in unusual localities this fact should be taken into consideration. The cyst-wall of an uncomplicated atheroma is loosely attached, and can readily be removed by enucleation.

Mucous Cysts.—Cystic tumors with mucoid contents are comparatively rare if we exclude from this category retention-cysts with similar contents. They are analogous to atheroma in their etiology, except that the matrices are derived from the hypoblast and that the interior of the cyst-wall is lined by columnar epithelium. In place of atheromatous material the cysts contain mucus, which in old cysts is usually transformed in the course of time into a serous fluid. If the cyst is derived from a matrix representing squamous or ciliated epithelia, it is lined by cells representing the part or organ from which the epiblastic or hypoblastic matrix was derived. Frequent locations of these cysts are the orifice of the cervical canal of the uterus and the mucous membrane of the lips, mouth, pharynx, and intestinal canal. Mucous cysts seldom attain the size of a walnut, as, owing to the delicate structure of the cyst-wall, rupture takes place usually before the tumor reaches this size. The epithelial cells are generally arranged in a single layer, and are not stratified as in epiblastic epithelial cysts—an additional cause for the early rupture of these cysts that so frequently takes place. Many of the so-called "hydatid" cysts are mucous cysts, the mucoid substance having become transformed into a transparent serous fluid. Among the morphological elements in the contents of a mucous cyst are epithelial cells, free nuclei, cholesterol-crystals, colloid masses, and sometimes concretions. The mucous cysts

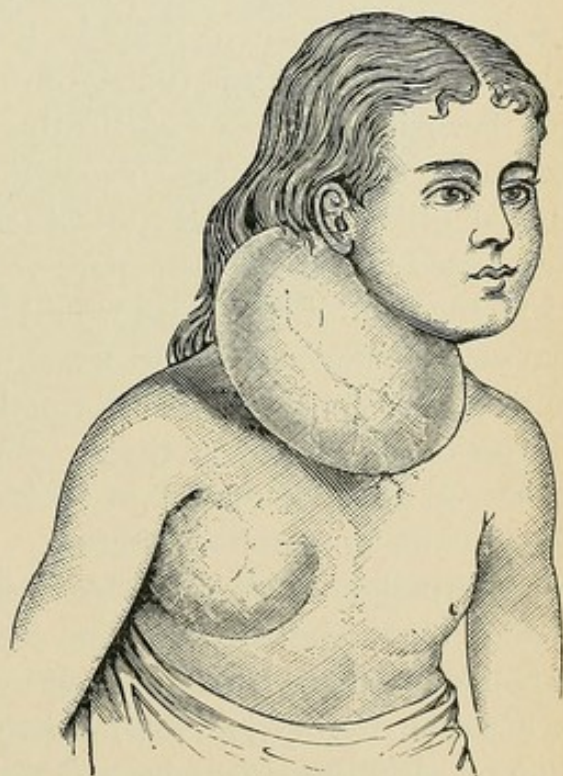


FIG. 91.—Congenital cervical cyst extending into the axilla (after T. Smith).

are usually globular in shape; owing to the fragility of the cyst-wall, they seldom become pedunculated. Extirpation and the complete destruction of the epithelial lining of the cyst by cauterization are the only two operative procedures which can be relied upon in preventing a recurrence. With very few exceptions, enucleation is impractical, owing to the great fragility of the cyst-wall.

Cysts lined by ciliated epithelial cells always have their origin from an embryonic matrix derived from parts and organs supplied with ciliated epithelium in the fetal state. Cysts of this kind have been found in the brain, the external ear, the liver, and the testicles.

Mesoblastic Cysts.—Cysts composed exclusively of tissue of mesoblastic origin are found most frequently in the region of the neck, where they have been described by the German authors as “hygroma” and by the English surgeons as “hydrocele of the neck.” This form of cyst is always of congenital origin; it occupies the deep tissues of the neck in front of the large vessels, and often extends from the hyoid bone down to the clavicle and even as far as the axillary space (Fig. 91). Congenital cysts of the neck often shrivel soon after birth and disappear spontaneously; at other times they increase rapidly in size. In a few instances they reappeared later in life, such a case being reported by Birkett. They are usually unilocular, but sometimes they are divided in part or completely into a number of compartments with similar contents. If the cyst is large and contains a clear serous fluid, it is translucent. The histology of these cysts has not been investigated sufficiently. The very fact that in the majority of cases they disappear spontaneously is sufficient proof that epithelial cells do not enter into their construction. Some authors have suggested that these spaces are ectatic lymph-spaces. If the cyst persists, the wall of the space would be sure to become lined by endothelial cells, as under such circumstances the connective-tissue cells on the surface would become transformed into endothelial cells. Such transformation of connective-tissue cells into endothelial cells is frequently observed in the formation of accidental bursæ and in the formation of false joints in ununited fracture. The attempt to remove such cysts by extirpation is attended by danger, and often has to be abandoned before the completion of the operation. The injection of irritating solutions has also been followed by disastrous consequences. Repeated evacuation by tapping, followed by the injection of a 5 per cent. solution of carbolic acid under strictest antiseptic precautions, is the safest and most efficient method of treatment. Cysts developing from an embryonic mesoblastic matrix after birth are formed in the same way as epithelial cysts. The central space in the matrix becomes lined by

endothelial cells; serous contents accumulate and distend the space. The spontaneous disappearance of endothelial cysts is of frequent occurrence, as the endothelial cells may at any time revert into their former condition, and the cyst-contents are more amenable to absorption than are the products of epithelial cells. If the cyst is emptied by absorption of its contents and the endothelial cells lining the cyst-wall are brought in contact, permanent obliteration of the space will follow.

Thyroid Gland.—A true cyst of the thyroid gland commences as such. The formation of the cyst is not preceded by any considerable production of glandular tissue. The glandular tissue is scanty. In

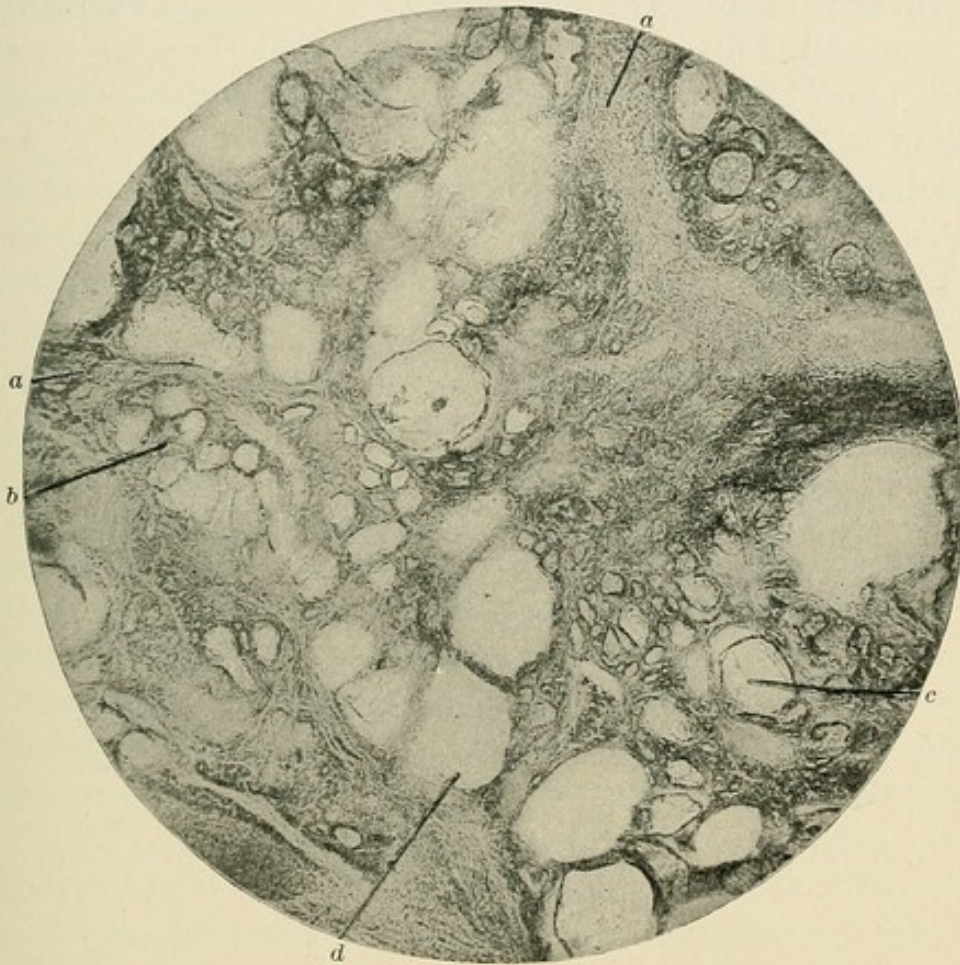


FIG. 92.—Adeno-cystoma of thyroid gland; $\times 85$ (Surgical Clinic, Rush Medical College, Chicago): *a, a*, stroma; *b*, follicles of gland slightly enlarged; *c*, colloid cyst; *d*, two colloid cysts separated by a thin septum.

cystic degeneration of an adenoma of the thyroid gland cyst-formation takes place usually at different points, and the glandular part of the tumor predominates (Fig. 92). The cysts enlarge by the breaking down of the thin compartments between smaller cysts, and the cystic nature of the tumor becomes clinically apparent only after the larger part of the glandular structure has been destroyed by degeneration. In a true cystoma the cavity is formed by expansion of the epithelial cells from a central point of the tumor-matrix, and the tumor is more

frequently unilocular than multilocular. Of course, a number of cysts may form simultaneously and coalesce into one common cavity, but this occurrence is rare as compared with adeno-cystoma. A cystoma of the thyroid gland can usually be recognized without difficulty, but if any doubt exists, this can be set aside effectually by an exploratory puncture. Enucleation is the proper treatment for cystic tumor of the thyroid. If this operation cannot be done on account either of calcareous degeneration of the cyst-wall or of firm adhesions with the surrounding tissues, a partial thyroidectomy is indicated. Laying open of the cyst freely by incision, followed by vigorous application of the actual cautery so as thoroughly to destroy the cellular lining of the interior of the cyst-wall, will also effect a radical cure, but this treatment consumes more time and will leave a more unsightly scar than either enucleation or extirpation.

The writer has recently treated successfully a cyst of the thyroid gland the size of a hen's egg by a single tapping, followed by the injection of 2 drams of a 10 per cent. emulsion of iodoform in glycerin.

Mammary Gland.—Retention-cysts and adeno-cystoma of the mammary gland occur much more frequently than true cysts. In both instances the cysts are frequently multiple, and seldom do they attain great size. Bryant divides cysts of the mammary gland into three varieties: 1. Cystic degenerations of the breast, met with in the aged as well as in glands which have long ceased to be active—"involution-cysts," as they are called; 2. Cystic tumors of the gland, single or multiple, of glandular, duct-, or connective-tissue formation, *without* intracystic growths; 3. Cystic tumors of the breast, of whatever kind, in which papillomatous, adenomatous, sarcomatous, or carcinomatous intracystic growths are present.

A true cystic tumor commences, like all true cystomata, in the centre of a matrix of embryonic epithelial cells, the epithelial cells becoming attached to the surrounding connective tissue, which becomes the stroma of the tumor. The products of epithelial proliferation accumulate in the central space and form the contents of the cyst. Serum, or serum altered by the presence of blood or cholesterin-crystals, is usually found as the characteristic contents of such a cyst. The tumor grows slowly in size, displaces the surrounding tissues, and often reaches an enormous size. Paget refers to a case in which the tumor contained nine pounds of serous fluid. He remarks, very correctly, that tumors which contain the simplest fluids and which have the simplest walls are apt to grow to the largest size. Thickening of cyst-walls and, much more, their calcification are here, as elsewhere, signs

of degeneracy and of loss of productive power. A true cystoma of the mammary gland is characterized clinically by its progressive growth, its simple contents, and the thinness of the cyst-wall.

Another form of cyst of the mammary gland is described as "proliferous cyst," in which, from the cyst-wall, papillary excrescences project into the cyst, resembling the same kind of cyst in the ovary. This kind of cyst, however, more frequently occurs associated with adenoma or sarcoma of the breast than as a distinct anatomical variety of cystoma.

Enucleation is the proper treatment of cystic tumors of the breast; if this operation does not succeed on account of firm adhesions or of degeneration of the cyst-wall, the excision of a small zone of gland-tissue with the cyst will ensure a radical cure.

Ovary.—As cysts of the ovary have so many different histogenetic sources from which they take their origin, and as the different localities correspond with so many structures of different embryonic origin, the student must familiarize himself with the development of the ovary in the embryo in order to enable him to trace the different kinds of cysts to their proper embryonic matrices (Fig. 93).

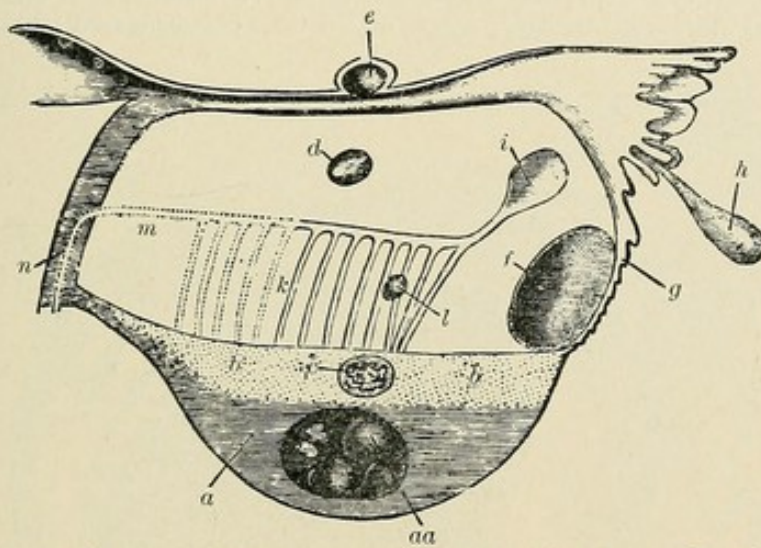


FIG. 93.—Schema of tubo-ovarian apparatus, to show the various points of origin of cystic growths (after Doran): *aa*, multilocular glandular cyst, developed in *a*, ovarian parenchyma; *c*, papillary cyst, developed in *b*, tissue of the hilum of the ovary; *d*, unilocular cyst of the broad ligament, free from the parovarium; *e*, unilocular cyst of the broad ligament, situated just above the Fallopian tube, but not united to it; *f*, similar cyst near *g*, utero-ovarian ligament; *h*, hydatid of Morgagni, which is never the starting-point of a large cyst; *i*, cyst developed at the expense of the horizontal canal of the parovarium; *l*, cyst developed at the expense of the vertical tube (according to Doran, these are the papillary cysts of the broad ligament); *m, n*, course of the obliterated canal of Gärtner: papillary cysts may be developed at any portion of this canal (Coblentz), and these cysts may be the origin of papillary cysts connected with the uterus, *n*.

The size of the cyst will depend on the vegetative capacity of the cells of the tumor-matrix. The nature of the contents of ovarian cysts is determined by the histological character of the tumor-cells and by the type of degenerative changes which these cells undergo. The hydatids

of Morgagni consist of an exceedingly delicate cell-wall and a trans-

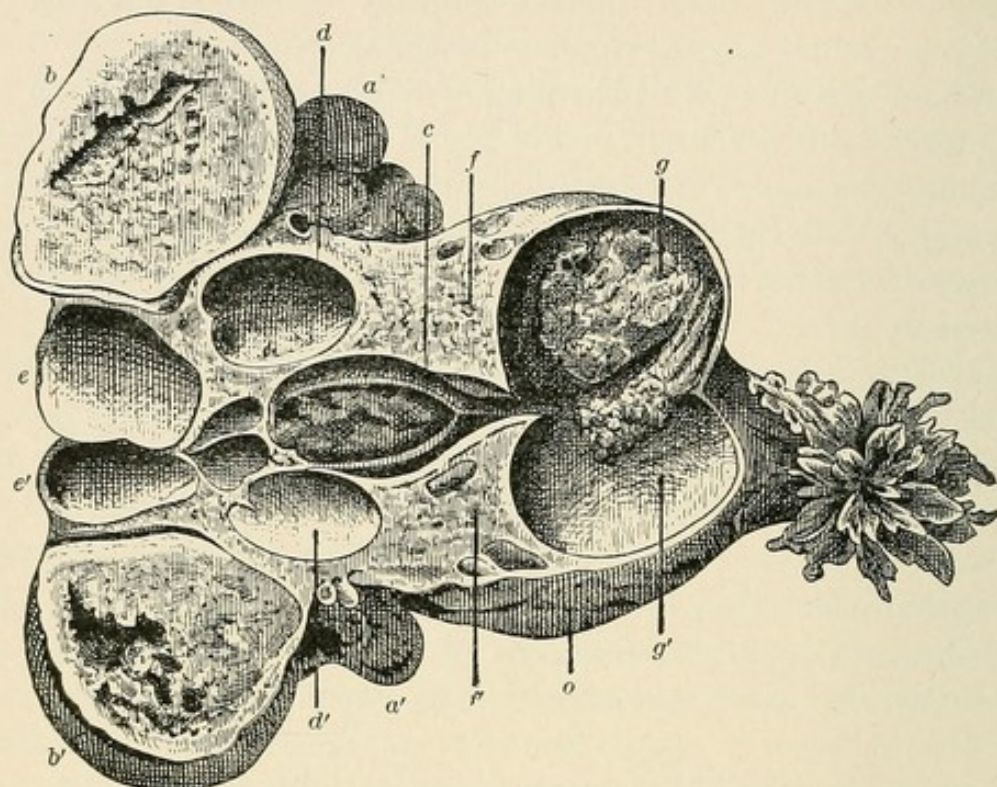


FIG. 94.—Cystic disease of the ovaries: serous and myxomatous multiple follicular cysts (after Pozzi): *a, a'*, small myxomatous cysts; *b, b'*, large myxomatous cysts; *e, e'*, follicular cysts with fluid contents; *c, g, g'*, follicular cysts with caseous contents; *o, f, f'*, ovarian tissue containing small follicular cysts.

parent clear serum as contents, and they seldom exceed the size of an

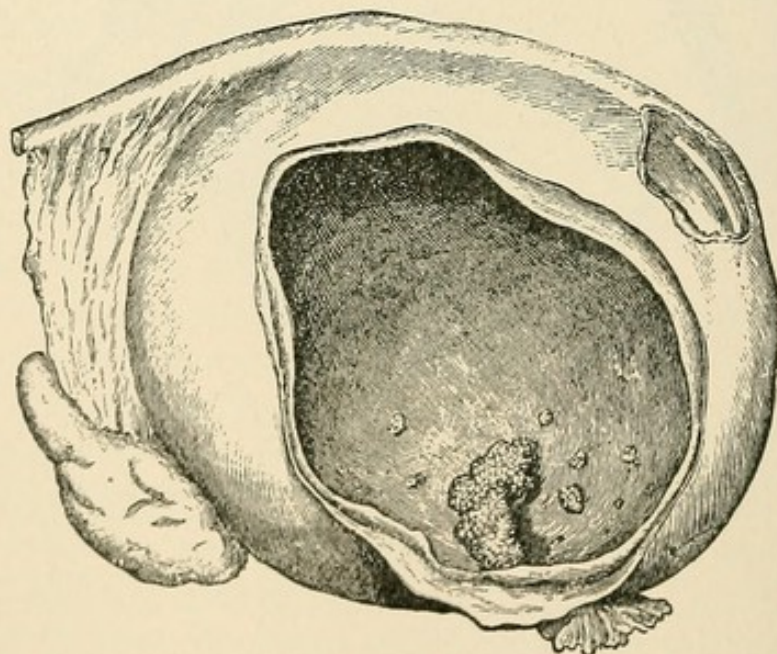


FIG. 95.—Papillary cyst starting from the hilus of the ovary (after Doran). On the left lower extreme of the picture is the ovary, which is almost intact. The cyst is developed within the broad ligament, which is opened so that we may see above a portion of the Fallopian tube. An opening has been made in the cyst-wall to show the papillary vegetations within.

ordinary marble. They are usually pedunculated, and are discovered only in opening the abdomen for other indications.

The multiple cysts with serous contents that characterize the cystic ovary as described by Rokitansky hardly ever exceed in size a cherry-stone (Fig. 94).

Ovarian cysts of this variety are always complicated by sclerosis of the interstitial tissue. In a very instructive paper on ovarian papilloma Coblenz gives an accurate histogenetic account of this variety of ovarian cysts. The author comes to the conclusion that the Pflüger-Waldeyer epithelial sacs, as well as the medullary tubules of Kölliker, may give rise to the formation of cysts, but that from the former the glandular, and from the latter the papillary, variety are produced. At any rate, the papillary cysts are genetically and anatomically analogous to the papillary formation of the mucous membranes, whether they are in the interior of cysts or whether they spring from the surface of the ovary. In the latter case the tumor may have developed from the surface of the ovary or may have reached this locality from the interior of a cyst. Proliferous cysts spring either from the surface of the ovary or from rests of fetal tubules in the ovary (Fig. 95). The cystic spaces are usually small, and the proliferating masses in their interior are large.

Papillary growths on the surface of the ovary, and similar vegetations reaching the surface after perforation of a proliferous cyst, spread

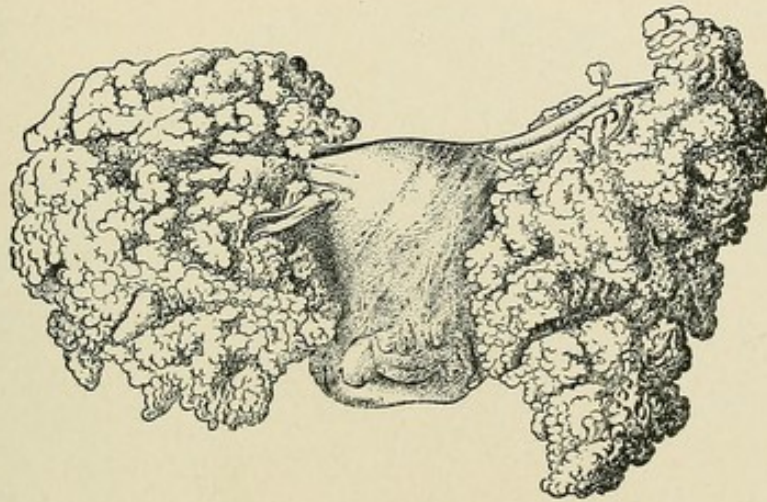


FIG. 96.—Papillary tumor of ovary covering the whole of both broad ligaments (after Pozzi).

to the surrounding parts, often imbedding ovary, tube, ligament, and uterus (Fig. 96). The histological structure of a papilliferous tumor of the ovary is well shown in Figure 97.

Proliferous cysts of the ovary are more likely to return after operation than are any of the other benign tumors. If the tumor develops from the surface of the ovary, or if the operation is postponed after a proliferous cyst has been perforated, fragments of the tumor frequently remain, and it is from these fragments that the recurrence takes place. Recurring tumors have no pedicle and are usually extensively adherent,

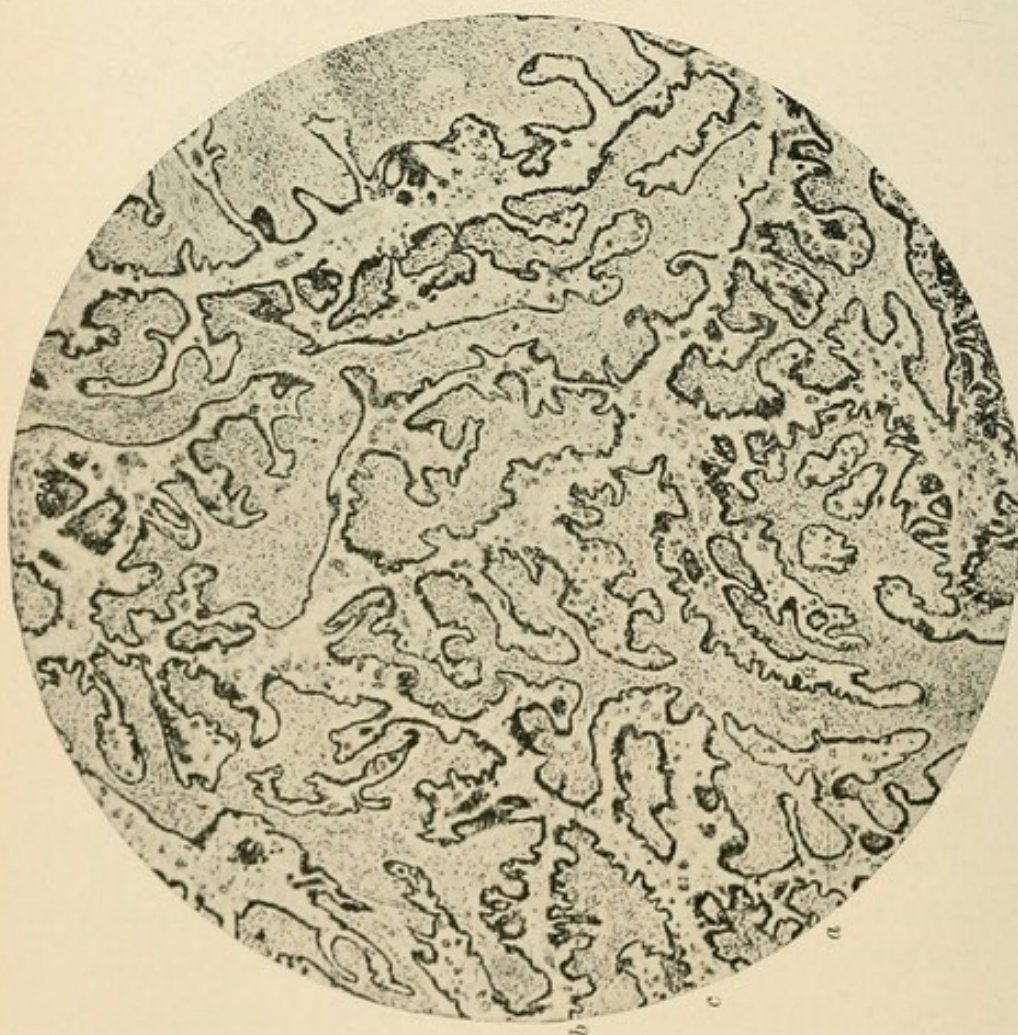


FIG. 97.—Papilliferous cyst of ovary (after Karg and Schmorl). The interior of the cyst is filled with dendritic branching papillary vegetations which project from the cyst-wall. *a*, stroma containing many spindle-cells; *b*, columnar cells in one layer; *c*, cyst-spaces containing degenerated epithelial cells.

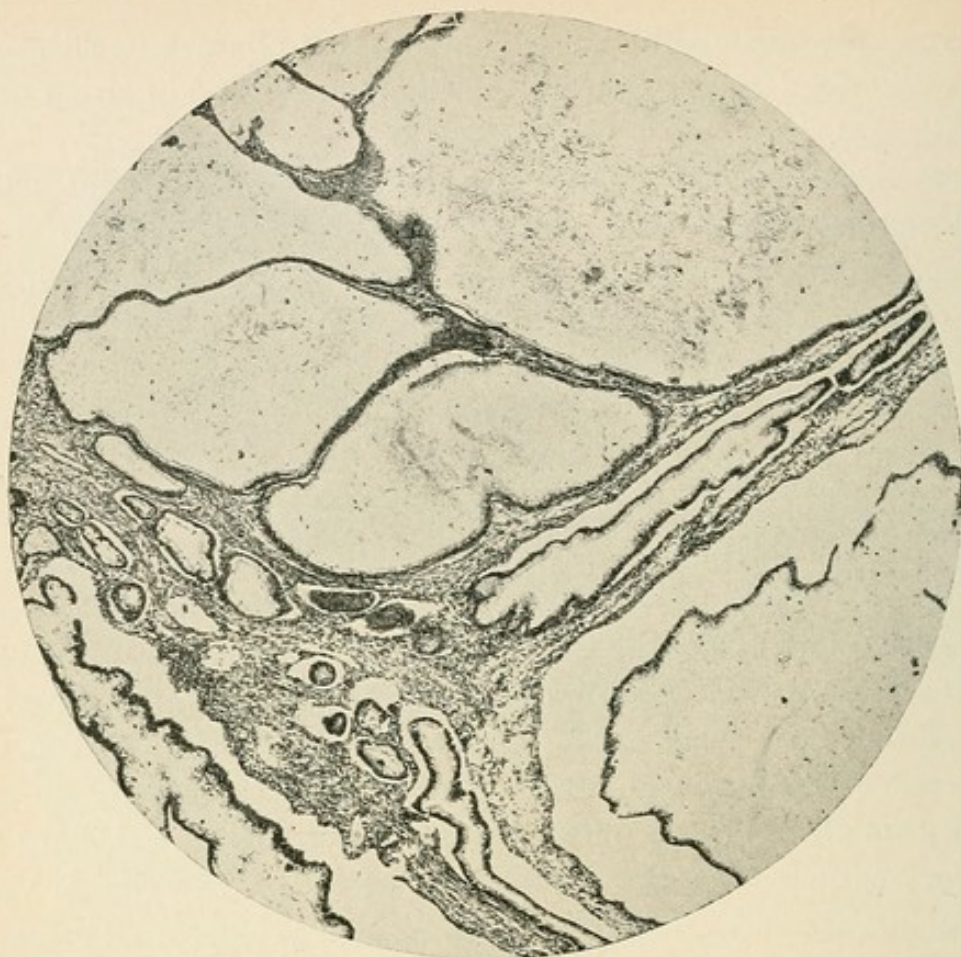


FIG. 98.—Adeno-cystoma of the ovary; $\times 40$ (after Karg and Schmorl). The tumor is composed of cysts varying in size and separated by septa of different widths. In the broad septa smaller cysts can be seen. The cysts are lined by columnar epithelium and contain a finely-granular colloid material.

rendering their removal difficult and sometimes impossible. If the tumor-tissue comes in contact with the peritoneal surface, ascites sets in, still further complicating the case.

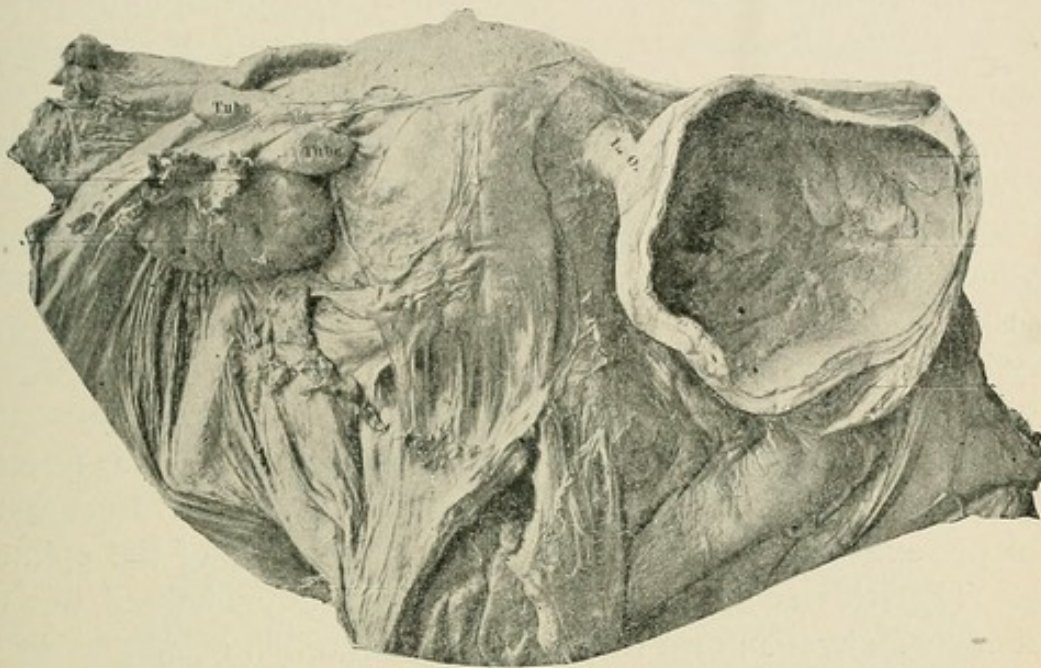


FIG. 99.—Adeno-cystoma of right ovary (after Winckel). In the anterior wall of the large cyst a number of small prominences indicate the location of smaller cysts.

Glandular cysts of the ovary always occur as a multiple affection (Fig. 98). By breaking down of the septa the cavities enlarge (Fig. 99). The contents undergo various regressive changes and vary

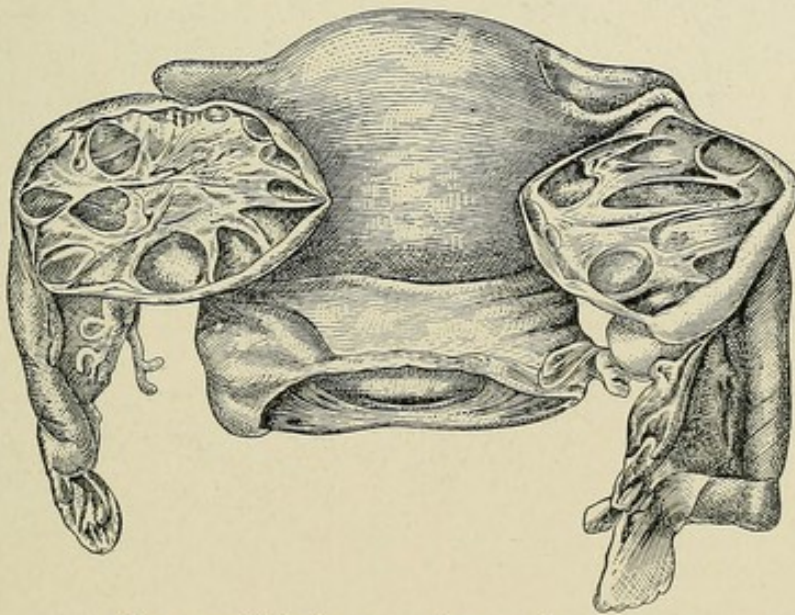


FIG. 100.—Follicular cysts of ovary (after Barnes).

greatly in different cysts of the same tumor. Some cysts contain a jelly-like, amorphous mass, others a clear serum, and still others a serous fluid stained by the admixture of blood.

The origin of simple cysts of the ovary has been the subject of careful investigation, but has not definitely been settled. The so-called "follicular cysts" are dilated Graafian follicles. All the histological elements of a normal follicle are found in such cysts. The cysts are numerous and are separated by septa of connective tissue (Fig. 100). The spaces are lined by columnar epithelium, and ova have been found in their interior by Ritchie, Webb, Tait, and Rokitansky. The cysts contain usually clear serum; occasionally the serum is of a yellowish color, and sometimes it is otherwise stained by the admixture of blood. Sometimes the epithelial cells undergo myxomatous degeneration (Fig. 101).

Hydrops of the follicles of the ovary is usually a symmetrical affection occurring in both ovaries at the same time. Follicular cysts of the ovary seldom result in the formation of large tumors. It was formerly believed that most of the simple ovarian tumors resulted from distention of pre-existing Graafian follicles by proliferation of the epithelial lining. That this is not the case is now generally admitted, but that occasionally an ovarian cyst may have such an origin cannot be denied.

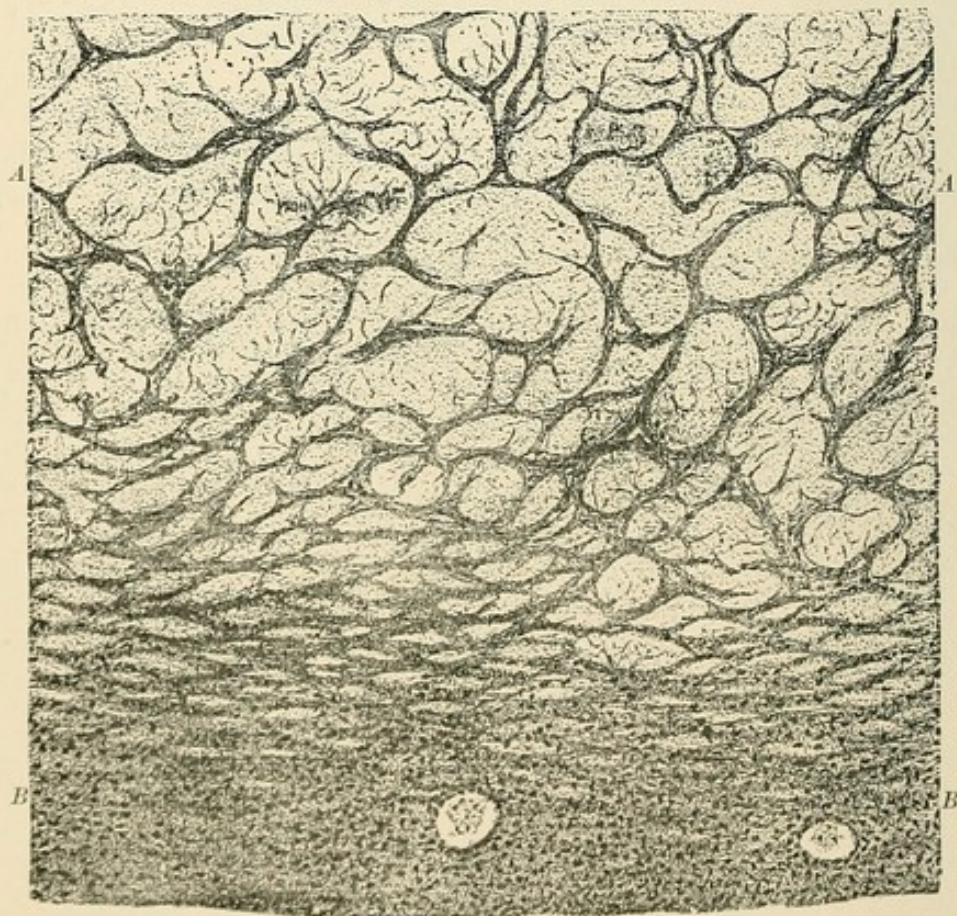


FIG. 101.—Follicular cyst of ovary with myxomatous degeneration: $\times 50$ (after Pozzi): *A, A*, loose myxomatous tissue toward the interior of the cyst; *B, B*, dense myxomatous tissue toward the external surface.

If in a Graafian follicle a matrix of embryonic epithelial cells should

exist, we can readily understand that the follicle would become the cyst-wall, while the matrix would furnish the contents. Neumann examined a monolocular ovarian cyst which contained four liters of fluid, and found that the cyst had developed from a Graafian follicle. The deposit which formed in the fluid after standing for some time contained epithelial cells of the membrana granulosa and innumerable ova with a distinct zona pellucida. Neumann estimated the number of ova at many thousands. The majority of simple ovarian cysts undoubtedly originate from embryonic tubular rests.

Cysts of the corpus luteum were ascribed by Rokitansky to pregnancy, but Gottschalk found them also in nullipara. The contents of a

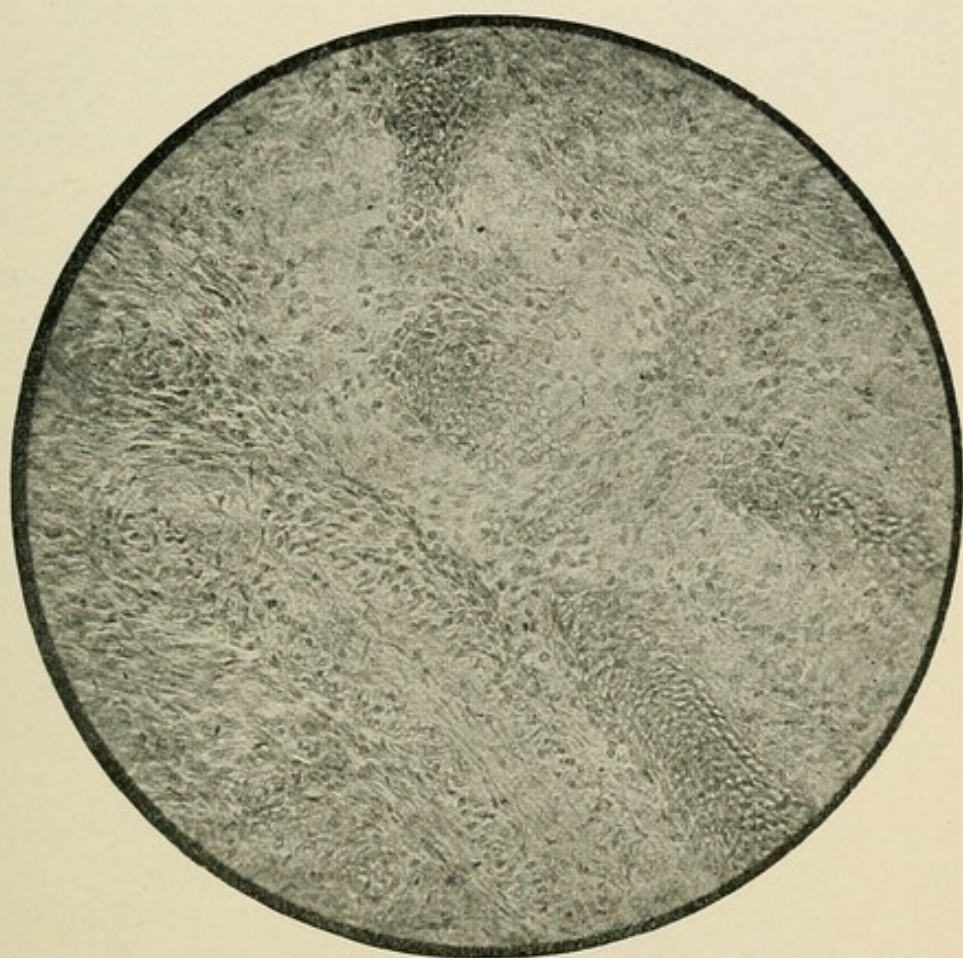


FIG. 102.—Corpus luteum; $\times 350$.

corpus luteum of the ovary without cystic degeneration are shown in Figure 102, which shows the epithelial cells of the follicle and remnants of the blood-clot. Cystic degeneration of a follicle may lead to the formation of cysts as large as an apple. Nagel has seen them as large as an adult's head. Cysts of the corpus luteum (Figs. 103, 104), as well as follicular cysts, are not cystic tumors, but are retention-cysts.

The parovarium (Fig. 93, *k*) is frequently the seat of cyst-formation.

This structure is an embryonic remnant, and consequently it frequently contains the essential tumor-matrix. Cysts of the parovarium (Fig. 105) are also called "cysts of Rosenmüller's organ," because their origin in the broad ligament, in which they are situated, corresponds to the seat of these embryonic remains. Verneuil, De Sinéty, and

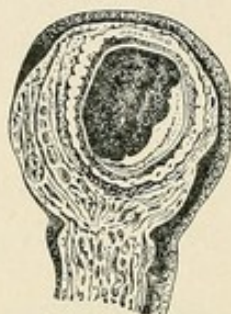

FIG. 103.—Cyst of the corpus luteum; natural size (after Nagel).

Doran believe that these cysts are developed in the connective tissue independently of the parovarium. Supernumerary ovaries must also be remembered as a possible source of such cysts.

According to the structure of the cyst-wall and the character of

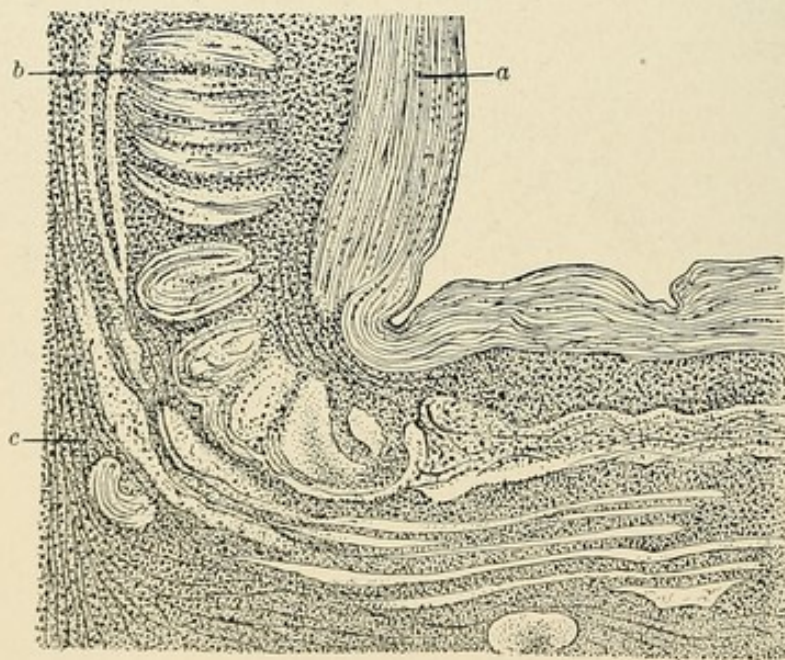


FIG. 104.—Cyst of the corpus luteum; $\times 50$ (after Nagel): *a*, connective tissue of the internal surface, epithelium removed; *b*, yellow layer of corpus luteum; *c*, normal tissue of the ovary near the hilum.

the contents, cysts originating from the parovarium or in its immediate vicinity are divided into—1. Hyaline cysts; 2. Papillary cysts; 3. Dermoid cysts. Cysts developing from this locality do not reach a large size, and they contain a serous fluid. Their removal is attended by difficulty, owing to the absence of a pedicle.

Morgagni's hydatids (Fig. 106) are small, translucent, pedunculated

cysts attached to the fimbriated extremity of the Fallopian tubes. According to Waldeyer, these cysts are caused by partial distraction of Müller's canal by fixation of a part of this structure to the diaphragmatic band of the primary kidney. These cysts are perfectly harmless, and never exceed in size a hazelnut.

Intraligamentous cysts of the broad ligament often attain the size of a fetal head, contain a clear serous fluid, and are lined by squamous, ciliated, or columnar epithelial cells, according to the origin of the tumor-matrix. In diagnosis they are often mistaken for ovarian cysts and for the different varieties of retention-cysts of the Fallopian tube.

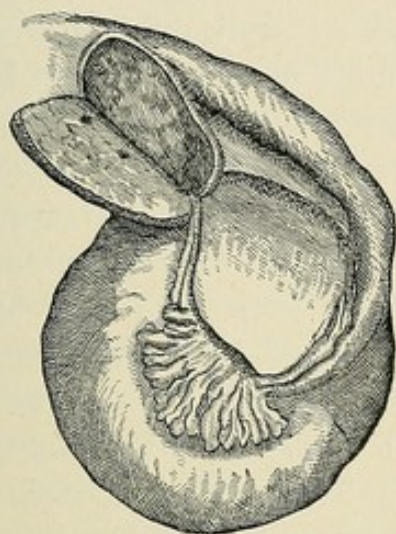


FIG. 105.—Unilocular parovarian cyst of the broad ligament (after Doran). To the left and above is the incised ovary, which is seen to be free. The elongated Fallopian tube is spread over the surface of the cyst.

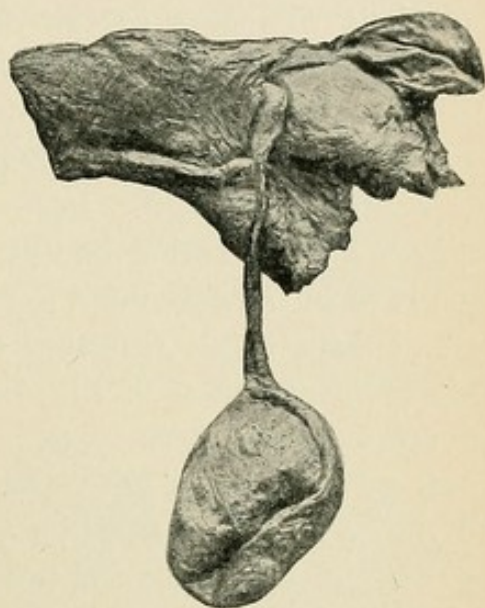


FIG. 106.—Morgagni's hydatid (after Winckel).

Their removal by enucleation is one of the most difficult of all pelvic operations. Tapping these cysts is not attended by much risk, and the operation has occasionally resulted in a permanent cure.

Treatment.—The proper treatment of an ovarian cyst, irrespective of its origin and size, is removal by abdominal section. If no contraindications exist, the operation should be performed as soon as the diagnosis can be made. Under strict antiseptic precautions the abdomen is opened to the requisite extent through the linea alba. After removal of the contents of the cyst by tapping the tumor is drawn forward into the wound and its pedicle is ligated after transfixion by a double ligature of silk, and the cyst is severed at a safe distance from the ligatures, in order to prevent hemorrhage from slipping of the ligatures. The stump should be dusted lightly with iodoform, after which it is returned into the abdomen and the external incision is closed in the usual manner. If the adhesions are firm, it is advisable to leave the peritoneal covering attached to the adherent organs to prevent visceral

injuries. In aseptic cases drainage may usually be dispensed with unless made necessary by hemorrhage, when a Mikulicz drain should be employed. In closing the abdominal incision the peritoneum and the fascia of recti muscles should be sutured separately. The silk-worm gut should embrace all tissues except peritoneum.

Vagina.—Kossmann attempts to prove that Gärtner's ducts are identical with Wolff's ducts; that, therefore, where they remain they open into the sinus urogenitalis between the urethral orifice and the introitus vaginæ; that as a rule they usually obliterate, but that in some mammals, and abnormally in man, the obliteration of a part may not take place, and that, therefore, we may in the human female find their remnants in the anterior vaginal wall down toward the urethral orifice. Nagel, on the other hand, seems to prove by his and other excellent researches that Wolff's ducts have no part in the development of the vagina, which proceeds from the lowest points of the united Müller's ducts. Islets of epithelial cells, which subsequently become hollow and constitute the beginning of cyst-formation, have been seen by Ackeren and Schueller in early embryonic life. Vaginal cysts, except those resulting from retention of secretions, arise from embryonic remnants of the distal part of Gärtner's duct. The writer has removed two such cysts, as large as a hen's egg, filled with mucus. These cysts are lined with stratified epithelium. Their enucleation from the vagina is not attended by any special difficulty.

Testicle.—Cysts of the testicle were described by Astley Cooper as "hydatids," and Curling included them under the general term "cystic disease of the testis." Cystic tumors of the testicle are cysts which are developed independently of pre-existing glandular structures, in contradistinction to spermatocele, which forms in consequence of a mechanical obstruction interfering with the escape of the physiological secretion of this organ. From the category of cystoma of the testicle must also be excluded the different varieties of hydrocele. The Wolffian body enters largely into the composition of the testicle, and is without doubt the source of many cystic formations; simple examples are the cysts of the organ of Giralès. The hydatids of Morgagni and other rests of Müller's duct are possible starting-points of cysts. The cyst-wall is composed of an abundant new growth of connective tissue lined by columnar, ciliated, or rarely by stratified epithelium. How far the simple stratified cysts are derived from adult spermatic tubes, how far from spermatic tube-rests which have failed to unite with Wolffian-duct tubes, it would be difficult to decide. That some of the sperm-containing cysts owe their origin to these rests seems very probable; indeed, Paget suggested that in these

cysts spermatozoa were secreted by the lining membrane. Not long ago the writer removed a cystoma of the testicle, and found in the contents of the cyst numerous spermatozoa and a few epithelial cells. The tumor was perfectly encapsulated, with no connection whatever with the glandular apparatus of the testicle, and was enucleated with ease. Occasionally, cystic tumors of the testicle are multilocular.

Enucleation is the proper treatment. During the operation the same precautions must be observed as in the removal of adenomata of this organ, to prevent injury to the spermatic cord or the testicle. After enucleation the visceral layer of the tunica vaginalis should be sutured by a buried row of catgut sutures.

Eye.—The iris and the cornea are the most common localities of cysts of the eyeball. In the iris they occur most frequently upon the anterior surface as sessile or pedunculated cysts containing a serous fluid or a sebaceous material. Mr. Hulke collected 21 cases of cysts of the iris, and found that in 17 cases the cyst-formation was preceded by an injury. He suggests that some of these cysts originated from portions of Descemet's membrane that may have been torn from the cornea and implanted on the iris.

Corneal cysts (Figs. 107, 108) are caused most frequently by implantation of corneal tissue resulting from operations or injuries. This cause of cyst-formation has been studied carefully by Treacher Collins.

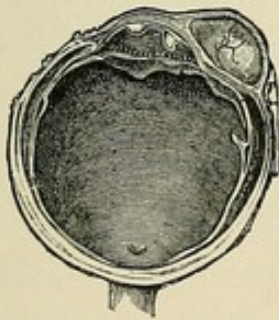


FIG. 107.—Large implantation-cyst of the cornea following an injury (after Collins).

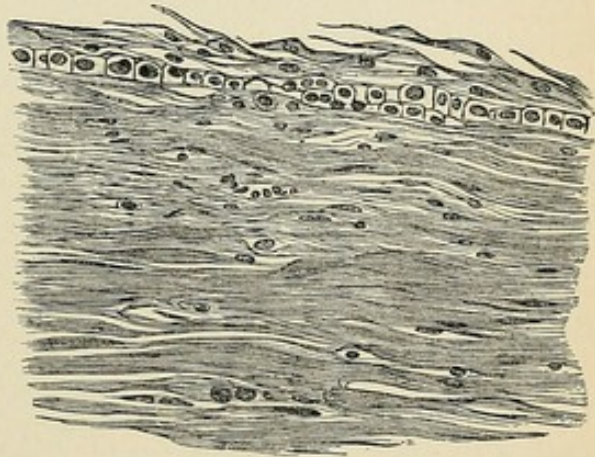


FIG. 108.—Section of the cyst in Figure 107 (highly magnified), showing the laminated epithelium (after Collins).

The cysts of the cornea following an injury are produced in the same manner as the traumatic epithelial cysts described in the beginning of this section. They arise from transplantation of conjunctival epithelium into the deep tissues of the cornea.

Cysts of the Vitello-intestinal Duct.—The profession is greatly indebted to J. Bland Sutton for a more thorough understanding of cysts of the vitello-intestinal duct and cysts of the urachus. His investigations have done the most toward enabling surgeons to refer

hitherto obscure cysts in these localities to their origin from remnants of embryonic life. Cysts of the vitello-intestinal duct connected with the umbilicus of babes and young children, and varying in size from a pea to a cherry, are of frequent occurrence. They are usually pedunculated, and are composed of unstriped muscle-fibre, mucous membrane, Lieberkühn's follicles, and columnar epithelium collected in a mass. These cysts may enlarge, rupture spontaneously, and leave a sinus from which escapes a watery discharge. In rare cases that part of the vitello-intestinal duct connected with the ileum becomes the seat of cyst-formation. Such a case was reported by Roth. Occasionally the entire duct remains patent, when part of the intestinal contents escape from its opening at the umbilicus. Sutton has traced imperforate ileum to the vitello-intestinal duct.

Allantoic (Urachus) Cysts.—The urinary bladder of man presents at its apex an impervious cord, known as the *urachus*, which passes to the umbilicus. The duct is obliterated at birth, and in the adult lies in the subperitoneal tissue in the middle line of the anterior abdominal wall. If the urachus does not become obliterated in any part of its course, it becomes dilated, and the cyst is found outside the peritoneum and in close relation with the bladder. The whole of the intra-abdominal part of the urachus may remain patent and form a large urinary bladder. Shattock observed such a case. If the entire urachus remains open, urine escapes at the umbilicus. Tait reported a case in which he found a large cyst of the urachus beneath the abdominal wall. The surgical treatment of such cases is not well settled, and must be determined largely by the size and location of the cyst.

Cysts of the vitello-intestinal duct and the urachus are not cystomata, but are retention-cysts resulting from faulty development.

Bone.—True cystoma of bone is exceedingly rare. Engel describes the case of a female fifty-five years of age, the mother of six healthy children, who died of an acute affection and who had never exhibited symptoms indicative of any bone-lesion. At the post-mortem the entire skeleton was found occupied by cysts varying in size from that of a pea to three inches in diameter. The cysts contained a clear or a bloody serum. The cyst-walls consisted of a layer of connective tissue. In a few cases isolated cysts of considerable size have been found in different bones.

Bone-cysts developing from a displaced matrix of embryonic epithelial cells are most frequently met with in the maxillary bones.

Single cysts of the jaws are usually developed in connection with displaced or diseased teeth, and consequently are met with most frequently in young persons.

Malassez has made careful researches concerning the origin of cysts of the jaws, which have led him to the conclusion that they start from what he calls "débris paradentaires épithéliaux," which he was able to demonstrate in embryos as well as in the adult. Such epithelial nests are formed during intrauterine life by the mucous membrane covering the alveolar margin projecting into the tissues, where by constriction

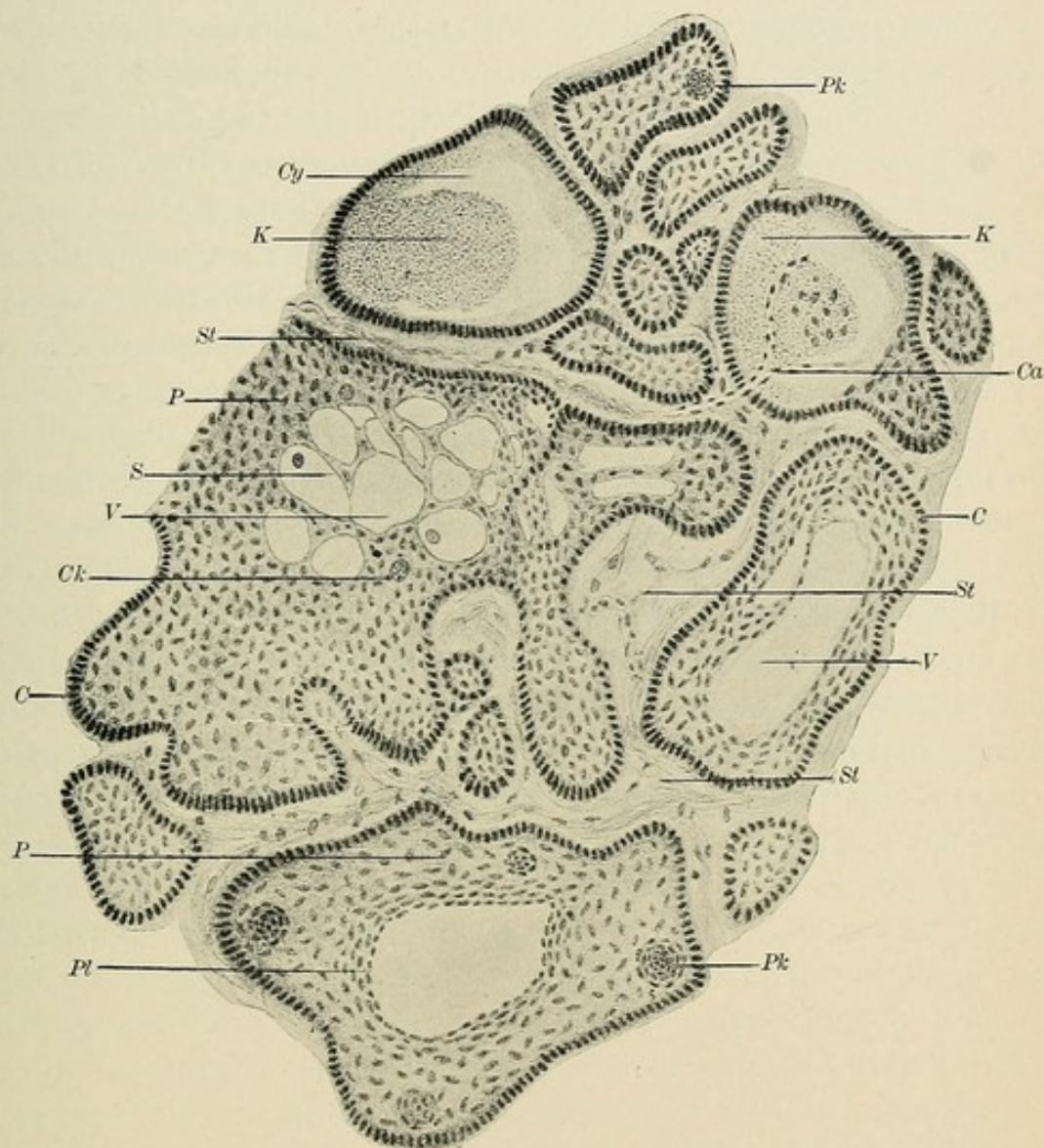


FIG. 109.—Multilocular cystoma of the lower jaw; vertical section through tumor, $\times 176$ (after Becker): C, cylindrical cells; P, polygonal cells; Pl, flattened polygonal cells; S, stellate cells; V, vacuoles; Cy, cyst; Pk, pearl-globe (Kugel); K, granular contents of cyst; Ca, capillary from stroma into alveolus; Ck, colloid mass; St, stroma.

at the surface isolation takes place, forming the tooth-germs, and from which buds may form, which serve later as the starting-point of cystoma. Allgayer and Grasse are of the same opinion. Such cysts are lined with epithelial cells, and contain usually a viscid yellowish fluid.

Multilocular cysts of the jaws (Fig. 109) are a great rarity. Re-

cently two such cases from the clinic at Bonn were described by Becker. This author found in literature sixteen additional cases. The lower jaw is more frequently the seat of this tumor. From this fact alone it is evident that displaced dental germs are not the cause of these cysts, as most authors claim. In the upper jaw such cysts may rupture into the antrum of Highmore. They are found more frequently in the region of the molar and bicuspid than in that of the other teeth. The youngest patient was twelve years, the oldest seventy-two years of age. The growth, which commences during childhood and puberty, is slow. Trauma and inflammatory affections are the exciting causes. According to the location of the matrix the cyst will project either from the outer or the inner side of the jaw.

The crackling sensation (*bruit de parchemin*) as a diagnostic sign in the examination of multilocular tumors of the jaw was described by Runge in 1775, and later by Dupuytren. Fluctuation appears when the bony wall has been absorbed, and is consequently a later sign. Ulceration of the gums does not take place. Such tumors often attain an enormous size. Falkson and Bryk describe a case in which the tumor weighed one and a half kilograms and reached from the zygomatic arch to the sternum. On section through the tumor a system of hollow spaces was disclosed. Some of the cysts communicated with others. The septa are usually membranous. These cysts contain a viscid fluid sometimes mixed with blood. The size of the cysts varies from minute spaces to that of a hen's egg. The inner surface of the cysts is smooth. In the study of these cysts three stages are apparent: 1. Cellular cords; 2. Alveoli; 3. Cysts.

XVI. CARCINOMA.

THE subject of carcinoma is one of immense etiological and clinical interest. The etiology has been investigated and discussed for centuries, and, although great progress has been made in tracing the histogenetic origin of carcinoma to its proper source, the explanation of the real cause awaits discovery. The etiology has recently received renewed interest from the bacteriological researches that have been made to prove the microbic origin of carcinoma. As we shall see farther on, no positive proof has been furnished so far that carcinoma is a microbic disease. The clinical interest of carcinoma arises from the prevalence of this affection and the inadequacy of the present surgical resources to cope with it successfully. To what fearful extent carcinoma figures as a cause of death can be learned from the fact that in England and Wales during ten years (1860-1870), 2,379,622 persons above the age of twenty died, and that this number includes 81,699 deaths from carcinoma, the deaths from this cause constituting to all others a ratio of 1:29. There can be but little doubt that this disease is on the increase. The dread of carcinoma is almost universal. Its terrors have been described in prose and in poetry. Shakespeare alludes to it in *Hamlet*: "And is't not to be damned, to let this canker of our nature come in further evil?" Not only the profession, but also the public, is aware of the great shortcomings of surgery in its treatment. The impression prevails among the people that it is incurable. The great mass of the people have abandoned all hope of the receipt of permanent benefit from the recognized surgical craft for this affection, and seek aid from so-called "cancer specialists" that exist everywhere and fatten on the credulity of an army of despondent, almost desperate, cancer patients. This sad condition of affairs, and with it the remunerative occupation of this horde of pretenders, will cease to exist when the discovery of the real cause of carcinoma is made and when successful therapeutic measures are established upon such basis. The writer has great confidence in future investigations in this direction. A great number of tireless, honest investigators are at work, and the prophesied results will be realized in time.

Definition.—*Carcinoma is an atypical proliferation of epithelial cells from a matrix of embryonic cells of congenital or post-natal origin.*

This definition includes what is known of the histogenetic origin of carcinoma. It refers the tumor to its primary location in mesoblastic tissue, and the origin of its cellular elements to a matrix of embryonic epithelial cells. *The heterotopic location of the epithelial cells distinguishes carcinoma from all the benign epithelial tumors.* Atypical proliferation of epithelial cells means their growth and multiplication in a locality where epithelial cells have no legitimate citizenship. The matrix may occupy such a location from the very beginning when embryonic cells have been displaced into mesoblastic tissue during the development of the embryo in the case of congenital matrices; or when in a burn or a wound or an inflammatory process embryonic cells become buried in the mesoblast after destruction of the *membrana propria* in matrices of post-natal origin; or, finally, if the matrix is confined to the epiblastic or hypoblastic tissues, the carcinoma dates back to the time when the embryonic cells passed through and beyond the *membrana propria* into the vascular mesoblastic tissues.

Views Past and Present regarding the Origin and Nature of Carcinoma.—The old authors were familiar with the gross appearances and the clinical aspects of carcinoma. The division into open and subcutaneous carcinoma was made at an early day; the former was described as *cancer apertus*, and the latter as *cancer occultus*. Celsus understood under the term "cancer" the several forms of gangrene. Galen insisted on an early diagnosis, which he based almost exclusively upon its clinical course. *Ætius* gave an accurate description of carcinoma of the uterus. The classical description of cancer by *Soranus* would be no discredit to a modern work on general pathology. All malignant growths were included under the head of cancer. The first attempt to describe tumors upon an anatomical basis was made by *Johannes Müller* in his work on *The Structure of Morbid Growths*, published in 1838. *Virchow* traced the tumor-cells to their histological origin, and thus laid the foundation for a rational classification. He was also the first to describe the alveolar structure of carcinoma, and he called attention to the resemblance of carcinoma-cells to epithelial cells. He believed that both stroma and the epithelial cells were produced by the connective tissue.

The microscope was made available as a means of investigating the structure of tumors by *Schleiden* and *Schwann*. *Müller* in 1836, in a preliminary communication, divided tumors into "benign" and "malignant," by which terms he meant tumors that were curable or incurable by operation. *Bichât* described carcinoma as a subepithelial tumor, and distinguished a stroma which he believed consisted of degenerated connective tissue and of cells derived from the epithelial layer. *Laennec*

divided tumors into "homologous" and "heterologous," and among the latter included tubercle, encephaloid, melanosis, and scirrhus. Lobstein, while admitting the correctness of this division, believed that the difference between the two kinds of tumors was due to a species of lymph, which, according to the character of the tumor, is either *euplastic* or *cacoplastic*. Müller maintained that the structure of benign and malignant tumors was identical, and that the classification into homologous and heterologous tumors was based on ignorance of their microscopical structure. He, however, recognized a neoplastic form of cell-elements, and in the examination of tumor-tissue under the microscope he speaks of normal tissue, granules, cells, and new connective tissue. From that time dates the description of a morphologically specific caudate cancer-cell which was regarded as the essential element of cancerous infiltration—an opinion which prevailed at his time, but which was not shared by Müller. Lebert and Hannover revived again the theory of the existence of a specific cancer-cell, but, instead of the caudate cell, described a more primitive structure. Lebert separated carcinoma of the skin from carcinoma of internal organs, and called it *cancroid*. About the same time Ecker examined microscopically three specimens of carcinoma of the lip, and, finding no foreign heteroplastic cells, declared them to be a simple hypertrophy of the papillæ. Mayo discovered general infiltration in a similar tumor, and therefore classified it with what was then generally recognized as cancerous tumors.

Rokitansky classified carcinoma of the skin with glandular carcinoma, and regarded it as a variety of medullary fungus, differing from carcinoma proper only by the form and aggregation of its cells. Lebert modified his views regarding the structure and nature of *cancroid* after he discovered that in some cases it gave rise to glandular and general infection, and after having found in it the cell-forms which he regarded as characteristic of carcinoma. In 1845 he distinguished three kinds of carcinoma of the skin: 1. Papillary excrescences with inflamed, indurated base and superficial ulceration; 2. Papillary proliferations of the cauliflower kind with enlargement of the sebaceous glands; 3. Epithelial neoplasms consisting of a fibrous framework, its meshes filled with epithelial cells. Ecker, Mayo, and Lebert referred the origin of the new epithelial cells to proliferation from pre-existing mature epithelial cells, while Virchow, Rokitansky, and Neumann claimed that they were the product of metaplastic proliferation of the connective tissue. The glandular origin of carcinoma of the skin was studied by E. H. Weber, and later by Gluge. Ecker, Mayo, Lebert, and Rokitansky believed that carcinoma resulted from tissue-proliferation of the papillæ of the skin. Virchow applied the term *cancroid* to surface carcinoma

in which, in the tumor-tissue, spaces are formed and are occupied by epithelial cells. Führer called attention to the possible influence of irritation caused by the hair in the production of carcinoma of the lip in men. Robin believed that carcinoma of the skin originated in the sebaceous glands.

Hannover originated the term *epithelioma* for carcinoma of the skin and mucous membranes—a term which has caused a great deal of confusion in distinguishing a benign from a malignant epithelial tumor. He asserted that carcinoma of the skin originated from the rete Malpighii, and not in the glandular appendages of the skin. Verneuil and Förster observed cases of carcinoma of the skin that originated in sweat-glands. A parallel to the history of surface carcinoma is that of a form of ulceration of the skin that was called *ulcère cancroïde* by Lebert, *ulcus rodens* by Paget, and *ulcus phagedænicum* by Von Bruns. Many English authors adhere to the term *rodent ulcer*, and describe under it something which is supposed to be different from true carcinoma. Modern writers, with few exceptions, look upon rodent ulcer as a variety of carcinoma of the skin. Förster observed fatty degeneration of the tissues in carcinoma of the skin, besides a mucous metamorphosis of the cell-masses in the alveoli. Colloid degeneration was found only in exceptional cases. It was ascertained later that the cylindroma of Billroth also represents only a secondary change occurring in surface carcinoma. In but a few instances was a primary carcinoma found away from the epiblastic or hypoblastic tissues. Virchow reports a primary cancrioid in the tibia; O. Weber, in the inferior maxilla; Paget, in the inguinal glands. In all these and in similar cases the proliferation had its origin from a displaced matrix of embryonic epiblastic or hypoblastic tissue. Cohnheim went a step farther, and claimed that carcinoma did not originate by proliferation from mature epithelial cells, but that it was produced, independently of mature pre-existing tissue, from a matrix of embryonic epithelial cells, and he advanced the theory which assigns to the origin of all tumors a matrix of embryonic tissue. This theory has been upheld strongly by Waldeyer and a number of modern writers. It goes farther toward explaining the origin of tumors than any other theory heretofore advanced. Until quite recently carcinoma was regarded as a local manifestation of a general dyscrasia. It was supposed that the essential cause existed in the blood, and that the tissues the seat of tumor-formation were acted upon by a specific virus. Virchow assumed the existence in the tissues of a primary carcinoma of a *seminium* which, by being brought in contact with lymphatic and other tissues, reproduced the disease in other localities, and which by its action upon the adjacent tissues gave rise to local

infection. He asserts that in the primary formation no doubt there is produced a contagious material which acts upon the tissues with which it comes in contact in the same manner as does the lymph in lymph-glands. The more anastomoses the affected parts have, the more such a result may be expected. Cartilage is almost exempt from local infection of a malignant growth, owing to the absence of blood-vessels and lymphatics. In malignant tumors in the epiphyseal region of the long bones the articular cartilage is often found completely separated, and shows the effect of pressure-atrophy rather than of direct implication by the tumor. He believes that local infection from a malignant growth takes place by the action of an infective fluid brought in contact with cells without the intervention of vessels or nerves. He admits that it is not known whether distant parts are infected in a similar manner or whether metastasis takes place by transportation of cells. He believes that the occurrence of metastatic carcinoma of the liver without carcinoma of the lung speaks against cellular transportation as a cause of metastatic tumors. W. Müller and Creighton believe that the virus produced in a carcinoma affects the tissues with which it is brought in contact like the spermatozoa affects the ovum, the cell-impregnation giving rise to tissue-proliferation.

Mr. Simon in a recent discussion on carcinoma took this standpoint. He attempted to show that the mere wandering of cancer-cells to parts distant from the primary tumor, and their overgrowth in their new location, did not explain the facts as observed in these tumors. He maintained that the essence of the specific force of malignancy is an impregnative or spermatic one, whereby the part primarily affected exercises on the tissue receiving its juices an influence which causes the latter "to fructify in conformity with its own deranged pattern." But then, again, holding these views, he still is able to see two functionally distinct classes of disease in cancerous and non-cancerous tumors. It is difficult to conceive how a modern pathologist could hold such views in the face of the numerous and conclusive proofs of dissemination of carcinoma by migrating and transplanted cells.

More recent researches have been made with a view of demonstrating the microbic origin of the primary and secondary tumors, but so far no conclusive proof has been furnished of the microbic origin of carcinoma. Our present knowledge concerning the origin and growth of carcinoma warrants us in making the statement that *carcinoma is the result of an atypical proliferation from a matrix of embryonic cells, and the local and general infections are caused by the local and general dissemination of carcinoma-cells.*

Histogenesis.—In discussing the histogenesis of carcinoma we shall take it for granted that all carcinomatous tumors spring from a similar matrix—that is, that they all have a similar histogenetic origin. It has been stated elsewhere that the histological structure of the tumor and its behavior to the surrounding tissues are modified by the type of the cells of which it is composed and the nature of its environment; but all cancerous tumors bear a resemblance to one another anatomically and manifest the same clinical tendencies. The idea that the old authors entertained in regard to the parasitic nature of tumors of all kinds, but especially of carcinoma, presents plausible features. Even normal cells, as Virchow says, live a parasitic life. In a stricter sense the term *parasitic* can be applied to cells which, when detached from their mother-soil, retain under favorable circumstances their vitality when transplanted into other localities, such as epithelial cells and cartilage-cells. If a piece of connective tissue should become detached and should engraft itself upon living tissue in some other place, it would have to be regarded as a parasite, as its existence would depend upon the abstraction of nutritive material from the new soil. The parasitic nature of malignant tumors is more marked than that of the benign growths, because a carcinoma or a sarcoma from its very commencement destroys pre-existing tissues, besides robbing the part in which it is located of a part of its nutritive supply.

Parasitism of tumors, in the sense in which the expression is used to-day, is much more limited in its significance than formerly. When used in its modern sense, the term signifies the presence in the body of growths which have no existence in the normal body. We now regard a tumor as an integral part of the organism, the product of tissue-proliferation from a matrix of embryonic cells.

The first attempt to trace tumors to their proper histogenetic source was made by Virchow, who believed that the carcinoma-cells, like the cells of nearly all tumors, were derived from the connective tissue. He found cells in carcinoma far away from normal epithelial cells, and from their resemblance to epithelial cells he called them *epithelioid* cells. He believed that these cells were produced in the localities in which he found them. Förster believed that the cells of the cylinder-celled epithelial cancrroid of the gastro-intestinal canal and the squamous epithelioma of the skin were produced by the pre-existing connective tissue of the part in which the tumor originated. Neumann supported Virchow's views in reference to the histogenetic source of the carcinoma-cells. Köster, a pupil of Recklinghausen, asserted that in carcinoma of the skin and the stomach the carcinoma-cells were derived

from the endothelial cells of the lymphatic vessels. Virchow describes cell-formation in carcinoma as follows: "A portion of a large granular cell becomes uniformly transparent, possibly beginning with a degenerating nucleus. This portion shows from the first a definite wall, which becomes thickened and similar in appearance to cartilage-cells. During this change the remainder of the old cell becomes more homogeneous and frequently disappears entirely." He considers the cavities, or vacuoles, in carcinoma-cells and in cartilage-cells identical. This condition seems to be the first step to overcome morphologically the apparently great differences between epithelial and cartilaginous structures. As illustrations of their close relation, instances of two tumors, one of the parotid gland and the other of the testicle, are given, in which tumors a portion was of epithelial and the remainder of cartilaginous structure.

Virchow's views prevailed until Remak established the doctrine of the independence of the different histological elements and founded the law of the normal succession of cells. His supported Remak's teaching in a most positive manner. The same author added to our knowledge of the histogenesis of epithelial tumors by excluding from them endothelial tumors. He regarded the endothelial cells as a variety of connective-tissue cell derived from a histogenetic source entirely different from the epithelial cells. In the light of recent embryological investigations, the doctrine of metaplasia as expounded by Virchow is no longer tenable. Connective tissue cannot produce epithelial cells, and epithelial cells cannot produce connective tissue. *The law of the legitimate succession of cells holds true in the growth of tumors, both benign and malignant, as well as in the production of normal tissue.* The origin of carcinoma-cells from mature pre-existing epithelial cells was accepted by Billroth, Lücke, Rudnow, Thiersch, Klebs, Rindfleisch, and others. Waldeyer went a step farther in explaining the difference between the origin of benign and malignant epithelial tumors when he defined a carcinoma as "an atypical epithelial tumor." With this definition he wished to draw a line between a benign and a malignant epithelial tumor. By an atypical proliferation of epithelial cells is meant a condition in which the new cells produced originally within the limits of epithelial tissue extend beyond the limits of the physiological type—that is, beyond the basement membrane. An adenoma (Fig. 110) as compared with a carcinoma (Fig. 111) is a typical tumor because the epithelial cells remain within their normal physiological boundary-line, the *membrana propria*.

By contrasting Figures 110 and 111 it will be seen at a glance what is meant by a "typical" and an "atypical" tumor. Adenoma of the

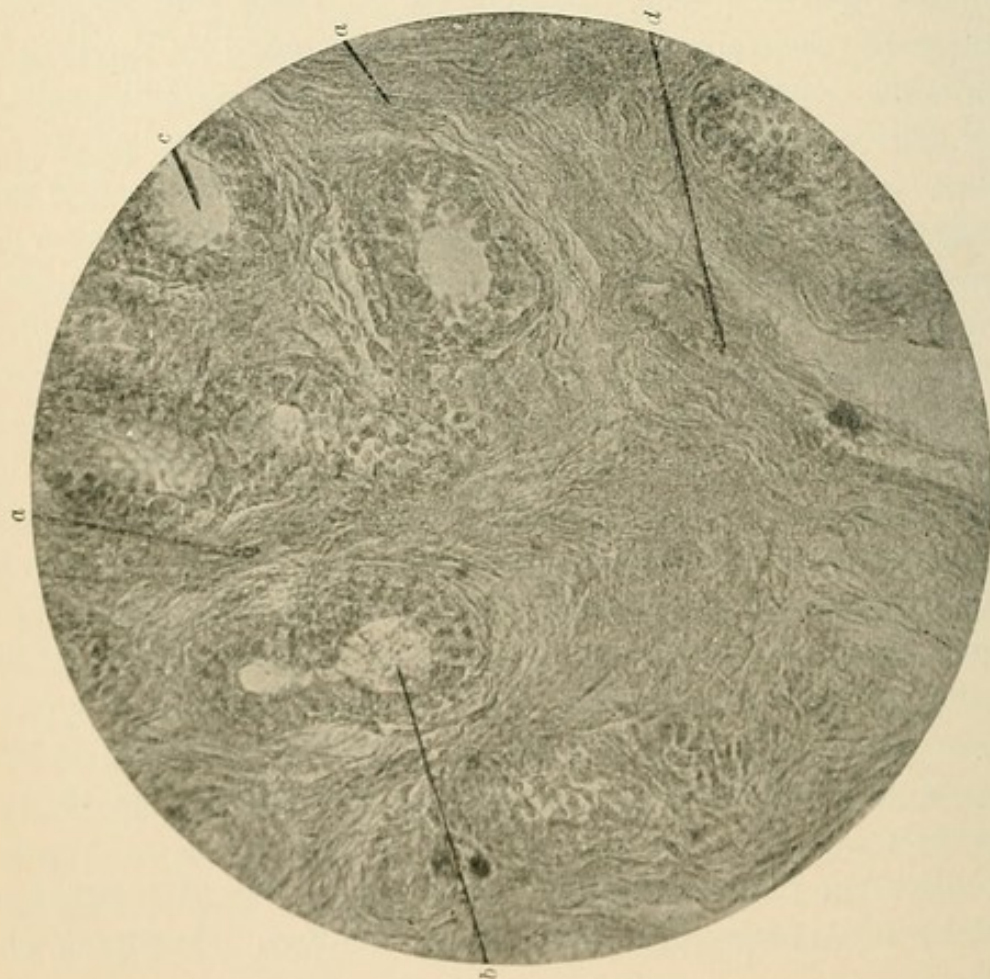


FIG. 110.—Adenoma of the mammary gland: typical benign epithelial tumor (Surgical Clinic, Rush Medical College, Chicago): *a*, connective-tissue stroma; *b*, tubule cut obliquely; *c*, tubule cut transversely; *d*, blood-vessels cut longitudinally.

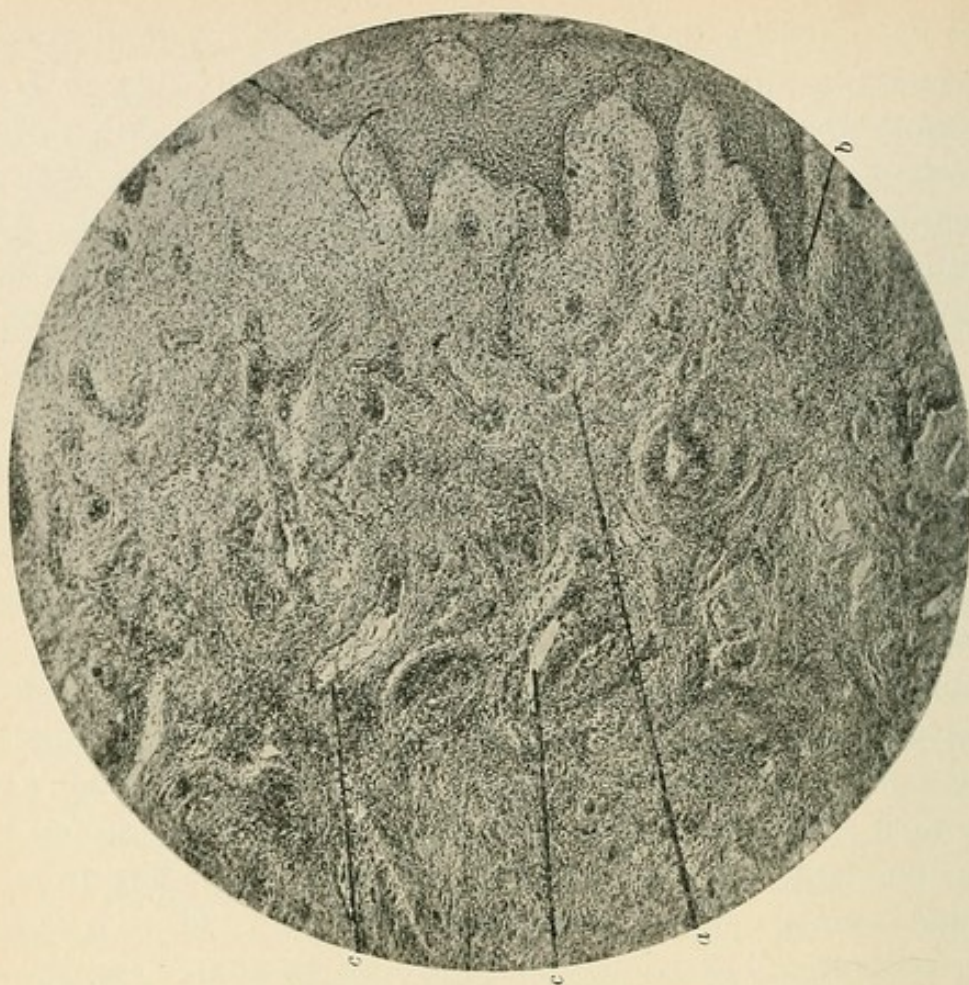


FIG. 111.—Carcinoma of the tongue: atypical malignant epithelial tumor (Surgical Clinic, Rush Medical College, Chicago): *a*, normal tissues of the tongue; *b*, epithelial cells invading the deep structures; *c*, blood-vessels.

breast is a typical epithelial tumor because the epithelial cells have at no place lost their normal relations with the connective tissue; the cells and the connective tissue are separated by the *membrana propria*. Carcinoma of the tongue is an atypical epithelial tumor because the new epithelial cells have passed beyond the *membrana propria* and are beginning to infiltrate the connective tissue. The proliferation here is atypical because the epithelial cells are produced in a tissue of a different type and in a place distant from that in which they normally originate.

To make the point between typical and atypical proliferation of epithelial cells still stronger the atypical proliferation will be defined as *the presence, growth, and multiplication of epithelial cells in the mesoblastic tissues*. Klebs defines this process very correctly as "a metastasis of epithelial cells."

Cohnheim believed in the epithelial origin of carcinoma, but asserted that mature epithelial cells are not capable of producing a tumor. He claimed that all tumors originate from a congenital matrix of embryonic cells. For carcinoma he assumed either a matrix of epithelial cells in localities in which epithelial cells normally exist, or a displaced matrix. From this standpoint all tumors are atypical. We shall, however, use the word "atypical" in the sense in which Waldeyer applied it. We shall hold fast to Cohnheim's theory regarding the histogenesis of carcinoma. *If a carcinoma always originates from epithelial cells, primary carcinoma in mesoblastic tissue is impossible from a histogenetic standpoint unless a matrix of embryonic epithelial cells has become displaced during the development of the embryo, or when epithelial cells have become buried in mesoblastic tissues, after birth, by injury or by disease.* Primary carcinoma of mesoblastic tissues is due to the presence of a displaced matrix of embryonic epithelial cells. It is from such matrices that primary carcinoma is occasionally observed in bone, in lymphatic glands, and in other mesoblastic tissues. Deep-seated carcinoma of the neck occurring independently of infection from another source originates either from branchial structures—branchiogenous carcinoma (Volkman)—or from an accessory or supernumerary thyroid gland—struma carcinomatosa accessoria (Guttman).

The origin of carcinoma in accessory organs must be taken into consideration in the diagnosis of primary carcinoma in unusual localities. A post-natal matrix of embryonic epithelial cells is more frequently the starting-point of carcinoma than was formerly supposed. Such a matrix is created in ordinary scar-tissue in scars following deep burns, in ulcers, and by the traumatic displacement of fragments of epithelial tissue.

HISTOLOGY.

All carcinomatous tumors are composed of epithelial cells and an alveolated stroma of connective tissue. One of the strongest arguments against the microbic origin of carcinoma is the histogenetic source of the carcinoma-cells. Pathogenic microbes act upon the tissues with which they are brought in contact, and the proliferation results in cells which correspond in type with the cells acted upon by the microbes. Carcinoma-cells multiply by karyokinesis. Soon after Flemming published the result of his observations on karyo-

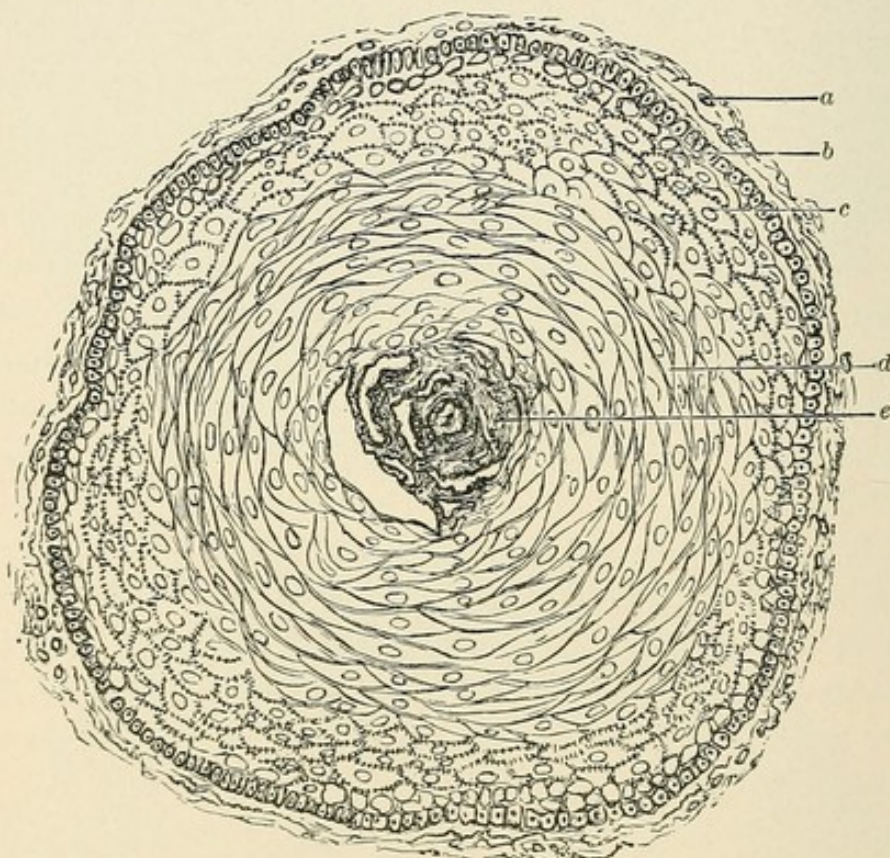


FIG. 112.—A cell-nest from a cancer of the lip; $\times 300$ (after D. J. Hamilton): *a*, the stroma of the alveolus in which the cell-nest is contained; *b*, small germinal cells of the periphery; *c*, prickle-cells; *d*, compressed squamous cells; *e*, degenerated cells in the centre.

kinesis, Filbry observed the same structural changes in carcinoma-cells. All preparations showed, without exception, the indirect mitotic segmentation of the nucleus. The best figures were seen in the marginal zone of the epithelial projections, while in sarcoma they were about the same throughout the tumor. The epithelial cells are derived from the essential tumor-matrix; the stroma consists of pre-existing connective tissue. The several varieties of carcinoma formerly separately described—epithelioma, scirrhus, encephaloid, colloid, glandular carcinoma—differ only in their structure from their location, the type of cells, or the kind and degree of degeneration of the tumor-tissue; the general plan of their histological structure is the same. For the purpose of avoiding

confusion the different histological forms of carcinoma will be described separately.

Squamous-celled Carcinoma.—The characteristic histological feature of every carcinoma is the alveolation of the stroma and the grouping of cells in its meshes (Fig. 112).

In carcinoma of the skin the squamous epithelial cells are arranged in concentric layers in the alveoli, forming the so-called "cancer-nests" or "epithelial pearls." The young cells occupy the periphery of the nest, the oldest cells being in the centre. Cell-degeneration always begins in the oldest cells in the centre of the nest. The alveolated structure of the stroma was first described by Virchow. The alveoli are formed by the colonies of cells which form in the connective-tissue spaces, each colony the offspring of a single epithelial cell which has found its way into the connective tissue. As the cell-mass increases in size the connective-tissue fibres are separated and form the alveolus. The epithelial cells act the part of a foreign body and increase the blood-supply to the tissues, thus increasing the vegetative capacity of the connective-tissue cells, which in turn results in increase of the stroma.

Klebs believes that the epithelial cells which have undergone carcinomatous degeneration are gradually transformed into connective tissue and form a part of the stroma. If such a transition occurs, the increase of stroma-tissue during the growth of the carcinoma could easily be explained. Hatschek and Rabl claim that mesoblastic cells are derived from epithelia. Recklinghausen and Köster have observed metaplastic tissue-changes in metastatic lymphatic carcinoma, where endothelial cells were transformed into epithelial cells. These views can no longer be held, as more recent researches have established upon a firm basis the law formulated by Remak and confirmed by His, that cells invariably produce their own kind, and no other. We must therefore assign to the pre-existing connective tissue the function of stroma growth.

The stroma is always infiltrated by leucocytes and young carcinoma-cells (Fig. 113, *a*). In rapidly-growing soft carcinoma the stroma is scanty, the alveoli is large, the cells are numerous, and the local infection

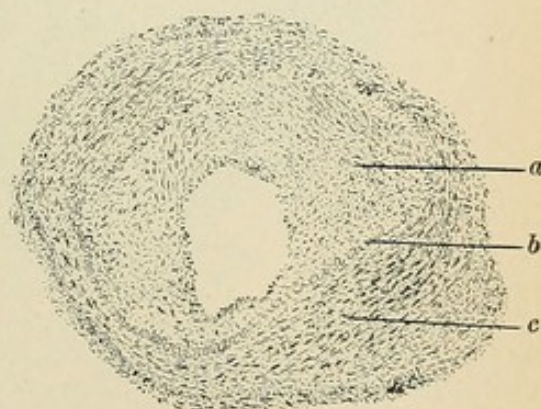


FIG. 113.—Artery from connective-tissue stroma of secondary carcinoma of the lower jaw: endarteritis deformans et obliterans; $\times 54$ (Surgical Clinic, Rush Medical College, Chicago): *a*, thickened proliferating intima; *b*, internal elastic lamina; *c*, tunica media.

is early and extensive. A well-developed, firm stroma renders the tumor hard and retards its growth and local infection. The vessels and lymphatics of a carcinoma are distributed through the stroma. The arteries in the carcinomatous tissue frequently undergo degenerative changes, which have not been studied with sufficient care since Thiersch first called attention to them.

Proliferating endarteritis has been found a rather frequent accompaniment of carcinoma in the laboratory of Rush Medical College, when there were no indications of the existence of the same condition of the

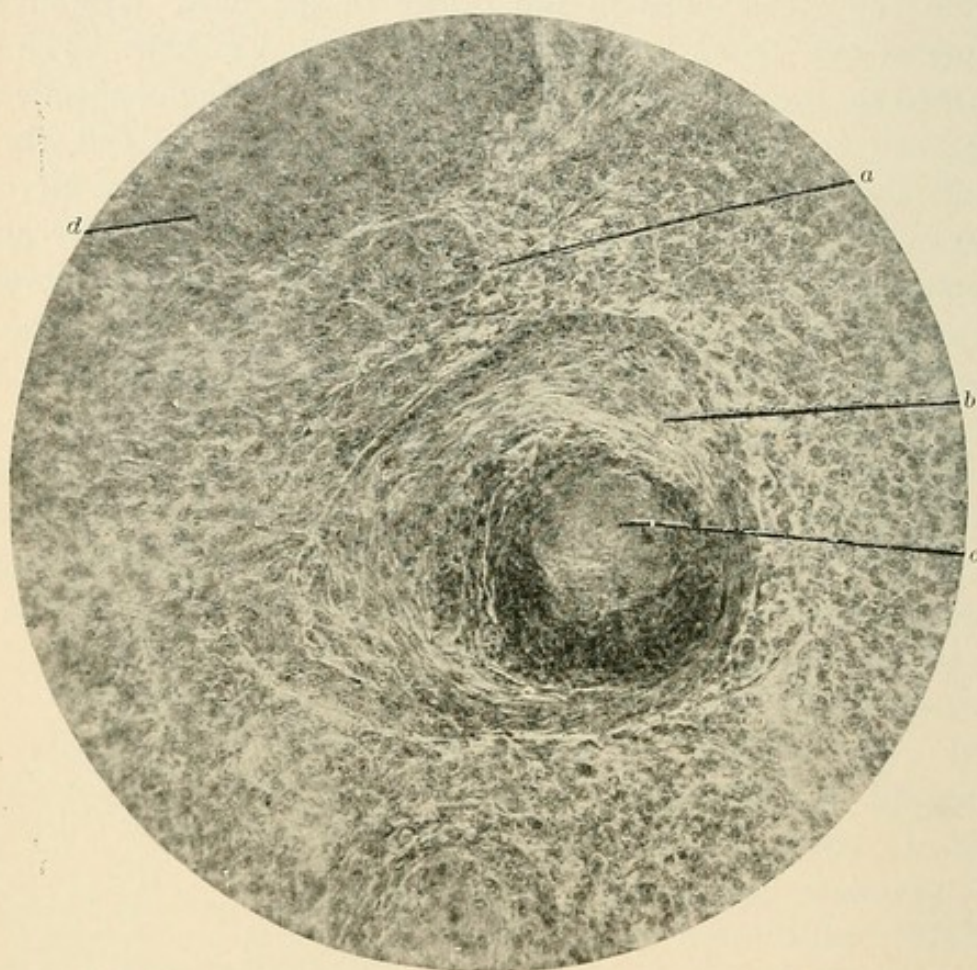


FIG. 114.—Carcinoma of the skin; $\times 450$ (Surgical Clinic, Rush Medical College, Chicago): *a*, stroma infiltrated by leucocytes and young carcinoma-cells; *b*, epithelial nest; *c*, colloid degeneration in centre of pearl; *d*, new cancer-nest.

arteries in any other part of the body. The existence of this form of arterial degeneration on a large scale cannot but give rise to serious nutritive changes of the tumor-tissue (Fig. 114). It is a subject that calls for further investigation.

Cylindrical-celled Carcinoma.—In carcinoma of the mucous membrane derived from the hypoblast the parenchyma of the tumor is composed of cylindrical cells arranged in the form of tubules in resemblance of tubular glands. The tubules correspond with the cell-nests of squamous-celled carcinoma (see Fig. 25, p. 66). The columnar epithelial

cells are arranged in a somewhat atypical manner in the crypts, forming a cellular lining of differing depths (Fig. 115). The tubules vary in size and shape, constituting in this respect a contrast to adenoma of the same part, in which symmetry of the tubules is preserved (Fig. 116). The stroma of the tumor is infiltrated with leucocytes and young carcinoma-cells (Fig. 116, *c*). The cells and stroma of cylindrical-celled carcinoma are prone to undergo mucoid and colloid degeneration.

Glandular Carcinoma.—Carcinoma of the acinous glands presents the same alveolation of the stroma as squamous-celled carcinoma. The morphology of the cells being similar, the glandular spaces correspond with the connective-tissue spaces, in which, in the latter variety, the epithelial cells establish centres of growth and form the alveoli. In glandular carcinoma the acini constitute the alveoli, and the interacinous connective tissue constitutes the stroma (Fig. 117). In hard, slow-growing glandular carcinoma the stroma is abundant and the alveoli are small. In soft, rapid-growing carcinoma, formerly called "encephaloid," the stroma

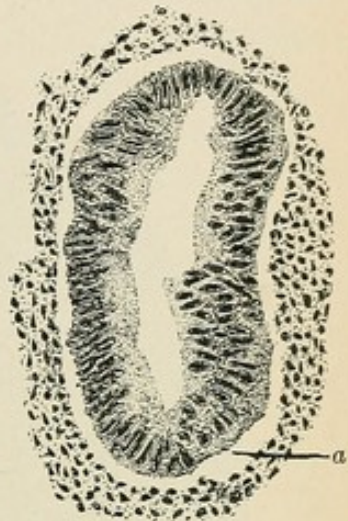


FIG. 115.—A single tubule from a carcinoma of the rectum, showing multiplication of cells in its lining: $\times 170$. At *a*, shrinkage due to hardening (Surgical Clinic, Rush Medical College, Chicago).

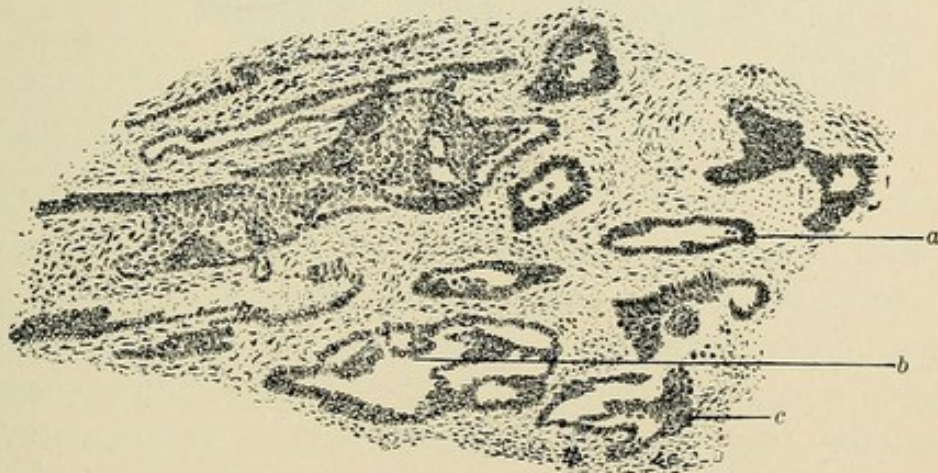


FIG. 116.—From carcinoma of the rectum; $\times 110$ (Surgical Clinic, Rush Medical College, Chicago): *a*, atypical tubule; *b*, intratubular growth of cells; *c*, extratubular infiltration.

is scanty and the alveoli are large. A strong reticulum imparts to the tumor benign qualities.

MALIGNANCY.

The clinical interest of carcinoma centres on its malignancy. Malignancy depends not upon the progressive increase in the size of the tumor, as is the popular belief, but upon the extension of the

tumor to near or distant parts and organs. The intrinsic tendency of carcinoma is to destroy life. For the lack of a better word, the process by which the tumor diffuses itself in its immediate vicinity, in the same region, and throughout the entire body, is termed "infection."

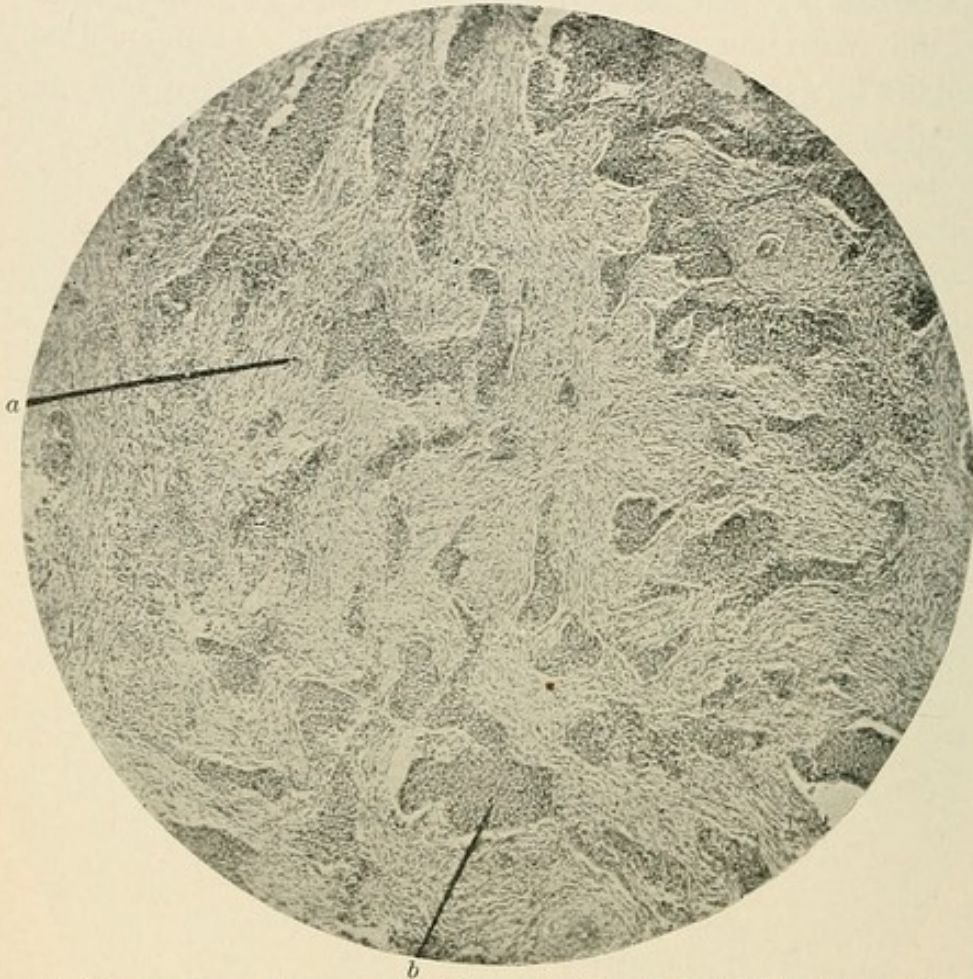


FIG. 117.—Glandular carcinoma of mamma; $\times 85$ (Surgical Clinic, Rush Medical College, Chicago): *a*, connective-tissue stroma; *b*, alveoli packed with epithelial cells.

By the term "infection" as applied to malignant tumors is meant the intrinsic capacity of their cells to leave the primary tumor, and by wandering into the surrounding healthy tissue to establish new centres of growth, or by being transported through pre-existing channels to reproduce the disease in the same region or in distant parts of the body. *It is this cell-migration, and the intrinsic capacity of the cells to reproduce themselves in new and strange localities, that distinguish malignant from benign tumors, and upon which depends their malignancy.*

Local Infection.—The power of epithelial cells to penetrate into the apparently healthy tissue, as seen and described by Waldeyer and Thiersch, is evidenced in the local diffusion of every carcinoma, but it does not explain the malignancy of the tumor, as normal epithelial cells do not possess the same power to proliferate in mesoblastic tissues as do the epithelial cells of a carcinoma. The epithelial cells have

therefore undergone a change, the true nature of which is unknown, which endows them with a greatly augmented vegetative capacity. In the present state of our knowledge we must attribute this increase of their formative power, not to a change in the cells themselves, but to an altered condition of the tissues which they inhabit. This latter condition we have described as a diminution of physiological resistance.

An anomalous location of epithelial cells under certain conditions may cause carcinoma; this anomaly, however, does not constitute the real cause, but is only an additional factor, and not an essential ante-

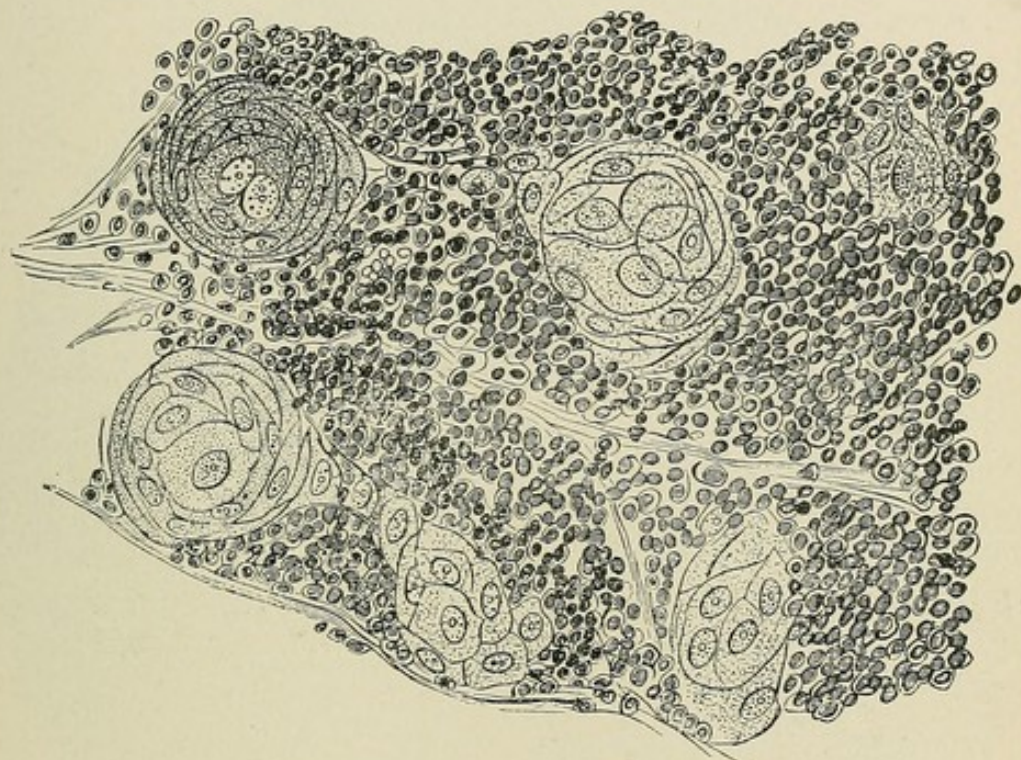


FIG. 118.—From an epithelial carcinoma of the clitoris: epithelial nests imbedded in a stroma infiltrated by small cells; $\times 250$ (after Perls).

cedent condition. Ribbert does not believe that the first changes in the growth of a carcinoma consist in infiltration of the underlying connective tissue. He claims that inclusion of epithelial cells takes place by an outward growth of connective tissue. He has observed as the first thing an active increase of the cellular elements of the sub-epithelial connective tissue. This causes a lifting up of the epithelial layer, which becomes irregular and convoluted. The increased connective tissue grows up among the epithelial cells, and causes irregular separation of the cells from their normal relations, so that they become divided into groups and islands surrounded by the new connective tissue. As the cells are now disconnected from the superficial cells, they cannot proliferate upward, and so must grow where the connective tissue will allow. They proceed in the direction of the least resist-

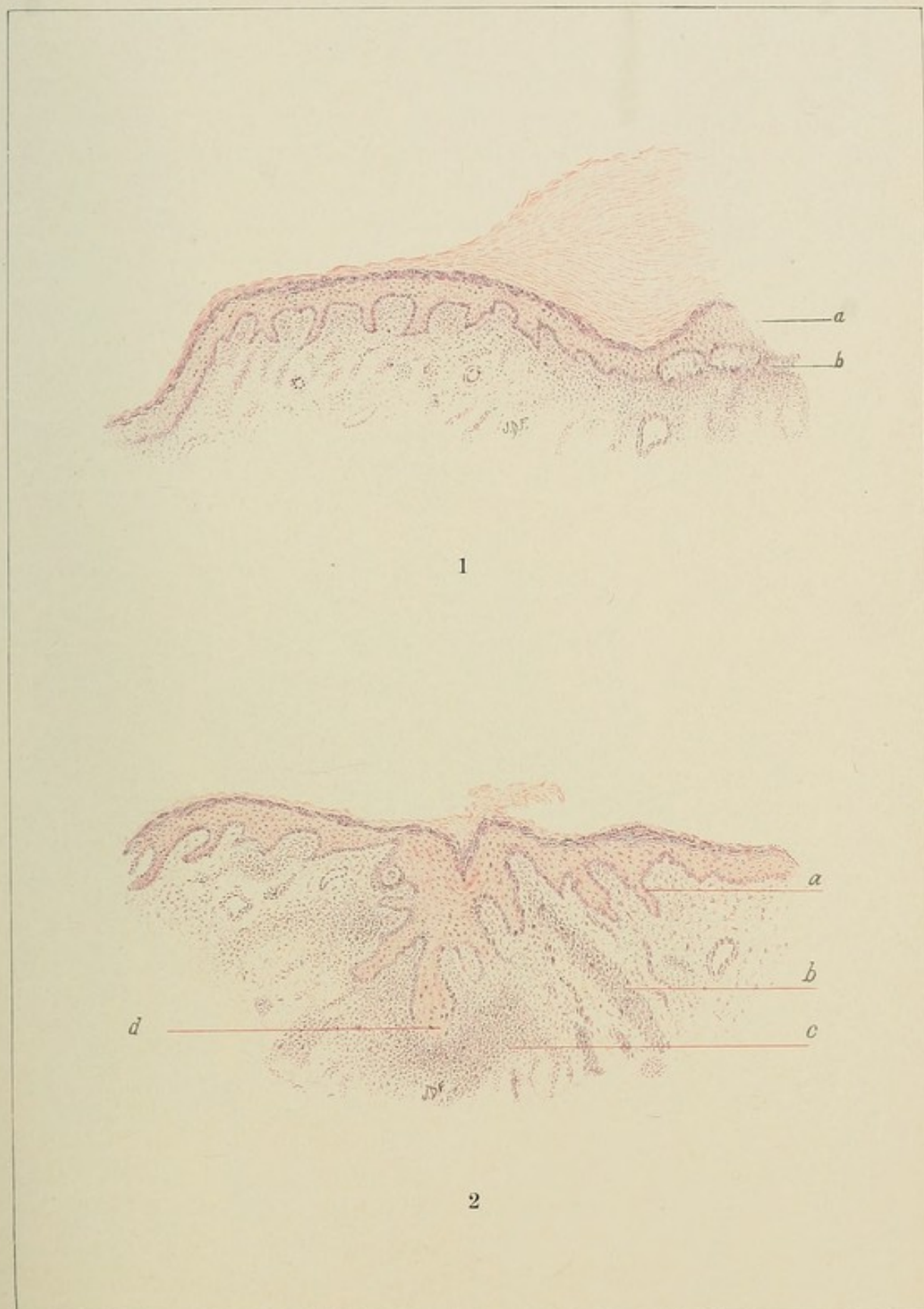
ance—namely, into the intercellular spaces and lymph-channels, and in this manner the carcinoma develops.

Every carcinoma has a benign stage. No matter where the matrix may be located, the cells composing it are at first isolated from the vascular tissues, and the carcinomatous stage begins with cell-migration. Local infection—that is, the growth of the tumor as a whole—is the result of cell-migration. The new epithelial cells, like the ameba and leucocytes, possess the power of independent locomotion. The ameboid

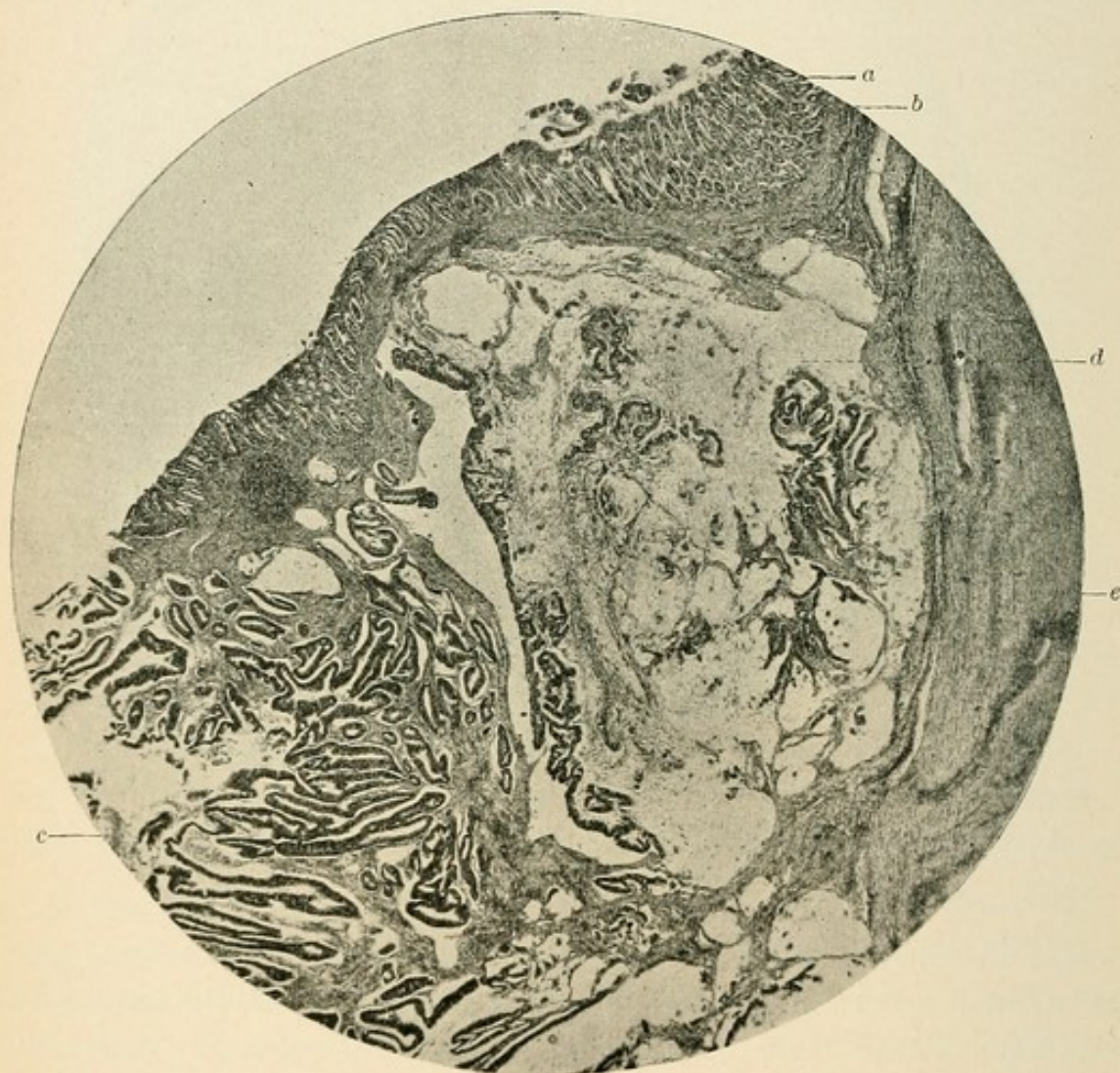


FIG. 119.—Colloid carcinoma of the colon: section through the margin of the tumor; $\times 21$ (after Karg and Schmorl). The tumor (c), which started in the mucous membrane (a), has perforated the muscular coat (b) and presents an adenomatous structure.

movements of carcinoma-cells were studied in 1872 by Carmalt in Waldeyer's laboratory. Cells of carcinoma of the breast obtained immediately after amputation constituted the material used. The cells were detached by scraping the cut surface of the tumor, and were kept immersed on the thermal object-table of Stricker. The isolated young cells manifested active ameboid movements, while the deeper cells in fragments of tissue remained motionless.



1. Beginning carcinoma of the lower lip; border of the tumor; $\times 160$: *a*, hypertrophic epidermis; *b*, membrana propria, continuity disturbed.

2. Beginning carcinoma of the lower lip; center of the tumor; $\times 160$: *a*, membrana propria still intact; *b*, engorged lymphatic; *c*, leucocytes; *d*, membrana propria ruptured; wandering of epithelial cells into the connective tissue.



In the stroma of every carcinoma small young epithelial cells besides leucocytes are found (Fig. 118). This infiltration of the tissues around a carcinomatous tumor was called by Waldeyer the "inflammatory zone." Leucocytes escape through damaged capillary walls and are present in large number in rapidly-growing carcinoma, but among them young carcinoma-cells can always be seen. All these young epithelial cells, as soon as they have isolated themselves from the primary tumor, assume an individuality of their own and establish independent centres of tumor-formation. In cylindrical-celled carcinoma the membrana propria of the tubules is often absent, bringing thus the carcinoma-cells in direct contact with the vascular connective tissue, which they infiltrate, increasing thereby the size of the tumor and the area of tissue-proliferation. The glandular tubules are irregularly branched, are devoid of the membrana propria, and are lined in places by three layers of columnar cells (Fig. 119). To the right of the tumor

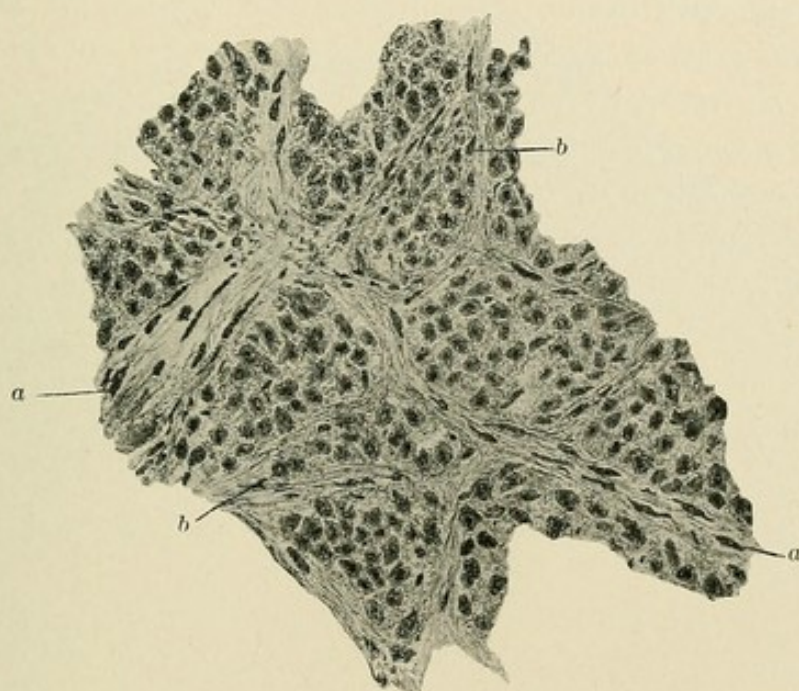


FIG. 120.—Rapid-growing carcinoma of the breast; $\times 115$ (Surgical Clinic, Rush Medical College, Chicago): *a*, vascular stroma; *b, b*, alveoli packed with large epithelial cells.

is to be seen a second carcinomatous nodule (*d*) which is undergoing colloid degeneration. Only at the periphery can carcinoma-cells be seen, while the centre of the space is occupied by colloid material and degenerated detached cells. The space is enclosed by the muscularis (*e*). In glandular carcinoma the infiltration takes place in all directions, and the tumor is surrounded on all sides by a zone of new alveoli, the contents of each alveolus being the product of proliferation of a single cell. New alveoli are also found in the stroma, especially in rapid-grow-

ing tumors, rendering the tumor softer by diminishing its stroma (Fig. 120, *b, b*).

The local infection of carcinoma takes place in the direction of pre-existing connective-tissue spaces, and consequently spreads most rapidly and becomes most extensive in cases in which the primary tumor is surrounded by an abundance of loose connective tissue. It is in such cases that the tumor attains the largest size. The local infection, however, does not remain limited to the connective tissue. *Carcinoma involves by local extension all tissues and organs, irrespective of their anatomical structure.* This is the most conspicuous pathological and clinical feature of all carcinomatous tumors. Johannes Müller called special attention to this property of carcinoma, and surgeons have always regarded this feature as of the utmost diagnostic value in the differentiation between benign tumors and carcinoma. Neumann described and illustrated carcinomatous infiltration of muscular tissue, guided by the belief that the carcinoma-cells were produced by the inter-muscular connective tissue. *The tissues and organs the seat of local, regional, and general dissemination remain passive in the growth of carcinoma; the increase in the size of the tumor is due exclusively to tissue-proliferation of wandering displaced carcinoma-cells. The cells of the regional and metastatic tumors are derivatives from the primary or maternal tumor. Diffuse local infection favors early regional and general infection.* It is on this account that glandular carcinoma is followed more constantly and at an earlier stage by regional and general infection than is squamous-celled or cylindrical-celled carcinoma. *A carcinoma of the cutaneous or mucous surfaces has only one direction in which to infiltrate the tissues, while a glandular carcinoma is surrounded by mesoblastic tissues on all sides, with a correspondingly increased area of infiltration.*

The progressive growth of a carcinoma is due to the establishment of independent centres of growth in the periphery of the tumor. It is for this reason that spontaneous sloughing of the tumor and its destruction by caustics is not followed by a cure, as is the case in benign growths.

Regional Infection.—It is a well-known clinical fact that a carcinoma, wherever it may be located, gives rise to infection of the lymphatic glands of the same region. Simon and Paget were of the belief that carcinoma extends from the primary tumor, not through any active part of the interposed lymphatic channels, but through the lymph. They explained regional infection as follows: 1. The disease in the lymphatic glands resembles the primary tumor, the deviation being dependent on the structures surrounding the carcinoma in the lymphatic gland; 2. It appears about midway in the course of the disease

toward death; 3. Usually the primary tumor makes more rapid progress, but occasionally the reverse is the case; 4. The disease extends along the lymphatics in the direction of the thoracic duct; distant lymphatics are rarely affected. Paget believes that minute fragments of the protoplasm of the cancer-cells, mingled with the blood, may be as effectual as whole cells in reproducing the disease.

The migrating young epithelial cells find their way into the lymphatic vessels within or near the primary tumor, are carried by the lymph-stream to the nearest lymphatic gland, which serves as a filter, arresting their further progress, and as soon as they become localized they establish new centres of growth in the lymphatic gland. There must exist in the primary tumor or in its vicinity favorable conditions for the entrance of the cells into the lymphatic channels.

Langhans made a careful study of injected preparations of the mammary gland, with the special object of ascertaining the relations of lymphatics to the acini and ducts of the gland. He found the acini

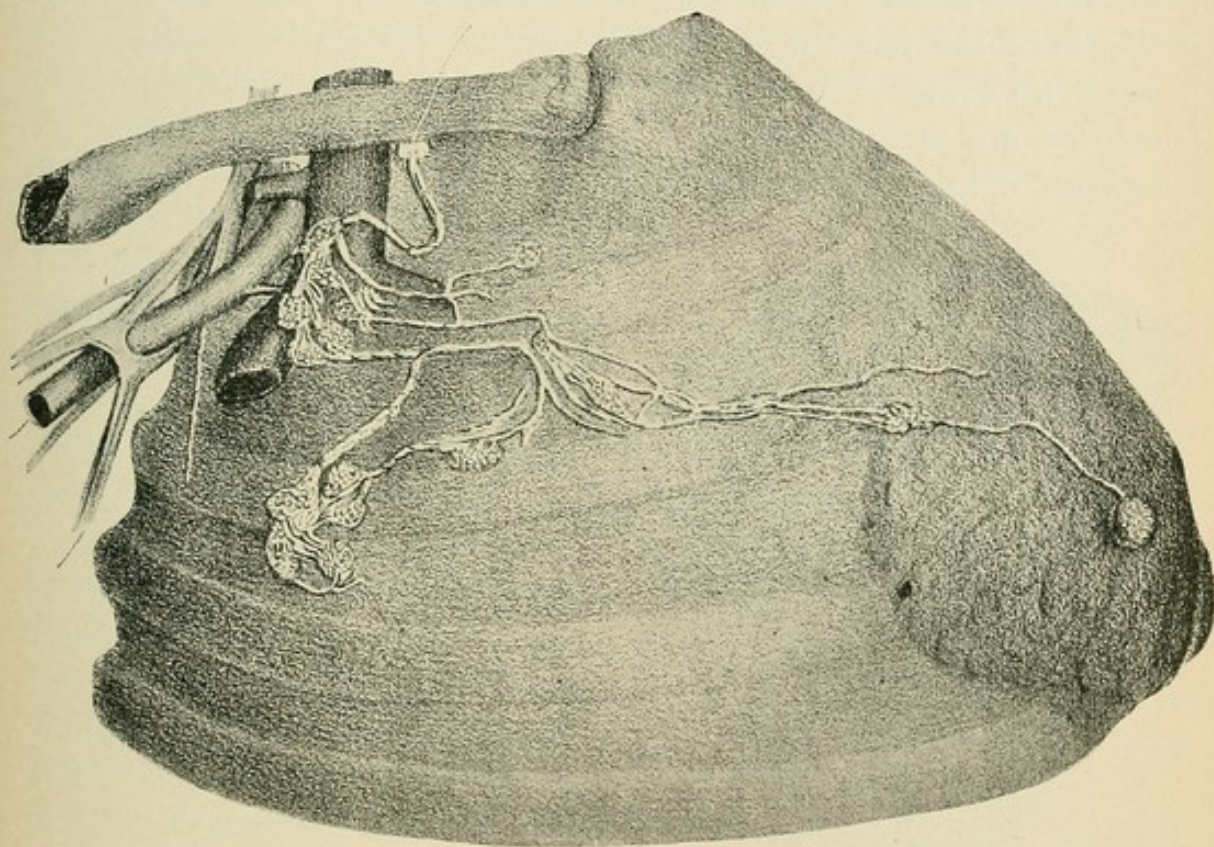


FIG. 121.—The internal lymphatics of the mammary gland injected, and terminating in two trunks in the axilla (after Astley Cooper).

and ducts surrounded by a delicate network of lymphatic vessels, but in none of the specimens did the lymphatic vessels reach the interior of the acini or ducts, or even the membrana propria. Such a direct communication between these structures is claimed by Ludwig Tomsa. The abundance of lymphatic vessels in the mammary gland is well

shown in Figure 121. The lactiferous tubes are also partially injected, and may be seen under the network of lymphatics. It is more than probable that normal lymphatic vessels are impermeable to emigrating epithelial cells, and that their entrance is effected by destruction of the wall of pre-existing lymphatics or through the defective walls of new lymphatic channels in the tumor-tissue. This subject is well worthy of a most careful investigation. Gussenbauer maintained that secondary carcinoma of the lymphatic glands results from the transportation of minute infective corpuscular elements which are carried from the primary tumor through the lymphatic channels into the lymphatic glands, where they infect pre-existing glandular tissue, bringing about a heterologous change in the tissue-elements resembling the structure of the primary tumor. He found in sections of glands recently infected, on staining with picro-carmin, minute granules of an intense red color in the cells of the infected gland-territory. The cells thus infected then presented various changes in their structure. This theory was in accord with views expressed by Virchow and Creighton, that cancer-cells are produced by the action of a virus or *seminium* upon mature cells. We have shown conclusively that the cells of which the primary tumor is composed are derived not from mature tissue, but from a matrix of embryonic epithelial cells, and we shall now proceed to prove that all

metastatic tumors, local, regional, and distant, owe their origin and growth to cells derived from the primary tumor.

Afanassiew made some very interesting investigations in Rudnew's laboratory at St. Petersburg concerning the growth of secondary carcinoma in the lymphatic glands. Inflammatory enlargement of the glands is observed only when the carcinoma has ulcerated, and is then caused by the entrance into the lymphatic system of pathogenic microbes or of chemical irritants. Enlargement of the lymphatic glands under other circumstances denotes the regional dissemination of the disease. The first changes observed

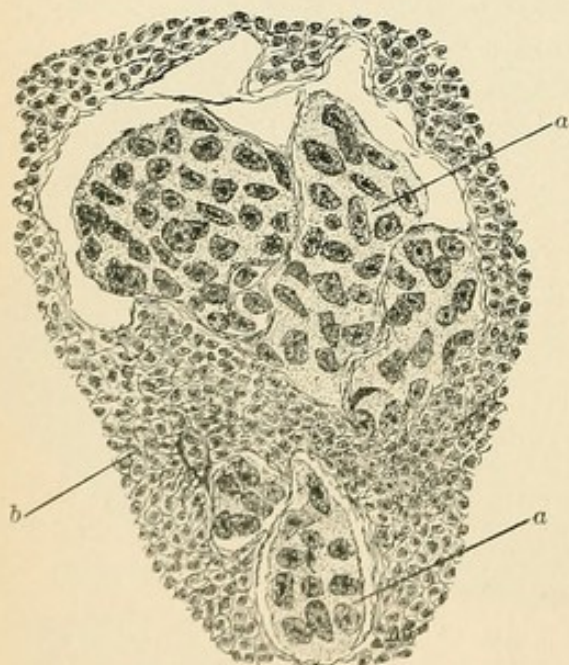


FIG. 122.—Secondary carcinoma of lymphatic gland; $\times 480$, reduced one-third (Surgical Clinic, Rush Medical College, Chicago): *a*, groups of carcinoma-cells; *b*, lymphoid corpuscles and reticulum. Each one of the epithelial nests is the product of tissue-proliferation of a single carcinoma-cell.

in such glands are the presence of carcinoma-cells from the primary

tumor in the lymphatic channels, and irritation of the connective-tissue reticulum caused by the invaders. The lymphoid corpuscles take no active part in the process. As the carcinoma increases in size by proliferation of the transplanted carcinoma-cells new connective tissue is formed from the granulation-elements. The parenchyma of the gland is subjected to pressure and is gradually destroyed, its place being occupied by carcinoma-tissue. The carcinoma-cells that reach the interior of the lymphatic channels are conveyed with the lymph-current to the nearest lymphatic gland, in the meshes of which their onward course becomes arrested. As soon as a wandering carcinoma-cell has reached its destination it undergoes karyokinetic changes, and the product of tissue-proliferation constitutes the secondary glandular tumor, the connective tissue of the gland becoming its stroma (Fig. 122).

The stroma of the carcinoma is derived from the pre-existing reticulum of the gland, which reticulum is increased in consequence of the stimulation caused by the carcinoma-cells, which act the part of a foreign body. Simultaneously or in succession additional centres of growth may become established in different parts of the gland by new cells emerged from the primary tumor to the lymphatic gland. New centres of growth are, however, exhibited also by the migration of young epithelial cells from the first glandular focus along the lymph-spaces into other parts of the gland (Fig. 123, *c*).

The local infection of secondary tumors is as marked as that of the primary tumor, and takes place in the same manner. The cells correspond in shape, size, and manner of grouping to those of the primary tumor. The stroma is modified by the character and amount of connective tissue in the new

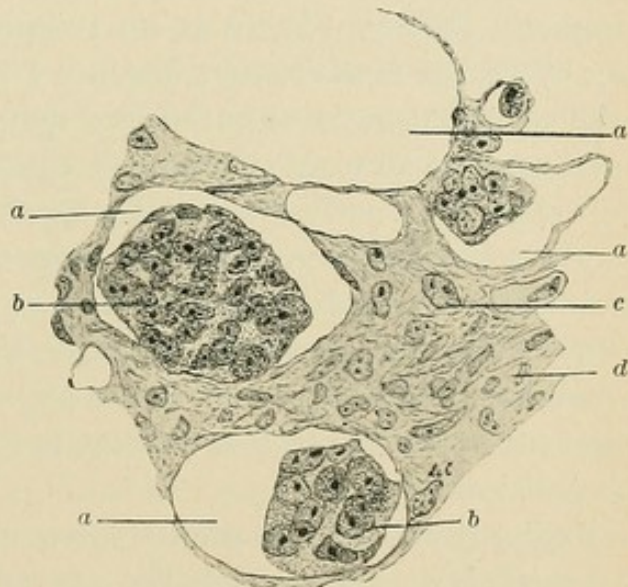


FIG. 123.—Secondary carcinoma in the lymph-spaces of a lymphatic gland, from a carcinoma of the abdominal wall; $\times 480$, reduced one-third (Surgical Clinic, Rush Medical College, Chicago): *a*, lymph-spaces; *b*, groups of carcinoma-cells; *c*, carcinoma-cells in the parenchyma of the gland; *d*, leucocytes.

locality. It has been known for a long time that a secondary tumor frequently grows much more rapidly than the primary tumor. This fact can readily be explained by assuming that the pre-existing connec-

tive tissue surrounding the secondary tumor is more scanty and of a looser structure than the stroma of the primary tumor. As the local infection in the lymphatic gland increases, the parenchyma of the gland disappears until its capsule becomes distended by carcinomatous tissue. During this time the capsule of the gland has become thickened in a vain attempt to limit further extension of the disease. As soon as the capsule is reached by the carcinoma-cells infiltration takes place, the capsule itself becomes carcinomatous, and the zone of infiltration extends now to the loose paraglandular connective tissue. Until now the gland has remained movable, but as soon as the disease reaches the surrounding tissues the gland becomes immovably fixed.

From what has just been said in reference to the local infection of lymphatic secondary carcinoma it will be seen that enucleation of carcinomatous glands is bad practice. Such practice prevails still to a large extent, and is responsible for the local recurrence that invariably follows such a procedure. Not only the paraglandular zone of infiltration remains, but also the connecting lymphatic channels.

Carcinoma of the lymphatic channels has not received the attention it deserves. The writer is firmly convinced that many of the secondary glandular tumors that have invariably been regarded as infected lymphatic glands were carcinomatous nodules which developed in the lymphatic vessels. There is no reason to doubt that carcinoma-cells may by mural implantation become arrested in lymphatic vessels and produce the same results as in a lymphatic gland. The number of nodules removed from the axillary space in operations for carcinoma of the breast frequently exceeds by far the number of normal lymphatic glands in that locality. *For the purpose of removing the zone of infiltration around carcinomatous glands, as well as with a view of removing all the connecting lymphatic channels, the radical operation for regional carcinoma should consist in the removal by clean excision of the entire lymphatic apparatus in that locality, with the surrounding connective and adipose tissue.*

Regional infection is always progressive. Epithelial cells from the first secondary tumor reach the efferent part of the lymphatic vessel and are conveyed to the second lymphatic gland, where the same process repeats itself, until finally, if the disease is allowed to pursue its course and the patient lives long enough, the last of the chain of glands is reached, when the cells from this tumor reach the thoracic duct and from there the general circulation, producing metastatic tumors in distant organs. Regional infection through the deep lymphatic glands begins near the primary tumor, and extends from there, from gland to gland, until the last filter is passed, when general infection

takes place. *Regional infection retards, and frequently prevents, general infection.* Surgeons are aware of the fact that in the most rapidly fatal cases the lymphatic infection is either entirely absent or, at any rate, not well marked. Usually the lymphatic affection occurs in the same region as that occupied by the tumor. For instance, in carcinoma of the breast the axillary glands on the same side, in carcinoma of the rectum the retro-peritoneal glands behind the rectum, and in carcinoma of the lip the submental and submaxillary glands, are affected. The writer not long ago observed a case of carcinoma of the breast with extensive regional infection of the axillary glands. Local recurrence soon after the operation was followed by enlargement of the inguinal glands first on one side and then on the other. Microscopic examination of sections taken from these regions showed typical glandular carcinoma.

Local infection through the superficial lymphatics of the skin travels as often against as with the lymph-current. The extension of carcinoma through the superficial lymphatics of the skin, as observed in cases of lenticular carcinoma, always reminds one of the manner of spreading of erysipelas. In such cases the lymphatic vessels take an important part in the diffusion of the disease. Lymphatic channels become blocked, the lymph-current is arrested, and consequently the direction of the dissemination of the disease is no longer governed by the lymph-stream. *The original infection takes place in all directions.* The swelling of the arm in extensive regional infection of the axillary glands is the combined result of lymphatic obstruction and pressure of the glandular tumors upon the large axillary vessels.

General Infection.—*General infection in carcinoma consists in the appearance of carcinomatous tumors in organs or tissues of the body that have anatomically no connection with the region occupied by the primary tumor.* Such tumors are called "metastatic tumors," and the process by which they are produced is termed "metastasis." Klebs speaks of a "cell-metastasis" in local and regional infection of a carcinoma, but we shall restrict the term "metastasis" to tumor-formation anatomically disconnected with the primary tumor. Carcinoma-cells retain their vitality and intrinsic power of tissue-proliferation during their journey through the lymphatic vessels and blood-vessels, and as soon as they become arrested by mural implantation or embolism they begin to proliferate and to produce tumors identical with the primary tumor. Metastatic carcinomatous tumors always occur in connection with a blood-vessel on the arterial side of the circulation. The process of distribution of tumor-tissue resembles embolism. *Generalization of carcinoma takes place in consequence of the entrance into the general circu-*

lation of carcinoma-cells or fragments of tumor-tissue, which, when arrested anywhere in the arterial system, constitute carcinomatous emboli from which the metastatic tumors grow. The entrance of carcinoma-cells into the general circulation is effected in two ways: 1. Direct entrance by perforation of a vein-wall by the tumor; 2. Migration of cells through the lymphatic system. In the first instance isolated tumor-cells may be washed away from the projecting tumor-mass, or fragments may be broken off and conveyed into the general circulation. In the second manner of general dissemination isolated cells reach the venous circulation through the thoracic duct by migration of cells through the lymphatic channels and glands from the primary tumor without causing lymphatic carcinoma; or, what is usually the case, carcinoma-cells enter from the last gland of the chain of lymphatic glands in the region occupied by the primary tumor, reach the thoracic duct, and from there the venous circulation. *The location of the metastatic tumors is determined largely by the size of the carcinomatous emboli.* Isolated small epithelial cells can pass through the pulmonary capillaries, reach the arterial circulation, and become arrested in the minute capillaries of some distant organ as minute emboli; or they adhere to the intima of the arterioles or capillaries, mural implantation takes place, and the cell becomes the starting-point of a metastatic tumor. Large tumor-fragments become arrested as emboli in the branches of the pulmonary artery (see Fig. 28, p. 77).

General dissemination by isolated cells frequently gives rise to miliary carcinosis; the fragments of tumor-tissue, to embolism of the pulmonary artery. A metastatic tumor of the lung becomes a distributing-point of carcinoma-cells, which from here reach the general circulation, becoming the direct cause of more remote metastatic tumors or, perchance, of miliary carcinomata. *All histological varieties of carcinoma may give rise to metastatic carcinoma, and all vascular organs of the body may become the seat of a metastatic carcinoma.* The type of cells of the primary tumor is reproduced in the metastatic tumors; that is, a squamous-celled carcinoma produces a squamous-celled metastatic tumor; a columnar-celled carcinoma, a columnar-celled metastatic tumor, etc. *It seems that this reproduction of tissue of a similar structure is a strong proof against the microbic origin of carcinoma, and a convincing argument in favor of the doctrine that carcinoma is the result of erratic growth of epithelial cells, and that local, regional, and general dissemination is caused by the migration and transportation of cells derived from the primary tumor.*

The lungs and the liver are the organs most frequently the seat of metastatic carcinoma.

Wagner of Chicago has collected fifteen cases of metastatic car-

cinoma of the choroid, and has made some interesting observations in reference to the manner of local diffusion of the metastatic tumors in this locality. Rapid local dissemination of the tumor in this locality appears to be one of its main clinical features. In the case that came under Wagner's observation, and illustrated by Figure 124, the primary tumor was a carcinoma of the stomach. If a large branch of the pulmonary artery is obstructed by a carcinomatous embolus, hemorrhage around the infarct is of frequent occurrence. Skrzeczka de-

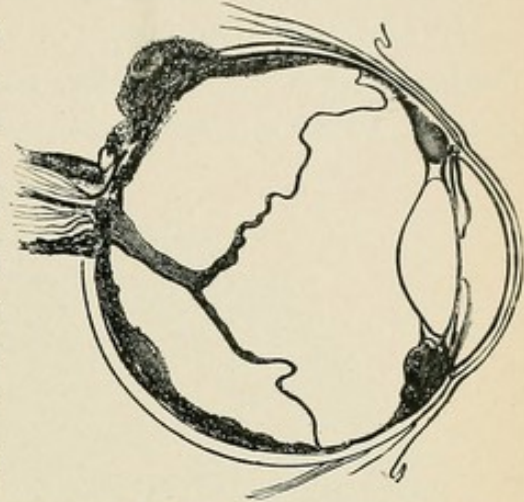


FIG. 124.—Metastatic carcinoma of choroid (after Carl Wagner).

scribes such a case. The entire lung was the seat of hemorrhagic infiltration. Lebert examined twelve cases of colloid carcinoma of the gastro-intestinal canal, and found metastasis in eleven of them. Hauser made a special study of metastatic carcinoma of the liver to determine whether the pre-existing liver-substance takes an active part in the growth of the tumor. He found that the parenchyma-cells in the vicinity of the carcinomatous nodules were destroyed and took no part whatever in the growth of the tumor, thus confirming the observations made by Thiersch and Waldeyer. It will be seen from Figures 125 and 126 that the glandular structure of the metastatic tumors corresponds with the type of the epithelial cells and the structure of the primary tumors.

If a carcinomatous embolus becomes impacted in an artery or in a branch of the portal vein, the metastatic tumor first fills the lumen of the vessel—that is, a carcinomatous thrombus forms around the embolus (Fig. 127). As soon as the pre-existing space in the lumen of the vessel becomes completely blocked by the endovascular metastatic carcinoma, the wall of the vessel becomes infiltrated and is soon incorporated in the tumor. After this time the paravascular tissues become successively involved, and on examining such tumors all traces of the original vessel-wall have disappeared and nothing remains to indicate the endovascular origin of the tumor.

Carcinoma of bone, with very rare exceptions in which the tumor develops from a displaced epiblastic matrix, is the result of metastasis. Metastatic carcinoma of bone (Fig. 128) is a frequent cause of so-called "spontaneous fracture." Fractures occurring under such circumstances should be called "pathological fractures," to distinguish them from fractures resulting from trauma. The writer has observed metastatic

carcinoma of bone most frequently in aged women suffering from latent carcinoma of the breast with moderate or no regional infection.

In metastatic carcinoma of bone spontaneous fracture usually occurs before any external swelling has developed. If life is sufficiently prolonged, a tumor appears later at the site of fracture. As Rokitsansky

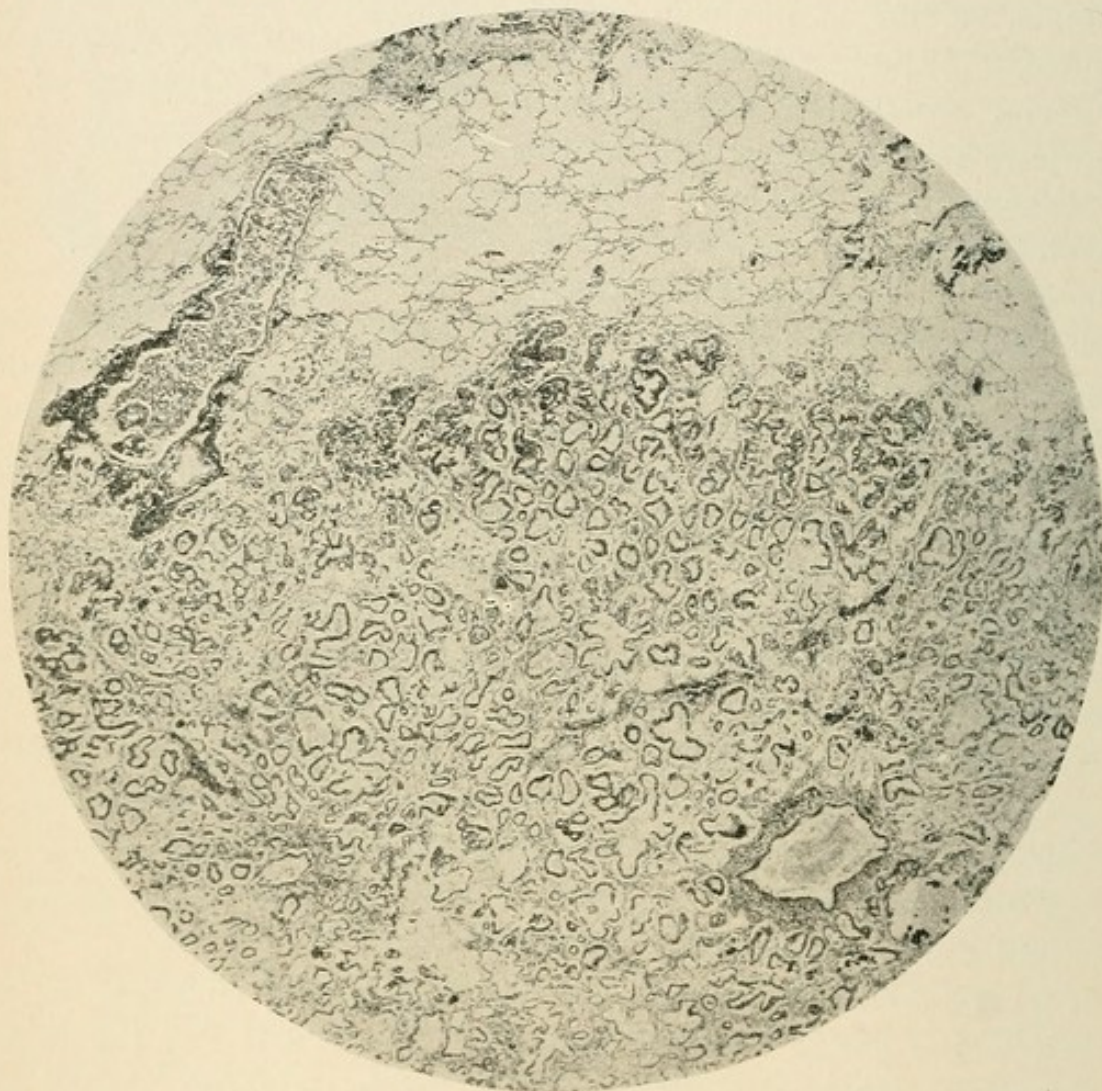

FIG. 125.—Metastasis of a rectal carcinoma in the lungs; $\times 36$ (after Karg and Schmorl). The nodule in the lung resembles in structure the primary tumor. It is composed of tubules lined by a single layer of columnar epithelium imbedded in a delicate stroma of fibrillated connective tissue. The emphysematous pulmonary tissue in the upper part of the picture is sharply defined against the border of the nodule.

says: "Cancer of the bone appears sometimes in the form of a nodule, of about the size of a walnut or a hen's egg, which is developed mostly in the medullary canal of the long bones; it displaces the bony tissue, and, producing atrophy of it by pressure, is frequently the cause of one or more spontaneous fractures of the bone which occur as the result of the most trifling causes." Union of the fracture by bony callus, despite the growth of the carcinoma, occasionally takes place.

In patients suffering from advanced carcinoma the bones often become so brittle that fracture occurs upon the application of slight force without metastatic carcinoma. Paget remarks: "But some of

the spontaneous fractures in cancerous patients are due to the wasting and degenerate atrophy which the bones undergo during the process of cancer, and which seems to proceed to an extreme more often than in any other equally emaciating and cachectic disease." There is, however, reason to believe that in most cases of spontaneous fracture with-

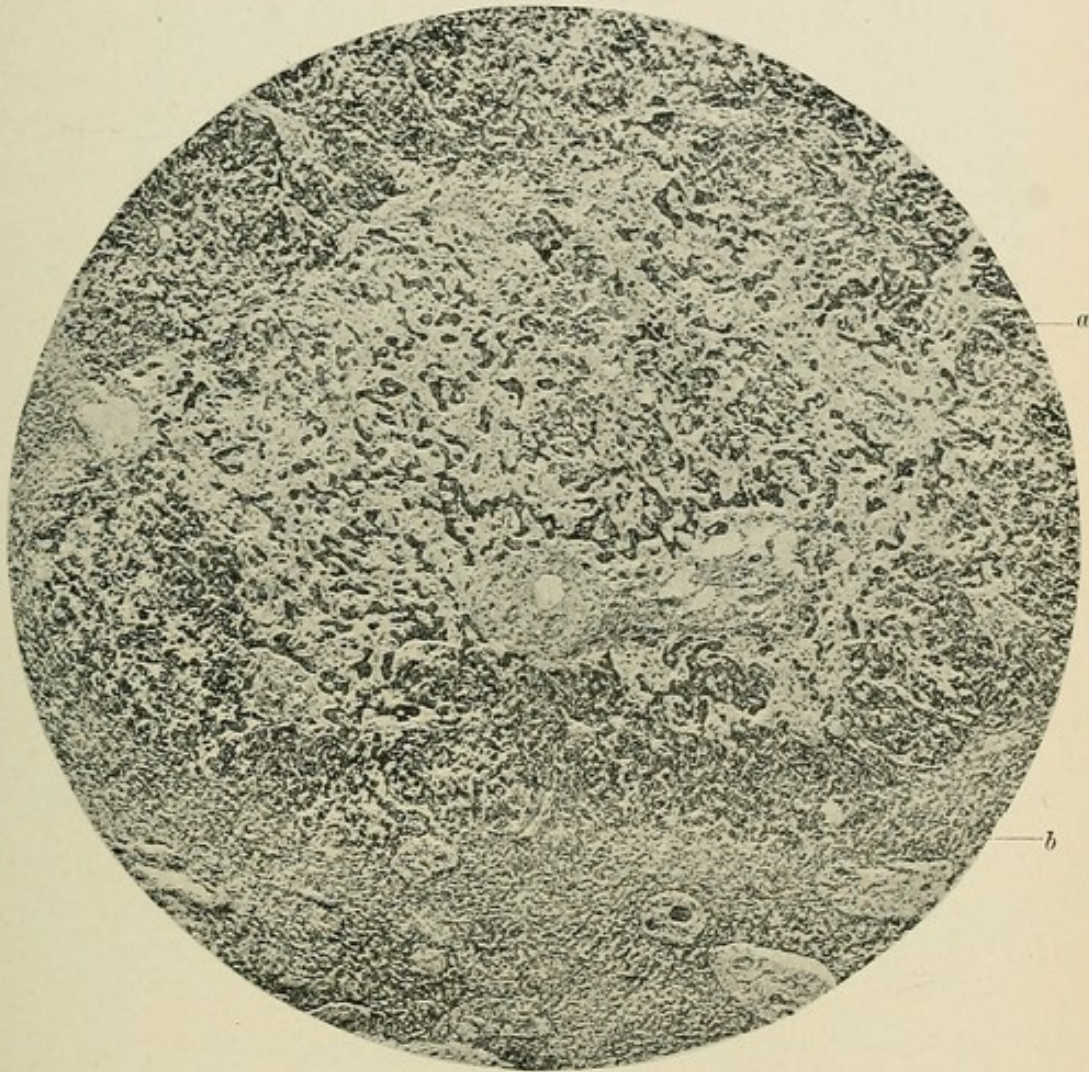


FIG. 126.—Metastasis of a carcinoma of the breast in the liver; $\times 40$ (after Karg and Schmorl). The carcinomatous nodule (*a*), which is quite sharply separated from the parenchyma of the liver (*b*), consists of narrow cellular cords imbedded in a coarse reticulum of connective tissue.

out tumor-formation, in which it was believed the fracture occurred without implication of the bone, the fracture was the result of the secondary bone-carcinoma, which was overlooked, life not being sufficiently prolonged for the appearance of a swelling. In favor of this view is the fact that pathological fractures under such circumstances are seldom multiple, which would be the case if the marasmus of carcinoma produced general atrophy of the bones. The carcinomatous material is previously deposited in the Haversian canals, along which it infiltrates the bone, producing enlargement of the canals.

Miliary carcinosis very closely resembles miliary tuberculosis.

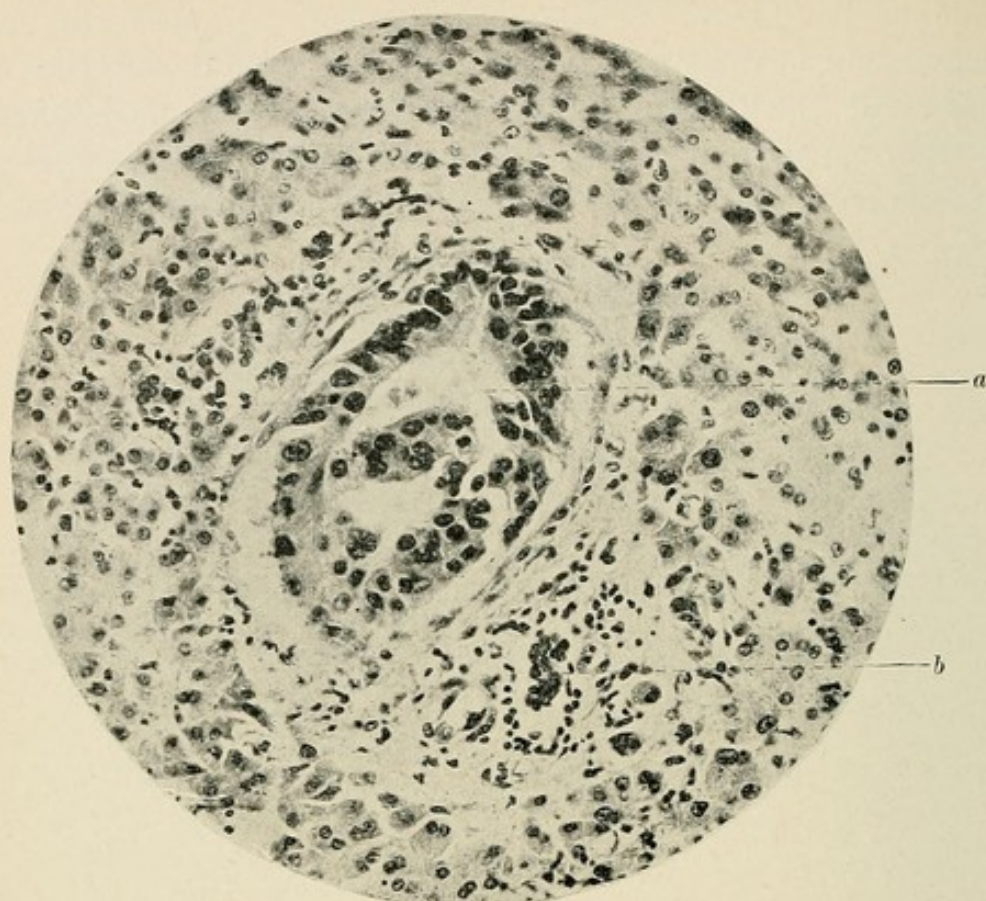


FIG. 127.—Carcinomatous embolus in a branch of the portal vein after primary carcinoma of the breast; $\times 250$ (after Karg and Schmorl). The branch of the portal vein (*a*) is dilated and filled by a plug of carcinoma-cells; *b*, bile-duct. The surrounding liver-tissue is normal.

Demme reported seven cases of miliary carcinosis, and, basing his

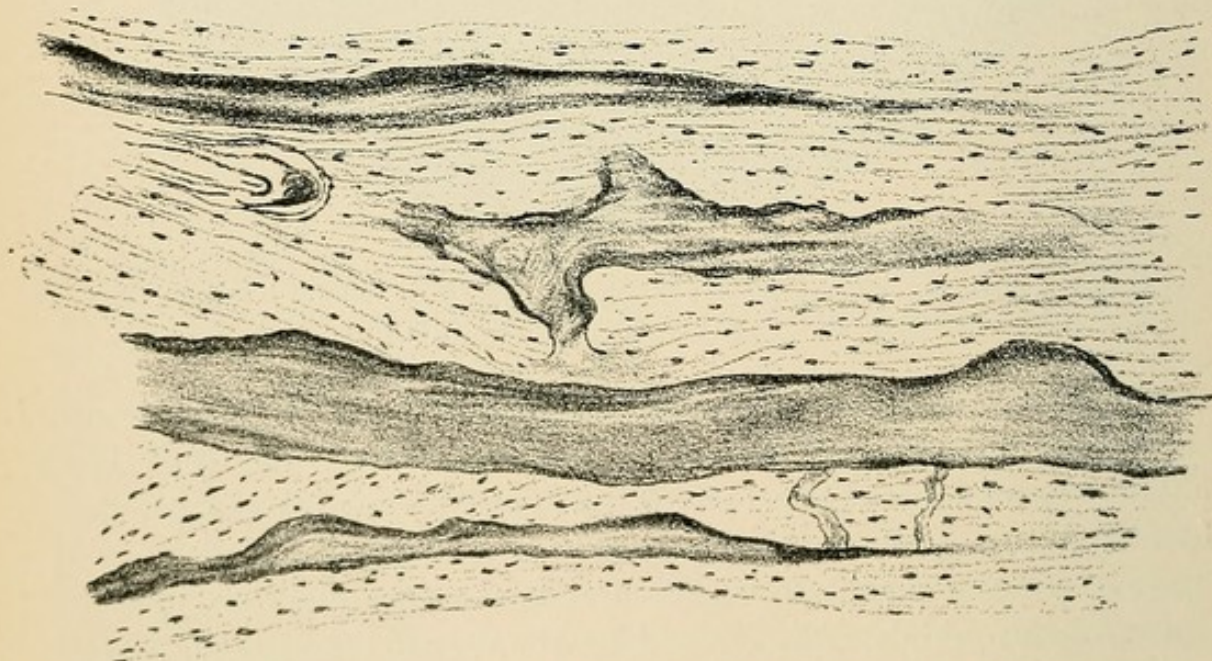


FIG. 128.—Metastatic carcinoma of bone (after Hickmann): enlarged Haversian canals filled with carcinomatous tissue.

opinion regarding its etiology upon a study of the clinical history of these cases, came to the conclusion that it is most frequently produced

by trauma. The diffuse general dissemination of carcinoma is usually initiated by a rise in temperature and by other febrile disturbances that

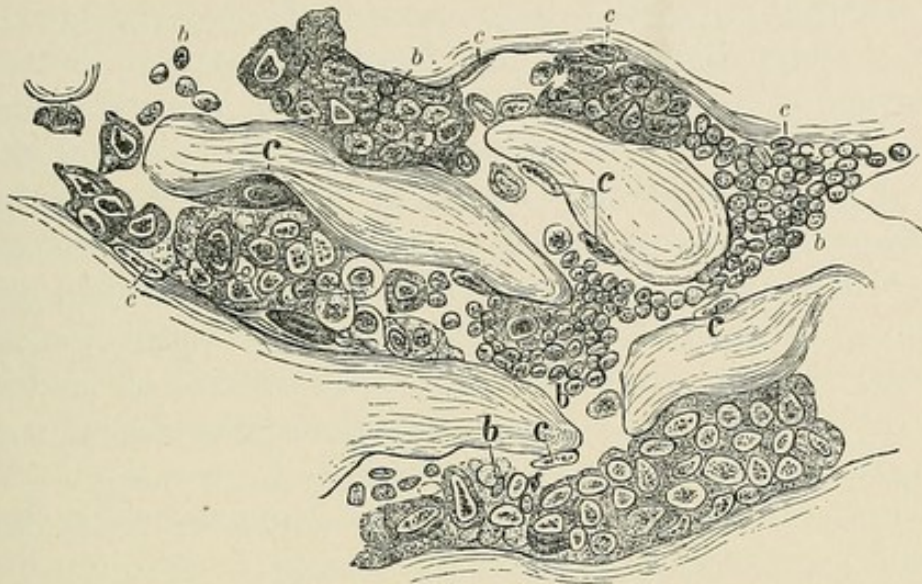


FIG. 129.—Carcinomatous capillary embolism of the choroid; $\times 320$ (after Perls): *b*, capillary net dilated and filled partly with red blood-corpuscles and partly with carcinoma-cells; *c*, large nuclei.

closely simulate the general symptoms which inaugurate and attend miliary tuberculosis. In almost all organs of the body, and more particularly upon the serous surfaces, innumerable nodules, from the size of a mustard-seed to that of a hempseed, appear. The nodules are produced by capillary emboli composed of carcinoma-cells (Fig. 129). Miliary carcinosis is a rapidly fatal affection. It is probably produced most frequently by perforation of a vein-wall by the primary or a secondary carcinoma, the epithelial cells of the projecting and rapidly-proliferating endovascular part furnishing the material for the diffuse embolic process.

ETIOLOGY.

Remaining true to the theory that all tumors originate from a matrix of embryonic cells of congenital or post-natal origin, we necessarily must regard the presence of a matrix of embryonic epithelial cells as the essential cause of carcinoma. In the absence of such an essential histological basis, no exciting cause or combination of exciting causes will result in the production of a carcinoma. The matrix of embryonic cells furnishes the essential material for the construction of a carcinomatous tumor; the exciting causes simply set in motion the machinery which increases the building material. We took it for granted that non-malignant epithelial tumors spring from a similar matrix. The question naturally arises, What influences or agencies determine the difference in the character of the tumors springing from a similar matrix? Two leading thoughts present themselves in answering this question: 1. The epithelial cells in the matrix of carcinoma are arrested

in their development and are set aside at an earlier stage, and the product of their tissue-proliferation will therefore be less specialized than that of epithelial cells which have reached a higher degree of differentiation. 2. The environment of a carcinoma-matrix offers less resistance to ingrowing of epithelial cells than does that of a papilloma or an adenoma. It is more than probable that the matrix of carcinoma is composed of cells of a lower degree of differentiation than that of a papilloma or an adenoma, and it is almost certain that the conditions under which a carcinoma-matrix assumes active tissue-proliferation result in a diminution of physiological resistance of the tissues in the immediate vicinity of the tumor-matrix. It remains for us to discuss more in detail the exciting causes concerned in awakening a dormant tissue-matrix to active tissue-proliferation.

Heredity.—In the majority of cases the tumor-matrix is congenital. In the remaining cases it is of post-natal origin, formed in pathological products in which some of the young epithelial cells fail to reach maturity and are buried in the scar-tissue following the healing of a wound or the repair of an inflammatory lesion. Friedreich records a case in which a carcinomatous mother gave birth to a child affected by carcinoma. A few cases of congenital carcinoma have been reported.

An hereditary disposition, predisposition, or aptitude, local or general, for carcinoma-growth is generally recognized. It is a difficult task to obtain accurate information concerning the frequency with which carcinoma occurs in the offspring of carcinomatous parents. In this respect statistics as well as many family histories are exceedingly unreliable. Mr. Cripps wishes to exclude from such statistics all cases bearing upon distant relatives, excluding even grandparents. In this way he reaches opposite conclusions from those of Sir James Paget, who recognizes heredity as a fruitful cause of carcinoma. Figuring on the cases from Paget's practice, Mr. Baker makes the statement that 22.4 per cent. of the cancerous patients were of one or more relatives with the same disease. He then gives a table of 103 cases in which one or more relatives were affected. These 103 cases representing only 22.4 per cent. of the total number examined, the whole number must have been 460. In these 103 cases, among the relatives are included aunts, uncles, first, second, and third cousins, great-aunts, and a great-uncle. Among the parents of cancerous patients the death-rate from cancer is—(1) According to Paget, 1 in 24.8; (2) according to Baker, 1 in 22.4; (3) according to St. Bartholomew's Hospital, 1 in 28. According to Mr. Cripps, among the whole community over twenty years of age the death-rate is 1 in 29.

In studying the influence of heredity it is not fair to exclude from

the statistics distant cancerous relatives, as has been done by Cripps, because it is well known that congenital deformities, physiognomy, and mental peculiarities frequently reappear several generations apart and in distant relatives. There is no reason to doubt that an aptitude for cancer is transmitted in a similar manner. In certain families the heredity of carcinoma has been shown in a marked manner. Paget relates a case in which a lady, two of her daughters, and eight of her grandchildren died of carcinoma. A still more marked and far-reaching hereditary influence has been referred to in the section on the Etiology of Tumors. Lebert relates two cases of colloid carcinoma of the rectum in which one of the parents in each case was similarly affected. To ignore the existence of an hereditary predisposition to carcinoma would be to ignore such a predisposition to the acquirement of all other pathological processes.

What such an hereditary predisposition consists of is not known. We regard it as a diminution of the physiological resistance of the tissues adjacent to the matrix. Such a resistance diminished or abolished, the tumor-matrix is no longer held in check, but assumes active tissue-proliferation, and the new cells infiltrate the tissues weakened by local or general causes.

Traumatism.—Injuries of various kinds have been regarded from time immemorial as a fruitful cause of carcinoma. Without the presence of the essential tumor-matrix no amount or kind of injury will produce a carcinoma. Injury of a part inhabited by the tumor-matrix will act as an exciting cause by diminishing the physiological resistance of the tissues adjacent to the matrix. Paget asserts that about one-fifth of those who have cancer ascribe it to injury. In some the cancer follows almost immediately after the injury; in others it follows as a more remote effect. In another and more frequent class of cases repeated injuries are necessary to produce this result.

Billroth maintains that in about 20 per cent. of all cases of carcinoma that came under his notice the growth of the tumor could be traced to an injury of some kind. Boll's statistics show a traumatic origin in 14 per cent., and Cohnheim in 350 cases estimated trauma as the principal exciting cause in about 20 per cent. Injuries to plants are quite frequently followed by tumor-formation. The immediate cause of tumor-growth under such circumstances is attributed by some authors (Williams) less to the injury itself than to a change in the nutrition of the tissues in the locality. Galls are produced by the instillation of the virus of gall-wasps into the tissues of oak-leaves. The virus comes in contact with only a few cells, and the new formation is due to proliferation of the infected cells. The structure of the

gall depends more on the kind of vulnerating insect than on the particular variety of oak. In the plant buds may form in any place where undifferentiated cells are present. The stimulants which determine the nutritive flux may be either intrinsic or extrinsic. It is well known that in plants injuries frequently result in the formation of a large number of adventitious buds. The initial cause of such variations is probably to be found in perversions of the secretions of the affected part. Injury to a part inhabited by a tumor-matrix alters normal nutrition, which must result in a diminished physiological resistance of the tissues to infective diseases as well as to tumor-growth.

Physiological resistance is illustrated by allowing one plant out of a number to go without water. Insect-stings in the weakly plant produce definite changes not produced in well-nourished plants. Local influences—and among them we must include trauma—which pervert nutrition diminish the physiological resistance of the tissues, and by doing so they become an exciting cause of carcinoma.

Age.—Carcinoma is most prevalent in persons of middle and past middle life. The tumor-matrix present at the time of birth or acquired later remains in a latent condition until the tissues undergo certain changes incident to advanced age, when there are created the local conditions necessary to enable the matrix-cells to resume their latent vegetative function and to assume active tissue-formation. That these senile tissue-changes are something different from ordinary marasmus caused by disease or by insufficient nourishment becomes evident from the fact that persons debilitated by disease or by starvation are not more liable to carcinoma than persons of the same age otherwise in perfect health. *If carcinoma develops in a young person, it is a proof that the cells of the tumor-matrix possess more than the ordinary degree of vegetative power, or that the person is unduly adapted to cancer-formation, or, finally, that the part which contained the tumor-matrix has been subjected to influences which produced changes in the tissues analogous to those found in the tissues of the aged—in other words, a local senility of the tissues.* Thiersch has shown that in the lips of old people the fibrous tissue wastes away while the glandular tissue becomes overgrown, this condition favoring the development of cancer.

The capacity of a part of the organism to resist a certain amount of pressure and still to preserve its histogenetic function will determine its vitality. If this power of resistance is lost, then the part becomes subject only to passive changes. This is the case for physiological as well as for pathological conditions, and as a rule the quantity of parenchymatous fluid is in direct proportion to the capacity of cell-production. This is the case in the skin of elderly persons as far as pertains

to the stroma. When in this weakened stroma there are present organic parts the histogenetic properties of which are still operative, those parts will proliferate and lead to a hyperplasia of the epithelial tissue which eventually predisposes to the development of carcinoma. It may be objected that the abundance of capillaries and their dilatation are in opposition to the theory of atrophic condition of the stroma as a cause of carcinoma, as claimed by Thiersch. This vascular change is, however, only a result of the rarefaction of the connective tissue with consequent diminished support against intravascular pressure.

As the blood furnishes a plasma to the tumor, and likely favors development much as a starting plant favors the growth of aphids, it is possible that in the aged there may occur blood-changes which favor the development of carcinoma.

Walshe has clearly shown that the mortality from cancer—that is, the number of deaths in proportion to the number of persons living—“goes on steadily increasing with each succeeding decade until the eightieth year.” His result is obtained from records of deaths, but it is almost exactly confirmed by the tables collected by Paget showing the ages at which the cancers were first observed by the patients or ascertained by their attendants.

PAGET'S TABLE SHOWING THE INFLUENCE OF AGE IN THE
DEVELOPMENT OF CARCINOMA.

Under 10 years	5	per cent.
Between 10 and 20 years	6.9	“
“ 20 “ 30 “	21	“
“ 30 “ 40 “	48.5	“
“ 40 “ 50 “	100	“
“ 50 “ 60 “	113	“
“ 60 “ 70 “	107	“
“ 70 “ 80 “	126	“

The influence of age in the production of carcinoma is pronounced; the tissue-changes enumerated by Thiersch offer the most plausible explanation of this influence, and can be applied with equal propriety to carcinoma of all parts of the body as to carcinoma of the lips and the skin.

Diet.—Diet appears to exercise some influence in the causation of carcinoma. Legrain states that epithelioma is unknown in Algeria, except as it appears in a European. This may possibly be due to the vegetarian diet without meat, and absolutely without pork. Verneuil and Reclus asserted long ago that the herbivora were much less liable to carcinoma than the carnivora; and they ascribe the sixfold increase in the number of patients suffering from carcinoma at their

hospital during the last forty years to the increased consumption of meat by the laboring classes.

Climate.—Climate and the attending habits of life and state of civilization appear to exert an influence in the causation of carcinoma. Walshe collected evidence that the maximum number of carcinoma patients are found in Europe, and that carcinoma is very rare among the people at Hobart Town and Calcutta and among the natives of Egypt, Algiers, Senegal, Arabia, and the tropical parts of America. Inquiries that have been made relative to the prevalence of carcinoma among the Indians of North America seem to show that they are singularly immune to this affection. Few authenticated cases of carcinoma have been reported among the Indians unaffected by advancing civilization.

Mental Depression.—A few pathologists have attributed to the nervous system an important part in the etiology of carcinoma. Mental depression has often been quoted as one of the causes in the production of carcinoma. While mental anxiety and worry of all kinds may favor the origin and growth of carcinoma by impairing nutrition, and thus diminishing the physiological resistance of the tissues in the vicinity of a tumor-matrix, we have no evidence that nervous influences exert a more direct effect in the causation of carcinoma. It is different with dread or fear of carcinoma. The writer recollects two patients who for no tangible reason whatever were in constant dread of the disease for many years, when finally their fears were realized. Apprehensions of this nature certainly exert a positive influence in the etiology of carcinoma.

Tuberculosis.—Rokitansky maintained that tuberculosis and carcinoma never existed at the same time in the same person. Other investigators have convinced themselves of the incorrectness of this assertion. Dittrich states that of one hundred and fifty cases, in only one did tuberculosis and carcinoma exist at the same time. Friedreich was the first to discover tuberculosis and carcinoma in the same organ. Recently there have been reported a number of well-authenticated cases in which carcinoma developed in tubercular affections of the skin. Tubercular lesions prepare the soil for carcinoma, and they may even furnish the essential post-natal matrix of embryonic cells.

Prolonged Irritation and Inflammation.—Long-continued local irritation is frequently the exciting cause of carcinoma. If the irritation is sufficient in intensity to stimulate the mature tissue-cells to proliferation, it may also furnish a post-natal matrix of embryonic cells, and consequently constitute both the essential and exciting causes.

The frequency with which carcinoma is met with in localities exposed to repeated and prolonged irritation points to the fact that the latter is often a cause of carcinoma. Carcinoma is frequently found about the orifices of the body—the lips, the cervix of the uterus, the rectum, and the nose—localities often exposed to irritation. The tobacco-pipe has often been quoted as a cause of carcinoma of the lip, but since the publication of Melzer's statistics the views on this subject have undergone a change. Carcinoma of the scrotum has been attributed to irritation caused by coal-dust: the effect of this source of irritation has, however, been over-estimated greatly. Abrasions, punctures of the skin, and small wounds have occasionally served as exciting causes. Unskilful shaving must also be enumerated as a possible cause. In one instance the writer saw a carcinoma develop from a small razor-cut. Similarly, insignificant lesions are often referred to as a possible cause of carcinoma. Chronic inflammatory lesions of all kinds and the remnants of acute inflammation have more often been starting-points of carcinoma than was formerly supposed or than many are willing to admit at the present time. Inflammation not only diminishes the physiological resistance of the tissues, but its product may also furnish a post-natal matrix of embryonic epithelial cells. In a chronic ulcer, for instance, young epithelial cells often become buried in the granulation-tissue, which may serve as a tumor-matrix, and assume active tissue-proliferation at any time when the local conditions are such as to permit such tumor-formation. The writer has repeatedly seen carcinoma develop in scar-tissue or upon the surface of a chronic ulcer (Fig. 130).

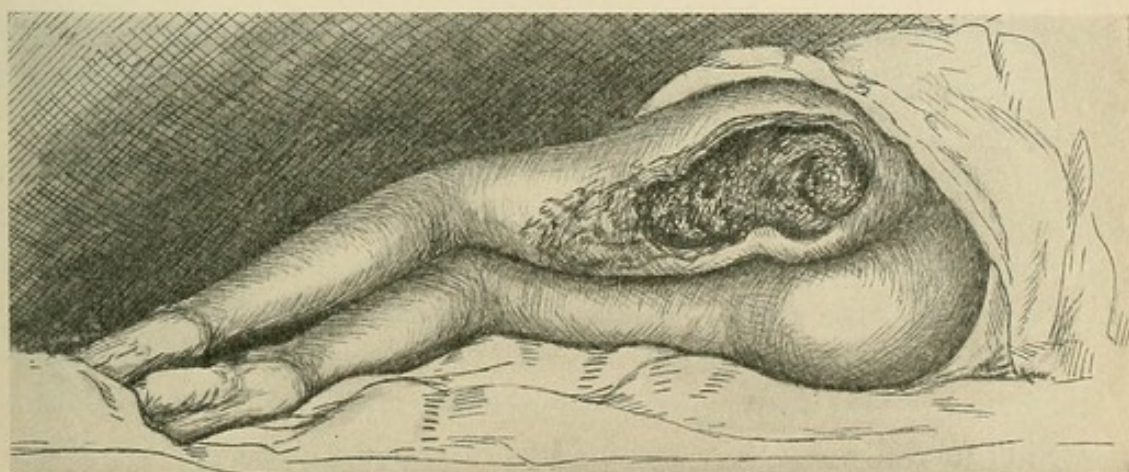


FIG. 130.—Extensive carcinoma which developed in the scar-tissue eighteen years after a severe burn involving the gluteal region and posterior surface of the thigh. Inguinal glands extensively involved.

Langenbeck observed three cases of lupus in which, after healing of the ulcerated surface, carcinoma developed in the scar-tissue. Similar cases have been referred to elsewhere.

Desbonnet has collected from different sources 86 cases in which epithelioma developed either in the scar-tissue following the healing of lupus or in active lupoid ulcerations. The largest number of cases occurred in persons between forty and fifty years of age. The carci-

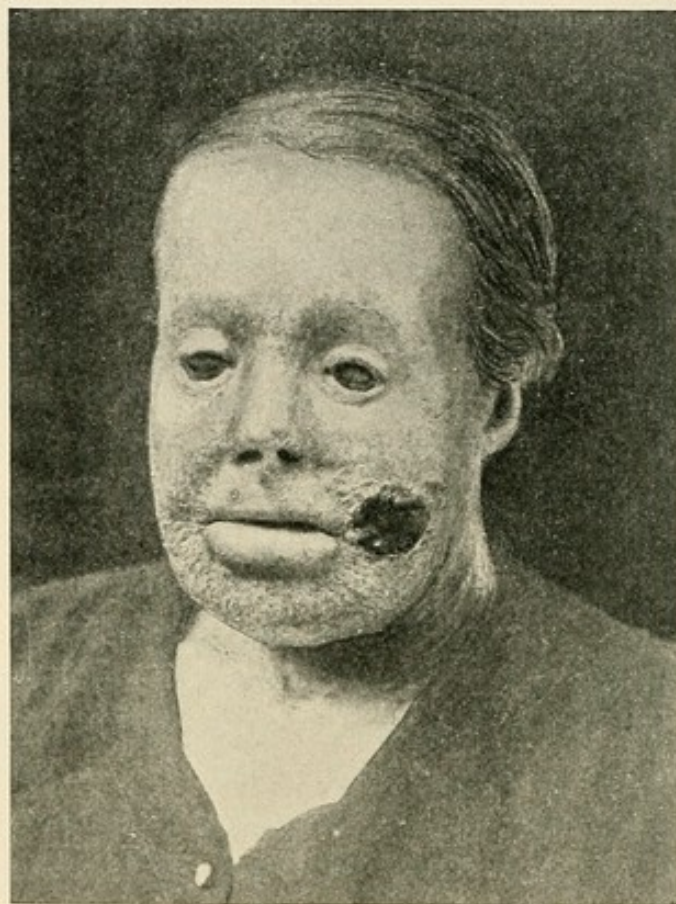

FIG. 131.—Epithelioma developing in lupus (after Desbonnet).

nomatous complications usually set in many years after the beginning of the tubercular process. Fig. 131 furnishes a good illustration of the appearance of an epithelioma upon a tubercular base.

Goodhart has called special attention to irritation as a cause of ichthyosis of the tongue and of carcinoma. It has been known for a long time that this superficial chronic inflammation of the tongue frequently precedes carcinoma of this organ. In more than one instance carcinoma of the tongue and of the mucous membrane of the cheek has been traced to displaced carious teeth and to the sharp margins of normal teeth.

One of the most instructive evidences of the influence of prolonged irritation and inflammation in the causation of carcinoma is chronic eczema of the nipple, known as "Paget's disease of the nipple." The etiological relation of this affection of the nipple to carcinoma of the breast was first pointed out by Sir James Paget. Mr. Butlin has corroborated Paget's views, and has shown that there can be traced struct-

ural changes extending from the diseased part of the skin along the epithelial linings of the gland-ducts in the nipple, and thence along their branches into the acini of the carcinomatous part of the gland. These acini "become dilated and filled with proliferating epithelium, which is at length, so to speak, discharged into the surrounding tissues." Paget says: "The cases of cancer thus following eczema are illustrations of a general rule that *a part which has long been the seat of constant or often-recurrent inflammation, or, if I may write intentional obscurity, of frequent or constant irritation, is apt to become cancerous* (the italics are the writer's). Similar instances of the rule are observed in tongues long affected with psoriasis or ichthyosis, in uteri long or often ulcerated, in scars that often 'break out,' in lower lips long cracked or excoriated, in warts often irritated, sore, and scabbed, sometimes in old scrofulous or other ulcers or in sinuses." Paget admits that irritation alone and of itself is not enough to produce carcinoma. He continues: "It may therefore be deemed very probable that the chief or sole effect of irritation is, by inducing a degeneration, to render the parts more fit for the invasion of a disease which is essentially of an internal origin."

Paget still adheres to the humoral etiology of carcinoma, but we assign, as he does, to chronic irritation and inflammatory products an important rôle in the causation of carcinoma by diminishing the physiological resistance and by occasionally at least furnishing at the same time the essential tumor-matrix of embryonic epithelial cells.

Another inflammatory product very often the starting-point of carcinoma is the wart. The warts upon the forehead and cheeks of aged persons (*verruca senilis*) most frequently undergo such a transformation. The only cases in which the writer has seen primary multiple carcinoma were those in which carcinoma had such an origin. The claim might be made that these papillomatous swellings were carcinomatous from the beginning. Examinations of numerous specimens of this kind have furnished pictures showing all stages of transition of an inflammatory swelling into a carcinoma, and there can therefore be no doubt of their primary inflammatory origin.

Microbes.—The local, regional, and general dissemination of carcinoma is strongly suggestive of the existence of some virus or microbe as the prime etiological factor of the origin and dissemination of carcinoma. In some respects carcinoma resembles several of the infective processes the microbic origin of which has been well established. The infectiveness of tuberculosis was recognized a long time before its microbic origin was demonstrated. Pathologists have made numerous experiments to prove the inoculability of carcinoma. Langenbeck

injected cancer-juice into the jugular vein of dogs, and it is asserted that in one instance the experiment resulted in carcinoma of the lungs. Novinsky in 1876, and later Wehr and Hanau, succeeded in inoculating animals, and Hahn and Bergmann have inoculated the human being.

Carcinoma has frequently been engrafted from one animal into another of the same species, and in some instances the experiment yielded positive results. The writer has made numerous experiments on dogs by implanting carcinoma and sarcoma from man, and the results were always negative. A slight induration around the implanted graft was all that was ever observed. Induration and graft all disappeared by absorption in the course of two or three weeks. The same results followed the implantation of malignant grafts from one animal into another of the same species. In a recent work Adamkiewicz declares that after implantation of a piece of a carcinoma in the brain of a rabbit death always took place in about two hours. In the brains thus inoculated were always found disseminated round-celled metastatic deposits of carcinoma which showed a tendency to break down in the centre. The carcinoma-cells nearly all disappeared from the engrafted piece, leaving only the stroma. Adamkiewicz believes that cancer-cells are living, independent organisms belonging to the class of protozoa. Geissler, who repeated the experiments of Adamkiewicz, found that fragments of carcinoma-tissue imbedded in the brains of rabbits produced no reaction and were absorbed like other aseptic absorbable substances. The views of Adamkiewicz regarding the origin of carcinoma are as fallacious as the hope he entertained of cancroin as a specific therapeutic agent has been shown to be unfounded. The search for a specific microbe dates back to the early days of bacteriology as a science. One of the first efforts in this direction was made in 1881 by Wédopil.

The excitement which Scheuerlen's alleged discovery of a specific bacillus of carcinoma produced spread over the world and stimulated others to renewed activity in the bacteriological investigation of carcinoma. For a short time Scheuerlen's claims were seriously entertained and considered, and Schill and Frère went to the trouble to dispute his claim to priority of the discovery of the carcinoma bacillus. Later, Darier, Wickham, Malassez, Albarran, and Soudakewitsch described coccidia-like bodies in tumors. These bodies were studied carefully in tumor-tissue by Pfeiffer, Sjöbring, Thoma, Podysoski, Delépine, and especially by Ruffer. The last author regarded them as psorosperms, and he studied their behavior to different kinds of staining material. He found them in the protoplasm of cells in all carcinomatous tumors. Stroebe, Steinhaus, O. Israel, Karg, Eberth, Ribbert, Hauser, and other

pathologists entertained more conservative views in regard to the etiological importance of these bodies in the causation of tumors. Many of these pathologists are of the opinion that the bodies which have been described as psorosperms are only the product of cell-degeneration.

The experiments of Ballance and Shattock in the cultivation of cancer on nutrient media, and the direct inoculation of cancer performed by Hanau, Klebs, and others, argue against a microbic origin of carcinoma. The sporozoa which have been found in cancer-tissue by different observers no doubt play their part in irritation, but there is so far no evidence that they are the cause of carcinoma.

The bacteriological examination of carcinoma tissue continues, one of the most recent efforts in that direction being that of Roncali. This author found in a carcinoma of the ovary numerous intracellular and intercellular blastomycetes in various stages of development, which he regards as the cause of the disease.

Kurloff considers it very desirable that those engaged in investigating the supposed organism of carcinoma should furnish with each published case the history of the patient and a clinical and pathologico-anatomical account of the tumor. Only by some such plan can we hope to systematize the results arrived at by different investigators. Korotneff discovered in carcinoma an organism which he called *rhopaloccephalus canceromatosus*. Kurloff found the same parasite in a vacuole within the epithelial cells of a carcinoma of the breast. Ohlmacher of Chicago made very extensive investigations concerning the etiological relation of sporozoa to carcinoma, and in a recent paper on this subject he pointed out that many objects have been described as the parasites of carcinoma because the subject has been treated unscientifically. A great number of reagents have been used, hence the diversity of results. Artificial products are sometimes found by the reagents. It has been found that sporozoa treated by different fixing solutions act differently. Some agents distort the spores and interfere with the subsequent staining. All the present methods of investigation are faulty, and no results are to be looked for until new methods are devised.

To prove the microbic origin of carcinoma it is necessary for bacteriologists to demonstrate the presence of the same organism in every carcinomatous tumor. They must isolate the organism and cultivate it outside the body upon artificial nutrient media, and with pure cultures they must reproduce the disease in some of the lower animals. This has so far not been done, and until it is done we have no right to claim for carcinoma a microbic origin. It has been shown elsewhere that the local and general dissemination of carcinoma is effected exclusively by cell-

metastasis and cell-transportation, and that the secondary and metastatic tumors are the exclusive products of tissue-proliferation of cells derived from the primary tumor. In all infective swellings the cellular elements are derived exclusively from the corpuscular elements of the blood and proliferation from pre-existing tissue. Carcinoma-tissue is derived exclusively from a matrix of embryonic epithelial cells. The pre-existing tissues remain passive in carcinoma as well as in all other tumor-formations.

De Morgan in 1874 said: "I can see no analogy between new growth, whether as innocent as lipoma or as malignant as cancer, and the products of true general or blood disease. From the first a tumor is a living, self-dependent formation, capable of continued growth by virtue of its own power of using the nutritive materials supplied to it. Nothing like this is seen in any of the blood diseases." Until additional and more positive light is shed upon the microbic origin of carcinoma we must adhere to the theory that *carcinoma is an atypical proliferation of cells from a matrix of embryonic epithelial cells of congenital or post-natal origin.*

PATHOLOGY.

The most important aberration of the normal growth in carcinoma consists in the presence of epithelial cells in vascular connective tissue. The epithelial cells retain their vegetative power in the new locality. The stroma is derived from the pre-existing connective tissue, and its abundance depends largely on the amount of connective tissue in the part affected and the intrinsic vegetative capacity of the epithelial cells. If the organ affected is dense and fibrous, the pre-existing material for the stroma is abundant, and the tumor, at least during its earlier stages, will be firm. If the epithelial cells proliferate slowly, the pre-existing connective tissue constituting the stroma is increased by the production of new connective tissue in response to the stimulation created by the carcinoma-cells, which act as an aseptic foreign substance. If the epithelial cells possess a maximum power of tissue-proliferation, the stroma is rapidly broken down, and little or no new connective tissue is formed, the resulting tumor grows very rapidly, is soft, and local infection takes place early and in a short time becomes diffuse. In hard carcinoma of the breast, the so-called "scirrhus," the stroma is abundant and the parenchyma is scanty. The same conditions are found in atrophic carcinoma and in *cancer en cuirasse*. In the so-called "encephaloid" carcinoma the conditions are reversed—a scanty stroma and an abundance of rapidly-proliferating cells.

Carcinoma is distinguished from all other tumors by the irregularity

of its surface and the existence of a wide zone of infiltration. Virchow years ago observed a zone of infiltration extending from three to four lines from the macroscopical boundary-line of the tumor. Waldeyer described this zone as the "inflammatory zone," because he found in the connective tissue numerous small cells. This zone often presents almost a typical appearance of tissue the seat of a chronic inflammation. The infiltration consists of leucocytes and small young epithelial cells which, like the leucocytes, wander by virtue of their ameboid movements into and along the connective-tissue spaces (Fig. 132). The

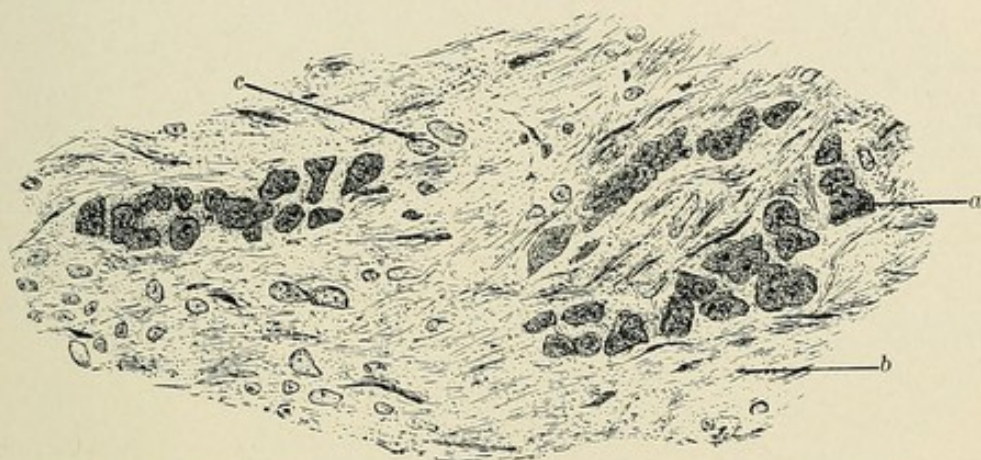

FIG. 132.—Zone of infiltration around carcinoma; $\times 330$ (Surgical Clinic, Rush Medical College, Chicago): section from near the macroscopical boundary-line of a carcinoma of the abdominal wall: *a*, young epithelial cells infiltrating the stroma, beginning formation of new alveoli; *b*, stroma; *c*, wandering leucocytes.

infiltration in rapid-growing carcinoma is so extensive that the connective-tissue spaces are packed with small round cells to such an extent as to obscure the stroma completely (Fig. 133, *c*).

The leucocytes escape from new imperfect capillary vessels or from vessels damaged by the tumor-tissue, and consequently are present in great abundance in rapid-growing tumors—a condition which exemplifies the well-known clinical fact that *the more closely a carcinomatous tumor resembles an inflammatory product, the greater is its malignancy*. The young epithelial cells possess the maximum capacity to change their location by ameboid movements; hence we find in the zone of infiltration exclusively young epithelial cells which have left the primary tumor and are actively engaged in increasing its area. From the surface of the carcinoma there project into the surrounding tissue tumor-masses which render its surface uneven and nodular. These projections of the tumor can be seen to greatest advantage in squamous-celled carcinoma. They appear first as conical or column-shaped infiltrations connected on one side with the primary tumor and projecting into the connective tissue on the other (Fig. 134). These projecting parts of

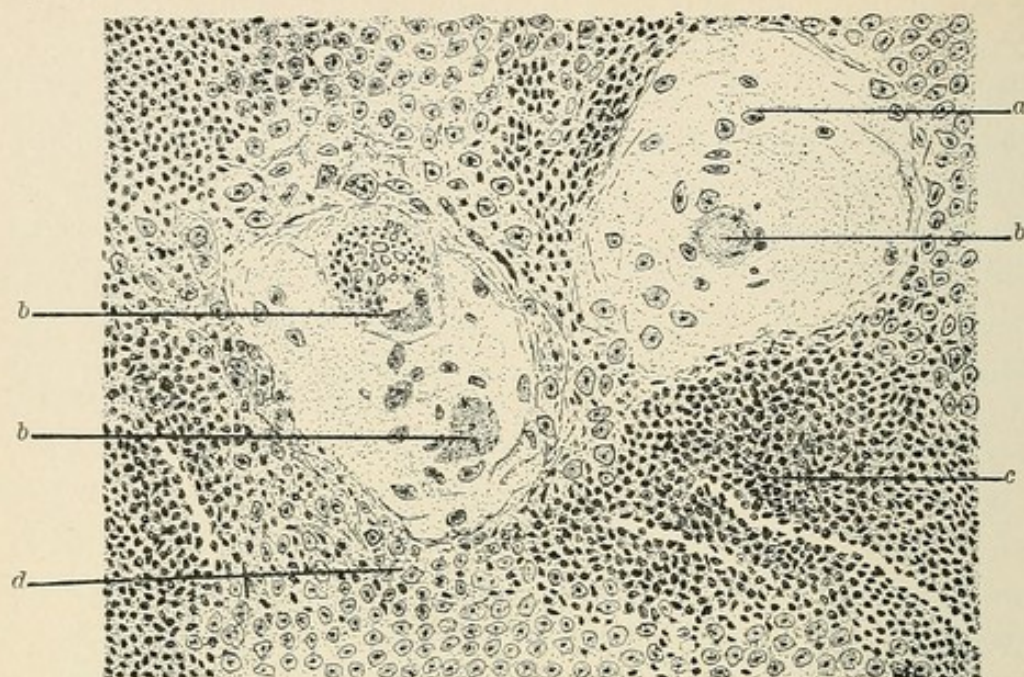


FIG. 133.—Extensive ground-cell infiltration at the margin of a carcinoma of the lower jaw; extension of disease from the lip; $\times 130$: *a*, carcinoma-cells wandering into site of former pearl; *b*, colloid material; *c*, round-cell infiltration; *d*, young carcinoma-cells.

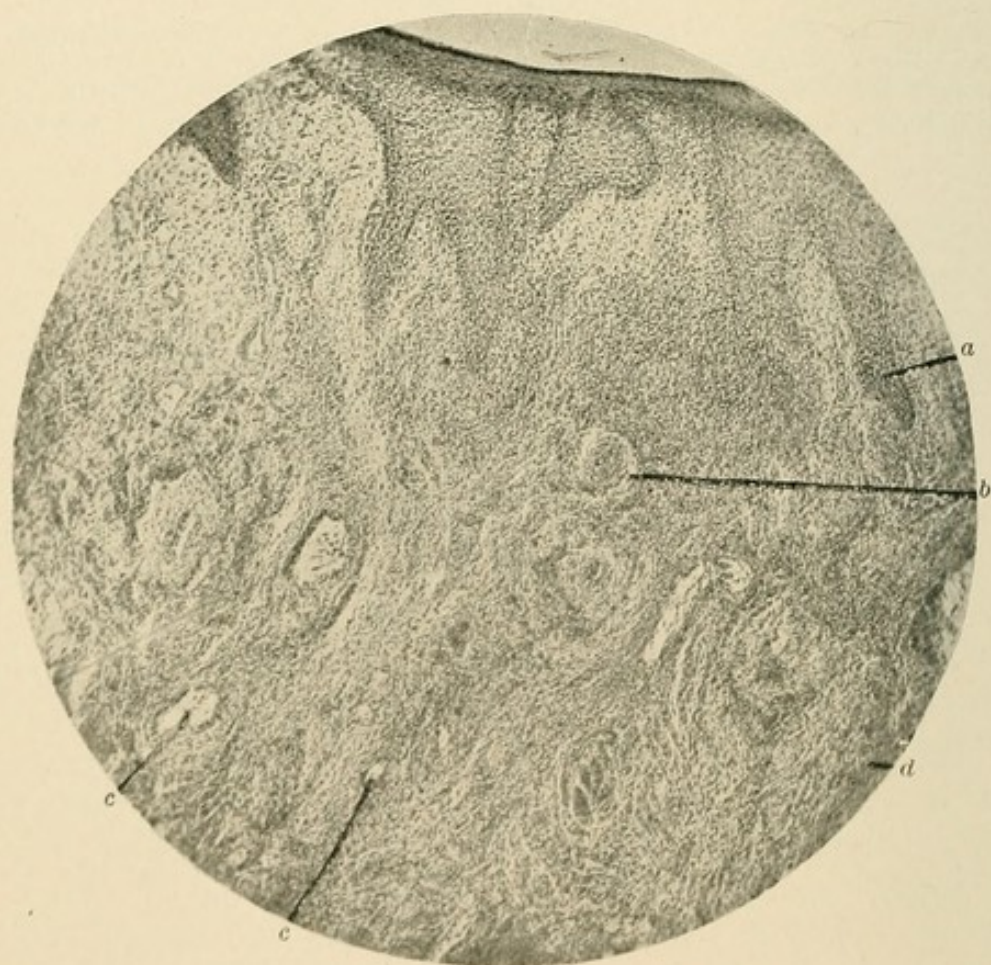


FIG. 134.—Carcinoma of the tongue; $\times 85$ (Surgical Clinic, Rush Medical College, Chicago): *a*, columnar projections of carcinoma-cells; *b*, epithelial nests; *c*, blood-vessels; *d*, submucous connective tissue.

the tumor impart to it from the very beginning a certain degree of immobility and cause the nodulated condition of its surface.

The stimulation of the tissues caused by the invasion of so many foreign bodies results also in the formation of new blood-vessels, brought about by a process of budding from the pre-existing blood-vessels adjacent to the tumor-matrix. The vascularization, not being

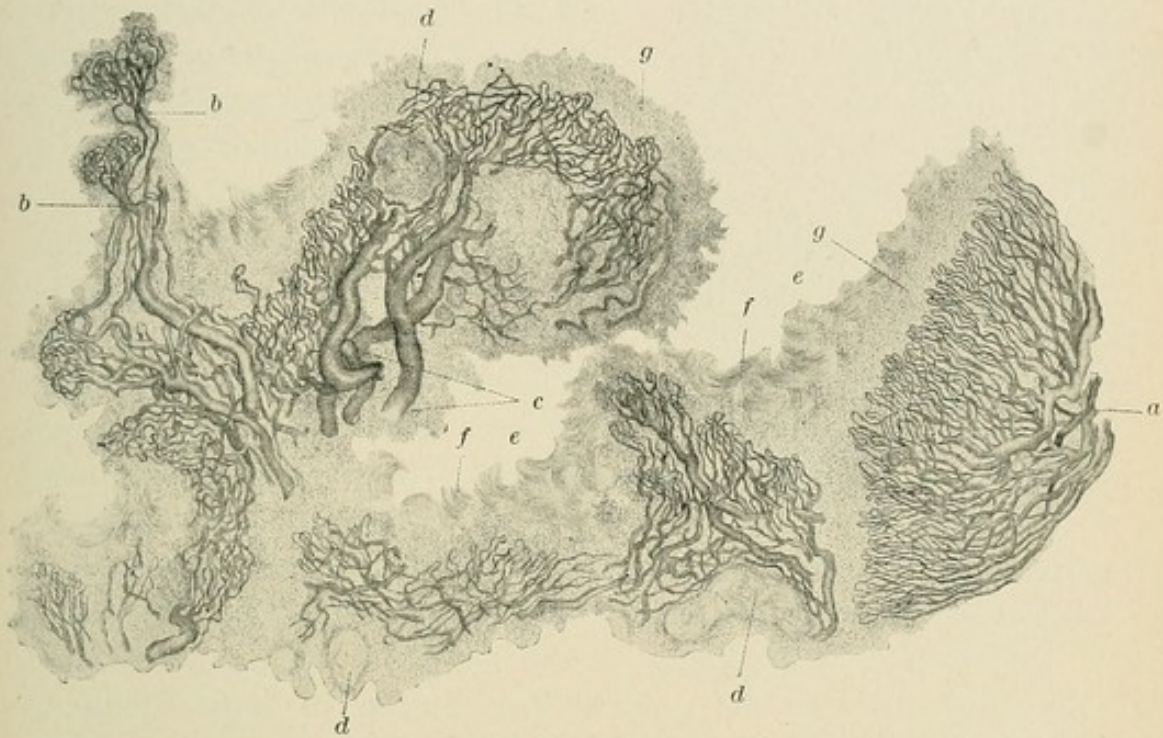


FIG. 135.—Deep-reaching epithelioma upon the leg, with papillary excrescences. Specimen injected. Section from the part of the tumor which occupied the cavity in the tibia; $\times 6$ (after Thiersch): *a*, new vessels composed of numerous loops; *b*, elongated pedunculated proliferation of vessels; *c*, large vessel-trunks which suddenly terminate in capillaries; *d*, compact masses of epithelial cells arranged in concentric layers, cut transversely or obliquely, and surrounded by vascular stroma; *e*, part of a cleft-like cavity containing epithelial debris; *f*, flat polygonal cells in irregular layers, answering to the horny epithelial cells of the skin; *g*, layer of cells representing the rete Malpighii.

under the normal control of the nervous tissue, and being in a district of planless tissue-proliferation, always assumes an atypical type. The epithelial cells in carcinoma are brought in direct contact with the new blood-vessels (Fig. 135, *d*).

Ribbert has recently advanced the theory that the histogenesis of carcinoma is caused by a proliferation of the connective tissue, which isolates the epithelial cells and brings them in contact with vascular tissue. This view has been vigorously opposed by Hauser and Notthafft, who have made observations on the penetration of epithelial cells during the early stage of the development of carcinoma.

The atypical vascularization of a carcinoma exerts a potent influence in determining its clinical course. Great vascularity is a prominent

feature of rapid-growing tumors. In slow-growing hard tumors the blood-supply is scanty. In atrophic carcinoma the vessels are compressed and often obliterated by the cicatricial contraction of the massive stroma. Perforation of a vessel-wall by tumor-tissue is apt to be followed by metastatic carcinoma or miliary carcinosis. Thrombosis of a principal vessel of the tumor results in speedy and extensive degeneration or necrosis of the tumor-tissue.

Carcinoma-cells retain their embryonic character and never reach maturity. The imperfect development of epithelial cells in carcinoma is one of the distinctive features between them and the mature epithelial cells of benign epithelial tumors. The juvenile condition of the parenchyma-cells of a carcinoma explains the rapid growth of the tumor and the early degenerative changes which take place in its tissues.

Thiersch has well said that the tissue of carcinoma is characterized from the start by degeneration. While the degeneration is progressing the parts first affected suffer a retrogressive change, without, however, it being followed by complete absorption. *The pre-existing connective tissue is utilized as a temporary scaffolding for the tumor-tissue.* The parenchyma-cells of all organs affected by carcinoma are subjected to pressure, undergo fatty degeneration, and are gradually removed by absorption as the tumor advances. The complete removal of glandular tissue in secondary carcinoma of the lymphatic glands furnishes a striking illustration of the gradual substitution of tumor-tissue for the pre-existing glandular structure. The connective tissue of the part affected furnishes the stroma of the tumor; this stroma is increased under favorable circumstances, but is likewise subject to degenerative changes and to gradual removal by the increasing number of cells.

The degenerative changes which occur most frequently in carcinoma-cells are—1. Fatty degeneration; 2. Colloid degeneration; 3. Mucoid

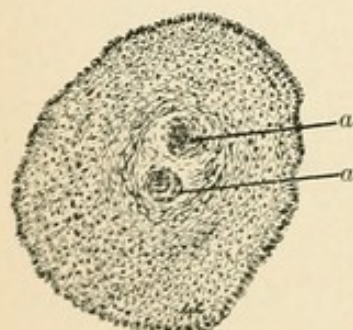


FIG. 136.—Epithelial pearl from carcinoma of skin of leg; $\times 110$, reduced one-fourth (Surgical Clinic, Rush Medical College, Chicago); a, a, centre of cancer-nests, showing fatty degeneration of cells.

degeneration. Fatty degeneration begins always in the centre of the alveoli, in the oldest cells, and in the parts most distant from the vascular supply. The cells in the centre of an epithelial nest (Fig. 136) show first in their protoplasm granules of fat which increase in size and number until the cell breaks up in fragments, leaving minute particles of fat and a granular detritus. Fatty degeneration begins at different points in the same alveolus (Fig. 137).

The product of fatty degeneration in squamous-celled and glandular-celled carcinoma in its naked-eye appearances resembles very much the contents of an ath-

roma. It is composed, like the latter, of detached dead and degenerated epithelial cells, granules of fat, and a granular detritus. While the centre of an alveolus is undergoing this change the disease extends in its periphery, where cell-proliferation is progressing in the outer layer of the younger epithelial cells. In ulcerating carcinoma of the lip and the skin the products of fatty degeneration, in the form of small plugs presenting the appearance of athematous material, can be squeezed out upon the surface by pressure. *The same condition is not met with in any other ulcer, and is therefore of the greatest diagnostic importance.* In glandular carcinoma the same kind of material can be squeezed from the surface on making a section through the tumor. Fatty degeneration of the parenchyma of a carcinoma is most marked in slow-growing hard tumors, and must be regarded as a favorable retrogressive change tending to retard the growth of the tumor.

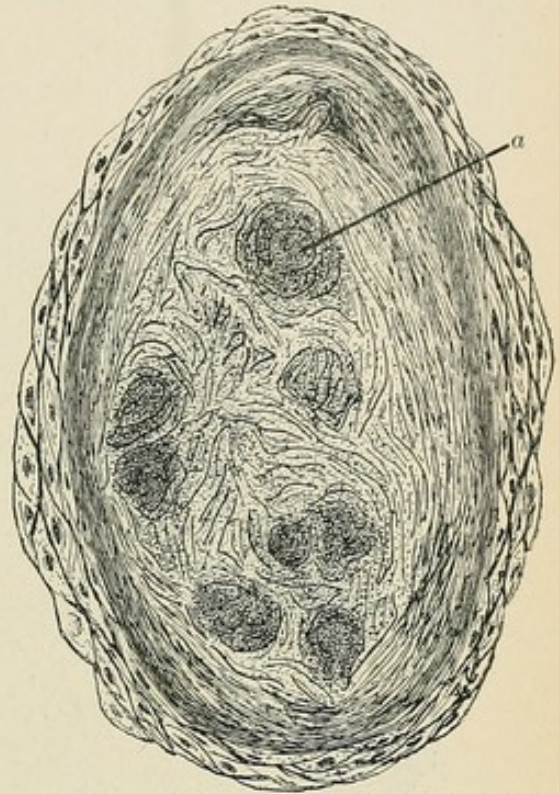


FIG. 137.—Multiple points of fatty degeneration in the same alveolus; $\times 480$ (Surgical Clinic, Rush Medical College, Chicago): *a*, highly refractile non-staining area.

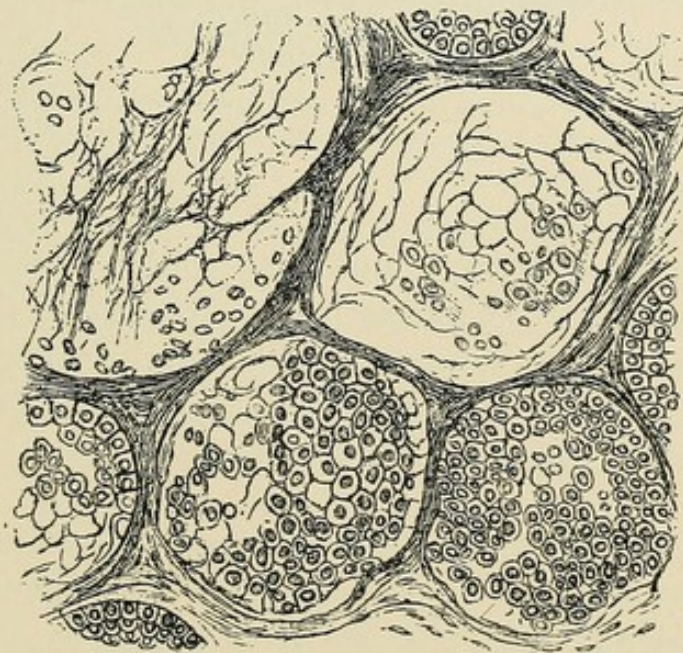

FIG. 138.—Carcinoma of the rectum with extensive colloid degeneration of the cells lining the tubules (after Perls). In the small alveoli, beginning colloid degeneration of the cells; the larger alveoli are distended by colloid material and are without attached cells.

Colloid degeneration occurs in the parenchyma and stroma of carcinoma, and is not limited to tumors of any particular type of cells (Fig. 139). Colloid degeneration of the stroma is found in rapid-growing glandular carcinoma. The colloid material is often so abundant as to obscure the cellular elements and the stroma—so much so

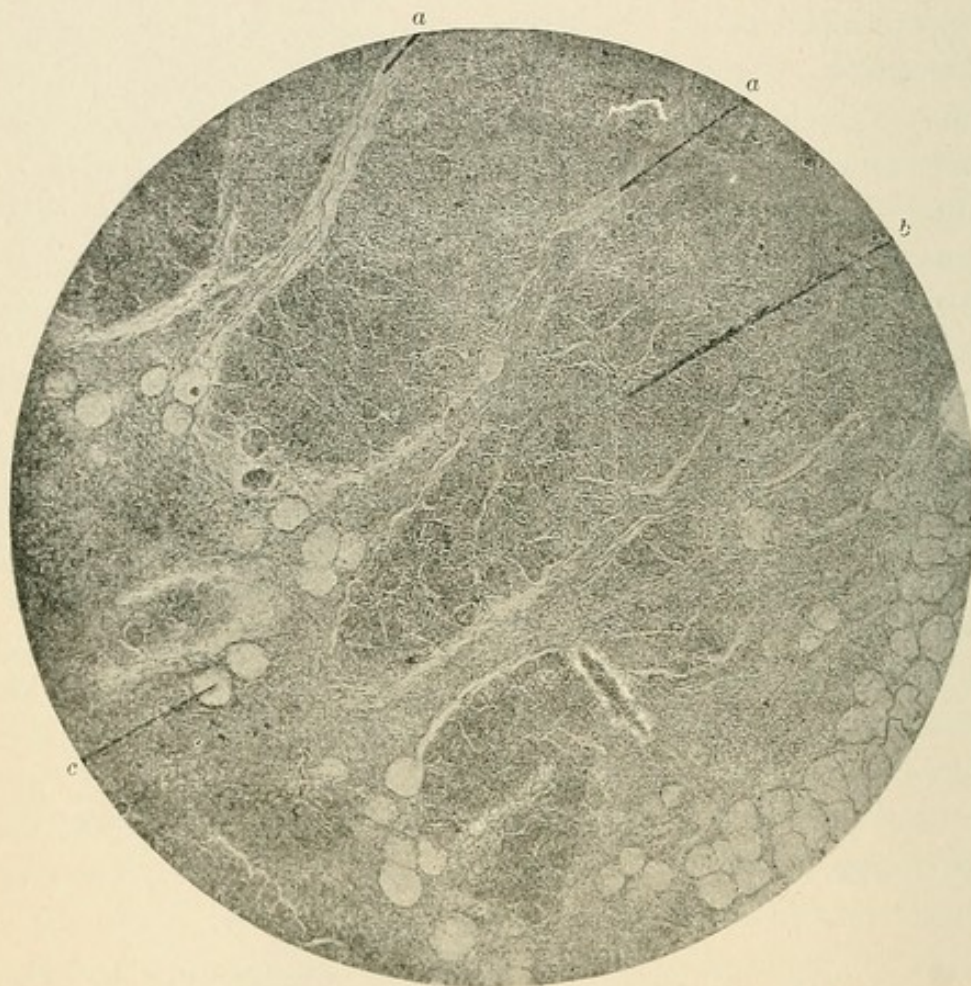


FIG. 139.—Colloid degeneration of stroma in carcinoma of the mamma ; $\times 350$ (Surgical Clinic, Rush Medical College, Chicago): *a*, stroma ; *b*, alveoli packed with epithelial cells ; *c*, colloid masses in stroma.

as to induce many authors to regard it as a special form of tumor. Lebert showed that what was known as "colloid carcinoma" is a carcinoma modified by the character of the regressive tissue-metamorphosis of its cells or its stroma, or both. Colloid degeneration is of very frequent occurrence in carcinoma of the alimentary canal, the favorite locality of what was formerly described as "colloid cancer" (Fig. 138).

Mucoid or myxomatous degeneration may occur in either the cells or the stroma of a carcinoma. Columnar-celled carcinoma is very apt to undergo this form of regressive metamorphosis. It is again the oldest cells that first undergo this change. In cylindrical-celled carcinoma, in which the cells are arranged in several layers, the layer next

to the lumen of the tubule is destroyed by the myxomatous process, and the mucoid material accumulates in the glandular spaces, forming cysts of various sizes (Fig. 140). If the areas of degeneration are

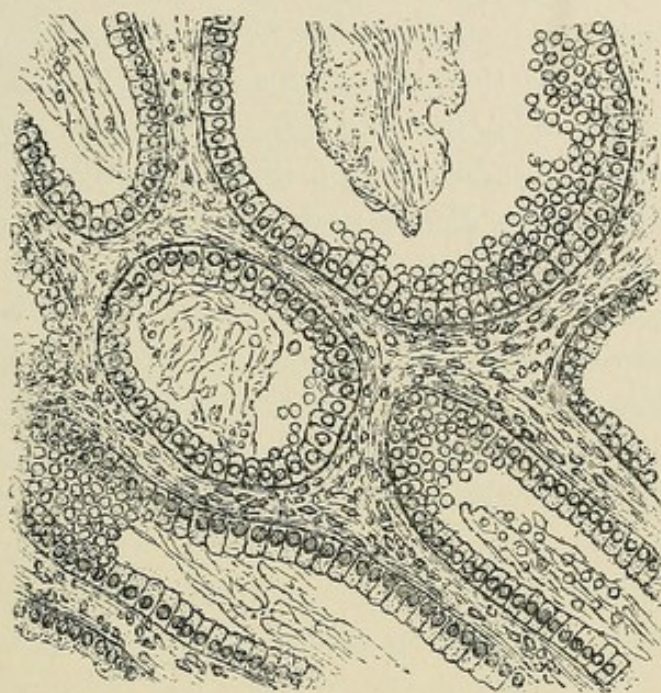


FIG. 140.—Cylindrical-celled carcinoma of stomach; $\times 250$ (after Perls). The cells in the central part of the alveoli are destroyed by myxomatous degeneration.

extensive, the consistence of the tumor varies in different places—a matter of importance in diagnosis. Secondary tumors are subject to the same degenerative changes as the primary. Ulceration in carcinoma of the skin and the mucous membranes is present almost from the beginning. Carcinomatous ulcers of the cutaneous surface are usually covered by a crust formed by inspissation of the secretion, which crust, if detached, uncovers an ulcer which bleeds upon the slightest touch. *An ulcer once formed remains permanently, increases in size, and manifests no tendency to heal.* The differentiation of such an ulcer from lupus and from ulcerating syphilitic affections is always difficult and sometimes impossible. When the tumor involves the skin or when a deep-seated carcinoma has reached the skin, ulceration takes place, the central part, being more abundantly supplied with epithelial cells and being less vascular, becoming the seat of necrotic changes. As soon as the continuity of the surface is destroyed, micro-organisms take a part in the subsequent work of destruction, as the tumor-tissue becomes the seat of suppurative inflammation. A carcinomatous ulcer is characterized by its deep, crater-like cavity, which again may present nodules, as well as by its thickened and indurated margins. The ulcer may also be flat where the thin infiltrations appear to be destroyed by ulceration. These ulcers are always surrounded by steep, abrupt

margins, and present a flat floor with few or no granulations, being thus distinguished from many other kinds of ulcers resulting from infective causes. Large ulcers are usually the seat of putrefactive processes and emit an exceedingly offensive odor. The putrefaction is caused by the presence of putrefactive bacilli which develop in the dead tissue attached to the ulcerated surface. A carcinoma covered by normal intact skin may become infected with pyogenic microbes by localization in the tumor-tissue of floating microbes. Suppurative inflammation of the tumor-tissue under such circumstances is attended by the usual symptoms which accompany acute inflammation. Temperature, rapid pulse, and other symptoms of sepsis, with increase of swelling, pain, tenderness, and œdema, are the symptoms to be relied upon in ascertaining the existence of this complication. If the tumor is large and the infection is extensive, a large part of the tumor may slough, leaving a crater-like excavation after the elimination of the dead material.

It will be necessary to add to the general remarks on the pathology of carcinoma a brief description of the

HISTOLOGICAL VARIETIES OF CARCINOMA.

Squamous-celled Carcinoma.—This variety of carcinoma develops upon the surface of the skin, and is usually described under the term "epithelioma." The term "epithelioma" has given rise to a great deal of confusion, as some authors describe under it a benign, and others a malignant, tumor of the skin or the mucous membranes. The word should be abolished in the nomenclature of tumors.

A squamous-celled carcinoma contains as the essential tumor-element squamous or pavement epithelium in imitation of the epithelial layers of the skin. The growth usually begins as a small surface defect—a crack or fissure of the skin covered by a crust. With the cancer-formation the epithelial cells dip down beyond the *membrana propria* into the subcutaneous vascular connective tissue. The tumor then is slightly elevated above the level of the surrounding skin, with a hard base, and with indurated margins from which infiltrations extend into the surrounding tissues. The tumor beneath the skin or under the ulcer appears to the palpating finger as a hard mass, almost of the density of a piece of cartilage. The tumor ulcerates early, as the oldest portion does not receive a blood-supply adequate to nourish its tissues. When the epithelial layer is destroyed the connective tissue furnishes the surface with a layer of vascular granulations; but an attempt in this direction is only partially successful, as some of the epidermal plugs penetrate deeply into the subcutaneous tissue. If these epidermal

plugs are carefully examined, their connection with the surface epithelia is readily traced by making the section in a right direction : if it is made oblique, the deeper parts of the tumor appear disconnected with the surface.

In the proper interpretation of the diagnostic significance of these epithelial plugs not only is their net-like branching characteristic, but of greater import are their shape and combination. Benign epithelial proliferations show the same regular form and arrangement of the cells as the normal inversions of the epidermis, and they gradually become narrower toward the depth, while in the carcinomatous epithelial proliferation the nature of the growth is revealed by the irregular arrangement of the epithelial cells and their relations to the connective tissue. New epithelial cells which form on the surface of granulations in the healing of a wound or an ulcer do not possess the power to penetrate into the deeper tissues, while penetration of the connective tissue is the most conspicuous pathological feature of carcinoma. The carcinoma-cells first penetrate the entire thickness of the skin, and later the subcutaneous connective tissue and any other tissue within their reach. Another important differential point is that in non-malignant affections of the skin the normal shape of the different forms of epithelial cells is maintained, while in carcinoma there is a great similarity in the shape of the cells. Epithelial pearls in non-malignant affections appear in the form of concentric layers of cells, with the oldest cells in the centre ; in carcinoma the cells of such a pearl are the product of tissue-proliferation of a single cell. In carcinoma the cells are often multinuclear, and only gradually, by flattening and arrangement in concentric layers, form the epithelial nests.

In ordinary granulation-tissue but few leucocytes are found ; in carcinoma they are abundant, especially near capillary vessels. In chronic ulcer of the leg, if malignancy sets in, young epithelial cells become buried underneath the benign granulations, and a carcinoma of considerable size may be produced by them before its presence would be recognized by surface indications. If a carcinoma of the skin is allowed to run its course undisturbed, regional infection is sure to take place, and other complications, in common with glandular carcinoma, set in sooner or later, furnishing an abundance of clinical evidence to prove the carcinomatous nature of the tumor.

The favorite localities of squamous-celled carcinoma are the lips, the skin of the face, the mouth, the nose, the ear, the penis, the vulva, and the anus. In the œsophagus it most frequently attacks that part of the tube which lies behind the cricoid cartilage and the bifurcation of the trachea. Carcinoma of the tongue commences most frequently at

the margin and base of the organ, at points irritated by sharp or defective teeth. Carcinoma is also quite frequent in the larynx, the vocal cords, and, as Störk has observed, from polypoid or papillomatous growths, warts, and scars in this organ. The deep, squamous-celled carcinomata originate from an incompletely obliterated branchial cleft (Volkmann), from remnants of the urachus and of dermoid tumors, or from a displaced matrix of embryonic cells in any part of the body. Friedländer found in the apex of the lung of a phthisical patient a squamous-celled carcinoma which projected into a principal bronchus. He believed that the columnar cells in this locality had become transformed into squamous epithelium, and he refers to the observations made by Griffini and Ziegler, who found pavement epithelium upon ulcerous, tubercular, and syphilitic defects of the trachea. It is, however, more probable that the carcinoma had developed from a displaced matrix of epiblastic tissue.

Erbse saw a case of squamous-celled carcinoma of the lung after perforation into the trachea of an œsophagus-carcinoma composed of epithelial cells resembling the primary tumor. Klebs thinks that cells entered the lung by aspiration before perforation occurred.

As compared with glandular carcinoma, squamous-celled carcinoma pursues a chronic course. This, as we have explained elsewhere, is to be attributed not so much to its lesser intrinsic malignancy as to the difference in the anatomical location of the two growths. If left to itself, squamous-celled carcinoma ultimately presents all the clinical features of glandular carcinoma.

Melanotic carcinoma is a pigmented squamous-celled carcinoma. It develops in structures which are pigmented—most frequently in pigmented moles. The pigment appears as granules in the protoplasm of the cells. This form of carcinoma is regarded as exceedingly malignant, giving rise to early and extensive regional infection and to general dissemination. The secondary tumors show the same structure, and are pigmented like the primary tumor.

Cylindrical-celled Carcinoma.—The cylindrical-celled carcinoma resembles the squamous-celled in so far that it develops upon a free surface, but it differs from it in the shape and arrangement of its cells. The cells are derived from the hypoblast, are columnar in shape, and are attached in single or multiple layers to the inner surface of imperfect tubules. The histological structure of a cylindrical-celled carcinoma is an imitation of gland-ducts and of mucous glands of the gastro-intestinal canal. The carcinomatous process begins with an anomalous vegetation of columnar epithelial cells. The membrana propria is defective at points, and permits the cells to escape from the tubules into the surrounding connective tissue, where they continue to

reproduce themselves by indirect cell-division. The connective tissue also proliferates and enters into the formation of the tumor. *The disconnected development of epithelial cells is an important factor in the local extension of the tumor.* It marks the first deviation from normal growth, and it is always followed by local and regional infection, and, as Lebert has shown, very frequently by general dissemination.

Metastatic tumors, especially of the bones, are often associated with a small primary tumor showing greater aptitude for local and general dissemination than does squamous-celled carcinoma. The primary tumor in such cases has often been overlooked entirely. Klebs believes that the extension to bone usually takes place through lymph-glands, especially those in the lumbar region.

Compared with squamous-celled carcinoma, cylindrical-celled carcinoma is a much more malignant affection. A partial explanation of this difference in their clinical behavior is the presence in the former of an abundance of firm connective tissue to serve the purpose of stroma, and in the latter of a scanty, loose bed of connective tissue.

Glandular Carcinoma.—The morphological prototypes of this variety of carcinoma in normal tissue are the acinous glands, some of which are derived from the epiblast and some from the hypoblast. The hard variety of glandular carcinoma has been called "scirrhus" for centuries, and this name still figures prominently in our modern text-books. The texture of the tumor varies according to the amount of stroma present. If the stroma is abundant and firm, the tumor is firm—the so-called "scirrhus;" if the stroma is scanty and the amount of tumor-cells is consequently increased, the tumor is soft, constituting what was formerly, from its resemblance in consistence and appearance to brain-tissue, termed an *encephaloid* or *medullary* cancer. If such a tumor ulcerated and fungous masses appeared on the surface of the ulcer, which bled easily on being touched, it was called *fungus hematicus*. Such a distinction between glandular tumors is no longer justifiable upon histological or clinical grounds, as the same tissue-elements are present in all varieties, only in different proportions, and all of these varieties result in regional, and frequently in general, infection. The classification of carcinoma should be made upon a histological basis, and if this is done, all malignant epithelial tumors of acinous glands must be brought under one head as *glandular carcinoma*.

Glandular carcinoma varies greatly according to the character of the mother-soil and the arrangements of its histological elements, but many of the features of the varieties formerly regarded as distinct types of tumors have so much in common as to constitute a well-defined form of carcinoma. The most distinguishing feature between

glandular carcinoma and carcinoma of the cutaneous and mucous surfaces is that the former gives rise to the formation of a large tumor. *The reason that a surface carcinoma does not form a large tumor is that it can grow in one direction only, and that, being exposed to frequent irritation of all kinds, and receiving its blood-supply only from one direction, it falls an early prey to ulceration. As soon as a surface carcinoma has ulcerated, the tumor-tissue is exposed to infection with pathogenic microbes, which infection, by producing a suppurative inflammation, aids in the destruction of tumor-tissue.* A glandular carcinoma is better protected against irritation, injury, and infection with pathogenic microbes, is surrounded everywhere by tissue, and receives its blood-supply from all sides, and it is for these reasons that the tumor attains larger size and that ulceration sets in later than in a surface carcinoma.

Carcinoma of the breast is the most familiar representative of the glandular group. In the hard glandular tumor the epithelial cells lose their typical shape sooner than in the soft variety, owing to the pressure to which they are subjected on the part of the massive stroma and to the scanty blood-supply. The defective acinous grouping of the epithelial cells (Fig. 141) points to a deeper nutritive disturbance than is the case in adenoma (Fig. 142), and should always be looked for in making a differential diagnosis by the aid of the microscope. The carcinomatous character of the tumor becomes evident when the tissues adjacent to the tumor are examined. If the tumor, for instance, is surrounded by fat, this tissue will be found infiltrated with new epithelial cells, and hence what might have been considered macroscopically as the most important features, adhesion and infiltration, become corroborated by examination of these tissues under the microscope. When the tumor starts in the acini of the gland—or, rather, when the tumor presents an acinous structure—the picture is entirely changed, as the histological arrangement in a hard glandular tumor presents no resemblance whatever to normal gland-tissue: the glandular tissue has given way to a firm, quite homogeneous, fibrous mass; only numerous, narrow, somewhat deeply-stained stripes indicate the location of the compressed, proliferating epithelial cells. *The carcinomatous tissue presents a peculiarly distinctive histological type. This tissue consists of a mixture of epithelial cells and connective tissue, the mutual topographical and numerical relations of which deviate completely from the normal structure of the mammary gland.*

The highest degree of atypical tissue-proliferation is met with in carcinoma of the mammary gland. The local infection extends along pre-existing connective-tissue spaces, and ultimately extends beyond the limits of the gland to the overlying skin and the wall of the thorax,

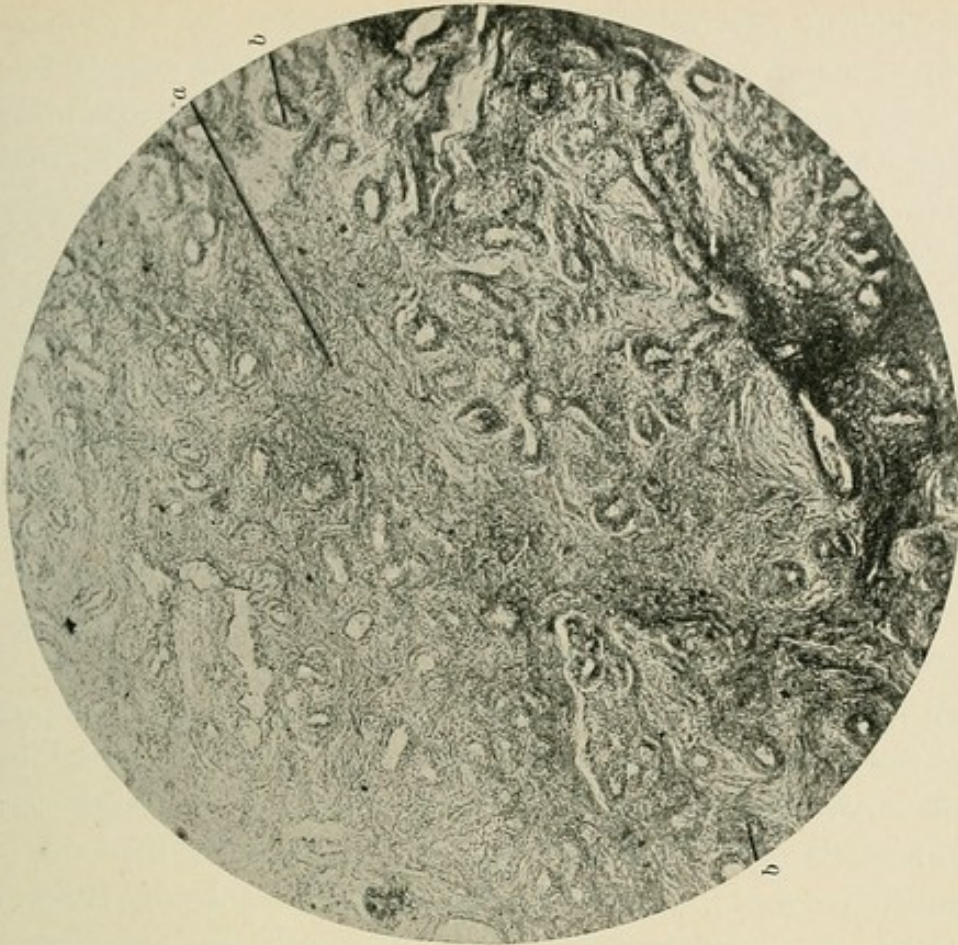


FIG. 142.—Adenoma of breast, showing typical grouping of cells; $\times 75$ (Surgical Clinic, Rush Medical College, Chicago): *a*, connective-tissue stroma; *b*, *b*, tubules lined by epithelial cells arranged in a typical manner.

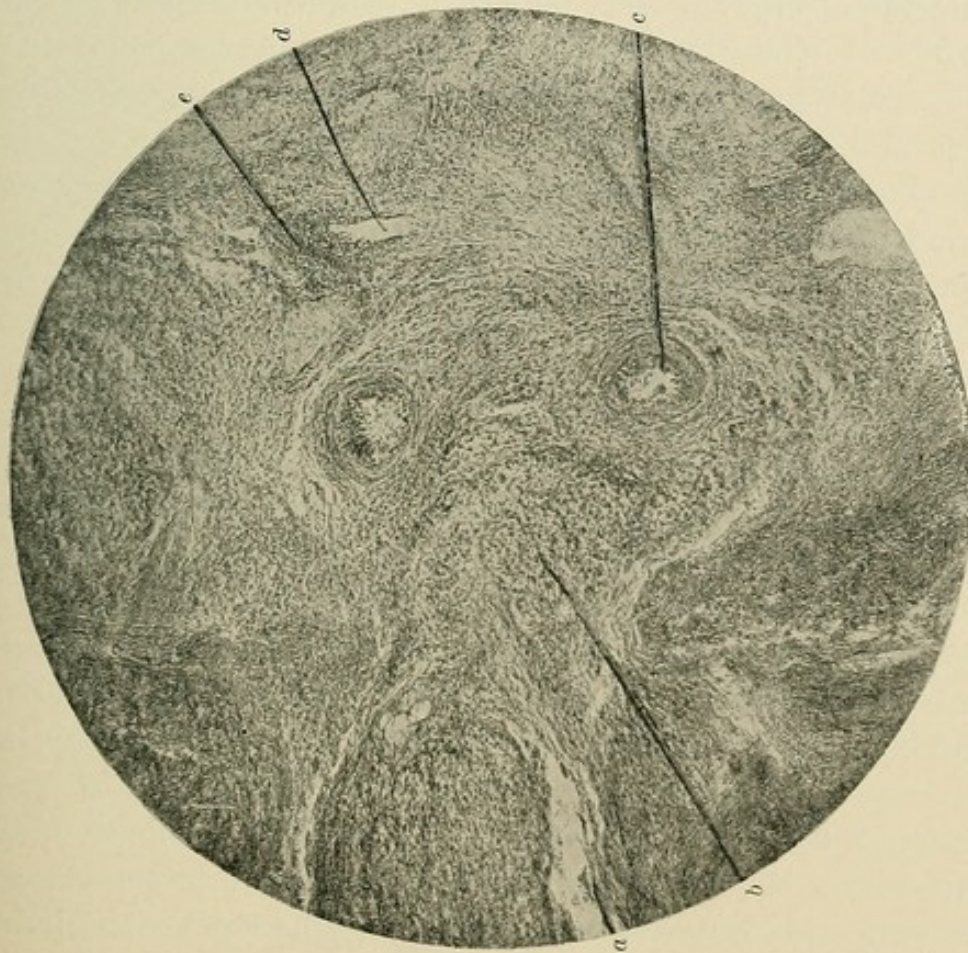


FIG. 141.—Carcinoma of the breast, showing faulty acinous grouping of epithelial cells; $\times 100$ (Surgical Clinic, Rush Medical College, Chicago): *a*, connective-tissue stroma; *b*, acinous, irregular grouping of cells; *c*, transverse section through blood-vessel walls very much thickened; *d*, oblique section of blood-vessel; *e*, infiltration by leucocytes around vessel.

which is frequently perforated by the growth, either by continuity of growth and successive involvement of the different tissues, or in the course of the lymphatics until the pleura is reached, when the disease spreads rapidly over the serous surfaces, usually resulting in hydrothorax. The serum in such cases is frequently stained by the admixture of blood. Glandular carcinoma is followed at an early stage by regional infection. The lymphatic glands nearest the organ affected, in the direction of the lymph-current, are usually involved first, when, step by step, successive glands are implicated until the entire chain of glands has become infected. General infection at this stage may occur at any time and may hasten the death of the patient. The glands most frequently the seat of carcinoma are the mammary, thyroid, parotid, submaxillary, ovary, testicle, kidneys, pancreas, and prostate.

DIAGNOSIS.

The difficulty in the diagnosis of carcinoma depends on the size and location of the tumor. In advanced carcinoma of the external parts of the body a correct diagnosis can often be made on first sight. The diagnosis of carcinoma of internal organs is frequently made only in the post-mortem room. The successful treatment of carcinoma depends upon an early and a correct diagnosis and prompt and thorough operative interference. The early diagnosis requires a careful study of the clinical history of the case, supplemented by a thorough examination of the tumor, and followed by a critical analysis of the signs and symptoms presented. In doubtful cases a correct diagnosis is possible only by differentiating from a supposed carcinoma swellings and tumors which simulate it—that is, by exclusion. Inoculation experiments and the use of the microscope may become necessary to make a differential diagnosis between carcinoma and some of the infective swellings. In obtaining the clinical history it is important to inquire into the family history in reference to the possible existence of an hereditary predisposition to carcinoma. To elicit information of value concerning this point it is necessary to trace back the family history for two or three generations, because such an hereditary predisposition does not necessarily occur in the immediate offspring of carcinomatous parents, but may appear in the second, third, or fourth generation. The writer knows of one family in which both parents died of carcinoma—the husband of carcinoma of the stomach, the wife of carcinoma of the uterus—and yet the children, one of whom has now reached his sixtieth year, have shown no symptoms of this disease. In tracing the family history in the cases of carcinoma that have come under his observation the writer has had patients tell him

repeatedly that one of the grandparents or great-grandparents died of carcinoma. It is also important to elicit the existence of malignant disease among more distant relatives, as the hereditary predisposition may follow with varying degrees of intensity different branches of the same family.

The age of the patient is an important element in the diagnosis of doubtful tumors. Carcinoma is a disease that in preference attacks persons of middle or past middle life. The aptitude for this disease increases after middle life. In very rare instances it has been of congenital origin or has developed during childhood. It is quite rare in persons less than twenty years of age, and is more common during the third decade of life. The writer has seen carcinoma of the rectum in a boy eighteen years of age, carcinoma of the breast in a girl twenty-five years old, carcinoma of the lower lip in a man twenty-seven years old, and carcinoma of the stomach in a man of thirty. Cases of carcinoma in persons less than thirty years of age are, however, extremely rare. A tumor of the lip occurring in a man less than thirty years of age is in all probability anything else than a carcinoma, while in persons past middle life the probability of its being carcinomatous is greatly increased. If a woman less than thirty years of age is suffering from pelvic distress, menorrhagia, and profuse leucorrhœal discharge, the probability of these symptoms being caused by carcinoma of the uterus is exceedingly small, while the same complexus of symptoms occurring in a woman at the time of the menopause or later points strongly in that direction. A solid tumor in females less than twenty-five years of age is usually of a benign nature, while its appearance in women past thirty years of age should arouse a strong suspicion of its malignant character.

Sex exerts a strong influence in determining the location of carcinoma. Pyloric obstruction of the stomach is caused by carcinoma much more frequently in men than in women. Carcinoma of the lip is extremely rare in women. Carcinoma of the breast in the male is an exceptional occurrence. Carcinoma of the genital organs is much more frequent in women than in men.

Rapidity of growth is a marked feature of carcinoma as compared with benign tumors. A rapid-growing tumor is therefore more apt to be mistaken for an inflammatory swelling than for a carcinoma. Rapidity of growth as a diagnostic evidence, however, must be weighed carefully before conclusions are drawn from it, otherwise the surgeon is very likely to be misled. A carcinoma may remain latent for many years before manifesting malignant qualities. An inflammatory swelling, as a rule, increases in size more rapidly than a carcinoma. Patients

have been sent to the writer repeatedly with the diagnosis of carcinoma of the breast, when the clinical history showed that the swelling had reached its maximum size in from four to six weeks—the result of an almost painless subacute suppurative inflammation of the breast. In rapidly-growing tumors particular pains should be taken to ascertain a possible source of infection. If, for instance, a tumor of the testicle attains the size of a hen's egg in a few weeks in a man more than thirty years of age, a suspicion of syphilitic infection should be excited. A gumma of the testicle will increase in size much more rapidly than a carcinoma of the same organ. *A rapid-growing carcinoma must be differentiated carefully from infective swellings of all kinds—gumma, tuberculosis, actinomycosis, and chronic suppuration.*

Tenderness and pain, although present to a more or less marked degree in advanced carcinoma, are symptoms of greater prominence in inflammatory affections. Non-professional men and women have an exaggerated idea of pain as a symptom of carcinoma. They are impressed with the belief, handed down for ages, that carcinoma is an exceedingly painful affection, and it is difficult to make them understand that carcinoma may occur as a painless affection. Carcinomata of the skin and mucous membranes are not attended by much pain. Patients who have suffered perhaps for a year or more from carcinoma of the rectum generally complain of but little pain, and seek medical advice for what they have regarded all along as piles. Carcinoma of the stomach is a comparatively painless affection, and the suffering caused by it is more from the mechanical obstruction than from the carcinoma *per se*. The temporary sharp, shooting, lightning pains so frequently described as a characteristic symptom of carcinoma are often entirely absent and are always of an intermittent character. The writer has frequently opened the abdomen for acute intestinal obstruction, and has found carcinoma of the intestine without the patient's having known that there was anything seriously wrong before the symptoms of acute obstruction set in.

Tenderness, a symptom of the greatest diagnostic importance in inflammatory affections, is usually entirely wanting in uncomplicated carcinoma. Dilatation of the superficial veins is the result of great vascularity or of deep-seated venous obstruction, and is present as frequently in infective swellings as in carcinoma. Redness is present in carcinoma when the tumor has reached and implicated the skin and is on the verge of ulceration. It is only under similar circumstances that it is present in infective swellings. Œdema, so significant of the presence of a deep-seated abscess, is present in carcinoma when the regional infection interferes with the lymphatic or venous circulation

or when the tumor has become the seat of infection with pus-microbes.

Primary multiplicity of the tumor seldom occurs in carcinoma, but is of frequent occurrence in the case of benign epiblastic, hypoblastic, and mesoblastic tumors. Carcinoma as a multiple affection is occasionally met with in the aged, when the disease originates by the transformation of senile warts into carcinoma. Cases of primary multiple carcinoma have been reported by Lücke, Winiwarter, Klebs, Kaufmann, Bucher, Walter, and Schimmelbusch. Schimmelbusch explains primary multiplicity of carcinoma by a process of implantation of carcinoma cells at a point opposite or some distance from the primary tumor, the latter furnishing the cells for the secondary tumor growth. Bucher attributes the occurrence of multiple carcinoma in the same organ to a multiplicity of points of irritation. Another potent cause for the occurrence of multiple carcinoma in the same organ or in different parts of the body is the presence of the essential tumor matrix in tissues disposed to tumor-formation, and subjected to the same influences which act as exciting causes. Recently there came under the observation of the writer a case in which four carcinomata of the face developed almost simultaneously. One tumor occupied the malar region on the left side; another, the lobe of the left ear; a third was situated over the angle of the lower jaw; and the fourth was a typical ulcerating carcinoma of the lower lip that had given rise to infection of the submental and submaxillary glands.

Benign tumors are always encapsulated, hence, unless bound down by surrounding tissues, are movable and have well-defined margins. Carcinoma is an infiltrating tumor, and has abrupt, well-defined margins. The infiltration gives rise to nodulation of its surface and to immobility of the tumor. *A nodulated fixed tumor is in all probability a carcinoma.* To test the mobility of the tumor it should be palpated carefully between the two index fingers to ascertain the points of fixation caused by the infiltration. An adenoma of the breast will slip between the fingers, while a carcinoma of the same size will be more or less fixed in its location by the peripheral parts of the tumor which project into the surrounding tissues.

Hardness of the tumor is usually recognized as a sign of malignancy. A fibro-adenoma could not be differentiated from a carcinoma by this sign. A carcinoma with a scanty reticulum and extensive degenerative changes is a soft tumor, resembling in this respect an adenoma with cystic degeneration. The diagnostic importance of this property of carcinoma has been overestimated greatly.

Fluctuation, when too much relied upon, leads to frequent mistakes

in diagnosis and treatment. It is present in cystoma, cystic adenoma, and inflammatory swellings with central softening, as well as in soft carcinoma with extensive regressive degeneration of the centre of the tumor. *Pseudo-fluctuation is often present in soft carcinoma without cystic degeneration.* This sign has often induced surgeons to puncture a malignant carcinoma under the belief that they were opening an abscess. Such mistakes, in addition to being a source of mortification to the surgeon, have always resulted disastrously to the patient by transforming a subcutaneous into an open carcinoma, with all the annoyances and dangers incident to such a change. *A suspicious fluctuating swelling should never be punctured or incised without having excluded the existence of a soft carcinoma, sarcoma, or granuloma by the use of the exploratory syringe.*

One of the important steps in the diagnosis of a carcinoma is the examination of the lymphatic glands. In suspected carcinoma of the lip, the submental and submaxillary glands; in tumors of the mammary gland, the glands of the axilla; in ulcerative affections of the cervix of the uterus, the sacral glands,—should be examined carefully. Many conclusions have frequently been drawn from the results of such an examination. In tumors of the breast a diagnosis of their benign nature has often been based upon the absence of palpable lymphatic glands in the axilla. Some excellent modern authorities continue to advise, when no enlarged glands can be felt in the axilla, that this region should not be invaded in operations for carcinoma of the mammary gland. This is teaching of a dangerous kind. The writer has frequently failed to find any evidences of regional infection by examination through the intact skin in cases of carcinoma of the breast, when during the operation, upon exposing the deep lymphatics of the axilla by free incision, numerous glands the size of a marble were found. *In obese women it is impossible by external palpation to detect glands the size of a pea or even that of a marble, and consequently such an examination cannot be relied upon in determining the extent of the operation beforehand.* Carcinoma of the skin does not give rise to early regional infection, and yet when the disease has become quite extensive exposure of the submental and submaxillary glands by a free incision frequently reveals the presence of glands, as large as a pea, which could not be felt through the intact skin. Examination of the retroperitoneal lymphatic glands in suspected cases of carcinoma of the uterus should never be neglected. In carcinoma of the skin of the extremities the glands in the different regions should be subjected to a scrutinizing examination. Enlarged glands under such circumstances have often been overlooked, and such oversights have been responsible for many

disappointing results. *Enlargement of lymphatic glands in the region occupied by the tumor, without ulceration of the surface and without involvement of the glands in other regions, is almost positive proof of the carcinomatous nature of the tumor. Enlargement of the lymphatic glands in the region occupied by an ulcerating tumor may be the result of infection of the lymphatic glands, in which case pathogenic microbes have entered the lymphatic channels through the surface defect. In lymphadenitis the glands are not so hard as in secondary carcinoma of the lymphatic glands, and are more tender on pressure. In ulcerating carcinoma the lymphatic glands in the region occupied by the tumor may be the seat of both microbic infection and cell-metastasis, when the local signs and symptoms correspond with this double infection. If from other evidences a diagnosis of ulcerating carcinoma can be made, the lymphatic glands should be subjected to treatment as though their enlargement were exclusively due to cellular infection. Universal lymphatic hyperplasia is one of the most important indications of syphilitic infection, and a tumor occurring in a person showing such a condition should be examined with the utmost care, to exclude the possibility of its being a gumma.*

The greatest difficulties are encountered in the diagnosis of ulcerating tumors. It is in such cases that it is so important to ascertain from the patient's statements the probable starting-point of the tumor. Epithelial tumors, with few exceptions, start in the tissues derived from the epiblast or the hypoblast—that is, in the skin, the mucous membrane, or the glandular tissue. If the tumor developed in the skin or the mucous membrane, it appeared first as a surface tumor, and could be moved only by moving the skin or the mucous membrane in which it originated; that is, it was in the beginning superficial and not covered by skin or by mucous membrane. If it developed in an acinous gland, it could be moved with the gland and was covered by skin or by mucous membrane. *All mesoblastic tumors start as subcutaneous or sub-mucous tumors.* Infective swellings seldom appear primarily as surface lesions. If they occur as lesions of the skin or the mucous membrane, the incipient swellings appeared as nodules covered by skin or by mucous membrane. If they originated in the connective tissue more distant from the skin, as is more frequently the case, the skin or the mucous membrane became involved later as the infection extended toward the surface.

The lesions most frequently mistaken for ulcerating carcinoma of the skin are tuberculosis, syphilis, actinomycosis, and chronic ulcers of the leg. The greatest diagnostic doubts arise in connection with ulcerating affections of the nose, face, lips, tongue, and cervix

uteri. It will interest the student to know that primary syphilis of the lip, tonsil, and vulva has repeatedly been mistaken for carcinoma. Such inflammatory swellings have been excised, and a correct diagnosis was only made, if the physician was honest enough to admit his mistake, after the appearance of secondary symptoms. In chancre the swelling appears rapidly upon the expiration of the usual period of incubation, and gives rise to regional infection of the lymphatic glands soon after the appearance of the first symptoms of local infection. Glandular infection is unusually severe and extensive in chancre of the lip. Tuberculosis of the nose attacks in preference the alæ, while syphilis attacks most frequently the septum. Carcinoma starts most frequently at the junction of the skin with the mucous membrane.

Tubercular and syphilitic ulcers often heal wholly or in part spontaneously or under proper local and general treatment. Carcinomatous ulceration may remain stationary for a long time, but never heals, and assumes sooner or later a progressive character. Syphilitic ulceration is preceded by gummatous infiltration, and examination of the whole body will usually reveal the marks of antecedent syphilitic lesions or the existence of such in other parts of the body, and among them hyperplasia of the lymphatic glands in the different regions, notably the post-cervical and cubital glands. With few exceptions carcinoma appears as an isolated affection, while syphilitic and tubercular ulcers often occur as a multiple lesion. Regional infection through the lymphatics is seldom present in tuberculosis and syphilis, but is a frequent complication

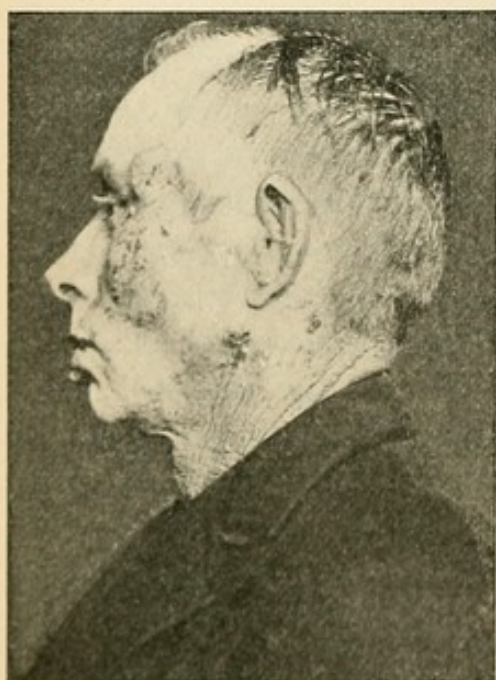

FIG. 143.—Carcinoma of the lower lip and multiple carcinoma of the face.

in advanced cases of carcinoma of the skin. Actinomycosis seldom presents itself to the surgeon except as a swelling connected with the maxillary bones, where it simulates sarcoma more closely than carcinoma. The discovery of actinomyces by the aid of the microscope, or the discovery of the fungus by the naked eye in the secretions as minute yellowish-gray particles, will settle the diagnosis. Sections taken from the margins of the ulcer in carcinoma will reveal the characteristic typical structure of the tumor, while the tissues from all infective swellings will exhibit the typical structure of granulomata. If the microscope is inadequate

to make a positive diagnosis, inoculation experiments will shed addi-

tional light and dispel doubt. Implantation of carcinoma-tissue and of tissue from a gumma in guinea-pigs and rabbits will yield a negative result, while inoculation with tubercular tissue will reproduce the disease in the animal.

The diagnosis of carcinoma of internal organs must often be based almost exclusively upon the functional disturbances produced by the tumor. A circular constricting carcinoma of the pyloric end of the stomach often eludes detection by external examination during the lifetime of the patient, but the symptoms produced by pyloric stenosis in men more than thirty years old strongly suggest as the mechanical obstruction a malignant tumor. Progressive intestinal stenosis in persons advanced in years points in the same direction. In aged men hematuria not caused by stone in the bladder indicates the probable existence of carcinoma of this organ. Œsophageal obstruction in persons past middle life is in the great majority of cases caused by carcinoma. In the absence of urgent indications for prompt operative interference the clinical history of the tumor should be followed carefully.

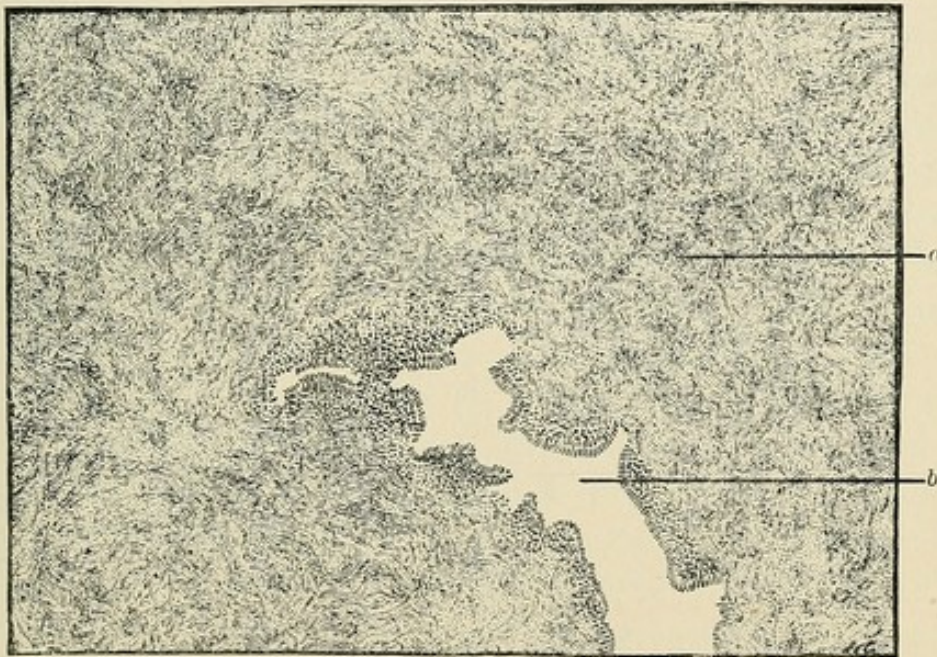


FIG. 144.—Fibro-adenoma of the breast, showing the epithelial cells lining the duct greatly increased in number, but in their normal anatomical locations (Surgical Clinic, Rush Medical College, Chicago): *a*, massive stroma of fibrous tissue free from epithelial infiltration; *b*, tubule cut longitudinally, lined by several layers of epithelial cells.

The rapidity of its growth and its extension to tissues irrespective of their anatomical structure should be noted carefully, and the microscope should be made use of as a diagnostic aid.

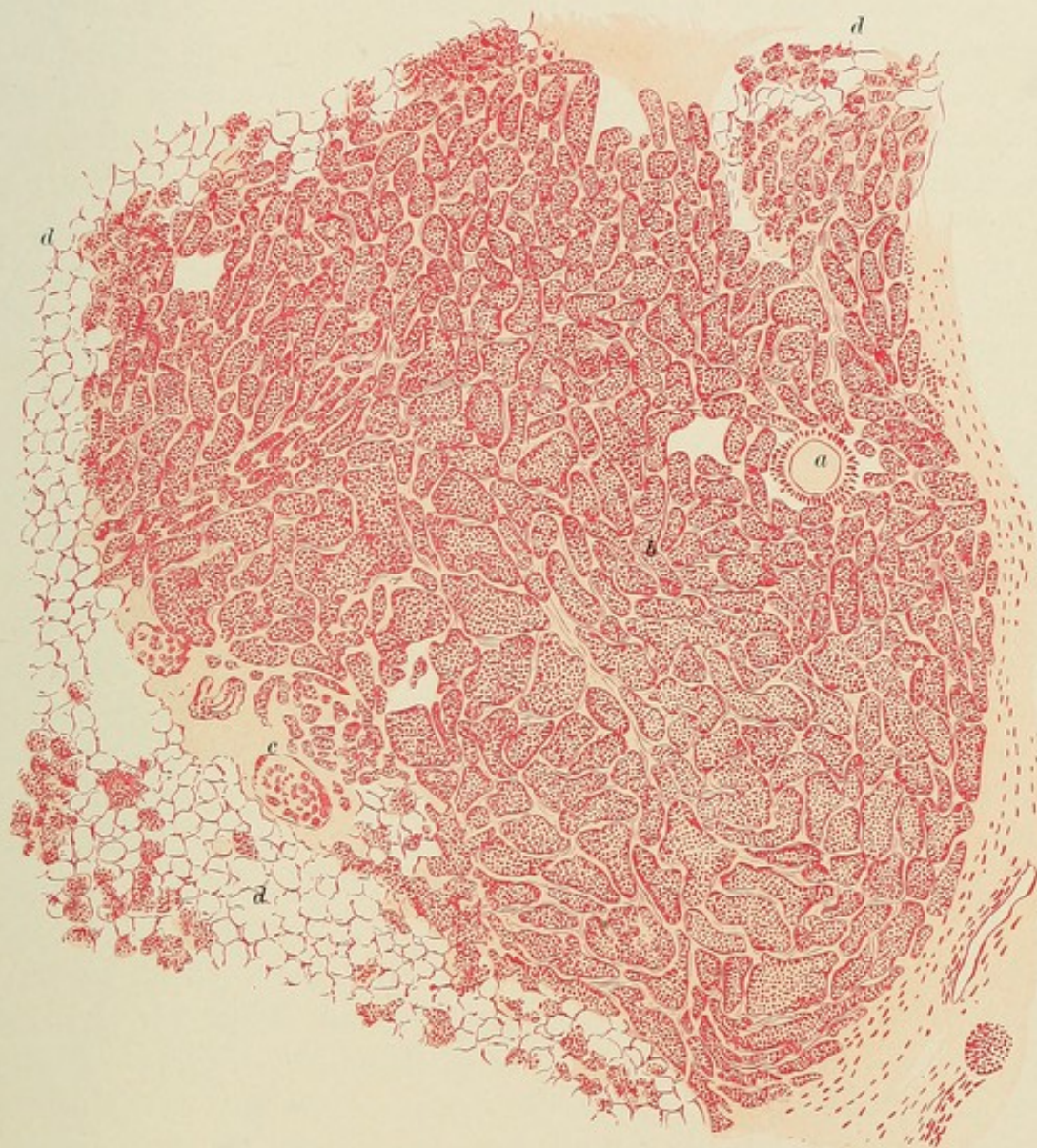
The first indication of the malignant nature of an epithelial tumor is cell-metastasis, upon which depends the local infection. In non-malignant epithelial tumors the normal relations between the epithelial

cells and the membrana propria are preserved. The epithelial cells may be increased greatly in number, the layers increased in number, and the cells closely packed and irregularly arranged, but the membrana propria remains as an impermeable wall (Fig. 144).


The most reliable evidence of the malignant nature of the tissues shown on Plate 5 is the infiltration by epithelial cells of the adipose tissue adjacent to the tumor. Normal adipose tissue does not contain epithelial cells: their presence in it could have occurred only by migration from a carcinomatous tumor in its vicinity. *The presence of young proliferating epithelial cells in any of the mesoblastic tissues is an unmistakable evidence of carcinoma.* In making a diagnosis of carcinoma under the microscope we search for the presence of epithelial cells in mesoblastic tissues, and when we find epithelial cells anywhere in vascular connective tissue in a state of proliferation, the diagnosis of carcinoma can be made with certainty. The student must make himself perfectly familiar with the morphological appearance of the different kinds of epithelial cells under different circumstances, so that he will be able to distinguish them at a glance from other histological elements. *The absence of epithelial cells in abnormal localities in a section from a suspicious tumor is no proof of the non-malignant nature of the tumor.* The section may have been taken from a part of the tumor devoid of carcinomatous tissue. If the microscope is to be relied upon as a diagnostic resource in the examination of a tumor, the sections must be taken from parts of the tumor where the growth is most manifest. Carcinoma grows by infiltration: the specimen to be examined should therefore be taken from the base or the periphery of the tumor, near its macroscopical boundary-line. If the first section under the microscope presents negative evidence, sections from different parts of the tumor must be examined in order to prove either its malignant or its benign character. In ulcerating surface carcinoma a fragment of tissue should be clipped with scissors from the indurated margin. In papillary excrescences a papilla is removed and examined. In deep-seated tumors Warren's harpoon is employed in obtaining the material for microscopic examination. From fragments of tissue thus obtained several sections are made and examined. The products of scraping or teasing preparations should not be used for the purpose of making a diagnosis by the aid of the microscope.

PROGNOSIS.

The prognosis of carcinoma is greatly influenced by the histological structure and the location of the tumor. Squamous-celled carcinoma is a much more chronic affection than cylindrical- and glandular-celled



Tubular carcinoma of mamma (after Klebs): *a*, milk-duct with hyaline contents; *b*, proliferating gland-tissue; *c*, group of acini, showing tissue-changes; *d*, adipose tissue with groups of epithelial cells near the tumor-tissue: the cells are not arranged in the form of acini. (Obj. 4, oc. 2.)



carcinoma. The location of a carcinoma influences the prognosis in two ways: (1) If the carcinoma is located on an exposed part of the surface of the body, the patient is soon made aware of its existence; his friends discover the tumor and remind him constantly of its presence, inducing the patient to seek timely medical advice. A tumor thus located is accessible to a radical operation. (2) In carcinoma of the internal organs the tumor, as a rule, is not discovered by the patient or his physician until extensive regional infection has made its complete removal impossible. A carcinoma of the breast is often only discovered accidentally after the axillary glands have become extensively involved. A patient suffering from carcinoma of the stomach is usually treated for indigestion, dyspepsia, or catarrh of the stomach for weeks and months until the clinical course has demonstrated the malignant nature of the affection long after the disease has passed beyond the reach of a radical operation. Examination of the stomach and the adjacent organs, including the retroperitoneal lymphatic glands, in the writer's fifteen cases of gastro-enterostomy revealed regional infection beyond the limits of a radical operation in all but one case, and in this case the patient had been reduced to a skeleton by the pyloric obstruction caused by a constricting circular carcinoma.

Women suffering from carcinoma of the uterus console themselves for months with the thought that they are undergoing the ailments incident to the menopause before they seek medical advice; and when this is finally done, in more than two-thirds of all the cases the disease has passed far beyond the limits of a successful radical operation. In the writer's practice less than 25 per cent. of the cases of carcinoma of the uterus were found within the justifiable limits of a radical operation. *The prognosis in operable cases of carcinoma must therefore largely rest upon the location of the tumor and the extent and accessibility of the regional infection.*

If the carcinoma involves a part or an organ inaccessible to operative interference—as the pancreas, for instance—the disease will pursue its typical course uninfluenced by treatment, and in the course of a year or two will result in the death of the patient. In carcinoma of the kidney this disease has usually progressed beyond the reach of a successful operation before its true nature is recognized. Such early operations as Israel's, in which the tumor was not larger than a cherry, would of course promise a permanent result, but diagnosis at such an early stage is possible only in the hands of expert diagnosticians, and will always be considered as an evidence of special skill and training.

The greatest progress in the treatment of carcinoma will have been made when we are placed in possession of an infallible means of early

diagnosis. The extent of the regional infection and the accessibility of the secondary tumors to operative treatment will also greatly modify the results to be expected from operative treatment. Even extensive regional infection of the axilla in cases of carcinoma does not preclude the possibility of a radical cure. On the contrary, limited axillary infection with enlargement of the lymphatic glands in the supraclavicular region is an evidence that the disease has passed beyond the reach of a successful operation. The appearance of a metastatic tumor or a miliary carcinosis seals the fate of the patient and furnishes a positive contraindication to local treatment with a view of removing the primary tumor. The average duration of life in carcinoma permitted to follow its own course is from two to three years. Death finally results from metastasis, septic infection, or exhaustion when the primary or any of the secondary tumors interfere with an important physiological function. Favorable indications, so far as the primary tumor is concerned, are hardness, slow growth, and its location in an organ not essential to the maintenance of life. Unfavorable conditions are rapid growth and softness of the tumor. The more a carcinoma resembles in its local behavior an inflammatory process, the greater is its malignancy and the greater the immediate danger to life. The writer has come to regard rapid-growing secondary tumors of the lymphatic glands, resembling in their physical properties and clinical aspects suppurative lymphangitis, as a *noli-me-tangere*. From a prognostic standpoint, imperfect removal of the primary tumor by caustics or by the use of the knife must be regarded as a measure calculated to aggravate the local conditions and to shorten life. Carcinoma grows much more rapidly, and terminates fatally sooner, in young than in old persons. As a rule, the malignancy of carcinoma is in an inverse ratio to the age of the patient.

TREATMENT.

Every modern writer on carcinoma insists upon the importance of early operative treatment. Carcinoma is no longer regarded as a constitutional or blood disease. It has a benign stage, during which it resembles benign epithelial tumors, and it is amenable to successful treatment by thorough removal. Every surgeon knows that complete removal by excision of a carcinoma of the lip during its early stages is seldom followed by local or regional recurrence, and that the operation furnishes almost certain protection against general dissemination. *What is possible in these cases is within the reach of successful surgery in the case of cylindrical-celled and glandular carcinoma, provided the operation is performed with the same thoroughness and under similar*

favorable conditions. In fact, the writer is of the opinion that the removal of the entire breast at a time when the disease is still local, and the extirpation of the uterus at a time when the disease remains limited to the cervical canal, would yield as satisfactory results as does early excision of carcinoma of the lip. The removal of an entire organ for carcinoma at an early stage of the disease can hardly fail in removing the zone of local infection. What surgery has to contend with is late operation. The writer is an ardent advocate of all legitimate attempts to eradicate carcinoma by operation, but is satisfied that the *furor operativus* has been carried too far at the present time in this department of surgery as well as in nearly all others.

The successful treatment of carcinoma requires a bold surgeon. A good and safe surgeon is guided by prudence and good judgment in the selection of his cases. Like a good general, he looks over the whole ground and estimates carefully the strength of his enemy before making an attack. The surgeon is too apt to look only upon the tumor, and to ignore the patient, when he decides upon the propriety of an operation. A remunerative fee or the fear that the patient might get into the hands of his competitors often deadens his sense of moral obligation toward his patient when he renders his final judgment concerning the propriety of an operation. For the welfare of the patient, the reputation of the surgeon, and the honor and good standing of the profession it is just as important to look for contraindications to, as for indications for, a radical operation. That the treatment of carcinoma has been marred by many sins of omission and of commission in the hands of competent surgeons goes without saying. The temptations to carry operative procedures to their maximum limits, and beyond, are greater in the treatment of carcinoma than in any other department of surgery. We find patients suffering from incipient carcinoma often averse to the use of the knife, but willing to lose their lives on the operating-table in attempts to secure relief when the disease has passed far beyond the limits of successful surgery. It requires moral courage to refuse an operation when such a patient begs his surgeon to perform it and is willing to shoulder all risks and responsibilities. *The surgeon has no moral right to become a legitimate executioner under any circumstances.*

A radical operation is contraindicated by—1. Extreme senile marasmus; 2. Extensive local infection; 3. Regional infection beyond the reach of complete removal of all the infected tissues; 4. General infection; 5. The coexistence of another disease which in itself will prove fatal in a short time.

It is difficult to set a limit by age to the operative treatment of car-

cinoma. The writer has removed successfully from the temporal region, in a lady eighty-five years of age, under partial anesthesia, a fungous carcinoma the size of a large orange. The large wound granulated in the course of two weeks, and healed by the aid of Thiersch's skin-grafts four weeks after the operation. The writer has seen patients not more than fifty years of age so marantic from senile degenerations that the smallest wound would probably have failed to heal. In persons past seventy years of age suffering from a slowly-growing carcinoma in a locality requiring a formidable operation it requires good judgment to decide whether an operation will benefit the patient or whether it will shorten life. It is in such cases that the extent of the operation must be planned carefully and the patient's strength be estimated before an operation is advised. If the local infection has extended so far that there is no prospect of healing the wound by plastic operations or by skin-grafting after the removal of the primary tumor, the patient's interests demand conservative treatment. Usually in such cases the tumor has so far infiltrated the deep tissues that a complete removal of all the infected tissues is impossible, and the wound-surface soon becomes the seat of a diffuse local return attended by conditions much more annoying and disagreeable to the patient than the primary tumor. It is the regional infection that renders the results of operations so problematical in the treatment of carcinoma. Every honest surgeon must confess that the permanent results of operations performed after regional infection had occurred are few and far apart. The disease may not return for one, two, or three years, but return it will, in the great majority of cases, sooner or later. The writer has seen local recurrence five and seven years after operation. The time set usually—three years—is therefore not reliable in drawing conclusions as to the permanency of the result after operations for carcinoma. *Permanent results will follow the operative treatment of carcinoma if the operation is performed before regional infection has occurred; on the contrary, non-recurrence will be the exception, and recurrence the rule, if the primary tumor is not removed until regional infection has set in.* If the regional infection is extensive, or if it occupies a locality not accessible to thorough removal of all infected tissues, the patient will be more comfortable, and will live longer, if no radical operation is performed. The writer regards the presence of carcinomatous glands in the supraclavicular space in carcinoma of the breast, and extensive infiltration of the sacral glands in carcinoma of the uterus, as contraindications to a radical operation. The existence of a metastatic tumor or of diffuse miliary carcinosis is, of course, an absolute contraindication to an attempt to remove the primary tumor. The existence of a carcinoma

in an unusual locality should induce the surgeon to make a critical examination for the purpose of detecting the primary tumor, as when the mother-tumor can be located operative procedure is out of the question, as the metastatic origin of the tumor first discovered has then been demonstrated. If a carcinomatous patient is suffering at the same time from an otherwise fatal disease, such as pulmonary tuberculosis, Bright's disease, diabetes, cerebral softening, locomotor ataxia, etc., it is wisdom on the part of the surgeon to withhold the use of the knife and to limit his efforts to palliation. Unfortunately, it is seldom that the surgeon has the opportunity to give the patient his advice in time. In the great majority of cases he has to deal with carcinoma after regional infection has set in, and in cases in which the disease has advanced too far for a successful radical operation he must content himself with resort to palliative measures.

Palliative Operations.—In inoperable subcutaneous carcinoma it should be the aim of the surgeon to preserve the cutaneous surface over the tumor intact so long as possible, as the misery which attends this condition is much less than in open carcinoma, and life is prolonged by the avoidance of septic infection. The surface of the tumor should be kept covered by aseptic absorbent cotton held in place by a circular bandage or by strips of adhesive plaster. If the skin becomes red and its perforation by the tumor-mass is threatened, the complication should be anticipated by a timely resort to antiseptic precautions, so that when an ulcer forms infection with pathogenic microbes will be prevented. The surface of the tumor should be disinfected in the same manner as in making preparations for an operation, after which it is covered by a few layers of iodoform gauze, over which is applied a thick compress of sterilized gauze, and the whole is covered by a filter of absorbent cotton. After the skin has given way the dressing is changed as often as necessary, and at each change the surface of the ulcer is washed with an antiseptic solution. Should the dry dressing prove a source of discomfort to the patient, it is replaced by a thick gauze compress wrung out of a saturated solution of acetate of aluminum and kept covered by an impermeable fabric like oiled silk, thin rubber sheeting, or mackintosh cloth. Attempts have been made, by covering large carcinomatous ulcers by skin-grafting, to render the condition of the patient more endurable by transforming the open ulcerating tumor into a subcutaneous lesion. These attempts have proved successful in some instances, but it is doubtful if the gain of such short duration will overbalance the pain and inconvenience caused by the scraping and the transplantation of Thiersch's skin-grafts. If the carcinomatous ulcer has become infected with pyogenic and putrefactive microbes, the sur-

geon has to contend with an additional evil. It is an exceedingly difficult task to render such a surface aseptic by chemical disinfectants. The surface is so irregular, and there are so many inaccessible nooks and corners which the solutions and powders cannot reach, that complete disinfection with chemical agents is usually not attained. The remedies which have proved most efficient in correcting the odor in such cases are Labarraque's solution of chlorinated soda, chlorine-water, aqueous solution of iodine and bromine, and iodoform in powder or mixed with boric acid (1 : 5). The strength of the solutions should not be such as to produce pain. If these milder measures do not succeed, a strong solution of chloride of zinc (25 per cent.) should be tried.

Of the modern deodorants in the treatment of open inoperable cases of carcinoma *aristol* deserves special mention. If an ointment dressing is indicated, *aristol*, with vaselin of suitable strength, is among the best (gr. xx to ʒij to ʒj). This or any other ointment will be more grateful to the patient if spread upon a thick layer of absorbent cotton, instead of lint or gauze. In carcinoma of the uterus, a deodorizing lotion is of the first importance, and one containing eucalyptus is preferable to a plain antiseptic solution. The vagina may also be loosely packed with cotton tampons, saturated with a mixture of *aristol* in albolin, 5 per cent. A pad of finely picked oakum should be placed over the vulva, as this material is hygroscopic and a good deodorant.

Temporary benefit is always derived from a vigorous use of Volkmann's sharp spoon. The necrosed tissue attached to the ulcerated surface is the soil in which the putrefactive bacilli live and multiply: their removal with the sharp spoon, including in the curettage also the fungous, bleeding masses, removes the culture-medium of the microbes which have caused the putrefaction, and will accomplish more than the use of chemical agents in rendering the ulcer aseptic. The scraping operation should be followed by the use of the actual cautery. The vigorous use of the flat point of the Pacquelin cautery will accomplish a great deal in this direction without the use of the sharp spoon. Scraping and cauterization have proved of great value in mitigating the distress in inoperable cases of carcinoma of the uterus, the breast, and the mouth.

The removal of a carcinomatous breast as a palliative measure is occasionally indicated when enough skin can be preserved to cover the wound, and in this manner transform an open into a subcutaneous carcinoma. The ligation of the principal artery to a part the seat of carcinoma is indicated only when hemorrhage is threatened or has actually occurred and cannot be controlled by more conservative

measures. In inoperable carcinoma of the uterus antiseptic vaginal injections should be employed at least once or twice a day. In carcinoma of the mouth an antiseptic gargle or spray is indicated. Tracheotomy in inoperable cases of carcinoma of the larynx, and colostomy in the same condition of the rectum, are exceedingly useful and grateful palliative operations. Gastrostomy in impermeable carcinomatous stricture of the œsophagus, gastro-enterostomy in pyloric carcinoma, and suprapubic cystotomy in advanced cases of carcinoma of the prostate gland, afford great relief and should always be suggested in appropriate cases.

Radical Operations.—Operations which are intended to remove all the infected tissues, local and regional, are called “radical” operations. *A radical operation is indicated in all cases in which general infection has not occurred, and the primary and original tumors are of such size and extent and are so located as to enable their complete removal by an operation not immediately endangering the life of the patient, and leaving a wound which can be closed by suturing or which can be healed by a plastic operation or by skin-grafting, and the patient's strength is such as to warrant the operation.*

If a radical operation is undertaken, it should be radical. The surgeon must not forget that carcinoma extends in the vicinity of the tumor along pre-existing connective-tissue spaces, and that consequently the zone of infiltration can be removed only by including with the primary tumor a wide strip of apparently healthy tissue on all sides. The incisions should be carried from four lines to an inch away from the macroscopical boundary-line of the tumor, according to the character of the tumor, its size, and its environment not only on one or two but *on all sides*. If the tumor is near the surface, the overlying skin should be removed. A zone of apparently healthy tissue at the base of the tumor as well as on the sides should be included in the excision. No blunt force should be used in the removal of the primary tumor; its removal must be effected by a clean dissection. Pressure and tearing are liable to give rise to traumatic dissemination. Grasping the tumor with vulsellum forceps is attended by the same danger. If vulsellum forceps are necessary to bring the tumor near the surface, the instrument should be so applied as not to penetrate the tumor. If the tumor is located in a part of the body from which the circulation can temporarily be excluded by elastic constriction, this should be made use of, as the bloodless procedure enables the surgeon to identify the tissues more accurately, and aspiration of tumor-cells or of fragments of tumor-tissue into the open lumen of cut veins is less likely to occur. If temporary hemostasis is inapplicable owing to the location of the

tumor, the hemorrhage should be arrested as the operation proceeds, for if this precaution is not practised projecting parts of the tumor may be overlooked and not again be found after the tumor has been removed. *The external incision must be made at a point which affords easy access to the tumor, and in a direction parallel with important muscles, nerves, and vessels. The external incision must be large enough to expose freely the entire periphery of the tumor to sight as well as to touch, and if this cannot be done safely by one straight or curved incision, it is joined at suitable points by cross cuts.* The margins of the wound during the operation must be kept out of the way by retractors. *The tumor and the surrounding zone of infiltrated suspicious tissue should be removed in one mass.* The removal of projecting portions after the removal of the tumor is bad practice and should be avoided.

The dissection must be made through healthy tissue outside the zone of infiltration from the beginning to the end of the operation. The employment of the dilute nitric-acid test, as suggested by Stiles, to ascertain during an operation whether or not all the diseased tissues have been removed, is not reliable and is of no use to the careful dissector. If the tumor after its removal is immersed in the 5 per cent. nitric-acid solution, the "boiled-egg" appearance upon some parts of the tumor will show that fragments of considerable size have been left behind, but it will fail in demonstrating that cellular remnants of the tumor have not been removed. In small carcinomata of the lip or of the skin presenting no evidences of glandular infection it is sufficient to excise with the tumor a zone of apparently healthy tissue in order to remove the peripheral invisible part of the tumor. In operating upon the lip it is not advisable to plan the details of a subsequent plastic operation, as there is great danger that the surgeon will be guided in the excision of the carcinoma by the plans of the restorative part of the operation. *The prime indication of the operation should be to remove all the diseased tissues, regardless of the cosmetic result.* After the carcinoma has been removed the surgeon sutures the wound in such a manner as to secure the best possible cosmetic results, or he resorts at once to a plastic operation.

In the removal of all carcinomatous tumors the incision or incisions should be made in the direction of the lymphatics, because it is in this direction that the local infection becomes regional. In glandular carcinoma the entire gland should be removed if the gland so affected does not perform a function essential to the maintenance of health and life. Partial removal of the breast or the parotid or submaxillary gland for carcinoma cannot be condemned too strongly. If any doubt exists in regard to the presence of regional infection,

the lymphatic glands through which regional infection would occur should be exposed by an incision, and if any of the glands are found enlarged, the entire chain of glands should be removed in one uninterrupted piece with the primary tumor. *In carcinoma of the breast the axillary region from the margin of the gland to the apex should be cleared of lymphatic glands and connective and adipose tissue, regardless of the condition of the glands.* Typical cleaning out of the axillary space is urgently indicated in all cases of carcinoma of the breast. The whole chain of glands, with the surrounding connective and adipose tissue, must be removed by a clean dissection. The same plan should be pursued in the removal of the external genitals with infection of the inguinal gland.

Enucleation of carcinomatous glands is invariably followed by recurrence. Rupture of glands by pressure or traction is apt to be followed by traumatic dissemination. The primary tumor and regional tumors and healthy glands, with the tissues surrounding them, should be removed in one uninterrupted piece: this will ensure the removal of the connecting lymphatic channels which are so often the seat of regional infection. The wound after the removal of a carcinoma should be covered at once by integument: if this cannot be done by the use of sutures, the surface should be covered by a plastic operation or by skin-grafting. Healing of the entire wound by primary intention should invariably be aimed at in the removal of a carcinoma by excision.

The use of caustics in the radical treatment of carcinoma has a limited field of usefulness. Caustics should be used only when patients object to the use of the knife, and their use should be restricted to small carcinomata of the skin. Chloride of zinc should be given the preference over arsenic or the mineral acids. The treatment by caustics is more painful than excision under local or general anesthesia, requires more time, and the cosmetic result is less satisfactory.

TOPOGRAPHY.

The study of the topographical distribution of carcinoma is an interesting one, as it tends to show that carcinoma is most frequently found in localities in which the most active and complicated tissue-changes take place in the embryo, and in situations most exposed to injuries, irritations, and other post-natal influences which result in diminution of the physiological resistance of the tissues. We also find it frequently in localities the favorite seat of benign epithelial tumors. The influence of age, sex, and occupation in determining the origin of carcinoma in certain parts and organs of the body has repeatedly been referred to.

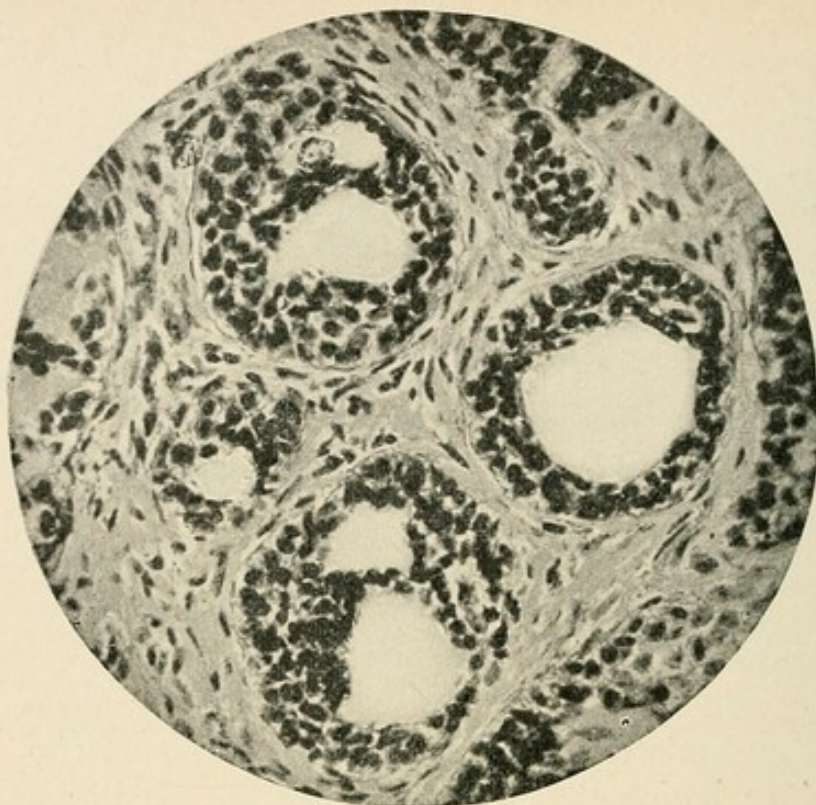


FIG. 145.—Carcinoma of the sweat-glands, showing the tubular arrangement of the tumor parenchyma (after Fordyce).

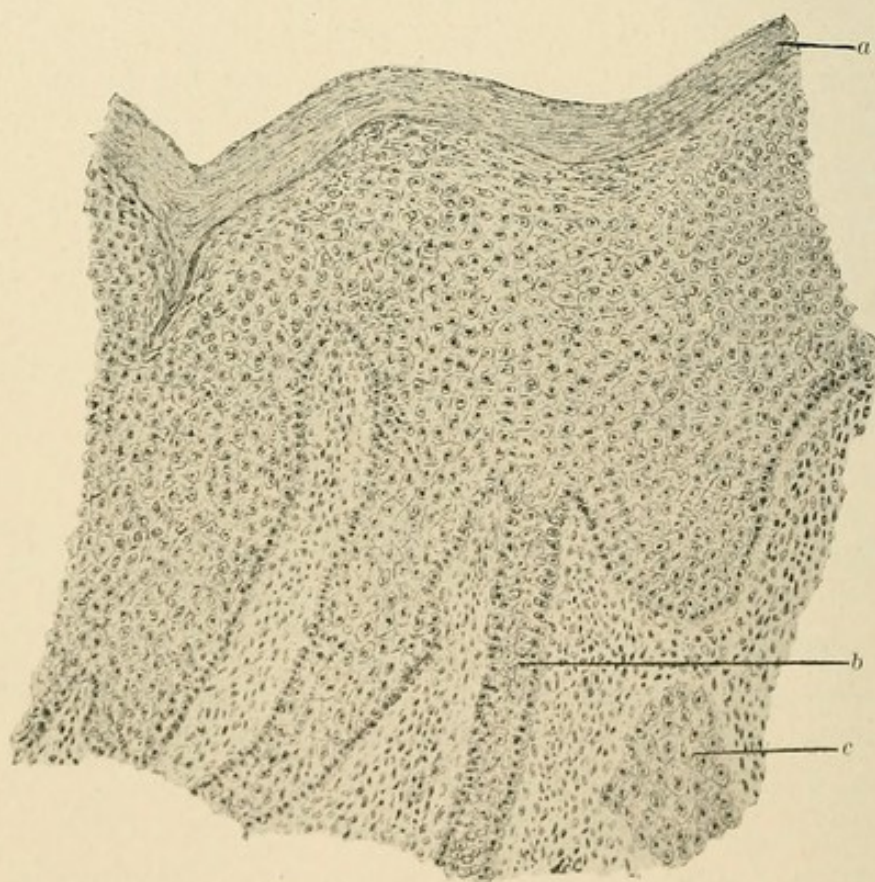


FIG. 146.—Carcinoma of skin of nates; $\times 110$, reduced one-third (Surgical Clinic, Rush Medical College, Chicago): *a*, hypertrophied stratum corneum; *b*, growth of epithelial cells into subcutaneous tissue; *c*, epithelial nest in vascular connective tissue.

Skin.—Squamous-celled carcinoma occurs most frequently upon the lower lip, the eyelids, the labia, and the glans penis; it is also frequent in the mouth, the œsophagus, the vagina, and about the cervix uteri. When the growth takes its starting-point in the sudoriparous or sebaceous glands, the cells of the carcinoma are cuboidal in shape and the growth presents a tubular structure (Fig. 145). The latter variety is most frequent on the nose and the eyelids, and is least malignant.

Histological Structure.—The manner of growth and the forms of epithelial tissue are varied, and the changes to which a carcinoma is subject are manifold. The stroma supplies the vascular part of the papillary excrescences, yields to the penetrating epithelial cells, surrounds the epithelial nests with a network of vessels, and finally becomes the seat

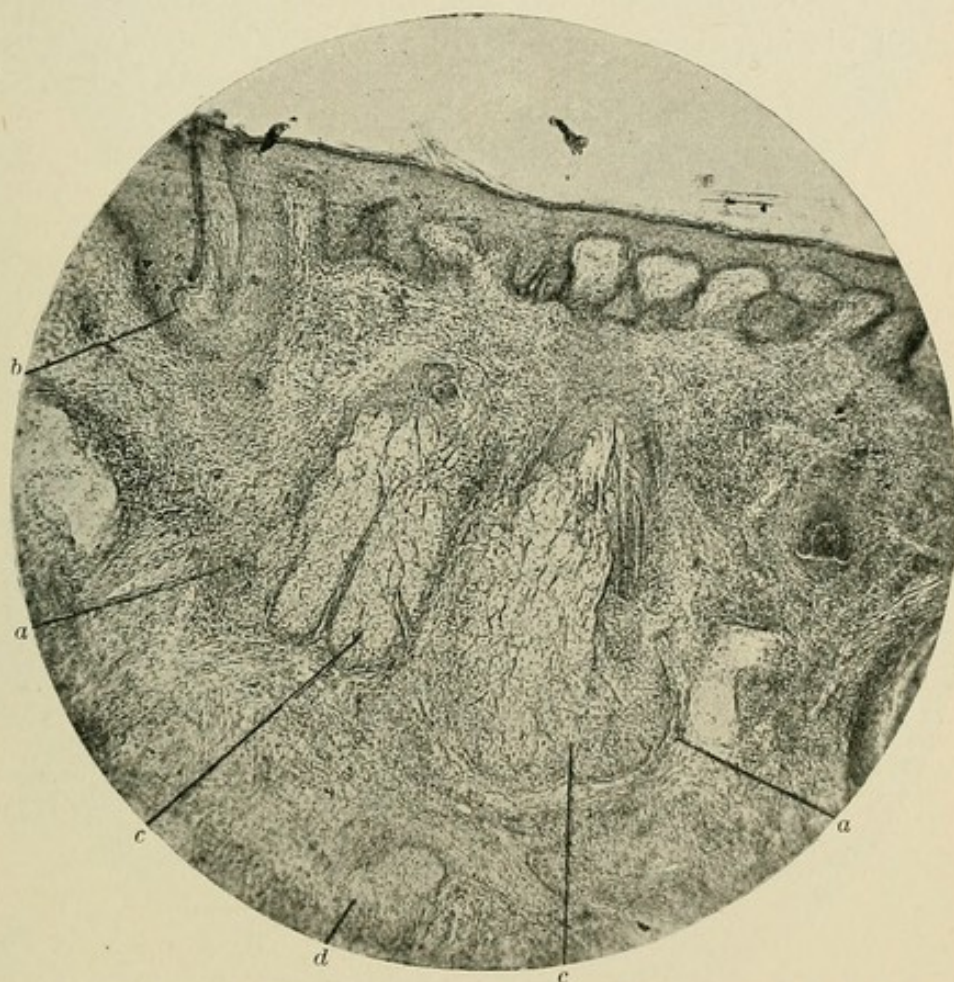


FIG. 147.—Vertical section through carcinoma of the skin; $\times 50$ (Surgical Clinic, Rush Medical College, Chicago): *a*, subcutaneous connective tissue and stroma of tumor; *b*, proliferation of epithelial cells into the connective tissue; *c*, sebaceous gland in a state of active tissue-proliferation; *d*, normal tissue not yet affected by the carcinoma.

of ulcerative destruction. The equilibrium between the hyperplastic masses of epithelial cells and the underlying vascular connective tissue is destroyed with the beginning carcinomatous process. Conditions

apparently leading to embryonal development of papillary and follicular structures appear to be arrested, and a functionally useless, planless growth supervenes. Generally the preponderant growth of epithelium initiates the change; this, however, is to be found not so much on the part of the proliferating epithelial cells as in a lessened resistance of the adjacent tissues. The first evidence of the appearance of epithelial cells in the vascular connective tissue underlying the epithelial layer of the skin announces the transition of the benign into the malignant stage of carcinoma (Fig. 146). Vertical section through a carcinoma of the skin in its earliest stages shows thickening of the layer of epithelial cells between the epidermis and the membrana propria (Fig. 146, *b*). As soon as the epithelial cells have reached the connective tissue they form nests. The glands of the skin in the area of carcinomatous infiltration assume more active tissue-proliferation, which results in increased secretion (Fig. 147). The stroma in the non-

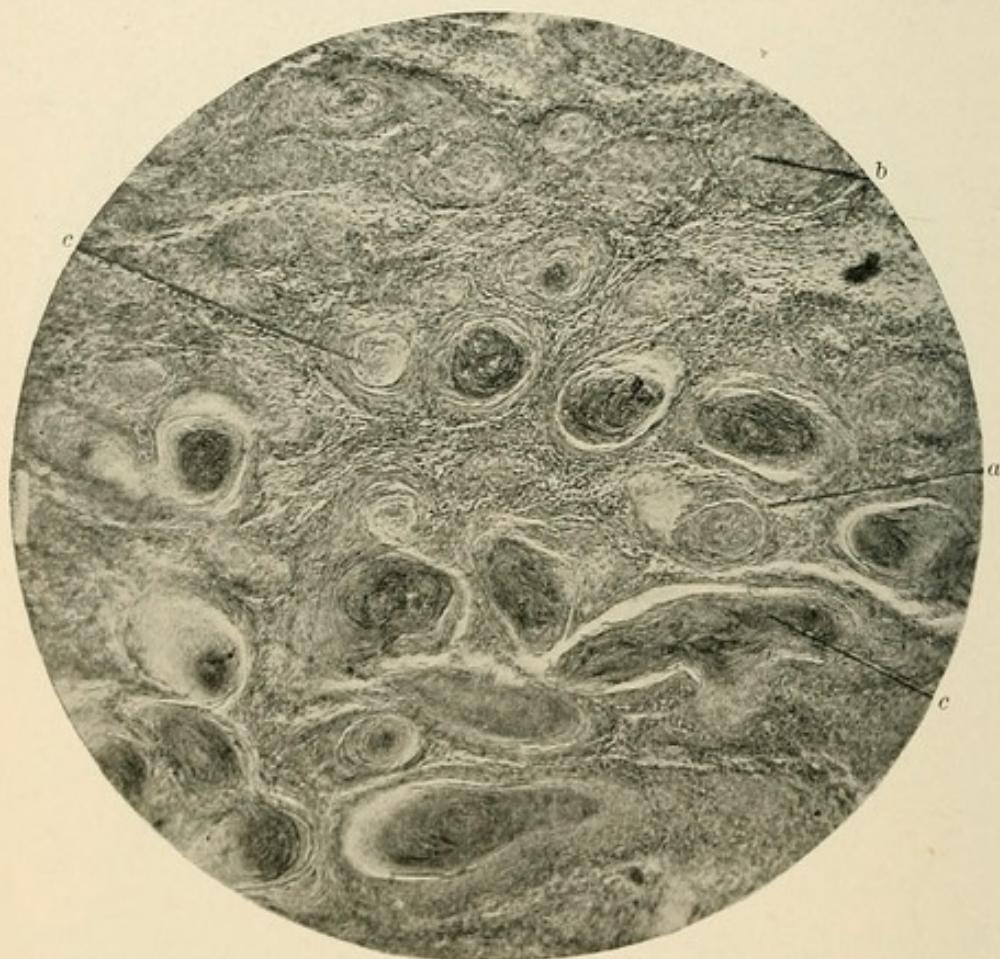

FIG. 148.—Carcinoma of the skin, showing alveolated structure of the stroma and numerous epithelial nests; $\times 150$ (Surgical Clinic, Rush Medical College, Chicago): *a*, stroma; *b*, epithelial infiltration of connective tissue; *c, c*, epithelial nests.

ulcerating part of the tumor increases in quantity by proliferation of the pre-existing cells caused by the presence of the numerous epithelial cells, which to them are foreign bodies. The alveoli of the stroma are

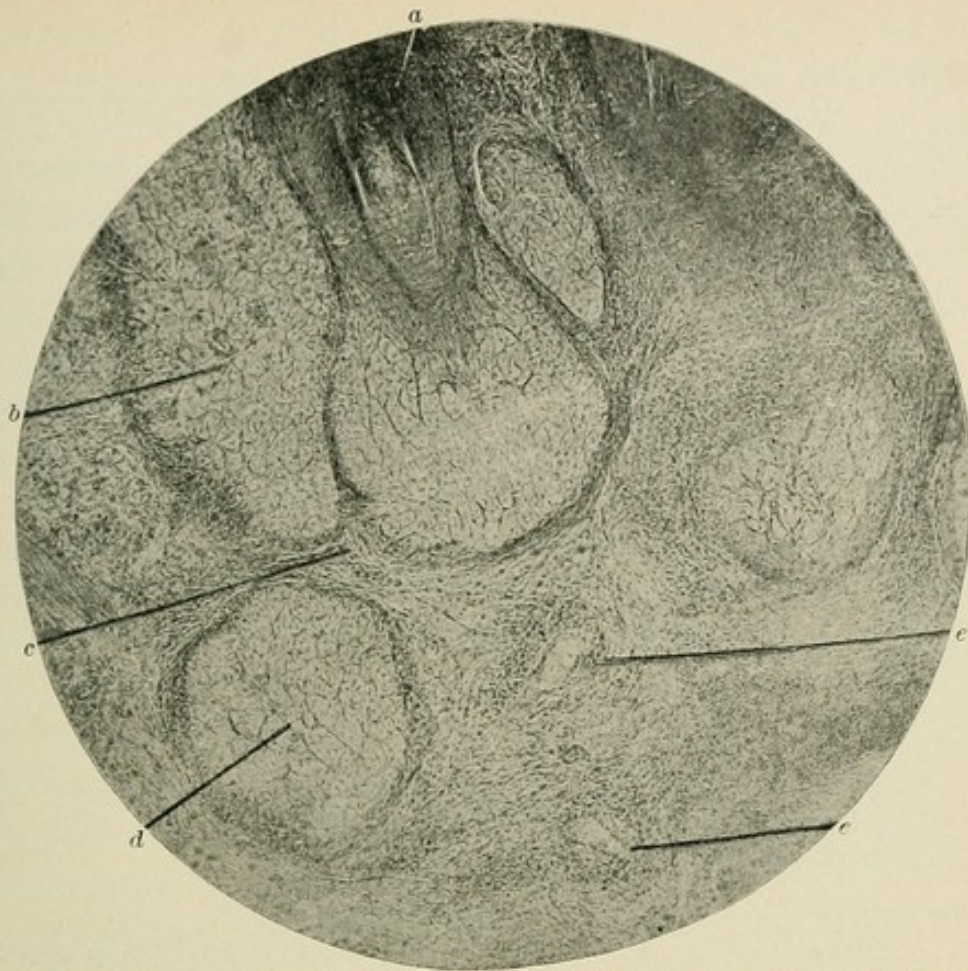


FIG. 149.—Vertical section through carcinoma of the skin, showing hair-follicle and epithelial nests; $\times 300$ (Surgical Clinic, Rush Medical College, Chicago): *a*, hair-follicle containing a hair; *b*, epithelial infiltration; *c*, stroma; *d*, large epithelial nest; *e, e*, beginning formation of epithelial nests.

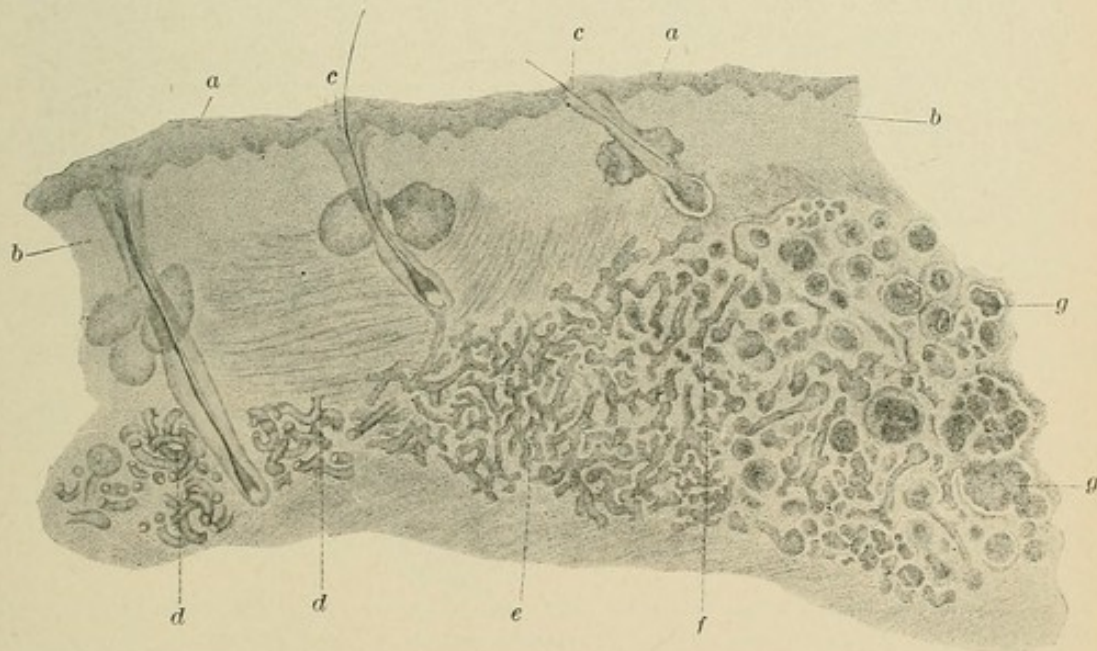


FIG. 150.—Carcinoma of the skin starting from epithelial cells of sweat-glands; $\times 18$ (after Thiersch): *a*, epidermis; *b*, cutis; *c*, normal lanugo-hairs with their sebaceous glands; *d*, convoluted sweat-gland with distinct lumen; *e*, branched and anastomosing proliferation of gland: lumen can be seen only in part; *f*, branched proliferation with terminal and lateral knob-shaped cellular projections; *g*, round masses of cells, separate or in several groups, which lie loose in spaces of the connective tissue, and which appear either as terminal knobs or as transverse sections of cellular strings.

packed with epithelial cells (Fig. 148). The progressive infiltration of the skin from the surface is well shown in Figure 149.

Thiersch has repeatedly traced the origin of carcinoma of the skin to sudoriparous glands. Carcinomata of such an origin present under the microscope a tubular structure resembling cylindrical-celled carcinoma of the mucous membrane (Fig. 150).

In superficial ulceration of a carcinoma of the skin the papillary structure of the skin remains, and the surface presents the appearance of an ordinary ulcer (Fig. 151). As soon as a surface carcinoma becomes the seat of microbic infection the connective-tissue stroma takes an active part in the suppurative process, as elsewhere. Destruction of the stroma by suppuration liberates the contents of the more superficial cell-nests, the contents being discharged with the inflammatory product. The progressive destruction of the stroma results in the

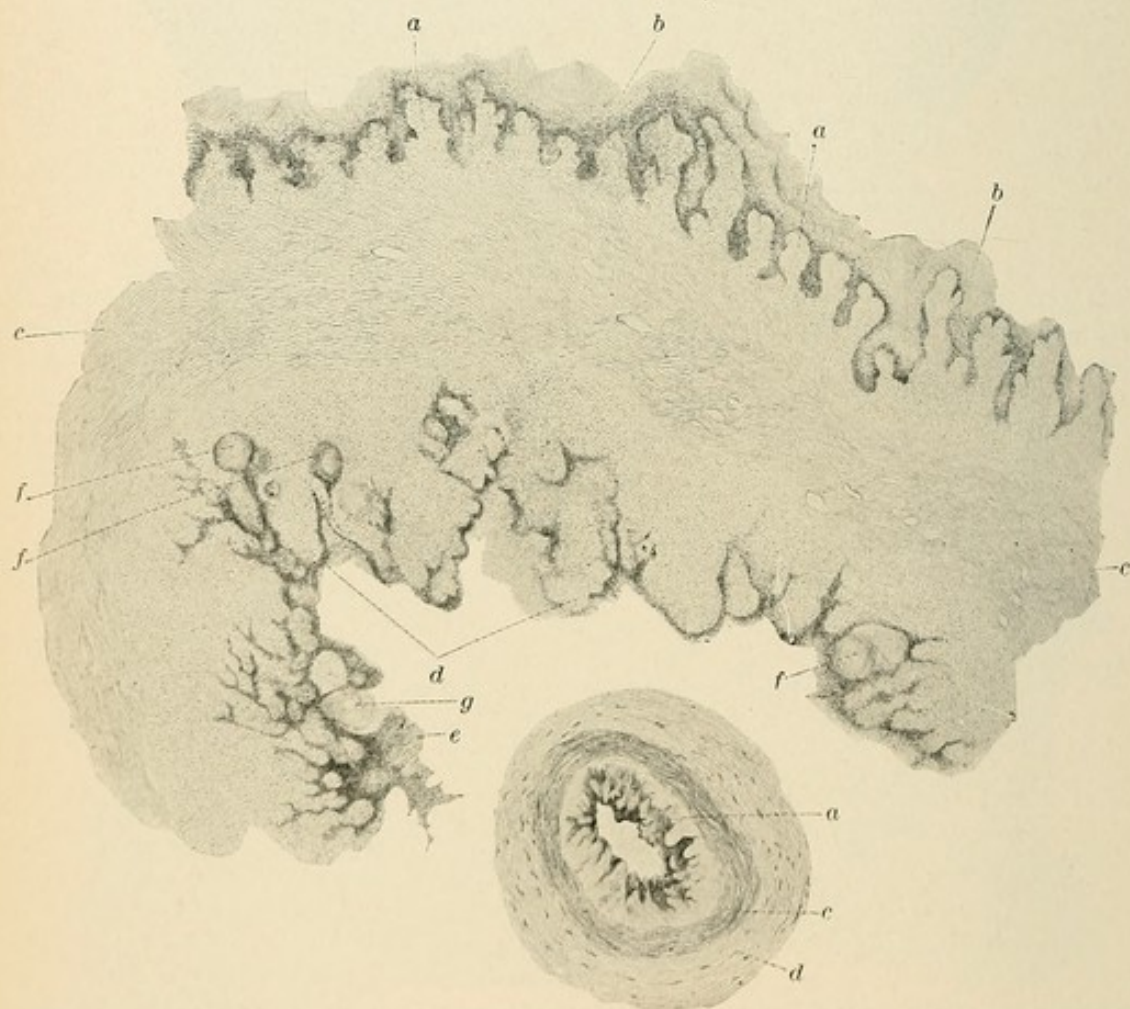


FIG. 151.—Deep carcinoma of the skin of the heel; vertical section; $\times 16$ (after Thiersch): *a*, papillæ of surface of ulcer; *b*, their epidermal covering; *c*, vascular stroma; *d*, inner surface of a parenchymatous cavity studded with papillæ; *e*, epidermal covering of papillæ; *f*, masses of cells in concentric layers in the interpapillary spaces; *g*, the same, belonging to the free epithelial masses.

increase in size and depth of the carcinomatous ulcer. In *ulcus rodens*, only one of the many varieties of carcinoma of the skin, the stroma is

very scanty; hence progressive increase in the size of the ulcer and slight induration of its base and margins are conspicuous pathological features.

Regional Infection.—Regional infection, usually a late occurrence in carcinoma of the skin, does not depend upon the size of the tumor or ulcer. The writer has seen glandular infection in connection with a carcinoma of the lip not larger than a pea, and has seen it absent in

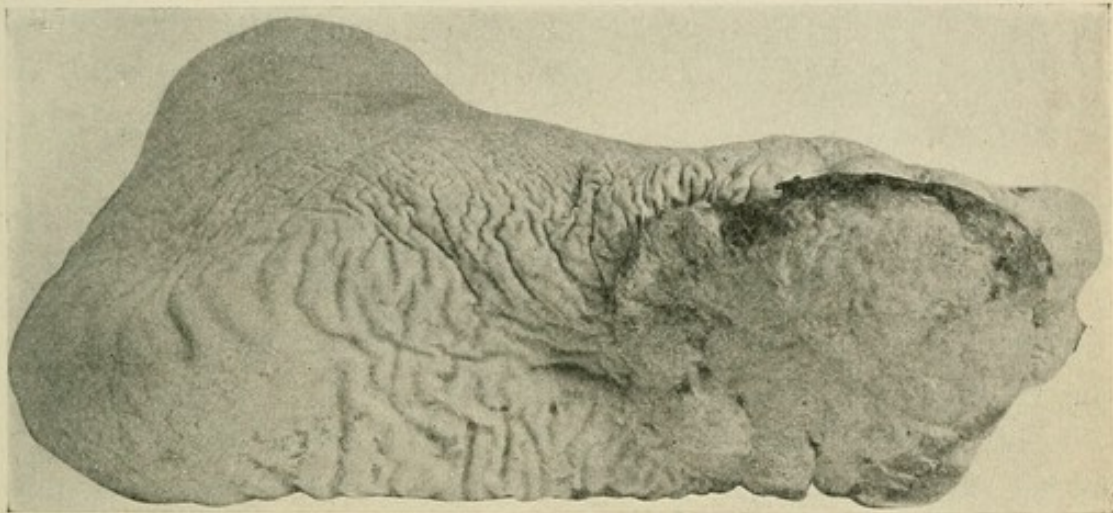


FIG. 152.—Carcinoma of the sole of the foot. The regional infection involved both the deep and superficial lymphatic glands of the leg and the anterior aspect of the thigh.

cases in which almost the entire lower lip was destroyed by the carcinoma. The occurrence of glandular infection appears to be influenced more by the diminished loss of resistance of the connective tissue than by the proliferation of epithelial cells. Of all the surface carcinomata affecting the skin, carcinoma of the lip is followed more constantly by regional infection than carcinoma of any other part of the body. The submental glands are usually first involved, later the submaxillary, and finally the cervical glands. The writer has seen the most malignant form of regional infection develop several years after the removal of a small carcinoma of the lip by using caustics or by employing the knife.

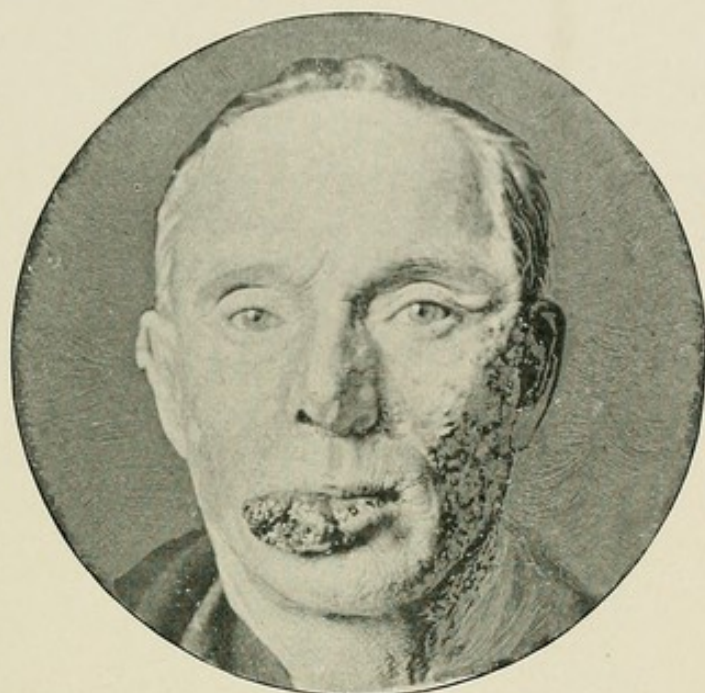For some reasons which remain unexplained, the upper lip is very seldom the seat of carcinoma, and in the few cases which have come under the observation of the writer there was no glandular infection. It has already been explained that the late glandular infection in carcinoma of the skin is attributable to the location of the tumor, and not to its lesser degree of malignancy than glandular carcinoma. A carcinoma surrounded on all sides by tissues has an extensive area of infiltration, while in surface carcinoma infiltration is limited to one direction. In the former instance the tumor is subjected to pressure which must

favor lymphatic infection, while in surface carcinoma this cause of dissemination of the tumor-elements is entirely wanting. The probable existence of regional infection must not be lost sight of in the operative treatment of surface carcinoma.

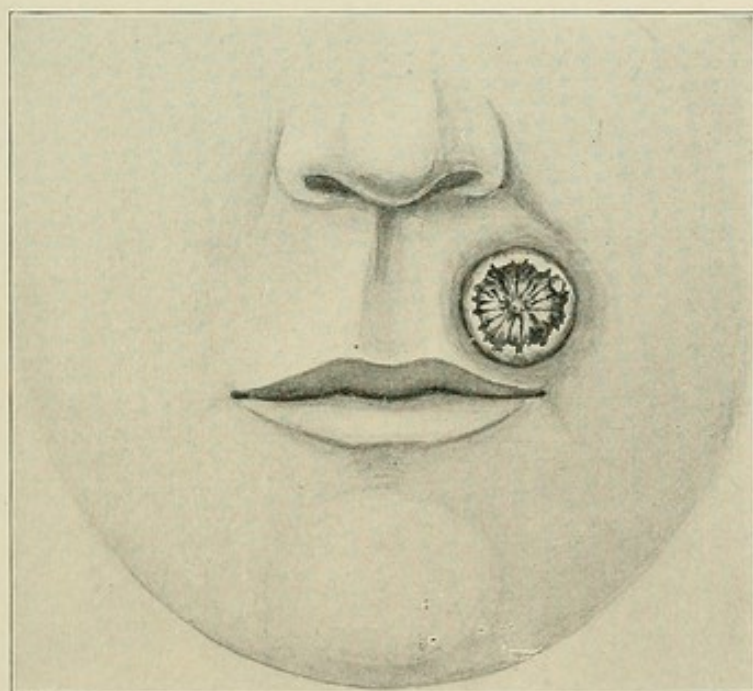
Degeneration of Tumor-tissue.—Fatty degeneration of the contents of the alveoli is the most frequent form of degeneration of carcinoma of the skin. In the older parts of the tumor the alveoli contain only the product of this form of degeneration, all the epithelial cells having undergone this change. In chronic cases calcification often follows fatty degeneration. Colloid and myxomatous degeneration, such constant regressive metamorphoses in glandular and cylindrical-celled carcinoma, occur less frequently, and never reach the same degree. Early ulceration is the most characteristic feature of carcinoma of the skin. The ulcer forms over the centre of the tumor, and spreads more or less rapidly in the direction of the base of the tumor and toward its periphery. As soon as the tumor-tissue is exposed the connective tissue takes an active part in the ulcerative process. If the resistance of the connective tissue is not much reduced, granulations spring up from the stroma, the base of the tumor as well as the margins of the ulcer become infiltrated with inflammatory product, and for a time it may seem that the inflammatory process has exerted an inhibitory influence on the local extension of the tumor. The inflammatory material, however, serves only a temporary purpose in retarding the extension of the tumor: the connective tissue and the exudation succumb to the combined effects of tumor-growth and microbic infection, and the disease resumes its progressive tendencies.

Lip.—*Clinical Course.*—Carcinoma of the lip usually commences at the junction of the mucous membrane with the skin. It seldom starts from the angles of the mouth and the upper lip. In a case of carcinoma of the upper lip that recently came under the observation of the writer the tumor appeared some distance from the margin of the upper lip (Pl. 6, Fig. 2). The patient was a man forty-five years of age. The tumor was noticed five years ago, when it was not larger than a millet-seed and appeared to be imbedded in the skin; a year later the tumor commenced to increase in size, an ulcer formed on its surface, and the base became very much indurated. The base of the tumor was of the density of cartilage; its surface was covered by fungous granulations. The margins of the ulcer were covered by the overlying undermined skin.

Carcinoma of the lower lip is common in men, but very rare in women. König estimates that the proportion of males to females is 20:1. Lortet's statistics show the proportion to be 7.6:1. Warren




1



2

1. Carcinoma of the lower lip. 2. Carcinoma of the upper lip.



observed 4 cases in women out of 73 cases, and states that 3 of the women were smokers. In 145 patients suffering from carcinoma Koch (Erlangen) attributed the affection in 15 to an injury. The tumor-formation is frequently preceded by a crack or a fissure or an eczematous condition of the margin of the lip. At a very early stage the centre of the indurated area ulcerates, and from the ulcerated surface the atheromatous contents of the exposed epithelial nests can be squeezed out. By extension of the ulcer the lower lip is destroyed (Pl. 6, Fig. 1), when the cheek, the chin, the lower maxilla, and the floor of the mouth are successively involved. The submental and submaxillary glands, which now have become enlarged, are often firmly attached to the lower jaw, simulating primary malignant disease of the periosteum or the bone. With few exceptions the disease, if allowed

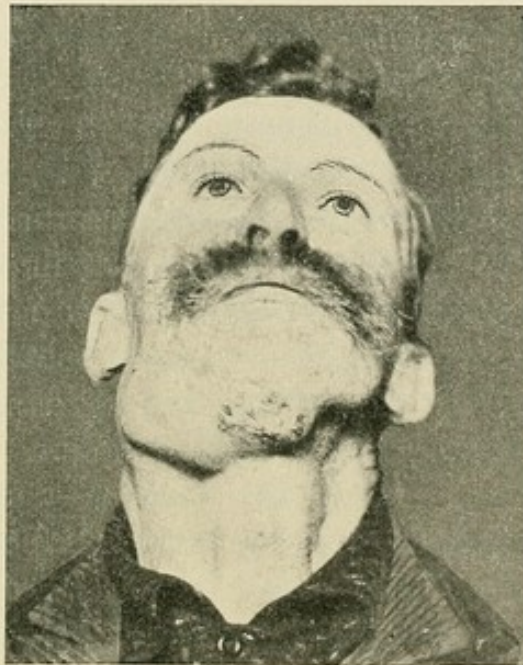

FIG. 153.—Secondary carcinoma of the submental and submaxillary lymphatic glands, following carcinoma of the lip.

to pursue its course, terminates fatally within from three to five years. Death results from marasmus, from sepsis, or from general dissemination of the disease.

Diagnosis.—The superficial diffuse form of carcinoma of the lip is frequently mistaken for eczema. The deeper layers of the skin are exposed, presenting a papillomatous appearance. The raw surface is constantly moistened by a serous transudation. Careful palpation will, however, detect in the skin and the mucous membrane an induration which is absent in eczema of the lip. Chancre of the lip develops rapidly and is attended at an early stage by diffuse glandular infection. Secondary syphilitic lesions of the lip start usually in the mucous

membrane of the mouth, and reach the lip by extension. Papilloma of the lip appears as a permanent tumor, and its base lacks induration. Primary tuberculosis of the lip is an exceedingly rare affection; it occurs almost from the beginning as a more diffuse affection than carcinoma, and it lacks the induration so characteristic of carcinoma. *Carcinoma of the lip appears as an ulcerating tumor with indurated base and margins, which tumor ultimately gives rise to regional and general infection.* If any doubt remains as to the nature of the tumor, a fragment of tissue should be taken from the base or margin of the ulcer, from which sections should be made for microscopic examination.

Face.—Carcinoma of the skin in other localities usually pursues a course similar to that of carcinoma of the lip. The face is the most frequent seat of carcinoma of the skin. O. Weber found in 740 cases of tumors of all kinds subjected to operative treatment 133 cases of carcinoma of the face. The ages of the patients vary from forty to eighty. According to Thiersch, carcinoma of the skin appears either as a superficial ulceration (*ulcus rodens*) or it penetrates the tissues deeply and involves the different structures successively. If the carcinoma starts from the appendages of the skin, the columnar epithelial cells are arranged in groups resembling tubules; if it is composed of squamous cells, it appears from the beginning as an infiltration with small epithelial cells, which before ulceration occurs fill the alveoli of the stroma. Like carcinoma of the lip, carcinoma of the skin begins as a minute surface defect with a limited area of induration at its base. From this point the ulceration spreads unequally in different directions, so that the ulcerated surface presents irregular outlines. In the superficial form of carcinoma peripheral extension takes place rapidly, but the destructive process is limited to the skin. In the penetrating or deep variety the ulceration extends at the same time in the direction of the base of the ulcer, involving successively different tissues irrespective of their anatomical character. In this variety the ulceration is generally preceded by a deep infiltration of the skin and the subcutaneous connective tissue. So long as the papillæ of the skin remain, the surface of the ulcer presents a papillary appearance. When the papillæ are destroyed, the epithelial nests are exposed, their contents escape with the inflammatory product, and the surface of the ulcer assumes a honeycomb appearance. The prognosis of this variety of carcinoma of the skin is more unfavorable than that of the superficial variety. The ulceration spreads very rapidly, and results in very extensive destruction of tissue in a remarkably short time. Lymphatic infection occurs frequently at quite an early stage, and occasionally death results from metastatic tumors. Carcinoma of the face

attacks most frequently the eyelids, the nose, and the malar and frontal regions. Carcinoma of the eyelids, if not removed in time, extends to the eyeball and the other contents of the orbit, causing not only loss of the eye, but also producing a frightful disfigurement.

Diagnosis.—Carcinoma of the face must be distinguished from tuberculosis, syphilis, suppurating benign growths, and retention-cysts. Tuberculosis of the face, the so-called "lupus," often appears as a multiple affection. The same can be said of tertiary syphilitic lesions. Multiple carcinomatous tumors are exceptional, and they almost always originate from the transformation of senile warts into carcinomata. Tubercular ulcers often heal, in part or completely, spontaneously or under appropriate local treatment—something never observed in carcinoma. The base of the tubercular ulcer presents to the palpating finger a doughy, œdematous sensation; the base and margins of the carcinomatous ulcer are firm and indurated. Careful examination of patients suffering from tertiary syphilitic affections of the skin usually reveals additional syphilitic lesions in other parts of the body, or traces of former affections that have healed. If any doubt remains, the patient should be given the benefit of the doubt by subjecting him to antisyphilitic treatment for a number of weeks. The differential diagnosis between carcinoma and tubercular affections of the skin may require the use of the microscope and a resort to inoculation experiments. The former will reveal the typical structure of the existing affection, and the latter will yield positive results if the lesion is tubercular, and negative if it is a carcinoma.

Operative Treatment of Carcinoma of the Lip.—The best curative and cosmetic results are obtained by early and thorough excision. If the tumor is small, the operation can be done without anesthesia; if large and if a plastic operation must follow to correct the defect, partial anesthesia will answer the purpose. The coronary artery should be compressed at both angles of the mouth by compression-forceps or between the thumbs and index fingers of the hands of an assistant. In diffuse superficial carcinoma of the lip involving only the mucous and submucous tissues the entire margin of the lip, from one angle of the mouth to the other, is excised. The incision is made at a safe distance (about half an inch) from the palpable margin of the tumor; the mucous membrane is then carefully stitched to the margin of the skin with fine catgut sutures (Fig. 154).

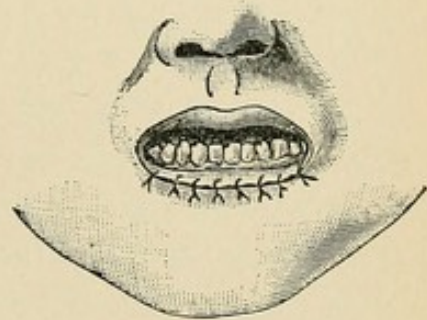


FIG. 154.—Suturing after excision of the entire margin of the lip for carcinoma (after Esmarch).

The cosmetic and functional results following this operation are entirely satisfactory. The lip is long enough to retain the secretions of the mouth, and there is formed from the mucous membrane a new prolabium which in the course of a few months resembles the normal prolabium in appearance.

If the tumor involves not quite one-half of the lip and has penetrated the tissues deeply, it is included in a V-shaped incision the apex of which must extend to the lower border of the jaw (Fig. 155). The

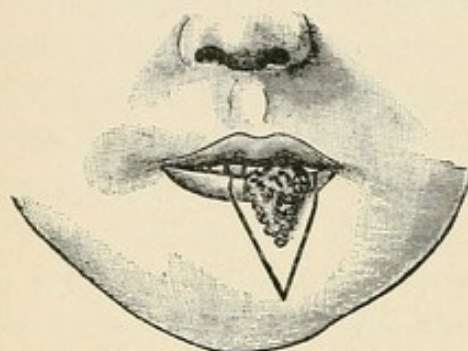


FIG. 155.—Wedge-shaped excision of the lip for carcinoma (after Esmarch).

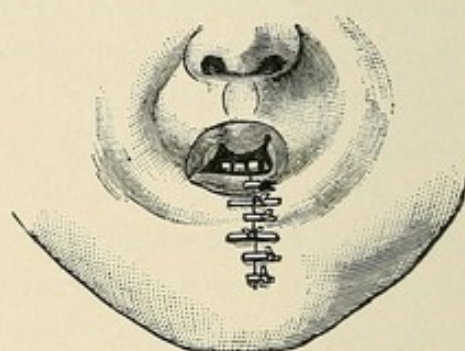


FIG. 156.—Operation completed (after Esmarch).

coronary artery is either twisted or included in one of the deep sutures. The deep sutures of silk or of silkworm gut should embrace all the tissues except the mucous membrane, which should be sutured with fine catgut from the mouth before the deep sutures are tied, in order to prevent the interposition of mucous membrane between the margins of the wound. The lower lip gradually elongates after the operation (Fig. 156).

If the tumor involves more than one-half of the lip, it should be excised by a curved incision, with the convexity directed downward, at least half an inch distant from the palpable margin of the tumor. The mucous membrane is then sutured over the surface of the wound to the skin. The semilunar defect, which is quite apparent after the operation, gradually diminishes in the course of time. If the whole or nearly the whole lip is involved, complete excision becomes necessary, and a new lip must be made by a plastic operation. Wölfler recently described an operation which yielded excellent results: After excision of the entire lip a curved incision about two inches below the margins of the wound, and extending a little beyond the angles of the mouth, is made through the skin and the subcutaneous connective tissue. The quadrangular flap is then so raised that its upper margin will occupy the normal level of the lip, when the flap is sutured to the anterior surface of the jaw with catgut sutures, so as to exclude from the wound the cavity of the mouth and to fix the new lip securely in its new place. The flap is retained by a proper dressing

in this position. After clearing out the submental and submaxillary spaces of lymphatics, the lower margin of the wound is sutured separately to the jaw and the new lip, and drainage is established through a small buttonhole in the centre at the most dependent part of the wound. If the whole wound cannot be covered with skin in this manner, the remaining surface should be paved with Thiersch's skin-grafts. As soon as the flap is detached the submental and some of the submaxillary glands come in view, and should be dissected out carefully with the adjacent connective and adipose tissue. Langenbeck restored the lower lip by taking a flap from the region of the neck (Figs. 157, 158). In this operation it is necessary, after the formation of the flap, to carry the incision downward in the median line to expose and remove infected lymphatic glands.

The great difficulty in Langenbeck's operation is that the free margin of the new lip cannot be covered with mucous membrane, and a certain amount of cicatricial contraction ensues during the healing of the wound. In Wölfler's operation there can often be preserved a

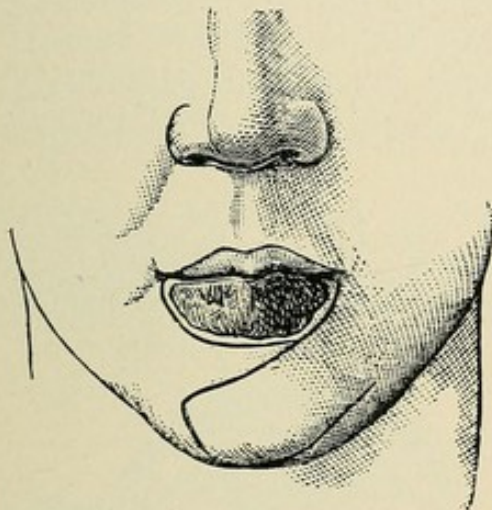


FIG. 157.—Langenbeck's method of restoring the lower lip after excision for carcinoma (after Langenbeck).

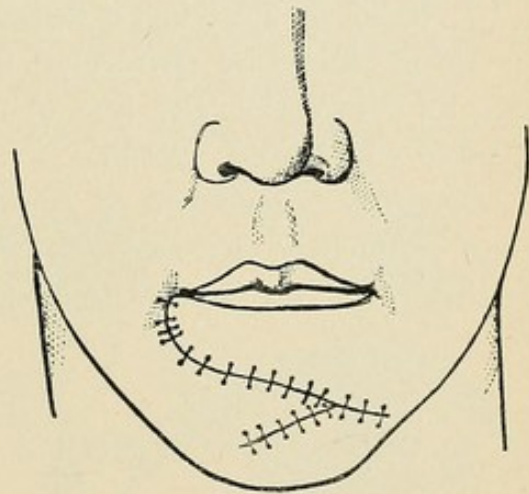


FIG. 158.—Operation completed (after Langenbeck).

narrow strip of mucous membrane with which to line the free margin of the lip and thus to secure in the course of time a normal prolabium. Partial excision of the upper lip is made in the same way as for carcinoma of the lower lip. If the entire upper lip has to be excised, the defect is restored after the method devised by Bruns (Figs. 159, 160). The two lateral flaps are brought down to the proper level, are united in the median line by a number of sutures, and are stitched to the margin of the wound below the nose; finally, the wound on each side is diminished in size as far as possible by suturing. In plastic operations a number of superficial sutures of horsehair are always of great service to bring the skin in accurate coaptation. The sutures should

be removed as soon as the union is firm enough to render them superfluous, which will be the case in from three to five days.

Sutures should be tied carefully, and only with firmness sufficient to bring the margins of the wound in contact. Tension from tying the

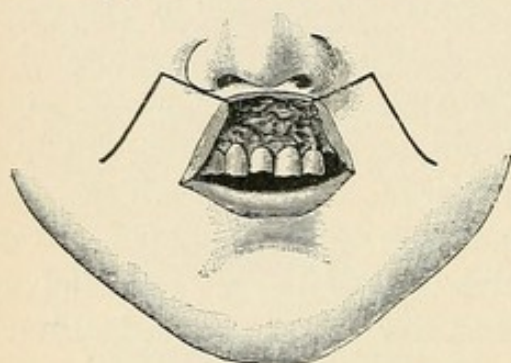


FIG. 159.—Cheiloplasty (after Bruns).

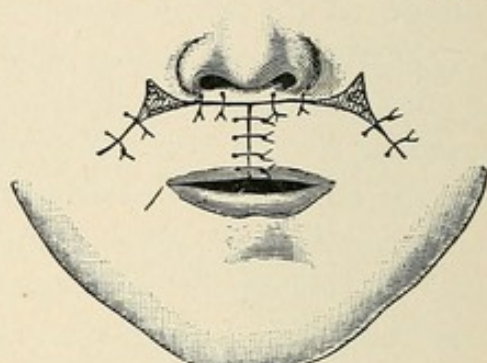


FIG. 160.—Operation completed (after Bruns).

sutures too tightly not only gives rise to pain, but also interferes with an ideal healing of the wound. A suture that causes undue linear compression should be removed at once. If the flap in plastic operation does not require an external mechanical support, the writer is not in the habit of applying a dressing in operations upon the lip. The operation should be performed under strict antiseptic precautions, and after its completion the line of suturing should be covered by a thin layer of carbolated vaselin.

Operative Treatment of Carcinoma of the Face.—The eyelids are quite frequently the seat of carcinoma. An early operation in this locality is of the utmost importance, as the disease always manifests

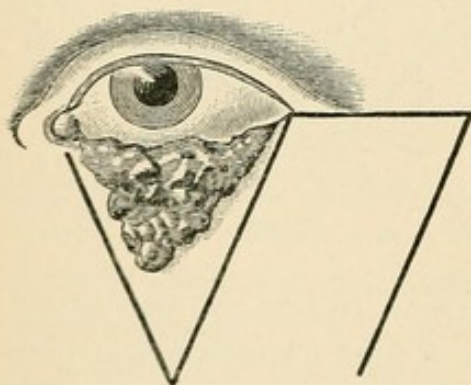


FIG. 161.—Blepharoplasty after removal of carcinoma of lower eyelid (after Dieffenbach).

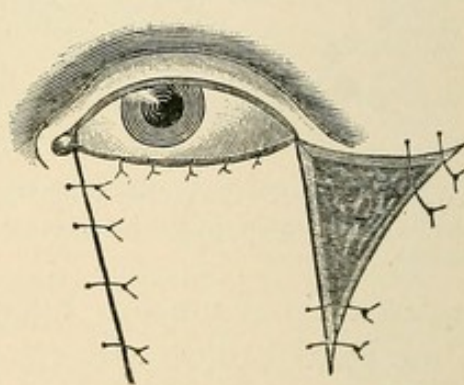


FIG. 162.—Operation completed (after Dieffenbach).

a tendency to extend to the eye and the other contents of the orbit. If the operation is performed before the conjunctiva has become involved, the functional and cosmetic results are satisfactory. The incisions circumscribing the tumor should be made at a safe distance, and the conjunctiva should be preserved carefully. The defect is remedied in a satisfactory manner by Dieffenbach's method (Figs. 161, 162). The tumor is included in a V-shaped incision, and the part to

be removed is carefully dissected away from the conjunctiva. If the tumor has reached the tarsal cartilage, this must be removed with the eyelashes. A square flap is now made by carrying a straight incision from the outer angle of the eye outward and backward, corresponding in length to the length of the eyelid, joined at the outer terminus by an incision extending downward and inward to a level with the apex of the V-shaped incision. The flap is now detached and by sliding is brought into its new location, when the operation is completed by suturing with fine silk, catgut, or horsehair, as shown in Figure 162. The wound-surface, which cannot be covered by suturing should be paved by Thiersch's grafts at once.

If the disease has extended to the conjunctiva, the entire eyelid must be removed. In such cases it is much more difficult to replace the parts lost by disease than those lost by the operation. Dieffenbach's method must be modified so far that the inner surface of the new eyelid should be covered with a Thiersch graft, which should be retained in its proper position by a few fine catgut sutures. Hotz has shown that conjunctival defects can be repaired successfully by skin-grafts. The writer has resorted to this expedient a few times in making new eyelids, and the results have been exceedingly satisfactory. The skin grafted soon adapts itself to its new location and serves a useful purpose as a sub-

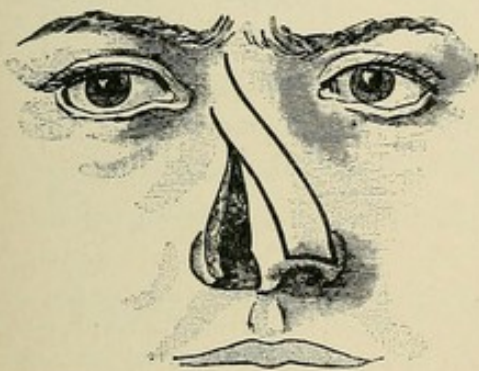


FIG. 163.—Partial rhinoplasty by taking a flap from the opposite side of the nose (after Langenbeck).

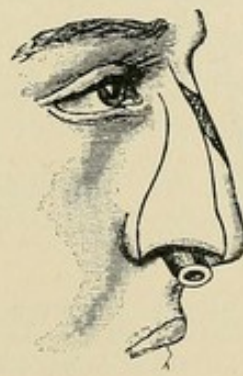

FIG. 164.—Partial rhinoplasty completed (after Langenbeck).

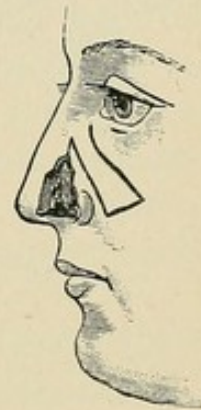

FIG. 165.—Partial rhinoplasty by taking a pedunculated flap from the face along the base of the nose (after Esmarch).

stitute for the conjunctiva. A new eyelid lined on both sides by skin is less liable to shrink and to become distorted than when skin-grafting is omitted.

Operative Treatment of Carcinoma of the Nose.—If only a part of one ala of the nose is affected, the carcinoma is excised by removing a wedge-shaped piece the entire thickness of the ala, and the defect is corrected by taking a flap from the opposite side of the nose, as advised by Langenbeck, or from the face near the base of the nose (Figs. 163,

164). The wound left on the opposite side of the nose after the removal of the flap should be covered by a pavement of Thiersch skin-grafts. The nasal defect after the excision of the carcinoma can also be remedied satisfactorily by taking a pedunculated flap from the face, as shown in Figure 165. If the margins of the nasal apertures are free, and the tumor occupies the bridge of the nose and has involved the bony framework, a very extensive operation becomes necessary. With knife, chisel, and saw, the tumor and the bony framework are removed to ensure complete removal of all diseased tissue. If the disease has reached the nasal cavities, extensive removal of the mucous lining of the nasal passages often becomes necessary. The resulting defect often presents alarming proportions, but it can be corrected in a very satisfactory manner by König's operation (Figs. 166, A, B, C).

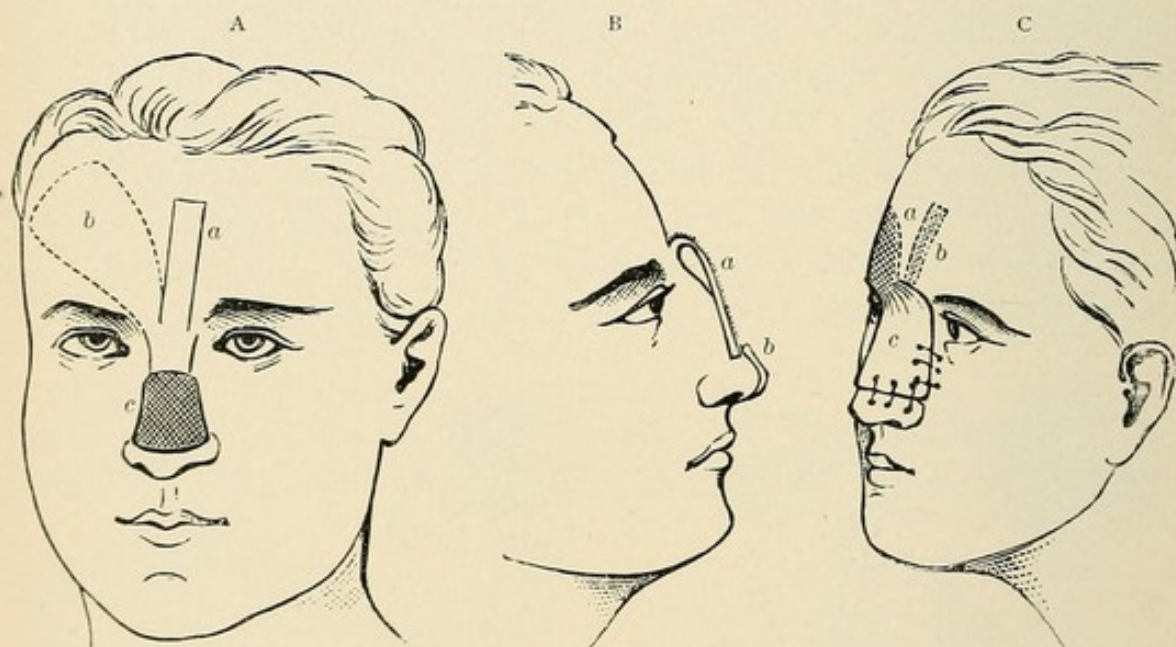


FIG. 166.—König's rhinoplasty. A: *a*, flap for building bridge of nose, including skin, periosteum, and a thin slice of bone; *b*, flap used to cover flap *a* and to furnish integument for the entire defect; *c*, defect caused by excision of tumor. B: *a*, flap *a* turned downward; *b*, lower end fastened in place with catgut sutures. The skin of the tip of the nose at *b* is left free, and to it flap *b* is sutured. C: *a*, *b*, defects over frontal bone; *c*, flap *b*, which covers the bony surface of flap *a*, and furnishes the cutaneous covering for the entire defect, sutured in place.

The reflected flap *a* furnishes a bridge of bone which prevents the sinking in of the nose. The defect over the frontal region caused by the removal of the flaps should be covered at once by large skin-grafts. If the entire nose has to be sacrificed, owing to the extent of the carcinoma, Thiersch's method of rhinoplasty recommends itself for restoring the lost organ. The new organ is made by taking a flap from each side of the face; these flaps are turned inward with the cutaneous surface downward, and are then united in the middle line with catgut sutures. A large pedunculated flap is then taken from the forehead

and is rotated into position and sutured in place. The two raw surfaces brought in contact unite rapidly, and as both sides of the alæ of the nose are lined by normal skin, the resulting shrinkage is moderate. The defects caused by the removal of the flaps are covered at once by Thiersch grafts.

Carcinoma of the skin in other parts of the face or the body is excised with the same thoroughness, making the incisions half or three-quarters of an inch away from the palpable margins of the tumor, and covering the defect either by a plastic operation, by skin-grafting, or by a combination of both these procedures. In performing primary skin-grafting it is very important to diminish the size of the wound by suturing its angles and by approximating the remaining margins of the wound by the use of tension-sutures. The best material for this purpose is coarse silk. The skin-grafts should be covered carefully by strips of protective silk over which an antiseptic dressing is applied, the whole being held in place by strips of adhesive plaster or by a plaster-of-Paris bandage, so that the grafts may not subsequently be disturbed. Unless positive indications arise, the first dressing should not be disturbed for three days. In place of Thiersch's grafts, it may be advisable under certain circumstances to use Wolfe's grafts. Grafts not deprived of all adipose tissue should not be used, as this method of skin-grafting, contrary to the assertions of Hirschberg, often results in failure.

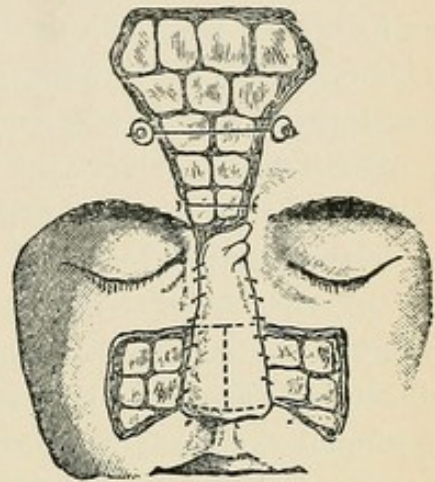


FIG. 167.—Rhinoplasty (after Thiersch).

Mouth.—Carcinoma of the mouth has the same structure as carcinoma of the skin, as the glands and the mucous membrane of this cavity have an embryonic origin similar to that of the skin. Before the fourth week in the life of the human embryo there is developed at the lower part of the face a broad transverse cleft: this is the primitive mouth. Developed as it is from the face, and carrying with it the covering of the face, the lining membrane of the mouth is derived from the epiblast. The buccal part of the epiblast forms a sac that is at first closed posteriorly. Not until the eighth or the ninth week is a communication established between the mouth and the pharynx. The mouth and the pharynx in the embryo are two separate cavities, the first having its origin in the epiblastic layer, the second in the hypoblastic layer and the visceral mesoblast. The glands in communication with the mouth are developed from the epiblastic lining of the

mouth. The mouth is covered by pavement epithelium several layers deep, the deeper or attached layer being generally columnar, while the superficial layer presents flattened scales. In the mouth, as in the skin, carcinoma starts either in the epithelial strata of the mucous membrane or in one of its glandular appendages, in the form of a hard nodule. The epithelial cells undergo fatty degeneration, so that when an ulcer has formed an atheromatous mass can sometimes be pressed from the centre of the ulcer. The base of the ulcer is indurated. The ulcer, instead of showing any disposition to cicatrize, enlarges in all directions.

The superficial variety, as in the skin, manifests no disposition to invade the deep structures. The nodular variety originates in the tubular mucous glands, and presents under the microscope a tubular structure. The tubules are lined with one or more layers of columnar epithelial cells. This form from the very beginning penetrates the tissues deeply after invading one of the maxillary bones at an early stage. As a primary tumor, carcinoma of the mouth is rarely developed in localities other than the lips, the gums, the salivary glands, the tongue, the tonsil, and the palate. The labial glands are much more numerous in the lower than in the upper lip, and they are almost entirely absent about the angles of the mouth; which absence may tend to explain why carcinoma affects the middle of the lower lip more frequently than the upper lip and the angles of the mouth. Carcinoma of the mouth is frequently attributed to smoking, but in the East, where this habit is most common and is carried to excess, carcinoma of the lip and the mouth is very rare. This fact would seem to prove, if smoking is an etiological factor, that it is not the traumatism resulting from the pipe, but the heat, that is the active agent, as long pipe-stems are used by the Orientals and the smoke is passed through water before it reaches the mouth.

Carcinoma of the mucous membrane of the cheek is sometimes preceded by a patch of leukoplakia. The influence of chronic irritation in producing carcinoma is well shown in carcinoma in this locality, as the tumor very often corresponds in its location with the crowns of prominent upper and lower molar teeth.

Carcinoma of the gum starts often near the stump of a carious tooth. The bone is invaded so quickly that the disease is often mistaken for a primary bone affection. Lymphatic infection is a very early and conspicuous feature when the carcinoma involves either of the maxillary bones. The primary tumor is sometimes overlooked in such cases. A rapid-growing glandular tumor of the neck should remind the surgeon of the necessity of a thorough examination of the cavity of the mouth. Carcinoma of the mouth with early and extensive glandular

infection is a very rapidly fatal affection, the average duration of life being not more than six months.

Radical operations for carcinoma of the mouth always require an external incision. Intra-oral operations cannot be made with the requisite degree of thoroughness. The incision must be made in a location which affords the best access to the tumor, and in which the operation will leave the least disfigurement. If the upper maxilla is implicated, the same incisions are made as for partial or complete excision of this bone. If the lower jaw has become secondarily affected, the floor of the mouth is usually also extensively involved. In such cases a horseshoe-shaped incision corresponding with the lower border of the jaw from one angle to the other will afford ample space to remove a portion of the bone and to clear out the infected glands and other soft tissues requiring removal. In cases of extensive carcinoma of the mouth recurrence is very apt to take place even after the most extensive operations, owing to the early and extensive lymphatic infection.

Tonsil.—Carcinoma of the tonsil is a comparatively rare affection. Only two or three cases have come under observation in which the writer could satisfy himself that the disease had its primary origin in this gland. In one of the cases the tumor was mistaken for a long time for primary syphilis, and the patient had been subjected to anti-syphilitic treatment for several weeks, with, of course, a negative result. The infiltration spreads very rapidly, and early lymphatic infection is the rule. The disease in the course of two or three months extends to the base of the tongue, the pillars of the soft palate, and the pharynx. Salivation, pain, and dysphagia are early and distressing symptoms. As soon as the disease reaches the entrance of the larynx, hoarseness and difficult breathing set in. As the disease occurs only in persons advanced in years, the diagnosis is not attended by any difficulty. The malignancy of the tumor is pronounced by the clinical course, and all that remains for the surgeon to do is to differentiate between carcinoma and sarcoma. In carcinoma ulceration commences at an earlier stage than in sarcoma, and is more constantly attended by infection of the lymphatic glands, which infection is exceptional in sarcoma.

Operative Treatment of Carcinoma of the Tonsil.—The removal of a malignant tumor of the tonsil is one of the most difficult operations in surgery. At the time the operation is performed the disease has usually extended far beyond the limits of the organ primarily affected. The tumor must be exposed by an external incision, with or without temporary resection of the inferior maxilla. O. Weber recommended temporary resection of the inferior maxilla at a point corresponding with the third molar. The articular end of the bone is then turned

upward with the soft tissues. The ascending pharyngeal, lingual, facial, and carotid arteries can readily be tied in this incision. Mikulicz advises an external incision extending from the mastoid process to the hyoid bone, after which the ascending ramus of the jaw is denuded of its periosteum from the insertion of the masseter muscle as high up as possible, whereupon the ascending ramus of the jaw is enucleated. The tonsillar region is now freely exposed. Langenbeck recommends

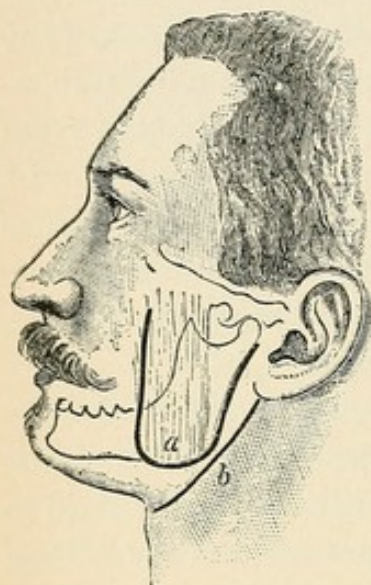


FIG. 168.—External incisions for extirpation of carcinoma of the tonsil: *a*, after Langenbeck; *b*, after Mikulicz.

temporary resection of the inferior maxilla (Fig. 168). Cheever of Boston, who recommends an incision along the anterior border of the sterno-cleido-mastoid muscle from the external ear in a downward direction, reports several cases operated upon successfully by this method. In two cases in which this operation was performed by the writer he resorted to Kocher's incision for the removal of the tongue, and, although both operations proved exceedingly difficult, he was satisfied with the room afforded by the incision.

Iodoform-gauze drainage should be employed both for the purpose of arresting parenchymatous oozing and to afford a free outlet for the primary wound-secretions. If temporary resection of the inferior maxilla is practised, the intentional fracture is sutured with silver wire or with chromicized catgut after the extirpation of the tumor.

Tongue.—Carcinoma of the tongue is one of the most distressing of all surgical affections. Unfortunately, the tongue is rather frequently the seat of carcinoma. The lingual glands are distributed at the root of the tongue, on the sides, and at the apex, and it is in these localities that the tumor has most frequently its starting-point. Very frequently the location of the tumor corresponds with a source of irritation caused by a prominent or carious tooth. Mechanical irritation from such a source continued for any length of time is very apt to become an influential exciting cause. The propor-

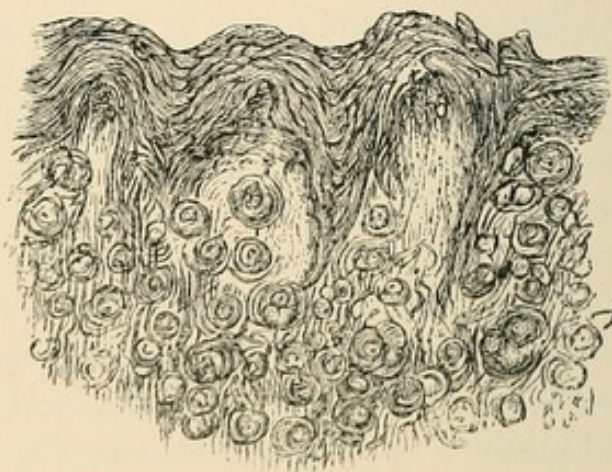


FIG. 169.—Carcinoma of the tongue, showing its papillary structure; $\times 100$ (after W. Fairlie Clarke).

tion of female to male patients is about 1:7. In the early stages, before ulceration has become extensive, the tumor retains on its surface the papillary structure of the tongue (Fig. 169). Infiltration from the surface soon results in the formation of epithelial nests in the underlying vascular connective tissue. The epithelial cells are closely packed in concentric layers in the alveoli of the stroma (Fig. 170).

Besides chronic irritation, the most frequent exciting causes of carcinoma of the tongue are psoriasis, leukoplakia, ichthyosis, and other chronic inflammatory affections of the surface of the tongue—a strong argument that chronic inflammatory affections are a frequent direct and indirect cause of carcinoma. Usually carcinoma of the tongue is a rapidly fatal disease, resulting in death within two years. Wölfler has called attention

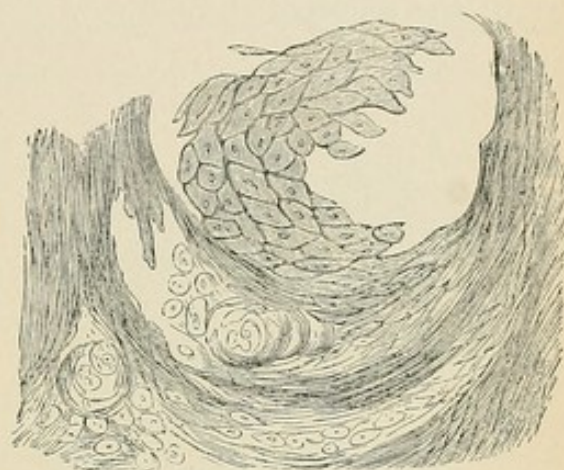


FIG. 170.—Carcinoma of the tongue: laminated capsule; $\times 200$ (after W. Fairlie Clarke).

to a more chronic form of carcinoma of the tongue in which a small flat carcinomatous ulcer may remain in a latent condition for many years. The tumor makes its appearance at the margin, tip, or dorsum of the tongue, as a firm nodule which soon begins to ulcerate in the centre. The infiltration and induration are well marked from the beginning. The primary tumor seldom or never occupies the posterior third of the organ. Glandular infiltration is an early sequence, and the floor of the mouth becomes involved at an early stage.

The pain in carcinoma of the tongue is quite severe and of a sharp, stinging character, extending also in the direction of the ear. The surface of the ulcer is either papillary or covered by gangrenous shreds. The induration of the base and margins of the ulcer remains throughout. Profuse salivation and difficulty in swallowing and in speech are conspicuous clinical features.

In the differential diagnosis tuberculosis, gumma, traumatic ulcer, and actinomycosis must be considered. Tuberculosis of the tongue occurs, with few exceptions, only in persons suffering from pulmonary tuberculosis. The tubercular sputum, coming in contact with some abrasion, results in inoculation. The tubercular ulcer is covered by fungous granulations, and lacks the indurated base and margins of carcinoma. Syphilitic lesions have frequently been mistaken for carcinoma, and *vice versa*. Gumma of the tongue is usually associated with other syphilitic manifestations of the tongue or of the cavity of the mouth.

The tongue itself is often deeply fissured. General hyperplasia of the lymphatic glands is an indication of syphilis, while regional infection speaks in favor of tuberculosis. A gumma of the tongue is not infrequently the starting-point of a carcinoma. This complication must therefore be looked for in syphilis of the tongue. If any doubt exists as to the differential diagnosis of carcinoma and syphilis, examination

of a section of the tumor under the microscope will clear up the uncertainty. In actinomycosis of the tongue the discovery of actinomyces under the microscope will render the diagnosis positive.

The prognosis of carcinoma of the tongue is always grave. Many of the reported permanent cures effected by operation were undoubtedly cases in which a gumma was mistaken for a carcinoma. Billroth and Kocher claim that the results after operations for carcinoma of the tongue are as favorable as those after operations for carcinoma of other organs. Winiwarter's statistics show that the mortality of extirpation of the tongue, which formerly was very great, has been reduced to 17.6 per cent. The diagnosis should be made early, and useless treatment by the application of caustics, etc. should give way to an early and thorough operation.

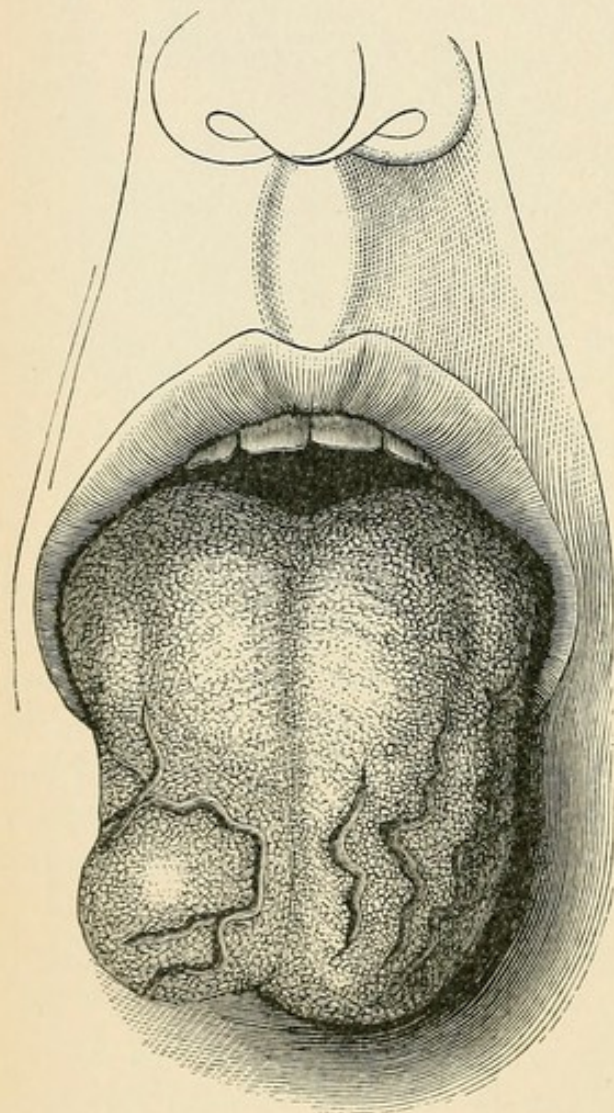


FIG. 171.—Syphilitic nodule and fissure of the tongue (after W. Fairlie Clarke).

Radical Operations for Carcinoma of the Tongue.—In all operations upon the tongue it is very important to disinfect the whole cavity of the mouth, as advised by Billroth. The fear of hemorrhage has in the past induced surgeons to substitute for the knife and scissors the *écraseur* or the galvano-caustic wire. The employment of these instruments did not always prevent hemorrhage when the tongue was amputated near its base, and for this and other substantial reasons they have almost entirely been abandoned. Mr. Hutchinson continues to use the *écraseur*, but he has few imitators. In all operations on the tongue the organ should be

pierced in the middle line near the tip with a large needle armed with heavy silk. With this thread, which is tied at the end, the tongue can be drawn and held in any direction during the operation. Preliminary ligation of one or of both lingual arteries as a prophylactic measure against hemorrhage is seldom practised at the present time, and is not to be recommended. Some surgeons employ temporary hemostatic

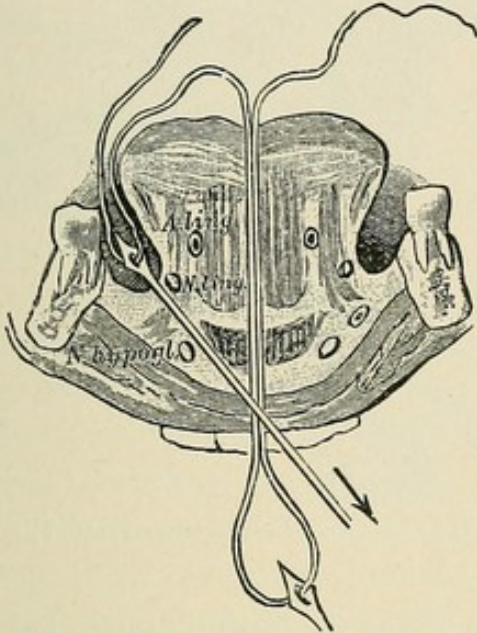


FIG. 172.—Temporary constriction of one-half of the tongue (after Esmarch and Kowalzig).

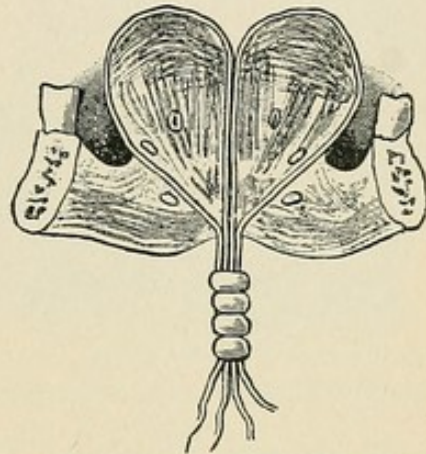


FIG. 173.—Temporary constriction of the whole tongue at its base (after Esmarch and Kowalzig).

measures during the operation (Figs. 172, 173). In applying temporary constriction the tongue is pierced in the middle at its base with a large needle armed with a long and strong silk suture. If it is the intention to constrict only one side, the needle is liberated and the suture is tied; if the whole tongue is to be rendered bloodless, the thread is cut near the needle and the two threads are tied on opposite sides. The writer has tunnelled the base of the tongue in the middle line with a small pair of hemostatic forceps, and has drawn through the tunnel a small rubber tube about twelve inches in length, cut it in the middle, and constricted each side by tying the rubber ligatures firmly enough to interrupt both the arterial and the venous circulation. This method of elastic constriction is to be preferred to the use of silk ligatures. If the surgeon has reliable assistants, preliminary elastic constriction is unnecessary, even if the entire tongue is to be removed.

If the tumor is small and can be removed effectually through the mouth by a wedge-shaped excision, the tongue is rendered accessible by the use of Whitehead's gag. The operation through the mouth is applicable when the tumor occupies the anterior third of the tongue. The line of incision should be made at least three-quarters of an inch distant from the palpable margin of the tumor. The thread with which the tongue is drawn forward is inserted in such a manner that it can be

used as a suture after excision of the tumor (Figs. 174-177). After the tongue has been drawn well forward the excision is made either with

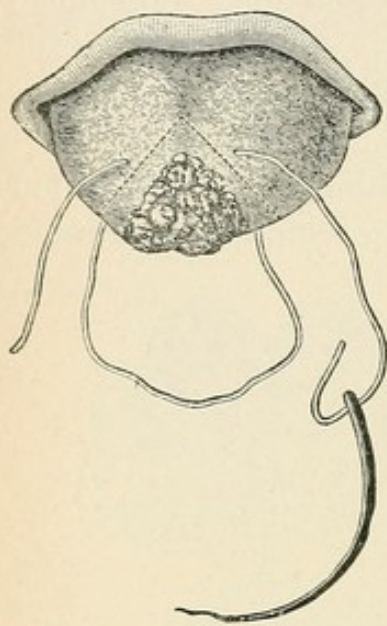


FIG. 174.—Insertion of traction-suture (after Esmarch).

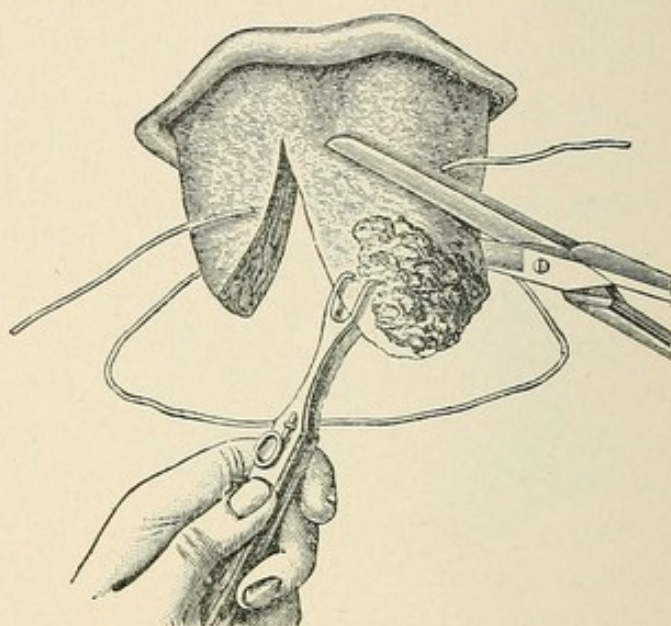


FIG. 175.—Excision of tumor (after Esmarch).

the knife or with scissors. The hemorrhage is readily controlled by accurate suturing. The deep sutures should include all the tissues, and if there is any tendency to inversion of the mucous membrane, this

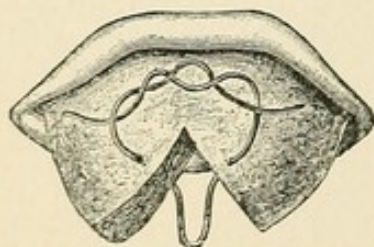


FIG. 176.—Tying of first suture (after Esmarch).

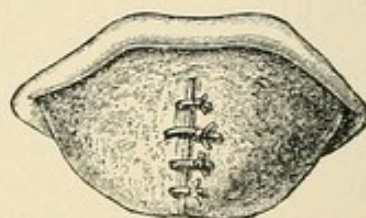


FIG. 177.—Operation completed (after Esmarch).

tendency should be averted by the use of a few superficial fine catgut sutures.

Whitehead removes the entire tongue through the mouth with scissors, and immediately grasps and ties the lingual arteries. Few surgeons perform Whitehead's operation—not because it is difficult and cannot be done safely, but because cases which require amputation of the entire tongue are complicated by regional infection, the treatment of which requires an external incision. Langenbeck makes an incision from the angle of the mouth downward, and divides the inferior maxilla transversely in the line of the external incision (Fig. 178). The ends of the bone are then drawn apart sufficiently to secure free access to the base of the tongue. After completion of the amputation the bone-ends are brought in apposition and are sutured with silver wire.

Regnoli devised an operation, later modified by Billroth (Fig. 179), by which the base of the tongue can be made freely accessible without dividing the inferior maxilla. The cavity of the mouth is opened by a horseshoe-shaped incision corresponding with the lower border of the jaw; the cavity of the mouth being opened, the tongue is drawn forward through the incision sufficiently to bring its base within easy reach. More recently, Kocher devised an incision by which the base of the tongue is reached from the side without dividing the jaw (Fig. 180). This incision is commenced below the ear, and is carried along the anterior margin of the sterno-cleido-mastoid muscle about five inches, when it is directed forward, and by a small turn upward is made to terminate near the symphysis of the chin. The flap of skin is then raised as far as the lower border of the jaw, and through this space the base of the tongue is reached. The tongue is then drawn through the incision and is amputated in the usual manner.

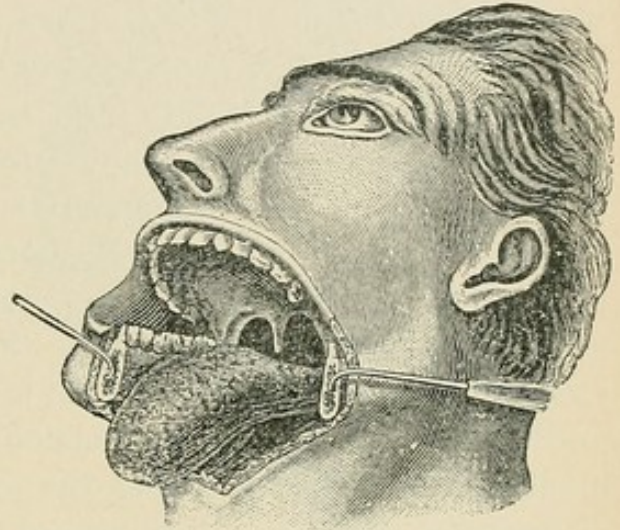


FIG. 178.—Amputation of the tongue by Langenbeck's method.

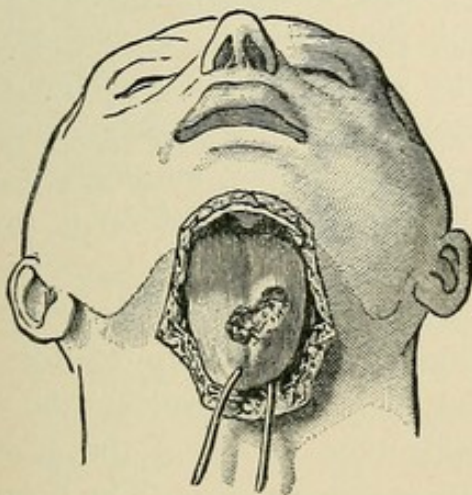


FIG. 179.—Amputation of the tongue according to Regnoli-Billroth.

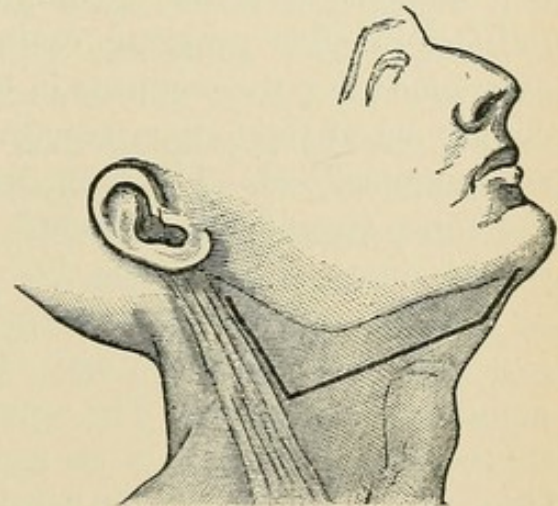


FIG. 180.—Kocher's incision in amputation of the tongue.

Kocher's incision affords the surgeon an excellent opportunity to remove all the submaxillary and submental lymphatic glands, but does not expose the base of the tongue as freely as the Regnoli-Billroth method. From experience the writer is satisfied that the Kocher method is well adapted for partial removal of the tongue, but when the entire organ is to be

amputated the Regnoli-Billroth method deserves the preference. After the tongue has been drawn well forward, before making the amputation, it has been the habit of the writer to insert on each side of the base of the tongue an additional traction-suture, with which to control the stump later. This is an exceedingly important precaution. After dividing the tongue by one stroke of the knife as far as the median line, the lingual artery is grasped and tied. The lingual artery on the opposite side is dealt with in a similar manner after the amputation has been completed. The parenchymatous oozing is moderate, and is controlled by suturing the stump. It is advisable to remove as much of the floor of the mouth as necessary, and all the infected lymphatic glands, before the tongue is amputated. The writer always resorts to partial anesthesia in performing the operation, for the purpose of securing the patient's co-operation in preventing the entrance of blood into the larynx. The two traction sutures are brought out of the mouth, and are used in fixing the stump in proper position for a day or two after operation. The wound is covered with adhesive iodoform gauze or with Whitehead's benzœe mixture. The external wound is closed except at a point best adapted for drainage. If necessary, the patient is nourished for a few days by introducing food into the stomach through an elastic tube or by rectal feeding. A saturated solution of boric acid should be used frequently as a gargle or mouth-wash. Careful attention in the after-treatment is of great importance in the prevention of acute pulmonary complications. The functional results are satisfactory after complete extirpation of the tongue. It has been ascertained that the criminals in Persia who were formerly punished by cutting out of the tongue recovered speech sufficiently to make themselves understood. The same has been observed after amputation of the entire tongue for carcinoma. The function of deglutition is preserved almost to perfection.

Parotid.—Carcinoma of the parotid gland does not occur in persons less than forty years of age. Carcinoma of the salivary glands is notoriously malignant. The acinous variety begins as a proliferation of the columnar epithelia of an isolated embryonic lobule of the gland (Fig. 181). The stroma is usually scanty in this variety. The tumor grows rapidly and gives rise to early lymphatic infection. Weber described a form of carcinoma of the parotid that closely resembles hard carcinoma of the breast. The tubular variety begins in the distal branches of the salivary duct, in the form of epithelial pearls of columnar epithelial cells which arrange themselves in the form of tubules, which multiply and grow into the substance of the gland. A rapid-growing tumor of the parotid gland in a person fifty or more years

of age is, with very few exceptions indeed, a carcinoma. The capsule of the gland is perforated at an early stage, when the tumor involves the overlying skin and the neighboring organs. The external ear, the malar bone, and the ascending ramus of the inferior maxilla are frequently implicated. In two cases that have come under the writer's observation paralysis of the facial nerve existed at the time the operation was performed. Regional infection extends to the deep lymphatics of the neck.

Extirpation of the Parotid Gland.

Extirpation of the parotid gland.—Extirpation of the parotid gland was first performed in America in 1804 by the father of J. Collins Warren. Brainard of Chicago performed the operation a number of times, and

strongly maintained its feasibility. König advises in the aged a partial excision of the gland, with a view of preventing facial paralysis if the tumor is not large. The writer is of the opinion that partial removal of the parotid gland for carcinoma is an unjustifiable and unsurgical procedure, as recurrence is sure to take place, and the recurrent tumor grows more rapidly than the primary growth. *Carcinoma of the parotid gland indicates complete removal of the gland with all other infected tissues, and is always followed by permanent facial paralysis.* The writer has removed the parotid gland for carcinoma six times without a death, and has never observed serious consequences from the facial paralysis. In one case there was removed, in addition to the tumor, the entire external ear; in another, the malar bone and part of the superior maxilla; and in a third, the ascending ramus of the inferior maxilla with the parotid. The overlying skin is generally found affected, and must be excised with the tumor. Preliminary ligation of the external or common carotid artery is unnecessary, as the external carotid artery can be ligated in the wound toward the completion of the operation. Liston and Dieffenbach recommended intracapsular enucleation. Roser removed the carcinomatous parotid gland piecemeal (*morcellement*).

The capsule of the gland should invariably be removed with the

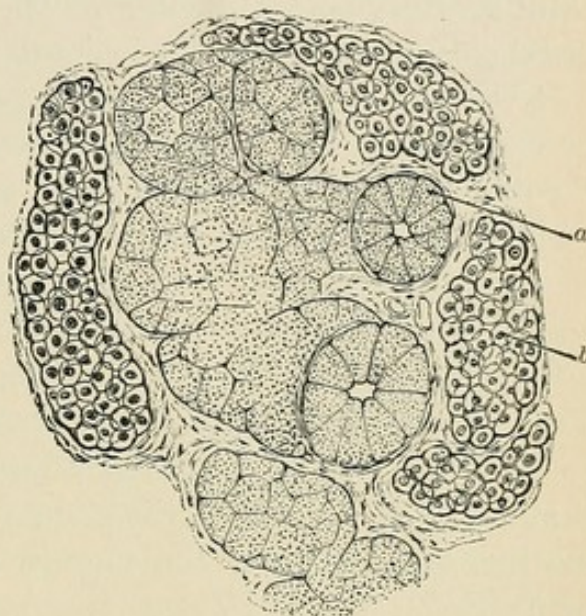


FIG. 181.—Adenomatous stage of a cancer of the submaxillary gland; $\times 350$ (after D. J. Hamilton): *a*, section of a normal acinus; *b*, an acinus distended with proliferating epithelium: other parts of the gland were completely cancerous.

tumor. If a large area of skin has to be excised, the part to be removed should be included between two elliptical incisions, the lower angle of the ellipse corresponding with the point where the external carotid artery is to be ligated. The temporal artery is ligated on the distal side and is secured by compression-forceps on the proximal side. The whole mass is carefully dissected all around; the dissection must be extended to the styloid process of the temporal bone. As soon as the external carotid artery comes in view it is isolated and is grasped with a pair of hemostatic forceps, the tumor is removed, and the artery is tied. The wound-surface being large, it is necessary to cover it by a plastic operation, which can be done by taking a pedunculated flap from the forehead or the scalp. The scalp defect is then covered with Thiersch's grafts. In the case in which the writer had to remove the external ear with the parotid a little opening was made in the large skin-flap, this opening corresponding with the location of the external meatus, and thus the function of hearing was preserved almost to perfection.

If the skin over the tumor can be preserved, the writer exposes the parotid gland by a curved incision, with the convexity directed downward, extending from the mastoid process to near the malar prominence, turns this flap upward, and then proceeds to remove the tumor as has been described. The results after this operation compare favorably with those of removal of the breast for carcinoma. If the deep cervical glands are infected, the incision must be extended downward along the anterior border of the sterno-cleido-mastoid muscle. *Carcinoma of the parotid gland should be removed as early and as thoroughly as possible, and the patient must be made to understand that the price he pays for a radical operation includes invariably a permanent facial paralysis.*

Thyroid.—Carcinoma of the thyroid gland is very rare in the United States. Malignant disease of this gland is usually associated with adenoma or with miasmatic struma, and is consequently more prevalent in localities where these affections are endemic. Carcinoma of the thyroid gland presents an additional interest from the fact that such tumors are by no means limited to the thyroid gland. Accessory thyroid glands are quite frequently found in the neighborhood of the thyroid, but thyroid tissue has a much more diffuse distribution in different parts of the body. It has been found in the bronchial glands, in the lungs, and in the bones in cases where the thyroid was enlarged, and its presence in these situations has been regarded as an example of metastasis. According to Piana, thyroid tissue occurs close to the aortic arch in the dog. The hyoid glands of Zuckerkandl and Kadyi,

which are well described by Streckeisen, consist of remains of the thyroid duct and of gland-tissue, and may become the seat of malignant as well as benign tumors.

Heterotopic tumors composed of thyroid tissue are excessively rare. Morris in 1880 described a case of pulsatile tumor of the skull in which it was shown under the microscope that the tumor was composed of thyroid tissue (Fig. 182). Coats reported a similar case. Gussenbauer found such a tumor in the vertebræ. That such a matrix should occasionally serve as a starting-point of carcinoma should be remembered when a primary carcinoma is found in tissues normally devoid of epithelial cells.

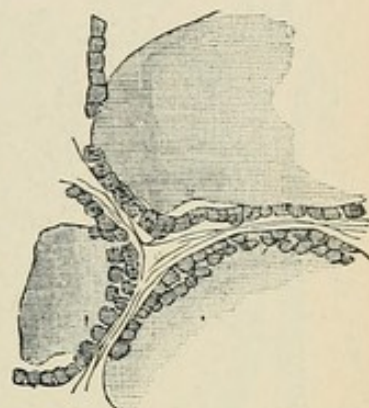


FIG. 182.—Microscopical appearance of pulsatile tumor of the skull (after Morris).

Carcinoma of the thyroid gland is met with most frequently in persons from thirty to fifty years of age. The tumor infiltrates the gland-tissue, and soon perforates the capsule and extends to the surrounding tissues, rendering the tumor immovable. Extension in the direction of the trachea gives rise to hoarseness and dyspnea. Destruction of the recurrent laryngeal nerves results in paralysis of the vocal cords. Wölfler describes a malignant adenoma of the thyroid gland—a tumor which under the microscope exhibited the same appearances as an adenoma, but which clinically pursued the same course as carcinoma. Histologically he recognizes three varieties: 1. Alveolar carcinoma; 2. Cylindrical-celled carcinoma; 3. Squamous-celled carcinoma.

Carcinoma of the thyroid usually proves fatal within a year. It starts most frequently in a pre-existing miasmatic struma or adenoma. *If a goitre that has remained stationary for a long time commences to increase rapidly in size without any apparent cause, it is more than probable that it has become the seat of a carcinoma, either by the tissues composing the pre-existing pathological product having undergone malignant transformation, or from the development of a carcinoma from a separate matrix of embryonic cells within or in the immediate vicinity of the infective swelling or the benign tumor.* Kaufmann recommended as a means of early and positive diagnosis *puncture of the tumor and examination under the microscope of fragments of tissue removed in this way.*

Extirpation of the Thyroid Gland for Carcinoma.—The only surgical treatment of carcinoma of the thyroid gland is early and thorough excision. The removal of a carcinomatous tumor of this gland is a much more difficult task than the enucleation of an adenoma or a cyst, as the tumor has usually perforated the capsule of the gland before the opera-

tion is undertaken. The excision of a carcinoma of the thyroid gland necessitates ligation of numerous and large veins (Figs. 183, 184). A

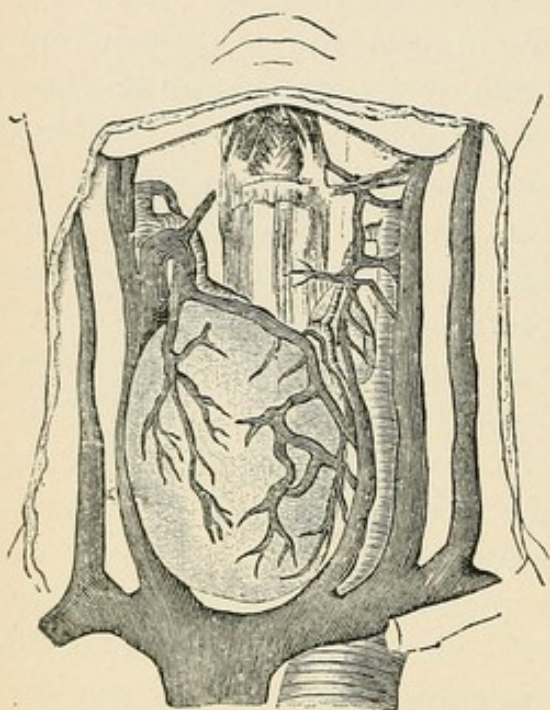


FIG. 183.—Tumor of the right lobe of the thyroid gland, showing ramification of superficial veins (after Kocher).

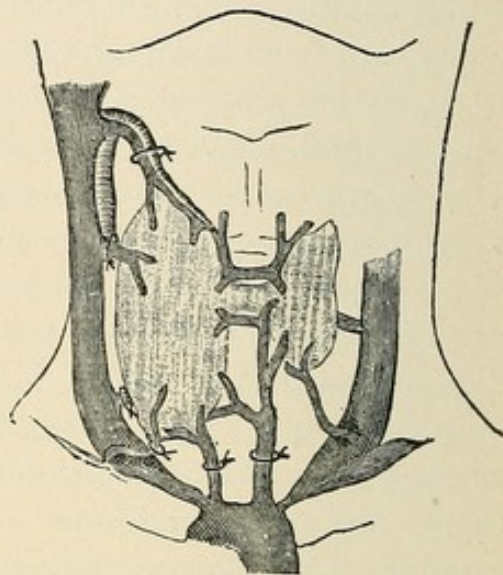


FIG. 184.—Schema showing points of ligation of large veins in extirpation of thyroid tumors (after Kocher).

curved transverse incision with the convexity directed downward will afford the best access to the base of the tumor. The large veins should be divided between a double ligature. A very useful instrument in making the dissection is Kocher's director (Fig. 185). Venous hemorrhage is more to be feared than arterial hemorrhage, and is more difficult to control. Injury to the recurrent laryngeal nerve has frequently happened during operations for malignant disease of the thyroid. Permanent paralysis of the vocal cord on the same side is a constant result of this accident. If the trachea has become involved, it is generally opened during the operation, and a tracheal cannula should be inserted at once.

The results of operations for malignant disease of the thyroid gland have not been very encouraging. Local recurrence is the rule, even if the infected lymphatics are carefully removed with the tumor. The operation, however, is one of great palliative value, and is the only means of preventing death from suffocation. In operating for malignant disease of the thyroid the whole gland should be removed, as it is much better for the patient to run the risk of



FIG. 185.—Kocher's director.

becoming later the subject of cachexia strumipriva than to take the chances of an early local recurrence.

Mammary Gland.—The greatest interest centres in carcinoma of the mammary gland, owing to the great frequency with which this organ is

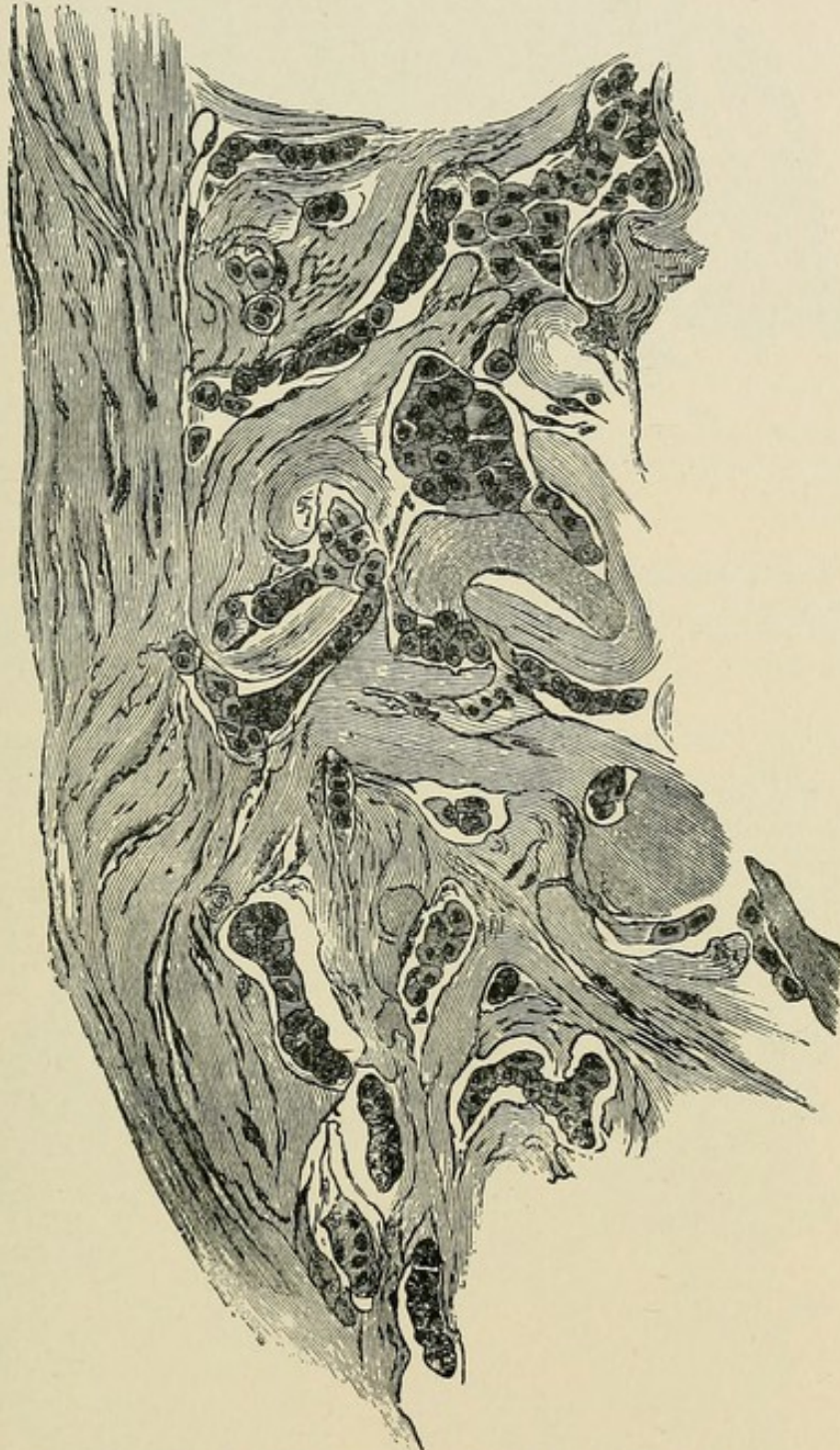

FIG. 186.—From carcinoma of mammary gland, showing infiltration of connective-tissue spaces with carcinoma-cells: connective-tissue endothelia can be seen in places lining the connective-tissue spaces; $\times 250$ (after Ziesing).

affected. The frequency of carcinoma as compared with other tumors of the breast is very great, as Billroth found in 440 tumors of the breast that only in 18 per cent. were the tumors of a non-malignant character.

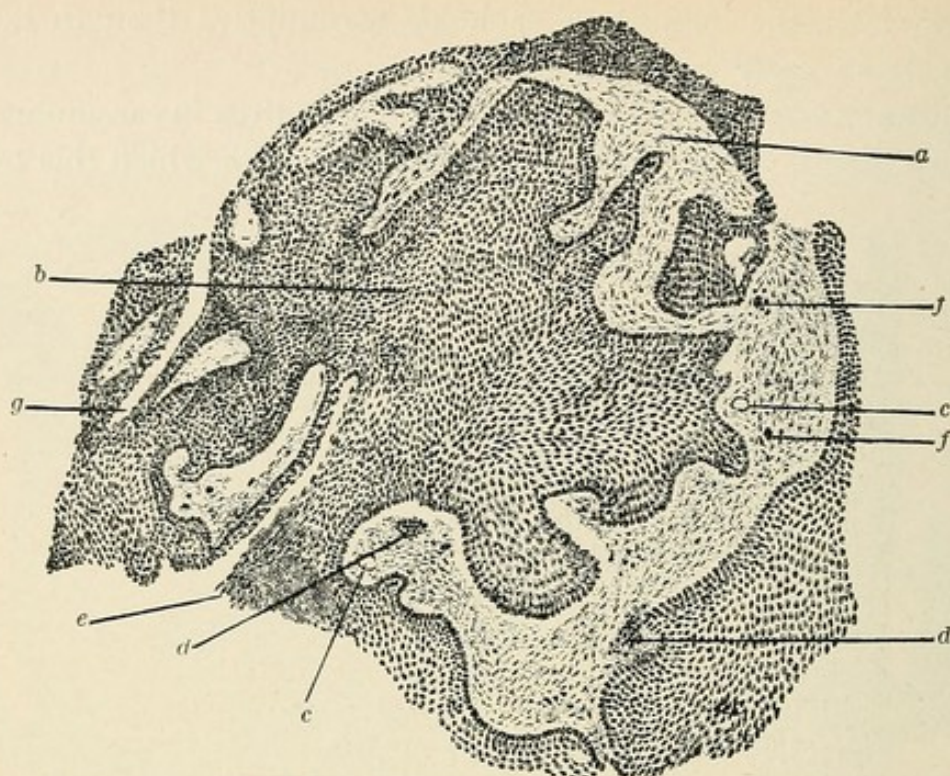


FIG. 187.—Acinous carcinoma of mammary gland; $\times 110$, reduced one-third (Surgical Clinic, Rush Medical College, Chicago): *a*, connective-tissue stroma; *b*, tumor-parenchyma; *c*, blood-vessels in stroma; *d*, wandering carcinoma-cells; *e*, area where recent hemorrhage has occurred; *f*, blood-pigment; *g*, shrinkage in hardening.

Histological Varieties.—The histological structure of a carcinoma of the mammary gland depends on the type of cells of which it is com-

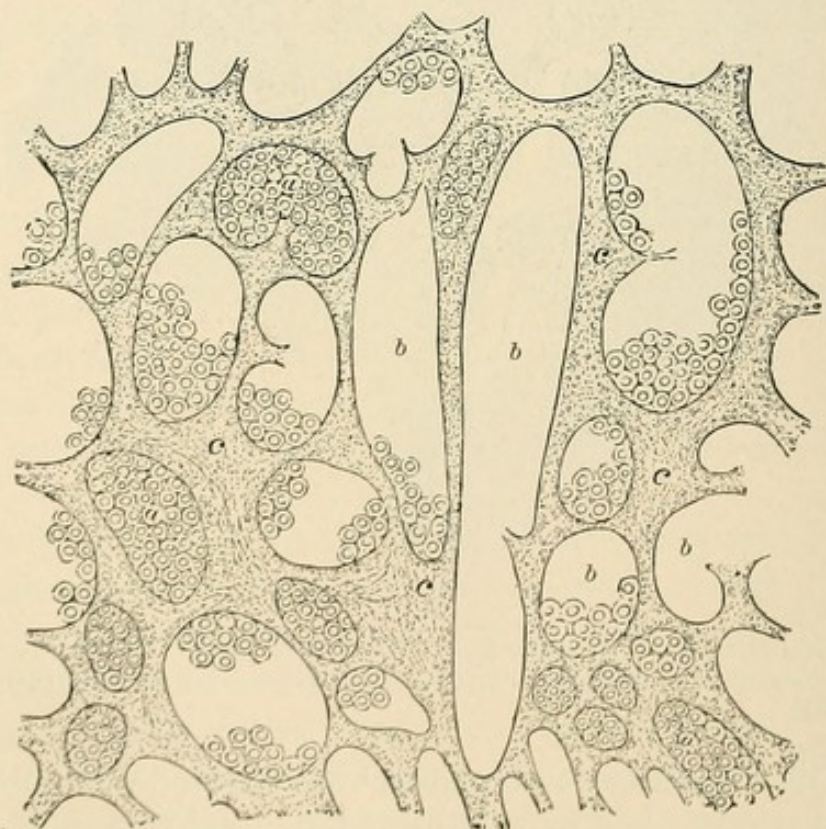


FIG. 188.—Alveolar carcinoma of breast (after König): *a*, alveoli filled with epithelial cells; *b*, empty alveoli; *c*, stroma infiltrated in places by small round cells.

posed and the amount and arrangement of its stroma. The embryonic matrix from which it develops is always derived from the epiblast, but

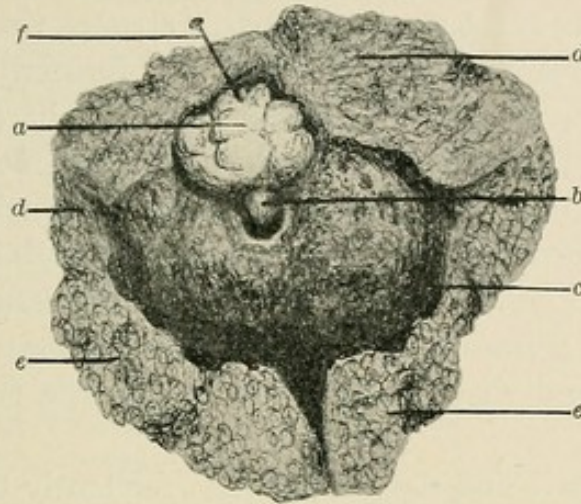


FIG. 189.—Tubular carcinoma in cystic tumor of the breast; natural size (Surgical Clinic, St. Joseph's Hospital, Chicago): *a*, tumor; *b*, pedicle; *c*, cavity of cyst; *d*, normal gland-tissue; *e*, adipose tissue; *f*, pin supporting tumor.

the morphology of the cells is determined by the part of the gland which the matrix represents. The product of tissue-proliferation represents either the acinous or the duct portion of the gland.

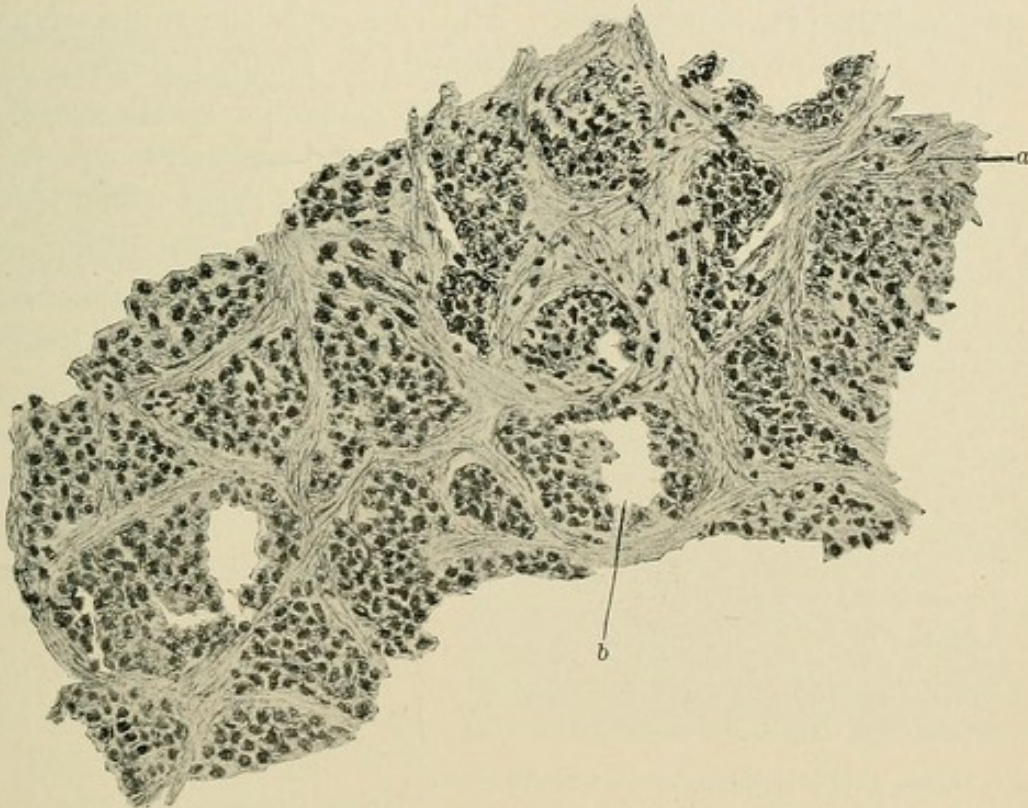


FIG. 190.—Section from tumor shown in Figure 191; $\times 185$: *a*, alveolated stroma infiltrated in some places by small cells; *b*, columnar epithelial cells filling tubular spaces.

Acinous Variety.—In this variety the cells are packed in the alveoli of the stroma very much in the same manner as in carcinoma of the

skin (Fig. 187). If the alveoli are large, we speak of "alveolar carcinoma," although the stroma of all carcinomatous tumors presents an alveolated structure (Fig. 188). If the parenchyma of the tumor predominates greatly over its connective-tissue stroma, the tumor is soft and very vascular, corresponding with what was formerly called "encephaloid" or "medullary" cancer. If the tumor is hard and nodulated, it answers to what is still being described as "scirrhus." If the cellular elements or the stroma, or both, undergo such extensive colloid degeneration that the tumor is largely composed of colloid material, it has been customary to call such a tumor a "colloid cancer." In acinous carcinoma of the mammary gland the cells infiltrate the connective-tissue spaces around the primary growth, and the tumor increases in size (Fig. 186).

Tubular Variety.—Tubular carcinoma frequently takes its starting-point in a pre-existing cystic disease of the ducts of the gland. The cells are either columnar or resemble columnar cells which line duct-spaces or infiltrate the connective-tissue stroma (see Plate 5). Tubular carcinoma is less malignant than the acinous variety. In one case the writer found in the breast of a woman thirty-five years old a tubular carcinoma which had existed for six months, and during this time it had reached the size of a walnut. The skin over the tumor remained unaffected, and the nipple was not retracted. Distinct fluctuation was felt. The cyst was excised. On laying it open a small quantity of mucoid material escaped. The



FIG. 191.—Tubular form of carcinoma of the breast: infiltration of the stroma by small round cells (after König).

interior of the cyst was occupied by a pedunculated papillary tumor (Fig. 189). Dr. Mellish, who examined the tumor and made the drawings, traced its pedicle to the orifice of a duct-like tract in the gland-tissue. This blind tract could be followed to the depth of about a quarter of an inch into the substance of the gland. There is no doubt that the tumor developed from the wall of a pre-existing duct, and that it caused by its presence in-

creased secretion and retention of the secretions which produced the cyst. Sections of the tumor showed a well-marked alveolated structure of its stroma, its spaces filled with columnar epithelial cells.

In typical tubular carcinoma the tubular arrangement is preserved in the new portions of the tumor. The *membrana propria*, however, is defective in many places and permits the infiltration of the stroma by new cells (Fig. 191).

Etiology.—Very little is known concerning the exciting causes of carcinoma of the breast. It occurs most frequently in women past thirty-five years of age; the soft variety is more frequent in young persons, and the hard variety in persons advanced in years. The rarity of the occurrence of carcinoma in men points to the frequently-recurring hyperemia of the mammary gland in females during pregnancy, lactation, and menstruation as an important etiological factor. That pregnancy and lactation are important causes is shown from the fact that in carcinoma of the breast in the female the proportion of the unmarried to the married, according to Bryant, is 1:3½; according to Baker, of 260 cases, 23 per cent. occurred in single and 72 per cent. in married women, and 4 per cent. in widows. In a small percentage of cases the disease had evidently a traumatic origin. Antecedent lesions of the breast, abscess, fissure of the nipple, and eczema appear to have acted as exciting causes or to have furnished besides the essential tumor-matrix. Occasionally an adenoma undergoes malignant transformation. The etiological relation between eczema of the nipple and carcinoma of the breast is now generally recognized. In a case that came under the writer's observation the eczema preceded the carcinoma by over five years, and during this time no evidences of the carcinomatous nature of the primary skin affection could be detected by the most careful and frequently-repeated examinations.

In 1874, Sir James Paget read a paper in which he discussed for the first time the connection of eczema of the areola of the breast with carcinoma, basing his remarks on fifteen cases which had up to that time come under his personal notice. Some of his remarks on this subject are quoted: "The patients were all women various in age, from forty to sixty or more years, having in common nothing remarkable but their disease. In all of them the disease began as an eruption on the nipple and areola. In the majority it had the appearance of a florid, intensely red, raw surface, very finely granular, as if nearly the whole thickness of the epidermis were removed—like the surface of very acute diffuse eczema or like that of an acute balanitis. From such a surface, on the whole or greater part of the nipple and areola, there was always a copious, clear, yellowish, viscid exudation. The sensations were commonly tinglings, itching, and burning, but the malady was never attended by disturbance of the general health. I have not seen this form of eruption extend beyond the areola, and only once

have seen it pass into a deeper ulceration of the skin after the manner of a rodent ulcer. In some of the cases the eruption has presented the characteristics of an ordinary chronic eczema, with minute vesications, succeeded by soft, moist, yellowish scabs or scales and constant viscid exudation. In some it has been like psoriasis, dry, with a few white scales desquamating, and in both these forms, especially the psoriasis, I have seen the eruption spreading far beyond the areola in widening circles, or with scattered blotches of redness covering nearly the whole breast. . . . But it has happened that in every case which I have been able to watch cancer of the mammary gland has followed within at the most two years, and usually within one year. The formation of cancer has not in any case taken place first in the diseased part of the skin. It has always been in the substance of the mammary gland, beneath or not far from the diseased skin, and always with a clear interval of apparently healthy tissue."

In view of the fact that eczema of the nipple is so constantly followed by carcinoma, and as the disease appears to resist all kinds of local treatment, Paget is in favor of early operative removal of the diseased breast as the only known prophylactic measure against carcinoma from this source.

Thin, who studied Paget's disease of the nipple from a histological standpoint, found first the skin of the nipple eczematous. The inflammatory process creeps then along the mucous membrane of the milk-ducts. Bryant estimates that carcinoma of the breast is hereditary in 10 per cent. of all cases. Sprengel traced a hereditary influence in thirteen out of 109 cases.

Symptoms and Diagnosis.—The acinous variety of carcinoma, by far the most frequent, commences as a hard nodule in the substance of the breast, most frequently near the periphery of the organ. If the tumor starts in an accessory mammary gland, it usually occupies primarily the base of the axillary space. The tumor is nodulated, and a certain degree of fixity can be detected almost from the beginning.

Tubular carcinoma starts more commonly nearer the nipple. As the tumor increases in size it approaches the surface: the skin is drawn inward, and soon becomes discolored in the centre—a condition which precedes ulceration. In soft tumors nodulation is less marked than in the hard variety, and the tumor closely resembles a sarcoma. Extensive fatty degeneration of the centre of the tumor and contraction of the stroma at this point leads to a depression which is often noticeable on the surface of the skin. Retraction of the nipple accompanies a similar condition, and is therefore most constant and well marked in hard carcinoma. It is the result of cicatricial contraction of the stroma,

which exerts traction upon the milk-ducts. A serous or sanguineous fluid can sometimes be pressed from the nipple, especially in cases of soft tumors. Soft tumors grow rapidly, being most malignant; the local infection spreads rapidly, the stroma being scanty, and the cells undergo early degenerative changes, especially of a colloid character. The tumor is soft, fluctuating, and resembles closely a subacute abscess or a rapid-growing sarcoma. Mr. Heath reports such a case: A few months before the examination the patient, a married woman twenty-four years of age, noticed in the left breast a swelling the size

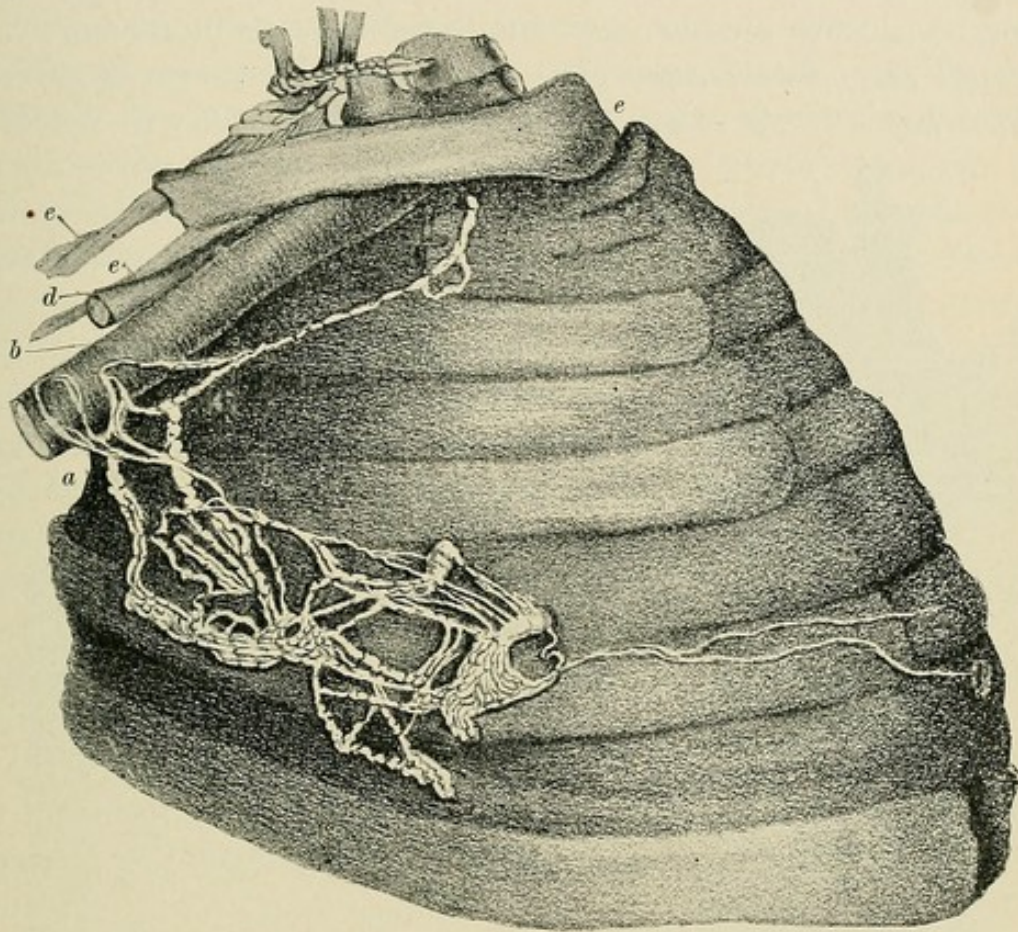


FIG. 192.—The lymphatics from the nipple to the axilla, placed upon the axillary vein, whence they mount to the under part of the clavicle, passing through an opening to terminate in the angle of the conjoined jugular and subclavian veins of the right side, at the lower part of the neck (after Astley Cooper): *a*, the nipple, with two absorbents from it passing upon the fourth rib, and then dividing into numerous branches which cover the intercostal spaces up to the third and down to the fifth rib; they then mount to the third rib, to the axillary vein (*b*), and pass on the inner side of that vein under the clavicle (*c*), where they are continued, through the opening, into the angle of the jugular and subclavian veins; *d*, the subclavian artery; *e*, *e*, axillary plexus of nerves.

of a hen's egg. The tumor developed rapidly without pain, and occasionally blood flowed from the nipple. A little later, in consequence of the large size of the breast and the copious discharge of blood from the nipple, she consulted Mr. Heath, who evacuated about a pint of a thin bloody fluid and injected tincture of iodine. This treatment was repeated on two other occasions. A few months later the breast was

removed. At this time there was at the site of puncture a fungous growth through which bloody, offensive fluid was escaping.

Simmonds has shown that colloid degeneration cannot occur independently of epithelial cells. When the cells undergo this process the stroma can take part, and in this manner greater or lesser portions of rapid-growing carcinoma are transformed into colloid material. In the atrophic form of carcinoma the stroma is very abundant, and the tumor in the central part shrinks because of the partial or total disappearance of the epithelial cells by fatty degeneration and because of the shrinkage of the massive stroma, which in itself favors fatty degeneration by causing pressure and by diminishing the blood-supply. *In nearly all cases which come under the notice of the surgeon glandular infection has already occurred.* It may be impossible to detect the

enlarged glands through the intact skin, especially in obese women, but their existence can generally be demonstrated at the operation.

The relation of the lymphatics to the mammary gland and their location and distribution are well shown in Figures 192, 193.

Careful anatomical researches made by Heidenhain have shown the existence of a dense network of lymphatics underneath the mammary gland in the adipose tissue, between it and the fascia of the pectoralis major muscle. He attributes the frequency with which local recurrence has followed the removal of the carcinomatous mammary gland to incomplete removal of the pectoralis fascia. In all cases this fascia should be removed thoroughly, which can only be done by taking away the superficial fibres of the muscle. In cases in which the diseased breast is attached to the muscle, the muscle should be removed completely. Stiles fully confirms the views expressed by Heidenhain by his own investigations. The latter author has also traced a connection be-

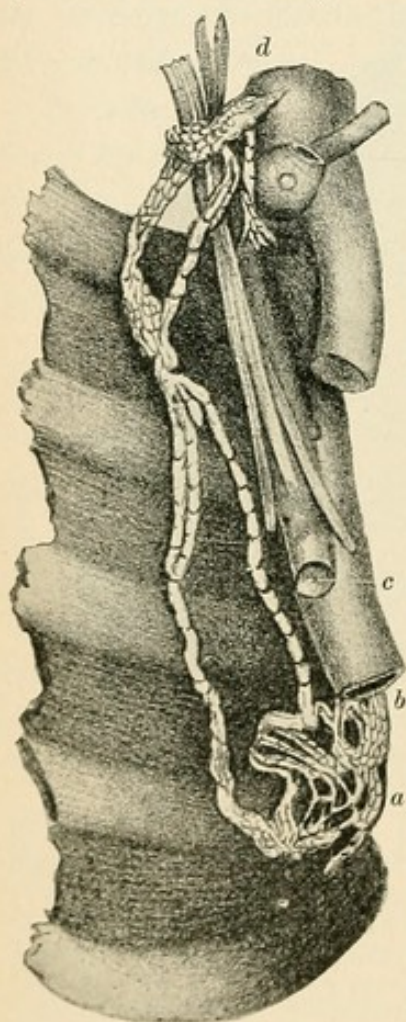


FIG. 193.—Shows the lymphatics (a) of Figure 192 passing under the blood-vessels (b), the axillary vein (c), the artery, across four of the upper ribs, joining with the anterior, entering the angle of the jugular and subclavian of the right side at d (after Astley Cooper).

tween the submammary lymphatics and the lymphatics accompanying the internal mammary artery.

The lymphatic glands nearest the mammary gland usually become affected first, when the regional infection extends in the direction of the apex of the axillary space. The glandular tumors are often more numerous than the normal glands, and some of them are tumors which have developed in the lymphatic vessels. The enlargement of the lymphatic glands belonging to the brachial lymphatics produces œdema of the arm—a condition which becomes aggravated by pressure of the tumors upon the axillary vein. Lymphatic enlargement usually takes place along the greater pectoral muscle, but, as pointed out by Astley Cooper, if the tumor is situated on the sternal side of the nipple the supraclavicular glands become involved by way of the internal mammary lymphatics. Metastasis takes place most frequently in the liver; next in frequency come the lungs, the pleura, and the brain. Török and Wittelshöfer have found metastasis in the bones of the skull. Metastatic tumors of the long bones frequently result in pathological fracture. Carcinoma of the vertebræ resembles clinically spondylitis. Billroth and König have observed metastasis most frequently in connection with slow-growing hard carcinoma, which corresponds with the results of the writer's observations.

In the hard variety the ulcer is at first superficial, and extends primarily more toward its periphery than in the direction of the tumor.

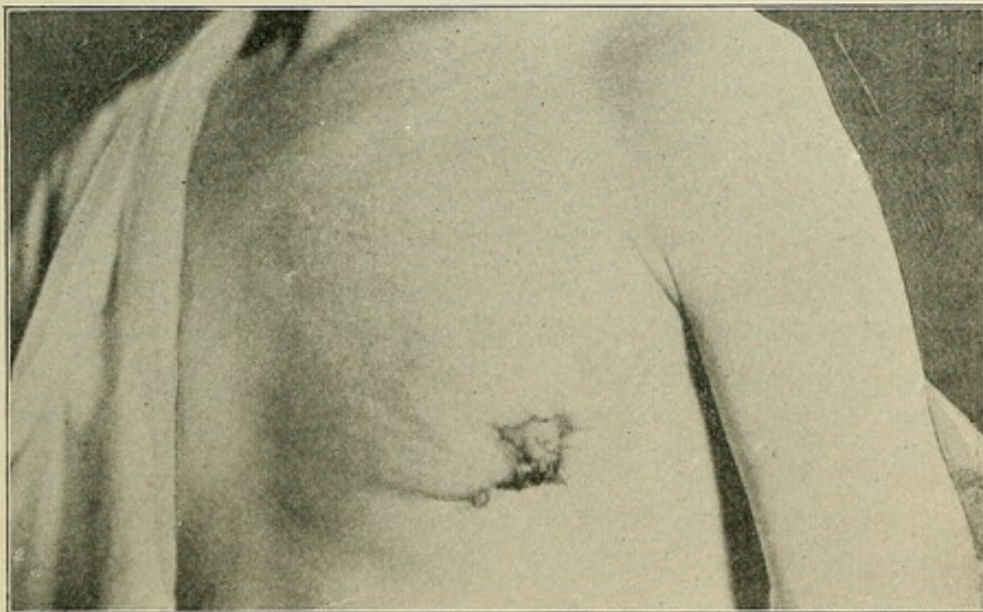


FIG. 194.—Carcinoma of the breast.

In soft carcinoma the superficial ulceration often gives rise to central sloughing of a considerable portion of the tumor; this sloughing, upon separation of the gangrenous part, leaves a crater-like excavation. Infection with pus-microbes hastens the destructive process, and the presence of putrefactive bacilli in the dead tissues causes putrefaction,

which is the source of the offensive odor which characterizes the discharge from soft carcinoma of the breast. Patients who have remained in good health until ulceration begins soon become cachectic from the absorption of septic material from the surface of the tumor and from the inflamed tissues. Pain may be almost entirely absent in soft carcinoma of the breast, the disease resembling in this respect sarcoma. In the hard variety the pain, of a shooting or lancinating character, is always present after the tumor has attained a certain size, but is variable in its intensity; it is always intermittent, and is apt to be aggravated during the night and after active exercise.

A rapid-growing tumor of the breast is a malignant tumor. To determine whether the enlargement of the breast is caused by an infec-

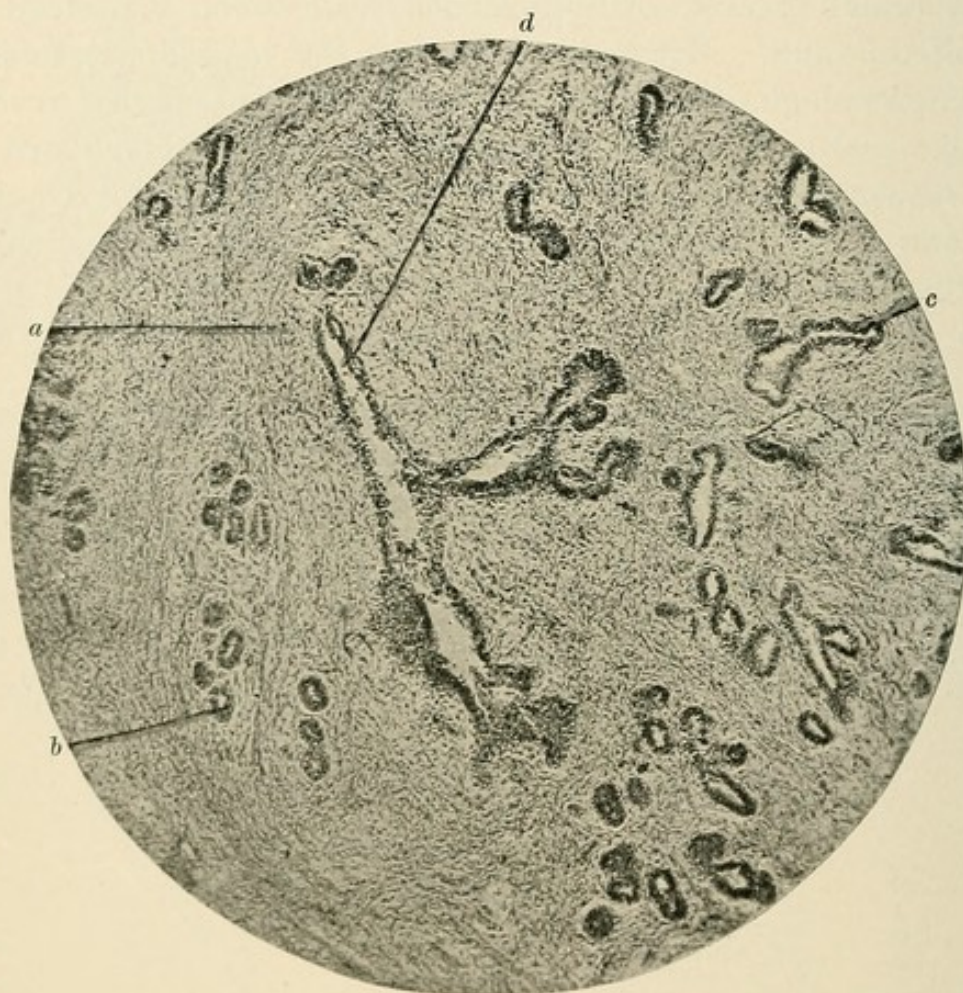


FIG. 195.—Adenoma of the breast; $\times 75$ (Surgical Clinic, Rush Medical College, Chicago): *a*, massive connective-tissue stroma; *b*, gland-ducts cut transversely; *c*, gland-ducts cut obliquely; *d*, cystic dilatation of duct.

tive swelling or by a tumor requires often a very careful examination. A subacute suppurative mastitis often resembles in its signs and symptoms a malignant tumor. The clinical history must be investigated carefully and all possible sources of infection be ascertained. If any

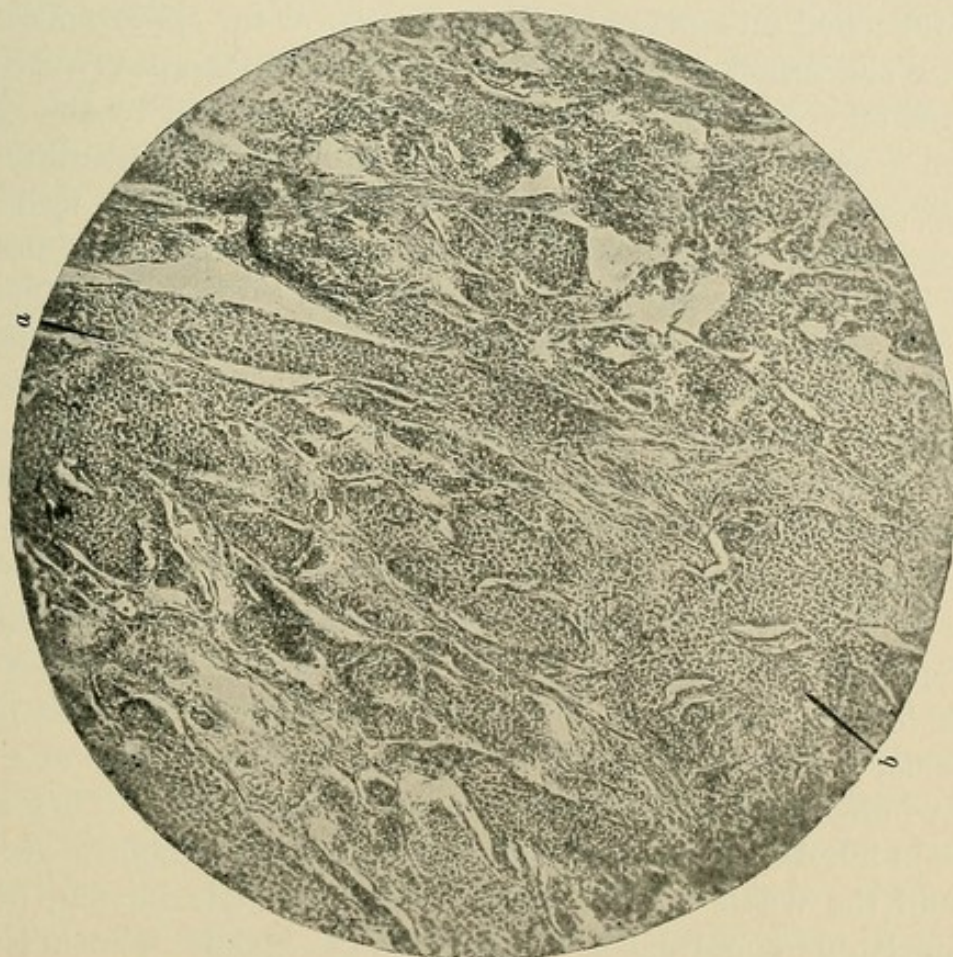


FIG. 196.—Carcinoma of the breast; $\times 85$ (Surgical Clinic, Rush Medical College, Chicago): *a*, alveoli filled with young epithelial cells.

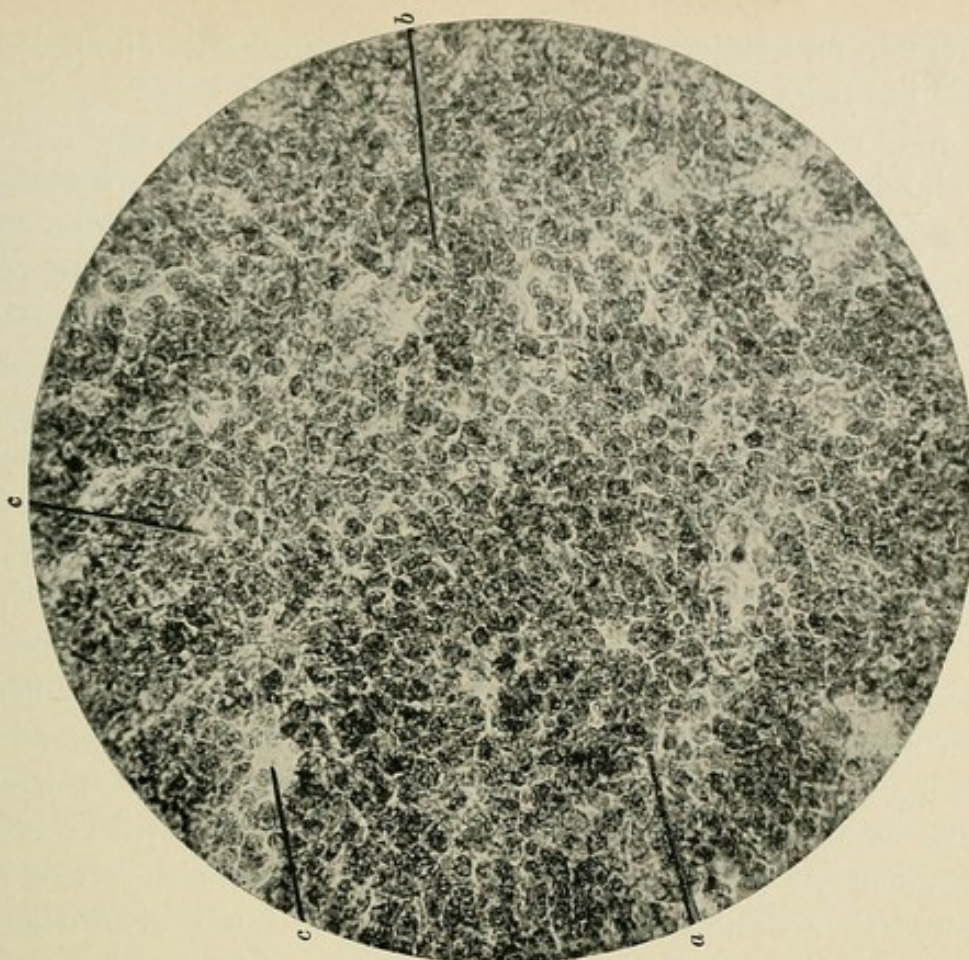


FIG. 197.—Round-celled sarcoma of the breast (Surgical Clinic, Rush Medical College, Chicago): *a*, very delicate connective-tissue reticulum; *b*, round sarcoma-cells; *c*, blood-vessels with imperfect vessel-wall.

doubt remain, an opinion should not be given until after an exploratory puncture has been made.

Tuberculosis of the breast often presents itself as a multiple affection, which is not the case in carcinoma. An adenoma without cystic degeneration hardly ever exceeds in size a walnut. Cystoma forms very slowly, fluctuates on palpation, and upon deep pressure offers a sense of elastic resistance. It is important to distinguish between sarcoma and carcinoma before an operation is undertaken, as the operative procedure will depend to a certain extent on the diagnosis. Sarcoma, as a rule, grows more rapidly than the hard variety of carcinoma. It appears as a smooth tumor, and it is seldom complicated by infection of the axillary glands. It occurs in persons of all ages, while carcinoma is seldom met with in women less than thirty years of age.

The examination of a section taken from the tumor under the microscope will enable the surgeon to make a differential diagnosis between adenoma (Fig. 195), carcinoma, and sarcoma. In adenoma the stroma is massive and the epithelial cells are limited to the space *inside* the membrana propria. A glance at Figure 196 will be sufficient to distinguish carcinoma from an adenoma. The epithelial cells here are limited to no one particular place, but are found everywhere and *in direct contact with the vascular connective tissue.*

Round-celled sarcoma of the breast, so far as the appearances of the tumor are concerned, very closely simulates the soft form of carcinoma. Under the microscope it is distinguished from the latter by the absence of a well-marked alveolar stroma, by the more uniform distribution of the cells, and by the sarcoma-tissue forming a part of the wall of the new blood-vessels (Fig. 197). The displacement of the gland-tissue by traction and by projecting parts of the tumor in carcinoma distinguishes this tumor from all other pathological products. Paget aptly says: "Moreover, mere indurations do not involve the skin, do not invade or infiltrate it, or produce in it any puckering or dimpling, as by drawing a part of it toward their own mass. In this, indeed, I think there may be an almost unfailing diagnostic sign."

Another important diagnostic feature of carcinoma that distinguishes it from all other tumors is its peculiar dissemination through the lymphatics of the skin after the tumor has reached the surface. Billroth has likened this to the manner of dissemination of papular exanthemata. Nodules appear in the skin in the vicinity of a carcinomatous ulcer, and feel like shot under the epidermis. They rapidly increase in number in all directions. The lymphatic channels are implicated, and the whole surface, if the disease spreads rapidly, presents an erysipelatous appearance. So long as the nodules remain isolated,

Velpeau called this condition *squirrhe disséminée ou pustuleux*, and when the nodules become united into a board-like mass, *squirrhe en masse*.

Cicatricial contraction is a prominent feature of this form of secondary carcinoma of the skin. The lymphatic vessels play here a more important part in the dissemination of the carcinoma than do the lymphatic glands. Carcinoma of the superficial lymphatics appears to be, if the expression be allowed, a *carcinomatous lymphangitis*. In some cases the deep carcinoma becomes adherent to the chest-wall and continues to contract, but at the same time continues to extend after reaching the gland in the opposite side. The chest-wall becomes fixed and respiration becomes difficult. The whole wall of thorax on the affected side is rendered immovable, board-like; this condition was called by Velpeau *cancer en cuirasse*. *Cancer en cuirasse is not a distinct anatomico-pathological or clinical form of carcinoma, as was formerly asserted, but is always the result of the extension of a glandular carcinoma to the lymphatics of the skin.* The writer has never observed it as a primary affection. It is a rather frequent complication of neglected carcinoma or of recurrent carcinoma of the breast, and is another form of regional infection, occurring later than regional infection through the deep lymphatic glands. When the tumor has reached this stage it is usually inoperable. Recurrence is almost sure to follow most extensive operations. Infection of the superficial lymphatics of the skin appears often in such an acute form that the temperature rises several degrees above normal, and in a few weeks the whole side of the chest becomes involved. New nodules appear every day, and the skin during the acute stage presents an erysipelatous blush.

In the rudimentary mammary gland in men occur nearly all the tumors that have been observed in the female, especially carcinoma. Schuchhardt recently collected 277 cases of carcinoma of the breast in males. When carcinoma develops in the male breast, it follows the same clinical course as in the female. Regional and general infection occur with equal frequency, and the disease proves fatal in about the same length of time as in the female.

Prognosis.—Birkett estimated the average duration of life of patients suffering from carcinoma of the breast, and upon whom no operation is performed, as being three and a half years. The duration of the disease is affected very much by the age and the constitution of the patient, the course being slower in the older and less plethoric patients. Astley Cooper's estimate is a fair one—namely, two years for the full development of the disease, and from six months to two years longer for a fatal termination. In some instances, particularly in the aged,

the disease pursues a very slow course, extending over a period of from six to fifteen years. In a case of pathological fracture of the upper part of the femur in a woman seventy-five years of age the writer accidentally discovered a small firm tumor in the left breast. On communicating this information to the patient she stated that she had first discovered a small lump in the breast twenty years previously. In this case, as in many other cases which finally terminate in metastasis, the tumor remained in a latent condition for twenty years.

The malignancy of carcinoma of the breast appears to diminish with advancing age. Soft carcinoma, observed most frequently in the young, leads to a fatal termination much more rapidly than the hard variety. The local infection progresses more rapidly, and the tumor attains a larger size, in the soft than in the hard variety. Patients suffering from the soft form of carcinoma of the breast are frequently carried off by some acute chest complication, and the autopsy reveals secondary tumors in the lung and the pleura. Tumors which have undergone colloid degeneration do not result in early regional infection: they pursue a comparatively benign course.

It is interesting to know what has been gained in the duration of life by operative treatment. Birkett estimates that patients who have been subjected to operative treatment live, on an average, four years, while the duration of life in those not operated on is three and a half years. Sibley, in 78 cases not operated on and in 63 operated on, ascertained that the latter lived one year and nine months longer than the former. Patients operated upon by Paget and Volkmann lived one year and two and a half months longer than those treated upon an expectant plan. According to Winiwarter, patients not operated on live 32.9 months, and those operated on 39.3 months. A certain percentage of those patients subjected to operative treatment remain free from a recurrence. Winiwarter ascertained that most of the relapses—that is, 82.4 per cent.—occur within three months after the operation. Relapses, however, may occur as late as ten years after operation. The extensive statistics of Winiwarter, Billroth, Oldekop, Esmarch, Henry, Breslau, Fischer, and Dennis show conclusively that operations undertaken before axillary infection has taken place yield the best results. Since surgeons have made it a rule to clear out the axilla in every case of carcinoma of the breast the results are becoming better. Dennis secured a permanent result in 25 per cent. of his cases. The average percentage of cases in which no recurrence takes place in the hands of other operators is, however, much less. The mortality of the operation under the influence of antiseptic measures has been reduced to from 5 to 7 per cent. The writer is confident that when the

public has become educated in reference to the necessity of early operations, and the profession recognizes the importance of carrying the incisions far beyond the palpable tumor and the infected glands, the percentage of permanent recoveries will be increased greatly, and the mortality of the operation, by a strict adherence to aseptic measures, will become reduced to 1 or 2 per cent.

Treatment.—The palliative measures in inoperable cases of carcinoma consist of such measures and palliative operations as have been described under the head of Palliative Treatment of Carcinoma. The contraindications to a radical operation are: Extreme old age; metastatic tumors; local or regional extension of the disease beyond the limits of a justifiable radical operation; the coexistence of other diseases which would in themselves tend to destroy life in a short time. It is useless to emphasize what is now insisted upon by all practical surgeons—that a radical operation should be performed before regional infection has taken place. *A radical operation should be performed as soon as a diagnosis has been made.* The diagnosis should be made positive either before or at the time of operation. *Upon the differential diagnosis between adenoma and carcinoma depends the thoroughness of the operation.* An adenoma is removed by enucleation; a carcinoma demands the removal of the entire breast. The removal of the entire mammary gland for adenoma is unwarranted; the removal of a carcinoma of the breast without removing the entire organ is almost sure to be followed by an early recurrence. If an unequivocal diagnosis of carcinoma is made, it is not only necessary to remove the entire breast, but all the connective and adipose tissue and lymphatic glands from the margin of the breast to the very apex of the axilla should be removed with the breast. The extent of a radical operation is reached by removing at the same time such parts of the pectoral muscles and the latissimus dorsi as may be deemed necessary. The removal of the entire upper extremity, as suggested by McGraw, and the resection of numerous ribs when the tumor has invaded the chest-wall, are beyond the limits of prudent surgery.

The field of operation should be prepared the evening before the operation by scrubbing with warm water and potash soap, shaving, and the energetic use of a 1 : 1000 solution of corrosive sublimate. The use of alcohol or of ether is useful in removing infectious material from the appendages of the skin. A compress of aseptic gauze wrung out of the sublimate solution should be applied, the moisture being retained by applying over the compress an impermeable fabric like gutta-percha paper, mackintosh, or oiled silk. The hands of the operator and his assistants are carefully disinfected, and the instru-

ments, ligatures, and sutures are sterilized by boiling for ten minutes in a 1 per cent. solution of carbonate of soda. No antiseptics are to be brought in contact with the wound. Gauze sponges should take the place of marine sponges. The chest of the patient should be raised slightly during the operation, and the body should be inclined toward the opposite side.

Unless the position of the tumor furnishes a contraindication, the incision should be made in such a manner as to include with the nipple an elliptical piece of skin, and should be carried along the border of the pectoralis major to the apex of the axilla (Fig. 198). The necessity of removal of an extensive area of skin was strongly emphasized by S. W. Gross. He made a circular incision around the breast and made no attempt to close the wound. This course should be pursued if the overlying skin is extensively involved, but if sufficient healthy skin remains, it is better to preserve enough to cover the wound. The hemorrhage which freely follows immediately the incision is made should be controlled by pressure—a duty incumbent upon the assist-

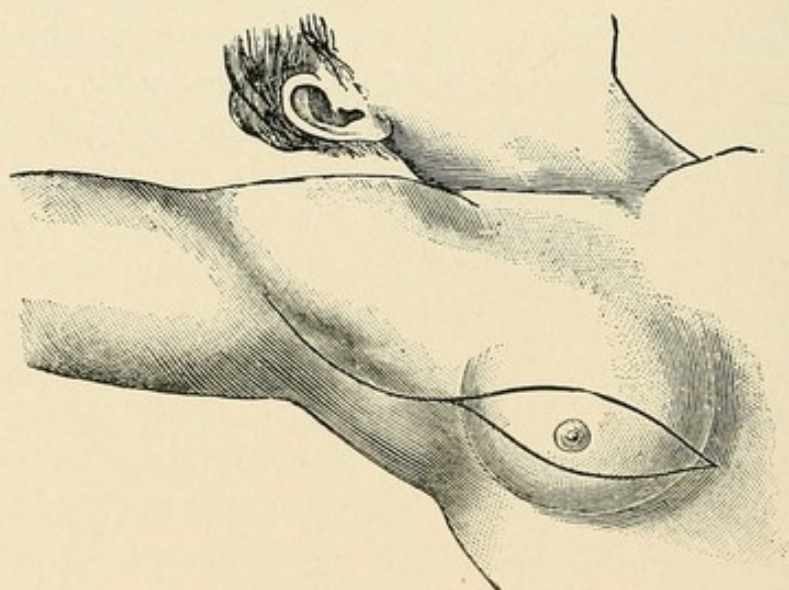


FIG. 198.—Incision for carcinoma of the breast (after Esmarch).

ant. The spurting arteries are then secured with compression-forceps, which must be relied upon as a hemostatic until the tumor and the axillary contents are removed, when every bleeding point is carefully tied with aseptic catgut. The breast with the pectoral fascia should be dissected out first, but should be allowed to remain in connection with the axillary glands. The large wound-surface is now covered with a compress of gauze during the dissection of the axillary space. If the carcinoma has extended beyond the capsule of the gland at its base, parts of the pectoralis major and minor and the serratus magnus and latissimus dorsi muscles may require removal; but such extensive

excision of muscular tissue as has recently been advocated by Halsted appears superfluous to the writer.

The guide to the axilla is the border of the pectoralis major in front and the latissimus dorsi behind. It is advisable to approach the axilla from the front. The skin, the superficial fascia, and the panniculus adiposus are reflected on each side sufficiently to expose the border of both these muscles. After clearing the border of the pectoralis major the space between this muscle and the pectoralis minor is inspected carefully, as a chain of enlarged lymphatics is frequently found in this locality. If the entire chain of glands can be removed by retracting the great pectoral muscle, this part of the operation is completed. If this cannot be done, the pectoral muscle is divided transversely as far as necessary, and after clearing out the axilla it is sutured with a row of buried catgut stitches.

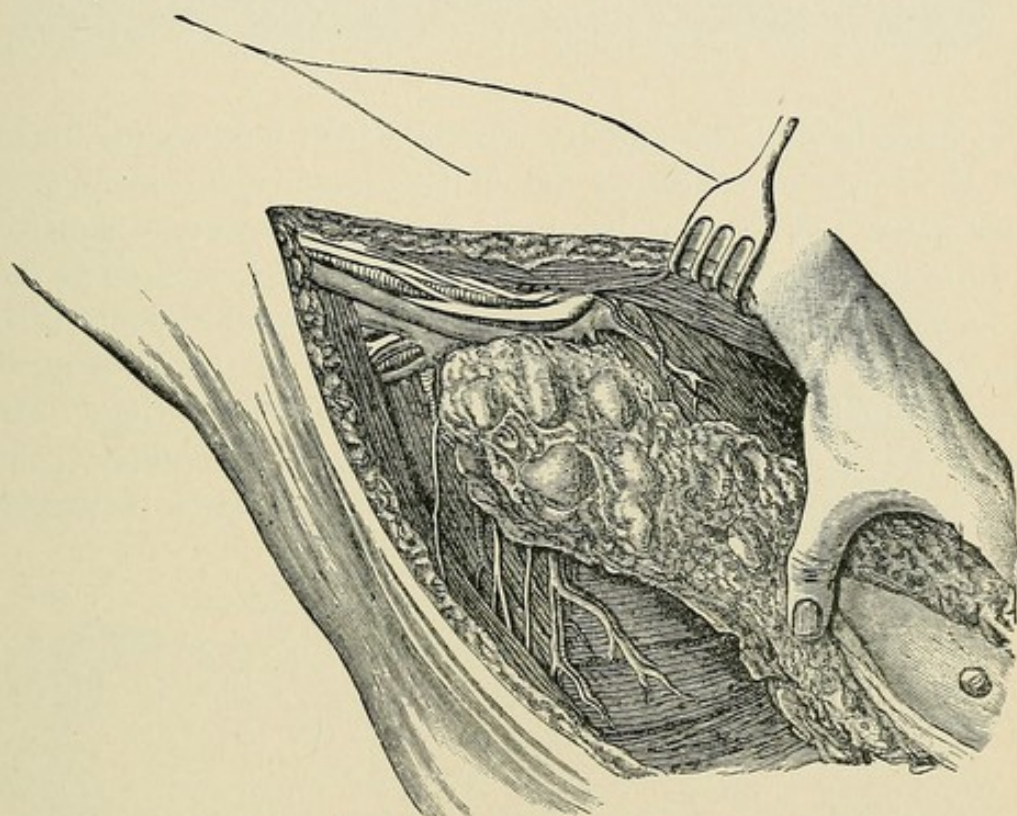


FIG. 199.—Dissection of the axillary space in operation for carcinoma of the breast (after Esmarch).

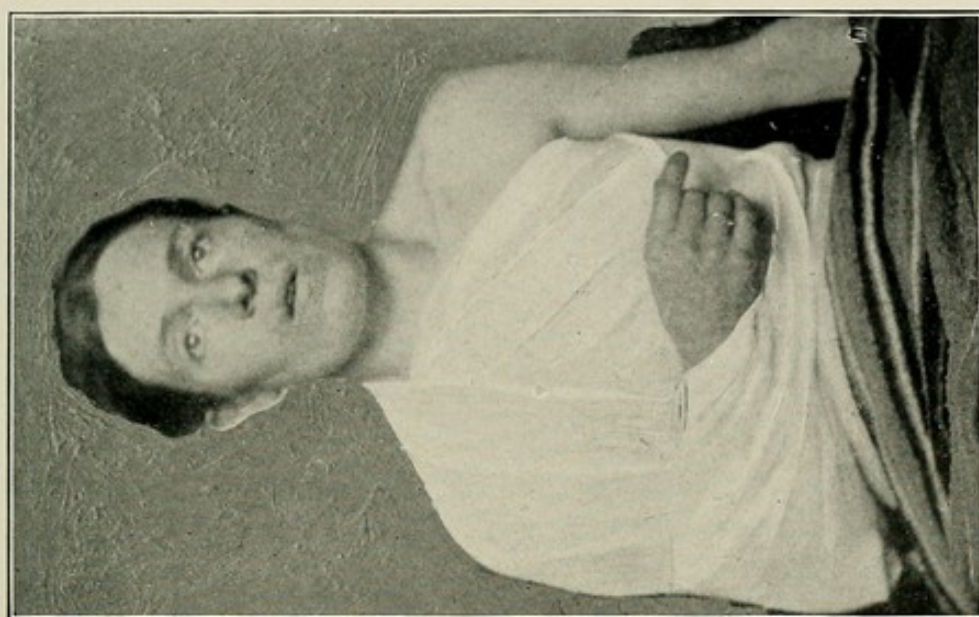
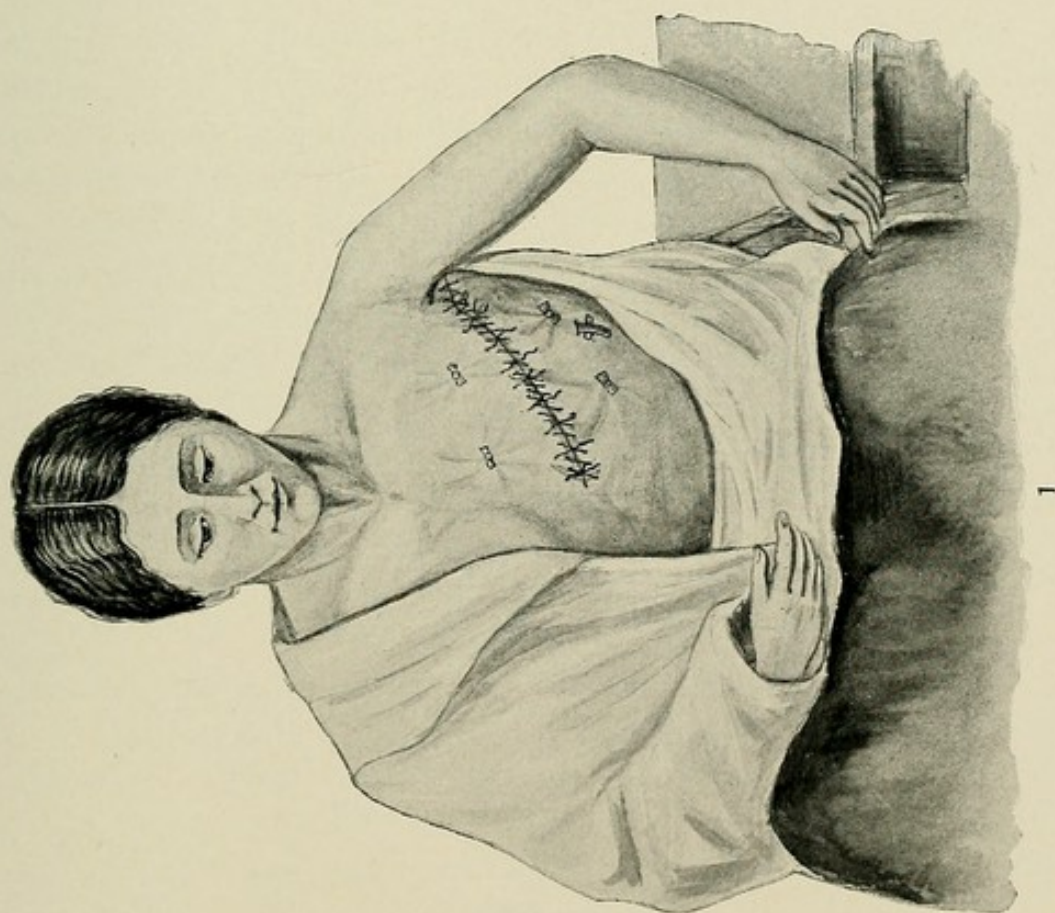
The next thing to be done is to clear the border of the lesser pectoralis muscle, which at the same time serves as a guide to the axillary vessels, which are the next landmarks to be sought for. The axillary vein can usually be found without any particular difficulty by making a blunt dissection with the finger, with Kocher's director, or with blunt-pointed scissors. *Before anything is done in the apex of the axillary space the large vessels must be well exposed to avoid unintentional injury, which is unlikely to occur if the vessels are exposed and are followed*

with the requisite care. The space in front of the axillary vessels is next cleared out; and it is here that the chain of glands must often be followed and removed as far as the upper border of the first rib. This part of the operation must be done slowly and carefully. Rupture of glands by pressure or by traction must be avoided. The dissection here must be made with the aid of blunt instruments. A number of small veins emptying into the axillary vein from below should be tied close to the axillary before being cut. Glands are often found attached to the vein, and their separation without injury to the vein requires patience and careful work (Fig. 199). If the vein is incorporated in a mass of carcinomatous glands and cannot be isolated, the part connected with the tumor should be removed between two catgut ligatures. This alternative, fortunately, does not present itself frequently, and resection of the vein must be avoided whenever possible. Small wounds of the axillary veins can safely be closed by lateral ligatures or by suturing, thus preserving the lumen of the vessel.


The space behind the axillary vessels, which next claims the attention of the surgeon, is cleared out in the same careful manner as the anterior space. When this has been done the dissection is continued in a downward direction. All spurting points are secured by hemostatic forceps. The preservation of the coraco-brachialis and of other smaller nerves traversing the axillary space, as recommended by Küster, is practised only when the regional infection is slight. In the majority of cases it is better to excise them with the axillary contents than to run the risk of making an incomplete operation by preserving them.

The removal of the string of glands in the direction of the subscapular artery often necessitates ligation of this vessel and its accompanying vein. If the disease is at all extensive, a considerable portion of the serratus magnus muscle must be removed. *The tumor, the adjacent tissues, and the axillary contents are to be removed in one continuous mass. All attempts at enucleation of infected glands will surely be followed by a speedy recurrence. Crushing or teasing of carcinomatous glands will be followed by traumatic dissemination of the carcinoma.* As soon as the tumor and the axillary contents have been removed all bleeding points must be ligated. *Careful hemostasis is an essential prerequisite to an ideal wound-healing.*

The wound inflicted by an operation of this extent is a very large one, and considerable parenchymatous oozing will occur after the patient rallies from the immediate effects of the operation and the anesthetic. If the wound is sutured throughout, accumulation of a considerable



1. Suturing the wound after operation for carcinoma of the breast. 2. Dressing after amputation of the breast for carcinoma.



quantity of blood and serum is almost sure to follow, often giving rise to painful tension, necessitating an early change of the dressing, the removal of one or more sutures, and the insertion of secondary sutures.

Ordinary tubular drainage is very unsatisfactory in preventing the accumulation of blood in the wound. The lumen of the tube becomes blocked by a blood-clot, and the fluid that escapes is at the sides, and not through the tube. Bergmann overcame these difficulties by packing the wound with iodoform gauze, which he removes on the second or third day, then closing the wound by secondary sutures. He and others have obtained excellent results by this treatment. The sutures can be inserted at the completion of the operation, but they are not tied until the gauze tampon is removed. In hospital practice this method of wound-treatment yields excellent results and is not attended by any additional risks of infection, but in general practice it is better to suture the wound and to drain with iodoform gauze. A strip of gauze folded upon itself several times should extend from the apex of the axilla to the most dependent part of the wound, where it is brought out through a separate incision about two inches in length. The wound is then sutured throughout. On the second or the third day the gauze drain is removed. In closing the wound the deep sutures of silk or of silkworm-gut are placed about an inch apart, and over them the skin is united accurately with a continued suture of fine catgut (Pl. 7, Fig. 1). After washing the surface with a solution of corrosive sublimate or of carbolic acid and drying it carefully, a copious antiseptic hygroscopic dressing should be applied. The line of suturing is dusted with a powder of iodoform and boric acid (1 : 5) until the sutures are buried under the powder. Eight layers of iodoform gauze are applied next to the wound, and over the iodoform gauze a large thick compress of sterilized gauze. Absorbent cotton is used as a filter over and around the gauze, including also the shoulder. The dressing is retained by a wide roller composed of several layers of gauze, and the arm is confined to the side of the chest with the same roller bandage (Pl. 7, Fig. 2).

The first dressing should not be changed for two or three days, when the gauze drain is to be removed, unless copious oozing saturates the dressing. When the outer dressing becomes simply stained at the end of the first twelve or twenty-four hours, the part stained should be dusted with iodoform and be covered with a thick compress of absorbent cotton retained by an additional bandage.

The deep sutures are removed at the end of eight or ten days. At this time only the superficial part of the catgut suture remains. If, not-

withstanding the strictest antiseptic precautions, infection has occurred, as will be indicated by a rise in the temperature on the second or the third day, no time should be lost in removing the dressing and some if not all of the sutures, and in establishing additional points of drainage. Antiseptic irrigation frequently repeated, and a compress kept moist with a saturated solution of acetate of aluminum, will then constitute the most important measures in the after-treatment.

If after the completion of the operation the wound cannot be sutured, the margins should be brought as close together as possible with tension-sutures, and the remaining surface should be paved with Thiersch's grafts. The results of skin-grafting performed under such circumstances are very encouraging. Skin-grafting enables the surgeon to secure primary healing of the wound under one or two dressings—a great gain in the management of such cases.

In a case recently under his care the writer resorted successfully to a plastic operation to remedy the resulting defect. The breast and skin on the opposite side were undermined, and with a flap (Fig. 200) taken from the abdomen the wound was readily closed.

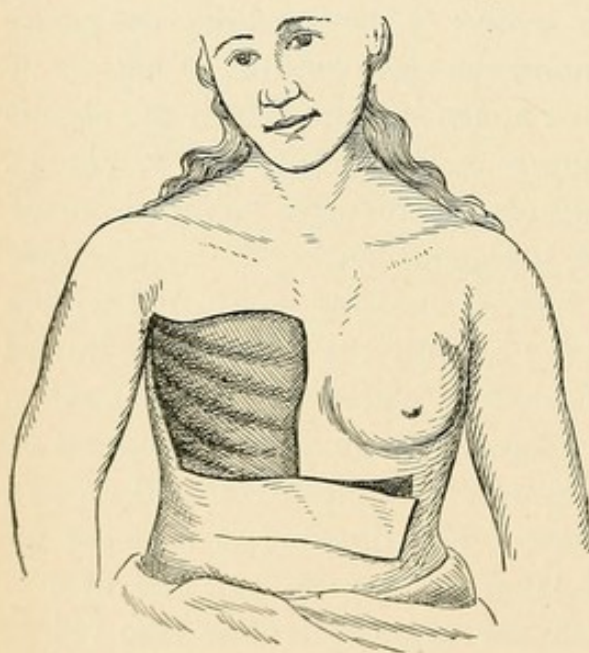


FIG. 200.

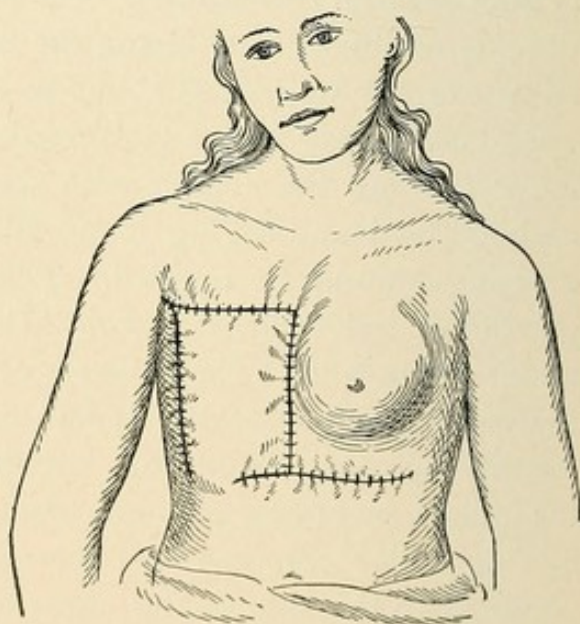


FIG. 201.

FIGS. 200, 201.—Plastic operation after excision of carcinoma of the breast.

The opposite breast was mobilized so that it occupied a position near the sternum (Fig. 201). With the exception of a slight marginal necrosis the flap survived, and the wound healed by primary intention.

After every operation for carcinoma of the breast it is important that the surgeon or the family physician should examine the patient every

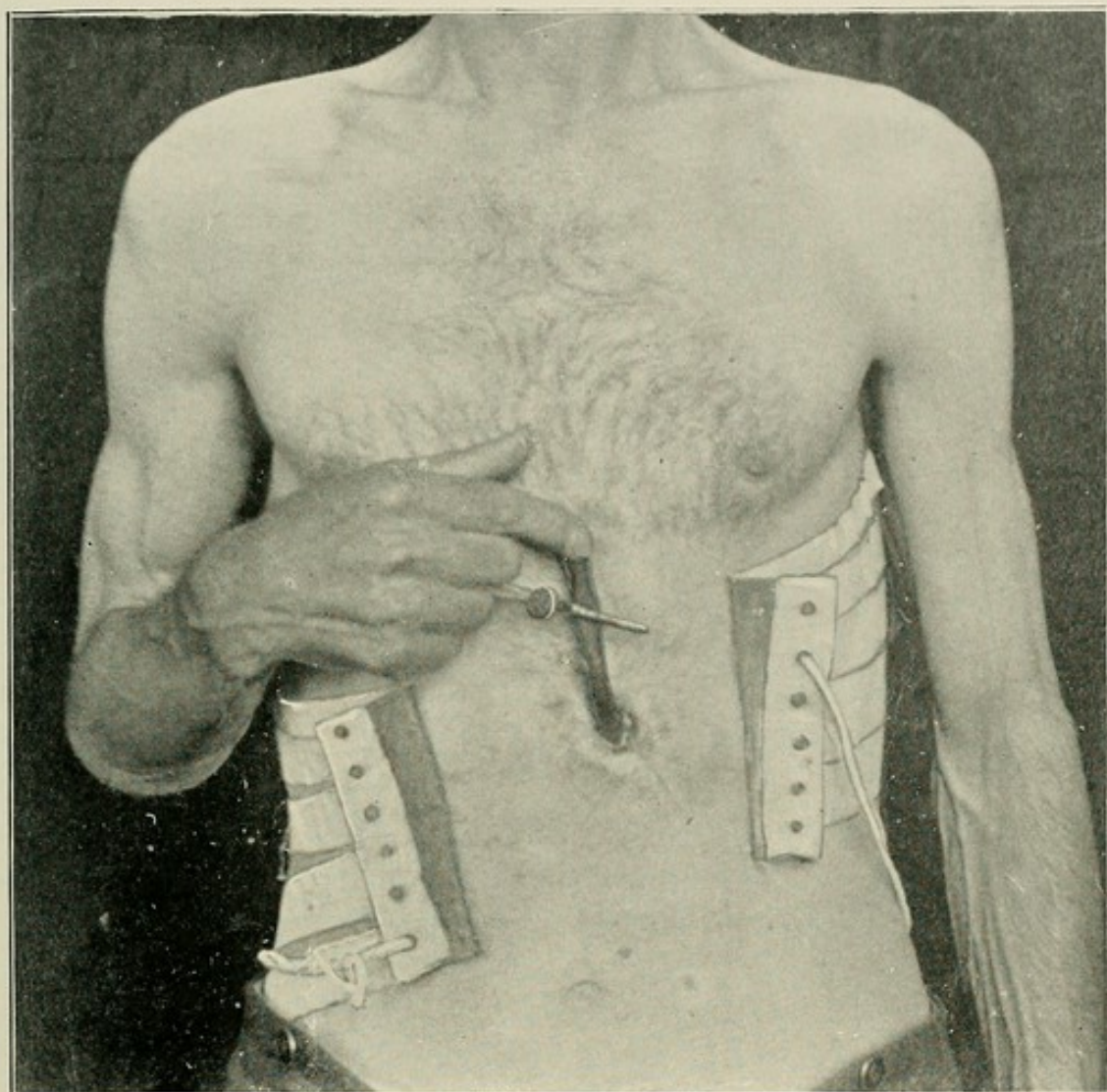
two or three months to determine whether or not a local recurrence has taken place. It is not a good policy to leave this matter to the patient or to her friends. The patient should know as little as possible about the object of these examinations. The first nodule that is discovered should be removed at once. This removal can usually be done with the aid of a local anesthetic. Every local recurrence should be met promptly by a thorough removal. The writer has repeatedly performed three and four operations for slight recurrence in the same patient, and has been able in this way to postpone the fatal termination, and in a few instances has gained complete control over the disease.

Œsophagus.—Carcinoma of the alimentary canal below the soft palate is composed of tissue derived from the hypoblast. The prevailing type of the epithelial cells of the tumor is the columnar. The pharynx is very seldom affected by carcinoma. The œsophagus, on the contrary, is quite frequently the seat of carcinoma. About half of the cases occur in the lower third, about one-third in the middle third, and the balance higher up. Mackenzie's observations led him to formulate different conclusions in reference to the part of the œsophagus most frequently affected. He based his statistics on 100 cases. Of these, 44 involved the upper third, 28 the middle third, and 22 the lower third. As Mackenzie was a throat specialist, it is to be expected that he was consulted more frequently by patients who suffered from carcinoma of the upper part of the œsophagus, which would explain the discrepancy existing between the statistics gathered by the general surgeon and those quoted by specialists in reference to the favorite seat of carcinoma of the œsophagus. All surgeons agree in the statement that cicatricial stenosis affects more frequently the upper, and carcinoma the lower, part of the œsophagus.

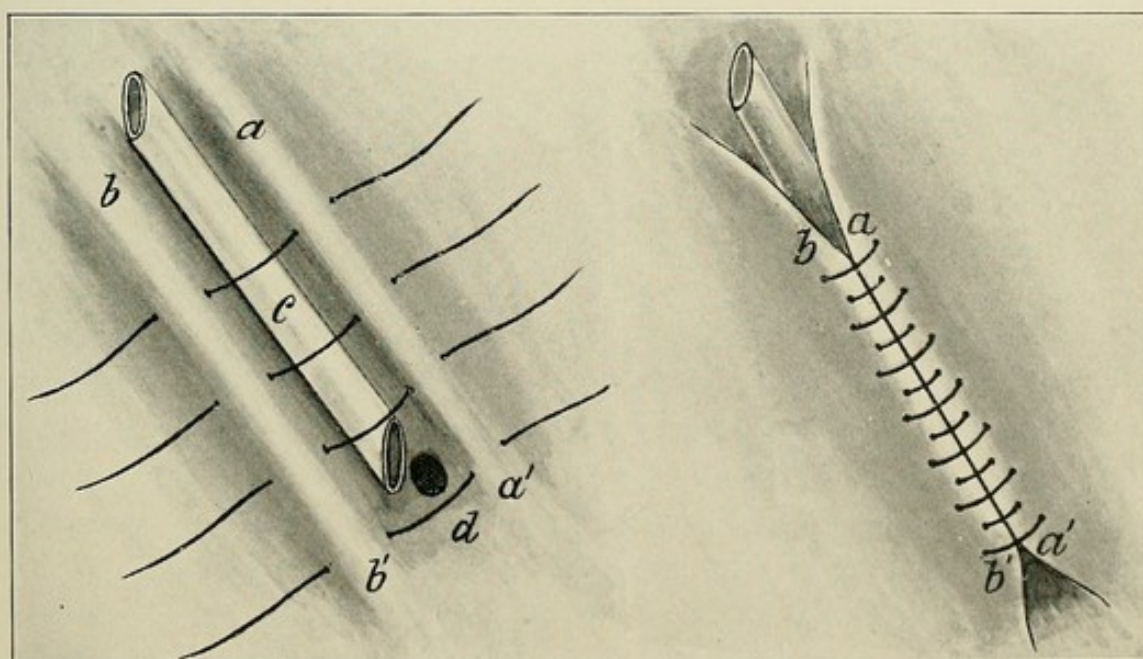
Carcinoma of the œsophagus appears in two different pathological forms: (1) the soft variety, which leads to early ulceration and perforation; (2) the hard form, which results in the formation of a circular stricture. The circular stricture seldom involves more than an inch of the œsophageal tube. Not infrequently perforation into the trachea, the posterior mediastinum, or the pleura takes place. The writer saw in Von Ziemssen's clinic a case which was frequently presented before the class to demonstrate the existence of a communication between the œsophagus and the trachea. A few moments after the patient drank a few tablespoonfuls of milk he was attacked by a violent fit of coughing which did not cease until the milk he had swallowed was expectorated. The post-mortem showed a carcinoma of the œsophagus that had perforated into the trachea. In some instances a fatal termination takes place from hemorrhage by perforation of the carcinoma into one of

the large blood-vessels. In some cases the disease results in death without having produced any symptoms of obstruction. In the majority of cases, however, the first thing that attracts the patient's attention is that he is not able to swallow solid food. This difficulty gradually increases until only liquids can be swallowed, and finally the obstruction becomes complete. The food that is swallowed is not ejected immediately, a variable interval elapsing until the food is regurgitated. One of the results of the obstruction is a dilatation of the œsophagus above the stricture; in cases of long-standing circular stricture the œsophagus becomes dilated into a large pouch holding a teacupful or more. *The food is not vomited, but is regurgitated, and is ejected unchanged.* As soon as the tumor interferes with deglutition marasmus very rapidly sets in, and death follows in a few weeks. Pain in the region of the tumor is slight or is entirely absent.

In the differential diagnosis between cicatricial stenosis and carcinoma of the œsophagus it is necessary in the first place to inquire carefully into the history of the case. Cicatricial stenosis usually develops after destruction of the mucous membrane by the swallowing of lye or of other caustic—an accident which occurs more frequently in children than in adults. Cicatricial stenosis occurs most frequently in children and young adults; carcinoma of the œsophagus is seldom met with in persons less than fifty years of age. *A gradually increasing stenosis of the œsophagus in persons advanced in life, in whom the clinical history does not reveal the existence of the usual causes of cicatricial stricture, is with very few exceptions indeed caused by a carcinoma.* The existence of the obstruction must be demonstrated by the use of the olive-pointed œsophageal bougie. The largest size is to be used first to determine the seat, and then the smaller points to ascertain the extent, of the stricture. *No force must be used in passing the instrument through the stricture.* Disregard of this advice has repeatedly resulted in perforation of the œsophagus and death from immediate and remote complications caused by this accident. The writer has personal knowledge of two such cases: in one the perforation was followed by fatal hemorrhage, in the other by septic peritonitis. Dilatation of a carcinomatous stricture is contra-indicated, as it not only aggravates the local conditions, but is also attended by the risk of perforation. The use of elastic tubes is not attended by the danger of perforation, and if the stricture is permeable they are used to introduce into the stomach liquids and finely-divided food suspended in liquids. A small rubber tube inserted into the stomach from one of the nostrils can be retained and used for stomach-feeding. As soon as stomach-feeding is impossible even with the aid of elastic œsophageal tubes, a gastrostomy should be performed. This




1



2

1. Witzel's method of performing gastrostomy. 2. Witzel's operation, showing tube buried by sutures.



operation should not be postponed too long. As a rule, patients are loath to accept this the last alternative to prolong their lives, and consequently frequently postpone the operation until it is too late.

Gastrostomy.—Fenger's incision has been rendered obsolete by the many recent improved methods of establishing an external gastric fistula in cases of œsophageal obstruction. The operation that has found more favor with the profession than any other is Witzel's (Pl. 8, Figs. 1, 2). One of the great difficulties to overcome in gastric feeding through an external fistula was the escape of food through the fistula after its introduction into the stomach. Witzel devised an operation that appears to answer all requirements better than any other. The abdomen is opened, under strict antiseptic precautions, through the left rectus muscle, a little to the left of the median line and a little below the tip of the xiphoid cartilage. The stomach is identified, and its anterior wall is brought well forward into the wound. A compress of gauze is packed around the projecting part of the stomach, and in its anterior wall there is made an opening large enough to insert a rubber tube a little larger than an ordinary lead pencil. The tube, about 6 inches in length, is then so inserted that its end projects well beyond the mucous surface of the stomach. There is then made in the anterior wall of the stomach a vertical groove deep enough to receive the rubber tube, when the serous surfaces are stitched together over and below the tube, so as to prevent the escape of fluid from the opening in the stomach into the peritoneal cavity. The tube is buried in this manner to the extent of two inches, when the stomach is fastened by stitches in the upper angle of the incision, and the balance of the wound is closed by suturing.

Mikulicz modified Witzel's operation by stitching the anterior wall of the stomach around the sutures over the tube to each side of the external incision before closing the wound up to the fistulous opening. This should invariably be done, as it affords an additional safeguard against the escape of stomach-contents into the peritoneal cavity.

If the patient is very much debilitated, stimulants and liquid food may be introduced at once into the stomach through the rubber tube. The distal end of the tube after feeding is either tied or compressed by a suitable clamp. The fistula established in this manner is oblique, and the internal opening is closed by a valve-like action of the upper part, which, even when the tube is removed, effectually prevents the escape of stomach-contents. Witzel recommends that after a few weeks the rubber tube be removed, and be inserted only when the patient feeds himself. The patient should masticate and insalivate the solid food before he pours or injects it into the stomach. The great mortality which has attended this operation so far is due to the fact that in the

majority of cases in which death resulted from the operation the patients had postponed it too long. If this operation is to prolong life, it must be performed in time, before the patient's strength has been reduced to the lowest ebb.

Stomach.—Carcinoma of the stomach, which is by no means a rare affection, occurs most frequently in persons from thirty to sixty years of age. Sutton refers to a case in which the patient, a girl, was only thirteen years old. The youngest patient that has come under the writer's observation suffering from this disease was a man twenty-five years old. The pylorus is the part of the stomach most frequently implicated. Lebert found the disease here in 51 per cent. of the cases he examined, and Brinton, Gussenbauer, and Winiwarter have shown that the proportion of cases in which the pylorus is affected is still greater: they estimate it at 60 per cent. As all parts of the mucous membrane of the stomach are freely supplied with tubular glands, the histological structure of carcinoma of the stomach mimics tubular glands. Sections from new parts of the tumor show under the microscope a tubular structure (see Fig. 140).

The character of the structure of the tumor is determined by the relative amount of epithelial cells to the stroma. If the parenchyma of the tumor largely preponderates over the stroma, the tumor grows rapidly, ulcerates early, and soon implicates the entire thickness of the wall of the stomach. These are the cases in which hemorrhage or perforation frequently terminates life at an early stage. In the hard variety of carcinoma of the stomach, found most frequently at the pyloric end, the tissues become infiltrated slowly and to a limited extent. The circumference of the entire pylorus becomes implicated in the form of a ring-like, circular induration. The connective-tissue stroma contracts, and the lumen of the pylorus is progressively narrowed until finally it becomes impermeable to the passage of food from the stomach into the duodenum. In other cases the disease infiltrates the wall of the stomach very extensively, but no contraction of the stroma takes place. These are the cases in which during life, although the pylorus may show extensive disease, symptoms of obstruction do not occur. In carcinoma of the cardiac end of the stomach a circular carcinomatous stricture presents the same clinical evidences as carcinoma of the œsophagus, and requires the same treatment. In carcinoma of the stomach located between the cardiac and pyloric ends the symptoms are often very vague. Vomiting at irregular periods after meals, hematemesis, indigestion, progressive marasmus, and in some cases a palpable tumor, suggest the existence of a malignant tumor in this part of the stomach. Circular constricting carcinoma of the stomach

gives rise to a clinical picture that is almost typical. Vomiting of unchanged or partly-digested food in from two to four hours after meals, attended by a sense of relief, gradual dilatation of the stomach, in advanced cases reaching as far as the pubes, and progressive emaciation, characterize the case. If the carcinoma appears in the form of a narrow constricting ring, it is often impossible to recognize the tumor by external palpation. If the tumor attains larger dimensions, it can be felt usually a little below the level of the normal pylorus, especially after the stomach has been emptied of its contents by the use of the elastic stomach-tube. Hemorrhage is sometimes profuse, and even fatal if a large vessel, such as the pyloric branch of the hepatic artery, has been eroded by the carcinoma. In pyloric obstruction the retention of food leads to fermentation, which aggravates existing indigestion and ends in causing dilatation of the organ.

The only disease which is likely to be mistaken for pyloric carcinoma is cicatricial stenosis of the pylorus. Cicatricial stenosis is the result of the healing of an antecedent ulcer in this locality, and the condition occurs, as a rule, in younger persons than does carcinoma. This form of obstruction is found more frequently in the female than in the male. The absence of a palpable tumor should not influence us in deciding in favor of the existence of a cicatricial stenosis, as frequently no tumor can be detected externally in cases of circular constricting carcinoma of the pylorus. Free muriatic acid is frequently absent in carcinoma of the stomach, but this circumstance is no unfailing test for malignant disease, as this acid may be absent in obstruction caused by non-malignant disease, and may be present during the early stage of carcinoma. The occurrence of vomiting in from one to three hours after meals in persons more than fifty years of age should excite suspicion of carcinoma. If the vomited material is mixed with grumous blood, presenting the appearance of coffee-grounds, if the vomiting is followed by a sense of great relief, and if the symptoms do not yield within a short time to the usual treatment, it is very probable that the patient is suffering from carcinoma of the stomach, although no palpable tumor may be present.

Inflation of the stomach after evacuating the organ by the use of the stomach-tube is the most reliable and safest way by which to determine the presence and extent of dilatation. The area of tympanites will at least approximately correspond with the size of the stomach. If the large curvature of the stomach reaches the umbilicus, the organ has become dilated. During the examination for a tumor of the stomach the patient should be placed in the dorsal recumbent position with the chest elevated and the legs and thighs flexed. Succussion

after the introduction of a small quantity of fluid into the stomach suggests very strongly the existence of dilatation (Bouchard).

Carcinoma of the stomach, with few exceptions, proves fatal within a year. Perforation into adjacent viscera, duodenum, and transverse colon may prolong life by creating a new outlet for the stomach-contents into the intestinal canal. If perforation into the free peritoneal cavity takes place, death from peritonitis usually ensues. Death from recurring hemorrhages follows the erosion of an artery of considerable size. In most instances of carcinoma of the pylorus the immediate cause of death is inanition resulting from the suspension of digestion caused by mechanical obstruction.

Metastasis occurs in connection with carcinoma of the stomach. When the carcinoma reaches and involves the peritoneal coat of the stomach, regional dissemination often takes place by the dispersion of carcinoma-cells or fragments of tissue over the adjacent serous surfaces. In this way the great omentum often becomes extensively infected. The lymphatic glands in the gastro-hepatic omentum are infected in more than two-thirds of the cases. The lumbar, cervical, and mediastinal lymphatic glands are occasionally the seat of regional infection.

Treatment.—Careful attention to the diet and the use of the siphon stomach-tube in the cases in which dilatation from pyloric obstruction has taken place are to be relied upon in the conservative treatment of carcinoma of the stomach. The internal administration of salol and bismuth affords relief when the obstruction has given rise to catarrhal inflammation of the gastric mucous membrane. The observation that carcinoma of the pyloric orifice of the stomach is frequently very limited in extent, and that patients succumb not so much to the malignant disease as to the effects caused by the mechanical obstruction, has induced surgeons to desist from operations for the removal of the carcinomatous pylorus.

Pylorectomy.—The first experimental pylorectomies on dogs were made in 1810 by Merem. Parts of the stomach were removed for other indications than carcinoma by Torelli and Esmarch. Accurate experimental investigations concerning the feasibility of pylorectomy for carcinoma were made by Gussenbauer, Winiwarter, and Kaiser. The pylorus was removed for the first time for disease by Péan. Billroth made the first successful pylorectomy. The success of the operation has not been what was expected from it. In 66 cases death occurred soon after the operation in 50. Only in a few cases was life prolonged for any considerable length of time. One of Wölfler's cases lived three and a half years after the operation. That the operation has not yielded better results is due to the fact that the local extension of

the tumor and the regional infection were such as to require very extensive operations, to the immediate effects of which many of the patients succumbed; and for the same reasons, in those that survived the immediate effects of the operation the disease returned soon afterward. In the fifteen cases of abdominal section made by the writer for carcinoma of the stomach the disease was found too extensive and regional infection too diffuse to warrant pylorotomy in all the cases but one, and in this one the circular carcinomatous stricture of the pylorus had resulted in such great impairment of the strength of the patient as to preclude the advisability of resorting to a pylorotomy.

Surgeons have gone too far in the radical treatment of carcinoma of the pylorus. In the writer's estimation the operation is warranted only if the disease remains limited to the organ primarily affected, and if the patient is strong enough to resist the immediate effects of the operation. The stomach is washed out immediately before the operation. If the organ is thoroughly emptied before the operation, there is hardly any need for the different mechanical devices (Fig. 202, A, B, C, D)

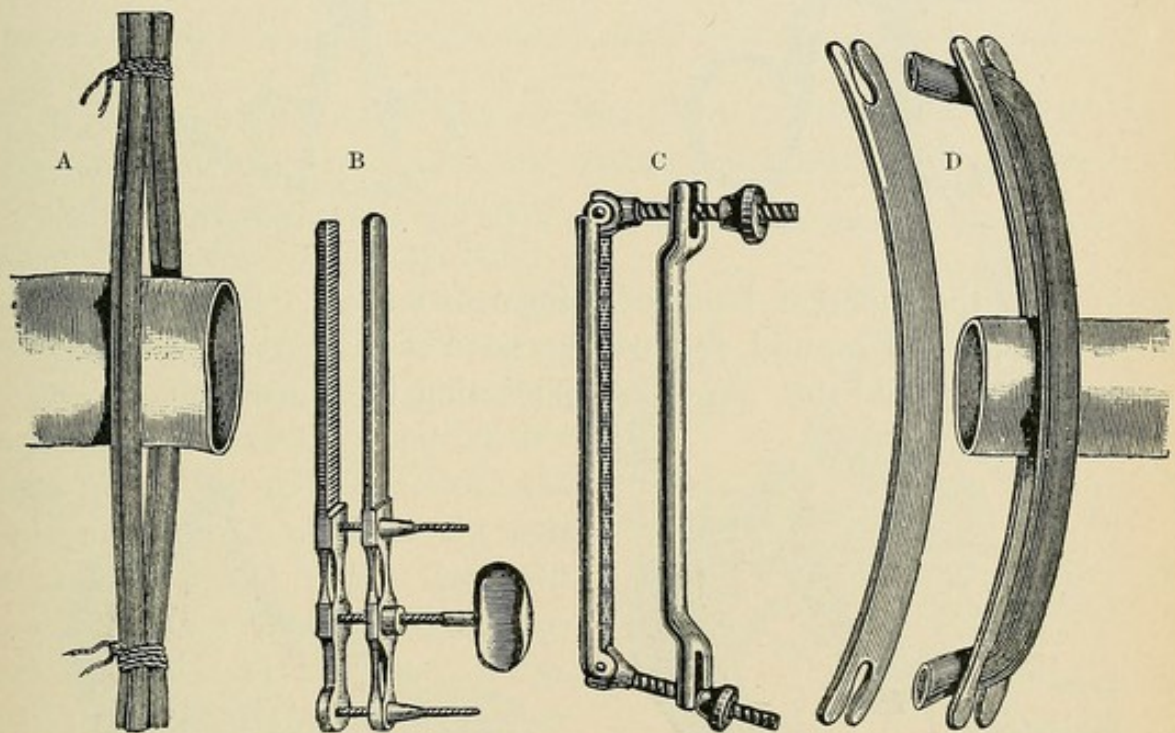


FIG. 202.—Intestinal and stomach clamps: A, after Rydygier; B, after Billroth; C, after Hahn; D, after Heineke.

which have been employed for the purpose of preventing the escape of duodenal and stomach-contents. Catch-forceps of special construction (Figs. 203, 204) have also been employed for the same purpose. For the prevention of the escape of intestinal contents nothing equals in efficiency and ease of application the elastic constrictor. A small rubber tube about a foot in length is drawn through a buttonhole made

with a pair of hemostatic forceps in the mesentery near its attachment to the bowel. This tube is tied with sufficient firmness to prevent the escape of intestinal contents. It is not in the way of the operator, and it is less likely to inflict unintentional injury to the bowel or the adjacent

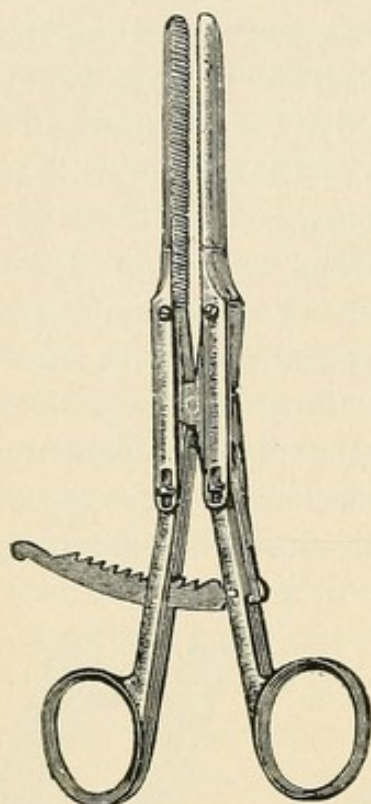


FIG. 203.—Intestinal forceps (after Gussenbauer).

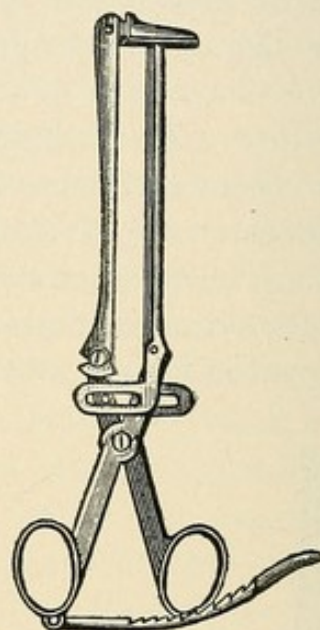


FIG. 204.—Intestinal forceps (after Küster).

parts than the different kinds of clamps or forceps. Sterilized gauze should be packed around and on the sides of the part to be resected, to absorb any fluid that might escape during the operation.

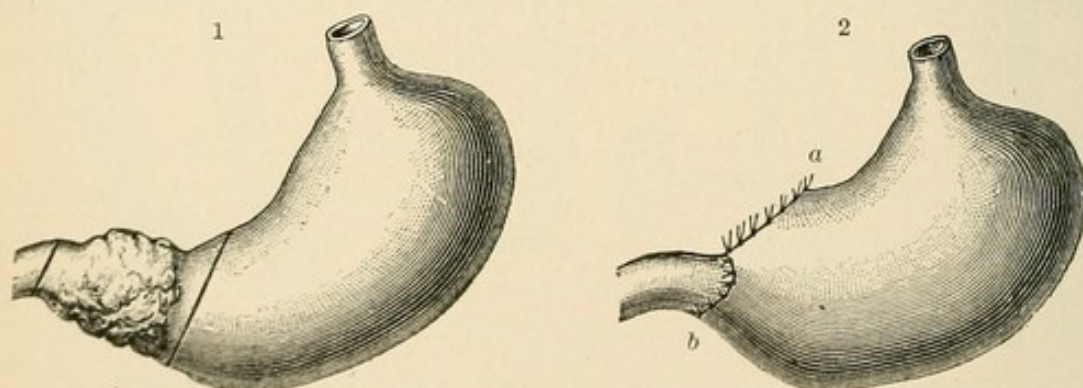


FIG. 205.—Resection of the pylorus after Billroth-Wölfler: 1, location and direction of visceral incisions; 2, suturing: *a*, occlusion-sutures; *b*, circular sutures.

The abdomen is usually opened in the median line, below the tip of the xiphoid cartilage, far enough to secure free access to the pylorus. Billroth prefers an oblique incision below and parallel to the right costal arch. The mesenteric attachment of the part to be resected

should be tied in small sections with fine braided silk. The lumen of the stomach is made to correspond with the oblique section of the duodenum by closing a part by Czerny-Lembert sutures before it is joined with the duodenum. The junction between duodenum and stomach is made with the same kind of sutures. The suturing is done in steps as the excision wound is enlarged. This method affords a better opportunity to coaptate the parts properly, and is attended by less hemorrhage, than if the excision were made at once.

Rydygier diminishes the size of the opening in the stomach from the larger instead of from the smaller curvature of the stomach (Fig.

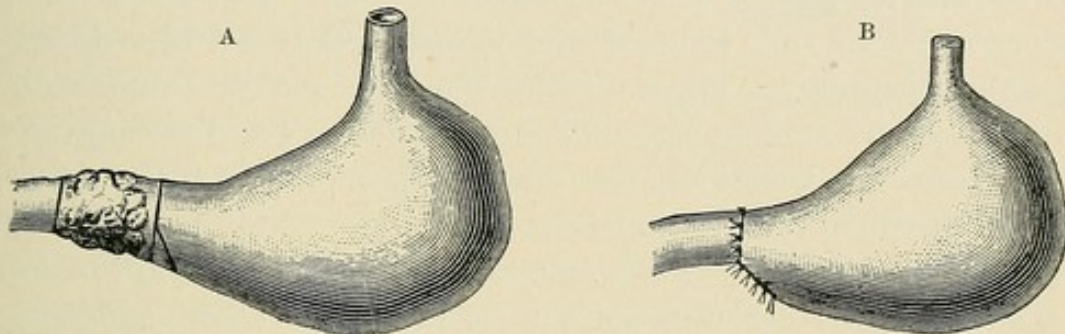


FIG. 206.—Resection of the pylorus (after Rydygier): A, location and direction of incisions ; B, sutures.

206, B). Canalization difficulties are less likely to follow the operation if the duodenum is united with the greater curvature of the stomach according to the Billroth-Wölfler operation than when it is attached to the lesser curvature, as recommended by Rydygier. The difficulties experienced in uniting the duodenum with the stomach when a large part of this organ has to be removed have led Billroth to combine pylorotomy with gastro-enterostomy in the operative removal of large carcinomatous tumors of the pyloric portion of the stomach (Fig. 207). The resected ends of the stomach and duodenum are closed by a double row of sutures, and a communication is established between the anterior wall of the stomach and the lower part of the duodenum or the upper part of the jejunum by making in each of these organs a longitudinal slit at least two inches in length and uniting them by Czerny-Lembert sutures. Tuholsky of St. Louis is an ardent advocate of this operation, but he advises that it should be done *à deux temps*.

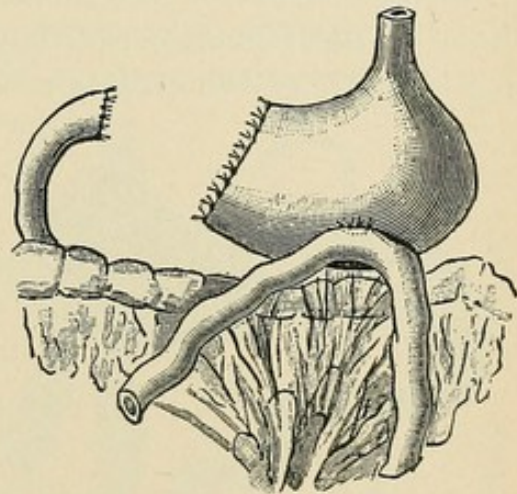


FIG. 207.—Resection of the pylorus with gastro-enterostomy (after Billroth).

Gastro-enterostomy.—The limited success of pylorectomy induced Wölfler to devise an operation for the relief of patients suffering from pyloric carcinoma too far advanced for a radical operation. This operation is called gastro-enterostomy, and consists in establishing between the stomach and the upper part of the intestinal canal a communication, thus excluding permanently from the gastro-intestinal canal the affected part. The stomach is prepared for the operation in the same manner as for pylorectomy. It is advisable to wash out the stomach daily at least for two days before the operation, and to nourish the patient during this time exclusively by rectal feeding. The intestinal canal should be cleared of its contents by a mild laxative or a high rectal enema. In one instance the writer performed this operation without an anesthetic. The only pain which the patient complained of was produced by making the external incision. The handling of the stomach and the intestines, the visceral incisions, and the suturing appeared to cause little or no pain.

If no contraindications exist, chloroform should be used in performing this as well as other operations on the gastro-intestinal canal, in preference to ether, as the use of chloroform is attended and followed by less retching and vomiting than is the case when ether is used. The abdomen is opened by a straight incision in the median line extending from the xiphoid cartilage to the umbilicus. The upper part of the intestinal tract, at a point about twelve inches below the pyloric orifice of the stomach, is brought forward into the wound with the anterior wall of the stomach.

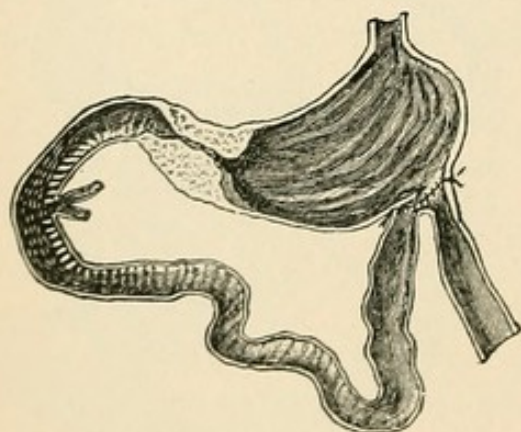


FIG. 208.—Formation of valve to prevent entrance of stomach-contents into duodenum (after Wölfler).

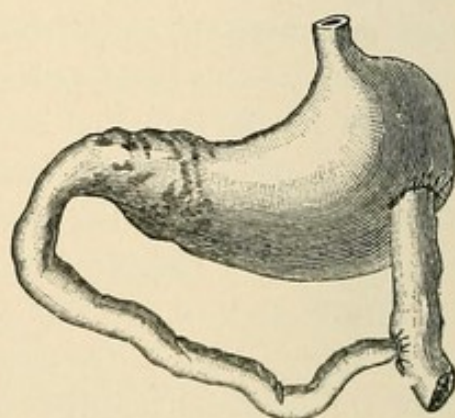


FIG. 209.—Implantation of duodenum into jejunum and jejunum into stomach (after Wölfler).

Gastro-enterostomy after Wölfler.—Wölfler intended to prevent the entrance of bile into the stomach, and of stomach-contents into the duodenum, by forming a valve by uniting the right half of the opening in the bowel with the intact stomach-wall, and only the left half with the margin of the opening in the stomach (Fig. 208). The same object

is attained if the bowel is completely divided at the junction of the duodenum with the jejunum, and the proximal end is implanted into the jejunum and the jejunum into an opening in the anterior wall of the stomach, as shown in Figure 209. Lücke reversed the position of the bowel as recommended by Rockwitz, in order to bring the peristaltic action of the intestine in accord with the movements of the stomach (Fig. 210).

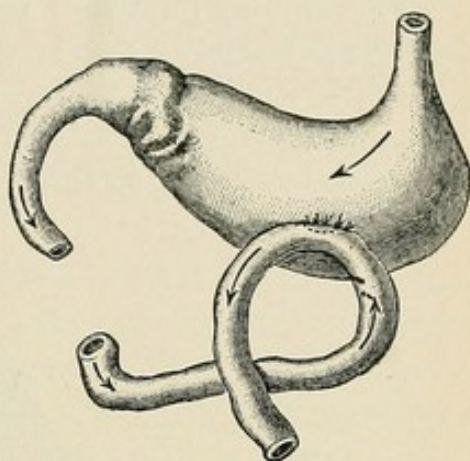


FIG. 210.—Gastro-enterostomy (after Lücke).

In making the communication between the stomach and the intestines large enough, some allowance must be made for cicatricial contraction of the opening. The visceral incision should be at least two inches in length. The stomach and the bowel should be united behind by sero-muscular sutures before the visceral incisions are made, as recommended by Lauenstein. After the incisions have been made the deep sutures are applied all around, when the incision is completed by a row of superficial sutures in front and on the sides.

Gastro-enterostomy after Senn.—The writer has made fifteen gastro-enterostomies by substituting in part for the sutures plates of decalcified bone with a central perforation at least two inches in length and three-quarters of an inch wide. The intestine is brought into the Rockwitz position and is united with the stomach behind by a row of sero-muscular sutures. An incision two inches in length is made in the stomach and the duodenum; the plates are then inserted, and are brought into proper position by making traction on the fixation-sutures; the lateral sutures, armed with needles, are now passed through all the tissues except the peritoneum, and the terminal sutures are brought out at the angles of the visceral wounds. An assistant coaptates the wounds, and the lower fixation-suture is tied with sufficient firmness to bring the parts in apposition without endangering their blood-supply by strangulation; next the terminal sutures are tied, and finally the superficial fixation-sutures. Before tying the last suture the margins of the wound must be carefully brought well between the plates to prevent eversion. All the sutures are cut close to the knot. The union is completed by stitching the serous surfaces over the

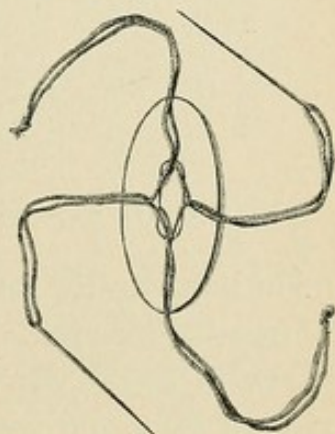


FIG. 211.—Moist perforated decalcified bone-plate.

anterior margins of the plates, thus completing the ring of superficial sutures (Fig. 212).

The results following the use of the bone plates in performing gastro-enterostomy have been most encouraging. The

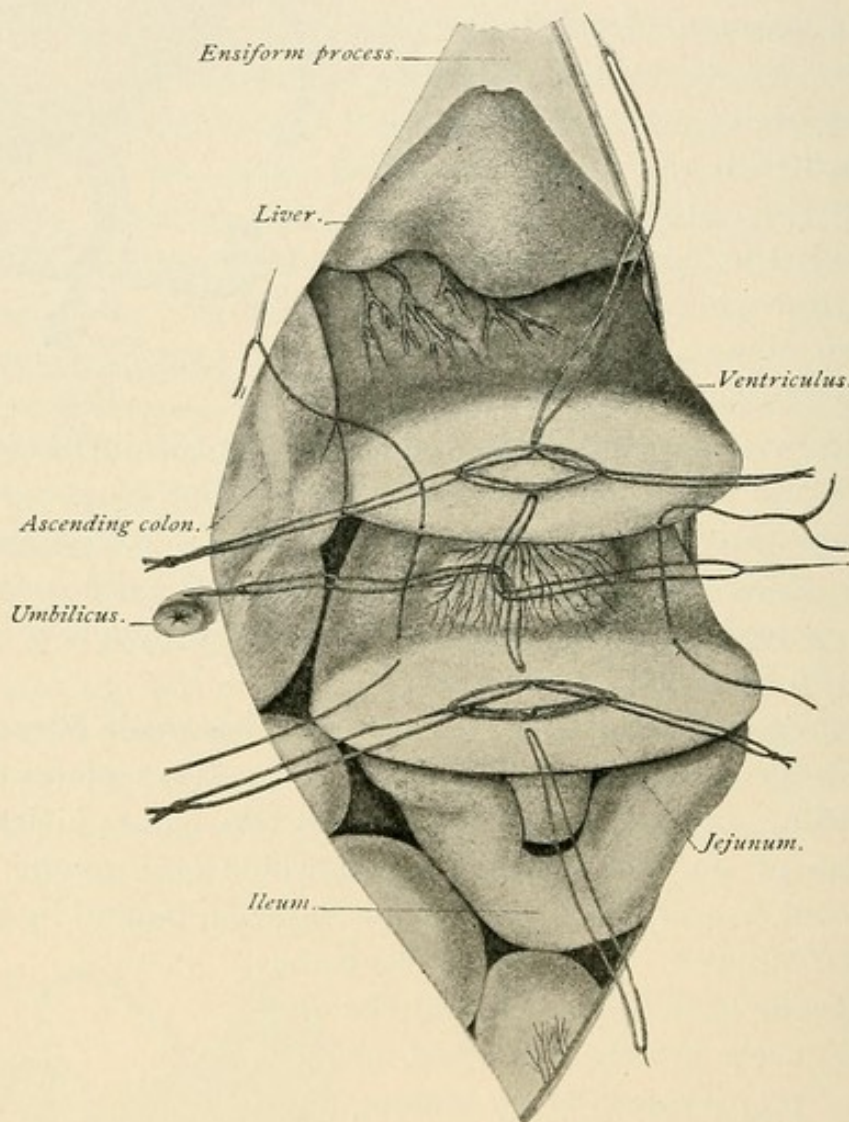


FIG. 212.—Method of performing gastro-enterostomy (illustration after Von Baracz).

union between the parts interposed between the plates can be hastened by free scarification. Since using plates with a perforation at least two inches in length the writer has seen no ill results from cicatricial contraction. In one case of pyloric carcinoma in a man thirty years of age, the patient, who was brought to the hospital on a stretcher, emaciated to a skeleton, gained sixty-five pounds in weight after operation, resumed his occupation, that of a butcher, worked for a year and a half, and then gradually sunk from the effects of the carcinoma. In another case, that of a man seventy years of age, emaciated to an extreme degree, the patient recovered sufficient strength to conduct his business for over a year after the operation. In a number of

instances the patients lived for three, four, and eight months in comfort and ease—a sufficient recompense for the risk assumed in subjecting themselves to a gastro-enterostomy. In the majority of cases of pyloric carcinoma the surgeon will have to content himself with making a gastro-enterostomy until by improved diagnostic resources we will be able to recognize carcinoma of the stomach early enough to warrant a more frequent recourse to a radical operation by pylorectomy or by partial gastrectomy.

Intestines.—Carcinoma is more frequent in the lower than in the upper part of the intestines. Of every 100 cases, 75 occur in the rectum; of the remainder, 23 would be localized in the large bowel and 2 in the small intestine, including the ilio-cecal valve, and would probably be distributed in the following manner: Small intestine and ilio-cecal valve, 2; cecum, 2; hepatic flexure of colon, 3; splenic flexure of colon, 4; sigmoid flexure, 10; intermediate segments of colon, 4 (Sutton). Carcinoma of the intestines represents in its minute structure the glandular appendages of the mucous membrane lining the intestinal canal (Fig. 213). The irregular tubules are lined with cylin-

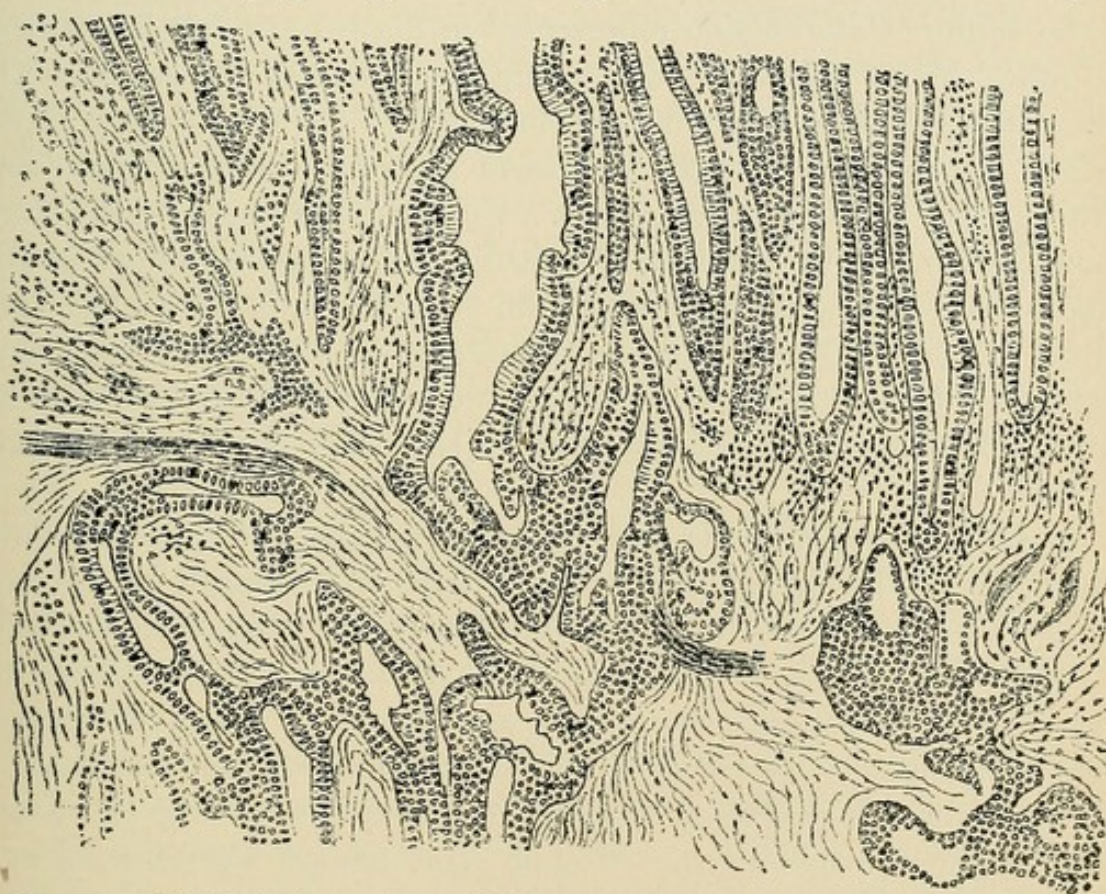

FIG. 213.—Cylindrical-celled carcinoma of the intestine; $\times 128$ (after Hauser): above, elongated and distended granular spaces; below, without a sharp border, these tubules terminate in irregular carcinoma-alveoli. The black points indicate cells undergoing karyokinesis.

drical cells. In the periphery of the tumor the cells which have parted from the parent soil and have escaped through the imperfect membrana

propria infiltrate the surrounding connective-tissue spaces, and the new cells which they produce arrange themselves again in tubular shape, the pre-existing connective tissue becoming the stroma of that part

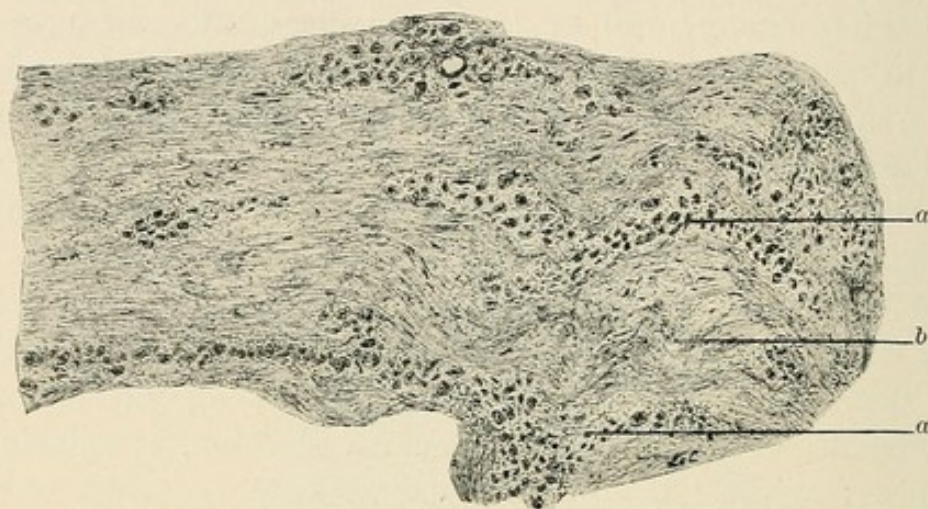


FIG. 214.—Periphery of cylindrical-celled carcinoma of the cecum; $\times 110$ (Surgical Clinic, Rush Medical College, Chicago): *a*, rows of carcinoma-cells in connective-tissue spaces; *b*, intervening connective tissue.

of the tumor. The section represented in Figure 214 was taken from the periphery of a circular constricting carcinoma of the cecum. The tumor had produced intestinal obstruction.

The parenchyma and the stroma of intestinal carcinoma are very apt to undergo colloid degeneration. Regional and metastatic infection occurs earlier and more constantly than in squamous-celled carcinoma. Carcinoma of the intestines is seldom recognized, or even suspected, before the tumor has produced symptoms of obstruction. Chronic obstruction from this cause is frequently attended by diarrhea, a symptom which frequently leads patient and physician into errors in diagnosis.

Acute obstruction is caused either by the affected segment of the intestine becoming invaginated or by a suddenly-developed paretic condition of the bowel above the seat of obstruction. Great hypertrophy of the muscular coat of the bowel above the obstruction is usually associated with chronic obstruction, and an acute attack is initiated when compensatory hypertrophy no longer keeps pace with the increasing mechanical impediment or when the narrowed part of the bowel becomes impermeable by impaction of some foreign substance or of a hardened fecal mass. In cases of acute intestinal obstruction in persons advanced in years the existence of a malignant intestinal tumor should be borne in mind. As in the pylorus, carcinoma of the intestine occurs either as a diffuse tumor attaining considerable size or as a circular constriction. The former variety is more liable to ulceration and

perforation; the latter gives rise to intestinal obstruction. In the constricting variety the tumor involves the entire circumference of the bowel, and by constriction of its stroma the lumen of the bowel is gradually reduced in size. The bowel on the distal side becomes much smaller in size, while on the opposite side of the constriction it becomes distended and all its coats are hypertrophied to some distance from the seat of obstruction. The catarrhal inflammation caused by the accumulation of feces and the greatly increased peristaltic action cause the frequent liquid discharges, which are taken only too often by the superficial observer as an indication of the absence of a mechanical obstruction. *Chronic intestinal obstruction caused by a carcinoma is attended by intermittent paroxysmal pain which is referred to the region of the umbilicus, irrespective of the anatomical location of the tumor.*

Operative Treatment.—Unless the tumor has given rise to a palpable swelling, the surgeon has seldom an opportunity to perform a radical operation until symptoms of chronic or acute intestinal obstruction set in. In making a laparotomy for intestinal obstruction the surgeon must be prepared to meet with such a condition. A radical operation is indicated if the carcinoma has not passed beyond the limits of the bowel and the patient's strength is adequate to resist the immediate effects of an enterectomy. If the patient has become prostrated from the effects of the intestinal obstruction, it is advisable to resort to the formation of an artificial anus above the obstruction, and to postpone the operation until his strength has been recuperated sufficiently.

Enterostomy.—If the tumor occupies the ilio-cecal region, a temporary artificial anus is established in the right inguinal region by bringing into the wound the first distended knuckle of the small intestine that presents itself. The intestine is united with the peritoneum of the external incision, and the bowel is opened by a transverse incision about an inch in length. If the carcinoma is located below the sigmoid flexure, a sigmoidostomy in the left groin is made. These operations are indicated in cases in which the obstruction is acute and the patient's general condition does not permit of an operation requiring more time.

Enterectomy.—The removal of a malignant tumor of the intestine requires an enterectomy. The removal of a limited segment of the bowel for malignant disease, if the patient's strength has not been too much exhausted and no regional infection has occurred, is a legitimate procedure, and is often followed by a permanent cure. The operation should not be undertaken if extensive malignant adhesions have formed or if the lymphatic glands have become extensively infected. The bowel on each side of the tumor should be constricted with a piece of

rubber tubing passed through an opening made in the mesentery near its attachment to the bowel (Fig. 215). Before the incisions through

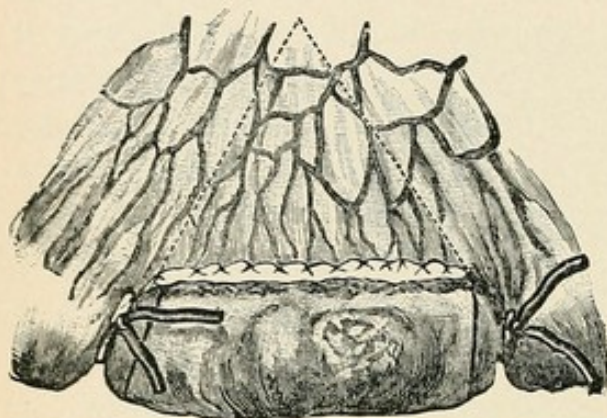


FIG. 215.—Separation of mesentery from bowel (after Kocher).

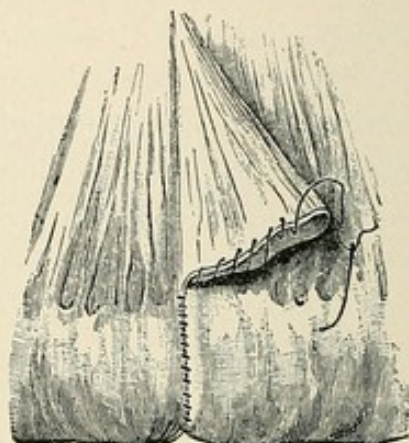


FIG. 216.—Circular suture and folding of mesentery after enterectomy (after Kocher).

the bowel are made the mesentery should be tied in small sections with fine silk. The bowel sections are made somewhat obliquely at the expense of the convex side, and the ends are at once united with a double row of sutures. The mesentery corresponding with the section of bowel removed should not be excised, but be folded upon itself, and the ligatured margin should be sutured as shown in Figure 216. If the lumina of the bowel-ends do not correspond in size, the smaller end

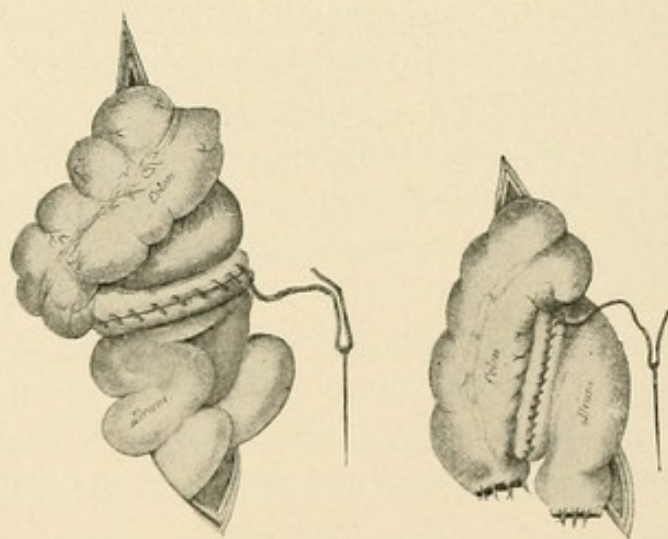


FIG. 217.—Restoration of the continuity of the bowel after resection of the cecum for carcinoma, with the aid of perforated decalcified bone-plates.

is cut more obliquely. If the difference in size is too great to be equalized by this method, as after excision of the cecum, both ends are closed, and the continuity of the bowel is restored by lateral anastomosis, by suturing, or with the aid of perforated decalcified bone-plates. The use of decalcified perforated bone-plates to restore the continuity of the bowel has been resorted to by the writer in three cases of resec-

tion of the cecum for carcinoma, and in every instance this method of approximation proved eminently successful (Fig. 217).

Intestinal Anastomosis.—If the carcinoma, by the promotion of carcinomatous adhesions with neighboring organs or by extensive regional infection through the lymphatic channels, has advanced beyond the limits of a radical operation, an intestinal anastomosis should be made. This operation consists in establishing a fistula between the bowel above and below the tumor. The operation can be done by making in the respective parts of the bowel an incision four inches in length, as advised by Abbe, and the union is effected by a double row of silk sutures. A single row of sutures might prove all-sufficient, but as a matter of safety a double row is preferable. The same object can be accomplished in a shorter time and with a greater degree of security by substituting for the inner row of sutures perforated decalcified bone-plates (Fig. 218). The anastomotic opening should correspond in size with the lumen of the bowel.

The use of the Murphy button would be attended by great danger in such cases, as the button would be just as likely to fall into the blind end of the bowel on the proximal side of the obstruction as into the opposite side. Besides, it has been shown by Keen and others that the opening, small in the beginning, is apt to become contracted beyond the limits of its requirements in a comparatively short time.

Rectum.—Carcinoma of the rectum occurs more frequently than carcinoma of the remaining portion of the intestinal canal, its greater frequency here being probably accounted for by the rectum being more often the seat of benign growths, of chronic inflammatory affections, and of prolonged irritations from different sources. The histological structure of most of the rectal carcinomata presents a tubular arrangement of the cells, surrounded and enclosed by a connective-tissue stroma which in the soft variety of tumors is exceedingly scanty, and in the hard, constricting variety is very abundant and compact (Fig. 219). In the rapidly infiltrating form the rectal tube becomes indurated

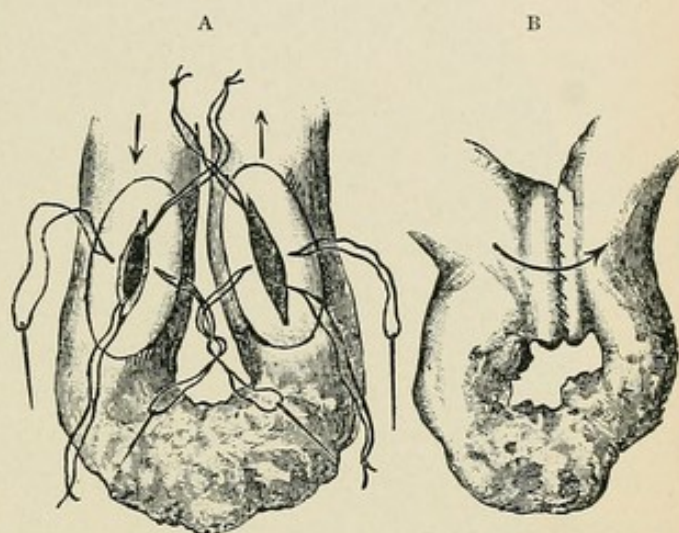


FIG. 218.—Intestinal anastomosis with the aid of perforated decalcified bone-plates in the operative treatment of inoperable carcinoma of the bowel (after Esmarch): A, plates *in situ*; B, operation completed.

and the surface ulcerates, but its lumen is not much reduced in size. In the circular constricting form the constricting ring is very dense and the lumen of the bowel is rapidly diminished in size. This is the form

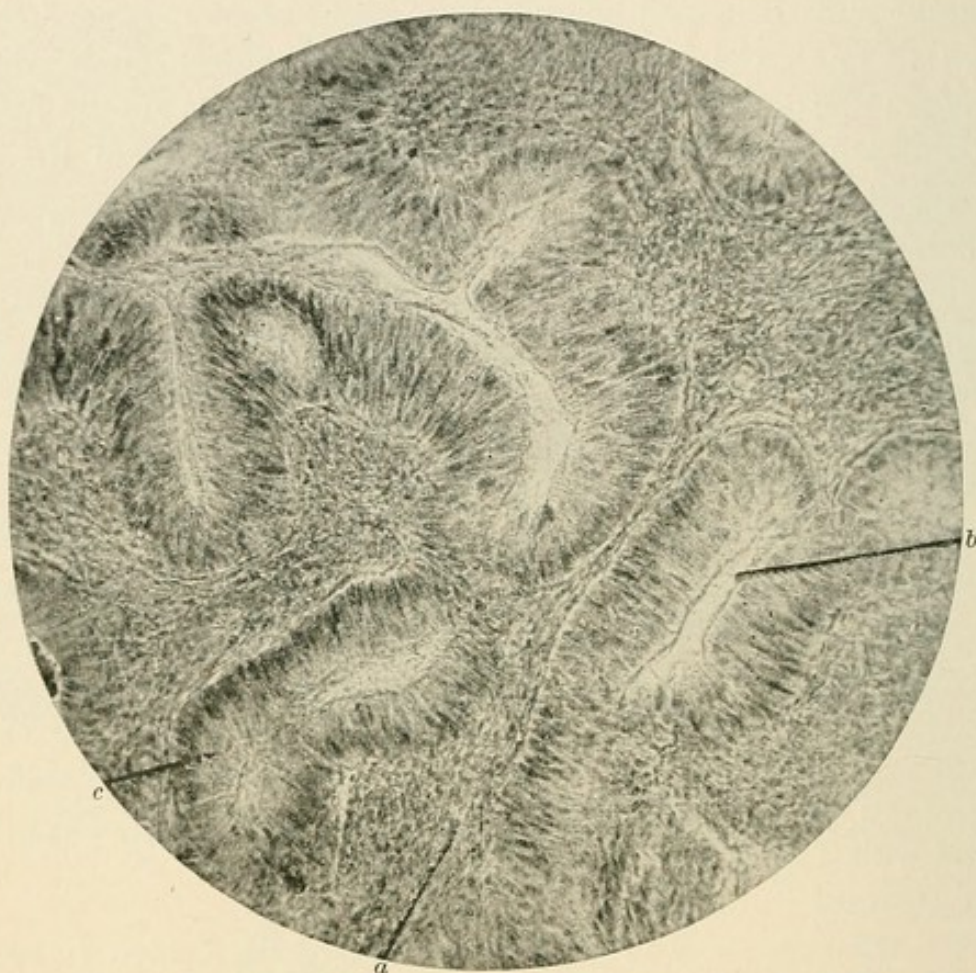


FIG. 219.—Cylindrical-celled carcinoma of the rectum; $\times 480$ (Surgical Clinic, Rush Medical College, Chicago):
a, connective-tissue stroma; *b*, atypical tubules of carcinoma; *c*, cylindrical epithelial cells.

of rectal carcinoma that produces obstruction and is most favorable to operative treatment, owing to the limited extent of the tumor and the dilated condition of the bowel above the obstruction, permitting the bowel to be drawn down after removal of the carcinomatous part.

The writer has already referred to a case that came under his observation of carcinoma of the rectum in a boy eighteen years of age. Carcinoma of the rectum, however, with few exceptions is a disease of advanced life. According to Hildebrandt's statistics, 16 per cent. of rectal carcinomata occur in persons less than forty years old, 54 per cent. in persons forty to sixty years of age, and 30 per cent. in persons from sixty to eighty years old. The carcinoma is located most frequently in the lower third of the rectum. The stagnation of feces aggravates the ulcerative process and produces at the same time a catarrhal proctitis above the tumor. Local extension takes place in the direction of the connective tissue outside of the rectum, in advanced cases rendering the rectum as immovable as though it were held in

a vise. Regional infection takes place in the rapid-growing variety at an early stage, and extends in the direction of the chain of sacral and lumbar lymphatic glands. In advanced cases the regional infection occasionally includes the inguinal glands. Metastasis of different organs hastens the fatal termination. The statement has already been made that cylindrical carcinoma gives rise earlier and more constantly to metastasis than does carcinoma representing epiblastic tissue.

Symptoms and Diagnosis.—Carcinoma of the rectum is not attended by much suffering until the tumor by its size or by constriction gives rise to obstruction. A sense of weight and an aching feeling in the sacral region, usually attributed to rheumatism or hemorrhoids, is about all the patient complains of during the early stages. The discharge of a little blood and mucus, and constipation alternated by diarrhea, are the symptoms which usually induce the patient to seek medical advice under the belief that he is suffering from piles. *Patients giving such a clinical history should always be subjected to a thorough rectal examination.* Digital exploration is more to be relied upon in conducting this examination than the use of the different kinds of rectal specula. The patient should be brought into the exaggerated lithotomy position. With the right index finger well lubricated the rectum is explored, and unless the carcinoma involves the first part of the rectum the tumor is discovered without any difficulty. In the constricting variety the lower end of the tumor with the constricted lumen feels very much like an enlarged lacerated cervix uteri. The size of the lumen and the mobility of the affected part are now determined, after which careful search should be made for enlarged lymphatic glands in the sacral fossa. If the tumor has infiltrated the rectal wall without having produced contraction, the rectum feels like a firm, unyielding cylinder with points of ulceration of its mucous lining.

In cicatricial stenosis of the rectum, the only condition liable to be mistaken for carcinoma, the stricture is usually near the anus, infiltration of the rectal wall is less marked, any considerable enlargement of the sacral glands is absent, and the stricture is often multiple, which latter is not the case in carcinoma. Should any doubt exist as to the differential diagnosis between these two rectal affections, a fragment of tumor-tissue should be removed and sections of it be examined under the microscope.

Indications for a radical operation are absence of paraproctitic infiltration and of extensive lymphatic infection, and a sufficient accessibility of the tumor to enable the surgeon to remove all the diseased tissue by a radical operation. Opposite conditions must be regarded as positive contraindications to any radical measures.

Palliative Operations.—In inoperable cases of carcinoma of the rectum the surgeon can do a great deal to alleviate the suffering of the patient by establishing an artificial anus in the left inguinal region. Removal of the carcinomatous tissue projecting into the lumen of the bowel by scraping, and linear rectotomy, for the purpose of ameliorating the symptoms due to obstruction, have become, for substantial reasons, obsolete measures. If the carcinoma produces obstruction, an artificial anus will benefit the patient in two ways: it will exclude from the fecal circulation the diseased part of the rectum, and at the same time will establish a free outlet for the intestinal contents. If an artificial anus is made under such circumstances, it should be made with a view of completely interrupting the fecal circulation and thus affording absolute rest for the excluded

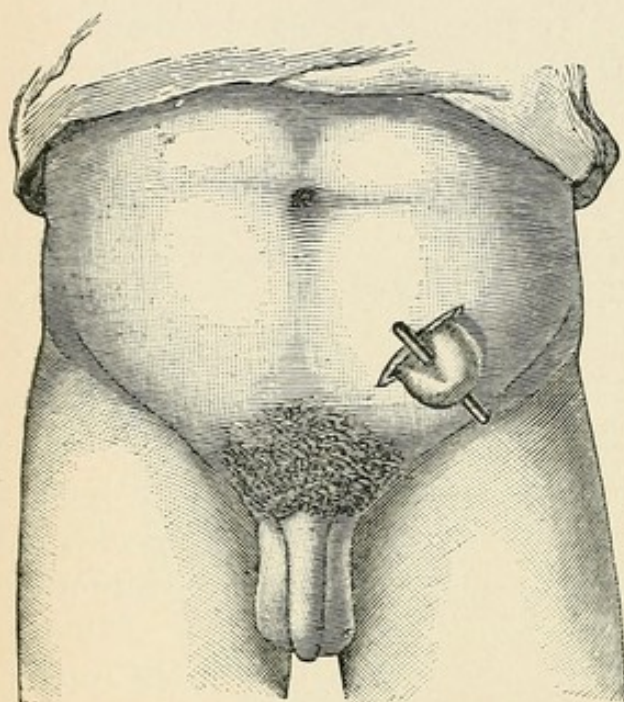


FIG. 220.—Maydl's inguinal colostomy.

part of the bowel. Maydl's colostomy (Fig. 220) will answer these requirements to perfection. An incision four inches in length is made about two inches above Poupart's ligament, halfway between the symphysis pubis and the anterior superior spinous process of the ilium, parallel with the fibres of the external oblique muscle. The muscular layers are separated as far as possible by the use of blunt instruments. The transversalis fascia and the peritoneum are incised to the extent of the external wound. Some care is now necessary to recognize, seize, and bring forward into the wound in proper position the sigmoid flexure. As soon as the proper loop has been found the mesentery near the bowel is tunneled with a hemostatic forceps, and a glass tube four inches in length, the size of an ordinary lead pencil, covered by several layers of gauze, is drawn through this opening with the forceps. The glass tube serves as a bridge for the prolapsed loop of the bowel. The two limbs of the bowel are now sutured together on each side by two sero-muscular sutures underneath the bridge (Fig. 221). Next, the prolapsed loop is sutured at its base to the parietal peritoneum by at least six points of suture, to prevent the escape of intestinal

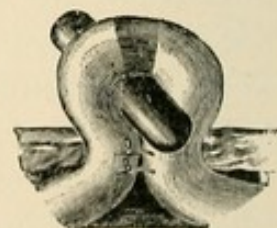


FIG. 221.—Maydl's colostomy, showing the position of the bridge and the sutures underneath it.

loops. If the symptoms are urgent, the base of the loop is surrounded by a ring of absorbent cotton fastened to the bowel and the skin by collodion; the bowel is then, at the most prominent part, divided transversely to the extent of at least two inches. If the symptoms are not urgent, it is much safer to postpone the opening of the bowel for two or three days, until the peritoneal cavity has become shut out by adhesions all around. If this course is adopted, an ordinary antiseptic dressing is applied, taking the precaution that the intestinal loop should not be subjected to harmful pressure. On the second or third day the dressing is removed, the collodion ring is applied, and the bowel is incised as indicated above. It is advisable to keep the bridge in place for at least a week or two, in order to secure at a point opposite to it the formation of an efficient spur. Complete section of the bowel at this time is recommended by some; but it is not necessary, as the spur, if well developed, will direct all the intestinal contents away from the lower part of the bowel, and the bowel on the distal side can be flushed from time to time as may appear necessary.

Extirpation of the Rectum for Carcinoma.—Extirpation of the carcinomatous rectum is now generally made through the sacral route. A long time ago, Kocher recommended removal of the coccyx as a preliminary step to the removal of the lower part of the rectum. Encouraged by the success attending the removal of the rectum from this direction, surgeons have become bolder and have sacrificed parts of the sacrum for the purpose of securing better access to the diseased rectum. The resection, temporary or permanent, of a part of the posterior bony wall of the pelvis has enabled surgeons to extend the field of radical operations upon the rectum for malignant disease.

The different points where the sacrum has been divided in the operation for extirpation of the rectum are shown in Figure 222.

As is the case with similar operations in other parts of the body, the application of the principle of sacral resection as a preliminary step to extirpation of the rectum has been carried too far. It appears to the writer unjustifiable to carry the resection of the sacrum as far as has been done by Volkmann and Rose. The simple removal of the coccyx will often suffice in affording ample room for the removal

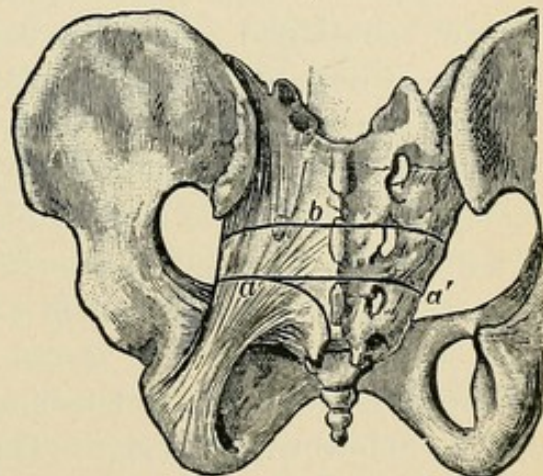


FIG. 222.—Resection of sacrum in extirpation of rectum for carcinoma: *a*, after Kraske; *a-a'*, after Bardenheuer; *b*, after Volkmann, Rosé.

of the lower part of the rectum, and Kraske's operation will usually accomplish all that could be desired in the removal of a carcinomatous rectum when the disease is within the limits of a justifiable operation.

The patient should be prepared for a number of days for the operation by dieting, laxatives, warm baths, and colonic irrigation, so as to secure for the part, as nearly as can be done, an aseptic condition. Immediately before the operation the lower part of the rectum should be flushed thoroughly with Thiersch's solution, and the external surface should be scrubbed thoroughly with warm water and potash soap, and later be disinfected with a solution of corrosive sublimate or of carbolic acid. After the patient is under the influence of an anesthetic he is placed face down upon a low table or a cot, the pelvis is elevated by placing under it pillows covered by rubber sheeting, and the thighs and the legs are flexed. This position diminishes the amount of venous hemorrhage, and the abdominal organs gravitate toward the chest, leaving the pelvis comparatively empty. An incision is then made in the median line from the centre of the sacrum to the verge of the anus. The coccyx is enucleated, and the lower two sacral vertebræ are isolated from the soft tissues by the use of the knife and the periosteal elevator. The sacrum is then divided transversely between the last two foramina with a large chisel and a mallet. All hemorrhage is then carefully arrested. After this step of the operation minute details as to the immediate arrest of hemorrhage by the use of hemostatic forceps must be carried out. By careful dissection between tissue-forceps the rectum is reached. As soon as this has been done cutting instruments should be used sparingly. The rectum should be *enucleated* rather than excised. Connective-tissue bands and muscles are isolated before they are cut. The proximal end of the tumor should be reached first. If the rectum has to be removed high up, the peritoneal cavity is opened carefully, and prolapse of intestines, as well as the entrance of blood into the peritoneal cavity, is prevented by packing the opening with gauze sponges well secured in a hemostatic forceps. When healthy tissue is reached, a strip of gauze is tied around the rectum sufficiently tight to prevent escape of intestinal contents, after which the bowel is divided below transversely. The bowel is then drawn downward, and the diseased segment is separated by a careful dissection. If possible, the external sphincter muscle is preserved. The course to be pursued now depends on how far the rectum has to be removed in a downward direction. If the distal end can be preserved, the surgeon can select one of two procedures. The proximal end can be united with the distal end by circular enterorrhaphy. Owing to the absence

of a peritoneal investment in the lower end, this procedure has not yielded good results. Hochenegg has suggested that the proximal end should be invaginated into the distal end and be sutured to a circular denudation at the anus. The results after this procedure have been more satisfactory than those after the first-named method. If the lower part of the bowel has to be removed, the resected end is drawn downward and is attached to the external skin by sutures. The bowel end must be ruffled so as to diminish its lumen before it is attached: this can be done with a circular purse-string suture of catgut. In either of these procedures the cavity of the wound is packed with iodoform gauze, over which the external wound is sutured except at from one to three places, where the gauze is brought out to the surface. The patient should be given a liquid diet for a few days, and small doses of opium to constipate the bowels temporarily. If no contraindications arise, the gauze should remain for at least a week. At this time the whole wound-surface is covered by a pavement of active granulations that will guard against infection later. The wound presenting such a condition heals in a remarkably short time.

If the rectum is amputated high up and the resected end cannot be brought down, a sacral anus is established by suturing the bowel into the upper angle of the external incision. The writer has pursued this course a number of times, and believes that an artificial anus in this locality has a number of advantages not possessed by an artificial anus devoid of a proper sphincter muscle lower down. Should the wound suppurate, enough sutures are removed to secure free drainage. In this event the dry dressing must give way to frequent antiseptic irrigations and to a compress of gauze kept moist with a saturated solution of acetate of aluminum or of boric acid.

If the carcinoma returns, little is to be expected from another operation, as the local recurrence is usually accompanied by extensive infiltration and lymphatic infection. The formation of an artificial anus in such cases is never indicated, as the recurring carcinoma does not cause constriction of the bowel, but extends to the pelvic connective tissue.

Liver.—Primary carcinoma of the liver is extremely rare. Riesenfeld, Klebs, and von Bergmann do not believe in the primary origin of carcinoma of the liver. In 1885, Harris of London collected 19 cases of primary carcinoma of this organ. In 6000 postmortems made by Virchow the liver was found to be the seat of carcinoma in 95 of these; the disease was secondary in 90, and primary in 5. Two cases of carcinoma of the liver have been subjected to operative treatment. In von Bergmann's case the tumor was located in a pedunculated lobe

of the liver, which was excised with the tumor. The patient recovered and remained in good health a year after the operation. Luecke operated successfully in two stages on a similar case, and the patient was free from recurrence at the expiration of two years. It is only in such isolated and favorable cases that operative treatment is indicated.

Testicle.—Carcinoma as compared with sarcoma of the testicle is an exceedingly rare affection. Sometimes it engrafts itself upon the basis of an antecedent benign tumor or an inflammatory affection. The

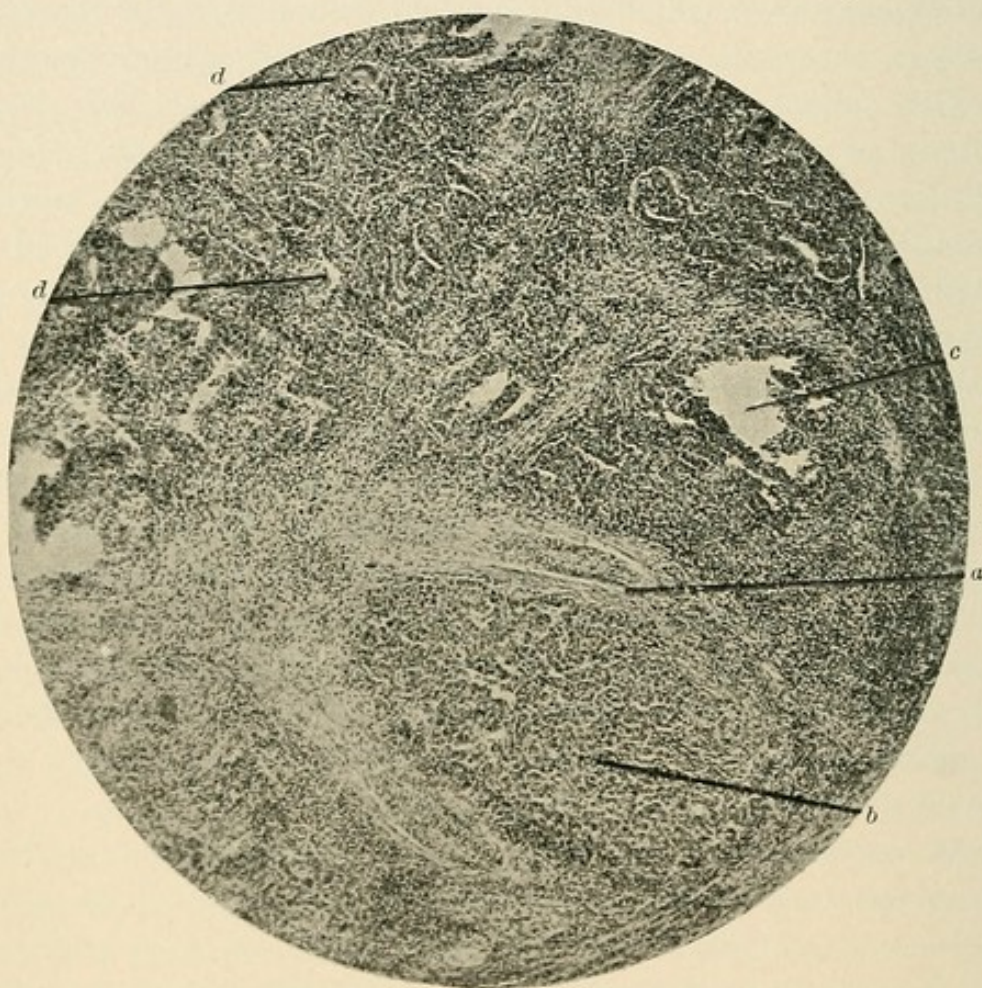


FIG. 223.—Carcinoma and tuberculosis of the testicle; $\times 85$ (Surgical Clinic, Rush Medical College, Chicago): *a*, stroma of carcinoma; *b*, alveolus packed with carcinoma-cells; *c*, focus of caseous degeneration; *d*, miliary tubercles in carcinoma-tissue.

section from which the illustration (Fig. 223) was taken was derived from a testicle that had been tubercular for a long time and had only recently commenced to increase rapidly in size. This specimen refutes the assertion made by Rokitansky, that tuberculosis and carcinoma exclude each other. There can be no doubt in this case that the tubercular epididymitis was the primary and carcinoma the secondary affection. Sutton has never seen a tubular carcinoma of the testicle. That

such a carcinoma occasionally, although rarely, occurs is shown by Figure 224. Langhans never saw hard, but always soft, carcinomata of this organ. He believes that the tumor starts from the epithelial cells lining the seminiferous tubules. He also calls attention to the transformation of an adenoma of the testicle into a carcinoma.

From a diagnostic point of view it is important to remember that tuberculosis almost always begins in the epididymis, and carcinoma in

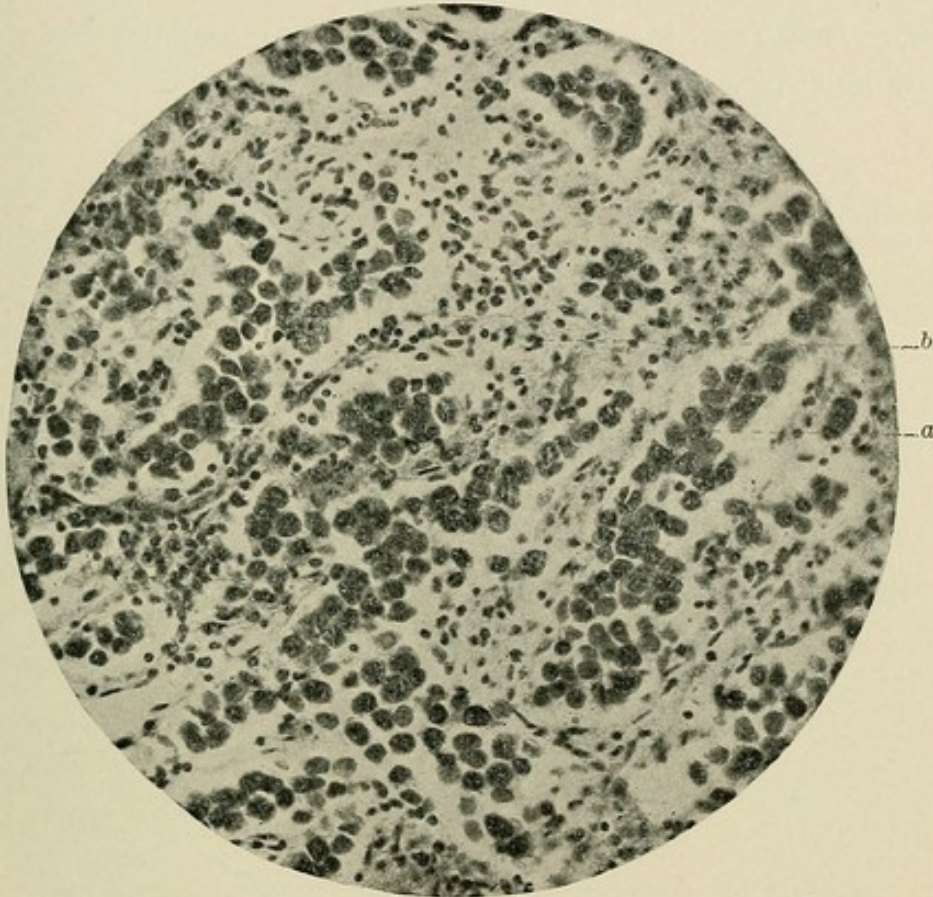


FIG. 224.—Tubular carcinoma of the testicle; $\times 270$ (after Karg and Schmorl). The tumor is composed of long, solid streaks of large epithelial cells (*a*). The nuclear structures cannot be seen, as the chromatin has been affected by the hardening solution, Müller's fluid. The stroma (*b*) is scanty and is rich in cells.

the testicle proper. As carcinoma of this organ is always soft, it is liable to undergo cystic degeneration—an occurrence which still further complicates the diagnosis. The regional infection extends along the lymphatics of the cord and from the cord to the iliac fossa. The tumor may attain the size of an adult's head.

Early removal of the testicle with its envelopes and the cord as far as it can be followed is the only operation that promises a permanent result. Kocher has observed cases in which the disease did not recur for four and a half, eight and a half, and ten and a half years after operation.

Penis.—Carcinoma of the prepuce and of the glans penis is observed in men past fifty years of age. Kaufmann estimates that one-third of all

the cases occur during the sixth decennium. Occasionally the tumor originates in Tyson's glands. Such a case is referred to by Tyson. Usually the tumor commences in the epithelial layer of the skin and of the glans penis, and presents itself as a cauliflower tumor with great induration at its base. The surface ulcerates early, and is usually the seat of a very offensive discharge.

The histological structure of carcinoma of the penis (Figs. 225, 226) resembles essentially squamous-celled carcinoma of the skin in other localities. Paget saw in a number of cases carcinoma of the penis preceded by balanitis. In other cases the disease starts in a pre-existing

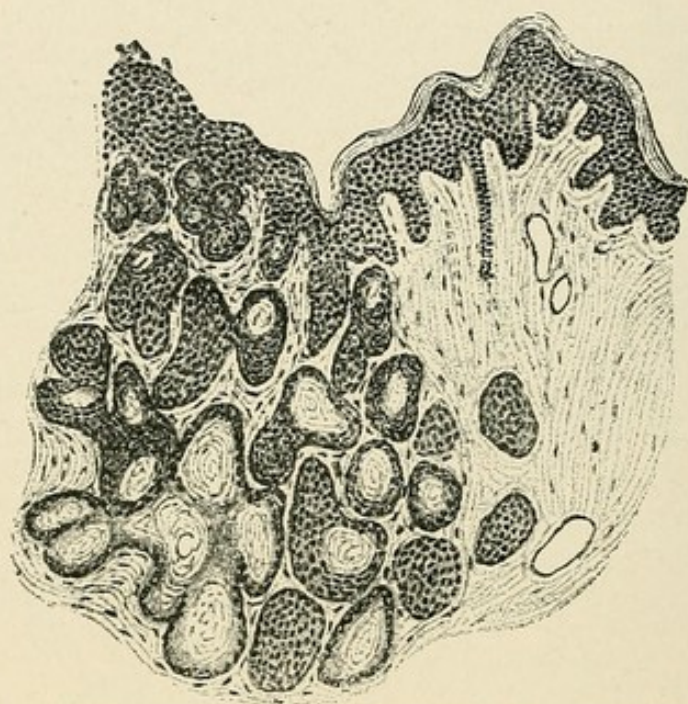


FIG. 225.—Squamous-celled carcinoma of the penis; $\times 150$ (after Perls): to the right, normal skin; to the left, proliferating epithelial projections with numerous cancer-nests.

inflammatory lesion of a more circumscribed nature. Injuries sustained during coitus, during masturbation, and by friction of the clothing may furnish the exciting causes in other cases.

It was formerly doubted that carcinoma of the penis could give rise to regional infection. Kaufmann and Gussenbauer have shown that carcinoma of this organ pursues the same course as carcinoma of the skin in other localities—namely, that regional infection occurs, as a rule, late, but that it is sure to ensue if the disease is allowed to pursue its own course. The writer has seen regional infection much more frequently in carcinoma of the penis than in carcinoma of the lip. The inguinal glands on both sides eventually become involved—a fact which has led to the conviction that it is necessary in most cases to resort at once to clearing out of the inguinal glands in all cases of carcinoma of the penis in which a radical operation is performed.

Amputation of the Penis for Carcinoma.—If the carcinoma is limited to the prepuce, and no evidences of lymphatic affection are present, the organ should be amputated behind the corona glandis. The penis is constricted at its base with a rubber cord or tube to render the operation bloodless. The section through the penis should be made with the knife in such a manner as to secure for the stump a cutaneous covering. The writer generally makes an oval anterior flap with which

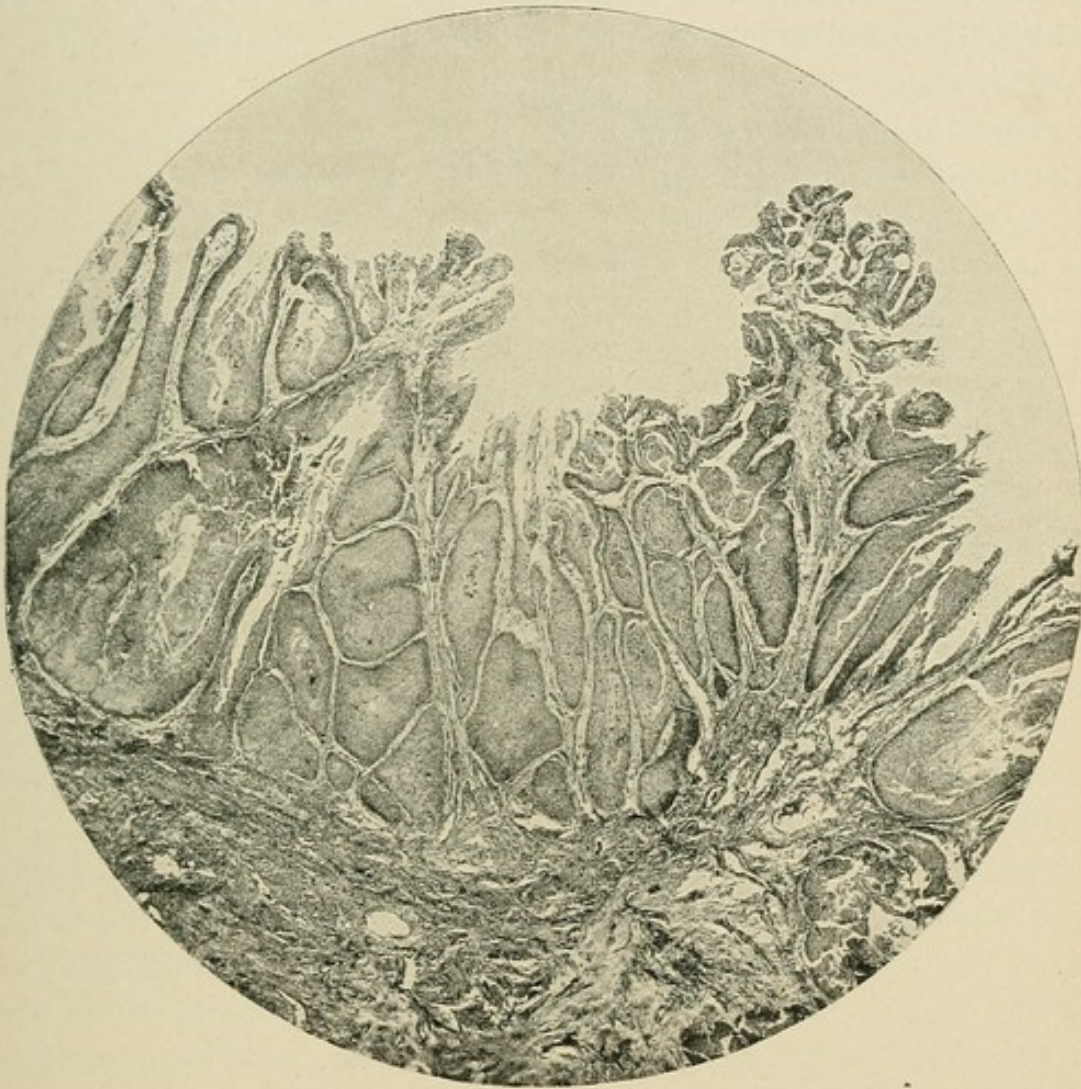


FIG. 226.—Papillary carcinoma of penis; $\times 10$ (after Karg and Schmorl). Between the enlarged papillæ, covered by thickened layers of epithelial cells, are found infiltrations of epithelial cells which in the vascular connective tissue show distinct cancer-nests.

to cover the corpora cavernosa. The mucous membrane of the urethra is stitched to this flap and to the adjacent skin. The dorsalis penis artery is ligated. The hemorrhage from the corpora cavernosa, at first profuse, yields to compression, hot water, and the sutures. A small dressing held in place with a number of strips of adhesive plaster finishes the operation. Rest for a few days in bed must be enforced. The suturing of the flap and the urethra should be done with fine cat-gut sutures, so as to obviate the necessity of removing them.

If the body of the penis is affected by extension of the primary tumor of the prepuce or the glans penis, the organ should be amputated close to the pubes, and at the same time the inguinal glands on both sides should be removed. The amputation is made with the knife and in the manner just described, but an outlet for the urethra is established in the perineum, as first recommended by Thiersch. The urethra is isolated, is brought out through a small buttonhole behind the scrotum, and is firmly anchored to the skin with a few sutures. In a case that recently came under the writer's observation the disease had extended along the penis and had involved the mons veneris as well as the glands in both inguinal regions. In this case the entire penis, part of the mons veneris, and both testicles were removed, and the posterior part of the scrotum was utilized as a covering for the enormous wound. The incision was extended on both sides the whole length of Poupart's ligament, and was joined over the large femoral vessels by a vertical incision reaching to the apex of Scarpa's triangle. The whole chain of glands on each side was removed with the penis in one continuous piece. The urethra was stitched to the margins of a small opening in the perineum. The shock from the operation required active treatment by stimulants. The patient rallied in the course of six hours and made an excellent recovery. Three months after the operation he returned to the hospital greatly improved in general health, but with a recurrence in the left groin. A second operation was performed, and a section of the internal saphenous vein was removed with the carcinomatous tissue by which it was surrounded. Six months after since the second operation there were no signs of further recurrence.

Ovary.—Carcinoma of the ovary occurs after the period of puberty as a comparatively rare affection as a primary tumor, in cystic tumors, and as the result of extension by contiguity of a carcinoma of an adjacent organ. Olshausen describes papillary carcinoma of the ovary as a primary tumor. The same author makes the statement that Klebs and Spencer Wells first called attention to this form of carcinoma of the ovary. The carcinoma appears as a malignant form of papillary or proliferating cystoma. Marchand has shown that this form of cystic tumor of the ovary gives rise to metastasis. In one case of papillary cyst of the ovary in a woman thirty-five years of age the writer found the tumor extensively adherent to the anterior abdominal wall. The tumor was, however, completely removed, and the patient made a good recovery. Six months later she again entered the hospital, and upon examination quite an extensive carcinoma was found in the scar just below the umbilicus. A considerable portion of the entire thickness of the abdominal wall, and including the whole scar, was resected. She

recovered without any untoward symptoms, but died a few months later from diffuse carcinosis of the peritoneum. Pfannenstiel and Olshausen have seen carcinoma develop in the scar following laparotomy for the removal of non-malignant ovarian tumors, and attribute its origin to implantation of epithelial cells from the tumor upon the wound-surfaces. In one of the cases reported by Pfannenstiel several years after the removal of a small simple cystic tumor of the ovary a typical adenocarcinoma developed in the abdominal scar. He came to the same conclusion as Olshausen, that the development of the carci-

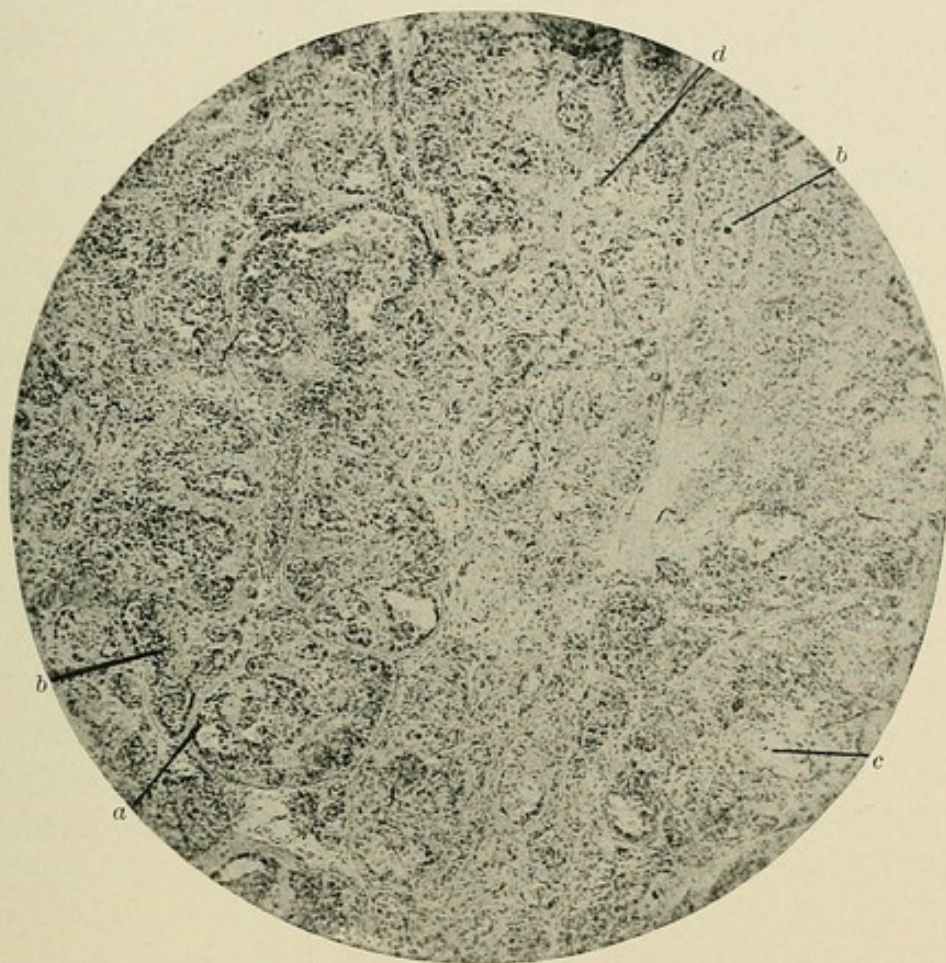


FIG. 227.—Carcinoma of the ovary; $\times 75$ (Surgical Clinic, Rush Medical College): *a*, scanty connective-tissue stroma; *b*, nests of epithelial cells; *c*, small colloid cysts; *d*, blood-vessel.

noma was referable to the cystic tumor; that epithelial cells from the benign cystoma became detached and implanted either in the abdominal cavity or in the wound, and eventually developed into a carcinoma. He is of the opinion that the last process did not follow immediately upon the epithelial deposit, but that first an adenoma developed, and from that a carcinoma sprang.

Rokitansky described a case of carcinoma of the ovary that started in a corpus luteum.

The occurrence of carcinoma in cysts, and the resemblance anatom-

ically of the carcinomatous and adenomatous proliferating cysts of the ovary, make it very difficult to distinguish, from the naked-eye appearances of certain cysts of the ovary, between malignant and non-malignant tumors. From a histological standpoint this difficulty is increased because endothelial tumors of a malignant character are included by some authors under the head of carcinoma. Endothelioma, which was first described by Birch-Hirschfeld as carcinoma of the lymphatics, constitutes a tumor composed of tissue derived from the mesoblast, and it will again be referred to in the section on Sarcoma. Carcinoma as a primary tumor of the ovary undoubtedly originates, as does adenoma, in a remnant of the fetal ducts (Fig. 227). The stroma is alveolated and is usually scanty; the cells are numerous, filling the alveoli and infiltrating the stroma. The tumor is soft and grows rapidly. Colloid degeneration affecting both the parenchyma and the stroma of the tumor results in the formation of cysts. Diffuse carcinosis of the peritoneum takes place when the tumor perforates the capsule of the ovary. Tumor-cells and fragments of tumor-tissue are disseminated over the peritoneal surfaces by the peristaltic action of the intestines; these cells and fragments of tissue become implanted at different places, and establish in this manner independent centres of tumor-growth everywhere.

Ascites is often the first symptom which induces the patient to seek medical advice. Ascites in the female occurring independently of the existence of organic disease of the liver, heart, or kidneys indicates the existence of either peritoneal tuberculosis, malignant disease of the ovary, or a movable solid tumor of the uterus or the ovaries. If the patient is advanced in years, the possibility of the primary affection being of a malignant character is greatly increased. Carcinoma of the uterus is exceedingly prone to extend to the ovaries. Winckel records a case in which, a year and a half after amputation of the cervix for carcinoma, the disease made its appearance in one of the ovaries, while no local recurrence had taken place.

Many gynecologists are opposed to radical measures in the treatment of carcinoma of the ovary. This sense of helplessness on the part of the surgeon when confronted by such a case has been created largely by the unfavorable experience of late operations. Usually, before a laparotomy is made, the disease has extended from the ovary to the adjacent organs. The broad ligament is often extensively implicated. The adherent omentum frequently shows evidences of extensive involvement, and sometimes diffuse miliary carcinosis is present. If the general condition of the patient is such as to warrant an exploratory incision, this should always be done, if for no other purpose than to

make a positive diagnosis. It is just possible that the ascites and the other conditions which have induced the surgeon to make a diagnosis of carcinoma may have been produced by other pathological conditions which are within reach of successful treatment by direct measures. The patient should therefore be given the benefit of the doubt by a resort to an exploratory incision. It appears that temporary relief and prolongation of life have been obtained in cases in which the disease returned later. The writer can recall at least three instances in which, by the removal of a carcinomatous tumor of the ovary with extensive adhesions, great relief was afforded and life was prolonged for from six months to a year. If the disease is limited in extent, the success of an operation should be the same as in operations for carcinoma of other organs similarly situated. If the attachments are such that the removal of the tumor would place the life of the patient in imminent danger, the operator should go no further, and should close the wound after having made a positive diagnosis.

Uterus.—Carcinoma of the uterus was known to the ancient authors, and has been described elaborately by Hippocrates, Celsus, Galen, Ætius, and others. In more recent times animated discussions have been carried on in regard to its starting-point. Cancroid, papillomatous carcinoma, scirrhus, and medullary carcinoma of the uterus have been regarded as distinct varieties of carcinoma. The histogenetic origin of carcinoma of the uterus, like that of carcinoma of other mucous surfaces, can be traced either to a matrix of embryonic cells in the epithelial lining or to a matrix representing the glandular appendages of the uterus.

Histogenesis and Histology.—The cauliflower excrescences of the cervix uteri, or the papillomatous variety of carcinoma, have been recognized for a long time as one of the most common malignant tumors of the uterus. How much confusion has existed in separating the malignant from the benign papillary tumors is evidenced from a description of them by Virchow in 1851:

“One must distinguish three different papillary tumors of the os uteri: the simple, such as Frerichs and Lebert have seen; the cancroid; and the cancerous: the first two forms together constitute the cauliflower growth. This begins as a simple papillary tumor, and at a later period passes into cancroid. At first one sees only on the surface papillary or villous growths, which consist of very thick layers of peripheral, flat, and deeper cylindrical epithelial cells, and a very fine interior cylinder formed of a scanty stroma of connective tissue with large vessels. The outer layer contains cells of all sizes and stages of development, some of them forming great parent structures with

endogenous corpuscles. The vessels are for the most part colossal, very thin-walled capillaries, which form either simple loops at the apices of the villi, between the epithelial layers, or toward the surface develop new loops in constantly increasing number, or, lastly, present a reticulate branching. At the beginning of the disease the villi are simple and close pressed, so that the surface appears only granulated, as Clarke describes it: it becomes cauliflower-like by the branching of the papillæ, which at last grow out to fringes an inch long, and may present almost the appearance of a hydatid mole. After the process has existed for some time on the surface, the cancrioid alveoli begin to form deep strings between the layers of the muscular and the connective tissue of the organ. In the early cases I saw only cavities simply filled with epithelial structures; but in Kiwisch's case there were alveoli on whose walls new papillary branching growths were growing—a kind of proliferous arborescent formation."

It will be seen from this description that the cauliflower excrescences in the two conditions distinguished by Virchow illustrate the usual clinical course of the most malignant growths of the cervix uteri. The growths which he calls "simple papillary tumors" represent the same form of carcinoma of the skin. The outgrowth of the papillary excrescences is always attended by infiltration of the deeper structures (Fig. 228). The tumor is composed of enlarged papillæ covered by

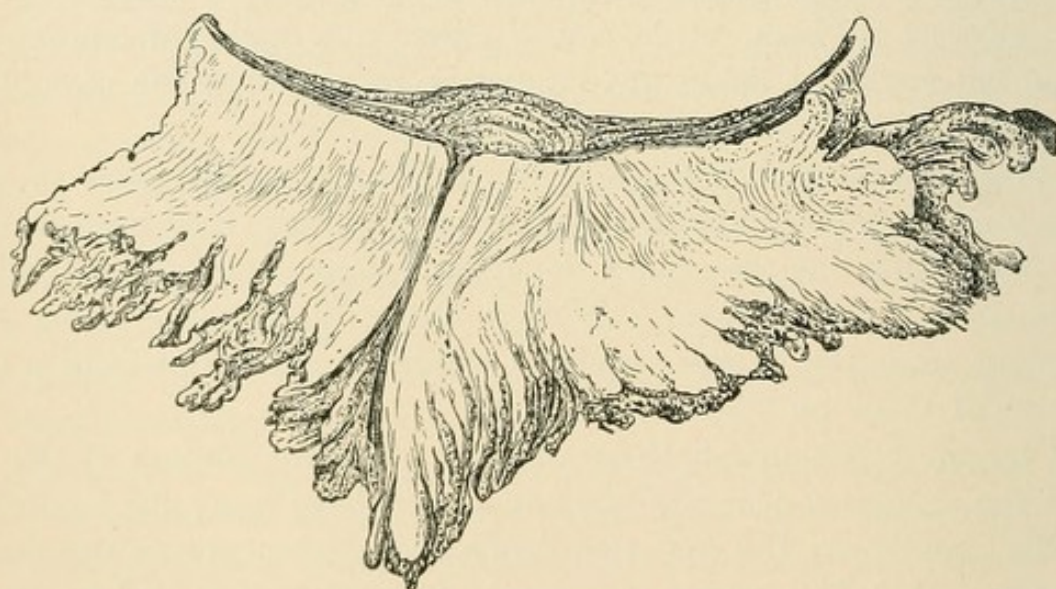


FIG. 228.—Papillary cancer of the cervix: pavement epithelium of the external os; section, natural size (after Pozzi).

squamous epithelial cells in greatly thickened layers. The enlarged papillæ form the branching projections. The tumor begins in that part of the cervix that is below the vaginal insertion, after it starts from cylindrical epithelium which has invaded the surface. It remains for

a long time local, but later local and regional infection is sure to take place, extending to the vagina, the body of the uterus, the pelvic connective tissue, and the lymphatic glands.

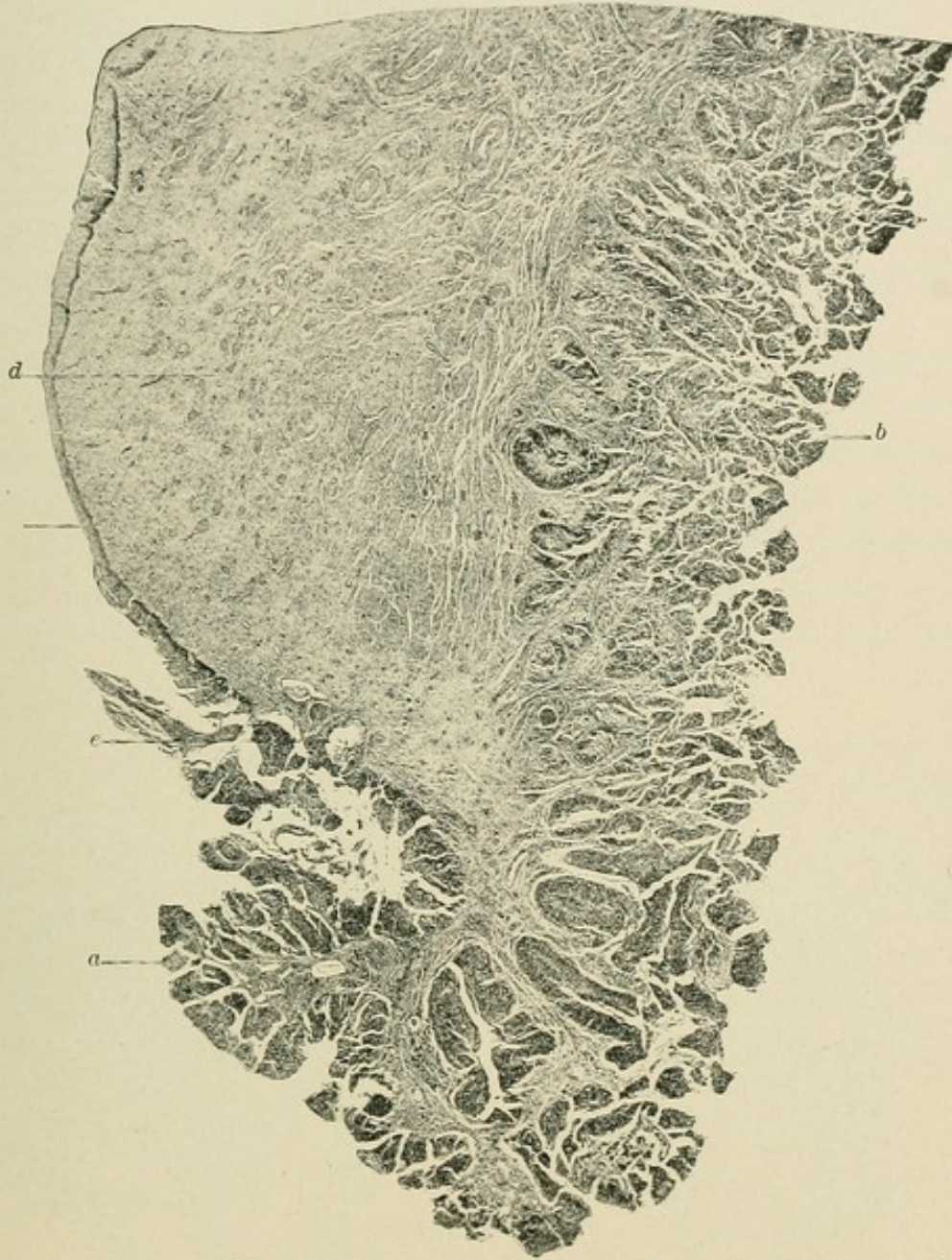

FIG. 229.—Carcinoma of the cervix uteri; $\times 12$ (after Karg and Schmorl): vertical section through the carcinomatous anterior lip of the cervix. The carcinoma commenced in the vaginal portion of the cervix. The mucous membrane of the cervical canal is completely destroyed. The tumor projects from the cervical canal, in the form of cauliflower excrescences (*a*), beyond the level of the squamous cells (*c*) of the anterior lip; at other points it infiltrates, in the form of solid strings of cells and nests of cells, the vascular muscularis (*d*); *e*, remnants of uterine glands lined with cylindrical cells.

In other cases the carcinoma appears as an induration without any papilliform projections. Ulceration in the centre of the growth takes place at an early stage, and continues to spread toward the periphery as well as in the direction of the base of the ulcer. These are the cases which correspond with the flat, squamous-celled carcinoma of the skin.

Carcinomata originating in the mucous membrane of the cervical

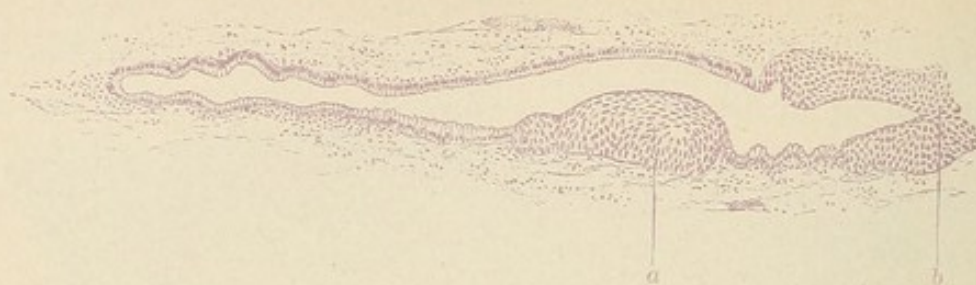

FIG. 230.—Uterine gland, showing very early malignant overgrowth of the columnar epithelium at *a* and *b* (after Boyce). (Obj. 1 inch, with eye-piece.)

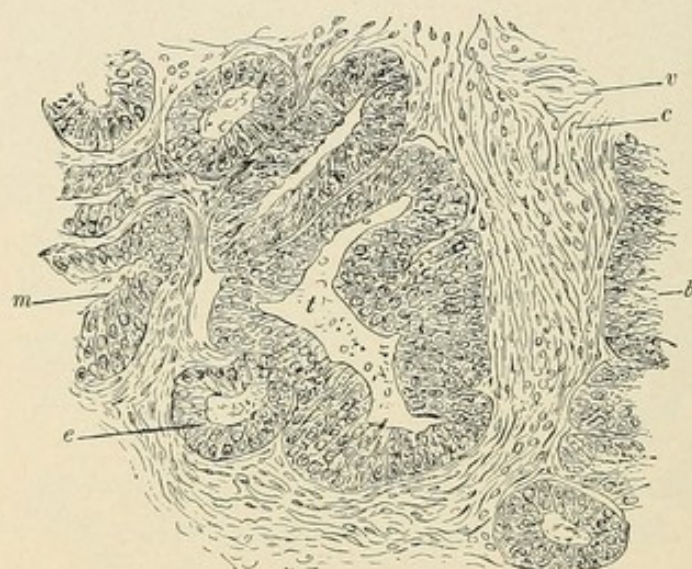


FIG. 231.—Cylindrical-celled carcinoma from the upper part of the cervix, invading the fundus; $\times 150$ (after Cornil): *m, e*, hypertrophied glands of the body of the uterus, like those of chronic metritis; *t*, enlarged glandular cavity, the walls showing many layers of epithelium; *b*, adjacent gland-wall in a similar state; *v*, vessels; *c*, connective tissue.

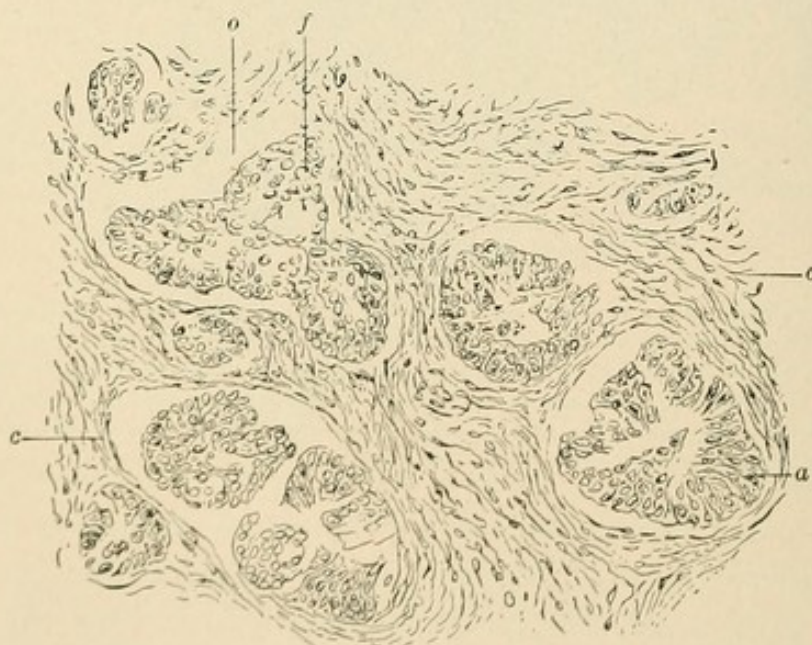


FIG. 232.—Cylindrical-celled carcinoma of the body of the uterus, extending from the cervix; $\times 150$ (after Cornil): *c, c*, connective tissue; *a*, cavity full of cells, the external layer being cylindrical: these cells have a tendency to become detached from the wall, well seen at *o*; *f*, cavity with mucous cells, and larger cells in mucous degeneration.

canal begin in the glands, and are composed of cylindrical cells arranged in tubular form in a stroma very variable in its relative proportions to the parenchyma of the tumor (Fig. 229). Primary carcinomata of the mucous membrane of the cervical canal and of the uterine cavity histologically resemble each other almost perfectly. The structure is in imitation of the mucous glands. The starting-point of the tumor is in a matrix of embryonic cylindrical epithelial cells that pre-exists in one of the glands or in their immediate vicinity, or that is formed later in these localities by post-natal causes. Boyce had an opportunity to study the incipient stage of a tumor with such an origin (Fig. 230). The illustration represents a complete uterine gland, the mouth of which (*a*) is stopped by an epithelial overgrowth of the columnar lining, and on whose wall (at *b*) a plaque of proliferated epithelium has formed in the midst of typically columnar cells. It is the beginning of a cancerous change which elsewhere in the uterus has advanced to completeness. Where the change is complete the glands have been converted into solid epithelial cylinders; these, together with the proliferating epithelium on the surface, have branched deeply into the stroma (Fig. 231).

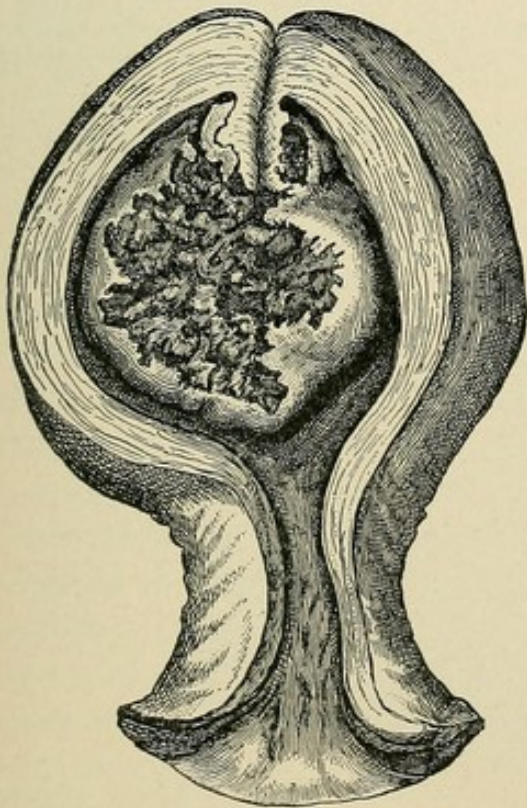


FIG. 233.—Carcinoma of the uterine mucous membrane, circumscribed form (after Pozzi).

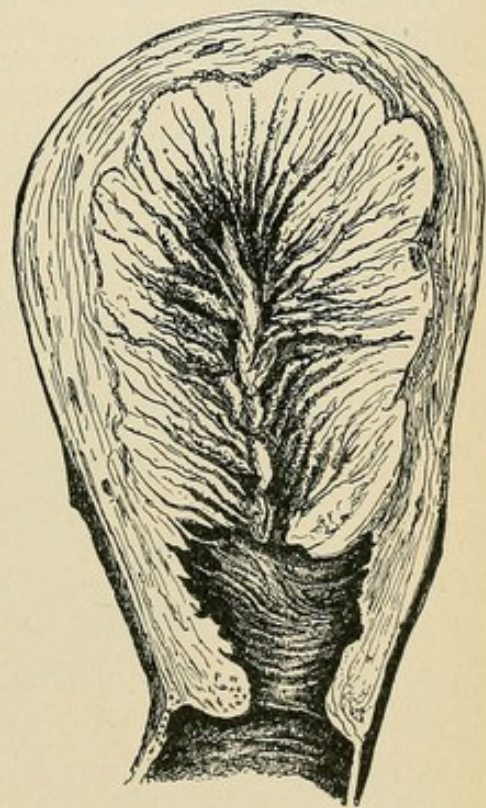


FIG. 234.—Carcinoma of the uterine mucous membrane, diffuse form (after Pozzi).

Cylindrical-celled carcinoma is much more malignant than the squamous-celled variety. Carcinoma of the cervical canal creeps along the

mucous membrane into the cavity of the uterus. The intra-uterine

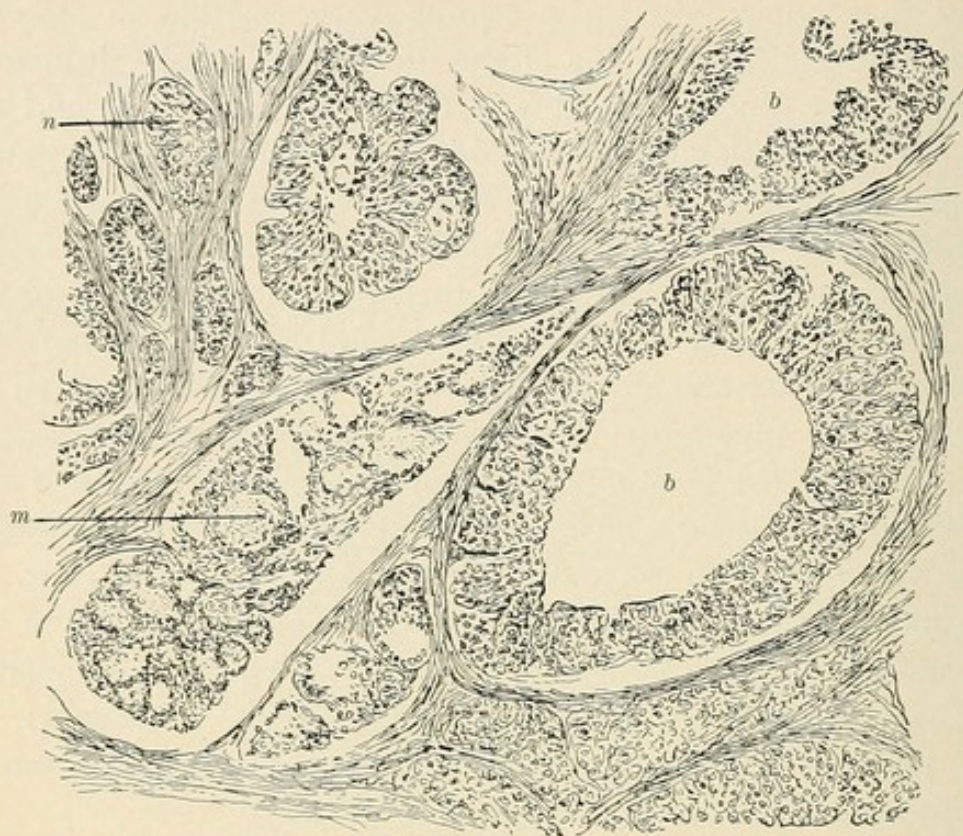


FIG. 235.—Primary carcinoma of the uterus; $\times 120$ (after Pozzi): *b, b*, lobules of the tumor; *m*, lobules showing empty spaces, which are either transverse sections of vessels or cavities filled with cells in mucous degeneration; *n*, smaller alveoli of the tumor. Nearly all these epithelial cells have a tendency toward isolation by the walls of the vessels that enclose them.

part of the tumor presents under the microscope a structure similar to that of the primary tumor (Fig. 232).

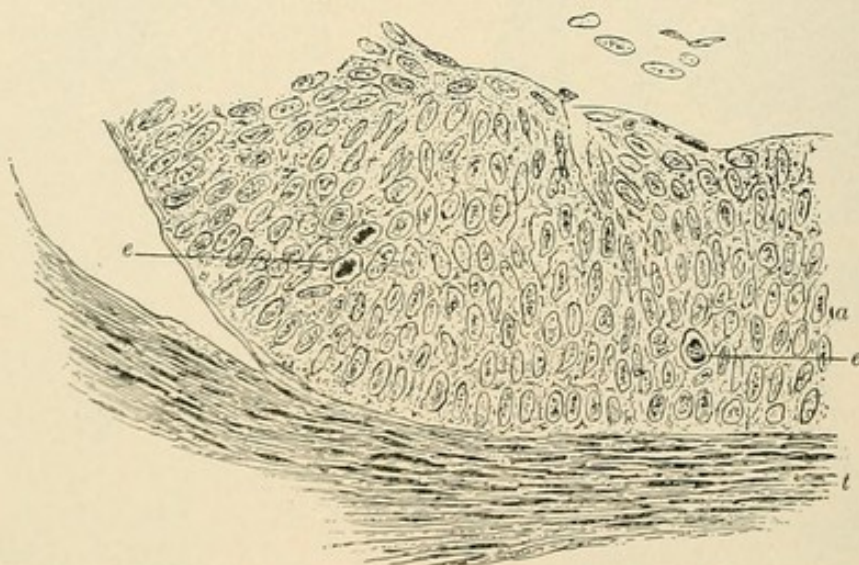


FIG. 236.—Primary carcinoma of the uterine body; $\times 300$ (after Cornil): *a*, numerous layers of stratified epithelium, the deepest being cylindrical; *e, e*, cells with karyokinesis; *t*, muscular tissue of the uterus, on which the cylindrical cells are directly implanted.

Primary carcinoma of the body of the uterus is a much rarer affection than carcinoma of the cervix. Clinically, carcinoma of the uterine cavity presents itself in two forms, the *circumscribed* (Fig. 233) and the

diffuse (Fig. 234). In the circumscribed form the tumor often attains considerable size before it breaks down, and frequently it assumes a polypoid shape. In the diffuse variety the mucous membrane is extensively involved from the beginning, and the disease infiltrates the muscular tissues in all directions, resulting in a uniform pear-shaped enlargement of the body of the uterus.

The structure of a primary carcinoma of the uterine mucous membrane, like that of a carcinoma of the cervical canal, is usually in imitation of the uterine glands. Cylindrical cells are arranged in a tubular form in an alveolated stroma (Fig. 235). The cylindrical cells are arranged in the tubules in one or more layers. If the layers are numerous, the cells most distant from the matrix become flattened and resemble squamous or pavement epithelium (Fig. 236). Mucous and colloid degeneration leads to dilatation of the tubules and the formation of cysts of small size. The stroma often undergoes similar changes. The infiltration of the cervix and body of the uterus imparts to the affected organ that characteristic hardness with which the surgeon becomes so familiar as an important point in differential diagnosis. The formation of large tumors is rendered impossible by the destructive ulceration which sets in at an early stage and continues in a progressive manner. In the papillary form the copious vegetations slough off, leaving large ulcerating defects.

Etiology.—Schroeder ascertained that 33 per cent. of all women who die of carcinoma succumb to carcinoma of the uterus. The only organs more frequently affected by carcinoma are the stomach and the mammary gland. Wagner estimated that of all persons who die of carcinoma, in one-fourth of them the uterus is the seat of the disease. From these statistics it is evident that the uterus is one of the organs which presents, next to the stomach, conditions, congenital or otherwise, most favorable to the development of carcinoma. The fifth decennium is the time of life most predisposed to the affection. A closer study of the statistics shows that the first five years after the cessation of menstruation furnish the largest contingent of cases. An hereditary predisposition was traced, according to different authors, in from 7.6 to 13 per cent. Winckel called special attention to the frequent occurrence of carcinoma of the uterus in tubercular families—another proof of the fallacy of Rokitansky's assertion that tuberculosis and carcinoma do not occur in the same person at the same time. Carcinoma occurs more frequently in married than in single women, and more frequently in sterile women than in those who have given birth to children. Of the women who have borne children, those who have passed most frequently through childbed are most disposed to carci-

noma of the uterus. Difficult or instrumental deliveries and abortions appear to exert an etiological influence. These different etiological influences have been studied by Winckel on the hand of an extensive clinical material that came under his own observation. There can be no question that trauma, inflammatory affections, and benign tumors, which are so frequently found in the cervix, constitute an important element in the production of carcinoma. The most important cause, however, to explain the frequency with which carcinoma selects this locality, is the fact that in the embryo the squamous epithelium of the sinus urogenitalis blends with the cylindrical epithelium of Müller's ducts at the external os of the cervix. It is at the point of junction of the epithelial cells of different embryonal origin and of different shape and function that carcinoma most frequently takes its starting-point. Embryonal cells are here in excess or they are displaced, and become later the essential tumor-matrix.

The reasons why carcinoma of the cervix appears in preference after the menopause are the same as Thiersch has advanced for carcinoma of the lip. The shrinking submucous connective tissue loses at this time its physiological resistance, thus opening pathways for invasion by epithelial cells. Emmet has called attention to laceration of the cervix as a cause of carcinoma. The writer is strongly inclined to believe that a laceration of the cervix may not only act as an exciting cause, but that, in addition, it may furnish the essential matrix of embryonic epithelial cells. It is not difficult to understand that during the healing of a laceration of the cervix new embryonal cells may become buried in the scar-tissue in an immature state, and remain in this condition, constituting a tumor-matrix of post-natal origin. E. Martin believes that acute infectious lesions of the vagina and the uterus, like gonorrhea, have an influence in the causation of uterine carcinoma—an opinion which receives the support of Winckel and others.

Symptoms and Diagnosis.—The symptoms which point to the existence of carcinoma of the uterus are (1) hemorrhage, (2) profuse and often very fetid vaginal discharge, (3) pain, (4) dysuria, and (5) rectal tenesmus.

If the patient has not ceased to menstruate, menstruation is profuse and prolonged. Greater significance attaches, however, to the occurrence of hemorrhage between the menses. Bleeding during the interval, occurring spontaneously or provoked by active exercise, by the use of the vaginal syringe, or by coitus, in a woman past thirty-five years of age is very suggestive of the existence of a carcinoma of the uterus, and should induce the medical attendant to make a thorough examina-

tion. The occurrence of hemorrhage after the menopause has a similar diagnostic significance.

A profuse watery discharge, stained at times with blood, is one of the earliest external evidences of papillary carcinoma of the cervix. The discharge is often very irritating, producing excoriation of the external genital organs, and often a catarrhal vaginitis. When the disease has advanced to extensive ulceration, or the papillary excrescences have become gangrenous, the discharge is always exceedingly fetid and profuse; at this time it also frequently contains fragments of cast-off tumor-tissue.

The pain, of a dull, aching, burning, or lancinating character, is referred most frequently to the back, the lower part of the abdomen, the hips, the iliac regions, and the thighs.

The retention of secretions in the uterine cavity by the blocking of the cervical canal by the tumor-tissue causes expulsive pains. If the carcinoma presses upon the bladder or has reached this organ by extension, urinary disturbances set in, varying in intensity from a desire to pass the urine more frequently than usual to the involuntary escape of urine through a fistula produced by destruction of the posterior bladder-wall by the tumor. The function of the rectum is disturbed by pressure or by the extension of the disease from the uterus to the rectum.

Constipation, tenesmus, and the escape with the feces of mucus or of mucus stained with blood are some of the indications showing the existence and extent of uterine carcinoma. If the disease has extended to the pelvic connective tissue or the peritoneum, it presents many symptoms and signs of parametritis and pelvic peritonitis—affections which must be excluded carefully in the differential diagnosis. Extensive local and regional infection is indicated further by great œdema of one or both lower extremities, caused by compression or thrombosis of one or more of the large veins in the pelvis, by ascites, by tympanites, and by carcinoma of the external genitals. Metastatic tumors in distant parts of the body would indicate that general infection has taken place.

It is unfortunate that the onset of the disease is so insidious, as patients, as a rule, consult the physician only after the disease has manifested itself by symptoms which belong to its advanced stages. Unless discovered accidentally in the examination for obscure pelvic affections, carcinoma of the uterus presents itself to the surgeon in the majority of cases in its advanced stages. As most if not all of the symptoms that have been detailed may be simulated by benign tumors of the uterus and by inflammatory affections involving this organ and

its appendages, a reliable diagnosis must rest upon a thorough examination.

In advanced cases, when the lower segment of the uterus is the seat of fungous masses or of a deep excavation with an infiltration of stony hardness at its base extending from the uterus to the parauterine connective tissue on both sides, completely immobilizing the organ, a positive diagnosis can be made by the mere touch of the finger. It is different in cases in which the disease is limited to perhaps one lip of the cervix, or where the disease originated primarily in the mucous membrane of the uterine cavity. In such cases it is sometimes exceedingly difficult to differentiate between chronic inflammatory affections, benign tumors, and carcinoma.

Laceration of the cervix with hypertrophy of one or more of its lips, and ectropion of the cervical mucous membrane with erosion, have frequently been mistaken for carcinoma. A hypertrophic lip of the cervix covered by papillary erosions presents to the palpating finger on passing it lightly over the surface a velvety softness, while on deeper pressure the hypertrophied tissues feel uniformly dense, but lack the stony hardness of carcinoma (Fig. 237). The carcinomatous cervix feels not only hard but nodulated, and if ulceration has taken place the surface of the

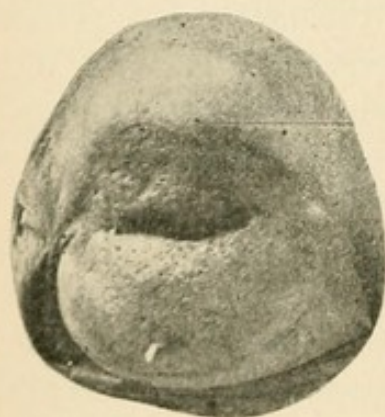

FIG. 237.—Broad erosions of both lips of cervix, with numerous glandular openings (after Winckel).

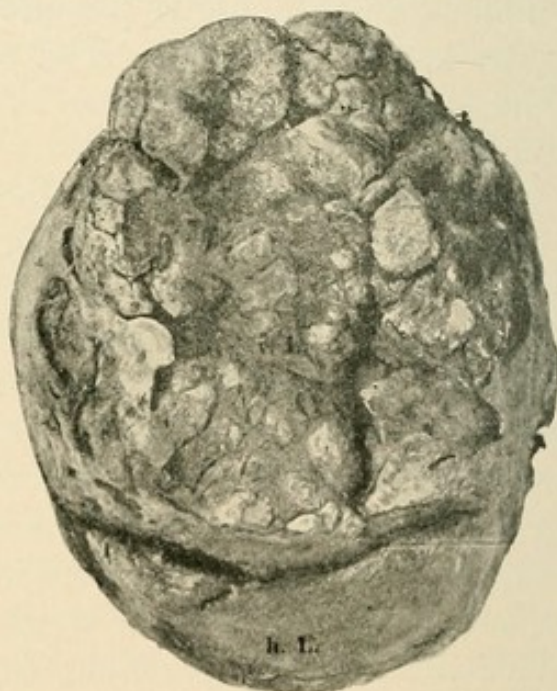


FIG. 238.—Papillary carcinoma of cervix limited almost entirely to the anterior lip (after Winckel).

ulcer is uneven and hard (Fig. 238). If the disease involves both lips at the same time and is limited in extent, the opening of the cervical canal is then surrounded by a ring-like induration of great firmness that does not yield on attempting to insert the tip of the index finger (Fig. 239).

Retention-cysts of the external os of the cervical canal might be

mistaken for carcinoma, as on palpation they feel quite firm, but lack the induration so characteristic of carcinoma, and on deep pressure a

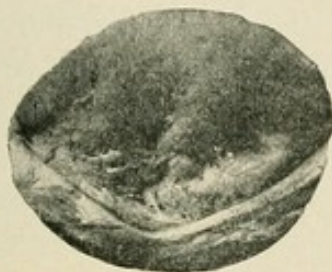

FIG. 239.—Papillary carcinoma of both lips of the cervix (after Winckel).

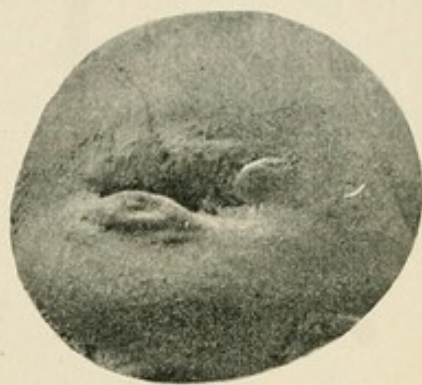


FIG. 240.—Large retention-cysts of both lips of the cervix (after Winckel).

sense of elastic resistance is produced. These cysts are also usually multiple, while carcinoma extends from one centre (Figs. 241, 242).

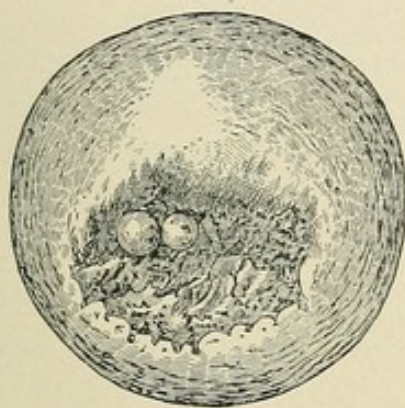


FIG. 241.—Beginning cancer of the cervix, ulcerative form (after Pozzi).

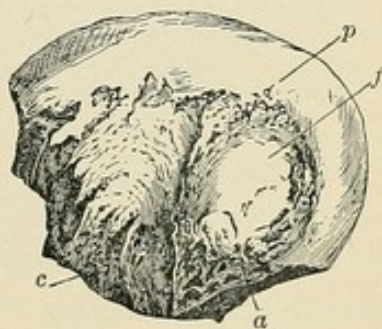


FIG. 242.—Cancer of the cervix, nodular form (after Pozzi): *p*, zone of intact pavement epithelium; *f*, cancerous nodule; *a*, external os; *c*, cervix.

In doubtful cases a diagnosis must be made by the use of the microscope. A small fragment of tissue near the margin of the supposed tumor is removed, and from it sections are made. In carcinoma the section will show atypical proliferation of epithelial cells in the form of solid cylinders and epithelial nests in the vascular stroma. In papillary erosions the section will show an increase of glandular structure, but the epithelium is separated from the submucous vascular connective tissue by the membrana propria. *No epithelial cells are found in direct contact with vascular connective tissue.*

Primary carcinoma of the body of the uterus is very rare, and especially so in women less than fifty years of age. It is attended by enlargement of the uterus, profuse and often fetid vaginal discharge, and fitful attacks of hemorrhage. As some of these symptoms attend adenomatous disease of the mucous membrane, it is often necessary to

remove with the sharp curette fragments of tissue for examination under the microscope. In adenoma the epithelial cells will be found to occupy their normal relative position to the basement membrane, while in carcinoma the epithelial cells, almost always of the cylindrical variety, will be found in and among the vascular structures and arranged in a tubular form (Fig. 243). Retained placental tissue and myoma of the uterus undergoing sloughing are conditions which might lead to errors

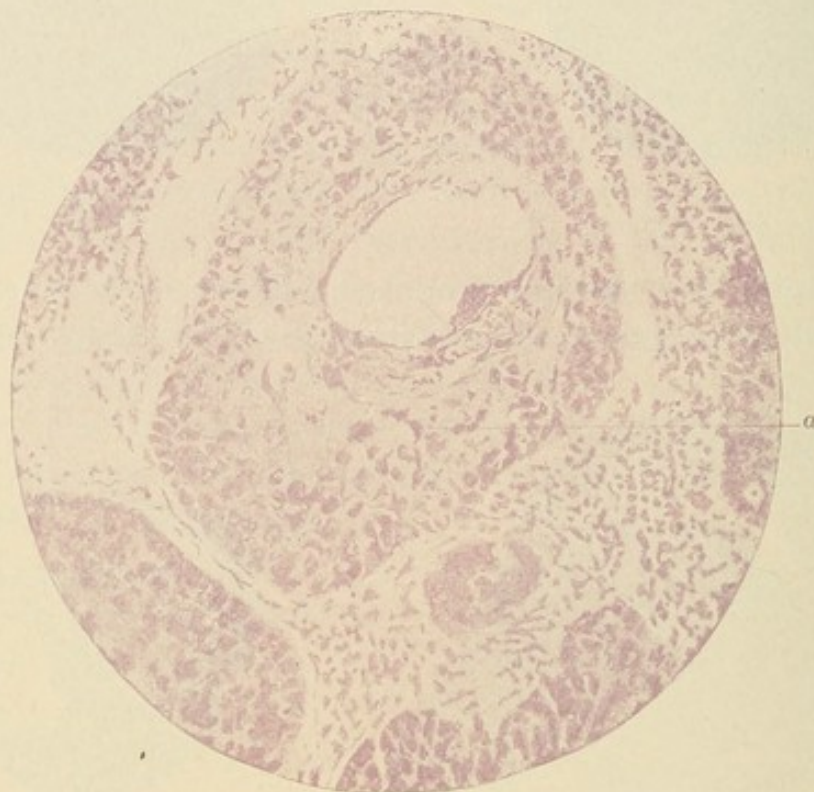


FIG. 243.—Atypical columnar epithelioma derived from uterine glands (after Boyce): *a*, the cancer-cylinder. (Obj. $\frac{1}{4}$ inch, without eye-piece.)

in diagnosis, and they must be considered carefully in making a differential diagnosis between primary carcinoma of the body of the uterus and other intra-uterine affections.

Supravaginal Amputation of the Cervix Uteri for Carcinoma.—The first supravaginal excision of the cervix uteri for carcinoma was made by Osiander. The operation was later perfected by C. J. M. Langenbeck and by Schroeder. This operation should be restricted to cases of carcinoma beginning upon the vaginal portion of the cervix and in which the disease has not extended to the body of the uterus. Surgeons are not agreed as to the value of this operation in the treatment of uterine carcinoma. The combined statistics representing cases from the practice of a number of able surgeons show a mortality of about 11.5 per cent. Some of the ardent advocates of this operation claim that in nearly half of the cases the carcinoma did not return after operation. Such a statement, however, must be accepted with a good

deal of allowance. On the contrary, the champions of hysterectomy underrate the value of this operation. Common sense would dictate that in a limited carcinoma of the external os it is no more necessary to remove the entire uterus than it would be to extirpate the whole of the lower lip in a beginning carcinoma of the lip. Here as elsewhere the surgeon must show good sense and judgment in selecting the cases for partial and those for complete removal of the uterus for carcinoma. Schroeder's operation is the one that promises the best results in well-selected cases.

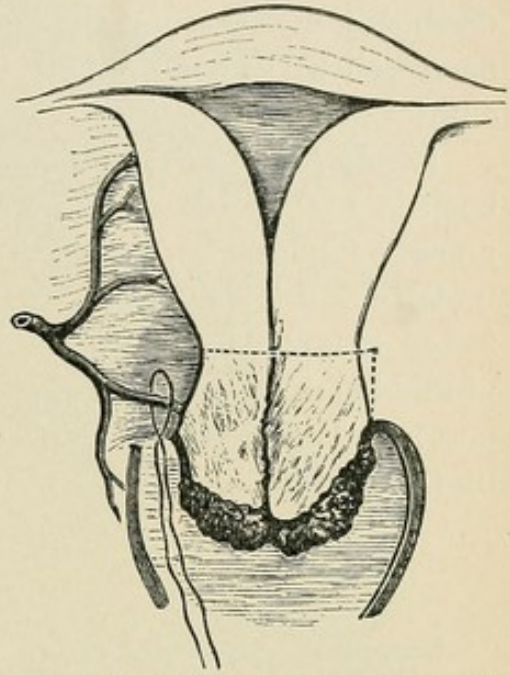


FIG. 244.—Schroeder's supravaginal amputation of the cervix for carcinoma, showing the extent of the excision and the ligature of the lower branch of the uterine artery (after Pozzi).

The uterus is drawn down to the vulva by a pair of vulsellum forceps, and a strong loop of thread is passed through and above each of the lateral culs-de-sac (Fig. 244). These loops serve to draw the parts down and to compress the uterine artery. The cervix is then isolated, through a circular incision made at the vaginal insertion, as far as the internal os. Spiriting vessels are at once tied. The dissection is made as far as possible by the use of blunt instruments, to guard against wounding the bladder or the rectum or opening unintentionally the peritoneal cavity. The anterior portion of the cervix is removed first, when the vaginal mucous membrane is stitched to the mucous membrane of the cervical canal. The same is done after the amputation of the posterior half of the cervix. Schroeder has excised with the cervix the upper part of the vagina when the disease had extended in that direction. Some surgeons employ no sutures after amputation of the cervix, but follow the use of the knife by that of the cautery (Koeberlé) or of chloride of zinc (Van de Warker). If all the diseased tissue can be removed—and these are the cases which are adapted for supravaginal amputation—it is advisable to suture the vaginal mucous membrane to the mucosa of the cervical stump, as otherwise a stenosis or a complete obliteration of the cervical canal may become a source of trouble and an indication for more operating in the future. The writer has seen at least two cases of supravaginal amputation of the cervix for carcinoma in which the suturing was omitted, and in which complete obstruction by cicatricial contraction gave rise to great pain during the menstrual

period, as all the menstrual discharge escaped into the peritoneal cavity, causing repeated attacks of pelvic peritonitis. In one of these cases removal of the uterine appendages disclosed both of the tubes greatly distended, the lumen at the fimbriated extremity having become greatly narrowed by firm adhesions, the remnants of repeated attacks of circumscribed peritonitis.

Vaginal Hysterectomy for Carcinoma of the Uterus.—C. J. M. Langenbeck in 1813 made the first complete vaginal hysterectomy for carcinoma. Sauter and Dubourg appear next in the list of surgeons who undertook this operation. Vaginal hysterectomy was revived and perfected in 1878 by Czerny. A radical operation for carcinoma of the uterus involving more than the cervix and limited to the uterus can be performed with less difficulty and greater safety by the vaginal than by the abdominal route. Freund's abdominal hysterectomy for carci-

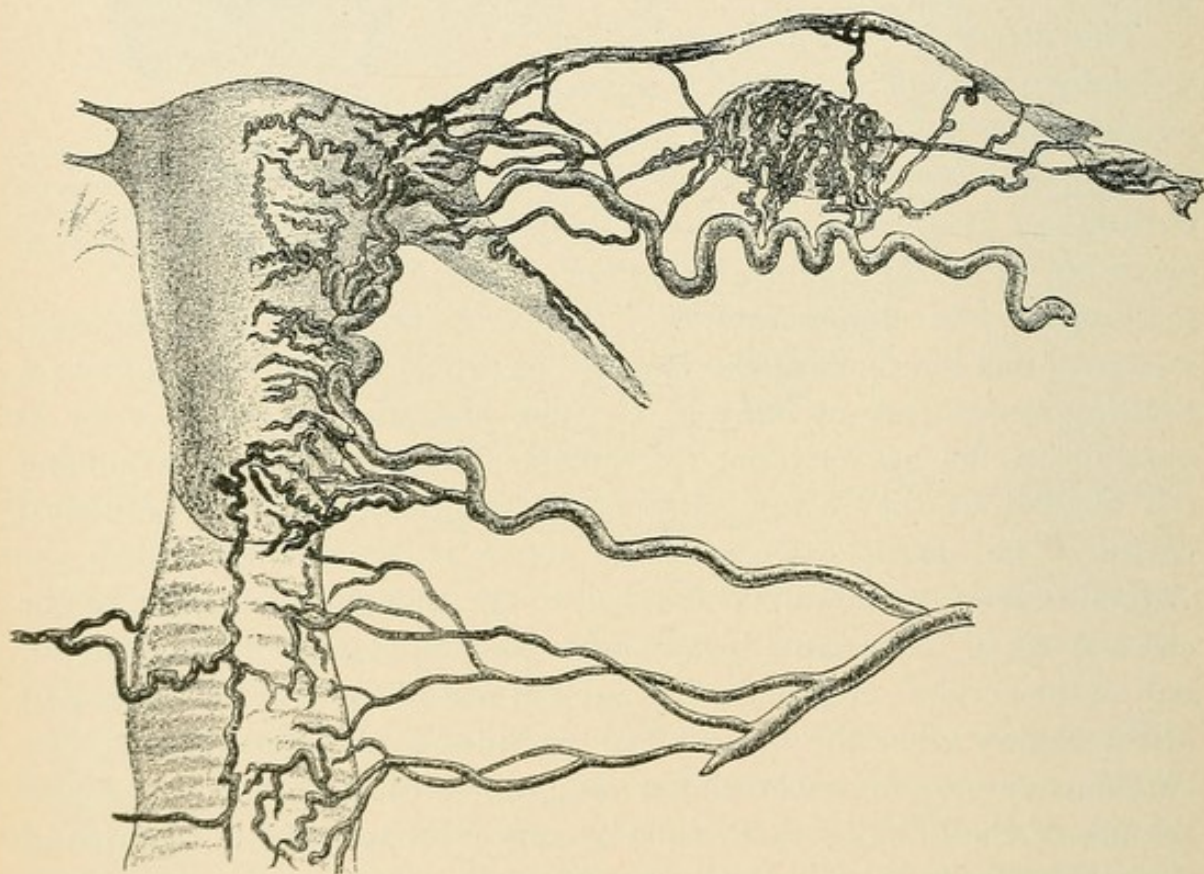


FIG. 245.—Vessels of the uterus: uterine and utero-ovarian arteries (after Pozzi).

noma has been replaced almost entirely by vaginal hysterectomy. Strict antiseptic precautions are necessary when the abdominal cavity is to be opened in the removal of a carcinomatous uterus. The vagina and the external genitals should be disinfected in the usual manner, and if the carcinoma has ulcerated extensively, a preliminary scraping is necessary for the purpose of removing necrosed infected tissue that would escape the ordinary means of disinfection. The patient should undergo

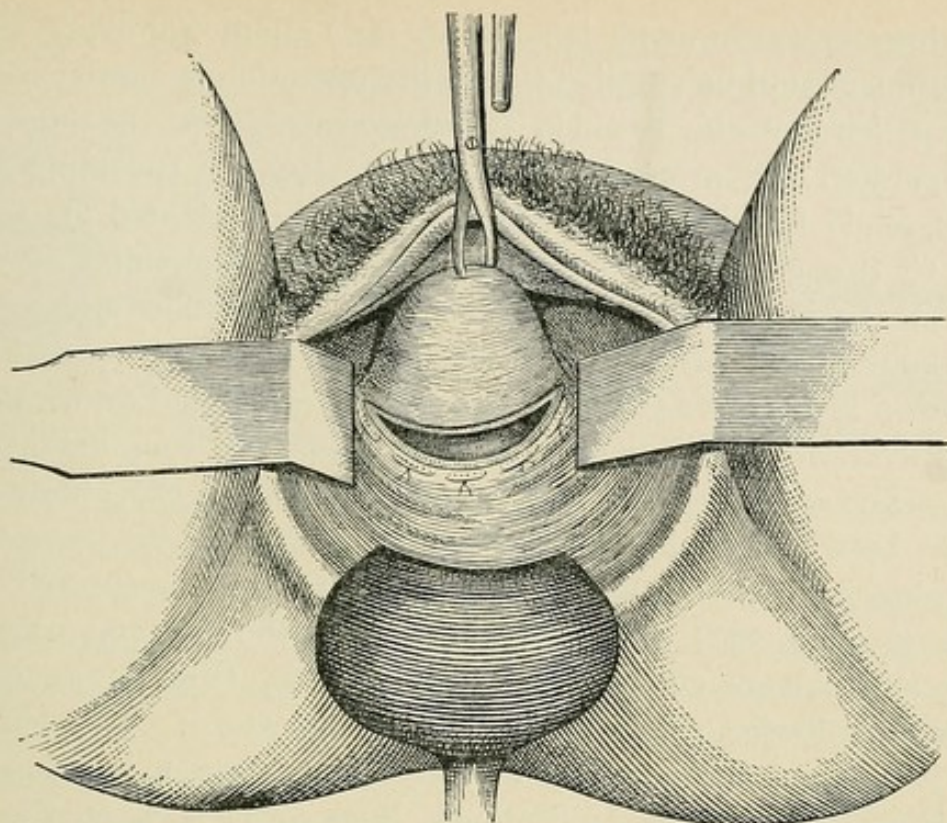


FIG. 246.—Vaginal hysterectomy : first step, opening the posterior cul-de-sac and suture of the peritoneum to the vaginal mucous membrane (after Martin).

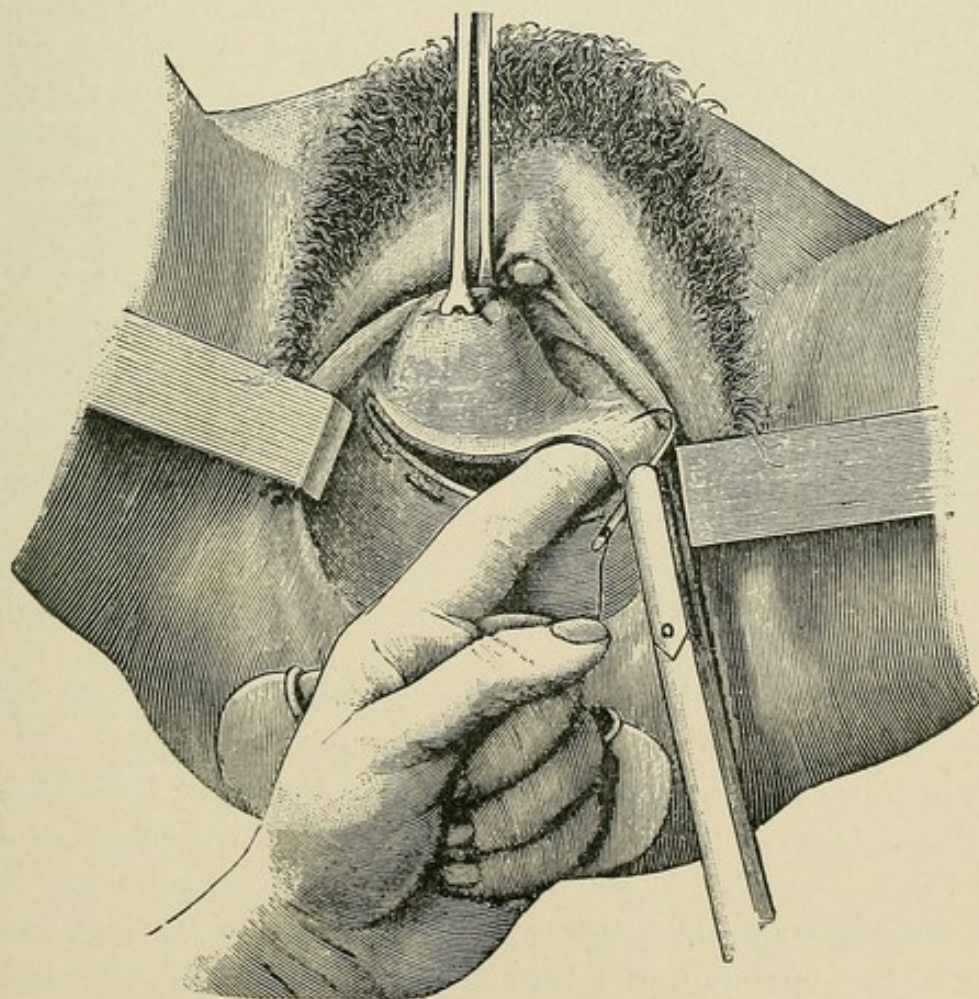


FIG. 247.—Vaginal hysterectomy : second step, ligation of the uterine artery (after Martin).

preparatory treatment as for laparotomy for a number of days. Bladder and rectum should be emptied before the operation is commenced.

The patient must be placed in the lithotomy position, the thighs being well separated and properly immobilized. Hegar's speculum and retractors, made for this special purpose, are best adapted for securing access to the uterus. The modern improved technique of vaginal hysterectomy has special reference to the prevention and arrest of hemorrhage. The principal vessels concerned in this operation are well shown in Figure 245. The uterus is secured and drawn down to the vulva in the same manner as in supravaginal amputation of the cervix. The operation is commenced by opening the cul-de-sac of Douglas by a curved incision behind the cervix at its junction with the vagina, when the vaginal mucous membrane is sutured to the peritoneum (Fig. 246). The suturing arrests the parenchymatous and venous hemorrhage completely. The next step (Fig. 247) consists in ligating the uterine artery on both sides *en masse*. The left index finger is inserted through the wound, and the exact location of the artery is ascertained by the pulsations; then, with a large curved needle armed with strong silk, the artery is included in a mass of tissue at each angle of the wound and is secured by drawing the ligature tightly. The cervix is then drawn backward and downward, and, by an incision at a safe distance from the palpable margin of the tumor, the circular incision is completed, the point of the knife being directed against the cervix to avoid wounding the bladder. The dissection between the bladder and the cervix is made chiefly by the use of the finger and of blunt instruments. Hemorrhage is arrested by points of suture on the cut surface of the tissues. The uterus is now retroverted sufficiently to bring the broad ligaments within easy reach, when they are tied in three parts. The uterus is now, by means of scissors, severed from all attachments, including the peritoneal reflection between it and the bladder, which attachment so far has been reserved to guard against infection. Prolapse of the intestines is prevented by elevating the pelvis or by means of a large sponge well secured in long hemostatic forceps.

The wound should be closed on each side by one or two sutures, leaving an opening in the centre for an iodoform-gauze drain. If ovaries or tubes present conditions requiring operative treatment, they should be removed; otherwise it is better to limit the operation to the removal of the uterus. If the bladder or the rectum should be injured during the operation, the visceral wound must be sutured. After completion of the operation the vagina is lightly packed with iodoform gauze. The packing and dressing should not be removed for from

three to five days unless hemorrhage or infection demands earlier interference. Ligation of the broad ligaments and blood-vessels is the

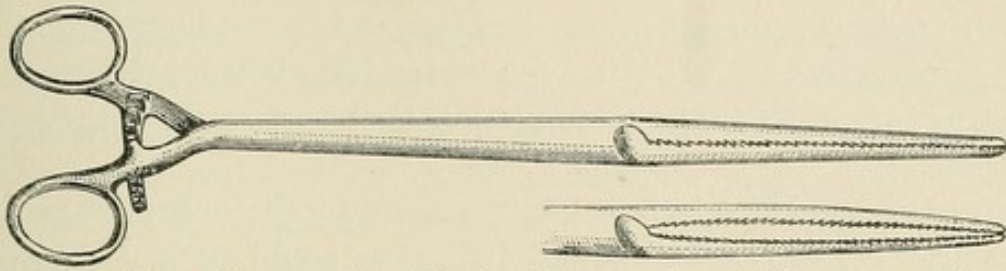


FIG. 248.—Bowed forceps for compression of the broad ligaments in vaginal hysterectomy (after Doyen).

correct surgical way in which to prevent and arrest hemorrhage in vaginal extirpation of the uterus.

Péan has substituted for the ligature long compression-forceps (Fig. 248). After detaching the cervix much in the same way as has been described, the broad ligament near the uterus is grasped with long, slightly curved catch-forceps, as shown in Figure 249. The forceps are prevented from unlocking by tying the handles together with a strip of gauze. After removal of the uterus the vagina is packed with gauze and the forceps are incorporated in the external antiseptic dressing. The forceps are removed at the end of the second day.

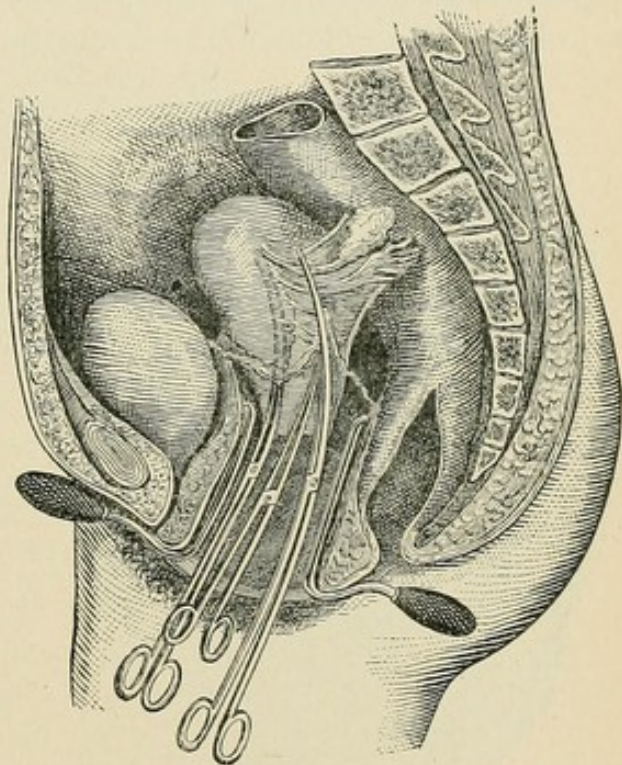


FIG. 249.—Vaginal hysterectomy: application of forceps and section of the base of the broad ligament (after Péan).

Many surgeons have adopted Péan's method of controlling hemorrhage in vaginal hysterectomy by permanent forceps pressure, but the procedure is open to a number of serious objections which do not apply to the use of the ligature, the most important being insecurity against secondary hemorrhage from slipping of the forceps and inability to carry out aseptic precautions to the required extent. The writer has always relied on the ligature, and has had no reason to change his views concerning its superiority over the forceps in the permanent arrest of hemorrhage in vaginal hysterectomy.

Extirpation of the carcinomatous uterus through the sacral route

was first practised by Hochenegg and is strongly endorsed by Czerny. The sacral resection is made in the same way as advised by Kraske for extirpation of carcinoma of the rectum. The sacral operation would certainly appear to present great advantages when the lymphatic glands and the connective tissue behind the uterus have become infected, as it secures better access to the retro-uterine tissues than does the vaginal operation.

Extraperitoneal enucleation, first practised by the older Langenbeck, and recently revived by Frank and Lane, has no future in the operative treatment of carcinoma of the uterus.

In inoperable cases of carcinoma of the cervix and uterus—and as such should be considered all cases in which, from the extent of the disease, complete removal of all infected tissues cannot be effected by either vaginal or sacral hysterectomy—the removal of fungous masses with a sharp spoon, followed by thorough cauterization with the Pacquelin cautery, constitutes an important palliative measure.

External Female Genital Organs.—Carcinoma of the external genital organs of the female is a comparatively rare affection. Its primary

starting-point may be either the labium majus, the labium minus, or the clitoris. Among 7479 women suffering from carcinoma, Winckel found that the vulva was the primary seat of the disease in 72, or about 10 per cent. of all the cases. The tumor begins as a firm nodule in the skin, with an indurated base. The tumor is covered at first by thickened layers of epithelial cells, which in the centre of the growth soon disappear by ulceration. Carcinoma of the vulva, according to Klob and Winckel, is always composed of squamous epithelial cells. As soon as ulceration has occurred, the opposite surface with which the tumor may come in contact is often similarly affected. The tumor does not attain any considerable

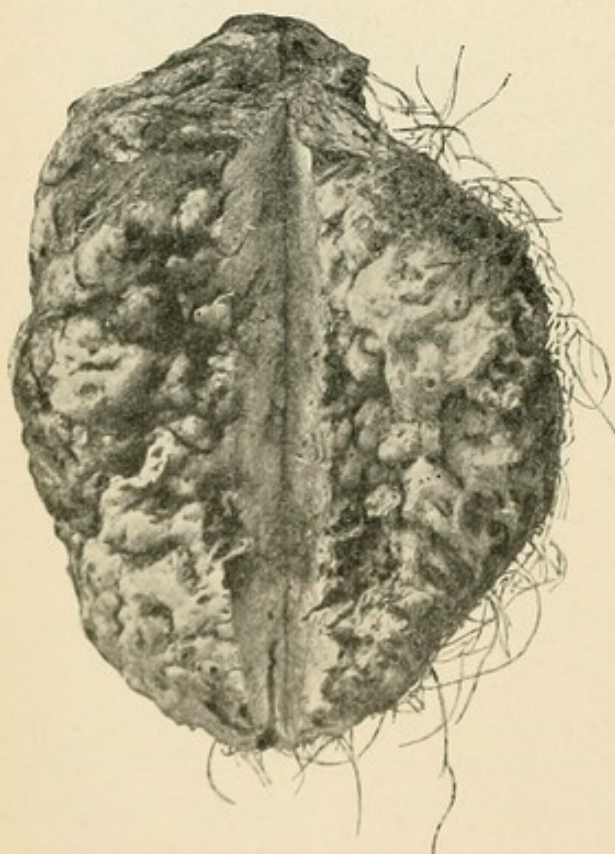


FIG. 250.—Carcinoma of the labium majus (after Winckel). The tumor is incised vertically, showing the appearance of its interior. The surface is nodulated, and on one side is a fringe of hair derived from the lesser labium.

size, as the older portions are destroyed by ulceration. The tumor

represented in Figure 250 was removed by Winckel. In another case the same authority satisfied himself that the carcinoma had originated in a congenital wart of the clitoris. The transformation of a wart of the lesser labium into a carcinoma is well shown in Figure 251.

Lymphatic infection is an early occurrence in carcinoma of the clitoris and vulva. A case of primary carcinoma of the clitoris in a woman sixty years of age came under the writer's observation six months from the time the tumor was discovered. Both greater labia were involved, and very extensive regional infection had taken place in both groins. In this case an oval flap was made by carrying a curved incision the whole length of Poupart's ligament on both sides, and then across the lower border of the mons veneris. This flap was reflected in an upward direction to a point where the femoral vessels pass underneath Poupart's ligament. An incision was then made downward to the apex of Scarpa's triangle on both sides. After reflection of the triangular flaps the whole chain of lymphatics was dissected out, being later removed with the mass containing the primary tumor and both

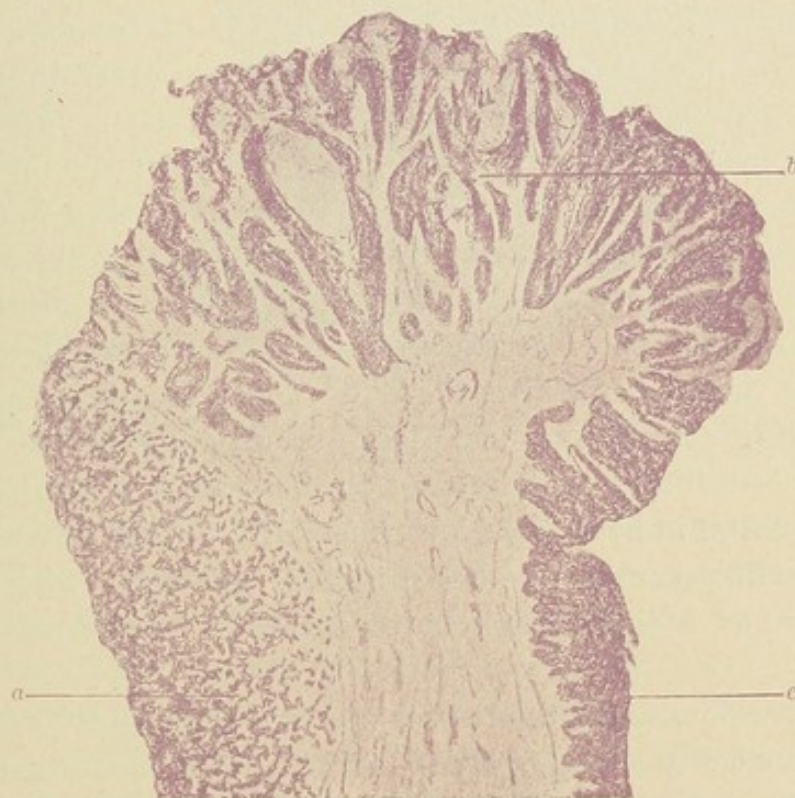

FIG. 251.—Cancerous transformation of the epithelium of the labium majus (after Boyce): *a*, normal epithelium; *b*, warty condition; *c*, malignant change. (Obj. $\frac{1}{4}$ inch, without eye-piece.)

the greater labia in one piece. The hemorrhage was controlled by compression and by hemostatic forceps during the operation. The excision had to be carried to the margin of the meatus and to the lesser labia on the sides. The oval flap was then drawn downward and stitched to the upper margin of the meatus, and the wounds caused by

excision of the labia were closed by stitching the lesser labia to the skin. The remaining parts of the wounds were closed in the usual manner. Primary healing of all the wounds on the right side took place; a slight suppuration interfered with the healing of the wound below Poupart's ligament on the opposite side. The patient left the hospital three weeks after the operation, and three months later was reported as being free from recurrence.

The only effective treatment of carcinoma of the external genital organs of the female is free excision. Large defects can be covered by sliding of the skin, and very large wounds heal in the most satisfactory manner. If the disease has resulted in infection of the inguinal glands, all the glands should be removed with the primary tumor in one continuous mass. This removal can be effected by extending the incision just below Poupart's ligament as far as the anterior superior spinous process, and joining it by a vertical incision extending from the femoral canal to the apex of Scarpa's triangle.

Eye.—Malignant tumors in the interior of the eye are sarcomata. The conjunctiva in rare instances is the seat of carcinoma. The tumor ulcerates early, and generally comes under the observation of the surgeon before extensive local or regional infection has occurred. Perforation of the eyeball takes place at the junction of the cornea and the sclerotic, as resistance to cell-invasion here is less than in the sclerotic or the cornea. Regional infection takes place through the pre-auricular and submaxillary lymphatics. The diagnosis should always be confirmed by examination of sections of the tumor under the microscope, as a positive diagnosis justifies the only radical treatment in such cases—enucleation, with clearing out of all the orbital contents.

Bladder.—Primary carcinoma of the bladder is a rare affection. It is more common in men than in women. It occurs as a sessile, indurated, ulcerating tumor or as a papillary growth. The latter form occurs often as a transformation of a benign papilloma into a carcinoma.

Villous carcinoma (Zottenkrebs) was first described by Rokitansky. It appears clinically as a projecting growth from mucous or other free surfaces. The villous growth consists, in its stem, of a fibrous structure, on which villous tufts are borne, as buddings or sproutings of the stem or its branches. The same kind of tumors are found in the interior of proliferous cysts. In some tumors the main stem is short and thick, and the buds aggregated in a cluster and nearly round; in others the stem is delicate and long, branching into secondary and tertiary tubes or offshoots. The blood-vessels are large, with thin and imperfect walls, resembling colossal capillaries.

Occasionally the urethra is the starting-point (Fig. 252). If in the female the urethra is primarily affected, the radical operation should be preceded by the formation of a suprapubic fistula. After this has been

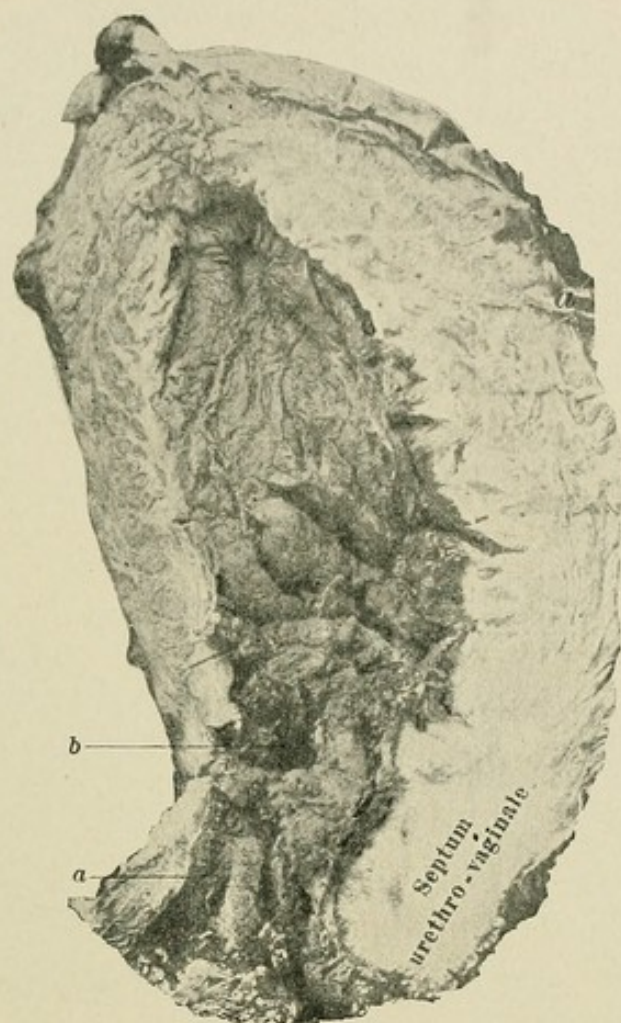


FIG. 252.—Primary carcinoma of the urethra in the female (after Winckel): *a*, urethra; *b*, fundus of the bladder.

established the entire urethra and the base of the bladder should be excised and the opening in the bladder be closed permanently. This operation has been performed successfully by Pawlik and Oviatt.

Carcinoma of the bladder frequently selects that part of the bladder-wall corresponding to the insertion of the ureters. Secondary carcinoma of the bladder from extension of the tumor from the prostate invades the base of the bladder; after the growth has reached the vesical mucous membrane it becomes diffuse, often blocking the orifice of the urethra with masses of tumor-tissue. After ulceration has set in shreds of carcinomatous tissue are often voided with the urine. The ulceration usually extends in the course of time over the entire surface of the tumor (Fig. 253).

The most prominent symptoms of carcinoma of the bladder are hemorrhage, frequent desire to urinate, and great pain after evacuation

of the bladder. Microscopical examination of fragments of tissue voided with the urine or removed in the eye of the catheter will often prove of great value in making a positive diagnosis. In women an incision through the vesico-vaginal septum, and in men a suprapubic cystotomy, will enable the surgeon to make a positive diagnosis, and will also afford relief by establishing a permanent fistula. If the carcinoma is superficial, removal after opening the bladder should be attempted. If the tumor involves the anterior wall or fundus of the bladder, the indication is for a radical operation by excision of the entire thickness of the bladder-wall beyond the limits of the tumor through an abdominal incision. If the carcinoma is so situated that the bladder end of one ureter has to be removed, the resected end should be implanted into a slit of the bladder, as advised by Van Hook, before the opening in the bladder is closed by suturing.

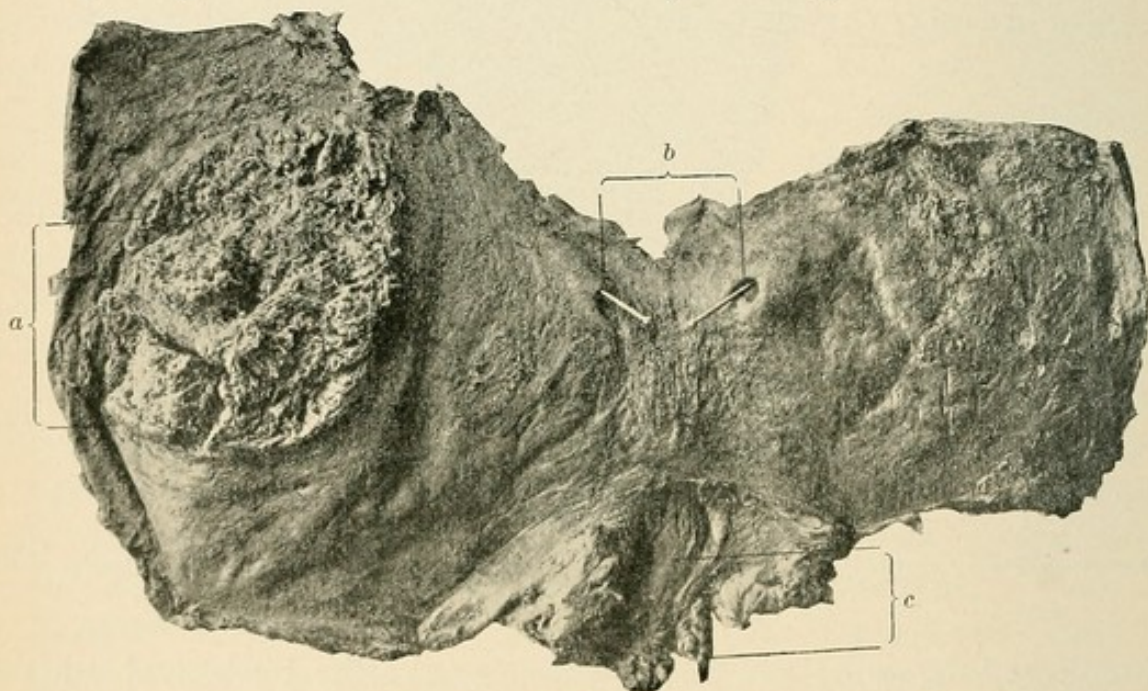


FIG. 253.—Papillary carcinoma of the anterior wall of the bladder in the female (after Winckel): *a*, papillary carcinoma; *b*, orifices of ureters; *c*, urethra.

In all these operations the bladder should be drained either by the use of a retaining catheter or through a separate opening. Scraping out of a carcinoma through either a suprapubic or a vaginal incision should not be considered even in the light of a palliative operation. All that can be done in a case of inoperable carcinoma of the bladder is to establish a permanent fistula to relieve the vesical tenesmus and to prevent retention of urine by closure of the urethral opening by the tumor or by blood-clots.

Kidney.—The kidney is more frequently the seat of sarcoma than of carcinoma. Carcinoma of the kidney is of the tubular variety. In a delicate, very vascular stroma the columnar epithelial cells are

arranged in the form of tubules. According to the degree of develop-

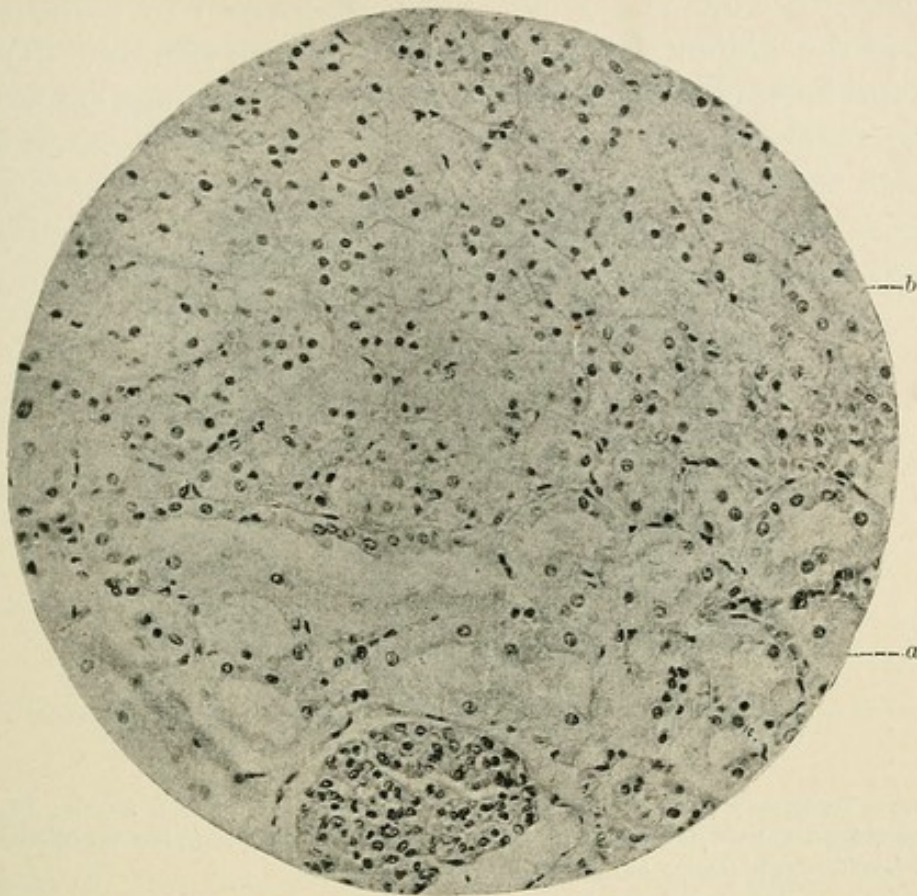


FIG. 254.—Displaced tissue from the suprarenal capsule in the kidneys; $\times 500$ (after Karg and Schmorl). The lower part of the picture is occupied by normal kidney-tissue (*a*), in which a glomerulus and transversely cut uriniferous tubules can be seen; the upper part is occupied by typical tissue from the suprarenal capsule (*b*), which is imbedded in the kidney-tissue.

ment of the stroma the tumor is either hard or soft, of slow or of rapid growth. In exceptional cases the tumor, instead of springing from a matrix of embryonic cells representing kidney-tissue, originates from a displaced matrix of epithelial cells derived from the suprarenal capsule. Such displaced groups of epithelial cells (Fig. 254) are found in the vicinity of the kidney, in the capsule, or in the parenchyma of the kidney itself (Klebs). Grawitz has shown that tumors originating from such a matrix represent to perfection, histologically as well as clinically, similar tumors of the suprarenal capsule. The tumor gradually displaces the parenchyma of the kidney, and when the pelvis and the ureter are reached it produces obstruction to the flow of urine secreted by the intact part of the kidney. Eventually the tumor may perforate the capsule of the kidney and extend to the adjacent organs. Lymphatic infection takes place at a comparatively late stage. If the tumor is large, it may produce intestinal obstruction by extending to the colon or by pressure. Hematuria is a frequent symptom after the tumor has invaded the pelvis of the kidney.

During life it would be, of course, impossible to distinguish a carci-

noma from a sarcoma. Advanced age and a nodular tumor would lead us to suspect carcinoma. James Israel discovered by palpation a carcinoma of the kidney not larger than a cherry, removed the kidney, and the specimen confirmed the diagnosis. The average surgeon would

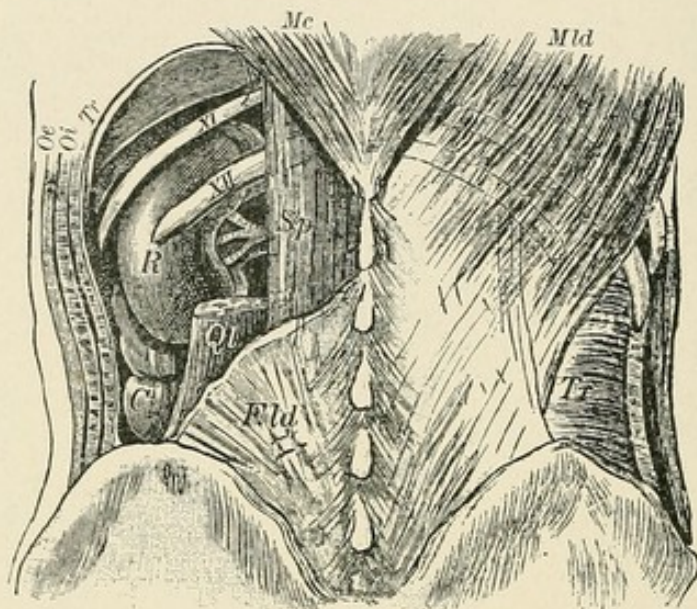


FIG. 255.—Topography of the renal region (after Esmarch): *Mc*, trapezius muscle; *Mld*, latissimus dorsi; *Sp*, sacro-lumbaris; *Ql*, quadratus lumborum; *Oe*, external oblique; *Oi*, internal oblique; *Tr*, transversalis; *Fld*, lumbo-dorsal fascia; *R*, kidney; *C*, descending colon.

have difficulty in detecting a tumor the size of a walnut, and consequently it is not very probable that another such early diagnosis will soon be recorded. If a diagnosis of the probable existence of a malignant tumor of the kidney can be made, it is the duty of the surgeon to make careful search concerning the condition of the opposite organ, and if this is satisfactory a radical operation is indicated if the disease has not extended beyond the capsule of the kidney. Partial removal of the kidney for malignant disease is not permissible.

Nephrectomy for Carcinoma of the Kidney.—The location of the kidney and its relations to the parts concerned in lumbar nephrectomy are shown in Figure 255. An accurate knowledge of the topographical anatomy of the renal region is an essential prerequisite in the performance of lumbar nephrectomy. A carcinomatous tumor of the kidney too large for the lumbar operation has in all probability reached the inoperable stage. The lumbar operation is therefore the one that will usually be selected to remove a carcinomatous kidney. The operation of nephrectomy was devised and performed in 1871 by Simon. The incision named after him was in reality planned by his pupil, Dr. Hotz, now of Chicago. One of two incisions is usually selected for the removal of the kidney through the lumbar region. Simon's incision, which gives the best access to the hilus of the kidney, is commenced over the eleventh

rib, at the outer margin of the sacro-lumbalis muscle, and is extended in a downward direction to a point halfway between the last rib and the crest of the ilium. If more room is needed, the incision can be extended farther down. König's incision, which affords the most room, extends from the twelfth rib, at the margin of the sacro-lumbalis muscle, directly down to near the crest of the ilium; it is then carried in a curve in the direction of the umbilicus to the outer margin of the rectus muscle. To enlarge the space between the last rib and the crest of the

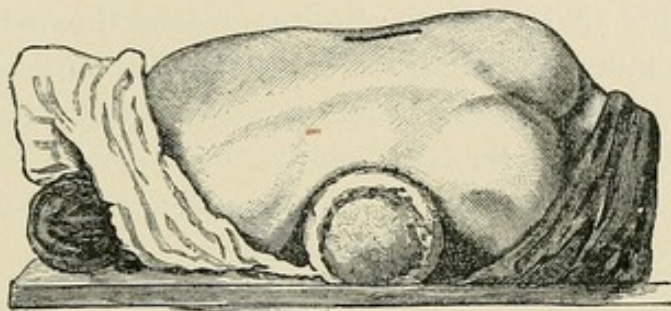


FIG. 256.—Position of patient and location of incision for lumbar nephrectomy according to Simon's method.

ilium a firm round cushion should be placed between the chest and the pelvis on the opposite side, and the patient is placed on that side (Fig. 256). The different muscular layers are divided separately, and all hemorrhage is carefully arrested before the fatty capsule of the kidney is opened. When the kidney has been reached the upper half is first separated with the index finger; then the kidney is seized with three fingers, drawn forward, and carefully isolated all around; when the hilus is reached the ureter and vessels are exposed by blunt dissection; all these structures are ligated *en masse*, and the kidney is separated by a cut at a safe distance from the ligature, after which ureter and vessels are ligated separately. Iodoform-gauze drainage and suturing of the balance of the wound complete the operation.

We have every reason to believe that if a diagnosis of renal carcinoma could be made at a time before the tumor has extended beyond the capsule and before it has given rise to regional infection, a nephrectomy would yield better results than most of the operations for carcinoma in other localities. Under such circumstances the removal of all carcinomatous tissue by a nephrectomy would be assured.

XVII. FIBROMA.

FIBROMA is a representative mesoblastic tumor. Connective tissue, which is found in all parts and organs of the body, is its prototype. We shall include in this class of tumors also the benign endothelial tumors, which have been described as endothelioma because the connective tissue and endothelial cells have a common embryonic origin. Histological investigations have shown that in the connective tissue may be formed, independently of pre-existing blood-vessels, vascular spaces lined with endothelial cells derived from connective tissue; and it is well known that during the cicatrization of blood-vessels after ligature and during plastic inflammation of serous surfaces endothelial cells are converted into permanent connective tissue. Fibroma imitates the normal connective tissue in the arrangement of its fibres. If the tumor is soft, the elastic fibres and connective-tissue corpuscles are arranged loosely and the cells are separated from one another by an abundance of intercellular substance (Fig. 257). In hard fibromata the areolar structure is lost, and the tumor presents to the

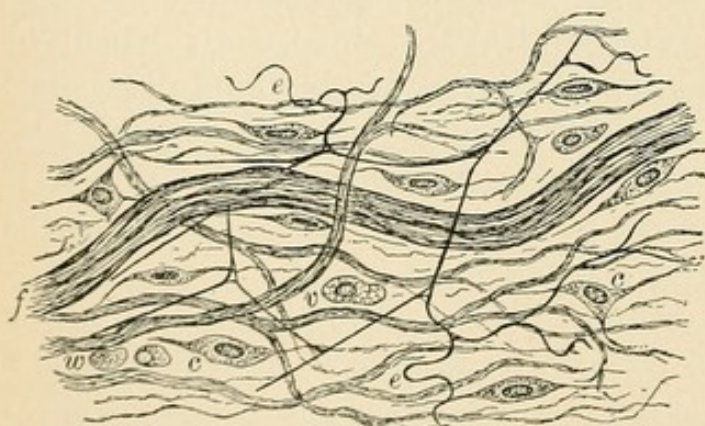


FIG. 257.—Subcutaneous areolar tissue (after Piersol): *c, c*, some of the connective-tissue corpuscles; *w*, migratory cells; *v*, plasma-cells; *e*, elastic fibres.

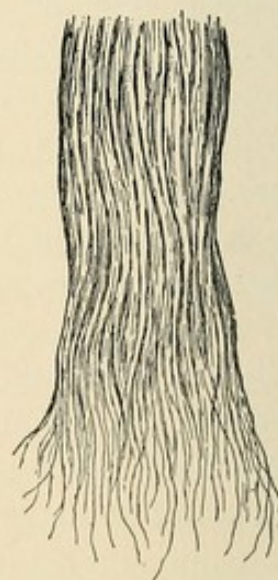


FIG. 258.—White fibrous tissue; one end of the bundle has been teased to display the component fibrillæ (after Piersol).

eye and to touch the appearance of firm white fibrous tissue in which the fibrillæ form bundles that run parallel, but more frequently interlace, forming coarser or finer meshworks (Fig. 258).

Fibromata occur in every part of the body supplied with connective tissue and blood-vessels.

Definition.—*A fibroma is a tumor composed of mature fibrous tissue derived from a matrix of fibroblasts.* This definition excludes from this class of tumors all swellings of infective origin and all benign tumors in which the predominating histological elements are not connective-tissue fibres, but epithelial cells. Virchow included elephantiasis and molluscum fibrosum among the fibrous tumors. We exclude these affections because their infective origin has been demonstrated satisfactorily. A great deal of confusion has been caused by some pathologists who continue to describe a papilloma as a fibroma. *In papilloma the epithelial cells compose the essential part of the tumor, the tumor develops from a matrix of epithelial cells, and the fibrous central part is furnished by pre-existing connective tissue which, under the stimulus furnished by the proliferating epithelial cells, undergoes hypertrophic changes.* We shall exclude from fibroma those tumors of the skin and the mucous membranes that have an epithelial origin and in which the epithelial cells take an active part in the growth of the tumor. These tumors have been described in a previous section of this work as *papillomata*. The connective tissue is the tissue chiefly predisposed to inflammation, and the frequency with which infections of all kinds occur in the connective tissue makes it often exceedingly difficult to distinguish practically between an infective swelling and a fibroma. It is for this reason that the adjective *mature* has been used in this definition. Connective-tissue corpuscles in inflammatory products do not reach the same degree of maturity as in fibroma, even if the inflammatory process is ever so chronic. Fibro-sarcomata, which by Paget and others have been described as fibroid tumors with a tendency to recurrence, are composed of connective tissue which has nearly, but not quite, reached maturity.

"Fibroid," "desmoid," "*corps fibreux*," are synonyms which even at the present time are occasionally used in place of fibroma.

Histogenesis and Histology.—The matrix of a fibroma is a group of congenital fibroblasts which in the embryo were set aside, failed to reach maturity, and remained in the connective tissue in a latent condition until, under the influence of local or general causes, they were placed in a condition to assert their intrinsic capacity to proliferate. If we imagine a number of embryonic connective-tissue cells arrested in their development and unutilized in the embryo, remaining in their primitive condition awaiting favorable conditions for their growth and reproduction, we can readily understand how in later life they would result in the production of tissue of a character differing from, although similar in structure to, the surrounding tissues (see Fig. 2, p. 28). Arrest of differentiation would affect the intercellular substance as well as the cells. From

an embryological standpoint a fibroma is never a heterologous or a heterotopic tumor, as connective tissue is found in all parts and organs of the body. A matrix of fibroblasts undoubtedly forms frequently in scars following wounds and injuries of all kinds and in the healing process after the subsidence of inflammatory affections. Keloid and other fibroid tumors of scars must have such an origin. A fibroma is always encapsulated, and can readily be enucleated. If it is located underneath a mucous membrane, the tumor-tissue frequently becomes œdematous. On section the surface shows a number of bands and bundles of connective tissue interlacing in all directions

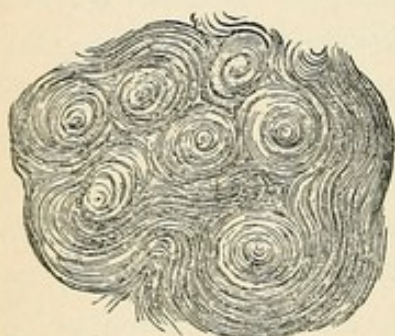


FIG. 259.—Hard fibroma from fascia of rib (after Lücke).

without any definite arrangement. The cut surface often shows concentric arrangement of the connective tissue in different parts of the tumor, as though the tumor had been growing from different centres. Billroth has shown that the centre of these concentric masses corresponds with the location of a blood-vessel. The firmness of the tumor depends on the amount of intercellular substance and the degree of compactness of the

tumor-tissue. In the hard variety the tumor is almost as firm to the

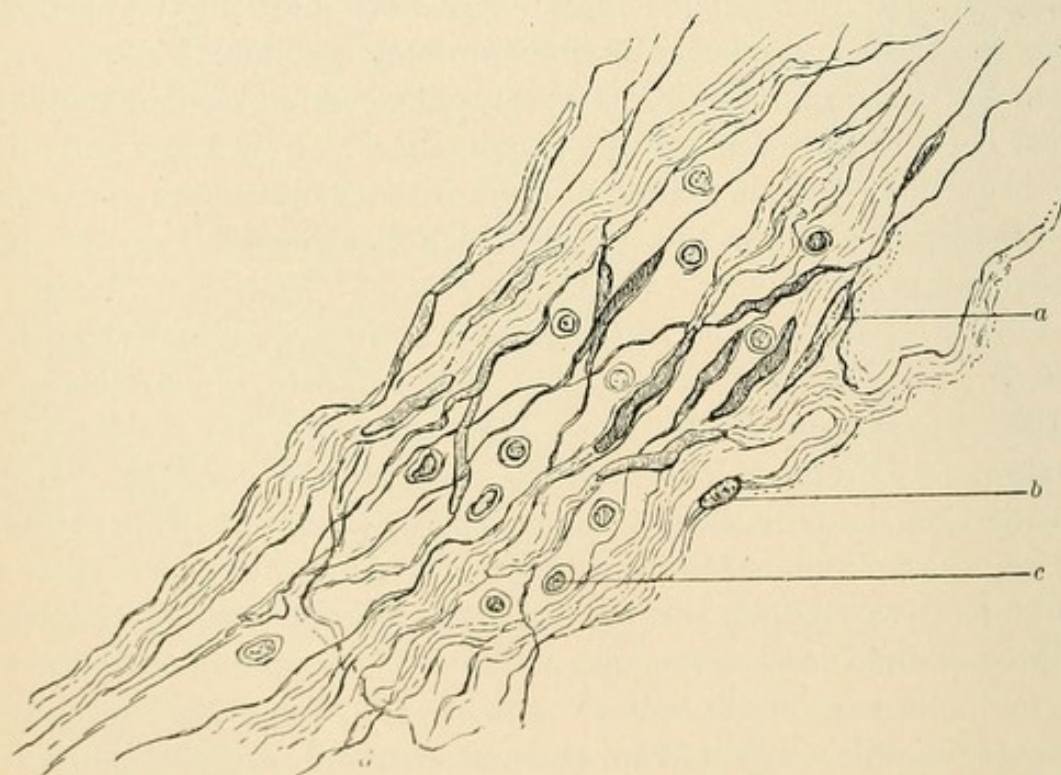


FIG. 260.—Fibrous tumor from the antrum of Highmore; $\times 450$ (after D. J. Hamilton): *a*, fusiform nucleus; *b*, younger nucleus of an oval shape; *c*, isolated fibroblast.

touch as cartilage, the intercellular substance is very scanty, and the fibrillæ are compactly arranged in wavy bundles or the fibres have a

concentric arrangement as shown in Figure 259. Sections under the microscope show that the wavy bundles of white fibrous tissue interlace and surround blood-vessels. On each bundle lies an oval or fusiform connective-tissue nucleus, as on any other fibrous tissue (Fig. 260). The younger parts of the tumor show young connective-tissue cells of round or oval shape.

The firmness and the histological structure of the tumor are not affected by the amount or the character of the connective tissue in which the tumor is developed. A fibroma in firm fascia may be soft, while a tumor in a soft vascular organ may be very dense. Fibroma in the soft parenchyma of the kidney may be very firm and be scantily

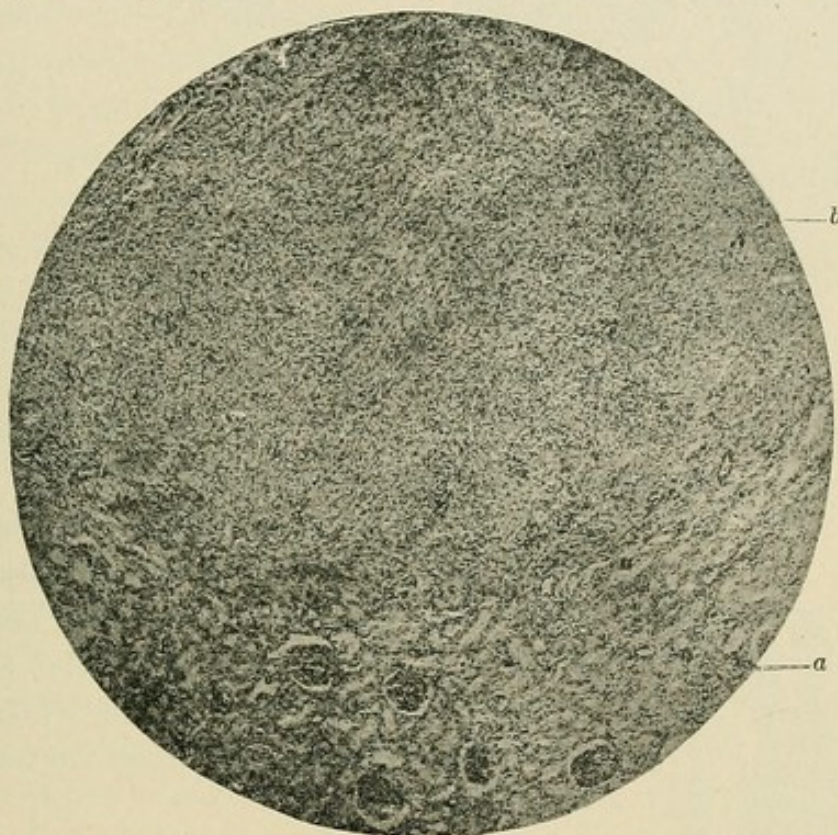


FIG. 261.—Fibroma of the kidney; $\times 38$ (after Karg and Schmorl). The renal tissue (*a*), which contains intact uriniferous tubules and glomeruli, is sharply separated from the tumor (*b*), which is composed exclusively of vascular fibrillated tissue. The bundles of fibrous tissue interlace in all possible directions, and include moderately numerous nuclei, which, according to the direction of the section, appear round or spindle-shaped.

supplied with blood-vessels, although surrounded on all sides by an exceedingly vascular tissue (Fig. 261). In typical fibroma the vessels are small and scanty. In a special form of fibroma—vascular spaces, containing venous blood, that appear anatomically as a transition form between angioma and fibroma—the atypical vascularization of the tumor reaches the highest degree. Rindfleisch classifies this rare form of cavernous fibroma with the fibromata. Nothing is known regarding the existence of lymphatics in fibroma, but it is probable that they are present in the soft variety. Nerves are probably not present in fibroma,

but if present, they are pre-existing nerves from the sheath of which the tumor has developed. In fibroma of the uterus muscle-fibres are so constantly found that Virchow classified fibrous tumors of the uterus with the myomata.

Retrograde Metamorphoses.—One of the frequent retrograde changes found in fibroma is myxomatous degeneration, due, in part at

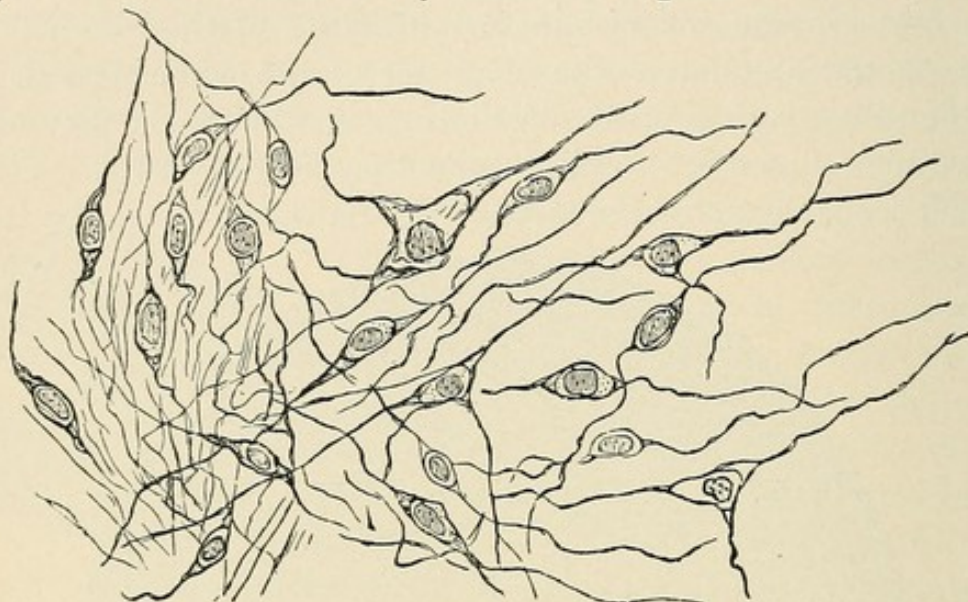


FIG. 262.—Myxomatous fibrous tumor of the deep fascia of the neck; $\times 450$ (after D. J. Hamilton).

least, to œdema of the intercellular spaces (Fig. 262). The tumor undergoing this change becomes softer, and in the course of time there may form cysts with mucous or serous contents. This form of degeneration is observed very frequently in submucous fibroma. In cystic myofibroma of the uterus there form cysts, often of enormous size, which it is impossible sometimes to distinguish from ovarian cysts.

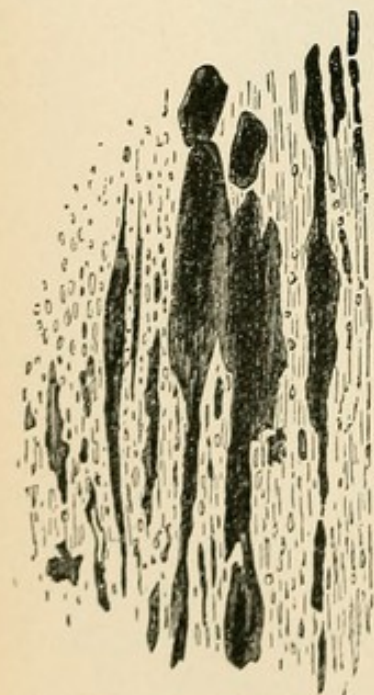

FIG. 263.—Calcareous deposit in a fibrous uterine tumor (after Dusseau).

Calcareous degeneration occurs in one of two ways: the tumor is either coated with a thin, rough, nodulated layer of a chalky substance, or a similar substance is deposited more abundantly throughout the tumor (Fig. 263). Calcification is preceded by coagulation-necrosis, and the place occupied by the tumour-tissue is taken by the earthy salts. Further growth of the tumor in parts which have undergone calcification is arrested.

Colloid degeneration does not occur in fibroma, as Mr. Symmonds has shown that it never takes place in the absence of epithelial cells. Fatty degeneration

is not as constantly found in fibroma as in epithelial tumors, but occasionally it not only takes place, but it may destroy large portions of the tumor.

The tumor when exposed to external irritation is subject to ulceration. Infection and suppuration may occur without exposure of the tissue of the tumor to direct infection by ulceration or injury. Gangrene may occur if in a pedunculated tumor the pedicle is twisted or the principal artery becomes blocked by a thrombus. Transformation of the tumor-tissue into a higher type is occasionally observed in fibroma. Ossification has been seen most frequently in fibrous tumors attached to bone (Fig. 264). It is difficult to decide in such cases whether the new bone is produced by transformation of fibrous tissue, or whether—what seems more probable—it is produced by displaced osteoblasts.

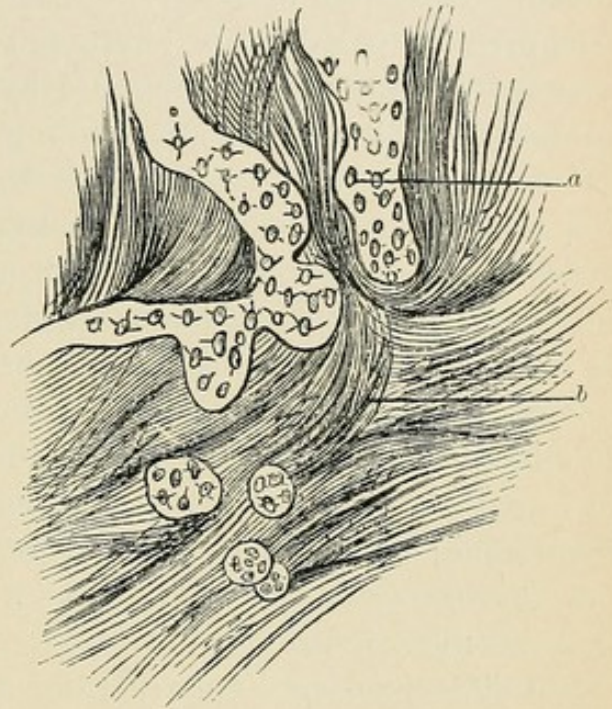


FIG. 264.—Ossification in a periosteal fibroma of the lower jaw (after Lücke).

Etiology.—Fibroma alone or in combination with other tumors—lipoma, angioma, adenoma—appears sometimes as a congenital tumor. Old age predisposes to epithelial tumors, while the aptitude for fibroma is lessened after the age of from thirty-five to forty years. The production of fibroma of the lobe of the ear by the wearing of ear-rings, of keloids in scars, and of desmoids in the abdominal wall of childbearing women, would indicate that trauma and irritation are potent factors in the etiology of fibroma. Virchow describes and recognizes an hereditary fibromatous disposition, and he alludes to an instance of the occurrence of multiple subcutaneous fibromata in members of the same family in three consecutive generations.

Symptoms and Diagnosis.—The growth of a fibroma is always slow. A simple, uncomplicated fibroma attains a certain limited size and then remains stationary. The large cystic fibroids described in some of the older text-books were sarcomata, as it is often stated that the tumor reached the size of a child's head in a year or less. Fibroma never pursues such a rapid course. Uterine myofibromata grow more rapidly than simple fibroids, are more vascular, and the muscular fibres

constitute the most important part of the tumor-tissue. The tumor is smooth and is always well encapsulated, hence movable unless restrained by adjoining firm resisting tissues. A fibroma of the breast can be moved among the tissues between two fingers without moving the gland—an important point in the differential diagnosis between fibroma and carcinoma. The tumor displaces, but does not infiltrate, the adjoining tissues. The pressure of a periosteal fibroma frequently results in great displacement of the bone by bending and by pressure-atrophy. If the tumor occupies a cavity, it may interfere with important functions. A fibroma of the nasal cavity interferes with respiration, and, when it reaches the pharynx, with speech and deglutition. A fibroma of the uterus, if submucous, causes hemorrhage; if subserous, it may by its size affect important functions. Pain and tenderness are absent unless the tumor is intimately connected with a sensitive nerve or unless it has become complicated by infection and inflammation. In fibroma ulceration is less likely to take place than in papilloma, because the tumor is covered at least by skin or by mucous membrane. If the skin or the mucous membrane becomes atrophied from pressure, ulceration is likely to ensue, commencing in that part of the surface in which nutrition has become most impaired.

In differentiating a fibroma from a papilloma it is important to trace the tumor by the aid of its clinical history and by a careful examination as to its origin in the mesoblastic tissues. A papilloma of the skin commences on the surface as an increase in the thickness of the epithelial layer of the skin; the papillary projections develop in consequence of an accompanying hyperplasia of the underlying pre-existing connective tissue. In fibroma of the skin the tumor starts in the connective tissue underneath the layer of epithelial cells, and pushes this layer before it. *A fibroma of the skin is therefore less liable to become pedunculated than is a papilloma.* A fibroma only becomes pedunculated if the skin over it is yielding, and after the tumor has attained at least the size of a pea or a cherry. In pedunculated fibroma the skin which covers the tumor becomes atrophic, smooth, and glassy, while in papilloma the epithelial structures increase with the size of the tumor. In deep-seated fibroma the diagnosis between it and sarcoma is determined by the clinical history and, if need be, by the removal of a fragment of tissue with a harpoon for microscopical examination. In cystic fibroma the use of the exploratory needle will often determine the character of the tumor.

Prognosis.—Fibroma may at any time undergo transition into a sarcoma. As Virchow says, "A fibroma only needs an increase in the size of its cells and a diminution of the cement-substance to change it

into a sarcoma." The hard variety is less apt to undergo this change than the soft, and particularly the pigmented, form. That irritation and incomplete removal should hasten, if not determine, the transformation of a fibroma into a sarcoma no one would dispute. The young connective-tissue cells in the periphery of the tumor require only the addition of conditions which enable them to leave the parent-tumor and to migrate into the surrounding connective tissue to become sarcoma-cells. A pure fibroma does not attain large size; hence the prognosis, aside from the possibility of the tumor undergoing transformation into sarcoma, must rest on the importance of the location it occupies. If it involve passages essential for important functions, the obstruction it produces may prove a source of danger. Fibroma of the respiratory and urinary passages affords an illustration in point. A submucous fibroma of the uterus may become the cause of debilitating and even fatal hemorrhages. A large interstitial fibroma of the uterus may destroy life by the size of the tumor interfering with important functions of the abdominal organs.

Treatment.—Operative treatment is indicated in fibroma in all cases in which the tumor is accessible, as by the removal of the tumor the patient is protected against a frequent cause of sarcoma. In uterine fibroma an exception must be made to this rule, as the danger attending the operation outweighs the risk of a possible transition of the tumor into a sarcoma. In fibroma of the uterus other indications must decide the necessity of operation. Fibromata should be removed by enucleation. Excision is necessary if the tumor has ulcerated on the surface or if the interior of the tumor has become infected and the resulting inflammation has produced adhesions between its capsule and the adjacent tissues.

TOPOGRAPHY.

Skin.—Fibroma of the skin occurs most frequently about the face, neck, shoulders, chest, and abdomen. It is of very slow growth, and seldom exceeds in size a pecan-nut. It appears first as a swelling in the connective tissue of the skin, which swelling projects toward the surface, becoming more and more prominent until the skin at its base becomes contracted and by the weight of the tumor elongated, resulting in the formation of a pedicle. In the course of time this pedicle becomes elongated and very slender. It contains in its centre the principal artery of the tumor, which artery sometimes, in consequence of an injury or of textural changes, becomes thrombosed—an accident which results in gangrene of the tumor and a spontaneous cure. The skin over the tumor atrophies, is thin and shining, and is usually thrown

into longitudinal folds. The tumor is soft, and under the microscope shows interlacing fibres with an abundance of intercellular cement-substance.

The diagnosis can be made without difficulty, as in papilloma, which is most frequently confounded with fibroma, the epiblastic part of the tumor predominates, and instead of a smooth surface presents a warty appearance. If the tumor has become pedunculated, it is connected with the body only by a cylinder of skin, which can be clipped with scissors on a level with the skin, and the resulting wound can be sealed with a cotton-collodion crust. If the tumor is sessile, the skin over it or at its base is incised sufficiently to permit the removal of the tumor by enucleation.

Mole.—A mole is a flat congenital fibroma of the skin. It is caused by fibroblasts in excess in the connective-tissue portion of the skin. Moles are usually pigmented, and giant growth is manifested by excessive growth of the appendages of the affected part of the skin, the hair, and the glands. Moles vary in size from that of a pin's head to that of the palm of the hand or even larger. The increase in size after birth reaches its maximum during childhood and up to the age of puberty, when the tumor generally becomes stationary. A mole is exceedingly prone to undergo transition into a carcinoma or a sarcoma, and for this reason should be removed if the area involved is not too extensive. A carcinoma or a sarcoma starting in a mole is usually pigmented; the resulting malignant tumor is either a melano-carcinoma or a melano-sarcoma—both of them exceedingly malignant growths, and very prone to early diffuse regional infection and general dissemination.

Spontaneous Keloid.—Under the term keloid Alibert described in 1814 an affection of the skin characterized by hyperplasia of the sub-epidermal connective tissue, with a strong inherent tendency to return after extirpation. He classified keloid into germinal and scar keloid. This affection was later described by Schwimmer, Kaposi, Dénériaz, and Warren. For some time doubt existed as to the occurrence of spontaneous keloid, owing probably to the rarity of the affection. A sufficient number of cases have, however, been recorded by reliable observers in which the clinical history revealed no antecedent scar. Warren divided keloid into (1) true keloid, (2) scar keloid, (3) hypertrophic scar. Warren claimed that the new connective tissue is produced by proliferation of the tissues of the adventitia of blood-vessels, as he found numerous round cells around blood-vessels, which he claimed were later transformed into connective tissue. From an anatomical standpoint he distinguished a scar keloid from a true keloid by the absence of papillæ in the former. According to Kaposi, the true

keloid occurs about once in every 2000 cases of skin affections of all kinds. It is found most frequently upon the sternum and upon the trunk, although occasionally the limbs, and especially the fingers and toes, are the seat of the disease. Nasse and Volkmann saw each a

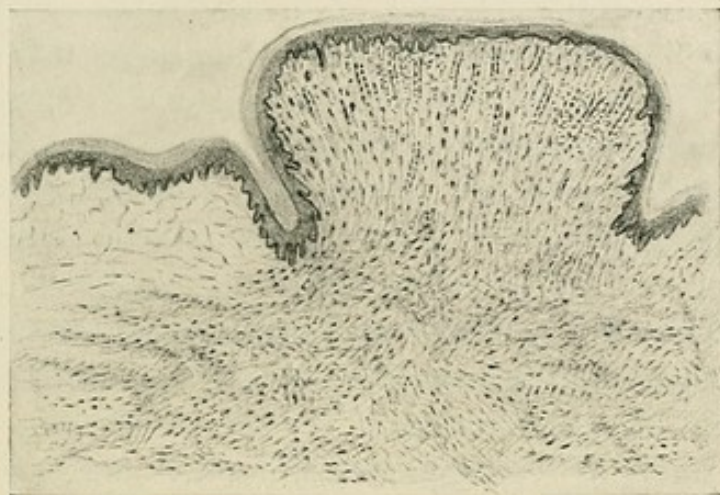


FIG. 265.—Spontaneous keloid (after Thorn).

case of multiple keloid of the fingers and toes. In Nasse's case repeated excisions of the tumors of the toes finally made removal of two toes by exarticulation necessary. The compact connective-tissue bundles of which a keloid is composed are found in the deeper layers of the corium. The fibers are arranged, as a rule, parallel to

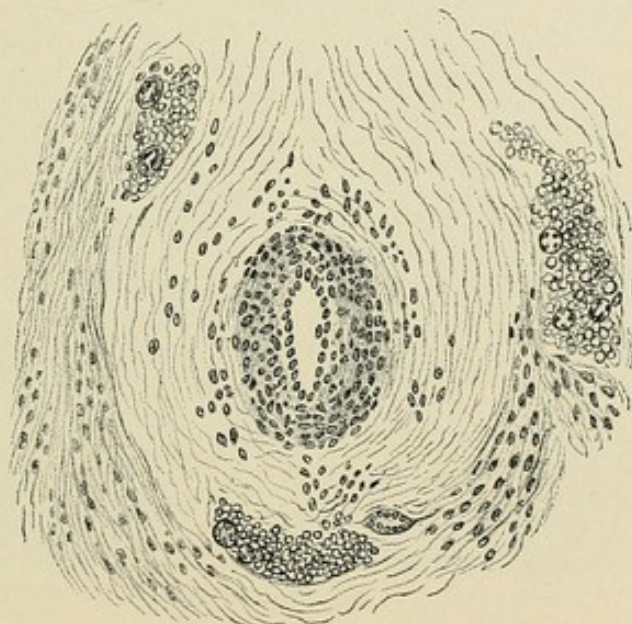


FIG. 266.—Blood-vessels and tumor-tissue as seen in spontaneous keloid (after Thorn).

the surface, and contain spindle-shaped nuclei; some of the fibers take an opposite course—this is especially the case near the surface of the tumor underneath the epidermis (Fig. 265). Thorn never saw in any of his specimens any indications that the fibers are derived

from the vessel walls. The round cells which are found interspersed between the keloid tissue Thorn is inclined to believe are the product of an inflammatory process near the surface of the tumor. The new tissue is unquestionably derived from the pre-existing connective tissue of the corium under the influence of an as yet unknown cause. The appearance of blood-vessels and the arrangement of fibers around them are well shown in Fig. 266. While keloid is an obstinate affection to all kinds of local treatment, it differs from sarcoma in that it remains limited to the tissues primarily affected and never gives rise to metastasis. After having attained a certain size it often remains stationary for an indefinite time. That such a tumor should occasionally undergo transformation into a sarcoma is not surprising considering the imperfect development of the tissues of which it is composed.

Scar Keloid.—Another variety of fibroma in the skin is the fibrous tumor which starts in scar-tissue following a wound, the healing of a




FIG. 267.—Large keloid of the neck.

burn, or other surface lesions, particularly tubercular ulcers. Alibert in 1814 was the first to describe this fibrous tumor, and from its resemblance to carcinoma he called it "keloid." Keloid resembles clinically some of the granulomata, and under the microscope it is a compromise between a fibroma and a sarcoma. Its frequent occurrence in tubercular scars and

in minute scars resulting from small punctured wounds has led the writer to suspect that it might represent a particular form of tubercular inflammation. We are, however, not in a position to prove its tubercular origin and nature, and its clinical behavior would certainly tend to negative the idea that it is a form of sarcoma. For the present we must include it among the fibromata, although strongly inclined to believe that before long it will have to be classified with the infective swellings. The colored race is peculiarly predisposed to keloid. The sting of an insect, the prick of a needle, or a small abrasion frequently acts as the exciting cause. The wearing of ear-rings is also a frequent cause.

The patient whose photograph is shown in Fig. 267 was the subject at the same time of numerous keloids of the skin of the chest and of the back.

Keloid sometimes affects different parts of the body at the same time, but always develops in a scar, which may be so small as to elude detection (Fig. 268). The tumor slowly increases in size up to a certain point, and after having remained stationary for from ten to twenty years may slowly disappear—one of the strongest proofs that it is not a true tumor. The keloid tissue is characterized by its great vascularity as compared with other fibromatous tumors and by the existence of numerous connective-tissue spaces lined with endothelial cells. The inflammatory part of a keloid is shown by the numerous leucocytes in the perivascular spaces. From the structure of a keloid it would be reasonable to assume that occasionally it is transformed into a sarcoma. The benign clinical aspects of a keloid render it easy to distinguish between it and a malignant tumor of the scar-tissue.

The treatment of keloid is extremely unsatisfactory. External applications and compression are useless. Recurrence even after thorough extirpation is common. The only treatment is by thorough excision. The incisions should include a zone of apparently healthy tissue at least a few lines in width. The scar following the operation should be protected carefully for a long time.

Mucous Surfaces.—Fibroma of the mucous surfaces resembles that of the skin in every respect except that the surface of the tumor

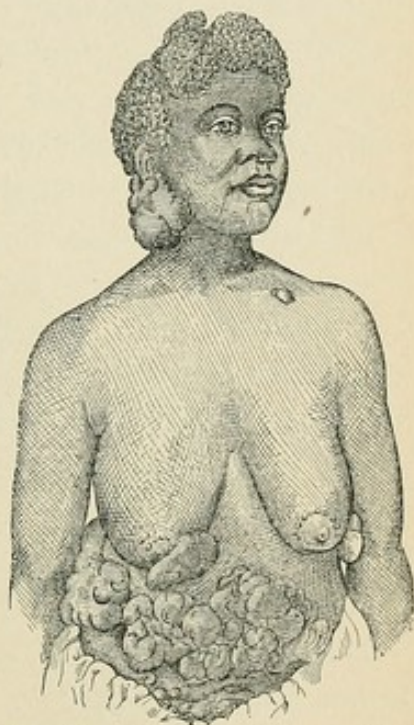

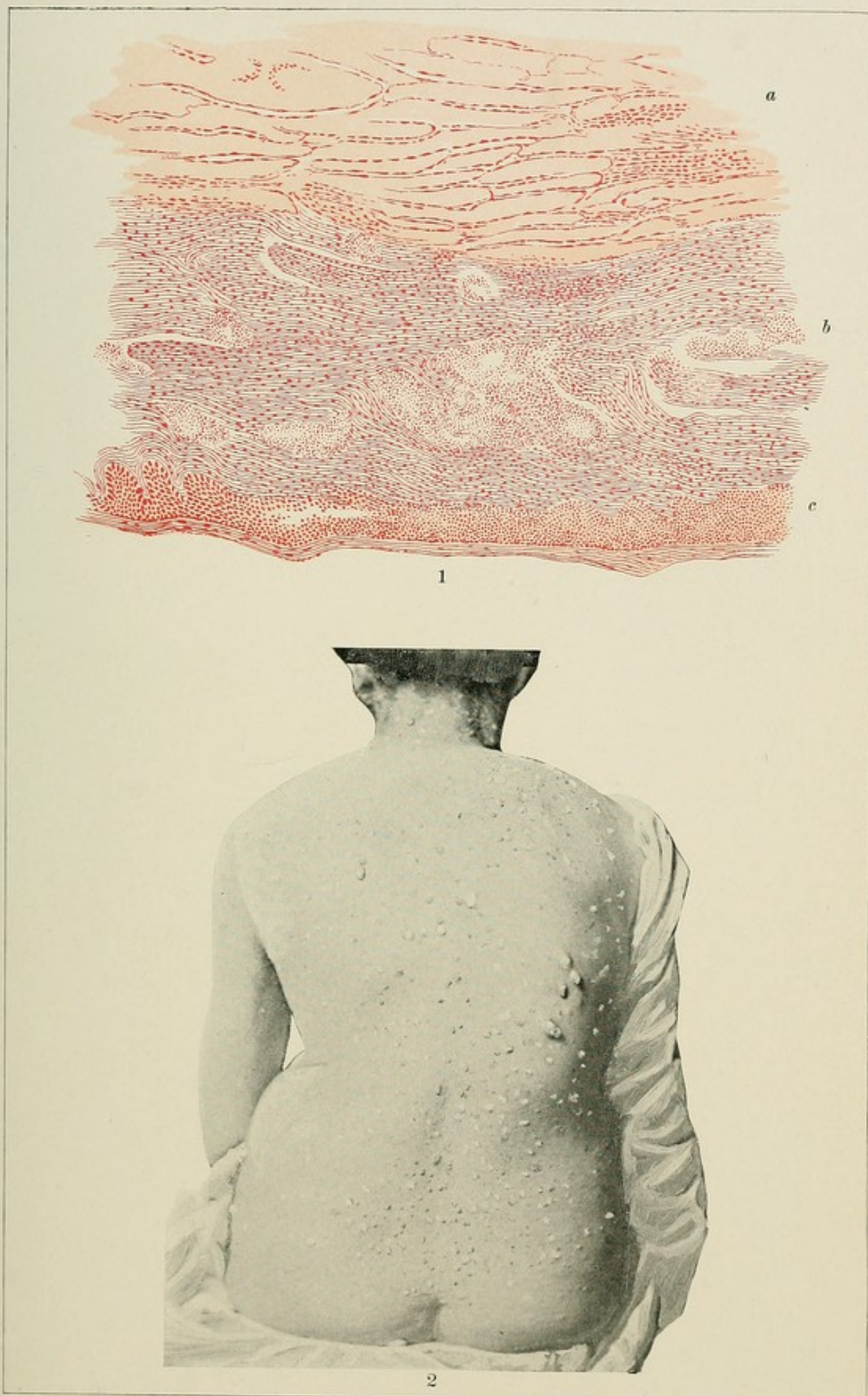
FIG. 268.—Multiple keloid in a colored woman (after Taylor).

is covered by mucous membrane instead of by skin, and that the tumor in this locality is more prone to œdema. Many of the polypoid growths in mucous channels are œdematous fibromata. If pendulous, they should be removed with the wire *écraseur*; if sessile, by excision or by enucleation.


Subcutaneous Connective Tissue.—Two kinds of fibroma, clinically distinct, are met with in the subcutaneous connective tissue—the painful tubercle and the soft multiple fibroma of Recklinghausen.

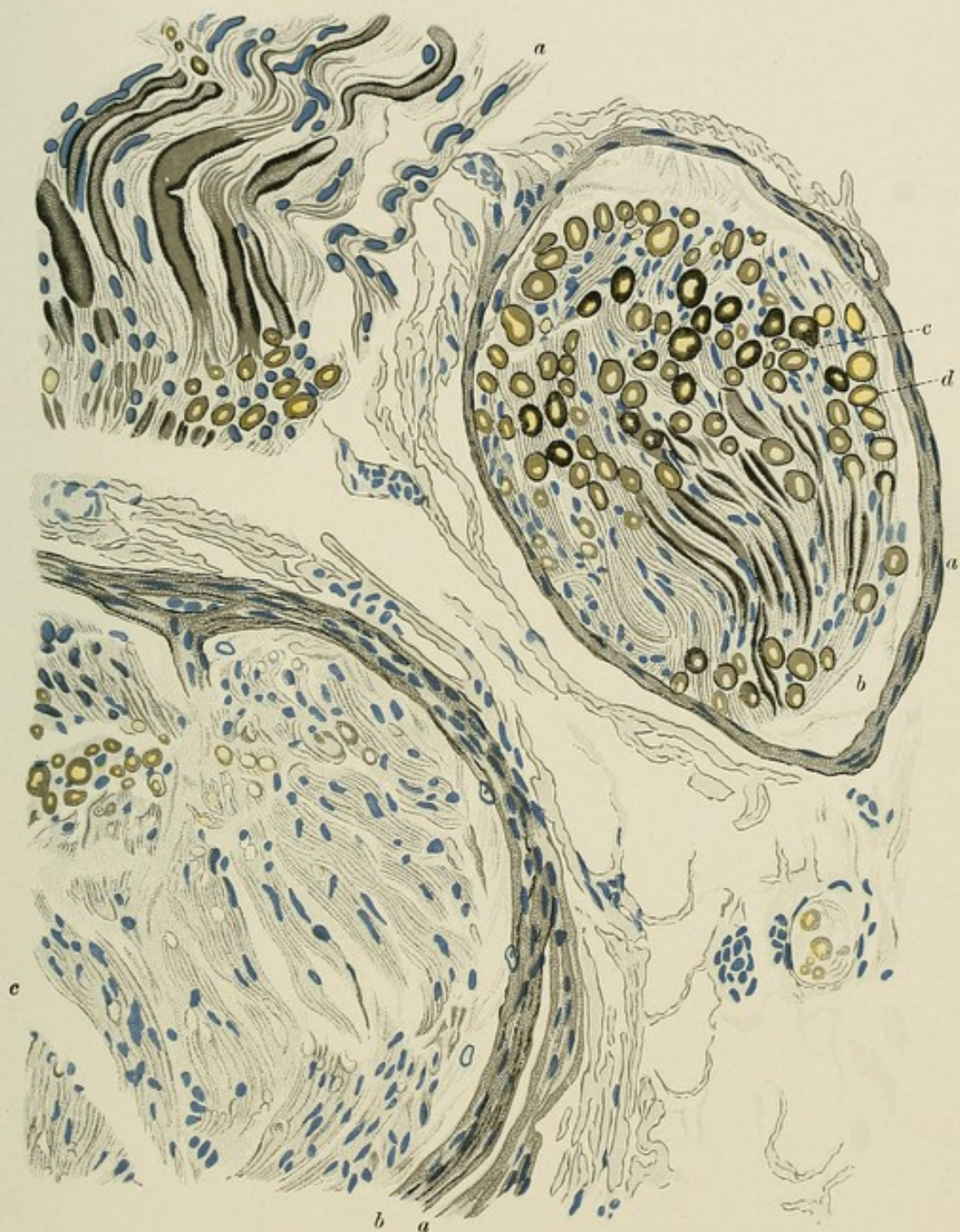
Painful Subcutaneous Tubercle.—This is a little hard tumor, not larger than a pea, noted for its painfulness, in the subcutaneous tissue. This tumor was first described by A. Petit, Cheselden, and Camper. The best description was given in 1812 by Mr. Wm. Wood. These tubercles are most frequent in the extremities, especially the lower. They are more frequent in women than in men, they rarely occur before adult life, and they are seldom multiple. Examined under the microscope, they are seen to be composed of dense fibrous tissue, with filaments laid inseparably close together in the fasciculi and compactly interwoven. The young cells in the periphery of the tumor contain large nuclei. The pain and tenderness appear either contemporaneously with the tumor or after the tumor has reached a certain size. The pain, which is usually paroxysmal, but which can always be provoked by pressure, is sometimes attended by muscular spasms. Velpeau regarded these tumors as neuromata. Dupuytren, who made several very careful dissections, was never able to trace their connection with nerve-fibres. Other surgeons have succeeded in finding the nerve-filaments with which these tumors are connected. In one case the writer could trace the nerve from the capsule of the tumor on both sides. The nerve was no larger than a fine silk ligature. There can be no doubt that these tumors are connected with sensitive nerve-filaments. Their removal by excision is often followed by recurrence. Successful removals of recurrent painful tubercles are reported by Sir James Paget and by Mr. Lawson Tait.

Multiple Subcutaneous Fibroma.—The true pathology of multiple fibrous tumors of the subcutaneous tissue was pointed out in 1882 by Recklinghausen. He ascertained that these tumors are invariably connected with the sheaths of terminal nerves. They are sometimes congenital, but they usually develop after puberty. In number they vary from a few to more than a thousand. In the case of Michael Lawler, described in Smith's monograph, they were estimated at least at two thousand. This affection was formerly known as "*molluscum fibrosum*" (Pl. 8, Fig. 2). In size these tumors vary from that of a hemp-seed to that of a filbert. In the course of time some of the




1. Keloid of external ear (after Klebs): *a*, dense fibrous cutis tissue with wide juice-canals, endothelial lining, and hyaline ground substance; *b*, fibrillated connective tissue with abundance of cells, with large vessels, perivascular proliferation, and at different places wide juice-canals; *c*, attenuated epidermis, the papillae having in part disappeared. (Obj. 5, oc. 3.) 2. Multiple subcutaneous fibromata.





Multiple neuro-fibroma, early stage (after Klebs): *a*, outer, *b*, inner nerve-sheath with endothelial hollow spaces; *c*, nerve-substance. (Zeiss, E. 2.)



tumors become pendulous. Histologically, these tumors are composed largely of fibrous tissue around and between bundles of nerve-fibres. On Plate 10 a number of nerve-bundles can be seen cut transversely. The connective tissue between the nerve-bundles has been changed but little; perhaps the connective-tissue spaces are somewhat dilated. Small round groups of nuclei stained blue with hematoxylin show the transverse cuts of blood-vessels. The connective tissue is greatly increased in the nerve-sheaths. The nuclei of the cells are oblong, oval, crowded closely together in the larger bundle (3), while the sheath of the smaller bundle contains fewer nuclei. The nerve-sheath can in many places be distinguished into an outer and an inner (*a* and *b*), as there can be seen between the fibres of the sheaths, arranged transversely, spaces which do not occupy in a continuous manner the entire periphery; there can also be seen, on the inner surfaces of the sheath, spaces which at some points are quite wide, and which (at 3) show oval nuclei in their walls. These spaces are in contact with the nerve-fibres and are traversed by delicate connective-tissue threads. In the longitudinal section (at 2) they can be seen in the same form. During the growth of the tumor the interstitial connective tissue proliferates and the nerve-bundles are separated more widely. Clinically these tumors form a contrast with the painful subcutaneous tubercle by the absence of pain and tenderness and by their multiplicity. Owing to the multiplicity of the tumors operative treatment is contraindicated. Should any of the tumors manifest malignant qualities, early and thorough excision is urgently indicated.

Abdominal Wall.—A peculiar form of deep-seated fibroma of the abdominal wall was first described by Nélaton. In his cases the tumors either occupied the iliac fossa or were located near the crest of the ilium. These places are the favorite localities, but the sheath of the rectus muscle is also not infrequently the starting-point of fibroma of the abdominal wall. The primary starting-point is most frequently near the peritoneum, so that the tumor projects at the same time into the peritoneal cavity, pushing the peritoneum before it while it becomes prominent on the surface. More than sixteen years ago Grätzer advanced the theory that these tumors originate at a point where the mesoblast divides into the peritoneum and the fibro-muscular layer. It is most frequently met with in women after delivery. W. Kramer reports a case in which the tumor was congenital. The patient was a girl four and a half years of age. Examination of the tumor after its removal showed that the congenital dermoid had recently been transformed into a sarcoma. Among 42 cases collected by Guerrien there were 39 women and only 3 men. Of the

4 cases which have come under the writer's observation, all were women, and in each of them the tumor appeared soon after child-bed. As compared with other tumors of the abdominal wall, fibroma occurs most frequently. Of 70 cases collected by Sanger, 60 were fibromata. More recently Dannhauer has collected 183 cases. The most important determining cause appears to be trauma. The greatest confusion has existed in regard to the proper classification of these

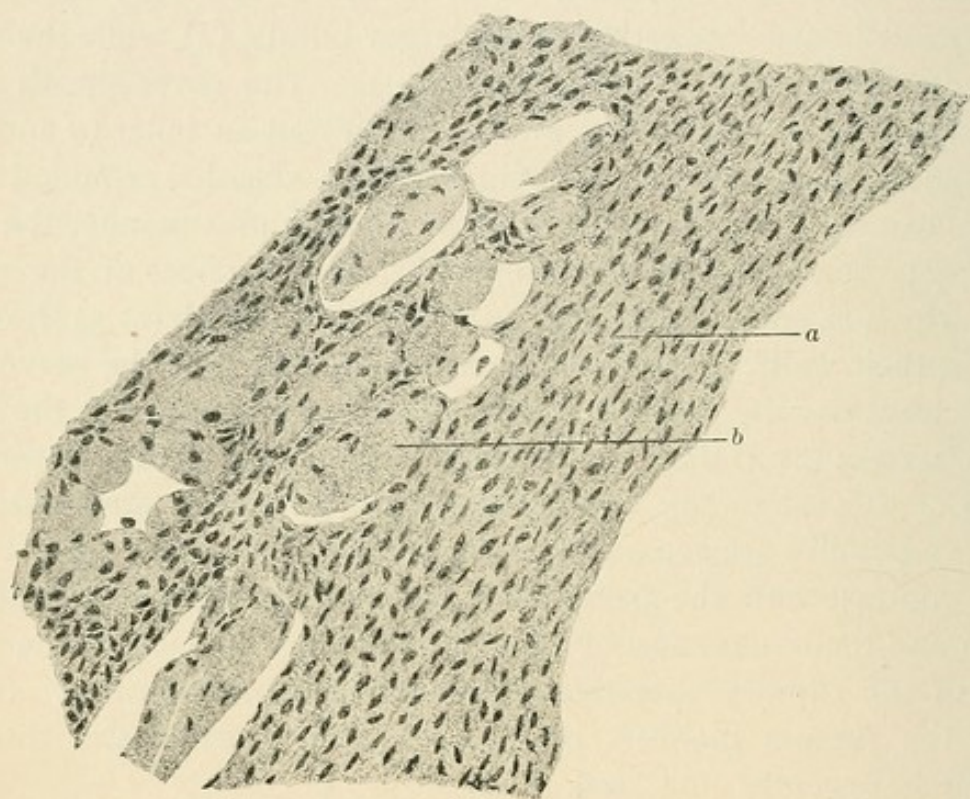


FIG. 269.—Desmoid fibroma of the abdominal wall; $\times 330$, reduced one-third (Surgical Clinic, Rush Medical College, Chicago): *a*, tumor-tissue; *b*, striated muscle-fibres in cross-section: the striæ have disappeared, and the muscle is degenerating and is infiltrated with young connective-tissue cells.

tumors. Some authors are inclined to regard them as a variety of fascial sarcoma. Their clinical course and histological structure do not justify their classification with the sarcomata. They seldom recur after thorough extirpation, and their histological structure bears a closer

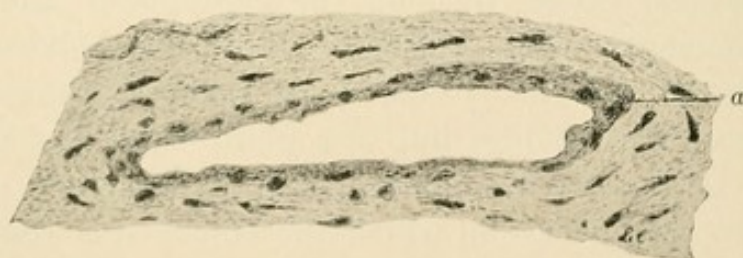


FIG. 270.—Vessel in a desmoid fibroma of the abdominal wall; $\times 330$ (Surgical Clinic, Rush Medical College, Chicago): *a*, vessel-wall.

resemblance to fibroma and keloid than to sarcoma. To distinguish them from ordinary fibroma it is well to retain the name *desmoid*,

a term applied by Müller to benign connective-tissue tumors (Fig. 269). The tumor-tissue is composed of young connective-tissue cells with a scanty intercellular substance. The cells infiltrate the adjacent tissues besides displacing them, in this respect differing materially from ordinary fibroma. The walls of the new blood-vessels in the tumor display an intimate relation with the tumor-tissue (Fig. 270). The endothelial cells lining the new blood-vessels are large, and the tumor-tissue forms the greater part of the vessel-wall.

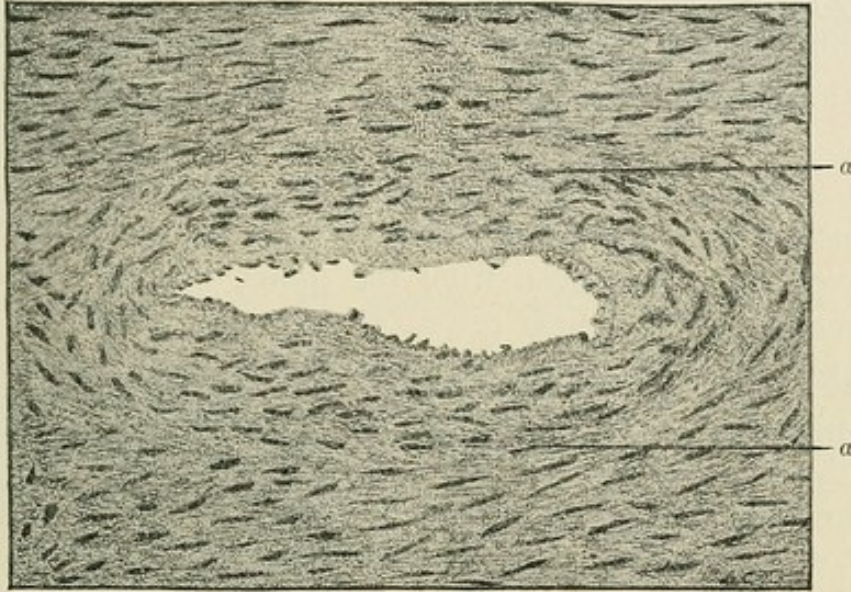


FIG. 271.—Relations between vessel-wall and tumor-tissue in a desmoid fibroma of the abdominal wall; $\times 330$, reduced one-third (Surgical Clinic, Rush Medical College, Chicago): *a*, junction of vessel-wall and tumor-tissue.

From the histological description of a desmoid tumor as given above it is evident that the encapsulation of the tumor is imperfect—an important point to be remembered in the operative treatment of such tumors. Desmoid tumors increase quite rapidly in size, sometimes reaching from the umbilicus to the pubes and from the anterior superior spinous process of the ilium to the median line. In three of the writer's cases the peritoneum was firmly attached and had to be excised with the tumor.

Enucleation of the tumor is liable to be followed by recurrence. In two of the writer's cases the tumor started in the iliac region, and in two in the sheath of the rectus muscle. All these cases recovered. In one of them a recurrence made necessary a second operation, after which complete recovery ensued.

The diagnosis is not always easy. If the tumor projects as much in the direction of the abdominal cavity as externally, it might easily be mistaken for an intra-abdominal tumor. The tumor moves with the abdominal wall, but this is also the case if an abdominal tumor has become attached to the parietal peritoneum anteriorly. The tumor is

firm and can generally be outlined accurately. In the excision of a desmoid tumor of the abdominal wall the surgeon must be prepared to resect the peritoneum, and must therefore make all the preparations required for abdominal section. The removal of such a tumor results in great defect of the abdominal wall, which defect must be corrected by suturing the peritoneum and the muscular layer separately with buried catgut sutures, including at the same time all the tissues in the deep sutures in order to approximate the surfaces of the wound accurately, so as to prevent the subsequent formation of a ventral hernia. As an additional safeguard it is necessary to instruct the patient to wear a well-fitting abdominal bandage for from six months to a year after the operation.

Nose.—Robert has shown that many of the naso-pharyngeal fibrous tumors start from the anterior lacerated foramen, the basilar process of the occipital bone, and even from the upper cervical vertebræ. The fibrous polypus of the nose grows slowly, and after it has reached a certain size protrudes in the direction of the nasal outlet or projects into the pharynx. From pressure the nose often becomes flattened and the mouth prominent, or the roof of the mouth is displaced downward. Digital exploration of the naso-pharynx is important to determine the exact location, size, and attachment of the tumor. If the tumor is not pedunculated sufficiently to enable its removal by torsion, its operative removal requires a bloody and often a dangerous preliminary operation to reach its base. If the tumor is attached in front of the naso-pharynx, the nostril is incised from within outward on the side of the septum as far as the nasal process, as advised by Dieffenbach and König; if this incision does not afford sufficient room, the nasal process is temporarily resected; and if still more room is required, the upper lip is divided in the median line and is dissected backward. If the base of the tumor can be reached in this manner, the tumor is drawn forward with vulsellum forceps and its attachment is severed with a narrow periosteal elevator or with blunt-pointed scissors. All operations for the removal of naso-pharyngeal growths requiring a preliminary bone operation should be performed under partial anesthesia, or, as the writer has been in the habit of calling it, "a talking narcosis."

Fibrous tumors of the nose and the naso-pharynx are exceedingly vascular, and their removal is attended by profuse and even fatal hemorrhage, notwithstanding the employment of prompt and efficient hemostatic precautions. In a case operated upon before the class in Rush Medical College, Chicago, in 1893, the writer took the precaution to make a preliminary tracheotomy. Two weeks later the operation was commenced by ligating the common carotid. Kocher's temporary

resection of the upper maxilla was then performed. The hemorrhage, notwithstanding compression and the use of hemostatic forceps, was alarming, and the patient nearly died upon the table from loss of blood.

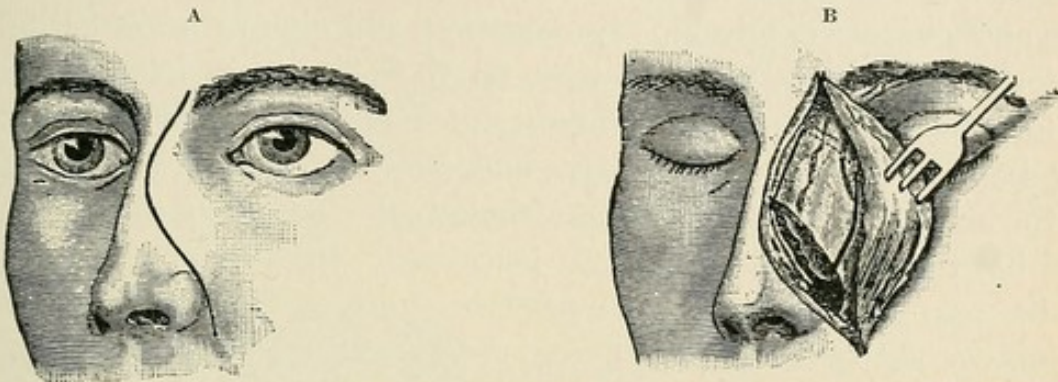


FIG. 272.—Resection of nasal process of the superior maxilla (after Langenbeck): A, external incision; B, line of section through nasal process.

Instead of slitting open the nostril, Langenbeck makes a curved lateral incision through which he resects the nasal process of the superior maxilla (Fig. 272). If the tumor obstructs both nasal passages, temporary detachment of the nose according to Rouge (Fig. 273) or Ollier (Fig. 274) will afford better access to the base of the tumor than will the unilateral incision.

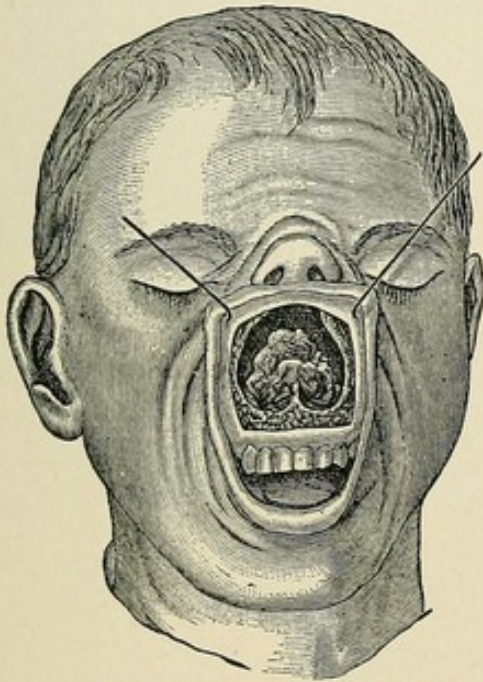


FIG. 273.—Temporary detachment of the nose according to Rouge.

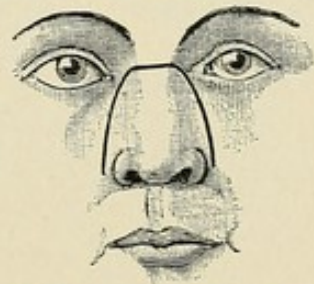

FIG. 274.—Temporary resection of the nose according to Ollier.

The bone-sections in making temporary resection of the nose should be made with a sharp chisel instead of with a saw. After the removal of the tumor the nose is replaced and the wounds are sutured accurately with fine silk or with silkworm gut. Bruns makes temporary resection of the nose by displacing it laterally. The removal of naso-pharyngeal tumors through the hard or the soft palate has been practised by Manné (1711), Dieffenbach, Hueter, and Nélaton. Demarquay and Trélat resected through an external incision the nasal process of the superior maxilla and the anterior wall of the antrum of

Highmore. The great deformity which followed this operation led Langenbeck in 1861 to devise temporary resection of the upper maxilla. Kocher has recently modified Langenbeck's operation. Temporary resection of the upper maxilla after Langenbeck and Kocher is a difficult and an exceedingly bloody operation, and should never be lightly undertaken. König lost a patient on the table from hemorrhage in performing Langenbeck's operation, and the patient mentioned on page 394 barely escaped the same fate, and later succumbed to the effects of the excessive loss of blood, although the common carotid artery had been tied as a prophylactic hemostatic precaution.

In naso-pharyngeal fibrous growths every attempt should be made to remove the tumor by less heroic measures than extirpation through the hard palate or after temporary resection of the upper maxilla, by the use of the wire *écraseur* or the galvano-caustic sling, the formal operation being reserved for the most desperate cases.

Tumors of the base of the skull which are behind the maxilla and grow into the temporal fossa can be removed only after a temporary resection of the maxilla.

Mammary Gland.—Most of the tumors that have been described as fibroma have been cases of adenoma. If the tumor contains any adenomatous tissue, it is an adenoma and not a fibroma, no matter how much fibrous tissue it may contain. Pure fibromata of the mam-

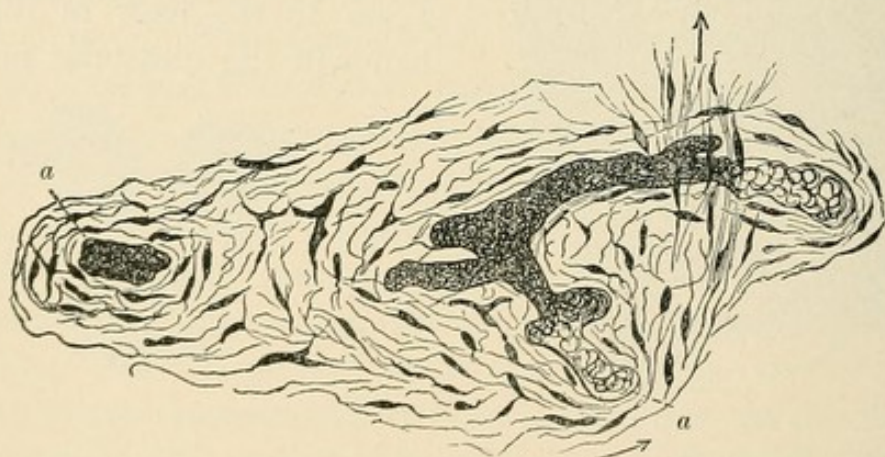

FIG. 275.—Fibroma of the mammary gland; $\times 250$ (after Perls). The fibrous tissue is swollen; the spaces with the nuclei appear as connective-tissue corpuscles; *a, a*, remnants of gland-ducts.

mary gland are exceedingly rare. They start in the interacinous or intertubular connective tissue, grow very slowly, and never attain large size. Pain and tenderness are either entirely absent or, when present, are not well marked. The fibrous tissue may surround and include pre-existing gland-ducts, in which event the cells become destroyed by pressure-atrophy, and the ducts in the course of time may become completely obliterated (Fig. 275).

Differential diagnosis between fibroma of the breast and adenoma is impossible without the use of the microscope. Fibroma is distinguished from sarcoma and carcinoma by its slow growth and by the mobility of the tumor in the tissues of the gland. Fibroma of the breast should be removed by enucleation. The recurrent fibroid tumor of the breast described by Paget is a spindle-celled sarcoma.

Uterus.—Fibroma of the uterus as a purely fibroid growth is exceedingly rare. With few exceptions the tumor contains muscle-cells, and has been described in the section on Myoma.

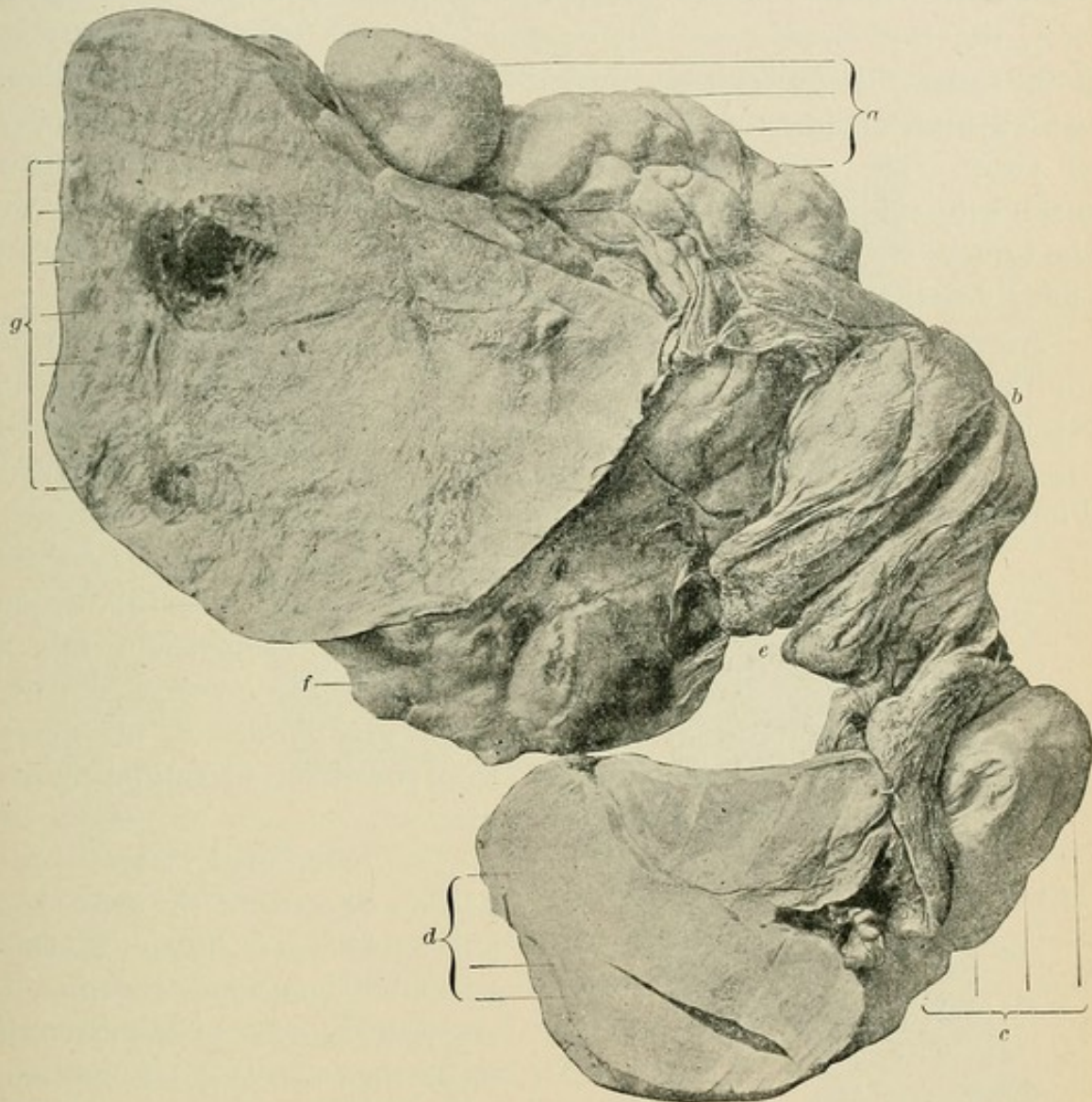


FIG. 276.—Fibroma of both ovaries; the right is as large as a kidney, the left larger than a child's head (after Winckel): *a*, surface of tumor on left side, with numerous nodules; *b*, fundus of uterus; *c*, surface of tumor on right side; *d*, section of right ovary; *e*, os uteri; *f*, surface of left ovary; *g*, cut surface of tumor on left side.

Ovary.—Fibromata of the ovary are so rare that Sutton regards them as pathological curiosities. The writer has met with two such cases. In one of them the tumor was recognized ten years before the

operation. The operation was postponed until the patient was driven to it by a very extensive ascites. The pedicle of the tumor was slender and there were no adhesions. The tumor weighed twenty pounds, was very firm, and was nodulated on the surface. Sections under the microscope showed nothing but wavy bundles of fibrous tissue interlaced in all directions. The blood-vessels were few and small. In the second case the tumor was about half as large and presented a similar structure. The enlargement of the abdomen due to ascites in this instance also induced the patient to submit to an operation. Both patients recovered from the operation and remain well up to the present time, the first twenty and the second two years after operation. In both cases the peritoneum was exceedingly vascular—a condition caused by its being thrashed, as it were, by the tumor, for a number of years. The writer has come to regard ascites as an important diagnostic evidence of movable solid tumors of the ovary. Neither of the tumors showed on section evidences of cystic degeneration. Occasionally both ovaries are affected at the same time (Fig. 276).

Ascites is usually the first thing noticed by the patient, and it is for this condition, and not for its cause, that the patient seeks relief. Ascites in the absence of malignant disease of the pelvic or abdominal viscera should remind us of fibroma of the ovary as the possible cause. Fibroma of the ovary occurs most frequently in women between twenty

and forty years of age. Leopold mentions 13 cases at from five to thirty years of age, and only 4 at thirty to forty years. Ferrier removed a fibroma of the ovary from a woman seventy-six years old.

The differential diagnosis between a fibroma of the ovary and a desmoid cyst is difficult, and between a fibroma and a pedunculated myofibroma of the uterus is impossible, without an exploratory laparotomy. Removal by laparotomy is a safe operation, and if the tumor is completely removed recurrence never takes place.

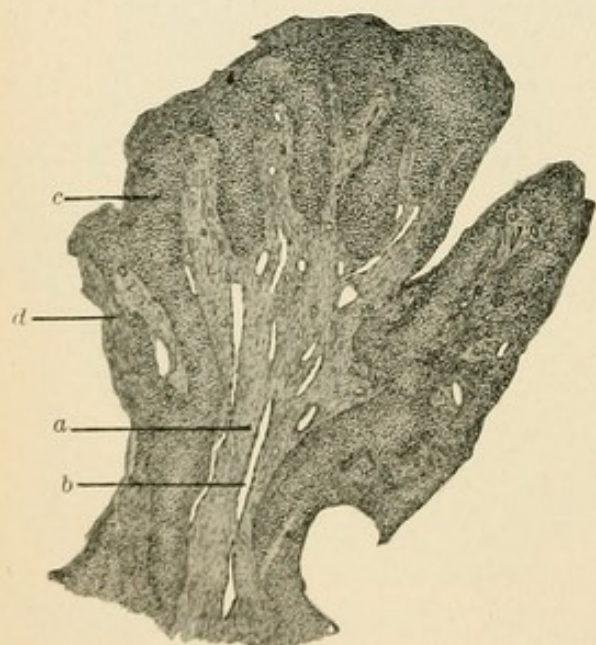


FIG. 277.—Papilloma of the vulva; $\times 25$ (Surgical Clinic, St. Joseph's Hospital, Chicago): *a*, stroma of loose connective tissue; *b*, blood-vessels; *c*, epithelium; *d*, horny layer.

Vulva.—Tumors are rare as compared with chronic infective swellings of the vulva. Fibroma occurs less frequently than papilloma,

is found more often upon the labium majus than upon the nymphæ, and appears first as a soft swelling with a broad base. It is of slow growth, does not attain large size, and may become pendulous by elongation of the skin covering it. Fibroma, which can be distinguished from papilloma by the smoothness and thinness of the overlying skin, is not as often multiple as is papilloma. Sections of a papilloma show that the greater part of the tumor is composed of epithelial cells attached to a vascular stroma (Figs. 277, 278). A vertical section of a fibroma would show the skin covering the tumor to be atrophied and the tumor-tissue to be composed exclusively of interlacing fibres or bundles of fibres of connective tissue.

Fibromata of the vulva may be enucleated, or their pedicles may be cut, without danger of hemorrhage, as the blood-supply is scanty.

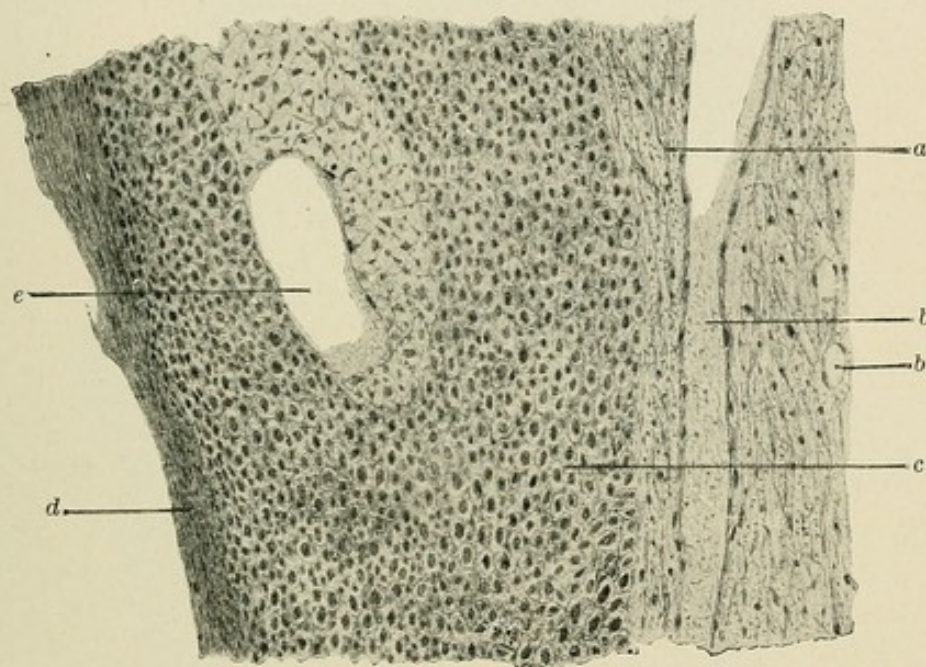


FIG. 278.—Periphery of tumor shown in Figure 276 ($\times 140$): *a*, stroma; *b*, blood-vessels; *c*, very thick stratum of epithelial cells; *d*, horny layer; *e*, loss of substance probably caused by degeneration.

Gums.—Formerly all tumors of the gums were included under the name of “epulis.” Microscopical examination of different tumors has shown the necessity of differentiating between sarcoma, carcinoma, and fibroma of the gums. Fibroma of the gums appears as a bone-swelling covered by the mucous membrane; the tumor grows slowly and does not return after thorough removal. The term “epulis” should be restricted to designate a fibroma originating from the gums or from the periodontal membrane. Local irritation caused by a decayed tooth or by incrustation upon the teeth is the most frequent exciting cause of fibroma of the gums. The tumor is seldom larger than a walnut, and its base is often constricted into a short pedicle. Mr. Hawkins made the assertion that fibroma of the gums, the fibrous epulis, grows, like

most of the other fibrous tumors, from the bone and periosteum and continuous with them.

The radical removal of a fibroma of the gums can be effected only by excision of the alveolar border of the jaw. This excision can be done, after the extraction of one or more teeth, with the chisel or with a narrow metacarpal saw. In benign fibrous tumors of the alveolar border and the gums it is unnecessary to resect the jaw in its entirety, as recommended by Gross and others.

Periosteum and Bone.—The maxillary bones are the most frequent seat of fibroma. The fibrous tumor of these bones is very hard, has a

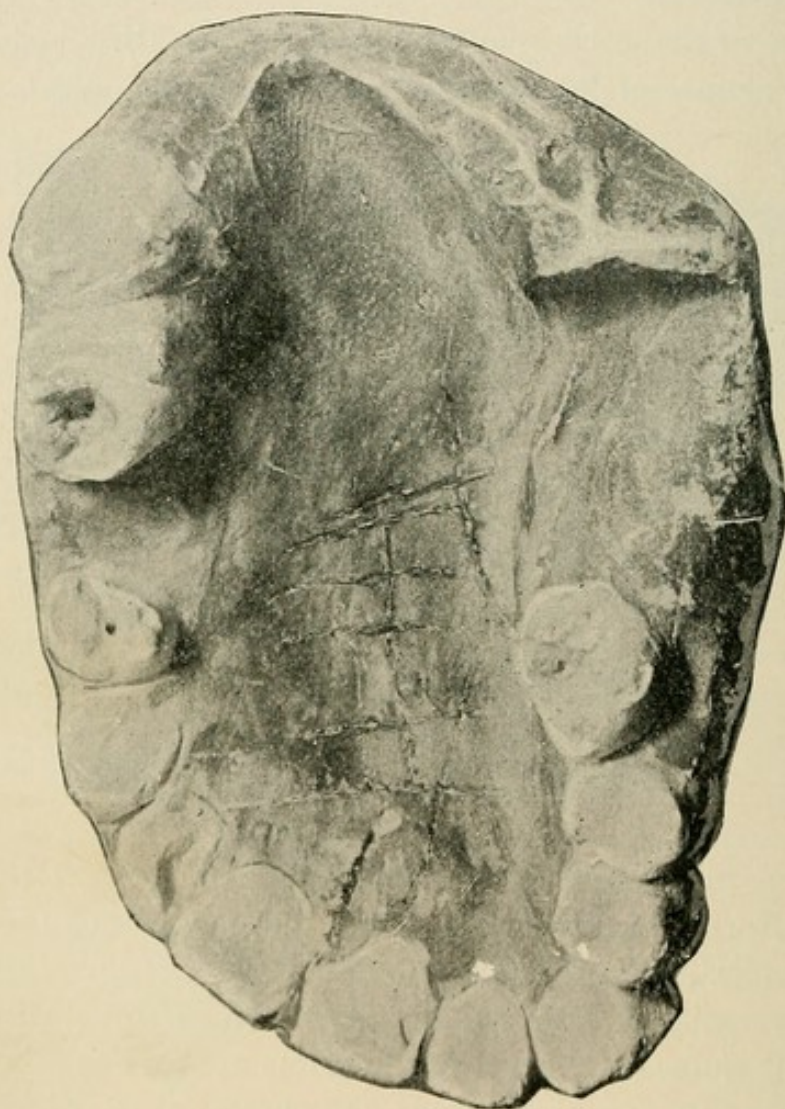
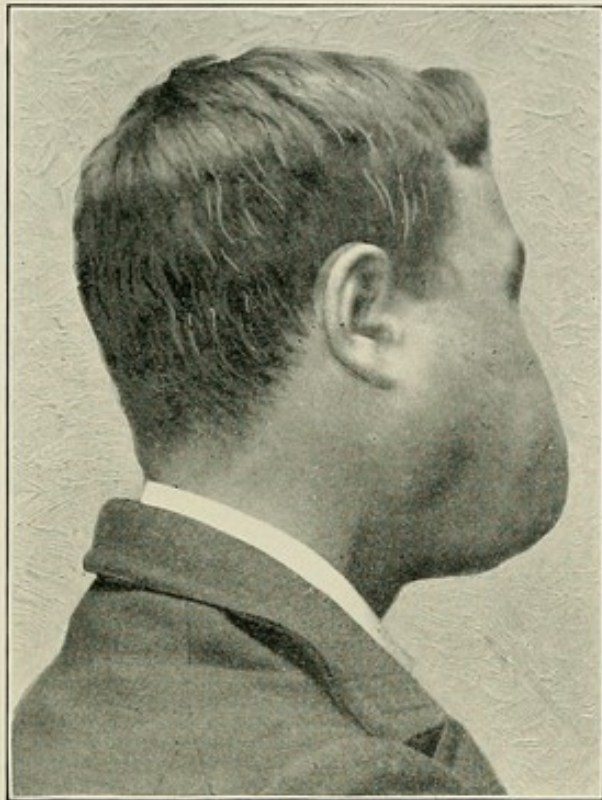


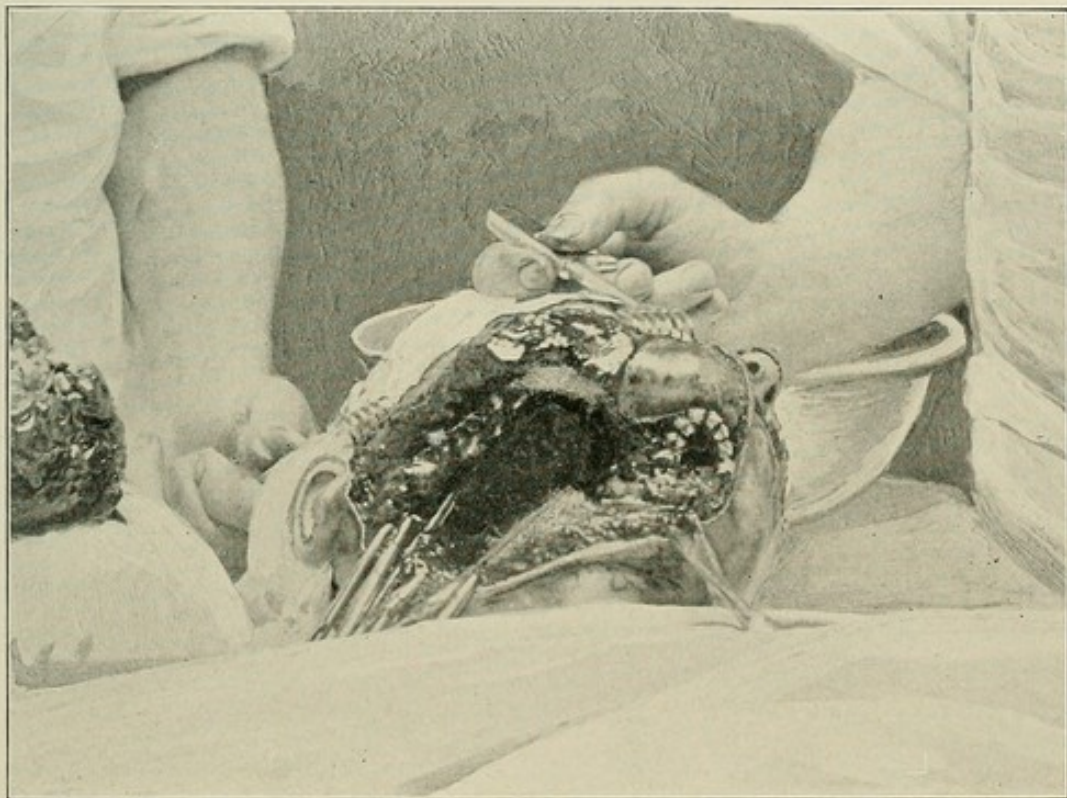
FIG. 279.—Distortion of dental arch caused by the tumor represented on Plate 10.

smooth surface, and is covered by skin and mucous membrane. Cystic degeneration occasionally takes place. It is difficult to determine whether these tumors start from the periosteum or from the connective tissue of the bone. They do not infiltrate the bone to which they are attached, but cause pressure-atrophy and distortion of the bone.

The tumor represented on Plate 11 (Fig. 1) occurred in a man twenty




1



2

1. Enormous fibroma of the upper maxilla. 2. Showing condition of parts immediately after excision of the tumor.



years of age, and was first discovered when he was ten years old. In 1890 it was only partially removed through a small incision. Two years before the operation the patient consulted a prominent surgeon, who pronounced it a sarcoma and refused to operate. When the patient came under the writer's observation the tumor had become very prominent in the cavity of the mouth—so much so that deglutition and speech were greatly affected. The tumor was removed, through the incision shown on Plate II (Fig. 2), by enucleation, without any special difficulty. The wound healed promptly, leaving a deep depression in the right cheek, where the tumor had been most prominent. No recurrence had taken place two years after the operation. Sections of the tumor examined under the microscope showed the typical structure of a dense fibroma.

Small fibromata of the jaw can be removed through the mouth, but large tumors must be enucleated through an external incision.

Serous Surfaces.—Papillomatous and fibrous tumors of the serous surfaces are rare, and their structure is very similar to that of the same kind of tumors of the skin, except that in place of epithelial cells the tumors are covered by endothelial cells—in the former variety by numerous strata, in the latter usually by a single layer. Benign fibrous and endothelial tumors are found most frequently upon the peritoneum and upon the synovial membrane of joints. When such a tumor becomes pedunculated it is often detached and remains in the cavity as a foreign body.

Cholesteatoma.—Closely allied to psammoma is cholesteatoma, first described by J. Müller. It was later described by Cruveilhier as *tumeur perlée*, or pearl tumor. The tumors do not exceed in size a cherry. They present a pearl-like metallic lustre, and they are found most frequently at the base of the brain, imbedded in the tissues of the pia mater. In this locality these tumors are often found so closely aggregated as to form nodulated masses an inch or more in diameter. Within a very delicate membrane there is found a fatty substance in concentric leaf-like layers. Microscopical examination of the layers shows that they are composed of large cells between which globules of fat and cholesterin-plates are seen. The pearl-like appearance of the tumor is due not to the cholesterin, but to the compact layers of the cells. The cells are derived from endothelium, and not from epithelium, as was formerly supposed. Recently some doubt has been raised as to the endothelial origin of cholesteatoma. J. Bland Sutton and Ribbert support their epithelial origin. Ribbert has examined a case in which there was nothing to indicate that the three-layered epithelial coat of the inner surface of the tumor had any connection with the endothe-

lium of the pia. The very sharp line of demarcation between the epithelium and the normal pia mater made the idea of the origin of the tumor from separated epithelial cells seem very probable. This idea has a strong support in the case described by Bonorden, in which the tumor contained glands and hair-follicles, structures belonging only to the external skin. Beneke has shown that the meningeal steatomata are produced by proliferation of the endothelial cells of the pia. He bases his opinion upon the fact that silver staining yields the outlines of endothelial cells, which would not be the case with epithelial cells.

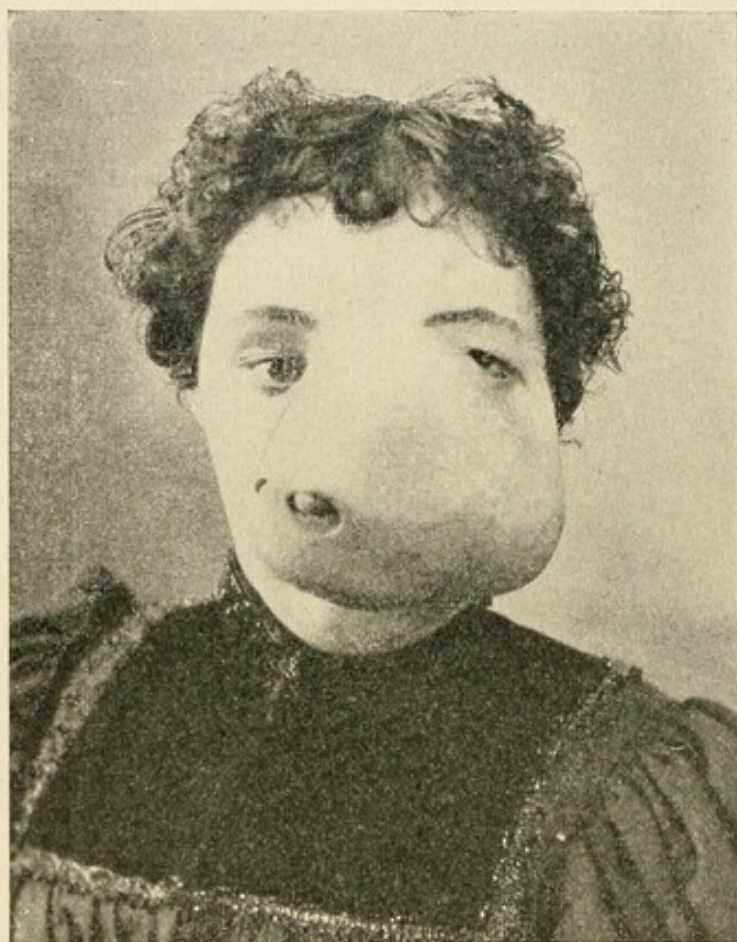

FIG. 280.—Fibroma of upper jaw.

Cholesteatoma is found, besides, in the meninges and the ventricles of the brain, in bones, especially the petrous portion of the temporal bone, and in the mastoid process, in the testicle, and in the ovary. In the meninges of the brain cholesteatoma probably starts in the perivascular lymph-spaces. Rindfleisch very strongly maintains that these tumors in the meninges of the brain are of endothelial origin. Wendt believes that in the petrous portion of the temporal bone cholesteatoma is produced by inflammation of the middle ear resulting in desquamation and accumulation of epithelial cells, but he has described also genuine cholesteatoma of endothelial origin in the drum of the

ear. In tumors of the pia mater belonging to this category this membrane surrounds the tumor mass, but the space is not lined by endothelial cells. Ziegler found hair in some of these tumors, in which case we must assume for some of them an epithelial origin from a displaced tumor-matrix; but these cases must be exceedingly rare. Eberth found that in cholesteatoma of the pia mater the first change that is seen in the formation of the tumor is the appearance of protoplasmic masses which surround the vessels like a sheath. In the sheath irregular nuclei are seen, besides giant-cells. Virchow and Eberth claimed that these cells were epithelial cells produced by heteroplastic proliferation of the connective tissue. This view is, of course, no longer tenable, as we have shown repeatedly that epithelial cells are never produced from connective tissue. Cholesteatoma never gives rise to metastasis, and it manifests no tendency to invade surrounding tissues to any extent, resembling in these respects psammoma, with which it is histologically and clinically so closely allied.

XVIII. LIPOMA.

Definition.—*A lipoma is a circumscribed or diffuse tumor composed of fatty tissue produced from a matrix of lipoblasts.* The subcutaneous fatty tissue is the favorite seat of lipoma. Toldt ascertained that in the embryo the panniculus adiposus is formed by cell-islets, the so-called "fat-organs," each of which has a separate and independent blood-supply. These islets are separated from one another by connective tissue. Young fat-cells are called "lipoblasts." Their number and activity, as well as the assimilation of fat from the blood or the food, determine the amount of fat. Each fat-lobule has its own artery and capillary circulation, terminating in a common vein. The lobule therefore represents an organized unity, like an acinus in the liver. According to Virchow, the lipoblasts develop from fetal myxomatous tissue into which the mature fat-cells can revert. If the cells of any of these fat-forming centres should become arrested in their development and remain in a quiescent state, it is easy to see how at any time, by their resuming active tissue-proliferation, they could give rise to a fatty tumor. Having become emancipated, as it were, from the organ-

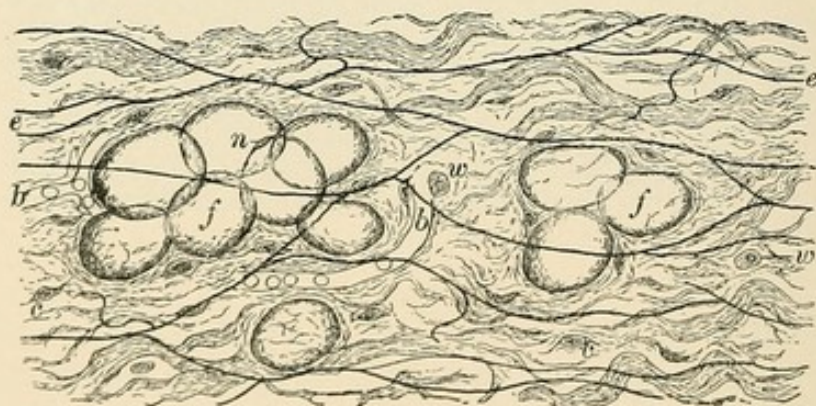


FIG. 281.—Fat-cells imbedded in subcutaneous areolar tissue (after Schiefferdecker): *f*, fat-cells; *n*, nucleus; *c*, connective-tissue corpuscles; *w*, migratory cells; *e*, elastic fibres; *b*, capillary blood-vessels.

ism, their growth, development, and reproduction would no longer be controlled by the laws which regulate normal nutrition. It would be difficult to explain localized hyperproduction of fatty tissue in any other way.

Histology.—The fat-cells in a lipoma, as in normal adipose tissue, represent connective-tissue cells with oily contents. The cells are

round or oval sacs; the transparent contents are limited by a delicate envelope composed of cell-membrane and of an extremely thin layer of protoplasm. The nucleus is located on one side of the sac (Fig. 281).

There is nothing to distinguish a fat-cell in a lipoma from a fat-cell in normal adipose tissue. The cells occur in groups supported and held together by areolar tissue through which ramifies a rich vascular network. The amount of stroma varies: in the soft lipomata it is very scanty, so that under the microscope it is difficult to recognize it, it being almost completely overshadowed by the fat-cells. In the hard lipoma the fibrous structure of the tumor is well developed and the fat-cells are crowded into the large areolæ of the stroma. Some lipomata are exceedingly vascular, and we then speak of a *lipoma telangiectodes*. In other instances the stroma contains venous channels of large size, when the tumor is called *lipoma cavernosum*. The writer has met with such vascular lipomata most frequently in congenital lipoma.

Regressive Metamorphoses.—The stroma of a lipoma is more prone to undergo retrogressive metamorphosis than is the parenchyma of the tumor. The most frequent degenerative change observed is myxomatous degeneration of the stroma. The connective-tissue fibres are separated by the myxomatous material, and the stroma presents the appearance of juvenile connective tissue. The tumor or part of a tumor undergoing this process becomes softer. Calcification of the stroma arrests the growth of the tumor affected by this change, the parenchyma-cells degenerate, and the tumor becomes eventually completely petrified. Burow found cholesterin in a large lipoma of the axilla. The lime-salts found in a calcified lipoma are carbonate and phosphate of lime. Fürstenberg found in the fat-cells lime-salts in combination with fatty acids. Ossification of parts of the stroma occurs in rare cases. Oil-cysts have been found in the interior of fatty tumors, and are supposed to have been formed by atrophy of the cell-envelopes and accumulation of their contents in the stroma.

Anatomical Varieties.—All lipomata are encapsulated. The capsule is perfect in the circumscribed variety; in the diffuse form the tumor sends out into the surrounding loose connective tissue prolongations which sometimes are not discovered in the removal of the tumor, and lead to a recurrence of the growth. The diffuse form frequently occupies a large territory, as, for instance, the anterior surface of the neck. The *lipoma arborescens* or *racemosum* described by J. Müller is a branching fatty tumor (Fig. 282). It is found most frequently in the knee-joint, where it starts beneath the synovial mem-

brane, and, pushing this before it, sends branching lobes into the joint. Lipoma arborescens is also found quite frequently as a diffuse tumor under the peritoneum and the pleura.

Symptoms and Diagnosis.—Lipoma frequently occurs as a congenital tumor. Sometimes it is found as a symmetrical affection—for instance, the simultaneous occurrence of a lipoma in each axillary space. The writer has observed such a case in a woman fifty years of

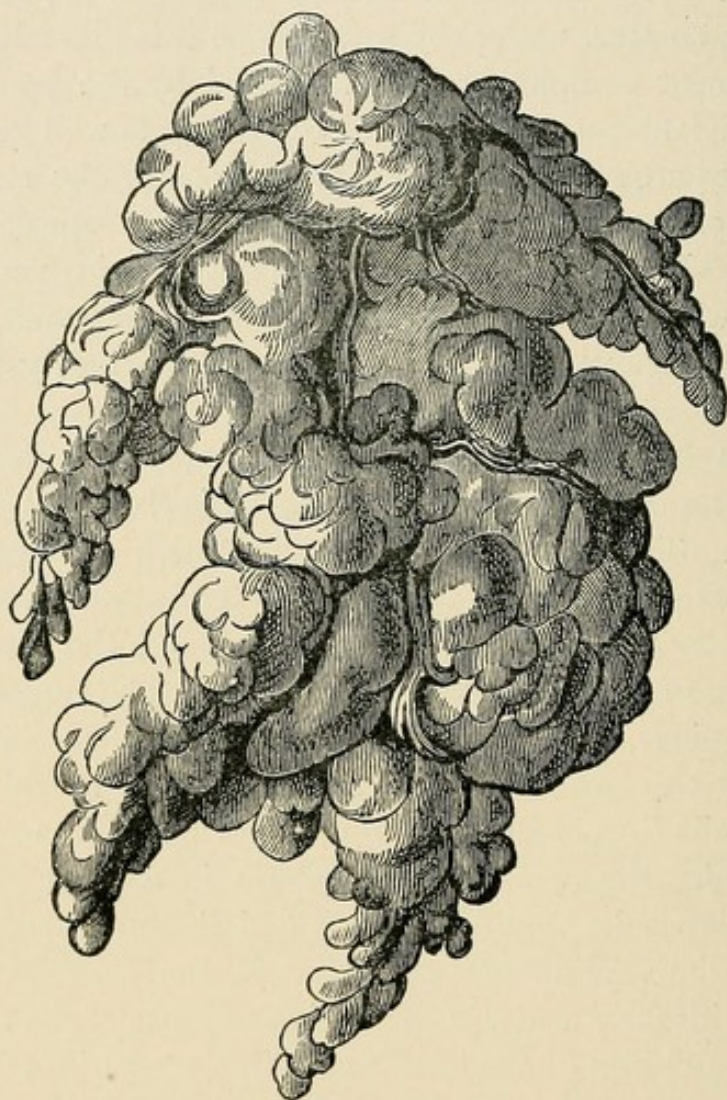


FIG. 282.—Lipoma arborescens (after Lücke).

age. Billroth, in a paper published shortly before his death, called attention to the occurrence of symmetrical lipoma. As a post-natal tumor it commences most frequently after puberty. Its growth is always slow. Sometimes it remains stationary for a certain length of time, when, without any apparent provocation, it resumes its growth. It attains occasionally an immense size. Rhodius recorded a case in which the tumor weighed sixty pounds. Tumors weighing more than ten pounds, however, are very rare. If the tumor is subcutaneous, the skin over it, from tension, atrophies, and ulceration from impaired nutri-

tion may take place. In other instances ulceration is caused by a trauma or in consequence of irritating applications. Infection of a fatty tumor through a break in the surface is frequently followed by intense phlegmonous inflammation of the stroma of the tumor, extensive gangrene, and profuse suppuration.

Examination of a tumor complicated by acute inflammation might lead the surgeon to suspect a malignant growth. Under such circumstances a careful consideration of the clinical history will prevent a mistake in diagnosis. A soft lipoma imparts to the palpating finger a sense of fluctuation. Pseudo-fluctuation of soft tumors has led to many mistakes in diagnosis. Chelius compares the sensation felt on palpating a lipoma to that felt on compressing a bag filled with cotton. If the tumor is hard, the resistance to pressure is of a firm, elastic kind. A subcutaneous lipoma is a lobulated, movable tumor. Its slow growth differentiates it from sarcoma. A lipoma, however, may attain considerable size before being discovered by the patient, and surgeons have often been misled by dating the origin of the growth to its accidental discovery by the patient. In doubtful cases the negative result of an exploratory puncture will prove of great value in differentiating between a lipoma and an infective or cystic swelling. The recognition of a cavernous or telangiectatic lipoma is often impossible. This combination tumor should be suspected if under pressure the tumor is diminished in size, but the effect of pressure is less marked than in cases of deep-seated angioma.

Prognosis.—The prognosis in lipoma is favorable. Transition into sarcoma is less frequently observed than in any other kind of benign mesoblastic tumors. Myxomatous degeneration of the stroma often initiates the transition of a lipoma into a sarcoma. This transition occurs most frequently in intermuscular lipomata. The first case of this kind was described by Förster. Virchow examined three fatty tumors which had undergone this degeneration, and made the statement that their malignancy depended upon the extent of the degeneration. The fat-cells are not affected by this change. Waldeyer showed that myxolipoma can give rise to metastasis. In a mesenteric tumor of this kind he found metastatic deposits in the liver and lungs. The pressure-effects are also less marked, owing to the location of the tumor being usually in places where the surrounding tissues are yielding. Even the large subserous lipomata seldom give rise to any serious functional disturbances. Patients with fatty tumors seek surgical advice more frequently for cosmetic reasons or for inconveniences attending the presence of the tumor than for the relief of suffering or the functional disturbances.

Treatment.—The only proper surgical treatment of lipoma is removal by excision. Lipoma of the abdominal cavity is rarely or ever recognized before the abdomen is opened. *The removal of a subcutaneous lipoma must be done under strictest aseptic precautions, because the bed of the tumor presents the most favorable conditions for progressive infection.* The numerous large connective-tissue spaces which are exposed by the removal of the tumor and the abundance of connective tissue forming its bed are admirably adapted for a diffuse infection. Before antiseptic surgery came in use numerous instances of progressive phlegmonous inflammation, sepsis, and pyemia occurred after the removal of small lipomata. The surgeon must not be lulled into a sense of ease and security offered by an easily-removable lipoma in undertaking its removal by enucleation. *He must make as careful preparations to procure asepsis as though he were to operate upon the abdominal cavity.* Owing to the attenuated skin overlying tumors immediately under the surface, the incision, as a rule, should be made, not over the centre of the tumor, but at its base. A semilunar incision in this location will secure more room than a straight one. After reflection of the flap the capsule of the tumor must be found, and in the enucleation which follows it is taken as a guide. Bands of connective tissue which convey the blood-vessels to the tumor should not be torn, but should be cut with scissors or with a knife. *Tearing must be avoided.* After the enucleation all bleeding points are tied. As few blood-vessels are cut in the operation, the wound can be sutured throughout. Drainage is unnecessary. The dressing must be applied with care in order to bring and to hold the wound-surfaces in uninterrupted apposition. If the wound is sealed with cotton and iodoform collodion, an elastic dressing is applied over it to aid the sutures in securing and maintaining accurate coaptation of the wound-surfaces. In the majority of cases general anesthesia is superfluous in the removal of a lipoma.

TOPOGRAPHY.

Subcutaneous Adipose Tissue.—By far the greatest number of fatty tumors originate in the panniculus adiposus and present themselves as lobulated movable subcutaneous tumors. In this locality the tumor is occasionally multiple, from two to ten or more appearing simultaneously or in succession. Lipoma is found most frequently upon the neck (Fig. 283), shoulders, chest, abdomen, arms, and thighs. Grosch collected 716 cases of solitary lipoma, and found their regional distribution, in the order of frequency, as follows: Neck, back, thigh, forearm, volar side of hand and foot; the scalp only in exceptional cases. It appears, then, that lipoma occurs most frequently in localities where

the skin is scantily supplied with glands. Symmetrical lipomata Grosch regards as of neuropathic origin. Lipoma of the scalp is very rare. In this locality the tumor is flattened and never becomes pendulous. Lipomata in localities where the skin is loose often become pedunculated.

A neuropathic cause of symmetrical lipomata has been assumed by some. Madelung observed the growth of fatty tumors at the insertion of the deltoid muscle following neuralgia and tremors which occurred in consequence of contusions. In one of the two cases which

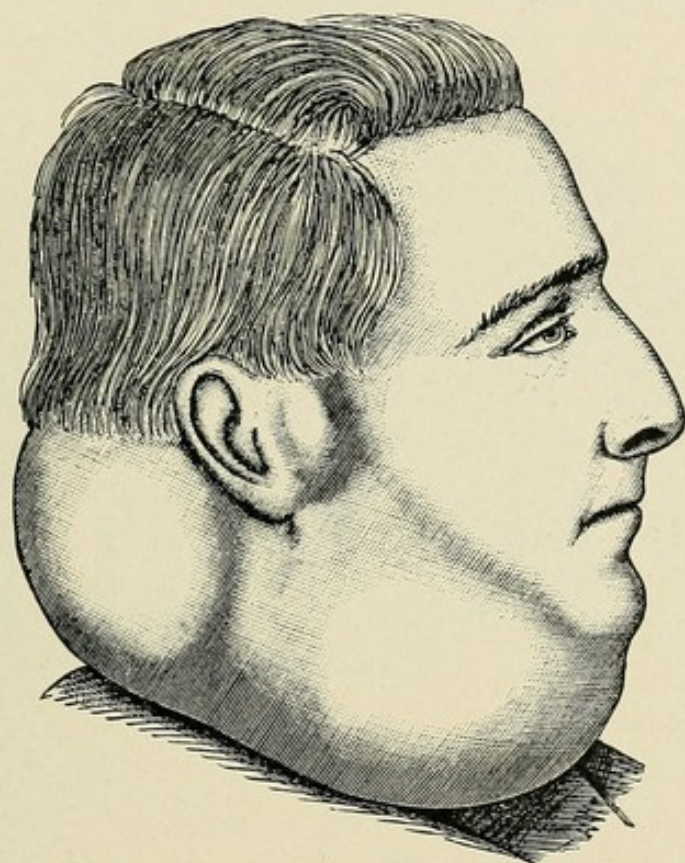


FIG. 283.—Diffuse lipoma of the neck (after Baker).

he reported the neuralgia disappeared after extirpation of the tumor. Mathieu in 1890 described a case in which sciatic neuralgia attended two pairs of lipomata, one on the trochanter major, of the size of the head of a new-born child, and two smaller ones, of the size of a fist, on the inner side of the knee. Other tropho-neurotic affections complicated the case. Targlowa recorded a case where symmetrical lipomata, seven pairs, had developed in a man affected with general paralysis. The tumors occupied the neck, the zygomatic and mastoid processes, the subclavicular, the deltoid, and the sacral region of both sides. Cases of the same nature are reported by Oldham, MacCormac, Hutchinson, C. Beck, and others. In Beck's case the tumors occupied the neck, the parotid, and the mastoid regions on both sides. The

writer has seen only one case of diffuse lipoma of the neck, and in this instance the swelling extended diffusely around the whole neck and came up well in front of both ears. Diffuse lipoma is not encapsulated.

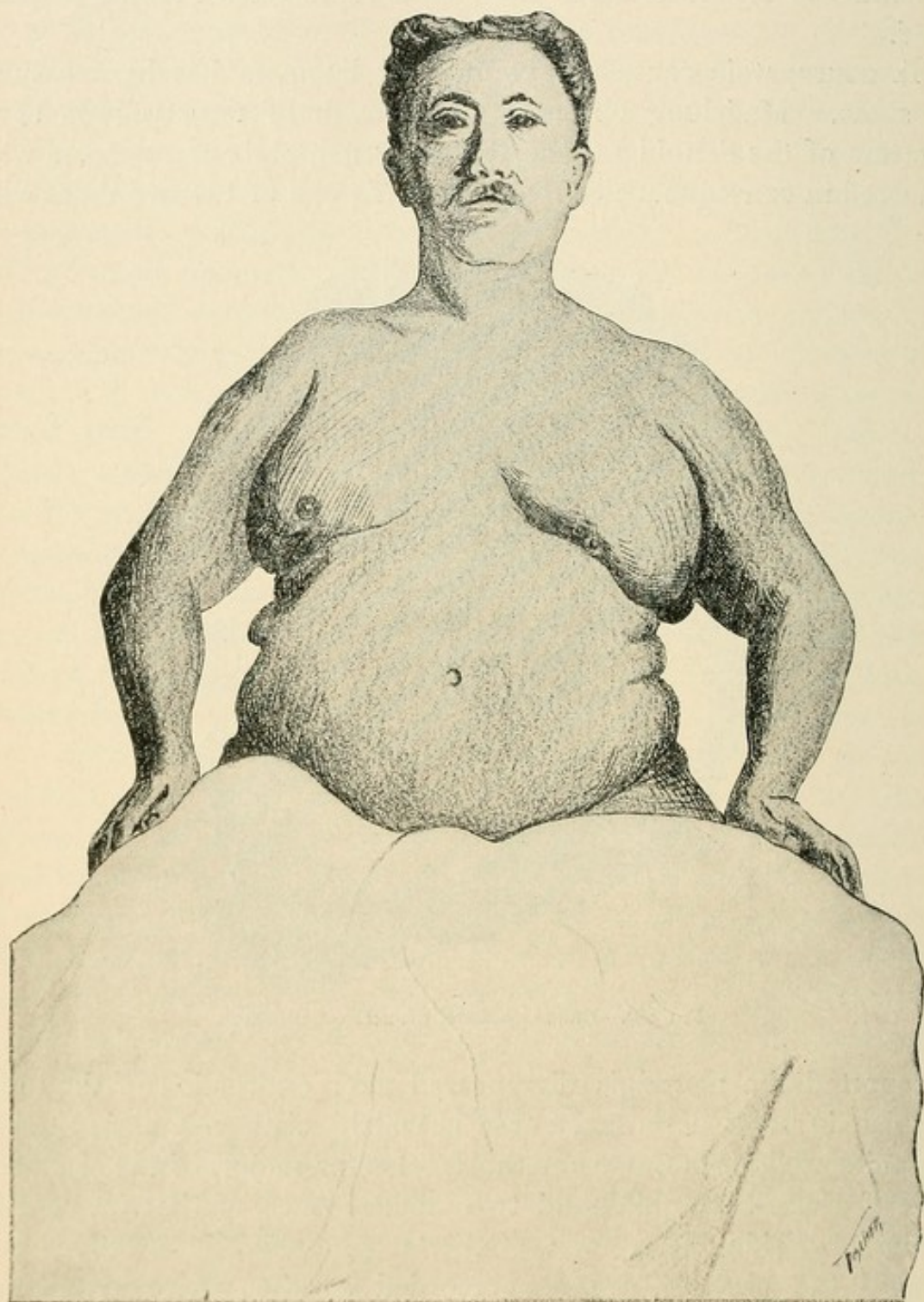


FIG. 284.—Symmetrical lipoma of the axillæ.

The fat bears a coarsely granular appearance, due to being bound up in small lobules, which causes it to resemble omentum in its structure.

Operative treatment in diffuse lipoma is not indicated, as a rule, as the tumor usually becomes stationary.

The palm of the hand is occasionally the seat of a lipoma. The tumor in this locality might be mistaken for tuberculosis of the tendon-sheaths or for a plexiform neuroma. The very slow growth and the absence of pain are important factors in differentiating lipoma from neuroma and inflammatory swellings.

Eyelids.—The “fibroma lipomatodes” of Virchow, the “xanthoma” which is usually found upon the eyelids, appears as yellowish or brown spots, and consists of large fat-cells with a reticulated protoplasm. The tumor is sometimes quite diffuse and large. Some authors have described xanthoma as a variety of endothelioma, but the cells of endotheliomata contain no fat except as a product of degeneration. The coloring-material is lipoxanthin, belonging to the class of blood-pigments. Klebs proposes for these tumors the name of *lipoxanthoma*. Xanthoma may occur as a primary lesion in other parts of the body, more especially where the skin is exposed to repeated injuries.

Subserous Lipoma.—The peritoneum, like the skin, rests upon a bed of fat, the thickness of which varies considerably. This layer of fat is sometimes the seat of very large fatty tumors. In Carlsberg's case the tumor weighed thirty-five pounds and was in part petrified. Terillon removed a subperitoneal lipoma weighing fifty-seven pounds. Homans of Boston removed two large retroperitoneal fatty tumors. Josephson and Vestberg have collected 30 cases of multiple, retroperitoneal lipomata, of which 3 have been seen personally. The point of origin of these tumors is always retroperitoneal, and never mesenteric, although they may encroach upon the mesentery secondarily. In the diagnosis it is stated that an abdominal tumor which presents none of the evidences of malignancy, but which increases rapidly in size, which displaces the large intestine to one side, which presents pseudo fluctuation, and which is hard in some places, is surely a retroperitoneal lipoma. If the tumor is perceptible beneath the abdominal wall, in the lumbar region, and if it tends to return to its former position by a kind of spring, due to its elasticity, when one tries to pull it away from the abdominal wall, its retroperitoneal location can be assumed with a great deal of certainty. The authors advise surgical intervention, calling attention to the fact that in certain cases resection of a portion of the large intestine will be made necessary for the removal of a tumor which has involved the entire thickness of the mesentery, if one wishes to avoid gangrene of the intestine. The removal of large lipomata by laparotomy is a very dangerous operation: of 10 cases, only 3 recovered. Smaller lipomata cause no serious symptoms, and when incidentally discovered can be safely removed by enucleation. They

are frequently found in connection with femoral and inguinal herniæ. Roser believed that lipoma in subperitoneal spaces usually occupied by herniæ is a frequent cause of hernia. A subperitoneal tumor of the anterior abdominal wall sometimes, by displacing the abdominal muscles, becomes subcutaneous, especially near the umbilicus. If the tumor is situated between the folds of the broad ligament, it simulates very closely an ovarian tumor. The removal of omental lipoma has proved more successful than the removal of tumors from behind the

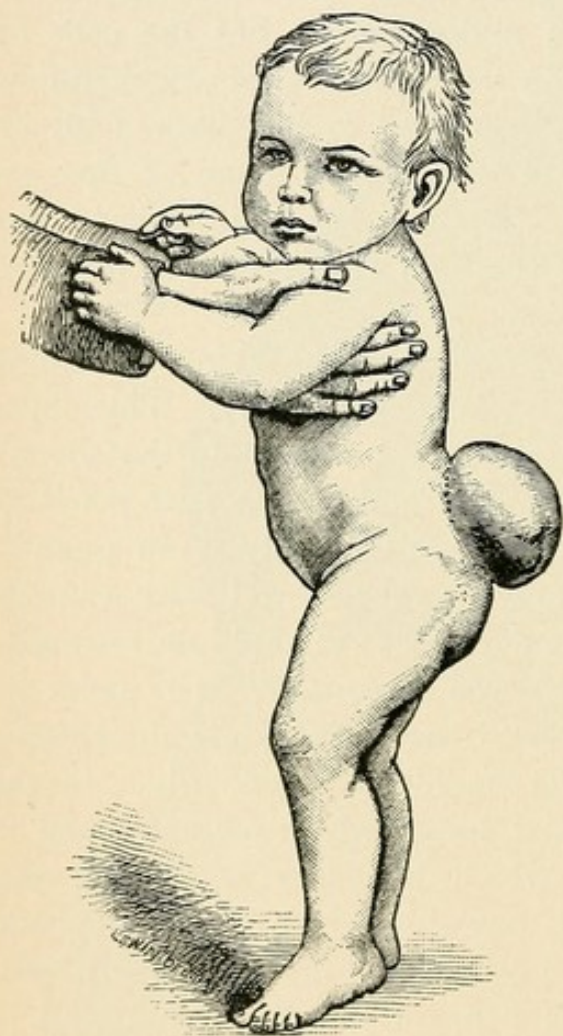


FIG. 285.—Meningeal lipoma simulating a spina bifida in a child eight months old (after Témoin).

peritoneum of the posterior abdominal wall. Meredith removed successfully an omental lipoma weighing fifteen and a half pounds. Förster saw one that weighed fifty-three pounds. Waldeyer described a lipo-myxoma of the mesentery that weighed sixty-three pounds.

Subserous lipoma of the colon is met with occasionally. The appendices epiploicæ are often the seat of polypoid lipomata. Lipoma of the abdominal organs and of the subperitoneal layer of fat are not recognized before the abdomen is opened. If abdominal section reveals the existence of a lipoma in the retroperitoneal space, its removal should not be attempted if, as is so often the case, it dips down deeply on the side of the vertebral column, unless the tumor interferes with an important function or is the cause of pain. If the tumor is more favorably located, the peritoneum

covering it should be incised over the most prominent part of the tumor, and the tumor should be removed by enucleation. After the tumor is removed the peritoneal incision should be sutured.

Submucous Lipoma.—Submucous lipoma of the gastro-intestinal canal is rare. Virchow examined a submucous lipoma of the stomach as large as a walnut. Turner has seen a fatty tumor, the size of a large walnut, growing in the submucous tissue of the large intestine and projecting into the lumen of the bowel near the ileo-cecal valve. Submucous intestinal lipomata may cause intussusception, and thus become

a source of danger to life. A few instances of submucous lipoma of the larynx have also been reported.

Meninges of the Brain and Spinal Cord.—Lipoma of the meninges of the brain and spinal cord is a heterotopic tumor which develops from a displaced matrix of lipoblasts. Tauber records a case where the tumor was located in the tubercula quadrigemina on the right side, and had given rise to destruction of brain-tissue from pressure. Rokitsansky has seen cases of lipoma upon the internal surface of the dura mater and in the lateral ventricle. Polypoid masses of fat are occasionally associated with protrusions of the spinal or cerebral meninges, and fatty tumors may be found as a pathological curiosity in the central nervous system. Chiari found two lipomata the size of a pea under the arachnoid, and Weichselbaum found one in the posterior lobe of the hypophysis in a soldier twenty-two years old. Lipomata are frequently observed at the seat of a spina bifida occulta, which may even penetrate inside the theca (Fig. 285).

In the cases of meningeal tumors examined by Recklinghausen and Obre the tumors contained striped muscular fibres, showing that the matrices were composed of displaced fetal tissue. A lipoma complicating a spina bifida greatly complicates the diagnosis. The presence of a solid tumor over the spine in children should induce the surgeon to look for, and to be prepared to treat, a spina bifida at its base.

Intermuscular Lipoma.—Fatty tumors in rare instances have been found between nearly all the great muscles, and have given rise to great difficulty in diagnosis. Myxo-lipoma, according to Lücke, occurs most frequently below the gluteal fold, between the muscles of the thigh, and frequently penetrates the ischiatic foramen.

Intermuscular lipoma being more liable than superficial tumors to undergo transition into sarcoma, their operative removal is rendered so much more imperative.

Periosteum.—As a heterotopic tumor lipoma of the periosteum must be mentioned. Sutton collected nine such cases representing so many different bones. The heterotopic nature of periosteal lipomata has been established by microscopical examination, which in each specimen showed traces of striated muscle-fibre. Without an exploratory incision or an examination of tissue removed it would be next to impossible to make a positive diagnosis.

Joints.—Subserous lipoma of joints, from the location of the tumor, appears as a diffuse growth. The lobes of the branching tumor present a racemose or arborescent appearance; hence these tumors are known and described as *lipoma arborescens*. So far, 16 cases of lipoma of the

knee-joint have been recorded. In this joint Schmolck describes two varieties: (1) the diffuse and (2) the circumscribed. The diffuse variety is not a tumor, but an inflammatory swelling of a tubercular nature with fatty degeneration of the synovial villi. The circumscribed form has, according to König, its starting-point in the retrosynovial fat-tissue in the same manner as the retroperitoneal lipoma. The tumor projects into the joint through a rent in the synovial membrane caused by an injury or otherwise. Subsynovial lipoma is found most frequently in the knee-joint, but has also been seen in the shoulder-joint. The fringes of the tumor are covered by the synovial membrane. If the tumor disturbs the function of the knee-joint, its removal by arthrectomy is indicated. Thorough removal under strict aseptic precautions is not followed by recurrence and yields a satisfactory functional result.

Tendon-sheaths.—Lipoma outside the tendon-sheaths has been described by Ranke and Trélat. It is found most frequently along the tendon-sheaths of the flexor tendons of the hand. Lipoma inside the tendon-sheaths springs from the adipose tissue of the mesotendon. It develops usually as a multiple tumor which presents an arborescent appearance, and it is easily mistaken for tuberculosis of the tendon-sheaths and for plexiform neuroma. According to Hammann, Sprengel, and Haeckel, it can be treated successfully by excision.

Eye.—Subconjunctival lipoma is a rare affection of the eye. It occurs most frequently near the point where the conjunctiva is reflected from the lower lid to the eyeball, and it is almost confined to children. As a rare retrobulbar benign tumor a lipoma is found in the cushion of fat behind the eyeball, producing, according to its size, more or less displacement of the eyeball.

Broad Ligament.—Lipoma of the broad ligament as a subserous tumor is very rare. Pozzi saw a case of this kind in which the tumor was mistaken for an ovarian tumor because of the misleading sense of fluctuation. The patient suddenly died of embolism three days after an exploratory incision.

Vulva.—Lipoma of the vulva arises in the fatty tissue of the mons veneris, and often reaches large dimensions. Stiegele operated on one which weighed ten pounds. In one of Bruntzel's cases the tumor increased greatly in size during pregnancy.

Scrotum.—Lipoma of the scrotum occurs rarely as a subcutaneous tumor. Fatty tumors of the cord often reach considerable size. Park successfully removed a large lipoma of the cord, and he refers to a number of similar cases. Sarazin has collected from different sources 26 cases of lipoma of the spermatic cord.

XIX. MYXOMA.

THE frequent occurrence of myxomatous degeneration of the stroma of benign and malignant tumors and the rarity with which pure myxomatous tumors are found have induced some authors to abandon myxoma as a separate class of tumors and to include it among the fibromata. Myxoma is a tumor which presents so many characteristic peculiarities that it is well to give it a separate place in the classification of tumors, and not to regard it as a variety of œdematous degeneration of other connective-tissue type of tumors.

Definition.—*A myxoma is a tumor composed of mucous tissue resembling Wharton's jelly in the umbilical cord.* Virchow selected Wharton's jelly of the umbilical cord as a prototype of the tissue of which a myxoma is composed (Fig. 286).

In the embryo the connective tissue is identical in structure with Wharton's jelly. The meshes of the cellular network are occupied by a semi-gelatinous, indifferent, and but slightly differentiated intercellular substance containing few fibres and occasional wandering cells. During the development of myxomatous into connective

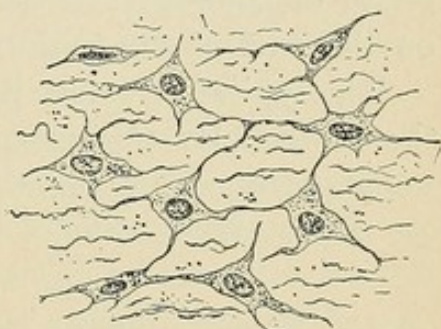


FIG. 286.—Connective-tissue cells from young umbilical cord: processes of cells unite to form protoplasmic network; fibrous elements slightly developed (after Piersol).

tissue the fibrous tissue in the meshes becomes more abundant, while the intercellular substance is diminished in quantity. If a group of cells should become arrested in their development at an early stage and be set aside, it is to be expected that tissue-proliferation from them would result in a connective-tissue tumor of lowly-organized tissue—a myxoma. On the contrary, arrest of development at a later stage would result in a tumor-matrix which would produce a connective-tissue tumor of a higher type—a fibroma. *The stage at which development of the mucous cells in the embryo is arrested determines whether the tumor from such a matrix is to be a myxoma or a fibroma. The intrinsic capacity of mature connective tissue to revert to its original embryonic state accounts for the frequency with which the stroma of all tumors undergoes myxomatous degeneration.* A post-natal

matrix of myxoma is created if the pre-existing connective-tissue cells revert to their original embryonic state and remain unspecialized.

Histology.—The histological structure of a myxoma is subject to many variations. The variable structure depends on the amount and character of the intercellular gelatinous substance and the abundance and vascularity of its stroma. Mucin is a substance which in the living body is rapidly destroyed and eliminated. In a myxoma the retention of this substance gives rise to hydropic conditions, and this retention occurs in myxomatous tumors if the production and absorption of mucin are arrested.

Myxoma may occur as a clear, colorless, gelatinous mass which differs from fluid only in its greater consistence. The delicate stroma of such a jelly-like mass contains small blood-vessels which nourish the lowly-organized tumor-tissue. Such tumors are found in the antrum of Highmore. In the firmer variety the translucency is lessened by a more copious stroma and by larger blood-vessels. The prognosis in the latter form is less favorable than in the former, on account of the more active cell-proliferation. The capsule of a myxoma is composed of connective tissue which has become condensed by pressure on the part of the tumor-tissue.

The typical myxoma is composed of a network of branching cells, the intercellular substance in its meshes being composed of a gelatinous homogeneous substance which contains mucin. The nuclei of the cells are large. If the cells of the tumor are few and the stroma is in an

extremely hydropic condition, the tumor is called a *hyaline myxoma* (Fig. 287, A). If the cells are more abundant and less stellate, it is called a *medullary myxoma* (Fig. 287, B). If the tumor is very vascular, we speak of a *myxo-angioma*. Klebs found that myxomatous degeneration takes place in cells which are in close proximity to blood-vessels, and that it appears first as a vacuole in the protoplasm of the cell.

As a component part of other

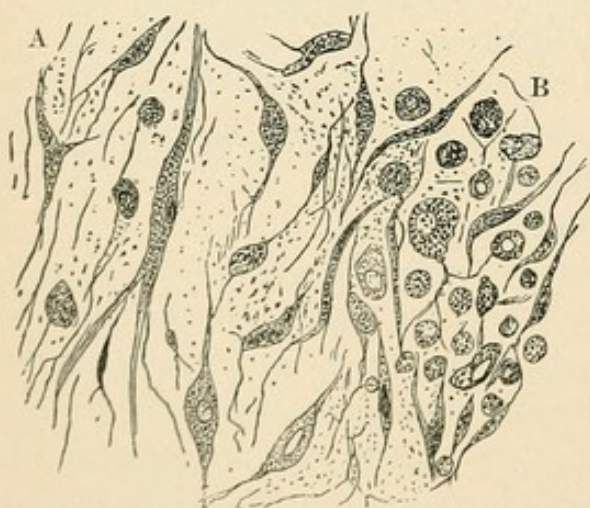

FIG. 287.—Myxoma: transition of (A) hyaline form into (B) medullary form; $\times 250$ (after Perls).

tumors, benign as well as malignant, myxomatous tissue is very common, in which case the nomenclature of the tumor is modified by substituting a compound word for the single word and retaining the name of the primary tumor, as adeno-myxoma, chondro-myxoma,

myxo-carcinoma, myxo-sarcoma, etc. The most frequent combination is myxoma with lipoma, *lipoma myxomatodes*.

Etiology.—Congenital myxomata have been reported by C. O. Weber, Schuh, and others. No age is exempt, but they are met with most frequently in young adults. The most potent exciting causes are chronic irritation and inflammation. The formation of nasal myxomata is frequently preceded by chronic catarrhal inflammation. Myxomatous polypi of the external auditory meatus are most always associated with chronic inflammation of the external ear.

Symptoms and Diagnosis.—A myxoma is a soft, gelatinous, translucent, interstitial, sessile or pedunculated growth. It is of slow growth, and as a surface tumor it does not attain large size. Its growth is unlimited if it receives its blood-supply from the entire periphery, as is the case in interstitial myxoma. The diagnosis is not attended by any difficulties if the tumor is accessible to sight and touch. Its color and consistence distinguish it from fibroma, adenoma, and the malignant tumors. Fluctuation is a constant sign, owing to the softness of the tumor-tissue. The transition of a myxoma into a sarcoma should be suspected when the tumor without any obvious cause begins to grow rapidly. In such cases an examination of the tumor-tissue under the microscope should be made before an operation is undertaken, as a correct diagnosis is of paramount importance in planning and executing an operation of sufficient thoroughness to remove all the infected tissues in case the tumor has become malignant. *If the microscope is to be relied upon in ascertaining whether or not malignant transition has taken place, tissue from the new part of the tumor must be obtained for examination.* Serious blunders in practice have arisen from the examination of old portions of the tumor, in which portions no traces of malignant transition could be seen. Wherever possible, tissue from the base of the tumor should be taken for microscopic examination, as it is here that malignant transition is most frequently initiated.

Prognosis.—A pure myxoma is a benign, local, encapsulated tumor. Myxoma has received an unenviable reputation from a prognostic standpoint from the fact that it has been so often confounded with malignant tumors that had undergone myxomatous degeneration, and from the frequency with which it undergoes transformation into sarcoma. A pure myxoma does not give rise to local, regional, or general infection. The implication of adjacent tissues, regional infection, and general dissemination are positive proofs either that the primary tumor was malignant and had undergone myxomatous degeneration or that the tumor is no longer a myxoma, but is a sarcoma produced in consequence of transformation of a benign into a malignant tumor. In

rendering a prognosis in cases of myxoma the aptitude of such a tumor to undergo malignant transition must be remembered. The greater liability of myxoma than of fibroma to become transformed into a sarcoma is due to the more lowly organized cells of which its matrix is composed.

Treatment.—Remembering the liability of myxoma to transition from a benign tumor into a sarcoma, it is necessary to emphasize the importance of early and thorough removal. Imperfect removal by operation or incomplete destruction by caustics has frequently been followed by a sarcomatous recurrence. The irritation incident to such imperfect treatment has proved sufficient to bring about a transition of the remnant of the tumor into sarcoma. The writer has more than once seen such a transformation follow incomplete removal of nasal polypi with the snare. It is especially necessary to remove the base of the tumor; complete removal is seldom accomplished with the snare or by torsion. A hyaline myxoma of a mucous surface is so friable that its complete removal cannot be effected by avulsion. If the tumor is so located that its base cannot be reached for its removal by the snare or by avulsion, these procedures should be followed by cauterization with the Pacquelin cautery, in order to destroy every remaining vestige of the tumor. The removal of an intermuscular myxoma must be done with the utmost care, as the tumor usually has prolongations into the loose connective tissue surrounding it; these prolongations might be overlooked, and if not removed would become the source of a certain and early recurrence.

TOPOGRAPHY.

Skin.—Myxoma of the skin occurs as a sessile or pedunculated tumor, but is rare as compared with fibroma or with papilloma. Myxomatous tumors of the skin are most frequent in the neighborhood of the perineum and the labia in women. In young persons these tumors possess a regular, usually oval, outline. Later in life they shrink, and the surface of the tumor assumes a lobulated appearance. These tumors ordinarily occur in the labium majus, although they may be found in the nymphæ or in the perineum.

Sessile myxomata are very prone to recur after removal, unless especial care is taken to carry the incisions beyond the limits of the capsule. Enucleation is often attended by rupture of the capsule; consequently this method of operating cannot be relied upon for complete removal of the tumor unless its capsule is unusually firm.

Intermuscular Spaces.—Myxoma, like lipoma, is sometimes found to occupy the intermuscular spaces, and in this locality frequently

exists in combination with lipoma. The favorite locality, as has been pointed out by Lücke, is the space between the external and internal hamstring muscles, below the gluteal fold. These tumors are of slow growth and may reach great size. The writer has seen a myxoma the size of an adult's head between the adductor muscles of the thigh. In the excision of deep-seated myxoma it is often necessary to excise some of the connective tissue around it in order to remove all the myxomatous tissue.

Nose.—Unmixed myxoma occurs more frequently in the sub-mucous tissue of the nasal cavities than in any other locality. It starts usually in the mucous membrane overlying the turbinated bones, and only in exceptional cases in the frontal sinus or in the antrum of Highmore. The tumor is usually multiple, often from three to six being found in one nasal cavity. Frequently both nasal cavities are simultaneously affected. The growths may project anteriorly or in the direction of the pharynx. During moist weather the tumors absorb moisture, swell, and produce more obstruction than during dry weather. If numerous and large, they distend the nose; and when located in the frontal sinus bulging at the inner angle of the orbit takes place, like that produced by hydrops or by empyema of this cavity.



FIG. 288.—Myxoma of nose (Surgical Clinic, Rush Medical College, Chicago): *a*, delicate connective-tissue stroma; *b*, granular amorphous myxomatous material, non-staining; *c*, nuclei; *d*, blood-vessels.

A nasal myxoma appears as a jelly-like, translucent mass which moulds itself to the cavity of the nose. It is covered by mucous membrane paved with columnar or stratified epithelium. Under the microscope the tumor-tissue appears like very œdematous connective tissue. The great mass of the tumor is composed of myxomatous tissue in the meshes of the reticulum of connective tissue and parenchyma-cells (Fig. 288). The blood-vessels traversing the connective-

tissue stroma are usually quite large with very thin vessel-walls. Nasal myxoma occurs most frequently in persons from the age of puberty to that of fifty years.

The removal of nasal myxomata is by no means an easy operation. Avulsion with the different kinds of forceps devised for this purpose is usually followed by recurrence owing to incomplete removal of the tumor; the use of the snare gives better results, but recurrence is by no means infrequent. In cases in which a permanent cure followed these procedures, usually a part of the turbinated bone to which the tumor was attached was removed with the tumor. König's operation should be resorted to if snaring and avulsion have not resulted satisfactorily. This operation consists in cutting through the ala of the nose on the side of the septum from within outward as far as the bony framework, thus rendering the base of the tumor more accessible. After locating the attachment of the tumor the index finger should be inserted into the nasal passage from the pharynx, and with it the tumor is pushed forward, when it may be removed with the snare or, what is perhaps better, the sharp spoon. If the tumor is attached far back, a temporary resection of the nose may become necessary to effect complete removal. This preliminary operation becomes absolutely necessary in the removal of polypoid tumors of the nose that have undergone malignant transformation.

Middle Ear.—Myxomatous tumors in the external meatus are frequently preceded by chronic or acute inflammation of the middle ear and by perforation of the drum. These tumors usually spring from the mucous lining of the tympanum, filling this cavity and projecting into the external meatus through a perforation in the drum, causing deafness. Jacobson suggests that myxoma of the middle ear may in some instances arise from vestiges of connective tissue in this locality—an opinion which will be sustained by all who adhere to Cohnheim's theory regarding the origin of tumors.

The operative treatment of aural myxomata should be consigned to skilled aural surgeons, as the reckless use of instruments and of caustics in the middle ear is calculated not only to destroy hearing, but may even be followed by fatal cerebral complications.

Nerve-sheaths.—Myxomatous tumors are not infrequently found in the central nervous system, the brain and the spinal cord. Myxoma of the sheaths of peripheral nerves is called *neuroma myxomatousum*. The tumors often occur multiple, and they have been found in connection with diffused nerves (Fig. 289). They often produce serious functional disturbances in the form of neuralgia or paralysis. The most frequent seat of myxomatous tumors of the nerve-sheaths is the optic nerve.

Glands.—In the mammary and salivary glands, the ovary, and the testicle myxomatous tumors occur frequently, but usually in combi-

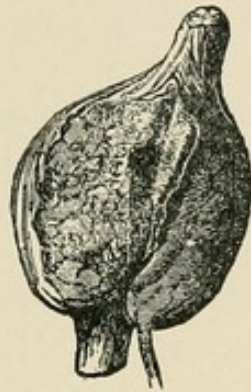

FIG. 289.—Myxoma of the sheath of the ulnar nerve (after Hüter).

nation with other benign tumors or as the result of regressive metamorphosis of benign or malignant tumors.

XX. CHONDROMA.

CHONDROMA is a tumor which, according to its structure, is a close imitation of hyaline, reticulated, or fibrous cartilage. It occurs in parts of the body in which cartilage exists in the fetus, as in the epiphyseal extremities of the long bones, or it springs from an island of displaced cartilage-cells, as in the connective tissue, the parotid gland, the testicle, and the ovary.

Definition.—*A chondroma is a tumor composed of cartilage which is the product of tissue-proliferation from a matrix of chondroblasts.* This definition refers all cartilaginous tumors to a matrix composed of embryonal cartilage-cells.

Origin.—It has been customary to attribute to the connective tissue under certain conditions a chondrogenetic function. It is not more likely that connective tissue can produce cartilage than that it can produce epithelial cells. In the study of the origin of tumors we must adhere closely to the teachings of Remak and Thiersch, that tissue begets tissue of its own kind. We have traced adenomata to localities where, in a normal condition, neither glands nor epithelial tissue exists, and we have to account for the presence of the tumor-matrix by the displacement of islets of adenoid tissue during the development of the embryo. We have to assign to heterotopic chondroma a similar origin by assuming as its starting-point the presence of a matrix composed of embryonic cartilage-cells or chondroblasts. Chondroma is sometimes produced by a simple outgrowth from pre-existing cartilage, that, as a rule, attains no great size. Virchow names these growths *ecchondroses*, and cites as their best examples outgrowths from the cartilages of the ribs, the cartilages of the amphiarthrodial joints, the cartilages of the trachea and the bronchial tubes, and from the cartilage between the basi-sphenoid and occipital bones in the young cranium. In such

cases we must assume the existence of a superabundance of chondroblasts which produce the localized hyperplasia, but which do not result in the formation of large tumors, owing to the inhibitory influence exerted upon the growth by the surrounding normal cartilage.

In the majority of cases cartilaginous tumors are found connected with the bones and the joints. Virchow, in his classical article on "Chondroma," places great stress on the frequency with which such tumors spring from the epiphyseal cartilage. He found frequently in this locality, in adults, remnants of unossified cartilage a centimeter and more in diameter. Such islands of cartilage-tissue are frequently seen in the epiphyseal extremities of the long bones in rickety subjects.

It is well known that rickety persons are exceedingly prone to cartilaginous tumors. Virchow believes that a deficient blood-supply is often the cause of arrested ossification in such cases. The influences that excite proliferation in such embryonal remnants of cartilage are rickets and an hereditary predisposition. In glands and in other parts of the body in which normally no cartilage is found the tumor springs from a displaced matrix of chondroblasts. Förster describes two cartilaginous tumors of the lung, as large as a bean, that had undergone partial ossification. In these cases the matrix was derived from the cartilage-rings of the bronchial tubes.

Heterotopic chondroma occurs most frequently in the parotid gland and about the external ear, from tumor-cells which are derived from the cartilage of the external ear. In the vicinity of the external ear and the neck they occur as remnants of the first branchial cleft. Wartmann made a careful study of eight cases of chondroma in which the tumor developed independently of bone or cartilage. He is of the opinion that the tumor-elements start from ordinary fibrillary connective tissue, some of the fibres of which undergo hyaline degeneration; the connective-tissue fibres proliferate actively, and form groups of cells which become surrounded by a capsule and are transformed into cartilage-cells. Other cells assume a stellate form; the projections form free anastomoses with similar structures which constitute a network, the intercellular hyaline substance becoming softer, forming myxomatous spaces. Both forms of cells, prior to encapsulation, present glycogen reaction, which with the perfection of the capsule disappears.

It is of course difficult to trace a tumor to its primary histogenetic origin, but it is no more difficult to explain the occurrence of chondroma in connective tissue from a displaced matrix of chondroblasts

than to explain its presence in other tissues normally devoid of cartilage-tissue, for which such an origin is generally conceded.

Histology.—The structure of a chondroma depends on the kind of cartilage it represents.

Hyaline chondroma is composed of a uniform, dense, cartilaginous mass in which islands of cartilage can be seen surrounded by ground substance. The islands of cartilage-cells are not larger than a line or a line and a half in diameter (Fig. 290). The stroma of the tumor is

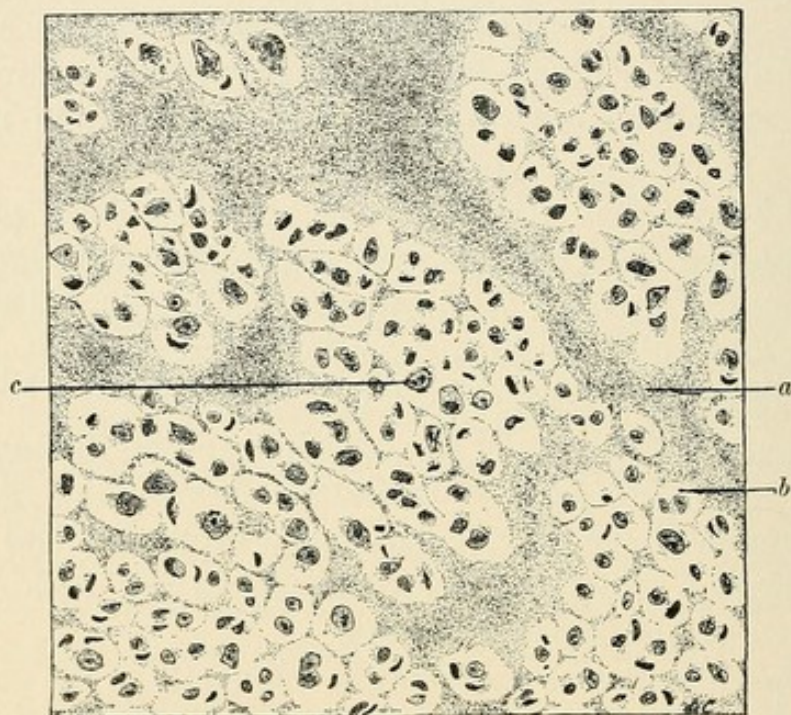


FIG. 290.—Hyaline chondroma of ilium; $\times 130$ (Surgical Clinic, Rush Medical College, Chicago): *a*, amorphous and granular stroma; *b*, cartilage-cells and capsule; *c*, cells in course of segmentation.

supplied with blood-vessels, but the cartilage-masses are devoid of vessels of any kind. The spaces in which the cartilage-cells are enclosed are called "lacunæ." The interior of these spaces is lined by a membranous structure from which the cells, after death, separate by shrinkage. The spaces are sometimes branched, and they have been described as "branched cells."

Fibro-chondroma.—These tumors occur most frequently in the capsule of joints and in the fibrous structures adjacent to the parotid gland. In the latter location the tumor often reaches the size of a hen's egg. The tumor resembling fibro-cartilage is not so sharply circumscribed as is the hyaline variety. The tumor-tissue consists of a uniform mass composed of fibrous tissue in the meshes of which cartilage-cells are uniformly distributed throughout (Fig. 291). The cells frequently contain oil-globules.

Reticulated Chondroma.—In this variety of chondroma the fibrous

tissue is arranged in a reticulate manner and the spaces are occupied by groups of cartilage-cells (Fig. 292). The vascular system of chondroma is imperfect. Lymphatics and nerves have not been found.

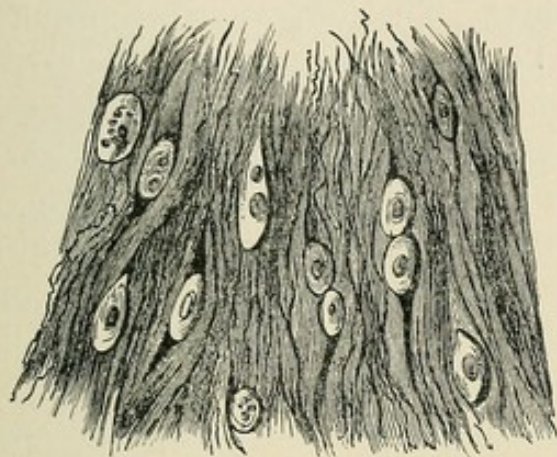


FIG. 291.—Fibro-chondroma from a cartilaginous tumor of the parotid gland (after Lücke).

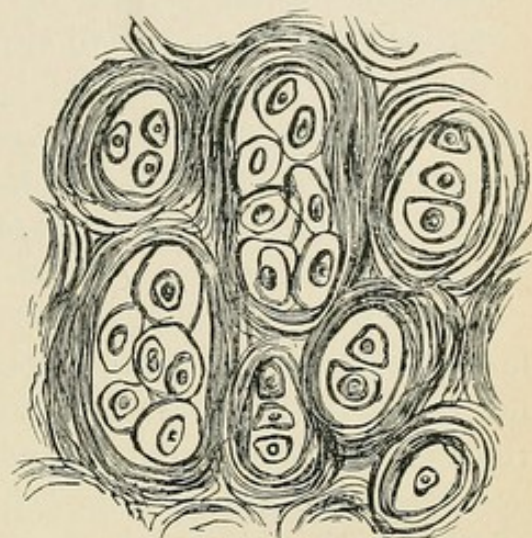


FIG. 292.—Reticulated chondroma from index finger (after Lücke).

Retrogressive Metamorphoses.—Calcification is the most common regressive metamorphosis; it begins at circumscribed points of the

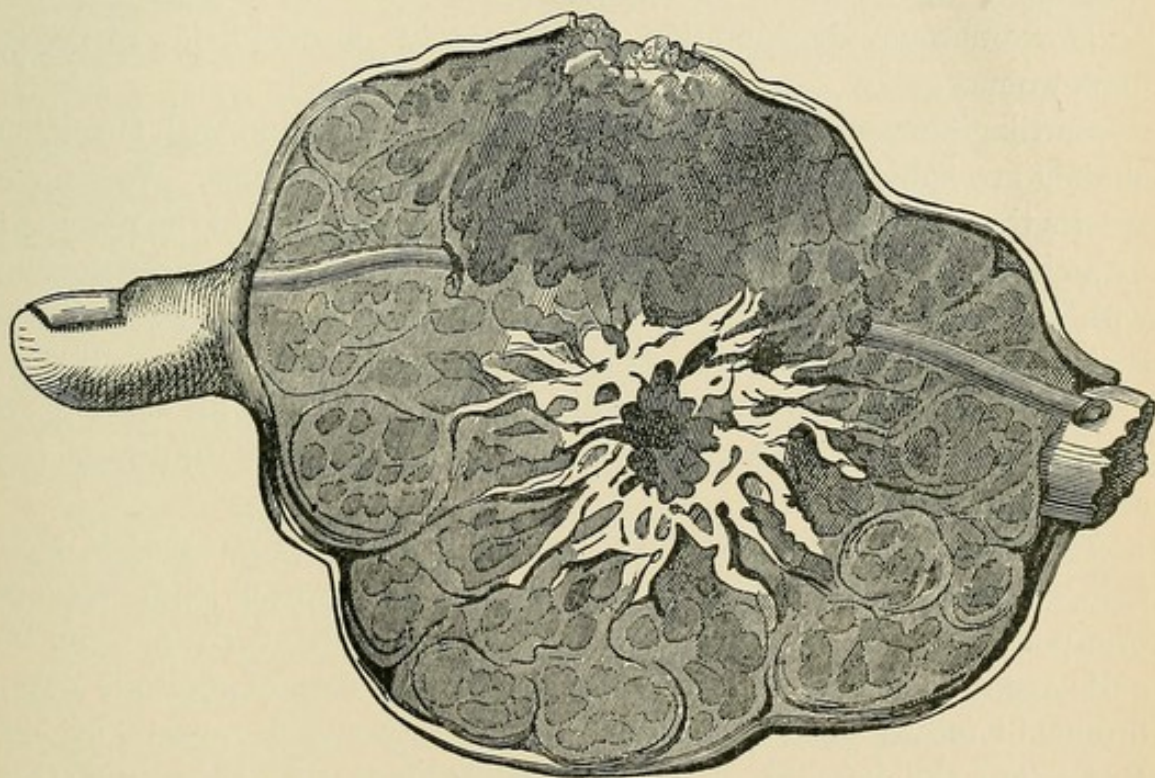


FIG. 293.—Chondroma of index finger, showing central ossification and lobulated structure of the tumor (after Lücke).

tumor, and often terminates in the formation of large plates which are exceedingly hard and which have often been mistaken for bone. The

granules of chalk form first in the capsules and later in the cells, and deposition in the intercellular substance takes place later.

Cystic degeneration is often found in the interior of chondroma. Sometimes the tumor presents a honeycombed appearance from the presence of numerous small cysts. Coalescence of many cysts results in the formation of large irregular cavities. The softening which results in the formation of cysts is preceded by fatty degeneration of the cartilage-cells. Fat-granules appear at different points in the protoplasm of the cells, and the fatty degeneration finally terminates in the dissolution of the cells. At the same time the intercellular substance undergoes mucoid liquefaction. Hemorrhage into the cysts results in discoloration and pigmentation of the cyst-contents. If a cyst by ulceration on the surface is opened, there forms a fistulous tract which resists all treatment short of extirpation of the tumor.

Development of cartilage-cells into bone is observed in chondromata of bone and periosteum as well as in those of soft parts. Complete ossification of the tumor has never been observed. The new bone appears in the form of spiculæ representing cancellated bone (Fig. 293). The spiculæ of bone form septa between the cartilage-masses. Very frequently small islets of bone are found disseminated throughout the tumor.

Myxomatous degeneration is frequently observed in glandular chondroma.

Cartilaginous tumors have always been looked upon with suspicion, as they are liable to undergo transformation into sarcoma. Wartmann asserts that embolism may occur in the centre as well as in the periphery of a chondroma, and that from the emboli secondary tumors develop with the assistance of the endothelial cells of the blood-vessels, the seat of the embolic process. It is more than probable that in all cases in which a chondroma invaded adjacent tissues, and in all instances in which metastasis occurred, the tumor had undergone transition into sarcoma.

Etiology.—We have reason to assert that a chondroma cannot occur independently of the existence of a congenital matrix of chondroblasts or a post-natal matrix of embryonal cartilage-cells derived from the periosteum or the bone. O. Weber describes a case of multiple chondroma of fifteen years' duration in a man twenty-five years of age. Regarding the heredity, it has been ascertained that the grandfather, the father, the brother, and one sister were also affected with the same disease. He alludes to similar cases proving the heredity of chondroma.

Chondroma of bone occurs usually before or at the age of puberty,

while in other tissues it frequently appears later in life. Trauma appears to exert a powerful influence in stimulating a latent matrix of embryonal cartilage-cells to active tissue-proliferation. O. Weber proved by statistics that in one-half of all cases of chondroma the origin of the tumor could be traced to a trauma.

Rachitis is a frequent exciting cause of chondroma of bones. We can readily understand that the serious changes which occur in this disease in the bone surrounding a matrix of chondroblasts would excite tumor-growth by diminishing the physiological resistance of the adjacent tissues.

Symptoms and Diagnosis.—A chondroma, from the unequal growth of its different parts, always appears as a lobulated tumor. Lobulation increases with the size of the tumor. In central chondroma of the long bones the tumor is surrounded by a shell of bone that becomes thinner as the tumor increases in size; this shell eventually disappears entirely by absorption. Periosteal and glandular chondromata are never surrounded by a complete shell of bone. Occasionally an attempt at the formation of such a shell can be seen, but it is always imperfect.

A chondroma displaces, but does not infiltrate, the adjacent tissues. So long as it remains as a benign tumor it is surrounded by a capsule which completely separates it from the adjacent tissues. The tumor is hard except at points where cysts may have reached the surface of the tumor, which upon palpation would impart a sense of fluctuation. A chondroma may attain the size of an adult's head, but it may become stationary at any time, especially at the age of puberty. Ossification arrests tumor-growth in that part of the tumor which is the seat of such a transition. Tumor-growth is also arrested by calcification. Epiphyseal chondroma often appears in many of the long bones at the same time, and is commonest in rickety subjects. Chondroma always grows slowly. Its growth is not attended by pain or by tenderness. A tumor in the vicinity of a joint may by its presence interfere with full motion. The slow growth and the frequency with which it occurs as a multiple affection distinguish chondroma from osteo-sarcoma.

The differential diagnosis between chondroma and osteoma can often only be made by resorting to *akidopeirasty*. If the tumor is an osteoma, the advance of the steel needle will be arrested when the surface of the tumor is reached; if the tumor is a chondroma, the needle can be forced into the substance of the tumor.

Prognosis.—Aside from the aptitude of a chondroma to undergo transformation into a sarcoma, the prognosis is favorable. Epiphyseal chondromata may impair the range of motion of adjacent joints, but

otherwise functional disturbances do not occur. Glandular chondromata usually become stationary after they have reached a certain, and usually a very moderate, size. A chondroma upon the inner surface of the pelvis in females may complicate labor and necessitate Cesarean section. A chondroma of the shaft of the long bones may cause such a degree of atrophy of the bone by pressure that fracture will occur upon application of slight force. Chondromata of the bones usually become stationary after the completion of ossification of the skeleton.

Treatment.—The removal of a chondroma is indicated only in exceptional cases. The removal of an epiphyseal chondroma should not be attempted unless the tumor interferes materially with the function of an important joint or unless by pressure upon a nerve it causes pain. The removal of such a tumor should not be undertaken lightly, as during the operation recesses of the joint may be opened or bursæ overlying the chondroma may communicate with the joint. If the chondroma completely surrounds a long bone, its extirpation is out of the question, and amputation is only justifiable if the tumor is very large or its interior has become infected through a suppurating superficial cyst. Chondroma of the fingers, if pedunculated, can readily be extirpated. The same treatment will suffice in similar tumors of the shafts of the larger bones. Large encircling tumors of the phalanges may require amputation.

In the removal of a chondroma of the long bones it must be remembered that the tumor usually has a central origin, and that removal on a level with the bone is generally followed by recurrence. The central part of the tumor must be removed with gouge and hammer to guard against a recurrence. The removal of chondromata of the soft tissues should be done by enucleation. If a chondroma manifests malignant properties, no time should be lost in making a correct diagnosis by the microscopical examination of sections of the tumor taken from the parts which are most suspicious; in case the microscope reveals evidences of a malignant transition, the most radical measures must be resorted to, in removing not only the tumor, but also the adjacent infected tissues.

TOPOGRAPHY.

Chondroma occurs most frequently in connection with bone and in organs situated in a locality where displacement of chondroblasts is most likely to occur. A post-natal matrix can occur only in bone-producing tissues, in bone, and in periosteum.

Cartilage.—The overgrowth of cartilage Virchow calls "ecchondrosis." Localized ecchondroses occur in four favorite localities—namely,

along the edges of articular cartilages, of the laryngeal cartilages, of the cartilages of the ribs, and of the triangular cartilage of the nose. The tumors never attain large size, and they resemble in many respects the osteomata. Ecchondrosis of the articular cartilage is found most frequently in persons past middle life, in connection with the condition known as "rheumatoid arthritis." Bruns collected 14 cases of laryngeal

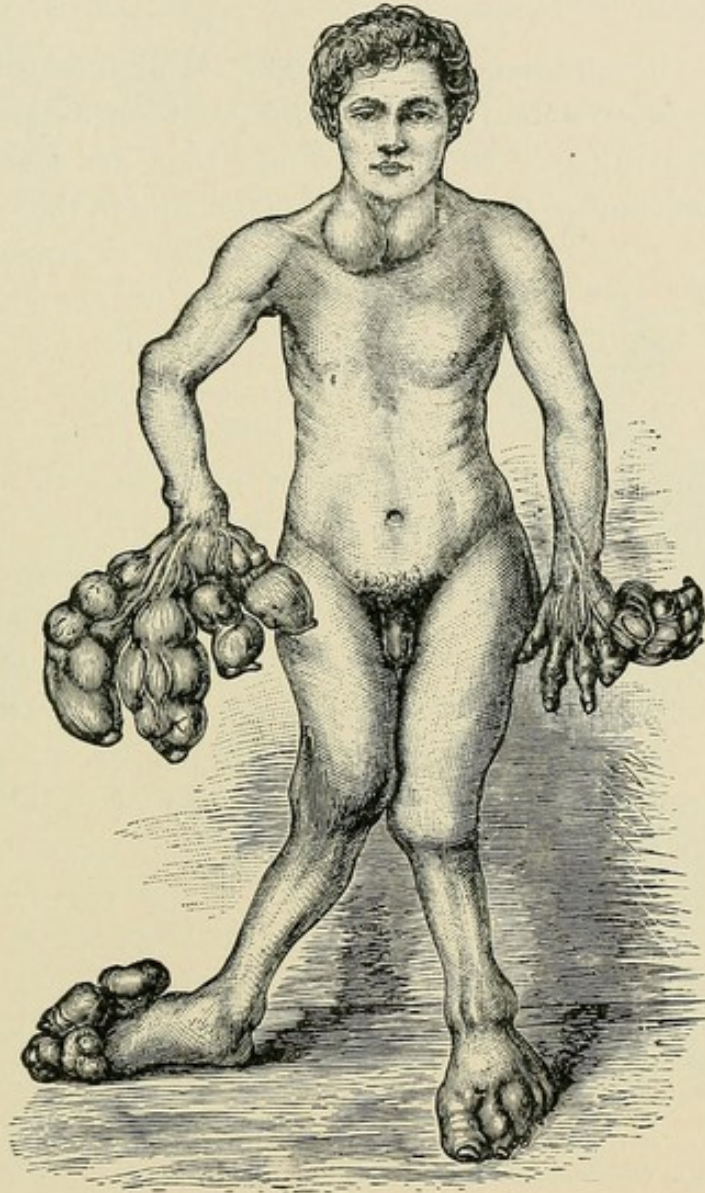


FIG. 294.—Lad twenty years of age with multiple chondromata (after Steudel).

chondromata; of these, 8 were connected with the cricoid, 4 with the thyroid, 1 with the arytenoid, and 1 with the epiglottis. Small chondromata of the triangular nasal cartilage are quite common. They are sessile, and they hardly ever exceed in size a pea.

Bone and Periosteum.—The existence of islands of cartilage in the interior of the long bones near the epiphyseal cartilages has been demonstrated by Virchow and others. A chondroma of bone always

springs from such a matrix or from a matrix of post-natal origin produced by the bone-forming cells of the marrow or the periosteum. Periosteal chondroma is rare, and springs from a matrix of displaced chondroblasts or from a post-natal matrix produced by the cambium. The greater frequency of chondromata in rickety subjects is due, as Virchow pointed out, to the existence of islands of cartilage that have failed to undergo ossification, and which serve the purpose of a tumor-matrix.

Epiphyseal chondromata often appear simultaneously in different parts of the skeleton, notably in the epiphyseal extremities of the long bones. The phalanges of the fingers and toes are favorite localities (Fig. 294). The tumors are always lobulated, and in the central variety,

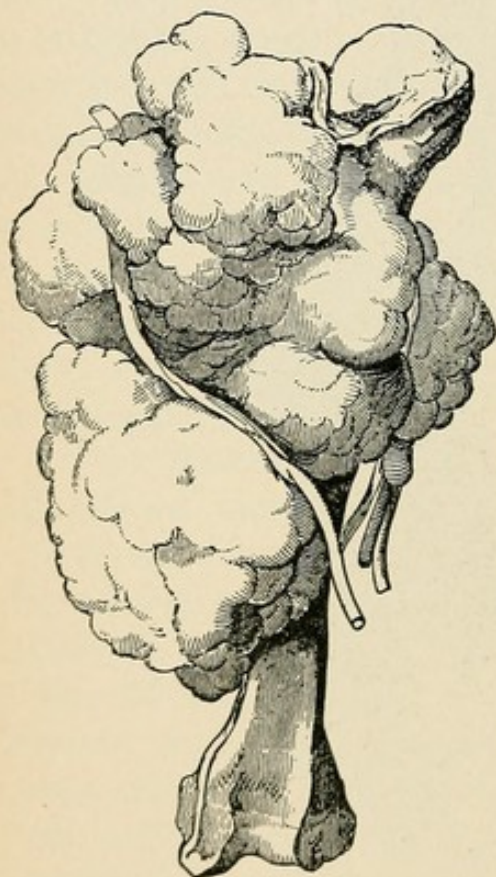

FIG. 295.—Chondroma of humerus, showing relations of tumor to vessels and nerves (after Liston).

when the tumor is covered by a thin shell of bone, a crackling sensation is produced on pressure. In the superficial form enucleation can be effected without difficulty, while in the central variety it may become necessary to remove the remnants of the tumor with chisel and hammer. Unless the tumor interferes seriously with the function of a joint or causes pain by pressure upon a nerve (Fig. 295), operative treatment is not indicated, as in the majority of cases limitation of the growth takes place at the age of puberty. If the tumor causes great inconvenience from its weight or becomes the seat of ulceration, amputation may become necessary. A resort to a mutilating operation may become necessary if a fracture occurs at the place where the bone has become partially destroyed by the tumor.

Joints.—Floating or loose cartilages are found most frequently in the knee- and elbow-joints. They are in the majority of cases sub-synovial chondromata which are formed at the margin of the articular cartilage, project into the joint, become pedunculated, and finally are detached, changing their position in the joint with the movements of the joint. A less frequent source of such loose fragments of cartilage in joints is the detachment of fragments of the articular cartilage by a trauma. The ecchondroses of the articular cartilage exhibit under the

microscope a cartilaginous structure which has undergone partial calcification. They vary in size from a pea to double the size of the patella. In many instances the articular ecchondroses are multiple. Benth removed 1532 loose cartilages from the shoulder-joint of a girl. The presence of the foreign movable body usually produces hydrops of the joint. Impaction of the cartilage between the articular surfaces is attended by sudden pain and fixation of the joint—symptoms which continue until the cartilage becomes displaced to a part of the joint where its presence is less harmful.

The most characteristic symptoms of a loose cartilage in a joint are attacks of sudden pain and arrest of function of the joint when the cartilage gets between the opposed surfaces of the joint, followed, as a rule, by more or less serous effusion into the joint.

The removal of such cartilages from joints calls for special anti-septic precautions. Before the incision is made the cartilage should be immobilized in a sacculus of the joint by transfixing it with a stout aseptic needle. After the removal of the cartilage the capsule of the joint should be sutured separately with one or two catgut sutures before closing the external wound. The joint should be immobilized for at least a week or two.

Salivary Glands.—Chondroma is found much more frequently in connection with the parotid than with the submaxillary gland. Of 12 cases of chondroma in the soft tissues observed by Bryant, 9 occurred in the parotid, 2 in the submaxillary, and 1 in the leg. Chondroma is found in connection with the salivary glands more frequently than any other benign tumor. Lücke and König have shown that the tumor springs from the capsule of the glands or from the surrounding connective tissue, and as it enlarges it grows into the glands and becomes bound up with the gland-substance. The growth of such tumors is always very slow. They seldom exceed in size a walnut. They are movable and lobulated, and displace the surrounding tissues.

The proper treatment is enucleation. This operation requires special care in the removal of benign tumors of the parotid gland, in order to prevent injury to the facial nerve and to Stensen's duct. The external incision must be made with special reference to these structures, and the deep dissection must be made between two dissecting-forceps, dividing the tissues only after they have been identified. Incomplete removal of cartilaginous tumors is very often followed by transformation of the remnant of the tumor into a sarcoma. A case of this kind has recently come under the writer's observation. A chondroma in the parotid gland in a woman thirty-five years of age had existed for twenty years. It was removed partially by a timid surgeon. Two

years later, when the case came under the care of the writer, there was found in the scar and involving the entire gland a sarcoma larger than a hen's egg. This case and many similar cases must impress the surgeon with the importance of a careful and complete removal of all cartilaginous tumors when a radical operation is deemed advisable.

Testicle.—In rare cases the testicle is the seat of pure and of mixed chondromata. Kocher recorded eight cases of pure chondroma. O. Weber saw a case of congenital chondroma of the testicle. The cartilage is usually hyaline, seldom fibrous. The great liability of chondroma of the testicle to undergo malignant transformation is shown by the fact that in half the cases regional and general infection were noted. Paget reports a number of such cases in detail. The tumors are very hard and lobulated, with softer portions between the nodules. Unless the tumor is very small enucleation should give way to castration.

Ovary.—Chondroma of the ovary occurs very rarely as an isolated separate tumor. Kiwisch reported two cases of cartilaginous tumors of the ovary, but only in one case was the diagnosis corroborated under

the microscope. Klob has shown that the cartilage in such tumors appears in the form of large fenestrated plates in the periphery of the tumor, or forms granular prominences, or, finally, is disseminated through the fibrous stroma in groups of cartilage-cells the size of a pea.

Connective Tissue.—In exceptional cases chondromata occur in the subcutaneous and deep connective tissue in different parts of the body. Their origin in such unusual localities must be sought in displaced matrices of chondroblasts. The tumors

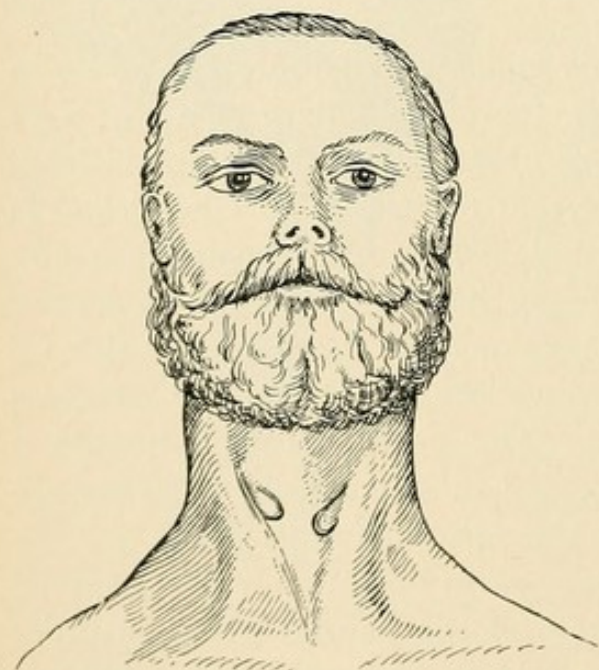


FIG. 296.—Accessory auricles of neck (after C. Beck).

are met with most frequently in situations where such displacements are most liable to occur—that is, in localities in close proximity to parts containing cartilage in the embryo.

Chondroma Branchiogenes.—Chondromata in line with the first branchial tract spring from displaced islands of cartilage derived from the external ear. Some of the cartilaginous tumors in the vicinity of the hyoid bone may derive their matrix from the hyoid bone and larynx,

as suggested by Callender. A number of writers have described accessory auricles in lines of the branchial tracts. Beck of Chicago recently described such a case. Some of these isolated islands of cartilage have become the matrix of cartilaginous tumors the size of a hen's egg and larger. Heusing describes the case of a large cystic chondroma of the neck. In Schäffer's case the tumor was of the size of an egg, beneath the skin on the side of the neck. Beck described a case of accessory auricles of the neck in a man forty-eight years old (Fig. 296).

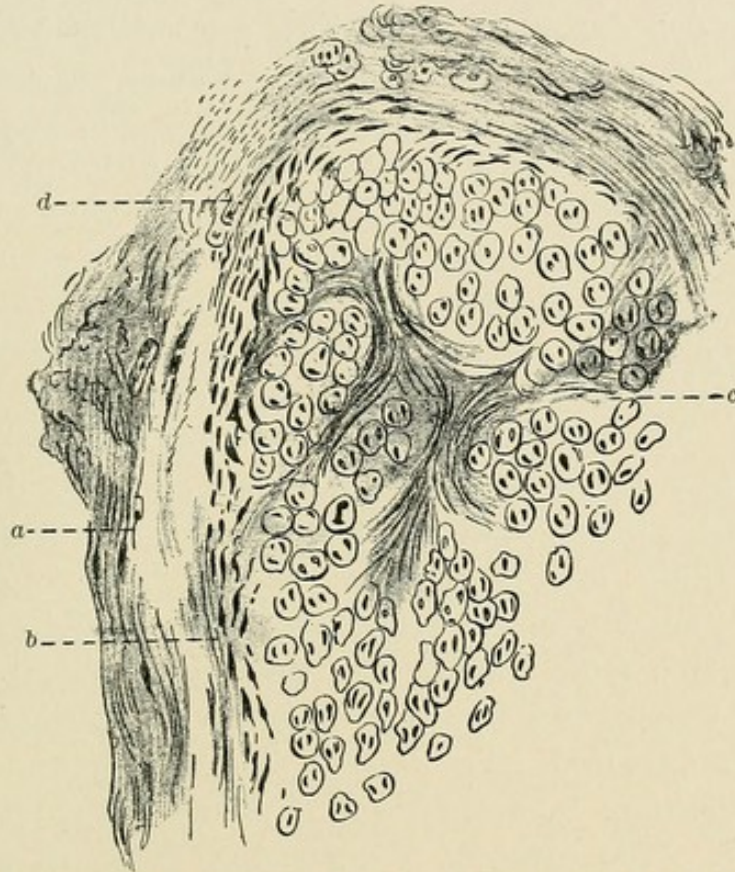


FIG. 297.—Cartilage from accessory auricles of neck (after C. Beck): *a*, perichondrium; *b*, new cartilage-cells under perichondrium; *c*, reticulum; *d*, islands of cartilage-cells surrounded by stroma of fibrous tissue.

He removed a particle of one of the cartilaginous masses and subjected sections of it to microscopical examination. The sections showed the typical structure of cartilage (Fig. 297).

In the majority of cases of branchiogenous chondroma the matrix remains latent until after the age of puberty, as in most of the fourteen cases so far reported the tumors did not develop until some time after puberty.

XXI. OSTEOMA.

Definition.—*An osteoma is a tumor which possesses a structure resembling that of cancellous or compact bone, produced from a congenital or post-natal matrix of osteoblasts.* Osteomata occur usually in connection with some part of the skeleton, but they are also found in parts and organs that have no genetic relations with the skeleton, as in the pia mater and the brain. It is doubtful if the tumors which are not in connection with bone present the structure of bone so perfectly as do osseous tumors of the skeleton. Fleischer described an osteoma of the tendon of the ilio-psoas muscle in which he found the Haversian canals and the medullary tissue arranged in the same typical manner as in normal bone. In another heterotopic osteoma described by the same author the tumor was situated upon the inner surface of the dura mater. In both instances bone-production was traced to the connective tissue and independently of the presence of osteoblasts. According to Fleischer's interpretation, the connective tissue at the seat of tumor-formation became more vascular and presented active tissue-proliferation, and was transformed into hyaline masses in the interior of which the bone-cells appeared. The hyaline lumps become coalescent and undergo calcification. Osteoblasts were active in the further development of bone. The capacity of connective tissue to produce bone has been recognized for a long time, and this view of the bone-producing power of connective tissue is accepted by most of the modern pathologists.

A distinction must be made between calcification and ossification of connective tissue. The production of bone is carried on in the embryo by a distinct and specific part of the mesoblast, resulting in the formation of the skeleton and the growth of bone, and the production of new bone can take place only from a matrix of cells derived from the osseous system. *The displacement of osteogenetic matrices into the surrounding tissues is as liable to occur as the displacement of matrices of epiblastic and hypoblastic tissue. Heterotopic osteomata are usually found in close proximity to a bone. Heterotopic matrices of osteoblasts usually result in imperfect development of the tissue of the tumor.* Virchow found in the apex of the lung an osteoma in which Haversian

canals and medullary spaces were absent. Steudener found a number of small osteomata near the trachea, but entirely distinct from its rings. Lesser found in the lung an osteoma which presented under the microscope all the histological elements and the typical structure of bone.

The metaplastic theory concerning the origin of bone is no longer tenable. A careful etiological distinction must also be made between a true osteoma and an exostosis. The origin of the former must be restricted within the limits of the definition to a growth of bone from a matrix of osteoblasts either in the bone or by displacement from a bone, while the latter is the result of a localized or diffuse hypertrophy usually following a reparative process.

Histogenesis.—The osteomata representing compact bone are usually found upon the surface of bone, and they appear to be produced from the periosteal osteoblasts, as in the case of bony tumors of the flat bones of the skull and of the shafts of long bones; or they begin as chondromata, and proceed most commonly from the epiphyseal lines and from the places of origin of ecchondroses. The latter group of tumors, which have therefore a mode of origin distinct from the preceding, are usually pedunculated, are covered with cartilage, and possess a cancellous structure continuous with that of the bone from which they arise. Osteomata from a displaced matrix of osteoblasts are found most frequently at the insertion of tendons. Ossification of the deltoid from the shouldering of arms in the soldier, ossification of the adductors of the thighs in cavalrymen, and the more diffuse bone-formation in myositis ossificans do not belong to osteoma, but occur as one form of muscular degeneration.

Histology.—In spongy osteoma (Figs. 298, 299) the cancellated structure of the bone is well shown in decalcified stained sections. If the tumor starts in the bone, it is surrounded by a zone of connective tissue which separates it from the surrounding tissues. In the ivory-like tumors upon the surface of the cranial bones and the shaft of the long bones the lamellæ are so compact that the medullary spaces and the blood-vessels cannot be identified. The section of such a tumor resembles ivory in compactness. In periosteal osteoma the tumor is at first not connected with the underlying bone, and at this stage can readily be detached. Later the surface of the tumor becomes attached to the bone and receives from it a part of its vascular supply. After the union has become complete a section through the tumor does not show the line where the union was effected.

In the development of an osteoid chondroma into an osteoma the different phases of transition of cartilage into bone-tissue can be observed. Osteoma is almost immune to the different regressive meta-

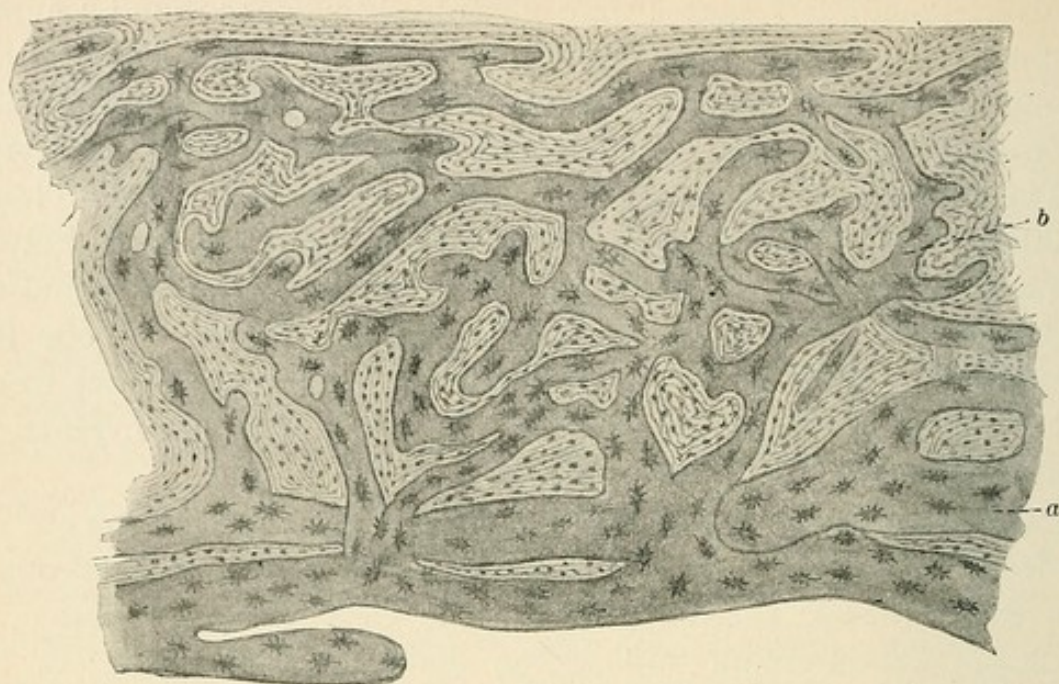


FIG. 298.—Spongy osteoma of cranium; $\times 250$ (after Perls): *a*, old bone-tissue with thick cancelli parallel with the surface; *b*, young spongy bone-tissue with irregularly-arranged cancelli.

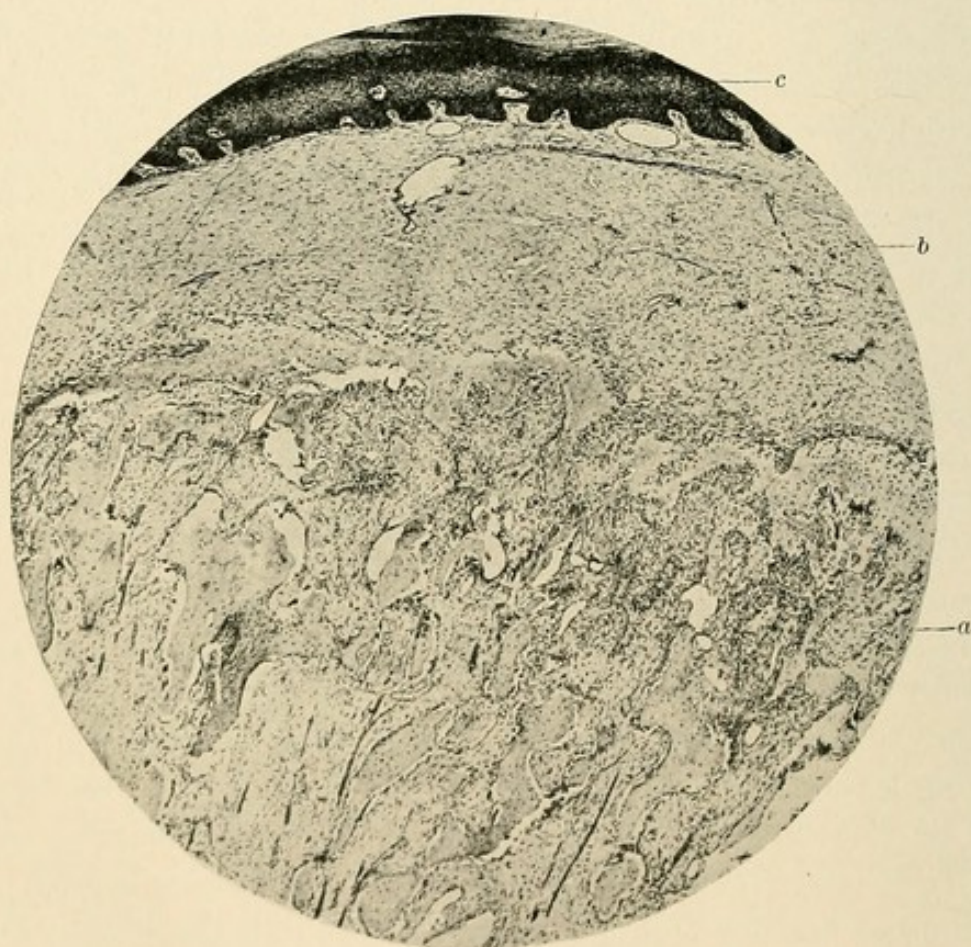


FIG. 299.—Osteoma of finger; $\times 30$ (after Karg and Schmorl). The tumor (*a*), separated by a narrow zone of connective tissue (*b*) from the epithelium of the surface (*c*), consists of cancellous tissue. The narrow cancelli with delicate contour include the bone-cells, which appear as minute black dots and are covered on the surface with cells arranged like epithelium. Between the cancelli is a substance like myeloid tissue, which toward the periphery of the growth shows many nuclei.

morphoses which have been described in connection with the other benign mesoblastic tumors.

Transformation of an osteoma into a sarcoma has never, to the writer's knowledge, been observed.

Anatomical Varieties.—*Osteoma durum* or *eburneum* resembles ivory by its hardness; it is found most frequently upon the outside of the skull. *Osteoma spongiosum* resembles the cancellated structure of bone, and usually takes its origin from the epiphyses of the long bones. As the tumor is usually covered with a thin crust of cartilage, Virchow used the term *exostosis cartilaginea*. *Enostosis* is a term applied to a bony tumor which originates in the interior of a bone. *Exostosis apophytica* is a term introduced by Virchow to denote the origin of a bony tumor in a tendon independently of the bone to which it is attached. A *tubercous osteoma* is an osseous tumor with a contracted, pedunculated base, as is the case in osteomata of the frontal sinus, the antrum of Highmore, and the orbit. *Callus luxurians* is a term used to designate an osteoma produced at the seat of a fracture (Van Heekeven).

Symptoms and Diagnosis.—An osteoma always grows very slowly, and becomes stationary after it has reached a certain limited size. It is not attended by pain or by tenderness. The slow growth and the absence of pain and tenderness distinguish it from inflammatory swellings of bone. Sarcoma of bone is usually a painless affection, but it increases in size more rapidly than osteoma, and its growth is *progressive*. Osteoma is frequently a multiple affection like chondroma, while sarcoma as a primary disease of bone seldom if ever appears except as an isolated tumor. The differential diagnosis between an osteoma and a chondroma can often be made only by resorting to akidopeirasty.

Prognosis.—The prognosis in osteoma is always favorable. Transformation into sarcoma does not take place, and regressive metamorphosis of any kind is almost unknown. In the female, pelvic osteomata may become a source of danger to life by interfering with the passage of the child through the pelvis. As the osteoma rarely attains great size, ulceration of the skin is seldom observed. Osteomata in mucous cavities occasionally necrose and give rise to a continuance of supuration until they are removed by operation. Osteoma of the orbit by displacing the eyeball may cause impairment of vision and expose the eye to destructive inflammation from exposure.

Treatment.—The indications for surgical interference in the treatment of osteoma are the same as in chondroma. This statement should be modified in so far that operative removal is less urgently

demanded in osteoma than in chondroma, because in chondroma there is some liability of the tumor undergoing malignant transformation, which is not the case in osteoma. The removal of an osteoma of bone should be done either with a fine saw or with a sharp, thin chisel.

TOPOGRAPHY.

Cranial Bones.—The cranial bones are the most frequent seat of osteoma durum, or ivory exostosis. The tumors, which are occasionally multiple, are found most frequently upon the frontal bone, especially at or near the superciliary arch. The tumors are smooth with a wide base, and the overlying skin is usually intact. In consequence of a trauma or of the application of irritating salves or lotions ulceration of the skin will occasionally ensue.

Osteomata of the cranial bones must be distinguished from syphilitic exostosis by a careful inquiry into the history of the case and by the

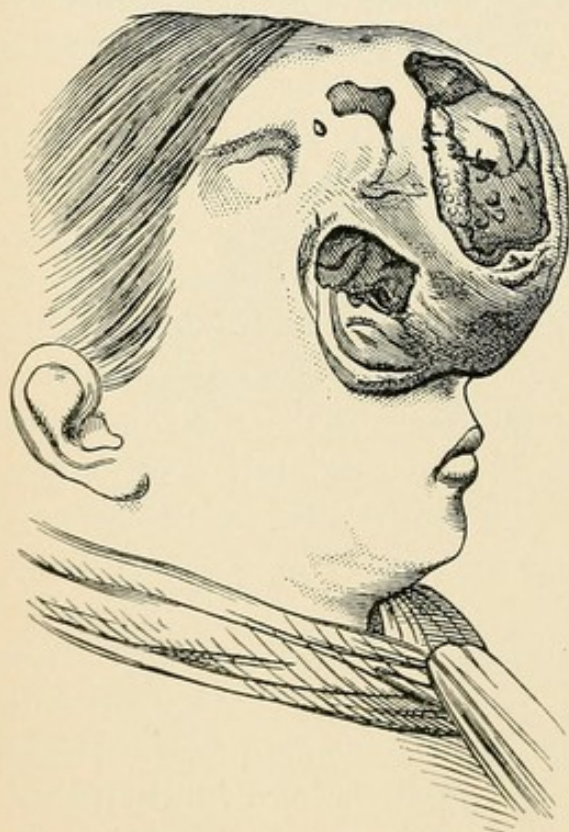


FIG. 300.—Osteoma durum of the frontal bone with superficial ulceration (after Textor). Tumor removed by Textor.

exclusion of all signs and symptoms suggestive of an inflammatory origin. The removal of such tumors, in the absence of complications such as shown in Figure 300, is usually done only for cosmetic considerations. If an operation is decided upon, it should be performed under strictest antiseptic precautions, with a view of obtaining primary healing of the wound and of preventing necrosis, and possibly also pyemic complications, which might result from suppurative infection. The tumor should be well exposed by a semilunar incision following its base. After reflecting all the soft tissues with the skin-flap, the tumor should with a very

fine saw be sawed off even with the surrounding bone. For this purpose the writer prefers a scroll saw to the metacarpal or butcher's saw. By using the scroll saw the cut surface can be made to correspond with the outlines of the surface occupied by the tumor. After all hemorrhage has been arrested the soft parts are replaced carefully and are sutured with fine catgut or with horse-hair. The wound should be

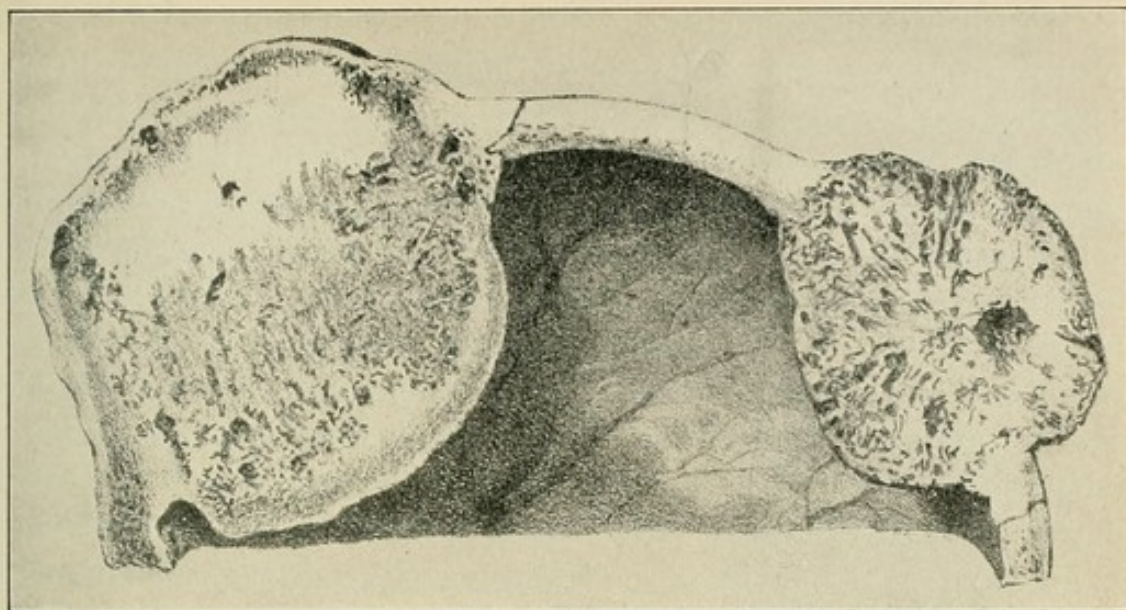


FIG. 301.—Osteoma of the skull, transverse section (Bruns).

sealed with cotton and iodoform collodion, over which an elastic compress is to be applied for the purpose of keeping the flap in uninterrupted contact with the sawn surface of the bone. In *Guy's Hospital Reports* for 1864 four cases of ivory exostosis of the skull are described. In all of them the tumors were removed with a fine saw, as they were too hard to chisel.

The internal surface of the skull is occasionally the seat of an osteoma. The small conical exostoses which Virchow describes as occasionally growing from the upper surface of the basilar process into the

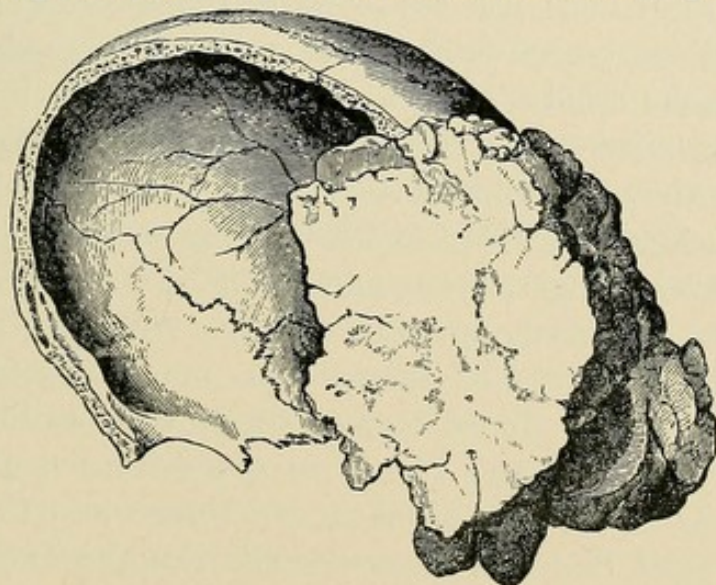


FIG. 302.—Osteoma of the frontal sinus (after Paget).

cranial cavity are ossifications of outgrowths of cartilage connected with the basicranial synchondrosis, and a thin layer of cartilage often remains on the surface of the tumor. Osteomata have been found upon the inner surface of nearly all the cranial bones, but more especially upon the frontal. Endocranial osseous tumors, when they reach consider-

able size, disturb the function of the brain by causing irritation and pressure-atrophy, which are frequently manifested by well-defined focal symptoms.

Frontal Sinus.—Osteomata of the frontal sinus belong to the tuberous variety. Their origin from islands of persistent cartilage has been described fully by J. Arnold. A very interesting specimen representing an osteoma in this locality has been preserved in the museum of the Royal College of Surgeons, London. Many of these tumors extend into the orbit, and others sometimes enter the cranial cavity through the orbital roof. The tumor in this locality sometimes attains a very large size, growing externally and in the direction of the cranial cavity. One of the largest specimens of this kind is in the Museum of the University of Cambridge, England. Clark, who examined this tumor, found in the hardest parts neither Haversian canals nor lacunæ; in the less hard parts the canals were very large and the lacunæ were not arranged in circles around them; and everywhere the lacunæ were of irregular or distorted forms. In a case examined by Turner the bony growth from the inner table and orbital plate of the left frontal bone, which had a knotted, irregular, cerebral surface, caused a considerable indentation in the anterior part of the left frontal lobe of the cerebrum. In the absence of suppurative inflammation of the frontal sinus the presence of the tumor is indicated by an expansion of the anterior wall of the sinus and by displacement of the eye if the tumor has extended in the direction of the orbit. Headache and focal symptoms would point to the extension of the tumor toward the cranial cavity.

Suppurative inflammation often results in detachment of the pedicle of the tumor, when the osteoma becomes a sequestrum in the suppurating cavity. Cases of this kind have been described by Dolbeau, Volkmann, Badal, Fenger, Socin, and König.

An osteoma large enough to expand the frontal sinus should be removed by operation. The operation is not a difficult one if the osteoma has necrosed. In such cases the anterior wall of the sinus is resected with the chisel and the loose sequestrum is extracted, after which the cavity is carefully disinfected, drainage into the nasal cavity is established, and the wound is sutured with the exception of the lower angle, which is used as an additional point for drainage. If the osteoma remains attached, its removal is attended by more difficulty and requires a larger opening. In such cases it would be advisable to make a temporary resection of the anterior wall of the frontal sinus, in order to prevent the unsightly deformity which follows the loss of so much bone. The pedicle of the tumor should be traced carefully

to its point of attachment to the bony wall of the sinus, when it is severed with a chisel.

External Meatus.—Osteomata of the external meatus, which are not uncommon, are of importance, as they are apt to obstruct the meatus and cause deafness. The tumors always spring from an island of cartilage-tissue; these islands are present in great numbers during the development of the external ear. Seligmann has given a very accurate description of osteoma of the external meatus. If the tumor encroaches sufficiently upon the meatus to threaten deafness, it should be removed with a small chisel and a hammer after detaching from it freely the surrounding soft tissues.

Jaws.—Osteoma of the jaws is of very rare occurrence, and some of the tumors described as such have been cases of odontoma. The tumor may appear as an enostosis or an exostosis, and usually belongs to the hard variety. Removal is necessary only if the tumor interferes with speech or with mastication or if it causes an unsightly deformity.

In the case of symmetrical osteomata of the upper maxillæ described by Hutchinson the tumors had taken their starting-point from the nasal processes (Fig. 303). Paget describes a specimen of an osseous tumor of the lower jaw. The tumor appeared as a nodulated mass nearly three inches in diameter, invested the right angle of the jaw, and was in its whole substance as hard and as heavy as ivory. He refers to another specimen in which ivory-like osseous tumors were formed in connection with the outer and inner surfaces, especially the latter, close to the alveolar border. Osseous tumors of the jaws are more frequent in the lower animals than in man. The antrum of Highmore and the nasal processes of the superior maxillæ are sometimes the seat of large and disfiguring osseous tumors.

Brain.—Heterotopic osteomata are occasionally found in the brain. Some of these tumors are connected with the meninges; others have their origin in the brain independently of its envelopes. These tumors spring from a displaced matrix of cartilage-tissue or of osteoblasts. Maschede describes an osteoma which was attached to the pia and

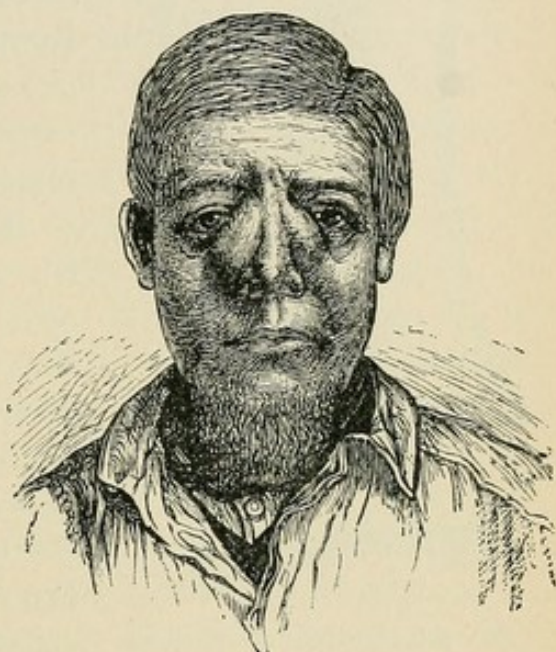

FIG. 303.—Symmetrical osteomata of nasal processes of maxillæ (after Hutchinson).

which produced epilepsy and idiocy. Bidder found an irregular denticulated osteoma four centimeters in diameter in the left corpus striatum. The patient was the subject of contracture of the left arm and leg since infancy, the left leg being shortened two centimeters. In the case reported by Ebstein the tumor was located in the cerebellum and produced no symptoms. In operations upon the brain for epilepsy or other focal or cerebral symptoms osteoma as a possible cause should be remembered.

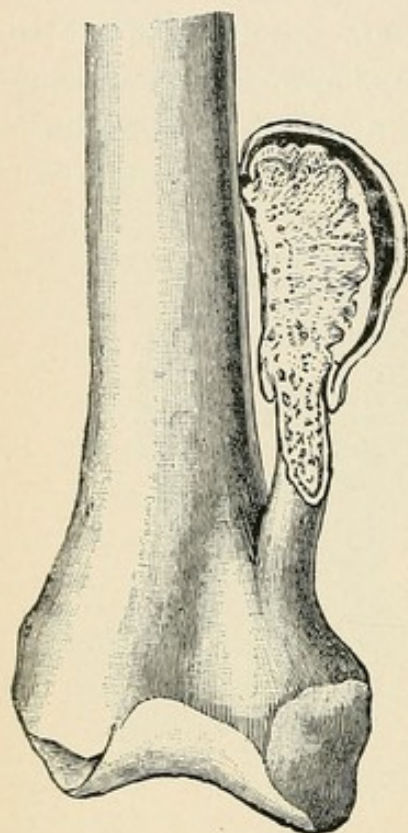


FIG. 304.—Exostosis of the femur (after Orlow); its surface was clad with cartilage and surmounted by a bursa.

Epiphyses of the Long Bones.—By far the greatest number of osteomata occur in the epiphyses of the long bones. Their origin is similar to that of chondromata in the same locality, only that in this instance the chondroblasts undergo a higher degree of development and the chondroma is transformed into an osteoma. Syme met with cases of epiphyseal osteoma in which the tumor was surrounded by a sort of synovial capsule; in other cases the tumor projects into the joint.

Epiphyseal osteomata are often multiple like the chondromata, and are nearly always covered by a thin crust of cartilage, resembling in this respect the articular extremities. The tumors, which are composed of cancellous bone-tissue, are often supplied on their surface with a bursa interposed between the tumor and the fascia, tendons, or muscles overlying it. Occasionally an osteoma is pedunculated, and frequently it has a broad base. The tumors are painless, but they often produce pain by pressing on adjacent nerves.

A favorite locality for osteoma is above the inner condyle of the femur (Fig. 304), close to the insertion of the adductor magnus. In this locality the tumor is peculiarly apt to acquire a narrow, pedunculated base. The pedicle of such a tumor may occasionally fracture, as happened in the cases reported by Paget and Lawrence. Epiphyseal osteomata, unless of great size, seldom interfere with the functions of adjacent parts, and unless this is the case operative treatment is contra-indicated.

Muscles and Tendons.—Osteomata are occasionally found in soft parts as distinct and discontinuous tumors invested with capsules of

connective tissue. Paget refers to a tumor of soft cancellous tissue occupying the dorsal surface of the trapezial and scaphoid bones, completely isolated from them and from all the adjacent bones. In the museum of St. George's Hospital, London, is a tumor formed of compact bony tissue that lay over the palmar aspect of the first metacarpal bone, loosely imbedded in the connective tissue, and easily separated from the flexor tendons of the fingers.

Exostoses tendineæ have frequently been observed. The bony growth originated in the tendon, independently of the bone to which the tendon was attached. Folk removed an exostosis apophytica which was attached with a broad base to the sacrum and which terminated in a conical projection several inches in length in the gluteus maximus.

Seat of Fracture.—Under certain circumstances the callus in the repair of a fracture is so profuse that a large bone-tumor remains after consolidation has been completed. Van Heerkeven applied to this condition the term *callus luxurians*. A good example of this condition is furnished by the bony hyperplasia which often occurs around a fractured rib in a lower animal. Such enormous permanent callus-formation has been observed by König and others as one of the remote results of fracture. In some cases it has been impossible to make a differential diagnosis between an osteoma at the seat of fracture and an osteo-sarcoma. The tumor under such circumstances springs from a post-natal matrix of osteoblasts produced by the injury. The difference between a superabundant callus and an osteoma at the seat of a fracture is that in the former case the provisional callus disappears or is at least greatly diminished in size, while an osteoma remains permanently as a bone-tumor. The operative removal of such an osteoma may become necessary if the tumor implicates important muscles, vessels, or nerves. An operation should not be undertaken until by the clinical course the true nature of the tumor has been revealed, by which means only is it possible to make a differential diagnosis between a superabundant provisional callus, an osteo-sarcoma, and an osteoma.

Orbit.—Osteoma of the orbit occurs either as a primary tumor, when it is attached to the bony wall of the orbit, usually on the nasal side, or the tumor reaches the orbit from the frontal sinus or from the antrum of Highmore. In the latter case the appearance of the tumor in the orbit is usually preceded by signs and symptoms which point to its primary location in either of the adjoining cavities. In a case of orbital osteoma that recently came under the observation of the writer, considerable exophthalmus was observed and the eye was displaced outward. Beneath the orbital arch a hard tumor could be felt under the upper eyelid, at the inner angle. The tumor, which was exposed by

an incision along the superciliary arch, was an inch and a half in length, and was attached to the inner wall of the orbit by a contracted, almost pedunculated, base. The tumor was detached from the bony wall with a narrow chisel, and was removed without inflicting any injury upon the more important contents of the orbit. The eye after the operation gradually resumed its normal position. If the tumor is located primarily in the frontal sinus or in the antrum of Highmore, its removal must be preceded by a temporary resection of the anterior wall of the cavity in which it is located.

Eye.—Schiess-Gemuseus collected eight cases of osteoma of the eyeball. In each case the tumor occupied the elastic lamella and the choroid capillaries.

Subungual Osteoma.—The last phalanx of the great toe is not infrequently the seat of a subungual osteoma. It always grows on the margin, and usually on the inner margin, of this bone. The tumor projects under the edge of the nail, lifting it up, and thinning the skin that covers it until an excoriated surface is presented at the side of the nail. The growth of the tumor is usually very slow, and when it has reached a diameter of from one-third to one-half an inch it becomes stationary. The extirpation of subungual osteoma with cutting-forceps must be preceded by partial or complete removal of the nail.

XXII. ODONTOMA.

Definition.—*An odontoma is a tumor composed of dental tissue in varying proportions and in different degrees of development, arising from teeth-germs or from teeth still in the process of growth.* This definition and the description of the different varieties are gleaned from Sutton's excellent work on *Tumors*, which contains the most accurate account of tumors of dental origin.

Sutton's Classification of Dental Tumors.—

- | | |
|--|----------------------------|
| 1. Epithelial odontome, from the enamel-organ. | |
| 2. Follicular odontome, | } from the tooth-follicle. |
| 3. Fibrous odontome, | |
| 4. Cementome, | |
| 5. Compound follicular odontome, | |
| 6. Radicular odontome, from the papilla. | |
| 7. Composite odontome, from the whole gum. | |

1. **Epithelial Odontomes.**—These tumors occur, as a rule, in the mandible; but they have been observed in the maxilla (Sutton). They are encapsulated and contain numerous small cysts. In color they resemble myeloid sarcoma, for which they have been mistaken. They consist of branching and anastomosing columns of epithelium, portions of which form alveoli. Although they may occur at any age, they are most frequent at the age of puberty.

2. **Follicular Odontomes.**—The follicular odontomes are the dentigerous cysts. They occur commonly in connection with teeth of the permanent set, and especially with the molars. The tumors often attain large size. The wall of the cyst may be very thin, so that it crepitates under pressure. The cavity contains a viscid fluid and the encysted tooth, which is often imperfectly developed.

Dentigerous cysts rarely suppurate. Three cases of follicular odontome have come under the writer's observation. In one case the cyst was as large as an orange, and contained an imperfectly developed molar tooth and a clear viscid fluid. In the second case a fistulous opening led into the bone above the permanent molars, and necrosis of the maxilla was suspected. The patient had been treated for a long time for suppuration of the antrum. At the bottom of the cyst part of a molar tooth was found.

A follicular odontome invariably occurs in connection with teeth the eruption of which is retarded or prevented owing to their being developed in an abnormal position, whereby they become impacted by the surrounding bone. These tumors appear at a period of life succeeding that at which the alveolar portions of the maxillæ are in a state of active development, in which they readily furnish an amount of bone sufficient to perfectly envelop the tooth. The capsule of the tooth, the remains of the enamel-organ, has been shown by Tomes to be, after the calcification of the enamel, quite free and detached from that structure, and therefore, being attached only to its surroundings, will be carried away from the surface of the enamel with them; there will thus be left a space into which, as a matter of course, serous fluid must under atmospheric pressure be effused, and thus there is formed a cyst, the walls of which will be the dental capsule, including the projecting crown of the tooth (Coleman).

3. **Fibrous Odontomes.**—The fibrous capsule of a tooth, composed of an outer firm wall and an inner loose layer of tissue, may become thickened, constituting with the contained tooth a fibrous odontome. Such a tumor is often mistaken for a fibroma, especially if the tooth be small and ill-developed. Under the microscope fibrous odontomes present a laminated appearance with strata of calcareous matter. Rickets appears to play an important part in the production of fibrous odontomes.

4. **Cementomes.**—A cementome is a fibrous odontome which has undergone ossification. The tooth in such cases is encapsuled in a mass of cementome. Cementomes occur most frequently in horses. Tomes describes a tumor of this kind which weighed ten ounces. Sutton refers to one which weighed seventy ounces.

5. **Compound Follicular Odontomes.**—“If the thickened capsule ossifies sporadically instead of *en masse*, a curious condition is brought about, for the tumor will then contain a number of small teeth or denticles consisting of cementum or of dentine, or even ill-shaped teeth composed of three dental elements—cementum, dentine, and enamel” (Sutton). As many as four hundred denticles have been found in a single tumor. Tumors of this character have been seen in the human subject. Tellander met with a case in a woman aged twenty-seven.

6. **Radicular Odontomes.**—“This term is applied to odontomes which arise after the crown or the root has been completed and while the roots are in the process of formation” (Sutton). In the specimen represented in Figure 305 the outer layer of the tumor is composed of cementum; within this is a layer of dentine, deficient in the lower part of the tumor; and inside this dentine is a nucleus of calcified pulp. A number of radicular odontomes have been observed in the human subject. Suppuration is a common complication of these tumors.

7. **Composite Odontomes.**—These are hard tooth-tumors which bear little or no resemblance in shape to teeth, but which occur in the jaws. The tumors, which consist of a disordered conglomeration of enamel, dentine, and cementum, arise from an abnormal growth of all

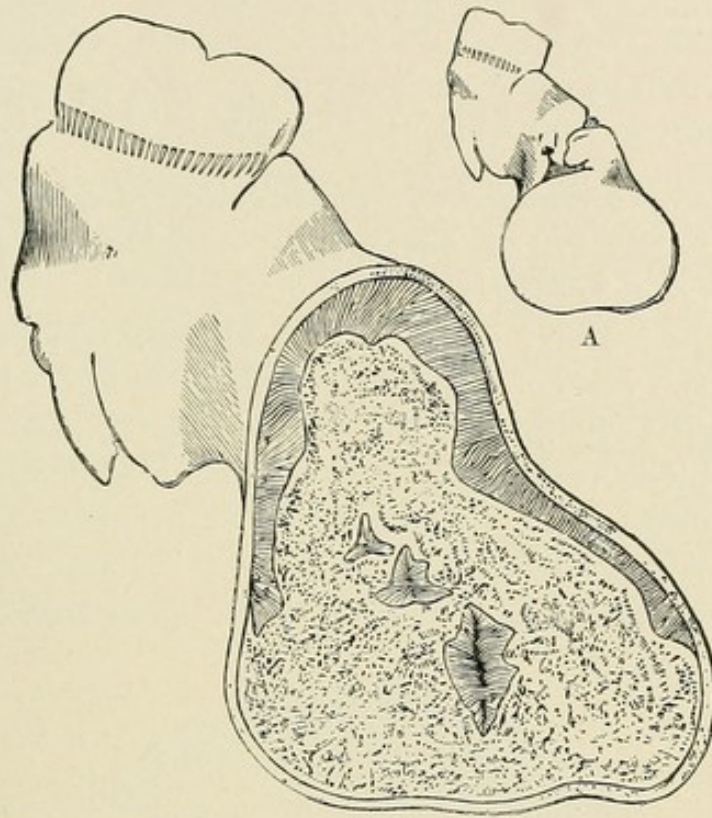


FIG. 305.—Radicular odontome from human subject (after Salter): A represents the natural size of the specimen.

the elements of a tooth-germ (Fig. 306). In the majority of cases the tumors are composed of two or more tooth-germs indiscriminately fused (Sutton). It is supposed that odontomes are more frequent in the lower than in the upper jaw, but there is good ground for the belief that many such tumors have been described as exostoses of the antrum.

The diagnosis of dental tumors is very obscure, and in consequence of faulty diagnosis uselessly severe operations have often been performed for the removal of tumors of this kind. It is important to examine solid and cystic tumors of the jaws, especially if they occupy the site of tooth-germs, with special reference to their possible dental origin. A diagnosis once made, a successful operation can be performed with little mutilation. The bone surrounding the tumor is removed by subperiosteal resection, when the tumor can be enucleated or removed with gouge and mallet. The cavity is tamponed for a few days with iodoform gauze.

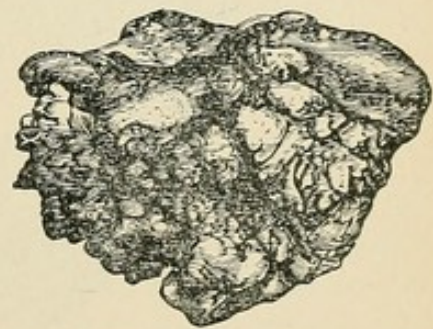


FIG. 306.—Composite odontome from a young lady aged eighteen; natural size (after Heath).

XXIII. ANGIOMA.

Definition.—*An angioma is a tumor composed of blood-vessels produced from a matrix of angioblasts.* Angiomata were formerly described as “teleangiectasia,” “angiotelectasia,” “angioma pleni-forme,” “erectile tumors,” and “nævi.” Virchow included all vascular tumors under the head of angioma. Tumors composed of lymphatic vessels are called “lymphangioma,” to distinguish them from tumors composed of blood-vessels, and this is what is generally understood by the unqualified term “angioma.” The definition excludes from this class of tumors all swellings caused by dilatation of pre-existing blood-vessels, aneurysm, and varicose veins. The angiomatous tumor

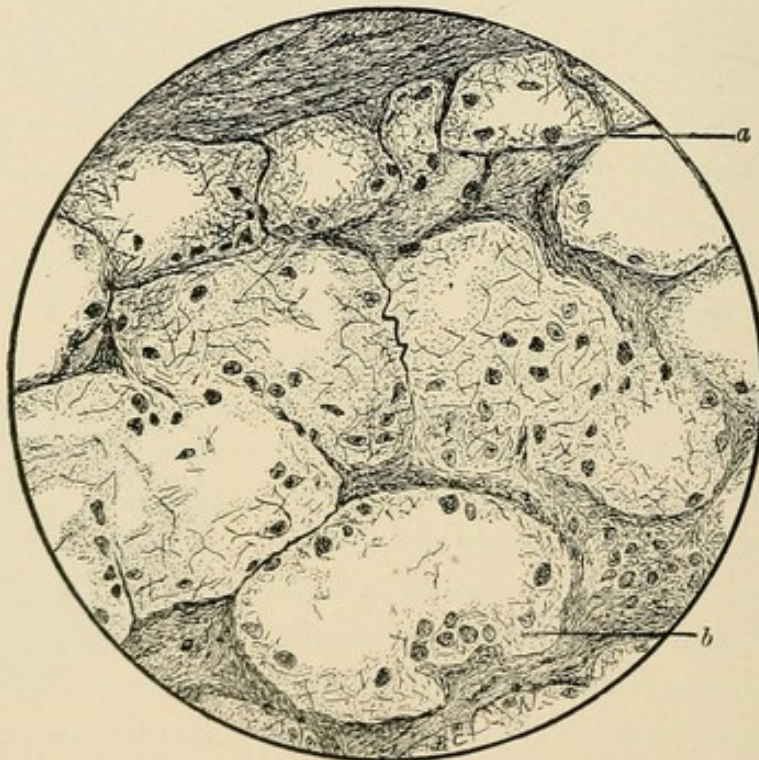


FIG. 307.—Angioma of tongue, showing newly-formed blood-spaces not yet in connection with pre-existing vessels; $\times 330$ (Surgical Clinic, Rush Medical College, Chicago): *a*, angioblast; *b*, newly-formed spaces filled with delicate fibrous network and amorphous material.

is composed of new blood-vessels which are in communication with the adjacent vessels, interstitial tissue composed of the pre-existing tissues in which the tumor develops, and the blood contained in the vascular spaces. The size of the tumor is very variable at different

times and under different circumstances, according to the anatomical structure of the vessels and the amount of blood the vessels contain.

Histogenesis.—Weil in a study of the growth of angioma came to the conclusion that the origin of new blood-vessels is as variable as is the formation of new embryonal vessels. He found projecting from the wall of old and new capillary blood-vessels streaks of protoplasm which showed nucleated projections which in the course of time became laminated and were traversed by blood from the pre-existing vessels. In other places he found proliferation of the endothelial cells which formed buds and projected into the surrounding tissues. These masses of endothelial cells form new vessels by the formation of hollow spaces which communicate with the vessels from which they originated. Rokitsky has seen and described the formation in the connective tissue of blood-spaces discontinuous with pre-existing blood-vessels, and which only later entered into communication with them (Fig. 307). In a case of pulsating cavernous tumor of the spleen Langhans noticed an extraordinary proliferation of the endothelium of the venous spaces, and to this proliferation he ascribes the growth of the tumor, in opposition to the theory advanced by Rindfleisch, and the illustrations which accompany his paper appear to justify his conclusions. If the matrix of angioblasts forms a part of the vessel-wall, the new blood-vessels are formed by budding, and are in communication with the pre-existing vessel from the beginning. If the angioblasts have become displaced into the connective tissue, the tumor-tissue becomes vascular after the new blood-spaces have formed a communication with the pre-existing vessels.

Histology.—Angioma is closely related to endothelioma, as its cellular elements possess the shape and arrangements of their mother-soil. The angioblasts are a modified form of fibroblasts. Their intrinsic function is to produce new blood-vessels.

In the growth of normal blood-vessels the angioblasts furnish the essential tissue-elements of blood-vessels; the blood-vessels reach their requisite normal size, when the process becomes stationary. The angioblasts from which an angioma develops observe no such limitation of function; their function is a progressive one, and their product of tissue-proliferation results in the formation of atypical blood-vessels which are not required by the part in which they are produced, and which constitute the essential tumor-tissue. The vascular spaces, whether capillary, venous, or arterial, are lined with endothelial cells the product of the angioblasts. In a growing angioma new blood-spaces continue to form, and again enter into communication with the older vascular spaces (Fig. 308). As the blood-spaces are formed by the production of an

intima from the angioblasts, active proliferation takes place in the remaining tissues of the vessel-wall. Connective tissue and muscle-

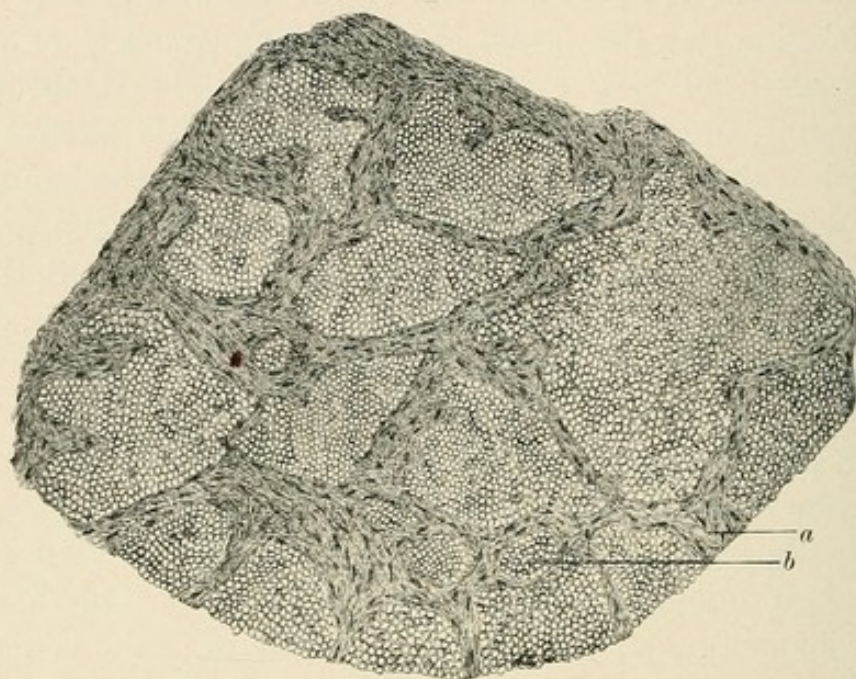


FIG. 308.—Angioma of the back; $\times 110$ (Surgical Clinic, Rush Medical College, Chicago): *a*, wall of blood-spaces; *b*, newly-formed blood-spaces.

fibres derived from the pre-existing blood-vessels are produced, forming the outer and middle coats of the new vessels (Fig. 309). The

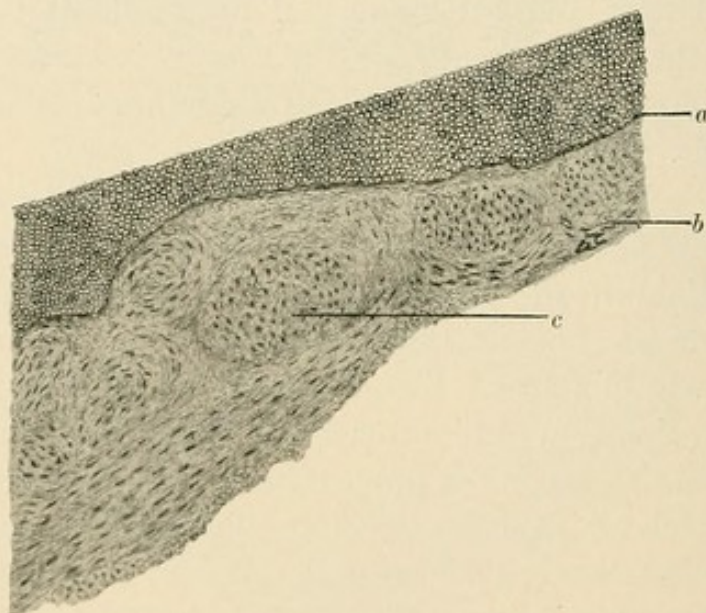


FIG. 309.—Angioma of rib, showing new vessel-wall; $\times 110$ (Surgical Clinic, Rush Medical College, Chicago): *a*, intima; *b*, adventitia; *c*, proliferating cell-areas in the media.

limits of the tumor, as in all benign growths, are well defined, as will be seen in Figure 310.

Angioma as a component part of other tumors gives rise to the different combination tumors in which the angiomatous part so often

constitutes what imparts to the tumor its most serious clinical aspects, as in angio-lipoma, angio-fibroma, angio-adenoma, angio-sarcoma, and angio-carcinoma. The communication of all angiomas with blood-vessels is very free. Virchow and Maier have shown that an angioma of the liver can be injected from the hepatic artery and vein and from the portal vein.

Complications.—According to the number and activity of the angioblasts, the tumor may grow rapidly, may remain stationary, or in exceptional cases may disappear spontaneously. Inflammation occur-

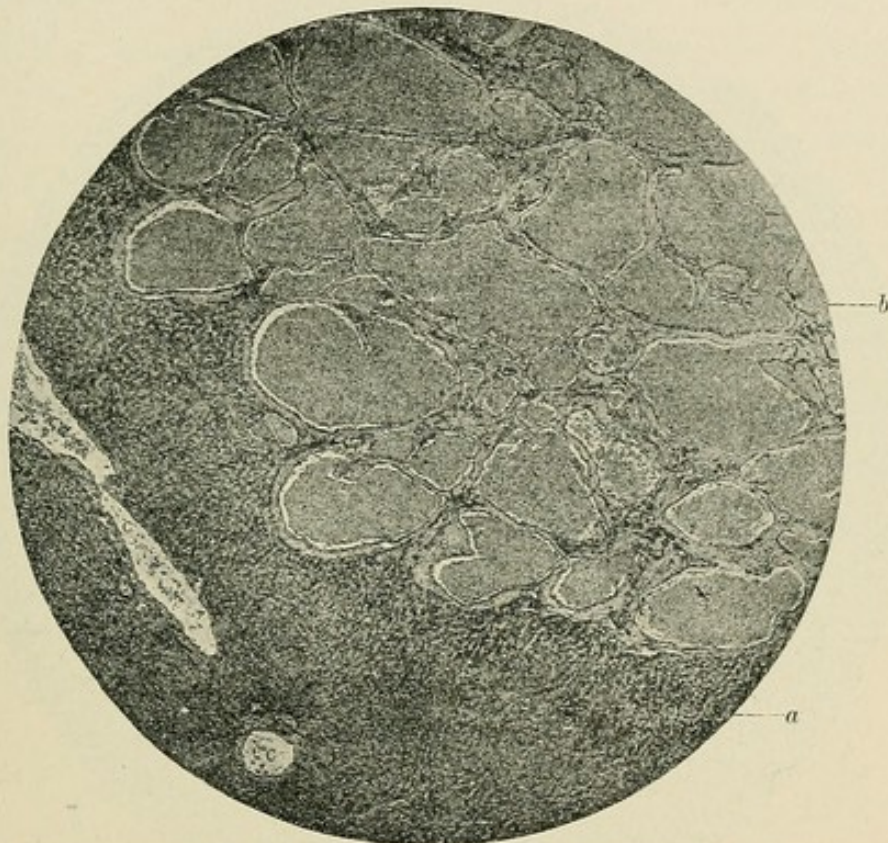


FIG. 310.—Cavernous angioma of liver; $\times 30$ (after Karg and Schmorl). The tumor (*a*), which shows a well-defined border at its junction with the liver-tissue (*b*), exhibits a structure similar to cavernous tissue. The tumor consists of irregular spaces lined with endothelial cells and separated by their connective-tissue septa. The hollow spaces contain blood; *c*, a hepatic vein.

ring spontaneously or produced by artificial means occasionally results in a permanent cure. This complication may, however, become a source of danger to life from septic thrombo-phlebitis. In venous angioma there sometimes forms a thrombus of a plastic character that may result in the formation of a phlebolith or vein-stone. Extensive thrombosis is one of the ways in which finally all the blood-vessels become obliterated. Transformation of an angioma into the most malignant form of sarcoma is by no means rare. Such a transition is shown in Figure 311. The tumor from which the section represented in Figure 311 was taken was a superficial capillary angioma of

the face that had become stationary during childhood in a man twenty years of age. Without any obvious cause the tumor commenced to grow very rapidly, and when removed it showed the typical structure of a round-celled sarcoma. The section represented in the illustration was taken from the periphery of the tumor. Calcification of the stroma of the tumor and of the vessel-walls arrests the further growth of the tumor. The angiomata are occasionally the seat of a striking hyaline or colloid change, a cylindromatous appearance often being given to the tumor.

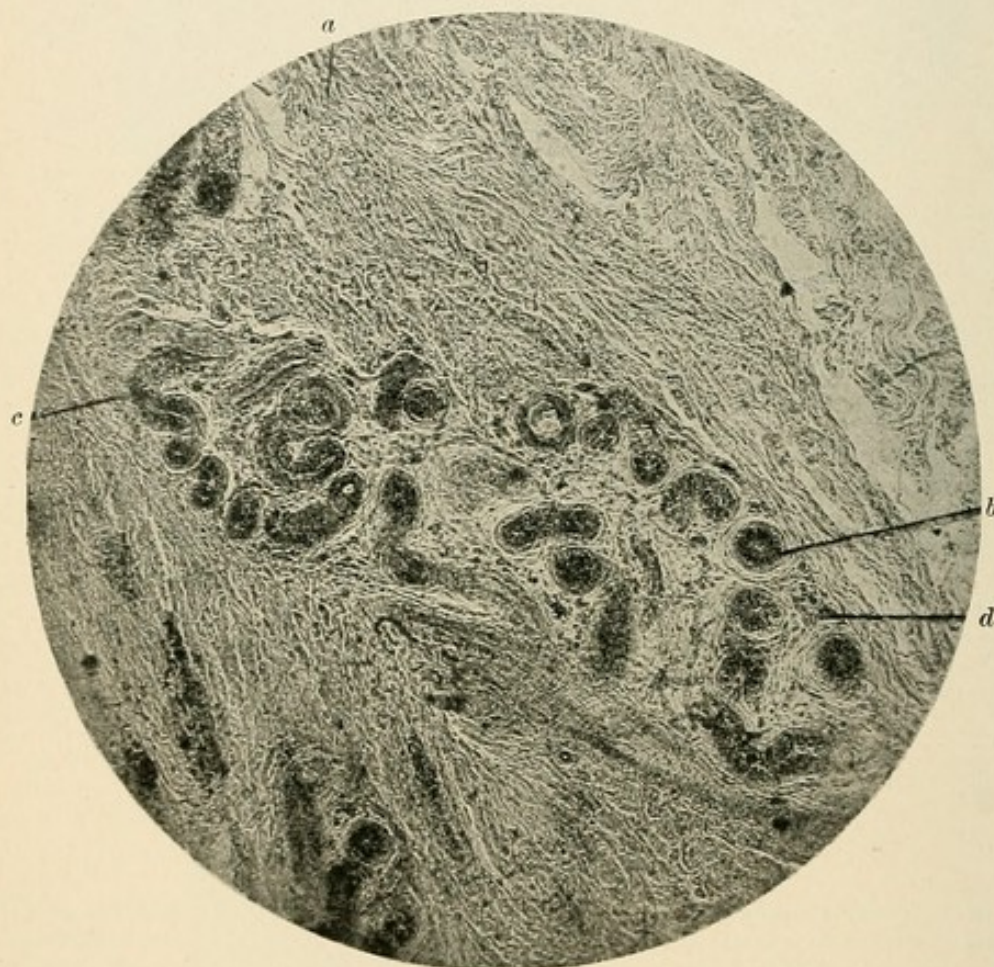


FIG. 311.—Capillary angioma undergoing transformation into a sarcoma; $\times 55$ (Surgical Clinic, Rush Medical College, Chicago): *a*, connective tissue; *b*, capillary vessel cut transversely; *c*, capillary vessel cut obliquely; *d*, group of sarcoma-cells.

Anatomical Varieties.—The division of angioma into anatomical varieties is based on the kind of vessels the tumor-tissue represents. In superficial angioma the color of the tumor indicates its structure and the kind of blood it contains. An arterial angioma presents the bright-red hue of arterial blood; the red color of a capillary angioma is of a less bright hue; and the venous or cavernous angioma presents the dark-blue appearance of venous blood.

Capillary Angioma—A capillary angioma, known as simple *nævus* or “mother’s mark,” is the incipient form of vascular tumor. Its

favorite sites are the skin of the face and the orbit. The tumors are flattened or slightly pendulous, and they are blue, pink, or purple in color. The difference in color, varying from a pink to a livid tint, depends, according to Billroth, upon whether the vessels be situated superficially or deeply. The most superficial form of capillary angioma is known as a "port-wine stain." If the terminal veins are involved, the tumor is more prominent and of a darker color. The tumor can usually be emptied of its blood by pressure; sometimes, however, this cannot be done. The dilated capillaries and veins are separated by a variable quantity of connective tissue. If the connective tissue is abundant, the tumor is firm; if scanty, it offers little resistance to pressure. As a rule, the tumor-tissue does not extend beyond the subcutaneous cellular tissue. The vessels are arranged in small groups from the size of a hemp-seed to that of a pea, consisting of dilated capillaries and venulæ arranged around the appendages of the skin (Fig. 312).

All capillary angiomata are congenital. They may be so small that

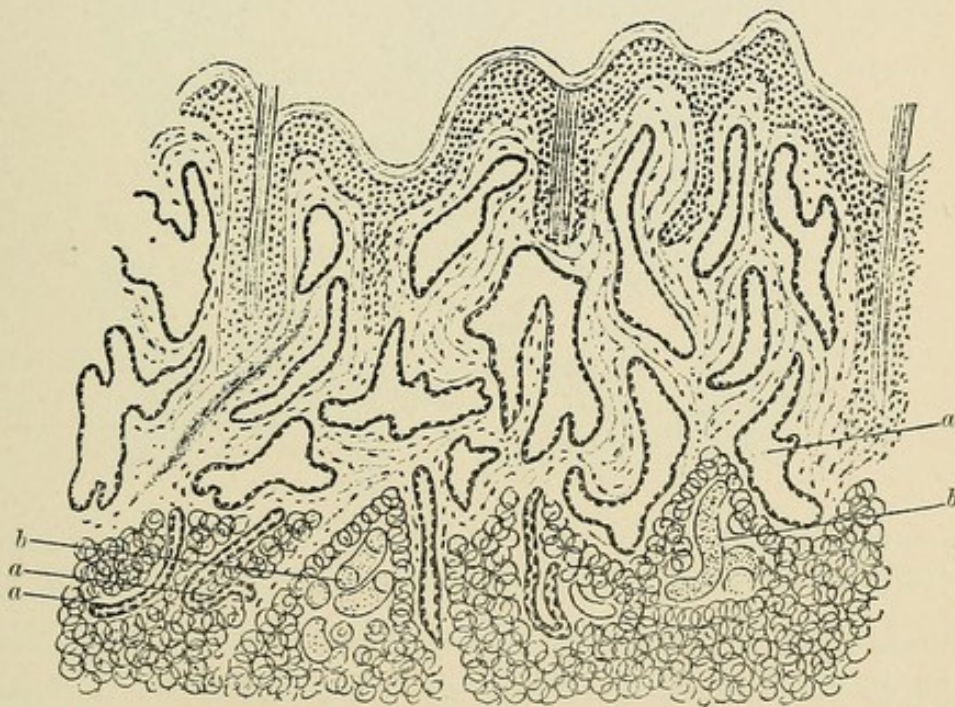


FIG. 312.—Capillary angioma of the skin (after Perls). In the upper layer of the skin can be seen capillaries dilated into cavernous blood-spaces. In the fatty layer only a few capillaries (*a*), somewhat dilated and with thickened walls, can be seen; *b*, a sweat-gland.

they cannot be detected at the time of birth, but they soon begin to increase in size, whereas the cavernous angiomata are not always congenital and may develop at any time after birth. Their growth is best studied in the subepithelial fat, where the tumor forms small cellular masses of angioblasts and connective-tissue corpuscles.

Cavernous Angioma.—The cavernous angiomata form tumors of

larger size than the capillary variety, and are composed of irregular blood-spaces which communicate freely with one another. The new blood-spaces are formed by angioblasts in the cellular connective tissue. Cavernous angiomas are found in the deep connective tissue, in the bones, the liver, the spleen, and the kidney, and are composed of a tissue almost identical with that of the corpus cavernosum penis—that is, of irregular blood-spaces communicating freely with one another and separated by fibrous septa of variable thickness (Fig. 313). The walls

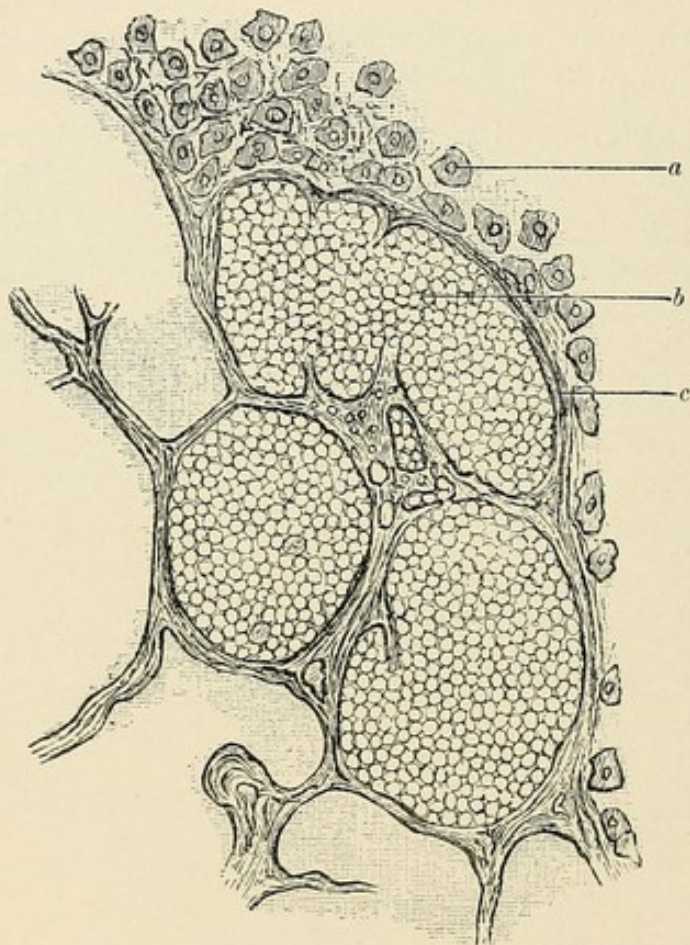


FIG. 313.—Cavernous angioma of the liver; $\times 350$ (after D. J. Hamilton): *a*, liver-cells at margin of the tumor; *b*, blood contained in the cavernous spaces; *c*, walls of the cavernous spaces.

of the blood-spaces are lined by endothelium. The formation of new blood-spaces takes place in the fibrous septa and in the periphery of the tumor. Cavernous angioma is a much more formidable tumor than a superficial nœvus, as its tendency to progressive growth is much greater and from its deeper location it involves more important structures. A simple nœvus may, however, later in life become converted into a cavernous angioma.

Plexiform Angioma.—Plexiform angioma, which is a true angiomatous tumor, and not an aneurysm, has been known as “aneurysm by anastomosis” or “cirroid aneurysm”—terms that should no longer be employed to designate an arterial angioma. Plexiform angioma con-

sists of a number of tortuous blood-vessels of moderate size arranged parallel with one another. These tumors, which are composed of arteries alone, of veins, or of arteries and veins in equal proportions, are found most frequently about the forehead, the temporal regions, the fingers, the anus, and the legs. The largest angioma that came under the writer's observation was in the axilla of a boy seventeen years old. The tumor had existed for many years and had undergone active growth for two years. It had reached the size of a child's head.

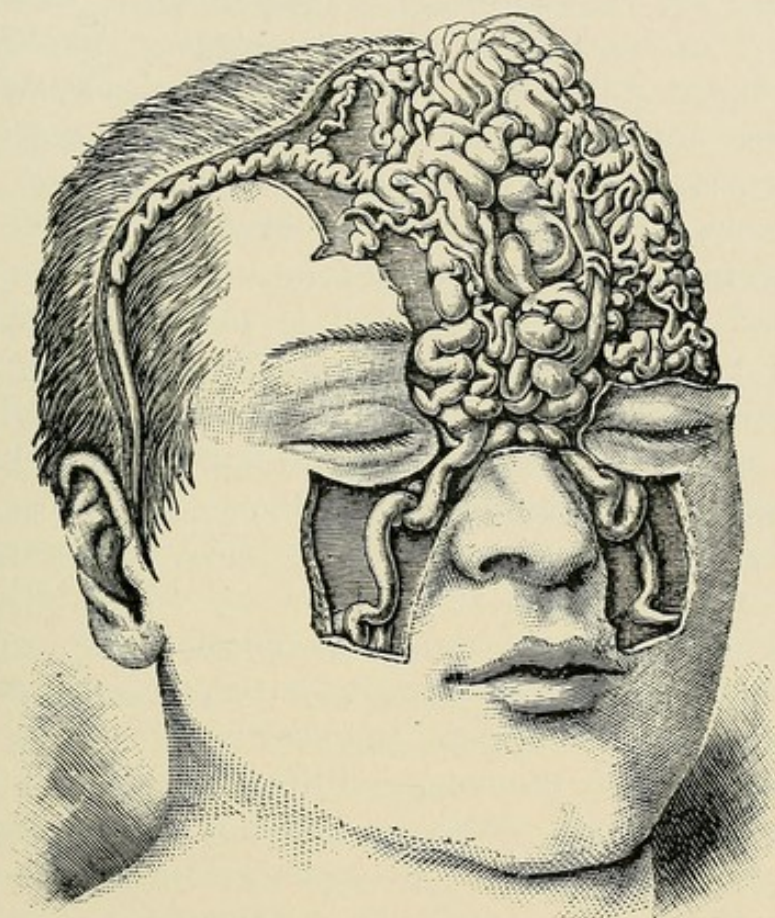


FIG. 314.—Dissection of a plexiform angioma of the forehead (after H. Müller).

Some of the veins were as large as the thumb, and the arteries, several in number, were about the size of an ordinary lead-pencil. Pulsations and bruit were well marked and extended along the subclavian vessels. Preliminary to excision, on two different occasions two of the largest arteries that fed the tumor were ligated. The operation of excision, despite the preliminary deligation, was an exceedingly bloody one. At least fifty compression-forceps were required, and nearly as many points were ligated after the excision of the growth. The boy made a good recovery, notwithstanding the excessive loss of blood.

The tumors are found most frequently in young adults, and they almost always, sooner or later, manifest progressive tendencies. Plexiform angioma in many instances develops in pre-existing blood-vessels,

being then caused by an excessive quantity of angioblasts in the vessel-wall. During the growth of the tumor there are produced new blood-vessels which remain in communication with the lumen of the vessel similarly affected. Bruit and pulsation are usually frequent, and the size of the tumor is greatly diminished by pressure. In cases of epicranial plexiform angioma the bone beneath the tumor undergoes pressure-atrophy, so that deep depressions occur, and even perforation of the skull may take place.

Symptoms and Diagnosis.—The diagnosis of a surface angioma can be made from the color of the tumor alone. The color depends on the kind of blood the tumor contains, and is also modified, according to Billroth, by the amount of tissue over the tumor. In most instances the color of the tumor disappears under pressure, and returns with the entrance of blood into the tumor-tissue. In plexiform angioma pulsation and bruit are frequently present, and the tumor almost disappears under pressure. Any and all of the causes which increase intravascular pressure, as coughing, laughing, straining, and active exercise of all kinds, increase the size of plexiform and cavernous angiomata. In plexiform angioma, if the tumor is subcutaneous, the tortuous vessels can be outlined distinctly.

The differential diagnosis between intracranial angioma and angioma of other internal organs and aneurysm is impossible. A positive differential diagnosis between pulsating inflammatory swellings and angioma can be made by resorting to an exploratory puncture.

Prognosis.—Surface angioma in exceptional cases becomes converted into a plexiform angioma, and not infrequently it serves as a starting-point for sarcoma. With the exception of these possible terminations it is a benign affection. In some cases a spontaneous cure is effected; in other cases a cure follows inflammation occurring accidentally or produced intentionally. In cavernous and plexiform angiomata the prognosis is more grave. Inflammation of such tumors may result in septic thrombo-phlebitis, pyemia, and death. Wounds of angiomata may give rise to serious and even fatal hemorrhage. The progressive growth of a plexiform angioma may interfere by pressure with the function of important adjacent organs. Ulceration may result in serious hemorrhage or may give rise to dangerous inflammatory complications.

Treatment.—The probability of the occurrence of a spontaneous cure in angioma is so small that operative treatment should be instituted in appropriate cases as soon as the tumor is discovered. In the superficial variety, the so-called "port-wine mark," operative treatment is contraindicated if the tumor is diffuse—that is, if it occupies an area

larger than a silver dollar. If the tumor is limited, excellent results are obtained by electrolysis. Only a small part of the surface should be treated at each sitting, and the operation should be repeated every few days. Among the other surgical resources which have been employed in the treatment of ordinary nævus may be mentioned ignipuncture, coagulating injections, ligature, and the application of caustics. Ignipuncture with the needle-point of a Pacquelin cautery is an excellent method of treating superficial angiomas in localities not easily accessible to excision, as the soft palate and the mucous membrane of the mouth and the pharynx. The method can also be employed in the removal of surface angiomas in parts of the body not exposed, as the chest, abdomen, arms, and legs. The scarring following ignipuncture is much greater than after excision. The needle should be heated to a dull-red heat, as puncturing with a needle heated to a white heat is likely to give rise to hemorrhage. The punctures should be made a few lines apart and in a circle corresponding with the periphery of the growth. The central portion may be treated in the same manner at the same time, or this part of the tumor may be treated later. If the tumor is larger than a half-dollar, a number of sittings are necessary to complete the treatment. Before puncturing the surface should be made aseptic, and after the puncturing it should be protected carefully against infection.

Coagulating injections in the treatment of angiomas are mentioned simply for the purpose of condemning them. Their employment has produced instant death from embolism, and has frequently been followed by suppuration and ulceration.

The ligature causes pain and sloughing, and the resulting scar is more unsightly than that following excision. The ligature is now seldom used in the treatment of angioma. The same may be said of percutaneous threads saturated with coagulating solutions. Nitric acid has been recommended strongly by Billroth and others in the treatment of circumscribed superficial angiomas. All caustics are inferior to the use of the knife.

The fear of hemorrhage attending the excision of angiomas is unfounded, provided the incisions are not made through, but outside of, the tumor-tissue, or, as Sutton so happily says, "if the nævus is cut out, not cut into." The writer never encountered troublesome hemorrhage when this advice was followed in the excision of angiomas.

The ideal treatment of angioma is excision. The incision should be made a few lines away from the visible boundary of the tumor, on the sides as well as at its base. The bleeding vessels can be caught at once

with hemostatic forceps, the surgeon being enabled to remove the growth quickly before the bleeding points are tied. Circular pressure some distance from the periphery of the tumor is a material aid in diminishing the amount of bleeding. If the wound cannot be closed by suturing, the surface should be covered at once by a Wolfe graft or by Thiersch grafts.

The surgical treatment of plexiform angioma has so far not yielded very encouraging results. Ligature of the principal artery of the part occupied by the tumor has not proved satisfactory. Ligature of the arteries supplying the tumor has not yielded much better results. In tumors of moderate size and readily accessible on all sides, excision offers the best prospects. If the tumor is large, as in the case mentioned on page 455, it is well to tie several of the larger vessels prior to the excision. If it is important to make the incision some distance away from the growth in the excision of an ordinary *nævus*, this advice applies with still greater force to the excision of a plexiform angioma. The principal vessels which nourish the tumor should be exposed and be secured with hemostatic forceps before they are cut. Pressure is an important factor in removing provisional hemostasis in the excision of a plexiform angioma. In such cases the skin over the tumor should be reflected and preserved if it is intact. If the angioma involves the skin, this must be excised with the tumor, and the resulting wound-surface is paved at once with Thiersch grafts.

TOPOGRAPHY.

Skin and Mucous Membranes.—The skin and the mucous membranes are the seats of capillary angioma. The face and the mouth are the favorite localities. The most superficial form, the "port-wine mark," frequently is very extensive, occupying the larger part of one side of the face, and in some instances even one half of the body. This variety of tumor is occasionally converted into a cavernous or a plexiform angioma. Breschet relates the case of a girl who was born with a port-wine mark on the external ear. The tumor remained stationary for several years, when it became the seat of pulsation, ulcerated, and bled freely from time to time. In her eighteenth year all the arteries in the temporal region were consistently enlarged, as was also the occipital, which, together with the tumor, made a pulsating swelling of considerable size. At the necropsy it was ascertained that the arteries had such thin walls that they could hardly be distinguished from the accompanying veins. Breschet believed that the arteries communicated directly with the veins. In another case observed by Breschet an insignificant angioma behind the ear was followed by dilatation of the

carotid artery on the same side to three times its natural size; the aorta and the common iliac artery showed similar changes, while the arteries of the extremities were normal in size and in structure. The disease in this case was progressive, extending from the congenital angioma to the vessels mentioned by an uninterrupted process.

The most typical structure of angioma of the skin is seen in the growing tumors in young children. The appendages of the skin in the part affected undergo hypertrophy. In port-wine mark the skin is but little thicker than normal; the epidermis is thinner than normal, the papillæ are flattened, and the epithelial depressions between them are more shallow. The arteries and veins can be distinguished without difficulty, and the dilated capillaries can be identified readily. A closer study of the process under the microscope reveals the places where the new vessels permeate the fatty tissue. Klebs has seen the angioblasts form solid cylinders of cells which project into and displace the adipose tissue and which mark the beginning of a new blood-vessel. These cell-masses are in immediate connection with open vessels, and within the mass can be seen red corpuscles which push before them the cellular wall. The new vessel is at first composed simply of a tube of endothelial cells. Weil has seen how the angioblasts in pre-existing vessels proliferate and form cell-masses outside the vessel-wall; these masses become hollow cylinders and form new vessels. The same process is observed in arteries which supply the fat-tissue. According to Ziegler, this process is characterized by active karyokinetic changes. The new endothelial cells perforate the muscular coat, and outside form cell-masses which are transformed into new blood-vessels. Klebs is inclined to believe that other angioblasts find their way through the muscular coat by ameboid movements. Most of the new vessels are formed from the capillaries in the form of solid buds of new endothelial cells. The process is accomplished exclusively by the angioblasts.

All the superficial angiomata are congenital. Port-wine marks seldom increase much in size after birth. The deeper variety often appears as small red dots not larger than a pin-head at the time of birth, but later they increase in size. These small tumors should be destroyed by ignipuncture as soon as they are discovered. If the tumors are larger than a split pea and occupy exposed parts of the body, they should be excised. If the wound is too large to be closed by suturing, it should be covered at once by skin-grafts.

Deep Connective Tissue.—The deep connective tissue is the seat of cavernous or plexiform angiomata. The tumors may have their primary origin in the skin, and reach the deep connective tissue by

extension, or may originate primarily in the connective tissue. The formation of blood-spaces is not always the result of dilatation by growth of the vessel-wall, but is also produced by confluence. The vessel-walls, at points where they come in contact, undergo absorption by pressure-atrophy and impaired nutrition. In cavernous and plexiform angioma the skin overlying the tumor is usually intact if the tumor originated primarily in the deep connective tissue. In large pulsating tumors the skin is subjected to pressure, becomes atrophic, and, in consequence of impaired nutrition or of injury, ulceration may ensue, giving rise to recurrent hemorrhages and to infection. Venous cysts, which often result from passive dilatation of veins, are a form of deep varices, and do not belong to tumors. In other cases such cysts occur as a congenital affection, and are discontinuous from pre-existing vessels. These cysts are produced by a displaced matrix of angioblasts.

The frontal and parietal regions are favorite localities for deep angiomata. The tumors are usually congenital, but from their deep location they are not discovered until they become larger. W. Koch reports a case where, immediately after birth, an angioma the size of a walnut was discovered above the right clavicle; the tumor could be seen through the normal intact skin. Uninterrupted slow growth took place until the child was eighteen months old, when it died. The tumor then measured fifteen inches in a horizontal and seven inches in a vertical direction. After the fourth month pressure had no effect in diminishing the size of the tumor, but brought on asphyctic symptoms. Post-mortem examination showed that the tumor was made up of three compartments which communicated with one another, of which only one compartment answered to the external swelling. Of the other compartments, one occupied the deep region of the neck, and the third occupied the anterior mediastinum and the right pleural cavity, where it had displaced the lung. The chambers contained spaces variable in size occupied by fluid and coagulated blood. The right subclavian vein was absent, and the tumor was undoubtedly composed of the tissues which were intended for its structure.

In a case of cavernous angioma of the arm Esmarch removed in a man twenty-eight years old fifty-four tumors, each of which communicated with veins. The first tumor appeared about the region of the wrist when the patient was six years old. Esmarch believed that the tumors developed from pre-existing veins.

The legs and arms, and more especially the fingers, are sometimes the seat of plexiform angioma. Vascular tumors of the fingers should be excised; if their size renders this procedure impracticable, multiple ligation should be tried before resorting to amputation. Deep plexi-

form angiomata of the leg and the arm are always grave affections. If the extent of the tumor contraindicates excision, multiple ligation should be tried; in some cases this procedure may be followed by excision. In the gravest cases amputation may become necessary. Plexiform angioma of the frontal, temporal, and occipital regions should be treated by excision with or without preliminary ligation of the principal vessels supplying the tumor, according to the size of the tumor and the accessibility of the vessels which feed it.

Bones.—Most difficult to explain is the origin of vascular tumors of bone, called by Virchow *myelogenous angiomata*. There is good reason to believe that pulsating sarcoma of bone has often been mistaken for so-called "aneurysm of bone." Only a very few well-authenticated cases of myelogenous angioma of bone have been recorded. Dupuytren ligated the femoral artery in a case of pulsating tumor of the tibia, and the tumor disappeared, but returned (sarcoma) after seven years. Virchow in a case of cavernous angioma of the liver found also two similar growths in two separate vertebræ. Klebs saw a case of genuine bone-aneurysm and cavernous angioma in the same patient. The case occurred in Krönlein's practice. The patient was a woman twenty-four years old. The tumor was of one year's standing, and occupied the upper portion of the vertebral column and the lateral aspect of the neck. The tumor was covered by a thin shell of bone, and presented neither bruit nor pulsation. On incising the tumor there was found a blood-cyst from which at one point there was free hemorrhage. It was ascertained that the hemorrhage was from the vertebral artery. As the vessel could not be ligated, hemorrhage was arrested by grasping the bleeding point with a hemostatic forceps which was incorporated in the dressing. Death occurred from sinus-thrombosis. The necropsy showed that the vertebral artery was bent at an acute angle and terminated in a network of vascular spaces, and that through a small opening these spaces communicated with a large blood-cyst. The third and fourth cervical vertebræ were involved by the tumor. Microscopical examination of sections of the tumor showed giant-celled sarcoma.

Angioma of bone, as angioma in other localities, is always produced by the formation of new blood-vessels from a matrix of angioblasts. The differential diagnosis between angioma of bone and myeloid sarcoma is impossible. In doubtful cases, in view of the fact that the more benign forms of sarcoma have been treated successfully by a local operation, it is advisable to resort to removal of the diseased tissue with a sharp spoon. Should the subsequent clinical course and microscopical examination of the tissue removed reveal the sarcomatous nature of the

tumor, amputation should be performed as soon as evidences of a recurrence show themselves. *Angioma of bone is an exceedingly rare affection, whereas myeloid sarcoma is common*—facts which should not be forgotten in the differential diagnosis between these two affections of bone.

Intracranial Angiomata.—Demme has described blood-cysts of the superior longitudinal sinus that perforate the skull and appear externally as pulsating vascular tumors. A positive diagnosis between such cysts and an extracranial plexiform angioma must be made before an operation is decided upon. Akidopeirasty with a fine needle will show whether or not the skull has been perforated. Intracranial angiomata may belong to blood-cysts of bone developed from the vasa nutritia of the parietal bone. As the walls of such cysts are lined by endothelial cells, the cysts are undoubtedly produced by angioblasts, possibly aided by mechanical causes. Other cysts communicating with the longitudinal sinus are multilocular. Bruns cites such a case. The cyst, which was discovered when the patient was fourteen years old, was situated in the parietal region and was composed of veins covered by normal skin. The cystic spaces communicated freely with one another. In a case of large plexiform angioma of the frontal region, the writer, in excising the tumor, found at its base large veins which communicated with the longitudinal sinus. The hemorrhage from this source could be controlled only by compression. Death resulted from suppurative sinus-phlebitis.

Angioma in the central nervous system occurs where the vessels are all new, all of them starting from the pia. Brunetti found such a tumor the size of a pea in the fourth ventricle. Klebs found a similar growth upon the surface of the middle lobe.

Liver.—Cavernous angioma of the liver is of common occurrence. It appears in the form of round or wedge-shaped spaces filled with blood in parts of the organ not occupied by parenchyma. The spaces are nearly uniform in size. New spaces form in the fibrous septa and in the periphery of the tumor. It has been asserted that the cavernous spaces are formed by dilatation of pre-existing vessels accompanied by pressure-atrophy—an opinion which receives the sanction of Ziegler. Such a view is untenable, as the structure of the tumor does not represent the conditions produced by vascular obstruction. The endothelial cells which line the spaces are attached to and supported by a strong scaffolding of connective tissue. In the neighborhood of such angiomata no evidences of inflammation can be found. Johannes Müller found in the lining of such spaces large spindle-shaped cells which are the endothelial cells. The number of these cells is not

the same in all parts of the wall: they are most numerous where the process of cell-proliferation is most active, and less numerous where the growth of the tumor has become stationary. Similar tumors are found less frequently in the spleen and the kidney.

Mammary Gland.—In rare instances the mammary gland is the seat of an angioma. Sutton relates the case of a boy, seventeen years of age, who as a child had an ordinary nevus of small size in the skin above the left nipple. For many years this nevus gave no trouble; it then gradually increased in size until the whole breast was converted into a cavernous angioma three inches in diameter. At intervals the surface ulcerated, and profuse hemorrhages were the consequence. Another and larger angiomatous tumor of the breast came under the observation of Smage.

Tongue.—The tongue is not infrequently the seat of simple and cavernous angioma. In a lad fifteen years old the writer successfully removed a tumor the size of a pullet's egg. The excision was greatly facilitated by elastic constriction of the affected side of the tongue.

Muscles.—Cavernous angiomata of the voluntary muscles have been observed by a number of surgeons. In the clinic of Rush Medical College, Chicago, such a case came under the care of the writer during the session of 1894. The patient was a boy sixteen years of age. The tumor, which was first discovered five years previously, extended from a point three inches above the patella, over the outer aspect of the thigh, ten inches in an upward direction. The swelling was oblong, very prominent and firm when the patient was standing, but disappeared almost wholly when he was placed in the recumbent position with elevation of the affected limb. The tumor, which was removed by excision, involved the outer part of the extensor quadratus femoris muscle, and extended on the outer side as far as the intermuscular septum. A strip of the muscle three inches wide and eight inches in length was removed, and on examination it was found to contain numerous vessels the size of a crow's quill. The hemorrhage upon the removal of the elastic constrictor was very profuse, and about fifty vessels had to be ligated before it was controlled. The boy made a good recovery and regained perfect use of the limb. The formation of a muscle-hernia was prevented by careful suturing of the fascia lata with a separate row of buried catgut sutures and rest in bed for six weeks.

Liston removed a cavernous angioma from the popliteal space in connection with the semimembranosus muscle. Holmes Coote removed a similar tumor from the deltoid, and Campbell de Morgan removed one from the semimembranosus in a girl ten years old.

In the diagnosis of muscular angiomata the variable size of the tumor in different positions of the body is an important element.

Larynx.—Except in the tongue and the rectum, angioma of the mucous membranes is very rare. It has been observed in the larynx in a few instances, springing from the vocal cords, the ventricular bands, from the ventricle, and from the sinus pyriformis. Angiomata of the larynx are either sessile or pedunculated. They are rarely larger than a haricot bean, and are red or purple in color. They should be removed with the snare, with the aid of the laryngoscope.

XXIV. LYMPHANGIOMA.

Definition.—A *lymphangioma* is a tumor composed of lymphatic vessels produced from a matrix of angioblasts. The lymphatic vessels of the tumor are new structures containing lymph, and they constitute the essential part of the tumor. Their walls are more delicate than those of angioma, but they are composed of the same histological elements. A lymphangioma is a firmer tumor than an angioma, as the connective tissue between the vessels is more abundant.

Anatomical Varieties.—Wagner divides lymphangioma into—1. Capillary; 2. Cavernous; and 3. Cystic. In the *capillary* variety the tumor is composed of lymph-spaces and lymphatic vessels which constitute an anastomosing network. The *cavernous* variety is composed of a framework of connective tissue with communicating spaces which contain lymph. The *cystic* form presents to the naked eye an appearance of a convolution of large and small vesicles with translucent walls containing lymph. These vesicles are dilated new lymphatic vessels which have lost in part or completely their connection with the lymphatic system. Such cysts can be produced experimentally in rabbits by forcing atmospheric air under considerable pressure into the abdominal cavity. Under such conditions the air is forced into the lymph-spaces, especially those of the pelvis, producing rapid dilatation.

Histology and Histogenesis.—In capillary lymphangioma the new vessels are formed by angioblasts in the wall of pre-existing lymph-spaces by a process of budding, in the same manner as in capillary angioma. As the vessels are composed of exceedingly delicate walls lined with endothelial cells, they dilate earlier and under less pressure than in angioma, consequently cystic dilatation takes place at an earlier period and to a greater extent. Capillary lymphangioma is always congenital, whereas the cavernous and cystic varieties may develop at any time after birth. The beginning of a capillary lymphangioma manifests more or less swelling before its lymphangiectatic character can be discerned. Microscopically, lymphangioma of the tongue, a comparatively frequent affection, appears in the form of a symmetrical swelling of the tongue, while the same affection of the skin begins in the subcutaneous connective tissue as a softer swelling with ill-defined borders. The loose connective tissue is oedematous, and

only in cases where large quantities of clear lymphatic fluid escapes can we suspect the existence of dilated vessels. In specimens that are somewhat finer, spaces can be seen traversing the tumor, while the delicate walls of the ectatic lymphatic vessels and cysts collapse so that the openings in the vessels cannot be seen. Microscopical examination, unless carefully conducted, may lead to errors in diagnosis, as the specimens often present more the appearance of hyperplasia of the tongue than that of dilated lymph-channels. In lymphangioma of the

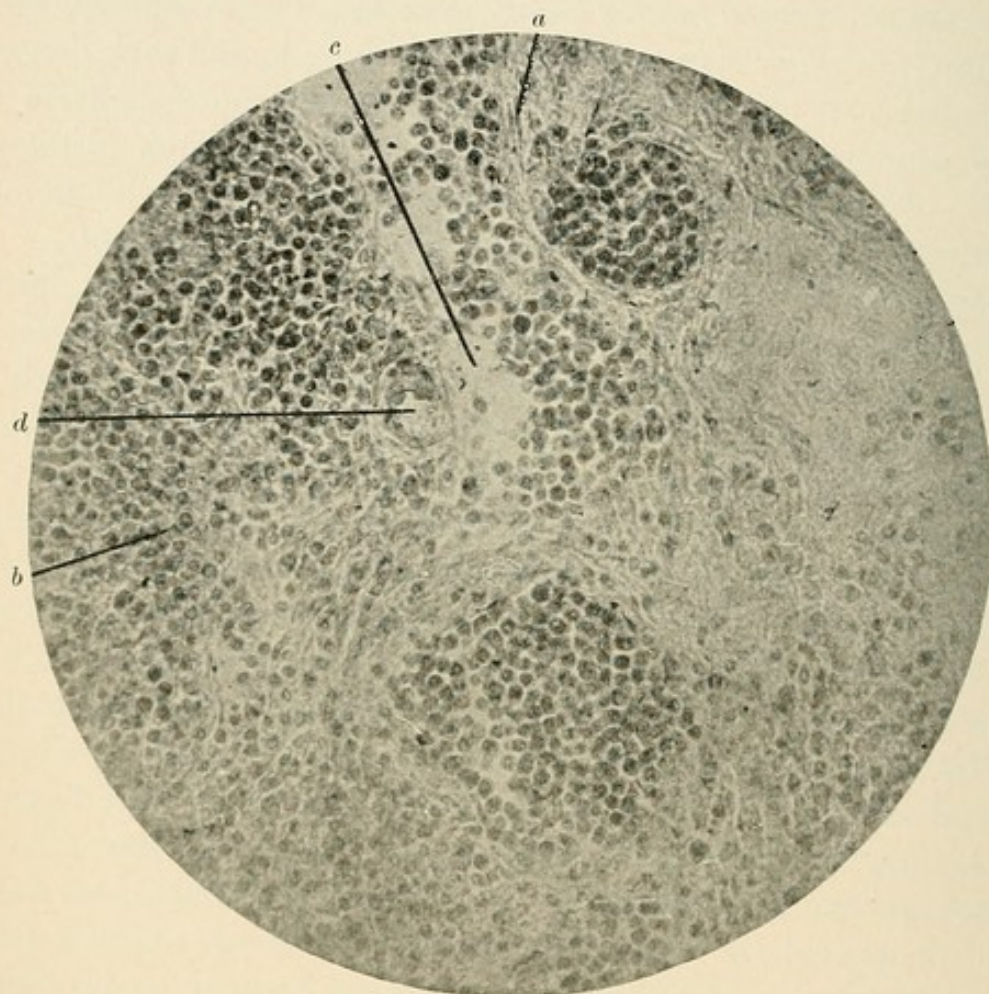


FIG. 315.—Lymphangioma of the skin; $\times 375$ (Surgical Clinic, Rush Medical College, Chicago): *a*, connective-tissue reticulum; *b*, round cells (lymphoid cells); *c*, lymph-space; *d*, blood-vessels.

tongue young muscle-fibres are met with, which proves that the muscular tissue is also increased in quantity. In the subcutaneous tissue the growth of lymphangioma is attended by an increase of connective tissue (Fig. 315).

The subcutaneous lymphangioma differs from *elephantiasis arabum* by the tumor being composed of new lymphatic channels instead of dilated diseased pre-existing vessels, as is the case in elephantiasis. Lymphangioma of the tongue (Fig. 316), or, as it is called, *macroglossia*, is always a congenital tumor. It commences with an enlargement of the blood-vessels; the veins are thin-walled, but a new tissue-product

cannot be recognized so far. On the contrary, the new lymph-spaces are dilated and are paved with numerous large nuclei. The dilatation of the lymphatic spaces progresses parallel with the new tissue-proliferation. The muscular bundles are at some points ensheathed by

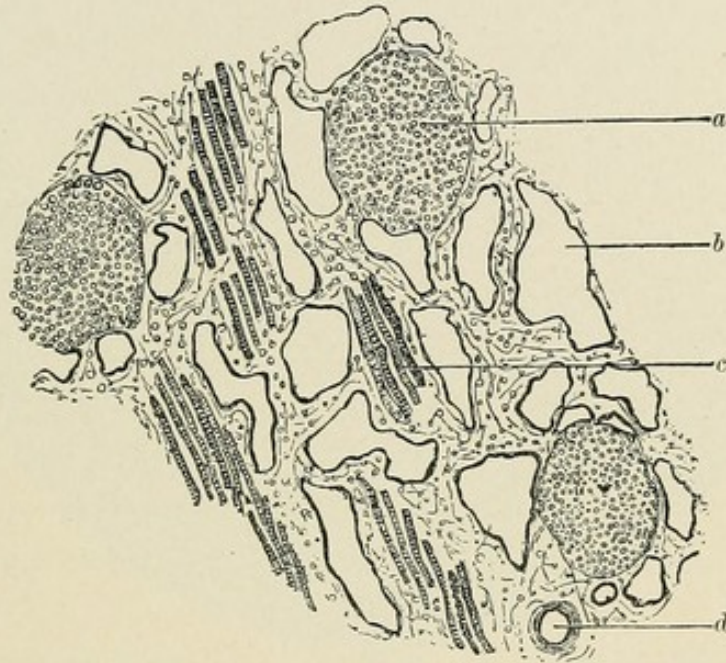


FIG. 316.—Lymphangioma of the tongue; $\times 50$ (after D. J. Hamilton): *a*, lymphadenoid deposits; *b*, a cavernous lymphatic space; *c*, muscular fibres of tongue; *d*, a small artery.

lymphoid tissue. An increase of endothelial cells is apparent, but vessel-dilatation has not as yet occurred. At other points free hyperplastic lymphatic vessels are seen in the connective tissue. In the further development of macroglossia, angiomas as well as multilocular lymph-cysts appear. If angioma predominates, it is interesting to observe that the blood often circulates through the new dilated lymph-channels. Lücke observed that on puncturing such cysts, at first lymph escaped, and at subsequent repetitions of puncturing blood instead of lymph escaped. In such cases the communication between blood-vessels and lymphatic vessels is not accidental, but is due to an embryonal relationship between the two kinds of vessels. The new lymph-spaces contain at first a colorless fluid. Thrombi are also found, and their occurrence renders a diagnosis less difficult. Wagner found in the lymph ectatic muscular-sheathed hyaline thrombi, and this discovery made it easy to give a correct interpretation of their pathological significance. Lewinski described a case of calcification of lymphatic thrombi in a boy twelve years old suffering from lymphangioma of the scrotum.

Cavernous lymphangioma (Fig. 317) presents upon section a honey-combed appearance, the spaces being separated by their septa lined

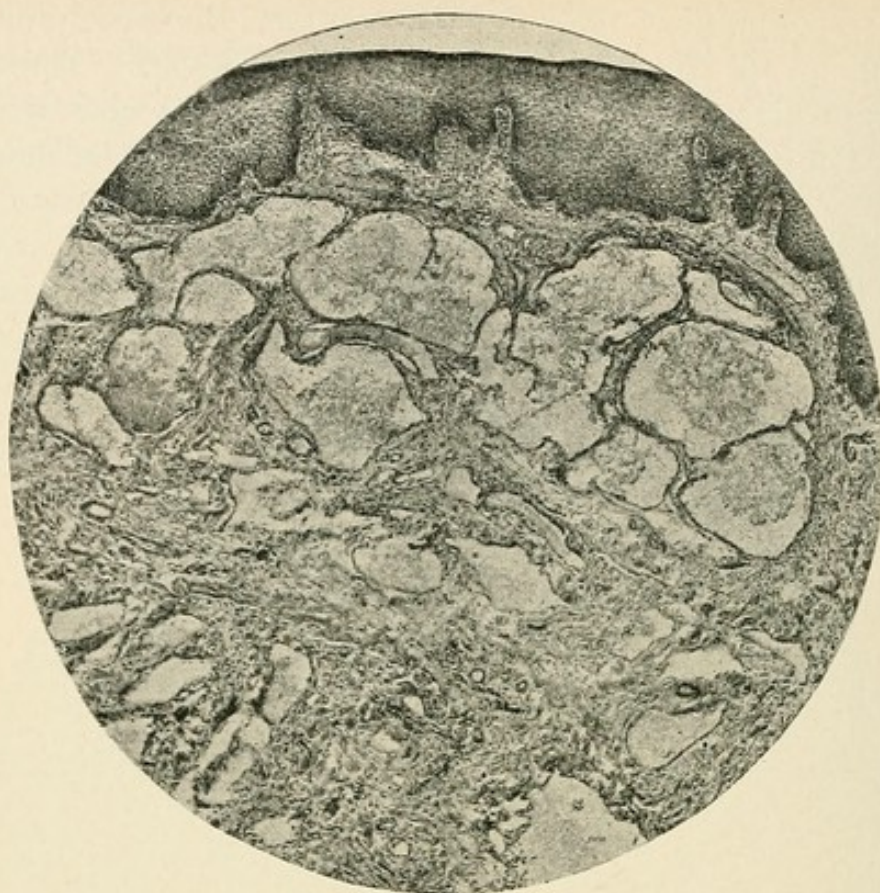


FIG. 317.—Lymphangioma of the lip; $\times 55$ (after Karg and Schmorl). In the connective tissue under the epithelium numerous lymph-spaces of different size, lined by endothelial cells, are seen; these spaces contain a few finely granular leucocytes in a mass of lymph (coagulated by hardening).

with endothelium. The septa are perforated, so that all the spaces communicate with one another. In other cases the interior of the tumor is

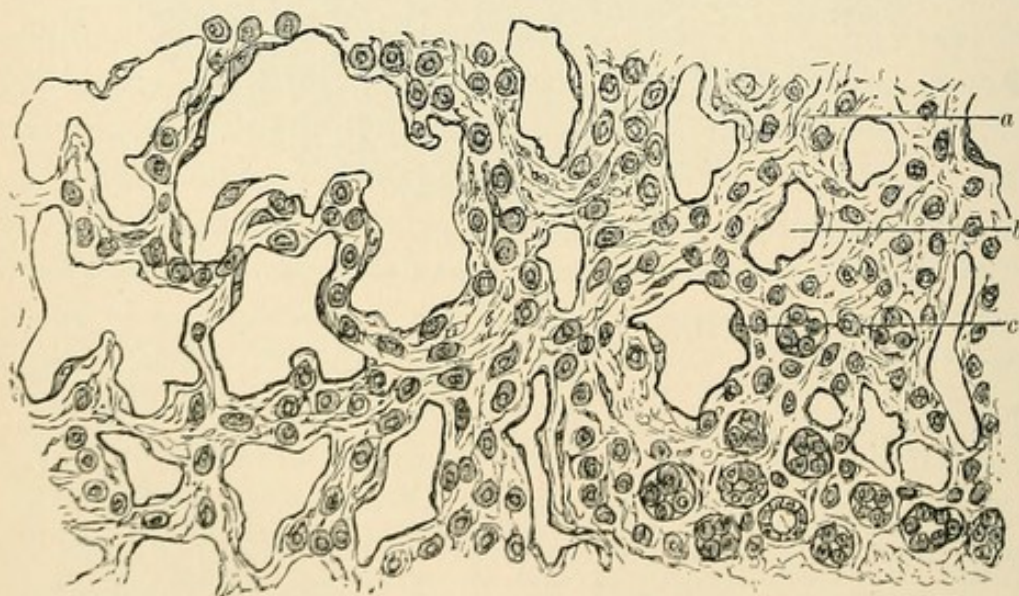


FIG. 318.—Lymphangioma of the orbit; $\times 350$ (after D. J. Hamilton); *a*, stroma of the walls of the cavernous spaces; *b*, a cavernous lymphatic space; *c*, endothelium lining the space.

occupied by larger spaces, as though coalescence had taken place by the breaking down of septa (Fig. 318). The spaces not only undergo

cystic dilatation, but are enlarged by coalescence. In some cases hyperplasia of the other tissues also takes place.

Cystic lymphangioma differs from the cavernous variety only in that the individual separate spaces arising from new and dilated lymph-channels possess forms which correspond with their origin: they are more or less globular in shape, corresponding in this respect with the rosary-like appearance of the lymphatic vessels during the early stages of the growth of the tumor. Cysts of large size are produced by the confluence of numerous smaller spaces. The cystic variety is more prone to progressive growth than the cavernous; in this respect the distinction between the two varieties is of importance from a prognostic standpoint. This difference in the clinical aspects of these tumors applies only to cases where the cysts are multiple, as when only one cyst is present its increase in size takes place more on account of retention of secretions than by tissue-proliferation. The skin covering the tumor is at first intact. As the tumor increases in size it may become hyperplastic or it is thinned out by pressure from beneath, constituting an important element in the production of ulceration.

Cystic lymphangioma of the neck has seldom been interpreted correctly, and has been described under the vague terms of "cyst hygroma," "hydrocele of the neck," "cystic tumor of the neck," "serous cyst," etc. Förster first pointed out the correct histogenesis of cystic lymphangioma of the neck. He demonstrated the endothelial nature of the lining of the cysts by silver-staining. He also showed that these cysts communicated with the lymphatic vessels. Luschka asserted that the serous cysts of the neck originate from the *glandula carotica* or from the *glomeruli of the arteria intercarotica*, but in two cases at least Arnold was able to show the presence of these organs in a normal condition in connection with the cysts. Klebs, who found in a large cyst of this kind lymphatic glands in the cyst-wall, believes that the glands occasionally take part in the production of the cyst. In none of these cases was a connection found between the cavity of the skull and the cyst, hence meningocele takes no part in their production; neither was there found any connection between the skull and the cyst, hence meningocele can be excluded as a factor in their causation. If located in the neck, the cyst may extend in an upward direction as far as the cavity of the mouth and downward as far as the mediastinum. If very large the cysts become pendulous. Besides the cysts which can be seen with the naked eye, endothelial proliferation and the formation of new lymphatic vessels can be seen under the microscope in the adjacent connective-tissue spaces. In the neck the tumor follows the direction of the lymphatics, along the large blood-vessels and the inter-

muscular septa. In cases where proliferation is active the blood-vessels are also enlarged, and many of these tumors attain the structure of a

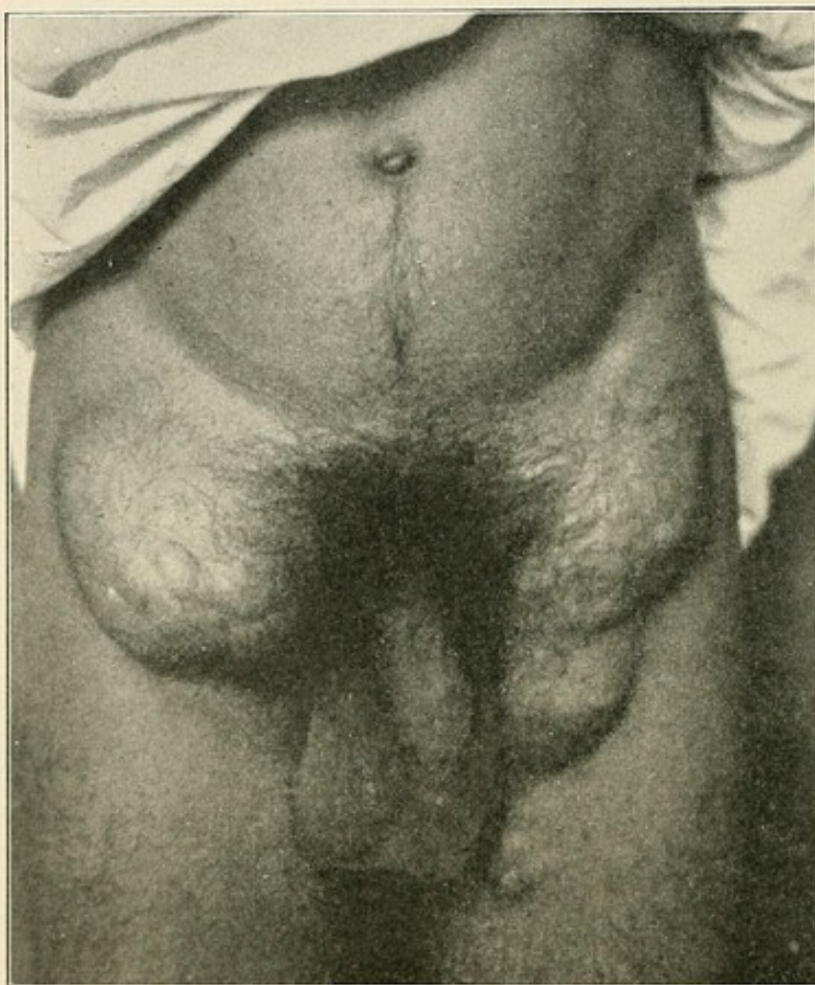

FIG. 319.—Hæmo-lymphangioma of the groin. Patient a native of the West Indies. Tumor successfully removed (Senn).

mixed tumor—a *hæmo-lymphangioma*. In such instances the transformation of lymph-cysts into blood-cysts, as first described by Lücke, takes place.

Multilocular lymphangioma is also found in glandular organs. Weichselberg reported a case of lymphangioma of the mesentery. It was a flat tumor, the size of the palm of the hand, between the layers of the mesentery at a point corresponding with the upper portion of the ileum. It contained a fluid which by chemical tests and by microscopical examination was shown to be chyle. In the same category belong the congenital cysts of the lung described by Virchow. These cysts might be regarded as dilated lymphatics, but the active endothelial proliferation which is always found present in the smallest lymphatic channels speaks in favor of their being true tumors.

The kidney is another organ in which multilocular lymphangioma is occasionally met with. The histological structure of the cysts in

this organ is a counterpart of angioma of the liver. The tumor is composed of multiple spaces lined by a single layer of endothelial cells and communicating freely with one another. The multilocular structure of the tumors distinguishes them from retention-cysts of the uriniferous tubules. Klebs describes a specimen of multilocular lymphangioma of the kidney.

Varicose lymphangioma must be distinguished from simple dilatation of pre-existing lymphatic vessels. It differs from lymphatic varicosity by the absence of obstruction and by an abnormal increase in the amount of lymphatic structures. Dr. Busey, in his monograph on *Congenital Occlusion and Dilatation of Lymph-channels* (1878), describes minutely a case that came under his observation. The disease was congenital and involved one of the lower extremities, and, as the post-mortem showed, extended behind the peritoneum far up into the pelvis. The child lived a little more than a year. He collected in addition 87 cases. In some of them the disease was limited to fingers and toes, and resulted in great hypertrophy of all the tissues, including the bones. In Busey's case the surface of the limb was covered with translucent vesicles which contained a serum-colored fluid. The sweat-glands were found enormously hypertrophied.

A lymphangioma, wherever it occurs, is characterized by the formation of new lymphatic structures, the process extending to places in which, in normal condition, no lymphatics are found.

Lymphangioma may occur almost in any part of the body if it springs from the perivascular lymph-sheaths. In some cases the proliferation is very active and the extension of the disease is progressive. The endothelial cells are large, and the connective-tissue reticulum is infiltrated with lymph-corpuscles (Fig. 318). Langhans, in a child seven years old, saw the disease affect the perivascular lymph-sheaths in almost the entire panniculus adiposus, while the large lymphatic vessels were free. The inguinal lymphatic glands were permeable to injection. Holmes, in a child three years old, saw a case where the disease was limited to the right leg. Extension to the external genital organs and the lymphatics of the groin and the pelvis took place when the child reached its seventh year. A somewhat similar case is the one reported by Busey. In this instance the disease extended very rapidly, and when the child died the corresponding side of the pelvis was found extensively involved.

Regressive Metamorphoses.—The connective-tissue stroma of lymphangioma is subject to nearly all the retrograde tissue-metamorphoses found in other tumors. The most frequent forms of degeneration met with in such tumors are fatty degeneration and calcification.

Myxomatous degeneration is liable to occur in large tumors in which the connective tissue is abundant. Cystic degeneration by the breaking down of fibrous septa, caused by pressure-atrophy, is of frequent occurrence, especially in tumors in which the tissue-proliferation is very active and their growth, consequently, rapid. The pathological complication that occurs most frequently is thrombosis. Aseptic thrombosis renders the affected part of the tumor harder, and frequently results in arrest of growth, as the removal of the thrombi is followed by obliteration of the vessels by granulation and cicatrization. The enlargement of the tumor caused by this accident under such favorable circumstances is followed by progressive shrinkage which attends the obliteration of the vessels. Of more serious import is septic *thrombo-lymphangitis*, which occurs most frequently in connection with ulceration of the surface of the tumor. The ingress of pyogenic microbes through such an infection-atrium results in suppurative inflammation of the walls of the infected lymphatic channels and of the interstitial connective tissue. If the suppurative infection is severe, the resulting inflammation assumes a phlegmonous character and may successively involve the entire tumor, attended by all the risks to life incident to septic infection and pyemia. The septic thrombo-lymphangitis is usually accompanied by a septic thrombo-phlebitis. In septic thrombo-lymphangitis the thrombi are not observed, but they undergo puriform softening.

The transformation of a lymphangioma into a lympho-sarcoma is possible, and there is good reason for believing that in cases in which the disease extended over a large territory in a short time, resulting in death, such a transformation had occurred.

Symptoms and Diagnosis.—Lymphangioma in the majority of cases presents itself as a congenital affection with an intrinsic tendency to increase in size after birth. In some cases the growth is very rapid, involving different regions successively, and resulting in death by the tumor interfering with important functions. If the tumor is not complicated by inflammation, it is pale and the overlying skin is intact. The density of the tumor depends on the amount of connective tissue it contains and on the presence or absence of thrombosis. The effect of pressure is more marked if the tumor is composed of new blood-vessels as well as lymphatic channels—that is, in cases of hemo-lymphangioma. If the skin or the mucous membrane is broken and the surface defect communicates with lymphatic spaces, lymph in varying quantities escapes. *The escape of lymph is the most reliable diagnostic element in the differentiation between a lymphangioma and other tumors or inflammatory swellings.* The surface of the tumor is

often undulated from the presence of superficial cysts. Lymphangioma of the tongue and the lips can usually be recognized without much

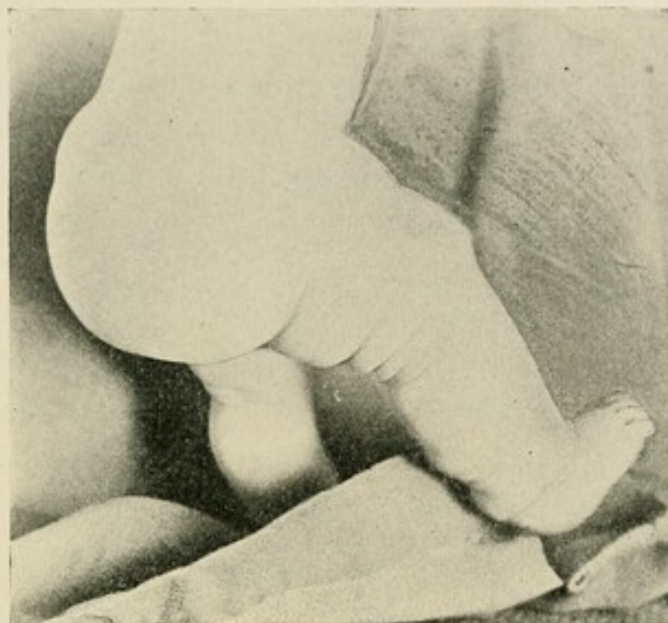


FIG. 320.—Author's case of lymphangioma involving the gluteal region and lower extremity. The gluteal tumor was successfully removed; no recurrence.

difficulty. In both instances all the tissues implicated by the tumor are in a hypertrophic condition and constitute a part of the swelling. *Lymphangioma is ordinarily not limited by a well-defined capsule, as the connective tissue in the periphery of the tumor is progressively invaded by new lymphatic vessels.*

Cystic tumors of the neck, of lymphatic origin, are almost always congenital, are thin-walled, and contain a clear serous fluid; or, if hemorrhage into the cyst has taken place, the serum is discolored by the admixture of blood. The use of the exploring syringe will frequently render material aid in the differential diagnosis between cystic lymphangioma and other cystic tumors and inflammatory swellings. If the exploratory puncture yields first lymph, and later lymph and blood or pure blood, the diagnosis of hemo-lymphangioma is established. In the differentiation between a lymphosarcoma and lymphangioma the use of the microscope may be required.

Prognosis.—With few exceptions, lymphangioma is a chronic affection and does not tend to destroy life. Great enlargement of the tongue in macroglossia may interfere with speech and deglutition. A cystic lymphangioma of the neck may become a source of danger by interfering with deglutition and respiration. In rapid-growing tumors the prognosis should be guarded, more especially if cystic degeneration is a permanent feature. The liability to infection, and also to trans-

formation into sarcoma, should not be forgotten in the prognosis of lymphangioma.

Treatment.—Complete excision is indicated if the tumor can be removed safely. Partial excision is indicated in lymphangioma of the lip and the tongue if the tumor interferes with deglutition, speech, or respiration, or for cosmetic reasons. In the removal of cystic tumors of the neck, of lymphatic origin, it must be remembered that the cyst-wall is in close relation with the large vessels, and that parts of the tumor often dip deeply into the intermuscular septa. Amputation in uncomplicated lymphangioma of the extremities is not a justifiable procedure. In cystic tumors of the neck not amenable to enucleation or excision a cure may be effected by free excision, cauterization of the interior of the cyst with the Pacquelin cautery, and packing of the cavity with iodoform gauze. In progressive inoperable cases parenchymatous injection of a 10 per cent. solution of chloride of zinc may be tried with a view of arresting further growth by cicatricial contraction.

TOPOGRAPHY.

Tongue.—Lymphangioma of the tongue is known as *macroglossia* (Fig. 321). Clinically, the condition manifests itself as a congenital enlargement of the tongue, implicating mainly its anterior two-thirds. The growth is progressive, and when the organ becomes too large to be accommodated by the cavity of the mouth, its tip protrudes from the mouth. The irritation and repeated injuries of the enlarged organ by the teeth during mastication, and the exposure of the organ to external influences after it protrudes from the mouth, aggravate the condition by producing inflammation of the surface of the tongue or of the tumor-tissue itself. The disease begins in the submucous connective tissue, but later implicates the muscular tissue of the tongue. Capillary lymphangioma of the tongue is limited to its surface, and appears in the form of enlarged papillæ.

The proper treatment consists in partial excision of the tongue if the organ has become sufficiently enlarged to interfere with mastication and speech. In some cases the lymphangioma is complicated by angioma, which calls for special prophylactic precautions to control the hemorrhage during the operation. Lymphangiomata of the cavity of the mouth have been described by Sachs.

Lips.—Lymphangioma of the lips is called *macrochilia*. Billroth described a case that came under his own observation. The patient, who was fifteen years of age, was born with a diffused tumor of the upper lip, which projected considerably beyond the lower lip. The

tumor was painless, firm, pale, and hard, and could not be diminished in size by pressure. It was often the seat of inflammation, and it bled readily on being handled or when injured. The tumor was extirpated. A section through it showed that it was composed of a firm framework of connective tissue, the meshes of which were occupied by coagula

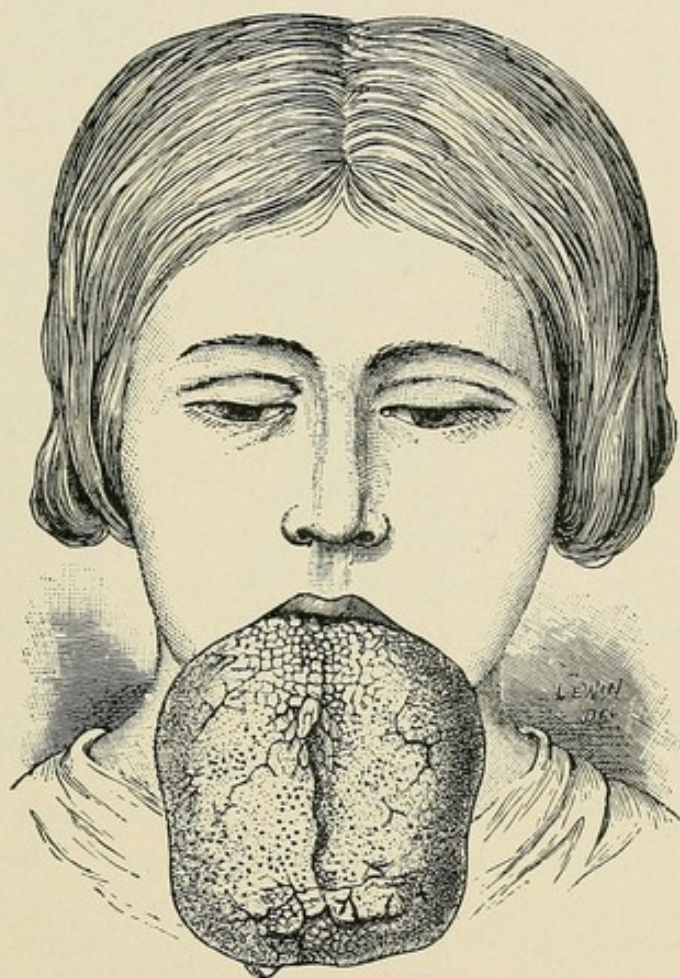


FIG. 321.—Macroglossia in a girl eleven years old (after Humphrey).

and a serous fluid. The spaces were lined by endothelial cells, and the connective tissue contained many elastic fibres. The fluid contained lymphoid corpuscles.

Macrochilia is very rare, and in the cases which have been described it was always congenital. As the disease is sure to become complicated by repeated attacks of inflammation, it should receive attention during infancy or childhood. If the tumor is limited in extent, as in Billroth's case, it should be removed by excision. If it is too extensive for complete removal, the size of the lip should be reduced to the desired extent by wedge-shaped excisions. Under such circumstances Lannelongue's sclerogenic method of treatment deserves a trial.

Neck.—Many cases of congenital hydrocele or serous cysts of the neck are of lymphatic origin. Usually, although not always, they are

congenital. The development of the capsule is very imperfect as compared with true cystomata in the same locality. Arnold divides these tumors into superficial and deep. The former are situated between the skin and the platysma; the latter, beneath the platysma, usually along the anterior surface of the larger vessels. The deep tumors generally reach the greater size. They may surround the whole neck, and may extend beneath and below the clavicle, in the direction of the axillary space. In an upward direction they may encroach upon the cavity of the mouth. Rokitansky and Gurlt believed that these cysts originated in the connective-tissue spaces during intra-uterine life. The formation of multilocular cysts they explained by assuming that collections of serous fluid formed in different parts of the connective tissue at the same time. It would be impossible to explain why similar hydropic conditions of the connective tissue should not take place in other parts of the body if hydrocele of the neck had such an origin. Luschka maintained that serous cysts of the neck originated in the ganglion caroticum—a theory which does not deserve further consideration, since Arnold found this ganglion intact in two cases of hygroma of the neck. The existence of an endothelial lining of the cyst in all cases and the presence of lymphoid tissue in the cyst-wall leave no doubt that in the majority of cases of serous cysts of the neck, of congenital origin, we have to deal with *cystic lymphangioma*. The serum contained in these cysts is often stained by the admixture of blood, in which event the cysts lose their translucency. If the diagnosis is not clear, an exploratory puncture will provide the desired information. The tumor either remains stationary after birth or increases very rapidly in size. In the former case no treatment is indicated, as a spontaneous cure not infrequently takes place; if this should not be the case, operative treatment is postponed until the child is older. In rapid-growing tumors death often results from pressure of the tumor on the trachea, the œsophagus, and the large vessels and nerves of the neck. In such cases urgent symptoms call for aspiration, which may be repeated as often as the pressure-symptoms demand it. In older children strong enough to withstand the immediate effects of a radical operation, the tumor should be excised, in whole or in part, under strict antiseptic precautions. If complete removal is impracticable, the part of the cyst-wall which remains should be seared with the actual cautery sufficiently deep to destroy its endothelial lining, and the wound should be packed with iodoform gauze. Injections of iodine are too uncertain and dangerous. Injections of carbolic acid after tapping are less objectionable, and should be resorted to if partial or complete excision of the sac is contraindicated.

Subcutaneous and Submucous Connective Tissue.—Most of the chronic lymphatic affections of the subcutaneous connective tissue are of an infective origin and nature. They are caused by the *filaria sanguinis hominis*, and they are prevalent in southern countries, where this parasite has its habitat. Reference has been made to a case of almost general lymphangioma of non-infective origin. True lymphangiomatous tumors of the submucous and subcutaneous connective tissue are exceedingly rare (Fig. 322). Steudener described a cavernous lymph-

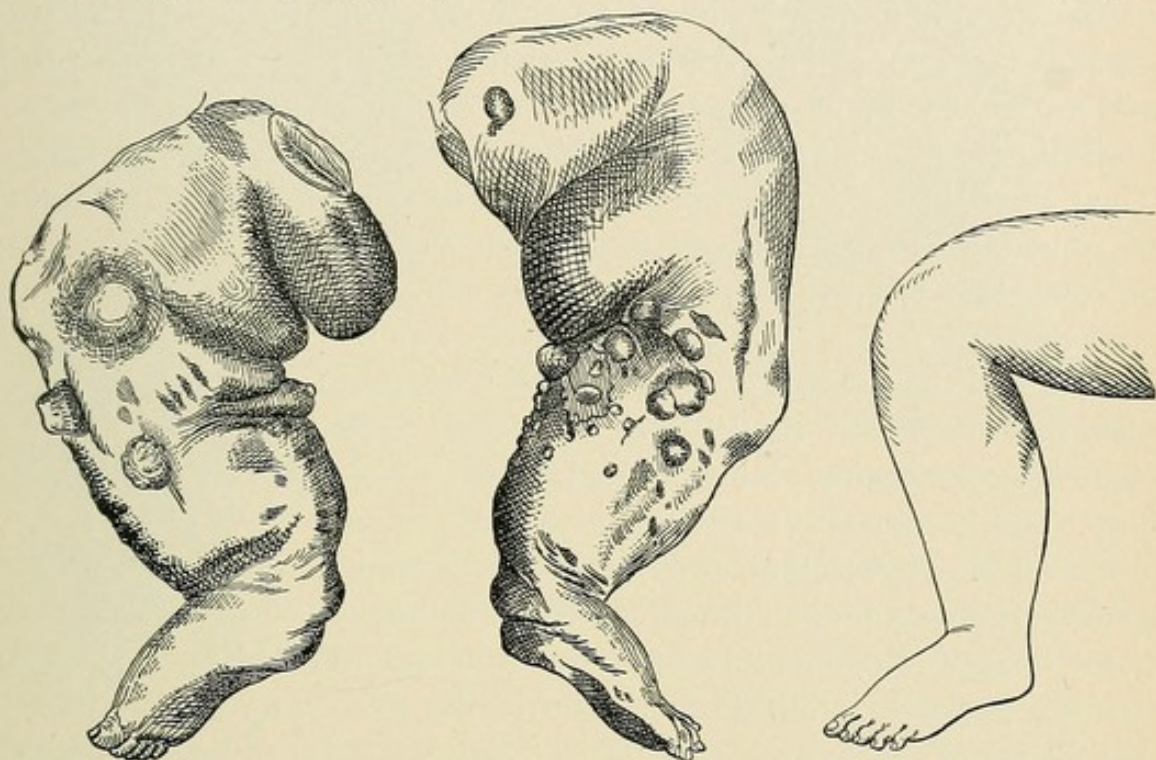


FIG. 322.—Busey's case of lymphangioma.

angioma of the conjunctiva. Biesiadecki found a small lymphangioma in the subcutaneous connective tissue. Gjorgewic found a similar tumor, the size of a fist, in the subcutaneous tissue of the thigh in a girl nineteen years old. In this case large quantities of lymph escaped through two small openings. Reichel described a congenital lymphangioma, the size of a pigeon's egg, which he found in the perineum. More comprehensive statistics of lymphangioma can be found in the monographs on this subject by Busey and Wagner.

Uterus.—The lymphatic origin of some of the cystic tumors of the uterus has been established by Leopold and Fehling. These cysts contain a fluid which coagulates on exposure to air, and which is often stained by the admixture of blood. The cyst-wall is lined by endothelial cells. Many of these cysts are multilocular, the septa being composed of firm fibrous tissue. The new cysts show in their interior, on silver staining, the characteristic reaction of endothelium. In most instances these cysts occur in connection with myofibromata.

XXV. LYMPHOMA.

UPON histogenetic, histological, and physiological grounds tumors of the lymphatic glands should be excluded from tumors of the true glandular organs. The lymphatic glands are mesoblastic structures, and are not secreting organs. They are hematoplastic organs, physiologically closely allied to the medullary tissue of bone and the spleen. They are composed of lymphoid corpuscles and a delicate reticulum of connective tissue enclosed in a firmer capsule of connective tissue. They contain normally no epithelial cells (Fig. 323). The lining of the lymphsinuses and the follicles is composed of numerous plate-like connective-tissue cells, in places these elements constituting almost an endothelial covering. The lymphatic vessels and glands are found wherever blood-vessels are present; besides, lymphspaces are found in the cornea. In the submucous tissue lining the different hollow viscera lymphoid tissue is found as a diffuse infiltration in the form of follicles (Fig. 324).

As a lymphatic gland is not a true gland, the tissue composing it is called, from its resemblance to glandular tissue, *adenoid* tissue; and as it produces the lymph, it is also called *lymphoid* tissue.

Its essential histological element is the lymphoid cell or lymphoid corpuscle, the product of proliferation of the plate-like connective-tissue cell.

Definition.—*A lymphoma is a benign tumor formed of lymphatic tissue produced from a matrix of lymphoblasts.* In no department of surgical pathology do we meet with more confusion than in the differentiation between benign and malignant tumors and infective swellings of the lymphatic glands. Virchow includes under the term "lymphoma" all tumors and swellings composed of lymphoid tissue. Many authors still continue to speak of a "primary carcinoma" of the lymphatic glands. Some pathologists entirely ignore the existence of non-malignant tumors of the lymphatic glands. This confusion of terms and pathological conditions was increased when Billroth introduced the term "malignant lymphoma." At the present time it is

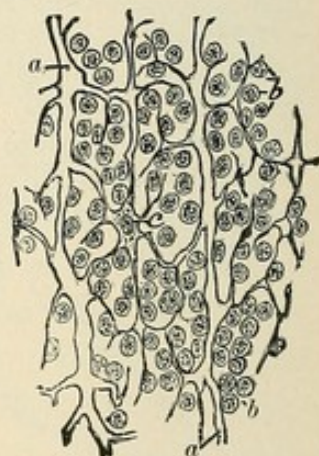


FIG. 323.—Elements of adenoid tissue from partially brushed section of lymphatic gland of a child (after Piersol): *a*, fibres of reticulum; *b*, lymphoid cells; *c*, expanded connective-tissue plate.

easier to say what a lymphoma is not than what it is: it constitutes in surgical pathology at the present time a veritable *lucus a non lucendo*.

Lymphoid tissue is exceedingly susceptible to infection, and is therefore predisposed to acute and chronic inflammation; it is also frequently the seat of sarcoma, but lymphoma, in the restricted sense

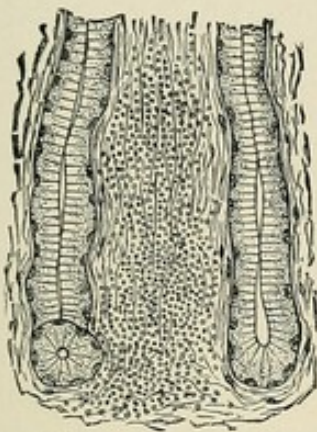


FIG. 324.—Diffuse lymphoid tissue occupying deeper layers of mucosa of human stomach (after Piersol). The lymphoid cells infiltrate the fibrous tissue between the glands without being definitely limited.

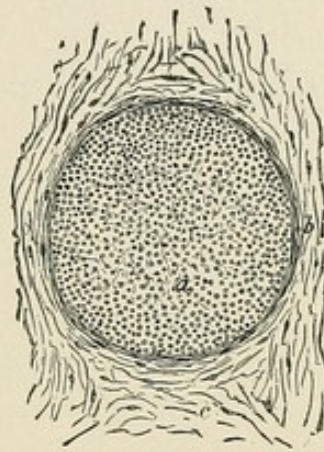


FIG. 325.—Simple lymph-follicle from the conjunctiva of a dog (after Piersol): *a*, lymphoid tissue limited by the fibrous capsule (*b*); *c*, surrounding connective tissue.

in which this term will be used here, is exceedingly rare. The resemblance in the structure of tumors and infective swellings of lymphatic glands is so close that a reliable differentiation must be based on the clinical aspects and the etiology of the different affections of the lymphatic glands. Enlargement of the lymphatic glands may be due (1) to infection, (2) to sarcoma, (3) to carcinoma, or (4) to lymphoma. The acute affections of the lymphatic glands, characterized by rapid enlargement, pain, tenderness, and fever, are produced by the entrance into the lymphatic system of pyogenic microbes, of the *bacillus malleus*, or of pre-formed septic material. If the process is chronic, the immediate cause is usually the virus of either syphilis or tuberculosis. In leukemia and pseudo-leukemia the infection is diffuse and is unattended by the usual symptoms which indicate the existence of an acute or a subacute inflammation; the glandular affection either appears diffusely from the beginning or becomes diffuse during its course. These affections point so strongly to the existence of a microbic origin that no doubt can be entertained as to their infective origin. Sarcoma invades successively the glands of the same chain, and frequently terminates fatally by general metastasis. Carcinoma of the lymphatic glands is always a secondary affection; it never occurs as a primary disease, as the lymphatic glands do not contain the essential histological elements—epithelial cells. *Lymphoma is a tumor of the lymphatic*

glands composed of lymphoid tissue; the growth remains as a local affection, and appears clinically as an encapsulated tumor which manifests no tendency to implicate adjacent glands, and which is never complicated by affections of other blood-producing organs. The lymphoblasts of the matrix of the tumor produce lymph-corpuscles which are not transformed into leucocytes, but which remain in the reticulum of the tumor as the essential tumor-elements. Lymphoma is a functionless tumor, in this respect differing from the hyperplastic, highly active glands in leukemia.

Histology and Histogenesis.—*A lymphoma is not produced from pre-existing adenoid tissue, as are the infective swellings. It is the product of tissue-proliferation from an embryonal matrix of lymphoblasts of congenital or post-natal origin. A lymphoma is a tumor which has no more connection with the adjacent lymphatic channels than an adenoma has with the surrounding ducts of a gland. The connective-tissue plates, modified endothelial cells of the matrix, the lymphoblasts, produce the lymph-corpuscles which are the essential histological elements of the tumor (Fig. 326).*

In its structure a lymphoma bears a strong resemblance to myeloma (Pl. 12, Fig. 1). The lymphoid cells are so numerous that often they almost completely obscure the stroma. The capsule of the tumor is firm, being composed of concentric layers of fibrous tissue.

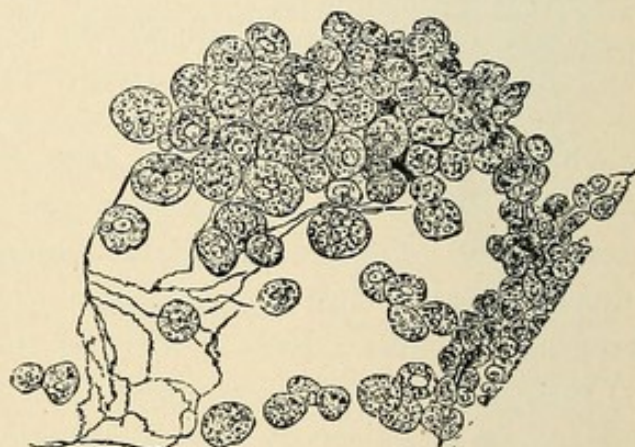
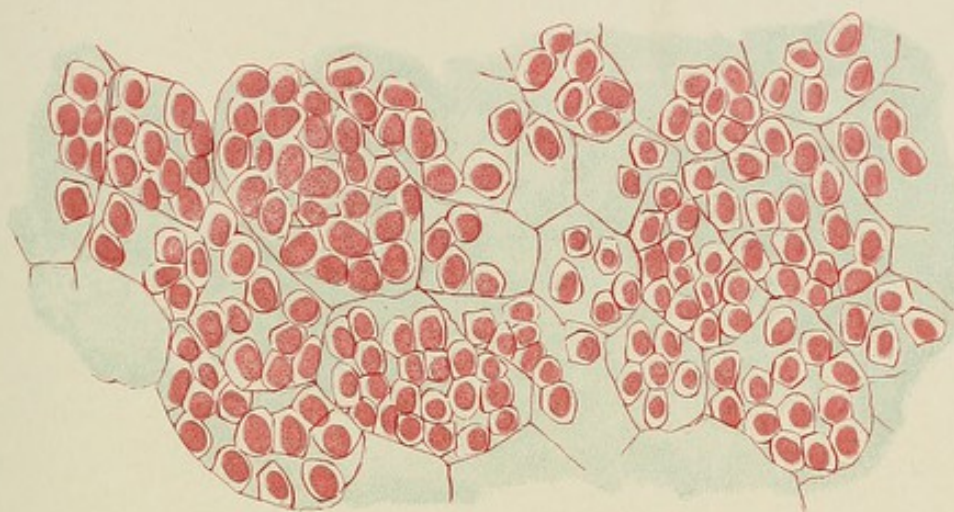


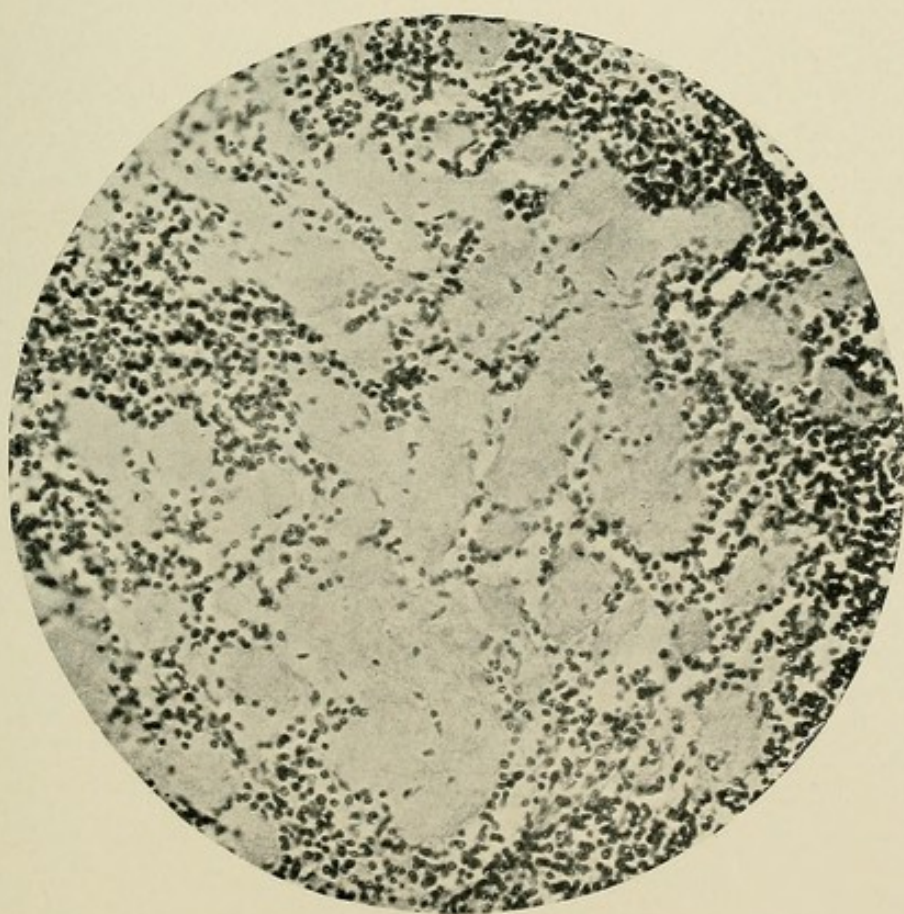
FIG. 326.—Lymphoma, showing lymphoid cells and delicate reticulum (after Paget).

The atypical structure of the tumor is characterized by the absence of well-defined lymph-sinuses, while the follicular structure is well preserved. The surface of the tumor is smooth, and lacks completely the prolongations into the surrounding connective tissue that are such conspicuous features of lymphangioma. The lymphoid corpuscles, which are only occasionally present in lymphangioma, form the bulk of the tumor in lymphoma.

Retrograde Metamorphoses.—Permanency of the tumor-tissue as compared with the inflammatory products which constitute the infective swellings is one of the most important elements in the differentiation between a lymphoma and the different forms of inflammatory swellings of the lymphatic glands, both acute and chronic. Suppuration can occur only if the tumor becomes the seat of infection with pyogenic




1



2

1. Myeloma of rib (after Klebs): myeloid cells with large nuclei in a delicate network of connective tissue.
2. Hyaline degeneration of a lymphatic gland (after Karg and Schmorl). The reticulum of the gland has been transformed into a shining, structureless framework. The hyaline masses are confluent in some places; between the masses in the centre of the field are scanty remnants of gland-tissue. The glandular structure is more abundant in the peripheral portions of the picture.



microbes, and caseation can take place only in the event of the tumor becoming infected with tubercle bacilli. A lymphoma may attain considerable size before any degenerative changes occur, in this respect differing greatly from suppurative, tubercular, glandulous, septic, and gonorrheal adenitis. Myxomatous degeneration of the stroma may occur—a change which renders the tumor softer—or the tumor may become harder by an increase of the connective-tissue reticulum. A hyaline degeneration such as that shown on Plate 12 (Fig. 2) sometimes inaugurates graver degenerative changes in a lymphoma. Calcareous degeneration preceded by fatty degeneration has been observed. Small cysts occasionally form by dilatation of follicles. A lymphoma, after having remained stationary for a long time, may become transformed into a sarcoma.

Symptoms and Diagnosis.—Lymphoma is a rare tumor of the lymphatic glands, if we exclude, as should be done, all infective swellings. It is found most frequently in the region of the neck, in the groins, the axillæ, the mediastinum, and the retroperitoneal space—that is, in localities in which the lymphatic glands are most numerous. Lymphoma occurs most frequently in young adults. If several tumors appear at the same time, they increase in size at the same rate, and are movable, painless, and not tender on pressure. The skin over the tumor remains intact. The tumor is smooth and is surrounded by a perfect capsule. Extension to other glands never takes place, as is the case in sarcoma and in infective swellings. All signs and symptoms of inflammation are absent. The general health is not impaired. The tumor or tumors, if large, may cause pressure upon important organs, and in this way may become a source of danger. In the differential diagnosis between lymphoma and other tumors and swellings of the lymphatic glands it is important to consider the following affections: lymphangioma, sarcoma, lymphadenitis, tuberculosis, glanders, leukemia, pseudo-leukemia, and syphilis.

Lymphangioma.—Lymphangioma occurs as a more diffuse tumor and is not encapsulated. In many cases lymph escapes from one or more openings in the tumor—an occurrence never observed in lymphoma.

Sarcoma.—Lympho-sarcoma appears first as a single tumor, which is followed by successive infection of glands in the same region, usually in the direction of the lymph-stream. The tumors grow very rapidly, and general infection not infrequently takes place.

Lymphadenitis.—Acute suppurative lymphadenitis is attended by fever and all the local signs and symptoms of inflammation, and is always attended by lymphangitis between the infection-atrium and the

inflamed glands. In the chronic form the symptoms of inflammation are often masked, so that the source of infection is overlooked and the accompanying or preceding lymphangitis is not recognized. The disease may be limited to one or two glands, which renders it still more obscure. Some tenderness is, however, always present, and foci of suppuration can often be detected by palpation or by exploratory puncture.

Tuberculosis.—Glandular tuberculosis is a progressive disease. The affection extends from gland to gland in the infected region. Regressive metamorphoses, coagulation-necrosis, caseation, and liquefaction of the cheesy product are early and almost constant manifestations. The extension of the disease beyond the capsule of the gland in advanced cases is also an important factor in distinguishing between a lymphoma and swellings of an infective origin.

Glanders.—Glanders occurs, if it affects the glands, as an acute or a subacute diffuse affection, in this respect differing entirely from lymphoma, which remains as a local tumor. The discovery of the bacillus of glanders in the inflammatory product will render the diagnosis positive.

Leukemia.—Leukemia, as was correctly shown by Virchow in 1845, appears as a hyperplasia of all hematoplastic organs—the spleen, the lymphatic glands, and the marrow of bone—and is characterized by a specific pathological change in the blood—an excess of white blood-corpuscles. The increase in the number of leucocytes that typifies this disease led Bennet to apply to it the term *leucocythemia*. Neumann added to the splenic and lymphatic forms the myelogenous variety. The lymphatic glands in different parts of the body become enlarged and hard, and, as a rule, this process is attended by enlargement of the spleen and by a simultaneous affection of the marrow of the bone, which affection is often manifested by tenderness over the junction of the xiphoid cartilage with the sternum and over the epiphyseal extremities of the long bones. The excess of leucocytes in the blood is never absent, and from a slight change during the incipency of the disease may reach such an extent that the red and white corpuscles are present in the same proportion. Neumann traced in the blood of leukemic patients cells intermediate between the red and the white corpuscles—small nucleated red corpuscles.

In the commencement of the disease it is often difficult, if not impossible, to differentiate simple leucocytosis and leukemia by microscopical examination of the blood. Huss thinks that if the proportion of white to red corpuscles is increased to 1 : 20, such blood is leukemic blood; but this is not always the case. Staining of the

blood-corpuscles with eosin is an important diagnostic aid. Leukemic blood always contains *eosinophilous cells*. In doubtful cases microscopical examination of the blood will succeed in making a positive differential diagnosis between lymphoma and enlargement of the glands attending leukemia. W. S. Church reports a case of leukemia in which

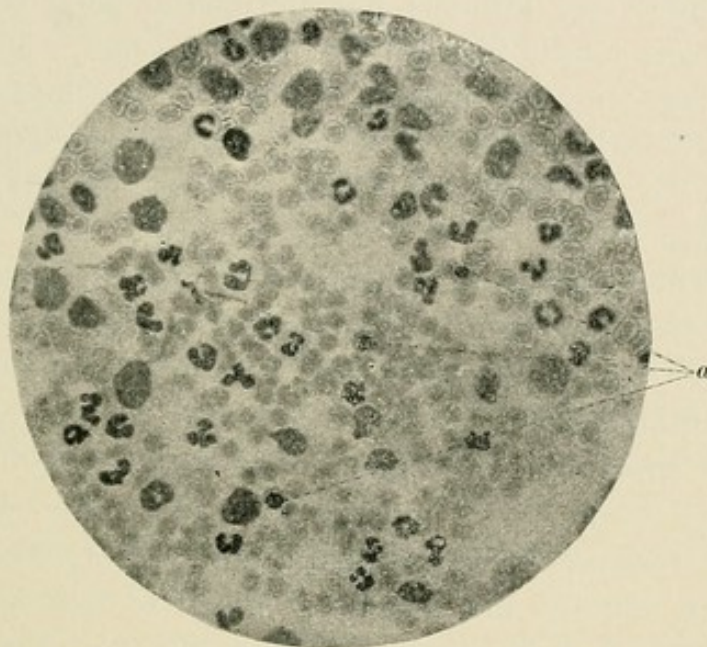


FIG. 327.—The blood in leukemia (after Karg and Schmorl). Besides the pale-red blood-corpuscles are leucocytes in various forms, the number of the leucocytes being immensely increased. The smaller leucocytes contain irregular lobulated nuclei; the larger ones contain large nuclei equally stained throughout; *a*, nucleated red blood-corpuscles.

only the thoracic and abdominal lymphatic glands were found enlarged at the post-mortem examination. Murchison records the case of a child twelve years old, in whom no enlargement of any subcutaneous lymphatic glands existed, who died with "lymphatic new formations" in the liver and enlargement of the glands in the fissure of the liver. In Church's case the disease was attended by fever, which he regards as of diagnostic importance in the differentiation between leukemia and malignant tumor.

Pseudo-leukemia.—This affection of the lymphatic glands, known also as "anæmia lymphatica," "Hodgkin's disease," "adenie" (Trousseau), "malignant lymphoma" (Billroth), and "lympho-sarcoma" (Virchow), resembles lymphoma more closely than leukemia. It is unquestionably an infective disease in which the undiscovered microbe selects the lymphatic tissue as its field of action. The lymphatic glands of one region of the body, most frequently the cervical, become successively enlarged, forming hard masses, to be followed by a similar condition of the glands in other regions of the body. The disease is attended by progressive anemia, but the blood-changes which have been described as occurring in leukemic blood are absent. In this

disease the lymph-cells are increased in number in the meshes of the enlarged glands, and the cortical and medullary portions of the glands cannot be distinguished from each other. The disease sometimes remains stationary for a certain length of time. The spleen, the tonsils, and the marrow of the bones are frequently implicated. Metastasis in the liver and kidneys has frequently been observed. The disease terminates fatally in from one to two years. The appearance of enlarged glands in the different regions of the body distinguishes this disease sufficiently from lymphoma, in which such a dissemination is never observed. Lymphoma, being a strictly local disease, is not attended by impairment of the general health.

Syphilis.—Enlargement of lymphatic glands in syphilis after the disease has become general is not limited to one region: all the glands are more or less implicated. In primary syphilis the extension of the disease to the lymphatic structures is indicated by enlargement (bubo) of the glands which are in connection through lymphatic channels with the primary sore. We must restrict the term "lymphoma" to non-malignant tumors of the lymphatic glands, single or multiple, but their number is limited and usually confined to one region in which an infective origin can be excluded either by a careful study of the clinical aspects or by bacteriological examination. As has previously been stated, lymphoma is quite rare. The writer has seen these tumors in the cervical and axillary regions and in the groins. The tumors are movable, painless, and firm, and may in the course of several years attain the size of a hen's egg. The tumors may occur at any time of life, but they are most frequently met with in young adults. After the tumors have reached a certain size they become stationary throughout life, unless they become the seat of infection or undergo transformation into sarcomata. They do not return after extirpation, and they become dangerous only when from their size they exert harmful pressure upon important adjacent organs.

Treatment.—The proper treatment of lymphoma is enucleation. The tumors are always well encapsulated, and there is no danger of recurrence after complete removal by this method.

XXVI. MYOMA.

MYOMA was first described as a distinct variety of tumors by Virchow. It has often been mistaken for fibroma, on account of the predominance of fibrous tissue in many of the myomatous tumors. Fibrous tumors which contain muscular fibres should be classified with the myomata, and not with the fibromata, as the muscle-fibres constitute, from a histogenetic standpoint, the essential part of the tumor. In myoma the concentric striated appearance so characteristic of a proper fibroma is frequently less marked, and the substance of the tumor seems to be more homogeneous in its structure. Fibrous tissue is always present in varying proportions, and often is so abundant as almost to obscure the essential tumor-tissue.

Definition.—*A myoma is a tumor composed of muscle-tissue produced from a matrix of myoblasts.* Vogel called them "muscular tumors;" Virchow, "myomata." Zenker made a subdivision of this group of tumors necessary, as he described tumors which were composed of striated muscular fibres, while before his time it was believed that all myomatous tumors were composed of unstriated muscular fibres. A tumor composed of striped muscular fibres is called a "rhabdomyoma" or "myoma striocellulare," whereas a tumor composed of unstriated muscular fibres is called a "leiomyoma" or "myoma lævicellulare." For the sake of brevity we shall describe the two histological varieties as rhabdomyoma and leiomyoma. There are many reasons to believe that a myoma springs from a matrix of myoblasts independently of the pre-existing muscular fibres between which the tumor takes its origin.

Embryology.—According to Rabl, the muscular tissue in the embryo is derived from a part of the mesoblast enclosed by the three-faced original vertebræ at a point, corresponding with the mesial junction, which is in contact with the nerve-tube, while the ventral-border surface, which adjoins the primitive aorta, becomes the sclerotoma, which forms the axial connective tissue, while the upper wall furnishes the skin with its connective tissue. The embryonal tissue destined to become transformed into muscular tissue develops into a large plate under the connective tissue of the skin, and sends forth, in the form of muscular buds, projections to the extremities. The con-

nective tissue cannot produce muscle-tissue, and when muscular fibres are found in a locality not normally supplied with this tissue, its occurrence is always due to an erratic deposition of embryonal cells during early life.

Rhabdomyoma.—Benign tumors composed of striated muscular fibres are exceedingly rare. They were first described by Zenker. Marchand, Eberth, and Cohnheim confirmed Zenker's observation and reported new cases. The tumors usually grow in connection with the kidney, sometimes in the testis, and they are always congenital. Recklinghausen found in several new-born children myomata the size of a pigeon's egg in the heart-muscle. Fibromatous and myomatous tumors of the heart have been described by Zander, Boström, and others.

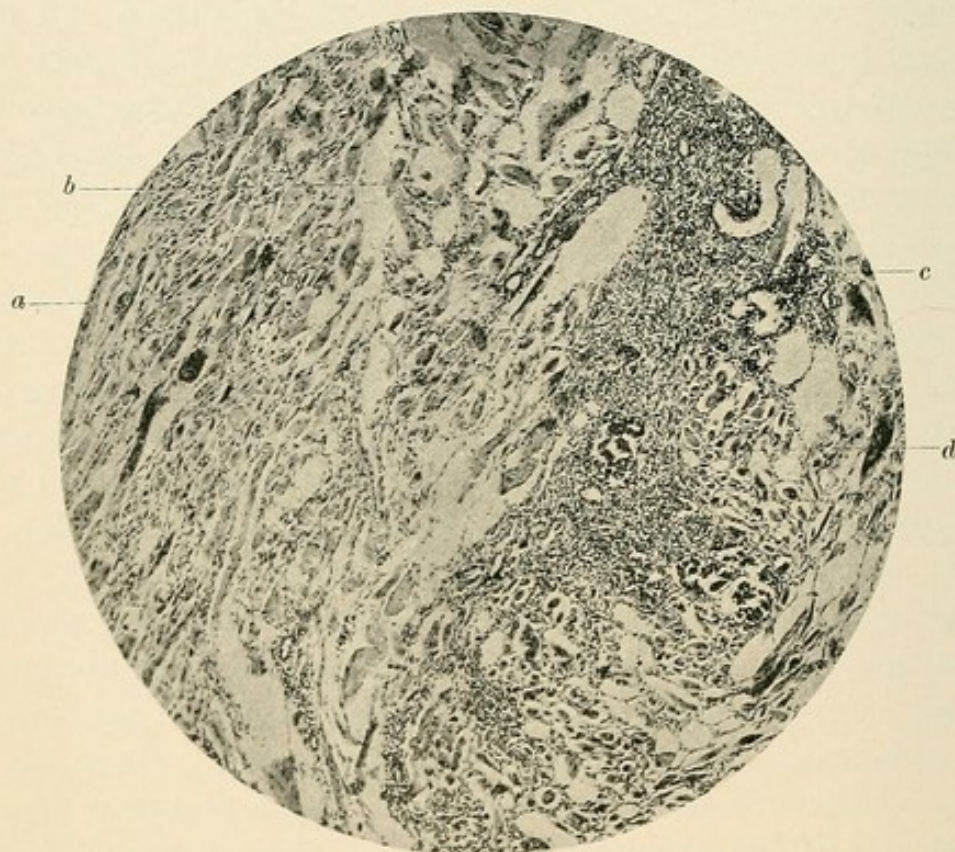


FIG 328.—Adeno-rhabdosarcoma of kidney (after Karg and Schmorl): the tumor (*a*) is composed of bundles of striated muscular fibres arranged in different directions; the striations can be seen by the aid of a magnifying lens. The interstitial tissue at *b* is scanty and the nuclei are small; at *c* the nuclei are larger and more numerous, and appear as round-celled sarcoma arranged in spaces (*d*) lined by cylindrical cells.

Rokitansky found a rhabdomyoma in the scrotum. Neumann observed a similar tumor in the same locality in a boy three and a half years old. It took its origin at the lower pole of the testicle, where the gubernaculum Hunteri has its point of attachment. The muscular fibres contained no glycogen, and the sarcolemma was imperfectly developed. Prudden found striated muscular fibres in a tumor of the parotid gland in a boy seven years old; Virchow, in the stroma of ovarian tumors; Senftleben, in cystoid tumors of the testicle; and Cattani, in a vesical

polypus in a boy twelve years of age. Huber, Boström, Marchand, and others have described cases of striated myosarcoma of the kidney in children. Striated muscular fibres are found more frequently as a constituent part of sarcoma of the urogenital organs than as the sole characteristic constituent of benign muscular tumors. The structure of such a complicated tumor is shown in Figure 328. Rhabdomyoma is interesting from an etiological standpoint, but it presents itself to the surgeon only as a pathological curiosity. We shall discuss in this section more in detail leiomyoma, which is of vastly more practical interest to the surgeon.

Leiomyoma.—Histology and Histogenesis.—Leiomyoma occurs most frequently in the uterus, Fallopian tubes, and gastro-intestinal canal. The tumor seldom presents the same parallel arrangement of the muscular fibres which in normal condition is the rule. The muscular fibres cross one another in all possible directions, so that in sections they are cut transversely, obliquely, and longitudinally (Fig. 329). Parallel with the bundles of muscular fibres are found the blood-vessels, which would indicate that the irregular distribution of fibres is determined by the irregular course of the blood-vessels (Fig. 330).

The irregularity in the arrangement of the muscular fibres is unfavorable to functional activity, as muscular contraction would produce a diminution in size of the tumor in all directions, and would thus diminish the lumina of all the vessels. In consequence of this arrangement the muscular tissue with the growth of the tumor is diminished, and is replaced largely by fibrous tissue. Even if the muscular tissue almost disappears during the growth of the tumor, its original character as a myoma is preserved from a genetic standpoint, and this tumor should be called a "myoma," and not, as was suggested by Müller, a "desmoid," or by Rokitsky, a "fibroid." As the connective tissue becomes more abundant, the muscle-fibres are compressed into streaks which are sometimes difficult of recognition.

The structure of a leiomyoma is influenced by the character of the muscular tissue in which it develops. The muscle-fibres are spindle-

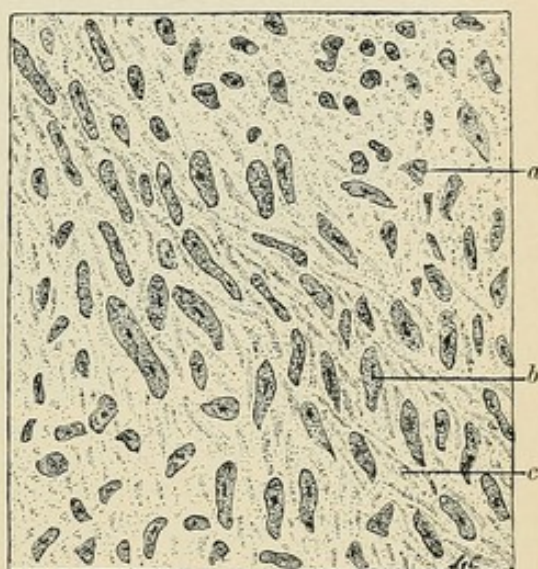

FIG. 329.—Myofibroma of the broad ligament; \times 480 (Surgical Clinic, Rush Medical College, Chicago): *a*, muscle-fibres in cross-section; *b*, muscle-fibres in longitudinal section; *c*, interstitial elastic fibres.

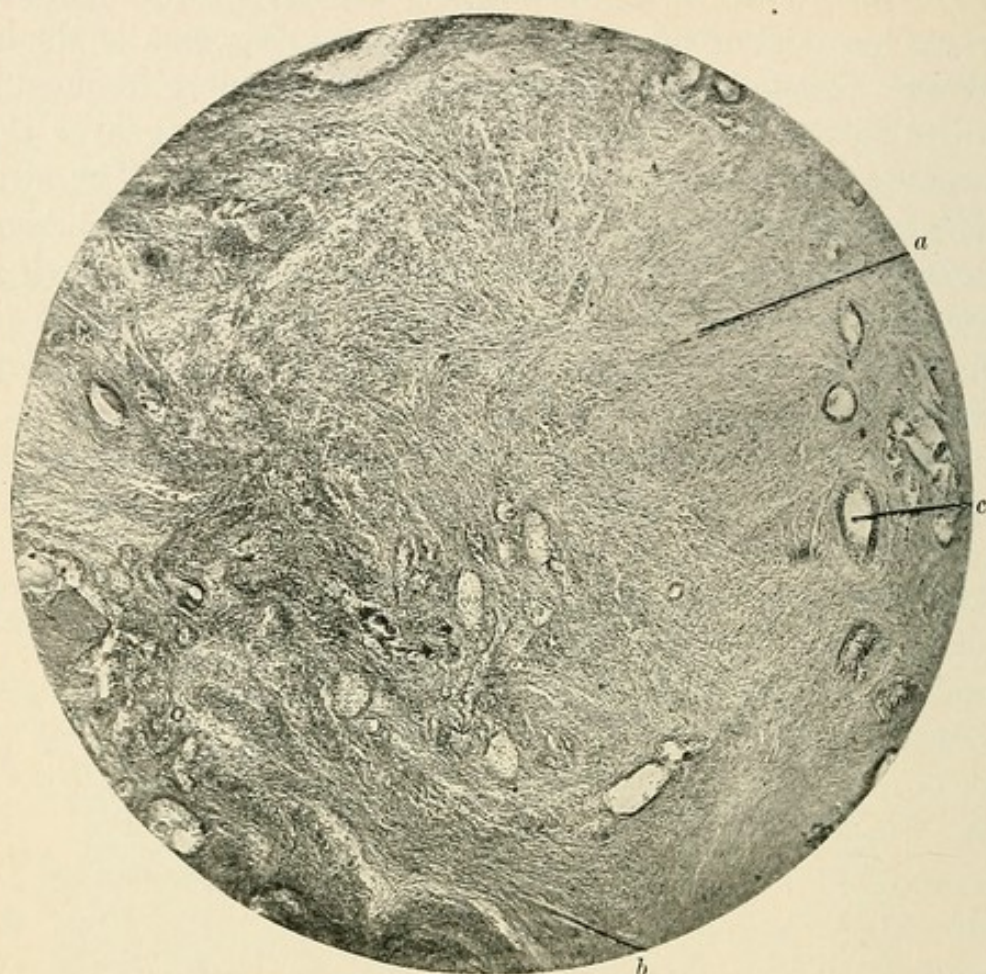


FIG. 330.—Myofibroma of the uterus; $\times 75$ (Surgical Clinic, Rush Medical College, Chicago): *a*, fibrous tissue; *b*, longitudinal section of muscle-fibres; *c*, large blood-vessels.

shaped, tapering into filamentous points, and contain near their centre the typical hammer-shaped nucleus (Fig. 331). In tumor-sections these filamentous ends of the cells are not shown, even if the section happens to fall parallel with the fibres (Fig. 332).

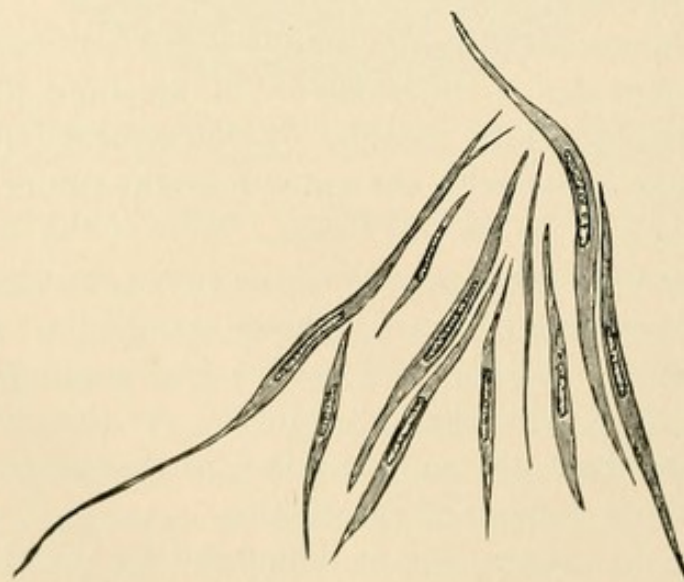


FIG. 331.—Muscle-cells from myoma of the uterus, isolated by the aid of caustic potash; $\times 250$ (after Perls).

In the uterus myofibroma is found as a round, firm-on-the-surface, uneven tumor. On section the surface is not smooth, as the fibres that are cut transversely contract more than those cut longitudinally. The color of the tumor is either a pure white or somewhat translucent, according to the preponderance of the muscular or of fibrous tissue.

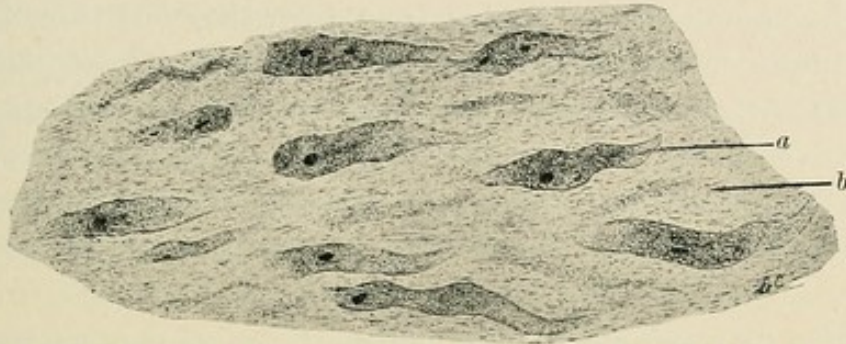


FIG. 332.—Myofibroma of broad ligament; $\times 510$ (Surgical Clinic, Rush Medical College, Chicago):
a, muscle-cells; *b*, intercellular fibrous tissue.

The section is mapped out into lobes by dense septa of fibrous tissue which traverse the tumor from the surface toward the centre. In these septa are found the larger arteries which supply the tumor with blood. The capillaries are collected mostly on the surface of the tumor, and terminate in veins which, if any obstruction exists, which is frequently the case, are often dilated into large channels. The capsule of the tumor forms at a late stage, when from pressure the surrounding tissue disappears by atrophy, and from its connective tissue the capsule is formed.

The earliest stages of the development of a uterine myoma has not been investigated sufficiently. Runge traces the origin of such tumors to round indifferent cells; Virchow, to a hyperplasia of existing muscular fibres. Kleinwächter found the smallest myomata supplied with a muscular pedicle which he believes springs from a blood-vessel. As endothelial cells cannot be transformed into muscular fibres, such a mode of origin is not probable. Kleinwächter's observations, however, show that muscular fibres are produced along capillary vessels, and the pedicle which he described may correspond to one of these vessels. The most recent observations of Hauser would indicate that the remains of the Wolffian ducts have something to do with causing the surrounding muscular tissue to develop into myomata. A number of observers have found inside of myomata epithelial collections in the form of cavities, canals, and cysts; a few containing ciliated epithelium. These structures need not necessarily have come from the Wolffian bodies; they might, as Hauser suggested, be derivatives from the uterine mucous membrane. Ribbert has a specimen in which a chain of epithelial cells extends seven or eight millimetres into the uterine

wall, and which in the section appear as isolated epithelial islands. The extreme tip of this chain lies against a small myoma, but does not penetrate into its substance.

Ricker found frequently in myomatous tumors epithelial structures, channels, etc., which he believed were derived from Müller's ducts. From such epithelial nests adenomata and cystic tumors may develop within or independently of myomatous growths. In the majority of cases the tumor no doubt springs from a matrix of myoblasts in the uterine tissue, while in exceptional cases the tumor may start from a similar matrix in the walls of blood-vessels. The round cells which have been found within and in the vicinity of recent myomata are fibroblasts, which always take part in the production of a myofibroma.

The shape of a myoma is also subject to influences exerted by the surrounding tissues. Pedunculation of submucous and subserous myofibromata of the uterus is of frequent occurrence. The tumor in

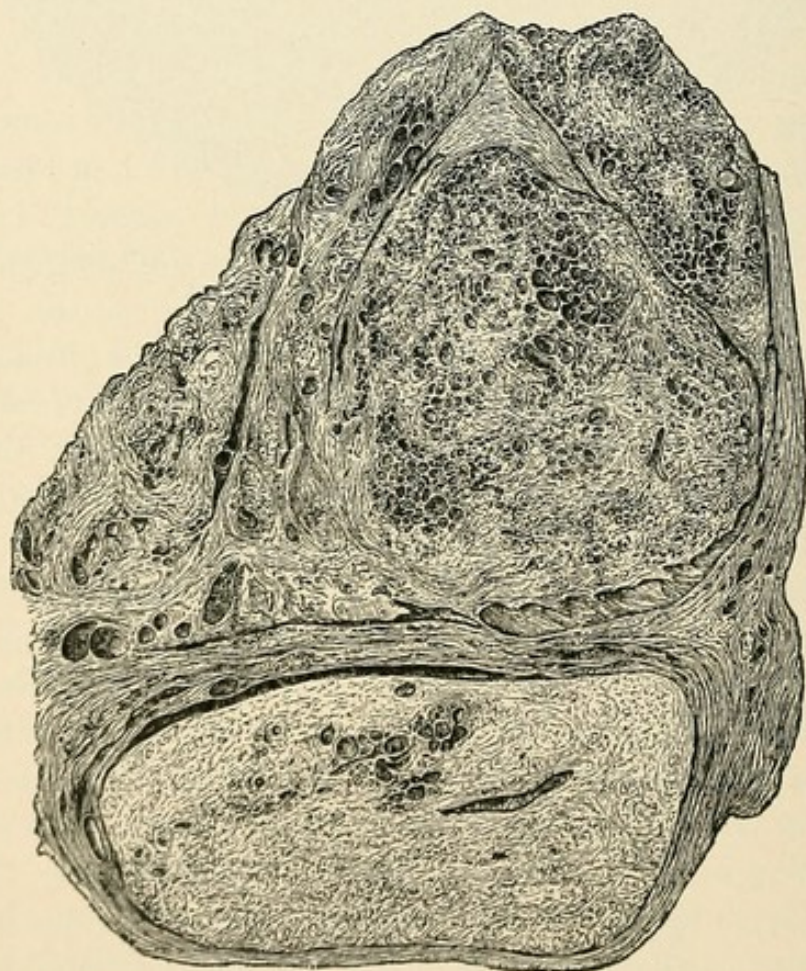


FIG. 333.—Very vascular uterine myoma seen in section (after Virchow).

either of these localities grows in the direction offering the least resistance, carrying before it the mucous membrane or the peritoneum, which, with the blood-vessels that supply the tumor, forms the pedicle.

Intestinal myofibroma develops usually not in the submucous muscular fibres, but in the middle coat, giving rise to diffuse thickening, and resulting often in the formation of a ring of tumor-tissue including the whole circumference of the tube.

The vascular supply of a myoma varies greatly. In dense tumors composed principally of fibrous tissue it is often exceedingly scanty. Virchow described an angiomatous myoma of the uterus. In tumors of this kind there are found numerous larger venous channels which communicate freely with one another. Wesener described a telangiectatic myoma of the duodenum.

Regressive Metamorphoses.—One of the most frequent causes of degeneration of the tissues of a myofibroma is œdema. The œdema is produced by venous obstruction resulting from twisting or flexion in the case of pedunculated growths, or from pressure or thrombosis in interstitial tumors. The serum distends the connective-tissue spaces, macerates the fibrous tissues, and crowds apart the muscular fibres, which at the same time become narrower from compression (Fig. 334).

Cystic degeneration is another regressive change quite frequently met with in uterine myofibroma. As recent investigations have shown, the formation of cysts is in all probability in the majority of cases due to distention of lymphatic spaces.

Hyaline degeneration and disappearance of the tumor-tissue by pressure-atrophy accompany the growth of lymphatic cysts. In a case, described by Klebs, of endotheliomatous proliferation in a uterine myofibroma the primary tumor was surrounded by round nodules, and in the kidney myomatous metastatic deposits were found. It is to be taken for granted that metastasis



FIG. 334.—Edematous myofibroma of the uterus; $\times 590$, reduced one-third (Surgical Clinic, Rush Medical College, Chicago): *a*, muscle-cells; *b*, œdematous intercellular substance.

of the myoblasts was caused by infiltration of the tumor by endothelial cells. Fatty degeneration and calcification in parts of the tumor are of frequent occurrence. Myxomatous degeneration of the fibrous part of the tumor is another not uncommon form of regressive metamorphosis. Finally, myofibroma may undergo transformation into sarcoma.

Symptoms and Diagnosis.—Myofibroma begins insidiously and grows slowly. Frequently its existence is suspected only after the

tumor has produced symptoms. A circular myofibroma of the œsophagus by encroaching upon the lumen of the organ may give rise to difficulty in deglutition and to other symptoms which suggest the presence of a progressive stenosis of the tube. A myoma of the intestine gives rise to no symptoms until the tumor produces intestinal obstruction by stenosis, invagination, volvulus, or flexion. An interstitial or subserous myofibroma of the uterus may attain large size before it produces pathognomonic symptoms. Its presence is discovered either during an examination for the cause of obscure symptoms, or accidentally by the patient after the tumor has become palpable above the pubes. A submucous myofibroma of small size may become the cause of severe and repeated hemorrhages. Myoma of the uterus is often multiple, converting the organ into a nodular, shapeless mass. Bimanual palpation shows that the tumor or tumors are attached to the uterus. In intra-uterine growths the cervix is often considerably dilated, and the tumor can be discovered by inserting the right index finger into the uterine cavity and pressing the organ with the opposite hand well down into the pelvis.

Prognosis.—The danger which attends myofibroma depends on the organ or part of an organ from which the tumor springs and upon the histological structure of the tumor. A circular myoma of any of the different parts of the digestive tube is more likely to result in obstruction than is a tumor involving only a part of the circumference of the tube. Progressive growth will take place in proportion to the amount of muscular tissue in the tumor. Tumors in which the muscle-fibres predominate grow more rapidly and attain larger size than the hard, fibrous variety. Great vascularity also tends to increase the growth of the tumor. Submucous tumors of the uterus undermine the health and shorten life from hemorrhages. Large interstitial and subserous tumors of the uterus may interfere mechanically with the functions of important abdominal organs. Uterine myomata sometimes give rise to sepsis from infection with pus microbes. Not infrequently a pregnancy results in dangerous, and occasionally in fatal, complications. The possibility of myofibroma undergoing transformation into sarcoma must not be lost sight of in rendering a prognosis.

Treatment.—Medical treatment in the management of myoma should be restricted to alleviation of the symptoms which a tumor may produce. The administration of ergot as a curative agent has not met the expectations of those who have given this drug a fair and prolonged trial. In bleeding uterine myomata rest and the internal administration or injection of ergot have yielded good results, but have no effect in arresting the growth of the tumor. The treatment

of uterine myoma by electricity, so strongly advocated by Apostoli, is still on trial. It has not yielded the results claimed for it, and seems fast giving way to operative measures. In the treatment of uterine myoma demanding operative measures the surgeon either resorts to removal of the tumor through the vaginal route, by abdominal hysterectomy or by myomectomy, or he seeks to arrest further growth of the tumor by diminishing its blood-supply by removal of the uterine appendages.

Myomata of the intestinal canal are not diagnosed before they give rise to intestinal obstruction, in which event a positive diagnosis should be made by opening the abdominal cavity, when the tumor is dealt with according to the indications that present themselves.

TOPOGRAPHY.

Uterus.—The uterus is by far the most frequent seat of myomatous tumors. For anatomical, clinical, and pathological reasons it has been

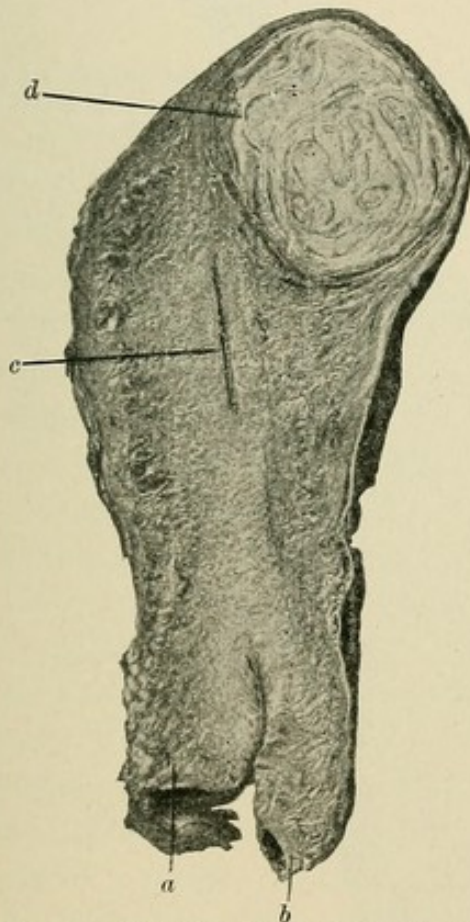


FIG. 335.—Myoma at the fundus of the uterus, growing outward (after Winckel): *a*, anterior lip; *b*, posterior lip; *c*, cavity of the uterus; *d*, tumor.

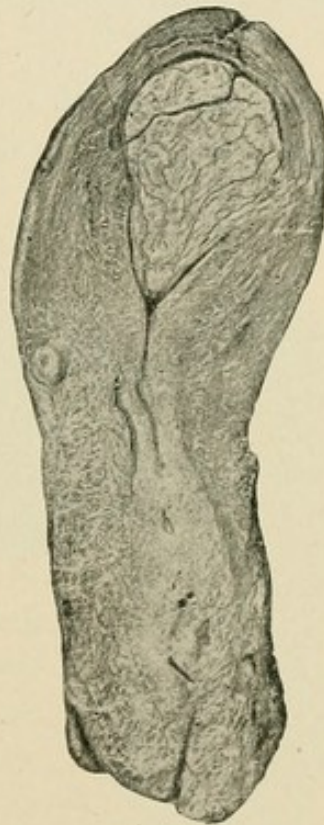

FIG. 336.—Myoma from fundus, growing inward (after Winckel).

customary to describe these tumors, according to their location, as—
1. Interstitial; 2. Submucous; 3. Subserous. A tumor that is primarily interstitial may eventually grow in the direction of the mucous or serous surface, and become a submucous or subserous tumor (Figs. 335, 336).

Interstitial—or, as they are also called, intraparietal—tumors may

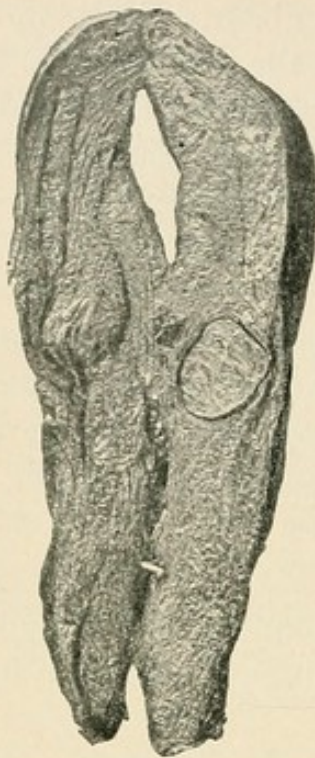

FIG. 337.—Two interstitial myomata near cervix (after Winckel).

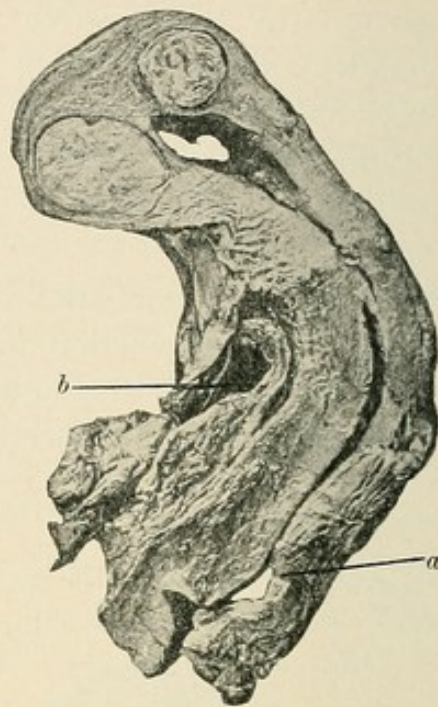


FIG. 338.—Two interstitial myomata near fundus (after Winckel): *a*, posterior lip; *b*, bladder.

start in any part of the uterine wall. A frequent location is near the cervix (Fig. 337). Another favorite locality is at the fundus

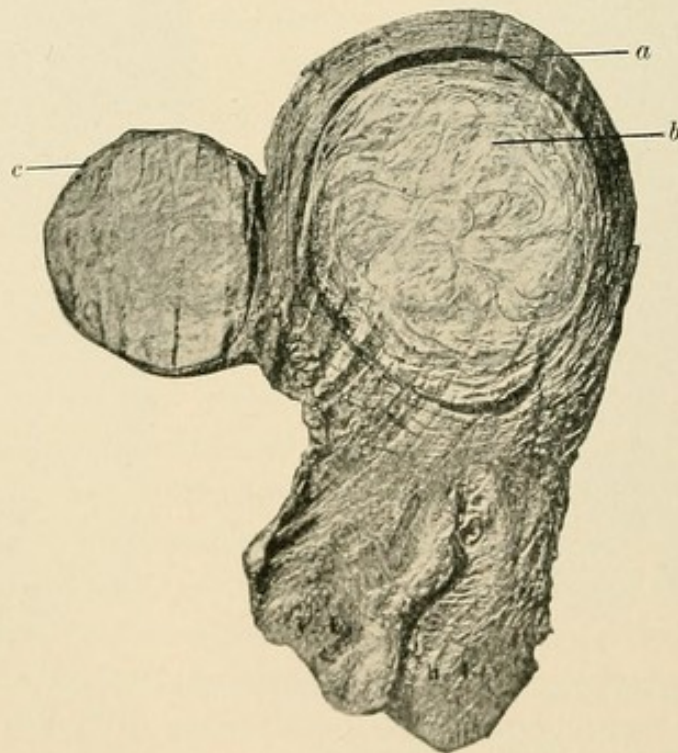


FIG. 339.—Subserous and submucous myomata (after Winckel): *a*, cavity of the uterus; *b*, submucous tumor; *c*, subserous tumor.

(Fig. 338). Not infrequently subperitoneal and submucous tumors are found in the uterus at the same time (Fig. 339). In multiple

myofibromata of the uterus tumors are often found in all three localities, and sometimes also in the broad ligaments.

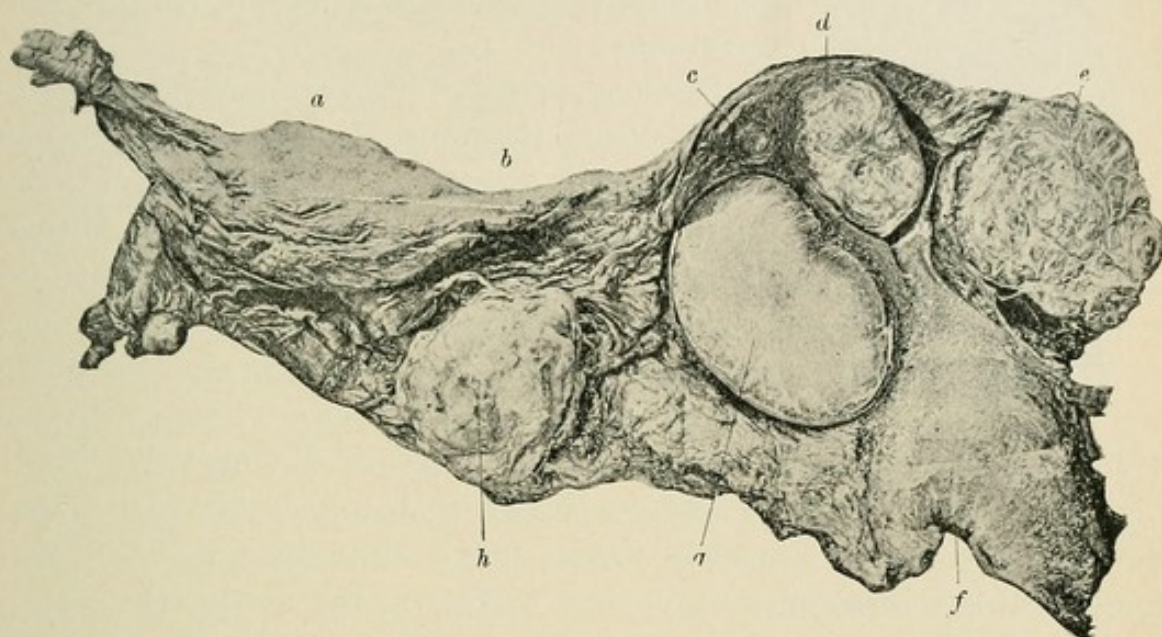


FIG. 340.—Multiple myofibromata of the uterus and broad ligament (after Winckel): *a*, right ovary; *b*, right Fallopian tube; *c*, interstitial myoma; *d*, submucous myoma; *e*, subserous myoma; *f*, orifice of uterus; *g*, interstitial myoma; *h*, intraligamentous myoma.

Uterine myomata become encapsulated at an early stage and grow in the direction offering the least resistance. If they are located nearer the external than the internal surface, they become prominent on the serous surface, and eventually may become pedunculated. If the reverse is the case, they finally become submucous, and pedunculation in this direction may take place. If the resistance is equal on all sides, they remain as interstitial growths. The vessels in the uterine wall, from which the tumor receives its nourishment, become dilated, forming a system of channels which communicate freely with one another and with the vessels of the tumor. The vessels appear like channels, devoid of a proper vessel-wall, but lined by an intima resembling the sinuses of the pregnant uterus (Fig. 341). In some instances myoma of the uterus is associated with other tumors of a benign type, the increased vascularity attending the presence of growths of the mucous membrane acting as an exciting cause in the production of the myoma

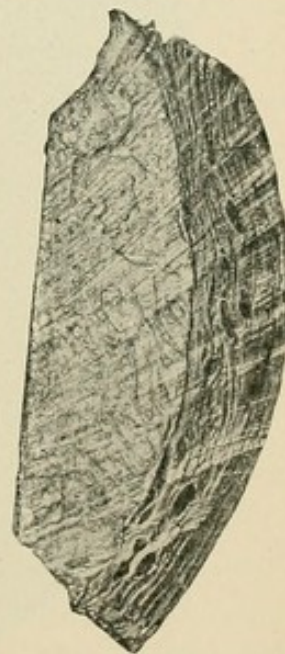


FIG. 341.—Cavernous wall of the uterus as found in connection with large myomata (after Winckel).

(Fig. 342). There is also reason to believe that the engorgement of the uterus which attends the presence of a myoma is favorable to the development of papilloma and adenoma of the uterine mucous membrane.

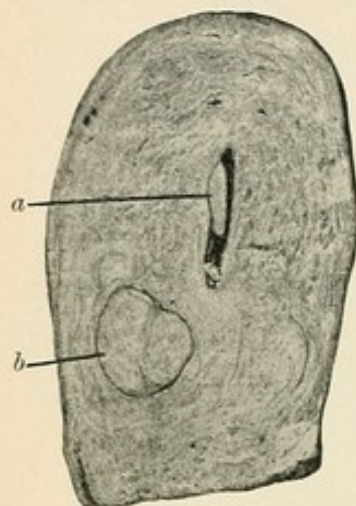


FIG. 342.—Myoma and adenoma of the uterus (after Winckel): *a*, adenoma of mucosa; *b*, interstitial myoma.

Histology and Histogenesis.—The proportion between the muscular fibres and fibrous tissue varies greatly. The hardness of the tumor increases with the amount of fibrous tissue it contains. The muscular fibres are larger than in the non-pregnant uterus and contain large nuclei. The arrangement of the fibres is very irregular; they interlace freely with one another and with the stroma of connective tissue. In sections the fibres that have been cut transversely retract much more than those divided longitudinally, imparting an uneven surface to the section (Fig. 343).

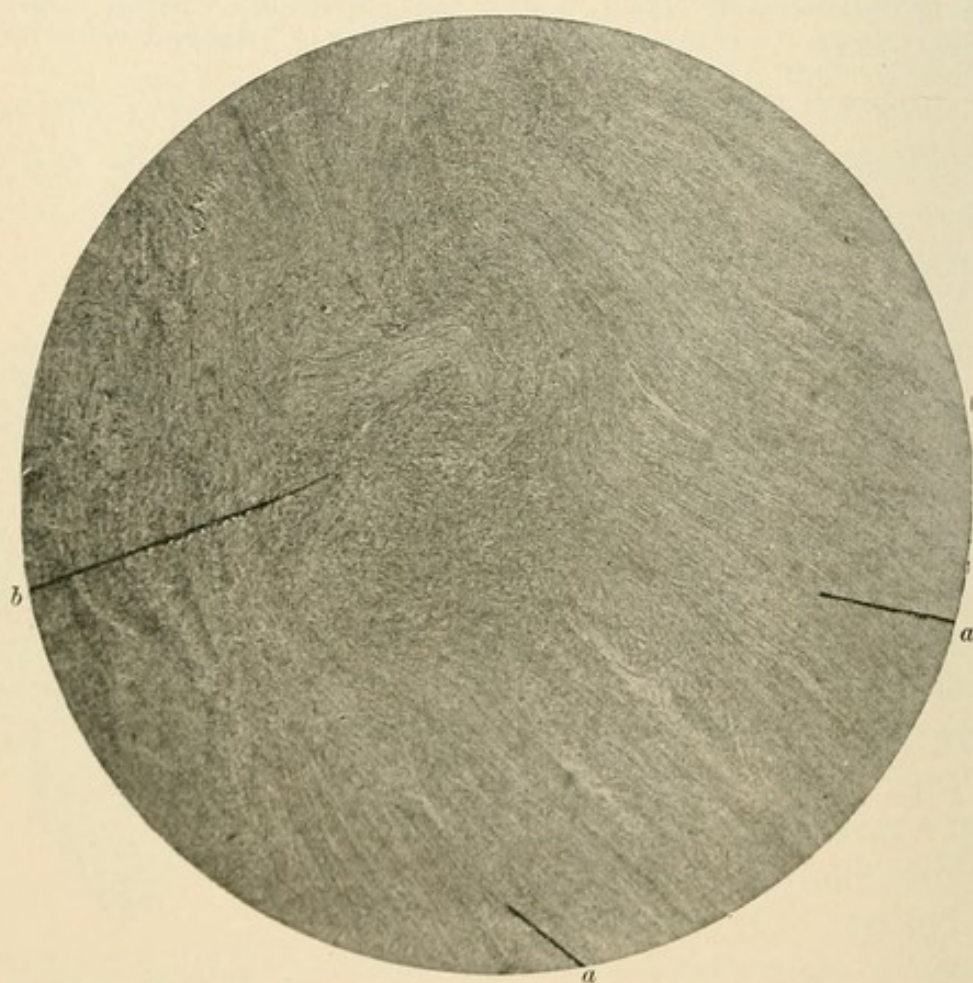


FIG. 343.—Myoma of the uterus; $\times 85$ (Surgical Clinic, Rush Medical College, Chicago): *a*, longitudinal section of muscle-fibres; *b*, transverse section of muscle-fibres.

Tumors in which the fibrous tissue predominates are firmer, less vas-

cular, and grow more slowly than those in which muscle-cells predominate. The vessels in the tumor itself are usually not large, and such tumors can be enucleated without difficulty so far as hemorrhage is concerned, provided the uterine tissue is not torn. In rare cases the tumor is very vascular and is permeated in all directions by cavernous spaces like those of the uterine wall, when the tumor is called *myoma telangiectodes*. If the lymphatic vessels between the muscular bundles and in the vicinity of the vessel-sheaths are dilated, we speak of a *myoma lymphangiectodes* (Leopold).

Recklinghausen has confirmed the theory of Coblenz, Doran, and Sutton that relics of the Wolffian body are very frequently the starting-point for many cystic and solid tumors in the appendages and the uterus. He advances the theory, however, very much further than any of the other observers. Following Babes, who in the year 1882 detected true epithelial growths in the interior of uterine myomata, he traces these growths, lined with epithelial cells, to the Wolffian ducts. He first discovered these adenomata in a large myoma, and afterward found similar growths—minute as a rule—in the tubes postmortem, mostly in old women. In cystic myomata of the uterus he makes a distinction between true glandular cysts and dilated lymphatic spaces and pseudocysts, developing in consequence of degeneration of the parenchyma of myomatous tumors.

Great dilatation of the lymphatic spaces in a myofibroma is the most frequent cause of cyst-formation. The muscle-fibres and the connective tissue are arranged in concentric layers around the vessels of the tumor—a condition which has induced some pathologists to assert that myofibroma of the uterus springs from the wall of pre-existing blood-vessels. The blood-vessels in a myofibroma, like those in any other tumor, are new structures formed from pre-existing blood-vessels in the vicinity of the tumor-matrix. Nerves have been found only in a few instances in myomatous tumors of the uterus. Bidder found nerve-fibres in one of these tumors.

Regressive Metamorphoses.—The degenerative changes that occur in a myoma of the uterus are dependent largely upon the location of the tumor. They occur most frequently, according to Lee, if the tumor is located in the body of the uterus. Originally most of the tumors are interstitial. Pedunculation diminishes the blood-supply of the tumor and brings about regressive metamorphoses. Pedunculated subserous tumors frequently undergo fatty degeneration and calcification. Calcification occasionally takes place in interstitial tumors, but,

according to Virchow, it has never been observed in polypoid growths projecting into the uterine cavity.

Subserous myomata frequently form adhesions with the surrounding viscera, and then receive a new blood-supply from this source. Whether pedunculated subserous tumors ever become completely detached is, according to Virchow, questionable. That such an occurrence is possible the writer is satisfied, as in one instance, in making a laparotomy for the removal of multiple myofibromata, there was found in the abdominal cavity a detached tumor as large as a small pear; the apex of the tumor tapered to a very small point, marking the place where the pedicle became detached.

The uterus may undergo serious pathological changes from traction on the part of a large pedunculated tumor, resulting in great elongation of the organ—hydrometra; and instances are on record in which the body of the uterus was severed from the cervix. If the tumor is surrounded on all sides equally by uterine tissue, pedunculation does not take place.

Intramural tumors frequently attain great size. Walter reports a case in which such a tumor weighed seventy pounds. The posterior wall at a point a little below the fundus is the favorite location for intramural tumors. The uterine cavity in such cases, if the tumor is large, may reach the size of the cavity of the pregnant uterus at full term. Lateral growth of a uterine myofibroma involves the broad ligaments, and the tumor becomes partly or wholly intraligamentous.

Intra-uterine growths attached by a broad surface result in enlargement of the uterine cavity in all directions, and the cervix becomes gradually obliterated in the same manner as in pregnancy. Intramural tumors may undergo fatty degeneration in the same manner as the muscular fibres of a pregnant uterus after delivery. Calcification frequently follows fatty degeneration. Myxomatous degeneration frequently takes place, during which mucin, nucleated round cells, and mucous cells appear, changing the tumor into a myxomyoma. The cysts which form in consequence of this form of degeneration are empty spaces between the bundles of muscle-tissue, and do not possess a proper cyst-wall. Œdema of the tumor-tissue also gives rise to the formation of spaces which resemble cysts. The so-called "fibrocysts" originate in this way or develop in consequence of an interstitial extravasation of blood. The cysts contain a synovia-like fluid often stained by the admixture of blood. In rare cases the tumor becomes exceedingly vascular by the formation of large venous spaces, when the tumor resembles a venous angioma. Such tumors increase in size

under influences which produce intravascular tension. The venous spaces occasionally, by such influences or by distention, become converted into blood-cysts. If in a myxomyoma the intercellular connective tissue begins to proliferate actively, the tumor undergoes transformation into a sarcoma.

Suppuration in myofibroma of the uterus has repeatedly been observed. This complication is announced by temperature, rapid pulse, and other symptoms indicative of pyogenic infection, and is attended by a sudden increase in the size of the tumor, by pain, and by tenderness. If the tumor takes its starting-point near the mucous membrane, it pushes the tissues before it as it projects in the direction of the uterine cavity, and soon it becomes submucous. Pedunculation of submucous myofibromata takes place most rapidly if the growth of the tumor toward the uterine cavity is not retarded by strong layers of muscular fibres. The nearer the tumor is to the mucous membrane, the more rapidly does pedunculation take place. Spontaneous detachment and escape of such tumors has repeatedly been observed. Intra-uterine myofibromata undergoing ulceration and sloughing have often simulated carcinoma of the cavity of the uterus. Transformation of intra-uterine myofibroma into carcinoma has never yet been demonstrated.

Etiology.—Myoma of the uterus has never been observed as a congenital tumor. The most important cause in exciting tissue-proliferation from the essential matrix of myoblasts is the congestion of the organ during menstruation. Winckel found in his cases the tumors subserous in 25 per cent., intramural in 65 per cent., and submucous in 10 per cent. Of 528 cases collected by Chiari, West, Beigel, Schroeder, and Winckel, 18 per cent. occurred in women between twenty and thirty years of age, 3 per cent. between thirty and forty, one-third of the whole number before the age of thirty-five, and one-fourth of the whole number had symptoms before the age of thirty. It is safe to assume that in the majority of cases the tumors appear during the latter part of the third and the beginning of the fourth decennium. The youngest patients suffering from myofibroma have been ten years of age (Beigel). Marriage increases the frequency of myoma of the uterus. In 33 per cent. of the married women the tumors caused sterility. Abortions and injuries to the uterus of all kinds must be regarded as exciting causes. Chronic inflammation of the uterus and its appendages is another fruitful source of tumor-formation.

Symptoms and Diagnosis.—The degree of suffering caused by

a uterine myoma does not depend on the size of the tumor: a tumor the size of a pea or a hazel-nut frequently produces graver symptoms than a tumor the size of a child's head. Small myomata often produce a complexus of nervous symptoms frequently mistaken for hysteria. The uterus is exceedingly tender to the touch; the organ is turgid and occasionally displaced, and rectal and vesical distress often obscures the original difficulty. As soon as the tumor is large enough to escape from the pelvis the subjective symptoms may disappear almost completely, and the patient, who has been, perhaps, a sufferer for years, is suddenly relieved and apparently restored to health. As the tumor increases in size new symptoms arise by its pressure anteriorly upon the bladder or posteriorly upon the rectum; circumscribed peritonitis, rotation of the uterus, or torsion of the pedicle gives rise to new symptoms which often force the patient to seek medical advice. If the tumor ascends into the abdominal cavity and does not become pedunculated, its growth is usually rapid, and the tumor often reaches an enormous size in the course of a few years. The abdominal cavity becomes greatly distended and its contents are subjected to pressure. If the tumor involve the lower segment of the uterus, its ascent into the abdominal cavity is impeded, and its increasing size results in impaction of the tumor in the pelvis, attended by the unavoidable pressure-symptoms which accompany such a condition.

The pain which attends a uterine myoma is caused by tension of the uterine wall and by pressure upon adjacent organs, and especially upon nerves. Pressure upon the sciatic nerve on one side will often produce sciatica, which, unless its cause is investigated, is often treated uselessly for months. Intra-uterine myoma is often the cause of expulsive pains which occur at irregular intervals. During the beginning of menstruation the symptoms are usually aggravated. Profuse menstruation is the most important symptom in submucous tumors. It is less constantly present in the interstitial form, and is entirely absent in subserous tumors. Menstruation is not only more profuse, but the duration of the period is also increased. The loss of blood not only undermines the patient's general health, but may become a source of danger to life. Hemorrhage is frequently aggravated by the coexistence of adenomata and by great vascularization of the tumor. The menorrhagia is variable in its intensity. Sometimes several months will elapse without undue loss of blood, when, without any obvious cause, the hemorrhage returns with menstruation.

In submucous myoma there is present between the menstrual

periods a copious catarrhal discharge caused by the great vascularity of the uterine mucosa and the hypertrophic condition of the glandular appendages. The cervix is soft and easily dilatable, and when the tumor has reached the internal os it can readily be discovered by a digital examination. Expulsion of the tumor by uterine contractions and traction upon the tumor not infrequently result in inversion of the uterus. After the tumor has reached the vagina it is exposed to infection; ulceration and sloughing may occur, and under such circumstances the patient's life is in danger from pyemia and septic peritonitis.

The growth of uterine myomata is usually arrested with the cessation of menstruation. The tumors at this time, as a rule, not only cease to grow, but are also reduced in size by fatty degeneration and shrinkage. The danger to be apprehended from uterine myomata is greater if the tumors occur at an early age.

The progressive anemia which inevitably attends the repeated hemorrhages and bleeding myomatous tumors of the uterus, and the profuse offensive discharges caused by ulceration and sloughing, have often given rise to mistakes in diagnosis, prognosis, and treatment. Tumors producing such conditions differ clinically from malignant affections principally in the length of time since the first symptoms appeared.

The diagnosis of small myomata is always difficult and frequently impossible. An increased localized resistance in some part of the uterine wall is often the only evidence of the existence of a small myoma. As soon as the tumor becomes prominent on the surface of the uterus, its presence can be ascertained by bimanual palpation, as it moves with the uterus, which is not the case if the swelling consists of the remnants of a hematocele or of pelvic peritonitis. Repeated examinations are at times necessary to avoid errors in diagnosis. A careful use of the uterine sound is often invaluable in distinguishing between tumors of the uterine wall, ovarian tumors, and inflammatory swellings. It is understood that the use of the sound should be restricted to cases in which a pregnancy can safely be excluded. Auscultation should never be omitted, as in more than one-half of all cases of large uterine myomata a bruit can be heard. The removal of fragments of tissue by harpooning is a harmless procedure if done under proper antiseptic precautions, and the microscopical examination of sections made from such fragments is of great value in differentiating between a benign and a malignant tumor of the uterus. Digital exploration of the uterine cavity for submucous myomata can be done to greatest advantage

during menstruation, as at this time the cervix is most dilatable. If the tumor involve one of the lips of the cervix, its presence should be suspected if the lip is enlarged and unusually vascular. If the tumor in this locality is large, it is often difficult, if not impossible, to find the os uteri, which may be displaced above the pubes or against the promontory of the sacrum, according to whether the tumor involves the posterior or the anterior lip.

The greatest difficulties are often encountered in making a differential diagnosis between myofibroma and pregnancy. Numerous are the instances in which experienced surgeons have opened the abdominal cavity with the expectation of removing a myofibroma or an ovarian tumor, when a direct examination revealed a pregnancy. Such mistakes have frequently been made, and will continue to be made in the future. The surgeon is often misled by misstatements on the part of the patient. Exploratory laparotomy will occasionally be resorted to in settling the doubt in certain obscure cases: this is as far as the surgeon should go. After the abdomen has been opened and the uterus exposed to sight and touch, it is not difficult to recognize a pregnant uterus. The thoughtless use of the trocar under such circumstances has brought great reproach upon surgery in many a community. The writer has twice been in the unenviable position of having to close the abdomen over a pregnant uterus: in one instance a double uterus misled him, and in the other a pregnancy was overlooked in a woman over fifty years of age who had not borne children for twenty-five years. Fortunately, both patients recovered without any untoward symptoms, and were delivered at full term of healthy children. In myoma the resistance is greater than that of a pregnant uterus, and the swelling is more circumscribed. In pregnancy the lower segment of the uterus presents a characteristic bluish-red color, and both uterine arteries are enlarged—conditions that are not present to the same degree in myoma. Examination of the breasts should never be omitted. Repeated examinations are often necessary to exclude the possibility of a pregnancy. In doubtful cases not calling for prompt active interference it is advisable to postpone operative measures until a sufficient time has elapsed to exclude a pregnancy. If for any reason it is deemed necessary to establish a positive diagnosis, an exploratory laparotomy is justifiable, but the trocar should not be used until by careful examination the possibility of a pregnancy can safely be excluded.

The affections that call for special attention in the differential diagnosis of uterine myoma are retroflexion, endometritis and parenchym-

atous metritis, hematocele, pelvic peritonitis, ovarian tumors, pyosalpinx and hydrosalpinx, chronic inversion of the uterus, retroperitoneal tumors, and malignant tumors of the uterus. Myofibromata of the uterus appear more frequently as multiple tumors than as an isolated affection, and, unless the uterus has become adherent, if it is the seat of multiple tumors the nodulated mass is movable. Chronic inversion can readily be distinguished, by the use of the sound, from partial or complete inversion produced by a myoma. In affections of the ovaries and tubes the swelling can usually be separated from the uterus, especially if the patient be examined under the influence of an anesthetic, which examination should never be omitted in doubtful cases.

Prognosis.—The prognosis of myofibroma of the uterus is more grave than is generally supposed. Winckel's statistics show that in about 10 per cent. of all cases death ensues after a longer or shorter duration of the affection. Hemorrhage and uremia are the most frequent immediate causes of death. The profound anemia which is such a common occurrence in submucous tumors is incompatible with the performance of important functions for any length of time, and, besides, a chronic progressive anemia engenders fatal complications, such as thrombosis, embolism, and pulmonary œdema. In rare cases the patients succumb to the immediate effects of hemorrhage alone, when death is usually preceded by convulsions and coma. Organic disease of the kidneys is produced by compression of the ureters. If the tumor distends the abdominal cavity, death results in consequence of dyspnea caused by compression of the contents of the thorax. Infection of the tumor has resulted in death from sepsis, pyemia, peritonitis, and exhaustion from prolonged suppuration. In other cases death is produced by the complications arising from abortion or from delivery at full term. In 119 cases of myomata of the uterus complicated by pregnancy, collected by Soloczinow, in 21 cases the patients aborted, and in 98 they were delivered at full term.

It has been observed that tumors that remained perhaps stationary for a long time begin to grow rapidly during pregnancy. This is particularly true of the soft variety and of cavernous myoma. Both these forms of uterine myoma are interstitial, and hence become surrounded on all sides with large blood-vessels which develop during pregnancy.

A great deal has been said regarding the spontaneous disappearance of uterine tumors and the curative effects of certain non-operative measures. A myoma seldom if ever diminishes in size during the

active sexual life of the patient, whereas the menopause, whether natural or brought about by the removal of the uterine appendages, has a decided influence in arresting further tumor-growth, and is usually followed by fatty degeneration of the muscular fibres and shrinkage, if not total disappearance, of the tumor. Virchow thinks it unlikely that complete disappearance by retrograde metamorphoses ever takes place, and it has never, to the writer's knowledge, been proved by dissection. The muscular fibres under favorable circumstances degenerate and are removed by absorption, but the connective-tissue stroma remains; hence it is the soft myomata that are diminished in size under conditions which induce fatty degeneration of the parenchyma of the tumor.

The liability of a myofibroma to undergo transformation into a sarcoma has repeatedly been referred to. Virchow has described a number of such cases. A most interesting case of malignant transformation of a myoma of the stomach has been reported by Brodowski. The tumor, after it had undergone this transition, caused myosarcomatous metastatic deposits in the liver. The metastasis of muscle-fibre is almost unique, but it has been observed in a case of myosarcoma of the kidney that produced similar metastatic deposits in the diaphragm (Eberth).

The prognosis of the operative treatment of myofibroma of the uterus has become vastly better since aseptic surgery has more generally been adopted, and since the technique of the different operative procedures has been so decidedly improved during the last ten years. Only twelve years ago laparo-hysterectomy had a mortality of from 30 to 35 per cent. in the hands of expert surgeons; to-day the mortality probably does not exceed 10 per cent., and some operators have reduced it to 5 per cent. The success of the operative treatment will be improved with a better selection of cases and a still more improved technique of the different operative procedures.

Treatment.—The treatment of uterine myofibroma should not be neglected, as much can be done in retarding the growth of the tumor by rational treatment. All measures that diminish the blood-supply to the uterus are calculated to diminish tissue-proliferation, and thus retard tumor-growth. The patient must be advised to avoid active exercise, such as dancing, skating, horseback riding, or the climbing of heights, and should remain the greater part of the time in the recumbent position during menstruation. Constipation is a common evil in nearly all patients suffering from uterine myoma. The bowels should be kept in a soluble condition by the administration of saline laxatives,

enemata, or by the use of glycerin suppositories. If pain is a conspicuous symptom, it should be controlled by the administration of the milder narcotics, such as potassic bromide, hyoscyamus, and belladonna. Preparations of opium and of chloral hydrate must be used with the greatest caution and restriction, lest patients become habituated to their use. Warm baths are nearly always beneficial and grateful to the patients. The use of pessaries is occasionally indicated if the uterus has become displaced, and can be replaced and held in its normal position by a proper mechanical support. The internal use of ergot was strongly recommended by the late M. H. Byford. Favorable results were also obtained by its subcutaneous administration in the clinic of Hildebrandt at Königsberg. The writer believes the general experience in the use of this drug coincides with that of Winckel, who states that he has observed in several instances, under the prolonged use of ergot, decided diminution in the size of the tumor, but in none of them was there a complete disappearance.

Ergot has little or no effect in the treatment of hard myofibromata. Its therapeutic value as a palliative is limited to the soft myomatas and teleangiectatic varieties. Large and long-continued doses not infrequently produce ergotism, especially in very anemic patients. The writer has found a combination of ergotin, extract of *nux vomica*, and sulphate of iron to be of more value in checking hemorrhage than ergot alone. Parenchymatous injections of ergotin, as advised and practised by Delore, have yielded no better results than the internal or subcutaneous use of this drug; besides, the procedure is attended by considerable risk of infection.

Curetting of the uterine cavity has yielded good results in diminishing the hemorrhage. The effect of this treatment is particularly well marked if the mucous membrane is the seat of adenomata, as is so often the case. The insertion of strips of gauze saturated with tincture of the sesquichloride of iron into the uterine cavity has also been found useful in diminishing the hemorrhage. Hot vaginal douches have also proved beneficial. The tincture of digitalis alone or in combination with ergot has a well-earned reputation for diminishing hemorrhage, especially in patients suffering at the same time from a weak heart. During the interval between the menstrual periods the different preparations of iron with strychnia have a salutary effect. In patients greatly reduced from repeated and severe hemorrhages intravenous infusions of a physiological solution of salt will be indicated if stimulation by ordinary means is not sufficient to maintain the requisite degree of intravascular tension.

Electrolysis has had quite an extended trial, but it has not yielded the anticipated results. Kimbal and Cutter inserted strong needles seven and a half inches in length not far apart into the substance

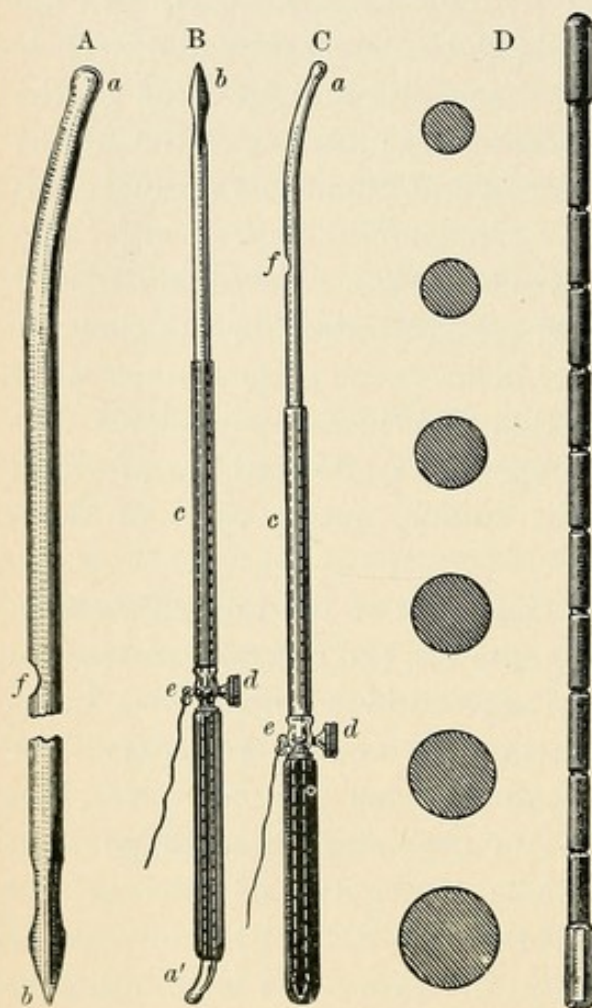


FIG. 344.—Apostoli's uterine electrode: A, natural size of the instrument; a, ordinary hystrometer; b, trocar for puncture; f, notch marking average depth of uterus; B and C, entire instrument, reduced to one-third size, in c, celluloid handle, to protect the vagina; e, electrode; d, thumb-screw, to regulate length of exposed sound; D, carbon electrode for galvano-chemical cautery, one-third size.

of the tumor and passed through them the electrical current. In 2 cases death resulted from peritonitis; in 23 the tumor is said to have diminished in size; in 10 no effect whatever was produced. Apostoli and his followers have revived this treatment, and have claimed that in some instances the tumor disappeared completely. Apostoli increased the strength of the current from 100 milliamperes, used first, to 250 milliamperes. One of the poles is applied to the abdomen by means of a moist clay electrode, and the other pole is introduced into the uterine cavity in the form of an insulated sound. The electrode is pushed into the substance of the organ "after preliminary puncture where we desire to hasten the demolition of the neoplasm, or where the cervix is impermeable or inaccessible."

It is difficult to conceive in what way complete removal of

the tumor is accomplished. That electrolysis combined with rest will diminish hemorrhage and in a certain percentage of cases bring about reduction in the size of the tumor no one will deny, but as a curative measure its claims have been, to say the least, over-estimated. In many cases the treatment has produced complications that proved fatal, and in others it has necessitated operative treatment. The reputation of this method of treatment will diminish with the improved results following operative procedure.

Operative Treatment.—Myomata of the lower segment of the uterus accessible from the vagina should be removed by enucleation. The use of the *écraseur* and of the galvano-caustic wire should be

displaced by this operation. In cases of intra-uterine tumors the adjustment of the wire is attended by the greatest difficulties, and not infrequently there is left a part of the tumor, which is responsible for many recurrences of pedunculated benign tumors. The twisting off of a pedunculated growth if the pedicle is narrow is usually attended by satisfactory results, but the operation of enucleation is applicable in all such cases and is attended by less risk.

Vaginal Enucleation.—This operation is the ideal one in all cases in which the base of the tumor can be reached. In tumors of the cervix and in pedunculated tumors of the uterine cavity the base of the tumor can be reached without much difficulty. The tumor should be brought down as far as possible by the use of one or more vulsellum forceps, when the mucous membrane covering the pedicle is divided by a circular incision sufficiently far away from the attached part of the pedicle to allow the cuff of mucous membrane to cover the entire wound after the enucleation has been completed. The mucous membrane is then detached with a pair of blunt-pointed scissors or with Pozzi's enucleator (Fig. 345). Very little hemorrhage is caused during this part of the operation. By reflection of the cuff of mucous membrane the pedicle, containing the principal blood-vessels of the tumor, is reduced considerably in size, and at the same time the capsule of the tumor is exposed thoroughly at the base of the tumor. The tumor is then enucleated if the pedicle is broad, or if it is narrow the tumor is wrenched from its base by twisting it around its axis. The danger of hemorrhage attending this operation has been over-estimated greatly. If the mucous membrane is divided by a circular incision and reflected, and the tumor is removed by the use of blunt instruments or by torsion, the hemorrhage is very slight. After the removal of the tumor the wound is tamponed with a long strip of iodoform gauze, which is allowed to remain for three or four days. After the removal of the gauze the mucous membrane will cover the granulating surface, and healing of the entire wound is effected in a few days.

The writer has enucleated in this manner tumors the size of a child's head attached by a pedicle to the fundus of the uterus. If the pedicle is short, traction upon the tumor sufficient to partially invert the uterus will facilitate the operation. After the removal of the tumor the inversion usually corrects itself, otherwise the fundus is pushed into its



FIG. 345.—Pozzi's enucleator.

normal position. If the tumor occupies either the anterior or posterior lip and is sessile or interstitial, it is exposed by an incision parallel with the long axis of the uterus, and as soon as its capsule has been reached it is grasped with vulsellum forceps and is removed by enucleation. Care must be exercised to make the blunt dissection close to the capsule, as otherwise the laceration of uterine tissue might result in troublesome hemorrhage.

Vaginal Myomotomy.—If the tumor is too large to be removed through the vagina by enucleation, it often becomes necessary to remove the growth by fragmentation or *morcellement*. Péan, who practised this operation on a large scale and carried its indications to their utmost limits, successfully removed through the vagina by this method many large myomata which other surgeons would have attacked by an abdominal section. The operation is especially intended for sessile and interstitial myofibromata of the body of the uterus. Péan employs in this operation forceps of special construction

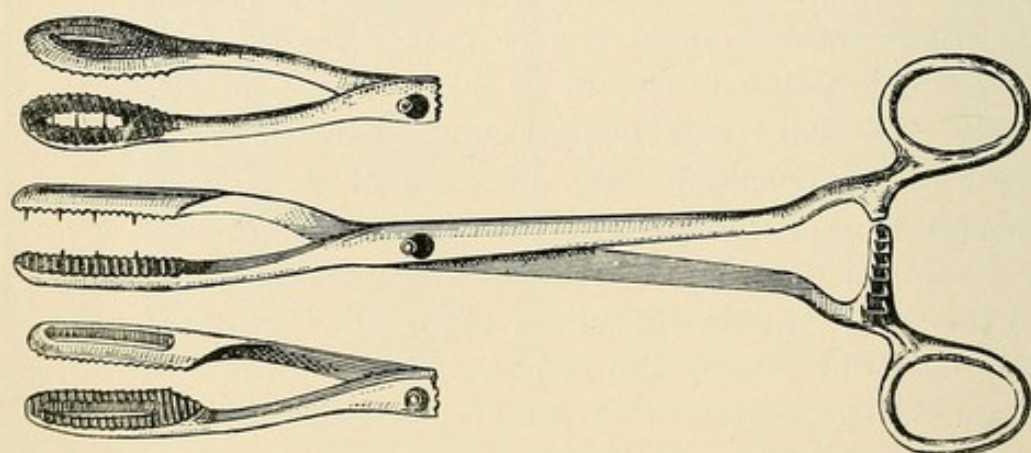


FIG. 346.—Péan's forceps, serrated and with teeth, for morcellation of myofibromata.

(Fig. 346), with which he performs morcellation of the tumor. It is the object of the operation to remove the tumor piecemeal, and not by enucleation. The tumor is attacked from the centre, and fragments are removed in the direction of the periphery until all tumor-tissue has been removed.

The first step of the operation consists in rendering the tumor accessible. This is done by detaching the cervix in the same manner as in performing a vaginal hysterectomy, only that opening of the peritoneal cavity is carefully avoided. Hemorrhage during this step of the operation is controlled by the use of hemostatic forceps. After the cervix has been isolated it is incised, and the incision is carried into the uterus as far as the tumor. The tumor is then carefully located with the finger, after which the morcellation is begun in the centre of the growth. The vagina is retracted by elbow retractors, so as to

expose the field of operation as thoroughly as possible for the fingers and forceps. When the tumor has been reached it is drawn down with vulsellum forceps and a deep incision is made into it parallel with its long axis. The sides of the tumor are then grasped with forceps, retracted, and fragment after fragment is drawn down with forceps and removed with scissors or with a bistoury (Fig. 347).

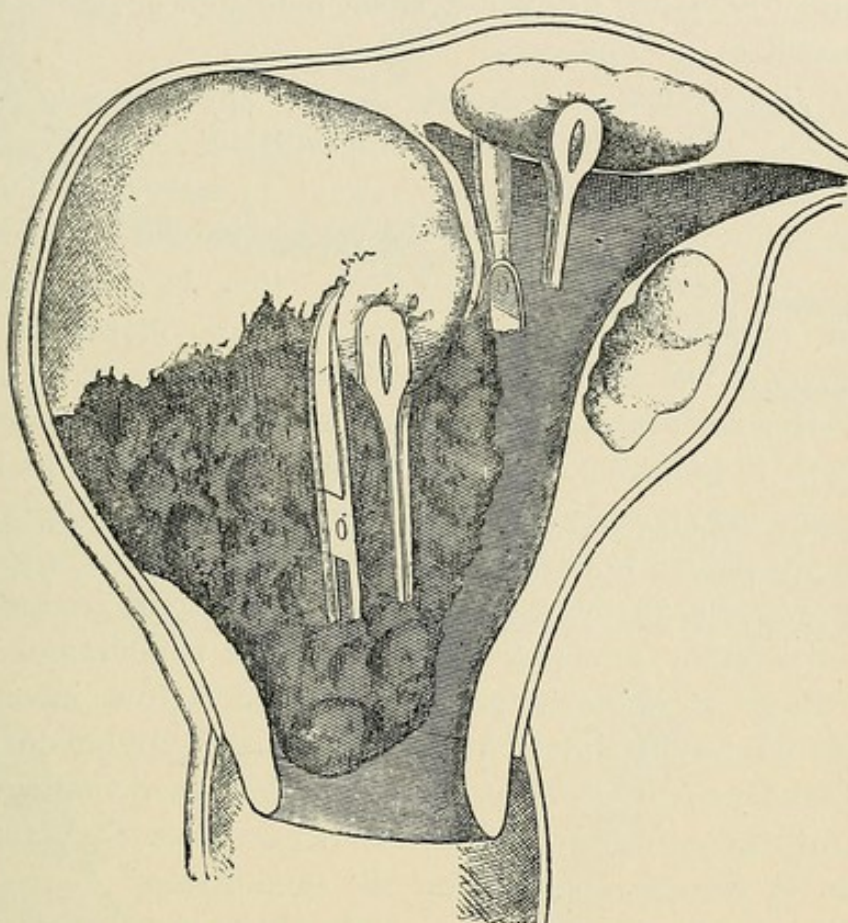


FIG. 347.—Removal of myofibroma by morcellement (after Péan).

After the removal of the lower part of the tumor by this method the upper portion can often be detached by traction and twisting. Bleeding vessels are caught with forceps and tied. When the tumor is very large, Péan excises the two cervical lips, and after the removal of the tumor sews the lips of the vaginal wound. If the peritoneal cavity is opened, Péan advises that the wound should be closed with sutures. If more than one tumor is present, the operation is repeated until all the tumors are removed. After the removal of the tumor, if the cervical lips have not been amputated—which is necessary only in exceptional cases—the cavity is cleansed thoroughly by mopping, and after hemorrhage has been attended to carefully it is packed with a long strip of iodoform gauze. If compression-forceps are used in arresting the hemorrhage, they are removed after thirty-six or forty-eight hours. The cervical as well as the circular incision is closed by

suturing. The iodoform-gauze tampon is brought out of the cervix into the vagina.

There can be but little doubt that Péan and his followers have carried vaginal myomotomy by morcellation too far. The average aseptic surgeon will obtain better results by laparotomy than by piecemeal extraction if the tumors are large, multiple, and subperitoneal. The operation, however, has a legitimate field, and it will undoubtedly find favor with many operators.

Vaginal Hysterectomy.—Removal of the entire uterus for myofibroma has been performed by Péan, Sängér, Richelot, Terrier, Leopold, and others. The mortality has been about 13 per cent. Tumors not too large to be removed through the vagina should be removed by enucleation or morcellement—operations that have yielded better results than vaginal hysterectomy, and with less mutilation.

Laparotomy.—The removal of myofibromata through an abdominal incision or the removal of the uterine appendages to arrest further tumor-growth is indicated in cases of myofibromata in which vaginal operations are inapplicable and the tumors threaten to destroy life, or incapacitate the patient from following her occupation, or cause sufficient suffering to warrant an operation. Contraindications are cessation of growth of the tumor, unimpaired health of the patient, and advanced age. If a tumor at the menopause causes no serious inconvenience, conservative treatment should be pursued. Soft myomata are more frequently subjected to operative treatment than hard tumors, because, as a rule, they grow more rapidly and occur more frequently in the young than in women approaching the menopause.

Abdominal section for myofibroma should be done under the same strict aseptic precautions as in other operations requiring opening of the abdominal cavity. The patient should be placed on a course of preliminary treatment, including a daily warm bath, laxatives, and a restricted diet, for at least three or four days before the operation.

Salpingo-oöphorectomy.—The removal of the uterine appendages is indicated in the operative treatment of myofibroma of the uterus in which enucleation is impossible and the tumor or tumors have not produced serious pressure-symptoms. Arrest of menstruation, effected by the removal of the uterine adnexa, exerts the same effect on uterine myofibroma as the natural menopause. The tumors, as a rule, not only cease to grow, but also are materially reduced in size by fatty degeneration and shrinkage. Salpingo-oöphorectomy yields the best results in soft multiple myomata occurring in women from twenty to thirty-five years of age. The danger attending this operation in well-selected cases is very small. The first operation of this kind for uterine myoma was

performed in 1876 by Trenholme. Tait and Hegar prefer it to other operations in the majority of cases. If the uterus is movable and the tumors are not large, the uterine appendages can be removed through

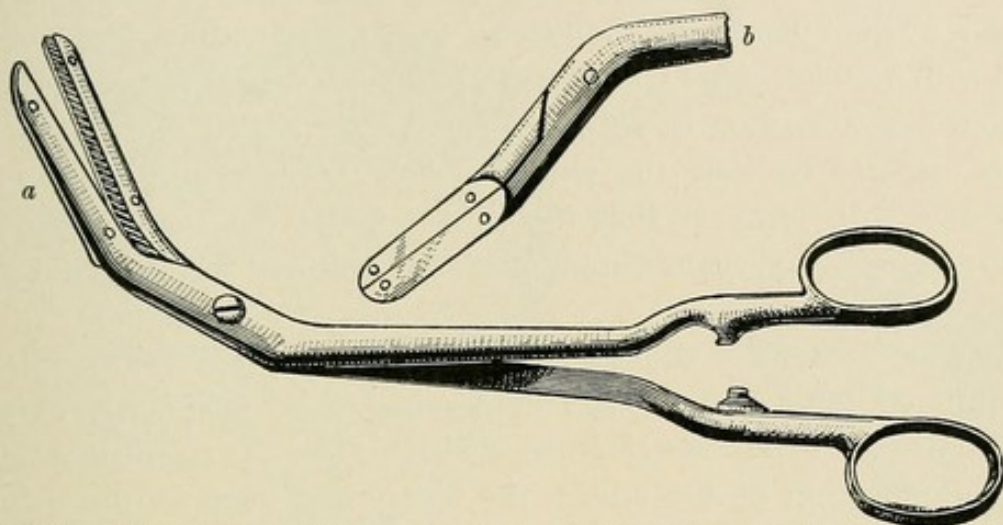


FIG. 348.—Hegar's forceps for cauterizing the pedicle in castration: *a*, upper surface: *b*, under surface with ivory plate.

a two-inch median incision. If the ovaries are imbedded in inflammatory adhesions, it is often exceedingly difficult to find and isolate them. Under such circumstances it is advisable to enlarge the incision to the

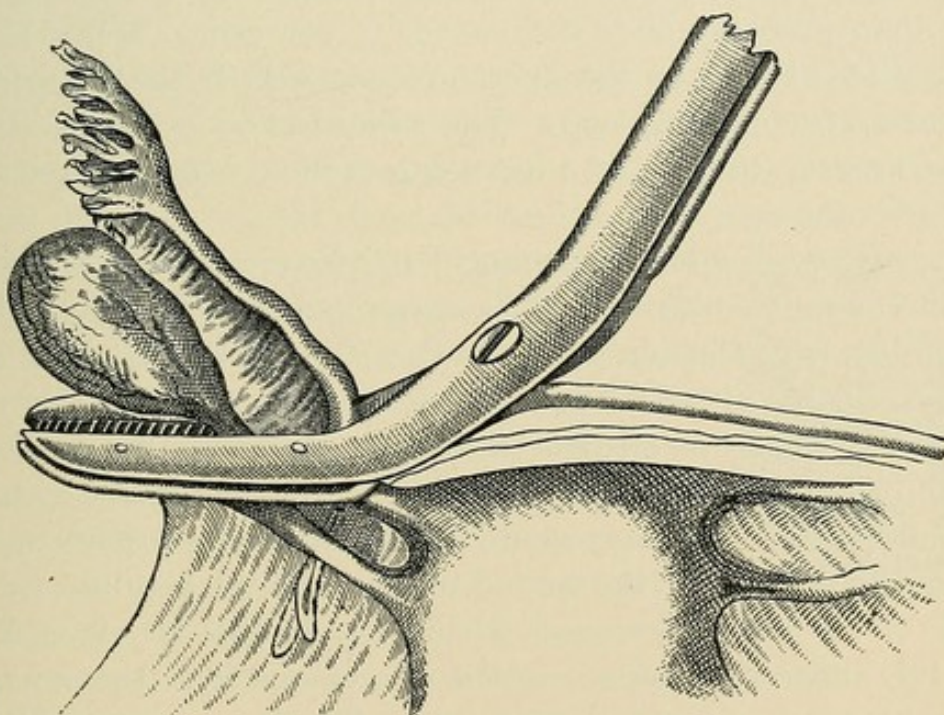


FIG. 349.—Castration (after Pozzi): the tube and the ovary are seized in Hegar's forceps; the ligature is passed around the pedicle by a blunt needle.

requisite extent, so that the surgeon can not only feel but see what he is doing. The operation will prove of value only if every vestige of ovarian tissue is removed or destroyed. For this reason many opera-

tors advise that the stumps should be cauterized thoroughly after the ovaries and the tubes have been removed. For this purpose a forceps of suitable construction should be employed (Fig. 348). The pedicle below the forceps, consisting of the broad ligament, the Fallopian tube, and the ovarian ligament, should be transfixed with a blunt needle armed with medium-sized Chinese silk; the silk is then cut in the centre and each part is tied on its respective side, after which one of the ligatures is made to encircle the whole pedicle. The tying must be done slowly and with jerks, so that the ligatures may cut their way deeply into the tissues to prevent slipping. The ligatures are then cut short to the knot.

The cauterization of the stump outside the compression-forceps is an additional safeguard against hemorrhage, and frequently destroys ovarian tissue that has escaped the scissors. For the purpose of aiding the mummification of the stump the writer has been in the habit of covering it with a thin film of iodoform before dropping it into the abdominal cavity.

Wiedow collected 149 cases of castration for myofibroma, and found that in 54 cases the tumors underwent shrinkage and hemorrhages ceased. In 15 cases the result was fatal. The mortality of this operation has been reduced greatly since Wiedow's statistics, and at the present time probably does not exceed 5 per cent. Menstruation is either arrested at once by the operation, and with it the hemorrhages, or it ceases a few months later. The writer has seen tumors the size of a fist shrink to the size of a hen's egg in the course of three or four months after the operation.

Laparo-myomectomy.—In pedunculated intraperitoneal myofibroma of the uterus the pedicle should be transfixed and securely tied, close to the uterus, with medium-sized Chinese silk. As little of the uterine tissue as possible should be included in the ligatures. The uterine tissue in the vicinity of a tumor is always quite vascular and is easily cut by the ligature—an accident which is invariably followed by troublesome hemorrhage. In a case where this occurred the writer was forced to suture the margins of the wound to the parietal peritoneum of the margins of the external wound, when he was able to make efficient use of the antiseptic tampon, which was placed over the now extra-peritoneal wound and compressed under the deep sutures which controlled the hemorrhage. Two days after the operation the sutures were cut and re-tied after the removal of the tampon.

Intraperitoneal Enucleation.—This operation is adapted for single tumors of moderate size. The uterus should be brought well forward into the wound and be surrounded by a gauze compress wrung out of

warm sterilized water. As a provisional hemostatic precaution the uterus is constricted by an elastic cord above the cervix (Fig. 350). The uterine tissue covering the tumor is then incised at a point where

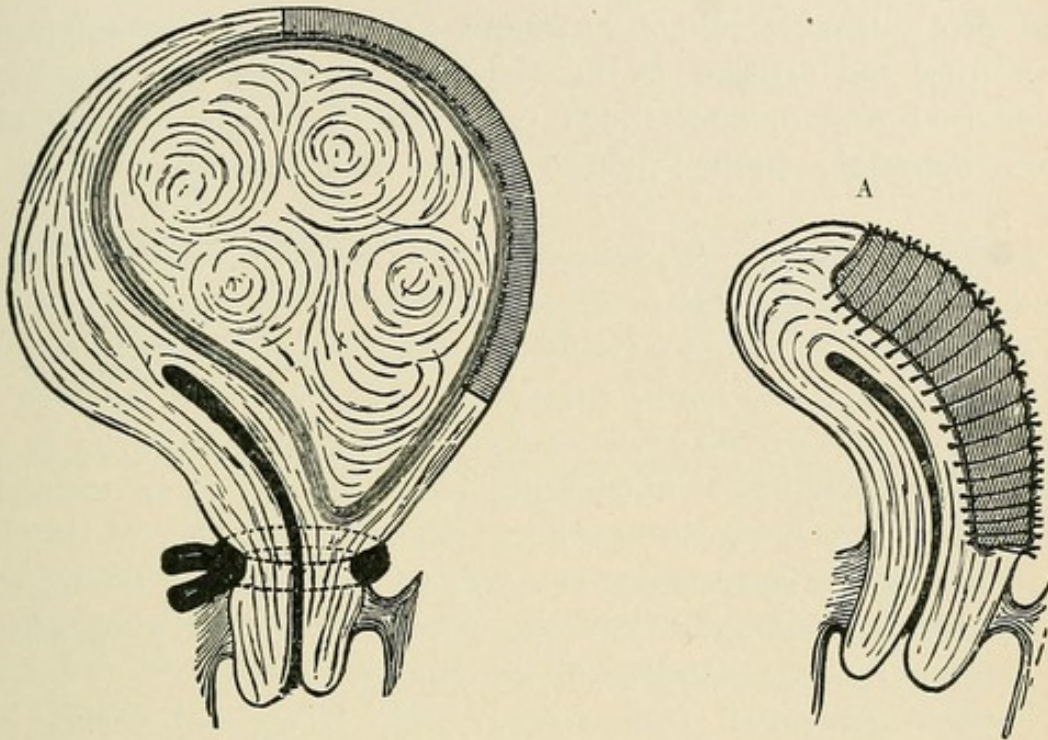


FIG. 350.—Enucleation of an interstitial myoma; A, disposition of sutures after enucleation (after Pozzi).

the large vessels can be avoided, when the tumor can easily be shelled out from its bed with the fingers or with the aid of blunt instruments. Occasionally strong septa of fibrous tissue passing from the adjacent tissues into the tumor have to be cut with scissors. Bleeding points are at once ligated with catgut. When the cavity is large Martin uses a cross-drain passed through the cervix into the vagina. The cavity is closed by several rows of catgut sutures, as shown in Figure 350, A. It has happened in 10 cases out of 16 in Martin's practice that the uterine cavity was opened. He recommends suturing of the mucous membrane with a continuous catgut suture. The writer has had excellent results from tamponing the cavity with a long strip of iodoform gauze which was brought into the vagina through the cervix as shown in Figure 351. The wound over the gauze tampon is sutured in the same manner as after Cesarean section.

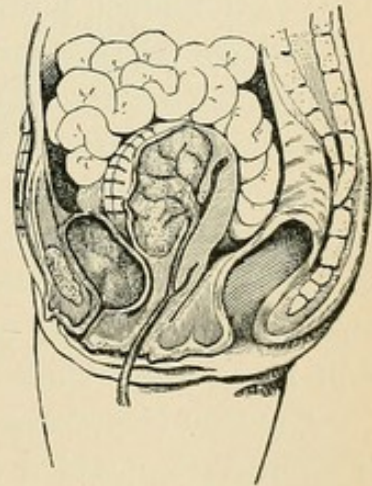


FIG. 351.—Vaginal drainage of cavity after intraperitoneal enucleation.

The gauze tampon answers an excellent purpose in arresting the

parenchymatous oozing, and serves also as an efficient capillary drain. It should not be removed before the third or fourth day after operation. In favorable cases several subserous and interstitial myofibromata can be removed successfully by enucleation. Should the hemorrhage prove troublesome, the wound can be made extraperitoneal by suturing the margins of the visceral wound to the margins of the external wound, after which the hemorrhage can be controlled by the antiseptic tampon placed under the provisional deep sutures.

Laparo-hysterectomy.—Laparo-hysterectomy has been performed too frequently in the treatment of myofibromata. It is a mutilating operation, and as such it should be limited to cases not amenable to successful treatment by less heroic measures. The operation includes the removal of a part or the whole of the uterus with the tumors in one mass. This operation is undergoing rapid changes in its technique. The methods now being discussed and advocated by different surgeons are—(1) Complete laparo-hysterectomy; (2) Partial hysterectomy with intraperitoneal treatment of the stump; and (3) Partial hysterectomy with extraperitoneal treatment of the stump.

Complete Abdominal Hysterectomy.—Bär, Krug, and others have taken advantage of Trendelenburg's position in the complete removal of the uterus for myofibroma. The operation is not a difficult one, as, after tying off the broad ligaments and ligation of the uterine arteries, hemorrhage is under control, and Trendelenburg's position secures ready access to the floor of the pelvis in suturing the pelvic wound. It is well known, however, that myofibromata of the uterus, with few exceptions, involve the upper part of the organ, and that the cervix and the lower part of the uterus are free, and do not require removal on account of pathological indications. The best surgery is always conservative surgery. In operations for benign tumors healthy organs or parts of healthy organs should not be sacrificed unnecessarily. The writer is inclined to believe, notwithstanding the satisfactory results of this operation so far as the mortality is concerned, that its popularity will be of short duration.

Laparo-hysterectomy with Intra-abdominal Treatment of the Pedicle.—This operation, which was introduced by Schröder, has been but little modified since his time. The broad ligaments in each side are tied off with two or three separate ligatures of silk or with the chain ligature (Fig. 352) before they are cut between the ligatures and compression-forceps on the uterine side. After the uterus has been brought well forward upon the surface of the abdomen it is constricted above the cervix with a strong rubber cord. The uterus is then surrounded with

compresses of guaze, which are also made use of to prevent intestinal prolapse. The incisions through the uterus below the tumors are then made behind and in front in an oblique downward direction,

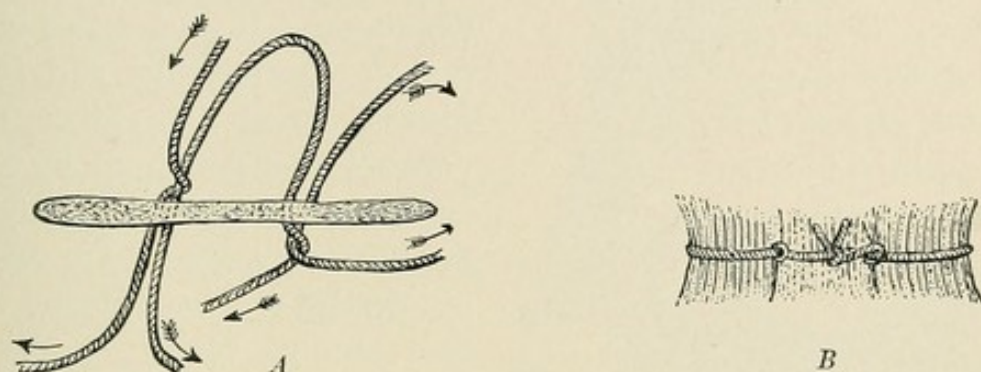


FIG. 352.—Chain ligature (after Pozzi): A, separate ligatures as introduced, showing the method of looping; B, the same, tied.

so that the lower portion of the part removed presents the shape of a wedge. All visible vessels are tied. The mucous membrane below the cone-shaped excision, to the depth of half an inch or

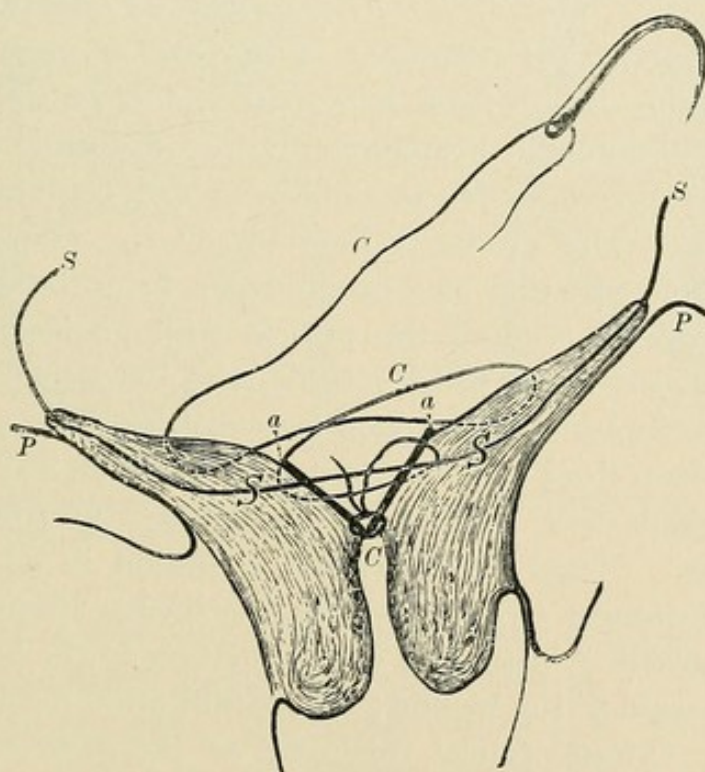


FIG. 353.—Schröder's intraperitoneal suture of pedicle: S, deep suture, passed at once under the whole bleeding surface; C, continuous suture of catgut in different terraces, bringing together the whole wounded surface, whose lower portion is marked by the heavy line *a a*, formed by the cauterized uterine cavity; P, peritoneal investment.

more, is either cauterized or excised, after which the wound is sewed transversely with several rows of catgut, as shown in Figure 353.

The last row of sutures brings the serous surfaces over the wound in accurate contact (Fig. 354). After a careful toilet the pedicle

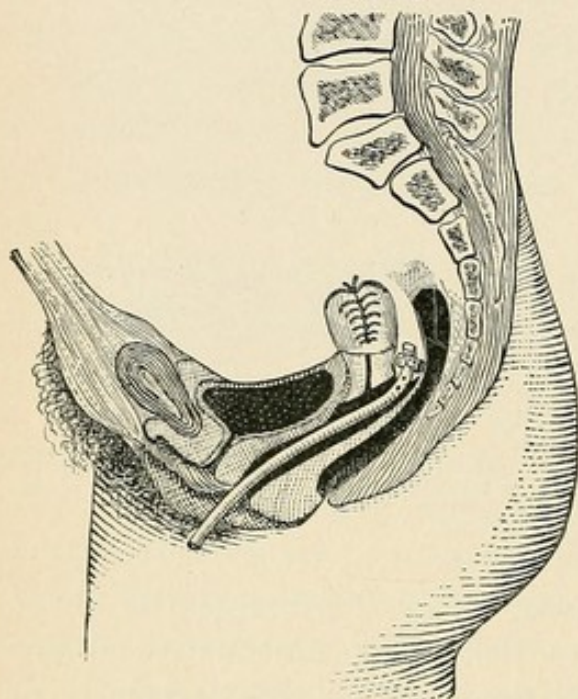


FIG. 354.—Vaginal drainage with a cross tube after abdominal hysterectomy (after Martin).

is dropped and the external incision is closed. The two great dangers which attend this operation are hemorrhage and sepsis. Martin aimed to reduce these dangers to a minimum by establishing drainage from the cul-de-sac into the vagina. The danger of infection is always greater when the uterine cavity is opened. Schröder's operation is an ideal one, and it is to be hoped that the technique will become so perfect that it will yield as good results as when the pedicle is treated by the extraperitoneal method.

Laparo-hysterectomy with Extraperitoneal Treatment of the Ped-

icle.—The extraperitoneal treatment of the pedicle aims to eliminate or to minimize the danger from hemorrhage and sepsis. G. Kimball first proposed abdominal hysterectomy for interstitial myofibroma, and his patient recovered. He was followed by Koeberlé and Péan in rapid succession. The uterus is liberated in the manner described above. Elastic constriction as a prophylactic hemostatic agent is also employed. Koeberlé secured the pedicle with an instrument of his own device, the *serre nœud*, which is still quite extensively used. It is a miniature wire écraseur, with which he constricted the pedicle, tightening the wire loop from time to time until it cut its way through the tissues; this result was generally accomplished in from twenty to twenty-five days. Hegar modified the operation in so far that he excluded the peritoneal cavity from the mortifying stump by suturing the pedicle below the constricting elastic ligature to the parietal peritoneum of the margin of the wound; this modification marked a decided advance in the extraperitoneal treatment of the pedicle. Koeberlé's wire loop and the elastic ligature used by most surgeons in the extraperitoneal treatment of the pedicle to control hemorrhage and to effect gradual division of the pedicle are objectionable, as they invariably give rise to necrosis or sloughing of the stump—a condition which has been a frequent remote source of infection and of ventral hernia, and which prevents rapid healing of the wound.

If the amputation has to be done close to the cervix in cases in which the uterus is not much elongated, harmful and painful tension has been one of the drawbacks of Hegar's operation. The writer aimed to overcome this difficulty by making, below the level of the rectum, through the broad ligaments, a peritoneal cuff long enough to permit the balance of the pedicle to recede, and at the same time to shut out completely the peritoneal cavity. A circular incision is made through the peritoneum, at a point corresponding with that at which the broad ligaments have been divided. The peritoneum is then, with the fingers and by means of blunt instruments, peeled off from the pedicle to the point at which it is desired to apply the elastic constrictor—that is, beyond the limits of the part to be removed. If the incision is not extended into the muscular tissues, this part of the operation is attended by very little hemorrhage. The peritoneal cuff is now sutured with catgut to the parietal peritoneum all around in the lower angle of the incision, and the balance of the incision is closed (Fig. 355). A solid

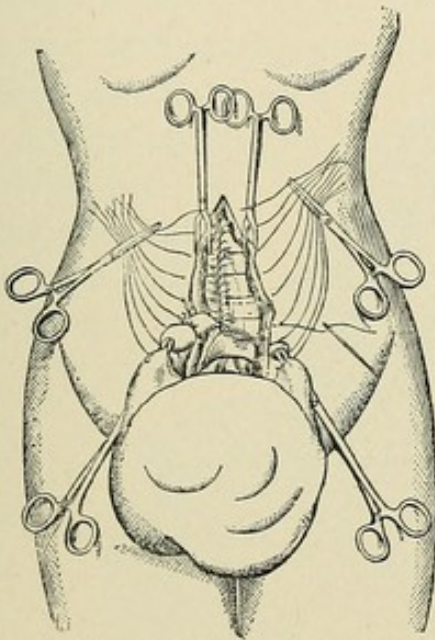


FIG. 355.—Extraperitoneal abdominal hysterectomy: elastic constrictor in place; balance of wound sutured.

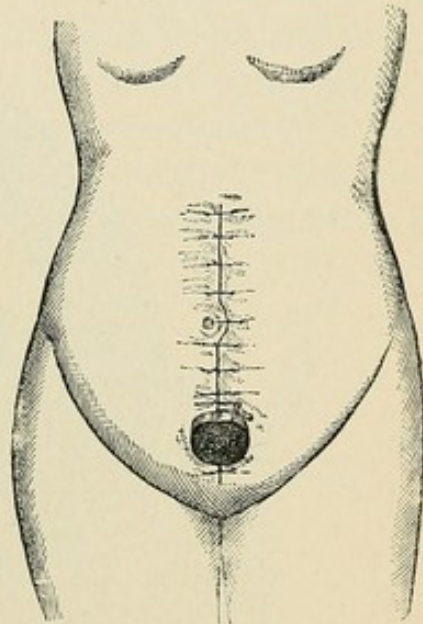


FIG. 356.—Extraperitoneal abdominal hysterectomy: operation completed.

rubber cord is now tied firmly around the denuded pedicle, and the uterus is amputated about an inch above it. Thorough cauterization of the stump and of the uterine cavity as far as the elastic ligature is advisable. Gauze is now packed around the pedicle as far as the bottom of the peritoneal cuff, after which the usual external dressing is applied (Fig. 356). As the pedicle is not fixed with pins or needles, it sinks back and all tension is avoided. The writer made nineteen consecutive operations by this method, and not only did all the patients recover, but they never complained of a single untoward symptom.

The ligature with the stump usually came away about the twenty-fifth day, after which the wound rapidly healed. This peritoneal cuff is transformed into a solid string which makes no traction on the scar, and which so far has not given rise to ventral hernia.

The only drawback of this method of operating is the inevitable necrosis or sloughing of the stump, something in common with Hegar's and Koeberlé's operations. The writer has recently abandoned the elastic ligature, and instead has resorted to ligation of the uterine arteries and suturing of the cut surface; the results have been very satisfactory. The operation is performed in the manner just described until after the amputation of the uterus. The elastic constrictor may be

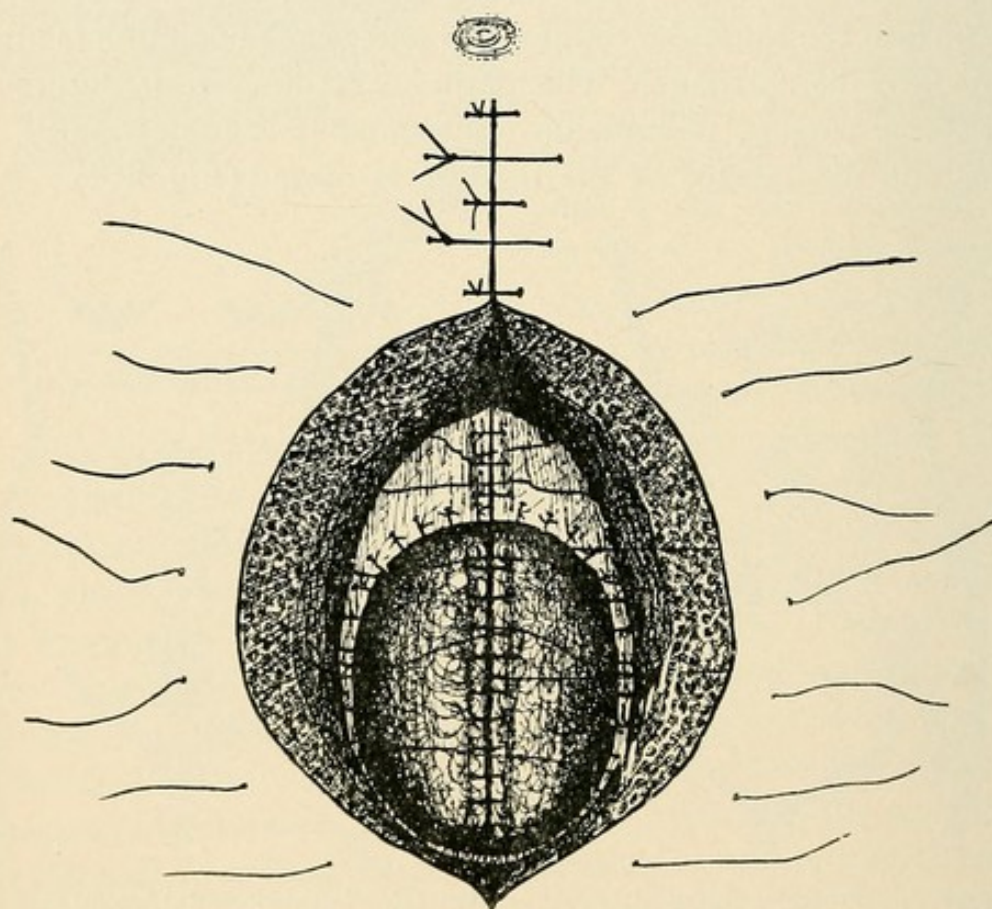


FIG. 357.—Extraperitoneal abdominal hysterectomy without the use of the elastic constrictor or the wire loop: operation completed.

dispensed with if both uterine arteries are tied immediately after they are divided, and parenchymatous oozing is arrested by suturing the cut surface with several rows of catgut sutures. A small strip of mucous membrane is then excised, after which the cut surfaces are brought together with several rows of catgut sutures (Fig. 357). The pedicle is accessible at all times in case of hemorrhage. By abandoning the elastic ligature sloughing of the stump is avoided and the wound heals by primary intention. The space around the sutured pedicle is packed with iodoform gauze. Secondary sutures are in place, and are pro-

visionally tied in a loop over the gauze packing. On the second day the gauze is removed and the sutures are tied.

A little oozing has been observed in several cases operated upon by this method. In some of the cases the external gauze dressing had to be changed at the end of the first twenty-four hours. All the patients operated upon by this method recovered without any complications whatever. Until the intraperitoneal treatment of the pedicle has been made safer, the writer regards this method of disposing of the pedicle preferable, as it gives the surgeon access to it should any complications set in.

Broad Ligament.—Myofibroma of the uterus not infrequently extends between the folds of the broad ligaments, and the tumor becomes in part intraligamentous, greatly complicating the operations for its removal. As the connective tissue of the broad ligament contains unstriated muscular fibres, it is not surprising that occasionally there is met with in this locality a myoma which has developed independently of the uterus. Tumors in the broad ligament seldom attain great size and usually give rise to but little disturbance, but occasionally they rapidly increase in size and produce pressure-symptoms which may require operative interference. The tumors occurred in women past thirty-five years of age in the eleven cases so far reported. In one instance the tumor weighed sixteen pounds; usually the tumors did not exceed the size of a fist.

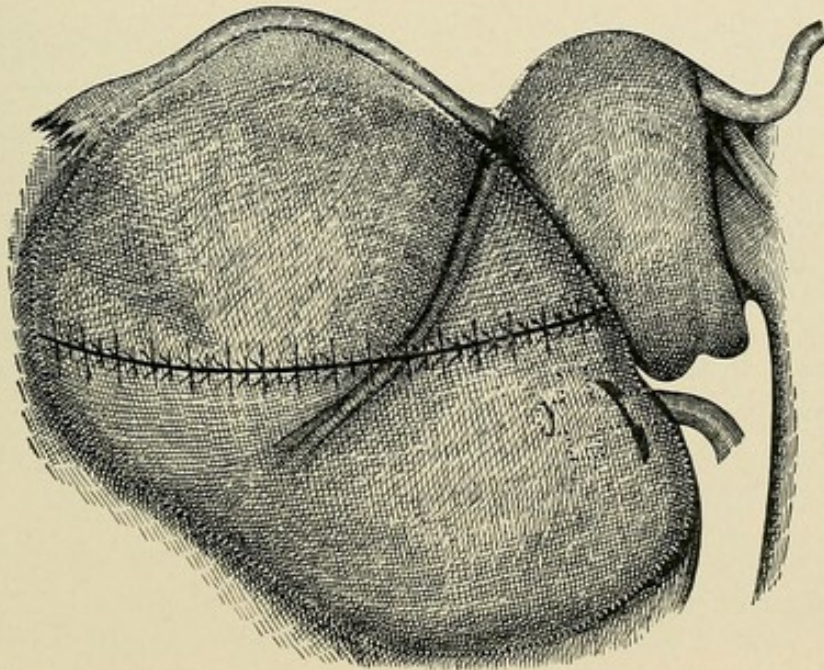


FIG. 358.—Myofibroma in the broad ligament: decortication and suture of the cavity and drainage by the vagina (after Martin).

It would be next to impossible to diagnosticate a myoma of the broad ligament without an exploratory laparotomy. If such a tumor

is revealed by an exploratory laparotomy and its removal is deemed necessary, this should be done by enucleation. Large vessels should be avoided so far as possible in cutting down upon the tumor. The enucleation is to be done exclusively with the fingers and with blunt instruments. If the cavity is not large, the wound can be sutured after the hemorrhage has been arrested completely. If parenchymatous oozing is troublesome or if the cavity is large, drainage into the vagina by means of a cross-tube, as advised by Martin and Kaltenbach, should be resorted to (Fig. 358). The wound is sutured throughout with special reference to bringing the serous surfaces in accurate apposition. Infection from the vagina is prevented by iodoform-gauze packing, which should also embrace the distal end of the tube. The drain may be removed as soon as all discharge from it has ceased.

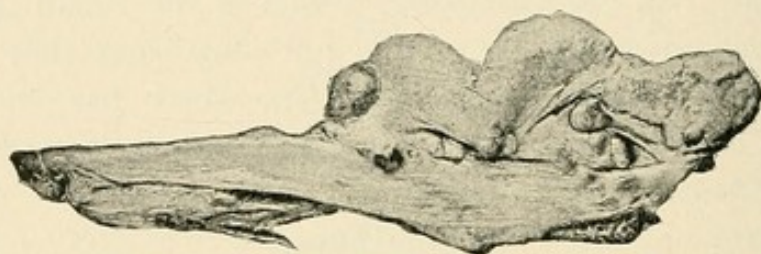

FIG. 359.—Subserous myofibroma of Fallopian tube (after Winckel).

Fallopian Tube.—Myofibroma of the Fallopian tube is exceedingly rare. Winckel describes such a specimen (Fig. 359). In this instance

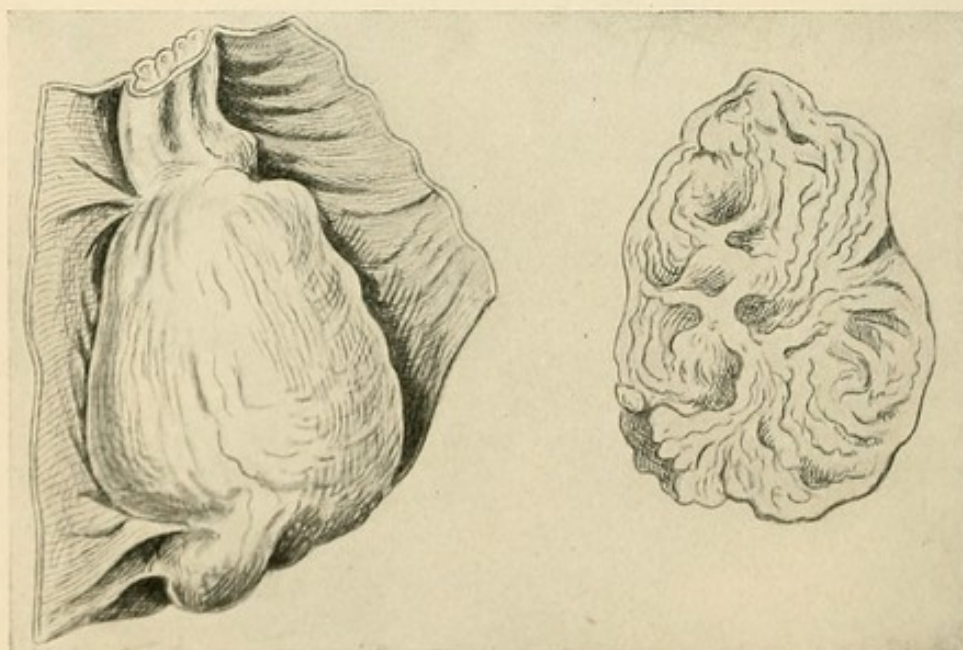


FIG. 360.—Myofibroma of the round ligament (after Heydemann).

the tumor was small, oblong, and immediately underneath the peritoneum. Sutton saw only one specimen, and in this case the myoma was associated with dermoid cyst of one of the ovaries. The tumor,

which was of the size and shape of a Tangerine orange, involved the whole thickness of the tube.

Round Ligament.—The first operation for myofibroma of the round ligament was performed by Sir Spencer Wells in 1865. In the year 1882 Säger collected 12 cases, and classified tumors of the round ligament according to their anatomical location into (1) intraperitoneal, (2) intracanalicular, (3) extraperitoneal. In the 12 cases reported by Säger the tumor was intraperitoneal in only 3, on the left side twice, and on both sides once. If the tumor occupies the inguinal canal, it simulates very closely an irreducible inguinal hernia. Such cases have been reported by Polaillon, Heydemann, and others. The differential diagnosis of intraperitoneal tumors of the round ligament and myofibroma of the uterus can only be made by a direct examination through an abdominal incision.

Alimentary Canal.—Myomatous tumors of the alimentary canal are rare.

Pharynx.—Myomata of the posterior wall of the pharynx have been described by Middeldorpf. They are either sessile or pedunculated. The sessile tumors cause pressure-symptoms of various kinds according to their size and location. Polypoid growths, from their mobility, often produce acute attacks of dyspnea, and even death, when they become displaced into the entrance of the pharynx. They should be removed with the galvano-caustic wire, as their point of attachment is usually so low down that arrest of hemorrhage by other measures usually proves inefficient. The tumor is made accessible by exciting vomiting; the tumor is then seized and drawn out at one angle of the mouth, when the wire loop is pushed over it and adjusted.

Œsophagus.—Hilton Fagge reports the cure of a myomatous tumor of the œsophagus in a man thirty-eight years of age. The tumor was situated in the anterior wall just below the level of the bifurcation of the trachea. Virchow refers to a specimen which he found at the cardiac end of the œsophagus. In neither of these cases was the tumor pedunculated.

Stomach.—Virchow makes the statement that myomata are more frequent in the stomach than in any other part of the digestive tract. We have already referred to a myoma of the stomach that was converted into a sarcoma. If the tumor should occupy the pyloric extremity and produce obstruction, a gastro-enterostomy should be performed in preference to making an attempt to remove the tumor by enucleation or by excision.

Small Intestines.—Myoma of the small intestines has been described by Flenier, Aufrecht, Wesener, and Böttcher. In Flenier's case the

tumor produced invagination, and enterectomy was performed successfully by Czerny. In nearly all cases which have so far been reported the tumors were located in the upper part of the intestinal canal.

Rectum.—The rectum is more frequently the seat of myoma than any other part of the intestinal canal. On the mucous surface the tumors appear either as sessile tumors or as polypoid growths. König removed a pedunculated tumor in the region of the prostate gland in a man; in a girl eighteen years of age he removed a myomatous tumor with a long pedicle. A few years ago the writer removed by laparotomy a subserous myoma from the rectum of a woman forty-five years old. The probable diagnosis was either a pedunculated myofibroma of the uterus or a dermoid cyst of the ovary. The tumor, which had been growing for ten years, was movable. From its size it produced distressing pressure-symptoms. On opening the abdominal cavity a smooth, hard, movable tumor was found, covered by peritoneum. In seeking for its attachment a broad pedicle was found behind the uterus and extending in the direction of the pelvis. Uterus, ovaries, and tubes were normal. The peritoneum was incised where the pedicle appeared to be narrowest, and the tumor was enucleated. As soon as the tumor was removed gas escaped, and an examination revealed, in the anterior wall of the rectum, an opening large enough to admit two fingers. With a moist compress the intestines were protected, and after cleansing the wound an attempt was made to close the opening by suturing. Owing to the depth of the rectal opening the suturing was unsatisfactory. A large drain was placed *vis-a-vis* with the sutured place and was brought out at the lower angle of the wound. Iodoform gauze was packed around the tube. The remaining part of the external incision was sutured. On the second day gas and feces escaped; otherwise there were no untoward symptoms. The intestinal fistula swelled in the course of a few weeks, after which the patient recovered quickly and perfectly, and remains well at the present time. Microscopical examination of sections of the tumor showed the typical structure of myofibroma.

Bladder.—According to Virchow, myoma of the bladder can develop only in the prostatic portion of the urethra and the base of the bladder. Belfield's investigations have shown that myomata of the bladder not only occur as tumors projecting into the bladder, but that they also may grow in the direction of the perivesical tissues. Myomata of the bladder are comparatively rare. Terrier and Hartmann have recently gathered the particulars of 16 cases from different sources. Of 15 cases in which the clinical history was given with sufficient detail, there were 7 women and 8 men. The age varied from

twelve to seventy-four years. In structure the tumors are in many respects analogous to uterine myofibromata. The tumor originates in the muscular layers of the bladder. Projection takes place most frequently in the direction of the bladder. In the 16 cases reported this was the case in 10 instances; in 4 the growth was external; in 1 case, a diffuse infiltration; in 1 case growth occurred in both directions. The part of the bladder which the tumors occupy is most variable: six times they were in the region of the trigone; three times in the anterior wall; two were at the summit; one in the posterior wall and trigone; one case included nearly the entire bladder-wall except the right side; one was a multiple tumor, and invaded both the anterior and the posterior walls. In size they varied from a walnut to that of a child's head. They appear either as rounded or lobulated tumors. They are likely to be pedunculated, but may be sessile or even infiltrative; in the first instance they are easily removed. The presence of the tumor sooner or later causes cystitis, ureteritis, and obstructive lesions of the kidney. Pressure-symptoms are frequently present. When the tumor projects into the bladder hæmaturia is one of the most frequent symptoms. Intravesical exploration does not always give much assistance to reach a correct diagnosis. Hypogastric, vaginal, and rectal palpation, and especially bimanual examination under the influence of an anæsthetic, are much more satisfactory, and in most instances the site and size of the tumor can thus be determined. The treatment necessarily must vary according as the growth is external or internal. In the subperitoneal variety the usual rules of abdominal surgery will apply. Removal by enucleation through an abdominal incision and suturing of the visceral wound will usually lead to a satisfactory result. In the intravesical form removal by perineal section, vaginal section, and hypogastric section, or combinations of these, have each their advocates. At the present time, however, the advantages of hypogastric section, as shown by Guyon, are especially marked in the removal of this form of tumor. Knox and Gussenbauer observed cystic degeneration in vesical myomata, and Volkmann observed partial necrosis. König removed through a perineal incision a tumor the size of a pigeon's egg from the caput gallinaginis in a boy twelve years old. Volkmann removed a similar tumor by suprapubic cystotomy.

XXVII. NEUROMA.

Definition.—A neuroma is a tumor composed of nerve-tissue produced from a matrix of neuroblasts or fibroblasts, according to the anatomical structure of the tumor. Virchow made a distinction between benign nerve-tumors according as the tumor is composed of medullated or of non-medullated nerve-fibres, designating the former *neuroma myelinicum*, and the latter *neuroma amyelinicum*. This anatomical distinction is retained at the present time. By far the greatest number of benign tumors of the nerves belong to the amyelinic variety, as they do not contain a numerical increase of medullated nerve-fibres. Some of these tumors have already been discussed in the section on Fibroma. The nerve-sheaths not infrequently contain matrices of fibroblasts from which true fibromata develop, the pre-existing nerve-fibres being simply an accidental anatomical constituent of the tumor. In other cases the fibrous tissue is more intimately intermingled with terminal nerve-fibres, as in cases of amputation-neuroma.

Embryology.—In the embryo the neural canal consists at first of a solid cylinder of epithelial cells developed from the epiblast. During the differentiation of these cells there forms a supporting framework of which the neuroblasts constitute the essential element. They are the "germinal cells" of His, and they multiply by karyokinesis. Further differentiation of the neuroblasts results in the formation of ganglion-cells and conducting cells. The conducting cells, which are connected with nerve-fibres and acquire sheaths of greater or lesser thickness, are known as the medullated and the non-medullated fibres.

In the central nervous system the connective tissue is represented by neuroglia. Ranvier asserts that the processes of the pia mater and the vessels are surrounded by a sheath of neuroglia. It is, however, difficult to determine just where the connective tissue ends and the neuroglia begins. In the brain and the spinal cord the connective-tissue tumors, benign and malignant, develop from the neuroglia. Bürgner and Klebs regard the nuclei and the protoplasm of the sheath of Schwann as neuroblasts. From these neuroblasts new nerve-fibres are produced in the case of myelinic neuroma, and the proliferation from them is concerned in the repair of nerves after injury or disease.

Histology and Histogenesis.—The structure and origin of a neur-

oma depend upon the nerve-trunk or the part of the central nervous system from which the tumor springs. A tumor produced from nerve-cells or neuroblasts is composed very largely of nerve-tissue, whereas a tumor produced by proliferation of neuroglia or from fibroblasts contained in the nerve-sheath is more akin to a fibroma than to a neuroma. Virchow classifies neuromata as follows:

1. Hyperplastic fascicular neuroma: $\left\{ \begin{array}{l} a. \text{ White, containing medullated} \\ \text{nerve-fibres;} \\ b. \text{ Gray, containing non-medul-} \\ \text{lated nerve-fibres.} \end{array} \right.$
2. Hyperplastic medullary neuroma, usually occurring in the brain or as a congenital tumor.
3. Heteroplastic medullary neuroma, found in the ovary by Virchow and Gray, found in the testicle by Verneuil.

The majority of neuromata are simply fibrous tumors lying along the course of a nerve or attached to the nerve-terminations in a stump. True nerve-tumors are most common on the ears, the eyelids, and the side of the face. They usually have a plexiform appearance, and these ramifications can be felt under the skin (Fig. 361). The tumor consists of a fibrous framework through which run bundles of nerve-fibres, some of them completely medullated, others only partially so (Fig. 362). Large ganglion-cells with characteristic nuclei and nucleoli are also sometimes found imbedded in the tumor-mass. Waldenström, who doubts the correctness of Virchow's idea that a neuroma is composed largely of nerve-fibres without medullary sheath, regards them as fibromata originating from the interstitial connective tissue.

Westphal has traced neuromata of the skin to the endoneurium. The nerve-fibres in neurofibromata undergo a change which is conceded by nearly all observers, in that the medullary sheath undergoes atrophy, and that the nerve-sheaths become the seat of hyaline degeneration, which was first noticed and described by Schuster. The enlargement of a nerve-end in amputation-neuroma is due to an abundant formation of small myelinic fibres produced from the neuroblasts

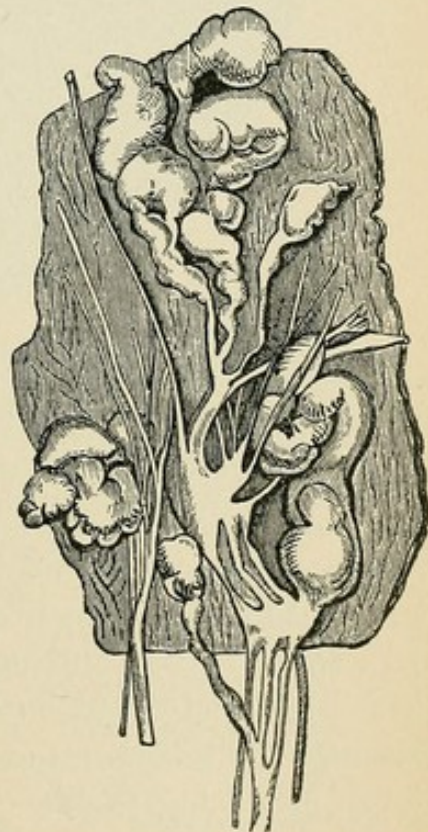

FIG. 361.—Portion of a neuroma from the right ear (after Bruns).

which have been exposed for a long time to irritation caused by cicatricial tissue. It is well known that an amputation-neuroma will only develop in connection with scar-tissue and the irritation incident to the

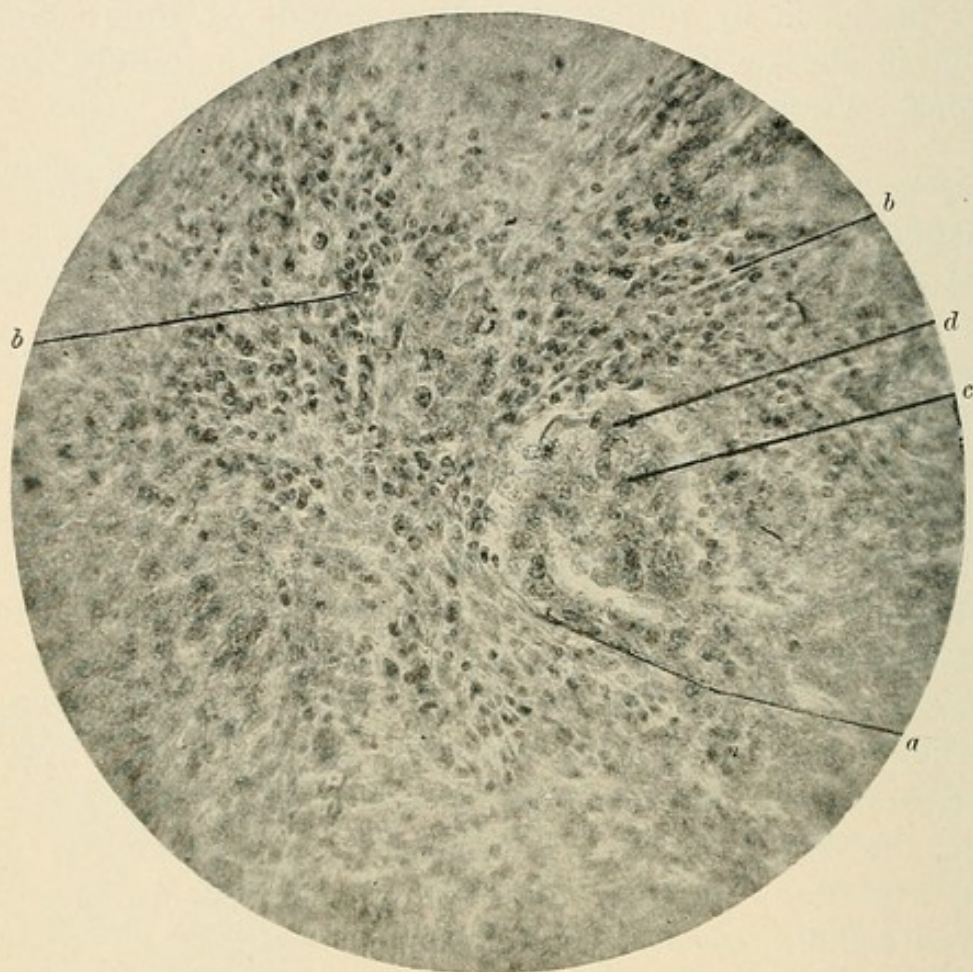
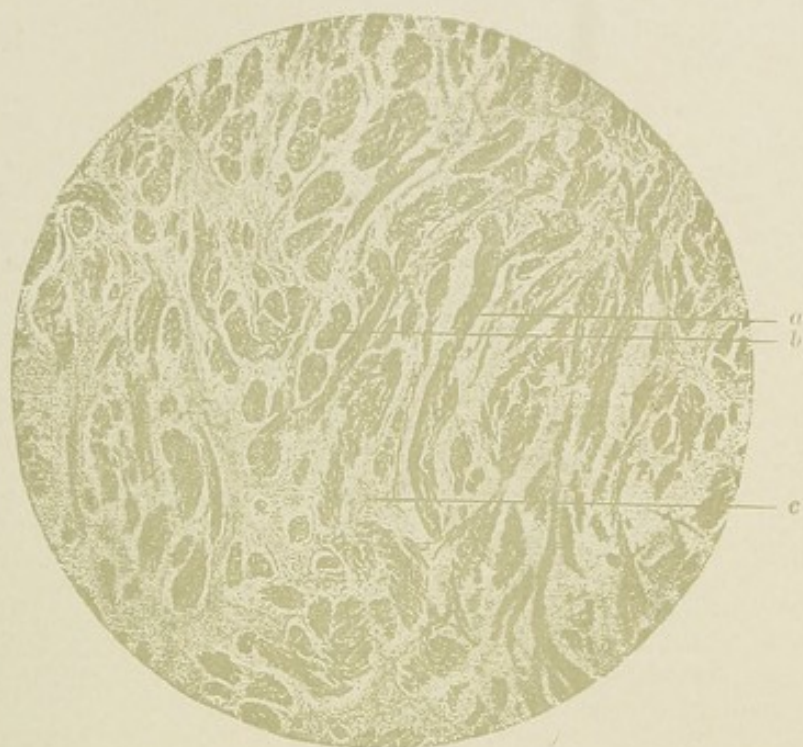

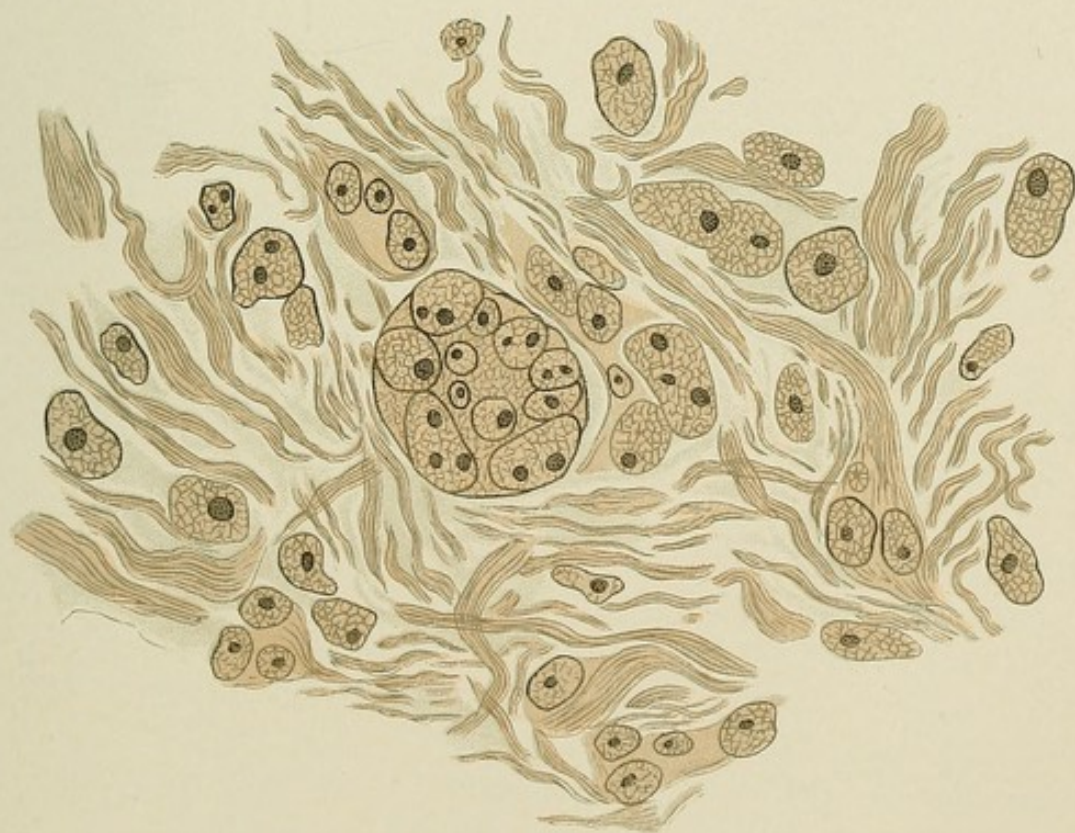
FIG. 362.—Transverse section of a painful subcutaneous tubercle (Surgical Clinic, Rush Medical College, Chicago): *a*, fine connective-tissue reticulum; *b*, axis-cylinders; *c*, nerve-bundle cut transversely; *d*, neurilemma, somewhat thickened.

conditions producing it. Witzel has recently shown that in many cases the neuroma is found attached to the end of the bone in the stump. The tumor presents itself in the form of a bulbous enlargement of the end of the nerve, which closely resembles a spring onion in outline (Fig. 363). Cross-sections of such tumors show the numerical increase of myelinic nerve-fibres (Pl. 13, Fig. 1). Under the same influence the fibroblasts proliferate and greatly increase the amount of connective tissue, producing thus a true neurofibroma. In the majority of cases the tumor is limited and forms the bulbous extremity of the nerve; in some instances, as in the case reported by Hayem and Gilbert, the nerve is at this time enlarged for a very considerable distance, the enlargement being due to an abundant formation of small myelinic fibres and to hyperplasia of the pre-existing interstitial connective tissue.

Every surgeon of large experience knows that an amputation-




1



2

1. Simple neuroma after amputation (after Boyce): *a* and *b*, nerve-bundles; *c*, connective tissue. (Obj. 1 inch; osmic acid.) 2. Neuroma of the fourth ventricle (after Klebs). (Nigrosin and hæmatoxylin; Zeiss, $\frac{1}{2}$, 2.)



neuroma in some cases is exceedingly prone to return after excision, and these cases are undoubtedly those in which the nerve is enlarged far beyond the bulbous extremity. The writer has known instances in

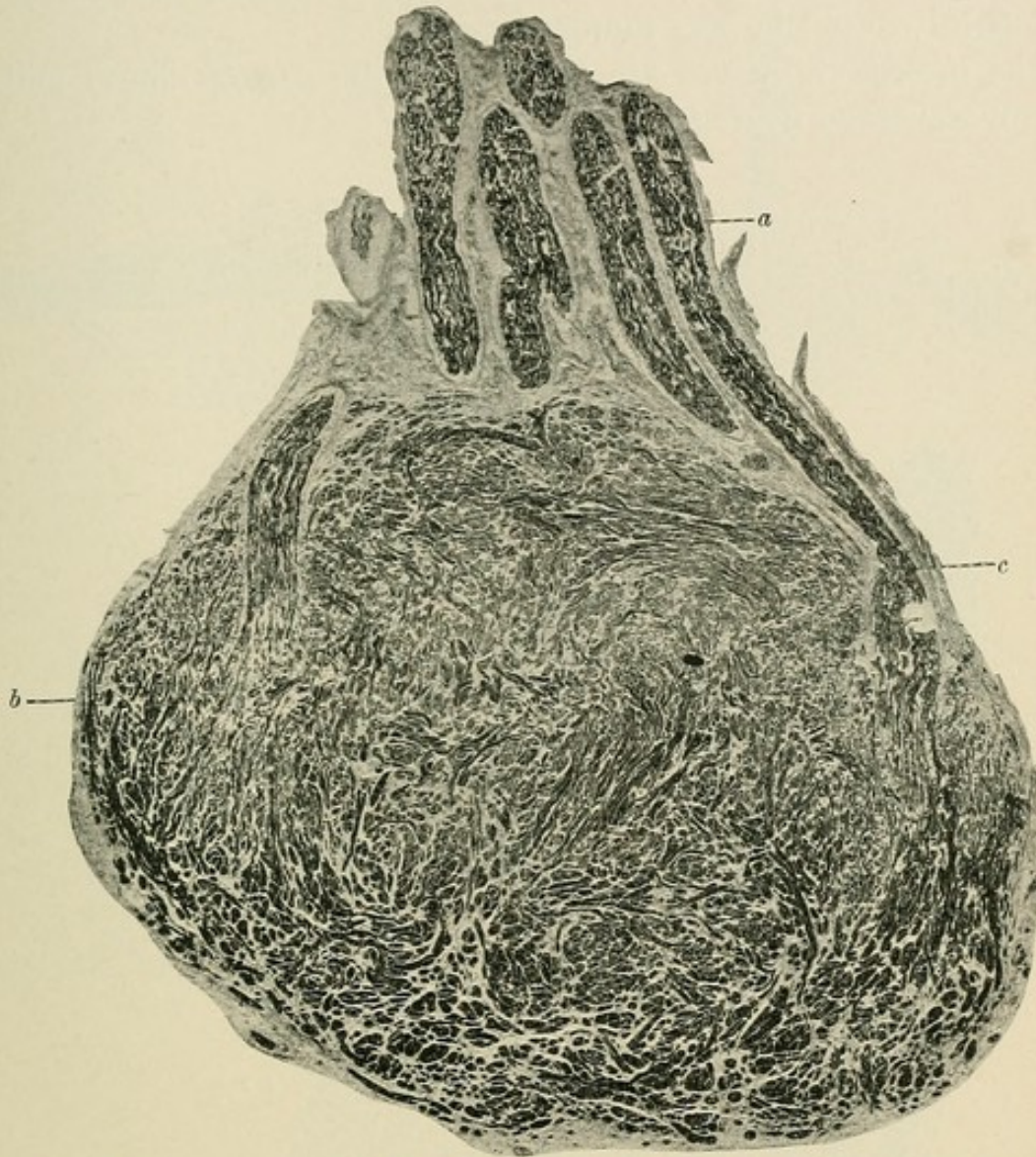


FIG. 363.—Amputation-neuroma (after Karg and Schmorl). Upon the crural nerve (*a*) is seen the bulbous tumor (*b*), which has been produced by proliferation of the bundles of nerve-fibres. The tumor is composed of interlacing myelinic nerve-fibres; at *c* is seen a bundle of nerve-fibres which is divided into numerous filaments in a downward direction.

which such neuromata were excised four and five times, and an early recurrence of the pain, with return of the tumor, followed each operation. In one case a cure was finally effected by excising four inches of the sciatic nerve, far beyond the apparent limits of the tumor.

Klebs is of the opinion that neuromata of the central nervous system are not composed, as is usually asserted, of cells derived exclusively from neuroglia, but that the nerve-cells take an active part in their development (Pl. 13, Fig. 2). He consequently regards them not as histioid but as organoid tumors. He proposes the name "neuro-

glioma" in place of "glioma." With due deference to the weight of opinion of this author, it must be maintained that in glioma the neuroglia-proliferation furnishes the bulk of the tumor, and that the nerve-cells constitute an accidental product incident to the increased vascularity caused by the tumor-formation.

The mesenteric nerves are occasionally the seat of diffuse miliary fibromyxomatous neuromata (Fig. 364).

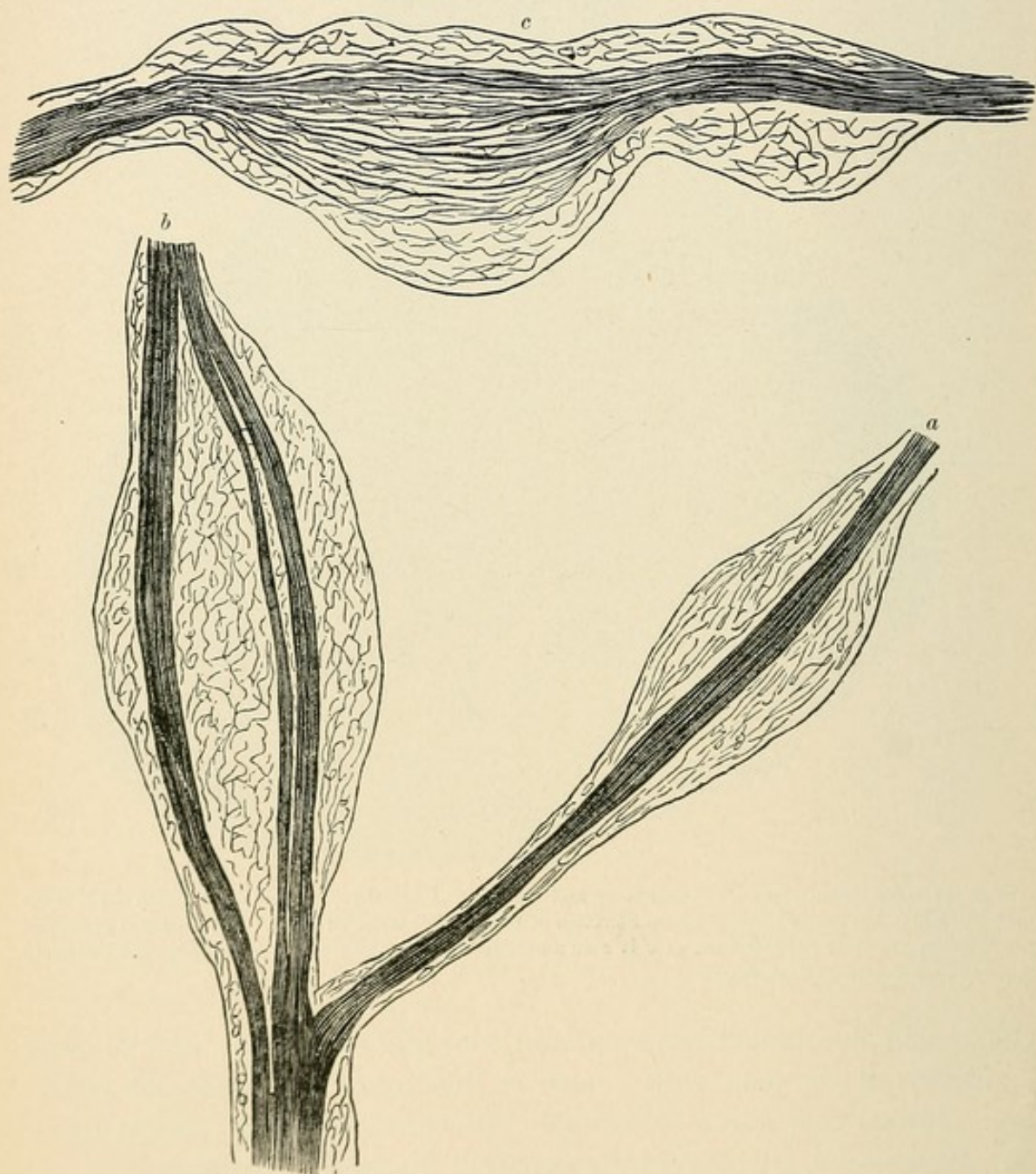


FIG. 364.—Miliary fibromyxomatous neuromata of the mesenteric nerves; $\times 50$ (after Perls). In the nodule (a) the nerve passes unchanged through the centre of the swelling; in b it is separated by myxomatous degeneration of the perineurium into two bundles; in c its fibrillæ are separated.

Neurofibroma is occasionally diffuse, following different nerve-trunks, when it is called a "plexiform neurofibroma." The tumors often attain

great size, imbedding the nerve-trunks in large masses of fibrous tissue (Fig. 365). Marchand, who reports two cases of this affection, regards the tumor as a cylindrical fibroma of the nerve-sheaths. In one case,

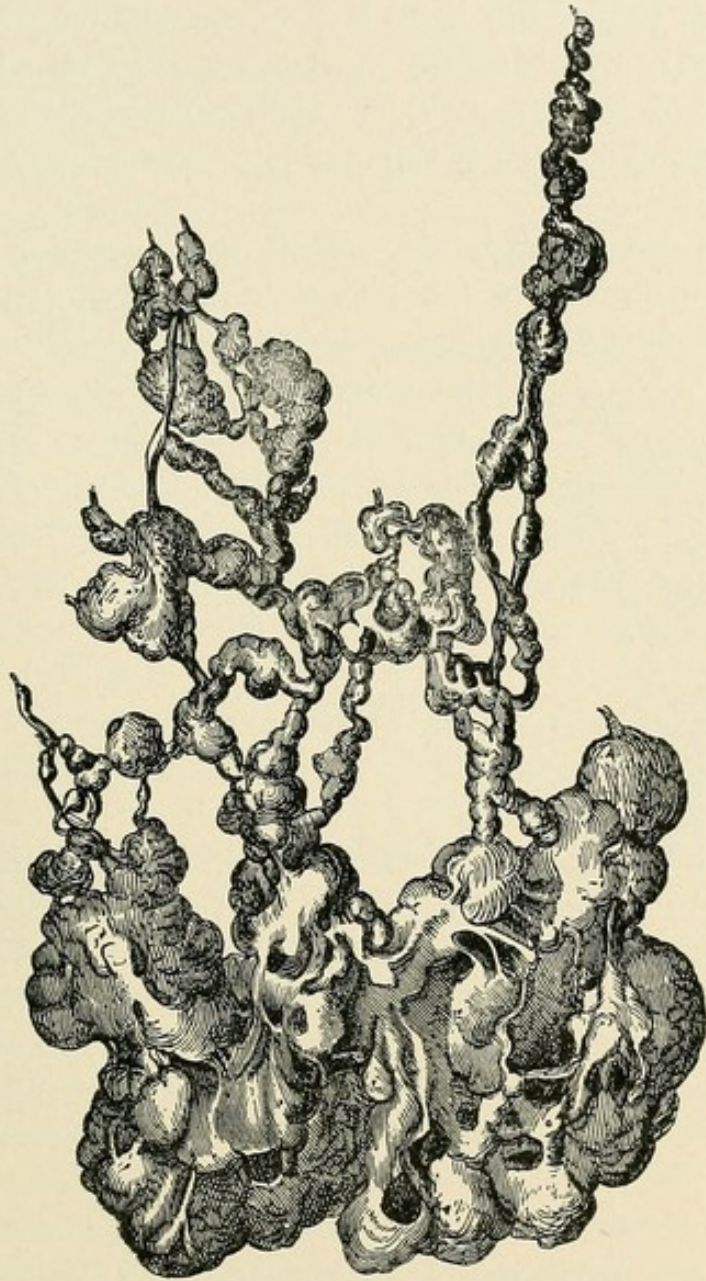


FIG. 365.—Plexiform neurofibroma of the plexus pudendus and ischiadicus, one-fourth natural size (after O. Weber). The whole mass forms a tumor weighing several pounds.

a boy twelve years old, the tumor involved the upper lid of the left eye and the adjacent part of the temporal region; at the same time it penetrated deeply into the orbital cavity. It was first noticed when the child was six months old. The second case was a boy eight years old. The tumor was soft, extended from a point behind the right ear in the direction of the temporal region and beyond the parietal eminence, and projected an inch beyond the surrounding skin. The tumor in each case was composed of convoluted cords which contained remnants of

nerve-fibres. Schwann's sheath was intact, consequently the tumor must have developed from the perineurium, with participation of the walls of the blood-vessels. In the only case of plexiform neurofibroma that has come under the writer's observation, the tumor, which occupied the palmar side of the hand and extended along the branches of the median nerve which supply the thumb and the index finger, was several inches in length, quite hard, and presented the characteristic convoluted appearance. The tumor was extirpated, and did not return after the operation.

Regressive Metamorphoses.—With the exception of plexiform neurofibroma, benign tumors of nerves do not attain large size. After they reach the size of a hemp-seed or that of a walnut they remain

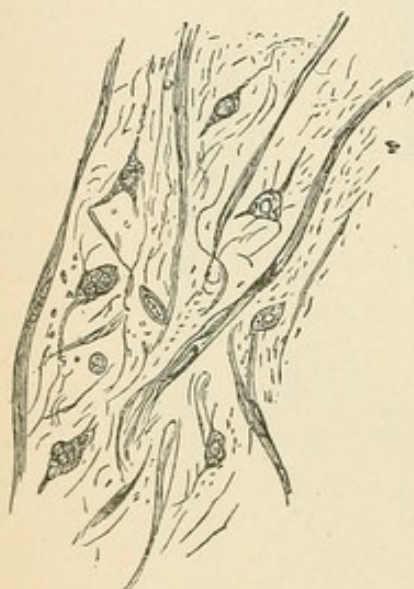

FIG. 366.—Fibromyxomatous tissue from specimen shown in Figure 372; $\times 250$.

stationary. They are not much disposed to regressive metamorphosis. Besides hyaline and myxomatous degeneration, no other retrograde pathological changes have been observed. The liability of a neuroma to become transformed into a sarcoma is perhaps a little greater than that of a simple fibroma, more especially in cases in which the tumor has undergone myxomatous degeneration.

Etiology.—In many instances neuroma appears as a congenital tumor, particularly the heterotopic variety and plexiform neuroma. Plexiform neuroma has usually been met with in young persons, and the growth of the tumor was in most instances referred to infancy or early childhood. The heredity of neuroma, like that of many other forms of benign tumors, is unquestionable. The heredity of multiple neurofibromata is particularly well marked. Chronic inflammatory affections of the nerve-sheaths or of tissues in close proximity to nerve-trunks is a potent exciting cause. The traumatic influence in the etiology of neuroma is well shown in the case of amputation-neuroma. Wounds and contusions may exert a similar influence in exciting a latent tumor-matrix to active tissue-proliferation.

Symptoms and Diagnosis.—The symptoms produced by a neuroma consist in varying degrees of functional disturbance of the nerves which are the seat of the tumor. With the exception of amputation-neuroma and the subcutaneous painful tubercle, pain and tenderness are not conspicuous symptoms unless the tumor causes nerve-compress-

sion, as when the tumor is located in a bony channel through which the nerve passes. In multiple neurofibromata of the skin pain and tenderness are usually absent. In some cases in which pain is absent it can be produced by pressure. With the exception of plexiform neuroma, the tumor is circumscribed, encapsulated, and movable; it is smooth, and often is spindle-shaped. In multiple neurofibromata the diagnosis is not difficult, as tumors can be felt in the course of different nerves. A plexiform neuroma can be distinguished from an arterial angioma by the size of the tumor, by its undergoing no changes under pressure, by placing the part in different positions, and by the absence of pulsations and bruit.

Prognosis.—The prognosis in neuroma is favorable, aside from the liability of the tumor to undergo transformation into sarcoma. The tumor does not involve adjacent tissues, and metastasis has never been observed. In the painful varieties the general health of the patient is often undermined by the loss of sleep and by inadequate out-door exercise. The rapid growth of a neuroma that has been stationary for a long time is a probable indication that malignant transformation has occurred.

Treatment.—Operative treatment in multiple neurofibromata is contraindicated unless some of the tumors should cause pain by pressure, when, if accessible, such nodules are to be removed by excision. Amputation-neuroma must be excised with the surrounding scar-tissue, and the section of the nerve must be made beyond the limits of the disease. If the nerve above the bulbous tumor is enlarged, it must be followed sufficiently far and excised with the tumor in order to guard against a recurrence of the neuroma. A plexiform neuroma must be excised if all parts of the tumor can be reached, as eventually the tumor may attain great size, and the nerves imbedded in the fibrous mass are destroyed in the course of time. Painful subcutaneous tubercles should be excised. The removal of circumscribed tumors of nerve-trunks must be effected without destroying the continuity of the nerve. This can be done without difficulty by enucleation. After the affected nerve has been exposed the capsule of the tumor is incised in the direction of the nerve-fibres and the tumor is enucleated. The writer recently removed from the median nerve above the wrist-joint a tumor the size of a hickory-nut. The patient was a girl twenty years of age, and the tumor had been growing for five years. It was centrally located. On the surface of the tumor could be seen bundles of nerve-fibres. The capsule of the tumor was incised between the visible nerve-fibres, after which the tumor was enucleated without difficulty. The nerve-sheath was sewed with fine catgut. The wound,

which was sutured throughout and was then sealed with aseptic cotton and iodoform collodion, healed by primary intention. The pain and the prickling sensations which the tumor had produced disappeared slowly after the operation.

TOPOGRAPHY.

Multiple Neurofibromata.—Superficial multiple neurofibromata of the skin have been described in the section on Fibroma. The relation of these tumors to the nerve-sheath was first pointed out by Recklinghausen. The deeper nerves are occasionally the seat of multiple neurofibromata in which nearly all the nerves of the body may become involved. The tumors are due to multiple matrices of fibroblasts or of fibroblasts and neuroblasts.

Sorzka does not believe that the development of multiple neurofibromata is caused by metastasis, as has been claimed by some authors; he attributes them to a congenital disposition of the nerves, so that the tumors may appear simultaneously or in rapid succession at different points independently of the primary tumor. In nearly all cases the patients were children or young adults.

Heusinger records the case of a sailor twenty-three years old in whom all the nerves were affected by numerous nodular enlargements. Not a nerve in the entire body was found normal. The enlargements were caused by increase in the connective tissue. The axis-cylinders were normal. There was neither pain nor tenderness.

Prudden reports the case of a girl twenty-five years of age who during convalescence from variola became paraplegic, and during this time multiple neuromata appeared. At the post-mortem more than a thousand tumors were found, affecting not only the peripheral branches and the sympathetic, but also the cranial nerves and the pneumogastric. Under the microscope these tumors showed an enormous increase of the intrafascicular as well as the perivascular connective-tissue fibres. The nerve-fibres were not increased in size or in number. Only one tumor, in connection with a branch of the lumbar plexus, contained within its capsule cells resembling ganglion-cells of the sympathetic nerve.

Virchow collected thirty cases of multiple neurofibromata, which he calls "general neuromatosis." In one case he found five hundred, in others from eight hundred to a thousand, tumors.

In multiple neurofibromata operative treatment is contraindicated unless one or more of the tumors, occupying localities in which pain from pressure is produced, are accessible, in which case the tumors should be excised.

Cranial Nerves.—The cranial nerves are frequently the seat of neuromata. If the tumor occupies that part of a nerve which passes through a bony canal, intense pain, usually diagnosticated and treated as neuralgia, is the result. Sensory nerves are more frequently affected than motor nerves. According to Virchow, among the nerves of special sense the acoustic nerve is the most frequent seat of neuroma. Neuroma of the facial nerve is exceedingly rare. Jocqs collected sixty-two cases of neuroma of the optic nerve. Myxofibroma is the kind of tumor most frequently found in this locality. Myofibromata do not extend to the globe, but are apt to involve the intracranial portion of the nerve. They are painless tumors, but affect and destroy vision at an early stage. Perls has described a true neuroma of the optic nerve the size of a hen's egg. The new nerve-fibres were not supplied, like the normal fibres of the optic nerve, with a nucleated sheath. The specimen showed also that the new nerve-fibres were formed, not by coalescence of spindle-cells, but by prolongations of the individual cells. Toynbee reported several cases of neurofibroma of the acoustic nerve, and in every case the tumor produced progressive deafness.

Spinal Nerves.—The roots of the spinal nerves are frequently the seat of neuroma. Owing to the depth of the location of the tumor, it is seldom recognized during life. Chavasse reports a case in which the tumor, occupying the cervical region, was removed with a fatal result, the patient dying of septic spinal meningitis.

Upper Extremity.—Neuroma of the axillary plexus has been observed and has successfully been removed. The operation in this locality is difficult, owing to the proximity of the large vessels and to the number of large nerve-trunks. The ulnar, radial, and median nerves are more favorably situated for the successful removal of neuromata. The writer has referred to a case that came under his observation, in which the tumor, which involved the median nerve just above the wrist, simulated ganglion almost to perfection. A case of plexiform neuroma of two digital branches of the same nerve has also been alluded to by the writer.

Lower Extremity.—The sciatic nerve below its exit from the pelvis is occasionally the seat of a neuroma, but is more frequently the seat of neuro-sarcoma. Benign tumors may occur in any part of its course, and are occasionally multiple (Fig. 367).

The removal of tumors of a benign character from large nerve-trunks calls for special care. *Nerve-resection is unjustifiable. The continuity of the nerve must be preserved.* The tumor is exposed by an incision parallel with the nerve; if the tumor is centrally located, the

mantle of overlying nerve-tissue is incised between the visible bundles of nerve-fibres, after which the tumor is enucleated. In central neuro-

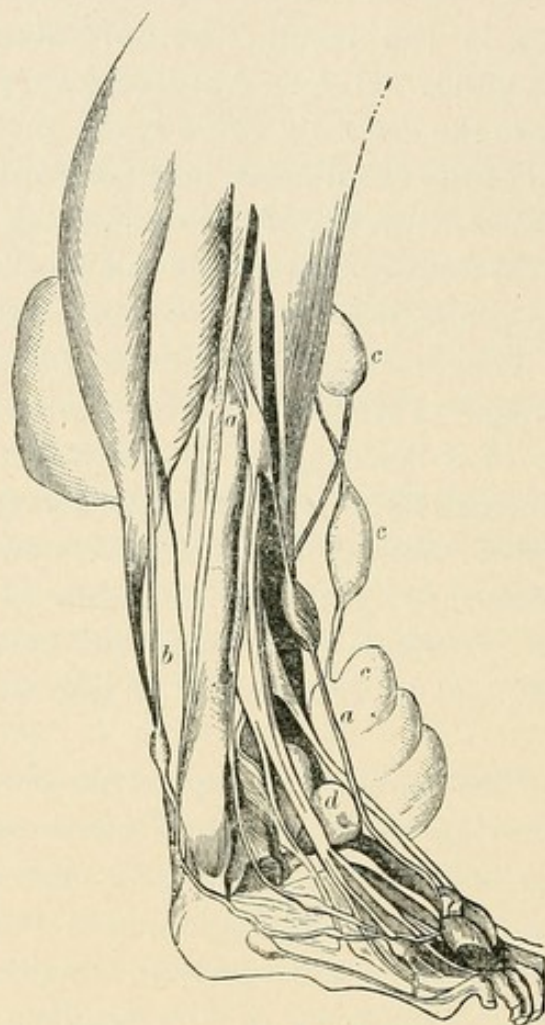


FIG. 367.—Lower extremity from a case of multiple neurofibromata; one-third natural size (after Perls): *a*, superficial peroneal; *b*, sural nerve; *c*, superficial branches of saphenous major nerve; *d*, tumor upon deep peroneal.

fibromata that are accessible to operation removal should be advised, as the pressure-atrophy caused by the tumor will ultimately destroy the function of the nerve.

Plexiform Neuroma.—Plexiform neuroma is always congenital. The tumor may not be detected at the time of birth, but it is always found in children and young adults, and the clinical history frequently dates back to early infancy. In most of the cases that have been examined carefully the mass of the tumor was composed of fibrous tissue in which the nerves were found imbedded. Bruns found in some specimens a marked increase of nerve-fibres. The tumors are found most frequently in the temporal region, the neck, and the side of the face, but they may affect almost any part of the body. Christôt reports two cases in which the tumors were located upon the cheek and the neck. Czerny observed a case in which the tumor involved the lumbar

plexus. In this case the patient was also the subject of a very large congenital fibroma of the skin. He found in the tumor, besides fibrous

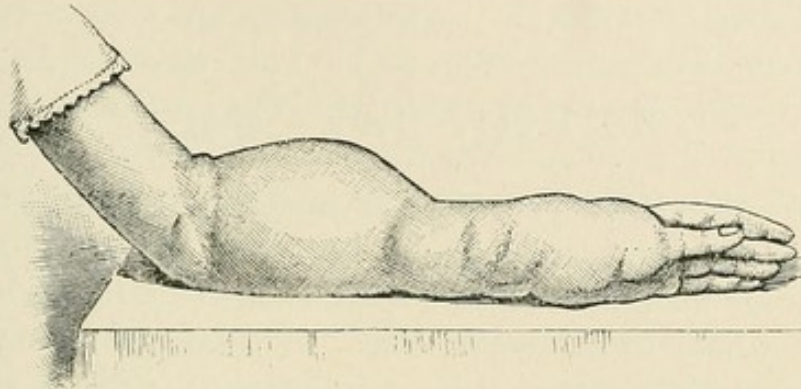


FIG. 368.—Arm in which the musculo-spiral nerve was neuromatous (after Campbell de Morgan).

tissue, new non-medullated nerve-fibres. Campbell de Morgan met with a plexiform neuroma of the musculo-spiral nerve and its branches (Fig. 368). The patient was a young lady. The tumor, which was not painful, had undergone myxomatous degeneration.

Plexiform neuromata are painless tumors which grow slowly, but which may attain large size. The affected nerves become tortuous, because they increase in length as well as in circumference. The ramifications correspond with the directions of the branches of the nerves that become successively involved. Thorough excision of the tumor is the only proper surgical treatment.

Vulva.—Neuroma of the vulva is a pathological curiosity. In one case reported by Simpson the tumor appeared as a painful nodule near the urinary meatus. Another case is reported by Kennedy. In this case the tumor appeared as multiple subcutaneous tubercles exquisitely tender to touch.

Prepuce.—A number of authors have described a very painful recurring herpes of the prepuce, which they regarded as being of a nature similar to herpes zoster (Hebra, Mauriac, Verneuil, Kaufmann). The attacks occur every four or five weeks, are preceded by pain in the back and along the thighs, and subside in the course of a few days. In 1860, Verneuil resorted to circumcision in the treatment of this obstinate affection, and effected a permanent cure. He found in the specimen removed a peculiar form of neuroma (*neurome cylindrique plexiforme*), which in its distribution and structure resembled plexiform neuroma.

XXVIII. SARCOMA.

It is less than fifty years since all malignant tumors were included under the one term "carcinoma." Johannes Mueller found and described in some malignant tumors spindle-shaped cells, but he regarded them as a variety of carcinoma-cells. A description of similar cells was later given by Valentin. Lebert in 1845 made these cells the basis for his fibroplastic tumor. In 1847, Virchow introduced the term "sarcoma," and upon a histological basis separated from carcinoma a large group of malignant tumors. He asserted that the spindle-cells were not characteristic of sarcoma, and he called attention to the different forms of sarcoma-cells. He relied upon the relation of cells to the reticulum in making a differential diagnosis between carcinoma and sarcoma. He placed special stress upon the absence of a well-marked stroma and alveolar grouping of the cells. Follin called sarcoma *plasmôme*. Rindfleisch called attention to the histological resemblance of sarcoma to granuloma. By degrees pathologists were brought to admit that under the term "sarcoma" must be included all malignant tumors originating from tissue of mesoblastic origin. *Carcinoma represents the malignant tumors of the tissues of epiblastic and hypoblastic origin. Sarcoma represents the malignant tumors of the tissues of mesoblastic origin.* As the typical tumor-element of the former the embryonal epithelial cell is recognized; of the latter, the embryonal connective-tissue cell is the prototype.

Definition.—*Sarcoma is an atypical proliferation of connective-tissue cells from a matrix of fibroblasts of congenital or post-natal origin.* This definition acknowledges the connective tissue as the sole origin of sarcoma. Histological investigations have shown that sarcoma originating in the different parts and organs always begins in the connective tissue primarily, and that the other tissues are involved secondarily—that is, by extension. Sarcoma springs from the subcutaneous or intermuscular connective tissue, fascia, submucous and subserous connective tissue, the neuroglia of the central nervous system, the lymphoid tissue, the periosteum, the marrow of bone, and the stroma of other tumors. Only the cartilage is exempt as a primary starting-point of sarcoma. The atypical proliferation of the connective-tissue cells is evidenced from the fact that the sarcoma-cells do not

reach maturity, and that they invade the adjacent tissues and very frequently give rise to metastasis. We have already shown, in connection with carcinoma, that mature normal cells never take an active part in the formation of a malignant tumor. The same remarks apply to the essential cause of sarcoma. The mature connective tissue is acted upon by microbic causes, and if these causes are not sufficiently intense in their action to destroy the tissue, it proliferates and forms granulation-tissue, of which the different infective swellings, the granulomata, are composed.

It is impossible to explain satisfactorily the origin of a tumor from pre-existing normal connective tissue without assuming the presence of a localized specific microbic cause. It is true that the different forms of sarcoma resemble more closely chronic inflammatory processes than does carcinoma, but we are not yet, and probably never will be, in possession of demonstrative proof of the microbic origin of sarcoma. We are therefore forced to conclude that sarcoma-tissue is produced from a matrix of embryonic connective-tissue cells of congenital or post-natal origin.

Of all tumors, sarcoma probably develops more frequently from a matrix of embryonic connective-tissue cells or fibroblasts than any other tumor. The matrix is composed of the same kind of cells as the matrix of fibroma, except that the cell-development was arrested at an earlier stage. The cells of a sarcoma as compared with those of a fibroma possess greater reproductive power, but do not reach the same degree of development, owing to a more imperfect specialization of the cells of which the matrix is composed. Every surgeon knows that trauma plays a more important rôle in the etiology of sarcoma than in that of carcinoma. The trauma in sarcoma not only acts as an exciting cause in stimulating a latent matrix to active proliferation, but it frequently produces at the same time the essential cause, a post-natal matrix of granulation-tissue. It would be difficult to explain satisfactorily in any other manner the frequent origin of sarcoma in inflammatory products and at the seat of a fracture. As the endothelial cells are only a modified form of connective-tissue cells, malignant endothelial tumors will be included among the sarcomata.

Histology and Histogenesis.—The presence of a reticulum in sarcoma was formerly denied. Ackermann and others have shown that a reticulum is always present. In some specimens the stroma is well marked; in others it is so fine that it is almost hidden by the tumor-cells. Teasing preparations of hardened specimens shows the fibrillated structure best. Ackermann claims that the reticulum of sarcoma is the product of sarcoma-cells. Schwann asserted that embryonal

connective-tissue cells elongate and break up into fibrillæ until the cells are lost. His views were supported by Virchow, Danders, and Kölliker. Virchow denied that fibrillæ are produced by the breaking up of cells. Lücke and Rindfleisch were of the same opinion. The origin of normal connective tissue from a blastema was asserted by Bizzozero, Kollmann, Valentin, M. Schulze, and Bruecke. Ackermann studied fibrillation in spindle-celled sarcoma, and observed that fibrillæ were produced by splitting up of the protoplasm of the cells. The fibrillæ in sarcoma resemble the same structures in connective tissue. The reticular arrangement of the fibrillæ has been explained by union occurring between projections of different cells. The meshes of this reticulum become apparent when filled with fluid or cells. If the meshes are empty, they collapse. A jelly-like substance is always present in embryonal connective tissue, and is always found in the connective-tissue spaces. This substance, which is a mucin-serum, can be seen best around transverse sections of fibrillæ. In old portions of the tumor this material is scanty, as the fibrillæ become more compact by contraction. Cicatricial contraction does not occur from loss of substance, but from the disappearance of the intercellular substance. Many authors consider this substance, with the fibrillæ, as one body which constitutes the cement-substance. Bizzozero says the stroma of a sarcoma is either soft, amorphous, mucoid, or jelly-like, at times more compact and fibrillated.

The intercellular substance holds a relation to the question of the origin of fibrillæ. If the fibrillæ originate from the blastema, they form a part of the cement-substance; if they are a product of cells, they are derivatives of these structures, which would leave the mucin-serum only as the proper cement-substance.

In sarcoma cell-proliferation takes place in the immediate vicinity of blood-vessels, and is controlled and influenced by them. Spindle-cells are formed in the adventitia; these cells either cannot be distinguished from the cells of this part of the vessel-wall or they differ only in size. The cells either come in direct contact with the vessel-wall or are separated from it only by a gelatinous layer. The latter contains the sarcoma-cells, few in number, imbedded in a fine net-like ground-substance, the wide meshes of which contain the mucin-serum. There grow into the tumor young buds of capillary vessels which have imperfect walls; the cells arrange themselves into minute cylinders, the centres of which correspond with new blood-vessels.

The intimate relations of the walls of new blood-vessels with the parenchyma of the tumor is the characteristic feature of sarcoma. As sarcoma, starting from a central point, extends almost equally in all directions,

the resulting tumor usually approaches a globular shape, unless at some points obstacles to its growth are presented. In organs where the structure is uniform throughout, as in the brain, tumors grow in a globular shape, while in organs presenting parallel arrangement of

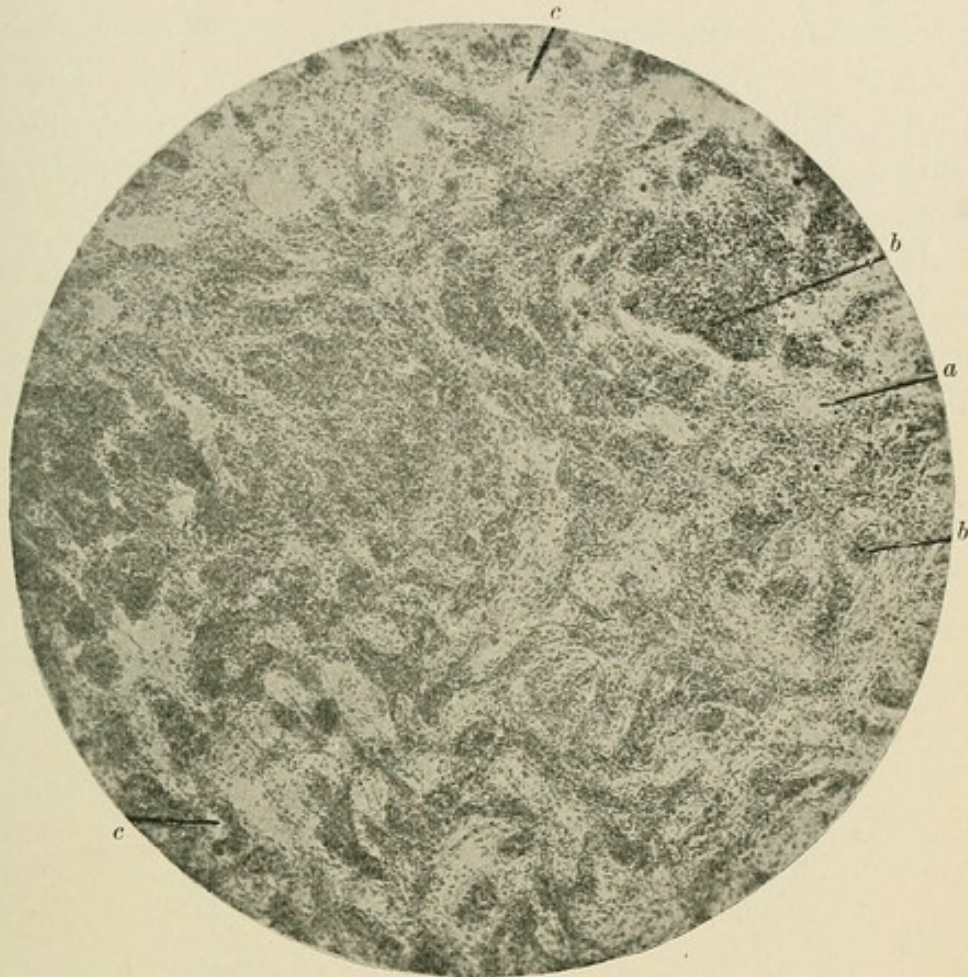


FIG. 369.—Sarcoma of skull, showing capillary vessels, the walls of which are composed in part of sarcoma-cells (Surgical Clinic, Rush Medical College, Chicago): *a*, delicate stroma of connective tissue; *b*, groups of small round cells; *c*, new capillary vessels.

the structures the tumor assumes an oblong shape, as is the case in muscles and long bones. In bone the tumor either destroys the bone-tissue or pushes the compact layer before it. All these properties of the tumor indicate the presence of great tension, which can be referred to increased blood-pressure. This increased pressure can be explained readily in the case of sarcoma from the presence of numerous and dilated blood-vessels. In many cases the tumor is composed largely of new blood-vessels with the characteristic cells interposed between them. In the vascular variety of sarcoma the tumor differs from an angioma in the greater amount of tissue which exists between the vessels and in the greater firmness of this tissue. In fibro-sarcoma the vessels are scanty, but are gradually increased in size. The vessels in sarcoma remain patent in the cut surface, as in cases of papilloma.

The spindle-cells with a scanty intercellular substance constitute the walls of the new capillary blood-vessels, as was first shown by Waldeyer. In all capillary vessels the endothelial cells are preserved. In a new sarcomatous growth the vessels increase in size and are later pushed apart by the cellular elements. The walls are thin and remain thin, so that finally the lumina of the vessels appear to be surrounded by only a single layer of endothelial cells (Fig. 369, *c*). The circulation in the capillaries is active and the blood-pressure is considerable, and, as the walls are weak, the blood-pressure is communicated to the tissues of the tumor, in which event the tumor pulsates.

In all histological varieties of sarcoma the cells are characterized by the existence of a large nucleus, which in young tumors almost obscures the cell-protoplasm. In the spindle-cells the nucleus is centrally located (Fig. 370). The giant-cells are multinuclear (Fig.

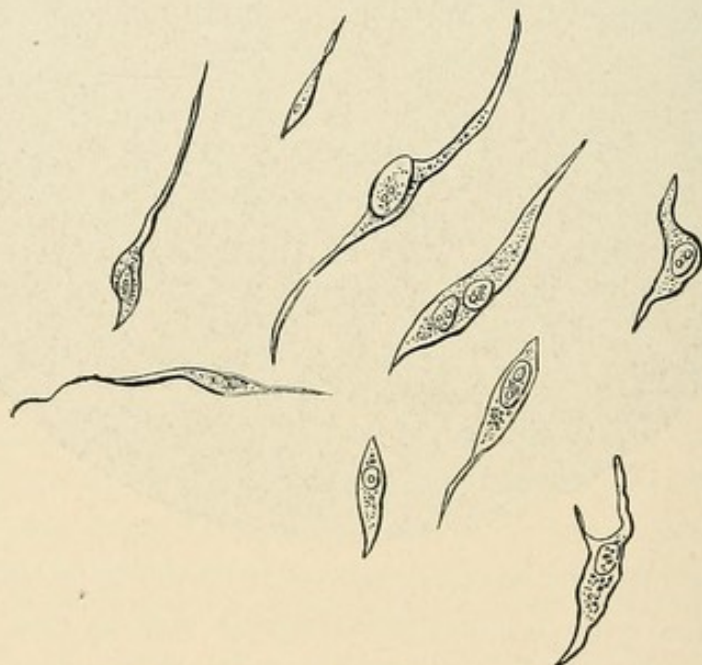
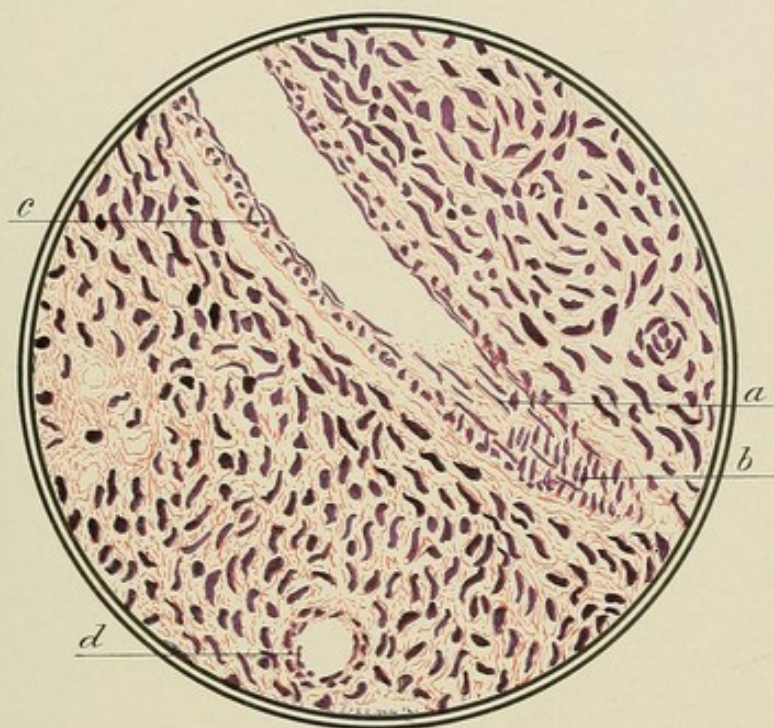


FIG. 370.—Spindle-cells from sarcoma (after Lücke).

371). The cells vary greatly in size and shape, but a certain uniformity is observed in each tumor. The shape of the cell is not only greatly influenced by the structure of the mesoblastic tissue in which the tumor originates, but also by the cell-environments. The cells are often moulded into different shapes by pressure. The shape of the nucleus is determined by the shape of the cell. The nucleus is always clear, well-defined, and surrounded by a proper nuclear membrane. The contents of the nucleus vary according to the age of the cell. In young and rapid-growing sarcoma the contents are rich in chromatin; later the chromatin is diminished and there appears a beautiful network of chromatin threads that do not readily absorb staining material. One or two nucleoli which are deeply stained are always present. In young



Fibro-sarcoma of the base of the tongue, recurrent seven times : $\times 500$; *a*, longitudinal fibres of vessel ; *b*, circular fibres of vessel ; *c*, vessel cut transversely ; *d*, endothelial layer of vessel.



tumors, besides cells, leucocytes are always present, but their number is usually limited. They are most numerous along the course of blood-vessels. Although the imperfect condition of the capillary walls would appear to favor emigration of leucocytes, the escape of leucocytes is limited. Leucocytes are found in abundance only in young and rapid-growing tumors. In a specimen examined by Klebs he found the large vessels of the tumor partly closed by normal white thrombi. The existence of the leucocytes in the tumor is of short duration.

Sarcoma-cells reproduce themselves by karyokinesis, as was first observed and described by Van Henkelem. The same method of cell-reproduction in sarcoma has been studied by Aryama and Klebs. Distinct alveolation of the stroma of sarcoma is observed only in exceptional cases.

Billroth in 1869 introduced the term *alveolar sarcoma*, and included in this variety of sarcoma all tumors in which the connective-tissue stroma showed a reticulated structure, in the meshes of which the sarcoma-cells are arranged in groups (Fig. 372). He insists that such tumors are often wrongly considered as carcinomatous from the size of the cells and the alveolated structure of the reticulum. As such tumors are found in localities devoid of epithelial cells, they must be classified with the sarcomata. In these cases the reticulum is composed of the pre-existing connective tissue of the part in which the tumor grows. A good illustration is furnished by the malignant primary tumors of the lymphatic glands. Although the alveolated structure of the reticulum of some sarcomatous tumors is undisputed, the arrangement of the cells in the alveoli is different from that in carcinoma, in that the cells are not arranged in concentric compact layers. Alveolation is observed most frequently in sarcoma of endothelial origin.

Pacinotti demonstrated the existence of lymphatics in sarcoma by injections of asphalt dissolved in chloroform. Lymphatics were found both in the parenchyma and in the capsule of such tumors.

Morphology of Sarcoma-cells.—The morphology of sarcoma-cells is less uniform than that of carcinoma-cells. Many pathologists, but more especially Rindfleisch, have considered different forms of cells as

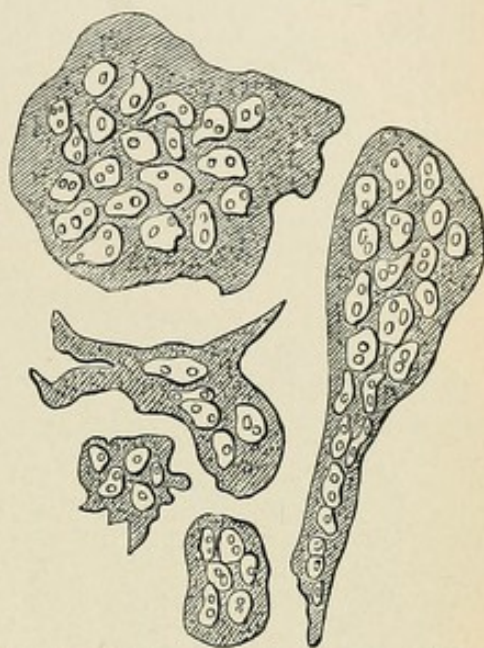


FIG. 371.—Giant-cells from sarcoma (after Lücke).

belonging to the same kind, differing only in reference to the degree of development. Rindfleisch believed that round-cells are converted into spindle-cells, and *vice versâ*. Ackermann and Klebs have seen no such transition. No intermediate forms have been found.

Histological Varieties.—*Round-celled Sarcoma.*—It is not necessary to make a histological or clinical distinction between large and small round-celled sarcoma. Some tumors are composed exclusively of round cells, and as these cells, according to Ackermann, lack the power of fibrillation, the tumors possess a minimum amount of inter-

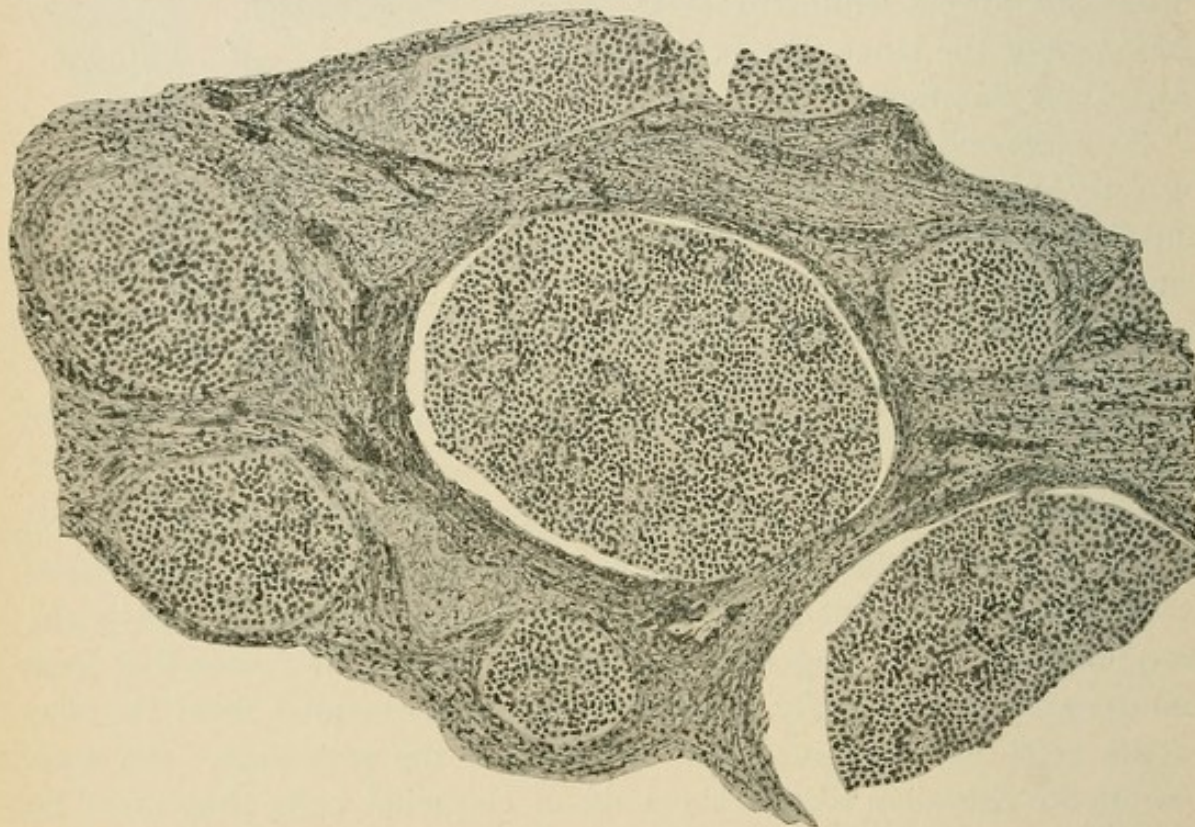


FIG. 372.—Alveolar sarcoma; $\times 100$ (Surgical Clinic, St. Joseph's Hospital, Chicago).

cellular substance, are soft, and grow rapidly. The appearance of sections of round-celled sarcoma under the microscope bears a strong resemblance to granulation-tissue, from which, without the aid of a clinical history, it is difficult to distinguish it (Fig. 373). In some tumors the round cells are scattered between the spindle-cells and the giant-cells (Fig. 374). In the genuine round-celled sarcoma starting in tissues other than lymphatic glands, the separate phases of development occur in the same order as in spindle-celled sarcoma, and are more accurately defined than in the latter. In the first place, the vessels are dilated and new ones are formed, which show the same character as in spindle-celled sarcoma. According to Ehrlich, the round cells always appear in close proximity to the vessel-wall. The vessel-lumina are more patent, and the walls of the vessels are lined with well-devel-

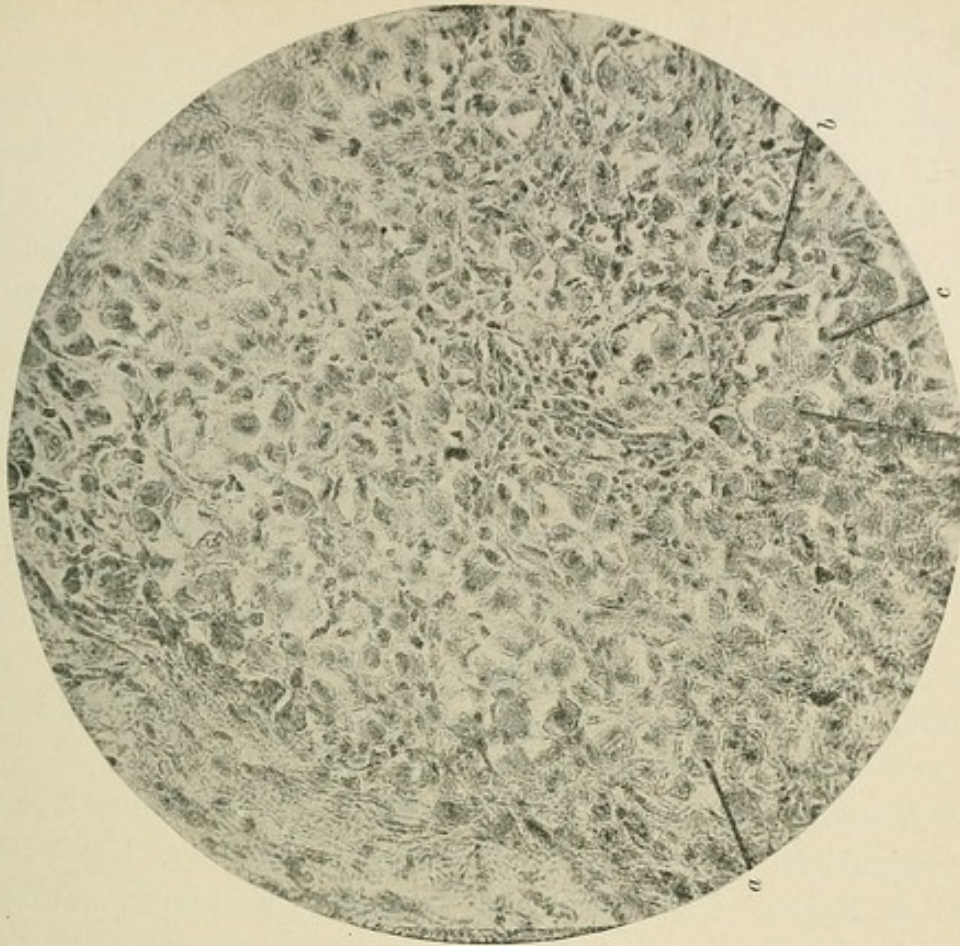


FIG. 374.—Mixed-cell sarcoma of bone; $\times 480$ (Surgical Clinic, Rush Medical College, Chicago): *a*, round cells; *b*, spindle-cells; *c*, giant-cells.

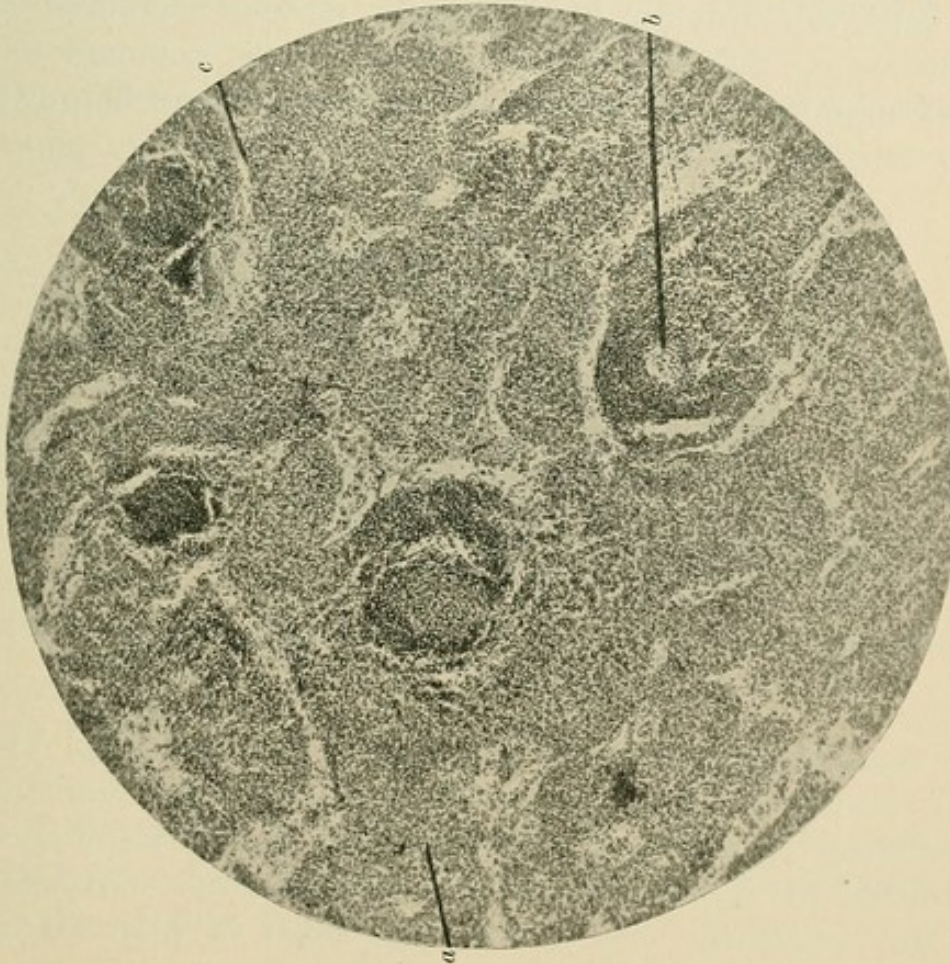


FIG. 373.—Round-celled sarcoma; $\times 50$ (Surgical Clinic, Rush Medical College, Chicago): *a*, round sarcoma-cells; *b*, round sarcoma-cells more densely packed; *c*, defects caused by shrinkage during hardening of specimen.

oped endothelia. The round cells which compose the principal mass of the new tissue are distinguished by their large nuclei containing an abundant supply of chromatin. A superficial examination reveals the picture of an inflammatory process. A careful examination, however, shows that the cells are arranged in rows along the course of blood-vessels, which peculiar arrangement constitutes one of the most reliable diagnostic evidences of the character and variety of the tumor. If these rows of cells are examined more carefully, it becomes evident that they are the product of connective-tissue proliferation. Very frequently short rows of four or five quadrangular cells are met with, densely packed, which are joined on the sides by triangular cells. The cells in such circumstances lose their round shape from mutual pressure. Round cells differ from spindle-cells in that the cell-segmentation by indirect division more speedily extends from the nucleus to the cell-proliferation. Mitotic figures are never present. Between the round cells are found leucocytes, which are recognized by their small and intensely stained nuclei.

Spindle-celled Sarcoma.—This is the “fibro-plastic tumor” of Lebert, the “fasciculated sarcoma” of Cornil and Ranvier, the “recurrent fibroid” of Paget. The subdivision into small and large spindle-celled sarcoma is superfluous; the difference is simply one regarding the size of the cells, the structure of the tumors representing these varieties being the same. Spindle-celled sarcomata are the commonest of this group of tumors, and are found most frequently in dense fibrous tissues,

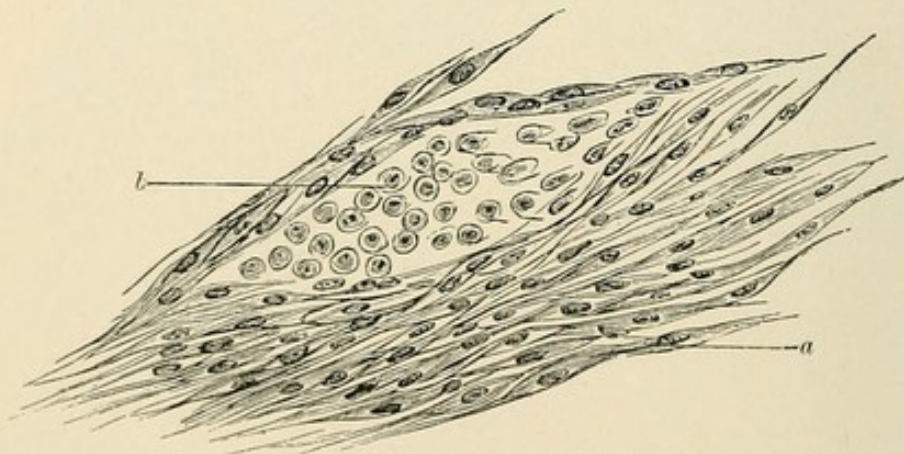


FIG. 375.—Small spindle-celled sarcoma; $\times 300$ (after D. J. Hamilton): *a*, the spindles exposed entire; *b*, the same cut across.

such as the skin, the periosteum, and the sheaths of muscles. The inter-cellular substance is very variable: in some cases the tumor is composed almost exclusively of cells; in others the stroma is so copious as to justify the name *fibro-sarcoma* or *fasciculated sarcoma*—terms which are frequently used in the designation of hard sarcomatous

tumors. The cells are frequently arranged in fascicles which surround the blood-vessels. The spindle shape of the cells can be shown best in separating the cells from hardened specimens by teasing. In sec-

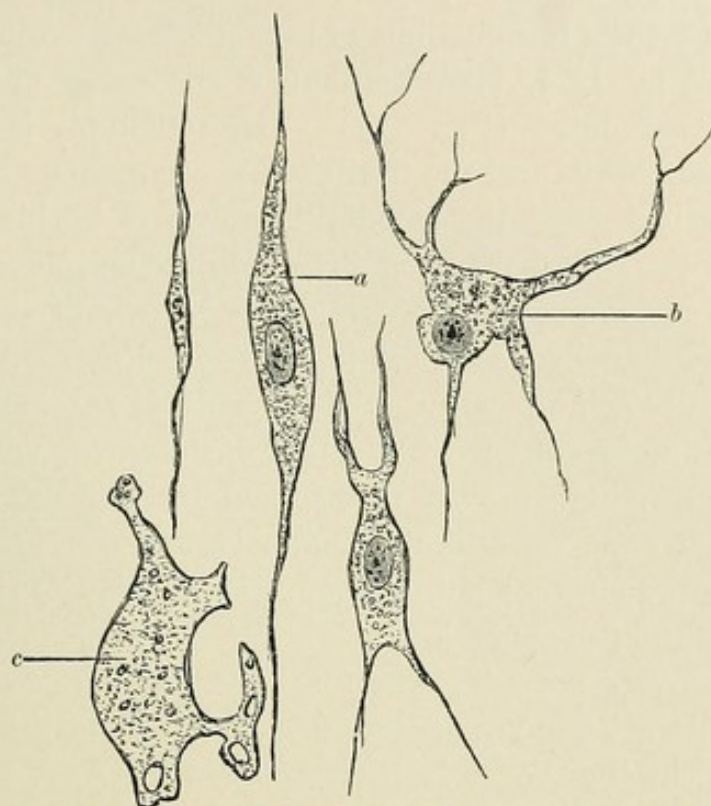


FIG. 376.—Large spindle-celled sarcoma; $\times 400$ (after D. J. Hamilton): *a*, ordinary spindle; *b*, branched flat cell; *c*, flat endothelium-like cell.

tions the shape of the cells will depend on the direction of the section. Cells that are cut transversely appear as round or oblong nucleated

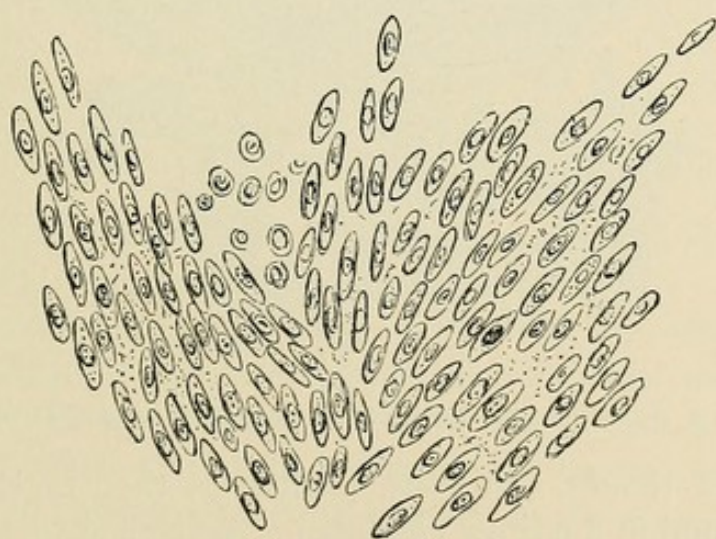


FIG. 377.—Oat-seed-like spindle-celled sarcoma; $\times 300$ (after D. J. Hamilton).

cells; if the section is made oblique, the cells appear ovoid, and the spindle shape is preserved only if the cut falls parallel with the cells (Fig. 375). The spindles interlace in bundles at somewhat obtuse angles.

The large spindle-cell is three or four times larger than the small cells, and some of the cells frequently show a number of terminal prolongations (Fig. 376).

Another variety of sarcoma-cell, differing from spindle-celled sarcoma only in that the terminations of the spindles are more obtuse, has been described by D. J. Hamilton under the name of "oat-seed-like spindle-celled sarcoma" (Fig. 377). The reticulum is composed of connective-tissue fibrils and the fibrillated prolongations of the spindles. The spindle-cells possess the maximum power of fibrillation. In sections in which the cells have been brushed out the reticular spaces are not empty, as in carcinoma, but contain a network of the finest fibrils. The large spindle-celled sarcoma is usually softer than tumors composed of small spindle-cells. Spindle-celled sarcoma grows less rapidly than tumors composed of other histological varieties of cells. The degree of malignancy is determined by the abundance of the stroma. If the connective-tissue stroma is well developed, the tumor is hard and grows slowly; if the stroma is scanty, the tumor is correspondingly soft and more malignant.

Giant-celled Sarcoma.—This tumor consists of various forms of cells, of which the large, many-nucleated cell, resembling the myeloplaques or osteoclasts in the bone, is the prototype. Giant-celled sarcoma arises pre-eminently from bone (Fig. 378), but similar tumors are also

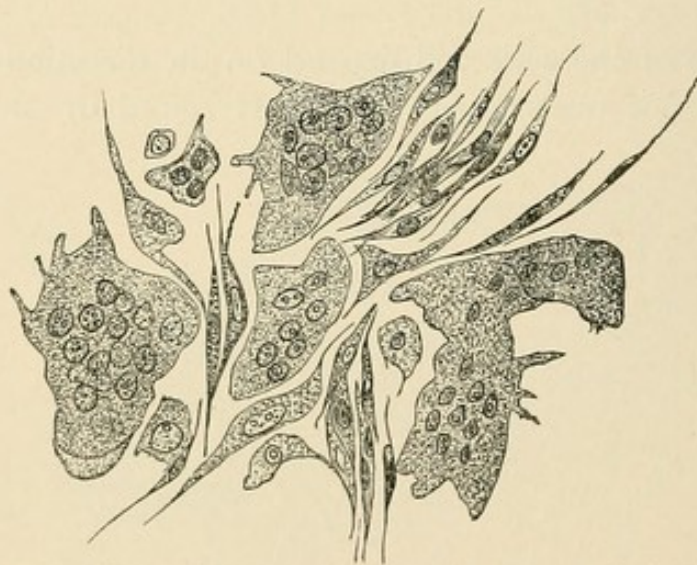

FIG. 378.—Giant-celled sarcoma from upper jaw; $\times 230$ (after Perls).

found in other tissues. In bone, giant-cells, the "myeloplaques" of Robin, are found in a normal condition. According to Kölliker, these cells act the part of osteoclasts, or bone-destroyers. In connection with bone giant-celled sarcomata occur as tumors which are clinically very different from one another. The periosteal form is most frequently found in the alveolar sockets of the teeth (epulis), where the tumors

manifest the lowest degree of malignancy. The myelogenous form is productive of early metastasis—an occurrence which often takes place before the primary tumor is detected. The so-called "malignant epulis" is composed mostly of spindle-cells (and between them, here and there, a giant-cell with multiple nuclei in the centre of the cells) and round-cells (Fig. 379). If such a tumor is carefully examined, it will be seen

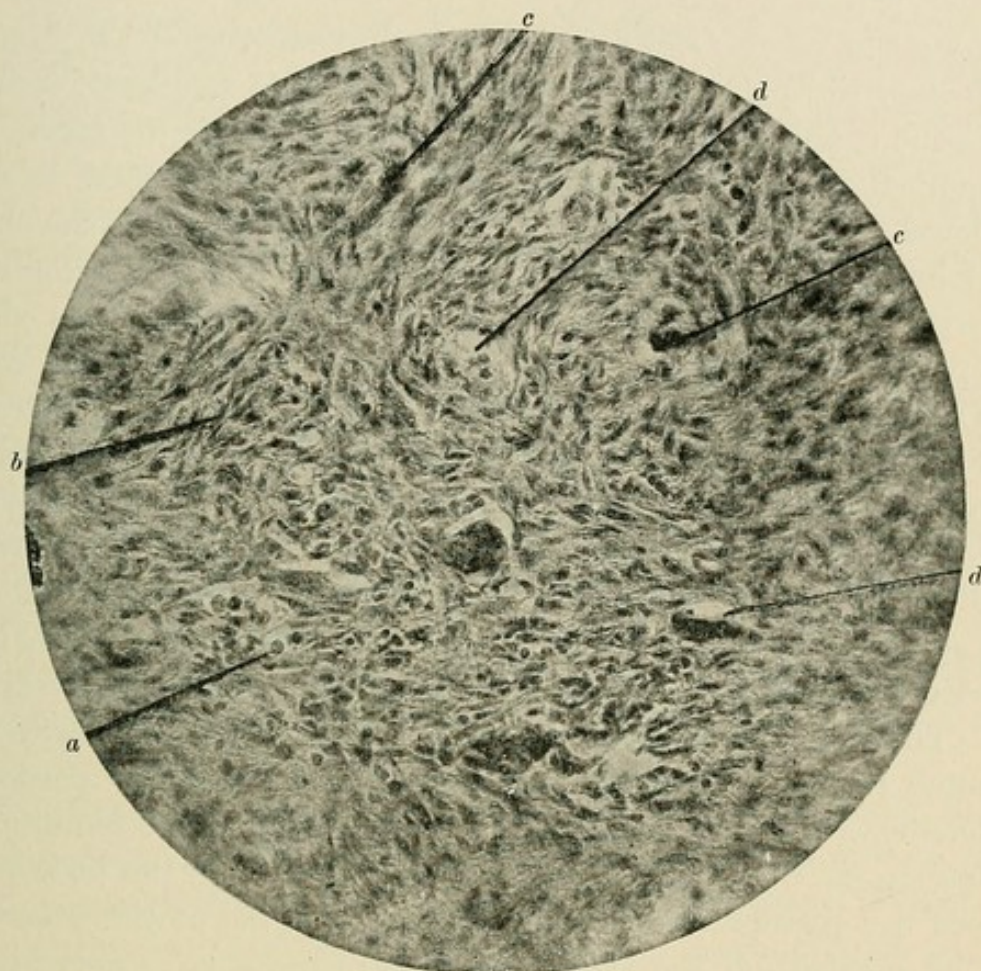


FIG. 379.—Sarcomatous epulis; $\times 480$ (Surgical Clinic, Rush Medical College, Chicago): *a*, small round cells; *b*, spindle-cells; *c*, *c*, giant-cells; *d*, *d*, blood-vessels.

that the giant-cells are derived from the bone; hence it is easily understood that a local recurrence can be prevented only by removing with the diseased gingiva the superficial portion of the bone where the tumor is attached. Another diagnostic sign may be mentioned, the brownish color of the tumor-tissue—an appearance which characterizes all giant-celled sarcomata. The greater danger which attaches to the central or myelogenous form consists in the greater vascularity of the tumors, as within them the vessels undergo an astonishing degree of development and dilatation. The arteries are frequently so numerous and so large, and their walls are so thin, that the pulsations are imparted to the tumor-tissue. Other tumors of the same kind have undergone angiomatous degeneration to such an extent that they are

often mistaken for blood-cysts, and their true nature can often be ascertained only by the aid of the microscope. The great vascularity of these tumors makes a diagnosis between aneurysm of bone and sarcoma difficult. Distinguished surgeons have ligated large arteries on the proximal side on the supposition that the pulsating tumor was an aneurysm, when the subsequent clinical history revealed the sarcomatous nature of the tumor.

During the earliest stage of the tumor no swelling of the bone can be detected, the pain is slight, and tenderness is frequently wanting. If the bone is opened at this stage, its interior presents the appearances of a hemorrhagic focus. The blood in some parts is fluid, in others coagulated. More important from a diagnostic standpoint is the absorption of bone, if such has already taken place. If considerable of the bone has been removed by absorption, or if perforation has already taken place, the diagnosis no longer remains doubtful. The earliest stages of the development of myeloid sarcoma consist of dilatation of the medullary vessels in the immediate vicinity of the tumor-matrix, followed by active cell-proliferation. Sections of the tumor show a variety of color: some parts of the cut surface are dark red, brownish, or yellow; others are of a pearly whiteness. The brownish-red spots which appear isolated and scattered through the substance of the tumor are most characteristic. Some tumors contain cysts with clear contents. The white parts of the tumor are frequently dotted with small pigmented points. All these different parts of the tumor correspond with definite histological changes. In the red patches the blood-vessels have undergone the greatest degree of dilatation. In the brown spots the cells are pigmented with the coloring material of the blood. In the white portions of the tumor the blood-vessels are scanty and the tumor-tissue is composed largely of spindle-cells.

The nuclei of giant-cells, like those in other forms of sarcoma, have a granular structure. They are surrounded by a nuclear membrane, and they contain often large nucleoli of a homogeneous structure; others can be considered as compound or giant-nuclei.

From a histological point of view two kinds of giant-cells are found in sarcoma. In one kind the cells appear as aggregations of nuclei, in the interior of which a well-defined nuclear space may be seen occupied by nucleoli which lie free in the space or are imbedded in a somewhat clearer granular ground-substance; in the other form proliferating nuclei are found within the nuclear membrane. The giant-cells cannot be considered as a further development of the normal giant-cells, as they are found in localities where the latter are absent. In a case of primary sarcoma of the epistropheus and secondary aneurysm of the

vertebral artery, quoted elsewhere in detail, Klebs was able to trace the origin of giant-cells to osteoblasts in the decalcified bone specimen.

Van Henkelem claims that sarcoma-cells cannot produce mature tissue, and that in this respect they differ from ordinary embryonal connective-tissue cells. This function, however, is not entirely wanting, but is greatly diminished. In epulis this tissue-transformation is seen to a certain extent, as most of the sarcoma-cells are converted into tissue of a higher physiological type, and in periosteal sarcoma new bone is frequently found as one of the constituents of the tumor. The giant-cells are endowed with fibrillating power, in this respect being closely allied to the fibroplastic cells; this function explains the more benignant character of giant-celled as compared with round-celled sarcoma. Arnold found in tumors giant-cells surrounded by small spindle-cells.

Destruction of giant-cells by fibrillation may be seen in the oldest portions of tumors. In giant-celled sarcoma there may always be found spindle-cells in greater or lesser abundance.

Mixed-cell Sarcoma.—In mixed-cell sarcoma none of the cells which have been described are found as the exclusive tumor-elements. Pure round-celled and spindle-celled sarcomata are not infrequent. In the remaining sarcomatous tumors there is a mingling of spindle-cells, round cells, and giant-cells in varying proportions. Such a tumor is shown in Figure 379.

Mixed-cell sarcoma is found most frequently in myeloid and periosteal sarcomata. The degree of malignancy of such tumors depends on the preponderance of non-fibrillating tumor-elements. In the most benign forms the fibrillating cells are present in abundance, the tumor is hard and of slow growth, while the reverse histological structure results in opposite conditions which determine greater malignancy.

Melano-sarcoma.—Pigmented sarcomata, which form a distinct and separate group of tumors, surpass any other histological form of sarcoma in malignancy. These tumors are characterized by early regional and general dissemination. The primary tumor is always found in tissues which, in a normal state, contain pigment; hence the tumors occur most frequently in the skin and the eye. Melano-sarcomata are particularly prone to develop in pigmented warts and moles. If the primary tumor occurs in tissues in which, in a normal condition, pigment material is absent, we must assume the presence of pigmented cells deposited in the tissues by errors of development—that is, the existence of a matrix of pigmented cells. The pigment is not derived from the coloring material of the blood, as was formerly supposed, as

Nenski has shown the presence in the pigment material of sulphur, which is a constituent of some of the mesoblastic tissues. It is possible that iron may take a part in the pigmentation, but this supposition is improbable. Dressler found iron in the coloring material *melanin*. Rindfleisch was quite positive that the melanin is derived from the hematin of the red blood-corpuscles. Kolaczek, who made a careful study of eight cases of melanotic tumors with a view of ascertaining the source of melanin, maintains that it is not produced by metabolic activity of cells, but is derived from the coloring material of the blood. Gussenbauer claimed that thrombosis is the cause of pigmentation in tumors, but this position is no longer tenable. Virchow was the first to show that the pigmented cells are first stained diffusely a yellow color, and that the pigment-granules form later. Eiselt found that the

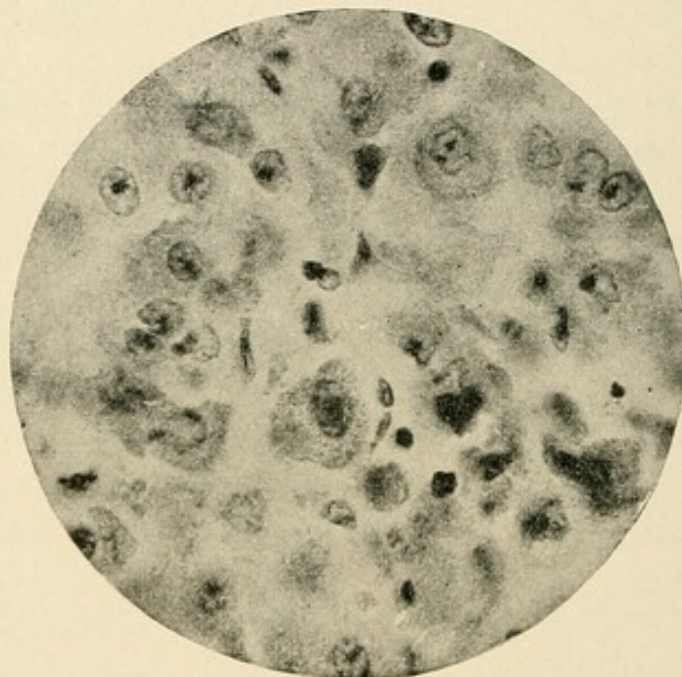
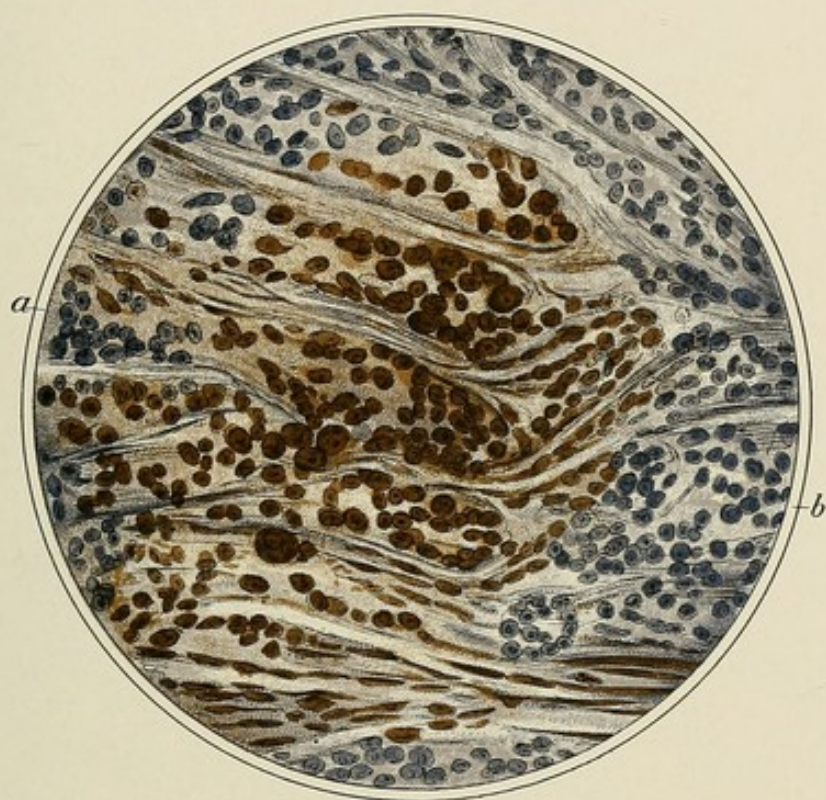


FIG. 380.—Cells from melano-sarcoma of skin; $\times 720$ (after Karg and Schmorl). The protoplasm of the large tumor-cells is filled with fine granules of pigment material, so that the cells appear as though they were covered with a thin film of coal-dust.

pigment material which is eliminated through the urine in persons suffering from melano-sarcoma is identical with the coloring material of the blood.

In Oppenheimer's case, studied by Nenski, the epithelial cells in the kidneys and alveoli of the lungs were stained yellow. The pigmented cells receive their material from the tissue-juices. A few years ago Lanz injected an emulsion of fragments of melanotic tumors of the skin, brain, liver, and spleen of a man into the spleen of a guinea-pig. The health of the animal was not at once affected, but it died six weeks later with an accumulation of pigment in almost every part of its body, so that Lanz felt assured there was a new formation of pig-



Melano-sarcoma of the skin, showing irregular distribution of pigment material with tumor-tissue : *a*, pigmented part of tissue; *b*, tumor-tissue without pigment (Surgical Clinic, Rush Medical College, Chicago).



ment. The presence of pigmented cells of normal or abnormal origin is essential for the occurrence of melano-sarcoma. The tumor-growth takes place by proliferation of pigmented cells. Pigmentation of the tumor-cells follows the course of blood-vessels, but is irregularly distributed through the tumor-tissue (Fig. 380).

The unequal distribution of the pigment is particularly well marked in the metastatic tumors. The pigmented cells are the carriers of the coloring material. The cut surface of melanotic tumors presents often almost a black appearance, and shows certain parts of the tumor more deeply stained than others. The metastatic tumors closely resemble the primary tumor so far as the pigmentation is concerned. Pigmented sarcoma-cells do not fibrillate, which fact explains the great malignancy of melanotic sarcoma. The fibroplastic part of such tumors is always composed of spindle-cells which are not pigmented.

Alveolar Sarcoma.—In alveolar sarcoma, as has been stated previously, the reticulum of the tumor is composed of a meshwork of

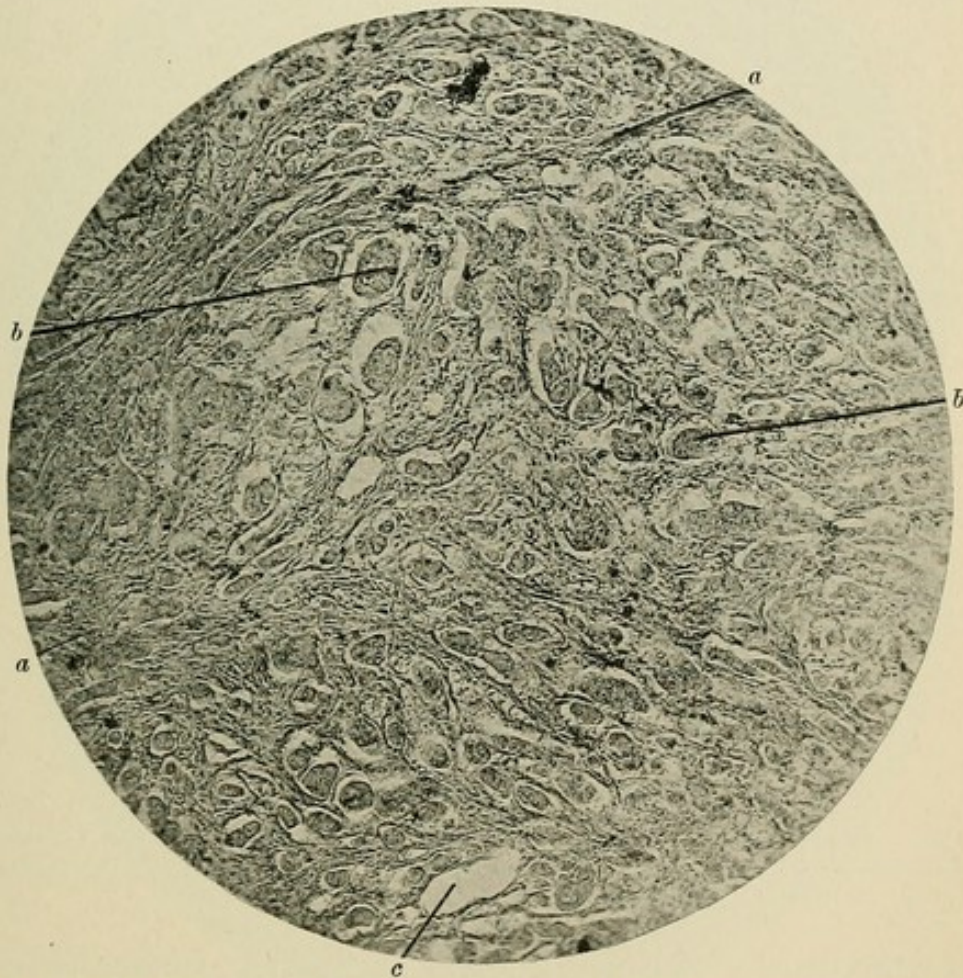


FIG. 381.—Alveolar sarcoma of skin; $\times 85$ (Surgical Clinic, Rush Medical College, Chicago): *a*, alveolated connective-tissue stroma; *b*, group of round sarcoma-cells somewhat shrunken from hardening; *c*, a space, surrounded by connective-tissue recticulum, from which the cell-contents have been lost during preparation of specimen.

delicate fibres of connective tissue, in the spaces of which are found

groups of round sarcoma-cells not arranged in compact concentric layers as in carcinoma (Fig. 381).

Alveolar sarcoma grows very rapidly, and the tumor-tissue is subject to early degenerative changes. The blood-vessels follow the connective-tissue stroma, but do not traverse the alveoli, the cell-contents of which, owing to an inadequate blood-supply, undergo early regressive metamorphosis. This form of tumor, which in some cases at least is determined by the new formation and the peculiar arrangement of the blood-vessels, is found most frequently in the skin, the lymphatic glands, the bones, and the pia mater.

Angio-sarcoma.—Kolaczek described this variety of sarcoma, known also as *siphonoma*, *cylindroma*, etc. These tumors are usually of a more or less tuberos structure; their consistence varies from a jelly-like

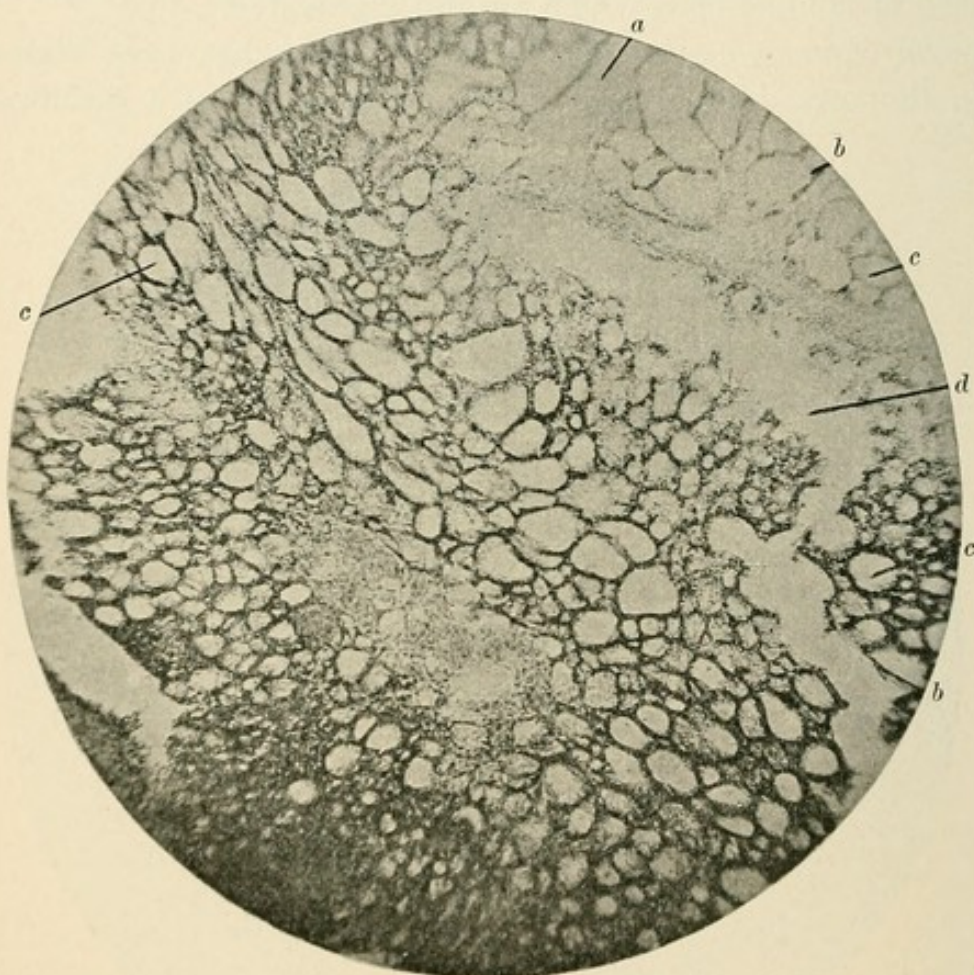


FIG. 382.—Angio-sarcoma of the orbit; $\times 75$ (Surgical Clinic, Rush Medical College, Chicago): *a*, connective-tissue capsule or stroma; *b, b*, cells lining the spaces; *c, c, c*, lumina of dilated new capillary vessel; *d*, a tear in the specimen caused by handling

mass to the density of cartilage. On section the surface presents an alveolar structure, but seldom regular, to which, in addition to great vascularity, occasionally blood-cysts and hemorrhages impart a variegated appearance. Under the microscope angio-sarcomata present usually a reticulated, seldom an alveolar, structure (Fig. 382). The cells are

arranged in the form of strands corresponding with the blood-vessels located in their centre; if the vessels do not contain blood, the tumor simulates carcinoma. The cells, which are epithelioid in shape and are normally multinuclear, often show prolongations, and their margins are not so sharply defined from the ground-substance as in carcinoma.

The ground-substance is composed of all possible forms of connective tissue—homogeneous, granular, myxomatous, cellular, and fibrillary. The vessels are numerous, large, and always capillary, and the intercellular tissue is scanty, imparting to the structure an angioma-tous appearance. In many forms the cells are closely grouped around the vessels, as if they were developed in their wall and had closed sheaths around them. The masses of cells thus formed, with a blood-vessel for a centre, may be packed closely together in long strings with more or less frequent anastomoses, or they may be arranged in rounded groups, giving the tumor an alveolar appearance. Sometimes the walls of the blood-vessels and the adjacent tissues, in these as in other forms of tumors, undergo hyaline degeneration, giving to the whole or to parts of the tumor a more or less gelatinous appearance.

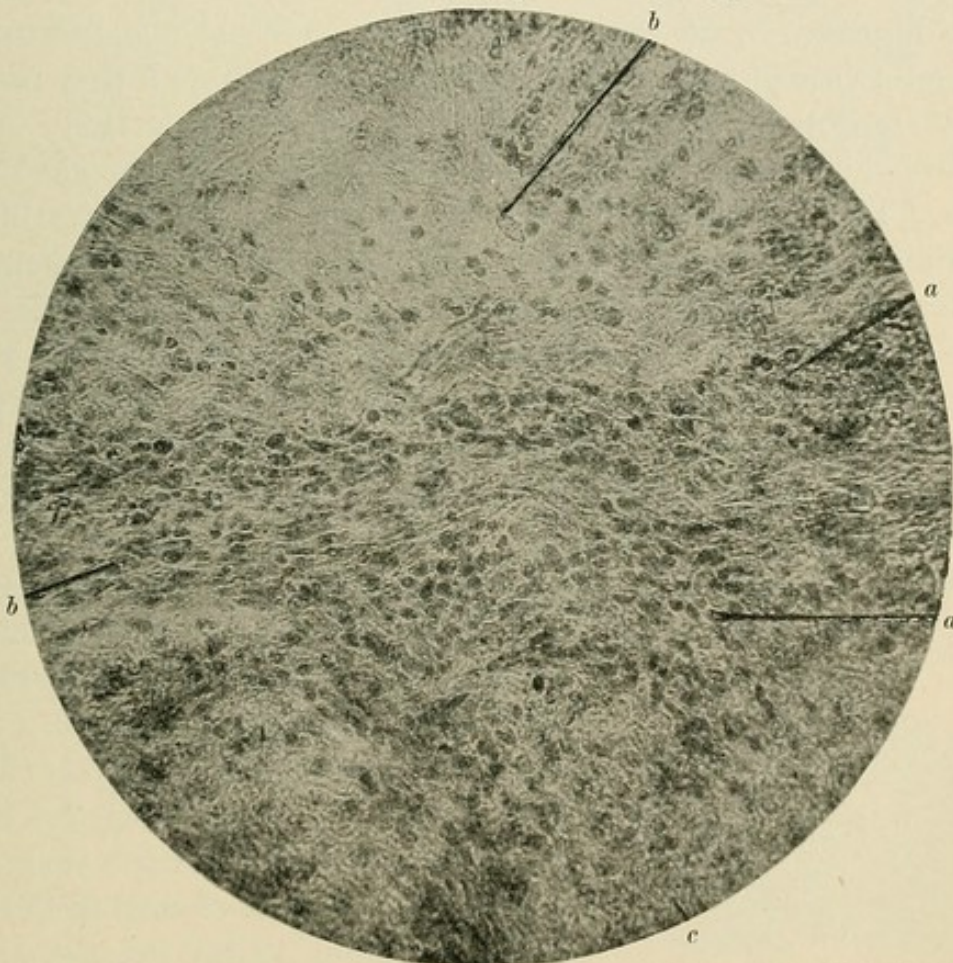


FIG. 383.—Endotheliomatous sarcoma of the pleura; $\times 350$ (Surgical Clinic, Rush Medical College, Chicago): *a*, round cells; *b*, *b*, oblong cells; *c*, delicate reticulum.

Angio-sarcomata are quite rare, and are most frequently found

about the head. In 46 out of 60 cases this part of the body was affected. In the only case which came under the writer's observation the tumor involved the skin over the frontal bone, at a point near the hairy scalp. Ackermann saw a case of angio-sarcoma of the corpora cavernosa of the penis. The growth of the tumor is slow. Recurrence after excision is rapid. Only in five cases did the tumor give rise to metastasis.

Endotheliomatous Sarcoma.—It is very probable that in angio-sarcoma the angioblasts take an active part in the production of the tumor, in which event this tumor should be classified with the sarcomata of endothelial origin. Malignant tumors which spring from matrices of embryonal endothelial cells are sarcomata. The structure and vascularization of endotheliomatous sarcoma (Fig. 383), as seen in primary malignant tumors of the serous membranes, are almost identical with sarcoma of connective-tissue origin. The cells are round, oval, and sometimes cylindrical or cuboidal, the latter modifications in shape occurring in consequence of pressure. The connective-tissue stroma is more abundant than in round-celled sarcoma, and is packed more densely in the stroma-spaces.

R. Volkmann, on the basis of 54 cases of endothelioma, believes that these tumors are of mesoblastic origin, and that although they resemble in many respects sarcoma they should be classified separately.

Endotheliomatous sarcoma not infrequently contains cholesterol-crystals. The tumor, which may be nodular and of considerable size, or multiple, is found most frequently in the pleura, the peritoneum, the pia mater, the ovary, the testicle, the lymphatic glands, and the brain. Nepvue describes an endothelial sarcoma of the pleura in a child seven years of age, the tumor simulating pyothorax. The tumor was the size of an adult's head, and displaced the lung. Exploratory puncture made the diagnosis of a solid tumor possible, and no operation was undertaken.

Glioma.—Sarcoma of the connective tissue of the central nervous system, the neuroglia, is called "glioma." It is the most frequent of all brain-tumors. The tumor is composed of small round or oval cells in a mesh-work of exceedingly delicate fibrillæ (Fig. 384). In some cases the tumor-cells are spider-like (Fig. 385). The quantitative relation of cells to the fibrillated reticulum varies greatly, and, as Miura pointed out, the cells may be more abundant at the margin of the tumor. In exceptional cases the cells assume a spindle shape.

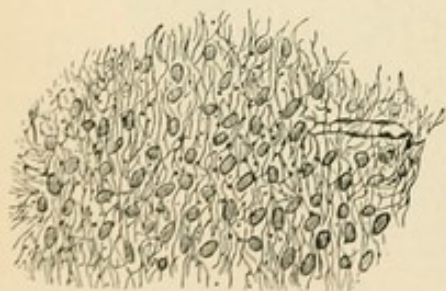


FIG. 384.—Glioma of the corpora quadrigemina; $\times 250$ (after Perls).

Owing to the delicate structure of the reticulum and its great vascularity, glioma is a soft tumor, and when centrally located in the brain is globular in shape. Gliomata sometimes have a well-defined border, but more frequently it is impossible to determine where the tumor ends and the healthy tissue begins. They are found most frequently in the posterior segment of the lateral ventricles, but they may occur in any part of the brain and spinal cord, and not infrequently they attain

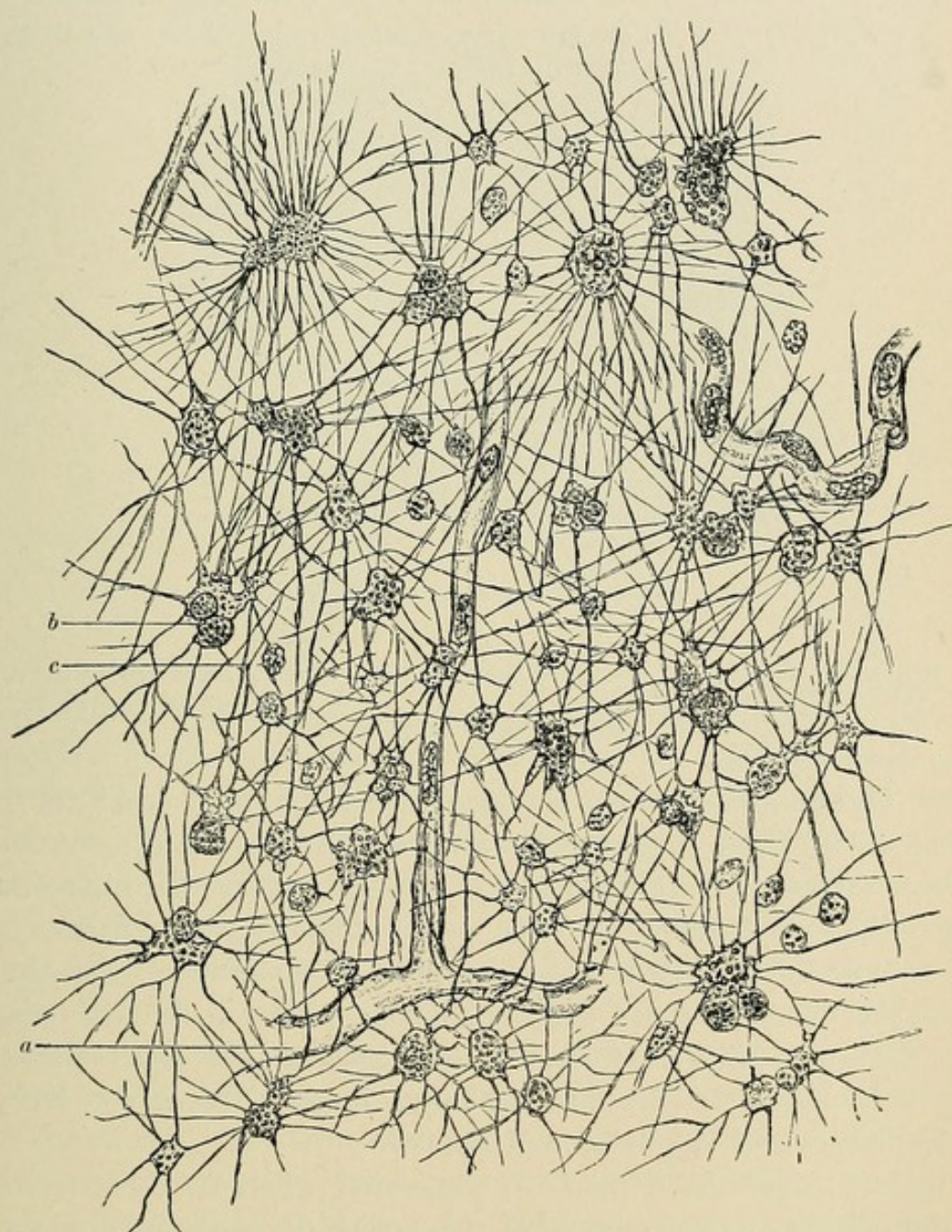


FIG. 385.—Gliomatous tumor of the brain, from a boy; $\times 350$ (after D. J. Hamilton): *a*, blood-vessels; *b*, spider-cell with double nucleus; *c*, small round cell.

the size of a fist or a child's head before death ensues. The tumor is grayish-white in color, with reddish-pink lines indicating the location of the blood-vessels. Klebs and Bertheau insist that the nerve-cells

take part in the production of the tumor, as they found nerve-cells as one of its component parts. This opinion is not generally endorsed.

The growth of a glioma is slow, and in other ways it pursues a more benign course than the connective-tissue or the myeloid sarcoma. Metastasis in the pia mater of the brain and the spinal cord was observed in one case by Lemcke. The liability to hemorrhage constitutes one of the immediate sources of danger. Gliomata have also

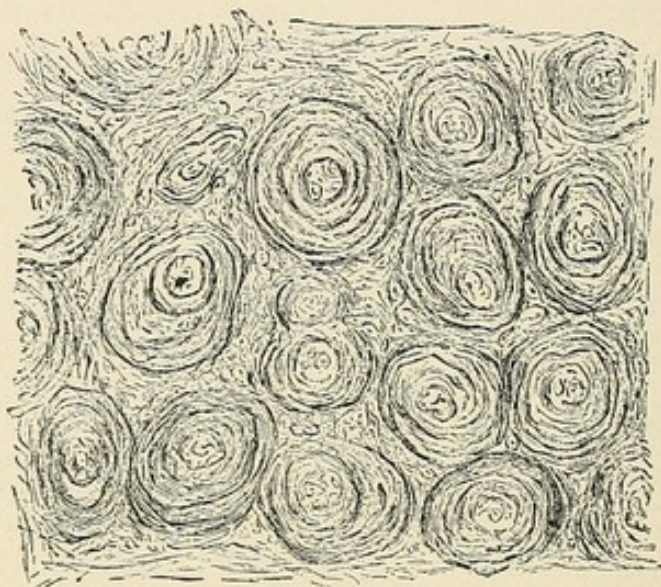


FIG. 386.—Microscopical appearance of a typical psammoma.

been found in the spinal cord by different observers, and in the acoustic nerve by Virchow. Glioma of the retina is an affection of childhood. In the cases reported the ages of the children varied from two to four years. The tumors often extend along the optic nerve and form large retrobulbar tumors. Recurrence after enucleation of the eyeball is frequent. From the orbit the tumor frequently extends to the cranial cavity, either along the optic nerve or through the orbital fissure. As a heterotopic tumor glioma has been found in exceptional cases in the kidney, the ovary, and the testicle. Knapp reported the first case in which the tumor gave rise to metastasis. Similar cases have since been reported by Schiess-Gemuseus, Hofmann, Rusconi, Bizzozero, Dreschfeld, Nellessen, and Heymann and Fiedler.

Helfreich reported a case of congenital glioma of both retinae. Eisenlohr believes that glioma of the retina develops from nests of mesoblastic cells from the vitreous body that fail to undergo complete development, and from which the tumor subsequently takes its origin.

Psammoma.—Psammoma is an endothelial growth of the envelopes of the brain that was first described by Virchow as a separate tumor. Although this tumor lacks the clinical features of sarcoma, Virchow

included it with the sarcomata. Sutton refers it to an epithelial matrix in the villous processes of the choroid plexus; but as it is found more frequently in localities where there are normally no epithelial cells, it is advisable to include it among the connective-tissue type of tumors. The tumor is composed of onion-like cell-masses separated by a stroma of connective tissue. These concentric bodies consist of endothelium-like cell-nests arranged around blood-vessels, which in the course of time become infiltrated with calcareous salts. The relation of the tumor-tissue to blood-vessels is well shown in Figure 387.

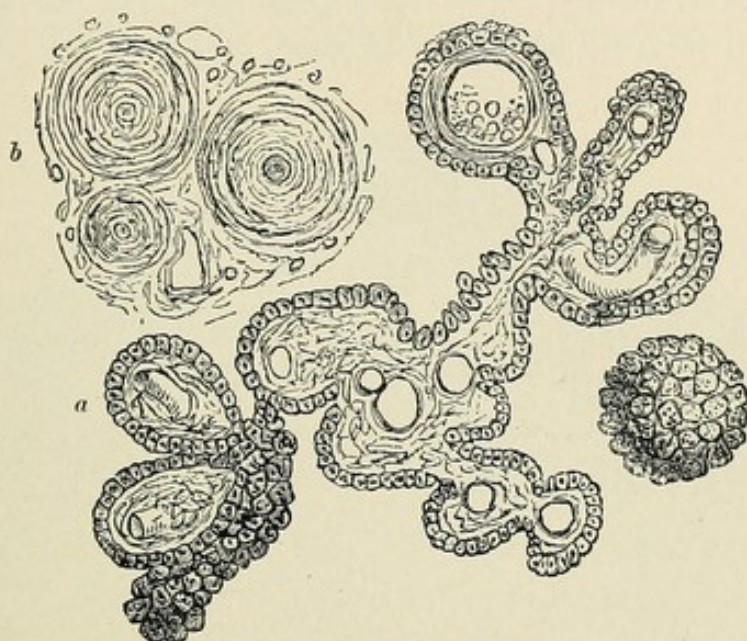


FIG. 387.—Psammoma from choroid plexus; $\times 300$ (after D. J. Hamilton): *a*, branching vessels with the cell-nest-like bodies upon them; *b*, cell-nests calcified.

It was first believed that the dura mater was the favorite seat of psammoma, but more extended observations have shown that it occurs most frequently in the choroid plexus and in the ventricles of the brain. Progressive growth of the tumor is arrested by fatty degeneration of the tumor-cells and by calcification. The tumors, which usually vary in size from a pea to that of a walnut, are often symmetrical, occupying in the brain the same location on both sides. In the lateral ventricles a tumor of fair size may not give rise to any symptoms; in other cases it has caused cerebral disturbances of different kinds, and focal symptoms which pointed to the location of the tumor. If the tumor does not undergo calcification, its growth is progressive, and it eventually destroys the life of the patient.

Psammoma of the spinal membranes is very rare. The clinical history of all such cases has been one of slow progressive paralysis and death.

Regressive Metamorphoses.—The absence of a well-developed reticulum, the great proliferating activity of the cells, and the atypical vascularization of sarcoma render the tumor liable to early and extensive degenerative changes. Fatty degeneration is common, but calcification is only observed in psammoma. The granular detritus in fatty degeneration is either absorbed or, by the addition of serum, remains as a turbid fluid which occupies spaces surrounded by tumor-tissue, forming cysts without a proper cyst-wall.

The imperfect development of the walls of blood-vessels is the cause of frequent hemorrhages into the substance of the tumor, where the blood either coagulates, is absorbed, or remains in a fluid state.

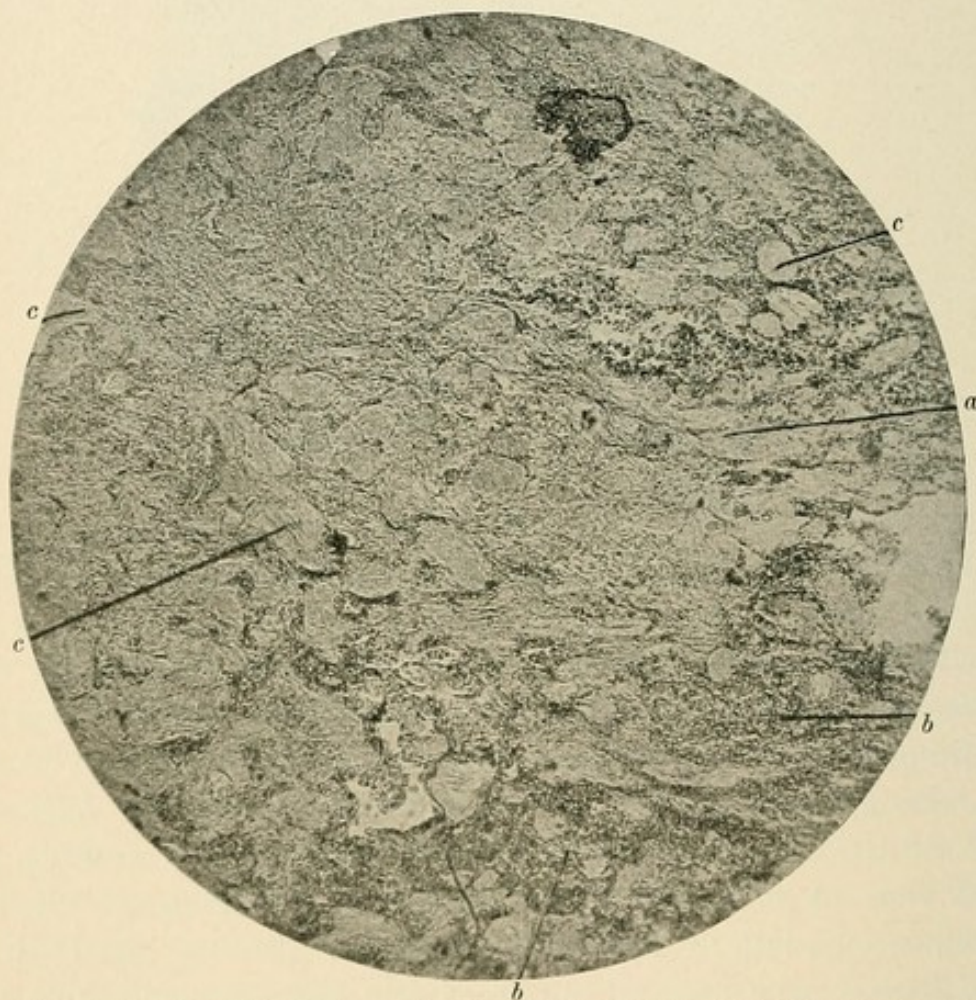


FIG. 388.—Myxomatous degeneration in sarcoma; $\times 75$ (Surgical Clinic, Rush Medical College, Chicago):
a, connective-tissue stroma; *b*, *b*, sarcoma-cells; *c*, *c*, *c*, myxomatous tissue.

The staining of the tissues of the tumor in the vicinity of ruptured capillaries is one of the characteristic features of most of the sarcomatous growths. The liability to hemorrhage is increased by the extension of fatty degeneration to the capillary walls. If the hemorrhage is copious, the tumor-tissue is compressed by the extravasated blood, and a blood-cyst forms, which frequently adds to the difficulty in diagnosis.

The sudden increase in the size and tension of the tumor should lead to the suspicion that a free hemorrhage has taken place into the substance of the tumor. In subcutaneous sarcomata this accident is often announced a day or two later by discoloration of the skin. Hyaline degeneration is not as frequently observed in sarcoma as in carcinoma.

Myxomatous degeneration is of frequent occurrence in sarcoma. The myxomatous degeneration, as seen in Figure 388, begins at different points at the same time, usually in the oldest parts of the tumor, when, by confluence of the spaces, a large territory of myxomatous tissue is formed. Both stroma and cells undergo this change, but the blood-vessels remain intact for a long time (Fig. 389). In myxo-sar-

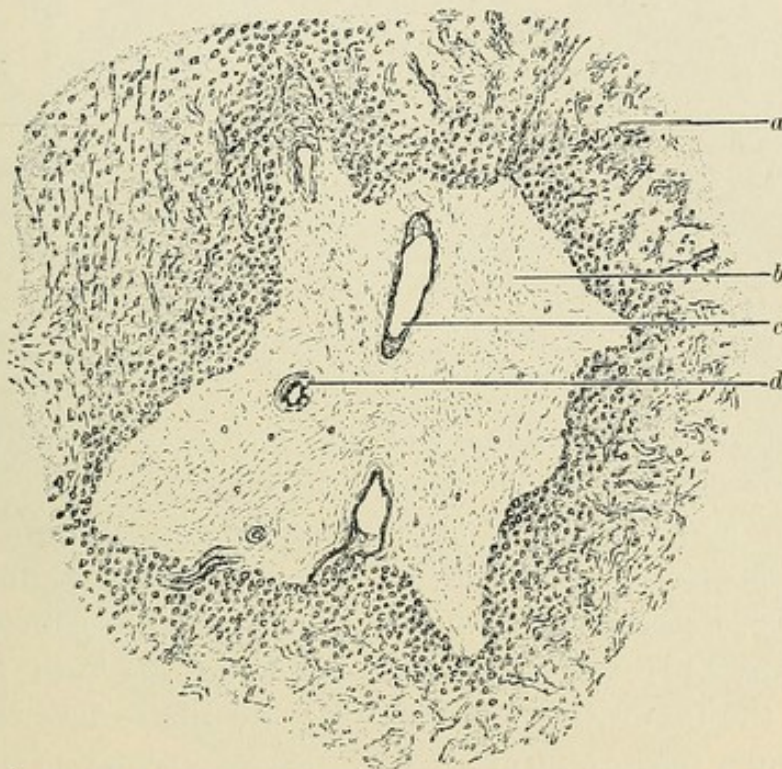


FIG. 389.—Myxomatous cavity in the centre of a sarcomatous tumor; $\times 40$ (after D. J. Hamilton): *a*, substance of the tumor as yet unaffected with the degeneration; *b*, the clear myxomatous part; *c*, a vein; *d*, an artery in the midst of the mucoid.

coma the cells become macerated in the sero-mucin—several delicate processes which form a network in the meshes of which the myxomatous material is deposited—and the tissues assume the appearance of what was formerly called “net-cell sarcoma.” With the myxomatous degeneration the tumor becomes softer, and a sense of fluctuation is felt on palpation if the degeneration has become extensive.

Caseation has been observed in sarcoma as another form of regressive metamorphosis. It begins in different parts of the tumor at the same time, and by the coalescence of different foci large cavities filled with cheesy material are formed. It is questionable if such a regres-

sive metamorphosis is possible without infection of the tumor with tubercle bacilli. The structure of the vessels in the tumor is such that localization of floating microbes easily occurs, and it is more than prob-

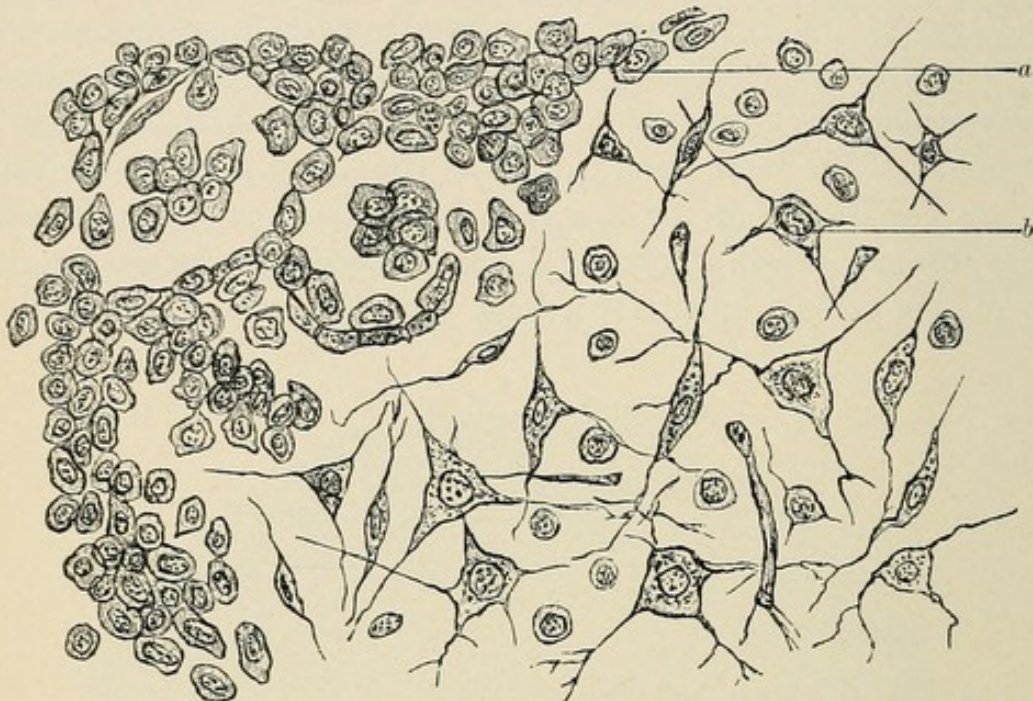


FIG. 390.—Portion of the edge of the myxomatous space shown in Figure 400; $\times 450$ (after D. J. Hamilton): *a*, the edge of the tumor; *b*, the branching cells lying in the clear mucoid.

able that future investigations will show that caseation in sarcoma follows in consequence of infection with tubercle bacilli.

Ulceration and sloughing take place as soon as the tumor, by invasion and pressure, reaches a free surface. The sloughing is often very extensive, attended by a foul-smelling discharge caused by infection with putrefactive microbes. Sloughing of the skin relieves the tension, and the tumor-tissue projects beyond the surface defect in the form of fungous masses, furnishing a good representation of what was called by the old authors the *fungus hæmatodes*. Infection of the tumor may occur without ulceration by localization of floating pus-microbes in the defective capillary vessels by mural implantation. With the occurrence of this complication the symptoms of an acute phlegmonous inflammation are superadded to the symptoms caused by the tumor. When extensive sloughing is the result of such an acute inflammation, although the inflammatory process may destroy apparently the entire tumor, a spontaneous cure is never effected in this way.

The transformation of sarcoma-tissue into tissue of a higher physiological type is observed most frequently in connection with sarcomatous epulis and periosteal sarcoma, and in rare instances in glandular sarcoma. In periosteal sarcoma new bone is almost constantly produced. Frequently, if not always, the new bone is produced through

the medium of cartilage-cells, as cartilage-cells and bone-cells are often found side by side in the same specimen (Fig. 391). In some cases the process of development is arrested with the formation of cartilage. Especially is this the case in glandular sarcoma (Fig. 392).

Durham observed two cases of ossifying sarcoma. One of the patients was a man seventy-three years of age, who, when a boy twelve years of age, sustained a severe burn in the iliac region, extending to the median line. The tumor originated in the scar, and contained, besides the usual sarcoma-cells, cartilage-cells and well-developed bone.

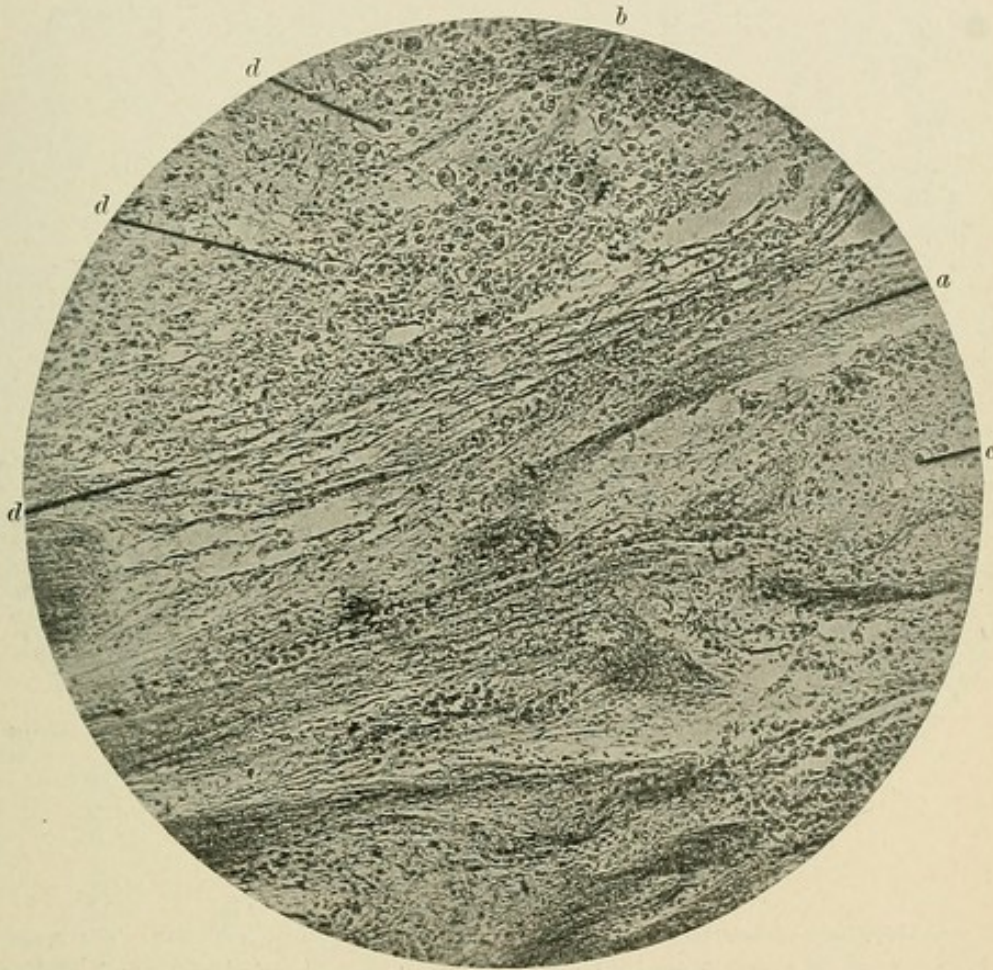


FIG. 391.—Ossifying periosteal sarcoma of the humerus; $\times 75$ (Surgical Clinic, Rush Medical College, Chicago): *a*, connective-tissue stroma; *b*, round sarcoma-cells; *c*, cartilage-cell; *d, d, d*, bone-cells.

The other case was a sarcoma of the breast in a woman twenty-seven years old. Ossification of a sarcoma tends to retard tumor-growth, and it must be regarded as an indication that the tumor will pursue a chronic course.

Local and General Infection.—The growth of a sarcoma takes place exclusively by proliferation of the cells composing the embryonal matrix. The type of the cells is determined by the location and the stage of arrest of development of the cells of the matrix. A matrix representing lymphoid tissue will produce, as a rule, round cells

and giant-cells, while a connective-tissue matrix produces more frequently spindle-cells. If the cells of a connective-tissue matrix are arrested at an early stage in their development, the probability is strong that the tumor produced from the matrix will be a round-celled

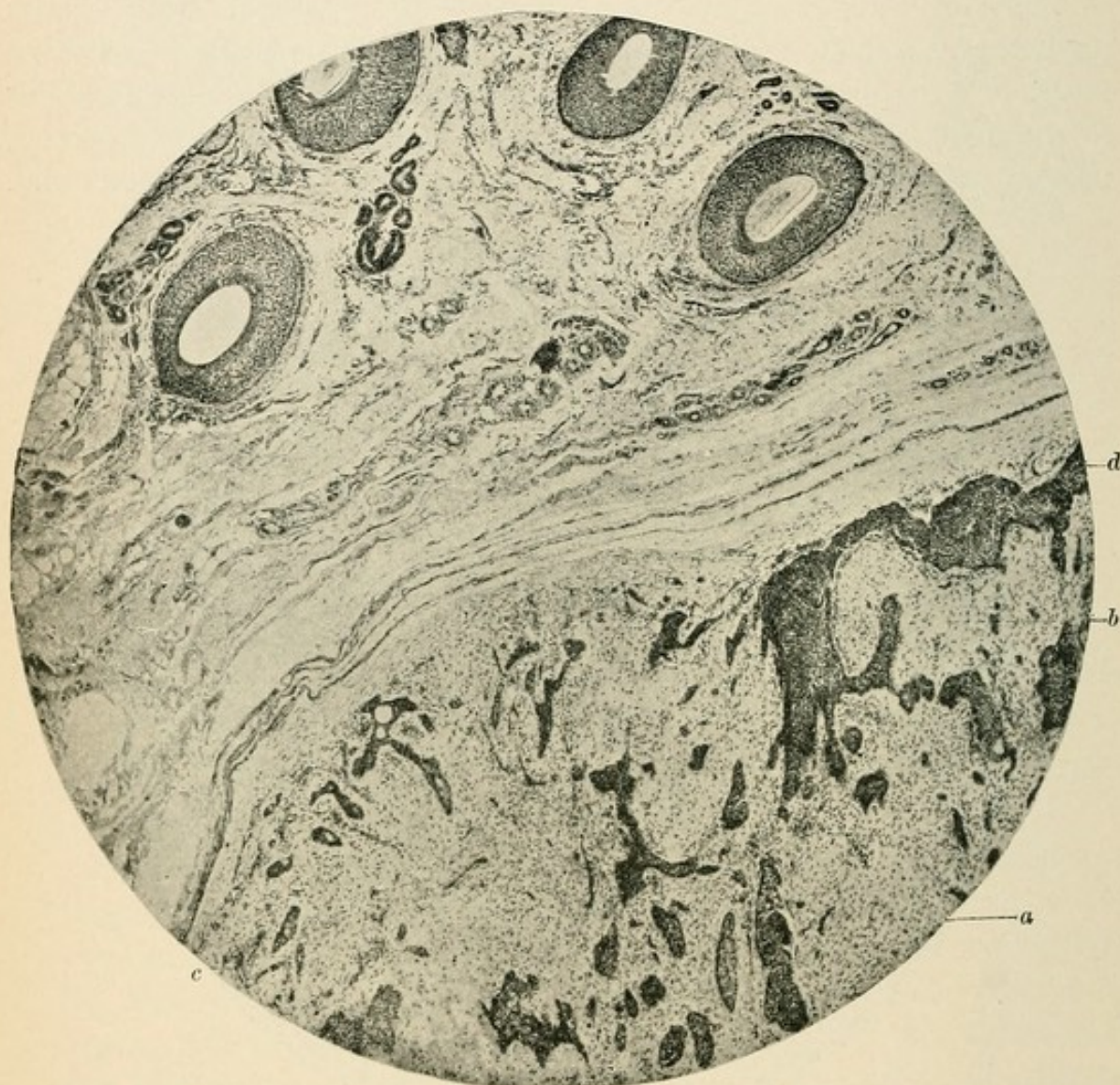

FIG. 392.—Myxo-chondro-sarcoma of parotid; $\times 38$ (after Karg and Schmorl). The upper half of the picture consists of the subcutaneous tissue, in which hair-follicles and sweat-glands may be seen. From this tissue the tumor can be distinguished sharply by its peculiar structure. In the ground-substance, which is composed partly of connective tissue (*a*), partly of myxomatous tissue (*b*), and partly of cartilage (*c*), are imbedded strings of cells (*d*). These are made up of small endothelial cells.

sarcoma. The rapidity of the growth of the tumor is largely influenced by the stroma. An abundant stroma retards tumor-growth, whereas a tumor composed almost exclusively of cells will grow rapidly. The stroma acts like a filter: the denser it is, the greater will be the difficulties met with by the cells in leaving the primary tumor and reaching the surrounding tissues.

A great deal has been written concerning the capsule of a sarcoma. *To the naked eye many sarcomata appear to be encapsulated. Microscopical examination of the capsule and of the tissues immediately outside*

of it shows that what appears to be a capsule is the connective tissue around the periphery of the tumor, which tissue has become condensed by pressure, but which holds in its meshes young sarcoma-cells, which are also found in a zone of lesser or greater width in the adjacent tissues. The enucleation of a sarcoma is invariably followed by a speedy local recurrence—the best possible proof that the capsule does not indicate the limits of the tumor, and is in reality a pathological delusion.

The growth of a sarcoma is rapid in proportion to the activity of cell-migration. The young sarcoma-cells leave the primary or mother-tumor and migrate into the surrounding connective-tissue spaces, establishing wherever they become located independent centres of tumor-growth. The pre-existing connective tissue serves the purpose of a temporary framework or stroma, which is later removed and replaced

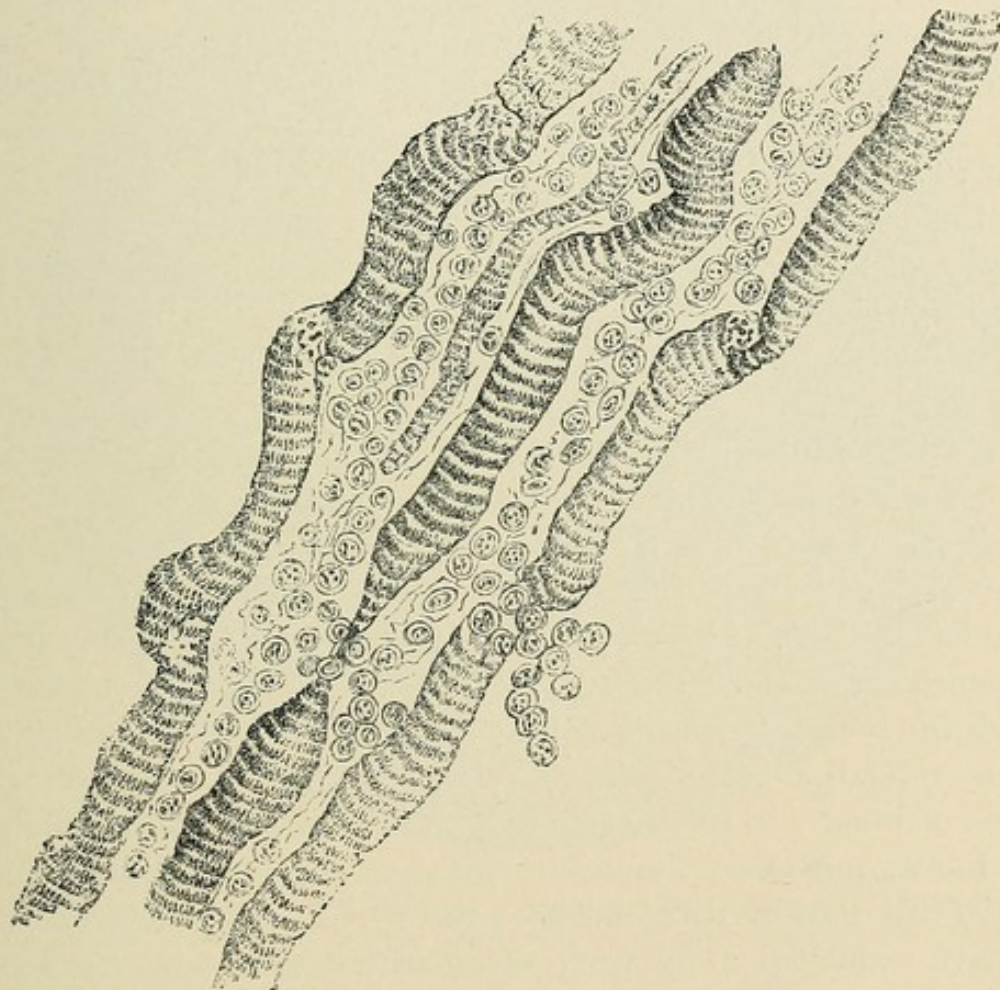


FIG. 393.—Small round sarcoma-cells infiltrating muscular fibre at some distance from the tumor; $\times 450$ (after D. J. Hamilton).

by the product of fibrillation of the sarcoma-cells. Sarcoma displaces tissue to a greater extent than carcinoma, but it eventually invades and destroys adjacent tissues regardless of their anatomical structure. The tumor grows in the direction offering the least resistance, in this respect resembling benign tumors, but no tissue, no matter how dense it may

be, offers an impermeable barrier to its local extension. Of all the tissues, cartilage offers the greatest resistance to progressive local extension of sarcoma. In sarcoma of the epiphyseal region of the long bones the articular cartilage is often found completely detached, showing but slight traces of the destructive action of the tumor; but ultimately even this structure gives way and the joint becomes involved. In sarcoma of the intermuscular connective tissue the muscle-fibres are destroyed some distance from the tumor by cell-infiltration (Fig. 393).

Sokolow made some very interesting investigations concerning the behavior of muscle-fibres in sarcomatous tumors. He came to the conclusion that the muscle-fibres take no active part in the growth of sarcoma, but are removed by the infiltrating cells.

While the central part of a sarcoma is undergoing regressive metamorphoses the peripheral growth adds to the size of the tumor. It is in the periphery that the most active tissue-changes are observed. If the tumor is located in parts that offer equal resistance to the extension of the tumor, it always assumes a globular shape. Surface sarcomata are flat tumors. The tumor also becomes flattened beneath firm fasciæ. If the tumor perforates a dense structure at a point corresponding with the centre of a tumor, the tumor grows with great rapidity on the surface upon which the perforation opens. It is in this manner that a sarcoma of the dura mater, after perforation of the cranium, assumes the shape of a sleeve-button, the contracted portion corresponding with the perforation in the bone, and the flattened masses with the primary tumor of the dura and its external pericranial portion.

Regional extension of a sarcoma takes place along the sheaths of blood-vessels and nerves, seldom through the lymphatics except in cases of lympho-sarcoma. As lymphatics have been demonstrated in sarcoma, it is somewhat singular that regional infection so seldom takes place through the lymphatic vessels. That local and regional extension takes place by migration of sarcoma-cells is well shown in cases of central sarcoma of bone. In these cases minute sarcomatous tumors are often found in the medullary tissue at a distance from the primary tumor, with perfectly healthy tissue between them. We can only assume that cells have wandered away from the mother-tumor into the myeloid tissue, and that the young daughter-tumors are the product of tissue-proliferation of these cells, which have reproduced the tumor in the same tissue in the neighborhood of the primary tumor. Barth ascertained that in local recurrence of spindle-celled sarcoma the disease is rendered much more malignant by an increase of the round cells and a decrease of the spindle-cells.

Metastasis.—General dissemination in sarcoma takes place much

more frequently and at an earlier stage than in carcinoma. In this regard sarcoma is much more malignant than carcinoma. Small round-celled sarcoma gives rise to metastasis much more frequently than do spindle-celled and giant-celled sarcoma. The smaller the cells, the greater the liability to early and extensive general dissemination. The intimate relations which exist between the blood-vessels and the tumor-tissue in sarcoma serve to explain the frequency of metastasis. Isolated cells can permeate the vessel-wall, and are then carried with the blood-current to distant parts or organs, where, after the cells have

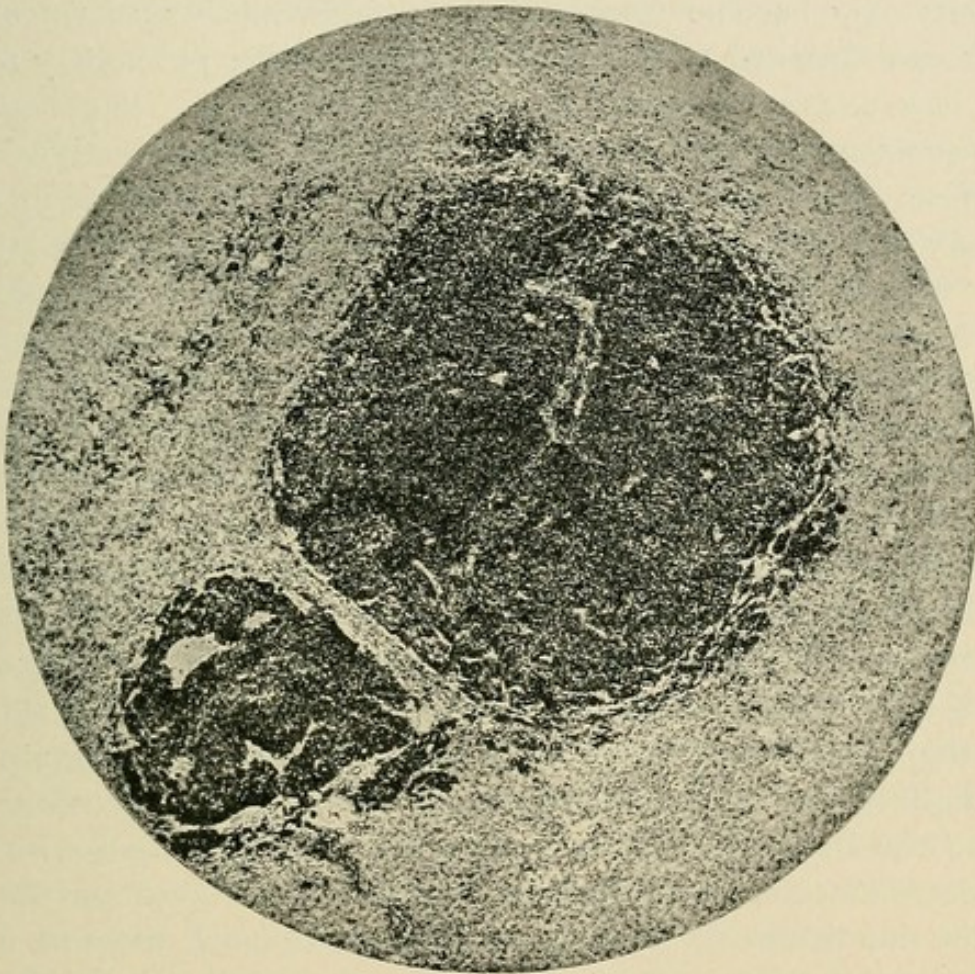


FIG. 394.—Metastasis of a round-celled sarcoma in the liver; $\times 40$ (after Karg and Schmorl). Both tumor-nodules are composed of round cells, and can be distinguished clearly from the adjacent liver-tissue. In the vicinity of the sarcomatous nodules the liver-cells are flattened. Several capillary vessels in the vicinity of the tumors are blocked by tumor-cells.

become implanted upon a vessel-wall, there are produced secondary or metastatic tumors which resemble the primary tumor in every respect. In round-celled sarcoma the metastatic tumor is composed of round cells; in spindle-celled sarcoma the metastatic tumor is composed of spindle-cells; and in melano-sarcoma the metastatic tumor is composed of pigmented cells. In the very rare cases of myosarcoma the metastatic tumors contain muscular fibres which answer in their structure to

the fibres of the primary tumor. Brodowsky recorded a case of myosarcoma of the stomach with metastases, and found in the secondary metastatic tumors small unstriped muscular fibres. Birch-Hirschfeld examined a case of myosarcoma of the uterus which contained, besides flat muscular fibres, many small muscular fibres and cells which appeared to be a transition into spindle-cells. The metastatic tumors which were found in the liver and the bronchial glands showed a similar structure (Fig. 394).

Very frequently the tumor grows into the lumen of the vessel, which then becomes closed by a sarcomatous thrombus from which fragments may become detached; these fragments may form emboli and become arrested in the distal branches of the pulmonary artery, where new centres of tumor-growth are established.

Melano-sarcoma has the reputation of giving rise frequently to early and diffuse metastasis. The whole surface of the body is at times studded with innumerable pigmented nodules, and many of the internal organs may be affected similarly. Mr. Holden reports the case of a boy ten years old upon whom two operations were performed for sarcoma of the parotid. After the second operation both testicles became sarcomatous almost simultaneously. At the post-mortem very diffuse metastasis was found involving the subcutaneous and internal lymphatic glands.

The extent to which various organs become implicated in some cases of general dissemination of sarcoma is well illustrated by a case minutely reported by Förster. The patient was a man thirty-seven years of age. The primary tumor was a small round-celled sarcoma of the thigh. A year later the post-mortem showed metastatic tumors in the right and left submaxillary regions, the scalp, the axillæ, the skin covering the breast, the thyroid gland, the pleuræ, the large bronchi, the pericardium, the peritoneum, the mesentery, the omentum, the pancreas, the duodenum, the ascending colon, the stomach, the dura mater, and the pituitary body. In the brain there were six nodules. Strange as it may appear, the liver and the spleen were free.

Etiology.—An hereditary predisposition to sarcoma must be recognized. In a few instances sarcoma occurred as a congenital tumor. Although no age is exempt, sarcoma is met with most frequently in children and in young adults. Sarcoma of bone is rare in the aged. Glandular sarcoma is more frequent during old age. At the age of puberty the genital organs are more frequently the seat of sarcoma than at any other period of life. That sarcoma not infrequently starts in chronic inflammatory products is well known. Chronic irritation is often an exciting cause. The inflammatory tissue produced under

such circumstances undoubtedly furnishes frequently the essential tumor-matrix. Sarcoma occurs at times in scar-tissue in which there are buried unspecialized connective-tissue cells which only await the influence of conditions, local or general, which will enable them to assume active tissue-proliferation. The subcutaneous and the deep connective tissues are frequently the starting-points of sarcoma. The serous membranes are more commonly affected than the submucous connective tissue. The lymphatic glands, the periosteum, and the marrow of bone are favorite localities for the development of the primary tumor. Of the glandular organs, the thyroid, the testicle, the ovary, and the mammary gland are most frequently affected. Sarcoma of the central nervous system and its envelopes is of common occurrence.

The influence of trauma is more pronounced in the etiology of sarcoma than in that of carcinoma. Not infrequently a bruise or a contusion acts as the exciting cause. The development of a sarcoma at the seat of a fracture has repeatedly been observed. The writer has referred to such a case that came under his observation. Mr. Griffith records a very similar case. The patient was a man twenty-one years of age who sustained a fracture of the femur at the junction of the middle and lower thirds. The usual treatment by rest and fixation of the fragments was carried out for five weeks, when the limb was immobilized in a plaster-of-Paris bandage. Ten weeks after the accident a swelling was observed where the bone had been fractured. The patient refused an amputation at this time. Five months after the accident the thigh was enormously enlarged, the skin was tightly stretched, the superficial veins were coursing in the form of dark broad bands, and the whole surface was intersected with silvery streaks. The patient died less than eight months after the injury. The post-mortem revealed that the shaft of the femur had disappeared, except two small pieces of detached bone about an inch in length, forming the anterior wall at the lower end, and a piece about four inches long and one inch in width at the upper end. The articular cartilages were intact. The tumor was a spindle-celled sarcoma that weighed twenty-five pounds.

The influence of trauma in the production of sarcoma should be remembered in the examination of remote swellings appearing at the site of an injury. The immature callus in fractures, failing to undergo transformation into tissue of a higher physiological type, in rare cases becomes the sarcoma-matrix. In injuries of the soft tissues there may be produced a similar matrix, which becomes the starting-point for the sarcoma. The influence of trauma and of chronic irritation in the pro-

duction of sarcoma is shown most conclusively in connection with the origin of sarcoma in warts and pigmented moles. A wart which is the seat of chronic irritation not infrequently becomes the starting-point of a sarcoma. The subepithelial connective tissue in a state of chronic inflammation reverts to its embryonal condition and furnishes the essential tumor-matrix (Fig. 395). A pigmented mole may remain harmless

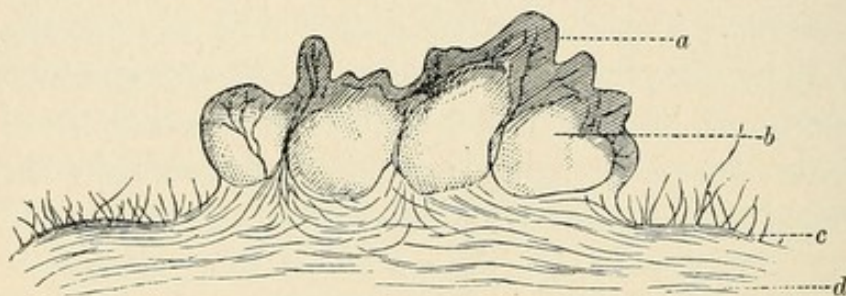


FIG. 395.—Sarcoma which originated in a wart of the scalp (after Lücke): *a*, granulating ulcer of the surface; *b*, sarcoma-tissue; *c*, level of the skin; *d*, cutis.

throughout a lifetime, but when it is exposed to chronic irritation or becomes the seat of an injury it is exceedingly prone to undergo transformation into a melano-sarcoma.

Symptoms and Diagnosis.—The diagnosis of sarcoma must be based upon a careful study of the clinical history of the case and a minute examination, which, if need be, should be supplemented by exploratory puncture and by microscopical examination of sections of fragments of tissue removed with the harpoon-trocar. A failure to elicit from the patient and his friends a clear clinical history has led to many serious mistakes in diagnosis and treatment. The most important points to be brought out in the clinical history are the length of time the tumor has existed and its primary anatomical starting-point. The statements made by patients are often vague and unreliable. For instance, a tumor may have existed for several months, when from the patient's statements it often appears that it has developed suddenly; or the tumor is often discovered accidentally after it has existed for some time and has attained considerable size. This fact should be borne in mind, as otherwise the tumor might be mistaken for an infective swelling.

As inflammation always affects vascular connective tissue, and thus shares with sarcoma the same anatomical location, an accurate knowledge of the primary anatomical starting-point of a sarcoma is of special value in the differential diagnosis between sarcoma and carcinoma and benign mesoblastic tumors. Let us take, for the purpose of illustration, a malignant tumor involving the bones of the cranial vault. In differentiating between a sarcoma and a carcinoma it is important to ascer-

tain from the patient whether the growth began in the skin as an ulcer, or whether the tumor made its appearance first under the intact skin, as it is plain that in the former instance the tumor would be a carcinoma with secondary implication of the bone, whereas in the latter case there could be no further doubt of the sarcomatous nature of the tumor. It would be immaterial, so far as the nature of the tumor is concerned, whether it originated in the dura mater, the bone, the periosteum, or the subcutaneous connective tissue. The subcutaneous origin of the tumor would exclude the possibility of its being a carcinoma, unless the tumor developed from a displaced tumor-matrix composed of epithelial cells—a very rare occurrence indeed in this locality. *In the differential diagnosis it is exceedingly important to ascertain whether the tumor originated in epiblastic, hypoblastic, or mesoblastic tissues. With few exceptions malignant tumors originating in mesoblastic tissues are sarcomata, whereas all malignant tumors of epiblastic or hypoblastic origin are carcinomata.* In the examination of ulcerating malignant tumors the surgeon is often unable to make this distinction, and must rely upon the patient's statement regarding the early history of the tumor. With very rare exceptions primary malignant tumors of the lymphatic glands, the bone, and the connective tissue are sarcomatous. In malignant tumors of the glands it is, of course, impossible to decide whether the tumor started in the parenchyma or in the connective tissue—in other words, whether it had an epithelial or a connective-tissue matrix. In such cases we must rely upon the shape of the tumor and its relations to the adjacent tissue in distinguishing between a sarcoma and a carcinoma.

As a rule, sarcoma grows more rapidly than carcinoma. There are, however, exceptions to this rule. Malignant epulis and psammoma grow slowly, and in the latter tumor limitation of growth is often brought about by fatty degeneration and calcification. Billroth relates a case of sarcoma in the occipital region in which, during twenty years, fifty operations were performed.

Sarcoma is usually not attended by much pain unless a nerve is involved directly or by pressure. In a case of neuro-sarcoma of the median nerve reported by Volkmann the pain was severe in the region of the distribution of the nerve. Muscular atrophy was also a marked feature. Even in central sarcoma of bone the pain is usually not severe.

A sarcomatous tumor is usually globular, oblong, flat, or spindle-shaped, according to the location of the tumor and the anatomical arrangement of the tissues in which it is located. Its surface is smooth; its consistency is variable. In the soft tissues the tumor

is movable, in this respect differing greatly from carcinoma, in which fixation of the tumor is present almost from the beginning of the growth. Sarcoma attains greater size before ulceration occurs. The principal reason for this difference in the clinical behavior of sarcoma and carcinoma undoubtedly is to be found in the fact that sarcoma is always covered by intact skin or mucous membrane, while carcinoma begins as a surface affection. In large sarcomata the superficial veins are always enlarged. In soft tumors a sense of fluctuation is imparted to the palpating fingers. The margins of the tumor are more defined in sarcoma than in carcinoma. In carcinoma of the breast the tumor can be moved without moving the surrounding gland-tissue. In myelogenous sarcoma pulsations and bruit are often present. True aneurysm of bone is very rare. Klebs has never seen such a case. The differential diagnosis between an infective swelling and a sarcoma can often be made only by resorting to an exploratory puncture. If the diagnosis between a gumma and a sarcoma is not clear, the patient should be given the benefit of the doubt and should be placed on a vigorous antisyphilitic treatment for several weeks.

Billroth was the first to point out that regional glandular infection is very rare in sarcoma, while it is the rule in carcinoma. The regional infection is in the direction of intermuscular septa and along the sheaths of blood-vessels and nerves. Metastasis occurs earlier and more frequently in sarcoma than in carcinoma. The general health is usually little impaired until ulceration or general dissemination takes place.

In sarcoma of the serous surfaces the primary tumor gives rise to multiple growths by cells becoming detached, displaced, and implanted at different points. In sarcoma of the internal organs the presence of the tumor is usually not suspected until symptoms are produced from pressure. Mr. Barclay reports a case of sarcoma of the anterior mediastinum in which the only subjective symptom was dyspnea. The sternum was slightly elevated, and the tumor extended above it into the tissues of the neck.

It has been ascertained by Ebstein, Pel, Renvers, Erb, Völkers, and Kast that the temperature rises in irregular curves in sarcoma of the internal organs. Priestly recently reported a case of sarcoma of the liver in which this phenomenon was regularly observed. In a case of sarcoma of the pancreas, mentioned to the writer by Drs. Vandeventer and Northrop of Marquette, Michigan, the evening rise in the temperature was so constant and persistent that the case was diagnosed as typhoid fever by a most competent practitioner. The thermometer should be employed as a diagnostic resource in cases of suspected sarcoma of internal organs.

Pathological fracture is frequently caused by myelogenous sarcoma and by metastatic carcinoma. In melano-sarcoma the color of the tumor and its origin in pigmented tissue render the diagnosis sufficiently positive. In glioma and psammoma of the central nervous system a probable diagnosis can often be made from the focal symptoms that are sometimes, but not always, present.

Prognosis.—The most malignant forms of sarcoma are soft and small-celled, and they are attended by rapid regional extension and early generalization. The degree of malignancy is determined by the rapidity of growth. In some cases the growth is so rapid that clinically the sarcoma resembles more closely an inflammatory process than a tumor. In one of Billroth's cases the tumor grew so rapidly that a diagnosis of furuncle was made. The patient died of pulmonary sarcoma in less than three months.

Mistakes in diagnosis are oftenest made in the most malignant forms of sarcoma. Slow growth indicates a more benign tendency of the tumor. Sometimes the primary tumor grows slowly, the secondary tumors very rapidly. Sarcoma leads to a fatal termination sooner than carcinoma. Melano-sarcoma is the most malignant of all tumors and the least amenable to successful treatment by operation. Local recurrence after operation is more frequent and takes place sooner in sarcoma than in carcinoma. Billroth maintained that a local recurrence may take place twenty years after the removal of the tumor. The same author was of the opinion that in many cases the recurrence after a thorough operation was due to inoculation of the margins of the wound with sarcoma-cells deposited there by the knife used in the operation.

Giant-celled and spindle-celled sarcomata offer the most favorable prognosis. The prognosis is, of course, greatly modified by the location of the tumor, the physiological importance of the adjacent tissues or organs, the degree of accessibility of the tumor, and the presence or absence of metastasis, but, on the whole, it is much graver in sarcoma than in carcinoma. The most favorable cases for successful operative treatment are sarcomatous epulis and myeloid sarcoma of bone.

Treatment.—If we have found it necessary to urge the necessity of early and thorough removal of carcinoma, this advice applies with double force to the necessity of early and thorough operations in the treatment of sarcoma. Sarcoma gives rise to local, regional, and general infection at an earlier stage than carcinoma; hence the disease passes sooner beyond the limits of a successful operation. In sarcoma the lymphatic glands do not stand guard between the primary tumor and the general circulation as in carcinoma, and metastasis follows

more frequently by the direct route through the blood-vessels of the tumor. Not infrequently a sarcomatous thrombus which does not quite block the blood-vessel forms in one of the vessels of the tumor and extends far beyond the limits of a radical operation. Billroth relates an instance in which such a thrombus formed in the spermatic vein in connection with a sarcoma of the testicle. The thrombus by proximal growth finally reached the right side of the heart, where it became attached to the septum between the ventricles, and the septum was finally perforated by the tumor. It is not difficult to conceive that the existence of such an intravascular extension of the tumor would preclude all possibility of a successful operation. *Operative treatment should be resorted to before regional and general dissemination of the tumor has taken place.*

The employment of efficient caustics in the treatment of incipient surface carcinomata is sometimes excusable, but in the treatment of sarcoma caustics should invariably be avoided. As soon as a diagnosis can be made the tumor should be removed by excision or by amputation. *A radical operation by excision offers the only reasonable prospect of success.* Local recurrences should be dealt with in the same manner as soon as their existence is discovered.

In the excision of a sarcoma a zone of apparently healthy tissue at least an inch in width should be removed with the tumor, if this can be done without coming in conflict with tissues and organs that do not admit of such a radical procedure. The skin overlying a sarcoma should invariably be removed with the tumor. In sarcoma of glands and of the uterus the whole organ must be removed. The incisions should be made in the direction of the large vessels of the part affected, not only for the purpose of exposing the vessels well with a view of guarding against unintentional injury, but also with the object of removing as much as possible of the connective tissue between the tumor and the vessels. In the radical operation for carcinoma the surgeon has in view the removal of the lymphatics in the region of the tumor; in operations for sarcoma he seeks to remove not only the proximal lymphatics—a possible route for regional infection—but he aims to remove as much as possible of the connective tissue in the region of the tumor, through which tissue local and regional infection takes place. In extensive sarcoma of the extremities amputation at some distance from the tumor is indicated in the majority of cases; whether the tumor has started in soft parts or in bone is immaterial.

Fascial sarcoma of the limbs so often involves important vessels and nerves that amputation is the only alternative. Resection in the continuity of a long bone is applicable in the case of the radius, the ulna,

and the fibula if the disease has not extended beyond the periosteum. Removal of central myeloid tumors by scraping has in a few cases recently been practised with success, but the cases are few for which this procedure is adapted, and it is always attended by great risks of a speedy recurrence, which, after it has manifested itself, calls for an amputation without delay. Operations for glioma of the brain have yielded a number of brilliant immediate results, but with few exceptions the operations were followed, as would be expected, by an early local recurrence. Sarcoma of large nerve-trunks usually requires amputation, as excision of an extensive section of a nerve would be followed by permanent paralysis and an early local recurrence. Operative treatment is contraindicated in the presence of metastasis and if the tumor cannot be removed completely, either on account of its size, its insufficient accessibility, or its implication of structures the removal of which with the tumor is not feasible or justifiable.

The administration of drugs has very generally been abandoned, as ample experience has demonstrated that we are not in possession of any remedy that exerts a curative effect upon sarcoma. Arsenic, so strongly advised by Billroth and others, has yielded negative results. It was urged that Fowler's solution should be given in gradually increasing doses both by the mouth and by parenchymatous injections until symptoms of intoxication are produced, when the use of the drug should not be suspended, but the doses should be diminished. The writer has resorted to this treatment in a number of instances, but has never witnessed even a retarding effect.

The beneficial effects of an intercurrent attack of erysipelas in cases of sarcoma have been noticed by different surgeons for a long time. Bush was the first to intentionally inoculate with erysipelas patients suffering from sarcoma, but his expectations were not realized. After the discovery of the streptococcus of erysipelas by Fehleisen numerous inoculations with pure cultures of this microbe were made in cases of inoperable carcinoma and sarcoma. A few cases appear to have been cured permanently; some were benefited, others were not improved, and in some death was caused by the erysipelas. These inoculations have been deprived of the risk to life by using sterile cultures of the streptococcus erysipelatis in place of active cultures. Coley and Bull report a series of cases in which this method of treatment appears to have been followed by encouraging results. It seems that the toxins of the micrococcus prodigiosus increase the curative effect of the toxins of the microbe of erysipelas. The treatment of inoperable cases of sarcoma by this method should be encouraged and persistently carried out. The directions for this treatment are laid down in the

section on the Treatment of Tumors. The writer has recently treated six cases of inoperable sarcoma with the combined sterilized cultures without any appreciable effect. It would be advisable to treat cases of sarcoma by this method after all operations, with the expectation that the treatment would prove useful in preventing a local recurrence.

The palliative treatment of inoperable cases of sarcoma is the same as in carcinoma.

TOPOGRAPHY.

Skin.—With the exception of the pigmented variety, sarcoma of the skin is rare. It occurs most frequently in scars, or by the transformation of the connective tissue of a wart or the stroma of a papilloma or a fibroma into a sarcoma. Independently of such pre-existing

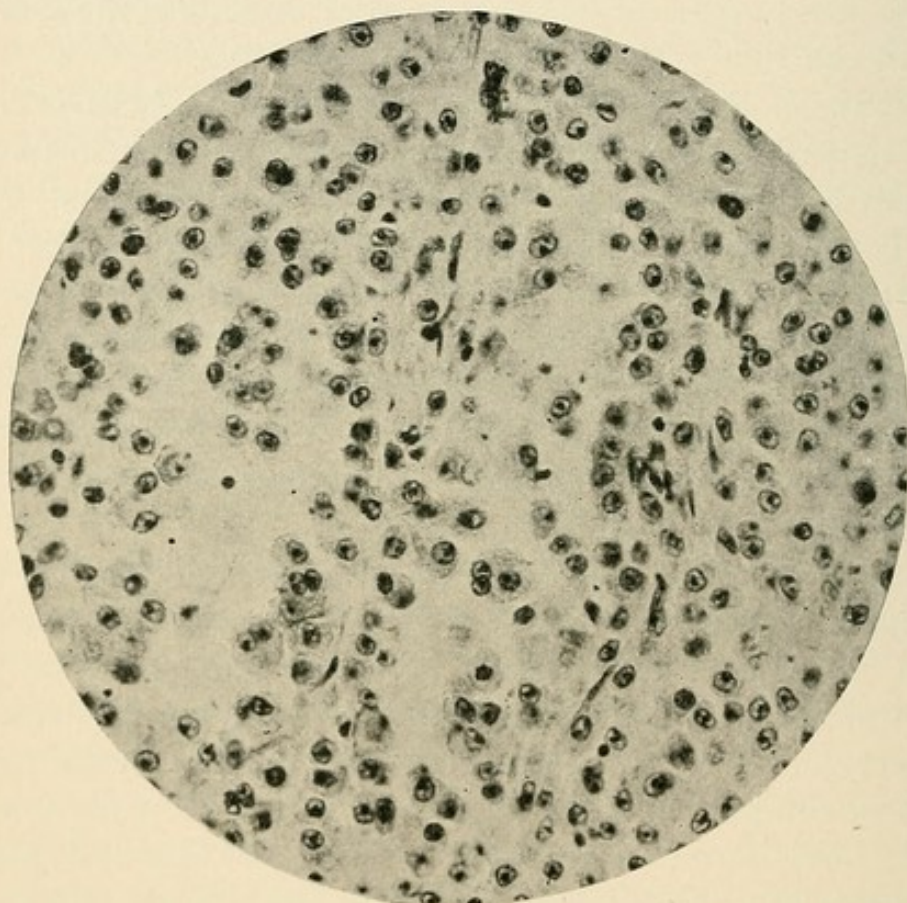


FIG. 396.—Large round-celled sarcoma of skin; $\times 250$ (after Karg and Schmorl). The tumor is composed of large round cells, which in some places, by crowding together, have been somewhat flattened. Most of the cells contain one nucleus; some of them are multinuclear. The intercellular granular substance is scanty, and can be seen only in certain parts of the field.

pathological conditions, its starting-point is in the subcutaneous connective tissue. That sarcoma is often caused by chronic irritation there is no doubt. In a case of sarcoma over the scapula the writer found that the location of the tumor corresponded exactly with a point where the suspender had produced the greatest amount of pressure and friction. Sarcoma may be composed either of round cells or of spindle-

cells, or these two kinds of cells may be present in varying proportions in the same tumor (Figs. 396, 397).

The most frequent form of sarcoma of the skin is the melano-sarcoma. This tumor originates either in a pigmented nevus, a wart, or the bed of a finger-nail. In either locality the tumor is so near the surface of the skin that ulceration is an early occurrence (Fig. 398). A melano-sarcoma seldom attains great size, because, as a rule, the tumor at an early stage reaches the surface of the skin and ulcerates.

Much of the pigment produced in melanotic tumors is eliminated through the urine. It not infrequently happens that the secondary

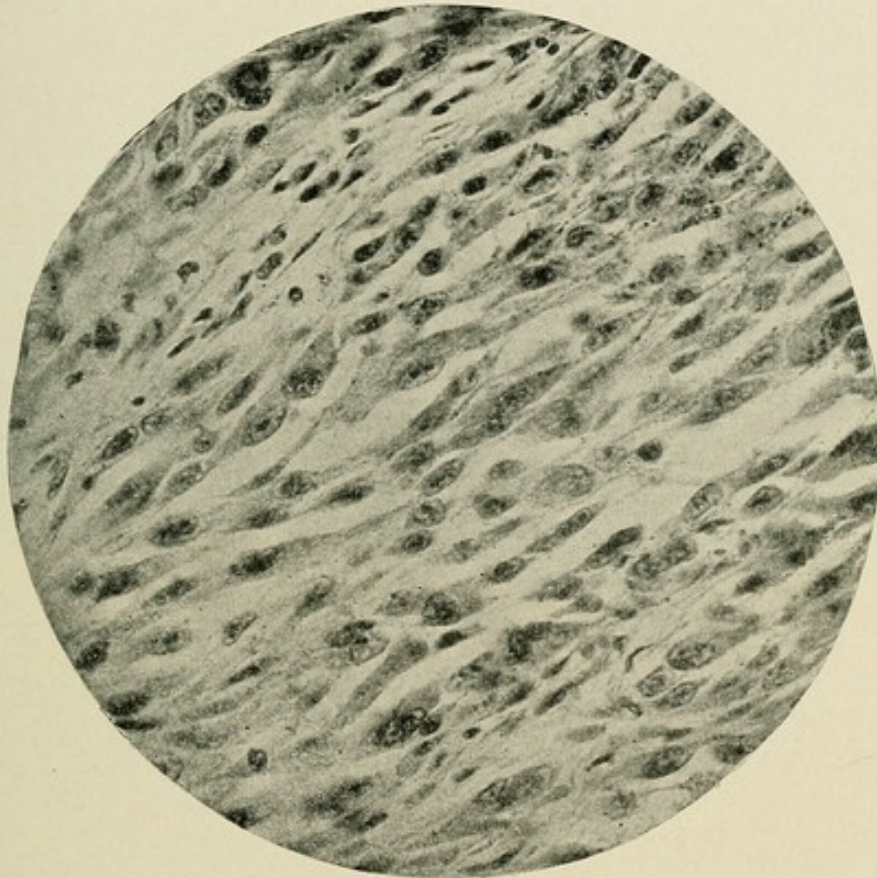


FIG. 397.—Small spindle-celled sarcoma of the skin; $\times 250$ (after Karg and Schmorl). The tumor consists of numerous bundles of spindle-cells, which have been cut longitudinally in the centre of the field, transversely in the periphery. A few cells contain fine granules of pigment, which appear in the picture as minute black dots.

lymphatic tumors grow very rapidly, while the primary tumor grows slowly or remains stationary. In melano-sarcoma regional infection is followed soon by general dissemination, although there are exceptions to this rule. Melano-sarcoma occurring in the matrix or the neighborhood of the nail presents itself at first as a black nodule which ulcerates early, and local, regional, and general dissemination follows rapidly. The great toe is most frequently thus affected. In a case which came under the writer's notice the matrix of the nail of the right index finger was the starting-point of the tumor. The patient, a tailor thirty-five

years of age, attributed the tumor to the prick of a needle. In this case the whole chain of glands from the primary tumor to the apex of the axilla became infected in less than three months, and death resulted from general dissemination within a year from the time the tumor was discovered. The case was treated repeatedly with caustics, which greatly aggravated the local conditions and hastened the fatal termination.

Melano-sarcoma of the skin is characterized by the pigmentation

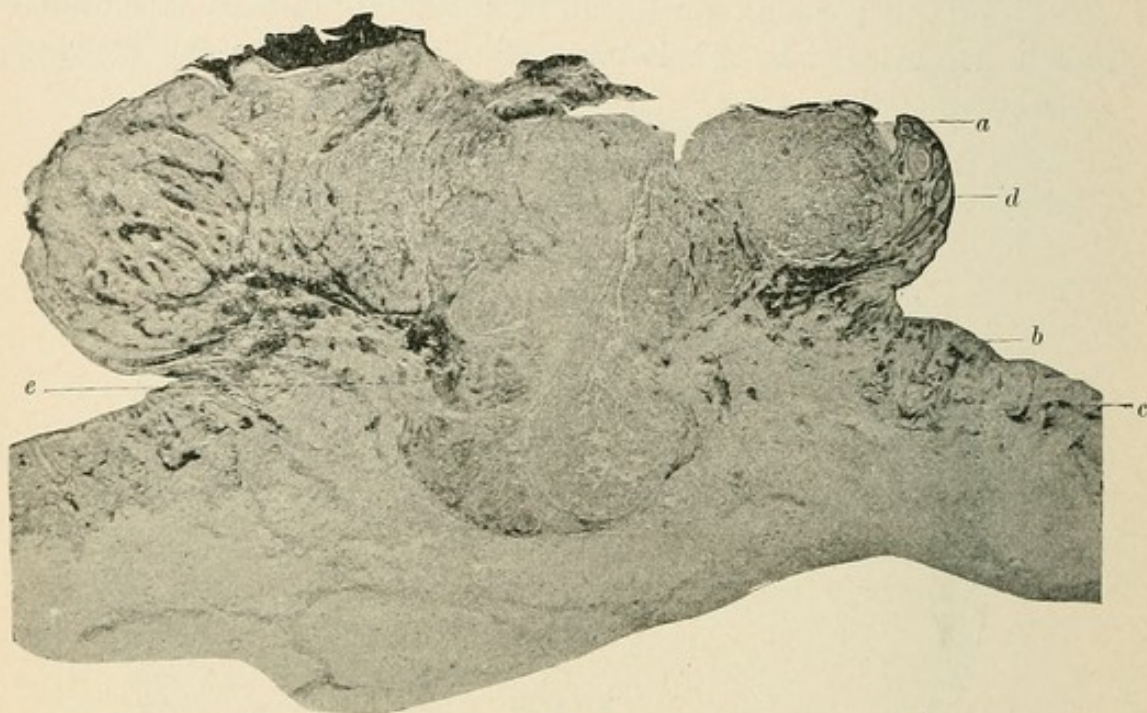


FIG. 398.—Melano-sarcoma of the skin; $\times 9$ (after Karg and Schmorl): vertical section through a melano-sarcoma of the skin of the arm. The tumor (*a*), which projects mushroom-like beyond the level of the surrounding skin (*b*) and penetrates into the underlying cutis (*c*), is composed of dense streaks of large round cells, which, with the magnification used here, cannot be seen. On the surface the tumor is ulcerated and covered with crusts which appear as dark homogeneous masses; at the margins the tumor is covered by epithelium (*d*) which has proliferated irregularly; at the border of the tumor, under the cutis, masses of pigment material are deposited (*e*).

of the primary and secondary tumors and by the rapidity with which local, regional, and general dissemination occurs.

The only proper treatment for melano-sarcoma of the skin is early excision of the primary tumor. If the tumor starts in the neighborhood of a finger-nail or a toe-nail, amputation is preferable to excision. In sarcoma of the skin occurring in other parts of the body, whether pigmented or not, the incisions should be made at least an inch distant from the visible and palpable margins of the tumor. It is very doubtful whether anything can be gained from an operation after extensive regional infection has occurred. Such cases should be treated by sterilized cultures of the streptococcus of erysipelas administered subcutaneously.

Submucous Connective Tissue.—As a primary tumor of the sub-

mucous connective tissue sarcoma is an exceedingly rare tumor. The

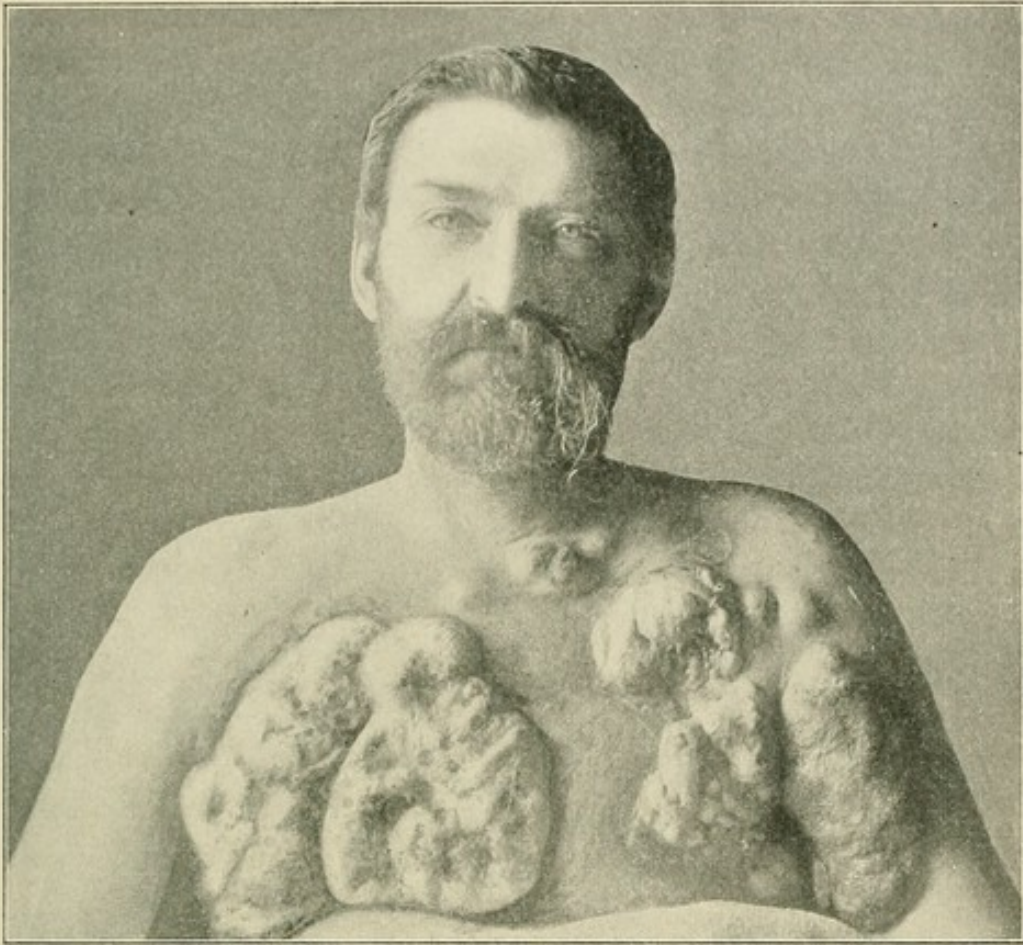


FIG. 399.—Melanotic sarcoma.

tumor in this locality does not become pedunculated: it remains ses-

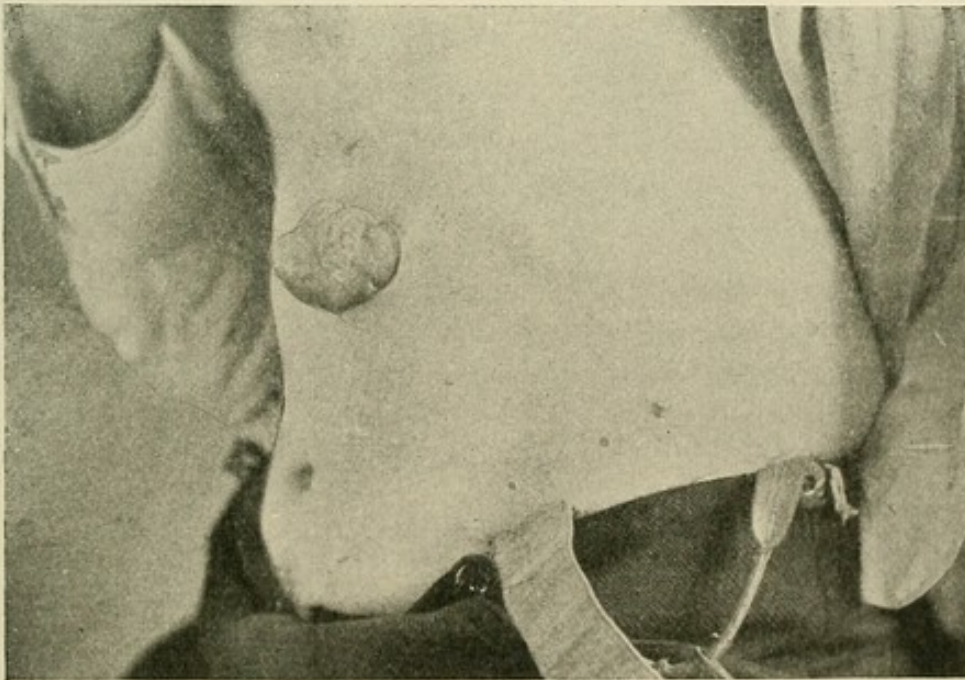


FIG. 400.—Sarcoma of the skin of the back.

sile, and ulceration sets in early and progresses with the growth of the

tumor. The œdema of the tumor-tissue that is almost a constant condition in submucous sarcoma imparts to the tumor under the micro-

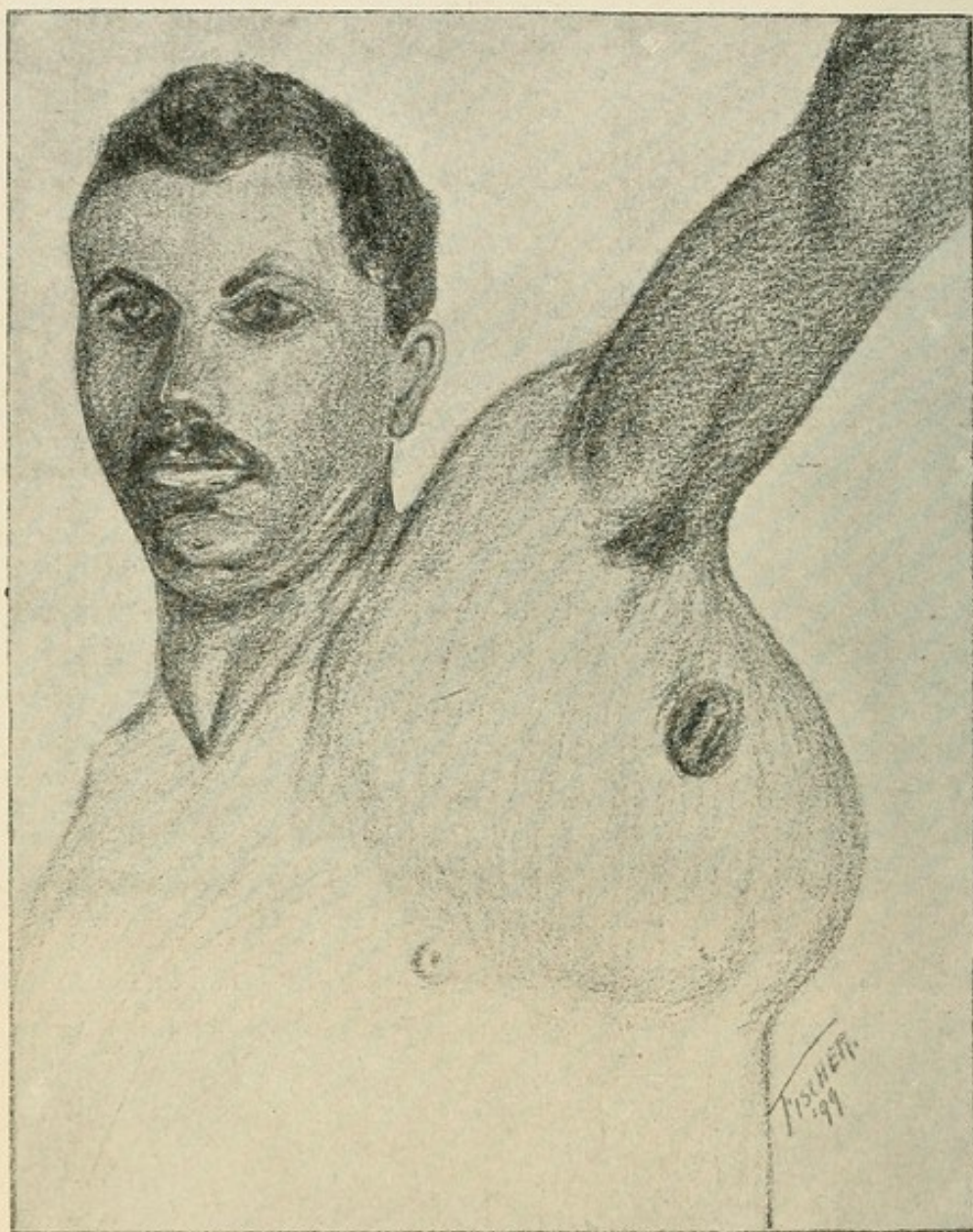
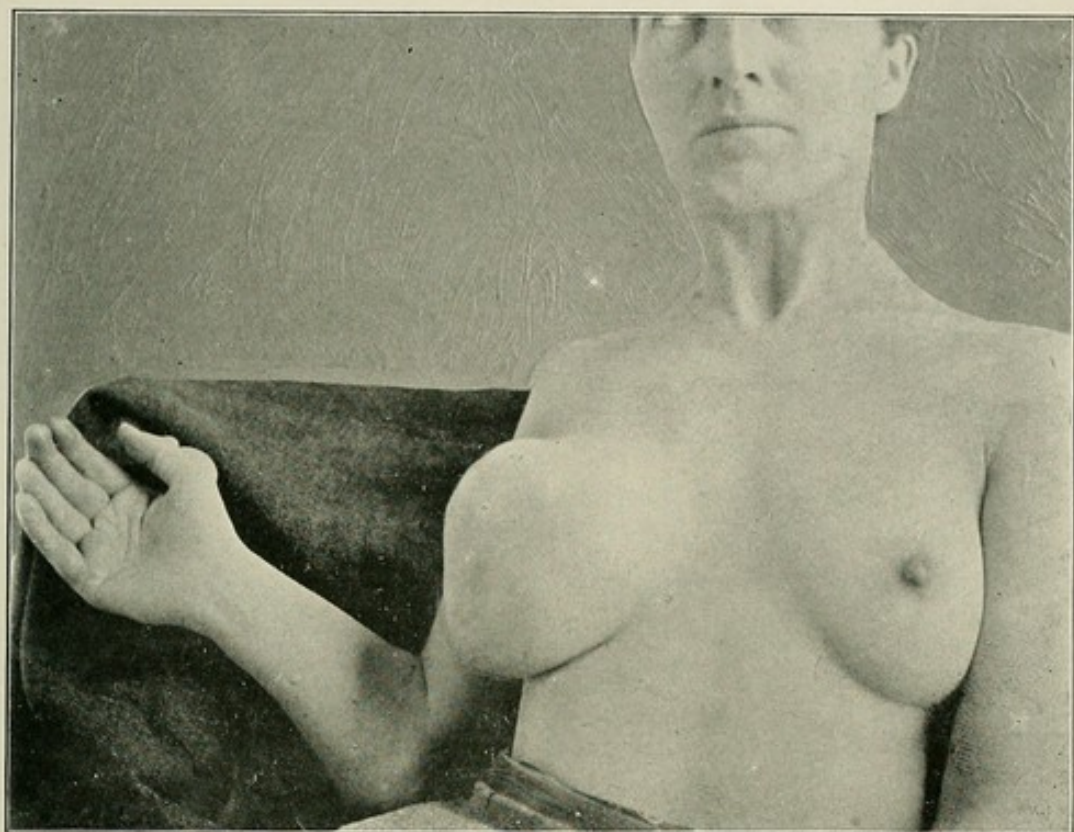


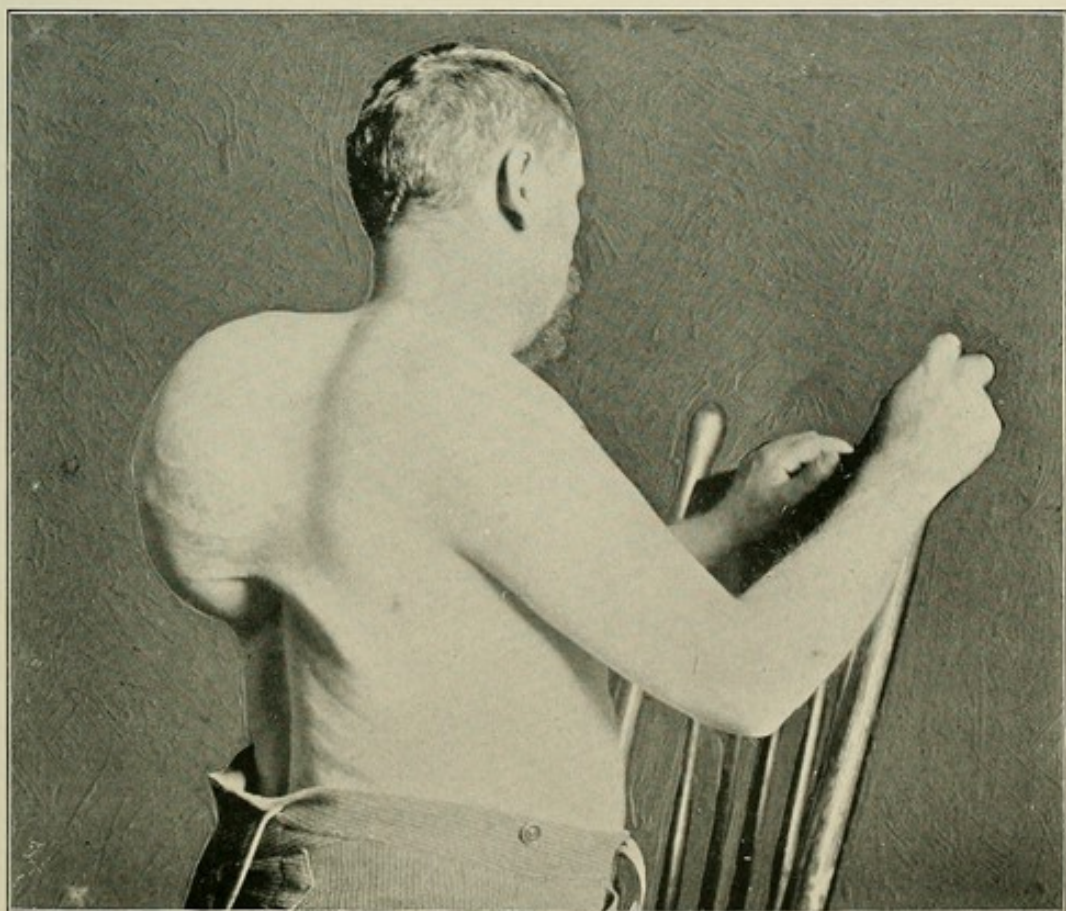
FIG. 401.—Fascial sarcoma of axillary space involving scapula, requiring amputation of the entire upper extremity.

scope a myxomatous appearance at an early stage and hastens the actual myxomatous degeneration. Sarcomata of the uterus and of the intestinal canal usually begin as submucous tumors.

Fascial Sarcoma.—Fascial sarcoma may appear anywhere in the deep connective tissue; it occurs most frequently, however, between the planes of large muscles, presenting itself as a smooth, globular, painless tumor which displaces and infiltrates the adjacent tissues. Unless bound down by resisting structures, the tumor is quite movable, and when it is soft pseudo-fluctuation is present. The tumor is composed of spindle-cells or of round cells, or these two kinds of cells may




1



2

1. Sarcoma of breast. 2. Enormous fascial sarcoma between scapulæ



occur in the same tumor. In some of the soft tumors the round cells are unusually large and multinuclear. The tumor, which develops within a few weeks after a contusion, follows the intermuscular septa and the sheaths of vessels and nerves; it differs from a myxoma and a lipoma by its rapid growth, and from inflammatory swellings by the absence of pain and tenderness. In large tumors central necrosis occasionally takes place. Hemorrhages into the substance of the tumor and myxomatous degeneration are of frequent occurrence. Regional infection takes place along connective-tissue routes, seldom through the deep lymphatics.

Sarcoma is met with most frequently in the deep connective tissue of the neck, the thigh, the leg, the arm, the abdomen, and the scapular region. During the college session of 1894 the writer removed from the interscapular region such a tumor, the circumference of which equalled that of a large soup-plate. Portions of the scapular muscles were removed with the tumor on both sides. The enormous wound was greatly diminished in size by the use of tension-sutures. About a week after the operation the patient contracted erysipelas, which commenced at the borders of the wound and spread over the entire surface of the chest, abdomen, neck, and upper extremities. The entire wound healed by granulation in two months, leaving a circular pale scar the size of the palm of the hand. No recurrence had taken place six months after the operation.

In fascial sarcoma of the trunk and neck the tumor should be removed as early as possible by a thorough excision, including with the tumor a wide zone of apparently healthy tissue. In fascial sarcoma of the limbs involving the principal vessels and nerves, amputation is indicated, and the operation should be performed at a safe distance from the tumor. If the tumor is located some distance from important structures and is limited in extent, excision may be tried. It has been the experience of the writer that such tumors deeply located return almost without exception after excision; this cannot be said of sarcoma of the superficial fascia. In the deep sarcomata the adjacent muscular fibres become infiltrated at an early stage, and the disease creeps along the connective-tissue spaces far beyond the proposed line of incision long before the operation is performed.

Fascial sarcoma in children is an exceedingly malignant tumor. In the winter of 1893-94 the writer had under his care, at the clinic of Rush Medical College, a girl eight years of age, who was otherwise in good health. Within two months a tumor the size of a child's fist had formed among the deep muscles of the calf of the leg, about three inches below the knee-joint. There was no pulsation; neither pain nor

tenderness existed. The skin over the tumor was normal. An exploratory puncture yielded blood. A diagnosis of fascial sarcoma was made, and the limb was amputated by the Gritti-Stoke supracondyloid operation. Primary healing of the wound took place. Two months after the operation a soft tumor appeared among the deep muscles over the posterior aspect of the stump, and unconnected with the scar. As soon as the parents' consent could be obtained amputation through the hip-joint was made; from this operation the little patient recovered without any untoward symptoms.

From his own experience the writer has come to regard amputation as preferable to excision in cases of deep fascial sarcoma of the limbs. It is possible that with the aid of sterilized injections of the microbe of erysipelas we will be able more frequently to dispense with mutilating operations.

Lymphatic Glands.—Primary sarcoma of the lymphatic glands, lympho-sarcoma, is a comparatively rare affection. The primary tumor

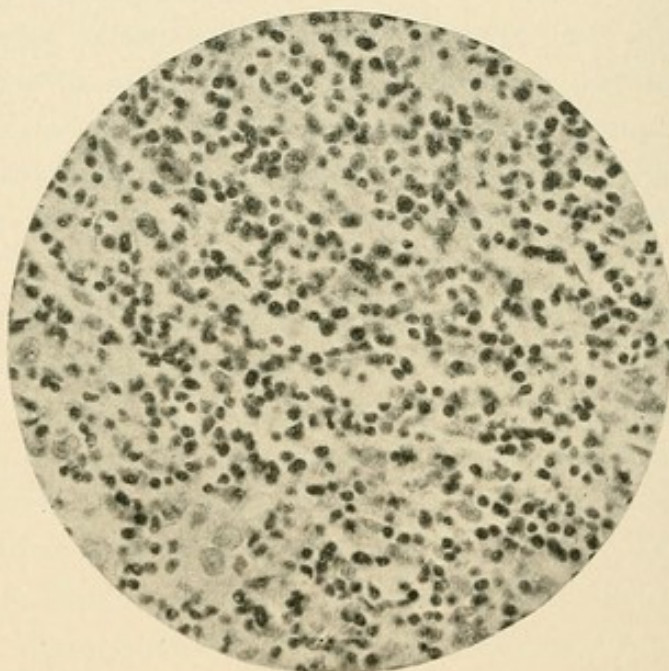


FIG. 402.—Lympho-sarcoma; $\times 270$ (after Karg and Schmorl). The cells of which the tumor is composed show the character of lymphoid corpuscles. Besides these small round cells there are seen larger cells with pale nuclei.

infects adjacent glands of the same region. The tumors, as a rule, present to the palpating finger a sense of elastic resistance. They are smooth and movable before the tumor perforates the capsule of the gland. The pre-existing glandular tissue takes no part in the growth of the tumor, and is gradually displaced by the tumor-tissue. The cells of which the tumor is composed are small round cells which are imbedded in an exceedingly delicate reticulum, the meshes of which frequently are occupied by a single cell (Fig. 402). The regional

infection is usually followed sooner or later by general infection, which in these cases is more frequently the result of migration of sarcoma-cells in the lymph-stream than of direct infection through a vessel-wall. The metastatic tumors present the same lymphoid appearance as the primary tumor. As soon as the capsule of the tumor is perforated by the tumor, the sarcoma involves the surrounding connective tissue; and when the disease in neighboring glands has reached the same stage, the glandular tumors are incorporated with the periglandular tumor-tissue in one mass, in which the separate glands can no longer be identified. At this stage the common tumor-mass frequently implicates the overlying skin, when ulceration and sloughing take place. Before dissemination and ulceration occur the health of the patient is but little impaired. When the glands occupy the region of the neck or the mediastinum, the tumors may cause great suffering and death from pressure.

The characteristic features of lympho-sarcoma are the successive enlargement of the glands of the region occupied by the primary tumor, followed by metastasis without leucocythemia. In leukemia other blood-producing organs become successively affected, and the blood under the microscope shows the characteristic textural changes. In pseudo-leukemia the glands in different parts of the body become enlarged. In tuberculosis the glands never attain such large size as in lympho-sarcoma without the occurrence of extensive regressive metamorphoses. In primary syphilis the enlargement of the glands can be traced to the proper source of infection; and in secondary and tertiary syphilis the glandular hyperplasia is universal and the swellings seldom exceed an almond in size.

The prognosis in glandular sarcoma is very grave, as recurrence after extirpation is the rule. An operation holds out encouragement if it be performed before the capsules of the affected glands have become perforated. As the deep glands are more frequently affected by sarcoma than the superficial glands, the operation is often very difficult on account of the close proximity to the tumors of important vessels and nerves. *Sarcomatous glands should never be enucleated. Even if the capsules of the glands are not perforated, young sarcoma-cells have passed through them into the periglandular connective-tissue spaces. The operative treatment of lympho-sarcoma consists in a clean and thorough excision of the glands with the surrounding connective tissue.*

An operation is justifiable only if there is reasonable hope, from the number and location of the glands, that all diseased tissue can be removed. Incomplete operations increase the malignancy of the tumor and hasten the fatal termination. The only exception to this rule arises

when the glandular masses threaten life from compression of an important organ, when the largest glands may be removed to meet urgent symptoms. In attempting to remove sarcomatous glands by a radical operation the region affected should be exposed freely by a large incision in a direction parallel with the chain of glands. If necessary, the overlying skin is included in two elliptical incisions. No blunt instruments should be used, and no attempt should be made to remove the glands by enucleation. The whole chain of glands, with the connecting lymphatic channels and the connective tissue surrounding the glands, should be removed by a clean dissection with scalpel and dissecting forceps. In the region of the neck, when the deep glands are the seat of sarcoma, it is often necessary to include also in the part to be removed several inches of the internal jugular vein, and sometimes it is necessary to include also the carotid artery and the pneumogastric nerve. Any or all of these structures should be saved if possible, but when they are implicated in the tumor they must be sacrificed fearlessly. The vessels are to be resected between two ligatures. Resection of the pneumogastric nerve has been performed by Kocher, Kappeler, the writer, and other surgeons without any immediate disastrous results; the operation is invariably followed, however, by permanent paralysis of the vocal cords on the affected side. Healing of the wound by primary intention should be aimed at in all operations for sarcoma, as healing by granulation cannot but favor a local recurrence.

Bones.—Sarcoma of bone is met with clinically more frequently than sarcoma of any other organ or tissue.

Müller assigned the name "osteoid tumor" or "ossifying fungus growth" to what we now recognize as sarcoma. Stanley called the same kind of tumor of bone "malignant osseous tumor." Müller was inclined to classify it with carcinoma. Similar tumors are occasionally met with independently of bone. Pott described such a tumor which lay "loose between the sartorius and vastus internus muscles." In the museum of St. Thomas's Hospital, London, there is a tumor like an osteoid carcinoma that was removed from near a humerus, and another from a popliteal space. In all these cases the removal of the tumor was followed by the growth of an ordinary sarcoma devoid of osteoid material.

The osseous part of the tumor is always attached to the bone from which the growth had its origin. The microscopic characters of the ossified part are those of true bone, but rarely of well-formed bone.

Among 19 cases collected by Paget, 5 of the patients were between ten and twenty years old, 9 between twenty and thirty, 4 between thirty

and forty, and 1 between forty and fifty. In more than one-half the cases the immediate cause of the tumor was attributed to an injury.

Although no age is exempt, sarcoma of bone occurs more frequently in children and young adults. The active physiological changes which take place during the development of the skeleton constitute a potent exciting cause. Sarcoma is found most frequently in that part of the bone where the circulation is most active—that is, in the epiphyseal extremities of the long bones and in the inner layer of the periosteum, the cambium. The most malignant form is the periosteal, and the most benign form is sarcomatous epulis.

Histological Varieties.—*Giant-celled or Myeloid Sarcoma.*—A sarcoma should be called “myeloid” or “giant-celled” if the tumor

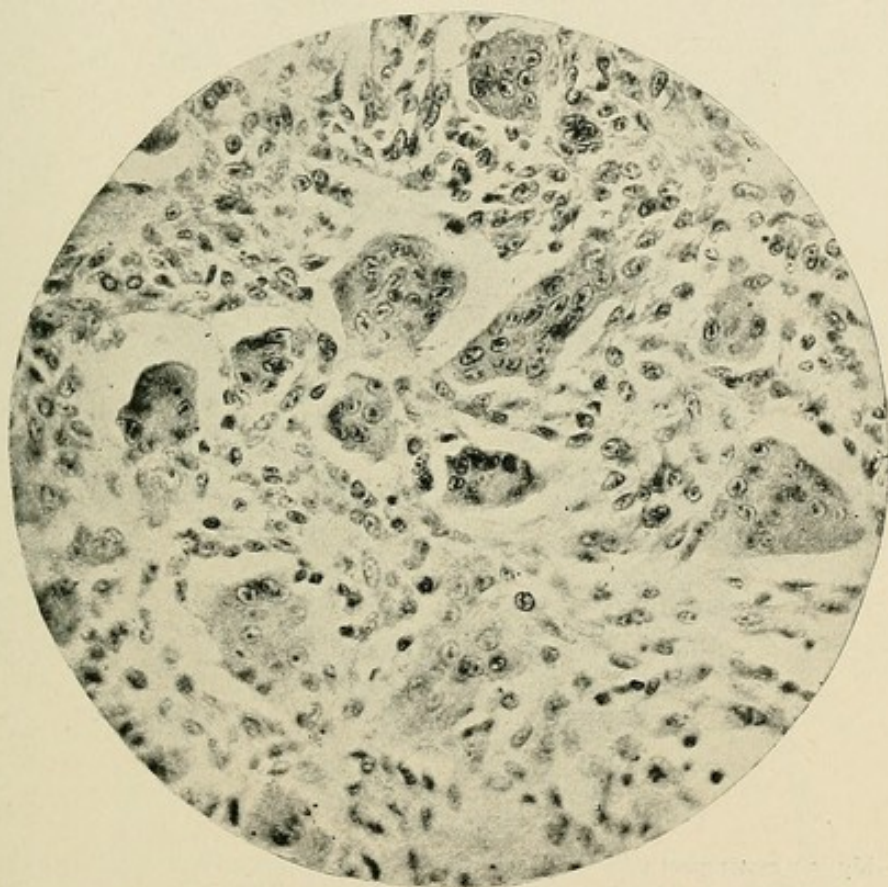

FIG. 403.—Giant-celled sarcoma of upper jaw; $\times 250$ (after Karg and Schmorl). Between the densely packed spindle-cells and round cells of the tumor are numerous multinuclear giant-cells variously shaped. The nuclei, which contain distinct nucleoli, are distributed equally through the protoplasm of the cells, in contrast to the giant-cells in tubercular products, in which the nuclei occupy the peripheral zone of the cells.

is composed in at least one-half of giant-cells. Many sarcomata contain giant-cells, but when these cells do not predominate the tumor is designated according to the cell-elements which form the greater bulk. A pure giant-celled sarcoma does not exist: we find at the same time between the giant-cells round cells, spindle-cells, or both (Fig. 403). The intercellular substance is scanty, amorphous, or in the shape of fibrillæ. The prototypes in normal tissue of the

giant-cells are the *myeloplaques* in the marrow of bone. Giant-celled sarcoma is rare in children and in the aged, and is found most frequently in the lower jaw, the femur, and the tibia. The tumor, which is not encapsulated, but is circumscribed, is of slow growth, of a red or brownish color, and is not prone to ossify or degenerate.

Cysts are produced by hemorrhage or by degenerative changes in tumors of large size. The vascular supply of these tumors is so great that pulsation and bruit are frequently present (Fig. 404).

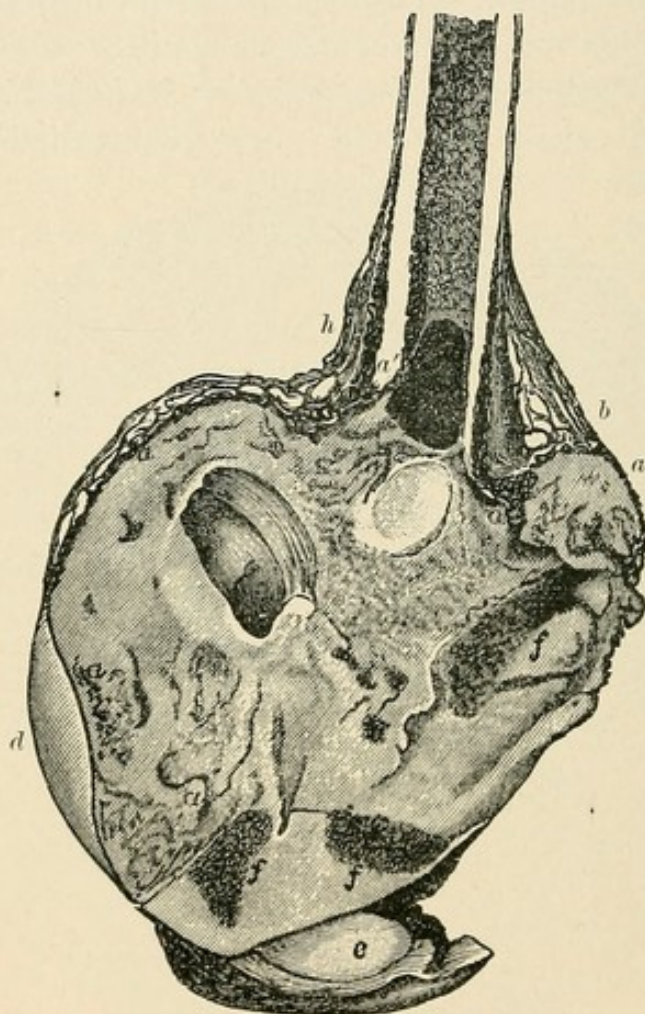
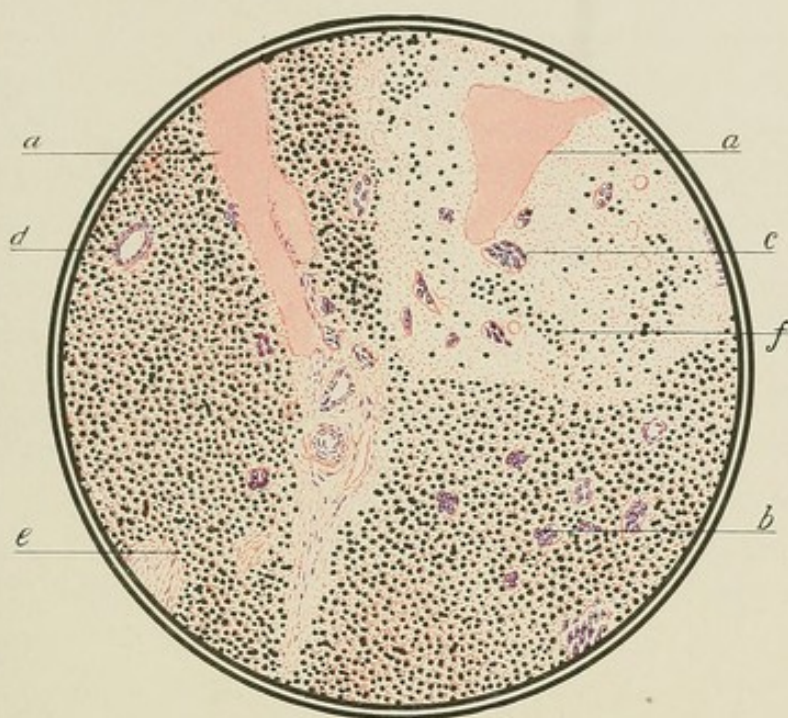

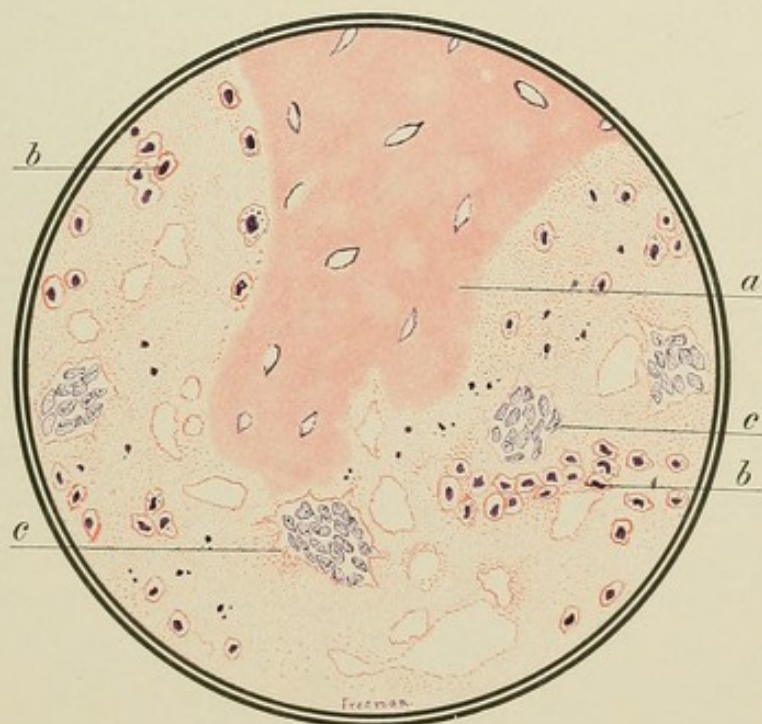FIG. 404.—Myeloid cystic giant-celled sarcoma of the lower epiphysis of the femur, from a girl twenty-two years old; longitudinal section, one-half natural size (after Ziesing). The lower end of the tumor is round and is covered by the articular cartilage (*d*); *e*, patella. The dark streak (*a*) indicates thickness and direction of the secondary shell of bone, which can be traced a certain distance along the outer and inner surfaces of the shaft of the bone (*a'*). The cyst-walls were smooth; some of the cysts contained serum, others extravasated blood (*f*).

The bone-producing function of myeloid sarcoma is always limited, and in many cases is entirely wanting—a circumstance which frequently results in pathological fracture.


Round-celled Sarcoma.—In this variety of sarcoma the round cells compose the entire tumor or the bulk of the tumor, the balance being represented by spindle-cells and a few giant-cells. Round-celled is more malignant than giant-celled sarcoma, more especially if the repre-



Osteo-sarcoma of the head of the tibia; $\times 200$: *a*, remnants of epiphyseal cartilage; *b*, giant-cells of tumor; *c*, giant-cells of tumor assuming osteoclastic function; *d*, vessels; *e*, tumor-stroma; *f*, large area of absorbed cartilage with infiltrating tumor-cells.



Osteo-sarcoma of the head of the tibia; $\times 500$: *a*, remnant of epiphyseal cartilage; *b*, sarcoma-cells infiltrating the area of absorbent cartilage; *c*, giant-cells with osteoclastic function. (Surgical Clinic, Rush Medical College, Chicago.)



sentative cells are small and when the tumor is located near the trunk. The long bones are most frequently affected, especially their epiphyseal extremities. The tumors are found oftenest in the upper end of the humerus, the lower end of the radius, the lower end of the femur, and the upper end of the tibia. The flat bones are also frequently affected. The round sarcoma-cells possess no fibrillating power; the tumor is therefore soft, is not encapsulated, and grows more rapidly than giant-celled sarcoma.

In both giant-celled and round-celled sarcoma the tumors, instead of producing new bone, destroy the pre-existing bone-tissue, thus in the case of the long bones leading to weakening of the shaft, so that often upon the slightest application of force, as turning in bed, a pathological fracture is produced. If the tumor is located centrally, the resistance being equal on all sides, a spindle-shaped enlargement of the bone is produced, the centre of the spindle corresponding with the primary location of the tumor. This enlargement is not caused by tumor-tissue of the bone, but by the expansion of the compact layer of the bone and the periosteum under the greatly increased intra-osseous tension. The compact layer is weakened by the destruction of pre-existing bone-tissue from within outward by the tumor. The sarcoma-cells act in the capacity of osteoblasts. New bone is produced by the periosteum when this is reached by the tumor (Fig. 404, *a*). If the tumor is not centrally located, or if it starts in the compact layer of bone, the tumor occupies one side of the bone, and will grow in the direction offering the least resistance—that is, away from the bone. In such cases pathological fracture is of less frequent occurrence.

Round-celled sarcoma gives rise to regional and general infection more constantly and at an earlier stage than giant-celled sarcoma. Round-celled sarcoma may originate from the inner layer of the periosteum, when the resulting tumor soon encircles the bone, and almost from the beginning implicates the connective tissue outside the periosteum, where the tumor exhibits more of the phenomena of a deep connective-tissue sarcoma than sarcoma of bone.

Spindle-celled Sarcoma.—A spindle-celled sarcoma is very rare in the interior of bone as a primary tumor. It originates most frequently in the periosteum, where, by continuity of tissue, it soon extends around the shaft of long bones, appearing as a fusiform tumor. Between the spindle-cells there are often found, in varying proportions, round cells, and sometimes giant-cells.

Periosteal sarcoma very often produces new bone, when we speak of an ossifying sarcoma. Ossification of the tumor takes place fre-

quently in sarcoma of the flat as well as in sarcoma of the long bones. The tumor is hard if ossification takes place on a large scale or if the tumor is composed almost exclusively of spindle-cells; it is soft in non-ossifying tumors composed in part at least of round cells and giant-cells.

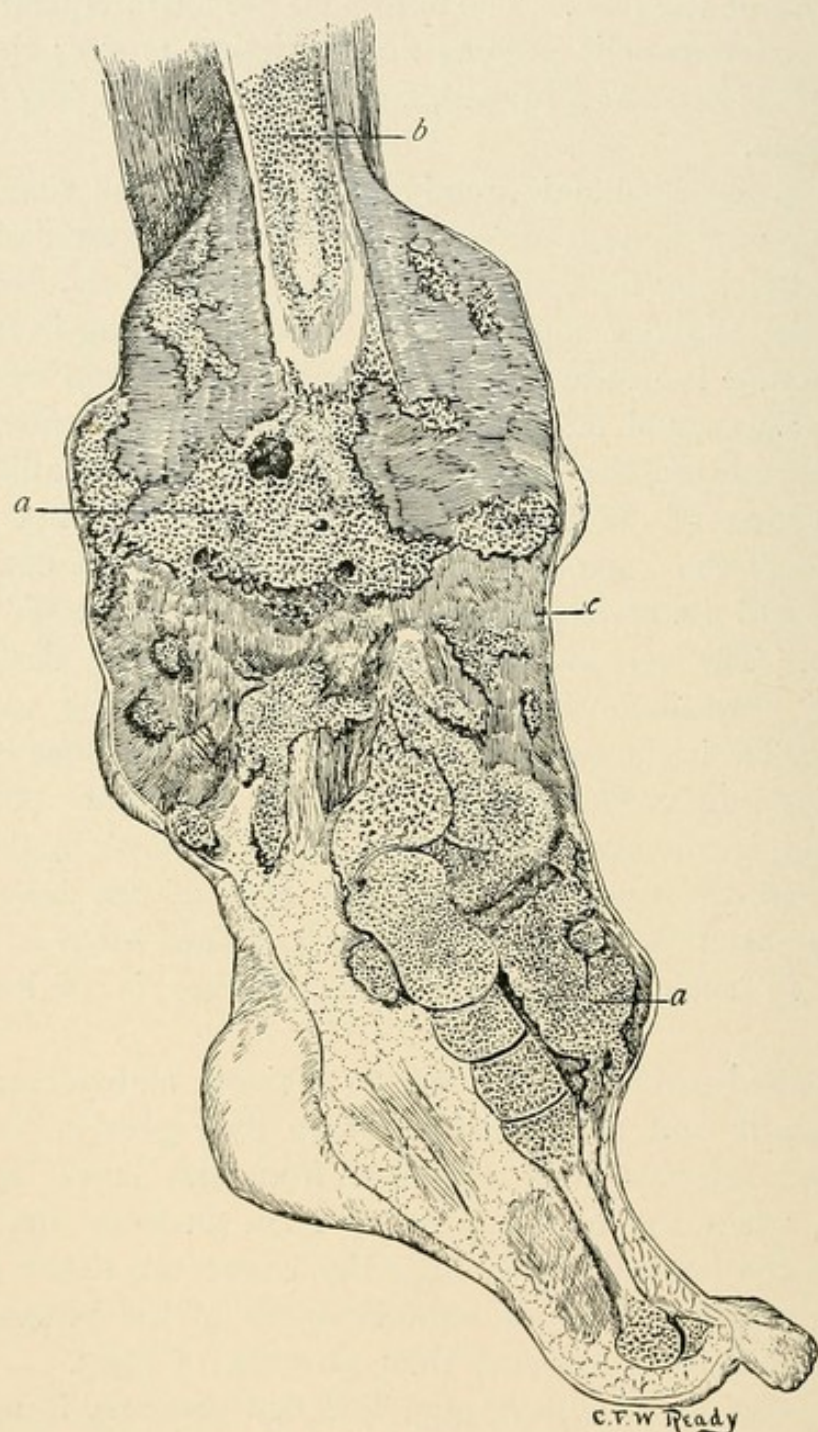


FIG. 405.—Periosteal bone producing sarcoma of the leg; starting-point in the tarsus. Vertical section through the limb removed by amputation: *a*, tumor-tissue; *b*, shaft of tibia; *c*, new bone.

In ossifying periosteal sarcoma the bone left after maceration consists of beautiful spiculæ, which radiate and branch from the affected bone (Fig. 405). Decalcified specimens show delicate trabeculæ, usually perpendicular to the old bone, and between them a very cellular tissue containing spindle-cells and round cells.

Pathological fracture does not occur in periosteal sarcoma, as the affected bone is not much weakened by the tumor. Clinically, periosteal sarcoma differs from primary sarcoma of bone by the existence of

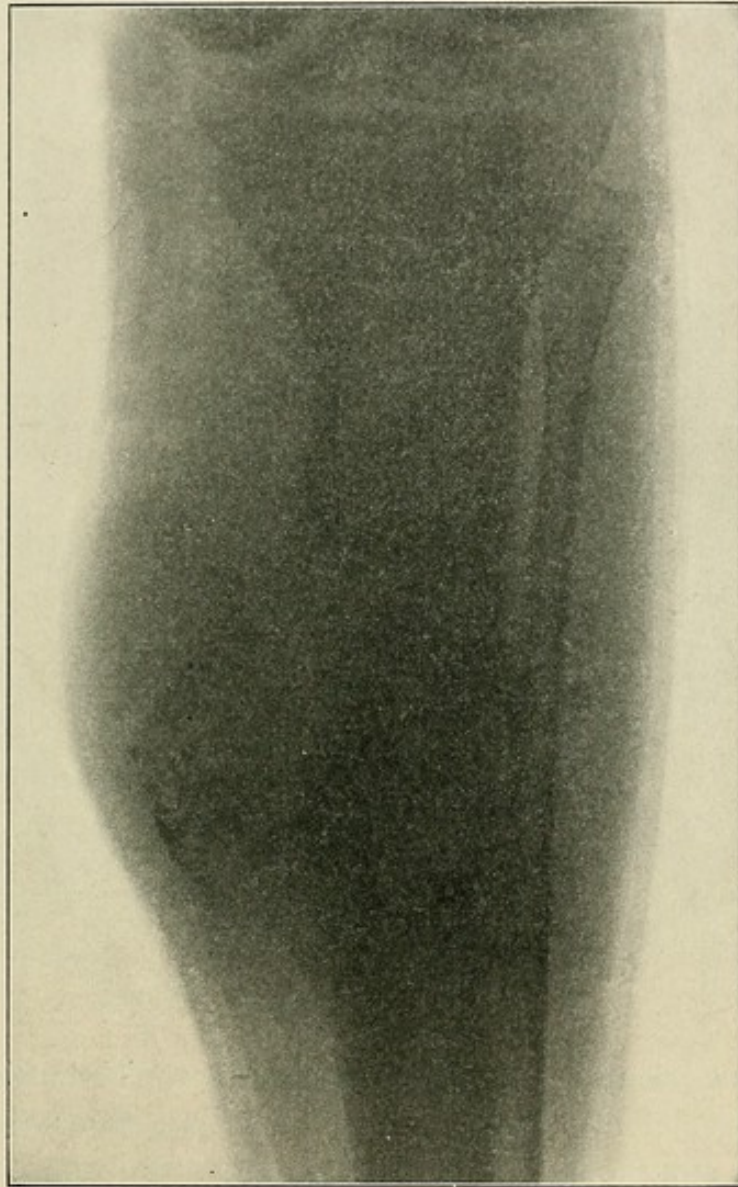


FIG. 406.—Periosteal sarcoma of the tibia (Surgical Clinic, Rush Medical College, Chicago).

greater pain and tenderness, by its greater malignancy, manifested by its more rapid growth, and by its tendency to give rise to regional and general dissemination. Sarcomata of some of the bones present such peculiar clinical features that a special reference to them is necessary.

Cranial Bones.—Periosteal sarcoma of the cranial bones forms at first an external tumor which attacks the bone beneath, often leading to diffuse secondary sarcoma of the dura mater, and even of the brain itself. Anatomically the tumor is characterized by massive radiating spiculæ of bone.

Myeloid sarcoma begins in the connective tissue or myeloid tissue of the diploë, and by its growth causes destruction of both tables of the bone, resulting in the formation of large intracranial and extracranial tumor-masses connected by a constricted portion which corresponds with the primary location of the tumor and the perforation in the skull. New bone is produced when the tumor has reached the periosteum, so that the tumor is covered externally by a thin shell of bone,

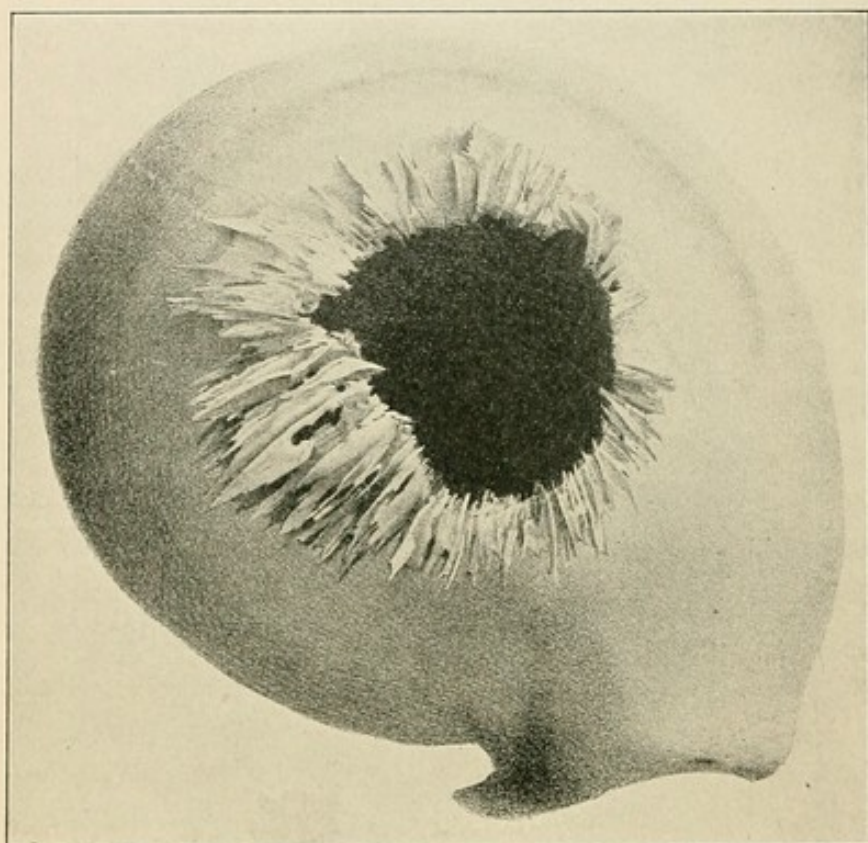


FIG. 407.—Perforating myeloid sarcoma of the skull (Bruns).

which, however, yields to the increasing intracranial tension when the tumor pulsates synchronously with the heart's action; the tumor also presents other symptoms which point to its partly intracranial location. In some cases no new bone forms, and pulsation appears as soon as perforation takes place. The tumor gradually becomes softer and softer, and finally implicates the overlying skin, when ulceration and sloughing hasten the fatal termination. The external tumor has been known to attain a bulk of half the size of the head. The intracranial extension of the tumor often causes well-marked cerebral symptoms.

Formerly, for obvious reasons, myeloid sarcomata of the cranial bones were regarded as absolutely fatal. Bold operation under strict antiseptic precautions has placed them within the reach of successful operations, provided the operative treatment be resorted to in time. The extension of the tumor to the dura mater does not preclude a successful operation, as during the last ten years large pieces of the

dura mater have been removed with the tumor without any immediate or remote unfavorable complications. During one of these operations Volkmann accidentally injured the superior longitudinal sinus, and the patient died on the table from the immediate effects of the entrance of air. Extirpation of these tumors requires the removal of the cranial wall as far as the limits of the intracranial part of the tumor, when, if the dura mater is affected, it is removed with the tumor. Special care is necessary to prevent the entrance of air and undue hemorrhage if a part of the superior longitudinal sinus has to be excised with the tumor. Air-embolism can be prevented with certainty by keeping the head on a level with the body during the operation; hemorrhage is guarded against by preliminary compression of the sinus outside the

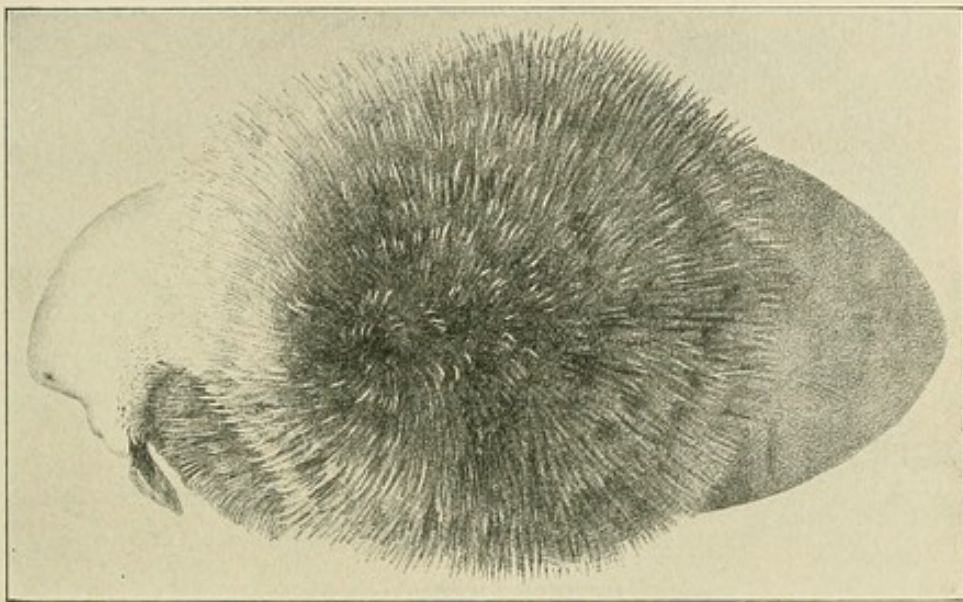


FIG. 408.—Macerated specimen of periosteal sarcoma of the skull (Bruns).

line of incision on both sides, or by excising the sinus between two ligatures. Hemorrhage from the sinus in accidental injuries is arrested by ligature, by suture, or by compression-forceps which are allowed to remain and are incorporated in the dressings and removed on the second or third day. The interruption of the circulation in the sinus is a harmless procedure if the wound remains aseptic; should suppuration set in, the patient is exposed to the dangers of septic sinus-phlebitis and its remote results, sepsis and pyemia. If a large part of the cranial wall has to be excised, the defect should be filled with an accurately-fitting plate of perforated decalcified bone, which furnishes a temporary protection for the exposed brain and aids the bone-producing tissues in greatly diminishing the size of the cranial defect. The wound is closed over the bone-plate by sutures except at the most dependent part, where tubular or capillary drainage is established. Serious brain-

symptoms usually indicate the extension of the tumor beyond the dura mater, and contraindicate an attempt to perform a radical operation.

Sarcomatous Epulis.—Sarcomatous epulis is a spindle-celled sarcoma of slow growth that usually springs from the alveolar border of the jaws, and involves the gum secondarily. Such tumors, although of slow growth, may attain considerable size and cause great deformity.

Malignant epulis is found most frequently in persons more than twenty years of age, and occasionally is seen in children. The tumor is sometimes so much contracted at its base that it appears as a pedunculated growth. The teeth are loosened, and are often extracted under the belief that the swelling is caused by disease of their roots. The tumor sometimes undergoes in part transformation into cartilage. The harder the tumor, the slower its growth and the less the liability to regional and general dissemination. If the tumor is allowed to pursue its own course, extension to the periosteum, usually over the outer surface of the bone, and destruction of the bone, are sure to follow. The small-celled variety of epulis is particularly destructive.

Tumors with intercellular substance are soft and grow rapidly. In soft tumors the round, non-fibrillating cells predominate. After the tumor has attained considerable size it is subjected to all kinds of injuries on the part of the teeth and by eating, and inflammation and ulceration set in, aggravating the local conditions and increasing the malignancy of the tumor.

Fibrous epulis is only attached to the bone ; sarcomatous epulis grows into the bone. A careful distinction between the benign and malignant forms of epulis is important from a practical standpoint, as in the former instance it is not necessary to extend the operation beyond the bone, whereas in malignant epulis, in order to remove all of the diseased tissue, it is necessary to resort at least to the removal of the alveolar border of the jaw, and in advanced cases, where the periosteum has become extensively involved, nothing short of resection of the jaw in its entirety will fulfil the pathological indications.

Sarcoma of the Jaws.—With few exceptions, tumors of the jaws are sarcomata. Giant-celled, round-celled, and spindle-celled tumors occur in the jaws. In the majority of cases the tumors are mixed-cell sarcomata. Their degree of malignancy is determined by the abundance of non-fibrillating cells. The round-celled variety is the most malignant, giant-celled the most benign, and in mixed-cell tumors the malignancy increases with the number of round cells. Myeloid central sarcoma is much less malignant than periosteal sarcoma, sarcomatous epulis excepted. Periosteal sarcoma of the lower jaw is especially a very malignant tumor. Myeloid central sarcoma of the lower jaw, on

the contrary, is a comparatively benign tumor. Sarcomata starting in the follicles of the teeth are mixed-cell tumors. In the early stages these tumors are encapsulated, but later they give rise to regional and general infection. "Sarcoma of a tooth-follicle only occurs in children, and is particularly apt to involve the germ of the first permanent molar" (Sutton). Myeloid sarcomata are rarely met with after the twenty-fifth year, whereas the periosteal variety occurs more frequently in persons advanced in years.

Naso-pharynx.—Spindle-celled sarcomatous tumors of the naso-pharynx usually spring from the under surface of the body of the sphenoid bone. Both nasal cavities are often occluded, and processes of the tumor extend forward into the nostrils and backward into the pharynx. These tumors are the source of great distress in preventing nasal breathing and sometimes interfering with deglutition; they are also attended by excruciating frontal headache. Hemorrhage is of frequent occurrence.

Nose.—Sarcoma of the nose is seldom seen except in persons between the ages of fifteen and twenty years. Nasal sarcomata frequently involve one or both antrums. A case of this kind is shown in Figure 409. In this instance pain was absent, the sense of smell was lost, and the sight of the right eye was impaired. Moore attempted to remove the tumor, but the patient died on the table in consequence of some interference with the respiration. Subsequent examination showed that the tumor was surrounded by a bony capsule and that its wall was continuous with that portion of the nasal septum formed by the mesethmoid.




FIG. 409.—Deformity produced by a sarcoma of the nasal septum (after Moore).

Vertebræ.—Primary sarcoma of the vertebræ is rare; metastatic tumors are of frequent occurrence. The writer has seen two patients die from the remote effects of metastatic sarcoma of the vertebræ. In the first case the patient was a girl fourteen years old suffering from a round-celled fascial sarcoma in the deltoid region. A few weeks after the operation she complained of pain in the lower part of the dorsal region. Kyphosis and complete paraplegia soon appeared, and were followed by a very extensive sacral decubitus, from the immediate

effects of which the patient died in less than six months after the operation. The second patient was a man sixty-five years of age, from whom there was removed a small round-celled sarcoma of the seventh rib on the right side. During the operation the pleural cavity was opened, the lung collapsed, and the patient nearly died on the table from the effects of the accident. The wound in the pleural cavity was stuffed with iodoform gauze, and the tumor was rapidly removed with a considerable portion of the parietal pleura. The patient rallied and recovered rapidly from the operation. The wound healed by primary intention, in a few days the air in the pleural cavity was absorbed, and the lung expanded. Several weeks after the operation, after the patient was able to leave his bed, intense pain in the middle dorsal region set in. A slight projection of one of the spinous processes of the middle dorsal vertebra was noticeable in a few weeks. Progressive paraplegia, retention of urine, and decubitus followed in rapid succession, from the combined effects of which the patient died four months after the operation.

Sarcoma of the vertebræ, whether primary or secondary, in its clinical aspects bears a close resemblance to acute spondylitis.

Diagnosis.—Mistakes in diagnosis are frequently made in cases of sarcoma of the bones. More than this, the diagnosis is often only made after the clinical history of the tumor has revealed its malignant nature. All histological forms of sarcoma of bone are characterized by progressive growth. The tumor is either soft or hard according to the histological type of the cells of which it is composed. Encapsulation, which may be present at first in some forms of sarcoma, disappears during the growth of the tumor, when, in degrees of intensity, local, regional, and general infection manifests itself. Local extension from tissue to tissue, irrespective of its anatomical structure, constitutes the distinctive feature between sarcoma and benign tumors of bone. In central sarcoma the extension to other tissues takes place through the blood-vessels of the bone, the Haversian canals, and after the compact layer of the bone has become perforated. Regional infection takes place in preference along the course of blood-vessels, nerves, and intermuscular septa, but in some cases the lymphatics are implicated. General dissemination may take place through the lymphatic channels, but in the majority of cases the tumor-cells enter the blood-vessels, or the tumor grows into a vein, and the emboli, large or small, are derived from the intravenous, sarcomatous thrombus.

Round cells and giant-cells destroy bone. In periosteal sarcoma bone-destruction and the production of new bone take place side by side. Periosteal sarcoma presents itself usually as a firm tumor attached

to or encircling the bone. Round-cell periosteal sarcoma is the most malignant of all bone-tumors. In its clinical aspects it more closely re-

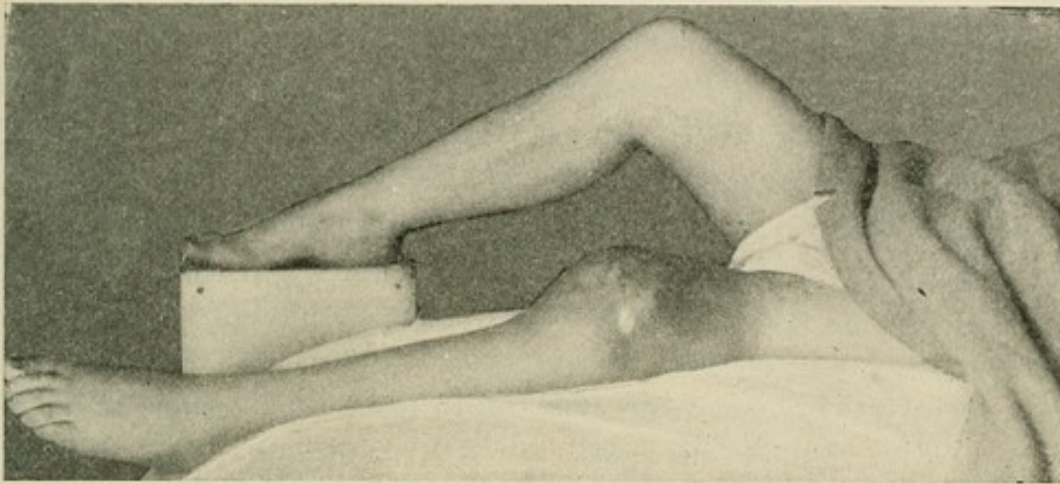


FIG. 410.—Sarcoma of the femur invading the knee-joint (Surgical Clinic, Rush Medical College, Chicago).

sembles an inflammatory affection than a tumor. Its great malignancy is manifested by rapidity of growth and by early regional and general infection. Local extension takes place along the periosteum to the underlying bone and the adjacent tissues. No new bone is produced. In central sarcoma of the long bones, as long as the tumor is covered by a thin shell of bone, pressure produces a crackling sensation. Pulsations are felt in perforating, non-ossifying sarcoma of the skull and in vascular myeloid central tumors of the long bones. A bruit is often heard in very vascular central sarcomata of the long bones. Glandular infection occurs most frequently in round-celled sarcoma of the jaws, the tarsus, the sternum, and the ilium. The signs and symptoms of sarcoma of the vertebræ resemble acute spondylitis. Pathological fracture is one of the consequences of central sarcoma of the long bones.

The affections most frequently mistaken for sarcoma are infective swellings, cysts, aneurysm, carcinoma, and actinomycosis.

Infective Swellings.—Subacute and chronic suppurative osteomyelitis has frequently been mistaken for myeloid and periosteal sarcoma, and *vice versa*. Primary osteomyelitis is a disease of childhood and young adults, the same as myeloid sarcoma. Periosteal sarcoma affects most frequently persons between twenty and sixty years of age. Central osteomyelitis is a very painful affection, whereas myeloid sarcoma produces little or no pain. Inflammatory affections occur more frequently in the young than tumors, the proportion being about 3:1. Injury may precede and constitute an etiological factor in both affections. Paget related an instance of a malignant tumor within and around the fibula that attained a large size within eight weeks after a strain or perhaps a fracture of the bone. The swelling both in osteo-

myelitis and in sarcoma of the long bones may be either fusiform or one-sided. The consistency of the swelling often offers no clue as to the nature of the enlargement. An inflammatory swelling may be very hard, and a sarcoma may be soft. A sarcoma may increase in size as rapidly as an inflammatory swelling. In chronic central osteomyelitis no external swelling may appear for months or years. If, however, careful observation shows that the enlargement is not increasing, this circumstance would be suggestive of osteomyelitis rather than of a malignant tumor. The condition of the skin over the swelling affords no trustworthy indication of the nature of the swelling. Enlargement of the subcutaneous veins is found in sarcoma and in deep-seated osteomyelitis before the abscess has reached the skin. The soft parts have their circulation uninterfered with until the tumor or the inflammatory process has implicated the skin by extension of the morbid process. *Œdema* is more suggestive of the presence of pus than of a tumor. Tenderness is always present over an osteomyelitic focus, and is absent or slight in central sarcoma. In periosteal sarcoma pain and tenderness are more conspicuous symptoms. The temperature may be normal in chronic osteomyelitis, and a slight rise of temperature is observed in pure cases of sarcoma. In periosteal sarcoma the temperature not infrequently rises three or four degrees above normal.

An exploratory puncture may prove useful as a diagnostic aid. In obscure cases an exploratory operation will often be the only means of differentiating a sarcoma from an infective swelling. The exploration in central disease of the bones should be carried not only down to, but into, the bone by the use of mallet and gouge. If the disease is inflammatory, the bone removed will present the structure of cancellous bone—that is, it will be more or less porous—and when the abscess-cavity is reached at least a few drops of pus will be discovered. If a tumor is exposed by the operation, tumor-tissue and no pus will be found. At this stage of the operation, in case of doubt the microscope may prove of great value in making a positive diagnosis.

Tuberculosis of the long bones usually affects the epiphyseal extremities, and the adjacent joint is frequently found implicated, while in sarcoma in the same localities joint-complications seldom occur, as the articular cartilage, although not impermeable to sarcoma, protects the joint for a long time. In advanced tuberculosis of the short and flat bones that has terminated in the formation of a tubercular abscess an exploratory puncture will reveal the true nature of the swelling.

Syphilitic gummata of bone or of periosteum have frequently been mistaken for sarcoma. Careful inquiry into the history of the case is important in cases in which there is any doubt as to the syphilitic nature

of the bone-affection. *Gummata often appear as a multiple affection, and careful examination of the patient will often reveal the presence of marks of antecedent syphilitic lesions or the existence of additional syphilitic affections. The histological structure of gummata under the microscope bears such a close resemblance to small round-celled sarcomata that microscopical examination should not be relied upon in making a differential diagnosis between gumma and round-celled sarcoma.* In doubtful cases the patient should be placed upon a vigorous antisyphilitic treatment for a few weeks, during which time the enlargement should be examined frequently in order to observe the effects of the treatment. If the enlargement is a sarcoma, the treatment will make no impression on the tumor; if it is syphilitic, a decided improvement will be noticeable in a few weeks.

Cysts of bone, parasitic and non-parasitic, grow very slowly, remain local, and are not apt to give rise to any subjective symptoms. They are also extremely rare.

In pulsating myeloid tumors of the long bones a careful examination must be made to distinguish them from true aneurysm. In many pulsating sarcomata no bruit can be heard, while in true aneurysm this symptom is present almost without exception. In aneurysm a more decided impression is made upon the swelling by compression of the principal artery on the proximal side than in pulsating sarcomata. In sarcoma a distinct crackling sensation is produced on making pressure upon the tumor as long as it is covered with a thin shell of bone.

The differential diagnosis between sarcoma and actinomycosis can only come in question in cases in which the jaws are the seat of the affection. Microscopical examination of fragments of tissue will show the presence of the essential cause, the actinomyces, if the enlargement is an actinomycotic swelling.

Treatment.—The operative treatment of sarcoma of bone is indicated in all cases in which there is reasonable hope that all diseased tissue can be removed and in which metastasis has not occurred. The last point is difficult to determine, as some sarcomata give rise to metastasis at a very early stage, and the metastatic tumors may be very small or may be located in internal organs, thereby eluding detection. Metastatic tumors of the brain are often attended by impairment of vision and by other focal symptoms. Metastatic tumors of the lungs and the pleuræ must be suspected if the patient has a hydrothorax. Ascites is another condition which sometimes develops in consequence of metastatic tumors of some of the abdominal viscera.

It is superfluous to insist that sarcoma of the bones should be operated upon at the earliest possible moment. Although the chances

for a permanent cure after early operations are not so favorable as in carcinoma, there can be no doubt that thorough operations in cases of sarcoma, performed before regional and general dissemination has occurred, will in a fair percentage of cases not be followed by recurrence of the tumor.

In central sarcoma the disease often has become diffused through the numerous imperfect blood-vessels before such a condition is suspected; and in periosteal sarcoma regional dissemination through the surrounding connective-tissue spaces often takes place at a very early period.

Long Bones.—In myeloid sarcoma of the long bones a conservative operation is justifiable in small tumors if the disease is limited to the bone. In slow-growing myeloid tumors favorably located removal of the tumor with the sharp spoon, the chisel, and the hammer has in a few instances yielded a satisfactory result. The cases adapted for this operation are, however, few and far apart. Resection of the bone in its continuity is another operation adapted for well-selected cases. It is inapplicable if the tumor involves the pancreas or the femur. This operation must be limited to the bones of the forearm, the clavicle, and the ribs. Many years ago the writer excised the inner two-thirds of the clavicle for central sarcoma. The patient was a boy sixteen years of age. The tumor, which was located near the sternal end, was larger than a hen's egg, had not extended beyond the periosteum, and was covered by an imperfect thin shell of bone. The boy recovered almost perfect use of the arm, and the tumor never returned. In 1876, Henry Morris excised the lower end of the right radius and the lower fourth of the ulnar for sarcoma. No recurrence had taken place sixteen years after the operation (Fig. 411). The patient recovered considerable use of the hand. A few other cases have been reported in which excision of a part of the shaft of the long bones yielded satis-

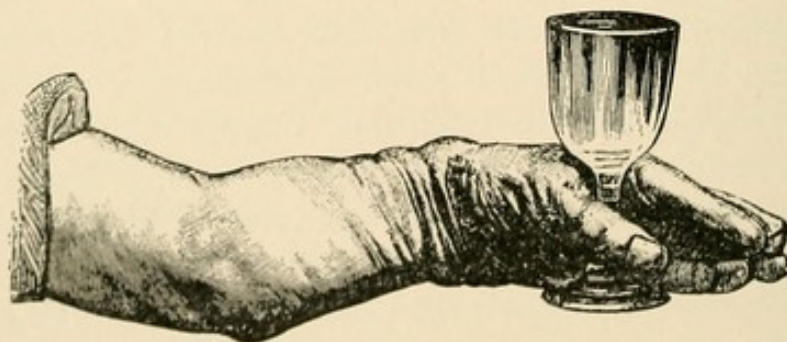


FIG. 411.—Forearm of a woman four years after excision of the lower fourth of the ulnar and the radius for a myeloid sarcoma of the radius (after Henry Morris).

factory results. In the majority of cases it is necessary to resort to amputation in sarcoma of the long bones.

Periosteal sarcoma invariably necessitates a mutilating operation. As a rule, the entire bone should be removed. In sarcoma of the bones of the forearm amputation should be performed at or above the elbow-joint; if the bones of the leg are the seat of the tumor, Gritti-Stokes's supracondyloid amputation will fulfil the pathological indications and will yield the most serviceable stump. In sarcoma of the humerus amputation through the shoulder-joint, and in sarcoma of the femur hip-joint amputation, is necessary. If the upper part of the humerus is affected, removal of the scapula and of part of the clavicle may become necessary; in myeloid sarcoma of the lower end of the femur amputation at the junction of the upper and middle thirds of the femur will in all probability remove all the diseased tissue.

Lower Jaw.—In sarcomatous epulis and in central limited myeloid tumors the continuity of the bone can often be preserved. In the former case the alveolar border and as much of the bone as may be deemed necessary are removed with the chisel. The tumor is exposed by an incision along the lower border of the jaw, the incision being large enough to give free access to the parts to be removed. With the bone a corresponding piece of the periosteum is removed. In central limited myeloid sarcoma the compact layer of the bone is removed with chisel and hammer, and the same instruments are employed in removing the tumor, including with it a zone of bone-tissue adjacent to the tumor. In periosteal sarcoma and in large myeloid tumors one-half of the bone must be removed, even if the tumor does not extend to the ascending ramus, as the proximal fragment is rather detrimental than useful to the patient later, and the severity of the operation is not increased by disarticulating the bone at the temporo-maxillary joint. The bone is exposed by an incision shown in Figure 412.

In operating for malignant disease no attempt should be made to preserve the periosteum. After the hemorrhage has been arrested by the employment of hemostatic forceps the symphysis of the bone is divided. One or two incisor teeth are extracted, when the bone is divided either with a Butcher saw or a chain-saw, as shown in Figure 412. If Butcher's saw is used, the section is made from without inward; if the chain-saw is employed, a tunnel is made with a narrow-bladed knife behind the symphysis mentis; through this tunnel the chain-saw is passed, and the bone is divided from behind forward. After the jaw has been detached from the soft parts to near the temporo-maxillary joint the disarticulation is effected by twisting the bone forcibly in the direction shown in Figure 413. The bone is wrenched from the joint for the purpose of preventing injury to the internal maxillary artery, which would be likely to occur if the disarticulation were done by the

use of cutting instruments. The mucous membrane should be sutured from the side of the mouth by a separate row of catgut sutures, to exclude the cavity of the mouth from the wound. The external wound

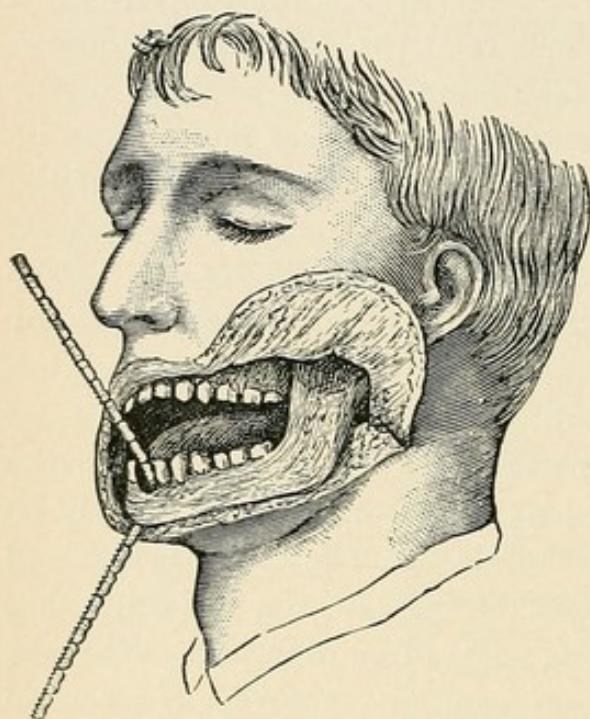


FIG. 412.—Excision of one-half of the lower jaw; external incision (after Esmarch).

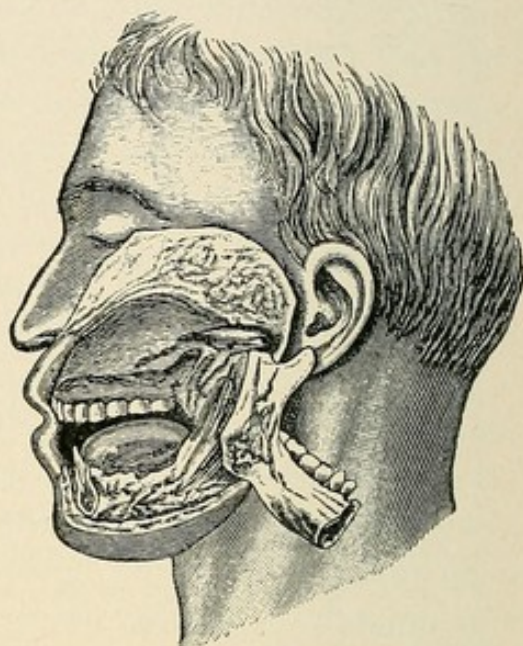


FIG. 413.—Disarticulation of one-half of the lower jaw by twisting (after Esmarch).

is sutured and drained in the usual manner. In some cases it is necessary to divide the lower lip in the centre, affording additional room.

Upper Jaw.—Localized myeloid tumors of the upper jaw and epulis

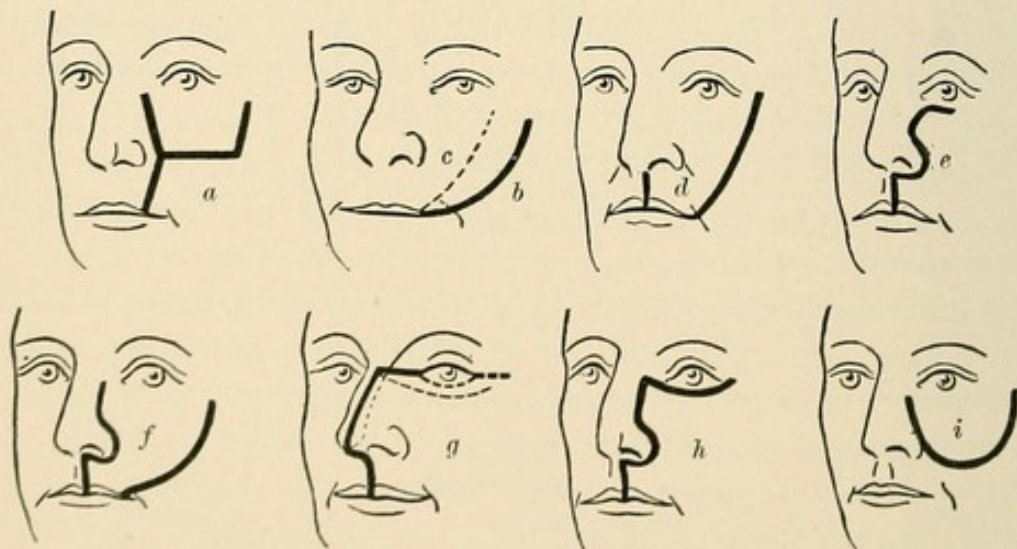


FIG. 414.—Incisions for resection of the upper jaw (after Esmarch): *a*, Gensoul's; *b*, Velpeau's; *c*, Syme's; *d*, Malgaigne's; *e*, Nélaton's; *f*, Fergusson's; *g*, Dieffenbach's; *h*, Weber's; *i*, Von Langenbeck's.

are treated in the same manner as similar affections of the lower jaw. In periosteal sarcoma and in tumors involving the antrum excision of the entire jaw is absolutely necessary. The incisions proposed by different

surgeons in exposing the upper jaw are shown in Figure 414. Of all incisions so far proposed, Weber's incision (Fig. 415) gives best access to the bone and leaves the least deformity. The upper lip is divided in the median line as far as the septum of the nose, when the incision is carried below the nostril on the affected side to the base of the nose, and along the side of the nose to a point a little below the level of the inner canthus of the eye, when it is extended outward below the eyelid as far as the external angle of the eye. The flap is now detached

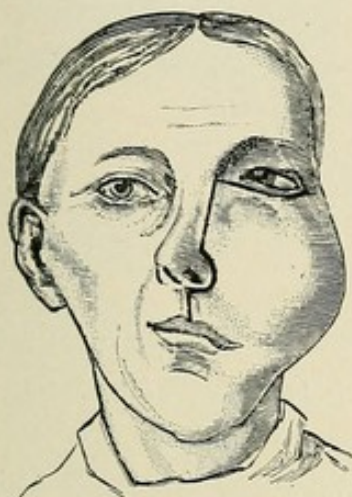

FIG. 415.—Weber's incision for excision of the upper jaw.

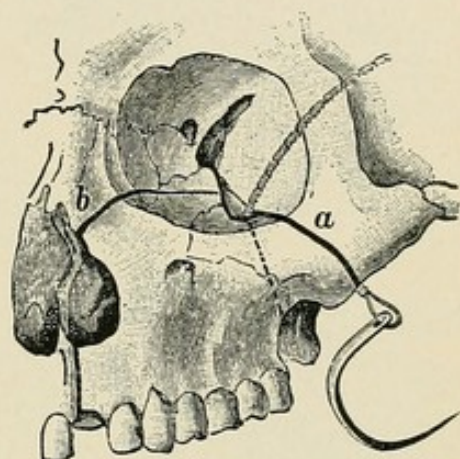


FIG. 416.—Bone-section in excision of the upper jaw (after Esmarch).

and turned downward and outward. In resecting the upper jaw for malignant disease the periosteum is removed with the bone. The orbital contents are carefully separated from the floor with a periosteal elevator. The malar bone is divided with a chain-saw fastened by a strong silk thread to a large curved needle. The needle, thus armed, is passed through the orbital fissure, along the posterior surface of the malar bone, and is brought out at the malar fossa, where the bone is divided (Fig. 416, *a*). The nasal process is next divided with cutting forceps (Fig. 416, *b*). The section through the junction of the maxillary bones is made with a chain-saw. The tampon which was inserted into the nostril before the operation was begun is next removed. A drainage-trocar is now inserted into the nostril, and is pushed into the mouth at the junction of the hard with the soft palate, and with it the chain-saw is drawn through the cavity of the mouth and nose (Fig. 417, *a*). After the extraction of one or two teeth at the point where the bone is to be divided, the section is made with the saw. The next step is to separate with the knife transversely the soft from the hard palate (Fig. 417, *b*). The bone is now loosened with an elevator inserted into the section made through the malar bone, whereupon the

bone is seized with Fergusson's lion-jaw forceps and twisted from its

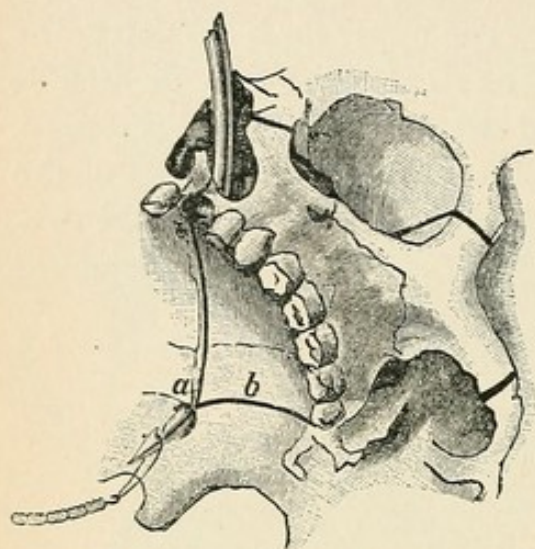


FIG. 417.—Showing line of median bone-section and method of applying chain-saw (after Esmarch).

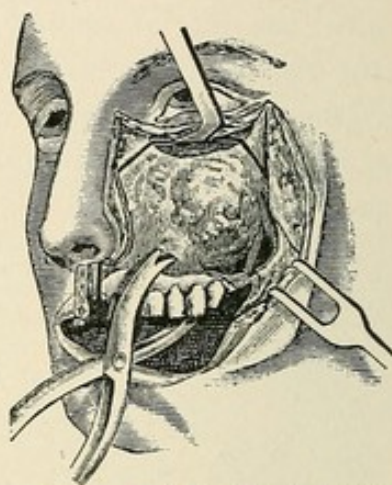


FIG. 418.—Removal of bone with Fergusson's lion-jaw forceps (after Esmarch).

location (Fig. 418). The internal maxillary artery is tied at the bottom

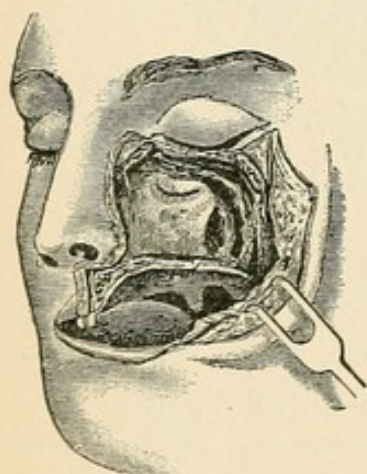


FIG. 419.—Wound-cavity after resection of the upper jaw (after Esmarch).

of the large wound if it bleeds. After hemorrhage has been arrested the cavity of the wound (Fig. 419) is packed with iodoform gauze and the external wound is sutured. Great care is required in the after-treatment. The patient should be kept in a half-sitting position for several days. Frequent use of an antiseptic mouth-wash and careful feeding constitute important features in the after-treatment. The tampon is removed at the end of three or four days, and, after carefully cleansing the wound, is replaced by a smaller one. The writer has frequently dispensed with the chain-saw in resection of the upper jaw, and has

relied on the chisel and strong cutting forceps. The operation, by substituting the chisel for the chain-saw, can be performed in half the time—an important matter in performing the operation without a full general anesthetic. The writer has been in the habit of administering subcutaneously $\frac{1}{4}$ grain of morphia immediately before the anesthetic is administered, and 2 ounces of whiskey by the mouth. As soon as the patient is unconscious the external incision is made, but the sections through the bone are not made until the patient can be roused sufficiently to spit out the blood which accumulates in the mouth. By pursuing this plan there is no danger of the entrance of blood into the bronchial tubes, and, although the patient continues to talk during the

balance of the operation, his recollection of the operation is very imperfect and indefinite—the best proof that the pain experienced was not severe. In some cases of extensive sarcoma of the upper jaw the writer has been obliged to remove the entire malar bone and the septum of the nose, and in several instances has followed the disease as far as the frontal sinus. In two cases, at the time of operation the orbital contents were removed, as the sarcoma had perforated the orbital floor. By using the chisel these additional operations can be done with ease and without adding much to the gravity of the operation.

Mammary Gland.—As compared with carcinoma, sarcoma of the mammary gland is a rare affection. It is met with most frequently in

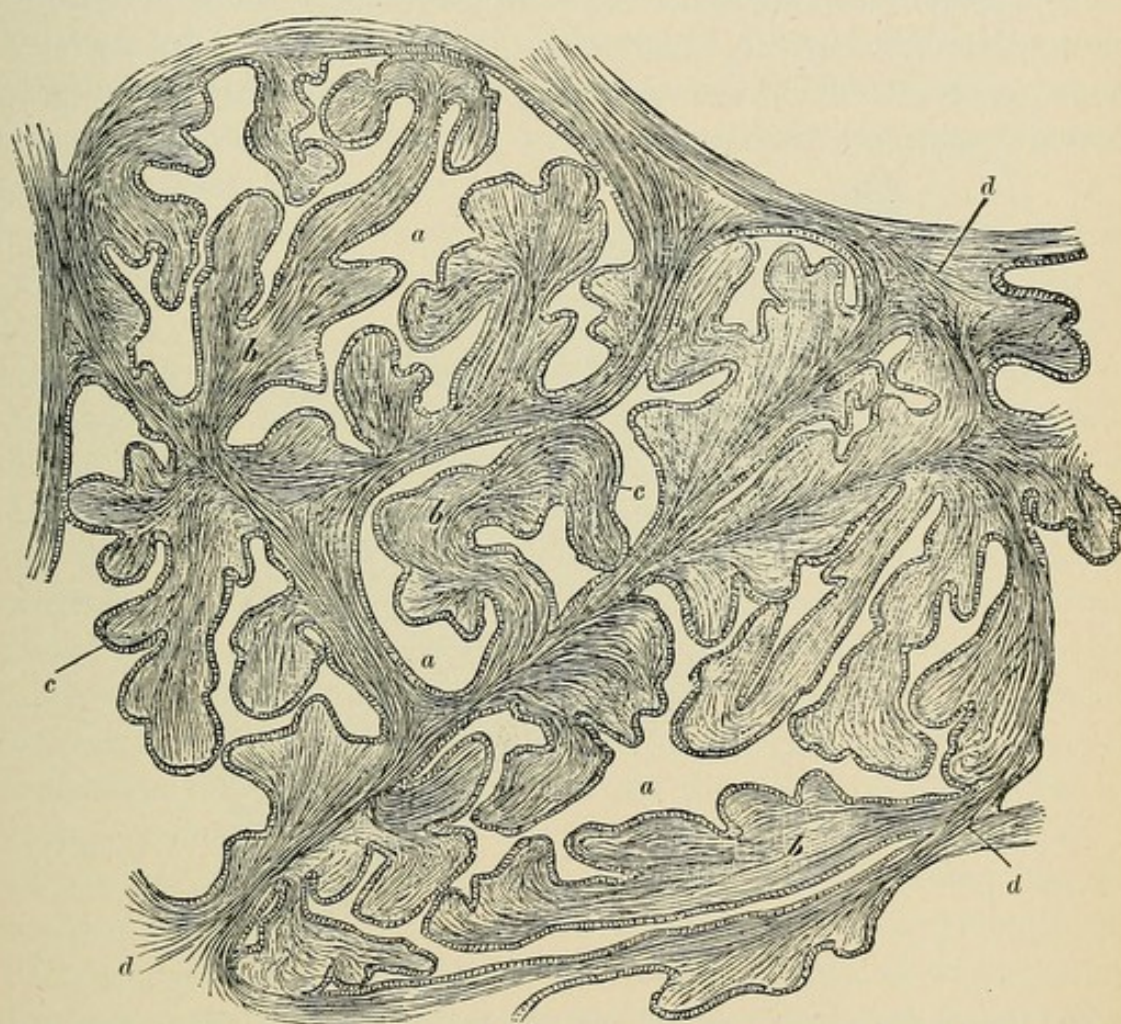


FIG. 420.—Cysto-sarcoma proliferum (after König): *a*, cysts; *b*, proliferating masses of sarcoma-tissue; *c*, cellular lining of cysts; *d*, stroma.

young women. It is composed either of round cells, of spindle-cells, or of a mixture of these two kinds of cells in varying proportions. The tumor begins in the periacinous connective tissue. During the growth of the tumor a part of the acini are destroyed by pressure; the ducts remain open, and as new tumor-tissue is added to their walls they become greatly distended (Fig. 420). In this way the dilated

ducts, compressed by the tumor-masses, become spaces which contain a mucoid material, and which are encroached upon by leaf-like masses of tumor-tissue. Virchow compares the appearance of sections of the tumor to that of a cabbage-head. The cyst-walls project into the spaces in the form of papillomatous dendritic branching formations. At other times the walls are perforated by the tumor-tissue, which then appears in the spaces as polypoid leaf-like masses. Johannes Mueller applied to this tumor the term *cysto-sarcoma proliferum phyllodes* (Fig. 421), and Astley Cooper called it "hydatid tumor." The pericanalicular proliferation projects into the dilated ducts and constitutes, with the intracanalicular excrescences, the proliferating masses. Gland-tissue is sometimes found in the tumor-substance which has grown around it, but it is soon removed by degeneration and by pressure-atrophy. The stroma of the tumor is very apt to undergo myxomatous degeneration.

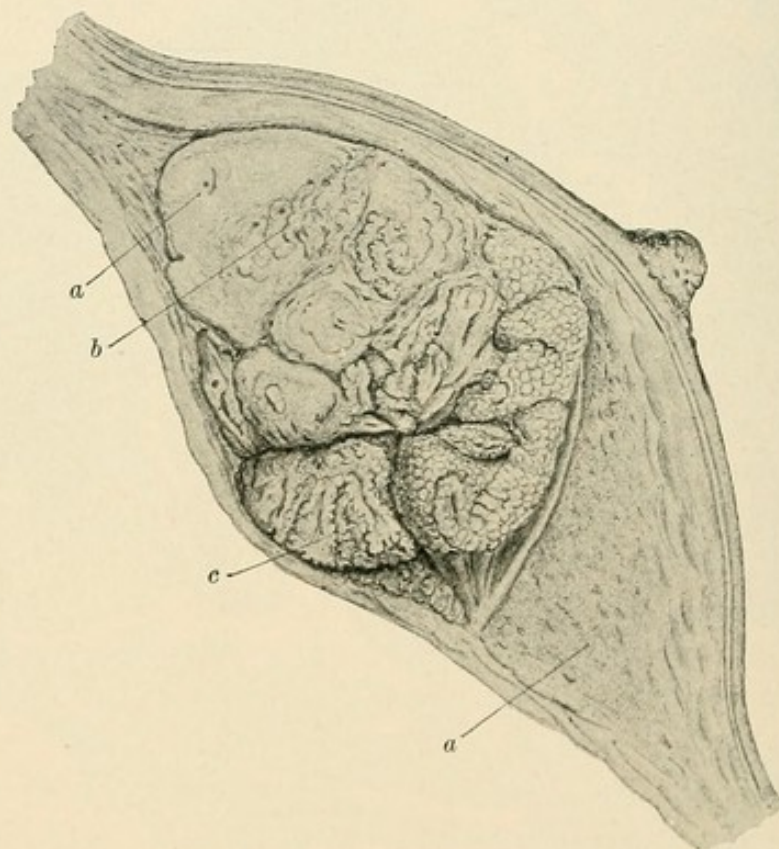


FIG. 421.—*Cysto-sarcoma proliferum phyllodes*; two-thirds natural size (after Haeckel): *a*, normal gland-tissue; *b*, myxomatous part; *c*, great proliferation in a cyst.

Round-celled sarcoma grows very rapidly; the tumor is soft (medullary sarcoma), and life is often destroyed in three or four months after the discovery of the tumor. The rapidity with which such tumors grow has often led surgeons to mistake them for abscesses, and abscesses have not infrequently been mistaken for sarcomata. A few years ago a woman forty years of age was sent to the writer by an able practitioner with the diagnosis of sarcoma. The enlargement

of the breast had begun two months before, had increased slowly, and was not attended by any considerable pain. The breast was the size of a child's head, smooth, and fluctuated on deep palpation. The skin over the swelling was movable and only slightly discolored. As the swelling came on some time after the patient ceased to nurse her child, the writer was led to resort to an exploratory puncture, and, somewhat to his astonishment, pus was withdrawn. The case revealed itself as a subacute submammary abscess. The cases are perhaps more frequent in which a rapid-growing sarcoma is mistaken for an abscess. The bistoury has often been plunged into such tumors with the intention of opening an abscess, when, to the great chagrin of the operator, only blood escaped. A puncture made under such circumstances often does an incalculable amount of mischief. It becomes the starting-point of ulceration and sloughing, which convert the subcutaneous sarcoma into a fungous bleeding mass and initiates the danger incident to suppuration, sepsis, and pyemia.

In spindle-celled sarcoma the tumor is firm, and regional and general dissemination is a later occurrence. Firm tumors are also less subject to cystic and myxomatous degeneration. Sarcoma of the breast manifests itself clinically as a rapid-growing tumor with a smooth surface, and it is more movable than sarcoma. The rapidity of growth distinguishes it sufficiently from adenoma, fibroma, and cystoma. The absence of cicatricial contraction in sarcomata explains why the nipple and the skin over the tumors are not retracted, as is often the case in carcinoma of the breast. Sarcoma of the breast is not attended by pain. The tumor attains greater size before it ulcerates than does carcinoma. In very rare instances patients suffer from sarcoma and carcinoma at the same time. Billroth relates an instance in which one breast was the seat of a carcinoma, and the other of a sarcoma. As young round-celled sarcoma-tissue resembles granulation-tissue, the microscope cannot be relied upon in making a differential diagnosis between sarcoma and chronic infective swellings. Enlargement of the axillary glands, so constantly observed in carcinoma, is seldom seen in sarcoma of the breast. After the tumor has perforated the capsule of the gland regional infection takes place in the direction of the connective-tissue spaces. Chronic suppurative mastitis and submammary abscess can be distinguished from sarcoma by resorting to an exploratory puncture.

The proper treatment in cases of sarcoma of the breast is an early and thorough excision. If the disease has not extended beyond the limits of the gland, the prospects of a radical cure are better in sarcoma than in carcinoma. It is essential not only to remove the

entire gland, but also to include with it the overlying skin and as much of the periglandular connective tissue as may be deemed necessary. As regional infection is very prone to extend along the connective tissue accompanying the axillary glands from the margin of the breast, the writer has been in the habit of laying the axilla freely open and clearing it out much in the same way as in operations for carcinoma, removing at the same time the fascia of the pectoralis major and the serratus magnus muscles. By undermining the skin for some distance on both sides and using tension-sutures the wound can usually be closed throughout: this procedure should be carried out whenever it is practicable in all operations for malignant disease of the breast.

In cases beyond the reach of a radical operation, treatment by subcutaneous injections of the sterilized toxines of the streptococcus of erysipelas recommends itself. Partial operations in sarcoma of the breast are not permissible, as they invariably increase the malignancy of the remaining portion of the tumor. In open fungous tumors the employment of strong antiseptic solutions will accomplish much in diminishing the intensity of the fetor and in retarding the sloughing process.

Thymus Gland.—Virchow pointed out that sarcomatous tumors of the anterior mediastinum having a regular outline are usually thymic in their origin; and recent observers, especially Letulle, have argued for a still more frequent recurrence of this place of origin than Virchow believed. In a paper on "The Clinical Study of Intrathoracic Tumors," by Pepper and Stengel, allusion is made to three cases of sarcoma of the thymus gland that came under the observation of the authors. As in the histological structure of this gland the lymphatic tissue is greatly in excess of the epithelial cells, it is to be expected that it would be more frequently the seat of mesoblastic than epithelial tumors.

Sarcoma of the thymus gland occurs more frequently in young adults than in persons advanced in years; but old age is not exempt, as in one of Pepper's cases the patient was fifty-six years of age. The tumor by its progressive growth gives rise to gradually increasing pressure-symptoms, upon which the physician must largely rely in making a probable diagnosis, combined with a careful study of the physical signs.

Salivary Glands.—The parotid gland is more frequently the seat of sarcoma than the submaxillary gland. The tumor presents itself as a smooth or lobulated, rapid-growing mass, which in a short time involves the entire gland, and after perforation of its capsule extends in all directions, notably beneath the sterno-mastoid muscle

toward the pharynx and the external ear, very frequently implicating the facial nerve as it issues from the stylo-mastoid foramen. The writer has seen two cases of parotid sarcoma in which the facial nerve was completely paralyzed at the time of the operation. In each instance it was found that the tumor had extended to the point of exit of the nerve from the stylo-mastoid foramen. Billroth estimated that three-fourths of all tumors of the parotid gland are of a sarcomatous nature. The largest number of patients suffering from parotid sarcoma are between thirty and forty years of age. Of the cases which have come under the writer's observation, the youngest was twenty-five and the oldest seventy-two years of age. Kaufmann, who has investigated the histology of sarcomatous tumors of the parotid gland more thoroughly than any other author, classifies these tumors, according to their structure, into pure sarcomata, fibro-sarcomata, myxo-sarcomata, and chondro-sarcomata. The pure sarcomata are composed either of round cells or of spindle-cells, and are encapsulated from the beginning. Fibro-sarcomata appear as hard, smooth, or lobulated tumors composed of spindle-cells. The tumors are also encapsulated, and the results of operation in this as well as in the first variety are favorable. Myxo-sarcomata often grow to the size of a child's head. The tumors are round and soft; the tissue is of a yellowish or reddish tint. The tumors contain myxoma-cells, spindle-cells, and round cells.

Chondro-sarcomata present a nodulated surface. From the capsule bundles of interlacing fibres extend into the substance of the tumor. The cartilage-tissue appears in islands dispersed throughout the tumor, some of them being as large as peas.

The great variety in the histological structure of sarcoma of the parotid renders the diagnosis often very difficult. From benign tumors it can be differentiated by the rapidity with which the tumor grows and by the regularity with which it extends ultimately beyond the limits of the gland. In carcinoma of the parotid lymphatic infection is observed at an early stage; in sarcoma regional infection takes place through the periglandular connective tissue. It is more probable that in chondro-sarcoma the islands of cartilage-tissue are formed from chondroblasts derived from the pinna and deposited in the substance of the parotid gland, than that they result from a development of sarcoma-tissue into tissue of a higher physiological type. In the more benign forms of sarcoma of the parotid extirpation of the tumor should be performed without division of the facial nerve. If the tumor grows rapidly or if it has involved the entire gland, a radical operation is necessarily followed by permanent facial paralysis. The technique of

the operation has been described fully in connection with Carcinoma of the Parotid Gland. In sarcoma of the submaxillary gland the whole gland and the surrounding connective tissue should be removed with the tumor.

Tongue.—Butlin regards sarcoma of the tongue as an exceedingly rare affection. Mr. Targett reports a case in which, in a patient twenty-five years of age, a sarcoma developed on the under portion of the left side of the tongue, involving at the same time the floor of the mouth. The tumor appeared as a hard, painless mass, and the mucous membrane over it was not ulcerated. It was removed through an incision of the cheek extending in a backward direction from the left angle of the mouth. Examination of sections of the tumor under the microscope showed it to be a round-celled sarcoma. In fifteen months it returned in the left submaxillary region and below the zygoma of the right side. Mr. Targett gives the history of two additional cases which occurred in Guy's Hospital. Sarcoma of the tongue must be distinguished from carcinoma, tuberculosis, gumma, and actinomycosis.

Tonsil.—Sarcoma of the tonsil is of more frequent occurrence than carcinoma. It also grows more rapidly and attains larger size before ulceration occurs than does carcinoma. Infection of the deep lymphatic glands, of such constant occurrence in carcinoma and primary syphilis, is absent in sarcoma. Excision of the tumor through Cheever's or Kocher's incision is the only proper surgical treatment, and should be done if all the diseased tissue can be removed and no indications of metastasis are present.

Intestinal Canal.—Sarcoma of the intestinal canal as compared with carcinoma is an extremely rare affection. It occurs most frequently in the upper part of the small intestines, about the ileo-cecal region, the colon, and the rectum. Rokitansky described spindle-celled sarcoma of the intestines that projected in a nodulated form into the lumen of the bowel. Billroth and Esmarch have reported cases of alveolar sarcoma of the rectum. Frerichs and Meyer have seen specimens of melano-sarcoma involving the intestinal canal. A sarcoma of the intestines never comes to the attention of the surgeon until the tumor has given rise to some form of intestinal obstruction. A sarcoma produces intestinal obstruction either by the tumor-mass filling the lumen of the bowel, by invagination, or by volvulus, and never by cicatricial contraction, as is so often the case in circular carcinoma. Sarcoma of the intestines begins in the submucous connective tissue, and is composed either of spindle-cells or of round cells; in both varieties and in mixed-cell sarcoma myxomatous degeneration is

a constant and early occurrence. A correct diagnosis is only made in the operating- or the post-mortem room.

If in operating for intestinal obstruction a sarcoma is found as its cause, an enterectomy is indicated if the tumor has not extended beyond the intestinal wall; if this extension has taken place, a radical operation is out of the question, and the surgeon must content himself with making an artificial anus above the tumor, or, what is better, an intestinal anastomosis.

Omentum.—The great omentum is occasionally the seat of primary sarcoma, and the tumor in this locality often attains an enormous size. The writer removed, in a man fifty years of age, the entire omentum for a tumor that weighed over thirty pounds.

Kidney.—Sarcoma of the kidney is more common than carcinoma. It is met with most frequently in children and young adults. The growth of the tumor is rapid, and the tumor usually reaches an enormous size before it destroys life. The mass is smooth, and pseudo-fluctuation is generally present. The tumor is composed usually of round cells. The malignancy of sarcoma of the kidney is very great, and recurrence after extirpation of the kidney is the rule.

Diagnosis.—The diagnosis of sarcoma of the kidney is usually not very difficult. The only affections for which it is liable to be mistaken are hydronephrosis, pyonephrosis, and on the right side a distended gall-bladder. Hemorrhage from the kidney in sarcoma occurs frequently, and its occurrence in children is very suggestive of malignant disease of the kidney. The retroperitoneal location of the tumor can be determined positively by inflation of the colon. If the tumor is intra-peritoneal, it will be displaced by the distended colon; if it is retroperitoneal, the tumor can be felt less distinctly in front, and where dulness existed before the inflation there is resonance due to the location of the distended colon in front of the kidney. Soft sarcomata of the kidney present pseudo-fluctuation on palpation, and if a large cyst occupies the anterior surface of the kidney, true fluctuation can be felt. In some cases tumor-tissue escapes with the urine, and examination under the microscope will be of great value in rendering the diagnosis positive. Buhl in his lectures on pathological anatomy used to cite and show a specimen in which the sarcoma-tissue extended from the pelvis of the kidney in a string-like projection to the meatus urinarius. In hydro-nephrosis and pyonephrosis, if any doubt exists between these affections and sarcoma, an exploratory puncture through the lumbar region is harmless, and will enable the surgeon to make a positive diagnosis. If the tumor is large, it can be felt immediately under the abdominal wall, when it feels like the back of a turtle. Ascites is usually present.

Extension to other organs and over the peritoneal surfaces is of common occurrence. If the disease is limited to the omentum, a radical operation is indicated.

Girls appear to be more predisposed to primary sarcoma of the kidney than boys. The tumor is composed of spindle-cells and large and small round cells. The origin from a matrix of embryonal cells is well shown in sarcoma of the kidney by the frequency with which striped muscular fibres are found in the tumor. Sarcoma of the kidney grows very rapidly and often reaches an enormous size. Tumors weighing ten pounds are not rare. The tumor is usually soft, and

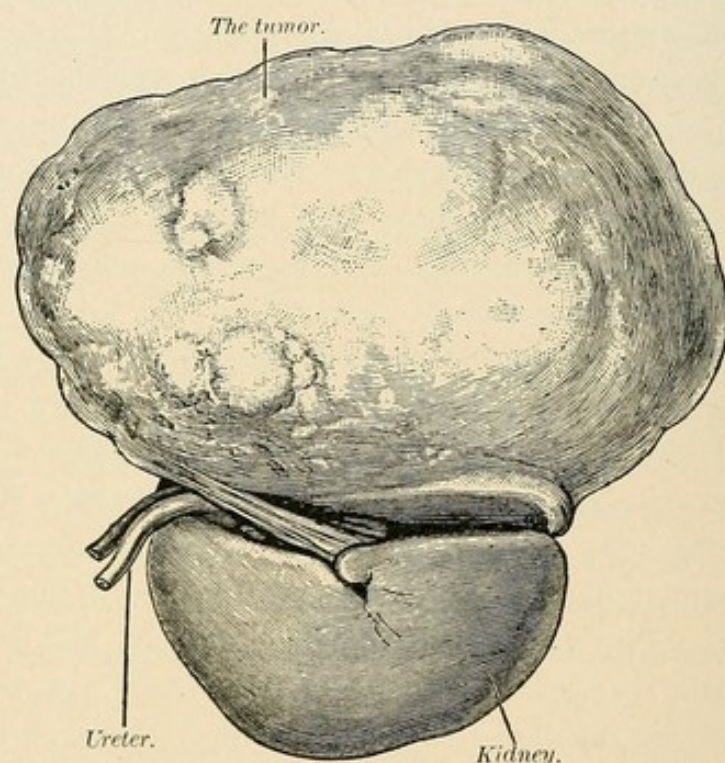
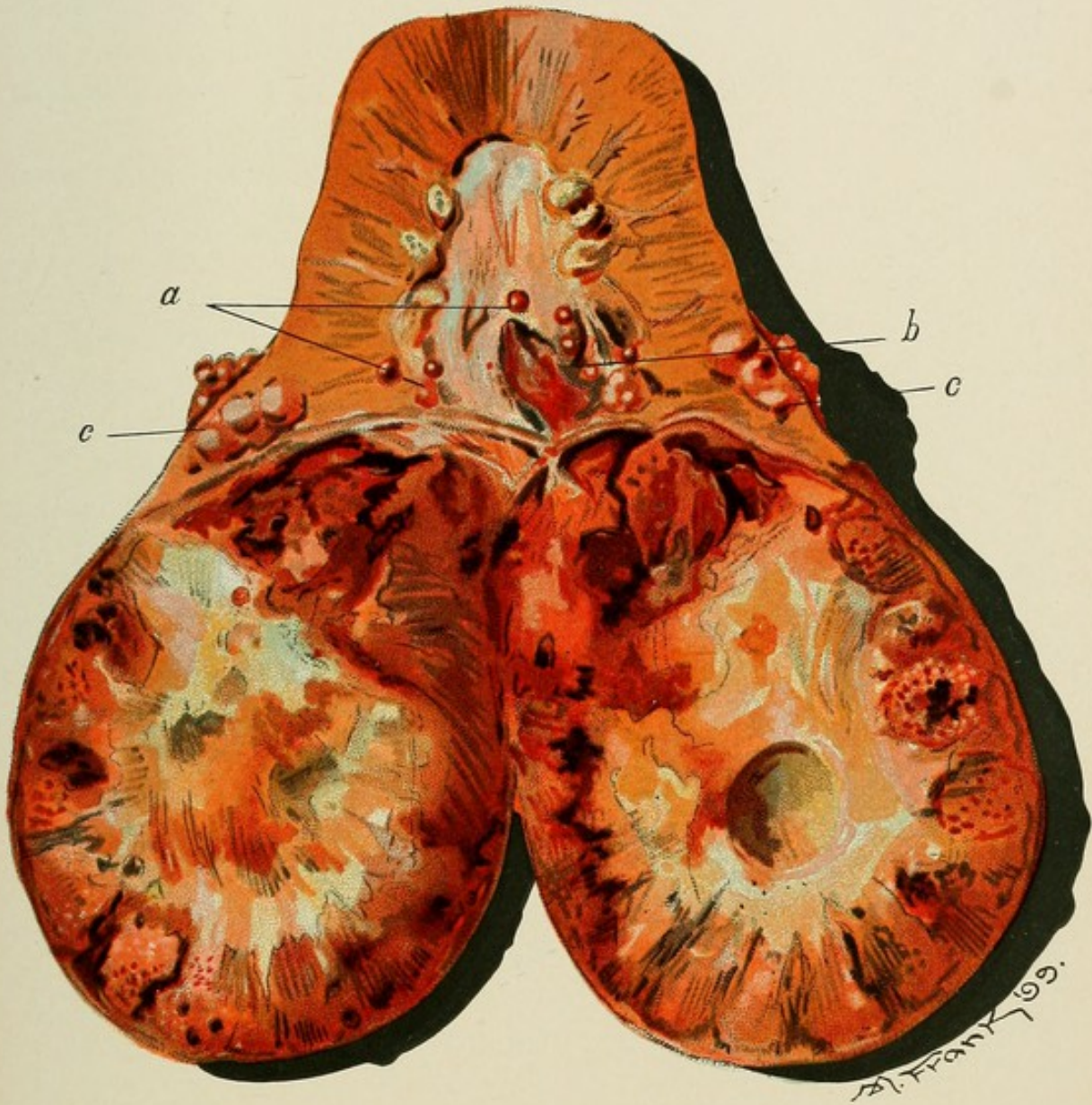



FIG. 422.—Renal tumor originating in an accessory adrenal (after Henry Morris).

cysts, large and small, are common. Hemorrhage into the cysts occurs frequently. In pyonephrosis an examination of the urine will throw much light on the kidney affection, and in case the ureter is completely obstructed, lumbar exploratory puncture will demonstrate the presence of pus in the pelvis of the kidney. In two cases of sarcoma of the kidney the writer found a large renal calculus in the pelvis. In one case the calculus was a perfect mould of the dilated pelvis and was in direct contact with the tumor-tissue. It is a question whether the calculus acted as an exciting cause of the tumor or whether it developed in consequence of the tumor.

Treatment.—As sarcoma of the kidney destroys life in such a short time, an early operation is indicated, provided the opposite kidney is in a healthy condition. This question can be determined by a careful



Sarcoma of the kidney. Nephrectomy. Recovery. *a*, Secondary tumors; *b*, polypoid projection of primary tumor into the pelvis of the kidney; *c, c*, invasion by tumor of the adjacent kidney-substance (St. Joseph's Hospital, Chicago).



analysis of the urine, and in females by catheterization of the ureter with Kelly's catheter. The mortality after the operation has been great. According to S. W. Gross, of 64 nephrectomies for malignant disease, 33 died—a mortality of 52.45 per cent. A number of the cases died later of metastasis or local recurrence, so that of all the cases, only 5 were alive and well two years after the operation. Notwithstanding these discouraging results, it is the duty of the surgeon to operate if the patient's strength is such as to warrant the operation, and if no indications are present that the tumor has extended beyond the organ primarily affected. Age is no contraindication to the operation. Steele of Chicago in 1894 successfully removed an enormous sarcoma of the kidney from a child only a little more than a year old. The child not only recovered from the operation, but afterward gained in general health. The mortality of intraperitoneal operation is over 50 per cent.; that of lumbar nephrectomy, about 25 per cent. *If the tumor is not too large to be removed through a lumbar incision, this method of operating should invariably be resorted to.* König's incision is the one that should be selected, as it affords more room than Simon's and inflicts less traumatism than Bardenheuer's. Tumors too large for the lumbar operation should be removed by an incision through the linea semilunaris. A tumor that is too large to be removed by lumbar nephrectomy cannot be removed by an extraperitoneal operation through an anterior incision, as has been claimed by some surgeons. If an extraperitoneal operation in part is attempted, the peritoneum will surely be torn during the operation. The external border of the rectus muscle serves as a guide in making the incision. The incision through the abdominal wall is made in the usual manner. After the abdominal cavity has been opened to the requisite extent, the kidney, covered by the parietal peritoneum, will at once come in view. The intestines are kept out of the way by aseptic gauze compresses. The peritoneum, covering the tumor is then carefully incised, and when the capsule of the kidney has been identified the kidney with the tumor is enucleated. If the hilum of the kidney cannot easily be reached, and the vessels and the ureter cannot be tied separately, these structures are grasped with a covered compression-forceps, the kidney is removed, and the ureter and the vessels are tied later. After arresting all hemorrhage the peritoneal incision through which the kidney was removed is carefully closed with fine silk or catgut sutures, and the external wound is closed in the usual manner. As the incision has been made through the abdominal muscles, at least four rows of sutures should be employed in closing the external incision. If for any reason it is deemed necessary to drain the retroperitoneal wound, a counter-opening should be

made in the lumbar region by tunnelling the tissues with a pair of strong and long hemostatic forceps from within outward, when the skin in the lumbar region over the point of the instrument is cut, and with the forceps either a tubular drain or a strip of iodoform gauze is drawn through. After this has been done the peritoneal wound and the abdominal incision are dealt with in the manner just described. From a woman thirty-eight years of age the writer removed a sarcoma of the kidney by laparotomy according to the method described. The tumor weighed eight pounds. No outward symptoms followed the operation, and the patient left the hospital at the expiration of five weeks. For several weeks her general health continued to improve, but four months after the operation a local recurrence could clearly be made out. The patient succumbed six months later, ten months after the operation. The tumor in this case was so large that intestinal obstruction was threatened on several occasions. The intestinal symptoms were produced by pressure of the tumor upon the colon. At the time of operation the colon was found in front of the tumor, stretched and flattened by it.

Uterus.—The first case of sarcoma of the uterus was described in 1860 by Mayer. The diagnosis was verified by a microscopical examination of the specimen by Virchow. Soon afterward Langenbeck reported a case of inversion of the sarcomatous uterus. In 1867, Veit was able to find only three recorded cases. In 1871, Keegar based his investigations on sarcoma of the uterus on nine cases which had been reported up to that time.

Diffuse sarcoma of the submucous connective tissue of the endometrium is much more frequent than sarcoma of the muscular wall of the uterus. Of 144 cases collected by Williams, one-third were limited to the mucous membrane of the cavity of the uterus. The tumor occurs as a diffuse infiltration or as a polypoid growth. In the diffuse infiltrating form the tumor is composed of round cells and spindle-cells with a very scanty intercellular substance (Fig. 423).

Klebs and Abel have found in the uterine mucous membrane a combination of carcinoma and sarcoma—a carcino-sarcoma. Diffuse sarcoma of the uterine mucous membrane grows very rapidly, destroying the glands and the mucous membrane and infiltrating the muscular wall of the uterus. Local infection spreads much more rapidly than in carcinoma.

The polypoid variety appears as a firmer tumor and contains more spindle-cells (Fig. 424).

In the more circumscribed form of sarcoma of the uterine mucous

membrane the tumor attains considerable size before it ulcerates and invades at its base the uterine wall (Fig. 425).

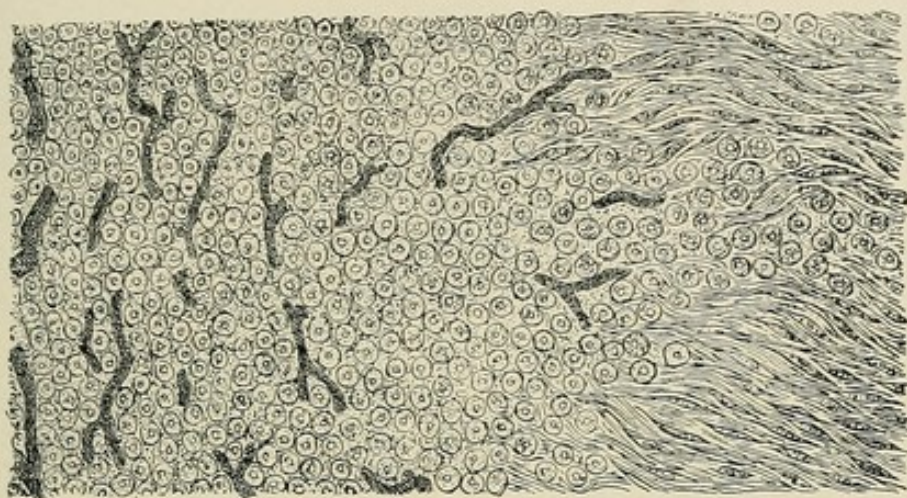


FIG. 423.—Diffuse sarcoma of the uterine mucous membrane (after Wyder). The neoplasm is separated from the peritoneum on the left by a well-marked layer of healthy muscular tissue several millimeters thick; the superficial portions toward the cavity of the uterus, on the right, are beginning to disintegrate. In the deeper parts are seen the connective-tissue fibres, rich in fusiform cells with long and short processes. Between them is an amorphous basement-substance with a large accumulation of cells, the nuclei of which appear to resemble those of the others. In the superficial portions the bands of the connective and muscular tissues have entirely disappeared, being replaced by round cells. The tumor is rich in vessels about which are foci of hemorrhage. In no part of the tumor can we find any trace of mucous membrane or of glands.

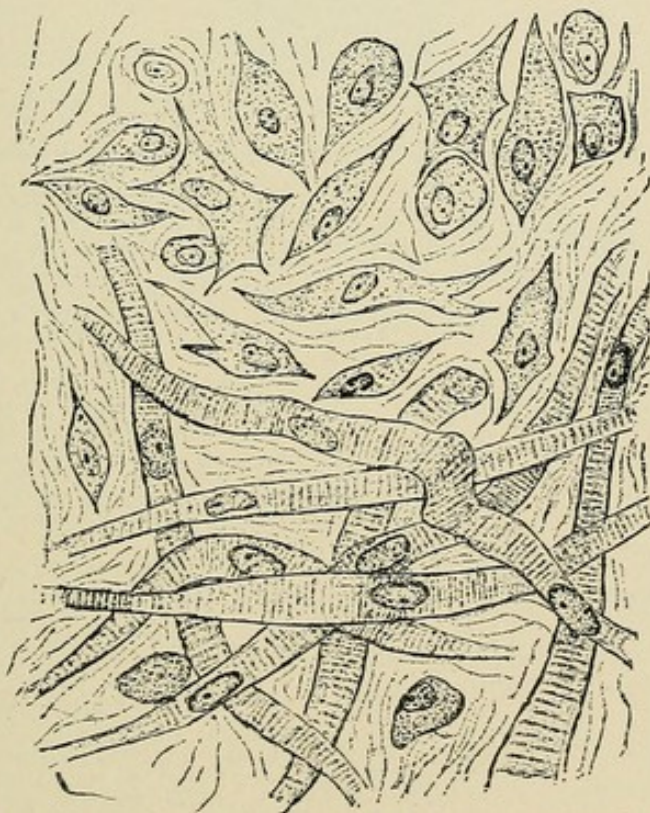


FIG. 424.—Cells from a spindle-celled sarcoma of the neck of the uterus (after Pernice). Some of the cells present a cross-striation.

Sarcoma of the muscular wall of the uterus is also either circumscribed or diffuse. The circumscribed form resembles myoma. In the diffuse variety the whole body of the uterus becomes enlarged.

Cyst-formation by degeneration or dilatation of lymphatics is common in both forms. In a few cases cartilage has been found in uterine sarcomata.

Sarcoma is most frequently met with in young women. It presents many of the clinical aspects of carcinoma. The discharge is, however,

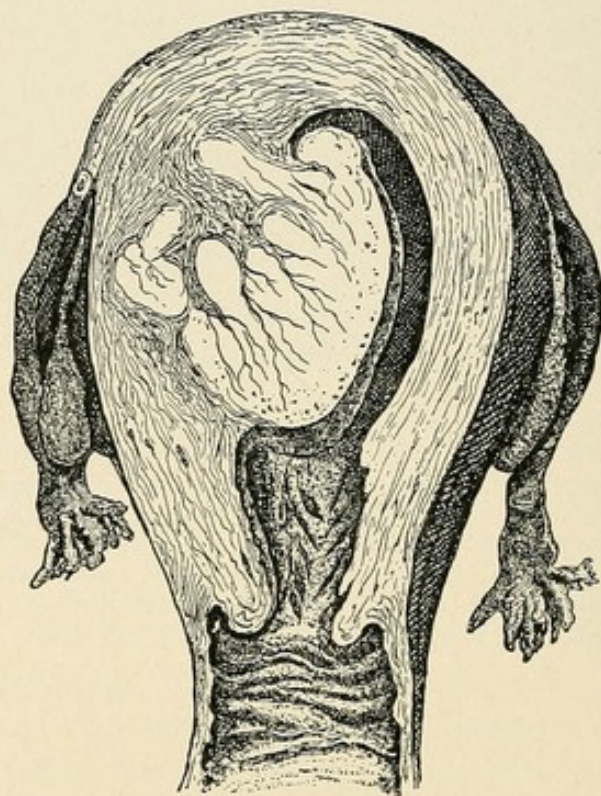


FIG. 425.—Sarcoma of the uterine mucous membrane (after Pozzi).

less fetid during the early stages, ulceration appears later, and the cervix is not so much dilated as in carcinoma. Infection of the retro-uterine glands, so common in advanced cases of uterine carcinoma, is absent in sarcoma.

The prospects of a permanent cure by operation are not so good in sarcoma as in carcinoma, as recurrence has followed early operations. Vaginal hysterectomy is indicated in all cases in which the sarcoma has not extended beyond the uterus.

Deciduoma Malignum.—This is a malignant tumor of the chorionic villi, first described by Säger in 1888. Since that time it has been described by different authors; and in 1895, when J. W. Williams wrote on this subject, he found 25 cases recorded, including his own. Histologically, this tumor differs according to the structure and nature of the cells of which it is composed. In some cases the tumor presented a carcinomatous structure, in others the structure corresponded with sarcoma, and in rare cases a combination of sarcoma and carcinoma. In the majority of cases, however, the sarcomatous nature of the tumor was unquestionable. In the sarcomatous form the tumor is composed

of spindle-shaped cells, containing large nuclei and polygonal or round multinuclear cells, with a very scanty or no well-defined reticulum. Pregnancy is the most important etiological element; all the cases having followed labor at full term, abortions, or hydatiform moles. Sanger divides the cases into two groups, according as they followed hydatiform moles or pregnancy. The age of the patients varied from seventeen to fifty-five years; the largest number of patients were between twenty and thirty years of age. The most important symptom is uterine hemorrhage following some form of pregnancy. The hemorrhage, as a rule, is not continuous, and appears either soon after delivery or some months later. The uterus is enlarged in proportion to the size of the tumor, and its walls are infiltrated by the growth. Recurrence after removal of the mass is the rule. The tumor gives rise to early and diffuse metastases. Secondary vaginal tumors constitute a characteristic clinical feature of this disease. The prognosis is very grave, as death usually occurs within six months from the appearance of the first symptoms. In the diagnosis the clinical history of the case, uterine hemorrhages, and vaginal metastases are the most important evidences to be taken into consideration. As the disease is so rapidly fatal, and, as a rule, the patients do not come under the care of a surgeon before metastasis has taken place, the treatment is of necessity only of a palliative nature. If the disease could be recognized before it has resulted in metastases, complete removal of the uterus would offer a fair chance of permanent recovery. Of eight hysterectomies performed for this condition, four died from recurrence of the growth; the other four recovered from the operation, but sufficient time has not elapsed to show that the operation proved curative.

Ovary.—Sarcoma of the ovary is of rare occurrence. Cohn estimates its frequency at about 1 per cent. in relation to cystic disease. It is usually bilateral, and it gives rise to ascites at an early stage. It is composed of spindle-cells or of round cells, the former variety being more frequent. According to Eckhardt and Pomorski, many sarcomata are of endothelial origin, springing from lymphatics or from blood-vessels (Figs. 426, 427).

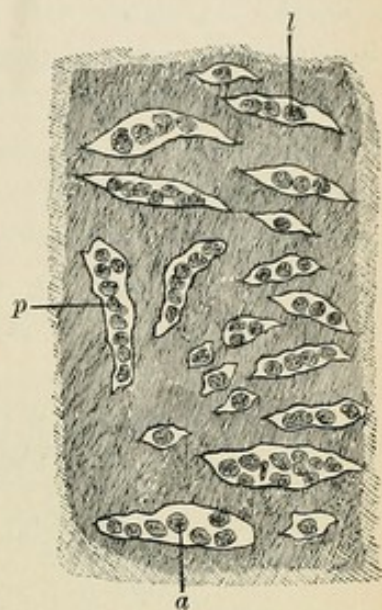


FIG. 426.—Endothelioma of the ovary; commencing proliferation of endothelium in the lymphatic spaces (after Pomorski): *l*, lymphatic space, with endothelial cells in the midst of an interstitial substance of the nature of connective tissue; *a*, alveolar dilatation of lymphatic space; *p*, proliferation of cells, which arrange themselves like a row of beads. (Hartnack; oc. 3, ob. 7.)

The symptoms of an ovarian sarcoma are those of rapidly-developing malignant tumors. The tumor is found in preference in young women. Ascites with hard nodular masses on one or both sides of the uterus should arouse suspicion regarding the malignant nature of the pelvic difficulty. The extension of the tumor to the tissues outside the tumor often renders an operation very difficult and results in early local recurrence. If the tumor is removed before it has extended to the broad ligament, the uterus, and other adjacent parts, a permanent cure is possible. Braun removed a sarcoma of the

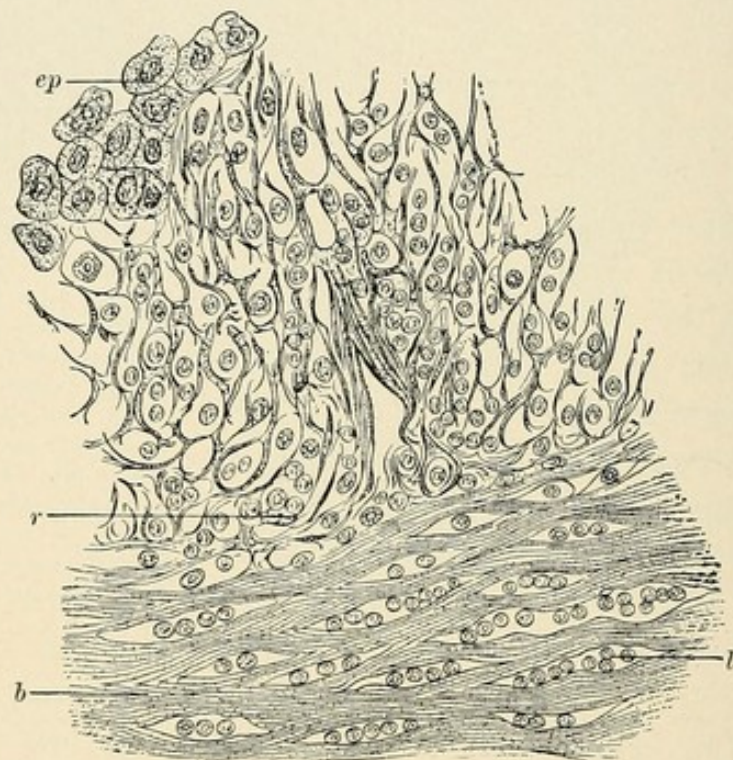


FIG. 427.—Endothelioma of the ovary; reticular modification of connective tissue under the influence of the endothelial proliferation (after Pomorski): *l*, lymphatic space elongated and becoming transformed into an alveolus; *b*, bundles of interstitial connective tissue; *r*, transformation of fibrous connective tissue in a reticulum; *ep*, transformation of epithelial cells into epithelioid cells; connection of the large cells with the ground-substance. (Magnification same as that of Figure 426.)

ovary, and the patient remained in good health eleven years after the operation.

Of 36 cases of ovarian sarcoma recently collected by Zangenmeister, and which were subjected to radical treatment, 4 died from the immediate and 3 from the remote effects of the operation, 3 from metastasis, 3 from local recurrence; in 6 cases the ultimate result could not be ascertained; 11 remained in good health and free from recurrence over four years, 2 after two years, and 1 died sixteen years after the operation from other causes.

Vagina.—Sarcoma of the vagina is found as a diffuse affection in children; in the adult it presents itself as a firm, circumscribed tumor manifesting little tendency to degeneration. As pathological curiosities

in this location there must be mentioned sarcomatous tumors, containing striated muscular fibres, and melanotic carcinoma.

Vulva.—Among 10,000 patients Winckel saw only 2 cases of sarcoma of the vulva. In one case the tumor was as large as a man's head, and was attached to the vulva by a pedicle the size of a child's arm. The patient was then twenty-five years of age. The tumor, which was first noticed when she was seventeen years old, was removed, and microscopical examination showed that it was a round-cell sarcoma. In the second case the patient was a multipara forty-six years of age. The tumor, which was as large as a child's head, sessile, hard, and lobulated, was removed, and examination showed it to be a myxo-sarcoma. Hildebrandt reports two similar cases. Other cases have been recorded by Kleeberg and by Gustav Simon.

Testicle.—Sarcoma of the testicle is not of frequent occurrence. Virchow maintains that it is found most frequently in children, boys, and old men. The writer has seen several cases of sarcoma in men from twenty to forty years of age. The tumor is composed of spindle-cells or of round cells, or it presents itself as a mixed-cell tumor. The round cells are very large and are often multinuclear. The tumor is quite firm, and on section presents a yellowish- or grayish-red color. It frequently begins in the epididymis. As the tumor increases in size the parenchyma of the testicle is displaced and destroyed. If perforation of the tunica albuginea has taken place, the tumor grows very rapidly. Extension along the spermatic cord results in speedy and extensive regional infection. Metastasis frequently precedes the fatal termination. Very often the same affection appears in the opposite testicle.

In the differential diagnosis of sarcoma of the testicle it is important to exclude carcinoma, tuberculosis, gumma, and hematocele. Figure 428 represents a sarcoma of the testicle that occurred in a child three and a half years old, and which was carefully reported by Neumann.

Castration is indicated if the spermatic cord is not affected or if the diseased part of the cord can be removed. In all operations for malignant disease the cord should be removed as high as possible. For this purpose the inguinal canal should be laid open, and by gradual traction as much of the cord as practicable should be brought down and liberated. Enlargement of the retroperi-

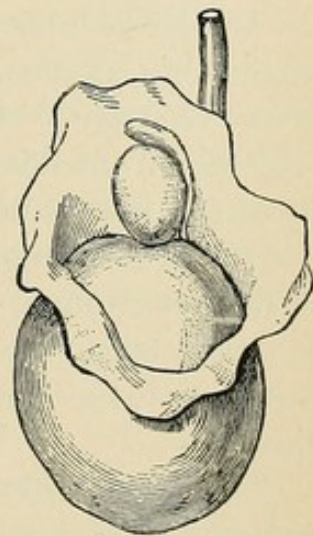


FIG. 428.—Myosarcoma of the testis (after Neumann).

toneal glands in the inguinal region contraindicates castration. Some of the sarcomatous tumors of the testicle contain striated muscular fibres, and in very rare cases the tumor is pigmented.

Brain and its Envelopes.—In the brain we have described, as peculiar varieties of sarcoma, psammoma and glioma. The dura mater is not infrequently the starting-point of sarcoma. The tumor destroys the bone over it, and appears, after perforation has taken place, as a pulsating tumor.

Operative treatment is contraindicated in psammoma and is of doubtful propriety in glioma. Bergmann for good reasons opposes intracranial operation for malignant disease. Surgeons, however, will continue to operate for glioma, as the tumor frequently produces focal symptoms which enable them to locate it with precision, and a positive diagnosis is usually made only after the tumor has been exposed or after operation, by examination of sections of the tumor under the microscope.

Sarcoma of the dura mater, if it could be diagnosed at an early stage, should be removed by operation. After the tumor has perforated the skull the intracranial part of the tumor is usually so extensive that an operation would prove of no avail.

Eye.—The optic nerve and its branches are not infrequently the seat of glioma. In the interior of the eye the malignant tumors are represented by melano-carcinoma and melano-sarcoma, the latter being much the more frequent. Pigmented sarcoma may arise from any part of the uveal tract—that is, from the pigmented tissue of the iris, the ciliary body, and the choroid. The commonest seat is the choroid.

The intraocular sarcomata are either round-celled, spindle-celled, or mixed-cell sarcoma. Sarcoma of the eye occurs most frequently in persons from forty to sixty years of age, but is occasionally seen in children. The tumor extends along the blood-vessels and the optic nerve. The increased intraocular tension results in sloughing of the cornea, when the tumor protrudes in the form of a pigmented fungous mass. Extension of the tumor along the optic nerve into the cranial cavity does not often take place. Metastasis at quite an early stage is of frequent occurrence, the tumor in this respect resembling melano-sarcoma of the skin.

Early enucleation is the only surgical resource in all cases of melano-sarcoma of the interior of the eye. This operation should be performed as soon as the tumor can be detected and diagnosed by the aid of the ophthalmoscope.

Bladder.—Sarcoma is a very rare affection of the bladder, and most of the cases so far reported were in young females. Küster

reported five cases, and one case came under the observation of König, who removed a pedunculated round-celled sarcoma the size of a hen's egg from the neck of the bladder by perineal section. Sarcoma in the bladder, in its structure and its manner of local extension, very closely resembles sarcoma of the uterus. It starts most frequently in the submucous connective tissue. In the differential diagnosis between sarcoma and carcinoma of the bladder it is important to remember that sarcoma is much the more rare, that it is found in preference in young females, and that ulceration occurs later than in sarcoma. The differential diagnosis between sarcoma of the bladder and benign tumors, and the treatment, are the same as in carcinoma.

Prostate.—Malignant tumors of the prostate start primarily in this organ, as the prostate is seldom affected secondarily either by extension of the tumor from an adjacent organ or by metastasis. Wyss collected 28 cases of malignant disease of the prostate in young boys less than ten years old. In all of the cases the prostate was the primary seat of the tumor. The symptoms resemble those of carcinoma of the same organ. Thompson has reported 18 cases of primary malignant tumors of the prostate. Kapuste has shown by his investigations that tumors of the prostate in children are usually sarcomatous, while carcinoma of this organ is a disease of advanced age. Besides the functional disturbances produced by the tumor, spontaneous pain, hemorrhages, and the escape of fragments of the tumor after ulceration has set in are the most conspicuous clinical phenomena.

Radical operations for tumors of the prostate have been performed by Billroth, Demarquay, Nussbaum, and others. In Nussbaum's and Billroth's cases a part of the rectum was removed with the prostate and a part of the bladder-wall. If the disease has not extended beyond the prostate—and these are the cases to which radical operations should be restricted—the prostate and as much of the neck of the bladder as is endangered by the tumor should be removed through the perineal incision devised by Zuckerkandl. The efficiency and safety of the operation would be enhanced by a preliminary suprapubic cystotomy.

XXIX. TERATOMA.

So far we have considered tumors composed of a single representative histological element. We have studied tumors composed of cells derived from one of the germinal layers—the epiblast, the hypoblast, and the mesoblast—and have found that the different classes of tumors represented the tissues of only one of these embryonal layers. The epiblast and the hypoblast were represented by papilloma, adenoma, and carcinoma; the mesoblast, by the different tumors representing the connective-tissue type of benign tumors and sarcoma. We now come to the last class of tumors that contain tissues and organs derived from two or all of the germinal layers.

Definition.—*A teratoma is a tumor composed of various tissues, organs, or systems of organs which do not normally exist at the place where the tumor grows. The highest type of a teratoma is a fetus in fetu. In the simpler varieties the tumor is composed of heterotopic tissues, such as bone, teeth, skin, mucous membrane, etc. All teratoid tumors are congenital; that is, the tumor either exists at the time of birth or the patient is born with the essential tumor-matrix. A teratoma never springs from a matrix of post-natal origin.*

Origin of Teratoid Tumors.—A tumor composed of a single representative histological element frequently starts from a matrix of post-natal origin, as the writer has aimed to show in connection with all the tumors so far discussed; but the more complicated matrix of a teratoma has invariably a congenital origin, and is produced in the embryo by errors of growth and by displacement of tissue by inclusion. Klebs classifies teratoma according to their origin into endogenous and ectogenous, the former arising from a matrix formed in the same individual, the latter from foetal inclusion. The latter mode of origin is possible, but certainly very rare. A case of this kind was recently reported from Gussenbauer's clinic by Pupovac. The patient was an infant, and the congenital tumor involved the side of the neck. Examination of the tumor showed embryonic tissue representing different parts of the body—bone, cartilage, muscle-, gland-, and brain-tissue. One of the strongest arguments in support of the correctness of Cohnheim's theory concerning the origin of tumors is furnished by the teratomata. Maas succeeded in producing dermoid cysts artificially in animals by implan-

tation of dermoid fetal tissue. He produced dermoid cysts in young rats by introducing into the peritoneal cavity pieces of skin and parts of limbs of new-born rats. After two and a half months he found small cysts containing pus, cholesterin, and hair. The lining of these cysts was composed of tissues representing all the histological elements of true skin.

A great deal of speculation has been rife in reference to the origin of the higher types of teratoma. Rauber pointed out that two embryos may spring up in union in the same blastoderm or close to one another, in which case they may afterward fuse. Fusion is more frequent at the caudal extremity, but occasionally it occurs at the cephalic end or elsewhere along the vertebral axis. In the subsequent growth the embryos usually develop unequally until one becomes a mere parasite on the other. In conformity with this explanation is the fact that dermoid teratoid formations in the region of the coccyx are proportionately common. At the cephalic end, in the region of the hypophysis, teratoid tumors are occasionally met with, the origin of which could be explained upon the same hypothesis. Williams, on the contrary, is firmly convinced that such tumors are produced not by blending of two distinct embryos, but by giant growth of undifferentiated cells: "Occasionally a mass of undifferentiated protoplasmic cells manifests reproductive properties similar to those of the hydra, so that from a single cell two or more individuals may proceed. Thus, when the division of the undifferentiated embryo into two symmetrical parts is complete, and each of these develops into a new being, homologous twins are the result; and this, so common a mode of reproduction in the lower animals and plants, is the only instance of reproduction by gemmation in the highest animals. In this way double monsters arise. The locality and degree of fusion present many variations. The usual points of attachment are the sacrum, sternum, umbilicus, and head. The sex of the individuals in homologous twins and double monsters is invariably the same. In other instances the distribution of protoplasmic cells in the embryo is unequal, so that only one of the two fetuses attains full development. The former are called 'autosites;' the latter, 'parasites,' because they depend for nutrition upon the body to which they are attached. The parasite is either attached to the surface of the autosite by implantation or is surrounded by the tissues of the autosite by inclusion. Sometimes only a part of a new individual is formed in such a manner, which gives rise to tumor-like formations called by Virchow 'teratoma.' Such tumors are found most frequently in the region of the ovaries, testicles, sacrum, and sella turcica. They represent imperfect parasitic fetuses. Partial fission of the embryo at the cephalic end gives rise, according to the degree of fission, to

duplication of the pituitary body, to the formation of two distinct and complete faces. Additional masses of protoplasmic cells result in the formation of all kinds of deformities, as supernumerary fingers and toes, supernumerary mammary and thyroid glands, and, if the cells only possess the intrinsic capacity to produce one tissue, all conceivable forms of local hypertrophies, such as angiomas, moles, warts, lipomas, etc."

There can be but little doubt that double monstrosities are the result of fusion of two distinct embryos, as symmetrical segmentations of an embryo to this extent in man and the higher animals is not likely to occur. We have also reason to believe that ectogenous and endogenous parasites originate in a similar manner, while the different varieties of dermoids, the teratomata proper, originate in the manner indicated by Williams and others.

Endogenous Teratomata.—These tumors are represented by the histioid and organoid varieties. The histioid variety is represented by heterotopic tumors, such as chondroma branchiogenes, branchial cysts, and the simplest forms of dermoid cysts. The organoid tumors spring from displaced embryonal matrices representing different tissues and organs, and occur in localities where in the embryo displacement of tissue has taken place. The capacity of tissue-proliferation of the cells of which the matrix is composed does not exceed that of the cells of the corresponding normal tissue. For instance, a dislocated tooth-germ will produce a tooth not larger than a normal tooth, and a dislocated acinus of a gland will produce an acinus which in size does not exceed the acinus of a corresponding normal gland.

Sutton describes a rare case of ovarian mamma removed from a woman twenty-six years of age, supposed to be suffering from tubercular peritonitis. Upon opening the abdomen a considerable quantity of pus escaped, mixed with hair and sebaceous material, showing it to be the remains of a dermoid cyst. On examination, a peculiar, rounded body, growing from the wall of the cyst, was found, recognized as an ovarian mamma, and removed. It presented an ordinary nipple and a cluster of glandular material, the ducts of which traversed the nipple.

The endogenous skin-teratoma is the most frequent form of fetal inclusion. Portions of the embryonal skin become buried in the mesoblast and are isolated by constriction from the skin, and serve later as matrices for dermoid tumors. In many endogenous teratoid tumors the matrix, derived in a similar manner, has a more complicated structure, and from it develop teeth, bone, portions of the alimentary canal, etc. In such a manner originate, in the interior of the skull, tumors containing striated muscular fibres (Arnold) and teeth (Hugo Beck).

Ectogenous Teratomata.—Ectogenous teratomata are produced by

the blending or fusion of two distinct embryos. The tumors originate either by the allantois of one fetus entering the cavities of the body of the other fetus, where its vessels enter into communication with those of the other, or by attachment between two impregnated ova, of which one grows around the other. In the first case inclusions, allantoid inclusions, are formed in connection with the umbilical cord and the placenta-like productions; in the latter instance the development of the included fetus is impaired by the greater development of the organs and tissues of the autosite, and often only remnants are found in the place formerly occupied by the parasitic fetus.

In the museum of the College of Physicians and Surgeons in London is the most perfect specimen of *fœtus in fœtu*. The autosite, a boy, lived to be fourteen years of age and was well developed. At the post-mortem there was found in the abdominal cavity a perfect, full-grown fetus surrounded by a sac or membrane.

Ahlfeld collected 20 cases of *fœtus in fœtu*, but he believes that in perhaps half of them the diagnosis was erroneous, dermoid cysts having been mistaken for *inclusio fœtalis*. Inclusion-cysts not only contain a diversity of tissue elements and organs, but they are almost always multilocular; while, on the other hand, dermoid cysts are lined with skin, which presents all the structures of normal skin—epidermis, rete

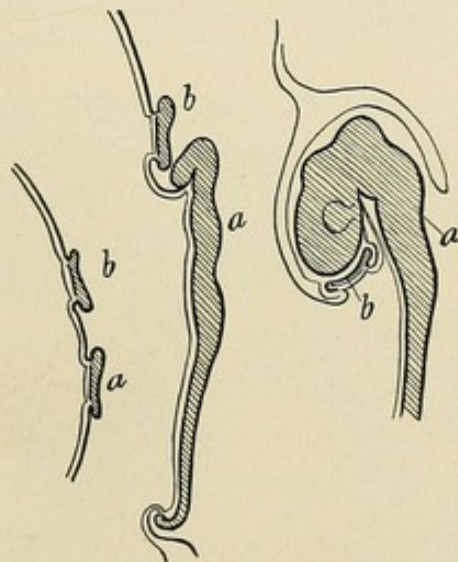


FIG. 429.—The inclusion of one embryo within the cephalic fold of the other (Ahlfeld).

Malpighii, papillæ, sweat and sebaceous glands, hair, teeth, etc.—and in most cases the cyst is unilocular (Fig. 429).

In some of these cases of fetal inclusion parts of the parasitic fetus grow, while other parts are dwarfed by insufficient vascular supply, cease to grow, and are removed by absorption.

To the pre-allantoid teratomata belong the fetal implantations in

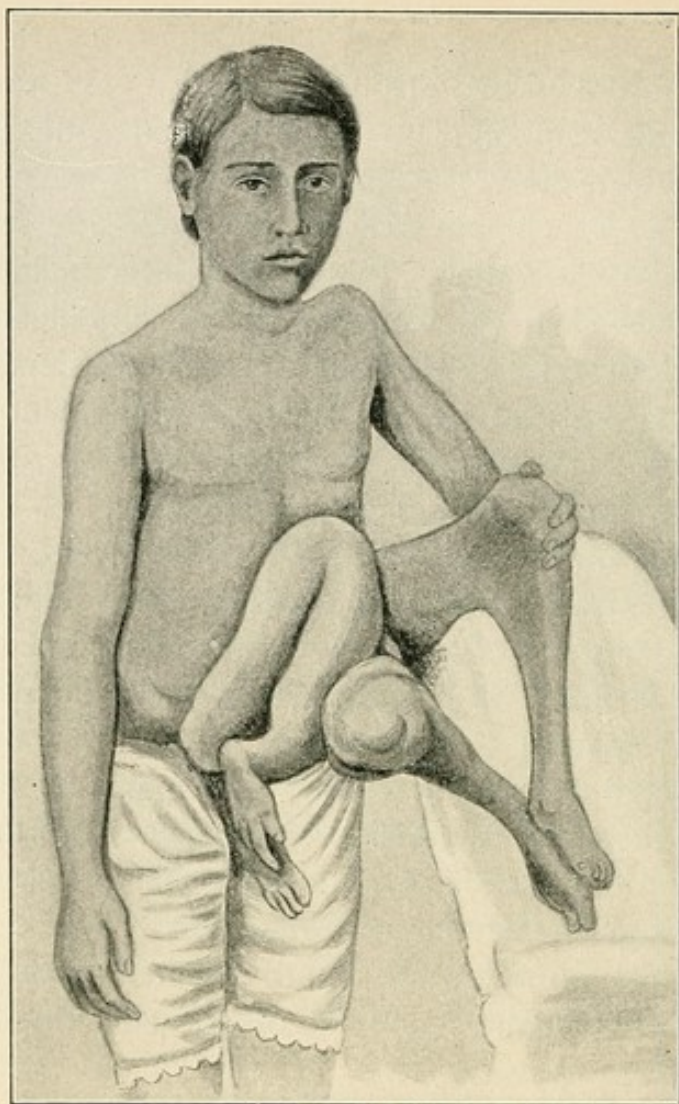


FIG. 430.—Laloo, a Hindoo with an acardiac parasite attached to the thorax.

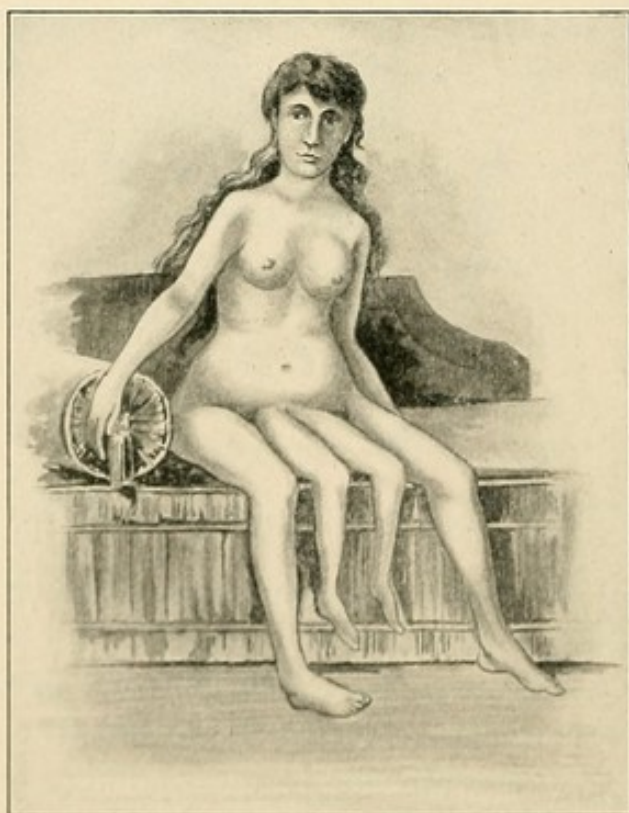

FIG. 431.—Dipygus (Wells).

which parts of the parasitic fetus are contained in cysts. Such cysts are found in the mediastinum, the brain, the abdomen, the ovaries, and the testicles. Ahlfeld separated from these tumors what he calls "fetal transplantation"—cases in which rudimentary fetal parts are engrafted upon the surface of the body. In partial fetal inclusions the acardiac parasite may present externally to the autosite all limbs (Fig. 430), or the upper part of the body may be destroyed by inclusion and the lower limbs may project from the autosite (Fig. 431).

The included parasitic fetus is often blighted at a very early stage, and none of its organs reaches a full degree of development. The more important organs either are absent or are present in only a rudimentary form. This form of teratoma has been well described by Sutton as "acardiac fetus."

In some cases the fetus consists simply of a shapeless mass in which only traces of the skeleton and of the more important organs are found. The sex is invariably the same as that of the autosite; the acardiac can occur only in plural births.

Acardiacs may appear in plural births as separate beings, or they may be attached to the twin autosite in a variety of ways. In a few instances the autosite and the acardiac parasite have lived and attained maturity.

The diagnosis of included parasites according to their location is usually impossible and is at all times uncertain. The recognition of parasitic fetuses or parts of them on the surface of autosites is attended by no difficulty.

Sutton has well said that parasitic acardiacs are in almost all cases so valuable as sources of gain in dime museums, fairs, shows, and large cities that the parents or the unscrupulous individuals who get possession of these children will not permit operative interference, and hence it is useless to discuss the propriety and feasibility of operation in cases of autosites bearing an acardiac fetus.

The different forms of superfetation and blending of twins by attachment or by allantoid inclusion, so interesting to embryologists and pathologists, are of little practical value to the surgeon. The surgical interest of teratoma attaches itself to those tumors caused by displacement of fetal tissues, parts, or organs, to which Virchow applied the term "teratoma," or, from their resemblance to a terato, "teratoid tumors." We shall discuss at greater detail the tumors included in this class—branchial and dermoid cysts.

BRANCHIAL CYSTS.

Tumors in the branchial clefts are not so very rare as was formerly believed. Chondroma branchiogenes was described in the section on

Chondroma. *Branchial fistulæ and cysts result from imperfect obliteration of one of the branchial clefts.*

Anatomy and Embryology.—Toward the end of the first month of fetal life we see under the frontal process, open in front and bounded on the sides by four plates, the pharyngeal cavity. The upper pair of plates constitute the first branchial arch. The next three pairs of plates make up the second, third, and fourth branchial arches, which decrease in size from above downward, so that their median interspaces in front are narrow above and wider lower down. Between each pair of branchial arches on each side remains a transverse cleft, the branchial clefts, which are obliterated during early fetal life, with the exception of the first one, from which the external auditory canal, the cavity of the tympanum, and the Eustachian tube are developed. From the second branchial arch are developed the styloid process, the stylohyoid ligament, and the lesser horn of the hyoid bone. The third arch forms the large horn and the body of this bone. The fourth arch assists in forming the soft tissues of the neck. The larynx, the trachea, and the adjacent glands are developed from other centres of fetal growth.

The primary starting-point of branchial cysts must necessarily correspond with the location of one of these branchial clefts, and clinical



FIG. 432.—Branchial cyst of the third branchial cleft in a woman thirty-eight years old.

observation has demonstrated that branchial cysts are most frequently found in the region of the second and third clefts, in the vicinity of the larynx and pharynx, and in intimate relation with the sheath of the large vessels of the neck, in contradistinction to dermoid cysts about the orbits and the scalp, which are more superficially located (Langenbeck).

We shall have frequent occasion to allude to the intimate connection of these tumors with the sheath of the large vessels of the neck, and consequently it is very important to study their anatomical relations to these important structures. The jugular vein is surrounded throughout its whole course in the neck by a distinct and separate sheath of areolar tissue, which on the outer side of the artery penetrates into the deep tissues of the neck, thus completely separating the two vessels. The jugular, enclosed in its sheath, may easily be drawn over the artery toward the median line without producing any change of location of the artery. The

vein being in front of the artery and covering half of the circumference of the latter, it can readily be understood that when the vein is drawn forward with its sheath it can be injured, while the artery is not exposed to the same danger. Branchial cysts of the second and third clefts are always found in the sheath of the large cervical vessels, usually in the carotid triangle above the omo-hyoid muscle. These cysts, which appear to occur more frequently on the left side of the neck, are invariably round or oval, with a smooth surface. The contents of these cysts being either fluid or semi-fluid, fluctuation can be felt, more particularly if the tumor is palpated between two fingers from the pharynx or the floor of the mouth and the external surface. Only lateral motion of the tumor is possible, on account of its peculiar attachments to the deep tissues of the neck. If the tumor is of only moderate size, the pulsations of the carotid artery can be felt on its inner margin. If the tumor is large, it overlaps the artery, and the pulsations of the vessel are communicated to the tumor. Small tumors can be made to pulsate by bending the head backward and in a direction opposite to the tumor.

History.—Branchial fistulæ, persistent branchial clefts, have been known longer than branchial cysts. It appears that Hunczowski more than a hundred years ago described two cases of congenital fistulous openings in the side of the neck. About fifty years later Roser made the statement that many of the so-called "ranulas" about the base of the tongue, the mucoid and dermoid cysts of the upper cervical region, are due to imperfect closure of one of the branchial tracts. All these tumors he included in one group under the name "branchial cysts." He described three distinct conditions which may result from entire absence or from imperfect obliteration of any one of the branchial clefts: 1. Branchial fistula, in case the entire tract remains open; 2. Cystic fistula, in case only one end of the cleft is obliterated, while the other open end communicates with the pharynx or with the cutaneous surface; 3. Branchial cysts, in the event that the cleft is closed at both ends, while between them it remains open, and by proliferation from the inner surface produces an accumulation—the contents of the cyst.

Hensinger in 1862 collected a number of cases of branchial cysts, and associated them with the branchial clefts discovered by Rathke. Branchial fistulæ are always congenital. Branchial cysts are congenital in the sense that patients are born with the tumor-matrix, which consists of the unobliterated portion of a branchial cleft; but the tumor frequently does not appear until the person arrives at the age of puberty, when, by the stimulus imparted by an increased physiological

function of the skin, active tissue-proliferation of the cells composing the cyst-wall sets in, resulting in the formation of the cyst-contents.

Although these cysts are by no means common, being less frequent than congenital branchial fistulæ, a sufficient number of cases have been placed on record to remove all doubt as to the etiological relations existing between imperfectly obliterated branchial clefts and the serous, the dermoid, and the so-called "deep-seated" atheromatous tumors of congenital origin located in the regions formed by the branchial arches. These tumors have been made a special object of study by Langenbeck, Lücke, Gurlt, Virchow, Schede, Esmarch, and Hensinger.

Classification.—Branchial cysts must be classified according to their contents. The cyst-wall being lined with epithelium displaced from the pharynx or from the skin, the only histological element in the contents is epithelium (Fig. 433). The wall is composed of con-

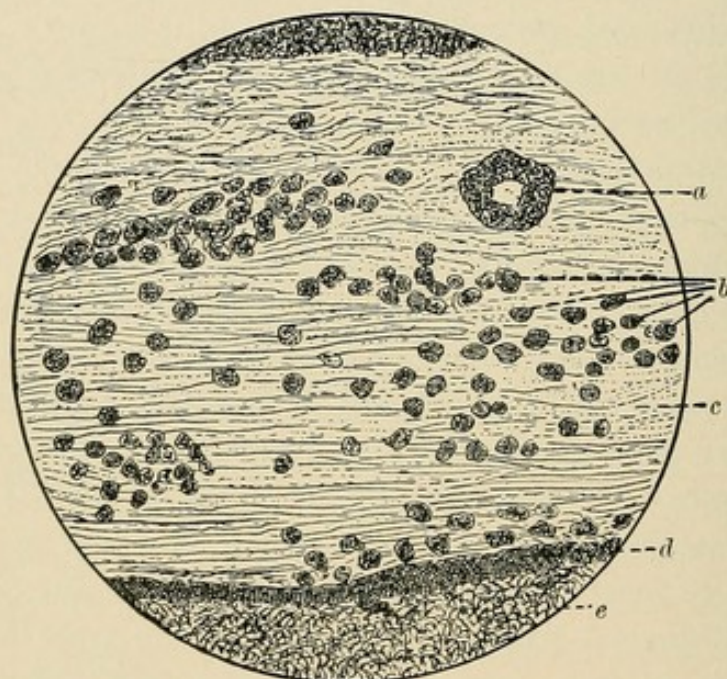


FIG. 433.—Structure of wall of branchial cyst, from case represented in Figure 444; $\times 280$: *a*, blood-vessel; *b*, inflammatory infiltration; *c*, connective tissue; *d*, epithelial lining of cyst; *e*, contents of cyst.

nective tissue lined on the inside with epithelial cells. In most instances the epithelium lining the cyst-wall and contained in the cyst-contents represents the epithelium of the skin (Fig. 434); but Rehn discovered, in a blind congenital fistula ending near the mucous membrane of the pharynx, ciliated epithelium, which, of course, must have been derived from the pharynx. Neumann found cylindrical and pavement epithelium in two cystic tumors of the neck; one of the tumors was congenital, while the other was developed in later years. The presence of ciliated epithelium may be explained by assuming its origin to have been in the upper part of the cleft, the fornix pharyngis, where these

fistulæ oftentimes end and where ciliated epithelium normally exists. The lower end was probably derived from the skin, and was lined with flat cells.

The physical and chemical properties of the cyst-contents will depend largely on the kind and degree of regressive transformation

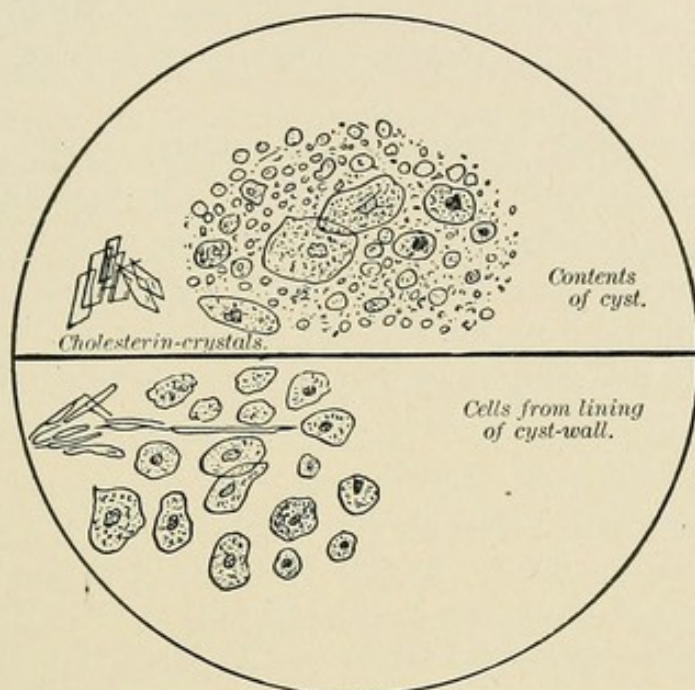


FIG. 434.—Contents of branchial cyst; $\times 140$.

of the epithelial proliferation. In making the character of the cyst-contents a basis for classification it is, however, important to remember that, as in ordinary retention-cysts, the contents of a branchial cyst are liable to undergo changes depending on the retrograde changes of the epithelial product, on hemorrhage and other transudations into the sac, or on the occurrence of inflammation in the cyst-wall itself. It is only during the earliest stages that the characteristic secretion is found in its purity. In the course of time the original character of the cyst-contents may be lost completely by retrograde metamorphosis or by the addition of new material.

Clinical experience and pathological investigations have shown that branchial cysts, according to the physical properties of their contents, may be divided into the following principal varieties: 1. Mucous cysts; 2. Atheromatous cysts; 3. Serous cysts; 4. Hemato-cysts. Variable as the contents of these different varieties of cysts may be, more uniformity is observed in the structure of the cyst-wall. In the beginning the cyst-wall consists of a connective-tissue capsule with an epithelial lining on its inner surface (Fig. 433), and a delicate layer of a loosely connected reticulum of connective tissue, the pericystium, which is very vascular and which covers the outer surface of the cyst.

A high degree of intracystic pressure may cause atrophy of the epithelial lining and thinning of the walls of the sac; on the contrary, inflammatory proliferation produces great thickening of the cyst-wall. While dermoid cysts contain the characteristic secretions of the skin and its appendages, the branchial cysts contain the product of epithelial cells, because their walls do not contain any hair-follicles, sebaceous glands, or sweat-glands, as the branchial clefts close before these appendages are formed.

Mucous Branchial Cysts.—As a primary tumor this form of branchial cyst is found in the upper part of the branchial clefts. The origin of mucous branchial cysts is attributable to an imperfect closure of the upper portion of a branchial tract; consequently the cyst-wall may derive its lining from the mucous membrane of the pharynx, and the retention of the physiological secretion produces a mucous cyst. Many of the so-called “ranular” cysts about the base of the tongue belong to this variety of tumors.

Congenital mucous cysts in the region of the base of the tongue and the sides of the larynx in the majority of cases are due to an imperfect closure of the upper portion of one of the branchial tracts.

Atheromatous Branchial Cysts.—This form of branchial cyst has been described as a deep-seated atheromatous cyst of the neck (Schede) and as a dermoid cyst of the sheath of the large vessels of the neck (Langenbeck). The cysts are usually located in the second or third branchial tract, in the region of the hyoid bone, and they are intimately connected with the sheath of the large vessels. They contain an atheromatous material resembling the contents of an ordinary retention-cyst of the sebaceous glands. They never contain lanuginose hair, as do many of the dermoid cysts. Gurlt mentions the great similarity existing between the contents of these tumors and those of some ovarian cysts. Besides fat-globules and epithelial debris these cysts contain an abundance of cholesterin-crystals and of small prismatic crystals which seem to be some form of inorganic salt, as well as lime in granular form. In some cases the inner surface of the cyst-wall is covered with papillomatous excrescences, the product of epithelial proliferation.

These atheromatous branchial cysts may occur in the first branchial cleft, as is shown by a case reported by Virchow, who described the cyst as an “auricular teratoma.” The patient was a seamstress twenty-four years of age. The tumor was first noticed when she was fourteen years old, when it was as large as a filbert; it increased slowly in size, and when first seen by Virchow it was as large as a goose-egg; it was located between the angle of the jaw and the mastoid process, and was

firmly attached to the sheath of the carotid artery. The cyst was filled with a creamy yellowish fluid which contained free fat and epithelium. The portion attached to the sheath of the vessels contained a plate of cartilage resembling the cartilage of the ear; hence Virchow designated the tumor as an "auricular teratoma." Virchow, who attributed the origin of this and of analogous growths to an imperfect obliteration of the first branchial cleft, in his classification of tumors includes among the teratoid tumors the cysts developed from branchial clefts.

Serous Branchial Cysts.—This form of branchial cyst is composed of thin cyst-walls and serous contents. The cysts very much resemble in structure and contents the lymphangiectatic cysts of the neck, for which cysts they have often been mistaken. They occupy one of the branchial clefts, and they are lined by epithelial instead of endothelial cells, as is the case in cysts originating from lymphatics. The lymphangiectatic cysts are usually congenital. We have seen that branchial cysts are not necessarily developed during intra-uterine life or soon after birth. All that is necessary is that the matrix for the cyst be present at the time of birth; from this matrix, at some future time, the tumor is developed. These tumors appear as either single or multilocular cysts with thin membranous walls; their internal surface is lined with epithelial cells. Besides serous fluid they contain epithelial cells and cholesterin-crystals. Clinically, they may be recognized from their location, their globular form, their soft fluctuating feel, and their painless growth. The existence of pavement epithelium upon the inner surface of these cysts has been demonstrated by Neumann and Baumgarten. When these cysts spring from the second or third branchial clefts they are usually deeply located. Hueter, in extirpating a tumor of this kind in a child two years of age, found that the tumor extended between the two carotid arteries back to the pharynx. That these tumors may sometimes grow to an enormous size is evident from a case reported by Treves. The tumor, which occurred in an infant, took its origin in the region of the inferior maxilla and occupied the whole side of the neck and the upper part of the thorax on the same side, whence it extended as far as the umbilicus. It contained one large and numerous smaller cysts, and it corresponded with the region of the second branchial tract. No histological report of the specimen was made. Vonwiller reports a case of double serous branchial cyst. The writer has seen a number of such cysts in young children. The cysts were either present at the time of birth or developed a few months later.

Hemato-cysts of Branchial Clefts.—In some instances of serous branchial cysts the fluid is discolored by an admixture of blood from minute hemorrhages into the sac; but when the contents are of such

dark color as to resemble venous blood the cysts are properly called "hemato-cysts," and from a pathological, clinical, and diagnostic point of view they constitute a distinct and well-marked variety of branchial cysts. Albert remarks that two kinds of these cysts have been observed: 1. Those which can be emptied by pressure and which are in direct communication with blood-vessels; 2. Those which are not affected by pressure, and which simulate the appearance of an ordinary serous cyst so closely that their nature is recognized only by exploratory puncture. The latter class of cysts, when they occur in the neck, usually belong to the branchial cysts, because they are observed during early life and originate in places which correspond with the location of branchial clefts. This variety of cysts has been called *hematocele colli* by Michaux, and *hematocele* by J. P. Frank. Aside from their origin from branchial clefts and the admixture of blood with the contents of serous cysts, hemato-cysts may develop from dilated veins, both extremities of the dilated portion undergoing contraction and finally complete obliteration, completely isolating the contents of the cyst from the general circulation. Again, a vein may dilate at one point, forming a pouch or a sac, and by contraction and obliteration of the orifice a blood-cyst is formed.

Hemato-cysts resemble serous cysts in every particular, with the exception of the presence of blood in their contents. Their diagnosis, however, is more difficult than that of serous cysts, and it should always be made by exclusion, due attention being given to the location of the cyst, its time of development, and the character of its contents. The last point can be settled definitely by an exploratory puncture.

Etiology.—Branchial cysts of the neck, as compared with other tumors in this locality, are of rare occurrence. The statistics of branchial tumors cannot be relied upon in estimating the comparative frequency with which these tumors occur, as many branchial cysts have been classified and described under the generic and indefinite term "cystic tumors of the neck," without regard to their etiology. Gurlt in 1855 compiled 44 cases of serous and 6 cases of atheromatous cysts. Since that time a great many more cases have been reported. The serous variety is more apt to develop early. The tumors are often congenital or appear during infancy or childhood, while the atheromatous cysts are most frequently met with in young adults. Of 53 cases tabulated by Schede, 9 occurred between the first and tenth years, 21 between the eleventh and twentieth, 10 between the twenty-first and thirtieth, 6 between the thirty-first and fortieth, 5 between the forty-first and fiftieth, and 2 between the fifty-first and sixtieth years. Like the dermoid cysts, the branchial cysts show a tendency to develop during

the period of puberty, at a time when the tissue of epiblastic origin enters upon a new and more active phase of development. The remnant of a branchial cleft may remain dormant as a matrix for the future growth of the tumor for an indefinite period of time, and become the seat of tissue-growth during puberty or upon the advent of any other determining cause or causes. There are undoubtedly many instances where remnants of fetal tissue remain latent in the branchial tracts throughout a long lifetime for want of an adequate exciting cause, which is necessary to stimulate into morbid activity the slumbering forces inherent in the histological elements of the matrix.

Diagnosis.—To diagnose the presence of a branchial cyst is often no easy task. The importance of the tissues and organs in close and intimate relation with these tumors renders it imperative upon the surgeon to make a correct diagnosis before an operation is undertaken for their removal. All signs and symptoms should be investigated carefully, and every diagnosis should be fortified by eliminating by exclusion the existence of all other forms of tumors and infective swellings. The following conditions may stimulate a branchial cyst:

1. Aneurysms; 2. Hemato-cysts and lymphangioma; 3. Dermoid cysts; 4. Retention-cysts; 5. Lymphangiectatic cysts; 6. Struma cystica. After eliciting a careful clinical history as to the location and the time of development of the tumor, these affections should be gone over seriatim in making a differential diagnosis between them and a branchial cyst. The exploratory syringe will frequently be called into requisition to ascertain the character of the cyst-contents.

Prognosis.—Branchial cysts, although heterologous formations, always remain purely local affections, manifesting no tendency to destroy life except when they are of a size sufficient to interfere by their presence with the performance of important functions of neighboring organs. The tumor may encroach upon the cavity of the mouth, interfering with speech, mastication, and deglutition, or it may compress the larynx or the trachea, thus interfering with respiration.

Branchial cysts manifest no tendency to spontaneous cure, and prove exceedingly rebellious to all kinds of treatment short of complete extirpation. In a case of branchial cyst of the second branchial cleft with mucous contents, the writer was informed by the patient that she had been operated upon more than fifty times, the tumor reappearing each time within a few weeks after the operation. That part of the cyst-wall which had not been extirpated was found greatly thickened and firmly attached to the internal carotid artery and the hyoid bone.

The serous variety is most amenable to the milder forms of treatment. Frequently the tumor attains a certain size and then remains

stationary, but the tendency is to increase in size progressively until important organs are encroached upon, when the suffering and distress occasioned demand prompt operative interference.

Treatment.—The inner surface of branchial cysts being lined with epithelium, it is evident that obliteration of the sac can be secured only after the destruction or removal of this epidermal lining. The surgical treatment must have for its object the production, in the interior of the sac, of an artificial inflammation of sufficient intensity to destroy the epidermal matrix, or complete extirpation of the cyst. The former procedure is exceedingly unreliable in its results, and extirpation in many instances may be looked upon as a formidable and dangerous operation. The following methods have been resorted to in the treatment of branchial cysts: 1. Incision; 2. Actual cautery; 3. Seton; 4. Puncture, with subsequent injection; 5. Extirpation; 6. Antiseptic drainage. In all cases where incision was practised the relief from existing symptoms was prompt. The cyst collapsed; a certain amount of inflammation followed; usually, after the healing of the wound there remained a small nodule which in a few weeks became the seat of active tissue-growth, and a speedy recurrence followed. The result was not materially modified in case the sac was drained and injected with iodine or with other irritating solutions.

In infants the laying open of cysts of the neck is a perilous plan of treatment. Volkers relates a case where a cystic tumor was laid open in a new-born child, which died sixteen days later in consequence of the operation.

In the case of serous cysts where the seton and iodine injections have occasionally been successful in producing obliteration, it seems to the writer that the same object would be accomplished more speedily and safely by incision and drainage, practised in a manner similar to that in Volkmann's operation for hydrocele.

Dieffenbach employed the actual cautery in opening the cyst in one of his cases, after he had made an unsuccessful attempt at removal by extirpation, and after incision had failed in producing obliteration of the sac. The use of the cautery also failed in producing obliteration of the sac.

It would seem to the writer that incision, combined with a use of the actual cautery sufficiently energetic to destroy the entire thickness of the epithelial lining, would be most applicable in the more dangerous and formidable class of cases—namely, in cysts that have become firmly adherent to the sheath of the larger vessels by repeated attacks of inflammation provoked by inefficient treatment. After cauterization the wound should be packed with iodoform gauze. If, during the

progress of the healing of the wound from the bottom by granulation, it becomes apparent that the entire matrix has not been destroyed, the use of the actual cautery can be repeated.

The seton has resulted in a permanent cure in a few cases of serous cysts, but its use should be abandoned, as the result is uncertain and the consequences are often disastrous. Butlin reports a case where, in a young child, a seton was passed through a serous cyst: death from inflammation followed on the third day. For this and other obvious reasons the seton should never be employed in the treatment of branchial cysts.

Esmarch's experience with puncture and injection of Lugol's solution of iodine (iodini, pot. iod., gm. 1.25; aquæ, 30.0) has been favorable. The following remarks were made by him on this subject at the fourth meeting of the Congress of German Surgeons:

"I have cured about a dozen cases by puncture and subsequent injection of Lugol's solution of iodine. Against this treatment it has been urged that complete extirpation of the cyst can always be done and is free from danger. I must deny this assertion, because in a majority of cases the cyst is adherent to the sheath of the internal jugular vein—a fact which may remind you of a paper on this subject by Prof. von Langenbeck, which served as an introductory to his *Archiv* in 1860. In this paper Langenbeck called special attention to the dangers connected with this operation. But even if the operation were free from danger, yet by resorting to it we obtain an unsightly cicatrix in the neck, to which the female sex objects. I can, on the other hand, recommend injections of iodine as an efficacious and entirely safe procedure. If some of you have failed to see its benefits, it is, I believe, because you have not had the necessary patience and perseverance. As a rule, I have repeated the operation whenever obliteration did not promptly follow the first puncture. It is very essential to irrigate the sac thoroughly before the introduction of the iodine. I have generally proceeded as follows: By means of a fine hydrocele trocar I empty the sac of its contents, and then make repeated injections of a 1 per cent. solution of carbolic acid. This removes the masses of epithelium adherent to the cyst-wall. I continue these injections until the water returns perfectly clear, and then I inject 10 to 20 grams of Lugol's solution of iodine, which, after gentle pressure to bring it in contact with the inner surface of the sac, is allowed to escape. The patient is then directed to return in six or eight weeks. Like a hydrocele, the cyst refills rapidly and becomes somewhat painful. If, after the lapse of time mentioned, it has not greatly decreased in size, I repeat the same operation and tell the patient to return in six months,

when the cyst will be found atrophied to a small tubercle. In most cases the cure has been permanent."

In the discussion which followed Langenbeck said: "I have treated a number of dermoid cysts with fatty contents by means of injections of iodine, but the injections always required repetition. I punctured the cyst with a large trocar, introduced a piece of elastic catheter, and made daily injections. A few cases were cured after three or four injections. In one case the tumor returned. I consider it very difficult to cure these fatty cysts with injections of iodine or any other substance."

Roser admitted that injections of iodine might succeed in serous and mucous cysts, but that they would prove of no avail in atheromatous cysts. Baum asserted that extirpation was an easy matter, and that these cysts could be removed without difficulty.

Bardeleben believed that some of these cysts, especially those which extend behind the sternum, could not be extirpated, but obliteration in one instance was accomplished by antiseptic drainage. Volkmann spoke in favor of extirpation, and warned against injections of iodine, as in case of failure they would render a subsequent excision more difficult.

It is evident that most German surgeons who have given attention to this subject have no confidence in the efficacy of iodine injections in obliterating branchial cysts. If we consider the numerous failures of iodine injections in cases of hydrocele, where the anatomical conditions for success are so much more favorable than in branchial cysts, we will be better prepared to appreciate the causes of the still more frequent failure of this method when used in the treatment of branchial cysts. Again, clinical experience has shown that a branchial cyst can be extirpated with comparative ease and safety before the cyst has become firmly fixed to the subjacent cervical vessels by inflammatory infiltration, and that in this class of cases iodine or any other injections will not only prove useless, but will render a subsequent extirpation still more difficult. In infants even simple tapping is not always devoid of danger, as one instance is recorded of death caused by puncture. The case occurred to Volkers, who tapped a cystic cervical tumor in an infant eight days old, the child dying of trismus on the third day.

Extirpation.—A positive diagnosis made, the best plan to pursue is to make an incision over the most prominent portion of the tumor, parallel with the sterno-mastoid muscle; in case the adhesions can be separated without endangering the deep cervical vessels, the entire cyst should be removed. If inflammatory infiltrations obscure the field of operation at the base of the tumor, and after careful examination

it is deemed inadvisable to perform complete extirpation, the sac should be opened and the lateral walls excised, and the epidermal matrix, which remains adherent to the sheath of the cervical vessels, can be destroyed completely by a careful but vigorous use of the actual cautery. The treatment of the wound should be conducted as in cases of complete excision. If an early diagnosis is made and prompt treatment is instituted, complete extirpation should always be attempted, and will in the majority of cases prove successful and comparatively free from danger.

Antiseptic Drainage.—In the case of infants and very young children suffering from large serous cysts it would be imprudent to resort to any of the severer measures with a view to a radical cure. In such instances drainage under antiseptic precautions should be resorted to as a temporary measure, and in some cases it may be followed by permanent results. The same course of treatment should be adopted in adults suffering from cysts which are inaccessible to any other operation and in which irritating injections are contraindicated.

The writer's experience in the extirpation of branchial cysts, amounting now to about fifteen cases, has been uniformly favorable. No deaths occurred from the operation, and in every case the result was permanent. In one case the internal jugular vein was cut in dissecting away the adherent inflamed sac from the vessels of the neck. The hemorrhage was controlled by the use of hemostatic forceps on both sides of the wound. The forceps were allowed to remain until the cyst was removed, when the jugular vein was completely divided and both ends were tied with catgut. The patient made an uneventful recovery.

Dragging upon the vein if the cyst-wall has become adherent should be avoided. Branchial cysts which have not become adherent by antecedent attacks of inflammation can readily be removed by enucleation.

DERMOID CYSTS.

A dermoid cyst is a teratoid tumor. It is called "dermoid" because it contains skin derived from the epiblast by displacement of an embryonal epiblastic matrix, from which, during the development of the tumor by proliferation of the skin and its appendages, the principal contents of the tumor are formed. In the simplest varieties of dermoid cysts the contents of the cyst are composed of epithelial proliferation alone, when nothing is found in the cyst but epithelial cells and their detritus mixed with serum, forming the peculiar atheromatous material which constitutes the characteristic contents of retention-cysts of the sebaceous glands. This kind of cyst is produced from a matrix derived

from the epiblast before differentiation has advanced to the formation of the appendages of the skin. A matrix derived from the epiblast after its differentiation into appendages of the skin (hair-follicles, sebaceous glands, and sweat-glands) has taken place not only yields epithelial cells, but produces also hair and the secretion of sebaceous glands and sweat-glands. In tumors from such a matrix hair is constantly found.

Superficial dermoid cysts are due to inclusions of parts of the epidermis, and which Chiari taught remained connected with the superficial epithelium. The fissural position of the dermoids—that is, their presence in places where foetal fissures had existed or where clefts were closed—supports such a conclusion. The deep-seated dermoids, in the abdomen, lungs, etc., must be explained by a complete separation of the epithelial cells from which they take their origin.

According to Epstein, in new-born infants it is not uncommon to find isolated pearls of epithelial cells which have become buried in the connective tissue by inclusion. It would therefore be more proper to look upon subcutaneous atheroma as the product of tissue-proliferation from such an isolated island of epithelial tissue, as was done by Heschl, than as a sebaceous cyst.

The difference between a dermoid and such an atheroma would be that in the former a whole section of skin had become buried, while in the latter only a projection of epidermis with a single hair had taken place.

Heiberg demonstrated the identity of the lining of a dermoid cyst of the neck with normal skin from a practical standpoint. He utilized the lining membrane as grafts in the healing of a large ulcer of the leg. The grafts united promptly with the granulating surface, and the new skin showed the same properties and structure as in cases of skin-grafting.

Some dermoids contain not only skin, but also mucous membrane, the latter owing its existence to a matrix derived from the hypoblast. The term "dermoid" is, however, also used to designate cysts with more complicated contents, such as teeth, bone, cartilage, and combinations of different parts and organs that could originate only from a displaced matrix representing different tissues and organs.

Definition.—*A dermoid cyst is a heterotopic tumor containing the product of epithelial proliferation, hair, teeth, etc.* Dermoid cysts were first described in 1852 by Lebert, who applied the term "dermoid" to all cysts lined by a cyst-wall resembling in structure that of the external skin. Dermoid cysts are found most frequently in the ovary and

in parts of the body where, during development, the different germinal layers meet, as about the orbita, the neck, and the coccygeal region. In 188 cases of dermoid cysts Lebert found that the ovary was the seat of the tumor in 129.

Histology.—The wall of a dermoid cyst is composed of connective tissue; its inner surface is often smooth, resembling a serous surface, but microscopical examination always reveals an epithelial lining composed, according to the character of the epithelial cells, of one or more

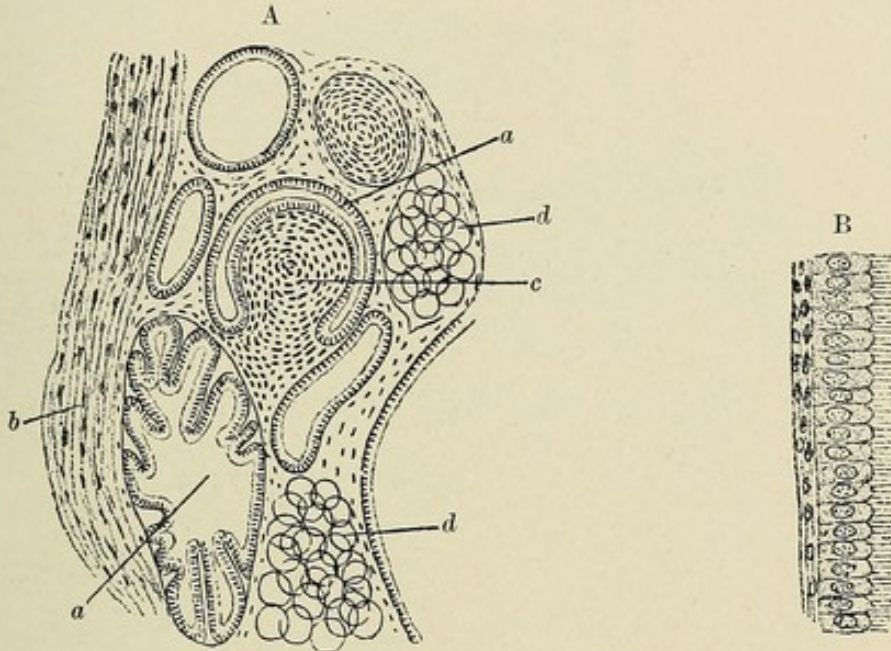


FIG. 435.—Section from a congenital teratoma of the coccygeal region; $\times 90$ (after Perls). A: *a*, ciliated epithelial lining of cysts; *b*, smooth muscle-fibres in which the striations are indistinct; *c*, cartilage; *d*, fatty tissue. B, wall of a cyst lined by ciliated epithelium; $\times 350$ (after Perls).

layers (Fig. 435). If the cysts are lined with columnar or ciliated epithelium, the cells are arranged, as a rule, in a single layer; if, on the

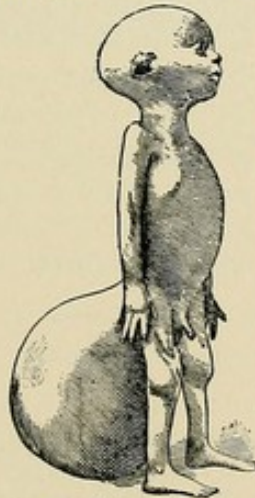


FIG. 436.—Sacral tumor (Mütter Museum, College of Physicians, Philadelphia).

contrary, the matrix represents skin in place of mucous membrane, pavement cells in many layers line the cyst. In cyst-walls supplied

with the appendages of the skin these appendages are seen and occupy the same relations to the cutis as in normal skin.

Hair is the most frequent of the many cutaneous appendages in dermoids. The hair in a dermoid, called by Virchow *lanugo*, is fine and of a blonde or light-brown color, even in negroes. In birds dermoids contain feathers; in pigs, bristles. In sequestral dermoids the hair is short; in ovarian dermoids it is often several feet in length. The hair in dermoids of aged persons turns white, and baldness of the

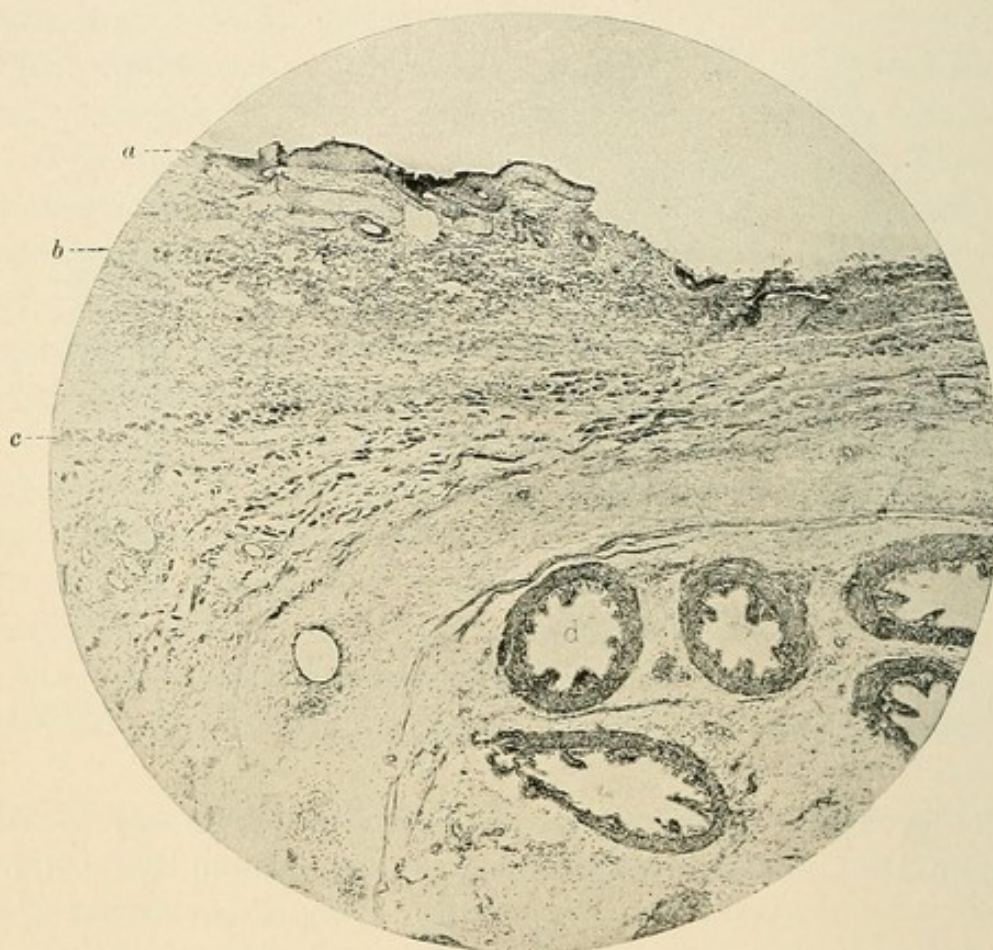


FIG. 437.—Dermoid cyst of ovary; section through wall; $\times 18$ (after Karg and Schmorl). On the surface, to the left of the picture, the cyst is covered with a thin layer of flat epithelial cells (*a*), with remnants of glands and hair; next follows the infiltrated corium (*b*), beneath which are bundles of flat muscle-fibres (*c*) cut transversely and longitudinally; *d*, hollow spaces surrounded by a layer of unstriped muscular fibres and lined with cylindrical epithelium; between these hollow spaces is myxomatous tissue.

inner surface of dermoid cysts is as often met with as baldness of the scalp. The hair grows, as on the skin, from perfect hair-follicles (Fig. 437).

Teeth and bone are found most frequently in ovarian dermoids. Teeth have also been found in dermoid cysts of the rectum and behind the rectum, in cysts of the first and second branchial clefts, and in exceptional cases in dermoids of the brain. The teeth are composed of dentine, enamel, and cementum, arranged in the same manner as in normal teeth, and they are developed on the same plan.

The so-called "epithelial pearls," resembling in structure the cholesteatomata, are also found in some dermoid cysts. They form where the epithelial cells are crowded together; they arrange themselves in onion-like layers (Fig. 438).

The cutaneous lining of dermoid cysts, like the external skin, is subject to the formation of benign and malignant tumors. Carcinoma may develop in a dermoid cyst. Benign epithelial tumors, papilloma, and adenoma are frequently met with.

Regressive Metamorphoses.—The degenerative changes which take place in a dermoid cyst consist in retrograde metamorphoses of the cells which constitute its lining, and which are detached and constitute a part of the cyst-contents. Squamous epithelium undergoes most frequently fatty degeneration. The contents of the cyst are then composed of granular detritus, free fat-globules, and cholesterin-crystals.

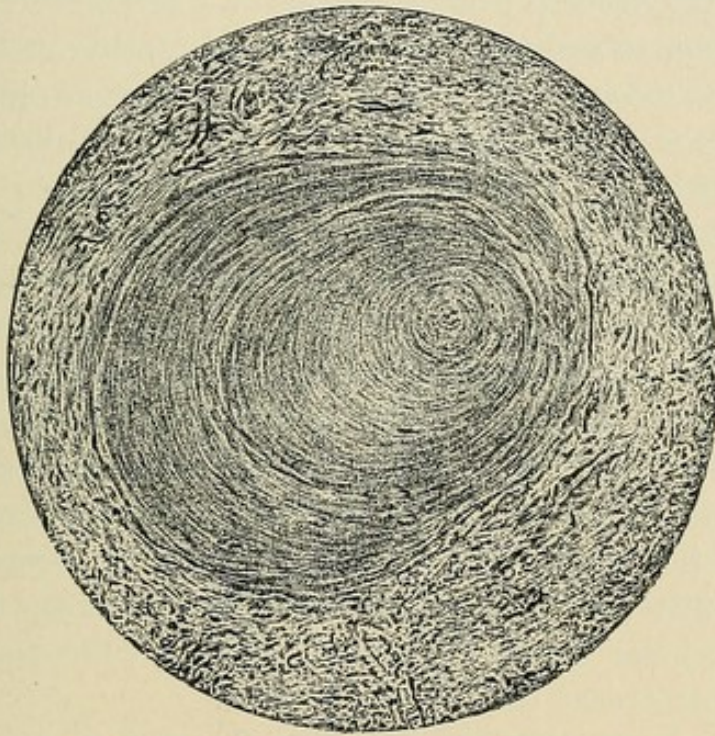


FIG. 438.—Epithelial pearl (after Kanthack).

Fatty degeneration of the epithelial cells in dermal tumors is often so extensive that the cyst contains pure oil. Mr. Hunter preserved a specimen of what he marked "oil from an adipose encysted tumor," taken from a cyst that grew between the bony orbit and the upper eyelid of a young man. The liquid fat burned with a very clear light and did not mix with water, and when it was exposed to cold it became as solid as human fat.

The hair which falls out in a dermoid cyst forms masses suspended in the emulsion. In cysts lined by columnar epithelial cells the glandular secretion is mucus, which accumulates in the cyst. In old cysts

the mucus is frequently transformed into serum. Inflammation of the interior of the cyst by the entrance into it of pyogenic microbes occasionally takes place, whereupon the products of the suppurative inflammation of the cyst-wall are added to the contents of the cyst, resulting in great distention; frequently the inflammation extends beyond the limits of the sac, producing, in the case of ovarian dermoids, peritonitis, and in other localities a phlegmonous inflammation. Inflammation always results in firm adhesion of the outer surface of the cyst-wall to the adjacent tissues or organs.

A dermoid cyst is not infrequently the starting-point of a carcinoma. Carcinoma of the branchial clefts, "*carcinoma branchiogenes*," was first described by Volkmann. Primary carcinoma in localities in which no epithelial cells exist not infrequently starts from a dermoid cyst that perhaps had never been discovered, or from a dermoid cyst-matrix.

Sarcoma may develop from a matrix of a dermoid cyst containing the essential tumor-matrix of embryonal connective tissue.

Diagnosis.—Dermoid cysts grow slowly and, as a rule, do not attain a very large size. With the exception of dermoids of the ovary, tumors larger than a hen's egg are rare. They produce no pain except from pressure or when they become the seat of inflammation. They develop most frequently during the age of puberty, although they occur sometimes as congenital tumors. They occupy localities where, during embryonal life, the most complicated tissue-changes take place. It has been asserted that the ovary is the most frequent seat of dermoids: this is probably a mistake; the impression has been caused by the fact that subcutaneous dermoids, constituting insignificant affections from an operative standpoint, are not recorded so constantly as dermoids of the ovary, which have a peculiar fascination for the abdominal surgeon. We have reason to believe that the subcutaneous tissue is the most frequent seat of dermoid tumors.

Dermoid cysts accessible to palpation fluctuate in proportion as the contents have undergone liquefaction. If the contents are solid and the cyst-wall is tense, fluctuation is absent. Subcutaneous dermoids are frequently mistaken for retention-cysts of the sebaceous glands. Retention-cysts of the sebaceous glands commonly occupy the hairy scalp, where dermoid cysts are comparatively rare. The retention-cysts usually retain their connection with the skin, while the skin is not connected with the subcutaneous dermoid. In dermoids of the ovary, as compared with other cysts, the slow growth of the tumor serves as an important point in the differential diagnosis. The differential diagnosis of sacral dermoids and of spina bifida is often very difficult, and conclusions should be postponed in doubtful cases until an

exploratory puncture has demonstrated the character of the contents of the cyst.

Prognosis.—The prognosis in dermoid tumors is generally favorable, as these tumors grow slowly and often reach only a certain definite size, thereafter remaining stationary. Ovarian dermoids often become dangerous to life from inflammatory complications. The contents of a dermoid cyst of the ovary must always be regarded as of an infectious nature. The escape of the contents into the peritoneal cavity during removal of a cyst has frequently caused septic peritonitis of a most violent character. The sudden increase in size of a dermoid cyst that has for a long time been in a quiescent state indicates either the existence of an inflammation or the transformation of a benign into a malignant tumor.

Treatment.—The proper surgical treatment of a dermoid cyst is complete extirpation. Tapping, seton, irritating injections, and caustics are all inappropriate measures in the treatment of dermoid cysts. In the removal of dermoid cysts it must be remembered that the tumor will surely return if the slightest particle of the lining of the cyst-wall is allowed to remain. The dissection is frequently a very difficult one, and recesses of the cyst-wall are often overlooked; these recesses become the starting-point of the recurrent tumor. If possible, the cyst should be removed without rupturing the cyst-wall. If this can be done, the surgeon has the satisfaction of knowing that the lining has been removed completely, and he can give the patient the assurance that no recurrence will take place.

In the extirpation of dermoid cysts a knife not much larger than a tenotomy-knife should be employed, and very little traction upon the cyst-wall should be made, as this is sometimes exceedingly fragile and easily torn.

TOPOGRAPHY.

Dermoid cysts are found most frequently in those parts of the body where, during the development of the embryo, the different germinal layers meet and blend; this is more especially the case with tumors of complicated structure, in the production of which all the germinal layers take part.

Trunk.—In the embryo the two lateral halves of the body blend in the median line posteriorly from the occipital protuberance to the coccyx. It is in the centre of the body, following the line of coalescence, that dermoids are found, more especially in the region of the sacrum and the coccyx. In this locality dermoid cysts are very apt to be mistaken for spina bifida if the opening in the spinal canal is small

and the integument covering it is normal. The difficulty in diagnosis is increased if, as sometimes happens, the spina bifida is associated with a dermoid. Wild has reported the case of a man twenty-two years old who was born with what was supposed to be a spina bifida in the lumbo-sacral region. The swelling never caused him any pain or inconvenience until it became inflamed, when it suppurated and opened spontaneously, discharging a large quantity of offensive pus, hair, and sebaceous material. The cyst was freely incised. Its wall showed numerous openings of sweat-glands, from which drops of sweat escaped when the patient perspired.

At the junction of the sacrum with the coccyx, and over the coccyx at a point corresponding with the post-anal dimple, dermoid cysts are quite frequently found. They are usually small, and they are often associated with a blind fistulous tract. In a number of cases where cysts in this locality had suppurated a small fistulous opening remained, and when this opening became closed the swelling reappeared and again suppurated.

In the removal of suppurating dermoids in the sacro-coccygeal region the careful use of the probe is necessary to ascertain the extent and exact location of the cyst. The writer has usually found more or less hair as a part of the cyst-contents. The displacement of skin takes place here so frequently because of the early adhesion of the skin to the underlying bone, and the subsequent growth of the surrounding fat and muscle-tissue, causing the dimpling, sinus-formation, or epithelial inclusions as the case may be.

No operation for a supposed dermoid anywhere over the spine should be undertaken until spina bifida has positively been excluded by an exploratory puncture, which can be repeated if necessary.

Thorax.—Dermoid tumors of the thorax are rare. They are found usually over the median part of the chest, over the sternum, or in the anterior mediastinum. Bramann reported a case in which a dermoid cyst of small size was located over the sternum, at the junction of the manubrium with the gladiolus, and a similar cyst in the anterior median line of the neck near the left cornu of the hyoid bone (Fig. 439). Cahan saw a dermoid cyst over the sternum in a child eight months old. The tumor at birth was not larger than a pea. Chitten removed a dermoid having the same situation from a female thirty-nine years of age; the cyst contained eleven ounces of atheromatous material.

The dermoids in the mediastinum spring from a matrix of skin that in the embryo became imprisoned between the two lateral halves of the sternum, becoming detached when coalescence of the sternum

took place. A remarkable specimen of this kind was presented by Mr. Kingdon to the museum of St. Bartholomew's Hospital, London. In the anterior mediastinum of a woman twenty-one years old a tumor, probably of congenital origin, contained portions of skin and fat, serous fluid, sebaceous material, and two pieces of bone, like parts of an upper jaw, in which seven well-formed teeth were imbedded.

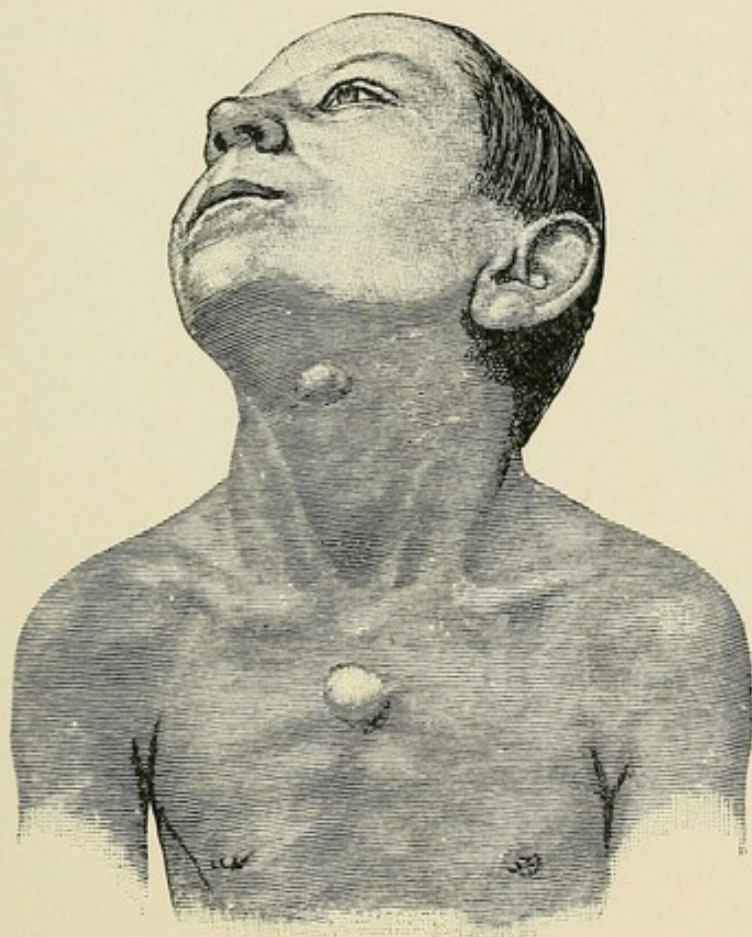


FIG. 439.—Dermoid situated over the junction of the manubrium and the gladiolus of the sternum; there was also a dermoid near the left cornu of the hyoid bone (after Bramann).

In a case of substernal dermoid which projected above the manubrium of the sternum, Roser incised the tumor; after decomposition of its contents had taken place he trephined the sternum, securing in this way efficient drainage.

A large dermoid cyst in the mediastinum may simulate inflammatory disease of the lungs or pleura or a malignant tumor. A suppurating dermoid with rupture into the bronchial tubes would perfectly resemble empyema unless hair were to be discovered in the expectorated material, making the diagnosis of dermoid cyst positive. In suppurating substernal dermoid it would be necessary to resort to resection of a part of the sternum over the cyst to secure efficient drainage and disinfection. Farther than this it would not be prudent

to extend the operative procedure, owing to the importance of the various organs to which the cyst-wall would necessarily be attached firmly.

Face.—Facial dermoids occur in the lines of the facial fissure in the embryo. The central portion of the face in the early embryo is an opening from which five fissures radiate (Fig. 440). "The upper pair

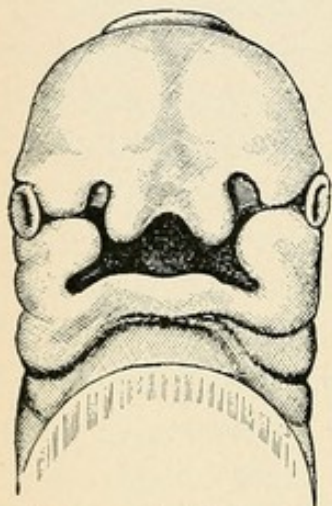


FIG. 440.—Head of an early human embryo, showing the disposition of the facial fissures (after His).

are the orbito-nasal; the two lower fissures are termed 'mandibular;' and a fifth, not shown in the figure, the 'intermandibular' fissure. The median fold projecting into the opening from above is the fronto-nasal process, which ultimately forms the nose. As it develops, a rounded prominence known as the 'globular process' forms at each angle and gives rise to a portion of the ala of the nostril and the corresponding premaxilla. These globular processes fuse together in the middle line to form the central piece, or philtrum, of the upper lip. The elongation of the fronto-nasal process necessarily lengthens the orbito-nasal fissures. Eventually the sides of the fronto-nasal plate coalesce super-

ficially with the maxillary processes in such a way as to leave a cleft on each side, which becomes the orbit, the line of union being permanently indicated in the adult by the naso-facial sulcus or groove, and indicated still more deeply by the lachrymal duct, which is a persistent portion of the original orbito-nasal fissure. The union of the fronto-nasal plate with the maxillary processes completes the nose, cheeks, and upper lip" (Sutton).

From the foregoing description of the development of the face it will be understood that dermoid cysts will appear in certain definite positions, such as the inner and outer angles of the orbit, the upper eyelid, in the naso-facial sulcus, on the cheek slightly posterior to the angle of the mouth, in the middle line of the chin, and on the nose. Dermoid cysts in all these localities seldom exceed a filbert in size. They often contain hair, and they sometimes contain pure oil. The underlying bone shows a shallow or deep depression after their removal. They are firmly attached to the bone; they are frequently congenital; fluctuation is distinct; and the skin overlying them is normal. The most frequent location of dermoid cysts of the face is at the outer angle of the eye. In this situation the orbital arch of the frontal bone often shows a depression deep enough to hold one-half of the cyst. If the cyst occupies the inner angle of

the eye, the nasal process of the frontal bone suffers from pressure-atrophy. The depression in the bones of the face caused by tumors

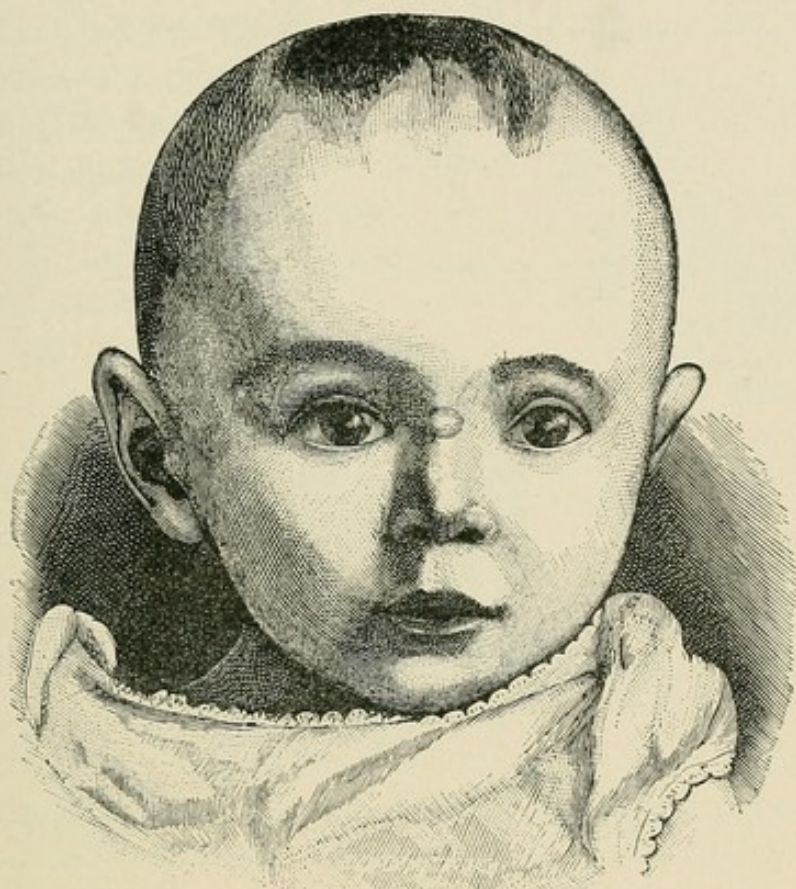


FIG. 441.—Dermoid arising in naso-facial sulcus (after Bramann).

that have existed for a long time diminishes somewhat after their removal, but is never entirely effaced—a matter to be taken into consideration when patients, especially young girls, request an operation for cosmetic reasons.

Nasal dermoids are situated either on the side or over the centre of the nose (Fig. 441).

Palate and Pharynx.—In the hard palate very complicated teratoid tumors containing even a part of a limb have been found. The soft palate is more frequently the seat of ordinary dermoids than the hard palate (Fig. 442). The tumors may attain the size of a hen's egg; they contain often numerous epithelial pearls, and the stroma frequently undergoes myxomatous degeneration. As these tumors are always encapsulated even when pendulous, they can be removed by enucleation.

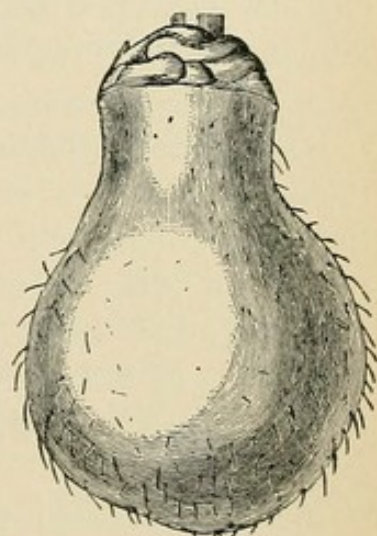


FIG. 442.—Pedunculated dermoid tumor from the pharyngeal aspect of the soft palate (after Arnold).

Scalp and Dura Mater.—Retention-cysts of the sebaceous glands of the scalp may occur on any part of its surface, while dermoid cysts, owing to the manner of development of the cranium in the embryo, are found almost exclusively in the median line, at the occipital fontanelle, and over the anterior fontanelle. Occasionally these tumors are connected with the dura mater. Sutton describes such a specimen. Cases have been recorded in which the tumor reached the size of a cocoanut. As these tumors are congenital and are most frequently located over the anterior fontanelle (Fig. 443), it is not astonishing

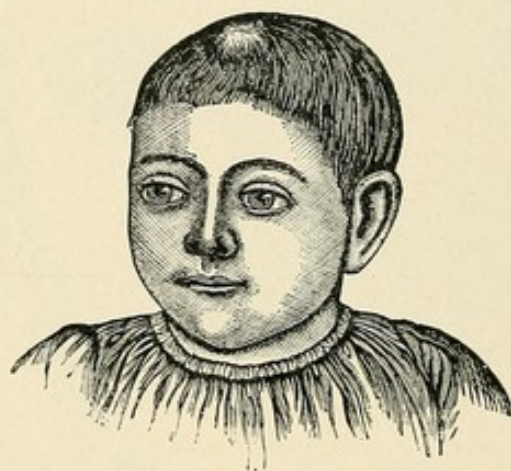

FIG. 443.—Congenital tumor over the anterior fontanelle (after Hutchinson).

that they have usually been mistaken for meningocele. This deception is increased from the fact that in some cases the tumor pulsates. Such a case was published by Arnott. In the case recorded by Giraldis aspiration was performed and a clear serous fluid was withdrawn, but when the tumor was removed some time later it was found to be a typical dermoid.

Dermoids of the scalp are underneath the periosteum; they produce great defects in the bone from pressure. In some instances the pressure-atrophy was so extensive that the bone was perforated. In other cases the tumor was surrounded by a new wall of bone. In rare cases dermoids originate in the bones of the skull. According to Mikulicz, the petrous portion of the temporal bone, the occipital bone, and the frontal bone are the most frequent seats of dermoids.

In the differential diagnosis between retention-cysts of the scalp and dermoid cysts it is important to remember that the former never appear before puberty, while the latter are either congenital or, at any rate, occur during infancy or childhood. The wall of a dermoid cyst is much thinner than that of a retention-cyst. Dermoid cysts are less apt to become infected than retention-cysts.

In the operative treatment of dermoid cysts the possibility of a connection with the dura mater should not be forgotten.

Eye.—The first cases of open dermoids of the bulb were described in 1853 by Riba. Sutton classifies open dermoids of the conjunctiva with moles. They occur most frequently at the margins of the cornea, and usually in the line of the palpebral fissure. In the embryo the tissue which becomes the conjunctiva is continuous with the skin, and by differentiation is derived from the skin. If a part of the epiblast that is intended to form conjunctival tissue should become transformed into skin, it will remain as skin and will form an open dermoid, such as that shown in

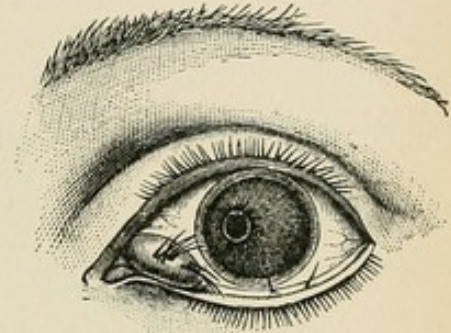


FIG. 444.—Mole on the caruncle, associated with an eccentric pupil (after Demours).

Figure 444. Open dermoids of the bulb are consequently frequently complicated by congenital defects of the upper eyelid, especially the one known as "colombo," which corresponds in its location with the dermoid of the conjunctiva.

Tongue.—Barker collected sixteen cases of dermoid tumors of the tongue and made a special study of their anatomical location. Bryk, who made a most valuable contribution to this subject, removed a tumor, the size of a fist, which filled the entire cavity of the mouth and formed a large swelling in the upper anterior part of the neck, whence it was successfully removed. Bauer and Linhart reported similar cases. Güterbock removed from the lateral aspect of the base of the tongue a cyst of this kind that contained atheromatous material and fine hairs.

Central lingual dermoids are rare. Richet removed one from a child a few days old. Sutton reports, in a man twenty-four years of age, a case of central lingual dermoid which during nine years had been operated upon, without success, seven times. Sutton found the cyst firmly adherent to the body of the hyoid bone, and extending from the genio-hyoglossi to the foramen cecum. Dermoids lying in the middle of the tongue arise in the lingual duct, which extends from the foramen cecum on the dorsum of the tongue to the posterior surface of the body of the hyoid bone. They originate from unobliterated parts of the duct, in the same manner as the branchial cysts originate from partially obliterated branchial clefts. An enormous tumor of this kind was removed from a negro by Wellington Gray (Fig. 445). The tumor contained forty ounces of atheromatous material. In a case operated upon by Stephen Paget, in a child four years old, the

tumor was congenital and contained a yellowish serum. A rare form of tumor of the tongue in the neighborhood of the foramen cecum resembles in structure thyroid tissue. Bernays, who removed such a tumor from a girl seventeen years of age, traced its origin to the lingual




FIG. 445.—Large lingual dermoid protruding from the mouth (after Gray).

duct. Similar cases have been reported by Butlin, Rushton, Parker, and Wolf. Wolf believed that thyroid tumors of the tongue originate from accessory thyroid glands.

Small lingual and sublingual dermoids can be removed successfully through the mouth by enucleation, as the tumors are always well encapsulated; and, unless the walls have become firmly adherent in consequence of inflammation or of inadequate treatment, enucleation can be effected without difficulty. If the tumors are too large for intra-oral operation, they should be removed through a median incision extending from the symphysis mentis to the upper border of the thyroid cartilage. As soon as the pericystium is reached the enucleation is begun. The operation is facilitated by removing the contents of the cyst, after which the sac can be removed through a small incision. In several cases the writer has been able to remove sublingual dermoids the size of a goose-egg through a small incision in the mouth by first evacuating their contents, and then dragging the sac out in the same manner as in the removal of the sac of a retention-cyst of the sebaceous glands.

Rectum.—Dermoids of the rectum and of the space between the rectum and the sacrum are not uncommon; they usually occur as congenital tumors. Sutton explains their embryological origin as follows: "In the early embryo the central canal of the spinal cord and the alimentary canal are continuous around the caudal extremity of the notochord. This passage, which brings the developing cord and gut into such intimate union, is known as the 'neurenteric canal.' When the proctodeum invaginates to form part of the cloacal chamber, it meets the gut at a point some distance anterior to the spot where the neurenteric canal opens into it; hence there is for a time a segment of intestine extending behind the anus, and termed in consequence the 'post-anal gut.' Afterward this post-anal section of the embryonic intestine disappears, leaving merely a trace of its existence in the small structure at the tip of the coccyx, known as the 'coccygeal body.'"

There is good reason to regard the post-anal gut as the source of that variety of congenital sacro-coccygeal tumor named by Braun and several writers who followed him "congenital cystic sarcoma." What was regarded by Braun as tumors of Luschka's gland and congenital cystic sarcoma are thyroid-dermoids.

Diverticula from the central spinal canal forming cysts are sometimes displaced laterally, as in a case operated upon by Wolff in Central Africa, the specimen of which was examined by Virchow. Manuel refers to two dermoid tumors situated in the loose connective tissue between the peritoneum and the levator ani. König observed in a young girl a case of suppurating dermoid in the same location; from the tumor numerous pieces of bone, teeth, and hair escaped. In rare cases such tumors are also found between the bladder and the rectum.

Thyroid-dermoids in the coccygeal region acquire a large size (Fig. 446). Middeldorpf first associated them with the post-anal gut. In the interior of the tumor are spaces or cysts lined by columnar epithelium; these spaces contain a ropy mucus.

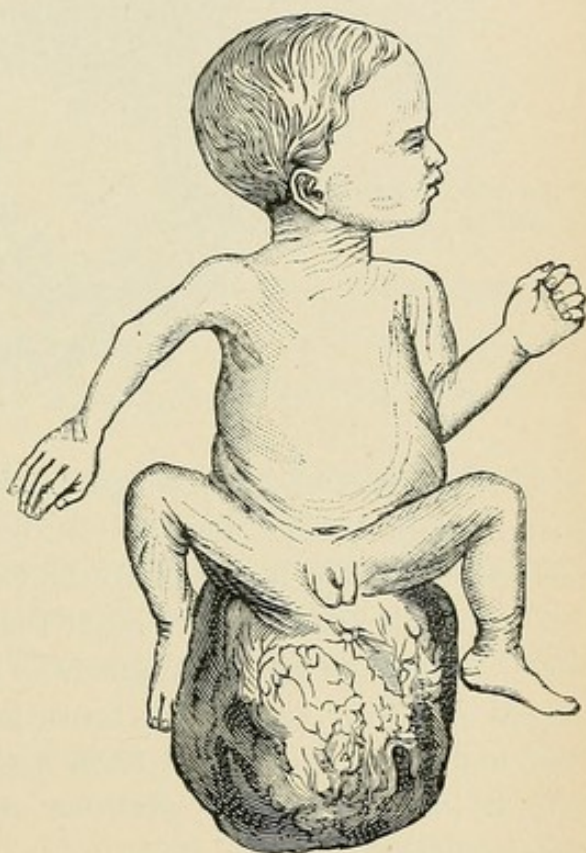

FIG. 446.—Thyroid-dermoid (after Hutchinson).

Dermoid cysts between the rectum and the sacrum often attain great size, and frequently they suppurate. They are found as frequently in men as in women. Interesting cases of dermoids in this location have been reported by Bryant, Ord, and Page.

Open dermoids of the rectum and bladder were first described in 1874 by Danzel and Martini (Fig. 447). The tumors are furnished

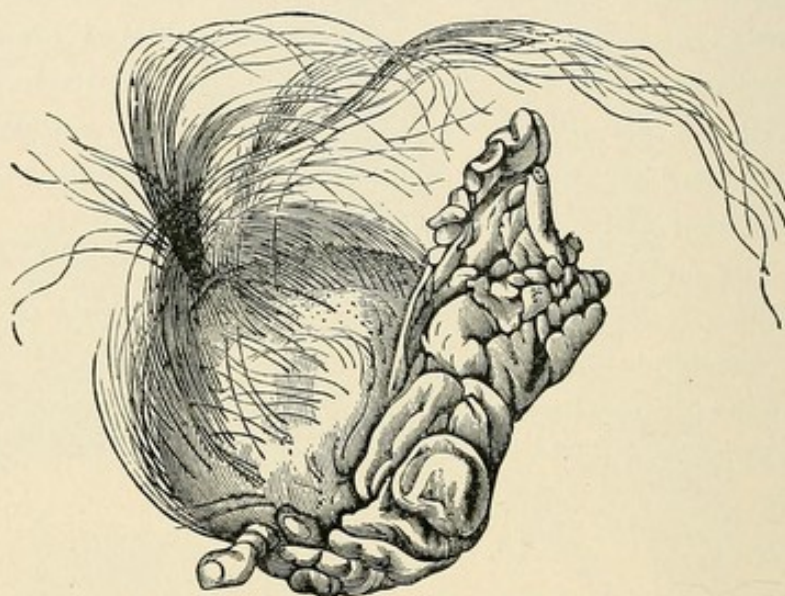


FIG. 447.—Rectal dermoid (after Danzel).

with long locks of hair that protrude from the anus; sometimes they also contain teeth. It was formerly supposed that dermoids of the rectum originated in the ovary and reached the rectum by invagination—an opinion which is no longer tenable. In Danzel's case the tumor was as large as an apple and was said to contain brain-substance enclosed in a bony capsule; a tooth projected from the tumor. Clutton removed a rectal dermoid from a girl nine years of age. In the rectum as well as in the pharynx dermoid tumors eventually become pedunculated.

Auricle.—The external ear in the embryo is formed by coalescence of a number of tubercles. If, during the process of fusion, an island of skin becomes buried, it forms a matrix from which at any time a dermoid cyst may grow. Dermoids of the auricle never attain large size, and they are usually mistaken for sebaceous cysts. The tumor sometimes occupies the groove between the pinna and the mastoid process.

The removal of pedunculated open dermoids of the rectum offers no difficulties; on the contrary, the extirpation of perirectal tumors requires often a formidable operation. Usually the difficulties of operative removal are increased by inflammation and suppuration, which render the dissection tedious and difficult. The writer remembers dis-

tinctly a case of post-rectal dermoid which had suppurated and ruptured just below the coccyx. When the case was examined there was found an opening, large enough to admit three fingers, lined by skin and leading into a cavity, the size of a child's head, lined with hairy skin. In this case the decision was against operative interference, as the cyst-wall gave rise to no inconvenience, and the writer could hardly imagine in what manner such a large cavity could be made to heal after dissecting out the entire sac.

In suppurating dermoids it may become necessary to make counter-incisions for the purpose of establishing more efficient drainage; and the removal of the entire cyst-wall in suppurating post-rectal dermoids may require excision of the coccyx and of one or more of the sacral vertebræ as a preliminary step to the removal of the tumor.

Tumors which are attached to the sacrum should not be removed, as they may be connected with the spinal canal.

Ovary.—Olshausen, who collected from different sources statistics of 3275 cases of ovariectomies, ascertained that dermoid tumors were represented by about $3\frac{1}{2}$ per cent. Ponpinel collected 44 cases in which both ovaries were similarly affected.

Histology and Histogenesis.—Waldeyer offered a novel explanation of the origin of dermoid tumors in the ovary. He maintained that the normal epithelial cells of the ovary, which must be considered as undeveloped ovum-cells, under certain circumstances, without intercurrent of spermatozoa, undergo a parthenogenetic development during which they furnish, in the direction of an imperfect embryonal development, products different from themselves. This theory could hardly be entertained seriously at the present time, in view of the embryological investigations which have been made regarding the origin of similar tumors in other organs. Epithelial cells cannot produce bone; and teeth only grow from a matrix of cells producing their essential histological parts, dentine, enamel, and cementum.

Dermoids of the ovary arise, as do dermoids of any other part or organ, from matrices derived from an erratic development in the embryo. In the embryo the ovaries develop from the genital ridge, which

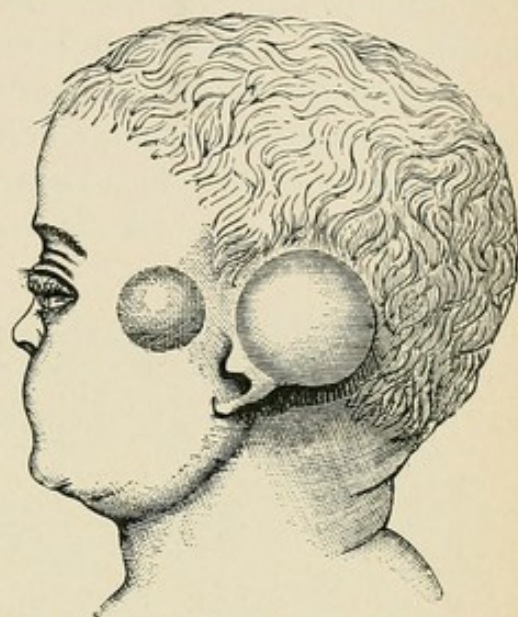


FIG. 448.—Dermoid of the auricle and nevus of the palpebral conjunctiva (after Lannelongue).

at an early date is intimately associated with the cells lining the peritoneum and connected with the peritoneal funnels. The origin of the Wolffian duct is intimately connected with the epiblast; consequently the ovaries are the seat of the most complicated histological processes during their development, and must necessarily frequently become the seat of rests which, when excited to active tissue-proliferation, furnish

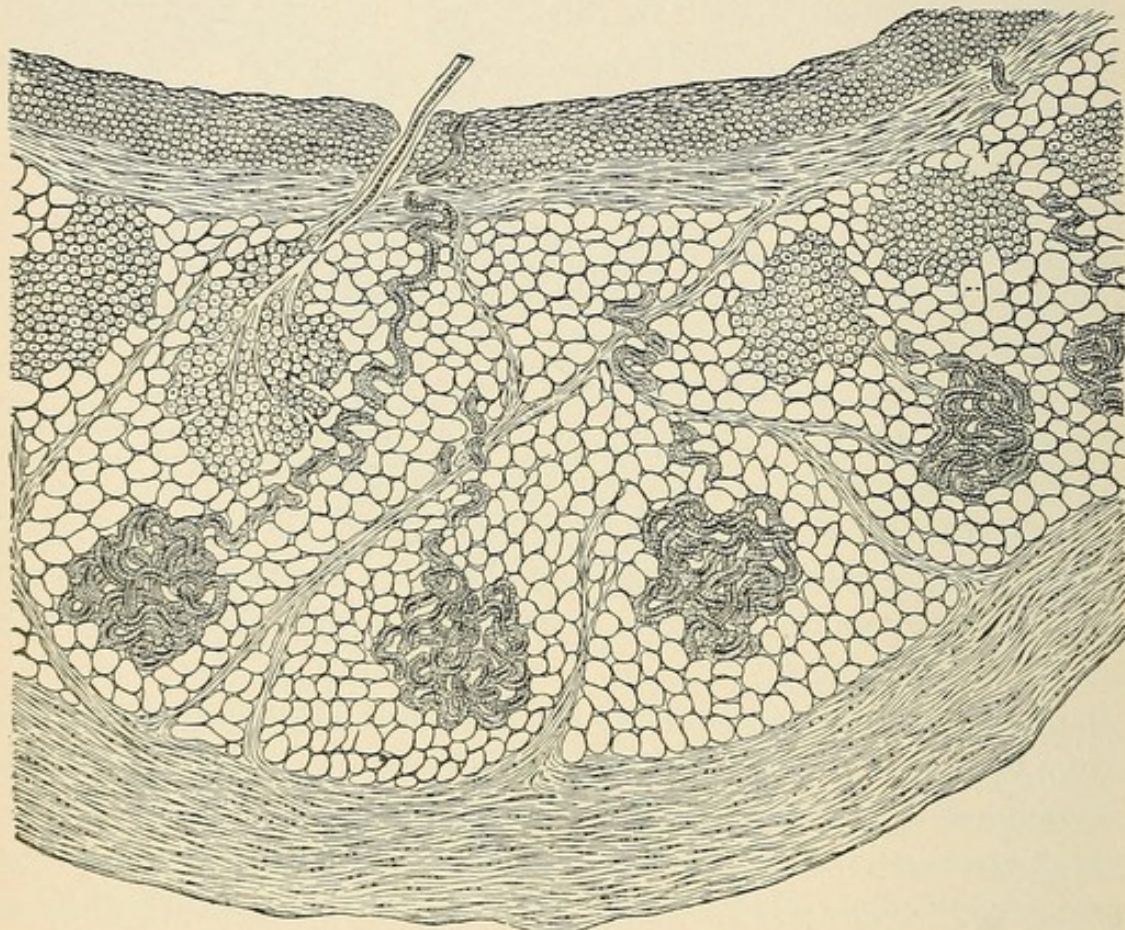


FIG. 449.—Dermoid cyst of the ovary (after Wyder). The cyst-wall was filled by a fatty mass enclosing reddish hairs. The structure of the wall is seen to be like that of the skin. The upper stratum in the illustration (the inner layer of the cyst) is formed of closely-packed cells, flattened toward the surface by mutual pressure. Beneath are two layers of fibrous tissue separated by loose adipose tissue. The fibrous stroma of the latter is formed by fibrillæ from the two connective layers. An important detail of this specimen is the presence of sweat-glands by the side of sebaceous glands and hair-follicles.

the material for the different kinds of dermoids. We observe here the simplest kinds of dermoid cysts, containing nothing but atheromatous material, as well as the most complicated forms, in which there are found not only hair and teeth, but also brain-tissue, mucous membrane, and incomplete skeletons. So many fetal parts are sometimes found in dermoid tumors of the ovary that they have been regarded as instances of ovarian pregnancy, and have been the means of questioning the morality of many innocent patients.

Cyst-walls which represent the external skin in their structure frequently contain all the appendages of the skin (Fig. 449). The papillæ of the skin are usually not well developed; in other instances they

become the seat of papillomatous excrescences. Cysts with a dermal lining contain the product of epithelial proliferation, which forms a pul-taceous mass, variable in its consistency, resembling in every respect the contents of sebaceous cysts. The lanuginose hair may consist of a fine down or may grow to the length of several feet (Fig. 450). The hair is of a yellowish or reddish color, and as it is shed from the fol-licles it accumulates in the cyst in masses pasted together by the seba-ceous material.

Plates of compact bone are frequently found in the cyst-wall; they are sometimes connected by a fibrous union, as was first pointed out by Labbé and Verneuil. The teeth, which are never perfect, project

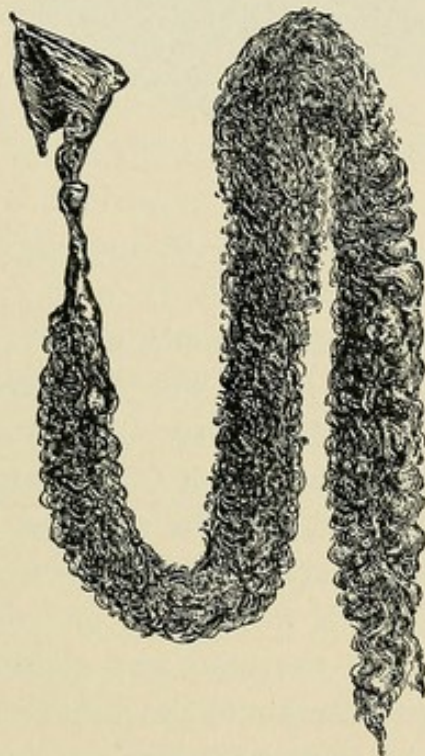


FIG. 450.—Switch of hair five feet long taken from dermoid cyst (after Mundé).

into the cavity; they are often loosely inserted into imperfect alveoli, and they may vary in number from one to several hundred. Auten-rieth found in one dermoid cyst over three hundred teeth. The teeth are often surrounded by tufts of hair (Fig. 451). Cruveilhier quotes a case where nails were found in a dermoid cyst. In a specimen examined by Baumgarten, besides skin, hair, and teeth, there was found a body which represented an imperfect eye. Brain-matter was found by Virchow, Key, and Rokitansky; other pathologists have found nerve-filaments supplying the teeth. Cholesterin-crystals are usually present in abundance in the atheromatous material in der-moid cysts.

Mucous cysts in dermoid cysts of the ovary are derived from rests

of the embryonic intestinal canal. They are lined with columnar epithelium. The contents of such cysts consist of mucus, and in cases of long standing the mucus is often converted into a serous

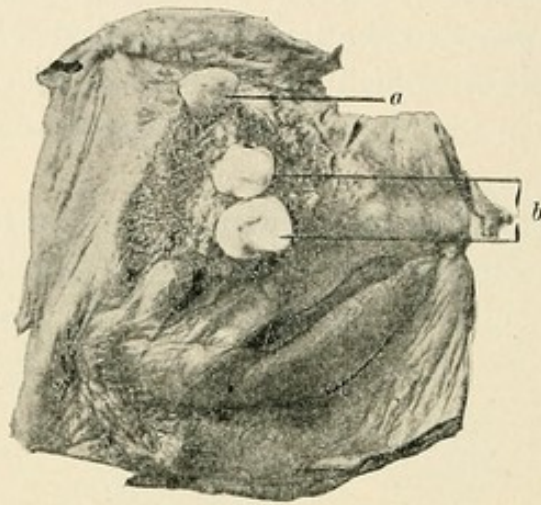


FIG. 451.—Part of cyst-wall from dermoid cyst of ovary (after Winckel): *a*, canine tooth; *b*, two molar teeth.

fluid and the stroma is very likely to undergo myxomatous degeneration.

Clinical Aspects.—Ovarian dermoids grow very slowly, but they may eventually attain great size. The beginning of the growth can usually be traced to the age of puberty. The tumor-matrix participates in the increased physiological activity observed in the skin and its appendages at this time. At first the tumor is movable and painless. Localized peritonitis, which undoubtedly occurs frequently in consequence of a mild infection, is productive of pain and is followed by adhesions. If the tumor is movable and pedunculated, it may rotate on its axis, thus leading to torsion of the pedicle. This accident results in serious disturbances of the circulation in the tumor. If the veins are more obstructed than the arteries, there results intense venous congestion, manifested by pain and by an increase in the size of the tumor. If the circulation is completely interrupted in acute torsion, gangrene of the tumor and death from septic peritonitis will follow. If the circulation is interrupted more gradually, the tumor often receives a new blood-supply from adjacent organs through adhesions. In a few cases of this kind the pedicle disappeared entirely and the tumor was found attached to adjacent organs. Such a tumor, which had become attached to the omentum, from which it received its blood-supply exclusively, was removed by Sir George Humphrey.

Very often a dermoid tumor is associated with cystic disease of the ovary, in which case it is overshadowed by the symptoms produced by the cystic part of the tumor, which is frequently the largest part of the

mixed tumor. There may be a dermoid cyst on one side and a mucoid cyst upon the other. Rupture of a dermoid is often the cause of a fatal peritonitis. In a few instances this accident has been followed by multiple secondary dermoids on the peritoneum. The secondary tumors, each of which is furnished with a tuft of lanugo-like hair, are usually the size of a cherry, and occur in clusters or imbedded in adhesions.

The entrance of pyogenic microbes into a dermoid cyst, either through a small perforation in the intestine, by puncture with an aspirating needle, or by the localization of floating microbes, produces a suppurative inflammation with all its immediate and remote consequences. Death from peritonitis is a frequent termination of this complication. If the peritonitis is circumscribed, rupture of the cyst occurs, with escape of its contents at the umbilicus or through the rectum, vagina, or bladder.

The escape through the sinus of hair, teeth, or fragments of bone indicates the character of the cyst. Spontaneous healing of the fistula in such cases seldom if ever takes place unless the entire cutaneous lining of the cyst is destroyed by the inflammation.

In the removal of ovarian dermoids the trocar must be used with caution, as the escape of the contents of the cyst may cause septic peritonitis or dissemination of the tumor by epithelial infection.

The removal of suppurating dermoid cysts which have ruptured on the surface or into one of the adjacent organs is always an exceedingly difficult operation, and one attended by great risks to life. Many cases of suppurating dermoid cysts have been mistaken for extra-uterine pregnancy.

In dermoid cysts which are adherent to the floor of the pelvis extirpation through the sacral route offers great advantages.

Scrotum.—There is no doubt that most of the cases of dermoid tumors of the testicle that have been reported were not within the testicle, but were upon it—that is, were dermoids of the scrotum. That dermoids in this locality are not common is evident from the fact that Kocher found only fourteen cases recorded in literature. The teratoid tumors of the scrotum are always congenital, and a correct diagnosis is generally made only after the character of the contents has been ascertained by suppuration and rupture or during an operation for removal of the tumor. Verneuil attributed their origin to fetal inclusion—*inclusion scrotale et testiculaire fœtus in fœtu*. Lebert and Paget regarded them as heterotopic tumors. They originate undoubtedly, like the dermoids of the ovary and of other organs, from misplaced matrices of embryonal tissue. Scrotal dermoids present often a very complicated structure. The simplest cysts contain sebaceous material

and hair. In the more complicated cysts brain-substance, striated muscular fibres, and bone have been found. The cysts grow slowly; occasionally they suppurate and rupture spontaneously, in which event the character of the escaping material indicates the nature of the cyst.

The testicle is usually found atrophied from pressure and functionally useless. If the cyst is extirpated, the testicle should be removed with the tumor. Extirpation of the tumor without castration has not yielded satisfactory results.

XXX. RETENTION-CYSTS.

ALL true tumors are composed of new tissue produced from matrices of embryonic cells. All inflammatory swellings are composed of, or are derived from, pre-existing tissue. It remains for us to discuss in this section a form of swelling composed of a sac of pre-existing tissue, with an accumulation of some one of the secretions or excretions of the body as its contents.

Definition.—*A retention-cyst is a swelling due to the retention in a pre-existing space of a physiological secretion or excretion by obstruction of the outlet of a gland.*

The enlargement of a part should be named in accordance with the histogenetic source of its cellular elements, according to which a "hypertrophy" consists of a numerical increase of the tissue-elements of a part or an organ. The term "tumor" should be restricted to a localized production of tissue independently of mature normal cells; "inflammatory swellings" should include all enlargements consisting of cells derived from the blood or by proliferation of mature tissue, or of accumulations of serum or synovia in pre-existing spaces; and "retention-cysts" should occupy the ground covered by the definition preceding this paragraph.

The greatest confusion exists in the minds of the student in differentiating, from etiological and pathological standpoints, between the different kinds of cysts; this confusion is largely due to the manner in which the subject is treated even in the most recent text-books. A cystoma is a true tumor in which both walls and contents are new products derived from a tumor-matrix.

We have seen that all tumors undergo cystic degeneration by regressive metamorphoses or by the cells producing a secretion which accumulates in the tumor-tissue, owing to the absence of an excretory duct. A cyst may also form in consequence of the extravasation of blood into tumor-tissue or into normal tissue; and, lastly, many so-called "pseudo-cysts" are produced by transudations into pre-existing serous spaces. It would be just as proper to call a hydrops of the knee-joint a "hydrothorax," or a hydrocephalus a "cyst," as a hydrocele.

Pathological accumulations of synovia or of serum in serous cavi-

ties and in parasitic cysts do not come under the head of retention-cysts. They are inflammatory products, and have no place in a treatise on tumors. The writer will therefore exclude from this section the hydroceles, diverticula, bursæ, neural cysts, and parasitic cysts. A true retention-cyst can form only in organs that produce a physiological secretion or excretion which is discharged by an outlet upon the skin or upon a mucous or serous surface; in other instances the secretion is absorbed at the place where it is produced.

The only instance in which, normally, a glandular secretion is discharged into a serous cavity is furnished by the Graafian follicles of the ovary. The secretion of the follicles of the thyroid gland in a normal condition is absorbed; but if, for any reason, absorption is suspended, the follicles become dilated and eventually form retention-cysts.

Histology.—The cyst-wall is composed of the connective tissue, basement membrane, and epithelial lining of the follicle, tubule, acinus,

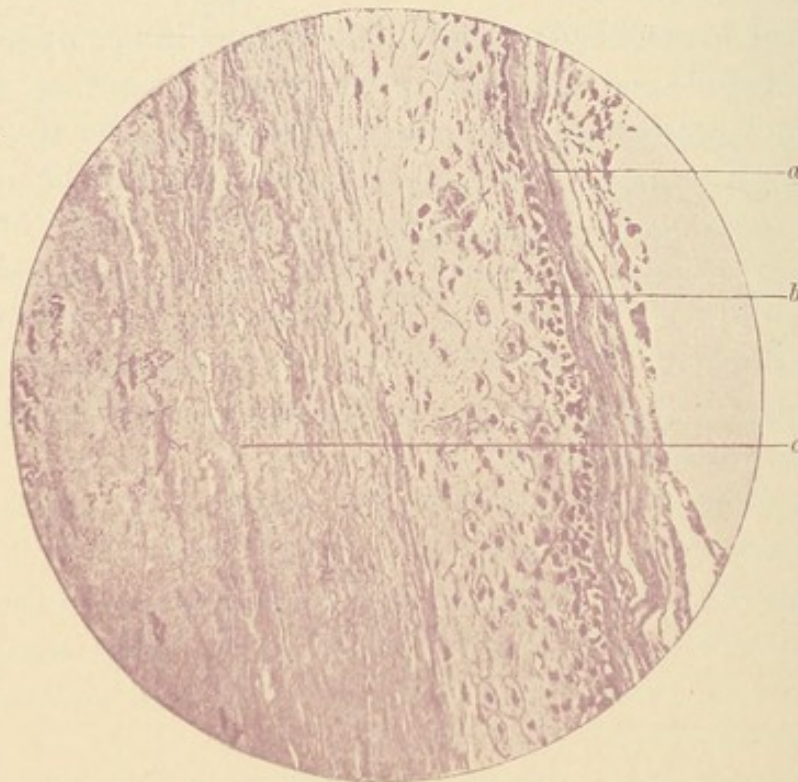


FIG. 452.—Wall of atheromatous cyst (after Boyce): *a*, fibrous wall; *b*, epithelial layer; *c*, horny amorphous transformation of epithelium. (Obj. $\frac{1}{4}$ inch, without eye-piece.)

or duct which has become obstructed. The amount of connective tissue as compared with the normal structure of the part affected varies greatly. If the obstruction is acute and the part on the distal side continues to secrete, the pre-existing spaces, according to the activity of the physiological function of the part affected, dilate rapidly, resulting in distention of the gland or duct, with thinning of the wall. If the obstruction forms slowly and the amount of the retained secretion

accumulates slowly, the cyst-wall is often enormously thickened by the formation of new connective tissue. The best illustration of the former condition is furnished by acute hydronephrosis, and of the latter by sebaceous cysts. The epithelial cells which line the cyst-wall correspond in structure and manner of arrangement with the epithelial cells which exist normally in the lining of the obstructed space.

Cysts of glands lined by stratified epithelium show stratified layers of squamous epithelium (Fig. 452). If the cyst forms in a duct or a gland lined by columnar epithelium, the cyst, at least in its early stages, is lined by columnar epithelium.

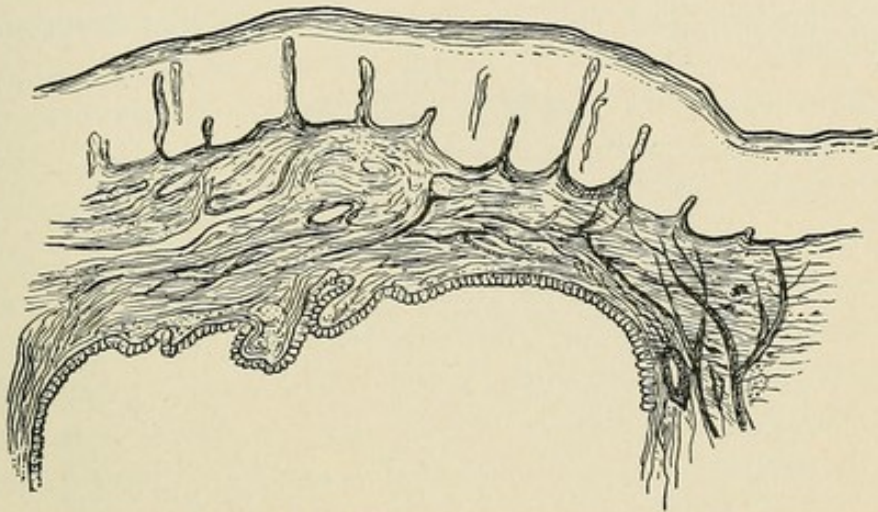


FIG. 453.—Section of the wall of a cyst of the vagina (after Schröder). The external surface is the pavement epithelium of the vagina; the internal, the cylindrical epithelium of the cyst.

In branchial cysts, as well as in retention-cysts of other tubes or ducts lined by similar epithelium, the cyst-wall is always found lined by ciliated epithelium. Through great pressure the columnar epithelium is often flattened, resembling squamous epithelium, but it always retains its intrinsic capacity to produce, under more favorable auspices, cells of its original type.

Retention-cysts result from mechanical obstruction of the outlet of glands, leading to the accumulation of the secretion behind the point of obstruction. If the obstruction is located near the point at which the secretion is produced, the cyst forms at this point, as is the case in obstruction in a ductlet of an acinus of a gland. If the obstruction is located in a duct some distance from the point at which the secretion is produced, the obstructed duct becomes distended and forms the wall of the retention-cyst.

The cyst-contents are subject to various changes. If inflammation of the cyst-wall occurs, the contents of the cyst are modified by the addition of inflammatory products. Hemorrhage into the cyst, according to its amount, may simply stain or may constitute the bulk of the

cyst-contents. In cysts lined by stratified epithelium the product of epithelial degeneration forms the well-known atheromatous material, which is subject to still further changes. In young cysts this material appears as a hard mass composed of cells arranged in concentric layers, while in old cysts the cells disintegrate and the detritus is suspended in a serous fluid, presenting the appearance of a thin emulsion. The addition of fat- and cholesterin-crystals further modifies the appearance of the cyst-contents. In mucous cysts the mucoid material is frequently transformed into a clear serous fluid. Cysts frequently become isolated from the gland in which they originated by complete obliteration and detachment of the duct. In retention-cysts that have not been the seat of inflammation the outside of the cyst-wall is surrounded by

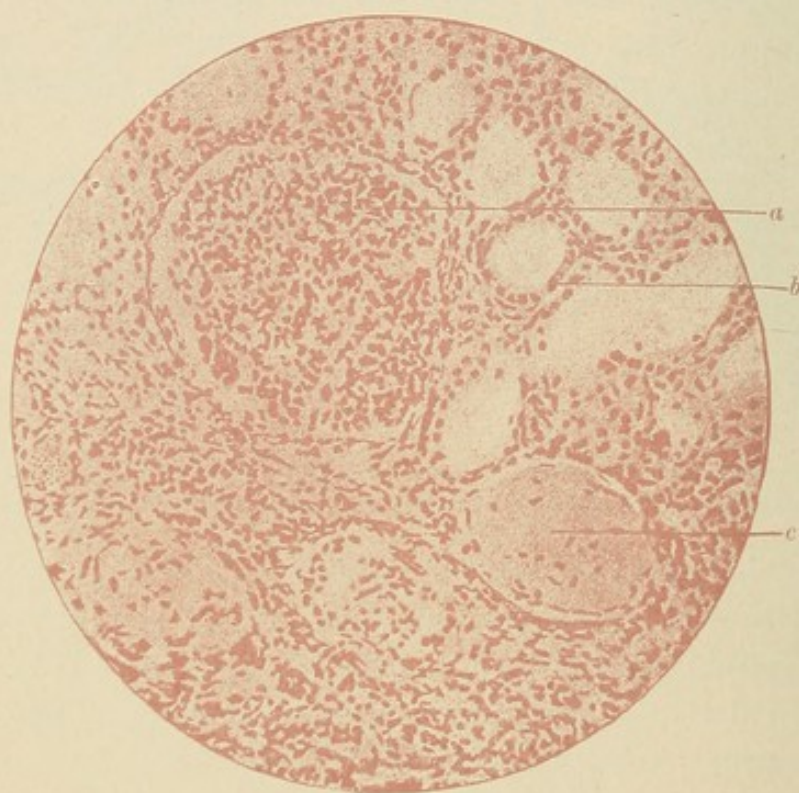

FIG. 454.—Chronic interstitial nephritis (after Boyce): *a*, glomerulus with connective-tissue cell-proliferation; *b*, commencing cystic dilatation of renal tube; *c*, fibroid glomerulus. (Obj. $\frac{1}{4}$ inch, without eye-piece.)

a delicate, loose, vascular layer of connective tissue which supplies the cyst with blood-vessels, and which is such an important structure in removing cysts by enucleation—the pericystium.

Etiology.—The mechanical obstruction which is invariably the cause of retention-cysts may be—1. Inflammation; 2. Cicatricial stenosis; 3. Tumors; 4. Flexion of a duct, and 5 valvular closure; 6. Altered secretion; 7. Impaction in the duct of a foreign body, a concretion, or a parasite. By far the most frequent cause of mechanical obstruction is inflammation and its consequences.

The effect of inflammation in the production of an obstruction to the

outflow of a secretion can be studied most profitably in the kidney. In chronic interstitial nephritis the over-production of connective tissue obstructs the outflow of urine by obstructing the tubules (Fig. 454). The cicatricial contraction of the connective tissue narrows the tubules, resulting in increased intratubular pressure and destruction of the tubule above the seat of obstruction.

The immediate effects of acute inflammation of the mucous membrane of a gland-duct is well illustrated in catarrhal duodenitis, which so constantly results in retention of bile and in icterus. Catarrhal inflammation of the mucous membrane of the cecum is a frequent cause of retention of secretion in the appendix vermiformis, resulting from narrowing of the lumen of the organ on the cecal side. Acute inflammation, as a rule, gives rise to temporary obstruction, which disappears with the subsidence of the inflammation. The acute inflammation, however, may be followed by conditions resulting in permanent obstruction from cicatricial contraction or flexion of a gland-duct. Cicatricial stenosis of a duct follows most localized ulcerative processes. Valvular obstruction may exist as a congenital affection, as is the case in hydro-nephrosis developing in consequence of a valvular obstruction at a point where the ureter expands into the pelvis of the kidney; or it may exist in consequence of inflammation. The secretion of a gland may be so altered that it cannot escape through the normal outlet of the gland: this condition in itself would result in accumulation and progressive increase of the mechanical difficulties, as the retention of the secretion would naturally produce irritation, and the irritation would give rise to progressive stenosis of the outlet of the gland.

The effect of the impaction of a concretion in the gland-duct in producing obstruction is well shown in cases of impaction of a biliary calculus in the cystic or common duct, and of a renal calculus in the ureter. In rare cases a gland-duct is made partially or completely impermeable by the impaction of a foreign substance or of one of the large parasites which infest the human body. Tumors may produce obstruction of a duct by growing into its lumen, by compression, or by the production of a flexion.

Symptoms and Diagnosis.—The swelling increases in size slowly or quickly according to the degree of obstruction, the size of the gland, the character of its secretion, or the quantity of secretion produced. An atheromatous cyst increases very slowly in size, while an acute obstruction of the duct of the gall-bladder or of the ureter results in rapid destruction of the obstructed organ and the formation of a swelling of considerable size in a short time. The writer has made numerous experiments on dogs to ascertain the immediate effects of complete

obstruction of the ureter. The ureter was cut transversely about three inches below the pelvis of the kidney; the proximal end was tied in a knot, and loosening of the knot was prevented by tying it with a catgut ligature. Almost all the animals survived the operation. They were killed in from a few days to six months after the operation. Considerable destruction of the pelvis of the kidney and the ureter was observed a week after the operation. The distention continued progressively, so that after three months the kidney on the side operated upon was at least four times as large as the opposite one. After six months the kidney consisted simply of a large bag filled with a clear fluid. To the naked eye all kidney-tissue appeared to have been removed by pressure-atrophy, but under the microscope sections of the thin cyst-wall showed normal kidney-tissue, but in an exceedingly atrophic condition.

It is of interest in this connection to relate the effects of nephrotomy on the kidney. Soon after a lumbar renal fistula was established the amount of secretion began to increase, and it was shown by examination of the kidney at different periods after the nephrotomy that regeneration of kidney-tissue occurred, so that in a few months the kidney nearly recovered its normal size and function.

Rapid growth of the cyst in some organs which produce large quantities of secretion—as, for instance, the liver and the pancreas—is prevented by the absorption of the secretion. Mechanical obstruction of the common bile-duct does not produce marked distention of the bile-duct or gall-bladder, because the bile is removed by absorption, which in this instance is well demonstrated by the progressive icterus which follows the obstruction. The intensity of the icterus is a good indication of the extent of the obstruction. Obstruction of the cystic duct leads to distention of the gall-bladder, because the secretions of the gall-bladder are not removed to the same extent by absorption.

The writer made a long series of experiments on dogs for the purpose of studying the effects of obstruction of the pancreatic duct in the production of cysts of the pancreas. He had been led to believe that mechanical obstruction to the escape of pancreatic juice was the principal factor in the etiology of pancreatic cysts. The pancreatic duct was divided near the duodenum, and the distal end was obstructed in various ways. In some of the cases the distal end was left open, the gland continued to secrete, and the pancreatic juice was absorbed from the abdominal cavity as rapidly as it escaped into it, without any detriment to the animal; in fact, animals thus treated were after several weeks in a better condition than when the distal end was tied. In the

numerous experiments made by dividing the duct and ligating the distal end, only in one case did the writer find, after many weeks, the duct uniformly dilated to the size of an ordinary lead-pencil; in the other cases little or no dilatation of the duct was produced by the ligation. The pancreatic juice was absorbed as fast as it was produced, and in the case in which the dilatation of the duct reached the size of a lead-pencil there were found in the pancreas textural changes which must have seriously interfered with auto-absorption of its secretion. Cyst-formation to any considerable extent is therefore only to be expected in obstruction of the outlet of glands the secretion of which is not amenable to auto-absorption and in which the obstruction to the escape of the secretion is complete.

Pain is present, as a rule, only in cases in which rapid distention takes place and the swelling acquires considerable size. Pain becomes a conspicuous clinical feature in all cases of retention-cysts complicated by infection and inflammation.

Retention-cysts are much more liable to become infected than other cysts, because the spaces which serve as starting-points for the cysts not infrequently contain, in a normal condition, pathogenic microbes, or when the obstruction is incomplete, as is most often the case, microbes enter later. The microbes in retained secretions are much more liable to assert their specific pathogenic qualities than when the same number are present in the space in a normal condition, because they are retained with the secretion, and the latter frequently constitutes a favorable culture-medium for their growth and reproduction. The retention of the secretions can often be ascertained by evidences pointing to their absorption, as is the case in absorption of the common bile-duct; or it can be learned from examination of the secretion, as is always done by examination of the urine in suspected renal affections.

The location of the cyst is of great importance in the differential diagnosis between retention-cysts and other cysts. A retention-cyst always occupies the location of the affected organ. An atheromatous cyst can occur only in parts of the skin in which sebaceous glands normally exist. A retention-cyst of the gall-bladder will occupy the position in which the gall-bladder is normally situated. A hydro-nephrotic kidney will be found in the location normally occupied by the kidney. A retention-cyst, from its size, may wander away from the place at which it had its starting-point, but the early history of the case usually points to the position normally occupied by the affected organ.

The character of the contents of a retention-cyst can often be ascertained only by an exploratory puncture.

Prognosis.—The danger to life from a retention-cyst depends upon the physiological importance of the organ affected and upon the occurrence of complications. Small retention-cysts of unimportant glands not only are harmless, but give rise to no symptoms. Retention of urine caused by obstruction of one or of both ureters may destroy life in a short time. Rupture of a retention-cyst of any of the abdominal organs often results in fatal peritonitis. All retention-cysts are apt to become infected, when the complicating suppurative inflammation and its consequences constitute the chief sources of danger.

Treatment.—The treatment of a retention-cyst has for its aims the removal of the primary cause, the obstruction, and, if this cannot be done, the establishment of an external fistula or the extirpation of the cyst. If the outlet of the gland has become obstructed by inflammation, the rational treatment consists in combating the inflammation. If the duct of a gland has become blocked by the impaction of a concretion or a foreign substance, the removal of the impacted body, if this can be done, is indicated. If the duct has become completely obliterated by cicatricial stenosis, the formation of an external or an internal fistula or extirpation of the cyst constitutes the proper surgical treatment. If the lumen of the duct has become narrowed by inflammatory thickening of its mucous lining, the removal of intracystic pressure by the formation of a temporary external fistula is often the most efficient way in which to subdue the inflammatory affection and to restore the normal size of the passage. Should this treatment not yield the desired result, a radical operation will prove safer after inflammation has subsided.

In the extirpation of retention-cysts surrounded on all sides by tissues, the cyst should be exposed by an incision made in such a way as to render the cyst most accessible, and as soon as the pericystium is reached the cyst should be enucleated by the use of the fingers and of blunt instruments, and, if the cyst is not too large, without rupturing the sac. If the sac, as the result of inflammation, has become adherent to the adjacent tissues, it can be removed safely and completely only by a careful dissection. In retention-cysts which have ruptured externally and which cannot be removed safely a radical cure can often be effected by enlarging the fistulous opening sufficiently to render the whole interior of the cyst accessible, after which the epithelial lining may be destroyed by deep cauterization with the Pacquelin cautery; the cavity is then packed with iodoform gauze until the surgeon can satisfy himself that every particle of mucous membrane has been destroyed, when the wound is allowed to heal by granulation.

TOPOGRAPHY.

Thyroid Gland.—The thyroid gland is one of the ductless glands, and in case the secretion from any part of the gland fails to become absorbed, it accumulates in one or more follicles of the gland, resulting in a simple cyst or in follicular cysts. We have already described cystoma and adenomatous cysts of the thyroid gland, as well as cystic degeneration of other tumors of this organ, but follicular cysts are the genuine retention-cysts of the thyroid gland. The pre-existing connective tissue of the gland forms the capsule of the cyst, which in its interior is lined by endothelial cells; these cells, as cystic dilatation proceeds, are very apt to disappear, leaving the cyst-wall bare or barren. By the coalescence of several follicular cysts there are formed cysts of considerable size that fluctuate distinctly. Cholesterin-crystals are frequently found in retention-cysts of the thyroid gland.

Unless complicated by inflammation, retention-cysts of the thyroid gland can readily be removed by enucleation. Their treatment by tapping followed by the use of irritating injections is uncertain and unsatisfactory.

Ovary.—The ovary is another organ in which we find genuine retention-cysts. If, from thickening of the walls of a Graafian follicle, rupture and escape of the ovum fail to take place, the follicle becomes distended and a follicular cyst is the result. All the large ovarian cysts are tumors which develop from a tumor-matrix, as an adenoma, a cystoma, or a dermoid. The impression still prevails that many of the large cysts of the ovary are retention-cysts. This view is no longer tenable, as it has been shown that single follicular cysts of the ovary do not acquire a size larger than that of a walnut, and that by coalescence of several cysts masses larger than a fist are seldom met with. (See Fig. 100, p. 193.) The imprisoned ovum in the hydropic follicle is destroyed. These cysts contain a clear yellowish or bloody serum. In one case Pozzi found, besides serous cysts, others which contained a cheesy or lardaceous material which he regarded as the product of epithelial degeneration. The cysts are lined by cylindrical epithelium, and upon the most prominent parts of the cyst-wall small blood-vessels are visible. Ovula have been found in retention-cysts of the ovary by Ritchie and Webb, Lawson Tait, and Rokitansky. Very often both ovaries are simultaneously affected.

The removal of retention-cysts of the ovary is more akin to a castration than an ovariectomy, so far as the technique and the ease with which the operation can be performed through a small incision are concerned.

Skin.—The skin is the seat of retention-cysts of the sebaceous glands and the sweat-glands, the former of which are by far the most frequently affected. The sebaceous cysts are also called "atheromatous cysts," from the character of their contents. They are found most frequently in the scalp, but they may occur in the skin of any part of the body where sebaceous glands are present. As the sebaceous glands are connected with hair-follicles, the retention-cysts frequently contain fine lanuginose hair.

Comedo represents the smallest sebaceous cyst. The outlet of the gland is obstructed by a minute black mass which completely blocks the lumen of the duct. If the duct of a comedo becomes completely obliterated by cicatricial contraction, and its contents inspissate,

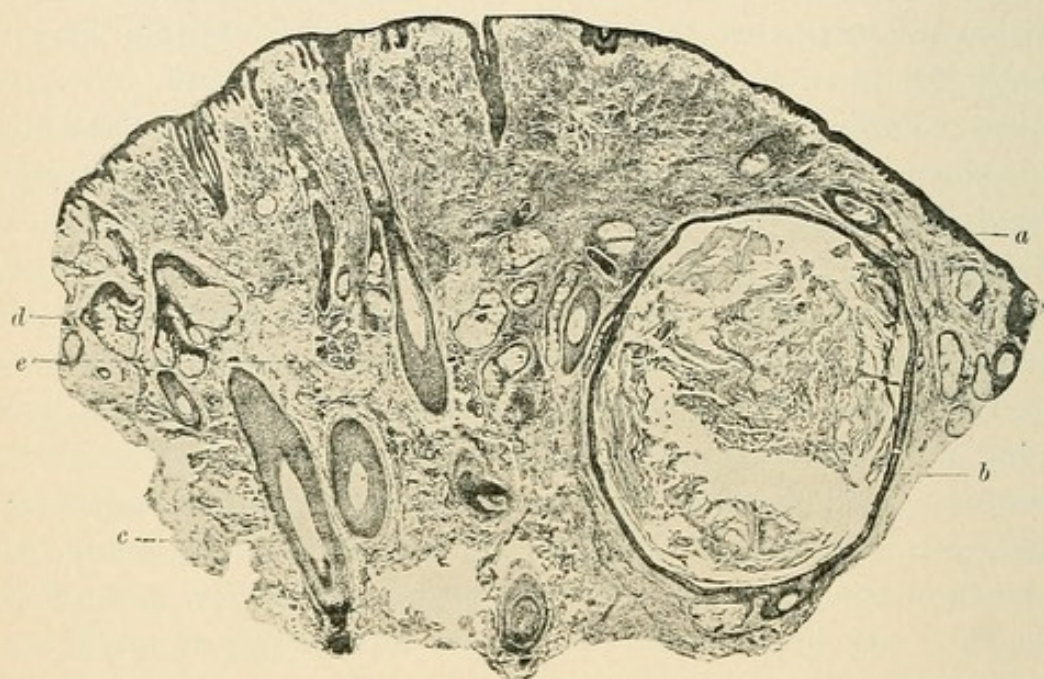


FIG. 455.—Atheromatous cyst of the skin of the cheek; $\times 18$ (after Karg and Schmorl). Under the normal epithelium (*a*) lies a small atheromatous cyst, the wall (*b*) of which is composed of connective tissue in which can be seen remnants of sebaceous glands flattened by pressure; the cyst is lined by stratified layers of squamous epithelium; the pultaceous contents consist of fat-needles and plates of cholesterol; the cutis is infiltrated; *c*, shaft of hair; *d*, sebaceous gland; *e*, sweat-glands.

it presents itself under the epidermis as a small white spot, but slightly elevated, which is called a *milium*. The different forms of acne are comedos in a state of inflammation.

In the deeper forms of sebaceous cysts the cyst-wall is separated from the cutis and the connection with the skin is finally lost (Fig. 455).

Astley Cooper first pointed out that sebaceous cysts result from obstruction. The obstruction is first the result of accumulation of the secretion at the inflamed outlet of the gland, while material from without forms the black plug in comedo; later the inflammation results in cicatricial stenosis, and finally in complete obliteration of the duct and

isolation of the cyst from the skin. The cyst is surrounded by the vascular pericystium and is lined by stratified epithelial cells. The exfoliated cells in young cysts are closely packed together in concentric layers. When they undergo fatty degeneration they form the characteristic pultaceous atheromatous contents. Besides this material sebaceous cysts contain cholesterin-crystals, and often lanuginose hair. In old cysts the sac becomes very much thickened, so that it can easily be extracted. At the same time the atheromatous material frequently undergoes liquefaction, so that the contents appear as a thin emulsion. The contents of the cyst are apt also to undergo cretification, in which event the cyst shrinks and can be felt as a hard mass under the skin. In sebaceous cysts of the scalp a deep dent in the bone, produced by pressure-atrophy, marks the location of the cyst after extirpation. Sebaceous cysts often appear multiple in the scalp and other parts of the body, notably the face and the scrotum.

Inflammation and suppuration of a sebaceous cyst may terminate in a permanent cure if the entire lining of the cyst is destroyed; if this is not effected, suppuration continues, and sometimes a fungous mass of granulations appears, suggesting a transformation of the lining of the cyst-wall into a carcinoma. The origin of carcinoma in a cyst-wall that had undergone this change has been observed.

A sebaceous cyst that has never been the seat of inflammation can be removed quickly by enucleation. The skin covering a sebaceous cyst is usually bald, but before performing this little operation it is advisable to shave the surface a little beyond the margin of the cyst, to disinfect the skin very thoroughly, and to resort to every other antiseptic precaution, as infection is very liable to occur during this operation, and has occasionally resulted in the death of the patient. Carelessness in performing this otherwise insignificant operation is inexcusable.

The best method in removing a sebaceous cyst quickly and thoroughly is to transfix the base of the swelling with a narrow bistoury, to cut through its centre from within outward, then to grasp the cyst-wall where it is thickest—which is at one of the angles of the wound—with a pair of rat-tooth forceps, and by gentle traction extract the cyst. Every particle of the lining of the cyst-wall must be removed, otherwise a recurrence is sure to take place. After carefully arresting the hemorrhage the wound is closed by two or three sutures of fine catgut; over the sutures an antiseptic dressing is applied; this dressing is held in place in such a manner as to exert gentle pressure, in order to keep the skin in contact with the opposite side of the wound. If compression is omitted the parenchymatous oozing will furnish enough

blood to form a swelling the size of the cyst, preventing an ideal healing of the wound, besides increasing the risk of infection.

Inflamed sebaceous cysts must be removed by excision, as enucleation usually fails on account of the presence of firm adhesions between the capsule and the adjacent tissue. If the scalp is the seat of numerous sebaceous cysts, and the patient desires their removal at one sitting, it is better, from a cosmetic as well as a surgical point of view, to shave the entire scalp, thereby enabling the surgeon to procure for the different fields of operation a perfectly aseptic condition.

Very little is known regarding retention-cysts of the sweat-glands. Verneuil described adenoma, and Foerster described retention-cysts of the sweat-glands, and there can be no doubt, owing to their great resemblance, that one has been mistaken for the other. As a pathognomonic symptom is mentioned the occasional appearance of moisture upon the surface of the swelling, caused by leakage through a partially obstructed duct.

Cysts of the sweat-glands are naturally of a very glandular type, resembling the cystic adenomata in general. The few cases that have been recorded were found in the skin of the face and in the vicinity of the external ear. The cyst-wall is so delicate that the swelling can be thoroughly removed only by excision.

Mucous Membrane.—The mucous membrane anatomically resembles very closely the external skin; but, instead of stratified layers of squamous epithelium, it is with few exceptions lined by columnar epithelium in a single layer, and is more richly supplied with glands. The mucous crypts present in all of the mucous membranes are the analogues of the sebaceous glands of the skin, and retention of their secretion results in the formation of cysts resembling the three varieties of sebaceous cysts—comedo, milium, and deep cysts. Crypts are found in the mucous membrane of the bladder, the ureters, and the biliary ducts. In the neck of the uterus they are normally in a cystic condition, and are described as the ovules of Naboth. They are especially well developed and very long in the mucous membrane of the intestinal canal and the uterus.

The post-tracheal glands occupy the entire thickness of the tracheal wall, and when obstructed they form retro-tracheal cysts. If the crypts are superficial, their cysts resemble the comedos and acne of the skin; if they are deep, retention of their secretion results in the formation of larger swellings.

The columnar epithelial cells are attached to the basement membrane of the delicate cyst-wall, and they produce the mucus, the characteristic contents of a cyst of the mucous membrane. By pres-

sure the columnar epithelial cells are often flattened, appearing under the microscope as squamous cells. The mucus in old cysts is usually liquefied and converted into a serous fluid, so that old mucous cysts present themselves as serous cysts. These cysts were called by the old authors "hydatids."

Inflammation of the cysts transforms mucous cysts into acne and molluscum in the same manner as retention-cysts of the sebaceous glands of the skin are formed. If the larger mucous cysts become elongated, polypoid, we speak of *polypi cystici* or *hydatidosi*. This form of mucous cyst is seen frequently in the rectum and in the neck of the uterus.

Mucous cysts of the mucous membrane of the mouth are quite common. They contain a viscid fluid, and after spontaneous rupture

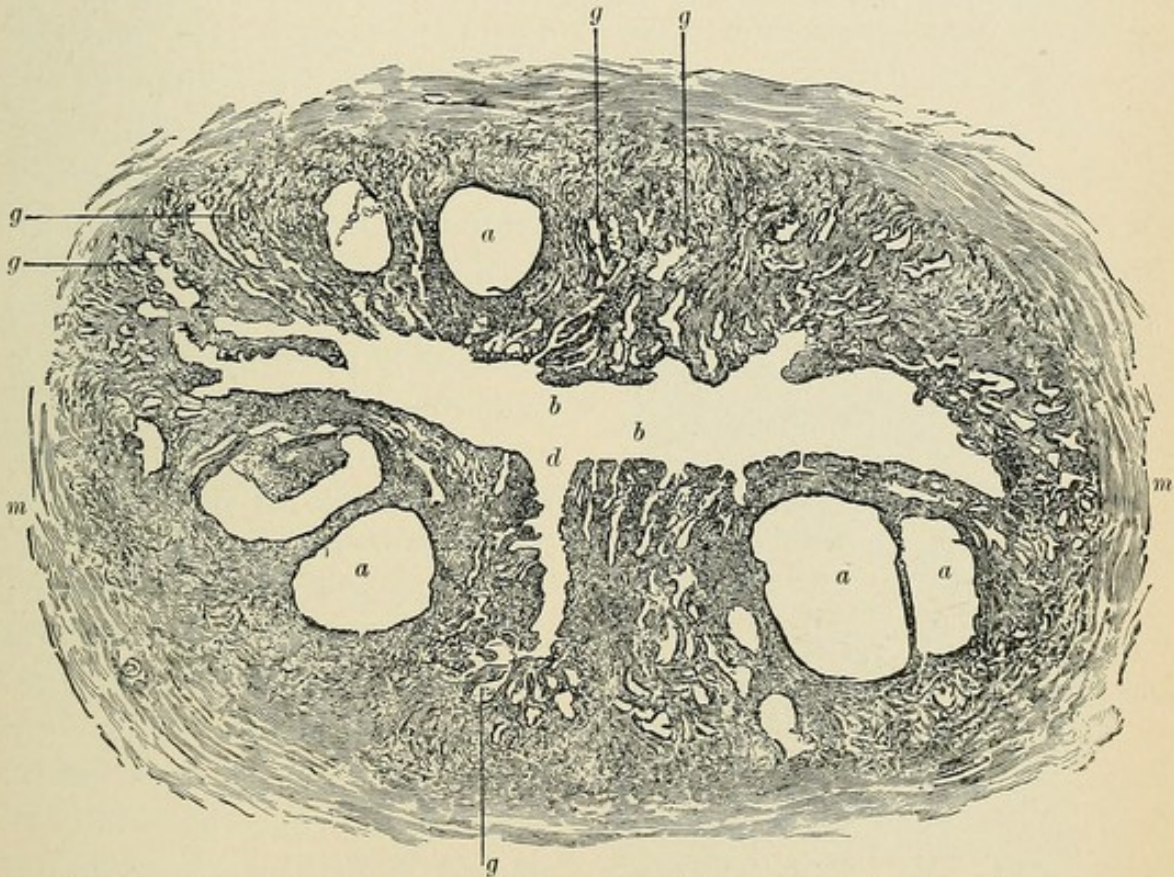


FIG. 456.—Transverse section through the upper part of the cervix, showing the entire mucous membrane (after Cornil). The central cavity is the cervical canal; *b, b*, internal surface of mucous membrane, presenting small folds, superficial glandular depressions, and large incisions of the arbor vitæ (*d*); *g, g*, deep glands; *a, a*, ovules of Naboth; *m, m*, muscular tissue of the uterine wall.

they often leave a circular deep ulcer, which usually heals promptly after thorough cauterization with nitrate of silver. They are met with most frequently in the mucous membrane of the lips. Their walls are exceedingly delicate, and the mucous membrane covering them is so thin that it is generally excised with the cyst.

Multiple mucous cysts of the inner surface of the lips result in

such great thickening of the lips that they appear to be double. The removal of the cysts restores the normal size and shape of the lips.

Cysts of the soft palate, especially of the pillars in the vicinity of the tonsils, which are of such frequent occurrence, are retention-cysts. They never attain large size, and they can be destroyed effectually by ignipuncture.

In the antrum of Highmore there have been found mucous cysts of such enormous size that they not only filled the entire cavity, but also caused distention of the bony walls (Giraldès). Such cases have usually been mistaken for hydrops of the antrum, as the cyst-wall was not discovered. Retention-cysts of this size in the antrum of Highmore should be removed after making a temporary resection of the anterior wall by detaching from the mouth, with a small chisel, a quadrangular muco-osseous flap on three sides, and fracturing its

fourth or upper side, and by raising the flap exposing the antrum so thoroughly that every part of it is accessible to direct treatment. Free drainage through the nose should be established before the flap is brought down and fastened in place by a few points of chromicized catgut sutures.

The ovules of Naboth are of special interest to gynecologists. These mucous crypts are of unusual size in a normal condition; when the cervix is in a condition of chronic inflammation they become greatly enlarged, frequently acquiring the size of a filbert (Fig. 456). The cyst-wall of dilated Nabothian glands is exceedingly delicate, and the mucous membrane over the glands is atrophied. They often rupture spontaneously, and they are frequently punctured in the treatment of chronic cervical metritis.

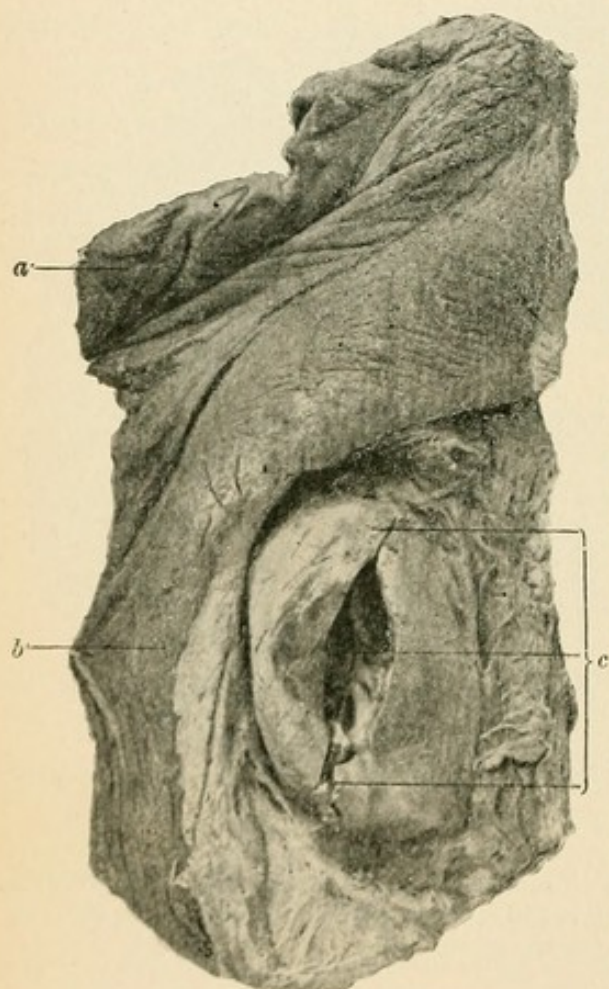


FIG. 457.—Retention-cyst of Bartholin's gland (after Winckel): *a*, left labium minus; *b*, left labium majus; *c*, cyst laid open.

The glands of Bartholin, which Henzier called "vulvo-vaginal" from their location, and which have also been called "Duverney's" or "Cowper's glands," are frequently affected by chronic inflammation

of their excretory duct and retention of their contents. The cysts are located on the internal aspect of the labium majus (Fig. 457). The swelling, which often acquires the size of a walnut, is either unilocular or multilocular, is generally unilateral, and is elongated in the axis of the greater lip. Either the duct or the gland, or both, may be affected. In the former case the cyst is superficial; in the latter instance it is more deeply located. The cysts contain mucus, to which is often added blood or inflammatory products.

In the differential diagnosis of cysts of Bartholin's glands it is important to consider solid tumors in that locality, hydrocele, hematocele, hernia, other cysts, and abscesses. Cysts of Bartholin's glands are exceedingly apt to become infected; they then appear clinically as abscesses. Incision affords prompt relief, but seldom effects a cure. Retention and inflammation repeat themselves from time to time until the whole cyst-wall is extirpated. In open suppurating cysts the advice of Pozzi should be followed—to inject the cyst with hot spermaceti before the dissection is commenced, as otherwise there is a great probability that the removal of the lining of the cyst will be incomplete. Pozzi recommends the same procedure in the extirpation of non-suppurating cysts. After tapping the cyst and washing it out with hot water he injects melted paraffin at a low temperature. When the cavity is distended ice is applied, and after the mass has been solidified the dissection is begun with the anesthesia produced by the cold, and by cocaine if necessary.

Hydrokolpos.—A retention-cyst of the vagina is produced by obliteration of the cervix above and atresia of the lower part of the vagina; the mucus secreted by the vaginal glands accumulates in the intervening part of the vagina, which becomes the cyst-wall. Winckel describes a case of this kind in a woman fifty-seven years of age who died of carcinoma of the rectum. The atresia of the cervix and the vagina occurred independently of the rectal carcinoma, as can be seen from the illustration (Fig. 458). Atresia of the lower part of the vagina, acquired or congenital, in menstruating women would result in hematokolpos instead of hydrokolpos.

Hydrometra.—Hydrometra occurs in women after the menopause. It is one of the conditions attending senile involution of the uterus; it results from stenosis or complete closure of the cervical canal produced by chronic catarrhal cervical endometritis, enlargement of the Nabothian glands, and sharp posterior flexions of the uterus. Sometimes obliteration of the lower part of the uterine cavity leads to hydrometra of the upper part (Fig. 459). As the uterine glands continue to functionate, and the escape of secretion is prevented by obstacles in the

lower part of the uterus or cervix, accumulation leads to distention of the cavity, and in the course of time the mucus is converted into serum, hydrometra resulting. In women before the menopause the

same conditions result in hemato-metra. Hydrometra in the aged, resulting from imperfect closure of the cervical canal or the lower part of the uterine cavity from stenosis or retroflexion, is very apt to be followed by pyometra, and the offensive discharge incident to this condition has frequently been taken as

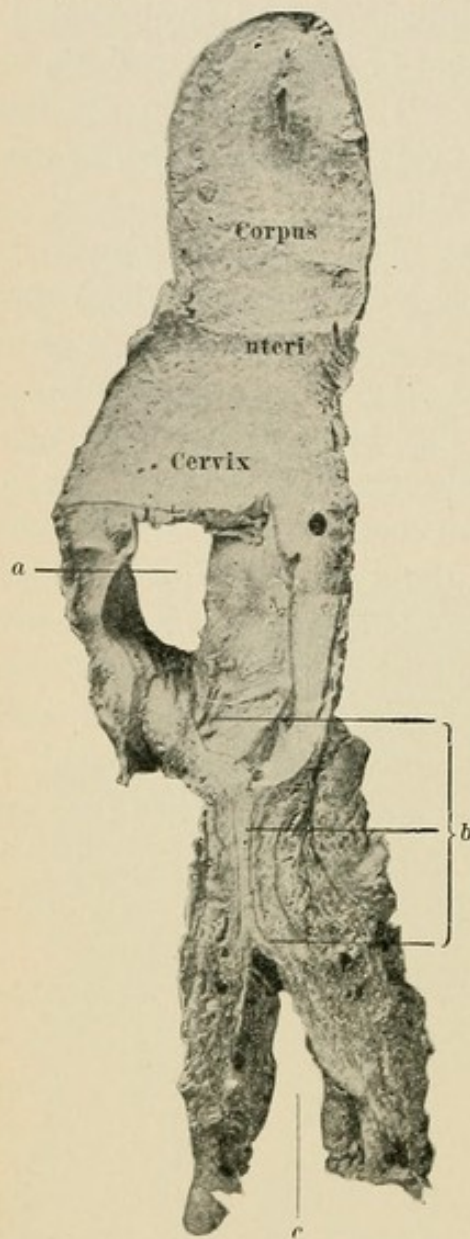


FIG. 458.—Acquired hydrokolpos in a woman fifty-seven years of age (after Winckel): *a*, vaginal cyst; *b*, several inches of vagina obliterated by cicatricial contraction; *c*, lower end of vagina.

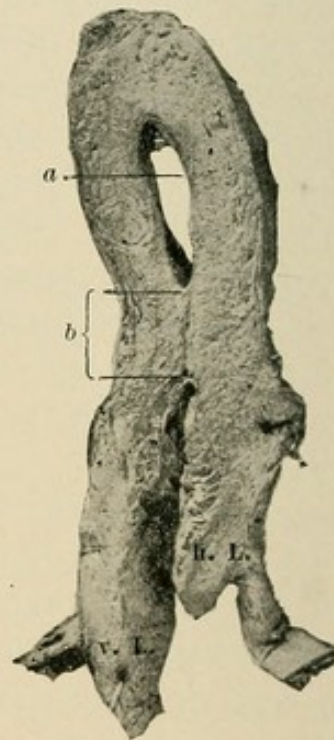


FIG. 459.—Hydrometra in a woman past the menopause (after Winckel): *a*, hydrometra; *b*, obliteration of lower part of uterine cavity.

an indication of the existence of malignant disease of the uterine cavity.

Hydrosalpinx.—Hydrosalpinx results from partial or complete closure of the fimbriated extremity of the Fallopian tube and obstruction to the escape of secretions on the uterine side, and retention of the secretion produced by the mucous glands in the mucous lining of the tube. The tubes may be partially or completely closed—the *tubæ apertæ* and *tubæ occlusæ* of Froriep. As closure of the distal end of the tube occurs usually from adhesions produced by pelvic peritonitis,

the affection is frequently bilateral, as is the case in pyosalpinx. The lumen of the tube on the uterine side in a normal condition is quite small; frequently it is narrowed by the catarrhal salpingitis which precedes the peritonitis, or the escape of the tubal secretion is prevented by valvular closure of the orifice.

By far the most frequent cause of catarrhal salpingitis, and of the subsequent pelvic peritonitis which obliterates the fimbriated extremities of the tubes, is gonorrheal infection. If the infection is of a mild character, little or no pus is produced, and the retained secretion in the tube consists at first of mucus which is later changed into serum, the characteristic contents of a hydrosalpinx. The serum frequently leaks into the peritoneal cavity, producing recurrent attacks of plastic peri-

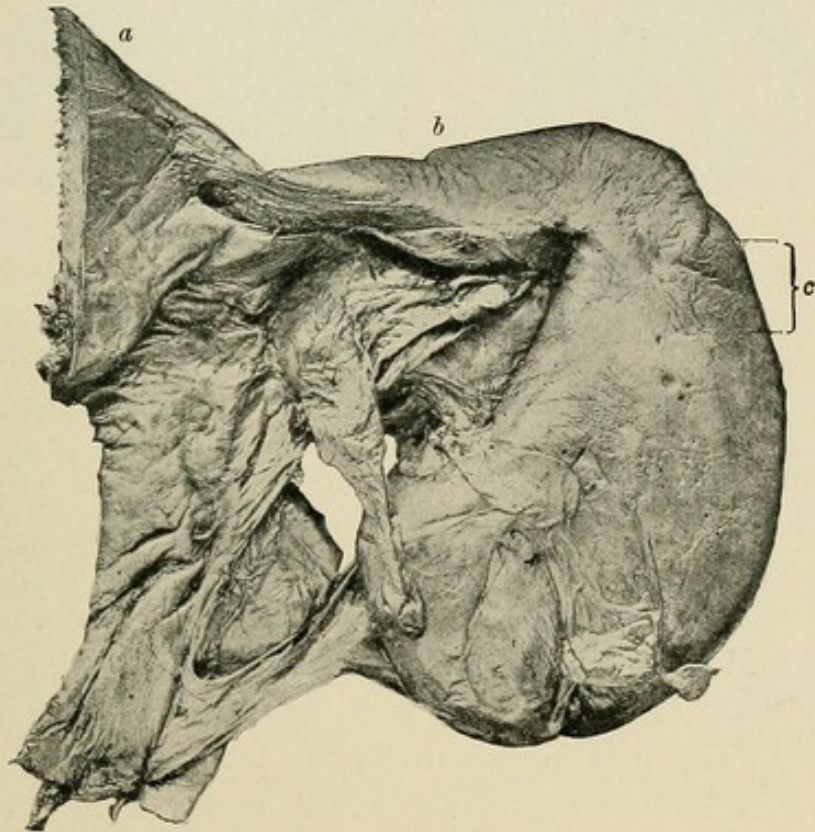


FIG. 460.—Hydrosalpinx (after Winckel): *a*, fundus uteri; *b*, tube; *c*, hydrops of tube.

tonitis if the fimbriated extremity of the tube is only partially closed; or it escapes at times through the uterus in the form of intermittent profuse serous discharges. If the entire tube becomes distended, the swelling assumes a sausage-like shape, as the tube is not only dilated, but is also elongated (Fig. 460). The tube is often displaced by adhesions. If only a small part of the tube remains patent, the swelling is round or oval in shape.

Hydrosalpinx is rare as compared with pyosalpinx, but in the majority of cases it precedes the latter affection. If gonococci are present in sufficient quantity, the suppurative inflammation of the

mucous membrane of the Fallopian tube converts the hydrosalpinx into a pyosalpinx. This change in the pathology and clinical aspects of the tubal affection is sure to occur if, as is so often the case, the interior of the tubal swelling becomes the seat of secondary or mixed infection with pus-microbes.

The removal of the uterine appendages in cases of single or double hydrosalpinx is a much easier and less dangerous procedure than in cases of pyosalpinx. There is here a rich field for conservative surgery, as in many cases mutilating operations can be rendered unnecessary by

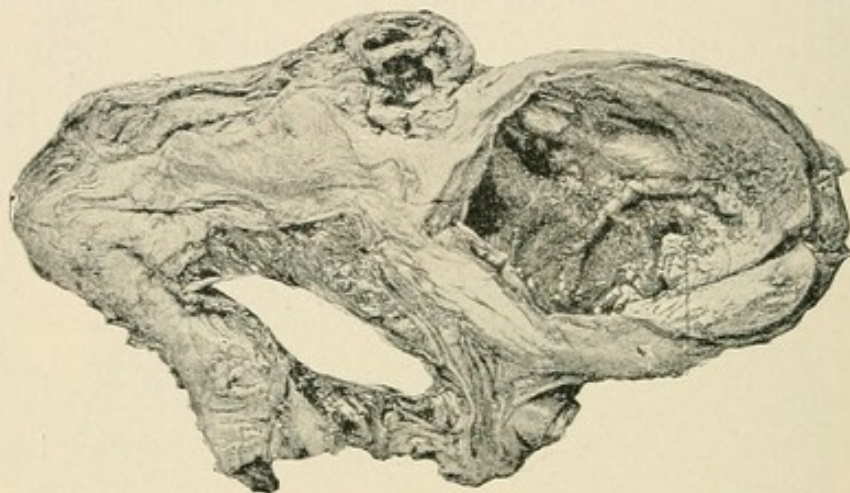


FIG. 461.—Hydrosalpinx, tube laid open (after Winckel).

intelligent and persistent treatment aimed at restoring the free communication between the uterus and the tubes by appropriate intra-uterine and intra-tubal applications combined with other treatment calculated to eliminate the primary cause of the tubal obstruction.

Trachea and Bronchial Tubes.—Retention-cysts of the trachea are rare. They occur in the posterior wall, because here the tracheal rings are defective. The first indication of the formation of a cyst is the appearance of a shallow depression, which as it deepens posteriorly is deflected laterally by the œsophagus and the spine. As the cyst elongates its base contracts, the cyst finally becoming pedunculated; eventually the pedicle may disappear, the cyst becoming completely isolated from the trachea. Such cysts may appear behind the clavicle and may otherwise mimic retro-sternal struma and dermoid cysts. Textor operated upon a cyst of this kind successfully. In bronchiectasis saccululation may take place to such an extent that cavities of considerable size communicate only through a small opening with the bronchial tube from which they started. The bronchial secretion is usually mixed with an offensive purulent discharge.

Appendix Vermiformis.—Affections of the appendix vermiformis are attracting a great deal of attention. Virchow showed years ago

that the appendix is richly supplied with glands; he also described a retention-cyst of the appendix as large as a fist. In this case the long narrow organ, obstructed on the cecal side, had become so much distended that the swelling was globular in shape. He also called attention to the fact that an obstructed appendix frequently gives rise to typhlitis.

Attention has elsewhere been called to the pathological conditions usually found in cases of stricture or of cicatricial closure in different parts of the lumen of the appendix. The writer has never seen retention-cysts of the appendix holding more than a teaspoonful of mucus, but he has been informed by Hecktoen of Chicago, who had an immense experience in the post-mortem room, that on several occasions he found retention-cysts of the appendix vermiformis of the size of a hen's egg. It can readily be conceived that obstruction at the cecal end of the appendix might result in considerable distention of the lumen of the appendix on the distal side. In the cases which have come under the writer's observation the stenosis or obliteration was characterized more by increase in the thickness of the wall of the appendix than by dilatation. In the absence of a sufficient number of pus-microbes in the excluded portion of the lumen of the appendix, the mucous glands being in an active functional activity, the intracystic pressure would eventually lead to dilatation and cyst-formation. Cysts of the appendix vermiformis should be borne in mind in the differential diagnosis of obscure swellings in the ileo-cecal region.

The proper treatment of a retention-cyst of the appendix vermiformis is excision of the appendix. Rupture of the cyst should be avoided if possible, and proper preparation should be made for this accident by excluding the intestines from the field of operation with aseptic compresses. The appendix should be amputated near the cecum by the subserous circular method.

Bile-ducts.—Retention of bile in any part of the bile-ducts is followed by absorption of the serous portion, leading to inspissation. In the inspissated bile there remain cholesterin, bilifulvin, and hematoïdin.

Cysts as large as a walnut, containing inspissated bile, are sometimes found in the substance of the liver. In obstruction of the hepatic and common ducts moderate distention of the bile-ducts takes place, but the formation of large cysts is prevented by the absorption of the retained bile. If this auto-absorption is interfered with by inflammatory processes affecting the bile-ducts and the connective tissue of the liver, retention of the bile produced by some intact portions of the liver takes place, and the bile-duct, and, in case of obstruction of the common duct, the gall-bladder, become greatly distended.

The gall-bladder is that part of the bile-tract most apt to undergo cystic dilatation. Retention of the secretions of the mucous crypts of the mucous membrane of the gall-bladder occurs most frequently in consequence of obstruction of the cystic duct by impaction of a biliary calculus or by cicatricial stenosis. The latter is not infrequently one of the remote consequences of the injuries inflicted by the passage of a gall-stone. The pressure exerted by the gall-stone and the irritation and inflammation caused by the calculus result in destruction of the mucous membrane, and during the healing of the defect the lumen of the duct becomes narrowed and even completely obliterated. The gall-bladder under such circumstances may become enormously distended—much more so than if it contain bile.

As no bile can enter the gall-bladder if the cystic duct is obstructed, and the bile that may be present is soon absorbed, the organ contains at first mucus, which later is transformed into a serous fluid; hence the term "hydrops of the gall-bladder," or "hydrocholecyst." A moderately distended gall-bladder presents a pyriform shape, with the narrow part of the swelling directed toward the liver.

Hydrops of the gall-bladder, unless complicated by localized peritonitis, is not attended by much pain, nor does it give rise to much inconvenience unless the swelling is very large. A dull aching pain is occasionally complained of. The suffering frequently attending this condition is referable to the presence of a stone in the cystic duct, giving rise to those characteristic paroxysmal pains known as "biliary colic." In obstruction of the cystic duct icterus either is entirely absent or is slight and usually of short duration. Infection of the interior of a gall-bladder either by extension of a suppurative inflammation of the bile-ducts or through a small fistulous opening between the gall-bladder and an adherent intestinal loop converts the hydrops into an empyema of the gall-bladder. The inflammation of the mucous membrane diminishes or arrests the functions of the mucous crypts, and pus soon takes the place of the serous fluid.

Hydrops of the gall-bladder has occasionally, from the size of the swelling, been mistaken for ovarian cyst. In distention of the gall-bladder the early clinical history of the case points to a swelling in the upper and right part of the abdominal cavity, while ovarian cysts are first discovered by the patient when the tumor rises out of the pelvis. An ovarian cyst can always be reached with the finger from the vagina, while this can seldom, if ever, be done in a distended gall-bladder. In distention of the gall-bladder the early clinical history points to the existence of causes leading to obstruction of the cystic duct, while in ovarian cyst the early symptoms are referred to the pelvis. Tumors

and cystic disease of the right kidney have often been mistaken for a distended gall-bladder, and *vice versa*. In renal affections a careful study of the clinical history of the case and chemical and microscopical examination of the urine will yield valuable information. The retro-peritoneal location of a tumor or a swelling of the kidney can usually be demonstrated satisfactorily by rectal insufflation—an important diagnostic resource in differentiating between an intraperitoneal and a retro-peritoneal tumor or swelling. Another condition rendering a positive diagnosis of a distended gall-bladder often impossible is echinococcus-cyst of the lower surface of the liver. Hirschberg strongly urged the employment of the exploring needle in the differential diagnosis of fluctuating tumors or swellings in the region of the gall-bladder. This very useful diagnostic resource, if properly employed, is harmless in case the tumor or cyst is adherent to the anterior abdominal wall. We have no reliable means of ascertaining the presence and exact location of mural adhesions. The writer believes, with König, that exploratory puncture should never be resorted to in the diagnosis of tumors or cysts in this locality unless there is positive evidence that the puncture can be made without invading the peritoneal cavity. The information derived from an exploratory puncture does not balance the risks to which it exposes the patient. Should the puncture be made through the peritoneal cavity, and the cyst should prove to be an echinococcus-cyst, the escape of its contents into the preperitoneal cavity would be sure to result in dissemination of the parasitic disease and an early fatal termination. Should the cyst prove to be an empyema of the gall-bladder, escape of pus through the puncture could hardly fail to produce a diffuse septic peritonitis.

Short of an exploratory puncture, we are not in possession of any means to make a positive differential diagnosis between a hydrops and an empyema of the gall-bladder. As we have advised against the use of the exploring needle, it is evident that in doubtful cases the surgeon should resort to an exploratory incision, fully prepared to do what is necessary after a correct diagnosis has been made. The patient should understand that the operation is performed in the first place for the purpose of ascertaining the nature of the swelling, and that after this has been done the necessary operative procedure will follow. An exploratory incision, in the writer's estimation, is safer and will yield more reliable diagnostic information than an exploratory puncture. Several incisions have been suggested to expose the gall-bladder to direct surgical interference. Billroth preferred an incision parallel with and about a finger's breadth below the costal arch. Other surgeons advise a vertical incision extending from the cartilage of the eighth

rib downward. Langenbeck in performing cholecystectomy makes a vertical incision from the costal arch to the outer border of the rectus muscle, and joins it by a shorter incision extending from the upper angle of the wound as far as the ensiform cartilage. Czerny makes an incision from the ensiform cartilage to just above the umbilicus, and joins it by a transverse incision extending through the rectus muscle on the right side. By reflecting the triangular flap the under surface of the liver is well exposed. The exploratory incision should be made over the centre of the swelling, from the costal arch downward. This incision will answer well if the conditions revealed require a simple cholecystotomy, and if it is deemed necessary to extirpate the gall-bladder, the incision can readily be converted into Langenbeck's incision. If a hydrops of the gall-bladder is found, the gall-bladder should be emptied by aspiration, after which it is drawn forward into the wound, and is held in place with forceps, or, still better, with two silk threads passed through the serous and muscular coats, one on each side of the proposed incision. After packing gauze around the empty bladder to protect the peritoneal cavity, an incision large enough to admit the index finger is made in the long axis of the gall-bladder, and through this incision, with finger and probes, search is made for the cause of obstruction. If a calculus is found in the cystic duct, it should be removed or crushed, after which the margins of the visceral wound are stitched to the parietal peritoneum in the upper angle of the wound, for the purpose of establishing a temporary biliary fistula. The balance of the external incision is closed by buried and deep sutures. If the cystic duct is found completely obliterated, the gall-bladder should be extirpated. In empyema the same surgical procedures are indicated. A cholecystenterostomy is absolutely contraindicated except in irremediable occlusion or obliteration of the common bile-duct.

Closely allied to hydrops of the gall-bladder are cysts of the pancreas.

Pancreas.—The pancreas, like other secretory organs, is prone to become the seat of cystic swellings, the result of obliteration or obstruction of the common duct or of one or more of its branches. Cysts originating in this manner are true retention-cysts, containing the physiological secretion from the distal portion of the gland-tissue, with perhaps accidental products, such as altered secretions, blood, and the products of inflammation.

Of the five cases of cyst of the pancreas which the writer has seen, detailed mention will be made of the first case that came under his observation :

Volz, æt. nineteen, laborer, German, was admitted to Milwaukee

Hospital November 28, 1884. He was small for his age and not robust, but he claimed that with one exception he had never been sick, and that no hereditary tendency to disease existed in his family. Five weeks previously, while enjoying perfect health, he was thrown from a wagon, striking the ground on the left side of the abdomen, a heavy keg falling upon his back and increasing the force of the fall. The pain felt immediately after the accident was confined to his back, at the point where he was struck by the keg, but it was not sufficient in intensity to prevent him from following his occupation as a mason's apprentice. In a few days, however, diarrhea set in, persisting for two weeks and greatly reducing his strength and weight. If he had any fever during this time, it was not sufficiently severe to attract his attention. His appetite was not impaired, and, although he vomited occasionally, neither the vomiting nor the diarrhea seemed to be aggravated by the time of eating or the kind or variety of food. After two weeks he noticed in the left hypochondriac region a tumor which was round, smooth, and painless. The tumor increased rapidly in size, and soon gave rise to a sensation of fulness in the stomach, and later on to regurgitation and vomiting soon after meals. His appetite was slightly impaired. At this time the patient was treated for a short time by Dr. F. H. Day of Wauwatosa, Wisconsin, who resorted to symptomatic treatment, and, observing no improvement, referred him to the writer for diagnosis and, in case it should be deemed advisable, surgical treatment. On his admission to the hospital he presented a considerable degree of emaciation and complained principally of a sensation of fulness and weight in the region of the stomach, which was always aggravated after meals and only relieved by vomiting. On inspection a tumor was found occupying nearly the whole epigastric and the entire left hypochondriac region, its most prominent point being to the left of the median line and about three inches below the xiphoid cartilage. Percussion revealed a line of dulness extending from the left nipple to within an inch of the umbilicus; posteriorly the dulness reached from the eighth to the lower margin of the twelfth rib; in the epigastric region a limited area of tympanitic resonance was discovered along the costal arch of the lower ribs on the right side. Palpation showed distinct fluctuation, the wave being conveyed from side to side across the whole area of dulness. The tumor was round in contour and presented a smooth surface. The measurements were as follows: From the left nipple to the lowest point downward, 22 centimeters; transverse diameter, 21 centimeters; anterior circumference, 63 centimeters. The heart was pushed upward so that the impulse of the apex could be felt distinctly in the fourth intercostal space. The stomach

was artificially distended with carbonic-acid gas, when it was ascertained that it was pushed to the right and compressed by the tumor. The liver appeared to be unaffected by the tumor, as on percussion it was found in its normal location and of natural size. Both lumbar regions were tympanitic. No evidences of ascites existed. Firm pressure over any part of the tumor could be made without causing pain. The peculiar fremitus often felt in cases of echinococcus-cysts was absent. No pulsations could be felt in the tumor, and no impulse was

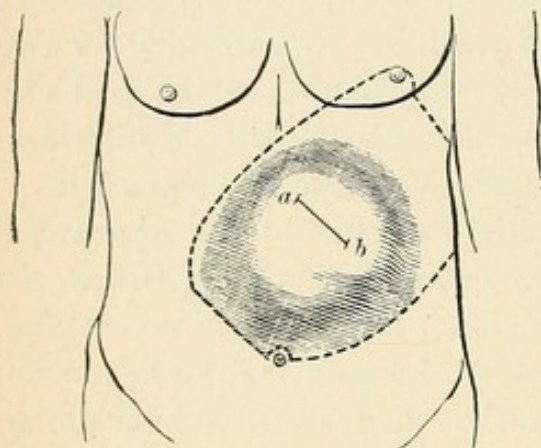


FIG. 462.—Cyst of the pancreas: space within dotted lines indicates area of dulness; *a-b*, line of incision.

imparted to it by the underlying abdominal aorta. The relative position of the tumor was changed during forcible inspiration and expiration. For the purpose of ascertaining the nature of the contents of the tumor a hypodermic needle was thoroughly disinfected and introduced at a point where the tumor was most prominent; when in place, the distal end of the syringe moved upward and downward synchronously with the respiratory movements, showing that

the adhesions with the parietal peritoneum, if any existed, were slight. The fluid removed, which was somewhat viscid and slightly opalescent, was alkaline in reaction and contained a considerable proportion of albumin, as it coagulated on applying heat and nitric acid. Under the microscope it showed only a few morphological elements, epithelial cells, a few leucocytes, and granular matter, but neither hooklets nor cholesterin-crystals.

By exclusion the diagnosis was narrowed down to one of two things—a sterile echinococcus-cyst or a cyst of the pancreas. Against the former spoke the rapid growth of the tumor, its primary origin away from the liver, its favorite location, the presence of a considerable amount of albumin, and the absence of hooklets, the presence of which are diagnostic of echinococcus-cysts. In favor of a pancreatic cyst spoke the history of traumatism in the region of the pancreas, the rapid growth of the tumor, and the early disturbance of digestion as manifested by diarrhea and vomiting, presumably caused by the partial or complete retention of the pancreatic secretion. As the treatment remained the same in either case, it was decided to perform laparotomy, to stitch the cyst-walls to the peritoneal covering of the wound in the absence of adhesions, and to open and drain the cyst after adhesions had formed. This procedure was deemed preferable to the use of the

trocár or the aspirator, as it would with certainty prevent extravasation of the cyst-contents into the peritoneal cavity, and the drainage-tube would guard against reaccumulation of the fluid, thus affording an opportunity for the cavity to undergo obliteration by adhesion of the inner surfaces of the cyst-walls. The patient, being cognizant of the fact that no other form of treatment would promise any relief, readily assented to the operation proposed. Every precaution was observed to render the operation aseptic. The patient was given several baths; the parts were shaved, and were carefully disinfected with a 5 per cent. solution of carbolic acid; the instruments, sponges, and operating-room were prepared as for an ovariectomy. Before ether was administered the stomach was emptied and washed out by means of an elastic stomach-tube, with a view to prevent retching and vomiting during and after the operation. An incision five inches in length was made obliquely over the most prominent portion of the tumor, about three inches below, and parallel with, the left costal arch. A portion of the rectus abdominis muscle was divided. After dividing carefully all the tissues down to the peritoneum all hemorrhage was completely arrested.

On opening the peritoneal cavity the omentum was brought into view, the portion exposed containing an artery and a vein of considerable size. As these vessels were placed in a vertical direction, they crossed the wound, and it became necessary to apply a double ligature, the omentum being then incised between the ligatures to the extent of about three inches. The omentum was slightly adherent to the parietal peritoneum and the surface of the tumor. Through the omental incision the tumor could be seen and felt distinctly, presenting a smooth, whitish, and glistening surface. As it had formed at least slight adhesions, it was decided to complete the operation. This plan was the more willingly adopted as it was evident that the intracystic pressure was great and the cyst-walls were thin, which would render stitching them to the margins of the wound difficult and unsafe. The surface of the tumor was then seized with two dissecting forceps about an inch apart, and gentle traction was made during incision and evacuation of the cyst, so as to prevent all risk of extravasation of fluid into the peritoneal cavity. The peritoneal covering was picked up and nipped, and a grooved director was inserted into the opening made: owing to the thinness of the walls of the sac, it penetrated the interior, and fluid escaped along the groove with considerable force. The opening was enlarged with the knife, when the fluid gushed forth in jets and was caught in basins. The contents were removed as completely as possible by making external pressure and by placing the patient on his side. As the cyst was emptied its walls were drawn forward into the

wound and stitched to the peritoneum, which had previously been united with the skin. The interior of the cyst was explored by inserting the index finger, which passed directly backward toward the tail of the pancreas. The bottom of the cavity could, however, not be reached. The inner surface of the cyst was smooth. Two large drainage-tubes were inserted to the bottom of the cyst, and the remaining portion of the wound was united in the same manner as after ovariectomy, except that the rectus muscle was sutured separately. The fluid removed, estimated at three quarts, presented the same appearance as that removed by exploratory puncture. The wound was dressed with a large antiseptic compress, which was retained *in situ* with an elastic rubber bandage. This bandage of rubber webbing not only retains the dressing perfectly, allowing at the same time the movements of the chest and the abdomen, but has an additional advantage, inasmuch as it exerts equable pressure—an important element in the after-treatment of all abdominal operations.

The patient never vomited during or after the operation, and experienced immediate relief on removal of the pressure caused by the tumor. The pulse never rose over 90°, and the highest temperature observed was 100° F., the day after the operation. The appetite increased, and no unpleasant subjective symptoms were complained of at any time. On the third day the dressing showed moisture on the external surface, and it was changed. The gauze was saturated with the secretions from the cyst. The wound looked healthy, but the surrounding skin, as far as the dressing had extended, was red and macerated, and the epidermis could be removed in large flakes, leaving beneath a raw surface. The changes in the skin presented the appearances described by Kulenkampff and Gussenbauer, and claimed by them to be due to the digestive power of the pancreatic juice. The excoriated surface was sprinkled with salicylic acid and was again covered with a Lister dressing. On account of profuse secretion from the cyst the dressings were changed every few days, and at every change the skin was found excoriated as far as it had been moistened by the secretion. At the end of the first week the sutures were removed and no further dressings were applied, whereupon the skin healed without suppuration, and only a minimum amount of pus escaped through the fistulous opening with the secretion. The secretion became clearer after the operation, and continued to be discharged in varying quantities for almost four weeks. One of the drainage-tubes inserted at the time of the operation was removed at the first change of the dressing, and the second was gradually shortened, being entirely removed three weeks after the operation. At the end of the second week the cyst was

explored with a disinfected probe which passed to a depth of eight inches in the direction of the tail of the pancreas. The fistulous tract soon became live with granulations and grew smaller in length and diameter; at the end of eight weeks it was very narrow, so as to admit only a small probe, which could be passed only to a depth of four inches. The skin around the fistulous opening was drawn inward, forming a deep funnel-shaped depression.

January 22, 1885, the patient was discharged cured. The fistula was completely closed. Retraction of cicatrix was very marked. The general health was good, the digestion perfect. No swelling could be felt in the region of the pancreas.

Remarks.—It was the intention of the writer to collect some of the secretion for the purpose of ascertaining its digestive properties on different articles of food, but before this could be done the amount secreted daily became so small that it was impossible to obtain corroborative diagnostic evidence from this source. The anatomical location of the tumor, its relations to the surrounding organs, its rapid growth, and the character of its contents can leave no possible doubt that we had to deal with a genuine retention-cyst of the pancreas. The question naturally arises, What was the cause of the obstruction? The history of the case points clearly to traumatism as the exciting cause. The patient had been in good health until he received the injury, and since that time he had not been well, although he continued at his work for some time afterward. Whether the diarrhea from which he suffered for the first two weeks resulted from injury to the pancreas we are unable to prove, but it may be possible that a retention of the pancreatic secretion occurred after the traumatism, and that the diarrhea may have been produced by the absence of the fluid in the intestinal tract. As the patient at this time was not under medical observation, the character of the stools was not ascertained. As the injury was inflicted in the region of the pancreas, it is reasonable to assume that the pancreatic duct and the parenchyma of the gland were lacerated at a certain point, producing obstruction to the outflow of the secretion from the distal portion of the organ, the nature of the injury and the manner of obstruction being the same as in cases of rupture of the male urethra. It would be difficult to imagine that the common duct could be distended by the accumulation of the retained fluid to such an enormous extent in such a remarkably short time, hence we are forced to conclude that laceration of the duct took place, and that the pancreatic fluid infiltrated the gland, the cyst being formed at the expense of its parenchyma and by distention of the capsule of the organ. The cyst-wall anteriorly was so thin that after cutting the

peritoneal covering the grooved director penetrated directly into the interior of the cyst without more than the slightest force being used, showing that nothing but a little connective tissue was interposed between the peritoneum and the cyst-contents. The rapid growth of the cyst would indicate that the obstruction occurred at some distance from the caudal extremity of the gland, thus making a considerable portion of the secreting tissue contributory to the formation of the cyst. The early cessation of the discharge of the secretion through the abnormal outlet would tend to prove either that after the removal of the intracystic pressure the duct again became permeable, and thus furnished a free passage to the secretions into the intestinal canal through the natural channel, or that the gland-tissue in the vicinity and distal to the cyst had been destroyed.

In regard to the operation, it is necessary to say that the writer deviated from the usual plan in not making the incision through the linea alba. The incision was made over the most prominent part of the tumor, for the following substantial reasons:

1. If adhesions had formed, they would naturally begin at a point where the tumor impinged most firmly against the anterior abdominal wall.

2. Incision over the most prominent portion of the cyst would afford the best point for effective drainage.

The band of connective tissue which would result from atrophy and obliteration of the cyst would form a permanent bridge between the cicatrix of the abdominal wound and the gland, consequently it is advisable to establish this necessary evil where it will do the least harm by interfering with the functions of important organs.

Aspiration of the cyst was not practised, because the exploratory puncture had demonstrated that firm adhesions had not taken place, and in the absence of these it was feared that some of the cyst-contents might escape into the peritoneal cavity and produce peritonitis. The maceration of the skin was the result of the digestive action of the pancreatic juice, and this phenomenon furnished strongly corroborative diagnostic evidence in this as well as in previous cases.

Since this case was reported with six others which the writer had collected at that time, about thirty new cases have been recorded in literature, and in nearly all of these the formation of an external fistula resulted in a permanent cure.

Pathology and Morbid Anatomy.—Cysts in the pancreas always result from retention of the secretion and subsequent dilatation of the secretory duct, or, in case of laceration of this structure, from extravasation of the secretion into the parenchyma of the gland and subse-

quent distention of its capsule. The size of the cyst is modified by the character and seat of the obstruction and by its relative position to the secreting gland-structure. The walls of the cyst are usually thin from over-distention in cases of rapid-growing cysts, or much thickened when the growth of the tumor has been slow and accompanied by chronic proliferation and induration of the connective tissue. The cyst-walls in chronic cases may become cartilaginous or even ossified. The inner surface is either smooth or presents evidences of degeneration similar to those occurring on the internal surface of arteries in the later stages of endarteritis. If the canal of Wirsung is obstructed at or near its proximal end, the entire duct and its branches may become dilated, presenting the appearance of varicose veins, or a more uniformly rounded cyst may form, of the size of an orange, a child's head, or even so large as to occupy the whole abdominal cavity, as in Boze-man's case. As the cyst increases in size the gland-structure disappears by absorption in consequence of intracystic pressure. The cause which constitutes the obstruction will often also lead to destruction of the parenchyma of the organ by inducing a chronic interstitial pancreatitis which is followed by cirrhosis or fatty degeneration of the organ. Virchow alludes to cysts of the pancreas under the name of *ranula pancreatica*, and describes two essential and distinct varieties. In the first class the entire duct is found dilated, resembling in appearance a rosary. In the second variety the outlet of the excretory duct is obstructed, and behind the seat of obstruction the duct undergoes cystic dilatation. He mentions a case that came under his observation where such a cyst had attained the size of a fist. He believes that cicatricial contractions or the pressure of tumors upon the duct constitutes the most frequent source of obstruction. Pancreatic juice in its purity is found only in small and recent cysts. Later on, in old or large cysts, various accidental products are added. Albuminoid degeneration or suppuration not infrequently takes place, or hemorrhage may occur, so that the cyst-contents assume a bright-red or chocolate color. Pepper found in such a cyst numerous crystals of hematoidin, while Hoppe found in another instance urea in the proportion of 0.12 per cent. as one of the constituents of the contents of the cyst. The pressure of the cyst upon neighboring organs will result in secondary pathological conditions which will interfere with the physiological performance of the functions of other organs, thus endangering the life of the patient.

Etiology.—The causes which result in the formation of small cysts of the pancreas, or cysts which result from compression by tumors which in themselves do not admit of an operation for their removal,

and which at the same time constitute a source of danger to life, do not come within the scope of this discussion. In the latter instance the cyst is simply a sequence of the primary cause, and as such it will seldom, if ever, become the sole or direct object of surgical treatment. The causes of retention in cysts amenable to operative treatment are ones which in themselves do not imperil the life of the patient. They may be classified as follows: 1. Obstruction to the outflow of the secretion from impaction of calculi in the common duct or in its branches. 2. Partial or complete obliteration of a portion of the duct from cicatricial contraction. 3. Sudden or gradual obstruction of the duct, without diminution of its lumen, from displacements of the pancreas.

Calculi.—The impaction of the pancreatic duct at its outlet may be caused by the presence of a biliary calculus in the ductus communis choledochus, at the junction of the former with the latter. A case of this kind has been reported by Engel. In such cases the obstruction gives rise to retention of the secretions from the liver and the pancreas and to dilatation of the excretory ducts in both organs. Calculous concretions in the pancreatic ducts have frequently been observed to give rise to retention-cysts. Johnson has collected thirty-five cases in which, upon post-mortem examination, stony concretions were found in the pancreas. Incrustations are not as frequent as free concretions. Gendrin has described a pancreatic cyst where the normal pancreatic secretion was converted into a fatty, chalky pap. The causes which produce a concretion in the pancreatic duct are chemical changes in the secretion itself or an obstruction to its free exit by inflammatory changes in or around the common duct. The degree of dilatation, other things being equal, is in direct proportion to the completeness of the obstruction to the outflow of the secretion. It may be well to allude to the possibility that in some instances a pancreatic calculus may remain stationary for an indefinite period of time in the duct, giving rise to no symptoms and to only partial obstruction, until, by the action of some determining cause, it is forced into a position where it effects complete mechanical obstruction to the outflow of the fluid and a rapid increase in the size of the cyst. As an impacted biliary calculus may give rise to pancreatic obstruction, so a pancreatic calculus, when it is impacted at a point where compression of the common bile-duct can take place, will produce icterus and dilatation of the gall-bladder and the bile-ducts. Meckel has reported such a case.

Among the specimens of pancreatic cysts so far examined which were caused by concretions, none of them had attained the size of those which have been submitted to surgical treatment. As in most of these preparations the calculi did not completely fill the calibre of the duct,

they caused only partial obstruction, which would furnish an explanation of the slow growth and the comparatively small size of the tumor. In the specimen described by Gould it appears that the common duct at its entrance into the duodenum was completely closed by two calculous concretions. This cyst had attained considerable size; in fact, it is the largest cyst on record where it was proved that the dilatation was caused by the presence of a calculus. As in the successful operations on cysts of the pancreas it has been impossible to ascertain the exact nature of the obstruction, the possibility of retention from a calculus cannot be eliminated with certainty.

Cicatricial Contraction.—Cicatricial contraction is always the result of an antecedent inflammation. The cicatrix may be located in the peripancreatic tissue or in the substance of the gland itself. Hoppe made a post-mortem examination of a patient who had been deeply jaundiced during life. The gall-bladder and the bile-ducts were distended with bile which contained blood; the pancreatic duct was also cylindrically dilated, and many of its branches were distended into cysts the size of a hazelnut. The cause of retention of both secretions was found in a dense cicatrix which surrounded both ducts at their duodenal termination. Interstitial inflammation in the gland itself, with subsequent cicatricial contraction, is one of the most frequent causes of retention. Wyss has reported a case where the interstitial inflammation was limited to portions of the head of the pancreas through which the common bile-duct and the ductus Wirsungii passed, and which had resulted in dilatation of the latter and of its branches, which again compressed the bile-duct, producing in this manner intense icterus. Bécourt has given a description of a similar specimen which he found in the Strassbourg Pathological Museum. The patient had died of icterus. The gall-bladder and the bile-ducts were found distended; the pancreas was converted into a dense tissue, which, being cut into, presented a chalky deposit four to eight inches in length and of a yellowish color. The duct of Wirsung was dilated to such an extent as to form a large cyst which occupied the whole length of the pancreas, its walls being inseparable from the substance of the gland. In this case the interstitial inflammation was more extensive and the cyst was much larger. In the cases reported by Pepper and Hjett the obstruction was due to the same cause. In Curnow's case the common duct had become obliterated at its entrance into the duodenum by catarrhal inflammation. The pancreas was atrophic, and its duct was filled with numerous calculi. The pancreatic juice had become inspissated. The cystic duct of the gall-bladder was impermeable, while in the common bile-duct a number of small gall-stones were found.

The writer has failed to find in literature an allusion to stricture of the duct the result of traumatism. The pancreas is an exceedingly slender organ, of loose and somewhat friable texture, and hence, although remotely located and well protected by surrounding organs, it is more frequently the seat of injury than has generally been supposed. If the stomach be empty and the abdominal muscles be relaxed, a blow over the region of the pancreas may result in serious contusion or laceration of the organ without rupture of its envelope. Again, a well-directed blow over either extremity of the gland may cause a laceration of its tissue by traction force, the organ being securely fixed in its place by firm connective-tissue attachments. The clinical history of several cases of rapid-growing cysts tends to prove that obstruction occurred in this manner. If the duct escapes injury, the cicatricial contraction attending and following the reparative process in the lacerated gland-tissue will gradually compress the duct, or by lateral traction change its direction and thus impede the outflow of the secretion. If the duct is ruptured at the time of injury, its lumen may become completely filled by a thrombus which renders it impermeable, giving rise to retention and extravasation of the secretion primarily, and secondarily to definitive occlusion of the duct by cicatricial contraction at the point of injury. The writer is quite convinced that in the case reported the retention was the direct result of traumatic stricture of the common duct. Although this view is not supported by evidence from post-mortem examinations, it is confirmed by analogous production of cysts in other locations. It is evident that this class of cases would furnish the most favorable conditions for successful surgical treatment.

Obstruction from Displacement of the Pancreas.—As the pancreas is retained in its normal transverse position by the surrounding organs and connective-tissue attachments, a relative change of position of portions of the gland would result in a bending of the organ and obstruction in the duct at the point of flexion. This condition was the cause of retention in a case related by Engel, who found in a woman sixty years of age that the tail of the pancreas formed a right angle upward with the principal duct of the gland. A dislocation of this kind can occur in one of the following ways: (1) Abnormal relaxation of the connective-tissue attachments of the gland, permitting a portion of the organ to descend by its own weight lower in the abdominal cavity. (2) Pressure upon the gland by tumors or exudations. (3) Cicatricial contractions in the substance of the organ or in the peripancreatic space.

That the whole pancreas can become displaced is proven by the case reported by Dobrzycki. A man fifty years of age fell a distance

of some yards. After the fall there arose symptoms similar to those of a floating kidney. By palpation the displaced organ could be located. Saline fluid resembling pancreatic juice was vomited. In the hypogastrium could be felt a movable tumor corresponding in position and shape with the pancreas.

Diagnosis.—The question of diagnosis can be entertained only in cases where the cyst has attained very considerable proportions. The most important points to be taken into consideration are the history of the case, the anatomical location of the tumor, and its relations to the surrounding organs. The cases which have been reported have occurred exclusively in adults. Sex appears to exert no determining influence. In a number of cases the clinical history points distinctly and forcibly to traumatism as the exciting cause. In Gussenbauer's case the beginning of the illness was traced to indiscreet eating and drinking.

In all instances of cystic tumors in the region of the pancreas close inquiry should be made to ascertain the existence of antecedent inflammatory affections of the organ or in its immediate vicinity. A history pointing toward the existence of a biliary or a pancreatic calculi will also prove valuable in arriving at positive conclusions. Rapid growth of the tumor speaks in favor of its pancreatic origin. In Gussenbauer's, Kulenkampff's, and the writer's cases the tumors attained an enormous size within a few weeks. Considering the relations of these cysts to important surrounding organs, it is remarkable that they give rise to no serious symptoms aside from the pressure they exert upon adjacent organs. Pain is not a constant symptom, and when it is present it is due more to the causes which produce the cyst than to the cyst itself. In this respect cysts of the pancreas form a counterpart to malignant disease when it affects this or neighboring organs. Emaciation is due either to coexisting affection of the gland or to the impairment of function of important organs by pressure of the cyst. It is never as marked in these cases as in malignant disease. The supervention of fatty stools would point toward the existence of some coexisting serious lesion of the pancreas rather than to the existence of a simple cyst of the organ. This symptom was not found present, or it was overlooked, in all cases which have been operated upon. Of 28 cases of steatorrhea which were compiled by Ancelet, 16 were examined post-mortem. In 5 of these there was occlusion of the ductus choledochus and pancreaticus; in 3, occlusion of the pancreatic duct alone; in 1, inflammation of the pancreas and some of the adjacent organs. In the remaining cases disease of the liver and the bowels, or only marasmus, was found. In 13 cases of pancreatic calculi collected by Johnson only in 3 were fatty stools

observed; in 6 cases, diarrhea; in 4 cases, melena; and constipation in the remaining 6. The presence of fat in the stools is a symptom of great importance in the recognition of pancreatic disease, but that it is not of absolute diagnostic significance is proved by the well-known fact that the same condition will follow upon the obstruction of the biliary passages and affections which impair the functional activity of other organs of digestion.

Obstruction of the principal duct impairs digestion more than when its distal extremity or one of the accessory ducts is involved. The actual illness of the patient is usually preceded for a variable length of time by more or less marked symptoms of gastro-intestinal derangement, accompanied in some instances by pain in the region of the pancreas.

A peculiar color of the skin, which is believed by some to be characteristic of pancreatic disease, must be mentioned, as it was observed in several cases of calculous affection and cysts of the pancreas. The appearance presented by these patients is variously described as being unhealthy, pale-yellow, dirty, or earthy. The intimate relations of the cyst to the celiac plexus will explain the cause of celiac neuralgia which is met with in some of these cases. Atrophy of the celiac plexus from long-continued pressure may give rise to mellituria for the same reason that Klebs has affirmed—that partial extirpation or atrophy of the celiac plexus will cause the presence of sugar in the urine. Diverse diseases of the pancreas have also been known to produce diabetes mellitus. Cases of this kind have been reported by Cowley (1788), Bright, Elliotson, Frerichs, Fles, Hartsen, Silver, Recklinghausen, Munk, Seegen, and Friedreich. Klebs demonstrated by his experiments that complete extirpation of the pancreas or ligature of its duct invariably gave negative results so far as diabetes was concerned, and this may account for the fact that no sugar was found in the urine of the case reported on page 679. The cyst, when examined early, before it has attained considerable size, is always found in the region normally occupied by the pancreas. The exact location, however, is not always uniform, as it will depend upon the portion of the pancreas from which the cyst has taken its primary origin. It may be situated below the right lobe of the liver, as in Kulenkampff's case; in the epigastric region, as in Gussenbauer's case; or in the left hypochondrium, as noted in the writer's case. When the tumor has attained a large size or occupies the whole abdominal cavity, it will be difficult, and in the latter instance impossible, to determine by any known means its primary origin. In such cases it is of paramount importance to study its relations to adjacent organs. The tumor is invariably situated

in the bursa omentalis, and from this point, as it increases in size, it encroaches upon the space occupied by adjacent organs. The stomach is pushed forward in all cases, and later to the right. The transverse colon is displaced downward, the spleen to the left, and the diaphragm and the contents of the chest upward. The cyst being in direct contact with the diaphragm, it usually ascends and descends with the respiratory movements of the chest.

In doubtful cases it will become necessary to inflate the stomach and colon, with a view to ascertain their position relative to the cyst. If the patient is a female and the tumor occupies the entire abdominal cavity, it will simulate cystic disease of the ovary so closely that a differential diagnosis between the two is impossible. The cases reported by Lücke, Bozeman, and Rokitsansky furnish adequate proof of the correctness of this statement. The proximity of the abdominal aorta is such that the impulse of the artery is imparted to the tumor, which, however, pulsates only in one direction—away from the artery—a fact which will always distinguish it from an aneurysm. Unless the cyst is exceedingly tense, a sense of fluctuation is always imparted by palpation. Palpation is rendered difficult on account of the deep location of the pancreas and the rigidity of the recti abdominis muscles. The normal pancreas can be felt under certain favorable conditions. Concerning this point Sir William Jenner says: "By deeply depressing the abdominal walls about a hand's breadth below the umbilicus, by then rolling the subjacent parts under the hand (the stomach and colon must be empty), it might be possible to detect it in an individual who is thin and whose tissues are lax." In case the examination is rendered difficult on account of great rigidity of the abdominal muscles, this obstacle can be overcome by examining the patient while under the influence of an anesthetic. An exploratory puncture with a fine and perfectly aseptic needle of a hypodermic syringe will not only add material diagnostic information by revealing the character of the cyst-contents, but the procedure will also settle the question as to the existence or the absence of adhesions between the cyst-walls and the parietal peritoneum. In the differential diagnosis the following affections will come up for consideration: 1. Malignant disease of the pancreas or of the adjacent organs; 2. Aneurysm; 3. Echinococcus-cysts of the liver, spleen, or peritoneum; 4. Affections of retroperitoneal lymphatic glands; 5. Hydronephrosis or pyonephrosis; 6. Cystic disease of the suprarenal capsule; 7. Circumscribed peritonitis with exudation; 8. Ascites; 9. Cystic disease of the ovary.

Malignant Disease of the Pancreas and of the Adjacent Organs.—Carcinoma and sarcoma of the pancreas or of the adjacent organs, as

in every other locality, always manifest their presence by their most characteristic clinical features—pain, emaciation, and progressive local and general infection. The age of the patient and the previous history of the case will also furnish important diagnostic information. Large pancreatic cysts are unilocular, while, on the contrary, if a malignant tumor has undergone cystic degeneration, usually more than one cyst can be recognized. Hardness and irregularity of surface speak in favor of malignancy; smoothness and a regular round or oval contour of the tumor are constant features of a pancreatic cyst. The time that has elapsed since the beginning of the illness is also of importance. A rapid-growing pancreatic cyst will in two or three weeks assume a size which even for a malignant tumor would require as many months.

Aneurysm.—An aneurysm of the abdominal aorta can be distinguished from a pulsating pancreatic cyst by its pulsations being felt in all directions and by the presence of a bruit. As a further test the suggestion of Dr. Pepper may be resorted to—that of placing the patient in the genupectoral position, when the tumor, by gravitation, will leave the aorta and all pulsation will cease. Steady pressure will diminish the volume of an aneurysm, but it will have no effect on a cyst of the pancreas.

Echinococcus-cysts.—An echinococcus-cyst of the liver, the spleen, or the peritoneum could easily be mistaken for a cyst of the pancreas. The peculiar fremitus sometimes felt on palpating an echinococcus-cyst should always be sought for. Multiplicity of cysts would decide in favor of something else than a pancreatic cyst. The presence of hooklets in the aspirated fluid would furnish positive evidence in favor of the presence of an echinococcus-cyst, while their absence would not exclude the possibility of the tumor being a sterile echinococcus-cyst. As the surgical treatment in both instances would be identical, it is sufficient for practical purposes to narrow the diagnosis down to a probable existence of either affection.

Affections of Retroperitoneal Lymphatic Glands.—Neoplasms, inflammation, suppuration, or hypertrophy of the retroperitoneal glands behind the pancreas might simulate a pancreatic cyst, and as a wrong diagnosis in such an event might prove disastrous to the patient and reflect discredit upon the surgeon, every diagnostic resource should be exhausted in order to prevent such an error. Enlargement of the lymphatic glands sufficient in extent to simulate a pancreatic cyst would almost of necessity give rise to serious constitutional disturbances and to extension of the disease to neighboring organs.

Hydronephrosis or Pyonephrosis.—In hydronephrosis or pyonephro-

sis the early clinical history will present a group of symptoms pointing toward some lesions in the pelvis of the kidney or in the ureter. A chemical and microscopical examination of the urine may furnish conclusive evidence of the existence of some renal affection which has produced the obstruction. Tumors of the kidney usually occupy a lower place and are more laterally located than tumors originating in the pancreas. In case of a pancreatic cyst the lumbar region below the kidney is tympanitic, which is not the case in hydronephrosis or in pyonephrosis. In case of doubt an exploratory puncture may enable us to arrive at a positive conclusion.

Cystic Disease of the Suprarenal Capsule.—The suprarenal capsule may be the seat of cystic degeneration, and may simulate a cyst of the pancreas so closely that a differential diagnosis is impossible. In Gussenbauer's case the diagnosis remained doubtful between a cyst of the pancreas and a cyst of the suprarenal capsule. The bronzed skin so frequently observed in diseases of the suprarenal capsule has also been seen in affections of the pancreas. As the operative treatment in either case would be the same, it is not essential for practical purposes to make a positive diagnostic distinction between the two.

Circumscribed Peritonitis with Exudation.—Primary peritonitis with a circumscribed exudation in the region of the pancreas would reveal a history pointing toward an inflammatory affection accompanied by the usual symptoms attending inflammation of the peritoneum. Fever, pain, and tenderness are symptoms which are either foreign to the history of cysts of the pancreas, or, when present, are less intense than in peritoneal inflammations. In peritonitis the exudation would necessarily be in the peritoneal cavity, while pancreatic cysts always occupy the omental bursa.

Ascites.—The question of diagnosis between a cyst of the pancreas and ascites can arise only in case the whole abdominal cavity is distended by the tumor or the effusion. The causes which produce ascites must be considered separately and individually; as they are usually of such a character as to exclude a suspicion of pancreatic disease, a satisfactory diagnosis can be reached without an exploratory puncture, but if any doubt remains, this harmless procedure will furnish the requisite information.

Cystic Disease of the Ovary.—From the cases reported we have gleaned that in at least three cases large cysts of the pancreas were mistaken for cystic disease of the ovary by surgeons of prominence and ability who made thorough and repeated examinations. It is not difficult to conceive that in case the tumor has assumed such dimensions as to fill the entire abdominal cavity, it would be impossible to

differentiate between a cyst of the pancreas and one of the ovary, even by a most scrutinizing examination. The physical signs presented by either condition resemble those of the other so closely that they cannot be relied upon in discriminating one from the other. The early history of the case, if it can be obtained from a reliable source, is of more diagnostic value. In pancreatic cysts the early symptoms are usually referred to disturbance of the digestive functions, and the patient has been aware of the presence of a tumor in the upper portion of the abdominal cavity. An ovarian tumor necessarily begins in the opposite portion of the abdominal cavity, and gives rise to pelvic distress and disturbances of the menstrual function. As the surgical treatment in both instances would be the same, it is practically not essential to make a positive distinction between the two before an exploratory incision will reveal the true nature and origin of the cyst. In recapitulation it may be stated that a positive diagnosis has so far not been made in a single instance, and that for all practical purposes it is only essential to make a probable diagnosis between a pancreatic cyst, or some other kind of a cyst which would call for the same kind of surgical treatment. In very obscure cases an exploratory incision, under antiseptic precautions, for diagnostic purposes is a justifiable procedure.

Prognosis.—Physiologists are agreed in assigning to the pancreas a most important function in the digestion of organic food. We know that by a special ferment it assists in the transformation of starch into dextrin and sugar, and aids in the digestion of albumins and fat. We should naturally expect that in diseases of this organ the digestion of these substances would be impaired in proportion to the amount of gland-tissue destroyed. On the contrary, we have abundant evidence to show that even total disorganization or destruction of the pancreas is not incompatible with normal digestion and perfect health. It would seem that in the absence of the pancreatic secretion other organs assume a vicarious action, and digestion proceeds unimpaired. It is also important to remember that even a large cyst of the pancreas does not necessarily result in extensive destruction of the gland, and that the remaining gland-tissue continues to secrete and discharge a sufficient amount of pancreatic juice. In Bozeman's case the cyst occupied the entire abdominal cavity, and yet at the operation the greater portion of the gland was found healthy in structure. The integrity of the structure and function of the gland depends less on the pressure of the cyst than on the causes which were concerned in its production. The dangers arising from the cyst itself consist in—1. Its interference with the functions of other abdominal organs by pressure;

2. Rupture of the cyst and escape of its contents into adjacent hollow organs or into the peritoneal cavity. Compression of the stomach and interference with its normal peristaltic action are constant when the cyst has developed to any considerable size. When such is the case, vomiting soon after meals takes place, as was noted in a number of cases reported. When the cyst is of very large size, almost all the abdominal organs suffer by compression, and both digestion and absorption are impaired by mechanical pressure. The diaphragm being at the same time pushed upward, the heart and the lungs are displaced in the same direction, and embarrassment of circulation and respiration follows as a necessary sequence. Like any other benign abdominal tumor, the cyst proves dangerous to life by interfering mechanically with the functions of more essential and important organs. The second source of danger is rupture of the cyst and escape of its contents into adjacent organs—an accident which may be followed by immediate death from hemorrhage, or by which the life of the patient is placed in jeopardy by suppurative inflammation in the interior of the cyst, or by peritonitis in case the contents have escaped into the peritoneal cavity. In Pepper's case the immediate cause of death was hemorrhage consequent upon rupture of the cyst into the stomach. At the post-mortem examination there was found in the stomach and the intestines a large quantity of blood which had entered through an opening, about half an inch in diameter, close to the proximal termination of the ductus communis. A probe passed through this opening directly entered a cyst in the head of the pancreas. A communication with any portion of the gastro-intestinal tract would almost of necessity lead to infection and suppurative inflammation in the interior of the cyst; this infection, under unfavorable circumstances, might lead to a fatal termination from septicemia or from extension of the inflammation to adjacent organs. The prognosis may be said to depend (1) on the nature and cause of the obstruction, (2) on the size of the cyst, and (3) on the absence or presence of complications.

Treatment.—In the treatment of a pancreatic cyst the indications are the same as in the treatment of any other kind of cysts, namely—
1. Extirpation of the cyst; 2. Evacuation of its contents and obliteration of the cyst.

Extirpation was attempted in Bozeman's and Rokitansky's cases, in the former instance with complete success; in the latter the operation was not completed, and the patient died a few days afterward of septic peritonitis. It is proper to state that in both cases the operation was done for the removal of a supposed ovarian cyst, and that a correct diagnosis was made in the first case during the operation, after the

pedicle was traced to the pancreas and the intact portions of the gland were identified. In the second case the post-mortem examination revealed the true nature and location of the cyst. The brilliant result obtained by Dr. Bozeman is well calculated to stimulate others to follow his example. Extirpation of the cyst would guard most effectually against the formation of a permanent pancreatic fistula; but, on account of the deep location of the pancreas, the shortness or absence of a pedicle, and the many obstacles thrown in the way of the operator by adjacent organs, the procedure becomes one surrounded by innumerable difficulties, and in the present state of our science it is of doubtful propriety. Simple evacuation of the cyst-contents by means of the aspirator offers two principal objections against its adoption in the treatment of cysts of the pancreas: 1. Escape of cyst-contents into the peritoneal cavity; 2. Reaccumulation of secretion.

Reasoning from analogy, we should naturally expect that when pancreatic juice is brought in contact with the peritoneum, it would produce a destructive effect upon it by its digestive properties, or it might even be followed by diffuse peritonitis. In opposition to this assumption, it is affirmed that in experiments on the pancreas it happens quite frequently that pancreatic juice escapes into the abdominal cavity, from the cannula introduced into the pancreatic duct, without any bad results on the animals. Concerning this point Heidenhain says: "The animals do not suffer from this circumstance, as the duct is regenerated in spite of the wounded surface being bathed in the secretion. Nevertheless, it is difficult to explain this. Why do not the wounded and suppurating tissues undergo digestion by the pancreatic juice? The efficacy of the albumin-ferment is destroyed in some way, probably by being changed into zymogen, the living tissues having on the juice the effect observed by Podolinski on treating the pancreatic juice with pulverized zinc or yeast-ferment. Although small quantities of pancreatic juice may escape into the peritoneal cavity of an animal without any serious consequences, we have no evidence to show that the peritoneal cavity in man is possessed of the same immunity against such accident, and it would not be prudent to expose a patient to such risk until more light is thrown on this subject by further observation and experiment. At the same time, we must not forget that pure pancreatic juice is found only in small cysts, as the contents of large cysts have undergone various transformations, and are mixed with different accidental products which might prove an additional source of danger in producing peritonitis. In all the cysts where a pancreatic fistula was established the artificial opening continued to discharge the secretion for a variable period of time, and in

two cases the discharge had not ceased at the time the report was made, and hence reaccumulation would have been inevitable in case the fluid had been removed by aspiration. For these reasons the treatment by aspiration should be limited to cysts of moderate size and where adhesions have formed between the cyst and the anterior walls of the abdomen. In cases presenting these favorable conditions aspiration deserves a trial, and the operation may be repeated as often as required, or until symptoms arise which call for more radical measures. The needle should always be disinfected thoroughly by passing it through the flame of a spirit-lamp and by dipping it in a 5 per cent. solution of carbolic acid. The puncture is made obliquely, so as to prevent the formation of a fistulous opening. The fluid should be withdrawn slowly, and the cyst be emptied as completely as possible.

After the operation gentle pressure should be made over the cyst by applying a compress and an elastic bandage. The safest and at the same time the most efficient treatment consists in establishing a pancreatic fistula. The operation which accomplishes this purpose most safely and in the shortest time consists in exposing the cyst by an incision, stitching its walls to the margins of the wound. The same aseptic precautions must be observed before, during, and after the operation as in any other abdominal operation. The stomach being generally pushed forward, upward, and toward the right by the cyst, it is advisable to empty this organ completely as a preliminary measure by abstinence of food and by the use of the siphon irrigator. Except in the writer's case the incision was always made in the *linea alba*. It seems to the writer that the incision should always be made over the most prominent part of the tumor, and as nearly as possible over the seat of obstruction. In following this rule we select the place where we are most apt to find adhesions, and at the same time we establish the straightest and most direct route to the primary origin of the cyst. An incision through the *linea alba* or parallel with the costal arch will afford the easiest access with a minimum risk of injury to important parts. The external incision should be at least four inches in length, while the peritoneum should only be opened to the extent of two inches for the purpose of making an exploratory examination, the incision being enlarged as occasion may require. If adhesions are found between the cyst and the omentum and the omentum and the parietal peritoneum, the cyst is punctured with an exploratory needle, and, if the diagnosis is corroborated, the operation is finished by incising and draining the cyst. If no adhesions are found between the omentum and the peritoneum, the former is incised so as to expose the cyst-wall, when either of the following plans may be pursued: The

parietal peritoneum is stitched to the skin with catgut. The margins of the omental wound are pushed back under the abdominal walls so as to expose the cyst freely, when the wound is packed from the bottom with iodoform gauze, and an aseptic dressing is applied and retained for six or eight days, or until adhesions have formed between the cyst and the margins of the wound, which have effectually shut off the peritoneal cavity, when the cyst is incised and drained.

Suturing of the cyst-wall to the margins of the wound as a preliminary operation should never be resorted to, as, on account of thinness of the cyst-walls, there is danger of escape of fluid into the peritoneal cavity from the punctures made by the needle—an occurrence which the procedure was intended to obviate. With proper care, however, the operation can be completed at once. The cyst-wall is grasped with two many-toothed forceps, and is drawn forward so as to bring it in accurate and close contact with the margins of the wound, when the fluid is removed with an aspirator or a trocar with the same care as in emptying an ovarian cyst. As the cyst becomes empty it is pulled through the wound, obviating any further danger of escape of fluid into the peritoneal cavity. When the cyst is nearly empty it is freely incised and sutured to the peritoneal lining of the abdominal wound. The drainage-tube should be fully three-quarters of an inch in diameter, and must reach from the bottom of the cyst to the surface of the wound. After emptying the cyst completely by compression and placing the patient on his side, a large Lister dressing is applied for the purpose of guarding against infection and to absorb the secretions. Frequent change of dressing may be required on account of copious escape of pancreatic secretion. Past experience would dictate the advisability of protecting the skin against the digestive action of the pancreatic juice by freely applying carbolated oil. The antiseptic dressings should not be abandoned until the peritoneal cavity has become completely closed by firm adhesions and the size of the cyst has been reduced to a fistulous tract. The drainage-tube is shortened from time to time as the depth of the fistulous opening is diminished by obliteration of the cyst from the bottom of the tract. The speedy obliteration of the cyst will depend on the continuance, abatement, or removal of the obstructing cause or upon the condition of the gland-tissue distal to the seat of obstruction. If the stricture in the common duct of the pancreas is complete and of a permanent character, the obstruction will continue, and if healthy gland-tissue remains on the distal side, the fistula will continue to discharge pancreatic juice. If the inflammation which caused the obliteration of the duct subsides, and the passage again becomes permeable, the natural outlet will again be established

and the artificial duct will become obliterated. If an impacted calculus has caused the retention, and the fistula continues to discharge, a careful examination should be made to detect the calculus, and if found, an effort should be made to remove it through the fistulous opening. If the obstruction has become permanent and the gland-tissue on the distal side has become destroyed either by the cause or causes which produced the obstruction or by the intracystic pressure, that portion of the organ has been deprived of its functional capacity, and, as no pancreatic juice is secreted, definitive obliteration of the cyst and permanent closure of the fistulous tract will take place in a comparatively short time.

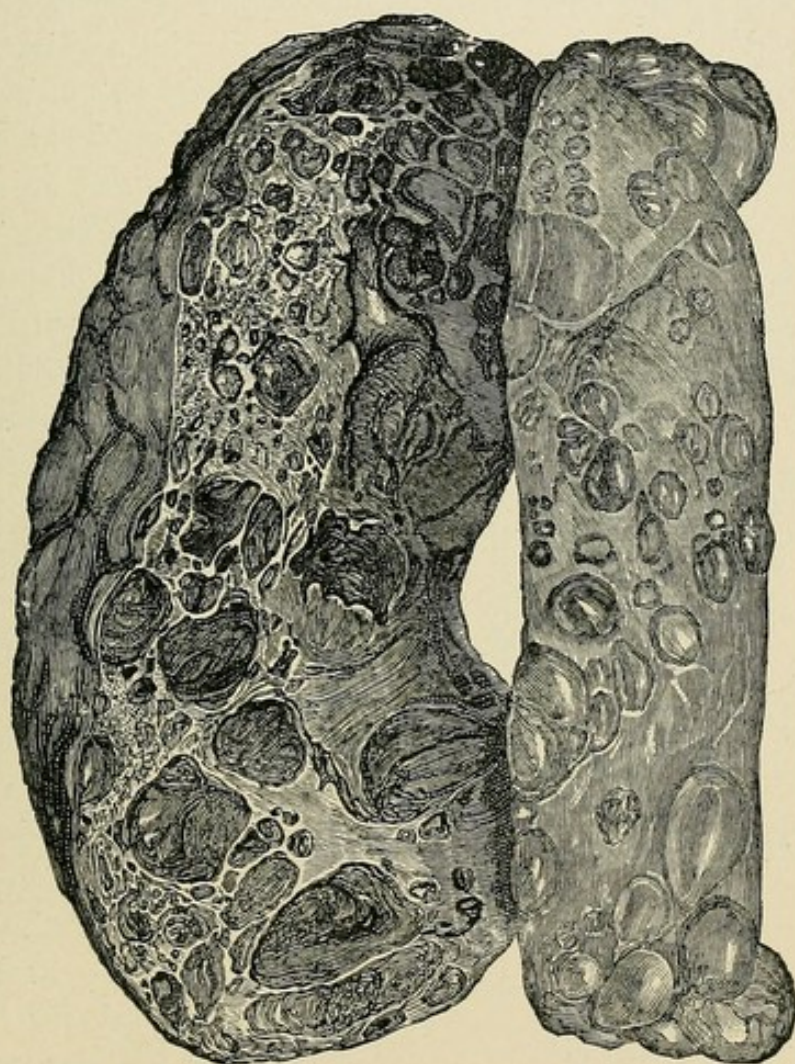


FIG. 463.—Congenital cystic kidney (after H. Morris).

Kidney.—Retention-cysts of the kidney occur in the substance of the kidney, constituting the *hydrops renum cysticus*, or the pelvis of the kidney becomes distended from obstruction anywhere in the urinary passage below—a condition called *hydronephrosis*.

Cystic Hydrops of the Kidney.—Retention-cysts of the kidney frequently occur as a congenital affection. In the congenital as well as

in the acquired forms the cyst-formation is due to occlusion of uriniferous tubules. According to Erichsen, however, they may also form in connective tissue, in which the fluid is formed in the same manner as in hydrocele. Congenital cysts of the kidney are frequently found on both sides, and so large that the swellings distend the fetal abdomen to its utmost capacity. The kidney is in some cases a huge collection of cysts with little or no kidney-tissue (Fig. 463), and the children are born dead or die soon after birth. At other times the cysts are small and the kidney is contracted and is composed almost exclusively of connective tissue. The obstruction of the uriniferous tubules during intra-uterine life is caused, as in the formation of cysts later in life, by a general nephritis causing blocking of the tubes either by casts or epithelial debris or by hyperplasia of the interstitial connective tissue. A localized connective-tissue hyperplasia extending from the pelvis of the kidney, resulting from *nephro-pyelitis fibrosa*, *pyelo-papillitis fibrosa ascendens*, or a *nephritis urica*, from failure of union between

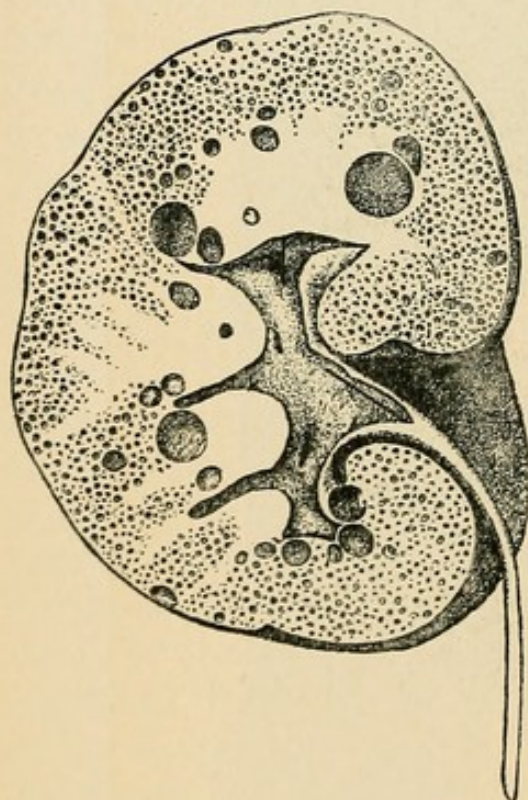


FIG. 464.—Congenital cystic kidney, early stage (after Shattuck).

the renal and collecting tubules, or from rests of the Wolffian or supra-renal bodies, may cause blocking of the tubes. The cysts appear in different parts of the kidney (Fig. 464). The spaces, which are lined with cubical or flattened epithelium, appear to be smooth-walled. As the cysts enlarge many of them fuse and form large cavities, so that ultimately the kidney acquires a honey-comb appearance. In the adult, cysts of this kind may form from small cysts which originated during intra-uterine life. In other cases they are the result of an interstitial nephritis (Fig. 454). The cysts at first contain urine, or at least urinary salts, which later disappear and are replaced by serum. Children born alive with

double cystic disease of the kidney usually die of uremia in a short time. In the adult the same condition is developed in the course of a chronic interstitial nephritis, which generally affects simultaneously both organs, in which case surgical treatment is out of the question. In children with congenital unilateral cystic kidney nephrectomy is indicated if the size of the swelling interferes with important functions.

Hydronephrosis.—The effect of chronic obstruction to the outflow of the urine can be studied profitably in cases of stricture of the urethra or enlargement of the prostate. Dilatation of the urinary passage occurs from the seat of obstruction and ascends progressively the entire length of the urinary apparatus. In prostatic or urethral obstruction the bladder first becomes dilated, the valves guarding the ureteral orifices are rendered incompetent, the ureters dilate, and finally the back pressure results in distention of the pelves of both kidneys, producing a double hydronephrosis.

Unilateral hydronephrosis is the result of obstruction of the ureter. Abnormal intracystic pressure often results in a localized yielding of the bladder-wall, sacculation, and eventually the formation of a pouch which communicates with the bladder only through a very narrow opening. The presence of a stone in such a pouch frequently eludes detection with the sound, and offers great difficulties in its removal either by the perineal or the suprapubic route. In exceptional cases a diverticulum becomes completely detached from the bladder by obliteration of the communicating opening. Virchow saw such an isolated diverticulum in the perineum.

In cases of unilateral hydronephrosis with a patent ureter Virchow years ago pointed out a valvular obstruction caused by a congenital or an acquired defect at a point where the ureter dilates to form the pelvis of the kidney. This defect consists of an abnormal obliquity of the ureter at this place. The most frequent causes of obstruction of the ureter are impaction of a calculus, stricture, pressure, and the extension to the ureter of a carcinoma of the uterus. Retroversion of the uterus and benign tumors of the uterus and the ovaries may compress one or both ureters to such an extent as to cause hydronephrosis. If the obstruction is located at the *ostium urethrale pelvicum*, in the form of an impacted calculus, a stricture, or a valve, the accumulation of urine leads to progressive dilatation of the pelvis of the kidney and to atrophy of the kidney-substance from pressure, so that in the course of time the kidney is converted into a sac composed apparently of a fibrous wall, and containing no longer urine, but a serous fluid. If the pelvis of the kidney does not yield to the abnormal pressure, pouches form, while other parts of the kidney show to a lesser extent the effects of pressure. If the ureter is occluded or obliterated below the pelvis of the kidney, the part of the ureter above the obstruction dilates simultaneously with the pelvis of the kidney. If the obstruction is not complete, the urine escapes from time to time and the swelling diminishes in size or disappears altogether, to reappear

with the accumulation of urine, constituting what is called an *intermitting hydronephrosis*.

Congenital impermeability of the ureter results in congenital hydronephrosis, unilateral or bilateral according to whether one or both ureters are defective.

Hydronephrosis, like all other retention-cysts, is prone to become the seat of secondary pathological conditions by the entrance into the dilated pelvis of the kidney of pyogenic microbes. The suppurative inflammation which then ensues converts the hydronephrosis into pyonephrosis. The suppurative pyelonephritis destroys the atrophic parenchyma of the kidney, so that ultimately nothing remains but the dilated capsule of the kidney filled with pus. Infection most frequently takes place by an ascending suppurative ureteritis, or it may occur by pus-microbes which reach the kidney through the circulation.

From a diagnostic point of view hydronephrosis is a retroperitoneal cyst which begins in a region occupied by the kidney. If the swelling is large enough to be palpable, fluctuation can usually be felt. In cystic kidney the surface of the organ is usually uneven from the presence of a number of cysts of unequal size. A hydronephrotic kidney presents itself as a smooth swelling.

The most important point in the differential diagnosis of hydronephrosis and of intra-abdominal fluctuating swellings and tumors is to demonstrate the retroperitoneal location of the swelling, which in doubtful cases can be shown satisfactorily by rectal insufflation. In women catheterization of the ureters as described and practised by Kelly will often enable the surgeon to demonstrate not only the existence but also the exact location of the ureteral obstruction. If the swelling can be located positively in the retroperitoneal space, a lumbar exploratory puncture under strict antiseptic precautions is not only permissible but will settle the diagnosis between hydronephrosis and pyonephrosis and malignant tumor of the kidney. A careful chemical and microscopical examination of the urine will often indicate the kidney as the primary seat of the swelling.

Treatment.—In unilateral hydronephrosis the opposite kidney undergoes compensatory hyperplasia. Experiments and clinical observation have shown that one healthy kidney is sufficient to eliminate the urea, and numerous cases have been recorded in which a hydronephrotic kidney was removed without any immediate or remote ill results. The kidneys are, however, subject to so many accidents and diseases that there is no excuse for sacrificing a kidney unless its parenchyma has been destroyed or the continuity of the urinary passage cannot be restored by some of the operative procedures that have recently been

devised. The writer, who cannot agree with Morris and Sutton that, in case the opposite kidney is in a healthy condition, the hydronephrotic kidney should be removed, has shown that mechanical obstruction of the ureter in dogs produces progressive hydronephrosis, and has demonstrated, by microscopical examination of the capsule of the cyst, the existence of atrophic kidney-tissue and the capacity of this tissue to regenerate after a nephrotomy. It is different in cases of hydronephrosis complicated by suppurative pyelonephritis. In such cases the parenchyma of the kidney, already atrophic from pressure, is quickly destroyed by the suppurative inflammation. In uncomplicated hydronephrosis it is the duty of the surgeon to relieve tension and to secure a new outlet for the secretion by a lumbar nephrotomy, and at the same time to search for and remedy the obstruction that has caused the hydronephrosis. Recent advances made in ureteral surgery dictate such a conservative course. It is certainly easier to extirpate a hydronephrotic kidney than to remove its primary cause, but this fact is no argument in favor of mutilating surgery. With this additional indication to meet, the kidney and the upper part of the ureter should be exposed by König's incision. This incision will expose the pelvis of the kidney and the upper part of the ureter for a thorough examination by sight and touch. If the ureter below the pelvis of the kidney is not dilated, the obstruction must be sought for at the pelvic orifice of the ureter, through an incision into the lowest portion of the dilated pelvis. If an impacted stone is found, it is extracted, and the permeability of the ureter is demonstrated by catheterization. If a valve in the form of a projecting spur caused by a too oblique insertion of the ureter is found, it can be excised and the mucous membrane be sutured with fine catgut; or if this procedure is impracticable, the ureter may be cut transversely below the pelvis, the proximal end tied, and the distal end implanted into a slit in the dilated pelvis, in which location it may be fixed by a few superficial sutures; the wound in the pelvis may then be closed, and an external temporary urinary fistula established by an incision through the convex side of the kidney, the fistula being kept open by a tubular drain. If the ureter at this point is completely obliterated, a similar procedure is indicated. If it is narrowed by cicatricial stenosis, a plastic operation such as the one devised by Heineke-Mikulicz for cases of cicatricial stenosis of the pylorus will yield an excellent result, as has been shown by the experience of Fenger.

Impacted calculi and cicatricial stenosis nearer the bladder are attended by dilatation of the ureter above the obstruction; the obstruction will therefore be found at the lower end of the dilated ureter.

The lower end of the ureter can be reached through the sacral route. If the cicatricial stenosis is found at or near the insertion of the ureter into the bladder, transverse section, ligation of the bladder-end, and implantation of the upper end into a slit of the bladder, as advised by Van Hook, will restore the continuity of the urinary canal. In all these operations upon the ureter it is advisable to establish a temporary renal fistula in the lumbar region; this fistula should be maintained until the patency and efficiency of the ureteral part of the urinary passage have been demonstrated. If a considerable part of the lower portion of the ureter is impermeable, implantation of the upper portion into the rectum—an operation the feasibility of which has been demonstrated by the experiments of Reed and the clinical experience of Chaput and others—should be considered. The writer is firmly convinced of the propriety of restricting primary nephrectomy in hydronephrosis to cases in which the surgeon can satisfy himself that the opposite kidney is intact, and in which the parenchyma of the affected kidney has been destroyed. In all other cases a nephrotomy should be made, and, if possible, the ureteral obstruction be removed at the same time or subsequently. In the opinion of the writer, it is much better to subject the patient to the slight inconvenience of a permanent renal fistula than to deprive him of an important organ capable of parenchyma-regeneration. The writer has a number of patients who wear a tube of special construction to which is attached a rubber receptacle: the patients are perfectly comfortable, and they prefer this condition rather than subject themselves to a secondary nephrectomy. In a number of such cases it has been observed that while the escape of urine soon after the operation was scanty, the amount of secretion gradually increased until after a few months the diseased kidney secreted nearly as much urine as the opposite one—the best possible proof that the atrophic kidney-tissue after the operation resumed its former physiological importance.

Hydronephrosis caused by obstruction of the ureter from malignant disease does not justify surgical interference. In hydronephrosis produced by pressure upon the uterus the cause of compression should be removed. This includes the removal of benign pelvic tumors, inflammatory adhesions, and the correction of displacement of a pathological or a pregnant uterus.

Testicle.—Cysts of the testicle arising from “rests” have been considered in the section on Cystoma. We shall describe here cysts resulting from obstruction of spermatic tubes. Such cysts are usually thin-walled, spherical or oval cysts, imbedded in and loosely connected with the tissue of the cord. They may occur singly or in a group.

Their most frequent seat is just above the epididymis, but they may be found in any part of the spermatic cord. Mr. Lloyd and Mr. Liston discovered, independently of each other, spermatozoa in the contents of these cysts. Roth traces spermatic cysts to the retention of fluid from congenital vasa aberrantia. Silcock attributes them to cystic dilatation of tubules. The various forms of seminal cysts have been described fully by Curling. The capsule of the cyst is composed of connective tissue lined with squamous epithelium. Kocher and Rosenbach demonstrated by fine dissections of specimens the connection of the spermatoceles resulting from retention with the spermatic tubules. Rupture of retention-cysts on the surface of the epididymis and the testicle and rupture of Morgagni's hydatid (Roth) give rise to spermatozoa in the fluid of hydrocele. Spermatoceles, which occur in persons after the age of puberty, grow slowly and occasionally attain large size. Paget removed from a cyst of this kind, in a man seventy years old, eighteen ounces of a milky fluid which contained spermatozoa, and Stanley removed twenty-five ounces in a similar case. The cyst from which the fluid was obtained, which furnished the histological elements for Fig. 465, occurred in a man seventy-four years of age, and had

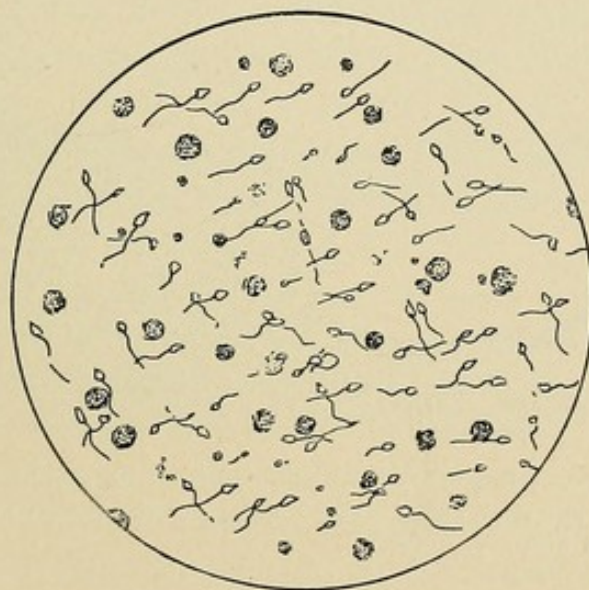


FIG. 465.—Contents of spermatocele, showing spermatozoa and epithelial cells ; $\times 350$.

attained the size of a filbert. The patient was suffering at the same time from double epididymitis and hypertrophy of the prostate gland. The swelling is smooth, fluctuates, and in many cases is translucent.

The treatment consists in tapping with or without the injection of carbolic acid, incision of the cyst, suturing of the cyst-wall to the skin, and drainage as in Volkmann's operation for hydrocele. In the case of small cysts that give rise to no inconvenience operative treatment is contraindicated. In cases in which repeated occurrences take place

after tapping and injection, excision of the sac is indicated, and the operation yields good results.

Mammary Gland.—In the mammary gland during lactation retention of milk in the gland-ducts occurs quite frequently in connection with obstruction produced by acute or chronic interstitial mammitis. This form of retention-cyst is called *galactocoele*. If the obstruction of the duct remains permanently, the cyst-contents change. The milk is either transformed into a cheesy mass or is absorbed, being replaced

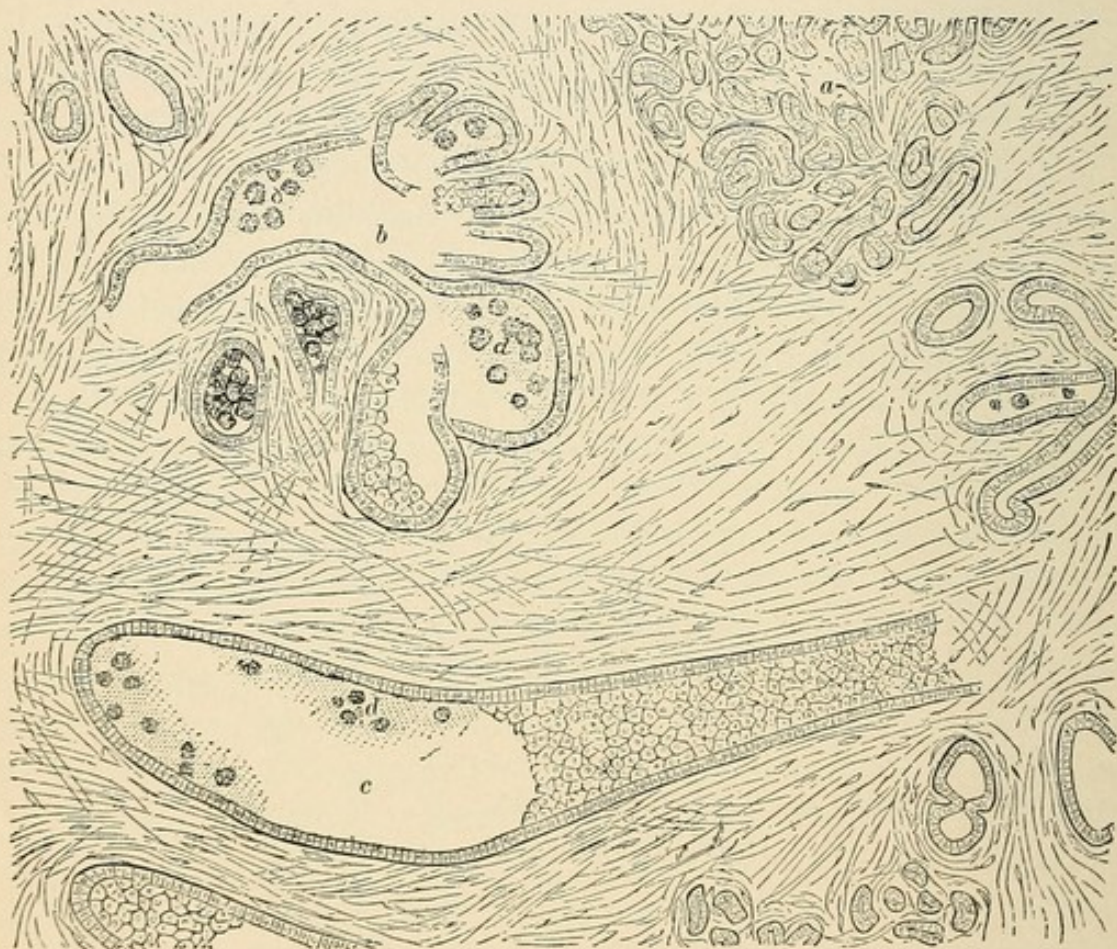

FIG. 466.—Circumscribed interstitial mastitis with cyst-formation (after König): *a*, normal acini; *b*, transition of normal acini into small cysts; *c*, dilated duct; *d*, colostrum-corpuscles. The interstitial connective tissue is infiltrated with young cells.

by a serous fluid which is often stained by the admixture of blood. In the causation of genuine cysts of the mammary gland, usually some form of obstruction leads to dilatation of the lacteal ducts. In some cases the cysts communicate with one another; in others multiple cysts appear simultaneously or in succession independently of one another. Sometimes such cysts attain an enormous size. Mr. Paget quotes a case in which a cyst of this kind contained nine pounds of limpid "serosity" which had developed in three months in a woman thirty years of age. In this case the walls of the cyst were thin and the

fluid was serous. Degeneration of the cyst-wall retards or arrests growth, rendering the lining membrane which secretes the contents barren.

Multiple cysts are often produced, as pointed out by König, in consequence of chronic interstitial mastitis, which obstructs the milk-ducts (Fig. 466). This form of interstitial mastitis with cyst-production has often been mistaken for carcinoma.

Chronic interstitial mastitis occurs, according to König, as a circumscribed and diffuse affection. Another variety of retention-cyst occurs in elderly women, frequently as a multiple affection, in consequence of senile involution of the breast. The cysts give rise to no pain, but occasionally they are the starting-points of carcinoma. The cysts are small, and they contain a mucoid substance which causes them to assume a bluish tint when the breast is examined after removal.

In galactoceles complicated by inflammation a free incision relieves the pain and tension and is followed by a speedy obliteration of the cyst. In chronic cases incision followed by cauterization and packing of the wound with iodoform gauze, or excision of the cyst, is indicated. Chronic interstitial mastitis with cyst-formation, if circumscribed, indicates partial excision of the breast. If the disease is diffuse, the entire breast should be removed. Involution-cysts require no surgical treatment.

Salivary Glands.—A retention-cyst of the ducts of the sublingual and submaxillary salivary glands is called a "ranula." Retention-cysts of Stensen's duct have been seen and described by Bruns, but they are exceedingly rare. Various interpretations have been given as to the origin and nature of the sublingual cysts that were formerly classified under the head of "ranula." Pauli believed that they consisted of a dilated Wharton's duct, in which case he called the swelling a "ptyal-ectasis," or, after rupture of the duct, an accumulation of saliva in the connective tissue, in which case he called the swelling a "ptyalocoele." Virchow, for good reasons, objected to the latter mode of origin, as he asserted that the saliva extravasated into the connective tissue would become absorbed. Fleischmann claimed that the salivary ducts could not dilate to the extent seen in cystic swellings under the tongue. He believed that these cysts are hygromata of the base of the genio-glossus muscle. Gurlt and Bernard asserted that the submaxillary gland secreted a mucoid substance analagous to the contents of the cysts so frequently found on the side of the tongue. Ptyalin and rhodankalium, however, have never been discovered in the contents of a ranula. The absence of these two substances in the contents of a ranula is, however, no proof that the cyst is not a dilated duct of a

salivary gland, as the cyst-contents undergo chemical changes which make it impossible to refer the secretion back to its proper origin by chemical examination.

Bernard and Weber not only detected the orifice of the duct upon the wall of a retention-cyst of Wharton's duct, but they succeeded in inserting through the orifice a fine probe into the cyst, thus establishing beyond all doubt the connection of the cyst with the duct. Neumann in a supposed case of ranula excised a part of the cyst-wall, and on examination of sections under the microscope he found the cyst lined with ciliated epithelium. This induced him to regard the foramen cecum as the starting-point of the cyst. Bochdalek showed that the foramen cecum in some cases does not terminate in a blind sac, but extends in the direction of the median glosso-epiglottic ligament. The posterior end of this prolongation possesses numerous mucous glands, of which several are situated in the floor of the mouth, on the side of the tongue, and hidden by the genio-glossus muscle. Recklinghausen is of the opinion that most of the cysts which heretofore have been called "ranula" are cysts which originate from Blandin-Nahn's gland in the substance of the tongue. He bases this opinion upon the form and growth of the cysts as well as the character of their contents. In multilocular ranula remnants of gland-tissue have been found in the cyst-wall.


From these remarks it will appear that many of the mucous cysts in the floor of the mouth do not always consist of a dilated duct of one of the salivary glands and retained saliva. That retention-cysts of the salivary ducts occur has been shown by the investigations of Bernard and Gurlt. Richet in one case found as the cause of the obstruction a fragment of a grass-blade lodged in the duct, and the duct behind the obstruction was dilated into a cyst.

Kölliker, Bernard, and Birkett claim that Rivini's duct is as often the seat of retention-cysts as Wharton's duct. The writer, in several cases of dilatation of Wharton's duct to the size of a walnut, has not only discovered its orifice upon the wall of the cyst, but by pressure has been able to empty the cyst through the constricted orifice. In many cases of ranula the outlet of the duct is not completely closed, but is contracted. Stenosis and cicatricial obliteration of Wharton's and Rivini's ducts are caused by inflammation and cicatricial contraction, producing incomplete or complete obstruction and retention of saliva, which at first constitutes the contents of the cyst, but which undergoes speedy chemical changes.

A retention-cyst of the ducts of the salivary glands appears clinically as a cyst with very thin walls and with mucous contents. The

cyst is usually somewhat elongated in the long axis of the tongue: it may become so large as to interfere with the free movements of the tongue, and at the same time may appear as a swelling of considerable size in the submaxillary triangle.

The removal of a ranula by excision is the surest and shortest way to effect a radical cure. The cyst cannot be enucleated, as the cyst-wall is exceedingly delicate and firmly attached. Excision is not applicable in all cases. The second method of treatment is the one usually resorted to; this method consists in excision of a large part of the cyst-wall, after which the cavity is packed with iodoform gauze to prevent the healing of the incision. The gauze packing should be changed daily until the margins of the wound have healed, thus securing a free and permanent outlet for the duct.



INDEX.

- ADENOMA, 152
 diagnosis, 175
 etiology, 155
 history and pathology, 153
 in animals, 58
 of digestive tract, 157
 of Fallopian tubes, 161
 of kidney, 175
 of lachrymal gland, 172
 of liver, 173
 of mammary gland, 167
 of nasal cavities, 159
 of ovaries, 161
 of parotid gland, 172
 of prostate gland, 171
 of skin, 157
 of testicle, 172
 of thyroid gland, 162
 of uterus and its appendages, 159
 prognosis, 176
 sebaceum, 157
 sudoriparum, 157
 treatment, 176
- Akidopeirasty, 98
- Anastomosis, intestinal, 339
- Angioma, 448
 anatomical varieties, 452
 complications, 451
 definition, 448
 histogenesis, 449
 histology, 449
 intracranial, 462
 of bones, 461
 of deep connective tissue, 459
 of larynx, 464
 of liver, 462
 of mammary gland, 463
 of muscles, 463
 of skin and mucous membranes, 458
 of tongue, 463
 prognosis, 456
 symptoms and diagnosis, 456
 treatment, 456
- Angio-sarcoma, 451
- Animals, tumors in, 57
- Apostoli's uterine electrode, 506
- Atheroma, deep-seated, 183
- BLEPHAROPLASTY, 286
- Blood-corpuscles, immigration of, into parenchyma of tumor, 111
- Branchial cysts. See *Cysts*.
- Bronchocele, 162
- CARCINOMA, 203
 cylindrical-celled, 214, 252
 definition, 203
 diagnosis, 256
 etiology, 231
 age, 234
 climate, 236
 diet, 235
 heredity, 232
 mental depression, 236
 microbes, 239
 prolonged irritation and inflammation, 236
 traumatism, 233
 tuberculosis, 236
 factors in the production of, 86
 general infection, 225
 glandular, 215, 253
 histogenesis, 208
 histology, 212
 local diffusion, 216
 malignancy, 215
 of bladder, 372
 of cervix uteri, supravaginal amputation for, 364
 of external female genital organs, 370
 of eye, 372
 of face, 282
 diagnosis, 283
 operative treatment, 286
 of internal organs, diagnosis, 263
 of intestines, 335
 enterectomy for, 337
 enterostomy for, 337
 intestinal anastomosis for, 339

- Carcinoma of intestines, operative treatment
 of, 337
 of kidney, 374
 nephrectomy for, 376
 of lip, 280
 clinical course, 280
 diagnosis, 281
 operative treatment, 283
 of liver, 345
 of mammary gland, 303
 acinous variety, 305
 etiology, 307
 prognosis, 315
 symptoms and diagnosis, 308
 treatment, 317
 radical operations, 317
 of mouth, 289
 radical operations for, 291
 of nose, operative treatment, 287
 of œsophagus, 323
 diagnosis of, differential, 324
 gastrostomy for, 325
 of ovary, 350
 of parotid gland, 298
 extirpation for, 301
 of penis, 347
 amputation of penis for, 349
 of rectum, 339
 extirpation of rectum for, 343
 palliative operations, 342
 symptoms and diagnosis, 341
 of skin, 275
 degeneration of tumor-tissue, 280
 histological structure, 275
 regional infection, 279
 of stomach, 326
 gastro-enterostomy for, 332
 pylorotomy for, 328
 treatment, 328
 of testicle, 346
 of thyroid gland, 300
 of tongue, 292
 radical operations for, 294
 of tonsil, 291
 operative treatment of, 291
 of urethra, 373
 of uterus, 353
 etiology, 359
 histogenesis and histology, 353
 symptoms and diagnosis, 360
 vaginal hysterectomy for, 366
 origin and nature, 204
- Carcinoma, pathology, 242
 prognosis, 264
 regional infection, 220
 secondary, growth of, 222
 local infection of, 223
 squamous-celled, 213, 250
 treatment, 266
 palliative operations, 269
 radical operations, 271
 ulcerating, difficulty in diagnosis of, 261
 Carcinoma-cells, degenerative changes in, 246
 Carcinosis, miliary, 229
 Caustics in treatment of tumors, 120
 Cementomes, 446
 Cervix uteri, supravaginal amputation of, for
 carcinoma, 364
 Chassaignac's chain écraseur, 125
 Cheiloplasty, 286
 Cholesteatoma, 401
 Chondroma, 422
 branchiogenes, 432
 definition, 422
 etiology, 426
 histology, 424
 of bone and periosteum, 429
 of cartilage, 428
 of connective tissue, 432
 of joints, 430
 of ovary, 432
 of salivary glands, 431
 of testicle, 432
 origin, 422
 prognosis, 427
 retrogressive metamorphoses, 425
 symptoms and diagnosis, 427
 treatment, 428
 Clamps, intestinal and stomach, 329
 Colostomy, inguinal, Maydl's, 342
 Comedo, 666
 Cornu cutaneum, 142
 Cystoma, 178
 diagnosis, 180
 etiology, 180
 of bone, 201
 of broad ligament, 197
 of eye, 199
 of mammary gland, 188
 of ovary, 189
 origin, 194
 treatment, 197
 of parovarium, 195
 of testicle, 198

- Cystoma of thyroid gland, 187
 of vagina, 198
 prognosis, 181
 topography, 181
- Cysts, allantoic (urachus), 201
 branchial, 623. See also *Teratoma*.
 anatomy and embryology, 624
 antiseptic drainage in treatment of, 635
 atheromatous, 628
 classification, 626
 diagnosis, 631
 etiology, 630
 extirpation of, 634
 history, 625
 iodine injections in treatment of, 633
 mucous, 628
 prognosis, 631
 serous, 629
 treatment, 632
 dermoid, 635. See also *Teratoma*.
 definition, 636
 histology, 637
 hemato-, of branchial clefts, 629
 mesoblastic, 186
 mucous, 185
 of corpus luteum, 195
 of jaws, 201
 of vitello-intestinal duct, 199
 ovarian, 189
 retention-. See *Retention-cysts*.
 sebaceous, 666
 traumatic epithelial, 181
- DECIDUOMA maligna, 612
- Dermoid cysts. See *Cysts*.
- Desmoid fibroma, 392
- ÉCRASEUR, wire, 126
- Embryo, differentiation of tissue in, 23
 germinal layers of, origin and disposition, 25
- Embryonic tissue of post-natal origin, transformation of, into malignant tumors, 84
- Enkatarrhophy, 182
- Enterectomy, 337
- Enterostomy, 337
- Epulis, sarcomatous, 590
- Exostosis, 56
- Exploratory syringe, value of, as an aid in diagnosis, 101
- FERGUSON'S percutaneous ligature, 125
- Fibro-chondroma, 424
- Fibroma, 378
 definition, 379
 etiology, 383
 histogenesis and histology, 379
 of abdominal wall, 391
 of gums, 399
 of mammary gland, 396
 of mucous surfaces, 389
 of nose, 394
 of ovary, 397
 of periosteum and bone, 400
 of serous surfaces, 401
 of skin, 385
 of subcutaneous connective tissue, 390
 of uterus, 397
 of vulva, 398
 prognosis, 384
 retrograde metamorphoses, 382
 symptoms and diagnosis, 383
 treatment, 385
- Fœtus in fœtu, 621
- Forceps, bowed, 369
 intestinal, 330
- GALACTOCELE, 706
- Gastro-enterostomy, Lücke's operation, 333
 Senn's operation, 333
 Wölfler's operation, 332
- Glioma, 554
- Gumma of liver, 104
- HARPOON, Warren's, 103
- Hegar's forcéps, 511
- Hydatids, Morgagni's, 197
- Hydrokolpos, 671
- Hydrometra, 671
- Hydronephrosis, 701
- Hydrops renum cysticus, 699
- Hydrosalpinx, 672
- Hysterectomy, complete abdominal, 514
 vaginal, for carcinoma of uterus, 366
 for myofibroma of uterus, 510
- INCLUSIO fœtalis, 621
- Infection, general, 76
 glandular, sarcoma as a cause of, 51
 local, 75
 meaning of word as applied to tumors, 74
 regional, 75
 carcinoma as a cause of, 51
- Inflammation, effect of, on tumors, 51


- KARYOKINESIS, 30
 Karyomitosis, 31
 Keloid scar, 388
 spontaneous, 386
 Knaurs, 55
 Kocher's director, 302
 Koch's syringe, 118
 Koderick's rosary instrument, 124
- LAPARO-HYSTERECTOMY or uterine myofibro-
 ma, 514
 with extraperitoneal treatment of the pedi-
 cle, 516
 with intra-abdominal treatment of the pedi-
 cle, 514
 Laparo-myomectomy, 512
 Laparotomy for myofibroma of uterus, 510
 Leiomyoma, 487
 histology and histogenesis, 487
 Lipoma, 404
 anatomical varieties, 405
 arborescens, 413
 definition, 404
 histology, 404
 in animals, 57
 intermuscular, 413
 of broad ligament, 414
 of eye, 414
 of eyelids, 411
 of joints, 413
 of meninges of the brain and spinal cord, 413
 of periosteum, 413
 of scrotum, 414
 of subcutaneous adipose tissue, 408
 of tendon-sheaths, 414
 of vulva, 414
 prognosis, 407
 regressive metamorphoses, 405
 submucous, 412
 subserous, 411
 symptoms and diagnosis, 406
 treatment, 408
 Lipoxanthoma, 411
 Liver, carcinoma of, 345
 Lymphangioma, 465
 anatomical varieties, 465
 definition, 465
 histology and histogenesis, 465
 of lips, 474
 of neck, 475
 of subcutaneous and submucous connective
 tissue, 477
 Lymphangioma of tongue, 474
 of uterus, 477
 prognosis, 473
 regressive metamorphoses, 471
 symptoms and diagnosis, 472
 treatment, 474
 Lymphatic glands, enlargement of, 51
 Lymphoma, 478
 definition, 478
 histology and histogenesis, 480
 retrograde metamorphoses, 480
 symptoms and diagnosis, 481
 treatment, 484
 Lympho-sarcoma, 580
- MACROCHILIA, 474
 Macroglossia, 474
 Maisonneuve's constrictor, 123
 Manec's percutaneous ligation of a tumor, 124
 Melano-sarcoma, 549
 of skin, 576
 treatment, 576
 Metastasis during the growth of a malignant
 tumor, 76
 Microscope, value of, as an aid in diagnosis,
 103
 Microtome, freezing, 107
 Mole, 386
 Morcellement, 508
 Myofibroma, regressive metamorphoses, 491
 symptoms and diagnosis, 491
 Myoma, 485
 definition, 485
 embryology, 485
 in animals, 57
 of alimentary canal, 521
 of bladder, 522
 of broad ligament, 519
 of Fallopian tube, 520
 of œsophagus, 521
 of pharynx, 521
 of rectum, 522
 of round ligament, 521
 of small intestines, 521
 of stomach, 521
 of uterus, 493
 etiology, 499
 histology and histogenesis, 496
 prognosis, 503
 regressive metamorphoses, 497
 symptoms and diagnosis, 499
 treatment, 504


- Myoma of uterus, treatment, complete abdominal hysterectomy, 514
 curetting, 505
 electrolysis, 506
 ergot, 505
 intraperitoneal enucleation, 512
 laparo-hysterectomy, 514, 516
 laparo-myomectomy, 512
 laparotomy, 510
 salpingo-oöphorectomy, 510
 vaginal enucleation, 507
 hysterectomy, 510
 myomotomy, 508
 prognosis, 492
 regressive metamorphoses, 491
 symptoms and diagnosis, 491
 treatment, 492
- Myomotomy, vaginal, 508
- Myxoma, 415
 definition, 415
 etiology, 417
 histology, 416
 of glands, 421
 of intermuscular spaces, 418
 of middle ear, 420
 of nerve-sheaths, 420
 of nose, 419
 of skin, 418
 prognosis, 417
 symptoms and diagnosis, 417
 treatment, 418
- NEPHRECTOMY, 376
 for carcinoma of kidney, 376
- Neurofibromata, multiple, 532
- Neuroma, 524
 definition, 524
 embryology, 524
 etiology, 530
 histology and histogenesis, 524
 of cranial nerves, 533
 of lower extremity, 533
 of prepuce, 535
 of spinal nerves, 533
 of upper extremity, 533
 of vulva, 535
 plexiform, 534
 prognosis, 531
 regressive metamorphoses, 530
 symptoms and diagnosis, 530
 treatment, 531
- Neuromata, Virchow's classification of, 525
- ODONTOMA, 445
 definition, 445
 Sutton's classification of, 445
- Odontomes, composite, 447
 compound follicular, 446
 epithelial, 445
 fibrous, 446
 follicular, 445
 in animals, 57
 radicular, 446
- Onychogryphosis, 150
- Onychoma, 150
- Onychomycosis, 150
- Osteoma, 434
 anatomical varieties, 437
 at seat of a fracture, 443
 definition, 434
 histogenesis, 435
 histology, 435
 in animals, 57
 of brain, 441
 of cranial bones, 438
 of epiphyses of the long bones, 442
 of external meatus, 441
 of eye, 444
 of frontal sinus, 440
 of jaws, 441
 of muscles and tendons, 442
 of orbit, 443
 prognosis, 437
 subungual, 444
 symptoms and diagnosis, 437
 treatment, 437
- Ovary, glandular cysts of, 193
 hydrops of follicles of, 194
 papillary growths of, 192
 proliferous cysts of, 192
 simple cysts of, origin of, 193
- PACQUELIN cautery, 119
- Papilloma, 137
 diagnosis, 149
 fibrous, 144
 hard, 139
 histology and pathology, 137
 of brain, 149
 of digestive tract, 144
 of female organs of generation, 146
 of respiratory tract, 144
 of skin, 141
 of urinary organs, 145
 prognosis, 149

- Papilloma, soft, 139
 topography, 141
 treatment, 150
- Papillomata, transformation of, into malignant tumors, 140
- Parotid gland, extirpation of, 299, 301
- Péan's forceps, 508
- Pozzi's enucleator, 507
- Psammoma, 556
- Ptyalectasis, 707
- Ptyalocele, 707
- RANULA, 707
 pancreatica, 685
- Renal region, topography of, 376
- Retention-cysts, 657
 definition, 657
 etiology, 660
 histology, 658
 hydrokolpos, 671
 hydrometra, 671
 hydrosalpinx, 672
 of appendix vermiformis, 674
 of bile-ducts, 675
 of kidney, 699
 treatment, 702
 of mammary glands, 706
 of mucous membrane, 668
 of ovary, 665
 of pancreas, 678
 diagnosis, 689
 etiology, 685
 pathology and morbid anatomy, 684
 prognosis, 694
 treatment, 695
 of salivary glands, 707
 of sebaceous glands, 184
 of skin, 666
 of testicle, 704
 treatment, 705
 of thyroid gland, 665
 of trachea and bronchial tubes, 674
 prognosis, 664
 symptoms and diagnosis, 661
 treatment, 664
- Rhabdomyoma, 486
- Rhinoplasty, 287-289
- Röntgen rays in diagnosis of tumors, 102
- SALPINGO-OÖPHORECTOMY for myofibroma of uterus, 510
- Sarcoma, 536
 alveolar, 552
 beneficial effects of erysipelas in, 573
 capsule of, 562
 definition, 536
 endotheliomatous, 554
 etiology, 566
 fascial, 578
 giant-celled, 546
 histological varieties, 542
 histology and histogenesis, 537
 in animals, 57
 metastasis in, 564
 mixed-cell, 549
 of bladder, 616
 of bones, 582
 giant-celled or myeloid, 583
 round-celled, 584
 spindle-celled, 585
 treatment, 595
 of brain and its envelopes, 616
 of cranial bones, 587
 of eye, 616
 of intestinal canal, 606
 of jaws, 590
 of kidney, 607
 diagnosis, 607
 treatment, 608
 of long bones, 596
 of lower jaw, 597
 of lymphatic glands, 580
 of mammary gland, 602
 excision of, 603
 of naso-pharynx, 591
 of nose, 591
 of omentum, 607
 of ovary, 612
 of prostate, 617
 of salivary glands, 604
 of skin, 574
 of submucous connective tissue, 576
 of testicle, 615
 of thymus gland, 604
 of tongue, 606
 of tonsil, 606
 of upper jaw, 598
 excision of, 599
 of uterus, 610
 of vagina, 614
 of vertebræ, 592
 diagnosis, 592
 of vulva, 615
 prognosis, 571

- Sarcoma, regressive metamorphoses, 558
 round-celled, 542
 spindle-celled, 544
 symptoms and diagnosis, 568
 treatment, 571
 caustics in, 572
 palliative, 574
- Sarcoma-cells, morphology of, 541
- Swellings, infective, 593
- Syphiloma, 91
- Syringe, exploratory, Senn's, 100
- TERATOMA, 618
 definition, 618
 diagnosis, 640
 of auricle, 650
 of eye, 647
 of face, 644
 of ovary, 651
 clinical aspects, 654
 histology and histogenesis, 651
 of palate and pharynx, 645
 of rectum, 649
 of scalp and dura mater, 646
 of scrotum, 655
 of thorax, 642
 of tongue, 647
 of trunk, 641
 origin, 618
 prognosis, 641
 regressive metamorphoses, 639
 treatment, 641
 by antiseptic drainage, 635
 by extirpation, 634
- Teratomata, ectogenous, 620
 endogenous, 620
- Thyroid-dermoids, 649
- Thyroid gland, extirpation of, 165
 partial, 166
 infective swelling of, 163
 tumors of, differential diagnosis, 164
 treatment, 165
- Tongue, amputation of, for carcinoma, 294-298
- Traumatism, influence of, in transformation of benign into malignant tumors, 85
- Tumor-cells, degeneration of, amyloid, 45
 colloid, 44
 fatty, 43
 hyaline, 45
 mucoid, 44
- Tumors, accidental ulceration in, 52
- Tumors, anatomy of, 34
 and inflammatory swellings, differences between, 20
 benign and malignant, clinical aspects of, 71
 exciting causes effecting a transformation into malignant, 80, 83
 biology of, 37
 blood-vessels of, 35
 calcification or cretification of, 47
 capsule of, 51
 carcinomatous, location a factor in determining the malignancy of, 111
 caseation of, 46
 classification of, Cohnheim's, 132
 Senn's, 136
 Virchow's, 131
 Williams's, 133
 congenital, etiology of, 60
 connection of, with mother-soil, 97
 definition, 19
 diagnosis, 88
 auscultation and percussion in, 102
 clinical history in, 88
 crepitation in, 102
 examination of patient, 91
 of tumor, 94
 length of time tumor has existed, 89
 location, 89
 pain, 90
 pulsation, 101
 rapidity of growth, 89
 tactile examination, 96
 tenderness, 90, 101
 effect of local irritation on, 39
 etiology, 60
 age, 65
 climate, 65
 contagion, 70
 heredity, 61
 inflammation, 69
 irritation, 69
 race, 64
 sex, 67
 social status, 68
 traumatism, 68
 frequency of recurrence after extirpation, 78
 grafting of a malignant upon a benign, 53
 growth of, 38
 hemorrhage into, 47
 histogenesis, 23

- Tumors, history, 17
 in animals, 57
 adenomata, 58
 cystic tumors, 59
 epithelial tumors, 57
 lipomata, 57
 myomata, 57
 odontomes, 57
 osteomata, 57
 sarcomata, 57
 teratomata, 59
 inflammation in, 51
 in plants, 55
 intrinsic tendency to destroy life, 79
 lymphatic vessels of, 35
 malignant, 74
 mobility, 73
 morphology, 28
 nerves of, 36
 operative interference in the treatment of, 112
 origin and nature, 17
 ossification, 47
 parasitism, 208
 pathology, 42
 prognosis, 108
 pulsating, 39
 radical operations for, contra-indications to, 129
 recurrence of, explanation of, 73
 relation of, to adjacent tissues, 40
 relative frequency of, in different organs, 71
- Tumors, resistance and consistence of, 98
 teratoid, origin of, 618
 treatment, medical, 113
 palliative, 129
 surgical, 115
 by avulsion, 126
 by cauterization, 119
 with arsenic, 121
 with caustic potash, 120
 with chloride of zinc, 121
 with chromic acid, 121
 with nitric acid, 121
 by écrasement lineaire, 125
 by extirpation, 126
 by galvano-caustic wire, 124
 by galvano-puncture, 116
 by injection of erysipelas toxines, 118
 by ligation of blood-vessels, 116
 by ligature, 123
 by parenchymatous injections, 117
 typical and atypical, 209
 ulceration of, 52
 Tumor-tissue, pathological changes in, 43
- ULCERS, spontaneous, 52
- VEINS, thrombosis of, 50
- Villous carcinoma of bladder, 372
- WARREN'S harpoon, 103
- XANTHOMA of eyelids, 411





CATALOGUE
OF THE
MEDICAL PUBLICATIONS
OF
W. B. SAUNDERS & CO.,
No. 925 WALNUT STREET, PHILADELPHIA.

Arranged Alphabetically and Classified under Subjects.

THE books advertised in this Catalogue as being *sold by subscription* are usually to be obtained from travelling solicitors, but they will be sent direct from the office of publication (charges of shipment prepaid) upon receipt of the prices given. All the other books advertised are commonly for sale by booksellers in all parts of the United States; but books will be sent to any address, carriage prepaid, on receipt of the published price.

Money may be sent at the risk of the publisher in either of the following ways: A post-office money order, an express money order, a bank check, and in a registered letter. Money sent in any other way is at the risk of the sender.

See pages 32, 33 for a List of Contents classified according to subjects.

LATEST PUBLICATIONS.

- American Students' Medical Dictionary. See page 34.
American Text-Book of Physiology—Second (Revised) Ed. Page 7.
Friedrich and Curtis on Nose, Throat, and Ear. See page 34.
Le Roy's Histology. See page 34.
Ogden on the Urine. See page 34.
Pyle's Personal Hygiene. See page 34.
Salinger and Kalteyer's Modern Medicine. See page 34.
Stoney's Surgical Technic for Nurses. See page 34.
Hyde and Montgomery's Syphilis and Venereal Diseases—Revised and Enlarged Edition. See page 15.
International Text-Book of Surgery. See page 15.
Garrigues' Diseases of Women—Third (Revised) Edition. Page 13.
American Text-Book of Dis. of Eye, Ear, Nose, and Throat. Page 5.
Saunders' American Year-Book for 1900. See page 8.
Levy and Klemperer's Clinical Bacteriology. See page 17.
Scudder's Treatment of Fractures. See page 26.
Senn's Tumors—Second Edition. See page 27.
Beck on Fractures. See page 9.
Watson's Handbook for Nurses. See page 31.
Heisler's Embryology. See page 15.
Nancrede's Principles of Surgery. See page 20.
Jackson's Diseases of the Eye. See page 16.
Kyle on the Nose and Throat. See page 17.
Penrose's Diseases of Women—Third (Revised) Edition. Page 20.
Warren's Surgical Pathology—Second (Revised) Edition. Page 31.
Saunders' Medical Hand-Atlases. See pages 2, 3, 4.
American Pocket Medical Dictionary—Third (Revised) Ed. Page 12.

SAUNDERS' MEDICAL HAND-ATLASES.

VOLUMES JUST ISSUED.

Atlas and Epitome of Special Pathological Histology. By DR. H. DÜRCK, of Munich. Edited by LUDVIG HEKTOEN, M. D., Professor of Pathology, Rush Medical College, Chicago. In Two Parts. Part I. *Just Ready*, including the Circulatory, Respiratory, and Gastro-intestinal Tract, with 120 colored figures on 62 plates and 158 pages of text. Price, \$3.00 net. Parts sold separately.

Atlas and Epitome of Diseases Caused by Accidents. By DR. ED. GOLEBIEWSKI, of Berlin. Translated and edited with additions by PEARCE BAILEY, M. D., Attending Physician to the Department of Corrections and to the Almshouse and Incurable Hospitals, New York. With 40 colored plates, 143 text-illustrations, and 600 pages of text.

Atlas and Epitome of Gynecology. By DR. O. SCHÄFFER, of Heidelberg. Edited by RICHARD C. NORRIS, A. M., M. D., Gynecologist to the Methodist Episcopal and the Philadelphia Hospitals; Surgeon-in-Charge of Preston Retreat, Philadelphia. With 90 colored plates, 65 text-illustrations, and 308 pages of text.

IN PRESS FOR EARLY PUBLICATION.

Atlas and Epitome of Obstetrical Diagnosis and Treatment. By DR. O. SCHÄFFER, of Heidelberg. Edited by J. CLIFTON EDGAR, M. D., Professor of Obstetrics and Clinical Midwifery, Cornell University Medical School. 72 colored plates, numerous text-illustrations, and copious text.

Atlas and Epitome of the Nervous System and its Diseases. By PROF. DR. A. VON STRÜMPPELL, of Erlangen. Edited by EDWARD D. FISHER, M. D., Professor of Diseases of the Nervous System, University and Bellevue Hospital Medical College, New York. 83 plates and a copious text.

Atlas and Epitome of General Pathological Histology. With an Appendix on Pathohistological Technic. By DR. H. DÜRCK, of Munich. Edited by LUDVIG HEKTOEN, M. D., Professor of Pathology, Rush Medical College, Chicago. With 80 colored plates, numerous text-illustrations, and copious text.

IN PREPARATION.

Atlas and Epitome of Orthopedic Surgery.

Atlas and Epitome of Operative Gynecology.


Atlas and Epitome of Diseases of the Ear.

Atlas and Epitome of General Surgery.

Atlas and Epitome of Psychiatry.

Atlas and Epitome of Normal Histology.

Atlas and Epitome of Topographical Anatomy.



THE AMERICAN TEXT-BOOK SERIES.

AN AMERICAN TEXT-BOOK OF APPLIED THERAPEUTICS.

By 43 Distinguished Practitioners and Teachers. Edited by JAMES C. WILSON, M.D., Professor of the Practice of Medicine and of Clinical Medicine in the Jefferson Medical College, Philadelphia. One handsome imperial octavo volume of 1326 pages. Illustrated. Cloth, \$7.00 net; Sheep or Half Morocco, \$8.00 net. *Sold by Subscription.*

"As a work either for study or reference it will be of great value to the practitioner, as it is virtually an exposition of such clinical therapeutics as experience has taught to be of the most value. Taking it all in all, no recent publication on therapeutics can be compared with this one in practical value to the working physician."—*Chicago Clinical Review.*

"The whole field of medicine has been well covered. The work is thoroughly practical, and while it is intended for practitioners and students, it is a better book for the general practitioner than for the student. The young practitioner especially will find it extremely suggestive and helpful."—*The Indian Lancet.*

AN AMERICAN TEXT-BOOK OF THE DISEASES OF CHILDREN. Second Edition, Revised.

By 65 Eminent Contributors. Edited by LOUIS STARR, M.D., Consulting Pediatricist to the Maternity Hospital, etc.; assisted by THOMPSON S. WESTCOTT, M.D., Attending Physician to the Dispensary for Diseases of Children, Hospital of the University of Pennsylvania. In one handsome imperial octavo volume of 1244 pages, profusely illustrated. Cloth, \$7.00 net; Sheep or Half Morocco, \$8.00 net. *Sold by Subscription.*

"This is far and away the best text-book on children's diseases ever published in the English language, and is certainly the one which is best adapted to American readers. We congratulate the editor upon the result of his work, and heartily commend it to the attention of every student and practitioner."—*American Journal of the Medical Sciences.*

AN AMERICAN TEXT-BOOK OF DISEASES OF THE EYE, EAR, NOSE, AND THROAT.

By 58 Prominent Specialists. Edited by G. E. DE SCHWEINITZ, M.D., Professor of Ophthalmology in the Jefferson Medical College, Philadelphia; and B. ALEXANDER RANDALL, M.D., Professor of Diseases of the Ear in the University of Pennsylvania. Imperial octavo, 1251 pages; 766 illustrations, 59 of them in colors. Cloth, \$7.00 net; Sheep or Half Morocco, \$8.00 net. *Sold by Subscription.*

Illustrated Catalogue of the "American Text-Books" sent free upon application.

AN AMERICAN TEXT-BOOK OF GENITO-URINARY AND SKIN DISEASES.

By 47 Eminent Specialists and Teachers. Edited by L. BOLTON BANGS, M. D., Professor of Genito-Urinary Surgery, University and Bellevue Hospital Medical College, New York; and W. A. HARD-AWAY, M. D., Professor of Diseases of the Skin, Missouri Medical College. Imperial octavo volume of 1229 pages, with 300 engravings and 20 full-page colored plates. Cloth, \$7.00 net; Sheep or Half Morocco, \$8.00 net. *Sold by Subscription.*

"This volume is one of the best yet issued of the publisher's series of 'American Text-Books.' The list of contributors represents an extraordinary array of talent and extended experience. The book will easily take the place in comprehensiveness and value of the half dozen or more costly works on these subjects which have heretofore been necessary to a well-equipped library."—*New York Polyclinic.*

AN AMERICAN TEXT-BOOK OF GYNECOLOGY, MEDICAL AND SURGICAL. Second Edition, Revised.

By 10 of the Leading Gynecologists of America. Edited by J. M. BALDY, M. D., Professor of Gynecology in the Philadelphia Polyclinic, etc. Handsome imperial octavo volume of 718 pages, with 341 illustrations in the text, and 38 colored and half-tone plates. Cloth, \$6.00 net; Sheep or Half Morocco, \$7.00 net. *Sold by Subscription.*

"It is practical from beginning to end. Its descriptions of conditions, its recommendations for treatment, and above all the necessary technique of different operations, are clearly and admirably presented. . . . It is well up to the most advanced views of the day, and embodies all the essential points of advanced American gynecology. It is destined to make and hold a place in gynecological literature which will be peculiarly its own."—*Medical Record*, New York.

AN AMERICAN TEXT-BOOK OF LEGAL MEDICINE AND TOXICOLOGY.

Edited by FREDERICK PETERSON, M. D., Clinical Professor of Mental Diseases in the Woman's Medical College, New York; Chief of Clinic, Nervous Department, College of Physicians and Surgeons, New York; and WALTER S. HAINES, M. D., Professor of Chemistry, Pharmacy, and Toxicology in Rush Medical College, Chicago. *In Preparation.*

AN AMERICAN TEXT-BOOK OF OBSTETRICS.

By 15 Eminent American Obstetricians. Edited by RICHARD C. NORRIS, M. D.; Art Editor, ROBERT L. DICKINSON, M. D. One handsome imperial octavo volume of 1014 pages, with nearly 900 beautiful colored and half-tone illustrations. Cloth, \$7.00 net; Sheep or Half Morocco, \$8.00 net. *Sold by Subscription.*

"Permit me to say that your American Text-Book of Obstetrics is the most magnificent medical work that I have ever seen. I congratulate you and thank you for this superb work, which alone is sufficient to place you first in the ranks of medical publishers."—ALEXANDER J. C. SKENE, *Professor of Gynecology in the Long Island College Hospital, Brooklyn, N. Y.*

"This is the most sumptuously illustrated work on midwifery that has yet appeared. In the number, the excellence, and the beauty of production of the illustrations it far surpasses every other book upon the subject. This feature alone makes it a work which no medical library should omit to purchase."—*British Medical Journal.*

"As an authority, as a book of reference, as a 'working book' for the student or practitioner, we commend it because we believe there is no better."—*American Journal of the Medical Sciences.*

Illustrated Catalogue of the "American Text-Books" sent free upon application.

AN AMERICAN TEXT-BOOK OF PATHOLOGY.

Edited by LUDVIG HEKTOEN, M. D., Professor of General Pathology and of Morbid Anatomy in the University of Pennsylvania; and DAVID RIESMAN, M. D., Demonstrator of Pathological Histology in the University of Pennsylvania. *In preparation.*

AN AMERICAN TEXT-BOOK OF PHYSIOLOGY.

By 10 of the Leading Physiologists of America. Edited by WILLIAM H. HOWELL, PH.D., M.D., Professor of Physiology in the Johns Hopkins University, Baltimore, Md. Second edition, revised and enlarged, in two volumes.

"We can commend it most heartily, not only to all students of physiology, but to every physician and pathologist, as a valuable and comprehensive work of reference, written by men who are of eminent authority in their own special subjects."—*London Lancet.*

"To the practitioner of medicine and to the advanced student this volume constitutes, we believe, the best exposition of the present status of the science of physiology in the English language."—*American Journal of the Medical Sciences.*

AN AMERICAN TEXT-BOOK OF SURGERY. Third Edition.

By 11 Eminent Professors of Surgery. Edited by WILLIAM W. KEEN, M.D., LL.D., and J. WILLIAM WHITE, M.D., PH.D. Handsome imperial octavo volume of 1230 pages, with 496 wood-cuts in the text, and 37 colored and half-tone plates. Thoroughly revised and enlarged, with a section devoted to "The Use of the Röntgen Rays in Surgery." Cloth, \$7.00 net; Sheep or Half Morocco, \$8.00 net.

"Personally, I should not mind it being called **THE TEXT-BOOK** (instead of **A TEXT-BOOK**), for I know of no single volume which contains so readable and complete an account of the science and art of Surgery as this does."—EDMUND OWEN, F.R.C.S., *Member of the Board of Examiners of the Royal College of Surgeons, England.*

"If this text-book is a fair reflex of the present position of American surgery, we must admit it is of a very high order of merit, and that English surgeons will have to look very carefully to their laurels if they are to preserve a position in the van of surgical practice."—*London Lancet.*

AN AMERICAN TEXT-BOOK OF THE THEORY AND PRACTICE OF MEDICINE.

By 12 Distinguished American Practitioners. Edited by WILLIAM PEPPER, M.D., LL.D., Professor of the Theory and Practice of Medicine and of Clinical Medicine in the University of Pennsylvania. Two handsome imperial octavo volumes of about 1000 pages each. Illustrated. Prices per volume: Cloth, \$5.00 net; Sheep or Half Morocco, \$6.00 net. *Sold by Subscription.*

"I am quite sure it will commend itself both to practitioners and students of medicine, and become one of our most popular text-books."—ALFRED LOOMIS, M.D., LL.D., *Professor of Pathology and Practice of Medicine, University of the City of New York.*

"We reviewed the first volume of this work, and said: 'It is undoubtedly one of the best text-books on the practice of medicine which we possess.' A consideration of the second and last volume leads us to modify that verdict and to say that the completed work is in our opinion *the best* of its kind it has ever been our fortune to see."—*New York Medical Journal.*

Illustrated Catalogue of the "American Text-Books" sent free upon application.

AN AMERICAN YEAR-BOOK OF MEDICINE AND SURGERY.

A Yearly Digest of Scientific Progress and Authoritative Opinion in all branches of Medicine and Surgery, drawn from journals, monographs, and text-books of the leading American and Foreign authors and investigators. Arranged with critical editorial comments, by eminent American specialists, under the general editorial charge of GEORGE M. GOULD, M.D. Volumes for 1896, '97, '98, and '99. One imperial octavo volume of about 1200 pages. Cloth, \$6.50 net; Half Morocco, \$7.50 net. Year-Book of 1900 in two volumes—Vol. I., including *General Medicine*; Vol. II., *General Surgery*. Prices per volume: Cloth, \$3.00 net; Half Morocco, \$3.75 net. *Sold by Subscription.*

"It is difficult to know which to admire most—the research and industry of the distinguished band of experts whom Dr. Gould has enlisted in the service of the Year-Book, or the wealth and abundance of the contributions to every department of science that have been deemed worthy of analysis. . . . It is much more than a mere compilation of abstracts, for, as each section is entrusted to experienced and able contributors, the reader has the advantage of certain critical commentaries and expositions . . . proceeding from writers fully qualified to perform these tasks. . . . It is emphatically a book which should find a place in every medical library, and is in several respects more useful than the famous 'Jahrbücher' of Germany."—*London Lancet.*

ABBOTT ON TRANSMISSIBLE DISEASES.

The Hygiene of Transmissible Diseases; their Causation, Modes of Dissemination, and Methods of Prevention. By A. C. ABBOTT, M.D., Professor of Hygiene and Bacteriology, University of Pennsylvania; Director of the Laboratory of Hygiene. Octavo volume of 311 pages, containing a number of charts and maps, and numerous illustrations. Cloth, \$2.00 net.

THE AMERICAN POCKET MEDICAL DICTIONARY.

[See *Dorland's Pocket Dictionary*, page 12.]

ANDERS' PRACTICE OF MEDICINE. Third Revised Edition.

A Text-Book of the Practice of Medicine. By JAMES M. ANDERS, M.D., PH.D., LL.D., Professor of the Practice of Medicine and of Clinical Medicine, Medico-Chirurgical College, Philadelphia. In one handsome octavo volume of 1292 pages, fully illustrated. Cloth, \$5.50 net; Sheep or Half Morocco, \$6.50 net.

"It is an excellent book,—concise, comprehensive, thorough, and up to date. It is a credit to you; but, more than that, it is a credit to the profession of Philadelphia—to us." JAMES C. WILSON, *Professor of the Practice of Medicine and Clinical Medicine, Jefferson Medical College, Philadelphia.*

ASHTON'S OBSTETRICS. Fourth Edition, Revised.

Essentials of Obstetrics. By W. EASTERLY ASHTON, M.D., Professor of Gynecology in the Medico-Chirurgical College, Philadelphia. Crown octavo, 252 pages; 75 illustrations. Cloth, \$1.00 net; interleaved for notes, \$1.25 net.

[See *Saunders' Question-Compends*, page 23.]

"Embodies the whole subject in a nut-shell. We cordially recommend it to our readers."—*Chicago Medical Times.*

BALL'S BACTERIOLOGY. Third Edition, Revised.

Essentials of Bacteriology; a Concise and Systematic Introduction to the Study of Micro-organisms. By M. V. BALL, M.D., Bacteriologist to St. Agnes' Hospital, Philadelphia, etc. Crown octavo, 218 pages; 82 illustrations, some in colors, and 5 plates. Cloth, \$1.00; interleaved for notes, \$1.25.

[See *Saunders' Question-Compends*, page 23.]

"The student or practitioner can readily obtain a knowledge of the subject from a perusal of this book. The illustrations are clear and satisfactory."—*Medical Record*, New York.

BASTIN'S BOTANY.

Laboratory Exercises in Botany. By EDSON S. BASTIN, M.A., late Prof. of Materia Medica and Botany, Philadelphia College of Pharmacy. Octavo volume of 536 pages, with 87 plates. Cloth, \$2.00 net.

"It is unquestionably the best text-book on the subject that has yet appeared. The work is eminently a practical one. We regard the issuance of this book as an important event in the history of pharmaceutical teaching in this country, and predict for it an unqualified success."—*Alumni Report to the Philadelphia College of Pharmacy*.

BECK ON FRACTURES.

Fractures. By CARL BECK, M.D., Surgeon to St. Mark's Hospital and the New York German Poliklinik, etc. 225 pages, 170 illustrations. Cloth, \$3.50 net.

BECK'S SURGICAL ASEPSIS.

A Manual of Surgical Asepsis. By CARL BECK, M.D., Surgeon to St. Mark's Hospital and the New York German Poliklinik, etc. 306 pages; 65 text-illustrations, and 12 full-page plates. Cloth, \$1.25 net.

"An excellent exposition of the 'very latest' in the treatment of wounds as practised by leading German and American surgeons."—*Birmingham (Eng.) Medical Review*.

"This little volume can be recommended to any who are desirous of learning the details of asepsis in surgery, for it will serve as a trustworthy guide."—*London Lancet*.

BOISLINIERE'S OBSTETRIC ACCIDENTS, EMERGENCIES, AND OPERATIONS.

Obstetric Accidents, Emergencies, and Operations. By L. CH. BOISLINIERE, M.D., late Emeritus Professor of Obstetrics, St. Louis Medical College. 381 pages, handsomely illustrated. Cloth, \$2.00 net.

"A manual so useful to the student or the general practitioner has not been brought to our notice in a long time. The field embraced in the title is covered in a terse, interesting way."—*Yale Medical Journal*.

BROCKWAY'S MEDICAL PHYSICS. Second Edition, Revised.

Essentials of Medical Physics. By FRED J. BROCKWAY, M.D., Assistant Demonstrator of Anatomy in the College of Physicians and Surgeons, New York. Crown octavo, 330 pages; 155 fine illustrations. Cloth, \$1.00 net; interleaved for notes, \$1.25 net.

[See *Saunders' Question-Compends*, page 23.]

"We know of no manual that affords the medical student a better or more concise exposition of physics, and the book may be commended as a most satisfactory presentation of those essentials that are requisite in a course in medicine."—*New York Medical Journal*.

BUTLER'S MATERIA MEDICA, THERAPEUTICS, AND PHARMACOLOGY. Third Edition, Revised.

A Text-Book of Materia Medica, Therapeutics, and Pharmacology. By GEORGE F. BUTLER, PH.G., M.D., Professor of Materia Medica and of Clinical Medicine in the College of Physicians and Surgeons, Chicago; Professor of Materia Medica and Therapeutics, Northwestern University, Woman's Medical School, etc. Octavo, 874 pages, illustrated. Cloth, \$4.00 net; Sheep, \$5.00 net.

"Taken as a whole, the book may fairly be considered as one of the most satisfactory of any single-volume works on materia medica in the market."—*Journal of the American Medical Association*.

CERNA ON THE NEWER REMEDIES. Second Edition, Revised.

Notes on the Newer Remedies, their Therapeutic Applications and Modes of Administration. By DAVID CERNA, M.D., PH.D., formerly Demonstrator of and Lecturer on Experimental Therapeutics in the University of Pennsylvania; Demonstrator of Physiology in the Medical Department of the University of Texas. Rewritten and greatly enlarged. Post-octavo, 253 pages. Cloth, \$1.00 net.

"The appearance of this new edition of Dr. Cerna's very valuable work shows that it is properly appreciated. The book ought to be in the possession of every practising physician."—*New York Medical Journal*.

CHAPIN ON INSANITY.

A Compendium of Insanity. By JOHN B. CHAPIN, M.D., LL.D., Physician-in-Chief, Pennsylvania Hospital for the Insane; late Physician-Superintendent of the Willard State Hospital, New York; Honorary Member of the Medico-Psychological Society of Great Britain, of the Society of Mental Medicine of Belgium. 12mo, 234 pages, illustrated. Cloth, \$1.25 net.

"The practical parts of Dr. Chapin's book are what constitute its distinctive merit. We desire especially to call attention to the fact that on the subject of therapeutics of insanity the work is exceedingly valuable. It is not a made book, but a genuine condensed thesis, which has all the value of ripe opinion and all the charm of a vigorous and natural style."—*Philadelphia Medical Journal*.

CHAPMAN'S MEDICAL JURISPRUDENCE AND TOXICOLOGY. Second Edition, Revised.

Medical Jurisprudence and Toxicology. By HENRY C. CHAPMAN, M.D., Professor of Institutes of Medicine and Medical Jurisprudence in the Jefferson Medical College of Philadelphia. 254 pages, with 55 illustrations and 3 full-page plates in colors. Cloth, \$1.50 net.

"The best book of its class for the undergraduate that we know of."—*New York Medical Times*.

CHURCH AND PETERSON'S NERVOUS AND MENTAL DISEASES. Second Edition.

Nervous and Mental Diseases. By ARCHIBALD CHURCH, M.D., Professor of Clinical Neurology, Mental Diseases, and Medical Jurisprudence in the Northwestern University Medical School, Chicago; and FREDERICK PETERSON, M.D., Clinical Professor of Mental Diseases, Woman's Medical College, N. Y.; Chief of Clinic, Nervous Dept., College of Physicians and Surgeons, N. Y. Handsome octavo volume of 843 pages, profusely illustrated. Cloth, \$5.00 net; Half Morocco, \$6.00 net.

CLARKSON'S HISTOLOGY.

A Text-Book of Histology, Descriptive and Practical. By ARTHUR CLARKSON, M.B., C.M. Edin., formerly Demonstrator of Physiology in the Owen's College, Manchester; late Demonstrator of Physiology in Yorkshire College, Leeds. Large octavo, 554 pages; 22 engravings in the text, and 174 beautifully colored original illustrations. Cloth, strongly bound, \$4.00 net.

"The work must be considered a valuable addition to the list of available text-books, and is to be highly recommended."—*New York Medical Journal*.

"This is one of the best works for students we have ever noticed. We predict that the book will attain a well-deserved popularity among our students."—*Chicago Medical Recorder*.

CLIMATOLOGY.

Transactions of the Eighth Annual Meeting of the American Climatological Association, held in Washington, September 22-25, 1891. Forming a handsome octavo volume of 276 pages, uniform with remainder of series. (A limited quantity only.) Cloth, \$1.50.

COHEN AND ESHNER'S DIAGNOSIS. Second Edition, Revised.

Essentials of Diagnosis. By SOLOMON SOLIS-COHEN, M.D., Professor of Clinical Medicine and Applied Therapeutics in the Philadelphia Polyclinic; and AUGUSTUS A. ESHNER, M.D., Professor of Clinical Medicine in the Philadelphia Polyclinic. Post-octavo, 417 pages; 55 illustrations. Cloth, \$1.00 net.

[See *Saunders' Question-Compends*, page 23.]

"We can heartily commend the book to all those who contemplate purchasing a 'compend.' It is modern and complete, and will give more satisfaction than many other works which are perhaps too prolix as well as behind the times."—*Medical Review*, St. Louis.

CORWIN'S PHYSICAL DIAGNOSIS. Third Edition, Revised.

Essentials of Physical Diagnosis of the Thorax. By ARTHUR M. CORWIN, A.M., M.D., Demonstrator of Physical Diagnosis in Rush Medical College, Chicago; Attending Physician to Central Free Dispensary, Department of Rhinology, Laryngology, and Diseases of the Chest, Chicago. 219 pages, illustrated. Cloth, flexible covers, \$1.25 net.

"It is excellent. The student who shall use it as his guide to the careful study of physical exploration upon normal and abnormal subjects can scarcely fail to acquire a good working knowledge of the subject."—*Philadelphia Polyclinic*.

"A most excellent little work. It brightens the memory of the differential diagnostic signs, and it arranges orderly and in sequence the various objective phenomena to logical solution of a careful diagnosis."—*Journal of Nervous and Mental Diseases*.

CRAGIN'S GYNÆCOLOGY. Fourth Edition, Revised.

Essentials of Gynæcology. By EDWIN B. CRAGIN, M.D., Lecturer in Obstetrics, College of Physicians and Surgeons, New York. Crown octavo, 200 pages; 62 illustrations. Cloth, \$1.00 net; interleaved for notes, \$1.25 net.

[See *Saunders' Question-Compends*, page 23.]

"A handy volume, and a distinct improvement on students' compends in general. No author who was not himself a practical gynecologist could have consulted the student's needs so thoroughly as Dr. Cragin has done."—*Medical Record*, New York.

CROOKSHANK'S BACTERIOLOGY. Fourth Edition, Revised.

A Text-Book of Bacteriology. By EDGAR M. CROOKSHANK, M.B., Professor of Comparative Pathology and Bacteriology, King's College, London. Octavo volume of 700 pages, with 273 engravings and 22 original colored plates. Cloth, \$6.50 net; Half Morocco, \$7.50 net.

"To the student who wishes to obtain a good *résumé* of what has been done in bacteriology, or who wishes an accurate account of the various methods of research, the book may be recommended with confidence that he will find there what he requires."—*London Lancet*.

DA COSTA'S SURGERY. Second Ed., Revised and Greatly Enlarged.

Modern Surgery, General and Operative. By JOHN CHALMERS DA COSTA, M. D., Professor of Practice of Surgery and Clinical Surgery, Jefferson Medical College, Philadelphia; Surgeon to the Philadelphia Hospital, etc. Handsome octavo volume of 911 pages, profusely illustrated. Cloth, \$4.00 net; Half Morocco, \$5.00 net.

"We know of no small work on surgery in the English language which so well fulfils the requirements of the modern student."—*Medico-Chirurgical Journal*, Bristol, England.

DE SCHWEINITZ ON DISEASES OF THE EYE. Third Edition, Revised.

Diseases of the Eye. A Handbook of Ophthalmic Practice. By G. E. DE SCHWEINITZ, M.D., Professor of Ophthalmology in the Jefferson Medical College, Philadelphia, etc. Handsome royal octavo volume of 696 pages, with 256 fine illustrations and 2 chromo-lithographic plates. Cloth, \$4.00 net; Sheep or Half Morocco, \$5.00 net.

"A clearly written; comprehensive manual. One which we can commend to students as a reliable text-book, written with an evident knowledge of the wants of those entering upon the study of this special branch of medical science."—*British Medical Journal*.

"A work that will meet the requirements not only of the specialist, but of the general practitioner in a rare degree. I am satisfied that unusual success awaits it."—WILLIAM PEPPER, M.D., *Professor of the Theory and Practice of Medicine and Clinical Medicine, University of Pennsylvania*.

DORLAND'S DICTIONARY. Third Edition, Revised.

The American Pocket Medical Dictionary. Containing the Pronunciation and Definition of all the principal words and phrases, and a large number of useful tables. Edited by W. A. NEWMAN DORLAND, M. D., Assistant Demonstrator of Obstetrics, University of Pennsylvania; Fellow of the American Academy of Medicine. 518 pages; handsomely bound in full leather, limp, with gilt edges and patent index. Price, \$1.00 net; with thumb index, \$1.25 net.

DORLAND'S OBSTETRICS.

A Manual of Obstetrics. By W. A. NEWMAN DORLAND, M.D., Assistant Demonstrator of Obstetrics, University of Pennsylvania; Instructor in Gynecology in the Philadelphia Polyclinic. 760 pages; 163 illustrations in the text, and 6 full-page plates. Cloth, \$2.50 net.

"By far the best book on this subject that has ever come to our notice."—*American Medical Review*.

"It has rarely been our duty to review a book which has given us more pleasure in its perusal and more satisfaction in its criticism. It is a veritable encyclopedia of knowledge, a gold mine of practical, concise thoughts."—*American Medico-Surgical Bulletin*.

FROTHINGHAM'S GUIDE FOR THE BACTERIOLOGIST.

Laboratory Guide for the Bacteriologist. By LANGDON FROTHINGHAM, M.D.V., Assistant in Bacteriology and Veterinary Science, Sheffield Scientific School, Yale University. Illustrated. Cloth, 75 cts.

"It is a convenient and useful little work, and will more than repay the outlay necessary for its purchase in the saving of time which would otherwise be consumed in looking up the various points of technique so clearly and concisely laid down in its pages."—*American Medico-Surgical Bulletin*.

GARRIGUES' DISEASES OF WOMEN. Third Edition, Revised.

Diseases of Women. By HENRY J. GARRIGUES, A.M., M.D., Professor of Gynecology in the New York School of Clinical Medicine; Gynecologist to St. Mark's Hospital and to the German Dispensary, New York City, etc. Handsome octavo volume of 783 pages, illustrated by 367 engravings and colored plates. Cloth, \$4.00 net; Sheep or Half Morocco, \$5.00 net.

"One of the best text-books for students and practitioners which has been published in the English language; it is condensed, clear, and comprehensive. The profound learning and great clinical experience of the distinguished author find expression in this book in a most attractive and instructive form. Young practitioners to whom experienced consultants may not be available will find in this book invaluable counsel and help."—THAD. A. REAMY, M.D., LL.D., *Professor of Clinical Gynecology, Medical College of Ohio*.

GLEASON'S DISEASES OF THE EAR. Second Edition, Revised.

Essentials of Diseases of the Ear. By E. B. GLEASON, S.B., M.D., Clinical Professor of Otology, Medico-Chirurgical College, Philadelphia; Surgeon-in-Charge of the Nose, Throat, and Ear Department of the Northern Dispensary, Philadelphia. 208 pages, with 114 illustrations. Cloth, \$1.00 net; interleaved for notes, \$1.25 net.

[See *Saunders' Question-Compends*, page 23.]

"It is just the book to put into the hands of a student, and cannot fail to give him a useful introduction to ear-affections; while the style of question and answer which is adopted throughout the book is, we believe, the best method of impressing facts permanently on the mind."—*Liverpool Medico-Chirurgical Journal*.

GOULD AND PYLE'S CURIOSITIES OF MEDICINE.

Anomalies and Curiosities of Medicine. By GEORGE M. GOULD, M.D., and WALTER L. PYLE, M.D. An encyclopedic collection of rare and extraordinary cases and of the most striking instances of abnormality in all branches of Medicine and Surgery, derived from an exhaustive research of medical literature from its origin to the present day, abstracted, classified, annotated, and indexed. Handsome imperial octavo volume of 968 pages, with 295 engravings in the text, and 12 full-page plates.

POPULAR EDITION: Cloth, \$3.00 net; Half Morocco, \$4.00 net.

"One of the most valuable contributions ever made to medical literature. It is, so far as we know, absolutely unique, and every page is as fascinating as a novel. Not alone for the medical profession has this volume value: it will serve as a book of reference for all who are interested in general scientific, sociologic, or medico-legal topics."—*Brooklyn Medical Journal*.

"This is certainly a most remarkable and interesting volume. It stands alone among medical literature, an anomaly on anomalies, in that there is nothing like it elsewhere in medical literature. It is a book full of revelations from its first to its last page, and cannot but interest and sometimes almost horrify its readers."—*American Medico-Surgical Bulletin*.

GRAFSTROM'S MECHANO-THERAPY.

A Text-Book of Mechano-Therapy (Massage and Medical Gymnastics). By AXEL V. GRAFSTROM, B. SC., M. D., late Lieutenant in the Royal Swedish Army; late House Physician City Hospital, Blackwell's Island, New York. 12mo, 139 pages, illustrated. Cloth, \$1.00 net.

GRIFFITH ON THE BABY. Second Edition, Revised.

The Care of the Baby. By J. P. CROZER GRIFFITH, M.D., Clinical Professor of Diseases of Children, University of Pennsylvania; Physician to the Children's Hospital, Philadelphia, etc. 12mo, 404 pages, with 67 illustrations in the text, and 5 plates. Cloth, \$1.50 net.

"The best book for the use of the young mother with which we are acquainted. . . . There are very few general practitioners who could not read the book through with advantage."—*Archives of Pediatrics*.

"The whole book is characterized by rare good sense, and is evidently written by a master hand. It can be read with benefit not only by mothers but by medical students and by any practitioners who have not had large opportunities for observing children."—*American Journal of Obstetrics*.

GRIFFITH'S WEIGHT CHART.

Infant's Weight Chart. Designed by J. P. CROZER GRIFFITH, M.D., Clinical Professor of Diseases of Children in the University of Pennsylvania, etc. 25 charts in each pad. Per pad, 50 cents net.

GROSS, SAMUEL D., AUTOBIOGRAPHY OF.

Autobiography of Samuel D. Gross, M.D., Emeritus Professor of Surgery in the Jefferson Medical College, Philadelphia, with Reminiscences of His Times and Contemporaries. Edited by his Sons, SAMUEL W. GROSS, M.D., LL.D., and A. HALLER GROSS, A.M. Preceded by a Memoir of Dr. Gross, by the late AUSTIN FLINT, M.D. Two handsome volumes, over 400 pages each, demy octavo, gilt tops, with Frontispiece on steel. Price per volume, \$2.50 net.

HAMPTON'S NURSING. Second Edition, Revised and Enlarged.

Nursing: Its Principles and Practice. By ISABEL ADAMS HAMPTON, Graduate of the New York Training School for Nurses attached to Bellevue Hospital; late Superintendent of Nurses and Principal of the Training School for Nurses, Johns Hopkins Hospital, Baltimore, Md. 12 mo, 512 pages, illustrated. Cloth, \$2.00 net.

"Seldom have we perused a book upon the subject that has given us so much pleasure as the one before us. We would strongly urge upon the members of our own profession the need of a book like this, for it will enable each of us to become a training school in himself."—*Ontario Medical Journal*.

HARE'S PHYSIOLOGY. Fourth Edition, Revised.

Essentials of Physiology. By H. A. HARE, M.D., Professor of Therapeutics and Materia Medica in the Jefferson Medical College of Philadelphia. Crown octavo, 239 pages. Cloth, \$1.00 net; interleaved for notes, \$1.25 net.

[See *Saunders' Question-Compends*, page 23.]

"The best condensation of physiological knowledge we have yet seen."—*Medical Record*, New York.

HART'S DIET IN SICKNESS AND IN HEALTH.

Diet in Sickness and in Health. By MRS. ERNEST HART, formerly Student of the Faculty of Medicine of Paris and of the London School of Medicine for Women; with an INTRODUCTION by SIR HENRY THOMPSON, F.R.C.S., M.D., London. 220 pages. Cloth, \$1.50 net.

"We recommend it cordially to the attention of all practitioners; both to them and to their patients it may be of the greatest service."—*New York Medical Journal*.

HAYNES' ANATOMY.

A Manual of Anatomy. By IRVING S. HAYNES, M.D., Adjunct Professor of Anatomy and Demonstrator of Anatomy, Medical Department of the New York University, etc. 680 pages, illustrated with 42 diagrams in the text, and 134 full-page half-tone illustrations from original photographs of the author's dissections. Cloth, \$2.50 net.

"This book is the work of a practical instructor—one who knows by experience the requirements of the average student, and is able to meet these requirements in a very satisfactory way. The book is one that can be commended."—*Medical Record*, New York.

HEISLER'S EMBRYOLOGY.

A Text-Book of Embryology. By JOHN C. HEISLER, M.D., Professor of Anatomy in the Medico-Chirurgical College, Philadelphia. Octavo volume of 405 pages, handsomely illustrated. Cloth, \$2.50 net.

HIRST'S OBSTETRICS. Second Edition.

A Text-Book of Obstetrics. By BARTON COOKE HIRST, M.D., Professor of Obstetrics in the University of Pennsylvania. Handsome octavo volume of 848 pages, with 618 illustrations, and 7 colored plates. Cloth, \$5.00 net; Sheep or Half Morocco, \$6.00 net.

"The illustrations are numerous and are works of art, many of them appearing for the first time. The arrangement of the subject-matter, the foot-notes, and index are beyond criticism. As a true model of what a modern text-book on obstetrics should be, we feel justified in affirming that Dr. Hirst's book is without a rival."—*New York Medical Record*.

HYDE AND MONTGOMERY ON SYPHILIS AND THE VENEREAL DISEASES. Second Edition, Revised and Enlarged.

Syphilis and the Venereal Diseases. By JAMES NEVINS HYDE, M.D., Professor of Skin and Venereal Diseases, and FRANK H. MONTGOMERY, M.D., Lecturer on Dermatology and Genito-Urinary Diseases in Rush Medical College, Chicago, Ill. Octavo, nearly 600 pages, with 14 beautiful lithographic plates and numerous illustrations.

"We can commend this manual to the student as a help to him in his study of venereal diseases."—*Liverpool Medico-Chirurgical Journal*.

"The best student's manual which has appeared on the subject."—*St. Louis Medical and Surgical Journal*.

INTERNATIONAL TEXT-BOOK OF SURGERY. In two volumes.

By American and British authors. Edited by J. COLLINS WARREN, M.D., LL.D., Professor of Surgery, Harvard Medical School, Boston; and A. PEARCE GOULD, M.S., F.R.C.S., Lecturer on Practical Surgery and Teacher of Operative Surgery, Middlesex Hospital Medical School, London, Eng. Vol. I. *General Surgery*.—Handsome octavo, 947 pages, with 458 beautiful illustrations and 9 lithographic plates. Vol. II. *Special or Regional Surgery*.—Handsome octavo, 1072 pages, with 471 beautiful illustrations and 8 lithographic plates. Prices per volume: Cloth, \$5.00 net; Half Morocco, \$6.00 net.

JACKSON'S DISEASES OF THE EYE.

A Manual of Diseases of the Eye. By EDWARD JACKSON, A.M., M.D., sometime Professor of Diseases of the Eye in the Philadelphia Polyclinic and College for Graduates in Medicine. 12mo volume of 535 pages, with 178 beautiful illustrations, mostly from drawings by the author. Cloth, \$2.50 net.

JACKSON AND GLEASON'S DISEASES OF THE EYE, NOSE, AND THROAT. Second Edition, Revised.

Essentials of Refraction and Diseases of the Eye. By EDWARD JACKSON, A.M., M.D., Professor of Diseases of the Eye in the Philadelphia Polyclinic and College for Graduates in Medicine; and—

Essentials of Diseases of the Nose and Throat. By E. BALDWIN GLEASON, M.D., Surgeon-in-Charge of the Nose, Throat, and Ear Department of the Northern Dispensary of Philadelphia. Two volumes in one. Crown octavo, 290 pages; 124 illustrations. Cloth, \$1.00 net; interleaved for notes, \$1.25 net.

[See *Saunders' Question-Compends*, page 22.]

"Of great value to the beginner in these branches. The authors are both capable men, and know what a student most needs."—*Medical Record*, New York.

KEATING'S DICTIONARY. Second Edition, Revised.

A New Pronouncing Dictionary of Medicine, with Phonetic Pronunciation, Accentuation, Etymology, etc. By JOHN M. KEATING, M.D., LL.D., Fellow of the College of Physicians of Philadelphia, and HENRY HAMILTON; with the collaboration of J. CHALMERS DaCOSTA, M.D., and FREDERICK A. PACKARD, M.D. With an Appendix containing Tables of Bacilli, Micrococci, Leucomaines, Ptomaines, etc. One volume of over 800 pages. Prices, with Ready-Reference Index: Cloth, \$5.00 net; Sheep or Half Morocco, \$6.00 net. Without Patent Index: Cloth, \$4.00 net; Sheep or Half Morocco, \$5.00 net.

"I am much pleased with Keating's Dictionary, and shall take pleasure in recommending it to my classes."—HENRY M. LYMAN, M.D., *Professor of the Principles and Practice of Medicine, Rush Medical College, Chicago, Ill.*

KEATING'S LIFE INSURANCE.

How to Examine for Life Insurance. By JOHN M. KEATING, M.D., Fellow of the College of Physicians of Philadelphia; Vice-President of the American Paediatric Society; Ex-President of the Association of Life Insurance Medical Directors. Royal octavo, 211 pages; with two large half-tone illustrations, and a plate prepared by Dr. McClellan from special dissections; also, numerous other illustrations. Cloth, \$2.00 net.

KEEN'S OPERATION BLANK. Second Edition, Revised Form.

An Operation Blank, with Lists of Instruments, etc., Required in Various Operations. Prepared by W. W. KEEN, M.D., LL.D., Professor of the Principles of Surgery in Jefferson Medical College, Philadelphia. Price per pad, blanks for fifty operations, 50 cents net.

KEEN ON THE SURGERY OF TYPHOID FEVER.

The Surgical Complications and Sequels of Typhoid Fever.

By WM. W. KEEN, M.D., LL.D., Professor of the Principles of Surgery and of Clinical Surgery, Jefferson Medical College, Philadelphia; Corresponding Member of the Société de Chirurgie, Paris; Honorary Member of the Société Belge de Chirurgie, etc. Octavo volume of 386 pages, illustrated. Cloth, \$3.00 net.

"This is probably the first and only work in the English language that gives the reader a clear view of what typhoid fever really is, and what it does and can do to the human organism. This book should be in the possession of every medical man in America."—*American Medico-Surgical Bulletin*.

KYLE ON THE NOSE AND THROAT.

Diseases of the Nose and Throat. By D. BRADEN KYLE, M.D., Clinical Professor of Laryngology and Rhinology, Jefferson Medical College, Philadelphia; Consulting Laryngologist, Rhinologist, and Otologist, St. Agnes' Hospital. Handsome octavo volume of about 630 pages, with over 150 illustrations and 6 lithographic plates. Price, Cloth, \$4.00 net; Half Morocco, \$5.00 net.

LAINÉ'S TEMPERATURE CHART.

Temperature Chart. Prepared by D. T. LAINÉ, M.D. Size 8 x 13½ inches. A conveniently arranged Chart for recording Temperature, with columns for daily amounts of Urinary and Fecal Excretions, Food, Remarks, etc. On the back of each chart is given in full the method of Brand in the treatment of Typhoid Fever. Price, per pad of 25 charts, 50 cents net.

"To the busy practitioner this chart will be found of great value in fever cases, and especially for cases of typhoid."—*Indian Lancet*, Calcutta.

LEVY AND KLEMPERER'S CLINICAL BACTERIOLOGY.

The Elements of Clinical Bacteriology. By DR. ERNST LEVY, Professor in the University of Strassburg, and FELIX KLEMPERER, Privat docent in the University of Strassburg. Translated and edited by AUGUSTUS A. ESHNER, M.D., Professor of Clinical Medicine in the Philadelphia Polyclinic. Octavo, 440 pages, fully illustrated. Cloth, \$2.50 net.

LOCKWOOD'S PRACTICE OF MEDICINE.

A Manual of the Practice of Medicine. By GEORGE ROE LOCKWOOD, M.D., Professor of Practice in the Woman's Medical College of the New York Infirmary, etc. 935 pages, with 75 illustrations in the text, and 22 full-page plates. Cloth, \$2.50 net.

"Gives in a most concise manner the points essential to treatment usually enumerated in the most elaborate works."—*Massachusetts Medical Journal*.

LONG'S SYLLABUS OF GYNECOLOGY.

A Syllabus of Gynecology, arranged in Conformity with "An American Text-Book of Gynecology." By J. W. LONG, M.D., Professor of Diseases of Women and Children, Medical College of Virginia, etc. Cloth, interleaved, \$1.00 net.

"The book is certainly an admirable *résumé* of what every gynecological student and practitioner should know, and will prove of value not only to those who have the 'American Text-Book of Gynecology,' but to others as well."—*Brooklyn Medical Journal*.

MACDONALD'S SURGICAL DIAGNOSIS AND TREATMENT.

Surgical Diagnosis and Treatment. By J. W. MACDONALD, M.D. Edin., F.R.C.S., Edin., Professor of the Practice of Surgery and of Clinical Surgery in Hamline University; Visiting Surgeon to St. Barnabas' Hospital, Minneapolis, etc. Handsome octavo volume of 800 pages, profusely illustrated. Cloth, \$5.00 net; Half Morocco, \$6.00 net.

"A thorough and complete work on surgical diagnosis and treatment, free from padding, full of valuable material, and in accord with the surgical teaching of the day."—*The Medical News, New York.*

"The work is brimful of just the kind of practical information that is useful alike to students and practitioners. It is a pleasure to commend the book because of its intrinsic value to the medical practitioner."—*Cincinnati Lancet-Clinic.*

MALLORY AND WRIGHT'S PATHOLOGICAL TECHNIQUE.

Pathological Technique. A Practical Manual for Laboratory Work in Pathology, Bacteriology, and Morbid Anatomy, with chapters on Post-Mortem Technique and the Performance of Autopsies. By FRANK B. MALLORY, A.M., M.D., Assistant Professor of Pathology, Harvard University Medical School, Boston; and JAMES H. WRIGHT, A.M., M.D., Instructor in Pathology, Harvard University Medical School, Boston. Octavo volume of 396 pages, handsomely illustrated. Cloth, \$2.50 net.

"I have been looking forward to the publication of this book, and I am glad to say that I find it to be a most useful laboratory and post-mortem guide, full of practical information, and well up to date."—WILLIAM H. WELCH, *Professor of Pathology, Johns Hopkins University, Baltimore, Md.*

MARTIN'S MINOR SURGERY, BANDAGING, AND VENEREAL DISEASES. Second Edition, Revised.

Essentials of Minor Surgery, Bandaging, and Venereal Diseases. By EDWARD MARTIN, A.M., M.D., Clinical Professor of Genito-Urinary Diseases, University of Pennsylvania, etc. Crown octavo, 166 pages, with 78 illustrations. Cloth, \$1.00; interleaved for notes, \$1.25.

[See *Saunders' Question-Compends*, page 23.]

"A very practical and systematic study of the subjects, and shows the author's familiarity with the needs of students."—*Therapeutic Gazette.*

MARTIN'S SURGERY. Seventh Edition, Revised.

Essentials of Surgery. Containing also Venereal Diseases, Surgical Landmarks, Minor and Operative Surgery, and a complete description, with illustrations, of the Handkerchief and Roller Bandages. By EDWARD MARTIN, A.M., M.D., Clinical Professor of Genito-Urinary Diseases, University of Pennsylvania, etc. Crown octavo, 342 pages, illustrated. With an Appendix on the preparation of the materials used in Antiseptic Surgery, etc., and a chapter on Appendicitis. Cloth, \$1.00 net; interleaved for notes, \$1.25 net.

[See *Saunders' Question-Compends*, page 23.]

"Contains all necessary essentials of modern surgery in a comparatively small space. Its style is interesting, and its illustrations are admirable."—*Medical and Surgical Reporter.*

McFARLAND'S PATHOGENIC BACTERIA. Second Edition, Revised and Greatly Enlarged.

Text-Book upon the Pathogenic Bacteria. By JOSEPH McFARLAND, M. D., Professor of Pathology and Bacteriology in the Medico-Chirurgical College of Philadelphia, etc. Octavo volume of 497 pages, finely illustrated. Cloth, \$2.50 net.

"Dr. McFarland has treated the subject in a systematic manner, and has succeeded in presenting in a concise and readable form the essentials of bacteriology up to date. Altogether, the book is a satisfactory one, and I shall take pleasure in recommending it to the students of Trinity College."—H. B. ANDERSON, M. D., *Professor of Pathology and Bacteriology, Trinity Medical College, Toronto.*

MEIGS ON FEEDING IN INFANCY.

Feeding in Early Infancy. By ARTHUR V. MEIGS, M. D. Bound in limp cloth, flush edges, 25 cents net.

"This pamphlet is worth many times over its price to the physician. The author's experiments and conclusions are original, and have been the means of doing much good."—*Medical Bulletin.*

MOORE'S ORTHOPEDIC SURGERY.

A Manual of Orthopedic Surgery. By JAMES E. MOORE, M. D., Professor of Orthopedics and Adjunct Professor of Clinical Surgery, University of Minnesota, College of Medicine and Surgery. Octavo volume of 356 pages, handsomely illustrated. Cloth, \$2.50 net.

"A most attractive work. The illustrations and the care with which the book is adapted to the wants of the general practitioner and the student are worthy of great praise."—*Chicago Medical Recorder.*

"A very demonstrative work, every illustration of which conveys a lesson. The work is a most excellent and commendable one, which we can certainly endorse with pleasure."—*St. Louis Medical and Surgical Journal.*

MORRIS'S MATERIA MEDICA AND THERAPEUTICS. Fifth Edition, Revised.

Essentials of Materia Medica, Therapeutics, and Prescription-Writing. By HENRY MORRIS, M. D., late Demonstrator of Therapeutics, Jefferson Medical College, Philadelphia; Fellow of the College of Physicians, Philadelphia, etc. Crown octavo, 288 pages. Cloth, \$1.00; interleaved for notes, \$1.25.

[See *Saunders' Question-Compends*, page 22.]

"This work, already excellent in the old edition, has been largely improved by revision."—*American Practitioner and News.*

MORRIS, WOLFF, AND POWELL'S PRACTICE OF MEDICINE. Third Edition, Revised.

Essentials of the Practice of Medicine. By HENRY MORRIS, M. D., late Demonstrator of Therapeutics, Jefferson Medical College, Philadelphia; with an Appendix on the Clinical and Microscopic Examination of Urine, by LAWRENCE WOLFF, M. D., Demonstrator of Chemistry, Jefferson Medical College, Philadelphia. Enlarged by some 300 essential formulæ collected and arranged by WILLIAM M. POWELL, M. D. Post-octavo, 488 pages. Cloth, \$2.00.

[See *Saunders' Question-Compends*, page 22.]

"The teaching is sound, the presentation graphic; matter full as can be desired, and style attractive."—*American Practitioner and News.*

MORTEN'S NURSE'S DICTIONARY.

Nurse's Dictionary of Medical Terms and Nursing Treatment. Containing Definitions of the Principal Medical and Nursing Terms and Abbreviations; of the Instruments, Drugs, Diseases, Accidents, Treatments, Operations, Foods, Appliances, etc. encountered in the ward or in the sick-room. By HONNOR MORTEN, author of "How to Become a Nurse," etc. 16mo, 140 pages. Cloth, \$1.00.

"A handy, compact little volume, containing a large amount of general information, all of which is arranged in dictionary or encyclopedic form, thus facilitating quick reference. It is certainly of value to those for whose use it is published."—*Chicago Clinical Review*.

NANCREDE'S ANATOMY. Sixth Edition, Thoroughly Revised.

Essentials of Anatomy, including the Anatomy of the Viscera. By CHARLES B. NANCREDE, M.D., LL.D., Professor of Surgery and of Clinical Surgery in the University of Michigan, Ann Arbor. Crown octavo, 420 pages; 151 illustrations. Based upon *Gray's Anatomy*. Cloth, \$1.00 net; interleaved for notes, \$1.25 net.

[See *Saunders' Question-Compends*, page 23.]

"For self-quizzing and keeping fresh in mind the knowledge of anatomy gained at school, it would not be easy to speak of it in terms too favorable."—*American Practitioner*.

NANCREDE'S ANATOMY AND DISSECTION. Fourth Edition.

Essentials of Anatomy and Manual of Practical Dissection. By CHARLES B. NANCREDE, M.D., LL.D., Professor of Surgery and of Clinical Surgery, University of Michigan, Ann Arbor. Post-octavo; 500 pages, with full-page lithographic plates in colors, and nearly 200 illustrations. Extra Cloth (or Oilcloth for dissection-room), \$2.00 net.

"It may in many respects be considered an epitome of Gray's popular work on general anatomy, at the same time having some distinguishing characteristics of its own to commend it. The plates are of more than ordinary excellence, and are of especial value to students in their work in the dissecting room."—*Journal of the American Medical Association*.

NANCREDE'S PRINCIPLES OF SURGERY.

Lectures on the Principles of Surgery. By CHAS. B. NANCREDE, M.D., LL.D., Professor of Surgery and of Clinical Surgery, University of Michigan, Ann Arbor. Octavo volume of 398 pages, illustrated. Cloth, \$2.50 net.

NORRIS'S SYLLABUS OF OBSTETRICS. Third Edition, Revised.

Syllabus of Obstetrical Lectures in the Medical Department of the University of Pennsylvania. By RICHARD C. NORRIS, A.M., M.D., Demonstrator of Obstetrics, University of Pennsylvania. Crown octavo, 222 pages. Cloth, interleaved for notes, \$2.00 net.

PENROSE'S DISEASES OF WOMEN. Third Edition, Revised.

A Text-Book of Diseases of Women. By CHARLES B. PENROSE, M.D., PH.D., Formerly Professor of Gynecology in the University of Pennsylvania; Surgeon to the Gyneccean Hospital, Philadelphia. Octavo volume of 531 pages, handsomely illustrated. Cloth, \$3.75 net.

"I shall value very highly the copy of Penrose's 'Diseases of Women' received. I have already recommended it to my class as **THE BEST** book."—HOWARD A. KELLY, *Professor of Gynecology and Obstetrics, Johns Hopkins University, Baltimore, Md.*

POWELL'S DISEASES OF CHILDREN. Second Edition.

Essentials of Diseases of Children. By WILLIAM M. POWELL, M.D., Attending Physician to the Mercer House for Invalid Women at Atlantic City, N. J.; late Physician to the Clinic for the Diseases of Children in the Hospital of the University of Pennsylvania. Crown octavo, 222 pages. Cloth, \$1.00; interleaved for notes, \$1.25.

[See *Saunders' Question-Compends*, page 21.]

"Contains the gist of all the best works in the department to which it relates."—*American Practitioner and News.*

PRINGLE'S SKIN DISEASES AND SYPHILITIC AFFECTIONS.

Pictorial Atlas of Skin Diseases and Syphilitic Affections (American Edition). Translation from the French. Edited by J. J. PRINGLE, M.B., F.R.C.P., Assistant Physician to the Middlesex Hospital, London. Photo-lithochromes from the famous models in the Museum of the Saint-Louis Hospital, Paris, with explanatory woodcuts and text. In 12 Parts. Price per Part, \$3.00. Complete in one volume, Half Morocco binding, \$40.00 net.

"I strongly recommend this Atlas. The plates are exceedingly well executed, and will be of great value to all studying dermatology."—STEPHEN MACKENZIE, M.D.

"The introduction of explanatory woodcuts in the text is a novel and most important feature which greatly furthers the easier understanding of the excellent plates, than which nothing, we venture to say, has been seen better in point of correctness, beauty, and general merit."—*New York Medical Journal.*

PRYOR—PELVIC INFLAMMATIONS.

The Treatment of Pelvic Inflammations through the Vagina. By W. R. PRYOR, M.D., Professor of Gynecology in New York Polyclinic. 12mo, 248 pages, handsomely illustrated. Cloth, \$2.00 net.

"This subject, which has recently been so thoroughly canvassed in high gynecological circles, is made available in this volume to the general practitioner and student. Nothing is too minute for mention and nothing is taken for granted; consequently the book is of the utmost value. The illustrations and the technique are beyond criticism."—*Chicago Medical Recorder.*

PYE'S BANDAGING.

Elementary Bandaging and Surgical Dressing. With Directions concerning the Immediate Treatment of Cases of Emergency. For the use of Dressers and Nurses. By WALTER PYE, F.R.C.S., late Surgeon to St. Mary's Hospital, London. Small 12mo, with over 80 illustrations. Cloth, flexible covers, 75 cents net.

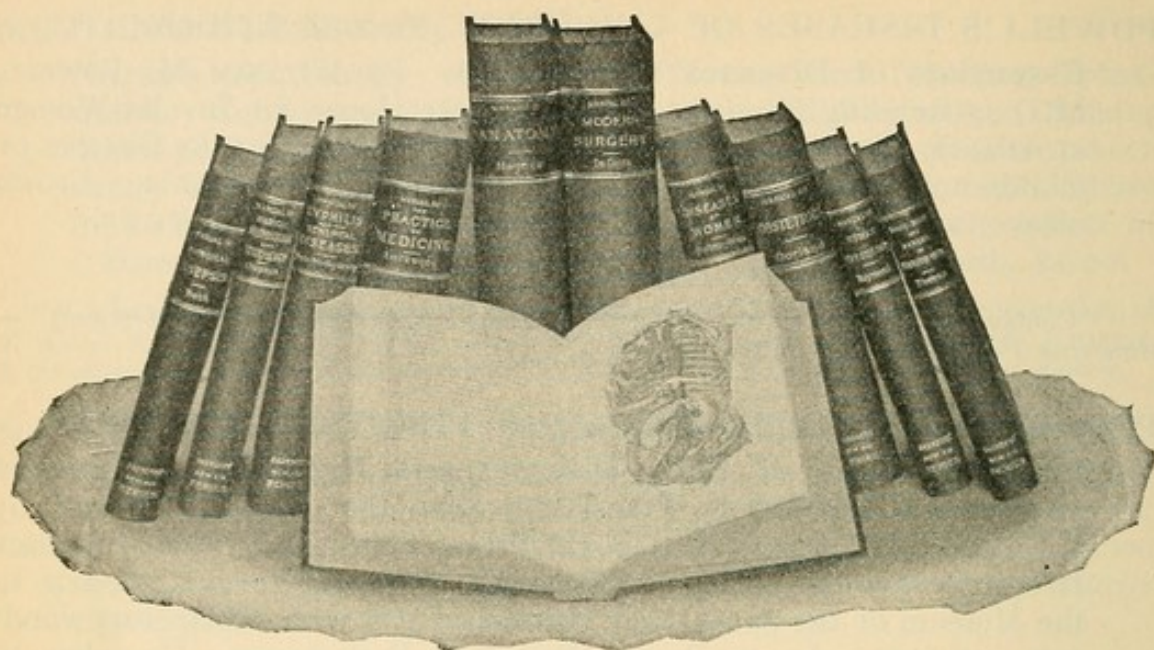
"The directions are clear and the illustrations are good."—*London Lancet.*

"The author writes well, the diagrams are clear, and the book itself is small and portable, although the paper and type are good."—*British Medical Journal.*

RAYMOND'S PHYSIOLOGY.

A Manual of Physiology. By JOSEPH H. RAYMOND, A.M., M.D., Professor of Physiology and Hygiene and Lecturer on Gynecology in the Long Island College Hospital; Director of Physiology in the Hoagland Laboratory, etc. 382 pages, with 102 illustrations in the text, and 4 full-page colored plates. Cloth, \$1.25 net.

"Extremely well gotten up, and the illustrations have been selected with care. The text is fully abreast with modern physiology."—*British Medical Journal.*



Saunders' New Series of Manuals

for Students
and
Practitioners.

THAT there exists a need for thoroughly reliable hand-books on the leading branches of Medicine and Surgery is a fact amply demonstrated by the favor with which the SAUNDERS NEW SERIES OF MANUALS have been received by medical students and practitioners and by the Medical Press. These manuals are not merely condensations from present literature, but are ably written by well-known authors and practitioners, most of them being teachers in representative American colleges. Each volume is concisely and authoritatively written and exhaustive in detail, without being encumbered with the introduction of "cases," which so largely expand the ordinary text-book. These manuals will therefore form an admirable collection of advanced lectures, useful alike to the medical student and the practitioner: to the latter, too busy to search through page after page of elaborate treatises for what he wants to know, they will prove of inestimable value; to the former they will afford safe guides to the essential points of study.

The SAUNDERS NEW SERIES OF MANUALS are conceded to be superior to any similar books now on the market. No other manuals afford so much information in such a concise and available form. A liberal expenditure has enabled the publisher to render the mechanical portion of the work worthy of the high literary standard attained by these books.

Any of these Manuals will be mailed on receipt of price (see next page for List).

Saunders' New Series of Manuals.

VOLUMES PUBLISHED.

PHYSIOLOGY. By JOSEPH HOWARD RAYMOND, A.M., M.D., Professor of Physiology and Hygiene and Lecturer on Gynecology in the Long Island College Hospital; Director of Physiology in the Hoagland Laboratory, etc. Illustrated. Cloth, \$1.25 net.

SURGERY, General and Operative.—By JOHN CHALMERS DACOSTA, M.D., Professor of Practice of Surgery and Clinical Surgery, Jefferson Medical College, Philadelphia; Surgeon to the Philadelphia Hospital, etc. Second edition, thoroughly revised and greatly enlarged. Octavo, 911 pages, profusely illustrated. Cloth, \$4.00 net; Half Morocco, \$5.00 net.

DOSE-BOOK AND MANUAL OF PRESCRIPTION-WRITING. By E. Q. THORNTON, M.D., Demonstrator of Therapeutics, Jefferson Medical College, Philadelphia. Illustrated. Cloth, \$1.25 net.

SURGICAL ASEPSIS. By CARL BECK, M.D., Surgeon to St. Mark's Hospital and to the New York German Poliklinik, etc. Illustrated. Cloth, \$1.25 net.

MEDICAL JURISPRUDENCE. By HENRY C. CHAPMAN, M.D. Professor of Institutes of Medicine and Medical Jurisprudence in the Jefferson Medical College of Philadelphia. Illustrated. Cloth, \$1.50 net.

SYPHILIS AND THE VENEREAL DISEASES. By JAMES NEVINS HYDE, M.D., Professor of Skin and Venereal Diseases, and FRANK H. MONTGOMERY, M.D., Lecturer on Dermatology and Genito-Urinary Diseases in Rush Medical College, Chicago. Profusely illustrated. Cloth, \$2.50 net.

PRACTICE OF MEDICINE. By GEORGE ROE LOCKWOOD, M.D., Professor of Practice in the Woman's Medical College of the New York Infirmary; Instructor in Physical Diagnosis in the Medical Department of Columbia College, etc. Illustrated. Cloth, \$2.50 net.

MANUAL OF ANATOMY. By IRVING S. HAYNES, M.D., Adjunct Professor of Anatomy and Demonstrator of Anatomy, Medical Department of the New York University, etc. Beautifully illustrated. Cloth, \$2.50 net.

MANUAL OF OBSTETRICS. By W. A. NEWMAN DORLAND, M.D., Assistant Demonstrator of Obstetrics, University of Pennsylvania; Chief of Gynecological Dispensary, Pennsylvania Hospital, etc. Profusely illustrated. Cloth, \$2.50 net.

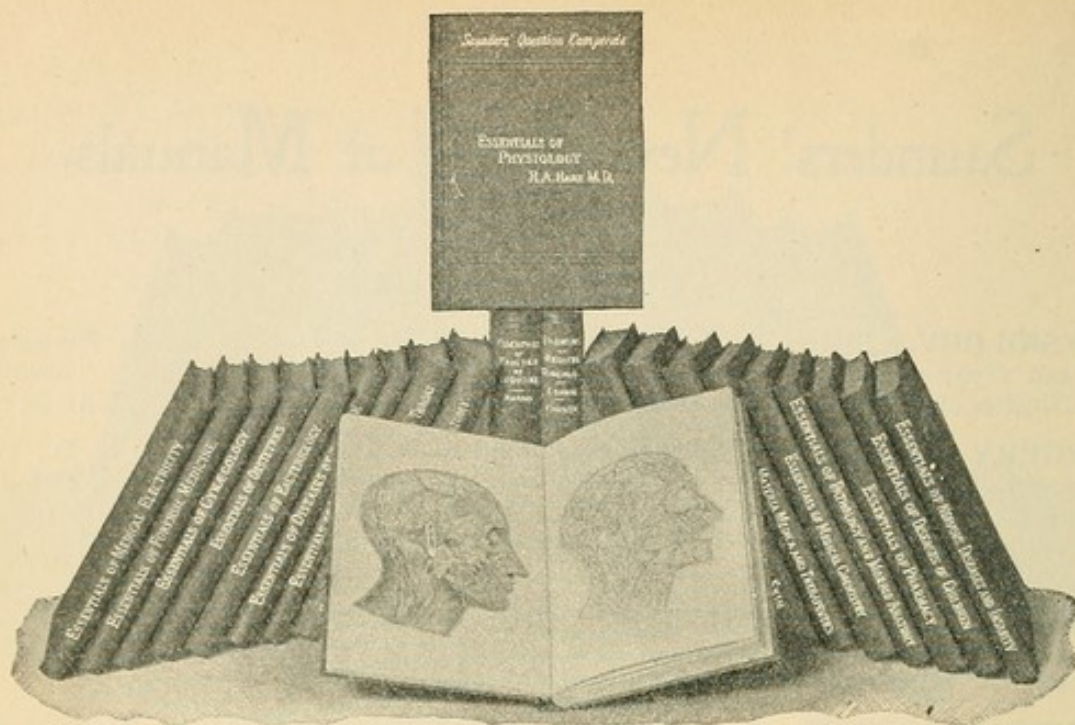
DISEASES OF WOMEN. By J. BLAND SUTTON, F.R.C.S., Assistant Surgeon to Middlesex Hospital and Surgeon to Chelsea Hospital, London; and ARTHUR E. GILES, M.D., B.Sc. Lond., F.R.C.S. Edin., Assistant Surgeon to Chelsea Hospital, London. Handsomely illustrated. Cloth, \$2.50 net.

VOLUMES IN PREPARATION.

NERVOUS DISEASES. By CHARLES W. BURR, M.D., Clinical Professor of Nervous Diseases, Medico-Chirurgical College, Philadelphia; Pathologist to the Orthopaedic Hospital and Infirmary for Nervous Diseases; Visiting Physician to the St. Joseph Hospital, etc.

* * * There will be published in the same series, at short intervals, carefully-prepared works on various subjects by prominent specialists.

Pamphlet containing specimen pages, etc. sent free upon application.



SAUNDERS' QUESTION COMPENDS

Arranged in Question and
Answer Form.

THE MOST COMPLETE AND BEST
ILLUSTRATED SERIES OF
COMPENDS EVER ISSUED.

Now the Standard Authorities in Medical Literature

with Students and Practitioners in every City of the United States and Canada.

OVER 175,000 COPIES SOLD.

THE REASON WHY.

They are the advance guard of "Student's Helps"—that DO HELP. They are the leaders in their special line, well and authoritatively written by able men, who, as teachers in the large colleges, know exactly what is wanted by a student preparing for his examinations. The judgment exercised in the selection of authors is fully demonstrated by their professional standing. Chosen from the ranks of Demonstrators, Quiz-masters, and Assistants, most of them have become Professors and Lecturers in their respective colleges.

Each book is of convenient size (5 x 7 inches), containing on an average 250 pages, profusely illustrated, and elegantly printed in clear, readable type, on fine paper.

The entire series, numbering twenty-three volumes, has been kept thoroughly revised and enlarged when necessary, many of the books being in their fifth and sixth editions.

TO SUM UP.

Although there are numerous other Quizzes, Manuals, Aids, etc. in the market, none of them approach the "Blue Series of Question Compends;" and the claim is made for the following points of excellence:

1. Professional distinction and reputation of authors.
2. Conciseness, clearness, and soundness of treatment.
3. Quality of illustrations, paper, printing, and binding.

Any of these Compends will be mailed on receipt of price (see next page for List).

Saunders' Question-Compend Series.

Price, Cloth, \$1.00 per copy, except when otherwise noted.

"Where the work of preparing students' manuals is to end we cannot say, but the Saunders Series, in our opinion, bears off the palm at present."—*New York Medical Record*.

1. **ESSENTIALS OF PHYSIOLOGY.** By H. A. HARE, M.D. Fourth edition, revised and enlarged. (\$1.00 net.)
2. **ESSENTIALS OF SURGERY.** By EDWARD MARTIN, M.D. Seventh edition, revised, with an Appendix and a chapter on Appendicitis. (\$1.00 net.)
3. **ESSENTIALS OF ANATOMY.** By CHARLES B. NANCREDE, M.D. Sixth edition, thoroughly revised and enlarged. (\$1.00 net.)
4. **ESSENTIALS OF MEDICAL CHEMISTRY, ORGANIC AND INORGANIC.** By LAWRENCE WOLFF, M.D. Fifth edition, revised. (\$1.00 net.)
5. **ESSENTIALS OF OBSTETRICS.** By W. EASTERLY ASHTON, M.D. Fourth edition, revised and enlarged.
6. **ESSENTIALS OF PATHOLOGY AND MORBID ANATOMY.** By C. E. ARMAND SEMPLE, M.D.
7. **ESSENTIALS OF MATERIA MEDICA, THERAPEUTICS, AND PRESCRIPTION-WRITING.** By HENRY MORRIS, M.D. Fifth edition, revised.
- 8, 9. **ESSENTIALS OF PRACTICE OF MEDICINE.** By HENRY MORRIS, M.D. An Appendix on URINE EXAMINATION. By LAWRENCE WOLFF, M.D. Third edition, enlarged by some 300 Essential Formulæ, selected from eminent authorities, by WM. M. POWELL, M.D. (Double number, \$2.00.)
10. **ESSENTIALS OF GYNÆCOLOGY.** By EDWIN B. CRAGIN, M.D. Fourth edition, revised.
11. **ESSENTIALS OF DISEASES OF THE SKIN.** By HENRY W. STELWAGON, M.D. Fourth edition, revised and enlarged. (\$1.00 net.)
12. **ESSENTIALS OF MINOR SURGERY, BANDAGING, AND VENEREAL DISEASES.** By EDWARD MARTIN, M.D. Second ed., revised and enlarged.
13. **ESSENTIALS OF LEGAL MEDICINE, TOXICOLOGY, AND HYGIENE.** By C. E. ARMAND SEMPLE, M.D.
14. **ESSENTIALS OF DISEASES OF THE EYE, NOSE, AND THROAT.** By EDWARD JACKSON, M.D., and E. B. GLEASON, M.D. Second ed., revised.
15. **ESSENTIALS OF DISEASES OF CHILDREN.** By WILLIAM M. POWELL, M.D. Second edition.
16. **ESSENTIALS OF EXAMINATION OF URINE.** By LAWRENCE WOLFF, M.D. Colored "VOGEL SCALE." (75 cents.)
17. **ESSENTIALS OF DIAGNOSIS.** By S. SOLIS COHEN, M.D., and A. A. ESHNER, M.D. Second edition, thoroughly revised. (\$1.00 net.)
18. **ESSENTIALS OF PRACTICE OF PHARMACY.** By LUCIUS E. SAYRE. Second edition, revised and enlarged.
20. **ESSENTIALS OF BACTERIOLOGY.** By M. V. BALL, M.D. Third edition, revised.
21. **ESSENTIALS OF NERVOUS DISEASES AND INSANITY.** By JOHN C. SHAW, M.D. Third edition, revised.
22. **ESSENTIALS OF MEDICAL PHYSICS.** By FRED J. BROCKWAY, M.D. Second edition, revised. (\$1.00 net.)
23. **ESSENTIALS OF MEDICAL ELECTRICITY.** By DAVID D. STEWART, M.D., and EDWARD S. LAWRENCE, M.D.
24. **ESSENTIALS OF DISEASES OF THE EAR.** By E. B. GLEASON, M.D. Second edition, revised and greatly enlarged.

Pamphlet containing specimen pages, etc. sent free upon application.

SAUNDBY'S RENAL AND URINARY DISEASES.

Lectures on Renal and Urinary Diseases. By ROBERT SAUNDBY, M.D. Edin., Fellow of the Royal College of Physicians, London, and of the Royal Medico-Chirurgical Society; Physician to the General Hospital; Consulting Physician to the Eye Hospital and to the Hospital for Diseases of Women; Professor of Medicine in Mason College, Birmingham, etc. Octavo volume of 434 pages, with numerous illustrations and 4 colored plates. Cloth, \$2.50 net.

"The volume makes a favorable impression at once. The style is clear and succinct. We cannot find any part of the subject in which the views expressed are not carefully thought out and fortified by evidence drawn from the most recent sources. The book may be cordially recommended."—*British Medical Journal*.

SAUNDERS' MEDICAL HAND-ATLASES.

For full description of this series, with list of volumes and prices, see page 2.

"Lehmann Medicinische Handatlanten belong to that class of books that are too good to be appropriated by any one nation."—*Journal of Eye, Ear, and Throat Diseases*.

"The appearance of these works marks a new era in illustrated English medical works."—*The Canadian Practitioner*.

SAUNDERS' POCKET MEDICAL FORMULARY. Fifth Edition, Revised.

By WILLIAM M. POWELL, M.D., Attending Physician to the Mercer House for Invalid Women at Atlantic City, N. J. Containing 1800 formulæ selected from the best-known authorities. With an Appendix containing Posological Table, Formulæ and Doses for Hypodermic Medication, Poisons and their Antidotes, Diameters of the Female Pelvis and Fœtal Head, Obstetrical Table, Diet List for Various Diseases, Materials and Drugs used in Antiseptic Surgery, Treatment of Asphyxia from Drowning, Surgical Remembrancer, Tables of Incompatibles, Eruptive Fevers, Weights and Measures, etc. Handsomely bound in flexible morocco, with side index, wallet, and flap. \$1.75 net.

"This little book, that can be conveniently carried in the pocket, contains an immense amount of material. It is very useful, and, as the name of the author of each prescription is given, is unusually reliable."—*Medical Record*, New York.

SAYRE'S PHARMACY. Second Edition, Revised.

Essentials of the Practice of Pharmacy. By LUCIUS E. SAYRE, M.D., Professor of Pharmacy and Materia Medica in the University of Kansas. Crown octavo, 200 pages. Cloth, \$1.00; interleaved for notes, \$1.25.

[See *Saunders' Question-Compends*, page 21.]

"The topics are treated in a simple, practical manner, and the work forms a very useful student's manual."—*Boston Medical and Surgical Journal*.

SCUDDER'S FRACTURES.

The Treatment of Fractures. By CHAS. L. SCUDDER, M.D., Assistant in Clinical and Operative Surgery, Harvard Medical School. Octavo, 433 pages, with nearly 600 original illustrations. Cloth, \$4.50 net.

SEMPLE'S LEGAL MEDICINE, TOXICOLOGY, AND HYGIENE.

Essentials of Legal Medicine, Toxicology, and Hygiene. By C. E. ARMAND SEMPLE, B.A., M.B. Cantab., M.R.C.P. Lond., Physician to the Northeastern Hospital for Children, Hackney, etc. Crown octavo, 212 pages; 130 illustrations. Cloth, \$1.00; interleaved for notes, \$1.25.

[See *Saunders' Question-Compends*, page 21.]

"No general practitioner or student can afford to be without this valuable work. The subjects are dealt with by a masterly hand."—*London Hospital Gazette*.

SEMPLE'S PATHOLOGY AND MORBID ANATOMY.

Essentials of Pathology and Morbid Anatomy. By C. E. ARMAND SEMPLE, B.A., M.B. Cantab., M.R.C.P. Lond., Physician to the Northeastern Hospital for Children, Hackney, etc. Crown octavo, 174 pages; illustrated. Cloth, \$1.00; interleaved for notes, \$1.25.

[See *Saunders' Question-Compends*, page 21.]

"Should take its place among the standard volumes on the bookshelf of both student and practitioner."—*London Hospital Gazette*.

SENN'S GENITO-URINARY TUBERCULOSIS.

Tuberculosis of the Genito-Urinary Organs, Male and Female. By NICHOLAS SENN, M.D., Ph.D., LL.D., Professor of the Practice of Surgery and of Clinical Surgery, Rush Medical College, Chicago. Handsome octavo volume of 320 pages, illustrated. Cloth, \$3.00 net.

"An important book upon an important subject, and written by a man of mature judgment and wide experience. The author has given us an instructive book upon one of the most important subjects of the day."—*Clinical Reporter*.

"A work which adds another to the many obligations the profession owes the talented author."—*Chicago Medical Recorder*.

SENN'S SYLLABUS OF SURGERY.

A Syllabus of Lectures on the Practice of Surgery, arranged in conformity with "An American Text-Book of Surgery." By NICHOLAS SENN, M.D., Ph.D., Professor of the Practice of Surgery and of Clinical Surgery in Rush Medical College, Chicago. Cloth, \$2.00.

"This syllabus will be found of service by the teacher as well as the student, the work being superbly done. There is no praise too high for it. No surgeon should be without it."—*New York Medical Times*.

SENN'S TUMORS. Second Edition, Revised.

Pathology and Surgical Treatment of Tumors. By N. SENN, M.D., Ph.D., LL.D., Professor of Surgery and of Clinical Surgery, Rush Medical College; Professor of Surgery, Chicago Polyclinic; Attending Surgeon to Presbyterian Hospital; Surgeon-in-Chief, St. Joseph's Hospital, Chicago. *Second Edition, Thoroughly Revised.* Octavo volume of 718 pages, with 478 illustrations, including 12 full-page plates in colors. Prices: Cloth, \$5.00 net; Half Morocco, \$6.00 net.

"The most exhaustive of any recent book in English on this subject. It is well illustrated, and will doubtless remain as the principal monograph on the subject in our language for some years. The book is handsomely illustrated and printed, and the author has given a notable and lasting contribution to surgery."—*Journal of the American Medical Association*.

SHAW'S NERVOUS DISEASES AND INSANITY. Third Edition, Revised.

Essentials of Nervous Diseases and Insanity. By JOHN C. SHAW, M.D., Clinical Professor of Diseases of the Mind and Nervous System, Long Island College Hospital Medical School; Consulting Neurologist to St. Catherine's Hospital and to the Long Island College Hospital. Crown octavo, 186 pages; 48 original illustrations. Cloth, \$1.00; interleaved for notes, \$1.25.

[See *Saunders' Question-Compends*, page 21.]

"Clearly and intelligently written."—*Boston Medical and Surgical Journal*.

"There is a mass of valuable material crowded into this small compass."—*American Medico-Surgical Bulletin*.

STARR'S DIETS FOR INFANTS AND CHILDREN.

Diets for Infants and Children in Health and in Disease. By LOUIS STARR, M.D., Editor of "An American Text-Book of the Diseases of Children." 230 blanks (pocket-book size), perforated and neatly bound in flexible morocco. \$1.25 net.

The first series of blanks are prepared for the first seven months of infant life; each blank indicates the ingredients, but not the quantities, of the food, the latter directions being left for the physician. After the seventh month, modifications being less necessary, the diet lists are printed in full. Formulæ for the preparation of diluents and foods are appended.

STELWAGON'S DISEASES OF THE SKIN. Fourth Ed., Revised.

Essentials of Diseases of the Skin. By HENRY W. STELWAGON, M.D., Clinical Professor of Dermatology in the Jefferson Medical College, Philadelphia; Dermatologist to the Philadelphia Hospital; Physician to the Skin Department of the Howard Hospital, etc. Crown octavo, 276 pages; 88 illustrations. Cloth, \$1.00 net; interleaved for notes, \$1.25 net.

[See *Saunders' Question-Compends*, page 21.]

"The best student's manual on skin diseases we have yet seen."—*Times and Register*.

STENGEL'S PATHOLOGY. Second Edition.

A Text-Book of Pathology. By ALFRED STENGEL, M.D., Professor of Clinical Medicine in the University of Pennsylvania; Physician to the Philadelphia Hospital; Physician to the Children's Hospital, etc. Handsome octavo volume of 848 pages, with nearly 400 illustrations, many of them in colors. Cloth, \$4.00 net; Half Morocco, \$5.00 net.

STEVENS' MATERIA MEDICA AND THERAPEUTICS. Second Edition, Revised.

A Manual of Materia Medica and Therapeutics. By A. A. STEVENS, A.M., M.D., Lecturer on Terminology and Instructor in Physical Diagnosis in the University of Pennsylvania; Professor of Pathology in the Woman's Medical College of Pennsylvania. Post-octavo, 445 pages. Flexible leather, \$2.25.

"The author has faithfully presented modern therapeutics in a comprehensive work, and, while intended particularly for the use of students, it will be found a reliable guide and sufficiently comprehensive for the physician in practice."—*University Medical Magazine*.

STEVENS' PRACTICE OF MEDICINE. Fifth Edition, Revised.

A Manual of the Practice of Medicine. By A. A. STEVENS, A. M., M. D., Lecturer on Terminology and Instructor in Physical Diagnosis in the University of Pennsylvania; Professor of Pathology in the Woman's Medical College of Pennsylvania. Specially intended for students preparing for graduation and hospital examinations. Post-octavo, 519 pages; illustrated. Flexible leather, \$2.00 net.

"The frequency with which new editions of this manual are demanded bespeaks its popularity. It is an excellent condensation of the essentials of medical practice for the student, and may be found also an excellent reminder for the busy physician."—*Buffalo Medical Journal*.

STEWART'S PHYSIOLOGY. Third Edition, Revised.

A Manual of Physiology, with Practical Exercises. For Students and Practitioners. By G. N. STEWART, M.A., M.D., D.Sc., lately Examiner in Physiology, University of Aberdeen, and of the New Museums, Cambridge University; Professor of Physiology in the Western Reserve University, Cleveland, Ohio. Octavo volume of 848 pages; 300 illustrations in the text, and 5 colored plates. Cloth, \$3.75 net.

"It will make its way by sheer force of merit, and amply deserves to do so. It is one of the very best English text-books on the subject."—*London Lancet*.

"Of the many text-books of physiology published, we do not know of one that so nearly comes up to the ideal as does Prof. Stewart's volume."—*British Medical Journal*.

STEWART AND LAWRENCE'S MEDICAL ELECTRICITY.

Essentials of Medical Electricity. By D. D. STEWART, M.D., Demonstrator of Diseases of the Nervous System and Chief of the Neurological Clinic in the Jefferson Medical College; and E. S. LAWRENCE, M.D., Chief of the Electrical Clinic and Assistant Demonstrator of Diseases of the Nervous System in the Jefferson Medical College, etc. Crown octavo, 158 pages; 65 illustrations. Cloth, \$1.00; interleaved for notes, \$1.25.

[See *Saunders' Question-Compends*, page 21.]

"Throughout the whole brief space at their command the authors show a discriminating knowledge of their subject."—*Medical News*.

STONE'S NURSING. Second Edition, Revised.

Practical Points in Nursing. For Nurses in Private Practice. By EMILY A. M. STONEY, Graduate of the Training-School for Nurses, Lawrence, Mass.; late Superintendent of the Training-School for Nurses, Carney Hospital, South Boston, Mass. 456 pages, illustrated with 73 engravings in the text, and 8 colored and half-tone plates. Cloth, \$1.75 net.

"There are few books intended for non-professional readers which can be so cordially endorsed by a medical journal as can this one."—*Therapeutic Gazette*.

"This is a well-written, eminently practical volume, which covers the entire range of private nursing as distinguished from hospital nursing, and instructs the nurse how best to meet the various emergencies which may arise, and how to prepare everything ordinarily needed in the illness of her patient."—*American Journal of Obstetrics and Diseases of Women and Children*.

"It is a work that the physician can place in the hands of his private nurses with the assurance of benefit."—*Ohio Medical Journal*.

STONEY'S MATERIA MEDICA FOR NURSES.

Materia Medica for Nurses. By EMILY A. M. STONEY, Graduate of the Training-School for Nurses, Lawrence, Mass.; late Superintendent of the Training-School for Nurses, Carney Hospital, South Boston, Mass. Handsome octavo volume of 306 pages. Cloth, \$1.50 net.

The present book differs from other similar works in several features, all of which are intended to render it more practical and generally useful. The general plan of the contents follows the lines laid down in training-schools for nurses, but the book contains much useful matter not usually included in works of this character, such as Poison-emergencies, Ready Dose-list, Weights and Measures, etc., as well as a Glossary, defining all the terms used in Materia Medica, and describing all the latest drugs and remedies, which have been generally neglected by other books of the kind.

SUTTON AND GILES' DISEASES OF WOMEN.

Diseases of Women. By J. BLAND SUTTON, F.R.C.S., Assistant Surgeon to Middlesex Hospital, and Surgeon to Chelsea Hospital, London; and ARTHUR E. GILES, M.D., B.Sc. Lond., F.R.C.S. Edin., Assistant Surgeon to Chelsea Hospital, London. 436 pages, handsomely illustrated. Cloth, \$2.50 net.

"The text has been carefully prepared. Nothing essential has been omitted, and its teachings are those recommended by the leading authorities of the day."—*Journal of the American Medical Association*.

THOMAS'S DIET LISTS. Second Edition, Revised.

Diet Lists and Sick-Room Dietary. By JEROME B. THOMAS, M.D., Visiting Physician to the Home for Friendless Women and Children and to the Newsboys' Home; Assistant Visiting Physician to the Kings County Hospital. Cloth, \$1.50. Send for sample sheet.

THORNTON'S DOSE-BOOK AND PRESCRIPTION-WRITING.

Dose-Book and Manual of Prescription-Writing. By E. Q. THORNTON, M.D., Demonstrator of Therapeutics, Jefferson Medical College, Philadelphia. 334 pages, illustrated. Cloth, \$1.25 net.

"Full of practical suggestions; will take its place in the front rank of works of this sort."—*Medical Record*, New York.

VAN VALZAH AND NISBET'S DISEASES OF THE STOMACH.

Diseases of the Stomach. By WILLIAM W. VAN VALZAH, M.D., Professor of General Medicine and Diseases of the Digestive System and the Blood, New York Polyclinic; and J. DOUGLAS NISBET, M.D., Adjunct Professor of General Medicine and Diseases of the Digestive System and the Blood, New York Polyclinic. Octavo volume of 674 pages, illustrated. Cloth, \$3.50 net.

"Its chief claim lies in its clearness and general adaptability to the practical needs of the general practitioner or student. In these relations it is probably the best of the recent special works on diseases of the stomach."—*Chicago Clinical Review*.

VECKI'S SEXUAL IMPOTENCE.

The Pathology and Treatment of Sexual Impotence. By VICTOR G. VECKI, M.D. From the second German edition, revised and enlarged. Demi-octavo, 291 pages. Cloth, \$2.00 net.

The subject of impotence has seldom been treated in this country in the truly scientific spirit that it deserves. Dr. Vecki's work has long been favorably known, and the German book has received the highest consideration. This edition is more than a mere translation, for, although based on the German edition, it has been entirely rewritten in English.

VIERORDT'S MEDICAL DIAGNOSIS. Fourth Edition, Revised.

Medical Diagnosis. By Dr. OSWALD VIERORDT, Professor of Medicine at the University of Heidelberg. Translated, with additions, from the fifth enlarged German edition, with the author's permission, by FRANCIS H. STUART, A. M., M. D. Handsome royal octavo volume of 603 pages; 194 fine wood-cuts in text, many of them in colors. Cloth, \$4.00 net; Sheep or Half Morocco, \$5.00 net.

"Rarely is a book published with which a reviewer can find so little fault as with the volume before us. Each particular item in the consideration of an organ or apparatus, which is necessary to determine a diagnosis of any disease of that organ, is mentioned; nothing seems forgotten. The chapters on diseases of the circulatory and digestive apparatus and nervous system are especially full and valuable. The reviewer would repeat that the book is one of the best—probably *the best*—which has fallen into his hands."—*University Medical Magazine*.

WATSON'S HANDBOOK FOR NURSES.

A Handbook for Nurses. By J. K. WATSON, M.D., Edin. American Edition, under supervision of A. A. STEVENS, A.M., M.D., Lecturer on Physical Diagnosis, University of Pennsylvania. 12mo, 413 pages, 73 illustrations. Cloth, \$1.50 net.

WARREN'S SURGICAL PATHOLOGY. Second Edition.

Surgical Pathology and Therapeutics. By JOHN COLLINS WARREN, M.D., LL.D., Professor of Surgery, Harvard Medical School. Handsome octavo, 832 pages; 136 relief and lithographic illustrations, 33 in colors; with an Appendix on Scientific Aids to Surgical Diagnosis, and a series of articles on Regional Bacteriology. Cloth, \$5.00 net; Half Morocco, \$6.00 net.

"A most striking and very excellent feature of this book is its illustrations. Without exception, from the point of accuracy and artistic merit, they are the best ever seen in a work of this kind. Many of those representing microscopic pictures are so perfect in their coloring and detail as almost to give the beholder the impression that he is looking down the barrel of a microscope at a well-mounted section."—*Annals of Surgery*.

WOLFF ON EXAMINATION OF URINE.

Essentials of Examination of Urine. By LAWRENCE WOLFF, M.D., Demonstrator of Chemistry, Jefferson Medical College, Philadelphia, etc. Colored (Vogel) urine scale and numerous illustrations. Crown octavo. Cloth, 75 cents.

[See *Saunders' Question-Compends*, page 21.]

"A very good work of its kind—very well suited to its purpose."—*Times and Register*.

WOLFF'S MEDICAL CHEMISTRY. Fifth Edition, Revised.

Essentials of Medical Chemistry, Organic and Inorganic. Containing also Questions on Medical Physics, Chemical Physiology, Analytical Processes, Urinalysis, and Toxicology. By LAWRENCE WOLFF, M.D., Demonstrator of Chemistry, Jefferson Medical College, Philadelphia, etc. Crown octavo, 222 pages. Cloth, \$1.00 net; interleaved for notes, \$1.25 net.

[See *Saunders' Question-Compends*, page 21.]

"The scope of this work is certainly equal to that of the best course of lectures on Medical Chemistry."—*Pharmaceutical Era*.

CLASSIFIED LIST OF THE MEDICAL PUBLICATIONS

OF
W. B. SAUNDERS,
925 Walnut Street, Philadelphia.

ANATOMY, EMBRYOLOGY, HISTOLOGY.

Clarkson—A Text-Book of Histology, . . .	11
Haynes—A Manual of Anatomy, . . .	15
Heisler—A Text-Book of Embryology, . . .	15
Nancrede—Essentials of Anatomy, . . .	20
Nancrede—Essentials of Anatomy and Manual of Practical Dissection, . . .	20
Simple—Essentials of Pathology, . . .	27

BACTERIOLOGY.

Ball—Essentials of Bacteriology, . . .	8
Crookshank—A Text-Book of Bacteri- ology, . . .	12
Frothingham—Laboratory Guide, . . .	13
Levy and Klemperer's Clinical Bacte- riology, . . .	17
Mallory and Wright—Pathological Technique, . . .	18
McFarland—Pathogenic Bacteria, . . .	19

CHARTS, DIET-LISTS, ETC.

Griffith—Infant's Weight Chart, . . .	14
Hart—Diet in Sickness and in Health, . . .	15
Keen—Operation Blank, . . .	17
Lainé—Temperature Chart, . . .	17
Meigs—Feeding in Early Infancy, . . .	19
Starr—Diets for Infants and Children, . . .	28
Thomas—Diet-Lists, . . .	30

CHEMISTRY AND PHYSICS.

Brockway—Essentials of Medical Phys- ics, . . .	9
Wolff—Essentials of Medical Chemistry, . . .	31

CHILDREN.

An American Text-Book of Diseases of Children, . . .	5
Griffith—Care of the Baby, . . .	14
Griffith—Infant's Weight Chart, . . .	14
Meigs—Feeding in Early Infancy, . . .	19
Powell—Essentials of Dis. of Children, . . .	21
Starr—Diets for Infants and Children, . . .	28

DIAGNOSIS.

Cohen and Eshner—Essentials of Di- agnosis, . . .	11
Corwin—Physical Diagnosis, . . .	11
Macdonald—Surgical Diagnosis and Treatment, . . .	18
Vierordt—Medical Diagnosis, . . .	31

DICTIONARIES.

Dorland—Pocket Dictionary, . . .	12
Keating—Pronouncing Dictionary, . . .	16
Morten—Nurse's Dictionary, . . .	20

EYE, EAR, NOSE, AND THROAT.

An American Text-Book of Diseases of the Eye, Ear, Nose, and Throat, . . .	5
De Schweinitz—Diseases of the Eye, . . .	12
Gleason—Essentials of Dis. of the Ear, . . .	13
Jackson—Manual of Diseases of Eye, . . .	16
Jackson and Gleason—Essentials of Diseases of the Eye, Nose, and Throat, . . .	16
Kyle—Diseases of the Nose and Throat, . . .	17

GENITO-URINARY.

An American Text-Book of Genito- Urinary and Skin Diseases, . . .	6
Hyde and Montgomery—Syphilis and the Venereal Diseases, . . .	15
Martin—Essentials of Minor Surgery, Bandaging, and Venereal Diseases, . . .	18
Saundby—Renal and Urinary Diseases, . . .	26
Senn—Genito-Urinary Tuberculosis, . . .	27
Vecki—Sexual Impotence, . . .	30

GYNECOLOGY.

American Text-Book of Gynecology, . . .	6
Cragin—Essentials of Gynecology, . . .	11
Garrigues—Diseases of Women, . . .	13
Long—Syllabus of Gynecology, . . .	17
Penrose—Diseases of Women, . . .	20
Pryor—Pelvic Inflammations, . . .	34
Sutton and Giles—Diseases of Women, . . .	30

MATERIA MEDICA, PHARMACOL- OGY, AND THERAPEUTICS.

An American Text-Book of Applied Therapeutics, . . .	5
Butler—Text-Book of Materia Medica, Therapeutics and Pharmacology, . . .	10
Cerna—Notes on the Newer Remedies, . . .	10
Griffin—Materia Med. and Therapeutics, . . .	14
Morris—Essentials of Materia Medica and Therapeutics, . . .	19
Saunders' Pocket Medical Formulary, . . .	26
Sayre—Essentials of Pharmacy, . . .	26
Stevens—Essentials of Materia Medica and Therapeutics, . . .	28
Stoney—Materia Medica for Nurses, . . .	30
Thornton—Dose-Book and Manual of Prescription-Writing, . . .	30

MEDICAL JURISPRUDENCE AND TOXICOLOGY.

Chapman—Medical Jurisprudence and Toxicology, . . .	10
Simple—Essentials of Legal Medicine, Toxicology, and Hygiene, . . .	27

NERVOUS AND MENTAL DISEASES, ETC.

Burr —Nervous Diseases,	9
Chapin —Compendium of Insanity,	10
Church and Peterson —Nervous and Mental Diseases,	10
Shaw —Essentials of Nervous Diseases and Insanity,	28

NURSING.

Griffith —The Care of the Baby,	14
Hampton —Nursing,	14
Hart —Diet in Sickness and in Health,	15
Meigs —Feeding in Early Infancy,	19
Morten —Nurse's Dictionary,	20
Stoney —Materia Medica for Nurses,	30
Stoney —Practical Points in Nursing,	29
Watson —Handbook for Nurses,	31

OBSTETRICS.

An American Text-Book of Obstetrics,	6
Ashton —Essentials of Obstetrics,	8
Boisliniere —Obstetric Accidents,	9
Dorland —Manual of Obstetrics,	12
Hirst —Text-Book of Obstetrics,	15
Norris —Syllabus of Obstetrics,	20

PATHOLOGY.

An American Text-Book of Pathology,	7
Mallory and Wright —Pathological Technique,	18
Semple —Essentials of Pathology and Morbid Anatomy,	27
Senn —Pathology and Surgical Treatment of Tumors,	27
Stengel —Text-Book of Pathology,	28
Warren —Surgical Pathology and Therapeutics,	31

PHYSIOLOGY.

An American Text-Book of Physiology,	7
Hare —Essentials of Physiology,	14
Raymond —Manual of Physiology,	21
Stewart —Manual of Physiology,	29

PRACTICE OF MEDICINE.

An American Text-Book of the Theory and Practice of Medicine,	7
An American Year-Book of Medicine and Surgery,	8
Anders —Text-Book of the Practice of Medicine,	8
Lockwood —Manual of the Practice of Medicine,	17
Morris —Essentials of the Practice of Medicine,	19
Stevens —Manual of the Practice of Medicine,	29

SKIN AND VENEREAL.

An American Text-Book of Genito-Urinary and Skin Diseases,	5
Hyde and Montgomery —Syphilis and the Venereal Diseases,	15

Martin —Essentials of Minor Surgery, Bandaging, and Venereal Diseases,	18
Pringle —Pictorial Atlas of Skin Diseases and Syphilitic Affections,	21
Stelwagon —Essentials of Diseases of the Skin,	28

SURGERY.

An American Text-Book of Surgery,	7
An American Year-Book of Medicine and Surgery,	8
Beck —Fractures,	9
Beck —Manual of Surgical Asepsis,	9
DaCosta —Manual of Surgery,	12
International Text-Book of Surgery,	15
Keen —Operation Blank,	17
Keen —The Surgical Complications and Sequels of Typhoid Fever,	17
Macdonald —Surgical Diagnosis and Treatment,	18
Martin —Essentials of Minor Surgery, Bandaging, and Venereal Diseases,	18
Martin —Essentials of Surgery,	18
Moore —Orthopedic Surgery,	19
Nancrede —Principles of Surgery,	20
Pye —Bandaging and Surgical Dressing,	21
Scudder —Treatment of Fractures,	26
Senn —Genito-Urinary Tuberculosis,	27
Senn —Syllabus of Surgery,	27
Senn —Pathology and Surgical Treatment of Tumors,	27
Warren —Surgical Pathology and Therapeutics,	31

URINE AND URINARY DISEASES.

Saundby —Renal and Urinary Diseases,	26
Wolff —Essentials of Examination of Urine,	31

MISCELLANEOUS.

Abbott —Hygiene of Transmissible Diseases,	8
Bastin —Laboratory Exercises in Botany,	9
Gould and Pyle —Anomalies and Curiosities of Medicine,	13
Grafstrom —Massage,	14
Keating —How to Examine for Life Insurance,	16
Rowland and Hedley —Archives of the Roentgen Ray,	21
Saunders' Medical Hand-Atlases,	2, 3, 4
Saunders' New Series of Manuals,	24, 25
Saunders' Pocket Medical Formulary,	26
Saunders' Question-Compends,	22, 23
Senn —Pathology and Surgical Treatment of Tumors,	27
Stewart and Lawrance —Essentials of Medical Electricity,	29
Thornton —Dose-Book and Manual of Prescription-Writing,	30
Van Valzah and Nisbet —Diseases of the Stomach,	30

BOOKS JUST ISSUED.

THE AMERICAN ILLUSTRATED MEDICAL DICTIONARY.

For Students and Practitioners. A Complete Dictionary of the Terms used in Medicine and the Allied Sciences, with a large number of Valuable Tables and Numerous Handsome Illustrations. Edited by W. A. NEWMAN DORLAND, M. D., Editor of the American Pocket Medical Dictionary. Handsome large octavo, 800 pages, bound in full limp leather, and printed on thin paper of the finest quality, forming a handy volume, only $1\frac{1}{4}$ inches thick.

This is an entirely new and unique work, intended to meet the need of practitioners and students for a complete, up-to-date dictionary of moderate price. The book is designed to furnish a maximum amount of matter in a minimum space and at the lowest possible cost. It contains double the material in the ordinary students' dictionary, and yet, by the use of a clear, condensed type and thin paper of the finest quality, is only $1\frac{1}{4}$ inches in thickness. It is bound in full flexible leather, and is just the kind of a book that a man will want to keep on his desk for constant reference. The book makes a special feature of the newer words, and defines hundreds of important terms not to be found in any other dictionary. It is especially full in the matter of tables, containing more than a hundred of great practical value. A new feature is the inclusion of numerous handsome illustrations, many of them in colors, drawn and engraved specially for this book. These have been chosen with great care and add infinitely to the value of the work. The book will appeal to both practitioners and students, since, besides a complete vocabulary, it gives to the more important subjects extended consideration of an encyclopedic character.

BÖHM, DAVIDOFF, AND HUBER'S HISTOLOGY.

A Text-Book of Human Histology. Including Microscopic Technic. By DR. A. A. BÖHM and DR. M. VON DAVIDOFF, of Munich, and G. C. HUBER, M. D., Junior Professor of Anatomy and Histology, University of Michigan.

FRIEDRICH AND CURTIS ON THE NOSE, THROAT, AND EAR.

Rhinology, Laryngology, and Otology in their Relations to General Medicine. By DR. E. P. FRIEDRICH, of the University of Leipzig. Edited by H. HOLBROOK CURTIS, M. D., Consulting Surgeon to the New York Nose and Throat Hospital.

LEROY'S HISTOLOGY.

The Essentials of Histology. By LOUIS LEROY, M. D., Professor of Histology and Pathology, Vanderbilt University, Nashville, Tennessee.

OGDEN ON THE URINE.

Clinical Examination of the Urine. By J. BERGEN OGDEN, M. D., Assistant in Chemistry, Harvard Medical School. Handsome octavo volume of over 408 pages, with 54 illustrations and 11 full-page plates, many in colors.

PYLE'S PERSONAL HYGIENE.

A Manual of Personal Hygiene. Edited by WALTER L. PYLE, M. D., Assistant Surgeon to Wills Eye Hospital, Philadelphia. Octavo volume of 344 pages, fully illustrated.

SALINGER AND KALTEYER'S MODERN MEDICINE.

Modern Medicine. By JULIUS L. SALINGER, M. D., Demonstrator of Clinical Medicine, Jefferson Medical College, and F. J. KALTEYER, M. D., Assistant Demonstrator of Clinical Medicine, Jefferson Medical College. Handsome octavo volume of over 800 pages, fully illustrated.

STONE'S SURGICAL TECHNIC FOR NURSES.

Surgical Technic for Nurses. By EMILY A. M. STONEY, late Superintendent of the Training-School for Nurses, Carney Hospital, South Boston, Massachusetts.

