

**A treatise on aneurism : with numerous additions, and a Memoir on the ligature of the principal arteries of the extremities / by Antonio Scarpa ... ; with engravings ; translated from the Italian, with additional cases and an appendix, by John Henry Wishart.**

### **Contributors**

Scarpa, Antonio, 1752-1832.  
Wishart, John Henry, 1782?-1834.  
Francis A. Countway Library of Medicine

### **Publication/Creation**

Edinburgh : printed for Stirling and Slade ; London : Baldwin, Cradock, and Joy, and T. and G. Underwood, 1819.

### **Persistent URL**

<https://wellcomecollection.org/works/ftj2vs96>

### **License and attribution**

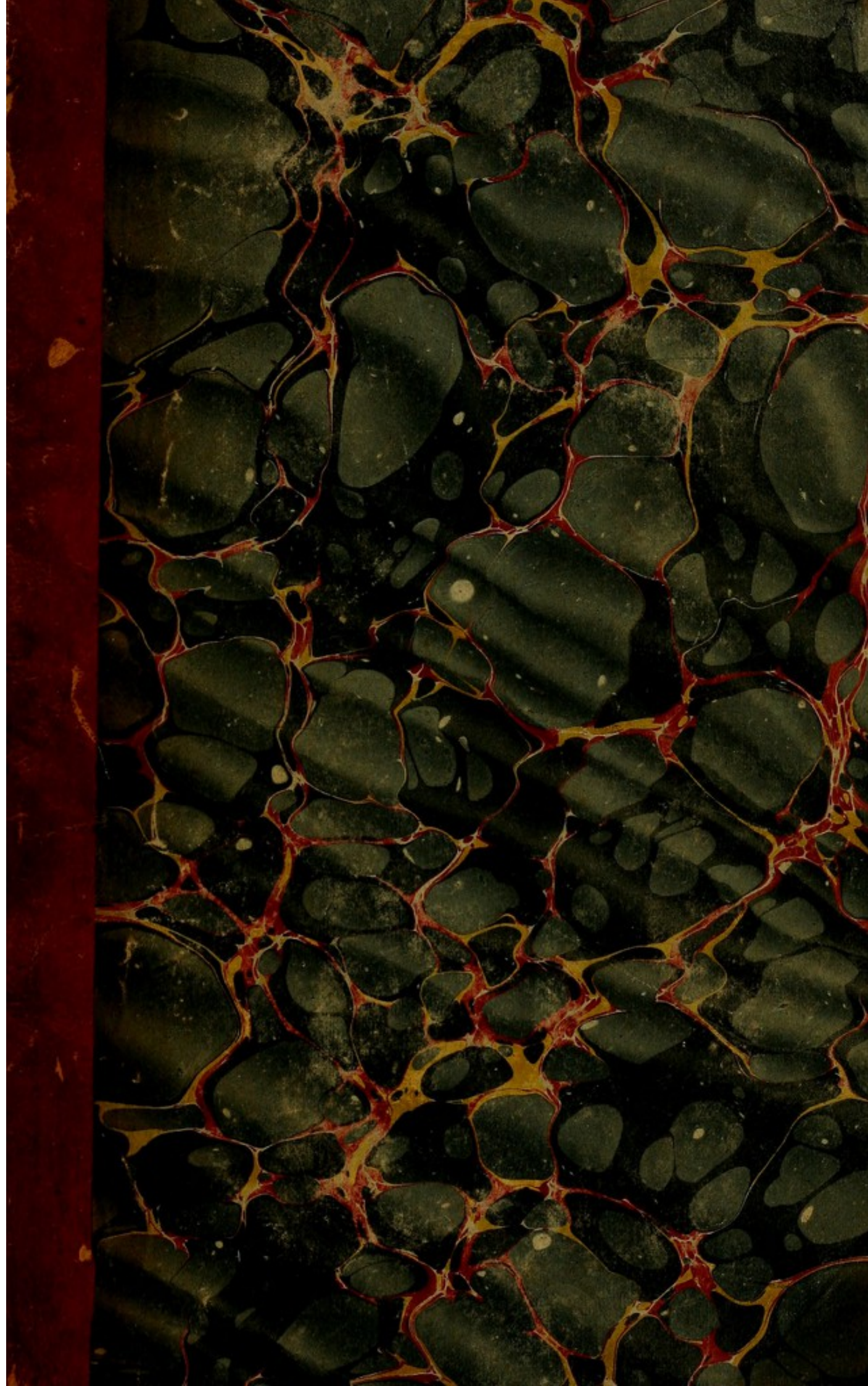This material has been provided by This material has been provided by the Francis A. Countway Library of Medicine, through the Medical Heritage Library. The original may be consulted at the Francis A. Countway Library of Medicine, Harvard Medical School. where the originals may be consulted. This work has been identified as being free of known restrictions under copyright law, including all related and neighbouring rights and is being made available under the Creative Commons, Public Domain Mark.

You can copy, modify, distribute and perform the work, even for commercial purposes, without asking permission.



Wellcome Collection  
183 Euston Road  
London NW1 2BE UK  
T +44 (0)20 7611 8722  
E [library@wellcomecollection.org](mailto:library@wellcomecollection.org)  
<https://wellcomecollection.org>







Willow Leaves Gr.
















*Half-Buck*

A  
TREATISE  
ON  
ANEURISM,  
WITH NUMEROUS ADDITIONS,  
AND A  
MEMOIR ON THE LIGATURE  
OF THE  
PRINCIPAL ARTERIES OF THE EXTREMITIES.

By ANTONIO SCARPA,

EMERITUS PROFESSOR, DIRECTOR OF THE MEDICAL FACULTY OF THE IM-  
PERIAL AND ROYAL UNIVERSITY OF PAVIA, KNIGHT OF THE ROYAL  
ORDER OF THE IRON CROWN, MEMBER OF THE ROYAL ACADEMY OF  
SCIENCES OF PARIS, LONDON, BERLIN, &c. &c.

WITH ENGRAVINGS.

---

TRANSLATED FROM THE ITALIAN,  
WITH ADDITIONAL CASES AND AN APPENDIX,  
By JOHN HENRY WISHART,

FELLOW OF THE ROYAL COLLEGE OF SURGEONS, AND MEMBER OF THE  
ROYAL MEDICAL AND CHIRURGICAL SOCIETIES, OF EDINBURGH,

*SECOND EDITION.*

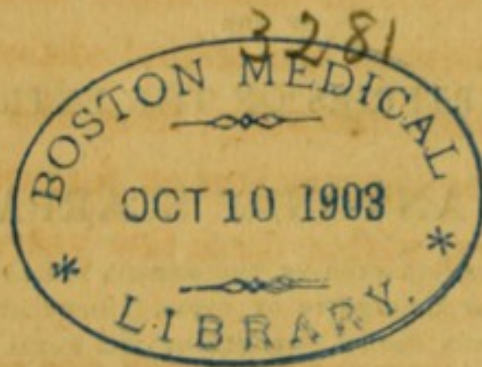
---

EDINBURGH :

PRINTED FOR STIRLING AND SLADE, EDINBURGH ;  
BALDWIN, CRADOCK, AND JOY, AND T. AND  
G. UNDERWOOD, LONDON.

---

1819.





## ADVERTISEMENT.

---

THE interest excited by the appearance of the former edition of this work, and the success attending the sale of it, have, for a considerable time, directed my attention to the publication of a second edition. This seemed to be the more necessary, from the number and importance of the observations on Aneurism published in this country, within these few years.

IN the course of corresponding with the author, he informed me, that he had been engaged in making a series of experiments on the Ligature of Arteries, and that he had sent me a copy of his work, requesting that I would translate it. From some hitherto unexplained causes, this copy never reached me, and it was not till June 1818, that Professor Maunoir of Geneva, when in London, on being informed of this circumstance, very obligingly sent me his own copy.

IN the Appendix to the Memoir on the Ligature of Arteries, I found that the author had amply supplied the deficiencies of his work on Aneurism, by an account of the modern publications which have appeared in this country; these additions I have inserted in their proper places in the present edition.



IN the Appendix, I have given an account of some cases of Axillary Aneurism, in which the Subclavian Artery had been tied with various success. I am indebted to my friend, Dr. Monteath of Glasgow, for the history of the very rare case of the recurrence of the disease in a case of Popliteal Aneurism, nine months after the femoral artery had been tied in the upper third of the thigh.

I HAVE also added several important cases which I have met with in my own practice, and in that of other surgeons of this place.

It was my intention to have introduced throughout the work the Nomenclature of Dr. Barclay; but on reflection it appeared unnecessary, except in some parts of the anatomical description, where a difference existed between the names employed by the author, and those generally used by the surgical writers of this country.

IN the former edition, several cases were inserted in the Appendix, which, in the alterations since made by the author, have been introduced into the text. The references to some of these cases have, in a few instances, been omitted to be deleted, which omission the reader will rectify.



THE

## AUTHOR'S PREFACE.

---

THE Society of Medicine of Paris proposed, for the year 1798,\* as the subject of a prize essay, the following questions relative to aneurism. In what cases is the assistance of the surgeon necessary, and in what circumstances are internal remedies, diet, and rest sufficient to effect the cure of aneurism? When the assistance of the surgeon is necessary, what are the cases in which compression may be employed with success as a method of cure, and when ought the ligature of the aneurismatic artery to be preferred to compression? Farther, when the ligature is indicated as the only method of cure, is it proper to make two ligatures; that is, one above and the other below the aneurism; or is the upper ligature sufficient? In the last place, in what cases is it proper to open the aneurismal sac, and cut it out? and in what cases is it better to leave it to the powers of nature? in short; what

\* Prix proposés par la Société de Médecine de Paris dans sa première séance publique, le 27 Prairial, an. v. 15 Juin 1797.



are the advantages and disadvantages of the different methods hitherto known for operating on aneurism? When these questions reached me, I found that I had a sufficient number of observations and facts to answer, as I thought, in an adequate manner, the whole, or the greater number of them; but a variety of circumstances prevented me from finishing and presenting my memoir in time to that illustrious Medical Society, to which I consider it a great honour to belong. Afterwards, on reflecting that the observations and facts, upon which I rested my opinion with regard to the true nature of aneurism in general, were only hinted at in that essay; and farther, that the operative part itself of external aneurism required a more extensive explanation than the narrow limits of a dissertation would allow, I changed my intention, and instead of finishing that small treatise, I undertook the present work, as it appeared to me to be necessary to young students, after the brilliant and rapid progress which this branch of surgery has made within these few years, by means of the united labours of many celebrated men, among whom Haller, Monro, Hazon, John Hunter, Home, Murray, Palletta, Deschamps, Forster, Hartley, John Bell, Maunoir, deserve particularly to be mentioned.

I HAVE, for many years past, been in the habit of mentioning repeatedly to my hearers in the Clinical School, that the history of this disease was still incomplete and defective. Therefore, one of the principal objects which I have had in view, in treating of



this very important subject, was that of demonstrating the insufficiency of the doctrine, which is commonly taught in the schools of surgery, with regard to the manner in which aneurism is formed, and consequently the erroneous division, adopted by writers on this subject, of aneurism into *true*, *spurious*, and *mixed*; primarily *false*, subsequently *false*; and the like. For, after a very considerable number of investigations, instituted on the bodies of those who have died of internal or external aneurisms, I have ascertained, in the most certain and unequivocal manner, that there is only one kind or form of this disease; viz. that caused by a solution of continuity or rupture of the proper coats of the artery, with effusion of blood into the surrounding cellular substance; which solution of continuity is occasioned sometimes by a wound, a steatomatous, earthy degeneration, a corroding ulcer, a rupture of the proper coats of the artery, I mean the internal and muscular, without the concurrence of a preternatural dilatation of these coats being essential to the formation of this disease; and therefore, that every aneurism, whether it be internal or external, circumscribed or diffused, is always formed by effusion.

IN instituting these researches on the dead bodies of aneurismatic patients, I have employed the greatest possible care, especially in unfolding the proper coats of the injured artery; and I have paid particular attention in separating the cellular substance, and the other membranes and aponeurotic layers which co-



ver the artery, as well as the aneurismal sac, to compare in succession, and in their natural situation, the texture and limits of all these membranous layers, in order to ascertain, with clearness and precision, what share the proper coats of the artery have in the formation of the sac, and what is formed by the cellular substance, which in the sound state forms a sheath to it externally, and by the other membranes and aponeuroses surrounding it. The uniform result of all these researches has been, that aneurism, in whatever part of the body it is formed, and from whatever cause it arises, is never occasioned by the dilatation, but by the rupture or ulceration of the internal and muscular coats of the artery, and consequently that these coats have not the smallest share in the formation of the aneurismal sac.

AFTER having ascertained, in the dead subject, the constancy of this fact, I turned my attention to the examination of the most celebrated descriptions and figures which we have of aneurisms; and, from all these descriptions and figures, published by their authors as so many examples of true aneurisms, or aneurisms from dilatation, I have been induced to draw a precisely contrary conclusion; that is, that all these aneurisms had been formed by a rupture or ulceration, and none of them by a dilatation of the proper coats of the artery. Such is the power of truth, that it even shines through the darkness which, in addition to the difficulties of the investigation, authority and preconceived opinions sometimes oppose to it.



THESE ideas, with regard to the nature and characters of aneurism, do not, it is true, as yet point out the road to any effectual attempt for the cure of internal aneurisms, or of those which are situated beyond the reach of the hand of the surgeon ; but this is not the case with regard to external aneurisms. And if, in surgery, it is generally allowed to be true, that the accurate knowledge of the nature of a disease, and of the parts which it affects, contributes very much to suggest to the surgeon the most secure, easy, and speedy method of operating for removing and curing it, the opinions which I am going to state on the subject of external aneurisms cannot fail to produce useful changes in this branch of practical surgery. For obtaining and promoting still more these advantages, I have occupied myself with investigating what is the operative process which nature, assisted by art, and sometimes even of herself alone, employs for the cure of aneurism. I have found that she performs this curative process in two ways : in the first, by means of the adhesive inflammation, and precisely in the same manner as she cures simple wounds by the first intention, the artery is converted for a certain space above and below the injury, into a perfectly solid ligamentous cord : in the second way, likewise, by means of the adhesive inflammation, she changes the soft cellular substance of the incipient aneurismal sac into a capsule, with thick firm sides, adhering strongly to the surrounding parts ; within this membranous capsule a small coagulated clot of blood is formed, which being applied firmly to the lips of the wound or laceration



of the artery, opposes the discharge of blood, and serves instead of a cicatrix of the artery, the canal of which continues pervious as before the accident. Of these two kinds of cure of aneurism, however, the first only can be called truly complete and radical. According to these principles, and following the natural order of the subject, I did not find it difficult to determine the cases and circumstances in which compression may be employed as a method of cure, and when the ligature of the aneurismatic artery ought to be preferred to compression. With regard to the advantages and inconveniences of the different methods hitherto known of operating for aneurism, the elucidation of this point seemed to me to depend, in a great measure, upon the solution of the following problem, viz. What is the degree of importance of the principal arterial trunk of a part, especially of a limb, for the preservation of the circulation and life of the limb itself? or, in other words, What is the power of the collateral vessels for supplying the functions of the principal arterial trunk of a limb, whenever the course of the blood through that trunk is interrupted in the vicinity of, as well as at a considerable distance above, the seat of the aneurism? For the more accurate solution of this problem, I have found it necessary and useful to repeat the observations relative to the arterial system of the superior and inferior extremities, both with regard to the large trunks, the collateral branches, and their principal anastomoses.

WE are indebted to Haller for much important



knowledge on the subject of the anastomoses of the arteries of the superior and inferior extremities; which knowledge has contributed very much to encourage the timid and doubtful minds of modern surgeons, to place more hope than our predecessors in the number and activity of the collateral vessels, and of their anastomoses, for the preservation of the circulation and life of a limb, after the ligature of its principal arterial trunk. Murray has resumed the same subject, in that part which regards the arteries of the lower extremities, from the pelvis to the knee; but if I may express freely what I feel on this point, the tables of the arteries of the extremities published by Haller, as well as those of Murray, on account of their smallness, their insulated state, and the separation of the arteries from the other parts contiguous to them, are not sufficient to place this important subject in that point of view which is necessary for producing in the readers the effect that is desired, and for impressing on the minds of surgeons that degree of conviction which is necessary for persuading them completely that these collateral branches and anastomoses are sufficient to supply the want of the principal arterial trunk, and preserve the circulation and life of the parts situated below the ligature. In Haller's tables, as well as in those of Murray, there is not that combination of facts and circumstances, as it is usually termed, which is required for a complete demonstration of the very important subject of which we are treating. For, with regard to the arteries of the lower extremities, neither is the number of the



arteries of the pelvis, and of their anastomoses with the femoral artery, sufficient, nor are their position and ramifications well expressed. And with regard to the arteries of the superior extremities, there is wanting in the tables published by Haller a figure representing distinctly that combination of the communications of the arteries of the neck with those of the arm, without which communications it is impossible at one view to make young students understand, and to give an account of the considerable anastomoses existing between the arteries of the neck and of the superior arteries of the scapula with the inferior scapulars, and between these and the arteries of the humerus and arm. Besides, in the tables above quoted, the anastomoses themselves, on account of the smallness of the figures, appear too minute, not very pervious, and uncertain, and rather calculated to perpetuate in less informed surgeons, in similar cases, the language of timidity and doubt, than that of courage and confidence, founded upon anatomy and the provident resources of nature. Kirkland \* on this subject says: ‘ Indeed I am fearful wrong conclusions, ‘ drawn from anatomy, have here (as in other instances) led us out of the way. For, from seeing ‘ the distribution of the arteries when filled with wax, ‘ it has been supposed the circulation of the blood ‘ could not be carried on in the parts below, where ‘ the passage of the blood through the main trunk ‘ was stopped. Even Mr. Cheselden was so biassed

\* Thoughts on Amputation.



‘ by this theory, that he could not believe the surgeon who told him that he had tied up the humeral artery in the middle of the arm with complete success.’ Certainly whoever regulated his opinion according to coarse injections of the limbs, would never be induced to suppose that there existed in nature a sufficiently considerable number of collateral vessels and anastomoses for carrying on the circulation, and preserving the life, in the parts below the ligature of the large arterial trunk of an extremity. But fine and fluid injections, and the careful inspection of the minute arteries of the extremities when injected, shew clearly not only the existence, but the multiplicity and extent of these arterial communications through the whole length of each limb; and anatomy, therefore, instead of leading surgeons on this point out of the way, even furnishes them with one of the strongest arguments to prove the possibility of this wonderful phenomenon, and the mechanism by which it is effected. I have therefore thought it proper to supply this defect, by substituting, instead of Haller’s and Murray’s plates, as far as regards the theory and practice of the operation for aneurism of the superior and inferior extremities, some other plates, copied not from the dead bodies of children, as they have done, but from adult subjects, preserving as much as possible the situation, course, and natural size of the principal arteries, of their collateral branches and anastomoses, and at the same time the respective position of the muscles between which these arteries run.



THIS anatomical labour has been followed by several experiments made in the dead body by means of very fluid injections, after having tied the trunk of the femoral and brachial arteries at different distances from their origin, with the view of proving, notwithstanding the ligature of the principal channel, the possibility of the passage of the blood by the collateral vessels from one extremity of a limb to the other. These experiments, which had been also made previously by skilful anatomists and surgeons, along with the many observations in the living body which we are now in possession of, with regard to the preservation of the inferior and superior extremities after the ligature of their principal arterial trunk, even very near to its origin, will, I hope, suffice to dissipate completely any remains of perplexity, or any kind of difficulty, which might have been entertained with regard to the surprising power which the collateral vessels and anastomoses have in carrying on the circulation, and preserving the life of the limb, below the ligature of the principal arterial trunk of the leg or arm.

THE result of these experiments, conjoined with the perfect knowledge which we are now in possession of with regard to the nature and proximate cause of aneurism, and the different degrees of resistance which the coagulated layers contained in the aneurismal sac oppose to the current of the blood within it, point out to me, in the clearest and most precise manner, in what circumstances it is proper to apply two



ligatures, and when the application of one ligature only to the trunk of the artery, even at a great distance above the aneurism, may be sufficient to effect the radical cure of the disease without touching the aneurismal sac, or evacuating the clots of blood with which it is filled, or, in other words, by leaving the absorption and disappearance of the grumous blood, and at the same time also of the aneurismal sac, to the powers of nature alone. The degree of our knowledge at present with regard to the widely-extended sphere of activity of the absorbent lymphatic system, accounts for the numerous facts which may be mentioned of this kind of absorption, and at the same time shews with how great confidence this part of the cure of external aneurism may be intrusted entirely to the powers of nature.

LED, therefore, naturally, by the subject itself, which I propose to treat of, I have proceeded to give minute details of the operation for aneurism in the ham, of that in the thigh, and in the groin; then of that in the bend of the arm, along the humerus; and, lastly, that in the axilla. I have pointed out the great advantages derived from the Hunterian or Anel-  
lian method of operating, both on account of the facility of the execution on the part of the surgeon, as well as the safety and diminution of the pain on the part of the patient; in doing which, I have not, however, omitted to explain the particular circumstances in which the old method of operating, or that of the incision of the aneurismal sac, and the double liga-



ture, is sometimes preferable to the modern, in which one ligature only is applied to the artery above the seat of the tumor, leaving the aneurismal sac entirely untouched.

My attention has been particularly directed to the subject of secondary hemorrhage, which is deservedly so much dreaded by surgeons, after the ligature of the great arteries in general, and in particular after the operation for aneurism. I have found, that, in order to avoid this formidable accident, it is necessary, in the *first* place, that the ligature be applied to the denuded artery, stripped of every part, and even of the pulpy cellular substance surrounding it; in the *second* place, that the pressure applied to it by means of the ligature bring the two opposite sides into firm contact, without constricting them circularly; and, in the *third* place, that the ulcerative process of the portion of artery tied do not precede the adhesive process. For obtaining all these advantages, I have pointed out the utility of the method which practice has taught me to be the most effectual.

To the plates of the arteries of the extremities I have added some others, representing aneurisms of the arch of the aorta, of the thoracic trunk of that artery, of the carotid, popliteal, femoral, and brachial arteries. I have done so in order to demonstrate to my readers what I have explained with regard to the true nature and character of aneurism in general, as likewise the better to point out to them the plan



which I have followed in the examination of this kind of disease in the arterial system.

IN the *last* place, I have related some histories of aneurism of the superior and inferior extremities, among which there is the very rare case of an aneurism that had appeared on the spine of the tibia, a little below the knee. The account of the greater part of these cases is intended not only to increase the number of the facts proving the utility of the Hunterian method for the radical cure of aneurism, but likewise to illustrate several points of practice which I have explained in the course of this work, as well as to make known some peculiarities that have occurred to me in the treatment of this disease. Upon which subject I think it proper to state, for the benefit of those who are not as yet well informed in such discussions, that the well-founded confidence in the propriety and utility of the Hunterian method, in opposition to the opinion of Mr. Bromfield,\* has been at the

\* Chirurg. Observ. and Cases, vol. i, pag. 306. 'From observing,' says he, 'that, after the operation for aneurism in the bend of the arm, the collateral vessels have become dilated sufficiently to carry on the circulation, and preserve the life of the subjacent limb, the most extravagant propositions have been by some suggested, viz. that the tying of the principal trunks of the arteries of any of the extremities when wounded, may be done with a fair prospect of preserving the limb. I once,' he adds, 'saw an attempt of this kind made in a case of aneurism situated in the cavity of the ham, on which experiment I shall make no farther remark than that the patient died. And I dare believe, that the embarrassments which occurred, as well as the accidents in the operation, will deter the operator from making a second attempt, should a similar case offer for his assistance.'



present day carried so far, that Mr. Home, one of the most celebrated of Mr. Hunter's pupils, and one of the most zealous promoters of this method, did not hesitate to operate for an aneurism situated in both hams in the same patient, at the interval only of a fortnight between each operation ; which attempt was attended with the most complete success.\*

If Bromfield, in using these expressions, did not mean to speak of the common method of operating for the aneurism in the ham, but of the ligature of the superficial femoral artery, it is fortunate for mankind that his authority had not such weight as to dissuade Mr. Hunter, and after him other celebrated surgeons, from so important and useful an attempt, as that of the ligature of the principal artery of a limb, in a case of a wound or aneurism.

\* Transactions of a Society for the Improvement of Medical and Chirurgical Knowledge, vol. ii, page 235.



# CONTENTS.

	Page
CHAP. I. <i>Of the Femoral and Popliteal Arteries</i> .....	1
II. <i>Corollaries</i> .....	20
III. <i>Of the Arteries of the Scapula and Arm</i> .....	28
IV. <i>Corollaries</i> .....	45
V. <i>Of Aneurism in general: and in particular, of the Aneurism at the curvature, and in the trunk of the Thoracic and Abdominal Aorta</i> .....	54
Supplement to Chap. V, § 1, 35 .....	115
VI. <i>Of the Aneurism of the Popliteal and Femoral Arte- ries</i> .....	128
VII. <i>Of the Aneurism of the Brachial Artery</i> .....	174
VIII. <i>Of the Cure of Aneurism in general</i> .....	202
IX. <i>Of the Cure of the Popliteal Aneurism</i> .....	241
Supplement to Chap. IX, § 20.....	305
X. <i>Of the Cure of the Femoral Aneurism</i> .....	315
Supplement to Chap. X, § 20 .....	353
XI. <i>Of the Cure of the Brachial Aneurism</i> .....	354
Supplement to Chap. XI, § 18, 19 .....	411
XII. <i>Of the Aneurismal Varix</i> .....	420
Supplement to Chap. XII, § 16.....	438
CASE I. <i>Popliteal Aneurism</i> .....	443
II. <i>Popliteal Aneurism of long standing, and of extraordi- nary size</i> .....	447
III. <i>Aneurism situated in the lower part of the Ham, and in the upper part of the calf of the Leg</i> .....	451



## Contents.

	Page
CASE IV. <i>Popliteal Aneurism</i> .....	457
V. <i>Aneurism in the top of the Thigh</i> .....	460
VI. <i>Femoral Aneurism</i> .....	456
VII. <i>Aneurism in the bend of the Arm</i> .....	468
VIII. <i>Wound of the Humeral Artery</i> .....	471
IX. <i>Corrosion of the Humeral Artery, occasioned by gan-             grene in the bend of the Arm</i> .....	475
X. <i>Singular case of Aneurism situated on the spine of the             Tibia, in the vicinity of the Knee</i> .....	478
 Appendix .....	 485

---

### *Memoir on the Ligature of the principal Arteries of the Extremities.*

**MEMOIR**  
**ON THE**  
**LIGATURE OF THE PRINCIPAL ARTERIES**  
**OF THE EXTREMITIES.**







## PREFACE.

---

THE experiments of Dr. Jones on *Hemorrhage* and on the *Ligature of Arteries* excited my curiosity. I have repeated them carefully on animals; and I have instituted some new ones on them, that gave me results, which, applied to the practice of surgery, led me to draw conclusions totally opposite to those which had been deduced by that author.

He was of opinion, that to obtain the quick and firm closure of the tied artery, it is of great consequence to rupture, in tying the ligature, the internal and middle coats of the artery, leaving merely its external cellular sheath undivided. I have, on the contrary, observed, both in animals and in man, that the speedy and steady union and closure of the artery are obtained, by tying it so as to preserve uninjured all the three coats of the arterial tube; and that this union is accomplished with, at least, equal quickness and firmness, as when the two internal coats of the artery have been ruptured by the ligature.

Dubois, Assalini, and Crampton had had some presentiment of this fact, when they compressed, with their metallic instruments, the femoral artery in man, so far as to place the two opposite parietes of the artery in firm contact. But the proper degree of importance has not been attached to these facts; either because they seemed, perhaps, too few in number,



and not sufficiently supported by general and firm principles, or because these metallic instruments, to be introduced into and retained, for a certain time, in the bottom of the recent and exquisitely sensible wound, were, not without very just cause, considered as injurious to the artery and to the wound, in consequence of their weight pressing upon the subjacent parts, and being with difficulty kept in an accurate correspondence with the direction and depth of the wound.

Having now proved, by steady and incontrovertible facts contained in this Memoir, that the speedy union and complete closure of the artery can be obtained without previously rupturing its two internal coats; and that this is effected, at least, as quickly as when the two internal coats of the artery have been divided by the ligature, I could no longer hesitate upon the choice of the operative process for the ligature of the great arteries of the extremities. The step which remained to be taken for the improvement of surgery, consisted principally, and, perhaps, solely, in adapting the usual ligature in such a manner as not to occasion injury to any of the coats of the artery, and that it should not be the cause of unnecessary irritation to the wound, and, at the same time, that it should be calculated for retarding, as much as possible, the *ulcerative* process of the tied artery.

As experience, in like manner, had demonstrated, that, on the completion of the course of the *adhesive* inflammation in the tied artery, it is not at all necessary, nor of any advantage, to wait for the separation of the ligature, as is generally done; and that it is even practicable, or rather beneficial, to free the artery and the wound as quickly as possible from the presence of a foreign body, it becomes a subject of



the greatest importance to fix upon a mode of ligature, by means of which we may with facility, and without any risk of wounding the subjacent artery, remove the ligature as soon as the union and closure of the arterial tube have been completed. This takes place in tolerably healthy patients in a few days after the operation.

I flatter myself that I have fulfilled both of these indications; and, farther, by placing these facts and these points of practice in the clearest light, that I have contributed to the perfecting the Hunterian operation.

With regard to the appendix, it is proper to observe, that since the year 1804, the period of the publication of my Treatise on Aneurism, to the present day, the surgical science, as might be expected, has undergone many and valuable improvements on this important subject. In the *first* place, what I stated with regard to the success of the ligature of the femoral artery above the origin of the profunda, for the cure of inguinal aneurism, has been confirmed by many splendid examples, in addition to those I related, more especially, of the ligature of the femoral artery performed with success above the femoral arch, and, properly speaking, within the abdomen. In like manner, since that period, the axillary artery above the origin of the profunda humeralis, and even the subclavian itself, have been repeatedly tied with success for the cure of aneurism situated in the upper part of the cavity of the axilla. In the *second* place, the possibility, which I anticipated, of curing the carotid aneurism by means of the ligature of the principal trunk of this artery, has been confirmed by many important cases. *Finally*, The confidence of surgeons in the great resources of nature, for the preservation




of the circulation and of the life of the parts more remote from the heart than the ligature of the principal arteries of the extremities, and the reliance upon the beneficial operations of nature in co-operating with art in repairing great injuries done to the animal organization, have been carried even so far as to have risked, with success, the ligature of the internal iliac artery for the cure of a *spontaneous* aneurism of the gluteal artery.

Besides these remarkable facts, several anatomico-pathological observations have been published in support of what I have asserted with regard to the essence and immediate cause of aneurism, as also on the difference existing between this disease and the morbid *dilatation* of the artery. Concerning this pathological distinction, some writers, still adhering to the ancient doctrine, had expressed considerable doubts.

To place, therefore, my work on aneurism on an equality with our present knowledge in this department of surgical science, it was necessary that the substance of these facts, and some improvements which I have since made, should be added. These considerations at first excited the desire of giving a new edition of this work; but afterwards I was deterred from this, by the very great expense, and, still more, by the just and due reflection of not injuring those who had already purchased this expensive work. I, therefore, thought it more judicious to publish separately these additions, and, by means of references to the places of the work to which they apply, to attain the object which I had in view.\*

\* The author's object has been completely attained, by the publication of a new edition of the translation of his work, allowing these additions to be inserted in their proper place.






# MEMOIR\*

ON THE

## LIGATURE OF ARTERIES



THE success of the Hunterian operation for the cure of external aneurism, depends, in a great measure, on the simple and expeditious manner, as well as upon the care with which the principal artery of the affected limb is tied. But to be more precise.—It depends on the moderate laceration of the parts, and the least possible detachment of the artery from the cellular substance surrounding it; on no rupture taking place of its coats; on the proper degree of excitement, and of *adhesive* inflammation produced in the artery by the ligature encircling it. By means of this inflammation, and likewise by the intervention of the coagulable lymph effused within and without the inflamed arterial tube, it closes steadily, and in a short time, at the place where it has been tied.

This process of union between the two opposite internal parietes of the inflamed artery, kept in mutual contact, does not differ essentially from that of the re-union of a simple wound, nor materially from that where reciprocal and firm adhesion is formed between *similar* parts inflamed and closely applied to each other: whether this be effected merely by the inosculation of vessels, or by means of the organisable coagulable lymph, or by both of these modes of union conjoined. In each of these cases, in order



that the adhesion be complete and permanent, besides the concurrence of a proper degree of vitality and of energy in the disjoined parts, it is necessary that the mechanical means employed for their approximation be not too irritating, that the inflammation artificially excited may not exceed the limits of the *adhesive* stage.

Guided by these principles, surgeons have been for a long time engaged in the discovery of a mode of tying the principal arteries of the extremities, which should satisfy the indication, both in regard to the simplicity and quickness of the operation, and in regard to the speedy and permanent closure of the tied artery, in order that the same means should prevent *secondary hemorrhage*, one of the most dangerous accidents to which the Hunterian operation is exposed.

To attain this object, some applied round the artery several ligatures at a short distance from each other, with the view of increasing the number of the points of contact and of union in the artery, and tightening those ligatures gradually which were most distant from the heart, that the impulse of the blood should be insensibly retarded towards the point of complete constriction and closure of the tied artery. Others reposed the greatest confidence in the practice suggested by *Ætius*, or rather *Celsus*,\* the employment of two ligatures, with the division of the artery in the interspace. Others preferred to these methods

\* *De Medicina*, lib. v, cap. xxvi, § 21. Quæ (arteriæ) sanguinem fundunt apprehendendæ, circaque id quod ictum est duobus locis deligandæ, intercidendæque sunt, ut in se ipse coeant, et nihilominus ora reclusa habeant.

After these directions, there only remained a short step to be taken to the practice of tying arteries by means of the *tenaculum* and ligature after amputation. And nevertheless many ages elapsed before this happened.



one *circular* ligature only, formed of small twine in preference to tape, because the former ruptures the internal and middle coats of the artery more quickly than the latter, leaving the external undivided; which rupture of the two internal coats, the supporters of this doctrine considered most proper for promoting and increasing the action of the *adhesive* inflammation, and, consequently, accelerating the union and closure of the arterial tube. Others, confirming the advantage of one ligature only in preference to a number, excluding even that called the *reserve* ligature, found the interposition of a cylinder of linen spread with plaster, between the knot and the artery, not less useful than necessary in order to prevent, rather than to favour, the rupture of the two internal coats of the artery; and the latter were of opinion, not without good reason, that the external cellular sheath of the artery alone, was not, in every case, or variety of circumstances, capable of resisting the impetus of the blood with equal force as when all the three coats of the artery were preserved uninjured. Some surgeons proposed to constrict the artery by means of metallic instruments, in the form of a *tourniquet* or *forceps*, to be introduced into and retained in the wound during all the time requisite for obtaining the adhesion and obliteration of the constricted artery. More recently, to obviate the inconvenience of the ligatures hanging out of the wound, it has been proposed\* to tie the artery in several places by means of fine silk threads; then to cut them off close to the knot, and to procure the re-union of the wound, trusting that no injury would accrue from the presence of these foreign

\* Lawrence, Med. Chirurg. Transactions, vol. vi.



bodies left in the bottom of the wound; because from being likewise animal substances, they are, as is alleged, in course of time more easily absorbed than any other extraneous substance, or they remain inclosed in sacs of coagulable lymph, and are, consequently, incapable of doing any injury.

In this contrariety of opinions and of practices so frequently changed, the suspicion arose that the theory on this subject did not in every point agree with the fact. On this account I thought it would reward my labour to repeat and vary the experiments which had been already made by others, on animals and on man; to compare the facts with the opinions, and on the fixed rule of the principles above established with regard to the means employed by nature for the reunion of simple wounds, and for the union of *similar* parts kept in firm contact with each other, to separate, in discussing this important subject, what was true and constant from that which is purely hypothetical or accidental, and thereby determine which of the many modes of ligature of the great arteries hitherto known deserves the exclusive preference, both as being the most simple operation and uniformly the most successful. The experiments which I undertook have farther had the effect of enabling me to elucidate another question not less important than the preceding; whether having the absolute certainty of the complete and firm closure of the artery which has been tied, it is necessary to wait, as is usually done, until the *ulcerative* process induced by the pressure of the ligature separates it from the artery, or if it be possible and advantageous to remove the ligature immediately after the *adhesive* inflammation has run its usual course, that is, three or four days after the ligature has been applied. Experience, as I shall de-



monstrate, has declared in favour of this second practice.

With regard to the first branch of the subject, if there can be no doubt that the preference to be given to one method of operating over several others directed to the same end, ought to be taken from the simplicity and its constant success, I do not hesitate to declare, from my own experience as well as the experience of others, that for obtaining the quick and permanent closure of the principal arteries of the extremities, the choice falls upon the single ligature with the interposition of the small cylinder of linen spread with ointment between the tape and the artery. This mode of ligature already recommended by the greatest masters of the art of surgery, Parey,\* Heister,† and Platner,‡ preserves all the coats of the artery entire; it is easily and quickly applied; and it is sufficient of itself alone, or by means of simple pressure, to produce quickly in the artery the proper degree of *adhesive* inflammation which is required for the speedy union and complete closure of the arterial tube. And considering the great number of cases of this kind which have terminated favourably, compared

\* Oeuvres, liv. xii, chap. xxxiii, p. 478. Puis tu lieras ton fil assez serré sur un petite compresse de linge en deux, ou en trois doubles de la grosseur d'un doigt, qui en gardera qui le noeud n'entre dans la chair, et l'arretera surement. Je te puis assurer, que jamais, après telle operation on ne voit sortir une gutte de sang des vaisseaux ainsi liés.

† Institut. Chirurg. Pars. II, Sect. I, cap. xviii. Atque arteriam in loco altiori, superinducto prius arteriæ linamento, vel tenuiori spleniolo quodam lineo, probe ligare.

‡ Institut. Chirurgiæ Ration. § 440. In the period subsequent to these authors, some, interpreting improperly their directions, interposed a small compress between the first and second knot of the ligature, when they ought to have placed it between the artery and the ligature.



with others in which a totally different mode of ligature had been employed, I do not hesitate again to assert, that the good effects of this practice will always correspond with our expectations, in every case where the ligature with the interposition of the small cylinder has not been applied upon a portion of artery disorganised, or deprived of its vitality, or in patients very much debilitated; such a misfortune would be inevitable whatever mode of ligature was employed.

In a combination of circumstances equally favourable to the success of the Hunterian operation, the same cannot be said with regard to a number of ligatures applied in succession along the artery, and tightened gradually as they are more distant from the heart. These multiplied ligatures, and these superfluous precautions for stopping the impulse of the circulation, cannot fail to be hurtful. For, besides the very considerable separation, which, in following this practice, it is necessary to make for laying bare, and insulating such a portion of artery as is required for the arranging three or four ligatures at a proper distance from each other, the stream of blood, although small, which flows under the first ligature, is sufficient to prevent the formation of the coagulated clot at that part, and defeats the action of the *adhesive* inflammation, by removing constantly the coagulable lymph, which is gradually effused within the artery, and prevents in the same manner the *vascular* union of the two opposite parietes of the artery. Farther, as soon as these first ligatures, only half tied, occasion the *ulcerative* process, and afterwards the corrosion of all the three coats of the artery; which happens much more quickly than surgeons generally suppose, especially under the pressure of the



*circular* ligature, as the artery is still kept pervious to the blood, *secondary* hemorrhage is the necessary consequence; to which misfortune the patient is left equally exposed by the ligature of *reserve*, although it be merely slightly tightened, or only applied around the arterial tube.

In circumstances similar to the preceding, with regard to the healthy state of the parts on which the operation is performed, and the good constitution of the patient to be operated on, experience has demonstrated the inconstancy of the success of the two ligatures, with the division of the artery in the interspace. Numerous examples of the failure of this mode of operating are already generally known to the profession, and there are very many expert and ingenious surgeons, who do not dissemble the disadvantages and uncertainty of this practice. If, as some have asserted, *secondary* hemorrhage never or very rarely happened in consequence of this mode of ligature, it is not probable that Cline\* would have suggested, what Richter† had long ago proposed, a third ligature, passing one of the ends of the thread through the sides of the divided artery, in order to make a knot which should prevent the slipping off of the ligature.

Cooper, in his first operation for aneurism of the carotid, did not dare to divide the artery between the two ligatures, for fear, as he expresses it, that the

\* Med. and Chirurg. Journal, vol. viii, p. 5.

† Anfangsgründe der W. A. K. 1. Band. p. 226. If the artery is of a large size, one end of the ligature is to be drawn, by means of a needle, through the artery, anterior to the place where it is tied. The two ends are then to be tied together, and, as usual, allowed to hang out at the wound.



principal ligature, or that nearest to the heart, should be forced off by the impulse of the blood, as had occurred to him after the ligature of the femoral artery at the top of the thigh, performed in a similar manner. The same disagreeable and dangerous accident happened to Abernethy, which was ascribed to general morbid causes. Monteggia,\* where he speaks of the ligature of *reserve*, expresses himself in the following manner.—“ It succeeded completely in a case where the first ligature had escaped from the artery which I had divided in the middle between the two ligatures, a few hours after an operation performed on the humeral artery.” In like manner, the slipping of the principal of the two ligatures occurred to this skilful surgeon, “ eight days after an operation for popliteal aneurism.” And in another place he adds, “ I ought not to conceal, that, in a case operated on by another surgeon in this hospital, in tying the artery of the thigh for an aneurism in the ham, and then dividing it, I was told that hemorrhage supervened on the nineteenth day.” This accident is also mentioned by Assalini.† Professor Morigi, a learned and expert operator, having tried Celsus’ method upon the femoral artery, could not escape, a few days after, *secondary* hemorrhage; for which reason he returned to his usual mode of ligature with the interposition of the cylinder of linen, of the success of which he had had constant proofs. And I could increase very much the enumeration of the unfortunate results of the Celsian ligature in cases in which there was neither a diseased state of the artery, nor a weak and sickly constitution of the patient operated on, if the examples above quoted, and the celebrity

\* Instit. Chirurg. T. 11, Ed. Seconda, p. 92, 95, 97.

† Manuale di Chirurgia, Parte I, p. 97.



of the surgeons referred to, were not more than sufficient to prove the imperfection of this mode of ligature, which, not without good reason, has been at intervals employed and laid aside, since the time of Celsus and *Ætius* to that of *Abernethy*, *John Bell*, and *Maunoir*. I mention, at intervals, for at periods subsequent to the time of the Arabian physicians, many surgical writers have not even mentioned the division of the artery or vein between the two ligatures, and others confined this practice to the smaller arteries only, or veins punctured or wounded without being divided, and so deeply situated as to be tied only with the greatest difficulty and danger. The complete division of these smaller arterial or venous ramifications, every professional person knows, excites the contraction of their canal, and facilitates the application, to their mouths, of topical astringents, and the compressing apparatus; which is not adequate, in most cases, for curing the injury or simple puncture of the large arteries.

I do not propose to enter upon the investigation, whether the chief cause of subsequent hemorrhage after the division of the artery between the two ligatures, is to be referred to the slipping of the artery out of the noose, or because the ligature, although sunk deep between the ruptured internal coats of the artery, is forced off by the impulse of the circulation; or lastly, because the depression of the ligature, tightened only around the external cellular sheath of the artery, the only one remaining undivided, is the principal reason why the ulceration produces its destructive effects on the artery sooner than when all its three coats have been preserved entire. It appears to me, from an attentive consideration of the facts, that it may be affirmed, without fear of error,



that the severe accident of *secondary* hemorrhage will take place frequently, in following this practice, or whenever the artery has been divided too near to the two ligatures; and especially if close to that ligature which is nearest to the heart. This being consistent with reason and experience, the consequence which naturally follows from what I have premised is, that, at least, the two ligatures, with the division of the artery in the interspace, do not furnish the prudent surgeon with a mode of ligature in which he can confide, in those cases in which the smallness of the space, the depth at which the artery to be tied lies, and the importance of the parts, by which it is surrounded, do not permit it to be separated and insulated to such an extent as is required for dividing it with a probability of the division of it being sufficiently distant from the two ligatures. Such, for example, are the cases of ligature of the carotid in the vicinity of the sternum; of the iliac above Poupart's ligament, and, properly speaking, in the abdomen; of the *internal* iliac, a little below its origin from the *common* iliac; of the axillary artery between the point of the coracoid process, and the acromial portion of the clavicle; of the subclavian in its passage between the scaleni muscles; in which cases, and in all which situations, it is not possible, without great difficulty and danger, to lay bare and insulate the artery to be tied, but for a very small space, which would not be sufficient for allowing the artery to be divided between, and at a proper distance from both ligatures. These cases, therefore, are so many exceptions, at least, to be made to the practice of Celsus and Ætius.

Whenever the circumstances now detailed only allow a very small portion of the artery to be laid



bare and insulated, if, before the union and complete closure of the artery, the principal ligature is forced off, it becomes very difficult, and sometimes impossible, in so confined and deep a situation, to apply another ligature to the mouth of the divided artery. And if it be the inferior, or not the principal ligature, which relaxes before the closure, and if the artery is one of those which keep up a full and extensive communication with collateral branches, such as the carotid, the tibial, ulnar, or radial, in consequence of which there is a strong retrograde impetus of the blood, the re-application of the ligature is equally difficult as in the first case, and hemorrhage, therefore, for the most part, inevitable. This misfortune would not happen, although both of the ligatures were to become relaxed, immediately after they were applied, if the artery were not divided in the interspace, and it would leave the possibility of tightening them with success.

But supposing even, that in every case of aneurism, it were possible to lay bare and insulate such an extent of the artery as would allow the application of two ligatures at a proper distance from each other, it has not been hitherto demonstrated, in my opinion, wherein consists the advantage of this division of the artery, especially as considered to be an effectual means of preventing *secondary* hemorrhage. The supposing the arteries to resemble so many tense cords, capable of retracting with great force, when they have been divided, is an exaggerated idea; and the comparison which some authors draw between the effects of the division of a large artery after amputation of a limb, and the shortening of the same artery, after its division between the two ligatures for the cure of aneurism, is not accurate. For after



the amputation of a limb, the divided artery retires in consequence of its elasticity and tonic power, and at the same time by the simultaneous shortening of the divided muscles, as well as of the cellular substance to which the artery is conjoined. On the contrary, in the operation for the cure of aneurism, the divided artery retires only in consequence of its own elastic and tonic power, the muscles and interposed cellular substance remaining in their natural position. Dr. Jones, a careful observer of the physiological and pathological phenomena of arteries, did not find, no more than any other careful anatomist, any longitudinal fleshy fibres in the structure of arteries; and, if we except Morand, no accurate dissector conceived himself warranted by dissection to ascribe to arteries any other peculiar retractive force, than that just pointed out; a weak force indeed, to trust to, for the attainment of the great object of preventing *secondary* hemorrhage, by the contraction and shortening of a large arterial canal.

No surgeon can deny, that hemorrhage after amputation of a limb is much less frequent than after the single *circular* ligature of an artery, or after the application of two ligatures, with the division of the artery in the interspace, for the cure of aneurism. This difference of success does not depend upon the more or less retraction of the artery in the one case, than in the other, but on this, in my opinion, that after amputation the surgeon draws out the end of the divided artery, ties it at a proper distance from its mouth, without detaching it, or insulating it from the cellular substance which surrounds it, or dividing it from the very minute vessels from which it receives its nourishment and life. Let the same precautions and care be used in the case of the oper-



ation for aneurism, with regard to the connections of the artery, as are employed after amputation, and without being obliged to divide it, the same results will be obtained, and these more certainly and steadily, if we avoid rupturing with the ligature the internal and middle coats of the artery.\* The advantage which some surgeons expect from the retraction of the divided artery between the two ligatures, will be equally obtained from placing the operated limb merely in a proper relaxed posture. Heister,† Callisen,‡ and Richter§ were well acquainted with this fact, and, therefore, did not hesitate to assert, *that the division of the artery between the two ligatures is, at the most, an indifferent operation.*

But I am of opinion, that this mode of ligature suggested by Celsus, cannot even be considered as

\* The failure of the ligature of the principal artery of a limb after amputation, takes place, for the most part in those cases, where, from internal or external causes, the stump is attacked with that species of mortification called Hospital Gangrene, which preventing or impeding the action of the *adhesive* inflammation of the tied artery, while the ulcerative process, promoted by the pressure of the circular ligature, opens the artery still in a state pervious to the blood.

† Institut. Chirurg. vol. i, page 425. Vincita, prouti diximus, arteria, proximo sub vinctura loco transversa concidi a quibusdam solet, quo scilicet, retractis, et clausis arteriæ vulneratæ oris, profusiones sanguinis periculosæ melius præcaveantur. Verum noxium, vel saltem supervacuum, hoc ipsum negotium esse judico, atque ipsemet hanc operationem bis institui, ut arteriam non præciderim, et feliciter nihilo minus agrotos curaverim.

‡ Principia System. Chirurg. vol. i, pag. 478. Arteriam inter vincula mediam discindere, ob extremorum retractionem, noxium et superfluum merito habetur.

§ Elem. di. Chirurg. vol. i, cap. xiii, p. 232. The dividing the artery, after it has been tied, is not only useless, but even injurious, because if hemorrhage were to occur, it would be very difficult to find it again, and tie it a second time.



a matter of indifference, on account of the above-mentioned obligation which it imposes on the surgeon to lay bare and detach a large portion of the artery from the contiguous parts. Dalrymple,\* in his account of the ligature of the *common* carotid artery for the cure of an aneurism situated in the orbit, wrote, that his two ligatures were applied at the distance of *an inch and a quarter* from each other, which distance he was enabled to adopt, because the aneurism was not situated in the neck. And it would be impossible to lay bare the artery to an equal extent, when the aneurismal tumor is situated at the upper part of the groin, or in the upper part of the axilla. But supposing even that it were possible in every case to lay bare a considerable portion of artery, and even more than *an inch and a quarter*, what would become of these two considerable insulated portions of artery included between the two ligatures? These portions of artery, as every one foresees, are very soon converted into a dead and putrid substance, which rests upon the bottom of the wound, from which it cannot be removed, until the two ligatures are separated. This dead substance necessarily irritates the wound, and much more than a pledgit of soft ointment, which it is wished to exclude even from the first dressing, as likely to oppose the union of the wound, under the erroneous supposition that this union could take place, in spite of the presence of the two ligatures hanging out of the wound, and of a sphacellated substance seated at the bottom of it. To this we may add those copious suppurations and sinuous ulcers, which are the necessary consequences of extensive and deep incisions and laceration of the cellular substance; these suppurations, if they do not

\* Medico-Chir. Transactions, vol. vi.



destroy the patient, exhaust his strength, and protract and render doubtful the event of the Hunterian operation.

The laying bare and insulating a large portion of artery, in order to avoid the danger of *secondary* hemorrhage, sometimes exposes the patient to another inconvenience, not less severe than the above mentioned, that is the absolute necessity, in some cases, of tying the principal ligature too near to the origin of a large *lateral* branch, as for example, in a case of inguinal aneurism, situated *an inch and a quarter* below the origin of the profunda femoral artery. In this, as well as in other similar and not unfrequent combinations of circumstances, if the surgeon were to propose to employ the two ligatures with the division of the artery in the interspace, he would be under the necessity, in order to preserve a proper distance between the two ligatures, to apply the upper ligature immediately below the origin of the profunda; in consequence of which a coagulum would neither be formed, nor could the union and closure of the artery be effected. On the contrary, by employing only a single ligature at *an inch and a quarter* below the origin of the profunda, he would obtain speedy and complete success by a simple and expeditious operation.

To all these arguments in opposition to the doctrine of Celsus and Ætius, may be added, that the English school, in which the practice of employing two ligatures, with the division of the artery in the interspace, has been more than any where else in vogue, has now laid it aside, and substituted one or the single ligature in its place. This appears from what is stated in Hodgson's\* work, a modern writer on this subject, who expresses himself in the follow-

\* A Treatise on the Diseases of Arteries and Veins, p. 222.



ing terms.—“ Experience has amply proved the safety of employing a single ligature ; and it is at present used by many of the most experienced practitioners in this country.” This change of opinion and of practice, the fruit, undoubtedly, of the experience of distinguished men, and of careful and impartial observers, while it fully confirms my assumption, still shows how great was the prudence of the above celebrated masters of the art, who had directed the attention to the imperfection of this mode of tying the large arteries of the extremities, which reason and experience now condemn to perpetual oblivion.

In conformity to the principles above laid down, with regard to the means which nature employs for the union of simple wounds, and for the adhesion of *similar* parts when inflamed, and kept in firm contact with each other, there can certainly be no doubt with respect to the preference to be given to the single ligature, compared with a greater number. And there can be no grounds for disputing, that the single *circular* ligature is sufficient to procure the speedy and steady closure of the arterial tube, whenever there is the concurrence of all the circumstances capable of inducing in the tied artery the proper degree of *adhesive* inflammation above and below the place where the ligature has been applied.

But, to be candid, this happy combination, capable of producing the quick and precise degree of *adhesive* inflammation, which, immediately after the artery is tied, effects the *vascular* adhesion of its opposite internal parietes, and the formation of the lymphatic coagulum, does not invariably take place. It happens sometimes, at least in man, that, either from general debility, or a partial relaxation of the artery, the pressure made by the *circular* ligature produces



the ulcerative process more quickly in the artery than the *adhesive* inflammation. The circular ligature in fact ulcerates the artery in general about the third day after the operation; the *adhesive* inflammation does not always complete its course in this period of time. The same delay of the union between the two opposite internal parietes of the artery may happen from causes quite different from these just mentioned; viz. from the excess of stimulus applied to the artery, and from too great a degree of inflammation produced in it. On these accounts, the single circular ligature of the artery, without any modification or precaution to prevent these accidents, and more especially *secondary* hemorrhage, cannot be considered as the best means which surgery possesses for obtaining the closure of the artery, with the greatest possible certainty.

No one versed in the history of modern surgery can be ignorant, that after the first unsuccessful attempts made by Mr. Hunter, with the application of several ligatures, he himself, and afterwards the greater part of the most celebrated surgeons, only employed one *circular* ligature, to which was added, as it was called, the *ligature of reserve*. Notwithstanding, the misfortune of *secondary* hemorrhage was not unfrequent on the seventh or eleventh day after the operation. Many complained of it, and I among the number; on which account, I adopted the method, which has since always been successful, of interposing between the artery and the knot a small cylinder of linen spread with ointment, as a means capable of preventing, or, at least, of greatly retarding the melancholy effects of the *ulcerative* process produced by the *circular* ligature. Is it probable that the single *circular* ligature, which was then used



with doubtful success, although by the greatest surgeons, should have now become, as is pretended, the most certain method, in every variety of cases, of preventing *secondary* hemorrhage? It is now wished to ascribe these failures of Mr. Hunter and of many other operators, not to the circular ligature, but to the improper treatment of the wound in general, and in particular to the introduction into it of lint, and more especially to the irritation occasioned by the ligature of *reserve*. But, besides its being proved that Mr. Hunter, after his first trials, simplified his mode of local treatment, that all skilful surgeons confined themselves even from the first dressing, to the covering of the lips of the wound with a pledgit of soft ointment; and, finally, that the greater number of them omitted the use of the *reserve* ligature; yet if we ingenuously confess the truth, even after these reforms, the misfortune of *secondary* hemorrhage has not been rendered less frequent after the single, simply *circular* ligature of the artery. Farther, if the *circular* ligature were so certain a method as is pretended, why was it, not long ago, laid aside, and that of the two ligatures with the division of the artery in the interspace, substituted instead of it? Why search for a better, when we were already in possession of the best?

The unlimited confidence, which is now reposed in the single *circular* ligature, is rested, as it appears, upon the results of the experiments performed on this subject by Dr. Jones.\* This careful observer has confirmed what had been pointed out by Desault, with regard to the first effects of the circular ligature on the coats of the artery; viz. the immediate rupture of its internal and middle coats, leaving

\* On Hemorrhage, &c



the external undivided. And it is in consequence of this fact, that the circular ligature, especially when small twine is used, as being the most proper for easily rupturing the two internal coats of the artery, is considered as the best qualified for producing the most speedy and firm closure and obliteration of the arterial tube. But from this very fact, the rupture of the two internal coats, with regard to which there can be no doubt, it is most evident, that, at the first instant after the operation, the whole impulse of the circulation is supported merely by the external cellular coat of the artery. Nature, adds this author, comes to the assistance of art. There is first formed within the cavity and on the orifice of the artery the clot of blood, which, during the first minutes after the operation, resists the impetus of the blood; then the *adhesive* inflammation ensues in all the three coats of the artery, in consequence of which a considerable quantity of coagulable lymph is effused without and within the artery, and also between the layers of these coats; then a portion of this lymph is employed in cementing together the edges of the divided internal coats, and in agglutinating firmly the coagulum to the internal parietes of the arterial canal; the other portion of coagulable lymph serves to thicken the coats of the artery, as well as to glue its external surface to the cellular substance, and to the muscles from which it had been detached. The rupture of the internal and middle coats of the artery occasioned by the ligature, according to this author, far from being a circumstance unfavourable to the speedy and firm union and complete closure of the artery, is rather, in his opinion, most favourable, in so far as the internal wound made in the artery, like a strong stimulus, accelerates over the



whole surface of the arterial tube, the occurrence of the *adhesive* inflammation, and actively promotes both without and within it a more copious secretion of coagulable lymph, than would occur without this previous internal wound. This coagulable and organisable lymph, in the last place, nature makes use of to convert the artery into a solid cylinder, above and below the place where the ligature is applied, at different distances from the principal point of union.

Without at all detracting from the well-merited praise of this distinguished author, I may be permitted to mention, that some of the inferences drawn by him, in consequence of his experiments on animals, do not coincide in every circumstance with other similar experiments which I have several times repeated; these results afterwards applied to the practice of surgery, produced, as shall appear, the most advantageous effects in the perfecting of our science.

In the *first* place, however great we may suppose the elastic and tonic power of the external cellular coat of the artery, it can never be so strong as to oppose to the impetus of the blood, a resistance equal to that which would be offered to the impetus of the circulation by all the three coats of the artery preserved entire. An evident proof of this is, that the circular ligature, especially that formed of twine, always quits the artery much sooner than that with which the artery has been tied, so as not to cause any injury to its external or internal coats. It is also a fact well known to anatomists, that several individuals have, from birth, the arterial system formed of very fine coats. And it is equally well known to them, that the injection not unfrequently fails in



consequence of this congenital thinness of the layers forming the artery, which are lacerated by the impulse of the matter injected, however moderate. How much more readily will this happen in the living subject with this conformation, in which, to the tenuity of the coats of the artery is added the rupture by the ligature of its two internal and principal coats. Being unable, therefore, to foresee, in the living body, what is the degree of density of the arteries, it is better, without doubt, all other circumstances being equal, to tie the artery so that all the three coats are preserved free from injury. It is well known that the corrosion of the inner coat from internal causes, if the adhesive inflammation does not intervene in due time, is soon followed by the infiltration of blood through the layers of the middle coat, and its effusion externally, at first as an ecchymosis, afterwards as an aneurismal tumor. And if this takes place on the inner coat only being corroded, it will more readily happen in cases of delayed adhesive inflammation, the middle coat being also destroyed. It is true, that even in this second case, if, immediately after the rupture of the two internal coats, the artery is affected by the proper degree of *adhesive* inflammation, which fortunately happens in most cases, (otherwise, if it was not the case, there would be very few cases of success of the *circular* ligature), the union and closure quickly take place, and with an equally favourable event as when the two internal coats of the artery have remained undivided. But this is not invariably the case, at least in man, for the reasons above pointed out, and the *adhesive* inflammation does not always commence, as in animals, so quickly as to produce its beneficial effects on the coats of the artery immediately after



the ligature is tied. And in the meantime, during this delay of the *adhesive* inflammation, the ulcerative process occasioned by the pressure of the ligature attacks, more quickly even than surgeons generally suppose, the external cellular sheath of the artery, sinks into it, and penetrates to the cavity of the artery, still pervious, and more speedily, unquestionably, than if it had to pass through all the three coats of which the artery is composed. Whether the slow progress of the *adhesive* inflammation arises from general debility of the patient, or partial relaxation of the artery, it has not the same influence in retarding the progress of the ulceration, which continually goes on until it produces the most fatal effects. Farther, in debilitated individuals, although the approach of the *adhesive* inflammation has not been greatly retarded, it sometimes happens that the coagulable lymph effused into the cavity of the artery, and the clot, do not acquire the due degree of consistence and tenacity as speedily as in robust patients, which is requisite for agglutinating firmly together the opposite internal parietes of the artery kept in mutual contact. Both of these dangers, without doubt, are avoided, or are removed to a distance, by the preserving undivided all the three coats of the tied artery under the pressure of the ligature. In an equality of circumstances conducing to the success of the Hunterian operation, it is not, in my opinion, a fact demonstrated, as it is presumed to be, that the rupture of the internal and middle coats of the artery contributes more effectually to excite the *adhesive* inflammation and union of the artery, than the simple compression and close contact of its two opposite internal parietes, sound and uninjured. And if, in cases of so great importance



as the present, it were allowable to conjecture, we would rather say, that the rupture of the two internal coats would be more likely to produce in the cavity of the artery, the *ulcerative* than the *adhesive* inflammation, considering that the solution of continuity caused by the ligature has a greater affinity to a lacerated and contused wound than to a simple incised wound. The ligature, after rupturing the two principal internal coats composing the artery, does not then place the ruptured edges in mutual contact; for the ligature, sinking into the rupture, rather separates them from each other, and only constricts the two opposite puckered parietes of the external cellular sheath of the artery.

Farther, that, in a similarity of circumstances for obtaining the speedy union and complete closure of the tied artery, the *adhesive* inflammation is excited by the simple compression only, with equal quickness and activity, as when the two internal parietes of the artery have been recently ruptured by the ligature, is a fact equally certain, being confirmed by repeated experiments both on animals and in the human body.

Similar parts in general, and in a particular manner the membranes called *serous*, to which class is referred the internal coat of an artery, when compressed and kept in close contact with each other, in individuals sufficiently healthy, are in a remarkable manner prone to the *adhesive* inflammation, at the place and around the place of the compression, and show a singular tendency to effuse coagulable lymph, when inflamed, without these phenomena being preceded by abrasion or rupture of these membranes. We observe this happen daily between the lungs and the pleura, between the peritoneum and the viscera of the abdomen, and between the vaginal coat and the tes-



ticle. And to prove that the same phenomenon also takes place between the two opposite internal parietes of an artery merely kept in close contact with each other, without previous abrasion or rupture, there is no occasion to recur to analogy of what happens under the same circumstances in other similar parts of the body, as there are numerous examples of the speedy union and perfect closure of arteries by means of the *adhesive* inflammation, in consequence of simple compression only exercised on them, while all their parts are preserved entire. Dubois\* obtained this quick adhesion by means of the *serre noeud* of Dessault. Assalini,† by compressing the artery with his forceps; and Crampton‡ met with the same success, employing a compressing instrument similar to the *presse artère* of Deschamps. To these may be added the very numerous cases of obliteration of arteries in consequence of pressure exercised on them by contiguous tumors, or by an aneurismal sac particularly situated, and adhering to the artery above the point of the laceration of its canal, which laceration is the immediate cause of the aneurismal tumor. Before surgeons gave the preference to the ligature over compression for the cure of external aneurism, it cannot be questioned, that by means of compression applied to the artery above the place of the injury of it, speedy and complete cures of this disease have been obtained; and if the compressive apparatus does not always produce the same good effects, it may be ascribed to the being unable to apply it so as to cause a sufficiently steady pressure on the artery to be obliterated. In fact, compression in general succeeds per-

\* Leveillé, Nouvelle Doctrine, t. iv, p. 247, 260.

† Manuale di Chirurgia, loc. cit.

‡ Med. Chirurg. Transactions, vol. vii.



fectly when it can be applied to a denuded artery, behind which, there is a point of resistance. Samuel Formy,\* in a case of a wound of the large artery of the arm, laid it bare, and having placed a cylinder of linen on it, and over that graduated compresses retained by a proper bandage, arrested the hemorrhage and effected the closure of the artery. Guattani† laid bare the femoral artery as it passes under Poupart's ligament, compressed it against the ramus of the pubes by graduated compresses retained firm by a roller, and obtained the speedy obliteration of it. Flajani, in similar cases, has employed compression with equally good success. Buzani,‡ a surgeon of Turin, having laid open an aneurism at the bend of the arm, and laid bare the artery which had been wounded in bleeding, placed on it some pieces of touchwood one over the other, and above these some graduated folds of linen to the level of the integuments, secured with a circular roller; and the patient in a short time was perfectly cured. Garneri§ witnessing this fact, performed the same operation on a lady in whom the artery of the arm had been wounded in blood-letting; and five days after the application of the compression to the denuded artery, he found it obliterated. This skilful surgeon adds, that he had employed compression on the denuded artery in another lady for the same accident, and with similar equally prompt success.

There are strong arguments for supposing that there is no occasion for very strong stimuli for excit-

\* *Traité Chirurg. des bandes larges, emplâtres, compresses.* Montpellier, 1652.

† *De Aneurismate Historia*, xv.

‡ *Opere di Bertrandi, Trattato delle Operaz. t. iii, p. 287: the Editors.*

§ *Bertrandi loco cit.*



ing inflammation in arteries ; and that in some subjects, probably the very irritable, the arterial system has too great a tendency to undergo violent inflammation under the application of even moderate stimuli. And, in general, the aptitude of an artery to inflame, ought not, it would appear, to be less than that possessed by the muscular and cellular parts, considering that arteries are composed of the same substances, endowed with a considerable degree of vitality ; and farther, that they are furnished with numerous very minute vessels of every sort.\* Hodgson, after amputation of the thigh, found in the dead body of the patient, that the inflammation of the internal coat of the femoral artery had extended from the place of the ligature to the heart. I have observed the same fact in two cases, in the same circumstances as the preceding. Cline and Abernethy have met with this phenomenon after the ligature of the femoral artery for the cure of aneurism ; and the celebrated Professor Morigi observed the same melancholy accident in a patient who had been operated on for popliteal aneurism. Hoehme found the hypogastric arteries inflamed in an infant, in consequence of the ligature of the umbilical arteries. The veins are, undoubtedly, more prone than the arteries to violent inflammation ; for, on tying the safena in the vicinity of the knee, we see in most cases inflammation excited in the vein so violent, as to extend in a short time along the venous system to the heart, and producing symptoms not unlike those of typhus fever. The inflammation in arteries from the stimulus of a ligature, or of compression, fortunately very rarely proceeds so far, and, in general, is confined to the distance of an inch, or a little more above and below

\* Ruisch. Thes. Anat. iv, tab. iii. Epist. Anat. iii.



the ligature. On this point, it is ascertained from repeated experiments on animals, that two hours after the application of the ligature, (without the tape\* having produced any injury of the internal coats of the artery), there appears, on the internal membrane of the arterial canal opposite to the point compressed, a *reddish line* which denotes the beginning of the consecutive *adhesive* inflammation. Twenty-four hours afterwards, this *reddish line* is found spread over the whole circumference of the internal surface of the artery, to the extent of an inch above and below the ligature, but on the part nearest to the heart the redness is more intense, interspersed with numerous very minute blood-vessels, some of them even visible to the naked eye. Through the whole tract occupied by the inflammation, the internal coat of the artery loses its natural shining appearance, and its peculiar smoothness; it becomes thicker than natural, and resembles a villous red membrane, more similar, in some respects, to the inflamed internal membrane of the palpebræ, than to the internal polished and tense coat of an artery.

The important point of this discussion will, therefore, be reduced to the placing beyond any doubt, whether, in circumstances equally favourable to the success of the Hunterian operation, all its three coats being preserved entire, the artery will inflame and unite with the same quickness, at least, as when its two internal coats have been ruptured by the ligature. To this very important object were directed the following experiments.—

\* The author employs the word *tape* (nastrino) to signify a ligature composed of from four to six waxed threads, according to the size of the artery to be tied.—T.



## EXPERIMENT I.

IN two sheep of the same age and strength, I tied the left carotid artery; with this difference, that in one of these animals I interposed between the artery and the tape a proper cylinder of linen spread with plaster; and in the other I tied the artery *circularly* by means of a small cord or twine. Both were killed on the completion of the fourth day after the operation. In the former the left carotid, for the space of an inch and a half externally around the place where the ligature was applied, was observed to be covered with glutinous lymph, which united it to the circumjacent parts. The ligature was easily separated from it by cutting down upon it on the cylinder, which protected the subjacent artery from injury. Immediately under the cylinder, the external cellular coat of the artery, instead of being livid and contused, was not only in a healthy state, but even thicker and more fleshy than natural. Having laid open the carotid lengthwise, there presented, above and below the ligature, a bloody clot of a conical figure, having its base in the vicinity of the constriction formed by the ligature. The internal coat was uniformly inflamed for the space of an inch and a little more, above and below the ligature, but more intensely on the side nearest the heart. There was no mark of rupture of the internal coat. The principal clot, or that with its apex turned towards the heart, was thicker and longer than the other, and its base was firmly united to the internal parietes of the artery by means of a glutinous substance. This union appeared evidently to be formed by *organisable coagulable* lymph effused into the cavity of the in-



flamed artery. At the precise point where the ligature was applied, where the two opposite internal parietes of the artery had been kept in firm contact, they had formed a mutual adhesion by *vascular inosculation*.

In the other sheep, in which the left carotid had been tied *circularly* with twine, the artery was found covered externally with coagulable lymph, as in the preceding. The ligature was with great difficulty removed, on account of its being sunk and almost entirely concealed between the two ruptured internal coats. On laying open the artery lengthwise, it was found inflamed above and below the ligature to an equal distance as in the preceding, and more particularly on the end next the heart. There was an evident rupture of the two internal coats, and the union had taken place only between the two opposite parietes of the external cellular sheath of the artery constricted by the ligature. Between the ruptured and indented edges of the internal coats, and the centre of the arterial tube, was observed, as it were, a curtain or veil of a glutinous substance, reddish and transparent, formed by *organisable coagulable* lymph. Of the two bloody polypous clots, that nearest to the heart was the thickest and the longest, and adhered the most firmly by its base to the internal parietes of the artery by means of the intervening coagulable lymph. The external cellular covering of the artery was evidently attacked by ulceration, and, in some points, had become very thin, so that very little force would have torn it, although only four days had elapsed since the time the ligature was applied; this had not taken place in the other sheep in which the cylinder had been used.



## EXPERIMENT II.

IN two other sheep, the left carotid was tied, with the interposition in both of the cylinder of linen spread with plaster, between the artery and the tape. At the end of the fourth day the ligature was removed in one of these animals, and the wound united by two sutures; in the other the ligature was allowed to remain in its place. Both were killed on the ninth day after the operation. In the former the carotid was found completely closed, and impervious to the blood, both in consequence of *vascular inosculation*, and by means of effused glutinous substance. The principal polypous clot, on the ninth day, was very large, and firmly united at its base to the internal parietes of the artery, and by the points of *vascular* union of these coats. The uninjured internal coat of a pale red colour, was thicker than natural. The coagulable lymph effused externally to the artery, had united it so firmly to the cellular substance and muscles of the neck, that it would have been impossible to have separated it from them without laceration.

In the other sheep, in which the ligature with the interposed cylinder had remained in its place till the ninth day, the same series of phenomena were met with as in the preceding, except that on the ninth day the tape, where it rested on the denuded posterior surface of the artery, had begun to produce the *ulcerative* process, which, however, had only attacked the external cellular sheath; but the danger of the artery being opened was still very remote, as the ulceration would have had to penetrate the middle and



internal coats, which had acquired a greater degree of consistence than usual.

### EXPERIMENT III.

THE same experiment was repeated on two other sheep. In the first, the ligature of the left carotid was removed at the beginning of the third day; in the other at the end of the fourth day, after the operation. Both were killed on the ninth day. On comparing these arteries with those of the preceding experiments, no remarkable difference was perceived with regard to the complete closure of the arterial tube, and with regard to the firm adhesion of the two polypous clots to the internal parietes of the artery, and the points of *vascular* union between them; so that the obstacle opposed to the passage of the blood appeared to have been as strong on the third, as on the completion of the fourth day, after the application of the ligature.

### EXPERIMENT IV.

HAVING performed the same experiment on a strong and healthy dog, the same results were obtained. The ligature was removed from the carotid on the fourth day, and the animal killed on the ninth. The only additional circumstance remarked was, that, besides the firm *vascular inosculation* between the two opposite internal parietes of the artery, the coagulable lymph effused within the artery was in proportionably greater quantities than in the sheep; and that in an equal time from the application of the ligature to the death of the animal, the coagulable lymph had



acquired a greater degree of solidity than in the other animals submitted to the same experiment. All the coats of the artery were unusually thickened, and externally presented the appearance of a ganglion at the place where they had been tied. Internally the canal of the artery was impervious for the space of an inch from the ligature towards the heart. It appears probable, from this fact, that the speedy closure of the artery, and the quickness with which the coagulable lymph becomes indurated and organised, is in direct proportion with the greater vitality and vigour of the animal on which the experiment is performed.

#### EXPERIMENT V.

THE same investigations were performed on a strong and lively cow; the right carotid was tied with the interposition of the cylinder of linen. The ligature was removed on the fourth day, and the wound immediately united with two stitches. The animal was killed on the fourteenth day after the removal of the ligature. There was found external to the artery, a great quantity of indurated coagulable lymph, which had converted the part of the neck surrounding the artery, into a mass of hard and irregular substance, through which the artery appeared to pass. The proper coats of the artery were there very much thickened. On laying open the artery lengthwise, it was found completely closed at the point of approximation between its two opposite internal parietes. The principal coagulum extended an inch and a half from the point of vascular union towards the heart, and had contracted



adhesions with the internal parietes of the artery, not only at its base, but through the whole space which it occupied within the cavity of the artery. This coagulum, as well as the similar one situated in the opposite direction to the ligature, was of a pale red colour, in consequence of the absorption of the red particles, and the remains of it consisted in a great measure of *organisable coagulable* lymph. The *vascular* union, and the strong adhesion of both of these coagula to the internal parietes of the artery, had evidently opposed an insuperable resistance to the course of the blood.

## EXPERIMENT VI.

A LIGATURE was applied to the carotid of a horse, and removed on the fourth day; the animal, after this, was kept alive for twenty-eight days. The carotid was found closely surrounded and inclosed in a compact substance of an oval shape, and about an inch in thickness. On opening the artery lengthwise, it was found to be filled at the place where it had been tied, by a thick pyramidal polypous coagulum, above and below the place of the ligature, of a yellowish colour, and firmly adhering to the internal parietes of the arterial tube, especially at its base, at the point of *vascular inosculation* between the internal coats. The adhesion at that place was so strong, that it was impossible to detach the polypous coagulum from the sides of the artery, which was nearly converted, for the space of about an inch and a half, into a completely solid cylinder, together with the fibrous substance with which it was filled. It is ascertained in fact, from other similar ex-



periments, in which the animals, after the ligature was removed, were kept alive for three or four months, that the two polypous coagula, the one below, and the other above the place of the ligature, first become pale, then contract in size, and the artery is at last converted into a perfectly solid ligament.

I have mentioned repeatedly, that in none of the animals on which the ligature of the artery was performed with the interposition of the cylinder of linen spread with plaster, was the smallest mark found of rupture of the internal and middle coats of the artery. In spite of this, in order to corroborate still more this important point of the subject under consideration, Signor Mislei, the able professor in the Imperial and Royal Veterinary School of Milan, was so obliging, at my request, to confirm the truth and steadiness of this fact, by a variety of other experiments.

About the middle of the neck of a pony, he tied the right carotid artery by means of a tape, with the interposition of an adequate cylinder of linen, so that the two opposite internal parietes of the artery were brought completely in contact with each other, as two equal planes placed one over the other: he then brought the lips of the wound together. Two hours afterwards he re-opened the wound, and having applied a second ligature in the vicinity of the first, on the side next the head, he divided the carotid in the middle between the two ligatures, in order to ascertain that the first ligature had been sufficient to stop the flow of the blood. Two or three drops were discharged from the part which was contained between the two ligatures. He then proceeded to the examination of the internal cavity of the artery, and only found in it a *red circular line*, corresponding to



the part externally occupied by the tape, without there being the smallest mark of rupture of the internal coat of the artery. In another horse he tied the right carotid, with the interposition of the cylinder of linen, and in the same animal he tied the left carotid with a ligature only. Two hours afterwards he examined the cavity of the right carotid, and only found the above-mentioned *reddish circular line*, without the smallest injury of the internal coat. On the contrary, the left carotid, which had been tied with the cord, was found internally divided, and as it were, *corroded like a row of indentations*, in consequence of which, the subjacent muscular coat of the artery could be seen more coloured than natural, between the two edges of the laceration. The same results were obtained from experiments made upon another horse, twenty-four hours after the ligature; and in the whole, in this first period after the ligature, although the internal membrane had not been ruptured, the inflammation of the artery was found sufficiently great, and extending to an inch and more above and below the ligature, but more intense on the side nearest to the heart.

It results from these facts, in the *first* place, That surgery possesses a mode of tying the large arteries with facility and simplicity, by means of which the flow of blood through them may be completely interrupted, without rupturing any of the coats with the ligature. In the *second* place, That the two opposite internal parietes of the artery, kept in close contact with each other, are affected by the *adhesive* inflammation with equal quickness and activity, as when they have been previously ruptured by the *circular* ligature, by means of a cord.

Dr. Jones was of opinion, that if several circular



ligatures with twine were applied to a large artery, contiguous to each other, which is as much as to say, if as many ruptures were made, in succession, and the ligatures immediately removed, and the artery left to itself, the *coagulable* lymph, which is effused in great quantity into its cavity from the inflamed edges of the ruptures, would be sufficient, without any other assistance of art, to produce the obliteration of the arterial tube. But this doctrine has been contradicted, and found to be false by other similar experiments, performed with this view by his countrymen;\* and it is now proved, that, for obtaining with certainty the union and complete closure of the artery, it is necessary, not only that its internal membrane inflame, and pour out a sufficient quantity of coagulable lymph into its cavity, but that the two opposite internal parietes of the artery, during the course of the *adhesive* inflammation, be kept in mutual and firm contact with each other.

Professor Mislei had the laudable curiosity to try whether, if the artery were tied with the interposition of the cylinder of linen, in animals advanced in life, infirm and unhealthy, the union and obliteration of the arterial tube would still be obtained. He devoted to these investigations two horses and a mule, almost exhausted of strength from old age, and chronic diseases. In the first he removed the ligature from the carotid after thirty-one hours, in the second, after fifty, and in the third, after forty-four hours. In all the three he found the flow of blood interrupted in the artery which had been tied. In the second, the adhesion of the two polypous coagula at their basis to the internal parietes of the artery

\* Hodgson, loc. cit. pag. 228.



was already so strong, that it appeared to form a part of the artery, from which it could not be detached without the assistance of the knife. In the mule, killed seventeen days after the ligature had been removed, he not only found the artery impervious to blood, but almost entirely converted into ligament. He had nearly equal success, in another old horse, and in a hard-worked pony, from which, after forty-two hours, he had removed the ligature of the carotid. These facts confirm still more how prone the arteries are to re-act and to inflame, even under the moderate stimulus of pressure, and of approximation of their opposite internal parietes, without there being any necessity for stronger excitement, and still less of that very powerful one, the rupture of their two internal coats.

Since it is, therefore, proved, that the rupture of the internal and middle coats of the artery is not at all either necessary or useful, nor renders the union and obliteration of the artery more speedy and firmer than when all the three coats of the artery have been preserved perfectly entire; and that constricting the two opposite internal parietes of the artery merely to touch each other, without rupture, as one would do between the point of two fingers, the stimulus of the simple pressure is sufficient to excite quickly in them the proper degree of *adhesive* inflammation, and the sufficiently copious secretion of *organisable coagulable lymph* within and without the tied artery, by which is effected the *vascular* union, and the *organisable* glutinous cohesion. There can be, therefore, no room for hesitation with regard to the preference to be given to that mode of ligature, which re-unites in itself the triple advantage of preserving entire all the three coats of



the artery ; of exciting quickly, and in a proper degree, the *adhesive* inflammation in them ; and of retarding as much as possible, the ulcerative process of the arterial tube.

This triple advantage is obtained by employing the small tape composed of waxed threads, in place of a cord, and interposing between it and the artery the cylinder of linen spread with plaster, under the following conditions.—1. Only to insulate and detach the artery to be tied to the small extent, for allowing a ligature to be passed around it. 2. That the cylinder of linen do not exceed in length a line, or a little more above and below the breadth of the tape, which is about a line for the large arteries of the extremities. 3. That the constriction of the ligature be not too great, but nevertheless sufficient to bring into close contact the two opposite internal healthy parietes of the artery. 4. That the ligature be never applied immediately below the origin of a large *lateral* branch.

It has been alleged, that the small cylinder occasions great irritation in the wound, and the death of the portion of artery upon which it presses. This objection applies, in my opinion, to the practice of those who interposed, between the artery and the knot, a piece of cork or wood ; but it can never apply to a cylinder of linen covered with plaster, which, placed between the tape and the artery, rather acts as a cushion than as a body likely to bruise. It has been already remarked in the above-mentioned experiments, that on the fourth, and even on the fifth day after the operation, the cylinder of linen, far from having induced contusion or death of the artery, had even contributed to cause a thickening of its external cellular sheath, greater than natural.



The size of the cylinder, as it only exceeds a very little the breadth or thickness of the artery, very slightly increases the circumference of the arterial tube, without pressing at all on the bottom of the wound, or forcibly separating its sides. This mode of ligature, in short, confers on the surgeon the inestimable advantage of being able, if required, to remove the ligature quickly and easily, by cutting it upon the cylinder of linen, without the risk of wounding the subjacent artery. This cannot be done without great difficulty and danger, when the artery has been constricted circularly by the cord, and when it is sunk deep, and, as it were, entirely hid between the two ruptured internal coats of the tied artery: I say, with danger, should the artery have unfortunately remained pervious to the blood, after the third day.

None of the metallic instruments hitherto proposed for placing and keeping the two opposite internal parietes of the artery in close contact, give the same advantages which are derived from the cylinder of linen, whether we consider the simplicity of this mode, or the preservation, by means of it, of the artery and adjacent parts, from all those inconveniences, which are inseparable to the presence of hard bodies introduced and kept for several days in the bottom of a wound, especially when recent, where they can be with difficulty retained in a proper direction, and at that depth, so as not to exercise a hurtful pressure upon the wound and important parts in its vicinity. And with regard to the forceps of Assalini, \* Monteggia observed: *If the obliteration of*

\* *Instituzioni de Chirurg.* ediz. second. loc. cit. Cumano, although he obtained, on the fourth day, the closure of the femoral



*the artery is retarded, the forceps equally divides the artery by causing the death of the included portion. I also saw, in one case, the extremity of the instrument resting at the bottom of the wound on the subjacent femoral vein, rupture its anterior half also, although we were sure that it had not been included by it.*

To the advantages of this method of tying the arteries, may be added, the very important one of retarding the *ulcerative* process in the artery. For it is proved by experiment, that the circular ligature with the cord affects the artery the third day after the operation, while it is not till the fifth or sixth day, interposing the cylinder of linen, that marks are found of ulceration on the posterior surface of the artery, where the tape pressed on it denuded.

Another of the principal and useful consequences, which is immediately derived from the above-mentioned experiments, relative to the quick and firm union of the artery preserved from the injury of its internal coats, is the furnishing us with the solution of the second question proposed at the beginning of this Memoir: if it is a necessary and useful practice, in order to obtain with certainty the permanent obliteration of the artery, to wait, as is usually done, for

al artery for the cure of a popliteal aneurism, by means of these forceps, did not conceal that the cure of the wound was rather difficult, and that singular phenomena occurred especially on the first days. And comparing the ligature with the forceps, he adds, that if an equal result is derived from the one and the other means, I am of opinion, that the preference will be given to the ligature rather than to any other instrument, unless the latter is brought to perfection, in such a way as not to have to fear the inconveniences, from which I have not found it exempt, in spite of the success of my operation. *Annali di Med. del Dottore Omodei. N. IX. Settembre 1817, pag. 309.*



the spontaneous separation of the ligature: or, in other words, if it is of advantage, that the *ulcerative* process of the artery succeed the *adhesive*, and complete the operation by corroding the artery at the precise point of its *vascular* union, until the ligature is detached by it.

On this point I begin by observing, that the obstacle which, on the third or fourth day after the operation, is opposed to the current of the blood through the tied artery, does not consist in the *vascular inosculation* only of its two opposite internal parietes, but in it together with the hinderance presented to the impetus of the circulation by the two polypous coagula adhering firmly to the internal parietes of the artery, and more strongly, in particular, at the base or point of their *vascular* union. For the polypous coagulum, above and below the seat of the ligature, fills exactly, and like a firm plug, closes up the canal of the artery, so that it would, perhaps, be alone sufficient to oppose a powerful resistance to the impulse of the blood. As soon as the coagulable lymph, by means of which both coagula have become firmly adherent to the internal parietes of the arterial tube, has acquired all the tenacity and consistence of which it is susceptible, which, in sufficiently healthy individuals, never fails to take place within the space of three or four days after the operation, the blood no longer passes either directly, or by regurgitation, although the *vascular inosculation* be still too feeble to resist of itself alone, the impetus of the circulation. Beyond the fourth day, after the application of the ligature, by a fortunate combination of circumstances, in proportion as the two coagula, and the principal one which has its apex turned towards the heart, diminish in size in consequence



of the absorption of the red particles, the remaining substance becomes more indurated, and gradually as the canal of the artery contracts, it becomes organised, and is assimilated, to use the expression, with the artery itself, which is at that part at last converted into a solid ligament.

If, therefore, on the third or fourth day after the operation, the *vascular* adhesion between the opposite internal parietes of the artery, and the obliteration by means of the two coagula, are so firm as to resist the impulse of the blood, there is no rational motive for waiting, beyond this time, for the spontaneous separation of the ligature, or for allowing it, by the delay, to *ulcerate*, and even open the artery at the principal point of its adhesion, and resistance to the impulse of the blood. Therefore, it is proper and of advantage to remove the ligature on the third or fourth day after the operation, and this may be done not merely with impunity, but with advantage, for many reasons, especially that of perfecting the Hunterian operation.

In this point of view only, every professional man will foresee the great importance of this practice for promoting the success of the Hunterian operation. For, removing the ligature on the third or fourth day, we succeed in preventing *secondary* hemorrhage even in the case, where, in consequence of the slow approach of the *adhesive* inflammation, the *ulcerative* process threatened to open the artery still pervious to the blood. Besides, we obtain another no less important benefit, that of being able, on the renewal of the first dressings, after the discharge of the matter of the first unavoidable suppuration, to place the edges of the wound in mutual contact, and effect the cure of it by the *first intention*. Farther, the ex-



ternal surface of the artery no longer occupied by the ligature, is disposed, by means of the coagulable lymph effused externally, to resume quickly its continuity with the cellular substance, and the muscles, from which it had a few days before been separated; all which parts compressed together with the artery into a dense, compact mass, contribute very much to strengthen the points of union, and of obliteration of the arterial tube. The early removal, from the bottom and sides of the wound, of every foreign body, has the advantage of avoiding the copious and long-continued suppurations, and of escaping those inconveniences which arise from the tedious separation of the ligature, more particularly the concealment of the ligature itself among the muscles; as it sometimes happens, that the ligature, although loosened, allows the exuberant surrounding parts to cover it, and conceal it so deeply, that in consequence of that, after a long period of time, it is necessary to dilate the wound to its bottom, by means of prepared sponge, in order to be able to see and divide with safety the loop of the ligature. If even, following the practice above mentioned, recommended by Lawrence, it were proved that the *fine threads of silk*, he proposes, from being animal substances, were, in process of time, absorbed, or remained inclosed in capsules of organisable coagulable lymph, and, therefore, were not injurious, this mode of ligature would always be inferior to that where, very soon after the operation, we are permitted to free the wound from every foreign body. Farther, these numerous threads of silk tied on the artery, and left in the bottom of the united wound, must promote the *ulcerative* process of the artery before quitting it, which, in my opinion, ought always to be avoided.



Whether one of the principal arteries of the extremities is tied on account of a wound, or for the performance of the Hunterian operation, the period for removing the ligature on the third or fourth day is the more convenient, from coinciding with the renewal, in general, of the first dressings, and on account of the incipient suppuration having relaxed the wound, and rendered it less sensible. To this general rule, however, there is one exception, viz. the case of great and evident debility of the patient from sickly constitution, or very advanced age. It is observed, that in such patients the re-union of a simple wound is very frequently protracted to the sixth day. In other cases, in which the *vascular* union takes place more speedily, we not unfrequently find that, from the want of the quick consolidation of the coagulable lymph, the adhesion of the lips of the wound is still so weak, that its edges could be very easily separated. Consequently, in weak patients, it is frequently proper to keep the simple wound in a state of apposition for some days longer than the fourth day. It is probable, that the same delay sometimes occurs also with regard to the union of the two opposite internal parietes of the artery, in individuals of weak and unhealthy constitutions, or very debilitated from old age, in whom we daily observe, that even the slightest wound remains unusually pale, depressed, and not supplied with tenacious coagulable lymph proper for conjoining firmly the disunited parts. Prudence, therefore, and analogy, admonish us, in weak and extenuated patients necessarily subjected to the Hunterian operation, to delay the removal of the ligature to the completion of the fifth or sixth day, but under the express condition, that the ligature has been applied with the interposition



of the cylinder of linen, as it is proved, that the *circular* ligature with the cord causes ulceration of the artery before the third day, and it is not till the sixth day that the external cellular sheath of the artery begins to be affected by it, if the former mode of ligature is employed.\* After the sixth day, in very debilitated patients, if the *vascular* union between the two opposite internal parietes of the artery, and the glutinous adhesion of the two polypous coagula to the internal surface of the artery have not taken place, neither of them will afterwards occur; and it would not only be a useless but a dangerous practice, to leave the ligature for a longer time, as it would infallibly occasion the complete corrosion of the artery still pervious to the blood. It is better, therefore, even in the most debilitated individuals, before

\* Not long ago, in a stout young man 23 years of age, who had an aneurism in the bend of the arm in consequence of venesection, and in whom the *circular* ligature of the artery had been employed above and below the puncture of it, the attending surgeon wishing to remove the ligature on the fourth day, began with the lower one. On making a very slight effort, it was detached along with a portion of the ulcerated artery, which deterred him from making the same attempt on the upper ligature, for fear of hemorrhage, and because it was found impossible to overcome the difficulty of removing with safety, or without injuring the artery, the ligature concealed and buried between its ruptured internal coats. Fortunately the patient was young, and sufficiently robust, and the union of the artery had taken place previous to the third day, or before the *ulceration* and *death* of the artery caused by the pressure of the *circular* ligature. Farther, admitting the advantage (which cannot be called in question) of the removal of the ligature on the fourth day after the operation, it follows, of consequence, that for this reason only, laying aside all the other very great objections already mentioned, the *circular* ligature would require some alteration, as it cannot be removed without very great difficulty.



the termination of the sixth day after the operation, to remove the ligature, and re-unite the external wound, although the pulsation is afterwards renewed in the subjacent aneurism, rather than expose the patient to the melancholy consequences of *secondary* hemorrhage, and, perhaps, even to the last resource of amputation of the diseased limb. Nor will the patient, by following this practice, have lost every benefit of the operation: For, however debilitated we may suppose the patient who has undergone the Hunterian operation, he will never be so much reduced that the tied artery will not be susceptible of some, although small degree of adhesive inflammation. However imperfect it may be, it will never fail to cause the whole of the coats of the artery to become thickened at the place previously occupied by the ligature, with a greater or less diminution and contraction of the canal of the artery. This contraction will impede the impetus of the column of blood within it, and against the aneurismal sac, and will allow the formation there of the polypous layers, which becoming gradually thicker, will prevent the increase of the tumor, and will perhaps also at last allow nature an opportunity of performing what is called a *spontaneous* cure.

Where even in healthy patients in the vigour of life the Hunterian operation has been undertaken under auspices less favourable than the above mentioned, that is, in cases of *ulcerous*, *steatomatous*, or *scaly* morbid state of the artery at the exact point of the ligature, which the prudence of the operator cannot always foresee, what injury could accrue to the patient from the separation of the ligature on the fourth day after the operation? None in my opinion. For, leaving the ligature until it was spon-



taneously thrown off, as the portion of artery subjacent to the ligature has no disposition to assume the *adhesive* inflammation, and, in the meantime, the *ulcerative* process, although retarded by the interposition of the cylinder of linen, at last corrodes and opens it, *secondary* hemorrhage will always be the necessary and inevitable consequence of this practice. On the contrary, on removing the ligature from the artery on the fourth day, and arresting in time the *ulceration* of its coats, if immediately on the removal of the ligature the pulsation is renewed, as ought to happen in the subjacent aneurism, the operator is informed, that the artery, although in a healthy patient, has not at the point where it was tied the conditions necessary for effecting its closure; therefore, he prepares to re-apply the ligature above the former, with the hope of finding the artery in a sound state. This is always performed with great precipitation and difficulty at the moment of hemorrhage bursting out, and in the depressed and agitated state of mind of the patient, who is often also harassed with convulsive affections. Farther, it is proper to remark, that after the appearance of hemorrhage, the ligature applied above does not in most cases make it less necessary for the surgeon to apply another below the place of the erosion and rupture of the artery, in order to stop the regurgitation of the blood; this inferior ligature is not necessary when the upper has been applied before the breaking out of the hemorrhage.

After repeated experiments on animals, I had no hesitation as to the success of this undertaking in the human subject also. I was not ignorant how fallacious and dangerous it is to expect, that a great surgical operation, because it has succeeded in animals,



ought to have an equally favourable event in man. I knew that animals sometimes are exposed to dreadful injuries without sinking under them; which has not been granted to the human species. But here the discussion did not regard the laying bare any of the principal viscera, and still less the injury of any of them. The investigation was directed to the ligature of the principal artery of an extremity, not preceded by extensive injury of parts necessary to the continuance of life, nor accompanied by unbearable pain, the closure of which artery did not require more vigour in the patient than the accomplishment of the re-union of a simple wound. To accomplish this, the powers of life in them are not inferior to those of animals. The correctness of my induction has been proved by facts, as shall appear from the history of the three operations which within a short period of time have been, at my request, performed by Palletta, chief surgeon of that great emporium of every kind of disease, the great hospital of Milan, followed by a fourth operation performed in the hospital of Pavia.

#### CASE I.

JOHN BAPTISTA PIROLA of Vedano, 40 years of age, was received into the hospital of Milan, for a popliteal aneurism, the 24th December 1816. He was born of healthy parents, and having never suffered any ailment in his youth, he had always struggled with fatigue, without ever experiencing any injury from it. His first business was that of a bleacher; then fate ordained that for many years he followed the military life.



When 31 years of age, having contracted venereal ulcers and buboes, he was put under a mercurial course, and used 34 frictions with the ointment. He was completely cured of this disease: for, besides not having suffered any bad consequence from it, he was able, as formerly, to resume and endure the fatigues of military duty. After obtaining his discharge, he resumed his former trade, which he carried on for four years. About a year and a half ago, from the dread of being again called on to serve in the army, he was attacked by fever, which terminated in two weeks, and his disquietude of mind being removed, he continued his business.

Towards the middle of November 1816, he perceived a slight swelling at the lower part of the left inferior extremity, particularly towards evening, which diminished by rest. Not long afterwards, he observed a small tumor in the ham, hard, indolent, and pulsating. The swelling increased in a few days, accompanied with pain in the knee, and down the calf of the leg; and the pulsating tumor having gradually increased, he was confined to bed on the 19th December.

Having been admitted, as above stated, into our ward on the 24th December, on examining the limb the aneurism was found to be as large as a turkey's egg; the limb slightly swelled and painful; the pulse calm; his habit of body rather meagre.

On the 25th December and following days, in order to moderate the arterial vibrations, he was ordered the digitalis, and the limb was embrocated with vinegar; these remedies had the effect of mitigating the pain, of lessening in some measure the tumor, and restoring composure to the patient; and on the 31st December, a poultice of Armenian bole, with the



white of eggs, was substituted, applied over the tumor, and a moderately tight bandage to the whole limb.

January 1st.—The patient had suffered some uneasiness from the bandage, although the pulsation of the tumor had abated, and the pulse was unchanged.

January 2d.—On renewing the bandage he felt so great uneasiness, that the tumefaction and tension of the gastrocnemii muscles, as well as the pain, increased; in consequence of which the bandage was entirely removed.

On the 5th and following days the tension and pain abated, which allowed room for deliberating on the operation, which was wished for by the patient himself.

Therefore, on the morning of the 8th January the patient was operated on, by surrounding the insulated artery with a round cord, and placing over the artery the small cylinder, on which the ligature was tied, according to Scarpa's directions.

Although the operation was of short duration, and from the leanness of the patient, the artery easily laid bare, yet either from extreme sensibility or from fear the pain he suffered was very great, such as I never recollect to have remarked it in other patients.

The pulsation in the tumor immediately stopped. The patient soon after felt a heat in the extremity of the tibia and on the dorsum of the foot, though the latter was almost quite cold to the touch. The uneasiness continued for several hours after the operation, during which time it was necessary to introduce the catheter. In the course of the night he passed urine in the natural way; the heat of the limb abated; the pulse was calm.

On the morning of the 9th the aneurismal sac diminished to one-half; no uneasiness in the limb,



except the coldness of the foot. On the 10th the patient still more tranquil. He was allowed soup and nourishing food. The foot has no feeling.

On the morning of the 12th (the fourth day after the operation) the wound was examined for the first time, and was found in a state of moderate and healthy suppuration. The ligature was divided, which on the cylinder as a guide, was easily effected, and freed the artery from the foreign body, and it was likewise found to be agglutinated and closed, no more pulsation being felt below the ligature, nor any troublesome symptom, except that already mentioned, the coldness of the foot.

On the following day he had an attack of most acute pain in the foot, which was allayed by a full dose of laudanum. Strengthening remedies continued, with wine; there being no fever, the wound of a red colour and the *pus* healthy; the edges have a tendency to adhere spontaneously, which is promoted by the application of adhesive straps.

From the 14th day the state of the patient went on progressively improving, the aneurismal tumor being diminished to the size of an empty bag; the appetite greater; the tongue clean; the pulse strong; the nights quiet, in consequence of good diet, wine and laudanum prescribed in proper doses.

Notwithstanding these internal precautions, and local stimulants, dry gangrene of the foot supervened. It was, therefore amputated (27th February), and the stump cicatrised. The patient was at last cured.

REFLECTIONS.—Mortification of the foot, fortunately a very rare accident after the ligature of the femoral artery, has no concern with the principal object of this case, viz. that of demonstrating that the ligature may be removed from the great artery of a limb



of a sufficiently healthy man, the fourth day after the operation, without the pulsation being renewed in the subjacent aneurismal sac. Therefore, we may with safety, on the renewal of the dressings after the Hunterian operation, unite the external wound and cure it by the *first intention*. And if in this patient the unusual accident of the mortification of the foot is to be attributed, as is probable, to the extraordinary tightness and rigidity of the lateral branches of the femoral artery; as this unfavourable combination of circumstances would contribute to increase more than usually the impetus of the blood against the place where the artery had been tied, so this same disadvantageous circumstance, for the cure in general, becomes evidently an additional argument to prove, the greatness of the resistance opposed to the impulse of the blood by the *vascular* union between the two opposite internal parietes of the artery, together with the adhesion of the polypous coagulum to them above and below the place of the ligature, although it be removed on the fourth day after the operation.

## CASE II.

SIGN. CARLO MAJERNO, employed in the imperial customs of Milan, 60 years of age, labouring under pneumonia, had the misfortune, at the third bleeding, to have the brachial artery wounded. He, however, employed the same phlebotomist for two other bleedings, by which the disease was removed. I mentioned that the patient was aware as well as the surgeon of the unfortunate circumstance, the latter merely applied a slight bandage. An aneurism immediately formed between the arm and fore-arm, with dis



ting pulsation. The accumulation of the clots which retarded the course of the lymph, caused a sort of œdema at the upper part of the arm and at the lower part of the fore-arm. The bandage now became unbearable from the pain it occasioned, and the prickling sensation in the fingers.

In this state, on the 24th March 1817, at ten o'clock, with the assistance of the skilful surgeons Mazzi and Mazzola, and exactly twenty-one days after the accident, I operated on the patient about the middle of the arm, surrounding the artery with a tape, interposing the small cylinder of linen spread with plaster.

On tying the ligature, the pulsation of the tumor immediately ceased. The fore-arm and hand retained their heat; the tension of the tumor diminished, and the following day a pulsation like a thread was perceived in the radial artery. Every thing else went on as usual.

On the 28th, (the fourth day after the operation), at ten o'clock the wound was uncovered for the first time; there was a plentiful suppuration, and on removing the dressing, I was able, with a pair of forceps, to raise the ligature a very little, and divide it with a pair of fine scissors. As soon as the ligature was divided, the small cylinder was observed to be loose, and was removed from the inner side of the artery, by means of a pair of forceps. I supposed that the slackening of the ligature was the effect of the suppuration, which had diminished the swelling of the cellular substance, and rendered the separation of the ligature easy, although the artery lay very deep.

The progress of the cure was not interrupted by any accident. The 10th April, (the 13th day after



the operation), the patient got out of bed, and the following days continued to sit up to dinner. The tumor was diminished to one-half, and the wound on the 17th April would have been healed, had it not continued to discharge the lymph collected in the cellular substance. The edges of the wound were kept together with adhesive plaster, and the pulse at the wrist was re-established.

About the end of the same month the cure was complete,

REFLECTIONS.—This case is in many respects very important. In the *first* place, because it proves the advantage of the removal of the ligature from the artery on the fourth day after the operation. In the *second* place, because the ligature having been found slightly loosened, so as to allow a pair of scissars to be passed between it and the cylinder, it is probable that the union and closure of the artery had been effected prior to the fourth day after the operation. It shows, in the *third* place, that the Hunterian or Anellian operation ought to be preferred to the incision of the aneurismal sac, whenever the effusion of arterial blood, in consequence of the wound or rupture of the artery, into the surrounding cellular substance at the place of the injury, and the thrombus or coagula of blood found there, do not threaten the arm with torpor, inflammation, or gangrene, in consequence of the excessive distention and pressure.



## CASE III.

JOSEPH TASSI, a coachman, 50 years of age, of a sanguine temperament, very corpulent, came into this hospital on account of an aneurism in the right ham, which had come on within a month, without his having perceived it, or that he had made any over-exertion, except that of frequently mounting and dismounting from the box when he accompanied travellers. He had, indeed, not been exempt from local venereal affections, of which, however, he had been cured for several years. He was likewise much addicted to drinking. The aneurismal tumor was as large as an egg; pulsated regularly, and from the wave of blood striking the fingers, it appeared to be entirely fluid, and that there were neither clots nor fibrous layers in it. The leg was completely in a natural state. And in fact he walked about the town without support, and without feeling any great uneasiness.

On the 30th June 1817, at seven o'clock, he was operated on by Dr. Biraghi, assistant clinical surgeon. The femoral artery being laid bare, an eyed probe was passed under it, which was threaded with a ligature, and withdrawn; then the small cylinder of linen spread with plaster was placed over the artery, and the ligature was tied with a running knot or single loop, in order to be more easily removed without being divided. And as sometimes a slight constriction or small obstacle serves to stop the course of the blood through the artery, and to make it take an opposite direction, therefore I wished to try this means, both to ascertain the degree of constriction, as well as to find an easy way of removing the liga-



ture. In fact, the pulsation, both under the ligature and in the ham, immediately ceased on a slight constriction, and it was not necessary to draw the running knot any tighter. A knot was put on the running portion of it, in order to distinguish it.

The two first days of July nothing occurred deserving of being noticed, the patient having slept quietly. The operated limb was a little warmer than natural, and the tumor diminished about one-half.

On the 3d July, at seven o'clock, (the third day after the operation), I resolved to have the ligature removed. Therefore, laying hold of the running end of the ligature marked with the knot, and introducing a finger over the artery, on the cylinder, (which, considering its depth, might have been too much elevated and displaced), the end of the ligature was gradually drawn, and being moistened with *pus*, it could only run very slowly; however, the knot being untied, the ligature was withdrawn entire, and then the cylinder, without any derangement of the wound.

On the 4th July, the upper part of the thigh was attacked by erysipelas, without having been preceded by the usual symptoms which appear on the commencement of erysipelas. The wound fully suppurated.

5th July.—The aneurismal tumor was almost imperceptible in the hollow of the ham. The erysipelas not attended with very great heat, and the slight fever proportioned to the suppuration.

On the 2d and 3d days after the removal of the ligature, having made the aneurism be examined by various assistants, in order to ascertain if any blood passed through the sac; some denied decidedly that there was the sensation in the cavity, not to say of pulsation, but not even of any kind of motion;



others asserted that they perceived an obscure motion, almost of imperceptible oscillation. Although this might depend upon the pulsation of the arteries of the fingers of the examiners, yet I again requested the same persons, on the fourth day, to apply their hand to the aneurism, which they all acknowledged to be diminished in size, but still the opinions were divided. Some conceived that they felt some fluid running deeply and obscurely within the sac; others thought this sensation imaginary. From this difference of opinion, it was concluded, that no blood passed from the trunk of the femoral artery into the sac, but some small drops of blood were thrown into the trunk of the popliteal artery from the anastomosing branches.

On the 6th, 7th, and 8th days after the removal of the ligature, there was no change. Fever very slight; quiet sleep; erysipelas diminished; wound still foul.

On the 9th day, the erysipelas having almost entirely disappeared, the quantity of pus being diminished, the edges of the wound were still more brought together; the aneurismal tumor was not only found much smaller than before, but likewise *indurated*, a sure mark that the small stream of blood which had passed from some small anastomosing branch into the popliteal artery, or into the sac below the ligature and the point of obliteration of the trunk of the femoral artery, was unable to distend the sac, or prevent the formation of the polypous layers within it, by which the blood was at last completely excluded, and the passage through the sac closed.

From this period all went on well, and the cure was not retarded by any other accident. The patient was completely cured, and about the end of the fourth week after the operation, in the cavity of the



ham, there was merely a knot about the size of a button.

REFLECTIONS.—This case confirms the fact, that in young and healthy individuals, even in their fiftieth year, there is no risk of the pulsation being renewed in the subjacent aneurismal sac, on the removal of the ligature from the principal artery of a limb, merely the third day being completed after the operation.

In the act of removing the ligature, there can be no doubt that it is of great consequence that the artery is not rudely handled or stretched. And, indeed, if, on untying the running knot, the subjacent knot could be with the same facility untied, we could not wish for a better mode of performing this part of the operation. But the knot, although a simple one, is not so readily untied, or the running knot, on account of the moisture with which the threads forming the ligature are soaked, or because the ligature has been previously waxed. Perhaps this purpose might be effected by placing, before tying the knot, a thread longitudinally, on each side of the cylinder, and, at the time of removing the ligature, making a noose with each end of these threads, and drawing them in opposite directions, undo the knot without displacing or stretching the artery. In the meantime, until experience confirms the advantages of this practice, this part of the operation will not be found very difficult, if the surgeon introduce the point of the finger of his left hand along the ligature hanging out of the wound, to the bottom of it, to rest the nail exactly on the knot formed by the ligature; then with his right hand let him pass the point of a bistoury at the side of the nail, and with it divide the ligature



on the cylinder of linen, without the risk of wounding any part, or disturbing the artery at all.

With respect to the deep and obscure pulsations which in this case were perceived by some of the surgeons in the aneurismal sac, I consider it as demonstrated, that this phenomenon takes place more or less in the greater number of cases, in which the Hunterian operation is performed, and particularly in cases of recent aneurism, formed by blood still in a fluid state. For, in these circumstances, a certain number of small anastomosing vessels almost always regurgitate blood into the principal trunk from below the ligature, as far as the aneurismal sac, and into the sac itself. But these small streams of blood, as they are not sufficient to distend the sac of the aneurism, nor to prevent the formation of the polypous layers in it, cannot retard or oppose any great hinderance to the cure of the disease.

#### CASE IV.

JOHN BAPTISTA BOERCI, a ploughman, 45 years of age, on the 16th October 1817, fell from a tree upon a hedge, and received a wound from a sharp piece of wood about three inches long, on the inner side of the left humerus, at the lower part. The blood immediately flowed per saltum, and in such quantity, in a short time, that, according to the patient's account, it might amount to three pints. Fortunately the patient had the presence of mind and strength sufficient to tie a neckcloth tight round his arm above the wound, so as completely to stop the flow of blood.



On being brought to the hospital at Pavia, he was placed under the care of the skilful surgeons, Molina and Fenini. On examining the wound, they immediately discovered the wound of the brachial artery, above which it was immediately tied by means of a ligature composed of four waxed threads, with the interposition between the knot and the artery of a cylinder of linen spread with plaster. After the ligature of the artery was completed, and the blood allowed to resume its course, not a single drop being discharged by *regurgitation*, (probably in this case from the resistance being great, which was opposed by the inferior coagulum to the reflux blood from the small *anastomosing* vessels of the profunda humeral running into the brachial under the ligature), no ligature was applied to the lower end of the artery. The edges of the irregular wound were laid down and brought together, except at the part opposite to the ligature.

The arm, below the ligature, felt rather cold. It was warmed by the use of bladders half full of warm water, and a few hours afterwards it was found even warmer than natural.

The two following days nothing particular occurred.

At the end of the third and beginning of the fourth day after the operation, the ligature was removed with the greatest facility, by passing the points of a pair of scissars between the ligature and the cylinder of linen. There being no appearance of hemorrhage either at the removal of the ligature, or the following days, shewed, that in the course of three days there was a complete union and obliteration of the artery. Afterwards there was only a slight inflam-



matory swelling of the arm; the suppuration of the wound moderate and healthy, and in five weeks it was completely healed.

The pulsation of the radial and ulnar arteries at the wrist was longer than usual of being perceptible to the touch. The patient, however, completely recovered the use of his arm.

---

AFTER the printing of this Memoir was finished, Professor Mislei, already repeatedly commended, transmitted to me the following account of some experiments made by him, in order to confirm the truth of what I had remarked, with regard to the effects of the *circular* ligature, which produces ulceration of the artery more rapidly than the ligature with the interposition of the cylinder of linen.

“As” (observes Professor Mislei) “it appears from the experiments already mentioned to you, that the ligature with the tape, and the interposition of the small cylinder of linen spread with plaster, allowed to remain three or four days on the artery, excites an ulcerative process in its coats, which does not fail gradually to corrode them completely; I wished to ascertain, by means of new experiments, if the circular ligature has the effect, in similar circumstances, of exciting this process more quickly or more slowly than the other.

“On the 8th of July, therefore, in the manner already described, the left carotid was laid bare in a large old horse affected with glanders, in which the preceding day the penis had been amputated for purposes foreign to the present subject; having



raised the artery, by means of an ensiform probe, from the bottom to the surface of the wound, a tape composed of four waxed threads was passed under it with the usual curved needle; it was tied with a simple knot, so tight as to stop the flow of the blood, and secured by a second simple knot. The carotid was then replaced in its natural situation, and having brought out the ends of the ligature at the lower angle of the wound, the edges of it were brought together, and retained by means of two stitches of interrupted suture, having previously interposed between them a pledget of tow dipped in water, to prevent them adhering. Three days afterwards the sutures were divided, and separating carefully the lips of the wound, the ligature passed round the artery was dexterously cut with a pair of scissars, and removed. I then observed attentively this tube at the place where the ligature had been applied, and I plainly perceived its first coat corroded, and the middle one also destroyed to about a third of its thickness; the edges of the wound were again brought together, and kept in contact by means of a long strip of linen spread with adhesive plaster, and ten days afterwards the animal was killed. On examining the carotid, it was found surrounded with a quantity of coagulated lymph, completely cut across, and its two large orifices, shining, of a whitish yellow colour, and reverted like the ends of a divided intestine; from the bottom of it there protruded a small part of the clot occupying the cavity of both ends of the arterial tube, converted into a fetid substance, of a soft consistence and an ashy colour. On laying open the arterial tube, it shewed that the remaining co gulum began to partake of the same decomposition.



“ Although the result of this first experiment might be adequate to solve the problem, whether the ulceration takes place more quickly after the artery is tied according to the method you have proposed, or after it is tied circularly, yet I was not convinced, and my perplexity arose from the doubt that I had tied the artery too firmly with the ligature; and, consequently, that instead of exciting the adhesive process in its parietes, it had produced the ulcerative process. These doubts, therefore, induced me to make a second attempt.

“ On the 4th August, having applied a ligature of the same size with the preceding round the carotid of an old glandered mare, affected with general stiffness of the limbs, I tied it with a simple knot, so that in spite of the rigidity of its parietes, they were approximated with the least possible puckering. Thirty-seven hours afterwards the ligature was removed, and the wound was dressed in the usual way; it was beginning to suppurate. The following day, that is, twenty-four hours after the ligature was withdrawn, on proceeding to examine the mare, I perceived from the lower angle of the wound an oozing of pale blood, resembling the washings of flesh. This having brought me into a dilemma, I immediately resolved to examine from whence this oozing proceeded. The dressings were scarcely removed, and the edges of the wound separated, when there immediately gushed out in large jets a bright vermilion-coloured blood, leaving no doubt that it proceeded from the carotid itself. At the moment, by a rapid dissection, the wound was enlarged to a sufficient size, and the artery laid bare, so as to allow another ligature to be applied both above and behind the point from which the effusion proceeded. And



not to omit other analogous experiments on the same subject, I resolved to apply above, that is, nearer to the head, a circular ligature, and at the lower part, or towards the heart, another broad one, with the interposition of the cylinder of linen.

“ In order to determine more correctly the nature of the injury of the artery which had caused the effusion of blood, the whole portion of it included between the two ligatures was removed and examined. I found that the artery was divided to more than a third of its diameter, and not by the scissars which had been used to cut the knot, but by the ligature, as implicit confidence might be placed in the form of the division, and the irregularity of its edges. I forgot to mention that the division of the artery was on its anterior surface, and exactly at the place where the knot of the circular ligature rested.

“ After applying the two ligatures, the edges of the wound were brought together with several turns of the twisted suture; but thirty-nine hours afterwards they were found lacerated, and the pins dropped out. At this period the circular ligature was removed from the artery, and at the moment I observed that its external coat, at the place surrounded by the ligature, was corroded, as well as the middle partly so. The edges of the wound were again brought together, and supported by a band round the neck. Two days after that, or eighty-seven hours after the application of the ligature, the second was removed with every possible care, or the one in which the cylinder had been interposed between the artery and the knot. At this time I examined both the anterior and the posterior part of the artery; the former was tinged of a deeper red colour than natural, and the whole space on which the ligature rested flattened,



and its external coat not affected by the slightest erosion ; the latter portion was found furrowed, where the ligature had rested on it denuded. Not to omit any thing, I may add, that the small free portion of the artery, or that superior to the ligature, appeared to be as it were soft and wasted. The edges of the wound were afterwards approximated, and retained by a proper bandage. Three days afterwards the wound was found pale, with reverted edges, very much swelled, hard, and lardy, and there was not a single point of it from which there was any exudation. To restrain this inflammatory process, which had begun so rapidly, this enormous wound was washed with a lotion of aqua lauro-cerasus diluted with a third of common water, and its irregular edges were united as well as possible, and supported with a long strip of adhesive plaster, applied in a spiral direction round the neck, and the whole was covered with a compress dipped in the aqua lauro-cerasus, retained by a proper bandage. The following day the appearance of the wound was changed, and about the third it began to suppurate ; at last, on the fourth day, it became of a vermilion colour, its edges flattened, so that the lower was almost completely in contact with the upper ; in a word, it might have been expected that the cicatrix would be formed at the end of fifteen or sixteen days. But about the twelfth day after the removal of the ligature, when the wound was still open and suppurating, the animal was found stretched out, scarcely breathing, and drowned in its own blood pouring out from the wound. Surprised at this unexpected accident, I made the cloths be removed which the man in attendance had applied to stop the copious hemorrhage. Having cleared away the



blood, which was ascertained to have flowed from the upper part of the wound, that is, from that end where the carotid had been tied with the ligature only, this portion of it was laid bare, and it was found completely wasted at the place where it had been tied, and the free portion, or that inferior to it, dissolved and embedded in matter. The superior portion of the artery surrounded by dense puriform matter, with its orifice open, shaped like a funnel with its lips everted, rugged and thickened. Finally, the other portion of the carotid, which had been tied with the interposition of the cylinder, was found closed in the midst of bloody lymph, smooth and impervious for the space of fully half an inch, forming, with the lymph, so compact a whole, that they could with difficulty be separated from each other.

“ From the success of these, although not numerous experiments, it is easily perceived, that of the two modes of ligature, the circular induces the soonest the ulcerative process of the artery; and, consequently, there can be no doubt of the preference to be given to the ligature proposed by you. This ligature, properly tightened, and allowed to remain on the artery during the time requisite for the completion of the *adhesive* process, never ruptures its internal coat, nor induces ulceration of the other external coats. On the contrary, the ligature with the cord alone, without the interposition of the cylinder of linen, however moderately it may be tightened, always ruptures the internal coat of the artery, and inevitably excites in the two other external coats an ulcerative process, which in a short time completely corrodes and destroys it.”



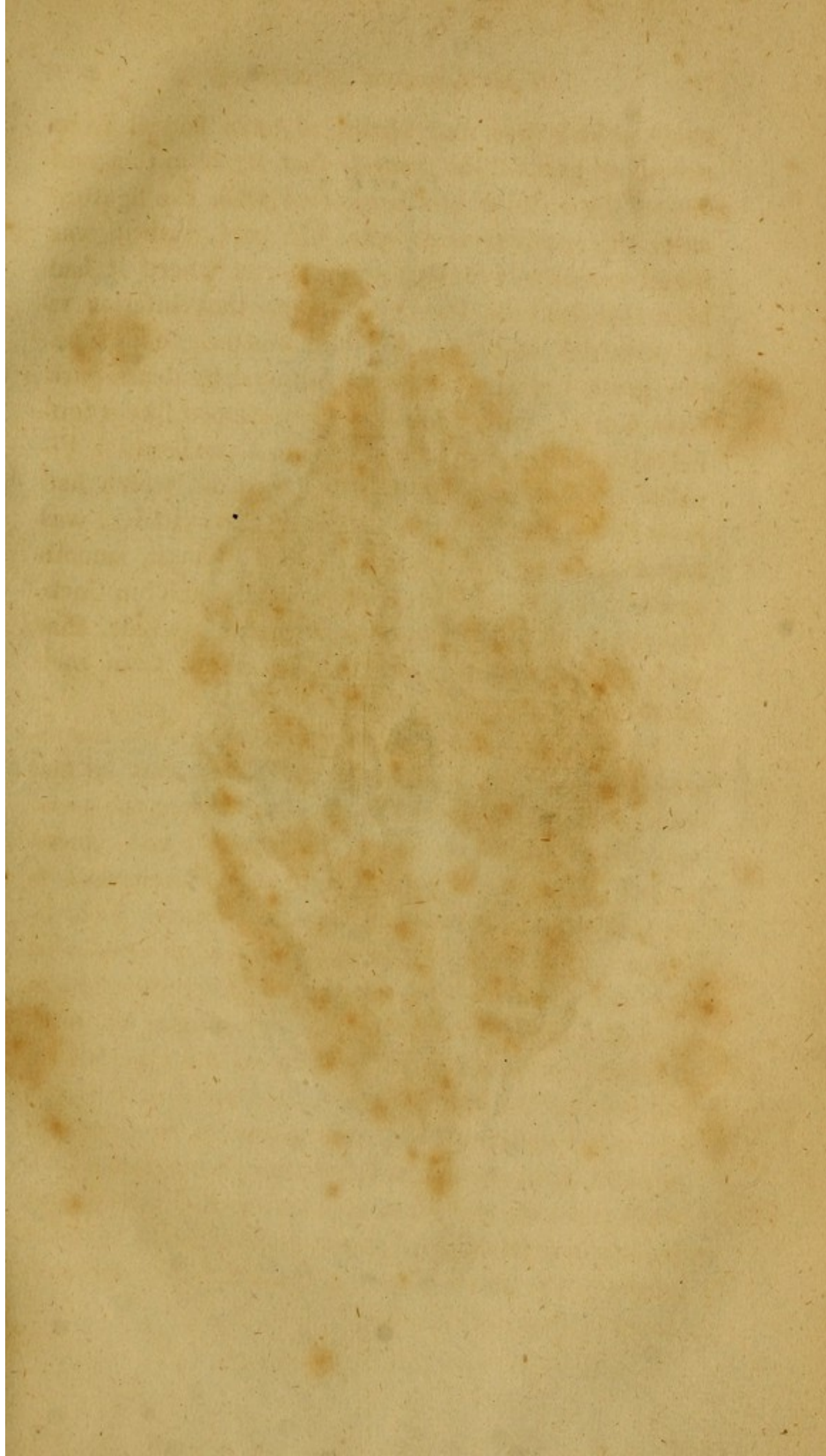




PLATE I.

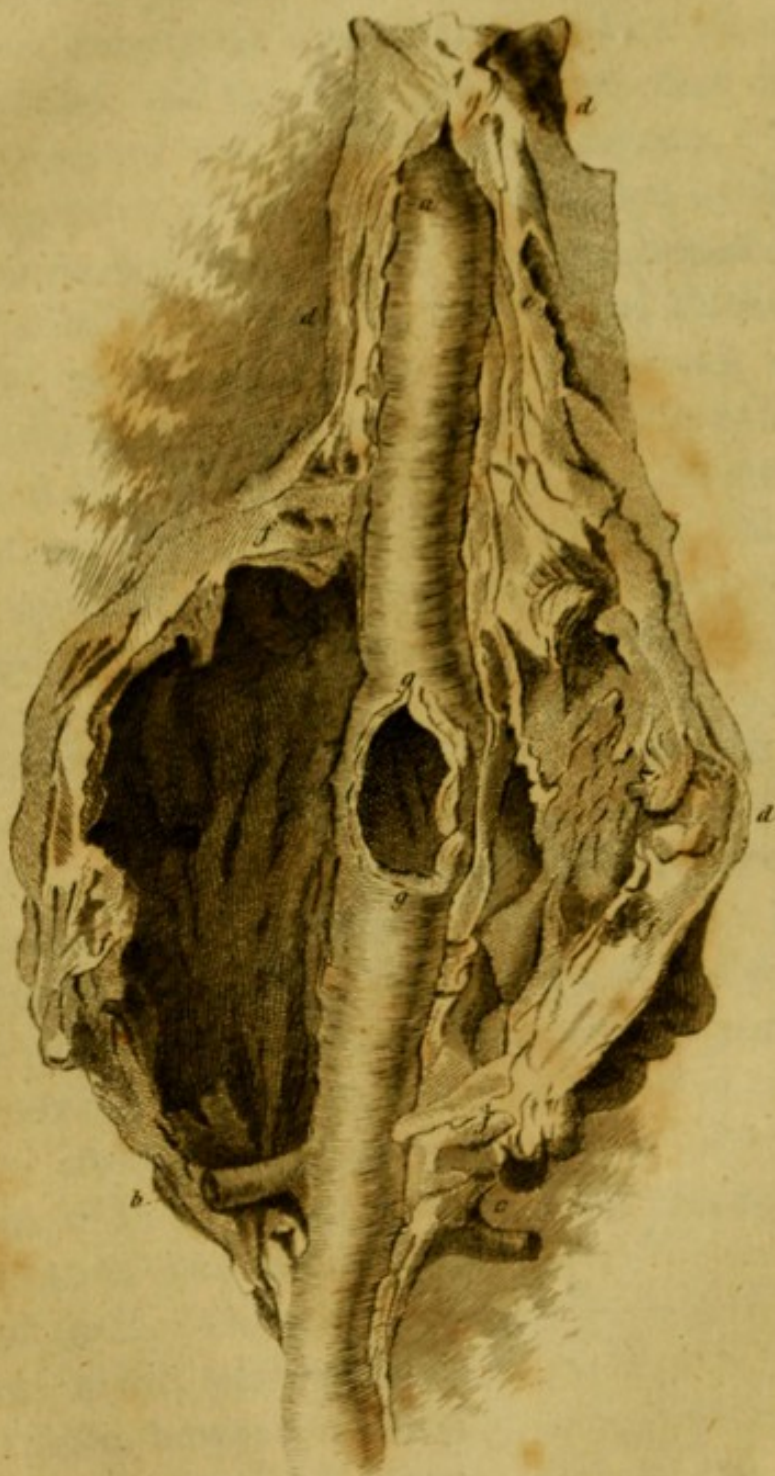




PLATE II.

Fig. 1.

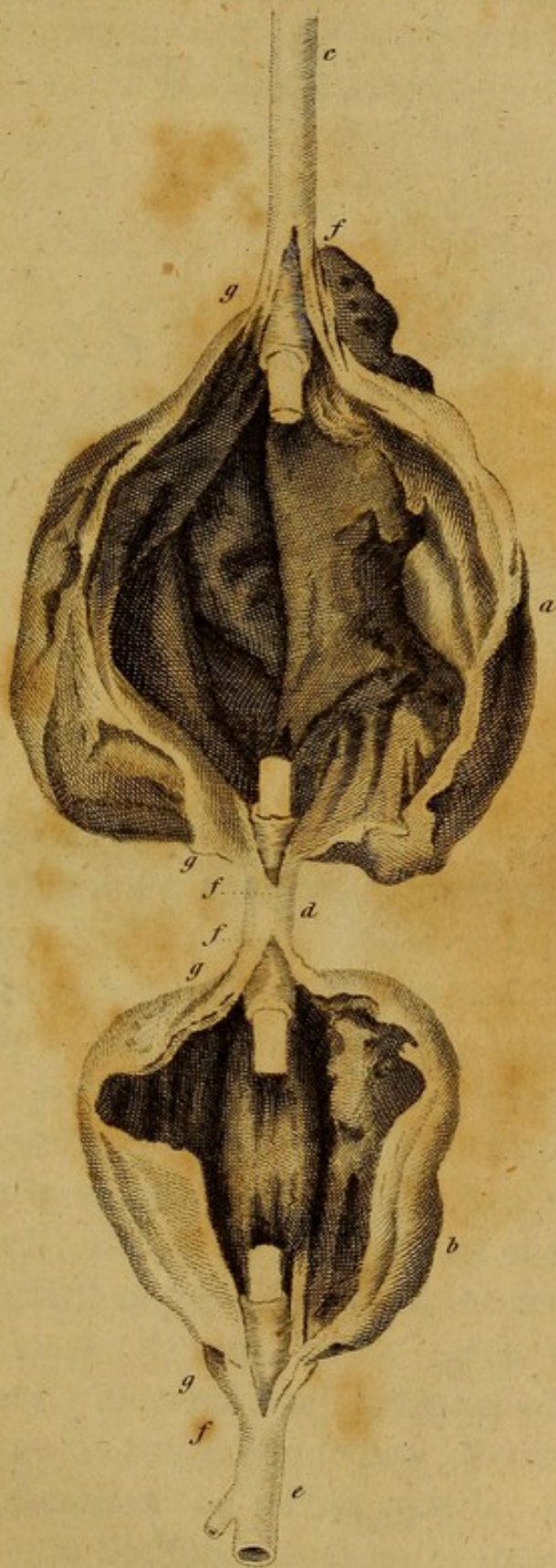


Fig. 2.



Fig. 5.



Fig. 3.

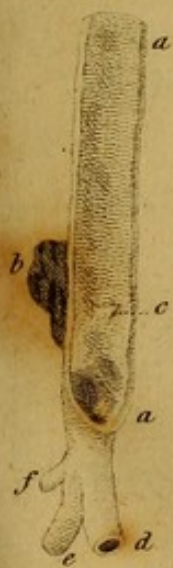
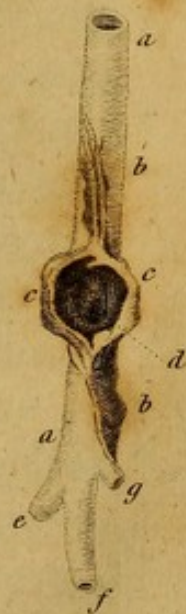
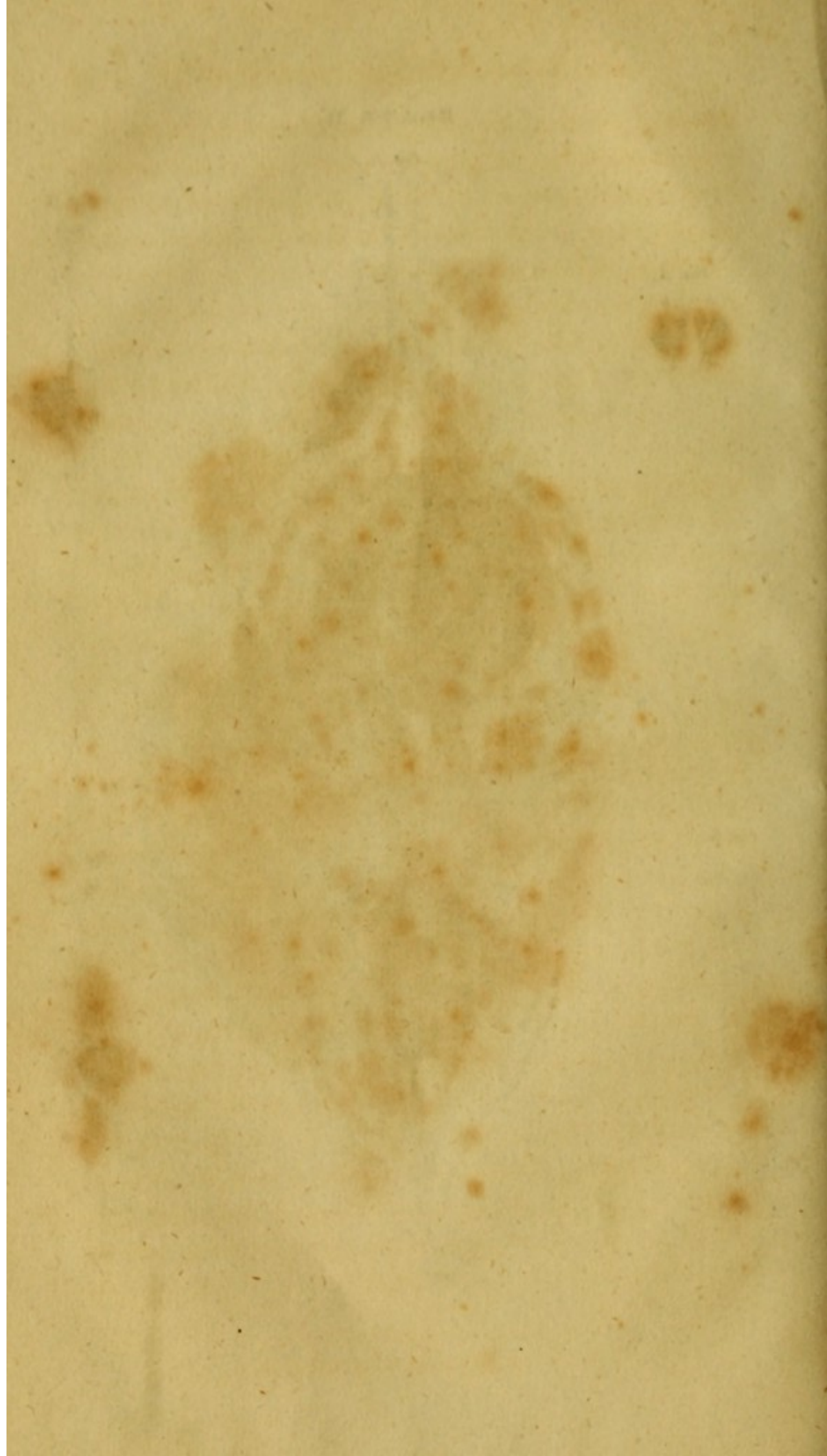Fig. 4.









A

# TREATISE

ON

# ANEURISM.

---

## CHAPTER I.

### OF THE FEMORAL AND POPLITEAL ARTERIES.

THE *anterior* or *external* iliac,<sup>1</sup> a little before it passes out of the pelvis under the crural arch, gives off the epigastric artery, which ascends obliquely from without,<sup>2</sup> forwards and upwards, towards the lower extremity of the rectus muscle of the abdomen. In the male, as it passes near to the crural arch, it gives off, to the spermatic cord, a branch which anastomoses with the spermatic artery, and is dispersed on the cremaster muscle, and on the vaginal coat of the testicle. The epigastric then ascends behind the rectus muscle, having previously, in some cases, given off the obturator artery. Several small branches of the epigastric artery, go to the integuments of the abdomen, and to the sheath of the rectus muscle; and several others sink into the other muscles of the abdomen, as

<sup>1</sup> Iliac portion of the crural artery.

<sup>2</sup> From the lateral and sternal aspect.



well as into the rectus. Among these, a large branch ascends along the internal margin of the rectus muscle to anastomose with the mammary artery; it also communicates successively with the thoracic and intercostal arteries. The proper trunk of the epigastric artery keeps behind the rectus muscle, and as it ascends, it increases remarkably the number of the inosculation with the mammary, thoracic, and intercostal arteries.

§ 2. Opposite to the origin of the epigastric artery, or a little lower, the *anterior* iliac gives off the abdominal artery. This artery<sup>1</sup> takes a retrograde course between the abdominal muscles, directing itself towards the spine of the os ilium. It supplies, in the first place, branches to the inguinal glands, to the iliacus internus muscle, to the beginning of the sartorius, and it anastomoses with the cutaneous inguinal branch of the posterior or *profunda femoral* artery. The abdominal artery then ascends between the *internal* oblique, and transversalis abdominis muscles, following the curvature of the spine of the os ilium, as far as the eighth rib. During the whole of this course, it gives branches to the muscles of the abdomen, to the psoas, to the iliacus internus, and to the anterior crural nerve, and terminates in repeated anastomoses with the ileo-lumbar, with the lumbar, with the intercostal, and with the thoracic arteries.

§ 3. The *anterior* iliac artery, as it passes out of the abdomen, under the crural arch, receives the name of *femoral* artery.<sup>2</sup> This large artery, in its

<sup>1</sup> Some anatomists call this artery the lesser external iliac, others the circumflex of the ilium.

<sup>2</sup> Inguinal portion of the crural artery.



course from the crural arch to its first division, runs in a triangular cavity formed by the convergence of the iliacus internus, psoas, and pectineus muscles; it passes over the femoral vein, which lies over it above the crural arch, and it rests upon a layer of dense cellular substance, which fills up this triangular cavity. On the fore part the femoral artery is covered by the aponeurosis of the muscle of the fasciata, by some inguinal glands, and by the common integuments. The femoral artery, at the distance of one inch, or one and a half, very rarely two inches, below the crural arch, in a well-formed adult, of the ordinary stature, divides into two principal branches, the *superficial* and *profunda* femoral arteries.

§ 4. The *superficial* femoral artery gives off, in the first place, the *superior external*<sup>1</sup> pudic artery. This artery, situated a little below the common integuments, crosses the heads of the pectineus and gracilis muscles; it then gives branches to the inguinal glands, to the scrotum, to the fat about the pubes, and lastly, anastomoses with some ramifications of the epigastric artery.

§ 5. At a short distance below the origin of the *superior external* pudic artery, the *superficial* femoral gives off the *inferior external* pudic artery,<sup>2</sup> which, in the same manner as the *superior*, passes across on the heads of the pectineus, adductor *longus* femoris and gracilis muscles, and then is reflected upon the skin of the scrotum, and on the integuments of the penis, along which it extends as far as the prepuce. This artery gives off several branches to the cellular membrane, to

<sup>1</sup> The first inguinal pudic.

<sup>2</sup> The second inguinal pudic.



the integuments of the abdomen, and to the inguinal glands, and anastomoses in different places with the arteries of the penis, arising from the *common pudic*<sup>1</sup> artery, which is a considerable branch of the ischiatic artery. Besides the two external pudic arteries, a third is not unfrequently found, which, in the subject from which the drawing was taken, arose from the internal circumflex artery.

§ 6. The trunk of the *superficial femoral artery*, after giving off the two *external pudic* arteries, descends obliquely from without, towards the inner side of the thigh, and sinks gradually deeper in the cellular substance, as it passes down the thigh, within the triangular space left by the adductor *secundus* and vastus *internus* muscles. Towards the middle of the thigh, the trunk of the *superficial femoral artery* is situated very deep in the triangular space between these two muscles; but this arterial trunk is likewise crossed and covered by the sartorius muscle, so that the pulsation of the *superficial femoral artery*, can only be felt in the adult, by pressing strongly with the finger at that place.

§ 7. The branches given off by the *superficial femoral artery*, below the origin of the *inferior external pudic*, are nearly the following. Some arteries going to the sartorius muscle; some to the cruralis and to the vastus *internus*; some to the gracilis and semimembranosus muscles. Those arteries which go to the vastus *internus*, are of considerable size, and, therefore, after having ramified within that muscle, they anastomose in the lower part of the thigh, with some ramifications of the *profunda femoral artery*,

<sup>1</sup> Pelvien pudic.



with the *great* anastomotic branch of the popliteal artery, and with the articular arteries of the knee. Of the arteries passing into the sartorius, gracilis, and semimembranosus muscles, some are distributed within these muscles, and others having passed through their substance, are dispersed on the integuments of the inner side of the thigh.

§ 8. The *superficial* femoral artery, having reached the lower third of the thigh, passes through the adductor *magnus* from before backwards, in the space between the vastus *internus* and the beginning of the tendon of the long portion of the adductor *magnus* muscle. From that place, the *superficial* femoral artery descends posteriorly<sup>1</sup> into the cavity of the ham, where it is surrounded and covered by a large quantity of cellular substance and fat, together with the vein and the great sciatic popliteal nerve, which lies over it, and it is protected on each side by the tendons of the flexor muscles of the leg.

§ 9. A little before it passes through the adductor *magnus* muscle, and therefore, before it descends into the cavity of the ham, the *superficial* femoral artery gives off a large branch, to which Murray<sup>2</sup> has given the name of *inferior perforant* of the *superficial* femoral. This artery runs posteriorly in a transverse direction, to the lower and back part of the thigh, concealed in a great measure by the fibres of the adductor *magnus* muscle, and by the short head of the biceps cruris, to which it gives a branch. Another branch proceeding from the same artery, enters the lower and posterior part of the femur, and constitutes the *inferior*

<sup>1</sup> Poplitead.

<sup>2</sup> In Aneurysmata femoris observat. fig. iii, t. iv.



*nutritious* artery of that bone. From thence the *inferior perforant* artery of the *superficial* femoral is concealed in the substance of the *vastus externus* muscle, within which it gives off numerous branches, and then in the vicinity of the knee, it anastomoses with the *superior external* articular, and with the *external circumflex* artery, a considerable branch of the *profunda* femoral. Farther, some branches of the *inferior perforant* artery of the *superficial* femoral, sink into the lower portion of the *adductor magnus*, into the *semitendinosus*, *semimembranosus*, and into the short head of the *biceps cruris*.

§ 10. The *superficial* femoral artery, as soon as it enters the cavity of the ham, receives the name of *popliteal* artery. The first branches which go off from the *popliteal* artery, are the *great anastomotic*,<sup>1</sup> and the *superior internal* articular artery of the knee.<sup>2</sup>

§ 11. The *great anastomotic* artery, from the cavity of the ham, ascends towards the inner, lower, and fore part of the thigh, covered by the fibres of the *vastus internus*, and after making several serpentine turns, sinks into that muscle. This artery, subdivided into many branches, is distributed partly to the fibrous bundles of the *vastus internus* muscle, and partly anastomoses with the branches already described, which are given off by the *superficial* femoral, to the upper part of that muscle. Farther, the *great anastomotic* communicates with the ramifications of the *external circumflex*, a branch of the *profunda* femoral, and with branches of the *superior internal* articular artery.

<sup>1</sup> Murray, loc. citat. fig. i, w.

<sup>2</sup> Proximo-articular on the tibial aspect.



§ 12. The *superior internal* articular artery, given off by the popliteal, descends towards the internal condyle of the femur, between the tendon of the long portion of the adductor *magnus* of the thigh, and the *vastus internus*. Having reached the vicinity of the internal condyle of the femur, it sends off the artery of the periosteum, and at the same time, the artery of the spongy bony substance of that condyle. This artery, after having made several anastomoses with the superior arteries of the periosteum of the thigh-bone, with the *superior external*<sup>1</sup> articular, with the *great* anastomotic, and with the *superior internal* articular artery, is covered by the common tendon of the extensor muscles of the leg, and at last enters the spongy bony substance of the internal condyle of the femur. The *superior internal* articular artery then divides into two branches, the *superficial* and the *profunda*. The latter branch of the *superior internal* articular artery, having passed beyond the capsular ligament of the knee, rests upon the periosteum covering the lateral surface of the internal condyle of the thigh-bone, and having reached the margin of the internal condyle, where it begins to be covered by cartilage, it divides into numerous minute branches, which penetrate by as many small holes, into the spongy bony substance of the internal condyle of the femur. The *superficial* branch of the *superior internal* articular artery extends upon the capsular ligament of the knee, assists in forming a beautiful vascular net-work on the inner side of the knee, spread over the patella, and anastomoses in several places with the *deep* branch of the *superior internal* articular artery, with the *great* anastomotic and with the articular arteries of the opposite side of the knee.

<sup>1</sup> Proximo-articular on the fibular aspect.



A considerable branch of this artery runs on the edge of the internal *semilunar* cartilage, then passes under the patella, and enters the cavity of the knee-joint. There are several branches of the *superior internal* articular artery, which we ought not to omit mentioning, distributed upon the sheath of the tendons of the flexor muscles of the leg, and from thence forming arches of communication between the *superior* and *inferior* articular arteries of the knee. It is likewise proper to remark, that in some subjects, a second *superior internal* articular artery is met with, but when it does exist, it is much smaller than the first; it is sometimes distributed wholly to the periosteum covering the posterior and lower surface of the thigh-bone, and to the sheaths of the semimembranosus, seminervosus, and sartorius muscles; and sometimes it runs on the inner side of the knee, and joins the vascular plexus formed by the *superior* and *inferior* articular arteries.

§ 13. The *inferior internal*<sup>1</sup> articular artery arises from the popliteal artery, low down in the cavity of the ham, and frequently, by a common trunk, with the arteries proper to the muscles of the calf of the leg. The *inferior internal* articular artery runs obliquely from above, downwards, and from behind, forwards, between the gastrocnemius and popliteus muscles. It ascends on the head of the tuberosity of the tibia, covered by the tendons of the semimembranosus, seminervosus, and sartorius muscles, as well as by the internal lateral ligament of the knee. There, after having given small twigs to the popliteus muscle, to the posterior *crucial* ligament, and to the *capsular* liga-

<sup>1</sup> Disto-articular on the tibial aspect.



ment, the *inferior internal* articular artery is reflected from below, upwards upon the tibia, and forms a vascular plexus, which extends a good way on the ligament of the patella, and upon the patella itself, anastomosing in several places with the *superior internal* articular artery, and with the articular arteries of the opposite side, or the *external* arteries of the knee.

§ 14. The *superior external* articular artery arises from the outer side of the popliteal artery; it ascends above the outer condyle of the femur, and furnishes branches to the periosteum covering the lower and back part of that bone; and also, to the sheath of the tendon of the biceps cruris muscle, to the articular capsule of the knee, to the plantaris, and to the outer head of the gastrocnemius muscle. Having passed the insertion of the biceps cruris muscle, the *superior external* articular artery divides into a *deep* and *superficial* branch. The *deep* branch having given some twigs to the vastus *externus* is spread in numerous twigs on the periosteum covering the lower and lateral extremity of the femur; some of these twigs communicate with the superior arteries of the periosteum of that bone, and especially with that which penetrates its internal condyle. The *deep* branch then ramifies on the periosteum covering the external surface of that condyle, and upon the external lateral ligaments of the knee; and when it reaches the place where the external condyle begins to be covered with cartilage, it divides into numerous small branches, each of which enters into the spongy bony substance of that condyle. The *superficial* branch of the *superior external* articular artery passes over the common tendon of the extensor muscles of the knee, and distributing several branches above and below the patella,



anastomoses with the *external* circumflex artery, with the perforating, and with the articular arteries of the opposite or inner side of the knee.

§ 15. The *inferior external*<sup>1</sup> articular artery derives its origin from the outer side of the popliteal artery, immediately below the articulation of the femur with the tibia. This artery, covered by the plantaris and gastrocnemius muscles, and also by the external lateral ligaments of the knee, ascends and appears on the outer side of the knee, a little above the head of the fibula. From thence it runs along the *semilunar* cartilage of the same side, as far as the patella, sending small branches within the articulation of the knee, and lastly, anastomoses with the *superior external* articular artery, with the *superior internal* articular under the ligament of the patella, and with the *recurrent tibial* articular artery.

§ 16. The *middle* articular artery, called by Haller *azyga*, presents many varieties with respect to its origin. For it sometimes arises from the posterior surface of the popliteal artery, sometimes it is only a branch of the *superior internal* articular artery, sometimes it comes off from the *superior external* articular artery. In whatever way the *middle* articular artery arises, after a short space, it sinks posteriorly into the ham in the hollow between the condyles of the os femoris; it ramifies upon the *crucial* ligaments, upon the *semilunar* cartilages, and within the knee it anastomoses with those branches of the articular arteries which dip into the cavity of the joint, as has been described above.

<sup>1</sup> Disto-articular on the fibular aspect.



§ 17. The *recurrent tibial* articular artery arises from the *anterior* tibial, a little after it has passed through the interosseous ligament, ascends from below upwards, and comes out at the knee through the head of the *tibialis anterior* muscle. It is ramified upon the periosteum of the tibia, and anastomoses with the *external* articular arteries which are nearest to it, and likewise unites with the *internal* articular arteries of the knee, by means of the communication which the *recurrent tibial* articular artery has with the vascular plexus spread over the patella.

§ 18. The popliteal artery, after giving off the articular arteries of the knee, supplies on both sides considerable branches to the muscles of the calf of the leg, viz. the popliteus, plantaris, soleus, and gastrocnemius; some of these branches likewise are ramified on the periosteum of the tibia, on the large popliteal nerve, on the posterior surface of the articular capsule of the knee, and on the tendons of the flexor muscles of the leg; others descend superficially and immediately under the skin of the calf of the leg, and extend as far as the foot, following the direction of the tendo-achillis. After this, the popliteal artery deep under the muscles, divides into the *anterior* and *posterior* tibial arteries. Thus far of the *superficial* femoral:—we now proceed to trace the *profunda* femoral artery.

§ 19. The *profunda* femoral, situated behind the *superficial* femoral artery, descends in the triangular fossa formed by the convergence of the *iliacus internus* and *pectineus* muscles, at its beginning from the inner towards the outer part of the thigh, then in a contrary direction from the outer towards the inner part of the limb. It then dips down considerably in



the space between the vastus *internus* and adductor *magnus* muscles of the thigh.

§ 20. The *profunda* femoral artery, a little after its origin, sends off the *external cutaneous* branch of the thigh; this branch, after being distributed upon the iliacus internus muscle; upon the head of the rectus femoris; upon the sartorius muscle, and after various anastomoses with the abdominal artery, pierces the aponeurosis of the muscle of the fascia lata, near the spine of the os ilium, and is distributed on the skin covering the hip. Another branch arising from the trunk of the *profunda* femoral artery, is distributed upon the sartorius muscle, and on the skin covering it.

§ 21. The most considerable branches which arise from the *profunda* femoral artery, immediately after its origin, are the circumflex arteries of the thigh, viz. the *internal*<sup>1</sup> and *external*<sup>2</sup> circumflex arteries. The *internal* circumflex artery runs across under the trunk of the *superficial* femoral, and sinks deep in the space left by the pectineus, iliacus internus, and psoas muscles. It then runs round behind the neck of the femur, and proceeds in the hollow which lies between the *lesser* and *great* trochanter. The first branch which goes off from the *internal* circumflex artery, is that which sinks into the iliacus internus and psoas muscles, and anastomoses with the *cutaneous* branch of the *profunda* femoral artery. From the convexity of the *internal* circumflex, arises in the first place the *external pudic* branch, which, after having given some small twigs to the pectineus muscle, and

<sup>1</sup> Larger circumflex.

<sup>2</sup> Smaller circumflex.



to the superior portion of the adductor *secundus*, is dispersed on the integuments around the pubes, and on the root of the scrotum; in the next place the branch which forms the anastomosis between the *internal* circumflex and obturator arteries, and lastly, in succession, those twigs which go to the *external* obturator muscle, and to the ligamentous capsule of the articulating head of the femur with the ilium. Nearly from the same convexity of the *internal* circumflex artery, arise the branches which sink into the pectineus, gracilis, adductor *primus* and *secundus* muscles, and supply the skin adjoining these parts; some of these anastomose with the *external pudic*<sup>1</sup> branches of the *superficial* femoral artery. The *internal* circumflex artery then bends very much behind the *lesser* trochanter. It divides there into two branches, one of which subdivided into smaller ones, dips into the flesh of the superior portion of the adductor *magnus* muscle of the thigh; the other is hid behind the *lesser* trochanter, and assumes the name of *posterior* trochanteric artery. This artery, having formed some anastomoses with the obturator artery, runs under the neck of the femur in the hollow situated between the *great* and *lesser* trochanter, and having reached posteriorly the vicinity of the inferior edge of the quadratus femoris muscle, it divides into two branches, one of which from the direction they take, is called *ascending*, the other *descending*. The *ascending* branch goes up towards the great trochanter, and after having given branches to the quadratus femoris, to the gemelli, and obturator *internus* muscles, and to the articular capsule of the head of the femur, anastomoses with a branch of the ischiatic artery; then with the *deep*

<sup>1</sup> Inguinal pudics.



*common* pudic artery, with the trochanteric branch of the external circumflex, and with the trochanteric branch of the *first* perforating artery. The *descending* branch of the *internal* circumflex artery comes out from under the edge of the *quadratus* femoris muscle, or between this muscle and the head of the adductor *magnus* of the thigh, and then dividing into several small branches, forms a considerable anastomosis with the ischiatic artery, and is finally distributed upon the long head of the biceps cruris, on the semi-membranosus, seminervosus, and adductor *magnus* muscles.

§ 22. The *external* circumflex artery arises from the *profunda* femoral artery, sometimes at the distance of an inch, sometimes of an inch and an half below the origin of the *internal* circumflex, near to the insertion of the iliacus internus muscle. This large artery takes an oblique direction from within, to the outer part of the thigh, and is covered by the sartorius, rectus, vastus externus, and fascialis muscles. A little after its origin, the *external* circumflex artery divides into several branches, some of which may be called *transverse*, others *descending*. One of the *transverse* branches having run some way behind the rectus muscle of the thigh, to which it gives a few branches, sinks into the muscle of the fascia lata, and having passed through the aponeurotic sheath of this muscle, it goes with some other branches to the skin of the top of the thigh, and from thence along the spine of the os ilium to the gluteus *minor*. Other *transverse* branches are distributed partly to the iliacus internus muscle, and partly to the articular capsule of the head of the thigh-bone; in this part they anastomose repeatedly with the branches proceeding from the *inter-*



*nal* circumflex and obturator arteries. One of the most considerable of the *transverse* branches of the *external* circumflex, is the *anterior* trochanteric artery, which, after having given some branches to the superior part of the cruralis muscle, to the articular capsule of the head of the femur, and to the spongy substance of that bone, pierces the head of the vastus *externus* muscle, and runs on the back of the great trochanter, where it forms a beautiful vascular plexus, by means of which the *anterior* trochanteric artery anastomoses with the *posterior* trochanteric of the *internal* circumflex, with the branch of the *deep common* pudic artery, and with the trochanteric branch of the *first* perforating artery.

§ 23. Among the *descending* branches of the *external* circumflex artery may be mentioned, those which enter the cruralis, the vastus *internus*, and the rectus muscle of the thigh. Some of these last branches having passed through the rectus muscle, are distributed anteriorly on the skin of the thigh; others extend as far as the patella, where they anastomose with the *superior* articular arteries of the knee, arising from the popliteal artery. From both of these *descending* branches of the *external* circumflex, the thigh-bone receives small *nutritious* arteries. The principal *descending* trunk of the *external* circumflex artery runs on the outer side of the thigh, between the vastus *externus* and cruralis muscles, to which muscles, especially to the vastus *externus*, it furnishes many branches; it then extends down to the knee, where it evidently anastomoses with the perforating arteries of the *profunda* femoris; with the perforant of the *superficial* femoral, and with the *superior* articular arteries of the knee.



§ 24. The *profunda* femoral artery, after having given off the circumflex arteries, bends from the outer towards the inner side of the thigh, and descends very deep in the triangular space left by the *vastus internus* and adductor *secundus* muscles. The most considerable branches which come off from this lower curvature of the *profunda*, besides those which it furnishes to the gracilis and adductor muscles, are the arteries called perforating, distinguished from each other by the names *first*, *second*, *third*, and *fourth* perforating arteries. The last perforating artery, however, is only, properly speaking, the continuation or extremity of the trunk of the *profunda*.

§ 25. The *first* perforating artery pierces the thigh from before, backwards, in the space between the insertion of the pectineus muscle and the adductor *brevis* and *vastus internus*, and appears posteriorly at the distance of about two inches and a half below the *quadratus femoris* muscle. After having given some small branches to the muscles in the neighbourhood of which, or through which it passes, and especially having furnished the *superior nutritious* artery of the femur, the *first* perforating artery divides into two principal branches, one of which is called the trochanteric, the other the transverse. The trochanteric branch of the *first* perforant, is distributed on the *great gluteal* muscle, within the substance of which it anastomoses with the ramifications of the posterior iliac artery; it then ascends along the *great trochanter*, and anastomoses in several ways and directions with the other trochanteric arteries of different origins, such as those arising from the two circumflex arteries, and with the *common pudic* artery. The *transverse* branch of the *first* perforant having sent several small branches



through the aponeurosis of the muscle of the fascia lata, as far as the skin, is concealed in the substance of the vastus externus muscle, within which it anastomoses with the ramifications of the *external* circumflex, and with those of the inferior perforating arteries. In the subjects in which the descending branch of the *internal* circumflex does not furnish a sufficient number of branches to the heads of the flexors of the leg, these muscles receive them from the *first* perforating artery.

§ 26. The *second* perforating artery is reflected from before to the back part of the thigh, piercing the adductor *magnus* muscle in the space between the adductor *primus* and *secundus*. Having passed through the adductor *magnus* muscle, to which it gives some branches, the *second* perforating artery subdivides into several branches, which dip into the long head of the biceps flexor cruris, into the semimembranosus and seminervosus muscles. In some subjects, this artery forms a communication with the trochanteric and transverse branches of the *first* perforating artery.

§ 27. The *third* perforating artery is reflected from before, to the posterior part of the thigh, crossing the aponeurotic insertion of the adductor *secundus* muscle, and, at the same time, the fibres of the adductor *magnus*. This artery runs over the upper part of the short head of the biceps flexor cruris, and from thence penetrates the substance of the vastus *externus*; and within that muscle it anastomoses with the *transverse* branch of the *first* perforant, with those of the great *descending* branch of the *external* circumflex artery, and with the perforant of the *superficial* femoral.

§ 28. The *fourth* perforating artery, the continua-



tion or extremity of the trunk of the *profunda* femoral artery, divides into several branches, which run into the long and short portions of the biceps flexor cruris, and then into the semitendinosus, semimembranosus, and into the lower extremity of the adductor *magnus* femoris.

§ 29. It is necessary to state, that the *third* perforating artery, and the *transverse* branch of the *first*, after being minutely distributed through the muscular substance of the vastus *externus*, anastomose repeatedly with each other, and with the *descending* branch of the *external* circumflex artery, and that, in the vicinity of the patella and on the top of the knee, these arteries communicate with the perforant of the *superficial* femoral, and with the *superior* articular arteries which arise from the popliteal artery.

§ 30. The anastomoses and communications between the arteries of the periosteum of the femur, and the *superior* articular arteries of the knee, form likewise an object of consideration, both to the anatomist and to the surgeon. From the branch of the *external* circumflex, which enters the cruralis muscle, are sent off smaller branches, which are dispersed on the periosteum of the anterior and internal surface of the head of the thigh-bone; round which place they form an extensive vascular plexus, intermixed with other arterial twigs coming from under the vastus *externus* muscle. Nearly about the middle of the thigh-bone, the *profunda* furnishes a considerable arterial branch to the periosteum, which separating into branches, upwards and downwards, along the bone, increases considerably this vascular net-work of the periosteum, and keeps up, by its numerous inosculation,



an easy and abundant communication, both with the superior arterial branches of the periosteum coming from the *external* circumflex artery, and with those derived from the arteries situated on the posterior surface of the bone under the vastus *externus* muscle. This vascular plexus, distributed abundantly on the periosteum of the femur, at last, in the neighbourhood of the knee, forms repeated and distinct anastomoses with the popliteal artery, by means of the branch which it gives to the periosteum covering the bone in the vicinity of the condyles, and likewise by means of the *superior* articular arteries of the knee.



## CHAPTER II.

## COROLLARIES.

§ 1. ALL the anastomoses described in the preceding chapter, as well as all those numerous communications which, on account of the smallness of the arterial vessels by which they are formed, I have omitted to mention particularly, are naturally distinguished into two orders; the one, including those anastomoses which take place between the arteries of the parietes of the abdomen and thorax, and of the inside of the pelvis with the *common* femoral artery; and the other, those which occur between the *superficial* and *profunda* femoral arteries along the thigh, and over the whole circumference of the knee.

§ 2. With regard to the first order of anastomoses, or that between the arteries of the trunk of the body, and the arteries of the lower extremities; if, from any cause whatever, the passage of the blood through the *external* iliac artery be impeded or wholly obstructed in that portion lying between the origin of the *internal* iliac artery and the crural arch, the blood of the aorta will not fail to find other ways of passing from the trunk of the great artery into the *superficial* and *profunda* femoral arteries. For the epigastric artery, by its position, by its size, and by its anastomoses, is capable of conveying the blood to the *common* femoral artery, as it is about to come out from under the crural arch, from the *internal* mammary, from the intercostal, and from the thoracic ar-



teries, by means of the numerous communications which the epigastric artery has with those of the thorax.<sup>1</sup> The same derivation is caused by the abdominal artery, in similar circumstances; for, by the medium of its repeated anastomoses with the ramifications of the ileo-lumbar, of the lumbar, and of the inferior intercostal arteries,<sup>2</sup> it may, as well as the epigastric, convey a considerable quantity of blood to the *common* femoral artery, from the parietes of the thorax, of the abdomen and loins, before this artery passes from under the crural arch, even although the passage of the blood within the pelvis, by the *external* iliac artery, be impeded or totally obstructed.<sup>3</sup>

§ 3. Immediately after passing the crural arch, the external pudic arteries, by their communications with the cutaneous branches of the epigastric artery upon the bend of the thigh, the abdomen, and upon the

<sup>1</sup> See Haller. Fascic. Anat. vi. Tab. 1.

<sup>2</sup> Haller. Fascic. Anat. viii. Tab. art. tot. corp. anter.

<sup>3</sup> The epigastric vein may do, and has sometimes done the same in an inverted sense, or according to the current of the venous blood. The celebrated Mr. Cline having found in the body of a man the inferior vena cava obliterated a little above its bifurcation, in consequence of a steatomatous tumour, which had formed in the cellular substance behind the peritonæum, and which occupied a part of the pelvis and lumbar region, remarked that the epigastric veins were become as large as the little finger, and that the superficial veins of the abdomen, as well as the lumbar, and those of the internal cavity of the abdomen, were in a similar manner very much dilated; the internal mammary vein likewise greatly enlarged, and also the epigastric, with which it anastomosed, opened, as usual, into the superior cava, near to the origin of the subclavian veins; by which circumstance the venous blood of the lower extremities was poured into the superior cava, by means of the mammary vein, and into the inferior cava, by the lumbar veins, above the compression caused by the steatomatous tumour.



external parts of generation, and by means of their anastomoses with branches of the abdominal artery, and with those of the *common* pudic artery, contribute very much to increase the derivation of the blood of the aorta into the *superficial* femoral artery immediately below the crural arch.

§ 4. The conspicuous anastomoses which the two circumflex arteries of the thigh make with the *internal* iliac, with the ischiatic, with the *common* pudic,<sup>1</sup> and with the obturator arteries, attract, to use the expression, and greatly accelerate the current of blood from the internal part of the pelvis into the *profunda* femoral artery. For, the internal circumflex artery anastomoses in the first place with the *external* pudic arteries, by means of the branch which it gives to the root of the scrotum and penis; it then communicates, in the seat of the foramen ovale, with the obturator artery; and, whether this last artery comes off from the epigastric, or from the *internal* iliac, the effect is the same in respect to the transmission of the blood from the aorta into the *profunda* femoral artery, without passing through the *external* iliac; then the *internal* circumflex artery constitutes a considerable anastomosis with the ischiatic, and *common* pudic arteries, by means of the *posterior* trochanteric branch, by which means the arterial blood of the cavity of the pelvis flows into the *profunda* femoral artery, independent of any *obliteration*, or obstruction of the *external* iliac artery.

§ 5. The other route of communication of the *profunda* femoral artery with the arteries contained in the cavity of the pelvis, by means of the *external* circum-

<sup>1</sup> Pelvien pudic.



flex, is equally evident, and worthy of attention. For, the *transverse* branches of this artery, those which go upwards towards the hip, upon the *gluteus medius* muscle, anastomose with the posterior iliac artery, and those which pass beyond the muscle of the fascia-lata communicate with the muscular and cutaneous arteries of the hip and side, and the *anterior* trochanteric branch anastomoses on the great trochanter with the ischiatic, with the *common* pudic artery, with the *posterior* trochanteric branch of the *internal* circumflex, and with the trochanteric branch of the first perforating artery; which last branch likewise anastomoses in several places, with the gluteal and *posterior* iliac arteries coming out of the cavity of the pelvis. The blood, therefore, which comes out of the pelvis to the side and hip, meets the course of the two circumflex arteries of the thigh, through which it is carried to the trunk of the *profunda* femoral, even although the passage of the blood through the *external* iliac artery, in the vicinity of the crural arch, be shut and obliterated. Some years ago, Dr. Baillie, physician to St. George's hospital, London, found, in the body of an adult male subject, the crural artery obliterated above the *profunda* femoral, without its having occasioned the loss of the circulation or life of the limb below. This very important observation was also made by Guattani, by Gavina, and afterwards confirmed by several other surgeons of great reputation. The explanation of this phenomenon may be clearly deduced, in my opinion, from the anastomoses just described.

§ 6. With regard to the second order of anastomoses, or those which take place between the *superficial* femoral and popliteal arteries with the *profunda*, along the course of the thigh, and round the knee; or, what signifies the same thing, between



the two great femoral arteries and the popliteal, there are two routes which the blood takes, the one or other of which is more or less easy and free, according as the *superficial* femoral artery is obstructed or tied near, or at a distance from the place where the *superficial* femoral perforates the adductor *magnus* muscle of the thigh, to descend into the ham. One of these routes is by the great branches which the superficial femoral artery gives to the vastus internus muscle, communicating, at the lower part of the thigh, with the great anastomotic branch of the popliteal artery. By these branches, on the *superficial* femoral artery being obstructed or tied a little before it passes through the adductor *magnus* muscle, to descend into the cavity of the ham, the blood finds a ready and easy passage, from the *superficial* femoral above the place of the ligature, into the popliteal artery, by the communication between these large branches and the *great anastomotic* branch.

§ 7. When this route is obstructed, from the ligature having been applied very high up on the *superficial* femoral artery, as in the upper third of the thigh, the passage of the blood through the trunk of the artery is supplied by the anastomoses which take place between the *profunda* and the *superficial* femoral just about to become popliteal, in particular by the anastomoses kept up by means of the *external* circumflex and the perforating arteries, with the inferior branches of the *superficial* femoral, and with the articular arteries of the knee.

§ 8. For, the smaller *descending* branches of the *external* circumflex artery, inserted into the vastus internus, cruralis, and rectus femoris muscles, anasto-



mose at the lower part of the thigh with the *great anastomotic* branch of the popliteal artery. The *great descending* artery of the *external* circumflex, and all, or a great many of the perforating arteries of the *profunda* femoral by means of their *transverse* branches, which sink into the substance of the *vastus externus* muscle, anastomosing with each other, at last communicate with the great perforant artery of the *superficial* femoral, which last artery joins the *superficial* femoral, at the part where it passes through the adductor *magnus* muscle, to descend into the cavity of the ham. In consequence of this, the blood which runs by the *external* circumflex, and by the perforating arteries of the *profunda*, after having supplied the fibres of the above mentioned muscles, and in particular those of the *vastus externus*, is at last conveyed into the popliteal artery by the *great anastomotic*, and by the perforant of the *superficial* femoral artery.

§ 9. But, still lower, and even in the cavity of the ham, the blood enters the popliteal artery, conveyed by the branches above mentioned of the *external* circumflex, and of the perforating arteries of the *profunda* femoral, by means of the numerous anastomoses which all these arteries have with the articular arteries of the knee, and with the *recurrent* tibial articular artery. Then the branch of the *external* circumflex, which descends along the rectus muscle of the thigh, anastomoses with the *superior internal* articular artery of the knee, with which artery the *great anastomotic* of the *superficial* femoral also communicates. In a similar manner the *great descending* branch of the *external* circumflex, the *transverse* branches of the perforating arteries of the *profunda*, and the perforant of the *superficial* femoral, anastomose on the top, and



round the *outer* side of the knee, with the *superior external* articular artery. The two *superior* articular arteries of the knee then communicate repeatedly with the *inferior* articular arteries, and at the same time with the *recurrent tibial* articular artery. From which it follows, that the blood of the *profunda* femoral is conveyed into the popliteal artery at the upper part of the ham, by the *great anastomotic* branch, and the perforant of the *superficial* femoral artery, and that it comes into it at the lower part of the ham, by the conspicuous anastomoses which the *profunda* femoral keeps up with the *superior* and *inferior* articular arteries of the knee.

§ 10. To all this ought to be added the communication which the *profunda* femoral has with the popliteal artery, by means of the arteries of the periosteum covering the femur. The two principal arteries of the periosteum covering the anterior and lateral inner surface of that bone, the one arising from the branch of the *external* circumflex artery, which sinks into the cruralis muscle, the other, which comes off from the trunk of the *profunda* femoral artery, after having united with many other branches of this class, which the perforating arteries spread upon the periosteum of the posterior and outer surface of the bone, form together an extensive and minute vascular net-work.<sup>1</sup> This extends to the lower part of the thigh-bone, and finally anastomoses with the artery which the popliteal sends to the periosteum, in the neighbourhood of the internal condyle of the femur, and communicates at the same time with the branch of the *superior*

<sup>1</sup> Haller. Elem. Physiolog. In integro periostio humeri, femorisve nullus est ramus ad quem ex omni alio ramo ejus membranæ libera via non sit.



*internal* articular artery of the knee, and then it penetrates the spongy bony substance of that condyle. From thence it follows, that a portion of the blood of the *profunda* femoral artery is conveyed along the periosteum into the popliteal artery; and it is further observable, that the principal *nutritious* arteries of the femur come off superiorly from the *first* or *second* perforating artery, and that at the lower part these *nutritious* arteries come off from the perforant of the *superficial* femoral. So that, since the *superior* nutritious arteries of the thigh-bone communicate with the *inferior nutritious*, in the internal texture and spongy substance of the bone, and sometimes also before their entrance into the bony substance of the femur,<sup>1</sup> it may be inferred, that also, by the *nutritious* arteries of the bone, nature has formed a passage for the blood of the *profunda* into the *superficial* femoral artery, in the vicinity of the place where the latter artery begins to become popliteal. And then, if to all these be added the many other anastomoses, however minute they may be, which take place between the arteries running in the cellular substance, and the almost innumerable others of the integuments, which cover the lower extremity from the top of the hip to the knee, (the origin of which tegumental arteries is partly from the *profunda*, partly from the *superficial* femoral artery), a great addition is made to the number of ways by which, in a case of obstruction or obliteration, or of the artificial ligature of the *superficial* femoral artery, at different points of its whole course, from under the origin of the *profunda* to the knee, the blood may notwithstanding pass into the popliteal artery, and consequently into the arteries of the leg and foot.

<sup>1</sup> Haller. Fascicul. anat. v. tab. iii. n.



## CHAPTER III.

## OF THE ARTERIES OF THE SCAPULA AND ARM.

§ 1. THREE great trunks go off from the arch of the aorta ; the *inominata*, from which arise the right carotid<sup>1</sup> and subclavian;<sup>2</sup> then the left carotid<sup>3</sup> and the left subclavian.<sup>4</sup> The left subclavian ascends to the neck in a less oblique line than the right. The most considerable branches, which both on the one and the other side of the body, are given off by the subclavian artery, are the vertebral, the *internal* mammary, the *superior* intercostal,<sup>5</sup> and the *inferior* thyroid arteries. The anatomical history of the latter artery is inseparable from the description of the arteries of the arm ;\* both because it furnishes very considerable branches to the scapula, and because it forms round the scapula considerable anastomoses with the principal trunk of the arm, above and below the clavicle and in the axilla, and with several of the other great branches of the brachial artery.

§ 2. The *inferior* thyroid artery arises from the subclavian opposite to the origin of the vertebral artery. At its beginning, the *inferior* thyroid gives off three considerable branches, viz. the *superior* scapu-

<sup>1</sup> Right cephalic.

<sup>2</sup> Subclavian portion of the right brachial.

<sup>3</sup> Left cephalic.

<sup>4</sup> Subclavian portion of the left brachial.

<sup>5</sup> First intercostal.

\* Walter therefore, has not without reason, called this artery *juguli et scapulæ communis*. Progr. de vasis vertebr. p. 11.



lar, the *transverse* cervical of the neck, and the *ascending* cervical artery.

§ 3. The *superior* scapular artery follows the course of the clavicle. This artery furnishes cutaneous branches to the *sternal* portion of the clavicle, which anastomose with the *superior* thoracic arteries, and with the *internal* mammary; some sink into the beginning of the sterno-mastoid and sterno-hyoid muscles; others into the subclavian and serratus *magnus* muscles; others into the coraco-hyoid muscle, and into the membranes of the vena cava, of the jugular and subclavian veins; and also, into the neighbouring lymphatic glands, and into the integuments of the neck, and of the top of the shoulder. Towards that portion of the clavicle which is called *humeral*, the *superior* scapular artery divides into two branches of unequal size; the smaller of these advances under the clavicle in the fossa *supra-spinata* of the scapula; where having divided into other smaller twigs, it anastomoses repeatedly with the *transverse* cervical thyroid artery, with the continuation of the trunk of the *superior* scapular, with the *humeral* thoracic, and contributes to form a beautiful vascular plexus, extending over the acromion, and on the *humeral* extremity of the clavicle. The large branch, or rather the continuation of the trunk of the *superior* scapular artery, after having anastomosed in the fossa *supra-spinata* with the smaller one, and having given branches to the capsular ligament of the humerus, as also to the supra-spinatus muscle, descends by the fissure between the root of the acromion, and the neck of the scapula, and there, sometimes in one, sometimes divided into two branches, unites with the *inferior circumflex* scapular artery, and forms with it an ar-



terial anastomotic circle, which surrounds the scapula.

§ 4. The second branch of the *inferior* thyroid artery, or the *transverse thyroid* cervical artery, (*transversalis colli*), in its course across the lower part of the neck, gives branches to the elevator muscles of the angle of the scapula, to the *middle* and *posterior* *scaleni* muscles; to the acromion, and then divided into smaller twigs ascending along the neck, it sinks into the head of the trapezius, and into the splenius muscle of the head and neck, at which part this artery anastomoses with the occipital artery, and then sends down twigs to the lower portion of the trapezius, and to the muscles of the back.

§ 5. The third branch of the *inferior* thyroid artery, or the *ascending* cervical, (*ascending thyroid*), proceeds upwards in the neck, along the transverse processes of the cervical vertebræ, between the *scaleni* muscles and *rectus anterior* of the head. This artery gives branches to the sterno-mastoid, coracohyoid, to the *anterior* and *middle* *scaleni* muscles, to the levator of the angle of the scapula, to the splenius muscle of the head and neck, to the par vagum, to the *superior* cervical ganglion of the intercostal nerve, and to the lymphatic glands and integuments of the neck; it then anastomoses at the upper part with the occipital artery. The *deep* branches which go off from this artery, are distributed upon the *inter-transverse* muscles of the neck, on the origins of the *scaleni* muscles and *rectus anterior* of the head. Others of these *deep* branches of the *ascending thyroid* cervical artery, sometimes more, sometimes less numerous, enter the vertebral canal by the same holes through which the



spinal cervical nerves come out, and are distributed upon the meninges, which cover the spinal marrow of the neck. The superior branches of the *ascending* cervical artery, constitute a conspicuous and double anastomosis with the vertebral artery.

§ 6. The trunk of the left *inferior* thyroid artery, which is more particularly described here, bends behind the carotid of the same side, and from the curvature which it makes, gives off a branch which ascends on the anterior surface of the cervical vertebræ, and is distributed to the rectus *anterior* of the head, and longus muscle of the neck, to the bodies of the cervical vertebræ, and to the *middle* cervical ganglion of the intercostal nerve; then this branch, divided into other smaller ones, enters by the lower holes between the vertebræ of the neck, into the vertebral canal, and in these places anastomoses with the *deep* branches of the *ascending thyroid* cervical artery above described, and with those of the *descending* pharyngeal artery.

§ 7. The trunk, properly so called, of the *inferior* thyroid artery, is reflected from without, to the inner part of the neck, towards the gland of the same name, in which it anastomoses very frequently with the branches of the *superior* thyroid artery. It likewise gives many branches to the larynx, to the trachea, to the broncheal glands, and to the œsophagus.

§ 8. The subclavian artery bending from within the chest outwards, runs between the *anterior* and *middle* scaleni muscles. Having passed beyond these muscles, the subclavian artery inclining from above



downwards on the first rib, gives off the *profunda* cervical artery, which having given several branches to the *scaleni* muscles, and to the levator of the angle of the scapula, divides into two branches of unequal size, one of which is the *posterior ascending* cervical, the other the dorsal artery of the scapula.

§ 9. The *posterior ascending* cervical branch of the *profunda* subclavian cervical artery, after being distributed on the levator of the angle of the scapula, and under it to the *serratus superior posticus*, perforates the levator muscle; it then ascends on the posterior surface of the neck, and sinks into the head of the *splenius* muscle of the head, and still deeper into that of the neck, and in succession into the *trachelomastoid*, *rectus major posticus*, and *inferior oblique* muscles of the head, and into the periosteum of the upper cervical vertebræ. Some other branches of this artery enter the *trapezius* muscle, and others anastomose on the top of the scapula with the *transverse thyroid* cervical, and with the *inferior circumflex* scapular arteries.

§ 10. The other branch, the continuation of the trunk of the *profunda* subclavian cervical, or the dorsal artery of the scapula, runs deep under the insertion of the levator muscle of the angle of the scapula, and of the *rhomboideus* muscle, and extends downwards along the base, and sometimes under the base of the scapula. In the space which this artery runs in the back, it supplies branches to the *trapezius*, to the *serratus posticus superior*, and to the *serratus magnus*, *interscapularis*, and to the *rhomboideus major* and *minor* muscles, as also to the *longus* of the back and *sacro-lumbaris* muscles. The dorsal artery



of the scapula anastomoses with the *superior* scapular artery, and with the *transverse* arising from the *inferior* thyroid artery, at the place corresponding to the top of the scapula; and at the lower part of the scapula, the dorsal artery communicates with the *inferior circumflex* scapular artery, and with the dorsal branches of some of the intercostal arteries. Sometimes the dorsal artery of the scapula does not come off from the *profunda subclavian* cervical, but from the *transverse thyroid* cervical artery.

§ 11. The trunk of the subclavian artery, a little after the origin of the *profunda* cervical, gives off a small artery, to which might, with propriety, be given the name of subscapular artery. This artery, after having given branches to the plexus of the brachial nerves, with which it intermixes, and sometimes another small branch which runs upon the fossa *supra-spina*, where it anastomoses with the *superior* scapular artery, enters and is dispersed within the subscapularis muscle.

§ 12. The subclavian artery having descended under the clavicle into the cavity of the axilla, receives the name of axillary artery. There go off, in the first place, from the axillary artery, the thoracic arteries, sometimes three, four, or six in number. The *first*, or *superior* thoracic, gives branches to the first intercostal muscles, to the pectoralis *minor*, to the skin of the chest, and anastomoses in several places with the *internal* mammary, and *superior* intercostal arteries. The trunk of the *first* thoracic is incurvated, and descends between the pectoralis *minor* and serratus *magnus* muscles, as far as the fourth or fifth rib; it gives branches to these muscles, and renews the anastomoses



which it has in the spaces between each rib, with the *internal* mammary, with the intercostal, and with the *second* and *third* thoracic arteries.

§ 13. The *second* thoracic, or the acromial artery, arises from the axillary in the vicinity of the second rib. It supplies branches to the pectoralis *minor*, and serratus *magnus* muscles. A branch of it runs along the *sternal* portion of the clavicle, is dispersed on that bone, and then goes to the subclavian muscle, and to the origin of the sterno-mastoid. Above the place of the articulation of the clavicle with the sternum, this artery anastomoses with the *superior thyroid* scapular, with the *internal* mammary of both sides, and with the superior intercostal arteries. The trunk of the *second* thoracic has numerous ramifications within, and under the pectoral muscle, and in the fleshy bundles of the deltoid muscle. It then sends off the acromial artery, properly so called, in the space between the pectoral and deltoid muscles; this acromial artery takes a retrograde course, covered by the deltoid muscle, and proceeds along the anterior margin of the *humeral* portion of the clavicle, and from thence upon the acromion, as far as the spine of the scapula, in which space it anastomoses in several places with the *superior* scapular and *transverse* cervical arteries arising from the *inferior* thyroid; and lastly, with the *profunda subclavian* cervical and circumflex arteries of the humerus.

§ 14. The *third*, or *long* thoracic, or external mammary artery, gives branches to the pectoralis *minor*, to the serratus *magnus* and intercostal muscles, to the superior axillary gland, and to the gland of the mamma; it afterwards anastomoses in several places with



the *first* thoracic, with the *internal* mammary, and with the *inferior* intercostal arteries, as far as the fifth rib.

§ 15. The *fourth*, or *axillary glandular* thoracic artery, (*thoracica humeraria*), which is sometimes only a branch of the *inferior* scapular artery, gives several branches to the *great* rotundus, (*teres major*), to the *great* dorsalis, the *serratus magnus*, the *subscapularis*, and to the long portion of the *triceps extensor* muscle, where it anastomoses with the *profunda* humeri, and then sends off several other branches to the lymphatic glands, situated in the cavity of the axilla. The thoracic axillary artery then extends downwards, as far as the sixth or seventh rib, where it anastomoses with the *long* thoracic, with the *intercostal* and *internal* mammary arteries.

§ 16. The axillary artery continues to descend in the cavity of the axilla, resting upon the head of the *subscapularis* muscle, to which it gives several small branches, as well as to the cords which form the root of the median nerve, which surround the artery, and also some small branches to the superior axillary lymphatic glands. On reaching the anterior margin of the scapula, the axillary artery gives other twigs, which spread upon the beginning of the *coraco-brachialis* muscle, and on the articular ligamentous capsule of the humerus; and then the *great inferior* scapular artery comes off from the trunk of the axillary artery.

§ 17. The *inferior* scapular artery gives off, in the first place, one or more branches, which partly sink into the *subclavian* muscle, and are partly dispersed



upon the periosteum of the hollow of the scapula, where they form arches of communication with each other, and with the *superior thyroid* scapular artery. (See Haller Fasc. vi, tab. ii, fig. 11.) Other branches, proceeding from the same origin, go to the *small* and *great* rotundus, (teres major and minor), and to the great dorsalis (latissimus dorsi) muscle. The *inferior* scapular artery then turns from the inner to the outer side of the scapula, and assumes the name of circumflex artery of the scapula. The circumflex artery, covered by the infra spinatus muscle, ramifies freely on the dorsum of the scapula. One great branch of this artery goes upwards between the cervix and the root of the coracoid process of the scapula, and there forms the great anastomosis between the *superior thyroid* scapular, and the *inferior axillary* scapular artery. From these anastomoses are given off branches, which spread upon the ligamentous capsule of the head of the humerus, and upon the *long* portion of the triceps extensor muscle of the arm. The *great* rotundus, (teres major), and the great dorsalis muscles, also receive branches from the circumflex artery of the scapula. Farther, this circumflex artery anastomoses in many places, and especially along the spine, and base of the scapula, with the *transverse thyroid* cervical artery, with the *profunda subclavian* cervical, and with the dorsal artery of the scapula, and with the inferior intercostals, whether the dorsal artery of the scapula comes off from the *thyroid* cervical, or from the *profunda subclavian* cervical artery.

§ 18. A little below the origin of the *inferior* scapular, the two circumflex *humeral* arteries arise from the axillary artery, viz. the *anterior* and *posterior*; they sometimes come off by a distinct, sometimes by



a common origin from the axillary artery. Sometimes the *anterior circumflex humeral* arises from the *inferior scapular* artery.

§ 19. The *anterior circumflex* of the humerus, invariably smaller than the *posterior*, is covered by the superior portion of the coraco-brachialis muscle, and by the short head of the biceps, to which it furnishes branches, as also to the great rotundus, (teres major), and dorsalis (latissimus dorsi) muscles, in the vicinity of their insertion into the humerus, and sometimes likewise to the subclavius, and to the beginning of the brachialis internus muscles. The *anterior circumflex* artery having reached the anterior internal surface of the head of the os humeri, is reflected upwards, and disperses numerous branches to the articular capsule of the head of that bone. The trunk of this artery goes backwards along the furrow in the tuberosity of the head of the humerus, within which the long tendon of the biceps muscle runs, and ramifies upon the tendons of the supra-spinatus and infra-spinatus muscles, and then anastomoses repeatedly with the *superior thyroid* scapular, and with the *posterior circumflex* artery of the humerus. Another branch of the *anterior circumflex* artery, descends along the humerus, resting upon the insertion of the *great dorsalis* muscle, and gives branches backwards towards the acromion, which communicate with those of the *superior thyroid* scapular artery, with those of the *acromial* thoracic, and of the *posterior circumflex* of the humerus. There are some other more considerable branches than the preceding, sent off from the lower part of the *anterior circumflex* artery, which form a conspicuous anastomosis between the *anterior circumflex* artery, the *profunda* humeri, and the *posteri-*



or circumflex artery of the humerus. The continuation of the trunk of the *anterior* circumflex artery of the humerus penetrates the bundles of the deltoid muscle, within which it communicates with branches of the *posterior* circumflex, the description of which follows immediately.

§ 20. The *posterior* circumflex artery of the *humerus* surrounds the neck of that bone, from the inner to the outside, passing between the insertion of the great and little rotundus, (*teres major* and *minor*), and the *long* head of the triceps extensor, to which muscles it gives branches, as well as to the coraco-brachialis, and to the *short* head of the triceps extensor muscle, and at the same time to the periosteum of the *os humeri*. This artery also gives several branches to the articular capsule of the head of the humerus, which anastomose with those which come from the union of the *superior thyroid* scapular with the *inferior* scapular artery. The principal trunk of the *posterior* circumflex artery gives numerous branches to the muscular fibres of the deltoid muscle, and anastomoses on the edge of the acromion, with the vascular net-work formed by the junction of the *superior thyroid* scapular, with the *transverse subclavian* cervical artery; it then communicates with the *anterior* circumflex, and with the *profunda* humeri. The axillary artery, under the place where it gives off the *posterior* circumflex artery, assumes the name of humeral artery.

§ 21. The humeral artery, from the edge of the great rotundus, (*teres major*), and great dorsalis, (*latissimus dorsi*), ascends gradually from within the cavity of the axilla forwards, and proceeds along the



inner side of the biceps and brachialis muscles. Several branches are given off from the inner side of the humeral artery, which sink into the coraco-brachialis, biceps and brachialis muscles, and likewise into the periosteum of the bone. Some of these branches follow the median nerve. Then, at a little distance from the edge of the tendon of the great dorsalis muscle, the profunda humeral artery arises from the common humeral artery. This artery sometimes goes off from the *inferior* scapular, or from the *posterior* circumflex artery of the humerus.

§ 22. The profunda humeral artery, sometimes double, runs for a certain space along the internal surface of the humerus, between the *long* and *short* heads of the triceps extensor muscle; it is then hid, and reflected from the internal and lower to the external and upper side of the humerus. The first branches, which go off from the profunda humeral artery, sink into the *long* and short heads of the triceps extensor muscle, where some of them anastomose with the *posterior* circumflex artery of the humerus. The coraco-brachialis, the brachialis internus, and the inferior portion of the deltoid muscle, receive some branches from it. There is constantly given off from the profunda humeral a considerable artery, which, after having given branches to the biceps, to the lower portion of the deltoid, and to the brachialis internus muscles, runs behind the coraco-brachialis, and is dispersed upon the periosteum of the os humeri, in the vicinity of the insertion of the great dorsalis muscle; there, having divided into several branches, it sends some retrograde ones, which anastomose with the two circumflex arteries, and others bending from above, downwards, which are



distributed upon the periosteum of the humerus, The continuation of this artery penetrates into the os humeri, and constitutes the *superior nutritious* artery of that bone. The trunk of the profunda humeral artery, accompanied by the radial nerve, surrounds the os humeri, and re-appears on the external and superior edge of that bone; from thence it descends along the linea aspera, towards the superior or *external* condyle of the humerus, and then divides into *radial* and *ulnar* branches. The radial branches of the profunda humeral artery proceed superficially along the linea aspera of the os humeri, between the *short* belly of the triceps extensor muscle and the humerus, furnishing branches to that muscle, to the brachialis internus, and to the supinator *longus* muscles. The principal of these branches sink deep between the *external* or superior condyle of the humerus, and the radialis *longus* and *brevis* muscles, and anastomose with the recurrent radial artery. Another of the *radial* branches of the profunda humeral artery, or rather the continuation of the trunk of that artery, extends on the outer surface of the superior condyle of the os humeri, and there anastomoses repeatedly with the *interosseous* recurrent artery, and with the collateralis *profunda* of the elbow. The *ulnar* branches of the profunda humeral artery are distributed partly to the two united heads of the triceps extensor muscle, partly extend under that muscle, among its fibres, and finally anastomose in the bend of the elbow, in the neighbourhood of the *internal* or inferior condyle of the humerus, with the collateralis *profunda* of the elbow. In some subjects, these arterial *ulnar* branches come off from the profunda humeral artery much higher up; on which point see Haller, *Fasc. Anat. viii. tab. art. tot. corp. post, dexter. u. x. y.*



§ 23. The humeral artery, continuing its course along the internal edge of the biceps muscle, and gradually advancing more forwards, gives branches to the biceps and brachialis internus muscles, and to the periosteum of the humerus. It supplies likewise the triceps extensor muscle. It then gives off the *superior* collateral, and, a little lower, in the vicinity of the bend of the arm, the *inferior* collateral artery. In the interval between the origin of the two collaterals, several small arteries come off from the trunk of the humeral, which sink into the brachialis internus and triceps extensor muscles, and into the periosteum of the lower portion of the humerus, forming many arches of communication with each other, and with the neighbouring arteries; one of these enters into the humerus, and constitutes the *inferior nutritious* artery. The *superior* collateral artery descends along the inner side of the humerus, in the course of the ulnar nerve. It gives branches to the triceps brachialis muscle, and, in the vicinity of the internal condyle of the humerus, anastomoses with the *inferior* collateral, and with the *anterior ulnar* recurrent arteries. Having made this considerable double anastomosis, the *superior* collateral artery bends behind the internal condyle, and enters the posterior fossa of the humerus, under the insertion of the tendon of the triceps brachialis muscle. The *superior* collateral artery then forms an arch, situated deep between the olecranon and the inferior extremity of the humerus, which anastomoses with the profunda humeral artery, with the recurrent *interosseous*, and with the *deep* branch of the *ulnar* recurrent artery, and it gives branches which insinuate themselves into the cavity of the articulation of the elbow. Some branches of the *superior* collateral artery, at first dis-



tributed upon the muscles, reunite afterwards with this arterial arch, under the insertion of the triceps brachialis muscle.

§ 24. The humeral artery, in the bend of the arm, or a little above it, resting on the brachialis muscle, divides into the radial and ulnar arteries.

§ 25. The radial, just at its origin from the humeral, or a little below, gives off the recurrent *radial* artery. The recurrent *radial* artery is reflected in the bend of the elbow, between the tendon of the biceps and supinator *longus* muscles, in the neighbourhood of the radial nerve. This artery gives branches to the supinator *longus* and *brevis*, to the two radiales muscles, to the brachialis internus, to the periosteum of the head of the radius, and of the lower extremity of the humerus, and to the ligaments which surround the junction of these bones. Then the recurrent *radial* artery, covered by the heads of the radiales and supinator *longus* muscles, having divided into several branches, runs above the articular radial condyle of the humerus, going from the inner towards the outer side of the elbow, in which place it anastomoses repeatedly with the profunda humeral, and with the recurrent *interosseous* artery,

§ 26. The ulnar artery, in like manner, not long after its origin from the humeral, gives off the recurrent *ulnar* artery. This last artery is distinguished into *superficial* and *profunda*. The *superficial ulnar* recurrent artery passes back between the pronator *rotundus*, (pronator teres), the brachialis internus muscles, and the *inner* condyle of the humerus. It gives branches to these muscles, to the periosteum, and to



the skin which covers the *internal* condyle of the humerus; it then anastomoses a little above the internal condyle, with the two collateral branches of the humeral artery. The recurrent *profunda ulnar* artery is then hid between the internal condyle of the humerus and the olecranon, and having passed the heads of the flexor muscles of the fingers, and the extensor ulnaris of the carpus, to which muscles it gives branches, it communicates with the recurrent *interosseous* artery, and then appears on the external surface of the elbow; from thence it ascends between the internal condyle of the humerus and the olecranon, and in the posterior fossa of the lower extremity of the humerus, anastomoses with the arterial arch of the *profunda* collateral artery of the elbow. It ramifies upon the olecranon, and communicates with the vascular plexus, formed by the union of the interosseous recurrent and profunda humeral arteries, and gives branches to the articular capsule, and to the internal parts of the articulation of the elbow.

§ 27. The recurrent *interosseous* artery ascends along the supinator *brevis* and anconeus muscles, as far as the articular head of the radius, and gives branches to the joint of the elbow; then, on the posterior surface of the internal condyle of the humerus, it anastomoses with the recurrent *radial*, with the *profunda* humeral, and with the arterial arch of the *profunda* collateral artery of the elbow. A branch of the recurrent *interosseous* artery, covered by the anconeus muscle, advances upon the olecranon, where it anastomoses with the *profunda ulnar recurrent* artery.

§ 28. The arteries which ramify upon the perios-



teum of the humerus arise from various sources. The superior arteries of the periosteum come from the scapular, and from the circumflex arteries of the humerus; lower down, from the profunda humeri, and from the humeral artery; still lower, from the recurrent *radial* arteries, from the *superficial ulnar* recurrent and collateral arteries. Farther, the periosteum receives some small arteries from the humeral branches, and from the profunda humeral artery, which ramify within the brachialis internus and triceps extensor muscles. All these arteries of the periosteum communicate with each other, both on the anterior and posterior surface of the humerus, and all of them finally anastomose with the recurrent *radial*, *ulnar*, and *interosseous* arteries.



## CHAPTER IV.

## COROLLARIES.

§ 1. As, in the inferior extremity, the arterial anastomoses are arranged by nature into two orders; into the one between the arteries of the abdomen, thorax and pelvis, with the common femoral artery, both above and immediately below the crural arch; and the other, including those anastomoses which occur between the *superficial* femoral and the *profunda*, along the thigh and round the knee; so in the same manner, in the superior extremity, two orders of arterial anastomoses are also met with; the one between the arteries of the neck, thorax, and scapula, with the subclavian and axillary arteries; the other between the brachial and the *profunda* humeral arteries, along the humerus, and round the elbow.

§ 2. In the supposition, therefore, that the course of the blood is interrupted through the axillary artery, from some morbid indisposition, or intentionally, and by the assistance of art, from the site of the clavicle, as far as the origin of the *inferior* scapular artery, the arm is not thereby deprived of circulation and life. For the blood propelled through the *inferior* thyroid artery, and through that tract of the subclavian intervening between its origin, from the arch of the aorta, beyond the scaleni muscles and first rib, takes the route of the *superior thyroid* scapular arteries, of the *transverse thyroid* cervical, of the *transverse subclavian* cervical, and dorsal artery of the sca-



pula, and passes into the *inferior* scapular artery, and from thence into the axillary artery, under the place of the obstruction, after having completed the circle of the scapula. In the greatest degree of derivation, the blood may be drawn from the vertebral and occipital arteries, to the place just mentioned, by means of the communications which these two arteries have with the *deep* and *superficial* branches of the *ascending* thyroid artery, with the superior branches of the *transverse thyroid* cervical and *subclavian* cervical arteries. In every case, therefore, where the obstruction is only a little below the clavicle, the axillary artery may be supplied with blood from the *internal* mammary, and from the superior intercostal arteries, by the numerous anastomoses which these arteries have with the thoracic arteries. The blood may also be derived from the *transverse* cervical and *superior* scapular arteries, by means of the communication which these arteries have on the acromion, and in the superior fossa of the scapula, with the *acromial* thoracic artery.

§ 3. Although the derivation of the blood of the aorta into the axillary artery, by the route of the *inferior* scapular, were prevented, nevertheless the blood of the *superior thyroid* scapular, and of the *transverse* cervical arteries, might be conveyed from the aorta into the axillary artery, under the origin of the *inferior* scapular, by the two considerable circumflex arteries of the humerus. For, the *posterior* circumflex artery of the humerus communicates, on the articular capsule of the head of that bone, with the two scapular arteries; and further, with the *superior thyroid* scapular, and with the *transverse* cervical arteries, in several places, along the acromion and spine of the



scapula. The *anterior* circumflex artery intermixes, in these anastomoses, with the superior scapular and cervical branches of the thyroid artery, and communicates likewise with the *posterior* circumflex. From which circumstance, the blood of the aorta finds several ways of passing into the axillary artery, by the arteries of the neck, and of those of the top of the scapula, although there be an obstruction of its trunk below the origin of the *inferior* scapular artery.

§ 4. If the obstruction to the passage of the blood is still lower, under the origin of the *inferior* scapular artery, as, for example, opposite to the insertion of the great rotundus, (teres major), and great dorsalis muscles, then the blood of the aorta, from the arteries of the neck, as has been just mentioned, passes into the circumflex arteries of the humerus, and from these into the trunk of the humeral artery, by means of the considerable anastomoses which these two circumflex arteries have with the profunda humeral artery.

§ 5. In whatsoever manner the great humeral artery may be compressed, obstructed, or tied, for a considerable space below the place corresponding to the insertion of the great rotundus, (teres major), and great dorsalis muscles, that is to say, below the origin of the profunda humeral artery, the course of the blood is not therefore intercepted to the forearm and hand; because, in these circumstances, the blood of the axillary artery takes the route of the profunda, and in that way enters the radial, ulnar, and interosseous arteries, below the bend of the elbow, through the medium of the recurrent *radial* and *ulnar* arteries.



§ 6. If the obstruction to the course of the blood through the humeral artery is only a little above the bend of the elbow, then the blood of the axillary artery, besides the channel of the profunda humeral, takes also that of the collateral arteries: from these arteries it enters partly into the *superficial ulnar* recurrent, partly runs along the *superior* collateral artery, behind the internal condyle of the humerus, into the *deep anastomotic* of the elbow, and then by the *posterior ulnar* recurrent, the recurrent *interosseous*, and the recurrent *radial* arteries, along with the blood conveyed by the profunda humeri, into the principal arteries of the fore-arm, below the bend of the elbow.

§ 7. And farther, there is another mode of communication, as has been mentioned in speaking of the inferior extremity, viz. that which takes place between the arteries of the neck, scapula, and humerus, with those of the fore-arm, below the bend of the elbow, by means of their numerous communicating arteries on the periosteum of the humerus: for the arteries of the periosteum are derived from many sources, especially from the two circumflex arteries of the humerus, from the profunda humeral, from the *superior* and *inferior* collaterals, and from the humeral artery for a long space. All these arteries of the periosteum of the humerus, by means of repeated arches, communicate with each other along the whole os humeri, both on its anterior as well as its posterior surface. This vascular net-work is then found to anastomose at the upper part with the arteries descending from the neck to the acromion, round the articulation of the humerus with the scapula, and upon the capsular ligament of the head of the humerus; and at the lower part it anastomoses with the *radial*



*ulnar*, and *interosseous* recurrent arteries, by which channels the blood finds a passage from the top of the arm into the arteries of the fore-arm, upon the periosteum of the humerus, by means of these arteries, and within the substance of the bone, through the superior and inferior nutritious arteries, although the principal trunk of the humeral artery be obstructed at a greater or less distance above the bend of the arm.

§ 8. And if, as has been mentioned with regard to the thigh and leg, we add to all these anastomoses existing among the arteries of the superior extremity, the almost innumerable communications which occur between the arteries of the common integuments, and of the cellular substance, both subcutaneous, and intermuscular, through the long tract from the neck to the fingers; which arteries are derived from many distinct origins, and constitute together a vast vascular plexus, extended over the whole length of the superior extremity, the sum of the described anastomoses is so prodigiously increased, that no one, who is well acquainted with this structure, would hesitate for a single moment to believe, that the humeral artery may be safely tied at any point, even in the cavity of the axilla, without any fear of destroying the circulation and life of the lower part of the limb.

§ 9. The ancient surgeons were only acquainted with a few of these arterial communications in each of the extremities; but ever since the art of injection was introduced into anatomy, and cultivated, this communication has been discovered to be very much extended, not only between the arteries of the distinct parts of each limb, but also between those of different divisions of the arterial system. To this system may



be justly applied the saying of Hippocrates, *in toto corpore unus consensus et una conspiratio*; for it may be boldly stated, that the whole body is an anastomosis of vessels, a vascular circle. This fact is so true, that although in some rare cases there may occur a constriction and obliteration of the trunk of the great artery of the body, (I mean the aorta), immediately below the arch which this artery makes, the circulation through the rest of the body, from the neck to the feet, is not thereby stopped or obstructed. For M. Paris,\* who happened to observe this rare occurrence in the body of a woman, viz. the constriction and obliteration of the tube of the aorta, a little beyond its arch, found in that case, that during the life of the woman, the blood sent by the heart was conveyed into the trunk of the aorta below the place of the constriction, through the subclavian, axillary, and cervical arteries, into the mammary, intercostal, diaphragmatic, and epigastric arteries: and that from thence it was conveyed to the viscera of the thorax and abdomen, and to the lower extremities. Stenzel† found in the body of a man two *steatomatous* tumors formed in the substance of the membranes of the aorta, immediately below its arch, which almost entirely closed its tube, though this subject had always the habit of body of a well nourished and robust man. Mekel‡ in the bodies of two subjects, found the aorta just below its arch, so much thickened and constricted, that the blood impelled by the heart could pass with

\* Journal de Desault, t. 11, p. 107.

† Dissert. de steatomatibus aortæ. Hæc corpora fere cor magnitudine æquabant ut omnem propemodum exeunti e sinistri cordis thalamo sanguini spatium præcluderent.

‡ Mem. de L'acad. R. de Berlin, 1756. Observ. xvii, xviii. Stoerk relates a similar observation. Ann. Med. 11, p. 171.



great difficulty, and in small quantity, and regurgitated so strongly towards the heart, that it had lacerated the *semilunar* valves; notwithstanding which, there was no appearance, in these subjects, of the viscera of the abdomen, or the inferior extremities, having been deprived of the usual quantity of blood circulating in them. I have repeatedly had occasion to observe, what others may likewise see at pleasure, that on tying tightly the aorta in the dead subject, immediately below its arch, in order to throw with great force the injection into the arterial vessels of the head and arms, a very fluid injection has likewise found its way, by the vessels of the neck, by the subclavian, by the dorsal, and especially the two upper intercostal arteries, into the arteries of the thorax, and to those of the abdomen, and for a long space, even to the principal arterial trunks of the lower extremities. All surgeons now know, that in brute animals, one, or even both carotid arteries may be tied, without the circulation of the blood through the external or internal parts of the head being impeded or greatly disturbed. In the thorax, the mammary, mediastinal, and intercostal arteries, keep up a numerous and free communication between each other, and at the same time between the trunk of the thoracic aorta, and the continuation of the ventral aorta. In the abdomen, the remarkable arches formed by the cæliac and mesenteric arteries, although each of these arteries seems to define the limits of each viscus to which it is destined, form nevertheless all together a numerous series of anastomoses among these ventral arteries. In the fetus, the two great arteries of the body, the pulmonary artery, and the aorta, anastomose together in such a manner, that the pulmonary artery in the fetus may be said to be continued into the aorta. The same



may be said of the arteries both of the superior and inferior extremities. For if, in the former, as well as in the latter, the arteries communicate with each other from their origin to their termination, following the constant rule, that every great anastomosis of a limb comprehends within it a connection like the links of a chain; which is as much as to say, in the inferior extremities, the first great anastomosis includes the connection of the pelvis and thigh; the second, that of the femur with the tibia; the third, that of the tibia with the foot, in such a manner, that, all these circles communicating together, the passage of the blood from the first to the last of these anastomoses is perfectly free. In the same manner we observe, in the superior extremity, that the first great circle or anastomosis includes the union of the scapula with the humerus; the second, that of the humerus with the fore-arm; and the third, that of the fore-arm with the hand, and the blood, passing from the one to the other of these anastomoses, traverses the whole length of the superior or inferior extremity, whether one of the principal arteries of the limb be pervious, or be from some accident obliterated, or artificially tied.\*

§ 10. Further, it has always appeared to me worthy of attention, in the distribution of the arteries to all the parts of the body, and more particularly with regard to the arterial anastomoses of the extremities,

\* *Arteriæ cum arteriis ita amice conspirant, ut non tantum sua in se mutuo oscula inserant, sed et altera in alterius territorium digressa late diffundetur, ita quidem, ut confinium quibus sese attingunt limites ab anatomicis ad unguem definiri neutiquam possint, exceptis iis locis in quibus natura septo cava divisit, et limites diversi agri fixo descripsit termino. Hebenstreit Dissert. de arteriarum confiniis.*



that the farther these anastomoses are removed from the trunk towards the extremity of the limbs, the larger and more manifest they become. The anastomotic arteries round the elbow are undoubtedly of a very conspicuous size; but the anastomoses in the hand, formed by the two *palmar arches*, are much larger, each of which *arches* equals the diameter of the ulnar and radial arteries by which they are formed. From each of these *arches* go off two arterial branches for every finger, which have frequent communications with one another, and one evident anastomosis on the points of the fingers. In like manner, the arterial communications round the knee, are, without contradiction, equally conspicuous; but far more distinct and evident is the anastomosis in the foot, formed by the *plantar arch*, in which the posterior tibial artery unites with the peroneal, and to which is added the anterior tibial artery, where it sinks between the root of the great toe and the one next to it, so that the arch just mentioned is formed by the re-union of the three principal arteries of the leg. Farther, every toe, as the fingers, is supplied with two arteries anastomosing in several places, and meeting together on the point of each toe. These facts show clearly, that nature has provided amply for the easy and equable distribution of the blood through the extremities, not only by means of numerous anastomoses, but also by forming these anastomoses the larger, in proportion to the greater distance of the parts from the heart, and, therefore, the less the impetus which the blood receives from it.



## CHAPTER V.

OF ANEURISM IN GENERAL ; AND IN PARTICULAR, OF  
THE ANEURISM AT THE CURVATURE, AND IN THE  
TRUNK OF THE THORACIC AND ABDOMINAL AORTA.

§ 1. IT is a great error, if I may be permitted to say so, although one which has been for a long time introduced into medicine, to suppose, that the aneurism at the curvature, or in the trunk of the aorta, produced by a violent and sudden exertion of the whole body, or of the heart in particular, and preceded by a congenital relaxation of a certain portion of this artery, or by some internal morbid cause, capable of weakening its coats, ought always to be considered as a tumor formed by the distention or dilatation of the proper coats of the artery itself, that is, of its internal and fibrous coats. In opposition to this doctrine, which has been generally adopted in the schools, there is nothing in all pathology, which, in my opinion, can be more easily demonstrated than the contrary, or that the aneurism at the curvature, or in the thoracic or abdominal trunk of the aorta, is not produced by a dilatation, but by a corrosion and rupture of the proper coats of the aorta, and consequently by the effusion of arterial blood under the cellular sheath, or any other membrane which covers externally the injured artery. If the aneurism which sometimes occurs in the aorta, immediately after this artery passes out of the heart, be sometimes preceded by a certain degree of dilatation of this artery, this, properly speak-



ing, is not essential to constitute the disease; both because this dilatation of the whole tube of the artery is not a constant occurrence in aneurism; or rather in most cases the aneurism at the curvature of the aorta occurs without this artery being at all, or sensibly dilated beyond its natural diameter; and also, because in those rare cases, in which the aneurism is preceded and accompanied by a certain degree of dilatation of the whole diameter of the curvature of the aorta, there is a very marked and evident difference between an artery simply enlarged in diameter, and the capsule which forms the proper aneurismal sac.

§ 2. Several circumstances have given rise to this erroneous opinion, with regard to the nature and immediate cause of aneurism of the aorta. In the first place, and I am sorry to be under the necessity of mentioning it, the little pains which medical men have hitherto bestowed in the dissection of the bodies of those who have died of aneurism: after opening the thorax, they have contented themselves with dividing the sac of the aneurism, and viewing, with useless curiosity, the various and numerous layers of grumous and polypous blood with which the tumor is filled, without examining into the relations between the membranous texture of the aneurismal sac and the proper coats of the injured artery: in the second place, the false analogy between varix and aneurism, commonly received by medical men as true: in the third place, the occurrence of aneurisms of the aorta so large as to raise and even perforate the bones of the thorax, without a single drop of blood being effused into the cavity of the chest: and finally, the having observed that the aneurismatic aorta, as well as the proper sac of the aneurism, were both covered by a *common smooth*



membrane, and therefore that both of these parts were included in a *common external covering*, like that which covers the artery in the sound state. All these circumstances have contributed to support this error.

§ 3. But if any person, who is not prejudiced in favour of the common doctrine with regard to the nature and proximate cause of this disease, will examine, not hastily and superficially, but with care and by dissection, the intimate structure and texture of the aneurism of the aorta, unfolding with particular attention the proper and common coats of this artery, and in succession those which constitute the aneurismal sac, in order to ascertain distinctly the texture and limits of both, he will see clearly, that the aorta, properly speaking, contributes nothing to the formation of the aneurismal sac, and that, consequently, the sac is merely the cellular membrane, which in the sound state covered the artery, or that soft cellular sheath which the artery received in common with the neighbouring parts. This cellular substance, being raised and compressed by the blood effused from the corroded or lacerated artery, assumes the form of a circumscribed tumor, covered externally, in common with the artery, by a smooth membrane, such as the pleura in the thorax, and the peritonæum in the abdomen.

§ 4. I do not pretend to deny, that sometimes, in consequence of congenital relaxation of the proper coats of the aorta, at its exit from the heart, a certain degree of yielding of these coats may contribute to the rupture of the aorta at this place, and by that means to the formation of an aneurism, which in this case is likewise conjoined with a certain degree of preterna-



tural dilatation of the whole tube of the artery.\* I only deny that dilatation of this artery precedes and accompanies every aneurism of the aorta, and am unwilling to admit, that, in the formation of this formidable disease, the proper coats of the aorta ever yield so much to distention as to form the aneurismal sac. With regard to this point, it is a fact worthy of the attention of medical men, and of all those who wish to investigate this subject, that the root of an aneurism of the aorta, in whatever point of this artery it appears, never includes the whole circumference of the tube of the artery; but that the root constantly occupies and involves only the one or the other side of the artery, from which side the aneurismal sac rises and enlarges in the form of an appendix or tuberosity, more or less large and extended, according to the circumstances of the place, or of the period of the disease; while, on the contrary, the dilatation of the artery occurs constantly in the whole circumference of the tube, and therefore differs essentially from aneu-

\* Wintringham found, that the resistance of the coats of the aorta becomes less, the nearer this artery is to the heart, in the portion of 1794 to 1000. *Experim. inquir. on some parts of the animal structure*, *Experim. 15*; which is, as if one were to say, that the larger the artery is, the more easily it is ruptured by the force of the distention, although the increase in diameter be more evident in a large than in a small artery.

Hunter is likewise of opinion, that the muscular coat of the arteries increases in density in proportion as the artery proceeds from the trunks to the branches. He observes, that the increase of the elastic power in the large arterial trunks is well calculated to re-act against the great force of the heart; and that, *vice versa*, the increase of the muscular power, with the diminution of the elasticity in the smaller arteries, is well fitted for accelerating the course of the blood in the extreme minute arterial vessels. And it is also from this that Mr. Hunter proved the equability of the circulation through the whole course of the arterial system.—*Posthumous Works, Treatise on the Blood*.



rism. The smallest arteries of the uterus, for example, assume, in pregnancy, a size three or four times greater than that which they had before impregnation. The arteries of a large incysted tumor, those of the obstructed spleen, and the lateral arteries of a large trunk, through which the course of the blood has been interrupted, dilate beyond what any one would imagine; but the enlargement of these arteries always takes place through the whole circumference of their tube; and a tuberosity is never observed to arise from any side of these dilated arteries, and a receptacle is never formed by their coats, similar to the sac of an aneurism. This invariable fact, with regard to the form of the aneurism of the aorta, cannot fail to point out to the attentive observer, that there ought to be, as there really is, a remarkable difference between a dilated artery and an aneurismatic artery, although these two affections are sometimes found combined together, especially at the beginning of the aorta, as it comes out of the heart. Further, if we consider in general, that the dilatation of an artery may exist without any affection, properly speaking, organic, the blood being always contained within its cavity; that in the tract of artery, somewhat increased in diameter, there are never formed nor collected any grumous blood or polypous layers; that the dilatation of the diameter of an artery never becomes of such a size as to form a tumor of considerable bulk; and lastly, that as long as the continuity of the proper coats of the artery remains uninterrupted, the circulation of the blood is not at all, or not so sensibly changed, then we shall be obliged to allow, that aneurism differs essentially from dilatation of an artery. I have many strong reasons for supposing that the polypi, so called, found in the beginning of



the aorta, (with regard to the existence of which, physicians of the former century made so much noise), are only aneurisms from previous rupture of the proper coats of the arch of the aorta, in the sacs of which, and not in the enlarged capacity of the arch of the aorta, the stagnating blood, as they supposed, formed that stratified concretion which they improperly compared with the polypi of the nose and of the uterus.

§ 5. Morgagni\* has observed and described the difference which exists between these two affections, in the commencement and in the curvature of the aorta. But notwithstanding, it is rather surprising that he should have placed them in the same order of diseases; and he has even taken occasion from that to establish two kinds of aneurism of the arch of the aorta; one, in which the tumor occupies the whole circumference of the arterial tube, the other, in which the aneurism only affects one side of the artery. This last kind he however mentions distinctly to be the one which is most frequently met with in the dissection of dead bodies.† Morgagni, though this fact was known to him, did not think it proper to make any change, which he might with propriety have done, in the com-

\* Neque enim dubito, quin memineries, fuisse olim aneurysmata a me devisa, in ea quæ vas æque in omnem partem expansum format, et in ea quæ sacci instar a vasis latere excrescunt. Epist. xvii, art. 27, De sed. et caus. morb. This division was also adopted by Schedeiberus, Act. Erud. Lips. an. 1731, and by Valcarenghius de Aortæ aneurysm, Ob. i; by Sauvages, Nosol. method., who gave the name of cylindrical aneurism to the simple increase in diameter of the great artery.

† Loc. cit. epist. xviii, art. 37. Cum aneurysmata quatuor habeam a Cl. Vulpio infarcta, et siccata, eaque omnia sint in arteriæ magnæ aut arcu, aut eo tractu, qui inter arcum et cor interest: eorum unum est primi generis, tria secundi.



mon doctrine of aneurism. The observations, however, which I shall relate in this chapter, will, I flatter myself, clearly shew, that there is only one form of aneurism, viz. that which occurs in some point of the parietes of the artery, from the rupture of its proper coats; whether the aneurism be complicated with a certain degree of enlargement of the tube of the artery, as sometimes happens at the arch of the aorta, in the vicinity of its exit from the heart, or without this enlargement of the diameter of the artery, as happens generally, and indeed almost constantly, in cases of aneurism of the thoracic and abdominal aorta.

§ 6. In consulting the ancients, we do not find in the writings of the Greek and Arabian physicians any mention of *internal* aneurisms. Nor ought that to excite wonder in those who know that these nations were forbid to open human bodies, and that, in brute animals, this organic disease of the great internal arteries is very rare. It was not till about the year 1557, that any certain knowledge was obtained with regard to the existence of *internal* aneurisms. At that period, Vesalius pointed out\* this disease in the person of Leonard Velserus, in whom, after a fall from a horse, a pulsating tumor had appeared in the back, near to the spine. It is proper to mention, that from that period, in the books of medicine, no other case of this kind has been recorded; for in the year 1595, Silvaticus,† who published a parti-

\* Bonnet, Sepulcr. Anat. lib. iv, sect. 2. From the account of what was found in the body, it clearly appears that the aneurisma had been formed by a rupture of the ventral aorta. See on this what has been written by Saporata, De Tumor. præternat. lib i, cap. 43.

† De aneurysmat. tractatio, an. 1595.



cular treatise on aneurism, did not speak at all of *internal* aneurisms, nor did he make any mention of that of the curvature of the aorta, though it is by no means a very rare disease. Riolanus, in the year 1658, many years after Silvaticus, said only,<sup>1</sup> that aneurisms of the aorta arise sometimes, though very rarely, from great thickness and strength of the coats of the artery; and Elsnerus,<sup>2</sup> in the year 1670, when he published the observations of Riva, with regard to aneurism of the arch of the aorta, prefixed to these observations the title *De paradoxico Aneurysmate Aortæ*, as if they related to a thing almost incredible.

§ 7. The Greek and Arabian physicians, for these reasons, only made mention in their works of *external* aneurisms, or of those which fall under the inspection and the operation of the hand of the surgeon. And as they wrote only of that which they had repeatedly and attentively observed, without prejudice, they of course spoke only of aneurisms by *effusion*. Galen,<sup>3</sup> Ætius,<sup>4</sup> Paulus,<sup>5</sup> Actuarius,<sup>6</sup> Haly,<sup>7</sup> Albucasis,<sup>8</sup> Oribasius,<sup>9</sup> Avicenna,<sup>10</sup> all hold the same language; and although some of these writers introduce the distinction, that external aneurisms are produced in three ways, viz. by *anastomosis*, by *diapædesis*, and by *diæresis*, they all agree in affirming, that external aneu-

<sup>1</sup> Enchirid. Anat. lib. v, cap. 46.

<sup>2</sup> Acad. nat. cur, an. i, decad. i, obs. 18.

<sup>3</sup> Method. Med. cap. vii—de Tumoribus, cap. vii.

<sup>4</sup> Tetr. iv, Serm. iii, cap. x.

<sup>5</sup> De re Med. lib. vi, cap. 37.

<sup>6</sup> De Meth. Med. lib. iii, cap. 2.

<sup>7</sup> Lib. viii, cap. 17.

<sup>8</sup> Chirurgia, lib. ii, cap. 49.

<sup>9</sup> Lib. vii, cap. 13, 14.

<sup>10</sup> Lib. i, par. ii, cap. 4.



risms are not formed in any other way than by the extravasation of blood under the skin. Some of the modern physicians conceived that they had found in the works of *Ætius* some expressions, from which it might be inferred that this writer had distinguished aneurisms into *true* and *spurious*. On examining the text with attention, we find no certain evidence of this; but undoubtedly, that he had distinguished external aneurism by effusion into *circumscribed* and *diffuse*, which distinction is accurate, and conformable to the phenomena which this disease presents. With regard to this subject, it is proper here to remark, that by the word *dilatation*, the Greek and Arabian physicians, in speaking of *external* aneurism, never pretended to signify, as we do, the expansion of the proper coats of the diseased artery, but only to express that tumor which the effused and coagulated arterial blood forms in the cellular membrane under the skin. *Ætius* precisely states, *oritur dilatatio, aut dum sanguis, et spiritus ex arteriis prosultant; aut dum oscula ipsorum aperiuntur, aut dum rumpuntur. Sanguis autem et spiritus paullatim excreti sub cute colliguntur*. In the same manner *Actuarius*: *porro arteriam secare plurimum negotii exhibet, siquidem sanguinis fluxus, qui ægerrime sisti possit, et arteriæ dilatationes, quas aneurysmata Græci nominant, hinc oboriri solent*. What other kind of dilatation can ever occur, whether the aneurism be formed by blood issuing from the extremities of the arteries, or oozing out through the pores of their coats, as the ancients thought, or from a wound of the artery, except that produced by the blood having escaped under the skin into the cellular membrane which surrounds the injured artery? *M. A. Severinus*,\* guided by observation, and by expe-

\* De nov. observ. abscess. cap. 7.



rience in surgery, was so much convinced that *external* aneurisms were all occasioned by a rupture, or by a wound of the artery, and that consequently they were only formed by blood effused into the subcutaneous cellular membrane, that he thought proper to refer the history of this disease to the chapter *De abscessibus sanguifluis*. Silvaticus also, a very skilful physician, and well versed in the works of the ancient Greek and Arabian physicians, confirms this fact, relative to the opinion which the ancients entertained concerning the nature and character of *external* aneurism. For he writes : *est aneurysma tumor a sanguine calidissimo, tenui, vaporosoque ex arteria sub cutem effuso productus. Arteriæ divisionem, quomodocumque factam sucæ generationis occasionem esse dicendum est. Effluere autem ex arteriis sanguinem, vel per anastomosim, hoc est apertis vasis osculis ; vel per diapedesim, id est rarefactis ejus tunicis ; vel per diceresim, id est ruptis, vel exæsis illis.*

§ 8. Fernelius, as far as I know, was the first who conceived the idea of publishing the theory of the *dilatation* of the coats of the arteries, as the proximate cause of aneurisms, particularly of *internal* aneurisms, or as applicable to those of the curvature and trunk of the aorta, arising from internal, and not evident causes. He conceived,\* that the internal spontaneous aneurism consisted in a morbid distention of all the coats of the artery, just as is observed to take place in the coats of the veins, in the case of varix. Any one not acquainted with the history of medicine would perhaps suppose that Fernelius was induced to publish this new theory, quite different from that of the Greek and

\* Opera omn. de extern. corp. affect. lib. vii, cap. 3



Arabian physicians, in consequence of repeated researches on the dead subject, and of exact comparisons of the nature of the proper coats of the artery, and of those which constitute the aneurismal sac. If they would wish to be fully informed of this, they will find, that the theory of Fernelius, far from having been deduced from observation on the dead subject, was only the result of his own imagination, and of an hypothesis which he drew from this false conjecture, viz. that the effused arterial blood would be immediately converted into a putrid mass, whenever the aneurismal sac was not formed by the proper coats of the artery; and that the arterial blood would never form a *pulsating* tumor, when the tumor was not circumscribed and formed by the proper coats of the dilated artery. These two inconclusive ideas were the basis of the theory of Fernelius; notwithstanding, they were soon afterwards refuted by Silvaticus;\* and although, I believe, at the time of Fernelius, there was not one distinguished surgeon, who had not repeatedly had occasion to observe aneurism in the bend of the arm occasioned by a wound of a lancet, and consequently from effusion of arterial blood into the surrounding cellular substance, which, nevertheless, was circumscribed, pulsated, and contained blood perfectly free from putrefaction, though long effused; yet the theory of Fernelius was received by many as a matter of fact, and, what is still more wonderful, has been regarded as such, even to the present day, by the greater number of physicians and surgeons. I omit inserting here the long list of those who adopted this opinion, and shall content myself with mentioning Forestus only,† on account of the singularity

\* See note, No. 1, appendix.

† Oper. Med.



of the following circumstance; for, while this author used every force of reasoning to maintain that the internal spontaneous aneurism is formed by the dilatation and distention of the coats of the artery, he adduces, in proof of that opinion, an observation, the only one of the kind to be found in all his works, from which a precisely contrary conclusion may be fairly deduced, viz. that the aneurism which he describes was not formed by a dilatation, but by a rupture of the coats of the artery, and consequently by an effusion of arterial blood into the surrounding cellular substance.

§ 9. Such was not the opinion of Sennertus;\* for, guided by solid anatomical knowledge, and by mature reflection upon the phenomena which precede and accompany *external* as well as *internal* aneurism, he differed in opinion from Fernellius, and appeared inclined to believe, that the proximate cause of internal aneurisms consisted, not in the dilatation, but in the rupture of the internal proper coats of the arteries; the external membrane, or the external cellular coat of the arteries remaining untouched; which external cellular membrane, when elevated and distended by the

\* Oper. omn. t. v, lib. v, part i, cap. 43. Atque ita proxima causa Aneurysmatis est arteriæ tuniciæ internæ aperitio, exterioris vero dilatatio. Aperitur autem frequentissime sectioni dum imperiti chirurgi pro vena arteriam, vel cum vena arteriam perforant. Id enim si fit, externa tunica facilius, utpote mollior, et venarum tunicis cognata, coalescit; intimior vero durior aperta manet; unde per foramen sanguis, et spiritus vitalis errumpere conatur, atque ita externam tunicam distendit, et hoc tumoris genus efficit. Idem accidere potest, si a vehementi sanguinis arteriosi impetu, vel causa externa violenta, nimiaque arteriæ distensione, interna tunica arteriæ rumpitur, externa, quæ ad extentionem magis apta est, salva, et incolumi.



extravasated arterial blood, forms ultimately the aneurismal sac. He says, that as in the aneurism which arises in consequence of a puncture of the artery at the bend of the arm, the external cellular coat of the artery, being soft and flexible, heals, while the internal coat of the artery, being hard and rigid, does not cicatrise at all, and remains open at the place where it was wounded; so, every time this internal coat of the artery is ruptured by a violent impetus of the heart, the external membrane of the artery, from being soft and easily distended, is elevated by the effused arterial blood, and is gradually converted into an aneurismal sac. Upon this point it appears that Sennertus had derived some light from the works of F. Hildanus.\* For, this celebrated practitioner had already explained, nearly in the same terms, his opinion with regard to the manner in which the aneurism in the bend of the arm is formed, in consequence of a puncture made with a lancet in the brachial artery. Sennertus went a step farther, in applying the same theory to the explanation of *internal spontaneous* aneurism, independent of a wound, or other external violence done to the principal trunks of the great arteries. Both Hildanus and Sennertus therefore were of opinion, that, whenever the arterial blood was

\* Oper. omn. Centur. III, obs. 44. Duplici tunica arteriam donatam esse Galenus testatur, quarum exterior tenuis, et mollis ex rectis et obliquis fibris contexta; interior altera fere, eodem Galeno monente, quintuplo durior, et densior est. In aneurysmate itaque interiorem tunicam rumpi, exteriorem vero dilatari verosimile est. In hoc autem viro, etsi ambo tunicae scalpello perforatae essent, exterior tamen, quia tenuis, et carni atque venis proxima, mox iterum coaluisse mihi videtur; interior autem, cum propter motum vehementem, et continuum, necnon duritiem simul claudi non potest, sanguis paullatim per eam in exteriorem tunicam infuebat, eamque extendebat.



much diffused round the place of the rupture, and the internal as well as the external membrane of the artery ruptured, the tumor thus formed would be neither *circumscribed*, elevated, nor *pulsating*; but that in similar circumstances the extravasated blood would corrupt and occasion inflammation and gangrene in the neighbouring parts. In this supposition, likewise, these two celebrated writers have not deviated far from the truth; as these are indeed the most frequent consequences of the *diffuse* aneurism. Their doctrine with regard to the nature and true character of aneurism was judiciously approved of and published by Barbette,\* Diemerbroech,† Jons-  
tone,‡ Gouey,§ and many others whom it would be too tedious to mention.

\* Oper. med. et Chirurg. part ii, cap. 16. Aneurysma est tumor præternaturalis ab arteriæ ejusdam ruptura exorta, continuo pulsans, digitis libenter cedens, ast etiam facile rediens. Arteriæ omnes, exceptis iis, quæ per cerebrum, partesque omnes alias consistentes magis dispersæ sunt, tunica duplici gaudent. Harum interna corrosa, aut rupta, externa in tantum extendi potest absque ruptura, (quidquid etiam contradicant alii), ut aneurysma cause-  
tur. Nihilominus, ubi tumor hic pugni magnitudinem habet, haud fieri potest quin simul etiam externa corrosa, aut rupta sit. Anatome sententiam nostram confirmat; artis chirurgicæ studiosi etiam mecum inquirant.

† Oper. omn. lib. vi, cap. 1. Ratio docet, quod arteriæ nisi a transversis fibris firmarentur, per magnas pulsationes nimis dilata-  
rentur, et dilatatæ manerent, utpote destitutæ fibris a quibus rursus contrahi possunt. Hæc enim causa est aneurysmatis, quod, tunica cum suis fibris rupta, sanguis in primam, seu extimam tuni-  
cam illabatur, quæ ob mollitiem mox extenditur, sicque ibi tumor generatur.

‡ Sintagma med. pag. 548. Aneurysma tumor est ab arteriæ tunicæ interioris apertione, exterioris dilatatione exortus.

§ La véritable Chirurgie, pag. 231. La vray aneurisme est une tumeur sanguigne faite dans le propre canal de l'artère et dont



§ 10. Dr. Freind, in his History of Medicine, under this head, says, that upon the whole subject of aneurism, he had been able to find only a successive series of hypotheses and conjectures, and everywhere involved in obscurity and confusion.\* It is not conceivable, he remarks, how the rupture of the internal membrane of an artery should not be immediately accompanied by that of the external one also, as the external is less dense and firm than the internal coat. The same difficulty had already been stated by Muraltus,† who however admitted the possibility of this fact, in the case where, during the time which the process of ulceration takes up in removing the continuity of the internal coat of the artery, the external membrane of the artery acquired a density and firmness much greater than that which it naturally has, preserving at the same time sufficient flexibility to yield gradually to the impulse of the arterial blood, and to permit it to be raised into a tumor by that which was extravasated. To confess the truth, far

la cause se trouve, dans l'acrimonie de quelque humeur, qui a rongé la tunique interieure de ce vaisseau, ensorte que le secousses reiterées du sang ont forcé les tuniques exterieures à s'étendre, de maniere que il s'est formé comme une espece de cul-de-sac, dans lequel le sang arteriel est entré pour former une tumeur qu'on appelle aneurisme.

\* Hist. Med. Paulus. Neque argumentum de quo scribere aggressi sunt, neque id ipsum, quod super argumento suo scripserint satis comprehendentes.

† Ephem. nat. cur. Decad. ii, an. 3. Rupturam interioris tunicae ex triplici substantia constantis, exterioris autem extensionem admitti vix posse. Cum vix credibile sit internam, et crassam satis rumpi posse, externa tenuissima salva remanente; nisi forte internam duriusculam a sanguinis stagnantis acrimonia erodi, externa interim crassiori reddita, et sanguini irruenti extensioni sua, utpote molliori, amplius spatium cedente, dicere liceat.



from finding, as Dr. Freind writes, hypotheses, contradictions, and confusion in the doctrine of Hildanus, and Sennertus, and of others who, following the instructions of these two illustrious authors, have made mention of the nature and proximate cause of *internal* spontaneous aneurisms, I am rather of opinion that these two celebrated physicians are the only ones, who, with regard to this point, have come near to the truth; and that, on the contrary, the modern physicians, entirely from having abandoned the steps marked out by these two distinguished men, have greatly receded from the straight path, which would have conducted them to the perfect knowledge of the true nature of this disease. The repeated investigations which I have made with regard to this important subject, authorize me to assert, that Hildanus and Sennertus had only a short step to make, to give to their theory concerning the proximate cause of aneurism all that degree of demonstration and proof, of which the subject is susceptible. This short step consisted in determining, with anatomical precision, the relations of the proper coats of the artery with its external cellular covering, and in demonstrating, by means of accurate dissections of arteries, both in the sound and morbid state, what share the proper and constituent coats of the artery had in the formation of the aneurismal sac, and what belonged to the cellular covering and the other adventitious membranes surrounding the affected artery; these are the circumstances which I now propose to detail, and to place, as far as lies in my power, in the clearest light.

§ 11. The covering of the artery, which former anatomists, almost to the present day, have mentioned amongst the component coats of an artery, is by



no means such as they have described it, but is merely an adventitious sheath,\* or cellular covering, which the artery borrows, or receives in common with the parts, in the vicinity of which it runs; by means of this cellular sheath the artery is kept in its place, as within a soft bed, and connected to the parts surrounding it, such as the membranes, the viscera, the nerves, the aponeurotic and ligamentous fasciæ, the muscles and periosteum. On cutting an artery across in its natural situation, it is observed to be inclosed in a sheath of soft, spongy, easily distended cellular substance, within which sheath, the segment of the cut artery retires and conceals itself. This cellular sheath, most evident round the great arterial trunks, is in some places more dense and abundant, in others less so. It is found in considerable quantity, and very dense round the curvature and trunk of the aorta, the carotid arteries, the mesenteric and renal arteries; but less so round the trunk of the brachial, femoral, and popliteal arteries. In all these parts, the cellular sheath, soft and easily distended, is only a continuation of the cellular membrane of the neighbouring parts. The pleura lies over the cellular sheath of the arch of the aorta, and over that of the thoracic aorta; and that of the abdominal aorta is covered by the peritoneum. Both of these smooth membranes surround and adhere closely to the aorta for two thirds of its circumference. The great arteries of the extremities, which run between the muscles, and under the aponeurotic and ligamentous fasciæ, are not covered, in addition to the cellular substance, by a smooth membrane, such as the pleura and peritoneum, but they are surrounded

\* *Monro's works.*—*Ludwig de arteriarum tunicis.* *Haller Elem. Phisiol.*—*cellulosa adscititia.*



by a cellular sheath, which, although it is here and there filled with an oily substance, may notwithstanding be demonstrated to be distinct from the membrane properly called adipose, and which serves, as in the other parts of the body, to inclose the tube of the artery, and connect it to the contiguous parts.

§ 12. If, leaving the aorta in its place, as well as the viscera near it, a little air, or any other fluid, be injected by a small hole made artificially between the cellular covering and the subjacent muscular, or proper fibrous coat of the artery, the matter injected raises and elevates into a tumor, the cellular membrane which closely embraces the artery, without properly destroying its cells, which it fills and distends in a remarkable manner. If the matter which is injected be capable of coagulating, such as melted wax, and if it be pushed with much force, it is observed, that the cellular sheath of the artery is not only raised over it like a tumor, by the impetus of the injection, but the internal cells of that covering are also lacerated, and on examining afterwards the capsule of the artificial tumor, it appears as if it were formed of several layers, rough and irregular internally, smooth and polished externally. The same thing happens if air be pushed with much force, or any liquid substance capable of coagulating, within the artery, so that by the excess of the impulsion, the proper or internal and muscular coats burst at some point of their circumference; in which experiment, as in the first, the cellular sheath of the artery is observed to be raised after the manner of a tumor or aneurism. Nicholls\* repeated this experiment several times before the Royal Society of London. ‘If any one,’ says he,

\* *Philosoph. Transact. an. 1728, No. 402.*



‘ wishes to convince himself of the truth of this fact,  
‘ on the point of the different resistance of the coats of  
‘ an artery, he will have the pleasure of seeing it proved  
‘ by experiment : let him force air into the pulmonary  
‘ artery, and of the two proper coats of the artery, the  
‘ internal will be ruptured, while the external, which is  
‘ not ruptured at all, will form aneurismal tumours  
‘ over the artery.’ The internal membrane of an artery, although thin, being, however, very compact and smooth, is that which opposes the greatest resistance to the impulse of the air, and prevents, more than any other, the bursting, or preternatural dilatation of the arterial tube. As soon as the internal coat of the artery is ruptured, the muscular coat is likewise ruptured, or is immediately torn, and allows the air, or any other fluid injected with force into the tube of the artery, to flow into its external cellular sheath. If, as Nicholls has likewise remarked, the muscular coat of the artery, and the cellular sheath which surrounds it externally, were of the same texture, the argument of those who think that the muscular coat cannot be ruptured by the force of the blood, without the external cellular sheath being likewise torn, would have more force than it actually has ; since, according to these principles, it would be possible, by approximation at least, to calculate the resistance of both of these coats, in proportion to their density, brittleness, or extensibility. But this cannot be done in the present question, and the error consists in this, that the resistance opposed by the muscular coat to the fluid, which having ruptured the internal coat, endeavours to pass through it, depends less on the different layers of its fibres and their density, than upon their brittleness, and the small degree of cohesion these muscular fibres have with each other ; which de-



gree of cohesion is certainly less strong than physiologists commonly suppose. On the contrary, the external cellular sheath of the artery, being of an interlaced texture, the thin laminae of which it is composed, are not simply applied to one another, but reciprocally intermixed, reticulated, and connected in several ways closely together : although much less dense than the muscular or fibrous coat of the artery, yet it is capable, by yielding gradually to the impulse of the blood, of supporting great distention, without being torn or ruptured ; points which have been confirmed by observation and experiment.\* On the contrary, the veins which want entirely, or at least have not any evident muscular fibrous coat, as the arteries have, if we except the great venous trunks in the vicinity of the heart, yield much more to the distention of the blood without being ruptured than the arteries do. It is wonderful to see in injections of the dead subject, to what degree of size the jugular veins yield, without being lacerated. The same happens likewise in the cava, the veins of the extremities, those which cover the prostate gland, the hæmorrhoidal veins, those of the gravid uterus, and those which surround the vagina. No artery of equal diameter could yield to such a degree of distention as a vein does without being ruptured. And since it is certain, that the principal difference, in the structure of the arteries and of the veins, consists in the veins having the internal coat more flexible and distendible than that of the arteries, and in the veins wanting entirely, or in great part, the rigid and brittle muscular and fibrous coat ; therefore, it is easily understood, why, on account of the rigidity and brittleness of the

\* I have repeated the experiments of Nicholls several times, and always with the same success as the author had obtained.



proper arterial coats, and of the kind of contact which exists between them, the fibres of their muscular membrane are more disposed to be ruptured, from the violent impetus of the blood, than the veins, or the external elastic cellular sheath which surrounds the arteries.\*

§ 13. The phenomena which are observable in the artificial distentions of the thoracic or abdominal aorta, present themselves likewise, in my opinion, in the case of a morbid degeneration of the internal coat of the artery, during which, that coat becomes in some places weak, or very rigid and friable, and is thinned, separated, or ruptured, by the repeated jets of blood thrown from the heart. The internal coat of an artery being ulcerated or lacerated from a slow internal cause in some point of its circumference, the blood impelled by the heart begins immediately to ooze through the connections of the fibres of the muscular coat, and gradually to be effused into the interstices of the cellular covering, which supplies the place of a sheath to the injured artery, and forms, for a certain space, a kind of *echymosis*, or *extravasation of blood*, slightly elevated upon the artery. Afterwards, the points of contact between the edges of the fibres of the muscular coat being insensibly separated, the arterial blood penetrating between them, fills and elevates, in a remarkable manner, the cellular covering of the artery, and raises it after the manner of an incipient tumor. Thus, the fibres and layers of the muscular coat being wasted or lacerated, or simply separated from each other, the arterial blood is carried with greater force, and in greater quantity than before, into the cellular sheath of the artery, which it forces more outwards,

\* Walter Mem. de l'acad. de Berlin, an. 1785.



Finally, the divisions between the interstices of the cellular coat being ruptured, it is converted into a sac, which is filled with polypous concretions, and with fluid blood, and at last forms, properly speaking, the aneurismal sac; the internal texture of which, although apparently composed of membranes placed one over the other, is, in fact, very different from that of the proper coats of the artery, notwithstanding the injured artery, both in the thorax and in the abdomen, as well as the aneurismal sac, is covered externally, and inclosed within a common smooth membrane.

§ 14. In the very considerable number of aneurisms of the arch, and of the thoracic and ventral trunk of the aorta, commonly regarded by medical men as *true* or *incysted*, or as formed by a dilatation of the proper coats of the great artery,\* which I have had an opportunity of examining, I have not found a single one, in which the rupture of the proper coats of the artery was not evident, and in which, consequently, the aneurismal sac was produced by a substance completely different from the internal or muscular coat of the injured artery. To ascertain the truth, and confirm the constancy of this fact, it is not necessary that one should be possessed of uncommon knowledge in the art of dissection, but only that he be disposed to see things as they really exist, and that he undertake to examine the aneurism in the situation in which it is found, and without removing the parts which surround it, or at least that he do this with due circumspection. For, as I have asserted above, very often the examination which is made by medical men, of internal aneurisms in the dead subject, consists of little more than a simple division of the fundus of the tumor, without paying attention to the cellular sheath which surrounds

\* See Appendix, note 2.



the artery, above and below the place of the aneurism, and without examining the disposition and particular characters of the proper coats of the aneurismatic artery, and comparing it with the substance which forms the parietes of the aneurismal sac; and what is still worse, the aneurism is examined by some, after being removed from the body, and filled with some substance, or dried; in which preparations, there is nothing to be seen but confusion and obscurity, in every thing which relates to the true nature and structure of the parts by which the tumor is formed.

§ 15. A circumstance very important to be known relative to this subject, has been hinted at above; viz. that the aneurismal sac never comprehends the whole circumference of the injured artery, but only a portion of the arterial tube, to which the tumor is united on the one or the other side. At this place, the aneurismal sac presents, as it were, a species of constriction, or neck, beyond which the sac of the aneurism is more or less enlarged, or expanded, and sometimes to an enormous degree.\* This circumstance would never accompany aneurism, or rather, quite the contrary would be found, if the aneurismal sac were produced by an equable distention of the tube and of the proper membranes of the aneurismatic artery. For, in incipient aneurisms, at least, the greatest effect of the

\* The best plates which we have of internal aneurisms, represent the above-mentioned circumstance. See the figure given by Littre *Mém. de l'acad. Royal de Paris*, an. 1707, speaking of which aneurism, he adds; *en se rabatant sur toute la partie superieure, anterieure de la poitrine, depuis une aisselle, jusqu' à l'autre, et en formant une poche assez semblable à une bouteille, dont le cou avoit été au dedans de la poitrine, et le fond au dehors.*

See likewise Ruisch, fig. 38, annexed to his *Observ. Anat. Chirurg. Obs. xxxvii.*



distention acting upon the tube of the artery, the greatest size of the tumor ought to be in the artery itself, or in the beginning or root of the tumor, and the least at its fundus. But observation demonstrates, that, whether the aneurism be recent and small, or of long standing and large, the passage from the artery is always narrow, and the fundus of the aneurism, the farther it is removed from the artery, the more it is enlarged. Another circumstance worthy of attention on this head, which I have likewise pointed out above, is, that the aneurismal sac is always covered by the same soft distensible cellular substance, which in the sound state surrounded the artery, and united it to the adjacent parts; which soft cellular substance, supposing it to be an aneurism of the arch, or of the thoracic trunk of the aorta, is covered by the pleura, and if the aneurism is in the abdomen, by the peritoneum, which membranes include the aneurismal sac, together with the ruptured artery, and presents externally, a continued, smooth, shining surface, as if the artery alone was in that way dilated.

§ 16. But if, instead of dividing, as is commonly done, the fundus of the aneurismal sac, the aorta be divided lengthwise on the other side, and opposite to the constriction or neck of the tumor, the place of the ulceration, or of the rupture of the proper coats of the artery, immediately appears within the artery, on the side opposite to that where the incision was made, and the fissure which has taken place is immediately discovered, the edge of which is sometimes fringed, often callous and hard, like that of a fistula; through which fissure the arterial blood had formed itself a passage into the cellular sheath of the artery, afterwards converted into an aneurismal sac. If, as some-



times happens in the arch of the aorta in the vicinity of the heart, the artery, before being ruptured, has suffered some degree of enlargement beyond its usual diameter, it appears at first sight that there are two aneurisms; but the constriction or neck which the aneurismal sac next to the artery presents externally, points out exactly the limits, beyond which the internal and muscular coat of the aorta had not been able to resist the distention, and have therefore been torn by it, and shews clearly the difference existing between an aneurism and a simple enlargement in diameter of the tube of the aorta in the vicinity of the heart.

§ 17. The rupture in the artery is always small in proportion to the large size of the aneurismal tumor; so that when the arch of the aorta has suffered some degree of dilatation before bursting, as sometimes happens near its passage out of the heart, on making an incision on one side into the aneurismal sac, and on the other into the tube of the artery lengthwise, two sacs present themselves, separated from each other by means of a partition or diaphragm lacerated in its middle; which partition is formed of nothing else than the remains of the internal and muscular coats of the ruptured artery. And as the limits of the proper coats of the aorta, and the beginning of the cellular aneurismal sac, are marked externally by that kind of constriction or neck which the tumor presents in the vicinity of the artery; in the same manner, internally, this partition, torn in its middle, determines the precise point of the rupture of the proper coats of the artery occupied by aneurism.

§ 18. All this acquires a degree of demonstration and certainty, to which nothing can be opposed, by



carefully dissecting the proper coats of the ruptured aorta in its situation, and comparing them at the same time with the cellular substance forming the aneurismal sac; for, in the incision made in the direction of the axis of the aorta, and in its side opposite to that where the rupture has taken place, its proper coats are found either perfectly sound, or a little weakened and intermixed with earthy points, but still capable of being separated distinctly into layers from one another; when, on the contrary, in the opposite side of the aorta, where the ulceration or laceration exists, its proper coats are met with unusually thin, blended together, and with difficulty, or in no way capable of being separated from each other, intermixed very often with heterogeneous substances, which render them brittle like the shell of an egg; and lastly, disorganized and torn at the place where they form that species of partition, which marks the limits between the ruptured artery and the entrance of the aneurismal sac. Continuing to separate these coats from within outwards, we come to the cellular sheath which surrounds the aorta externally.\* Then, on removing the cellular pulpy sheath of the aorta, it is found smooth externally, like the artery; villous, cellular, and irregular internally, extending from the circumference of the tube of the artery over the neck and fundus of the aneurismal sac. This external covering or sheath of the artery actually appears, to those who are not sufficiently skilled in such dissections, as if the artery were dilated under it to such a degree as to form the aneurism; and it has still more that appearance if the aneurism is very large and of long standing, since in this case the cellular sheath of the artery becomes unusually thick and pulpy, and because it adheres very firm-

\* Pl. 1, *dd, e, fff.*



ly to the subjacent muscular coat of the artery at the stricture or neck of the aneurismal sac. But even in these cases, as well as in those of recent and small aneurisms of the aorta, by employing care, we may at last succeed in separating, without laceration, this cellular sheath from the tube of the artery, above and below the injury, and successively from the subjacent muscular coat, as far as the neck or root of the aneurism.\* It is then clearly perceived that the muscular coat of the aorta does not pass beyond the partition which divides its tube from the entrance of the aneurismal sac; and it is distinctly observed, that the fibres and layers of the muscular coat are not prolonged over the aneurismal sac, but terminate like a fringe, or in obtuse points, at the edge of the rupture of the artery. On which account, nothing can be more evident than that the aneurismal sac does not belong at all to the artery, and that, properly speaking, it is only the cellular sheath, which in the sound state covered and connected the artery to the neighbouring parts, which being elevated by the effused blood, at first in the manner of an *echymosis*, then distended and compressed, has acquired that degree of density, and of additional hardness and thickness, as if it had been formed by the proper coats of the artery, prodigiously relaxed, distended, and thickened. These appearances the more readily lead to error, as both the injured artery and the aneurismal sac, as has been frequently mentioned, are covered by a common smooth membrane externally, such as the pleura in the thorax, and the peritoneum in the abdomen.

§ 19. The favourers of the contrary opinion do not deny that the artery is sometimes ruptured in internal

\* Pl. 1, *fff*, *g g*.



aneurisms, but they only admit this in those cases in which the dilatation of the artery has been carried to a prodigious extent. The invalidity of this opinion appears to me to be clearly proved by the rupture of the artery being constantly met with, whether the internal aneurism be small or large, and the artery be a little, or, as most frequently happens, not at all dilated. And this opinion is likewise contradicted by its being now ascertained, that the internal and muscular coats of the artery terminate evidently in the fringe, or hard margin of the orifice of the partition, and that the aneurismal sac is not at all formed by the proper coats of the artery, but by the cellular sheath which surrounds it. In the large aneurisms in which the partisans of the common doctrine admit the rupture of the artery, a double rupture is always found, the one of the artery, the other of the aneurismal sac; and this last is that which actually kills the patient, by changing the aneurism from the *circumscribed* into the *diffused* state. The erroneous opinion, that the large arteries, and especially the trunk of the aorta, are as it were insulated, or covered only by a very fine membrane, adhering firmly to the subjacent muscular coat, and easily lacerated, has given rise in all probability to the belief, that the ulceration or rupture of the internal proper coats of the aorta could not take place, without this thin tense membrane covering the artery externally being likewise torn. Undoubtedly, if this were the case with regard to the external cellular sheath of the arteries, it would necessarily follow, that the blood should be effused into the thorax and abdomen, in every case of rupture of the abdominal or thoracic aorta. Indeed, we sometimes see this happen in practice, by the combination of some particular circumstances; for, if unfortunately the rupture of the



internal and muscular coats of the aorta happens in such a point of the artery, where externally there is only a thin tense membrane closely applied to the aorta, instead of a corresponding soft cellular sheath, we see that this external thin membrane is likewise comprehended in the rupture of the proper coats of the artery, and that therefore sudden death takes place, from the inevitable effusion of blood into some of the principal cavities, especially the thorax. Such is the case whenever the internal and muscular membranes of the aorta are ruptured in that portion of the artery included within the pericardium, which is only covered by a thin reflected layer of it. In this particular circumstance of place and structure, as soon as the proper coats of the aorta are ruptured, this thin membrane is lacerated at the same time, and the blood is immediately effused into the cavity of the pericardium. An example of this kind is related by Walter, and illustrated by a figure;\* by the Berlin Physicians;\* and several other fatal accidents similar to these are recorded by Morgagni.\* I have likewise observed a case similar to the preceding, the history of which I think proper to relate here. Joseph Varani, 22 years of age, a corporal of the 4th company of pioneers, while he was conversing cheerfully with his companions, suddenly fell down dead. This man, formerly by trade a shoemaker, had been repeatedly infected with lues venerea, and had also several times undergone a mercurial course. He had never, however, complained of difficulty of breathing, and his pulse had never been found irregular or intermitting, not even a few weeks before his death. On examining his body, the pericardium immediately presented itself quite distended with blood. The aorta

\* See the Appendix, notes, No. 3, 4, 5.



in the vicinity of the heart, at the distance of half an inch above its valves, where it began to be incurvated, presented externally a tumor of the size of a nut, which opened by a small hole within the pericardium. The reddish, and as it were, ecchymosed membrane, of this tumor diminished in thickness in proportion as it approached the place of the rupture, round which it was very thin. On making an incision into the concave part of the aorta, on the side opposite to the seat of the tumor, its internal coat, where it corresponded to the base of the tumor, was quite rough, corroded, interspersed with yellow hard spots, and actually *ulcerated* for the space of an inch in circumference. In the centre of this ulcerated tract, both the internal and muscular coats of the artery formed a slight pit, into which the point of the fore-finger could be introduced, so that any one, who had contented himself with the appearance of the parts, would have said, that this small tumor, which appeared externally on the beginning of the curvature of the aorta, was formed solely by the weakened and distended proper coats of the artery, or that this tumor was a *true* aneurism. But on removing carefully from the curvature of the aorta its external cellular sheath, and consequently the reflected lamina of the pericardium, leaving the subjacent fibrous coat untouched, I found that this reddish and ecchymosed sac was formed solely by the cellular sheath, and by the reflected lamina of the pericardium. This cellular capsule, at its base, adhered very firmly to the irregular edges of the ulceration, and rupture of the proper coats of the aorta, in such a manner that the limits of the one and of the other could be clearly distinguished. On which account, in this case there were two ruptures, as in all others of sudden death caused by aneurism, the



one in the proper coats of the artery, the other in its external cellular capsule. The thin, tense, reflected lamina of the pericardium, being provided with very little soft cellular substance under it capable of extension, when raised to the size of a nut, not being disposed to yield any further, burst,\* and allowed the blood to escape into the cavity of the pericardium. But this is not the case in the other parts of the aorta, in its curvature without the sac of the pericardium, nor in its thoracic and abdominal trunks; through all which tract the cellular sheath of this artery, far from being a fine tense pellicle, adhering firmly to the muscular coat, as within the pericardium, is, on the contrary, a pulpy weak covering, allowing itself to be easily distended. Whence it happens that this cellular sheath is well fitted for yielding to the impulse of the arterial blood which is effused, and, by yielding, it allows itself to be formed into a sac, which strengthened internally by the addition of the polypous layers, and externally and anteriorly by the pleura in the thorax, and the peritoneum in the abdomen, opposes sometimes for a very considerable time the sudden fatal effusion of blood into these cavities.

§ 20. Of all the causes capable of producing the rupture in any part of the proper coats of the aorta, especially the internal, I have great reason to believe, that the slow morbid *ulcerated, steatomatous, fungous, squamous* degeneration of the internal coat of the artery, has a share in it much more frequently, than violent exertions of the whole body, violent blows, or an increased impulse of the heart. The artery is nourished, and increases in the same manner as all the other

\* The pathological preparation mentioned here is preserved in the museum of this university.



parts of the animal body, it is vascular and organized, and therefore must be subject to the diseases, to which vascular and organized parts are liable. And it is a fact, of which no doubt can be entertained, that the proper coats of the aorta, and especially the internal coat, are subject from a slow, internal cause, to an *ulcerated* and *steatomatous* disorganization, as well as to a *squamous* and *earthy* rigidity and brittleness.<sup>1</sup> Read upon this subject, what has been written by Bonetus,<sup>2</sup> Lieutaud,<sup>3</sup> Morgagni,<sup>4</sup> Haller,<sup>5</sup> Lancisi,<sup>6</sup> by Guattani,<sup>7</sup> Matani,<sup>7</sup> Borsieri,<sup>7</sup> Desault;<sup>7</sup> and farther, let any one skilled in the dissection of the human body, consult his own observation, and it will appear, that these morbid degenerations of the internal coat of the arteries are very frequent, especially in the curvature, thoracic, and abdominal trunks of the aorta. And this is not to be considered as a peculiarity of the coats of the artery: for, we have cases of *ossifications* of the pericardium, and of the heart, and of *steatoms* and *ulcerated* corrosions of the heart, from internal un-

<sup>1</sup> Schulzius mentioned, that he had seen in a mare, the artery which runs along the colon, occupied by aneurism, the centre of which was full of small worms. Acta nat. curios. vol. i, obs. 219, p. 519. The tumor was of the size of a large nut, hard, and of an oval figure. A probe passed readily along within the artery, but at the place of the tumor, it seemed to pass through a ball of hair or wool. On opening the artery lengthwise, the author found, that its coats, at the site of the tumor, were three times thicker than natural. On examining the inside of the tumor formed by the thickened coats of the artery, he observed, that its substance was quite cellular, and that the cells were full of capillary worms twisted together.

<sup>2</sup> Sepulcret Anatom.

<sup>3</sup> Histor. Anatomico-med.

<sup>4</sup> See note in the Appendix, No. 6.

<sup>5</sup> De Aneurysmat. propos. 30, 31, 32.

<sup>6</sup> De extern. Aneurysmat.

<sup>7</sup> See in the Appendix, notes No. 7, 8, 9, 10.



known causes.\* The case of conversion of the coats of the aorta into a steatomatous tumor, related by Stenzel, and illustrated by figures, is very remarkable. (*Dissert. de Steatomatibus Aortæ*, 1723). ‘*Altera harum excrescentiarum,*’ says he, ‘*in angulo aortæ ubi incurvatur sita erat; altera vero aliquantulum ab hac distans descendentem occupabat ramum. Hæc corpora in tantam istum canalem molem extenderant, ut ipsum ferme cor magnitudine æquaret, omneque propemodum exeunti a sinistro cordis thalamo sanguini spatium præcluderet. Hi tumores, digitis admotis pressi, plane non cedebant, nullamque, ob summam qua pellebant duritiem, foveam relinquebant; hinc unum de his incidendum, cultroque, atque examini anatomico subjiciendum esse necessarium ducebamus; quo dissecto et aperto, membrana satis crassa et firma, vitulino crassitie corio æmula, illo tamen adhuc durior, colore albicante ad incarnatum accedente prædita, striisque multis per totam superficiem notata oculis occurrebat nostris. In hujus cavitate materia quædam sebosa, et adipi perquam similis firmiter compacta inveniebatur.*’

Crell, speaking of a state of hardness of one of the coronary arteries of the heart, remarks; ‘*exteriolem quidem tunicam nihil a statu naturali recessisse, sed duriolem intus nucleum recondere apparebat. Dissecto secundum longitudinem canale, interior ejus tunica, quam nerveam dicunt, integra manserat, transparente itidem per illam corpore alienæ indolis, coloris ex albo flavescentis, cujus majorem crassitiem circa*

\* Walter Mem. de Berlin, an. 1785. One of the most remarkable ossifications of the heart is delineated and described by Samuel Foart Simmons, in pl. vii, annexed to vol. i of the Medical Communications, pag. 228.



ramorum imprimis e trunco egressum advertebam. Cum quale illud esset corpus durum, quave ratione illud pervenerit scire averem, atque omni ex parte arteriam versans, interiorē forte tunicam leniter comprimerem, materiem illi quæ in atheromate, vel meliceride alias continetur, similem, per poros ejus erumpere videbam, qua sub specie vermiculari expressa, maxima illius pars solidior, cæterum ejusdem coloris, intus remanebat, ut ex hujus induratione illam generatam esse, si diutius ibidem hæsisset, pariter exhalante parte tenuiore, coagulandam, dubitare non liceret.' (*Dissert. de art. Coronaria instar ossis indurata*).

One of the most remarkable cases of ulceration of the internal membrane of the arteries, is published by Meckel, (*Acad. de Berlin, 1756*). 'Ayant ouvert l'aorte, je la trouvai à un pouce de distance de ses valvules toute ulcérée, extrêmement inégale, et déchirée. Les cavités étoient remplies partout de pus blanc, entre lesquelles étoient des parties non cohérentes de la tunique nerveuse, qui flottoient librement.' The observation by Weitbrecht is equally deserving of being known, both on account of the fact, and the manner in which it is expressed, (*Comment. acad. Petropolitanæ, t. iv*). 'Cor igitur exscindo cum vasis adhærentibus summa cura, et apertis cavitatibus, invenio corrosas, et tanquam a muribus exesas tunicas aortæ, immediate supra valvulas semilunares, et membranam adiposam, quæ vasorum e corde egredientium principia cingere solet, in regione sternum respiciente perforatam.' See farther, *Acta Medica Berolin*, dec. i, vol. viii, p. 86. Sandifort, in plate iii, annexed to his *Observ. Anatom. Patholog.* has delineated this sort of ulceration of the aorta, to which he adds: 'in hac etenim aorta, ad omnia arteriarum intercostalium cri-



ficia, interna tunica tota consumpta erat, atque exesa, sic ut in omnibus illis locis de hac membrana nihil omnino superesset.'

But, as I have already mentioned, the *softening*, *ulceration*, and subsequent *rupture*, are not morbid states so peculiar to the arteries, as not sometimes also to attack the heart. Several examples of ulceration of the parietes of the heart have been recorded by Bonetus, (Sepulch. Anat.) Johnston relates a case of softening, (Memoirs of the Medical Society of London, vol. i.), in which the substance of the heart was so dissolved and *putrid*, as he expresses it, that the point of the finger passed through it with the slightest pressure. Morand, (Acad. Royal des sciences de Paris, an. 1732), relates two cases of this kind, the one in the Duchess of Brunswick, the other in a person of rank, who died the same year, from a rupture of one of the ventricles of the heart; on which subject he adds: 'Pour expliquer comment, dans le deux cas que j'ai rapportés, les ventricules du coeur ont pû s'ouvrir sans cause extérieure, il faut remarquer, que dans le premier, il y avoit une érosion aux fibres charnues du ventricule droit, qui sembloient avoir été ulcérées, et creusées peu à peu jusqu'au trou qui ouvroit le ventricule; et que dans le second la chaire du coeur étoit devenu molle au point, qu'en quelque endroit pu'on presentat le bout d'une sonde, sans l'appuyer, elle entroit, et traversoit le coeur par le simple poids de l'instrument, qui n'est pas considérable. Donc la rupture de cet organe sera raisonnablement attribuée à l'amollissement de ses fibres, ou à un ulcere qui en aura usé l'épaisseur.' These diseases, which sometimes soften the substance of the heart, and dispose it to ulceration and rupture, are likewise common in the arteries.



§ 21. Lancisi mentions, that hypochondriac and scorbutic persons, hysterical women, and those who have been affected with lues venerea, are particularly predisposed to the *ulceration* and *disorganization*, (*diloricatio*), as he expresses it, of the proper membranes of the artery. Morgagni\* has made the same remark. A great number of observations on this subject have successively confirmed this fact, and likewise demonstrated, that patients affected with lues venerea are, much more frequently than any others, affected with a *steatomatous*, *ulcerated* degeneration of the internal coat of the arteries. So great a disorder as the ulceration of a large artery ought certainly to be preceded by a state of disorganization, or of excessive relaxation of the artery, more particularly in the part corresponding to the seat or root of the aneurism, since aneurisms are observed to arise in persons, in whom it is impossible in any way, to trace the origin to external violence applied to the artery, or to an increased impetus of the blood circulating in it. If the force of the circulation were capable of rupturing a great artery, aneurisms would be frequent in consequence of acute and violent fevers; and if a general relaxation of the whole body occasioned the rupture of arteries, aneurisms ought to be very frequent in dropsical patients, in those predisposed to paralysis, or in those in whom the bones become soft; in which patients, experience shews, that the contrary always happens.

\* Epist. xviii, art. 27. Nullus tamen dubito quin erodentia corpuscula eorum humores, qui lue venerea infecti sunt inquinantia, et in aliis etiam, quæ minime osseæ sunt, partibus subsistendo se produnt; sic et in arteriarum quoque tunicis non secus atque in scorbuticis, et hystericis, haud raro subsistant quas hic illic erodendo infirmant, atque dilatationibus obnoxias reddunt.



§ 22. But whatever be the state of this point, both of these morbid states of the artery always commence in the internal coat of the diseased artery, or in the space between it and the muscular coat, which in the sound state is filled by a very fine down, called by Haller the *cellulosa secunda* of the artery. At the beginning of the disease, the internal coat of the artery loses, for a certain space, its beautiful smoothness, and becomes irregular and wrinkled. It afterwards appears interspersed with yellow spots, which are converted into grains, or earthy scales, or into *steatomatous* and *cheese-like* concretions, which render the internal coat of the artery very brittle, and so slightly united to the adjoining muscular coat, that upon being merely scratched with the knife, or by the point of the nail, pieces are readily detached from it, and on being cut, it gives a crackling sound, similar to the breaking of the shell of an egg. This ossification of the artery cannot be said to be proper to old age, since it is sometimes met with in patients who are not much advanced in life. The whole of the side of the artery, in that part which is occupied by the morbid affection, is for the most part hard and rigid, sometimes soft and fungous, and, in most cases, the canal of the artery is preternaturally constricted. In the highest degree of this morbid disorganization, we find, on the inside of the artery, true *ulcerations*, with hard and fringed edges, fissures, and lacerations of the internal and fibrous coats of the artery. Some have thought, that, when this *steatomatous*, *earthy* induration of the coats of the artery happens, and produces a constriction of the canal of the artery, it contributes very much to the formation of aneurism above the place of the stricture, in consequence of the resistance which that stricture opposes to the blood sent from



the heart. There appears to be some degree of truth in this opinion, with regard to the aorta at its origin from the heart, where, as I have repeatedly remarked, this artery shews a particular disposition to yield to an enlargement in diameter in its whole circumference; but the same disposition does not exist in its thoracic and abdominal trunks, nor in the arteries of the second order, such as the femoral and popliteal. In all the cases in which the stricture occurs in some point of the aorta, from below its curvature, as far as the iliac, and from thence to the popliteal artery, the aneurism constantly arises in the part where the *steatomatous, earthy* disorganization of the proper coats of the artery has occasioned the constriction of its tube. The aneurism occurs there, as I have demonstrated above, because the internal coat being *ulcerated* or *ruptured*, the blood oozing through between the layers of the muscular coat is effused into the cellular substance, which is raised in the manner of an *ecchymosis*, and is afterwards converted into an aneurismal sac. Morgagni\* and Nicholls† had occasion to observe the commencement of an aneurism under the appearance of ecchymosis, or extravasation of blood, which is a rare occurrence. In the history which the latter has given of the dissection of the body of George II, late king of England, he says, that he found a fissure in the internal surface of the aorta, through which a small quantity of blood had recently passed and formed an *ecchymosis*, pointing out the real state of an incipient aneurism of the aorta, and confirming a point of doctrine published by the same author, with regard to this subject,—that the external or cellular coat of the aorta can support the

\* See § 19.

† Philosoph. Transact. vol. lii, an. 1761, part 1.



impulse of the arterial blood without being ruptured, although there be an ulceration, or laceration of the internal coat, which he calls ligamentous. Indeed, after due consideration of this matter, it cannot be otherwise: for, whenever the rupture or ulceration of the internal coat of the aorta is narrow, or of little extent, and deep seated, the blood which oozes insensibly through the muscular coat stops under the external cellular sheath, without raising it, exactly in the manner of an *extravasation*, or *ecchymosis*; but as soon as the quantity of blood collected there is capable of raising this external cellular covering of the artery, it is necessarily converted into a *pulsating tumor*, and aneurismal sac.

§ 23. Finally, there are not many descriptions and figures of aneurism of the aorta which are perfectly accurate. Nevertheless I shall point out the few examples of this kind with which I am acquainted, which will contribute very much to put in a clear light all that I have said with regard to the true nature and character of this disease, to which descriptions and figures I shall add some of my own. In the plates and figures, carefully delineated, I have remarked that the engraver, in copying exactly the object which he had under his eye, has proved the contrary of what the author has written on the same subject, of which we have several other examples in anatomy.

§ 24. In Lancisi \* we read the following account of the dissection of an aneurism of the aorta. ‘*Extractis cruoris grumis, in cystidis fundo foramen spectavimus apertum in facie antica summitatis arcus arteriæ mag-*

\* De Aneurysmat. propos. xxii.



næ, parumper deorsum inclinatum. Erat autem foramen fere rotundum, æqualemque habebat diametrum ei monetæ, quæ vulgo appellatur *un Giulio*. In ejus vero foraminis circumferentia callus quidam durus supereminebat, ea tamen lege, ut in situ magis declivi eadem durities esset complanata, et fere horizontalis cum interiore superficie sacculi aneurismatici. After the explanation which has been given in this chapter, it is easy to understand, that this aperture, equal in circumference to a *Julio*\* observed by Lancisi in the bottom of the aneurismal sac, was the rupture which had taken place in the internal and muscular coats of the aorta, and that the elevated hard margin was the partition, or the boundary between the proper coats of the aorta, and the beginning of the cellular aneurismal sac.

§ 25. Dr. Pierce Dod † mentions, ‘ We found, on  
 ‘ opening the thoracic aorta, that this artery had re-  
 ‘ tained its natural diameter. But continuing to di-  
 ‘ vide the artery from below upwards, as far as the  
 ‘ origin of the right subclavian, (which was nearer than  
 ‘ usual to the beginning of the left carotid), we found  
 ‘ a preternatural circular opening in the aorta, about  
 ‘ half an inch in diameter. On carrying the incision  
 ‘ through this aperture within the aneurismal sac, we  
 ‘ observed that its edges were hard, and almost carti-  
 ‘ laginous, and seemingly the remains of the fibres of  
 ‘ the muscular coat of the artery. Upon a nicer in-  
 ‘ spection, we found, in fact, that these remains were  
 ‘ fibres torn from the muscular coat of the aorta,  
 ‘ which, terminating here, the aneurism immediately  
 ‘ increased to two inches in diameter, and continued

\* A Roman coin, about the size of a shilling.

† Philosoph. transact. an. 1728.



‘ to enlarge the farther it proceeded towards the clavicle and neck. The tumor was covered by the external membrane of the artery, which had yielded to the prodigious distention without being ruptured.’

§ 26. The celebrated surgeon Palletta\* has given the detail of what he found in the bodies of two men, who died of aneurism of the aorta, which I shall relate in his own words.—‘ On dividing the integuments, and separating them from the chin to the umbilicus, and from the lateral parts of the tumor, a great ulcerated cavity was observed, and the whole superior part of the first bone of the sternum and sternal extremity of the clavicle were carious. On removing the sternum, a tumor of prodigious size immediately presented itself, which extended into all that space, from the heart upwards, occupied by the lungs as far as the pharynx, of an extraordinary hardness, and covered by the mediastinum and pleura, and it also formed several projections forwards, the greatest of which at the upper part, having become visible externally, pulsated above the edge of the right clavicle. The right cavity of the thorax contained a yellowish fluid, with some membranous concretions spread over the lung. In the left, the lung had contracted a firm adhesion with the pleura; these two viscera being in other respects sound. The superior and external part of the tumor, which was ulcerated, communicated with the cavity of the aneurism, and the exit of the fluid blood was prevented by the polypous concretions which it contained. The carotid arteries (although the right

\* Giornale di Venezia, an. 1796, Aprile, No. iv.



‘ was at first conceived to be morbidly dilated) were  
‘ in their natural state. The vena cava remained  
‘ pervious; not so the external jugulars; especially  
‘ the left, which in passing over the tumor was  
‘ completely obliterated near its origin from the sub-  
‘ clavian. The right, on the other hand, had be-  
‘ come very large, and flattened. From the exter-  
‘ nal parts we proceeded to the internal, and on di-  
‘ viding the pericardium, the coats of which were  
‘ much thickened, it was found full of a reddish  
‘ lymph, in greater quantity than usual, and its in-  
‘ ternal surface was covered by thick floating flakes;  
‘ the heart also, not increased in size, was covered  
‘ by these flakes like fringes, which also surrounded  
‘ all the origin and termination of the great blood-  
‘ vessels. It was an aneurism of the aorta, formed  
‘ in the middle space between the origin of the sub-  
‘ clavian artery, and the sigmoid valves. One would  
‘ have conceived that the artery was enormously di-  
‘ lated, the whole aneurismal sac was so smooth and  
‘ solid. However, on opening the artery from its  
‘ beginning to the arch, at the place internally where  
‘ it forms the great sinus, a round aperture appeared,  
‘ of the size of a twenty-penny piece,\* and blocked  
‘ up by a thick fibrous coagulum. Along the sinus of  
‘ the aorta another coagulum was found, in the form  
‘ of a polypus, partly red and partly white. The ar-  
‘ tery was not dilated; the whole of its surface had  
‘ that appearance of health and strength which is ob-  
‘ served in the sound arteries. All the blood which  
‘ filled the aneurismal sac had passed by the artifi-  
‘ cial hole into the neighbouring cellular substance  
‘ under the pleura, and had distended it in such a  
‘ manner as to resemble a *true* aneurism.’

\* Nearly as large as a halfpenny.



The other history relating to this subject, mentioned by this celebrated author, is equally accurate and interesting.—‘ I observed,’ says he, ‘ not long ago, a spurious internal aneurism in a man, in other respects well made, and of a good constitution. He fell upon his back, and after the fall a fixed pain arose on the left side of the spine, near to the first false ribs. The pain increased, and was accompanied by a pulsation, which continued till his death. It happened suddenly, as is usually the case in such affections, and the left cavity of the thorax, on being laid open, was found full of blood and serum. On raising the lung, the aneurismal sac immediately presented itself, lying upon the vertebral column, of an oval figure, which might actually have been taken for a *true* aneurism, and might have been supposed to have burst at the instant of death, as the rupture was evident, through which all the blood collected in the thorax had been discharged. But this supposed state was ascertained to be a *false* aneurism; for, on dividing the aneurismal sac, and separating it a little from the spine, the descending thoracic aorta was observed to be of its natural size, and sound, except a hole capable of admitting a pea, formed laterally, and at the upper part of its tube, and therefore it did not correspond to the aperture in the aneurismal sac, towards the left cavity of the thorax. This sac was formed by the pleura, greatly distended, which had at last burst, and left no room for doubt that the aneurism, from its very commencement, was of the kind denominated *false*, or in other words, an aneurism arising from the rupture of the artery at the time of the fall.



§ 27. I found a state of parts very similar to this in the aneurismatic patient from whom I have taken fig. 1 and 2 of pl. ix ;\* the history of which I shall here relate. Pasqual Castiglioni, 45 years of age, of a stout but slender habit of body, addicted to the pleasures of wine and women, having served 25 years in the Austrian army, came to this hospital the 5th of November 1801. He said, that he had been subject, for about six months, to almost constant pains in the lumbar region, stretching over the abdomen.† The pains were more violent during the night than in the day time, and were accompanied by difficulty of breathing, languor, and ardor urinæ. The urine was quite cloudy, of a dark red colour, with a chalky sediment, and in the moments of greatest spasm the tension and weight extended to the testicles, especially to the left. For four months after the attack of pain, this patient had not had recourse to any method of cure, but trusting entirely to his own knowledge, took some rhubarb and diuretics, and had his loins stung with nettles ; after which, for eighteen days the diurnal pains seemed to him to have been rather relieved. The pains recurring again, he put himself into the hands of a physician, who conceived the disease to be rheumatism ; in consequence of which, he made him apply blisters, and use sudorific decoctions, which only caused a greater exacerbation of his disease. Another physician was consulted, who supposing that there were calculi in the kidneys, prescribed for him the volatile liniment, soap pills, and emollient decoctions, but all without

\* See plate 1 of this work.

† See a case very similar to this described by Sir John Pringle, *Essays and Obs. Physical and Literary*, of Edinburgh, t. iii, p. 200 ; *ibid.* *Monro*, case x, pag. 225 ; *Walter. Mem. de Berlin*, an. 1785, p. 56, tab. i, ii.



any advantage. Indeed, there were none of the proper symptoms of nephritis present. A fixed pain extending to the left lumbar region; an almost continual restlessness; a regular pulse; no fever; no vomiting; the lower extremities sometimes quite cold, while the upper extremities, and especially the head, perspired copiously, from the violence of the pains, which attacked him for the most part in the afternoon, or during the night, and extended to the left lower false ribs, to the loins, to the left thigh, and sometimes to the left testicle. These pains were more acute in rainy or windy days, than in serene weather. Opium alone, in large doses, combined with assafoetida, and gentle friction with oil of amber, procured him some relief.

The patient preferred lying on his left side, or bent forwards when he sat up in bed. No pulsation was felt in the left lumbar region, either by the patient or by the assistants. This unfortunate man, in the morning of the 15th February 1802, was found dead in his bed, lying on his left side.

On opening the abdomen, and removing the intestines, there appeared along the left lumbar region, as far as the crural arch of the same side, a black coloured swelling, apparently gangrenous, which appearance was however only caused by black coagulated blood, extravasated behind the peritoneum. On examining the aorta from the heart downwards, in its proper situation, when I came to about eight fingers-breadth before the thoracic aorta passes under the crura of the diaphragm, the aneurism presented itself, resting on the bodies of the lower vertebræ of the back, and I then ascertained the true nature of the disease.

Having evacuated this great collection of extravasated grumous blood from the abdomen, by which



the peritoneum had been raised from the appendices of the diaphragm, as far as the left crural arch, I remarked that the effused blood had formed deep excavations in the substance of the left psoas muscle, so as to disorganize the lumbar nerves, and injure the *anterior crural* and *obturator* nerves. This accounted for the very acute pains felt by the unhappy patient in these parts, and for the sense of coldness which he experienced in them. From these deep pits, which had been filled with grumous blood, my fingers passed freely behind the peritoneum, between the appendices of the diaphragm within the thorax, behind the pleura, and from thence into the cavity of the aneurism, which rested, as I have said, upon the inferior vertebræ of the back, and was full of grumous blood. The thoracic aorta, examined on its anterior surface, seemed to pass over the aneurism, without having any share in the formation of it; and the more so, as this artery had preserved its natural diameter in its whole course. I submitted the particular conformation of this aneurism to a careful examination. Having raised the pleura which covered the trunk of the thoracic aorta, as well as the aneurism anteriorly and laterally, a thick pulpy cellular substance presented itself, under the pleura. Having separated slowly the cellular sheath which surrounds this artery in the natural state, all round the thoracic aorta, for a considerable way above and below the aneurism, I saw plainly that it was this pulpy cellular substance, this natural external sheath of the artery, quite distinct and capable of being separated from the subjacent muscular coat, which being raised by the effused arterial blood, had been converted into an aneurismal sac.\* Having

\* Plate 1, *dd*, *ee*, *fff*.



then made a longitudinal incision into the thoracic aorta, on its anterior surface, and in that space where this artery seemed to run uninjured over the aneurism, there immediately appeared opposite to the incision, or in the posterior side of the artery, a rupture a little more than an inch in diameter, with irregular, hard, callous edges; through which rupture my finger passed into the large aneurismal sac. The tube of the thoracic aorta was not at all dilated at the place of the rupture. The edges of the laceration still preserved the characters of the proper coats of the artery, especially of the muscular coat, and there was an evident difference, at the edges, between the truncated extremities of the fibres of the muscular coat, and the beginning of the cellular pulpy aneurismal sac,\* over which, as I have mentioned, the pleura extended, as well as over the trunk of the thoracic aorta. Having then turned the thoracic aorta along with the aneurism, from the left to the right side of the vertebral column,† I found that the aneurismal sac, on the side next to the bodies of the inferior vertebræ of the back, was wanting for a certain space, and that there the place of the sac was supplied by a portion of the bodies of the dorsal vertebræ, partly corroded, with the exception of the intermediate cartilages, which, as other surgeons have remarked, remain in similar circumstances, uninjured longer than the bony substance. On examining attentively the internal surface of the posterior part of the aneurismal sac, or that which was next to the vertebral column, there appeared in the bottom of the sac, a rent, or passage from the posterior side of the thoracic aorta into the aneurismal sac, and this posterior side of the artery,

\* Plate 1, *g g, f f f.*

† Plate 1, *g g, f f.*



resembling a partition \* perforated in its middle, marked the boundaries between the proper coats of the artery, and the beginning of the cellular aneurismal sac. The trunk of the thoracic aorta, examined also on its posterior surface, was not at all dilated beyond its natural diameter. Its internal coat, round the place of the rupture, had lost its natural smoothness, and was here and there covered with earthy scales, and ossified points; which appearance was also observed in this patient, on the internal coat lining the curvature of the aorta, in the vicinity of the heart.

§ 28. In addition to what has been explained in the preceding case, I shall now add the following history. The patient was a shoemaker, who had for a long time had a pulsating aneurism, which protruded outwards on the right side of the thorax in the interspace of the upper true ribs. The tumor had pulsed strongly till the death of this unfortunate man, which happened unexpectedly. He had said, that the cause of his disease was the constant percussion of the leather against his breast in working. On opening the body, I found that the aorta, which was scarcely more dilated than usual, was evidently drawn from the left to the right side, and that it, together with the large aneurismal sac, had so much contracted the cavity of the thorax, that the right lung was rolled up, and appeared as if a great part of it had been wanting. The aneurismal sac was united firmly to the upper part of the pericardium, and at the point of firmest union between these parts a rupture had taken place, through which the blood of the aorta had been poured in great quantity into the pericardium, and had occasioned the sudden death of the patient. The aneurismal sac,

\* Plate 1, g g.



by its long pressure against the upper true ribs of the right side, in the vicinity of the sternum, had caused a corrosion of some of these ribs. To ascertain, however, completely the nature and intimate structure of this aneurism, I began by removing from the arch of the aorta its natural cellular sheath from below upwards as far as the root of the aneurism, so as to lay bare the muscular coat of the arch of the aorta in all this space. Having done this, I made an incision into the artery lengthwise on the side opposite to the root of the aneurism. I then discovered within this artery, on the opposite side, the place of the rupture of its proper coats; which rupture was surrounded by an irregular callous margin, as is usually observed in a fistulous opening. This portion of the side of the lacerated artery appeared to be in fact a partition ruptured in its middle, and placed between the cavity of the artery and that of the aneurismal sac. The ruptured fibres of the muscular coat of the arch of the aorta evidently terminated in the margin of this rupture. Continuing then to separate carefully the natural cellular sheath of the curvature of the aorta, and separating it from the subjacent muscular coat, there could be nothing more evident than that this cellular sheath was the same which was converted into an aneurismal sac, covered anteriorly by the pleura, and for a certain space also by the upper part of the pericardium, with which the sac had contracted a firm adhesion. Having opened the aneurismal sac anteriorly, or on the side, which was beginning to protrude out of the right side of the thorax, there appeared evidently within the cavity, and at the root of the sac, the rupture of the proper coats of the artery, and there was a very marked difference between the cellular pulpy texture of the aneurismal sac and the fi-



brous structure of the partition, lacerated in its middle, and quite peculiar to the artery. The internal coat of the curvature of the aorta, especially on the side of the rupture, was interspersed with yellow specks and earthy scales, which had rendered it at that place rigid and brittle.

§ 29. With regard to the figures and plates of aneurism of the aorta, I shall point out here, for the convenience of students, those few figures which appear to me to have best expressed the facts which I have explained. The first design of an aneurism of the aorta which was published, as far as I know, is that of William Riva,\* which, although roughly delineated, shews nevertheless plainly enough the proximate cause of this disease. For it represents the aneurismal sac divided by an incision through its fundus and neck, as far as the arch of the aorta; and under the letters H H is distinctly seen the place of the rupture of the proper coats of the artery, and at the same time that species of partition perforated at its centre, formed by the side of the lacerated artery, which points out the exact boundary between the ruptured artery, and its cellular sheath converted into an aneurismal sac.

§ 30. In the figure published by Dr. William Hunter,† of an aneurism of the arch of the aorta, the sac of which had been divided in the vicinity of its neck or root, the boundaries of the rupture of the aorta, and the beginning of the cellular sac of the aneurism, are distinctly seen. This author, who, with many others, was of opinion, that the aneurismal

\* Acad. nat. cur. An. i, Decad. i, Obs. xviii.

† Medical obs. and inquiries, vol. i, pl. iv, fig. i, G G.



sac was only the dilated artery, found himself not a little embarrassed when he undertook to explain how the aneurismal sac in the vicinity of the arch of the aorta had a sort of stricture or neck, and the more so, that of five aneurisms which he had had an opportunity of observing, four had this stricture.\* He said, that this neck or stricture was occasioned by the resistance which the fundus of the aneurismal sac had met with against the sternum, by which the whole tumor had been flattened. In saying so, Dr. Hunter shewed that he did not know that the same form is presented by aneurisms which beat against bones, as well as by those which do not, and that the aneurisms of the common trunk of the carotid and right subclavian arteries,† which do not beat against any hard body, have likewise a neck, or a sort of stricture. If Dr. Hunter, instead of examining aneurisms of the arch of the aorta out of their situation, and dried, as he was accustomed to do, had dissected them *in situ*, and in a recent state, and had at the same time separated and compared the proper coats of the injured artery with the substance composing the aneurismal sac, he would not so easily have allowed himself to be deceived, by seeing that the artery, as well as the sac of the aneurism, were covered by a common

\* Loc. cit. In four of the five cases that have fallen under my examination, it was very plain that the anterior part of the curvature of the aorta was protruded into a sacculus, with a stricture between it and the rest of the aneurism. Here, I presume, the arterial coats must have been weakened by pressure, and the resistance of the sternum and ribs must have made the protruding part swell out in its lateral circumference. Whence a stricture between this sac and the rest of the aneurism, and the appearance of the whole as of a double aneurismal sac, one part communicating with the other by a narrow orifice. Page 343.

† Loc. cit. Pl. i, fig. iv, vol. iii.



smooth membrane, or by the pleura ;\* and he would have ascertained, that this neck, or stricture at the root of the aneurism, was nothing but the boundary between the proper coats of the lacerated aorta, and the beginning of the cellular aneurismal sac, which, from mechanical necessity, was obliged at this place to assume the above described form.

§ 31. A very marked example of this is furnished by the figure of an aneurism communicating with the common trunk of the carotid and subclavian, described and delineated by Bayford.† The small tumor was large at its fundus, and constricted at the root, where it began to go off from the artery. On opening the artery lengthwise, on the side opposite to the seat of the small aneurism, it was found that the hole of communication between the tube of the artery and the aneurismal sac was little more than three lines, ‡ while the fundus of the tumor was about two inches in diameter. This hole was produced by the rupture of the artery, a portion of the coats of which formed internally a kind of partition between the artery and the aneurism, and externally that appearance of stricture or neck which was observed at the root of the aneurismal sac. The same author has likewise given the description and an accurate figure of an aneurism of the ruptured abdominal aorta, § in which case he remarks, that the

\* Loc. cit. vol. i. That this peculiar sac was not formed in consequence of a rupture in the artery at that place, was plain from the different degrees of it in these four different cases, as well as from an obvious continuity both of the surface and substance of the artery in all of them. Page 344.

† Loc. cit. vol. iii, pl. i, fig. i, iv, v.

‡ Loc. cit. pl. iv, fig. v.

§ Loc. cit. pl. i, fig. ii, fig. ii and iii.



artery was not at all dilated beyond its natural diameter.

§ 32. Mr. Thomson has published the figure of an aneurism of the arch of the aorta,\* which deserves to be considered with attention; for, it represents in the same preparation the two distinct affections of the artery immediately after it passes out of the heart, that is, the equable enlargement in diameter of the whole tube of the artery,† and that which, properly speaking, constitutes aneurism. This figure besides shews, in the most distinct manner, the stricture or neck,‡ which is invariably presented by the root of the aneurism in the boundary common to the proper coats of the ruptured artery, and to the beginning of the cellular aneurismal sac,

§ 33. The figures published by Roloff,§ Verbrugge,|| and Guattani,¶ likewise represent accurately the curvature of the aorta, and at the same time the aneurism, which takes its origin not from the whole circumference of the arterial tube, but from one side of the artery only. In some of these figures of the aneurism of the arch of the aorta in the vicinity of the heart, the complication of the increased diameter of the whole canal of the artery is marked, in others it is not; for such is the nature of the case; because aneurism often exists without any previous dilatation of the arterial tube, and because, if we except, as I have several times mentioned, the curvature of

\* Loc. cit. vol. iii, pl. ii.

† Loc. cit. F.

‡ Loc. cit. G.

§ Acad. R. de Berlin, an. 1757.

|| De Aneurysmate, Tab. v.

¶ De extern. Aneurysm. Tab. ii, fig. i, ii. Tab. iv, fig. ii.



the aorta in the vicinity of the heart, in which situation only, this complication of an enlargement of the arterial canal in diameter and of an aneurism \* sometimes happens. In the rest of the aorta, from its curvature downwards, the aneurism always takes place without any evident dilatation of the tube of the artery. In all the above-mentioned figures, there may be distinctly perceived the limits between the proper coats of the lacerated artery, and the beginning of the cellular sac of the aneurism.

§ 34. Marcot,† in the description which he gives of an aneurism of the aorta, eight inches below its origin, says, that the tumor was about the size of the fist, but that the aperture of communication between the trunk of the aorta, and the aneurismal sac, was not more than fifteen lines in length, and eight in breadth. Notwithstanding the great difference of size of the tube of the aorta, compared with the aneurismal sac, and the smallness of the aperture, by means of which the aorta communicated with the sac of the aneurism, this author was of opinion, that the aneurism was formed by the dilatation of the coats of the aorta. Figures 1, 2, 3, 4, subjoined to his memoir, prove precisely the contrary of what the author has asserted; that is, that the aneurismal sac did not belong at all to the artery. I am very desirous that my readers should compare all, or at least the greatest part of the

\* Walter, Mém. de Berlin, an. 1785. D'autant plus, que les membranes de l'artère pulmonale, et de l'aorte sont plus déliées, et plus molles à proportion de ce qu'elles sont plus voisines du coeur, ce qui les rend plus faciles à ceder, et à s'élargir. C'en est assez pour faire comprendre non seulement comment les anéurismes existent plutôt dans ces endroits que partout ailleurs, mais encore pourquoi ils y acquierent le plus de grosseur.

† Mém. de l'acad. R. des sciences de Paris, an. 1724, p. 414.



figures of aneurism referred to in this and the preceding paragraphs, as I am certain, that the inspection of the figures pointed out, will contribute very much to render more plain, what I have proposed to demonstrate with regard to the true nature, and proximate cause of this disease.

§ 35. Whenever an aneurismal sac of an immoderate size beats violently, and for a long time against a bone, as the sternum, ribs, clavicle, and vertebræ, it invariably happens, that the bones are in the end corroded, so that the aneurismal sac elevates the integuments of the thorax, or of the back, and pulsates immediately under the skin. To explain this phenomenon, some writers have had recourse to the abrasion of the bones, occasioned by the afflux and reflux of the arterial blood within the cavity of the aneurismal sac; others have thought, that it was the effect of a power of dissolving the bones, or of a *bone-dissolving* quality, existing in the blood. But both these theories are, in my opinion, unsatisfactory; because the bloody coagulated layers which form at an early period, and continue incessantly to accumulate one above the other, from the circumference to the centre of the tumor, prevent the bones from coming in contact with the fluid blood, and remove them from it; and because this *bone-dissolving* quality attributed to the blood, is by no means proved by certain or direct experiments; the contrary even appears to be the case, from the observations made by Sir John Pringle, with the intention of ascertaining it. There are numerous examples of extravasated blood remaining stationary, and in contact with the bones, without either the soft or the hard parts having received any injury from its presence, whenever there had not occurred a strong pressure



caused by the extravasated blood on the soft parts, and on the bones. Else \* relates the case of a man, who, in consequence of a violent contusion, had for more than two years, a great extravasation of blood, which extended from the axilla along the inner side of the humerus, as far as the elbow. This man having died of a quite different disease, it was found, in the dissection of his body, that this vast effusion of blood had been formed by a rupture of one of those *deep* seated veins, which accompany the brachial artery. The blood had been for a long time in contact with the bone of the humerus, and surrounded the brachial artery; nevertheless, the humerus remained uninjured.† And although some, as happened to Sandifort,‡ have contracted ulcers in their hands in making the dissection of large aneurisms protruding out of the thorax, and which had already passed into the state of gangrene, it would not be lawful to infer, that an ichor so pungent, as to ulcerate not only the soft parts, but the bones also, flowed out of the blood contained in the cavity of the aneurism. It is evident, that in this case, the causticity is to be referred to the state of putridity produced by the gangrene, not only in the bloody clots contained in the tumor, but in the substance containing the aneurismal sac, and in the parts with which it is in contact. Every doubt on this subject is more particularly removed, by the fact of corrosions being produced in the bones by the aneurismal sac, though it remained entire on that side which rested upon, and compressed the bones. Ruysch relates two of these cases in his anatomical observations; and Du Vernoy has inserted in the acts of Petersburg,

\* Medical Obs. and Inquiries, vol. iii, p. 172.

† See Appendix, note 11.

‡ Nova acta acad. Cæs. Leopold. t. iv, p. 31.



the case of an aneurism of the aorta, which had produced excavations in the vertebræ, though they were still found to be covered by a membrane. And Vacca, in a history which he has published of a popliteal aneurism, operated upon by Mr. Hunter's method, mentions, that he found, fifty-two days after the operation, that the parietes of the aneurismal sac were almost every where approximated and united; that the sac was uninjured on the side which rested upon the posterior surface of the tibia near the head of that bone; but that, notwithstanding, on removing the sac, the bone was found to be carious behind it.

§ 36. The explanation which, to me, seems the most plausible, of this phenomenon, is that which is drawn from the analogy of other phenomena similar to this, and which we see frequently occur in the living solid, by means of the increased activity of the *absorbent lymphatic system*. It is a certain fact, proved by innumerable observations and experiments, that in order to excite and increase the activity of the absorbent lymphatic system, and to raise it to so high a degree, as to obtain by means of it, the destruction of a certain portion of the solid parts of an animal, it is sufficient to compress the parts which we wish to be absorbed with such a degree of force, especially from within outwards, that the compressed parts be thereby deprived of a considerable part of their natural vitality, and of their usual nourishment, so that in this respect the compressed parts are, to use the expression, inferior in vitality to the contiguous parts possessed of their full nutrition and vitality. The absorbent lymphatic system, which might, not without reason, be called the system of destruction of the animal body, and



which would be so in fact, if the individual parts of the animal were not constantly renewed by the arterial system, absorbs continually and rapidly, and at every point, the particles of the compressed parts, having little or no nourishment, in comparison with the contiguous parts, and deprived of that degree of vitality, which enabled them to resist the destruction. The mouths, therefore, of the absorbent vessels, produce in the compressed parts, a solution of continuity, and a destruction of substance proportioned to the extent, depth, and force of the compression, and to the deficiency of nourishment and vitality, which these parts previously received from the arterial system. It is from this circumstance, that we see the skin absorbed, or which signifies the same thing, become ulcerated for a certain space, in consequence of a long continued recumbent posture; that we see every day parts become corroded and ulcerated, from an ill applied, and too tight bandage; that we observe foreign bodies pushed by the force of nature from within the animal body towards the surface, by pressing on the parts which surround them, causing them to be absorbed or ulcerated, and thereby making themselves a passage through them outwards; that the matter of abscesses, although by nature not caustic nor corrosive, by pressing the skin, and elevating it greatly in some point, causes the skin at the part of the greatest pressure, to be absorbed by the lymphatic system, or ulcerated, and allows the matter to be discharged; that incysted tumors, such as the *melicerous*, *atheromatous*, *steatomatous*, the *lupice*, and *fungous* tumors of the dura mater, the contents of which no person has hitherto demonstrated to be possessed of a caustic, and still less



of a *bone-dissolving* quality, by the long pressure upon the bones, at last occasion a portion of them to be absorbed, and thereby a cavity to be formed in the bones, into which a portion of this incysted tumor insinuates itself; and many other facts of this kind, which I omit mentioning. Now, if this be a fact, proved by the attentive observation of the phenomena of the animal economy, and by daily experience in surgery, it is no longer, in my opinion, obscure, why the aneurismal sac, having acquired an immoderate size, so as to press strongly against the bones, should be capable, by its pressure alone, of occasioning the excessive absorption, and consequently, the destruction of a portion of the bones on which it presses, and of forming a passage for itself through the substance of these bones. For, as soon as the aneurismal sac, by the force of the heart, and by the firm collection of grumous and polypous blood, is pressed strongly against the sternum, ribs, clavicle, or vertebræ, the point of contact upon which the greatest force of the pressure falls, loses its natural nourishment and life, and thence, both the compressing portion of the sac, and the compressed portion of the bone, are subjected to absorption and destruction. The lymphatic system, therefore, absorbs all the compressed, weakened, and atonic substance, (no longer in a state of being repaired by the arterial system), both of the aneurismal sac and of the bones; in the latter there are formed deep excavations through their whole thickness, so that, at last, the coagulated blood of the aneurism, having passed through the bony substance of the sternum, ribs, or vertebræ, is raised below the integuments, and there forms a *pulsating* tumor. This being the state of the parts, the same destructive process is renewed in the soft parts which cover the tumor externally; I mean the muscles and the com-



mon integuments. For, the coagulated clot of the aneurism, having passed through the substance of the bones, continues to press the muscles and skin as before, from within outwards, and these parts, at the point of the greatest pressure, are thereby deprived of the due degree of nourishment and life, which is necessary in the living solid, to enable it to counterbalance the power and the destructive effects of the absorbent system. The absorbent lymphatics, therefore, as they have done in the bony substance, attack, consume, and ulcerate the muscles and integuments, and carry the ulceration so far, as to render the skin very thin, so that it at last bursts, and occasions a fatal hemorrhage. In cases of this kind, in which the surgeon, by means of spirituous and strongly stimulant applications, succeeds in hardening, in the manner of dried leather, the thin and dead portion of integuments opposite to the point of the greatest pressure made by the clot of the aneurism, the lymphatic system turns its destructive action no longer upon the dead portion of integuments, but upon the edges between the hard coriaceous eschar, and the living skin, from which it detaches the eschar all round, forming a deep furrow of separation; and then, on the bursting of the aneurism, the coagulated clot rushes out with a circular piece of hard coriaceous integuments adhering to its upper part. In the bodies of those who have died from the effects of this formidable disease, the attentive examination of the excavation formed in the bones of the sternum, ribs, clavicle, or in the bodies of the vertebræ, has clearly shewn, that no part of this was to be ascribed to the moist caries, nor to the acrimony of the coagulated clots, or of the fluid blood; and that there were only distinctly observed,



the usual marks of the absorption caused by the mouths of the lymphatic vessels; that is, these excavations were similar in some measure to the gnawing of moths.

§ 37. From all that has been hitherto said with regard to aneurism in general, and more particularly of that of the aorta, it appears to me, that we may with certainty conclude, 1st, That this disease is invariably formed by the rupture of the proper coats of the artery. 2dly, That the aneurismal sac is never formed by a dilatation of the proper coats of the artery, but undoubtedly by the cellular sheath which the artery receives in common with the parts contiguous to it; over which cellular sheath the pleura is placed in the thorax, and the peritoneum in the abdomen. 3dly, That if the aorta immediately above the heart appears sometimes increased beyond its natural diameter, this is not common to all the rest of the artery, and when the aorta in the vicinity of the heart yields to a dilatation greater than natural, this dilatation does not constitute, properly speaking, the essence of aneurism. 4thly, That there are none of those marks regarded by medical men as characteristic of aneurism from *dilatation*, which may not be met with in aneurism from *rupture*, including even the circumscribed figure of the tumor. 5thly, That the distinction of aneurism into *true* and *spurious* adopted in the schools, is only the production of a false theory; since observation shews, that there is only one form of this disease, or that caused by a *rupture* of the proper coats of the artery, and an effusion of arterial blood into the cellular sheath which surrounds the ruptured artery.



## SUPPLEMENT TO SECT. I.

Hodgson\* and Burns,† accurate writers on the diseases of arteries, have fully confirmed the truth of the pathological distinction which I have made between morbid *dilatation* of an artery and *aneurism*. *The circumstances, the former observes, in which these two diseases, considered pathologically, differ from each other, are very remarkable ; and, therefore, they require to be discriminated.* This author also remarks, that in those cases, however rare, in which the aneurism has originated in a softening of the coats of the artery, either on one side or through the whole circumference of the arterial tube, the rupture of the artery, and, therefore, the formation of the aneurism, is necessarily preceded by dilatation, more or less considerable, of all the coats of the aneurismatic artery ; but from this greater or less dilatation of the proper coats of the artery, which sometimes precedes aneurism, it cannot be with propriety inferred, that the two diseases, in a strict pathological sense, ought to be included under the same denomination.

From the great number of anatomico-pathological

\* Treatise on the Diseases of Arteries and Veins, p. 58.

Scarpa acknowledges the existence of that state of preternatural dilatation of an artery which I have described, and mentions the frequency of its occurrence in the ascending aorta. He details some of the circumstances in which it differs from aneurism, although he admits that the two diseases frequently exist in the same vessel ; and observes, that they have generally been confounded under the same denomination. The circumstances, however, in which they differ are so remarkable, that, in a pathological point of view, they require discrimination.

† Observations on some of the most frequent and important Diseases of the Heart, and Aneurism.



observations which we possess, with regard to the diseases of arteries, it results, that aneurism, preceded merely by softening of the coats of the artery, with partial distention, or with distention of the whole circumference of the arterial canal, is a rare occurrence, and much less frequent than aneurism from rupture simply, or without previous softening, with morbid *dilatation* of the artery. Morgagni, in fact, wrote, that the aorta in the vicinity of the heart is sometimes dilated beyond its natural size through its whole circumference; but that it is a very rare occurrence. Burns is of the same opinion; for, in fifteen cases of aneurism of the arch of the aorta, he only met with one in which the aneurism had been preceded by morbid dilatation of all the coats of the artery. The inspection of the dead subject attests that we very rarely meet with the unnatural softening of the layers composing the arteries uncomplicated with other morbid affections, such as the *steatomalous, squamous, or ulcerated* degeneration of these coats, in consequence of which the internal and middle are more frequently subjected to be corroded or ruptured, than dilated and forced outwards, like the finger of a glove, by the impulse of the circulation. And if sometimes the internal and middle coats yield at one point to the distention, in other adjacent points they are ruptured or corroded.

In many places of this treatise I have spoken of morbid *dilatation* of an artery, especially of the arch of the aorta; and I have repeatedly quoted more than one example of aneurism, ingrafted, to use the expression, in one of these unnatural *dilatations* of the arch of the great artery; consequently, there could be no doubt, whether I allowed or not, the possibility of the occurrence of morbid *dilatation* of an artery, with or without aneurism. And as I have never excluded



the preternatural *dilatation* from the catalogue of the diseases of the arterial system, so in no place of my works have I excluded, from the number of occasional causes, the softening of the coats of the artery with dilatation of a portion of it, or of its whole circumference; considering this morbid dilatation always as a disease completely distinguished by its proper and peculiar characters from that which constitutes aneurism. On this point I have endeavoured not to leave my readers in doubt, knowing that I wrote at a period when physicians and surgeons generally were of opinion that all aneurisms from internal causes, and more particularly that at the arch of aorta, were merely dilatations of the proper coats of the diseased artery.

Hodgson \* has given a drawing of a large aneurism of the thoracic artery, three inches and a half in length, and three inches in breadth, in which it is quite evident that the proper coats of the thoracic artery, before being corroded or ruptured, had been slightly dilated or protruded outwards on one side of the artery.

On comparing this small protrusion with the large cyst of the aneurism, we evidently perceive that that small dilatation did not form any considerable part of the large aneurismal sac. There is nothing more true, wherever we find a portion of artery morbidly softened, and, therefore, easily distensible, that it yields and is protruded outwards by the impulse of the blood, before being corroded or lacerated. And if, speaking of the arch of the aorta or of the thoracic portion, the dilatation of their coats at one point of their circumference is not for the most part more than a few lines, reason concludes that this disten-

\* Plate iv, fig. 5.



tion, as an occasional cause of aneurism, ought to be almost imperceptible in the principal arteries of the extremities, at least in most cases.

But because aneurism of the curvature of the aorta or thoracic artery is sometimes preceded at that part, at its commencement, by partial or general unnatural enlargement of these arteries, morbidly soft and yielding, it does not necessarily follow that *dilatation* of an artery and aneurism are the same identical disease. The above mentioned writers have carefully avoided this inaccuracy in which those persist, who, in spite of the evidence of facts, have their mind still occupied by the ancient doctrine of the schools, with regard to the formation of aneurism, especially when proceeding from internal causes.

The distinction which was formerly made of this bloody pulsating tumor into *true* and *false*, displayed the imperfection of the pathological ideas which were formed with regard to this disease: for there is here nothing *false*, except the definition of the disease. If we consider, without prejudice, the morbid *dilatation* of an artery, it exhibits peculiar characters, so distinct from those which accompany aneurism, that if it is thought proper to give to one of these diseases the name of aneurism, it is absolutely necessary to mark the other by a different name, if we wish to speak with truth and precision. Nor could the unnatural *dilatation* of the arterial tube be ever justly called *incipient* aneurism, both because the partial enlargement, or the enlargement of the whole circumference of the artery, wants the proper and distinctive characters of aneurism, and because in the greater number of cases of aneurisms the unnatural *dilatation* has no share, not even as an occasional cause in its formation.

It has been proved by anatomico-pathological investigations, that the morbid *dilatation* is circum-



scribed by the proper coats of the diseased artery; and that the internal surface of the capsule, formed by the partial or total protrusion of the arterial tube, is never filled with polypous laminæ, or layers of fibrine, disposed over each other; which laminæ, or layers of fibrine, never fail to be formed in greater or smaller quantity in the cavity of an aneurism. And it has been undoubtedly from mere conjecture that it has been asserted, that these layers or polypous laminæ of the blood, which are not met with in the cavity of small *dilatations* of arteries, are found in large *dilatations* of them. This is absolutely contradicted by numerous careful observations instituted with this intention. I have before me a morbid dilatation of the arch of the aorta in the vicinity of its origin from the heart, which is six inches in length and five in breadth, within which there is not the smallest fibrous concretion disposed in layers, as is always found in aneurisms. Aneurism, on the contrary, acquires its capsule from the parts surrounding the wounded or corroded artery, into which capsule the blood entering as into an unnatural receiver, and quite out of the current of the circulation, moves more slowly, and constantly deposits these laminæ of fibrine, sometimes in so great quantities as to fill the whole cyst. With regard to this phenomenon, it is worthy of the attention of pathologists, that if accidentally furrows or fissures are formed on the internal surface of the morbid *dilatation*, it is only in these fissures and rough places that the fibrine of the blood is deposited and attached, while the whole of the rest of the internal surface of the bag is completely free from them. These fissures and inequalities of the internal surface of the morbidly *dilated* artery, properly speaking, are so many beginnings of another disease



of the artery quite different from *dilatation*, that is, of aneurism subsequent to the *dilatation*. For, in process of time, these fissures, sinking so deep as to penetrate through the internal and middle coats of the artery, an aneurism is not long of arising on its external capsule, at first in the form of an *ecchymosis*, then of a bloody pulsating tumor, ingrafted, to use the expression, in the morbid dilatation. Burns, in fact, met with all these circumstances in that solitary case of unnatural *dilatation* of the aorta, of fifteen cases of aneurism of this artery which he examined, all which were occasioned by rupture, without any mark of preceding morbid *dilatation*. In this case of preternatural *dilatation*, the internal membrane of the capsule, he wrote, was marked by long irregular fissures full of coagulable lymph; but there was no such concretion on the rest of the internal surface of this sac. In this complication of disease, although rare, in which the aneurism has supervened to *dilatation*, this difference is still more evident; for the sac of the aneurism is full, and thickened by numerous polypous layers, while the subjacent capsule formed by the *dilatation* of the proper coats of the artery is smooth, and not covered with laminæ or layers of fibrine.

Besides this distinctive character of the two diseases, there are others not less deserving of the attention of pathologists. Because where the morbid *dilatation* is partial, or on one side of the artery, like a thimble, for very frequently even in the arch of the aorta this partial dilatation does not exceed the size of half a bean, the entrance for the blood into this capsule is as large as the bottom of the sac. But where the unnatural *dilatation* occupies the whole circumference of the arterial tube, the tumor formed



there always retains a *cylindrical* or *oval* form : and if it is situated in such a manner that it can be compressed, it yields very readily to pressure, and almost disappears ; and in the dead body of those who have been affected with it, the tumor is found much smaller than it appeared to be, when they were alive. Aneurism occurs with very different appearances. This bloody pulsating tumor, whether it has been preceded by dilatation of the proper coats of the artery, as an occasional cause or not, always has its origin from one side of the ruptured or corroded artery. The entrance for the blood is contracted in proportion to the size of its fundus ; it assumes an irregular shape ; yields with difficulty to pressure ; retains nearly the same size in the dead body that it had in the living ; in short, the more the unnatural *dilatation* of an artery increases in size, the thinner its proper coats become ; on the contrary, the more an aneurism increases, the thicker its sac becomes. These facts, with regard to the essential differences which exist between these two diseases, will be more fully illustrated by the following very important anatomico-pathological observation instituted by the distinguished Professor Vacca of Pisa.\*

‘ A man about sixty had had for twenty-four years  
‘ a pulsating tumor on both sides of the upper part  
‘ of the thorax, exactly in the situation of the sub-  
‘ clavian and axillary arteries, which extended down-  
‘ wards from the scaleni muscles opposite to the  
‘ neck of the humerus. The right tumor was of a  
‘ cylindrical shape, as large as a small hen’s egg ; *on*  
‘ *pressure it disappeared entirely.* The left one was

\* Sprengel. Storia delle Operaz. di Chirurg. Trad. Ital. Parte II, p. 294.



‘ larger, and of an irregular form. The patient hav-  
‘ ing died, the professor opened his body. It is pro-  
‘ per, before proceeding farther, to remark, that after  
‘ the death of the patient, the right tumor *had dimi-*  
‘ *nished more than a half, so much so that there was*  
‘ *scarcely any sensible fulness at the place where dur-*  
‘ *ing his lifetime there was rather a considerable tumor.*  
‘ This was not the case on the other side, in which  
‘ the prominence appeared after death *nearly in the*  
‘ *same degree* as before. On raising the clavicle, and  
‘ stripping the artery of the cellular substance sur-  
‘ rounding it, it was observed that its external sur-  
‘ face was uninjured; and the artery, retaining its na-  
‘ tural caliber at the point where it passed between  
‘ the *scaleni* muscles, then increased uniformly in ca-  
‘ pacity, below the level of the inferior margin of the  
‘ first rib. At this point the *cylindrical* tumor was  
‘ at one place interrupted by a circular constriction,  
‘ below which the artery again began to enlarge, un-  
‘ til on reaching the situation of the neck of the hu-  
‘ merus it gradually returned to its natural diameter.  
‘ On the left side, on raising the integuments, an a-  
‘ neurismal sac presented itself. The axillary artery  
‘ was dilated a little more than that on the opposite  
‘ side, and a constriction was observed equal to that  
‘ on the right side. On the anterior surface of the  
‘ artery, lower than this constriction, three openings  
‘ were perceived, each of which was about the dia-  
‘ meter of a common writing quill. On making an  
‘ incision longitudinally into the dilated artery, it was  
‘ observed, that the parietes of the portion above the  
‘ constriction were untouched, while at the posterior  
‘ part of the inferior portion there was a fourth  
‘ opening larger than the former, from which the



‘ blood had flowed in greater quantity into the sac,  
‘ and the artery was immersed in this fluid.’

This rare case, which has been considered by some as an incontrovertible instance of *true* aneurism, in the sense formerly adopted in the schools, or of aneurism from the natural expansion of the proper coats of the artery, when considered attentively, merely exhibits on the right side an example of a morbid *dilatation* of the whole circumference of the subclavian artery; and on the left side an aneurism from rupture of the artery at four places, preceded, as an occasional cause, by softening, with a preternatural dilatation of the subclavian artery.

These two diseases, from being situated within the view of the eye and of the hand, presented diagnostic characters. For, the *cylindrical* shape of the small tumor on the right side, its yielding readily to pressure, so as to disappear entirely, marked the morbid *dilatation* of the right subclavian artery; and the *irregular* form, the hardness, *the resistance to pressure*, of the left tumor, indicated the presence of an aneurism from rupture of the artery, although both tumors were pulsating.

It is impossible to distinguish the one of these diseases from the other, when they are situated in any of the principal cavities of the body. The symptoms occasioned by the pressure of the tumor on the viscera of the thorax or abdomen, cannot fail to be nearly the same, whether they proceed from morbid *dilatation*, or from aneurism of the arch of the aorta, or of its thoracic trunk. In like manner, the assistance intended to alleviate the inconveniences produced by these diseases, if we wish to retard their fatal termination, must be the same for both forms of the disease. With regard to this, however, there is



a great difference in the two forms of organic derangement of the arterial system. For where there is an internal aneurism, there may be some faint hope of a radical cure by the efforts of nature and of art; which hope can never be entertained in a case of morbid *dilatation*. Experience has shown us that the so called *spontaneous* cure of internal aneurism may be effected whenever the impulse of the circulation being artificially retarded, the polypous layers completely fill the aneurismal sac. After this is effected, nature completes the rest of the cure, as she does after the ligature of the principal artery of an extremity; with this difference, that in the *internal* aneurism, the fibrous plug fills up the ruptured side of the artery, without intercepting the course of the blood through it; while, in *external* aneurism, the fibrous thrombus blocks up the sac and the canal of the artery at the same time. This fortunate combination of circumstances can never be expected to take place in a case of morbid *dilatation*; for, in that case, although the impetus of the circulation be diminished, there can never be a formation of the polypous laminae within the cavity of the cyst formed by the preternatural *dilatation* of the proper coats of the artery. This consideration adds additional weight to the arguments already adduced, in confirming what I have asserted with regard to the essential difference which exists in a pathological, as well as a clinical sense, between preternatural *dilatation* of an artery and aneurism.

§ 35. Note, No. 11, in the Appendix. Towards the end of this chapter, when I related the history of the *anomalous* bloody tumor, similar to what had been described by M. A. Severinus, it was



the first time that this formidable disease had attracted my attention. Being, however, not sufficiently acquainted with the investigations into the nature of it, (as I confess I am still even now), I confined myself to give as circumstantial an account as possible of the phenomena by which it had been preceded and accompanied. I am now aware that this terrible disease was the same as that to which modern surgeons have given the name of *fungus hæmatodes*, *soft cancer*, or *malignant spungoid tumor*. I have subsequently had an opportunity of examining several of these bloody tumors of a malignant nature, situated in various parts of the body, such as the leg, the upper part of the thigh, the fore-arm, the scapula, the mamma, and the eye-ball. In the dead bodies of these patients, as well as in the first case which I described, I have always found the internal structure of the tumor, resembling the texture of the human placenta, loaded with black blood; and in all the patients, on injecting water into the principal artery of the diseased part, the injection was freely effused within this bloody spungy substance, issuing from almost innumerable mouths of very minute vessels, probably corroded by the acrid matter generated in the tumor.

In all the patients which I have examined, the bloody tumor at its commencement was of an irregular and depressed shape; it was elastic to the touch, without any evident change of the skin, and without great pain. In all the cases it became painful, with an appearance, at different parts, of fluctuation, and it was covered with varicose veins as soon as it began to raise the skin. On bursting spontaneously, there protruded, sometimes in less than 24 hours, a *lobular, soft, reddish fungus*, resembling in some measure the



cortical substance of the brain, minutely injected with blood, and covered with a transparent glue: on the slightest touch blood was discharged from the fungus in great quantities, and then a very fetid thin matter. This melancholy stage was followed by sfacelus of the *lobular* fungous substance, beginning in the centre, and extending to the circumference, with sudden depression of strength of the patient, constant fever, and death in the midst of the most cruel pains, which opium, even in large doses, had no power to allay. In one of these unfortunate patients, in whom the malignant fungus occupied the middle of the leg, a little before death the same disease appeared in the lower cluster of the inguinal glands of the same side.

The excision of the malignant fungus, although performed at a great distance from its apparent limits, had never been followed by a permanent cure. It always recurred in six months or a year, even after the cicatrix was completed. The experience of others, as well as my own, has convinced me, that where the malignant tumor occupies one of the extremities, the least uncertain mode of cure is the amputation of it before the tumor bursts, and allows the protrusion of the fungous substance; under the condition, however, that the removal of the limb is performed above the joint of the diseased portion of the limb; that is, in the humerus, if the malignant tumor occupies the fore-arm. This circumstance points out the incurability of this tumor, as far as our present knowledge with regard to it goes, when it is situated at the top of the thigh, on the hip, the groin, the clavicle, in the mamma, or in the eye-ball.\*

The malignant nature of this tumor in some re-

\* *Malattie degli Occhi*. Ediz. quinta, vol. ii.



spects, in my opinion, is more fatal than that of cancer, as I have mentioned at the place quoted, in speaking of the *fungus hæmatodes* and cancer of the eye.

The celebrated Boyer\* is of opinion, that *fungus hæmatodes* is sometimes congenital, and is confounded with the spots or *nævi materni*. This is possible; but hitherto I have not had an opportunity of observing one case of it. The diagnosis could not be either difficult or obscure, when we reflect that the red spots at birth, the *nævi materni*, *tuberculi varicosi congeniti* are, from their commencement, marked by peculiar characters, quite different from those exhibited by incipient *fungus hæmatodes*.

\* Traité des Malad. Chirurg. T. ii.



## CHAPTER VI.

OF THE ANEURISM OF THE POPLITEAL AND FEMORAL  
ARTERIES.

§ 1. HAVING completely proved, as it appears to me, the non-existence of what is called *true* aneurism, or aneurism from *dilatation*, in the largest of all the arteries of the human body, the aorta, in which none of those conditions supposed to be requisite for the formation of this disease depending upon excessive distention of the proper coats, the internal and muscular of the artery, seemed to be wanting; no one I believe, after this, would be easily led to imagine, that the *true* aneurism, or aneurism from *dilatation*, takes place in the arteries of the second order, such as the popliteal, femoral, brachial, carotid, and the like. In these arteries, whether we consider the force and velocity with which the blood is impelled in them, or the diameter, thinness, and small power of extension of their proper coats compared with the aorta, we must be completely convinced, that the possibility of the formation of *true* aneurism, or aneurism from *dilatation* in the arteries of the second order, is much less than in the aorta. The force of this argument is increased, if we compare the great disproportion between the diameter of any of the arteries of the second order, particularly of the popliteal, with the large aneurism, which is not unfrequently formed in the ham, (the formation of which has likewise been ascribed to *dilatation*), and the size of the artery



from which it is derived. It will appear still more obvious, if we reflect upon the causes which most frequently give rise to this disease, and if, at the same time, we allow the due weight to observations carefully made on the bodies of those who have had the misfortune to be affected with aneurism in one of the arteries of the second order. For, observation and experience have demonstrated, that the popliteal aneurism, in most cases, appears in consequence of violent exertions or strains of the ham, as usually happen in those who carry great weights; and also in coachmen, in postillions, in footmen who stand behind carriages, in fencing-masters, in those who daily run messages, or make long journeys on foot, in a word, in all those who are exposed to causes capable of producing a laceration, rather than a dilatation of the artery.

§ 2. I flatter myself, that no one will suppose, that these investigations, with regard to the true nature of *external* aneurisms, can be of little or no use in the cure of this disease. For, although it might unfortunately be too true with regard to *internal* aneurisms, where the hand of the surgeon cannot afford any relief, yet, with regard to *external* aneurisms, it is indisputable, that the accurate knowledge of the nature and proximate cause of this affection, may have, and actually has, as I shall point out, a great influence both upon the choice, and employment, of the most effectual means for retarding the fatal progress of the disease, and also, on the radical cure of it. It may guide us, at the same time, to the solution of that important problem, which is at present the subject of discussion among surgeons;\* with regard to the selection of that

\* Prix proposés par la société de Médecine de Paris dans sa première séance publique, le 27 Prairial, an. v. June 15, 1797.



method of operating, from those of which we are already possessed, the easiest to be performed on the part of the surgeon, and the least painful and dangerous to the patient. If, for example, it is once demonstrated, that the sac of the *internal*, as well as of the *external* aneurisms, is never formed by the dilated proper coats, but by the dilatation of the cellular sheath which surrounds the injured artery, and of the superincumbent aponeurotic, ligamentous fasciæ; is it not a very great error which the operative surgeon commits, to persist in separating the aneurismal sac from the surrounding parts, as if it were an integral part of the artery? and all this from a fallacious and useless hope of being able to tie the artery above and below the root of the aneurism, in a shorter and more secure way, by following the direction of the sac. If it is once proved, that *external* aneurism, far from being formed by a dilatation, is always caused by a laceration of the artery, occasioned by violent exertions, or by a slow morbid *steatomatous*, *ulcerated*, *squamous* degeneration of its proper coats, would the tying of the artery, in the vicinity of the aneurism, or at a considerable distance from the rupture or ulceration of the artery, be a matter of indifference to the surgeon and to the patient? If both the small and the great extensive *external* aneurisms originate from a rupture, or from a slow ulceration and morbid disorganisation of a certain space of the proper coats of the artery, would the cure which is proper in the first, be likewise suitable in the second case? Would not the ligature be the means to be adhered to in every case, in every circumstance of external aneurism, as the most secure, and from its nature, not dangerous? If in the treatment of incipient *external* aneurisms, the mode of cure by compression has sometimes succeeded, ought we to say



that it has happened from the arterial blood in these cases not being extravasated, but remaining inclosed within the proper coats of the dilated artery, and that these coats, by means of the compression, have again contracted, and re-acquired their primary impelling force? Finally, if *external* aneurism, whether it is small or large, be constantly formed by a *laceration* or *ulceration* of the proper coats of the artery, what will then be definitively the cases, in which we may repose confidence in compression as a method of cure, and in what would it be proper immediately, and without hesitation, to have recourse to the ligature of the injured artery?

§ 3. All these important questions relative to the cure of external aneurisms, shall be discussed in the course of this work. In the meantime, in the commencement of this design, it will be proper to proceed to demonstrate, not only in the way of reasoning, but at the same time by observations, facts, and careful dissections of external aneurisms, that, in the arteries of the second order, such as the popliteal and femoral, as well as in the aorta, aneurism, whether it be small, or large and of long standing, is not produced in any other way, than by the laceration or ulceration of the proper coats of each of these arteries, without any previous dilatation of their canal. To attain this end, nothing appears to me more convenient, than to collect for investigation, the principal, and most celebrated cases which we have of this kind, to which I have added some of my own, illustrated with figures drawn exactly from the morbid state of the parts, which I have carefully examined. I shall begin by the relation of the case observed by Dr. Donald



Monro\* and Mr. Arnaud,† as one, which, from a combination of circumstances, all capable of leading to error, appeared to the greater number of physicians and surgeons, as the most proper for confirming the common doctrine with regard to the existence of *true* aneurism, or aneurism from *dilatation* of the proper coats of the artery.

§ 4. John Parker, 48 years of age, after having been affected with lues venerea, and having undergone the operation for strangulated hernia in the left groin, when the wound was nearly healed, perceived a small tumor in the left ham, which the attending surgeon imagined to be a slight swelling of the glands. In January 1760, another tumor of the same kind appeared in the right groin, and about a month afterwards, a third tumor appeared, not unlike the former, about the middle of the right thigh. On the 19th March of the same year, the patient was brought to the hospital. The tumor of the left ham was *circumscribed*, of the size of a large hen's egg, and had a strong pulsation, but did not occasion any pain or swelling of the leg. That in the right ham was large and *diffuse*; had a pulsation, and caused pain and swelling of the corresponding leg. The swelling in the right groin was about the size of a small hen's egg; and that situated in the middle of the thigh, was about the size of a pigeon's; both of these were *pulsating* and *circumscribed*, but gave no pain. A consultation was called, and it was agreed that the case was incurable, and that it ought to be treated only by palliative remedies. About the end of April, the pulsating swelling in the right ham was increased to a

\* Essays and Observ. Phys. and Literary of Edinburgh, vol. iii.

† Memoires de Chirurgie, vol. i.



prodigious size, and occasioned most excruciating pains; afterwards, the integuments covering it began to inflame, and at last the tumor burst, and gave rise to a fatal hemorrhage. In the body of this patient, the aorta and iliac arteries were in a sound state. On the contrary, the right femoral artery,\* about a quarter of an inch below the origin of the epigastric artery, was dilated, and the dilatation extended down for  $2\frac{3}{4}$  inches, and had exactly the appearance of an egg. Below this tumor, the right femoral artery continued for about  $2\frac{1}{4}$  inches, as in the sound state, and then began to be again dilated into an oval swelling of nearly two inches long. The artery re-assumed its natural size for another inch and an half; but afterwards, was dilated as before, into another small sac, which had not been observed during the patient's life. Lastly, the femoral artery having returned to its natural size and form, continued so, as far as the ham, and there opened into the great aneurismal sac, the bursting of which had been the immediate cause of the patient's death. The blood contained in this sac was in contact with the posterior and inferior surface of the os femoris, which it had stripped of its periosteum, and rendered rough and carious. The left femoral artery, a little below the crural arch, formed a swelling about the size of a nut, which had only been observed about two days before the patient's death. No other tumor was found in this femoral artery, except in the ham, where it was dilated into a sac capable of containing six or eight ounces of fluid.

§ 5. Dr. Donald Monro considered these enlargements of the femoral artery, as so many aneurisms

\* *Essays and Observ. Phys. and Lit. of Edinburgh*, vol. iii. plate 1.



from *dilatation*. Indeed, they had all the external appearances of it, and seemed formed for giving credit to the common opinion with regard to the nature of this disease. Mr. Arnaud, however, did not fail to remark, that the coats of which these tumors were formed, far from having become thin, were unusually hard and thickened; which was not very consistent with the idea of their originating from the proper coats of the dilated artery. Dr. Monro, the father, having carefully examined these arteries supposed to be affected with aneurism from *dilatation* in several places, wrote to his son in the following terms.\*—‘ The aneurismal sacs you sent to Edinburgh were dissected by your brother, in my presence; the appearances were the following.—The external loose cellular, and the cellulo-membranous coats being dissected away carefully, the circular fibrous, commonly called muscular, coat, was evidently seen continued on all the three small sacs in every part of them, but was thicker there than in the sound part of the artery.’ And, *what is worthy of the greatest attention*, ‘ in the most enlarged part of the sacs, an extraneous substance, resembling a soft steatomatous matter, was intermixed with the muscular fibres. The cellular substance lining the inside of the muscular coat, was considerably thicker than natural, and had much the same appearance of an extraneous substance filling its cells. The internal membrane of the artery adhered so firmly to these cells, that it could not be separated, but seemed thicker than in a sound state † Though the circular fibres could be observed at the sides of the incision made into the fore part of the sac of the left ham, as represented in your figure;

\* Loc. cit. pl. 1, fig. 9, 10.

† Loc. cit. pl. 1, fig. 10.



‘ yet, as the dissection was continued backwards to-  
‘ wards the most distended part, these muscular fibres  
‘ became less observable, and could not be traced.  
‘ Whether this apparent defect of them here was  
‘ owing to a much greater proportion of the extra-  
‘ neous substance above mentioned, or to their having  
‘ been destroyed by the great distention, is difficult  
‘ to determine. The internal cellular coat of this  
‘ sac was considerably thicker than in the smaller  
‘ ones, but of the same texture. The most internal  
‘ membrane was in a thickened adhering state. In  
‘ the part of the great sac of the right ham which  
‘ came to Edinburgh, no circular fibres could be seen,  
‘ and the structure was otherwise much the same as  
‘ that now described of the back part of the sac in the  
‘ left ham.’\*

§ 6. It clearly results from these accurate dissections and observations of Dr. Monro, the father, that the tumors supposed by Dr. Donald to be so many aneurisms from *dilatation* of the popliteal and femoral arteries, were, properly speaking, only steatomatous thickenings of the proper coats of the two arteries, and that these thickenings of the proper coats of the artery, instead of forming sacs, or receptacles for the arterial blood, rather diminished the natural diameter of the artery. In the left ham, from the artery on the posterior

\* This kind of degeneration of the coats of the artery into steatomatous tumors, had been observed before in the aorta, by Stenzel. (See above, chap. v, § 20.) And I am of opinion, that those thickenings of the subclavian and ulnar arteries, described and delineated by Kaltschmied, were of the same nature, which he considered to be true incipient aneurisms. *Programma de variis præternaturalibus in sectione cadaveris inventis.* See Haller, *Disput. ad morb. histor. t. ii.*



part of the *steatomatous swelling* having burst, and thereby actually given rise to an aneurism, the sac of which was formed by the cellular substance of the ham, and by the neighbouring ligamentous *faciæ*, the tumor in that part was necessarily unfurnished with circular fibres, and a muscular coat, as they never extend beyond the bursting of the artery. Dr. Monro, the father, had already said in another place, that he had repeatedly had occasion to see\* the cavity of large arteries, almost entirely closed by *steatomatous* and *purulent* concretions; and that this case observed by his son, was another example of the same.

§ 7. The following case, which is likewise related by Dr. Donald Monro,† was similar to the preceding, and equally calculated to lead into error with regard to the existence of aneurism from *dilatation*. A middle-aged countryman, feeling himself tired, sat down to rest, and in supporting his hand upon his thigh, felt an extraordinary pulsation there. From that time forward, a small tumor, pulsating strongly, was observed in the vicinity of the place where the femoral artery passes into the ham. This tumor acquired by degrees so very considerable a size, that it was thought advisable to amputate the thigh. This was done, but the patient died the next day. On examining the amputated part, it was found that the femoral artery in the ham, was enlarged to the size of a small hen's egg; but this swelling was formed by the proper coats of the artery not *distended*, but

\* Monro's Works. I have more than once observed the cavity of a large artery almost blocked up by a *steatomatous* thickening of this coat, (the internal), and frequently I have observed *purulent* matter collected in it.

† Loc. cit. case ix.



*thickened, and hardened* with a diminution of the canal of the affected artery; and farther, it was observed for several inches below the tumor, that the artery was surrounded with small *steatomatous* tumors. The same diseased state was also found in the cavity of the abdomen; and it was observed in this patient, that the arterial system was so weak and brittle, that on attempting to inject the emulgent arteries, they burst, upon a very small degree of force being used to push forward the injection.

§ 8. The tumor \* which Guattani took for a *true* aneurism, was undoubtedly an instance of the same morbid *steatomatous* state of the proper coats of the artery. In the figure which he has given, there is observed distinctly the thickening and enlargement of the proper coats of the artery, produced by the addition of extraneous matter, with a considerable diminution of the diameter of the artery at the part of the morbid disorganization of its coats. And the other case, observed and described by Gavina,† seems to be of the same nature. He found in the body of a man, who was supposed to have died of a *true* aneurism of the femoral artery, the artery not dilated, but converted for a certain space into a hard tumor, from a thickening of the coats of the artery, and, as he very properly expresses it, resembling a sponge dipped in wax.

§ 9. Several years ago I had an opportunity of dis-

\* De extern. aneurysm. tab. ii, fig. iii.

† Guattani loc. cit. ob. xvii. Arteriæ iliacæ ovalem hanc partem polyposa substantia variæ densitatis adeo infarctam esse adnotabam, ut tunicarum ejusdem forma penitus distincta, in uniformem massam ceræ imbutæ similem transformata videretur.



secting an aneurism apparantly *true*, or from *dilatation* of the popliteal artery, which was about the size of a small hen's egg. This aneurism occurred in the body of a pale, emaciated, middle-aged countryman, who had been affected with a pulsating tumor for four years, without having felt any considerable pain from it, and without its having induced any swelling of the leg. The death of this man was occasioned by a chronic tubercular affection of the lungs, complicated with hydrothorax. The left popliteal artery, low down between the heads of the gastrocnemius muscle, was elevated into a blackish tumor, and, as it were, covered by *ecchymosis*. To the touch it was rather of a firm consistence, and in some points even hard. On removing carefully the cellular sheath which covered the tumor and the artery, and along with it the greatest part of what formed the *ecchymosis*, the circular fibres appeared upon the tumor, precisely as in the figures of Monro and Guattani, continued from those which formed the muscular coat of the popliteal artery, above and below the tumor. These fibres upon the tumor were thicker and more rigid than those which surrounded the tube of the sound artery. On introducing a probe by the upper part of the popliteal artery, it met with obstructions on passing through the tumor. Having divided the tumor in the direction of the artery, I found that it was formed by the proper coats of the popliteal artery, particularly the internal coat, unusually thickened, brittle, intermixed with a matter partly caseous, partly earthy, and having exactly the appearance of a piece of sponge dipped in wax. The internal coat was rough for a considerable way, both above and below the tumor; and that coat, along with the muscular coat, contributed by their unnatural thickness to narrow greatly the



tube of the artery; or in other words, produced an effect quite the contrary of what ought to have taken place, if the tumor had been formed by a *dilatation* of the coats of the popliteal artery. The ecchymosis covering the tumor shewed that the blood had begun to ooze through the connexions of the fibres of the muscular coat. It is probable, if this patient had lived a little longer, that he would have met with the fate of John Parker, in whom the *steatomatous* tumor of the right popliteal artery had changed into an aneurism, from the rupture of the thickened coats of the artery.\*

§ 10. I have shewn, in the preceding chapter, that the *steatomatous* degeneration of the proper coats of the artery is not the only morbid state which disposes it to burst in some point of its circumference. I have pointed out other affections to which the membranes of the arteries are subject, equally capable of occasioning this fatal accident, such as the squamous induration with rigidity, the ulceration, the excessive relaxation and softness of the arterial coats, especially in those places in which the arteries are more particularly exposed to the action of external agents. Each of these morbid states of the arterial coats, and in particular of the internal, produces aneurism in the arteries of the second order, as in the aorta, by occasioning a rup-

\* *Salii diversi tractatus de feb. pest. cap. xxi, De affect. particul.* It seems that this author was acquainted with the *steatomatous* affection to which the arteries are subject. For, he says, *obstruuntur arteriæ a duplici causa, nam vel ex succis frigidis, vel ex crudo tuberculo in iisdem genito, obstructione laborant. Ubi enim humores crassi, et viscosi in ipsis arteriis infarcti fuerint, vel ubi phyma aliquod seu tuberculum crudum in iisdem genitum erit arteriæ obstruuntur.*



ture or laceration of the internal coat, and allowing the blood to ooze out, or to be effused into the cellular membrane surrounding the affected artery. It has been remarked above, that in the cases of *steatomatous* degeneration of the proper coats of the artery, with great thickening of these coats, although there were several pulsating tumors in the same patient, no proper aneurism was formed in any part of the whole arterial system, except where, besides the *steatomatous* swelling, there also existed a rupture of the internal coat, or of it, along with the muscular; and that consequently an effusion of blood into the cellular membrane, surrounding the artery in the manner of a sheath, had also taken place. The following observations will confirm still more the truth of this fact.

§ 11. Guattani, in his first case, has given us the account of an aneurism, which extended from the middle of the thigh to the calf of the leg. On opening the tumor, and evacuating the grumous blood, he did not find that the artery had been converted into a sac, but that it was lacerated for a long space; so that, as he observes, it was impossible to discover the sound portion of the tube of the artery, until he had made an opening with his fingers and the knife above the tumor.\* In the second case he relates the history of a man of about 25 years of age, of a slender make, obliged by his trade to raise very heavy weights, in whom an aneurism suddenly appeared in the ham, which in a short time increased to eight fingers-breadth in circumference. Considering, in this case, the oc-

\* Loc. cit. Arteriæ lacerationem tantam ostendi, ut superiorem integrum ejus truncum vinculo adstringere non antea potuerim, quin mihi per ipsum femur digitis ferroque iter aperuissem.



casional causes which are capable of producing violent strains of the ham, and observing the rapid increase of the tumor, no person, I suppose, will imagine, that this aneurism was formed suddenly by the distention or dilatation of the proper coats of the popliteal artery, but that it undoubtedly arose from a rupture of these coats.

The fact, which the author relates in his fourth case, is particularly worthy of attention. An aneurism, supposed to be an abscess, was opened in a coachman. The immoderate hemorrhage was repressed by strong compression; the wound of the ham suppurated, and the patient was cured. Five years afterwards he died of a quite different disease. On examining the ham, the popliteal artery was found converted into a continued solid cord, without there being the least appearance of any portion of the artery having been changed into an aneurismal sac.

In the sixth case, Guattani speaks of a popliteal aneurism, he supposed to be a *true* one, which occurred in a man whilst in the act of raising a weight; under this exertion the patient evidently felt something burst in his ham. Two months after the accident, the tumor had acquired the size of a goose's egg.

In the tailor, who forms the subject of the twelfth case, the popliteal aneurism burst, and the patient thereby lost his life. In the dead body there was no appearance of dilatation of the proper coats of the popliteal artery, but merely a laceration of about three inches in length.

The fifteenth case contains the history of an aneurism of the femoral artery, in the vicinity of the crural arch, which was cured by an incision and compression. With regard to which case Guattani allowed,



that the immediate cause of it had been the laceration, and not the dilatation of the artery.

The same circumstance was likewise very evident in the subject of the seventeenth case, in which the aneurism extended above and below the crural arch; for, on opening the tumor, and evacuating the clots of blood, the *external* iliac artery was found torn for more than four fingers-breadth in extent, without the proper coats of the artery having, by their dilatation, contributed in the least to the formation of the aneurismal sac.

In the body of a young man about 28 years old,\* who had had an aneurism in each groin of the size of an apple, Guattani found that the aneurism of the left groin had been formed by a laceration of the femoral artery; but with regard to that of the right groin, it would seem that the author did not observe that it was not an aneurism, but a *steatomatous* tumor of the proper coats of the artery, which clearly appears from the description and figure which the author has given of it.†

In the twentieth case, Guattani relates the history of a young man, 30 years of age, who had a true aneurism at the top of the calf of the leg. On dissecting the ham, the popliteal artery was found not to be at all dilated, but *lacerated*.

Lastly, Guattani records the case of a young man of about 30 years of age, of a soft fibre, having been affected in his early youth with lues venerea, who, in the act of lifting a great weight, slipped with his right foot, and then trying to support himself on his left, felt a severe pain in the thigh of that side, which forced him to allow himself to fall down. The pains

\* Histor. xviii.

† Tab. xi, fig. iii, of Guattani oper. citat.



ceased by the employment of proper remedies; they afterwards recurred as violent as before, and at the same time a tumor was observed about the middle of the thigh, which had all the characters of an aneurism. The pains and the swelling increased successively, and the patient felt suddenly, in the deep part of the tumor, a crepitation just as when one tears a piece of linen. Five hours after, the patient experienced the same disagreeable feeling, and after other four hours, a similar sensation, though less violent than the former; after this, the tumor increased greatly, and shortly thereafter, the patient having fallen into a state of extreme langour, was attacked with a convulsion, during which he expired. On opening the tumor, it was found to contain about three pounds and an half of blood, partly coagulated, partly fluid. In the bottom of the sac, the femoral artery was perceived not *dilated*, but *lacerated* for about two fingers-breadth in length. Below the place of the laceration there was a tumor nearly of the size of an egg. On opening this tumor, it was observed, that the canal of the artery, where it passed through the centre of it, was unusually contracted, and the tumor was formed by a morbid thickening of the proper coats of the artery, the internal of which was ulcerated in two places.\* This pathological state of the artery, as represented by Guattani and Monro, deserves to be considered with the greatest attention by surgeons, both because it opens the way to many useful reflections on the diseases of the arteries in general, and in particular on the nature and character of aneurism, and as it conduces likewise, as will be seen in the sequel, to

\* Loc. cit. Singulare femoris aneurysm. Hist. v, fig. 4.



establish advantageous precepts with regard to the radical cure of this disease.

§ 12. The result therefore of the examination of all the cases of aneurism of the popliteal and femoral arteries related by Guattani is, that none of the cases which he observed and described, furnishes an example of *true* aneurism; that they even prove the contrary, and shew that the external aneurisms, of which he has given an account, had all been produced in consequence of either a *rupture* of these arteries, occasioned by violent exertion, or of a *steatomatous* degeneration of their proper coats, or of an *ulceration* and corrosion of these coats.

§ 13. A similar conclusion may also be drawn from the observations of Flajani.\* ‘Fulgenzio Aquilano,’ (says he, in his third case), ‘about 32 years of age, ‘of a cachetic temperament, much addicted to hunting, about the beginning of July 1781, stumbled in walking through a thick wood. He made a great exertion to save himself; but notwithstanding, he had a violent fall. In falling, he felt a crack in his ham, as if the os femoris had been fractured. On rising from the ground, he could with difficulty proceed as far as his own house. The pain obliged him to keep his bed for several days. It abated by rest, and the patient was again able to walk about. Towards evening, however, he observed that the affected knee was larger than the sound one. He perceived afterwards, that there was a swelling in the ham, which had a strong pulsation. Amputation was per-

\* Nuovo metodo di medicare alcune malattie spettanti alla chirurgia.



‘ formed, and on the examination of the amputated  
‘ part it was found, that the popliteal artery *was*  
‘ *nearly of its natural diameter*, and that at the dis-  
‘ tance of three fingers-breadth from its division into  
‘ the posterior tibial artery, *there was a hole*, from  
‘ which the aneurismal sac had been formed.’

The same author (Osserv. V) relates the case of James Sartori, about 50 years of age, of a bilious parched temperament, and much addicted to drinking and hunting, who, in returning from the country, was suddenly attacked with a violent pain in the back part of the knee, attended with a crepitation not unlike that which is felt on tearing a piece of cloth. He was obliged to throw himself on the ground, and in a little while he rose up and went home, which he with difficulty effected, and was forced immediately to go to bed. The pain was moderate during the night, therefore he rose early, but was obliged very soon to return to bed, as he felt the same painful sensation as on the preceding day. After six days of rest, he was able to walk and stand on his feet without great inconvenience; but it is worthy of remark, that towards evening the pain always increased, and the leg swelled so much as to confine him to bed. Six months having elapsed, he was visited by a practitioner, who advised him to keep himself very quiet, to lose a little blood every two months, and to compress the tumor with a leaden plate. These prescriptions having proved unsuccessful, the patient resolved to come to the hospital. I found (continues Flajani) the leg and foot much swelled, and at the upper part of the ham, almost as high as a third of the thigh, the tumor was observed of the size of a large pear, and externally of a livid colour. I compressed it with the palm of my hand, and perceived a deep pulsation in it. The pa-



tient could not bear the compression, and it was found, that, in addition to the tumor, which was much increased in size, there was conjoined a swelling, extending from the groin over the whole limb. The pulse was very low; black spots were observed, and the foot was perfectly cold. Three days afterwards the patient died. In the dissection of the body (adds this author) I found almost the whole crural artery aneurismatic, beginning four fingers below Poupart's ligament. In proceeding towards the ham, it increased in bulk, and its component coats were rendered so compact, that they approached to a bony nature. The aneurismal sac *formed by the popliteal artery* was found open, and at its under part, near its division, the artery was quite impervious.

§ 14. Of these two cases related by Flajani, the first was, without doubt, an aneurism from a rupture of the popliteal artery. The second, in my opinion, was likewise so. For, the long space of the femoral artery, which the author found enlarged in diameter according to the longitudinal axis of the artery, did not constitute an aneurism; and the aneurismal sac in the ham could not have been formed by the membranes of the popliteal artery, since its proper coats, as the author expresses it, were become so compact, that they approached to the nature of bone. Farther, the aneurismal sac at its lower part was quite impervious, which could not have been the case if it had been formed by the proper coats of the artery.

§ 15. Warner\* mentions that he opened an aneurism of the popliteal artery, supposing it to be a tumor of a different nature. He proceeded instantly to the amputation of the limb, and saved the patient.

\* Philosoph. Transact. an. 1757, pag. 363.



On examining the amputated part, he found the femoral artery in the vicinity of its division into anterior and posterior tibial, not *dilated*, but *lacerated* longitudinally, and *indurated* for more than four inches.

§ 16. Several years ago I examined carefully, in a butcher, a very large popliteal aneurism, with which he had been affected for a long time. The tumor had increased to a very great size, and threatened to burst, on which account I was obliged to amputate the thigh. The preparation is preserved in the pathological cabinet of this university. On dividing longitudinally the artery on one side, and the aneurism on the other, and cleaning it thoroughly from the clots of blood, I saw distinctly at the bottom of the sac the popliteal artery, which, near the place where the femoral artery perforates the long portion of the adductor magnus muscle, was lacerated for the space of an inch and an half. Above and below the laceration the canal of the popliteal artery was sound, and of its natural size, except that, when stripped between the fingers, the coats of it appeared to me less firm than usual. Observing attentively the fissure, as it appeared in the bottom of the sac, I discovered distinctly the limits of the ruptured artery, and the beginning of the cellular aneurismal sac. For, as the popliteal artery was lacerated on one side, the inside of the tube could be distinguished beyond the edges of the rupture, situated more deeply ; and it appeared in the form of a furrow, the edges of which marked the limits between the arterial tube and the beginning of the sac of the aneurism.

§ 17. Such was nearly the form of the lacerated artery in the popliteal aneurism presented by



M. Hernu\* to the Society of Medicine of Paris, as an example and undeniable proof of the existence of the popliteal aneurism from dilatation of the proper coats of the artery. Whoever will bestow a little attention upon the figure of this aneurism which Hernu has given, will see pointed out, at the bottom of the sac, that furrow above described, which is nothing but the uninjured side of the artery opposite to the place of the rupture. And, in the same figure, the limits of the rupture of the proper coats of the artery may be distinguished from the beginning of the cellular aneurismal sac, which is likewise distinguished internally from the tube of the artery at its beginning by the remains of a strip of the torn arterial coats. However, this furrow, formed by the side of the artery opposite to that where the rupture has happened, is not observed equally clear and distinct in every individual case of aneurism of the femoral and popliteal arteries; for sometimes the artery bursts completely, or nearly in the whole circumference of its tube, and then very little or none of the uninjured side of the artery remains in continuity with the inferior portion of the artery. In these circumstances, the two apertures of the ruptured artery are more distant from each other than in the first case; and on detaching the two extremities of the ruptured artery from the cellular membrane, and from the aneurismal sac, which surrounds and conceals them, it will be found that the two portions of the divided artery are not at all increased beyond their natural diameter, and that their muscular coat, instead of being expanded over the

\* Recueil Periodique de la Societ  de Med. de Paris, tom. x, fig. 1, A. See also Guattani, tab. ii, fig. 2, o o. Watson, Medical Communications, t. i, plate vi, C.



aneurismal sac, never leaves the canal of the artery, but evidently terminates at the circular edge of the rupture.

§ 18. Paletta was obliged to amputate the left thigh of a middle-aged man on account of an aneurism. I had an opportunity of examining carefully the amputated part. The popliteal artery had burst very high in the ham, or about two inches below its passage through the long portion of the adductor *magnus*, and the continuation of the artery was observed at the under part of the ham, covered by the muscles of the calf of the leg. The superior portion of the popliteal artery was not at all dilated beyond its natural diameter. Around the place of the rupture the torn edges of the artery could be distinguished from the neighbouring parts, and the limits of the proper coats of the artery, and the beginning of the cellular aneurismal sac, could be clearly perceived. On separating carefully the cellular membrane surrounding the popliteal artery, I found, as is seen in aneurisms of the aorta, that the fibres of the muscular coat stopped short at the edges of the rupture of the artery, and were not at all continued upon the aneurismal sac, and that therefore the sac did not belong in the smallest degree to the coats of the artery. The cellular aneurismal sac, covered by the ligamentous and aponeurotic fasciæ, was inclined towards the external condyle of the femur. In the beginning of the dissection, when the integuments of the ham and the expansion of the *fascia-lata* were scarcely removed, there appeared, on the greatest convexity of the tumor, the great popliteal and the cutaneous nerves so much distended by the subjacent tumor, that they resembled more two large fasciæ than nervous trunks.



§ 19. The following case will support what has been deduced from the preceding. A man about 37 years of age, of a robust constitution, by trade a gardener, in the year 1799 received a very violent blow of a sabre on the left parietal bone, and on the same side of the face; in consequence of this accident, even after the wound was cured, he remained almost paralytic of the whole left side. In course of time, and by the use of proper remedies, he recovered in a great measure the power of moving the left arm, but not so well that of the left lower extremity. In the winter 1803 he ascended mount Varallo, which he performed with great difficulty and labour, on account of the deep snow and ice over which he was obliged to pass. After returning home, he resumed his occupation of a gardener. Not long afterwards, however, he was attacked by a deep seated pain in the whole left knee, with difficulty of moving it. In the month of May of the same year, he observed that a small pulsating tumor was forming in the lower third of the left thigh, or nearly at the place where the *superficial* femoral artery perforates the tendon of the adductor *magnus* muscle. The patient afterwards perceiving that the swelling went on continually increasing, came to the hospital of Pavia the 24th July of the same year. The tumor at this period was about six inches in longitudinal diameter, and extended a little also towards the posterior part of the thigh, and to the top of the ham. The leg of that side was the same as the sound one. On the 3d August Dr. Volpi performed the Hunterian operation on this patient, which he executed with the greatest possible precision. Every thing went on well till the 9th day, when the patient was attacked by a severe pain in the false ribs of the left side, with great difficulty of breathing and cough; then by typhus



fever, with puriform expectoration, and colliquative diarrhæa. In this state, in spite of the best assistance of art, on the 16th day after the operation the wound became livid and sanious. On the 18th the ligature of the artery was nearly separated, and the bulk of the aneurism was very much diminished. Notwithstanding this, the patient sunk under the violence of the pulmonic affection. On dissection, the left lobe of the lungs was found putrified and melted down, and the left cavity of the breast full of puriform matter.

We then proceeded to the examination of the inferior aneurismatic extremity.\* Having laid bare the aneurismal sac, and along with it the *superficial* femoral artery, as far as the cavity of the ham, it was found, that, instead of one, there were two aneurisms; the first, and the largest,† situated above the passage of the femoral artery to the ham; the other, smaller,‡ situated at the top of the ham. The small space of about an inch and an half of sound artery|| between the two aneurisms disappeared when the leg was half-bent, and made it appear as if there had been only one tumor instead of two. The femoral artery, both above and below, and between the two aneurisms, had preserved its natural diameter.§ On opening the two aneurisms, the orifices of the femoral and popliteal arteries appeared in each of them; and they were not only burst laterally for a small space, but ruptured in their whole circumference.¶ But, as the aneurismal sac surrounded and included within it a certain

\* Pl. ii, fig. 1.

† ————— a.

‡ ————— b.

|| ————— d.

§ ————— c d e.

¶ g g g g.



space of ruptured artery, I employed every possible care to follow the artery within the substance of the sac, to discover if the muscular coat of the artery advanced over the beginning at least of the aneurismal sac. I found that the external cellular covering of the artery\* separated from it to form part of the sac, but that the muscular coat of the artery † never left the tube of the vessel, and its fibres were seen terminating at the edge of the circular rupture. It therefore clearly appeared, that it was not a dilatation, but a double rupture of the artery, which had given rise to these two aneurisms. Whoever will compare this figure with plate 1, will see clearly that the formation of this disease is absolutely the same, both in the trunk of the aorta, and in the arteries of the second order.

§ 20. Morgagni ‡ relates, that a man of about 40 years of age died of an aneurism of very considerable size in the vicinity of the right groin. In the dissection of the body, performed by Valsalva, it was found that the femoral artery, moderately enlarged in size,

\* Pl. ii, fig. 1, *ffff*.

† ——— *gggg*.

‡ De sed. et caus. morb. epist. 50, art. ii, 55. Viro quadraginta annos nato parvus, sed pulsans tumor circa inguen dexterum sensim aboritur. Triennii spatio indies augetur, grandisque fit. Quarto circiter ante obitum mense doloribus vexare incipit, magnoque, et æquali œdemate universum illum artum inferiorem tumefacere. Mense ultimo atrocissimi dolores fiunt, neque ad tumorem solum, sed et aliquando infra maleolum internum: quo uno loco, et sævientibus duntaxat doloribus, pes sentiebat, omni alioquin sentiendi, et movendi facultate privatus. Nulla unquam toto hoc mense a cruciatibus quies, nullus somnus, donec languentibus viribus, aliquot dies semisopitus æger jacuit, atque ita defecit. Aneurysmatis hujus ingens erat cavum; nam a cute summi femoris anteriore ad crassissimum nervorum omnium cruralem posticum perveniebat.



was in several points *corroded* and *lacerated*. In like manner, he mentions, that in the body of a man who had a popliteal aneurism the femoral artery was found a little larger than usual, where it passes through the tendon of the adductor *magnus*, but that a little below, the artery was *lacerated* and *wanting*.\*

§ 21. Mr. Home, in the account which he gives of Mr. Hunter's method of curing the popliteal aneurism, relates the following case. John Lewis, a negro about 43 years of age, received a blow on the anterior part of the right thigh. A month afterwards, he perceived that a small tumor had formed at that place. The tumor increased to such a degree as niebat. Et arteria quidem cruralis, ex cujus dilatatione tumor incipiebat, mediocriter dilatata reperta est; sed aliquot locis dilacerata, aut erosa, per hæc ea copia, eoque impetu sanguinem ejecerat, ut partim corrosis, partim cedentibus musculis, ingens, ut diximus, cavum effecisset, illumque ipsum, quem memoravimus nervum sic erosisset, vix ut paucae fibræ superessent per quas superior ejus pars cum inferiore committeretur.

\* Loc. cit. Cruralis arteria jam inde ubi a latere femoris anteriore ad posteriora deflectit, statim dilatari incipiebat. Deinde ad tractum dimidiæ circiter ulnæ frustra arteriæ truncum quæsiuisses; in sura demum rami in quos se dividit apparebant. Toto illo autem tractu nihil nisi ingens cavum sanguine fœdum, erosis videlicet omnibus, atque adeo prorsus absumptis nervo, et vena, quæ inter imos a tergo provenientes ossis femoris processus, arteriæ comites se addunt; vix hujus tunicarum reliquæ aliquæ supererant ossibus adhærentes. Ossa autem ipsa quoque erant ex parte erosa, nempe illorum, quos modo dixi processuum posterior facies, et summæ fibulæ. Morgagni in this, as in many other places where he mentions the dilatation of arteries, means an enlargement according to their longitudinal diameter, which, as I have mentioned in several places, has nothing in common with aneurism, and may exist without it; and therefore, if this enlargement of the artery, according to its longitudinal diameter, is sometimes met with, it never constitutes the aneurismal sac, and consequently has nothing to do with the aneurism.



to occupy two thirds of the thigh, and was accompanied by a strong pulsation. This tumor was considered to be a case of *true* aneurism, or from dilatation of the proper coats of the artery. The dissection of the body shewed that the femoral artery was not at all dilated, but *ruptured*.

§ 22. A man about 48 years of age,\* in entering suddenly a dark room, struck his left groin violently against the corner of a table. About ten days after, he perceived a swelling in the place, about the size of a pigeon's egg, which was thought to be an indurated glandular swelling. The patient, however, finding that it increased daily, consulted Mr. Clarke, surgeon, who was immediately satisfied that the disease was a femoral aneurism. Three months after, the tumor had acquired the size of a melon, and the throbbing pulsation was so strong as to raise the bed-clothes. The aneurism degenerated into gangrene, burst, and allowed the escape of a great quantity of grumous putrid blood, without, however, any hemorrhage taking place. The surgeon being surprised at so unexpected an occurrence, introduced his finger into the bottom of the aneurismal sac, and could feel no longer a pulsation in the femoral artery. He supported the strength of the patient, and succeeded in obtaining the separation of the gangrene. Unfortunately the patient was soon after attacked by a severe acute affection of the breast, which hurried him to his grave. The dissection of the body shewed that the femoral artery was not at all dilated, but *lacerated*, and that the artery had closed spontaneously, or by the usual effect of gangrene, for a certain space above and below the laceration.

\* Duncan Med. Comment. Decade ii, vol. iii.



§ 23. John Robertson, by trade a carpenter,\* in full health, the 23d of December, being in liquor, fell several times in the streets. On the 26th he perceived a small swelling in the middle of his left thigh, accompanied with pain and strong pulsation. By the 3d of January, the swelling having acquired a considerable size, the patient was brought to the hospital. Next day a consultation was held, and all the surgeons were of opinion, that the tumor was an aneurism from *effusion*, occasioned by the *rupture* of some large artery of the thigh. It was determined that the tumor ought to be opened, and if the ruptured vessel was found to be only a branch of the crural artery, that it ought to be tied; but if it was the trunk of the crural artery which was ruptured, that amputation ought immediately to be had recourse to. The tumor was opened, and as it was the trunk of the femoral artery which was ruptured, the amputation was immediately performed.

§ 24. The following case forms an interesting contrast with the preceding with regard to the method of cure employed by the celebrated surgeon Desault.† Charles Lorenzo Miglio, a goldsmith, 37 years of age, of a bilious constitution, in the 20th year of his age had a gonorrhæa, accompanied with bubo. The gonorrhæa continued for a long time; the bubo suppurated, and healed in the course of two months, without it having been necessary to employ internally any mercurial preparation. From that period to his 36th year, this man enjoyed good health. Afterwards he had the itch, which was cured by the use of sulphur

\* Essays and Observ. Phys. and Liter. of Edinburgh, vol. iii. Case vii of Monro.

† Journal de Med. de Paris, t. lxxviii.



internally, and frictions externally. He continued healthy; and it was not till a year after, or on the 10th of August 1787, that he felt a numbness in the left leg and knee, which lasted till the 17th of the same month, at which time a swelling, with some pain, appeared in these parts. A surgeon applied emollient cataplasms, and purged him twice. By the use of these remedies the swelling and pain were removed. In proportion as these symptoms disappeared, a tumor, having an evident pulsation, was perceived towards the inferior and internal part of the thigh; and this determined the patient to consult Desault. The tumor occupied the lower third of the thigh, a little above the place where the femoral artery passes through the tendon of the adductor magnus muscle. M. Desault undertook the cure of this aneurism by opening it in its whole length, and evacuating the clots of blood; on removing which, he found the femoral artery bare at the bottom of the sac, and in its anterior surface, a rupture of about two inches in length presented itself, without there being any appearance of the artery having been in the smallest degree enlarged in diameter. M. Desault tied the artery above and below the rupture; and although the subsequent cure was not exempted from dangerous vicissitudes, the patient recovered, and preserved the use of the whole inferior extremity.

§ 25. John Lazardoux,\* a carpenter, 29 years of age, had been affected for six months with a tumor in the left ham, which had all the characters of a *true* aneurism. The disease at first shewed itself with pain of the leg, and the appearance of a small swelling, which remained stationary for three months; it then

\* Caillot. Essay sur l'Aneurysme, pag. 96.



enlarged in size considerably; and the increase was perhaps owing to an exertion which he made to support a load of wood. The patient was operated upon by Boyer, according to the old method, by the incision of the aneurismal sac. On removing the clots of blood, the ruptured part of the popliteal artery appeared in the bottom of the sac, and it was distinctly perceived that the internal and muscular coats were not *dilated*, but *lacerated* at the place through which the blood had been effused into the cellular substance of the ham.

§ 26. Paletta\* affirms, that in his extensive practice, he has never had occasion to see any other kind of aneurism of the popliteal and femoral arteries, than that from *rupture* of their proper coats. Among the histories of this disease, which he has published, I shall here only relate those which have presented him with an opportunity of examining the parts affected after death.

‘ A middle-aged schoolmaster,’ says he, ‘ of a  
‘ meagre pale habit of body, came into the hospital  
‘ with two distinct tumors in the right thigh, the  
‘ one situated towards the end of the triceps muscle,  
‘ the other two fingers-breadth above the internal  
‘ condyle; they were not very painful, and without  
‘ any discoloration of the skin; however, there was  
‘ an evident fluctuation in them, and the whole leg  
‘ and foot were œdematous. An incision was made  
‘ into the lowest tumor, being the most elevated, and  
‘ the cellular membrane was immediately observed to  
‘ be filled with blood, a few drops only of which were  
‘ discharged; the fluctuation remaining still evident.  
‘ I immediately suspected that it was an aneurism;

\* Giornale de Venezia, Febbrayo, 1796, No. 11.



‘ I therefore applied my hand to both tumors, to  
‘ ascertain the truth of my conjecture; but I could not  
‘ perceive either pulsation, or that dull sound, which,  
‘ it is pretended, is met with in the *false* aneurism.  
‘ Under these circumstances, I did not choose to pro-  
‘ ceed farther with the knife; I therefore bound up  
‘ the wound in the œdematous leg. The day after,  
‘ about three ounces of blood were discharged from  
‘ the incision. The patient was tormented with most  
‘ acute pain of the thigh, and a sense of great tension,  
‘ although no greater swelling was perceived than  
‘ usual. As a farther aggravation of his suffering,  
‘ the patient was affected with anxiety, general pale-  
‘ ness, a very small pulse, and syncope, which car-  
‘ ried him off the third day after he was taken ill.  
‘ This disease, of which it was impossible to trace any  
‘ predisposing cause, increased, from a small nut,  
‘ gradually to the size of the fist; and the increase was  
‘ perhaps more rapid after the application of emollient  
‘ poultices, with the intention of bringing the tumor  
‘ to suppuration. On making an incision lengthwise  
‘ in the thigh, and laying bare the crural artery, it was  
‘ found to be sound in its whole course, till the place  
‘ where it passes under the os femoris, where it was  
‘ open for about the space of an inch on its anterior  
‘ surface, or precisely opposite to the posterior sur-  
‘ face of the bone, two fingers-breadth above the  
‘ joint of the knee. The extravasated blood was part-  
‘ ly collected under the sartorius muscle, between the  
‘ end of the triceps, vastus internus, and rectus  
‘ muscles, thus forming suddenly a more conspicuous  
‘ tumor. This blood consisted of blackish clots.  
‘ Another portion of it had made a way between the  
‘ triceps, gracilis, and biceps muscles, along the inter-  
‘ nal part as far as the middle of the thigh, and seem-



‘ ed to consist of purulent serum, containing small  
‘ clots of blood swimming in it. Lastly, the fibrous  
‘ part had become dense, and was collected in greater  
‘ quantity towards the ham, and under the skin cover-  
‘ ing the superior portion of the gastrocnemii muscles.  
‘ The artery was not observed to be dilated at any  
‘ point beyond the aperture, although it was insulated  
‘ on every side, and, to use the expression, suspend-  
‘ ed in the cellular membrane.’

‘ A man of short stature, with a curvature of the  
‘ lower extremities from rickets, with which he had  
‘ been affected in his youth, in the 30th year of his age,  
‘ was exposed to the infection of gonorrhæa with bubo.  
‘ Six years after this misfortune, in the winter of 1781,  
‘ he was attacked by rheumatic pains of the thighs and  
‘ legs, of which it was impossible to learn the progress  
‘ or termination, as the patient was unable to state the  
‘ phenomena that had occurred during his indisposi-  
‘ tion. From about this time, however, the com-  
‘ mencement of the aneurism of the right ham may  
‘ probably be dated, as it was of the size of a turkey’s  
‘ egg, and not very hard, with an evident pulsation.  
‘ As there was some swelling of the calf of the leg,  
‘ it was thought that the bandage recommended  
‘ by Genga, moistened with the vulnerary water of  
‘ Theden, might be employed with permanent advan-  
‘ tage. But neither the bandage, nor compresses of  
‘ gall-nuts softened in red wine, produced the least  
‘ favourable change in two months; and the pains in  
‘ the aneurism, with the swelling of the leg, were ra-  
‘ ther increased, on which account I thought it would  
‘ be better to suspend every kind of application, and  
‘ then proceed to the operation pointed out by Mr.  
‘ Hunter. But the aneurismal tumor augmented ra-  
‘ pidly; the skin inflamed, and, to crown all, a fever



‘ supervened, with shooting pains in the tumor, espe-  
‘ cially during the night, great restlessness and ema-  
‘ ciation, so that there was no longer room to think  
‘ of an operation. The knee soon after began to swell,  
‘ and two blackish spots appeared in the ham, from  
‘ which there oozed a bloody sanies, in such quantity  
‘ as to moisten the bed-clothes. The œdema occupied  
‘ the leg, which had become heavy and torpid, with a  
‘ stinging sensation in it. In a short time the leg lost all  
‘ sensation, and became very cold; a large gangrenous  
‘ eschar covered the aneurism; the pulsation disap-  
‘ peared, the skin of the leg became livid, and the  
‘ pains and fever went off. At last the eschar burst,  
‘ and there issued out a few clots of blood; then a  
‘ great quantity of fluid blood; the pulse was not to  
‘ be felt; the patient implored relief from the oppres-  
‘ sion which overwhelmed him, and suddenly died.  
‘ The crural artery was laid bare from its origin, as far  
‘ as the aneurism; an incision was made into it, and in  
‘ its whole course there was not observed either *ossi-*  
‘ *fication*, inflammation, rigidity of the coats, or ob-  
‘ struction of its canal. The opening of the artery  
‘ was oblique, or cut like a writing pen, with the edges  
‘ glued to the neighbouring cellular membrane, with  
‘ which they formed one substance. The rupture,  
‘ which was about an inch in extent, was situated above  
‘ the division of the artery into the branches of the leg.  
‘ The *anterior* tibial artery remained pervious to a  
‘ probe, and was nearly in its natural state; the *posterior*  
‘ was obstructed by a sort of spongy substance, which  
‘ hindered the passage of a probe. The sac was  
‘ found full of clots and concretions of coagulable  
‘ lymph. The periosteum and the ligaments of  
‘ the joint, had contracted a leaden colour; and a  
‘ yellowish colour, accompanied with a little indura-



tion was communicated to the adjacent cellular substance, to the fat, and also to the bundle of popliteal nerves. In short, it was obvious, that the arterial cylinder had not suffered *any dilatation* from its commencement, to the rupture situated in the cavity between the two condyles of the femur.'

' A married man, about 42 years of age, a silk-spinner, of a stout constitution, and who had always been healthy, if we except a fever of the acute kind, with which he had been affected in his twenty-fifth year, the cause of which was ascribed to a violent fright, having been in danger of his life. In carrying a great weight, he felt as if a fibre had broken in the thigh, but was unable to assign the period when it happened. About a year after, he began to suffer violent shooting pains in the left ham, which he supposed to be rheumatic, without any local swelling or inflammation. To allay these pains he applied flour and warm resolving herbs, with very little relief; and in a short time, a small circumscribed throbbing tumor, as large as a nut, was discovered at the pained part. It increased to the size of the fist in six weeks, and he applied at the hospital about the 5th June 1792. In addition to the pulsating aneurism, and a swelling of the left leg, the patient had a certain frequency and vibration of the arteries, and an extraordinary pulsation of the heart, which did not leave any room to doubt of the existence of an internal aneurism. Having tried, without benefit, cold local baths, and a compressing bandage, the leg and foot were attacked with gangrene. After it had stopped short in the lower third of the leg, amputation was performed. On examining the amputated part, the aneurismal sac was found full of very hard clotted blood, which stopped up the inferior passage



‘ of the popliteal artery, and had so impeded the circulation of the blood, as to cause the supervention of gangrene. On the anterior part of the sac, at a point where it was open, the internal condyle of the femur was carious. The gangrene, which externally had confined itself to the integuments of the lower third of the leg, proceeded upwards internally along the cellular membrane, as far as the middle of the leg. The left cavity of the chest contained a little water; the heart was flaccid and sound. The aorta was likewise sound, except that its arch appeared to me to be a little more enlarged than natural. All the other vessels had their natural diameter. The extremity of the divided artery next to the thigh, was blocked up by a white coagulum, on removing which, although sixteen days were elapsed, the canal was still found open to its extremity.’

§ 27. It appears to me unnecessary to relate a greater number of facts than have been already stated, in order to prove the non-existence of *true* aneurism, or aneurism from dilatation of the proper coats of the popliteal or femoral arteries; and the more so, as several other cases, which I could adduce, are perfectly similar to the preceding, both with regard to the occasional and proximate causes which have produced them, and as to the results of the careful injections in the bodies of those who have suffered from this formidable disease. The proximate cause of the popliteal or femoral aneurism, has been found invariably to arise from the *rupture*, and never from the *dilatation* of the proper coats of the artery in the manner of a sac. The disposition to this affection might, in some patients, be referred to a *steatomatous, earthy, ulcerated* degeneration of the internal coat of the artery; in others, to a



*rheumatic* virus; in others, to the *venereal* poison which had exercised its influence on some point or portion of the whole arterial tube. And although a violent exertion of some of the inferior extremities had very often given rise to the disease, it is nevertheless very probable, that in those patients who were attacked by this disease, it ought to be ascribed in part to the violence of the force, in part to the unnatural relaxation, and excessive brittleness of the proper coats of the artery, especially at the place where the rupture and aneurism had occurred; since the same violent exertions do not produce a popliteal or femoral aneurism in every person, when there is not at the same time a local disposition to rupture.

§ 28. M. Deschamps,\* in all the histories of popliteal aneurism which he relates, mentions the bursting of an artery. To reconcile the facts to the common doctrine of *true* aneurism, he says, that the popliteal aneurism ceases to be *true* from the time the tumor has acquired a certain size; for, in this case, the proper coats of the artery become thin, and burst, and the edges of the rupture remain firmly attached to the neighbouring cellular membrane, which being compressed by the blood, and by external agents, becomes thickened, and then forms the greater part of the aneurismal tumor.† But the first part of this reasoning is merely a gratuitous assertion, and even

\* Observ. sur la Ligature des principales artères des extrémités.

† Loc. cit. notes, p. 10. Il paraît que l'on est actuellement convaincu qu'un anéurisme cesse d'être vrai, dès qu'il a pris un certain degré de croissance; que les parois des artères amincies s'effacent, disparaissent, et que les bords de la rupture adhèrent fortement au tissu cellulaire, qui comprimé, s'épaissit, et constitue presque tout le sac anéurismatique.



contrary to the most certain and established facts which we have on this subject; since it is demonstrated, that in the popliteal and femoral aneurisms, the tube of the artery is never dilated at a given point, in the manner of a sac; and that, if sometimes the popliteal or femoral artery is found to be somewhat greater than usual in diameter above the seat of the aneurism, this enlargement, in the first place, does not happen in every case, or it may be naturally so; and if even it should happen to be larger than natural, it would neither constitute the proximate cause of the aneurism, nor form the aneurismal sac. In the second place, if what M. Deschamps asserts were founded on fact, the sac in the incipient small popliteal or femoral aneurisms, ought always to be found covered by the muscular coat of the artery; and in the large aneurisms of this order, a portion at least of the sac, in the vicinity of the injured artery, ought to be evidently formed by the proper coats of the dilated artery; since it is not to be presumed, that after the rupture of the aneurismal sac, which was before formed by the artery alone, the muscular coat should retract so far, as to be re-applied to the tube of the injured artery, and disappear. But from what has been said above, it appears, that instead of this, quite the contrary is met with in the careful examination of the aneurisms of these arteries.

§ 29. The brittle nature of the proper coats of the arteries, especially when that disposition is rendered greater by the morbid *steatomatous, scaly, ulcerated* degeneration, does not readily permit the artery to be distended without being ruptured; it is even probable, that as in every rupture of an artery from violent exertion, the proper coats being much more brittle than



their external cellular sheath, are ruptured, while the external remains entire; and this is one of the principal reasons why in aneurisms, especially of the ham and thigh from a sudden exertion, the tumor is almost constantly *circumscribed*, and resembles a *true* aneurism. But however capable of dilatation an artery may be supposed to be, it will never be so beyond a given proportion to its natural diameter. But there is no proportion between the usual diameter of the popliteal or femoral arteries and an aneurism of these arteries when they have acquired the size of a goose's egg, or of the fist. We have observed in the preceding chapter, that the greatest of all the arteries, the aorta, in the vicinity of the heart, where it has its greatest diameter, if it sometimes yields to dilatation, the dilatation never takes place but in a certain proportion with the natural size of the artery, beyond which, if the aorta is forced to enlarge, it bursts in some point of its circumference. What then would happen if the popliteal or femoral arteries, having become weakened, or too rigid, and brittle in some part of their circumference, were strongly distended by the impetus of the arterial blood? Whoever has had an opportunity of dissecting aneurisms of the popliteal artery, cannot fail to have seen, that the two orifices of the artery are never situated at the two extremities of the sac, but on one side, and sometimes at a little distance from one another; that is, the superior orifice of the ruptured popliteal artery is as far distant from the inferior as the size of the rupture in it, which sometimes extends an inch or an inch and a half in length. If it were true that the aneurism was formed by the dilatation of the proper coats of the artery, since the bloody tumor is constantly formed on the one or other side of the artery, and never compre-



hends the whole circumference of the tube, it would be necessary to suppose, that the portion of the anterior or posterior side of the artery equal to an inch and an half in extent, and sometimes much less, was susceptible of such a dilatation as to form a sac of the size of a goose's egg or of the fist in the cavity of the ham, which, comparing the small extent of the distended side of the artery with its small density and capability of extension, approaches to perfect absurdity. That the popliteal or femoral aneurism is never preceded by dilatation at the place of the disease of the proper coats of the artery, is proved by the inspection of the disease, as well as by the careful comparative dissection of the coats of the artery and those of the aneurismal sac, the first of which are muscular, the latter wholly cellular; and it is further confirmed from the artery constantly preserving its cylindrical form both above and below the root of the aneurism; whilst, if the artery formed the aneurismal sac before being ruptured, it would be always found at some distance above the tumor, of a funnel shape, the base of which would be in the sac, the apex in the superior orifice of the artery. But the contrary of this is always observed, and the popliteal and femoral arteries are always found to preserve their cylindrical form immediately above the root of the sac, into which the artery has rather the appearance of penetrating farther, than of expanding its coats to form the parietes of that receptacle of the blood, and to take a part in its formation. The figures published by Walter\* and by Guattani† shew clearly the truth of this fact, and confirm still more what has been said above

\* *Observ. Anatom. Tab. viii, M.*

† *Oper. citat. Tab. v, fig. i, M. M. Tab. ii, fig. ii.*



with regard to the true nature and proximate cause of the popliteal and femoral aneurisms.

§ 30. With regard to the structure and connexion of the aneurismal sac of the ham with the neighbouring parts, it is proper to remark, that the sac is always formed in part by the cellular sheath surrounding the artery, and partly by an aponeurotic layer of the muscle of the *fascia-lata*, or by the aponeurosis of this muscle spread immediately below the integuments of the ham. This aponeurotic web of the ham, although not so dense as that covering the lateral part of the knee, is nevertheless sufficient to resist strongly the distention which may be made from within outwards, and the more so, as it receives in the cavity of the ham an addition of several ligamentous filaments artificially interwoven with it, which run across obliquely from one side to the other. These ligamentous bands include on both sides of the ham the insertions of the tendons of the flexor muscles of the leg, and serve to protect the parts which run in the cavity of the ham, and also contribute to prevent the too great separation of the tendons of these muscles. Under these ligamentous bands, in the sound state of the parts, the popliteal nerves, the vein, and still deeper the artery, are found united together by means of a dense compact cellular substance. Between the popliteal artery and the posterior surface of the femur, the cellular substance is weaker and less compact than on the anterior surface, where it is covered by the ligamentous bands and by the integuments. On which account, the internal coat of the popliteal artery being ruptured or corroded, the blood oozes through the muscular coat, and is effused into the cellular sheath, like an ecchymosis, and is after-



wards raised in the form of a tumor. The resistance opposed to the effusion of blood being made partly by the cellular membrane, partly by the ligamentous bands, which, as I have mentioned above, also oppose the separation of the tendons of the flexors of the leg, it therefore happens that the popliteal aneurism assumes rather an elongated form, according to the longitudinal axis of the knee, than a round figure. And as the cellular sheath of the popliteal artery is weaker and less dense on the side next to the posterior and inferior surface of the femur, than on the opposite or anterior side, therefore it more commonly occurs that the aneurismal sac is large and dense on the side of the integuments, while it is thin on the side corresponding to the bone, and sometimes wanting, as in the large popliteal aneurisms of long standing, in which the clots of blood are very often found in contact with the periosteum, and sometimes with the substance of the femur and its condyles.

§ 31. The femoral artery also, in its long course from the crural arch to its passage through the tendon of the long portion of the adductor magnus, is covered by the aponeurosis of the muscle of the *fascia-lata*, but not equally so in the whole of this course. For, the portion of this artery extending for about four inches below the crural arch, is surrounded by a cellular membrane much denser than lower down, being a continuation of the cellular membrane which lies behind the peritoneum, and accompanies the crural vessels without the abdomen for a certain space, known formerly under the name of *processes* of the *peritoneum*. Farther, the femoral artery, at the top of the thigh, is protected anteriorly by an aponeurotic layer of the *fascia-lata*, much thicker and denser than



that covering the artery at the lower part and in the rest of the thigh. On which account the femoral aneurism, which forms at the top of the thigh, retains very often for a long time its *circumscribed* form, and increases more slowly than that which occurs in the middle or lower part, where the artery, being surrounded by a cellular substance very capable of distention, and not sufficiently supported by the aponeurosis as at the upper part, allows the effused blood more easily to elevate the integuments, and sometimes to proceed backwards between the bundles of the adductors of the thigh, as far as to press upon the great sciatic nerve, and injure it sometimes so much as to make the patient lose the sensation and motion of his inferior extremity. This point deserves the most attentive consideration, as it has great influence both upon the prognosis and plan of cure to be adopted for the radical cure of the femoral aneurism.

§ 32. The marks by which surgeons generally\* conceived it to be possible to distinguish a *true* aneurism, or aneurism from *dilatation*, from a *spurious*, or an aneurism from *effusion*, have never existed, if I may be permitted to say so, except in the brain of those who have proposed them. They say, that the *true* popliteal or femoral aneurism may be distinguished from the *spurious*, because the former at its commencement is small, circumscribed, indolent, without

\* Petit. Mém. de l'Acad. R. des Sciences de Paris, an. 1736, pag. 244. Petit, after enumerating the characteristic marks of true and false aneurism, adds ; les différences caractérisent si parfaitement ces deux maladies, qu'il semble qu'on ne devoit jamais prendre l'une pour l'autre. C'est cependant ce qui arrive quelquefois. J'ai observé plusieurs fois, qu'un anéurisme par dilatation peut paroître et même devenir anéurisme par épanchement, et qu'un anéurisme par épanchement peut paroître anéurisme par dilatation.



any change in the colour of the skin covering it, easily compressed, but, on removing the compression, immediately re-appearing as before; that it augments slowly, and in proportion as it increases, the pulsation in it becomes weaker and obscure, until it disappears entirely; which appearances are said to be reversed in *spurious* aneurism, with the farther addition of a kind of hissing noise, where the strong pulsation declines, and in retiring from the centre of the aneurism, a sort of small trembling or oscillation, which is not met with in *true* aneurism. But nothing can be more inconsistent with the truth than this account of the symptoms characterizing true aneurism. We may have a most convincing proof of this in the aneurisms from the puncture of an artery, in which, if the wound has been very small, the same symptoms present themselves as in the *false* aneurism so called, which have been considered as proper and peculiar to the *true* aneurism, although there be nothing more certain than that the tumor has been formed by a puncture, and effusion of arterial blood. Whenever the laceration or ulceration of the internal coat of the artery, from an internal slow morbid cause, is not extensive, so that the blood oozes slowly through the interstices of the fibres of the muscular coat, and when the cellular substance surrounding the artery is dense, and sufficient to resist the impulse of the arterial blood, which endeavours to expand, the pulsating bloody tumor remains small and circumscribed, with very little pain, without any discoloration of the skin covering it, compressible and elastic. But in proportion as the rupture or ulceration of the artery increases in size, and the cellular substance surrounding it yields to the infiltration and distention produced by the effused blood, the tumor necessarily increases, loses that



flexibility and elasticity which it had at the beginning, and the numerous firm layers of blood, which form in it, at last render the pulsation also obscure. A further proof of the fallacy of the common doctrine of the distinctive marks of the *true* and *false* aneurism, may also be deduced from the fact, that in those cases in which the pulsating tumor of the artery is formed by a *steatomatous* thickening of its proper coats, the aneurism is hard and incompressible, precisely as the aneurism from *effusion* is said to be, although in the former case it has been demonstrated, that there is a very inconsiderable effusion of blood into the cellular substance surrounding the artery, or at least nothing more than an ecchymosis.

§ 33. The very acute pain, and the swelling and torpor of the leg, which sometimes accompany the popliteal and femoral aneurisms, are not, properly speaking, occasioned by the morbid state of the proper coats of the artery, but by the pressure exercised by the effused blood upon the parts surrounding the affected artery. The aneurism of the ham, or of the thigh, on its first appearance, and when it is small, occasions little or no inconvenience; but as soon as the quantity of effused blood makes a considerable addition to its size, it occasions violent pain, gives great uneasiness to the patient from the violence of its pulsation, especially if the patient is plethoric, and does not submit often enough to venesection; and it at last produces the swelling and torpor of the leg. The small *steatomatous* throbbing tumors in John Parker, which were taken for so many *true* aneurisms, did not, for a long time, excite any remarkable inconvenience to the patient, but immediately after the one in the right ham



burst, and actually gave rise to an aneurism, the pains appeared, and the leg began to swell. The patient of whom Guattani\* speaks, continued pretty well for two complete years; but as soon as the patient perceived the repeated crack of something in his thigh, and a sound similar to the tearing of a bit of cloth, the tumor increased rapidly by the effusion of blood, the pain was most acute, with enormous swelling of the whole limb. Even independent of the *steatomatous* thickening of the proper coats of the artery, in a case of slow ulceration of these coats, especially the internal one, as long as the rupture is small, and the cellular sheath of the artery sufficiently resistant, and strengthened by the ligamentous bands, and aponeurotic layers, so that the effused blood remains *circumscribed* within a small space, the pain in the seat of the disease, and the swelling of the leg, do not incommode the patient, and are of little consequence. But as soon as the ulceration and corrosion † of the internal coat of the artery have made a certain progress, and the rent in the artery is enlarged by the increased impetus of the blood, or by a violent exertion, the tumor quickly acquires an increase of size, and the violent symptoms above mentioned arise, from the strong distention of the adjoining parts, and the compression of the great femoral and popliteal nerves. In the inveterate, and enormously large aneurism of the ham, the great popliteal nerves are always found stretched on the convexity of the aneurismal sac, of a reddish colour, tinged with blood, hard, and converted into a large compact filamentous expansion, and incapable of supplying vitality to the leg and foot.‡

\* Loc. cit. Singulare femoris aneurysma, hist. v.

† Guattani, p. 192, fig. 4.

‡ Guattani, tab. v, fig. 1, g g.



§ 34. From the series of facts detailed in this chapter, it follows,—1. That the proximate and efficient cause of the popliteal and femoral aneurisms, as has been mentioned in treating of the aneurism of the aorta, is always the *rupture* or the *ulceration* of the proper coats of the artery: 2. That the cause of this rupture is some violent exertion, combined, for the most part, with a congenital relaxation, or with a *steatomatous* or *ulcerated* degeneration of some portion of the proper coats of the artery, and more particularly of the internal coat: 3. That the *steatomatous*, *squamous*, *ulcerated* disorganisation of the proper coats of the femoral and popliteal arteries, takes place sometimes in one point only of the artery, sometimes in several places, and at different distances from each other, in the whole course of these arteries: 4. That the marks regarded as characteristic of the distinction of the *true* from the *false* aneurism, are inadmissible, and are contradicted by the known nature and characters of this disease, and by the attentive observation of the phenomena which accompany it: 5. That no other distinction ought to be admitted in the doctrine of aneurism, than that of *recent*, and *inveterate*, or of *long standing*; *circumscribed*, and *diffuse*.



## CHAPTER VII.

## OF THE ANEURISM OF THE BRACHIAL ARTERY.

§ 1. SURGICAL writings contain many histories of aneurism in the bend of the arm, produced by the puncture of the brachial artery in venesection, or caused by a deep wound inflicted at the bend of the arm, along the inner side of the humerus, or in the axilla. No doubt certainly can exist with regard to the nature of this aneurism; it is evidently formed by *effusion*. Although Morand\* and some other surgeons have found that, along with the aneurism caused by the wound of the brachial artery, the diameter of that vessel is sometimes unusually enlarged through its whole length, above the seat of the tumor; this enlargement, which is a very rare occurrence, might have existed naturally, and before the puncture of the artery. And if it even happened frequently, it could not with justice be said, as I have remarked in several places, that the increase of size of the trunk and branches of an artery lengthwise, is essential to constitute an aneurism, and still less, that to this equable enlargement of the tube of the brachial artery was to be referred the formation of the aneurismal sac in the bend of the arm, along the inner side of the humerus, or in the axilla, in consequence of a puncture or wound of the brachial artery.

\* Mém. de l'Acad. R. de Chirurg. t. v, pag. 167, 8vo.



§ 2. It cannot fail, therefore, to excite surprise,\* that men acquainted with anatomy, and experienced in surgery, such as Molinelli,† Guattani,‡ and so many others, who had undoubtedly had frequent opportunities of examining the aneurism in the bend of the arm, caused by the puncture of a lancet, should have persisted in the belief, that the tumor was formed by the dilatation of the proper coats of the brachial artery; and that following these false principles, they, in the act of operating, should have taken the trouble to separate the aneurismal sac carefully from the neighbouring parts, as if it belonged to the artery, and were formed by the dilatation of its proper coats. Mr. Macgill,§ pre-occupied by this false opinion of the nature of this disease, attempted to effect this separation in the act of operating on an aneurism at the bend of the arm, caused by an unfortunate venesection; but as he observed that the operation did not go on well, and was even very difficult and trouble-

\* Lassus writes very well on this subject, *Med. operat.* t. 11, pag. 426. Ce sont les mauvaises définitions qui ont contribués plus qu'on ne le croit à perpetuer l'erreur. On s'est laissé conduire par les mots que par les choses, et l'on a mieux aimé redire une erreur, que de prendre la peine de vérifier si ce que l'on disoit étoit vrai ou faux.

† *Comment. Acad. Bonon.* t. 11. Cum mihi observationes aliquot in promptu essent, ad vera præsertim cubiti aneurysmata pertinentes ob læsam forte inter mittendum sanguinem a chirurgo brachialem arteriam oborta. Atque ut sacci internam faciem omitam cum interna arteriarum facie maxime congruentem, arteriæ utique in saccum explicari ipsæ, extendique conspicebantur.

‡ *Loc. cit.* Hanc autem partium separationem, etiam in posteriori tumoris sede, eousque peregi, donec validum in nervum inciderim, qui arteriam contigue comitatur, et donec membranis omnibus et musculis tumorem ita extricaverim, ut eum possem superius, atque inferius vinculis coercere.

§ *Medical Essays of Edinburgh*, vol. ii.



some, from the capsule containing the clots of blood adhering everywhere very firmly to the surrounding parts, and being in some points very thick, and in others thin and easily lacerated, he adopted the better practice of dividing the sac, and evacuating the grumous blood. After this, he immediately discovered, at the bottom of the sac, the precise place where the artery was punctured. Dr. Monro, who was present at this operation, said,\* that he had before had strong reasons for believing that the true aneurism was a very rare disease, yet on seeing the tendinous aponeurosis of the bend of the arm laid bare, he had for a moment almost changed his opinion; for this aponeurosis seemed to be the muscular coat of the artery dilated like an aneurismal sac. Dr. Monro adds, I would have fallen into this error, if Mr. Macgill had at once divided the tumor in its whole length, instead of separating the aponeurosis from the neighbouring parts. It is not improbable that several other surgeons, among those who have taught that true aneurism sometimes occurs at the bend of the arm after venesection, have been likewise deceived by the aponeurotic membrane of the bend of the arm, which assumes the appearance of a fibrous layer lying over the aneurismal sac, and so strongly adhering to it, that it can with difficulty be separated.

\* Monro's Works, N. 14. Notwithstanding my theory and dissections had brought me to think true aneurisms to be at least a very uncommon disease, yet when I saw Mr. Macgill lay the tendinous aponeurosis bare, I was ready to have renounced my opinion, being persuaded it was the muscular coat of the artery; till he most dexterously prosecuted the aponeurosis to its rise from the biceps, and so fully convinced me of the mistake into which I should most readily have been led, without discovering it, if the operation had been performed in the more speedy way of laying the whole tumor open by one incision.



§ 3. But what, in my opinion, has more than any thing else given credit to the possibility of the formation of *true* aneurism in the bend of the arm after venesection, was the theory of those who supposed, that whenever the lancet only penetrates the cellular membrane and the muscular coat of the artery, leaving the internal coat entire, the aneurismal sac is formed by the internal coat, which is forced gradually outwards by the blood, between the lips of the wound of the two external membranes of the artery superficially injured. Guattani\* considered this as a certain fact, and compared the distention and protrusion of the internal membrane of the artery to that of the peritoneum in the formation of an hernial sac. This is the reason, he says, why the aneurism at the bend of the arm appears sooner or latter after the wound, and without producing any change in the colour of the integuments, and why it assumes a round form, and throbs strongly. To understand fully the invalidity of this doctrine, it is only necessary to have examined the structure and properties of the internal coats of the arteries, the thick and brittle texture of which does not support any considerable degree of distention without being ruptured. On injecting air forcibly into an artery which has been for a long time macerated and deprived at different places of its muscular coat,

\* Loc. cit. Prout in missione sanguinis ex basilica vena, magis aut minus alte demergitur scalpellum, non raro pertudi arteriam contingit. In illa autem si ferri mucro ad cavum usque haud pertingat, sed ex quinque arteriarum componentibus tunicis duas tantum aut tres confodiat, verum progignitur aneurysma. Immixto enim in vulnerata sede adverso conatu, arteriosus sanguis integras adhuc membranas jugiter feriens, eas pedetentim ita distendet, ut herniosæ tandem reddantur, indolentemque ocyus, seriusve pariant tumorem, qui non solum nativo gaudebit colore par-tis, et rotunda, vel ovali figura, sed sensibili quoque, eaque sat valida pulsatione.



small pellucid vesicles arise in these places, formed by the internal coat of the artery, and these vesicles readily break, if the air is forced in with a little more violence. But in the recent unmacerated artery, not even these small vesicles are formed, and the internal coat of the artery is ruptured by the impulse of the air, without forming any protrusion. Some observations made by Haller\* on the mesentery of frogs, appear to me to have contributed to give credit to this doctrine. In these observations he asserted, that he had seen *true* aneurisms formed in the mesentery of frogs, and that he had himself produced them artificially, by insulating and stretching the arteries of the mesentery, and making an incision into them with the point of a lancet. But is it certain and demonstrated, that Haller, in these fine microscopic observations, had completely stripped any of the arteries of the mesentery of the frogs, of the whole cellular substance surrounding it? Is it proved, that in stretching the mesentery upon the apparatus of the microscope, he had not ruptured some ramification? That no rupture had happened in the act of insulating or stripping, as he expresses it, the artery which in the sequel becomes aneurismatic? And admitting, (which is far from being proved), that by this kind of experiment he had seen *true* aneu-

\* Deux Memoirés sur le mouvement du sang. Mém. i, p. 9. C'est mal-à-propos que quelques écrivains ont cru devoir retrancher l'aneurisme vrai du nombre des maladies chirurgicales. Je l'ai vu se produire, comme j'ai déjà dit, sans pouvoir en assigner la cause, et j'ai appris dans la suite à le produire aussi souvent que je l'ai voulu. Je separe pour cela les deux lames du mésentere des deux cotés d'une artere, je la secoue ensuite de la maniere à la degager tout-à-fait des liens celluloux qui l'affermissent; et je ne tarde pas après ces preparatifs, à voir naitre un aneurisme, qui se forme également après une incision, et surtout après la piqure de l'artere.



risms produced under his eye, it does not follow, that those, which he had caused to arise by means of the incision or puncture of one of these arteries, deserve such an appellation, where, if an aneurism had been formed, it could not have been produced in any other way than by the effusion of the arterial blood into the cellular membrane surrounding the punctured artery.

§ 4. The fallacy of this opinion appears still more clearly from the following experiments.\* Mr. Hunter having laid bare the carotid artery of a dog for the space of an inch and an half, and having separated at the same time the external cellular sheath from the artery, and then the muscular coat, layer after layer, until the remaining coat of the artery was so thin, that the blood could be seen shining through it, left the dog at liberty. Three weeks after, the dog was killed, and on examining the neck, it was found that the lips of the wound had contracted and closed over the artery; that all the parts surrounding the place of the incision had consolidated, and formed a strong knot of re-union with the artery; that finally, the carotid artery, in the whole space where it had been stripped of its cellular sheath, and of the greater part of its muscular coat, had neither diminished nor increased in diameter. It has been objected to this fact, that the lips of the wound having been left to themselves, had immediately closed upon and covered the denuded and weakened portion of the artery, and that this had secured it against any rupture, and the aneurismatic dilatation. In order to ascertain the importance of this objection, Mr. Home instituted

\* Transactions of a society for the improvement of medical and surgical knowledge, page 144, vol. i.



the following experiment. He laid bare the femoral artery of a dog, about two inches below Poupart's ligament, for about an inch in length. He separated and dissected off as much of the muscular coat of the artery as was sufficient for seeing the blood circulating within it, through its pellucid internal coat. The lips of the wound were kept separated by the interposition of dressings. The dog did not show any signs of being much incommoded by the wound, and it was cured by the second intention. After six weeks the dog was put to death; and the femoral artery was then injected, that it might be examined with the greatest possible accuracy. It was found, as in Mr. Hunter's experiment, that the artery had neither increased nor diminished in diameter at the place where it had been weakened by the separation and removal of the muscular coat. I have also repeated this experiment twice; first on the carotid of a large dog, and secondly on the carotid of a sheep, by dissecting off the muscular coat, layer after layer, until the internal coat appeared quite bare, and by the interposition of lint I brought the wound to suppuration, and healed it by the second intention. Four months after the cure, I observed in both animals, that the carotid artery, in the whole of the space from which the muscular coat had been removed, was surrounded by a puffy, hard cellular substance, adhering firmly to the internal coat of the artery, which at first sight, on viewing it externally, appeared to be a little enlarged in size; but on opening it on the opposite side, lengthwise, I distinctly observed, that the canal of the artery was neither increased nor diminished in diameter, and that the external swelling depended entirely on the thickened and indurated cellular substance, which surrounded it at the place corresponding to the cicatrix.



§ 5. The proximate cause, therefore, of the aneurism which is formed in the bend of the arm after venesection, as also that which occurs in the brachial or axillary artery, produced by a wound, may invariably be traced to the incision or solution of continuity of the two proper coats of the artery, and the consequent effusion of blood into the cellular substance surrounding the injured artery. The effect is the same, whether from an internal morbid affection, capable of ulcerating or corroding the internal and fibrous coats of the artery, the blood be effused into the neighbouring cellular sheath surrounding the artery, which it raises after the manner of an aneurismal sac, or, the wound of the integuments having closed, the blood issue from the wounded artery, and be diffused in the surrounding parts. The solution of continuity in the integuments, cellular membrane, and aponeurosis covering the artery, consolidates quickly in these cases; while, on the contrary, the proper coats of the artery remain separated at the place of the puncture or wound; and, therefore, as was observed by Hildanus and Senertus,\* the arterial blood not finding any longer a direct way to spring outward, through the integuments, infiltrates, as in the internal aneurisms produced by the ulceration or corrosion of the internal coat, into the cellular substance, covering externally the wounded artery, and fills it in the manner of an *ecchymosis*; it then distends and elevates it in the form of a tumor, and the cellular divisions being destroyed, converts it at last into a firm capsule, or aneurismal sac.

§ 6. I have said, in another place, and it is proper to repeat it, that the greater or less resistance oppos-

\* Chapter v, § 9.



ed to the impetus of the blood, during the time of its extravasation or effusion, by the interstices of the cellular substance surrounding the artery, by the ligamentous fasciæ and aponeuroses lying over the aneurismal sac, is the true reason why the aneurism sometimes presents itself under the form of a small *circumscribed*, and sometimes of a large and *diffuse*, tumor. The rapidity or slowness of the formation, and appearance of the tumor outwards, likewise depend upon the same cause. For, with regard to the aneurism at the bend of the arm, it may be remarked, that it scarcely appears, or is small and stationary, whenever the puncture made in the artery is very minute, and the inflammation excited by the stimulus of the effused blood, or by the artificial pressure made upon the cellular substance surrounding the injured artery, has contracted its cells, and produced such an adhesion of it to the artery, and to the ligamentous and aponeurotic fasciæ, as to oppose a strong obstacle to the further exit of blood, and to the formation of clots. On the contrary, if, by the size of the wound inflicted in the proper coats of the artery, the column of blood which issues from it is large, and vibrating strongly, if the cellular substance surrounding the wounded artery is loose, and easily distended, and if the ligamentous aponeurotic fasciæ only oppose a weak resistance, the aneurism suddenly appears externally, and increases and dilates rapidly. And even in those cases, in which the aneurism at the bend of the arm was at its commencement very small and circumscribed, and has remained long stationary, if the wound of the artery is enlarged by an exertion of the arm, by a blow inflicted on it, or by the increased impetus of the blood in the brachial artery, so that the column of blood, endeavouring to issue



out, overcomes the resistance of the cellular membrane, and of the ligamentous aponeurotic layers at the bend of the arm, the aneurism, from being very small and stationary, is suddenly elevated, increases rapidly, and threatens to become diffused along the inner side of the humerus, and rises up as far as the axilla in the course of the humeral artery. It is observed in the *circumscribed* aneurism, that the disposition of the polypous concretions, filling the sac, varies according as the aneurism, which was small at first, has increased in bulk slowly, and at intervals, or has acquired a prodigious size all at once, and soon after the artery was wounded. In the first case, the bloody thrombus, or *couvercle*, as Petit calls it, having adhered to the artery opposite to the lips of the wound, stops the effusion of the blood. Some time after, the impetus of the blood detaches this *couvercle* on the one or other side, pushes it aside, and forms a new coagulated layer over the first, then a third layer over the second, and so on successively, and in proportion to the bulk which the tumor acquires. Of all these layers, disposed in the manner of concentric circles, the first being the nearest, and still in part adhering to the artery, is the smallest, and the most compact. In the second case, the thrombus is not properly in layers, but rather in form of a concrete mass; and what has been said here on the subject of aneurism of the brachial artery, in consequence of the puncture of a lancet, is understood to be applicable to the aneurism of the femoral and popliteal arteries, according as the aperture from which it is derived is small or large, and the formation and increase of the tumor slow or quick.

§ 7. Surgeons have generally taught, that in the



bend of the arm, at the usual place of bleeding, it is the aponeurosis of the biceps muscle, covering the cellular substance which surrounds the artery immediately under the integuments, which opposes more strongly than any other ligamentous or aponeurotic sheath, the augmentation and quick increase of the aneurism at this place. This opinion appears to me to have originated from inattention: for the aponeurosis of the biceps, where it leaves the tendon of this muscle, is not more than half an inch in breadth.\* It then descends obliquely, from the outer to the inner side of the arm, enlarging gradually; but it does not form a broad expansion, until a good way below the bend of the elbow, and it does not begin to cover the heads of the *radialis internus*, *palmaris longus*, and *ulnaris internus* muscles, till about three inches below their origin from the internal condyle of the humerus; that is, in other words, far below the bend of the arm. From which circumstance, the aponeurosis of the biceps, being situated lower than the place where venesection is usually practised, can, in the greater number of cases at least, contribute but little or not at all to strengthen the cellular substance surrounding the injured artery, and therefore cannot oppose the rapid increase of the aneurism; and it is the less capable of doing so, as has been said, from its not being more than half an inch in breadth, where it crosses the bend of the arm.

§ 8. In examining the bend of the arm immediately below the integuments, there is nothing which I find contributes so much to increase the resistance of the sub-

\* Camper. *Demonstr. Anat. Patholog.* tab. ii, fig. 1, 11. Haller *Fascicul. Anat.* vi, tab. iii, fig. 4, i. *Bicipitis tendo superficialis.*



jacent cellular substance, as a fascia or ligamentous web or expansion, which, after having covered the body of the biceps muscle, extends itself over the whole course of the humeral artery, and is firmly implanted into the internal condyle of the os humeri.\* This ligamentous expansion has a triangular shape, the base of which extends from the tendon of the biceps muscle, to the internal condyle of the os humeri, and the apex of it is extended on the inner side of the humerus towards the axilla, in the course of the humeral artery. Immediately under the integuments, this triangular ligamentous expansion adheres to the skin; more deeply, it forms a kind of duplicature, or elongation, which is inserted into the os humeri lengthwise, just at the space left between the origins of the brachialis muscle, and the two lower heads of the triceps extensor of the arm. The humeral artery and the median nerve, kept in their situation by the cellular sheath and this ligamentous expansion, run in the furrow formed between it and the internal margin of the biceps muscle. The base, or inferior portion of this triangular ligamentous expansion, becomes larger and firmer the nearer it approaches to the internal condyle of the humerus; and before being inserted into this condyle, it forms as many folds and sheaths as there are heads of muscles attached to it. And since this ligamentous web has a triangular form, with its base in the bend of the arm, and the vertex in the axilla, it follows of course, that below the base of this expansion, there is an oval space† filled with cellular substance, the transverse extent of which, is equal to the distance between the tendon of the biceps muscle and

\* Sabatier gives the name of intermuscular ligament to this ligamentous web. *Traité d'Anat.* t. i, p. 290.

† Camper. *loc. cit.* Fig. 1, E, L, S. Fig. 11, C, D, E, F.



the internal condyle of the humerus. This oval space goes on gradually contracting, the farther it ascends from the bend of the arm, along the internal margin of the biceps muscle towards the axilla, where it terminates in a point.

§ 9. This disposition of the part shows, why the aneurism which forms in the bend of the arm in consequence of venesection, for the most part assumes an oval figure, exactly similar to that of the cavity, extending below the ligamentous web, from the tendon of the biceps muscle, to the internal condyle of the os humeri; and likewise, when the aneurism arising from the puncture of a lancet becomes *diffused*, why it extends from the place of the venesection upwards rather than downwards, and rather along the internal than the external side of the humerus. It farther explains, why this *diffuse* aneurism takes the form of a triangle with the base in the bend of the arm, and the vertex towards the axilla, along the course of the humeral artery. For, attending to what has just been said, the blood which runs along the interstices of the cellular sheath surrounding the humeral artery, is at last inclosed within a triangular space, formed on one side by the internal margin of the biceps muscle, and on the other by the prolongation of the ligamentous web, inserted lengthwise into the humerus. And it is observable, in this case, or in the *diffuse* aneurism, that the clots of blood are found for a certain way in contact with the periosteum of the humerus, in the space between the origins of brachialis muscle, and the inferior portions of the triceps extensor of the arm; while in the first case, or in the *circumscribed* aneurism, which occupies only this oval cavity, the clots of blood do not rest, properly speaking, on the denuded articular ends of the hu-



merus, but rather on the fibres and heads of the brachialis, triceps extensor, and pronator teres muscles; in which respect, the *circumscribed* aneurism in the bend of the arm differs remarkably from that in the ham, as in the latter the posterior surface of the aneurismal sac is immediately in contact with the periosteum covering the posterior and inferior surface of the os femoris.

§ 10. In consequence of the limits fixed by nature to the ligamentous *intermuscular* expansion of the humerus, it follows, that the aneurism caused by a wound or ulceration of the internal coat of the axillary artery above the apex of this triangular ligamentous expansion, will be always *diffused*; since all this portion of the brachial artery is only surrounded by a loose soft cellular substance, and not strengthened by any aponeurotic or ligamentous expansion. The aneurism from a wound of the humeral artery will likewise be *diffused*, whenever the artery has been wounded or ulcerated laterally, so that the blood passes out of the triangular space above described, and from thence into the cellular membrane, which keeps united the bodies of the muscles placed along the humerus.

§ 11. In the aneurism at the bend of the arm in consequence of venesection, it is the trunk of the humeral artery which is punctured, unless in those cases, which are not very frequent, where the division of the artery takes place high up, and, as sometimes occurs, in the vicinity of the axilla. I have convinced myself repeatedly of the truth of this fact, by putting in pins, as Dr. Monro did, into the place where venesection is usually performed, and more especially by introducing them through the cicatrix of former bleed-



ings. In all these experiments I have found, that the pin pierced the trunk, or in the immediate vicinity of the trunk of the humeral artery, above its division into radial and ulnar, or entered the radial artery under the median vein; but so near to the origin of this artery, that the injury, in the living state, might have been regarded as made in the trunk of the humeral artery.

§ 12. It is a thing worthy of remark, that while aneurisms are not unfrequent in the aorta, and in the great artery of the thigh and ham, from an internal cause, or from a morbid disposition of the artery, especially of its internal coat, aneurisms of the brachial artery from an internal cause, such as the *steatomatous, ulcerated, earthy* degeneration, are very rare. It is not easy to give a reason for this difference, even if we are willing to admit, that the arterial system, the farther it proceeds from the heart, the more it loses its vitality, and capability of resisting the internal and external causes which may produce a solution of continuity in it; and if we even allow, that the inferior extremities are more exposed to external injuries, and to violent exertions, than the superior. Notwithstanding all this, the superior extremities are not exempted from this affection, and we have some examples of aneurism of the brachial artery, arising from an *internal* cause, or caused by an ulceration and rupture of the humeral artery independent of wounds, which I shall now relate.

§ 13. Thomas Cook,\* a soldier of the 3d regiment of foot-guards, in the beginning of the year 1759,

\* *Essays and Observ. Phys. and Liter. of Edinburgh*, vol. iii, case 11, tab. 2.



perceived a swelling in the vicinity of his left arm pit, for which he could assign no cause; as he had never received any contusion on that part, nor overstrained himself. Mr. Fordyce, the surgeon, discovered it to be an aneurism, but had not courage to attempt the cure of it. In the meantime the tumor went on daily increasing, and the patient was directed to St. George's hospital. The swelling extended down in the course of the brachial artery, and had an evident pulsation. The physicians and surgeons of the hospital were of opinion, that it was not proper to attempt any operation, as they thought the tumor was situated too high up; and they therefore advised the employment of no other remedies but palliatives and anodynes. After this, the tumor increased greatly along the internal side of the humerus, and the pulsation gradually ceased. In the beginning of December, the aneurism burst, and the patient died of the hemorrhage. In the dissection of the body, it was found, that the brachial artery had been ulcerated and lacerated near the axilla; that the large aneurismal sac seemed at first sight to be formed by the coats of the artery, though in reality it was not so; that the tube of the artery was but very little enlarged in diameter, where it opened into the aneurismal sac; that the brachial artery was impervious for about half an inch below the rupture; and lastly, that the radial and ulnar arteries were pervious, but somewhat smaller than usual.

§ 14. 'A nun,\* of a scorbutic habit, and who had  
'been subject to frequent palpitation of the heart, and  
'spitting of blood, perceived one day a crash in her  
'left arm as if a sinew had burst, to use her own words,

\* Paletta. Giornal. di Venezia. Marzo 1796.



‘ and from that moment a small tumor formed at  
‘ the inner part of the arm, a little above the internal  
‘ condyle of the humerus, which pulsated, and was  
‘ circumscribed, without any œdema externally. The  
‘ whole brachial artery pulsated, and its motions were  
‘ quite evident to the eye. The arm, however, was  
‘ feeble and a little wasted. Theden’s bandage ap-  
‘ plied to the fingers and arm was of no sensible ad-  
‘ vantage, but still less in the sequel, when in de-  
‘ scending a stair, she broke the lower extremity of  
‘ the left humerus, at a little distance from the aneu-  
‘ rism. This accident, in addition to the pain, brought  
‘ on a soft œdematous swelling of the fore-arm and  
‘ hand, which did not disappear until some time after  
‘ the perfect consolidation of the fractured bone, which  
‘ was accomplished in 45 days. In the meantime, the  
‘ aneurism had enlarged very much, and became more  
‘ painful, and the pulsation changed into a reciprocal  
‘ motion of the blood from the aneurism to the heart,  
‘ and from the heart towards the aneurism, with a  
‘ troublesome sense of oppression. With the suc-  
‘ cessive increase of the pain, the veins of the fore-  
‘ arm and hand became turgid; the aneurism, and  
‘ then the fingers, became livid; and having lost all  
‘ power of supporting the arm, it fell like a piece of  
‘ lead upon the bed when it was raised. The aneu-  
‘ rism afterwards extended over the whole lower  
‘ extremity of the humerus; which, conjoined with  
‘ the most violent pulsations and frequent faintings,  
‘ accelerated the death of the patient.’ Although  
the dissection of the body was not performed, the  
author had no doubt, that this aneurism was occa-  
sioned by the ulceration and rupture of the brachial  
artery.



§ 15. Alexander Meniconi,\* a young man, of a plethoric temperament, in lifting a heavy weight from the ground, suffered a violent sprain of all the muscles of the right arm, and particularly of the flexors of the fore-arm. For many days he was unable to make use of the elbow joint, on account of the pain, and a kind of lividity which appeared the following day on the inside of the arm. He kept it at rest, and applied for several days compresses dipped in vinegar and water. The pain gradually abated, the discoloration went off, and he resumed his trade of a carrier. He continued in his employment for six months, using his arm freely. After this time he began to feel some pain when he raised any weight from the ground. The pain increased to such a degree, that he could not make use of his arm any longer. Although he had observed for some months a small swelling above the bend of the arm, he never supposed that the pain could arise from it, as it was of the natural colour, and indolent. One day, having met in the street a physician from Colonna, his native country, he told him of his uneasiness, and shewed him the tumor. This physician, after having examined it, told him it was a dangerous swelling. He continued nevertheless to make use of his arm; but at last the swelling having increased considerably, by the advice of the same physician he came into this hospital to be cured. I found, on inspecting the part, about three inches above the inner condyle of the humerus, a tumor of the size of a large nut, soft, of a brown colour; and on compressing it with my fingers, it partly disappeared, and was accompanied by a pulsation cor-

\* Flajani. Collezione d'osserv. e rifles. di chirurgia, t. ii, pag. 22, osserv. vii, of a true aneurism of the right arm.



' responding to the systole and diastole of the heart.  
 ' The patient told me, that if he kept his arm bent,  
 ' he did not feel any uneasiness, but felt pain if he kept  
 ' it extended. The patient having assured me that  
 ' he was determined to submit to any operation to be  
 ' relieved from this affection, I prepared him for the  
 ' compression, as the least painful mode of obtaining  
 ' a cure. I made him lose some blood, put him on a  
 ' low diet, and the third day applied a compress dip-  
 ' ped in Theden's vulnerary water, and secured it  
 ' with a moderate compressive bandage, which ex-  
 ' tended below the axilla, and terminated above the  
 ' condyles of the humerus. This produced some  
 ' numbness in the whole arm, although it was not  
 ' very tight, as the pulsation could be readily felt in  
 ' the radial artery. A second bleeding appeared to  
 ' me to be necessary to weaken the system, and the  
 ' following day a laxative was given, which produced  
 ' an abundant discharge of bilious matter. On the  
 ' fourth day I renewed the bandage, and I found the  
 ' tumor of the same size. The compression conti-  
 ' nued for 32 days, did not produce any diminution  
 ' of the tumor; it was only a little flattened, and  
 ' the fore-arm and hand became œdematous and be-  
 ' numbed. Dreading that the aneurism would pass  
 ' into the *spurious*\* by continuing the compression, I  
 ' proposed the ligature. The patient having consent-  
 ' ed to the operation, I immediately prepared all the  
 ' necessary apparatus, consisting of two crooked  
 ' needles with waxed threads, a bistoury, hooks, a pair  
 ' of forceps, a tourniquet, and the ordinary dressing,  
 ' consisting of caddis, compresses, and circular band-  
 ' ages. The next day I proceeded to the operation.

\* The author considered this tumor to be a true aneurism, or  
 from a dilatation of the artery.



‘ The patient being brought to the edge of the bed, I  
‘ applied the tourniquet near the axilla, which I gave  
‘ to the care of an assistant, who supported the upper  
‘ part of the arm; another managed the fore-arm, and  
‘ a third handed me the necessary instruments. Hav-  
‘ ing tightened the tourniquet sufficiently to stop the  
‘ flow of the blood in the artery, I detached the skin  
‘ from its adhesion to the tumor, and formed a trans-  
‘ verse fold of it, and divided it by an incision, which  
‘ laid bare the cyst of the aneurism. With the bis-  
‘ toury I extended the incision of the skin and cellu-  
‘ lar membrane as far as the cord of nerves and the  
‘ artery. After having cleaned the wound of the  
‘ blood, to distinguish the artery from the nerves, I  
‘ made the tourniquet be slackened, and discovered  
‘ the artery by its pulsation, under which I easily  
‘ passed the hook with a blunt point, to separate it  
‘ from the nerve, and with the crooked needle passed  
‘ the waxed thread, and applied the ligature. Having  
‘ tied the artery above, I dilated the wound at the  
‘ lower part, and in the same manner applied the li-  
‘ gature to the artery below. The aneurismal tumor  
‘ became flaccid, and the pulsation ceased. I applied  
‘ a few strips of lint spread with unguentum rosæ  
‘ over the lips of the wound, three compresses and a  
‘ circular bandage. I loosened the tourniquet a little,  
‘ so that the blood might pass by the collateral ves-  
‘ sels. I placed the limb in a proper posture, and or-  
‘ dered him an anodyne sedative draught. He passed  
‘ the whole day and night in perfect quiet, and the  
‘ pulse was scarcely feverish. The second and third  
‘ day were much the same, only there appeared a  
‘ stain of pale blood on the dressings. On the morn-  
‘ ing of the 4th day I removed the bandage and the  
‘ compresses, and left only the lint, which was stick-



‘ing to the lips of the wound. That day he had a  
 ‘little fever, which went off in a sweat during the  
 ‘night. On the morning of the 5th, a slight pulsa-  
 ‘tion of the radial artery could be felt; and on re-  
 ‘newing the dressings, I found the suppuration esta-  
 ‘blished, and the aneurismal tumor partly suppurat-  
 ‘ed. On the 11th and 12th days the ligatures came  
 ‘away, and I then slackened the tourniquet still more.  
 ‘On the 20th, the wound was clean, and filled with  
 ‘healthy granulations. On the 41st he was dismissed  
 ‘from the hospital perfectly cured.’

§ 16. All that I have said in this and the preceding chapter with regard to the nature and proximate cause of the aneurism of the popliteal, femoral, and brachial arteries, is likewise applicable to the aneurisms of other external arteries of the body, such as the carotid, temporal, auricular, occipital, external mammary, palmar, tarsal, and all others of a smaller size. The aneurisms of these arteries, for the most part occasioned by violent blows or by punctures, and formerly considered as *true* aneurisms, are only bloody swellings from an effusion caused by the rupture or puncture of an artery, and the extravasation of blood into the surrounding cellular substance. Sometimes, indeed, in the neck, mistakes have been committed, and a disease has been supposed to be an aneurism, when it was only an indurated gland, as the thyroid, or some enlarged lymphatic gland, which received the impulse from the carotid artery, on which it rested. Haller\* mentions a patient, who was supposed to have an aneurism of the carotid artery, in whom after death that artery was found in a sound state. Notwithstanding this, examples and un-

\* Opusc. Patholog. Obs. vi.



doubted proofs are not wanting of aneurisms having happened from the rupture of the carotids. A case is related by Harderius,\* and another by Rumlerus,† in both of which the pulsating tumor was formed by effusion. The first was in a soldier, in whom the carotid had been punctured; the second in a man, in whom, in the act of raising a heavy weight, and carrying his head and neck very far backwards, the left carotid burst. Several years ago I likewise saw and examined an aneurism of the right carotid in a soldier, who having been precipitated with his horse from the walls of Mantua, suffered a most severe twist and sprain of his neck. The swelling occupied the right side, behind the angle of the jaw, extended outwards, was as large as the fist, and pulsated with great violence. Six months after, I was informed that this poor man had lost his life in the hands of an ignorant quack, who had opened the tumor, supposing it to be an abscess. In another case of aneurism of the carotid artery, Dr. Piccinelli, first surgeon of the hospital of Bergamo, my respectable friend, procured me an opportunity of examining the parts in the body after death. The history of the disease is as follows. Lucretia Boffetto, 44 years of age, was admitted into the hospital of Bergamo the 16th of February 1803, on account of a pulsating tumor, of the size of two hens eggs, which she had had for three months, on the left side of the neck, and which was considered to be a *true* or *incysted* aneurism. It was impossible to discover its cause. The patient could give no other account, than that scarcely three months were elapsed since she had observed this tumor in her neck, which, instead of yielding to the use of internal or external remedies,

\* Observ. in Apiario, observ. 86.

† In Welschius, observ. 81.



went on every day very visibly increasing. She had also for two months had a venereal ulcer on the left labium pudendi, though without enlargement of the inguinal glands, and with no manifest symptoms of lues. The patient was extremely exhausted when she came into the hospital, nevertheless it was necessary to repeat at intervals small evacuations of blood, as this was the only mode of diminishing the painful distention of the tumor, and of procuring her some relief. In spite of this the tumor increased, and occupied the space between the clavicle and the angle of the lower jaw. The 2d of April of the same year, the skin of the left side of the neck being prodigiously distended, burst, and gave rise to a round ulcer, which eroded the aneurismal sac, and laid bare the first coagulated layer of the aneurism, without being followed by hemorrhage. The 13th of the same month the skin covering the apex of the aneurismal sac began to break and to ulcerate, and the ulceration went so deep, that on the 8th May, at four in the afternoon, it penetrated the cavity of the aneurism, from which there issued suddenly twelve ounces of blood. This was sufficient to cause the woman, already much exhausted, to fall into a faint, from which she recovered, and, after having taken a little wine, she expired about midnight. On opening the body, the aneurism was found to be situated in the left carotid, the origin of which artery in this subject deviated from the common arrangement, by arising from the *innominata*; that is to say, the *innominata* gave off the two carotids and the right subclavian. Walter and Malacarne had already in another case observed and delineated this variety.\* The arch

\* Mém. de Berlin. 1785, Tab. iii, fig. i. Ce cas merite attention uniquement à cause de son extreme rareté. Malacarne Osserv. di Chirurgia, part ii, pag. 119, fig. iii.



of the aorta and the heart were sound ; the pulmonary artery was a little larger than usual ; the left carotid, from which the aneurism arose, was everywhere of its natural diameter ; the aneurismal sac had formed an adhesion with the thyroid gland. On laying open the aneurismal sac from its apex, or the place of the second rupture, to the lower part, and evacuating the clots of blood, the left carotid appeared at the bottom of it ruptured on one side for the space of six lines. Between the superior and inferior apertures of the ruptured artery, its opposite sound side formed a kind of furrow. The diameter of the artery was not at all enlarged, not even at the place where it had burst. On examining these parts attentively likewise on their posterior surface, or that next the vertebræ of the neck, and on opening the left carotid lengthwise, I clearly perceived that it had preserved in its whole course its natural diameter ; that the opposite side of the artery had been lacerated for the space of six lines, and that consequently its proper coats had no share in the formation of the aneurismal sac, the formation of which was clearly perceived to belong to the sheath and cellular substance surrounding the artery in the sound state. The whole of this history, especially what relates to the preservation of the natural diameter of the aneurismatic carotid artery, and the manner in which the rupture had occurred in one of its parietes, leaving a kind of furrow at the place of the injury, will, I flatter myself, contribute not a little fully to convince those who have still any doubt respecting what I have said with regard to the nature and proximate cause of aneurism in general, and in particular of that of the popliteal and femoral arteries.

But to return to the aneurism of the carotid, if we reflect that this artery, both the common and cerebral,



has, like all the other arteries, not only its cellular sheath, but that this sheath is denser, firmer, and more elastic than that of any other external artery of the body, and that this dense firm elastic covering strengthens greatly the canal of the artery, and maintains it in its particular and unvaried course, it may be easily understood why, when this artery is punctured or lacerated in any part, it occasions an aneurism, which increases slowly, and retains for a long time the form of a *circumscribed* tumor, although in the neck there be all those circumstances which would rather dispose to the formation of a *diffuse* aneurism.

If I wished to proceed farther in the enumeration of the different places in which aneurisms are formed by the rupture of arteries of the second and third order, I might include in the class of these diseases those extravasations of arterial blood which occur within the head from the rupture of the *meningeal* artery, in which the blood effused between the dura mater and the cranium presses the dura mater inwards in the manner of a tumor, compressing the brain, as the aneurism happening from the rupture of the internal mammary, or any of the intercostal arteries, does with respect to the heart or lungs. I might then come to the aneurisms of the cæliac, splenic, hepatic, mesenteric, and renal arteries, of which I would have several examples to relate, if I did not consider it at present more proper, after all that has been said of the *internal* aneurisms, as well as of the *external* which occupy the arteries of the second order, to confine myself to the consideration of those which affect the *smaller* external arteries.

§ 17. Therefore, with regard to the aneurisms of the external arteries of the body of a smaller size, the



rupture of the temporal artery, in consequence of a blow, is not at all a rare case, the integuments covering it remaining uninjured, under which the effused blood collecting itself forms a *circumscribed* swelling with pulsation, and all the characters which were said to be proper to the *true* aneurism.\* Palletta mentions,† that ‘ a corpulent man, of ordinary height, in beating his head against a wall, caused such a contusion of the right temple, that, in addition to the ecchymosis, there *arose a small tumor* of the canal of the temporal artery, which burst sixteen days afterwards, and, in consequence of the great loss of blood, obliged the patient to come to the hospital, where the hemorrhage was stopped by compression. In the course of thirteen days the dressings were found to be covered with pus ; the healthy wound, as large as a crown-piece, healed in twenty-six days, without any remains of morbid pulsation.’ I have twice had occasion to observe and cure the aneurism of the temporal artery proceeding from a violent contusion of the temple. The *circumscribed* and *pulsating* tumor had so much the characters of a *true* aneurism, that it might easily have misled any one who was not previously informed of the contrary. On opening the tumor, I found the artery ruptured, and I accomplished the cure by means of compression.‡ A similar

\* Bartolino epist. med. 55, Centur. iii. Cavallini Collez. istor. t. ii.

† Giornale di Venezia loc. cit.

‡ In the Salzburg. Zeitung for October 1805, the following case of aneurism of the occipital artery is related. The patient, when about 19 years old, had received a blow on the nape of the neck ; soon after, a small swelling about the size of a nut gradually formed. It bled repeatedly, and during ten years various remedies were employed without effect. At last the artery was secured



*circumscribed pulsating* tumor was observed upon the auricular artery, behind the helix of the left ear, in a young man 25 years of age,\* in consequence of having received a wound at that place. Of the same nature, or from a rupture or laceration of the artery, was the aneurism of the external artery of the nose, mentioned by De Haen;† that of the intercostal artery and of the heel, spoken of by Ruisch;‡ that of the frontal artery, the history of which is recorded in the Acts of Leipsig;§ and that of the hand related by Becket.|| Guattani¶ relates the case of an aneurism of the palm of the hand, in the site of the palmar arch; and whilst he shews himself to be persuaded that it was a *true* aneurism, he declares, that, on opening the tumor, he found the artery opened, not dilated by a ligature above and below the aneurism, and the patient, in the course of a month, was completely cured. See Ludov. Meyer, Dissert. Inaug. de Aneurysmate arteriæ occipitalis, 1804. T.

\* Klaunig, Ephemerid. nat. cur. cent. iii, obs. 66, an. 1715. Erat is juvenis an. 25 cui post auris sinistrae helicem ramus posterior arteriæ carotidis gladio transcindebatur. Suppressa hæmorrhagia aneurysma a loco transcissæ arteriæ ad lobum auris usque se extendens, crassitiem duorum pollicum adæquans, et tam vehementi pulsu præditum, ut aurem hinc inde commoverit. Compressio nullam attulit utilitatem. Interim tumor gangrenam minabatur, et rupturam a parte conchæ auris; deinceps per duo ostia sanguis arteriosus uno impetu tanta vi prorumpebat, ut duo chirurgorum manus hæc ostia comprimentes vix sufficerent ad inhibendum. Detecto tumoris fundo hianti arteriæ injecta fuere aliquot frustra aluminis crudi, et adhibitis stipticis pluribus plumaceolis omnia optime firmabantur. Cum sequenti die hæmorrhagia recurreret, arteriæ iterum aluminis frustula et lintea carpta profunde intrudebantur. Suppuratio inde, &c. &c.

† Rat. medendi, part iv, pag. 11.

‡ Thesaur. Anat. ix, N. V. Obs. Anat. Chirurg. 38.

§ An. 1699, pag. 51.

|| Chirurgical Observations.

¶ De extern. Aneurysm. Hist. xxi.



ed. Hildanus\* and Tulpius† mention aneurisms observed by them between the thumb and fore-finger, of the nature of which there can be no doubt, the patient having, some time before the appearance of the tumor, pricked himself at that part. Guattani likewise ‡ relates the history of a small pulsating aneurism on the tarsus, which had the principal characters of a *true* aneurism; and he remarks, that although there are only small branches of the anterior tibial artery on the dorsum of the foot, nevertheless, some of these branches being injured, may be elevated into an aneurism. But since it appears from the history, that this pulsating tumor on the tarsus had appeared after a bleeding performed there, it may be safely inferred that the aneurism was not formed by the dilatation of the proper coats of the artery, but by a solution of continuity or wound of them, and effusion of blood into the surrounding cellular substance, as happens, in short, in the formation of aneurisms in general, either of the aorta, or of the arteries of the second or third order.

\* Centur. iii, obs. 44.

† Oper. med. lib. iv, observ. xvii.

‡ Loc. cit. Hist. xii.—quod, licet in pedis dorso non nisi tenuissimæ tibialis arteriæ anterioris propagines disseminentur fieri tamen possit, ut læsæ in aneurysma etiam ipsæ assurgant.

Richter, in the 4th vol. of his *Chirurg. Bibliothek*, mentions a case of rupture of the left pharyngeal artery in a girl about seven years old, occasioned by a violent exertion on being pulled forcibly to the ground backwards. The girl was immediately seized with headach, pain under the left ear, and an uncommon drowsiness. In eight days after the accident a swelling appeared on the left side of the throat, extending up as far as the mastoid process, and downwards to the clavicle. As a fluctuation was perceived in it, an opening was made, by which a quantity of bloody serum was discharged, and the child soon after died. The tumor was found to contain coagulated blood, which had insinuated itself into the interstices of the contiguous muscles.—*T.*



## CHAPTER VIII.

## OF THE CURE OF ANEURISM IN GENERAL.

§ 1. IT is a certain and incontrovertible fact in practical surgery, that a complete and *radical* cure of aneurism cannot be obtained, in whatever part of the body this tumor is situated, unless the ulcerated, lacerated, or wounded artery, from which the aneurism is derived, is, by the assistance of nature, or of nature combined with art, obliterated and converted into a perfectly solid, ligamentous substance, for a certain space above and below the place of the ulceration, laceration, or wound. This fact, proved by a long series of observations, authorizes us, with regard to the radical cure of this disease, to conclude, that all those deviate far from the truth, who think, when the radical cure of an aneurism is obtained by means of compression, that it is effected by the pressure strengthening the dilated proper coats of the artery, and restoring, especially to the muscular coat, the power of propelling the blood along the tube of the artery, as it did previous to its supposed *dilatation*. M. Petit and Foubert did not adopt this opinion, but thought that the curative process which nature sometimes employs for curing this disease, consists in a species of clot formed by the *fibrine* of the blood, by means of which it closes the laceration, ulceration, or wound of the artery, and that this clot firmly agglutinated to the edges of the laceration, or to the lips of the wound, resists sufficiently the impulse of the arterial blood, to



preserve the continuity of the coats of the injured artery, and to maintain the tube of the artery in a pervious state. Haller was of this opinion, and mentions, that he had seen this kind of curative process of aneurism, occasioned by the puncture of an artery, begin before his eyes in the mesentery of a frog. For, he says, that he had observed, that there is formed all round the incision of the artery a kind of speck or cloud, which, from being quite red at first, becomes afterwards pale at the edges. In the middle of this cloud, continues he, a clot is found, formed by the reunion of the globules of the blood, the motion of which is moderated a little opposite to the seat of the clot, and then it resumes its course. There can be no doubt, Haller adds, that it is a coagulated fluid which closes the lips of the wound of the artery. I have seen, he proceeds to state, red globules pass from the artery, by two or three channels, through the cloud, and ooze out between the layers of the mesentery. The hemorrhage re-appears every time the artery is scratched, and the gluten removed which had closed the wound of it. I have opened, continues Haller, an aneurism of this kind in a frog, from which no blood has issued, and I have found that it was formed by a membrane which surrounded it circularly, having a small fissure closed by a clot of blood. I have observed on other occasions, that this blind membranous sac was gradually filled with blood, which was conveyed to it from the heart, and that when the sac was filled, the blood passed onwards, and took the route of a neighbouring lateral branch.\*

\* *Mémoire I. sur la circulation du sang, pag. 116.* Il se forme autour de l'incision une espece de petite tache comme une nuage, qui d'abord est toute rouge, elle change ensuite et palit dans les bords.



§ 2. Whoever has accurate and extensive practical knowledge on this subject, cannot deny that this beneficent process of nature sometimes takes place, especially in the case of aneurism in the bend of the arm from the puncture of a lancet. I shall relate a very marked example of it,\* where the bloody thrombus had not only closed the wound of the brachial artery made by the lancet, but in which the apex of the thrombus interposed between the lips of the wound was likewise converted into a hard substance, and adhered so firmly to the artery externally, that on viewing the artery on the inside, it was covered at the place of the wound by a solid cicatrix, or by something similar to a cicatrix. But this case of conversion of the clot into a substance resembling the internal coat of the artery, or, if any one chooses rather to say, this cicatrix of the wound of the artery, is a very rare occurrence, and so rare indeed, that I do not know if there is another perfectly similar recorded in the books of surgery. More commonly, when the circumstances are sufficiently favourable for nature repairing the injury of the artery by means of the throm-

bords. Au milieu on trouve le caillot formé par la reunion de quelques globules; le mouvement du sang se ralentit peu à peu dans l'artere même jusqu'à ce que ce fluide ayant passé au delà du caillot, reprenne sa premiere route. Il est bien sûr, que c'est une liqueur coagulée qui forme la playe de l'artere. J'ai vu des globules rouges se frayer à travers ce brouillard, deux ou trois routes pour se jeter par la plaie entre le slames du mesentere. Et l'hémorragie reparait également, quand on ratisse l'artere, et qu'on ôte le gluten qui en ferme la playe. J'ai coupé un aneurisme de cette espece, il n'en coula rien, et j'ai trouvé une membrane, qui l'environnait circulairement, avec une petite fente bouchée par un petit caillot. Je vis ce sac borgne se remplir peu-à-peu de sang qui lui venoit de la colonne du cœur, comme la plus forte; quand il fut rempli, le sang passa outre, et se jeta dans un rameau voisin.

\* Chap. xi, § 9.



bus, or clot of coagulated blood, the adhesion of the thrombus to the lips of the wound is so weak and imperfect, that it cannot be regarded as a *radical* cure. For, when some time has elapsed after the supposed cure, sometimes even years, on the occasion of a blow or exertion, the thrombus is removed from the wound of the artery, and the aneurism re-appears as before. The first case cannot, strictly speaking, be reckoned among the number of the radical cures. For, whether the clot is converted into a substance resembling a cicatrix, or if a cicatrix is really formed at the place of the wound of the artery, as in other simple wounds, as the portion of the coats of the artery occupied by the cicatrix assumes a certain degree of cartilaginous or bony rigidity, (as was the case in the patient I examined, in which respect it differs greatly from the natural flexibility of the proper coats of the artery); so this portion of artery occupied by the cicatrix is always found in a state ready to burst and break, if the arm is by any accident violently stretched or struck at the place where the artery has been wounded. On which account, I repeat it again, the cure cannot, in similar cases, be with justice regarded as *radical*.

§ 3. The obliteration, therefore, of the artery, and the conversion of it into an impervious and ligamentous substance, for some space above and below the injury, is the only means of producing a truly and permanently *radical* cure of aneurism. Whenever the ulcerated, lacerated, or wounded artery is accurately compressed against a hard body, such as the bones, it ceases to pour blood into the surrounding cellular sheath, because its sides are kept in firm contact, for a certain space above and below the laceration or wound; and because, being irritated by the



compression, an *adhesive* inflammation ensues, by means of which these coats contract a firm adhesion to each other, and are converted into a perfectly solid and ligamentous cylinder. This change of the artery into a perfectly solid and impervious body, as a cause effecting the *radical* cure of aneurism, is proved, as I have already mentioned, by a very long series of observations on the dead bodies of those who some time before had been radically cured of an aneurism, whether this cure had taken place spontaneously, or by the assistance of art. For it has been found in all of these cases, that there was an approximation and complete adhesion of the internal surface of the two opposite sides of the injured artery, above and below the seat of the aneurism, and the artery itself was at that place impervious and ligamentous. Among the many examples of this kind, illustrated with plates accurately delineated, it will be sufficient that young surgeons read those related by Molinelli,\* Guattani,† and White.‡ And the same fact is observed in the dead bodies of those in whom the aneurism has disappeared spontaneously, or without any topical astringent having been applied to the pulsating tumor, or any bandage, or any kind of compression or ligature applied upon it. Valsalva § preserved in his museum the knee of a man, in which there was seen the cavity of the popliteal artery obliterated for a certain space along the ham, in consequence of an aneurism, of which he had been cured spontaneously, after long

\* Act. Acad. Bonon. t. ii.

† De extern. Aneurysm, tab. i, fig. 2.

‡ Cases in surgery, p. 139.

§ Morgagni de sed. et caus. epist. 1. art. 10. Benevoli dissert. observ. xi. Flajani loc. cit. p. 50.



rest. Mr. Ford<sup>1</sup> found the popliteal artery converted into a perfectly solid, hard, and ligamentous cylinder, in the body of a man 35 years of age, who, after having been long confined to bed for other reasons, observing a very spare diet, was cured of a popliteal aneurism, as large as a hen's egg. Surgeon Paoli<sup>2</sup> proposed the amputation of the thigh to a man who had a popliteal aneurism, to which the patient refused to submit. Some time after, the aneurism burst, but not a single drop of fluid arterial blood was discharged, and the patient recovered. A case nearly similar to this is related by Guattani;<sup>3</sup> and another may be found, which was recorded nearly a century before by Moinichen.<sup>4</sup> Mr. Hunter found<sup>5</sup> the femoral artery in like manner quite impervious, and obliterated at the place which had been included by the ligature, in the body of a man, who, fifteen months before, had undergone the operation for popliteal aneurism. Boyer<sup>6</sup> found the femoral artery perfectly obliterated at the place of the ligature, in a man who eight years before, had been operated upon for an aneurism in the ham, by Mr. Hunter's method. Petit<sup>7</sup> mentions, that the advocate Vieillard was observed to have an aneurism at the bifurcation of the right carotid, for the cure of which he was prescribed a very spare diet, and forbid every kind of violent exercise. Three months after this prescription the tumor had evidently diminished, and at last was converted into a small,

<sup>1</sup> Journal de Londres, vol. ix.

<sup>2</sup> Massotti sull' Aneurisma, p. 23.

<sup>3</sup> De extern. aneurism, histor. v.

<sup>4</sup> Observ. Med. Chirurg. obs. xiv.

<sup>5</sup> Transactions of a Society, &c. See also, Appendix, account of a dissection by M. Deschamps. T.

<sup>6</sup> Caillot Essay sur l'Aneurisme.

<sup>7</sup> Acad. R. des Sciences de Paris, an. 1765.



hard, oblong knot, without any pulsation. This patient having died of a stroke of apoplexy, his body was examined, and the right carotid artery was found to have been completely closed up, and obliterated from the place of its bifurcation, as far as the subclavian artery of the right side. M. Desault\* had an opportunity of examining a popliteal aneurism in the body of a patient in whom the spontaneous cure was just beginning. He found a very hard bloody thrombus, which extended for three fingers-breadth within the tube of the popliteal artery, above the aneurismal sac. This thrombus was so hard, that it had been able to resist the force of the injection thrown in by the corresponding iliac artery, and had obliged the injection to pass to the subjacent leg and foot, by the lateral vessels. And, since it is a certain and demonstrated fact, that, even after the *spontaneous radical* cure has been completed, the artery is found perfectly closed up, and converted into ligament, it is proper to mention, that this spontaneous cure, as well as the artificial, has two stages; in the first, the entrance of the blood into the aneurismal sac is interrupted; in the second, by the powers of nature, the parietes of the artery are made to approach to each other, and are afterwards firmly agglutinated together, and converted into a solid cylinder. This theory is supported, by the tumor, in the artificial as well as in the spontaneous *radical* cure of aneurism, beginning to lose its pulsation, and then diminishing and disappearing. The objection therefore was just, and conformable to the truth, which Morand† made to the theory of Petit, in relation to the bloody thrombus,

\* Journal de Méd. de Paris, t. 71, p. 430.

† Mém de l'Acad. des Sciences de Paris, an. 1736.



which the latter regarded as the principal means which nature employs for stopping hemorrhage. Morand shewed, that the thrombus stops the course of the blood only for a short time, but that which properly prevents the return of the hemorrhage is the contraction of the artery upon itself, the disappearance of the thrombus, the obliteration of the tube, and the cicatrisation of the divided artery.\* The ar-

\* With regard to the suppression of hemorrhage, the author, and all the writers mentioned by him, seem to have erred in the account which they have given of this important phenomenon, from having attended exclusively to one stage of this process only, while they entirely overlooked, or very much undervalued, the other steps of it. So far as their observations went, they were accurate, and conformable to the truth; but, from being confined to one stage of the process, they were inadequate to the explanation of the series of changes on which the suppression of hemorrhage from divided or wounded arteries is now found to depend. From the experiments performed, in conjunction with Dr. Thomson of Edinburgh, by Dr. Jones, as related in Dr. Jones' Treatise on hemorrhage, &c. we are now authorized to conclude, that a variety of circumstances concur in the natural suppression of hemorrhage. The chief of these are the retraction and contraction of the divided artery; the weakening of the impetus of the blood, after the first sudden effusion of it is diminished; the effusion of blood into the cellular substance, and into the sheath of the artery; the formation of a coagulum which finally closes up the mouth of the artery, thus forming the primary complete obstruction to the further discharge of blood. A clot is also formed within the artery; but as it seldom fills the canal of the vessel, or if it does fill it, as it does not adhere to its internal coat, its formation is to be considered as merely accidental, and appears to depend on the stoppage of the circulation between the first collateral branch and the mouth of the artery, after it has been closed by the external coagulum. Soon after the formation of these coagula, an effusion of lymph takes place within the artery, which adheres firmly to its internal coat; and, as the contraction of the vessel gradually proceeds, an approximation and firm union of the sides of the artery



teries have naturally a great tendency to contract and obliterate, and are in fact closed up and obliterated readily whenever the blood ceases to flow through them. Haller saw this power of contraction of the arteries in the mesentery of frogs, although he asserts, that the arteries of this animal have no muscular coat.\* Kirkland,† in the numerous experiments which he made on animals, found that the arteries, when strongly compressed or tied, were in a day or two after closed and obliterated for a certain space below the compression or ligature; and in a case of aneurism in the bend of the arm, operated upon by the ligature of the artery, he found in the body, after death, that the brachial artery had been converted into a solid cylinder only three days after the operation. It is not improbable, that, in the cases of spontaneous *radical* cure of external aneurisms, (which are indeed very rare), there concurs also a particular position of the aneurismal sac; by means of which, this sac being compressed by the ligaments and tendons, makes such a fold as to compress with an equable force, as in the artificial compression, the trunk of the injured artery, at its entrance into the sac, and is therefore capable of producing the approximation of its sides; and at last, on the *adhe-*

are produced, the canal of the artery is obliterated, and at last converted into a ligamentous substance. *T.*

\* Mémoire i, sur la circulation du Sang, p. 117. Il y a encore une autre façon, dont les playes des artères se ferment; c'est par la contraction de leur membrane, non qu'elle soit musculeuse, car il n'y en a point de paraille dans les artères des grenouilles; mais par une attraction naturelle, qui rapproche les fibres vers l'axe qui les ramene au contact du reste de la membrane, et qui a lieu même dans les artères du cadavre.

† On Amputation.



sive inflammation coming on, the tube of the artery is also obliterated ; this constitutes the second stage of the *radical* cure of the disease.

§ 4. This union of the internal sides with obliteration of the tube of a large artery, sometimes happens also in consequence of a violent contusion of the artery, especially if immediately, or a little after the accident, the course of the blood within the contused artery is artificially interrupted. On this subject Morand relates the following fact.\*

In the month of December 1735, a countryman received a violent contusion on the inner side and middle of the humerus, along the course of the brachial artery. The external veins were ruptured, and the loss of blood arising from them was stopped by the surgeon, by the ordinary means. The hemorrhagy having recurred, in spite of a very tight bandage, the surgeon applied a tourniquet above the place of the injury, and supposing that the loss of blood proceeded from the trunk of the brachial artery, he was of opinion that amputation ought to be performed. Two days had elapsed from the time of the accident, when Morand was called in ; he found an eschar on the injured place, which appeared to him only to affect the integuments. The fore-arm and hand, which were of their natural colour, and not much swelled, retained their natural heat and life, but the pulse was totally wanting. Morand supposed that this want of the pulse was owing to the tourniquet being too tight. On loosening the tourniquet, not a drop of blood was discharged. The brachial artery pulsated above the place of the contusion, as far as the seat

\* Mém. de l'Acad. R. de Paris, an. 1736.



of the eschar, but could not be felt beating under the eschar, and still less at the wrist. Notwithstanding the want of the pulse, as the fore-arm and hand preserved their natural colour and heat, amputation was not had recourse to. Having placed the arm in a position favourable to the course of the blood, and applied proper topical remedies, the ecchymosis and swelling abated, and on the eleventh day the suppuration began to detach the cutaneous eschar. The pulse however did not return, and the arm continued in a state of numbness, and began to decay, and the patient complained of a severe pricking sensation within it. In the course of six weeks the pulse was not at all sensible; it then re-appeared gradually, but remained afterwards weak, although the patient had recovered the use of the injured arm.

This singular case, says Morand, presents to us very important conclusions. It is probable, says he, that the stopping of the pulse ought to be ascribed to a change having taken place in the trunk of the brachial artery, corresponding to the place of the contusion. And what can this change be, he adds, except an approximation and contraction of the sides of the artery; in consequence of which, the internal parietes have contracted an adhesion to each other. And it is a thing worthy of remark, that this adhesion of the internal parietes of the artery, in the direction of its axis, took place quickly. If the limb continued to live, and if the pulse re-appeared, it was owing to the circulation having been re-established gradually, by means of the collateral vessels.

§ 5. In those cases in which the aneurism is affected deeply by gangrene, it is not difficult to comprehend how the injured artery is closed immediately



above the aneurismal sac, and how consequently the gangrene produces the same effect as the compression, or the ligature of the artery. For, on the appearance of the gangrene, the whole part that surrounds the root of the aneurism is affected by violent inflammation, by which the coats of all the vessels of the part are thickened, their opposite sides made to approach each other, and become so firmly agglutinated together as to be closed up; or a dense, compact, bloody coagulum is formed within them, which shuts up the canal of the vessels, and interrupts completely the course of the blood within them. The obstruction of all the vessels of a part affected by gangrene, not only in the place occupied by the mortification, but likewise at some small distance above it, is a constant fact, proved by repeated observations. If in a patient attacked by gangrene of the lower part of the leg, the vena saphena be divided longitudinally at the usual place of bleeding, the blood within the vein is found to be coagulated, and adhering to its sides, and not a drop of fluid blood issues from the incision, although the person survive for some time, and the vein remain open.\* The injection of the dead bodies of patients, who have died in similar circumstances, shews that the canal of the arteries is closed and obstructed at the edges of the gangrene; which arteries, as well as the veins, are pervious and open, as in the sound state, immediately above the limits of the mortification. Whenever, therefore, gangrene attacks deeply the root of an aneurism, the sphacelation which follows it, and the bursting of the integuments, and of the aneurismal sac, are never accompanied by a fatal hemorrhage; because this gangrenous process

\* Maunoir Mém. Physiolog. et. Prat. sur l'Aneurisme, p. 129.



has closed up not only the small, but also the great arterial trunks, above the place of the injury, and the patient is cured of the gangrene and of the aneurism, if he has strength sufficient to resist the destructive action of the sphacelus upon the vitality in general. When a patient dies of hemorrhage from gangrene, or sphacelus of an aneurism, he dies, because the gangrene or sphacelus have only occupied the integuments and a portion of the sac, and have left untouched the rest of the root of the aneurism, especially the arterial trunk, from the laceration or wound of which the aneurism is formed.

§ 6. M. Deschamps says,\* that every surgeon has a particular opinion of his own, with regard to the manner in which the cavity of an artery is obliterated; but that every surgeon, if he is a man of integrity, will agree, that we have not as yet any positive and well determined practical knowledge on this subject. I on the contrary find, that with regard to this point, there can be but one opinion, and I think, that this opinion is firmly supported by practical observations, and by certain and constant facts, and that it is proved by daily experience in that part of surgery which relates to the cure of wounds by the first intention. ' There is nothing more manifest, and better known in surgery, than that the *adhesive* inflammation is the principal means by which the parts divided in the living solid, as well as those organically separated, when kept in mutual contact, contract a firm adhesion to each

\* *Observ. et reflex. sur la ligature des artères*, pag. 52. Chacun se fait un opinion particulière sur la manière d'effacer la cavité d'un artère; mais si l'on est de bonne foi, on conviendra, que nous n'avons encore à ce sujet aucune connaissance pratique bien déterminée.



other. The *adhesive* inflammation is that power to which we are indebted for the re-union of simple wounds, and for the coalescence of some parts together, often to the great advantage of the whole animal economy; provided this kind of inflammation does not exceed certain limits, beyond which it changes into *suppurative*, or destructive inflammation, or as is commonly said, occasions an abscess. It is, for example, by means of the *adhesive* inflammation, that the smooth surface of the lungs adheres to the pleura in violent peripneumony, and in penetrating wounds of the thorax, with injury of the lungs themselves; that the intestine contracts an adhesion with the mouth of the hernial sac in the incarcerated, and inflamed hernia; that the wounded, inflamed intestine, when replaced in the abdomen, adheres to the peritoneum; that the vaginal coat of the testicle unites firmly to the albuginea in the radical cure of hydrocele; that sinuous ulcers, made to inflame artificially, and then compressed, are cured by the first intention. And not to wander from the consideration of the blood vessels, it is the *adhesive* inflammation which sometimes after venesection, causes the obliteration of the divided vein for a certain space, and if this inflammation passes beyond certain limits at the place of the bleeding, and is changed into the *suppurative*, it occasions a small abscess where the vein was opened, which is ascribed by ill-informed surgeons improperly to some defect of the lancet, or to the puncture of some nervous or tendinous filament.\* It is this

\* The great veins also are sometimes closed, and obliterated spontaneously. See Morgagni de sed. et caus. morb. epist. lvi, art. 10. Haller. opusc. patholog. ob. xxiv. Vena cava inter renales venas, et iliacas concreta fuit, ut nihil cavitatis loco superesset nisi fibrosa quædam,



process of *adhesive* inflammation which nature, by itself alone, or assisted by art, employs for agglutinating, and uniting firmly together, the two opposite parietes of an artery, whenever the internal surface of these parietes is placed, and kept in firm contact by means of some accidental pressure, or by a methodical bandaging; and there is no essential difference in the process of adhesion between the lips of a simple wound, or between the surface of an intestine with the peritoneum, or of the vaginal coat of the testicle with the albuginea, and the manner of union of one side of an artery with its opposite side. I have more than once seen the commencement of this process of obliteration of the cavity of an inflamed artery, in the bodies of those who have died soon after amputation, in the inflammatory state of the stump; and not long ago, I met with the same phenomenon in a certain portion of the femoral artery, which a week before had been injured by a musket ball. That is, I found, that the proper coats of the artery at that place were become thicker than usual, and that the internal coat was of a deep red colour, and covered with an exudation of coagulable lymph, on removing which mucous exudation, the internal surface of the artery appeared to be converted into a pulpy, villous substance, very vascular, and much disposed to contract an adhesion with its opposite side, if by means of a methodical compression both of the parietes of the inflamed artery had been approximated, and kept in firm contact with each other, as is practised in the cure of simple wounds, by the first intention.

quædam, quasi carnea, pulposa et dura caro. Concretæ venæ rationem, fateor, me non intelligere, cum in eo cadavere nulla causa tanta venam comprimere apta, neque ullum in arteriis vitium repertum fuit. See also Maunoir loc. cit. p. 15.



§ 7. In order that the compression may produce the union of the two opposite sides of an artery with each other, and at the same time the *radical* cure of the aneurism, it is therefore necessary, that, besides the state of vitality of the coats of the artery, of which I shall speak afterwards, the degree of pressure applied upon the artery, be such as to place the two opposite parietes of the injured artery in firm and complete contact, and that it be at the same time capable of exciting the *adhesive* inflammation in the proper coats of the artery. Without the concurrence of these circumstances, the compression does not prove beneficial, or only produces an incomplete cure; for, whenever the compression is not sufficient to place the two opposite sides of the artery in complete and firm contact, and does not excite in them the *adhesive* inflammation, including also the root, properly speaking of the aneurism; and when the inflammation affects only the cellular substance surrounding the artery, and the parts contiguous to it, this cellular substance, and these parts only contract an adhesion with each other, and are converted into a hard, compact substance, while the canal of the lacerated or wounded artery remains open and pervious as before the use of the compression. It therefore follows from this, that if, from any accident, the cohesion of the cellular sheath of the artery, with the neighbouring parts, is afterwards weakened, and the coagulated clot removed from its situation, which kept the thick and compact cellular substance closed after the manner of a small coriaceous capsule applied forcibly to the laceration, or wound of the artery, the arterial blood is again effused, and causes the aneurism to re-appear. It is further necessary, that the point of the compression fall above the laceration, or wound of the artery. For,



if the compression falls below the injury, instead of being a method of cure of the aneurism, it rather occasions the tumor to augment to a much greater size, and to increase in a shorter time, than it would have done if the compression had not been employed at all; as, it is a well known fact, that compression applied to an artery below the place of the wound, accelerates greatly the afflux to the wound, and the effusion of blood through it. Instruments have been invented resembling a tourniquet, by means of which, it was intended to compress the artery with precision, at the place which the surgeon should find most convenient for this purpose, and without retarding the return of the venous blood; the shape of these instruments has been delineated by almost all the authors of systems of surgery. But in this, as in many other circumstances, experience has shown, that not unfrequently those discoveries which in theory seem to be the most convenient and useful, are not so in practice; and experience has taught us, precisely in the case of which we are speaking, and especially in a case of aneurism in the ham, and in the bend of the arm, that the bandage which is at the same time, *expulsive* and *compressive*, is greatly to be preferred, when necessary, to the above-mentioned instruments.

§ 8. Among the number of favourable circumstances, which are necessary, in order that the compression prove an effectual mode for accomplishing the radical cure of aneurism, I have mentioned, that it is necessary, that the coats of the artery possess, at the place of the compression, such a degree of vitality, as to be capable of feeling the stimulus, to use the expression, and of inflaming. This important requisite is sometimes wanting in that portion of ruptured, or



lacerated artery, which is contiguous to the place of the injury, and therefore in such a case, *cæteris paribus*, the compression, although practised with the rules of art, is not sufficient to close and obliterate the artery above the root of the aneurism. I have already shewn, that in spontaneous aneurisms, or those from a slow internal morbid cause, from original or acquired diathesis, or from excessive local relaxation, the proper coats of the artery round the edge of the rupture, ulceration, or laceration, are in a state of disorganization, deprived of vitality, and consequently no longer susceptible of *adhesive* inflammation, nor of undergoing any process of union or coalescence. When, for example, the aneurism has had as a proximate cause, a *steatomatous* degeneration of the proper coats of the artery; when it has been preceded by a slow ulceration of the internal coat of the artery; when it has originated from a state of excessive *relaxation*, or of *earthy* hardness, with *brittleness* of the arterial coats, there can be no doubt that the portion of artery all round the root of the aneurism, or that which surrounds the edge of the rupture or laceration, at a greater or less distance above the place of the injury, will never be affected by *adhesive* inflammation, although compressed with accuracy, and with the most precise rules of art, so as to bring the two opposite sides of the artery into complete and firm contact; and the parietes of the artery at that place will never form a firm cohesion with each other, so as to be capable of obliterating the tube of the artery, and converting it into a perfectly solid cylinder. This difficulty, suggested by reasoning, by analogy, and by an accurate knowledge of the nature of this disease, in cases of spontaneous aneurism, is brought to demonstration, and clearly proved. For, in the bodies of those who



have died some time after the ligature of the femoral artery on account of an aneurism, in which the cohesion had not taken place at the part where the ligature was applied, on account of the morbid state of the proper coats of the artery at that place, it has been found,\* that the internal coat of the artery above, and below the seat of the ligature, was disposed to thicken and inflame; but that, at the place of the ligature, the proper coats of the artery, and especially the internal coat, were always of a whitish colour, and not at all disposed to feel the stimulus of the pressure, or of the cause intended to produce the inflammation, as those parts generally are which have become inert and deprived of their vitality. The learned and experienced surgeon Vacca,† operated upon a popliteal aneurism according to Mr. Hunter's method, in an old and sickly patient. The femoral artery remained tied in this patient for 25 days, without discharging a drop of blood; but after this time, repeated hemorrhages occurred. On examining the body after death, Vacca found, that in spite of so long a contact, a coalescence had not taken place between the parietes of the artery, and a clot had not been formed sufficiently firm to stop up entirely its tube. On opening the femoral artery in its whole length, he observed, that the internal membrane of this artery was very much thickened, every where indurated, and in several points cartilaginous; that at the place of the ligature, the wrinkled parietes of the artery approached each other, but left a small hole in the middle above a line in circumference, the sides of which were not united, and through which a little injection had escaped,

\* Transactions of a society for the improvement, &c. vol. ii, p. 255.

† Istoria d'un aneurisma del poplite operata col metodo d'Hunter.



and had forced out a clot of a conical figure six lines in length, with its base towards the wound, and the apex towards the heart.

§ 9. There are some surgeons who have adopted the maxim of employing compression in every case of aneurism, whether the aneurism be small, *circumscribed*, soft, flexible, indolent, or form an elevated, *diffuse*, hard, and painful tumor. In the latter case, experience however shews, that compression, besides being useless, is hurtful; because it occasions an increase of the swelling in the part subjected to the pressure, makes the tumor compressed on one side to augment greatly on the other, and very often accelerates the appearance of gangrene. Others, especially those who adhere firmly to the common doctrine of aneurism distinguished into *true*, or from dilatation, and into *false* or from effusion, are of opinion, that only in the case of aneurism from *effusion*, every kind of bandage ought to be laid aside, as adapted rather to make the aneurismal tumor increase, than to procure the diminution of it. But since it is now demonstrated, that this distinction of aneurism into *true* and *false* does not exist; that all aneurisms are formed by effusion; and that there are numerous and well authenticated histories of *radical* cures of aneurism by means of the bandage and of compression; so the doctrine of these authors, with regard to the propriety or impropriety of compression, requires to be explained with more perspicuity than they have done, in order that it may not cause confusion and perplexity in the mind of the young student. A bandage, of whatever kind it be, which compresses the aneurism, and constricts at the same time circularly the affected part, is always injurious, and ought un-



doubtedly to be left off. The bandage likewise, which, compressing only the aneurism, directs the point of pressure below the place of the injury in the artery; that which, on account of the great size, and exquisite sensibility of the aneurism, the depth of its root, and the fleshiness of the parts which surround the tumor, is not sufficient to compress the artery against the bones, so as to bring the two opposite sides of the artery into mutual and firm contact; and lastly, the compression that is applied upon a spontaneous aneurism, the origin and progress of which shew, that it has arisen after a *steatomatous, ulcerated, earthy* degeneration of some portion of the coats of the injured artery, ought to be considered as an useless, or rather hurtful method, and as these writers have mentioned, ought to be entirely laid aside. In cases completely opposite to those just pointed out, it is equally certain, that the bandaging has produced, and may produce *radical* and complete cures of aneurism, and that, consequently, it is not a method to be entirely excluded from surgery.

§ 10. The compression would certainly be a less fallacious method for the *radical* cure of aneurism, if we could, in every case, apply the pressure to the injured artery, denuded, and without the interposition of the parts that surround and cover it. For, in similar circumstances, we might ascertain the sound place of the artery above its laceration, and we might be enabled to calculate with sufficient precision, the force which it would be proper to employ, in order to bring the two opposite sides of the artery, which we wish to obliterate, into firm contact with each other; and further, the piece of sponge, and compresses which are placed over the artery, might be moistened with some astringent proper for causing a contraction



of the artery, and for exciting the *adhesive* inflammation in its compressed coats. This manner of applying the compression proves in fact very useful and efficacious, for the *radical* cure of the aneurisms of the arteries of the third order, which lie close upon the bones, or in the vicinity of them, when denuded by means of the incision of the aneurismal sac; as is practised in aneurisms of the temporal and occipital arteries, of those of the face, of the radial artery, of that of the tarsus and the like. Examples likewise are not wanting of the success of the compression upon some of the great arteries of the limbs when denuded, such as the brachial,\* and the femoral,† both in the middle of the thigh, and even at the crural arch.‡ But after having duly considered the subject, if the surgeon hesitates to lay bare one of the large arteries of the second order, he possesses a method much more expeditious in its execution, and more certain in its event, than that of the compression, I mean the ligature of the artery. For this reason, in similar cases, surgeons, rather than lay bare the great arteries affected with aneurism, give the preference very justly to the ligature.

§ 11. By the ligature of the great arteries as a radical method of cure of aneurism, I do not mean a noose, with which the artery is constricted circularly, but I wish to be understood to speak of a pressure

\* Emrich dissert. inaug. de stupendo aneurysmate brachii. Trew aneurysmatis spurii historia, et curatio. Flajani Collezione d'osservazioni, tom. ii, osserv. vi, pag. 19. Garneri, see Bertrandi trat. delle operazioni, tom. iii, annotazioni, p. 207.

† Heister dissert. chirurg. de art. cruralis vulnere periculosissimo feliciter sanato.

‡ Guattani de extern. aneurysm. histor. xv.



made by a ligature of convenient breadth upon the artery, by means of which its two opposite sides are brought into mutual and firm contact, without the noose resting or pressing strongly upon the sides of the artery, which is flattened, rather than constricted circularly. And it is in this manner, that the surgeon avoids the danger of the rupture of the artery, and of a secondary hemorrhage, and that he is assured of obtaining the approximation of the two compressed sides of the artery, as if they were two smooth planes placed one over the other, and that they contract an adhesion to each other. It is not without reason, that surgeons, hitherto, with regard to the subsequent cure, have apprehended the danger of secondary hemorrhage, which frequently occurs in consequence of the ligature of the large arteries of the second order, such as those of the extremities. They have expressed much surprise, why this severe accident is not equally frequent after the ligature of the same arteries in amputation, as in consequence of the ligature for the radical cure of aneurism. But it would seem, that they had not reflected sufficiently, that the circumstances, though apparently similar, are not in fact in both cases the same. That the impetus of the blood towards the stump, is not equal to that sent to a large artery of a limb when tied, which preserves entire all its ramifications; that the artery, in this second case, is very seldom tied by the greater number of surgeons, so completely denuded and separated from the surrounding parts, as after amputation; and that the course of the *adhesive* inflammation in the second case is longer, and less easily moderated than in the first; each of which circumstances shall be treated of severally in the course of this work.



§ 12. It is a very great inconvenience attending the use of the ligature, as well as the application of the compressing bandage, that the ligature is applied to a disorganised portion of artery, not capable of feeling the irritation, and of inflaming, and consequently not susceptible of adhesion. This inconvenience may occur, if the ligature is applied in the vicinity of the injury, or laceration in the artery occasioned by a morbid degeneration of its proper coats, as most commonly happens in the aneurisms from an internal cause, or in the *spontaneous* aneurisms, as they are called. It may, however, be prevented, by leaving the aneurism untouched, and by tying the artery above it, sometimes at a considerable distance from the place of the injury in the artery, if the nature of the parts, the depth in which the ruptured artery lies, and other circumstances require it. For, with regard to the grumous blood which is left in the aneurismal sac, which has not been opened, it is gradually absorbed, either in whole or in part, by the surprising activity of the absorbent lymphatic system. In aneurisms from a wound, we have nothing to dread, as the artery above and below the incision preserves its natural vitality, and disposition to inflame and adhere. Generally in applying the ligature to any of the great arteries of the second order, besides the caution of compressing rather than constricting the artery circularly, the surgeon will recollect, that he ties and constricts a living part, upon which the more he increases the degree of pressure, the more he accelerates the ulceration, and thereby the premature division of it. The degree of constriction ought to be such, as to place the two opposite sides of the artery in firm contact, but still to preserve as much vitality, as to resist the ulceration during all that time, which is necessary for the *adhesive* inflammation pro-



ducing the union of the sides of the artery, and at the same time the obliteration of its canal. After this time has elapsed, the *ulcerative* process detaches the ligature, together with a portion of the tied artery, but not a drop of blood is thereby discharged.

§ 13. It is a thing truly worthy of remark, that the obliteration of the cavity of a tied artery is not properly confined to the place of the ligature, and to that portion to which the *adhesive* inflammation has extended, but even after the inflammation has ceased, and the union of the two opposite parietes kept in firm contact has taken place, the obliteration continues successively to go on under the ligature, to extend sometimes a great way, and as far as the seat of a large anastomosis. This, properly speaking, is not a power of which the arteries alone are possessed, but it is common to all the other canals of the animal body, which in the same manner as the arteries, have a natural tendency to contract as soon as the fluid which usually flows in them ceases to pass. When the trunk of an artery is tied a considerable way above the root of an aneurism, the column of blood, which from any of the anastomosing vessels, endeavours to enter into the trunk below the ligature, and to pass from thence into the aneurismal sac, has never force sufficient to distend the sac, and overcome the resistance opposed by the clots contained in it. The blood, therefore, which enters into the trunk below the ligature, and above the root of the aneurism, being at first retarded in its course, and then conveyed into the inferior anastomoses, leaves entirely the principal trunk which continues to contract, and becomes obliterated as far as the root of the aneurism inclusively. The blood, wherever it meets with an obstacle to its passage, avoids it, provided it has a more



easy channel for continuing its course, according to the law of the vascular system, which we call *derivation*.\* We see in fact, in the child soon after birth, that the blood of the pulmonary artery finding a more easy course through the lungs than by the ductus arteriosus, leaves this canal to enter into the lungs; that on tying the umbilical vein, the course of the blood from the vena portæ through the liver being accelerated with a new force, leaves the ductus venosus which used to pour it into the subjacent vena cava; that the blood of the ventral aorta, on the cord being tied, takes no longer the route of the umbilical arteries, but that of the arteries of the inferior extremities. Supported by these facts, it may be established as a theorem in physiology, that whenever the blood meets with a powerful obstruction in its passage to a given place, through an artery, it leaves that artery to enter into another, and the artery which has been abandoned diminishes gradually in diameter, until it is entirely obliterated. Whenever, therefore, the pulsation of the aneurism, after the ligature of a large artery of the second order, such as the femoral, continues or re-appears, instead of recurring, as some surgeons have done, for the explanation of this phenomenon, to the lateral vessels anastomosing with the trunk below the ligature, and above of the aneurism, the more simple and true explanation of this phenomenon is, that the arterial trunk has not been tied with sufficient force, to bring the

\* Haller. Deux Mémoires sur le mouvement du sang, mém. i, pag. 43. Si, par exemple, on lie les artères mesenteriques d'une grenouille, qui ne seraient que de vaisseaux capillaires dans un chien, le sang reste d'abord immobile dans le rameau qu'on a lié, sans qu'il se forme aucune enflure; bientôt après il retrograde dans les rameaux voisins, et laisse son vaisseau entierement vide jusqu'à la ligature, et rempli au dessous par le sang qui y étoit, et dont la ligature a arrêté le mouvement.



sides of it into complete and firm contact with each other.\*

§ 14. From this, two important practical precepts relative to the *radical* cure of external aneurism, may be deduced; in the first place, that the complete cure of this disease may be obtained by tying the artery in the vicinity of the wound, or laceration in it, as well as by applying the ligature at a considerable distance above the place of the injury; without, at the same time, making an incision into, or opening the aneurismal sac. In the second place, that by not opening the aneurismal sac for the cure of this disease, (having in view the resistance which the clots contained in the tumor oppose to the blood which endeavours to enter the aneurismal sac from above downwards, or from below upwards), the ligature applied above the place of the rupture or wound of the artery only, leaving the tumor untouched, renders it unnecessary for the surgeon to apply a second ligature below the place of the injury. The propriety of the one or the other

\* The recurrence of the pulsation in the aneurismal sac after the artery has been tied, has been observed by Mollinelli, and other writers; but the most accurate, and, in my opinion, the most satisfactory explanation of this phenomenon, was first given by Mr. Home, in the case of John Clegg, who had two popliteal aneurisms. On the evening after the performance of the second operation, a slight pulsation was felt in the aneurismal sac. The pulsation increased for two or three days; it then gradually diminished; and in eight days after the operation, it was scarcely perceptible. Mr. Home very judiciously observes, ‘the only way in which the pulsation could recur in the tumor, after it had been stopped, must be by means of anastomosing branches; and if the branch which renewed the communication had its origin near the ligature, it is probable, that in the progress of the cure, the femoral artery became obliterated higher up than the origin of this branch, and shut it up.’ T.



method of operating is determined by the combination of circumstances, which shall be afterwards explained.

§ 15. At the beginning of this work, it appears to me that I have reduced, to the most complete demonstration, what Haller has already asserted ;\* that is, that the ligature of the *superficial* femoral artery may be performed with the same confidence of success, as the ligature of the brachial artery ; or, in other words, without any fear of destroying the circulation, or depriving the subjacent limb of its vitality. And indeed the numerous and conspicuous anastomoses which are met with all round the knee, correspond exactly with those which are observed round the elbow, and at the bend of the arm. And this, as I have mentioned in another place, is not a peculiarity of the arteries of the extremities ; but it is a general rule which nature has followed in the distribution of all the arteries,

\* Icon. Anat. Fascic. v. Quare, cum arteriæ articulares superiores, super articulationem genu ortæ, ad utrumque latus patellæ plerumque magnis ramis descendant, seque immittant in inferiores arterias in tibia sub poplite natas, adparet utique arteriam popliteam fere eadem cum spe inter duos condylos ligari posse, aut excindi, si aneurysma id requisiverit, et æque bonam spem post eam resectionem de tibia pedeque superesse, ac quidem de brachio optima est, quando arteria brachialis in flexu cubiti ligatur, et in anastomosibus illis fiducia chirurgi ponitur, quas alias dicemus, et quarum precipuæ sunt inter arteriam profundam humeri atque arteriam perforantem tendineum interseptum brachialium musculorum, et inter arteriam ulnarem atque radialem, et interosseam dorsalem. Speravit has anastomoses communicantes vir Ill. Heisterus de genu morbis, n. 77. Winslovius, ut suo loco exposui, non ignoravit ramos descendentes arteriæ cruralis, atque utriusque tibialis sibi inosculari. Ex eo auctore eam spem repetiit Cl. Guenault, in disp. Parisiis, an. 1742, proposita in hunc sensum : non ergo in vulnere arteriæ cruralis continuo ab amputatione auspicandum.



that the superior trunks communicate with the inferior, by means of the lateral vessels. It is a certain and well known fact, that, after the principal trunk of an artery is tied, the lateral branches of it not only carry on the circulation in the parts below the ligature, but that they likewise do so with greater quickness and activity than they did before, when the course of the blood was unimpeded through the principal trunk. This evidently arises from the increase of pressure which the blood that takes the route of the lateral vessels receives, as well as from the enlargement in diameter which these vessels acquire. It is observed, in fact, after amputation of the thigh, that during the time that the blood flows in a full stream from the *superficial* femoral artery, very little or no blood is poured out by the lateral vessels; while, as soon as the *superficial* femoral artery is tied, the blood issues with impetuosity from the small arteries which run along, within the vasti and cruræus muscles; and on these smaller arteries also being tied, the blood immediately oozes out from the minute arterial vessels of the muscles and cellular membrane. And, further, that on the principal trunk of an artery being tied, the lateral branches of it gradually acquire a diameter much greater than they had before the ligature of the trunk, is a fact proved by many observations. After amputation of the thigh, performed on account of an aneurism situated in the ham, the size and position of which could not fail to impede very much the course of the blood through the trunk of the femoral artery, it has been repeatedly remarked, that, although both the trunk and the greater and smaller branches of the femoral artery had been tied with the greatest accuracy, the patients have been in danger of losing their life, on account of re-



peated copious hemorrhages from the innumerable small lateral vessels, that had become unusually enlarged. In several cases, during the treatment, and especially after the *radical* cure of popliteal aneurism, by means of the ligature of the *superficial* femoral artery in the upper third of the thigh, all the ramifications of the recurrent popliteal arteries have been felt beating strongly around the knee. I observed attentively this phenomenon in a patient whom I cured of an aneurism in the upper part of the thigh, by means of the ligature of the *superficial* femoral artery, in the vicinity of the origin of the *profunda*.<sup>\*</sup> Boyer,<sup>†</sup> in the body of a man, who some years before had been operated upon for an aneurism in the ham, but who had afterwards died from a caries of the tibia, found, that the arterial branch which runs through the substance of the sciatic nerve was dilated so much as to be equal in diameter to the radial artery. White,<sup>‡</sup> in dissecting the arm of a lady, who fifteen years before had been operated upon for an aneurism in the bend of the arm, found that the trunk of the brachial artery was obliterated, and converted into a completely solid cylinder for the space of three inches below the place of the ligature, and as far as the division of the brachial artery into radial and ulnar, but that the recurrent radial and ulnar arteries had acquired so large a diameter, that, taken together, they exceeded the size of the brachial artery above the place of the ligature. Wilmer mentions, that he had seen an injection of the lower extremity, taken from the dead body of a man, whose history he did not well recollect, in which the femoral artery had been previously obliterated for the

<sup>\*</sup> Case v, at the end of this work.

<sup>†</sup> Caillot Essay sur l'Aneurysme, p. 16.

<sup>‡</sup> Cases in Surgery, p. 139, pl. vii, fig. 1 and 2.



space of two or three inches, and in which the collateral arterial branches were observed to be so wonderfully dilated, that it might be safely affirmed that the circulation was carried on in the limb, independent of the principal trunk.\* As a further proof of this, we know for certain, that in the dead body the injection passes more freely from the one extremity to the other of an aneurismatic, than of a sound limb;† and, what is still more wonderful on this point is, that even in limbs affected with aneurism, in which we do not observe any evident increase of the diameter of the lateral vessels, the injection passes from the one extremity to the other with more facility than in sound limbs. On which account, if in aneurismatic limbs the injection of melted glutinous substances passes with so great readiness, we may from thence safely infer, how much more easy the passage of the fluid and vital arterial blood ought to be, impelled with regularity by the force of the heart, accelerated by the pressure towards the lateral vessels, and by the oscillation of the flexible and living vessels themselves. Morgagni‡ considered it as a rare and surprising fact, that in the dead body of a man, whose arm Molinelli preserved by means of the ligature of the brachial artery, no other communication was found between the trunk of the brachial artery and the arteries of the fore-arm,

\* Cases and Remarks in Surgery, p. 173.

† John Bell, Discourses on the Nature and Cure of Wounds, p. 46.

‡ Loc. cit. epist. l, art. 8. Nulla inveniri arteria potuit, quæ pro ipsa communicationem inter superiorem ejus truncum, et radialem, ulnaremque arterias servaret præter unam, eamque non solum mire flexuosam, sed tenuem adeo, ut difficillimum sit intellectu, quomodo radialis arteria influente tam paucò sanguine, et per tot flexus traducto æque pulsare ac altero in brachio posset, tum æque esse brachium utrumque et nutritum, et robustum, aut certe ad actiones æque idoneum.



than that carried on by a small and tortuous artery, although the arm of that man had continued to be as well nourished, and as strong as the other, and the radial artery pulsated with equal force, as in the sound arm. And, supposing that the injection of all the anastomotic arteries of the flexure of the arm had been made in the dead body of this man by Molinelli with due care, it would be a very clear proof, that, even in the case where the anastomotic arteries of the bend of the elbow do not dilate, after the ligature of the principal arterial trunk of the limb, these anastomotic arteries, such as they are, are sufficient to carry on the circulation, and preserve the strength of the operated limb. On which subject it is proper here to observe, that, although it be self-evident that the circulation through the collateral vessels ought to be much more easy and quick, the lower down the ligature is applied to the principal trunk, yet experience shews, that this difference is not to be estimated very high, and that a greater latitude may be given to this precept than reasoning alone seems to suggest. For it appears, that in a case of popliteal aneurism, *cæteris paribus*, the success is the same, whether the femoral artery be tied very low down in the vicinity of the knee, or in the upper part of the thigh.

§ 16. What I have hitherto said with regard to the communication and passage of the blood from the one extremity to the other of an aneurismatic limb, ought not, however, to be taken in so general a sense, as to be considered as applicable to all the cases of aneurism, and to every subject. For, this facility of the passage of the blood through the lateral vessels is not the same in subjects of all ages, and in the same subject it is not the same in the inferior, as in the supe-



rior extremity. In young subjects, or those who do not exceed forty-five years of age, the force with which the blood is impelled, and circulates, as well as the oscillation and vitality of the arteries, are much greater than in old persons. Anatomists know, that to obtain a fine injection, it is necessary, in the first place, to choose the body of a young or middle-aged subject. Beyond the forty-fifth year the arterial system begins to become rather rigid, does not yield to distention, and has a disposition to form here and there scales of ossification, especially in the arteries of the inferior extremities; for, in those of the superior extremities, ossification is very rare, even in persons advanced in life. In the same subject there is always, and at every age, a very great difference between the force and the velocity of the circulation in the parts, according to their greater or less distance from the heart; so that, in a parity of age, and other circumstances relative to aneurism, on the principal arterial trunk of an upper extremity being tied, the hope of success will always be greater, than when the principal artery of a lower extremity is tied. The difference which exists between the vitality and the velocity of the circulation of the superior extremities, in comparison with that of the inferior, is so well marked, that, when all circumstances are equal, we daily see wounds and fractures of the superior extremities heal more quickly than those of the inferior; which circumstance seems to be referable to no other reason, as I have mentioned, than the greater vicinity of the superior extremities to the centre of circulation and life.

§ 17. The greatest of all the obstacles which can oppose the success of the cure of an aneurism, espe-



cially that in the ham or in the thigh, arises undoubtedly from the rigidity, atony, or disorganization of the principal anastomoses between the superior and inferior arteries of the ham and of the leg, sometimes depending upon the advanced age of the subject, or on it together with the large size of the inveterate aneurism, which, by the long-continued pressure, has caused a great change in the neighbouring parts. It sometimes also depends upon the *steatomatous, ulcerated, earthly, cartilaginous* disorganization of the proper coats of the artery, which is not confined to the seat of the rupture, but extends a great way above and below the aneurism, and includes at the same time the principal popliteal *recurrent* arteries, and with these the *tibial* arteries, and in some cases small spaces of the whole line of the *superficial* femoral artery. Sometimes the pressure exercised by the large aneurismal sac has extended to the posterior and inferior surface of the thigh-bone, which it has stripped of its periosteum, and rendered carious. In this unfortunate combination of circumstances, the ligature of the principal aneurismatic trunk, although it be applied with the most exact rules of art, and at a considerable distance above the seat of the aneurism, either does not produce the union and obliteration of the aneurismatic arterial trunk, or, if it produces it, does not procure a *radical* cure; the increased force of the pressure made upon the blood in the lateral vessels, both before and after the ligature of the principal trunk, not being sufficient to overcome the resistance opposed to it by the straitened and rigid anastomoses of the ham, and by the narrow passage from these anastomoses into the tibial arteries. The leg, therefore, after, as well as before the operation, is deprived of the quantity of arterial blood necessary for the preservation of its nourishment and



vitality. On which account, we cannot hope for a favourable event from the operation of the ligature of the principal artery of the lower extremities in the radical cure of aneurism when the patient is much advanced in life, languid, and sickly ; when the internal coat of the artery is rigid, and incapable of union at the place to which the ligature is applied ; when the aneurism is of long standing, and of considerable size, accompanied with symptoms of caries of the posterior and inferior surface of the thigh-bone, or of some portions of the head of the tibia, occasioned by the long pressure of the aneurismal sac against these bones ; when the subjacent leg is weak and cold, without any evident pulsation in the artery of the tarsus ; or when it is cold, and at the same time very much swelled, heavy, and œdematous. These circumstances contraindicating the operation, deserve the most serious attention. For, a certain disposition which some surgeons have to operate in every person, in all cases, and in every circumstance, might make the operation for aneurism fall into discredit, when performed either according to the old or according to the new method, if aneurisms of the class that I have just mentioned, in which the operation is contraindicated, came unfortunately under the treatment of these surgeons. And they would not fail, perhaps, in order to cover their inconsiderateness, to wish to prove, by a series of unfortunate facts, the inefficacy of this operation. Prudent persons, and those instructed in the art, will be on their guard against these assertions, and will consider it as a fact, that on the occurrence of aneurism, except in the cases just mentioned, the principal trunk of the injured artery may be tied with impunity at a considerable distance above the place of the injury, and therefore that the fatal consequences



of this operation are for the most part imputable to the complication of the disease, to the impropriety of the operation, or to the inaccurate performance of it.

§ 18. The obliteration, therefore, of the artery for a certain space above and below the ulceration, laceration, or wound of it, forms the primary indication which the surgeon has to accomplish in the *radical* cure of aneurism, whether he thinks proper to employ compression, or the ligature of the injured artery. All the other means of cure are only secondary and auxiliary. Internal remedies contribute to effect it, in so far as they tend to moderate the impetuosity and excessive determination of the blood towards the place where the artery has been compressed or tied. These remedies are, evacuations of blood in young, very robust, and plethoric patients, low diet, diluent drinks, gentle laxatives and glysters, complete rest of body and mind, and cool air. In weak patients, or those who have become so, not on account of their advanced age, but by the acuteness of the pains, the long want of rest, or previous repeated and large evacuations of blood, if there is reason to believe that the deficiency of the vitality may oppose the supervention of the *adhesive* inflammation, and consequently the union of the two opposite sides of the compressed or tied artery, tonics and cordials ought to be given internally, a moderate diet, administered at short intervals; corroborant and slightly stimulating topical applications are to be used externally. It not unfrequently happens, that after the separation of the ligature, a secondary abscess is formed in the bottom of the wound, which degenerates into a sinuous ulcer, either because the ligature has been too long of being detached, or because the position given to the operated part



during the treatment has rendered the complete evacuation of the matter difficult. This accident may be cured by facilitating the discharge of the ligature, which has already become flaccid, after the sides of the tied artery have contracted a firm adhesion to each other, by laying open the sinuous ulcer, or placing the operated part in a more favourable position; and likewise, by employing the expulsive bandage, by destroying the fungous flesh, and by inducing a healthy granulation in the bottom of the wound.

§ 19. Debilitating remedies, abstinence, a milk diet, perfect rest, are almost the only means which art can suggest and employ in cases of internal aneurism, and these only in order to retard the fatal progress of a disease from its nature incurable by the hand of the surgeon. Indeed, how could a remedy be applied to an aneurism of the pulmonary artery, or of the arch of the aorta, the extravasated blood of which, by compressing the lungs, prevents the patient inspiring the quantity of atmospheric air necessary for the production of the animal heat, and for the oxigenation of the blood? How could he be relieved from the painful respiration, from the threatening of suffocation, from the turgescence of the vessels of the face, from the delirium, from the coldness of the extremities, want of sleep, and hectic fever? In the great difficulty of breathing, with which these unfortunate persons are by degrees affected, the evacuation of blood is of very great use; but as evacuations of blood cannot always be frequently repeated, so in some cases we may with advantage substitute instead of these the immersion of the hands and feet into tepid water, friction of the extremities, iced water given internally, with a small quantity of Hoffman's liquor anodynus mineralis. Some



temporary relief in the greatest difficulty of breathing is obtained by sinapisms, either simple, or rendered more active by a small quantity of powdered cantharides, applied to the arms, to the thighs, or feet, by their suspending or removing that state of spasm and constriction with which the viscera of the thorax are affected. In those cases in which the aneurismal sac has corroded the bones, and appears externally, as on the outside of the sternum, ribs, clavicles, or vertebræ, the surgeon ought to abstain from every kind of compression upon the tumor, as the pressure would not cause the aneurism to diminish in the least, and by forcing it inwards, it might occasion it to compress more strongly than before the important viscera which are in contact with it. In the last period of the disease, when the most prominent portion of the sac protruding from the thorax, together with the integuments covering it, passes into gangrene, and the whole is converted into a sphacelated eschar, the little which remains for the surgeon to do, is reduced to the abstaining from the employment of emollient applications, and to the using, instead of these, astringents and stimulants, such as vinegar impregnated with sea salt, camphorated spirit of wine, the vinous decoction of the aromatic herbs, with the addition of sea salt, myrrh, and aloes; in short, all those topical applications which are capable of hardening, and rendering the gangrenous eschar, to use the expression, coriaceous, so that it may resist as long as possible the fatal rupture of the aneurism.\*

\* Some years ago, a case of aneurism of the aorta occurred in Guy's hospital, which had destroyed a portion of the sternum, formed a large tumor externally, and threatened to burst. Mr. Astley Cooper preserved the life of the patient for several days by applying



§ 20. Lastly, With regard to the assistance of the hand in the *radical* cure of external aneurisms by means of the ligature of the artery, whether it is thought proper to open previously the aneurismal sac, or to leave it untouched, the operation requires intelligence and dexterity on the part of the surgeon. The first of these he will acquire by means of dissection, and he may obtain the second by practising the operation of the ligature upon the dead human subject, and successively upon brute animals. I have frequently had an opportunity of applying the ligature on the arteries of brute animals; and some experiments which I made with regard to the *transfusion* of the blood \* have proved to me, that a surgeon may, without difficulty, acquire, by practising on animals, a certain tact, to use the expression, and an unusual degree of quickness and dexterity in laying bare, separating, and handling the arteries and tying them, although they be wounded, and pouring out blood with impetuosity, as likewise in giving to the ligature that due degree of constriction proportioned to the size and density of the artery to be tied.

applying successive layers of adhesive plaster over the tumor; in this manner aiding and imitating nature. T.

\* Rosa. Lettere Fisiologiche.



## CHAPTER IX.

### OF THE CURE OF THE POPLITEAL ANEURISM.

§ 1. SINCE there are only two methods in surgery for accomplishing the radical cure of external aneurisms, *compression* or the *ligature* of the injured artery, it is necessary, in treating of popliteal aneurism, to begin with examining in what circumstances the preference ought to be given to the one or to the other of these two methods of cure. In the first place, compression is not a mode in which much confidence of success can be placed for procuring the radical cure of popliteal aneurism, except in those cases in which it is very probable that the rupture of the popliteal artery is owing to an external cause, as, for instance, a wound or violent strain, rather than a slow morbid degeneration and subsequent ulceration of the proper coats of the artery; in the second place, it cannot succeed unless, at the seat of the tumor in the ham, there is a possibility of pressing the two opposite parietes of the lacerated popliteal artery against the inferior and posterior surface of the thigh-bone; and, in the third place, the degree of pressure which can be employed must be sufficient to excite deeply in the proper coats of the popliteal artery the *adhesive* inflammation, by which this artery is finally converted into an impervious, ligamentous substance.

§ 2. The combination of these three circumstances in relation to the popliteal aneurism, without which



the compression is of no avail, or rather injurious, is indeed a very rare occurrence. For, we shall even suppose (which is very rarely the case), that the coats of the popliteal artery have not been so much disordered and disorganized from internal causes previous to the violent straining, as to have lost, for a certain space above and below the rupture, all disposition to inflame and adhere together, the surgeon has for the most part many other very great difficulties to encounter, which prevent him applying upon the artery that exact and steady degree of pressure which is requisite for obtaining the complete and radical cure of the aneurism in the ham. It is necessary that the compressing force applied to the aneurismal sac of the ham press down and remove from the artery the concentric coagulated layers of blood, so that the pressure may fall precisely on that portion of the popliteal artery immediately above its rupture. This cannot take place except in a case of very recent popliteal aneurism, of very small size, and in which the cellular membrane and ligamentous bands surrounding the popliteal artery permit the clot of blood to retire from the place it occupied, and descend below the laceration in the artery which we wish to compress. Besides this, it is necessary that the compression do not injure the great sciatic nerve, especially its large tibial branch. This is very difficult to effect, both because this nerve runs on the back of the aneurismal sac, and because it is situated superficially and immediately below the integuments and aponeurosis of the ham, and too great a compression of it is sufficient of itself to render this mode of cure of the popliteal aneurism insupportable and ineffectual. We may farther add, that, in order that the compression be effectual, it is necessary that the laceration or corrosion



of the popliteal artery be neither too high up in the ham, as, for instance, at the place where the femoral artery passes through the tendon of the long portion of the adductor *magnus* muscle, nor too low in that cavity, so as to be seated under the heads of the great muscles of the calf of the leg, where the popliteal artery divides into the tibial arteries. For, in the first case, or when the rupture is too high in the ham, the compression, on account of the straitness, deepness, and obliquity of the place, can with difficulty cause the two opposite parietes of the popliteal artery to approach above the seat of its rupture or ulceration. In the second place, when the rent of the artery is too low in the ham, the deepness of the situation, in like manner, and the thickness of the surrounding muscles of the calf of the leg, render the force of the pressure on the artery ineffectual. And suppose, that notwithstanding, in this last case, the surgeon, by increasing very much the compressing force, succeeds in compressing the popliteal artery against the posterior surface of the heads of the tibia, the obstruction of the *inferior* articular arteries, and, what is still more important, of the tibial arteries, and the gangrene of the leg, are the inevitable consequences of such an attempt. In relation to this point, Guattani,\* with his usual ingenuity, remarks, ‘ I have been engaged in searching  
‘ for a mode of compression, by means of which I  
‘ might be enabled to cure the aneurisms that oc-

\* De externis aneurysmat. pag. 74. Studui quoque ut viam invenirem aliquam ad ea persananda aneurysmata, quæ in superiori suræ parte contingunt, in quadam scilicet ex tribus arteriis; quæ sunt tibialis anterior, tibialis posterior, et peronea; sicuti etiam ad ea aneurysmata persananda, quæ obsident extremum popliteæ, priusquam in tres prædictas arterias ea diducatur. Sed licet quater id pertentaverim, nunquam tamen ex animi sententia res hactenus mihi cessit.



‘ cur at the upper part of the calf of the leg, which  
 ‘ affect one of three arteries, viz. the *anterior* tibial,  
 ‘ the *posterior* tibial, and peroneal, as well as those  
 ‘ which are situated in the lower portion of the pop-  
 ‘ liteal artery, just before it divides into these great  
 ‘ branches. But although I have now made the at-  
 ‘ tempt four times, the event has not hitherto corre-  
 ‘ sponded to my wishes.’

§ 3. On this important subject, it does not appear to me to be difficult to establish a fixed rule, by which every surgeon may be enabled to determine, without hesitation, the cases in which it is proper to employ the compression, as a radical mode of cure of the popliteal aneurism. This rule, in my opinion, might be the following. The compression is contra-indicated, whenever the popliteal aneurism is *spontaneous*, or not depending upon a wound, or extraordinary violent stretching of the artery; when the popliteal aneurism is of long standing, and of prodigious size; when it is very hard; when it occasions acute pain, and sympathetic fever; when it has produced considerable swelling of the leg and foot, with a diminution of their heat; and when the aneurismal sac is situated too high, or too low, in the ham. On the contrary, the surgeon’s hopes of a cure being obtained by compression, will be well founded, in every case where the popliteal aneurism is very small, recent, and produced by a violent stretching of the artery; when it is indolent, soft, and yields to the pressure of the hand; when it is situated exactly in the middle of the cavity of the ham; and when it is not accompanied by swelling or numbness of the leg and foot. If, however, notwithstanding the combination of all these favourable circumstances, which, I again repeat,



is very rare, on the first methodical application of the compression, pain shall be excited in the tumor of the ham, which the patient finds not easy to bear, and if the leg becomes swelled and torpid, the surgeon will consider these symptoms as absolutely contraindicating the compression, and, notwithstanding the concurrence of the favourable circumstances now mentioned, he ought immediately to desist from the use of the compressing bandage. We have many examples in practice of this unfortunate combination of things, on account of which, in spite of the most promising hope, it has been necessary to desist from the compression very soon after it was applied. Nevertheless, as the desisting immediately from this method does not expose the patient to any danger; and besides, as we have the account of a great many successful cures of recent popliteal aneurism, obtained by means of compression, related both by the ancient as well as by the modern surgeons, of whom it is sufficient to mention Guattani and Flajani only, I therefore think that every sensible and humane surgeon, whenever this combination of favourable circumstances presents itself, ought to employ for some time the compression, as a method of cure of popliteal aneurism, instead of proceeding immediately to the operation and ligature of the artery; to which operation it is always time to have recourse, as soon as the first trials, prudently made, have shown the inutility of the compression.

§ 4. The compression of the popliteal aneurism is performed in the following manner. In the first place, an expulsive bandage is applied to the toes, and to the leg, nearly as high up as the knee; then two large compresses are laid across, on the centre of the aneu-



rismal tumor, extending above and below the patella, and including the knee. A third compress, narrower, but longer than the others, is placed on the internal surface of the thigh, in the course of the *superficial* femoral artery. The first circle is made with a very long roller, three fingers broad, on the centre of the tumor; then it is to be passed round the tumor, above and below the knee, so that the whole is accurately and equably compressed. The bandage is then to be carried upwards, encircling the thigh as far as the groin, observing carefully that every circle of the roller covers the other by a little more than one-half of the breadth of the bandage, and it then terminates with a few circular turns round the loins. The last turns at the top of the thigh should be less tight than the others, and the nearer these turns, in ascending, approach to the origin of the *profunda* femoral artery, the less tight they ought to be; since, in proportion to the advantage derived from moderating the impetus of the blood in the *superficial* femoral artery, will be the injury occasioned by preventing the free course of the blood in the *common* and *profunda* femoral arteries. This bandage should be frequently moistened with Theden's vulnerary water, or with vinegar and water, chiefly in order to keep it tense; since neither these fluids, nor the so much celebrated plaster of Riverius, made of Armenian bole, terra sigillata, vinegar, and white of an egg, nor the gall-nuts, nor ice, are of themselves capable of causing a contraction of the artery, or of the aneurismal sac, without the compression. On every renewal of the bandage, the pressure on the tumor must be made stronger than before; and in proportion as the small, soft, and not painful aneurism in the ham diminishes, the number of the com-



presses is to be proportionally increased, so that the narrowest enter the bottom of the ham, and press on the popliteal artery exactly above the place of the injury, whilst the other compresses form outwardly, and above the ham, a prominence sufficiently great, that the force of the pressure may fall entirely on the artery which we wish to obliterate, without compressing the tendons of the flexors of the leg, or of the muscles of the calf of the leg, in the manner of a hard ligature. Galen, as I shall mention in another place,\* put a piece of sponge immediately on the aneurismal tumor, and over the sponge graduated compresses, on which he tightened the compressing bandage.

§ 5. During this treatment, although the leg and foot should swell a little, provided violent and intolerable pains of the ham do not supervene, under the moderate and methodical pressure, and if the tumor decreases visibly, and does not beat so strongly as it did before, the surgeon may continue the application of the compressive bandage with hopes of success. In the meantime, if the patient is young and healthy, it will be proper that he lose some blood occasionally, and that he be kept on a very spare diet. If all goes on well, experience has shewn, that in the course of about three months the tumor gradually becomes smaller, loses its pulsation, and is reduced at last to an indolent tubercle, of the size of a bean. This state of things, however, ought not to be considered too soon as equivalent to a *radical* cure. Experience has shewn, that even when the disease is reduced to this state, the surgeon cannot pronounce with certainty that the cure is quite complete. † For in many of

\* Chapter xi, § 4.

† Palletta Giornale di Med. di Milano, t. vi, p. 183.



those cases, in which the popliteal aneurism has been reduced, by means of compression, to the size of a bean, the artery has not been properly obliterated above the place of the injury, but there has only been formed a coagulated thrombus, which blocked up the rupture of the artery, and on this thrombus being removed by the impetus of the blood, and by the motions of the leg and knee, the popliteal aneurism appeared in the same place as before. On which account it will be proper that the surgeon should, in similar cases, continue the application of the compressive bandage for some time longer than three months, and that he should allow the patient to walk but very little, and with great circumspection.

§ 6. It is proper again to repeat, notwithstanding all that I have several times mentioned, that the combination of the circumstances which favour the success of compression, as a method of cure of the popliteal aneurism, is a very rare occurrence; and that, most frequently, even in those cases in which every thing seems to favour the employment of this method with great hopes of success, the first attempts made with the bandage will prove, that, far from being beneficial, they rather do harm. On which account, whenever the compression is not indicated, and in like manner even when it is indicated, but in the first trials proves so painful that the patient cannot bear it, and when the swelling and numbness of the leg increase at the same time with the pain in the ham, it ought to be a fundamental precept in practice, to lose no time in useless attempts of this sort, and, if there are no reasons for the contrary, depending on the great age of the patient, or other local complications of disease, to proceed immediately to the operation of tying the ar-



tery. For, the longer we delay, the greater is the risk of the aneurism increasing in size; and, what is still worse, by delaying, the patient incurs the farther danger of the posterior and inferior surface of the femur being deprived of its periosteum, and even corroded, as usually happens in the progress of those large aneurisms of the aorta, which press on the sternum, the ribs, or the bodies of the vertebræ, and terminate in the destruction of their substance. Acrell is of opinion, that the operation for the popliteal aneurism cannot be deferred, without great danger, beyond a month after the appearance of the tumor; but this opinion appears to me to be much exaggerated, and in no way agreeing with the observations and numerous facts we are in possession of, from which we would draw a contrary conclusion; or at least, I am inclined to believe, that the possibility of the success of the operation extends to a much longer period than that which has been fixed by that (in most respects) justly celebrated surgeon.

§ 7. The operation for the popliteal aneurism (having in view the general indication of cure of this disease) consists in suppressing, by means of the ligature, the course of the blood through the popliteal artery, so that the current of blood, which passed by this artery, is conveyed to the leg and foot by the different channels of the lateral anastomosing vessels. The effect, in respect to the primary indication which the surgeon proposes to accomplish, is the same, whether the ulcerated or lacerated popliteal artery is tied in the ham, a little above the place of the injury which has given rise to the aneurism, or whether this ligature is applied on the inner side of the thigh, in the middle, or at the top of the thigh; that is, we intercept the flow



of the blood by the popliteal artery into the aneurismal sac, and successively obtain the obliteration and conversion of the ulcerated or lacerated popliteal artery into an impervious ligamentous cord.

§ 8. Every person who considers the facility, as well as the success attending the method at present practised by surgeons for the cure of the aneurism at the bend of the arm, occasioned by a puncture of a lancet, (I mean by laying open the aneurismal sac, evacuating the clots of blood, and tying the brachial artery in the bottom of the sac, above and below the place of the wound), would be inclined to pronounce in favour of this mode of operating for the radical cure of aneurism in the ham. But if, conversant in anatomy, and well acquainted with the causes producing the one or other of these aneurisms, he will bestow more mature reflection on this point, he will find that the circumstances, apparently similar in both cases, are not so in reality, in relation to the parts between which both of these aneurisms are situated, and to the causes from which these bloody tumors are derived. For, in the bend of the arm, the trunk of the humeral artery is found at a small depth, in comparison with the situation of the popliteal artery. The humeral artery can be easily brought into view, through the whole of the space which the surgeon finds necessary to enable him to separate it from the median nerve, to tie it without difficulty, and draw the ligature of a proper degree of tightness above and below the wound, without the smallest danger of obliterating, or including in the ligature, any of the more important anastomoses destined for maintaining the circulation and life of the subjacent part of the limb. In the aneurism at the bend of the arm,



from the wound of a lancet, we never happen to find the bony substance of the lower extremity of the humerus bare in the bottom of the aneurismal sac. The proper coats of the humeral artery, if we except the solution of continuity made in it by the puncture of the lancet, are in a sound state round the place of the injury, and not at all disorganized, but disposed to inflame and adhere together. Finally, in the superior extremities, the vitality of the arterial system in particular, as of all the other parts, is greater than in the inferior extremities. On the other hand, in the ham the popliteal artery lies very deep. The space is very limited and narrow, within which the popliteal artery can be brought into view and tied, with the security of not including along with it, or destroying some of the principal anastomoses formed by the articular arteries of the knee. The management of the instruments, and especially of the needles, is very difficult, in order, at the depth, to make the ligature pass exactly behind the denuded popliteal artery alone, without including other parts in it : and it is no less difficult to draw the ligature on the popliteal artery with a proper degree of tightness in so deep a situation. The popliteal aneurism is, in most cases, the effect of a slow morbid disorganization of the proper coats of the popliteal artery ; this disorganization, sometimes *steatomatous*, sometimes *ulcerated*, sometimes *earthy* and brittle, renders the ligature useless, when it is applied in the ham, and in the vicinity of the aneurism, either because the ligature easily breaks the artery, or because its morbid degeneration at this place renders it incapable of undergoing the adhesive inflammation. Besides, it very frequently happens, that the ulceration or laceration of the popliteal artery is so high up in the ham, that, in order to ap-



ply a ligature, it is necessary to divide the long portion of the *great* adductor muscle, and make a passage through it to the thigh; or it is situated so low down in the calf of the leg, that it is impossible to avoid either including in the incision, or in the ligature, the inferior anastomotic articular arteries of the knee, on the preservation of which depends, in a great measure, the circulation and life of the subjacent part of the limb. Guattani\* encountered, as was to be expected, so many difficulties, when the aneurism was situated low down in the cavity of the ham, that he did not venture to attempt the ligature of the popliteal artery above and below the tumor, from the dread of including the sound inferior arteries in the ligature; and he was still farther dissuaded from this attempt, by considering the thickness of the muscles of the calf of the leg, covering the aneurismal sac. If we add to all this the violence which must be done, in every case, during the operation, to the great sciatic nerve, which an assistant must hold drawn to one side of the wound nearly the whole time of the operation; if we calculate the other great difficulties; and if it happens, as occurred to Masotti, † that the popliteal artery is so firmly united, and, as it were, con-

\* Do extern. Aneurism. p. 74. Superioris suræ. Non equidem periculum feci vincendum tantum arteriæ in principio et fine tumoris, ob difficultatem inter tam validos musculos eam separandi arteriam, quæ aneurysmati affecta fuerit, extricandique a reliquis partibus tumorem integrum, absque eo quod sanæ etiam arteriæ eodem tempore præcidantur. Nec ausus instituere arteriæ ejusdem vincturam, aperiendo prius, evacuandoque aneurysmaticum saccum; altitudo enim muscularis, ingensque tumor, quem ego semper offendi, (semper enim hujusmodi agrotantes ad chirurgiam sero confugiunt), nimis difficile reddunt invenire modum vincendi duo orificia cum aneurysmaticæ arteriæ sacco communicantia.

† Dissert. sull' Aneurysma, p. 53.



fused with the vein, the nerve, the tendons of the neighbouring muscles, and the periosteum, the cavity of the ham presents the appearance of an intricate mass of parts, not easily separated from one another. Lastly, we must not pass over in silence, that, after the division of the aneurismal sac in the ham, there remains a large deep wound, laying open the whole cavity of the ham; which wound, in most cases, changes into a foul ulcer, accompanied by copious suppurations, which exhaust the strength of the patient, and occasion successively fistulous sinusses, complicated with caries of the articular heads of the femur and tibia. If the patient is not hurried into his grave by these affections, and if even a cicatrix forms in the ham, it very rarely happens, that after so great a destruction of cellular substance, which occupied the cavity of the ham in the sound state, the patient does not remain with an incurable contraction of the knee, and perpetual lameness. Masotti,\* whom I have already mentioned, relates the case of a patient operated on for a popliteal aneurism, in whom the subsequent suppuration destroyed the soft parts in the cavity of the ham, to such a degree as not to leave any vestige of artery, vein, or sciatic nerve; from which circumstance, the patient remained all the rest of his life paralytic of that leg, with wounds and fistulæ all round the knee.

§ 9. Young surgeons will find in Guattani† a very expressive and faithful delineation, of the very great difficulties and dangers which are met with in the operation for popliteal aneurism, performed according to the method which was then commonly employ-

\* Loc. cit. p. 17, 24.

† De externis Aneurysm. Hist. i.



ed, or by means of the incision of the sac. ‘ Having  
‘ premised (says he) the proper precautions, I made  
‘ an incision in the popliteal aneurism, lengthwise,  
‘ and having evacuated the grumous blood, I found  
‘ the popliteal artery *lacerated in so great an extent*,  
‘ that it was impossible to apply the superior ligature,  
‘ until I had made a way upwards through the thigh,  
‘ with my fingers and the knife. Preparing then to  
‘ tie the popliteal artery, under the aneurism, I was  
‘ very much surprised to find this artery abher-  
‘ ing to the femur, like an aponeurotic expansion,  
‘ just as the aorta is sometimes found to have con-  
‘ tracted a morbid adhesion with the bodies of the ver-  
‘ tebræ, and this abhesion prevented me applying the  
‘ lower ligature, with the accuracy which is required  
‘ in such cases. On loosening the tourniquet, no  
‘ blood issued from the place of the upper ligature.  
‘ I was, however, very much annoyed by the muscu-  
‘ lar arteries, which having been unavoidably divided,  
‘ on account of the great extent of the wound, pour-  
‘ ed out a great deal of blood, which I endeavoured  
‘ to stop by compression. I was induced to do this,  
‘ as the ligatures would not have been sufficient to  
‘ stop the hemorrhage completely, and because the  
‘ patient did not seem to have sufficient strength to  
‘ enable him to bear so long and so severe an opera-  
‘ tion. Having therefore filled the large cavity of  
‘ the ham with dry lint, supported by compresses and  
‘ a circular bandage, I finished the operation, leaving  
‘ the tourniquet applied in case of accidents. The  
‘ day after, although the tourniquet was loosened,  
‘ gangrene nevertheless appeared on the knee, and the  
‘ following day the patient died.’ A similar account,  
perhaps still more minute and explicit than that of



Guattani, of the difficulties and dangers of this operation, is given by M. Deschamps.\*

§ 10. I am aware that other examples of success may be brought in opposition to this unfortunate case; but I likewise know, and many other surgeons agree with me in opinion, that these fortunate cases have been at all times very rare, and that the greater number of patients with popliteal aneurism, who have submitted to the operation by the incision of the sac, have died in convulsions before the third day, or have been attacked by gangrene of the knee, leg or foot, a few days after the operation. And it is certainly to be attributed to no other reason, than the too frequent unsuccessful event of this operation by the incision of the aneurismal sac, that men, very celebrated for their learning, and long experience in surgery, such as Mr. Pott,† M. Deschamps,‡ and Palletta,§ have

\* See Appendix, note, No. 12.

† Chirurgical Works, t. iii, pag. 414. Sorry I am to find myself obliged to say, that as far as my observations and experience go, such operation, however judiciously performed, will not be successful, that is, will not save the patient's life. In both these aneurisms, the femoral and poplitean, it most frequently happens, that the artery is not only dilated and burst, but it is also distended some way above the dilatation, particularly in the poplitean. This may very probably be one reason why the ligature is in general so unsuccessful.

‡ Loc cit. pag. 68. On cite ici quelques exemples de réussite; deux on trois par M. Pelletan, un par Desault, et aujourd'hui un à l'hôpital de la charité; mais les non-succès les a-t-on comptés? Plusieurs fois depuis, Desault n'a pas réussi. Il y a plusieurs années, une malade que j'ai opérée à l'hôpital de la charité a eu la jambe sphacelée; un opéré dernièrement a eu la même sort. En général dans les opérations on a toujours grand soin, comme je viens de le remarquer, de noter ses succès; mais les non succès on les passe sous silence. J'apporterai en preuve l'assertion d'un  
de



openly declared, that till he discover a better mode, amputation of the thigh ought to be preferred to the incision of the popliteal aneurismal sac. Wilmer states distinctly, that the operation for aneurism had been performed several times in the hospitals of England, within the course of a few years, but that he had not heard of a single case which had done well.\* And although of late years, improvements have been made on the needles for applying ligatures to arteries when deeply seated, and although instruments have been invented for compressing the great arteries, yet no useful or essential change has been made in the general plan of the operation for popliteal aneurism by the incision of the sac. For notwithstanding these improvements on the instruments, there exist still the same difficulties, and the same dangers depending upon the depth and extent of the wound in the ham, on the injury done to the great sciatic and tibial nerve, on the state of disorganisation of the proper coats of the popliteal artery, both at the place of the rupture and where the ligature is applied; and also, on the popliteal aneurism being sometimes situated too high or too low; and finally, on the very severe consequences of an ulceration so extensive as that of the whole cavity of the ham.

de nos plus celebres praticiens, qui dernièrement, et en public, a dit, en parlant de cette operation, que s'il avoit le malheur d'être attaqué d'un anéurisme de l'artère poplitée, il prefereroit l'amputation de sa cuisse à l'operation.

§ *Giornale di Venezia* Marzo 1796, n. iii. Those, says he, who were operated on in this manner by my predecessors, had all an unfortunate termination.

\* *Cases and Remarks in Surgery*, p. 180. It hath been done several times within these few years in our public hospitals, but I have not heard of any one case where it answered the intended purpose.



§ 11. The above-mentioned difficulties and dangers, which are so often, not to say always, met with in performing the incision of the aneurism in the ham, and successively in tying the popliteal artery, immediately above the place of the injury, (some of which very great difficulties are of such a nature, that they cannot be foreseen by the surgeon before the incision and evacuation of the aneurismal sac), may be avoided by applying the ligature to the femoral artery in the thigh, higher up than the seat of the disease, instead of applying it to the popliteal artery in the ham, immediately above the root of the tumor, and by leaving the aneurismal sac quite untouched. The phenomena which present themselves after this operation, which is simple and not very difficult to perform, are the immediate diminution of the aneurismal sac; the stopping of the pulsation in it; the disappearance of the pain, which was before occasioned by the distention of the aneurismal sac. These phenomena are followed, in the course of a few weeks, by the obliteration of the popliteal artery in the ham, which was lacerated or ulcerated, or in some other way diseased or disorganised; the absorption of the extravasated coagulated blood in the aneurismal sac, and the gradual diminution, and final disappearance of the aneurism in the ham, with the exception sometimes of a slight induration caused by some portion of the compact cellular substance which formed the aneurismal sac, or some remains of the fibrous part of the blood. This slight hardness, which occurs in the bottom of the cavity of the ham, does not afterwards occasion any inconvenience to the patient, and does not at all hinder him in performing the motions of the knee and leg with quickness and safety.



§ 12. The ligature of the *superficial* femoral artery, as an effectual method of curing the popliteal aneurism, frees the surgeon from the great perplexities in which he is involved, with regard to the seat and greater or less extent of the rupture of the popliteal artery, and also, from the doubts and uncertainty in relation to the complications of this disease, depending upon the morbid state of the proper coats of the popliteal artery, such as their *steatomatous*, *ulcerated*, *squamous* degeneration, and from the difficulties likewise produced by the intricate mass formed by the popliteal artery, with the vein, sciatic nerve, and other parts contained in the cavity of the ham. For, in following this method of cure, it is of little consequence to the surgeon whether the rupture of the popliteal artery has happened high up in the ham, or even at the place where the femoral artery passes through the long portion of the *great* adductor muscle, or if it has occurred low down, and in the vicinity of the *inferior* articular arteries of the knee. The surgeon is little, or not at all anxious, whether the brittleness, or *steatomatous*, *ulcerated*, *earthy* morbid state of the proper coats of the popliteal artery, extends even for a considerable way above and below the place of the rupture, or whether the popliteal artery is firmly agglutinated with the vein and sciatic nerve, or adhering to the adjoining parts, and even to the periosteum covering the posterior and inferior surface of the os femoris. Since, in whatever part the laceration is found, however brittle, diseased, and incapable of the *adhesive* inflammation, the proper coats of the popliteal artery may be, for a certain distance above and below the root of the aneurism, as soon as the *superficial* femoral artery is tied in the thigh, the popliteal artery ceases to pour blood



into the cavity of the ham, and is obliterated afterwards at the upper part, and the same takes place in the lower part below the root of the aneurismal sac. When the rupture of the popliteal artery has occurred high up in the ham, this circumstance, far from being disadvantageous to the happy event of the cure, as it certainly is in the old manner of operating by the incision of the aneurismal sac, is rather favourable; since the higher up in the ham the laceration or ulceration of the popliteal artery has happened, there remains in the lower part of the ham the greater number of anastomotic articular arteries uninjured, and communicating with the superior ramifications of the *superficial* femoral artery and of the *profunda*, and with the branches of the *superior* articular arteries. In this case, it is true, we run a risk of destroying the *superior internal* articular artery, as it arises from the popliteal immediately after its entrance into the cavity of the ham; but we save the *superior external* articular, the two *inferior* articular arteries, the *azyga* of the knee, and the recurrent tibial. The blood therefore which passes from the superior branches of the *superficial* femoral artery, and from those of the *profunda* into the *superior internal* articular artery, if it cannot get from this last artery into the popliteal, takes the route of the *superior external* articular, of the *inferior internal* and *external* articular, and recurrent tibial arteries, and is poured into the popliteal artery below the laceration and aneurismal sac in the ham. The possibility of this, is proved by the numerous and constant anastomoses which all the articular arteries of the knee have with each other; and this point is likewise confirmed by injections, and in the most convincing manner by the following fact. A man, who had been cured by the assistance of nature, of an



aneurism situated in the upper part of the ham of the left inferior extremity, in such a manner however, that in the course of the cure, the orifices of the superior articular arteries had been obliterated, having afterwards died of a stroke of apoplexy, Desault \* injected the whole limb, in order to examine the part accurately. He found that the injection had passed both into the *superior* and into the *inferior* articular arteries, and that the superior articular arteries which had not been able to discharge the blood into the popliteal at the top of the ham, had transmitted the injection from the one to the other articular artery, and that they served, to use the expression, as intermediate canals between the great femoral arteries and the *inferior* articular and tibial arteries. Farther, he found in the substance of the sciatic nerve, an artery so much enlarged, as to form a communication between the sciatic artery and the *posterior* tibial. In the same manner, when the laceration or ulceration of the artery has taken place low down in the ham, since in performing the new method, it is by no means necessary either to open the aneurismal sac, or to apply a second ligature below the rupture of the popliteal artery, as I shall afterwards demonstrate, so the risk of destroying that portion of the popliteal artery, from which the tibial and *inferior* articular arteries arise, is not a subject of perplexity and of new fears to the surgeon, as they were to Guattani; in relation to which point, read case iii, at the end of this work. To all these reasons, which are alone sufficient to induce us to give the preference to the new method of operating over the old, we may add, that the incision of the integuments, and of the cellular substance, to bring into view and tie the *superficial* femoral artery at

\* See Appendix, note, No. 13.



the middle or in the upper part of the thigh, is in no way to be compared to the large and deep division which it is necessary to make in the ham for laying bare the popliteal artery; that the ligature, according to the new method, being applied at a considerable distance from the place of the injury of the popliteal artery, it is much more probable, that it will include a sound portion of the artery, than when it is applied in the vicinity of the root of the popliteal aneurism; that no great nerve in the performance of the new method, appearing on the fore part, retards the operation, or renders it difficult or very painful to the patient. And lastly, it may be mentioned, that the supuration occasioned by the incision of the integuments and cellular substance of the thigh, which is necessary for laying bare the *superficial* femoral artery, never produces so great a waste of substance, as is caused by the incision of the popliteal aneurismal sac, and the prodigious sloughing of the whole cavity of the ham, which is the consequence of it.\*

§ 13. Some† have objected, that the *superficial* femoral artery, not being completely obliterated from below the ligature applied in the thigh, to the place of the ulceration or laceration of the popliteal artery, the

\* Deschamps, loc. cit. pag. 76. Celle d'Hunter exige une incision de deux pouces de longueur aux tégumens; il ne s'agit que de soulever le bord du muscle couturier, très mince dans la partie de la cuisse où l'opération se fait. Le paquet des vaisseaux immédiatement placé dessous, est à decouvert et facile à saisir; la plaie a peu d'étendue en longueur, et n'a pas, pour ainsi dire, de profondeur; on a l'avantage d'opérer promptement, et d'une manière sûre, et ce qui est un grand avantage, sur une partie qui n'est point altérée. Le gonflement qui suit l'opération est peu sensible, la suppuration est légère et la cure plus prompte.

† Caillot. Essai sur l'Aneurysme, p. 77.



collateral branches of the superficial femoral, which go off from above the ligature, communicating with the trunk of this artery below the ligature, and with the articular arteries of the knee, and severally with the *great* anastomotic artery, may continue to pour blood into the aneurismal sac, and thereby keep up the popliteal aneurism as it *was* before the operation. This objection, which is only a repetition of what Molinelli\* had already advanced, rather as a sort of conjecture, than as the result of practical observations and experiments, with regard to the case of aneurism at the bend of the arm, operated on by Anel, without the incision of the aneurismal sac, is rendered void by facts in support of the contrary with regard to the popliteal aneurism; which facts are now so numerous, that they can no longer be regarded as rare events, or merely accidental occurrences. The facts, as I have said above, shew, that after the ligature has been properly applied to the *superficial* femoral artery, at the middle, or in the upper part of the thigh, the popliteal aneurism invariably lessens; that the pulsation in it immediately ceases; that from that moment, the aneurismal tumor gradually diminishes in size, and finally disappears altogether. These circumstances would not indeed invariably take place, if by means of the collateral anastomotic arteries given off from the

\* Comment. Acad. Bonon. t. ii. Ut vero arteriarum aneurysmati insertarum numerus, et dispositio latiore acumen videantur non admittere; sic Anellianam operationem de qua agitur administrandæ rationem (quæ hujusmodi est, ut saccum, et continuatos cum trunco ramos retegat, hos deinde vinciat, illum intactum relinquat) inutilitate jam suspectam multo reddunt, et merito suspectiorem.—Non intelligo qui deprimi, et extenuare aneurysmatis saccus possit, in quem, ne totidem dicam, quot aliquando vidimus, ut unus adhuc, aut alter eorum similis sanguinis rivus, post injecta vincula, pergat indesinenter influere.



*superficial* femoral above the ligature, the passage of the blood into the trunk of the femoral artery below the ligature still remained open, and from this artery, and at the same time from the articular arteries of the knee into the aneurismal sac. If Mr. Hunter in his first trial, found that the *superficial* femoral artery remained pervious for a certain space below the ligature applied in the thigh,\* he however observed, that this artery was closed at its entrance into the aneurismal sac in the ham. The proof alleged by Guerin,† of the ligature of the femoral artery not being always sufficient to hinder the increase of the popliteal aneurism, because, that in a man operated on by him who died suddenly of hemorrhage in the night of the fourth day, the tumor was found of a greater size than it was before, is too inconclusive and inaccurate, to be opposed to the numerous other facts which may be adduced to the contrary. He ought to have shewn, in the most certain and unquestionable manner, that the superficial femoral artery had been tied with sufficient precision, and that the ligature had not slipped from the artery before the death of the patient. In the body of the man who had been operated on by Chopart, in whom the *superficial* femoral artery, a short time after the operation, was obliterated only for three fingers breadth below the ligature applied in the thigh, it was found, however,‡ that the *superficial* femoral artery, at its entrance into the aneurismal sac in the ham, was completely closed by a hard, tenacious clot of blood. Desault,§ in the body of a man, in whom the so called *spontaneous* cure of a popliteal aneurism by the

\* Transactions of a society, &c. vol. i.

† Journal de la Soc. de Santé de Paris, n. iii, p. 197.

‡ Deschamps loc. cit. p. 56. See case xi, at the end of this work.

§ Chap. viii, § 3



assistance of nature was just beginning, likewise found, that a very hard bloody coagulated clot extended from the aneurismal sac in the ham within the femoral artery, and cut off all communication between this artery and the aneurism; and that the resistance of this coagulum was such, that the injection thrown in by the iliac artery, was obliged to pass to the leg and foot by the collateral arteries anastomosing with the articulares of the knee, and what is of importance to remark, without being at all poured into the aneurismal sac in the ham. In the body of another man operated upon by Deschamps,\* who died from an infiltration of purulent matter in the thigh, the *superficial* femoral artery was found remarkably diminished in diameter from below the ligature downwards, and the aneurismal sac in the ham was likewise very much diminished in bulk, and only contained a hard clot, and no fluid blood in its centre. ‘ Boyer † dissected  
 ‘ the body of a man who had died of an acute disease,  
 ‘ who eight years before had undergone the operation  
 ‘ for an aneurism in the ham, performed according to  
 ‘ Mr. Hunter’s method. Deschamps had been the  
 ‘ operator, Boyer had assisted him. The operation  
 ‘ had had the most complete success, and the patient  
 ‘ had been perfectly cured. The obliteration extend-  
 ‘ ed a little above and below the ligature; it was limit-  
 ‘ ed both above and below to the place from which a  
 ‘ middling sized branch arose. The portion of ar-  
 ‘ tery included between the obliterated point and the  
 ‘ aneurismal point was not obliterated, and the branch-  
 ‘ es which went off from it, communicated evidently  
 ‘ with those which came off from the crural artery,  
 ‘ below the part obliterated. *The portion, how-*  
 ‘ *ever, of the artery which had formed the tumor or*

\* Loc. cit. pag. 59.

† Vacca, I storia d’un aneurisma del poplite, p. 34.



‘ aneurism, was entirely obliterated, presented at that  
 ‘ point a considerable hardness, and was quite full  
 ‘ and perfectly solid. The obliteration of the popli-  
 ‘ teal artery extended about fifteen or sixteen lines,  
 ‘ and the popliteal artery below this obliteration re-  
 ‘ sumed its natural diameter.’ Vacca\* mentions,  
 that, in the body of a patient 64 years of age, who had  
 been operated on for a popliteal aneurism by the mode  
 of tying the femoral artery, in whom, from the dis-  
 eased state of the proper coats of the artery, and from  
 other unfavourable circumstances, which could not be  
 foreseen, even after the long period of fifty-two days,  
 the union of the two opposite sides of the tied artery  
 had not taken place, he found that, while the femoral  
 artery above the place of the ligature, as well as the  
 collateral vessels, preserved a considerable diameter,  
 greater than usual, the femoral artery below the liga-  
 ture gradually diminished in diameter, in proportion  
 as it proceeded downwards from the wound, or the  
 place of the ligature, so that it was nearly obliterated  
 some lines above where it loses the name of popliteal  
 artery, and divides into the tibial arteries. At this  
 point, the two sides of the popliteal artery were be-  
 come much thicker than usual, and presented a very  
 small aperture, from which there was an opening into  
 a membranous sac, the parietes of which, had almost  
 everywhere approached and adhered together.† These  
 facts prove, that the *superficial* femoral and popliteal  
 arteries, as well as the aneurismal sac, after the ap-  
 plication of a ligature in the middle or at the top of  
 the thigh, are capable of opposing the entrance of the  
 blood into them, which is conveyed by the collateral

\* Loc. cit. pag. 31.

† See also, in the Appendix, an account of a dissection by M.  
 Deschamps. T.



vessels given off from the femoral above the place of the ligature; and that they have at the same time, a tendency to contraction and obliteration, by means of which, after the ligature of the principal trunk, either no blood at all enters the aneurismal sac by the collateral vessels, or if a small quantity enters at first, it is not sufficient, either from its quantity or from the impetus with which it is impelled, to continue the aneurism in the ham, or to prevent the gradual contraction or disappearance of its sac. The coagulated clots which fill in concentric layers the cavity of the aneurismal sac, and that portion of blood stagnating in the tube of the femoral artery from the place of the ligature downwards as far as the aneurism, oppose so strong a resistance to the streams of blood, which, from the collateral vessels, endeavour to enter the femoral artery below the ligature, and to get into the cavity of the aneurismal sac, that it is easier for the blood to pass from these collateral vessels into the open articular arteries of the knee, and from thence into the tibial arteries below the aneurism, than to overcome the resistance opposed to them by the hard, and tenacious bloody coagulum which fills up the aneurismal sac, and the portion of femoral artery between the ligature and the aneurism. Haller\* observed in the mesentery of frogs, that wherever the arterial blood found an obstacle to the continuance of its course through one artery, it became at first stationary for a little; it then took a retrograde motion towards the first anastomosis above the obstruction, and by that at last quickly resumed its course towards the subjacent parts. The same thing takes place, undoubtedly, in the lower extremity after the ligature of the femoral artery, both in relation to the blood which runs

\* Mém. i, sur le mouvement du sang, pag. 43.



through those collateral arteries which arise from the femoral artery above the point of the ligature, as well as by those collateral branches which endeavour to pour blood into the femoral artery below the ligature, and into the aneurismal sac obstructed by the coagulum. This is the more easily prevented, as the articular arteries of the knee, even before the operation, are in general unusually dilated, and offer an open and expeditious route into the arteries of the leg below the aneurismal sac. We have, besides, demonstrated above, that even in a case in which the one or other of the *superior* articular arteries of the knee no longer opens into the popliteal, the blood nevertheless continues its course to the leg; for the *superior* articular arteries of the knee serve as a sort of intermediate canal between the collaterals of the *superficial* and *profunda* femoral, with the inferior articular arteries of the knee. And this is confirmed by a fact, which, from the frequency of its occurrence, may be regarded as invariable; that immediately after the ligature of the *superficial* femoral artery, the articular arteries of the knee beat with uncommon force, and sometimes as strongly as the radial artery at the wrist, which would not happen, if from the lateral vessels the blood found a greater facility in entering the femoral artery immediately below the ligature, and thence into the aneurismal sac, than in passing, as it does, through the same collaterals into the articular arteries of the knee, and from thence into the tibial arteries below the aneurismal sac.

§ 14. The objection, therefore, is of no weight, that the complete obliteration of the superficial femoral artery not taking place immediately after the operation, below the ligature as far as the aneurismal sac,



the blood being conveyed by the collateral vessels into the tube of the femoral artery below the ligature, and into the aneurismal sac, may keep up and even increase the popliteal aneurism as it did before. For precisely the contrary of all this is proved by the dissection of the bodies of those who have died from other causes, after having been operated on for popliteal aneurism by means of the ligature of the femoral artery in the thigh, and by the inspection of the lower extremities of some others, where nature alone has begun a radical cure of this disease, in which cases the entrance of the femoral artery into the aneurismal sac has been invariably found obliterated, and where, if the femoral artery from below the ligature as far as the ham, has, in some rare cases, been found open, it was only so irregularly or at intervals, and these spaces were full of half fluid or coagulated blood. The same fact, or the diminution and disappearance of the popliteal aneurism, after the ligature of the femoral artery has been accurately performed, in the middle or at the top of the thigh, is proved in the living subject, in the most convincing manner, by constant observation, which would not happen, if it were so easy, as some pretend, for the blood of the collateral vessels to enter the aneurismal sac, or to flow into the trunk of the femoral artery immediately below the ligature. In support of this consideration we may add, that these phenomena are exactly in conformity to the laws of derivation, by the power of which the arterial blood is constrained to run in greater quantity, and with greater velocity, towards those places where it meets with the least resistance, which resistance being much greater in the canal of the femoral artery below the ligature to the ham, and into the aneurismal sac, on account of the partly hard,



partly coagulated and polypous blood, which fills up these routes and stagnates there. And as the blood finds much less resistance in the dilated, pervious, numerous anastomoses above and round the knee, rather than force the obstructed portion of the femoral artery which is below the ligature and in the aneurismal sac, occupied by a hard tenacious coagulum, the blood necessarily takes the easy course of the articular arteries of the knee, and from these passes readily into the tibial arteries below the root of the aneurismal sac. And although in the examination of the body of some of those who have died soon after the ligature of the femoral artery, and in some others even several years after they had undergone this operation, it has been found, that the femoral artery below the ligature as far as the ham was still pervious at intervals, we cannot from thence infer that this would be an obstacle to the *radical* cure of the popliteal aneurism. Because, in the first place, in all those patients who have been the subject of similar researches, the entrance of the femoral artery into the aneurismal sac has been constantly found shut; because, the artery being obliterated at intervals from the ligature downwards, the blood can never have a free passage within it to the ham; and lastly, because, if in the course of time the aneurismal sac is obliterated, we may with much greater reason assert, that, after a still longer period of time, the femoral artery ought also to be entirely obliterated in all those spaces that have remained filled by a portion of coagulated blood; recollecting also, that the coats of an artery are possessed of a vitality and of an elastic power much greater than that with which the cellular substance forming the aneurismal sac is furnished.\*

\* Chap. viii, § 3.



§ 15. If, therefore, the resistance of the hard coagulated clot inclosed in the aneurismal sac, and the half-curdled coagulated blood, which at intervals obstructs the *superficial* femoral artery below the ligature, oppose a sufficient hinderance to the blood, which endeavours to enter from the collateral vessels, and oblige it by the laws of derivation to continue its course through the anastomotic arteries of the knee, and from these into the tibial arteries, the same resistance will also necessarily produce another advantage, that is, it will oppose the return or regurgitation of the blood from the tibial arteries into the sac of the aneurism. During this state, the absorption of the coagulum filling the aneurismal sac will take place, as it actually does, and then the aneurism contracting itself, and the popliteal artery being obliterated along with it, this artery will be converted into a ligamentous substance, impervious for some way above and below the ulceration or rupture. This contraction and obliteration of the popliteal artery does not, however, pass beyond the orifices of the *inferior* popliteal articular arteries, because these orifices are below the coagulum which fills the aneurismal sac, and because the column of blood conveyed by these inferior articular arteries keeps the channel from the collateral vessels into the tibial arteries open and free. And, indeed, in all the dissections of the bodies of those who have undergone the operation for popliteal aneurism by means of the ligature of the femoral artery in the thigh, the communication between the *inferior* articular and the tibial arteries has always been found open. It is therefore a thing very deserving of our admiration, how the lamellated coagulum contained in the aneurismal sac, which before the operation was one of the most fatal consequences of the ulceration or rup-



ture of the popliteal artery, after the ligature of the femoral artery is changed immediately into one of the principal means of cure of the aneurism. From which circumstance we may draw a useful conclusion in practice, viz. that in the operation for the popliteal aneurism by means of the ligature of the superficial femoral artery in the middle or at the upper part of the thigh, it is not necessary to apply a second ligature below the place of the laceration in the popliteal artery; since, for the reasons mentioned, the blood can neither flow back from the *inferior* articular and tibial arteries into the aneurismal sac, nor can the obliteration of the sac and of the popliteal artery, after the ligature of the femoral artery, descend so far below the ulceration or laceration as to shut up the communication between the *inferior* articular arteries of the knee and the tibial arteries; which is to be regarded as a favourable circumstance, and one of the most conducive to the perfection of the *new method* of performing this operation.

§ 16. Although the term *new method* is at present used in the schools to indicate the operation for the popliteal aneurism, which is performed by the ligature of the *superficial* femoral artery in the middle or at the upper part of the thigh, without opening the aneurismal sac, or evacuating the grumous blood contained in it, nevertheless this mode of curing aneurism by means of the ligature of the great artery of a limb, without touching the aneurism, and leaving it wholly to the powers of nature, and especially to those of the lymphatic absorbent system, is of a much more remote date than the time in which Mr. John Hunter lived, or the year 1785. For the history of this discovery goes as far back as the time of Anel, not



however, as some think, still farther back, to the era of Guillemeau and Thevenin, from whom (in other respects celebrated surgeons) it is wished to make us believe that Anel had derived his first ideas relative to this manner of radically curing aneurism. Anel\* being in Rome, undertook the cure of an aneurism in the bend of the arm in a missionary, and performed it in the following manner. Having laid bare the brachial artery above the seat of the aneurism, he separated it for a certain space from the cellular substance, and tied it with two threads contiguous to each other. On loosening the tourniquet, he found that the pulsation in the tumor had ceased. The day after, the pulse appeared at the wrist. On the third the dressings were renewed, and spirituous fomentations were applied to the whole fore-arm and hand. The first thread came away from the wound on the 17th day after the operation, the second on the 27th day, and not long after the wound healed. The aneurismal tumor gradually diminished spontaneously, in such a manner, that after the cure it was impossible to recognise where the aneurism had been situated. Generally, says Anel, the aneurismal sac is opened; I, on the contrary, says he, left it entire, considering it to be certain, that the blood contained in the sac of the aneurism would be dispersed of itself, precisely as it happened. In this manner, continues Anel, the operation was more simple than that which is usually practised. For, he observes, in tying the brachial artery, I made an incision less than that which is practised when the aneurismal sac is opened, therefore the scar resulting from it was smaller than usual. We have been lately informed, that M. Mirault† has repeated

\* See Appendix, note, No. 13.

† Caillot *Essay sur l'Aneurisme*, ag. 72.



this mode of operating on the aneurism at the bend of the arm, occasioned by the puncture of a lancet, following exactly Anel's method, and that the operation has been followed by the most happy and complete success.

§ 17. It is therefore a certain fact, which has been known for a long time to well-informed surgeons, to name only Molinelli\* and Heister,† and even before anatomy had furnished us with certain and accurate ideas of the arterial system of the extremities, and of the numerous anastomotic recurrent arteries at the bend of the elbow and round the knee, and likewise long before we were acquainted with the wonderful power and activity of the absorbent lymphatic system, that in a case of aneurism at the bend of the arm, if the brachial artery is tied above the seat of the aneurism, the aneurismal tumor being left quite entire, the aneurism immediately diminishes after the ligature of the great artery of the arm, ceases to beat, and finally disappears spontaneously, or by the powers of nature alone, without the fore-arm or hand losing their circulation, nourishment, or life. In the time of Anel, as well as of Molinelli and Heister, the surprising action of the absorbent lymphatic system was not sufficiently known; therefore, at that period, for the explanation of this phenomenon they had recourse to a certain internal motion of the blood, which made it re-enter from the sac into the wounded artery, and obliged it to continue its course within it. At present it is easy to make the transition from this false theory, and to appreciate the fact of the spontaneous disappearance of the aneurism in consequence of the liga-

\* Acad. Bonon. t. ii.

† Institut. Chirurg. t. i.



ture of the principal artery, by the injury of which it is formed; and this fact forms one of the most brilliant eras in the history of modern surgery. Now, if these phenomena, I mean the ceasing of the pulsation, and the total disappearance of the aneurism spontaneously, take place in the bend of the arm after the ligation of the brachial artery above the seat of the aneurism, what argument can we adduce in opposition to prove, that in a case of popliteal aneurism, the *superficial* femoral artery being tied, the pulsation of the aneurism in the ham ought not likewise to cease, while it gradually diminishes in bulk, and finally disappears altogether spontaneously, without the loss of the circulation and life of the leg and foot? The circumstances are the same in the bend of the arm as in the ham, both in relation to the arterial anastomoses and to the activity of the absorbent lymphatic system. The only objection which any one could reasonably offer on this subject would be this; that in proportion to the age of the patient and the size and duration of the aneurism, there is, *cæteris paribus*, more vitality in the superior than in the inferior extremity; that the aneurism in the bend of the arm is invariably formed by a wound or puncture of a lancet, while that of the ham is for the most part occasioned by a laceration, ulceration, or disorganization of a certain space of the popliteal artery. But this exception is not sufficient to introduce any change in the propriety of following the same method of operating for the cure of both of these aneurisms. For, although it be generally true that the force of the circulation and the vitality are greater in the superior than in the inferior extremities, it is likewise a certain and demonstrated fact, that in patients of an age not very languid or sickly, the force of the circulation in the lower extremities is suf-



ficient to accomplish the cure of the popliteal aneurism. The state of rupture or disorganization of the popliteal artery at the place of the aneurism, and likewise for some way above and below the tumor, does not oppose any obstacle to the cure, when we consider that the ligature is applied at a great distance from the injured place, and in the perfectly sound portion of the femoral artery. The exception now mentioned, finally, loses all its weight, when we compare the advantages of the new method with the very great difficulties and dangers which are met with in operating on the popliteal aneurism by means of the incision of the sac of the aneurism.

§ 18. MR. JOHN HUNTER was undoubtedly the first who proposed and performed\* the ligature of the superficial femoral artery in the thigh for the *radical* cure of the popliteal aneurism, leaving the aneurismal sac in the ham perfectly untouched. Mr. Hunter, according to all appearance, was not acquainted with what Anel had done in the case of aneurism at the bend of the arm; and even those who published the first happy success obtained by Mr. Hunter, made no mention of Anel's method. Mr. Hunter, therefore, in trying this new mode of cure for the popliteal aneurism, had no other guide than his own sublime genius, always active and unceasingly employed, so long as he lived, in extending the boundaries of the natural sciences, and of the arts useful to mankind, especially that of surgery. He, as well as his contemporaries, discouraged by the continual disasters accompanying the common method of curing the popliteal aneurism by means of the incision of the sac, and full of confidence in the resources which nature has reserved to

\* In St. George's hospital, London, 1785.



herself in the anastomoses of the superior extremities round the elbow, and of the inferior extremities round the knee, and fully aware of the prodigious efficacy of the absorbent lymphatic system, proposed to try this new plan of operating. The happy event which followed in the first patient on whom he operated, and the other similar fortunate successes obtained by him, as also those which in the sequel occurred in the hands of other surgeons, proved the justice as well as the great utility of the plan conceived for the cure of the popliteal aneurism; which discovery will form an eternal monument of glory to its author.

§ 19. It has been said, that the first trials made in France with Mr. Hunter's method did not prove successful. But on this subject it is proper to observe, that, in the patient operated on by M. Desault,\* the circumstances were not at all favourable to the success of the operation, and that the operation itself was not performed exactly according to Mr. Hunter's method. For, in the course of the cure, the aneurismal sac of the ham opened of itself, and caused a corruption of the soft parts and caries of the tibia, of which the patient died some months after the operation. Farther, the *superficial* femoral artery was not laid bare, and tied at the middle, or in the upper part of the thigh, as Mr. Hunter had done, but in the vicinity of the knee, or a little above the place where

\* Deschamps loc. cit. p. 39. M. Desault est le premier en France qui ait pratiqué l'opération de l'anéurisme poplitée, suivant la méthode d'Anel; mais il y a apparence que les circonstances qui accompagnaient la maladie étaient peu favorable au succès de l'opération, puisque la tumeur s'ouvrit, et que le malade plusieurs mois après périt des suites de cette maladie compliquée de carie au tibia.



the artery perforates the tendon of the adductor *magnus* femoris, to descend into the ham; a situation very disadvantageous for allowing the femoral artery to be laid bare, and tied with facility at a small depth, and without dividing muscular parts. In the other patient operated on by M. Chopart,\* it is said that the collateral vessels, and anastomotic arteries of the knee, had not corresponded with the intention of the operation; which remains still to be proved; since no mention is made of the age or constitution of the patient, nor of what bulk the popliteal aneurism was, nor of the date of the appearance of the tumor: all which circumstances may be of such a nature as to make an attentive surgeon foresee the inutility of the old, as well as of the modern method of operating. For we ought not to pretend, as I have already said, in speaking of the cure in general, that the new method may be practised with success in every individual case of popliteal aneurism, and in whatever manner the disease may be complicated, depending upon the advanced age, the weak, and general sickly constitution of the patient, on the duration and very considerable size of the aneurism, on the state of inflammation, and of the aneurismal sac threatening to burst. Art has its limits; and since these points, relative to the diagnosis and prognosis of this disease, have been taken into more mature consideration,† the success of

\* Deschamps loc. cit. Mais il n'étoit point au pouvoir de l'opérateur d'établir des collaterales propres à transmettre une suffisante quantité de sang aux parties, au dessous de la ligature.

† Deschamps loc. cit. p. 85. La méthode de Hunter ne devra point être employée si la tumeur anéurismale est douloureuse; encore moins si l'extérieur est frappé d'une inflammation qui annonce une rupture des tégumens; si le genou, ou la jambe est engorgé; si le malade souffre dans cette partie; car, dans ces cas, il est presque certain



the Hunterian operation has been more frequent also in France, and I may now say in all Europe. This has, at the present day, been carried so far, that Mr. Home did not hesitate lately to perform this operation on a patient, who had a popliteal aneurism in both hams, only interposing the space of fifteen days between each operation; which attempt was attended with the most complete success.\*

§ 20. I now proceed to the detail of Mr. Hunter's operation for the radical cure of popliteal aneurism, and I shall mention those changes which, practice has suggested to me, ought to be made in it. Having arranged every thing with regard to the apparatus,† and a sufficient number of assistants being procured; having placed the patient on the edge of the bed, with his back and head a little more elevated than the hips,

certain que le liquide contenu a éprouvé déjà une décomposition, et que le Kyste est enflammé, ou au moins dans une disposition prochaine à l'inflammation, et que la tumeur doit s'ouvrir; ce qui mettroit par la suite le chirurgien dans la nécessité d'inciser le sac pour le vider du sang corrompu qu'il contient, d'où résulteroit une double opération.

Nous avons eu, à Paris, quatre exemples de la ligature de l'artère fémorale à sa partie moyenne, à l'occasion de l'anéurisme de l'artère poplitée. Les opérations ont été faites publiquement à l'hospice de Chirurgie, et à l'hôpital de la Charité; elles ne peuvent, ainsi que leurs résultats être révoquées en doute. De ces quatre opérations une seule a été suivie du sphacèle à la jambe. On peut donc dire que la méthode de Hunter a eu du succès sur les trois-quarts des opérés. Loc. cit. p. 64.

\* Transactions of a Society for the Improvement of Med. and Chirurg. knowledge, t. ii, p. 235.

† This apparatus consists of a convex-edged bistoury; a small spatula; an eyed needle; two waxed ligatures, each of them two lines in breadth; a small cylinder of linen rolled up, six lines in length and three in breadth; a tenaculum, and waxed threads for the ligature of the small vessels; lint, and a six-headed bandage.



with the leg and thigh of the affected side in a state of semiflexion, and supported on a pillow, the surgeon will direct one of the assistants to place himself at the side of the patient, so that he can, if required, compress the femoral artery as it passes out below the crural arch : I say, if it is requisite ; for, except in the event of some unlucky or unexpected accident in the course of the operation, it is proper that the surgeon should have a full view of the pulsations of the femoral artery. The surgeon pressing with his fore-finger, will explore the course of the *superficial* femoral artery, from the crural arch downwards, and when he comes to the place where he does not feel any more, or very confusedly, the vibration of the *superficial* femoral artery, he will there fix with his eye the inferior angle or extremity of the incision which he proposes to make for bringing this artery into view. This lower angle of the incision will fall nearly on the internal margin of the sartorius muscle, just where this muscle crosses the course of the *superficial* femoral artery, and at the apex of the triangle formed by the convergence of the adductor *secundus* and vastus *internus* muscles of the thigh. A little more than three inches above the place pointed out, the surgeon will begin the incision of the integuments and cellular substance with the convex-edged bistoury, and will carry the incision along the thigh, in a slightly oblique line from without inwards, following the course of the femoral artery as far as the point fixed with the eye, or to the apex of the triangle formed by the intersection of the two just mentioned muscles, and where this vertex is crossed by the sartorius muscle. He will divide, with one firm stroke, the skin and cellular substance, down to the thin aponeurotic expansion of the muscle of the fascia-lata, which



covers the course of the *superficial* femoral artery; then with another stroke of the bistoury, with his hand free and unsupported, or upon a furrowed probe, he will divide along the thigh, and in the same direction as the external wound, the thin aponeurosis just mentioned,\* and introducing the fore-finger of his left hand into the bottom of the incision, he will immediately feel the strong beating of the *superficial* femoral artery, and this without the necessity of removing the internal margin of the sartorius muscle from its position, or at least very little. With the point of the fore-finger of the left hand already touching the femoral artery, the surgeon will separate this artery from the cellular substance which ties it laterally and posteriorly to the contiguous muscles; making the point of the same finger pass gradually under and behind the superficial femoral artery, (supposing that the surgeon has not enormously large fingers), he will raise it alone from the bottom of the wound, or, when it cannot be avoided, along with the great femoral vein. If it is along with the femoral vein, holding the artery and vein thus raised, and almost without

\* Although the aponeurosis of the fascia-lata on the inner side of the thigh, where it covers the great femoral vessels, is very thin, when compared with that which covers the external surface of the thigh; yet, in laying bare the superficial femoral artery, it is proper to divide this aponeurosis, not only for the space of an inch, or as much as is required for insulating, raising, and tying this artery, but likewise above and below, in the whole length corresponding to the external wound. For, if this practice be neglected, it most frequently happens, that in the succeeding inflammatory stage, the bottom of the wound swells and becomes very tense; the inflammation is quickly prolonged through the aponeurosis of the fascia-lata, and the matter which is formed below it, not finding an easy exit by the wound, occasions abscesses, which very much retard the cure of the patient operated on for aneurism.



the wound, the surgeon, with a bistoury or spatula, or simply with the fingers of his right hand, will cautiously separate the vein from the artery, only in the space corresponding to the point of the finger which supports the artery. He will then pass behind the denuded raised artery a large, eyed, crooked needle, with a blunt point, carrying in the eye near to the point two waxed ligatures, each composed of six threads. After this the surgeon will withdraw the fore-finger of his left hand, on the point of which he kept the femoral artery raised from the bottom of the wound, and will proceed to the ligature of the artery. He will stretch the two extremities of the tapes, in order to place them near each other; he will then make with each a simple knot, and before tightening it on the artery, he will place between it and the knot a small cylinder of linen rolled up, six lines in length and three in breadth, over which cylinder he will tighten both ligatures with a simple knot, and with such a degree of force as he thinks necessary to bring the opposite sides of the femoral artery into complete and firm contact, not forgetting, however, that he compresses a portion of living solid. Over the first knot he will make a second, likewise a simple one. In making the simple knot, the surgeon is enabled to calculate the force which he employs in constricting the artery, which he cannot so well ascertain when he employs the double, or surgeon's knot, as it is called. Having made the ligature on the artery, he will cut away the ends of the ligatures on a level with the skin, or will bring them towards the upper angle of the wound, and cover them with a bit of linen. He will cleanse the wound from blood, and wash it with tepid water. He will then fill the bottom of the wound with soft lint, and cover the lips of it with a pledgit of



simple ointment, and place over it a compress, retained by the six-headed bandage. He will lastly put the patient in a convenient posture; he will cover the leg and foot of the operated side with warm flannel, or with bladders filled with tepid water, and will make him take three ounces of an emulsion, with fifteen or twenty drops of Sydenham's laudanum.

§ 21. The insulation of the *superficial* femoral artery, with the point of the finger passed behind and under the artery, corresponds nearly to the space which the two ligatures, placed near to one another, ought to occupy. Therefore, from not destroying more of the cellular substance which binds the artery to the neighbouring parts, than is necessary for placing the two ligatures, the artery continues to receive its nourishment and life immediately above and below the place of the ligature; which is an inestimable advantage, both with regard to the inflammatory course which the artery must pass through at the place of the ligature, and near to it, and with regard to the desired effect depending on this inflammation, I mean the adhesion of the opposite sides of the tied artery to each other. Mr. Hunter, in his first trial, applied four ligatures to the femoral artery, at a short distance from each other, to which he gave different degrees of tightness, so that the last or undermost was the one which really constricted and obliterated the tube of the artery. His motive for doing this, it clearly appears, was in order to moderate the impetus of the blood towards the principal ligature. But in doing so, he did not advert, that the three upper imperfect ligatures in contact with the artery, excited it to inflame violently, to suppurate, and to divide too soon, and thereby occasioned the severe accident of secondary



hemorrhage They were therefore omitted by him in his subsequent trials. For the same reason, I think, that, far from doing good, the placing at the upper part the ligature of *reserve* rather does harm; for this ligature destroys a greater tract of cellular substance, and insulates the femoral artery more than is necessary; and because experience has shewn, that whenever it has been necessary to have recourse to the ligature of *reserve*, it has rarely produced the good effect which was expected from it; as, on account of the retraction of the ruptured artery, it has been found, almost in every case, below the point of the artery which it was wished to compress. Farther, there is no great nerve which gives any trouble in the performance of this operation; for there are only filaments of the anterior crural nerve\* on the anterior and internal surface of the thigh, and at the precise place where the *superficial* femoral artery is laid bare, there are no nervous twigs met with, except those which unite together to form the saphena nerve; thin filaments, which may be divided without any injury, in the act of bringing the artery into view. As to those nervous twigs which adhere to the *superficial* femoral artery, they may be separated in laying bare and separating the artery from the cellular membrane; or, if they even remain along with the artery included in the ligature, the loss of them has no material influence in relation to the sensation and motion of the lower extremity.

§ 22. The phenomena which follow this operation are, the total ceasing of the pulsation of the aneurismal tumor in the ham; the immediate sensible de-

\* Fischer. tab. nerv. extrem. infer. tab. iv, fig. 1.



pression and flaccidity of the aneurism; the disappearance of the pain in the seat of the tumor; the strong vibration of the articular arteries round the knee. The temperature of the leg and foot of the operated side remains, for some hours after the operation, lower than that of the sound limb, and the patient sometimes complains of a creeping sensation in the affected limb, or as if water were running down through the leg and foot. But by continuing the application of the flannel, and of the bladders half full of tepid water, and using frictions with some spirituous liquor, as camphorated spirits of wine, these parts soon re-acquire their original heat; and even in general, twenty-four hours after the operation, the heat of the operated limb, as ascertained by the thermometer, exceeds considerably that of the sound one. Afterwards, the increase and diminution of the heat of the operated limb, compared with the sound limb, is irregular, until the fifteenth or eighteenth day after the operation; after which time the heat of both inferior extremities comes to an equilibrium.

§ 23. The diet of the patient should be such as is proper in wounds of considerable importance. The dressings should not be removed till suppuration has begun, that is, not before the fifth day, in the cold season of the year. The dressing will consist in covering the ulcer with a pledgit of lint spread with any simple ointment, such as that made of wax and oil, which lint the surgeon will take care, at every dressing, to introduce to the bottom of the ulcer, so that the lips of it may not approach too quickly, and contract adhesions to each other, so long as the ligatures remain in it. Towards the fifteenth or eighteenth day after the operation, generally the one or other, or



both of the ligatures are expelled from the wound together with the cylinder of linen. If occasionally at the time mentioned, and after the union of the sides of the tied artery has taken place, the ligatures are not disposed to come away, but are only relaxed in the loop, a probe is to be introduced into the noose, and along it the blunt point of a pair of scissars, with which the noose of the ligatures is to be cut, and then withdrawn from the bottom of the wound. After this there only remains a simple ulcer to be healed, the bottom of which (provided the surgeon has employed proper care to prevent the union of the external lips of the wound) will rise regularly, and finally cicatrize, without the cure being retarded by purulent infiltrations or sinusses. And, in order more certainly to prevent these infiltrations of matter between the interstices of the muscles of the thigh, it will be proper, after the ligatures have come away, to keep the patient sitting on his bed, with his hips elevated as much as possible, and to apply a moderate compression to the thigh, extending from its upper part downwards, as far as the upper angle of the wound, by means of a bandage similar to the *spica of the groin*, which, after some turns round the pelvis, descends circularly along the thigh. It will likewise be proper that the patient should soon begin to extend and bend the knee gently, in order to prevent the rigidity of this joint, which might occur from the knee remaining long in a state of semiflexion. It happens in some particular cases, and principally when the ligature of the femoral artery is longer than usual of being detached, that the cellular substance which surrounds and accompanies this artery, above and below the place of the ligature, inflames violently, and becomes mortified, without the adjoining parts partak-



ing of the affection. In these circumstances, the sinuous ulcer which is formed above and below the ligature, and in the course of the tied superficial femoral artery, does not heal until that portion of dead cellular substance is completely detached and expelled from the wound. This, in regard to the portion of cellular membrane, extending from the upper angle of the wound towards the bend of the thigh, is not long of taking place, after the ligature of the femoral artery has come away; but it is not equally so in regard to that other portion of mortified cellular substance extending along the superficial femoral artery, from the inferior angle of the wound downwards, or in the vicinity of the place where the superficial femoral artery perforates the long head of the adductor magnus muscle to descend into the ham. In this case the portion of dead cellular substance occasions an abscess with a generation of air, which protrudes in the direction of the superficial femoral artery in the vicinity of the knee, and at the same time between the lower heads of the gracilis and semimembranosus muscles, with œdema round the lower part of the thigh and knee, with fever, a small frequent pulse, and great prostration of strength. The matter contained in this abscess can with difficulty be discharged, even after the ligature has separated, at the lower angle of the wound, and the small quantity which issues is putrid, fetid, and accompanied with bubbles of air. On the appearance of this accident, which is for the most part after the twentieth day from the operation, it is absolutely necessary to make a counter-opening in the vicinity of the knee, in the direction of the superficial femoral artery, and, if necessary, also between the lower heads of the gracilis and semimembranosus muscles. From these openings there issues at first a



thin pale-coloured matter, very fetid, with a burst of air; it is then followed by the portion of dead and corrupted cellular substance; when this is detached and expelled, the general symptoms abate, the œdema round the knee disappears, the matter becomes healthy, the wounds puts on a florid colour, and quickly cicatrizes. The accident just mentioned, however, as far as I know from my own experience, and the experience of others, takes place very rarely, in consequence of the operation we are treating of.

§ 24. While the wound goes on cicatrizing, the popliteal aneurism diminishes daily in circumference and depth, and by degrees the tendons of the flexor muscles of the leg are every day discovered more distinctly at the sides of the tumor. Towards the fortieth or the fiftieth day, the popliteal aneurism is found to be reduced to a small bulk, and the patient may then get out of bed. At first, notwithstanding the precautions which have been taken, he sometimes finds a difficulty in extending his knee completely, and especially in resting the weight of his body on it; but, encouraged and assisted by the use of embrocations and frictions, repeated several times a-day with warm olive oil all round the knee, and along the flexor muscles of the leg, he at last comes, one or two weeks after he has got out of bed, to extend the leg perfectly, and to use it equally well as the sound one. The time in which the total absorption and disappearance of the aneurismal sac in the ham is effected, is in proportion to the size of the tumor, and the age and constitution of the patient affected with it. For the most part in the young and robust, in whom the popliteal aneurism does not exceed the size of a goose's egg, the disappearance of the tumor is ef-



fectured in seven or eight months, and only leaves a very small, hard, indolent knot, which occasions no inconvenience, and does not impede the motion of the limb.

§ 25. Of all the steps of this operation, the following points deserve particular attention. 1. The place of the incision which I prefer, is in the upper part of the thigh, or a little higher than the place where Mr. Hunter used to perform it; in order to avoid the necessity of removing too much from its situation, or of turning back the sartorius muscle, for bringing into view and tying the *superficial* femoral artery below it. 2. The manner of insulating the *superficial* femoral artery from the cellular substance with the point of the finger, rather than with a cutting instrument, in order to prevent in this way the division of any collateral branch, and the insulating the artery only in that space which is required for the application of two ligatures near to each other, and of a cylinder of linen corresponding exactly to the breadth of the point of the finger, or a little more. 3. The ligature by means of two waxed tapes, of convenient breadth, placed behind and round the artery, near to each other, with the interposition of a roll of linen, of a cylindrical form, between the artery and the knot. 4. The express omission of the ligature of *reserve*. 5. The giving the preference to the simple, rather than to the double, or surgeon's knot. 6. The unremitting attention, during the subsequent cure, that the lips of the wound do not approach too near, and still more that they do not adhere together, before the ligatures and the roll of linen are expelled from the wound, and till the bottom of the wound has risen nearly to a level with the integu-



ments. 7. The timely incision or counter-opening in the case, although it is not frequent, of an abscess forming in the vicinity of the knee, along the course of the superficial femoral artery, occasioned by the portion of cellular substance surrounding the artery passing into mortification.

§ 26. Modern surgeons have found great fault with the needles commonly employed in the operation for aneurism; principally, because they are of such a form and curvature, that the point cannot be raised without pressing strongly with their handle against the recent and sensible lips of the wound. This is very true with regard to the ligature of the popliteal artery in the bottom of the ham, but the same difficulty does not occur in the ligature of the *superficial* femoral artery in the upper part of the thigh, especially if the surgeon takes the precaution of raising with the point of the fore-finger of his left hand the artery alone, or along with the vein, before passing with his right hand the needle armed with the two tapes behind the artery; for, in this manner of operating, the femoral artery is not found very deep-seated in the wound, and therefore the common eyed-needle for aneurism is sufficient for the purpose. In regard, also, to the tightening the knot upon the femoral artery, at the place where I have pointed out the incision ought to be made, there is no occasion to have recourse to any instrument, and still less to that denominated *presse-artère*, which some surgeons direct to be left in the bottom of the wound for some days; for it is certain, that the surgeon's fingers are sufficient to draw the knot, and tie the superficial femoral artery, at the place above pointed out, with the greatest facility,



simplicity, and accuracy; which I can assert, from my own and repeated experience.

§ 27. As in all the cases in which it is proper to tie one of the great arteries of the second order, so in the new method of curing popliteal aneurism, one of the accidents which is more than any other to be dreaded, is *secondary* hemorrhage, whether it happens from over anxiety to remove the ligature, or from a premature laceration of the proper coats of the artery, brought on by too tight a ligature. This severe accident happened repeatedly to Mr. Hunter himself, after the ligature of the *superficial* femoral artery, and has happened to many other celebrated and skilful surgeons after him; and it is a fact well worthy of mature reflection, that this disaster, for the most part, occurs between the tenth and fourteenth day after the operation. I have already said, that the ligature of *reserve*, most generally does not answer the intention, and that even, in all probability, it is to be reckoned among the causes producing this accident, to remedy which, the surgeon and assistants do not always arrive in sufficient time, from the patient losing a considerable quantity of blood, and from the strong commotion of his mind, bringing along with it consequences fatal to the event of the cure. Reflecting on this very important point of the cure of popliteal aneurism, and considering at the same time, that *secondary* hemorrhage very rarely, or never happens, in consequence of the ligature of the *superficial* femoral artery after amputation of the thigh, in which this artery is drawn out and tied separately; and that on the other hand, this disaster was very frequent after amputation of the thigh, when the surgeons were in the habit of per-



forating the flesh with a crooked needle, and of tying the artery along with a great quantity of muscular and cellular substance, I think we may from thence justly conclude, that the *secondary* hemorrhage, in the case of aneurism, may be ascribed to the one or other of the two following causes, viz. to the inaccuracy of the surgeon in separating the *superficial* femoral artery from the cellular sheath in that portion over which he intends to apply the ligature, or to the too great force which he employs in tightening the artery circularly. The union of the two opposite sides of an artery, as I have mentioned several times, only takes place by means of the *adhesive* inflammation, to excite which, and in order that it may produce the desired effect, it is necessary that the artery be not insulated too much, or beyond the limits of the ligature; that the degree of pressure be such as to put and keep the two opposite sides of it in complete and firm contact; that the irritation caused by the pressure, be sufficient to produce inflammation in the proper coats of the artery, without their passing immediately into a state of mortification from a want of vitality. If this degree of pressure is too small, the artery does not inflame sufficiently, and is not obliterated, but is rather wasted slowly, and then bursts; if the pressure is too great, and especially upon an artery insulated in a greater space than is required for the ligature, it mortifies, ulcerates, and opens before the sides of it have adhered to each other, both at the place of the ligature, and for a certain space above and below it.

§ 28. Both of these accidents may be avoided, by separating with the point of the finger, and insulating the *superficial* femoral artery from the cellular substance, in that portion only corresponding to the space



which the ligature ought to occupy, which space is a little more than four lines. In stripping the artery in that part of its cellular sheath, it is to be done so that the ligature falls on the proper coats of the artery only, so that the surgeon can calculate with precision the degree of pressure which he ought to employ for keeping the two opposite sides of the artery in mutual and firm contact, without danger of being lacerated by the tapes, or thrown into mortification. The Arabian physicians, as I shall shew in another place, were very careful in the performance of this important article of practice, relative to the ligature of the great arteries of the extremities; for they invariably, before tying one of these arteries, not only laid it bare accurately for a certain space, but likewise, that the ligature which they applied might not include other parts than the denuded artery, they lifted up the artery with a blunt hook. The two waxed tapes which I propose to employ, placed contiguous to each other, each of which is two lines in breadth, rest upon a convenient space of denuded artery, on which account they can with difficulty produce its division. As the ligatures are only tightened upon the artery by the intervention of a cylinder of linen, placed on the artery lengthwise, and as the transverse diameter of this cylinder projects a little beyond the sides of the artery, it therefore follows, that when the knot is conveniently tightened, the sort of ligature formed by it is not, as commonly happens, a circular strangling, or puckering of the proper coats of the artery, but, properly speaking, an approximation of the two opposite sides of the artery for the space of four lines, or as if the artery in all that space were kept compressed and held between the points of the two fingers. This, in my opinion, is the best mode the surgeon can take



to prevent the rupture of the coats of a great artery, and to hinder their too rapid mortification, to excite in them a due degree of adhesive inflammation, to promote the union and obliteration of the cavity of the artery, and thereby remove the danger of *secondary* hemorrhage. Mr. Burchall,\* in tying the *superficial* femoral artery circularly, as is generally practised, exposed the patient a few days after to a most dreadful *secondary* hemorrhage. He immediately passed a second ligature above the first, he inserted between the artery and the knot a cylinder of plaster, and then not a single drop of blood appeared during the whole time of the cure.

Mr. Thompson Forster,† besides the small compress or cylinder of linen, wished that over this there should be placed lengthwise a segment of a cylinder of wood, three quarters of an inch in length, and a third of an inch in breadth; but experience has convinced me, that the cylinder of linen alone answers the intention perfectly well. It is a constant fact, that the ligature applied in this manner, or by the interposition of a cylinder of linen, is much longer of being detached from the artery than the ligature performed in the common way. Experience has demonstrated to me, that the ligature applied in the first way is not detached from the femoral artery till the eighteenth, twentieth, twenty-first day, very rarely or never before the fourteenth day after the operation; while it is well known, that the ligature applied upon the same artery in the ordinary way, quits its hold most frequently the seventh or tenth day after the operation; a period at which surgeons are usually on their guard, from the

\* Medical Obs. and Inquiries, vol. iii, p. 108.

† Medical Facts and Observ. vol. v, p. 6.



fear of a *secondary* hemorrhage. If, as I have said above, to avoid this severe accident, it is necessary that the *ulcerative* process of the artery at the place of the pressure caused by the ligature happen after the *adhesive* process is perfectly completed, it is evident that the first mode of ligature, as that which is longer of coming away from the artery, will favour more than the other the perfect adhesion and obliteration of the artery, and will therefore more effectually remove the danger of secondary hemorrhage. This mode of preventing *secondary* hemorrhage, it is here proper to remark, is not at all new. The interposition of a small compress between the artery and the ligature, before drawing the knot, was practised by the ancient, especially the Italian, surgeons. They have all taught this precept relative to the ligature of arteries, particularly of a large size, and I do not know why so judicious and useful a practice has been abandoned. Heister \* even speaks of it diffusely. Bertrandi also mentions it, in his *Trat. delle Operazioni*, t. iii, p. 195. And, in my opinion, it is incomprehensible why M. Deschamps † should regard this practice as useless and hurtful, while he found it convenient and useful to interpose, between the ligature and the artery to be tied, the metallic plate of his *presse artère*.

§ 29. Ætius, ‡ after tying the brachial artery in two places at a short distance from each other, divided the artery between the two ligatures. Celsus § likewise mentions this practice, which was performed by many

\* Institut. Chirurg. t. i, p. 269.

† Loc. cit. p. 35.

‡ See chap. xi, § 21.

§ De medicina, lib. v, cap. 16.



surgeons in less remote times, as Severinus, Gouey, and others, whom I omit mentioning, and then abandoned by all good practitioners.\* At present, Mr. John Bell† and M. Maunoir‡ seem inclined to recal into use this method of tying the great arteries, or to finish the operation by the complete division of the arteries between the two ligatures, from the persuasion which they entertain of the efficacy of this method in preventing *secondary* hemorrhage. Maunoir asserts, that the muscular coat of the arteries is furnished not only with circular, but also with longitudinal fibres; and he is pleased to estimate the muscular retraction of the arteries at six lines, and at other six the retraction depending on the elasticity of the arteries themselves. I really do not know if any one has hitherto demonstrated the existence of longitudinal fibres in the muscular or in the *internal* coat of the arteries, as Van Swieten pretends; but I am convinced that it requires a weight of eight pounds at least to break the femoral artery. It will be difficult for any one to persuade us, by a simple assertion or theory, that the action of the longitudinal fibres of the muscular coat of the femoral artery, however it may be excited by the irritation produced by the ligature, ever comes to exercise a force of retraction equal to eight pounds weight. The success obtained by Maunoir in a fox and in the arm of a man, are not sufficiently satisfactory to prove, that this division of the

\* Heister. Instit. Chirurg. t. i, pag. 270. Callisen. Principia System. Chirurg. t. i, § 946. Arteriam inter vincula mediam discindere ob extremorum retractionem nocuum et superfluum merito habetur.

† Discourses on the nature and cure of wounds.

‡ Mém. Physiol. et pratique sur l'Aneurisme, et sur la ligature des artères.



artery between the two ligatures is a sure method, excluding every other, of preventing *secondary* hemorrhage; for a very considerable number of facts may be related, from which it appears, that the femoral and brachial arteries have been tied in the common way, without *secondary* hemorrhage having occurred. Maunoir, in proof of his assumption, ought to have instituted comparative experiments, similar as to the circumstances of disease and of the subject; \* on which point I can affirm, that in two cases, in which the ligature was applied after the method of Maunoir or *Ætius*, by two Italian surgeons celebrated for their learning and skill in practice, in both a *secondary* hemorrhage took place. Supposing even that this pretended favourable success of the method of *Ætius* was invariable, we would have to examine whether this depended more upon the hindered or apparent force of retraction of the arteries by means of the division, than upon the great care which the surgeon ought necessarily to employ in performing this operation, by removing the artery from the cellular substance accurately, and from the parts surrounding it, before tying it, just as is done after amputations, in which the artery is drawn out alone, and is constricted in a degree proportioned to its size and density; and these are the circumstances which are very often omitted or neglected in the case of the ligature of an artery on account of an aneurism. In the method of tying the great arteries, which I propose to recal into use, not only all these minutiae are attended to, especially that of carefully denuding the artery as *Ætius* did, but also, by means of the interposition of the cylinder of linen between the artery and the knot, the artery is guarded from the circular constriction, which I re-

\* Vacca' loc. cit. pag. 40.



gard as a very important article to be fulfilled, and likewise from the excess of pressure on its proper coats, which might produce laceration or mortification of the coats of the tied artery before the union and obliteration had taken place. And since the method which I have pointed out would include one of the principal advantages resulting from that of *Ætius*, viz. the laying the artery completely bare, and as I can adduce a considerable number of comparative facts in favour of this method, as capable of preventing *secondary* hemorrhage, it appears to me, that, in the actual state of our knowledge, the preference ought to be given to the above-described method of tying the large arteries by the interposition of the cylinder of linen, rather than to that of the circular ligature, and division of the artery between the two ligatures, the advantages of which last method in preventing *secondary* hemorrhage have not yet been proved in a satisfactory manner either by theory or by practice.

§ 30. With regard to the keeping the lips of the wound slightly separated after tying the superficial femoral artery, and until the ligature is expelled from the bottom of the ulcer, the utility of this plan of cure is proved both by the unpleasant consequences which resulted in Mr. Hunter's first trials,\* when he healed the wound by the first intention, as well as by the advantages which he derived from following a local mode of treatment quite different from the first. For keeping the lips of the ulcer separated, I do not mean the cramming the sore with lint, but only the interposition at pleasure of a pledgit spread with simple ointment between the edges of the sore, so that its lips

\* Transactions of a Society for the improvement of Med. and Chirurg. Knowledge, vol. i.



may not approach too near, and still less form adhesions with each other, and prevent the exit of the ligature and of the matter. This precept, however, is only, properly speaking, the general rule adopted by all good practitioners in the treatment of ulcers which, from their situation and depth, and from the presence of foreign bodies in the bottom of them, may be complicated with phlegmonous congestions or purulent infiltrations under the aponeurosis and in the interstices of the muscles, whenever they are prematurely closed. Mr. Home,\* notwithstanding the unfavourable results obtained by his great master, persisted nevertheless in the opinion, that, after the ligature of the femoral artery, it was proper to heal the wound by the first intention. But the facts which he himself relates are in opposition to his doctrine. For, of four patients, whose history he has related, in the two first indeed the cure was effected by the first intention; but in the third, on the separation of the ligature, a very considerable quantity of matter issued out by the wound, which continued for a long time, and obliged him to employ a compressing bandage to prevent the infiltration. In the fourth patient the ligature remained so firmly embedded and compressed between the fleshy fibres at the bottom of the wound, that it could not be extracted till about a month after the operation.

§ 31. The aneurism in the ham, especially the *circumscribed*, produced by a wound of the popliteal artery, such as the stab of a sabre, sword, knife, or bayonet, or by a musket ball, the external wound being closed and cicatrized, may be radically cured by the

\* Transactions of a Society for the improvement of Med. and Chirurg. Knowledge, tom. ii.



new method, or by the ligature of the *superficial* femoral artery, as is done in that arising from an internal cause. If the aneurism in the bend of the arm caused by the puncture of a lancet may be radically cured by means of the ligature of the humeral artery above the aneurism, leaving the aneurismal sac untouched, as was done by Anel and Mirault, there is no reason to doubt that the same good effect will follow after the ligature of the femoral artery for the cure of aneurism in the ham produced by a puncture or wound of the popliteal artery. For, whether the blood be effused in the ham from a laceration or ulceration, or from a wound of the popliteal artery, the nature of the disease is the same; and further, in the case of a wound, if we except the solution of continuity produced by the wounding instrument, the surgeon has the full assurance that the proper coats of the popliteal artery are not at all disorganized for any space above and below the place of the injury, which there are strong reasons for suspecting takes place when the popliteal aneurism is occasioned by internal and not evident causes. And with regard to the old mode of operating, we must not flatter ourselves, that the aneurism of the ham being produced by a puncture or wound of the popliteal artery, there are therefore fewer difficulties to be encountered by the surgeon in the incision of the aneurismal sac, as was done formerly, with the intention of tying the artery in the bottom of the sac itself. Observation and experience have shewn, that whatever be the kind of aneurism of the ham, these difficulties are the same,\* depending upon the depth and narrowness of the place, the opening which it is necessary to make in the ham, the in-

\* Deschamps. loc. cit. pag. 25. Blessure de l'artère poplitée.



jury done to the sciatic and tibial nerves, the difficulty of the undertaking of tying the popliteal artery accurately, and drawing the knot with a proper degree of tightness at that depth above and below the place of the wound; and finally, on the danger of dividing or including in the ligature one or more of the *inferior* articular arteries, and on the extent of the wound to be cured; all which very great difficulties and dangers may be avoided by means of a simple and expeditious operation, as is that of the ligature of the femoral artery a little above the middle of the thigh.

§ 32. In a case of popliteal aneurism of very large size, of long standing, and ready to burst, in a patient rather at an advanced period of life, with great swelling and œdema, and little sensibility of the leg and foot, with acute pain in the seat of the tumor, with well founded suspicions of corrosion of the inferior and posterior surface, as well as of the heads of the femur and tibia, with a thin state of the aneurismal sac and of the integuments, and symptoms of approaching rupture, the circumstances are such, that a cure could neither be affected by the old nor by the new method of operating. Experience has unfortunately shewn, that even amputation of the thigh, always uncertain in its event, is still more so when performed on account of a popliteal aneurism, of which, except the fact unhappily too often confirmed by experience, no plausible reason or explanation can be adduced. This combination of circumstances puts the patient in imminent danger of losing his life, and the surgeon in a state of great perplexity about the plan he ought to follow. Penchienati\* thought,

\* Mém. de l'Acad. R. de Turin, an. 1784, 1785.



that in this extreme case it would be less hurtful to amputate the leg than the thigh; but hitherto surgery has not supplied us with facts confirming the justice and utility of this doctrine. I am inclined to think, that, instead of amputating the leg, it would be more useful in this case to disarticulate it at the knee. In the first place, because, as has been inculcated by Hildanus, and afterwards by Brasdor,\* and from what I have had repeated occasions to observe, disarticulations are much less subject to be followed by severe symptoms than amputations; in the second place, because, in making the disarticulation of the knee, turning the patella upwards, dividing the *lateral* and *crucial* ligaments, and carrying the incision posteriorly downwards towards the calf of the leg, the aneurismal sac is evacuated in such a manner, that the popliteal artery may be tied beyond it as high up as the seat of the rupture requires. I would not dread much in this case the corroded state in which the posterior and inferior surfaces of the thigh-bone are usually found, since this is, properly speaking, not a caries, but rather an excess, to say so, of absorption of the bony substance, occasioned by the violent pressure which the aneurismal sac, and the clots contained in it, have exercised on the bones; on which pressure being removed, there is every reason to believe that the bony substance will re-acquire enough of vitality at the place of the corrosion, to assume the process of granulation and cohesion with the soft parts which surround the stump. There would be more cause, in cases of very large aneurisms of long standing, to dread the state of

\* Mém. de l'Acad. R. de chirurgie, t. v. Le danger de l'amputation est en raison de la quantité retranchée de la surface de la plaie, de la nature des parties coupées, et des accidens qui peuvent suivre l'opération.



*steatomatous, ulcerated, earthy* disorganization of the popliteal artery in the cavity of the ham, and at a considerable distance also above the place of the rupture, from which the ligature applied in the ham would be rendered unsuccessful; in regard to which accident, it would be a subject of discussion, whether, before disarticulating the leg at the knee, it would be proper to tie the *superficial* femoral artery in the upper part of the thigh rather than in the ham. In the perplexed circumstances of which we are speaking, considering as proved the almost constant unhappy event of amputation of the thigh in similar cases, I would not hesitate a moment to adopt the plan of operating just pointed out; that is, I would prefer the disarticulation of the knee to the amputation of the thigh; and I would previously apply the ligature of the *superficial* femoral artery in the upper part of the thigh before disarticulating the leg at the knee. There can be no doubt, that, by operating in this way, the surgeon would have the greatest probability of tying the femoral artery, not only quickly, but also of tying it in a place where the coats of the artery would be sound, and in a state of undergoing the adhesive inflammation. Farther, by making the disarticulation of the leg, the surgeon would not be under the necessity of seeking, sometimes with great labour, the popliteal artery in the deep recess of the cavity of the ham, and be obliged perhaps also to divide the long portion of the adductor magnus, in order to make a way for tying the artery at a place where the coats of it did not partake of the disorganization which aneurism usually produces. The Arabian physicians tied the humeral artery in the vicinity of the axilla before proceeding to the incision of the aneurism in the bend of the arm, and notwithstanding this, the cavity of the bloody tumor passed



regularly through the stages of suppuration to granulation and cicatrization, without there being any remarkable change in the circulation or life of the rest of the arm. There is no reason to suppose that the same thing would not take place with regard to the stump after the disarticulation of the leg at the knee, although the *superficial* femoral artery were previously tied in the upper part of the thigh. Examples and facts may be adduced in confirmation of this assertion. Mr. Antrobus,\* surgeon, relates the following case. A man had his foot mortified after a malignant fever. By the use of bark and other proper remedies, the gangrene stopped, and separated two inches above the ankle. In spite of this, it was thought expedient to amputate the leg of this man at the usual place below the knee. Having cut it off, on relaxing the tourniquet, not a drop of blood issued from the great arterial trunks, nor could any pulsation be felt in these trunks at any point. Notwithstanding this, the fourth day after the operation the wound of the stump was found in a state of healthy suppuration, which was followed by a cicatrix, as in common cases. Wilmer† mentions, that he had observed a case similar to the preceding in a man, in whom, both at the time of the amputation and after it, no blood issued from the arterial trunks, and in whom nevertheless the stump suppurated and healed without interruption; from which this author very properly concludes, that in both of these cases the collateral vessels alone had had sufficient force to promote the suppuration and healing of the wound of the stump, and in the first case even at a considerable distance below the place of the obstruction or obliteration of the principal arterial

\* Med. Observ. and Inquiries, vol. ii, pag. 152.

† Cases and remarks in surgery, pag. 175.



trunk of the lower extremity. In the case, therefore, of popliteal aneurism of long standing, just about to burst, and complicated with all the inconveniences now mentioned, on account of which the whole inferior extremity cannot be preserved either by the old or by the new method of operating, if, instead of amputating the thigh, the preference were to be given, as it appears ought to be done, to the disarticulation of the leg at the knee, or to the amputation below the knee, the ligature of the superficial femoral artery in the upper part of the thigh, besides being applied in the sound part of the artery, would not at all hinder the collateral vessels having force sufficient to promote the suppuration, granulation, and healing of the stump. However, in the circumstances we are treating of, excluding entirely the amputation of the thigh, and adopting the maxim of tying the superficial femoral artery in the upper part of the thigh, experience and observation must determine whether the leg should be amputated below the knee, rather than disarticulated at the knee.

Finally, it has been remarked,\* that in some cases, after Mr. Hunter's operation, mortification has attacked one or more of the toes, but that it has been confined to the toes. This accident, to the best of my knowledge, is very rare, and probably only occurs in some individuals advanced in life, or extremely weak and unhealthy. At any rate, if this should happen in any of these enervated individuals, the patient may console himself for the loss of one or two of his toes with the cure of a popliteal aneurism, having avoided submitting to the painful and dangerous incision of the ham, and to the tedious suppurations and corruption which follow it.

\* Deschamps loc. cit. p. 114.



SUPP. to § 20.—John Hunter, for the cure of popliteal aneurism, tied the femoral artery a little below the middle of the thigh. He was therefore under the necessity of making the incision of the integuments and of the cellular substance of the thigh in a direction not quite parallel to the sartorius muscle; and he was obliged to raise and turn back the internal margin of this muscle, to lay bare sufficiently and tie the femoral artery before it passes to the ham through the tendon of the great adductor muscle. At this lower portion of the thigh the femoral artery is more deeply situated than at any other part of its course; consequently, it is always difficult and tedious for the surgeon, and painful to the patient, to lay it bare and tie it even in lean subjects. And this displacement and reverting of the internal margin of the sartorius muscle were reckoned amongst the principal causes of the copious and long suppurations, and of the sinusses by which the operations for aneurism performed by this illustrious surgeon were often followed.

Subsequent to that period, the greater number of surgeons have prudently preferred tying the femoral artery at the upper third of the thigh, that is, about four or at most five inches below Poupart's ligament, directing the incision of the integuments and of the cellular substance of the thigh close to the internal margin of the sartorius muscle. The course of this muscle is easily perceived under the skin, by turning the knee of the patient a little inwards before beginning the operation. At the upper part of the thigh the femoral artery is quite *superficial*: And its pulsation may be distinctly felt on pressing with the fin-



ger from the femoral arch to the point where it is crossed by the sartorius muscle. A little above this point, the artery is easily reached, and may be tied with equal facility without removing the sartorius from its natural situation or direction. At this place the ligature may be applied at a sufficient distance below the origin of the profunda femoral artery, without any risk of the blood, which diverges through this great lateral vessel, being a hinderance to the formation of the coagulum and the union of the two opposite internal parietes of the tied artery. The vicinity of the trunk of the saphena vein, whether it is single or double, and the proximity of the great lymphatic vessels ascending along the inner surface of the thigh, have never given occasion to any accident of importance in consequence of the incision made at the top of the thigh. To all these arguments may be added, that tying the femoral artery at the upper third of the thigh, there are good reasons to expect that the ligature will be applied where the artery is healthy, as this hope increases in proportion of the greater distance of the ligature from the ham, where the artery is in a diseased state. Farther, the more distant the ligature is from the ham, the less is the danger of the inflammation produced by the ligature extending to the aneurismal sac situated in the ham, and occasioning troublesome accidents.

It is a fact clearly and fully demonstrated by anatomy, and by surgical experience, of which there can be no doubt, that the circulation and life go on equally well in the operated limb, whether the femoral artery is tied at the upper or lower third, or in the cavity of the ham. Injections in the dead subject, and more especially the numerous operations of the ligature of the femoral artery at the upper part



of the thigh successfully performed, have placed this fact in the clearest light ; so that whoever should persist, from ignorance in anatomy or of the great resources of nature, or from excessive timidity, in the practice of tying the femoral artery at the lower third of the thigh, for the cure of popliteal aneurism, could not fail to encounter the disapprobation of all learned and skilful surgeons. And he would be still more reprehensible, should he persevere in the antiquated method of tying this artery in the cavity of the ham, thus preferring a laborious and dangerous operation to another directed to the same end, easily performed, and much safer.

It has been doubted, \* whether an aneurism at the upper part of the calf of the leg can be cured by means of the ligature of the femoral artery at the upper third of the thigh. And it appears that it was in consequence of this doubt that the author gave the preference to the ancient rather than the modern operation. Nevertheless, in the patient on whom the old operation was performed, the operator assured himself, *that on compressing the femoral artery at the upper part of the thigh, the tumor at the top of the calf ceased to pulsate ; and that, if the compression was continued for some time, the swelling of the calf partly disappeared, became softer and yielding, as it were, almost in a natural state, and on removing the compression, the tumor again became hard, and the pulsation was again felt.* If therefore in this case, *on compressing the femoral artery at the upper part of the thigh, the pulsation was stopped in the aneurism at the upper part of the calf,* it was evident that the aneurism might have been cured by means of the li-

\* Instituto Ital. di Scienze ed Arti, vol. i, Parte ii, pag. 266.



gature of the trunk of the femoral artery in the upper third of the thigh; which would have been much preferable to the exposing the patient to the great dangers inseparable from the incision of the ham. The *third* case recorded at the end of this work, which the operator undoubtedly was not unacquainted with, is a most convincing proof of this point.

It is of no avail the bringing forward the opinion already refuted, that the higher in the thigh the femoral artery is tied, the more uncertain is the event of the cure of popliteal aneurism, on account, as is said, of being deprived of the action of the muscular branches which arise from the trunk of the femoral artery, in the interval between the ligature and the aneurismal sac. The invalidity of this objection is proved, as has been already said, by anatomy, and the practice of surgery. And it is a manifest error to suppose that the muscular branches given off from the trunk of the femoral artery to the muscles of the thigh remain inefficient, and empty of blood, because the trunk from which they arise has been tied in the upper third of the thigh. These muscular branches, immediately after the ligature of the trunk of the femoral artery, are filled with blood from the numerous and easy anastomoses, which they maintain between the ramifications of the profunda femoral with the external circumflex, and with the perforantes. From all these arteries, immediately after the ligature of the trunk of the femoral artery, the blood passes into the muscular branches, as if it had been propelled into them directly from the trunk of the femoral artery, and from these, after supplying the muscles of the thigh, it descends into the *recurrent* arteries of the knee and into the *recurrent* tibial. For, the circuit which the current of blood is obliged to take after the



ligature of the principal trunk, is compensated by the increased velocity communicated to the column of blood which passes through the profunda femoral artery. This is rendered evident, immediately after the ligature, by the increased vibrations of the arteries which surround the knee, and the increase, soon after, of the heat of the whole of the operated limb.

It has again been stated as an objection, the possibility that, on the femoral artery being tied in the upper part of the thigh, one or more of the anastomotic branches may regurgitate the blood in the interspace between the ligature and the aneurism, and even into the aneurismal sac, and cause a renewal of the pulsation in the ham, and render the operation ineffectual. Far from denying the possibility of this communication, I am even of opinion, that it takes place in all such cases; but it does not necessarily follow, that the progress of the cure ought to be interrupted. For that stream of blood which regurgitates into the femoral artery below the ligature, has not force sufficient to distend the aneurismal sac, and in consequence of its feebleness and retarded velocity, it deposits in the sac the layers of lymph until it is completely filled, and thus closes up the entrance into the aneurismal sac. In the meantime, the absorption diminishes the size of the tumor, and completes the cure, as appears from case v, at the end of the annexed Memoir on the Ligature of Arteries. We must except, however, the case of wound of the popliteal artery, or of imprudent opening of the aneurism in the ham, in which cases the ligature of the femoral artery at the upper or lower third of the thigh would not be sufficient to suppress the hemorrhage, for reasons contrary to those



I have pointed out, on account of which it would be necessary to tie the popliteal artery above and below the wound, in order to cure this accident.

With regard to these anastomoses, it is a circumstance worthy of attention, that although immediately after the ligature of the principal trunk of the lower limb, all the lateral branches arising from the profunda and the rami *anastomotici* enlarge very much beyond their natural size, yet in progress of time, it is not all, or rather very few of these anastomosing branches which keep up the communication with the parts situated below the ligature of the principal trunk. White,\* as far as I know, was the first to remark this singular phenomenon, and to represent it in a plate copied from the arm of a woman who had been operated on for aneurism at the bend of the arm fourteen years before. The same remark has since been repeated with regard to the ham; and it is not unusual, on employing care, to find at the bend of the arm, and in the ham, besides the usual few anastomoses with the *articulars*, some other small communications between the arteries of the cellular substance and those of the capsular ligaments and of the periosteum, which have become singularly tortuous and serpentine, extending below the joint, and uniting with the ulnar or radial, very far down in the fore-arm, or with the tibials in the leg, at a great distance below the articulation † of the knee.

The Hunterian operation, wonderfully efficacious in the cure of aneurism of the bend of the arm, of that in the ham, and at the upper part of the calf of the leg, is not equally effectual in the cure of aneurism situated on the back or palm of the hand, or the

\* Cases in Surgery, an. 1770.

† Journal de Medicine par M. Leroux, T. 38.



dorsum or sole of the foot. The free communication which the two ulnar and radial arteries keep up with each other in the hand, and the tibial arteries in the foot, in spite of the ligature of the brachial or femoral, or even of one of the two large arteries of the fore-arm or of the leg, cause the blood of the *arteria socia* to flow back with force sufficient to keep up the aneurism either in the hand or foot. Of the latter I have seen two cases. In the first, the tumor as large as a nut was situated at the upper part of the tarsus; and in the second the pulsating tumor occupied the sole of the foot near to its outer margin. In neither was the ligature of the anterior tibial artery sufficient to stop the pulsation, and it was necessary to lay open the tumor, and have recourse to compression to stop the blood which was propelled in a retrograde direction by the *arteria socia*. The same occurred in the following case, which was communicated to me by my pupil, Morigi, junior.

A country girl, 33 years of age, of a weak constitution, was afflicted for several years, without any evident cause, with a small pulsating tumor under the sole of the foot near to its outer margin. She had not attended to this disease, because it gave her very little uneasiness. The tumor increased to the size of a pigeon's egg, became painful, and at last prevented the girl standing erect. At first compression was tried, along with low diet and complete rest for five months; after which the tumor had diminished very much, and seemed not to pulsate. The patient, in fact, thought herself cured, and wished to resume her usual occupation. But a month afterwards the tumor re-appeared as large as before, pulsating and painful. It was observed, that compression applied to the *anterior* tibial artery, at the place where it



passes over the dorsum of the foot, suspended entirely, or almost entirely, the pulsation of the small tumor. This artery was therefore tied exactly where it passes out between the tendon of the anterior tibialis muscle and the extensor of the toes. After this the pulsation was stopped, or became very obscure for nine days, and the tumor was diminished a little in size. On the tenth day the pulsation re-appeared, but not quite so strong as before the ligature of the *anterior* tibial artery. The insufficiency of this mode being also proved, the small aneurism was laid open in the direction of the outer margin of the foot. The jet of reflux blood was repressed by filling the aneurismal sac with caddis dipped in spirit of wine, secured by a proper bandage. On the fifth day after the operation, the dressings being loosened, there was a slight appearance of blood, which was stopped by the application of compresses, and of a second roller. On the 16th day suppuration appeared through the dressings, and on renewing them, granulation was found to have begun at the bottom and on the sides of the wound. In course of time the wound was brought to the state of a simple ulcer, and was not longer than usual in cicatrizing, although some small abscesses formed, at intervals, on the dorsum of the foot.

If, in a similar case, it were possible to tie the artery above and below the disease, this would be the best method of cure; but the circumstances of the situation do not allow this to be done without extensive incisions of the sole of the foot, on which account, after tying the *anterior* tibial artery, where it passes out to the dorsum of the foot, and thus having stopped one of the currents of blood which distended the small aneurismal sac, the other might be restrained by



compression, without the necessity of tying the posterior tibial artery.

This mode of operating is applicable with equal success to the cure of the small aneurism of the back or palm of the hand. In bleeding a man of eighty years of age in the hand, the dorsal artery of the thumb was wounded. Hemorrhage returning several times, and compression applied to the wound not being sufficient to stop it, the surgeon resolved to tie the radial artery at the wrist. After cutting off this direct current of blood towards the injury, compression to the wound was sufficient to stop the impetus of the retrograde blood of the ulnar artery. Three months afterwards this man having died, the radial artery was found for the space of three fingers breadth below the ligature contracted and rendered impervious, and the *dorsal* artery was likewise become impervious from the root of the thumb to the beginning of the palmar arch.

Monteggia \* deviated from his usual accuracy when he proposed to stop the hemorrhage from a wound of the radial or ulnar artery, by means of the ligature of the trunk of the brachial artery above the internal condyle of the humerus. Anatomy and the experience of surgeons have demonstrated the inefficiency of this method, the more inefficacious the nearer the injury of the radial or ulnar artery is to the wrist. And the same is the case with regard to hemorrhage arising from a wound of either of the tibial arteries at the middle or lower part of the leg. In all these cases of hemorrhage it is absolutely necessary to expose the wounded artery in the fore-arm or

\* Instit. Chirurg. Ed. seconda, vol. iii, pag. 177.



leg, and tie it above and below the place where it has been wounded.

Since the publication of this work, the manner of tying the principal artery of the extremities for the cure of aneurism has been improved, as will appear from the subjoined Memoir on that subject. In the first place, it has been observed to be of great importance not to detach or insulate the artery too much, but merely as much as is required for allowing a ligature to be passed round it. In the *second* place, that two ligatures are not at all necessary, to be tied contiguous to each other, in order to augment the points of pressure, one ligature composed of six waxed threads being sufficient for the large arteries. In the *third* place, that the ligature of *reserve*, as it is called, is more hurtful than useful. And that for passing the ligature round the artery, a small *eyed* spatula of flexible silver, a little broader than the ligature, has been found more convenient for this purpose than the needle usually employed in this operation. The fine flexible spatula, with an oval shaped eyed point, passes more easily than the usual needle between the artery and the vein and nerve; divides the intermediate cellular substance without tearing it, and without insulating the artery farther than is necessary for passing the ligature round it. Farther, the great flexibility of the instrument allows it to adapt itself, at the moment, to the depth of the parts where it is employed.



## CHAPTER X.

### OF THE CURE OF THE FEMORAL ANEURISM.

§ 1. THE aneurism, which forms in the course of the *superficial* femoral artery, sometimes occupies the lower part, sometimes the middle or upper part of the inner side of the thigh, and sometimes arises very near to the crural arch. This aneurism is often occasioned by a wound of the superficial femoral artery inflicted by a pointed or cutting instrument, or by a musket ball; sometimes, like the popliteal aneurism, it arises from a slow morbid internal cause, such as a partial congenital relaxation of the artery, or a *steatomatous, ulcerated, earthy* disorganization of some portion of its coats, in consequence of which, on the occurrence of any accidental blow or violent strain, the artery bursts at that place, and an effusion of blood then takes place all round the vessel, and an aneurism is formed. In a case\* which came under my own observation, the occasional cause of the femoral aneurism was a violent exertion which the patient had made to free himself from a painful cramp of the fleshy part of the leg of the same side.

§ 2. If, as has been shown, the ligature of the humeral artery cures radically the aneurism in the bend of the arm, and if the obstruction and obliteration of

\* Case v.



the *superficial* femoral artery in the upper part of the thigh are sufficient to effect the *radical* cure of the popliteal aneurism, without the circulation being hindered by it, or the life of the leg and foot diminished, no one, I should suppose, would have any hesitation in believing, that the same expedient, or the ligature of the *superficial* femoral artery above the seat of the rupture of this artery in the thigh, will be a method equally effectual as in the case of popliteal aneurism, and even more certain in its effects for *radically* curing the femoral aneurism, without intercepting the circulation or cutting off the life of the subjacent limb, whether the aneurism occupies the lower part, the middle, or top of the thigh. For if, among the circumstances which secure the favourable event of the radical cure of the popliteal aneurism, we reckon one of the principal to be the preserving entire and pervious all or a greater part, especially of the *inferior* articular arteries of the knee, this favourable circumstance will certainly never fail to be present in the case of femoral aneurism, as the seat of the tumor is above the cavity of the ham, and so high, that the aneurismal sac cannot in any way compress or affect any of the anastomotic articular arteries of the knee, and still less the inferior ones of this class of arteries of the ham. It is of little importance that the trunk of the *superficial* femoral artery become impervious below the ligature, and be converted into a ligament. For, to preserve the circulation and life of the corresponding leg and foot, it is sufficient that the collateral branches which go off from the *superficial* femoral above the ligature, combined with those of the *profunda*, communicate with the recurrent articular arteries of the ham; a circumstance which in similar cases is never prevented.



§ 3. The first case of this kind, as far as I know, of which there is any mention in the records of surgery, is that related by M. A. Severinus,\* from which it appears, that in a case of aneurism of the thigh, about eight fingers-breadth below the groin, occasioned by a musket ball, the femoral artery was tied above and below the rupture, with the most complete success. For, as Severinus relates, the patient by this means preserved not only the life, but likewise the power of making use of the lower extremity operated on, as well as of the sound limb. The noble boldness of M. A. Severinus, in tying the femoral artery in this case, cannot be sufficiently commended, as he acted contrary to the opinion of all the other medical men, except a certain Joannes Trullus; and still more, as it was opposed by the doctrine of Galen,† who, in speaking of the thigh, had declared, that it was impossible to save any one in whom the great artery of the thigh was wounded. It is a singular thing, that, even to the present day, the cure of which M. A. Severinus speaks, has been regarded by some as marvellous, and by others as referable only to a particular conformation‡ of the subject he operated upon, in whom it was supposed that the femoral artery was double, or divided into two, as the brachial is sometimes observed to be divided very high up, and even in the axilla into radial and ulnar arteries. And I am sorry to be obliged to mention among these, my master,

\* *Chirurgiæ efficacis*, part ii. *Ennaratoria*.

† *De usu Partium*, lib. iii, cap. 9. *Arteria namque insigni earum quæ illie, in femore statutæ sunt, vulnerata, nullo pacto servatur.*

‡ Heister. *de arteriæ cruralis vulnere periculosissimo feliciter sanato*, Dissert. § vi. *Imo si forte non nisi unicus arteriæ cruralis truncus hoc in femore adesset sicut sæpe observari solet, subinde ne ligatura quidem arteriæ læsæ ad sanandum hoc malum sufficere.*



Morgagni,\* who regarded this fact as a problem difficult of solution, except we admit, in the patient operated on by Severinus, the possibility of a double *superficial* femoral artery; and this ought to excite the more surprise, since we know, that at the time when Morgagni wrote upon this point, the tables of Haller were in every body's hands, in which were represented the vascular system of the lower extremities, and at the same time the anastomoses between the branches of the *superficial* and *profunda* femoral with the recurrent articular arteries of the ham.

§ 4. By whatever cause the femoral aneurism is produced, whether it be by a wound, or laceration, or by a *steatomatous*, *ulcerated*, *earthy* disorganization, with corrosion and rupture of some portion of the *superficial* femoral artery; since, in both of these cases, the immediate cause of the aneurism is the same, (viz. the rupture of the artery, and consequent effusion of blood into the cellular substance surrounding the artery), the indication of cure in all these circumstances must also be the same; that is to say, the obliteration of the *superficial* femoral artery above and below the place where the artery was wounded, lacerated, or ulcerated. I have remarked,† that the aneurism, which, from any of the above-mentioned causes, is formed in the lower part, or in the middle of the thigh, most frequently becomes in a short time *diffused*, while that which appears at the top of the thigh, as far as the distance of eight fingers-breadth below the crural arch, remains for a long time *circumscribed*. This diversity of form, extent, and quickness of increase between the inferior and superior aneurisms of the thigh, depends, as I have

\* De sed. et causis morb. epist. i, art. 12.

† Chap. vi, § 31.



said, upon this, that the inferior aneurism is only covered by a thin aponeurotic web of the fascia-lata, by a weak cellular substance, only opposing a feeble resistance to the blood, which by its quantity and weight, and by the declivity of the place, makes itself a passage between the *second* and *third* adductor muscles on the posterior surface of the thigh. On the other hand, the aneurism which arises at the top of the thigh, and in the vicinity of the crural arch, rests upon a layer of firm cellular substance, and is covered anteriorly by a portion of compact aponeurosis, extending from the fascia-lata upon the groin and upon the crural arch, by which the extravasated blood not being able to sink easily deep between the muscles of the top of the thigh, nor force the integuments outwards, generally forms at this place a *circumscribed* pulsating tumor, which remains very often stationary for a long time.

§ 5. Of the two methods which surgery possesses for effecting the radical cure of aneurism, *compression* and the *ligature*, the former is completely excluded in a case of femoral aneurism, as invariably, or at least for the most part, useless and hurtful. The *superficial* femoral artery is not placed directly opposite to the thigh-bone, as the popliteal artery is, so as to be sufficiently and steadily compressed against that bone. The direction which it would be required to give to the compressing force would be from the inner towards the outer side of the thigh, subjecting at the same time the bodies of the adductor muscles of the thigh, which the patient cannot endure. And not being able to make the compression succeed in obliterating the artery, the pressure cannot fail to be an useless and hurtful method; both because, without pro-



ducing the end for which it was applied, it would cause the skin and aneurismal sac to mortify, and because it would make the aneurism, from being *circumscribed*, become *diffused*, and the extravasted blood would force a way for itself between the adductor muscles on the posterior surface of the thigh, with great destruction of the cellular substance that ties these parts together, and would injure the great sciatic nerve. The compression then is equally inapplicable in the aneurism at the top of the thigh; because the cellular stratum upon which the femoral artery rests, although firm and compact, cannot offer a sufficient resistance to the compressing force, so as to keep the two opposite parietes of the artery in complete and firm contact; and because it would be injurious to the circulation and the life of the subjacent limb, if the compression were, without necessity, employed high up, and applied against the edge of the pubes, where the femoral artery passes out below the crural arch, and above the origin of the *profunda*. For which reason, the ligature of the *superficial* femoral artery is the only and truly secure expedient which the surgeon has for the radical cure of the femoral aneurism. This operation, which is precisely the same as I have described in the preceding chapter, the sooner it is performed after the appearance of the aneurism, the more successful it is; since it is evident, that the smaller, the more *circumscribed* and recent the aneurism is, the less is the state of atony of the surrounding cellular substance, the quicker the absorption of the grumous blood, and the more rapid the disappearance of the tumor.

§ 6. That Mr. Hunter's method, or we might say Anel's, may be employed with hopes of success



for the radical cure of femoral aneurism, is a fact, proved both by dissection, and by those very facts which attest the favourable event of the cure of the popliteal aneurism, by means of the ligature of the femoral artery in the upper part of the thigh. I shall nevertheless relate some cases, which will serve more fully to confirm this truth. "Cauzat,\* a man about fifty years of age, a ropemaker, perceived a small tumor, of the size of a nut, in the superior and interior part of the left thigh. This tumor, when the patient was visited for the first time by the surgeon Lacoste, about six weeks after its appearance, was of the size of a small egg, and was accompanied by all the marks which characterize an aneurism. This disease was attributed to having taken mercury in too great quantities at different times. The cramps were blamed, by which the patient had often been tormented, and still more the violent motion in the exercise of his trade. The rapid progress of the tumor determined the surgeon Lacoste to perform the operation of the ligature of the femoral artery above the seat of the aneurism. Having therefore laid bare the femoral artery, he passed two ligatures round it, and placed them contiguous to one another. He tightened the inferior ligature, which not long after became loose, and obliged him to draw the upper one. On the tenth day after the operation, a hemorrhage appeared, which was ascertained to depend upon the femoral vein having been included and cut through by the ligature; but it was easily stopped. After this nothing worthy of remark occurred, and the patient was cured in the course of fifty-seven days.

\* *Recueil Periodique de la Societ  de Med. de Paris*, N. xxvi.



The femoral aneurism, immediately after the upper ligature was tied, became soft and indolent; it then gradually diminished in bulk, and, five months after the operation, was found reduced to the eighth part of its former size. The patient, after he was cured, did not require any support in walking."

"Carthy, an artisan, thirty-seven years of age,\* came into the hospital the 30th July 1794, to be cured of a femoral aneurism. The patient, nine months before, had perceived that there was a tumor at the place where the femoral artery is about to pass through the triceps muscle, to which he at first paid little attention, as it did not give him any remarkable uneasiness, and did not prevent him working. This tumor, which arose spontaneously, and had not been preceded by any external violence, remained stationary for about six months; it then began to be painful; no pulsation was evident in it till it had acquired the size of an egg. At this time the patient was advised to foment the part, and to anoint it with liniments; then to compress the tumor with a bandage; but all to no purpose. In the meantime, the tumor increased to a considerable size, and the whole of the subjacent limb became preternaturally swelled. The patient was of an hypochondriac, irritable temper, and low-spirited, and complained of acute pain in the whole of the affected limb, which however seemed to be relieved by the compression applied to the tumor. He was in this state when he came into the hospital. Having premised a venesection, the use of purgatives, and low diet, we proceeded to the operation the 11th of August. This operation consisted in laying bare the femoral artery by means of an inci-

\* Forster. Med. Facts and Observ. vol. vi, p. 115.



sion along the edge of the sartorius muscle, beginning about an inch below the origin of the *profunda*. Having denuded the artery, and passed a ligature round it by means of an eyed probe, the artery was tied, interposing between the artery and the knot a small compress of linen, and over it a segment of a cylinder of wood. The ligature being tied, the pulsation immediately ceased in the whole of the artery below. A second ligature was applied about half an inch above the first, to be used in case of a *secondary* hemorrhage occurring. Ten days after the operation the first ligature came away easily, and the day after the second was also detached. The bulk of the tumor went on decreasing gradually, and in seven weeks the femoral aneurism was completely absorbed, so that the patient left the hospital perfectly cured." The author makes the following remarks. 1. That although the femoral aneurism in this case was very large, yet the swelling of the limb was much less than in cases of popliteal aneurism of equal size. 2. That the femoral artery being tied very high up, the operation was followed by milder symptoms than when the artery is tied lower down in the thigh. 3. That the ligature came away of itself the tenth day, without occasioning any *secondary* hemorrhage. 4. That the aneurismal tumor was absorbed in a shorter time than is usually required in a case of popliteal aneurism, in similar circumstances.

I have likewise operated upon, in the same manner, and with complete success, a very large femoral aneurism, \* situated much higher up in the thigh than either of the cases just related, as the tumor was si-

\* See Case v.



tuated little more than two inches below the origin of the *profunda* femoral artery. I had in this case an opportunity of comparing nearly all that had been observed by Mr. Forster. For, in the patient on whom I operated, although the tumor was about the size of an orange, yet the leg and foot were not at all preternaturally swelled; the operation was not followed by symptoms of any importance; and the absorption certainly went on more rapidly than usually happens in a case of popliteal aneurism of equal size.

§ 7. Whether the femoral aneurism is produced by an internal cause, that is to say, by a morbid state, or ulceration of some portion of the proper coats of the femoral artery, or by a cutting instrument, or fire-arms; provided the tumor is *circumscribed*, has increased slowly, and is not accompanied by symptoms of excessive distention of the parts which it occupies, and in particular of the integuments, Mr. Hunter's operation will always be the most expeditious, secure, and least painful method for the patient, which surgeons can employ for the radical cure of this disease. But in that species of femoral aneurism which is occasioned by a cutting instrument, or by fire-arms, it not unfrequently happens, that on account of the large laceration made obliquely in the femoral artery by the wounding instrument, the blood issues with so much impetuosity, and is effused in such quantity into the surrounding cellular substance, that in a short time it forms on the inside of the thigh a *diffuse* aneurism of prodigious size, by which the muscles being forcibly separated, and the integuments greatly raised, the vast tumor occasions intolerable pain, violent fever, prostration of strength, and threatens to inflame and burst.



In these urgent circumstances, the operation of Mr. Hunter is too slow in its effect to produce that degree of diminution of the tumor required for removing the excessive distention occasioned by the extravasated blood; therefore, in similar cases, it is proper to proceed quickly to the incision of the tumor, to evacuate the clots of blood, and to tie the femoral artery above and below the wound. This may be performed with the more confidence, as, the aneurism being produced by an incision or laceration of the artery, from an external cause, the artery preserves its disposition to unite, and to obliterate its canal immediately above and below the place of the injury. The inner side of the thigh, besides, allows an opportunity of performing this operation without great difficulties; which cannot be said in relation to the aneurism of the popliteal artery, by whatever cause it is produced.

§ 8. The operation to be performed is nearly the same as was performed in a similar case, with perfect success, by M. A. Severinus. The patient is to be brought to the edge of the bed, and an assistant is to be directed to compress the femoral artery as it passes out below the crural arch, making use of his thumb, or of a compress in the form of a seal, or a bandage rolled hard. The operator, with a convex-edged bistoury, will, with one stroke, divide the bloody tumor, in its whole length, in the direction which the *superficial* femoral artery naturally takes, endeavouring, as much as possible, to make the incision pass through the wound, or cicatrix left by it. Having evacuated the clots of blood, and washed the bottom of the tumor, the surgeon will immediately see the artery, and discover the place where it has been



wounded.\* The surgeon will introduce through the incision or rupture a large probe, or a female catheter, and will raise the artery with it, while he detaches it with the point of his fore-finger for a small space from the cellular substance at the upper and lower part of the wound, and from the great femoral vein; then, by means of an eyed needle, he will pass behind it a waxed ligature about two lines in breadth. Then, turning the probe from above downwards, he will raise the lower portion of the femoral artery, behind which, and below the wound of the artery, he will pass in the same manner a waxed ligature similar to the first. He will then tie the artery above and below the wound, attending to place between the artery and the simple knot a roll of linen. Having suspended the compression at the crural arch, if any

\* M. A. Severinus was so much surprised at the readiness with which, after evacuating the clots of blood, the wounded femoral artery presented itself, on account, as he very justly remarked, of the separation which the blood had produced in the muscles of the thigh, and of the insulated state of the femoral artery, that he was induced to advise surgeons, in order to profit by this advantage, not to undertake the operation till as late as possible, unless they were forced to do it by hemorrhagy. ‘*Multa equidem,*’ says he, ‘*in hoc casu sunt admiranda; tria tamen omnem admirationem superant; quorum primum, quod intervallo quadraginta dierum sanguis extra vas citra insignem putredinem potuerit conservari. Secundum, quod ita sanguis musculos ab invicem divulgavit, ut eodem grumoso extracto, statim obvia nobis fuit arteria, ac si arte muscoli separati fuissent, qui operandi commoditatem miram præbuerunt, unde hoc casu edoctus, omnibus non esse statim ad operationem confugiendum consulo, sed post adhibitam omnem industriam imo tardius quam serius, nisi hæmorrhagia ad manus cogat. Tertium, et ultimum, quod natura post alligatam arteriam eodem modo partem aluisse, ac si ab integra arteria irrigata fuisset, ut nec minor mole, aut altera debilior robore remanserit. De efficaci medicina.*’



small arterial branch pours out blood, he will tie it separately, in the usual manner; otherwise, having again washed and cleaned the bottom of the bloody tumor, he will fill it with soft lint. The threads of the ligature should be placed in the two angles of the incision, taking care to roll them up in a piece of fine linen; and the part is to be covered with a compress retained by the four-headed bandage. The other parts of the cure will be conducted as has been mentioned in the preceding chapter.

§ 9. It is a very embarrassing and difficult situation in which the surgeon is placed in regard to the aneurism of the thigh, when the aneurism is inguinal, or occupies the top of the thigh a little below the crural arch. For setting aside the uncertainty in which the surgeon is, whether the rupture of the artery include with the *superficial* femoral artery the origin of the *profunda* also, and whether the morbid state of the proper coats of the artery extend far above the place of the injury, the narrowness and shortness of the space between the point of the passing out of the artery from the abdomen, and the top of the tumor, do not allow the operator to bring the femoral artery conveniently into view, in order to be able to tie it; or, in doing this, he is under the necessity of denuding this artery so high up, and so near to the crural arch, that he is obliged to include in the ligature with the *superficial* femoral artery the origin of the *profunda* also; which combination of circumstances is one of the most unfavourable to the success of the operation. This article, therefore, deserves the most serious attention.

§ 10. We learn from dissection, that the bifurcation of the common femoral artery into *superficial*



and *profunda* in a middle-aged man, takes place at an inch and an half, sometimes at an inch and three quarters, very rarely at two inches, below the crural arch, never below this point. In twelve subjects of the same age and stature, in which I measured the distance between the crural arch and the origin of the *profunda* femoral artery, I found that this statement was correct. Now, supposing that the top of the femoral aneurism reaches to two inches below the crural arch, (a very high position in the bend of the thigh), and admitting also that the size of the aneurism is equal to a large hen's egg, since it appears from certain and repeated observations, that the rent in the artery always corresponds to the centre of the tumor, or even, as some pretend, to the lower third of the tumor,\* the rupture of the artery in the case we are speaking of will be a little more than an inch lower than the top or upper part of the aneurism; that is, the rupture would be three inches below the crural arch. Allowing the maximum of the distance from the crural arch to the origin of the *profunda* femoral artery, that is, two inches, there will remain in this case somewhat more than an inch of *superficial* femoral artery, upon which the ligature might be applied without including the origin of the *profunda*. If the aneurism was twice as large as a hen's egg, the distance remaining the same, that is, two inches between the crural arch and the top of the tumor, and supposing that the place of the rupture of the artery corresponds to the middle or lower third of the tumor, there would be an opportunity of tying the *superficial* femoral artery at two inches below the origin

\* Deschamps. Recueil Period. de la Société de Méd. de Paris, t. x, p. 57.



of the *profunda*; a circumstance still more favourable than in the first case to the success of the cure.

§ 11. Since, therefore, the space of two inches from the crural arch to the top of the aneurism is too short for bringing into view and tying the *superficial* femoral artery, without running the risk of being obliged to tie at the same time the origin of the *profunda*, while from the top of the tumor to its middle there is enough of *superficial* femoral artery to allow of its being tied, independent of the *profunda*, it is evident, that in this case the best plan to follow is that of opening the tumor, by making an incision into the aneurismal sac from below to its upper part, in the manner and with the precautions I am going to point out. Having placed the patient in an inclined position on the edge of the bed, with the thigh and leg slightly bent, a skilful assistant is to compress the common femoral artery as it passes out below the crural arch. The surgeon will introduce a sharp pointed bistoury into the lower part of the tumor, so as to enter the cavity of the aneurism, and with one continued stroke he will divide the tumor from below upwards to the top of the tumor, and contiguous to the fingers of the assistant who makes the compression. Having evacuated the clots of blood, and cleaned the bottom of the tumor with a sponge, the surgeon will immediately see at the bottom of it the rupture of the artery. He will introduce from below upwards, by this fissure, a silver female catheter, with which he will raise the *superficial* femoral artery. In doing this, he will take particular care to separate the *superficial* femoral artery from the *profunda*. This care is very necessary, as the *profunda*, immediately after its origin, runs for the space of an inch so near



to the *superficial* femoral artery, that both of these arteries seem there to form only one cord. Having then separated these two arteries from one another, the surgeon, by means of the eyed needle, will pass a waxed ligature, about two lines broad, behind the *superficial* femoral artery, and he will take care to place it in the middle space between the edge of the rupture and the origin of the *profunda*; then turning the point of the catheter from above downwards, he will raise the superficial femoral artery also below the rupture, round which he will in the same manner pass a second waxed ligature. He will tie the artery first at the upper part, then below the fissure, making a simple knot, and interposing a roll of linen between it and the artery, and over the first he will make a second knot. He will direct the assistant to suspend the compression; and if blood is thrown out by any small artery, he will secure it in the usual manner. Finally, having washed and cleaned the bottom of the aneurism, and arranged the ligatures in the angles of the wound, he will fill the cavity of the tumor with soft lint, over which he will apply a compress retained by a six-headed bandage. The advantages of this mode of operating, over Mr. Hunter's method, in the case of which we are treating, appear evident, from observing, in the first place, that the surgeon is not hindered by the fingers of the assistant who applies the pressure: in the second place, that he obtains a sufficient space for laying bare the *superficial* femoral artery, and for separating it accurately from the *profunda*: that, in the third place, he can safely tie the *superficial* femoral artery above the rupture, preserving the origin of the *profunda*; which he could not do, for want of sufficient room, if he employed Mr. Hunter's method.



§ 12. The case is much more alarming and puzzling when the aneurism is properly inguinal, and when it ascends so high as with its apex or upper part to occupy not only the crural arch, but extends likewise to the crest of the os ilium. Calculating even that the rupture of the artery corresponds to the middle point, or to the lower third of the tumor, it always happens that the ligature cannot be applied without including the origin of the *profunda* along with the *superficial* femoral artery. Here, therefore, the question occurs, whether, in similar distressing circumstances, the surgeon may tie the *common* femoral artery, with confidence of preserving the circulation and life of the lower part of the limb; in like manner, if he may flatter himself that so great a work may be accomplished by the action of the arteries serving as auxiliaries to the femoral. And supposing, even after the femoral artery is tied, that so great a diminution in the quantity of the blood, (which in a given time used to invigorate and nourish the whole inferior extremity), may be made with safety, we must ask, if it is to be expected that the impulse which the blood receives from the auxiliary vessels, or those of the third order, can be sufficient to keep up the circulation and life of the subjacent foot, placed at so great a distance from the heart, or centre of circulation. At first sight, and even from the most accurate anatomical knowledge we are in possession of, with regard to the arterial system of the inferior extremities not affected with aneurism, it would seem that we ought to have very little, or absolutely no confidence, of preserving the lower extremity after the ligature of the *common* femoral artery; nevertheless, some practical observations, instituted by men worthy of credit, authorize us to maintain the contrary, and to admit the possibility



of this surprising phenomenon, as well as to admire the extensive powers of nature, by means of which, and of apparently small resources, she is capable of repairing great losses.

My own practice stops here entirely, and I have merely as a guide the observations of Guattani, Gavina, Clarke, Mayer, the only ones with which I am acquainted. Guattani \* relates the history of one Felix Morelli, by trade a goldsmith, who had an inguinal aneurism, which extended from the pubes to the crest of the ilium, and by which he was reduced to a deplorable state. This able surgeon undertook the *radical* cure of it, by means of compression applied to the denuded common femoral artery, against the os pubis, or against the ramus of this bone, extending towards the acetabulum. Seeing the impossibility of commanding the stream of blood by means of pressure made by an assistant upon the crural arch, the operator directed the surgeon Massimini to open the large inguinal aneurism from the top to the bottom. The blood instantly rushed out *per saltum* with great impetuosity, and successively in such quantity as to fill two large vessels, more than which

\* De Aneurysm. Hist. xv. En quomodo hæc observatio duas illas sustulit dubitationes, quæ meum animum devexabant ; quum enim compressio, quam iliaca externa perpessa est, tanta fuerit, ut major fieri non posset ad inhibendum, ut ne vel minima sanguinis guttula per eandem transiret, mihi tuto colligere datum fuit, sanguinem universum, a quo articulus nutrimentum susceperat, per internam tantum iliacam dilatum esse ; quumque hoc aneurysma, etsi ab interna causa productum, pressionis beneficio fuerit sanatum, mihi evidenter innotuit ; compressionem valere ad aneurysmata qualibet persananda, sive causa eadem progignens externa fuerit, sive fuerit interna.—Hæc autem adeo stabilis atque perfecta sanatio fuit, ut paucos post menses Morellus baculum pariter deposuerit, nullumque aliud in illo incommodum relictum præter exiguam claudicationem.



was not collected, and was estimated to be about twelve pounds. After so great and so sudden an effusion of blood in a patient already much debilitated, Guattani proceeded to apply the compression on the denuded *common* femoral artery as it passes out from under the crural arch, and opposite to the ramus of the pubes, employing a number of graduated compresses, and a very tight bandage. The event of this operation was, that the hemorrhage was not only stopped by means of the compression of the denuded *common* femoral artery, but likewise the *common* femoral artery was obliterated as it passes out from below the crural arch. In the sequel, the wound suppurred kindly, and was covered by a cicatrix. The author assures us that the patient preserved the power of using the inferior extremity which had been operated on, and that he had no other inconvenience than a slight degree of lameness. The observation made by Gavina,\* and related by Guattani, tends to prove the same assumption. A man about 40 years of age, by trade a cook, of a cachectic venereal habit of body, and exhausted by a slow continued fever, had had an aneurism for three months in the left groin, of the size of a large fist, occasioned by an internal cause. The aneurism was attacked with gangrene, by which in a short time the aneurismal sac was destroyed, and at the same time the *common* femoral artery was obliterated for a considerable space from the crural arch downwards. The gangrenous parts separated notwithstanding, and the wound began to approach to a cicatrix, when the patient, greatly debilitated, was carried off by marasmus. In the course of about five weeks that this man lived after the obliteration of the *common* femoral artery above the origin of the *profunda*,

\* Loc. cit. Hist. xvii.



not only the circulation and life of the whole limb below were preserved, but also the auxiliary arteries coming from within the pelvis shewed that they had sufficient force to limit the progress of the mortification in the parts round the aneurism, and to commence the process of cicatrization with great hopes of a cure. Gavina makes the remark, very justly, that this man did not die from a want of circulation and life in the subjacent limb, but from the inevitable effects of the extreme general debility. The case of the man observed by Dr. Clarke\* was similar to this, in whom an aneurism supervened, after a violent blow in the left groin, which in the space of three months increased to the size of a melon, and was attacked by gangrene, and burst, without occasioning any loss of fluid blood. In this patient, as in the subject of the preceding case, the gangrene separated completely: and although the *common* femoral artery was obliterated above the origin of the *profunda*, the circulation and life of the subjacent limb were preserved. The wound had nearly healed, when the patient, from his own great want of care, exposed himself to an attack of an acute affection of the breast, of which he died. A country-man, 60 years of age, Mayer relates,† had a tumor in the groin for three years, caused by having lifted from the ground and carried a great weight. He told me, that the tumor at first appeared about the size of an egg, and that it gradually became painful, and increased to the size of a small child's head. The thigh and leg were swelled, and nearly as thick as his waist. On examining the tumor, and observing it to be situated at the place

\* Duncan Med. Comment. Decade ii, vol. iii.

† In Schmucker's Vermischte Chirurgische Schriften, 3. Band, pag. 327.



where *femoral* herniæ usually appear, Mayer adds, I conceived it to be a hernia; but as my attempts to reduce it did not succeed, I persuaded the patient to submit to the operation, as the only means of saving his life. It was undertaken by me in presence of Dr. Blumenthal. After dividing the integuments, I found the fascia-lata much distended, which I perforated cautiously with the point of a bistoury, from which opening blood issued out as from a fountain, and I then discovered an actual pulsation in the tumor, and I was convinced at that moment of its being a case of aneurism. I abandoned all further operation, and covered the tumor with a compress retained by the *spica* bandage. I removed the dressings 48 hours after, and, to my great satisfaction, I found the tumor very much diminished. I afterwards renewed the dressings, and applied the expulsive bandage to the whole limb, and over the tumor some compresses, which I secured with a bandage kept moist with Theden's vulnerary water. Two days after, I renewed the bandage, as it had become loose, and found the wound almost quite closed, and the tumor still more diminished. At the end of three weeks, the aneurism, by this method of cure, was reduced to the size of an apple. I then applied to it a plate of lead covered with leather, which did not occasion any inconvenience to the patient; and he is now so well that he can do any kind of work. Here Mayer's account finishes. I am sorry not to have been able to find any farther account of the final event of this disease, and principally, whether the residuum of grumous blood was afterwards entirely dissipated.\*

\* See Appendix, additional cases of inguinal aneurism, by Messrs. Abernethy, Freer, and Tomlinson. These cases point out a more certain and better mode of operation than that recommended by the author. T.



§ 13. If these facts should seem too few in number to authorize the ligature of the femoral artery above the origin of the *profunda*, they will be sufficient, in my opinion, to make every surgeon not lose hope altogether of success in these extreme cases, by tying or compressing the denuded *common* femoral artery against the ramus of the pubes, particularly if the subject of the operation is young and vigorous. Channels are certainly not wanting for the blood to pass from the great arteries of the pelvis to those of the thigh.\* The smallness only of their branches, without paying due attention to their number and to the multiplicity of their anastomoses, and experiments imperfectly performed on the dead subject, by means of coarse, coloured injections, after tying the *common* femoral artery,† have rendered it doubtful whether these auxiliary arteries be sufficient to preserve parts of so great size and extent as those which form the lower extremity. But besides that the cases now mentioned, which have occurred in the practice of surgeons, prove the possibility of this fact, some physiological reflections may likewise be adduced in support of its truth. For, if we do not scruple to tie the *superficial* femoral artery in the upper part of the thigh, because experience has taught us, that the collateral branches of this artery which are given off above the ligature, and those of the *profunda* femoral artery, anastomose with the articular arteries of the knee, there is no reason why we should not repose an equally well-grounded hope in the large arteries of the cavity of the pelvis, (as large as the femoral artery itself), the collateral branches of which artery, having scarcely passed out

\* Chap. ii, § 4.

† Penchienati. Mém. de l'Acad. R. de Turin, an. 1784, 1785, première partie.



of the pelvis, anastomose with the two great circumflex arteries of the thigh, and with the superior perforantes of the *profunda*. These anastomoses are not less, either in size or number, than those which occur round the knee; they are even, in point of diameter, greater, that is, in the proportion existing between the size of the hip and top of the thigh with the circumference of the knee; to which we may add, that the former, or the arteries which come out of the pelvis, are nearer to the impulse of the heart than the latter. The conclusions which are drawn from coloured liquors injected in the dead subject by the common iliac artery, after tying the femoral above the origin of the *profunda*, easily lead to error with regard to the natural pervious state and communication of that artery with the arteries of the thigh, both because the injection, in parts torn all round, recedes in various ways on the first obstruction it meets with, and because there is a great difference between the current of the injection of an inert fluid forced artificially through dead vessels, and the natural current of the blood impelled along living vessels. And in the same living subject, there is a great difference between the force with which the blood is conveyed by the lateral vessels of a limb perfectly sound, and that within the same lateral vessels of a limb, the principal artery of which has been gradually contracted, compressed, and obstructed, by the slow formation of an aneurism. For, from the moment in which the blood begins to be retarded in its course through the *superficial* femoral artery, or through it together with the *profunda*, the auxiliary arteries of the cavity of the pelvis are prepared, to use the expression, and gradually disposed to an equable dilatation, in order to supply more effectually the circulation and life of the whole inferior



extremity, whenever the course of the blood is completely intercepted and suppressed through the *common* femoral artery. We cannot, therefore, without error, calculate from the natural and usual caliber of the collateral branches of these arteries of the pelvis, and of their anastomoses with those of the thigh in a sound state of the limb, how great will be their dilatation and power of transmitting the blood to the thigh, when, from the obstruction occasioned, for a long period of time, by the aneurism, these auxiliary arteries of the pelvis have acquired a size much greater than that which they commonly have. Besides this, I repeat it again, there is such a difference between an injection within dead vessels, and the circulation of the blood through the same living vessels, that we should not therefore infer from the first what ought to be the difficulty or facility of communication of the auxiliary vessels, and of the principal trunks of a part.\* With regard also to the greater permeability of the lateral vessels of the pelvis of an aneurismatic limb, compared with the same vessels in a limb not affected with aneurism, we may consider Guattani's important case, *De inguinis, cruralisque art. aneurysm. hist. xvi.* In a man about 30 years of age, says he, dying of an inguinal aneurism, occasioned by a rupture of the fe-

\* On this point, it is an object worthy of curiosity and admiration to observe the manner in which we succeed in making a frog inject a coloured substance into its sanguiferous system, of itself or by means of the force of its heart and arteries. This is done by introducing gradually into the one or other of the auricles of the heart of this animal, by means of a small tube, a coloured fluid, such as spermaceti dissolved in cold water. The heart and arteries of the animal impel this injection into the finest vascular extremities of the viscera, and of the other parts, where it is undoubtedly not possible to make it pass by means of the same injection performed with a syringe in the dead body of the frog.



moral artery above the crural arch, or an inch below the origin of the internal iliac, who was carried off by the acuteness of the pains, and the violent fever brought on by the vast quantity of blood effused into the lumbar region and along the thigh, without gangrene, however, of the leg and foot, although the rupture of the femoral artery above the crural arch was of more than two months standing. On making an incision into the femoral artery in the body of this man, from the place of the rupture till where this artery acquires the name of popliteal, it was found to have gone on contracting more and more as it descended towards the ham, and in the vicinity of the ham it scarcely admitted a very small Anel's probe for the puncta lacrymalia. This same artery in the ham resumed its natural size. Having made a ligature on the femoral artery above and below the rupture in the abdomen, and injecting water by the common iliac artery, having first cut off the foot of the same side, it was observed, that the coloured water came out by the arteries which ramify round the articulation of the foot. Having tied the femoral artery in the thigh, in order to close the small passage which remained in it, the injection continued to issue out by the arteries of the foot as before. On tying together with this artery the popliteal also, the injection continued to flow out by the arteries of the amputated foot, but with difficulty, and in small quantity. From this case, it appears to me, may be deduced three very important corollaries. 1. That on the femoral artery being tied above the *profunda*, the internal iliac artery furnishes enough of blood for the preservation of the whole inferior extremity. 2 That on tying the femoral artery in the groin, or in the upper part of the thigh, that artery has a tendency to close spontaneous



ly, and to be obliterated along the thigh as far as the ham. 3. That the femoral artery in the ham retains its natural size, from receiving at this place the principal currents of blood, which is conveyed from the internal iliac, and other anastomosing vessels, into the articular arteries of the knee, and from these into the trunk of the popliteal, provided this last artery is in a sound state at the points of communication with these articular arteries of the knee. We may add to all this, that Dr. Baillie also found, in the dead body of an adult man, the femoral artery obliterated above the *profunda*, without its having occasioned the loss of the circulation, or deprived the corresponding leg and foot of their life.

§ 14. Having therefore demonstrated by facts the possibility of preserving the circulation and life of the whole inferior extremity, notwithstanding of the obliteration of the femoral artery above the origin of the *profunda*, it seems to me a point on which there can no longer be any dispute, that in a case of aneurism situated so high in the groin, and so near to the crural arch, that it is indispensable to procure a steady obstruction of the common femoral artery, it would be better to tie the artery immediately above the origin of the *profunda*, or in the vicinity of the crural arch, than to entrust this very important part of the operation and cure to compression, although applied to the denuded artery, unless the destruction of the artery is so great and so close upon the crural arch, that a sufficient portion of artery does not remain without the crural arch to allow a ligature to be conveniently applied. In this case there would certainly be nothing else to be done than what was practised by Guattani with complete success in the person



of Morelli; and this likewise in the supposition, that the coats of the ruptured artery were not in such a state of disorganization as not to be capable of *adhesive* inflammation. But if there be a sufficient tract of sound artery below the crural arch, on which the ligature can be applied, which the surgeon may infer from measuring the distance from the crural arch to the centre or lower third of the tumor, to which the fissure in the artery corresponds, he will proceed boldly to the operation, weighing well in his mind, however, that not being able to reckon on the co-operation of an assistant for suppressing the current of blood through the ruptured femoral artery, the whole depends upon his own intrepidity, knowledge, and dexterity of hand. Having therefore prepared the usual apparatus for aneurism, and placed the patient as has been already mentioned, the surgeon will plunge a straight bistoury into the lower part of the tumor, and with a firm and quick stroke will divide the aneurismal sac in its whole length, and likewise lay bare the crural arch. The clots will rush out, and the jet of fluid blood will be violent and dreadful; but, without losing a moment of time, the surgeon will introduce the fore-finger and thumb of his left hand through the clots and fluid blood, and proceed directly to lay hold of the trunk of the femoral artery immediately above the place of the rupture, and consequently stop the impetuosity of the hemorrhage. He will accomplish this with so much the less difficulty, from the artery at the bottom of the aneurismal sac being found insulated, as Severinus observed to his great astonishment, and has pointed out to others;\* and the more that the anterior crural nerve is separated

\* § 8 of this chapter.



from the artery on the outer side, behind the external margin of the psoas muscle;\* the principal ramifications of this nerve are all inclined towards the crest of the ilium, so that the femoral artery is covered only by the large femoral vein. The surgeon then holding the artery firmly compressed, immediately above the rupture, and laying aside his knife, will with a spatula endeavour to separate the vein from the artery for a small space, in order that he may be able to pass between them and behind the artery the eyed needle carrying a waxed ligature two lines in breadth. An assistant will draw out the ligature from the needle, and make a simple knot with it, while the surgeon, with his right hand, will place a roll of linen between the artery and the knot. The assistant will then draw the knot, and tie the *common* femoral artery. The surgeon being now at full liberty to use both hands, will apply the second ligature below the rupture, raising the artery by means of a large probe or a female catheter, it being a matter of no moment whether the ligature includes the *profunda* together with the *superficial* femoral artery or not. The dressing and subsequent treatment of the wound will be quite the same with that which has been already detailed.

§ 15. The whole of this important subject of the aneurism at the top of the thigh will be very much illustrated by the reflections which will be suggested, as we proceed, by the following case,† published by M. Deschamps. “ Albert Brondex, a man of letters, 60 years of age, of a serous rather than a sanguineous constitution, came into the hospital of la Charité the 10

\* Fischer. tab. nerv. extrem. infer. tab. iii, iv, fig. 1.

† Recueil Period. de la Societé de Med. de Paris, tom. v, No. xvii.



Vendémiaire, year viii, (2d Oct. 1797). He had a circumscribed tumor at the top of his left thigh, nearly seventeen inches in circumference, which extended as far as the bend of the thigh, and only left the breadth of a finger between it and the crural arch. This tumor was instantly recognised to be a *true* aneurism, as it had all the characters of one. This disease had appeared six months before, under the form of a small tubercle situated in the course of the femoral artery, five fingers-breadth below the bend of the thigh. The fourth day after the patient's admission into the hospital, the tumor continuing to make progress, I assembled, says Deschamps, nine surgeons in consultation, Allen, Brasdor, Boyer, Corvisart, Cullerier, Marigues, Pelletan, Percy, Thouret. After the examination of the patient, I proposed that the ligature of the femoral artery should be performed below the aneurismal sac, pointing out how difficult it would be to compress the artery above the tumor in a secure and steady manner during the whole time of the operation, as likewise to be able to extend the incision of the tumor so high, and so near to the place of compression, as would be necessary for laying bare the artery conveniently, and to allow a ligature to pass between two arterial canals, of so great importance, and so near to one another, as the *superficial* and *profunda* femoral arteries. The dangers of a considerable loss of blood in a patient already very weak, and sixty years old, were also represented. On account of these circumstances, I proposed the ligature of the artery to be performed below the aneurism, trusting that the blood stopped there would be coagulated within the aneurismal sac, and from thence upwards as far as the origin of the *profunda*. After an hour's discussion, on collecting the votes, three were in favour of the inci-



sion of the aneurism, and six for the ligature of the artery to be applied below the aneurism. Having prepared the apparatus, I undertook the operation in presence of the above-named surgeons. I made an incision about two inches and an half in length in the course of the femoral artery, below the tumor, and towards the middle of the thigh. Having divided the integuments and the aponeurosis of the fascia-lata, I proposed to raise the sartorius muscle, which, as is well known, covers the femoral artery at that place. I searched for the femoral artery there for some time, but to no purpose. I prolonged the incision a little more upwards, and removing and separating the muscular fibres towards the inside of the thigh, I followed the course of the *great* adductor muscle, along which the cord of vessels of the thigh runs. I again sought for the artery in the situation which it usually occupies naturally, but it was not possible to feel the slightest pulsation produced by it. Several repeated the same search, and all without success. We adopted the expedient of searching for the femoral artery elsewhere. One of the surgeons introduced his finger into the bottom of the wound towards the site of the aneurism, and he thought that he felt the artery towards the inner side of the thigh under the sartorius muscle. I insulated this muscle, but this was likewise an useless measure, and no pulsation appeared below the finger in whatever place it was applied. To observe the bottom of the wound with greater precision, it was proposed to cut across the sartorius muscle. In spite of my repugnance, I yielded to the proposal; but this was likewise performed without any benefit. Finally, we returned to our first idea, that is, that the artery had not at all changed its position. A nervous filament which usually accompanies the femoral artery,



which I had divided to free the patient from the violent pain which he felt at the knee whenever this filament was touched, confirmed me in this opinion. I passed a needle below the place where we were persuaded the cord of femoral vessels was, and, for a greater security, I included in the noose a portion of the great adductor muscle. Having passed through the ligature, I raised its extremities, and applied my finger upon the parts included in the loop, to observe if the blood filled and distended the artery; but nothing of all this was observed. I notwithstanding drew the ligature tight, making use of the *presse-artère*, and above this ligature I placed another in *reserve*. The patient lost less than three ounces of blood during the whole operation. I then introduced a small dossil of lint into the bottom of the wound, and made the leg and foot be fomented by means of bags filled with warm sand. The patient, however, was very much enfeebled on account of the length of the operation, which had lasted nearly an hour, and on account of the acute pains occasioned by the distention and by the stretching during the repeated searching for the femoral artery. The progress of the tumor continued as before. On the fifteenth and sixteenth, the tumor had reached almost to the crural arch, and began to grow livid at the upper part, although the thigh and leg preserved their natural heat; and the thigh was not very painful, although a little swelled. On the sixteenth, a part of the dressing was removed, and the ligature was tightened, having become somewhat slack. On the seventeenth, every thing was as on the preceding day; the pulse, however, was frequent, small, and contracted. In the night between the seventeenth and eighteenth, the patient complained more than usual of pain in the thigh, and com-



plained more particularly of a dull pain in the aneurism, the bulk of which did not cease to increase. I visited the patient at one o'clock in the morning, and I found there was a sensible infiltration along the outer side of the thigh, without any hardness. The aneurism still remained circumscribed. On the eighteenth, the fourth day after the operation, we examined the patient with all that attention which his situation required. The aneurism, as I said, had continued to increase: the pulsation in it was evident; the thigh and leg were swelled. All these circumstances proved in an evident manner that the ligature below the aneurism had not produced the effect for which it was applied. The appearance of the patient promised very little. The small, contracted, frequent pulse, and advanced age, together with all the other reasons which I have enumerated in speaking of the consultation, contraindicated a second operation, which, however, the critical circumstances of the patient required to be performed, if we did not wish to abandon him to a certain and speedy death. The incision of the aneurism was decided upon, which was performed the same day, the eighteenth, four hours after mid-day, in presence of the surgeons Marigues and Valentin. A firm oblong compress was prepared, fixed to the extremity of a handle, that it might have the double advantage of occupying less room, and of being kept firmly in its situation upon the crural arch by a strong and intelligent assistant. Another assistant was placed near the first, to assist him, and supply his place, if it should be required. Having placed the compress on the femoral artery as it passes out from under the crural arch, I opened the tumor from its upper third downwards. The aneurismal sac, including the skin and the first lamellated layers, was more than a finger and an



half in thickness. In the act of the incision a great quantity of fluid arterial blood issued out, together with a mass of clots about the size of the fist. The aneurismal sac when evacuated left a space greater than before between the point of compression and the upper angle of the incision; therefore, by means of this, I extended the incision upwards to the fingers of the assistant who compressed the artery, in order the better to discover the place of the rupture of the artery, which I had not been able to see distinctly through the blood which overflowed that cavity. Having done this, I introduced through the rupture of the femoral artery the end of a probe, in order to raise the artery as much as possible, and to tie it accurately; but the loss of blood obliged me to accelerate the application of the ligature. By the direction of the touch, and pressing the probe and the artery between my fingers, I passed the needle behind the artery kept somewhat raised. I then drew the ends of the ligature upwards, and pressing the artery against the loop with my finger, the blood stopped. I placed a ligature of *reserve* above this ligature. I drew the artery tight with the interposition of the *presse-artère*, and applied a second ligature with a double knot below the sac, because the blood seemed to flow back from below upwards. After drawing these two ligatures, no more blood appeared in the aneurismal sac, which was filled with soft lint, and covered with a pledgit spread with liniment of *arcæus*. The *presse-artère*, which had remained in the first wound made at the middle of the thigh, was removed, as being of no use. The patient, in spite of the quickness of the operation, lost so great a quantity of blood, that he fell into a deadly faint, and expired about eight hours after. On the dissection of the body the following appearances presented



themselves. 1st, The *profunda* femoral artery, which goes off from the *common* femoral artery in general at an inch and an half or two inches from the crural arch, arose in this subject from the *common* femoral at ten lines only from the crural arch. The *profunda*, as is usually observed, gave off the two circumflex arteries, which had in this subject a greater diameter than usual. The trunk of the *profunda* also was equal in diameter to that of the *superficial* femoral artery. The superior articular arteries of the knee were likewise evidently more than usually dilated. The *profunda* femoral artery adhered to the aneurismal sac in such a manner, that it was raised with the sac whenever the *superficial* femoral artery was raised by means of the point of the probe introduced into that artery; from which circumstance it was almost impossible to make the needle pass between the *superficial* femoral artery and the *profunda* without wounding the *profunda*, or at least without including both of these arteries in the ligature. 2dly, The ligature applied in the first operation comprehended along with the *superficial* femoral artery also the great femoral vein, and at the same time a portion of the fibres of the great adductor muscle. In the second operation, the upper ligature compressed the artery three lines above the aneurismal sac, and included besides a third of the whole circumference of the *profunda* femoral artery, so that this last artery had been perforated through and through by the needle. The ligature of reserve was found between the *profunda* and *superficial* femoral arteries. The lower ligature included the *superficial* femoral artery six lines below the aneurismal sac, where the femoral vein had been likewise transfixd by the needle. 3dly, The *superficial* femoral artery was found lacerated for the space of



two inches, at the distance, however, of other two inches and eight lines from its origin, or from the crural arch downwards. The entrance and outlet of the aneurismal sac had the form of a funnel. The dilatation of the artery at the centre of the aneurism could not be estimated with precision, on account of this artery being confounded with the cellular substance which formed the greater part of the aneurismal sac. At an inch below the sac there was an enlargement on the posterior surface of the tube of the *superficial* femoral artery, that is, an incipient *true* aneurism, the internal surface of which was smooth, polished, and not at all changed. All the rest of the *superficial* femoral artery was in a sound and natural state. 4thly, The thigh was occupied by a purulent infiltration, which extended on the surface of the thigh, situated anteriorly and externally below the aponeurosis of the fascia-lata. There was no appearance of suppuration between the muscles lying in the vicinity of the first operation ”

§ 16. The greater number of surgeons only publish the histories of the successful cures, and draw a veil over the unsuccessful, from which, however, great benefit might be derived for the advancement of the art of surgery. The knowledge of facts, and the avoiding the errors committed by others, are, in my opinion, more useful than the mere precepts which are taught in the schools. M. Deschamps is one of the small number of those who have felt the force of this truth and who are more anxious for the progress of surgery, and the good of mankind, than for empty fame. He, after the example of Hippocrates, has related ingenuously, both the good and bad success which he has had in the different modes of curing ex-



ternal aneurisms. On which account, he deserves great praise, as well as for his learning and skill in all the other branches of his profession. The history above related furnishes us with valuable ideas, and very important precepts, relative to the radical cure of the aneurism at the top of the thigh. It shews us, in the first place, that the ligature of the superficial femoral artery, applied below the aneurism, far from being a method conducive to the obliteration of the aneurismal sac, and of the artery above the tumor, contributes, on the contrary, greatly to accelerate the enlargement of it, and clearly proves to us at the same time, how great injury the compression may occasion, whenever the pressure falls below the rupture of the artery, or below the centre of the aneurism, from the difficulty of the situation, the size of the tumor, or from the carelessness of the patient, or surgeon. In the subject of the present case, the aneurism first appeared in the form of a small tubercle, situated in the course of the *superficial* femoral artery, at five fingers-breadth, or at least four inches below the crural arch. Now, if we were even to suppose, that the origin of the *profunda* femoral artery had been an inch and an half below the crural arch, it might from the very first have been boldly asserted, that the point of the rupture of the *superficial* femoral artery was two inches and an half below the origin of the *profunda*, a space sufficient to allow the ligature to be applied without including the origin of the profunda. But the dissection of the body shewed that this space was more than three inches in length; since it was found, that in this subject the *profunda* femoral artery arose from the *superficial* only ten lines below the crural arch. Although, therefore, after six months the aneurism had reached very high in the groin, and



so far as to cover even the crural arch, it might have been with good grounds concluded, that there was enough of space for tying the *superficial* femoral artery below the origin of the *profunda*, and above the seat of the rupture. This was also rendered more probable, from observing, that notwithstanding of the very high degree of the disease before the operation, the leg and thigh were not swelled, and the circulation in these parts went on with sufficient freedom. I omit remarking, that in the first operation, which lasted nearly an hour, for discovering the femoral artery, this operation might have been very much shortened, and have saved the patient from the acute pains, if the operator, instead of making the incision towards the middle of the thigh, had made it higher up, and as near as possible to the upper part of the thigh, or where the femoral artery readily presents itself, and at very little depth, and where it is not covered or crossed by the sartorius muscle. And, with regard to the second operation, M. Deschamps divided the aneurism from the upper third of the tumor downwards; he therefore met with difficulties in laying conveniently bare the precise place of the rupture of the artery, and was obliged to return to the prolonging the incision, not only to the top of the tumor, but even as far as the hand of the person who made the compression on the crural arch. This, since it was necessary to do it, would have been much better done at first, and with less loss of blood, by dividing the tumor with one stroke of the bistoury, from the bottom as far as the crural arch. Further, if, in the case we are speaking of, the superficial femoral artery was raised with the point of the probe, and then the hemorrhagy suppressed by the operator pressing the artery between his fingers and the point of the probe, there can be



no reason for accelerating the operation with such haste as to run the risk of wounding the *profunda* with the needle, or of including it in the same ligature along with the *superficial* femoral artery; both of which accidents happened. The ligature of large vessels ought never to be applied or tightened at random. It was almost impossible, says M. Deschamps, to avoid this accident, because the *profunda* femoral artery followed the aneurismal sac whenever the *superficial* femoral was raised with the point of the probe. In saying so, it appears that M. Deschamps had forgot, that after death he found the ligature of reserve placed precisely and accurately between the *superficial* femoral artery and the *profunda*; which proves, that, without precipitation, he might have been able to place the other ligature also between these two great vessels, without wounding either of them.\* Farther, with regard to some other useful deductions which might be drawn from the examination of this case, I refer to what has been said in § 9 of this chapter.

§ 17. Re-assuming what has been said in this chapter with regard to the cure of the femoral aneurism, we may conclude, 1<sup>st</sup>, That the compression, if the integuments are entire, cannot be employed in any case of femoral aneurism, whether the aneurism occupies the lower part, the middle, or the top of the thigh 2<sup>dly</sup>, That the aneurism of the lower part, middle, or top of the thigh, at the distance of about four inches from the crural arch, if it is *circumscribed*, may be radically cured by Mr. Hunter's method. 3<sup>dly</sup>, That

\* Loc. cit. Un peu plus haut (à huit lignes) du sac je passai la ligature d'attente précisément entre les artères femorale, et profonde; parceque dans cet endroit la profonde n'étant point unie à la femoral, je pus saisir l'intervalle pour y passer l'aiguille.



when the aneurism is large and *diffuse*, and when, on account of the great distention produced by the effused blood in the surrounding parts, it threatens inflammation and gangrene, the best expedient is the incision of the aneurism, the quick evacuation of the clots and the ligature of the artery, above the laceration or wound of the artery. *4thly*, That in the aneurism at the top of the thigh, in the vicinity of the crural arch, there may be a rule by which we may determine the place of the rupture of the artery, and consequently the length of the *superficial* femoral artery, which may be tied below the origin of the *profunda*. *5thly*, That when the rupture affects the *superficial* femoral artery so high up as to include the origin of the *profunda* also, so that the ligature of necessity falls upon the *common* femoral artery immediately below the crural arch, the surgeon ought not therefore, all the other circumstances being favourable, to despair of the success of the cure; since dissection and practical observations prove, that the arteries of the cavity of the pelvis may amply supply the circulation, and preserve the whole of the subjacent limb.

CONTIN. of § 20.—In treating of inguinal aneurism, situated close to the femoral arch, I did not hesitate to assert, in consequence of repeated injections in the dead body, and more especially of the interesting cases related by Guattani, Gavina, Clarke, and Mayer, and of one by myself, that the trunk of the femoral artery might be tied above the origin of the *profunda*, without the subjacent limb being necessarily deprived of circulation and life. This important fact has been subsequently confirmed by many other



successful cases not only of ligature of the femoral artery above the profunda, but even above the femoral arch, and, properly speaking, within the abdomen; so that, at the present day, for the cure of inguinal aneurism situated in the vicinity of the femoral arch, no learned or skilful surgeon hesitates to undertake this operation with well-grounded hopes of success. The following is the mode of performing it.

The patient being placed horizontally on the edge of the bed, with the buttocks a little elevated, an incision is to be made in the integuments in the natural direction which the femoral artery takes in passing out of the pelvis. In an adult subject, the incision is begun about half an inch below the *superior spine* of the ilium, and about an inch and an half distant from it towards the *linea alba*. From thence it is carried down nearly to the femoral arch, and not lower, to avoid wounding the spermatic cord or epigastric artery. The aponeurosis of the external oblique is then divided to the same extent, and the point of the finger introduced at the lower angle of the wound, and on it are carefully divided the two muscular layers formed by the internal oblique and transverse muscles, taking great care not to injure the subjacent peritoneum. This accident may be guarded against by gently pressing back, with the point of the conducting finger, the peritoneum on its first appearance under the divided muscular layer of the transverse muscle. After this is done, the point of the finger will be found to be placed immediately on the iliac artery in the vicinity of the lower angle of the wound, and a little above the origin of the epigastric artery. This is the place where the iliac artery rises up from the side of the pelvis to pass over



the horizontal ramus of the os pubis,\* from whence it again descends under the femoral arch to the bend of the thigh. If we wished to lay bare this artery beyond this point, nearer to its origin from the common iliac, it would be necessary to push the point of the finger very deep into the cavity of the pelvis along the inner side of the os ilium, following the bend which this artery makes in passing to the horizontal ramus of the os pubis, where it is easily discovered, and lies almost superficial. This place is the most convenient for the application of the ligature; and the more advantageous from being immediately above the origin of the epigastric artery. At this place, therefore, the ligature is applied, with the interposition of a proper cylinder of linen spread with plaster between the artery and the knot. The artery being over the vein at this place in the natural structure, facilitates the application of the ligature. The whole is to be covered with a pledgit of soft ointment retained by a *spica* bandage. Supposing the patient to be sufficiently stout, on the fourth day after the operation, on removing the dressings, the ligature is to be removed, by dividing it on the cylinder of linen; the edges of the wound are then brought together, and as soon as the diminution of the suppuration permits, are united by the *first intention*.

It appears, from the operations recorded, that of

\* Haller. Fasc. Anat. *arteriæ pelvis*, Tab. i, ii, Z. C. The bend which the iliac artery makes from its origin from the *common iliac* to the top of the horizontal ramus of the os pubis, that is, first descending into the pelvis, then ascending over this horizontal ramus of the os pubis, resembles very much what is commonly called by our Hydraulic Engineers *salto di gatto*.



twenty-two patients,\* on whom it has been performed, fifteen have been cured.

The repeated success of this operation has so much increased the boldness of surgeons, that they have not hesitated to attempt with success the tying even of the *internal* iliac artery for the radical cure of an aneurism of the hip arising from internal causes. Previous to this very singular fact, there was only one case of aneurism of the hip occasioned by a wound of the sciatic artery, cured by that skilful and able surgeon John Bell,† not without great difficulty and imminent danger to the life of the patient. This large aneurism had been caused, as was said, by a wound of the sciatic artery contiguous to where it passes out of the pelvis, inflicted by the sharp blade of a long pair of scissars. On dividing the immense tumor and evacuating the coagula of blood, estimated at eight pounds, the fluid arterial blood sprung out with so much impetuosity, and in such quantity, that the patient fell down to all appearance dead. The intrepid operator applied his finger to the divided trunk of the sciatic artery, passed a ligature round it above and below the injury, which was tied by an assistant, and the large sac was filled with lint. The most powerful means were employed for restoring the nearly exhausted strength of the patient. The extensive wound supplicated for about seven months. There was afterwards a very tedious exfoliation of the os sacrum and ilium. At last, after the patient had been lame for some time, he recovered his former health. The aneurism of the hip operated on by

\* Hodgson loc. cit. p. 417.

† Discourses on the nature and cure of wounds, p. 78.



Stevens\* had been occasioned by internal causes, probably by a *softening* or *ulcerated* degeneration of the coats of the sciatic artery. A female slave had been affected, for nine months, without any evident cause, with a pulsating tumor on the left hip, contiguous to the tuberosity of the ischium, about the size of a child's head. At its commencement the tumor did not excite any considerable pain; but afterwards she experienced so violent and acute pain that she was ready to submit to any operation rather than remain in her miserable state. I consulted, says the author, Drs. Lang and Van Brackle, and suggested to them to tie the *internal* iliac artery as the only radical mode of cure. To which proposal they having consented, the operation was performed the 27th December 1802, in their presence, as also of Mr. Nelthrop and Mr. Ford, the manager of the estate. An incision, about five inches in length, was made on the left side, in the lower and lateral part of the abdomen, parallel with the epigastric artery, and nearly half an inch on the outer (or lateral) side of it. The integuments and abdominal muscles were successively divided. The peritoneum was separated from its loose connexion with the iliacus internus and psoas magnus, and pushing it towards the centre of the pelvis, as far as the division of the common iliac artery. In the cavity now made, I felt for the internal iliac, insinuated the point of my fore-finger behind it, and then pressed the artery betwixt my finger and thumb. Dr. Lang now felt the aneurism behind; the pulsation had entirely ceased, and the tumor was disappearing. In consequence of his asserting this, I passed a ligature behind the artery, and tied it about half an inch below its origin from

\* Med. Chirurg. Transactions, vol. v.



the common iliac. After the ligature was tied, the tumor gradually diminished. About the end of the third week the ligature came away. The wound continued always healthy, and the cure was completed in six weeks. The author concludes by saying: When he was about to leave the West Indies, about the beginning of May 1814, more than seventeen months after the operation, the woman was in good health.

Every surgeon well acquainted with anatomy will anticipate the great difficulty which must be experienced in the performance of this operation even by the most intrepid and skilful surgeon, and will understand the great danger to which the patient is exposed from the extent and depth of the wound, and especially from the extensive separation, which is necessarily made, of the peritoneum from the iliacus internus and psoas muscles in the internal part of the pelvis, in order to allow the internal iliac artery to be compressed between the finger and thumb: in consequence of these difficulties and dangers this will always be a very uncertain operation. At all events, this is a very valuable fact in the practice of surgery, whether it be considered as an improvement of the art, or as a farther proof of the great powers of nature in assisting the cure of extensive and deep injuries.



## CHAPTER XI.

### OF THE CURE OF THE BRACHIAL ANEURISM.

§ 1. **T**HE aneurism of the arm, arising from a rupture or ulceration of the brachial artery, occasioned by a slow disorganization in some point of the proper coats of this artery, is, as we have remarked,\* a very rare disease; while, on the other hand, the occurrence of aneurism is but too frequent in the bend of the arm, produced by the puncture of a lancet, or along the inner side of the arm and axilla, by a wound made by a pointed instrument, or by fire-arms. This circumstance is precisely the contrary of what we have seen happen in the lower extremity, in which, more commonly, the aneurism in the ham, of the lower part, middle, or top of the thigh, originates from a slow, *steatomatous, ulcerated, earthy* disorganization, or preternatural relaxation of a certain portion of the proper coats of the popliteal and femoral arteries; which indisposition, produced gradually by internal causes, on the supervening of any external violence, prepares and brings on in the artery, in one or sometimes more places, a total solution of continuity, and consequently an effusion of arterial blood into the cellular substance which surrounds the affected artery.

§ 2. If the brachial artery is unfortunately pricked in bleeding at the bend of the arm, it is very easy for

\* See Chap. vii, § 12.



the surgeon to make the small wound of the integuments heal in a few hours, if it is placed and kept in contact by the usual means of compression. But, since the union does not take place equally in the subjacent divided coats of the artery, or does not take place between these and the posterior side of the vein, or with the cellular or other parts contiguous to the injured artery, so, for the most part, this accident occasions an effusion of arterial blood into the cellular substance surrounding the wounded brachial artery, from whence arises the aneurism in the bend of the arm. Genga\* very judiciously remarks on this subject, that neither the stream of blood from the vein per saltum, nor the seeing that the blood which flows out is of a much more florid colour than before, are sufficient marks to warrant the assertion, that the brachial artery is wounded; since the flow of venous blood per saltum may depend upon the pulsations of the subjacent artery, which is situated very superficially, and almost immediately below the divided vein; as likewise, because in all venous hemorrhages, the blood, though black at first, is changed to a florid colour, as, on the first portion being discharged, the veins receive fresh blood from the corresponding arteries. To ascertain, by means of a certain and undoubted mark, says he, whether the blood comes from the vein or from the artery, place the point of the fore-finger at the distance of about a finger's-breadth below the wound, and make there a slight compression; for, if the vein has been wounded, the blood will stop, being prevented from ascending and circulating upwards towards the axilla; but if the artery shall have been wounded, the blood will not only flow

\* Anatomia Chirurgica, p. 208.



as before, but with even greater impetuosity, not being allowed to run down through the compressed artery. When the brachial artery has actually been wounded, as the solution of continuity made in the proper coats of the artery by the point of a lancet is in general a very small wound, so, in most cases, the blood which issues out by it only produces at first a small pulsating tubercle, not painful, and without an evident change of colour in the skin covering it; and this tubercle remains sometimes stationary for a considerable time. But, in other cases, not long after the accident, the pulsating tumor increases; and it does so in proportion to the subsequent widening of the lips of the wound in the artery, according to the increased impetus of the arterial blood towards the injured part, and the diminution of the resistance which was at first opposed to the exit of the blood, by the cellular substance and ligamentous bands covering the wounded artery. In these circumstances, as soon as the extravasated blood has overcome the first barriers, it makes itself a way easily along the course of the humeral artery upwards, on the inner side of the humerus to the axilla, and the aneurism in the bend of the arm, from being *circumscribed*, becomes *diffused*; the whole arm becomes swelled, painful, and is placed of itself, to use the expression, in a state of flexion; the skin of the bend of the arm, and of the inside of the humerus, appears tense, shining, of a red-livid colour, and very painful; at last a fever attacks the patient; and in this state of the symptoms, if the patient is not quickly relieved, the great quantity of extravasated arterial blood rises so far as to fill the axilla, and then the subjacent hand and arm are soon after attacked by gangrene.



§ 3. The aneurism occasioned by a wound of the humeral artery, along the inner side of the humerus, by a stab of a sword, knife, or bayonet, forms more quickly than the aneurism occasioned by the small puncture of a lancet in the bend of the arm, and the former acquires a greater size in a much shorter time than the latter. From what has been said, this happens not only in the first case, on account of the size of the wounding instrument, but likewise on account of the flaccidity and easily distending nature of the cellular substance which surrounds the humeral artery, along the inner side of the humerus, as far as the axilla ; which artery, on the other hand, in the bend of the arm, is covered and strengthened by a firm aponeurotic expansion. The wounds of the humeral artery, inflicted by fire-arms, do not, for the most part, give rise to aneurism immediately after the accident, but rather some days after, that is, on the falling off of the eschar produced by the violence of the injury done to the proper coats of the artery, and to the parts surrounding it. All these circumstances, however, ought not to be regarded as absolutely proper, and peculiar to the brachial aneurism in the bend of the arm, or along the inside of the humerus, in consequence of a wound. For the same phenomena may also be met with in aneurism of the inferior extremities, whenever this disease is produced by a wound of the popliteal or femoral artery, inflicted by a pointed or cutting instrument, or by a musket-ball.

§ 4. The aneurism in the bend of the arm, occasioned by the puncture of a lancet, may be radically cured by *compression*, as long as it is just beginning, and only forms a small, pulsating, *circumscribed tu-*



bercle, without inflammation of the skin covering it, and when it is little or not at all painful; and when it occurs in young persons, in children, slender women, and in persons much emaciated, in whom the brachial artery a little above the bend of the arm is nearly superficial, and resting upon the bone of the humerus, in the vicinity of its internal condyle. Numerous examples of completely radical cures of this disease may be found recorded in almost every book of surgery, from the time of Galen to the present day. One of the most celebrated cures of brachial aneurism is that which the Parisian physician, M. Bourdelot,\* effected in himself, by means of compression. In the very interesting history of the cure of this disease, obtained by Galen,† by means of compression, it seemed to me to be a thing very worthy of remark, that among the parts composing the compressing apparatus, he made use of a sponge, in order, as it appears, to keep up an equable and steady pressure on the aneurism. I do not find among the moderns, and not even immediately after Galen, any surgeon who employed the sponge, if we except, in the present day, Mr. White,‡ in those cases only in which the sponge may be applied to the wound of the denuded artery, with the view of stopping the hemorrhage. The moderns indeed direct, that we ought to apply upon the aneurism to be compressed, chewed paper, touchwood, or agaric; but it remains still to be ascertained, whether these substances produce the same good effects as are obtained by the sponge frequently moistened, in the case of which we are treating, where a constant and equable

\* Blegny. Zodiac med. Gallic. t. 11. Martii, p. 43.

† Method. Med. lib. v, cap. 7.

‡ On the topical application of the Sponge in the stoppage of Hemorrhages.



compression is necessary, without running any risk of causing the parts compressed to mortify. *Vidimus enim, Galen writes, in mulieribus, et pueris, tum conglutinatas arterias, tum carne undique circumdatas, idque in fronte, maleolo et articulo brachii, summæque manus medio. Simile quiddam aliquando in agresti contigit juveni, dum sanguinem sibi mittendi veris tempore curat, quod nostratibus maxime est in usu. Cum enim medicus qui venam incisurus erat brachium hominis deligasset, contigit attolli veluti in gibbum arteriam; itaque hanc pro vena medicus divisit. Exigua sane incisio erat. Sanguis autem flavus, et tenuis, et fervidus statim ejaculabatur, idque cum quodam veluti saltu. Ac medicus quidem, ut erat admodum juvenis et operum artis parum peritus, venam se incidisse putabat. Ego vero cum quodam alio ex iis qui aderant medicis utique seniore, ubi quod acciderat adverti, præparato ex emplastrorum genere quod sanguinem supprimit medicamento, tum incisionem curiose conjunxi, tum super medicamen illico imposui, ac spongiam molliissimam extrinsecus super hoc deligavi. Mirante vero qui hanc arteriam inciderat insolitam nostram in hoc casu providentiam, indicavimus homini rem factam, et postea quam incisi hominis diversorium exissemus, jussimusque ne vel solveret nobis absentibus, vel ante quartum diem id aggrederetur, sed ita ut erat deligatum haberet, spongiam duntaxat desuper madefaciens. Postea vero quam in quarto solventes plane conglutinatam incisuram invenimus, rursus idem medicamentum imponere jussimus, tum simili modo deligare, nec multis postea diebus solvere. Atque ita percurata est hujus hominis incisa arteria, sola omnium, quas in cubito incisas vidi. Nam reliquis omnibus aneurysma, aliis majus, aliis minus supervenit.*



§ 5. If Galen, in his extensive practice, did not obtain the same fortunate success in other cases of aneurism in the bend of the arm, from the wound of a lancet, that might perhaps be ascribed to his not having been present at the time of the accident, as he was in the case above related. For we must allow, that if the opportunity of curing this disease at its beginning be lost, the difficulties are every instant increasing, which may oppose the obliteration of the artery, and consequently the radical cure of the aneurism in the bend of the arm, by means of compression. With regard to this compression, and the manner of employing it, surgeons agree, that the preference ought to be given to that which, beginning from the fingers, extends gradually to the axilla. This is commonly called, in the medical schools, Theden's bandage; when in fact, and for the honour of the Italian school, it ought to be called the bandage of Genga. And, that there may be no doubt about this, and to explain the fact with the greatest possible clearness, I shall here describe this bandage in the author's own words.\* “In the month of May 1673,” says Genga, “the artery was wounded in bleeding, in one Cefanassi, a man 60 years of age, of a sanguineous temperament. I immediately prepared, as well as the shortness of the time permitted, the proper dressings. I applied to all the fingers, with small rollers, an expulsive bandage to each finger, and then with a long roller, about three fingers-breadth, I began in the same manner to bandage the hand, ascending as far as the place of the wound, over which I applied a thick compress made of fine linen, moistened in an astringent composition made of *terra sigillata*, arme-

\* *Anatomia Chirurgica*, p. 219.



an nibole, dragon's blood, bloodstone and gypsum, all mixed together with the white of an egg and plantain water, and I then placed over it a thick plate of lead, somewhat larger than the coin called *testone*,\* and applying over it a few more compresses, I made three or four turns with the same roller, somewhat tight, over the place of the injury, and still more so above the elbow. Having done this, I applied on the inside of the humerus, from the place a little below the axilla, and a little higher than the internal apophysis of the humerus, a round piece of wood as thick as the finger, about half a hand's-breadth in length, rolled up in linen, like the splints which are used in fractures, in order that the veins and arteries which pass at this place being compressed by it, (which compression is better performed, the bit of wood being round, and not flat), the free and impetuous current of blood to the wounded artery might be prevented; this piece of wood was fixed by sewing it to the compresses and bandages, and supporting it with a firm roller. I again began to pass over all the already-mentioned bandages another roller, likewise expulsive, beginning and following an inverse order, the better to fix the first bandage, and I placed the arm, making the elbow form an obtuse angle. I farther ordered, that these bandages should be from time to time moistened with a liquor made of plantain water and rose vinegar, to which I made likewise be added the juice of plantain, evergreen, and the tops of bramble, extracted by expression from these simples, with the addition of a number of bruised green cypress nuts. Towards evening blood was drawn from his left arm, which was repeated several times in the

\* An Italian coin, nearly as large as a halfcrown piece.



course of the cure. The diet prescribed was very thin and cooling, particular attention being paid however to the strength of the patient, who bore the whole very well, being of a robust habit; and indeed, such was the spareness of his diet, that it was sufficient rather to hinder him from dying, than to make him live comfortably. I continued, without ever taking off the bandage, the use only of the vinegar and water, with the above-mentioned juices, bathing the bandages until a week was elapsed, not so much to keep the part cool, as to preserve the bandages tight, as they usually slacken easily. Having resolved to uncover the wound on the morning of the eighth day, on removing the bandages the wound in the skin was found completely agglutinated; but on the artery remaining for some time without the constriction, there was observed at the place of the wound some greater beating, and a little elevation; on which account, that the artery might not again be filled, and pour out blood under the skin, I immediately returned to the use of the bandage and former dressing, and it was not again uncovered for fourteen days more; after which, on removing the bandage, and leaving the limb without any tight bandaging for some little time, the artery was not observed to make any considerable motion. With all this care to secure still more from any unhappy accident, and to be very cautious, and not to lose the advantage which had been gained, I again renewed the usual bandages and dressing, and continued the position, and the bandages were not removed till the twenty-second day; on which day, removing all the bandages, the arm was left at liberty, recommending to the patient not to use the part much, especially in violent motions; and thus the cure was finished; after which Cefanassi lived till the



summer of 1684, when he died of a different disease."

§ 6. The description given by Genga of this bandage is a model of precision and perspicuity, worthy of imitation in similar matters. I wish however, that young surgeons should be informed, that, whether it be immediately after the accident of the wound of the brachial artery, or even after the aneurism has begun to form, it is always a proper and useful rule, before applying the bandage of Genga, and during the time employed in applying it, to make the brachial artery be compressed by a skilful assistant above the clavicle, against the first rib ; for this facilitates very much, in the act of applying the compression, the bringing the two opposite sides of the wounded artery into mutual and firm contact, and the keeping them so afterwards, in order to obtain in the sequel the cohesion and obliteration of the wounded artery. M. Desault, in a case of aneurism in the bend of the arm, employed with success a particular kind of bandage and compression of his own, which deserves likewise to be mentioned here.\* He placed a hard and firm cushion as a point of support along the elbow, or a splint made of lath or wood, furnished with a small cushion, so that the point and sides of the elbow were included as it were in a semi-canal. Upon the wound of the artery, or on the incipient aneurism in the bend of the arm, he applied graduated compresses, which he secured by a figure-of-eight bandage, similar to what is used in bleeding ; in such a manner, however, that the whole bend of the arm was covered by it. By the precaution of using this cushion and semi-canal, including

\* See Appendix, note, No. 15.



the point and sides of the elbow, the principal point of compression falls upon the centre of the aneurism, or upon the wound of the artery which we wish to obliterate, without the bandage retarding in any degree the current of the blood through the lateral vessels, and still less hindering the return of the blood by the superficial and deep veins of the arm. If we wished to employ this kind of bandage, it would be useful, I think, previous to the compression of the axillary artery above the clavicle, to apply the bandage of Genga from the fingers to the bend of the arm, then to place the semi-canal of Desault, and a cylinder of linen along the brachial artery, as far as the axilla, and after making as many circles round the bend of the elbow as to cover it, to continue the bandage, ascending along the humerus upon the cylinder, as far as the axilla and scapula ; in which manner, the advantages of the two above-described methods of Genga and Desault would be combined in one.

§ 7. We soon learn from the first trials, whether the compression will succeed or not as a radical method of cure of the aneurism in the bend of the arm. For if, during the two first days, the patient cannot bear the bandage, and if the tumor below it, instead of diminishing, increases, is raised and spreads, if pain is excited in the tumor, and the skin covering it threatens to inflame, we cannot depend upon the bandage as a method of cure. La Faye\* pretended, that the compression ought to be tried in every case of aneurism in the bend of the arm, whether the aneurism was recent and *circumscribed*, or of long stand-

\* Dionis. Cours d'operations, note, p. 695.



ing and *diffuse*, in order, if not to cure it, at least, as he thought, to dispose the collateral anastomosing vessels to enlarge, and so prepare them to carry on the circulation, and preserve the life of the subjacent arm and hand, immediately after the ligature of the wounded brachial artery. This doctrine has likewise been published by some surgeons, on the subject of popliteal and femoral aneurisms; but experience has shewn, that these fears and anxieties of the surgeons of former times, with regard to the power of the collateral anastomosing vessels, in supplying the want of the principal arterial trunk, were ill founded, and that consequently, whenever the compression of the aneurism in the bend of the arm is contraindicated by the size of the tumor, by the thickness of the coats of the sac, by the pain and redness of the skin, by the tumor being *diffused*, the employment of the compressive bandage does great harm on all these accounts, and sometimes makes us lose the opportunity of obtaining those advantages which are constantly derived, in similar cases, from effectual practice, employed in time.\*

§ 8. If, fortunately, from symptoms quite opposite to the above mentioned, there is reason to hope that

\* Molinelli, speaking of an aneurism in the bend of the arm, which was of two months standing, very judiciously observes: ‘ Compressionem antea nullam adhibuerat ad continendum tumorem, neque ut in posterum adhiberet auctor fui. Nam qui mediocriter, et brevi comprimentes tumorem digitos, quod sæpe expertus essem, non ferebat, cum adduci non poteram, ut crederem, validiorem compressionem, et multo magis diuturnam esse laturum. Præter quam quod in ea, de qua modo mentionem feci, membranarum duritie, atque renisu, quem illa fructum tandem habitura esset non videbam, etiam si ferre potuisset.’ Comment. Acad. Bonon. t. ii.



the compression is likely to prove useful, the surgeon ought to be very careful to moderate the impetus of the circulation by means of evacuations of blood proportioned to the constitution of the patient, and by a very strict diet; that the bandage continue to press equably, and that it be gradually increased in force, to such a degree, as not only to make the tumor disappear by degrees, but likewise to compress the artery sufficiently to excite the *adhesive* inflammation in the proper coats of the artery, and therefore that it be capable of producing the obliteration of the artery for a certain space above and below the injury. And, even when the surgeon shall believe that he has effected this, it will be proper that the patient do not leave off the bandage for several months after, and that he be upon his guard never to make any violent motions with the arm which has been wounded. For it has repeatedly happened, that the surgeon and patient, contenting themselves with observing that the aneurism in the bend of the arm has been reduced in a short time to the size of a small knot, not pulsating nor painful, by means of the compression, have left off the use of the bandage, and the disease, not long after the supposed complete and *radical* cure, has been renewed, on a violent exertion of the arm.\* This misfortune is to be ascribed to the degree of compression, and of the *adhesive* inflammation having been able to make the artery contract an adhesion with the cellular substance and the ligamentous bands surrounding it, and to convert the small aneurismal sac into a firm, thick knot, so that the bloody lamellated coagulum contained in the sac was kept firmly applied to

\* Flajani, Collezione d'Osserv. e Rifless. di Chirurg. t. ii, osserv. 10.



the lips of the wound of the artery, and closed it in the manner of a plug; but the degree of pressure made by the bandage has not been sufficient to press the artery against the lower extremity of the humerus, so strongly as to obliterate the wounded artery, and convert it into a ligament for some space above and below the injury. An example of this occurred to me in the person of Antonio Gallina of Albuzzano, a countryman, 23 years of age, of a very slender habit of body, who having been attacked by inflammation of the chest, was bled in the left arm, on which occasion the artery was punctured. The incision of the integuments closed immediately by means of a tight bandage, and it was not till after he was cured of the peripneumony, that the patient complained of a tumor as big as a small nut in the bend of the left arm, precisely at the place where he had been bled. The tumor pulsated strongly, and had all the characters of a circumscribed aneurism. I ordered the patient to be transferred into the school of practical surgery. As he was very much debilitated, and the aneurism small, yielding, and not at all painful, I undertook the cure by means of the compression, in the manner described by Genga, on the 8th of February 1793. The cure went on so well, that towards the middle of April of the same year there remained of the whole tumor only a small tubercle, as large as two peas, which did not at all incommode the patient, and did not prevent him making freely the motions of flexion, extension, and rotation of the fore-arm; on which account, notwithstanding my remonstrances, he wished to leave the hospital, and resume his usual labours in the country. On the 30th November of the same year, this patient most unfortunately received a blow with a stick on the inner side of the left arm,



which in a few days occasioned an abscess all round the elbow and bend of the arm. The patient was placed under the care of our skilful surgeon M. Volpi, who was not informed of any of the preceding circumstances of the case. The abscess was opened by an incision, exactly at the place which had been previously occupied by the aneurism. A great quantity of matter was discharged; there then appeared at the bottom of the wound a small bloody clot, on the removal of which, the arterial blood issued out with great impetuosity. From a complication of other very severe circumstances, depending upon the general and local state of the patient, I was of opinion, as well as M. Volpi, that amputation was indispensable. On examining afterwards the amputated arm, I immediately discovered the wound which had been made in the brachial artery by the point of the lancet; it was about a line in extent, and although several months had elapsed since the accident, it had the appearance of a recent wound. The brachial artery had preserved its natural diameter at the place of the injury, and the apparently radical cure consisted therefore in nothing more than the closing of the wound of the artery, by means of the application of the coagulated clot opposite to the lips of the small wound of the brachial artery.

A case similar to this, but much more singular in relation to the time at which the disease was renewed, is related by Saviard.\* There appear-

\* *Journal des Savans*, an. 1691. Il y avoit un corps etranger qui étoit collé sur l'artère, et que le sang artériel s'échapoit par un petit endroit qui étoit détaché depuis peu, et qui avoit causé tout le désordre. Au reste, ce corps etranger n'étoit autre chose qu'un sang fibreux et coagulé, revêtu d'une membrane du côté qui ne regardoit point l'artère, et du côté qui la regardoit il s'étoit formé une petite enfonçure en forme de voûte.



ed, says he, in a man, after an evacuation of blood, an aneurism in the bend of the arm as large as a nut. He had this aneurism for sixteen years, without having been prevented by it from following his trade, which was that of a collier. On a sudden the aneurism increased to such a height, as to occasion so great a swelling in his arm, that it was almost becoming gangrenous. The operation was performed in this man; and it was found, that the coagulated bloody clot, which had been for so long a time adhering to the lips of the wound of the artery, had been detached from it for a small space. Of these facts of apparent cure of aneurism in the bend of the arm, in consequence of compression, Foubert\* has recorded several others, which he had very carefully observed. ‘In the year 1672, (says he), I was called six leagues from Paris to visit a man 70 years of age, who had been wounded in the artery by a country surgeon. The blood had been stopped by means of compresses, a plate of lead, and a very tight bandage, which I loosened, as the arm threatened to gangrene; and instead of the bandage, after having conveyed the patient to Paris, I contented myself with substituting a less firm compression. Seven or eight days after, on examining the bend of the arm, I found there a small aneurism as large as a walnut. I then applied a more accurate compression than before, by means of chewed paper, graduated compresses, a bandage, and a machine, differing from that denominated *ponton* in this, that it only compressed the tumor, and left the vessels which carry back the blood at liberty. No swelling supervened, and the pulse was soon after perceptible. Eight days after I renewed

\* Mém. de l’Acad. R. de Chirurgie, t. vi, in 8vo, p. 251.



the dressing, and I found no longer any mark of the tumor. In forty days the patient seemed to be cured, and I permitted him to make a moderate use of his arm. Some months after, this patient was struck with an apoplexy, and died. I obtained permission to examine his arm. I removed the cord of vessels from their situation, four fingers above and below the place where the artery had been wounded; and in separating the artery from the other vessels, I observed a small knot which corresponded to the place of the cicatrix, and which seemed to be formed by a firm cohesion having taken place between the aponeurosis of the biceps muscle, the cellular capsule of the artery, and the lips of the wound of the artery, as they were all glued together. Having opened the artery on the posterior part, or opposite to the place of the wound, a round hole was found at the place of the puncture, which corresponded to the small knot; which hole was closed up by a small indurated clot of blood; and this clot, like the head of a nail, appeared to keep these parts united together, and formed the cicatrix.' 'It is probable,' the author adds, following the opinion of M. Petit, 'that the cure of these diseases always takes place in the same manner, and that consequently the compression, continued for a long time, may cure this kind of wound. Foubert then proceeds to relate a second fact, to the following purport. 'In the year 1748, I visited a man upwards of seventy-five years of age, who had been bled on account of a retention of urine; he begged me to loosen the bandage, for the surgeon, after having bled him, had tied his arm very tight, as he had found great difficulty in stopping the blood. On examining the arm (says Foubert), I found it very much swelled from the place of the bleeding as far as the axilla.



Having sent for the surgeon, he owned to me that the artery had been wounded. I removed the bandage entirely. I applied my thumb firmly upon the incision to press out the clotted blood interposed between the lips of the wound, and in the pit formed by my thumb I placed a piece of chewed paper, and over it graduated compresses, and then a roller. But there was notwithstanding a very considerable extravasation extending from the place of the bleeding as far as the axilla, which formed a projection in the direction of the brachial artery. I covered the humerus and the arm with compresses dipped in spirit of wine, in which there was dissolved some camphor and sal ammoniac. The pulse disappeared for some time. Eight or nine days after, I renewed the dressing, and had reason to be pleased with the state of the parts. There was no tumor at the place of the bleeding, but there was some ecchymosis around it. On re-applying the bandage, I only made that degree of pressure which I thought sufficient to complete the cure. The arm nevertheless remained swelled, and the effused blood formed an abscess. In fact about three weeks after the accident, I was obliged to make an incision, from which there issued some black fetid blood. But all went on well at the place of the bleeding, when new symptoms, depending on the retention of urine, carried off the patient. I made the cord of vessels in the bend of the arm be removed from their situation, in order to examine what had taken place in relation to the wound of the artery. I found that the trunk of the brachial artery had been opened some lines above its division, that the opening was round, and filled with a clot of blood, which had become so hard as to allow us to hope that the patient would have obtained a complete



cure, if he had not died from the violence of the other disease.'

§ 9. All these cases are far inferior to that which I shall now relate, both in relation to the methods of cure which were employed, and the singular manner in which I found the wound of the brachial artery, in consequence of a bleeding, closed in the dead body; from the subject of which I have taken figures 2, 3, 4, 5, of plate ii. The history of this case was communicated to me by Monteggia, a celebrated professor of surgery in Milan. 'A man, 76 years of age, feeling a numbness in his left arm, which made him dread an apoplexy, was bled in the left arm in the median basilic vein. The blood came with great force, velocity, and *per saltum*, and in fine could not be stopped, so that two other surgeons were sent for, as the first could not succeed in closing the vein; it was at once ascertained that the artery had been wounded. At last, by means of small cushions, firmer compresses, and a tight bandage, the flow of blood was stopped. The part began to swell, with acute pain. The patient remained in bed. The day after, a particular swelling was observed, evidently pulsating in the bend of the arm, and the tight bandage was repeated, similar to that which is used in bleeding, but with more numerous turns. The third day, that is, the 21st March 1801, I was consulted (continues Monteggia) in this case, and found a very great swelling, extending over the whole limb, that is, over the whole arm, fore-arm, and hand. The bandage caused such insufferable pain, that it was necessary to remove it. The external wound of the bleeding was found to be sufficiently closed as not to pour out any more blood. The most elevated part of the swelling at the bend of



the arm, for the extent of half a hand's breadth in circumference, was felt not to be formed by blood infiltrated, as in the rest of the arm and fore-arm, but collected into a mass, fluid, undulating to the touch, and with a remarkable pulsation, and a kind of hissing noise, which terminated insensibly at the edges of this central collection of fluid blood. In this state it was my opinion, that the best practice was to adopt the method recommended by Mr. B. Bell and Mr. Latta, that is, to leave off all bandaging (as was indeed done), and to apply only a small compress, as in bleeding, with two or three turns of a soft roller, merely for affording a little support to the vein, that the subjacent aneurism might not fill it again, and this only for two days, when it was also left off. The arm was placed nearly extended upon a pillow, with the hand elevated. The great swelling would not allow it to be kept bent, not even in an half bent position. The whole limb was frequently fomented with cold vinegar and water. The pains abated as soon as the bandage was removed, and the day after, the swelling and tension were found already diminished, and even the pulsation in the centre of the tumor was sensibly abated; and this favourable beginning went on rapidly advancing during the succeeding days. On the twenty-ninth I substituted a fomentation of camphorated spirit of wine; but whether this was unseasonable, from there being some remains internally of inflammatory irritation in the wounded part, or from having placed the arm rather more bent than usual, not upon a pillow as before, but in a sling, or because some turn of the simply retaining bandage caused some constriction, from a displacement of some of the cloths of the fomentation; in four hours after, the patient began to feel rather acute pains in the arm,



and the swelling and tension were much increased. The arm was therefore again placed on the pillow, fomenting it as before with vinegar and water, to which there was afterwards added only a little extract of lead, and the bandage was entirely removed, although it had been simply retaining and soft. The state of the arm immediately improved. A few days after, another slighter and transient exacerbation occurred, occasioned probably by some exertion; but however, every thing went on well, and the man in forty days was perfectly cured of his aneurism, there remaining only a slight œdema of the arm and hand, which was treated with corroborants and the expulsive bandage. There was merely a weakness and inflexibility of the fingers, caused probably by the long want of motion; from which affection, rendered perhaps more obstinate by the advanced age of the patient, it was impossible to relieve him. The pulse of the injured arm was equal to that of the other, and even at the greatest height of the aneurism was felt distinctly. In December 1802 this man was attacked by a catarrhal affection of his lungs and retention of urine, and died the 12th of the same month. In the body, on examining the arm, every thing was found in a natural state, except that on the posterior and external side of the humeral artery in the bend of the arm there was attached a dark-coloured body,\* as large as a nut, enveloped and attached to the artery by means of the cellular substance.† Thus far the detail which I received from Monteggia. I afterwards proceeded to examine attentively the pathological preparation he transmitted to me. The brachial artery had preserved exactly its natural diameter;‡ and on opening it on

\* Pl. ii, fig. 2, 3, b.      † Pl. ii, fig. 2, 3, a a.



the side opposite to the dark-coloured body, there was distinctly perceived on the inside of it the cicatrix<sup>1</sup> of the puncture which had been made in it by the lancet. On dividing this dark body vertically,<sup>2</sup> it appeared to be formed by a firm and large cellular capsule, although it was originally only a continuation of the soft cellular substance which surrounded the rest of the brachial artery. Within this hard rigid sac there was a clot of compact blood, nearly of a triangular figure.<sup>3</sup> One of the angles of this clot, of a whitish colour,<sup>4</sup> was formed rather by the fibrous substance than by the crassamentum of the blood. This angle insinuated itself into a fossa,<sup>5</sup> formed by the separated lips of the wound of the artery, which this clot closed up like a plug, and adhered firmly to the lips of it. Having removed all of this clot from thence, and introducing a probe into the bottom of this cavity, it was seen, and distinctly felt, that this small cavity corresponded exactly to the place of the cicatrix of the internal membrane of the artery.<sup>6</sup> The probe, even on using force, did not pass through the cicatrix into the tube of the artery. The bottom of this cavity<sup>7</sup> was hard and rough, and seemed to be hollowed out of a substance partly cartilaginous, partly earthy; and this circumstance was still more evident on passing the point of the knife over it.

§ 10. There can be no doubt that in this singular case there was not only, as in the preceding, the fibrous clot, which in the manner of a plug closed up the wound of the artery, but likewise that the lips of

<sup>1</sup> Pl. ii, fig. 3. c.

<sup>5</sup> Pl. ii, fig. 4, d.

<sup>2</sup> ——— 4, c c.

<sup>6</sup> ——— 3, c.

<sup>3</sup> ——— 5, a a.

<sup>7</sup> ——— 4, d.

<sup>4</sup> ——— 5, b b.



the wound, on the side of the cavity of the artery, were closed up by some kind of cicatrix. This cicatrix, if it may be called so, differed from the cicatrix of the simple wounds of other soft parts in this, that it was cemented, to use the expression, by an earthy substance, and that in this respect it had a greater analogy with the callus of the bones after a fracture, than with the re-union of the wounds of soft parts. In this particular case the artery had not been wounded anteriorly, but a little to the outer and posterior side; which circumstance may be ascribed to the custom which some surgeons have of pushing in the lancet nearly horizontally, and transversely, from the fallacious idea of avoiding, in this manner, the artery. It is wonderful how, in this case, on laying aside every kind of compression and bandage, nature was of itself capable of stopping the progress of the effusion of blood. And farther, it is not improbable that the sudden and violent attack of *adhesive* inflammation contributed greatly to this, and that the situation also of the small puncture of the artery, a little external and posterior, far from having been disadvantageous, rather contributed, by means of the approximation of the parts surrounding the artery, to the more rapid cohesion of the cellular substance, which formed the aneurismal sac, with the lips of the wound of the artery, and thereby to the formation of the solid clot, which put a stop to the farther flow of blood. Finally, this particular case is no objection, as I have said in another place, to my considering the cure of the aneurism in the bend of the arm by compression, whenever there remains in that place a tubercle containing a clot of blood, however hard and coagulated it may be, as an imperfect cure, and therefore subject to relapse. The cure in this



case of which we are speaking was not, strictly speaking, complete and *radical*, although there was in addition a kind of cicatrix on the side of the internal membrane of the artery; for the lips of the wound of the artery were still separated on the side of the small sac, and the cicatrix on the inside of the artery had without doubt changed for some way the natural flexibility of the proper coats of the artery; and this degree of rigidity had necessarily disposed the artery at that place to burst on the supervening of any violent internal or external cause. And though in this case, in which the compression could not be borne by the patient, and the disease was left entirely to nature, the event of it was favourable within certain limits, nevertheless, I believe that no one would allow himself to be induced by any of these rare successes to regard as a good general rule, that, whenever compression cannot be employed, he ought to wait, trusting too much to the powers of nature, rather than proceed without delay to the operation of the ligature of the wounded artery, which is a certain means of establishing a lasting cure, and much less formidable than surgeons commonly suppose. Farther, even before Foubert, in the year 1732, M. Petit \* had presented to the Academy of Sciences the brachial artery of a man who had died suddenly two months after this artery had been punctured six lines above the place of its bifurcation. There adhered externally to the artery at the place of the puncture a small coagulated clot, which the author called the *couvercle*. Internally, within the tube of the artery, the clot or *couvercle* insinuated itself between the lips of the wound of the artery, without, however, protruding at all with-

\* Mém. de l'Acad. R. des Sciences de Paris, an. 1735.



in the cavity of the wounded artery. M. Petit nevertheless observed, that on pressing this clot externally, it passed through the lips of the wound into the tube of the artery; which circumstance the author expressed in fig. 3, annexed to his memoir. This observation differs a good deal from that which I have just related, and serves even to shew still farther, that this means of cure of the wound of the artery is uncertain and precarious, although Petit has endeavoured to prove that the coagulated *couvercle* is formed by a substance analogous to that of a cicatrix. Besides, Petit himself observes that this *couvercle* can never be a means capable of stopping the hemorrhage, except in the case in which the wound of the artery is very small, or, to speak more properly, a mere puncture; since, if the incision of the artery were extensive, the impetus of the blood would constantly displace the *couvercle*, and the hemorrhage, or effusion into the cellular substance, would continue without intermission. The same objection may be made to the opinion of Arnaud, who thought that the great secret of the art of curing external aneurisms by means of compression, consisted in finding a mode of forcing the coagulum of blood to go back by the orifice of the wounded artery, and to shut up this orifice after the manner of a plug. *Mémoires de Chirurg.* vol i, pag. 191. Such a method will never produce a *radical* cure, and exempt from relapse, as facts have repeatedly proved.

§ 11. If the compression is inadmissible, because, although the aneurism in the bend of the arm be small and *circumscribed*, it is foreseen that this method cannot be employed in such a manner as to cause a total obliteration of the artery at the place of the injury; or because the rapid increase of the tumor, the excess-



ive hardness of it, the acute pain which it occasions, the swelling of the arm, the symptoms of suppuration or gangrene require a speedy remedy, the surgeon will immediately proceed to the operation of the ligature of the brachial artery. This operation, as has been mentioned in speaking of the radical cure of the femoral aneurism, may be performed in two different ways; the one is that of M. Anel, or the ligature of the humeral artery above the seat of the aneurism, leaving the aneurismal sac quite untouched; the other by means of the incision of the aneurismal sac in the bend of the arm, and the ligature of the humeral artery in the bottom of the sac, above and below the place of the wound made by the lancet.

§ 12. The first, or Anel's method, deserves to be preferred to the second, in those cases in which the aneurism in the bend of the arm is *circumscribed* and of moderate size, and not accompanied by violent inflammation and swelling of the whole arm, from the excessive distention caused by the clots of effused arterial blood, which is as much as to say, in circumstances nearly similar to those in which the compression may be tried. In the combination of circumstances contrary to this, or in the urgent symptoms now mentioned, which unfortunately is the most frequent case, and where the most pressing indication is that of removing quickly the excessive distention occasioned by the clots of extravasated blood, the second method, or the incision of the aneurismal sac, is to be preferred. Whenever Anel's method is indicated, it is to be performed in the following manner. Having placed the patient at the edge of the bed, with his arm separated from his breast, and firmly supported, the surgeon will press with the point of the finger



immediately above the seat of the aneurism, and running upwards between the internal condyle of the humerus and the inner edge of the biceps muscle, he will search for the course of the humeral artery, which he will discover by its pulsations. He will have it in his option either to fix the place of the incision, for laying bare the humeral artery immediately above the aneurism, or much higher, and in the long space between the origin of the *superior* and *inferior* collateral arteries. Having determined the most proper point for this, or where the humeral artery is found most superficial, he will divide the integuments in the course of this artery, and at the same time the cellular substance, for the space of about two inches and an half, and introducing the finger of his other hand into the bottom of the wound, he will feel the denuded humeral artery, and, if it is not sufficiently laid bare, will divide, with his hand unsupported, the parts which still cover it, observing to introduce the edge of the knife on the side next to the internal margin of the biceps, to avoid dividing any of the numerous muscular branches which go off from the opposite side of the humeral artery. He will then insulate with the point of the finger the trunk of the humeral artery alone if he can, or together with the median nerve and vein, and raise it a little from the bottom of the wound. He will separate the median nerve and the vein for a small space from the artery, and with the eyed needle he will pass behind the artery a waxed ligature two lines in breadth. Having allowed the artery to fall to the bottom of the wound, he will proceed with both hands to lay hold of the ligature, with which he will make a simple knot, and, before drawing it tight, an assistant will place the roll of linen between the artery and the knot. Having tightened the



artery, the surgeon will examine the aneurism, and if the pulsations in it have ceased entirely, he will make a second knot over the first; he will clean the wound, will fill it with soft lint, cover it with a compress retained by a six-headed bandage, and place the operated arm in a convenient situation, in a state of semi-flexion. The choice which the surgeon has of laying bare the humeral artery either immediately above the aneurism, or at the different points from the bend of the arm to the middle of the humerus, does not produce any change in the principal anastomoses of the humeral artery between the branches which go off above the ligature and the radial, ulnar, and interosseous recurrent arteries. For, notwithstanding the ligature be applied nearly at the middle of the humerus, the origins of the profunda humeral and *superior* collateral arteries remain entire, two very conspicuous canals, and sufficient to supply the circulation and life of the fore-arm and hand, although the course of the blood be interrupted through the principal trunk. This truth is proved by injections in the dead body, and confirmed in the living, by the case related by Anel, and by that related in the present day by Mirault.\* Whoever, after these directions, shall have the treatment of a *circumscribed* aneurism in the bend of the arm, will no longer follow, I flatter myself, the method of those† who, supposing this tumor to be formed by the dilatation of the humeral artery, divided first the integuments over the tumor, insulated the sac, and sought for the humeral artery above and

\* Chap. ix, § 5, 16.

A few years ago, in the Royal Infirmary of Edinburgh, Mr. Gillespie performed this operation in this manner in a case of aneurism at the bend of the arm after venesection. One ligature was applied about two inches above the tumor, and in three weeks afterwards the patient was dismissed cured. T.

† Chap. vii, § 2.



below the aneurism, in order to tie it in two places, and then endeavoured to make the sac mortify, and come away piece-meal, and be expelled from the wound in the same manner as the ligature. All this long and unnecessary process of operating, suggested by false ideas with regard to the nature of this disease, and of the parts which are affected by it, will be excluded for ever from good and rational surgery, and the operation reduced to the greatest simplicity, that is, to the ligature of the humeral artery above the aneurism, leaving it untouched, which will free the patient from the pains of a tedious, unnecessary dissection, from the necessity of a second ligature below the tumor, and from the unavoidable inconveniences of a copious suppuration, which is required to facilitate the separation of the aneurismal sac from the bottom of the wound.

§ 13. The other method of operating, or that by the incision of the aneurismal sac, is performed in the manner I am now about to detail. Having brought the patient to the edge of the bed, so that the affected arm, removed from the side, rests upon a firm pillow, the surgeon will apply the tourniquet to the upper part of the humeral artery in the vicinity of the insertion of the pectoral muscle; or, when the whole arm is swelled and painful, he will cause the artery to be compressed by an assistant above the clavicle against the first rib. With a straight bistoury he will open the aneurism with one stroke from below upwards, passing at the same time through the integuments, ligamentous fasciæ, and aneurismal sac, observing that the incision pass through the middle of the cicatrix of the integuments, left by the lancet. All this is to be done in the supposition that the aneurism forms a tumor sufficiently elevated. But supposing that the



tumor was depressed, as in the recent *diffuse* aneurism, the surgeon will use a convex-edged bistoury, with which he will divide the parts cautiously, to such a depth that the bloody clot appears; then having introduced the finger of the other hand through the clot and within the tumor, along it he will divide the tumor in its whole length in the direction of the humeral artery. In the very act of dividing the aneurismal sac, the compressed mass of clotted blood will burst out, and will be followed by a jet of a portion of fluid blood. Having cleaned the bottom of the aneurismal sac with a soft sponge, the humeral artery immediately presents itself to the surgeon in the bottom of the sac, and at the same time the precise place where it has been opened by the lancet, especially if the aneurism, although *diffuse*, be elevated and pointed. Having then laid aside the knife, and taking in his right hand a large strong probe, he will introduce it through the wound made by the lancet within the tube of the artery from below upwards, and with it will raise up the artery, while with the point of the fore-finger of the left hand he will separate it from the flaccid cellular substance, which keeps it tied laterally and posteriorly to the neighbouring parts, and he will continue to do this till the point of the finger shall have passed behind the artery, which he will raise from the bottom of the sac alone, or along with the median nerve. If it is along with the median nerve, having drawn back the probe, he will separate gently with the fore-finger and thumb of his right hand the nerve from all that portion to which the ligature is to be applied. This separation of the nerve from the artery is easy, and often very readily performed, from the median nerve very frequently not adhering firmly to the humeral artery, or from the clots of blood having already caused a separation of it. Having sepa-



rated the humeral artery from the nerve\* for a small space, the surgeon will pass the eyed needle, armed with two waxed threads of convenient breadth, from the inner towards the outer side of the arm, behind the artery, still supported with the point of the fore-finger of his left hand; after this he will withdraw the fore-finger of his left hand, and will allow the artery to fall to the bottom of the sac. He will then proceed to make the ligature, that is, with one of the ligatures he will tie the artery a little above the place of the wound made with the lancet, and with the other he will do the same below the wound, making a simple knot, and interposing a cylinder of linen between the artery and the knot. After having done this, the surgeon will direct the pressure to be removed from above the clavicle, or the tourniquet to be loosened, and if no arterial blood appears, he will clean the cavity of the tumor, and finish the operation in the manner above described.

\* I cannot comprehend why, on this subject, Mr. Sharp has observed, that the ligature of the median nerve along with the artery is an accident which can almost never be avoided, although those who have written on surgery recommend it to be avoided. *Critical Inquiry*, chap. vii.

No one can regard it as a matter of indifference, in the act of stopping the current of blood to the arm through the great artery, to deprive it also of the influence of one of its greatest nerves. And setting aside even this reflection, if it has been shewn that the security of the ligature of a great artery depends very much upon tying the artery denuded, the including of the median nerve cannot fail to oppose the success of the operation. Molinelli himself has not passed over in silence the inconveniences of such a practice; for he writes,—‘*Nervo etiam ac vena rem ut celerius expedirem quam possem, simul cum arteria comprehensis. Qua ex re gravius paulo indoluit quam cum seorsim constringeretur arteria. Ac tum de amisso præsertim manus sensu motuque quæstus est. Hic avulsum sibi, sublatumque fuisse quidquid ejus artus infra vincturam erat conclamavit, negabat omnino se has partes habere amplius, quod antea non fecerat.*’ *Loc. cit.*



§ 14. It ought not to be concealed, that even the most ancient medical men knew,\* that, in spite of the ligature of the trunk of the brachial artery, the circulation and life continued as before in the subjacent fore-arm and hand. Nor, after so ancient and well authenticated traditions, can I discover the reason why the surgeons who came afterwards, and almost to the present day, have never prepared to perform this operation but with great perplexity, and never without having at the same time the instruments for amputation in readiness. At present, in consequence of the diligent anatomical investigations with regard to the distribution and anastomoses of the vascular arterial system of the arm, the explanation of this phenomenon is no longer doubtful or obscure; and farther, if the ligature of the brachial artery applied towards the middle of the arm leaves a free and easy passage to the blood by the *profunda* humeral artery, and by the *superior* collateral to the anastomoses of the flexure of the elbow, the ligature of the brachial artery, a little above where venesection is practised, renders this passage of the blood still more expeditious, on account of the channel opened by these two arteries, and at the same time by the *inferior* collateral artery. It is to be observed, however, that the beating of the radial artery is not immediately felt at the wrist in every case after the ligature of the brachial artery; for the pulse sometimes does not appear for some days after the operation; at first after the manner of a deep tremor, then of a weak, and at last of a strong and natural pulsation; which circumstance does not produce any sensible change in the vitality of the arm or hand. And this is an additional argument among the many

\* *Ætius, Paulus.*



others of this kind which may be adduced in order to prove, that for the preservation of the circulation and life of a part, it is not necessary that the arterial blood circulate in it in such quantity, and with such impetuosity, as to cause an evident pulsation of the arteries of the part which it supplies.

§ 15. In the greater number of persons the brachial artery divides into radial and ulnar very near to the bend of the arm, or upon the lower end of the brachialis muscle. In some individuals, however, this division of the brachial artery takes place much higher up, that is, above the middle of the humerus, and sometimes in the axilla. Among the preparations of this anatomical cabinet there are two of this kind, in which the division of the brachial artery is seen as high up as the insertion of the great pectoral muscle. Laurent,<sup>1</sup> Bidloo,<sup>2</sup> Petsche,<sup>3</sup> Winglerius,<sup>4</sup> Schmide-lius,<sup>5</sup> Heister,<sup>6</sup> Monro,<sup>7</sup> Hunter,<sup>8</sup> and Ludwig,<sup>9</sup> have described and delineated these various divisions of the brachial artery at different distances above the bend of the arm. In those subjects in which this division of the brachial artery occurs high up in the humerus, it is constantly observed that the radial and ulnar arteries descend along the inner side of the humerus near to one another, and that when they have reached the bend of the arm, one of them, the radial, is

<sup>1</sup> *Histor. Anatom.* pag. 146.

<sup>2</sup> *Observ. Chirurg.* pag. 64.

<sup>3</sup> *Sylog. Observ. Anatom.* N. 54.

<sup>4</sup> *Exposit. Anat.* N. 143.

<sup>5</sup> *Dissert. Epistol. de varietatibus vasorum*, fig. 1.

<sup>6</sup> *De Art. Cruralis vulnere Dissert.* fig. 4, *Comp. Anat.* not. 66.

<sup>7</sup> *Monro's Works*, N. 14, plate ii, fig. 5.

<sup>8</sup> *Medical Observ. and Inquiries.*

<sup>9</sup> *De variantibus arteriæ brachialis ramis* progr. 1767.



raised, and becomes unusually superficial precisely at the place where venesection is usually practiced. This was perhaps the case of the young man of which Galen \* made mention, when he said, *contigit atolli veluti in gibbum arteriam; itaque hanc pro vena medicus divisit.* In a case of wound or aneurism in the bend of the arm in a patient with such a conformation, where the radial and ulnar arteries run on the inside of the humerus, parallel and contiguous to each other, it might very readily happen that the surgeon, in performing the operation, would include both arteries in the ligature. The mistake, indeed, would not be of great consequence, since, according to all the calculations, the ligature of these two arteries in the bend of the arm, or even higher up, would not produce consequences different from those which the ligature of the single and principal trunk of the brachial artery produces above the division of the radial and ulnar arteries. For, in the former, as well as in the latter case, the passage of the blood would remain equally open by the *profunda* humeral and two collateral arteries to the anastomoses formed by the recurrent arteries of the elbow. However, we must allow, that it would render the operation more complete to avoid in similar cases the tying of both of these arteries, as it is only necessary to tie the one which has been wounded. And the surgeon will certainly avoid this inconvenience, if he will always proceed in the operation of which we are speaking according to the rules above laid down; that is, if, after having evacuated the clots, carefully cleaned the bottom of the aneurismal sac, and exposed the place where the artery has been wounded, he will introduce a probe into

\* See above, § 4.



the tube of the injured artery, and raise it upon it, while with the point of the fore-finger of the other hand he endeavours to insulate it from the neighbouring parts, to separate it for a small space from the median nerve and vein, and tie it carefully denuded above and below the place of the wound.

§ 16. Whichever of these two methods of operating is employed, the subsequent treatment is the same as that which is practised after the ligature of the *superficial* femoral artery. This consists chiefly in keeping the external lips of the ulcer gently separated, until the ligatures have separated, and till the bottom of the wound has risen nearly to a level with the integuments. If any of the ligatures is longer than usual of being detached, that is beyond the twentieth day, and if the loop is observed to be relaxed, it will be proper to pass a probe, or a fine conductor, within the loop, and upon it a pair of scissors, to divide the noose, and then to withdraw the threads of the ligature from the bottom of the wound. After the ligatures have come away, the surgeon or the assistants will pay particular attention to make the operated arm of the patient be extended and bent gently several times a day, in order to prevent the rigidity of the joint of the elbow: an accident which never fails to happen when this practice has been neglected beyond the fortieth day.

§ 17. The method of operating for the cure of the humeral aneurism, occasioned by a wound of a sword, knife, or bayonet, or of fire-arms, is perfectly similar to that hitherto explained. This aneurism is generally *diffuse*, and therefore requires a method of cure no less efficacious than speedy to remove the ex-



cess of the distention of the integuments and interstices of the muscles, produced by the numerous clots of extravasated blood; which method of cure, for the reasons mentioned, can only be that of the incision of the aneurism, the evacuation of the bloody clots, the insulation and ligature of the denuded humeral artery above and below the place of the wound. Upon this point, after all that I have said in relation to the steps of the operation of the aneurism in the bend of the arm, by the incision of the sac, there remains nothing else to be added on the subject of the *diffuse* humeral aneurism, the operation being precisely the same in both cases. It is only proper to remark, that whenever the humeral aneurism, (and this may also be said of the femoral, or of any other external part of the body), has been produced by a wound inflicted laterally in the artery, it is not a matter of indifference to make the incision of the aneurism in one place rather than in another; for if unfortunately the brachial artery has been wounded, not perpendicularly and on the fore part, but latterly and a little posteriorly, and in such a manner that its posterior side has been considerably opened\* by the wounding instrument, as by a sword, knife, or musket ball, it may happen that the surgeon, following the ordinary plan of making an incision into the aneurism anteriorly, and even after having laid the artery accurately bare, finds himself placed in the embarrassing situation of not being able to discover the precise place where the artery has been wounded, and consequently not to be able distinctly to ascertain where to

\* I allude to a large wound, not to a small incision made laterally and posteriorly in the artery, such as the prick of a lancet, as in the case above related, § 9.



place the ligatures. And the difficulties are still further increased, on this account, that the blood does not flow out, at least *per saltum*, from the denuded artery, which beats as in the sound state. This is occasioned by the pressure which, at the moment when the arm is extended, the surrounding parts make against the wound of the artery, which prevents the discharge of blood, and conceals from the eyes of the operator the exact place of the injury in the artery. The surgeon, then doubtful if it is really the trunk of the brachial artery which has been opened, or a large branch of it, which he cannot ascertain, contents himself with filling the aneurismal sac with lint, and replacing the arm in a state of semiflexion. But no sooner are the dressings applied, than they are tinged with fresh blood. He renews the dressing, without having been more fortunate in discovering from whence so much blood comes. The hemorrhage recurs again repeatedly; the patient's strength is exhausted; and the surgeon, no wiser than he was at first, not to leave the patient to a certain death, resolves to amputate the arm.

This important point of practice will be illustrated by the following history.\* 'A young man, 25 years of age, in the act of parrying a blow of a knife, was wounded in the arm. The knife entered by the outer edge of the biceps, and wounded the posterior part of the humeral artery. The arm swelled prodigiously. The extravasted blood extended from the elbow to the axilla, and the fore-arm was covered with ecchymosis down to the wrist. M. Deschamps undertook the cure of it some days after the accident, making an incision through the integu-

\* Deschamps, Obs. et Reflex. sur la ligature des principales artères blessées, Obs. 1.



ments and the aneurism, along the course of the humeral artery, for the space of five inches from the insertion of the deltoid muscle downwards; he then evacuated the clots of blood, and laid bare a considerable portion of the humeral artery. On suspending the compression, which an assistant made above the clavicle, the operator and assistants were very much surprised at not immediately perceiving the place where the humeral artery had been wounded, and more particularly at not seeing a drop of blood discharged from it, although it beat at every point like a sound and uninjured artery. After searching for a quarter of an hour, some thought that the humeral artery had actually been wounded, others not. It was resolved to pass round the humeral artery a waxed thread, to be drawn in case of the hemorrhage recurring; and in the meantime to apply a compressive apparatus to the denuded artery. To pass the waxed thread more conveniently round the humeral artery, M. Deschamps dilated the wound made by the knife, introduced his finger by it from below upwards, towards the axilla, and having reached a certain height, he passed the needle and thread round the artery, six lines higher up than the place to which the point of his finger had reached. The compression on the denuded artery was then applied, but so as not to suppress the pulse at all. The day after, at four in the morning, the blood burst out, but was stopped by a greater degree of pressure. The following day the hemorrhage reappeared, and was likewise suppressed by the same means. On the fourth day the loss of blood recurred with greater violence, and more alarming than before. At mid-day again a hemorrhage. The dressings were removed, in the hope of discovering at last the exact place from which the blood issued, but to no purpose.



M. Deschamps then tied the ligature. The instant that the knot was drawn, the blood gushed out and filled the cavity of the wound, and shewed that the ligature had been applied below the place where the humeral artery had been wounded. The operator immediately passed another thread behind the artery above the first, and tied it. The hemorrhage was immediately stopped, but it was too late; for the strength of the patient was already exhausted, he soon after lost all sensation, and expired. On examining the body, it was found that the humeral artery had been wounded, obliquely and posteriorly, from the outer towards the inner side of the arm, for the space of two lines lengthways, and opposite to the lower edge of the great pectoral muscle; that the wound was above the origin of the superior *profundæ* humeral arteries; that the first ligature had been applied about four lines below the wound of the artery, and the second ligature about five lines above it.

§ 18. It appears to me, that in the case just related, if the operator had deviated from the general rule, or, instead of making the incision of the bloody tumor on its anterior surface, following the course of the humeral artery, if he had enlarged the wound made by the knife, he might by this have succeeded in discovering the exact place where the humeral artery had been opened, and thereby have been able with certainty to apply the ligature above and below the place of the injury in that artery. What I here assert is self evident. For if, in order to pass the first ligature, M. Deschamps had enlarged the wound made by the knife, introduced his finger from below upwards towards the axilla, made the ligature pass six lines above the point of his finger, since in the



dead body it was found that this ligature was situated only four lines below the wound of the artery, it is evident, that if he had, along his finger, or on a conductor, continued to enlarge the wound for ten lines more upwards, he would have succeeded in discovering the place of the wound of the humeral artery, and might have applied a quick and sure remedy.\* Farther, whether the loss of the arm would have been inevitable, in consequence of the humeral artery having been wounded so high in the axilla, as to be situated above the origin of the *profundæ* humeral arteries, (since there are sometimes two of these arteries), is a question different from the first, and shall now be examined separately.

§ 19. As experience has shewn, that, on the *common* femoral artery being tied, compressed, or in any other way obliterated, as it passes out below the crural arch, and above the origin of the *profunda*, the

\* With regard to this point, it appears to me, that, when the brachial artery is wounded on the outer side of the arm, instead of enlarging the wound and tying the artery as the author recommends, it would be better to operate in the following manner. Let a probe be introduced by the wound of the integuments, and an incision made upon it, on the inner side of the arm, along the course of the artery ; at which place it lies quite superficial. If the wound in the artery is discovered, on the vessel being laid bare, it may be tied in the usual manner ; but if the wound cannot be discovered, as frequently happens, let a ligature be then passed round the artery and tied. If this ligature is applied below the wound, the blood will immediately rush out, and will direct the surgeon where to apply a second ligature above the injury. If no blood is discharged on the ligature being tied, it will shew that the artery has been secured above the wound ; and experience shews that it is immaterial, whether a second ligature be applied below the injury or not, as any hemorrhage which may occur would be easily restrained by a moderate degree of compression. *T.*



patient nevertheless preserves the whole of the corresponding inferior extremity, it may be asked, in like manner, if it is possible to obtain the same advantage for the preservation of the arm, whenever necessity requires the axillary artery to be tied above the origin of the *profunda*, or of the two *profundæ* humeral arteries? With regard to this point, anatomy in the first place shews us, that as the arteries of the cavity of the pelvis communicate repeatedly on the outside with the circumflex arteries, and with the *profunda* femoral, so those of the neck, and especially of the *inferior* thyroid, and those coming off from the trunk of the subclavian, winding round the scapula, communicate repeatedly with the inferior scapular, with the circumflex arteries of the humerus, and then with the *profunda* humeral below the origin of this artery. In Chapter IV, I entered expressly into very minute details relative to the anastomoses of the arteries of the neck, scapula, and top of the arm, and I employed the greatest possible attention, in order to render these anastomoses clear and distinct; from which it appears, that we may tie the axillary artery above the origin of the *profunda* humeral, with as much confidence as we tie the *common* femoral artery, above the origin of the *profunda*; that we may have even more confidence in the case of which we are speaking, considering that the anastomoses of the scapula and top of the humerus ought to yield more easily, to convey the blood from the neck, thorax, and scapula, into the superior extremity, than those of the inside of the pelvis to the inferior extremity, if we reflect that the former are nearer to the heart, and to the centre of the impulse of the blood, than the latter. This truth resting upon dissection, is farther proved by the following practical observation. Mr. Hall,



surgeon,\* was called to a man living in Cheshire, who had received a wide and deep wound by a scythe in the cavity of the axilla, which had divided the axillary artery. The wounded person fainted from the great loss of blood, which contributed in a great measure to his safety, as he was at that time without any assistance. Mr. Hall was passing by accident in that neighbourhood, and had with him neither his instruments nor sewing needles. Notwithstanding this, as the laceration in the axilla made by the scythe was very wide, this surgeon took hold of the wounded artery with his fingers, exactly at the place where it had been divided, and kept it firm, until he could procure some thread, with which he tied it circularly. The man recovered, and retained the use of his arm, except that in that arm the pulse remained a little weak and tremulous.† There are likewise some examples of a large wound of the axillary artery being cured by nature, in cases where her beneficent operation was not prevented by a violent impetus of blood sent from the heart; that is to say, after a profuse hemorrhage. There is a very celebrated case related by Van-Swieten,‡ in which, although the arm remained emaciated and weak, it was not however deprived entirely of life, although all the circumstances of this accident lead us to suppose that the axillary artery had been contracted and obliterated, or that this artery had been obstructed by the presence of a coagulated clot, firmly adhering within the tube of the artery. Besides this, it is to be observed that the median nerve might have been much injured along with the artery,

\* John Bell, *Discourses on the Nature and Cure of Wounds*, p. 59.

† See Appendix, Mr. Keate's case of axillary aneurism. *T.*

‡ See Appendix, note, No. 16.



or some other nervous trunk of the arm, to which was to be ascribed, in part, the state of emaciation and debility in which the arm continued, rather than this accident should be considered as the effect only of the impeded course of the blood through the axillary into the brachial artery. It may perhaps be objected to this, that two great practitioners in surgery, Desault and Pelletan, have performed the ligature of the axillary artery without success ; but on this subject it is necessary to mention,\* that one of the patients died of hemorrhage during the operation, because the ligature of the axillary artery being tightened by chance, the artery was not included in it ; and that the other patient died a few days after the operation, from gangrene of the whole arm, owing to the brachial nervous plexus being included along with the artery. And indeed, although sometimes in a case of aneurism in the bend of the arm, the median nerve has been tied, without any great injury, along with the humeral artery, I do not therefore believe that any one will be easily persuaded that the plexus of brachial nerves may be also tied, with impunity, along with the axillary artery ; and still less, that the brachial plexus may be tied with a knot, without great risk, even for a few minutes only, as was done by Desault, until he had succeeded in securing the axillary artery. For, the tying the nerves tightly, even for a few minutes, is equivalent to cutting them ; and they do not recover their activity, although the ligature be removed immediately after. I am so fully persuaded, by anatomy, that the arm may be saved notwithstanding the ligature of the axillary artery, independent of the plexus of brachial nerves, that I venture to predict, that the

\* Caillot. *Essai sur l'Anéurisme*, p. 84, 86.



time will come, and that ere long, in which surgeons will wonder at our doubts on this subject, as we have been astonished at the perplexity and fears of our predecessors on the point of the ligature of the brachial artery, so high up as the middle of the humerus, and of the femoral artery in the upper part of the thigh, or only at four fingers below the crural arch, without the subjacent limb being deprived of its circulation and life.\*

§ 20. In the case of its being necessary to perform the ligature of the axillary artery, the surgeon will have it chiefly in his mind, that nothing will tend more to embarrass him in the execution of the operation, and prevent its success, than an ill-judged smallness of the first incision, that is, of the integuments of the axilla and of the other parts which cover it, and conceal the wound of the artery. Having therefore placed the patient on a table of a convenient height, with his arm removed as far as possible from his breast, and kept firm in that position, a skilful assistant will make the compression of the axillary artery above the clavicle, and opposite to the first rib. If the wounding instrument has passed from below upward, directly into the

\* I wish to be understood as speaking of the injury of the axillary artery, not complicated with other severe accidents. For, whenever the great artery of a limb, especially in the vicinity of any joint, has been lacerated by a musket ball, by a severe blow, or the passage of a cart-wheel over it, and the injury is complicated with a great contusion of the muscles, and especially with a fracture of the bones, and great extravasation of blood, and general atony of the whole limb, I have invariably observed, that the ligature of the great artery of this limb, at whatever distance from its origin, is of no use, and that the amputation or disarticulation, timely performed, is the only means which can save the life of the patient.



cavity of the axilla, the surgeon will dilate the wound freely upon a sound or conductor, or along his finger, and as high up as is sufficient for bringing into view a considerable portion of the axillary artery, and for shewing the exact place where it has been wounded. If the wounding instrument has run obliquely, or from above downwards, through a portion of the *great pectoral* muscle, and from thence into the cavity of the axilla, the surgeon will not hesitate a moment to divide across the lower edge of the *great pectoral* muscle, and upon the conductor or the point of his finger introduced into the wound, he will make a large incision, so as to discover clearly and distinctly the injured place of the axillary artery. The thoracic arteries, which shall be included in this incision, should be tied immediately, and after evacuating the clots of blood, and cleaning the bottom of the wound with a sponge, however great and extensive it may prove to be, the axillary artery, and the place where it has been wounded, will appear the better. As this artery in the axilla is imbedded in the cords of the brachial plexus,\* so in order to draw it easily from this bed, the surgeon will lay hold of it denuded with the forceps at the place of the wound made in the artery, and will draw it towards him; after this, he will separate it from the soft cellular substance surrounding it, which is very easily done, having drawn the artery out a little from the one or other of the sheaths formed for it by the roots of the median nerve, with the eyed needle he will pass round it two waxed ligatures, with the first of which he will tighten the artery above the wound, and with the other below the wound, placing the roll of linen between the simple knot and the denuded artery. After this, he will clean the

\* *Tabulæ neurologicæ.* Tab. iii, U. U. 177-181.



bottom of the wound, will fill it with soft lint, and cover it with a compress supported by a four-headed bandage crossed upon the shoulder; he will bring the arm close to the patient's breast, and conduct the rest of the cure in the manner repeatedly mentioned in the preceding chapters, both as to what regards the fomentations, and the means for drawing the blood down from the top of the scapula to the hand, and with regard to the treatment of the wound; principally attending to that part of the cure, which is intended for preventing the stagnation of the matter, and the formation of sinusses.

§ 21. In speaking of the popliteal aneurism of long standing and of prodigious size,\* accompanied with swelling, numbness, and coldness of the subjacent leg and foot, as well as with symptoms threatening an approaching rupture of the skin covering it, in a sickly and debilitated patient, it has been said that in this particular extreme case, neither the old nor the new method could be practised with any hopes of success, and still less could much confidence be reposed in the amputation of the thigh; for which reason I stated, that in similar distressing circumstances, the disarticulation of the leg at the knee, seemed to me to be preferable to any method we are at present acquainted with, premising the ligature of the *superficial* femoral artery in the upper part of the thigh. Similar very urgent circumstances may likewise present themselves in a case of large axillary aneurism, from a wound inflicted in that artery very high up in the cavity of the axilla; and from this wound being complicated with a fracture of the os humeri, in the vicinity of its articulating head with the scapula, and from the enormous size of the bloody tumor, and the great pressure exercised by

\* Chapter ix, § 32.



it on the surrounding parts, and the long delaying of the surgeon having occasioned an approaching, or almost inevitable gangrene of the fore-arm and hand. In the midst of so many and so imminent dangers, there does not remain in this case of axillary aneurism, as in that of a prodigious popliteal aneurism of long standing, any better practice to be adopted than that of the disarticulation of the humerus from the scapula, and successively the ligature of the axillary artery above the place where that artery has been wounded.

§ 22. The simple and expeditious manner in which we at present perform the operation for aneurism in the bend of the arm, whether it is by Anel's method, or by means of the incision of the aneurismal sac, forms an interesting contrast with the manner of performing this operation, as was in use in the times of *Ætius*,\* and *Paulus of Ægina*;† which ancient mode I think proper to relate here for the convenience of students, in order that from this and the great progress of anatomy, they may know the high degree of perfection which surgery has reached in the present times. *Ætius*, far from applying the tourniquet, or compressing the humeral artery, in order to moderate and suppress the course of the blood for a given time, as we do, marked the course of the humeral artery from the axilla to the elbow; then following this direction, at three or four fingers below the axilla, where the artery seemed to him to beat most strongly, he divided the integuments; he then uncovered the humeral artery, laid it gradually bare, and separated it with singular attention from the cellular substance; he then raised it by means of a blunt hook, and tied it

\* See appendix, note, No. 17.

† See appendix, note, No. 18.



in two places at a short distance from each other ; he next divided the artery between the two ligatures, and filled the wound with powdered frankincense and lint. Having done this, he proceeded properly to the operation for the aneurism in the bend of the arm. He then opened the aneurismal sac, sought for the wounded artery in the bottom of it, tied it above and below the wound ; then, as before, divided it between the two ligatures, and applied the above-mentioned dressing, intrusting all the rest of the cure to suppuration, as we do, and to the curative powers of nature. Paulus of Ægina also, if it was a case of aneurism, which we call *diffuse*, made an incision into it lengthways, he likewise separated the artery carefully from the cellular substance, tied it with two ligatures at a short distance from each other, and punctured it in the middle space between them, to discharge the blood which it contained ; in which circumstance he differed from Ætius, who, instead of puncturing, divided the artery across between the two ligatures. If, however, the aneurism was of that kind which we call *circumscribed*, Paulus laid hold of the bloody tumor with his fingers, perforated it at the base with a needle armed with two threads, one of the threads he tied upon the upper half of the tumor, and the other upon the lower, exactly as was done by him for destroying the *staphyloma*, and which is now practised for removing large hæmorrhoids. Not sufficiently content with this, Paulus cut away, along with the skin, that portion also of aneurismal sac remaining on this side of the ligatures. He did not mention, however, how he stopped the course of the blood before proceeding to the one or the other of these operations ; and I cannot well comprehend, how he, who knew, that both the *diffuse* and *circumscribed* aneurisms were formed by extravasted blood, and con-



sequently by a wound of the artery, could flatter himself with curing the *circumscribed* aneurism, simply by the ligature of the sac, when he might have effected it more quickly, and with greater security, by laying bare the artery, as in the first case, and by tying it above and below the wound. In which respect, it appears to me, that Paulus does not merit the eulogium which Dr. Friend has bestowed on him in his *History of Medicine*.

§ 23. The cure of the external aneurism, which is formed by a rupture of any of the superficial arteries of the third order, such as the temporal, occipital, *external* mammary, that of the palmar arch, of the tarsus, and the like, is easily performed, because these arteries are of a small diameter, and because they are close upon bones, against which they may be conveniently compressed, with security of success, or tied in the ordinary manner.\* The cure of these aneurisms is accomplished by opening them from the upper to the lower part, with one stroke of a bistoury, and tying the lacerated artery in the usual way, or by means of the tenaculum and waxed thread; or if the mouth of the artery, or of several small arteries, is so lacerated and bruised, that it cannot be conveniently drawn out with the hook, and tied at the bottom, or in the sides of the aneurismal sac, it is to be compressed against the bones, applying over the open orifice of

\* Theden, in speaking of the laying open of gun-shot wounds, mentions the case of a man who was shot through the right hip. As the wound did not heal, an incision was made through the great and middle glutei muscles, by which the gluteal artery was wounded. The wound was immediately filled with compresses secured by a long roller, the hemorrhage, however, could not be stopped, and the patient died. See appendix, for an account of Mr. J. Bell's case of gluteal aneurism.—T.



the artery, a piece of sponge well dried, and above it, graduated compresses, and a bandage adapted to the place occupied by the disease, such as the *knotted* bandage for the temple; the cap of Hippocrates for the forehead, crown, or occiput; the *circular* bandage of the body for the thorax; that of venesection for the hand, for the tarsus, and the like. Farther, as in all cases of hemorrhage suppressed by means of the ligature, and more particularly when a stop is put to the flow of blood by means of compression, so in the cases of aneurism of which we are now speaking, the dressing ought not to be removed from its situation, until suppuration has commenced, taking great care that the bandage exercise a sufficient and steady pressure. Tulpius, in the case quoted above,\* of aneurism occurring between the thumb and fore-finger from a puncture, applied upon the tumor an astringent plaster, and over it a plate of lead, which were compressed by means of a proper bandage, and in this manner, according to Heister's account, the patient was cured in the course of four months. This cure, however, might have been very much shortened, by the incision of the tumor, and by compressing the denuded artery, or tying it in the usual way.

§ 24. Harderus, in his *Apiario observationum*, *Observ.* 86, speaks of an aneurism of the carotid artery, which appeared in consequence of a wound of the neck by the point of a sword. A surgeon, he adds, undertook to cure this aneurism by the operation; but as, after opening the tumor, he was unable to make a sufficient compression, the patient died in his hands from hemorrhage. Acrell † gives

\* Chap. vii, § 17.

† Chirurgische Forfälle, 1. Band. pag. 255.



the account of an aneurism, which he called *true*, of the left internal carotid artery, caused by a wound of a musket-shot, in which the ball entered on the anterior side of the neck, between the trachea and the trunk of the left carotid. This aneurism, by means of a graduated compression, applied in such a manner as was compatible with the injured part, gradually diminished, so that the artery at the end of six months, had, according to the opinion of the author, re-acquired its strength and natural diameter. What seems more probably to have been the fact in this case is, that a coagulum had formed, and that it having stopped the effusion of blood, had allowed the lymphatic system to absorb that portion of blood which had been before extravasted, and which formed the bulk of the tumor. A case nearly similar to this, may be read in the notes added by Van-Horne to the work of Botalus *de vulneribus sclopet.* cap. xv, pag. 6. Anatomy, and experiments performed on brutes, furnish us with a certain and constant fact with regard to this subject; that is, that the ligature of one of the carotids, may be made without the animal giving evident signs of the functions of the head being disordered.\* I have made a great many of these experiments, and always with the same success. Another fact, equally certain, is, that on the carotid artery being obliterated below the aneurism, the tumor gradually diminishes in bulk,

\* Hebenstreit, in the 5th volume of his translation of Mr. B. Bell's system of surgery, mentions a case which he had met with, where the external carotid artery was wounded in the extirpation of a scirrhus tumor. The profuse hemorrhage, which instantly ensued, would soon have destroyed the patient, if the surgeon had not immediately recollected himself, and tied the trunk of the artery. The operation was successful, and the patient lived many years after it. See in the appendix, an account of cases where the carotid artery has been tied with success.—T.



and disappears, in the same manner as the aneurism in the bend of the arm, or thigh, operated on by the Anelian or Hunterian method. This fact is proved by the observation of M. Petit,\* quoted above, made upon the dead body of the advocate Vieillard, who, during his lifetime, had been cured by the powers of nature of an aneurism in the bifurcation of the right carotid artery, by means of the spontaneous obliteration of that portion of carotid, which extended from the right subclavian artery to the origin of the aneurism. The truth of these facts, therefore, being established, and supposing the case that the aneurism of the carotid was situated so high in the neck, as to leave below it a sufficient space for allowing the aneurismatic carotid artery to be brought into view, and tied separately from the par vagum, it appears to me, that the proposal of applying the ligature of the carotid below the seat of the aneurism ought not to be rejected, and that in similar cases the operation ought to be attempted.† Certainly, by operating in this way, there would be no necessity for having recourse to any means for moderating the flow of the blood during the time required for the application of the ligature, and we would run no risk of an alarming and fatal hemorrhage, as there is every reason to believe would happen, by

\* Chap. viii, § 3.

† Mr. Astley Cooper performed the operation of tying the carotid artery on account of a carotid aneurism in a woman aged 44 years. The ligature came away the twelfth day after the operation; on the seventeenth day from the operation, inflammation began in the aneurismal sac, which proceeded to suppuration, and produced such pressure on the trachea and œsophagus, as to make respiration difficult, and deglutition impossible, and on the twenty-first day from the operation, she died. The case is published with plates, in the first volume of the memoirs of the Medical and Chirurgical Society of London.—T.



making the incision of the tumor, in order to evacuate the clots of blood, and tie the carotid in two places in the bottom of the aneurismal sac. I am perfectly aware, considering the shortness of the human neck, of its being a different thing the laying bare the carotid in brute animals and in man; but if it has been acknowledged to be possible to perform œsophagotomy in man, I am convinced that laying bare and tying the carotid separate from the par vagum, would be equally so, provided, I repeat it again, the rupture of the carotid had taken place high up, and in the vicinity of the angle of the lower jaw, and provided that the bloody tumor be not of a very large size, and consequently leave sufficient room below it towards the sternum, for being able to reach the carotid; an operation not at all bloody, if it is performed in such a manner as not to touch the aneurismal sac.

SUPP. to § 18.—At this place I did not disapprove of laying bare the axillary brachial artery by an incision made in the direction of the cavity of the axilla, and then tying the artery above the place where it had been wounded: on the contrary, this is the practice which ought to be followed. I merely wished to point out to the young surgeon, that before proceeding to the ligature of this or of any of the other large arteries of the extremities which had been wounded, the surgeon ought previously to ascertain the precise place of the wound of the artery; so as not to operate at random, and fail in the operation, whenever the ligature should chance to be applied below the place where the artery had been wounded. On this account I proposed the dilatation if necessary of the external wound, until the exact part where the artery had been wounded, could be



discovered with the eye or finger. This direction will be illustrated by the following fact.\*

A boy about 14 years of age, in playing with a companion, was wounded by a blow of a sabre in the left shoulder. The point of the instrument had penetrated by the superior and posterior portion of the shoulder obliquely upwards towards the cavity of the axilla. The violent jet of blood from the wound was immediately stopped by pressure, which, however, was not sufficient to prevent the formation of an extensive aneurism in the cavity of the axilla. The two Maunoirs, skilful surgeons, of Geneva, were called to the assistance of this boy. One of them introduced his finger into the bottom of the wound, with the point of which he ascertained exactly the point where the axillary artery had been wounded; for although the artery pulsated feebly, as soon as he withdrew the point of his finger, he felt the jet of blood flowing from the artery strike against it. In the meantime, the other of these two able operators made an incision through the integuments of the axilla in the natural course of the axillary artery, and divided the aneurismal sac, from which he removed all the grumous blood. Then, at the bottom of the sac, appeared the brachial plexus of nerves, and in the middle of it the axillary artery. The point of the finger of the first surgeon, introduced into the bottom of the wound from the shoulder, and resting on the point of the artery from which the blood flowed, pointed out to the second operator the exact place of the wound of the artery, and where the ligature ought to be applied, which was immediately done with the greatest facility and with success. For, in spite of

\* Journal de Med, vol. 40, Mars, 1811.



the infiltration of blood in the axilla, the artery was distinguished from the nervous cords of the brachial plexus and from the vein, and was tied above and below the place where it had been injured, and divided between the two ligatures; the injury was close to the head of the humerus. The boy recovered the use of his arm, with the exception of the first phalanx of the three last fingers, which was destroyed by dry gangrene.

§ 19. The possibility of preserving the superior extremity after the ligature of the axillary artery, even above the origin of the profunda humeral, that is, between the aneurism situated at the upper part of the axilla and the clavicle, has been confirmed by several other important cases besides those which I have related.

In October 1799,\* a young soldier about 25 years of age was severely wounded in the hand by a musket-ball, in consequence of which, five weeks afterwards, he lost three of his fingers. The stumps of the fingers were scarcely healed, when, without any evident cause, the arm began to swell and abscesses formed around the wrist. After opening these abscesses, the arm still continued to swell. The pulse was no longer perceptible; and, to complete his unfortunate state, a circumscribed pulsating tumor appeared in the cavity of the axilla of the same arm. A few days afterwards, the apex of this aneurism became thin, and at last burst, with a violent jet of blood, which was stopped by means of compression applied above the clavicle. In this alarming state, Mr Keate, the author of this case, formed the reso-

\* London Medical Review and Magazine.



lution of tying the subclavian artery, as high up above the axilla as possible, or as near as possible to the inferior margin of the clavicle. With this view, he divided the integuments and the pectoral muscle across, close to the inferior margin of the clavicle, beginning the incision about an inch from the sternal extremity of the clavicle, obliquely downwards, as far as the line which divides the pectoral from the deltoid muscle, thus avoiding the trunk of the cephalic vein. He then introduced his finger into the bottom of the incision, with the point of which he discovered the subclavian artery, and passed a ligature around and tied it; but he immediately perceived that he had unfortunately tied it below the rupture. Therefore, without delay, he passed a second ligature higher up, which had the desired effect. For a few days after, the swelling of the arm abated, the ligatures were detached, and the patient recovered the use of his arm.

In another case similar to this related by Chamberlaine,\* the aneurism in the cavity of the axilla was formed in consequence of a wound of the axillary artery, and the tumor was as large as an orange. This surgeon, having made an incision along the lower edge of the clavicle, three fingers breadth from its sternal extremity, and terminating at about an inch from the acromion, and a second incision, perpendicular to the first, a portion of the pectoral and deltoid muscles was detached from the clavicle. The subclavian artery was brought into view, which was tied, not without some difficulty. The incision was healed in four weeks. The operated arm continued, for some weeks, weaker than the other arm.

\* Med. Chirurg. Transactions, vol. vi.



By inspecting plate v, No. 48, annexed to my work, we can easily understand how much more expeditiously this operation might be performed by one incision only along the lower edge of the clavicle, than by dividing the pectoral muscle, even in a perpendicular direction.

The patient being seated on a chair with the shoulder rather depressed, an assistant placed behind him, keeps him firmly in this situation. The operator begins the incision of the integuments about an inch from the sternal extremity of the clavicle, continuing it downwards along the lower edge of the clavicle towards its acromial extremity, as far as the furrow, separating the pectoral from the deltoid muscle. He separates to an equal extent the attachments of the pectoral muscle from the clavicle, and turns them a little backwards; after this the lesser pectoral muscle comes into view, which, being given off from the coracoid process, intersects the lower angle of the incision. The operator introduces the point of his finger between the point of the coracoid process and the lower edge of the clavicle, and discovers the subclavian artery surrounded by a loop of the brachial nervous plexus along with the vein. Having separated the artery from the vein, and laid aside the nervous loop, he applies the ligature to it with the interposition of the small cylinder spread with plaster.

§ 24. I did not hesitate to admit the possibility of curing aneurism of the carotid, by means of the ligature of the artery in the space between the upper part of the sternum and the aneurismal sac. A few years afterwards, the celebrated surgeons, Abernethy



and Cooper, confirmed by cases the truth and utility of my assertion.

The subject of Mr. Cooper's case was a porter 50 years of age. Six months previously to the operation, the aneurism of the left carotid was not larger than a walnut, and occupied the space between the lower jaw and the thyroid cartilage. For five months the patient had laboured under great pain of the side corresponding to the tumor, as well as with a troublesome sensation of pulsatory motion in the brain. His voice was hoarse and his breathing difficult, apparently the effect of the pressure of the swelling on the larynx. His appetite was sometimes affected by it, and he often became sick while eating, but did not vomit. He had a sense of coldness succeeded by heat in his left ear. Upon attempting to stoop, he had an insupportable feeling as if his head would burst; a giddiness; loss of sight; and almost total insensibility. The left eye appeared smaller than the right. At the time of the operation, the tumor had acquired the size of a pullet's egg, and extended from below the angle of the lower jaw to the division of the common carotid. The operation was performed by tying the trunk of the carotid, between the upper part of the sternum and the tumor. No accident worthy of remark retarded the cure, and three months afterwards the man resumed his occupation. After the lapse of eight months he enjoyed good health, and the tumor had disappeared; there was merely a diminution of the pulsation of the temporal and facial arteries of the left side.

Several other cases similar to this have subsequently occurred. The ligature of the carotid was also



employed to effect a radical cure of an aneurism situated in the cavity of the orbit of the left eye,\* but with doubtful success, as shall be mentioned in the sequel.

The following is the manner of performing this operation. The patient being laid in a horizontal posture, and the head secured by an assistant, the surgeon makes an incision through the integuments of the neck, from the upper part of the sternum upwards along the inner edge of the sterno-mastoid muscle, for about two inches in length, or a little more. The length of this incision is sufficient for laying bare the sterno-hyoid and sterno-thyroid muscles.† Turning the chin of the patient a little towards the affected side, in order to relax the sterno-mastoid of the same side, and laying gently aside the sterno-hyoid and sterno-thyroid muscles towards the trachea, the large jugular vein ‡ is brought into view. This vein, from its size, and from its alternate swelling out and depression, corresponding to inspiration and expiration, would retard the operation. On this account, the surgeon pushes it gently towards the outer side of the neck, and the assistant secures it there with his finger. The common carotid appears immediately under the large jugular vein. The operator with his hand unsupported, then divides the firm cellular sheath inclosing this artery, for two or three lines. This greatly facilitates the separation of it from the *par vagum*, and allows an easy passage under and round it to the *eyed* small flexible silver spatula, armed with a ligature. Lastly, the ligature is tied on the cylin-

\* Trattato delle Malattie degli Occhi, ediz. quinta, vol. ii, Capo vi.

† Sull' Aneurisma, &c. Tavola v. 98.

‡ Tabulæ Neurologicæ, Tab. I, B. B. P.



der of linen, spread with plaster, and the same dressings are applied as in all other operations of this kind. The best posture for the patient to be placed in, is with his head bent forwards on the chest, in which position it must be retained by a suitable bandage.

It is impossible that the hope of success can be the same whether the common carotid is tied for the cure of an aneurism situated in the neck, or for that formed in the cavity of the orbit; for, in the latter case the favourable circumstances are not the same as in the former, although the disease has taken place in the ramifications of the carotid. And if we reflect, they are the same in the case of aneurism of the cavity of the orbit, as those which render unavailable the Hunterian operation in cases of wounds of the large arteries of the fore-arm, and of the leg, in the vicinity of the hand and foot; that is, on account of the retrograde impulse through their free mutual anastomoses. In the same manner the ramifications of the right carotid, as those of the fore-arm and leg, have a free and ample communication with those of the left, and with those of the vertebinals, consequently rendering of little or no advantage the ligature of the trunk of one of the carotids for curing an aneurism formed in their distant ramifications, and in the vicinity of their communication with their fellows. In the successful case already referred to,\* it appears, from subsequent cases, that the favourable event is to be ascribed to the profuse loss of blood which the patient suffered after the ligature of the common trunk of the carotid, assisted by the debility of the circulation, and the formation of the fibrous laminæ,

\* Trattato delle Malattie degli Occhi.



completely filling up the aneurismal sac situated in the cavity of the orbit. Dalrymple of Norwich, in a second case of aneurism of the orbit, as I have been informed, was not equally successful, the pulsating tumor having re-appeared in the orbit a few months afterwards.\*

\* This account of Mr. Dalrymple's case of Aneurism by anastomosis in the orbit, was transmitted to me by him, and thus communicated to the author. The statement given by Mr. Dalrymple at that time does not coincide with the history of the case afterwards inserted in the *Medico-chirurgical Transactions*, vol. vi. In that work he concludes the case in the following words: 'Of her present state it only remains for me to observe, that, after a lapse of nearly two years, her cure appears complete:—nor can I, at this period, entertain a fear of a recurrence of the disease, notwithstanding the apprehension which, in reference to cases of this kind, have been felt and expressed by the great master of our art.'—*T.*



## CHAPTER XII.

## OF THE ANEURISMAL VARIX.

§ 1. SURGEONS understand by the name of *aneurismal varix*, that particular kind of aneurism, in which the blood effused from the wounded artery, is not contained in a sac formed by the cellular substance surrounding the injured artery, but by the cavity of the coats of the neighbouring vein, lying immediately over the injured artery. This particular kind of aneurism may occur in any part of the body, where the veins lie close upon the arteries: and Lassus mentions, that he had seen, in company with several other professional persons, an aneurismal varix in the cavity of the ham, occasioned by a wound of a sword, which had transfixed the popliteal vein and the artery at the same time.\* However, this accident more commonly occurs in the bend of the arm, in consequence of a bleeding incautiously performed. For, whenever the point of the lancet, having pierced the vein through and through, enters the subjacent artery, the arterial blood, favoured by the approximation of the two vessels, instead of being effused into the cellular substance, passes directly into the vein lying over it, and raises it in the manner of a varix, and returns by it to the heart.

§ 2. In order, therefore, that after a venesection, an aneurismal varix take place rather than an aneurism, it is necessary that there be the concurrence of

\* Med. operat. t. ü, p. 442.



two circumstances: 1. That, on withdrawing the wounding instrument, the incision made through the vein, and the opening made in the artery, be exactly in the same direction: 2. That the solution of continuity in the integuments of the anterior side of the vein unite, and consolidate by the first intention, as in the common cases of venesection, while the wound of the posterior side of the vein, and that of the anterior surface of the artery, remain open, and so exactly communicating with each other, that the arterial blood finds greater facility in entering from the artery into the vein, than in being effused from the artery into the surrounding cellular substance.

§ 3. If one of these two circumstances be wanting, either because the wounding instrument has entered the artery a little obliquely from the vein, or because the vein has not approached sufficiently to the artery, on account of the cellular substance lying between them, the arterial blood, most frequently, does not produce the *aneurismal varix*, or, if it does indeed produce it, the disease is always complicated with effusion of arterial blood into the cellular substance, or with an aneurism, and aneurismal varix at the same time; in which case, the small aneurismal sac serves as a short canal\* of communication between the artery and the vein; so that in this case it may with propriety be said, that there are formed from the same cause two distinct diseases, placed the one over the other, that is, an aneurism, and an aneurismal varix.†

§ 4. The aneurismal varix forms always a *circumscribed* tumor; aneurism does not always do so.

\* Med. facts and observ. vol. iv, p. 115, c, b.

† Ibidem, c, a a.



The cellular substance which constitutes the sac of the aneurism, does not always resist so strongly the impetus of the arterial blood as the coats of the vein do. Aneurism, therefore, not unfrequently, from being *circumscribed* at first, becomes *diffuse*, extends along the course of the wounded artery, compresses strongly the surrounding parts by the coagulated clots of blood contained in it; occasions acute pain and inflammation, and threatens the gangrene of the part where it is situated. The aneurismal varix, on the contrary, is always *circumscribed*, increases very slowly, does not occasion considerable pain to the patient, and as it augments, it extends invariably, sometimes more, sometimes less, above and below the place where the bleeding has been performed; and this extension is in proportion to the greater or less force with which the arterial blood is thrown from the artery into the vein, and the greater or less resistance opposed by the valves situated in the vein below the place of the venesection; and lastly, according to the greater or less number of veins communicating with the aneurismal varix.

§ 5. The aneurism and the aneurismal varix, both pulsate after the manner of arteries. The aneurismal varix pulsates in that manner, because the vein receives the stream of arterial blood at intervals, and *per saltum*. And since, on account of the wound of the lancet made in the artery being in general very small, the arterial blood passes through a narrow hole of communication between the artery and vein, so the arterial blood in the act of entering the cavity of the vein, and spreading in it, excites a sort of hissing or whizzing noise, accompanied by a singular tremulous motion of the coats of the vein, which tremulous motion gradually abates, and ceases altogether at a cer-



tain distance above and below where the venesection has been performed. This noise of the vein is rendered still more sensible, if one extremity of a probe be rested upon the aneurismal varix, and the other end of it be held between the teeth. The vein, in all this, similar to the sac of the aneurism, is only passive. For, if blood is made to pass from the carotid artery of a calf into the jugular vein of a sheep, by the intervention of the dried gut of a fowl, which I have done repeatedly, both the gut and the vein pulsate, exactly as the arteries do, and in both, a tremulous motion is felt, a noise very much resembling that which is met with in the aneurismal varix.

§ 6. As a considerable portion of arterial blood, which ought to descend to the arm and hand by the radial and ulnar arteries, turns into the vein in the bend of the arm ; so it necessarily happens, that in the arm affected by aneurismal varix, the pulse at the wrist becomes less strong and vibrating than that of the sound arm ; and that also in progress of time, the pulse is rendered still less sensible to the touch, on account of the arteries of the fore-arm (being defrauded, to use the expression, of the usual quantity of blood), having a continual tendency to contract.

§ 7. The marks, therefore, by which the aneurismal varix in the bend of the arm may be distinguished from aneurism, are numerous and evident. The seat of the aneurismal varix is generally in the basilic vein, which appears dilated in an unusual manner, forming an oblong tumor of the size of a walnut, if the disease is recent, and of a small elongated nut, if the disease is of somewhat long standing. The small tumor has in its centre the cicatrix of the bleeding.



The vein is less dilated, the more it is removed from the cicatrix of the bleeding, and for the most part the vein at the distance of two inches and an half above and below the tumor, resumes or retains its natural size. The small tumor, as has been mentioned, pulsates after the manner of the arteries, with a tremulous motion, and hissing noise, which is sometimes so great, that the patient cannot sleep, if he is lying with his head low, and resting on the injured arm. The trunk of the brachial artery, from the axilla, as far as the place where it has been wounded by the lancet, vibrates with extraordinary force. The aneurismal varix does not cause any change of colour, or inflammation of the skin, and the pain excited is inconsiderable. It is flexible, and when compressed by the fingers it diminishes, yields, and empties itself of the blood which it contains; but, on removing the pressure, it rises again, and is filled with arterial blood as before; which phenomenon happens in like manner, when the arm has been tied firmly below the aneurismal varix, and consequently below the bend of the arm. On the contrary, the aneurismal varix becomes flaccid, falls down, and almost disappears, if the patient keep his arm raised for some time towards his head. The same thing happens when the small tumor is compressed in such a manner, that the point of the finger pressed down deeply, rests upon the opening in the artery, or if a tourniquet is applied and tightened upon the humeral artery in the vicinity of the axilla.

§ 8. Farther, when the aneurismal varix is complicated with incipient aneurism, formed by blood extravasated into the cellular substance situated between the artery and vein, through which small aneurism \*

\* Loc. cit. *a*, *c*, *b*.



the one vessel communicates with the other by means of an intermediate canal, besides the marks above mentioned, a second tumor is met with at the place where the bleeding has been performed, and immediately behind the posterior side of the aneurismal varix; and this tumor pulsates in like manner, and disappears when compressed; and it is felt clearly by the touch that it is as it were united to the subjacent artery, and that the aneurismal varix forms no part of it, but merely lies over it. This second tumor remains stationary as long as the arterial blood continues to pass with a certain degree of facility from the artery into the vein. On a change taking place in the above-mentioned circumstances, the tumor lying below the aneurismal varix increases very much, and is converted into a large aneurism, sometimes even diffused.

§ 9. From a passage in Sennertus,\* it seems we may infer, that that great practitioner had had an opportunity of observing this disease; but not having recognised its nature, he had classed it among the ordinary aneurisms in the bend of the arm in consequence of venesection. Dr. William Hunter† is, without doubt, the first to whom we are indebted for the accurate ideas we are at present in possession of with regard to the nature of this disease. Upon which

\* Oper. Omn. t. v, lib. v, part i, cap. 43. Novi vicinam meam quamdam, cui imperitus chirurgus, dum venam secare deberet, arteriam aperuit, quæ jam ultra trigesimum annum aneurisma nucis juglandis magnitudine in cubiti flexura interna habet et alias satis commode hactenus valet. Sibilus non saltem digitis sentitur, sed etiam admota aure; quod fit ob spiritus vitalis per angusta meatibus motum.

† Medical Observations and Inquiries, vol. i, ii.



point, however, I cannot omit mentioning, that Guattani,\* at the same time as Dr. Hunter, or certainly before Dr. Hunter's investigations with regard to this particular kind of aneurism were known in Italy, had published the history of two cases of aneurismal varix, with regard to the true nature of which disease described by Guattani there cannot be the smallest doubt. It may therefore be said, that he had an equal share in the merit of the discovery.

§ 10. The prognosis of this disease differs, according as the aneurismal varix is simple, or complicated with a small aneurism situated between the artery and the wounded vein. In the simple aneurismal varix, whether it is recent or of long standing, provided the orifice of the posterior side of the vein remains connected in such a manner with that of the anterior side of the artery, so that the arterial blood passes freely from the latter into the former, without being at all effused round the artery into the neighbouring cellular substance, the consequences of the disease, as far at least as appears from the observations hitherto made, are not for the most part to be feared, provided the patient is very careful not to make violent and frequent motions with the affected arm. For, as soon as the basilic vein, and together with it some other veins of the bend of the arm communicating with the basilic vein in the vicinity of the seat of the pulsating varix, has acquired a certain degree of dilatation above and below the bend of the elbow, the aneurismal varix invariably becomes stationary during all the rest of the life of the patient who is affected with it, to whom it does not occasion any other inconvenience than

\* See Appendix, note, No. 19.



sometimes a sense of transient numbness, or some momentary debility of the whole arm and hand. The prognosis is not equally favourable in the case of aneurismal varix complicated with incipient aneurism situated between the artery and the wounded vein. The arterial blood in its passage through the cellular capsule of the small aneurism into the vein, does not preserve constantly and entirely its fluidity, as in the preceding case, but stagnates always a little during this passage in the small sac, and gradually leaves there some fibrous layers. If in similar circumstances the patient does not abstain entirely from exercising his arm with force, and from making violent motions, the coagulated blood, and the layers and clots of it situated below the varix, gradually enlarge the aneurismal sac, and in progress of time increase it to such a height, that, compressing the contiguous parts, it excites pain and inflammation in them, threatens to become diffuse, and even to burst externally; in a word, the patient is under the necessity, in order to save his arm and his life, of submitting to the operation which is practised for aneurism in the bend of the arm.

§ 11. The cure of the simple aneurismal varix, that is, when there is a free and immediate passage for the blood of the humeral artery into the basilic vein, although the disease has been of some months standing, and the basilic vein be considerably enlarged, will consist chiefly in ordering the patient, in the most precise manner, to abstain from fatiguing the arm with violent exercise, and to keep it as little as possible hanging by his side. Dr. Cleghorn\* suggested, very

\* Medical Observations and Inquiries, loc. cit.



prudently, to a journeyman shoemaker, who had met with a similar misfortune, to change his trade, and to learn that of weaving hair for making wigs. Any kind of compression or bandage whatever, which is not sufficient to obliterate the vein and approximate it firmly to the artery opposite to the place of the wound, or which is not sufficient to render the artery imperious at the seat of the puncture made by the lancet, never can be a radical means of cure. A bandage employed with the view of preventing the basilic vein receiving the blood, which is sent into it from the humeral artery by the unnatural anastomosis, might cause the arterial blood to infiltrate into the cellular substance lying between this artery and the vein, and produce a disease worse than the first, viz. an aneurism, and would make it increase rapidly if the aneurism was once begun. Experience, on the contrary, has shewn us, as has been already mentioned, that the natural resistance of the coats of the basilic vein, and of the other veins communicating with it in the vicinity of the aneurismal varix, beyond a certain degree of distention, is equiponderant, to use the expression, with the impetus of the blood thrown in by the artery, and that in this state of circumstances the aneurismal varix remains stationary for a long series of years, and during all the life of the patient who has met with this misfortune. A middle-aged lady, of a very good constitution, was affected, in consequence of a bleeding, with an aneurismal varix, of the size of a large elongated walnut, in the bend of the right arm, exactly in the basilic vein. Two years after this accident, as she saw that the tumor had increased a little, she was deeply afflicted by the dread of its coming to burst. She consulted me on that account; and as the state of anxiety in which the patient lived,



proved to her a disease worse than the aneurismal varix, I therefore directed her to wear day and night, all along the right arm, as far as the shoulder, immediately above the skin, a sleeve of silk wove with an elastic stitch, exactly similar to the elastic stockings of English manufacture; farther, that she should endeavour to keep her arm always a little elevated. The application of the elastic sleeve was sufficient to calm the mind of the patient. Fourteen years have now elapsed since the accident; and she even lately has assured me by letter, that the tumor had not at all increased since the first time that I had seen her; that she does not suffer any inconvenience in the arm, except some transient numbness, especially in great and sudden changes of the atmosphere. In the lady who was the subject of the first of Dr. Hunter's observations, after thirty-five years the aneurismal varix was nearly in the same state in which it was soon after the accident. Dr. Cleghorn's patient after twenty years had not experienced any other change than a little more swelling of the veins in the bend of the arm communicating with the aneurismal varix, and that notwithstanding he made use of his arm as before, and had resumed his trade of shoemaker.\* Mr. Pott asserts, that he had seen the aneurismal varix in three different persons, in none of which the operation was necessary. The same thing was remarked by Mr. B Bell,† by Garneri,‡ and by several other surgeons worthy of credit.

§ 12. There are some examples of a radical cure of the aneurismal varix obtained by means of com-

\* Bell. A System of Surgery, vol. iii, p. 203, note.

† Loc. cit.

‡ Bertrandi Oper. Post. Delle operaz, chirurg. t. iii, p. 208.



pression. Indeed, if the regular compression, continued for a long time, has been sometimes sufficient for curing radically the aneurism in the bend of the arm and in the ham, we may conclude from analogy, that the same means, in a similarity of favourable circumstances, may produce the radical and complete cure also of the aneurismal varix. Whenever the compression of these parts against the bone is such that it falls exactly upon the wounded place of the vein and artery, and that the sides of both of these vessels are brought and kept in perfect and firm contact for a proper length of time, on the supervention of the *adhesive* inflammation excited by the pressure, there can be nothing to hinder the coats of these vessels contracting a firm adhesion to each other, and producing a cure, whether it is effected by the obliteration of the vein only at that place, and the firm approximation of it to the wounded artery, so as to oppose a firm and secure barrier to the discharge of the arterial blood, or whether it is accomplished by means of the obliteration of the vein, together with the humeral artery, for some space above and below the wound made by the lancet. The two Brambillas\* have communicated two examples of similar cures. The first was in a woman thirty years of age, in the sixth month of pregnancy, in whom, after having been bled in the left arm, there appeared an aneurismal varix, accompanied with extensive ecchymosis and painful swelling, although not inflammatory, along the biceps muscle. The cure was undertaken four days after the accident by means of compression, by placing upon the tumor a ball of lint dipped in styptic water ; over this, graduated compresses, and a roll-

\* Acta Acad. Cæs. Rég. Joseph. t. i.



er with many circles round the bend of the arm. In the course of six months, the most scrupulous attention being paid to the renewal of the bandage when it began to relax, the patient was radically cured. The other case was of a boy fourteen years of age, in whom the compression was employed a fortnight after the appearance of the aneurismal varix. In the course of fourteen weeks of assiduous treatment, this boy was cured, and there only remained at the place of the aneurismal varix a very small hardness about the size of a pea. Guattani,\* in a similar case of aneurismal varix, after having shewn and instructed a country surgeon in the manner of applying the compression and the bandage upon the pulsating tumor of the basilic vein, sent the patient home, and from the account given him by the surgeon of the place, he was afterwards informed that the patient was cured. Monteggia† likewise obtained the cure of an aneurismal varix which was of a month's standing, and this he effected by means of proper rest and compression. He observed in this case, that a coagulum was formed in the varix, which then became hard, lost its pulsation, and soon after disappeared.

§ 13. As from what has been said it appears that compression does not produce the complete cure of this disease, except in so far as it occasions the union of the opposite sides of the vein or artery, or of both together, above and below the injured place, and that it is a certain fact, that whenever the compression is not sufficient to do this, far from being a means of cure, it rather puts the patient in great dan-

\* De Spur. Brach. Aneurysm. histor. iv.

† Instituzioni Chirurgiche, t. i, pag. 187.



ger of the aneurismal varix becoming complicated with aneurism, so it will be prudent in the surgeon not to try the compression, except in cases of recent, very small aneurismal varix, in young or very slender persons, in whom it is clearly seen that the vein is in contact with the artery, and that both of these vessels can be firmly and steadily compressed against the lower extremity of the bone of the humerus in the vicinity of the internal condyle. In young and thin persons the point of the wound made in the artery may be determined in most cases with the greatest precision. For, by pressing firmly the point of the finger upon the centre of the varix, we may distinctly feel the orifice of the artery from which the blood passes out of the artery into the vein, and in some cases so plainly, that it would be possible to pass a pin through the skin and vein, and introduce it directly by that orifice into the tube of the artery. In cases, therefore, quite opposite to this, that is, when the aneurismal varix is of very long standing in persons with fleshy arms, in whom, in compressing the centre of the tumor, the orifice of the artery, from which the blood passes into the vein, cannot be distinctly felt; when both of these vessels cannot be compressed so completely against the os humeri as to bring their opposite sides into firm and steady contact with each other; when, lastly, from some particular circumstances, the surgeon cannot give assiduous and careful attendance on the patient, the best measure that can be adopted will always be, not to risk the compression of the aneurismal varix, but to rest satisfied with giving the patient those directions which I have mentioned above.

§ 14. Poor people, obliged to lead a laborious life,



do not always pay sufficient attention to these directions. They return to their trades, and to the violent exercise of the affected arm, and sooner or latter, if the aneurismal varix be from the first complicated with incipient aneurism, a considerable portion of the arterial blood oozes out, and stagnates in the cellular substance between the artery and vein; the aneurism then becomes prominent, as well as the vein; and the former ceasing to be *circumscribed*, threatens to become *diffused*. In this very urgent state, the surgeon will not hesitate to perform the Anellian operation, if the aneurism is still small and *circumscribed*. For it is evident, without my mentioning it, that on suppressing the current of blood through the trunk of the humeral artery, the aneurismal varix must disappear, and no more blood passing from the artery into the vein, both the wound of the artery, as well as that of the posterior side of the vein, must of necessity close and cicatrize. But if the aneurism is *diffused*, the surgeon will give the preference to the incision of the aneurismal sac, with those cautions which the complication of the two diseases, lying the one over the other, requires; and these I shall now point out.

§ 15. In this second complicated case, or of aneurismal varix and *diffuse* aneurism, having applied the tourniquet upon the trunk of the humeral artery in the vicinity of the axilla, the surgeon will open the aneurismal varix in its whole length, and will dry the cavity thoroughly with a soft sponge; after this, he will discover at the bottom of this cavity, the orifice made by the lancet in the posterior side of the dilated vein. Having introduced a probe by this orifice, he will perceive that he has penetrated into a second sac below



the first, but not into the artery, from the facility with which he moves the probe all round, and the difficulty of pushing it in the direction of the arm lengthways; or according to the course of the humeral artery. Therefore, upon the probe as a guide, he will dilate this orifice with the point of the bistoury, or with a pair of scissars, and at the same time, open through its whole extent the second lower sac also, which is formed by the cellular substance, or the proper aneurismal sac, which he will find full of clots and coagulated layers of blood. Having evacuated the clotted blood, and cleaned this second sac also with a sponge, the wound of the artery will present itself at the bottom of it, and having introduced a probe through this orifice, he will find that he can make it pass easily upwards and downwards along the course of the humeral artery. By means of the introduced probe he will raise the humeral artery, will separate it with the point of the fore-finger of his left hand, from the cellular substance which keeps it united to the contiguous parts, then from the median nerve and vein if he think it proper, in order to lay bare the artery as completely as possible; he will then tie it above and below the wound, following the rules laid down in the preceding chapters. The following case will illustrate more fully the method of operating just described.

§ 16. John Hartley,\* a youth about twenty years of age, presented himself at the Liverpool infirmary in May 1791. His account of himself was, that he had been bled in the right arm in the preceding January; that he had more than usual pain at the time, and thought he had been pricked too deep; that he continued his work, (that of a wheel-wright), for a week

\* Medical Facts and Observations, vol. iv.



after the operation, and then perceived a small hard tumor immediately under the orifice, which had gradually increased to the size of a walnut. Mr. Park, the surgeon, observed that the tumor pulsated like an aneurism, and on pressure, disappeared in a considerable degree, but not entirely; from which it was evident, that the whole of the arterial blood contained in it, was not in a state of fluidity, but that some coagulum was formed. The hissing and peculiar thrilling sensation which characterize the aneurismal varix, were very plainly perceptible for a certain distance from the centre of the tumor towards the axilla. The basilic vein was a good deal distended, but not in the degree which Doctors Hunter and Cleghorn describe in their cases of varicose aneurism, the tumor being still on the increase, though slowly. Although the blood of the wounded humeral artery passed into the basilic vein, yet there was reason to suspect, from observing, that on pressure being applied, a portion of coagulated blood remained behind, that this communication did not take place with such facility as to secure the patient from being afterwards exposed to the necessity of undergoing the operation of the ligature of the humeral artery. He was therefore advised to refrain from making violent exertions with his right arm, and to return to the hospital as soon as he perceived any remarkable change in his right arm. He returned again to the infirmary a few months afterwards, when it was remarked, that the tumor had manifestly increased, and with great rapidity; that is, not in that slow gradual manner which is usually observed in the increase of the aneurismal varix.

On the 21st of January of the following year, he came into the infirmary on account of a violent pain which he felt in the tumor, accompanied by inflam-



mation and suppuration, and the tumor threatened to burst. This he attributed to accidental cold to which he had been exposed; but it seemed more probable, that it was to be ascribed to the sudden increase of the tumor. An emollient poultice was applied, and a tourniquet was put loosely round the arm, with directions that he should be closely watched day and night. The next morning the tumor burst; a small quantity of pus was discharged, the tumor subsided a little, and the patient became considerably easier.

On the 24th in the evening, the arterial blood burst forth with considerable force, the tourniquet was tightened by the nurse, and the surgeons were called as soon as possible. Having opened immediately the external sac, or the aneurismal varix, and evacuated the coagulated blood, an orifice was discovered at the bottom of the cavity, similar to that which is usually made in venesection, from which arterial blood flowed, on loosening the tourniquet. A probe introduced into this orifice,\* sunk nearly an inch deep;† but would not pass much more than half an inch upwards or downwards along the arm. On this account, Mr. Park, not being perfectly certain if the probe had entered the tube of the artery, or into a second sac, did not venture to apply a ligature to the artery. He therefore enlarged this orifice with the scissars, and he found that it led into a second sac below the first. Having evacuated the blood which filled it, he discovered at the bottom of this second and lower sac, the wound of the artery;‡ and a probe introduced into this, passed readily upwards and downwards in the direction of the artery. || Directed by this probe, a ligature was passed underneath the artery, above the

\* Loc. cit. pag. 115, b.

† Ibidem, c.

‡ Ibidem, d.

|| Ibidem, e, e.



orifice, and tied. On loosening the tourniquet, as the blood flowed out as freely as before, the humeral artery was also tied below the wound; and then no farther hemorrhage appeared.

The wound was kept open more than half an hour, (waiting to see if any more hemorrhage would take place), and then the dressings were applied, and the edges of the incision were brought together by means of slips of adhesive plaster.

The next day, the œdematous swelling that had taken place in consequence of the long continued application of the tourniquet, was considerably diminished. There was a sufficient degree of warmth and feeling in the fore-arm, and a faint pulsation was felt in the radial artery. After this, nothing remarkable occurred during the cure, excepting that the patient was so much threatened with symptoms of phthisis pulmonalis, as to make it necessary to send him into the country before the wound was completely cicatrized. By the 29th September, the patient was completely cured, had an evident pulsation in the artery at the wrist, though not quite so strong as in the other. Nevertheless, the operated arm was equally strong and well nourished as the other arm.

As Dr. Hunter (adds Mr. Park) judiciously and humanely published the result of his cases, with a view to prevent patients with aneurismal varix being improperly and unnecessarily exposed to the operation of the ligature of the humeral artery, so I think it incumbent on me to state this case, as a caution to inexperienced practitioners, whenever they meet with such appearances as the Doctor has described, but in a less degree, to be well assured that the veins will really dilate sufficiently to take off the whole of the blood poured out by the artery, before they give such



a prognostic as may lull the patient into a delusive and dangerous security, and neglect taking those precautions which are necessary for preventing the disease growing worse, which is as much as to say, for preventing the aneurismal varix being complicated with aneurism.

SUPP. to § 16.—As a farther illustration of what has been said in this chapter with regard to *aneurismal varix*, I subjoin the history of the following case related by Dr. Physick\* of Philadelphia. A man was bled in the basilic vein, without any difficulty being experienced, after the bleeding, in closing the vein. There merely remained at the wound an ecchymosis, which extended above and below the elbow. The ecchymosis disappeared in a few days, but a pulsating tumor was observed, which went on gradually increasing, with an evident unnatural dilatation of the basilic vein. In course of time, another swelling appeared higher up than this tumor, and on resting the finger on it, was felt that thrilling sensation which the blood produces when it passes by a wound from an artery into a vein. On pressing this swelling, which was evidently an aneurism, the orifice of communication between the aneurismal sac and basilic vein could be felt, which removed every doubt as to the nature of the complication of this case. For it was evident that the small pulsating tumor, which first appeared, was formed by the arterial blood effused into the cellular substance; and that the other preternatural swelling was formed by

\* Medical Museum, vol. i, p. 65.

A short abstract of this case was inserted in a note in the first edition, which is now left out, the author having introduced it into the text.—T.



the arterial blood passing from the sac into the basilic vein. In the more advanced stage of the disease, two years after the accident, the vein was so much enlarged that it threatened to burst. The fore-arm became emaciated and the hand cold. In these circumstances, the author of this case was of opinion, that the brachial artery ought to be tied above and below the aneurismal sac; which he, accordingly, did. About a quarter of an hour after the operation, the pulse re-appeared at the wrist, and in three weeks the wound was healed, and the patient recovered the use of his arm. On considering attentively all the circumstances of this case, it is proper to point out to the student, in the practice of great operations, that it being demonstrated by numerous cases, that the *circumscribed* aneurism at the bend of the arm may be cured perfectly well and radically, by one ligature only applied to the brachial artery above the aneurismal sac, the second ligature employed in the above-mentioned case was at least an unnecessary operation.

In the course of this work, I have entered into numerous details of the most expeditious and proper mode of laying bare the principal arteries of the extremities, and of the neck. To complete this subject, therefore, it only remains to me to notice this operation, in so far as regards the arteries of the third order, such as those of the fore-arm and leg.

#### RADIAL ARTERY.

IN order to lay bare the radial artery at the upper third of the fore-arm, apply a finger over the insertion of the tendon of the biceps. An incision is to



be made in the integuments a little below this insertion, in the oblique direction pointed out, by the inner edge of the supinator longus ; the incision should be about two inches and an half in length. Then divide the subjacent common aponeurosis, and remove a little the inner edge of the supinator muscle from the outer side of the arm. In this space the radial artery immediately presents, passing over the tendon of the pronator rotundus (teres) muscle, and it passes downwards between this tendon and the radialis longus. See CAMPER, *Anat. Demonstrat.* lib. i, tab. i, fig. ii.

#### ULNAR ARTERY.

FOR bringing into view the ulnar artery at the upper third of the fore-arm, examine first with the finger along the inner side of the ulna, the situation and breadth of the ulnaris internus muscle. Then make an incision from above downwards, beginning at the distance of two inches below the inner condyle of the humerus, following the direction of the inner margin of the ulnaris muscle for the space of two inches and an half. The common aponeurosis is then to be divided, and removing the radialis internus a little from the ulnaris internus muscle, introduce the knife between the latter and the palmaris. On passing the point of the finger through this opening, the ulnar artery will be felt. See Camper, loc. cit. There is nothing more easy than the laying bare these two arteries at the lower third of the fore-arm, in the vicinity of the wrist, where they are quite superficial,



## ANTERIOR TIBIAL ARTERY.

IN order to lay bare the anterior tibial artery a little above the middle of the leg, pass the finger along the outer side of the crest of the tibia, and ascertain the breadth of the anterior tibialis muscle. Along the outer margin of this muscle an incision is to be made through the integuments, two inches and a half in length, and to the same extent through the subjacent aponeurosis; the knife is then to be introduced between the outer margin of the anterior tibialis muscle and the extensor longus of the great toe. In this space, at the depth of about an inch, the anterior tibial artery is situated. Haller, *Icon. Anat. Fasc. v, tab. iv.* It is easy to lay bare this artery in the vicinity of the tarsus, as it passes out between the tendon of the anterior tibialis and that of the extensor muscle of the toes. Haller, *loc. cit.*

## POSTERIOR TIBIAL ARTERY.

THE laying bare the posterior tibial artery behind the internal malleolus is an operation easily performed. An incision about two inches long is made between the internal malleolus and the tendo achillis down to the posterior surface of the tuberosity of the tibia. At this depth run, as in a furrow, the tendon of the posterior tibialis muscle and that of the common flexor of the toes. Along with these two tendons, but a little nearer to the os calcis, the posterior tibial artery descends to the sole of the foot.



On the other hand, it is a very tedious and difficult task to lay bare this artery at the middle, or in the upper third of the leg, on account of the depth at which it lies. And the difficulties are increased by the resistance opposed by the spasmodic contractions of the strong bodies of the gastrocnemii and soleus muscles. At any rate, if circumstances require this artery to be laid bare, to tie it above and below an injury, it may be effected in the following manner. An incision is to be made three or four inches long, along the inner side of the crest of the tibia, and the origins of the soleus muscle are to be detached from it to the same extent, and to be turned back. Under the soleus muscle is found the aponeurosis, which, as a partition, separates the muscles of the calf of the leg into superficial and deep-seated. This aponeurosis being also divided, the posterior tibial artery may be seen or felt deep-seated, running on the posterior tibialis and flexor muscle of the toes. See Haller, loc. cit. tab. v.



## CASES.

## CASE I.

## POPLITEAL ANEURISM.

**JOSEPH FIORINI**, nurse of this hospital in Pavia, a stout corpulent man about 42 years of age, addicted to drinking of spirits, who had been infected several times with lues venerea, and cured repeatedly by the use of mercurial medicines, in the beginning of the year 1799, observed that he had a slight œdema of the right leg and foot during the day, which disappeared after a night's rest. He had always had from his early years a difficulty in walking, as of a person who has tender feet. Some months after, wishing to get entirely rid of this inconvenience, he applied the *expulsive* bandage; but as he perceived that the swelling during the use of the bandage, quitting his foot and leg, appeared upon his knee and thigh, he left it off. In September of the same year, he observed for the first time, that a tumor had appeared as big as a large nut, in the upper part of the cavity of the right ham, accompanied with slight pain. He applied emollient poultices to it, during the use of which the tumor increased considerably, so that in February of the year 1800, he was obliged to keep his bed. On



the 24th of the same month, I saw this patient for the first time. I found that he had a tumor in the cavity of the right ham as large as the fist, which pulsated strongly, and presented all the characters of an aneurism. I made an attempt to ascertain if the patient could bear compression; but after twenty four hours, I was sensible of the insufficiency of this method, or rather of the injury which it would have occasioned, had I wished to persist in the use of the compressive bandage. On which account, I immediately determined upon the Anellian or Hunterian operation, which I performed exactly in the manner described above.\* After I had tied the *superficial* femoral artery in the upper part of the thigh, the aneurism immediately ceased to beat; and from being tense and hard before the operation, it became, at the same moment that the artery was tied, soft and compressible. On comparing the circumference of the aneurism with the measure which had been taken of it before the operation, it was found, that the tumor had diminished some lines, by the cutting off of the column of blood which flowed into it by the *superficial* femoral artery. An hour after the operation, the patient complained of a painful sensation in the right groin, and corresponding testicle. This symptom was relieved by the application of a sponge squeezed out of warm water to the pained part. The patient passed the night quietly enough, except that he had some starting of the operated limb. Next morning he complained of a sensation, as if water was running down through his thigh to the right leg and foot. The heat of the operated limb exceeded that of the sound limb by some degrees,

\* Chapter ix, § 20.



On the second day, the patient was affected with a slight degree of fever. And as he had a bitter taste in his mouth, and as his tongue was covered with mucus, I ordered him a grain of tartar emetic, with three drams of cream of tartar, to be taken in a pound and a half of the decoction of the root of the dog-grass, in small doses. Towards evening he had two copious stools, and soon after taking the medicine, some vomiting. He rested quietly the whole of the night.

On the third day the fever was more brisk, and the pain re-appeared in the right groin and testicle, but was relieved as before by emollients, or the application for some hours of a poultice of bread and milk. This symptom recurred twice during the cure, before the sixteenth day after the operation, and was removed by the same remedies.

On the fourth, the fever was less violent than on the preceding day. There appeared in the wound symptoms of suppuration; I therefore changed the dressings, introducing a pledgit spread with simple ointment between the outer lips of the wound.

On the seventh day the wound was in full suppuration. From this to the eighteenth day, the patient felt no uneasiness, except a slight colick; from which he was successively relieved by the use of emollient and oily glysters.

On the eighteenth day after the operation, the bottom of the wound having already risen considerably, the ligature of the artery came away along with the matter, and at the same time the roll of linen. In the evening of the same day, the patient thinking it certain that he had nothing more to fear from hemorrhage, moved himself freely in bed; which pressed out, to use the expression, a little blood from the lips



and bottom of the wound, but it was stopped immediately on his remaining quiet, and by the renewal of the dressings.

On the twenty-sixth day after the operation, the wound had risen so much from the bottom, as to be on a level with the integuments, and it was not more than two inches in length, and half an inch in breadth.

By the 13th of April, the wound was completely cicatrized, and the aneurismal sac had already diminished more than two-thirds of the size it had before the operation. The leg and foot of the operated limb were perfectly similar to the leg and foot of the sound limb.

On the 14th of April, the patient began to get out of bed, and to step about a little with the assistance of crutches. On the 27th of the same month, he only required in walking the support of a stick.

About the middle of June of the same year, the patient of whom we are speaking was disposed to resume his occupation as nurse, when he was attacked by transient pains along the leg, and in the calf of the operated limb, without, however, any evident swelling of these parts. By a few days rest, and by means of mercurial frictions to the foot, leg, and ham of the same limb, these affections were removed in less than a fortnight, and Fiorini was at last able to resume his occupation. Eight months after the operation, the aneurismal sac, which before, as has been said, was as large as a fist, was found to be reduced to a small oblong knot, which did not excite any inconvenience. At present, five years have elapsed since the operation; and on examining carefully the ham of this man, I find, that even this small knot has entirely disappeared, and there is not the smallest mark of his having been affected with any disease in the ham.



## CASE II.

POPLITEAL ANEURISM OF LONG STANDING, AND OF  
EXTRAORDINARY SIZE.

ANTONIO VEGRINI, of San Leonardo, a meagre, emaciated, pale man, about 46 years of age, in the beginning of April 1799, was admitted into this hospital on account of a large aneurism, which he had had for nine years in the left ham, and which had lately occasioned him most accute pain, want of sleep, and fever. The tumor was one of the largest of any of this kind which I have ever seen, being as big as the head of an adult. The patient could assign no cause for the disease except his trade, which was that of a weaver. The skin covering this immense tumor, was tense, shining; in some places of a red livid colour; in others, intersected with large varicose veins; in others, very thin, and ready to burst. The fever by which the patient had been exhausted, had the type of a continual remittent. I made the patient take the bark, with the addition to each dose of a few drops of laudanum, and I ordered him to be fed with rich soups. Towards the end of April, although the fever was considerably abated, the excruciating pains, and the want of sleep, continued as before. I was very much puzzled about the practice which it was proper to follow for the benefit of this patient. The observations of the most celebrated practitioners with regard to the unhappy event of the amputation of the thigh in similar cases, presented themselves to me; and I had not at that time conceived the idea of tying the femoral artery in the upper part of



the thigh, and afterwards disarticulating the leg at the knee. On the other hand, the enormous size of the tumor, the very acute pains, and the want of sleep, which were occasioned by the excessive distention of the integuments, and the threatening of an approaching rupture of them, placed the patient in immediate danger of losing his life. Further, I was fully aware, that the posterior and inferior surface of the thigh, must be bare and corroded for a small space. However, I wished to try the Hunterian operation, with the hope, that when the principal current of blood towards the cavity of the tumor was suppressed, and the patient recovering some degree of general strength, there would then be time to reflect upon some other method, which if not capable of curing the patient radically, might at least tend to prolong his life. On the 28th of April, therefore, I performed on this patient, the ligature of the *superficial* femoral artery in the upper third of the thigh, which operation was very easy, on account of the emaciation of the patient. In the act of tying the artery, the acute pains of the ham abated as if by enchantment, and the aneurism lost the excessive degree of tension. The patient after the operation slept quietly for three hours. He was afterwards supported with good strong soup every two hours, and he passed the day and following night quietly.

On the third day, the suppurative fever began. On the fifth there appeared symptoms of incipient suppuration, and the dressings were changed. On the seventh, the fever abated completely, and the wound seemed to look well. I prescribed for the patient a decoction of bark. On the eighteenth day after the operation, the ligature and roll of linen came away spontaneously. On the thirty-sixth, the small incision was completely



cicatrized. Nothing could go on better with regard to the ligature of the femoral artery. The aneurismal tumor however did not suffer the changes corresponding to the intention; for, although it diminished a little at first, it afterwards remained stationary, and in an evident state of atony; and what is still worse, the skin covering it had begun to burst in two points; so thin had it become previous to the operation. Such was the state of affairs, when a student in surgery took the liberty, without my knowledge, to carry a surgeon of the Russian army to see the patient. Both of them, not aware of the particular circumstances of the case, handled and squeezed the tumor in such a rough manner, to ascertain whether there was any deep pulsation in it, that the whole aneurismal sac was burst by the pressure, and the clots of blood, with which the tumor was filled, issued out in great quantity, and without interruption, but not a drop of fluid arterial blood.

This happened in the evening. The following morning, I found the patient quite depressed in his mind, and very feeble, and he complained of intense pain in his ham. The clotted blood that had been discharged formed a very considerable mass. On examining the ham, I found, instead of the tumor, a vast cavity, in the bottom of which, a portion of the thigh bone was distinctly perceived to be bare and corroded. Mortification immediately attacked this large and atonic sac; every thing that art could suggest of any efficacy, was employed for raising and supporting the strength of the patient; but every assistance was unavailing, and he died three days after this accident. The foot and leg were not affected by the gangrene; which was farther confirmed by the dissection of the body publicly performed. It appeared farther from



the inspection of the body, that the *superficial* femoral artery, from the place of the ligature downwards, was contracted in diameter, and irregularly obliterated; that is, for three inches and an half below the ligature it was quite impervious; so that it was impossible to pass along it one of the finest probes. From thence downwards, this artery was likewise contracted, but pervious for some space; and this portion was occupied by a firm fibrous coagulum; it was then closed up anew to the vicinity of the ham, where it was all confusion, caries, and corruption.

This case will perhaps seem to some very little in favour of the Hunterian operation; but in my opinion it is very much so. For, it shews, that even in aneurisms of long standing and enormous size, in which every thing would seem to persuade us that the *superficial* femoral artery could not be tied without accelerating the appearance of gangrene in the subjacent leg and foot, the gangrene does not supervene in every case, without exception; since, in the patient of whom we are speaking, the circulation and life were preserved in the left leg and foot for forty days after the operation; and it was not the gangrene of the leg and foot, but the sphacelus of the atonic aneurismal sac, and of the integuments covering it, which, like a malignant vapour, extinguished in a short time the strength and life of the patient.

I forbear here forming any conjecture what would have happened, if instead of evacuating the clots of blood of this large aneurism all at once, the aneurismal sac had been allowed to empty itself slowly; as also to predict what would have been the effects of the slow suppuration of the sac, and of the corrosion of the posterior and inferior surface of the os femoris. I only mention, that in some similar cases, and in those



in which the spontaneous obliteration of the *superficial* femoral artery has taken place above the seat of the popliteal aneurism, and then the rupture and spontaneous evacuation of the aneurismal sac, a chronic, sinuous, fistulous ulcer has been formed there, but the life of the patient has been saved.\*

---

### CASE III.

#### ANEURISM SITUATED IN THE TOP OF THE CALF OF THE LEG.

CHARLES COMELLO of Casal Monferrato, 46 years of age, a master mason, a man of a good habit of body and tall figure, in the month of September 1803, having mounted to the roof of a church, to draw up a beam of enormous size, standing firm upon his legs, made a very violent effort, and, at the height of the exertion, was struck with an acute pain in the top of the calf of the right leg, which obliged him to give over working. Some days after this accident, the patient perceived, that in the lower part of the ham a tumor had appeared as large as a small hen's egg, accompanied with evident, or rather violent pulsation. This tumor was at once recognised by professional persons, to be an aneurism; the seat of which, on account of its being situated very low in the ham, was thought to be in the bifurcation of the popliteal artery. Evacuations of blood were employed for relieving the patient, as also, fomentations of vinegar, and embrocations of equal parts of spirit of wine, and tincture of myrrh; and compression was likewise tried by means

\* Guattani, de poplitis aneurysm. Hist. v. Masotti sull aneurisma, pag. 23.



of a plate of lead. Nevertheless, the tumor continued to increase, and about the end of February 1804, or at the time the patient was admitted into this school of surgery, the aneurism had increased to the size of a large Portugal orange, and pulsated violently. The subjacent leg, however, was neither painful, numb, nor swollen; and only swelled a little in the evening, when the patient stood long on his feet, or walked more than usual during the day.

The situation of this aneurism very low in the ham, and, properly speaking, at the top of the calf of the leg, presented to me a case quite similar to that described and delineated by Guattani,\* which kept me a little in suspense. For it occurred to my remembrance, that the very low and deep position of this tumor, Guattani had found to be one of the greatest obstacles which he had met with in the treatment of the disease, and on account of which he confessed at last, that he had been induced to consider it as incurable; since, says he, in similar cases, the compression, on account of the thickness of the parts covering the tumor, becomes painful, and cannot be borne by the patient, and is useless as a method of cure; and the ligature of the artery below the aneurism cannot be applied, without including in the ligature with the popliteal artery, the three principal branches which go down to the leg and foot.

After reflecting more maturely on the above-mentioned circumstances, as I knew, from dissection, that the *inferior* articular arteries of the knee communicate very low in the ham, and, properly speaking, in the calf of the leg, with the trunk of the popliteal artery; that a third *inferior* recurrent articular artery may

\* Loc. cit. De superioris suræ partis aneurismatibus, pag. 74. Histor. xx, tab. v, fig. 1. See above, chapter ix, § 8.



pour the blood of the *superior* articular arteries into the *anterior* tibial, independent of the channel in the cavity of the ham; that the rupture of the artery never corresponds to the under part, but to the centre or lower third of the whole aneurismal tumor; and finally, that in the case which I had in view, although the rupture of the popliteal artery had evidently taken place at the top of the calf of the leg, yet the pressure produced by the aneurism did not oppose any considerable hinderance to the circulation of the blood in the corresponding leg and foot, I determined upon performing the Hunterian operation on the patient, fully assured, not only of success, but likewise of being able to demonstrate, by this fact, that Mr. Hunter's method is very proper for curing radically even that form of popliteal aneurism, which, from being situated very low down in the ham, or, properly speaking, in the top of the calf of the leg, was conceived by Guattani to be incurable in any other way than by means of the amputation of the leg or thigh.

On the 25th of February, therefore, the patient submitted to the operation, in the presence of a number of students. With two strokes of the knife, the integuments and aponeurosis of the fascia-lata were divided, and the *superficial* femoral artery was brought into view in the upper part of the thigh; the artery was then insulated, and separated from the cellular membrane for the space of an inch, and tied, with the interposition of a roll of linen between the artery and the knot. The whole operation, and the subsequent application of the dressings, were performed in little more than two minutes; which I mention, not from ostentation, for that is far from my character, but only to shew still more the great difference between the easy, expeditious, and little



painful Hunterian operation, and the old mode of operating for popliteal aneurism, difficult in the execution, retarded by many and always new obstacles, and therefore very painful to the patient. Two hours after the operation, the patient complained of a violent sense of pain all round the knee, and of cold and numbness in the points of the toes. An emollient poultice, applied to the knee, allayed the pain in a few hours, and on wrapping the foot carefully in warm flannel, the toes recovered their natural heat. He was ordered an emulsion, with fourteen drops of laudanum in it.

26th.—The following day I found the patient slightly feverish, and complaining of severe pain in the top of the foot; I therefore ordered the whole foot to be covered with an emollient poultice.

27th.—The pain in the foot abated, and the patient rested for some hours. The pulsations of the articular arteries appeared round the knee, which had not been felt before, and during the intensity of the pain in this part.

28th.—The fever was more severe than on the preceding day. The pain recurred on the upper part of the foot, and was again relieved by the application of the emollient poultice. The patient complained of tension in the abdomen, to remove which a glyster was thrown up.

29th.—On renewing the dressings, the wound was found rather pale, moistened with a little ill-formed, serous matter.

1st March.—Towards evening the fever increased, and an erysipelas appeared, extending from the upper angle of the incision, towards the groin and hip.

2d.—The patient took half an ounce of soluble tartar, which procured a copious liquid stool. Notwithstanding the presence of the erysipelas, the wound



acquired rather a better colour, and began to discharge laudable pus.

3d.—The erysipelas had receded a little from the groin and hip, but had made its appearance below the inferior angle of the wound towards the knee.

7th.—The succeeding days, to the eleventh, the fever increased anew, as well as the inflammatory painful tension along the course of the *superficial* femoral artery, and it was very evident that the inflammation occupied the soft cellular substance which surrounds and accompanies this artery. Emollient poultices were employed locally, without intermission; and internally, antiphlogistic and slightly acidulous drinks.

11th.—At this period the patient had spontaneous evacuations by stool, of thin matter, with great relief. For the fever immediately began to disappear, and the painful inflammatory tension along the inside of the thigh gradually diminished.

12th.—The spontaneous discharges by stool continued with much relief for several days more. However, there remained an unnatural swelling along the course of the *superficial* femoral artery, and on pressing from the knee upwards, a great quantity of matter, of a dark ash-colour, and very fetid, was discharged from the lower angle of the wound.

18th.—The twenty-first day from the operation, after having separated the flesh from the bottom of the ulcer, by means of the introduction of a compressed piece of sponge, the ligature of the artery came away, and along with it the roll of linen. The patient being rather debilitated, was put upon the use of a decoction of bark, to be taken in the dose of three ounces three times a-day.

20th.—Although the patient sat up in bed a few hours every day, and had a good appetite, yet his



pulse, especially towards evening, was feverish, and a fetid, sometimes black matter, continued to be discharged from the wound in great quantity; and in addition to this, the swelling had increased on the inner and lower side of the thigh, along the course of the *superficial* femoral artery, and the knee was œdematous; and on pressing the femoral artery with the finger, from the lower angle of the incision towards the knee, a fluctuation was felt, with a sort of gurgling, as of air mixed with pus.

25th.—This occurrence determined me to make, about five inches below the lower angle of the wound, and in the direction of the *superficial* femoral artery, a counter-opening, from which there issued immediately black very fetid matter, with a burst of air.

26th.—The day after, the upper wound only afforded matter of good quality, and the œdema of the knee disappeared.

27th.—A piece of putrid cellular substance was discharged with the matter. I made a little of the extract of bark, and half a dram of vitriolic ether, be added to the decoction which the patient had been using.

29th.—From this time forward every thing went on progressively better, and about two weeks after, both the place of the upper incision for the ligature of the femoral artery, as well as the lower incision, or counter-opening, were completely cicatrized, and the patient began to get out of bed. The aneurism at this period was reduced from the size of a large orange to that of a large nut. From the very first moment that the patient began to walk about, he did not complain of any stiffness of the knee, nor of greater weakness in the operated than in the sound limb. Towards night, however, the right foot swelled a little; the swelling was removed, at first by means of a well-



adapted expulsive bandage, and then by a boot of linen. About the end of May, the patient had so far recovered his former strength, that he could take long walks; and as, of the whole aneurism of the calf of the leg, there only remained a small indolent tubercle, he returned home and resumed the exercise of his trade.

---

## CASE IV.

### POPLITEAL ANEURISM.\*

A MILLER, about thirty-three years of age, of a good habit of body, was admitted into the hospital of Piacenza the 10th March 1796, on account of a tumor in the right ham, which occasioned him much uneasiness and pain, and prevented him following his trade. I recognised, says Morigi, this disease to be an aneurism already arrived at a considerable height, as the size of it equalled that of a large fist. I learned from the patient himself, that, six years before, he had been affected with venereal pains, and although he had been cured of these, there remained nevertheless a pain in the great trochanter, with some fulness of the inguinal glands of the same side; which however, before the appearance of the aneurism, did not prevent him following his trade, carrying weights, and taking a great deal of fatigue.

This man was scarcely received into the hospital, when he was attacked by a gastric fever, that prevented the operation, which I would have immediately

\* This case was communicated to me by my learned and respected friend Dr. Morigi,



performed, because the aneurismal tumor had increased very much, and the leg was swoln and œdematous, shining, and affected by an extraordinary redness. All these symptoms increased daily more and more, and I almost despaired of being able to have recourse to the operation. At last, after the eleventh day, the patient being free of fever, and having sufficient strength, I resolved upon the operation, which was performed on the 28th March, in the following manner. I placed the patient upon an high bed, opposite to a window ; I made him lie not quite on his back, but a little on his right side, and made him extend the thigh and leg ; having observed, that on the thigh being extended, the sartorius muscle rises up, and leaves the artery less covered at the lower part of the thigh. In this position I made an incision in the skin and cellular substance along the course of the artery, about four inches and an half in length, the centre of which corresponded to the two lower thirds of the thigh ; I then proceeded gradually to lay bare the artery, which I separated carefully from the vein, and having passed under it a double ligature of waxed threads, with a proper instrument, I made with the lower one a single knot, which I drew gradually, and at different times, until I felt the pulsation disappear in the artery below the ligature. I then made another knot, and left the upper ligature in reserve. I brought the lips of the wound together, and kept them so with adhesive plasters ; and lastly, I applied a bandage, beginning at the upper part of the thigh, and carrying it as far as the knee. The patient suffered little during the operation. An hour after, on touching his leg, I found it to be a little colder than the other ; I therefore made it be rubbed gently with camphorated spirit of wine, and made warm cloths be applied to it. This was conti-



nued for some time ; the heat then returned to these parts, and afterwards there was no other assistance necessary than some anodynes, and a decoction of bark, on account of a slight fever that had supervened, and on account of the patient's weakness. On the third day I found the suppuration begun, which afterwards increased, and in spite of the bandage applied all over the thigh, the matter formed itself a way along the sartorius muscle, where it formed a sinus as far as the upper part of the thigh. I applied compresses over this sinus, retained by a bandage ; and in order that the matter might not stagnate too long, I made the wound be dressed twice a-day.

On the sixteenth day the ligatures came away spontaneously ; the sinus did not discharge any more matter, and the wound was cicatrized, except the place where the ligatures had been.

The twenty first day an unexpected hemorrhage occurred, which was stopped by the application of the tourniquet upon the place of the ligature. The following day I found a swelling along the sartorius muscle, at the place where the abscess had been, which swelling was produced by blood collected there. I removed the pressure made by the tourniquet, and the blood collected in the sinus ran out. I again applied compresses to the sinus ; but observing, that a little florid blood still flowed out from the wound, I applied the tourniquet anew to the same place as before, which had the desired effect ; for, three days afterwards, on removing the compression, no more blood appeared. I allowed the patient to move about a little in bed, and on the fortieth day after the operation, being completely cured, he was, five days afterwards, carried to his own house.

I have reason to believe that the above-mentioned



hemorrhage had been caused by the imprudent movement of flexion and extension, made by an officious surgeon, who thought that necessary at the time, to prevent an anchylosis.

---

## CASE V.

### ANEURISM AT THE TOP OF THE THIGH.

PETER FARINASSI, of Turin, hypochondriac and very irritable, reached the age of thirty-four years, without having been affected with any important disease, except gonorrhæas, which he cured, without using mercury either internally or externally. About the end of the year 1800, in the night-time, and while he was asleep, he was attacked by a most severe and painful cramp in the left thigh and leg, with a spasmodic bending of that leg, to get rid of which uneasiness he made a sudden and violent extension of the whole limb. In doing this, he felt as if some filaments had broken at the top of his thigh, and there remained a pain at that part, which continued to trouble him more than twenty days. He was advised to apply warm emollient poultices to the pained place, which afforded him some relief.

Not long after using these applications, a small pulsating tumor appeared at the pained part, which was immediately recognised to be an aneurism. In the course of fifteen months the tumor acquired the size of a large hen's egg, and it was then that the patient came for the first time to Pavia, to have my opinion



about it. I advised him to submit immediately to the Hunterian operation, since the circumstances of his disease were very favourable in every respect to the success of that operation.

After returning to Turin, he could not make up his mind to that, and contented himself, for the space of about ten months more, with compressing the swelling, and with losing blood frequently, especially when there was an evident increase of the noise and pulsation of the tumor. In spite of this, the aneurism augmented to the size of a large orange, on the top of which the skin, on account of the uninterrupted pressure upon the tumor, had become livid, thin, and threatened to burst. The base or centre of the aneurism was situated so high in the thigh, that on measuring the distance from the crural arch downwards, there were only two inches, or a little more, between the origin of the *profunda* femoral artery and the tumor. The subjacent leg and foot, however, were not at all preternaturally swelled.

The frequent evacuations of blood, the pains, want of sleep, and continual agitation of mind in which the patient lived, had reduced him to such a state of depression and emaciation, that, on returning to Pavia, he did not appear to be any longer in a condition to undergo a radical cure of his disease. Notwithstanding this, in reflecting upon the smallness of the incision which is made in tying the *superficial* femoral artery, and on the little importance of the symptoms consequent to this incision, I resolved to try it in this patient; the more so, as amputation was inadmissible, and the aneurism threatened to burst.

On the 3d of March 1803, in the presence of a number of students, having placed the patient in an inclined posture on the right edge of the bed, with the left



leg and thigh in a state of semiflexion, I placed myself on the right side of the patient, although I was to operate on his left thigh. An assistant was ready to compress the *common* femoral artery at the crural arch, whenever I should order him to do it; another assistant took charge of holding the left knee and leg firm; and a third handed me the instruments. With a convex-edged bistoury I made an incision of the integuments and cellular substance, two inches and an half in length, in the course of the femoral artery, beginning a little above the place where the *profunda* commonly arises. With a second incision, with my hand unsupported, I divided in the bottom of the first the aponeurosis of the fascia-lata, and having introduced the fore-finger of my left hand into the bottom of the wound, I separated the superficial femoral artery from the cellular substance which tied it to the neighbouring parts, and raised it with the point of the finger passed behind it, so that I could see it denuded, and distinct from the great femoral vein, and from the *profunda* femoral artery. Directed by the point of the fore-finger of my left hand, with which I raised the artery, I passed two waxed ligatures, each of them two lines in breadth, from my right to the left, by means of the eyed needle, then withdrawing the fore-finger of my left hand, with which I mentioned that I held the artery raised, and having arranged the ligatures contiguous to each other, I placed a roll of linen on the anterior surface of the artery, upon which I drew the ligatures with a simple knot, and with as much force as was sufficient completely to suspend the pulsations in the tumor, and to place the two opposite sides of the tied artery in firm contact. Over the first knot I made a second; I then cut off the greatest part of the length of the ligatures, nearly to



a level with the skin; the wound was filled with soft lint, upon which I placed a compress, supported by a four-headed bandage. The operation was finished in about two minutes, in which short time the patient shewed no symptom of suffering severely. According to the measures which had been taken, the ligature was placed about half an inch below the origin of the *profunda*. I did not think of leaving any ligature as a *reserve*, and the ligature made with the two threads contiguous to each other, with the interposition of the roll of linen, pressed the artery for the space of four lines, without constricting it circularly.

Two hours after the operation, the patient complained of great uneasiness all round the knee, as also of numbness and cold in the extremities of the toes of the corresponding foot. He took an emulsion, with twelve drops of laudanum; bladders filled with warm water were applied round his foot, and the knee was covered with an emollient poultice, which produced the desired effect; as, after two hours and an half, the uneasiness of the knee abated, and the toes became warm.

2d.—On the second day, after having passed a quiet night, it was found that the heat of the whole operated limb exceeded that of the sound. On grasping the knee with both hands, the noise and pulsation of the popliteal recurrent arteries, and of their anastomoses, above, and at the sides of the patella, with the collateral arteries of the thigh, was so violent, that they seemed like so many radial arteries. The patient was the first to remark this phenomenon. Towards evening a slight degree of fever occurred.

3d.—The third day the fever was rather increased.

4th.—The fourth he had passed a quiet night, and the fever was less than on the preceding day.



5th.—The dressings were changed, except the lint, which filled the cavity of the wound, in which the suppuration was not yet fully formed. The aneurism had already considerably diminished in size.

6th, 7th —The suppuration had not detached the lint from the bottom of the wound. The patient for these two days was very much troubled with a cough. In the evening he had a copious alvine evacuation, by means of a glyster; he took an anodyne arabic emulsion, and sweated during the night.

8th —The day after, the cough was almost completely gone, and the pulse regular. The suppuration having increased, disengaged the lint from the bottom of the wound.

13th.—The thirteenth day after the operation, the bottom of the ulcer having risen, the ligature appeared nearly on a level with the integuments.

14th.—The day after the ligature came away spontaneously, along with the roll of linen, without occasioning the smallest effusion of blood. The bottom of the wound looked well, granulating not more than a simple ulcer, of small extent and depth, and in fifteen days more it was completely cicatrized. In proportion as the patient recovered his strength, and took nourishment, the aneurism diminished in bulk in every dimension.

On the thirty-fifth day after the operation the patient got out of bed, and walked tolerably well, without the assistance of crutches; and he could not tell which of the two lower extremities was the weakest.

Nine weeks after the operation, the aneurism might be considered as entirely disappeared, since there was not the smallest elevation at the place which it occupied at the top of the thigh, and only on pressing, a



small portion of indurated cellular substance was felt there.

The 15th of May of the same year, the subject of this history was radically cured, and returned to Turin, his native place.

---

## CASE VI.

### FEMORAL ANEURISM.

LOUIS TRESPI, of St. Zenon, a stout country-man, twenty-five years of age, in attempting to bore a hole with the point of a knife through a thin wooden board, and the better to effect his purpose, having rested it against the inner side of his left thigh, the knife happening to pass through suddenly, wounded the femoral artery about the middle of the thigh. The blood rushed out in great quantity, and *per saltum*; but it was quickly stopped by the bye-standers, by the application of a number of compresses and a circular bandage; after which the patient was brought into this hospital. The surgeon of the ward into which he was put, dreading a renewal of the hemorrhage, did not uncover the wound till eight days after the accident, and then found that it was completely cicatrized. The patient the same day got out of bed, and walked about a little. The next day the surgeon observed that the cicatrix was raised, in the form of a tumor, as large as a small nut, and this tumor pulsated like an artery. Towards evening the patient had a slight degree of fever. The tumor went on daily increasing more and more, and on the eighteenth day after re-



ceiving the wound, the whole left lower extremity, from the foot to the knee, was considerably swelled. The following days the fever increased, with great prostration of strength, and the tumor at last was augmented to the size of two thick clenched fists.

Such was the state of the case when I visited the patient for the first time, and directed him to be conveyed into the School of Practical Surgery, where I undertook the operation the 22d of February 1794. Having made the femoral artery be compressed by a skilful assistant in the vicinity of the crural arch, I laid open, with one stroke of the bistoury, the large aneurism from the top to the bottom, making the incision pass through the middle of the cicatrix of the wound. Having evacuated a large quantity of clots of blood, and dried thoroughly the bottom of the wound, the injury of the *superficial* femoral artery presented itself to me : it was a little more than three lines long in an oblique direction to the artery. I introduced a large probe within it, with which I raised it, and then easily tied it circularly, and in the usual manner, above and below the wound, leaving besides at the upper part a ligature of *reserve*.\* I filled the cavity with soft lint, and covered the whole with a compress and a six-headed bandage.

After the operation was finished, which was of short duration, the patient fainted, but he soon recovered by smelling a little vinegar. He then complained of a troublesome creeping sensation through the whole

\* At that time experience had not taught me the great advantages which are derived from the interposition of a roll of linen between the artery and the knot, in order to guard the patient against the risk of subsequent hemorrhage ; nor had it demonstrated to me the little or no use which can be made of the ligature of reserve on the occurrence of secondary hemorrhage.



operated limb. He took an emulsion with eighteen drops of laudanum, after which he slept quietly for two hours. On awakening, he said that the operated limb seemed to him to be warmer than the sound one, and it was so in fact. The following day the fever was greater. His pulse, however, was not so small and contracted as before the operation.

On the fifth day, the swelling, which before the operation extended from the foot to the hip, had almost entirely disappeared, and suppuration had begun; on which account the dressings were renewed.

On the eleventh day an hemorrhage appeared, which was suppressed partly by drawing the ligature of reserve, but for the most part by means of compression applied to the bottom of the wound against the thigh-bone, by graduated compresses and a circular bandage. On account of this accident, however, the patient's mind was so much affected, that he was seized with convulsive motions over his whole body, which were only removed by a large dose of opium and strong restorative soups. The patient, the day after, began to take the decoction of bark with a little vitriolic ether in small doses.

On the twentieth day I found the patient quite free of fever. The ligatures were discharged from the wound, except one, which did not come away till the end of the fourth week. The wound notwithstanding became all at once stationary. This was occasioned by a sinus, which extended downwards from the lower angle of the wound for two inches and an half. After it was laid open by the knife, the wound resumed its course towards cicatrization, which was completed by the fifty-second day after the operation.

On the same day the patient got up, and walked a few steps with the assistance of a stick. In three



weeks more, he recovered his former strength, and left the hospital completely cured. About a year after, I saw this man in perfect health, and he assured me that the left limb was as strong as the right, and that he could carry considerable burdens on his back, as he used to do before the occurrence of the accident.

---

## CASE VII.

### ANEURISM IN THE BEND OF THE ARM.

JOSEPH LUCOTTI, of Volpedo Tortonese, a country-man, about 30 years of age, on the 10th August 1799, had himself bled in the right arm, in order to be freed from an obstinate pain in his head. The blood flowed with impetuosity and *per saltum*, and the surgeon had considerable difficulty in stopping it. Three days after, this man observed that he had a small pulsating tumor at the place where he had been bled, which was painful, and prevented him bending and extending his arm freely. The surgeon applied a bit of plaster to it; then perceiving that the tumor increased, he applied a poultice of bread and milk, in order to promote the supuration of it. Six days after using the poultice the tumor increased to an immoderate size, and had a strong pulsation. The patient then resolved upon coming to this hospital. I was not, however, consulted about the state of the patient till the 22d of September; the whole arm was then prodigiously swelled, and, as it were, phlegmonous. The next day I found it necessary to operate immediately on the pa-



tient, as the aneurism had become *diffused*, and threatened the most serious consequences.

Having applied a tourniquet on the humeral artery in the vicinity of the axilla, I made a large incision into the aneurism, following the course of the humeral artery in the bend of the arm, and carrying the incision through the cicatrix left by the lancet. The bloody coagulum rushed out by the large incision, and along with it a little fluid arterial blood; and having dried the bottom of the aneurismal sac with a sponge, the artery immediately presented itself to me, and it was observed to be wounded obliquely for the space of two lines. Through this aperture I introduced a steel probe, with which I raised the wounded artery, while with the fore-finger of the other hand I separated it from the cellular substance, which tied it laterally and posteriorly. I raised it together with the median nerve, from which I easily separated it for a small space above and below the wound. By means of the eyed needle, I passed two ligatures behind the artery, with which making a simple knot, and interposing a roll of linen between the knot and the artery, I tied it above and below the wound made by the lancet. On loosening the tourniquet, no blood flowed from the incision; I therefore filled the whole cavity of the aneurismal sac with soft lint, over which I applied a compress retained by a four-headed bandage; and, lastly, I placed the arm in a state of semi-flexion. The patient passed the whole day and the following night tolerably well. The morning after, he was seized with nausea, spasmodic constrictions in the fauces, and frequent attempts to vomit, during which he only rejected some frothy saliva. I ordered him the *mixtura ante-emetica* of Riverius, which he rejected the instant after he had taken it. The anxie-



ty and constriction of the fauces increased, the sweat was dropping from his head, and his face became gradually covered with a deadly paleness. A most violent effort at vomiting supervened, during which he threw up by the mouth a living lumbricus worm, a foot in length. After this he felt relieved for fully two hours; then the same symptoms of anxiety, of stricture in the fauces, cold sweat, paleness of face, and vomiting of frothy saliva, recurred as before. Recollecting the good effects which in a similar case I had obtained from fluid quicksilver given in large doses by the mouth, I made the patient swallow about ten drams, by weight, of quicksilver sublimed from cinnabar. As soon as he had taken this remedy, the efforts at vomiting and the stricture of the fauces ceased, and in the space of three quarters of an hour all the alarming symptoms abated, and the patient fell asleep. The remaining part of the day he was able to refresh himself with soup and a few spoonfuls of wine. The following day I ordered him to take powders composed of semen santonici and powder of jalap, and I directed purgative glysters to be thrown up. This had a surprising effect; for he passed by stool a very great mass of lumbrici twisted together, and perfectly similar to that which he had rejected by the mouth; after which he felt himself completely free of every inconvenience of this kind, and recovered his spirits and strength. The suppurative fever came on, and it was very moderate. The fifth day the dressings were removed, and the matter was found to be of good quality, and the ulcer had an healthy appearance. The phlegmonous swelling of the arm had disappeared, and the heat of the hand became two degrees higher than that of the other hand.

On the eleventh day after the operation the lower



ligature came away spontaneously, and on the thirteenth the upper ligature of the artery also. There therefore remained only a simple ulcer to heal, which advanced rapidly to cicatrization.

I employed the most unremitting attention in order to prevent the rigidity of the flexure of the arm, directing the operated arm to be brought every day gradually from the state of flexion to that of extension.

On the thirty-fourth day after the operation the wound was completely cicatrized, and the patient left the hospital perfectly cured.

---

## CASE VIII.

### WOUND OF THE HUMERAL ARTERY.

MARGARET GHERLASCHI, of Tor'd'Arese, 40 years of age, weak and emaciated, on the 20th September 1802, in handling a knife, wounded herself on the inner side of the left arm, not far from the internal condyle of the humerus. The vermilion-coloured blood, which issued out *per saltum*, shewed the surgeon of the place that the humeral artery had been wounded. This surgeon succeeded with difficulty in stopping the hemorrhage by means of graduated compresses and a circular bandage, after which the woman was brought to this hospital. The surgeon of the ward in which this woman was placed, after untying the tight bandage, saw only a little blackish half coagulated blood flow from the wound, and observed that there was besides this an ecchymosis, which extended from the wound on the inner side of the arm



as far as the axilla, without there being, however, any remarkable swelling of the arm. He therefore contented himself with treating the wound as a simple ulcer.

After seventeen days of this treatment, the ulcer having already contracted very much, and apparently nearly healed, the woman was preparing to leave the hospital. During the night, after having made some violent exertions with the affected arm, she felt that arm become evidently swelled from the elbow to the axilla. In the morning, on uncovering the wound, the surgeon of the ward found a bloody coagulum, as large as the point of the finger, protruding between the lips of the small ulcer. Having been called in, in this state of the case, I found a *diffuse* aneurism extending from the bend of the elbow to the axilla, and therefore proceeded immediately to the ligature of the wounded humeral artery.

A skilful assistant having applied the compression to the brachial artery above the clavicle against the first rib, I dilated the ulcer upwards and downwards, in order to bring the injured humeral artery into view; but it was not so easy, as it usually is immediately after the bleeding, or after the formation of the prominent aneurismal sac, to see the denuded artery in the bottom of the wound, and the wound made in it, and still less to determine with precision the proper place for the application of the ligatures. For although, on suspending the compression above the clavicle, the point from which the arterial blood flowed *per saltum*, pointed out the place where the humeral artery had been wounded, yet on account of the preceding *adhesive* inflammation, and of the subsequent suppuration, there was such a confusion and conglutination of parts to each other, that it was impossible to



distinguish properly the trunk of the humeral artery from the rest of the parts, and to insulate it in a convenient manner, in order to tie it with accuracy, and without the interposition of muscular or cellular substance. Therefore, without losing time in painful and useless searches, I formed the resolution of prolonging the incision for some inches upwards along the inner edge of the biceps, and consequently in the direction of the humeral artery. In this manner I brought the humeral artery very quickly into view at a convenient place, and I was able at once to separate it from the median nerve and the vein, and tie it singly with a simple knot, with the interposition of a roll of linen between the artery and the ligature. I did not trouble myself with tying the artery below the ulcer, or at the lower angle of the long incision, both because I would have been unable to distinguish the artery in that intricate mass of substance adhering together, and because I was persuaded that the blood which flowed back from that part might be stopped by means of a moderate compression, and of lint dipped in spirit of wine, with the addition of a few drops of vitriolic acid, which in fact took place.

The lengthening of the incision upwards procured the farther advantage of allowing the discharge of a very considerable quantity of those clots of blood which filled the arm from the elbow to the axilla, in which cavity principally they formed a tumor of prodigious size.

Immediately after the operation, the hand was rather cold, but two hours after it became warm, and towards evening of the same day it was very warm.

Notwithstanding the evacuation of that enormous mass of bloody clots which filled the inner side of the humerus and the cavity of the axilla, it is proper to



mention, that the great preceding distention produced by these clots had already brought on an atony of the integuments and subjacent cellular substance of these parts, in a woman previously very much debilitated and emaciated. For, some days after the operation, the integuments burst through all that space, and exposed a foul ulcer, extending from above the *internal* condyle of the humerus along all the inner side of the humerus to the cavity of the axilla. The progress of the corruption was stopped by means of the use of bark both internally and externally, of strong soup, and cordial remedies. And it was worthy of observation, that the portion of the bend of the arm where the artery had been wounded, and where the effused blood had only collected in small quantity, remained unaffected by the corruption, while the other portion was gangrenous from the lower angle of the wound to the axilla.

On the eleventh day after the operation, the ligature of the artery, along with the roll of linen, was discharged spontaneously from the wound. In progress of time, the very extensive ulcer from the elbow to the axilla afforded an healthy suppuration, and in the course of three months, by means of the expulsive bandage applied to each of the fingers, and from thence to the axilla, it at last healed completely.

The first day after the operation, the brachial artery only gave the sensation of a small, deep tremulous motion; afterwards the pulsation of this artery became manifest, and at last even strong. The attention to move the flexure of the arm of the patient every day had the effect of preventing the rigidity from beginning in the bend of the arm. This woman at present makes use of the operated arm with the same facility and strength as she does of the other.



Although the humeral artery had been tied in the lower third of the humerus, in all probability the ligature was made below the origin of the *superior* collateral artery. The hand was cold for two hours, but afterwards became warmer than the other. The great extent of the ulceration from the bend of the elbow along the whole inner surface of the humerus into the cavity of the axilla, with large portions of integuments detached like fringes, and the state of corruption destroying the parts extensively ulcerated, seemed to indicate a general atony of the whole arm. Notwithstanding this, and in spite of the ligature of the trunk of the principal artery of the arm, every thing went on with regularity towards a cure, and nearly as in an arm, the principal artery of which has not been tied.

---

## CASE IX.

### CORROSION OF THE HUMERAL ARTERY, OCCASIONED BY GANGRENE OF THE FLEXURE OF THE ARM.

MAURO CREMASCHI of Belgiojoso, a boy about 13 years of age, completely blind from his infancy, was brought into this hospital to be cured of a scrofulous ulcer, surrounded with hardness of the cellular substance, and situated in the vicinity of the internal condyle of the right humerus. After this boy had been about a week in the hospital, the ulcer became foul, and at last was attacked by the hospital gangrene. This happened about the beginning of September 1795. The tenth day of the same month there was so great a loss of substance caused by the gangrene, that



the ulcer already extended more than three inches above and below the internal condyle of the humerus. On introducing the finger into the bottom of this cavity, the trunk of the humeral artery was felt beating almost quite bare, and it was dreaded, not without great reason, that this artery would every moment be corroded, and burst. To add to the distress, the strength of the patient, of a very weakly constitution, was very much sunk, and he was from time to time attacked by subsultus tendinum and hickup. The gangrene was still extending, and prevented the amputation of the humerus.

What I so much dreaded happened the following day. The humeral artery, being corroded, burst. The surgeon in attendance, who never left the patient, applied pressure to the brachial artery above the clavicle, and proceeded immediately to the ligature of the artery, although obscured by the gangrenous substance. Nevertheless, the place of the rupture was discovered, and a probe being passed through it into the tube of the artery, it was raised in the midst of the sphacelus, and tied first above and then below the rupture. The whole wound was sprinkled with powder of bark, and a little camphor, and covered with soft lint, retained by a four-headed bandage. The uninterrupted attention in administering the bark internally, with the addition of vitriolic ether, strong soups given frequently, and a little wine, succeeded in restoring the boy's strength, and rescuing him from danger.

Immediately after tying the artery the pulse disappeared, and the hand became cold; four hours after, however, it became as warm as the other, and the boy complained of a troublesome sensation of creeping in the hand.



12th September.—After a copious evacuation by stool, of fluid matter, the patient slept quietly for three hours, and his strength was a little better than before. The hand continued cold. At the wrist a deep trembling was felt in the radial artery, which disappeared if this artery was pressed a little more than usual.

13th.—The heat of the operated hand and arm exceeded that of the sound arm by three degrees. The swelling of the whole arm was very much diminished, and the fever was less than on the preceding day. On removing the dressing, it was found that the gangrene had stopped, and was even disposed to separate at some points.

14th.—The patient has passed a quiet night, and at day break had a liquid stool, with much relief. The fever is less than yesterday. The gangrene has separated at three places, and has left the subjacent parts of a bright red colour.

17th.—The temperature is the same in both arms; fever very slight. The patient begged earnestly for a little solid food, and he was allowed the quarter of a fowl. He continues to take the decoction of bark, but at longer intervals.

20th.—The gangrene has separated completely, and the wound looks well. The upper ligature of the artery came away with the dressings.

22d.—The lower ligature has likewise come away. The patient is free of fever, and the bottom of the wound nearly on a level with the integuments.

25th.—The operated arm allows itself to be bent and extended easily. The patient himself, with the assistance of the other hand, places this arm slowly sometimes in a state of flexion, sometimes of extension.



29th.—The wound is almost completely cicatrized.

1st October. The little patient passes several hours a-day sitting in a chair, with his arm supported in a sling.

10th.—The wound is completely healed. The patient can move his arm; but he cannot extend it completely, on account of the strong bridges formed by the cicatrix, after so great a destruction by the gangrene of the integuments and cellular substance in the bend of the arm. The pulse of the radial artery is still very weak.

25th.—After frictions several times a-day with warm olive oil and axunge, on the cicatrix and all round the elbow, the patient moves his arm better than before, although he cannot yet extend it fully. At this period he was carried back to his own house, having preserved his arm; which, if the general rules had been strictly adhered to, ought perhaps to have been amputated.

---

## CASE X.

SINGULAR CASE OF ANEURISM SITUATED UPON THE SPINE OF THE TIBIA, IN THE VICINITY OF THE KNEE.

A YOUNG country-man, 24 years of age, apparently of a good constitution, had for a long time had a pulsating tumor upon the spine of the left tibia, about six fingers below the patella. The bone of the tibia formed the base of this tumor, and therefore it was hard at its root; but at the apex, and above the spine of the tibia, it was soft, and on applying the hand



there, a strong pulsation was felt in it, which raised the hand as a large aneurism does. There was some swelling also behind the tibia, and in the upper part of the calf of the leg; but the greatest elevation of the pulsating tumor, was, properly speaking, upon the spine of the tibia.

On questioning the patient with regard to the origin of his disease, he said, that about seven years ago, an ox had struck him with its horn at that place; that afterwards a small tumor had appeared there, which however, some days after, disappeared; that for three years subsequent to this accident, he had not felt any inconvenience in that part; that after that time, he had perceived in the same place, or on the spine of the tibia, a pulsating but indolent tumor, the cause of which, had been ascribed to a tight ligature, which he had been accustomed to wear immediately below the knee, and perhaps also to a long journey he had made on foot; that, lastly, the pulsating tumor had increased gradually to the size of the fist, however, without having been obliged on account of it, to confine himself to bed. Doctor Morigi of Piacenza, was the first who examined this patient attentively; and as he was convinced, that the singularity of the case would interest me very much, as in truth it did, he directed the patient to me at Pavia, with permission to retain him in the Practical School, if I chose to do so, for the public advantage.

From the examination which I made, I was clearly of opinion that this tumor was an aneurism. The difficulty turned upon determining, whether the pulsating bloody tumor proceeded from a wound of the popliteal artery, or of the *posterior* or *anterior* tibial arteries, or of the interosseous artery. I was inclined to believe, that it was formed by a rupture of the an-



terior tibial, and that the extravasated blood, by resting upon the anterior surface of the tibia, and compressing it, had excited the absorption and destruction of a portion of the body of that bone. After considering every thing in relation to the cure, and especially reflecting upon the loss produced in the tibia very near to the knee, I was of opinion, that the amputation of the thigh, or the disarticulation of the leg at the knee, was to be preferred to any other operation. The patient refused to submit to it, and returned to his own home in the district of Piacenza. The patient passed one year more in this state; he then had the misfortune to receive accidentally a blow on the tumor, and to fall several times upon the diseased knee; by which accidents, pain was excited in the place of the tumor. Being incapable after some time of moving about any more, weak and emaciated, he resolved to return again to the hospital of Piacenza, imploring that operation, which a year before he had refused to submit to.

The celebrated Morigi amputated the limb of the patient above the knee, and cured him. Immediately after, he injected the popliteal artery with wax, and sent me the pathological preparation in order that I might examine it.

Having removed the integuments, I immediately proceeded to search for the great arterial trunks of the ham, and I was very much surprised to see, that the popliteal artery, as well as the two tibial and interosseous arteries, were in the most perfectly entire state. Afterwards, what principally fixed my attention was, the finding the aneurismal sac quite covered with arterial vessels, of a much greater size than that of the proper arteries of the cellular substance, and those of the periosteum.



On opening the aneurismal sac according to the length of the spine of the tibia, I found that the sac of it was full of polypous layers, after the manner of aneurisms, and that the wax which had been injected by the popliteal artery, was mixed with these layers of blood. The parietes of the aneurismal sac, on removing the polypous layers, were in some places six, in others four, in others three lines in thickness. On examining then attentively the substance composing the parietes of this aneurismal sac, it was evidently the periosteum of the tibia, thickened, fleshy, and covered by the compact subcutaneous cellular substance. The inner substance of this sac was villous, irregular, and similar in some measure to the placenta, on the side which is attached to the uterus. On introducing the fingers into the bottom of this aneurismal sac, there were felt fragments of the body of the tibia which had been corroded and absorbed; and it was distinctly perceived, that the lower portion of the body of the tibia was no longer in continuity with the upper; while the thickened periosteum of the portion of the tibia which was wanting, and which formed the aneurismal sac, was in continuity with the periosteum of the rest of the tibia, above and below the corrosion of it. The fibula was untouched.

After cleaning thoroughly the inside of the aneurismal sac, it was wonderful to see from how great a number of arterial orifices the wax injected into the popliteal artery, soon after the amputation, had been effused into the cavity of the aneurism. After the examination of these parts, I was of opinion, that the disease at first had only been a softening of a portion of the inside of the body of the tibia, followed by an absorption of the substance of that bone from the inner towards the outer side, the periosteum covering it re-



maining entire, and in a state of perfect vitality ; in the second place, that the greater than usual afflux of blood, and of the other humours to that part, had, as usually happens in the capsules of encysted tumors, thickened the periosteum, and greatly enlarged in diameter the proper arteries of this membrane. From the open extremities of these arteries of the periosteum, the arterial blood being poured in great quantity, and with great impetuosity into the cavity left by the portion of the tibia which had been absorbed, this periosteum compressed and thickened, with the addition of the subcutaneous cellular substance, had been converted into a pulsating, or aneurismal sac.

At the time that I was recording the history of this disease, Mr. Pearson published in the second volume of the *Medical Communications*, the account of a bloody pulsating tumor on the spine of the tibia, very similar, as appears to me, to the above described. This author was mistaken, as I was also, in conceiving the proximate cause of the tumor to be a dilatation or rupture of the *anterior* tibial artery. The patient's thigh was likewise amputated, and from the inspection of the amputated parts, Mr. Pearson was of opinion, that the pulsation of the tumor on the spine of the tibia, was to be ascribed to the impulse which the tumor received posteriorly from the popliteal artery. Upon which point it may be remarked, that also in the case described by Mr. Pearson, the injection thrown in by the popliteal artery was poured into the aneurismal sac, without any evident rupture of the great arteries of the ham ; and that in the very act of amputating the thigh, as Mr. Pearson remarks, the blood regurgitated from the aneurism by the popliteal artery, with an evident depression of the pulsating tumor occupying the spine of the tibia ; which proves, that the



arterial blood was easily poured out, and in great quantity, from the popliteal artery into the cavity of the tumor, by means of the extraordinary dilatation of the arteries of the periosteum, arising from the popliteal artery.

What happened in the sequel of the cure of the patient, whose history I have here related, confirmed me very much in the above-mentioned opinion, with regard to the nature and proximate cause of this disease. For the patient of whom I have spoken, having enjoyed a very good state of health for five successive years after the amputation, in the winter of 1797, began without any evident cause, either internal or external, to complain of a kind of pain in the extremity of the stump of the thigh. Not long after, the stump enlarged so much, that the patient could with difficulty apply the wooden leg to it, which he had hitherto worn easily. Morigi visited the patient, and besides the increased size of the stump, found, what was still more extraordinary, that the stump itself was an aneurism, or at least that it pulsated after the manner of a large aneurism. The patient after a few days rest in the hospital, left it; but he was not lost sight of. Some months after, it was observed, that not only the stump, but likewise all the rest of the amputated thigh, nearly as far as the loins, was increased in size, and pulsated like an aneurism; and farther, that on handling the remains of the thigh, a crepitation was felt deeply in it, as if fragments of broken bones, an unequivocal proof, that the bony substance had been softened, then absorbed, the soft parts covering the diseased parts remaining untouched. Towards the end of the summer of 1798, this unhappy man, exhausted by a slow fever, came again into the hospital, and died a few days after. The femoral arterial vessels were im-



mediately injected, and the preparation being separated from the pelvis, was sent to me, to be placed along with the first.

On opening the tumor lengthwise, for so the remains of the amputated thigh might be called, I found it full of bloody polypous clots, similar to those which are found in the cavity of an aneurism. The substance of the os femoris had been absorbed through the whole space from the apex of the stump, to the vicinity of the *great* trochanter, and the absorption was about to proceed likewise to the neck of the thigh-bone. The periosteum of all this portion of the thigh-bone, from the stump to the trochanter, had remained untouched, thickened, interspersed with blood vessels very much dilated, and converted into a sheath which supplied the place of an aneurismal sac. Both of these preparations are preserved in the pathological cabinet of this university.\*

\* This case differs essentially from that described by Preussius, inserted in the *Ephemerides naturæ curiosorum*, an. 1715, cent. iii, iv, observ. xix, under the title, *Tumor aneurysmaticus genu sinistri, incisione tandem cauta feliciter persanatus*. This tumor was only properly a great ecchymosis, which happened in a nun from long kneeling on the hard ground.



## APPENDIX.

---

[NOTE, No. 1, p. 64.]

QUAESITU dignum multis visum est, cur in aneurysmate effluxus ex arteria ad cutem sanguis et imputris, et immutatus longo satis tempore servetur. Sane vero imputrem multo temporis spatio eum servari certum est, quando gangræna, sphacelus, syderatio, affectuumve sanguinem putrescentem comitantium aliquis, nisi longo tempore intercedente aneurysmati accedat. Illud sanguini huic ex arteria ad cutem effluxo evenire innotuit, quod lacustri aquæ in ipsius lacus alveo imputri permanenti, quanquam non fluat sed persistat. Id propterea fieri philosophorum multi dixerunt, quia quæ assiduo ab ipso laco educitur aqua, vel a terræ rivis, vel a sole assidue ebibitur, et a flumine, fonte, marive lacum producente assidue, et multo cum fænore resarcitur, et ad illum transmittitur, ut huic motum quemdam aquæ secretiorem corruptionem impredientem colligere liceat; secus ac paludibus eveniat, in quibus cum nihil assidue fluat, et sæpe non refluat, putrescunt majori ex parte aquæ. Pari itaque, aut certe non multum dissimili ratione, imputris in aneurysmate diu permanet sanguis, quia ob naturalem arteriæ pulsationem a causa præternaturali sine dubio auctam, et ob spirituosam sanguinis arteriosi conditionem, arteriæ foramine illius ingressum, et egressum minime recusante, fluit assidue et refluit in hoc tumore sanguis. Adde et eumqui tumore afficitur, vana quadam evanescentis per



compressionem tumoris delectatione allicitum, sæpius illum comprimere, huicque effluxum sanguinem cum non effluxo misceri, et qui semel exiliit alias intus permanere. Loc. cit.

[NOTE, No. 2, p. 75].

Except *Monro*, *Hazon*, *Palletta*, *Maunoir*.

*Monro* writes, that he considered the true aneurism, so called, as very rare ; both because the greater number of cases which we have of this disease are aneurisms from a rupture of an artery, and because, in none of these cases has it been mentioned, that the aneurismal sac was formed of a fibrous layer similar to that of the muscular coat of the artery, as ought to have been the case, if the aneurismal sac had been produced by a dilatation of the tube of the artery. See *Monro's* works, No. 13.

*Hazon* has very sensibly expressed doubts on the doctrine generally received with regard to true and spurious aneurisms ; observing, ‘ *Facilem hac in re fuisse errori locum. Quippe factitias, vel cellulares quascunque membranas, densas, sanguine indurato, fluidoque distentas pro veris arteriæ tunicis promptum erat accipere, cum tamen diligenti examine, mediis his in cellulis arteria sauciata non dilatata reperiatur.*’ See *Haller, Disput. Chirurg. t. v, p. 213.*

*Palletta*. It is conceived, says he, that aneurism is formed for the most part by a certain dilatation or expansion of the arterial coats ; I, however, in the dissection of aneurisms, have never found a real dilatation of the arterial trunk. Those who have operated upon aneurisms have never found the trunk of the artery simply dilated. I have always seen a hole in the artery, more or less large, sometimes in form of a rent, sometimes more or less callous, and, as it were, like the orifice of a fistula. See *Giornale di Venezia*, an. 1796, No. 1.

*Maunoir* says, ‘ *Prenons un anéurisme de l’aorte pectoral, ou de l’artère pulmonaire ; un obstacle à la circulation dans quelque partie, l’action du cœur continuée, et une disposition particuliere dans ces artères produisent sa dilatation. Mais les tuniques internes ne prétent pas à un développe-*



ment étendu ; cette dilatation ne va jamais bien loin. Elles se rompent dans un point et la tunique externe, ou celluleuse fait poche et s'oppose seule à l'effusion du sang, qui passe par la déchirure des tuniques internes. La poche augmente, le sang dissequé quelquefois l'artère dans toute sa circonférence, et elle se trouve dans le centre de l'anéurisme entièrement baignée dans le sang aneurismal. See *Mémoire Physiolog. et Prat. sur l'Anéurisme*, p. 30.

[NOTES 3, 4, 5, p. 82].

Program. de Aneurysm. Vid. Haller *Disput. Chirurg.* t. v. Pollicis intervallo ab arteriæ magnæ origine cordeque aneurysma ovi minoris magnitudinis in pericardio obortum. Fissura pisum admittebat. Homo derepente mortuus est, effuso sanguine in pericardium.

*Acta Medic. Berolin.* vol. viii, p. 86. Pericardium autem erat admodum tumidum, quo dissecto ingens quantitas extravasati sanguinis cavitatem vel saccum ejus replebat. Exterso sanguine in conspectum veniebat foramen, vel ruptura ad triobolarem magnitudinem accedens in trunco aortæ, ubi ex sinistro ventriculo cordis procedit. Ubi locus rupturæ penitus inspiciebatur, interior arteriæ tunica in circumferentia aperturæ erosa esse notabatur.

De sed. et caus. Morb. epist. xxvi, art. 7. Magna arteria inventa est rupta qua proxima est cordi ; pericardium autem inde plenum omnino coagulati sanguinis.

Art. 17, loc. cit. Mox ea dissecta conspexi toto hoc amplo tractu quo dilatatam aortam fuisse dixi, intus asperam et inæqualem ob rigidas ac duras lamellas osseas, ita crebras atque confertas, vix ut exigua quædam intervalla relinquerent inter se. In quibus intervallis cum arteriæ tunicæ interiores exesæ, et exulceratione quadam attenuatæ perspicerentur, mirum erat uno tantum loco, haud procul a corde, ad posteriorem, eandemque sinisteriorem partem id demum accidisse, quod tot aliis antea poterat. Scilicet per unum ex hujusmodi intervallis sibi viam sanguis paulatim fecerat, et sub tunicam venerat arteriæ externam, quam ab interioris primum deducendo, attolendoque, sicut ampla quasi ecchi-



mosis docebat, quam ipsi sibi conerescens effecerat, tum deinde magis distendendo, uno in loco perruperat, intraque pericardium se effuderat.

Art. 21. loc. cit. Truncus denique aortæ ipsius ab eo loco unde primum ad superiora emittit ramum, ad cor usque, et maculis distinctus, et sulcis erat exaratus; sed his ita confusis, et abnormibus, ut nihil nisi perpetua, et summa hujus faciei inæqualitas appareret. Sed præter hanc, quædam quasi exulceratio occurrebat, duobus circiter supra semilunares valvulas digitis, qua arteria dexteriores spectat, et posteriores; in eaque exulceratione tria, quatuorve erant profundiora foramina, sed forma angulosa potius quam rotunda. Ab iis obliqui canaliculi extrorsum acti ad exteriorem aortæ laminam pervenerant, multoque humori crassiorem factam, in ejusque rubedinis medio lacerata demum lamina, sanguis sibi viam in pericardium fecerat per foramen interioris simile et ejusdem fere magnitudinis.

Loc. cit. epist. xxvii, art. 28. Arteria magna rupta intervallo digiti circiter transversa. Et ruptio quidem non erat magna; sed prope ipsam, et circa omnem aortæ basem, vetus quasi sugillatio apparebat e nigro sanguine sub exteriori tunica restitante; quæ sugillatio per universum pulmonem se extendebat, præsertim vero circum majoris arteriæ pulmonaris ramos. Præterea facies interior arteriæ magnæ tota erat prominentiis, et pustulis plena, quarum utræque per ejus omnes, quotquot aperti sunt, ramos pergebant. Manuoir Mém. Physiolog. et pratiq. sur l'Anéurisme, p. 36.

[NOTE, No. 6, p. 85.]

De sed. et caus. morb. epist. vii, art. 9; xxiv, art. 17; xxvii, art. 2, 20; xl, art. 24; xxiv, art. 16; xi, art. 15. Advers. anat. ii, animad. 41, epist. xxiii, art. 4.—Tota enim aortæ interior facies a corde ad eam usque sedem, quæ orificiis subest arteriarum emulgentium, si cum reliqua usque ad divisionem in iliacas conferretur, manifesto ab naturali, quæ in hac erat albedine, et lævitate ad flavedinem inclinabat, et inæqualitatem, quæ oculis paulo attentius defixis in eo esse videbatur, quod alibi in leves prominentias se at-



tollerent, alibi in exiguos sinus subsideret. Verum hæc omnio superficie tenus; nisi quod paulo supra valvulas arcum erat spatiolum, ubi quasi ab erosione non nihil excavata, divisas quæ suberant fibras ostendebat. In vicinia autem arteriarum emulgentium, lamella intima leviter admoto ungue nullo negotio abradebatur.

Epist. xlv, art. 23. Incisa arteria magna, et sanguine, quo non carebat effuso, ostendit tota interiore facie a corde ad romos, saltem usque ad emulgentes, particulas quasdam albidiores, et lineas nonnihil extantes; præterea non eo solum, quo modo dicebam tractu, sed et alibi, quantum ex dissec-tis quibusdam ejus ramis agnovimus, intimam tunicam facile adeo a proxima sejungendam, ut levissimam scalpelli frictionem magna ejus frustula sequerentur.

Epist. xi, art. 15. Præterea in quodam arteriæ magnæ trunculo concretionem, inter tunicas ex flava materia, media inter mollem atque friabilem, parvam illam quidem, sed ita introrsum extuberantem reperimus, ut trunculi cavum angustius faceret.

Epist. iv, art. 21. Arteriæ magnæ truncus a corde ad eum usque locum unde incipit descendere, exterius quidem facie inæquali, non secus ac si in tuborum modum quodantenus hic illic assurgeret; sed interius toto eo spatio nihil nisi superficies rugosa, vix duobus locis, iisque exiguis, indicia nondum maturæ ossificationis.

Epist. xviii, art. 2. Cum enim ab iliacis usque intus esset magnis albidis maculis, incohamentis videlicet futuræ ossificationis ita variegata, ut paucis, parvisque locis secundum naturam se haberet—quo toto tractu lucida intus erat arteria, et inæquali pluribus in locis superficie, eo toto quem modo dicebam tractu, ea potissimum duritie fuit, ut vi etiam magna adacto cultro vix posset discindi, apparente in sectionibus substantia inter cartilaginis, et ligamenti naturam media.

[NOTE, No. 7, p. 85.]

Opusc. Patholog. obs. xxii. In fæmina aorta continuo ubi ex corde prodiit amplissima fuit, ut ambitus quinque



unciarum, et duarum linearum esset. In ea dilatatione, quem aorta sedes vertebrae nunc vicina terminabat, plurimum fuit quasi ulcerum, cum membrana interior arteriae in eminentes, fluctuantesque cristas mutata esset, undique lacera, et discerpta.

Obs. xxiii. In ipsa arteria multae squamae albae, callosae, puri quasi plenae intercurrerunt, quales supra descripsimus.

Obs. xlvii. Ego vero cum ante aliquot annos adeo frequentes osseas laminas repererim, tandem in viri arteria aorta callosas passim, et flavescentes sedes observari, quae versus ipsius vasis cavitatem convexae imminebant; eas aperui; nam membrana interna integra adhuc claudebantur; reperi succum flavum in cellulosa secundam arteriae clam effusum, quae inter musculares fibras et intimam tunicam est. Mollis succus erat, pultaceus, non dissimilis ejus qui in atheromate reperitur.—In universum in sanguine materies est apta producendo ossi, quae adeo frequentur in cellulosa spatium internum, interque convexam superficiem membranae intimae arteriarum, concavamque membranae musculosae extremitatem effunditur, et caseosa primo, inde callosa, quasi coriacea, demum osseae squamae sit simillima. Elem. Physiolog. t. viii, p. 316.

[NOTE, No. 8, p. 85.]

De Aneurismat. part ii, § 62. Id tamen admiratione, et animadversione simul dignum videtur, spuria nimirum aneurysmata frequentiora esse quam plerique medicorum censeant, ceu iteratae ostendunt cadaverum incisiones. Quam multos profecto ex forti apoplexia protinus ereptos assidue conquerimur, eosque vere apoplecticos occubuisse dictitamus: attamen dissecto nonnunquam cadavere, nullum in nervis et cerebro, aliisque partibus vitium deprehensum fuit, sed arteriae alicujus disciscio, omniumque tunicarum ejusdem erosio reperta est.



## [NOTE, No. 9, p. 85.]

Institut. Medic. t. iv, cap. 11. Sæpe arteriarum tunicæ aut ab acri humore ibi deposito, aut acri ex stagnatione facto intus eroduntur, et sanguinem in pericardium, in pectoris cavum, aut alia proxima loca tam lacerata, ac erosa quam rupta effundunt. Interdum intus osseæ evadunt, aut ossiis squamis obducuntur.

## [NOTE, No. 10, p. 85.]

Journal. de Med. de. Paris, t. lxxi, p. 141. La crosse de l'aorte considerablement dilatée; sa face interne noirâtre, et fongueuse avec pluseiurs petits tubercules assez durs, enduite d'un sang grumeleux à demi coagulé, et tres noir. L'épaisseur des parties de cette artère était au moins de deux lignes, et en grande partie formée par la tunique interne, dont le tissu mollasse, et tumefié était de couleur purpurin, ce qui la faisait aisément distinguer de la tunique charnue, qui la recouvre, laquelle était saine, et d'un gris jaunatre, c'est à dire, de couleur ordinaire.

## [NOTE, No. 11, p. 109.]

A very rare case of extravasated blood, proceeding, according to all appearances, from the minute arterial extremities, or more probably from the weakened, lacerated, or ulcerated veins, was observed by Lamorier, in a Spanish pilgrim about 70 years of age, who had from his birth had a bloody tumor in the right arm, which extended from the shoulder to the fingers. Mémoires de la Société de Montpellier, t. 1, pag. 245. Cette extrémité était noirâtre tirant en quelques endroits sur la couleur livide; elle n'avait par-tout guère plus de la moitié de son volume naturel; elle était inégale, mais sans dureté; on n'y appercevait aucune battement, et lorsqu'on la pressait avec le doigt, on sentait la meme resistance que l'on eprouve lorsqu'on manie une rate de veau, ou de



mouton distendue par le souffle. D'ailleurs, cette partie ne fût jamais douloureuse, et les mouvements n'en furent jamais interrompûs. Lorsq' on piquait le malade avec une epingle, en quelques endroits, que ce fût de l'épaule, du bras et de l'avant bras, ou de la main à la profondeur d'un demi ligne, le sang dardait à la distance d'environ deux pieds sans le secours d'aucune ligature, et il jaillissait pendant une, ou deux minutes. Lorsque le malade élevait le bras sur la tête, on voyait sur le champ se former une tumeur considerable sur l'omoplate, et sur le grand pectoral, après y avoir vû descendre à travers la peau le sang depuis les doigts, la main, l'avant bras et le bras, et à mesure que ces deux tumeurs se formaient, la main, l'avant bras, et le bras perdoient environ le deux tiers de leur volume.——J'ouvrais la peau pour voir la substance des muscles, et je ne trouvais par tout que de filaments entremêlés de vesicules tres dilatés, qui communiquaient les unes aux autres, par de pores tres sensibles. La substance de ces muscles approchait beaucoup de celle de Placenta; mais beaucoup plus de celle d'une rate de veau, ou de mouton bien distendue par le souffle. Les os de cette partie n'avaient guere plus de la moitié de leur volume naturel; leur figure était irreguliere; leur surface inégal, et leur substance spongieuse.

This fact, although rare, is not the only one of the kind. Marc. Aurel. Severinus de nov. observatis abs. cap. vii, de abs. sanguifluis, has not only recorded the history of a case very similar to the preceding, but he has likewise given a drawing of it; and it is singular, that the subject of this observation was likewise a Spaniard. In speaking of tumors formed by extravasated blood, this author adds, *Sed istos omnes facile superat casus Hispani cujusdam, gracili, adustoque habitu hominis, cui brachium ad summum humerum, et anteriorem thoracem parte quæ alas spectat tam nimium extumuerat, tam ample distentum fuerat, ut confectus dolore perierit. Cujus turgoris immanitatem videre medici et chirurgi omnes sacri incurabilium domicili; qui tumor sic nobis opificum manu representatus est.*

Monteggia mentions, in the first part of his *Institutioni Chirurgiche*, cap. vii, § 238, that he had several times seen this disease, and he remarks, that if it is opened, the patient



has a very short time to live ; for, he is either exhausted by the hemorrhage, or, if the internal concretions close up the vessels, he dies from the gangrenous putridity, which inevitably comes on after the tumor is opened.

I have only once, in the course of my practice, had an opportunity of observing this bloody tumor, which occurred in a priest about fifty years of age, robust, and much addicted to drinking strong liquors. The tumor, about the size of a calf's head, occupied the left axilla, and extended upon the corresponding side of the breast above the clavicle, and over the scapula, nearly as is seen in the figure which Severinus has given of it. The tumor had an elasticity similar to that of the white swellings of the joints, and was not very painful to the touch. It appeared intersected here and there by veins very much enlarged, and the skin at the middle of the tumor, for a certain space, was livid, and gave a sensation of a deep seated fluctuation, without there being, however, the smallest pulsation in it. The pains which this patient suffered day and night were very severe ; and in the latter periods of his life, he could only lie upon his back, and with his left arm removed as far as possible from his breast. Opium in large doses no longer procured him any relief. All that I could gather with regard to the commencement of this dreadful disease was, that in the month of December 1802, without any evident cause, he felt some pain under the left axilla, which gradually increased more and more. On examining the part, a tumor was discovered of a moderate size, not at all prominent, and without any change of colour of the skin. This tumor was considered to be of a glandular nature, and as such, treated with resolvents and emollients, in order to bring it to suppuration. In spite of this, the tumor went on increasing rapidly, and in the course of five months, acquired the size I have just mentioned.

To assure myself more fully of the nature of this disease, and in order to try to afford the patient some relief, I perforated the tumor with a small trocar, at the point where the skin was livid, and the fluctuation most evident. About three ounces of black blood were discharged by the canula, with a small quantity of glutinous yellow serum. This was done to-



wards evening, and the patient passed an unusually quiet night; but the day after, the pains recurred with as much violence as before. In the course of a few weeks after the puncture, the integuments mortified at the place where they were livid, and having burst, there protruded through them a substance similar to a sponge dipped in blood, from which there was a constant oozing of black blood, mixed with glutinous serum. The patient was for some days after the rupture of the tumor, free from pain; but his strength being quite exhausted, he soon after expired.

On dissecting his body, I removed that large portion of sponge dipped in blood, which presented itself through the burst skin, which substance, on being thrown into water, floated like the lungs. Having washed this substance, I perceived distinctly that it was only the cellular substance of the axilla distended with blood, and similar in some measure to that of the human placenta. I injected water into the large brachial trunks as they pass out of the neck between the *scaleni* muscles. The water rushed out by an innumerable series of orifices of vessels, evidently corroded, and overflowed everywhere the bottom and sides of the tumor, as if it came from a watering pan, and nearly as is seen in making the injection of the uterus of a woman who has died soon after the extraction of the placenta. There was no indurated gland in the axilla, or in its vicinity. Some of the upper ribs were bare, but not carious. It appears, that in this terrible disease, there happens on a large scale, what we see occur in miniature in those livid spots on the legs, and on other parts of the body of scorbutic persons, formed by an oozing of blood, or rupture of the small arterial and venous vessels.

Besides the upper part of the arm, and in the vicinity of the axilla and scapula, these bloody tumors are likewise formed within the glands of the neck, especially in the thyroid gland, as also within the gland of the mamma affected with scrofula, of which I have lately seen an example in a lady, in whom the right mamma affected with scrofula, acquired in a short time, the circumference of two hands breadth and an half, from blood effused into the cavity of the mammary gland. These bloody tumors are dis-



tinguished from aneurism by this ; that they are not pulsating ; that an extravasation of fluid may be immediately discovered in them ; that they are surrounded by livid varicose veins ; and that they are of a dark colour, where the skin covering them is transparent:

[NOTE, No. 12, p. 255.]

Observ. et Reflex. sur la ligature des principales artères, pag. 75. L'opération de l'anéurisme par incision du sac exige une incision des tégumens de la longueur de six à sept pouces ; on pénètre ensuite à la profondeur quelquefois de trois pouces dans la tissu cellulaire entre les muscles, en tâchant d'éviter le nerf crural. Dans tout ce trajet on peut entéresser des petites artères qui se distribuent aux muscles, et qu'on doit lier par prudence. Le sac ouvert, on en extrait les caillots et le sang qu'il contient ; à différentes reprises, on est dans la nécessité de laver, nettoyer, et frotter pour ainsi dire, tout l'étendue de cette énorme surface intérieure, soit avec la charpie, soit avec une éponge fine ; des aides sont obligés d'écarter les lèvres de la plaie pour que l'opérateur voie le fond, et par conséquent de les tirailler. La plaie nettoyée, la crevasse artérielle est à decouvert ; ce n'est qu'en molestant la partie, que l'on serre les ligatures à cette profondeur. Si quelques collatérales se rendent dans l'artère entre les deux ligatures, ainsi que l'a remarqué Molinelli, comme on est dans l'incertitude sur le point de l'artère qui fournisse le sang, on est obligé de faire une compression dans la crevasse artérielle, ou d'y porter des astringens ou des caustiques. La longueur de l'opération, les douleurs qu'éprouve le malade, l'érétisme, le gonflement inflammatoire qui suit de près, et qui est proportionné à l'étendue du désordre ; ensuite un dégorgement abondant, une grande suppuration, le contact de l'air dans une plaie de cette étendue, les petites foyers purulens qui résultent de sa profondeur, et du rapprochement de ses lèvres, les sinus qu'on a bien de la peine à tarir, les gonflements subsequens auxquels ils donnent lieu, quelquefois les absces consecutifs ; enfin la longueur de la cure, déterminée quelquefois par la cavité



qui résulte de la saillie des tendons flechisseurs, quand la jambe ne peut être alongée; telles sont les suites assez ordinaires de la méthode d'opérer par l'incision du sac aneurismal.

[NOTE, No. 13, p. 260.]

Journal de Méd. de Paris, t. 71, pag. 444. L'injection avait aussi pénétré dans les artères articulaires tant supérieurs que inférieurs, ainsi que dans les artères jumelles, mais elle n'avait pu y passer, que des ramifications dans les branches, et dans les troncs; ceuxci n'étoient injectés que jusqu'à une certaine distance de l'artère poplitée, d'ou elles partent, et dans laquelle l'injection n'avait pu pénétrer jusqu'à leur origine; de sorte qu'elles n'avaient été que des moyens de communication, ou des intermedes entre les branches qui descendent de la femorale et des perforantes, et celles des tibiales, tant antérieurs, que postérieurs, qui remontent sur l'articulation. On trouva dans l'épaisseur du nerf sciatique une artère assez grosse, qui avait été aussi injectée, et qui établissait une anastomose, entre l'artère sciatique et la tibiale postérieure. On peut aisément se former l'image de ce qui se passa lorsque le cours du sang n'eut plus lieu à travers la tumeur, et se rendre raison comment cette révolution a pu se faire sans que aucun trouble, ni aucun accident en aient été les suites.

[NOTE, No. 13, p. 272.]

Suite de la nouvelle méthode de guérir les fistules lacrymales. Turin, 1714, pag. 251. We must at least allow, that if, on this subject, Anel had derived instructions from Guillemeau and Thevenin, he has made a very important and useful change in the method practised by these two surgeons; for they, as appears from their works, as well as Aetius and Paulus, after having applied the ligature to the artery, two or three fingers-breadth above the tumor, opened the aneurismal sac, while Anel left it untouched; in which consists the simplicity of the operation, and the uti-



lity of the discovery. And, in order to remove all controversy on this point of surgical history, I shall here transcribe what the two just quoted authors have written on the subject.

Guillemeau, *Oeuvres de Chirurgie*, chap. vi, p. 698, relating the history of the cure of an aneurism in the bend of the arm, in the son of a M. de Belleville, enters into the detail of this operation in the following words.—Premièrement je remarquay sur le cuir l'artère en la superieure partie de l'avant-bras ainsi qu'elle descend de l'aisselle, au ply du bras, trois doigts au dessus d'iceluy, et en ceste mesme partie suivant ce que j'avais remarqué, je fis une simple incision en long au cuir, qui estait comme separé à l'endroit de l'artère, ou elle se rencontre au toucher, et l'ayant ainsi découverte, passay par-dessous, avec une grosse esguille courbe, une petite fisselle desliée; puis avec icelle fisselle je liai la dite artère au double noeud; cela fait, tout le sang grouméle, et autre caillé contenu en la tumeur fust osté, puis les parois de la tumeur furent lavées avec eau de vie, en laquelle j'avois fait dissoudre un peu d'ægiptiac pour corriger la pourriture jà commencée en ceste partie: un mois apres le malade fut parfaitement guery sans estre aucunement estropié de son bras: de quoy j'ay esté infiniment esmerveillé. Si en quelque autre partie exterieure, il se presente au chirurgien pareil anéurisme il peut seurement découvrir le corps de l'artère vers sa racine et partie superieure, et la lier de mesme façon, sans autre ceremonie.

Thevenin *Oeuvres*, chap. xxxviii, p. 55. La cure ne reussit pas qu'aux petits anéurismes, ou les artères sont faciles à lier, et non en celles qui sont à la gorge, aixelles, aynes, et autres parties ou il y a de grands vaisseaux. Si l'anéurisme est petit, il se peut lier en la mesme façon que la varice, qui est qu'ayant premièrement decouvert le vaisseau par une incision à la peau, on fait une ligature au dessus et au dessous de l'anéurisme, et on coupe l'artère au milieu. Les autres se contentent après avoir decouvert l'artère de la lier seulement au dessus, puis l'ouvrir avec la lancette pour la degorger; par exemple, si elle est au ply du coude, on fait une incision en long en la partie interieure, et inferieure du bras, à l'endroit ou passe l'artère; laquelle estant decouverte, on la lie de mesme que la varice; puis



on ouvre l'anéurisme pour evacuer le sang contenu dans la tumeur; si non, on le peut lier en cette sorte. Le malade estant situé commodément, on passe une grande aiguille enfilée d'une bonne ficelle au travers de bras, en la partie intérieure et moyenne de l' humerus proche l'os, embrassant tous les vaisseaux, et ayant mis une bonne compresse large et epaisse de quatre doigts entre l'entrée et la sortie de l'aiguille, on serre fortement la ficelle; par ce moyen la ligature ne fait si grande douleur, et ne peut couper les parties qu'elle embrasse. Après, on fend en long la tumeur qui est au ply du coude, tant pour la dégorgier que pour decouvrir le vaisseau, lequel on lie, et coupe à la façon de la varice, puis on oste la ligature qui est au-dessus.

Besides, it is evident, that the two authors just mentioned, in treating of aneurism, have only copied *Ætius* and *Paulus of Ægina*; and it clearly appears, that *Thevenin* proposed sometimes two, sometimes three operations in one for the cure of this disease, while *Anel* practised one only.

[NOTE, No. 15, p. 368.]

*Journal de Chirurg.* t. ii, p. 36. Un enfant de six ans de la Paroisse de belon près la Ferté-Vidame eut en 1784, l'artère brachiale ouverte dans une saignée de la veine basilique. L'hémorrhagie fût considerable, et le chirurgien eut beaucoup de peine à l'arreter par la compression. Le sang fût cependant contenu; mais il se forma à l'endroit de la saignée une tumeur qui avait un pouce et demi de diamètre. On la traita comme un absces ordinaire avec de maturatifs, et l'on se proposait d'en faire l'ouverture lorsque je fus consulté pour la première fois, et que je reconnus tous les signes d'un anéurisme faux. Mon opinion effraya les parents qui appellèrent différentes personnes de l'art, dont le jugement fut le meme, et qui opinèrent pour l'opération. Choisi pour la faire, je m'en defendis en faisant envisager à la famille les avantages, et les inconveniens qui pouvaient en résulter. J'annonçai qu'il serait toujours temps d'en venir à ce moyen extrême, et je conseillai la compression, en assurant qu'il n'y avait aucune danger de la tenter.



L'inquiétude des parents les determina à conduire leur enfant à Paris, ou l'on consulta à l'Hotel Dieu M. Ferrant, qui decida l'operation d'une manière très pressante. On pris ensuite l'avis de M. Louis, qui se rangea du mien. On eût de nouveau recours à moi. Je plaçai un point d'appui en forme de coussin et un peu fêrme à la partie posterieure du bras et de l'avant bras. J'appliquai plusieurs compresses graduées sur la tumeur, et fis un bendage semblable à celui de la saignée, à cela près, que les tours de bande etaient plus multipliés. Le malade porta ce bendage pendant un an. La tumeur à cette epoque avait entièrement disparu, et l'enfant, qui a maintenant quinze à seize ans, jouit de la meilleure santé. Son bras est de la meme force que l'autre, et conserve la meme grosseur.

## [NOTE 16, p. 400.]

Comment. in Aphorism. Boerhaav. t. i, § 161. Vulnerabatur in pago vicino inter pocula rusticus cultro sub axilla, et discissa arteria axillari incredibili impetu exiliebat sanguis: brevi post concidens credebatur expirasse, et pro mortuo deponebatur. Sequenti die dum accedebant illi, qui publica auctoritate occisorum cadavera examinare debebant, ut de vulnerum lethalitate ad judices ordinarios renunciarent, invenerunt aliquem adhuc calorem circa thoracem; cæterum nulla vitæ signa: differebant scrutari vulnus per aliquot horas: incepit sensim parum reffocillari vulneratus, quem tamen brevi perituum existimabant omnes. Sed præter omnium opinionem, diu in summa tali debilitate manens vulneratus evasit tandem. Brachium autem illius lateris aridum, et exsuccum penitus mumie fere instar tota vita mansit. Si ergo in tam magna arteria et cordi adeo vicina potuit fieri consolidatio, apparet non tam facile desperandum esse, etiam in periculossissimis vulneribus arteriarum: modo nullis stimulis vinosis, vel cardiacis augeatur debilis vita in talibus vulneratis forte plures evaderent.



## [NOTE 17, p. 403.]

Tetr. iv, serm. iii, cap. 10. At vero quod in cubiti cavitae sit aneurysma hoc modo per chirurgiam aggredimur. Primum arteriam superne ab ala ad cubitum per internam brachii partem delatam signamus: deinde in eadem interna brachii parte simplicem sectionem, tribus aut quatuor digitis infra alam per longitudinem facimus, ubi maxime ad tactum arteria occurrit, atque ea paulatim denudata, deinceps incumbentia corpuscula sensim excoriamus, ac separamus, et ipsam arteriam cæco uncino attractam duobus fili vinculis probe adstringimus, mediamque inter duo vincula dissecamus, et sectionem polline thuris explemus, ac linimentis inditis congruas deligationes adhibemus. Postea vero tumorem in cubiti cavitae, sive flexura securi secamus, nihil amplius verentes sanguinis eruptionem. Tunc grumis evacuatis, arteriam unde sanguis prodiit perquirimus, et repertam uncino attractam, sicut priorem constringimus, ac dissecamus, rursusque thuris polline sectione expleta, puris generationem procuramus.

## [NOTE, No. 18, p. 405.]

De re med. lib. iv, cap. 37. Quæ vero in extremis partibus, et artubus, aut in capite contingunt aneurysmata, ea sic aggredimur. Si ex apertione tumor factus est, sectionem rectam in longitudinem cuti infligimus; deinde disparatis per hamulos labiis, veluti in vasorum exsectione dicebamus, excoriantes, et per apta ad hoc instrumenta a membranis repurgantes, arteriam nudabimus, et acus sub ea transmissione, et per duo fila deligatione usi, ubi prius intermediam arteriæ partem scalpello punxerimus, et quod continetur in ea evacuaverimus, suppurante curatione utemur, donec deligata filorum vincula excident. Si vero ex arteriæ ruptione deligatio facta est, totum ipsum quantum ejus fieri potest uno cum cute digitis prehendere oportet: deinde infra apprehensam acu traicere, quæ duplicem filum



trahat, et post trajectionem, ipsam duplicis fili ansam dissecare, et sic per duo fila tumorem hac illac deligare, veluti de staphilomate dicebamus. Quod si timor sit ne fila dilabantur, etiam alia acus transmittenda est, quæ priorem per totum premat, similiterque duplex filum trahat, et, ansa dissecta, sic per quatuor fila tumorem deligabimus, aut aperto juxta medium tumore, per excretionem ejus quod in ipso continetur, cutem amputamus, et quod deligatum est relicto, et splenio vino et olio imbuto imposito, curatione per linimenta utemur.

[NOTE, No. 19, p. 426.]

De cubiti flexuræ aneurysm. obs. iii, iv. Cicatricem igitur ego in basilicæ venæ sede longitudinalem conspiciens, ibidem quoque tuberculum deprehendi spherica donatum figura, cerasumque sua magnitudine adæquans, quod dolore omnino vacuum cum esset, nativoque partis colore præditum, vehementer tamen pulsabat, et sibilo quodam satis violento comitabatur. Tuberculum hoc, si digitis comprimeretur, illico evanescebat, sed illico pariter sui juris factum revertebatur. Satis quoque tactus beneficio patebat memoratum sibilum fieri a sanguine, qui per angustum foramen in tuberculi centrum evibraretur.

In speaking of the second case : accuratam hujus postremi descriptionem omittam ; hoc tantum adnotans Morellum hunc xii, kal. Feb. ex sinistro brachio sanguinem sibi detrahi jussisse ; ad hæc, intervallo septuaginta quinque dierum, non valde increvisse tuberculum aneurysmaticum, quum magnitudinem hactenus non eccederet phaseoli, ac denique basilicam venam factam fuisse sensibilibiter varicosam ; in reliquis enim omnibus hoc aneurysma supra descriptum tuberculum penitus referebat. Negari sane non potest duo hæc allata aneurysmata a duabus differre eorundem speciebus, ad quas post Paulum Eginetam, aneurysmata omnia penes chirurgos redacta sunt. Præter enim memoratum sibilum, ac non naturalem tuberculi pulsationem a brachiali trunco minime dependentem omni modo per solam digitorum pressionem abolitio ejusdem tuberculi,



absque eo quod alibi sanguis tumorem pareret, neque veri, neque falsi aneurismatis ordinarium profecto symptoma fuit. Et revera putandus ne sanguis tam celeriter in eandem arteriam unde prodierat per digitorum pressionem redigi potu-isse? Id autem rationi valde consentaneum non est. Si autem ille se in arteriam non infert, quonam quæso abiturus est? per cellularem ne tunicam diffundetur? minime gentium; nam in eadem se ipsum manifestaret. Ad hæc, quomodo intelligi potest tam parvum intra quinque, et septuaginta dies aneurysmatis incrementum? Quomodo poterit varicosa explicari venæ basilicæ affectio? Qua tandem fieri ratione valuit, ut sanguis intra aneurysma perpetuo fluidus permanserit, neque in duram massam concreverit, ut in omnibus, seu veris seu falsis aneurysmatibus jugiter contingere animadvertimus.

Plurima a me instituta in duobus hisce brachiis experimenta, quæ brevitæ studens silentio prætereo, me impulserunt ut crederem in utroque aneurysmate venæ basilicæ vulnus, vulnusque subjectæ arteriæ brachialis per compressivam cincturam ita invicem in modum anastomoscos coaluisse, ut sanguis e foramine arteriæ prodiens per venæ foramen intra basilicam se recta intulerit, et cum venoso commixtus sanguine breviorum cum eo circulum absolverit. Ea igitur causa cur aneurysma tam lente increverit; cur sanguis in illo fluidus permanserit, et cur sola digitorum pressione illico tuberculum penitus evanuerit. Hæc enim omnino, ni fallor, inde fluxisse putanda sunt quod sanguis in venam statim ingrederetur.

---

As a farther illustration of what the author has said on the subject of internal aneurism, I shall add two cases: the first is an example of the complication of the disease with dilatation, and the second shows the effect of low diet and evacuations in retarding the fatal termination, and is also an example of what is called the spontaneous cure during such treatment.



About the end of February 1817, I was asked by Dr. Spens, physician to the Royal Infirmary, to bleed Mr. G., a French teacher in this place. He was affected with a swelling of the neck, all round, which was very firm and painful, and there was an oblong spot, resembling erysipelas, on the right side of it. His face was also swollen, and his eyes turgid and suffused. He was also affected with dyspnœa, a sense of tightness, or great uneasiness in the upper part of the thorax, which he could not well describe; difficulty of swallowing; frequent cough, headach, and with numbness of the right arm. The dyspnœa and headach, in general, much increased in the horizontal posture. P. about 100, and full.

In a few days the swelling extended down the chest, and pitted on pressure. A puffy swelling, resembling emphysema, appeared on the back of the right hand, with slight swelling of the arm: it went off in a few days.

About the 3d March, both arms became swelled, particularly the right, and for several days he found the swelling vary considerably according to his posture in bed. The scrotum also became greatly distended as in a case of general dropsy. The swelling of the arms increased rapidly, and that of the right to an enormous size. On the night of the 6th it burst at the elbow and wrist; and the cuticle of the scrotum also gave way, and a prodigious quantity of watery fluid was discharged from all these places. General and local bleeding were tried freely at first, with active purging, but without avail. He died on the 8th.

The dissection of the body was performed in presence of Drs. Spens, Rutherford, and Barclay. On laying open the thorax, the integuments were found much loaded with fat, and very thick; serum flowed out from the incisions. The lungs on both sides were sound and collapsed: several pints of dark-coloured fluid in both cavities of the thorax, and about eight ounces of a similar fluid in the pericardium. The heart was very soft, flaccid, and contained scarcely any blood: on cutting into it, the valves were sound. On laying open the aorta, it was found dilated into a very large sac; and on enlarging the incision, the sac was observed to contract, and again to enlarge, so that there were two cavities communicating freely with each other: the contracted ori-



fice into the second sac, was about an inch and half in diameter. The first sac, or the proper cavity of the aorta, contained fluid blood; the second sac was filled with layers of coagulated blood of a lamellated appearance; and the inner surface of the cavity was lined with a redish polypous substance, adhering so firmly to the parietes, that it could not be separated without the use of the knife. The dilatation extended as far as the arteria innominata: after the left subclavian was given off, the aorta resumed its natural size; its inner surface was of a very bright red colour.

I have been unable to obtain any correct account of this patient's state previous to the time when Dr. Spens first saw him. He recollects that Mr. G. mentioned to him, that he had sometimes felt or heard a peculiar noise or sound in the upper part of his chest.

---

## CASE II.

ELIZABETH ANDERSON, aged 40, November 1, 1814, of a slender and delicate make. There is situated immediately at the top of the sternum, betwixt the origin of the sternocleido-mastoidei muscles, a strong pulsating tumor, about the size of a walnut, which beats from 92 to 94 times in a minute, and is synchronous with the pulse at the wrist, which is rather strong. The left carotid artery beats much stronger than the right. The end of the left clavicle, which articulates with the sternum, is raised from its situation; it is very painful to the touch, and the pain extends along it, down the humerus to the elbow-joint of the same side. There is no displacement of the right clavicle; and the pain, though not so severe, goes along it as on the opposite side. She likewise complains of a pain over the sternum. Occasionally during the day she feels a pulsation at the ensiform cartilage of the sternum, which continues only for a minute or two at a time. She has slight difficulty of breathing towards morning; a difficulty in swallowing any thing; slight cough; headach, increased upon lying down in bed; and she feels a stiffness about the mus-



cles of the back of the neck, and is unable to raise her head from the pillow without assistance. She is naturally of a costive habit; seldom has a stool without the assistance of laxatives, which she has been in the habit of taking for some time past. Appetite bad; sleeps little from the pain of the clavicles; catamenia regular; countenance pale and sickly; legs slightly œdematous towards evening.

It is about a year since she first observed this affection, without being able to assign any cause for it. Of late it has increased considerably. Says that she is very weak, and unable for any exertion.

December 20.—Complains of a fulness and severe pain of her head. Tumor is gradually increasing. Ft. V. S. ad  $\text{℥xv}$ . et capiat. Sulph. magnes. cochleare parv. omni mane.

January 13, 1815.—Tumor much larger within these few days, and complains of a strong beating in both the carotids. Complains much of the pain of her head and want of sleep.

Applic. Cucurbit. Nuch. et abstrah. Sanguinis  $\text{℥x}$ .

Cap. Pil. ex opii gr. i omni nocte.

Contin. sal. u. a.

January 25.—A small quantity of blood was obtained by the application of the scarificator and cupping-glasses, which gave but temporary relief to the pain of her head. Two or three days after the cupping it became more severe, and continued so till to-day, when it has abated a little. Tumor seems to increase rapidly in size. Both clavicles are now displaced considerably; and the swallowing is much more difficult of late. Pulse varies from 90 to 100. Appetite much impaired. Countenance very pale.

Contin. Medicament. u. a.

January 30.—Pain of head has been much easier for these few days past; some sleep from the use of an opiate; little difference in the size of the tumor. Both clavicles are considerably removed out of their situation, and very painful to the touch. When she moves her right arm suddenly, she feels something give a jerk under the scapular end of the clavicle. Pulse in general about 100, and pretty strong.

February 12.—Pain of her head continues much the same. The right clavicle is now elevated much above the



left, which was formerly the highest, and is exquisitely painful to the slightest touch of the finger. The tumor seems to be considerably increased; part of the upper triangular portion of the sternum appears to be absorbed. The pulsation of the right subclavian artery is very strong. The difficulty of swallowing is increased, and the difficulty of breathing great, only in the horizontal posture. Appetite very indifferent; belly always slow; P. about 100.

Contin. Sal. et Pil. Opiat. u. a.

March 27.—Since last report her general health has been much improved, till within these eight or ten days, when the symptoms have become more urgent. Externally the tumor is apparently no larger, but rather less perceptible, owing to the rising up of the sternal end of the right clavicle; there is a severe pain extending from it into the axilla, down the back of the arm to the points of the fingers. When this arm remains at rest for any time, the hand falls asleep, (as she expressed it), and she is unable to raise it up to her head without very great difficulty, as if from weakness. There is likewise pain in the other clavicle, and in general over the sternum. The pulse at both wrists is of the same natural strength and the same quickness, beating from 95 to 100 in the minute. Difficulty of swallowing is not increased, and no more difficulty of breathing than formerly. She feels very fatigued after speaking for any time. Pain of head is very severe. Sleeps little; only doses for an hour or two during the night, in consequence of the pains in the clavicle, and in general she takes two grains of solid opium every night. Appetite bad; has had sickness at stomach for some days past; keeps her body open by the use of the salts.

April 3.—Thinks herself better, but the numbness and pain of the right arm are still increasing. The headach is worse; tumor seems to be much the same. The left clavicle appears to be a little more out of its situation, and the arm on this side is now likewise affected with the pain, as likewise the whole arm with weakness. Sleep is very much disturbed. Appetite no worse since last report; P. 88, and of the same strength at both wrists; but the pulsation of the left carotid artery is much stronger than the right.

5th.—Pain of head more severe; other symptoms as before,



Scarcely can sleep any at all. Yesterday forenoon she felt as if a ball came up her throat, which she says almost choked her at the moment; this sensation returned during the night; it gradually went off of its own accord.

9th.—Tumor and most of the other symptoms much the same, excepting the breathing, which has been worse ever since she felt the uneasiness in her throat. She was obliged to walk out last night; and after returning she found her left leg very much swelled from the foot upwards. The right was very little affected. The swelling disappeared during the night. P. 96.

18th.—Has been rather worse for some time. Sternal end of the right clavicle is now almost completely dislocated: by placing the finger on the end of it the articulating cavity can be distinctly felt, filled up by a portion of the tumor, which is easily compressed. Pain is almost intolerable. Still sleeps very ill. Pulse from 96 to 100. Swallowing and breathing are both very difficult.

June 1.—General health improved. There seems to be no further enlargement of the tumor, but the right clavicle is still gradually getting farther out of its situation. Swallows easier. Difficulty of breathing increased. Right arm continues painful and weak. Pain of head rather abated. Belly more regular. Was cupped since last report, without relief to any of the symptoms. Pulse 96.

8th.—Symptoms rather increased again. The tumor occasioned by the elevation of the end of the right clavicle greatly increased since last report, and very painful. For several days past she has complained of pain in swallowing; the difficulty of breathing worse, and much troubled with a dry sonorous cough. Pain of head worse, as well as the pain of the right arm. The pulsating tumor seems to be increased dextrad. The right carotid artery beats very strongly. Appetite pretty good. Sleeps very indifferently. Pulse 106. B. open by the use of laxatives.

12th.—The sternal end of the right clavicle very much elevated from its situation, accompanied with great pain extending over the whole of the shoulder and part of that side of the thorax, down the arm as formerly, which she says is very cold. She has a very troublesome cough, giving the



sensation as if something was sticking in her throat ; her breathing is particularly difficult, so much so that she is under the necessity of continually sitting in the erect posture in bed ; scarcely sleeps any ; head painful ; feet swell towards evening ; perspires very much during the night. P. 102. The pulse of the right arm is evidently stronger than the left. Swallowing still very painful. Appetite failing ; tongue foul ; belly reg. ; countenance pale ; integuments over the tumor slightly inflamed.

19th.—There seems to be a portion of the right clavicle absorbed ; the pulsating tumor projects a considerable way beyond its situation, much resembling the small end of an egg ; ever since last report the extremity of the tumor has been more or less of a yellowish colour ; cough and difficulty of breathing worse ; other symptoms much the same. Cont. Pil. Opii. &c. et Capt. Troch. glycir. cum opio. I. pro re nata.

September 26.—Since last report she has been bled several times, which gave temporary relief to the difficulty of breathing. Pain of the right arm not so severe. There seems to have been very little alteration in the size of the tumor till within these few days, when in the course of 24 hours, her breathing became very difficult, but at that time there was no alteration externally in the tumor. On pressing gently with the fingers above the sternal end of the left clavicle, a small tumor, the size of a gooseberry, with a distinct pulsation corresponding to that of the larger tumor, can be felt, and at this time also there was no discolouration of the integuments : her cough is very distressing to her. P. pretty quick.

To-day, (26th), there is a very great enlargement of the external tumor, and the integuments of the most prominent part are of a yellowish colour ; she can scarcely speak loud enough to be distinctly understood. Countenance pale, and emaciated. Has a great desire to sleep, but is prevented by the cough. She is obliged to sit in the erect posture in bed ; can take no food ; P. 120 ; that of the right arm stronger than that of the left ; B. regular. Utat. M. Pectoral. Oleos.

27th.—Tumor a little larger, and the integuments at the



most prominent part are of a darkish brown colour; other symptoms much the same as yesterday.

28th.—Tumor seems to be increased in every direction. The breathing, swallowing, and speaking, are all performed with the greatest difficulty; however, the integuments are not of such a dark yellow as yesterday. The right clavicle very much pushed forward to-day. Cough excessively troublesome, with a pretty copious expectoration. P. 112; that of the right arm not so strong as it was yesterday: says she feels herself extremely weak.

29th.—Much the same as yesterday. Pulse 120. Lips encrusted with a dark brown fur; still getting weaker.

October 1.—To-day the tumor seems to be decreased externally, and no discolouration of the integuments. Breathing very much affected. P. 120, and weak; that of the right not stronger than the left, but if any thing rather weaker.

6th.—Upon the 3d, 4th, and 5th, there was no alteration of any of the symptoms. To-day she is evidently weaker; and during last night the attendants say that she spoke incoherently; but the breathing is easier, and the cough not so troublesome, with the expectoration more free, some of which was streaked with blood. Tumor still continues to lessen externally. P. 104, and of moderate strength. There is a miliary eruption over the throat and chest. She in general has these parts covered with extra flannel. The pulsation in the tumor is not nearly so strong as it was.

11th.—The right arm is nearly half as small again as the left; at present, the pulse is about 112 in both, and of the same strength. Pulsation in the tumor very weak.

13th.—Is not quite so well to-day. The dyspnœa is worse, and the cough more troublesome. Tumor considerably smaller, but the pulsation stronger. Both the carotids beat very strong, particularly the right. She can swallow liquids pretty well, but can't get over solids. Miliary eruption still observed. P. 140.

She gradually got weaker and weaker till the 22d, when she died, without there being any alteration of the symptoms.



## DISSECTION.

From the aorta at the beginning of the arch, and close to the origin of the arteria anonyma, a tumor was found arising, of the size of a large orange. It contained no fluid blood, but was full of light brown coagula, which by their pressure on the top of the sternum and extremity of the right clavicle, had produced a considerable absorption of them, and had also caused absorption of 5 or 6 of the rings of the trachea, with which they lay in contact. The aorta was very much dilated from the heart to the origin of the aneurism. The corpuscula morgagni were ossified, and a scale of bone, nearly the size of a sixpence, projected through the internal coat near the opening into the tumor. The opening into the tumor was oval, and about the size of a shilling; the edges were quite smooth, and the internal and middle coats could be traced for some lines on the surface of the sac. A coagulum lay hid and inclosed in a sac on the left side of this tumor, and pressed on the articulation of the left clavicle, of which it had caused absorption. It was attached to the arch of the aorta, betwixt the origin of the arteria anonyma and left carotid, by a pedicle about the size of a goose's quill, but no cicatrix whatever, or opening, could be observed in the aorta. The lungs adhered to the pleura costalis on both sides.

In the former edition of this work, I mentioned that several cases had occurred where the iliac artery had been tied with success, and the number of cases, as the author has observed, is now so great, that no well-informed surgeon can hesitate about the safety of tying that artery. It seems, therefore, unnecessary to detail any additional cases on that point.

Only one instance has been communicated to me where the disease returned, in a case of popliteal aneurism, after the ligature of the superficial femoral artery. This singular case was under the care of Dr. Monteath, junior, of Glasgow, to whom I am indebted for the following account.

Glasgow, 27th February, 1819.—“ Charles Urquhart, sawer, put himself under my care, about a year ago, for



the cure of a popliteal aneurism, about the size of a large orange, which had commenced about three months previously to that period. In the presence of several of my professional friends, I applied a single ligature on the femoral artery, in the upper third of the thigh. The pulsation of the tumor instantly ceased; the wound healed by the first intention, except where kept open by the ligature, which came away on the 30th day. By this time the tumor was diminished to one-half of its original size, and in other two months was as completely removed as any aneurismal tumor I have ever seen; a small hard knot only remaining, in which no pulsation whatever could be felt. The limb was affected with the usual debility arising from diminished activity of circulation, for five or six months after the operation."

" Three months ago, to my great astonishment, this patient called on me, and informed me that the tumor had reappeared, and it was rather larger in size than a plum. The pulsation in it was distinct, though not so strong as in ordinary aneurism. For a month I merely observed the progress of this very uncommon circumstance; and as the size of the tumor and strength of the pulsation increased progressively, I tried the effect of bandaging the limb, with a compress over the tumor, allowing the patient to walk about. Some weeks trial of this convinced me of its inadequacy to produce a cure. I therefore recommended strict confinement, with still more perfect bandaging. To this he consented; but as I had told him that the cure might be tedious, he begged leave of me to visit some relations in Edinburgh, before submitting to the necessary confinement; at which time you saw him in the Royal Infirmary.\*

" On his return to Glasgow, I confined him to bed; bled him once freely, and put him on a spare diet. A thick compress was placed over the tumor, and the limb was firmly bandaged by a roller from the toes to the groin. Three days trial of very firm bandaging and confinement seemed

\* The tumor was then as large as a magnum plum, pulsating very strongly. The femoral artery pulsated strongly as far as the cicatrix, but no pulsation could be felt below that place. Compressing the artery firmly above the cicatrix stopped the pulsation in the tumor.



to produce no good effect; a tourniquet was therefore applied over the tumor, and screwed as tight as he could bear it. In half an hour it became insupportable, causing violent irritation and tingling in the leg and foot. It was accordingly removed; and from the moment he was not sensible of the pulsation. Next day I was agreeably surprised to find, on examination, the tumor without pulse, and its contents firm from coagulation. From that day the tumor has been daily diminishing in bulk, and is now reduced one half. He however continues the bandage, and I shall direct him to persevere in its use for some time. An ultimate cure in this way can hardly be doubted."

I am happy to be enabled to confirm the justness of Dr. Monteath's conclusions. In a letter of the 28th August, he informs me that he had recently seen Urquhart, who is very grateful for his cure. The limb is nearly as strong as the other, and there is less of the small induration which usually remains in the ham after the cure of popliteal aneurism.

In this case the disease had returned, probably owing to some large branch going off above the place where the ligature had been applied, communicating with the popliteal artery in the vicinity of the aneurismal tumor. Had the compression failed, Dr. Monteath expressed his intention of passing a ligature round the inguinal or external iliac artery, which would surely have affected a cure, as the circulation through the limb would have been thus more effectually retarded, than by the ligature of the superficial femoral artery.

In treating of popliteal aneurism of very great size, and of long standing, with the suspicion of a diseased state of the bones forming the joint of the knee, the author has pointed out the great difficulty in determining what line of practice ought to be followed. He is decidedly against amputation of the thigh, and appears inclined to recommend the amputation at the knee-joint as the best practice to be employed, premising the ligature of the femoral artery in the upper third of the thigh. In a matter of so great difficulty and importance, the history of the following case cannot fail to be interesting, where amputation of the thigh was performed with success.



JAMES JACKSON, aged 46, a labourer, was admitted into the Royal Infirmary, under the care of Mr. Gillespie, on the 31st January 1815, on account of a very large, firm, and slightly elastic tumor, occupying the left ham, and swelling out on each side of the knee-joint, which measures 22 inches in circumference. The surface of the swelling is smooth. It extends upwards and downwards to a great extent, but is quite defined. He complains of constant pain in it, much increased by pressure, at times more severe than usual, and is then attended with a sensation of throbbing. The knee-joint is in a half-bent position ; and the slightest attempt to move it, excites most excruciating pain. The integuments covering the tumor are slightly œdematous, and a little inflamed on the fibular side. No pulsation can be felt in the swelling : though its bulk cannot be diminished by pressure on the superficial femoral artery, yet it is rendered evidently less tense. The foot and leg are very much swollen, and pit on pressure ; the heat of the limb is natural. Pulse 112 ; rather weak ; tongue foul ; bowels slow ; appetite good.

About six months ago, in the morning, subsequently to having exerted himself very much the preceding day, in carrying stones to a building, he felt a severe pain in the left ham, and on examination, observed a tumor about the size of a small plum, with very evident pulsation. It continued to increase in size, with pulsation at times so evident as to be felt through the bed-clothes, until it attained its present size, when the pulsation was no longer perceptible. There are several cicatrices on the neck ; he never had any venereal complaint, and never took mercury. Previous to his admission into the hospital, poultices had been applied to the tumor.

February 2.—The inflammation on the tumor having become much darker, and the integuments very thin, by the advice of a full consultation of the surgeons, Mr. Gillespie amputated the thigh, rather higher than usual, above the knee : about eighteen vessels were secured ; the patient bore the operation well, which was rather tedious from the number of vessels to be secured. On being put to bed he had a large opiate. About seven o'clock P. M. hæmorrhage



occurred, and on opening out the stump, a large vessel was discovered bleeding freely: It was secured, and the stump allowed to remain open for about an hour, when all hæmorrhage ceased, and the stump was again dressed in the usual way.

On the 6th February the stump was dressed; a considerable part adhered; discharge profuse and tinged with blood. On the 7th several ligatures came away, and the discharge was improved: the patient was allowed a bit of beef steak and four ounces of wine. On the 11th, pulse 96; stump looking well; only four ligatures remain; his wine increased to twelve ounces. The 18th all the ligatures discharged; every thing going on favourably; and on the 17th April, the stump was quite healed, and the patient left the hospital.

#### DISSECTION OF THE LEG.

On dissecting the leg, the tumor on the posterior part of the knee-joint was found covered by a strong tendinous aponeurosis, in a very tense state. Beneath this was found an aneurismal sac of great size. It occupied the whole cavity of the ham, bounded on each side by the muscles forming the hamstrings, which were stretched and much wasted. The tumor extended for three or four inches above the extremity of the thigh-bone, and downwards on the calf of the leg to the extremity of the fleshy belly of the gastrocnemii muscles, which formed the posterior parietes of the sac, towards its lower part, and were reduced to a very thin layer by absorption. The sac contained a great quantity of fibrine coagulated, in layers, part of it adhering to the internal surface of the sac, particularly at the upper part, and also large clots of recently coagulated blood. The femoral artery was traced to the sac at the upper extremity, and was found entering it at the upper part, or rather towards the posterior aspect. It communicated with the sac by an open mouth, to which the parietes of the sac were attached, and formed a continuous surface. Below this, within the sac, there were no traces of the artery. At the lower part of the sac, and also rather towards the posterior



surface, about six inches from the orifice, at the upper part, the popliteal artery was found communicating with the sac in a similar manner; but a conical plug, of about one-third of an inch in length, was in the orifice of the artery. The coats of the artery were sound; several large branches were given off from it before entering the sac, and also immediately after emerging from it. The popliteal artery gave off the anterior tibial about two inches after emerging from the sac. The popliteal nerve was found passing over the posterior surface of the sac in a stretched state, and adhering to the surrounding parts, in consequence of the inflammation. The large vein was also found at the upper part, passing over the posterior surface of the sac, below the nerve. On tracing it, it was found to become completely closed when it reached the middle of the tumor, and below this no remains of it could be found. The saphena vein was also found running along the surface of the sac, on the inner belly of the gastrocnemius externus. It was thickened in its course; and at the ham its cavity was found to be firmly closed by adhesion. On putting the fingers to the bottom of the sac, the bones were not felt denuded; but on dissecting off the sac, the posterior surface of the head of the tibia, and the triangular space of the posterior part of the femur, were found denuded of periosteum, and affected by absorption. Contiguous to the absorbed part, both on the tibia and femur, the periosteum was thickened, and slight osseous deposition had commenced.

---

*The following Account of a Dissection of the Femoral Artery is extracted from a Memoir of M. Deschamps, inserted in the Mémoires présentées à l'institut des sciences, &c. vol. i, p. 251, an. 1805. See p. 207 and 265.*

GALIMART, a hackney-coachman, 34 years of age, of a good constitution, enjoying in other respects perfect health, on the 7th April 1792, was operated on for a considerable



aneurism of the popliteal artery, according to Mr. Hunter's method in the Hospital la Charité. Excepting a slight hemorrhage that occurred on the ninth day, which was quickly stopped, the patient did not experience any accident: he left the hospital completely cured on the 17th May following, the fiftieth day from the operation. The 21st June, on being presented to the academy of surgery, he enjoyed the perfect motion of his knee; the remains of the tumor were scarcely perceptible to the touch; a pulsation was observed in an artery running on the left side of the knee, near the place where the tumor had been situated: at last he resumed his employment as a coachman.

Galimart died in the Hospital la Charité, the 20th October 1799, in consequence of a pulmonary complaint, nearly eight years after the operation had been performed on the popliteal artery.

The following appearances presented themselves in the limb injected, with great attention, from the left internal iliac artery: the arteries were dissected and carefully preserved.

1. The profunda, the size of which is nearly equal to that of the femoral artery, came off at two inches from the crural arch, and gave off the external circumflex artery, about a finger's-breadth from its origin.

2. The femoral and popliteal arteries preserved their natural diameter as far as the tumor, except at the middle of the femoral artery, the place of the ligature, where it was obliterated for the space of two inches and an half: the artery, at this place, did not appear to have been divided by the ligature, as it really was, and the divided parts were not retracted; but, at the time of the dissection, a ligamentous shapeless mass was observed. Below this obliteration, two branches came off from the femoral artery, at an angle rather less than a right angle. The external branch, about a line and a half in diameter, was given off immediately below the obliteration, and ran about seven lines, in which space it received a branch which arose from the femoral artery immediately above its obliteration; it then divided into two branches, the one of which anastomosed with a branch, arising from the same place, which before joining this branch, received another communicating with the femoral artery, two



inches and an half higher up ; and another, proceeding from above downwards, anastomosed with a branch of the external circumflex.

The other branch given off by the femoral artery, was about  $2\frac{1}{4}$  lines in diameter, situated on the inner side, lower down than the other, about an inch below the obliteration : it ran about the distance of seven or eight lines, and anastomosed with a principal branch of the profunda femoral artery, which appeared either to come from the first perforant, or to be the continuation of the profunda, and with a twig of the inferior branch of the external circumflex, which descending between the rectus and triceps muscles of the thigh, divides into two branches, connected at the lower part by an arch, from the anterior part of which a branch goes off communicating with the superior articular arteries.

The sciatic nerve, in its whole length, was accompanied by several very tortuous arteries of considerable size, arising from the first and second perforant, the superior of which was nearly as large as the radial artery.

3. With regard to the tumor situated immediately above the condyles, it was reduced to the size of a very small olive : it appeared to be formed of a ligamentous solid substance : the popliteal artery, at that place, was obliterated for the space of an inch and seven lines. Above this obliteration, the external articular and several internal articular arteries, of considerable size, came off, among which, a large branch descended on the inner side of the knee, and joined the popliteal artery below the tumor, and before its division into the posterior tibial and peroneal arteries. The other superior internal articular arteries anastomosed with branches of the circumflex, especially with a descending branch of the profunda, in the substance of the middle part of the triceps muscle. The other superior articular arteries, both internal and external, communicated, by means of very numerous anastomoses, with the inferior articular arteries, which, by several ramifications, but principally by two trunks, much enlarged in diameter, communicated with the popliteal artery below the obliteration.

Several branches arising from the popliteal artery, above its obliteration, descended in the substance of the parietes of



the old sac, so that, on dissection, they at first appeared to pass through the tumor: these branches afterwards anastomosed with those ramifying on the substance of the parietes of the sac. A branch was observed, nearly a line in diameter, which, turning behind the sciatic vessels and nerve, formed a tortuous arch upon the external condyle of the femur, then proceeded obliquely from below upwards, and anastomosed with the inferior branch given off by the femoral artery below its obliteration, where it has been mentioned it was joined by a branch which seemed to be the continuation of the profunda.

4. The arterial branches which are given off by the trunk of the internal iliac artery, did not appear to be either more numerous, or of larger size, than in the natural state; as their anastomoses with the branches of the profunda did not present any thing worthy of remark, they were not preserved.

From these anatomical observations, M. Deschamps remarks, we may conclude, 1. That the course of the blood, in this subject, was only interrupted in the femoral artery for the space of  $2\frac{1}{2}$  inches; that below the obstruction the arterial canal resumed its natural diameter; that the blood was conveyed into it by two enlarged collateral branches. 2. That the blood which passed into the femoral artery below the obstruction, passing from a small into a large canal, lost its impulsive motion; that this blood circulating slowly in the lower part of the femoral artery, had no longer any action either upon the aneurismal sac, which necessarily from the first ceased to increase in bulk, nor upon the mass of blood contained in it, which then, being left at rest, of necessity coagulated. 3. That the blood continued to circulate through the superior articular into the inferior articular arteries, to pass into the popliteal artery below the aneurismal sac. 4. That the constriction of the femoral artery had stopped for a short time, but did not interrupt the circulation in the part below the sac. 5. That it is not so much to the quantity of blood which reaches the tumor that it owes its enlargement, as to the impulse which the sac receives from the column of blood which strikes it every instant.



The two following cases are inserted, to point out an occurrence by which the success of the operation for popliteal aneurism is occasionally prevented, and to shew that the gangrene sometimes arises from the collateral arteries not having dilated sufficiently to carry on the circulation independent of the principal trunk. This unfortunate accident is most frequently observed to take place when the soft parts surrounding the knee-joint have been affected with violent inflammation, in consequence of the excessive distention caused by the great size of the aneurismal tumor. The account of the first case, I received from my friend Mr. Langmore, who had the more immediate direction of the patient.

JOHN WILLIAMS, seaman, 45 years of age, about six months before he applied for assistance at the London hospital, discovered a small tumor in his ham, which gradually increased to the size of an egg; it gave him no pain, till about a week previous to his being admitted into the hospital. He was operated on for aneurism,\* Wednesday, July 24, 1804, by Mr. Blizard; after the operation, being put to bed, he took gr. xxx tinct. opii; was free from pain, the leg was well covered with wool. Slept little during that night and next day, but was perfectly easy; his leg was warm, but he complained of slight coldness in his toes; towards evening, however, of that day, the coldness of the toes went off. Friday, four stools, after taking magnes. sulph. ʒj. In the evening, toes being again rather cold, they were rubbed with the hand, and additional wool applied. Saturday morning, one stool, slept well. Sunday, foot and toes rather colder, very good night. Monday, foot cold; discolouration of the integuments, particularly about the ankle. †Mist. salin. omitted; ordered to be fomented, and the beer poultice applied to the

\* The artery was tied below the under and inner edge of the sartorius muscle.

† He took the mist. salin. from the first of his coming into the hospital, which, after the operation, was continued.



foot and leg every eight hours, and half a pint of wine in twenty-four hours, and common diet.\* Tuesday, mortification spreading, fomentation and poultice continued every six hours, ordered lbj of wine in twenty-four hours, with porter at his dinner, and tinct. opii gtt. 40 hora somni; this day the wound was opened for the first time; it was healed except where the ligatures were. Knee rubbed with lint. camphoræ; had rather a bad night. Wednesday, a pretty good night, mortification spreading. Pulse during the whole of this time regular, and very little increased in frequency; at 12 o'clock took pulv. jalapii ℥j, which procured two stools. Thursday, an indifferent night; no stool; tinct. opii increased ten drops; pulse 100. Friday morning, one stool; had a good night, mortification not spreading, pulse 140, and very small; but towards evening more full and regular; ordered decoct. pulv. et tinct. cinchonæ cum conf. aromat. Saturday, limb much the same; tongue clean; pulse 100; had a good night, no stool. Sunday, indifferent night; one stool; limb the same; pulse 106. Monday, pretty good night, tongue clean, pulse rather quicker. Tuesday morning, pulse 170, very bad night, no stool; in the evening pulse 140. Wednesday, pulse 120; took pulv. jalapii ℥j, after which he had four stools. Thursday, mortified parts beginning to separate; good night; pulse 90, and regular. Friday, had a good night; pulse good; limb the same; one stool; ligatures came away. Saturday and Sunday, remained much the same. Monday, one stool, very good night; pulse regular. Tuesday morning, very indifferent night, pulse 120, and fluttering; at noon more regular; evening, pulse 98, one stool.

Wednesday, August 14.—Three weeks from the first operation, mortified parts having considerably separated, amputation above the knee was performed by Mr. Blizard; after the operation he was perfectly easy; took 50 drops of tinct. opii; in the evening free from pain, pulse good. From this time till September 9, 26 days after the second operation, he continued mending, when an abscess was discovered under the fascia of the same thigh, which contained a

\* Before this, he was on low diet.



considerable quantity of matter. From this time he began to sink, and died six days after.

FRANCIS BALLON,\* 54 years of age, a grenadier in the regiment of Winning, was admitted into the royal Hospital of la Charité at Berlin, on account of a popliteal aneurism in the right ham, on the 1st April 1804. On his admission, the disease had already advanced so far as to threaten to burst. The swelling in the ham extended about eight inches in length, and was rather larger than an ostrich's egg. On compressing the trunk of the crural artery below Poupart's ligament, the aneurism diminished about one-third, and filled itself immediately on the pressure being removed. The skin covering the aneurism was of a dark red colour, and at the part where the tumor came to a point, uncommonly thin and shining. The affected limb had no motion at the knee-joint; and any attempt to move it excited most excruciating pain; and the patient had not been able for four months past to make any use of the limb. In other respects there was no remarkable change of the affected limb below the aneurism. The general health of the patient was not very unfavourable, if we except a slight degree of fever, with quickness of pulse, towards evening.

The patient mentioned, that, about two years before, he had had the misfortune to receive a blow from the pole of a carriage below the ham, and that he had felt a severe pain in that part for a long time, and at last observed a swelling about the size of a walnut. In September last, before going to parade, he struck the outside of this knee with his hand, to dust off some powder that had fallen on his gaiter, upon which a pain suddenly arose in that ham, and he immediately perceived a swelling there; on account of which he was admitted into the regimental hospital.

M. Mursinna, the surgeon-general, saw this patient on the 1st April, and resolved to try the operation for aneurism according to Mr. Hunter's method, which was performed on the seventh.

\* Extracted from Mursinna's *Neues Journal für die Chirurgie, &c.* Drittes Stuck, 1805.



Two hours after the operation, the leg, as high as the knee, was cold, and evidently swelled. The patient complained of pain at the place of the ligature, and was restless for two hours more, when the upper part of the calf of the leg became warm. He took ten drops of the tinct. opii crocata, and these symptoms soon after abated; and the same dose was repeated about seven o'clock.

On the third day the pulse was still full, hard, and frequent; the heat of his skin was moderate; the leg, as far as the ankle-joint, was warm; but the foot was cold, though not without feeling; the skin of the foot was shrivelled, and formed small folds. The patient felt a burning pain at the place of the ligature extending over the whole wound. Soon after the supervention of these pains, an equable heat was diffused over all the limb, which came to a moderate height, and about mid-day was attended with a gentle moisture. Towards evening the folds of the skin of the foot disappeared, and the natural warmth was observed to be returning; the foot retained its natural colour, and was not painful to the touch; but the toes were still shrunk, though not without feeling. On pressing the veins with the finger, the under part swelled, which showed that the circulation went on, though no pulsation could be felt in the arteries.

The patient was more uneasy on the night between the 11th and 12th April; the pain, in particular, of the affected limb increased very much, and extended upwards to the abdomen along the course of the blood-vessels; the pulse at the same time was small and quick, and the heat very great. A dose of eight drops of the tinct. of opium quickly removed these symptoms; the patient slept quietly for an hour, and drank his coffee with a good appetite at 5 a. m.

In the morning he had a more severe attack of pain in the thigh; but a dose of the tinct. of opium again procured an abatement of these symptoms, and by degrees they entirely disappeared, except a burning sensation which began in the knee, and extended to the sole of the foot. The wound in the thigh was covered with healthy pus, having been dressed for two days preceding with a pledgit of mild ointment.



The aneurism remained the same as it was before the operation.

The patient went on very well till the 19th April. All the toes, except the little one, were extended; and the skin covering them and the foot was of natural colour, and warm. But towards evening of this day the back of the foot began to swell, and the colour of the skin became darker than before. The temperature of the extremity was increased at this place, especially where the toes join the metatarsal bones.

Friction with a spirituous liniment was repeated every hour, and the limb fomented with a decoction of chamomile and arnica flowers.

On the morning of the following day, after a very uneasy night from the pains chiefly round the knee, the top of the foot was observed to be of a deep purple colour, and covered with small vesicles filled with lymph.

This place was not rubbed any more, but merely fomented with cloths dipped in the same mixture warmed; the friction, however, and fomentation, were continued over the rest of the limb.

On account of these symptoms, the patient was ordered to take a spoonful of an aromatic infusion of bark every hour; and on the pains returning, he took fifteen drops of a mixture of equal parts of tinct. opii. and ether. sulph. The posture of the limb was frequently changed, to prevent, if possible, the increase of the gangrene; but notwithstanding this, on the evening of the twenty-first it passed into sphacelus, and extended, although slowly, as far as the tarsus. It was quite superficial, as was evident from the appearance and the feeling of the toes remaining unchanged.

23d.—As the patient nauseated the bark, and had rejected it once, it was omitted, and a spoonful of the following mixture given every hour.

R Æther. Sulph. ʒij.

Syrup. Simp. ʒij.

Aq. Menth. Pip. ʒviij.

Tinct. Cinnam. ʒiij. m.

As Professor Mursinna, in examining the aneurismal tu-



mor, conceived that there was matter in it, a deep fluctuation being felt, he plunged a lancet into the swelling. No matter, however, was discharged, not even fluid blood. Two clots of a coagulum were pressed with difficulty out of the wound after it had been enlarged. As much of the grumous blood was evacuated as possible, to give the joint more freedom, and to assist the circulation, as Professor Mursinna thought that the gangrene of the skin of the foot was to be ascribed to the pressure of the tumor. The gangrene was stationary. This wound was filled with a little charpee dipped in equal parts of camphorated spirit of wine and oil of turpentine, and covered with a pledgit of digestive ointment, retained by slips of adhesive plaster. The wound in the thigh was healing rapidly. The leg was now fomented with dry warm cloths, and it was occasionally wrapt in very warm woollen cloths. The foot was dressed as before.

25th.—The dressings were renewed; and on removing the plasters from the aneurismal tumor in the ham, a quantity of ichorous matter burst out, after which nearly twice as much coagulated polypous blood was pressed out. The lips of the wound were quite flaccid, and the knee-joint collapsed; but nevertheless it still continued very painful when moved, and the pain shooting from it to the abdomen and foot was not abated. The same dressings were applied as the day before. The ligature of the femoral artery came away. This wound was much smaller, and the discharge from it was healthy.

26th.—The gangrene of the foot had increased considerably, and not in the same relation as formerly. A great quantity of acrid fetid ichor flowed from the ham. On dressing it, the articular surfaces of the knee-joint could be distinctly felt bare, and they were discovered to be rough in several places. On moving the knee gently, which was attended with great pain, nearly a cupful of cheesy-like matter was discharged. The fever now began, especially towards night, to suffer an evident exacerbation, with a small, quick, contracted pulse, dry skin, great heat, distressing thirst, and restlessness. The appetite was still good; and



on the fever remitting, the patient slept quietly for some hours daily ; and he was not so much emaciated.

27th to 28th.—No change. To day the patient vomited as he was about to take his mixture, which was therefore omitted, and he only took the tinct. opii when the pains were very severe. The gangrene had extended to the joint of the foot, but did not affect the toes ; and a line of separation was observed to be formed. About 2 p. m. the patient had a severe cold fit, which lasted nearly half an hour, and was followed by a dry heat, and at last by sweating. These symptoms altogether continued about two hours, after which the patient slept quietly for five hours, and was much refreshed.

29th.—Had passed a tolerable night ; in the morning had profuse sweatings, after which he felt much weaker. The separation of the gangrenous part was more evident, and a tolerably consistent matter was discharged. All the dressings were continued. About one o'clock p. m. the patient had a severe feverish attack, which had the same course as the preceding day ; but all the symptoms were more severe, and of longer duration. The sweating also was very profuse and clammy, and during it the extremities were cold. The patient's strength began to sink ; his eye was languid and sunk ; a diarrhæa and sopor came on ; his appetite failed.

30th.—The feverish fit came on about ten, and lasted till five o'clock, and returned at eight in the evening, with a short cold shivering. The diarrhæa increased very much, the symptoms of sopor were greater, his appetite was quite gone, and the wounds discharged unhealthy matter. There could be no hope of the patient's recovery.

1st May.—Subsultus tendinum and hickup came on alternately, the stupor increased, the extremities were cold, the skin was swelled, and covered with a clammy sweat, and the breathing very laborious. The edges of the wound of the knee-joint and of the gangrened spot became discoloured and very foul. The sopor passed into stupor, fæces and urine voided involuntarily, the pulse became small and



intermitting, the eyes closed, and he died the 3d May at six o'clock.

### DISSECTION.

THE limb was injected from the iliac artery the day after the patient's death. The superficial femoral artery was filled with the wax both above and below the ligature, as far as the aneurism. The place where the ligature was applied was completely cicatrized. It was found that the injection had passed into the femoral artery by the articular arteries of the external condyle of the femur, which communicated freely with it, and were very much enlarged. The popliteal artery below the aneurism, or the dilated part, which was about two inches in length, was not filled with the injection. The gangrenous suppuration during the last days of the patient's life had caused a great destruction of the neighbouring parts, and after his death the corruption had increased very much. The profunda femoral artery, and all its branches, were very much dilated, and filled with wax. By means of a branch of this artery, which descends to the patella, and the large branch which supplies the vastus externus muscle, uniting together within that muscle, and afterwards coming out at the outer edge of the ligament of the patella, a communication was formed with the anterior tibial artery. But although this communicating artery was a line and a half in diameter, none of the injection had passed into it or any of the vessels of the leg. The branch supplying the vastus externus at its entrance into that muscle was about the size of a goose's quill, but before it had reached the patella, it had diminished nearly two-thirds in diameter.

On examining the knee-joint, the articulating surfaces of the tibia and fibula, and also of the femur and patella, were found carious. The caries extended about three inches above the joint on the posterior surface of the femur, and a still greater portion of the tibia and fibula were destroyed; and there could be no doubt of the caries having existed before the operation. None of the vessels of the glutæi muscles were unusually dilated.



*Mr. Keate's Case of Axillary Aneurism, see p. 400.*

MR. KEATE, surgeon-general to the army, in the *London Med. Review and Magazine* for 1801, has given the account of a case of aneurism in the axilla, successfully treated by the ligature of the subclavian artery. The patient, 25 years of age, was a soldier in the 29th foot. In October 1799, he was wounded in the hand by a musket-ball, and about five weeks after the accident, three of his fingers were amputated. On the 18th March 1800, the stumps were not healed; the arm was tumefied; matter formed repeatedly near the wrist, which, when evacuated, did not diminish the swelling, but in succession occupied several parts of the arm, and was attended with an incompressible hardness. The pulse could not be felt. At length a circumscribed tumor was observed in the axilla, which at first was scarcely distinguishable from the surrounding tumefaction: it soon became more prominent, and a strong pulsation was felt in it. In a few days, the apex of the tumor was so thin, that the stream of blood could be distinctly felt to come against the sac *per saltum*. The pulsation suddenly disappeared; the tumor became hard, and continued to enlarge. In about a fortnight after the pulsation was first observed, the tumor burst, and a small quantity of arterial blood was discharged; but the hemorrhage was suppressed by compression for a few days, when it recurred, and was stopped by the assistant-surgeon compressing the subclavian artery against the first rib.

‘ In this state,’ Mr. Keate remarks, ‘ I saw the patient, and, however bad the prospect, I determined upon taking up the artery above the diseased and ruptured part, in its passage over the first rib. Accordingly, I made an incision obliquely downwards; divided the fibres of the pectoral muscle that lay in my way; and when I came to the artery, passed a curved blunt-pointed silver needle armed double, as I conceived under the artery, and tied two of the ends. After a careful examination, finding that the artery pulsated below the ligature, I determined on passing another ligature



higher up, and nearer to the clavicle : I therefore passed the needle deeper, evidently including the artery.'

In a few days after the operation, the swelling of the arm began to subside, the wounds suppurated, and the ligatures came away with the dressings. The arm afterwards recovered its feeling, and the patient regained, in a great measure, the entire motion of the shoulder and elbow joints ; that of the wrist had been lost before the operation.

Mr. White of Manchester, in the 4th volume of the *London Medical Journal*, relates the case of a Captain M——, who had the axillary artery divided by a stab of a sword at the lower edge of the pectoral muscle. He immediately fainted from the profuse hemorrhage. An attempt was made to secure the artery, by passing a crooked needle under it ; but without success : a needle was then passed on each side of the divided artery, bringing both ends of the ligature through the skin, a short distance above the wound, inclosing a good deal of substance. On tying this ligature, the bleeding was stopped. The patient recovered gradually from his fainting ; the arm was cold, and no pulsation could be felt in it. On the third day, the arm was perfectly warm, and the veins were observed to be turgid with blood ; but on the fourth day, gangrene attacked the shoulder ; and he died on the evening of that day. On dissection, the axillary artery was found to be completely divided below the anterior circumflex artery of the humerus. The ligature had secured the end of the divided artery, and included three of the nerves. The vein was also wounded, but not included in the ligature.

When an aneurism occurs in the commencement of the axillary artery, it is necessary to tie the subclavian, one of the most serious operations in surgery, especially if the tumor has attained a large size, and has occasioned great displacement of the surrounding parts. Mr. Ramsden succeeded in tying the subclavian artery, although the clavicle was thrust considerably upwards. Sir William Blizard tied the subclavian artery, but the patient survived the operation only four days, although it was performed without difficulty.



The most interesting and important cases of the operation of tying the subclavian artery, are those related by Dr. Colles of Dublin.\* In the first case, the artery was tied, before it reaches the *scaleni* muscles. The tumor was in the right subclavian artery, extending from the sternal origin of the *sterno-mastoid* muscle along the clavicle, a little beyond the arch of that bone. It rose nearly two inches above the clavicle, of a conical form, the apex of the cone being situated at the outer edge of the *sterno-mastoid* muscle; the patient's general health was good, except a slight uneasiness he complained of in his chest.

The operation was performed with great skill by Dr. Colles, and after a very tedious and patient dissection, it was found that the aneurismal tumor extended so far as only to leave about a quarter of an inch of the artery in a sound state. On this the ligature was applied. Much difficulty was met with in passing it round the artery, and the pleura was supposed to be slightly wounded. Before tightening the ligature, the breathing of the patient had become laboured, and he complained much of an oppression at his heart. These symptoms increased to such an alarming degree, that it was thought prudent to leave the ligature so loose as not to constrict the artery. The distressing symptoms continued after the wound was dressed. On the following days, these symptoms were relieved by repeated bleedings and diluents. On the fourth day, he was seized with a rigor, which lasted ten minutes: his pulse and breathing were not affected by it; the wound was then dressed, and the ligature on the artery firmly tied, as the pulsation of the radial artery ceased. The patient did not seem to suffer much from the operation. After this the patient appeared to be doing well, when, on the morning of the ninth day, he took a sudden turn to the worse, appeared as if strangling, complained of his heart, and said there was some one pulling a cord round his neck. He became delirious, then lay insensible, his breathing very laboured, and he expired in nine hours after the unfavourable change came on. On dissection, the aorta was found diseased, and the disease extended into the subclavian, leaving

\* Ed. Med. and Surg. Journal, January 1815.



only a quarter of an inch of the artery sound, on which the ligature had been applied.

In the third case related by Dr. Colles, the artery was tied after it passed through the *scaleni* muscles. In this case, no particular difficulty occurred in tying the artery. No change was observable in the actions of the heart or respiration, and the patient felt no particular pain or sensation in the limb on tying the artery. In a very short time after the patient was laid in bed, he became restless, with a desire of constantly changing his posture; and his distress at first was similar to what is observed after amputation. But the symptoms gradually increased, and the second day he had a shivering followed by a hot fit, during which he became so outrageous, that he required two strong men to hold him. Mortification afterwards rapidly followed, and he died early on the morning of the fifth day. There was no unusual appearance of the heart or large vessels. The aneurism was nearly as large as a pullet's egg, and had reached nearly to the place where the ligature was applied. The artery immediately above the ligature was thrown into folds and furrows, which would seem to be the inevitable effects of tying an artery of so great a size. On removing the ligature, and slitting up the artery, its internal coat was found ruptured by the ligature, only at one part, to the extent of about one-fourth of its circumference. Through the remainder of the circle, the internal surface of the artery presented a white line, obviously produced by the tightening of the ligature. Two very small portions of coagulated lymph were found immediately above the ligature. The trunk of the artery below the ligature was rather small. The branches of the subclavian artery were not at all enlarged.

Dr. Post of New York, in September 1817, succeeded in curing a case of aneurism extending high up into the axilla, by the ligature of the subclavian artery above the clavicle. After the operation, the parts covering the aneurismal tumor became very thin, and burst on the eighth day, discharging some ounces of coagulated blood. On the tenth,



there was a similar discharge of four ounces of grumous blood, followed by the complete disappearance of all swelling of the part. On the eighteenth day, the ligature came away with the dressings. In four days more the wound was nearly healed. The tumor had entirely disappeared. The pulsation in the artery at the wrist was distinctly felt. The patient was daily recovering the use of his arm when he went home.

*Mr. J. Bell's Case of Gluteal Aneurism, see p. 407.*

A POOR man, a leech-catcher, from the north country, fell on the long-pointed scissars used in his trade, which entered his hip opposite to the place of the sciatic notch, where the gluteal artery comes out of the pelvis. The artery was wounded by the point of the scissars; a profuse hemorrhage ensued; and the patient fainted. The external wound was easily closed; the blood, however, continued to ooze out from the divided artery, and, in the space of six weeks, when he came into the hospital here, had formed a tumor of a very large size; the thigh was contracted; the ham bent; and the whole limb cold, benumbed, and useless.

The tumor, from having acquired so great a size, had lost the usual characters of aneurism: no pulsation could be felt in it. As some uncertainty prevailed with regard to the nature of the tumor, a consultation was called; and it was resolved that a small incision should be made into the tumor, to ascertain the nature of its contents; if it was found to contain matter, that the sac should be laid open; if blood, then it was to be considered as an aneurism, and treated accordingly.

An incision was therefore made into the tumor, and the sac was opened with the point of the knife, and a great quantity of coagulated blood was suddenly discharged. The opening was enlarged, and the clots of blood evacuated till the florid fluid blood began to flow out. The operator then enlarged the incision upwards and downwards; the whole of the clots were cleared out; and the fluid arterial blood



rushed forth with such impetuosity, that the patient fainted, his lips and face became livid, no pulsation could be felt at the wrist, and he was supposed to have expired.

Mr. Bell then enlarged his incision still farther, and thrusting his hand to the bottom of the wound, felt the artery beat under his finger; and the lips of the incision being kept separated by the assistants, he passed a ligature round the artery, and tied it above the wound. The artery had been cut completely across. The wound was dressed in the usual manner, and the patient put to bed in the operation room, for he was so much exhausted, that it was judged unsafe to remove him. He passed his fæces and urine involuntarily for some days after the operation, and was long in a very feeble state. However in the course of seven months, he was completely recovered; he was able to resume his trade; the contraction of his leg was removed; he could walk perfectly well, and enjoyed good health.

A case similar to the preceding, occurred to Dr. Jeffrey of Glasgow; but owing to the obstinacy of the friends of the patient, the operation was too long delayed; the tumor burst while the patient was at stool, and he immediately expired.



## EXPLANATION OF THE PLATES.

---

### PLATE I.

- a*, A posterior view of the thoracic aorta, or of the side next to the spine. The external cellular sheath being removed from this artery, shews its proper fibrous or muscular coat.
- b c*, The emulgent arteries.
- d d d*, The portion of the pleura which covers the anterior surface of the thoracic aorta.
- e e e e*, The cellular substance unusually thickened, which lies behind the pleura, and surrounds the thoracic aorta.
- f f f f f*, This cellular substance converted into the sac of the aneurism.
- g g*, Rupture of the posterior side of the aorta. At the edge of the rupture is seen the termination of the fibrous layers of the muscular coat of the thoracic aorta.

### PLATE II.—FIGURE I.

- a*, Femoral aneurism situated in the lower part of the thigh, in the vicinity of the place where the femoral artery descends into the cavity of the ham.
- b*, Popliteal aneurism.
- c*, Superficial femoral artery.
- d*, Portion of the popliteal artery between the two aneurisms.
- e*, Continuation of the popliteal artery.
- f f f f*, The external cellular sheath of the femoral and popliteal arteries, which contributed to the formation of both of the aneurismal sacs.
- g g g g*, Portions of the femoral and popliteal arteries covered by their proper muscular coat. See chap. vi, § 19.



## FIGURE II.

- a a*, The left humeral artery at the bend of the arm.
- b*, A small dark-coloured tumor situated on the external and somewhat posterior part of the humeral artery, about the size of a filbert, enveloped, and attached to the artery by means of the cellular substance surrounding the artery.
- c c*, A portion of the cellular substance, which after the manner of a sheath surrounded the humeral artery.
- d*, The ulnar artery.
- e*, The radial artery.
- f*, The recurrent radial artery.

## FIGURE III.

- a a*, The humeral artery opened longitudinally on its anterior surface.
- b*, The small tumor enveloped and attached to the artery.
- c*, Cicatrix of the internal membrane of the artery.
- d*, Radial artery
- e*, The ulnar artery.
- f*, Recurrent radial artery.

## FIGURE IV.

- a a*, The humeral artery.
- b b*, A portion of the cellular sheath of the artery.
- c c*, A small sac formed by the cellular substance covering the artery externally. This sac was thickened and firm, and resembled the sac of an aneurism.
- d*, A small pit pointing out the place of the wound made by the lancet. The bottom of this pit was closed up by a substance partly cartilaginous, partly earthy.
- e*, The ulnar artery.
- f*, The radial artery.
- g*, The recurrent radial artery.



FIGURE V.

*aa*, The lamellated coagulum of blood which was found within the small tumor or sac. Fig. 2, *b*; fig. 4, *cc*.

*bb*, This coagulum, divided by an incision, is observed to be formed of concentric layers of the crassamentum, and of the fibrous substance of the blood. The fibrine, distinguished from the crassamentum by its whitish colour, terminated in a point, and filled up the pit left by the wound made by the lancet. Fig. 4, *a*; fig. 3, *c*.







## INDEX.

---

### A.

*A***BSCESS** sometimes occurs after the operation in the thigh, 286.

*Acrell's* case of aneurism of the internal carotid, 409.

*Acrell*, opinion of, with regard to the timely operating in popliteal aneurism, 249.

*Ælius's* method of tying the brachial artery, 295.

—— mode of operating for the brachial aneurism, 405.

*Anel* performed the cure of a brachial aneurism, 272.

——'s mode of operating for the cure of brachial aneurism, 384.

*Antrobus's*, Mr. case of amputation without hemorrhage, 304.

*Aorta*, aneurism of the, sometimes accompanied by dilatation, 55, 503.

———, 97, 101.

———, figures of, 103, 104, 105, 106.

———, Burns' account of, 115.

———, Hodgson's account of, 115.

———, obliteration of the arch of the, observed by Paris, 50.

——— ruptured within the pericardium, 82, 83.

———, steatomatous tumors of the, 50.

———, thickening and constriction of the arch of the, 50.

*Arnaud's*, Mr. case of John Parker, 132.

———, theory of, with regard to the cure of aneurism, 383.

*Artery*, cellular sheath of the, 69.

———, effects of injecting air into the, 71.

———, rupture of the coats of the, always met with in aneurism, 75, 81.

*Arteries*, predisposing causes of the ulceration of the, 89.

———, diseases of the coats of the, 90.

*Articular* arteries beat strongly after tying the femoral artery, 231.

*Auricular artery*, aneurism of the, 200.



## Index.

- Axillary artery*, operation for tying the, 402.  
——— tied by M. Desault and Pelletan, 401.  
———, cases of a wound of the, 400, 412.  
——— *aneurism*, Mr. Keate's case of, 400, *note*, 413, 527.  
———, of long standing, operation for the, 404.  
———, Chamberlain's case of, 414.

## B.

- Baillie's*, Dr. case of obliteration of the femoral artery, 340.  
*Barbette* on the formation of aneurism, 67.  
*Bayford's* case of aneurism of the arteria innominata, 105.  
*Bell's*, Mr. B. opinion with regard to the aneurismal varix, 429.  
——, Mr. J. method of applying the ligature, 296.  
—— case of gluteal aneurism, 531.  
*Bertrandi*, mode of ligature mentioned by, 294.  
*Blizard's*, Mr. case of popliteal aneurism, 519.  
*Blood*, absorption of the, after the ligature of the artery, 273.  
*Bonetus'* cases of ulceration of the heart, 87.  
*Bourdelot's* case of brachial aneurism, 363.  
*Boyer's* case of obliteration of the femoral artery, 207.  
—— case of popliteal aneurism, 157.  
—— dissection of a case of popliteal aneurism cured by the ligature, 264.  
*Brachial aneurism*, description of, 174.  
——, proximate cause of, 181.  
——, from internal causes, very rare, 188.  
——, Flajani's case of, 191.  
——, Dr. Monro's case of spontaneous, 188.  
——, Palletta's case of, 189.  
——, Monteggia's case of, 377, 379.  
——, from a large wound, forms quickly, 362.  
——, cure of, by compression, 362.  
——, case of partial cure of, 372.  
——, by Saviard, 373.  
——, by Foubert, 374.  
——, Desault's bandage for the cure of, 368.  
——, Genga's bandage for the cure of, 365.  
——, Anel's method of cure of, 272.  
——, case of, by Mirault, 272.  
——, mode of operating for the, 384, 387.  
——, Anel's mode of operating for the, 384.



## *Index.*

- Brachial aneurism*, Ætius' and Paulus' operation for, 405, 406.  
——— from a large wound, cautions in operating on, 393.  
——— artery, Deschamps' case of a wound of the, 395.  
———, mode of operating in oblique wounds of the, 398, note.  
*Brambilla's* cases of aneurismal varix cured by compression, 430.  
*Burchall's*, Mr. mode of tying the femoral artery, 293.  
*Burns'* account of aortal aneurism, 115.

## C.

- Causes* producing a rupture of the arteries, 84.  
*Carotid aneurism*, Acrell's case of, 408.  
———, manner of operating for, 417.  
———, Mr. A. Cooper's cases of, 410, note, 416.  
———, case of, by Harderius, 195, 408.  
———, Dr. Piccinelli, 195.  
———, Rumlerus, 195.  
*Carotid artery*, Hebenstreit's case of a wound of the, 409, note.  
*Celsus*, ligature mentioned by, 295.  
*Chopart* found the artery closed at its entrance into the sac, 263.  
———, operation of, causes of its failure, 277.  
*Circulation*, rapidity of the, varies at different ages, 234.  
——— more free in an aneurismatic limb, 232.  
*Clarke's*, Dr. case of inguinal aneurism, 334.  
———, Mr. case of femoral aneurism, 154.  
*Cleghorn's*, Dr. case of an aneurismal varix, 427, 429.  
*Cline's*, Mr. case of obliteration of the vena cava, 20, note.  
*Coats of an artery*, disorganisation of the, prevents the cure of aneurism, 235.  
*Colles'*, Dr. cases of ligature of the subclavian artery, 529.  
*Compression*, manner in which it cures aneurism, 217.  
———, circumstances favourable to its success, 218.  
——— preventing its success, 219.  
———, cases in which it ought to be employed, 221, 222.  
——— not to be left off too soon, 371.  
——— applied to the denuded arteries, 222.  
———, symptoms contraindicating the use of, 369.  
———, Genga's mode of applying, 365.  
——— seldom applicable in popliteal aneurism, 242.



## Index.

- Compression*, mode of applying, in popliteal aneurism, 245.  
———, must not be continued too long, 248.  
——— improper for the cure of femoral aneurism, 319.  
——— employed for the cure of aneurismal varices, 430.  
*Cooper's*, Mr. A. cases of carotid aneurism, 410, *note*, 416.  
*Crell's* case of ossification of the coronary artery, 86.  
*Crural artery*, obliteration of by Baillie, Guattani, Gavina, 22.  
*Cure*, general, of aneurism, 202.  
——, incipient spontaneous, related by Desault, 264.  
——, spontaneous, of aneurism, singular case of, 204.  
—— of aneurism, auxiliary means for the, 237.  
—— by the supervention of gangrene, 213.  
——, causes preventing the, 235, 236.

## D.

- De Haen's* case of aneurism of the external nasal artery, 200.  
*Desault's* bandage for the cure of brachial aneurism, 368.  
—— case of ligature of the axillary artery, 401.  
—— case of popliteal aneurism, 155.  
—— spontaneous cure of popliteal aneurism, 208.  
—— operation, not the same as that of Mr. Hunter, 276.  
*Deschamps'* doctrine of true aneurism, 208.  
—— opinion of, with regard to the obliteration of arteries, 214.  
—— account of the dangers of the old method of operating, 255, and *appendix*, 495.  
—— on the advantages of Mr. Hunter's operation, 261, *note*.  
—— case of a wound of the brachial artery, 395.  
—— case of inguinal aneurism, 342.  
*Diet* of the patient after the operation for aneurism, 284.  
*Diemerbroeck's* account of the causes of aneurism, 67, *note*.  
*Dilatation* not essential to the formation of aneurism, 54.  
*Dionis'* mode of preventing the ligature slipping from the artery, 295, *note*.  
*Dod's*, Dr. P. account of an aneurism of the aorta, 93.

## E.

- Ecchymosis*, the incipient state of an aneurism, 91.



## Index.

*Ecchymosis*, observed by Morgagni and Nicholls, 91.

*Else's* case of extravasation of blood, 109.

### F.

*Femoral aneurism*, cure of, by the incision of the sac, 325.

————— cured by the ligature, 315, 319.

————— and *popliteal aneurism* not preceded by dilatation, 166.

————— *aneurism*, case and dissection of, 150.

————— *artery*, ligature of, first performed by Mr. Hunter, 275.

————— and *popliteal arteries*, brittleness of the coats of, 164.

*Fernelius's* theory of dilatation as the cause of aneurism, 63.

————— refuted by Silvaticus, 64.

*Flajani*, cases of *popliteal aneurism*, 145.

*Forestus* adopted the theory of Fernelius, 64.

*Ford's*, Mr. case of obliteration of the *popliteal artery*, 207.

*Forster's*, Mr. case of *femoral aneurism*, 322.

————— Mr. Thomson, mode of tying the *artery*, 293.

*Foubert's* theory of the general cure of aneurism, 202.

————— cases of *brachial aneurism*, 374, 375.

*Friend's*, Dr. remarks on the subject of aneurism, 68.

*Frontal artery*, case of aneurism of the, 200.

### G.

*Galen's* account of M. Bourdelot's case, 363.

————— used the sponge in the cure of *brachial aneurism*, *ib.*

————— case of a wound of the *brachial artery* in venesection, 364.

*Gangrene* sometimes cures an aneurism, 212.

*Garneri*, observations of, on aneurismal varix, 429.

*Gavina*, case of *inguinal aneurism*, 333.

*Genga*, marks of the *brachial artery* being wounded, 360.

—————, bandage of, described, 365.

*Gluteal artery*, Theden's case of a wound of the, 407, *note*.

—————, Mr. J. Bell's case of a wound of the, 531.

————— *aneurism*, Stevens' case of, 357.

*Gouey*, doctrine of, on the formation of aneurism, 67, *note*.

*Greek and Arabian* physicians only speak of external aneurism, 61.

*Guattani's* theory of the formation of the *brachial aneurism*, 177.

————— on the use of compression in *popliteal aneurism*, 243.



## Index.

- Guattani's* cases of aneurism from a rupture of the artery, 140.  
——— description of the dangers of the old method, 253.  
——— case of aneurism of the palmar arch, 200.  
——— case of aneurism of the tarsus, 201.  
——— case of inguinal aneurism, 333, 338.  
——— case of aneurismal varix cured by compression, 431.  
——— cases of aneurismal varix, 426, *appendix*, 501.  
——— case of steatomatous affection of an artery, 137.  
*Gavina's* case of steatomatous state of the femoral artery, *ib.*  
*Guerin*, objection of, to the ligature of the femoral artery, 263.

## H.

- Hall's*, Mr. case of a wound of the axillary artery, 400.  
*Haller's* experiments on the ligature of arteries, 227, *note*.  
——— experiments on the mesentery of frogs, 266.  
——— observations on the mesentery of frogs, 178.  
——— opinion of, with regard to the ligature of the femoral artery, 229, *note*.  
——— theory of the curative process of aneurism, 203.  
*Harderius'* case of carotid aneurism, 195.  
——— case of carotid aneurism, 408.  
*Heart*, ossification of the, 85, *note*.  
——— cases of ulceration of the, 88.  
——— cases of softening of the, *ib.*  
*Hebenstreits'* case of a wound of the carotid artery, 409, *note*.  
*Hemorrhage*, suppression of, theory of the, 209, *note*.  
———, theory of Petit and Morand, 209.  
———, *secondary*, causes of, 290, 291.  
———, mode of preventing, 291.  
*Hernu's* case of popliteal aneurism, 148.  
*Hildanus'* account of the proximate cause of aneurism, 66.  
——— case of aneurism between the thumb and fore-finger, 201  
*Home's*, Mr. experiments on the formation of aneurism, 180.  
———, Mr. explanation of the renewal of the pulsation, 228, *note*.  
———, Mr. case of femoral aneurism, 153.  
———, Mr. treatment of the wound after the operation, 299.  
*Humeral artery*, trunk of, always wounded in the aneurism at the bend of the arm, 187.  
*Hunter's*, Mr. experiments on the formation of aneurism, 179.  
———, Mr. first proposed the ligature of the femoral artery, 275.  
———, Mr. method of, not proper in every case, 277, *note*.



## Index.

- Hunter's*, Mr. method of, described, 278.  
———'s, Mr. method applicable to the cure of femoral aneurism, 320.  
———, Mr. not acquainted with Anel's operation, 275.  
———, Mr. used four ligatures in his first case, 282.  
———'s, Mr. case of obliteration of the popliteal artery, 207.  
———, Mr. found the artery closed at the entrance of the sac, 263.  
———'s, Dr. William, cases of aneurism of the aorta, 103, 104, *note*.  
———, Dr. W. first accurately described the aneurismal varix, 425.

## I. J.

- Inflammation*, adhesive, causes obliteration of arteries, 215.  
*Inguinal aneurism*, cure of, 327, 341.  
———, operation for, 354.  
*Internal aneurism*, means for retarding the progress of, 238.  
*Intercostal artery*, case of aneurism of the, by Ruisch, 200.  
*Johnstone* on the nature of aneurism, 67, *note*.  
———'s case of softening of the heart, 88.

## K.

- Keate's*, Mr. case of axillary aneurism, 527.  
*Kirkland's* experiments on the arteries, 210.

## L.

- Lacoste's* case of femoral aneurism, 321.  
*La Faye's* opinion with regard to the use of compression, 369.  
*Lancisi*, dissection of an aneurism of the aorta, 92.  
——— on the predisposing causes of ulceration of the arteries, 80.  
*Lassus'* case of aneurismal varix in the ham, 420.  
*Leg*, disarticulation of the, recommended, 302, 304.  
*Ligamentous* expansion in the bend of the arm, 185.  
*Ligature* of arteries as a radical cure of aneurism, 223.  
———, inconveniences attending the use of the, 235.  
———, phenomena subsequent to the use of the, 257.  
——— of the femoral artery, why it ought to be preferred, 258, 260.



## Index.

- Ligature*, mode of, proposed by the author, 281, 288.  
———, mode of applying the, recommended, 295.  
——— of reserve ought not to be employed, 283, 288.  
*Littre* on the constriction of the origin of the aneurism, 76, *note*.

## M.

- Macgill's* operation of a brachial aneurism, 175.  
*Marcott's* description of an aneurism of the aorta, 107.  
*Marks*, supposed, of true and spurious aneurisms, 169.  
*Maunoir's* method of applying the ligature, 296.  
*Mayer's* case of inguinal aneurism, 334.  
*Meckel's* case of thickening of the aorta, 50.  
——— case of ulceration of the aorta, 87.  
*Mirault* on the cure of a brachial aneurism, 272.  
*Molinelli's*, opinion of the formation of brachial aneurism, 175.  
——— case of ligature of the brachial artery, 233.  
——— objections of, to the use of the ligature, 262, *note*.  
——— remarks on the ligature of the nerve along with the artery, 389, *note*.  
———, opinion of, on the use of compression, 370.  
*Monro's*, Dr. senior, theory of the formation of brachial aneurism, 176.  
———, Dr. primus, dissection of Parker's case, 134.  
———'s, Dr. Donald, case of thickening of the femoral artery, 136.  
——— case of John Parker, 132.  
——— case of femoral aneurism, 155.  
*Monteggia's* singular cure of a brachial aneurism, 377.  
——— case of aneurismal varix cured by compression, 431.  
*Monteath's*, Dr. case of popliteal aneurism, 510.  
*Morand's* cases of softening of the heart, 88.  
——— theory of the suppression of hemorrhage, 209.  
——— case of obliteration of the brachial artery from a blow, 211.  
*Morgagni* observed aneurism accompanied with dilatation, 59.  
———'s cases of ruptured aorta within the pericardium, 82.  
——— case of inguinal aneurism, 152.  
——— case of obliterated vena cava, 215, *note*.  
*Morigi*, case of aneurism of the sole of the foot, 311.  
*Muraltus*, objections of, to the doctrine of Sennertus, 68.  
*Mursinna's* case of popliteal aneurism, 521.



## *Index.*

### N.

*Nicholls*, experiments of, on the cellular sheath of the artery, 71.

### O.

*Obliteration* of the artery, only radical cure of aneurism, 205.

———— of the popliteal artery, cases of, 206, 207, 208.

———— of the artery not confined to the place of the ligature,  
226.

———— of the brachial artery from a contusion, 211.

*Occipital artery*, aneurism of, 199, *note*.

*Operation*, steps of Mr. Hunter's, particularly to be attended to,  
288.

### P.

*Paletta's* cases of aneurism of the aorta, 94, 96.

———— cases of femoral and popliteal aneurism, 157, 159, 161.

———— dissection of a popliteal aneurism, 149.

*Palmar arch*, aneurism situated in the, 200.

*Paoli*, Mr. on the spontaneous cure of popliteal aneurism, 207.

*Paris'* case of obliteration of the arch of the aorta, 50.

*Park's*, Mr. case of aneurismal varix, complicated with aneurism,  
434.

*Paulus'* mode of operating for the brachial aneurism, 405, 406.

*Partition* separating the artery from the aneurismal sac, 78, 80.

*Pelletan's* case of ligature of the axillary artery, 401.

*Petit's* theory of the cure of aneurism, 202.

———— diagnosis of true and spurious aneurism, 169, *note*.

———— theory with regard to the clot or couvrecle, 382.

———— theory of the suppression of hemorrhage, 209.

———— case of obliteration of the carotid artery, 207.

*Pharyngeal artery*, rupture of, 201, *note*.

*Physick's*, Dr. case of aneurismal varix complicated with aneurism,  
438.

*Physicians*, Berlin, case of rupture of the aorta, 82.

*Piccinelli's*, Dr. case of carotid aneurism, with dissection, 195.

*Popliteal aneurism*, dissection of, 147.

————, cure of, 241.

————, by compression, 241, 242.

————, by ligature, 249.

————, by the incision of the sac, 250.



## Index.

- Popliteal aneurism*, diminution of, after the operation, 268.  
————— of long standing, new method of operating for, 301.  
————— from a wound, cure of, 299, 300.  
————— artery, case of steatomatous affection of, 137.  
*Post's*, Dr. case of ligature of the subclavian artery, 530.  
*Pott*, Mr. opinion of, with regard to the incision of the aneurism, 255, *note*.  
—————, with regard to the aneurismal varix, 429.  
*Presse artere*, use of, unnecessary, 289.  
*Pulsation* in the sac sometimes recurs after the artery is tied, 228, *note*.

## R.

- Radial artery*, pulsation of the, stopped by the ligature of the brachial artery, 390.  
————— divides sometimes higher up in the humerus, 391.  
————— mode of laying bare the, 439.  
*Riva's*, William, account of aneurism of the aorta, 103.  
*Ruisch's* case of aneurism of the intercostal artery, 200.  
*Rumlerus'* case of carotid aneurism, 195.

## S.

- Sac*, aneurismal, structure of the, 167.  
———, position of the, favours the spontaneous cure, 210.  
———, aneurismal, constriction of the, next to the artery, 76.  
———, pressure of the, causes an absorption of the bones, 108.  
———, absorption of, explained, 110.  
———, aneurismal, rupture of, cause of death, 81.  
*Salius* on the steatomatous state of the arteries, 139, *note*.  
*Sandifort's* case of ulceration of the aorta, 87.  
*Saviard's* case of incomplete cure of a brachial aneurism, 373.  
*Schulzius'* case of aneurism of the colic artery, 85, *note*.  
*Sennertus*, opinion of, 65, *note*, 66.  
————— describes a case of aneurismal varix, 425, *note*.  
*Severinus'* case of femoral aneurism, 308, 325, *note*.  
*Silvaticus*, treatise on aneurism, 62.  
*Sponge* used by Galen to form the compressing bandage, 363.  
————— Mr. White to suppress hemorrhage, *ib*.



## Index.

*Stenzel's* case of steatomatous tumors in the coats of the aorta, 50, 86.

*Stevens' case* of gluteal aneurism, 357.

### T.

*Tarsus*, aneurism of the, by Guattani, 201.

*Temporal artery*, aneurism of, from rupture, 199.

—————, Palletta's case of, *ib.*

*Theden's* case of a wound of the gluteal artery, 407, *note*.

*Theory* of the formation of aneurism, 54, 55.

*Thomson's*, Mr. case of aneurism of the aorta with dilatation, 106.

*Tibial arteries*, mode of tying the, 441.

*Toes*, mortification of the, after Mr. Hunter's operation, 303.

### V.

*Vacca's* case of dilatation and axillary aneurism, 121.

———— case of popliteal aneurism, 220.

——— dissection after the ligature of the femoral artery, 265.

*Valsalva's* case of obliterated popliteal artery, 206.

*Van-Swieten's* case of a wound of the axillary artery, 400.

*Vena cava*, Mr. Cline's case of, obliterated, 20, *note*.

*Vesalius* first mentioned internal aneurisms, 60.

*Varix*, aneurismal, Lassus' case of, in the ham, 420.

—————, sometimes complicated with aneurism, 421,  
case, 434.

—————, diagnosis of, from aneurism, 423.

—————, first described accurately by Dr. W. Hunter,  
425.

—————, supposed to have been known to Sennertus, *ib.*

—————, Guattani's cases of, 426.

—————, prognosis of, *ib.*

—————, cure of, 427.

—————, Dr. Cleghorn's suggestion for the, 428.

—————, by compression, 429.

—————, operations for the cure of, 433.

—————, complicated with aneurism, Dr. Physick's case  
of, 438.

*Ulnar artery*, mode of tying the, 440.



## *Index.*

### W.

*Walter's* case of rupture of the aorta within the pericardium, 82.

*Warner's* case of popliteal aneurism, 146.

*Weitbrecht's* case of ulceration of the aorta, 87.

*While*, use of the sponge by, 363.

——— dissection of an arm after the ligature of the brachial artery, 231.

*Wilmer's* case of enlargement of the collateral vessels, 232.

——— case of amputation after mortification, 304.

*Wound*, treatment of the, after the operation, 285, 287,

———, lips of, ought to be kept separate, 298.



