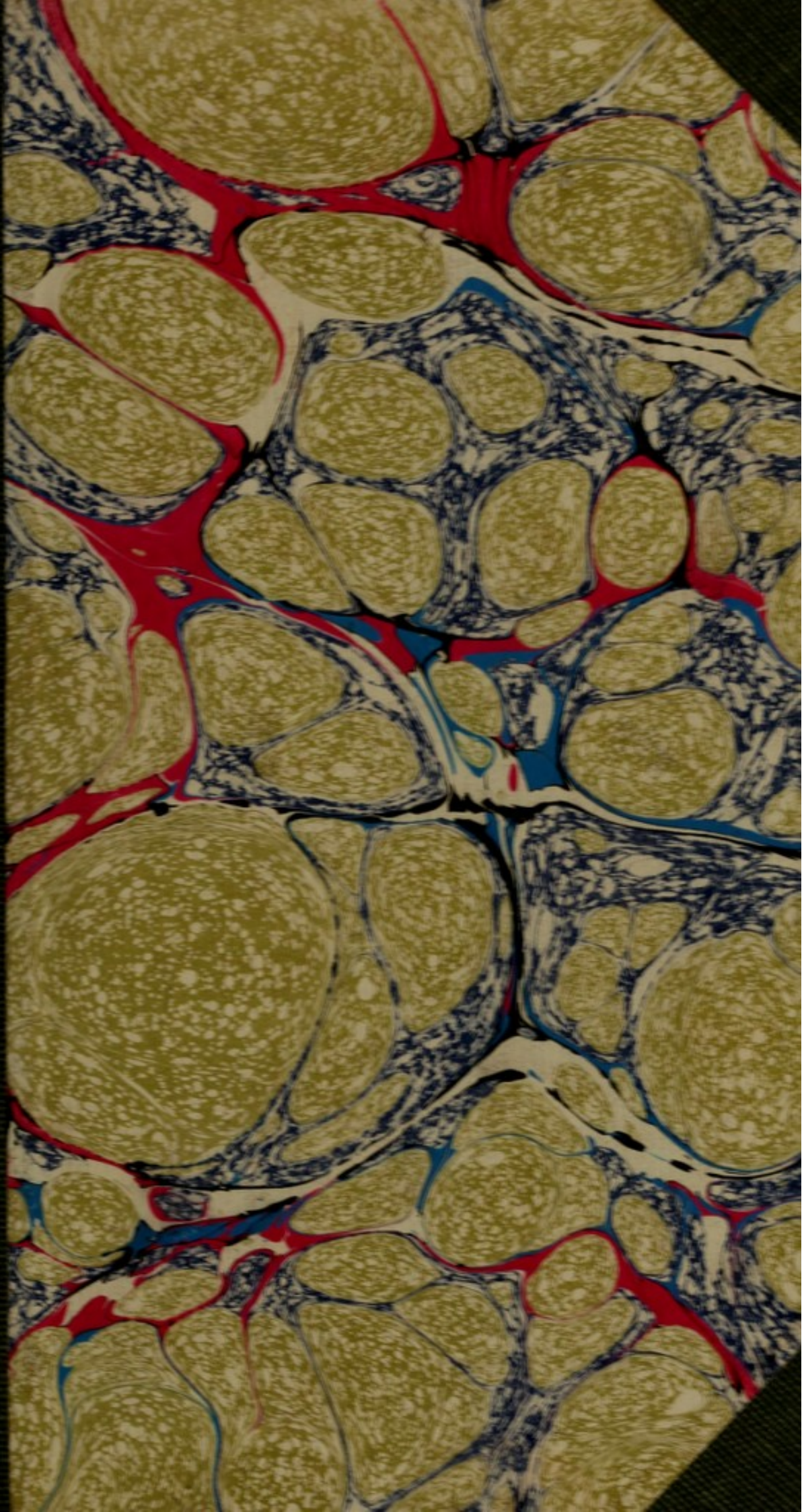

Compliments of
Dr. A. F. Sawyer

POPLITEAL ANEURISM

TREATED BY A NEW METHOD OF COMPRESSION.

REPORTED BY DR. A. F. SAWYER

(BY PERMISSION)

AT THE MEETING OF THE SAN FRANCISCO (CAL.) MEDICAL BENEVOLENT SOCIETY, FEB. 21st, 1879.

Green

Popliteal Aneurism

TREATED BY A NEW METHOD OF COMPRESSION.

Reported by Dr. A. F. Sawyer

(by permission)

At the Meeting of the San Francisco (Cal.) Medical Benevolent Society, Feb. 21st, 1879.

A. Burr

POPLITEAL ANEURISM

TREATED BY A NEW METHOD OF COMPRESSION.

I WAS consulted by Mr. A. B., æt. 62 years, in 1877, for a small tumor in the left popliteal space, about the size of an English walnut. He is a man of spare yet muscular habit, and has generally enjoyed good health, excepting an occasional rheumatic attack earlier in life.

For months he had suffered more or less from numbness and tingling in both lower extremities, with stiffness of the limbs, that had made walking and exercise difficult. There was no pain however in the tumor which was rather elastic to the touch, and no abnormal bruit or pulsation could be detected. The popliteal artery beat with a decidedly less impulse than its fellow. I suspected aneurism, but could form no certain opinion.

In the meantime he had an attack of typhoid fever. After his recovery he went to New York, and I saw nothing further of his case until November 20, 1878, when on his return to San Francisco, he again consulted me for a suspicious tumor that had began to develop itself in the *opposite* or *right* limb, involving the popliteal space, and especially extending up the inner side of the femur as far as its lower third. This was clearly an aneurismal tumor with the characteristic pulsation and bruit. I also found that the tumor, to which my attention had first been directed, had nearly disappeared, probably by absorption, and no pulsation could be detected either in the popliteal or in the lower third of the femoral artery on that side.

Hence I concluded that the tumor was an aneurism, as I had in the first place suspected, and also that it was a case of spontaneous cure, the clot having become condensed and finally absorbed, and that the specific features of the aneurism had been obliterated sometime prior to the period of my first examination. He first noticed a swelling on the inside and just above the *right* knee joint, about two months since. It was rather painful, but he attributed it to an attack of rheumatism. It gradually increased in size, and as the local symptoms became more annoying, it occasioned him great anxiety.

It proved to be clearly an aneurism of the *right* popliteal artery, a considerable swelling occupying the popliteal space, but the mass of it was located on the inside of the thigh and above the knee joint.

In searching for local causes of injury that might have affected the integrity of the vessel, he stated that he could think of nothing, unless he might on some occasion have strained the limb in assisting his servant to carry up and down stairs a heavy travelling trunk, which he had often done when changing from one locality to another.

This statement of the patient revealed at once the immediate cause of his aneurismal history. The constrained and awkward position of the body whilst engaged in tugging away at the end of a heavy trunk up and down a stairway, would cause particular tension on all the structures about the knee joint; and the brittle coats of an artery that had lost its natural elasticity from calcification or disease would be likely to yield, and an aneurism be the result.

A traumatic cause for the rupture of arteries, whether atheromatous or not, even including the trunk arteries of the great cavities of the body, is more common than usually supposed. Among other instances that have fallen under my observation recently, I would recall your attention to the case of aneurism of the 'Innominata,' which was exhibited at a previous meeting of this Society. The patient, was lying in bed, awake, with his hands clasped under his head, between occiput and pillow, when he began to sneeze, and before he could extricate his

arms from their constrained position, he felt a sharp cutting pain within the chest in the region of the innominate artery, which ever afterward continued with such intensity that necessitated medical advice and treatment, and a year elapsed before the aneurism had become sufficiently developed to be detected by the stethoscope of his professional adviser. Also another interesting case of spontaneous cure of popliteal aneurism from traumatic causes will presently be referred to in detail.

In Mr. B.'s case there was ample reason to suspect a generally atheromatous condition of the arteries of the lower extremities, as evinced by the pain and numbness pervading his limbs—"rheumatic or neuralgic" pains—his "legs going to sleep," as he expresses it, and requiring active friction to restore the circulation; an inability to make protracted walks, although a person naturally of an active habit—showing a circulation greatly obstructed, which sooner or later threatened senile gangrene.

The aneurism was now becoming quite painful, especially at night, and I ordered him to remain in bed and keep the limb supported on a pillow. Notwithstanding these precautions the tumor visibly increased, and the integuments assumed an inflammatory appearance, so that I was obliged to elevate the limb on an inclined plane, with iced applications externally, and to administer opiates freely to procure rest. His symptoms now became so urgent that abscess was threatened; the thigh swollen, measuring 17½ inches, two inches above the patella where the fullness was greatest, the measurement of the opposite limb being 13½ inches at the corresponding place; bright inflammatory redness of the skin, and tumefaction extending from the knee up to the groin, especially on the inner and superior aspects of the thigh, exquisitely sensitive to the touch, and accompanied with sharp, irritative fever; face anxious, brown and dry tongue, with a pulse variable from 120 to 130.

The present serious outlook of the case prevented the consideration of any form of operative procedure for his relief. Amputation was not to be thought of, as it would certainly

prove fatal in the gravity of the general symptoms that had now supervened.

Fortunately, by vigorous constitutional measures, and the continued application of iced compresses locally, these alarming symptoms subsided, and I could look about me for the next alternative. Hot applications invariably increased his pain and distress.

Dec. 17.—The patient's condition is as follows. Marked physical prostration; knee and lower part of thigh very tender, requiring unusual care when moved or handled; inflammatory effusion greatly diminished, the limb now measuring 16½ inches two inches above the patella; skin of inner and outer aspect of the thigh discolored, purplish and green, as appears after ecchymosis from an injury; no swelling or œdema in the leg below the knee; nervous tone of the patient much improved; tongue moist, with a brown center; takes food with relish; bowels flatulent, rather tender on pressure, not responding kindly to either laxatives or injections; rests well with an occasional opiate; pulse variable between 84, and 90.

As we were not likely to expect any material improvement in the condition of the patient whilst the irritation of the aneurism existed, it was determined to proceed at once to compress the femoral artery just below Poupart's ligament, with an apparatus described as follows:

A strong canvas bag was made (see drawing) about 3 inches in diameter and 2½ feet long, to contain 25 lbs. of fine bird shot, the lower end of the bag being contracted to retain a common hollow caoutchouc-ball, about 2½in. in diameter, which was to serve as a cork to prevent the escape of the shot, the weight of the shot above causing a protrusion of nearly one-half the lower hemisphere of the rubber ball below the free edge of the opening in the canvas bag. Care was taken previously to close the minute orifice usually found in these balls, so that the contained air could not escape when pressure was made upon it.

The tenderness of the tissues along the course of the femoral artery up to the division of the "Profunda femoris" was such

that neither Esmarch's apparatus, or any form of tourniquet that could be devised, or even digital compression, could be applied without causing intense pain, and hence the point to be selected for compressing the artery must be in the space either immediately above or below Poupart's ligament.

Some form of digital compression seemed to be the best adapted to the peculiarities of this case, and it was thought that the finger of the assistant or assistants would be much aided in compressing the vessel, by the elasticity of the caoutchouc-ball and the compressed air therein contained, as well as relieved from the direct pressure of the weight of the shot; and experimentally it was found to work admirably.

The weight was attached to a couple of compound pulleys, such as are used in reducing dislocations, and suspended from a hook in the ceiling. As the length of the cord permitted too much vibration, and caused unsteadiness in the apparatus, a strong metallic rod was supplemented to bring the pulleys as near the body of the patient as practicable.

The groin being shaved and powdered with chalk, the patient was put in position, and the weight adjusted, commencing with 15 lbs. This proved to be insufficient to overcome the friction of the apparatus, and 5 lbs. more were added. A strip of soft buckskin an inch in width and folded on itself was placed between the ball and artery to make the pressure more direct and to additionally guard against chafing.

The compressing apparatus thus contrived cut off the circulation of the aneurism, and worked so comfortably for the patient that the intervening fingers of assistants were not required. Curiously enough the pulsation of the vessel was transmitted through the apparatus with such force and regularity, that the pulse could be counted as accurately, by watching the vibrations of the rod at its point of attachment to the ceiling, as the finger on the radial artery could mark it.

10.50 a. m.—The compressor was adjusted and gr. ii of gum opii were administered.

1 p. m.—Compression has gone on uninterruptedly two hours and ten minutes. Patient complains of chafing of the skin. His body had become slightly displaced from gravitation downward in bed. Twenty minutes was lost in bathing and repowdering the skin and readjusting the apparatus, digital compression being imperfectly kept up in the interval on account of the sensibility of the tissues over the artery below the profunda femoris. The aneurism was somewhat shrunken and condensed, the skin presenting rather a purplish tint. Gr. i of gum opii administered.

2½ p. m.—Apparatus slightly displaced after one and one-half hours' compression, and twenty minutes lost, digital compression being kept up as well as possible in the interval. A glass of milk punch occasionally given. P. 80, soft and regular.

3½ p. m.—Apparatus readjusted, and ten minutes lost. Gum opii, gr. ii given.

4 p. m.—Fifteen minutes lost.

No further interruption occurred until 6 P. M., when the aneurism was examined, and it was found that all pulsation in the tumor had ceased. The weight was then removed. The corded femoral could be distinctly traced without pulsation for several inches above the aneurism. The tumor changed but little in appearance after the first two hours of compression. P. 90.

It will be observed that the compression was continued for six hours and ten minutes, less sixty-five minutes employed in readjusting the apparatus, when digital compression was imperfectly supplemented. During this time the patient was in excellent spirits, chatting with his friends, and suffering no pain at the point of compression except from the chafing of the skin previously referred to. He remarked often that his leg had not felt so comfortably for days previous to the operation. There was no appearance of bruise or contusion of the skin where the compressor had rested, and no tumefaction of the foot, ankle or leg below the knee. The temperature of the limb was exalted. The prickling and numb sensations were not perceptibly increased during the operation. In fact, when ques-

tioned, he spoke of the same feeling existing in the well or opposite limb as in the one operated upon.

The administration of opium was rather suggested to relieve the mental tension and anxiety of the patient during the operation, and could have been as well dispensed with.

The leg was then enveloped in raw cotton, retained by a flannel roller, and placed on an inclined plane.

Milk, milk punch and beef tea directed for his diet.

10½ p. m.—Foot warm and comfortable; bowels uneasy; p. 86. Hot fomentations over the abdomen. Temperature of the room to be preserved at 80 deg. F.

Dec. 18.—Patient rested well during the night, taking gr. iv of opium; foot and leg rather blanched in color; he has drank freely of beef tea and milk punch; temperature of limb natural; profuse cutaneous exudation over the whole body. Ordered sul. quin. gr. iiss, in infus. gent. comp. every four hours.

Dec. 19.—He bears nourishment and stimulants well. Some increase of fever; center of tongue dry and brown; nervous system irritable; p. 96, irregular; foot and leg exsanguinous; diminished warmth in foot. Limb repacked in layers of raw cotton, and surrounded with bottles of hot water.

Ordered—to relieve tenderness over bowels, spts. ammon. aromat. in camphor water, and turpentine to be added to fomentations.

Dec. 20.—Has taken gr. iv of gum opii during the night, and nourishment or stimulants every half hour. His stomach receives kindly all that is presented to it. He shows an improved condition this morning; is more cheerful and confident in tone; tongue moist, no thirst; p. 90, occasionally intermittent.

A suspicious marbled discoloration first observed about ends of toes and dorsum of foot. Sense of numbness continues, and spasmodic pains shooting down the leg. Temperature of foot the same as its fellow.

Dry dressings omitted, and strips of old blanket wrung out in hot infusion of chamomile flowers with alcohol applied to foot and leg. Hot bottles continued. A pill at evening, of calomel, ex. colocynth, rhei. et aloes āā, gr. i ; saponis, q. s.

Dec. 21.—General condition of the patient about the same. P. 84; toes more shriveled, discoloration extending over dorsum of foot; small vesications beneath the tendo Achillis. The leg as far as the knee has a pale withered appearance, the skin being drawn tightly across the spine of the tibia. The limb altogether has an unpromising look.

Bowels well washed out by an injection. Same local and general treatment continued.

Dec. 22.—Had a natural action of the bowels last evening. Is very comfortable and in good spirits this morning, after a good night's rest; bowels soft and natural; takes food and stimulants every half hour day and night; tongue moist, with brown center; p. 86.

No change for the better in the lower extremity. The anterior portion of the foot has the appearance of frost bite. For the first time the limb shows diminished temperature, and it is evident that dry gangrene, threatening the lower extremity below the knee, has supervened. As yet no line of demarcation between the dead and living tissues has shown itself.

On consultation with my colleagues, Doctors Swan and Kane, to whose intelligence and indefatigable attentions I have been so much indebted in the management of this case, I decided on immediate amputation.

At 12 M. the patient was placed under the influence of sulphuric ether, and the thigh amputated at its middle by the circular method. The femoral artery at section did not retract as usual. It was filled with old clot, and although not bleeding was ligated. Its coats had degenerated, the calcareous grit being readily seen and detected by the finger in the cut section of the vessel. About a dozen ligatures in all were required to make the wound dry.

Sutures and adhesive strap were applied to retain the edges of the wound in contact, and carbolised oil compresses with a roller to keep the dressings in place.

The patient bore the shock of the operation without material depression. A renewal of diet and treatment was ordered, substituting gtt. x, Tr. Ferri Chlo. as a solvent in the quinine solution in place of sulph. acid. aromat. Also the entire surface of the body to be bathed twice daily in hot water and alcohol to prevent excoriations, and preserve a healthy action of the skin.

DESCRIPTION OF THE ANEURISM.

An incision was made through its long diameter. The aneurismal sac contained ℥viii of dark fluid grumous blood, with small soft clots distributed through it; and the same amount of deposit of pale fibrinous lamina. Eight inches of the artery, including the popliteal and lower portion of the femoral as far as the opening of the m. abductor magnus was involved in the aneurism.

Beginning below, from the origin of the posterior tibial the popliteal artery for 3 inches was dilated in an ovoid form without rupture, and became suddenly constricted above to about the size of the finger, where it opened into the principal aneurismal cavity. This dilatation was 3 in. in diameter, and the walls of the sac were profusely studded with calcareous patches.

The femoral artery entered into the upper portion of the aneurismal tumor just below its escape from the m. abductor magnus, and for 5 inches no trace of the vessel could be detected. The fibres of the m. semi-membranosus, formed the principal external wall of this portion of the aneurism. The anterior surface of the os femoris, just above the expansion of the condyls for a space of two inches by an inch and a half, was roughened and eroded.

The femoral above, as far as its section made at the time of the amputation, was profusely marked with patches of calcification, and the annular deposits involved a large portion of the posterior tibial, causing almost a complete obliteration of this vessel. *(See plate.)*

It is to be observed that the aneurism, although its contents were partially condensed by the compressor, always had the feeling of fluctuation up to the time of amputation.

Dec. 29.—Seven days after amputation. Patient continues greatly prostrated, and is rather losing flesh instead of gaining, yet takes vast quantities of food and stimulants. Digestive powers well maintained. An occasional laxative pill, or enema administered. P. variable, from 84 to 96.

Stump examined for the first time; dressings dry; no serous or moist exudations from wound; edges of wound glued together; no apparent inflammatory excitement, and none of repair observed. The stump looks precisely as when dressed after the amputation, only more shrunken.

Carbolic acid dressings reapplied.

Jan. 4.—Patient shows signs of general improvement.

Stump redressed. Some suppuration, say ℥ss of healthy pus from the track of the ligature of the femoral artery. The wound has a remarkably healthy appearance, promising rapid cicatrization.

Jan. 10.—Patient continues convalescent. Stump redressed daily; only a few drops of pus from the track of the ligature during 24 hours. Sutures removed and edges of wound firmly adherent.

Jan. 23.—The patient is now gaining rapidly. He suffers considerably from neuralgic pains in the stump, and especially from a feeling of numbness and tingling in the well limb, requiring active friction to relieve him. The stump has nearly cicatrized, and there is scarcely action enough to detach the ligatures. Femoral ligature removed to-day.

Feb. 21.—The patient continues to improve in flesh and strength, and is now able to walk about his room on crutches. All the ligatures have fallen and the cicatrization of the stump is perfect.

The principle involved in the treatment of aneurism by compression is to either wholly interrupt the course of the circulation passing through the aneurism—or so to modify its force, as to allow a condensation of its contents. Of the various methods devised for this purpose, digital compression is the most desirable. Whilst it is equally as efficient mechanically as any other process, it is a comparatively painless procedure, where we are able to dispense with the use of anæsthetics, and it is also unaccompanied with marked physical shock or constitutional disturbance. The great difficulty in digital compression, is to secure a sufficient number of trained assistants, without hospital or college facilities to supply the skilled labor required.

Esmarch's bandage and tourniquet have shown, of late, remarkable work, to judge by the large and increasing report of successful cases, particularly in the treatment of popliteal aneurism, that have resulted from its use.

Its application (and the same may be said of the various other forms of the tourniquet that have been contrived for the purpose) is attended with prominent difficulties. Without going into detail, it is sufficient to note the intense and often unbearable pain that ensues when adequate compression is established, necessitating the administration of anæsthetics, if we wish to promote a rapid condensation of the clot, in a class of cases where the use of anæsthetics is accompanied with obvious danger to the patient, and increases the gravity of his position; or if the anæsthetics are dispensed with, the operation becomes tedious and uncertain in result, perhaps prolonging it for days, and which may finally have to be abandoned on account of the torture which the patient is no longer able to bear.

The shot-bag, corked with the caoutchouc ball, and suspended from a pulley, did more rapid gentle and efficient work in Mr. B.'s case, than could have been expected from digital compression, no matter how ably conducted, since the amount of compressing force to stop the pulsation could be accurately gauged with the stethoscope, and maintained at any desirable point, thereby avoiding the often unequal or excessive

application of force which naturally results from the varying physical strength of the many assistants who are required to supply their fingers where digital compression is employed.

This was well illustrated from the complaints of pain which our patient made whenever the digital compression was being employed in the intervals required for readjusting the mechanical compressor.

By experiments subsequently conducted on a person of full habit, whose arterial circulation was well covered with tissue, it was seen, when an inch caoutchouc ball was substituted for the larger ball, that the sub-clavian above the clavicle, brachial and external iliac arteries, could be as readily compressed as the femoral, and I have no doubt the common iliac, and perhaps the aorta, could be successfully reached in thin subjects.

From the success attending its application in the present instance, it would appear that this apparatus, or ingenious modifications of it by varying the size and form of the caoutchouc ball, can be adapted to all cases admitting of compression either by the fingers or the tourniquet.

Had there been no alternative but to ligate the femoral in this case, or had a primary amputation been imperative, secondary hemorrhage must have inevitably followed the operation and the patient lost. The interval of five days between the time of compressing the vessel and the amputation undoubtedly gave an opportunity for the collateral circulation to be established to a sufficient degree to secure the nutrition of the stump after amputation, and allowed the coagulum in the femoral artery to become so far organized as to diminish materially the danger of secondary hemorrhage. It will be recollected there was no hemorrhage from the femoral artery when the limb was amputated. But the arterial flow was very profuse from the smaller vessels in the stump, and a dozen ligatures were required to control it. Thus it is a fair conclusion, that the previous obliteration of the artery enabled the patient to overcome the serious accidents to be apprehended in amputation, particularly the danger of secondary hemorrhage, and the recurrence of gangrene in the stump, and really preserved the patient's life.

Several eminent authorities criticise unfavorably the application of artificial heat to the lower extremities after the arrest of the circulation. If the temperature of the foot is higher than natural, or is preserved at the normal standard, or if there are no symptoms of gangrene, there would be no necessity of encouraging an exalted temperature in the limb. The temperature of living blood is about 100°, F., and if loss of temperature occurs and other symptoms of gangrene are threatened, there would seem to be no good physiological reason why artificial appliances should not be employed to preserve or to restore the natural temperature of the limb ; in other words, to endeavor to supply to the blood the heat we see departing from it, which is one of the first indications of threatened dissolution of the tissues. In two cases of popliteal aneurism where the femoral was successfully ligated, no alarming local features were developed. In each case the leg was allowed to rest simply over pillows, and no local dressings were used. In a third case, a laborer, and a very muscular man, æt. about 40 years, came here for treatment from the country, with a very large acute aneurism in the right popliteal space, which occurred suddenly when he was at work wheeling coal in a hand-barrow up an inclined plane to the deck of a steamer. He felt something "snap" under his knee, and he could not complete his task.

The characteristics of the aneurism were obvious enough, and the leg and foot had become enormously tumid and painful. He was ordered to be removed where he could receive proper attention. When I made my visit the next day, to my surprise I found that all pulsation had ceased in the vessel, the leg and foot œdematous, and the temperature of the limb lowered. The limb was placed in the most comfortable position practicable on pillows, well enveloped in loose cotton, and jugs of hot water kept constantly applied, with opiates p. r. n., to relieve the intense distress he was laboring under. The warmth became gradually restored again to the limb, and day after day the tumefaction subsided, so that in about six weeks he was discharged with a spontaneous cure of the aneurism.

In this instance, certainly, no injury was done by artificial heat, and the natural inference was that it materially aided to save the limb.

In Mr. B.'s case, the wet, stimulating dressings were substituted for the dry, as senile, rather than moist gangrene was supervening, and it was desirable to supply the capillaries not only with heat but the moisture which the tissues were losing, and they did not add any complication to the case that could be appreciated. We can see no reason, if cold applications are sometimes of value in reducing the temperature of inflamed surfaces, why the judicious use of hot applications may not be indicated where the opposite conditions exist.

A most remarkable feature in the history of our case was the extraordinary and incredible amount of stimulants and nourishment, notably milk, and subsequently both fluids and solids, he took without disturbance of the stomach, or disorder of the digestive track. The accompanying record will serve as a type of the dietetic discipline for any twenty-four hours during the period of active treatment:

Dec. 23.—The day following the amputation. Diet, etc., for twelve hours:

8.30	P. M.	Milk punch and bath.
9.45	"	Beef tea.
10.15	"	Whisky.
10.30	"	Beef tea.
11.30	"	Quinine solution.
12.00	M.	Cup of tea.
12.30	A. M.	Gum opii, gr. i.
1.05	"	Beef tea.
2.00	"	Bath and whisky.
3.00	"	Milk punch.
4.00	"	Beef tea.
4.50	"	Quinine solution.
5.40	"	Whisky bath.
6.30	"	Milk punch.
7.45	"	Beef tea.
8.30	"	Whisky.

Then, again, Friday, January 24, when convalescing. Diet for twelve hours:

12.00 M.	Lamb chop and salad of artichoke; boiled rice and tea.
1.00 P. M.	Milk punch.
2.30 "	Baked apple and milk.
3.00 "	Milk.
4.00 "	Quinine and iron.
4.30 "	Milk.
5.30 "	Soup.
6.30 "	Fish, squabs, baked tomato.
8.30 "	Bath.
9.00 "	Quinine sol. and iron.
9.30 "	Milk punch.
10.45 "	Whisky.
11.00 "	Cup of tea.
11.30 "	Gum opii, gr. ii.
12.30 A. M.	Chicken, rice, tea and toast.

The patient when aroused, would take mechanically what was presented to him without apparent disturbance of his rest.

The bowels were moved at intervals of four or five days by the aid of a laxative pill, assisted if necessary by a simple enema. Yet the dejections were not what would be called copious. About the natural amount of clear urine was passed daily, notwithstanding his heavy perspiration. The temperature of the room was kept uniformly at 80°, F., which stimulated a most profuse exudation from the skin.

There was a two-fold object in view. Firstly, to prevent the abstraction of the general heat of the body by the surrounding atmosphere of the room in case of vital shock; and secondly, in the early history of the case, there had been so much irritability of the stomach and bowels with abdominal pains, tenderness, flatulency, etc., and such difficulty was experienced in regulating by treatment his digestive functions, that it was determined to call upon the skin for assistance, with unexpectedly happy results. The hint was derived from the observation of

the effects of the Turkish bath upon the animal economy in several instances of a perverted and deranged condition of the abdominal organs. And it was soon found that this drenching perspiration did not materially interfere with our patient's comfort. Care was taken by frequent rubbings of the surface of the body with warm water and alcohol to prevent chafing, and he escaped wholly the troublesome bed sores, as depressing to the patient, as they are vexatious to his medical attendant.

At the date of present writing, March 10, the patient is fast recovering his natural physical status. The feeling of numbness in the stump, especially after being an hour or two in a sitting posture, and the similar sensations formerly so troublesome in the other limb, are now rapidly disappearing. This numbness, continuing from the date of the amputation and the length of time that elapsed before any recuperative action was kindled up in the stump, shows how narrow was his escape from recurring gangrene.

He reports his sound limb as being in a much better condition than it has been for two years. It is gaining in size and strength, and what he calls his "rheumatic pains," are leaving him. There is now little doubt, that having encountered successfully the dangerous period of probation intervening between the obliteration from calcification of the old arterial system of the limb, and the time required to establish the collateral circulation in its place, his safety in the future is measurably increased, and danger from gangrene in that limb at least averted for years.

In concluding this paper, I would call attention to a very superior plan for the preservation of a large variety of pathological preparations in a dry state, instead of the ordinary immersion in dilute alcohol, particularly for the preservation of the morbid changes that occur in the circulatory system.

The plate illustrating the aneurism in this report was taken from a photograph of the specimen thus prepared. The parts are cleaned up as in any ordinary anatomical dissection, fatty

packing and loose tissue being removed as cleanly as practicable, sufficient of the adjoining tissues, muscles, etc., being preserved to at once indicate to the observer the natural relation of the parts *in situ*. The aneurismal cavity, or the heart, or the larger vessels, as the case may be, is stuffed with curled hair or wool, such as is used by upholsterers; the edges of the incision then stitched together to prevent shrinkage; and the whole allowed to dry by exposure to the air. Before drying, an arsenical bath for a few moments would prevent all danger from the ravages of insects.

After the specimen is dried, it is varnished with lac varnish (a solution of the gum in alcohol), which makes a thin transparent and impervious coat, and hardens the tissues wonderfully. Even when used on very fatty specimens the varnish hardens at once, so that they can be handled without greasing the fingers. The cabinet of the Society contains some very fine specimens of calcification of the valves of the heart, aorta, and aneurismal tumors *in situ*, in the tissues in which they have occurred, the calcareous plates being brought out in fine relief in the semi-translucency of the coats of the vessel.

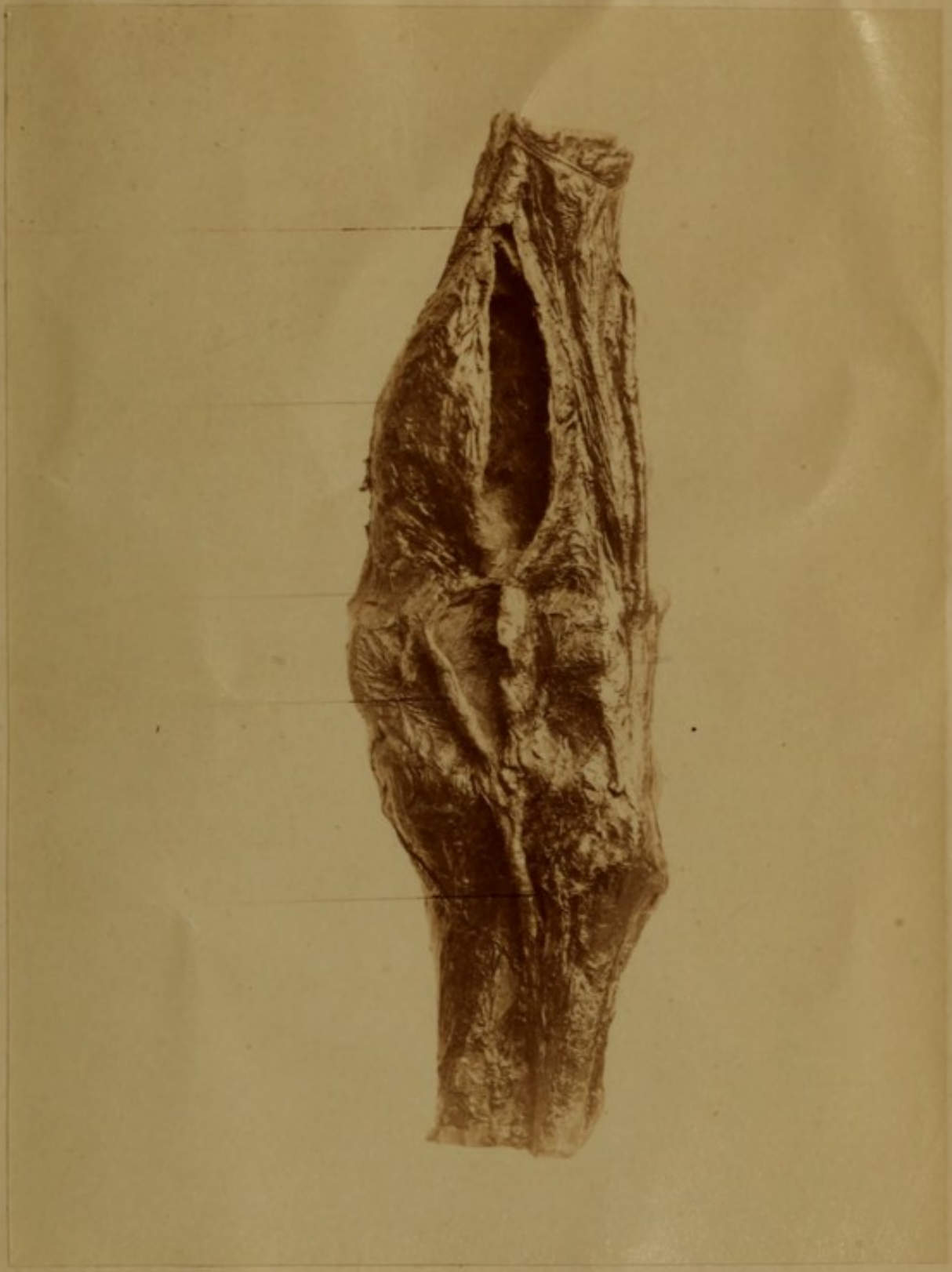

1.—Femoral artery, its orifice opening into the larger aneurismal cavity. Its roughened walls are well shown.

2.—Outer wall of cavity formed by m. semi-membranosus.

3.—Constriction of popliteal artery where it communicates with the larger cavity.

4.—Lower dilated portion of popliteal artery.

5.—Posterior tibial, with annular rings of calcification.