

A handy-book of ophthalmic surgery for the use of practitioners / by John Z. Laurence and Robert C. Moon.

Contributors

Laurence, John Zachariah.
Moon, Robert C.
Francis A. Countway Library of Medicine

Publication/Creation

London : Robert Hardwicke, 1866.

Persistent URL

<https://wellcomecollection.org/works/bwzh3m76>


License and attribution


This material has been provided by This material has been provided by the Francis A. Countway Library of Medicine, through the Medical Heritage Library. The original may be consulted at the Francis A. Countway Library of Medicine, Harvard Medical School. where the originals may be consulted. This work has been identified as being free of known restrictions under copyright law, including all related and neighbouring rights and is being made available under the Creative Commons, Public Domain Mark.

You can copy, modify, distribute and perform the work, even for commercial purposes, without asking permission.

**wellcome
collection**

Wellcome Collection
183 Euston Road
London NW1 2BE UK
T +44 (0)20 7611 8722
E library@wellcomecollection.org
<https://wellcomecollection.org>








28. D. 89

OPHTHALMIC SURGERY.



A HANDY-BOOK
OF
OPHTHALMIC SURGERY

FOR THE
USE OF PRACTITIONERS.

BY

JOHN. Z. LAURENCE, F.R.C.S., M.B. (UNIV. LOND.),

SURGEON TO THE OPHTHALMIC HOSPITAL, SOUTHWARK; EDITOR OF THE OPHTHALMIC REVIEW;
MEMBER OF THE HEIDELBERG OPHTHALMOLOGICAL SOCIETY, OF THE UNIVERSAL OPHTHAL-
MOLOGICAL SOCIETY, OF THE PATHOLOGICAL SOCIETY OF LONDON, OF THE HARVEIAN
SOCIETY, OF THE SOCIETY OF PRACTICAL MEDICINE OF PARIS, OF THE SOCIETY
OF GERMAN NATURALISTS AND PHYSICIANS.

AND

ROBERT C. MOON,

HOUSE-SURGEON TO THE OPHTHALMIC HOSPITAL, SOUTHWARK.

WITH NUMEROUS ILLUSTRATIONS.



LONDON:
ROBERT HARDWICKE, 192, PICCADILLY.
1866.

[All rights reserved.]


THE UNIVERSITY OF CHICAGO PRESS

1880

THE UNIVERSITY OF CHICAGO PRESS

4660

COX AND WYMAN,
ORIENTAL, CLASSICAL, AND GENERAL PRINTERS,
GREAT QUEEN STREET, W.C.



P R E F A C E .



IN writing these pages it has been our aim to bring the principles and practice of Modern Ophthalmic Surgery within a small compass, to supply the wants of the busy practitioner, who may have neither time, nor opportunity, to read the innumerable contributions that Ophthalmic surgery and science have received within the last fifteen years.

In describing symptoms, we have limited ourselves to those which are essential for the *recognition* of disease; in describing operations, &c., to those details which are essential for its *treatment*. At present it matters little to the practitioner whether glaucoma depend on a hypersecretion of the fluids of the eye, or on a rheumatic state of the circulation, or on an obscure affection of the ciliary nerves, &c. What he chiefly wants is, how to know glaucoma; and, when he knows it, how to treat it.

We have not, however, thought it foreign to our scope to introduce occasionally a few representative cases, which serve to illustrate preceding descriptions.

The practice we describe is that pursued at the Ophthalmic

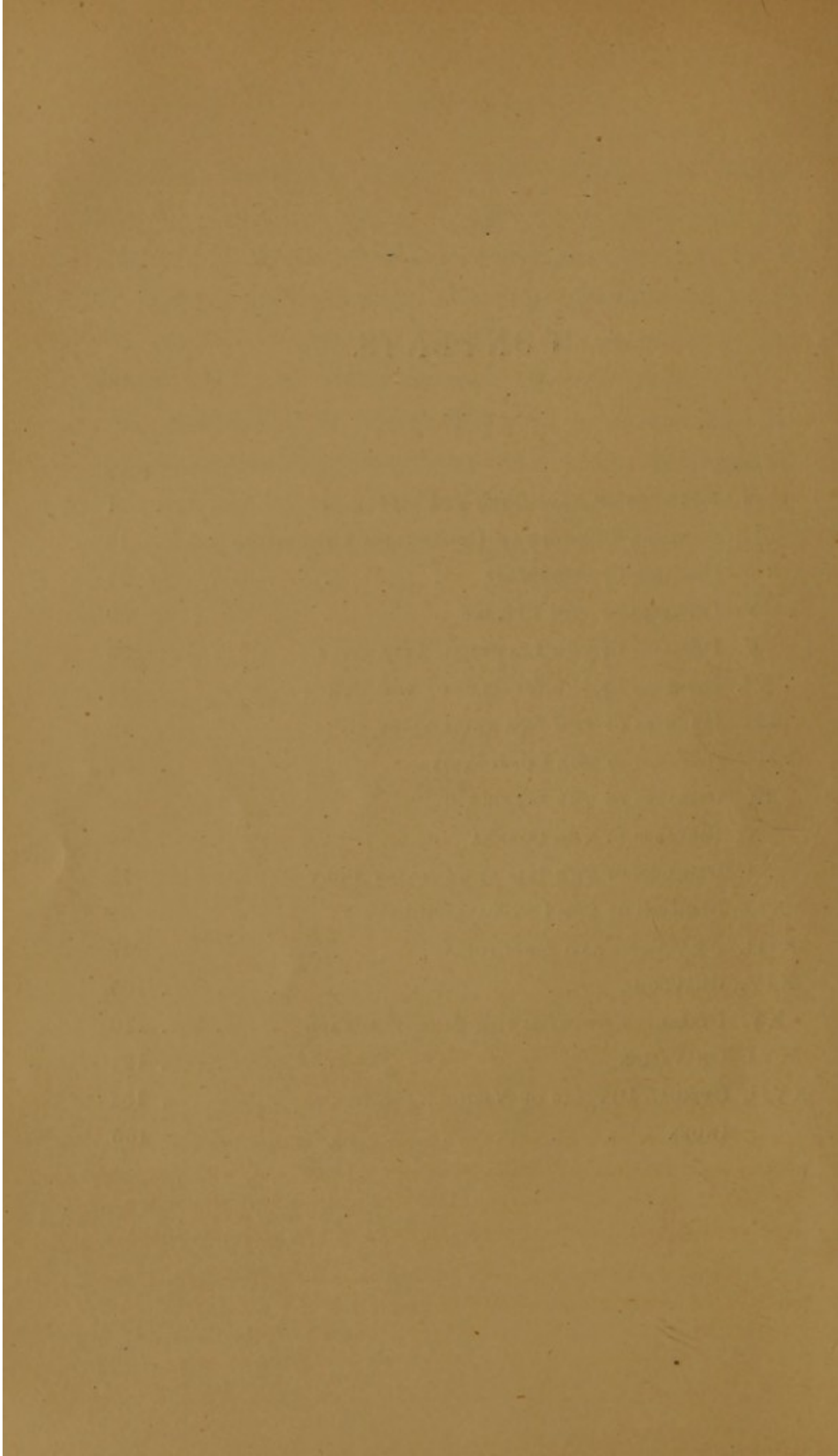
Hospital, Southwark, where 6,000 patients are treated annually. During a period of upwards of eight years the "letters" of all our patients have been preserved and bound up at the end of each year. Thus the experience, on which the practice we advocate rests, has the guarantee of the written records of several thousand observed cases.

In conclusion, it is our pleasing duty to acknowledge the valuable assistance we have received from Dr. Mackenzie, of Glasgow, Mr. Windsor, of Manchester, and Mr. Carter, of Stroud, during the progress of our work through the press.

LONDON, *May*, 1866.

CONTENTS.

CHAPTER	PAGE
I. METHODS OF EXAMINING THE EYE	1
II. GENERAL REMARKS ON OPHTHALMIC OPERATIONS	18
III. DISEASES OF THE ORBIT	24
IV. DISEASES OF THE EYELIDS	29
V. DISEASES OF THE LACRYMAL APPARATUS	35
VI. DISEASES OF THE MUSCLES OF THE EYE	41
VII. INJURIES OF THE EYE AND ORBIT	49
VIII. DISEASES OF THE CONJUNCTIVA	54
IX. DISEASES OF THE SCLEROTIC	62
X. DISEASES OF THE CORNEA	63
XI. DISEASES OF THE IRIS AND CILIARY BODY	72
XII. DISEASES OF THE CRYSTALLINE LENS	81
XIII. AMAUROSIS AND AMBLYOPIA	97
XIV. GLAUCOMA	105
XV. DISEASES AFFECTING THE WHOLE EYEBALL	110
XVI. ON VISION	121
XVII. OPTICAL DEFECTS OF VISION	132
INDEX	155





A

HANDY-BOOK OF OPHTHALMIC SURGERY,

FOR

THE USE OF PRACTITIONERS.

CHAPTER I.

METHODS OF EXAMINING THE EYE.

OBJECTIVE EXAMINATION.

The Objective Examination of an Eye should commence with an inspection of the eyelids and eyelashes ; then, the condition of the eyeball should be carefully noted—its size, form, position, mobility and power of converging with its fellow eye; the vascularity of the tunics ; the state of the cornea ; the colour, texture, and position of the iris ; the form, size, aspect, and movements of the pupil.* The *tension* of the eyeball may be determined by feeling its upper portion with the tips of the two fore-fingers through the closed eyelids. The globe should be steadied by the fore-finger of one hand, whilst that of the other, by counter-pressure, estimates the amount of resistance (hydrostatic pressure) exerted by the fluids of the globe on its coats.

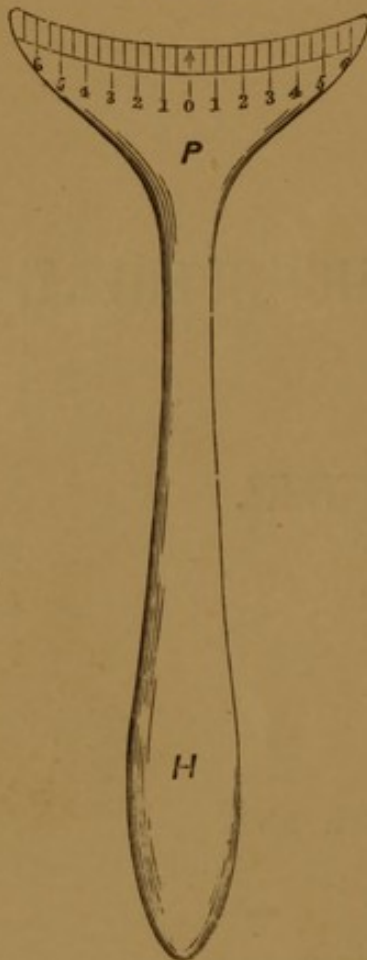
To measure the exact degree of any lateral malposition of the eyeballs, the strabismometer may be employed.

* The specific details will be found under the different diseases.

The Strabismometer.

The object of this instrument is to measure precisely and readily the amount of linear deviation of a squinting eye.

FIG. 1.



It consists of an ivory plate (*P*), moulded to the conformation of the lower eyelid, the free border corresponding to that of the lid. This border is graduated in such a manner that, while its centre is designated by 0, Paris lines and half-lines are marked off on each side of 0, in the manner indicated in the annexed figure. Attached to the plate is a handle (*H*). The application of the strabismometer is obvious. The border of the ivory plate is applied to that of the lower eyelid, the borders of the two corresponding. If the cornea is central, the vertical diameter of the pupil corresponds to 0; if inverted, to a graduation on the inner side of 0; if everted, to one on the outer side of 0. These remarks hold good when the patient regards a distant object.

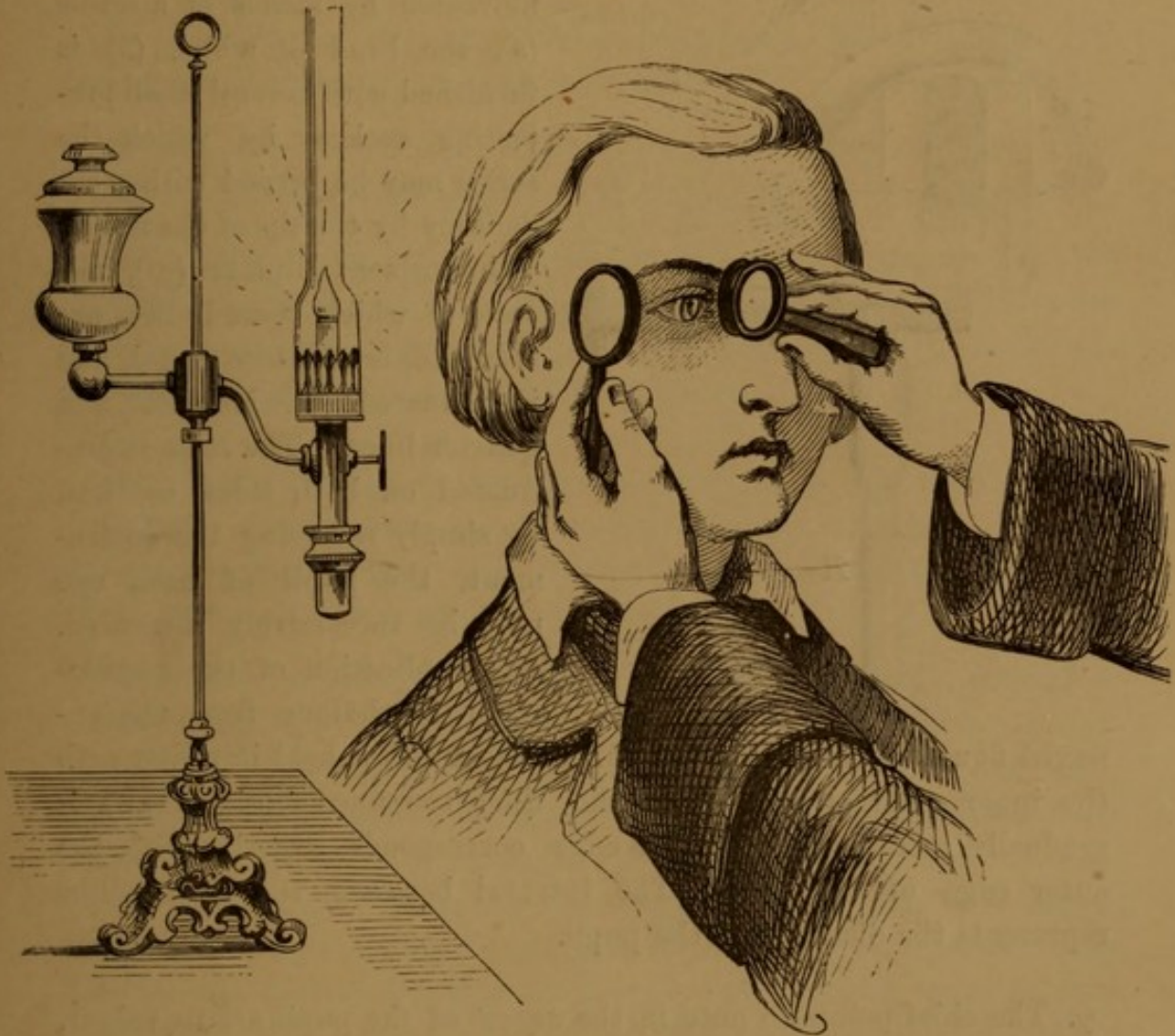
It will be readily seen that by the strabismometer the relative positions of the corneæ may be ascertained for all lateral positions of the eyes; and, further, that it is applicable to cases both of convergent and of divergent strabismus.

The *mobility* of the eye may be tested by requesting the patient to follow the surgeon's finger, as this is moved in different directions. Thus paralysis of any muscle may be detected. The method of diagnosing insufficiency of the internal recti will be found under "Asthenopia."

For the examination of the superficial structures of the globe a good illumination is required. It frequently happens that slight nebulæ of the cornea, minute deposits upon the iris and capsule of the lens, and delicate false membranes in the pupillary area, are overlooked when viewed simply by diffused daylight, but become plainly visible when the parts are inspected by the method of lateral illumination.

The method of lateral illumination should be conducted in a darkened room. By means of a 2-inch convex lens a cone of light from a lamp-flame placed on a level with, and to one side of the patient's eye, is directed upon the front of the eye. A magnified view of the thus illuminated parts may be obtained by viewing them through a second lens held directly in front of the patient's eye, as represented in fig. 2.

FIG. 2.



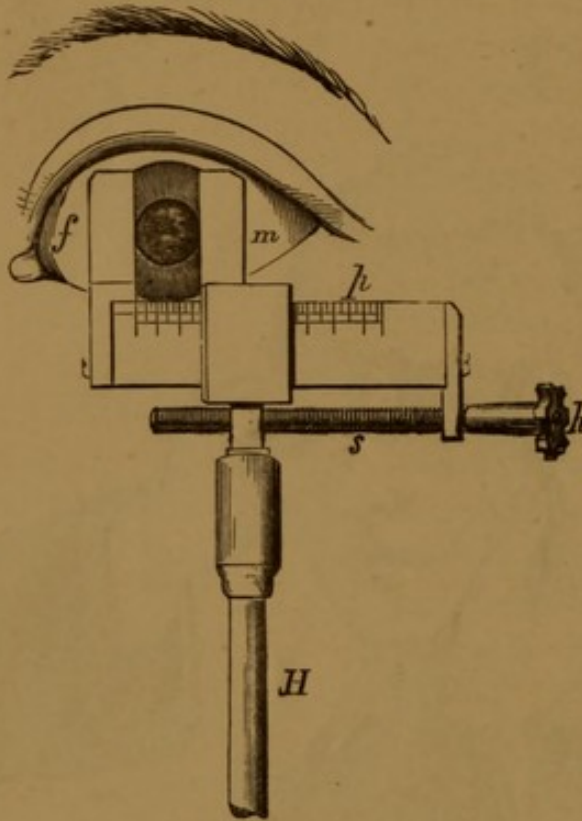
The PUPIL should be examined with reference to its form, size, aspect, and movements.

- a. The *form* of the pupil may be circular, balloon-shaped (from prolapse of the iris), or irregularly festooned (from synechia posterior). Cases of suspected iritis may exhibit no irregularity of the pupil till after the action of atropine, when their nature becomes apparent from such irregularities due to posterior synechiæ.

- β. The *size* of the pupil may be determined by measurements with the pupillometer.

The pupillometer consists essentially of two parts:—1. a pair of indices or “sights”; and 2. a graduated scale. The sights are

FIG. 3.



formed by two vertical, knife-edged, brass bars (indices); the one (*m*) fixed; the second (*f*) moveable by means of a screw (*s*), the head of which (*h*) is furnished with several small projecting spokes, by which the screw may be turned with great delicacy by the tip of the finger. The horizontal plate (*p*), the scale to which these indices are attached, is of white metal, and is graduated into whole, half, and quarter lines. The scale is graduated on both sides, so that, by simply reversing the instrument, the pupil of each eye may be successively measured. The application of the pupillometer is obvious from the annexed figure.

The edge of the fixed index (*m*) is held in a line with the inner edge of the pupil, and then the moveable one (*f*) is gradually screwed up till its edge corresponds exactly with the outer edge of the pupil. The interval between the two indices represents the diameter of the pupil.

- γ. The chief points to note in the *aspect* of the pupil are its colour, and the presence, or not, of any plastic deposits: these should be examined by lateral illumination.
- δ. The *movements* of the pupil in the healthy eye are of three kinds: reflex, sympathetic, and accommodative.

1. The *reflex* movement is produced by the direct action of light upon the retina of one eye alone, the other eye being closed: the pupil dilates or contracts, as it is either shaded from or exposed to light. In complete amaurosis this phenomenon of reflex action to light is absent.

2. The *sympathetic* movement is the contraction or dilatation of the pupil of one eye produced by the action of light upon that of the other ; thus, in healthy eyes, when light is allowed to fall upon one pupil, the other one contracts too.
3. The *accommodative* movement is associated with the contraction of the ciliary muscle and the convergence of the visual lines. The nearer the point accommodated for, the smaller will be the size of the pupil.

In dilatation of the pupil from belladonna, all the three preceding movements are completely absent.

In complete amaurosis of one eye the reflex movements of the pupil are absent, the sympathetic and accommodative ones present.

For examinations of the posterior segment of the eyeball, the ophthalmoscope is required ; but before proceeding to an exploration of the parts behind the pupil, it is, as a rule, necessary to dilate it artificially, if it be not already so from disease.

Artificial dilatation of the pupil is effected by the application of belladonna in the form of its active principle, atropine. As this drug is frequently employed in ophthalmic practice, a short description of its action may be properly introduced here.

Belladonna causes dilatation and immobility of the pupil, giving rise to an uneasy sensation of dazzling when the person regards a bright light ; it also paralyzes the ciliary muscle, and thus the effects of paralysis of accommodation are simulated. The nearest point of distinct vision recedes from the eye, so that the person becomes, for a time, as it were, presbyopic, but he recovers his distinct vision for near objects by the use of appropriate convex glasses. To most eyes distant objects also become indistinct ; in normal eyes, this probably depends on a paralysis of the usual tonicity of the ciliary muscle, and requires but a very low convex glass ($\frac{1}{8}$ to $\frac{1}{10}$) for its correction. But if the person is hypermetropic, and tolerably young, his vision for distant objects becomes extraordinarily deteriorated in consequence of his no longer being able to compensate the defective refraction of the eye by voluntary accommodation (*vide* "Hypermetropia"), and he requires, for the restoration of his sight, a convex glass corresponding in power to his absolute hypermetropia. Very weak solutions of atropine (gr. $\frac{1}{4}$ ad $\frac{3}{j}$) dilate the pupil, but have hardly any effect on the accommodation of the eye, and hence should be employed for ophthalmo-

scopic examinations ; * but if our object be to paralyze the patient's accommodation completely, in order to determine the whole amount of his hypermetropia, a solution of gr. iv. ad $\bar{3}$ j. should be allowed to act for two hours prior to investigating the refraction of the eye.

Solutions of belladonna and atropine are also in daily use in ophthalmiæ, especially the deep-seated forms, exerting a peculiar, not very well understood, sedative effect, and they also, by keeping the pupil dilated, obviate the serious consequences of contraction of the pupil, if iritic complications co-exist, or ensue ; *e.g.* from particles of lens-substance falling into the anterior chamber after operations for cataract.

As patients not unfrequently declare that they have been made "blind" by the application of atropine, it is of great importance, before applying it, to acquaint them with its probable action to produce a temporary loss of accommodative power, and a sensation of "dazzling" in bright light. This objection to the use of the drug has been, lately, partially removed by the introduction into practice of the Calabar bean, which has properties directly antagonistic to those of belladonna.

As a fit sequel to the action of Belladonna, we give that of the Calabar bean.

The Calabar Bean.—Solutions of the Calabar bean exert peculiar influences on the eye. Firstly, the pupil of the eye, to which the solution has been applied, contracts in about ten minutes, while that of the other eye is often slightly dilated ; to the eye with the contracted pupil objects at first appear, as if in twilight. As soon as the pupil begins to contract, the bean begins to stimulate also the ciliary muscle, and thus the refractive power of the eye becomes increased by the augmented convexity of the crystalline lens. The near-point approaches closer to the eye, which becomes comparatively myopic. Asthenopic symptoms result from using the affected and unaffected eyes together in binocular vision. The above change in the accommodation of the eye passes off in about six hours ; the contraction of the pupil in about three days. Hence it will be seen that the effects of the Calabar bean on the iris and ciliary muscle are the reverse of those of belladonna, but more transient in their character. (*Vide v. Gräfe's*

* In naturally moderately dilatible pupils a sufficient enlargement of the pupil for ophthalmoscopic purposes may be generally obtained by directing the patient to look at a distant object with the eye under examination, and to close the other one.

paper analyzed in the first number of the *Ophthalmic Review* pp. 36—45.)

The *Ophthalmoscope*.—Many forms of the monocular ophthalmoscope have been proposed; we shall only describe Liebreich's small one (fig. 4), as the most generally useful instrument we can recommend.

FIG. 4.

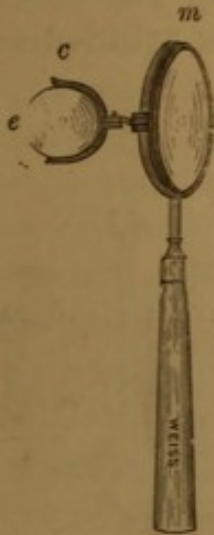
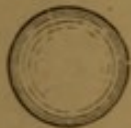LIEBREICH'S
OPHTHALMOSCOPE.

FIG. 4 a.



OBJECT-LENS.

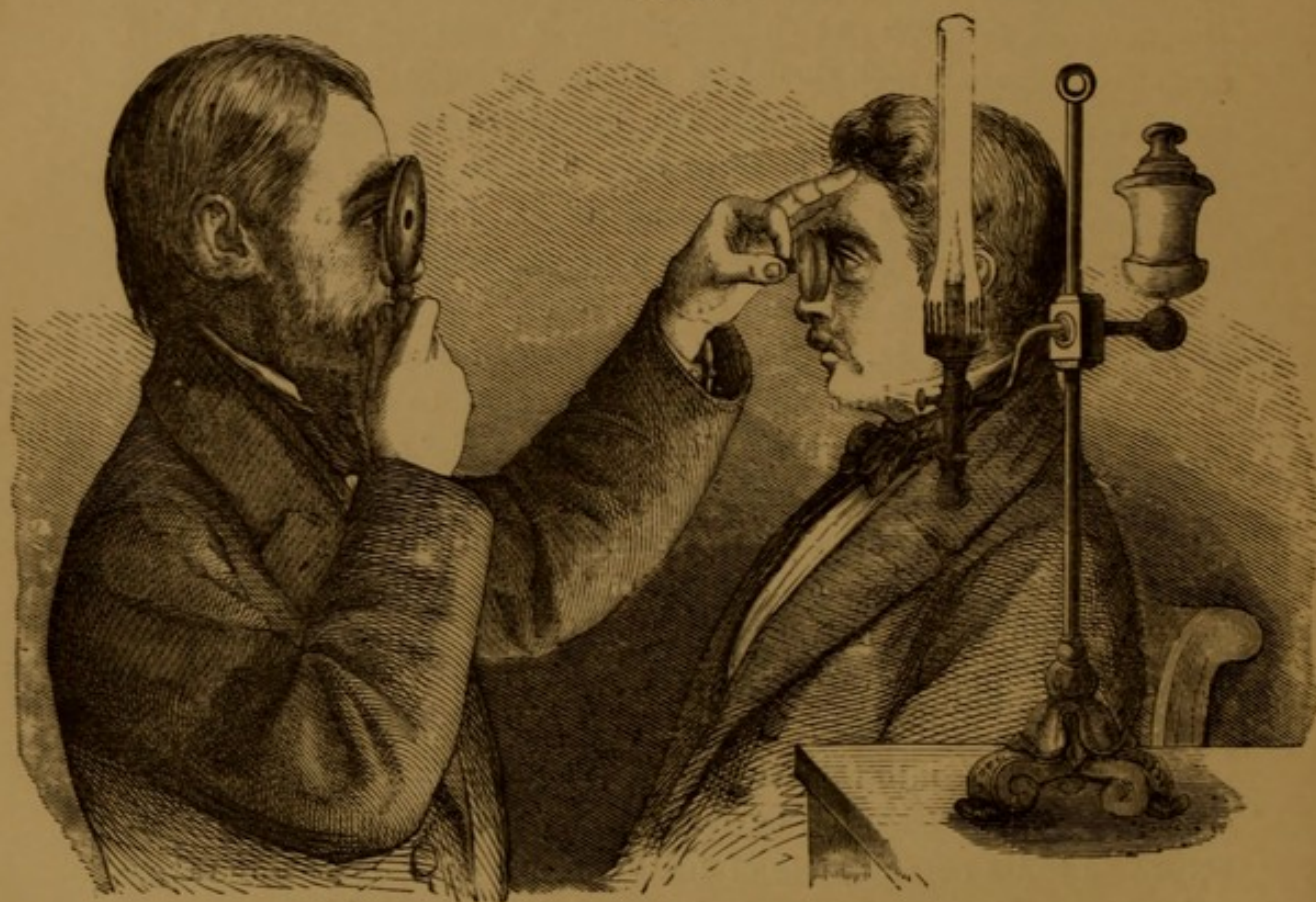It consists of a round, metallic, concave mirror, *m*, of about $1\frac{1}{2}$ in. diameter and 6 in. focal length, pierced by a central, circular aperture of about $\frac{1}{10}$ in., and mounted on a light handle from 5 in. to 6 in. long. Behind the mirror is a hinged clip, *c*, into which eye-pieces, *e*, may be adapted, and which should be sufficiently large to hold ordinary trial-glasses. The eye-pieces are concave lenses, varying in focus from 6 in. to 12 in., and convex ones of 10 in. and 12 in. focus. In addition to these there are two convex object-lenses (fig. 4 *a*), one of $1\frac{1}{2}$ in. to 2 in. focus, the other of $2\frac{1}{2}$ in. to 3 in. focus. In the use of the instrument the patient and surgeon sit, face to face, in a room from which all extraneous light is excluded by shutters, and an Argand lamp is placed at the side of and a little behind the patient's head, with the flame on a level with his eyes. The surgeon holds the mirror vertically, his eye always close to the aperture, and turns the handle round, till he succeeds in reflecting the light from the lamp-flame into the eye under observation. The pupil of this,

which it may, or may not, be necessary first to dilate with atropine, according to its natural state of dilatation, now appears of an orange-red colour. Commencing with the ophthalmoscope held about a foot from the observed eye, the observer may, by gradually approximating the mirror, illuminate successively the cornea, lens, and vitreous, and thus discover any opacities or other anomalies in these structures.* By approximating the mirror as closely as possible to the observed eye, compatibly with its due illumination, the optic nerve, yellow spot, and intra-ocular vessels may be seen, with, or without, the aid of an eye-piece; the choice of this depends on the relative refraction

* For this purpose a feeble illumination should be employed.

of the observed and observer's eyes. In this method of using the ophthalmoscope, which is termed the *direct* method, the natural lenses of the observed eye forming a convex triplet, an erect, virtual, magnified image of the parts is seen. But by the aid of one of the object-glasses a larger field of view and greater facility of observation are attainable. The surgeon holds the object-glass, about an inch from the patient's eye, whilst he holds the mirror with his right about 10 in. from the eye (fig. 5). By due adjustment of these distances an inverted real image of the fundus oculi may be seen. In this, the *indirect* method of observation, the rays of light reflected

FIG. 5.

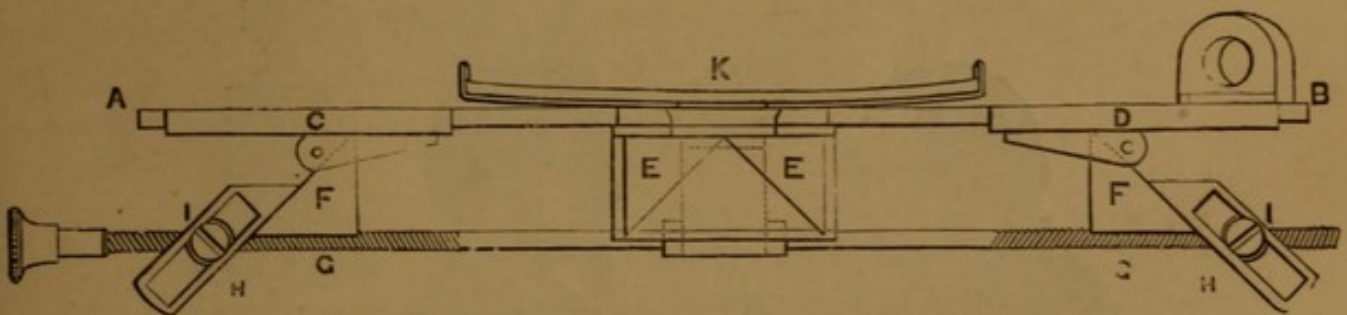


from the fundus oculi strike the object-glass, and form an inverted, real image, in normal eyes at, in myopic eyes within, in hypermetropic ones beyond, the focal length of the object-glass. The distance, at which the image is best seen, varies with the visual power of the observer. If the eye of the observer is normal, hypermetropic, or presbyopic, the inverted image is improved in distinctness by the addition of one of the convex eye-pieces. The annoyance produced by the reflections of the flame from the surfaces of the object-lens may be reduced to a minimum by employing a plano-convex lens,

its plane surface towards the observer, and inclining it sideways so as to throw the disturbing reflections out of the field of vision. When the patient looks inwards, the object-lens should also be similarly inclined, so as to avoid any distortion of the image of the fundus. The details of the fundus oculi, when viewed by means of monocular ophthalmoscopes, appear to be all in the same plane. The depression of a cupped optic disc, or the elevation of the retina by a sub-retinal effusion, would be rather inferred from the bending of vessels, by the changing of focus necessary for the clear definition of each part, by alterations in colour, illumination, &c., than from any appearance of actual relief. In order that such ophthalmoscopic appearances may be correctly interpreted, both eyes are required in the examination, and for this purpose binocular ophthalmoscopes have been invented, which supply in a high degree the deficiency so frequently experienced in using monocular instruments. Solidity of form, precise localization of the various objects seen in the fundus oculi, a natural play of, and entire absence of fatigue to the observer's eyes (which every one must have felt after any prolonged use of a monocular instrument), are amongst the chief advantages of the binocular ophthalmoscope.

The Adjusting Binocular Ophthalmoscope * (fig. 6), of Laurence and Heisch, is a modification of the original one of Dr. Giraud-Teulon. It has two reflecting prisms, E, E, behind the central aperture of a

FIG. 6.

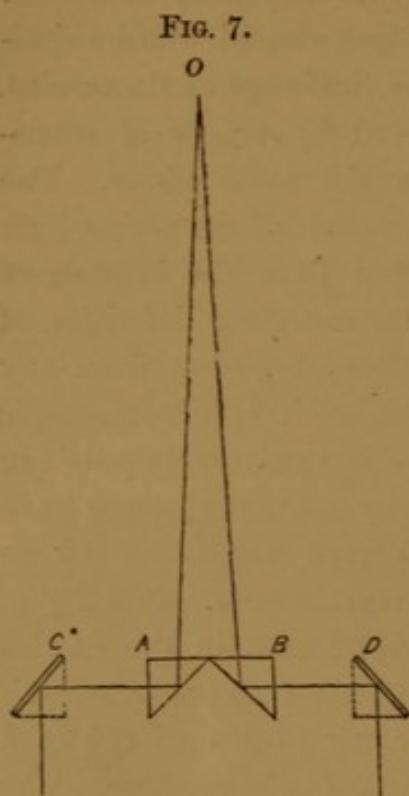


BINOCULAR OPHTHALMOSCOPE.

concave mirror, K, and two moveable ocular prisms, F, F, which shift upon an horizontal metallic plate AB, and can be adjusted to any required inclination by means of a screw, GG, carrying the nuts I, I, which work in the slots H, H.

* It may be had of Murray & Heath, 43, Piccadilly, London.

The optical action of the instrument is represented in fig. 7.

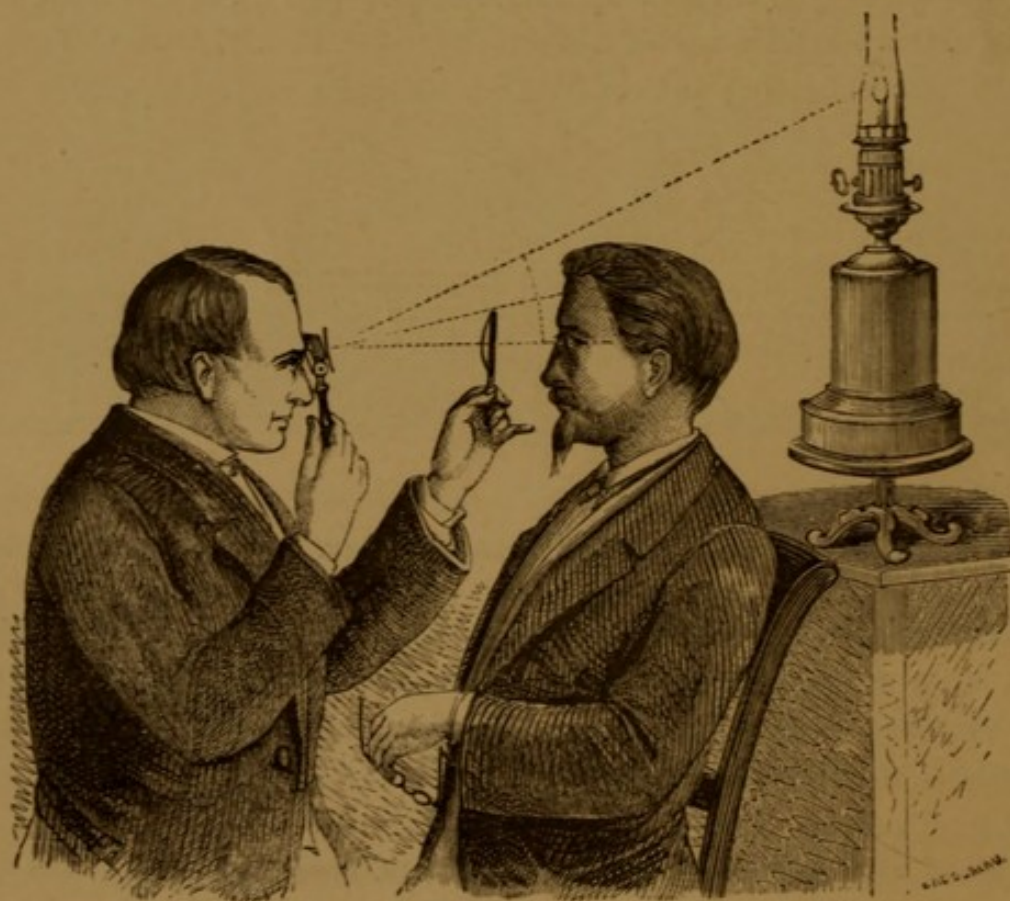


OA and OB are the extreme outer rays of a pencil proceeding from a point (O) of the inverted image formed by the ordinary object-lens; the ray OB is reflected by the prism B to the prism D, and hence to the observer's right eye placed behind D. Similarly, the ray OA is reflected to the observer's left eye. He then sees *two* images of the fundus oculi. By inclining the ocular prisms (D and C) inwards by the mechanism described at fig. 6, the two images are fused into *one*.

The manner of using this instrument differs but little from that of using an ordinary ophthalmoscope, excepting that the light is placed above the head of the patient, and in the same vertical plane as that of the eye to be examined (fig. 8).

The observer holds the instrument horizontally, with the ocular

FIG. 8.



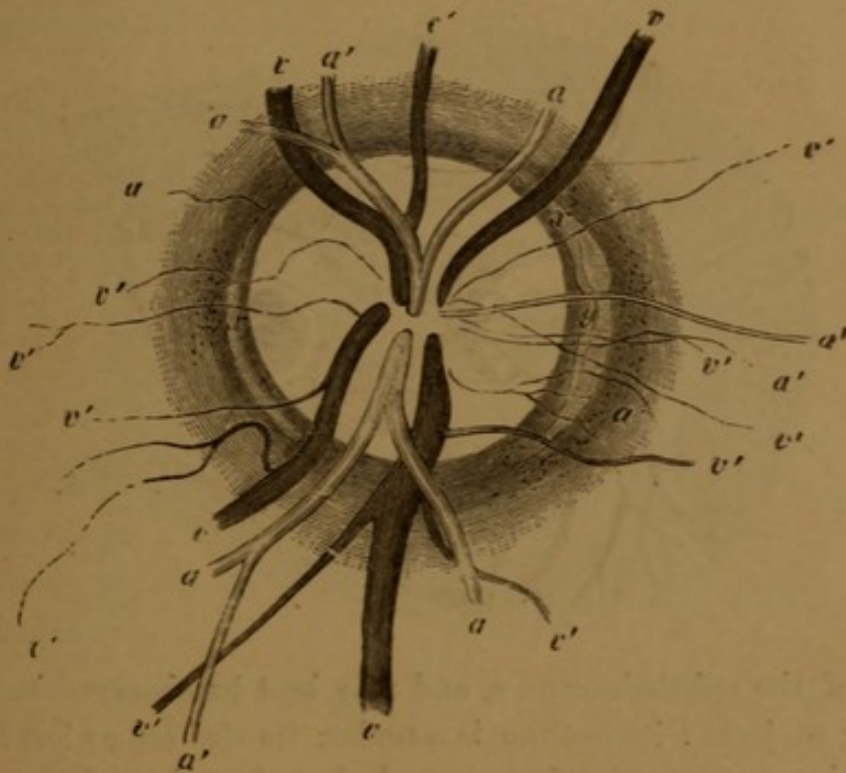
prisms opposite his eyes, and reflects the light into the eye of the patient by tilting the mirror on its hinge; in all other respects it is used as an ordinary ophthalmoscope.

Although the binocular ophthalmoscope may be employed for examining the erect image, it is more applicable to the indirect one.

Whatever form of ophthalmoscope is employed, considerable practice is required to gain dexterity in its manipulation. The first object generally selected for observation in the ocular fundus is the entrance of the optic nerve (papilla nervi optici).

The *Optic Nerve* (fig. 9) enters the globe $\frac{1}{10}$ th of an inch to the inner side of the macula lutea: to obtain a view of it, the patient should be desired to direct inwards the eye under examination. A practical method is: if the right eye is being examined, tell the patient to look at your right ear, and *vice versâ*. Should the patient, however, fail to

FIG. 9.*



obey these directions, the surgeon may readily bring the papilla into view by tracing up one of the retinal vessels to its origin. The general colour of the papilla is reddish-grey, its precise apparent tint being, however, somewhat influenced by the effect of contrast,

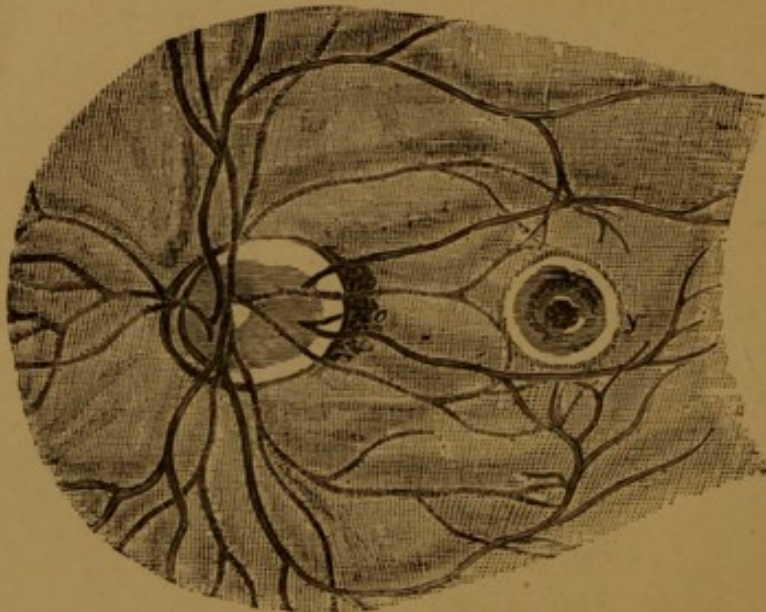
* a, arteries; v, veins; x, scleral zone.

according as the general tone of the fundus is either pale, or dark : the centre of the papilla is often its brightest part.

The *Retinal Vessels* radiate generally from the centre of the disc. One artery and two veins pass upwards, and the same number downwards. Soon after leaving the papilla they divide dichotomously and ramify over the fundus, the smaller branches being visible almost as far forwards as the ora serrata. The veins may, not unfrequently, be seen to pulsate spontaneously, and always so, if some pressure is exerted on the globe ; spontaneous pulsation of the arteries is a morbid phenomenon (*vide* " Glaucoma "). No vessels are seen to pass through the macula lutea, but one may generally be found curving above and another below it.

The *Macula Lutea* (fig. 10, *y*) may be examined by desiring the patient to look directly at the image of the flame formed by the

FIG. 10.



mirror of the ophthalmoscope, and may best be observed in the eyes of young subjects : its outline is circular, its size somewhat less than that of the papilla optica, its colour darker than that of the adjacent fundus ; at its centre a dark red spot (the *foveola*) may be observed, and around it a light bluish halo.

To those who desire to become more intimately acquainted with the varieties and applications of the ophthalmoscope, we can strongly recommend the treatise of Dr. Zander, edited by Mr. Robert B. Carter.

SUBJECTIVE EXAMINATION.

The subjective examination of an eye should commence with the investigation of its state of vision.

State of Vision.—The visual power, or, as it is technically termed, the “acuteness of vision,” is generally determined by graduated test-types; the scale we recommend is that of Dr. Snellen, of Utrecht. The visual angle under which an object is seen has been taken as the basis of the system.

The minimum angular magnitude of distinct vision is taken as 1 mt. The types are graduated in such a manner that their numbers correspond in Paris feet to the distance at which the breadth of the thick strokes of each letter subtends the above angle on the retina. If we are dealing with a normal eye, No. I. type ought to be distinctly legible as far off as one Paris foot, XII. at twelve feet, XV. at fifteen feet, &c. If we designate by S the acuteness of vision of a person, then, in the above examples,

$$S = \frac{1}{\text{I.}} = \frac{12}{\text{XII.}} = \frac{15}{\text{XV.}}, \text{ \&c.} = 1;$$

if, on the other hand, an eye to read I. has to approach to within half a foot from it, to read XII. three feet, to read XV. five feet, &c., then

$$S = \frac{\frac{1}{2}}{\text{I.}} = \frac{1}{2}; = \frac{3}{\text{XII.}} = \frac{1}{4}; = \frac{5}{\text{XV.}} = \frac{1}{3}, \text{ \&c.},$$

respectively. Or, if an eye at ten feet only reads XX., at five feet only XV., &c., then $S = \frac{1}{2}$ and $\frac{1}{3}$ respectively. S is considerably influenced by age. The following table exhibits the results of the investigation, by Dr. de Haan, of 281 cases of emmetropic eyes at different ages:—

At 10 to 20 years.....	$S = \frac{22\frac{1}{2}}{20}$
„ 30 years.....	„ $= \frac{22}{20}$
„ 50 „	„ $= \frac{18}{20}$
* „ 60 „	„ $= \frac{14}{20}$
„ 80 „	„ $= \frac{11}{20}$

*. *vid.* a case in Donders, p 235,

Madame K. aged 54. has vision = $\frac{21}{20}$. $H = \frac{1}{36}$

The test-types of Professor E. Jäger, of Vienna, consist of ordinary printers' letters ranging in size from No. 1 ("brilliant") to No. 20 ("8-line Roman"). Unlike the test-types in Snellen's more scientific system, Jäger's follow no other order than that of a gradual increase in the size of the letters. An eye with normal acuteness of vision should read Nos. 20 to 18 of Jäger at 20 feet.

A patient may be so amblyopic as not to be able to read CC (Snellen) at any distance. In such a case the ability to count fingers at different distances may be employed as a rough test of the patient's visual power. Or he may only be able to distinguish light from darkness; even so low a visual power as this admits of differences. These may be tested by placing the patient some six feet from an Argand gas-flame in a dark room: he may be able to distinguish either the slighter variations of intensity of illumination, as the flame is gradually lowered or raised, or only the two extremes—total darkness and intense light—as the flame is either all but extinguished or is raised to its utmost. If a patient cannot distinguish such extremes of illumination, he has no perception of light—he is "stone-blind." In all examinations of the perception of light, if one eye only be diseased, the other should be completely covered with a thick handkerchief. Mere closure of the sound eye will not do, as sufficient light will penetrate through its closed lids to indicate any changes in the illumination.

The *refraction* of the eye should be tested with low-powered concave and convex glasses. For the details *vide* the Chapter on the Optical Defects of Vision.

We may then test the power of adjustment the eye possesses to different distances—its *accommodation*.

The following formula expresses the extent or "range" of accommodation.

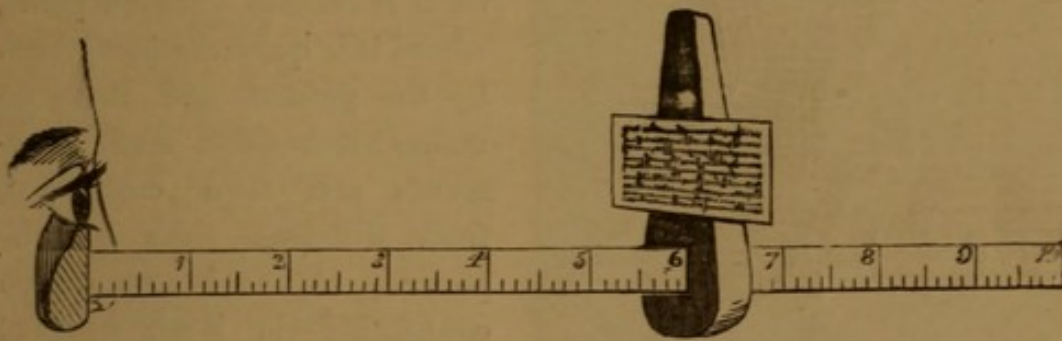
$$\frac{1}{A} = \frac{1}{p} - \frac{1}{r}$$

p representing the nearest point of distinct vision (*punctum proximum*), r the farthest point of distinct vision (*punctum remotum*), and $\frac{1}{A}$ the range of accommodation.

For determining the near-point, a sliding scale may be employed similar to the one represented in fig. 11. It consists of an ordinary shoemaker's rule, the fixed upright of which is cut down and notched

out for the reception of the patient's eye ; to the sliding upright are affixed three small springs, which retain in position an ordinary address-card, on to which the test-type (No. 1 of Jäger) is pasted. The fixed upright is held so as to correspond with the surface of the cornea, and by sliding along the other moveable one with the test-type

FIG. 11.



OPTOMETER.

The test-type is represented as exactly 6 inches from the patient's cornea. A grooved ring may be added at the corneal end for the reception of lenses.


attached to it, we can find and read off expeditiously the near-point (and approximatively the far-point in cases of high and medium degrees of myopia).

If a 10-inch convex lens be placed in the grooved ring, the far-point may be ascertained in all cases. If, for an eye (with suspended accommodation) to read the test-type distinctly, the sliding upright must be at 10 in., the eye is emmetropic ; if nearer, the eye is myopic ; if further off, hypermetropic.

The *field of vision* is the extent of surface visible at one time by an eye, which itself is immoveably fixed on any one given point. It may be roughly estimated by directing the patient to fix his eye steadily on that of the surgeon, whilst the latter moves his forefinger outwards from that point in various directions, remarking where, if anywhere, it vanishes from the patient's view, and taking care that the patient during the whole examination maintains his eye fixed in its central position. If an exact determination of the field of vision be required, the patient should be seated before a board on which is stretched a large sheet of dead-black paper. The patient should be 12 inches from this, and for the sake of comparing the results of different cases, the visual field should always be taken at one and the same distance. The surgeon then takes a piece of white chalk, attached to a long black handle, and on the centre of the paper makes

a cross (\times), on which the patient is to fix his eye steadily during the whole examination. The surgeon then, moving the chalk from the circumference towards the central cross, stops short, and marks with a dot

FIG. 12.



the point at which the patient first sees the chalk, perhaps but indistinctly. He then moves the chalk still further inwards, until it reaches a second point, where it is quite *distinctly* seen by the patient, and there he makes a second dot. Such movements are then conducted, from different sides of the paper. A line is now drawn connecting the inner series of dots and a second one connecting the outer. The space included by the inner line represents the field of distinct vision, that between the outer and inner lines the field of indistinct vision; or only one field, more or less distinct, may be traceable. The maps thus obtained exhibit the most varied forms, are not uncommonly of considerable diagnostic or prognostic value, and should be preserved with the records of cases. The adjoined diagram represents such a map.

A person may see perfectly with either eye separately, but not be able to use the two eyes harmoniously. Two cases present themselves.

1. The person only sees with one eye at a time; he does not enjoy *binocular* vision. Whether he do so, or not, is best ascertained by placing a piece of coloured glass before one eye, and a prism with its base upwards or downwards before the other, and then causing him to look at a candle-flame. If binocular vision is present, he sees two flames, one coloured, the other not, one above the other; if not present, he sees but one flame, coloured or not, accordingly as he sees with the one or other eye.

With moderately intelligent patients, a ready method is to direct them to look at a slide with words so arranged as to undergo an optical transposition when seen through a stereoscope; the word on the left hand of the diaphragm of the stereoscope appears to the patient to be on its right, and *vice versa*. For instance, supposing the words on the card to be

SIGHT | DOUBLE

they would appear through the stereoscope to a patient possessing binocular vision as

DOUBLE | SIGHT

But if the vision of either eye be defective, it is easy to determine the fact by the patient's statement as to which word he sees. In cases of squint, where no extreme amblyopia exists, the right or left hand word may be seen alternately, with greater or less distinctness, by closing either eye in turn, but the two words cannot generally be seen at once. Pictures may be employed in place of the words. This may be done by cutting any small picture in halves, and transposing the two sides. "*Optical transpositions*," embracing several subjects—principally of a comic character, prepared upon this plan, have been published by Mr. William Spooner, 379, Strand.

The above remarks, *mutatis mutandis*, are of course applicable to the case of a patient who is really blind of one eye.

Where blindness of one eye is simulated, the test is certain, if care is taken not to let the patient see the slide before putting it into the stereoscope—which for the purpose should be enclosed on all sides with ground glass. The patient would, from the fact of the transposition, expose the fraud by his own evidence, and condemn himself out of his own mouth.

Persons who do not possess binocular vision are incapable of appreciating the effects of the ordinary stereoscope.

2. The person uses both eyes, but cannot direct them to one and the same point at the same time—he then sees double. For the details of double-vision we refer the reader to the Chapter on the Diseases of the Muscles.

Other subjective symptoms of vision, such as half-vision (hemiopia), *muscæ volitantes*, *scotomata*, visual spectra (luminous appearances, iridescent vision, &c.), will be alluded to under the diseases of which they are symptoms.

Pain is a prominent symptom of many inflammations of the eye; but it should be borne in mind that the most serious mischief may be going on in the deeper structures without being indicated by any pain. The reverse of pain, *loss of sensibility*, is often observed in the cornea in cases of glaucoma, and we have also noticed that *leucomata* of the cornea are frequently remarkably devoid of sensibility.

CHAPTER II.

GENERAL REMARKS ON OPHTHALMIC OPERATIONS.

THE following general remarks on operations on the eye may prove useful to the practitioner :—

PRELIMINARY CONSIDERATIONS.

Before determining on an operation, it should be well considered whether the advantages likely to accrue from its performance are commensurate with the risks. To extract a cataract from an amaurotic eye, to attempt to restore vision by iridectomy in a case of confirmed glaucoma, &c., are extreme cases, which need but be adverted to ; but other more refined considerations may present themselves—the propriety of dividing the external rectus in a case of muscular asthenopia, of extracting a cataract from a patient who is blind of the other eye, and so forth.

Having once determined on an operation, some tact is required in proposing it to the patient. The surgeon should speak decidedly and to the point. Nothing tends more to shake a patient's confidence than a vacillating and doubtful demeanour on the part of the practitioner. The surgeon should neither commit himself to rash promises, nor intimidate his patient by needless anxieties. We would especially advise that the details of operations should not be entered into. To discuss them *can* do no good ; it *may* do some harm ; the patient broods over matters he but imperfectly understands ; his composure and spirits suffer, as well as his confidence in his medical attendant.

Before removing an eyeball, the patient should always be told, in the presence of a witness, exactly what is going to be done. We have known a case where a surgeon who neglected this precaution was threatened with an action ; for a popular notion prevails that in most operations upon the eye, it is completely removed from its socket, and, after certain mysterious manipulations, replaced.

Generally speaking,* no serious operation should be undertaken

* There are exceptions to this rule ; *e. g.* in acute glaucoma, the sooner iridectomy is performed, the better.

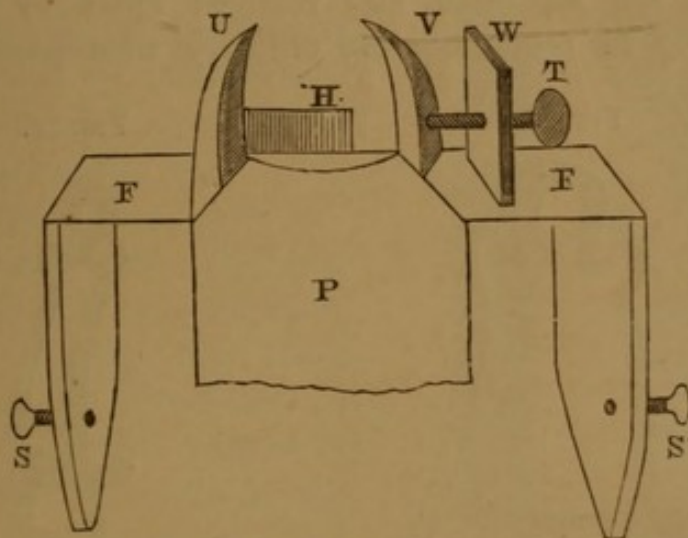
without submitting the patient to a few days' "preparation"; otherwise, should the case turn out badly, the surgeon will be sure to be blamed for the want of preparation. The preparation may be either real or simply the administration of some *placebo*. Some patients, especially those who have led a dissipated or exposed life, really require dietetic and general medical treatment previous to an operation.

THE OPERATION.

During the performance of all operations it is essential that the patient's head and eye be perfectly still. The parts to be operated on are so small, and in such close contact with one another, that any restlessness or sudden start on the part of the patient may cause the wounding of important structures, and possibly total loss of sight. It may be well, therefore, here to describe the apparatus and instruments in use for steadying the patient's head and eyes.

Immobility of the head is secured by Mr. Laurence's *head-rest* (or cephalostat), the construction of which will be understood by reference to the annexed figure:—

FIG. 13.



HEAD-REST, OR CEPHALOSTAT.

U, V are two uprights, concave internally, where they are lined with slightly-padded leather; V is moveable, horizontally, towards the fixed one (U) by a thumb-screw (T), which works through a nut let into the third (fixed) upright (W). P is an inclined, hard, padded pillow, sloping from between U and V downwards on to the operating-couch, to which the frame (F F) of the apparatus is fastened by two screws (S and S'). The patient lies upon the couch, with his head resting on the upper part of the pillow (P), between

the uprights (U and V). The moveable upright (V) is then screwed up, till it meets the corresponding side of the head, and between the two uprights (U and V) the head is thus firmly fixed. We need hardly say every part of this apparatus must be firmly constructed. The uprights (U and V) must thin off gradually upwards, as in the figure, so that their upper edges may not be in the way of the operator. By the space between their summits being less than that between their centres, the head is prevented moving forwards; the lateral compression prevents it moving sideways; a ridge of the pillow prevents it moving downwards; whilst a second, hollowed wooden one (H) prevents it moving upwards. In fact, if the apparatus is properly made, the patient's head is thoroughly and efficiently fixed.

With this apparatus, when chloroform is not given, we need no longer the hands of an assistant, so often in the way of the operator, to "steady" the head; or, if chloroform is given, we need not anticipate any of those convulsive starts of the head, not uncommon, especially when the patient is getting out of the influence of the chloroform. The apparatus, in fact, is a very useful assistant; for it does all that is required of it, without being in the surgeon's way.

The eyelids are separated and retained apart by means of a *speculum*. Fig. 14 represents the ordinary wire speculum, which,

FIG. 14.

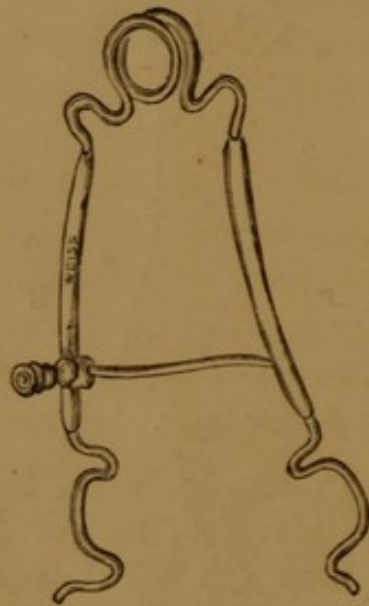
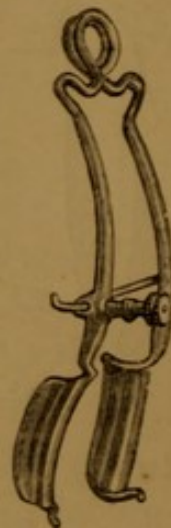


FIG. 15.



SPECULA.

however, has the disadvantages of—1st, not separating the lids in their entire length; and, 2nd, causing unequal pressure along the borders of the lids, so that, whenever the patient resists more or less

violently by spasmodic action of the orbicularis, the lids are forced over or under the wires, the part of the eyeball exposed to view being thus materially diminished. Mr. Laurence has obviated these difficulties, by substituting for the wires which should separate the eyelids grooves of metal, — troughs, so to say, which *receive* the eyelids and completely prevent their overlapping (fig. 15).

The screw upon the side wire is for the purpose of separating the lids to any required distance apart.

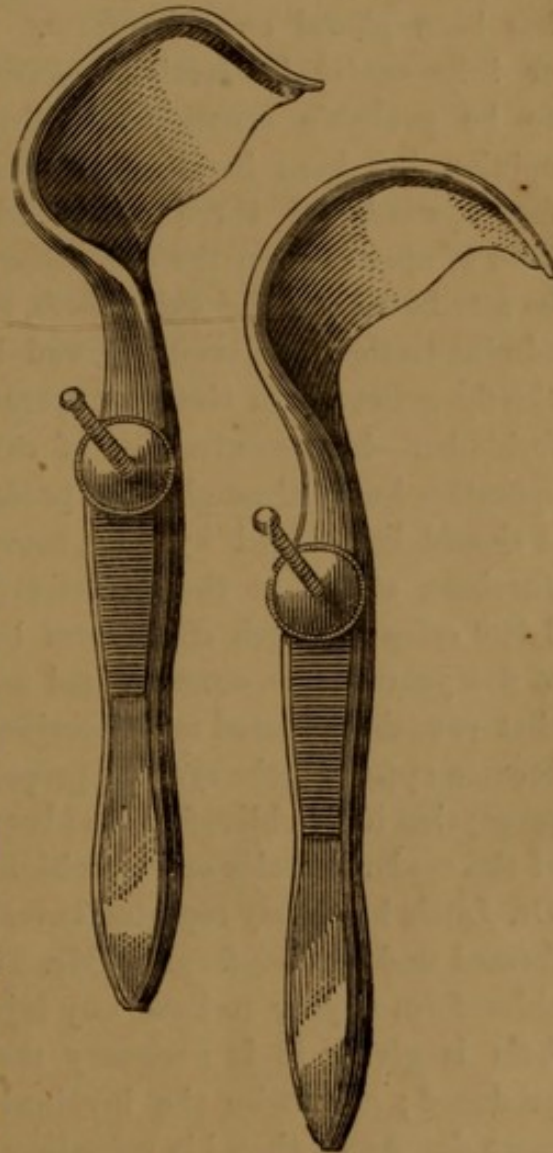
In most operations, such as paracentesis, iridectomy, and extraction, the globe should be fixed by seizing the conjunctiva and sub-conjunctival fascia at a point opposite to that at which the incision is commenced. The *forceps* for this purpose should be finely toothed; and if possible applied over the insertion of one of the recti muscles. Operations on the eyelids are greatly facilitated by the *eyelid tourniquet* of Dr. Snellen (fig. 16)—a vast improvement on the old ring-forceps (*pince-anneau*) of Desmarres—which are only well applicable to small tumours of the lid.

Mr. Laurence has slightly modified Snellen's forceps (fig. 17), and adopted the same principle to the lower eyelid. With these instruments all operations on the eyelids may be performed with the same facility as on the dead subject, the flow of blood being entirely checked, and sensibility also partially deadened.

With such a combination of fixing-apparatus as the head-rest, groove-stop speculum, and toothed forceps, we have over and over again operated without chloroform on irritable and unruly patients, to whom, either on account of the trifling nature of the

FIG. 16.

FIG. 17.



EYELID TOURNIQUET.

operation or for other reasons, it has been thought unadvisable to administer chloroform.

Chloroform.—The advisability of administering chloroform is determined to some extent by the wishes, but principally by the behaviour of the patient. A good test of his ability to bear pain is the introduction of a speculum. Should he, spasmodically, resent its presence, chloroform should be given, supposing him to be a fit subject for its administration; but if he appear to bear the speculum well, and promise to remain perfectly still, many operations, such as those on the lids and muscles, may be done without it.

The special dangers of chloroform in eye operations have been greatly exaggerated. In no operation on the human body is perfect quietude of the parts more required than in the extraction of cataract. Yet it is just in this very operation that the most emphatic veto has been placed on chloroform. Expulsion of the vitreous humour or intra-ocular hæmorrhage caused by vomiting, have been said to be probable consequences of its administration. Preconceived opinion has been invoked in place of experience. We have now for upwards of three years administered chloroform in every kind of operation on the eye without one single bad result that could be attributed to the chloroform, even although in several cases its administration has been followed by vomiting. We have found it chiefly indicated in the very operation in which it has been specially forbidden—in the extraction of cataract. How often have we seen operators hurry through this procedure, glad “to get it over,” lest it should be marred by some movement of the patient! Professor Jacobson stated at the Heidelberg Congress of 1864, that in about 1,500 cases in which chloroform had been administered, in a period of five years, on no occasion had any signs of danger occurred; and that vomiting exerted no deleterious influence, if, as soon as its advent became apparent, the eye was properly protected by a cotton-wool compress; that if the chloroform had been given to the full extent, no spasms of the ocular muscles or convulsions took place during the operation. Dr. Little has lately reported twenty flap-operations for cataract performed under chloroform by Mr. Thomas Windsor: “In no case did chloroform appear to have any injurious influence.”* When chloroform is given, it is necessary that complete anæsthesia should be produced; otherwise the involuntary movements of the patient are more dangerous than his voluntary ones would have been: the latter may be anticipated and controlled; the former cannot.

* *Ophthalmic Review*, vol. ii. p. 353.

Before operating, the surgeon should see that his patient is in a good light, and that every instrument he is likely to want is on a small table by his side. An assistant should hand each instrument as it is required, and cotton-wool and bandages should be ready in case of vomiting. It is of great importance that operations upon the eye should be performed deliberately, *slowly*, and precisely. So-called "brilliant" operations may end in dull results. Protracted instrumental interference with the parts behind the cornea is greatly to be deprecated, as it is frequently attended by unfortunate consequences. The instruments should be small, and introduced as few times as possible into the anterior chamber.

We have repeatedly remarked the unfortunate results that follow the slightest injuries—especially those of a contused character—inflicted on the iris; injuries which, as far as their immediate evidence is concerned, may completely elude the first observation of the operator. Scarcely any living structure inflames so readily as the iris; and from none is there a greater tendency to the spread of inflammation to the adjacent tissues.

Lastly, we would add, how greatly the results of operations on the eye depend on the care and solicitude bestowed on the after-treatment of the patients. It would lead us too far to enter into so wide a subject, nor would it tend to any good. It is one only to be learned by careful observation and experience.

CHAPTER III.

DISEASES OF THE ORBIT.

PERIOSTITIS OF THE ORBIT.

PERIOSTITIS of the orbit may be either acute or chronic. The pain accompanying it is widely spread, of a very severe character, and increases at night. When the anterior part of the orbit is affected, tenderness is experienced upon pressing the eyeball with the finger against some one spot of the orbital walls; but when the inflammation is limited to the posterior part, this sign may be entirely absent. Exophthalmos is sometimes produced, and the globe is often pressed downward or to one side. The protrusion of the eyeball develops itself very gradually, and in some cases does not occur at all. The skin and subcutaneous cellular tissue become involved only slowly; suppuration may, exceptionally, ensue in connection with the diseased membrane, and a vast infiltration of the cellular tissue may occur, when the original disease loses its own characteristics amidst the symptoms of the cellular infiltration. If the disease goes on, caries of the adjacent bones may result. The vision of the affected eye may be only slightly affected, or may become totally extinct. Diplopia is produced when the movements of the globe are interfered with.

The treatment of acute periostitis should be actively antiphlogistic. When the case has become chronic, the iodide of potassium combined with sarsaparilla should be given. If any swelling occur in which fluctuation can be felt, an exploratory puncture should be made, and free exit given to the fluid, if any escape.

Periostitis is sometimes followed by nodes, producing protrusion of the eyeball, which may yield to the exhibition of the iodide of potassium. The following case affords a good illustration of this:—

CASE 1.—*Periodic Exophthalmos of either Eye, dependent on Rheumatic Periostitis of the Orbit.*

Jane G., æt. 35, was admitted into University College Hospital, under the care of Mr. Erichsen, in the summer of 1854, for a protrusion of the right eyeball, that had existed for four months. The eyeball was considerably thrust

forward from its socket, but was itself not enlarged, nor could any tumour be felt behind it; but just below the external commissure of the eye-lids was a small, hard, but slightly elastic projection, connected with the margin of the orbit. The tunics of the eye were somewhat congested; the vision of either eye, tested roughly, appeared perfect. She experienced hardly any pain in the eye, but most severe pain commencing in the cheek-bone, radiating hence to the temple, forehead, and root of the nose. The eyes had been affected with nystagmus from childhood. The precise nature of this case of exophthalmos was very clearly brought out by several concomitant facts. These were, the existence of a number of hard tumours connected with bones or tendons; there were such growths on the inner aspect of the right tibia, over the left tibia, above the right elbow, and on the tendon of the right biceps flexor cruris. All these tumours presented the same characters; they were hard, smooth, and indolent, and had existed for about eleven years.

The protrusion of the eyeball and some of the tumours had on several occasions disappeared under treatment, and subsequently re-appeared. She had at times suffered severe pain in the legs, especially at night, when she got warm in bed. She had had rheumatic fever four times, and had suffered more or less from rheumatism for many years. Her general symptoms had often come on after exposure to cold, and were always aggravated by it. Her mother had suffered dreadfully from "rheumatics." The patient herself was of a lymphatic, highly nervous temperament: she positively denied ever having had any symptoms of syphilis. Her father, she "used to think, had something wrong:" she was a poor, weakly child when born; but was not aware of ever having had any blotches on the body. She was married, and had had one child, and one miscarriage. She had been salivated several times for rheumatism, and had taken "pounds" of iodide of potassium, which was the only medicine that ever dissipated the nocturnal pains in her legs. This patient was treated with iodide of potassium in the hospital, and, after a time, the exophthalmos disappeared, and she left convalescent.

In February of the following year she was re-admitted into the hospital for most distressing hemicrania on the right side. The eye was not protruded, but exhibited considerable conjunctivitis and chemosis; the orbital growth was still there. She again recovered under iodide of potassium.

The following year she was re-admitted for a relapse of her symptoms. This time they affected the opposite (left) side of her head; severe hemicrania and slight but decided exophthalmos. The right side of the head and the right eye had remained permanently well, since she was last in the hospital, some ten months previously.

CELLULITIS OF THE ORBIT.

CELLULITIS OF THE ORBIT is characterized by dull pains in the orbit, by more or less exophthalmos, and by limited mobility of the eye, caused by exudation into the cellular tissue, and by remarkable tenderness when the eye is pressed backwards against its cushion of fat. The sight of the affected eye may be only slightly impaired, or wholly extinct. The disturbance of vision is caused, either by the process of exudation extending to the cellular tissue of the optic nerve, or by

the retinal circulation becoming obstructed, followed by congestion and serous infiltration of the papilla. The amblyopia has also been known to result from a partial separation of the retina, due to obstruction of the choroidal circulation. The eyelids soon become red and œdematous, and suppuration readily occurs. The matter may either present itself behind the conjunctiva or beneath the skin of the eyelid. During the acute stage of cellulitis, active antiphlogistic treatment should be employed, but when signs of abscess have become manifest, lukewarm fomentations and poultices should be used, and, as soon as fluctuation is detected, the matter should be evacuated, by a free incision, at the spot where the abscess points.

CASE 2. — *Traumatic Cellulitis of the Orbit; Spontaneous opening of Abscess; Cure.*

Maria J., æt. 15, the night previous to her application at the hospital (May 25th, 1864), was struck on the left eye with a fencing sword. Considerable bleeding ensued from between the lids. When we saw her, there was considerable swelling of the lids and conjunctiva; the pupil was dilated and fixed, whilst that of the uninjured eye was contracted and active; she was suffering great pain in the eye and left side of the head; the state of vision could not be investigated from the agitated state of the patient, and from the great pain she was in. There was no external wound of the lid or eyeball. She was ordered two drops of *Liq. opii sed.* three times a day, and *Lot. plumbi*.

May 31st.—Lids still considerably swollen; considerable protrusion of globe, with loss of power of everting it, and diminished power of inverting it. Pupil widely dilated, fundus oculi normal; reads 16 (Jäger) close to her.

R Hydrarg. c. cret. gr. iii, omni nocte;
and Ol. Jec. aselli ʒj, ter in die.

Up to this time she had been treated as an out-patient; she was then taken into the hospital. After a time, pus began to discharge from an opening below the globe, and from that time, the symptoms gradually subsided. The *exophthalmos* and diminished mobility of the eye disappeared entirely; but the pupil of the injured eye still continued a line wider than that of the other eye, and the contractile power of the iris remained impaired. When last examined, she read with the injured eye (with 30 in. convex) No. 19 (Jäger) at 20 feet; with the sound eye without a glass No. 18 at the same distance.

TUMOURS OF THE ORBIT.

TUMOURS OF THE ORBIT, whatever their nature, give rise to a certain set of symptoms common to all. The eyeball is protruded from its socket—*exophthalmos*—its mobility in some directions, depending on the situation of the tumour, is impaired; in consequence of which, binocular diplopia may exist. The pressure on the eyeball may

impair, or altogether abolish, vision, cause more or less pain in the eye and orbit, and may even lead to destructive inflammation of the eye; or the tumour may destroy the orbital walls, invade the brain or antrum, and cause corresponding symptoms.

The following are the chief kinds of tumours met with in the orbit:—

1. *Periosteal Growths*.—These are usually of a syphilitic or rheumatic character; and often subside under the treatment of the diatheses in which they originated.
2. *Bony Tumours*.—These may resemble the preceding group in their origin, or may arise apparently from traumatic causes, or spontaneously. These tumours may be of a spongy, soft character, may be invested by a thin osseous shell, or may be of a firm, at times dense, ivory structure. The extirpation of these osseous growths, if deemed advisable, may be undertaken on general surgical principles.
3. *Encysted Tumours*.—These generally become apparent as tense elastic swellings between the eye and its socket. The cyst may contain a serous fluid, or solid, fatty, or boiled-rice-like matter, or even hairs, or aborted teeth. If the contents of the cyst are fluid, simple punctures, or punctures combined with iodine injections, snipping off the end of the tumour, and stuffing its cavity with lint, or applying caustic to it, may be tried, or its complete extirpation attempted, the last being the practice to be adopted in case the cyst has solid contents.
4. *Sarcomatous Tumours*.—Under this head are comprised all those solid growths not of a cancerous nature. They may be extirpated without or with the eyeball, according as this is, or is not, implicated in the growth.
5. *Cancerous Tumours*.—During the earlier stages of such tumours of the orbit, their situation may be diagnosed by the signs given at the head of this section as compared with those given under the head “Tumours of the Eyeball.” In the later stages, both forms of diseases, as regards course, treatment, and termination, are essentially the same.

CASE 3.—*Melanotic Cancer of the Orbit; Operation; Recurrence; and Death.*

A woman, æt. 62, had suffered for eight or nine months from a protrusion of the eyeball. The eyeball was protruded from its socket, but apparently not enlarged itself; it was insensible to light. The interior of the eye was illuminable, but no details could be observed. The patient suffered great pain, which she referred to the temple and side of the head.

Mr. Laurence removed the tumour together with the eyeball, which was found to be firmly embedded in its substance; the growth was enveloped in a fine pseudo-cyst of cellular tissue, and presented all the obvious and microscopic characters of melanotic cancer; the eyeball itself was free from any morbid deposit; the vitreous was fluid; the retina partly detached; the lens nebulous. The tumour recurred *in situ* in about three months, when Mr. Laurence transferred the case to Mr. Weeden Cooke. The patient died in about three months afterwards, by which time the secondary tumour of the orbit had attained the size of a cricket-ball, and melanotic deposits were found within the cranium.

6. *Aneurismal Tumours*.—Aneurism by anastomosis and true aneurism of the ophthalmic artery are rarely met with in the orbit. The chief distinctive signs of such tumours are their pulsation and their bruit. Ligature of the common carotid has, on several occasions, been successfully performed in this disease.

Anaemia with Exophthalmos?

CHAPTER IV.

DISEASES OF THE EYELIDS.

THE eyelids are subject to œdema, erysipelalous and phlegmonous inflammation and abscess, all of which diseases must be treated on general surgical principles.

OPHTHALMIA TARSI.

OPHTHALMIA TARSI, or inflammation of the edges of the lids, presents some special characters. It occurs in a sub-acute or chronic form, very commonly in scrofulous children. The tarsal borders of the lids become red and thickened, and matter accumulates at the roots of the lashes. These thus become glued together; especially the first thing in the morning. The tears secreted in excess, in consequence of the inflammation, overflow the palpebral sinuses, run down, and excoriate the skin of the cheeks. The lashes often become loose, and fall out; and, in old chronic cases, may all disappear, leaving a raw, red, smooth, and thickened margin to the lid, constituting that very intractable condition known as "lippitudo."

There are two very common conditions of the puncta lacrymalia, which are frequently met with in lippitudo (especially in old people), which may, if overlooked, render the most protracted treatment ineffectual. We find the puncta everted, turned away from the surface of the eyeball, or skinned over by plastic membrane. In either case they no longer fulfil their physiological function—that of receiving the tears as they distil down over the surface of the eyeball. Hence arise watering of the eye, a continuance of the chronic conjunctivitis, and even ectropion—all three effects acting and reacting on each other, so as to form an accumulated fund of discomfort to the patient. Such cases, after having been treated *ad infinitum* by all varieties of lotions and ointments, we have, over and over again, seen cured at once by slitting up the canaliculus. Effects had previously been mistaken for causes.

The treatment of ophthalmia tarsi consists in warm fomentations

or poultices to the edges of the lids, and removal of the crusts of matter, followed by the application of the red or yellow ointment to the diseased surface beneath. In the lippitudinous stage, occasional pencilling the tarsal conjunctiva just within the free edge of the lid with nitrate of silver will be found a valuable adjunct to the above treatment.

HORDEOLUM.

HORDEOLUM, or STYE, is a small boil situated at the edge of the eyelid. It should be treated in its incipient stage by cold applications; when suppuration has commenced, by warm poultices, and, if necessary, by a puncture with a lancet to evacuate the pus. Styes sometimes occur as evidence of a debilitated constitution, which must be treated on general principles; and, if we are not mistaken, styes may arise from injudicious and prolonged use of the eyes.

ULCERATION OF THE EYELIDS.

There are two specific forms of ulceration of the lids worthy of notice: the *syphilitic* and the *cancerous*.

Syphilitic ulceration of the eyelids is sometimes the consequence of direct application of the virus to the part, but more commonly is the result of constitutional infection. The ulcer has a great tendency to spread in spite of ordinary local applications, and frequently yields only to specific treatment. If the disease be purely local, it may be sufficient merely to touch every portion of the sore very carefully with nitric acid; but, if it be secondary, the ordinary general treatment for syphilis should be employed.

Cancerous ulceration of the eyelids is generally of the epithelial variety. It commences as an induration and slight elevation of the edge of the lid, generally towards one or other angle. The skin covering it may be natural in colour, or pervaded by varicose vessels. This stage of induration is followed by a process of ulceration, which is remarkable for its slow progress, but it may extend so far as to destroy the whole of the eyelid, attacking the periosteum and bones of the orbit, and spreading down the cheek. The surface of the ulcer is smooth, with irregular edges, and a thin ichorous discharge exudes. Cancerous ulceration of the lid may be distinguished from syphilitic ulceration by its slow progress, the very slight implication of the surrounding integuments, and the history of the case.

The treatment is complete excision of the affected parts, if possible, or the application of caustics (chloride of zinc), astringent lotions, &c.

Rodent ulcer?
Lupus?

We now come to the malpositions of the lids. These are three in number: ectropium, entropium, and ptosis.

ECTROPIUM.

(*Eversion of the Eyelids.*)

There are two chief forms of this disease:—

1.—*Ectropium from Inflammation.*

As an acute affection, this generally originates in purulent conjunctivitis; *e.g.*, that of new-born infants, and arises from a spasm of the inner fibres of the orbicularis, which, by their constricting action on the swollen conjunctiva, force this outwards between the edges of the tarsal cartilages. The treatment is that calculated to subdue the primary inflammation. (*Vide Conjunctivitis.*) Chronic ectropium is met with in young persons as a result of protracted ophthalmia tarsi, attended with superficial ulcerations and cicatrices at the edges of the lids; in old persons with relaxed eye-lids, chronic conjunctivitis is generally the first cause of the ectropium, which becomes subsequently aggravated by the eversion or skinning over of the puncta lacrymalia. In both the above forms of chronic ectropium, pencilling the everted conjunctiva with arg. nitrat. in a line internal to the commencement of the eversion, emollient applications to the adjacent skin, and slitting up the lacrymal canaliculi, if necessary, &c., are the most efficient treatment.

2.—*Ectropium from the Contraction of Cicatrices of the Skin.*

This is a common result of wounds, burns, or ulcerations of any extent, and is only to be cured by operation. In mild cases this may be limited to a simple excision of a fold of conjunctiva, with or without separation of the skin from the cicatrix. In more severe cases, Sir W. Adams's plan may be combined—that of excising a triangular piece of all the tissues of the lid, and bringing the edges of the gap together with fine hare-lip pins, with a view to shortening the morbidly elongated lid. In other grave cases Dieffenbach's plan may be adopted of excising the cicatrix by a triangular incision, its apex downwards, and bringing the edges of the adjacent skin together with pins. In many cases it is necessary to transplant from the temple or cheek a flap of fresh skin. (*Vide Oph. Rev.*, vol. i.)

* hardly sufficient —
Tarsoraphy?

ENTROPIUM

(Inversion of the Eyelids)

Most commonly results from long continued catarrhal or granular inflammation of the palpebral conjunctiva. Cicatrices from the incautious application of caustics to granular conjunctiva may favour or hasten entropium. As a consequence of the lid being inverted the lashes are brought in contact with the eyeball (trichiasis), and set up considerable irritation and lacrymation, and may even cause complete opacity of the cornea. After the disease has lasted for some time, the palpebral aperture becomes shortened; the stretched lids press upon the eye, causing a further source of irritation and discomfort. In elderly persons, and especially those in whom the skin of the lids is lax and redundant, entropium may originate in an attack of conjunctivitis, or may result from the closure of the lids necessary after the extraction of cataract and other operations on the eye. This form of entropium should be treated by the application of collodion to the skin of the lids. There are three modes of operating for the cure of entropium and trichiasis in general use, and, prior to the performance of either, division of the external commissure should be practised if the palpebral fissure be shortened:—

1. By removing simply a small portion of the skin and muscle of the lid parallel to its ciliary margin, and uniting the cut edges by sutures.
2. By excising a strip of the cartilage, uniting the margins of the groove thus left, and then bringing together the edges of the integument with silver wire or silk sutures.
3. By passing two or three threads, at about the distance of 3''' from one another, through the skin and muscle of the lid from above downwards, taking care that the counter-puncturation with the ligature needle is made a little above the ciliary margin. The two ends of each ligature are then tied tightly on the outer surface of the lid, and after three or four days the ligatures are removed. This plan has yielded very satisfactory and permanent results, so far as we have tried it. In no instance has the operation been followed by suppuration, as is stated to be the case with the method proposed by Dr. Pagenstecher. The following case shows that it is not necessary, as in Dr. Pagenstecher's operation, to include the border of the lid in

*Both operations
Amputation of the Hair follicles.*

the ligature, so that the subsequent irregularity and distortion of the edge of the lid are avoided.

CASE 4.—Thomas C., æt. 64, came to the hospital with complete ptosis of the right upper lid and entropium of the lower. There had been partial ptosis of both upper lids for fifty years, from a blow with a cricket-stump, causing a fracture of the right parietal bone (concussion, meningitis, &c.). During the last six months the ptosis of the right upper lid had become complete. Both lids of the right eye were treated in the manner last described. The ligatures were removed in a week, by which time the eyelashes had resumed their normal position, and the entropium of the lower lid was completely cured. On looking straight before him, the maximum separation of the right lids was about an eighth of an inch, that of the lids of the left eye a quarter of an inch. The operation on the right upper lid was repeated twice subsequently, which enabled him to open the eyelids to the extent of 4", so that the lower margin of the upper lid corresponded exactly with the upper margin of the pupil. No suppuration followed any of the operations.

PTOSIS.

Inability to raise the Upper Eyelid.

This arises from several causes. The chief varieties are—

1. Ptosis arising from increased weight of the upper eyelid. This is mostly due to exudation into the substance of the lid from long continued inflammation.
2. Ptosis arising from a traumatic cause, as division of the fibres of the levator palpebræ, or of the nerve which supplies this muscle.
3. Paralytic ptosis (*vide* "Paralysis of the Third Nerve").

If an operation is indicated, one of two procedures may be adopted. Either an horizontal elliptical piece of skin may be excised, and the edges of the incision brought together by sutures; or a few ligatures (silk or silver) may be passed from below upwards, and then tightened so as to include portions of the palpebral skin in their grasp. We have found this application of the ligature-operation for entropium simple and efficient; an instance of it is furnished by the preceding case.

TUMOURS OF THE EYELIDS.

The two varieties of tumours commonly met with in the lids are the fibrinous tumour, or *Chalazion*; and the albuminous, or *Molluscum*.

Chalazion is a fibrinous tumour of the average size of a small pea, situated generally in the cartilage of the eyelid; the skin covering

its external surface is moveable, and but slightly reddened ; the conjunctiva covering its internal surface is red and rather vascular, the tarsal cartilage at that point becoming thinned by absorption. As chalazia present no distinct cyst, they cannot be well dissected out ; they may be laid open from the inside by an incision with a lancet, and the contents—a greyish gelatinous substance—pressed out by the nails, or emptied with a scoop. Any refilling of the cavity by blood soon disappears.

Molluscum is a tumour varying in size from that of a pin-head to that of a large pea ; the skin over it is thinned and transparent, the tumour shining through as a round smooth white projection. After incision it may be squeezed out of its bed by the nails, when it is seen to be a hypertrophied sebaceous gland. Mollusca are generally met with in groups, and one crop often succeeds another. The whitish fluid which exudes from mollusca is said to have the power of producing others on any part of the skin it is applied to.

Encysted Tumours containing sebaceous material, hairs, &c., are sometimes met with at the outer edge of the eyebrow, and should be dissected out.

In addition to the above, *Nævi* and *Anastomotic Aneurisms* occur in the eyelids, and present the same general characters, and require the same treatment, as erectile tumours in other parts of the body ; greater care, however, being required to avoid any undue loss of skin, as in that case the resulting cicatrix might produce ectropium.

CHAPTER V.

DISEASES OF THE LACRYMAL APPARATUS.

THE lacrymal gland is, occasionally, the seat of inflammation and suppuration.

INFLAMMATION OF THE GLAND may be either acute or chronic. The symptoms are pain in the situation of the gland, fulness above the external angle of the eyelids, followed by a red tense swelling in this situation, and inability to raise the eyelid. If the disease progress, the eyeball is forced forward, and suppuration of the gland ensues. The treatment should be antiphlogistic. When fluctuation becomes distinct, the lancet should be employed.

ENLARGEMENTS OF THE LACRYMAL GLAND are of four different kinds : Hypertrophy, Chloroma, Scirrhus, and Medullary Fungus.

In the early stage of enlargement of the lacrymal gland the chief symptoms are protrusion of the eyeball and heat and pain in the situation of the gland. In the next stage, the skin of the upper lid becomes swollen and puffy, and a projecting tumour is evident under the orbital arch. If the tumour continue to enlarge, the eye is forced forwards, downwards, and inwards, until either the orbital walls expand, or the eyeball inflame, suppurate, and burst. The greater number of cases of enlarged lacrymal gland are of the nature of *Chloroma*, a fibro-plastic tumour, the peculiar characteristic of which is its greenish colour. Enlargement of the lacrymal gland in its early stage should be treated by leeches, blisters, and iodine ; but if those measures do not cure the disease, the gland should be extirpated. It may, in some cases, be also necessary to remove the eyeball. The diagnosis of an enlargement of the lacrymal gland from an encysted tumour of its substance can only be made by an exploratory puncture.

THE PUNCTA LACRYMALIA may be everted or obliterated ("skinned over") from long-continued ophthalmia tarsi or ectropium; in either case, the tears, failing to reach the orifices, flow over upon the cheek.

OBSTRUCTION OF THE CANALICULI may depend on a swollen state of their lining membrane, on a stricture at some part of their course, or on their bore being obstructed by an eyelash, which has entered through one of the puncta.

ACUTE INFLAMMATION OF THE LACRYMAL SAC leads to a circumscribed swelling, deep-seated pain, and exquisite tenderness in the situation of the sac. These symptoms may be preceded by redness and œdema of the lids. The swelling of the mucous membrane, from inflammation, obstructing the passage of the tears to the nose, these flow over upon the cheek. The affected side of the nose is generally dry. If the inflammation is not checked, the sac suppurates and bursts, a fistulous opening, often very difficult to close, remaining in the skin.

CHRONIC INFLAMMATION OF THE SAC is either the sequel of an acute attack, or the result of obstruction of the nasal duct. The tears, collecting at the inner angle of the eye, run down and excoriate the cheek. There is frequently more or less fulness at the inner canthus; on pressing this, tears, at first clear, but in later stages of the disease mixed with mucus, regurgitate through the puncta. The symptoms of inflammation of the sac are, in some cases, only slight, but in others so acute, as to lead to an abscess, which may burst and open through the skin. As the inflammation subsides, the opening in the skin may close, or remain fistulous (true fistula lacrymalis). In the latter case the adjacent skin generally becomes red and thickened, from the constant irritation of the tears, which trickle out of the opening instead of passing down the nasal duct. Repeated abscess of the sac may end in caries of the lacrymal or superior maxillary bone, the surfaces of which are felt to be rough when touched by a probe passed through the fistulous opening.

OBSTRUCTION OF THE NASAL DUCT may be either congenital or the result of inflammation of its lining membrane, or of stricture in some part of its course. It is the most common cause of inflammation of the lacrymal sac.

Treatment.—Eversion and obliteration of the puncta should be

created by slitting up the canaliculi. We will suppose the lower canaliculus of the right eyelid to be the one to be slit up. The surgeon stands behind the patient, whose head he receives and steadies against his breast. He takes one of the minute directors, manufactured for the purpose, with the right hand, and passes it by the punctum through the canaliculus into the lacrymal sac. He then transfers the director to the left hand, holding it with the thumb and forefinger, whilst with the middle finger he draws the lower eyelid outwards, so as to put the canaliculus on the stretch. With his right hand he passes a cataract-knife through the punctum, along the groove of the director, and thus slits up the canaliculus to any desired extent. This may be limited in the case of an obstructed or everted punctum; but should the slitting up of the canaliculus be performed as a preliminary step to the introduction of probes into the nasal duct, it must embrace the whole length of the canaliculus, to ensure which the edge of the knife should be raised well up, as it is withdrawn.

Finely-pointed scissors may also be used for incising the canal. Dr. Giraud-Teulon has invented an instrument which combines in itself

FIG. 18.



the director and cutting-blade (Fig. 18). We find, however, that this instrument is very liable to get out of order, especially from moisture getting into the groove.

Acute inflammation of the sac is treated by leeches and evaporating lotions. As suppuration commences, warm poultices should be substituted for the cold applications. If the abscess point, it should be laid open freely and the poultices re-applied.

As soon as the acute inflammatory stage is over, the lacrymal passages should be explored by a probe. If there be any obstruction of the nasal duct, endeavours should be made to restore its normal calibre by the systematic introduction of probes.

The first step is to slit up the canaliculus (generally the lower one). Thus, as first shown by Mr. Bowman, we are enabled to introduce probes of considerable size into the sac. These probes are made of various materials—silver, lead, whalebone, and the laminaria digitata. They are made of six different sizes; but in practice only the larger ones are to be recommended. The silver probes are most generally useful; the whale-bone ones are, from their flexibility, less liable to

injure the mucous membrane of the passages, but are from the same property less easy to guide; the laminaria ones, after they are in the passages, gradually swell up from the imbibition of moisture, and thus dilate them.

In introducing a probe, it should be passed horizontally along the floor of the canaliculus until it enters the sac and can be distinctly felt to touch the nasal side of that cavity. The probe is then slightly withdrawn, directed into the nasal duct, and passed gently downwards and somewhat backwards, until it reaches the floor of the nose, or comes in contact with some obstruction. In the latter case, we must seek to pass the probe through the stricture into the nose with the same gentleness and caution that we should observe in passing a bougie through a stricture into the bladder.

The above method of treatment by dilatation has found much favour both at home and abroad, and possesses great advantages over the old style, which we now only employ after every other plan of treatment has failed. The treatment of lacrymal strictures by the modern method is as superior to that by the style, as the periodical dilatation of a urethral stricture would be to that of the life-long retention of an instrument in the urethra.* On the introduction of this method, it shared the common fate of all novelties: it was either rejected *in toto* by those who either could not, or, what is worse, would not recognise its advantages; or, on the other hand, its value was, we believe, overrated by those who adopted it. We have ourselves pursued it from its first appearance: in many instances we have found it easy and efficient; in others it has proved difficult and unsatisfactory in its application. In such cases the lacrymal sac may be destroyed by caustics or the actual cautery—a procedure which, however apparently illogical in theory, has proved successful in practice.

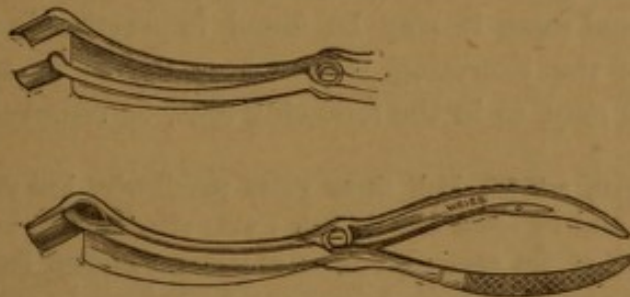
Obliteration of the Lacrymal Sac is performed in the following manner:—

The sac is opened by a free incision and thoroughly cleansed. After the bleeding has ceased, the lips of the wound are held apart by Manfredi's speculum (fig. 19), which is provided with a plate to protect the cheek from the caustic. The surgeon then freely cauterises the interior of the sac with a piece of lint steeped in some deliquescent caustic, such as butter of antimony or perchloride of iron, taking care

* This is our opinion; but it is only right to say that some surgeons still consider the style the best remedy for obstructions of the nasal duct.

to touch every part of the wall, and especially the lacrymal orifices. The after-treatment consists in iced-water applications for some hours after the operation, till all acute pain has subsided, when they may be replaced by warm poultices. In a few days the slough separates


FIG. 19.



and leaves a granulating surface, which may be dressed with dry lint. A leaden probe must now be introduced through the canaliculus (which should be slit up prior to cauterization), into the nasal duct, and must be there retained until the cicatrization of the wound is complete. By this means the tears will be encouraged to flow in their normal channel, and the external opening will rapidly heal.

After repeated inflammations of the sac, or after ineffectual attempts have been made to cure the disease by the above methods, the *style* may be tried. An incision is made with a narrow, straight bistoury just below the tendo oculi, which, on drawing the eyelids outwards, may be felt as a rounded cord, passing inwards from the inner canthus. The bistoury is then passed downwards and outwards into the lacrymal sac, and serves as the guide for introducing the style into the sac, after which the bistoury is withdrawn, and the style left in the sac. A silver style (fig. 20), about $1\frac{1}{4}$ inch long, with its neck at an obtuse angle to the shaft, and surmounted by a rounded head, is to be passed into the nasal duct. The style should previously be put through a piece of adhesive plaister to prevent it sinking into the sac. Every morning it must be removed and cleansed, and immediately replaced in the nasal duct.

FIG. 20.



EPIPHORA

is excessive secretion of tears. It may depend on mechanical irritation of the conjunctiva from a foreign body, from an inverted eyelash, &c., or on conjunctivitis or phlyctenular ophthalmia.* Epiphora may be

* why not also ulcer of cornea

also caused by disorders of the chylopoietic viscera, by worms, teething, &c., or may, as is well known, occur as a reflex nervous manifestation of mental emotion or hysteria. The treatment of epiphora must be directed to its cause. Epiphora must not be confounded with the accumulation of tears due to mechanical obstruction of the lacrymal excretory organs (*stillicidium lacrymarum*).

In exceptional cases it may be found impracticable to restore the perviability of the excreting lacrymal conduits: in such cases, the lacrymal gland may, as in the following case, be removed:—

CASE 5.—A man, æt. 25, had, three years previously, had the inner parts of his left eyelids burnt by some caustic soda; ever after this he had suffered from constant watering of the eye. No trace of either punctum lacrym. was seen. An ineffectual attempt was made to discover the canaliculi by excising the tissues over their presumed site. A little while afterwards, Mr. Laurence made an incision of about $1\frac{1}{4}$ in. below the supra-orbital ridge into the orbit, and was thus enabled to expose and remove the lacrymal gland, which was perfectly healthy. Within four days after the operation the watering of the eye had ceased; nor was the eye-ball unduly dry.

The operation for removing the lacrymal gland is so easy that it might not be unfairly argued, whether it do not deserve a more extended application, as a radical cure for cases of inveterate lacrymation. In fact, Bernard (*Annales d'Oculistique*, x., 193) made some such proposition upwards of twenty years ago.

CHAPTER VI.

DISEASES OF THE MUSCLES OF THE EYE.

No part of ophthalmic surgery has made greater advances of late than the pathology of the muscles of the eye; and it is but right to say, that these advances are chiefly due to the labours of Professor v. Gräfe, whose elaborate papers will be found in the "Archiv f. Ophthalmologie." The basis of his researches was the determination of the normal actions of the various ocular muscles. These actions are either those of association, or of concurrence of the eyeballs. If a person looks, say, to the right, the external rectus of the right eye is associated with the internal rectus of the left, and *vice versa* if he looks to the left. Here we have an example of the associated action of the two muscles. But if a person regards an object in the visual axis with both his eyes, the two internal recti act together, in harmony with the ciliary muscles. Here we have an example of concurrent (or accommodative) action of the ocular muscles. If the natural equilibrium of force of the muscles be disturbed, the optic axes are no longer directed to the same point, and double vision (diplopia) ensues. In the case of convergent squint, the resultant right-hand image belongs to the right eye, the left-hand one to the left. But if a divergent squint arise (either from excessive action of the external rectus, or deficient action of the internal rectus), then the images no longer correspond, but are crossed, *i. e.*, the right-hand image is perceived by the left eye, and *vice versa*.* In the above instances the double images exhibit simply a lateral separation; but it may be readily understood that if the superior or

* Double images may be produced artificially. Pressing the eye-ball, or eye-balls, inwards leads to corresponding double images; pressing them outwards, to crossed ones; and so forth. If we look at a distant object, but direct the eyes to a near one, corresponding double images arise; if we look at a near object, but direct the eyes to a distant one, crossed double images arise; and so forth. If a prism be held before the eyes, double vision ensues, varying in its characters according to the direction of the angle of the prism.

inferior rectus, or either of the obliqui, be affected, the double images will present corresponding differences of elevation and inclination. It may further be easily conceived that the ocular muscles may be so slightly affected (paralysed or contracted) that any deviation of direction of the eyeballs is quite inappreciable to the eyes of the observer. In such a case, we may, by an inverted order of reasoning, utilize the relative positions of the double images to determine which muscles are affected—in a word, substitute a subjective for an objective method of diagnosis.

It would be foreign to the scope of this work to give an analysis of the actions of the ocular muscles. This will be found elaborately treated of in Alfred Gräfe's "Klinische Analyse der Motilitätsstörungen des Auges." The following propositions form the basis of such an analysis.

- A. 1. The rectus internus moves the eye inwards.
 2. " externus " outwards.
 3. " superior " upwards and inwards, and inclines its vertical meridian inwards.
 4. The rectus inferior moves the eye downwards and inwards, and inclines its vertical meridian outwards.
 5. The superior oblique rolls the eye (inclines its vertical meridian) inwards, and moves the eye downwards and outwards.
 6. The inferior oblique rolls the eye (inclines its vertical meridian) outwards, and moves the eye upwards and outwards.

Hence may be deduced—

- B. 1. The eye is moved directly inwards by the rectus internus.
 2. " " outwards " externus.
 3. " " upwards " superior and the obliquus inferior.
 4. The eye is moved directly downwards by the rectus inferior and the obliquus superior.

C. Double images may exhibit :—

1. A lateral separation. This may be *corresponding*, *i. e.* the images correspond to their respective eyes : thus, if in a case of paralysis of the right rectus externus a red glass is held before the right eye, and a patient look at a flame, he sees two flames, a red one on his right and an uncoloured one on his left. Or the diplopia may be *crossed* : thus, if in a case of paralysis of the right rectus internus the same experi-

ment be performed, the red image appears on the left, the uncoloured one on the right.

2. A difference of level: one image appears higher than the other.
 3. An inclination: the images do not appear parallel, but inclined to one another.
- D.
1. In paralysis of the internal rectus, and consequent divergent squint, the images are crossed.
 2. In paralysis of the external rectus, and consequent convergent squint, the images are corresponding.
 3. In paralysis of the superior rectus the diplopia occurs:—
 - (a) only in planes above the horizon, and increases in degree with the elevation of the plane of vision.
 - (b) the image formed in the paralysed eye appears above that formed in the sound one.
 - (c) the images are crossed.
 - (d) the images are oblique, diverging upwards.
 4. The phenomena of paralysis of the inferior rectus may be deduced from A 4 and D 3.
 5. In paralysis of the superior oblique the diplopia occurs:—
 - (a) only in planes below the horizon, and increases with the depression of the plane of vision.
 - (b) the images are corresponding ones.
 - (c) the image of the paralysed eye appears lower than that of the sound one.
 - (d) the images are oblique, converging upwards.
 6. The phenomena of paralysis of the inferior oblique may be deduced from A 6 and D 5.

The following cases partially illustrate the above propositions:—

CASE 6.—*Paralysis of the external rectus muscle:—lateral, corresponding Diplopia.*

Ann Brown, æt. 24, admitted under the care of Mr. Laurence, on March 25th, 1862, on account of a "dazzled" state of her vision, which she especially noticed in going up or down stairs; but which was at once relieved when either eye was closed. We found the vision of either eye normal: when she used both eyes, her vision was confused; but no distinct double vision ensued, till we placed a coloured glass before either eye, and told her to regard a candle-flame. Then we found she saw two flames, which exhibited a simply lateral separation, thus: ||—the coloured flame appeared on the same side as that of the eye before which the coloured

glass was held. When the candle was held 3 feet from her—(1) when it was directly in front of her, she saw two flames, 3 inches apart; (2) when it was moved to her extreme left, this separation increased to upwards of a foot; (3) when it was moved to her extreme right, the double vision disappeared. This last result ensued in the first position of the candle, when a prism of 13° was held with its base outwards before the left eye. In all the experiments no difference of level, nor any obliquity of the images, was observed. We also observed an inversion of $1\frac{1}{2}''$ of the left eye; perfect power of inverting either eye; but deficiency of everting power of $2\frac{1}{4}''$ of the left external rectus muscle. The diagnosis was therefore,—uncomplicated, partial paralysis of the left external rectus muscle.

CASE 7.—*Paralysis of the right inferior rectus, and superior oblique muscles.*

Jane C., admitted under the care of Mr. Laurence, on March 26th, 1862, for double vision of two months' duration. When a piece of red glass was held before her right eye and she was told to look at a candle-flame, placed at a distance of 6 feet directly in front of her, and in the same plane as that of her eyes, she saw two flames, one above the other $\frac{1}{2}$; the lower one was red; the more the candle was lowered, the wider was the separation of the images, till when the candle was placed on the floor, the separation increased to one foot. When she looked upwards, no double vision ensued. For a level corresponding to that of her eyes, a prism of 13° corrected the double vision; its base having to be held upwards in the case of the left eye, and downwards in that of the right eye. The diagnosis was paralysis of the right inferior rectus and of the superior oblique.

CASE 8.—*Paralysis of the internal and inferior recti, and of the levator palpebræ.*
—*Recovery.*

John H. æt. 46, a mathematical instrument maker, a most intelligent man, was admitted November 5th, 1862. He was seized a fortnight previously with most severe pains in the right side of the head. After these ceased, the following symptoms arose.—*Right eye*: Ptosis, divergent strabismus of $2''$; pupil normal; with either eye vision perfect; with both eyes, crossed double vision. The further to the left the flame of a candle was moved, the greater the lateral separation of the images became. In the median, horizontal plane there was also a difference of level of the flames, that corresponding to the distorted eye being the lower: in a plane 10 inches above that of the eyes there was no difference in level of the images; but in a lower plane it increased. The diagnosis was paralysis of the internal rectus, inferior rectus, and levator palpebræ of the right eye. He was treated with colchicum and iodide of potassium: in 17 days he was completely cured.

At the risk of repetition we subjoin the general phenomena of paralysis of the third nerve.

PARALYSIS OF THE THIRD NERVE.

The paralysis may be complete or partial; and may affect one or more branches of the nerve. Cases of complete paralysis of all the branches of the third nerve exhibit the following signs:—Ptosis; divergent strabismus; complete loss of power of turning the eye

either inwards or upwards, and much impaired power of turning downwards ; a dilated fixed pupil ; in many cases crossed binocular diplopia.

From these signs the reader may easily infer those which a case of partial or limited paralysis of the branches of the third nerve would present. At the onset of the disease the cause of the paralysis should, if possible, be ascertained, and be sought to be removed on general medical principles. Operations should not be hastily resorted to, as many cases recover under general treatment after periods of variable duration. If, however, after prolonged treatment, no amelioration ensue, or if the affected muscles exhibit a tendency to morbid contractions, the external rectus should be divided, and the ptosis remedied by an operation. *Vide* "Strabismus" and "Ptosis."

STRABISMUS (SQUINT).

Strabismus is a mal-position of one or both eyes, which prevents the patient directing the two eyes simultaneously to one and the same point.

1. CONVERGENT STRABISMUS is an unnatural inversion of one or both eyes. If the squint is caused by some optical defect of the eye, one eye becomes straight when the other is excluded from vision, the *latter* eye then squinting. If this is, however, caused by paralysis of the external rectus muscle, the patient possesses little or no power of everting the affected globe. In the latter case, the squint depends either upon a simple want of power of abducting the eye, or upon a morbid contraction of the internal rectus, or upon these two circumstances conjoined. By far the greater number of cases of convergent strabismus, however, depend upon an optical defect of the eye. The eyes are generally *hypermetropic* (*vide* "Hypermetropia"). To see close objects accurately, the person endeavours to obtain a maximum amount of accommodation by converging his optic axes to a nearer point, than that at which the object is actually situated : double vision is the result of this disharmony. The patient instinctively gets rid of the double vision by inverting the one eye, preferring convergent strabismus and monocular vision to the annoyance of double images.* This form of strabismus is at first only periodic, and may be kept in abeyance by correcting the hypermetropia by appropriate convex glasses ; but it subsequently becomes constant and confirmed, and is then only curable by division of the internal rectus. The operation

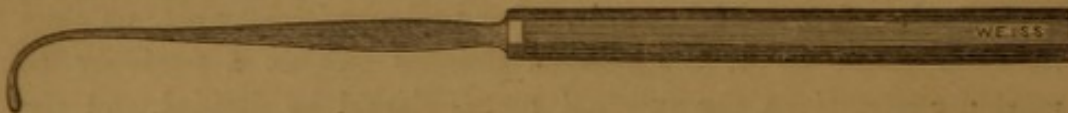* At the commencement of the disease, especially in young children, if we apply a strong solution of atropine, and thus paralyse the accommodation, the consensual squinting often disappears.

for division of the muscle is performed thus:—A fold of the conjunctiva, immediately over the insertion of the internal rectus (about two lines from the cornea), is raised by toothed forceps, and is divided

FIG. 21.





FIG. 22.



by a blunt-pointed scissors (fig. 21); the subconjunctival cellular tissue is similarly divided down to the sclerotic. The strabismus hook (fig. 22) is then slid beneath the muscle, which is divided by the scissors at its tendinous attachment to the sclerotic. The edges of the conjunctiva are united by a fine silken suture. Or the conjunctiva may be opened altogether below or above the insertion of the rectus tendon, and this divided, subconjunctivally, by scissors. After considerable experience of both methods, we give the preference to the former, which is also that adopted by v. Gräfe and Donders. The sinking in of the caruncula lacrymalis, the proptosis and the eversion of the globe met with, occasionally, after the division of the conjunctiva, are accidents which are rarely witnessed now-a-days, since the incisions are performed with greater caution than they were at the early periods of the operation. Much depends, too, in this point of view, on the form of instruments employed. The scissors should be narrow, long, probe-pointed, and sharp, and so adapted to divide the tendon with a minimum amount of separation of their blades. The hook should be fine and uniformly rounded: our own experience of flat hooks (fig. 23) is, that they are inconvenient, on account of being

FIG. 23.



available only in one direction, if we wish to avoid any injurious separation of the subconjunctival tissues.*

From the preceding it is evident that division of the internal rectus

* For further details, see *Oph. Review*, ii. p. 61 and seq.

corrects only the strabismus, not its cause. In many cases of long-standing strabismus, the inverted eye has become highly amblyopic: this depends, probably, on long disuse of the retina; for in no case that we have examined ophthalmoscopically have we been able to detect any organic changes in the fundus oculi at all commensurate with the functional disease. In such cases we must remain satisfied with the operation; but if a fair amount of binocular vision still exist, we must correct the hypermetropia, in which the strabismus originated, by convex glasses; otherwise there is great danger of the squint recurring. We here have found the stereoscope a valuable adjunct in the treatment after tenotomy. The patient should be instructed in the use of the transposition-slides spoken of at p. 17, and also in the essential nature of stereoscopic effect; for this latter purpose the best figures to employ are geometrical ones, destitute of shading, and thus incapable of misleading by the quasi-stereoscopic effect given by *chiaroscuro*. After the operation he should thus daily exercise his binocular vision with the stereoscope. Indeed, cases of periodic strabismus may be thus cured. In all cases we should, of course, also conjoin the glasses that correct any existing hypermetropia.

Strabismus convergens is said to be often the result of opacities of the cornea; but in the majority of cases hypermetropia is the true cause. In exceptional cases myopia lays the foundation of the inversion of the eye.

CASE 9.—*Hypermetropic Strabismus; Tenotomy; Relapse. Cured by correcting the Hypermetropia.*

Mr. Laurence operated by double tenotomy on a boy, *æt.* 11, for a concomitant convergent squint of the right eye, both eyes being hypermetropic to $\frac{1}{18}$, and having an acuteness of vision (S) of about $\frac{1}{2}$. Three weeks after the operation, the squint had recurred to the degree of 2'' in the right eye, although the tenotomy had been very complete. He was ordered to wear 16-inch convex glasses. When again seen, three weeks later, the squint had disappeared, and had not returned three months afterwards.

2. DIVERGENT STRABISMUS is an unnatural eversion of one or both eyes. This usually depends on myopia. Along with the myopia, however, certain concurrent circumstances are usually observed: enlargement of the globe, especially in its antero-posterior axis; insufficiency of the internal recti muscles; or excessive myopia of the deviated eye. At the onset of such a case a want of power of sustaining the convergence of the eyes (insufficiency of the internal recti—*vide* "Asthenopia") for near objects is observed, resulting ulti-

mately in a divergent squint of one eye, or less commonly of both. Very common causes of divergent strabismus are also amblyopia or amaurosis, from whatever cause they arise ; and paralysis of the internal rectus. In the first stages of myopic strabismus, concave glasses may be tried ; but when the squint is confirmed, division of the external rectus will be required. This is performed similarly to the division of the internal muscle, only that a much freer division of the conjunctiva and of its subjacent tissue is admissible, or even imperative. In extreme cases it may be necessary to transplant the tendon of the rectus internus forward at the same time that the rectus externus is divided. The stereoscope, as in the case of convergent strabismus, should be employed in the after-treatment.

[For further details of the pathology and treatment of strabismus, *vide* the several papers of v. Gräfe and Donders in the *Archiv f. Ophthalmologie* ; "On the Pathogeny of Squint," by Prof. Donders, translated by E. Perceval Wright, M.D. ; "Die Motilitätsstörungen des Auges," by Dr. Alfred Gräfe.]

NYSTAGMUS.

NYSTAGMUS is an involuntary oscillation of the eyeball. This affection depends, according to Böhm, either on an unnatural rigidity or the reverse of a muscle (mostly of the internal rectus), and is thus divided by him into two forms, tonic and atonic nystagmus. Mackenzie, with more reason, we think, considers it as caused by "clonic convulsion of the recti." Nystagmus is often congenital, and associated with strabismus, or with some optical or amblyopic defect of the eye. It has been treated by division of the internal recti muscles, and correction, as far as possible, of the visual defect ; but hitherto with but little success.

CHAPTER VII.

INJURIES OF THE EYE AND ORBIT.

CONTUSIONS AND ECCHYMOSIS OF THE EYELIDS are the results of blows or falls upon these parts. Ecchymosis of the lids is due to extravasation of blood into their loose areolar tissues. If the blow have been severe, leeches should be applied, followed by the use of evaporating lotions. Warm fomentations may in some cases afford relief.

INCISED AND LACERATED WOUNDS of the eyebrow and eyelids should be treated on general principles; great care should, however, be taken that the edges of the wound are accurately brought together and retained by a few points of interrupted suture. The silver wire suture may be employed advantageously in such cases. In examining a wound of the brow or lids, it should be bornè in mind that some portion of the instrument by which the wound was inflicted may possibly be concealed in the orbit.

The following remarkable case of the kind is reported by Mr. Carter, in the first volume of the *Ophthalmic Review*, p. 337 :—

CASE 10.—*Foreign Body impacted in the Orbit.*

“For my knowledge of the following case I am indebted to the kindness of Alfred Clarke, Esq., of Gloucester.

G. W., a hale, vigorous old man, turned 73 years of age, fell downstairs in the dark, being drunk, some time in the last few days of May. He did not lose consciousness from the fall. He injured the nasal side of the right eye, and bled very freely from the wound; but he did not seek medical aid till June 1st, when he went to Mr. Clarke, who found a ragged conjunctival wound and much swelling of the lids, and ordered a simple dressing. The patient presented himself at intervals until the 6th of June, when Mr. Clarke discovered the presence of a foreign body in the wound, but deferred its removal until the following day, when he visited the man at his home. He then felt the extremity of a piece of iron, which he seized with forceps and attempted to withdraw. By using considerable force, and after much time, he removed the entire shaft of a cast-iron hat-peg, measuring three inches and three-tenths in length, and weighing twenty-five scruples. On further inquiry, Mr. Clarke found that this hat-peg had been one

of a row, screwed to the wall near the bottom of the staircase ; so that the man must have fallen upon the end of the peg, and must have broken it by his momentum after it had become completely buried in his orbit. The base of the

hat-peg was still in its place in the row, and presented a recently fractured surface fitting accurately to that of the portion removed from the patient. The annexed woodcut represents the hat-peg and its base precisely of their natural size.

When the question arose with regard to the exact period of impaction, no one could answer it. There were the seven days during which the patient had been under medical observation ; but he could not remember on what day of the week he fell down, and could only say that it was four or five days before he went to the doctor. Four or five, with an illiterate old man, means simply *x* ; but it may be presumed that the actual period of impaction was between ten and twenty days. The patient recovered without a single unfavourable symptom.

To-day, November 12th, I have made a careful examination of the injured part.

The hat-peg appears to have lacerated the conjunctiva of the globe a little to the inner side of the cornea, and to have passed between the ocular muscles and the lacrymal apparatus without injury to either. About a line from the corneal margin, and below the horizontal meridian of the eye, there is an excrescence as large as a small hemp-seed, and resembling the little growths that sometimes follow operations for strabismus. From this excrescence, as an apex, a conical patch of vascularity, like a pterygium, extends to the caruncle, and the patient says that a few exceedingly small fragments of bone have worked out. The excrescence probably conceals the opening of a fistula ; but I sought vainly for such an opening with a probe. The vision and movements of the eye are unimpaired, and the lacrymal apparatus is perfect. But the excrescence, by resting on the margin of the lower lid, diverts a por-

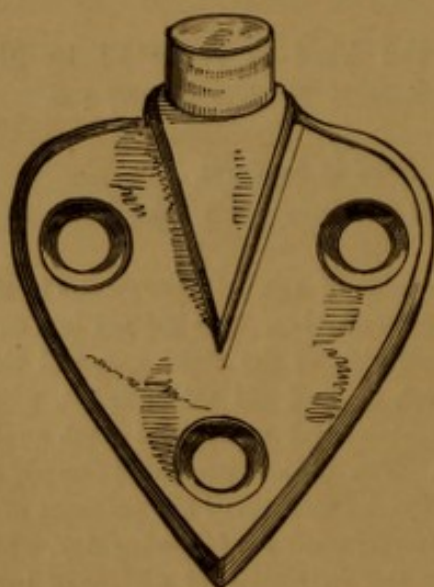


FIG. 24.

tion of the tears from their proper course, and occasions a slight epiphora. This is, indeed, the only inconvenience that the patient has sustained from the injury.

Mr. Clarke was compelled to use very considerable force to remove the hat-peg, and had to loosen it by lateral movements, as well as by direct pulling. Partly from this reason, and partly from his natural astonishment at its bulk and length, he can scarcely be certain of its direction; but, from the relation of its original position to the probable direction of the fall, as well as from anatomical considerations, and from his impression at the time, he thinks that its point must have been received in the antrum of the opposite side. The entire absence of head symptoms, however, must not be taken as conclusive upon this part of the question; since there are cases on record, perfectly authenticated, in which undoubted injuries to the brain have been recovered from without any symptoms that could have revealed their existence."

BURNS AND SCALDS may be produced by the direct application to the eyelids of fire, boiling water, or caustic fluids. Particles of hot metal and ignited gunpowder are also frequent causes of burns. Burns of the conjunctiva are very liable to produce symblepharon.

Particular care is required in the treatment of all cases of scalds and burns of the eyelids to prevent, on the one hand, occlusion of the lids from plastic union of their edges, and on the other, ectropium and lagophthalmos from contraction of the resulting cicatrix. To obviate the first evil, the patient should be directed to open the eyes frequently, and to apply a little simple ointment along the margins of the lids; to avoid the last two evils, the lids should be kept as much as possible on the stretch during the cicatrizing stage, and be bandaged with extreme care.

FOREIGN BODIES imbedded in the cornea should be removed with a small gouge, or a cataract needle; the gouge, however, is the more useful instrument (fig. 25). Where the epithelium of the cornea has been abraded, a drop of castor-oil is a very soothing application after the foreign body has been removed. If the foreign substance is buried in the conjunctiva, it must be seized with a fine pair of forceps, and a small portion of the conjunctiva, containing it, excised with curved scissors. A cursory examination of a patient's eye often fails to detect the presence of a foreign body; in which case the palpebral conjunctiva should be exposed and carefully examined. The inner surface of the lower lid is easily exposed by directing the patient to look upwards, at the same time that the lid is drawn downwards. To evert the upper eyelid, its free border should be held by the left thumb and forefinger, and be drawn downwards and forwards; the right thumb-nail, or a probe, is then applied over the attached border of the tarsal cartilage, and serves as a fulcrum on which the eyelid may be everted by the

FIG. 25.



left hand. The loose conjunctiva of the upper palpebral sinus may be still more completely exposed by forcing it downwards with the probe. A spill of blotting paper is very useful for removing particles which are loose in the eye. Foreign bodies in the cornea are generally imagined by the patient to be situated beneath the upper lid. Particles of mortar, or lime, should be carefully removed; the lids should be everted, and the surface of the eye syringed with water, or weak vinegar and water. Symblepharon is often produced by burns from lime. The conjunctival sac should be well syringed with water after injuries from acids or alkalies. Not unfrequently a foreign body may remain for a considerable time concealed under the upper eyelid, without either the patient, or the surgeon, being cognisant of its presence. Dr. Mooren relates a case of conjunctivitis which had been treated for four months by all kinds of eye-waters; upon the removal of a piece of straw, which lay concealed in the upper palpebral sinus, the disease at once disappeared.*

Foreign bodies, penetrating the cornea, may lodge in the anterior chamber, or, passing onward, may wound the iris or lens. A foreign body, if small, may leave no visible trace of its passage through the cornea; if it is seen in the anterior chamber, it should be extracted by fine forceps through an incision of the cornea; but if it is lodged in the iris or lens, the portion of iris with the foreign body should be excised forthwith. The question whether, or not, the opaque lens should be removed at the same time, will be referred to under the head of "traumatic cataract."

BLOWS UPON THE EYEBALL not unfrequently cause rupture of the cornea or sclerotic, dislocation of the lens, traumatic cataract, paralysis of the iris and ciliary muscle, hæmorrhage into the chambers of the eye, paralysis, or separation of the retina. We have also observed a case of central scotoma from an exudation in the macula lutea, as the result of a blow.

After receiving a severe blow upon the eye, the patient should be kept as quiet as possible; if either of the coats be ruptured, the eye should be carefully bandaged, and subsequent inflammation should be combated by free leeching and general antiphlogistic treatment.

WOUNDS OF THE CORNEA are often accompanied by wounds of the capsule and lens, which are distinctly visible by lateral illumination. If the cornea alone be wounded, and the iris be not prolapsed, it will be sufficient to bandage the eye with a compress, and apply cold water frequently; but if the lens be also wounded, there will be

* Ophthalmic Review, vol. ii. p. 310.

danger that the aqueous humour, having gained admission into its substance, may cause it to swell and press the iris forward, causing glaucomatous tension of the eyeball, and eventual loss of vision. In such a case, iridectomy should be at once performed. Should this fail to arrest the inflammatory action, the cataractous lens must be removed by the linear method.

FISTULA CORNEÆ.—This is the result of a penetrating wound of the cornea which has remained unhealed, but has become closed over by the conjunctiva. The consequence is, that the aqueous humour escapes from the anterior chamber, and elevates the conjunctiva in the form of a vesicle. The swelling should be removed with the scissors, and the corneal aperture touched with lunar caustic.

CHAPTER VIII.

DISEASES OF THE CONJUNCTIVA.

CONJUNCTIVITIS.

INFLAMMATION of the Conjunctiva is characterized by the following signs:—The conjunctival circulation of the globe, which in the uninflamed eye is hardly, if at all, seen, becomes now plainly visible as a network of florid-red, tortuous vessels, which may be moved by the finger over the subjacent sclerotic. The palpebral conjunctiva, when inflamed, has a scarlet, velvety appearance, without the individual vessels being separately perceptible. The eyelids generally participate more or less in the inflammation and become red, swollen, and tender. The pain is superficial, and is referred by the patients to the eyelids or the surface of the globe, and is often compared by them to that which would be caused by sand in the eye. The secretion from the inflamed conjunctiva varies in different groups of cases, and may be taken as the basis of the classification of the inflammations of the conjunctiva, which we now submit:—

1. *Aqueous Conjunctivitis*.—The discharge is of a watery nature, and is probably furnished partly by the mucous membrane, partly by the irritated lacrymal gland. Aqueous conjunctivitis occurs in two forms: as an acute disease, and as a chronic one. Acute aqueous conjunctivitis generally speedily yields to moderate local depletion and counter-irritation, followed by astringent lotions. In the more severe cases nitrate of silver drops may be necessary. (*Vide* under *C. mucosa*.) Chronic aqueous conjunctivitis requires a more prolonged treatment of a similar nature.

2. *Mucous Conjunctivitis*.—[Catarrhal Ophthalmia.]—The discharge is mucous and puriform. This inflammation may produce a mere slight mucous discharge, accompanied by a hardly perceptible congestion of the conjunctival vessels. It may, through intermediate stages, present signs of the most intense vascular reaction. The vessels

may be so turgid with scarlet blood, as to give way and pour forth extravasations ; the eyelids are greatly swollen and tender ; the discharge is profuse, and so glutinous, as to prevent the patient opening the eye in the morning, without great pain and suffering. Mucous conjunctivitis is also often met with in a subacute or chronic form. The most essential part of the treatment of mucous conjunctivitis is the application of nitrate of silver drops, varying in strength from gr. iv to gr. x ad ʒj, according to the severity of the symptoms, to the inflamed conjunctiva. Should the palpebral conjunctiva alone, or chiefly, be affected, then the eyelids should be everted, and there held together, by the surgeon's thumb and forefinger, so as fully to expose the palpebral, and at the same time protect the ocular conjunctiva from the action of the nitrate of silver drops, which are then allowed to flow from a camel's hair brush along the thumb-nail down on to the inflamed palpebral conjunctiva. After a few seconds this is carefully freed from any remaining nitrate by a second brush-full of warm water. Should the ocular conjunctiva participate to a marked degree in the inflammation, then the drops may be applied to the whole conjunctival surface. These applications may be repeated at intervals varying with the acuteness of the symptoms.—Some astringent drops (Vin. Opii, *e. g.*) may be applied every night, and some mild cerate night and morning to the margins of the lids, to prevent their agglutination. During the day the eyes may be bathed with warm or cold water, the choice of either being regulated by the patient's feelings. We have found it rarely necessary to resort to local depletion or counter-irritation.

3. *Purulent Conjunctivitis*.—The discharge is truly purulent in its character, and mostly very profuse. There are three forms of this disease which require special notice :

(a) *C. purulenta neonatorum*—the ophthalmia of new born-infants. This is a very characteristic inflammation. It generally occurs soon after birth. The eyelids are congested and swollen, and glued together ; on the surgeon's opening them, a profuse, thick, yellow discharge wells out ; on everting the lids, their conjunctiva is seen to be highly congested, swollen, and velvety ; the cornea may be cloudy, opaque, or ulcerated : the iris may be prolapsed through an ulcer which has perforated the cornea ; or the cornea may be more or less staphylomatous. Such are the conditions which may occasionally be met with in neglected or mistreated cases, and which furnish a large quota of the inmates of our blind-schools. Yet there

is perhaps no form of conjunctivitis more amenable to early and efficient treatment. The eyelids must be held open, and a strong solution of nitrate of silver (of a strength varying from gr. x to ʒss ad ʒj, according to the severity of the case) dropped by the surgeon on the eye; this application will be found to arrest the specific character of the discharge, and may be repeated at intervals of two or three days, the discharge being in the interim sedulously removed, as fast as it accumulates, by the nurse with an astringent lotion (alum or zinc). The discharge is contagious and will give rise to the most violent purulent conjunctivitis, if applied to a healthy conjunctiva, so that great care must be taken by the surgeon and the nurse not to use the sponges, brushes, &c., for other purposes. This treatment, with a little mild cerate to the edges of the lids, will generally suffice speedily to effect a cure. Scarification of the congested palpebral conjunctiva, inunction of the Ung. Hydrarg. nitric-oxyd., &c., have also been recommended; but we have never met with a case which did not yield to the treatment above described. For the treatment of the sequelæ of conjunctivitis purulenta neonat. *vide* corneitis, staphyloma.

(b) *Gonorrhœal Ophthalmia*.—This presents the symptoms of purulent inflammation of the conjunctiva in its most intense form. It often ends in destruction of the cornea, and total loss of vision. It is caused by the inoculation of gonorrhœal matter. The treatment is that applicable to the most severe forms of the preceding inflammation.

(c) *Egyptian Ophthalmia* is a contagious variety of purulent conjunctivitis, which is most frequently seen amongst persons who live together in masses—in armies, poor-houses, charity-schools, &c. It also appears to be almost endemic in certain warm climates, as in Egypt and India. It is a purulent ophthalmia of the most malignant and destructive type. It is characterised by a profuse discharge of puro-mucous matter, intense injection and chemosis of the conjunctiva, and affections of the cornea, from the slightest corneitis to ulceration, softening, gangrene, or staphyloma of this structure, and often excruciating pain. After the subsidence of the more acute symptoms, the eyeball may be found thoroughly disorganised and the palpebral conjunctiva left in an acutely granular condition, which keeps up a chronic corneitis from the friction of the roughened eyelids upon the cornea. The infectious nature of the Egyptian ophthalmia has been doubted, but not the contagious character of the purulent secretion itself, which gets inoculated from eye to eye by the use of the same towels, water, &c. The treatment must be of the most active nature.

That recommended for ophthalmia neonatorum may be adopted, combined with local depletion, purgatives, opiates, &c.

4. *Pustular or Phlyctenular Conjunctivitis.*—This is mostly met with in children. It is characterised by small vesicles or pustules, which usually occur at the margin of the cornea, and are connected with local injection of the ocular conjunctiva. It is unaccompanied by any severe pain or photophobia. The same treatment as that recommended for the milder forms of mucous conjunctivitis of the ocular conjunctiva may be employed. A small portion of the Ung. Hydrarg. Flav. Oxyd., applied every night between the edges of the lid, is a very satisfactory mode of treating this form of conjunctivitis.*

5. *Granular Conjunctivitis.*—This form of conjunctivitis is characterised by the presence of granular elevations on the palpebral

* The introduction of the yellow oxide of mercury ointment into ophthalmic practice is due to Dr. Pagenstecher. As we have found this ointment of extreme value in cases of phlyctenular conjunctivitis and corneitis, we extract the following directions for its preparation from Dr. Pagenstecher's paper upon the subject in the 2nd volume of the *Ophthalmic Review*:—"The mode of preparing the yellow precipitate, although well known, may be still worth mentioning. Care must be taken in the precipitation to obtain a pure oxyde, and not any of its compounds, to which precipitates of mercury have a great tendency—a fact which might detract from the efficacy of the preparation. The precipitation is effected by adding a solution of the chloride of mercury to a solution of potash, in such a way that there is always an excess of the latter. After the precipitate has deposited itself, the supernatant fluid is at once poured off, the precipitate thoroughly washed with distilled water, and dried by a gentle heat, with exclusion of daylight. Thus prepared, the yellow precipitate has a light-yellow (that of the yolk of egg) colour, and is an exceedingly fine powder, which, even under the microscope, appears completely amorphous."

"As regards the strength of the ointment, I generally use one drachm of oxide to one ounce of cold cream. This may appear very strong to some, but experience amply shows that, applied in proper cases, it does not in any way irritate too much. Idiosyncrasies may, of course, be observed, as in every remedy; and if the ointment in a given case irritates too much, its strength may be reduced to 30 grs. of oxyde to the ounce. I may further remark, the two constituents of the ointment must be rubbed up to a most intimate admixture, if it is to act well. The following are, then, the two formulæ:—

R. Hydrarg. oxydat. flavi, gr. xxx.

(via humida parati).

Ung. cetacei, ʒss.

Misce exactissime et fiat unguent.

Or, R. Hydrarg. oxydat. flavi, gr. xxx.

(via humida parati).

Ung. cetacei, ʒj.

M. exactiss. et fiat unguent."

v. p. 65

vid. U. S. Dispensary, p. 1168.
also Wecker's Vol. 2.

conjunctiva. These elevations are not granulations in the ordinary surgical sense of the word, as they are not preceded by any ulceration of the conjunctival tissue. Two well marked kinds of granulations occur in practice. They may be scattered, buff-coloured, translucent, hard granules the size of a pin-head. These often produce a peculiar corneitis (*vide* corneitis) by their friction on the cornea; or the same result may ensue in another way. The granulations disappear, exudation matter is effused into the conjunctival tissue, and this by its contraction gradually bends in the lid to such a degree as often to occasion entropium, with all its baneful consequences to the cornea. This form of granular conjunctivitis is the "conjunctivitis trachomatosa" of German authors. Or the granulations may be highly vascular and florid-red, bleeding at the least touch, large, closely packed together, and assuming an angular contour from their mutual contact. This fungoid species of granulations occurs most frequently in Egyptian ophthalmia (which see). The trachomatous variety of granulations is excessively difficult to cure radically. Scarifications, light applications of caustics, and astringent lotions will generally answer best. We have occasionally found liq. potassæ efficient, after all other topical remedies had been employed in vain. Inoculation of the conjunctiva with the pus of ophthalmia neonatorum, or the removal of the ocular conjunctiva, have also been extensively practised in obstinate cases of granular lids.

6. *Diphtheritic Conjunctivitis* is characterised by a hard, smooth, yellow, non-vascular exudation into the substance of the conjunctiva, causing arrest of the circulation, and hence danger to the cornea. The best treatment is scarifications and the energetic employment of warm applications in the diphtheritic, caustics and atropine in the secreting stage of the disease. Under any treatment one half of the cases usually do badly.

Having now disposed of the inflammations of the conjunctiva, we may pass on to the consideration of its other morbid conditions.

XEROPHTHALMIA.

XEROPHTHALMIA is a peculiar condition of the conjunctiva, which becomes quite dry, incapable of secreting its normal mucus, and acquires a shrivelled, skin-like (cuticular) character. Under such circumstances the cornea loses its polish and transparency, and vision is hence seriously impaired or practically abolished. Xerophthalmia

is an uncommon disease, originating in long continued irritation of the conjunctiva, either from conjunctivitis or the incautious application of caustics. It is an almost incurable condition, but may be ameliorated by fatty applications, or glycerine. In one case we obtained signal success with castor-oil drops.

CHEMOSIS.

CHEMOSIS, or Oedema of the sub-conjunctival cellular tissue, frequently accompanies conjunctivitis, and occurs in two forms, the serous and the phlegmonous. The serous appears as a translucent, pale, straw-coloured elevation of the conjunctiva, surrounding and partially encircling the cornea, the conjunctival vessels running over its surface. The phlegmonous form differs from the serous in the œdematous cellular tissue, being redder and harder, and hence more likely to exert injurious pressure on the cornea. Both forms should, if necessary, be treated by scarification with a lancet, or, if the vitality of the cornea should appear threatened, by excision of the morbidly thickened structures with curved scissors.

SYMBLEPHARON.

SYMBLEPHARON is a union of the eyelid to the eyeball by bands of plastic tissue, which may acquire the firmness and rigidity of tendinous structures. The disease generally results from the cicatrization of extensive breaches of surface. The remote causes of symblepharon are mostly burns, either from fire, or from caustic substances. The cornea may be more or less seriously damaged by the cause from which the symblepharon originated. If staphyloma of the cornea co-exist, it may cause considerable distress by its pressure on the adherent lids, as the symblepharon may be a source of great discomfort from the dragging sensations in the affected eye. It is not difficult to separate the morbid adhesions, but very so to prevent their reunion. To counteract this, Sir W. Wilde recommends union of the cut edges of the conjunctiva by sutures. Mr. Teale, jun., has reported three successful cases, in which, after dissecting the lid from the eyeball, he covered the raw surfaces thus left on these structures by flaps of healthy conjunctiva, derived from the inner and outer parts of the eyeball, respectively (*vide* Ophthalmic Hospital Reports for October, 1861).

Professor Arlt's method is sometimes useful. After chloroform has been administered, any pterygium-like process is seized with a

pair of Blömer's forceps tolerably near its point, a cataract-knife is introduced under it, and by this means it is carefully separated from the margin towards the centre of the cornea. The flap so formed is then dissected back from the sclera; a ligature provided with a needle at each end is now passed near its apex, and it is then so placed that its outer surface covered with epithelium is applied to the globe. The needles are next passed through the eyelid at the very bottom of the wound, and the ends of the ligature knotted over a roll of sticking plaster; in this way the tip of the flap is fixed at the bottom of the palpebral sinus. Some sutures are also applied to the surrounding conjunctiva, and cold fomentations applied. The ligatures are removed in 48 hours. (*Oph. Review*, i. 278.)

TUMOURS OF THE CONJUNCTIVA.

The conjunctiva is the seat of warty growths, polypi, adipose, sarcomatous and cartilaginous tumours. A peculiar *vascular growth* on the palpebral conjunctiva is not unfrequently met with. The growth, generally, has a triangular, flattened form, is soft, florid-red, and very prone to bleed. It may very appropriately be termed a "cock's-comb growth," and resembles closely the vascular tumours of the female urethra. It is often excessively difficult to cure. We have had a case of the kind, in a young girl, under treatment for some four years. As fast as we have excised or cauterised the growths, they have after a time recurred. An emollient plan of treatment has appeared to succeed best.

Melanosis of the conjunctiva is not unfrequently seen, either as a deposit at the edge of the cornea, or as a pendulous mass hanging from that structure. The treatment of these growths, when confined to the conjunctiva, consists in removing them by curved scissors.

The following is a case of melanotic tumour of the conjunctiva:—

CASE 11.—E. H., æt. 52, presented herself with a pyramidally-shaped growth, measuring 4" from above downwards, and about the same across at its base, which was attached to the cornea at its lower and outer quadrant, and also to the adjacent scleral conjunctiva, the apex of the tumour being free, and protruding from between the closed eyelids. The growth was soft, somewhat lobed, and of a deep slate colour. For upwards of twenty years there had been a minute brownish spot in the situation of the tumour, which had only grown large during the last six months. To its inner side were a few enlarged subconjunctival veins leading to it, as well as a large scleral discolouration.

On Jan. 19, 1863, Mr. Laurence removed the tumour with scissors, and on

microscopical examination it presented all the appearances of a cancerous growth. When the patient was last seen, after an interval of fourteen months, it was found that no return of the growth had supervened, and the eye was in a perfectly healthy condition, merely a small cicatrix of the cornea and adjacent conjunctiva indicating the former attachment of the tumour. An almost identical case is reported by Dr. Steffan, in Zehender's "Monatsblätter," ii., p. 81.

PTERYGIUM.

PTERYGIUM is a membranous formation on, or in, the ocular conjunctiva. It is generally of a triangular form, with the apex directed towards the cornea. In most cases the affection is confined to one eye, and originates from the semi-lunar fold or the caruncula lacrymalis. Two varieties are met with in practice, a thin, semi-transparent, slightly vascular form, *Pterygium tenue*, or one of a thicker, fleshy character, *Pterygium crassum*. Pterygium may originate in mucous conjunctivitis, in traumatic causes, or idiopathically; in the latter case being very prevalent amongst the natives of hot climates. Those affected with it, as a rule, suffer little or no inconvenience from its existence. If from its rate of progress, which may be almost imperceptible, it is deemed advisable to remove the growth, lest it encroach so far over the cornea as to cover the pupil, it may be easily effected with forceps and scissors; but under other circumstances all operations should be avoided, lest the resulting cicatricial fræna, by their hindrance to the movements of the eyeballs, cause the patient far more annoyance than the original disease.

CHAPTER IX.

DISEASES OF THE SCLEROTIC.

THE diseases of the sclerotic require but a very short separate notice, their descriptions being for the greater part comprised in those of other diseases.

SCLEROTITIS (*Rheumatic Ophthalmia*).

The vascularity in this form of inflammation differs from that of conjunctivitis. The vessels implicated are those of the sclerotic; they present a radiated, fasciculated arrangement; their contained blood has a venous hue, and they cannot be moved by any manipulation with the fingers. The pain also differs from that of conjunctivitis, in being much more severe and deep-seated, in being referred by the patient to the eyeball itself, to the circumorbital and temporal regions and to the tracks of the branches of the fifth nerve generally; it is nearly always much more severe at night than in the day. If the sclerotitis is uncomplicated with conjunctivitis, the discharge is of an aqueous nature; but in the majority of cases it is accompanied by mucous conjunctivitis, which gives rise to a mucous discharge. Sclerotitis is best treated by local depletion, counter-irritation, and opiates internally, combined with warm lotions of belladonna and opium. Mild cases will often yield to warm fomentations. Under any treatment, the eye had better be protected from the light by a shade.

SCLERECTASIA, OR STAPHYLOMA OF THE SCLEROTIC, will be referred to under the head of "Staphyloma."

FIBRO-PLASTIC TUMOURS.

Mackenzie speaks of a fibro-plastic tumour of the sclerotic, bearing an external resemblance to molluscum, and met with in scrofulous children. These tumours become destroyed by ulceration, which may extend to the cornea, and cause atrophy of the globe. He recommends leeches, counter-irritation, and general tonics.

CHAPTER X.

DISEASES OF THE CORNEA.

CORNEITIS.

CORNEITIS occurs in several distinct forms. In all, the cornea is more or less invaded by florid vessels, and clouded by effusion into its texture. In the acute forms of corneitis, this effusion may run on to purulent infiltration of the cornea (onyx), as is not uncommonly seen after unfavourable cataract-extractions, or it may lead to ulceration of the cornea. The character of the corneitis depends a good deal on the circumstances under which it originates. Thus a peculiar form of corneitis is known as

CORNEITIS INTERSTITIALIS S. DIFFUSA.

This is distinguished by a general, minute mottling of the whole structure of the cornea, a loss of polish of the corneal surface, which is at parts, especially its marginal ones, invaded by leashes of exceedingly minute vessels, by the dull leaden hue of the accompanying sclerotitis, by the comparatively slight vascularity of the conjunctiva, by the extremely chronic course of the disease, and by its generally occurring in young, delicate, or scrofulous subjects.* This is the form of corneitis which, according to Mr. Hutchinson's views, is connected with syphilis.

CASE 12.—*Corneitis Interstitialis in Utero.*

A child, 3 months old, was admitted for a congenital affection of the eyes. Both cornæ were extremely large and prominent; bluish-white at the centres, but sufficiently clear towards the periphery for the irides to be seen; the latter were apparently healthy. There was no abnormal vascularity; the tension was normal; the child was well nourished, and had never suffered from any inflammation since its birth; it appeared to perceive light well; no trace of syphilitic affection could be found.

* In many cases iritis also exists.

Corneitis pannosa is a well-marked form of corneitis, caused by the irritation of granular lids, or of inverted eye-lashes.

The opacity is uniform, but not dense, and is pervaded by isolated, long capillary veins; it is, moreover, limited to those parts of the cornea exposed to the source of irritation. Thus, in granular corneitis, only the upper half of the cornea, in nine cases out of ten, will be found affected, from the circumstance of the upper lid being a more frequent seat of granulations than the lower.

As a result of long-continued inflammation, the cornea becomes highly vascular, and its epithelium is thickened. This condition, from its resemblance to a piece of red cloth, has received the name of *pannus*.

Treatment.—Acute corneitis should be treated by local depletion, counter-irritation, and fomentations of belladonna or opium. Tonics may often be given with great benefit. Iodide of potassium, combined with bark, should be given in cases of interstitial corneitis. Iritic complications should be anticipated by the occasional application of atropine drops. If interstitial suppuration occur, and show no marked tendency to spread, it will be better not to interfere; but if it do, an incision may be made into the substance of the cornea (*paracentesis corneæ*). Paracentesis corneæ has been extensively practised by Professor Sperino, of Turin, and is strongly recommended by him as a method of treating this and various other diseases of the eye. The puncture should be made with a broad needle, at the margin of the cornea, and to its temporal side, in order that the surgeon may experience no difficulty in subsequently finding the wound. Repeated evacuations of the aqueous humour are effected by the introduction of a fine probe through the wound into the anterior chamber, slight pressure being made backwards upon the iris. This may be performed twice a day, or oftener, according to the severity of the symptoms.

In chronic corneitis, astringent and stimulant lotions and counter-irritation may be advantageously employed. In all cases, of course, if a cause exists for the corneitis, the former must claim our primary attention; if the corneitis depend on granular lids, it will subside as the granulations disappear; if on entropium, the rectification of the lid should be our first object. In addition to the general treatment of granular lids and pannus, two special methods are practised. The first is that of peritomy (or syndectomy), as practised by Scarpa and Furnari. It consists in removing nearly the entire conjunctiva around the cornea, together with as much of the pannous, corneal conjunctiva

as possible. The second method is that of inoculating the conjunctiva with the pus of the conjunctivitis purulenta of new-born infants. Violent inflammation ensues, resulting ultimately, if the case succeed, in disappearance of the pannus, and more or less clearing of the cornea.—*Vide* the “Ophthalmic Hospital Reports,” vol. iv. pt. 1.

PHLYCTENULAR CORNEITIS [“Scrofulous Ophthalmia” of authors] *w. p. 57.*
generally attacks children under the age of puberty, and is, in many cases, associated with general scrofula. It is attended by intolerance of light (photophobia), by spasm of the orbicularis, pain, and profuse lacrymation. It is characterized by vesicles [phlyctenulæ] or pustules at the margin of the cornea, or on the cornea itself. Leashes of vessels generally shoot from the conjunctiva towards the vesicles. As soon as these burst, from the overlying epithelium becoming detached, they pass into open ulcers, which may either heal or may penetrate deeply into the substance of the cornea. When the phlyctenulæ burst, the patient experiences some relief, and for a time the active symptoms subside. Phlyctenular corneitis is sometimes accompanied by a disease of the skin, as eczema, crusta lactea, &c. The phlyctenulæ generally leave specks, which may remain for a very considerable time.

Treatment.—We find that the most efficacious remedy is the yellow oxide of mercury ointment (referred to at p. 56), applied every night, combined with medicated (belladonna or camomile) fomentations during the day. Sudden immersion of the patient’s head in cold water is very beneficial in cases of extreme photophobia. If tonic treatment is indicated by the patient’s general condition, cod-liver oil, quinine, iron, &c., should be administered; arsenic internally is said to have a specific effect upon this and some other superficial inflammations of the eye. General hygienic and dietetic measures should be adopted.

ULCERATION OF THE CORNEA.

ULCERATION OF THE CORNEA may either be confined to its superjacent epithelium, or may extend to its proper fibrous structure. The superficial ulcers are irregular in shape, and have a tendency to spread in one direction, whilst they cicatrize in another; the deep ulcers are generally circular, or crescentic, and may penetrate so far as to perforate the cornea, causing evacuation of the aqueous humour and prolapse of the iris. A solitary vessel, or a leash of vessels, may often be seen to connect the ulcer with the neighbouring part of the

sclerotic or conjunctiva. Occasionally, when an ulcer has penetrated the proper substance of the cornea, the posterior elastic lamina being unable to withstand the pressure outwards of the aqueous humour, is protruded in the form of a small vesicle, which is termed a *hernia of the cornea*. Ulcers of the cornea are generally more or less opaque, and surrounded by a faint halo from effusion into the adjacent corneal substance. There is, however, a transparent form which is remarkable for its extremely chronic course. This ulcer varies from 1" to 1½" in diameter, is shallow, round and transparent, and looks like a mere chipping out of the cornea. The adjacent tunics are but little, if at all, affected. If the ulcer is situated over the area of the pupil, the patient experiences a dazzling sensation, which is produced by the irregular diffusion of the light over the retina (*irregular astigmatism*); straight lines appear as crooked ones, circles, as if bounded by various sinuosities, &c. The irregular astigmatism is sometimes accompanied by monocular diplopia and polyopia. In making an objective examination of transparent ulcers, it will be observed (1) that the corneal images of objects (*e. g.* of the frame of a pane of glass) are disturbed or broken; (2) that if we laterally illuminate a small spot of the iris, it appears as a dark centre, surrounded by a bright halo, the depression in the cornea dispersing the incident light, the immediate circumferential convexity condensing it. Upon examination with the ophthalmoscope, three appearances may be observed:— a narrow, bright ring, within this a dark field, and at the centre a minute brilliant spot, which, upon the observer moving his position, exhibits movements exactly opposite in direction. The bright ring is caused by light reflected from the margin of the ulcer; the dark field is its concave surface; the central bright spot, the inverted, real image of the flame formed by the central concavity, which acts as a concave mirror. Depressions in the cornea have also the effect of distorting the images of the optic disc and retinal vessels. In some cases they appear double, which phenomenon depends upon the same cause as the doubling of the papilla, &c., which is seen in cases of dislocation of the lens.

Ulceration of the cornea may result from mechanical or chemical injuries, from the irritation of granular lids, from severe catarrhal or purulent ophthalmia, from burst phlyctenulae, and from interstitial suppuration of the cornea. A debilitated state of the system may conduce to ulceration of the cornea, as is frequently observed during the convalescence from fevers and other exhaustive diseases.

Treatment.—In the treatment of ulceration of the cornea, it is

essential that the eye should be excluded from light and air, and, as far as possible, be kept in a state of repose. The best means of fulfilling these requirements is the application of a cotton-wool compress. The eyelids having been closed, the superficial parts of the orbit should be evenly padded with cotton-wool, and a bandage so applied as to maintain a slight and uniform pressure upon the eye.* Belladonna, either in the form of lotion (Ext. Belladon. gr. x, ad Aq. ʒj) or drops (Atropin. gr. ij ad ʒj), is of great value as a local application. When the ulcers are the result of burst phlyctenulæ, the yellow oxide of mercury ointment should be applied. It must, however, be used cautiously, or even for a time discontinued, if, after a few applications, the ulcer show a tendency to spread, or penetrate deeply, or if purulent secretion be exuded from its surface. If the ulcer threaten to perforate the cornea, the pupil must be kept fully dilated by atropine, and sometimes it may be necessary to relieve the intra-ocular tension by paracentesis or iridectomy. If a hernia of the cornea has occurred, the protruding portion must be snipped off, or destroyed by the application of lunar caustic. The protrusion, however, is very liable to recur again and again. If this happen, frequent evacuations of the aqueous humour may be beneficial.

On no account should the acetate of lead in solution be employed in the treatment of ulceration of the cornea, as some of it will, in all probability, be precipitated and become adherent to the surface of the ulcer and may even be permanently fixed in the cicatrix. Such deposits should be carefully removed with a small spatula. Chronic ulcers of the cornea, which show but little disposition to cicatrize, should be treated by the application of drops of the vinum opii every night, and the compressive bandage. In addition to the local treatment of ulcerations of the cornea, it may be necessary, in some instances, to administer tonics, as quinine, iron, or arsenic. The general treatment, however, must be guided by the state of the patient's health. The specks resulting from the cicatrization of ulcers of the cornea are densely opaque and generally remain permanently, although in course of time they may be diminished by contraction.

OPACITIES OF THE CORNEA.

OPACITIES OF THE CORNEA are generally the result of wounds, inflammation, or ulceration of that structure. The less degrees of opacity

* The healing of a corneal ulcer is a purely natural process: but how can we expect this to go on, if the raw surface is being constantly irritated by the friction of the lids in the act of winking?

in which the cornea still remains translucent, are termed *nebulae*; whilst those which are produced by the white cicatrices of ulcers or wounds are termed *leucomata*. *Nebulae* often originate in corneitis, which may either be primary, or secondary to some other condition, such as inversion of the eyelashes, granular lids, &c. ; in the latter case, of course, the cause of the nebula must receive our first attention in point of treatment. The opacity which persists after interstitial inflammation of the cornea is greyish ; it generally involves a large portion (principally the centre) of the cornea, and is not bounded by any distinct margin. Although the centre is the seat of the densest opacity, the circumference is often more or less mottled and hazy. Contrasting with these interstitial opacities of the cornea are those resulting from phlyctenular corneitis ; they are much whiter, they are smaller in size, and are distinctly circumscribed. Calcareous deposits upon the cornea are occasionally met with, and specks similar in appearance may result from the incautious use of lead-lotion to ulcers of the cornea.

Opacities of the cornea are in most cases a disfigurement to the patient, but do not cause a disturbance of vision unless they occur over the area of the pupil. If situated in the centre of the cornea, the amblyopia will advance *pari passu* with the size and denseness of the opacity.

The haziness around ulcers which are healing is an indication of the commencement of adhesive action, and will gradually disappear after the ulcers have cicatrized.

The method of lateral illumination (described at p. 3) is especially useful in examining opacities of the cornea.

Treatment.—*Nebulae* often disappear in great part spontaneously ; their absorption may be promoted by the insufflation of calomel, or the application at night of drops of oil of turpentine, diluted with half its bulk of olive-oil, or the yellow oxide of mercury ointment. Central opacities of the cornea sometimes obstruct vision to such an extent as to cause partial or even complete loss of useful vision. In such cases, after medical treatment has been fairly tried, the advisability of forming an artificial pupil may require consideration. The artificial pupil should be placed opposite to the clearest part of the cornea. An artificial pupil to the inner side is more serviceable than one to the outer side ; if placed upwards, it may be covered by the upper lid, and thus rendered of little use. In cases of central leucomata, the artificial pupil may be made either by irido-desis or iridectomy.—*Vide* "Artificial Pupil."

CONICAL CORNEA.

CONICAL CORNEA is a peculiar, morbid (softened ?) condition of the cornea, in consequence of which it becomes thinned and unusually prominent, assuming a more or less conical shape. This is generally betrayed by the peculiar reflection which the light incident on its surface undergoes, but may be overlooked, unless the cornea is viewed in profile, when its conical form becomes at once apparent. The surface of the iris assumes a waved appearance, owing to the unequally refracting curves of the cornea. Examined with the ophthalmoscope, the centre of the field exhibits an inverted image of the optic disc, retinal vessels, &c., upon the same principle that a strongly myopic eye does ; surrounding this is a dark ring, caused by the dispersion and total reflection of the light at the base of the central cone ; the external margin exhibits the usual red reflex, which any other fundus oculi would.

Vision in conical cornea is, from the irregular astigmatism, confused, or even practically useless. At the central portion of the cone the eye is myopic ; if this myopia is corrected by a concave lens, vision is materially improved. In some cases the apex of the cone becomes opaque. Repeated paracentesis corneæ, or making a slit-like (cat's) pupil by two irido-deses, are the operative measures that have been recommended. Upon the same principle as the latter, vision is sometimes improved by the patient looking through a minute aperture, or by the myositic effect of the Calabar bean.

ARCUS SENILIS.

ARCUS SENILIS depends, as first shown by Mr. Canton, on fatty degeneration of the cornea. It generally commences about the age of fifty. Two opaque arches are formed in each eye—an upper and a lower one, having their concavities opposed to each other. They are situated near to the line of junction of the cornea with the sclerotica, being, however, separated from the latter by a fine curvilinear interspace of cornea, retaining its transparency, through which the iris is distinctly visible. Gradually the extremities of the two arches become prolonged, and eventually they meet and coalesce, so as to enclose an elliptical space of clear cornea. The arcus senilis is often associated with fatty degeneration of the ocular muscles, and also of the heart.

CANCROID OF THE CORNEA.

CANCROID OF THE CORNEA is a rare disease. It may be illustrated by the following case :—

CASE 13.—*Cancroid of the Cornea and Upper Lid.*

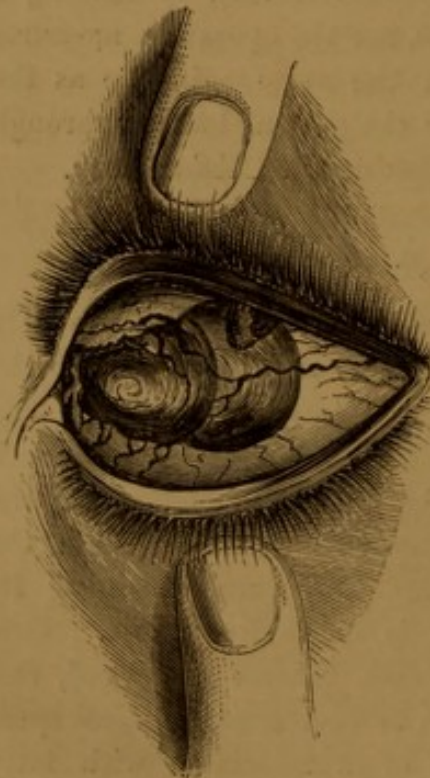
Jas. B—, æt. 26, was first seen at the Ophthalmic Hospital, Southwark, April 22, 1864. From childhood he had had a thickening of the right upper lid—from his description, chronic ophthalmia tarsi.

The eyelid appears to have been treated from time to time with caustics by various surgeons, and during the early part of 1863 he was under treatment at a London Ophthalmic Hospital for a "*Large cyst in the lower lid—cornea opaque and vascular—thickening of conjunctiva and granulation.*" The cyst was incised, he was directed to take three drops of liq. arsenicalis three times a day, and to apply sulphate of zinc drops daily to the eye.

The cyst was cured, but at the end of some months the eyelid remained in precisely its previous condition.

About the middle of October, 1863, the patient first observed a small growth from the surface of the globe, which continued to increase in size till he applied at this Hospital in the following April, when the eye presented the following appearances:—Occupying nearly the whole outer half of the cornea was a soft, vascular, conical growth, measuring about 4" transversely, about 3" from above

FIG. 26.



downwards, and rising $1\frac{1}{2}$ " above the surface of the cornea. The greater part of the tumour appeared to spring from the deeper layers of the cornea, the smaller portion on the outer side passing insensibly into the adjacent scleral surface. Numerous vessels passed from the highly congested conjunctiva to the surface of the growth; especially one large vein from the inner side.

The patient stated that he had experienced but little pain in the eye, and that the growth was but slightly sensitive to the contact of a foreign body, such as a fine probe.

The portion of the cornea not covered by the tumour was nebulous and highly vascular, and at its upper and outer part adherent to the upper lid, which was very much thickened and congested, and its palpebral surface roughened by minute fungoid elevations, having the character of surgical granulations. The visual power of the eye was reduced to mere quantitative perception of light.

On the day of his admission, Mr. Laurence removed a portion of the growth with the knife, after which it bled very freely. The raw surface was then touched with the solid nitrate of silver, which was twice

subsequently repeated, but eventually discontinued in consequence of the application causing most intense pain, and apparently doing but little good.

When seen on August 9th, the eye appeared to have undergone but little change, excepting that the conjunctiva was perhaps rather more vascular, and the apex of the growth was somewhat flatter, softish, uneven, and of a dirty white colour; numerous large tortuous vessels running to it, and ramifying over its surface. The protrusion of the growth between their edges prevented the complete closure of the lids. The upper lid was considerably thickened at its margin, and, projecting from its under surface, moving freely upon the cornea, were two lobular fleshy growths, each measuring about $1\frac{1}{2}$ " in length. He refused to have any further operative interference at that time, as the tumour caused him but slight inconvenience.

On May 17th the tumour presented a nodulated ulcerated surface, and measured 6" in length, 5" from above downwards, and $2\frac{1}{2}$ " from the base to the apex. It had insidiously increased in size, and continued to encroach upon the cornea. Mr. Laurence removed the front of the globe on the 20th of the same month, and upon examination, the growth was found to consist of granular cells of no very distinctive type.

HYPOPYUM.

HYPOPYUM is an accumulation of puriform fluid in the anterior chamber, occasionally attending the severer forms of inflammation, especially of the iris and cornea. Hypopyum, if allowed to proceed unchecked, may terminate in ulceration of the cornea, prolapsus iridis, and staphyloma. If the pus is large in quantity, or if it shows no signs of diminution under local and general treatment, a free incision through the cornea should be made with a keratome, when, even if the matter from its viscosity does not escape, all the symptoms will generally abate, from the relief to the ocular tension afforded by the incision.

CHAPTER XI.

DISEASES OF THE IRIS AND CILIARY BODY.

IRITIS.

ACUTE IRITIS (inflammation of the iris), in its earliest stage, presents the characters of sclerotitis, from which, however, it may generally be distinguished by a sluggish or fixed contracted pupil, and the history of the case. Very soon, however, lymph is thrown out by the engorged vessels of the iris, and the diagnosis of iritis is thus completed. The lymph is peculiarly plastic; it is often rust-coloured. In some cases the posterior surface of the cornea is sprinkled over with dots of lymph. This has a marked tendency to the pupillary margin of the iris, which thus gets attached to the capsule of the lens—*synechia posterior*. The adhesion to the lens-capsule may consist only in a few isolated tags: these might, and doubtless often do, pass unnoticed, from neglecting to drop a solution of atropine on the eye. Nothing remarkable is perhaps observed in a pupil, but that it refuses to dilate when shaded by the hand. But after the atropine solution has acted for a quarter of an hour or so, the adhesions of the iris to the lens-capsule are clearly brought out in the irregular, festooned margin of the pupil, which dilates at some parts, but is prevented doing so at others by the existing tags of adhesion. In severer cases, especially syphilitic ones, the entire pupillary border of the iris adheres to the capsule—*synechia annularis*. As a consequence of this, the communication between the anterior and posterior aqueous chambers is cut off. The middle part of the iris is then bulged forwards, often in the form of gibbous folds; its inner part retracted, so as to form a central small pit, in which lies the contracted pupil, which is generally, in such cases, grey and semi-opaque, from the capsule having become coated with a layer of lymph. In still worse cases, the entire posterior surface of the iris adheres to the lens-capsule—*synechia totalis*. Purulent

exudation is the exception in iritis ; it mostly occurs in cases of traumatic origin, *e. g.* after cataract operations. In some cases the pus gravitates to the bottom of the anterior chamber, constituting *hypopyon*.

Invaded by engorged vessels and lymph, the iris loses its natural tint : from blue it becomes greenish or pinkish, from hazel rust-coloured ; whilst its natural striated texture gives place to a dull uniform or rough surface, on which, especially in syphilitic cases, buttons of vascularized lymph may often be seen.

In severe cases, the inflammation rarely stops at the iris, but progresses to the vitreous and choroid : the former becomes turbid or altogether opaque, from the products of exudation, so that the fundus oculi is imperfectly or not at all illuminable by the ophthalmoscope. Choroiditis sets in : for the signs of this we refer the reader to the chapter on "Amblyopia."

Three principal varieties of iritis may be observed :—

1. *Idiopathic iritis*.—This, the least dangerous form, is attributable to exposure to cold, to rheumatism, &c. The tendency to adhesive inflammation is moderately marked ; the pain is generally severe, deep-seated, referred to the eyeball, circum-orbital and temporal regions, and generally worse at night ; vision is always more or less impaired. A somewhat peculiar, sub-acute form of iritis is met with in cases of phlyctenular and interstitial corneitis ; in these cases the pain is comparatively slight, or altogether absent, and the course of the inflammation very insidious.
2. *Syphilitic iritis*.—This, the most dangerous form, is a manifestation of secondary syphilis, the history and many of the signs (skin eruption, sore throat, &c.) of which will usually be found to have preceded or to accompany the iritis. It generally attacks both eyes. The marked feature of this form of iritis is the great tendency to effusion of lymph in the iris, leading to the worst forms of synechia, lens-capsule, vitreous, and choroid : hence vision becomes seriously impaired. The pain is often very slight ; the progress of the disease insidious.
3. *Traumatic iritis*.—This presents the general characters of idiopathic iritis, but is more inclined to purulent exudation. The aqueous humour is generally turbid, or even purulent, so as to obscure the iris.

Treatment.—The great point is to keep the pupil, from the very commencement of the disease, thoroughly dilated by atropine: the dictum that the iris will not dilate when inflamed, is a tradition unfounded in fact, and mischievous in practice. In the acute stages of iritis, leeches or cupping to the temples, warm fomentations, &c., are indicated. Internally we give the following:—

R Potass. bicarb., ʒij.
 Liq. opii sedativ., ʒss to ʒj.
 Tr. belladonnæ, ʒss.
 Mist. camph., ʒvi.
 ʒj every fourth hour.

Mercury is generally regarded as the *sine quâ non* in the treatment of iritis; we, however, do not give it; our cases, we find, get on as well without it.* Turpentine (ʒxxx—ʒj) has also been found a valuable internal remedy in the treatment of iritis.

In some cases we have found paracentesis of the anterior chamber remarkably efficacious. After all the acute symptoms have passed off, vision may remain seriously impaired from the affection of the vitreous or the choroid; in these cases we have seen extraordinary benefit from the administration of two to five grain doses of the iodide of potassium three times a day. We have often seen the improvement in vision and the illuminability of the fundus oculi proceed under this treatment quite *pari passu*. Some persons have a peculiar tendency to iritis; no sooner is one attack gone than another returns. Every succeeding attack of "recurrent iritis" inflicts its damage; an accumulation of attacks may practically destroy the eye as an organ of vision. In such cases, iridectomy is the only measure that will permanently arrest the disease. This answers two ends: it checks the iritis, and gives the patient a new pupil. The improvement in vision in such cases is, however, frequently less than might have been expected: this may depend on vitreous or choroidal complications, which must be then treated on their own merits.†

The ultimate result of iritis may be an obstructed or closed pupil: for this one of the operations for artificial pupil must be performed, the general application and performance of which operations we here introduce.

* Vide *Edinburgh Medical Journal* for December, 1862.

† Vide von Gräfe's Memoir, in the *New Sydenham Society's Works*, vol. i. p. 251.

ARTIFICIAL PUPIL.

The obstruction to the entrance of light into the eye, in cases demanding an artificial pupil, may be caused by opacity of the cornea, by blocking up of the pupil, or by both states combined. The conditions essential for the success of the operations for artificial pupil are a sufficient amount of transparent cornea, and a sufficiently healthy retina. The necessity of both eyes having lost all useful vision, or of the one to be operated on being free from inflammation, has lost much of its old significance. We shall describe the three principal operations.

1. *Operation by Excision, or Iridectomy.*—We shall suppose the case of a perfectly natural pupil obscured by an opacity of the cornea. The patient having been subjected to the full influence of chloroform, the eyelids are separated by a speculum. The eyeball is steadied by a pair of forceps, applied at a point opposite to that at which the artificial pupil is to be made. An incision with a keratome* (figs. 27, 28), or broad needle (fig. 29), is now made into the anterior chamber, on a plane with the ciliary border of the iris. Before withdrawing the keratome, a slight movement of its cutting edges should be made alternately upwards and downwards, in order that the inner portion of the wound may be sufficiently enlarged to correspond to the width of the outer. As the keratome is withdrawn, the iris may be prolapsed from the gush of aqueous humour; if so, it is laid hold of by the iris-forceps (fig. 30), drawn, if necessary, still further out, and cut off by scissors curved on the flat (fig. 31), care being taken to include the pupillary border of the prolapsed portion. Or the iris-forceps are introduced into the anterior chamber, with their blades closed; these are then allowed to separate apart; the iris is seized just external to its pupillary margin, is withdrawn through the corneal wound, and cut off with scissors, as before. Or, instead of the forceps, Tyrell's hook (fig. 32) may be employed for laying hold of the pupillary margin of the iris, in which case a less incision in the cornea is required. In all the steps of the operation, especially in the first step, great care must be taken not to wound the lens, otherwise a traumatic cataract will be formed. Iridectomy is also

* A keratome, the blade of which is bent at an angle of about 140° to the shaft (fig. 27), is, as a rule, preferable to a straight one (fig. 28), as with the latter there is greater danger of wounding the lens.

applicable to cases of synechia annularis or totalis, complicated with opaque capsule or lens. In the last case it has been recommended to extract the lens after iridectomy ; our experience of such extraction

FIG. 27.



BENT KERATOME.

FIG. 28.



STRAIGHT KERATOME.

FIG. 29.




BROAD NEEDLE.

FIG. 30.



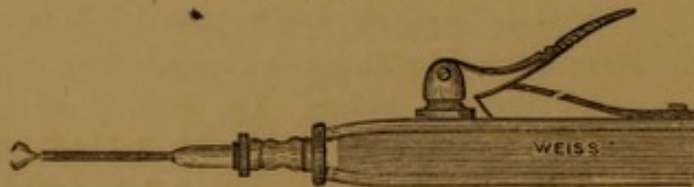
IRIS-FORCEPS.

FIG. 32.



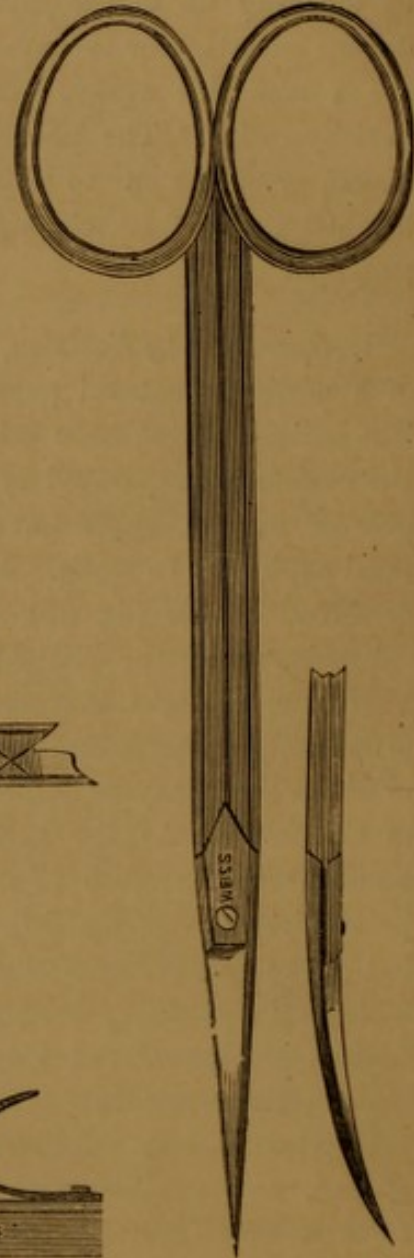
TYRELL'S HOOK.

FIG. 33.



CANNULA-FORCEPS.

FIG. 31.



IRIS-SCISSORS.

is very unfavourable ; a much better plan in such cases is to procure absorption of the lens by the operation of division.

2. *Operation by simply dislocating the Natural Pupil.*—For this purpose, Mr. Critchett's operation of irido-desis is the one to be em-

ployed. A small incision of the cornea near its margin is made by a broad needle. The iris is then seized, between its ciliary and pupillary borders, by cannula-forceps (fig. 33), and is drawn through a small loop of fine silk, previously placed over the corneal incision. When the iris is drawn out sufficiently, the ends of the loop are seized by an assistant, with two pairs of forceps, carefully drawn tight, and then cut off close to the knot. In the course of a few days the ligatured piece of iris sloughs off, and the pupil remains dislocated in its new position.

3. *Operation by Incision.*—This may be limited to a simple incision with Adams' iris-knife, or a broad needle; or the iris may be divided by two incisions, diverging from one another, by Maunoir's scissors, after a preliminary incision through the cornea with a keratome. This plan of operating is principally applicable to cases of closed pupil after cataract operations; when the iris is tightly stretched by synechiæ, but otherwise healthy, the simple incision may suffice, the linear wound widening out into a sufficiently large gap from the retraction of the iris; when the texture of the iris is impaired, the scissors may be employed, the loosened triangular small flap of iris shrivelling up, leaving a similarly shaped artificial pupil.

Besides the morbid conditions incidentally mentioned as requiring the formation of an artificial pupil, a large quota of cases is afforded by synechia posterior and blocking up of the pupil by lymph, caused by preceding iritis. To these cases iridectomy is most applicable. (*Vide* a paper by Mr. Windsor, on "Artificial Pupil by Iridectomy," in the *Ophth. Rev.*, p. 11.) In any case, a central pupil is more advantageous than one to the nasal side, and least of all an upward one, which would be nearly entirely covered by the upper lid.

PROLAPSUS IRIDIS.

Under this term is understood protrusion of the iris through an opening of the cornea. This opening may be caused by a wound or by ulceration. Traumatic prolapse of the iris will vary in extent with the size of the corneal wound, the force with which the aqueous humour gushes out, and the state of the iris, whether this be free or attached from previous inflammation. If the prolapse is of moderate size, and is immediately attended to, it may often be reduced by the surgeon's closing the lids, gently rubbing the cornea, and then suddenly ex-

posing the eye to a strong light. This two or three times repeated, generally succeeds in inducing the pupil to contract, and thus disengaging the prolapsed iris. If this is, however, strangulated in the wound, either the wound may be cautiously enlarged, or the prolapsed portion may be punctured, to allow any aqueous humour in the fold to drain off, before attempting the reduction by the above method; or it may be preferable to snip off the prolapsed portion with scissors. Traumatic prolapse is not an uncommon sequence of an extraction-operation for cataract. If it ensues during the operation, it may be treated on the above principles; but it also occasionally occurs slowly from imperfect union of the corneal section. It must then be treated on the same plan as prolapsus iridis following ulceration of the cornea. Penetrating ulcer of the cornea is a frequent source of prolapse. It can rarely be reduced, but may be diminished, or at any rate retarded in its progress, by occasional punctures, the application of solid nitrate of silver, and a compress-bandage. If an ulcer of the cornea threatens perforation, and is situate over the pupillary area, atropine should be employed to keep the iris out of the way of the opening. In cases of traumatic prolapse, the Calabar-bean extract has been recommended to contract the pupil.

Extensive prolapsus iridis, following ulceration of the cornea, generally leads to staphyloma.

IRIDEREMIA.

IRIDEREMIA, absence of the iris, may be total or partial (*Coloboma iridis*). It is occasionally met with as a congenital condition, when it appears to cause *per se* but little inconvenience to the patient; but is also often accompanied by nystagmus and convergent squint. A not uncommon cause of partial or even total separation of the iris from its ciliary attachment is blows on the eyeball, or accidents in the operation for artificial pupil.

Coloboma iridis is generally accompanied by a similar absence of the choroid and retina, the bare inner surface of the sclerotic appearing as an oval white spot, extending from the optic papilla to the ciliary processes.

PERSISTENT PUPILLARY MEMBRANE

Is a rare phenomenon, and is characterized by bands of adhesion passing from the front surface of the iris to the lens capsule, and is accompanied, or not, by remains of the membrane over the pupil.

IRIDODONESIS.

IRIDODONESIS, or tremulous iris, generally arises from the iris losing the support of the lens. It in this way sometimes follows cataract operations—extractions rarely, depressions more commonly; in the latter case from partial disorganization of the vitreous. From this cause, probably, the tremulous iris is not uncommonly observed in cases of amaurosis. It is an almost constant concomitant of dislocation of the crystalline lens. Finally, it may occur as a congenital defect, being often associated with congenital cataract, or nystagmus or even total amaurosis. The tremulous condition of the iris is only observed when the patient moves the eyeball, and in some cases even then requires very close attention for its detection. The iris itself is apparently intact, but rarely retains its contractile power. In all cases tremulous iris should excite our suspicion of some deeper-seated mischief.

MYDRIASIS.

MYDRIASIS is an unnatural dilatation and fixation of the pupil. It is a prominent symptom in total paralysis of the third nerve; it is generally more or less present in paralysis of the accommodatory apparatus, in amaurosis and the amblyopiæ, and can always be artificially induced by belladonna. In uncomplicated paralysis of the third nerve, the sphincter pupillæ is paralysed, and the resulting mydriasis is not complete. Extreme mydriasis depends on irritation of the dilatator, which may or may not be accompanied by paralysis of the sphincter.

MYOSIS.

MYOSIS is a very contracted state of the pupil, but it does not appear to be always a morbid condition. Any irritation of the eye may cause myosis. The myositic action of the Calabar bean is referred to at p. 6. As age advances, the pupil has a natural tendency to become contracted.

HIPPIUS.

HIPPUS is an alternating contraction and dilatation of the pupil, depending on clonic spasms of the iris. It may be seen any time during the first periods of the action of belladonna or the Calabar bean on the pupil, and is in the latter case accompanied by corresponding hippus of the ciliary muscle, giving rise to a peculiar form of hebetudo visus. (*Vide* v. Gräfe's Paper on the action of the Calabar Bean, in the *Ophthalmic Review*, p. 42.) Hippus may also occasionally be seen as an idiopathic affection of the iris.

CYCLITIS.

CYCLITIS, inflammation of the ciliary body, is evidenced by a circlet of radiating vessels around the corneal margin, the finest branches of the anterior ciliary arteries. The veins of the iris may be enlarged. There is tenderness in the ciliary region, and asthenopic symptoms to a greater or less degree. The sclerotic and iris are usually more or less inflamed. Cyclitis has a tendency to run a chronic course, and end in partial staphyloma of the sclerotic. The treatment is that recommended for iritis.

PARALYSIS OF THE CILIARY MUSCLE

Will be described in the chapter on "Optical Defects of the Eye."

CHAPTER XII.

DISEASES OF THE CRYSTALLINE LENS.

CATARACT.

CATARACT is usually defined to be an interruption to sight, produced by opacity either of the crystalline lens, or of its capsule.

When the disease is seated in the lens, or its capsule, it is called a *true cataract*; but when it consists of opaque matter (lymph or blood), deposited in front of the lens, it is denominated a *spurious cataract*.

Cataracts are also distinguished into *idiopathic*, *accidental (traumatic)*, or *congenital* cataracts—appellations sufficiently indicative of their different origins. The existence of cataract may be inferred from the following symptoms and signs:—

1. *Subjective symptoms*, derived from the patient's own sensations. The dimness of vision is, in idiopathic cases, gradual; in traumatic, more sudden; in congenital, from birth. It is in a direct ratio to the extent and denseness of the opacity. It is often, especially in senile cataract, less in a subdued, than in a strong light; this fact is due to the periphery of the cataract being usually less opaque, than its centre. The periphery, from the dilatation of the pupil in subdued light, becomes more or less exposed to the light, and thus vision is improved. The dimness of vision is compared by the patient to a cloud or mist before the eye; in advanced stages, as if vision were obscured by ground glass; till, finally, vision may become limited to a mere perception of light and shade. It is *per se* unaccompanied by pain, photophobia, flashes of light, iridescent vision, muscæ, or other ocular spectra, so common in amaurosis. Sperino, however, believes that cataract is not uncommonly accompanied by choroiditic symptoms.

2. *Objective signs*, derived from the surgeon's examination of the patient. The general appearance and aspect of a cataractous

patient differ from those of an amaurotic one. He has not that vacant stare ; he retains more or less power of directing the eyes to an object, and may possess a limited amount of power of finding his way about. There is no tendency to nystagmus, or to divergent squint ; the pupil is, generally, normal in its size and contractility. Advanced opacities may be seen at once ; but in less obvious cases, and, indeed, for the exact localization of the opacity in all, the pupil must be dilated by atropine. The patient is placed in a dark room, and the light from an Argand lamp, or from a candle, is concentrated on the pupil by a strong convex lens. Not only will the simple existence of opacities now become apparent, but also their nature and exact situation. Thus, seen by reflected light, they appear of their natural, generally grey, colour. The pupil is next to be examined by the light of a flame reflected by the ophthalmoscope into the eye. The opacities then appear as black streaks, from the interruption to the return of light from the fundus oculi ; or, in some cases, when the opacity is less dense and more diffuse, the ordinary red reflex of the fundus may be either more or less masked by a simple cloudiness, or, in advanced cases, may be altogether invisible from the denseness of the opacity. If this is either very slight, or dense, but limited in its distribution in the lenticular structures, the details of the fundus oculi may be more or less distinctly recognized by the aid of the usual object-lens, and thus valuable indications for treatment may be obtained. By the ophthalmoscope, the exact depth of any opacities in the transparent structures of the eye may be determined. Those opacities which lie anterior to the centre of rotation of the eyeball (*e. g.* in the cornea) have an apparent motion upwards as the patient moves the eye upwards ("positive parallax") ; whilst those posterior to that centre appear to execute motions exactly contrary to those performed by the eye ("negative parallax"). The extent of the positive, or negative, parallaetic movements serves to localize exactly the situation of an opacity. This localization of opacities may be less perfectly directly ascertained by focal illumination.

Several species of cataract have been recognized, which it is important, in a practical point of view, to diagnose.

Lenticular Cataracts originate, as their name expresses, in the substance of the lens proper. They are of a smoky ash-colour in old persons ; of a lighter, more bluish, and less translucent aspect in younger subjects. After extraction, senile cataracts, generally, appear

less opaque, and have an amber tint. The senile cataract may present an uniform, or more or less striated appearance, the striæ radiating generally from the margin, sometimes from the centre of the lens, and having a pearly opalescent appearance, like the fibres of satin-spar, or of crystallized stearine. In younger subjects the striation is, generally, irregular in its disposition, the striæ themselves having more the aspect of boiled rice, or they may be altogether absent. Congenital cataracts often present layers of perfectly transparent lens-substance, alternating with the opaque portions; if the margin of the lens is transparent, it is seen by the ophthalmoscope as a bright-red, narrow ring encircling a dark centre. The bulk of lenticular cataracts may be inferred by simple inspection, and by the degree to which they push forwards the iris and impede the action of the pupil. Lenticular or capsular opacities are very commonly met with in old people, without their being sufficiently extensive to constitute actual cataract.

Capsular Cataracts.—Opacities of the capsule may affect its anterior or posterior aspects. Capsular opacities are less symmetrical in their arrangement than lenticular ones, denser and mostly of a light grey, or chalk-like, appearance; when affecting the posterior capsule, they appear of a darker hue, and are more frequently striated and symmetrically arranged. A particular form of capsular cataract is that of a central, dead-white, opaque spot, which may project forwards to a certain extent from the surface of the capsule into the anterior chamber (*pyramidal, polar* cataract).

Other less common forms of cataract are:—*black* cataract, a lenticular form characterized by its intensely dark colour; *Morgagnian* cataract, in which the lens substance, more or less liquefied, is enclosed in an opaque capsule; *siliquose* cataract, in which an atrophied lens lies in a shrivelled capsule.

Practically, the most important distinction in cataracts concerns their consistence. The following general rules may be laid down:—cataracts in subjects under fifty years of age are usually soft; above that age, hard. Soft cataracts are more bulky; the opacity of a lighter, more white or bluish tint, and less symmetrical in its arrangement. These signs will generally suffice for diagnosis; in doubtful cases an exploratory puncture into the lens-substance may be made, prior to operating, with a fine division-needle. But now and then the most careful examination will not guard against errors of diagnosis in this point of view.

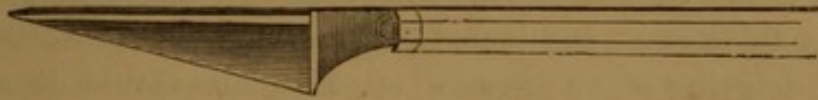Within the last few years attention has been directed to the presence of cataract in diabetic patients. Dr. S. W. Mitchell, of America, has found that cataract may be induced in some animals, as frogs, by administering large quantities of sugar, or injecting it under the skin; and Dr. B. W. Richardson has shown that the same result may be produced from chloride of sodium, alcohol, &c.

The only cure for cataract is an operation. Prior to determining on this, however, several circumstances must be taken into consideration. The most important point is the amount of sensibility of the retina to light. The patient is told to regard a flame in a dark room, and his power of telling, whether this is shaded by any object held before it, or not, tested. In this test the calorific rays of the flame should be excluded by a piece of blue glass, otherwise the patient may be really recognizing the rays of heat rather than those of light. If the patient is unable to give definite statements as to the presence and direction of the flame, any operation for the removal of the cataract would be useless. Any general tendency to inflammatory action, a low state of nutrition, chronic affections of the circulatory or respiratory organs, diseased states of the lids, or lacrymal structures, &c., are so many unfavourable circumstances against the success of an operation. We consider that if one eye be sound, but, as in senile cataracts, very liable to become subsequently affected, the other cataractous eye should be operated on. While the process of cure is going on in the operated eye, the patient has the advantage of the use of the other eye, in which the cataract is not sufficiently advanced to seriously interfere with its sight. If both eyes are affected with advanced cataract, some surgeons operate on both at once; this we consider ill-advised, as the result of an operation on one eye will often guide us in the subsequent treatment of the other. We remember seeing an operation by a justly eminent ophthalmic surgeon: after completing the corneal section on one eye, a large quantity of fluid vitreous escaped; notwithstanding this he, there and then, operated on the other eye; the same disastrous result ensued in this. In another case we knew of both eyes being lost from purulent inflammation. After having determined on an operation, the patient's diet should be regulated for a few days previously, and, if necessary, a purgative administered.

OPERATIONS ON HARD CATARACTS.

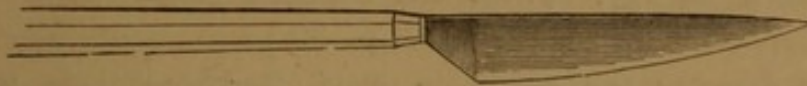The following instruments should be at hand for the ordinary flap-operation for hard cataract:—The cataract knife; the most commonly employed is Beer's knife (fig. 34). This has a triangular blade, the back in a line with the handle, the cutting-edge straight and inclined at an angle of about 15° to the back. Zehender recommends a

FIG. 34.



BEER'S CATARACT KNIFE.

FIG. 35.



ZEHENDER'S CATARACT KNIFE.

FIG. 36.




CYSTOTOME.

FIG. 37.



BISTOURY FOR ENLARGING SECTION.

FIG. 38.



CURETTE.

convex cutting-edge (fig. 35), *vide* his paper in the *Ophthalmic Review*, vol. i. p. 5. A needle bent at an angle near its point, called a cystotome (fig. 36); a probe-pointed, narrow bistoury (fig. 37); curved scissors (fig. 31); a sharp hook, silver spoons, and a curette (fig. 38); forceps of various descriptions, both for fixing the globe and for seizing any portion of the iris; eye-specula of different kinds; bandages, lint, and cotton wool.

The chief operation for hard cataract consists in extracting it through the opening made by forming a semi-circular flap of the

cornea. Some operators make the flap in the upper, others in the lower half of the cornea.

The eyelids may be held asunder, the upper one by the surgeon, the lower one by an assistant, and the eye-ball steadied by the gentle application of the surgeon's fingers to the globe: no pressure on the globe is at all admissible in this manipulation. Some surgeons employ specula, but we, from our own experience, consider their use hazardous in the flap-operation; others, in the downward section, fix the globe with forceps. The forceps should be applied by an assistant a little below the cornea, and include the subconjunctival fascia in their grasp; all dragging of, or pressure on, the globe should be avoided; before the corneal section is completed, the forceps should be disengaged. The surgeon steadies the upper part of the globe with his fingers in the usual way. [*Vide* Mr. France's paper in the "Ophth. Hospital Reports" for April, 1859, p. 20.]*

We may describe the operation itself after Mackenzie, to whose standard work we may refer generally as containing by far the best and most practical information, up to the date of its publication (1854), on all points connected with cataract. 1. The point of the knife is entered on the temporal side of the cornea, at the distance of $\frac{1}{20}$ of an inch from the sclerotic, the blade being kept strictly in a plane with that of the iris. 2. The point in first puncturing the cornea must do this perpendicularly to that structure; otherwise it might pass between its lamellæ, instead of entering the anterior chamber. 3. The point of the knife is directed towards the point of exit at the cornea, opposite to, and strictly corresponding with, the point of puncturation. 4. The knife is simply pushed slowly and cautiously onwards, so as to cut its way out by its purely progressive motion onwards, no sawing or dragging of the edge against the cornea being permissible. Many operators leave the last small portion of the cornea undivided by Beer's knife before proceeding to the next step of the operation. This consists in 5, lacerating the capsule of the lens sufficiently with the cystotome to permit of the exit of the cataract. If a small bridge of cornea has been left undivided, this may then be severed by a blunt-pointed knife or scissors. 6. The upper eyelid may now be allowed to drop. After a minute's pause, the eye is again opened, when a little gentle pressure and manipulation on it with the finger, or the back of the curette, will usually suffice to determine the exit of the

* For the method of fixing the head, the advisability of chloroform, &c., *vide* Chapter II.

lens through the corneal wound. The eyelids of both eyes are then closed with narrow strips of court-plaster, and both eyes covered with a light bandage. We prefer to the strips of plaster the compress-bandage; this consists in carefully and systematically padding the hollows of the orbit around the eyeball with shreds of lint or cotton wool, having previously laid a strip of linen, moistened with glycerine, over the closed eyelids, and then applying an oblique roll of bandage. The compress-bandage should be applied also to the eye not operated on. If this bandage is properly applied to both eyes, they are kept immoveable, without, at the same time, being exposed to any injurious direct pressure.

If the case goes on favourably, the corneal wound will be found united in a few days; but some time elapses before all signs of irritation of the eye have disappeared, when by the use of deep convex glasses the patient's vision becomes restored.

The immediate accidents incidental to extraction, with their appropriate treatment, may be briefly enumerated. Premature escape of the aqueous humour: if but a small puncture into the anterior chamber has been made, the operation may be deferred, or time allowed for the aqueous to be reproduced, before proceeding with the section. The iris coming into contact with the blade of the knife: gentle pressure through the cornea in the appropriate direction may be used to disengage the iris, or the section may be proceeded with and the portion of the iris left to its chances of excision or not. Prolapse of the iris: gentle friction on the ball through the closed lids and sudden exposure to light generally remove this; or it may be necessary to cut off the prolapsed portion with scissors. The lens falling down into a fluid vitreous: we must seek to hook out the lens with a sharp hook. Malpositions of the corneal flap must be remedied by gentle manipulation with the curette. Escape of vitreous: if this exceeds one-third, vision is generally lost. On completing the section of the cornea, it occasionally happens that the lens and a portion of vitreous suddenly gush out together through the wound. In such cases the operation must be at once concluded and a firm compress-bandage applied. Portions of the lens may break off and remain behind: these must, if possible, be removed by the curette or spoon, as nothing is more calculated to originate destructive inflammation. The accident most fatal to vision is hæmorrhage into the vitreous.

The consecutive accidents to extraction are referrible to the inflammation which not unfrequently sets in and mars the result

of the best-performed operation. Corneitis, suppuration, infiltration of the cornea, suppurative iritis, plastic iritis leading to closed pupil, purulent inflammation of the entire globe, ending in its atrophy, &c., are some of the fatal consequences on extraction.

If any undue sensation of heat occurs in the eye after extraction, we advise at once cold irrigation, to be followed up by local depletion, if necessary. Purulent complications are best treated with continuous hot-water pledgets and the compress-bandage. In the general treatment of the patient we must be guided by the constitutional symptoms, whether it is necessary to lower or to stimulate, although in the majority of cases the latter is indicated.

The ordinary flap-operation, as described above, has recently been modified by the introduction of iridectomy as a preliminary step to the extraction of the lens.

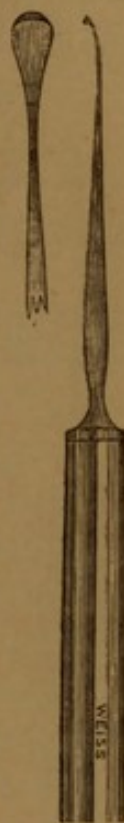Dr. Mooren performs iridectomy, and at a subsequent period extracts by the ordinary flap-operation. In 59 cases he had only 2 failures. Dr. Jacobson performs the iridectomy and extraction at the same time, making his section through the extreme anterior margin of the sclerotic, and performing the whole operation under chloroform. In over 140 cases he had only 3 failures. Of all flap-operations our own experience is in favour of Mooren's operation performed under the influence of chloroform.

* In 1860, Waldau (Schuft) proposed the following operation for cataract:—An incision with a lance-headed keratome is made into the cornea, half a line from its junction with the sclerotic, and embracing one-fourth of its circumference; a portion of iris is excised; the capsule of the lens is lacerated freely with a cystotome; a silver spoon is inserted into the corneal incision, and glided along the posterior surface of the lens, between this and its capsule; the lens, when fairly received into the bowl of the spoon, is then removed from the eye, as the spoon is withdrawn by the operator. We have practised this operation several times. The operation, properly performed, leaves, *per se*, nothing to be desired; but our ultimate results have often been anything but encouraging. Corneitis and iritis, or the two combined, have spoilt the results of the best-performed operations. We attribute this to two reasons:—Firstly, the incision of the cornea in this operation is too small: either the cortex of the lens is rubbed off during its extraction, or the iris and lips of the corneal wound are bruised. Secondly, the spoons are far too bulky: either the lens is broken, or the hyaloid fossa is ruptured. All these are so many circumstances highly calculated to

"in die Hornhaut dicht an der Iris" "Linsen" "

induce secondary, destructive inflammation. Mr. Critchett practised Waldau's operation extensively, perceived its faults, and, as we think, has succeeded in remedying them. He, in the first place, did away with the high, rising, useless edges of Waldau's spoon, and replaced its terminal one by an inverted edge (fig. 39), formed on the principle of a fish-hook, the barbed end—if we may be allowed the expression—being so fashioned as to glide easily along the posterior surface of the lens, but to seize the distal margin of the lens firmly in its grasp as soon as the operator attempts to withdraw the spoon from the eye. The spoon should be introduced behind the lens with great care: it should be insinuated, rather than forced onwards. In extracting the lens, the same care is required, so as neither to break nor dislocate the lens, nor rupture the hyaloid fossa. A second improvement was to enlarge the corneal incision from $\frac{1}{4}$ to $\frac{1}{3}$ of the cornea. The corneal incision had better be too large, than too small. We have practised this modification of Waldau's operation, and, as far as our experience extends, prefer it, in proper cases, to all other methods of extraction. In Waldau's original operation, the lens is spooned, or scooped out; in the modified one, it is drawn out. Hence this latter operation has been appropriately termed a "traction-operation."

FIG. 39.



V. Gräfe has (whether on sufficient grounds or not, time will show) given up all spoon-operations in favour of one of his own devising. He opens the extreme periphery of the anterior chamber by a narrow knife, represented at fig. 40 in its

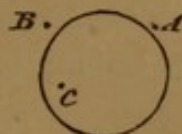
FIG. 40.



VON GRÄFE'S CATARACT KNIFE.

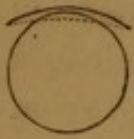natural size, by an incision A B ($4\frac{1}{2}$ — $4\frac{3}{4}$ long) through the sclerotic at the point A (fig. 41), $\frac{1}{2}$ external to the margin of the cornea, and $\frac{2}{3}$ below the level of its uppermost summit. The point of the knife is, in order to enlarge the internal corneal incision, in the first instance directed, not to the point of counter-puncture B, but to about the point C. After the knife has been entered fully three lines into the anterior chamber, its handle is depressed,

FIG. 41.



and its point directed to the point B of the sclerotic. Counter-puncturation is then effected, the knife-edge is directed abruptly

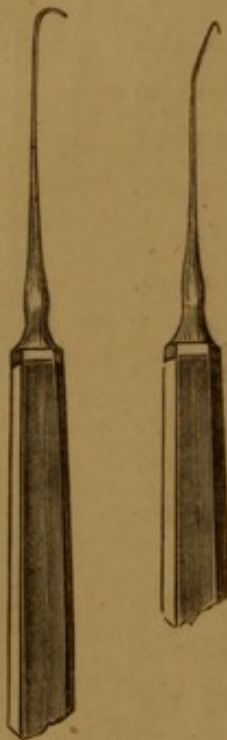
FIG. 42.



forwards, and the incision completed. In fig. 42, the uppermost, undotted line shows the section. The removal of a portion of iris and laceration of the capsule of the lens form the next steps. Gentle pressure is then made on the sclerotic above the incision, so as to

cause the lens to advance and finally escape through the wound; or, in the case of a hard lens adhering to its capsule, it may be

FIG. 43.



necessary to employ a blunt hook (fig. 43) to extract the lens. A. Weber uses a double hook, one hook being behind the other.

Waldau's and v. Gräfe's operations have certain advantages and disadvantages when compared with the old flap-operation. In this latter we have a large, gaping wound, with a flap which, turning like a door on its hinge, is liable to get displaced. The flap itself, both from its size and the structure of which it is made, is liable to lose its vitality. The contents of the globe are in a great measure deprived of their natural support. The iris is exposed to bruising and prolapse. The period of cure is tedious, and involves both much care and anxiety on the part of the surgeon. The new operations are nearly devoid of all the above disadvantages, but present others which we, however, con-

sider of less import. The chief one is the risk of destructive inflammation consequent on the introduction of spoons and hooks into the eye. This objection will, however, we feel convinced, be gradually entirely, as it is already partially in v. Gräfe's operation, eliminated. Secondary needle-operations on opaque capsule are more frequently necessary after the new operations. We may here incidentally allude to a peculiar form of interruption to the light produced by persistent capsule after such operations. The capsule is not opaque, but is variously folded, and thus a kind of irregular astigmatism is produced. A final—not very important—objection has been made that the increased size of the pupil deteriorates vision by leading to unusually large dispersion-circles.

[References on the Operation of Extraction:—Mackenzie's

“Treatise,” 4th ed.—*Archiv f. Ophthalm.*, vol. i., p. 158.—“Die verminderten Gefahren einer Hornhaut-Vereiterung bei der Staar-Extraction,” von Albert Mooren.—“Ein neues und gefahrloses Operations-Verfahren zur Heilung des Grauen Staars,” von Prof. Dr. J. Jacobson.—Pagenstecher’s Report analyzed in the first volume of the *Ophthalmic Review*. “Die Auslöfflung des Staars,” von Dr. A. Schuft; *Archiv f. Ophthalmologie*, vol. i. and xi. 3.]

OPERATIONS ON SOFT CATARACTS.

The safest operation is a simple division of the lens-substance with a straight (or curved), lance-headed needle (fig. 44). The operation requires to be repeated several times, but, generally, ultimately yields excellent results, ending, as it does, in an entire absorption of the opaque lens. In

FIG. 44.



CATARACT NEEDLE.

the first operation we may limit ourselves to a few punctures in the capsule, and in every succeeding operation it is always advisable not to attempt too much at once. If we lacerate the capsule too freely, portions of lens-substance may escape into the aqueous chamber, and set up sufficient irritation to require their extraction through a section of the cornea, a procedure which may seriously affect the result of the case. We have ourselves lately practised what may be termed a “subcapsular” division of the cataract, disintegrating the lens-substance through a minute aperture in its capsule. Another bad consequence of a too free division is a swelling up of the lens-substance, which sometimes ensues, and which may cause injurious pressure on the iris, and even glaucomatous complications. Latterly, the operation of Gibson, of Manchester, —“linear extraction”—has been much practised. It consists in making a small section in the cornea with a keratome, having about a week before lacerated the capsule with a needle; the lens-substance, if pulpy or fluid, in great measure escapes, or may be removed with the curette. Mr. Teale, jun., of Leeds, has lately removed the lens-substance by a “suction-curette.” These operations, if successful, are undoubtedly more rapid in their results; but our own experience leads us to think them less safe than simple division.

A simple traumatic cataract may be left to spontaneous absorption. Should, however, irritation of the iris arise, atropine should be applied; if the irritation runs on to actual iritis, perhaps accompanied by

tension of the globe, iridectomy, or even linear extraction of the lens, may be demanded.

For the treatment of closed pupil after cataract-operations, we refer to the article *Artificial Pupil*.

The best mode of treating capsular secondary cataract is division with a cataract needle. In some cases two needles may be simultaneously employed. They should be introduced through the cornea at opposite points, and be made to penetrate the opaque capsule close to one another. They should now be separated, and the capsule thus freely lacerated. Prior to operating, the pupil should be fully dilated, and the capsular bands carefully examined by means of lateral illumination, in order that the course of their fibres may be accurately ascertained. Several ingenious instruments—such as the cannula forceps (fig. 33) and the cannula scissors (fig. 45)—have been constructed for the separation and extraction of capsular opacities. The simple division of the bands with needles is, however, in the majority of cases, preferable to extraction with the forceps.

FIG. 45.



CANNULA SCISSORS.

Mr. C. R. Agnew, of New York, has very recently described another operation for secondary cataract. Chloroform is administered and the pupil dilated. A needle (fig. 44) is thrust from the nasal side through the cornea, about a line from the sclerotic, into the middle of the opaque membrane. An incision is made into the outer part of the cornea, and thus a small, sharp hook thrust into the opening in the membrane made by the needle. The membrane is fixed by the needle; the hook is then rotated, so as to tear and roll upon itself the membrane, which is then withdrawn on the hook through the opening in the cornea.

After the operation for cataract, the place of the absent crystalline lens will have to be supplied by a convex lens, and, as all accommodation is gone, the patient will require two glasses:—one for distant, one for near objects. In a general way, a $4\frac{1}{2}$ -inch convex will answer the first, a $2\frac{1}{2}$ -inch the second requirement. But each case must be tested on its own merits: thus an originally myopic eye will require

weaker, a hypermetropic eye stronger glasses than an originally normal eye.

We have met with cases in which, after the operation for cataract, in addition to the spherical lens, a cylindrical one was required for the attainment of the maximum degree of distinct vision. Thus, in a case we have recently observed, the patient had his visual power doubled by the addition of a 20-inch convex cylindrical lens to his $4\frac{1}{2}$ and $2\frac{1}{2}$ -inch spherical ones.

We have, in the above account of the operations for cataract, altogether passed over the once general operation of couching, as it is now universally considered only applicable to very few exceptional cases. Those who would wish to know anything about this operation, we refer to Mackenzie's work.

DISLOCATION OF THE LENS.

DISLOCATION OF THE LENS is most frequently the result of a blow upon the eye, although it occasionally occurs spontaneously. When the lens is separated completely from its attachments it may be displaced backwards into the vitreous, or forwards, through the pupil, into the anterior chamber. Sometimes the lens escapes through a rupture of the sclerotic, and is forced under the conjunctiva ; or it may even be completely ejected from the eye through a wound of one of its coats. Such an accident has occurred during the performance of iridectomy for the cure of glaucoma. There are many instances in which the displacement of the lens is only partial, in which case it may sometimes be seen swinging to and fro in the vitreous, being only attached at a small part of its circumference. A dislocated lens, generally, becomes more or less cataractous, or, indeed, may be opaque from the commencement. Occasionally, after needle operations upon soft cataracts, the opaque lens becomes dislocated into the anterior chamber. In a few cases the lens is said to have been abnormally situated from birth.*

Treatment.—As a rule, a dislocated lens should be extracted, especially if, either by its presence in the anterior chamber or by pressure upon the iris, it appears to set up irritation, and thereby induces a glaucomatous tension of the globe. However, should the patient object to operative measures, or the lens be rapidly absorbing, and be causing but slight reaction, the pupil should be kept fully dilated by

* Follin has recently described a case of double congenital dislocation of the lens.—*Med. Times and Gazette*, Feb. 17th, 1866.

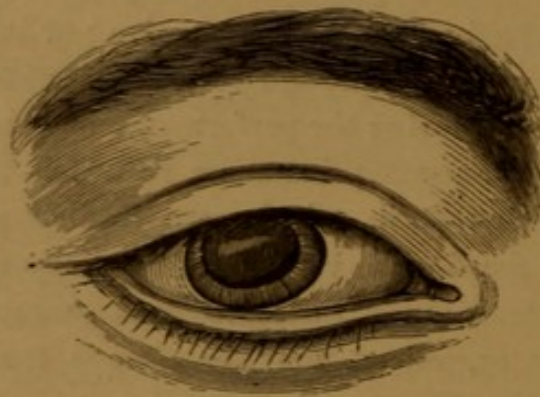frequent applications of atropine. Before incising the cornea, the lens should be transfixed with a cataract needle, in order that, when the aqueous humour flows out, the lens may not sink back into the vitreous, which in such cases generally undergoes dissolution. When an opaque dislocated lens is fixed behind the pupil, a well-placed artificial pupil may sometimes be made with advantage.

CASE 14.—*Traumatic Dislocation of the Lens; Extraction; Restoration of Sight.*

James H., aged 14, in the employ of a gas engineer, was standing, November 13, 1858, near one of his fellow-workmen, who was engaged in bevelling down a brass gas-tube with a chisel and hammer, when one of the brass shavings flew off, and struck him on the right eye. Two days after the accident he was admitted into the Ophthalmic Hospital, Southwark.

On the centre of the cornea was a transverse linear scar, marking where the brass-shaving had struck him. The capsule of the lens had a pearly, striated, semi-opaque aspect, and was transversely rent across below; through this rent the lens had escaped into the anterior chamber, and was swollen and opaque from imbibition of aqueous humour (fig. 46). The sclerotic and iris were somewhat inflamed. There was only slight pain in the eyelid. His vision with the injured eye was restricted to the power of distinguishing light from darkness.

FIG. 46.



22nd.—Mr. Laurence made a small opening in the cornea with Adams' iris-knife over the situation of the dislocated lens; some of the diffuent lenticular substance oozed out at once; the rest was removed with a curette. Slight prolapse of the iris took place, which was, however, at once replaced.

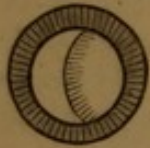27th.—Nearly all vascularity of the external tunics gone; pupil somewhat contracted; occupying its lower two-thirds is a grey, translucent membrane (capsule). He can distinguish persons in the street.

January 31, 1859.—Pupil of medium size, transversely elliptic in shape, freely contractile; from beneath its lower margin is just seen the edge of the remains of the opaque capsule of the lens. He can distinguish persons, carts, &c., in the road opposite the hospital. As the patient's sight was improving every day, Mr. Laurence dissuaded him from the use of any cataract-glass, till his eyesight had ceased improving any further.

CASE 15.—*A case of Dislocation of the Lens, with monocular Diplopia, and partial Paralysis of the Ocular Muscles.*

Joseph T—, æt. 49, applied at the hospital, Jan. 26, 1864, with chronic corneitis, pterygium, ptosis, and partial paralysis of the recti muscles of the left eye. Attention, however, was directed to the right eye in consequence of slight ptosis being observable in that one also. Upon examination, the globe was found to be non-evertible beyond the middle line, the power of raising it up being also very limited. The outer margin of the iris was strongly tremulous at the slightest movement of the globe. He attributes this condition of his eye to a blow which he received from a piece of brick, about twenty-two years ago.

FIG. 47. After fully dilating the pupil by atropine, the eye was examined ophthalmoscopically. The lens appeared immoveably dislocated inwards, and, perhaps, a little backwards, its dark margin being clearly visible a little towards the outer side.



The lens was cloudy, but still permitted the entrance of the optic nerve to be easily seen through it. Two images of the entrance might thus be seen—one, the larger, *not* through; and one, the less, through the lens. The entrance could also be distinctly seen in the *direct* image through the part where there was *no* lens, and was ill-defined and palish at its margin.

VISUAL POWER—

For distance—

Right eye. Cannot read No. 23 at a greater distance than 5'.

With $+3\frac{1}{2}$ reads No. 23 at 20'.

With a stenopæic aperture of $1''$, in addition to $+3\frac{1}{2}$, reads No. 22 at the same distance.

For near objects—

Reads No. 2 (almost No. 1) in a range of 4" to 6".

Neither stenopæic apertures, of a smaller diameter than the pupil, nor convex glasses improve vision for near objects.

A luminous point of from $\frac{1}{2}''$ to $1''$ in diameter appears to him double at about 2', the one seen on the left-hand side being slightly above the level of the other. With $+3\frac{1}{2}$ but one luminous point is visible at 2'; the second, however, becomes gradually apparent as he retreats from the point, till at about 4' the two are quite distinctly seen, appearing exactly the same, and holding the same relative positions, as they did previously at the distance of 2' without the convex glass.

Feb. 5.—All effects of the atropine have disappeared in the right eye, and the pupil measures $2\frac{1}{2}''$ in diameter.

At 4.0 P.M. The Calabar-bean extract applied.

4.15 ,, The pupil contracted to $1\frac{1}{4}''$ in diameter.

Reads No. 23 at 5'.

With $+4$ reads No. 23 at 20'.

p.p.* for No. 1 = 3'.

* p. p. = *punctum proximum*, the nearest point of distinct vision.

- 4.30 ,, The pupil measures 1" in diameter, nothing but lens being now behind the pupil.
The visual power remains as at 4.15.
- 5.30 ,, The pupil measures the same as at 4.30.
Reads No. 23 at 7'.
With — 4 reads No. 23 "beautifully well" at 20'.

But without this concave glass he cannot discern a letter of No. 23 at that distance.

The last observation made at 5.30, taken in conjunction with the one at 4.30, and the previous comparative experiment of a stenopæic aperture, made it evident that, although the diminution in size of the pupil, caused by the Calabar-bean, might in the first instance have produced a change in the visual power, yet from the fact that the pupil remained stationarily fixed, and the patient became highly myopic, the latter result could only be attributable to the action of the Calabar-bean on the apparatus of accommodation. That the patient did not see through the non-lenticular portion is proved by no trace of the margin of the dislocated lens being visible through the pupil at the time of observation.

CHAPTER XIII.

AMAUROSIS AND AMBLYOPIA.

UNDER this head we shall describe all those cases of obscurity (*amblyopia*) or annihilation (*amaurosis*, strictly so called) of vision, which depend neither on a material obstruction to (*e. g.* cataract, leucoma), nor on a misdirection of (*e. g.* by optical defects generally), the rays of light entering the eye. We retain the terms amaurosis and amblyopia rather in deference to their antiquity and popularity, than to their scientific value; for they are rather symptoms of disease than diseases themselves. The typical symptom is a diminution of the acuity of vision (S). In many cases this diminution occurs unequally in the field of vision, which should always be investigated (*vide pp.* 13 and 16). Prior to the invention of the ophthalmoscope, nothing exact was, or, indeed, *could* be, known of the diseases of the deeper structures of the eye, on which these defects of vision depended, excepting the scanty information afforded from time to time from the comparison of the anatomy of eyes, removed during life or after death, with the symptoms previously observed. Diagnosis became rather a matter of individual hypothesis, than of direct inference. We propose dividing amaurotic affections into two classes:—1st. those, the causes of which can be diagnosed by the ophthalmoscope; and 2nd. those, the causes of which cannot.

I. *Amaurosis or amblyopia depending on changes in the internal structures of the globe recognizable by the ophthalmoscope.*—These may depend on:—

A. CHANGES IN THE VITREOUS.*

These are opacities which may consist of lymph, detached pigment-shreds, &c., or coagula of blood. The latter may frequently be best seen by lateral illumination.

* Most of the impairments of vision from changes in the vitreous are due to the mechanical obstruction to light; we have, however, thought it best to introduce them here.

Hæmophthalmos, effusion of blood into the eye. This occurs in two chief forms, either into the aqueous or into the vitreous humours. It may be traumatic, from blows or wounds, *e. g.* in the operations for artificial pupil and cataract ; it may follow certain morbid conditions of the organ, *e. g.* tumours ; it may occur in patients exhibiting otherwise an hæmorrhagic tendency ; or it may ensue without any assignable cause. Blood in the anterior chamber forms a crimson mass, circular below and level above. In many instances the layer of blood shifts its position with that of the patient's head. The patient's vision is, *cæteris paribus*, not seriously impaired, so long as the blood does not rise to the level of the pupil. If the eye is otherwise healthy, the blood, if fluid, speedily gets absorbed ; but if clots form, these may remain stationary for a long while. Blood effused into the vitreous may be best recognized by aid of the ophthalmoscope, and by lateral illumination. It is much more slowly absorbed than when in the aqueous, and is altogether a much more serious affair. It generally impairs, or, if in any quantity, irreparably destroys, vision ; and, even if almost entirely absorbed, leaves floating shreds of coagulum in the vitreous, which deteriorate the patient's sight. The treatment of hæmophthalmos must be of an anti-congestive character. Local depletion, cold to the eye, purgation, moderation of diet, &c., are among the means to be employed.

Cases of Hæmorrhage into the Vitreous.

CASE 16.—Mary G., æt. 39, found one morning the sight of the left eye was nearly gone ; she had had no pain. With the affected eye we found she had only quantitative perception of light ; the other eye was somewhat amblyopic. The fundus of the left eye was not illuminable by the ophthalmoscope ; but lateral illumination exhibited a deep-seated crimson appearance. The fundus oculi of the right eye appeared normal. She was ordered a *placebo* : in three weeks she had recovered sufficient vision in the right eye to count fingers at 4 feet ; there was now a good reflex from the fundus, but the details were not definable.

CASE 17.—Charles E., æt. 23, observed in the right eye, eighteen months ago, on awaking in the morning, a dimness which went on increasing for eight months. He now has only quantitative perception of light with the eye ; the iris is bright green, that of the sound eye being light blue ; the vision of the sound eye is normal. The right fundus oculi is not illuminable by the ophthalmoscope, but exhibits a red reflex on lateral illumination ; the left one is normal.

SYNCHISIS is a term applied to dissolution and softening of the vitreous ; in some cases the dissolved vitreous holds numerous brilliant

scales of cholesterine in suspension, constituting *synchisis scintillans*, and offering a most beautiful ophthalmoscopic appearance.

B. CHANGES IN THE CHOROID.

1. *Choroiditis*.—The first stage of this disease may consist either in a hardly recognizable congestion of the choroidal vessels, or in more advanced vascularity. In the second stage we see the results of effusion. These appear with the ophthalmoscope either as a simple cloudiness of the choroidal structures, depending on serous effusion, or as yellowish-white patches of lymph, often bordered by black pigment; over these patches the retinal vessels may pass.

CASE 18.—*Choroiditis*.

Henry C., æt. 53; admitted July 14, 1862. For the last few months has noticed a mist coming over the right eye. Now he cannot distinguish the largest objects with the eye.—*Ophthalmoscopic appearances*: The fundus oculi is mottled white and red; some of the white patches with black pigment spots; one very large, whitish patch is traversed by fine blood-vessels, and surrounded by sub-retinal hæmorrhages. The optic entrance is small, ill-defined, and its vessels atrophied. He improved under the Hydr. bichlor.- and Tinct. cinchon.-drops, and local depletion.

2. *Atrophy of the Choroid*.—This generally originates from choroiditis. In the less advanced stages of the disease the choroid appears stretched and attenuated, the choroidal vessels being morbidly distinct; but, as the atrophy progresses, the choroid disappears more or less; the partially, or entirely, denuded sclerotic appears in its place in the form of white patches, commonly bounded by black pigment. Atrophy of the choroid is a usual concomitant of high degrees of myopia (*vide* "Myopia").
3. *Anæmia of the Choroid*.—This is characterized by a general pallor of the fundus oculi, and is usually associated with a corresponding condition of the retinal vessels.

C. CHANGES IN THE RETINA.

1. *Retinitis*.—In the earliest stage this is evidenced by enlargement and tortuousness of the retinal vessels, and sometimes by ecchymoses. Effusion is commonly serous (in choroiditis it is more often plastic), and advances often to a degree that the position of the optic disk is only indicated by the confluence of its

vessels. For the several forms of retinitis—*R. syphilitica*, *R. leucæmica*, &c., we may refer to the reference at the foot of this article. (For *Retinitis pigmentosa*, *vide* “*Hemeralopia*.”)

CASE 19.—*Retinitis of both eyes, followed by white atrophy of the optic papillæ.*

W. C., æt. 58; admitted to the Ophthalmic Hospital, Southwark, under the care of Mr. Laurence, on Sept. 1, 1863. Fourteen months before, he was struck on the right eye with a whip; directly, and ever afterwards, the sight of that eye became very dim. About a week ago, the sight of the left eye became similarly dim. We found with either eye he barely read No. 20 (Jäger).

OPHTHALMOSCOPIC APPEARANCES.—*Both eyes.* The optic papillæ invisible; their positions indicated by the convergence of the vessels and by a slightly lighter shade of the fundus. Arteries very contracted; veins much clearer; but either class of vessels at parts obscured, or altogether lost to view. Scattered, punctiform hæmorrhages.

Oct. 20. Optic papillæ well seen, but of a dead-white colour. Hæmorrhages gone.

Jan. 31, 1865. Vision about the same as when he first came. Ophthalmoscopic appearances unchanged since last report.

2. *Fatty degeneration of the Retina.*—The retina appears splashed over in a radiated manner with pearly, opalescent dots, accompanied by larger white patches; general retinitis; congested tortuous veins, and contracted arteries and capillary extravasations. This disease is seen in conjunction with albuminuria.

CASE 20.—*Retinitis albuminurica following Rheumatism.*

Edward W., æt. 33, a paper-hanger; admitted to the Ophthalmic Hospital, Southwark, under the care of Mr. Laurence, on March 7, 1864. Two years previously had an attack of acute rheumatism, during and after which for a short time he found his sight defective. Six weeks ago was again attacked with rheumatism, since which his vision has been impaired. He looks very pale and anæmic; urine slightly albuminous. With the *right* eye, at 20 feet cannot read No. 23 (Jäger); with the *left* one, with 8-inch convex, nearly reads No. 23; with either eye reads No. 16 at 5 inches.

OPHTHALMOSCOPIC APPEARANCES.—Contours of both papillæ obscured by effusion; linear and punctiform hæmorrhages. At the maculæ luteæ a large number of minute, glistening, stearine-looking spots, stellately arranged, splashed on, as from a drop of water falling on a piece of glass. The patient did not return to the hospital: later we heard he had died.

3. *Apoplexy of the Retina.*—Extravasations of blood, varying from the minutest spots of blood to those of enormous magnitude, may be seen in the structures of the retina by the ophthalmoscope.

CASE 21.—*Retinal Apoplexy.*

Mrs. J., æt. 47, had been subject to frequent attacks of inflammation (iritic) in the left eye; but one morning, on awaking, found the sight of the other eye almost gone. With the right eye she could distinguish neither near, nor distant objects, nor read the largest type. Externally, the eye presented no trace of disease, but the ophthalmoscope showed that the whole of the fundus oculi was strewed over with punctiform hæmorrhages, which nearly concealed the optic entrance. The treatment was leeching, cold, and large doses of iodide of potassium. After two months she was able to read No. 14 (Jäger), and all the internal hæmorrhages had completely disappeared.

4. *Anæmia of the Retina.* — Evidenced by general pallor of the fundus oculi, and by contraction and partial emptiness of the retinal vessels.
5. *Separation of the Retina* varies in degree from a mere linear detachment to that of its complete separation, when it assumes the shape of a funnel, the apex of which is at the optic papilla, the base at the circumference of the lens. It is commonly caused by serous effusion behind the retina. This, as best seen in the erect image, appears floating in the vitreous in grey undulating folds, over which the tortuous retinal vessels pass.
6. *Embolism of the Retinal Artery.* — Characterized by more or less complete emptiness of the retinal vessels, especially the arteries, which appear as red threads. There are dark coagula in the veins, which often exhibit a kind of peristaltic pulsation. Near the macula lutea, effusion into the retina may be observed, whilst the foveola appears unnaturally red. There is, generally, valvular disease of the left side of the heart. Embolism of the retinal artery causes sudden and complete blindness, which is only exceptionally so far recovered from as to enable the patient to read.

Hemeralopia (Retinitis pigmentosa).

It is only since the discovery of the ophthalmoscope that the pathology and diagnosis of this disease have become definite. The symptoms are an inability to see properly, as soon as dusk sets in, a gradual diminution of the excentric field of vision, whilst that of the central field may remain comparatively unimpaired; so that a patient with a field of vision of but a few inches in circumference

may within that limited field enjoy the most acute vision. As the disease progresses, the field of vision becomes gradually more and more concentrically contracted, till at last complete blindness ensues. The ophthalmoscopic signs of this disease are very characteristic: the fundus oculi becomes concentrically invaded by numerous, black pigment-patches, much like bone-corpuscles in their conformation; the optic nerve entrance and the retinal vessels become gradually atrophied with the progress of the disease. The pigment patches are probably, in some instances, derived from the choroid, in others are independent formations in the retina. Hemeralopia has hence recently been designated as *Retinitis pigmentosa*. It commences generally at a very early age, and resists all the plans of treatment that have hitherto been opposed to its progress. Sperino states that he has, in one case, arrested the progress of the disease by repeated paracenteses. (*Vide* Dr. Mooren's paper in the first volume of the *Ophthalmic Review* for a complete account of the subject.)

D. CHANGES IN THE OPTIC PAPILLA.

1. *Inflammation*.—The papilla appears congested and swollen, reddish-grey, cloudy and ill-defined, and may be the seat of capillary injection or ecchymosis; the arteries are constricted, the veins congested and tortuous. The disc may become completely obscured by effused lymph. It may be idiopathic, or may depend on intra-cranial causes.

The following case, similar to several others which we have seen, is highly characteristic of the disease:—

CASE 22.—*Acute Inflammation of both Optic Papillæ; Total Amaurosis; Partial Recovery.*

Thomas R. consulted Mr. Laurence on June 7, 1865. A fortnight previously he had had sub-acute rheumatism; from this he recovered in a week, when he felt across the forehead and temples a pain, which, however, was permanently relieved by medicine. On June 1 he noticed a swelling of the eyelids, and found his power of reading somewhat impaired in the morning; by the afternoon he could not read at all; by the following evening he could not see sufficiently to find his way about, and the next morning he could not see light from darkness. He then consulted an ophthalmic surgeon, who examined his eyes, and advised him to return in a few days.

Mr. Laurence saw him three days after he had become totally blind. He then had lost all perception of light; his pupils were dilated to $4\frac{1}{4}$ " ; he suffered no pain; the eyeballs presented no signs of external inflammation.

OPHTHALMOSCOPIC APPEARANCES.—Both optic papillæ rose-coloured, and almost

entirely concealed from view by white, irregularly disposed, striately-arranged exudation-masses; retinal arteries very much contracted; the veins of normal size; all the vessels covered by exudation for a short distance from their exit from the papilla.

He was treated by local depletion, calomel and opium, blisters, and latterly by quinine. He gradually improved, and by July 9 his state was as follows:—

Left eye.—Reads XII. (Snellen). The inner quarter of the field of vision is obliterated. The pupil is normal in size and action. The optic papilla is completely seen, but is unnaturally white, somewhat speckled, not flattened; the size of the vessels remains, as when he was first seen; but slight traces of the pre-existing exudation remain.

Right eye.—Reads CC (Snellen). Vision is too imperfect to admit of the field of vision being taken. The pupil is still dilated, and acts but feebly; the optic papilla and retinal vessels are precisely as in the left eye.

2. *Excavation (cupping) of the Papilla.*—This is evidenced by the papilla appearing (in the inverted image) more or less convex, by its sclerotic zone being morbidly widened, and by the retinal vessels at the margin of the nerve being abruptly bent, in advanced cases, to such a degree as to appear broken off, so that the retinal and papillary portions of a vessel seem entirely disconnected. All the above appearances may be occasionally seen, to a certain degree, in a perfectly normal eye, and in cases of advanced myopia, but are developed most highly in *glaucoma* (which see).

3. *Atrophy of the Papilla.*—This often accompanies excavation, but is also frequently seen as an independent condition. The papilla is morbidly white, often with a tendinous glistening aspect, and may be stippled (by the undue distinctness of the meshes of the lamina cribrosa), its margin abruptly defined, slightly irregular, or altogether misshaped. The retinal vessels are more or less constricted (atrophied?). In complete amaurosis from atrophy of the optic nerve the pupil is dilated and fixed. In many cases of amaurosis from atrophy of the optic nerves the disease may be traced to some affection of the brain, and may be accompanied by cerebral symptoms, such as hemiplegic manifestations; but we have met with many cases in which no such symptoms could be found to exist. By some (Wordsworth, Sichel, Hutchinson) atrophy of the optic nerve has been connected with excessive smoking.

II. *Amauroses and Amblyopix depending on changes not recognizable by the ophthalmoscope.*—This comprises a comparatively small number

of diseases of the eyeball itself. Paralysis of the retina cannot be recognized in its pure form by the ophthalmoscope: it is the probable immediate cause of the amaurosis of glaucoma. We have seen several cases of amaurosis which appeared, *viâ exclusionis*, only referrible to paralysis of the retina: amaurosis coming on, usually suddenly, after blows on the eyeball, without any changes in the fundus oculi recognizable by the ophthalmoscope.*

Under this category is comprised, however, a large number of amauroses which depend on causes altogether extrinsic to the eyeball. Loss of blood, pregnancy, epilepsy, syncope, hæmorrhage, effusions, and tumours of the optic nerve, of the orbit, of the parts within the cranium, &c., may all give rise to amaurosis.

The treatment of amaurosis will depend on its cause. Those cases which originate in inflammatory conditions may be treated topically and constitutionally on general principles; if amaurosis depend on constitutional disease, this latter must for the greater part absorb our attention; if on atrophy of the optic nerves, amaurosis is hardly amenable to any form of treatment.

[References: *Mackenzie's Treatise*, 4th ed., p. 1015, and seq., contains most valuable information on the general clinical history of amaurosis. For ophthalmoscopic details, *vide* Liebreich's *Atlas der Ophthalmoscopie*, and *The Ophthalmoscope*, from the German of Zander, by R. B. Carter, of Stroud.]

* Testelin has reported several similar cases (Zehender's "Monatsblätter für Augenh." p. 387).

CHAPTER XIV.

GLAUCOMA.

UNDER the term "glaucoma," Hippocrates comprehended all opacities behind the pupil. But the term soon became limited to those which were of a greenish colour, and were irremediable by operative measures. Brisseau, in 1779, originated the view that "green cataract" was an affection of the vitreous humour. A century later, Wenzel sought the seat of the disease in the retina and optic nerve—a view which was also adopted by Wardrop. Later still we find the arthritic and choroiditic nature of the disease assumed by Beer and Sichel. Weller then gave a very faithful picture of the symptoms, and spoke of the "great hardness" of the globe, and of a "feeling of tension in the eyeball as if it would burst." In 1830, Mackenzie gave as precise a history of the symptoms and intimate nature of the disease as would be possible at the present day without employing the ophthalmoscope. After the invention of this instrument, Ed. Jäger gave a faithful delineation of the appearances of the optic nerve entrance and retinal vessels, in a case of "amaurosis arthritica (glaucomatosa)." V. Gräfe then described still more definitely the peculiar appearance of the optic disc (erroneously considering it, however, as an undue *prominence* of that structure), and added a new sign in the "arterial pulse" of the retinal vessels. Weber gave the true interpretation of the apparent bulging of the nerve, by showing that it was really of the nature of an excavation, or "cupping," as it is technically termed. Thus the whole series of phenomena of glaucoma were at length referred to one cause—a morbidly increased tension of the tunics of the eyeball, produced by intraocular (hydrostatic) pressure of its contained fluids.

The following are the characteristic symptoms of glaucoma. An abnormal hardness (tension) of the eyeball; dilatation of the rectal

vessels; a partial loss of sensibility of the cornea, which, as the disease advances, loses its natural polish and may even become hazy; a diminished anterior chamber; a, greater or less, loss of contractility of the iris, ending in its atrophy; a dilated, greenish pupil; finally, a cataractous lens. The ophthalmoscopic signs are: excavation of the optic papilla (vide p. 103); pulsation of the retinal arteries; hæmorrhages into the internal ocular structures; turbidity of the vitreous. The subjective symptoms are: a hypermetropic and presbyopic state of vision; a diminution, followed by extinction, of eccentric vision, especially in the inner part of the field; dimness of vision, often first of a periodic character, ending in complete amaurosis; fiery and prismatic spectra; pain in the eyeball and along the course of the fifth nerve.

Glaucoma occurs in three distinct forms. In the acute form most of the above symptoms may come on within a few days, or even hours, attended by violent inflammation of the deeper tunics, and more or less complete amaurosis, constituting the "glaucoma fulminans" of recent German authors. In the subacute form the changes ensue more slowly; whilst chronic glaucoma is a most insidious form of the disease, often attended by symptoms of an atrophic, rather than of an inflammatory character, ending slowly, but surely, in the total extinction of vision. To the last category belong the "amaurosis with excavation" and the "glaucoma simplex" of continental writers.

Treatment of Glaucoma by Iridectomy.—In 1857, v. Gräfe, in an elaborate memoir on the entire subject, introduced his operation of iridectomy. He stated, as a matter of experience, that this operation yielded different results, according to the period at which it was performed. In all acute cases it completely restored vision, if performed within a fortnight of the attack. If performed at later periods of the disease, the results varied: in some cases, restoration of vision ensued after several weeks, or even months; in others, especially those attended with extreme limitation of the field of vision and marked excavation of the optic disc, the amelioration of sight was at the best but temporary; whilst in a third class of cases, in which all perception of light had been lost, iridectomy relieved pain, but had no influence on vision. Dr. Haffmanns, to whose excellent *résumé* of the entire subject* we owe the greater part of the preceding epitome,

* "Archiv für Ophthalmologie," viii. 2, p. 124.

remarks that in no other country did iridectomy meet with greater opposition than in England. This opposition, however, lost, we believe, much of its force by frequently proceeding from surgeons, who rejected the operation so unconditionally as not to hesitate to condemn it upon purely speculative considerations, without having had any personal experience of its effects. Indeed, so high at one time did this tide rise, that gentlemen, even of the highest professional standing, were induced to employ expressions and methods of discussion that reminded one rather of the virulence and acrimony of by-gone days than of the moderation that should prevail in discussing a question so momentous, not only to science, but to humanity at large.

The mode of performing iridectomy has already been described at page 75. When performed for glaucoma, the incision with the keratome should be made a little behind the corneo-sclerotic junction, and the portion of iris should be cut out completely, *i. e.* so as to include even its ciliary attachment. As previously mentioned, the anterior chamber is often considerably diminished in glaucoma, so that great care is required to keep the point of the keratome well forward, to avoid wounding the lens. This may, we believe, however, in exceptional cases become opaque if the keratome is withdrawn so suddenly as to let out the aqueous humour at one gush. A traumatic cataract, caused by the operation of iridectomy, is a most unfortunate occurrence. Hæmorrhage into the vitreous chamber, suppuration of part or all the globe, are also exceptional disasters consequent on iridectomy. But speaking generally, the operation *per se* may be regarded as one of a singularly innocuous nature.

We may discuss the effects of this operation, firstly, as pure matters of fact. From this aspect our own opinion and experience are that the influence of the operation on the restoration of vision is inversely proportional to the duration of the disease. In chronic glaucoma we have never seen it remarkably successful. Contrary to this observation, however, it is only right to add Dr. Haffmanns' testimony (Op. cit. p. 173), that in Donders's practice an arrest, or even a diminution of impending blindness, has been noticed not only in many cases of chronic glaucoma, but even in those of "amaurosis with excavation" ("glaucoma simplex"), in which tension of the tunics was a prominent sign. V. Gräfe says (Arch. f. Ophthalm. viii. 2, p. 303), that he can adduce numerous cases, which had been progressing from six months to three years, in which he has obtained the same results with a permanence, which he had the opportunity of testing for periods

v. p.
X

varying from one to three years. In addition to the diminution of intra-ocular tension effected by iridectomy, it appears to exert a generally favourable action on the nutrition of the eyeball: *e. g.* in promoting the resolution of inflammation, &c. We may next discuss the *rationale* of the operation. In this point of view iridectomy is singularly weak. Whilst nearly every other operation, not only in ophthalmic, but in general surgery, has some tangible reason to exhibit for its performance, iridectomy stands almost alone in the utter insufficiency of the various far-fetched explanations that have from time to time been assigned for its assumed efficiency. We cannot help thinking that the greater part of the benefit of the operation results from the largeness of the corneal incision, necessarily preliminary to the actual excision of the iris, and the consequent completeness of the relief to the intra-ocular tension thus implied; that a limited paracentesis corneæ is as inferior to "iridectomy" precisely in the same ratio as the temporary relief afforded by the mere puncture of an abscess is to the permanent relief given by a free incision. V. Gräfe assumes there can no longer be any question as to the comparative merits of iridectomy and paracentesis corneæ. Professor Sperino's recent work on the effect of repeated paracentesis of the cornea exhibits a different view of the question.

We are not in a position to offer an opinion on Sperino's practice. We may, however, mention that he often performs paracentesis corneæ as a preliminary to iridectomy, believing that it is calculated to obviate, in a certain degree, any risks, especially internal hæmorrhage, of the operation.

Iridectomy is undoubtedly *the* remedy for glaucoma—absolutely so in all acute cases, to temporize with which with useless remedies may, in the present state of knowledge, be regarded as almost criminal. But it is an undeniable fact—of which we have ourselves seen several examples—that certain sub-acute cases recover under general treatment, of which we regard belladonna and iodide of potassium internally, and atropine topically, as the most potent elements.

The following are instances of such recoveries:—

CASE 23.—*Presbyopia ; Double commencing Cataract ; Acute Glaucoma ; Recovery under medical treatment.*

Ann E., æt. 65, admitted to hospital Nov. 2, 1864. Has suffered from defective sight for fifteen or sixteen years. We found hypermetropia of $\frac{1}{30}$, presbyopia of $\frac{1}{7}$, and commencing cataract in either eye. Seventeen days subsequently she

re-applied at the hospital for the following symptoms:—Five days previously she was attacked suddenly, in the evening, with severe pain in the left eye, radiating in the direction of the branches of the fifth nerve. The sight of the eye became at the same time much impaired. Since the first attack the symptoms had gradually abated. When we examined her we found the following symptoms:—

Left eye.—Globe tense; conjunctival and rectal vessels much gorged. Pupil $2\frac{3}{4}$ "", oval vertically, fixed. Fundus oculi yields only a dull reflex. Can count fingers at 5'. On Nov. 2 she read at 20 feet No. 21 (Jäger).

Right eye.—Tension normal; no injection of tunics; pupil $\frac{3}{4}$ "", acts well. Reads, as on Nov. 2, with +50, No. 20 at 20'.

For some reason, which is not stated in the notes of the case, iridectomy was not performed on the left eye. Belladonna lotion, and aloes and myrrh pills o. n. were ordered.

On Jan. 2, 1865, the fundus oculi was clearly seen; nothing morbid was seen excepting (?) an extensive pulsation of the upper retinal vein. The only definite record of the patient's vision is that on Nov. 22 she, with the glaucomatous eye, read No. 23 (Jäger) at 20 feet.

Another patient, suffering from subacute glaucoma, from having hardly any perception of light, recovered so far, under similar treatment to that of Case 23, as to be able to read LXX. (Snellen) at 20 feet.

[References on the subject of glaucoma:—Mackenzie's "Treatise," 4th ed. p. 889 et seq.—Ed. Jäger, "Ueber Staar u. Staar-Operationen." Wien, 1854.—"Archiv für Ophthalmologie," i. 1, p. 371; viii. 2, pp. 303, 124.—"Études cliniques sur l'évacuation répétée de l'humeur aqueuse dans les maladies de l'œil," par C. Sperino. Turin, 1862.—*Lancet* for 1862, Nos. V. and IX.—XI.—V. Gräfe's Memoir "On Iridectomy in Glaucoma, and on the Glaucomatous Process," ably translated by Mr. Thomas Windsor, of Manchester. London, 1859; New Sydenham Society.]

CHAPTER XV.

DISEASES AFFECTING THE WHOLE EYE-BALL.

OPHTHALMITIS.

IN OPTHALMITIS the inflammatory process is not confined to one or two structures, but involves almost all the textures of the eye. The disease may occur idiopathically, or it may be of febrile, phlebitic, or traumatic origin. In all cases, however, the symptoms are similar, although the terminations may be different. At the commencement, the conjunctiva becomes œdematous, the aqueous humour is turbid, the iris contracted and discoloured, and the eyeball increased in tension. At the same time there will be deep-seated pain in the eye and orbit, extending to the forehead and temple; exquisite tenderness of the globe; photophobia; iridescent spectra; and a diminution of vision. After a while the eye begins to protrude, it appears as if greatly swollen, it becomes fixed, it suppurates internally, and its functions as an organ of vision are partially or completely abolished. The swollen appearance presented by the eye is not generally due to an enlargement of the ocular tunics, but to the exophthalmos and the chemosis of the conjunctiva. The annexed case is, however, an exception to this remark. The usual termination of the disease is rupture of the eyeball, or its capsule, followed by evacuation of the pent-up pus and fluids. In some cases the cornea becomes softened, like a piece of soaked parchment, and ultimately sloughs. When the ophthalmitis is of phlebitic or pyæmic origin, the prognosis should be guarded, as great danger to life may arise, either from extension of the disease to the cranium, or the implication of other important organs of the body. Should the patient survive, the eye will generally be disorganized, or if the organ burst, it will lose its natural form, and become atrophic.

Treatment. During the acute inflammatory stage, the treatment consists in the application of ice poultices to the eyelids, leeches to the

neighbourhood of the eye, free scarification of the conjunctiva, and frequent applications of atropine. As soon as the globe manifests an increase of tension, paracentesis corneæ may be performed. Active general antiphlogistic treatment should be also employed, and cupping or venesection may in some cases be required. In the suppurating stage, hot applications should be substituted for the cold ones, and as soon as fluctuation is felt, a free incision into the ocular capsule, by the evacuation of the fluid contained in its cavity, will afford great relief to the patient. The treatment in phlebitic ophthalmitis must not be so actively depleting as that employed in the idiopathic and traumatic varieties, and should have especial reference to the patient's general condition. In some instances, as in the following, it may be deemed advisable to remove the eye.

CASE 24.—*Traumatic Ophthalmitis ; Abscess in the Vitreous Chamber ; Detachment of Retina ; Removal of Eyeball.*

A little boy, five years of age, was brought to the Ophthalmic Hospital, Southwark, on April 14th, 1860. On the afternoon of the 11th, he was watching a man shooting for nuts at a target at Stepney fair, when he received the charge of the gun on his left eye. This charge consisted of a piece of steel wire about an inch long, sharpened to a point, and mounted into a piece of cane. The boy said the wire struck him just below the lower eyelid ; but there could not be discovered any traces of the injury there. On the upper part of the cornea, however, was evidence of a wound in the shape of a white cicatrix. The cornea generally was somewhat cloudy ; the pupil was one confused hazy disk, completely obscuring the deeper structures. The external tunics were highly injected. There was great lacrymation, intolerance of light, and some pain. Mr. Laurence wished to take the boy into the hospital, but the friends preferred his being treated as an out-patient. He was ordered leeches to the temple, warm fomentations, and belladonna ointment round the eye. By the 18th, the cornea had cleared ; but the anterior chamber was centrally occupied by an opalescent substance, which concealed all but the external margin of the iris. Slight swelling of the eyelids and chemosis had ensued. His bowels being costive, he was ordered two grains of calomel and a scruple of rhubarb immediately. The warm fomentations were continued.

On the 21st, the boy was again brought to the hospital. The case had now assumed a most formidable appearance. The eyelids were swollen out into a protruding tumour of the size of a small Tangerine orange ; they were tense, glossy, and livid. The narrow interval between the two eyelids was occupied by fluid and dried pus, in the midst of which the cornea could be partially seen. The patient was put under chloroform. Mr. Laurence, in the first instance, made several exploratory punctures around the eyeball into various parts of the orbit, cutting into the conjunctiva ; this was found to be of a brawny consistence, and to be extraordinarily thickened by interstitial deposit of plastic matter. The eye having in this way been partially peeled of its shell of hard chemosed conjunctiva, it became evident that the eyeball was itself greatly enlarged, and moreover

presented to the touch an unusual degree of elastic tension. Mr. Laurence therefore cautiously explored it with the point of a bistoury ; and, some pus exuding, the incision was at once enlarged, and very nearly two drachms of thick, yellow pus evacuated ; and at last a membranous body, like an hydatid, stained and infiltrated with pus, shot out. As the eyeball was completely disorganized, Mr. Laurence deemed it advisable to remove it. The operation-wound very soon granulated and closed.

Dr. Bader examined the eyeball. He stated that the hydatid-like body was "the pus-infiltrated retina ;" further, that "a thick layer of lymph was deposited upon the whole of the inner surface of the choroid ; the latter was sacculated, and thickened by greyish films of fibrine. The sclerotic was thickened, and numerous adhesions must have existed between it and the orbital tissue."

SYMPATHETIC OPHTHALMIA.

When an eye has undergone abnormal changes from an injury, or from acute inflammation of its deep structures, its fellow-eye is especially liable to be attacked by *sympathetic ophthalmia*. This is an alarming and, if not combated early, an intractable disease. The injuries which predispose to it are those implicating the iris and the ciliary region, more especially if a foreign body is present, acting as a source of irritation. The symptoms of sympathetic ophthalmia generally begin to appear from five to six weeks after the receipt of the injury ; in some cases, however, they do not begin till many months, or even years, afterwards. One of the earliest symptoms is *muscæ volitantes*, followed by dimness of sight and contraction of the field of vision. The pain and intolerance of light are in some cases very considerable ; in others they are almost completely absent. Inflammation of the iris and ciliary processes, occlusion of the pupil by lymph, opacity of the lens, and softening of the globe, are the most common objective symptoms. In some instances the sympathetic affection manifests itself by inflammation of the choroid or retina, or atrophy of the optic nerve.

Treatment. Foreign bodies should be extracted from the interior of the eye before sympathetic symptoms supervene. Enucleation of the injured globe is the only sure method of arresting sympathetic ophthalmia, and should be practised at an early stage of the disease, otherwise its beneficial effects will not be obtained. Von Gräfe has recommended that when irido-cyclitis persists, or where blood is effused within the injured eye, enucleation may be replaced by a seton passed through the vitreous ; for a sympathetic affection of the other eye has hardly ever been observed during acute purulent processes from panophthalmitis.

Absolute rest of the sympathetically affected eye should be strictly enjoined, and the patient for some time should be kept in a subdued light, and afterwards should not be permitted to go out of doors without wearing dark glasses. Atropine in solution, or belladonna lotion, should be applied frequently to the eye. For the treatment of iritic complications, see "Iritis." Operative procedures, such as the formation of an artificial pupil, and extraction of the lens, should be deferred until all signs of irritation have disappeared.

TUMOURS OF THE EYE-BALL.

Three chief forms of tumours occur within the eye :—

1. *Encephaloid Cancer of the Eye-Ball.*—This generally occurs in young children. The first indication of the disease is a yellow, metallic, glistening appearance, deep in the eye, accompanied by more or less loss of vision and dilatation of the pupil. The metallic appearance of the fundus oculi has given the disease, or rather the symptom, the designation of "cat's-eye." If the surgeon sees the case in this stage, he may, especially with the ophthalmoscope, observe a yellowish, lobulated tumour deep in the eye, and pervaded by vessels. After a time the pupil dilates still more, the lens and iris bulge forward, the former becoming gradually opaque, the anterior chamber diminished, and blood is effused either in the vitreous or aqueous humours. The globe becomes gradually enlarged, feels hard and doughy, or even fluctuating, its external surface is irregular, the conjunctival and sclerotic vessels are congested, imparting a general, dull-purple hue to the entire globe ; finally, the tunics of the globe yield at some point to the ever-growing intraocular tumour. During this stage of the disease there is usually more or less pain in and around the eyeball, often accompanied by frontal and general headache ; the little patient suffers from sleeplessness, loss of appetite, and febrile disturbance. After the tumour has burst through the tunics of the eye, the tension of these being thus relieved, many of the above symptoms cease, but are soon succeeded by others of a hectic type—emaciation to an almost incredible degree, night sweats, periodic heats, loss of appetite, sleeplessness, &c. These are due to the immense increase which now takes place in the cancerous mass, no longer confined within bounds by the ocular tunics. The tumour soon assumes all the characters of an encephaloid fungus. Its rate of growth is often something enormous ; its surface is the seat of a foul, ungranulated

ulcer, from which a thin, sanious, irritating, badly-smelling discharge exudes; more or less copious fluxes of blood ensue; secondary tumours form in the adjacent lymphatic glands of the cheek, parotid region, and neck; and finally the patient dies, either exhausted by the local effects of the tumour, or from secondary deposits in the brain or other vital organs. Nothing can be done to arrest or check this formidable disease. Extirpation of the globe has over and over again been performed with no other result than a recurrence of the disease in the orbit; nor can, in this disease, the doubtful advantage even of any retardation of its progress be predicted. The patient rarely survives two years from the commencement of the tumour.

CASE 25.—*Encephaloid Cancer of the Eyeball in a child; Removal of Eye; Recurrence of Disease in Orbit; Death.*

Esther T., æt. 3 years and 10 months, was admitted into hospital on Oct. 15th, 1859. The child was standing in a dark passage about a month previously, when the mother observed a peculiar whiteness in the eye: it looked like a "bull's-eye"; the father compared it to a "cat's-eye." In the outer part of the vitreous is a floating body, partly dead-white, partly jelly-like; on it are some vessels. The eyeball appears otherwise normal, and the child can distinguish objects in certain positions of the eye. In another eight months the pupil was blocked up by a substance of a yellowish-maroon colour; there was blood in the anterior chamber; the globe was somewhat shrunken and vision was entirely lost; and the child began to suffer pain. Three months later, the globe began to enlarge, its tunics became highly congested, the pain had increased, and the child began to lose flesh rapidly. On Sept. 5, 1860, Mr. Laurence removed the eyeball. Mr. Hulke dissected the eyeball. "The retina," he said, "was displaced towards the axis of the globe by soft, brain-like cancer of the choroid: it was thick and almost glutinous; its vessels were distended with blood and varicose; the other elementary tissues were not recognized; its outer surface was marked with pigment-epithelium from the choroid. Anteriorly, the retina enclosed a mortar-like, friable mass—*débris* of the vitreous humour (?). The cancer probably had originated in the chorio-capillaris, because a thin wall of multipolar pigment-cells (of choroidal stroma) separated it externally from the sclerotic, and its inner surface was bounded by traces of the hexagonal epithelium-cells and the elastic lamina. The ciliary body and iris were œdematous, and infiltrated with exudation-cells. The lens was thrust forward, pressing into the dilated pupil towards the cornea." The microscopic elements were considered decidedly malignant. In a month the growth recurred in the orbit. Dec. 14, 1860 (a few days before her death), the following note was taken:—"The right side of the face, from the level of the brow to that of the lower jaw, is concealed by an enormous fetid fungus of circular outline, with a diameter of $4\frac{1}{2}$ inches, of an almost black colour, from dried blood and discharge. The child is emaciated to a shadow."

2. *Scrofulous (or Tubercular) Tumour of the Eyeball.*—All the signs of the earliest stages of encephaloid cancer of the organ are

seen in this disease ; but after the tunics of the eye have given away, a puriform discharge is for some time poured forth, no fungus protrudes, and the eyeball, instead of enlarging gradually, shrinks, and finally atrophies.

3. *Melanotic Cancer of the Eyeball.*—This form of cancer occurs very rarely in young subjects, generally in persons past the meridian of life, and not uncommonly in eyes previously lost from injury or disease. The progress of the disease is very similar to that of encephaloid cancer of the eyeball, which, indeed, in its histological structure, it really is ; but it presents several points of difference. No metallic reflection is observed from the fundus oculi ; if any at all, it is of a brownish, or hæmorrhagic character ; indeed, the disease has, at its early stage, been mistaken for simple hæmophthalmos. After the eyeball has commenced enlarging, its surface assumes, in parts, a deep-brown, or dark leaden-coloured appearance. After ulceration of the tunics has ensued, the resulting fungus rarely attains the same enormous dimensions encephaloid tumours do, and the melanotic character of the disease is now quite obvious. The patients generally die from secondary visceral deposits, especially in the liver and lungs. Removal of the eyeball may, in this disease, retard the final catastrophe, but can lay no claims to the character of a remedy.

This is perhaps the most convenient place to describe the mode of extirpating the eyeball.

EXTIRPATION OF THE EYEBALL.

The sclerotal conjunctiva is divided by scissors, in a circular line, about a quarter of an inch from the margin of the cornea ; a strabismus hook is now passed beneath the tendons of each of the ocular muscles, and these are thus successively divided with scissors ; the globe is then dislocated forwards, out of its socket, by the fingers ; finally, the optic nerve is divided close to its ocular entrance by long narrow-bladed scissors, passed deep into the orbit behind the eye. If these four steps of the operation are duly performed, the eyeball is easily and cleanly removed from its socket. Extirpation of the eyeball may be required on account of tumours or abscesses in the eye ; sympathetic inflammation of one eye, the other having been lost by previous injury or disease ; destruction of the eyeball from injuries, &c. ; but it should not, as a rule, be performed so long as the patient still retains perception of light in the eye.

Graefe objects Archw. 9th. 76 p. 52 to enucleate if panophthalmia with exophthalmia

HYDROPTHALMIA (*Dropsy of the Eye*).

Hydrophthalmia occurs principally in cachectic individuals, and often may be seen to supervene on chronic inflammation of the tunics of the globe. The dropsy may be confined to the aqueous chambers, or vitreous body, or it may involve the whole eyeball. When the whole globe is distended, the disease has received the name of *buphthalmos*, from the resemblance of the eye to that of an ox. Dropsy not unfrequently takes place between the retina and choroid, here or between the latter and the sclerotic; each of which conditions has been already described at pp. 99, 101. In cases of dropsy affecting the anterior segment of the eyeball, the cornea is increased in diameter, and also somewhat in prominence; occasionally it is opaque, or nebulous; the anterior chamber is increased in depth; the iris is dull, and perhaps adherent to the capsule of the lens. During the early stages of hydrophthalmia the globe is increased in tension, but as the disease advances the eye becomes soft. From the increased size of the globe its movements are greatly impeded. The vision at first only becomes slightly affected, but the eye ultimately becomes more or less amaurotic.

Treatment.—Repeated paracentesis corneæ, the administration of tonics, and counter-irritation, are the remedies to be employed. Should these fail in arresting the progress of the disease, iridectomy may be performed. Sometimes hydrophthalmia is accompanied by so much pain and inconvenience to the patient as to call for the removal of the distended organ.

CASE 26.—*Hydrophthalmos, with Excavation and Atrophy of the Optic Papilla.*

James P—, æt. 19, was received at the Ophthalmic Hospital, Southwark, on July 11, 1864, for the purpose of having his left eyeball removed, it being so greatly enlarged as to be both inconvenient and, at times, painful to himself, and unsightly to his friends.

The eye was first observed to be enlarged when he was about three years of age. It continued to increase in size till his fourteenth year, since which time it does not appear to have grown larger; but the visual power gradually diminished, and the eye had been occasionally attacked with severe pain.

When admitted, the left eye was considerably larger than the right, the enlargement being especially in the upward, downward, and outer parts of the globe, its power of eversion being thereby much impaired. The eyeball was tense, and presented a livid injection, and distension of the entire sclerotic. The cornea of this eye measured 5", whilst that of the right (sound) eye measured but 4½" in

diameter. The anterior chamber of the diseased eye was remarkably deep. The pupil was irregular, and contractile to light, up to a diameter of $2\frac{1}{2}$ "', the right pupil contracting to $1\frac{1}{2}$ ". The vision of the diseased eye was reduced to mere quantitative perception of light. With the healthy eye he read No. 1.

On ophthalmoscopic examination of the fundus, the optic nerve was found to be atrophied, and cupped, the vessels being considerably displaced at the margin of the excavation.

Enucleation was performed by Mr. Laurence on July 13th. The globe after removal was found to measure $1\frac{1}{4}$ " in its longitudinal diameter from the vertex of the cornea, and $1\frac{1}{8}$ " in its transverse diameter. The sclera was so thinned that, on holding up the globe, the pupil appeared quite red by transmitted light, as if lit up by an ophthalmoscope. The vitreous was reduced to a fluid, like water. *The optic nerve was deeply excavated*, measuring about 1" in diameter, the displacement of the vessels being beautifully seen. This pathological verification of the ophthalmoscopic diagnosis lends interest to the case.

The following description of the microscopical examination of the eye has been kindly furnished us by Mr. Hulke:—"I can generally confirm the statement that the optic disc is cupped. The exact relations I cannot make out, for when I received the eye it had been already opened, the choroid, retina, and sclerotic were more or less separated, and the vitreous humour had escaped. Owing to the collapse of the opened globe and the disturbance of the coats, I found it impossible to make fair sections through the nerve. Two things struck me: 1. the great thickness of the choroid (especially in the posterior segment of the globe), due to great dilatation of its vessels, to œdema, and proliferation of stroma cells; 2. the extensive stripping of its hexagonal epithelium."

ENTOZOA.

According to Mackenzie, the following entozoa have been observed in the human eye and orbit:—

1. *Echinococcus hominis*, in the areolar tissue of the orbit.
2. *Cysticercus cellulosæ*, in the areolar tissue of the eyelids, under the conjunctiva, in the anterior chamber, and in the cornea.
3. *Filaria Medinensis*, under the conjunctiva.
4. *Filaria oculi humani*, in the crystalline.
6. *Monostoma oculi humani*, in the crystalline.
6. *Distoma oculi humani*, in the crystalline.

Since the introduction of the ophthalmoscope the cysticercus cellulosæ has also been observed between the retina and choroid, and in the vitreous humour. Liebreich, aided by the illumination from an ophthalmoscope fixed to his head, has extracted a cysticercus from the vitreous with cannula forceps.

For further particulars, respecting parasites in the organ of vision, see Mackenzie's "Practical Treatise," p. 1087; Von Gräfe's Paper in the *Archiv f. Ophthalmologie*, vol. vii.; and Liebreich's "Atlas," plate vii.

STAPHYLOMA.

Under this term is understood an unnatural bulging of the tunics of the globe. The most common form is that seen in the corneal region. These corneal protrusions generally arise from the cornea having become perforated by progressive ulceration. The iris then falls forwards, and adheres to the cicatricial tissue that subsequently fills up the gap in the cornea. This structure may also become atrophied around the original staphyloma, which thus extends from the intraocular hydrostatic pressure, pressing forwards the thinned cornea. In this way, or from progressive ulceration, a partial staphyloma corneæ gradually becomes a total one. Excepting in conical cornea, the staphyloma is always opaque, and of a whitish or bluish colour. If the staphyloma corneæ is small and partial, it may, if not situated over the pupil, not materially interfere with vision; if over the pupil, vision may be improved by a judiciously placed artificial pupil. Total staphyloma corneæ is accompanied by irremediable blindness. If by its size it protrude between the lids, and give rise to general irritation of the eye, it had better be removed. Healing generally takes place by the first intention, and leaves an excellent stump for the adaptation of an artificial eye. In some of the worst forms of staphyloma the entire eyeball becomes expanded to an extent that necessitates its enucleation.

In some cases, bluish protrusions are seen in the sclerotic; these are caused by thinning and bulging of that structure, the bluish colour being due to the prolapsed choroid. These sclerotic staphylomata usually do not admit of any treatment, excepting perhaps occasional paracentesis. The staphyloma posticum, which is such a characteristic sign in myopia, will be referred to under that head.

The removal of total staphyloma of the cornea and iris may be effected in the manner recommended by Mr. Critchett, as follows:—

Having separated the lids with the speculum, four small curved needles, armed with black silk, are passed through the globe from above downwards, in such a way that the punctures and counter-punctures of the needles exactly bound the intended line of incision. The needles which transfix the eyeball are allowed to remain with their extremities protruding until the abscission of the staphyloma is

accomplished. The latter should be commenced by an incision of the sclerotic to its temporal side, with a small cataract knife. An elliptical piece, a little smaller than that included between the points of entrance and exit of the needles, may then be excised, by means of blunt-pointed scissors introduced through the scleral opening. The needles are now drawn through, and the sutures carefully tied.

Dr. G. Borelli, in 1858 (*Giornale d'Oftalmologia Italiano*, vol. i.), introduced the following operation for staphyloma:—Two needles are passed crucially through the base of the staphyloma; a ligature is then twisted behind the needles around the staphyloma, and is firmly tied. The needles are either withdrawn or cut off at the ends, and a compress-bandage is applied. The strangulated portion soon sloughs off. This operation is said to yield a good stump, and in cases of partial staphyloma to leave the eye in a fit state for any further operations, such as iridectomy. (*Vide* Mr. Windsor's cases in the third volume of the *Ophthalmic Review*.)

ADAPTATION OF AN ARTIFICIAL EYE.

When an eye has been partially or wholly excised, or has atrophied considerably, the appearance of the patient may often be greatly improved by the adaptation of an artificial eye to the stump. The artificial eye has also the advantage of assisting the natural play of the lids, and thus preventing inversion of the lashes and its attendant evils.

Artificial eyes, vulgarly called "eye-limpets," are constructed of glass or enamel. The anterior surface is convex, with a representation of the iris and pupil upon it; the posterior is concave, to adapt itself to the form of the stump. The artificial eye should be thin and light, and it should be so made as to allow of its introduction without causing pain to the patient, and should admit of the perfect movements of the eyelids over its anterior surface. If fræna exist between the lid and the stump, the artificial eye may be correspondingly notched.

The mode of inserting and removing the eye is exceedingly simple. All manipulations should be conducted over a soft cushion, in order that the eye may not be broken in the event of its falling, and before introducing it, it should be dipped in tepid water. To insert it, the upper lid must be drawn upwards with the thumb of the left hand, whilst the upper border of the eye is slid by

the thumb and forefinger of the right hand under the lid into the upper palpebral sinus. The lower lid is now depressed, and the eye, with a little manipulation, glides into its socket.

In removing the eye the lower lid is depressed, and the patient's thumb nail, or a small hook, is inserted under the eye, which is tilted out of the lower palpebral sinus, and is then easily drawn from behind the upper lid. After removal, which should be done every night, the eye should be dipped in tepid water, cleaned, and carefully wiped.

If irritation of the conjunctiva ensue from the pressure of the artificial eye, its use for a time should be discontinued, and the socket should be syringed with cold water, or alum lotion.

If the insides of the eyelids become the seat of polypoid growths, they should be snipped off with scissors.

NEURALGIA OCULI.

A not very common disease, characterized by pain, often intense, of the globe, and not referrible to any organic changes in the eye itself. It is not unusually of an hysterical character. Neuralgia oculi must be treated on the same principles as neuralgia generally. Hypodermic injections of morphia, and the internal administration of quinine and iron, are among the remedies which should be tried.

CHAPTER XVI.

ON VISION.

THE eye, in its most important relations, is essentially an optical instrument, by which, through the medium of light, we take cognizance of the most obvious and necessary events of the external world.

For the sake of precision in the investigation of the laws according to which light is propagated through space, it is necessary to consider all luminous bodies as composed of an infinite number of infinitely small points, each of these points giving off, in all possible directions, an infinite number of straight lines of extreme tenuity. These lines of light are individually called *rays* of light, whilst the combined bundle of rays which emanate from, or converge to, a luminous point, is called a *pencil* of rays. If the component rays of

FIG. 47.

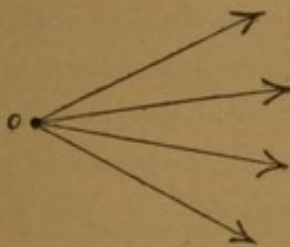


FIG. 48.

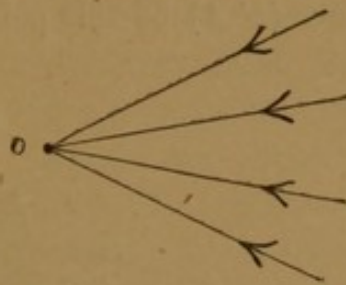


FIG. 49.




FIG. 47.—Divergent Pencil } *o*, luminous point, or *focus*.
 „ 48.—Convergent „ }
 „ 49.—Parallel „ }

a pencil of light, in their onward progress from their initial source—the luminous point—separate further and further from each other,

then we have a *divergent* pencil (Fig. 47); if, on the other hand, the rays approach each other closer and closer, as they proceed onwards to a point, then we have a *convergent* pencil (Fig. 48); whilst, lastly, if the rays of a pencil neither diverge nor converge in their onward course, we have a *parallel* pencil (Fig. 49). A point towards which rays converge, or from which they diverge, is termed, in the language of optics, a *focus* of rays, or, shortly, a *focus*.

Strictly speaking, no such rays as parallel rays exist in nature; but for the recipient surfaces we shall have to deal with (our eyes, lenses, reflectors, &c.), we may practically regard all rays of light which proceed from near objects as divergent, those from distant ones as parallel, whilst convergent rays are not to be found in nature at all, but may be produced by convex lenses.

We may now at once proceed to what is, for our purpose, the essential part of the subject—viz., the consideration of the properties of optical lenses.

The *double-convex lens* is represented in section in Fig. 50. It is formed by the apposition of the segments of two spheres; these, in the lenses in common use for spectacles, being of equal curvature.

Parallel rays, entering one surface of the lens, on their exit from the second surface, converge to a point at a fixed determinate distance from the lens.

This point, F (Fig. 50), is called the *principal focus* of the lens. The distance (FA) of this point from the contiguous surface of the

FIG. 50.

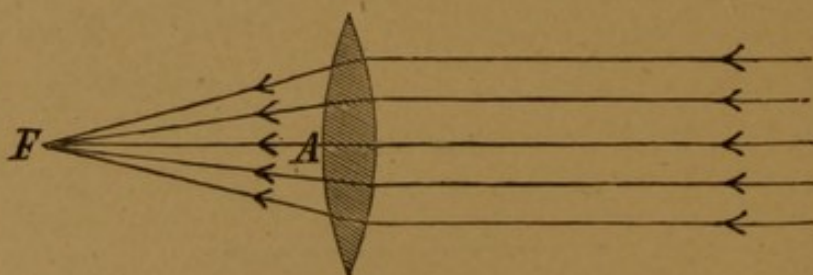


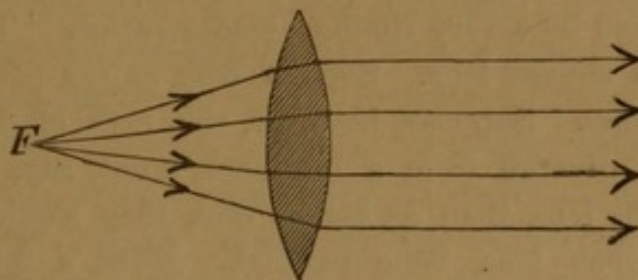
FIG. 50.— FA = principal focal length, in an equi-convex glass lens equals the radius of curvature.

lens is the *principal focal length* of the lens, or, briefly, its *focal length*. Thus we speak of convex lenses of 2, 3, 5, 8, &c., inches focal length, or, as they are commonly termed, 2-inch, 3-inch, 5-inch, 8-inch, &c., convex lenses—meaning thereby that they have the

property of bringing parallel rays to a focus, uniting them to points at distances from the lens of 2, 3, 5, and 8 inches respectively.*

Vice versá, rays of light which diverge from a point *F* (Fig. 51), situate at the focal length of the lens, issue from the other side in a state of parallelism. If an object be placed behind a convex lens at

FIG. 51.



a less distance than its focal length, an erect, magnified image of the object is perceived by an eye placed in front of the lens. The shorter the focal length of the lens, the greater its magnifying power — *e. g.* a 2-inch lens magnifies more, than a 4-inch lens. In reference to their respective magnifying powers, then, we should be wrong in designating the first lens as 2, the second as 4, which would imply the second were “stronger” than the first; but the more correct expression is to call the first lens a $\frac{1}{2}$, the second a $\frac{1}{4}$, the latter fraction being less than the former.

The optical effect of a combination of lenses in contact, both as regards its power and as regards the distance at which parallel rays impinging on the first lens are brought to a focus by the combination of lenses, is ascertained by adding together the several fractions which express the powers of the lenses. The resultant fraction represents the power of the single lens, which is, optically, equivalent to the combination. Thus, the focal length of an 8-inch and of a 5-inch convex lens placed together is $\frac{1}{8} + \frac{1}{5} = \frac{1}{3}$ nearly. The equivalent single lens is a 3-inch lens. Parallel rays impinging on such a combination will be brought to a focus at a distance of three inches.

We have now considered the optical effect of a convex lens on

* We may here call attention to the fact that, in the French trial-lenses, the focal lengths are given in Paris inches, whereas English opticians give theirs in English inches. 12 English inches = about $11\frac{1}{4}$ Paris inches; so that, *e. g.* if we find a patient requires a $22\frac{1}{2}$ -inch glass of the French trial-glasses, we should order him a 24-inch English glass. In the German trial-lenses (Paetz & Flohr's) the Prussian inch is adopted, which differs but slightly from the English inch.

parallel rays, *i. e.* such as emanate from objects at any distance greater than four feet from the lens. Suppose, however, the object to be situated at any less distance, but greater than the principal focal length, from the lens, then the rays of light which proceed from each luminous point are no longer parallel, but divergent. It will now be found the lens still retains its power of re-uniting the rays to a focus, but at a greater distance from the lens than its principal focus. This result may be explained by a very simple demonstration. Take the case, *e. g.* of a 6-inch convex lens. Such a lens unites parallel rays to a focus at six inches. Suppose, however, the rays of light, instead of being parallel, diverge from a luminous point, say, twenty inches distant from the lens, then, as before said, they would, after passing through a 20-inch lens, issue parallel. Now, a 6-inch lens may (according to the proposition before stated) be considered as equivalent to the combination of a 20-inch lens and a 9-inch lens; for $\frac{1}{6} = \frac{1}{20} + \frac{1}{9}$ (nearly). We may therefore assume that that part of the 6-inch lens which is equivalent to a 20-inch lens has been employed in converting the rays diverging from a point twenty inches from its surface into parallel ones; these then strike that remaining part of the 6-inch lens, which is equivalent to a 9-inch lens, and are thus brought to a focus at nine inches from the latter. So that the final result is, that rays diverging from a luminous point twenty inches from a 6-inch convex lens are brought to a focus at a distance of nine inches from its surface.

Fig. 52 illustrates graphically the presumed theory :—

FIG. 52.

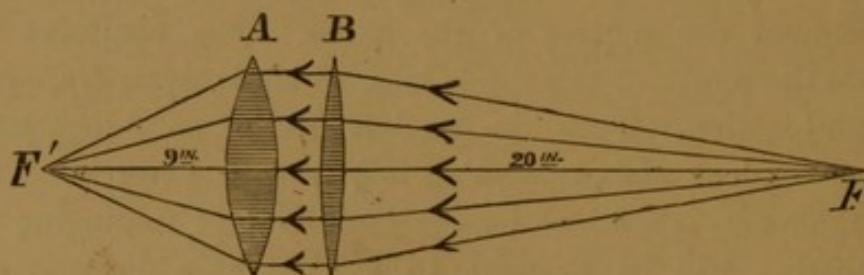


FIG. 52.— $B = 20$ -inch lens } Together equivalent to a 6-inch lens.
 $A = 9$ -inch lens }
 $F =$ a luminous point, 20 inches from B .
 $F' =$ focus of combined lenses, 9 inches from A .

If the luminous point be brought nearer and nearer to the lens, the focus of the emergent rays will move further and further off, till, when the luminous point arrives at the principal focus of the lens, the

emergent rays are not united to a focus at all, but, as already mentioned, issue parallel to one another.

We are now prepared to understand how a convex lens possesses the property of forming an *image* of an object placed in front of it. As before explained, every object in nature may be considered as composed of an infinite number of points, either in themselves luminous, or rendered so by incident light, every such luminous point emitting a pencil of divergent rays. If the rays of any one pencil are made to converge, the luminous point from which they in the first instance emanated is, so to say, reproduced at their point of union (focus). In this way, each luminous point of the object having its optical representative, an *image* of the object is formed. We understand, then, by the term "image" of an object its optical reproduction.

A *concave lens* has properties the reverse of those of a convex one. We shall limit our observations to the case of the equi-concave glass lens, of which a sectional figure is subjoined (Fig. 53).

The two sides of such a section, $A B$ and $A' B'$, are the concave sides of two circles—the circles of curvature. $C, C', C R, C' R'$ are the

FIG. 53.

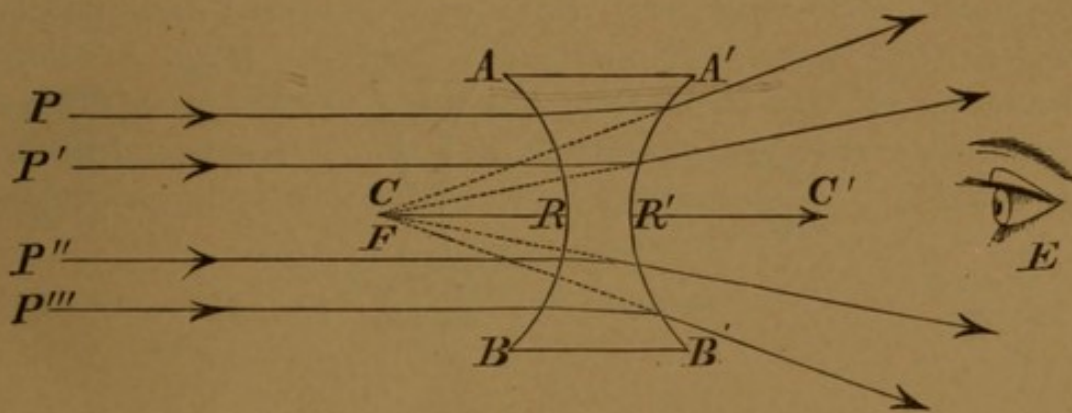


FIG. 53.— F =apparent focus, the dotted lines indicating the apparent path of the rays when they strike the eye, E .

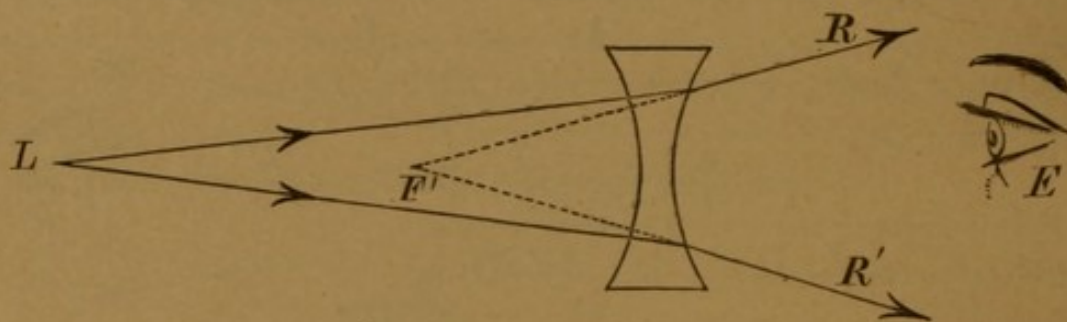
centres and radii of curvature, respectively. Parallel rays, $P, P', P'', P''',$ &c., striking one surface of the lens, have a *divergence* imparted to them on their exit, as if they proceeded from an imaginary focus, F , which is called the *principal focus* of the lens. $F R$ is the *principal focal length*, or briefly the *focal length*. In the equi-convex lens the focal length is measured *forwards* from the surface of the lens, in the same direction as the rays travel (converge to their focus); but in the case of the concave lens the focal length is measured *backwards*,

from R to F , in a direction contrary to the course in which the rays diverge *from* their focus. If, then, we agree to call the focal length of the convex lens positive, we must call that of the concave one negative; and such is the practice actually adopted.* We thus speak of a convex lens having, say, five inches positive focus, and a concave lens having five inches negative focus.

If the rays of light from a luminous point are already divergent, before they strike a concave lens, they are found, after their exit from the second surface of the lens, to have acquired a still greater degree of divergence, hence to appear *as if* they proceeded from a point nearer the lens than that which they really do proceed from (Fig. 54).

It is one of the laws of vision that we refer the origin of any rays striking the eye (E) to the position a luminous point (F' in the figure) would occupy which corresponds to the degree of divergence the rays (R and R') have, when they strike the eye. This luminous point or focus (F') may have no real existence; the rays of light may never have met there; in which case the focus is an "imaginary," "virtual,"

FIG. 54.

FIG. 54.-- L =Luminous point.

F' =Imaginary focus of the rays after their exit from the lens, the dotted lines indicating the apparent course of the rays.

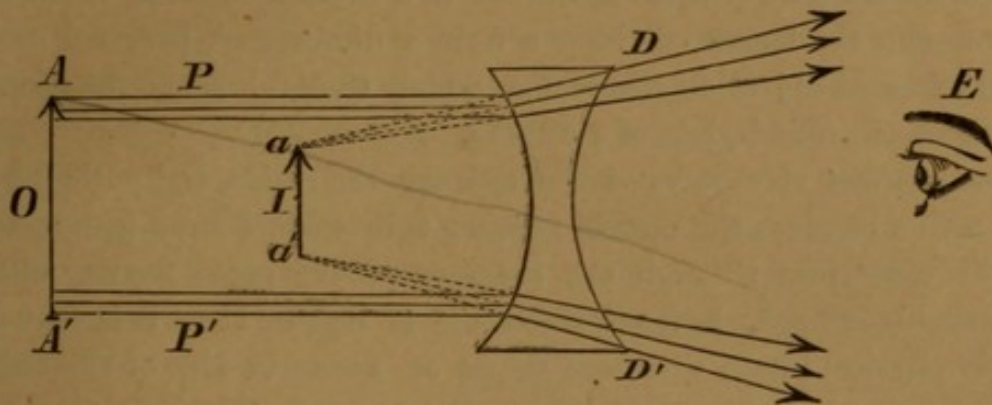
or "apparent" one, its position in space being fixed by the law of vision just mentioned. The dotted lines in both figures (53 and 54) indicate the apparent directions of the rays to the eye (E).

What holds good of a pencil of rays from one luminous point of an object, applies also to all. The consequence is that a concave lens forms an apparent image of any distant object precisely at its focal

* In English works on optics the reverse nomenclature prevails.

length; if the object is a near one, its image appears still nearer. Furthermore, the image is always erect and diminished (Fig. 55).

FIG. 55.

FIG. 55.—*O* = Object.*I* = Image.

P, P' = Parallel rays from the top and bottom points (*A, A'*) of the object, which, after emergence from the lens, are changed into rays (*D, D'*), having a divergence as if they proceeded from *a, a'* of the apparent image.

The "numbers" by which English opticians designate their convex spectacle-lenses correspond with the actual focal lengths (in English inches), but the numbers by which they name their concaves are arbitrary. The subjoined table (from Mackenzie) gives the focal lengths of concaves to which the numbers in question correspond. We give this table for the sake of completeness; but in practice we altogether ignore such an illogical nomenclature:—

Numbers.	Focal lengths in inches.	Numbers.	Focal lengths in inches.
1	48	7	9
2	36	8	7
3	24	9	5
4	18	10	4
5	14	11	3
6	12	12	2½

THE PHYSIOLOGY OF VISION.

The structures of the eye, regarded as an organ of vision, are of three kinds—optical, sentient, and accessory.

The *optical* structures of the eyeball are the cornea, the aqueous

humour, the crystalline lens, and the vitreous. These constitute a system of lenses which, for all practical purposes, may be regarded as equivalent to a single 1-inch glass, convex lens ; their action will be best understood by comparing the eye to a camera obscura. As in this instrument, the lenses of the eye form a diminished, inverted image of an external object on the retina, which thus fulfils the function of the sheet of ground-glass of a camera.

The *sentient* structures of the eye are the retina and optic nerve. The retina receives the optical image ; this is transferred (conducted) to the sensorium through the medium of the optic nerve, which, remarkably enough, is itself insensible to light. How it is that the purely physical image produces to us an accurate idea of the object itself, its position, size, form, colour, &c., is more than we at present know. But it is nevertheless remarkable, how perfectly the purely optical function of the eye must be exercised before vision can be accurate (*vide* following chapter).

The *accessory* structures of the eye are its extrinsic and intrinsic muscles, the choroid, and the sclerotic. The extrinsic muscles of the eyeball—the recti and obliqui—are its agents of movement, but take no direct part in the act of vision. The intrinsic muscles are the iris and ciliary muscle, the offices of which we shall discuss presently. The choroid probably fulfils two functions, serving, like the pia mater, as a matrix for the subdivision and extension of the vascular system of the eyeball ; and secondly, that of absorbing the redundant rays of diffuse light that, entering the pupil, might interfere with the clearness of the retinal image. The most important use of the sclerotic is to contain and protect the other more delicate structures of the eye, and to receive the insertions of the muscles of the eyeball.

For the distinct perception of objects their images must fall exactly on the retina. If a normal (“emmetropic”) eye be in a state of rest, the images of all *distant* objects fulfil this condition, and vision is perfect. Suppose, now, the eye, with its lenses still remaining in this state of equilibrium, be directed to a *near* object, the image would be formed behind the retina. We say “would be,” because, in reality, the retina having no power of locomotion backwards, only an indistinct, quasi-image is formed on it. The retina remaining stationary, an increase of curvature of the crystalline lens would bring the image forwards on to the retina ; and this is, in fact, precisely what occurs in the human eye. The images of near objects are brought forwards on to the retina by the

crystalline lens becoming more convex. This change in the convexity of the crystalline lens is what is known as the "power of accommodation or adjustment" of the eye, or simply the "accommodation" of the eye. By way of illustration, let us suppose that the eye, from having viewed a distant object, is all at once directed to one, say, at six inches off. If the latter be seen distinctly, it is evident, from the fact that the retina cannot move backwards, that the lenticular system of the eye must have increased in power. It has, in fact, increased by a quantity equivalent to a 6-inch glass convex lens. If we suppose the crystalline lens unchangeable in its power, Fig. 56 will represent the eye adapted for parallel rays (from the distant object),

FIG. 56.

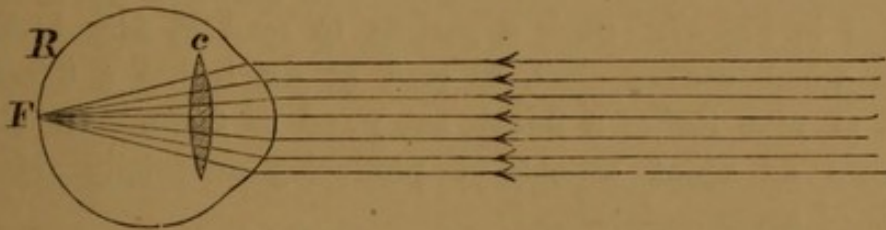


Fig. 57 the same eye plus a 6-inch glass convex lens placed before it. The effect of the latter is to convert the divergent rays (from the near object) into parallel ones, and these, then, will be focussed, as before, by the natural lenticular system of the eye. We have in the diagrams represented this process as if the additional glass lens were in front of the eye; really it is as if superimposed on the anterior surface of the crystalline. Now, it is found in practice that the proximity up to which different eyes can accommodate themselves varies greatly in different individuals and at different ages, and even in the two eyes of the same individual. One person may read a given type as close as three inches, whilst another may not be able to read the same type closer than thirty inches. In other words, whilst the former person possesses the power of increasing



FIG. 57.— $a b = 6$ inches.
c = crystalline lens.
R = retina.
l = 6-inch glass convex lens.

the convexity of his crystalline by a quantity equivalent to a 3-inch glass lens, the second cannot increase its convexity more than by a quantity equivalent to a 30-inch glass lens. We then say that the accommodative power of the first person is to that of the second as $\frac{1}{3}$ is to $\frac{1}{30}$, or as 10 is to 1; in other language, "the accommodation of the first equals $\frac{1}{3}$, that of the second equals $\frac{1}{30}$." The imaginary passive state of the crystalline which we have, for the sake of illustration, depicted in Fig. 57, is actually now and then met with in practice as the disease "paralysis of accommodation." This disease will be fully treated of in the following chapter. To illustrate, however, what we are now discussing, it may be said that in these cases the patients cannot see near objects distinctly, but we may restore their vision for them precisely in the manner delineated in Fig. 57. Such a patient to read at four inches requires a 4-inch convex glass, to read at six inches a 6-inch one, to read at nine inches a 9-inch one; and so forth. In atropine we possess an agent capable of producing artificially this same paralysis of accommodation.

When we, then, speak of a person possessing, *e. g.* $\frac{1}{6}$ accommodation, we simply mean he has the power of increasing the convexity of his crystalline lens by a quantity equivalent to a 6-inch convex glass lens; such a person can see distinctly both objects at a distance, and those which are six or more inches from the eye; but he cannot see objects distinctly nearer than six inches. A young healthy eye is generally endowed with an accommodation of $\frac{1}{4}$ for the two eyes used together, and say of $\frac{1}{3}$ for either used alone. As an illustration of the nature of accommodation, we may mention that after a person has brought an object (*e. g.* a fine print) as close to the eye as he can possibly see it distinctly, he may see it equally distinctly, when still closer, by the interposition of a convex lens—adding, in a word, an artificial amount of accommodation to that which the eye intrinsically possesses.

How is the amount of accommodation measured? In the case of a normal or simply presbyopic eye, by merely ascertaining the nearest point of distinct vision, the "near point." If the near point is *e. g.* six inches, the accommodation, which we will designate by $\frac{1}{x}$, = $\frac{1}{6}$.

The consideration of accommodation in myopic and hypermetropic eyes had better be deferred till we come to treat of those diseases respectively.

In what does the mechanism of accommodation consist? Probably

in the contraction of the circular fibres of the ciliary muscle, which the anatomical researches of Wharton Jones, H. Müller, Van Reeken, and Rouget, have shown to consist of two sets of fibres—a circular and a radiating. Has the iris any share in the act of accommodation? It is probably an auxiliary organ for distinct vision; for the pupil contracts when we regard near objects, and thus any slight circles of diffusion that might possibly arise in the retinal image from any inaccuracy in the degree of contraction of the ciliary muscle are probably cut off. The iris doubtless fulfils the further office of regulating, as a variable diaphragm, the amount of light that enters the eye.

A distinct image is formed on the retina of each of our two eyes. These images are probably not identical; indeed, we might say we know they are not; for if we regard, *e. g.* a solid cube, first with one eye, then with the other, we see two different perspectives of it. If we take an accurate drawing of each of these two perspectives, and place them respectively in the two compartments of a stereoscope, we see but one object, namely, the solid cube, of which the two drawings are the perspective projections. Binocular vision differs then, from monocular, in imparting to us, in an eminent degree, the idea of solidity and of the extension of bodies in three dimensions. The same idea is imparted to a less degree by monocular vision; in this case, however, it is the result of our judgment of the relative distances of different parts of the object from the eye, and of the effects of relief afforded by the lights and shadows.

CHAPTER XVII.

OPTICAL DEFECTS OF VISION.

A. ANOMALIES OF REFRACTION.

EYES may, in reference to their refractive powers, be divided into four classes :—

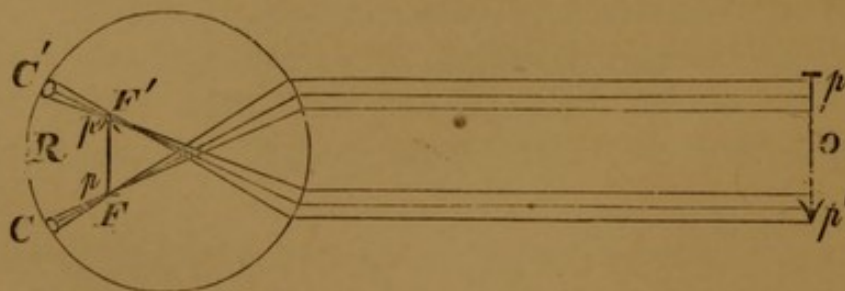
1. *Normal Eyes*.—Rays of light emanating from a distant object—parallel rays—are brought to a focus *on* the retina.
2. *Myopic Eyes* " *in front of* "
3. *Hypermetropic Eyes* " *behind* "
4. *Astigmatic Eyes* " in different places, accordingly as the rays strike different meridians of the cornea.

We shall now briefly indicate the leading features of the last three classes of eyes. (For the first class *vide* preceding chapter.)

I. MYOPIA.

In myopia the eye is either abnormally long, the refractive power of its lenses not being proportionately low to compensate for this excess of dimension, or the size of the globe being normal, the refraction of its lenses is excessive. Hence parallel, or not sufficiently (in proportion to the degree of myopia) divergent, rays proceeding from the luminous points of an object are reunited into their corresponding

FIG. 58.



points ("conjugate foci") in front of the retina: the rays of each cone diverging again from the foci (F, F' , fig. 58) are intercepted by the

retina (R), so that each *point* (p, p') of the object, instead of being reproduced by a corresponding point in the retinal image, is represented by a *circle* (C, C'), the transverse section of a cone; the different "circles of diffusion" necessarily partially overlap each other; and hence the resultant image is no longer a faithful reproduction of its original, but blurred and confused, and vision is proportionately defective. The far-point in myopia is at a definite distance from the cornea, the distance being inversely proportional to the degree of myopia. Cases may be met with in which the eye hardly deviates from the normal standard, the myopia being, say $\frac{1}{8}U$;* on the other hand, we have met with a case of myopia of $1/1\frac{7}{8}$, and cases of $\frac{1}{3}$, $\frac{1}{4}$, &c., are by no means rare. The excess of refraction of a myopic eye may be counterbalanced—the myopia corrected—by a concave lens, by which, in proportion to the depth of the latter, any desired degree of divergence may be conferred on the rays of light. In all that has preceded we have presumed the eye under examination to be not exercising any accommodation—to be "in a state of rest," as it has been termed.

In a general way, the following method will, in moderate myopics, readily give the correcting concave lens required:—Measure the furthest distance at which No. 1 of Jäger's test-types is distinctly legible. The concave glass required for distant objects will be found (by trial) to be of a somewhat longer focus than that indicated by the far-point thus found. If the myopia is high, but not excessive, and the power of accommodation limited, a lower-powered concave will be required for reading. In excessive degrees of myopia, dependent on serious organic changes in the internal tunics of the eye, no glasses should be permitted at all, at any rate, till these changes have by treatment been either subdued, or at least rendered persistently stationary.

Myopia may present one or more of the following objective signs:—There are undue prominence and size of the globe; a habit on the part of the patient of half shutting the eyes (to diminish the circles of diffusion: hence the origin of "myopia," from $\mu\acute{\nu}\omega$, I close, and $\acute{\omega}\psi$, eye); tenseness of the globe; deficient converging power from weakness of the internal recti muscles, terminating in extreme cases in divergent strabismus.

* This convenient method of notation was first introduced by Donders: the denominator indicates the far-point of the eye in question or the focal length of the concave-glass required to correct the myopia.

One of the heirlooms of traditional surgery is the supposed undue prominence of the cornea in myopia. Helmholtz and Donders have distinctly disproved the general truth of this statement by laborious measurements of the cornea by the ophthalmometer. Another set of very important diagnostic symptoms is that furnished by the ophthalmoscope.* These are the possibility of seeing the inverted image of the fundus oculi without the use of an objective—myopic refraction. To obtain a sufficiently extensive field of view, it is necessary to employ the ordinary objective—a lower one than is used for normal eyes. A very characteristic appearance is then usually seen. Embracing the optic papilla is a crescentic pale or white patch. It varies greatly in extent, being sometimes very narrow, sometimes very broad; generally situate between the optic papilla and yellow spot, not unfrequently, however, entirely surrounding the papilla. The retinal vessels coursing over the white patch are seen unusually well by reason of the contrast between their red colour and the subjacent white ground, and often pursue an unusually straight course. The crescent, or staphyloma posticum, as it is called, is mostly well defined, often very abruptly so, and not uncommonly bordered with a punctuated line of black pigment.

“Myopic refraction” may be considered pathognomonic of myopia; a staphyloma posticum almost so. Surgeons in military practice may be called upon to decide the question of the existence or not of myopia; in the event of prevarication on the part of the person under examination, the ophthalmoscopic tests of myopia will prove most valuable and decisive. Even in civil practice, these tests are sometimes of great utility.

In one case we observed the staphyloma to be fringed outwardly by a peculiar halo of regular short lines. In another rare case we observed with the ophthalmoscope the excavation of the staphyloma.

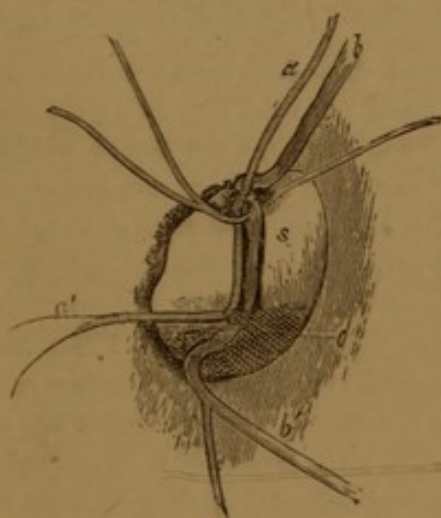
It occurred in a woman *æt.* 38. She had a myopia of $\frac{1}{9}$ in each eye, and possessed an acuteness of vision of about $\frac{1}{10}$. The annexed woodcut (Fig. 59) represents the inverted image of the staphyloma posticum of the right eye.

Sometimes, however, the crescent merges gradually into the surrounding redness of the fundus, and is, in cases of extreme myopia, not unfrequently accompanied by other isolated irregular white patches, intermingled with black pigment spots (*disseminated choroiditis*), by elongation, hyper-vascularity, atrophy, or excavation of the optic

* For further information on this point, consult the admirable edition of “Zander on the Ophthalmoscope,” by R. B. Carter, of Stroud.

papilla. V. Gräfe considers all these appearances as due to a diffused sclerotico-choroiditis, which, according to Follin, assumes an atrophic tendency in the involved tissues. Those myopic eyes which have been anatomically examined have generally displayed a marked elongation of the globe, especially so in the posterior hemisphere—hence the other name which has been applied to this peculiar pathological condition, viz., staphyloma posticum.* We have met with a few cases of myopia, one (Case 27) of the highest degree we ever saw ($1/1\frac{7}{8}$) in which no such staphyloma existed. In these it is fair to assume the myopia was caused by some abnormal refractive condition of the humours.

FIG. 59.



- S* = Excavated staphyloma posticum.
a = An artery passing over the bent vein, *b*.
b' = A second bent vein.
o = Deformed and atrophied optic papilla.

CASE 27.—*Progressive Myopia of $1/1\frac{7}{8}$, unaccompanied by Staphyloma Posticum or Buphthalmos.*

Lewis M., æt. 40, had lost the sight of the right eye for about fourteen years. He had been in the habit of using stronger and stronger glasses, till he was at

* The first anatomical description of staphyloma posticum is to be found in Scarpa's Treatise (translated by Briggs, 2nd edit., p. 399). In one of two dissections he found "there was a deficiency of the nervous expansion of the retina within the cavity of the staphyloma; that the choroid coat was very thin and discoloured at this part, and wanted its usual vascular plexus; and that the sclerotica, particularly at the apex of the staphyloma, was rendered so thin as scarcely to equal the thickness of writing paper." The predisposition to staphyloma posticum in the position it always constantly occupies is probably due to its being that of the protuberantia scleræ foetalis (v. Ammon), where the sclerotic, even at birth, is thinner than elsewhere.

last obliged to use a combination of two concave glasses to assist his vision, not having been able to procure any single one sufficiently strong for his purpose. One of these concaves was of $2\frac{1}{4}$ " focus; the two together equivalent to one of $1\frac{3}{4}$ " focus. His eye was not unduly prominent. There was no staphyloma posticum in the left eye; the right one had a divergent squint, and was filled with innumerable brilliant floating scales, which presented a very beautiful ophthalmoscopic picture (= synchisis scintillans). He read with his left eye No. 1 at $1\frac{7}{8}$ inches from the cornea—not further, not nearer. He preferred for distance 2-inch concaves to all others, and with these read No. 23 at about 10 feet, No. 22 at 9 feet, and No. 21 at $4\frac{1}{2}$ feet. Any tinting of the glasses made him see worse. We regret that we did not apply atropine, in order to determine the presence or absence of spasm of the ciliary muscle.

CASE 28.—*Myopia of $1/3\frac{1}{2}$.—Impossibility of wearing the reducing glasses on account of their "dazzling."—This remedied by tinting the glasses.*

Jane F., æt. 25, consulted Mr. Laurence on January 15th, 1862. He found that at about 15 feet she could not read No. 23; that the far-point for the right eye was, for No. 1, $2\frac{3}{4}$ ", for the left eye the same; whilst the near-point for each eye was respectively $2\frac{1}{4}$ " and $2\frac{3}{4}$ "; so that she possessed practically no accommodation. In each fundus oculi an extensive external staphyl. postic. was seen. The globes were full and prominent. With $3\frac{1}{4}$ -inch concaves she read Nos. 23 and 22 at a distance quite distinctly, but was obliged to use 5-inch concaves, which did not enable her to see so far off, on account of the distressing dazzling sensation the $3\frac{1}{4}$ -inch glasses caused her. This was the first case in which Mr. Laurence tried the effect of tinting the glasses, and on seeing her three months afterwards, she said she had constantly worn her tinted $3\frac{1}{4}$ -inch glasses, without ever again experiencing the "dazzling" sensation they caused before being tinted. In these cases we may sometimes with advantage substitute for a deep concave glass a more shallow one, in combination with a stenopæic apparatus: the effects are a larger, equally defined image, with a diminution of the amount of light.

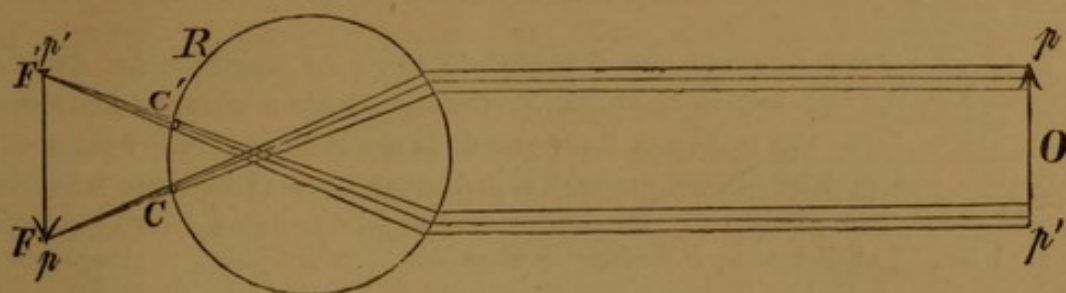
The prognosis in myopia depends a good deal on whether the above-named organic changes are excessive, and whether they are stationary or progressive. In unfavourable instances myopia may end in amaurosis, separation of the retina, or intraocular hæmorrhage.

II. HYPERMETROPIA.

Eyes affected with this anomaly are only adapted for the focussing of convergent rays. Speaking generally, all that has been above said of myopia may be reversed, *mutatis mutandis*, in the case of hypermetropia. Thus, the globe is disproportionately short in comparison with the refractive power of its lenses; parallel, divergent, or not sufficiently convergent rays would be, but for the intervention of the retina (*R*), brought to a focus (*F*, *F'*, Fig. 60) behind this structure which, as it is, receives a circle of diffusion (*C*, *C'*) for each

luminous point (p, p') of the object (O). The far-point may be said to be definite and negative.

FIG. 60.



The deficiency of refraction of a hypermetropic eye may be counter balanced—the hypermetropia corrected—by a convex lens. In determining the power of this latter, we must take into consideration a point not necessary to regard in the case of myopia. All hypermetropics, with a fair power of accommodation, habitually expend a portion of this to compensate, more or less, for the deficient refractive power of the eye. The function of accommodation, which by normal eyes is only employed for near objects, is thus by hypermetropic eyes partially, or even nearly exclusively, used for distant ones. In this way, high degrees of hypermetropia may be almost entirely masked. A certain convex glass, perhaps only a very low-powered one, will be found either to improve, or, at any rate, not to deteriorate vision for distant objects. If we now paralyze completely the power of voluntary accommodation by the application of a strong solution of atropine (gr. iv. ad ʒj), then the patient's vision will, from his power of neutralizing his hypermetropia having been thus destroyed, be found to be materially deteriorated, but may be again restored by a convex glass of a higher power than that required previous to the paralysis of accommodation. The existing hypermetropia may be thus said to consist of two parts, the “manifest” and the “latent” hypermetropia. The remedy for hypermetropia is a convex glass necessary to correct the deficient refracting power of the eye, the focal length of which can only be found by trial. We may, in practice, commence with that lens which corrects the manifest hypermetropia, and proceed by degrees to that which corrects the latent.

Hypermetropic patients generally have small, sunken eyes; are often asthenopic; are occasionally affected with convergent strabismus, and have an abnormally far near-point (most of the “singular cases of presbyopia occurring in young subjects” are really cases of hypermetropia). Ophthalmoscopically, hypermetropia is only detected

by the normal or myopic eye of the observer being able to recognize the details of the direct image of the fundus oculi without a concave eye-piece.

The following is one of the highest degrees of hypermetropia we have seen :—

CASE 29.—John Edwards was 6 years old when he was brought to Mr. Laurence at the Ophthalmic Hospital, Southwark, by his mother, on December 12th, 1860. Since the child was three years old she had observed his sight was defective, and that he always brought objects very close to his eyes when he wished to see them distinctly. Mr. Laurence found he required 5-inch convexes to read No. 22 at distance ; but after the eyes had been subjected to atropine for an hour he required $3\frac{1}{2}$ -inch convexes, with which he read No. 23 at 6 feet 9". The eyes were examined about twelve hours later, and 5-inch convexes were the glasses with which he obtained the most distinct vision for distance, reading with them No. 21. On examining his eyes ophthalmoscopically, no morbid appearances were perceptible in either fundus oculi ; but the direct image could be observed in either eye as far off as 3 inches from the cornea, after the full action of atropine. Both catoptric images from the lens-surfaces could be distinctly seen in each eye, proving it was not a case of congenital absence of the crystalline lenses. The case was seen again upwards of a year afterwards ; the boy ever since he was first seen wore 5-inch convexes. With these he read at 20 feet No. 21, without them he could not read No. 23.

III. ASTIGMATISM.

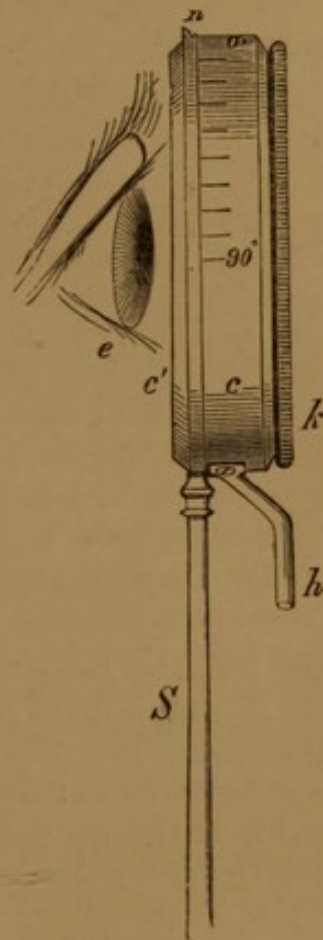
In astigmatism the refractive power of the eye differs in different meridians of the cornea. Astigmatism may be diagnosed by the following signs :—1. A defect in visual power of an optical nature not remediable by ordinary spherical lenses. 2. The patient's seeing a luminous point, not as a point, but, more or less, as a line. 3. An inability to perceive vertical and horizontal lines, or, more generally, lines having different inclinations, at the same time with equal distinctness. 4. Improvement of vision through a narrow slit in a card, with or without the addition of a spherical lens. Astigmatism may be remedied by cylindrical lenses, segments of cylinders, refracting only transversely to their axes.

In some cases of astigmatism the principal axes of curvature deviate more or less from the vertical and horizontal directions.

Astigmatic patients are remarkably sensitive to the slightest deviation of the axis of the cylindrical glass from that which most completely corrects the asymmetry, the least change of position of the axis at once lowering the acuteness of vision. It is, therefore, not only scientifically but practically necessary to be able to determine, and note for the guidance of the optician, the precise angular position of these axes.

The instrument [*Astigmometer*] (Fig. 61) for this purpose consists essentially of a circular, shallow, white-metal cell (*c*), into which the cylindrical glass is adapted by a collar (*k*). The cell is graduated in half its circumference into degrees, commencing at 0° , and extending on each side from 0° through all intermediate degrees to 90° . The cell is revolvable by a handle (*h*) at the opposite point of the circle to 0° , around a fixed second brass circle (*c'*); this latter is fixed to the stem (*S*) of the instrument, so that it can be held by the hand of the surgeon in front of the patient's eye (*e*). The circle (*c'*) has a notch (*n*) corresponding to its uppermost point when the instrument is held vertically. In using the instrument, the cell (*c*) is first brought by the handle (*h*) into such a position that 0° corresponds exactly to the notch (*n*); the cylindrical glass is now dropped into the cell (*c*), so that the axis of the lens corresponds to *n* and 0° , and is fixed in this position by the collar (*k*) which, to avoid any angular displacement of the lens, slides—not screws—into *c*. The instrument being now held vertically before the patient's eye in the same plane as the cornea, the handle (*h*) is turned round till the greatest definition of vision is obtained. The inclination of the axis of the lens is now read off by seeing to which of the degrees on *c*, *n* corresponds.

FIG. 61.



ASTIGMOMETER.

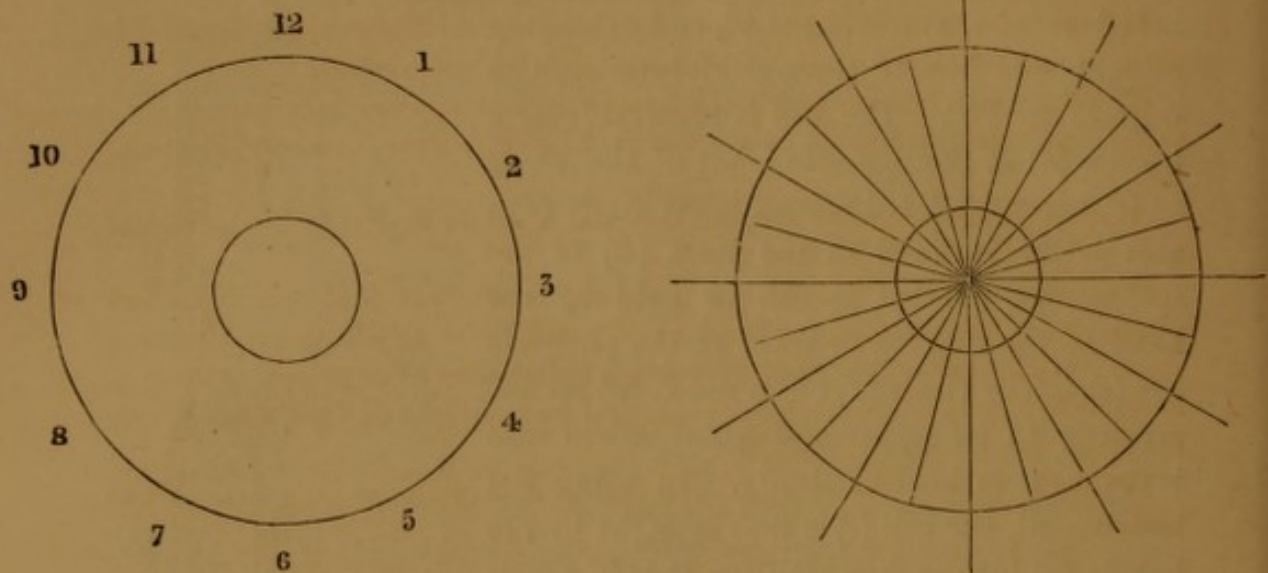
M. Javal has proposed a new method of determining the existence and amount of astigmatism.

The following is an extract from his very interesting Paper upon the subject in the *Annales d'Oculistique* for January and February, 1865.

"1. *Monocular Demonstration*.—Draw a circle with radii 15° from each other, and let the patient view this figure through a lens, which, for the sake of precision, I will suppose to be a 3-inch one. Withdraw the figure gradually, till all the lines become dim, or disappear, excepting one. Then try all your cylindrical concaves, one after another, beginning with the lowest powers, with their axes perpendicular to the radius, which has remained black, till you have found the glass which makes all the radii equally black. You have then at once diagnosed astigmatism, and determined the number and position of the correcting glass.

For every person with binocular vision the following procedure is much more preferable:—

FIG. 62.



“2. *Binocular Determination.*—We now add before the other eye a lens and a circle, identical with the preceding ones, the circle being first at the focal lengths of the glasses with their centres as far apart as the distance between the two eyes. The circles cannot be fixed, excepting the visual lines are parallel and the head straight. The relative position of the visual lines being a fixed one, this sufficiently guards against any changes of accommodation.

“That the patient may readily say what he sees, the radii are marked with the same numbers as the hours of a watch, and these numbers not being seen by the same eye as the radii, afford a constant test of binocular vision.

“M. Nacet has constructed an apparatus realizing the above conditions. By a simple mechanism the circles may be moved forwards or backwards, or the lenses may be decentrated, so as to always face the two images, and in less than a minute the whole series of cylindrical glasses may be submitted to the eye in any desired position.”

The following two cases illustrate the diagnosis and treatment of astigmatism:—

CASE 30.—*Myopic Astigmatism ($\frac{1}{25}$) from Unduly High Curvature of the Vertical Meridian, remedied by a Cylindrical Lens.*

Mr. A., æt. 24, consulted Mr. Laurence for acute asthenopic symptoms, which had become more especially severe during the time he had been reading hard for a University degree. He had for many years worn concave glasses, which he had found it necessary to change several times for others successively stronger, till he now used glasses of 5 inches focal length. There was no marked insufficiency of the internal recti muscles. Before examining his eyes with the ophthalmoscope, extensive staphylomata postica were expected, if not more serious organic lesions, of the fundus oculi. But the appearances were altogether at variance with the

“pour obtenir toujours la fusion des deux images”

apparently high degree of myopia present. In truth, there were hardly any appreciable deviations from the natural state of the fundus, nor was the indirect image definable without the use of an object-lens.

This led to the suspicion of the presence of astigmatism.

Left eye.—(1) With 6-inch concave at 8 feet vertical lines appear very indistinct, horizontal ones distinct, and *vice versa* with 14-inch concave.

(2) With 4-inch concave at 8 feet a luminous point appears as a narrow *horizontal* line, thickened at its centre with a 12-inch concave, as a narrow *vertical* line.

(3) Further investigation showed that the eye was myopic in the horizontal meridian to a $\frac{2}{20}$, in the vertical to a $\frac{3}{20}$.

With a combination of a 10-inch spherical concave and a 20-inch cylindrical concave (axis horizontal) the appearances (1) and (2) disappeared, and his *visual power was exactly double* of that with his old glasses on (from $S = \frac{1}{4}$ to $S = \frac{1}{2}$). For at 8 feet, with a 5-inch concave spherical lens on, he only read XXX; with the above combination he read XV.

The right eye was also astigmatic, though not to quite so high a degree as the left.

CASE 31.—*Hypermetropic Astigmatism* ($\frac{1}{18}$) *of Left Eye.*

Mary D., æt. 49, consulted Mr. Laurence on November 15th, 1862, on account of asthenopic symptoms. After repeated examinations, she was found to be emmetropic in the right eye, but in the left eye there existed a hypermetropia of $\frac{1}{18}$ limited to its horizontal meridian, as evidenced by the following facts:—

(1) Horizontal lines at 8 feet appear to her more distinct than vertical ones, and *vice versa* with 18-inch convex. 18-inch convex-cylindrical, axis vertical, makes both sets appear equally distinct.

(2) With 18-inch convex, a luminous point assumes an oval shape, the axis being slightly out of the vertical.

(3) With 18-inch convex, cylindrical, axis vertical, her visual power is doubled. She was also presbyopic with either eye to about a $\frac{1}{18}$.

With glasses corresponding to the above facts, she reads No. 2 at 11 inches, without any asthenopic symptoms.

IV. UNIOCLAR DIPLOPIA.

This form of double vision occurs when one eye alone is used. It is generally caused by some inequality of refraction of the eye. That this will explain such a case may be proved by looking with one eye partly through and partly not through a convex or concave lens held before the eye: two images of the object are at once seen. The same effect ensues from a drop of mucus on the cornea, from inequality or cicatrices of the corneal surface, from bands of adhesion in the pupillary area, from abnormalities of curvature or of position of the crystalline lens. (*Vide* Case 15.) If a myopic, hypermetropic, or presbyopic person regards a luminous point beyond his limits of

distinct vision, he sees a multitude of small images of it: these probably represent the multiple structure of the crystalline lens, and disappear on the respective anomaly of refraction being corrected by an appropriate lens.

B. ANOMALIES OF ACCOMMODATION.

I. PRESBYOPIA.

In young children the near point is about $2\frac{1}{2}$ " from the cornea; with the tenth year it commences to recede, till at the fortieth year it is about 9 inches from the cornea. This recession of the near-point then comes to be felt as a substantial defect, constituting "presbyopia." Hence it follows that the commencement of presbyopia depends on an arbitrary standard, according to Donders, as soon as the near-point is further than 8" from the eye. Such a standard will also vary with the occupation of the patient: *e. g.* presbyopia would be felt at an earlier age by a literary man than by a sailor. It is presumed to depend on an increased density of the lens, or on a deficient power of the ciliary muscle. Its remedy is the use of convex glasses. It bears no relation to the refraction of the eye *propr. sic dict.*, and may equally affect normal, myopic, hypermetropic, or astigmatic eyes.

The estimation of the *amount* of presbyopia in any given case will now claim our attentive consideration, as it affects the three classes of eyes.

1. *Presbyopia in Normal Eyes.*—Let a person be able to see with his naked eyes distant objects, but not near ones distinctly any closer than, say, fourteen inches, what amount of accommodation does he possess?—Answer: $\frac{1}{14}$.

According to Donders' assumed standard near-point of eight inches for the commencement of presbyopia, the minimum amount of accommodation a person must possess *not* to be presbyopic is $\frac{1}{8}$; but in our supposed case he has only $\frac{1}{14}$. Therefore the *difference* between these two fractions: $\frac{1}{8} - \frac{1}{14} = \frac{1}{19}$ (nearly)—expresses the deficit of accommodation—the presbyopia—the patient labours under. For distinct vision at eight inches he finds himself *minus* such an amount of accommodation as is equivalent to a 19-inch convex-glass lens.* If we, therefore, artificially supply him with such a lens, we at once

* Convex glasses in presbyopia act in two ways: (1) they increase the divergence of rays, (2) they magnify. We always find patients can read a smaller type with them.

correct his presbyopia, always with the proviso that, if he himself at the same time employs *all* his natural accommodation ($\frac{1}{14}$), he will then be able to read, work, &c., at eight inches. Few persons, however, would be able to endure such a strain on the ciliary muscle for any length of time without fatigue (asthenopia); but, on the other hand, few persons desire to employ their eyes continuously for so close a distance as eight inches. For such convenient distances as 10, 11, or 12 inches, convex glasses of 19 inches' focus will answer admirably without overtaxing the patient's natural power of accommodation. Thus, *e.g.*, for reading at 12 inches he will only have to use $\frac{1}{32}$ accommodation, which is about half of the entire amount he has ($\frac{1}{32} : \frac{1}{14} = \frac{1}{2} : 1$, nearly). At 19 inches off, with his presbyopic glasses of $\frac{1}{19}$ on, he will, of course, have to entirely suppress his accommodation. Beyond that distance he will not be able to see at all (nor will he require to do so) with his presbyopic glasses on. If $\frac{1}{a} =$ the presbyopic's natural accommodation, the glass he requires is then given by the formula, $\frac{1}{8} - \frac{1}{a} = \frac{1}{f}$, where $f =$ the focal length of the required glass. This result of theory must, however, always be checked by clinical observation. As a rule, on account of the convergence of the optic axes, the patient generally prefers a lower glass than the one given by the above formula. We may say, generally, that in prescribing a pair of glasses for a presbyopic, the object should be to reinforce his defective accommodation by convex lenses, neither so strong as to supersede his own remaining natural accommodation, nor so weak as to tax it further than it admits of.

Donders gives a table of what glasses are required at different ages in emmetropia (normal refraction of the eye), with normal acuteness of vision and accommodation, for writing, and for reading ordinary type.

a Age.	Glasses required.		d Distance of distinct vision.	e	
	b In present E.	c In original E.		R ₂	P ₂
48	$\frac{1}{6.0}$	$\frac{1}{6.0}$	14"	60"	10"
50	$\frac{1}{4.0}$	$\frac{1}{4.0}$	14"	40"	12"
55	$\frac{1}{3.0}$	$\frac{1}{2.5}$	14"	30"	12"
58	$\frac{1}{2.2}$	$\frac{1}{2.0}$	13"	22"	12"
60	$\frac{1}{1.8}$	$\frac{1}{1.6}$	13"	18"	12
62	$\frac{1}{1.4}$	$\frac{1}{1.2}$	13"	14"	12"
65	$\frac{1}{1.3}$	$\frac{1}{1.0}$	12"	13"	11"
70	$\frac{1}{1.0}$	$\frac{1}{7.5}$	10"	10"	10"
75	$\frac{1}{9}$	$\frac{1}{6.5}$	9"	9"	9"
78	$\frac{1}{8}$	$\frac{1}{5.5}$	8"	8"	8"
80	$\frac{1}{7}$	$\frac{1}{4.5}$	7"	7"	7"

"Column *b* gives the glasses required for *E* (*Emmetropia*), proved at the moment; *c* for *E* in youth, and therefore for *H* (*Hypermetropia*), *acquisita* at the time of observation; in both cases the diminished acuteness of vision belonging to the time of life is taken into account; *d* indicates the distance which is preferred for vision with these glasses; *e*, finally, the space through which they admit of acute vision, that is from *R*₂ with the least, to *P*₂ with the greatest convergence ($\frac{1}{A_2} = \frac{1}{P_2} - \frac{1}{R_2}$)."—Donders' work on Accommodation and Refraction, p. 220, 1.

2. *Presbyopia in Myopic Eyes*.—All the more highly myopic eyes, as a rule, are deficient in accommodation—more or less presbyopic, we might almost say. But presuming we adopt our previous standard of presbyopia, it is clear that the term is inapplicable to all degrees of myopia above $\frac{1}{8}$; for their far-point is already less than 8 inches, and *à fortiori* their near-point. But when we come to deal with low degrees of myopia, at a certain age, presbyopia is a very usual concomitant. For example, a person's eye presents this combination—(1) the far-point is 20 inches; (2) the near-point 12 inches. On account of (1) the patient is myopic; of (2) he is also presbyopic. He is short-sighted and long-sighted at the same time. His far-point is too close; his near-point too far. In fact, his

range of distinct vision with the unaided eye is comprised in a line of 8 inches. His power of accommodation $\frac{1}{A}$ is $\frac{1}{12} - \frac{1}{20} = \frac{1}{30}$. What glass would the eye require (abstracting ourselves for a moment from the co-existing myopia), using its entire $\frac{1}{30}$ of accommodation to read distinctly at 8 inches?

$$\frac{1}{8} - \frac{1}{30} = \frac{1}{10\frac{10}{11}}$$

a convex glass of 11 inches focal length, therefore, corrects the presbyopia, but we must also correct the myopia (of a $\frac{1}{20}$). In other words, from $\frac{1}{10\frac{10}{11}}$ we must subtract $\frac{1}{20}$, which gives $\frac{1}{24}$.* A convex

glass of 24 inches focus is the glass required to correct simultaneously the presbyopia and the myopia for near objects. Generally, if $\frac{1}{A} =$ the patient's accommodation, $\frac{1}{M}$ his myopia, the glass required to neutralize his presbyopia and myopia together is given by the formula $\frac{1}{F} - (\frac{1}{A} + \frac{1}{M}) = \frac{1}{F}$, F being the focal length in inches of the required convex glass. This patient required a 20-inch concave for distance, a 24-inch convex for near objects.

(3) *Presbyopia in Hypermetropic Eyes.*—A little reflection will show that in this combination the amount of latent hypermetropia is too small to require being taken into account. Having ascertained the amount of the manifest hypermetropia present, we may, of course, from the position of the near-point, readily estimate that of the presbyopia. For example, a person has a hypermetropia of $\frac{1}{10}$, but with his 10-inch convex glasses cannot see nearer than 24 inches. To see at 8 inches he will require glasses of $\frac{1}{10} + \frac{1}{8} - \frac{1}{24} = \frac{1}{5\frac{1}{2}}$ nearly; with $5\frac{1}{2}$ -inch convex glasses to read at 8 inches he will have to use all his natural accommodation ($\frac{1}{24}$), but does not for any distances further than 8 inches.

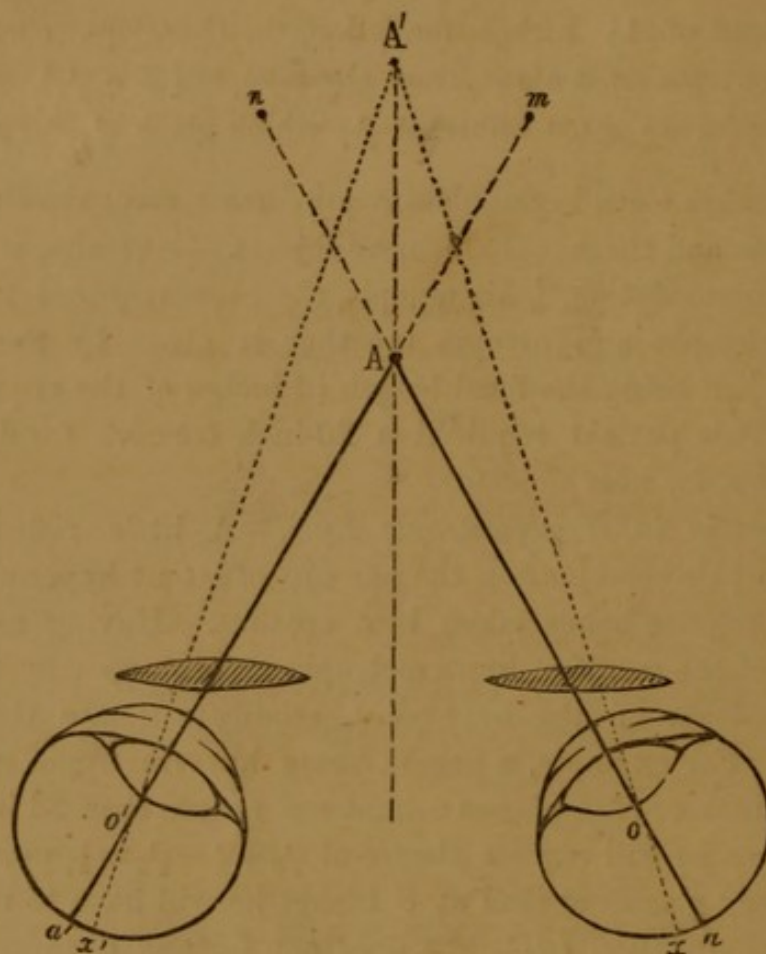
In the application of glasses for correcting presbyopia, certain circumstances attending the exercise of the two eyes together, *binocular vision*, have to be taken into consideration. This subject has been specially and philosophically studied by Dr. Giraud-Teulon, of Paris. The following is a short abstract of his views:—

Supposing the two presbyopic eyes (in fig. 63) at their maximum accommodation to have the near-point A', and that the two convex lenses produce virtual images of the point A at the same distance as

* We may carry this out in practice by ascertaining the near-point of the patient with his reducing concaves on. This, in the above case, is 30 inches. From $\frac{1}{8}$ subtract $\frac{1}{30}$, and from the result $\frac{1}{20}$, and the final result will be $\frac{1}{24}$, as before.

?
?
that of the near-point, then the eye o will perceive an image of A at n , and the eye o' one at m ; there will, in a word, be crossed diplopia; this is, however, overcome by the eyeballs converging to \underline{A} , by which means two images, m and n , are fused at the point A' . The eyes are then converged to \underline{A} , but accommodated for A' . Hence the natural

FIG. 63.



harmony of convergence and accommodation is broken. By using, however, only the external portions of the two lenses, the two images m and n may be fused without any such unnatural convergence of the globes, a physical (prismatic) action being substituted for a physiological. Dr. Giraud-Teulon hence advises the use of excentric lenses (*lentilles décentrées*), by which he states, no muscular effort being required, vision is rendered materially easier and less fatiguing.

II. PARALYSIS OF ACCOMMODATION.

The prominent diagnostic sign of paralysis of accommodation is an impairment of vision for near objects, whilst that for

- 4.37 ,, Both pupils measure 1''' in diameter.
 At 20' she reads No. 19
 Near-point for No. 1 = 3'' } with either eye.

With a stenopæic aperture of 1''' diameter, previous to the application of the Calabar bean, she could read No. 20 at 20', and No. 6 at 3''.

- 4.47. Both pupils contracted to $\frac{1}{2}$ ''' in diameter, but the visual power remains the same as at 4.37.

- 5.17. Both pupils measure $\frac{1}{2}$ ''' in diameter.
 At 20' she reads No. 19.
 (No convex or concave glasses improve) } with either eye.
 Near-point for No. 1 = 2''

With a stenopæic hole of $\frac{1}{2}$ ''' diameter, previous to the application of the Calabar bean, she read No. 20 at 20' and No. 1 at 3'', which shows that, in this case, the contraction of the pupil was a very important element in the improvement of vision both for near and distant objects.

R Haust. Quinæ cum Ferro, \mathfrak{z} j' ter die.'

When last seen, she had completely recovered her accommodation, she being able to read No. 1 at 3'', and No. 19 at 20'.

CASE 33.—*Traumatic Paralysis of the Circular Fibres of the Ciliary Muscle (and Iris), occurring in a case of Hypermetropia ($\frac{1}{18}$), corrected (partially) by Convex Glasses, or by the Calabar bean.*

Fanny V., æt. 28, presented herself at the Ophthalmic Hospital, Southwark, on August 20th, 1863. Eight days previously, whilst opening a lemonade-bottle, the cork flew out, and struck her on the left eye, causing great pain and dimness of vision, which continued till she came to the hospital. When the patient was seen, the pupil was observed to be dilated and fixed; she could read no less type than No. 16, and that but indistinctly. The fundus oculi was indistinct, as if from exudation.

R Potass. iodid., gr. ij, ter die.

August 24th.—The pain has left her; she now reads No. 14.

R Potass. iodid. cum

Quin. disulph., gr. i, ter die.

September 1st.—From the patient remarking to-day that her vision was greatly improved by looking through a pin-hole in a card, the optical condition of her eye was investigated more closely than had hitherto been done, the case having previously been taken rather for one of simple retinitis.

The pupil of the left (injured) eye measured 3'' in diameter, and was perfectly fixed, whilst that of the right measured but 2'' in the same light, and contracted with the greatest activity. There was no evidence of any dislocation of the lens, either in a tremulous condition of the iris, or in a direct objective examination. It was discovered in this latter that the direct image could be seen without the necessity of employing a concave eye-piece.

With the left eye at 20' she read No. 22 imperfectly, but through an aperture of $\frac{1}{2}$ ''' diameter she could read No. 20, or with +16 alone No. 18 well. Finding that with +16 she could distinguish a much smaller type than with an aperture of $\frac{1}{2}$ ''' diameter, it was clear that the defect in vision was rather dependent on

some deficiency in the refractive power of the eye than simply on the dilatation of the pupil.

At first, the right eye appeared to be emmetropic, as at 20' she could read No. 18 with ease. But finding that low convex glasses did not deteriorate vision for distance, and that the near-point of this (right) eye was unusually distant, viz. $8\frac{1}{2}$ ", we were induced to paralyze her power of accommodation in this eye; after which it was found that she could not read even No. 23, but with +16 she read No. 18 just as well as before any atropine had been applied, the direct image being also as clearly seen without an eye-piece in this as in the left eye.

With the injured eye she read No. 18 at about 13", but with +16 she read No. 8 at the same distance. A square of the Calabar bean paper was now put into the palpebral sinus of this eye. In ten minutes the pupil was contracted to a diameter of about 1" (a little larger); she now read at 20' No. 20 (which was a number lower than she could read through an aperture of 1" diameter previously to the application of the Calabar bean), and with +36 No. 19 well, her near-point for No. 10 being 18". Although the pupil continued to contract till at last it was only $\frac{1}{2}$ " in diameter (where it remained fixed), no further improvement in vision ensued for distance, but she could now read No. 8 at 4", and with +24 No. 2 at the same distance. This fact, combined with the previous observation made with the stenopæic hole, proved that the Calabar bean improved the patient's vision, not alone by its action on the pupil, but in a far greater degree by that on the ciliary muscle.

The nature of the case was now clearly made out—viz., that it was one of a tolerably high degree of hypermetropia of both eyes, and that the defect of vision noticed in the left eye was due to a paralysis of the ciliary muscle, which prevented the patient correcting her hypermetropia by voluntary accommodation, but which was entirely supplemented by convex glasses, or remedied to a great extent by the Calabar bean.

CASE 34. — *Paralysis of the Ciliary Muscle following suppressed Scarlatina.*

Amy M., æt. 7, a most intelligent child, was admitted on December 11th, 1863, as an out-patient at the Ophthalmic Hospital, Southwark, complaining of "dimness of sight." About six weeks previous to her admission she was suffering from suppressed scarlatina, and had lately experienced severe mental distress from the loss of a sister. On December 1st she complained of a "pricking" in the right eyelid, followed by impairment of vision for near objects, that for distant ones remaining unaffected. In about a week afterwards the same defect occurred in the left eye, and subsequently she complained of double vision. Each pupil measured 1" in diameter, and contracted with the greatest activity in full daylight. There was a very slight insufficiency of the internal recti muscles, otherwise the individual and combined movements of the eyeballs were perfect.

VISUAL POWER:—

For distance:—

Right eye at 17'	reads No. 20.		
With +40	" "	somewhat more clearly.	
Left eye	" "	imperfectly.	
With +40	" "	perfectly.	

For near objects :—

With either eye reads No. 14 at $8\frac{1}{2}$ ".

(No. 14 is the smallest type she can decipher.)

With +4 reads No. 1 at 4".

„ +6 „ „ 6".

„ +8 „ „ 8".

At 11.35 a.m. a square of Calabar bean paper was put into the right eye, and atropine (grs. iv ad ʒj) was applied to the left. At 12.5 the Calabar bean paper was removed, the right pupil having contracted to $\frac{1}{2}$ "', and the left being dilated to 2''' in diameter.

VISUAL POWER :—

For distance :—

Right eye at 20' reads No. 20. No glass appears to improve vision.

Left eye at 20' reads No. 21. She now requires +24 to read No. 20.

For near objects :—

Right eye: near-point for No. 12 = $2\frac{3}{4}$ ".

Left eye: „ „ No. 16 = 6".

A stenopæic hole of a smaller diameter than her pupils, applied previous to the Calabar bean, did not in the least improve the vision of either eye.

From the above observations, coupled with the fact that the direct image could be fairly seen without an eye-piece, it was inferred that this patient had been originally hypermetropic, and that she had partially lost the power of voluntarily accommodating the eye for distant as well as for near objects, which deficiency was, however, completely substituted by convex glasses, and to some extent temporarily remedied by the Calabar bean. The mother was directed to apply the Calabar bean extract to the child's eyes every morning; but about five weeks elapsed before she again made her appearance at the hospital. It was then found that the power of accommodation had been spontaneously and completely restored, and that she could now (January 26th, 1864) read No. 19 at 20', and No. 1 at 4", with either eye. This case is instructive in showing how careful one should be in attributing effects to therapeutic agents, as upon inquiry it was found that the Calabar bean had not been applied at all to the patient's eyes since her last visit to the hospital, and she had merely been staying for a short time in the country, where her health and sight had gradually improved.

III. ASTHENOPIA.

Asthenopia, or weak sight, is "that state of vision in which the eyes are unable to sustain continued exercise upon near objects although the patient, on first viewing such objects, generally sees them distinctly, can employ his sight for any length of time in viewing distant objects, and presents no external appearance of disease of the eyes."—[Mackenzie.] The symptoms of asthenopia are those of

muscular *fatigue* and nervous irritation. At first, as the word "fatigue" itself implies, they are not felt, but come on with a rapidity which may vary from a few seconds to an hour or more. Some patients cannot read two lines consecutively without an accession of asthenopic symptoms: they declare the letters "run into one another, and become misty and confused;" if they persist, the eyes ache and water till they are obliged to leave off from sheer pain and discomfort.* A little rest generally enables them to begin again; but the symptoms soon return with an intensity proportionate to the shortness of the interval of rest.

Asthenopia may be traced to three different causes:

1. *Optical Defects of the Eye.*

The most frequent optical defect is hypermetropia. Part of the accommodation of a hypermetropic eye is expended in neutralizing its defective refraction, and, as a consequence, when the patient employs his eyes on near objects, he unnaturally forces his accommodation, so that the ciliary muscle is wrought up to a degree of tension that soon obliges it to give in, and thus are caused all those symptoms of muscular and nervous irritation and fatigue, and consequent indistinctness of vision, which we have already described. You may for a few minutes sustain a heavier weight than your muscles will naturally support, but try to prolong the effort, and you will soon experience that sense of inability and fatigue which the ciliary muscle feels in another way.

But we have also met with several cases of asthenopia which were due to myopia or presbyopia. In short, any optical defect of the eye attended with limited power of accommodation may be the cause of asthenopia, and therefore it is always absolutely necessary in these cases to subject the eyes to a rigid optical examination.

2. *Deficient Power of the Internal Recti Muscles.*

Weakness of the internal rectus may affect that of one or both eyes—most commonly both. Such a case is detected by observing that, when we, covering one eye with the hand, direct the patient to

* The mistiness of vision that ensues is probably partially a reflex phenomenon, as almost certainly the aching, injection (sometimes observed), and suffusion are evidences of reflex-irritation of the fifth and sympathetic nerves.

regard a near object with the other, the covered eye deviates outwards—in a word, the patient has, under these circumstances, a divergent squint of that eye. As soon as we remove our hand, the divergent eye at once turns inwards, and resumes its symmetrical position to the other eye.* There are many cases of this infirmity which would be, and constantly are, overlooked, from neglecting this simple method of examination. Again, if we place before a healthy eye a prism with its base outwards or inwards, the person at first sees double ; but if the angle of the prism is not too great, he soon, in order to overcome the consequent double vision, squints respectively inwards or outwards with the eye before which the prism is held. In cases of weakness of the internal recti, this muscular power of neutralizing diplopia by convergence of the eye is diminished, that by divergence increased. If a prism with its refracting angle upwards be held before one eye, any object (such as a dot of ink on a piece of paper) seen with both eyes together appears double, the image through the prism being directly above that seen with the other (naked) eye, thus :—

• The faculty of single vision with two eyes is thus almost
• insuperably annihilated, on account of the very slight power we possess of isolating the action of either of the superior or inferior recti muscles so as to fuse the double images (as is readily done, as we have mentioned above, by the lateral ocular muscles). Under these circumstances, the accommodative action of the internal recti being no longer called into play, each eyeball assumes that position indicated simply by the relative strength of the internal recti. Should this be normal, the dots will assume the position delineated above ; but should either, or both, internal recti be preternaturally weak, the eyeball, or balls, will, from the preponderating strength of the external rectus, pass into a state of divergent squint, and thus

* In the first case the eye, excluded from common vision with its fellow-eye, is at liberty to assume that position indicated by the relative strengths of the two antagonist muscles, the internal and external recti. In the second case the participation in the act of vision forces the weak internal rectus to exert itself, to avoid the crossed double images that would necessarily result from any divergence of its eye. In this way an eye affected with weakness of the internal rectus assumes a divergence, if the patient is in reverie, if the affected eye becomes the subject of cataract, &c. In this latter case a successful operation for cataract may at the same time restore the symmetry of the eyeball. The test we have just been discussing becomes still more evident if the object be held, not directly on a level with, but above that of the eyes.

crossed double images arise. The final result is that the two dots exhibit in such a case not only a difference of height, but, in addition, a lateral crossed separation. The images then appear thus:—

• A second prism held with its angle outwards before the second eye destroys this lateral separation, leaving the difference of height unchanged. *The strength (= number of degrees) of the prism necessary for this purpose affords a direct measure of the degree of weakness of the internal rectus.*

It has been thought that weakness of the recti interni is confined to myopic patients, but it occurs also, although more rarely, in hypermetropic ones.

Asthenopia from this cause, occurring in a myopic patient, may be sometimes relieved by the use of glasses, which enable him to read at a sufficient distance from the eyes to moderate their convergence to a degree that entails but a very slight action of the affected muscles; or, by the systematic application of prismatic glasses with the bases turned outwards, the internal recti may be gradually strengthened in the effort they will instinctively make by convergence of the optic axes to overcome the crossed double vision the prisms would otherwise cause. Prismatic glasses with the bases turned inwards have no effect in radically curing the disease—on the contrary, rather encourage it, but render vision more distinct for the time, and relieve the asthenopia by supplementing the action of the internal recti. The last resource is total or partial division of the external rectus muscle.

3. *Hyperæsthesia of the Retina.*

Besides the above cases of asthenopia, we every now and then meet with ones which are attended by a generally low state of the system, and are often associated with photophobia. These generally get well under the use of tonic medicines and regimen, and therefore may not unreasonably be ascribed to hyperæsthesia of the retina, or perhaps they may even depend upon some temporary asthenic state of the organs of adjustment. The asthenopia often met with after exhaustive fevers, diphtheria, &c., probably belongs to this category.

Amongst the optical anomalies of vision may be classed the phenomena known as

Muscæ volitantes.

The patient perceives grey or black objects of various kinds and sizes, which he not uncommonly compares to small flies floating in

his field of vision. They are especially seen when the patient regards a bright surface, or in any general derangement of the system. *Muscae volitantes* are purely subjective phenomena, produced by opaque particles in the vitreous humour, which cast their shadows on the retina, and although the *muscae* do not constitute a serious disease, they are excessively annoying to the patient. The means best calculated to remove them are : general constitutional treatment, rest of, and cooling applications to, the eye, and the use of tinted glasses. These latter we have found especially useful : they act probably by diminishing the intensity of the shadows cast on the retina.

Patients sometimes complain of *fixed* darked spots (*scotomata*) in their field of vision. These *scotomata* may be due to deposits of blood, lymph, &c., in the vitreous, or to limited disease of the retina. In one case we found a *scotoma* to depend on a limited plastic exudation on the retina, in another case on a hæmorrhage in that structure.

14th July, 1866.

INDEX.

- ABSCCESS of lids, 29 ; of lacrymal sac, 36.
- Accommodation (optical) of eye, 129 ; contraction of pupil, in, 5 ; formula, for range of, 14 ; optical theory of, 129 ; mode of measuring, 130 ; paralysis of by atropine, 130, from disease, 147 ; mechanism of, 130 ; in hypermetropia, 137 ; anomalies of, 142.
- Acuteness of vision, 13 ; influence of age on, 13.
- Adams', Sir W.*, operation for ectropium, 31.
- Adjustment (optical) of eye, 129.
- Agnew's* operation for secondary cataract, 92.
- Albuminous tumour of lids, 33.
- Amaurosis, 97 ; dependent on causes recognisable by ophthalmoscopy, 97 ; dependent on causes not so recognisable, 103.
- Amblyopia, 97 ; in affections of the orbit, 24—27.
- Anastomotic aneurisms in lids, 34.
- Aneurismal tumours in orbit, 28.
- Anterior chamber, pus in (hypopyum), 71.
- Antrum tumours, invading, 27.
- Arcus Senilis, 69.
- Arlt's* operation for symblepharon, 59.
- Artificial pupil, 75 ; operations for, 75 ; by excision, 75 ; by incision, 77 ; by dislocation of pupil, 76.
- Artificial eye, 119.
- Arteries of retina, pulsation of, 12.
- Astigmatism regular, 138 ; mode of determining axes in, 139 ; cases of, 140 ; myopic, 141 ; hypermetropic, 141.
- Astigmatism irregular, due to ulcers of cornea, 66 ; ophthalmoscopic appearances of, 66.
- Astigmometer, 139 ; *Javal's*, 140.
- Asthenopia, 151 ; from optical defects of eye, 151 ; from weakness of internal recti, from hyperæsthesia of retina, 153.
- Atrophy of optic papilla, 103.
- Atrophy of choroid, 99.
- Atropia, sulphate of (see *Belladonna*).
- Beer's* cataract-knife, 85.
- Belladonna*, action of, 5.
- Binocular vision, 131 ; mode of testing, 16, 17.
- Binocular diplopia, 26.
- Blindness, simulation of, 17.
- Blows on eyeball, 52.
- Bony tumours in orbit, 27.
- Borelli's* operation for staphyloma, 119.
- Bright's disease of retina, 100.
- Broad needle, 76.
- Burns of eye, 51.
- CALABAR BEAN : antagonistic to *Belladonna*, 6 ; contraction of pupil from, 6 ; contraction of ciliary muscle from, 6 ; increased refractive power from, 6 ; approximation of near-point from 6.
- Cancer of eye-ball, 113.
- Cancerous tumours in orbit, 27.
- Cancerous ulceration of lids, 30.
- Cannula-forceps, 76.
- Canaliculi, stricture of, 36 ; mode of slitting-up, 37.
- Cannula-scissors, 92.
- Cancroid of cornea, case of, 70.
- Capsular cataract, 83.
- Caries of lacrymal bone or of superior maxilla from lacrymal disease, 36.
- Carter's, Mr.*, case of foreign body in orbit, 49.
- Cataract, chloroform in operations, 22 ; symptoms of, 81 ; lenticular, 82 ; capsular, 83 ; pyramidal or polar, siliquose, Morgagnian, 83 ; operations for—by extraction, 85—by solution, 91 ;

- secondary, 92; adaptation of glasses after operation, 92.
- Cataract-needle, 91.
- Cataract-knives, Beer's, Zehender's, 85; v. Gräfe's, 89.
- Catarrhal ophthalmia, 55.
- Caustics, incautious application of, to granular lids, 32.
- Cellulitis of orbit, 25.
- Cephalostat, 19.
- Chalazion, 33.
- Chemosis, 59.
- Chloroform, indications for administering, in operations on the eye, 22.
- Chloroma of lacrymal gland, 35.
- Choroid, diseases of, 99; inflammation of, 99; atrophy of, 99; anæmia of, 99.
- Choroiditis, 99.
- Chronic conjunctivitis, 29.
- Cicatrices of skin, ectropium from contraction of, 31.
- Ciliary muscle, its structure, 131; paralysis from Belladonna, 5; from disease, 147.
- Ciliary body, diseases of, 72; inflammation of, 80.
- "Circles of diffusion," 133, 136.
- Collodion in entropium, 32.
- Coloboma iridis, 78.
- Common-carotid, its ligature for aneurism in orbit, 28.
- Concave lenses, 125.
- Convex lenses, 122; combinations of, 123, 124.
- Contusions of eyelids, 49.
- Convergent rays of light, 122.
- Convergent squint, 45; its dependence on hypermetropia, 45.
- Conical cornea, 69.
- Contraction of pupil from Calabar bean, 6.
- Conjunctiva, diseases of, 54.
- Conjunctivitis, 54; aqueous, 54; mucous, 54; purulent, 55; purulent of infants, 55; gonorrhœal, 56; Egyptian, 56; pustular or phlyctenular, 57; granular, 57; diphtheritic, 58; trachomatous, 58.
- Conjunctiva, tumours of, 60; melanosis of, 60; vascular tumour of, 60.
- Cornea, wounds of, 52; fistula of, 53; foreign bodies on, 51;
- Cornea, loss of sensibility of in leucomata, 17; diseases of, 63; ulceration of, 65; "hernia of," 66; opacities of, 67; conical, 69; canceroid of, 70.
- Corneitis, 63; interstitial, 63; pannous, 64; phlyctenular, 65.
- "Crescent" (staphyloma pectinatum) in myopia, 134.
- Critchett's* operation of irido-desis, 76; for cataract, 89; for staphyloma, 118.
- Crystalline lens, diseases of, 81.
- "Cupping" of optic papilla, 103.
- Curette, 85.
- Cyclitis, 80.
- Cysticercus in eye, 117.
- Cystotome, 85.
- DAZZLING sensation caused by Belladonna, 5, 6.
- Desmarre's* "pince-anneau," 21.
- Detachment of retina, 28.
- Diabetic cataract, 84.
- Dieffenbach's* operation for ectropium, 31.
- Diffusion-circles, 133, 136.
- Diphtheritic conjunctivitis, 58.
- Diplopia, binocular, 41; unocular, 141.
- Direct method of examination by the ophthalmoscope, 7.
- Dislocation of lens, 92; cases of, 94, 95.
- Division of levator palpebræ, 33.
- Divergent squint, 47; its dependence on myopia, 47.
- Divergent rays of light, 122.
- Donders'* table of presbyopic lenses, 144.
- Double-vision, 17, 41, 42.
- Dropsy of the eyeball, 116.
- ECCHYMOSES of eyelids, 49.
- Ectropium, 29; *Dieffenbach's* operation for, 31; *Sir W. Adams'* operation for, 31; alterations in puncta from, 36.
- Embolism of retinal artery, 101.
- Emmetropic eyes, acuteness of vision in, at different ages, 13; determination of "far-point" in, 15.
- Encephaloid cancer in orbit, 27; of eyeball, 113.
- Encysted tumour in orbit, 27; of eyeballs, 35; of lacrymal gland, 35.
- Entropium, 32; operations for, 32, by ligature, 32.
- Entozoa in eyeball, 117.
- Enucleation of eyeball, 18.
- Epithelioma of eyelids, 30.
- Epiphora, 39.
- Erectile tumours in lids, 34.
- Erysipelas of eyelids, 29.
- Eversion of eyelids, 29, 31; of puncta lacrymalia, 31, 36.
- Everting eyelids, mode of, 51.
- Excavation of optic papilla, 103.
- Exophthalmos from orbital disease, 24; from dacryocystitis, 35.
- Extirpation of lacrymal gland, 35.
- Extirpation of eyeball, 115.
- Extraction of cataract: chloroform in, 22; flap operation, 86; *Mooren's*, *Jacobson's* and *Waldau's* (*Schuff's*)

- operations, 88 ; Critchett's operation, 89 ; v. Gräfe's operation, 89.
- Eye, objective examination of, 1 ; mode of testing mobility of, 2 ; subjective examination of, 13 ; injuries of, 49.
- "Eye-limpets," 119.
- Eyeballs, examination of, 1 ; mode of fixing, 21 ; blows on, 52 ; wounds of, 52 ; diseases of, 110 ; inflammation of, 110 ; tumours of, 113 ; cancer of: encephaloid, 113, melanotic, 115 ; scrofulous tumour of, 114 ; dropsy of (hydrophthalmia), 116 ; entozoa of, 117 ; staphyloma of, 118 ; neuralgia of, 120 ; extirpation of eyeball, 115.
- Eyelashes, inversion of, 32.
- Eyelash in canaliculi, 36.
- Eyebrow, wounds of, 49.
- Eyelids, operations on, 21 ; œdema and suppuration of, 26 ; inflammation of, 29 ; ulcerations of, 30 ; eversion of, 31 ; operations for, 32 ; tumours of, 33 ; nævi of, 34 ; wounds of, 49 ; mode of everting, 51.
- Eyelid-tourniquet, 21.
- "FAR-POINT," determination of, 15.
- Fatty degeneration of retina, 100.
- Fibrinous tumour of lid, 33.
- Fibro-plastic tumour on lacrymal gland, 35.
- Field of vision, 15.
- Fistula lacrymalis, 36 ; fistula corneæ, 53.
- "Fixing apparatus," 19, 20, 21.
- Flap-operation for cataract, 86.
- Focus, definition of, 122.
- Focal length of a convex lens, 122 ; of a concave lens, 125.
- Forceps for eyelid, 21.
- Foreign body in orbit, remarkable case of, 49.
- Foreign bodies on eye, 51 ; method of removing, 52.
- Foreign bodies on cornea, 51.
- Foveola, 12.
- Furnari's* operation of peritomy, 64.
- Giraud-Teulon's* "lentilles décentrées," 147.
- Glasses after operation for cataract, 92.
- Glaucoma, loss of sensibility in, 17.
- Glaucoma, 105 ; its history, 105 ; its symptoms, 105 ; its treatment by iridectomy, 106 ; by paracentesis, 108 ; by medicine, 108.
- Gouge for removing foreign bodies from cornea, 51.
- Gräfe's, Von,* operation for cataract, 89 ; cataract-knife, 89 ; cataract-hook, 90 ; on iridectomy in glaucoma, 106.
- Granular conjunctivitis, 57.
- "Groove-speculum," 20.
- Haan's, de,* table of acuteness of vision in emmetropic eyes at different ages, 13.
- Hæmophthalmos, 98 ; cases of, 98.
- Hæmorrhage in vitreous, 98 ; in anterior chamber, 98.
- Hat-peg impacted in orbit, 50.
- "Head-rest," 19.
- Hemeralopia, 101.
- "Hernia of cornea," 66.
- Hippus, 80.
- Hook for the operation for strabismus, 46 ; *Von Gräfe's,* for cataract, 90.
- Hordeoleum, 30.
- Hydrophthalmia, 116 ; case of 116.
- Hypermetropia, determination of "far-point in," 15, 136 ; "manifest and latent," 137 ; accommodation in, 137 ; objective signs of, 137 ; correction of, 138 ; case of, 138 ; with presbyopia, 145 ; as a cause of asthenopia, 151 ; as a cause of convergent strabismus, 45.
- Hypertrophy of lacrymal gland, 35.
- Hypopyum, 71.
- IDIOPATHIC iritis, 73.
- Images formed by convex lenses, 125 ; by concave, 127 ; formation of, on retina, 128.
- Indirect method of using ophthalmoscope, 8.
- Inflammation of lacrymal apparatus, 35 ; of eyeball, 110.
- Injuries of eye and orbit, 49.
- Internal recti, weakness of, 152.
- Interstitial corneitis, 63.
- Inoculation-treatment of pannous cornea, 65.
- Inversion of eyelashes and eyelids, 32.
- Iris-forceps, 76 ; -scissors, 76.
- Iris, injuries of, 23 ; diseases of 72 prolapse of, 77 ; absence of (iridderemia), 78 ; tremulous, 79 ; clonic spasm of, 80 ; its action in accommodation, 131.
- Iritis, 72 ; irregularity of pupil in, 3 ; idiopathic, 73 ; syphilitic, 73 ; traumatic, 73.
- Iridectomy, 75 ; in glaucoma, 106.
- Irido-desis, 76.
- Iridderemia, 78.
- Iridodonesis, 79.
- Jacobson,* his testimony upon the use of

- chloroform in eye operations, 22 ; his operation for cataract, 88.
Javal's Astigmometer, 140.
- KERATOME, 76.
- LACRYMAL apparatus, diseases of, 35.
 Lacrymal gland, enlargements of, 35 ; from inflammation, from tumours, 35.
 Lacrymal sac, inflammation of, 36 ; abscess of, 36 ; obliteration of, 38.
 Lacrymal fistula, 36.
 Lacrymal bone, caries of, 36.
 Lacrymal gland, excision of, 35, 40.
 Lateral illumination, 3 ; its value in examining superficial structures, 2.
 Lens, dislocation of, 92.
 Lenses, optical, their action, 122 ; convex, 122 ; concave, 125 ; effect of combining, 123.
 "Lentilles décentrées," 147.
 Lenticular cataract, 82.
 Leucoma, 68 ; loss of sensibility in, 17.
 Levator palpebræ, division of, 33.
Liebreich's ophthalmoscope, 7.
 Ligature of common carotid, 28.
 Ligature-operation for entropium, 32.
 Ligature-operation for ptosis, 33.
 Light, mode of testing, perception of, 14.
 Linear extraction of cataract, 91.
 Lippitudo, 29.
- MACULA LUTEA, its ophthalmoscopic characters, 12.
 Malpositions of eye, mode of measuring, 1.
 Malpositions of eyelids, 31.
 Melanosis of orbit, 27 ; of conjunctiva, 60 ; of eyeball, 115.
 Mobility of eye, mode of testing, 1.
 Molluscum, 33.
Mooren's operation for cataract, 88.
 Morgagnian cataract, 83.
 Mucous conjunctivitis, 54.
 "Muscæ volitantes," 154.
 Muscles of the eye, their action, 41, 42 ; paralysis of, 43.
 Mydriasis, 79.
 Myopia, 132 ; temporarily produced by calabar bean, 6 ; determination of "far-point" in, 15 ; correction of, 33 ; objective signs of, 133 ; ophthalmoscopic signs of, 134 ; staphyloma posticum in, 135 ; cases of, 135 ; tinting glasses in, 136 ; with presbyopia, 144 ; a cause of divergent strabismus, 47.
 Myosis, 79.
- NŒVI in lids, 34.
- Nasal duct, obstruction of, 36 ; probes for, 37.
 "Near-point," determination of, 15.
 Nebulæ, 68.
 Nerve, paralysis of the third, 33.
 Neuralgia of eye, 120.
 Night-blindness, 101.
 Nose, dryness of, 36.
 "Numbers" of lenses, 127.
 Nystagmus, 48.
- OBJECTIVE examination of eye, 1.
 Object-lens, reflections from surface of, 8.
 Obliteration of lacrymal puncta, 36 ; of lacrymal sac, 38.
 Oblique illumination (see Lateral illumination).
 Obstruction of canaliculi, 36 ; of nasal duct, 36.
 Oculomotorious, paralysis of, 33.
 Œdema of eyelids, 29, 36.
 Ointment, *Pagenstecher's*, 57.
 Operations, general remarks on ophthalmic, 18 ; preparations previous to, 19 ; without chloroform, 20 ; after-treatment, 23.
 Operations, necessity of a good light in, 23.
 Ophthalmiæ, Belladonna in the, 6.
 Ophthalmia tarsi, 29 ; eversion or obliteration of puncta lacrymalia in, 36.
 Ophthalmia neonatorum, ectropium resulting from, 31.
 Ophthalmia, catarrhal, 54 ; of new-born infants (neonatorum) 55 ; gonorrhœal, 56 ; Egyptian, 56 ; rheumatic, 62 ; "scrofulous," 63 ; sympathetic, 112.
 Ophthalmitis, 110 ; case of, 111.
 Ophthalmic operations, remarks on, 18.
 Ophthalmic artery, aneurism of, 28.
 Ophthalmoscope, *Liebreich's* small, 7 ; binocular, 8-10.
 Optic nerve, entrance of, 11 ; infiltration of, 25 ; diseases of, 102 ; inflammation of, 102 ; excavation of, 103 ; atrophy of, 103.
 Optic nerve, infiltration of, in cellulitis, 25.
 Optometer, 15.
 Optics of the eye, 121.
 Optical defects of the eye, 132 ; as a cause of asthenopia, 151.
 Orbit, diseases of, 24 ; caries of, periostitis of, 24 ; cellulitis of, 25 ; abscess of, 26 ; tumours of, 27.
 Oscillation of eyeballs (nystagmus), 48.
- Pagenstecher's operation for entropium*, 32 ; ointment, 57.

- Pain in inflammation, 17.
 Pannous corneitis, 63.
 Papilla optica, its appearance in health ; its diseases, 102 ; inflammation of, 102 ; excavation ("cupping") of, 103 ; atrophy of, 103.
 Parallel rays of light, 122.
 Paracentesis of cornea, in corneitis, 64 ; in glaucoma, 108.
 Paralysis of accommodation, produced by atropine, 5, 6, 130 ; from disease, 147 ; causes of, 147.
 Paralysis : of third nerve, 33 ; of ocular muscles of external rectus, 43 ; of inferior rectus, 44 ; of third nerve, 44.
 Perception of light, mode of testing, 14.
 Periostitis of orbit, 24.
 Periosteal growths in orbit, 27.
 Peritomy, 64.
 Phlyctenular conjunctivitis, 57.
 Phlyctenular corneitis, 63.
 "Pince-anneau," 21.
 Potassium, iodide of, in periostitis, 24.
 Polar cataract, 83.
 Presbyopia, in normal eyes, 142 ; table of glasses for different ages, 144 ; in myopia, 144 ; in hypermetropia, 145 ; Giraud-Teulon's decentration of lenses in, 147.
 Prolapse of iris, 77.
 Probes for nasal duct, 37.
 Pterygium, 61.
 Ptosis, 31 ; from traumatic causes, 32 ; paralytic, 33 ; operations for, 33.
 Pulsation of aneurismal tumours, 28.
 "*Punctum proximum*," determination of, 15 ; "*remotum*," determination of, 15.
 Puncta lacrymalia, diseases of, 29-31, 36.
 Pupil, aspect of, mode of measuring, movements of, 4 ; in amaurosis, 5 ; dilatation of, from Belladonna, 5 ; contraction of, from Calabar bean, 6 ; dilatation and contraction of, 79 ; artificial dilatation of, 5.
 Pupillometer, 4.
 Pupil, artificial, 75 ; dislocation of (irido-desis), 76.
 Pupillary membrane persistent, 79.
 Purulent conjunctivitis, 31, 55 ; of infants, 55 ; gonorrhœal, 56 ; Egyptian, 56.
 Pustular conjunctivitis, 57.
 Pyramidal cataract, 83.
- RAYS of light, 121 ; divergent, convergent or parallel, 122.
 Refraction, anomalies of in eye, 132 ; classification of eyes according to, 132 ; "myopic," 134 ; "hypermetropic," 138.
 Refraction of eye, mode of testing, 14 ; increased by Calabar bean, 6.
 Retinal vessels, as seen by ophthalmoscope, 12 ; their pulsation, 12.
 Retina, diseases of, 99 ; inflammation of, 99 ; fatty degeneration of, 100 ; apoplexy of, 100 ; anæmia of, 101 ; separation of, 101, embolism of central artery of, 101.
 Retina, hyperæsthesia of, a cause of asthenopia, 153.
 Retinal artery, embolism of, 101.
 Retinitis, 99 ; albuminurica, 100 ; pigmentosa, 101.
 Rheumatic ophthalmia, 62.
- SARCOMATOUS tumours in orbit, 27.
 Scalds of eye, 51.
 Scirrhus of lacrymal gland, 35.
 Scissors, for the operation of strabismus, 46.
 Scissors, iris-, 76.
 Scissors, cannula-, 92.
 Sclerotic, diseases of, 62 ; scleratitis, 62 ; staphyloma of, 62 ; tumour of, 62.
 Sclerectasia, 62.
 Scotomata, 154.
 "Scrofulous ophthalmia," 63.
 Secondary cataract, 92 ; Agnew's operation for, 92.
 Sensibility, loss of in eye disease, 17.
 Sentient structures of eye, 128.
 Separation of the retina, 101.
 Short sight, 132.
 Siliquose cataract, 83.
 Simulation of blindness, 17.
 Skinning over of puncta lacrymalia, 31, 36.
 Skin of eyelids, excising strip of, in entropium, 32.
 Snellen's forceps, 21.
 Speculum, wire, 20, "groove-speculum," 20 ; speculum used in obliterating lacrymal sac, Manfredi's, 39.
 Sperino's treatment by paracentesis of cornea of corneitis, 64, of glaucoma, 108.
 "Spoon-operation" for cataract, 88.
 Squint, 45.
 Staphyloma of eyeball, 118 ; operations for, 118, 119.
 Staphyloma posticum in myopia, 134.
 Style for lacrymal fistula, 39.
 Stereoscopic effects not appreciable by monocular vision, 17.
 Stereoscope, applied to the cure of strabismus, 47.

- Stricture of canaliculi, 36 ; of nasal duct, 36.
- Strabismus, 45 ; convergent, 45 ; divergent, 47 ; operation for, 46.
- Strabismometer, 2.
- Stye, 30.
- Subjective examination of eye, 13.
- Suction-operation for soft cataract, 91.
- Suppuration of lacrymal gland and sac, 35, 36.
- Superficial structures of eye, mode of examining, 2, 3.
- Symblepharon, 59 ; Teale's operation for, 59 ; Arlt's operation for, 59.
- Sympathetic ophthalmia, 112.
- Synchysis scintillans, 99.
- Synechia anterior and posterior, 72 ; annularis, 72 ; totalis, 72.
- Syndectomy, 64.
- Syphilitic, tumours of orbit, 27 ; ulcerations of lids, 30.
- Syphilitic iritis, 73.
- TARSAL** cartilage, excising strip of in entropium, 32.
- Teale's* operation for symblepharon, 59 ; suction-operation for soft cataract, 91.
- Tension of eyeball, mode of determining, 1.
- Test types, 13 ; Snellen's, 13 ; Jager's, 14.
- Third nerve, paralysis of, 33.
- Tinea tarsi (see Ophthalmia tarsi), 29.
- Tinted glasses in myopia, 136.
- Tourniquet for eyelids, 21.
- "Transposition-slides" for testing binocular vision, 16.
- Trachoma, 58.
- "Traction-operation" for cataract, 89.
- Traumatic cellulitis, 26.
- Traumatic iritis, 73.
- Tremulous iris, 79.
- Trichiasis, 32 ; operations for, 32.
- Tubercular tumour of eyeball, 114.
- Tumours of orbit, 26 ; bony, encysted, sarcomatous, cancerous, 27 ; aneurismal, 28.
- Tumours of eyeball, 113.
- Tumours of the eyelids, 33 ; erectile, 34 ; fibrinous, albuminous, 33.
- Tumours of lids, ring-forceps for, 21.
- Tumours of conjunctiva, 60.
- Tumours, fibroplastic of sclerotic, 62.
- Tyrell's* hook, 76.
- ULCERATION** of eyelids, 30.
- Upper eyelid, inability to raise, 33.
- Unicocular diplopia, 141.
- Waldau's* (Schuft's) operation for cataract, 88.
- Windsor* on chloroform in extraction of cataract, 22.
- Wire-speculum, 20.
- Wounds of eyebrow, 49 ; of eyelids, 49 ; of eyeball, 52 ; of cornea, 52.
- VASCULAR** tumour of conjunctiva, 60.
- Veins of retina, pulsation of, 12.
- Vision, on, 121.
- Vision, physiology of, 127 ; binocular, 131 ; acuteness of, 13.
- Visual angle, 13.
- Vitreous, diseases of, 97 ; blood in, 98.
- XEROPHTHALMIA**, 58.
- Zehender's* cataract knife, 85.

