

Principles and illustrations of morbid anatomy : adapted to the elements of M. Andral, and to the cyclopaedia of practical medicine, being a complete series of coloured lithographic drawings, from originals by the author : with descriptions and summary allusions to cases, symptoms, treatment, &c.; : designed to constitute an appendix to works on the practice of physic, and to facilitate the study of morbid anatomy in connexion with symptoms / by J. Hope.

Contributors

Hope, James, 1801-1841.
Francis A. Countway Library of Medicine

Publication/Creation

London : Printed for Whittaker & Co., 1834.

Persistent URL

<https://wellcomecollection.org/works/z89jsx79>

License and attribution

This material has been provided by This material has been provided by the Francis A. Countway Library of Medicine, through the Medical Heritage Library. The original may be consulted at the Francis A. Countway Library of Medicine, Harvard Medical School. where the originals may be consulted. This work has been identified as being free of known restrictions under copyright law, including all related and neighbouring rights and is being made available under the Creative Commons, Public Domain Mark.

You can copy, modify, distribute and perform the work, even for commercial purposes, without asking permission.




Wellcome Collection
183 Euston Road
London NW1 2BE UK
T +44 (0)20 7611 8722
E library@wellcomecollection.org
<https://wellcomecollection.org>


















Digitized by the Internet Archive
in 2011 with funding from
Open Knowledge Commons and Harvard Medical School



PRINCIPLES AND ILLUSTRATIONS
OF
MORBID ANATOMY:

OF THE
ELEMENTS OF A SURGEON.

OF THE
CHANGES OF NECTURAL MEDICINE.

ILLUSTRATED BY LITHOGRAPHIC DRAWINGS.

AND
A
DISCUSSION OF THE
DISPOSITION OF THE
CASES, SYMPTOMS, TREATMENT.

OF THE
MORBID ANATOMY IN CONNECTION WITH SYMPTOMS.

J. HOPKINS, M.D., F.R.S.

LONDON:
PRINTED FOR WHITTAKER, & CO., AVE MARIA LANE.

THE NEW YORK PUBLIC LIBRARY

MORRIS ANATOMY

BY J. MORRIS

WITH ILLUSTRATIONS BY J. MORRIS

NEW YORK: THE NEW YORK PUBLIC LIBRARY, ASTOR LENOX AND TILDEN FOUNDATIONS, 1900.

THE NEW YORK PUBLIC LIBRARY, ASTOR LENOX AND TILDEN FOUNDATIONS, 1900.

THE NEW YORK PUBLIC LIBRARY, ASTOR LENOX AND TILDEN FOUNDATIONS, 1900.

THE NEW YORK PUBLIC LIBRARY, ASTOR LENOX AND TILDEN FOUNDATIONS, 1900.

THE NEW YORK PUBLIC LIBRARY, ASTOR LENOX AND TILDEN FOUNDATIONS, 1900.

THE NEW YORK PUBLIC LIBRARY, ASTOR LENOX AND TILDEN FOUNDATIONS, 1900.

THE NEW YORK PUBLIC LIBRARY, ASTOR LENOX AND TILDEN FOUNDATIONS, 1900.

J. MORRIS, M.D.

THE NEW YORK PUBLIC LIBRARY, ASTOR LENOX AND TILDEN FOUNDATIONS, 1900.

THE NEW YORK PUBLIC LIBRARY, ASTOR LENOX AND TILDEN FOUNDATIONS, 1900.

PRINCIPLES AND ILLUSTRATIONS
OF
MORBID ANATOMY ;
ADAPTED TO THE
ELEMENTS OF M. ANDRAL,
AND TO THE
CYCLOPÆDIA OF PRACTICAL MEDICINE,
BEING A COMPLETE SERIES OF
COLOURED LITHOGRAPHIC DRAWINGS,
FROM ORIGINALS BY THE AUTHOR ;
WITH
Descriptions and Summary Allusions
TO
CASES, SYMPTOMS, TREATMENT, &c.
DESIGNED TO CONSTITUTE AN APPENDIX TO WORKS ON THE PRACTICE
OF PHYSIC, AND TO FACILITATE THE STUDY OF
MORBID ANATOMY IN CONNEXION WITH SYMPTOMS.


BY
J. HOPE, M.D., F.R.S.,

PHYSICIAN TO THE ST. MARY-LE-BONE INFIRMARY ; MEM. HON. DE LA SOCIÉTÉ DE STATISTIQUE UNIVER-
SELLE ; EXTRAORD. MEM. AND FORMERLY PRES. OF THE ROY. MED. SOC. ED., ETC.

Segnius irritant animos demissa per aures,
Quam quæ sunt oculis subjecta fidelibus, et quæ
Ipse sibi tradit spectator.—HORACE, *De Arte Poetica*.

LONDON :
PRINTED FOR WHITTAKER, & CO., AVE-MARIA LANE.

MDCCCXXXIV.



LONDON :
Printed by WILLIAM CLOWES,
Duke-street, Lambeth.

TO THE
HONOURABLE CHARLES HOPE,

LORD PRESIDENT OF SCOTLAND;

A MAN NOT MORE DISTINGUISHED FOR HIS PROFESSIONAL TALENTS THAN
ADORNED BY HIS PRIVATE VIRTUES,
AND BY THE ELEGANT TASTES OF AN ACCOMPLISHED GENTLEMAN AND SCHOLAR,

THIS WORK,

AN INADEQUATE TOKEN OF GRATITUDE FOR MUCH PAST KINDNESS,

IS RESPECTFULLY INSCRIBED

BY HIS OBLIGED AND OBEDIENT SERVANT,

THE AUTHOR.

13, Lower Seymour-street, London.

June, 1834.

TABLE OF CONTENTS

CHAPTER I. THE STATE OF THE COUNTRY

CHAPTER II. CHARLES HILL

CHAPTER III. THE COUNTRY

CHAPTER IV. THE COUNTRY

CHAPTER V. THE COUNTRY

CHAPTER VI. THE COUNTRY

CHAPTER VII. THE COUNTRY

CHAPTER VIII. THE COUNTRY

CHAPTER IX. THE COUNTRY

CHAPTER X. THE COUNTRY

CHAPTER XI. THE COUNTRY

CHAPTER XII. THE COUNTRY

CHAPTER XIII. THE COUNTRY

CHAPTER XIV. THE COUNTRY

CHAPTER XV. THE COUNTRY

CHAPTER XVI. THE COUNTRY

CHAPTER XVII. THE COUNTRY

CHAPTER XVIII. THE COUNTRY

TABLE OF CONTENTS.

DISEASES OF THE RESPIRATORY APPARATUS.

DIVISION I.

DISEASES OF THE PULMONARY PARENCHYMA.

Chap.		Page
I.	General Arrangement	1
II.	Acute Peripneumony	5
III.	Abscess of the Lungs	10
IV.	Gangrene of the Lungs	13
V.	Chronic Peripneumony	15
VI.	Pleurisy	18
VII.	Phthisis Pulmonalis, or Tubercular Consumption	25
VIII.	Pulmonary Apoplexy	38
IX.	Emphysema of the Lungs	41
X.	Encephaloid Tumour of the Lungs	45
XI.	Melanosis	49
XII.	Black Pulmonary Matter	53
XIII.	Œdema of the Lungs	54
XIV.	Ossification of the Pulmonary Substance; and Hydatids	55

DIVISION II.

DISEASES OF THE AIR-PASSAGES.

I.	Bronchitis	56
----	----------------------	----

DISEASES OF THE HEART.

I.	General Arrangement	65
II.	Pericarditis	67
III.	Carditis, Inflammation of the Internal Membrane, Softening, Abscess, Purulent Depositions, Ulcers, Perforations, Gangrene, Induration, and Anæmia	71
IV.	Hypertrophy.—Atrophy	78
V.	Dilatation, and real Aneurism or partial Dilatation, of the Heart	83
VI.	Fatty, Greasy, Cartilaginous, Osseous, Tubercular, Scirrhus, and Encephaloid degenerations of the Muscular Substance	86
VII.	Diseases of the Valves and Orifices	88
VIII.	Serous Cysts, and Hydatids	95
IX.	Congenital Malformations	96

DISEASES OF THE LIVER.

DIVISION I.

DISEASES OF THE PARENCHYMA OF THE LIVER.

Chap.		Page
I.	General Arrangement	97
II.	On the Structure of the Parenchyma of the Liver	99
III.	Hypertrophy of the White Substance (nutmeg liver)	102
IV.	The Granulated Liver	104
V.	Cancerous Tubera	113
VI.	Abscess of the Liver, consequent on capital Operations, Wounds, Uterine and Crural Phlebitis, Abscess in other parts, &c.	124
VII.	Inflammation of the Liver	131
VIII.	Congestion of the Liver	133
IX.	Hypertrophy, Atrophy, Induration, and Softening	ib.
X.	Adipose and Cholesterine Degeneration	135
XI.	Melanosia of the Liver	136
XII.	Serous Cysts, and Hydatids	ib.

DIVISION II.

DISEASES OF THE BILIARY APPARATUS	139
---	-----

DISEASES OF THE ALIMENTARY CANAL BELOW THE DIAPHRAGM.

I.	General Arrangement	145
II.	Hyperæmia of the Alimentary Canal	147
	—— independent of Disease	148
	—— from Disease	152
III.	Softening of the Alimentary Canal	163
	1. Natural consistence of the Mucous Membrane	164
	2. Softening from Putrefaction	165
	3. Solution by the Gastric Juice	ib.
	4. Softening from Disease	167
IV.	Ulceration of the Alimentary Canal	173
	1. Healthy state of the Mucous Glands	ib.
	2. Enlarged state from Cholera	179
	3. Enlarged state from Inflammation, which may be simple	180
	—— specific	185
	Ulceration of the Mucous Glands from simple Inflammation	186
	—— from specific Inflammation	190
	Ulcers from Tubercle beneath the Mucous Membrane	194
	Ulcers from circumscribed softening of the Mucous Membrane	195

Chap.		Page
	Ulcers from Inflammatory Excoriation of the Mucous Membrane	197
	Solitary Ulcers	200
	Ulceration from Gangrene of the Mucous Membrane . . .	201
	Cicatrization of Ulcers	202
V.	Hypertrophy, Scirrhus, and Cancer	204
	DISEASES OF THE PERITONEUM	223
	EXTERNAL CANCER	226
	DISEASES OF THE UTERINE SYSTEM.	
I.	Diseases of the Ovaria	233
II.	Diseases of the Uterus	241
	Inflammation	ib.
	Corroding Ulcer of the Os Uteri	249
	Cancer of the Uterus	250
	Fibrous Tumour of the Uterus	253
	Polypus of the Uterus	256
	Cauliflower Excrescence of the Os Uteri	259
III.	Diseases of the Fallopian Tubes	260
	DISEASES OF THE KIDNEYS	261
	DISEASES OF THE BLADDER	269
	DISEASES OF THE SPLEEN.	
I.	Diseases of the Fibrous Tissue	271
II.	Diseases of the Matter contained in the Splenic Cells . . .	ib.
	DISEASES OF THE BRAIN AND SPINAL CORD.	
I.	General Arrangement	276
II.	Inflammation	277
	1. Meningitis	ib.
	2. Cerebritis	282
III.	Softening	286
IV.	Suppuration, Abscess, and Ulcer	290
V.	Induration	291
VI.	Apoplexy	292
VII.	Hypertrophy, Atrophy, and Anæmia	296
VIII.	Tubercle; Scirrhus, Encephaloid, Fatty, Fibrous, Cartilaginous, and Osseous Productions; and Hydatids	297

1. The first of these is the fact that the
2. second is the fact that the
3. third is the fact that the
4. fourth is the fact that the
5. fifth is the fact that the
6. sixth is the fact that the
7. seventh is the fact that the
8. eighth is the fact that the
9. ninth is the fact that the
10. tenth is the fact that the
11. eleventh is the fact that the
12. twelfth is the fact that the
13. thirteenth is the fact that the
14. fourteenth is the fact that the
15. fifteenth is the fact that the
16. sixteenth is the fact that the
17. seventeenth is the fact that the
18. eighteenth is the fact that the
19. nineteenth is the fact that the
20. twentieth is the fact that the
21. twenty-first is the fact that the
22. twenty-second is the fact that the
23. twenty-third is the fact that the
24. twenty-fourth is the fact that the
25. twenty-fifth is the fact that the
26. twenty-sixth is the fact that the
27. twenty-seventh is the fact that the
28. twenty-eighth is the fact that the
29. twenty-ninth is the fact that the
30. thirtieth is the fact that the
31. thirty-first is the fact that the
32. thirty-second is the fact that the
33. thirty-third is the fact that the
34. thirty-fourth is the fact that the
35. thirty-fifth is the fact that the
36. thirty-sixth is the fact that the
37. thirty-seventh is the fact that the
38. thirty-eighth is the fact that the
39. thirty-ninth is the fact that the
40. fortieth is the fact that the
41. forty-first is the fact that the
42. forty-second is the fact that the
43. forty-third is the fact that the
44. forty-fourth is the fact that the
45. forty-fifth is the fact that the
46. forty-sixth is the fact that the
47. forty-seventh is the fact that the
48. forty-eighth is the fact that the
49. forty-ninth is the fact that the
50. fiftieth is the fact that the
51. fifty-first is the fact that the
52. fifty-second is the fact that the
53. fifty-third is the fact that the
54. fifty-fourth is the fact that the
55. fifty-fifth is the fact that the
56. fifty-sixth is the fact that the
57. fifty-seventh is the fact that the
58. fifty-eighth is the fact that the
59. fifty-ninth is the fact that the
60. sixtieth is the fact that the
61. sixty-first is the fact that the
62. sixty-second is the fact that the
63. sixty-third is the fact that the
64. sixty-fourth is the fact that the
65. sixty-fifth is the fact that the
66. sixty-sixth is the fact that the
67. sixty-seventh is the fact that the
68. sixty-eighth is the fact that the
69. sixty-ninth is the fact that the
70. seventieth is the fact that the
71. seventy-first is the fact that the
72. seventy-second is the fact that the
73. seventy-third is the fact that the
74. seventy-fourth is the fact that the
75. seventy-fifth is the fact that the
76. seventy-sixth is the fact that the
77. seventy-seventh is the fact that the
78. seventy-eighth is the fact that the
79. seventy-ninth is the fact that the
80. eightieth is the fact that the
81. eighty-first is the fact that the
82. eighty-second is the fact that the
83. eighty-third is the fact that the
84. eighty-fourth is the fact that the
85. eighty-fifth is the fact that the
86. eighty-sixth is the fact that the
87. eighty-seventh is the fact that the
88. eighty-eighth is the fact that the
89. eighty-ninth is the fact that the
90. ninetieth is the fact that the
91. ninety-first is the fact that the
92. ninety-second is the fact that the
93. ninety-third is the fact that the
94. ninety-fourth is the fact that the
95. ninety-fifth is the fact that the
96. ninety-sixth is the fact that the
97. ninety-seventh is the fact that the
98. ninety-eighth is the fact that the
99. ninety-ninth is the fact that the
100. hundredth is the fact that the

P R E F A C E.

THE want of a complete series of Illustrations of MORBID ANATOMY, in a form so compact and economical as to be generally accessible, is peculiarly felt at the present moment. "At no epoch," says Andral, "has Morbid Anatomy been so generally studied: it is this which has, as it were, inspired the idea of the splendid works undertaken within the last thirty years;—it is this which has almost exclusively enriched science with the fruits of them." It is only, in short, by the comparison of symptoms with *post-mortem* appearances that practical medicine can rest on a sure basis, and approximate to the nature of an exact science.

The difficulties which beset the study of Morbid Anatomy are great. Prejudice circumscribes the sphere of the private practitioner; while the brief time in general spared by the student for Hospital attendance, and the full occupation of that time by more *immediately* necessary studies, prevent him from making much progress during the period of his education. Should he attempt to improve his opportunities by reading, he finds that elaborate descriptions of morbid appearances present but indistinct images to his mind; those images, if not speedily embodied by a reference to nature, are evanescent; and, when compared with nature, they often place him in perplexing doubt respecting their

identity; from asking, he is deterred by the fear of betraying ignorance; from communicating, his teacher often refrains, apprehensive of wearying by superfluous repetitions.

Coloured delineations are better calculated than any other means to obviate these difficulties. They both render descriptions intelligible, and convey to the mind images so distinct as to be retained with facility until they can be impressed by comparison with nature. Once recognized as types of what has been seen, by occasional re-inspection, they stamp the image in faithful and indelible colours.

This is not the only advantage of delineations. As the number of *elementary* lesions, like the primitive words of a language, is comparatively small, a knowledge of these lesions (which it will be the object of the present work to convey) will greatly circumscribe the sphere of study, and lighten the burden of memory. Drawings, therefore, while they greatly curtail the labours of those who enjoy unlimited opportunities, enable others, less fortunate, to acquire a comparatively extensive and well-digested knowledge of Morbid Anatomy.

It is necessary to make a few observations respecting the plan of the work.

The arrangement is according to organs, as being best adapted to the study of the diseases of organs; but the lesions of each organ are considered in reference to the particular tissues which they occupy, on the principles of general anatomy. The descrip-

tions are, for the most part, copies of those taken from the original specimens. Reference is made, where desirable, to the corresponding descriptions of other writers, with the exception of the Cyclopædia, the alphabetical form of this work affording every facility of reference. The reader has only to turn, in the Cyclopædia, to the word which forms the heading of the Chapter in the Illustrations. Reference to the latter will be facilitated by a final general Index.

Having, with few exceptions, taken the histories of the cases personally, it is my object, from the funds thus supplied, to render the work as practical as is compatible with its character, by adverting very succinctly to the nature of each instructive case, and to the connexion between the lesion and the symptoms. To avoid interfering with the continuity of the subject, the cases are appended to the Description of the Plates.

The most important feature in representations of Morbid Anatomy is fidelity. I have, for this reason, taken the precaution of never drawing without the specimen before me, representations from memory being generally inaccurate; and to obviate changes of colour from decomposition or exposure to air, I have usually completed the drawings within a few hours after the specimen was removed from the subject.

Drawings illustrating French opinions, not familiarly known in this country, I have made in the French school; and, most commonly, from specimens selected either by the author of such opinions, or by professors thoroughly conversant with them. Free

access, through the politeness of the medical officers, to the rich and boundless resources of the hospitals *La Charité, Des Enfants*, and others in Paris, gave me ample latitude in this respect.

To the medical officers of St. George's Hospital, London, I am indebted for many valuable specimens.

The series of Drawings was, with a few exceptions of ordinary subjects, complete before the present Number was sent to press; but should the contributions of friends, and the immense field of Morbid Anatomy, constantly presented to me by the extensive Institution to which I am attached,* afford anything more interesting than what I possess, I shall not fail to avail myself of it.

I have endeavoured, to the utmost in my power, by personal superintendence, to ensure the accuracy of the lithography and colouring; and, as the labour of the artist is, throughout, in a great measure saved to the purchaser, I am not without hopes of having attained the object which I have had in view—of rendering these Illustrations the least expensive that have hitherto been published.

J. H.

13, Lower Seymour Street, Portman Square.

January 1, 1833.

* The St. Mary-le-bone Infirmary contains three hundred and fifty beds for patients, independent of about one thousand disabled or superannuated paupers, and between three and four hundred children. In addition to other diseases, it embraces those of infancy, of the puerperal state, and insanity.

DISEASES OF THE RESPIRATORY APPARATUS.

DIVISION I.

DISEASES OF THE PULMONARY PARENCHYMA.

CHAPTER I.

GENERAL ARRANGEMENT.

BEFORE entering on an illustrative description of the individual morbid states of the pulmonary parenchyma, it is desirable to make an arrangement of them according to their causes, and the tissues or parts which they affect. They will thus be seen to present broad analogies with the morbid states of other organs and tissues, by a knowledge of which analogies the subject will be greatly simplified; as the student will be enabled to refer each lesion to its appropriate and natural place, and to anticipate its general characters, relations, and bearings. In forming this arrangement, the plan of M. Andral, combining simplicity with precision, will be adopted as the model.

The pulmonary parenchyma, on being reduced to its elements, present three distinct and principal parts: 1. Cavities; (viz. the *air-vesicles*, consisting of the globular and slightly bulging extremities of the ultimate bronchial ramifications; 2. the walls of these cavities; (composed of a thin membrane, on which the vessels and nerves ramify in a state of extreme minuteness;) 3. the cellular tissue interposed between the air-vesicles. (*Précis*, ii. 502.)

All the morbid states of the pulmonary substance must necessarily be seated in one or other of these three parts; and on examining portions of diseased lung, dried, and sliced, it is seen that, however diversified the nature of the disease in the several portions, all are resolved into a congeries of tubes and cells, in the midst of which it is possible to distinguish the alterations that the interior of the cavities, their walls, and the interposed cellular tissue have respectively undergone. Such of these alterations as admit of being demonstrated by this mode of examination, are found to resolve themselves into certain morbid states similar to those which may attack any other organic canal surrounded by cellular tissue. By induction, therefore, it may be presumed that the same is the case with the alterations *not* capable of being demonstrated by drying and slicing the lung. By the analogy thus established, we are led to a more accurate and certain knowledge of the morbid states of the pulmonary substance than could be obtained by investigations confined to the substance itself; and we are enabled to say that all the diseases of the substance which produce anatomical changes, are reducible to LESIONS OF THE CAPILLARY CIRCULATION; OF NUTRITION, or of SECRETION.

LESIONS OF CIRCULATION.

I. *Hyperemia of the Lung.* This embraces: A, *Passive hyperemia*, whether mechanical or cadaveric; B, *Active hyperemia*, (peripneumony,) of which two of the three degrees, viz. *engorgement* and *hepatization*, come under the present head; C, *Gangrene*, resulting from hyperemia whether active or passive; D, *Pulmonary apoplexy*, when consequent on rupture of the vessels and extravasation into the cellular tissue. That variety of pulmonary apoplexy which consists in an exhalation of blood into the bronchial tubes, does not fall under the present head, being referrible to an alteration of secretion of the mucous membrane.

II. *Anemia of the Lung.*—A, Resulting from hæmorrhage;

B, from inadequate sanguification; C, from atrophy of the lung, observed principally in the aged.

LESIONS OF NUTRITION.

These are situated, according to the foregoing principles, either in the walls of the air-vesicles, or in the intervening cellular tissue. They consist (in the lungs, as in every other organ) of 1. an increase, 2. a diminution, or, 3. a perversion of the natural nutrition.

I. *Increased Nutrition, or Hypertrophy.*—Of this there are two forms: A, consisting of an augmentation of the number and size of the air-vesicles, without thickening of their walls,—consequently, without induration, but with amplification of the pulmonary substance. Here must be ranged a variety in which some of the vesicles and capillary bronchi are thickened as well as dilated, constituting one of the forms of pulmonary emphysema. B, consisting of thickening of the vesicular walls, with diminution or obliteration of their cavities,—consequently, with induration of the pulmonary substance. This form may occupy either large portions of the lung, or only single lobules, or even vesicles. In the latter case, according to the views of Andral, it constitutes the *pulmonary granulations* of M. Bayle.

Hypertrophic induration sometimes affects the interlobular cellular tissue, either separately, or in connexion with induration of the lobes.

II. *Diminished Nutrition, or Atrophy.*—In this there is a decrease in the number of air-vesicles, and an attenuation of their walls, often causing them to burst into, and coalesce with each other. Enlargement of the pulmonary vesicles from this coalition, no less than from the dilatation of each, before alluded to, constitutes *pulmonary emphysema*.

III. *Perverted Nutrition.*—This consists in a transformation of the cellular, into fibrous or cartilaginous tissue. Very rarely an osseous matter forms the vesicular walls.

LESIONS OF SECRETION.

These take place in the three parts before specified: viz. the cavities, their walls, and the cellular tissue. The resulting morbid changes are the same as in any other similarly constructed organ, but some are more frequent than others. Thus, the secretion of tubercle is more common in the lung than elsewhere, while that of pus, in the form of abscess, is more rare. Lesions of secretion comprehend,—

I. *The Secretion of Pus.*—This presents itself in the form either of *purulent infiltration*, (*ramollissement gris* of Andral,) constituting the third degree of peripneumony; or of *abscess*; or of *purulent depositions* in healthy lungs, consequent on suppuration after great operations of surgery, and existing in the form either of A, small abscesses, or of B, purulent infiltration of a limited number of lobules. II. *Tubercle*. III. *Calculous concretions*, generally connected with, and forming one of the terminations of tubercle. IV. *Melanosis*. V. *Hydatids*. (*Acephalocystes*.) VI. *Serous infiltration* into the cellular tissue, whether intervesicular or interlobular: constituting the *œdema of the lung* of M. Laennec. VII. *A secretion of air* into the interlobular cellular tissue, forming the *interlobular emphysema* of Laennec. Sometimes it is not a secretion, but the result of rupture of one or more pulmonary vesicles.

Such are the various morbid states of the pulmonary parenchyma. We now proceed to consider them individually, and in doing this, we shall not adhere to the above arrangement, but follow that best adapted to the study of the diseases of the organ; namely, grouping together such alterations as are peculiar to each disease.

CHAPTER II.

ACUTE PERIPNEUMONY.

FIG. 4. presents a remarkable exemplification of all the degrees of inflammation of the pulmonary substance co-existent in a single lung : viz. Deg. 1. *Engorgement* ; Deg. 2. *Hepatization* ; Deg. 3. *Purulent infiltration*, also *Gangrene*. The surface delineated is a flat section of the anterior part of the right lung.

Degree 1. *Engorgement*.—This is represented in the upper half of the superior lobe *a, b*. It is in an advanced stage, being on the eve of its transition into hepatization. It is heavier and firmer than natural, and barely floats in water. It pits on pressure, is rather lacerable, only slightly crepitant, and yields less sero-sanguinolent fluid than in an earlier stage of engorgement : its colour also has less of the deep purple hue. The aveolar or spongy texture is still feebly discernible.

In more recent *engorgement* the colour is of the deep rich purple represented in Fig. 7, *b* : the exterior is livid or violet, *d*. Spumous sero-sanguinolent fluid streams after the knife in great abundance. In proportion as the fluid becomes less spumous, the crepitation diminishes, and the friability increases, — changes resulting from a diminution of air, and an increase of fluid in the lung. In infants, the crepitation is proportionably less than in adults, because the pulmonary structure is more *dense* : i. e. the air-vesicles are smaller and more numerous.

Engorgement depends upon a congestion and stasis of blood in the walls of the capillary bronchi and air-vesicles. Whether it is retained in the vessels, or extravasated into the cellular tissue, or both, admits of doubt : I am inclined to adopt the first opinion. The effect of the congestion is to contract the cavities, and cause a glutinous secretion into them, which, *tinged with blood*, constitutes the characteristic expectoration in this de-

gree*. The *crepitant* ronchus, also a pathognomic phenomenon in engorgement, depends on the bursting of minute bubbles formed by the passage of air through the glutinous secretion. The seat of the phenomenon is confined to the vesicles and capillary bronchi. It differs from the *mucous ronchus* only in its superior *fineness*, the latter ronchus being seated in larger bronchial tubes. The sub-crepitant ronchus is a mixture of the crepitant with the finest mucous.

Degree 2.—*Hepatization* (*ramollissement rouge* of Andral) is represented in Fig. 4, extending from *b, c* to the opposite side, and occupying the lower half of the upper lobe. It is perfectly formed, and well characterised. It sinks in water, feels firm and heavy like liver, and does not crepitate. It is very lacerable, breaking up under moderate pressure with the fingers, and a section is followed by exudation of a very sparing quantity of bloody serum, without the slightest intermixture of air. The colour is a dull red with a leaden intermixture. This is variegated and made to assume a marbled aspect by dark blue spots of pulmonary matter, and by pale yellow streaks and clouds, formed by the bronchial tubes, the blood-vessels, and the hypertrophous interlobular partitions. The surface is *granular*,—a remarkable character, and dependent on tumefaction of the walls of the air-vesicles causing obliteration of their cavities. An extreme degree of this tumefaction destroys the granular appearance, by pressing together, and thus confounding the vesicles. A hepatized lung looks larger than natural; yet it is not, the appearance being occasioned by its retaining the size of the thoracic cavity, instead of collapsing when the chest is opened.

The colour of hepatization is not always similar to that delineated. Where there is less black pulmonary matter to form a contrast, the marbled appearance is less striking, and the general tint partakes more of light pink, as in Fig. 7, *c* and *g*.

In Fig. 4 the greyer portion of *b, c*, near the vessels, is in its

* Vide Laennec, *Traité de l'Auscult.*, i., 433, 2d edit.

passage into the stage of *purulent infiltration*, the red giving place to the grey, which, again, is diluted with scarcely perceptible lighter clouds from purulent deposition, showing itself in detached points. This portion is more friable, and the fluid, which oozes on pressure, is slightly purulent. The combination of colours in the transition of the second into the third degree is occasionally so beautiful as to present the appearance of granite composed of red and yellow feldspar, grey quartz and black mica (Laennec). The expectoration in the second degree of peripneumony is highly viscous, and tinged of a rust colour by blood.

In hepatization, the walls of the vesicles and minute bronchi, and likewise the intervening cellular tissue, being tumefied, so as to cause obliteration of all the cavities, there is no longer a crepitant ronchus. The consolidation, moreover, gives rise to dulness or percussion, and to bronchophony and bronchial respiration, the two latter signs being dependent upon the better transmission of the sounds of the voice and of respiration in the great bronchi, by a solid substance, than by the *rare* tissue of the healthy lung. The thickening of the vesicular walls may be seen by drying and slicing the lung. In mere *engorgement*, the walls, when dried, are not seen thickened, but merely red.

Peripneumony presents three striking varieties with respect to extent: *a.* it pervades whole lobes; *b.* it affects individual, detached lobules; *c.* it is confined to vesicles.

The form *a* is exemplified in Fig. 4, where all the lobes are affected. When this is the case, they are commonly inflamed in different degrees, as in the present instance, the inflammation appearing to be checked by the partitions between the lobes. So complete is the check in some cases, that I have seen the upper lobe in the state of purulent infiltration while the remainder of the lung was sound. Sometimes no check is given by the partitions. I have seen the whole right lung in a nearly equal degree of red hepatization. In such cases the inflammation probably begins simultaneously in all the lobes. With few exceptions, however, it commences in the lower lobes and gradually ascends. So much

as a whole lung and a half may be thus rendered impervious to air, but the patient dies from suffocation before the consolidation proceeds to a greater extent.

The form *b* is exemplified in Fig. 7, where, at *a*, are seen three detached lobules in the state of *hepatization*, surrounded by purple *engorgement*: at *g*, is a congeries of coalescing lobules in a state of *hepatization*: at *f*, they are less advanced. At *c*, is a mass on the verge of suppuration. The form in question is also exemplified in Fig. 9, on the surface of the lungs, where is a series of *hepatized red lobules*, *a*, accurately bounded by their partitions, within uninflamed, but *emphysematous pulmonary tissue* *b, c*. Inflammation of isolated lobules is most common in children. The form *c* is displayed in Fig. 1, taken from a child three years and a half old, who died of *pertussis*. Indurations, varying from the size of a pin's head to that of a small pea, and of a pinkish straw-colour, were disseminated throughout the whole lungs, but were most prevalent in the inferior lobes, which were in a state of *engorgement*. In some parts the indurations were in close proximity, but not in contact. Some of the smallest, on being bisected, appeared to have a small internal cavity, from which oozed a minute quantity of pus. It is probable that these were individual vesicles, and the larger, lobules, or portions of lobules. The present variety is also illustrated in Figs. 15 and 16, which represent the *pulmonary granulations* of Bayle, supposed to be miliary tubercles by Laennec and Louis, but referred by Andral to inflammatory induration. To this subject we shall revert in treating of chronic peripneumony.

Degree 3.—*Purulent Infiltration* (*ramollissement gris* of Andral. *Hepatization grise* of others).—This is exemplified in a very characteristic form and in progressively increasing degrees in Fig. 4, from *c* to *d*, and from *e* to *f*. At *c, d*, the red has been superseded, except a few faint clouds, by the straw-coloured yellow of the pus, which is seen to make its appearance at first in isolated spots. These coalescing, form irregular tracts of yellow, by the further extension of which the whole surface is at length

pervaded, as at *e, f*, leaving only a few small and pale red and blue spots—the former occasioned by divided blood-vessels—the latter by black, or, as in this and many cases, *blue* pulmonary matter, highly diluted with the pus. To the dilution is attributable the beautiful blues at *c, d*. Had the pulmonary matter been jet-black, the colour would have been ash-grey. Had there been little or no pulmonary matter, as is the case in the generality of children and infants, the colour would have been a clear pale yellow, as in Fig. 21, *c. c*. It is thus seen how much the colours of the morbid states depend upon those of the healthy lung.

At *c, d*, Fig. 4, the substance, though more friable, is nearly as firm, and the surface as granular, as in the preceding degree *b, c*. Very little pus follows the scalpel. At *e, f*, where the disease is more advanced, the substance is very soft, lacerable, and humid, the granular character has disappeared, and pus exudes abundantly on pressure.

In Fig. 8 is represented an extreme degree of the disease. The texture is so soft and lacerable as almost to be pulpy, and it actually resolves itself into a pulp under the slightest pressure with the fingers. It is dripping with pus, which streams from its surface to the table, where it presents the opaque drab-yellow aspect represented at *b. b*. Its odour is sweetish, but much less perceptible than that of pus from an external sore. Most frequently, indeed, it is totally devoid of scent.

Fig. 2 presents all the characters of purulent infiltration hitherto described, except the colour, which is a deep opaque chocolate, mottled with black pulmonary matter. This colour is referrible to engorgement with blood, the red particles of which have never been absorbed. I have frequently found this state in the peripneumony of exhausted and cachectic subjects, and especially after typhus fever. The patient, in the present instance, died of typhus, and had also an ossified aneurism in the muscular substance of the heart, forming a communication between the aorta and the left ventricle.

I have known peripneumony attain the third degree in three

days and a half: but, in general, from a week to a fortnight elapses. I have also known three weeks elapse without the disease advancing beyond the second degree.

The expectoration in the third degree is usually more or less purulent. The bronchi, terminating in a portion of lung infiltrated with pus, are commonly, but not always red, as those in Fig. 4, near *i*. The arteries and veins are in general healthy, as Fig. 4, *k*; but sometimes pus intermixed with blood and pale fibrine, has been found in the branches of the pulmonary artery leading to parts infiltrated, and the infiltration has appeared to depend principally on pus in the capillary ramifications. (Andral, Précis, ii. 533.) Andral thinks it probable that this is occasioned by a conversion of the fibrine of the blood into pus.

CHAPTER III.

ABSCESS OF THE LUNGS.

Pus deposited from peripneumony, in the pulmonary substance and forming a real abscess, is extremely rare. Laennec met with only five or six instances of it in twenty years. The abscesses were small, not numerous, and were scattered through lungs in the third degree of inflammation. The walls were formed of pulmonary substance infiltrated with pus and in a state of putrilaginous softening, which increased progressively towards the centre of the abscess. This description applies to a small abscess in Fig. 4, opposite to *d*. In a new-born infant at the Hôpital des Enfants-Trouvés, were found numerous large abscesses scattered throughout the lung, and totally dissimilar from tuberculous excavations. The cause assigned by Laennec for the rarity of abscess from peripneumony is, that in limited inflammation the patient recovers, and in extensive, he dies, before the pus has broken up the cellular tissue and resolved itself into an abscess.

Accidental pressure with the fingers sometimes gives the appearance of an abscess, which in reality did not exist.

Abscess after great Surgical Operations.—This is much more common than abscess from peripneumony. I have seen it in seven or eight cases. It presents itself in the form of depositions of various sizes in isolated points of healthy lung. It is exemplified in Fig. 11, taken from a case of amputation by Mr. Keate, which was followed by suppuration of the small veins of the stump. The part represented is a portion of the margin of the inferior lobe. The pleura is inflamed and coated with lymph, *a*, but the parenchyma, *g*, is sound, except amongst the depositions *e*, where it is slightly indurated. The depositions are in progressive grades. The earliest, *f*, present a bluish semi-transparent appearance, resembling cartilage, and feel like small hardish granules, though they admit of being broken up by moderate pressure. In the next grade, they become of an opaque straw-colour, and several coalescing form larger masses, as *b*. In the most advanced grade, *e*, they soften in the centre, and, on being opened, discharge thick pus intermixed with fragments of lymph, leaving cysts of from half a line to a line in thickness. In these examples the deposition seems to consist at first of lymph, rather than of pus; but in other parts of the same lung were small abscesses, Fig. 10, *a*, containing thin pale pus in very delicate cysts. At one part was a *gangrenous* portion surrounded by a thick cyst of softish yellow lymph. A section is made through it perpendicular to the plane of the pleura, *d*, Fig. 10, which covers its upper part, imperfectly concealing the black colour of the subjacent gangrene. This is a sloughy substance, collapsed so as to create a depression in the pleura, of a strong gangrenous odour, and yielding on pressure a thin blackish fluid, the expulsion of which leaves the cellular tissue in the form of a lax unsubstantial web. The surrounding lung was sound. In this case there were similar depositions in the liver. They may also occur in various other organs. In the liver, they are more common than elsewhere.

In place of, or co-existent with abscess, there is sometimes purulent infiltration of detached lobules; as in Fig. 13, taken from a case of amputation of the lower jaw by Mr. Brodie. The lobes infiltrated were of a uniform dun yellow colour, and the section was granular.

It is difficult to decide positively on the manner in which these depositions take place. M. Andral thinks that, in some cases, the pus, formed in, or introduced into, the channel of the circulation, escapes from it as through a filter into the pulmonary parenchyma, where it may assume the form either of an abscess, or of purulent infiltration. In other cases, he thinks that an unknown cause alters the blood, coagulates it in the pulmonary vessels, and transforms it, in the ramifications of these vessels, into a purulent matter. In the latter case, it does not form abscess, but merely infiltration. (*Précis*, ii. 536.) In the majority of instances which I have seen, including that of Fig. 11, the matter has appeared to consist, in the first instance, not of liquid pus, but of a substance analogous to the fibrine of the blood, which concretes and subsequently suppurates. It is scarcely possible to determine whether it is filtered from the blood; or whether, in consequence of the deposition of some purulent, or otherwise morbid particles in the pulmonary tissue, an inflammatory process is set up around them, which causes a fibrinous secretion, constituting the depositions. As the cyst of the gangrene, Fig. 10, was obviously produced in this way, the characters of which cyst are exactly similar to those of the concrete yellow depositions, we are led by analogy to conjecture that the latter were produced in the same manner. It may be remarked of purulent depositions in general, that they are commonly seated near the surface of the lungs, and especially at the thin margins of the inferior lobes.

CHAPTER IV.

GANGRENE OF THE LUNGS.

IN the lungs, as in any other part, gangrene may succeed every form of hyperemia, whether of mechanical or vital origin, if sufficiently considerable to impede, or to intercept, the afflux of arterial blood to the part. In some, a stasis of the blood is followed by gangrene with surprising facility. Certain poisons introduced into the circulation produce the same effect. Accordingly, gangrene may follow intense inflammation, as that producing hepatization: it may follow chronic inflammation or irritation, as that around tubercular excavations; and it may occur without the existence of any appreciable sign of irritation, as from poisons, idiosyncrasy, &c. It presents two varieties: A. *Uncircumscribed*; B. *Circumscribed*.

A. *Uncircumscribed Gangrene*.—This is very rare. Laennec saw only two cases. Three have chanced to fall under my observation, one of which is represented in Fig. 4. It presents a perfectly characterised exemplification of this form, and is, moreover, the manifest result of *acute* peripneumony—a connexion so rare that its reality was long doubted. Andral met with one similar case, (Clin. Med. II., case 63,) and one from *chronic* peripneumony. (*Ibid.* case 64.)

Fig. 4, from *d* to *e*, represents a mass of diffuse gangrene, surrounded by the third degree of peripneumony and occupying half of the middle, and nearly the whole of the inferior lobe. It descends through to the posterior pleura. On the side, *d, e*, it blends insensibly with the purulent hepatization: on the opposite side, *h*, it forms an imperfect shelvy cyst surrounding an excavation. The pulmonary tissue is extremely softened, so that, at any part, the finger pierces with facility through to the pleura. In the vicinity of the hepatization, at *d* and *e*, the gangrene maintains its form when cut, being still held together by the parenchymatous

cellular tissue; but in the centre, and still more in the cyst, it is resolved into a putrilaginous pulp, consisting partly of a thin brownish-black fluid, which accumulates in all the depressions, and partly of shreds and fragments of cellular tissue, from which the fluid has strained, and which may, in some parts, be drawn out into long irregular bands. The colour varies from yellow-brown to brown-black, deep muddy green, and dim dirty red, promiscuously intermingled. The gangrenous odour is insupportable. The cyst contained a coagulum of blood as large as an egg.

B. Circumscribed Gangrene.—In this variety a portion of lung, of variable size, is converted into a gangrenous eschar, (vide Fig. 10,) which, here as everywhere else, tends to bound itself and be eliminated. (*Précis*, ii., 510.) For this purpose, an inflammatory process is set up around the eschar, a cyst is formed, the suppuration of which detaches the slough, and this, reduced to a putrid pulp, finds its way into the neighbouring bronchi and is ejected with the expectoration. A cavity remains, which sometimes heals by the union of the lymph or false membrane constituting its walls; but which more commonly remains open and continues to secrete a gangrenous pus or sanies.

Fig. 14 represents a well-characterised cavity of this description. Its walls are dense, firm and dry like gristle, and a line or two in thickness. Their colour is grey, and, to the extent of from half an inch to an inch around the cavity, the lung is in the state of chronic induration, granular, semi-transparent, and of an iron-grey colour, much mottled with black pulmonary matter. This is the most common change which takes place around gangrenous abscesses; and, in the present instance, it pervaded two-thirds of the lung, the whole of this extent being occupied by numerous abscesses of various dimensions, from the size of a bean to that of an egg. The larger contained minor excavations, and were traversed in various directions by blood-vessels, mostly obliterated, but some open, and the source of hæmoptysis during life. In some of the cavities there was no cyst, and the bare pulmonary

substance formed an ill-defined boundary to the disease. In a few rare instances the lung around the cavities remains healthy. Gangrenous abscesses are sometimes much larger than those described. I have seen a case in which one vast cavern occupied nearly the whole of the left lung; and another in which more than a third of the left was excavated. Such are all the aspects and conditions ordinarily presented by gangrenous abscesses of the lung.

When gangrene communicates with the bronchi, it is detected with certainty and facility by the dirty black, green, or brown colour of the sputa, and by the insupportable fetor of the breath.

CHAPTER V.

CHRONIC PERIPNEUMONY.

ACUTE peripneumony, arrested by treatment or any other cause, may become chronic, and at the expiration of two months or more, may present the same three degrees, with all their characters, as in the acute affection: viz. *engorgement*, *hepatization*, and, more rarely, *purulent infiltration*. But chronic peripneumony, whether originating in acute, or in chronic irritation, may present another state unknown in the acute affection: viz. *indurated hepatization*. Fig. 3 (a view of a portion four times as large) represents this state. The side *a*, is extremely firm, dense and dry: the side *b* is equally tough, but more lax, being in a less advanced degree of induration. The ground colour of *a* is a pale yellow, which is tinged with red, and beautifully dappled with black pulmonary matter. I have never seen so brilliant a combination of colours in *acute* peripneumony. The texture is very granular. The ground colour of the side *b* is a deep purplish red, which is spotted with black pulmonary matter. A granular texture is scarcely discernible. No fluid exudes on making a section. This state, and that of Fig. 5, closely resemble red muscular fibre.

Fig. 3, *c*, is a septum between the lobes, thickened, indurated, and of a semi-cartilaginous appearance and texture.

Fig. 6 exhibits the same induration as Fig. 3, *a*, but the colour is a uniform pinkish grey, like the cortical substance of the kidney, and the density is the greatest that I have met with, being equal to that of the uterus. An indistinct granular appearance is produced by a pinker substance surrounded with a paler. No lobular partitions are visible. This form is very chronic. In Fig. 12 a pinkish grey indurated hepatization surrounds and circumscribes pulmonary apoplexy.

Fig. 5 represents *red* chronic induration, following acute peripneumony, which had been checked. It presents the same characters as Fig. 3, side *b*, except that it is rather more flabby, and yields a little sanguineous serosity on scraping. The principal object of this delineation is to display the hypertrophic development of the interlobular septa, which have become indurated like fibro-cartilaginous tissue, and present a bluish semi-transparent appearance. The thickening and induration are sometimes much greater than is here represented, forming considerable layers and masses instead of mere lines, which, encroaching on the lobules, causes either their atrophy or their condensation.

Induration may be not only of yellow, and red colour, but also of iron-grey, of brownish, and of black. The colour is, in fact, an accidental character, dependent on the presence, in variable proportions, of blood, and of black, or dark blue pulmonary matter.

The iron-grey induration mixed with black is seen in Fig. 14, already described. (Vid. *Circumscribed Gangrene*.) The grey part has a semi-cartilaginous appearance. The deposition of black matter is principally *consecutive* to the induration. Dark semi-cartilaginous induration exists most frequently in the vicinity of old tubercular or gangrenous excavations. Sometimes it appears to be the cause, rather than the effect of tubercles; as a few small scattered tubercles are occasionally found disseminated through a great extent of induration, which, consequently, cannot be regarded as originating in tubercular irritation. (Précis, ii. 521.)

Dark induration, though unfrequent, is more common than the yellow and red, which are extremely rare. All the varieties are attended with impermeability of the lung to air, and, consequently, with dulness on percussion.

In describing acute hepatization, it was stated that it might affect individual pulmonary vesicles. This affection may become chronic, and it then constitutes, according to M. Andral, the *pulmonary granulations* of M. Bayle, regarded by this author as an adventitious production *sui generis*, and by Laennec and Louis as the first stage of tubercle. The granulations are represented in Fig. 15, taken from a specimen which M. Andral did me the favour to approve as exemplifying his opinion. In the upper part, *d*, they are red and soft, *i. e.* incipient, being vesicles in the state of inflammation; in the lower part, *b*, they are harder, of bluish-grey colour, and of semi-cartilaginous transparency. The intervening lung is congested. In Fig. 16, the granulations are still harder, greyer, and more chronic; the surrounding inflammation has subsided and left the lung in a state of livid red congestion. The whole of both lungs was similarly affected in various degrees.

From examination of both the fresh and the dried lung, M. Andral is led to believe that pulmonary granulations are formed by the following series of alterations:—1. The walls of the vesicles become injected. 2. They tumefy, remaining red. 3. They lose the red tint and acquire the grey, at the same time thickening progressively more. 4. During the process of thickening, the cavity of the vesicle undergoes several changes; sometimes it dilates; sometimes it contracts; sometimes it is entirely obliterated, the granulation thus becoming complete. But this is not all. At each of the above periods of formation, the walls, instead of continuing merely to thicken, may either ulcerate, or secrete pus, or tubercle. (*Précis*, ii. 519.) In cases of pertussis I have several times found them to have secreted pus, which oozed from a central cavity, on making pressure or a transverse

section. Lobular and vesicular peripneumony are, according to my observation, frequent in pertussis, and are more common in children than in adults.

PLEURISY.

Serous membranes, whatever be their situation, present the same general anatomical and physiological characters: they therefore sustain similar structural and functional changes under the influence of disease. Any differences which they seem to manifest are more apparent than real, being connected with some circumstance peculiar to the individual membranes, which prevents the development of certain characters, though the natural *tendency* of the tissue is favourable to their production. Thus, redness is rarely manifested, (at least after death,) by the arachnoid membrane in a state of inflammation, because it is too delicate to admit the red globules of the blood in sufficient quantity. Yet there is no doubt of its being susceptible of inflammation, since it loses its transparency and secretes lymph and serum.

The morbid changes of the pleura may, therefore, be looked upon as exemplifying the changes incident to serous membrane in general. I shall, accordingly, treat the present subject in this point of view; and, in describing other serous membranes, I shall advert to such characters, and offer such drawings only, as will be calculated to display their individual peculiarities.

When inflammation of the pleura is only incipient, the increased redness is not seated in the membrane itself, but in the sub-serous cellular tissue. As the inflammation advances, the injection extends to the pleura itself, which then exhibits a greater or less number of vessels gorged with blood, and loses its transparence in proportion to the degree of injection. The vessels, if few, are straggling; if numerous, they anastomose, in an infinity of directions, so as to produce specks, patches, streaks, broad tracts of irregular form, and, more rarely, an equable diffuse

redness of various depths. In Fig. 11, *d*, under a false membrane, the colour is an intense purple. These appearances are too familiar to require further illustration by drawings.

The inflamed pleura is very rarely thickened: that which has been regarded as thickening, by authors who have supposed this lesion common, being nothing more than adventitious membrane investing its unattached surface or interstitial deposition in the sub-serous cellular tissue.

Thus, in Fig. 4, above *g*, the yellow portion is an *old* false membrane investing the pleura, with which it blends by two grades, the upper one thicker, opaque, and edged with a few loose ligamentous strings: the lower semi-transparent, and transmitting the deep brown-red of the subjacent pleura. Both layers may be dissected off. Between the pleura and the lung is a thick layer of soft, bluish, translucent, albuminous matter, *e*, of recent formation, deposited in the meshes of the sub-serous cellular tissue. The pleura between these two strata is of natural thickness, as seen at *f*. When the sub-serous tissue is softened by inflammation, the pleura may be peeled off with much more than ordinary facility.

The alterations of the pleura in tissue are far less important than those of secretion, and it frequently happens that while the latter are great, the former are not appreciable.

The natural secretion of the pleura is modified in quality and quantity. We shall first consider the modifications in quality leading to the formation of false membrane.

The fluid secreted by the inflamed pleura consists of two parts: the one becoming concrete, and composed of fibrine; the other remaining liquid, and composed of albuminous serum. The latter partly lodges in the meshes of the former, and partly strains away. (*Précis*, i. 479.) The concrete portion is known under the name of *false membrane*, the liquid under that of *serosity*.

No sooner is the inflammation established than the morbid secretion commences. The concrete part first shows itself under the form of a soft, plastic, unorganized matter, of semi-opaque yel-

lowish-white colour, which sometimes overspreads the membrane in a reticulated web, or thicker layer; sometimes forms detached granulations, as if deposited in single drops; and sometimes, falling entirely from the pleura, is suspended, in flakes, in the more or less limpid serosity secreted in conjunction with it.

As the inflammation advances, the thickness of the deposition on the pleura increases, and, though still unorganized, it tends to agglutinate the opposite surfaces. By the movements of these, it is often drawn out into bands, cords, and filaments of various lengths.

Where it forms a layer on the membrane, its surface is rough; the roughness consisting, while the layer is thin, either of small, irregular, mamillary protuberances, or of a delicate net-work.

As the layer becomes thicker, the protuberances partially coalesce, and the reticular intersections rise higher; the result being, in both cases, the formation of a more or less regular alveolar or honeycomb surface—a remarkable peculiarity of false membranes, as it takes place even before there are any traces of organization. (Précis, i. 480.)

Fig. 11 represents, at *a*, a false membrane with an *imperfectly* alveolar surface: its hue is a deep straw-colour. Instead of becoming alveolar, false membrane sometimes acquires a shaggy, flocculent character, which will be shown in drawings of pericarditis.

Fig. 8 exhibits, at *c*, a beautifully regular alveolar surface. The colour is a very delicate primrose, and the thickness is upwards of a line.

The areolæ may vary from the size of a pin's head to that of a pea, according to the thickness of the false membrane. When false membrane is deposited in isolated drops, it forms small granulations, often grey and semi-transparent, disseminated in greater or less abundance over the pleura. They sometimes pervade simultaneously the pleura, the pericardium, and the peritoneum.

On making an incision into a false membrane, and examining

it with a lens, it is seen to consist, even prior to organization, of filaments crossing each other in every direction, the interstices of which form cells. It is, in fact, ordinary cellular tissue in embryo. In the cells is lodged a portion of the serosity, the remainder having strained away.

The next change, which the false membrane undergoes, consists in the remarkable phenomenon of its becoming vascular or organized. Preparatory to this, the membrane becomes dryer, denser, more tenacious, and more intimately adherent to the pleura. It has been a subject of great speculation and research whether the blood is formed *intrinsically*,—within the false membrane itself, as in the embryo chick; or whether it is derived *extrinsically*, from the vessels of the pleura penetrating and discharging their contents into the organizable lymph. The arguments on both sides are strong,—indeed irrefragable,—and for a simple reason, that, according to the recent researches of Dr. Dollinger in Germany, both parties are right. This physician, confirming the results already obtained by others, has fully demonstrated that, in animal matter in the progress of formation, currents of liquids may establish themselves without the presence of canals to give them passage: they wind their way through the solids. The agency which gives birth to these currents is unknown; but Andral thinks, and with much apparent reason, that it is connected with electricity. (*Précis*, i. 379, note.) Supposing these currents to have taken place in any organizable matter, as a false membrane, they will tend to open their way into any pre-existing currents in their vicinity. Accordingly, in a false membrane, we may and ought to find, 1. blood disposed in points or lines, without being contained in vessels, and either derived from the pleura, or generated in the false membrane, or both. 2. Vessels not communicating with those of the surrounding tissues; 3. other vessels, communicating with those of the surrounding tissues. Further, it may happen that one or other of these three arrangements may predominate over the others, but all may be present. So little, indeed, do they exclude each other, that the existence of

one of them cannot be conceived but by that of all the others. (Précis, i. 484.)

It has been ascertained by experiments on living animals, and by pathological observations on the human species, that the process of organization sometimes takes place with astonishing rapidity, as within the space of twenty-four hours : while in other cases there is not a vestige of it at the expiration of several months. Chronic pleurisy, in particular, affords frequent exemplifications of the latter, lymph often remaining soft, friable, and amorphous to the last, without the slightest apparent attempt at organization. No general rule can be assigned for this : it appears to be connected with individual peculiarities.

In proportion as the circulation becomes established in false membranes, the redness, which accompanies the incipient stage of organization, gradually disappears, and with its disappearance the organization may be considered complete. The membrane now gradually assumes, in every respect, the aspect of a serous membrane or of cellular tissue ; and in this state it forms the adhesions of the pleura found in those who have formerly laboured under pleurisy. In some they are close, especially in cases of phthisis ; as if this were a provision to fortify the lung, and prevent the bursting of vomicæ into the cavity of the pleura. In others they are long, so as to allow free movement of the pleura costalis and pulmonalis on each other during respiration. When very old, they are extremely thin, and exactly resemble ordinary cellular tissue or the pleura itself, from which they may be dissected in the form of fine transparent layers. Sometimes, more especially after chronic pleurisy, a series of layers of this description are *found superimposed on each other*. Adhesions of the pleura may exist without occasioning the slightest functional derangement.

False membranes, during the progress and after the completion of their organization, may undergo a variety of morbid alterations. They may inflame, and re-produce false membrane : they may exhale blood ; and they may secrete tubercle, pus, or

melanosis. To the formation of tubercle they are more especially prone; and so brief a space as a fortnight from the commencement of the pleurisy, has been found sufficient to give birth to an abundant crop. (Andral, Clin. Med. ii. 543.) Further, false membranes may, by modified nutrition, be transformed into fibrous, (Fig. 4, *g*: the yellow part,) cartilaginous or osseous tissue,—changes from which *the pleura itself is almost entirely exempt.*

A variety of cases have afforded strong presumptive evidence that false membrane may, after a certain time, be completely absorbed; but this is rare.

The fluid exhaled by the inflamed pleura in conjunction with false membranous exudation may range in quantity from an ounce or two to several pints. It presents innumerable grades of difference, which may be distributed under the following general heads: 1. a colourless or lemon-coloured serosity, perfectly limpid and transparent. 2. The same limpid serosity, holding suspended a few coarse flakes of lymph, most of which subside when the fluid is at rest. When the flakes are abundant, they become partially dissolved, and render the fluid slightly turbid, like whey. This is a common variety. 3. A sero-purulent fluid, muddy, sometimes thick, and of yellow, greenish, grey, or brown colour. 4. Genuine pus. 5. A fluid like half-liquefied jelly, or melicere, generally contained in cysts of false membrane. 6. A bloody fluid, the sanguineous intermixture being sometimes slight, and, at others, so considerable as to form coagula. It is usually exhaled by organized false membrane.

CHAPTER VII.

PHTHISIS PULMONALIS, OR TUBERCULAR CONSUMPTION.

Tubercle.—The physical characters of tubercle are the following : it is a body of a yellowish white colour, of variable size and form, but most commonly roundish. It is hard, but friable, in its first stage. It afterwards softens and changes into a matter composed of tender curd-like fragments suspended in a sero-purulent liquid. Once broken up, tubercle tends to be eliminated, and when this has taken place, there remains, instead of the tubercle, an ulcerated cavity, which sometimes enlarges in all directions, sometimes remains unchanged for an indefinite period, and sometimes heals, either by cicatrization or by the conversion of its interior into a healthy surface.

Andral dates the existence of tubercle from the time when it presents itself in the *solid form* (Précis, i. 413); for though it is very probable that, at the moment of its deposition, it is in a liquid state, the fact has not yet been sufficiently demonstrated; and it is certain that, however small the tubercle, it is most frequently in the solid state that it is found.

Certain theories date the existence of tubercle from an earlier period. Thus Dr. Baron and M. Dupuy suppose that it commences as a transparent vesicle or hydatid. Observation has demonstrated the inaccuracy of this opinion, and shown that the vesicles in question are only accidentally coincident with tubercles, and are rarely seen in the human species. (Précis, i. 408.)

According to another theory, that of Laennec, tubercle commences as a grey and semi-transparent granulation, Fig. 19, *a*; in the centre of which an opaque yellowish white point is sooner or later developed, *b*; and this, gradually extending, *c*, eventually pervades the whole, *d*. Before the yellow transformation has taken place, the tubercle is called *miliary* by Laennec (De

l'Auscult, i. 535, 2d edit.); when turned yellow, it is his *yellow crude tubercle* (*tubercule jaune crue*, or simply *tubercule cru*.)

Laennec's view of the incipient state of tubercles embraces the *pulmonary granulations* of Bayle, which he, and also Louis, consider to be merely tubercles in the grey semi-transparent condition. Laennec accordingly denominates them *miliary tuberculous granulations*. They are represented in Figs. 15 and 16, and have been already described, under the head of CHRONIC PERIPNEUMONY, as being, according to Andral, nothing more than partial peripneumony, or an inflammatory thickening and consolidation of individual air-vesicles, passing through the several grades of redness and softness, Fig. 15 *a*, to greyness, *b*, and eventually to chronic induration, Fig. 16.

Although these small bodies may, like other forms of peripneumony, like false membranous granulations on serous surfaces, like hypertrophous mucous follicles, &c. suppurate, and thus give birth to tuberculous matter, presenting the appearance, as described by Laennec, of a central opaque yellowish spot; yet Andral denies that grey semi-transparent granulations are constantly and necessarily the origin of every tubercle. Were it so, the granulations should be found in all other situations where tubercle presents itself,—which is not the case. (Précis, i. 411.)

Cruveillier believes that he has detected tubercles in the liquid or purulent state, having, after the injection of mercury into the veins and its deposition in the lungs, found liquid purulent productions in the vicinity of others that were white and hard. This experiment, however, is not conclusive, as it is impossible to say how much of the effect is accidental.

Leaving this controverted subject, we proceed to the consideration of tubercle when it constitutes a solid yellowish white body, opaque, friable, and without a vestige of organization or texture.

When in this state, a tubercle, not larger than a pin's head, may increase in magnitude to the size of an orange. How is this increase effected? According to Laennec, by intus-susception. But this process can only take place in a living organized body,

which tubercle is not. It can only, therefore, augment in the same manner as inorganic bodies, namely, by juxta-position, of which Fig. 17 presents an exemplification. Opaque yellow tubercular substance, tinged of a bluish grey by blue pulmonary matter, is seen occupying whole lobules, *a*, the septa of which are red lines, becoming fainter in proportion as the approximation of the masses is greater, and eventually disappearing. At *b* the process of juxtaposition is seen in progress, the red lines consisting of inflamed pulmonary tissue interposed between the tubercular molecules. The same is seen in Fig. 21, from a scrofulous child in the Hôpital des Enfants. At *c, c* the cellular tissue between the molecules is only faintly visible, while, at the upper part, *e*, of the yellow masses, it is very distinct, and of semi-transparent bluish colour, gradually becoming thinner and paler in proportion as the tubercular deposition increases. At *b* are seen isolated yellow tubercles in chronic hepatization. At *f* are others in progress, but still deeply tinged with blood. At *d, d* the pulmonary tissue is healthy.

Fig. 22 represents the same formation of tubercle by juxtaposition, but the shapes are more angular. The tubercular substance is very dense and has not begun to soften. The interposed tissue is consolidated and of intense red colour.

Fig. 23 exhibits increase by juxtaposition on a much larger scale. The deposition commences in spots, *c*, and extends till it reaches the boundaries of the lobules, *b*, of which it assumes the angular forms; these, coalescing, and by pressure causing the disappearance of the septa, as at *a*, eventually form a compact, soap-like homogeneous mass. The whole lung was in this state, and the upper lobe contained numerous large and anfractuous caverns. The dark-red part is the pulmonary tissue gorged with blood and partly hepatized. This form of the deposition constitutes the *yellow tubercular infiltration* of Laennec. (Traité, i. 543.) It exists in those especially in whom the constitutional tubercular diathesis is strongly prevalent.

Round tubercles are formed by the same process of juxta-

position as larger masses, and they assume the round form because, beginning at a point, the apposition proceeds equally on every side. The original form, indeed, in perhaps every case, is round, the subsequent form being determined by the lobular septa or other external modifying circumstances.

The mode of tubercular deposition, therefore, may, in conformity with the above illustrations, be explained in the following way. In the spot where the tubercular secretion has commenced, each *living* molecule, instead of its natural exhalation, separates from the blood a molecule of tubercular matter, which, super-added to the molecules already secreted, contributes to increase their mass. Thus, then, every tubercle is infiltrated into the tissues where it exists. Sometimes vestiges of these tissues may still be recognised in the substance of the tubercular mass, as already shown in Fig. 17, *b*, Fig. 21, *e*, and Fig. 23; and to them are referrible the vessels which occasionally exist in the interior of tubercles. Sometimes the tissues totally disappear by compression. (*Précis*, i. 414.)

Tubercle may remain in the solid state hitherto described, for a time, varying from a few weeks to a number of years. According to my observation, tubercle, infiltrated in large conglomerate masses, soon softens, since it is in general connected with a highly tuberculous or scrofulous diathesis; whereas, isolated round tubercles, especially if not numerous, are those which remain the longest indolent.

The final transformations which solid tubercle undergoes are of two kinds: 1. cretaceous induration; 2. softening by supuration.

1. *Cretaceous Induration*.—This change consists in an absorption of the animal matter, and an augmented secretion of the calcareous, the latter and muriate of soda amounting to 96 per cent. instead of being 1,85 per cent. with 98,15 of animal matter, the proportions of ordinary solid tubercle. (*Thénard*.)

The induration exists in various degrees. The slightest is represented in Fig. 27, showing the section of a solitary tubercle

in healthy lung. In its physical characters, it only differs from ordinary tubercle in being dryer and presenting several irregular concentric circles of faun colour, where the calcareous deposition and induration are less considerable.

In Fig. 24 there is a higher degree of induration. The two largest tubercles have contracted, and partially left the walls of the cysts in which they are enclosed. They also present concentric circles of darker animal matter, irregular in form from the unequal contraction of the tubercles. They are so dense as to offer considerable resistance to the knife. The two round cavities are cysts, from which similar tubercles have been turned out. The cysts are composed of a fine, dense, fibro-cartilaginous membrane. It is not unusual for such cysts to be formed after the elimination of ordinary tubercle by softening, but very rare for them to exist at an anterior period. Bayle has described the latter state under the name of *encysted tubercle*. (*Récherches sur la Phthisie*, p. 21. See also Laennec, *Traité*, i. 550.) The pulmonary tissue around the tubercles, many of which are smaller than pins' heads, is crepitous, though black and somewhat condensed.

Fig. 29 represents calcareous induration in four successive degrees. The two tubercles *a* surrounded by red are little firmer than ordinary. They present, in their centres, the vestiges of cellular tissue tinged of blue-black colour. The contiguous one on the right is denser, especially at the opaque yellow spots in its interior. Beneath is an elongated bony tubercle, surmounted by a smaller. They have, by contraction, partially left their cysts, and, though not crisp, they are too hard to admit of being divided by a penknife. In the large cavity are seven loose bones, perfectly hard and crisp, by the contraction of which the cavity has been left. Its cyst is a fine smooth membrane. Scattered throughout the pulmonary tissue are a number of recent, yellowish grey tubercles, each enclosing three or four deep black spots, possibly formed by the dark pulmonary matter originally diffused over the whole extent of lung occupied by the tubercle, but

accumulated in spots by the interstitial deposition of the tubercular molecules. Andral has met with similar black spots in cretaceous tubercles, and he regards them as a melanotic secretion.

I have, in a few instances, seen cretaceous tubercles in a softened state. In general they have been of large size, viz. from that of a marble, as Fig. 27, to that of a walnut, and have existed in very limited number, and often in otherwise healthy lung. They consisted of softish flakes and grains of friable calcareous matter, intermixed with a very little purulent liquid. Andral describes similar cases, and he thinks that when the liquid part is absorbed, the condensation of the solid part is attended with contraction and puckering of the surrounding lung, as contraction has often been found in the vicinity of cretaceous tubercles. (*Précis*, i. 417.)

Black pulmonary matter is often very abundant in the vicinity of cretaceous tubercles, Fig. 24 and 29. I have also repeatedly found it impart its colour to a very dense and almost cartilaginous variety of round isolated tubercle, Fig. 20, which has little tendency to soften. It is, likewise, abundant in the vicinity of old tuberculous caverns, surrounded by induration. Hence, the chronic nature of the disease seems to be favourable to its production.

The second transformation of solid tubercle is—

2. *Softening by Suppuration.*—A rational theory of the process of softening was wanting, till the deficiency was supplied by my friend, Dr. Lombard, of Geneva, in an excellent Essay on Tubercles.* The cause of the softening, according to him, resides no more than that of its increment, in the tubercle itself. Each tubercular molecule, acting like a foreign body on the tissues with which it is in contact, occasions in every point of those tissues a secretion of pus, which *mechanically* effects the division of the

* The drawings of tubercular growth by juxtaposition were taken from cases which we examined together, as I had the pleasure of prosecuting many of my own researches on this subject with him in Paris.

tubercle into more or less numerous parts or fragments. Softening, then, is nothing more than the separation or disintegration of the tubercular molecules by pus, and the final result of the process is, as in the case of a foreign body, the expulsion of the tubercle. (Précis, i. 415.) Though the softening of tubercle most frequently commences in the centre, this is not universally the case, as has been imagined: if the tubercle be very small, it commences at the circumference.

By softening, a cavity is formed, called a *vomica* or *cavern*.

Caverns, formed by individual tubercles, are small, as that Fig. 7, near *c*, or several in Fig. 28, but they may enlarge by ulceration. Those formed by a congeries of tubercles, especially if completely infiltrating a series of lobules, as in Figs. 17 and 23, may be of great size, equal even to a whole lobe, as was the case in the superior lobe of Fig. 23. When large, caverns are generally *anfractuosa*, i. e. they consist of a number of minor cavities communicating by more or less spacious and tortuous passages, as Fig. 28, near *f* and *e*. Here, however, they are small. Sometimes caverns, even of a large size, are remarkably round, as Fig. 18. This is more the case when the round tubercle prevails. *Vomicæ* near the pleura may ulcerate through it. Nature, however, provides to the utmost against this accident, first, by exciting chronic inflammation and fibro-cartilaginous thickening of the sub-serous cellular tissue, as in Fig. 18, *c, c*; or an albuminous deposition, as in Fig. 28, *d, d*, which is lax, like white of egg two-thirds boiled, but eventually hardens into fibro-cartilaginous tissue. Secondly, by causing the formation of a dense fibrous false membrane on the serous surface of the pleura, as in Fig. 18, *b, b*, of yellow colour, and a line in thickness; also in Fig. 28, *g*, which is still thicker, and Fig. 26, *b*. Thirdly, by causing adhesions of the pulmonary to the costal pleura, an effect more common from tubercular irritation than from any other cause, few who die of phthisis being wholly exempt from such adhesions. They result from partial pleurisy. Should the cavern burst into the

cavity of the pleura, it discharges into it not only purulent matter, but also air, thus forming *pneumo-thorax*, which is generally fatal in a brief period.

Large caverns are often traversed by bands, Fig. 26. They consist either of indurated pulmonary tissue, or of blood-vessels obliterated and converted into fibrous cords. Sometimes there exists in them a contracted central canal, containing coagulated blood, and in a few instances the canal is larger, open, and on being divided, discharges fluid blood. From rupture of a canal of this kind I have seen twenty pints of blood ejected in about three months, by five attacks of hæmoptysis, the last of which was fatal.

The walls of caverns are in general either composed, as in Fig. 18, from *a* to *d*, of dense pulmonary tissue charged with tubercles; or they are in the state of grey or black induration, generally interspersed with tubercles, as *ibid.* from *a* towards *b*, or Fig. 26, between *a* and *d*, or Fig. 28, throughout the whole lower lobe, in which the semi-cartilaginous induration presents a beautiful grey colour, contrasting with red, where the induration is less. More rarely, the walls are composed of healthy lung. This is principally the case where the phthisis is not *constitutional*, but *acquired*, and the tubercles not numerous.

The internal surface of caverns is generally invested, partially or universally, with a species of membrane, represented in the cavity of Fig. 18. It is of an opaque whitish colour, but, being very thin, it transmits the colours beneath, and is darker or lighter according to their tint. Thus on the ramifying vessels it is seen to be pale, while in the intervening parts it is dark. It is commonly thicker, and therefore whiter, on the prominencies, as if these were favourable to its concretion. It is soft, has the friability of new cheese, or cheese-curd, and readily admits of being scraped off. Laennec supposes it to be a false membranous (*i. e.* fibrinous) exudation, continually regenerated underneath, while the surface peels off and is expectorated. (*Traité*, i. 547.) Andral considers it, and with better reason, to be nothing

more than the most concrete part of the purulent matter. It is only when there is a tendency to cicatrization, that real false membrane is secreted, and subsequently converted into fibro-cartilage, as explained below.

The bronchi of the portion of lung occupied by a cavern, generally open directly into it, having been cut abruptly off at the surface of the walls by absorption. The blood-vessels, on the contrary, being less susceptible of absorption, almost always remain unopened; and, as if pushed aside by the tubercular matter, they ramify, generally in a *flattened* form, but still with a visible prominence, on the surface of the walls, as in Fig. 18, under *a*, and in the cavity of Fig. 31, those only being obliterated which tend directly towards the cavity or the tubercular masses.

The contents of caverns, when small and of recent formation, generally consist of whitish, yellowish, greenish, or greyish pus, intermixed with more or less of a pulpy matter. When the caverns are older and larger the pus is more dirty, is diluted with a variable proportion of serous fluid, and contains fragments like the debris of tubercle, or flakes of concrete pus detached from the lining membrane. Sometimes loose portions of pulmonary tissue, liquid blood or coagula, or calcareous concretions are found intermixed with the other contents.

A tubercular excavation may heal, and the patient recover from consumption. This fact was ascertained by Laennec (vid. *Traité de l'Auscult.* i. 580.)

The healing takes place in three ways:—I. By the surface of the cavity becoming a healthy membrane, the cavity itself remaining open. This is beautifully illustrated by the remarkable case of which Fig. 31 is a diminished representation. The cavity exceeded the size of the largest orange, being, I believe, the most spacious of the kind on record. It occupied nearly the whole of the upper lobe of the right lung, and was taken from a female, who five years previously had presented all the symptoms of consumption. (Vid. Case.) The healing process takes place as follows:—The surface of the cavity secretes a fibrinous matter,

which by organization becomes a fibro-cellular membrane. This arrests the further progress of ulceration, and, instead of pus, exhales a clear sero-mucous fluid. The fibrous portion of the membrane next thickens and tends to become cartilaginous, while the cellular portion assumes the character of a mucous membrane, and becomes continuous with that of the bronchi. In Fig. 31 the thickened fibrous membrane is very conspicuous at the weakest side of the cavern, *b*, where there is interposed between it and the thickened pleura, *a* and *c*, only a very thin layer of condensed slate-coloured pulmonary tissue, *f, f*, dissected from *a* and *c*, and turned inwards. The fibrous layer gradually becomes thinner as it advances on the pulmonary substance at the base of the cavern, where it is barely distinguishable by its yellow cast. The whole cavity is lined by an extremely fine transparent mucous membrane, through which the ramifying blood-vessels are beautifully apparent. It passes, with a smooth edge, into numerous bronchial tubes communicating with the cavity. Through the largest of these a quill has been passed, re-appearing in the great bronchus, *e*, of the upper lobe : *d* is the apex of the lobe.

II. The second mode in which healing takes place is by the agglutination of the walls when in the healthy condition above described, the result being a thin, white, fibro-cellular line, in which large bronchial tubes are found to terminate abruptly.

III. The third mode is by the fibro-cartilaginous walls gradually increasing in thickness till they fill up the cavity, thus leaving a bluish or greyish white mass, as in Fig. 26, *d*, in which large bronchi sometimes terminate abruptly, as in the preceding case. Cicatrices of the two last kinds are not uncommon. (Vid. Laennec, *Traité*, i. 606.) When they occur near the surface of the lungs, they occasion, by their contraction, a puckering and depression of the pleura. (Ibid. i. 608.) Thus in Fig. 18, *b, b*, there is a puckering like the divisions of a decorticated orange, which, had the excavation cicatrized, would have increased and been accompanied with depression. (For the symptoms of healing, see *ibid.* 548, and Andral, *Précis*, tom. ii. 544.)

The cavities left by the contraction of cretaceous tubercles, as in Fig. 24 and 29, very frequently become healthy, and sometimes undergo obliteration by closing on the concretions.

It is very questionable whether tubercles can be absorbed previous to softening. Andral, judging from certain morbid appearances, is inclined to admit the bare possibility of the occurrence, (Précis, ii. 545); but the majority, including Laennec, are of the opposite opinion. (Laennec, *ibid.* i. 580.)

The most common situation for tubercles is the upper lobes. They seldom exist elsewhere without being found there also.

The pulmonary substance around tubercles may be healthy, indurated, or emphysematous. It is not unfrequently healthy while the tubercles are solid; but when they soften and form cavities, it usually degenerates. The change consists in a thickening and condensation of the vesicular walls, rendering the structure impervious to air. It presents a compact, greyish, semi-cartilaginous appearance, as in Fig. 26, and the lower lobe of Fig. 28. In other parts the lung is infiltrated with a gelatiniform matter, rendering it impervious, though causing a less degree of induration. The higher degree of induration Laennec has described under the designation of *grey tubercular infiltration*; while the jelly-like appearance, he has denominated *gelatiniform tubercular infiltration*, regarding the latter as a less advanced degree of the former, and considering both as a "semi-transparent and grey variety of *tubercular* matter." (Traité, i. 541-2.) By Andral these states are regarded as products of chronic inflammation, or irritation; since they may occur, independent of tubercle, from evident hyperemia. Emphysema around tubercles is not uncommon. The air-vesicles are enlarged by hypertrophy (*vid. infra*, Emphysema), for the purpose of enabling them to perform supplementary respiration. Sometimes their enlargement results from the coalition of several, in consequence of atrophy of their walls.

It has been a much agitated question whether inflammation can give birth to the tubercular secretion. Observation supplies

the following data on this subject:—1. In some cases no appreciable lesion of the pulmonary tissue is found in the vicinity of tubercles, nor have any symptoms revealed the existence of antecedent or concomitant inflammation or irritation. 2. In others, the lesions can only be regarded as consecutive to the tubercular deposition. 3. In others again (and these are not the least numerous class), the lesions have manifestly preceded the tubercles, and ought to be regarded as accessory to their production. These lesions are more particularly the following:—

A. Bronchitis, especially if extending to the finer tubes. B. Peripneumonic engorgement (Fig. 23.), and hepatization (Figs. 22 and 21, *b*), whether affecting whole lobes, a few lobules, or merely individual air-vesicles. C. Pulmonary apoplexy, the blood coagulating, becoming organized, and secreting tubercle. (Précis, ii. 550.) D. Irritative action excited by the injection of mercury into the bronchi, and which occasionally produces bodies like tubercles.

But, as Andral sensibly remarks, inflammation or irritation alone, without the concurrence of other causes, no more accounts for the formation of tubercles, than for the peculiarity of innumerable other alterations of nutrition and secretion, of which inflammation is so frequently the precursor: alterations which take place, not by it, but on the occasion of its occurrence. It is, in short, not a necessary, but an energetic auxiliary cause. Hence, “tubercle is to be considered as the result of a modification or perversion of secretion, which is often preceded or accompanied by active sanguineous congestion. This is the utmost that is known; all beyond is mere hypothesis.” (Précis, i. 438.)

The cause of the perverted secretion resides in a predisposition, either *innate*, when it is frequently accompanied with the well-known tubercular or scrofulous physical constitution,—or *acquired*, when it generally results from impoverishment of the blood and reduction of the vital powers. The innate predisposition is characterised by the formation of tubercles in many organs at once, and by the frequent absence of every appreciable phenomenon of

antecedent sanguineous irritation or congestion; the converse of which is the case in the acquired predisposition.

Though the tubercular secretion may take place in every tissue, the cellular is that in which it is by far the most common; whether the tissue be simple, as the sub-serous, sub-mucous, inter-muscular, or combined in compound organs, as in the lungs, liver, spleen, lymphatic glands, &c.

The organs most frequently affected in the adult, are, first the lungs, next the ileum, next the mesenteric glands, next the great intestine, &c. It is very rare, in adults, for tubercles to exist in other organs while there are none in the lungs.

In infants and children the order of frequency is different, viz. first the bronchial glands, then the lungs, next the mesenteric glands, next the spleen, next the intestines, &c. It is more common, in children, to find other organs tubercular while the lungs are exempt. In them, also, many organs are oftener affected at once, and the nervous centres are more frequently attacked. (Louis, Lombard.)

With respect to frequency at different ages, observation shows, that prior to the age of fifteen, tubercles are, beyond comparison, the most common between the fourth and fifth year, three-fourths of those who die presenting, according to the tables of Lombard, more or less tubercular disease in various organs. Between the fifth and fifteenth year the disease is more frequent than before the fourth. After the fifteenth it increases; only, however, in the lungs, intestines, and mesenteric glands. Hence, after this age, it has acquired the name of pulmonary consumption.

From eighteen to forty, it is very common, though less so than from four to five. Females are more subject to it before the age of twenty, and males between twenty-one and twenty-eight. In the lower classes of working people, who are ill-fed and much exposed, I have found, from extensive observation in the Edinburgh and St. Marylebone Infirmaries, that tubercle is very common even up to the fiftieth year.

CHAPTER VIII.

PULMONARY APOPLEXY.

PULMONARY apoplexy presents two varieties: 1, by exhalation; 2, by rupture.

1. *Pulmonary Apoplexy by Exhalation*—In this the blood is exhaled into the air-vesicles and extreme bronchi. A greater or less portion of it is usually expectorated: the remainder, coagulating in the vesicles and ultimate bronchi, presents the following characters, Fig. 34:—it is found in lumps, the ordinary size of which is from one to four cubic inches, and several of these may exist in one or both lungs. It is exactly circumscribed by an abrupt margin, as at *d*, and the induration is as great at the circumference as in the centre. This abrupt circumscription is occasioned by the septa of the lobules, which, by isolating each, prevent the direct extension of the effused blood into those adjoining. Sometimes, however, a portion of the edge, instead of being abrupt, is found to blend gradually, as Fig. 34, the mass *b*. This is caused by uncoagulated blood in the contiguous lobules. The appearance is not uncommon when the apoplexy is recent. It is more than probable that, if the lung could be inspected immediately after the occurrence of the apoplectic exhalation, blending redness would be found over a much greater extent around the coagulated mass; for the hæmorrhage is frequently far more copious than could proceed from so small an extent of lung as that occupied by the mass alone. In a short time, the uncoagulated blood is expectorated or absorbed, leaving the lung perfectly sound and crepitous, while the coagulated portion remains with the abrupt margins before described. This portion is of the deep colour of a clot of venous blood, the colour being referrible to the circumstance of stagnation; for blood, whether venous or arterial, whether in the vessels or out, becomes black

when stagnant. When death speedily succeeds the hæmorrhage, the mass is found semi-fluid and soft; but, if a few days intervene, during which the serum is absorbed and the fibrine becomes intimately combined with the pulmonary tissue, the induration is equal to that of the most complete hepatization. On scraping the surface of a section, a little very black and half coagulated blood exudes, but in much less quantity than the bloody serum of a hepatized lung. The surface of the section is granular, in consequence of the concrete blood moulding itself to the form of the air-vesicles. The appearance of the divided mass is perfectly homogeneous, the deep colour concealing every part of the natural pulmonary texture except the large bronchi and blood-vessels. The coats even of these are stained red. When the effusion is near the pleura, its dark colour is transmitted through the membrane, as at *a* and *b* of Fig. 34.

After the apoplectic mass has existed for some time, absorption of the deep red colouring matter takes place, and the tint becomes brownish or yellowish.

Copious hæmoptysis, when not dependent on the rupture of an aneurism, or of a considerable vessel into a tubercular cavern, is in general connected with pulmonary apoplexy; but the converse of this is not always true, apoplexy being occasionally produced without giving rise to hæmoptysis. Slight hæmoptysis, on the contrary, often occurs independent of apoplexy, being an exhalation from the surface of the bronchial tubes only, and not, as in the other case, from that of the air-vesicles. Laennec insists much on this distinction. (*Traité*, i. 256.)

Pulmonary apoplexy, by rendering the lung impervious to air, causes dulness on percussion, and absence of respiratory murmur. But unless the disease be of great extent and near the surface, these signs are concealed by the interposed healthy lung. A more constant phenomenon in the early stage, is the crepitant ronchus, occasioned by liquid blood in the vesicular structure around the mass. The examination for it should be made on the inferior and posterior part of the chest, the middle of the

lower lobes being the most common seat of apoplexy. In proportion as the blood is expectorated the crepitant ronchus ceases. A concomitant sign is, a bubbling ronchus in the great bronchi, occasioned by liquid blood in them also.

2. *Pulmonary Apoplexy by Rupture.*—This variety is an ulterior degree of the preceding; for the blood not only accumulates in the air-vesicles, but, by its excessive pressure, ruptures their walls, infiltrates the lung, and sometimes causes extensive laceration of its tissue. The slightest degree of it is most frequently found in the interior of a mass of the preceding variety, the centre of which is then soft, and occupied by a clot of pure blood. In an ulterior degree, the blood forms large coagula in cavities torn in the pulmonary tissue. Of this Fig. 32 presents an exemplification. *d* is a flat section, exhibiting an almost black colour: at *e* the clot is broken up, and there is seen an interval, from which the clot has been removed, in order to show the wall of the cavity, formed by healthy, but compressed pulmonary tissue. This clot penetrated, in a sinuous form, over an extent eight or ten times greater than that represented. Fig. 33 portrays an incision into another clot situated immediately beneath the pleura. The hæmorrhage is, in some cases, so profuse as to convert the greater part of a lung into one soft fluctuating mass, consisting partly of coagulated, and partly of liquid blood, intermixed with broken-down pulmonary tissue. Hæmorrhage to this extent may be fatal in a few hours, or even less: minor degrees may not produce the same effect for several days.

This variety of apoplexy may not only lacerate the lung, but also the pleura, and cause a discharge of blood into its cavity. This is rare. There appear to be only four cases on record.

The irritation occasioned by a subjacent clot, causes inflammation of the pleura and an effusion of lymph. Thus, Fig. 33, *a, a*, represents a recent false membrane, which, in its thinnest parts, transmits the dark colour of the coagulum beneath. In this Fig. the inflammation was limited; but in Fig. 32, *b, c*, it

was extensive. The possible occurrence of pleuritis is therefore to be anticipated in cases of great hæmoptysis.

Nature appears, in some instances, to make an attempt at reparation by causing the absorption of the effused coagulum. Thus, in Fig. 12, we see it surrounded by a cyst of dense chronic hepatization, the internal surface of which was probably designed for the purpose of absorption. (See also Bouillaud, *Archiv. de Med.*, Nov. 1826.)

Organic disease of the heart is by far the most frequent cause of pulmonary apoplexy. Of the cases which I have examined, amounting to a considerable number, upwards of two-thirds have been referrible to this cause. Contraction of the mitral valve, with hypertrophy of the right ventricle, is the lesion which, according to my observation, produces it more uniformly than any other. (See *Treatise on the Dis. of the Heart*, by the writer, p. 197.)

CHAPTER IX.

EMPHYSEMA OF THE LUNGS.

THERE are two varieties of Emphysema:—1. the *Vesicular*, (called also *proper pulmonary* by Laennec, without, perhaps, sufficient reason,) formed in some cases simply by the dilatation of the air-vesicles and ultimate bronchi, and in others by the rupture of their walls and the coalition of several; 2. the *Interlobular emphysema*, formed by the infiltration of air into the cellular tissue forming the septa interposed between, and isolating the lobules.

I. *Vesicular Emphysema*.—A healthy lung may be seen, through the transparent pleura, to consist of an infinity of minute spherical or oval air-vesicles, closely aggregated, and of dimensions about equal to the circumference of different sized pins.

The appearance is that of fine froth or spumous saliva under the pleura.

Vesicular emphysema presents an exaggeration of this appearance. It is delineated in Fig. 35. The vesicles (represented, in a single lobule, *a*, by black lines, their white parietes being too delicate to admit of imitation) are larger and less uniform in size than in the healthy lung, equalling, and sometimes exceeding, pins' heads of various magnitudes.

The interlobular partitions are rendered beautifully distinct in this specimen by the remarkable quantity of black pulmonary matter accumulated along them, the effect of which is further increased by the paleness of the lung, consequent on its emphysematous inflation, by which the blood is expelled. This distinctness serves to show more clearly that the lobules, by inflation, lose somewhat of their angular form and become more rounded. At the same time they bulge a little externally, so as to render the surface of the pleura hilly. These characters, namely, the paleness, the roundness, and the bulging, existing either in scattered lobules or in an assemblage of them, are the criteria by which even slight emphysema may be recognized more easily at a glance than by any other physical appearances. The same exsanguine character is seen in Fig. 9, *b*, and *c*; in Fig. 24, below *d*, where, however, there is still a light-red tinge; and in Figs. 36 and 38.

The vesicles may be enlarged to the size represented in Fig. 35, *a*, without rupture of their parietes; but when they exceed this size, it is generally in consequence of the rupture taking place, by which several vesicles are thrown together. Under these circumstances they may attain the size of peas or cherry-stones. Sometimes the vesicles of a whole lobule unite and form a single large cell; and, in extreme cases, even the lobular septa themselves give way, and several lobules, thrown together, form a spacious cavity, which is usually traversed by a few straggling web-like filaments of cellular tissue. This is beautifully exhibited in a dried specimen before me.

Sometimes, though rarely, enlarged vesicles project beyond the

level of the pleura, forming prominent globules, of which the bodies are larger than the bases. Three of small size are represented near the centre of Fig. 36. Several others, perfectly globular, and as large as marbles, existed in the same lung: *a* and *b* are blebs of unusual size, and of irregular form, each springing from a cavity or depression in the lungs formed by several united lobules. In a recent specimen before me, there are three conical blebs as large as eggs, and others in great number and of all sizes, occupying the diaphragmatic surface and anterior margin of the right lung.

Air is occasionally extravasated, by rupture of vesicles, into the cellular tissue uniting the pleura to the lung. The blebs which it forms may be distinguished from those above described by their moving about when pushed with the finger, and by their not making a permanent depression in the pulmonary substance.

The margins of the lungs, and the diaphragmatic surface, are the parts most subject to the extreme degrees of emphysema.

An emphysematous lung presents certain general characters. It rises, rather than collapses, on opening the chest; it is more elastic and incompressible, less crepitant, and specifically much lighter, than natural.

Vesicular emphysema has three principal causes. 1. *Hypertrophy*, by which the walls of the vesicles and minute bronchi are thickened, while their cavities are dilated. This state results from the part affected performing supplementary respiration for another part, or for the opposite lung, which is obstructed. 2. *Atrophy*, by which the vesicular walls are more or less absorbed, whence a coalition takes place. This results from age, or from the part not having been used for a certain length of time, in consequence of some impediment of the ingress of air. 3. Overdistension of the air-vesicles, occasioned by straining the breath, and by all causes of dyspnœa which stimulate the powerful muscles of inspiration to introduce additional air, before the retained portion has been sufficiently expelled. Chronic dry catarrh is one of its most ordinary causes. Vide Cyclopæd. vol. ii.

p. 25; also Dr. Williams's "Rational Exposition of the Physical Signs," &c. p. 93, for a good account of the mechanism of emphysematous over-distension.)

Vesicular emphysema is a very frequent cause of asthma.

II. *Interlobular Emphysema*.—This variety is represented in Fig. 38. The bluish band, which, with its ramifications, traverses, and by its transparency, contrasts with the pulmonary tissue, consists of air effused into, and splitting in two, the layer of cellular tissue forming the septa between the lobules. This splitting is strikingly displayed in specimens where much black pulmonary matter is accumulated along the septa; as a black line then bounds the emphysematous tracts on each side. Such was the case in the lung of Fig. 35, and it is less distinctly seen in Fig. 38.

Emphysematous bands are from one to five or six lines, and sometimes even an inch broad. They are broadest at the surface, and more particularly at the margins of the lungs, from which parts as a base they converge, like a wedge, on advancing into the pulmonary substance. This they penetrate deeply, and sometimes completely through to the opposite surface. From the broader bands, several of which occasionally run parallel from the borders of the lungs, narrower bands usually proceed in a transverse direction; and these, by uniting the former, may completely insulate the included lobules. Thus, in Fig. 38, several lobules are seen to be insulated.

The air often escapes from between the lobular septa into the cellular tissue between the pleura and the lung, and forms moveable air-blebs, which are a much more common result of this cause than of the rupture of air-cells in vesicular emphysema.

When interlobular emphysema reaches the root of the lungs, it soon extends to the mediastinum, and thence to the sub-cutaneous and inter-muscular tissue of the neck and body.

The most common cause of the present variety is, the forcible and prolonged retention of a full breath during violent muscular efforts, as in parturition, pertussis, fits of passion in children.

Hence it is probable that the effusion is occasioned by the rupture of air-vesicles, but this does not admit of anatomical demonstration. (Laennec, tom. i. p. 340-1.) A spontaneous exhalation of gas is possibly one of the causes. (Ibid. 342.)

Interlobular emphysema is very rare, and seldom co-exists with the vesicular. Its most characteristic sign is the *sudden* super-vention of dyspnœa after an effort, in connexion with the *dry crepitant ronchus*, with large bubbles. (Vid. Cyclopæd. ii. 28.) When the emphysema appears in the neck, there is no longer a doubt.

CHAPTER X.

ENCEPHALOID TUMOUR OF THE LUNGS.

THE term *fungus hæmatodes*, which, in a generic sense, embraces several morbid alterations of different nature, (see Précis, i. 178 and 499.) has been applied to those tumours more especially that are of an encephaloid nature. Hence it is common to hear it used as a designation of encephaloid disease of the lungs.

Encephaloid matter is one of the most marked and peculiar varieties of morbid organizable products. It is characterised by its perfect resemblance, in certain of its states, to softened cerebral pulp. Sometimes it exists alone, and sometimes it is deposited in the substance of other tumours; but no facts prove that it is one of the *transformations* of those tumours.

Its essential characters being the same, whatever be its situation, a description of it as affecting the lungs will apply to it as existing in other parts.

It has been described in a very elaborate and accurate manner by Laennec (Traité, ii. p. 52.) It may exist in three different forms:—1. encysted; 2. in irregular masses without cysts; 3. infiltrated into the tissue of organs. Each form presents three stages:—that of recent formation; that of maturity, when it most

resembles cerebral matter; and that of softening. The three forms so closely resemble each other, that an account of the first will leave little to be said of the other two.

I. *Encysted Encephaloid*.—Of this, Fig. 37 presents a well-characterized illustration. The size of the masses may vary from that of a pea or less, as seen in the figure, to that of a billiard-ball, of which the lower part of the lung delineated afforded several specimens.

The cysts consist of a fine flexible membrane, scarcely half a line thick, and of the semi-transparent greyish white appearance of cartilage. They adhere so slightly that the masses may with facility be turned out from them.

In the first stage, exhibited in the smaller masses, the encephaloid matter has considerable firmness, like concrete lard. Its colour externally is a yellowish white, or pearl-grey, without any intermixture of pink. It is subdivided internally into minute lobules by scarcely visible cellular lines, sometimes slightly vascular, which are disposed principally in a radiating direction from the centre, being at the same time somewhat tortuous or serpentine. This structure is best seen on examining a section by reflected light. The lobules also form slight elevations on the surface, when the cyst, which compresses and flattens them, is removed.

In the second stage, or that in which the resemblance to cerebral substance is the most complete, the internal structure of the tumours becomes more homogenous, their lobules being no longer discernible.

They are now, however, more distinctly divided into larger lobes, as in tumours *b*, *c*, and *d*, by an extremely fine cellular tissue, which not only invests the surface under the cysts, but penetrates into their substance. and, like the pia mater, forms the web in which ramify a great number of blood-vessels. These are much more developed in this, than in the preceding stage; and, minutely subdivided in the encephaloid substance, they give it the pink tinge which it presents in parts, as about *d*. Their coats

being very thin in proportion to their diameter, they are not only apt to become congested and form coarse straggling ramifications, as on tumours *b* and *c*, but towards the close of this stage they burst, and form the extravasations represented in tumours *a*, *b*, *d*, and *e*. In parts where there is not yet much vascularity, the colour, even in the second stage, is sometimes nearly as white as milk.

The third stage commences when the matter has acquired the consistence of pap, or of very humid brain softened by incipient putrefaction. It does not soften much beyond these degrees, nor does it ever, according to Laennec, undergo absorption or elimination, so as to leave a cavern. Encysted encephaloid tumours were found by this author only in the lungs, the liver and the cellular tissue of the mediastinum.

II. *Encephaloid in Masses without Cysts*.—This form is very common, and is found in every part of the body, but more especially wherever there is much lax cellular tissue. From the size of a mustard seed it may attain, and even exceed, that of a foetal head. The shape is in general irregularly round. Its internal structure and other characters are identical with those of the preceding variety. One immense mass of it not only occupied the lower three-fourths of the lung opposite to that represented in Fig. 37, but formed a tumour as large as a foetal head projecting externally through the ribs, three of which were eroded.

III. *Encephaloid infiltrated into the Tissue of Organs*.—The boundaries of the mass are not abruptly circumscribed, but blending, and the disease is less advanced at the margins than in the centre. From its being combined in different proportions with the various organic tissues in which it is developed, its aspect is very diversified. In a recent specimen before me, the infiltration is so complete, that the colour of the pulmonary substance has been entirely superseded by the pinkish white of the encephaloid matter; and the cellular tissue, intermixed with sinuous striæ of extravasated blood, presents an indistinctly radiating appearance

from the centres of the respective masses. This form passes through the same stages as the two preceding.

Such are the three forms of encephaloid disease ; but they may undergo further changes from the extravasation of blood. This may be so abundant during the stage of softening, as to pervade large portions or the whole of the mass, and, mixing with the cerebri-form pulp, give it the reddish-black colour and general aspect of a clot of pure blood. The extravasated blood soon undergoes decomposition ; the fibrine concretes, and, retaining the colouring matter, combines with the encephaloid, while the serum is gradually absorbed. These changes had taken place in the opposite lung to that represented in Fig. 37, the immense mass consisting partly of pure medullary matter like brain, and partly of a mixture of this, in some places with black coagula, and, in others, with concrete brownish fibrine in thick shaggy strata. When combined in the latter way, the matter loses all resemblance to brain, being of a deep red, brown, or blackish colour, and of a consistence allied to that of dryish friable paste. Hence it might be mistaken for a morbid product of a different species, did not some portions of the tumour, remaining exempt from extravasation, indicate its real nature.

Encephaloid tumours, existing in or near vital organs, as the brain, heart, lungs, may be fatal simply by compression, of which I recently witnessed an instance in the lungs. In this organ they do not constitute a variety of consumption, as supposed by Bayle. When so situated as to occasion a colliquative discharge, as for instance in the uterus, emaciation is the immediate effect. In other situations they may exist long without producing this symptom, but it never fails to supervene towards the fatal termination, and it then advances with rapid strides. Dropsy is likewise a frequent precursor of death, especially when the lungs, the liver, or the uterus are the seats of the disease.

Encephaloid tumours, even of considerable size, are not indicated by percussion and auscultation if the surrounding lung be healthy, as was the case in Fig. 37, since the resonance and

respiratory murmur remain complete. (Vid. Laennec, *Traité*, i. p. 531.)

My colleague, Dr. Sims, recently detected a case with great penetration by dulness of the right lung coinciding with immense dilatation of the external jugular veins, for which, as the circulation was little embarrassed, and the patient had not phthisical symptoms, nothing could account but a tumour compressing the descending cava, which was the case.

CHAPTER XI.

MELANOSIS.

MELANOSIS (from $\mu\epsilon\lambda\alpha\varsigma$, niger) is an accidental production, of which the distinctive character is a black colour. It was first described by Laennec in 1806.

The four forms into which it is distributed by Andral, are, 1. masses, encysted or not; 2. infiltrated in different tissues; 3. layers on the unattached surface of membranous organs; 4. liquid, either pure or mixed with other liquids. The fourth form is not recognized by Laennec, since he regards melanosis as a *tissue*. To those who, with Andral, consider it to be merely a simple deposit of colouring matter, its liquid state is as conceivable as its solid.

I. *Melanosis in Masses*.—This has two stages or states: A, the solid; B, the softened.

A.—In the solid state it presents the following characters: the colour varies from a yellowish-brown to a bistre-brown, a soot-black, as in Fig. 39, and a raven-black, as in Fig. 40. It stains white paper like Indian-ink. The form of the masses is sometimes exactly spherical, as in Fig. 39, and sometimes irregular, and even lobulated. The surface is either smooth, rough, or mamellated like a mulberry. The consistence varies between that of tallow and that of a lymphatic gland. The size, sometimes

not exceeding a mustard-seed, may attain that of a goose's egg. In Fig. 42 masses of the former size are seen through the pleura, each surrounded by a dark cloud. In the horse, conglomerate masses have weighed thirty-six pounds.

B.—Softening takes place, according to Laennec, from the centre towards the circumference. While slight, the mass maintains its form, but yields a brown or black liquid, intermixed with pulpy fragments of the same colour. When more advanced, the mass is resolved into a liquid black pulp, which, like tubercle, is eliminated by an expulsive process, leaving a cavity, disposed, according to circumstances, either to enlarge, to remain stationary, or to heal. Complete softening, however, is extremely rare, (Laennec, *Traité*, ii. 31,) and it is doubtful whether what have been considered as melanotic cavities (cases 20 and 21 of Bayle) are not merely tubercular excavations, or partial dilatations of the bronchi, in black and indurated pulmonary tissue.

It is even questionable whether melanosis found soft was not originally secreted in that state. (*Précis*, i. 450.)

Cysts are very rare. Laennec met with them only in the lungs and the liver, and but with one in the former. Breschet has seen them in the cellular tissue. Andral has never been so fortunate, nor has it occurred to myself. The cyst consists of cellular tissue about half a line thick. When not encysted, the masses in some cases adhere intimately, and in others so slightly as to admit of being removed in their entire state, without laceration.

Melanosis in mass is wholly destitute of organization: like tubercle, therefore, it is not a *tissue*.

II. *Infiltrated Melanosis*.—As melanosis in mass presents itself in the solid form, it is very conceivable that, when deposited in, and combined with, the tissue of an organ, it may occasion the solidification of that organ. In the great majority of cases, however, the induration which accompanies the blackened state of an organ depends, not on the melanotic deposition, but simply on chronic inflammation; for it is not uncommon in the lung, for instance, to find the same degree of induration present, in dif-

ferent parts, every grade of colour from light grey to black. Such was the case in Fig. 47, exemplifying what Bayle denominated *phthisis with melanosis*, a variety which cannot be admitted; as, on the same principle, it would be necessary to recognize all other colours of tubercular induration as so many varieties of phthisis.

In Fig. 44 the pulmonary substance, though extremely dark, owes its induration, occupying only a few lobules, to chronic inflammation, and not to melanosis; for the induration is seen to reside in the condensed cellular tissue, which, at *a*, is of a dirty-white colour, and at *b*, of a deep grey, while at *c*, where these changes are no longer visible, the induration ceases, the lungs being perfectly crepitant, though deeply coloured with black. But though the induration in this case was not from melanosis, the black colour indubitably was; since round melanotic masses, of the size of a pea, were disseminated in abundance throughout the lungs.

This case is calculated to display the artificial nature of the distinction between melanosis and ordinary *black pulmonary matter*; for had the round melanotic masses been absent, the colour would have been ascribed, on the principle of Laennec, (*Traité*, ii. p. 37,) simply to black pulmonary matter. (Vide *infra*, BLACK PULMONARY MATTER.)

In Fig. 40, melanotic infiltration co-exists with fibro-cartilaginous and osseous induration of the lung, the light-grey parts being cartilaginous, and the whiter osseous, and both presenting more or less red vascularity.

III. *Melanosis in layers on the free surface of Membranes.*—This is nothing more than false membrane coloured black, or, in other words, infiltrated with melanotic matter. It should properly, therefore, be ranged under the preceding head. The layers are found almost exclusively on the peritoneum, and after chronic peritonitis. They are occasionally seen on the adherent surface.

IV. *Liquid Melanosis.*—Black colouring matter may be se-

creted in the liquid form, 1. into cysts. MM. Trousseau and Leblanc found about eight ounces in a cyst above the kidney of a horse. I have seen half an ounce, like black oil paint, fill an ovarian cyst. 2. It may be secreted into various natural cavities. Thus the peritoneum, after chronic peritonitis, occasionally contains a deep-black liquid. The mucous membrane of the stomach, affected with acute, but more especially with chronic inflammation, sometimes secretes a fluid like coffee-grounds, or moistened soot. I have seen this yielded daily for six or seven months without being fatal. It is probably, in some instances, merely a sanguineous exhalation modified by a vitiated gastric juice; for I have often found it concrete in the blood-vessels, in cases where the mucous membrane had been destroyed by softening. (Vide infra, DISEASES OF THE STOMACH.) In other cases it is a morbid secretion from the blood.

Prout has seen urine of deep-black colour.

Chemical analysis informs us that melanosis consists of the various elements of the blood, combined with a black colouring matter more or less approximating to that of the blood, but not identical with it, carbon existing in it in unusual predominance.

My friend, Dr. Gregory of Edinburgh, found the black lungs of a collier to contain coal, which, on destructive analysis, yielded carburetted hydrogen and the other usual products.

Melanosis as affecting various Tissues.—In one or other of the above described forms, melanosis affects almost every tissue, but especially the cellular and adipose. In the cellular, it has been found under the skin, the pleura, Fig. 39, the pericardium, the peritoneum, the mucous membranes—especially that of the intestinal canal, between the fibres of muscles—comprising the heart, and at the base of the orbit. It has likewise been found in the substance of the skin, of mucous, serous, and serous false membranes, of arterial coats, in the interior of veins, (Précis, i. 465-6,) in bone, and in muscular fibre.

Of parenchymatous organs, it has been found very frequently in the lungs, rarely in the liver, never in the brain, occasionally in the mammæ, thyroid gland, and uterus, often in the ovaries, and various lymphatic glands.

It may exist in combination with other accidental productions, as scirrhus, encephaloid, tubercle. With the latter it is seen in Fig. 20, and in spots in the interior of tubercles in Fig. 29, unless it be preferred to give to this the appellation of black pulmonary matter. Andral states that he has once seen spots of the same kind in cretaceous tubercles, and he regards them as melanotic depositions. It may attack a great number of organs and tissues at once. I have seen it almost universal. It has been observed at as early an age as nine, but is most common in the advanced periods of life. It affects animals as well as man.

The symptoms which accompany melanosis are such as result—1. from chronic irritation, whether this be the cause or the effect of the depositions; 2. from mechanical compression of the organ in which any considerable tumours are developed; 3. from the co-existence of other morbid productions.

CHAPTER XII.

BLACK PULMONARY MATTER.

THIS designation has been given by Laennec to black colouring matter of the lungs when not attended with induration, in contradistinction to melanosis, of which, according to his view, induration is an essential character. Andral does not admit this distinction. "Black discolouration of the lung," says he, "with augmentation of its consistence, is nothing more, in a great number of cases, than black pulmonary matter, with the superaddition of a morbid induration wholly independent of it. In other words, the lung, affected with chronic irritation, blackens in the same way that an intestine does, which, similarly affected,

passes by degrees from the red to the brown, and even to the black colour. Often one of these tints changes into another by shades so insensible that it is impossible to say where the one commences and the other terminates. How, then, can it be said, at what degree of these shades commences the accidental production denominated melanosis?"

Black pulmonary matter, without induration, is compatible with a perfectly healthy state of the organ. Rare in early youth, it exists in the lungs of all adults, and increases with the progress of age. Sometimes it is confined to the interlobular septa, circumscribing the lobules with dark lines. These are very remarkable under the pleura in Fig. 35. More commonly it extends to the lobules also, forming specks, spots, or diffuse blackness. A beautiful spotted appearance under the pleura is seen in Fig. 35, and still more in Figs. 41 and 43. In the latter, which is not exaggerated, the spotting resembles that of a panther's skin. Fig. 45 displays diffuse raven blackness of great depth, mottled with tubercles apparent through the pleura. A similar blackness of the pleura existed in the lung from which Fig. 44 was taken, and which contained melanosis in masses. It is evident that in the last figures the black matter has very much the characters of melanosis, the spots presenting an analogy to melanosis in masses, while the diffuse blackness resembles the infiltrated form.

CHAPTER XIII.

CEDEMA OF THE LUNGS.

THIS affection, represented in Fig. 41, presents the following anatomical characters. When it is considerable and rather old, the lung is of a pale grey or tawny grey colour, with little or no intermixture of the natural pink, in consequence of a deficiency of blood in its vessels. It is denser and heavier than ordinary, pits

slightly on pressure, and does not collapse on opening the chest. Its crepitation, however, is little less than natural. An abundance of almost colourless, or light drab, transparent serum follows an incision. It is much more spumous from recent, than from old œdema. (Laennec, *Traité*, i. 352.) It is a very common affection, few persons labouring under chronic pulmonary congestion being wholly exempt from it.

CHAPTER XIV.

OSSIFICATION OF THE PULMONARY SUBSTANCE, AND HYDATIDS.

OSSIFICATION, independent of tubercles, is extremely rare. Fig. 40 presents an exemplification of it. The osseous formation is preceded by a fibro-cartilaginous deposition, in which the phosphate of lime is secreted. It is surrounded by melanotic blackness, and encloses several portions.

Hydatids.—Acephalocysts are the only variety hitherto found in the human lung. They present the same characters as in other parts of the body. A whole lobe has been found converted into one great hydatid.

DIVISION II.

DISEASES OF THE AIR-PASSAGES.

THESE affections are seated in the mucous membrane and the subjacent tissues. They comprise LESIONS OF CIRCULATION; viz. A. *Active Hyperemia* (Bronchitis); B. *Passive Hyperemia* (congestion). LESIONS OF NUTRITION; viz. A. *Hypertrophy* (thickening); B. *Atrophy* (attenuation). These may be accompanied with changes of form and dimensions. LESIONS OF SECRETION; viz. A. of the *gaseous*,—B. of the natural *serous exhalation*—lesions little understood;—C. of the *mucous secretion* (varieties in quantity and quality; also membraniform concretions, as in croup; calculous concretions, hydatids, and exhalation of blood).

CHAPTER I.

BRONCHITIS.

THE morbid states of the mucous membrane are identical from the glottis to the extreme bronchi. They may all, therefore, be comprised in one general description.

Affected with recent acute inflammation, the mucous membrane is of a bright red colour, similar to that of Figs. 48 and 51, but variable in depth. It may be partial or general, and in both cases may present more or less of a speckled, arborescent, streaky, cloudy, or uniform character.

Partial redness may be confined, 1. to the larynx and trachea alone; 2. to the great bronchi alone, in both of which cases the symptoms are those of an ordinary cold or mild bronchitis, unless

there be laryngitis; 3. to the minute bronchi alone, in which case, if the redness is extensive, the symptoms are severe, as great fever and dyspnœa, &c.

General redness, which is much more rare than partial, is extremely formidable, if suddenly established, as it may be attended with all the symptoms of asphyxia, and terminate fatally in a few hours. When taking place more gradually, as in rubeola and continued fevers, asphyxia usually does not occur, but the case is always one of severity. General redness is rarely chronic.

Bronchitis may either commence in the larynx and proceed to the capillary bronchi, or *vice versâ*. The upper lobes, according to Broussais, are the most frequently affected.

Chronic redness of the mucous membrane is more of a purplish, livid, violet, or deep brownish cast, all of which tints may be seen in the dilated bronchi, Figs. 50 and 52. In chronic bronchitis, especially if purulent, the mucous membrane is, in a few instances, perfectly pale.

In the larynx, trachea, and great bronchi, redness generally proceeds from inflammation; in the minute bronchi, it is frequently an effect of mechanical engorgement during life, or of sanguineous gravitation after death. Redness from all these causes must be distinguished from that occasioned by putrefaction; nor must it be confounded with the natural redness of the lungs apparent through the walls of the finer bronchial tubes.

Redness of the mucous membrane is not *necessarily* excited by the diseases of the pulmonary substance. Though generally present in peripneumony, it is occasionally absent. Unsoftened tubercles sometimes exist, even in abundance, without giving rise to it, but its absence is very rare when they have formed excavations. Hence the principal part of the irritation and expectoration in phthisis results from bronchitis. The red is generally deeper in the vicinity of the caverns. See Fig. 18, *e*.

Together with redness, bronchitis causes thickening of the mucous membrane. Of this there are two varieties:—1. from

mere sanguineous engorgement; 2. from increased nutrition, or hypertrophy.

I. The former is generally an effect of acute inflammation; and it is more especially dangerous in two situations; first, in the larynx (Fig. 48.), as in cases of laryngitis, croup, and scarlatina anginosa, in which I have several times seen it occasion suffocation—once within the last week. Secondly, in the small bronchi, where it is the cause of the asphyxia which may accompany universal, or very extensive acute bronchitis.

II. Thickening of the mucous membrane by hypertrophy is a result of chronic inflammation. It may be general or partial. The latter is illustrated by Fig. 53, where it contracts a large bronchus to one-third its natural calibre. The sub-mucous tissue contributes little to the thickening in the present instance. Contraction of the air-passages in various degrees, from this cause, gives rise to the *dry sibilous* and *sonorous ronchi*. (Vid. Cyclopæd., Bronchitis Chron.) Hypertrophy may not only thicken the mucous membrane, but modify its structure, and even convert it into a new tissue. Thus the membrane sometimes becomes villous like intestine, and sometimes it throws out tumours. The latter are found principally in or near the larynx. Fig. 49 affords a remarkable example of one springing partly from the larynx, but principally from the pharynx; *a* is the tumour, presenting a cauliflower structure, that is, it throws out radicles, which terminate, on the surface, in mamellated protuberances; these are soft, semi-transparent, pinkish, and yield an abundant secretion of pale pus, represented by the yellow and greenish parts on the surface; *d* is the margin of the pharynx bounding the tumour, except opposite to the epiglottis *b*, where it extends into the larynx; *c* is the left chorda vocalis with the sacculus in front; *e* is the cricoid cartilage, ossified, and held open by a piece of wood; *f* is the trachea, partly illuminated within by transmitted light. Fig. 46 represents syphilitico-mercurial ulceration of the fauces, *a, a*, and epiglottis, *b*; with hypertrophous papillæ, *c, c*, and vegetations extending into the larynx.

Hypertrophy may also affect the mucous follicles of the larynx, trachea, and bronchi, converting them into round white bodies, liable to be mistaken for tubercles. When inflamed they become red. Their ulceration will be explained below.

Softening of the mucous membrane is a frequent effect of bronchitis. In the larynx, where it has been principally noticed, the membrane appears like a pulp, barely covering the prominent parts, particularly the chordæ and thyro-arytænoid ligaments, and in many points it is sometimes entirely deficient. It invariably affects the voice, and is sometimes the sole cause of its hoarseness or extinction.

The existence of atrophy of the mucous membrane is to be inferred from analogy, but it scarcely admits of demonstration.

Ulceration of the mucous membrane may take place in the larynx, trachea, or bronchi. It is most common in the larynx. I have rarely seen it occur here in the chronic form unconnected with phthisis. *Idiopathic* laryngeal phthisis is, in fact, extremely rare; the hectic emaciation, &c., in cases where the larynx is affected, being, almost without exception, principally dependent on co-existent ulceration of the lungs.

Ulcerations may affect any part of the larynx, and, in number, form, and size, they may present every variety. Fig. 48 exemplifies all their most ordinary appearances. The larynx is laid open by a section through the front of the thyroid and cricoid (*b, b*) cartilages. Each chorda vocalis exhibits an ulcer on its margin. Sometimes the disease is restricted to one or two such. Between the chordæ are innumerable small cribriform ulcers covered with pus. On the cricoid cartilage is a deep ulcer of considerable size. Sometimes one such pervades half or more of the larynx, and completely denudes it of mucous membrane. Between the lower part of the chordæ are ulcers originating in inflammation of the mucous follicles. They present a double zone of red,—one round the base, and another round the excavated interior. These are still more distinctly displayed in the

trachea, Fig. 51, taken from the same subject. In this case, acute inflammation supervening, had given a florid red to the parts.

Ulcers are less common in the trachea than the larynx, and still less so in the bronchi. They do not, however, differ in character in these situations. They may result from acute, as well as from chronic inflammation. I recently saw a case of scarlatina anginosa, in which ulceration of the chordæ vocales with fatal tumefaction took place in a week. They are not rare in variola.

Ulcers commonly bound themselves in depth by occasioning hypertrophy of the sub-mucous cellular tissue; but sometimes they cause perforation into the contiguous parts; it is, however, commoner for perforation to commence externally, its most frequent causes being pulmonary vomicae, tubercular bronchial glands, and diseases of the aorta, oesophagus, and thyroid gland.

Bronchitis may cause disease, not only of the mucous membrane, but also of the other tissues composing the walls of the air-passages. 1. The cellular tissue interposed between, and uniting the other tissues, may become hypertrophous, indurated and even scirrhus, thus interfering materially with the functions of the parts, more especially of the larynx. It may become oedematous, and obstruct, or even close the glottis, causing suffocation. This is commonly connected with acute inflammation, but sometimes with chronic. In Fig. 48, *a*, over the arytaenoid cartilages, it was partly produced by both. The cellular tissue may also be the seat of purulent and tubercular depositions.

2. The cartilaginous tissue, especially of the larynx, may ulcerate or ossify. The latter is seen in Fig. 49, *e*. It is natural in the aged. The cartilages of the trachea are rarely diseased, those of the bronchi suffer more frequently, becoming enlarged, thickened or ossified, occasionally even in the minute branches. (*Précis*, ii. 492.)

3. The fibrous tissue may soften or become hypertrophous; and 4. The muscular may be hypertrophous, or softened. Occurring in the larynx, all these changes may impair or destroy the voice.

Dilatation of the bronchi, first described by Laennec (*Traité*, i. 206.), is one of the consequences of chronic bronchitis. It is conveniently divided into three varieties:—

I. Uniform dilatation may occupy the whole length of one or several branches, or even of nearly all the branches of a lung. Tubes scarcely capable of admitting a fine stiletto enlarge to the size of a crow-quill, a goose-quill, and even of a finger. It frequently happens that several branches thus dilated spring from a trunk of much less diameter. Sometimes a dilated branch regains its natural calibre a little below; more commonly it terminates in a blunt, round end or cul-de-sac, from which spring several minute twigs.

II. In the second variety, see Figs. 50 and 52, a bronchial branch presents, in one point only, a rounded dilatation, of any size between a mustard-seed and a walnut (as in Fig. 50), which might, at first sight, easily be mistaken for a healed tubercular cavity with smooth walls. Should several of these dilatations be contiguous to each other, they may form, by their communications, a sort of burrow (as Fig. 50, where the pin is inserted), filled with muco-purulent matter.

III. In the third variety, the bronchi present, over the extent of one or several branches, a series of dilatations, on each side of which the tube regains its natural calibre. These dilatations usually have thin and transparent walls, as in Fig. 52, *b*. They are often numerous. In a lung, of which a drawing is before me, there were between two and three dozen. Andral thinks this third variety most common in infancy.

Dilatation may be attended either with a natural state of the bronchial walls; a thickened state, from hypertrophy, of their various component tissues (Fig. 50); or an attenuated state, from atrophy, by which the walls are reduced to a mere membrane, wholly destitute of fibrous and cartilaginous tissues (Fig. 52, *b*), and sometimes so fine as to resemble the exterior pellicle of an onion, or the vesicular lungs of the frog tribe.

When dilatation of the bronchi is extensive, the intermediate

lung becomes reduced by compression to the same condensed, flaccid, and imperfectly crepitant state as is occasioned by empyæma or hydrothorax. Often, also, the pulmonary tissue surrounding the dilatations is in the state of grey or black induration.

Dilatation of the bronchi is rarely seen except in cases of chronic cough, whether attended or not with expectoration. It is, therefore, to be ascribed to the expansive pressure of the cough, the operation of which is favoured by the diseased and inelastic condition of the bronchial parietes. The dilatation is sometimes produced with considerable celerity in children affected with pertussis. In two or three months it may attain a considerable size. Of this I recently saw an instance. (For the symptoms, vid. Laennec, *Traité*, i. 212, and *Cyclopæd.*, *Bronchitis Chron.*)

The morbid secretions of the air-passages fall within the province of the semeiologist, and the reader is referred to the *Cyclopæd.*, *Bronchitis* and *Catarrh*; to Laennec, *Traité*, *Catarrh*; and to Andral, *Clin. Med.*, ii. 35.

Calcareous concretions in the bronchi, of which they sometimes take an exact mould, are essentially the same as those in the pulmonary substance. (Vid. *supra*, *Phthisis*.)

Exhalation of blood is treated of in the chapter on Pulmonary Apoplexy.

Membranous concretions of the air-passages, most commonly a product of croup, are formed by a plastic exudation, which, becoming concrete as soon as deposited, invests the internal surface of the passages with a layer of false membrane of variable extent, thickness, and consistence. The mucous membrane underneath is tumefied, and of a bright, deep, or livid red, either uniform or in patches. Sometimes the red is entirely absent.

The ordinary thickness of membranous concretions is about a line, but some are several lines, and others are so thin that the mucous membrane is apparent through them. Some are of almost pulpy consistence, while others are so firm that large por-

tions admit of being drawn out without sustaining rupture. The firmest part is usually in the upper portion of the trachea, of which it often takes a complete mould; the softness is greater at the two extremities, but especially in the bronchial tubes. The colour is a dirty yellowish white.

Membranous concretions may either be confined to the larynx and trachea, which is the most common case, or to the bronchi, or they may pervade all these parts simultaneously, existing in the form either of isolated patches, or of continuous layers. Sometimes they commence in the mouth, affecting the amygdalæ, velum palati, pharynx and nasal fossæ before descending into the larynx. This is more especially the case in adults. (Bretonneau.) Sometimes, again, they commence in the small bronchi, and ascend. Occasionally they have been found in the stomach, ears, anus, &c.

Bretonneau states that membranous concretions contain fibrine: according to Shwiltgué they consist of albumen united with carbonate of soda and phosphate of lime. They do not, in general, present any traces of organization, nor are the cases, designed to prove their vascularity, either numerous or satisfactory. The possibility of their organization, however, is theoretically admissible, but the process is, I imagine, anticipated either by death or recovery.

The affection is generally acute, but it is sometimes chronic, both as to its symptoms and duration. This may be the case in children, provided the membrane does not exist either in the larynx or the small bronchi; in adults it may occur even though the membrane do exist in the larynx.

The dyspnœa which accompanies a false membrane depends, says Andral, much less on its presence, except it be very thick in the larynx, than on the tumefaction of the subjacent mucous membrane, and often on the spasmodic contraction of the constrictor muscles of the larynx. The false membrane, of itself, produces suffocation principally when, developed in the fine

bronchial tubes, it intercepts the ingress of air, and thus prevents arterialization of the blood.

Infancy is the age most subject to membranous concretions of the air-passages, yet it is very rare to see them before the expiration of the second year. During this early period, however, the mouth, nasal fossæ, pharynx, and œsophagus, evince a remarkable disposition to the formation of false membranes; why they stop at the entrance of the larynx is not very obvious.

Intensity of inflammation is not the circumstance on which depends the formation of membranous concretions. For the inflammation is sometimes very slight; and observation has shown that the most intense inflammation, either arising spontaneously, or excited artificially by acids, chlorine, ammonia, &c., is often totally insufficient to give rise to a false membrane. A predisposition, therefore, is requisite for its formation. (Vid. Précis, ii. 483.) The important inference is, that, in the treatment, copious blood-letting is not the sole indication; in excess, it may possibly even favour the predisposition.

D I S E A S E S
OF
T H E H E A R T.

CHAPTER I.

GENERAL ARRANGEMENT.

THE diseases of the heart, as of all other parts, consist of lesions of circulation, of nutrition, of secretion, and of the nervous function.

LESIONS OF CIRCULATION.

I. *Hyperemia*. This may be: A, *Active* (pericarditis, carditis, and inflammation of the internal membrane and valves); B, *Passive* (congestion).

II. *Anemia*.

LESIONS OF NUTRITION.

I. *Hypertrophy*, A, of the muscular tissue, with or without dilatation; B, of the fibrous tissue, whence fibrous thickening and deformity of the valves and orifices.

II. *Atrophy*, with or without dilatation.

III. *Induration*.

IV. *Softening*, A, of the internal membrane; B, of the muscular tissue.

V. *Solutions of Continuity*.—A, ulcers of the external or internal membrane; or of the muscular tissue, with, or without perforation; B, rupture of the walls, columnæ carneæ, or chordæ tendineæ.

VI. *Congenital Lesions of Nutrition*, most frequently resulting from an arrest of the natural developement. They present three

principal classes : A, absence of the heart ; B, incomplete development of the heart ; C, excess of development of the heart.

LESIONS OF SECRETION.

The natural secretions of the heart consist of fat, and of the insensible exhalation of serosity, common to all living parts. Hence, there are two corresponding orders of lesions of secretion:—

I. *Lesions of the fatty or greasy Secretion*, this being either A, deficient ; or B, in excess.

II. *Lesions of the serous Exhalation*, either in the parenchymatous substance, or on the surface of the internal membrane.

The lesions in the parenchymatous substance, are, A, *œdema*, being simply an excess of the natural serous exhalation yielded by the cellular tissue. The remaining lesions of this class are perversions of the serous exhalation : viz. B, *a deposition of blood*, either in the substance, or at one of the surfaces ; C, *steatoma*, deposited in the fine cellular tissue uniting the internal membrane to the muscle. It is also deposited, and more frequently, on the valves, between their two layers, where it often becomes calcareous ; D, *ossification* of the cellular, the fibrous, or the muscular tissue.

The following lesions may appear in any part of the body where there is cellular tissue, and therefore in the heart : E, supuration and abscess in the muscular substance, either from disease of the part itself, or from deposition of pus conveyed by the blood : F, *tubercle* ; G, *scirrhus* ; H, *encephaloid* ; I, *serous cysts* ; K, *hydatids*.

The lesions of the serous exhalation on the surface of the internal membrane, are, A, *pus*—rare and even doubtful ; B, *false membrane*—rare.

LESIONS OF THE NERVOUS FUNCTION.

These fall within the province of the semeiologist. It is here only to be observed that they may produce many of the same symptoms as are occasioned by organic or inflammatory disease ;

and they are a frequent cause of organic disease. (Vid. Treatise on the Diseases of the Heart, by the Writer; *Palpitation* and *Angina*; or Cyclopæd. *ibid.*)

LESIONS OF THE BLOOD IN THE CAVITIES OF THE HEART.

A. *Polypi* formed before death: they sometimes contain pus, and occasionally become cartilaginous and osseous. B. *Vegetations* of the internal membrane are supposed, by Laennec and Andral, to be nothing more than adherent polypi. This question is not fully determined.

In describing the above morbid conditions of the heart, we shall, as before, group together the alterations peculiar to each disease of the organ, this plan being best adapted to the nosological study of disease.

The number of lesions of the heart requiring delineation is not considerable, as the majority consist of changes of size and form, which are as intelligible by description as by representation; and many others, such as abscess, ulcer, scirrhus, fattiness, &c., are the same as in other muscles, and are, therefore, too familiar to require illustration.

CHAPTER II.

PERICARDITIS.

IN the chapter on pleurisy, a detailed account is given of inflammation of serous membranes in general. Here, therefore, it will only be necessary to advert to leading points, more especially those which are characteristic of pericarditis in particular.

The anatomical characters of acute pericarditis are, 1. redness; 2. adherent lymph; 3. effused fluid.

I. *Redness.* This very seldom pervades the whole of the

inflamed portion. In Fig. 54, it is confined to the reflected pericardium, not existing on the heart, though the thickness of the lymph investing the latter indicates the intensity of the inflammation. The redness presents itself sometimes in numerous small scarlet specks, with a natural colour of the intervening membrane; sometimes in spots (Fig. 54, *a*) of various dimensions, formed by the agglomeration of specks; and sometimes in patches, *b, b*, of considerable extent. Even these, however, have, almost invariably, a dotted or mottled character.

The pericardium is very rarely thickened; that which is often regarded as thickening, being nothing more than superimposed and intimately adherent false membrane.

When acute pericarditis degenerates into chronic, the redness loses its brilliancy, sometimes becoming very deep and of a livid, a brownish, or a mahogany colour, Fig. 61, *a, a*, and sometimes acquiring a yellowish or cinnamon hue. In these cases the lymph often acquires the same hue. Beneath a layer of fawn-coloured lymph I have seen the surface of the heart present a bluish-white appearance (Fig. 64, *b, c*.) like the spots so frequently found on this organ, and represented in Fig. 59.

Redness does not afford positive evidence of inflammation unless conjoined with an effusion of lymph, or of flocculent or sero-purulent fluid.

II. *Adherent Lymph.* This is secreted in the fluid state, conjointly with serum. The latter partly strains away, and the lymph concretes and forms false membrane. This, when recent, as in Fig. 54, is of a pale straw, or canary colour, and of a tender, pulpy, and, at first, even gelatinous consistence, becoming firmer as it grows older. Though occasionally deposited in detached lumps and granules, it generally forms continuous layers, sometimes covering a portion only, but more commonly the whole, or nearly the whole, of the pericardium, as seen in the Fig. Its mean thickness is from a line and a half to three lines, but it may reach an inch, when accumulated by a series of recurrent attacks. Fig. 54 displays the most common appearances of

the unattached surface of recent lymph. In parts (not, however, so well marked in the present as in the other views), it is pitted with small depressions at tolerably regular intervals, presenting the aspect of a reticulation, or of the section of a coarse sponge. This occurs principally where the layer is thin; where it is thick, the surface is distributed into more spacious cells, often as large as a pea, and separated by coarser partitions. The partitions are sometimes irregular, being higher and thicker in one part than another; at other times they are very regular, as at *c*, in which case the appearance is analogous to that of the second stomach of a calf. Not unfrequently they are shaggy and flocculent, hanging in shreds like tow, as at the part *d*, on the heart. Occasionally they are very thick and rounded, somewhat resembling a congeries of small earth-worms, as in Fig. 61 on the heart. In Fig. 62, from a case which had become chronic, the surface of the lymph is disposed in transverse, and, as it were, plaited wrinkles, like undulations of sand on the sea-shore.

When lymph becomes old, it acquires a deeper hue, which varies between cinnamon, as Figs. 62 and 64, and an intense brown-red colour, as in Fig. 61. When of the latter colour, it usually secretes a bloody serum, as was the case in the present instance.

In some protracted cases, generally of at least two or three months duration, where, though adhesion of the pericardium has been established, inflammation has either recurred, or never been completely subdued, an additional deposition of lymph takes place interstitially, which, as before stated, may thicken the mass to the extent of an inch and upwards. Under these circumstances, it sometimes possesses a laminated texture, and the layers are progressively redder in proportion as they are nearer the heart; sometimes it exhibits different degrees of consistence at different parts, one being almost liquid and purulent, while another has a semi-cartilaginous density.

The object of nature in the effusion of lymph is, here as in every other part, to effect reparation. This it accomplishes by

causing adhesion of the pericardium, which arrests the further secretion of serum—the immediate cause of danger. (See Treatise by the Writer, p. 88.) The adhesion itself, however, by giving rise to hypertrophy with dilatation, in most instances ultimately becomes destructive to the patient.

In nine cases out of ten (Laennec), pericarditis is universal; and the adhesion to which it then gives rise is most frequently universal also. In partial pericarditis, when the portions inflamed are limited, adhesions are not close or intimate; for the adherent lymph is stretched into long loose bands by the gliding motion of the heart within the pericardium. But when the inflamed portions are extensive, this gliding motion is prevented, and partial adhesions may become intimate. Adhesions are occasionally partial, though the inflammation was universal. Sometimes the unattached parts suppurate and form detached abscesses around the heart.

The well-known appearance of opaque white spots on the heart, as in Fig. 59, is generally attributed to partial inflammation. They vary in extent from a few lines to two or three inches in diameter. Their thickness is about that of the nail; they consist of condensed false membrane, and may generally be dissected off without injury to the pericardium beneath. A pin is passed under the patch represented in the figure.

Sometimes lymph forms small, round, semi-transparent granulations on the pericardium.

III. *Effused Fluid.* The serum effused conjointly with the lymph, and straining away from it, is most commonly very transparent, and of a faint greenish-yellow, or a very pale fawn colour. Sometimes its transparency is diminished by particles, filaments, flakes, or fragments of imperfectly concrete or partially dissolved false membrane. The quantity of the fluid is in general considerable within the first three or four days of a universal acute pericarditis—not unfrequently exceeding a pint. Corvisart once found four. After the lapse of a few days more, however, it is commonly reduced by rapid absorption to a quantity little exceed-

ing that of the concomitant lymph. Sometimes it is wholly absorbed, nothing remaining but lymph.

Should the lymph form a false membrane without adhesion of the pericardium taking place, it becomes the secreting surface; and its secretion, though at first a clear serum, gradually becomes more and more turbid, milky, and opaque, until it eventually assumes a sero-purulent character. Rarely is pure pus found in the pericardium; probably because the patient dies from irritation before the suppurative process is fully established. Occasionally the fluid is bloody, and the lymph stained red with it, as in Fig. 61.

The effusion of blood results from the tenderness of the newly organized structure, whence it is prone to become congested and to effuse blood when subjected to any unusual cause of irritation or excitement. The excitement, in these cases, is, most probably, of an inflammatory nature, as I have generally found bloody false membrane to be connected with pain and a febrile movement.

Pericarditis originally chronic, is always universal; the redness is deeper and duller than in the acute; false membranes are often totally deficient, and when present, they are thin, soft, and fragile, frequently not presenting a trace of organization; finally, there is always an effusion of turbid, and sometimes strongly puriform fluid.

CHAPTER III.

CARDITIS, INFLAMMATION OF THE INTERNAL MEMBRANE, SOFTENING, ABSCESS, PURULENT DEPOSITIONS, ULCERS, PERFORATION, GANGRENE, INDURATION, AND ANEMIA.

THE most prominent anatomical character of carditis and inflammation of the internal membrane is preternatural redness. Redness, however, is not always inflammatory. For it is usually found in bodies opened, during warm or damp weather, more than

thirty hours after death. The internal membrane, in these cases, presents a scarlet, a brownish, or a violet-red like a uniform stain, either universally, or in a certain number of points only; while the walls of the heart, which, however, are not so frequently discoloured, are of a deep livid red, attended sometimes with patches of ecchymosis on their external surface. The redness is most considerable in plethoric subjects, and in those which, from a morbid state of the blood, putrefy with rapidity. In the latter the colour is always very dark. (Vid. Treatise by the Writer, p. 143, et seq.)

Mere exposure to air for a few hours will impart a bright red to a heart of healthy colour, a change familiar to the delineator of morbid anatomy from the inconvenience which it occasions him. It results from oxygenation of the blood.

These facts do not invalidate the evidence that redness may also be of an inflammatory origin. Andral, Dupuy, and Bouley found it in numerous horses which died of the epizooty raging amongst them in 1824, and were examined immediately after death. The reddened internal membrane admitted of being torn off with unusual facility, and three times Andral found small depositions resembling pus between it and the muscular substance. The latter was not only reddened but softened and friable. The left side of the heart was much more frequently affected than the right, and, in some cases, the disease was confined to the aortic valves, which were tumefied and friable as well as thickened.

The internal membrane of the heart is reddened in animals poisoned by corrosive sublimate, which inflames the heart as it does the mucous membrane of the mouth.

In man, redness of the internal membrane, or of the valves, without any other lesion, has been found in cases which presented many of the symptoms of pericarditis; namely, sudden dyspnœa, dull pain in the præcordial region, increased impulse of the heart, pulse irregular, unequal, and very frequent, bellows or rasping murmur. (Précis, ii. 279.) I have met with similar

cases. The redness of the internal membrane is portrayed in Fig. 60. On the muscle it is deep; on the mitral valve it is vivid.

Of universal carditis, *with effusion of pus generally* throughout the muscular tissue, a remarkable, and perhaps unique instance, was seen by Dr. Latham. "The whole heart," says he, "was deeply tinged with dark-coloured blood, and its substance softened; and here and there, upon the section of both ventricles, innumerable small points of pus oozed from amongst the muscular fibres. This was the result of a most rapid and acute inflammation, in which death took place after of an illness of only two days."

The deep red, such as I have seen it in carditis, is represented in Fig. 56. The muscular substance was softened.

Carditis not unfrequently accompanies pericarditis. Thus, in Fig. 64, the muscle is of a deep brown colour, and softened; and in Fig. 61 the incision into the muscular substance shows that its exterior, to the depth of two or three lines, is of a dirty cinnamon colour; and it is also friable,—changes resulting from partial carditis propagated from the inflamed pericardium. This discoloration is probably occasioned by an interstitial deposition of lymph. It is generally chronic.

The anatomical characters of carditis, then, according to the foregoing illustrations, are, deep redness, and sometimes a cinnamon or fawn-coloured hue, with softening and friability of the muscle. The characters of inflammation of the internal membrane are, redness either deep or vivid, with morbid lacerability and pulpiness of the membrane, and diminished adhesion to the subjacent parts.

Softening of the Heart. This affection being in many cases a result of inflammation, as above intimated, it may be here described. Whether originating in inflammation or not, it presents two varieties as to colour: 1. With increased redness, namely, claret, morone, red-brown, or violet colour, denoting an excess of blood in the muscle (as in Figs. 56, 64, *d*, and the detached

piece); 2. With diminished redness, namely, faint yellow, or fawn-coloured, like dead leaves (as in Fig. 58, and the edge of the incision Fig. 61), bespeaking a deficiency of blood. These tints are less frequently accompanied with softening than the red.

Softening may be universal or partial. When extensive, the heart, placed on a plane surface, does not maintain its round form, but subsides and becomes flattened. The ventricles, when opened by an incision, collapse, even though thickened. The muscular substance has a flaccid feel, tears with great facility, and is sometimes so soft and friable as easily to break up under slight pressure with the fingers.

It has been shown (p. 73) under what circumstances inflammation may give rise either to the red or the pale softening. It remains to be shown when they may occur without it. Red softening is frequently found in cases where there is a retardation of the venous circulation through the muscular substance, as in dilatation with attenuation, great obstruction of the mitral or tricuspid valve, &c.: also from putrefaction, and from a thin and deteriorated state of the blood, as in scurvy and typhus fever. Bouillaud ascribes the redness in the latter case to inflammation. The question is not satisfactorily decided.

Pale softening, independent of inflammation, has usually been found in subjects who have long been in a cachectic state, or who have been worn down by hectic or other slow fever.

Andral admits the following species of softening of the heart, in reference to the circumstances which precede or accompany it, or concur in its production.

1. Connected with active hyperemia of the heart.
2. Connected with anemia of the heart.
3. Connected with atrophy of the heart.
4. Connected with acute alteration of the general nutritive function (as in typhus).
5. Connected with chronic alteration of the general nutritive function (as in many chronic diseases).

6. Softening, which cannot, as yet, be referred to any morbid state either of the heart or of the system.

(For the symptoms of softening, see Treatise by the Writer, p. 292.)

Abscess of the Heart. This affection is very rare. It is a result of partial carditis. The size of the abscess may vary from that of a pea to that of a small egg. The muscular substance around is red and softened. It sometimes occurs in connexion with pericarditis, of which Fig. 57 presents an instance in a child ætat. seven. The abscess descended about two lines and a half into the muscular substance, and consisted of very pale concrete lymph, softened and containing liquid pus in the centre. A recent false membrane universally invested the pericardium. Laennec and Andral have each seen abscesses about the size of nuts in children under twelve, affected with pericarditis. (Précis, ii. 324.)

Purulent Depositions. These occur in cases where an old diseased and suppurating surface gives rise to the absorption of pus, which is carried by the blood and deposited in the tissue of various organs. The affection has already been described in the lungs, and it presents the same appearance in the heart, the substance of which around the depositions may be healthy. Andral saw a case in which, together with depositions in the substance of the walls, a considerable quantity of pus was mixed with the blood in the cavities of the heart, and was deposited, in several points, in long streaks on the internal surface.

Ulcers of the Heart. These are rare, but less so than abscesses. They may either be confined to the membranes of the heart, or may affect the muscular substance. The internal membrane is their most common seat. Their appearance does not differ from that of ordinary ulcers in muscular and membranous tissues. They, therefore, do not require delineation or further description. They originate either in pure inflammation, or in steatomatous depositions under the internal membrane. The latter is the most frequent cause.

Perforation. Ulcers affecting the muscular substance may either be very superficial, or may penetrate through to the pericardium. This may next give way, and perforation is then complete.

Though ulceration is its most frequent cause, perforation may have other sources : it may, for instance, follow softening, either general or partial. Sometimes no appreciable morbid state can be found in the situation where the perforation exists.

Rupture has sometimes been found to follow falls and violent efforts, and, in a few instances, it appears to have resulted from a strong mental emotion. Rupture from the latter cause, however, could scarcely take place without previous disease of the muscular substance.

It is most frequently in the left ventricle that rupture occurs, a circumstance which at first appears remarkable, since this ventricle is the strongest part of the heart. But, for the same reason, it contracts the most energetically; and as the rupture occurs during the contraction, and experience, further, shows us, that it is only strong muscles which undergo rupture from the energy of their own contraction, we have thus an explanation of the phenomenon.

Corvisart was the first who noticed and described rupture of the columnæ carneæ and chordæ tendineæ. Laennec and Bertin each met with an instance of the same. Violent efforts, as coughing, were the cause; the symptoms were, sudden and very severe suffocating dyspnœa, followed by all the general phenomena of organic disease of the heart.

Perforation of the heart is speedily, and, in general, instantaneously fatal; but it is not from the abundance of the hæmorrhage that death results; for the escape of blood is not very considerable, the quantity being limited by the pericardium. It is, therefore, more from the sudden disturbance of the function of the organ that its action is suspended.

Death may not, however, take place for several hours. Of ten cases mentioned by Bayle, eight died instantaneously, one in

about two hours, and another in fourteen. In the most protracted cases a solid coagulum or fibrinous concretion has been found plugging up the aperture.

Gangrene of the Heart. The existence of this has never been distinctly proved, and its occurrence is perhaps impossible; for, not only is the muscular tissue one of those least susceptible of it; but inflammation of the organ sufficiently intense to occasion it is fatal to the patient before gangrene can take place. Softening with putrefaction has often been mistaken for gangrene.

Induration of the Heart. This affection, being regarded by the majority of authors as a product of chronic inflammation, may be noticed here. Corvisart found induration carried to such an extent, that the heart, when struck, sounded like a dice-box or hollow horn vessel. On making an incision into it, great resistance was offered to the scalpel, and a singular crepitating noise was produced: yet the muscular substance possessed its proper colour, and did not appear converted into either an osseous, a cartilaginous, or any similar substance.

This affection is very rare. Laennec and Bertin met with it, affording a resistance to the scalpel, but not causing the crepitating noise; and the same has occurred to myself. It generally occupies the whole of a ventricle, but sometimes only a portion. It is seldom found but in connexion with hypertrophy. From this it is to be distinguished; for it consists, not merely in an increase, but in a perversion of nutrition.

Anemia of the Heart. In this affection the organ is characterised by a remarkable deficiency of colour, as after long maceration in water. It is represented in Fig. 55, where the tint is a dirty pinkish white.

Anemia is most frequently found in connexion with atrophy of the heart, and both sometimes succeed congestion and hypertrophy, thus conforming with the general principle, that one of the causes of anemia of an organ may be its antecedent hyperemia. (Andral.)

Anemia may also exist without atrophy, as in chronic diseases,

in the aged, and in some cases of dropsy. Other organs may, at the same time, be equally exsanguine. The most remarkable instance that I recollect to have seen was in the subject of Fig. 55, a man of seventy with pulmonary emphysema. The paleness was universal, but was particularly marked in the lungs.

CHAPTER IV.

HYPERTROPHY.—ATROPHY.

BEFORE describing these lesions of nutrition, it is necessary to advert to the natural dimensions of the heart. They are not absolute, but relative to the size of the body, the organ being, according to the criterion established by Laennec, about equal to the fist of the subject. The walls of the left ventricle should be a little more than twice as thick as those of the right, and they usually average about half an inch. The right ventricle has larger and more complicated columnæ carneæ. When incisions are made into the two ventricles, the walls of the left should stand open without collapsing, those of the right should collapse and efface the cavity.

In infancy and old age, the walls of the left ventricle, according to Andral, are three or four times as thick as those of the right. This estimate, according to my observation, is too high.

The muscular substance in hypertrophy is usually, though not necessarily, firmer and redder than natural.

The disease exists with different states of the cavities as to size, and this circumstance is made the foundation of a classification into the following varieties:—

I. *Simple Hypertrophy*, in which the walls are thickened, the cavity retaining its natural dimensions.

II. *Hypertrophy with Dilatation*. This, the *excentric* or

aneurismal hypertrophy of Bertin, presents two forms : A. with the walls thickened and the cavity dilated ; B. with the walls of natural thickness and the cavity dilated : i. e. *hypertrophy by increased extent of the walls*.

III. *Hypertrophy with Contraction*. In this, the *concentric* hypertrophy of Bertin, the walls are thickened and the cavity is diminished. Fig. 60.

Hypertrophy may either be confined to one or more cavities, or may affect all simultaneously. Sometimes one cavity is thickened while another is attenuated. The ventricles are more obnoxious to the disease than the auricles, because the latter are remarkably protected from retrograde pressure by their valves. The left ventricle is more frequently affected than the right, from being exposed to a greater variety of exciting causes. (See Treatise by the Writer, p. 187.)

When all the cavities are at once hypertrophous and dilated, the heart attains a volume, two, three, and occasionally even four times greater than natural ; its form, instead of being oblong, is spherical, its apex is scarcely distinguishable, and, as the diaphragm does not retire sufficiently to yield space downwards for the enlarged organ, it assumes an unnaturally horizontal position, encroaching so far upon the left cavity of the chest, as sometimes to force the lung upwards as high as the level of the fourth rib, or even higher. When great enlargement is accompanied by adhesion of the pericardium, the organ is secured by the attachments of the membrane, in a higher situation than its gravity would otherwise dispose it to assume ; and being thus impacted between the spine and the anterior parietes of the chest, it is apt to occasion a preternatural prominence of the præcordial region.

The left ventricle, being more prone to thickening, and not less to dilatation than the right, sometimes attains a volume seldom or never acquired by the right ; and when its enlargement is enormous, it occupies not only the left præcordial region, but extends far under the sternum, where its impulse and sound may be mistaken for those of the right ventricle.

The walls of the left ventricle, the natural thickness of which averages about half an inch in the adult, may be increased to the extent of one (Fig. 63), one and a half, or, according to some, of two inches. The cases are rare in which it exceeds an inch and a quarter. This was the thickness in Fig. 60. The situation of the greatest thickening is usually a little above the middle of the ventricle, where the columnæ carneæ take their origin. Thence, the thickness decreases rather suddenly towards the aortic orifice, and gradually towards the apex, where it is reduced to less than half. When hypertrophy maintains these proportions in different parts of the ventricle, the state is only an exaggeration of the natural form. The case is different when the hypertrophy takes place inwards and diminishes the cavity, for then the whole ventricle is nearly equally thickened, and its form is unusually globular.

The columnæ carneæ generally participate in hypertrophy (Fig. 60, where at *b*, they are immense); but sometimes, when there is much dilatation also, they appear to be stretched, flattened, and attenuated. The inter-ventricular septum, though belonging almost entirely to the left ventricle, is commonly less thickened than the external walls. When the left ventricle is greatly enlarged, the right, if unchanged, is applied, in a flattened form, to its superior and lateral part, and by contrast looks singularly small. But if, as generally happens, the right is elongated, it is, as it were, folded around the left.

When the right ventricle alone is hypertrophous, it may descend lower than the left, and constitute the apex of the heart. Its columnæ carneæ, naturally more numerous and complicated than those of the left, are more susceptible of thickening than the walls themselves. Hence the increased size of the columnæ is commonly the first object that arrests the attention, and to them alone is the hypertrophy in many instances confined. They are sometimes so curiously interlaced and attached, as to traverse the ventricle in every direction, subdivide it into various compartments, and, in some cases, almost totally to fill up its cavity. These

changes never take place to the same extent in the left ventricle. The total thickness of the walls of the right ventricle, naturally averaging three lines, rarely exceeds four or five; yet it has been known to attain from eleven to sixteen, as appears from the eighty-eighth case of Bertin, and one by Louis, in the *Archives de Médecine*. In a girl of nine years old I have met with it measuring six or seven lines, which is equal in proportion to nearly double that extent in the adult. Hypertrophy without dilatation is much more rare in the right than in the left ventricle. The greatest thickening of the right ventricle is near its base; lower down, though the columnæ carneæ be enlarged, their interstices are usually thin, and not unfrequently translucent.

Hypertrophy may not only be confined to a single ventricle, whether it be the right or the left, but it may be confined to particular parts only, as the base, the septum, the apex, the columnæ carneæ, or the external walls; the remainder of the cavity being either natural or attenuated. Again, a thickened ventricle may be contracted in one part, while it is dilated in another. In examining in the dead subject mixed cases of these descriptions, it is necessary to counterpoise the opposite conditions, to balance the hypertrophy against the extenuation, and the dilatation against the contraction, in order to determine which is the predominant affection.

The hypertrophy of the auricles is almost invariably of the second species, or that with dilatation. Laennec even states that he has never met with any other. The *simple*, and the *contracted* forms, however, are not without example. The thickening is diffused in a very uniform manner throughout the cavities, the musculi pectinati being the only parts in which it is more considerable than elsewhere; and as they are larger and more numerous in the right than in the left auricle, it is in the former that hypertrophy proceeds to the greatest extent. It occasionally renders the auricle nearly as thick as the right ventricle. This I have never known to take place in the left auricle. Sometimes the musculi pectinati are the only parts in which hypertrophy

shows itself. The thickening of the auricular walls seldom exceeds double the natural state, and, being even then inconsiderable, it may easily be overlooked by an inexperienced eye. When it amounts to a quarter of an inch, which is rarely the case, it is very perceptible.

Atrophy of the Heart.—The heart, like any other muscle, is liable to deficient nutrition. Burns found the heart of an adult not larger than that of a new-born infant; and the heart of a female of twenty-six not larger than that of a child of six. Bertin gives a similar case (66): I have met with the same, and numerous other instances are on record.

Atrophy commonly takes place under the influence of those causes which produce general emaciation: chronic diseases, for instance, as phthisis, chronic dysentery, diabetes, cancer, and malignant affections in general. Excessive bleeding is another cause. Laennec adduces an instance resulting from the treatment of Albertini and Valsalva, employed to cure hypertrophy.

Atrophy may also be occasioned by morbid productions, either liquid or solid, developed around the heart or in its substance. Bertin and Bouillaud found it in a case of hydro-pericardium; and Andral, in one of chronic pericarditis with extremely thick false membranes encircling the heart, between which membranes and the internal surface of the organ, only a very thin layer of muscular substance was interposed, and, in some points, even this was totally deficient. He also found only a few scarcely apparent muscular fibres in the walls of the right ventricle of a child aged three, of which the heart was as it were grooved round by a thick layer of tubercular matter. In these cases the atrophy may be regarded either as the result of compression, or of a kind of balance of nutrition.

Fattiness of the heart is another cause of its atrophy. I have seen the organ present only a few pale and scanty traces of muscular fibre, scarcely apparent amongst an excessive accumulation of fat. Less degrees of this state are not uncommon. (See *Fattiness*.)

The heart, when atrophous, generally contracts upon itself, so as to diminish its cavities. By this its walls are not only prevented from becoming materially thinner, but they sometimes become even thicker than natural. The latter condition may be distinguished from hypertrophy, not only by the general diminution of the volume of the organ, but also by the shrivelled and wrinkled appearance of its exterior.

Atrophy may also co-exist with dilatation. I have seen an enormous left ventricle so thin, that, about its apex, the pericardium and internal membrane were in contact. (Treatise, Lambert, p. 551.)

Individuals whose hearts are too small in proportion to the size of the body, are less subject than others to inflammatory complaints, but more prone to fainting from slight causes; and it is worthy of remark, that the female sex, who are more liable than males to the latter, have, in general, proportionally smaller hearts.

CHAPTER V.

DILATATION, AND REAL ANEURISM, OR PARTIAL DILATATION, OF THE HEART.

Dilatation of the Heart.—THIS consists in an amplification of one or more of its cavities. The muscular substance may be healthy in every form and degree of the affection, but in general it is not so. For when the dilatation is great, and the circulation, in consequence, much impeded, the muscle is usually more or less softened, flaccid, and lacerable, and, in some cases, of a deeper red, in others paler or more fawn coloured than natural. (See *Softening*.)

Dilatation presents three varieties according to the thickness of the walls :—

I. *Dilatation with Thickening.*

II. *Simple Dilatation*, in which the walls are of natural thickness.

III. *Dilatation with Attenuation* of the walls.

In the first and second varieties, a predominance of the dilatation over the hypertrophy, whence the symptoms are more those of dilatation, constitutes the only difference between these varieties and *hypertrophy with dilatation*, and *hypertrophy by increased extent, with natural thickness, of the walls*.

Two, or all three of the varieties of dilatation are occasionally found together in different parts of the same cavity.

The two first varieties having been described under HYPERTROPHY, the third variety, i. e. *dilatation with attenuation*, alone remains to be noticed. It is most common in the right ventricle, but is not rare in the left, and it often affects both simultaneously. I have seen the thickest part of an enormous left ventricle not exceed three lines, and, in other cases, I have seen it less than two. The columnæ carneæ are stretched and spread. The interventricular septum is less attenuated and softened than the other parts. Dilatation takes place more in the transverse than in the longitudinal direction of the ventricles; whence it communicates to the heart an unusually spherical form.

When both the auricle and ventricle are much dilated, it is not unusual to find the intermediate aperture widened, and its valve sometimes not large enough to close it. More commonly, however, the valve is enlarged also, and regurgitation is then prevented.

Dilatation is carefully to be distinguished from distension taking place during dissolution. A ventricle merely distended is enlarged, firm, and tense; but these conditions disappear when the blood is pressed out through the arterial orifices. On the contrary, when really dilated, it has no appearance of tension, but is even flaccid, and the enlargement persists after the blood has been expelled. The same criteria apply to the auricles, with the

addition, that, when they are distended, the dark blood within is distinctly apparent through their thinnest parts. Dilatation of the auricles is scarcely ever unattended with thickening.

Partial Dilatation, or real Aneurism of the Heart.—This affection consists of a pouch communicating with one of the cavities of the heart, and, unless very small, forming an external prominence. The size may vary from that of a nut to almost the volume of the ventricle itself, as in a case seen by Corvisart; but most commonly the tumours are not larger than a duck's egg. The walls of the heart around them are sometimes hypertrophous, and sometimes extremely attenuated. In a case seen by Bérard, a portion of the sac was formed simply by the pericardium and fibrinous layers within the aneurism.

The cavity is occasionally lined, and even filled, by dense fibrine in successive strata, exactly as in arterial aneurisms.

In a very few instances the internal membrane of the heart descends into, and lines the cavity; but much more commonly it does not, in consequence of the disease having originated in ulceration of the membrane. I have met with four instances of this affection under the same circumstances: viz. steatomatous degeneration of the aorta had caused the base of one of the sigmoid valves to give way, under which a canal was formed, leading to an aneurism in the muscular substance of the left ventricle and communicating by a second aperture with the cavity of the ventricle. In three of the instances the aneurism was not larger than a nut, or a walnut: in the third it equalled an egg, and was almost universally ossified. It is delineated in Fig. 67. Its walls are perfectly hard and rigid, except around its ventricular aperture *c*, one side of which, near *c*, has been slit open to display the cavity of the aneurism more distinctly. The slit margin consists of dense fibro-cartilage. The bony interior is somewhat blood-stained. No muscular substance invested the aneurism externally.

In the other three instances the internal surface of the cavities was formed by fibrous tissue, intermixed with steatomatous depositions. In none were there fibrinous layers or coagula.

In three of the cases a rasping-murmur accompanied the ventricular contraction : in the fourth, the physical signs were not noticed.

CHAPTER VI.

FATTY, GREASY, CARTILAGINOUS, OSSEOUS, TUBERCULAR, SCIRRHOUS, AND ENCEPHALOID DEGENERATIONS OF THE MUSCULAR SUBSTANCE.

THESE morbid affections may appear almost wherever there is cellular tissue ; and the muscular substance of the heart, therefore, is not exempt from them.

Fattiness.—A great excess of fat is sometimes deposited as a layer between the pericardium and the muscle, amongst the fibres of which it also frequently penetrates, and by pressure, or a balance of nutrition, causes their atrophy. In Fig. 59 the central reddish portion is the only part of the left ventricle not covered with fat, as at *a*.

Functional derangement is not occasioned by this affection, unless the accumulation be extreme, and rupture is very rarely one of its results.

Greasy degeneration.—This, according to Laennec, is an infiltration of the muscular substance with a matter presenting all the physical and chemical qualities of grease. It is seldom seen except near the apex. I have once seen it occupy the greater part of both ventricles. Its colour is a pale tawny yellow. It may be distinguished from softening by its greasing paper.

Cartilage and Bone.—These are rare in the muscular substance. Corvisart has seen the apex of the left columnæ carneæ converted into cartilage. Burns has seen the ventricles perfectly ossified, so as to resemble the bones of the cranium. Renaudin has found the left ventricle converted into a petrification, which, in some parts, had a sandy appearance, and, in others, resembled a saline crystallization.

The cellular tissue beneath the lining membrane is sometimes converted into fibro-cartilage : that beneath the pericardium may become either cartilaginous or osseous, and rings of bone, originating here, have been known to encircle the organ, and send off triangular processes both superficially towards the apex, and deep into the muscular substance.

Tubercle.—This, represented in Fig. 63, is rarely found, and only when the disease is very prevalent in other organs.

Scirrhus is still more rare. Recamier has seen the heart converted in part into scirrhus matter like the skin of bacon, in a subject who had also cancerous tumours in the lungs. In a case published in the *Mémoires of the Royal Society of Medicine*, for 1776, an ulcerated cancer occupied the whole posterior surface of the heart, having for its base only a few thin and softened muscular fibres. All around the ulcer the substance of the heart was remarkably indurated, and, as it were, scirrhus.

Encephaloid Disease.—This, also rare, has been found, 1. in the form of round tumours, varying between the size of a pea and an egg, or larger. Sometimes there have not been more than one or two : in other cases the disease has been so extensive as to occupy the greater part of the organ, more or less completely superseding the muscular tissue, and communicating to the exterior a lumpy or tuberos character. 2. It has been found infiltrated into the muscular tissue, converting it into a yellowish white cerebriiform substance, offering all the characters of encephaloid. Laennec found it forming layers from one to four lines thick, along the tract of the coronary vessels, between the pericardium and the heart. I have seen it forming tumours as large as nuts projecting into the auricles.

There are no characteristic symptoms of this disease as affecting the heart. (Vid. *Précis*, ii. 326, for cases.)

For a detailed account of Encephaloid in general, see p. 45.

CHAPTER VII.

DISEASES OF THE VALVES AND ORIFICES.

THE valves of the heart are composed of an extremely fine layer of fibrous tissue, interposed between a production and reduplication of the lining membrane, to which the fibrous layer is united by delicate cellular tissue. The fibrous tissue is prolonged from a dense whitish zone of the same, which encircles each of the orifices of the heart, and is, as it were, the tendon or point of attachment into which the muscular fibres of the organ are inserted. The lining membrane approximates closely in character to serous membranes: the valves, therefore, are of fibro-serous structure. The fibrous tissue in general is remarkable for its proneness to cartilaginous and osseous degeneration; whence we derive an explanation of the fact, that the valves and orifices of the heart are frequently affected with these degenerations, while the cavities, where they are invested solely with the lining membrane, are, in a great measure, exempt. It is also from the same cause that the bases and free margins of the valves are the parts most subject to the degenerations, the fibrous tissue being there the most abundant.

The diseases of the valves and orifices present themselves under five principal forms:—

1. Hypertrophy of the fibrous tissue.
2. Steatomatous depositions beneath the lining membrane.
3. Cartilaginous degeneration.
4. Calcareous degeneration.
5. Vegetations.

I. *Hypertrophy of the Fibrous Tissue.*—This is merely an exaggeration of the natural structure, and not a morbid production. The hypertrophy is sometimes so great as to form knots, tumours, or diffuse thickening of opaque yellowish-white colour, by which the valves and orifices are more or less contracted,

deformed, and obstructed. This is delineated in Figs. 69, 70, and 72. When the hypertrophy has attained a certain degree, the density of the tissue increases, its fibres disappear, and a cartilaginous transformation takes place. This is partially the case in Fig. 69.

II. *Steatomatous Depositions*.—The seat of these morbid productions is in the fine cellular tissue uniting the internal membrane to the tissue beneath. Though most common on the valves and in the aorta, they also occasionally present themselves on the internal surface of the muscular substance. They consist of an opaque, yellowish-white, friable matter, like cheese, though the consistence is sometimes considerably firmer. By their paleness and opacity, they contrast with the surrounding tissues, to the surface of which they usually give a slight degree of elevation and roughness. Their appearance is delineated in Fig. 68, from the aorta, this part displaying them more distinctly than the valves. In Fig. 66, *a*, they co-exist with a vivid scarlet stain of the aorta, and have led to a perforation, *b*, through the internal and middle coats.

Steatomatous depositions sometimes increase in softness and friability, and sometimes thicken, indurate, and acquire a close resemblance to cartilage. Not unfrequently, also, they become the seat of a calcareous formation, scales of which are seen in Fig. 68, *a*, of deep yellow colour and transparent.

III. *Cartilaginous Degeneration*.—Of this, it is only necessary to say, that it is usually a transformation of hypertrophous fibrous tissue, or of steatomatous depositions, and that it frequently precedes the formation of bone. The remarkable ring, smaller than a pea, into which the aortic valves are converted in Fig. 74, consisted of fibro-cartilage.

IV. *Calcareous Degeneration*.—This presents a marked difference of character, according as it is situated, A, in the cellular tissue uniting the various anatomical constituents of the heart, or B, in the hypertrophous fibrous, or fibro-cartilaginous tissues.

A. When in the cellular tissue, it consists of calcareous

matter, almost pure, or in great predominance over the animal, and, like vesical calculi, it has no organization or vitality. It either assumes the form of small, and sometimes semi-transparent scales, lying flat and superficial under the internal membrane, or between its reduplicated layers forming the valves, as in Fig. 71, *a*; or it exists, and more frequently, as yellowish opaque granules, the agglomeration of which forms concretions of various dimensions, from a mere point to the size of a horse-bean or more. It is this kind of concretion which is occasionally found in the muscular substance, as already described; but its most common seat is in the vicinity of fibrous tissue, namely, along the bases and margins of the valves, as in Fig. 73, *a*, *b*, and *c*, from the aortic valves.

When either the scales or the granules enlarge and acquire a rugged or acuminate surface, they cause absorption of the internal membrane, and come in immediate contact with the blood. So much, however, does this membrane resist destruction, that, in the form of a delicate, tense, bluish film, it covered the greater part of the bony ring round the mitral orifice. Fig. 71, *c*.

B. Calcareous salts deposited in fibrous or cartilaginous tissues, form osseous concretions, which, though they never exhibit either the external aspect or the intimate structure of bone, possess a degree of vitality in virtue of the considerable proportion of animal matter which enters into their composition. In general only a small part of the fibrous or cartilaginous mass is ossified.

The most common situation of this variety of calcareous deposition, is, in the fibrous zone at the base of the mitral and aortic valves, especially the former, which parts it sometimes converts into complete bony rings. Thus, in Fig. 71, both orifices are encircled by rings *b* and *c*, as thick as a quill.

The deposition is also common on the mitral and aortic valves themselves, in those parts where the fibrous tissue is most abundant: namely, at the free margins, and especially in the corpora sesamoidea.

Such is the nature of the four first forms of valvular disease.

We have now to notice some of their general habitudes, and the deformities to which they give birth, previous to describing the fifth form, viz. valvular vegetations.

Valvular disease is more rare on the right side of the heart than on the left, in the proportion, according to my observation, of about one to four and a half or five. When the two sides are affected simultaneously, which is almost always the case when the right side is diseased, it very rarely happens that the lesion on the right is not much less considerable than that on the left; and in all my cases, and nearly all those quoted by authors, the induration on the right side was merely fibrous or cartilaginous.

The cause of this difference has not been clearly determined. It is ascribed by Corvisart to the more decided fibrous organization of the left valves, and by Bertin, to the more stimulating nature of the arterial blood. Without pretending to decide on the value of these opinions, I am led to believe that a concurrent, if not a principal cause, is to be found in the greater pressure or strain to which the left valves are subject, in consequence of the superior contractile energy of the left ventricle, and the greater weight of the arterial circulation. The reasons for this opinion are given elsewhere. (Treatise, p. 166 and 311.)

The frequency of ossification after the age of sixty appears to me to be connected with two circumstances: first, the greater general ossific tendency prevalent in advanced age; and, secondly, the loss of elasticity in the arterial, as well as in all other tissues, at that age, whence the valves and arteries are less capable of resisting the distending force of the blood, and are consequently more liable to disease. (Vid. *ibid.* p. 166 and 314.)

The aspects of valvular deformity are so multifarious as to defy complete description. (Vid. Treatise, p. 311, and *Cyclopæd. Disease of Valves.*) A brief account of them will be sufficient here. Nor is it necessary to multiply pictorial illustrations beyond the exhibition of general characters; since, as particular

characters might be delineated almost indefinitely, to display them all would convey little additional information.

I have seen every degree of contraction of the aortic, mitral, and pulmonic valves up to the size of a smallish quill. In the pulmonic valves, contraction is extremely rare, and is generally connected with a morbid communication between the two sides of the heart. In the tricuspid valve, contraction is much more common than in the pulmonic, but the orifice seldom becomes narrower than the thumb.

The shape in the auriculo-ventricular valves may either be a ring, as in Fig. 72; a slit like a button-hole, as in Fig. 70, *a*, or an oval-shaped collar. The thickness of the border I have seen equal to a quill. When, under these circumstances, the membranous expanse between the border and the base is much contracted, the valve may be stretched tense over the orifice, as in Fig. 70, *c*; when that expanse is not contracted, the valve forms an infundibuliform projection into the ventricle, as in Fig. 72. When the chordæ tendineæ are shortened (a lesion generally accompanied with thickening), as is remarkably the case in Figs. 69, *a*, and 70, and less so in Fig. 72, the valve is held permanently open, so as to admit of regurgitation.

The base of the valves is contracted according to the thickness and situation of the morbid production. In Fig. 71 the straightening amounts to one-third, in both orifices.

The aortic valves are sometimes soldered together, so as to form a ring, as in Fig. 74. Their edges or bases may be partially destroyed by steatomatous disease, so that, having lost their fulcra, they are incapable of resisting regurgitation from the aorta. Osseous concretion, as in Fig. 73, *a*, *b*, and *c*, from the size of a pin's head to that of a horse-bean, and occasionally even of a pigeon's egg, may spring from the base or the edges of the valves, and project into the vessel. When the middle portions of the valves are ossified, they may either be merely crisp with thin scales, as in Fig. 71, *a*, or they may shrink, become united together, or curl up upon themselves, as in Fig. 65, either in the open

or shut position, contracting the aperture in a degree corresponding with the position and the immobility of the parts. An extremely narrow cleft may be the result.

V. *Valvular Vegetations*.—These formations bear a close resemblance to syphilitic warts and cauliflower vegetations on the external organs. Their form is in general irregularly spherical, oval, or cylindrical: their size varies between that of a small pin's head and a large pea; but, when isolated, they are occasionally as large as a horse-bean. Their surface is polished, but often lobulated like a raspberry: they are found either isolated, in clusters, or in closely agglomerated patches resembling cauliflower-heads. Their number is various: sometimes there are only one or two, and sometimes they pervade the whole of the valves, the tendinous cords, and a great portion of one of the auricles. Their colour, occasionally of a greyish or yellowish white, is more commonly heightened, universally or in parts, with light pink or red. Their texture is fleshy like the exuberant granulations of an ulcer, and they possess a similar translucency. Their consistence is variable; in general they are soft and humid, as if only recently and imperfectly organized, and they can then be easily scraped off with the handle of the scalpel; but sometimes they are firm, and cannot be detached without tearing with the nail or cutting with the edge of the scalpel. Firm vegetations are generally larger and more truly wart-like than soft.

Andral, who supports the opinion of Laennec, that vegetations are nothing more than small polypous concretions, adduces the following characters as best calculated to substantiate his views: "They sometimes," says he, "present, in different parts, different degrees of consistence: in some points blood is still seen in the liquid state; in others, it is coagulated, but the clot is soft and coloured;—a little farther, the colouring matter has disappeared, and the fibrine remains alone; this, in its turn, sometimes preserves its ordinary density, sometimes acquires an increased degree, and sometimes softens in such a manner that the

same portion of fibrine is seen, in a small space, gradually to lose its natural consistence, and to become transformed into a friable, pultaceous matter, resembling coagulated milk, concrete pus, boiled albumen, tallow, or animal jelly. Sometimes, in conclusion, every trace of solid matter disappears, and, in certain points of the vegetations, generally towards the centre, nothing is found but a liquid of variable quality."

An extravasation of blood into a vegetation would be sufficient to give rise to the above appearances; it is doubtful, therefore, whether they afford conclusive evidence that the bodies in question are polypi. I am inclined to believe, for reasons assigned elsewhere, (*Treatise*, p. 322, and *Cyclopæd. Dis. of Valves*,) that they result from inflammation modified by some other morbid action dependent either on the constitution, or on antecedent structural lesions of the parts affected. The part on which vegetations are seated is almost invariably diseased; being thickened, steatomatous, cartilaginous, ossified, ulcerated, or ruptured. When vegetations grow from a diseased, but *unbroken* surface, they may be numerous and occur in several parts at once; but when springing from a ruptured or ulcerated edge, they are few in number, often not exceeding one or two, are generally confined to that edge exclusively, and attain a larger size than any others.

The base and free margin of the valves are the most common seat of vegetations. Along these parts, but especially the latter, they are often arranged in a single row. They occur on both sides of the heart, but less frequently on the right. They are more rare in the auricles and ventricles than on the valves.

CHAPTER VIII.

SEROUS CYSTS AND HYDATIDS.

Serous Cysts.—THOSE hitherto found in the heart have not exceeded the size of an egg, and have generally been smaller than a filbert. Their most common situation is on the surface of the organ beneath the pericardium. Sometimes they are seated beneath the internal membrane, and project into the cavities of the heart. In other cases they are completely buried in the substance of the walls, making no projection either externally or internally.

From a single case seen by Andral, it appears that similar cysts may also be developed on the unattached surface of the lining membrane. "From one point of the walls of the right ventricle, near the auriculo-ventricular orifice," says he, "sprung a small serous cyst, of the size of a nut, and which adhered to the internal membrane of the ventricle by a thin pedicle, the texture of which resembled that of the membrane itself."

Serous cysts in the heart are, on the whole, very rare. I have not met with more than one after examining many hundred cases.

Hydatids.—The species denominated *cysticercus* has occasionally been seen in the heart. Andral once found three vesicles, each as large as a nut, transparent throughout, and presenting internally a white point, harder than the rest of the vesicle, which was by pressure made to protrude out of the interior of the vesicle like a head.

CHAPTER IX.

CONGENITAL MALFORMATIONS.

IT is not necessary here to give a detailed account of the multifarious malformations to which the heart is subject. (Vid. Treatise by the Writer, p. 457.) It will be sufficient to advert to the principle of their formation, which modern observation has shown to be of a simple nature.

The great majority of malformations result from a defect, or premature cessation of the process of developement. Hence they often represent the progressive states of the heart as seen in the animal scale, or in the successive degrees of developement of the human embryo.

The lowest degree is complete absence of the organ. This is natural in the embryo fœtus, and is seen in the more advanced, and even in the mature fœtus,—the place of the heart being in these cases supplied by a vascular net-work. (Précis, ii. 310.)

It is remarkable that, hitherto, acardia has been almost always attended with absence of the brain, and most frequently with absence of the spinal marrow also; and, further, that absence of the brain has, almost without exception, been attended with acardia.

Incomplete developement, or *atelocardia*, may present a deficiency of any part of the organ, either of an irregular nature, or as seen in the animal scale. (Vid. Cyclopæd. MALFORMATIONS.)

An excess of developement may also occur, consisting of a supernumerary ventricle, auricle, septum, or vessels. Several of these parts may be supernumerary at once, and even all the parts of the heart may be double.

DISEASES
OF
THE LIVER.

THESE are seated either in the parenchyma of the organ or in the biliary ducts.

DIVISION I.

DISEASES OF THE PARENCHYMA OF THE LIVER.

CHAPTER I.

GENERAL ARRANGEMENT.

LESIONS OF CIRCULATION.

I. *Hyperæmia*.—A, *Active*, viz. inflammation, acute or chronic; B, *Passive*, viz. from a mechanical obstacle to the free entrance of the blood into the right cavities of the heart; also from a spontaneous passive accumulation in the parenchyma of the organ similar to that which takes place in scorbutic gums. C, *Extravasation* into the parenchyma, constituting a kind of *hepatic apoplexy*.

II. *Anæmia*.—A, Dependent on general anæmia; B, dependent on disease of the organ.

LESIONS OF NUTRITION.

I. *Increased Nutrition* or *Hypertrophy*.—A, in which all the anatomical constituents of the organ are equally affected, whence there is no change in structural form. B, in which the red, or

the white substance exclusively, is affected. When either of the varieties A or B presents a distinct mottled appearance by the contrast in colour of the red and the white substances, it constitutes, what is, by a descriptive appellation, denominated the *nutmeg liver*.*

II. *Diminished Nutrition or Atrophy*.—Any or all of the anatomical constituents may be affected. There is diminution of volume, unless atrophy of one constituent is compensated by hypertrophy of another, or by morbid depositions. Atrophy may be accompanied with either induration or softening, and with any variety of colour.

LESIONS OF SECRETION.

The following appear to me to take place in the interior of the white or secreting substance, viz. A, all the varieties of granulations of the liver, as Figs. 75, 78, 79, 81, 82, 84, 89. B, *encephaloid*, and *colloid*, or glue-like matter, constituting the *tubera circumscripta* and *diffusa* of Farre, and the *cancer of the liver* of the old writers, as Figs. 90, 91, and 92. C, *a friable concrete matter like fibrine or tubercle*, Fig. 86, *h*, suppurating and forming isolated abscesses, *f*, which, by conglomeration, constitute masses, *b*. The disease appears to result from *pus*, conveyed into the liver by the blood from another suppurating part.

The following take place both in the red and the white substance, viz. D, *pus* from inflammation, whether infiltrated through the parenchyma of the organ or collected in abscesses; E, *Œdema*; F, *Hydatids*; G, *Serous cysts*; H, *Melanosis*.

* Andral includes, under the head of hypertrophy of one substance with atrophy of the other, the lobulated or granulated appearances of the liver. (Anat. Path. ii. 590.) As I believe that they result from a modified secretion, I refer them to the LESIONS OF SECRETION.

CHAPTER II.

ON THE STRUCTURE OF THE PARENCHYMA OF THE LIVER.

THE intimate structure of the liver has not been fully ascertained in a positive and satisfactory manner. If a healthy liver, somewhat congested with blood, be submitted to examination, it is found to present a uniform red aspect. But if the congestion be removed by slight pressure and washing, or an uncongested portion be taken, we find the organ to be composed of two substances, the one a brownish-red, and the other a yellowish-white.* These substances are still more apparent in livers rather deficient in blood, or from which the blood has been withdrawn by maceration for two or three days. In cases, on the other hand, in which there is an extreme deficiency of blood, the red substance loses its colour, and is less distinguishable from the white.

The two substances may, however, be best examined in cases where the white is hypertrophous, as in Figs. 76, 77, 80, 83, and 85. These present a general mottled aspect, which, on close inspection, is found to be produced, as in Fig. 80, partly by roundish granules of the white substance, (here stained green,) and partly by a coalision or concrescence of two or more of these granules, forming contorted, irregular tracts.

In livers, where the hypertrophy of the white substance is great, the tracts are so continuous that the white appears almost entirely to surround the red substance, as in Fig. 76, *a*; the reverse of which is the case when there is a predominance of the red substance.

At the peritoneal surface, *a*, Fig. 77, the white substance forms detached spots: at *b*, they coalesce, from being more abundant; and, at the section *c*, they form continuous tracts surrounding the red substance. These apparently trifling explanations are offered

* To avoid circumlocution, I shall henceforth call them red and white.

because, in the minds of young students, the subject often creates much perplexity.

Further, on still more closely examining with the eye or an ordinary lens, a macerated portion of liver, (especially if affected with hypertrophy of the white substance, as Fig. 83, lithographed through a lens immediately from the specimen; or Fig. 85, from the same liver, but lithographed without a lens, and of the natural size,) each granule of the white substance, whether detached or continuous with others, is seen to present a delicate central punctum of darker colour, and accompanied with a slight depression, most visible by reflected light. Is this a more lax and collapsing vascular tissue, of the erectile nature, destined for the accumulation of the bile, which imparts to it the dark tint?

Such being the forms presented by the red and white substances, we have next to inquire into their respective nature and function. The principal evidence on this subject has been derived from injections, and they have led to the conclusion, 1. that the red substance consists of the capillary vessels of the organ, constituting, with a little cellular tissue, a highly distensible structure like the erectile, and the chief seat of those extraordinary accumulations of blood which sometimes swell the liver to double its natural volume; 2. that the white substance is a secreting structure destined for the elaboration of the bile. It is believed that, into each granule of the white substance, there proceeds a ramification of the vena portæ, and another of the hepatic artery, conveying two kinds of blood, which, after sustaining a change in their nature, are carried away by a twig of the hepatic vein. In connexion with this change, a new fluid, the bile, is formed, and conducted off by an incipient biliary duct.

Whether the vena portæ, or the hepatic artery, secretes the bile, is to the present day problematical. Bichat favoured the latter opinion, and he is followed by a body of the first French physiologists. In this country it is more commonly believed that the vena portæ secretes the bile, while the hepatic artery is subservient to the nutrition of the organ. The latter, however, was

found by Abernethy to discharge the function of secreting bile in a case where the vena portæ was deficient. The experiments of M. Simon on pigeons have shown that, when the hepatic artery is tied, the secretion of bile continues; but that it is totally suspended when both the artery and the vena portæ are tied.

Mayo attributes the secretion both to the artery and the vein. "That the venous blood will serve," says he, "may be presumed from the experiments of M. Simon; and to employ it upon this object, as far as it will go, is consistent with the wise economy of nature."

The consideration of this subject has an intimate relation with morbid anatomy; for, as we shall presently see, there are states of the liver so exsanguine that the blood of the porta must be extremely, if not wholly, deficient; yet the secretion of bile often continues little impaired.

Ruysch was of opinion that the white granules were solid, and consisted of an interlacement of the capillary vessels above enumerated, with the addition of nerves and absorbents. Malpighi, on the other hand, believed that they were hollow, and formed follicles, or what were denominated *acini*, interposed between the extremities of the vessels bringing the blood, and the radicles of the biliary ducts. To this view the fact has been opposed, that injections thrown into the vena portæ pass into the biliary ducts without sustaining extravasation into the centres of the acini. We cannot, perhaps, hope to arrive at anything positive on this subject through the medium of injections alone, till the hepatic secreting element can be in some way expanded or evolved, so as to render the course of the injections cognizable by the eye, a point so admirably accomplished by Sir A. Cooper, in reference to that once mysterious organ—the thymus gland.

In devoting the above pages to the physiological structure of the liver, it is my object to inquire whether that structure, notwithstanding our limited knowledge of it, does not afford a clue to the process by which take place the various organic alterations

of the liver,—hitherto, so far as I can judge, unsatisfactorily accounted for. Nor will such an inquiry be one of mere idle curiosity; as, with reference to organic changes of so hopeless a description as those in question are considered to be, the first steps towards their cure or prevention must be made through a knowledge of their nature and formation; and as it is impossible to foresee to what important results such a knowledge may lead, the research should not be abandoned till the requisite light is obtained.

We shall consider in succession, first, ordinary hypertrophy of the white substance; secondly, the granulated liver; thirdly, tuberos, encephaloid, and other fungous degenerations.

CHAPTER III.

HYPERTROPHY OF THE WHITE SUBSTANCE (NUTMEG LIVER).

THIS is merely an exaggeration of the natural condition and appearance of the white substance. The red may either remain unchanged, or, as is much more common, may be rendered atrophous, perhaps in consequence of the pressure exercised on it by the white. Fig. 80 presents the ordinary appearance of this affection on a *general* or superficial survey, the deep bilious stain serving to give force to the contrast between the two substances. The colours may vary almost indefinitely, according to the proportions of blood and bile present; but those of a nutmeg, namely, a reddish brown and a brownish yellow, are the most common.

Fig. 85 presents a *minute* delineation of a still greater degree of hypertrophy of the white substance, with atrophy of the red; and Fig. 83 is a macerated portion of the same, magnified to double. They show, as already stated, the central puncta of the

white substance, and the manner in which it forms continuous tracts, variously contorted and convoluted. It is also to be noticed, in contra-distinction to the granulated degeneration, that the acini convey no idea of each being isolated by a cyst; but that they blend together, and even unite with the red substance by a soft outline, as is still more apparent where the red substance is little compressed, as in Fig. 80.

Laennec considered the white substance thus developed to constitute the first degree of an *accidental tissue* denominated *cirrhosis*, from its tawny yellow colour ($\kappa\iota\rho\rho\acute{o}\varsigma$, fulvus), a view which to me appears wholly inadmissible in the present case, the affection manifestly consisting in nothing more than hypertrophy of the natural secreting element.

Most livers in this condition are enlarged; and either softened or indurated, both of which states are generally attended with increased lacerability. From compression of the vascular or red substance, the disease is frequently attended with ascites. Yet the secretion of bile may be perfect, showing that it is independent of a natural quantity of the blood of the vena portæ. It is, however, usually irregular in its elimination, and, probably, in its secretion. A deficiency in the intestines is frequently attended with jaundice, and an excess, with bilious diarrhœa.

The nutmeg liver is less common before than after the middle age, and is most prevalent in dram-drinkers; but repeated attacks of chronic irritation or congestion may also give rise to it. Disease of the heart, offering an obstacle to the admission of blood into the right cavities, seldom exists long without producing enlargement of this kind. (Vid. Treatise on Diseases of the Heart, by the Writer, p. 269.)

Hypertrophy of the white substance is frequently, I suspect, the basis of the granulated alteration, next to be described.

CHAPTER IV.

THE GRANULATED LIVER.

VARIOUS other descriptive appellations, as *tuberculated*, *lobulated*, *mamellated*, have been assigned to this affection by different authors. Baillie confines himself to the term *tuberculated*: Cruveillier, to *granulated*: while Andral and others employ *lobulated* and *mamellated*. It is to this affection more especially that the term *cirrhosis* was applied by Laennec, in reference to the tawny yellow colour frequently presented by the granulations, as in Fig. 75, *c*. They are not, however, yellow in all cases, as Fig. 89.

Figs. 78, 79, 81, 82, and 84, illustrate different appearances of the disease under consideration.

The nature of granulations of the liver, and the mode of their production, have been the source of much speculation and various theories—none, however, capable of accounting satisfactorily for all their anatomical peculiarities. As a solution of the question would dissipate many difficulties in the descriptive history of the affection, precedence will be given to the consideration of this point; and first the opinions of authors will be presented.

Dr. Baillie, without offering any theory as to the mode of formation of granulations, merely expresses his opinion, that, though “this is the common appearance of what is generally called a scirrhus liver, it bears only a remote resemblance to scirrhus, as it shows itself in other parts of the body.” He is, “therefore, disposed to consider it as a peculiar disease affecting this viscus.” (*Morbid Anatomy*, p. 230.)

Laennec regards the yellow granulations (*cirrhosis*) as a peculiar degeneration,—an “accidental tissue of a special nature,” which may occur in a great number of other organs as well as in the liver.

Opposed to this opinion stands that of M. Boulland, which has obtained more consideration than any other of the present day. He regards this state of the liver (*Mém. de la Soc. Méd. d'Emulat.* tom. ix. p. 170, 1826.) "as a disunion of the two natural elements of the organ: the tawny yellow masses, constituting the (supposed) accidental tissue denominated cirrhosis, are nothing more than the secreting granulations (i. e. the white element), gradually undergoing disorganization in consequence of the obliteration of the vascular interlacement (i. e. the red element), and the obstacle to the hepatic circulation which results from it." Thus, according to this view, the granulations are not a new or accidental tissue, but merely an hypertrophous developement of the white or secreting element, gradually undergoing disorganization; while the red or vascular element becomes atrophous and obliterated.

Andral, adopting the opinion of Boulland (*Anal. Path.* p. 585.), considers granulations of the liver to constitute the second degree of hypertrophy of the white substance, the first degree being that represented Figs. 83 and 85. "In the case," says he, "of granulations of the liver, as in that of pulmonary granules, there is no necessity for supposing the production of any new tissue; a simple modification in the structure of one of the component parts of the organ being sufficient to account for them." He further thinks that the red substance may either continue in its natural condition, or be increased or diminished. "As it wastes away," he adds, "it becomes infinitely less vascular, and, in certain cases, is in a great measure transformed into cellular or cellulo-fibrous tissue, a state almost constantly accompanied by ascites."

Cruveillier, while, with Boulland, he considers it positive that granulations in cirrhosis are not an accidental tissue, denies the position of that author that there is disorganization; since the section of the granulations, examined by the microscope, presents the same spongy aspect, and the same texture, as a healthy liver.

Nor does he believe, with Andral, that granulations are formed by hypertrophy of the white substance at the expense of the red.

His view is as follows:—"Since, in the vicinity of large granulations, we find others extremely minute, and a great quantity of fibrous tissue filling the intervals between them, it is reasonable to think that cirrhosis consists essentially in *atrophy* of the greater number of the grains of the liver, and that the remainder become *hypertrophous*, as if to supply the place of those which had wasted away. But what is the cause of the atrophy? new researches are necessary to answer this important question."

Against this view it appears to me conclusive that there are livers, and a recent specimen of one is before me, in which the whole of the granulations are small, and so closely impacted, that scarcely the breadth of a hair intervenes between them. Fig. 84 illustrates the kind of liver to which I refer, except that here the granulations and interspaces are much larger.

Such are the opinions of authors. So far as I can judge from considerable researches, no idea of the nature and formation of granulations of the liver can be derived from examination of specimens in which they have attained a considerable size, as in Figs. 75, 78, 79, &c. It is necessary to select a liver in which they are developed in one part, and only incipient in another.

With a recent pale yellow specimen of this kind before me, and viewing it through a good lens, by a strong lamp-light, I see the following appearances: when a thin slice is laid flat on a plate, the moisture scraped off, and its surface smoothed by passing the side of a scalpel over it, the part where the granulations are only nascent, presents, in appearance, nothing more than the configuration of ordinary hypertrophy of the white substance, as in Fig. 85, the granulations not being, in the present view, cognizable by the sight. But on twisting the slice round a pair of forceps, so as to put its surface well on the stretch, a number of opaque white points, many not larger than grains of sand, start out in the midst of each portion of the white substance,

with which they contrast partly by a slight prominence connected with their greater density, and still more by their superior whiteness and well-defined circumscription.

Passing on gradually to parts where the disease is more advanced, the white points become progressively larger, while what was originally the white substance is resolved, by their encroachment, into a cellular tissue of darker colour, forming the cysts which so abruptly circumscribe and so invariably isolate the granulations, and which constitute, in conjunction with the compressed and no longer distinguishable red substance, the texture interposed between the granulations.

When the disease has proceeded thus far, all appearance of the natural structure of the liver is completely annihilated, and not the slightest clue can be obtained to the mode in which the granulations were originally formed. On the contrary, the appearance of such a specimen as Figs. 75 or 79 is eminently fallacious. For the first idea, perhaps, that would suggest itself to the examiner would be, that the granulations resulted from hypertrophy of the white substance, and the very last that could occur to him would be, that what was originally the white substance constitutes, in combination with the red, the fibro-cellular tissue—often extremely dense, interposed between the granulations.

From what has been stated, it results that granulations consist, not in mere hypertrophy of the white substance, but in an interstitial deposition in that substance, connected with a lesion of secretion. Whether this deposition is an accidental tissue or not, I leave others to decide; but to me it appears to result from an alteration in the form, rather than in the nature of the secretion; since the granulations present a texture, and discharge a function analogous to those of the natural white substance, a greater degree of density constituting the only very appreciable difference.

The present view accounts for several circumstances which have not been explained, and which are inexplicable, on the supposition that granulations are simply a result of hypertrophy of the white substance. These circumstances are, 1. that each gra-

nulation is always perfectly circumscribed and isolated by an interposed tissue, except at the peduncle, by which it receives its vessels, as Fig. 78, *a*; 2. that the granulations can be turned out from cysts formed by this tissue, *ibid.* *a* and *d*; 3. that they commence as points incomparably more minute than the smallest portions or acini of the white substance; 4. that the tissue interposed between the granulations is sometimes more abundant (as in Figs. 75 and 79) than the red substance of a healthy liver, while, at the same time, the volume of the organ is diminished, which diminution could not have taken place had the augmented quantity of the intermediate tissue resulted simply from hypertrophy of the red substance; for, both the red and the white substances being hypertrophous, the organ must have been enlarged.

The increase in the quantity of interposed tissue is often attended with induration, rendering it cellulo-fibrous, as in Figs. 75 and 78. This results from the compressed and impermeable state of the capillary vessels, whence also the colour is a pinkish semi-transparent grey instead of a deep brownish red. Further, is not the state of induration and capillary obstruction productive of atrophy of a certain number of the smaller granulations themselves, in consequence of a progressively increasing defect in the nutritive circulation? This appears probable, because, in cases where there is little induration of the interposed tissue, the number and proximity of the granulations is greater.

It may finally be asked, whether chronic inflammation or irritation contributes to cause the induration. It is consistent with analogy to suppose that the presence of bodies, like granulations, sometimes very dense, might occasion such irritation; but its external symptoms are not sufficiently manifest or constant to enable us to come to a positive decision.

The anatomical characters of granulated livers may now be described, and it will be found that such livers offer no difference in their essential or structural nature, the diversities in appearance being referable to the variable number, size, density, and

colour of the granulations and the state of the intervening tissue.

Figs. 75 and 78 present illustrations of the *cirrhosis* of Laennec in its most characteristic form. The surface of the liver is raised into a multitude of mamellated protuberances, which, in some parts, as 75, *a*, are remarkably spherical, and, in others, as the side *b*, are irregularly round. The general surface is further elevated into larger hills and valleys, arising from the variable size of the tumours, and the unequal contraction of the organ. The peritoneal coat has commonly a less tense, thin, and transparent appearance than natural, in consequence of the diminution of volume allowing it to contract upon itself. Hence, too, it is often wrinkled and puckered. In parts, also, it is thickened, opaque, and fibro-cartilaginous, changes evidently dependent on chronic inflammation. I have frequently noticed that it has a pink fleshy hue, as in Fig. 75, although the structure beneath be yellow. The diminution of volume of the liver often accompanies the advanced stage of the affection delineated, sometimes amounts to two-thirds, and it is always attended with deformity and increased density.

The section, *c*, Fig. 75, displays a multitude of granulations of tawny-yellow or bees'-wax colour, darker in the centre, and of irregularly rounded form, between the larger of which a number of smaller are interspersed, each being perfectly independent of the others, and circumscribed by the abrupt, cutting boundary of its cyst.

The substance of the granulations is so compact that, when cut, they present a perfectly flat surface. Their texture is close, but evidently organized. The tissue between them is cellulo-fibrous, very dense, and of a light pinkish-grey colour.

The same description applies to Fig. 78, (imitated from Cruveillier,) except that the brown-yellow colour is deeper and stains the peritoneum. This Fig. shows, at *a*, the isolation of the granulations, except at the vascular peduncle, while at *d*, is seen the manner in which they can be detached from their cysts. It is

only when the granulations are very firm that these appearances are so distinct. In the specimen, Fig. 89, where the granulations were flabby, they collapsed when detached, and left only indistinct vestiges of a cyst.

Fig. 79 illustrates granulations formed by the same process, but their colour is a remarkably brilliant yellow, and their consistence elastic, whence they rise above the level of the section and present a slightly rounded surface, as indicated by the shade on one side. The scanty proportion of intermediate vascular tissue, which forms a cyst for each granulation, is cellulo-fibrous, of pale-pinkish grey colour, and semi-transparent, (unavoidably blackened by the lithography), *c* is an opened blood-vessel. The exterior *a* displays the manner in which large protuberances are sometimes compounded of smaller. The liver was about double the natural size. The granulations, therefore, had preponderated over the atrophy of the natural elements.

In such livers, *cholesterine*, a fatty principle, has been found; but I am not certain that this was the case in reference to the specimen before us, as no mention is made of its greasing the scalpel, &c.

Fig. 81 represents a liver in which the granulations are of remarkable size, and the intermediate tissue is very scanty, but considerably charged with blood. The granulations are very consistent, as denoted by the flatness of their section, and are somewhat angular from reciprocal compression. *c, c,* are ruptures from a fall, showing the increased lacerability of the organ.

Fig. 82 represents one of the hardest livers that I recollect to have seen. It was double the natural size. Its cut resembled, in feel and flatness, that of new cheese or humid soap, and its colour was, at first, a yellowish grey, mottled with opaque-yellow spots; but, on exposure to air, pale narrow lines developed themselves, as represented in Fig. 84, circumscribing granulations of an angular shape, the centres of which were formed by the spots of Fig. 82, consisting of a matter like steatoma. In other parts of the same liver the granulations were much more minute, but

always slightly angular, in consequence of reciprocal compression.

Fig. 89 is a granulated liver of dim flesh-colour. It was diminished in volume, and the whole texture, though tough, was much more lax and flabby than natural. These characters are best shown by bending a slice, when the granulations start out from the convex surface in the prominent manner represented from *a* to *b*; but when, on the contrary, the slice is laid on a plane surface, the granulations collapse and lie flat, as from *b* to *c*. They could be detached, except at the vascular peduncle; but, from the laxity and scantiness of the intermediate tissue, the appearance of cysts was very imperfect. This state could not be called cirrhosis, as it is not yellow.

The illustrations now given embrace, I believe, all the important forms of the granulated liver; but numerous intermediate varieties may be found, presenting no real differences worthy of notice.

The affection is seldom found before the middle period of life, and spirit drinkers are beyond comparison the most subject to it.

Of the symptoms it may be said, that when the liver is much contracted, deformed, and indurated, ascites is its invariable result; but when it maintains its natural volume, the effusion, though a frequent, is not a necessary consequence.

The immediate causes of the ascites, according to Cruveillier, are, 1. the extension of the chronic irritation affecting the hepatic peritoneum, an irritation denoted by the thickening of that membrane; 2. the diminution of volume of the liver, and consequent alteration in its functions as an organ of hæmatisation. Under this head falls the obstruction offered by the indurated state of the organ to the return of the blood from the stomach, intestines, &c. through the system of the vena portæ.

Icterus is likewise a frequent symptom, the pressure of the granulations on the biliary pores preventing the free transmission of the bile to the ductus hepaticus. Hence the liver sometimes

becomes of a deep yellow or green colour, as in Figs. 78, 80, and 81. Occasionally the jaundice is permanent and the stain of the skin extremely deep. In such cases the blood is generally found fluid after death.

Progressive marcor almost always attends this affection, especially when advanced.*

* The remaining morbid alterations of the liver are reserved for the next number, as they will require illustration by reference to the plates of both numbers.

CHAPTER V.

CANCEROUS TUBERA.

THIS affection, denominated by Cruveilhier *Cancer in disseminated Masses*, by Farre *Tubera circumscripta* and *diffusa*, and by Baillie *Large White Tubercle*, and *Reddish Tumours*, (the latter meaning fungus hæmatodes,) consists of a deposition of *encephaloid* and *paste-like* matter in the parenchyma of the organ, forming rounded masses of variable consistence and appearance.

Cancer in disseminated masses has so great a predilection for the liver, that, according to Cruveilhier, of twenty cases affecting the system in general, nineteen are found in this viscus. He regards it as "perhaps the most frequent disease of the liver." According to my observation, the *nutmeg*, and even the *granulated* degenerations, are more frequent; but cancer is beyond comparison the most formidable malady, being always fatal, and scarcely less obscure in its diagnosis than insusceptible of alleviation by any remedial agents with which we are acquainted.

The remote causes and the essential nature of the affection are still as unknown as those of cancer in general. The texture and mode of growth of the tumours were long conjectural; but it will be shown in the subjoined illustrations that they are explicable on certain general principles connected with the structure of the liver.

Tubera present numerous diversities with respect to *form*, *number*, *size*, *situation*, *consistence*, and *texture*. These heads will be severally considered, and will be illustrated by Figs. 87 and 88, and from 90 to 97 inclusive; also by Fig. 99.

1. *Form*.—A glance at the Figs. will show that the form is always more or less spherical, and that the tumours are abruptly circumscribed, the larger being surrounded by a delicate film or

cyst, (as in Fig. 90, *h*,) which, loosely united to the hepatic parenchyma by fine cellular tissue and delicate blood-vessels, admits of separation by slight pressure. This separation is displayed in the Fig., the surfaces *h* and *g* having been denuded without rupturing their investing film or cyst. The same is seen in Fig. 88, *a* and *b*. The union with the liver is in general more intimate in proportion as the tumours are smaller, firmer, and of slower formation.

The transition from the morbid to the healthy structure is, in a few instances, rather gradual. This occurs when one tumour is formed by the coalition of several, originally detached, the intermediate spaces being gradually filled up by successive depositions. The process is seen in Fig. 94, and is most common in cases where the liver is crowded with hundreds of depositions of every size, as in the instance to which the Fig. refers.

Tubera, which project beyond the surface of the liver, have often a white fibro-cartilaginous dimple or depression in the centre, from which proceed radiating furrows and blood-vessels, their direction being connected with the eccentric growth of the tumours. These characters are displayed in Figs. 91, *d*, 92, *d*, and especially in 99. The superficial vascularity is greater in proportion as the hepatic substance is of a deeper red and has a freer circulation. The central depression is occasioned by an irritative or inflammatory condensation of the sub-serous cellular tissue, which is greatest at the point where the cancerous deposition commenced, namely, the centre. When the rapid development of the tumour does not afford time for this condensation, the depression does not take place. Accordingly, it is principally the hard and chronic tubera, and very rarely the soft, which present it.

2. *Number*.—I have never seen an instance in which there was only a single tuber. Rarely are there less than ten or a dozen, though some of these may be so small as easily to escape notice. The number is most frequently under fifty, but sometimes there are hundreds, and even thousands, as in case Fig. 94.

3. *Size*.—The smallest, consisting of a single grain, may not be larger than a mustard-seed, as in Fig. 94. By the agglomeration or juxtaposition of such grains, the volume may equal that of an orange, as in Figs. 91 and 92. When larger than this, they are generally formed by the coalition of two or more masses, as in Fig. 95. I have seen a series of such masses occupy nearly a whole lobe of the liver, and form a tumour equal in size to a foetal head.

The development of tubera is usually successive, not simultaneous, as is evinced by their being found in the same liver in every stage of progress; some only nascent, others on the increase, others mature, and others again undergoing softening and disorganization indicative of their decline. These various states are displayed in Fig. 92; also in Fig. 90.

4. *Situation*.—Tubera have a remarkable tendency to affect the surface of the liver,—a peculiarity which they display in common with abscesses in the liver and lungs resulting from phlebitis. They generally form projections beyond the level of the surface, as displayed in Figs. 91 and 92, which, when perceptible to the touch through the abdominal parietes, constitute a pathognomonic sign of the affection. When, however, the tumours are soft, the projections are often not only inconsiderable, but they yield to the touch; hence I have known the sign to fail even when the masses were large and numerous. The most voluminous tumours, according to Cruveilhier, are situated in the vicinity of the suspensory ligament and the fissure between the two great lobes.

5. *Consistence and Texture*.—In different livers, and also in the same, tubera are found presenting numerous grades of consistence, from scirrhus firmness to encephaloid softness. These various conditions are referred by Cruveilhier, who has written with much ability on this subject, to two principal varieties, which are compatible and may co-exist with each other, namely, the *hard* or *scirrhus* variety, and the *soft* or *encephaloid*. Each may offer many shades or sub-varieties, and pass through a more

or less numerous series of transformations. Many pathologists regard these two varieties merely as degrees of the same alteration, and designate the hard state by the epithet *period of crudity*, and the soft, by that of *period of softening*: a view which Cruveilhier properly considers as inadmissible, since the two varieties are almost always hard or soft from the first moment of their existence. He thinks it not improbable, however, that the hard variety is, in a few cases, transformed into the soft.

The distinction into the scirrhus or hard, and the encephaloid or soft varieties, is unquestionably both correct and convenient in a descriptive point of view; but I much doubt whether it is founded on any real difference in the essential nature of the alteration. I am disposed to believe, from observation of a rather considerable number of cases, that the difference in consistence is connected, mainly, if not entirely, with the mode of developement, the tumours being softer in proportion as their growth is more rapid. To this opinion I am led by the following considerations:—

1. The hard and soft varieties often co-exist in the same liver, and sometimes in close proximity with each other: hence it is to be presumed that they originate in the same predisposition.
2. When there are only a few tumours, of slow growth, they are generally hard: when there are a great number, and of rapid growth, as indicated by the sudden enlargement of the liver and the speedy supervention of urgent symptoms, they are commonly soft.
3. The internal structure of the two varieties, prior to their decline, is the same, the only differences being in the size of the areolæ, and the density of the septa.
4. The milky fluid yielded by both is the same, though thinner and more abundant in the soft.
5. The differences between the two varieties are not greater than those which exist between chronic firm tubercle, and rapid soft tubercular infiltration, the former of which is displayed in Fig. 29, and the latter in Figs. 17, 21, and 23.
6. As in the case of pulmonary tubercle, so in that of tubera of the liver, the differences in configuration, as well as in consistence, depend

on the mode of developement. This will be rendered more apparent by comparison of the following descriptions:—

Structural Characters of Hard Tubera.—They offer some resistance to the scalpel, and the hardest yield a very slight degree of the creaking sound produced by cutting ordinary scirrhus. The section, as Fig. 92, *b*, displays an areolar mesh-work, irregularly radiating from the centre. The areolæ, when not stained with blood, have the semi-transparent white appearance of paste or concrete lard. The reticulations are darker, yellower, and less transparent, being composed of the parenchyma of the liver, compressed, indurated, and converted into fibrous tissue by chronic irritation,—a state analogous to chronic induration of the lungs around tubercles. When even the hardest tuber is strongly compressed, as between a lemon-squeezer, it yields an unexpected quantity of milky juice, and there remains a broken up mass of opaque, yellowish, cellulo-fibrous tissue. In old tubera, nature appears sometimes to exercise this pressure: thus, in the centre of Fig. 97, the rounded areolæ, the milky juice, and with it the semi-transparency have disappeared, leaving an opaque, yellow, fibrous tissue, radiating in lines from the centre; but at the circumference the same change has not yet taken place, this part being of later formation. In tubera at a still more advanced period of decline, the change is often universal, as in Fig. 96; but the radiating linear arrangement is here obscured or destroyed by incipient disorganization.

Some hard tubera are very vascular, as Fig. 92, *b*: others are so pale that it requires close inspection to discern their fine and almost colourless vessels. In some, especially when declining, extravasations take place, and the black blood and fibrinous coagula, collected in masses, or diffused in granular spots, (as Fig. 93,) greatly disguise the structure of the tumour.

Structural Characters of soft Tubera.—Felt externally, these have a yielding elasticity closely resembling that of a subcutaneous abscess; sometimes the tension is such as to impart a

slight degree of elastic firmness, as in Fig. 88, *a* and *b*, and Fig. 90, *g*. When cut, they are soft and pulpy. Their colour partakes more of the greyish white, and less of the yellow, than the hard variety; their translucency is greater, their areolæ are larger, and their intersections, instead of being dense and thick, are eminently delicate and lax. Some of the tumours are universally pale, scarcely a red vessel being discernible: others, as Fig. 90, *f*, are extremely charged with tumid vessels, which readily burst, and form extravasations, either in small detached spots, similar to those in Fig. 37, *d* and *e*, (encephaloid of the lungs,) or pervading and imparting a rich purple red to the whole tumour, as Fig. 106, *a*, in the interior of which are several yellow spots, *b*, consisting of fibrine of the effused blood in progress of organization. Occasionally, an extravasation bursts the peritoneal coat of the liver. It is in the softest tubera that the greatest extravasations occur, because, as in the case of encephaloid or fungus hæmatodes in general, the vessels are more tender and less supported.

By submitting a slice of a soft tuber to a gentle jet of water, the milky juice is gradually washed out, and there remains a loose web of cellular and vascular tissue, much less abundant than in the case of hard tubera.

Now, the above differences admit of a simple explanation, on the view that, in the hard variety, the cancerous fluid is secreted slowly and sparingly into the interior of the acini (the white or glandular substance); whence there is not only a larger proportion of cellular and vascular tissue in a tumour of given dimensions, but that tissue undergoes induration and thickening in consequence of chronic irritation; whereas, in the soft variety, the more copious and rapid secretion of the morbid juice gives a predominance to the fluid constituents of the tumour, and time is not allowed for the process of induration of the cellular tissue.

According to this view, the complex, and indeed almost unintel-

ligible genera, species, and varieties into which some authors have attempted to distribute tubera, are merely accidental modifications of an identical alteration.

The distinctive feature by which Farre characterizes his *tuber diffusum* (the soft variety), is, that it is often diffused over other textures as well as the liver. Is not this diffusion ascribable simply to the greater prevalence of the cancerous diathesis? Thus we find tubercle more diffused in other texture, in cases where it exists in the lungs in the form of infiltration, a form usually connected with a strong tubercular diathesis.

Both varieties of tubera ultimately tend to disorganization. The hard variety breaks up into curdy fragments, intermixed with a sero-purulent fluid of a dirty yellow, green, or brown colour, as in the interior of the great tumour, Fig. 92. The soft variety resolves itself into a liquid, muddy-yellow pulp. The change usually commences in the centre. Effused blood may form fibrinous concretions and putrid sanies in both.

Seat of Tubera.—Some have supposed that tubera are independent formations in the substance of the liver, since they are often isolated by cysts, as in Fig. 90, *h*. To this view, Farre is inclined, though not without doubt as to its accuracy. The accompanying illustrations* clearly show that the hepatic tissue itself forms the basis or frame-work of the tumours, and that the glandular granules (the white substance) are the seat of the morbid deposition. Thus, 1. in Fig. 94, depositions are seen occupying only individual glandular granules or acini: at *b* they are coalescing, at *a* they have coalesced more completely, and in other parts of the same liver they formed hundreds of tumours of all dimensions, and in every conceivable degree of progress up to the stage of disorganization. The same is seen in Fig. 90,

* As nearly all the drawings were executed many years ago, before I had attempted to generalize on the subject, they cannot be supposed to favour any particular view.

where granular tumours, *b*, co-exist with others advancing, *a*, and others again in decay, *d* and *i*. We thus, as it were, overlook nature in the act of forming tubera from first to last.

2. In Fig. 90, the centre of the tuber *i* is deeply stained with greenish-yellow bile, proving that biliary ducts exist in the tumours.

3. Large trunks of blood-vessels, generally obliterated, may often be detected traversing the morbid masses. Several such existed in the tumour Fig. 87.

4. In the tumour Fig. 87, of the soft or encephaloid kind, and abounding with milky fluid, (which even oozes out when an incision is made into any unopened subdivisions of the mass, as *a* and *d*.) nature has been, as it were, surprised before the completion of her work; for, in the interior, and between the yellow depositions, several pinkish-grey, semi-transparent portions are seen, consisting of actual hepatic tissue, though partly consolidated, and stained here and there with extravasations from the larger blood-vessels. This tumour, in short, was manifestly formed by the successive juxtaposition and coalition of detached depositions—some occupying only single acini, others affecting two, three, or several contiguous ones, as seen in an earlier stage, in Fig. 94. On comparing the tumour, Fig. 87, with the tumour *b*, Fig. 86, (purulent depositions from phlebitis—vide Description of the figure,) it is obvious at a glance, that the structure of the two is identical; the latter displaying hepatic interspaces of semi-transparent grey colour, and the tracts, *d*, of large obliterated blood-vessels. And by referring to the other masses, *h* and *e*, of the same Fig. 86, the process by which the tumours are formed from their earliest state is palpable, i. e., by depositions in the glandular granules gradually coalescing. It is thus shown, in conformity with the proposition advanced, p. 101, that the natural structure of the liver affords an explanation of the structure and formation of cancerous tubera.

Origin of tubera, and anatomical element primarily affected.

—This subject is involved in much obscurity. From examination of a certain case, Andral is of opinion that “these so-called cancerous masses may arise from an effusion of blood, which, when coagulated within the substance of the liver, undergoes various changes from the perfectly fluid state until it passes into a substance possessing all the characters of encephaloid.” (*Anat. Path.* vol. ii. p. 589 and 600.) A coagulum of blood of this description is represented in Fig. 103, *a*; but neither in the present, nor in any other instance that I have seen, has the coagulum presented the structure and shape of a tuber. It therefore appears doubtful whether such effusions give birth to what can properly be regarded as tubera. Andral adds, “it is far from being proved that such is always the origin of these cancerous tumours,” and the account which he then gives of their mode of developement corresponds with that already offered, p. 119, in reference to Fig. 94.

Cruveilhier is of opinion that the capillary venous system is the element primarily affected. His arguments are as follows. Abscesses in the liver, consequent on great surgical operations, &c. (as Fig. 86)—an affection presenting a close analogy to cancerous tubera—originate in capillary phlebitis, consecutive to another remote phlebitis; and, in some cases, not only the capillaries, but even the great veins terminating in the abscesses, are inflamed over a greater or less extent, and contain pus or fibrinous concretions.* Now, it is not rare, in cases of cancerous tubera of the liver, to find one or several great hepatic veins filled with adherent cancerous masses: is it then not probable that the cancerous matter may be generated in the capillary, as well as in the great veins? Of this, Cruveilhier obtained what he regards as irrefragable evidence in two cases, where, having expressed from an incision made in a cancerous liver, a reddish-white, encephaloid matter, which moulded itself like vermicelli, and run out, in a convoluted form, to a great length, he perceived on the

* Fig. 110 presents an instance of these concretions.

section an orifice more considerable than the others, and on following it up, he arrived at a very large vessel, appearing to be a ramification of the vena portæ. He then dissected the vein with much attention, and found that, from its largest to its smallest divisions, it was filled with encephaloid matter, adherent to the walls, and perfectly similar to that expressed from the surface of the incision. He could easily follow the extremely dilated ramifications of the vein even into the areolæ of the tumours. The alteration was wholly confined to the vena portæ.

According to this view, then, it is the vena portæ which deposits the cancerous matter constituting tubera, and the deposition takes place into the white or glandular substance.

State of the hepatic tissue.—In most cases of tubera, the intermediate substance of the liver is perfectly healthy, as in Fig. 87. In others it is diseased, and hypertrophy of the white substance (nutmeg liver) is its most common alteration. Sometimes the organ is enlarged, even to twice, thrice, or four times the natural size, as in the case of Fig. 94: occasionally, on the contrary, it is contracted, either generally or partially. The reduction has been known to amount to upwards of five-sixths of the natural volume.

Colour being a contingent circumstance, principally dependent on the state of the sanguineous and biliary circulation, it may present any of its varieties according to the manner and degree in which that circulation is affected by the disease. When the tubera are very numerous, so as to compress the blood-vessels, the organ is generally exsanguine; and when the greater gall-duets are compressed, it is yellow, green, &c., from retention of bile.

When the afflux of blood to a portion of the liver is intercepted by the pressure of surrounding tumours, that portion, in a few instances, becomes atrophous, exsanguine, and sometimes converted into fibrous or fibro-cartilaginous tissue. The latter change is seen commencing in Fig. 86, *a*.

From all that has now been stated, the following summary may be drawn—

1. Tubera are formed by an infiltration of cancerous matter into the hepatic glandular grains (the acini).

2. The cancerous matter is essentially of the same nature in both the hard and the soft tubera; hardness being merely the result of chronic induration of the cellular tissue, connected with a slow and scanty effusion, and softness proceeding from the opposite circumstances.

3. Observation of cases, and the analogy presented by traumatic abscesses, render it not improbable that the disease commences in the vena portæ.

4. Soft tubera are connected with a stronger cancerous diathesis, whence the rapidity of their developement, and the diffusion of corresponding tumours through other organs.

Symptoms.—The symptoms are, in general terms, identical with those of chronic hepatitis with dyspepsia. Hence the affection is, in most cases, extremely obscure. The only pathognomonic sign consists in the enlarged liver presenting an irregular, lumpy surface, distinguishable through the abdominal parietes.

Causes of the symptoms.—When prominent tubera irritate the diaphragm, they cause chronic cough; and when the liver, by its size, encroaches on the lungs and heart, palpitation and oppression are the result. The stomach irritated by tubera, is affected, not only with the ordinary symptoms of dyspepsia, but sometimes with obstinate vomiting. Icterus is not very common—a circumstance attributable to the healthy condition of the hepatic substance in a large proportion of cases. When it does exist, it generally proceeds from compression of the great biliary trunks by the tumours. The secretion of bile being defective or excessive, there is constipation, or diarrhœa, sometimes alternating. The functions of hæmatosis and assimilation (to which the liver is subservient) being imperfectly performed, paleness and emaciation ensue. Acute pain in the region of the liver gene-

rally results from partial inflammation of its peritoneal coat, excited by the irritation of tubera at the surface. Thus in Fig. 99, the vascularity of the membrane over the tumours is remarkably great.

Ascites and anasarca result, not only from compression or obliteration of the vena portæ and venæ hepaticæ, but in many cases, according to Cruveilhier, from chronic irritation and inflammation of the peritoneum, consequent on the growth of the superficial tumours. The adhesions resulting from this chronic peritonitis constitute a medium by which the cancerous disease is transmitted to other organs as easily as by natural continuity of tissue. Hence the stomach and duodenum are doubly obnoxious to the malady, since they are not only united to the liver by the lesser omentum and capsule of Glisson, but, from their contiguity, are extremely liable to form adhesions likewise.

Treatment.—An effectual mode of treating cancerous tubera of the liver, equally with cancer in general, remains to be discovered; all remedies hitherto employed having been found unavailing. The only advantage at present to be derived from the diagnosis, is that of palliating with judgment, and not treating the patient with injurious activity for imaginary affections of a different nature.

CHAPTER VI.

ABSCCESS OF THE LIVER, CONSEQUENT ON CAPITAL OPERATIONS, WOUNDS, UTERINE AND CRURAL PHLEBITIS, ABSCCESS IN OTHER PARTS, &c.

ABSCCESS and purulent infiltration of the lung from these causes, have been briefly described at p. 11. The delineations there offered are on a small scale, since such appeared to me best calculated to display the first steps, and therefore the real nature, of

the morbid alteration. By comparing them with the illustrations of the same disease affecting the liver, Fig. 86, it will be manifest that the depositions take place by the same process in both organs; the differences in physical character being dependent solely on the different natural structure of the two viscera.

An anatomical account of the depositions in the liver, with a well-marked case, having been given in the Description of the Plates, Fig. 86, (to which I refer the reader,) it is unnecessary to revert to this part of the subject. We therefore proceed to consider the—

Origin and formation of the disease.—Some have maintained the opinion that the abscesses in question were nothing more than the developement of pre-existing tubercles—their views being, of course, directed more especially to the lungs. Of this doctrine it is sufficient to say that it is wholly untenable; all the phenomena of the malady, if accurately observed, being opposed to it.

Velpeau has of late years revived the discarded doctrine of the absorption of pus, of its circulating unchanged with the blood, and of its being deposited, equally unchanged, in the substance of various organs, without any appreciable inflammation of those organs. This doctrine, supported by MM. Maréchal and Eugène Legalois, and adopted by Andral, (Path. Anat., ii. p. 540,) reposes on the facts that depositions of pus have been seen by most modern pathologists of experience in the liver, lungs, spleen, brain, veins, in the right side of the heart, in clots of blood, in lymphatic vessels, in muscles, and in sinovial membranes, unaccompanied by any manifest anatomical vestiges of inflammation around them.

Quesnay, Morgagni, and more recently MM. Blandin, Dance, and Cruveilhier, have supported an opposite opinion: viz. that visceral abscesses are the result of a circumscribed inflammation of the viscus itself, occasioned by the presence of pus in the blood; and that this contamination of the blood is the cause,

not the effect, of the diminution or suppression of the primary suppuration, and of the concomitant constitutional disturbance.

This view has long appeared to myself the most simple and correct.* It rests on the following arguments, as sketched by Cruveilhier. 1. The formation of visceral abscesses is always accompanied by general symptoms of greater or less severity, which are wholly inexplicable from the state of the wound. 2. The absence of local symptoms in the viscera is no evidence of the absence of inflammation of those viscera; for, on the one hand, a great number of inflammations are unattended with pain; and, on the other, it is not rare to see visceral abscesses preceded and accompanied by pain of considerable acuteness. Tenderness of the liver to the touch, and local or general pleurisy, connected with superficial abscesses in the lungs, have frequently revealed the existence of the disease. In general, however, the inflammation is as latent as possible. 3. There undoubtedly exist a great number of abscesses, which do not present the slightest trace of inflammation exterior to the purulent cyst, as in Fig. 10, *a*; so that, in such cases, the pus has the semblance of having been deposited pure and simple in the tissue of the organ; but this absence of inflammatory appearances is only observed in abscesses which are completely formed; for if the patients die at a less advanced period of the malady, we meet with all the stages of circumscribed inflammation of the lungs or liver, as may be seen by reference to p. 11, in relation to Fig. 10; and also to Fig. 86 and its description, where it cannot be doubted that the lymph-like appearance of the depositions at *h*, and the state of the intermediate hepatic tissue in all the three masses, is connected with an inflammatory process. The designation of *lobular peripneumony* or *hepatitis* has been aptly applied to the disease by Blandin; the individual abscesses being often restricted to one or more lobules in the lungs, and to one or more acini in the liver.

* The observations at p. 12 were originally written before I was acquainted with the opinions of the above authors.

Supposing it then to be established, that visceral abscesses are formed by circumscribed visceral inflammations, it will next be inquired how a remote suppuration can give rise to these inflammations. The reply is—through the intervention of *phlebitis*. The following are the proofs.

Cruveilhier injected any irritant, as ink, into the femoral vein of a dog: in thirty-six hours the limb contained innumerable depositions of blood (*foyers sanguins, apoplectiques*) in the substance of the muscles and cellular tissue. The large veins were distended with concrete and adherent blood; the small veins leading to the sanguineous depositions were also full of concrete blood, while those leading to sound parts were free. When the animal survived the experiment, depositions of pus replaced those of blood, at the same time that pus replaced the coagulated blood in the veins.

The same results were obtained by the introduction of a mechanical irritant—a piece of wood—into the femoral vein. On the sixth day, when the animal died, all the veins, both large and small, of the inferior extremity, were injected with pus. When the muscles were divided, small collections of pus appeared here and there: they proved to be veins distended with pus, which could be pressed out with the utmost facility. Around these veins the muscular substance was red, lacerable, and, in short, in the state of red induration which precedes suppuration. It invariably happened that diseased veins conducted to these red indurations, and that healthy veins corresponded with sound portions of muscle. Had the animals lived longer, it is probable, thinks Cruveilhier, that purulent depositions would have replaced the red indurations, and that a small lacerated vein would have opened into each abscess.

Now, the morbid changes in these instances are identical with those so frequently following traumatic phlebitis. It is therefore to be inferred that, in both cases, there is the same relation of cause and effect. It was next, then, to be determined, in order

to account for visceral abscesses, in remote organs, what became of the pus generated by a primary local phlebitis when introduced into the torrent of the circulation; and as globules of pus cannot be distinguished and followed when mixed with the blood, experiments were made with mercury, which offered this advantage. When the metal was introduced into any part of the venous system, except that of the abdomen—even into the medullary interior of bones—it was invariably found in the lungs, each globule being surrounded, after a few days, by a patch of red induration,—later by a purulent deposition,—still later by a mixture of pus and tubercular matter; and, if the animal survived two or three months, the result was the formation of tubercles with a mercurial globule in the centre of each.

When the mercury was introduced into the venous system of the abdomen, the same effects were produced on the liver.

Hence, the lungs constitute an inevitable outlet or receptacle for foreign matters introduced into the general venous circulation; and the liver, for those introduced into the abdominal venous system. In most cases the barrier is insuperable, the foreign matter being either retained by the organ or eliminated with its other excretions; but in some cases, the lungs allow it to pass through the pulmonary veins, and the liver through the hepatic veins, into the general circulation. In this manner, therefore, a morbid cause may repeatedly traverse the whole capillary system, and successively form depositions in many different organs, and even in different points of the capillary system of the same organ. Thus it was that in the case illustrated by Fig. 110, coagula and purulent formations existed in the veins of every important organ; and thus also abscesses in the liver occur so often after surgical operations, which, in the first instance, affect not the abdominal, but the general venous system. When morbid matter is introduced by means of absorption,—as, for instance, from the alimentary canal,—the excretory powers of the system, naturally endowed with wonderful activity, are in general able to

eliminate it; but when it is introduced directly into the circulation or generated there, as by phlebitis, those powers are most commonly inadequate to the task of its expulsion.

The conclusions from the above experiment, which have been repeated and varied in an infinity of ways, are, "that pus in circulation with the blood is arrested in the different departments of the capillary system; that it may everywhere occasion *capillary phlebitis* or circumscribed inflammations, which run more or less rapidly through their successive stages till they terminate in abscess; that the pus, like mercury, is arrested most frequently in the lungs, next in the liver, and then in the spleen; that, like mercury, it may traverse the capillary system several times in succession, and occasion circumscribed inflammations in every part of the body." (Cruveilhier.)

But in addition to its effect in occasioning capillary phlebitis, pus, as already hinted, contaminates, alters the crasis, and causes the coagulation of the blood itself. Thus in the case of Fig. 110, fibrinous concretions in progress of suppuration, and originally nothing more than coagula, were found floating loose in the larger veins of almost every important organ. They had not resulted from local inflammation of those veins, since no trace of such inflammation was exhibited by the coats of the vessels, even where some of the coagula were slightly adherent. In the lungs alone was there capillary phlebitis, with red induration passing into suppuration.

Similar coagula, containing pus in their interior, have been found in the right cavities of the heart. These cases show that suppuration of coagula may take place by some peculiar modification of the blood itself, (Path. Anat. ii. p. 420,) independent of surrounding vascular connexions.

Andral, not recognizing capillary phlebitis as the cause of traumatic abscesses, supposes that a similar coagulation of blood and its suppuration in the smaller branches of the pulmonary vessels, constitute one class of the abscesses in question, (Path. Anat. ii. p. 541.), the other class being composed, (accord-

ing to his opinion already mentioned,) of pus separated as by a filtre in the tissue of organs. (Ibid. p. 540.)

It cannot be too often repeated that it is the contamination of the blood by pus, and not the local abscesses, which are the cause of the formidable constitutional symptoms attending these cases. No sooner has the deleterious intermixture taken place, than there succeeds a severe rigor, followed by typhoid, adynamic, and nervous symptoms, speedily terminating in death. Repeatedly have I seen the patient pass from a favourable to a hopeless state in the course of six, eight, or twelve hours.

Against the view that contamination of the blood and visceral abscesses result from the introduction of pus into the circulation, certain objections have been urged which require notice:—
1. Why, it is asked, do not visceral abscesses occur in cases of empyæma, lumbar abscess, and other great collections of pus,—collections which frequently undergo rapid and complete absorption? Because, it may be replied, the absorbents do not act on bodies in mass, but on their elements, which they probably decompose. Thus the most liquid part of pus disappears before the solid, the latter sometimes acquiring even a caseous consistence. In the same way, mercury introduced by the absorbents does not occasion visceral abscesses; nor do the innumerable unwholesome articles taken into the circulation through the medium of the alimentary canal.

2. In some cases of visceral abscesses, especially those connected with wounds of the head, no primary phlebitis, either contiguous to the suppurating part or remote from it, can be detected. This objection is explained by the fact that phlebitis of the bones themselves is one of the most frequent causes of visceral abscesses following wounds and surgical operations in which the bones are implicated. (Cruveilhier.)

3. Every phlebitis does not give rise to abscesses. This is because adhesive inflammation unites the coagula to the vein, and, should suppuration take place, the pus, circumscribed by the coagula, is prevented from penetrating into the circulation. It is

then either taken up by the absorbents, or it bursts through the walls of the vein and forms ordinary abscesses in the surrounding parts. Little danger, then, attends a local *adhesive* phlebitis, unless the situation or extent of the obliteration seriously interferes with the circulation. Thus obliteration of the cerebral sinuoses is fatal, because the venous circulation of the brain is arrested; and crural phlebitis, when extensive, may be followed by the formidable phenomena of phlegmasia dolens.

It is obvious that the utmost care should be taken to detect and arrest phlebitis in the first stage: for should suppuration take place, there is no certainty that the blood will not become contaminated; and, under these circumstances, the case is commonly hopeless.

CHAPTER VII.

INFLAMMATION OF THE LIVER.

INFLAMMATION of the liver is either *acute* or *chronic*. 1. *Acute hepatitis*.—This affection is rare in temperate, but frequent and destructive in tropical climates. It is attended with various shades and hues of increased redness. A frequent morbid appearance attending rapidly destructive inflammation in India, and occasionally seen in this country, is, an almost black colour, connected with great sanguineous engorgement, and most frequently accompanied with softening.

Abscess is a frequent result of inter-tropical hepatitis: in this country it is comparatively rare. It is sometimes attended with well-marked acute symptoms: in other cases, it supervenes slowly and insidiously, long after the acute attack appears to have subsided. Occasionally the symptoms are so obscure as scarcely to excite a suspicion of the liver being the seat of disease.

The abscesses (the appearance of which is too familiar to

require delineation) may be small, like peas or nuts ; or they may attain the size of eggs or oranges : not unfrequently they are enormous, converting a whole lobe, and even the whole liver, into a single purulent cyst. Abscesses are in general lined by a dense, whitish, false membranous cyst, and the surrounding hepatic substance is usually redder and more friable than naturally. The suppuration involves both the red and the white substance.

In chronic cases, we sometimes find small abscesses filled with thick, and even cheese-like matter, and presenting the appearance of softening tubercles. When abscesses reach the surface of the liver, they excite chronic peritonitis, by which adhesions are formed to the contiguous parts, and a channel opened for the discharge of the purulent matter. It may thus escape either externally through the abdominal parietes, or into the stomach, the ductus communis choledochus, the intestines—particularly the colon, and even through the diaphragm into the right lung. Of the latter, I have met with two instances, in one of which the patient recovered after expectorating two quarts of pus.

2. *Chronic hepatitis*.—This term is often applied in a very vague and indiscriminate manner to almost all chronic affections of the liver, though, in many instances, there is no evidence of their being of an inflammatory nature. Such for instance are the numerous varieties of nutmeg, granulated, and cancerous liver.

Chronic hepatitis may either be the consequence of an acute attack, or it may take place independently. Its anatomical characters usually are, more or less enlargement of the liver, increased depth of colour, abscesses, morbid lacerability, sometimes induration, and sometimes softening. It is difficult to determine anatomically, in cases preceded by acute hepatitis, where the acute affection terminates and the chronic begins ; since several of the morbid alterations, as, for instance, abscesses and softening, are the same in both.

CHAPTER VIII.

CONGESTION OF THE LIVER.

CONGESTION often occasions symptoms very similar to those of chronic hepatitis, except that they are less obstinate. It may result either from a passive accumulation connected with sluggish vascular action, or from mechanical obstruction to the passage of the blood into the right side of the heart. Hence, it is common in organic disease of the heart and in asphyxia. Infants dying of the latter, during parturition, have the liver so gorged with blood, that an extravasated layer sometimes overspreads its surface, beneath the peritoneum, and not unfrequently even bursts into the abdominal cavity.

Congestion may also be attended with extravasation into the hepatic parenchyma, as represented in Fig. 103.

In chlorotic females and others with a feeble circulation, congestion is a very common cause of aching and fulness in the right hypochondrium, with nausea, headache, and languor—symptoms in general promptly relieved by a brisk calomel purgative followed by a few doses of a saline aperient.

CHAPTER IX.

HYPERTROPHY, ATROPHY, INDURATION, AND SOFTENING.

Hypertrophy.—Hypertrophy of the white substance is treated of at p. 102; that of the red substance is illustrated by the remarkable and rare case Fig. 112; sometimes both substances appear to be simultaneously hypertrophous. In all these cases, the liver is generally enlarged. Enlargement may also occur without any manifest structural change, and affect either a part or the whole of the organ. Real enlargement must not

be confounded with tumefaction from mere sanguineous congestion.

The granulated degeneration (p. 104) is in some cases attended with contraction, and in others—especially when recent—with enlargement.

Cancerous tubera sometimes enlarge the liver merely by the amount of their volume ; but in other instances, the parenchyma itself is likewise hypertrophous, and in such cases the liver may attain a greater size than under any other circumstances. Thus in the case of Fig. 94, it was four or five times its ordinary dimensions.

The foetal and infantile liver is by nature disproportionately large, and in some subjects—generally those presenting other perversions of nutrition characteristic of a scrofulous diathesis—the inordinate size occasionally remains during childhood, and even during life ; being, as Andral well observes, one of the local signs of an affection really universal.

As enlargement of the liver is compatible with either an excess or a deficiency of both blood and bile, it may be attended with every variety of colour which those fluids can impart. It may also be accompanied with induration, with softening, or with a natural consistence, according to the character of the concomitant morbid alteration.

Atrophy.—This may be general or partial. Though the organ is most commonly diminished in size, it is sometimes not only of its natural dimensions, but even enlarged. This results from the deficiency of the proper parenchyma being replaced by cellular tissue—generally in a state of induration, and occasionally containing serous cysts and hydatids.

The granulated liver is frequently atrophous and contracted, and such I have occasionally found to be the case with the nutmeg liver.

Induration.—This is a frequent affection. It is generally connected with structural disease : viz. with the nutmeg, and, still more, the granulated degenerations ; but it may exist inde-

pendent of either, and it then appears to have its origin sometimes in chronic hepatitis, and sometimes in mere congestion—especially that proceeding from a permanent cause, as organic disease of the heart. The colour and size of an indurated liver vary indefinitely according to the nature of the primary lesion.

Softening.—Softening from acute inflammation sometimes amounts to actual pulpiness, offering scarcely the slightest resistance to the finger. Occasionally a sanious, puriform fluid is infiltrated through the whole of the part affected, and this may or may not be accompanied with circumscribed abscesses. The colour may be an ordinary, though muddy red; it may be preternaturally pale, or, when the inflammatory congestion has been great, as in India, it may be a deep black.

Chronic softening is more commonly pale, as if the vessels had not tone to circulate the blood. It has also more of a friable than of a pulpy character. It may accompany any structural disease of the liver.

CHAPTER X.

ADIPOSE AND CHOLESTERINE DEGENERATION.

FROM the experiments of Braconnet and Vauquelin, it appears that the liver naturally contains a small quantity of fatty matter, and that it also secretes another adipose principle, met with in other parts of the body likewise, and known by the name of *cholesterine*. Should the fatty matter and cholesterine happen to be secreted in increased quantities, or to be modified in their qualities, they impart to the liver a pale yellow, or yellowish grey colour, resembling decayed leaves, and attended with a diminution of consistence. The affection is represented in Fig. 107. Such livers grease the scalpel, and easily yield the oily principles by boiling; the quantity amounting sometimes only to a few drops, and occasionally to more by measure than the hepatic

parenchyma itself. In some cases, the secretion is infiltrated through the whole organ, and in others it exists only partially. Instead of being infiltrated, it is occasionally accumulated in circumscribed spots, like tubercle or pus, forming grey or white masses, which push aside the parenchyma of the liver, and present all the physical properties of fat. Such masses have been found, consisting exclusively of cholesterine. In almost every instance, fatty degeneration of the liver occurs in consumptive patients. Hence, Andral offers the hypothesis that as, in such persons, a sufficient quantity of hydrogen ceases to be eliminated by the bronchial mucous membrane, in the form of aqueous vapour, it is separated in excess from the blood in the hepatic parenchyma, and so produces the fatty matter. (Path. Anat., ii. 595.)

CHAPTER XI.

MELANOSIS OF THE LIVER.

THIS affection is very rare in the liver. It presents the same characters here as in other tissues: the reader is, therefore, referred for an account of it to the chapter on MELANOSIS, p. 49. Fig. 109 is an external view of melanosis of the liver. Some of the tumours are slightly elevated above the surface.

CHAPTER XII.

SEROUS CYSTS AND HYDATIDS.

THESE are more frequent in the liver than, perhaps, in any other organ except the kidney.

Serous cysts, also denominated *aqueous encysted tumours*, are

often confounded with hydatids, though essentially different; the latter being parasitic animals, and the former not. Serous cysts, represented in Fig. 108, are usually found at the surface of the liver, in which they make a depression, *b*, equal in depth to about one-third of their perpendicular diameter. They are covered by the peritoneum, which, when peeled off, as in the cyst *a*, leaves the tumour almost as transparent as water. The thickness of the cyst, together with the peritoneum, is seen at *c*. When, however, the tumour is large, the cyst is much thicker and stronger. The base, *b*, is traversed in an irregularly reticulated manner, by slightly elevated filaments of cellular tissue. The most common size of the tumours is that of a marble, but they may increase to a magnitude capable of containing many pints. The fluid is generally almost as clear and colourless as water; sometimes it has a slight amber tint, as in Fig. 108. After it has been poured off, I have commonly observed a few fine flakes of a concrete, glistening, greasy matter remaining in the cyst. The fluid, when analyzed, is found to consist of water containing the smallest possible proportion of albumen and other animal matter.

Serous cysts may inflame; whence their coats may thicken to the extent of two or three lines, may acquire a fibrous and fibro-cartilaginous density, and may even undergo ossification. The contained fluid may, at the same time, be rendered thick and purulent. The disease sometimes terminates, both in the liver and elsewhere, in fungous and hæmorrhagic, though not malignant ulceration.

From two cases by Mr. Brodie, (London Med. Gaz., vol. i. p. 334,) and from the able researches of Mr. Hawkins, (read to the Med. Chir. Soc., December 11, 1832,) it appears to be well established, that if the fluid be drawn off by a trochar before inflammation of the cyst has taken place, even though the tumour have attained the capacity of two or three pints or more, a favourable termination may be anticipated. Nor is this to be despaired

of even after inflammation has set in, and the nature of the fluid has been altered.

Hydatids.—These are found enclosed in a cyst, often very large, and occasionally attaining a size almost equal to that of the liver itself. Though, when small, the cyst may be thin and transparent, it sooner becomes thickened and indurated than the serous cyst; a circumstance attributable to the irritation constantly maintained by the enclosed animals. The external layers of a thick cyst are usually fibro-cartilaginous, while those within are soft and pulpy, as if formed by recent depositions of lymph. The fluid, at first watery and not coagulable by heat, soon acquires a mucilaginous consistence, and a greenish yellow colour; and keeping pace with the changes in the cyst, it eventually becomes thick, viscid, and purulent. Like the fluid of the serous cyst, it often contains a glistening greasy matter.

The hydatids vary much in number and appearance. Sometimes a single large hydatid almost completely fills a thin cyst; in other cases, a few globular hydatids, seldom larger than marbles and walnuts, float in a large quantity of thin fluid; in other instances, a great number of small hydatids are suspended in a thick, dirty, mucilaginous secretion; and, finally, we sometimes see the cyst filled with an immense mass of pulpy membranes, consisting of the remnants of extinct hydatids, as if the size of the cavity had been insufficient to allow the developement and maintain the vitality of so great a number beyond a certain point.

The symptoms of serous cysts and hydatids are of a two-fold nature; one class resulting from mere pressure of the tumour, and the other from inflammatory irritation of the cyst.

1. Pressure occasions a sense of weight and fulness in the region of the liver, with inability of lying in particular positions; operating in the direction of the lungs and heart, it gives rise to difficulty of respiration, cough and palpitation; interfering with the stomach, it excites nausea and vomiting; irritating the liver itself,

it occasions pain and tenderness in the right hypochondrium, with aching of the right shoulder; compressing the great biliary ducts, it breeds jaundice; and obstructing the circulation through the vena portæ, it leads to ascites. Should the increase of the tumour be gradual, these symptoms, with the exception of jaundice and ascites, may exist for several years without greatly deteriorating the general health; but, at length, constitutional disturbance, with emaciation, and frequently with jaundice and ascites, take place, and destroy the patient by gradual exhaustion.

2. The symptoms resulting from inflammatory irritation of the cyst, are much more serious and rapid. They are analogous to those of internal suppuration in general, and are fatal by hectic and marcor. If, however, a vent, either natural or artificial, be given to the matter, the cyst, in many instances, readily closes, and the patient recovers.

Hydatid cysts being much more apt to inflame than serous cysts, in consequence of the irritation of the contained animals, they constitute a proportionably more dangerous form of disease; and, on the same principle, those hydatid cysts are the least dangerous which contain the fewest hydatids in proportion to the quantity of fluid.

Serous and hydatid cysts may open externally, through the abdominal parietes; into the stomach or intestines; into the cavity of the peritoneum; into that of the pleura; and into the bronchi.

DIVISION II.

DISEASES OF THE BILIARY APPARATUS.

THE diseases of the biliary ducts and gall-bladder are the results of inflammation, acute or chronic, or of the presence of biliary calculi. They occasion little inconvenience, unless, by contracting

or obliterating the canals, they prevent the passage of the bile, the retention of which gives rise to formidable, and even fatal symptoms.

Acute inflammation, either originating in the biliary ducts, or propagated from the duodenum, may cause such tumefaction of the mucous membrane as greatly to contract, and even totally obliterate the tubes affected.

Chronic inflammation may occasion hypertrophy and induration of the mucous membrane, and subjacent cellular tissue, the effect of which is to contract or obliterate the ducts; but, should the bile, by its quantity, exert an unusual distensive power, the ducts, having lost a portion of their natural elasticity, may become dilated.

Inflammation, either acute or chronic, may cause softening, ulceration, and even perforation of the biliary ducts. In the latter case the bile escapes into the cavity of the peritoneum.

Inflammation causes the same alterations in the gall-bladder, as in the ducts. Its walls may be red, tumid, softened, ulcerated, or perforated; or they may undergo hypertrophy; and the sub-mucous cellular tissue may become fibrous, fibro-cartilaginous, tuberculous, calcareous, and even osseous. The interior of the gall-bladder may be the seat of various morbid secretions, as mucus, calculi, pus, blood, &c.

The gall-bladder may be affected with atrophy, by which its cavity may be greatly contracted or completely obliterated. The usual cause is an obstacle in the ductus cysticus preventing the ingress of bile; but the affection is frequently unconnected with any manifest cause.

Dilatation of the biliary ducts and gall-bladder is a common occurrence. It generally proceeds from an obstacle to the egress of the bile, as a calculus, fibro-cellular thickening of the ducts, external tumours compressing them, &c. The dilatation from these causes sometimes extends, in a very sensible form, even to the finest subdivisions of the biliary canals, while the large trunks may acquire the diameter of a finger or more. The pre-

sence of an enormous calculus has even been known to enlarge the ductus communis choledochus to the size of the duodenum. (Cruveilhier.) It is remarkable that, in consequence of the great dilatability of the gall-ducts, the bile will sometimes force its way past the largest calculi. The gall-bladder, under the influence of obstacles in the ductus communis choledochus, may acquire five or six times its natural magnitude.

To produce the above effects it is not always necessary that the obstruction should be very considerable. Thus Cruveilhier mentions a case in which cancerous lymphatic glands, compressing the ductus communis choledochus, had caused enlargement of the gall-bladder to the size of an ordinary bladder; yet slight pressure on it caused the bile to pour into the duodenum.

Further, cases have been met with in which the biliary ducts were as large as the vena portæ, without the presence of any obstacle impeding the passage of the bile. In such instances the dilatation must either be attributed to an obstacle which has disappeared, leaving the passages incapable of recovering themselves by their contractibility; or it must be ascribed simply to an inordinate secretion of bile causing their over-distention.

Alterations of the Bile, and Biliary Calculi.—No necessary relation of cause and effect can be traced between the alterations of the bile and those of the liver. The reason of this is, that derangements of secretion in general often depend more on lesions which elude our observation than on those which are apparent. Thus, by changing the food, or, in other words, modifying the blood, Majendie was enabled to alter at pleasure the composition of the bile.

Some bile is almost harmless, while that from other subjects is poisonous, producing pustules, ulcers, &c., on the tongue and lips, and even occasioning death.

The colour of bile may range from black to an almost transparent white, through numerous intermediate shades of green, brown, orange, and yellow. Its consistence may be as thick as pitch, or as fluid as water.

The different chemical elements vary in their nature and proportions. The yellow matter, or the resin, may be predominant; cholesterine may be superadded; and, in some cases, especially of fatty liver, little more is found than water and albumen.

Biliary calculi, sometimes merely a mixture of mucus and inspissated healthy bile, most frequently result from alterations of chemical compositions, the more insoluble principles being precipitated when existing in excess. Andral gives five varieties: viz. 1. consisting of the yellow matter of the bile; 2. of the resin; 3. of cholesterine; 4. of picromel; and, 5. of phosphate of lime. A sixth variety would comprise those consisting of several of the above constituents combined.

Some calculi are of a brilliant polished black, as Fig. 102, though they may be brown within; others are of a deep green, as Fig. 98; others are of a rich brown, as Fig. 101; and others are almost white. Some have a crystalline texture, and a brilliant semi-transparent fracture. Calculi may vary from the size of grains of sand to that of a pigeon's egg or more, as in Figs. 98 and 100. When many exist together in the gall-bladder, they have facets on them caused by contact and compression. Large calculi in the ducts are sometimes composed of smaller with facets, agglutinated together by inspissated mucus, as in Fig. 98.

Calculi are found—1. in the substance of the liver, as in Fig. 111, where they are surrounded by a fibro-cellular cyst; but whether they are deposited in the capillary gall-ducts, or in the interior of the acini, is uncertain; 2. in the larger ducts, especially the *hepaticus*, *cysticus*, and *choledochus*; 3. in the gall-bladder. In the latter, as many as a thousand have been found. It is by inflammation of the cystic mucous membrane, and scarcely ever by the mere circumstance of their presence, that calculi in the gall-bladder give rise to inconvenient symptoms.

From observations, principally on sheep, Cruveilhier is led to believe that inflammation, acute or chronic, of the biliary radicles,

may be the origin of a lesion commonly mistaken for tubercles. "Having," says he, "had occasion to examine a certain number of livers of new-born infants, studded with tubercles, and the tubercles, when cut, having presented a cavity filled with concrete bile, I have doubted whether these pretended tubercles were not the result of inflammation of the biliary radicles, which, obliterated at certain distances by adhesive inflammation, became biliary cysts." Some of the cavities were unilocular, as Fig. 114, *c*, and others were multilocular. Nearly all were, in the case represented by the Fig., filled with biliary concretions. Many of the tubercles, whether solitary, *b*, or agglomerated, *a*, were perfectly solid, of fibrous density, and were probably formed by the obliteration of cysts. The walls of the cysts, in all the cases examined by Cruveilhier, were very thick and resistant.

He is disposed to believe that biliary cysts may attain a considerable size; for in one case he found a multitude, of various dimensions, some as large as pigeon's eggs. They were partly at the surface, which they elevated, and partly in the interior, were completely isolated from the biliary ducts, and contained a liquid strongly tinged with yellow. They are represented in Fig. 115.

DISEASES
OF THE
ALIMENTARY CANAL
BELOW THE DIAPHRAGM.

CHAPTER I.

GENERAL ARRANGEMENT.

LESIONS OF CIRCULATION.

I. *Hyperaemia*.—This may exist, *first*, with a healthy state of the intestine, being a result of, A, a mechanical retardation of the blood from an obstacle in another part of the circulation, as in the heart, liver, or lungs: B, *post-mortem* gravitation of the blood to the most dependent parts of the canal: C, transudation of blood through the coats of the vessels, from cadaveric decomposition. *Secondly*, hyperaemia may result from disease of the intestine: viz. A, inflammation, acute or chronic: B, other irritations, as diarrhoea.

II. *Anaemia*.

LESIONS OF NUTRITION.

I. *Hypertrophy*, A, of the mucous membrane, embracing not only diffuse thickening, but partial or circumscribed excrescences constituting what have been denominated vegetations, polypi, fungi, cancer: B, of the mucous follicles: C, of the sub-mucous and sub-peritoneal cellular tissue, and of the muscular coat, lesions commonly denominated scirrhus of the stomach and intestines.

II. *Atrophy*, A, of the mucous coat: B, of the muscular: C, of all the coats.

III. *Softening*, A, of the mucous coat: B, of all the coats.

IV. *Ulceration*, A, from small spots of inflammation: B, from diffuse inflammation: C, from softening with or without injection: D, from preternatural development, generally inflammatory, of the isolated or the aggregated mucous follicles: E, from gangrene: F, from tubercles in the sub-mucous cellular tissue.

V. *Perforation*, A, from ulcers: B, from softening: C, from over-distension either by flatus, (seen only in animals,) by the effort of vomiting or straining, or by external pressure: D, perforation called *spontaneous*, the cause of which is doubtful: E, perforation *into* the canal, occasioned by abscesses, &c. exterior to it.

VI. *Changes of capacity, subsequent to various lesions of nutrition.**

LESIONS OF SECRETION.

I. *Morbid secretions in the mucous membrane*: viz., A, the natural secretions of mucus, perspirable vapour, and gases, increased in quantity: B, new secretions, namely, *a*, blood; *b*, melanosis; *c*, pus; *d*, tuberculous matter; *e*, false membrane; *f*, calculous concretions.

II. *Morbid secretions beneath the mucous membrane*: viz. *a*, blood; *b*, serum; *c*, fat; *d*, gases; *e*, pus; *f*, melanosis; *g*, tubercle.†

Of all the organs of the body the alimentary canal is that in which identity of lesions least frequently indicates identity of symptoms.

* For congenital lesions, a subject not requiring delineations, the reader is referred to Andral, Path. Anat. II. p. 153.

† For intestinal worms or entozoa, the reader is referred to Andral, Path. Anat. II., p. 209. After reviewing the anatomical alterations of the alimentary canal, this author proceeds to examine the functional derangements separately, and inquire to what anatomical condition of the canal each of them corresponds. To this instructive inquiry (ibid. p. 218) the reader is referred; also to a disquisition on the local origin of fever, (p. 242) and an account of the state of the alimentary canal in the diseases of the various organs.

Hence it is impossible to classify the lesions according to diseases; that is, according to groups of symptoms to which particular designations have been assigned, as enteritis, diarrhœa, &c.; I therefore propose to follow very nearly the above arrangement.

One of the greatest difficulties in the study of gastro-intestinal alterations is, to determine whether they are the results of disease of the part or not. With the view of diminishing this difficulty I shall, before illustrating the individual morbid alterations, present a sketch of the natural state of the part, and of the changes to which it is liable from causes independent of disease.

CHAPTER II.

HYPERÆMIA OF THE ALIMENTARY CANAL.

THERE are very few subjects in which redness may not be observed in some part of the alimentary canal. This has led to a double error. One party have regarded a degree of redness as natural; another have too constantly mistaken it for inflammation. The difficulty of steering between these two errors is great, and there is not any subject in pathological anatomy where, for the purpose of guiding the judgment, greater importance attaches to a precise knowledge of the natural colour of the part, and of its modifications unconnected with disease.

The natural Colour of the Alimentary Canal.

The intestinal mucous membrane of a living animal, during a tranquil state of the circulation, is observed to be of a red tint somewhat deeper than that of the mucous membrane of the cheek in a healthy man. This tint is replaced by uniform paleness, or, at the utmost, by a delicate rosy tinge when the animal is deprived of life without much loss of blood, which causes preter-

natural paleness, and without asphyxia, which causes mechanical injection. It thus appears that the mucous membrane, like the skin, tends to become pale after death. Accordingly, in the human species as well as in animals, it has been found of this colour in most cases of accidental death occurring during a state of perfect health.*

The pale colour, however, has not the same shades in all parts of the canal and at all ages. In the stomach, and still more in the great intestine, of the adult, it presents a dead-white hue, while in the duodenum and jejunum it is of an ashy or greyish white, which diminishes towards the end of the ileum. Such, then, is the natural colour in the adult.

In the fœtus and very young infant, the membrane is tinged of a rose-colour, which, gradually diminishing, is replaced in children by a milky and satiny whiteness: this becomes dimmer towards puberty, and, in the adult, passes into the ashy-grey shade above described. In the aged, the grey colour becomes more decided and general, being in some measure dependent on the dilated and congested state of the submucous veins, which impart a colour to the super-imposed membrane. In extreme old age, however, and in young children who have died of marasmus, the *maximum* degree of paleness is sometimes observed, being connected with the anæmia which exists under both these circumstances. I recently saw the intestine of an old man as white as if it had been long in maceration.

Hyperaemia independent of Disease of the Canal.

There are numerous circumstances preceding, attending, or following dissolution, capable of imparting a red colour to the alimentary canal. The causes operating before death are,—

1. Digestion. During chymification, the interior of the stomach, and during chylication that of the duodenum, jejunum and ileum, is observed in living animals to acquire an increased

* See numerous cases by Billard, "De la Membr. Muq." p. 5, et seq.

degree of redness; and this continues to a certain extent after death; for in the part where the process was going on at the moment of dissolution, the mucous membrane presents a beautifully delicate rose-colour.* It is not very appreciable below the duodenum.

2. All circumstances opposing the free return of the venous blood from the intestines to the right side of the heart; namely, asphyxia,—obstructions of the vena portæ, whether by disease of the liver, tumours situated in the course of its principal intestinal divisions or coagula in the vein itself; strangulation of the intestines; organic disease of the heart, and affections of the lungs attended with considerable dyspnœa. Asphyxia operates more or less in almost every case of slow and difficult dissolution. The effect of the above mechanical causes admits of ocular demonstration; for if a coil of intestine be denuded in an animal slowly suffocating, the redness is observed to become more deep and uniform in proportion as the dyspnœa increases: again, if the vena portæ be tied, not only does the mucous membrane become of a rich red, but the blood sometimes transudes through the walls of the vessels and either escapes into the cavity of the canal or forms ecchymosis in the submucous cellular tissue.

The redness from the present class of causes is, of course, less, in proportion as the body is, from any circumstances, in a more exsanguine state.

The degree of redness varies according to the intensity of the cause. In the lowest degree there is nothing more than a bluish intumescence of the larger sub-mucous veins; certain branches in the mucous membrane next become injected, presenting the different gradations of ramiform vascularity: finally, the capillary net-work is completely affected, and the result is a uniform red stain. These characters generally pervade a large extent of intestine: but if circumscribed, which is rare, they may form bands, patches, streaks, spots, or mere points: every appear-

* Billard, cases 9, 10, 11, and 12; also others at p. 80.

ance, in short, which we see produced by inflammation. In order, therefore, to determine whether the redness be inflammatory or not, accessory circumstances, presently to be described, must be taken into consideration.

Redness occasioned after death is referable to two principal causes: 1. gravitation of the blood; 2. its transudation through the parietes of its vessels. (Path. Anat. ii. p. 14.)

1. It has been proved by MM. Trousseau and Rigot, that in animals placed in every possible position immediately after death, the blood invariably gravitates to the most dependent parts of the intestines. The same has been fully confirmed by observation on the human subject. The redness may present all the characters just described as resulting from mechanical injection, except the transudation of blood into the interior of the canal.

Injection from gravitation or hypostasis commences immediately after death, and continues till the blood has cooled down to the point of coagulation. Hence it will be greater, *cæteris paribus*, in cases where the temperature is naturally or artificially maintained for an unusually long period, or where, from a morbid peculiarity, the blood remains in a preternaturally fluid state. It will also be greater in subjects abounding with blood, and in those affected previous to death with congestion of the portal system.

2. Transudation of blood through the walls of the vessels is the second cause of red colouration produced after death. It commences simultaneously with putrefaction, and takes place in all the vessels, large as well as small. Thus it forms the red spots almost always observed along the veins of the greater extremity of the stomach, when the subject is examined more than thirty-six or forty hours after death. These spots, extending and coalescing, constitute multiform groups, bands, streaks, &c.; and eventually, not only the tract of the vessels, but the whole surface of the organ becomes more or less uniformly tinged. When there is much congestion of the vessels, the mucous membrane, and, equally, all the other coats may become thoroughly soaked and reddened.

Complete transudation may take place within the brief space of twenty-four hours, provided putrefaction be favoured by a high summer temperature and atmospheric humidity. Under such circumstances blood may even transude into the interior of the canal.

Transudation from the spleen also, particularly when the blood of this organ is very liquid, may communicate a stain to the stomach.

The following table, taken from Billard, presents a synopsis of the characters of congestive redness as compared with inflammatory:—

Congestive Redness.

1. With or without manifest thickening of the membrane.*
2. Almost always in a depending part of the tube.
3. With general injection of the abdominal vessels.
4. With an obstacle to the course of the blood (as from obstruction in the vena portæ, liver, heart, or lungs).
5. Seldom consisting in an isolated injection, but often occupying a whole coil of intestine, or an entire intestine.
6. Without increased facility of detaching the mucous membrane, which can only be torn off in small flaps, as in the healthy state.
7. Without abundance or thickening of the internal mucous secretion, but sometimes with exudation of blood.

Inflammatory Redness.

1. With or without manifest thickening of the membrane.
2. Indifferently in a depending or non-depending part of the tube.
3. Without general injection of the abdominal vessels.
4. Without an obstacle to the course of the blood.
5. Sometimes consisting only in a limited local injection.
6. With friability of the sub-mucous cellular tissue, and the possibility of detaching the mucous membrane in large flaps.
7. With abundance and thickening of the intestinal mucous secretion, and sometimes with exhalation of blood.

* To make this character to a certain degree distinctive, it should be added that real thickening is frequent in inflammation; but that in congestion, there is merely vascular intumescence, and this not very appreciable except in extreme cases, and unfrequent in mere congestion, particularly in that resulting from gravitation alone.

Should lymph, ulcerations, enlarged mucous glands, or elevated, dark-red patches of mucous membrane of a fungous appearance, be observed, they afford additional evidence that the redness is inflammatory rather than congestive.

It is convenient to notice here the discolourations produced by intestinal gases and bile.

Blood inclosed in a bladder and immersed in different gases undergoes remarkable alterations of colour; and, accordingly, the same alterations are found to be sustained by blood exposed, through the parietes of its vessels, to gases developed in the intestines. As the gases are in general a result of putrefaction, it is commonly not until this process is considerably advanced, that the alterations take place. The prevailing colours are various tints of green and brown.

A rich yellow colour is not unfrequently imparted to the stomach and intestines by the bile, which, in such cases, instead of merely overspreading the mucous membrane in its ordinary manner, combines with it, and produces a stain incapable of being removed by washing. This is, by Andral and others, ascribed to the presence of an acid, which, setting the yellow matter at liberty, places it in circumstances more favourable to imbibition.

Yellow patches or bands of greater or less extent are sometimes seen in the mucous membrane of the duodenum or jejunum in its healthy state. The nature of these is not positively ascertained. Billard thinks that they take place subsequent to death.

Such are the varieties of intestinal discolouration resulting from causes independent of disease of the intestine itself.

Hyperaemia of the Alimentary Canal from Disease.

WE have now to examine redness produced by acute and chronic inflammation, and to endeavour to ascertain and illustrate the characters by which it may best be discriminated from passive redness.

In order to obtain the clearest and most unequivocal evidence of the effects of acute inflammation, it is best to adopt what in chemical language would be called a synthetic mode of proceeding: viz. to produce the inflammation by the introduction of irritating poisons into the stomach.

The results of such a process are found to be as follows:—

1. A slight irritation is productive of an arborescent or ramiform vascular injection. 2. When the irritation is greater, the intervals between the ramifications are more filled up, and the appearance is that of a minute capilliform net-work. 3. When the irritation is intense, as in Fig. 118, produced by a large quantity of arsenic, the interstices between the reticulations are completely filled up, and the result is a diffuse redness of greater or less depth. This redness is sometimes spotted, as in the present instance, by points of more intense inflammation, in many of which, extravasations exist, partly upon the mucous membrane, but principally in its substance, and in the subjacent cellular tissue.* In other cases, as when poisons of a different description are employed, the colour, instead of being red, is violet, brown, or black.

Now, all these appearances may occur in inflammation resulting from ordinary causes. We therefore proceed to examine them more in detail; and as it is desirable to give precision to medical language by the employment of conventional terms expressive of particular states, I shall adopt those of Billard, which are, perhaps, as unexceptionable as can be selected.

The alterations of colour of the mucous membrane are reducible to four principal species, namely, red, brown, slate-coloured, and black. Between each of these there are intermediate shades, which can be imagined or delineated with more precision than they can be described.

* The gangrenous spots and sloughs *a*, *b*, were occasioned by the stomach pump.—See Description of the Plates, Fig. 118.

The Red Colour.

THIS presents several varieties of aspect, which may be characterized by the following appellations:—1. Ramiform injection; 2. Capilliform injection; 3. Redness in patches; 4. Diffuse redness; 5. Speckled redness; 6. Streaked redness.

Before illustrating these varieties, it may be useful to remark of inflammatory redness in general, that it proceeds, in its formation, in the reverse direction of the mechanical congestions. In the latter, the injection commences with the great veins, and spreads from these to the capillaries. In inflammation, on the contrary, it most frequently happens that we find only the capillaries injected, while the vessels of larger diameter are devoid of colour. The absence, therefore, of general congestion of the abdominal vessels, affords an argument of much weight that the redness is inflammatory.

1. *Ramiform Injection*.—This is illustrated by Fig. 119, from the fundus of the stomach. It consists of small vascular ramifications, not appertaining to any principal trunk, and producing, by the elegance of their arrangement, an effect agreeable to the eye. Injection of the conjunctiva from a transitory irritation, or remaining after an acute attack, presents a perfect type of the present variety; and, in the mucous membrane, as in the conjunctiva, the appearance depends on the introduction of the red particles of the blood into vessels naturally not destined to receive them.

Ramiform injection is the result of an irritation so slight as to be incapable of propelling the blood into the finer capillaries of the mucous membrane. It is, therefore, either the first trace of a mild incipient inflammation, or the vestige of a more severe inflammation, which has nearly subsided. This form of inflammation may exist without producing appreciable symptoms.

When ramiform injection results from passive congestion, it is connected with some of the circumstances, 3, 4, or 5, in the table at p. 151.

2. *Capilliform Injection*.—When the preceding variety becomes so crowded with fine twigs as to lose its branch-like appearance, and form an inextricable reticular interlacement, it constitutes the present variety, represented by Fig. 116, from *a* to *b*. It sometimes surrounds, or is continuous with parts in a higher degree of inflammation, as the part *b, c*, of the same Fig.; and it occasionally forms beautiful zones around ulcers, especially those of Peyer's congregated glands in the ileum. When the injection is very minute and close, it may be mistaken, without careful inspection, for diffuse redness.

Capilliform injection may be attended with thickening of the mucous membrane, and softening of the sub-mucous cellular tissue, allowing the membrane to be peeled off in flaps of one, two, or three inches in length, from the edges of which blood oozes in minute drops. The redness is completely removed by maceration in water for twenty-four hours. This variety of injection, unless very limited in extent, is attended with sufficiently marked symptoms of inflammation. When retrograding, it returns to the ramiform state.

Passive capilliform injection occurs under the same circumstances, and may be discriminated by the same means, as passive ramiform injection, of which it is merely a higher degree.—(See Table, p. 151.)

3. *Redness in Patches*.—Of this, an exemplification is presented by Fig. 117, from the stomach. The patches are of a bright red colour, of irregular shape, most commonly of one or two inches in diameter, and have sound portions of mucous membrane interposed between them. Sometimes they are very limited in number and size, in which case the inflammation is slight; but in other cases they pervade a considerable extent of intestine, are attended with thickening and sensible elevation of the mucous membrane above the surrounding level, and with friability of the sub-mucous cellular tissue; they are overspread with a thick tenacious mucus, and occasionally even with flakes of false membrane; sometimes they terminate in minute ulce-

rations. These characters bespeak inflammation of high intensity.

Redness in patches, seated in the great intestines, particularly their lower part, is the most common morbid alteration presented by simple dysentery.* When seated in the ileum, it is attended with the symptoms of enteritis,† and is common in fever.

The present variety of redness is far from rare. Some authors have even regarded it as perhaps the most common product of simple inflammation of the mucous membrane. (Abercrombie.) This is very conceivable; for experiment and observation have proved that the healthy mucous membrane is not possessed of a high degree of irritability, and that irritants, as certain poisons, or foreign bodies impacted in the canal, only produce local redness in patches or streaks, bounded as it were to the sphere of action of the irritating agent.—(Billard, *De la Membr. Muq.* p. 201; Boulland, &c.)

Passive redness in patches is rare, and may be recognised by the circumstances mentioned in the table at p. 151, and by the absence of the other anatomical vestiges of inflammation just described.

4. *Diffuse Redness*.—This is represented by Fig. 116, *b* to *c*, but the colour may attain any degree of intensity, as that of Fig. 117 or 118. It occupies, as its name indicates, a considerable extent of surface; for instance, the whole stomach, the whole duodenum, or the whole ileum. In cases of spasmodic cholera in this country, I have, in several instances, seen it pervade, with a rosy colour, the whole of the stomach, duodenum and small intestines. In general, not only the mucous membrane, but all the coats, are more or less injected, and present a pink colour externally.

Diffuse redness is the result of a higher degree of inflammation than any other variety: in it, therefore, the other vestiges

* Vid. Cases 84 and 85, by Abercrombie, "On the Intestinal Canal."

† Ibid. Case 91.

of inflammation are in general more distinctly developed: viz. thickening and softening of the mucous membrane, facility of detaching it, and an abundance of thick adherent mucus, sometimes of a puriform aspect. More rarely we find a coating of false membrane. (Abercrombie, Case 89.)

The redness is completely removed by maceration for twenty-four hours, a circumstance justly regarded by M. M. Scoutteten, as affording evidence that the inflammation was acute; for when the redness has existed so long as to have become intimately incorporated with the membrane, it does not wholly disappear on maceration.

Diffuse inflammatory redness is more apt than other forms to be confounded with passive injection, because the latter likewise is commonly diffuse. Great attention must therefore be paid to the distinctive characters explained at p. 151.

The mucous membrane may acquire a diffuse red stain from blood effused into the canal (Billard, Case 37.), and from certain colouring liquids taken either as medicine or food (Ibid. Case 38.); for instance, black currants, infusion of logwood, &c.

It may here be stated that a secondary inflammation, supervening with much intensity in an organ exterior to the alimentary canal (as the uterus after parturition), may dissipate by revulsion the inflammatory redness of which the canal was anteriorly the seat; and, further, that if the inflammation had proceeded so far as to cause alterations of tissue, viz. thickening and softening of the mucous membrane, with facility of detaching it, these alterations prove the disappearance of the inflammation. (Billard, Case 39.)

5. *Speckled Redness*.—This variety has been aptly compared to the section of an inflamed brain. It may also be produced with great nicety by scattering fine grains of powdered vermilion on the moist surface of paper. Some of the grains form hard specks while others partially dissolve and form specks, with softened edges. The appearance is represented by Fig. 122. The specks may either be disseminated at intervals of five or six

lines, and present only a light rose-tint, or they may approximate within a line or two of each other, and attain the depth of a cherry-red. Sometimes they become more or less confluent, as in the Fig., and thus form either patches of variable extent, or zones encircling ulcers or the orifices of the stomach; or, finally, they form lines and tracts, apparently connected with the wrinkles of the stomach, and the plaits of the *valvulae conniventes*.

The nature of speckled redness leads to the belief that it is produced by extravasation from a certain number of minute vessels of the mucous membrane, taking place on the first inflammatory impulse. It is, therefore, to be regarded as a vestige of only slight inflammation, especially when not attended with thickening and softening of the mucous membrane, and an increased secretion of inspissated mucus.

Diffuse redness sometimes presents more or less of the speckled or spotted character, as seen in Fig. 117, and still more in Fig. 118. In the latter, the spots were probably occasioned by adherent particles of arsenic, from which, as nuclei, the inflammation was propagated to the intermediate parts.

Inflammatory speckled redness must not be confounded with that which may be produced artificially by scraping the mucous membrane with the edge or back of a scalpel. In this case, the pressure exercised by the instrument extravasates the blood contained in the vessels, and causes it to form speckled stains of the membrane, which cannot be removed by mere washing, though they yield to maceration. The mucous membrane, therefore, should never be examined by scraping with a scalpel, but the mucus should be detached either by washing, or by drawing the intestine with gentle pressure through the first finger and the thumb.

Speckled inflammatory redness must also be distinguished from the passive ecchymosis, which has already been noticed as occurring in connexion with mechanical injection of the alimentary canal. The presence of such injection, particularly if resulting

from an obstruction to the circulation, or from death by asphyxia, and the absence of vestiges of inflammation, must guide us in the diagnosis.

The spots of purpura hæmorrhagica, a rare affection, may be recognized by their large size, their almost black colour, and by their occurring simultaneously in the peritoneum, mesentery, omentum, and other tissues.

6. *Streaky Redness*.—This is not a very common variety. Fig. 121 exhibits a remarkably fine specimen of it. The summits of wrinkles in the stomach, and of the valvulæ conniventes in the parts below, are its ordinary seats. The number of the streaks, and the depth of their colour, vary according to the degree of inflammation. They are sometimes observed to occur in a part previously affected with chronic inflammation. The alteration is attended with thickening and softening of the mucous membrane, and an increased quantity of thick viscous mucus. By these characters it is to be distinguished from streaks produced by transudation consequent on putrefaction, and generally following the tract of the great veins.

Such are the varieties of inflammatory redness. We have now to notice two sub-varieties of hyperæmia, namely, of the villi, and of the follicles.

1. *Hyperaemia of the Villi*.—This is exemplified by Fig. 124. It is characterized by its dotted form. The surface of the membrane is overspread with a number of small red, black, or brown points, which are often so crowded as to leave no intervals exempt from the colour.* Each point consists of the summit of one of the villi—a fact which, as Andral observes, “ becomes particularly evident when the examination is made under water, as the innumerable filaments constituting the villi then become very apparent; sometimes they are coloured only at their free extremity, and sometimes through their whole extent. In certain cases the injection is confined solely to the villi, and there is no

* The grain of the lithography expresses these points very successfully.

trace of it in the membranous tissue from the surface of which they arise, and in which they are in a manner inserted." (Path. Anat. ii. p. 46.)

2. *Hyperaemia of the Follicles*.—This is exemplified by Figs. 130 and 131, to which the description of Andral accurately applies. "On hyperaemia of the follicles," says he, "appear to me to depend those red circles which are sometimes found scattered over the stomach or intestines. These circles, which are apparently formed by very small vessels interlaced in various ways, circumscribe a slight elevation of the mucous membrane, which is owing to the presence of a follicle, as Fig. 131, *b* and *c*. It often happens, that while the circumference of the follicle is thus defined by a vascular circle, another, smaller, but equally red, crowns, in a manner, the margin of its central orifice, as at *a* of the same Fig. This circle, like the preceding, consists of an assemblage of small vessels most minutely injected. We may find in the same intestine a great number of follicles which are thus injected only at their circumference and centre, while they remain white in the rest of their extent. Frequently, too, both the red circle of the circumference, and that of the central orifice, become larger, approach each other as they increase in size, and at last meet, which produces a uniformly red colour in several of the follicles, as Fig. 130. At other times, instead of these red circles, we observe some of a brown or black colour, which present, in other respects, the same arrangement. In certain cases, however, there is nothing to prove strictly that a follicle exists where the coloured circles in question make their appearance, as there is no prominence to be observed within the circle, no depression towards the central red point. If in such cases we admit the existence of hyperaemia, it can be only by analogy."

Hyperaemia affecting the large vessels exclusively is, in general, the result of a protracted inflammation or irritation, which is on the decline, or has wholly disappeared. The blood remains accumulated in the vessels, because, having been distended by the unusual quantity that traversed them as long as the irritation

continued, they remain passively dilated after the irritation has ceased. (Path. Anat. ii. p. 49.) This state is represented by Fig. 120, taken from a stomach affected with cancer and fungous excrescences of the mucous membrane. The gorged vessels are dilated veins (seen against the light), of which a plexus, similar to the one delineated, led to each of the principal diseased points, while the intermediate parts were comparatively exempt.

Similar congestion of the large vessels exclusively is seldom seen from mechanical injection or cadaveric gravitation, since these causes generally proceed further and likewise create injection of the small vessels. In extreme age the large veins alone are sometimes found turgid (as in Fig. 119.), in connexion with general turgescence of the venous system.

It is difficult to determine in all cases whether the colouring of the alimentary canal depends on acute, or on chronic inflammation or irritation; but it may be stated in general terms, *first*, that the red colour belongs principally to acute disease, though it is not uncommon in chronic, as, for instance, in protracted diarrhœa; *secondly*, that the brown, slate-coloured, and black belong almost exclusively to chronic disease, though they may also be occasioned by acute inflammation, especially that produced by certain poisons. To the consideration of the second class of colours we now proceed.

Brown Colour.—In nine cases out of ten, says Billard, this originates in inflammation, and indicates a chronic state of it, though the attack may, in the first instance, have been acute. The transition of the red colour to the brown may easily be traced. Thus, in Fig. 125, the part *a* is a reddish-brown; while above, the colour was a vivid red, and below, at *a*, it passes into a dark brown. Fig. 123 represents a deep red-brown or chocolate colour. Fig. 128, from the rectum, below a stricture, exhibits a pure marbled brown, while the part above the stricture, being more irritated, was a reddish-brown passing into violet. The more the brown colour recedes from the red, the older is in general presumed to be its duration: and a deep brown indicates a corresponding depth of the red, which gave rise to it, conse-

quently, a high degree of original inflammatory congestion. The brown colour usually presents either a diffuse, or a streaky and marbled aspect. Both result from corresponding forms of redness, which the brown colour has superseded. When the brown colour is a product of inflammation, it is generally attended with thickening and facility of detaching the mucous membrane. When it follows very acute inflammation, as in Fig. 125 (see Case), the membrane is softened almost to a pulp.

Slate Colour.—This colour, which ranges from a livid red, as in Fig. 127, to a deep grey, as in Fig. 129, may present the speckled, spotty, streaky, patchy, or diffuse forms, displayed by the red colour, and which the grey tints have merely superseded. What chemical or vital change of the blood determines the particular colour, whether it be of the grey or the brown class, is not understood; but the slate colour, no less than the brown, is found by experience to be, in nine cases out of ten (Billard), a result of chronic inflammation. In the Figs. referred to, the colours existed in the vicinity of old ulcers.

Black Colour.—Andral thinks that no other condition is requisite for this change of colour to take place than a simple diminution in the velocity of the capillary circulation. Accordingly, the black tint runs through a series of shades into red, which we may perceive becoming insensibly brown, and gradually arriving at the deepest black. Whether stagnation alone be the cause of the changes, or whether the presence of some other morbid agent, as inflammation or irritation, be not necessary, cannot be positively determined in the existing state of science; but the latter view appears to me to be more consistent with facts.

Fig. 124 presents an instance of a brilliant red black, mainly seated in the villi. The mucous membrane was not thickened or softened. The blackness was connected with chronic irritation and diarrhoea, and such is generally its origin. Andral has frequently noticed a fine ebony black in horses.

Fig. 125 represents a brown-black, produced by acute inflammation terminating in gangrene. The part delineated is the

head of the colon. At *a* the previous redness has been converted into a red-brown, and the mucous membrane is softened; at *b* the brown verges on a black, and the membrane is resolved into a soft disorganized pulp.

In Fig. 126, from the lower half of the same colon, the blackness is complete, and penetrates some depth into the muscular coat. The mucous membrane is completely disorganized. Such are the dark colours assumed by hyperæmia of the alimentary canal.

Of inflammatory hyperæmia, in general, it may be stated that certain parts of the alimentary canal are more subject to it than others. The stomach and the lower portion of the ileum come first in the scale of frequency; then follow, successively, the cæcum, the colon, the rectum, the duodenum, the superior part of the ileum, and the jejunum. (Andral.) This scale accords with the results of my own observation.

Hyperæmia of the mucous membrane from acute or chronic irritation may occur at all ages. It has been found in an unequivocal form even in the fœtus and the newly-born infant; and it is highly probable that the "delicacy" of infants is, in many instances, referable to it. During the period of lactation the affection is very common, and ignorance of this important fact is the cause of much mismanagement at that age with respect both to diet and medicine. As the infant at birth is peculiarly subject to mechanical congestion from numerous causes already noticed, great attention to these causes is requisite in order to distinguish this from inflammatory injection.

CHAPTER III.

SOFTENING OF THE ALIMENTARY CANAL.

IN order to judge of the existence of softening, and of its connexion with disease anterior to death, it is necessary to have a practical knowledge of the natural consistence of the mucous

membrane in the various parts of the canal, and to be acquainted with the softening to which it is liable after death from putrefaction, and from the solvent action of the gastric juice. Precedence will therefore be given to a brief consideration of these three points :—

1. *Natural Consistence of the Mucous Membrane.*

THE consistence of the gastro-intestinal mucous membrane is considered by the best authorities to be in general directly in proportion to its thickness. The scale, according to Billard, is 1. the duodenum, where the thickness and consistence are at the *maximum*; 2. the pyloric portion of the stomach; 3. its splenic portion; 4. the rectum; 5. the jejunum; 6. the ileum; 7. the colon, which presents the *minimum*. (De la Membr. Muq. p. 70.) This scale supposes that there is no intumescence of the membrane from inflammatory, or passive injection, nor atrophy from age or marasmus.

In the stomach, says Andral, we may allow the mucous membrane to be of the natural thickness, when, on making an incision in it, without dividing the sub-mucous cellular tissue, we can easily detach pretty considerable shreds with a forceps: the shreds should be larger in the pyloric, than in the splenic portion.

In the duodenum, a difference in the nature of the membrane, probably connected with the greater abundance of mucous follicles, renders us unable to detach so considerable shreds as in the stomach.

In the rest of the intestines, the rectum excepted, the mucous membrane, even in its natural state, breaks and tears whenever we attempt to detach any portion of it. If the membrane should become attenuated in consequence of a general defect of the nutritive powers, it at the same time becomes softer, without the previous or present existence of any process of irritation.

The thickness of the mucous membrane can only be estimated by its greater or less transparency. Thus, says Billard, when we

have torn off a few small shreds, which is effected with no little difficulty in the healthy state, we see these fringed, irregular, and scarcely bleeding portions curl up on themselves; and if we spread them on the finger, we see the latter as if through a piece of white crape. The opacity increases with the thickness.

2. *Softening from Putrefaction.*

PUTREFACTION does not operate till long after death. Andral has found the membrane not in the slightest degree softened in bodies kept eight or ten days, and in which the intestines were green, emphysematous, &c. After the tenth day it gradually softens; from the fifteenth to the eighteenth it becomes like pap, and from the twenty-fifth to the thirtieth it becomes completely undistinguishable. (Path. Anat. p. 30.) When exposed to the air at the temperature of ten degrees above zero, the membrane begins to soften on the sixth day, and is reduced to a fetid, greenish, and brownish pulp on the eleventh. Immersed in unchanged water, it is very perceptibly softened about the expiration of two months, but still retains a certain degree of consistence; at the end of the third month it is reduced to a kind of highly fetid purulent layer. (Billard, *ibid.* p. 417.)

From these facts it follows that as softening from putrefaction does not occur till long after the usual period when bodies are examined, the softening which is sometimes observed within twenty-four hours after death must either have taken place prior to that event, or have been occasioned by some other cause. The only cause with which we are acquainted is—

3. *Solution by the Gastric Juice.*

THE reality of this is presumed on the following grounds. In men, and still more in animals, examined shortly after death, the stomach has been found extremely softened, and even perforated, though no symptoms of any gastric affection, no deviation from perfect health, had been observed during life, and no vestiges of peritonitis were discoverable around the perforation. (Hunter,

Spallanzani, Gairdner, Carlisle and Cooper, MM. Trousseau and Bretonneau, Camerer, &c.) In Camerer's experiments on rabbits and cats, the softening only occurred in those cases where a healthy animal was killed a short time after the reception of food into the stomach and during the process of chymification. In those that had died of disease, and those also that had died a lingering death, the lesion was not found.

Again, not only has the stomach been perforated, but contiguous parts, though sound when the body was first opened, have, after the lapse of two days, been found remarkably softened and broken down where they supplied the place of the deficient parietes. (Burns.) Dr. M. Hall mentioned to me a case in which softening had affected an extensive tract along which gastric juice had trickled from a *post mortem* perforation through the stomach.

A strong corroboration of this view is derived from the fact that gastric juice, collected through a fistulous opening in the epigastrium, occasioned by a gun-shot wound, has been found to dissolve meat from the surface to the centre with great activity, "like a piece of gum arabic kept in the mouth." (Dr. Lovel, surgeon-in-chief to the armies of the United States.) Hence it is to be inferred, that the same fluid would dissolve the stomach itself when deprived of life. This inference is countenanced by a remarkable experiment mentioned by Camerer, which, "if it does not prove the action of the gastric juice on the walls of the stomach, proves at least that certain fluids contained in softened stomachs may produce softening in other stomachs when introduced into them." (Andral.) A fluid collected in the stomachs of two children that had died of a *gelatiniform softening* of that viscus, was introduced, in the dose of a drachm, into the stomach of a man not long dead, which was then kept for twelve hours at a temperature of 77° Fahrenheit. At the end of that period the membranes of the stomach were found dissolved through to the peritoneum wherever the fluid had been in contact with them. The same fluid was introduced into the stomach of a living rabbit without producing any bad effect: and on the animal being killed, its

stomach was found in the most healthy condition. On the contrary, another portion of the same fluid having been deposited in the stomach of a rabbit, after death, its parietes after a certain period exhibited a pultaceous softening. Now if, during life, the nerves distributed to the stomach from the pneumo-gastric and trisplanchnic be cut on each side, and the fluid be then introduced into the stomach of the animals thus treated, their stomach softens; but this effect does not ensue if the nerves be cut without applying the fluid.

To sum up, the following conclusions appear to me to be deducible from the above facts:—

1. That the vital powers protect the stomach from the solvent action of the gastric juice.
2. That when those powers are extinct the stomach may be softened or perforated by the gastric fluid.
3. That the softening will take place to the greatest degree where the stomach is exposed to gastric juice secreted in the greatest perfection and in the largest quantity, namely, in a healthy and vigorous animal killed suddenly during chymification.
4. That in those who sink under disease, or who die a lingering death, the gastric juice, probably from a defect either in quantity or quality, does not exert its solvent action after death in a very appreciable manner, and often not at all.
5. That a deficiency of nervous power, as that occasioned by dividing the nerves of the stomach, probably renders the viscus obnoxious to softening by the gastric juice during life.

Softening of the Alimentary Canal from Disease.

SOFTENING is one of the most frequent alterations of the alimentary canal. In the great majority of cases it is confined to the mucous membrane; but in others it affects all the coats.

1. Softening of the Mucous Membrane alone.

THIS lesion is of more frequent occurrence and more marked character in the stomach than elsewhere. It is exhibited, as

affecting the fundus of the stomach, by Fig. 132, where it was connected with inflammation. All its features are here particularly well developed: thus, where the softening is incipient, as in the red part round the margins *a*, *d*, *f*, the mucous membrane, though still forming an organized layer, no longer admits of being detached in shreds as described at p. 164, but breaks up into a pulpy substance when seized by the fingers or a forceps. Where the softening is further advanced, as in the portion *g*, the membrane is scarcely more than a disorganized pulp slightly adherent to the surface beneath. A little later, even this adhesion is overcome, the pulp is detached from patches of variable size and form, as at *c*, and the denuded sub-mucous cellular tissue then presents its ordinary bluish-white appearance. In Fig. 133, two-thirds of the stomach were similarly denuded, and in other instances it has been fully ascertained that nearly the whole of the viscus was in this state.

In general, however, softening of the stomach is partial, and the splenic portion is that most subject to it. "The disease when in this situation," says Andral, "is very often accompanied by a state of dilatation of the veins which run between the coats of the great extremity of the stomach; in such cases they are visible on its exterior, and their presence has more than once announced a softening of the gastric mucous membrane before the stomach was opened." This dilatation is extremely well-marked in Fig. 132, the brown streaks, *g*, being the outline of the veins apparent through the softened mucous membrane.

Where the membrane is deficient, at *c*, a further phenomenon has taken place, namely, the blood has curdled in the veins and accumulated at their two edges in dark-brown, interrupted coagula, closely resembling coffee-grounds.

The same condition is still more distinctly seen in Fig. 133, the veins here being larger and the disease of older standing. I imagine that the curdling is effected by the gastric secretion, operating through the denuded coats of the vessels: for when an exudation of blood takes place slowly into the stomach, the fluid

ejected has more or less of the coffee-ground character. Some years ago I attended a nervous, exsanguine female who vomited several ounces of a coffee-ground fluid, sometimes tinged with blood, every morning for six months, and finally recovered.

Softening of the mucous membrane occasionally forms only isolated spots, about half an inch or less in diameter, of irregularly circular form, and either redder (Fig. 134.) or whiter (Fig. 135.) than the surrounding membrane. The latter remains healthy, and is on the same level with the spots. Their number may vary from one or two to a dozen or more. (See cases, Andral, *Anat. Path.* ii. 94.) They may be the origin of certain ulcers of the mucous membrane, and when extending to all the coats may be the cause of many perforations. This variety of softening is not connected with inflammation of mucous follicles. The latter forms a distinct variety. (Sestier, Andral, Billard.)

Sometimes, again, softening occurs in lines, streaks, or sinuous bands, observed more especially in the stomach. These forms are not improbably attributable to the wrinkles which the organ forms during its state of contraction; for the summits of the wrinkles are occasionally the seat of inflammation, as displayed in Fig. 121, which may lay the foundation of the softening.

The colour of a softened mucous membrane depends in a great measure, according to my observation, on the previous tint of the membrane. If it was exempt from preternatural colouring, it either remains little changed from its ordinary whitish or greyish tint (whence the necessity of examining its consistence with the nail or a scalpel in all doubtful cases), or it becomes pale, and has a bluish or a dead white cast, most observable in the great intestine, or at the end of the ileum, the membrane in these parts being naturally the whitest. If the membrane was pink or rosy from inflammatory or other injection, it assumes a brownish-yellow or fawn-coloured tint, as in Fig. 132, *g*, one of the ordinary tints presented by stagnant or extravasated blood during the progress of its absorption.

If the membrane was of an intense red from excessive in-

flammation, as in Fig. 118, from arsenic, it may retain the tint for a time ; but if several days elapse before death, the softened part is generally found dimmer, browner, or more livid. Finally, the red colour may give place entirely to a deep brown or black, as in Figs. 125 and 126, from gangrene following acute inflammation.

Softening may be a result either of acute or chronic inflammation, or of a chronic process not manifestly inflammatory, and the nature of which is not perfectly understood. When occasioned by intense, acute inflammation, it may attain an advanced degree in the space of a few hours, as proved by the introduction of irritating poisons into the stomach. The symptoms of acute softening are, of course, those of *gastritis*, *enteritis*, or both—particularly, pain in the epigastrium, vomiting, and redness of the tongue.

Softening from chronic inflammation presents no symptoms different from those of the inflammation itself; and these symptoms (as protracted pain, tenderness on pressure, and a sensation of weight in the epigastrium) may exist without being attended with softening. Its presence, therefore, can never be stated as more than probable.

On the other hand, softening may exist without being attended with any of these symptoms, and in such cases it is impossible to assert positively that it is a result of inflammation.

Softening without symptoms of inflammation occurs in the advanced stages of many chronic diseases, especially those of the lungs, of which a striking instance is presented by the case of Fig. 133. (Vid. Descrip. of the Plates.)

I have so frequently noticed the following train of symptoms in the extensive Institution to which I am attached, and which, independent of patients, contains several hundred old people, that I am induced to offer Andral's account in his own words : "Softening of the mucous membrane of the stomach appears to me to be a common affection in old people whose digestion becomes disordered, their health having previously been very good. Their appetite first diminishes, they then lose it entirely, and, soon after, begin to feel the greatest dislike to all kinds of food. They

experience a constant feeling of uneasiness and weight, rather than actual pain, in the region of the stomach; and their tongue, which is usually natural, or else more or less thickly coated, grows red and dry occasionally. This state may continue for several months; the pulse then becomes more frequent, a considerable emaciation takes place, the strength rapidly declines, and the patients die without showing symptoms of a serious affection of any organ up to the last moments. On opening the body, there is nothing found but a more or less considerable softening of the mucous membrane of the stomach, with or without injection of its tissue."

In the remainder of the alimentary canal, precisely as in the stomach, chronic softening is often extremely ambiguous in its symptoms; as it sometimes occurs independent of pain or derangement of function in any marked degree; and, on the other hand, these symptoms are of common occurrence independent of softening. Instead, therefore, of outstripping the progress of science by premature attempts to define the connexion between the lesion and its symptoms, it is more prudent to confine ourselves to observation until we are in possession of more satisfactory data.

Andral draws our attention to a pretty numerous class of copious chronic diarrhoeas, in which, while the mucous membrane of the end of the small, or of the great intestine, is softened, the eye cannot perceive the slightest alteration, and we do not detect the lesion until, on attempting to detach the membrane with a scalpel, we find it remarkably soft, and sometimes even reduced to a pulp devoid of all traces of organization.

2. Softening of all the Coats of the Gastro-intestinal Parietes.

IN this affection the stomach and intestines become soft, friable, and in a manner dissolved, so as to tear with the slightest violence. Occasionally they have a semi-transparent, jelly-like appearance; whence the epithet *gelatiniform softening* or *degeneration* was applied to this alteration by Cruveilhier, who saw it prevail

epidemically amongst young children at Limoges, and who has described it with admirable accuracy.

Softening of all the coats may exhibit the same colours as are observed in softening of the mucous membrane alone; namely, a natural colour, an increased paleness, often with a bluish cast, a fawn-colour, and a red of various depths. Andral saw the whole stomach extremely softened and remarkably pale in a child affected with acute hydrocephalus, fatal on the fifth or sixth day, and of which the leading symptoms were, vomiting for two days, then convulsions, and, finally, coma; hence he infers that the progress of the softening had been acute, although its colour was pale. The reason of the paleness under such circumstances is not, in my opinion, perfectly understood, and requires further observation. On the contrary, he saw the whole stomach softened and resembling the pulpy part of a red cherry in another child, who had taken some sulphuret of potash a few months before death, and had subsequently been affected with constant vomiting.

Although general softening, like that of the mucous membrane alone, occurs most frequently in the splenic portion of the stomach, it has also been found in various parts of the small intestines, cæcum, and colon. It may take place at any period of life.

CHAPTER IV.

ULCERATION OF THE ALIMENTARY CANAL.

THE largest proportion of intestinal ulcerations being connected with disease of the mucous glands, we shall introduce the present subject by an account of the healthy state of these glands: since, without ceasing to be in their physiological condition, they may present several varieties of aspect, with which, for the purpose of diagnosis, it is of essential importance that the physician be acquainted.

Healthy State of the Mucous Glands.—Several authors had stated the existence of glands in the mucous membrane; but Peyer, in 1681, was the first to describe them. In 1715, Brunner published a work on the glands of the duodenum in particular, which have since been designated principally by his name; but, that Peyer was entitled to the honour of their discovery, equally with that of the Peyerian patches, will be apparent from his description—one so accurate as to be almost complete; and I therefore give it in full. “When,” says he, “we carefully examine the internal surface of the small intestines, we there see a great number of small glands, variable in size and form, sometimes isolated and sometimes agglomerated. Their existence at the end of the ileum appears to be indispensable and constant. They are more rare, or do not appear at all, at the commencement of the small intestine. The glandular plexus, which result from the union of forty, fifty, or an indefinite number of glands, have sometimes an olive or oval form, and on other occasions present angular or irregular figures. Their base rests on the middle tunic; their summit projects amidst the villi of the internal membrane. Their consistence is soft and pulpy, so that when we try to press out the mucous juice which they contain, we crush their proper substance. They have the

size and aspect of a grain of turnip-seed. They are but slightly apparent in the new-born infant; they are of a whiteness scarcely distinguishable from that of the internal membrane. They receive arteries and veins; and it is supposed that nervous filaments are also distributed to them. They are never met with at the adherent side of the intestine, but always at the free side. They are agglomerated in the ileum alone, and, in the other parts of the intestinal tube, are scattered and disseminated. We discover their excretory orifice on their summit. The ileum is their favourite seat, next the duodenum, then the jejunum, where they are rare. The patches, or glandular plexus, adhere to the cellular membrane, and diminish the transparency of the intestine in the spots which they occupy. The valvulæ conniventes never encroach upon the boundaries of these patches. There exists another species of glands in the cæcum, colon, and rectum;* they are exceedingly numerous, and are met with indifferently at the adherent, and the free side of the intestine." †

Though mucous glands exist in all persons, they are not, in some instances, apparent: while, in others, they are more than ordinarily developed. As it is only from the latter that distinct drawings can be taken, I shall resort to them for the purposes of illustration, requesting the reader to suppose that he sees a magnified view of the strictly natural state.

The Isolated Glands.—These are the most simple form of glands, being mere follicles or crypts. They are represented by Fig. 141. They are round, white, or greyish-white bodies; in the natural state not exceeding the size of a millet or a turnip-seed; but here equalling that of a mustard-seed, or more. They present a convex prominence of greater or less elevation according

* Here Peyer is incorrect. The glands differ from the isolated glands of the small intestines, only in being a little larger. There are no patches in the great intestine.

† Dissertat. de Gland. Intestinorum.

to their size, and are surmounted by a point, indicating their excretory orifice, but scarcely perceptible except by the microscope. They are soft, and admit of being crushed with great ease. In the duodenum, especially near the pylorus, they are exceedingly numerous, as seen in the present Fig. representing the part above and below the head of the pancreas, *b*. In the stomach they are less thickly disseminated, as may be seen in Fig. 145;* along the jejunum they become still less frequent, and in the two upper thirds of the ileum, are more rare than in any other situation. Even here, however, I have seen them scattered universally, at intervals of from half, to three-quarters of an inch, and as large as turnip-seeds, in a child *æt.* 10, who died of cholera. In the lower third of the ileum they are pretty numerous, as seen in Figs. 136 to 140, inclusive. In the great intestines they again become very frequent, as seen in Fig. 143, from a child, where they have acquired a preternatural dark grey colour. In the great intestines they are larger than elsewhere.

In adults the isolated glands are not so thickly disseminated as in children. Of this I judge from having examined many cases of cholera, at both ages, in which they were universally developed. They are found equally at the attached, and the free side of the circumference of the intestine, and in every part of the canal; which is not the case with the patches of Peyer presently to be described.

Fig. 144, representing the pylorus, *a*, and the duodenum, *b*, *c*, of a child, is introduced for the purpose of displaying the excretory orifices of tumid glands, rendered apparent by a green stain. It also well shows that the glands occupy the summits of the *valvulae conniventes*, *b*, equally with their intervals. The stained excretory orifices are likewise seen in Fig. 143, though the glands do not here appear to be tumid.

It sometimes happens that three, four, or more of the isolated

* I refer to this and the following Figs. to show the frequency, without reference to the size, of the glands.

glands are in contact, forming groups, as, for instance, at *a, a*, Fig. 140. It appears to me to be an unnecessary multiplication of names to give a separate appellation to such groups, as proposed by Billard (glandes *agminées* mucipares), since they are not likely to be confounded with the patches of Peyer.

The Patches of Peyer.—These (see Figs. 136 to 140, inclusive) are found in the lower third of the ileum, but especially in the last two feet. Their form is nearly always more or less oval, the long diameter corresponding, though not invariably (Fig. 137, *b*), with the axis of the intestine, of the circumference of which they occupy the free side exclusively. Their length increases in proportion as they are seated nearer to the cæcal valve; and, in the ileo-cæcal region, they are, in some cases, so large and numerous, as to cover nearly the whole surface of the intestine. The valvulæ conniventes always stop short abruptly at their edges, as seen in Fig. 150, *d, e*.

In their slightest degree of developement the patches of Peyer are so concealed beneath the mucous membrane, that, in order to detect them, it is generally necessary, after thoroughly washing the intestine, to hold it up against the light, when a slight opacity indicates their seats. On now examining them we find them bounded by a very slightly prominent wrinkle of the mucous membrane, while their surface has a somewhat puckered and uneven appearance.

In a higher degree of developement, the surface presents a few scattered, white, glandular elevations, not larger than turnip-seeds; and, in a still further degree (as Fig. 150, *d*), these elevations are universal, and the summit of each is surmounted by a grey point marking the excretory orifice. In this state the patches are raised from half a line to a line above the level of the mucous membrane; and, by this circumstance, as well as by the grey points, they are rendered sufficiently obvious to the eye. Within this degree of developement the affection is not necessarily to be considered morbid, for reasons which will presently be assigned.

Such are the isolated and the aggregated mucous glands of the intestines. We have now to inquire into the circumstances which attend, or occasion, their developement in an usual degree.

In the foetus they are scarcely perceptible; but they undergo a rapid increase after birth, and are more apparent in children than at any subsequent period of life. It is not uncommon, in them, to find the isolated glands enlarged to the size represented in Fig. 141, and the patches of Peyer, to that just described, though there had been no appreciable symptoms of any intestinal affection: and Andral, having found them thus developed in children who had died suddenly, in consequence of accidents, or of diseases totally foreign to the intestinal canal, thinks he may assume it as a fact, that they do not constitute a morbid state in childhood. I am inclined to believe that the high vascularity and irritability prevalent at this age, render the glands subject to temporary and physiological intumescence from healthy stimulants, particularly such as have an aperient tendency; for instance, recent fruits, vegetables, &c.

In confirmation of this view, and as illustrating the superior proneness of the glands to intumescence in children, I may refer to malignant cholera, in which I have almost invariably found the intumescence affect children, while, in adults, it is of comparatively unfrequent occurrence.

Independent of cholera, it is extremely rare, in adults, to see the glands developed to the extent which I have referred to as common in children, unless the patient have died of protracted diarrhoea, or been carried off by an intercurrent disease while convalescent from gastro-enteritis, or fever. In diarrhoea, it is principally the isolated glands that are enlarged; in fever, it is the patches of Peyer. The condition of the glands, in both these cases, is considered by Andral (Path. Anat. ii. 57.) to be that, not of mere intumescence, but of *hypertrophy*, resulting from the irritation with which they had been for some time affected. He

believes, therefore, that a great developement of the intestinal follicles is not a natural state in the adult. The state, however, when once excited, may, in some instances, continue to exist, without producing any ill effects; as is proved by the fact that it has been found, although the subjects of it had not laboured under any disease of the alimentary canal for a reasonable period before death. In the majority of cases, however, it does produce ill effects: namely, diarrhœa, dysentery, and general irritability of the intestinal canal.

At the same time it would be unphilosophical to assert, that the state in question, as affecting the adult, is necessarily, and in all cases, a result of disease; since, in some cases, it cannot be traced to any attack. Hence, though there is a probability that the attack may have been so light as to have been overlooked, we are bound to leave the point to be determined by future observation.

A very great developement of the mucous glands is common, though not constant, in some animals, during a state of perfect health: namely, in sheep killed in the slaughter-houses, and in dogs sacrificed to physiological experiments. This has been adduced as an argument tending to prove that a similar state is natural to the human species, and to the adult no less than to the child. The argument, however, is unsatisfactory; as it cannot be demonstrated, that, in the animals, the state did not, at some anterior period, originate in disease.

In conclusion, it appears to me that we may state, in general terms, of the mucous glands, that they are more apt to be developed in some individuals than in others: that, in children, the liability exists in a high degree; while, in adults, it prevails to so limited an extent, as, in most cases, if not in all, to require, for its production, a stimulus amounting to disease. Such is the account which I have to offer of the *healthy state* of the mucous glands. In employing this term I have sometimes exceeded its import. This was unavoidable; since, as the reader must have perceived, the boundaries between health and disease are, here,

ill defined, and what is health in one instance is disease in another.

The Mucous Glands in Malignant Cholera.

To the state of the mucous glands in malignant cholera I have already incidentally adverted. As this state is not one of health, and as general authority does not sanction its being classified with the effects of inflammation, it may be appended as a corollary to the present subject, with which it has some affinity from the circumstance, that the physical characters of the isolated glands when enlarged by cholera do not differ from those observed in children in a state of health. Accordingly I have used the same drawing (Fig. 141) to illustrate both. In cholera, it is principally children and young people who present the glandular enlargement. The number of pale, round bodies, like mustard-seeds, is often prodigious; they sometimes pervade every part of the canal, and they are attended by an excessive sero-mucous and albuminous secretion, of which they are no doubt the principal source. During the prevalence of spasmodic cholera in London in 1832, I witnessed numerous cases of this alteration. (For cases, see Description of the Plates, Fig. 141.) Two years previously, it prevailed at a boy's school in Clapham, having originated in the effluvium which escaped on opening a cess-pool. From one of the sufferers, I took the drawing of Fig. 141. Rœderer and Wagler have described and delineated the same, as occurring in an epidemic at Göttingen; two analogous cases are given by Billard (*De la Membr. Musq.*, Obs. 44 and 45), and many others are to be found in the writings of various authors.

The patches of Peyer I have not observed to be enlarged in cholera, except the case had lingered, and terminated with low fever, when their state was found to be that of ordinary inflammation, as described in the following section. We have now to trace the mucous glands through the state of inflammatory enlargement to that of ulceration.

Inflammatory Enlargement of the Mucous Glands.

INFLAMMATION of the mucous glands may be, 1. *Simple*, which usually commences in the acute form, and subsequently becomes chronic: 2. *Specific*, which is, in general, primitively chronic, and produces a widely different state of the glands from what occurs in simple inflammation.*

1. *Simple Inflammation of the Mucous Glands.*—We shall examine the isolated and the aggregated glands successively.

The isolated glands present several degrees of inflammatory developement, according to the intensity and duration of the inflammation. Fig. 144, at *b*, represents an early degree of it, in the duodenum, immediately below the pylorus *a*. The glands are the size of a hemp-seed, exhibit a very visible central orifice, are red like the inflamed mucous membrane itself, and bleed freely when divided.

Fig. 145 displays a further degree of the same in the stomach; in which organ it is very rare to see the disease so distinctly developed. The central orifices are unusually expanded; so as, in many, to present the appearance of ulcers.

Fig. 150, from the lower third of the ileum, is a beautiful specimen of enlargement of the isolated glands of the valvulæ conniventes exclusively. They present a considerable central orifice, and are stained yellow with bile. The whole length of the ileum was more or less affected in a similar manner.

At a more advanced period, the glands become much larger, as seen in Fig. 139, from the last foot of the ileum, some equalling, or even exceeding, a pea. Their summits become paler than their bases and areolæ; hence the appearance is very similar to that of distinct small-pox. The central orifice is not visible in these glands, being obliterated by tumefaction. The red colour has a

* M. Billard denominates these two varieties, the former *acute*, and the latter *chronic*; terms which do not appear to me to be sufficiently precise, as the former not unfrequently becomes chronic.

dim, brownish cast, in consequence of the inflammation having existed seven weeks, and being now on the decline. (Typhus, vid. case.)

In Figs. 148 and 149, where the inflammation was more recent, the red is extremely vivid. They represent the isolated glands of the ileum in their highest degree of developement. Some are much larger than ordinary peas, as Fig. 148, *d*; and 149, *b*; and present a broken, roundish, central orifice, with a sloughy interior, which occasionally encloses a small clot of blood. In others, the orifice is completely torn open, and displays a wide, yellowish, and greenish ulceration, as at Fig. 148, *e*.

When a puncture is made into those which have pale summits as Fig. 148, *b, b, b*, a sloughy pus, like that of a furuncle, escapes, and leaves a cavity, as at *f*. In those with vivid red summits, as *a, a, a, a*, the suppurative process has not proceeded so far, and only a little pus, with much blood, escapes on making an incision. In some cases, a thicker matter may be pressed out in the form of vermicelli, and resembling the sebaceous contents of a tumefied cutaneous follicle.* The isolated glands may present the same enlargement and ulceration in the colon as in the ileum, and as is here represented.

Wherever the glands are completely isolated, the inflammation may be confined to the gland and its areola, the intermediate mucous membrane being exempt; but, in the ileo-cæcal region, where the glands are naturally larger and more numerous, the approximation of their bases, as in Fig. 139, and still more in Fig. 140, *a, a*, causes the mucous membrane to participate in the inflammation. In fever, the inflammation generally originates in the glands, as here described; but this is not necessarily the case; for, occasionally, the mucous membrane is either simultaneously or previously attacked, particularly in ordinary enteritis.

After acute inflammation of the glands has subsisted for a

* Billard, *ibid.* Case 68.

certain period, it may subside without proceeding to ulceration, leaving the glands in a state of real hypertrophy. In this case, their redness having more or less completely disappeared, they form whitish and tolerably firm bodies, some with, and others without, an evident central orifice, the intermediate mucous membrane exhibiting little or no alteration. Such I conceive to be the case with the white bodies in Fig. 136, *c*; while, in Figs. 137 and 138, from a lower part of the same ileum, some hypertrophous glands are seen white, while others are still slightly red at the base; and the mucous membrane exhibits a few purplish clouds and streaks—the vestiges of disappearing vascularity.

Fig. 142 represents similar hypertrophy in the colon, near the caput cæcum; but, here, there was little induration; as the glandular orifices admitted of being distended to the size of a large pellet, (*e. g.* size No. 2.) thus disclosing a considerable cavity, filled with a purulent mucus, the source, no doubt, of the diarrhoea, with which the patient was affected.

When the inflammation has completely subsided, the hypertrophous glands, in some individuals, as already stated, produce no derangement of the chylopoietic functions; in others, diarrhoea, recurring at frequent intervals and from slight causes, is the result; and, in a third class, the diarrhoea is constant. The same differences in the symptoms are observed when the glands have become enlarged insensibly, and without signs of antecedent inflammation. (*Path. Anat.* ii. 66, 7.)

The reader must already have noticed, in referring to the plates, that the orifices of enlarged glands present several varieties in appearance. I revert, for a moment, to this subject, since ignorance of the fact might lead to great apprehension as to the real state of the glands. The orifices, then, may be of natural size, they may be enlarged, or they may be diminished. When of natural size, they have the appearance of a minute, greyish dimple; but sometimes they are inflamed; and they then present a small red spot, as in Fig. 131, *a*, which may extend, and meet the red areola, as in Fig. 148, *a, a, a, a*. Sometimes, again,

the orifices, though of natural size, are rendered more apparent by a brown, or a green stain, resulting from fæcal, and especially bilious matter. This is seen in Fig. 144, *c*, and in Fig. 150. The stain is also occasionally seen in glands of natural size, as in Fig. 143.

When a glandular orifice is enlarged, its expansion sometimes amounts almost to two-thirds the width of the base; in which case, it may be mistaken for an ulcer. This state is remarkably well seen in Fig. 145. It does not appear to me possible to assign a reason of general applicability, why some glands expand their orifices more than others. The expansion is probably effected by certain changes in the interior, which often elude anatomical investigation.

When the orifice is contracted, the effect is produced by tumefaction and hypertrophy of the parietes, as in Fig. 138, *c*, &c. The contraction sometimes leads to complete obliteration of the aperture; in which case, the accumulation of the fluids secreted within, may gradually form voluminous tumours. Such, though rare in man, are often found in the intestines of horses. Andral has seen them as large as an orange. The sub-mucous cellular tissue of hypertrophous glands participates in their hypertrophy. In animals, it is often transformed into fibrous, fibro-cartilaginous, and cartilaginous tissue, which considerably augments the thickness of the walls.

Such are the isolated glands when enlarged by simple inflammation: we now proceed to the aggregated glands, or patches of Peyer.

Fig. 146 represents a greatly enlarged state of a patch, before it has advanced to ulceration. It rises from one to two lines above the level of the mucous membrane; its edges are everted, so as to impend over the base; its surface is surmounted by numerous mamellated glandular prominences, *a*, *b*, intermixed with irregular, wrinkled elevations of the mucous membrane; its circumference is uneven and knobby; its consistence is firm; its

colour is a pretty deep pink, and it displays a considerable degree of tumid plumpness and tension.

Fig. 147 is a patch in all respects similar to the preceding, except that it is advancing to ulceration, and is slightly purulent in the centre. In these cases, the inflammation had probably not subsisted more than a week or ten days.

Fig. 136 to 140, inclusive, present thirteen patches of Peyer, in the seventh week of inflammation. Being chronic, they have lost the tumid tenseness of more recent patches, and exhibit a softer and less determinate outline. In other respects, their characters are the same. The whole have proceeded to ulceration, which forms, on their surfaces, innumerable small, ragged excavations, with sharp edges, best seen in the patches *a* and *d*, Fig. 139. The ulceration causes a depression of the centre of the patches, while the edges remain high, as is well seen at *b*, Fig. 138. When more advanced, it eats down the edges also, as the lower edge of patch *a*, Fig. 136, &c.

Round patches, which are so rare in comparison of oval, that some deny their existence, are seen at *a*, Fig. 137, and *c*, Fig. 140.

Two black, gangrenous sloughs are seen in the patches Fig. 136, *d*, and Fig. 139, *b*, which penetrate to the peritoneal coat, and would probably have perforated it, if the patient had survived a few days longer. This is not one of the least dangers of this affection. Such are the patches of Peyer in the state of simple inflammation.

Inflammatory enlargement and ulceration of the isolated and aggregated mucous glands of the ileum, constitute the *dothin-enteritis* (δόθινῆν, furunculus) of M. Bretonneau. The state is almost always attended with ataxic and adynamic or typhoid symptoms. Some have gone so far as to maintain the converse proposition: namely, that real typhus never exists without dothin-enteritis. My own experience is decidedly opposed to this view.

The mesenteric glands may become sympathetically inflamed and enlarged, in connexion with dothin-enteritis.

2. *Specific Inflammation of the Mucous Glands.*—This is almost invariably chronic, and it occurs in connexion with scrofula, tubercular phthisis, or glandular disease in general. The affected mucous glands may present the same characters, as to form, size, and situation, as in simple inflammation; but they are widely different in composition and consistence; being very white, and remarkably firm to the touch; having a clean cut, and yielding little or no fluid when divided or compressed. In the largest, the section is sometimes like lard at the circumference, and like putty in the centre. In others, the centre is rather more liquid than putty. The transformations, in short, are closely analogous to those of tubercle; and there can be little doubt that the deposition is of a tubercular nature.

The disease is more common in children than in adults; and it affects those especially, who, while labouring under a strumous tendency, are insufficiently clothed and unsuitably fed. I have seen numbers such admitted at the Hôpital des Enfants; and many come under my care at the St. Marylebone Infirmary, in connexion with which are schools, containing several hundred children. The disease is commonly followed by a similar affection of the mesenteric glands.

It is remarkable that the symptoms are totally different from those manifested by simple inflammation of the mucous glands; for, while the latter are typhoid, the former are those of tabes mesenterica, and of phthisis.

In the preceding pages I have described the intestinal mucous glands or follicles, *first*, in the healthy and scarcely apparent state; *secondly*, in a state of developement in which the isolated glands equal turnip, or even mustard-seeds, and the aggregated glands, or patches of Peyer, are slightly prominent, crimped, and speckled (*gaufrées*, Fig. 150, *d.*)—alterations which are sometimes found unattended with morbid symptoms in children, but rarely, if ever, in adults. I have, *thirdly*, noticed an analogous

state of the glands in malignant cholera; and, *fourthly*, I have described and illustrated, at considerable length, the enlargement of the glands occasioned by simple or acute, and by specific or chronic inflammation. These topics, it was stated, formed a necessary introduction to the subject of intestinal ulcerations, since by far the largest proportion of such ulcerations originate in disease of the mucous glands. I now proceed to treat of intestinal ulcerations in particular; and, in order to avoid withdrawing the attention from the subjects with which we have just been occupied, I shall first speak of ulcers from disease of the glands; and, subsequently, of those originating in other causes.

As the glands are subject to two varieties of inflammation widely differing from each other, namely, the *simple* or *acute*, and the *specific* or *chronic*; so they present two corresponding varieties of ulceration, which will be noticed in succession.

Ulceration of the Mucous Glands from Simple Inflammation.—This affection, it will be recollected, constitutes the *dothineritis* of M. Bretonneau—an inexpressive appellation. M. Cruveilhier has assigned to it the far more appropriate name of *acute follicular enteritis*; and it forms the bulk of those cases formerly denominated *adynamic* and *ataxic* fevers—the former epithet being used where prostration of the muscular power was the predominant symptom; and the latter, where derangement of the nervous function was the leading characteristic. It is only within the last twenty years that these fevers have been distinctly traced and ascribed to follicular inflammation. This, however, is not their sole cause. I am satisfied, from extensive personal observation, that a serious lesion of any vital organ, as the brain or the lungs, may give them birth.*

The passage of inflammation of the mucous glands into ulceration, is by grades so insensible, that, in describing the former, I have already unavoidably touched upon the latter, as the

* In a case of copious hæmoptysis, connected with tubercles, at present under my care, the symptoms are eminently those of adynamic and ataxic fever.

reader will perceive by referring back to p. 181, for the isolated glands; and to p. 184, for the plexus or patches of Peyer. Here, therefore, I resume the subject where we left off.

In the first degree of ulceration of the isolated glands, (Fig. 148 *d*, and 149 *b b*,) a purulent slough has recently escaped, and left a small, ulcerating, and sometimes bleeding cavity, with elevated, broken, and red borders.

In a second or middling degree, (Fig. 148 *e*,) ulceration has lowered the borders and expanded the interior, thus forming a wide cavity, lined by dirty, ragged, yellowish and greenish cellular membrane and semi-concrete pus, and surrounded by a red, abrupt, and still slightly elevated margin, the remains of the glandular tumour.

In the last degree, scarcely a trace of the glandular tumour exists, its borders having been eaten down by the extending ravages of the disease. The base of the ulcer now frequently reaches the muscular coat, which may be so cleanly dissected as distinctly to display its circular fibres. The edges are red, abrupt, and more or less thickened and indurated. The form of the ulcer is generally round or oval, unless two, three, or more isolated glands have coalesced, in which case the ulcer presents a resulting irregular shape. Thus, for example, where the glands are arranged along the *valvulæ conniventes*, (Fig. 150,) the ulcers, by coalescing, may form rings round the intestine, as is actually the case in Fig. 151.

The intestine is sometimes, as it were, riddled by a vast number of small ulcers. Fig. 133 represents an excellent specimen of this kind, from the colon, where the state is most commonly found. Each of the angular shaped cavities, as *b, b*, is the orifice of an ulcer, this shape being given by a soft intumescence of the mucous membrane, which tends to close the orifices. When stretched, they dilate to the size of peas or more, and present a smooth but abrupt margin. Most of the ulcers perforate the muscular coat, transverse bands of which are seen at *a, a*, crossing the larger confluent ulcerations. A few had perforated the

peritoneum and caused death by peritonitis. The mucous membrane was in parts very pale ; and in others it was clouded and marbled with delicate greenish-grey and livid-purple—vestiges of the chronic enteritis and colitis under which the patient had laboured for six weeks. These ulcers are remarkable for their great depth compared with their limited superficial extent. Hence they are peculiarly dangerous.

It is sagaciously remarked by Cruveilhier, that though the *varieties* of intestinal ulcerations are numerous, the *species* are few. This applies forcibly to the ulcerations formed by the patches of Peyer. It is in my power to present the reader with a multiplicity of large drawings, exhibiting almost endless varieties ; but as this would not only carry me far beyond my prescribed limits, but would tend to perplex, rather than to elucidate the subject, I shall content myself with making extracts exhibiting the *specific* characters, and shall endeavour to give such an account of them, as will enable the student to understand the varieties when presented to his view.

The varieties depend on differences in the number, the size, the form, and the situation of the ulcerated patches, and on the more or less advanced period of their progress. Thus, if the reader take the whole plate containing Fig. 136, and imagine that he sees twice or thrice the number of patches, mostly of the largest size, and several coalescing over the last six inches of the ileum, so as to form one vast ulcerated surface, he pictures to himself a variety of the disease which a novice would scarcely recognize as belonging to the same species. Again, one strongly possessed with the idea that the patches of Peyer are always the most numerous immediately above the cæcal valve, would feel perplexed at seeing this part almost exempt from disease, while the intestine six or eight inches above was extensively ulcerated. Yet such a variety is occasionally seen. Sometimes, again, the patches, instead of presenting abrupt and everted edges, rise with a very gradual slope. Sometimes only a part of a patch is swollen and ulcerated : we may, for instance,

see a patch like *a* or *b*, Fig. 137, placed in the midst of a merely pitted or crimped patch, (*gauffrée*) as *d*, *e*, Fig. 150. Sometimes, also, a patch may be universally swollen, as Fig. 146, yet present, in one limited point only, a deep sloughy ulcer, penetrating even through the muscular coat; and such ulcer may terminate in gangrene, as seen in Figs. 136 *d*, and 139 *b*.

Other varieties are connected with the different degrees or stages of the ulceration. A first degree is represented by Figs. 146 and 147, where suppuration has barely commenced, and has not yet sloughed through the summits of the numerous glands surmounting the surface. A second or medium degree is seen in Figs. 136 to 139, inclusive. Here sloughs have been thrown out, and they have left innumerable little ulcerated pits, appearing as if the mucous membrane had been riddled with perforations. In a last degree, this cribriform appearance has sloughed away, and the base of the ulcer, descending as deep as the muscular coat, presents a dirty yellow, green, or grey surface, formed by sloughy debris of the submucous cellular tissue, intermixed with fragments of concrete pus. In some parts the muscular coat is completely denuded; and not unfrequently it becomes implicated in the ulceration; in which case the peritoneum often proves an insufficient barrier, and the patient is carried off by perforation. The borders of the ulcer are more or less thickened, indurated, and red; and the *valvulæ conniventes*, stopping abruptly at its margins, often form large and prominent knobs. Fig. 152, *b*, *b*. It is principally where the ravages are thus deep and extensive that intestinal hæmorrhage takes place, since large vessels are apt to be opened by the ulcerative process. Where a number of confluent patches of Peyer, above the cæcal valve, have proceeded to the last degree of ulceration, the part may present one continuous raw and foul surface, only broken by a few scattered and prominent remnants of the mucous membrane formerly interposed between the patches.

In some instances, ulcers, originating in patches of Peyer, extend laterally and not longitudinally, so that their transverse

diameter eventually becomes the longer; whence a doubt might arise whether they had originated in the Peyerian patches. I am inclined to ascribe this to the tendency of the divided mucous membrane to retract laterally whenever the bowel is distended. Accordingly, the peculiarity exists principally, so far as my observation enables me to judge, in the oldest cases, where, of course, the most time is afforded for the retraction. See, for instance, the case of Fig. 152. This Fig. appears to me to correspond with what Cruveilhier has denominated *circumscribed gangrenous ulceration*—a variety of the worst species of disorganization, and it is a remarkably fine specimen. (See Description of the Plates, Fig. 152.)

Whenever a large extent of intestine has become ulcerated, the tube becomes more or less contracted, its walls thickened and indurated, and its exterior red, brown, or slate-coloured, and traversed by ramifying blood-vessels. By the latter appearances, indeed, we may generally recognize the seat of any considerable ulcer before the intestine is opened. Fig. 156 strikingly exhibits this slate-colour, together with a perforation. It is taken from the same case as Fig. 152.

Very rarely does ulceration advance to any extent, without the mesenteric glands, corresponding to the part affected, becoming similarly diseased. At first they enlarge in all degrees up to the size of a filbert, and present considerable hardness, and a red or inflamed section and exterior, as seen in Fig. 154, where a gland is denuded of its peritoneum. The interior next softens, becomes yellowish, and yields pus on pressure, as in Fig. 155, *b*; and sometimes a friable caseous matter, like concrete pus, forms in the inside and gradually extends to the circumference, as in Fig. 155, *a*. An abscess filled with liquid pus is seldom found in the acute disease, since the patient is carried off by the intestinal affection before suppuration can attain so advanced a degree.

Ulceration of the Mucous Glands from Specific or Chronic Inflammation.—This form of ulceration is found principally in patients who have long suffered under chronic affections: in

the scrofulous, the phthisical, those who die with white swellings, &c. (Billard de la Memb. Muq. p. 473.) The anatomical characters of the ulcers differ very considerably from those which we have just been studying; but the wide difference of the symptoms forms a still more substantial basis for the distinction of the two forms into separate classes. For while simple or acute ulceration is attended with symptoms of adynamic, ataxic, typhus, or putrid fever; specific or chronic ulceration is accompanied with those of phthisical, of mesenteric, or of scrofulous marasm. It does not manifest any very positive indication of its own presence in particular, even when its ravages are deep and extensive; for frequent returns of diarrhœa, its most characteristic symptom, often occur in the class of patients alluded to, wholly independent of intestinal ulceration.

At p. 185 an account is given of the state of the glands prior to ulceration. Fig. 161 represents a remarkably well characterized specimen of the ulceration, as affecting isolated glands of the ileum, in what may be called its second stage or medium degree. The diameter of the ulcers, measured from their exterior, is from two to six lines; the circumference, about thrice that length, the form being round or oval. The borders are high and rounded inwards, so as to resemble a ring or collar; they are hard, and creak under the scalpel, and their colour is pale where the intestine is little injected, as at *a*; but where the injection exists, as at *b*, *c*, they are purplish or livid externally, though much paler when divided: they bear, in fact, a close resemblance to the callous margins of an old, indolent, cutaneous ulcer. The ring is formed, in the smallest, partly by the remains of the base of the enlarged gland; but, in the larger, it is formed entirely by hypertrophy of the mucous membrane and of the sub-mucous cellular tissue. The base is of a dirty yellow, green, or grey colour, and consists, in some, of sloughy sub-mucous cellular tissue, intermixed with pus; and in others, more advanced, of debris of the disorganized muscular coat, and of the peritoneum beneath.

We shall have a perfect idea of the first degree of these ulcers, if we imagine those represented in the Fig. to be reduced to the size of small peas (as that at *c*, for instance), with their cavities a line broad, their borders more abrupt within, and their induration less considerable.

The last degree, we may also readily conceive, by imagining the ulcers to be more or less enlarged, their bases deeper, and their borders more broken and irregular. The ulcers may be found in all these degrees in the same subject; and it is not uncommon to observe some in the state of cicatrization, contiguous to others on the advance, a coincidence scarcely ever seen in acute follicular enteritis.

The ulcers formed by the patches of Peyer are larger than the above, in correspondence with the larger size of the patches; but they present the same characters with respect to induration, paleness of colour, &c. By coalition they may form vast ulcerations, with ragged, unequal, knotty, and almost scirrhus margins, and a foul irregular base, sometimes bounded solely by the peritoneum. The surface is, occasionally, traversed by bands of mucous membrane, which the ravages of the ulceration have as yet spared; and it is surmounted by a prodigious number of small, soft, and very lacerable nodules of mucous membrane, speckled with red marks, and bathed with a foul but inodorous pus. (Billard.)

Though the patches of Peyer are not found below the cæcal valve, the ravages of the chronic disease are not so frequently arrested by this valve, as those of acute follicular enteritis. In a large proportion of phthisical cases I have found the head of the colon ulcerated, as well as the end of the ileum, and sometimes to an equal degree.

The intestinal walls in the vicinity of extensive chronic ulcerations are almost invariably hypertrophous and indurated, like scirrhus, so as to creak under the scissars.

The mesenteric glands corresponding to the parts diseased, generally become affected in the same manner. In the first

stage, the hypertrophous glands consist of a pinkish grey semi-transparent substance of considerable firmness. A little later, opaque, dim yellow spots of tubercular matter are seen bedded in this substance, as in Fig. 158, *b*, and these spots appear to be formed by an inflammatory process; for vivid red vascularity is seen either in the midst, (Fig. 157, *a*.) or round the circumference (Fig. 158, *a*.) of the largest and brightest of them; and sometimes a mottled redness pervades a considerable part of the gland, as in Fig. 159, *b*. The tubercular matter is deposited interstitially, and forms masses by juxta-position, as in the case of pulmonary tubercular infiltration, Fig. 17. The most advanced of the masses are sometimes softened in the centre, and discharge a liquid pus when divided. It is not uncommon to find chains of knotty absorbent vessels, filled with tubercular matter, connecting the diseased glands with the intestinal ulcers.

The present subject may be concluded by the following summary, in the form of propositions, from M. Billard.

1. "The intestinal mucous glands and plexus may inflame, augment in size, open at their summits, and give birth to ulcers of greater or less magnitude and depth, according to the duration of the disease.

2. "These ulcerations may be acute (simple) or chronic (specific). The acute are found principally in the fever called putrid and adynamic: the chronic are met with in the intestines of the phthisical and scrofulous.

3. "In both cases, it is always in the ileo-cæcal region that these ulcers are observed: they are larger and more numerous in proportion as they are nearer to the cæcal valve, above and below which they progressively diminish in depth and in extent.

4. "Nearly all the ulcerations of the gastro-intestinal mucous membrane result from acute or chronic inflammation and disorganization of the mucous glands."

The last proposition is strongly expressed; yet observation will convince the student that it approximates much nearer to the truth than he would at first be inclined to believe.

We now proceed to study, in succession, the species of ulceration not resulting from enlargement of the intestinal mucous glands.

Ulcers from Tubercular Depositions beneath the Mucous Membrane.—These depositions take place in the submucous cellular tissue. The mucous membrane, being irritated by the presence of the matter, becomes congested and ulcerates, like the bronchial mucous membrane, in order to give exit to the tuberculous matter formed exterior to the cavity which it lines. (Andral, Path. Anat. ii. 112.) Fig. 160 represents these depositions in various grades of progress. At first they are small, semi-transparent, whitish granulations, of softish consistence, as *a*; they next become larger, harder, and of a more opaque white, rolling under the mucous membrane when fingered, and presenting a dry, lard-like section, more or less pulpy in the centre of the most advanced. They gradually perforate the mucous membrane, soften from the centre to the circumference, and thus form open ulcers, as at *b*. They are found principally at the lower part of the ileum and over the whole length of the great intestine. When numerous, they may give rise to a state of extreme disorganization. In the present case, for example, the whole colon was in the state represented by the Fig., viz. at all the black parts *c*, the mucous membrane was completely destroyed, and a carbonaceous matter had stained the bases of the ulcers. In the intervals, the membrane is much thickened, and projects in irregular knobs of a pulpy or fungoid character. Its colour is a dirty greenish-grey. The other intestinal coats are hypertrophous, and the tube is contracted. The patient had pulmonary and cerebral tubercle. (Vid. Case.)

It is a common supposition that such is the origin of the intestinal ulcers so frequently found in phthisical persons. This is occasionally the case; but by far the most common source is, the chronic or specific inflammation of the mucous glands last described. "In many phthisical persons," says Andral, "whose intestines were almost riddled with ulcers, I have found nothing

to prove that they had originated in tubercles beneath the mucous membrane." (Ibid. 112.) My own observation coincides with that of Andral.

Ulcers from circumscribed Softening of the Mucous Membrane.—M. J. Cloquet drew the attention of the profession, in 1818, to a variety of ulceration, the edges of which were clean and sharp, as if cut out by a punch, and presented neither redness nor tumefaction in any very manifest degree. "*First*," says he, "the ulceration commences by a dark line planted perpendicularly in the mucous membrane, and of which one edge only is seen on the internal side of the intestine; *secondly*, along this line the mucous membrane becomes disorganized and converted into a greyish diffuent pulp; these ulcerations are at first isolated, distinct, and, where the eschar which covers them falls off, are seen to be greyish, rounded, and encircled by flat vertically cut borders; *thirdly*, the borders of the ulcers speedily extend, tumefy, and coalesce with the adjoining ulcerations; *fourthly*, they commence in the great intestine, and thence mount to the ileum. At first the mucous membrane alone appears to be affected; the other tunics subsequently become involved." Commonly the muscular coat is at last destroyed, and the peritoneum forms the base of the ulcer. Very frequently this also yields; whence there are formed, in one or more points, rounded perforations, wider at the mucous than at the serous surface, and sometimes establishing communications between different regions of the alimentary canal. It is remarkable that before these perforations take place, they almost invariably give rise to local peritonitis, so that, the contiguous folds of intestine becoming matted together, effusion into the abdominal cavity is prevented; and it is not until the adhesions are torn asunder after death, that faecal matter issues from a previously concealed aperture, the borders of which are found coated with layers of coagulable lymph. We cannot here fail to recollect, that by opposing a similar barrier, nature wonderfully prevents the rupture of pulmonary vomicae into the cavity of the pleura. These ulcers are, in their com-

mencement, so different from those occasioned by follicular inflammation, that they scarcely admit of being ascribed to any other cause than circumscribed softening of the mucous membrane, originating in chronic inflammation. Accordingly vestiges of this inflammation are most commonly found in the portion of intestine affected, namely, a more or less grey colour, with thickening and diminished consistence, of the mucous membrane.

Fig. 162, a rare and remarkable specimen, affords more direct evidence of the inflammatory origin of the disease; for numerous rings are seen, some isolated, *a*, and others confluent, *b*, which have not yet passed from the red to the dark colour, while the included mucous membrane is considerably softened.

Fig. 164 exhibits the same when the mucous membrane has been detached, appearing as if cut out by a punch, and exposing the bluish white submucous cellular tissue.

Fig. 163 represents the disease much lower down the same colon. The softened mucous membrane has been detached; the ulcers have coalesced by extension, forming long, irregular, bluish and greyish white tracts of denuded submucous tissue, *a, a, a*, and the borders, *b*, have become tumid and red, projecting here and there in loose peninsular bands,* *c*. The specimen is, as it were, divided into three compartments by the longitudinal bands of the colon, which run in the direction *d, d*, and *e, e*; the compartment between *d, e*, is less ulcerated and more wrinkled than the other two. Lower down, the muscular coat had become ulcerated, and the disease presented an extreme degree of confused disorganization.

Andral and Billard think that most of the perforations of the stomach and intestines called *spontaneous* are attributable to this kind of partial softening, and to the ulceration which results

* These actually float at their edges, the specimen having been drawn under a thin layer of water, a plan which renders its characters much more distinct.

from it. Figs. 134 and 135, described at p. 169, exhibit partial softening in the stomach. The affection has been observed more frequently in children than in adults.

Ulcers from Inflammatory Excoriation of the Mucous Membrane.—The excoriations consist, at their origin, of a slight solution of continuity of the mucous membrane, occasioned by acute inflammation of greater or less severity. They may take place either in the centre of small red spots of injection, (Andral, Path. Anal. ii. 108) or, what is much more common, they may occur in the midst of diffuse redness, particularly that in patches, as described at p. 155, in reference to Fig. 117. In these cases there is not any proof of the excoriations having had their origin in mucous follicles. The characters of the excoriations are as follows.

On the surface of an inflamed red patch, Fig. 166, *a*, (from the colon,) are observed a great number of minute superficial abrasions of the mucous membrane, *b*. Their form is irregularly angular; their size, from half to one or two lines broad; their edges are ragged, bleeding, and intensely red; their base, consisting of the submucous cellular tissue, may either preserve its natural bluish-white appearance, or, as is more common, it may be variously discoloured by fecal matter or blood. This state may occur in any part of the intestines, but it is most common in the ileum and the great intestines.*

Excoriations, by enlarging and coalescing, as in Fig. 165, *d*, soon become converted into ulcers, which, though at first superficial,

* Dr. Abercrombie, in his Path. and Practical Researches on the Intestinal Canal, gives, in case 91, an instance of this disease in the ileum; and, in case 85, one of the same in the colon.

Fig. 165 represents excoriation in the œsophagus. All vivid redness has disappeared, and there remains only the dim greyish tint of chronic inflammation. At *c*, a number of excoriations are tending to coalesce; at *d*, an extensive patch has been formed by coalition. The base of all, though consisting of submucous cellular tissue, presents a dirty tinge, instead of the clean grey of a recently denuded portion *a*.

presently descend deeper, and their borders become thickened, elevated, impending, and rugged. In this latter state, by further extension and coalition, they may form any degree of deep, wide, and confused disorganization.

When intestinal ulcerations have proceeded to an advanced degree, whatever was their mode of origin, they present common characters, which render it almost impossible to distinguish them from each other. They have all more or less elevated, thickened, indurated, red, excavated, and irregular borders, with a base presenting many varieties as to colour, depth, and ruggedness. How, then, is the nature of their origin to be ascertained? This question is well answered by M. Billard:—"We shall recognize that the lesions proceed from one or other of the modes of ulceration described, when they offer, either in themselves, or around them, vestiges of the primitive alteration which they succeed. Thus, ulcers supervening upon a glandular eruption of the mucous membrane may be accompanied with some glands recently ulcerated: those which proceed from partial softening of the internal tunic will often be bordered by a blackish line, and cut out as if with a punch. Lastly, those produced by excoriations will be surrounded by excoriations in a more or less distinct form; and, if softening of tubercles has given them birth, tubercular matter will be found in their borders or in their vicinity. Further, ulcers of the muciparous glands occupy principally the ileo-cæcal region, and are accompanied by plexus of Peyer in a state of intumescence and incipient ulceration. Ulcers from softening almost invariably co-exist with local or general peritonitis, by means of which intestinal adhesions are formed. Finally, ulcerated excoriations will be found covered with bloody mucus."*

Gastro-enteritis and simple dysentery or colitis are the usual causes of ulcers from excoriation; and as the inflammation commonly operates over a large extent of surface, the ulceration, like-

* De la Memb. Muq., p. 507.

wise, is apt to be extensive. Thus, I have repeatedly seen the whole colon form one continuous tract of disease.

The symptoms vary in different cases and according to the progress of the disease. In general, however, when ulceration has subsisted for any considerable time, the patient becomes emaciated, hectic, and peculiarly withered. There is commonly tenderness of the abdomen on pressure, pain or soreness of a pretty constant character, and tormina and tenesmus before an evacuation. There is either a constant, or a frequently recurring diarrhœa,—in the latter case, often alternating with constipation. The appetite is sometimes ravenous, and sometimes fastidious and variable: ingesta generally occasion great uneasiness, and fluids will often create an immediate call to evacuate the bowels. It frequently happens that, when the diarrhœa is checked, nausea and vomiting supervene. The mouth and fauces are often tender and aphthous; and the tongue is almost always swollen, red, and glistening. The evacuations are, from time to time, slimy and bloody, and in general discoloured and offensive: when the ulceration occupies the lower half of the great intestines, the fæces may be purulent, but they can never be ascertained to have this character when the ulceration is above the cæcal valve. Sometimes copious hæmorrhage takes place, either in the liquid form, or in that of black clots intermixed with masses and shreds of fibrine. Occasionally, the symptoms of ileus supervene, in consequence of the peristaltic action being arrested and inverted by a thickened and rigid state of some portion of the canal.

These symptoms, usually classified under the general appellation of *chronic dysentery*, may occur, not only after dysenteric inflammation, but also when chronic ulceration has succeeded to acute follicular enteritis, from the immediate effects of which the patient had recovered. Thus, they existed to a certain extent in the case of Fig. 152. (See Case.) In fact, any very extensive chronic ulceration below the middle of the ileum may, according

to my observations, give rise to the symptoms in a greater or less degree; but they are always more marked when the great intestine is the seat of the disease.

Solitary Ulcers, the cause of which is obscure.—These have been found in the stomach, the ileum, and the great intestines; and occasionally in all these parts at once. There are seldom more than one or two together. In general, they have thick, hard, and excavated borders, and also, according to Billard, offer much resemblance to phagedenic ulcers of the lips and external organs. Their particular mode of origin has not been detected, and as they commonly steal on slowly and insidiously, they can only be ascribed, in general terms, to chronic inflammation.

It is remarkable that, in the stomach, ulcerations originate in chronic inflammation almost exclusively, acute gastritis being very rarely found to produce them. Cruveilhier has drawn the attention of the profession with his usual ability to *simple chronic ulcer* of the stomach—an affection little known as a particular disease, and confounded in practice, sometimes with chronic gastritis, and still more frequently with cancer. It is described by him as consisting in a spontaneous loss of substance, of variable dimensions, ordinarily circular, with excavated borders, and a grey and dense base. It is almost always single, and usually occupies either the smaller curvature or the posterior wall; sometimes it attacks the pylorus, and then assumes the form of a circular zone. Its progress is slow and gradual; it extends in surface, but still more in depth; and, if salutary adhesions do not oppose a barrier, the stomach is sooner or later perforated, and its contents effused into the peritoneal cavity. It is distinguished from the cancerous ulcer by its ground offering none of the attributes either of hard or of soft cancer,—not even the circumscribed hypertrophy which almost always accompanies cancer, and which has often been mistaken for the cancerous degeneration itself. The best diagnostic sign, however, is the curability of the simple ulcer. By extreme

abstinence and the mildest diet, it sometimes slowly heals, and leaves a smooth, depressed cicatrix, not unlike the foramen ovale of the heart. I refer the reader to Cruveilhier himself for an excellent clinical history of this dangerous affection.*

Ulceration from Gangrene of the Mucous Membrane.—I have endeavoured to explain at p. 162, and to illustrate by Figs. 125 and 126, that acute inflammation of the mucous membrane may be of such intensity as to terminate in mortification. The same effect may be produced suddenly by the introduction of corrosive poisons into the alimentary canal. The form, number, and size of the gangrenous portions vary, of course, according to the intensity of the cause, and the extent over which it operates. Thus, in the case of Figs. 125 and 126, the whole colon was gangrenous, from rapidly fatal dysentery. In chronic enteritis, on the contrary, small grey or blackish gangrenous patches are sometimes found, involving the muscular coat, and leading to perforations. For the aspects of gangrene resulting from corrosive poisons, I must refer the reader to Orfila, and especially to the beautiful illustrations of Dr. Roupel.† In all cases, the gangrenous odour is one of the most unequivocal signs of the disease, without attention to which, the colour, when only green, grey, or brown, might be deceptive.

When the gangrenous eschars have fallen off, or sloughed away, an ulcer remains. If acute inflammation subsist around, the borders of the ulcer are tumid, and of a livid red colour, as exceedingly well seen in Fig. 118; but where the gangrene is diffuse, the borders may be undefined, as in Fig. 125. The base may present various shades of dirty green, yellow, and black, as in Fig. 118; or it may be a mixture of jet black and deep grey, as in Fig. 126, where the fluid and pulpy debris of the mucous coat

* *Maladies de l'Estomac*, X^e Livraison. He may likewise consult Abercrombie on the Intestinal Canal, p. 19, with great advantage.

† This work,—the first, I believe, of its kind,—is a truly valuable addition to medical science—particularly at a period when forensic medicine is so extensively cultivated.

collect in black spots on the dark grey muscular coat, which is itself involved in the disease. Ulcers from corrosive poisons present particular colours, according to the nature of the poisons, which it would be foreign to my present purpose to notice.

Ulcers originating in gangrenous sloughing are, according to Andral, (*Anat. Path.* ii. 111,) very rare; nor have I myself seen more than two or three cases out of many hundreds. Fig. 167 represents a remarkably fine instance affecting the stomach, and following acute gastritis of extreme intensity. At *a*, deep inflammatory redness is seen; at *b*, the coats of the stomach are greatly softened, so as readily to admit of being torn into fragments, as here seen; *c* are two dark gangrenous spots, on the eve of separation; at *d*, separation has actually taken place, and the stomach and subjacent spleen are reduced to one pulpy, foul, and sanious mass of disorganization. A section of the spleen, *f*, shows the organ to be gorged with black blood.

Gangrene occasionally attacks existing ulcerations, whether affecting a large, or a limited extent of surface. A dirty, greenish grey colour; softened, friable, and broken-up borders; a foul, liquid surface, and especially the gangrenous fetor, are its characteristic signs. When acute follicular enteritis becomes gangrenous, the fever, according to Cruveilhier, has, in a pre-eminent degree, the ataxic type.

Cicatrization of Ulcers.—The possibility of cicatrization, formerly doubted, has of late years been fully ascertained. The process certainly takes place with difficulty, being opposed by the peristaltic movements, and by the irritation of fecal matter; but there are now few pathological anatomists of experience, who have not met with instances, in which, while some ulcers were in full activity, others were healing, and a third set had completely cicatrized.

Fig. 168 affords a perfectly characteristic specimen of the healing ulcer. A zone of dim purple redness, *a*, still surrounds it; but the margin, formerly high and abrupt, has become much flattened, and, where it presents a pale colour, *b*, it is rounded or

levelled down, so as to meet the base, *c*. It does not yet, however, unite with the base, but lies loose upon it, as here displayed by a shadow beneath.* The base itself consists of clean, bluish-white and minutely puckered submucous cellular tissue.

Fig. 169 represents a complete cicatrization. All redness has disappeared, the margins are on the same plane with the surrounding membrane, and a fine web-like production from their edges has overspread the base, and formed fine wrinkles, converging towards its centre. The production, which is destitute of villi, and slightly depressed, is, to all appearance, the commencement of a new mucous coat.

Where the ravages of the disease have been very extensive, as in Fig. 176, the cicatrix is covered by puckered cellular tissue, *a*, formed of white, thread-like filaments, crossing each other in all directions, and leaving pitted interstices. (See Descrip. of the Plate.)

When the muscular tunic has been ulcerated, the base of the cicatrix often consists of irregular, but smooth knobs and undulations, formed by broken remains of the muscular coat, which have granulated and healed over. This is represented in Fig. 170, from immediately above the cæcal valve. The dark colour is from chronic inflammation.

The treatment for chronic ulceration of the alimentary canal, should be prosecuted with great perseverance and patience; as the patient, if not scrofulous or consumptive, sometimes recovers from a state apparently the most hopeless. In reference to the disease itself, the least possible quantity of food, and of the least irritating nature, is desirable; but, as emaciation often becomes extreme, a certain quantity is requisite to support the powers of life; and the difficulty of the treatment consists in steering between these two extremes. The greater danger lies, according to my experience, on the side of giving too much, and too stimulating food. Aperients also are an evil; and an

* This shadow is produced by the specimen being drawn under water, which causes the loose edge to float.

advantage is gained in substituting the emollient lavement, where this fully answers the purpose; but sometimes it evacuates only the great intestines; and the flatulence, peristaltic movement, and even pain, occasioned by the obstruction above, create greater irritation and distress, and are consequently a greater evil, than a gentle aperient. In this case, from one to three drachms of castor-oil, or from fifteen to thirty grains of rhubarb and magnesia, every second or third night, will, in general, answer well,—particularly if a lavement in the morning be made to coincide with their operation. In few cases are the effects of good air, gestation, and a cheerful state of the mind, more beneficial than in these; as they enable the patient to turn to the best account the little nutriment that is allowed him.*

CHAPTER V.

HYPERTROPHY, SCIRRHUS, AND CANCER.

HYPERTROPHY may affect, either simultaneously or separately, the mucous coat, the submucous cellular tissue, the muscular coat, the subperitoneal cellular tissue, and, though rarely, the peritoneum itself. It may also affect only a single anatomical element of the mucous membrane, namely, the follicles, the hypertrophous state of which has already been described (pp. 181-2).

Andral shows that hypertrophy of the several coats and intermediate tissue does not constitute scirrhous or cancer, until, having attained a certain degree, it has become the seat of a new structure, and of morbid secretions. This is an important and instructive distinction; since as writers have been in the habit of applying the term *scirrhous* (which generally conveys the idea of a malignant disease) to mere thickening of the cellular

* See Descrip. of Plates, Fig. 170, case 2, for an instructive instance of presumed cicatrization and recovery.

or muscular tissues, not necessarily of a malignant nature. The relation between hypertrophy and carcinomatous disease will be made more apparent by examining them successively in the different intestinal coats.

A. *Hypertrophy, &c., of the Mucous Coat.*—The mucous membrane, affected with hypertrophy, may become thickened to the extent of one and a half or two lines, (Fig. 171, *a*,) and occasionally even to three or four.* It acquires a flabby solidity, and an increase of cohesion, so as to admit of being detached in large shreds without tearing. Its free surface may be of natural colour, which is rare; or it may present the ordinary tints of the chronic inflammation which gave rise to the thickening, viz., dim reds, slate-colour, (Fig. 171,) brown, and even black. Sometimes the substance of the membrane is pink, or even red; in which case, care must be taken to distinguish the hypertrophy from mere vascular tumefaction.

The hypertrophous mucous membrane most frequently preserves a smooth and even surface; but, occasionally, it is raised, by unequal thickening, into small, mammelated protuberances, separated by intermediate depressed lines. A remarkably distinct specimen of this is presented by Fig. 171. It constitutes the *muqueuse mammelonnée* of the French.

The parts most subject to hypertrophy of the mucous membrane, are, the stomach and the great intestine; and it proceeds to a greater extent in the latter than in any other part, the thickening sometimes amounting to three or four lines. The hypertrophy may either be diffuse, so as, for example, to occupy a great part, or the whole, of the stomach, the great intestine, &c.; or, on the contrary, it may be circumscribed and form either flat patches, or prominent tumours.

1. The flat patches are raised from half a line to two lines above the surrounding level, and are more or less round or oval. In short they bear a considerable resemblance to Peyer's patches

* Case by Billard, de la Memb. Muq., p. 597.

when preternaturally developed in the ileum. Their colour may be natural, or they may present the red, grey, or brown tints of chronic inflammation. Sometimes they are milk-white.

2. The prominent tumours have obtained the various designations of excrescences, vegetations, fungi, polypi, cancers. The accounts given of them by authors are somewhat inconsistent. Andral is of opinion that they "are nothing but various forms of hypertrophy of the mucous membrane, as any one may satisfy himself by an attentive dissection." (*Path. Anat.* ii. 59.) Billard thinks that "they are very distinct from cancerous degeneration;" yet, that they are not products of inflammation. (*De la Memb. Muq.* 401.) Cruveilhier, on the contrary, believes them to be of a cancerous nature; and this opinion I am inclined to favour, with respect to many of the excrescences, from the circumstance of having frequently found them in connection with cancer in other organs; but it also appears probable that some of the more simple excrescences are nothing more than hypertrophy of the mucous membrane, as supposed by Andral. I shall first endeavour to illustrate the general characters of the tumours by the plates; and then proceed to consider their structure, origin, and nature.

Fig. 174, *a*, represents six excrescences of small size. They have a soft, and pulpy, though resistant feel, are of pale colour, and adhere to the mucous membrane by a base not quite so broad as their crown. M. Rullier saw about eighty in one stomach, each of the bulk of a filbert, of firm tissue, and, says Andral, "evidently formed at the expense of the mucous membrane." Similar tumours are sometimes red. Andral saw forty such in the cæcum, of violet-red colour, and each nearly as large as a small bean. As these excrescences increase in size, the crown becomes broader, and turned over the base, like a mushroom; it also becomes subdivided into minor prominencies, and is streaked by numerous large vessels, and stained by ecchymosis; all which characters are exhibited by Figs. 172 and 174, *b*. In neither of the Figs. is the mushroom configuration manifest to the eye:

the reason of which is that the part which curls over the base, being of pulpy consistence, blends so softly with the mucous membrane as to appear to spring from it. But when the tumours are immersed in water, their edges float, and their peduncles then become visible. The subdivisions of Fig. 172, are also rendered more apparent by the water descending between, and separating them. Some of the subdivision are then seen to have more or less complete peduncles of their own. Andral mentions having seen seven such vegetations in one stomach, each about the size of a walnut. The intermediate mucous membrane was not altered in any appreciable manner.

The most common seat of vegetations is the stomach: after this follow in succession, the end of the rectum, the cæcum, the colon, the upper part of the rectum, the small intestines, and the duodenum.

Cruveilhier gives a minute account of the structure of vegetations, the accuracy of which I have more than once verified. When examined under water by a lens, they appear, according to this author, to be formed by innumerable fine blades or leaflets, (like hypertrophous intestinal papillæ,) of unequal length, Fig. 173, *a, a*, and pressed together: some of the blades are extremely thin, others are thicker; some have pointed extremities, *a, a*, others end in olive-shaped or mace-like swellings, *b*; occasionally, great numbers of them are grouped in a branch-like form around a common pedicle which supports them, *c*. All the tumours are essentially composed of an areolar filamentous web, formed at the expense of the mucous membrane, the submucous cellular tissue, and the muscular coat; which web, says Cruveilhier, is charged with a white, milk-like, or encephaloid matter, that may be squeezed out in a stream, as from a sponge. Finally, long and straight vessels, *d*, of venous appearance, in great numbers, and placed parallel to each other, traverse the tumours perpendicularly from their base to their surface, and run to the very ends of the blades, with which the surface is, as it were, bristled. When these vessels are much gorged, the surface of the excre-

scence presents the uniform, deep crimson colour of Fig. 174, *b*: when less gorged, the vessels present the straggling and ecchymosed appearance of Fig. 172.

In what texture do these excrescences originate? The one above referred to by Cruveilhier involved, as he states, not only the mucous membrane, but the submucous tissue, and even the muscular coat: the same I found to be the case with the tumour *b*, Fig. 174 (*c*, being the blue, hypertrophous submucous tissue), and also with the two tumours in Figs. 172 and 175: the same is believed to be sometimes the case by Billard; and Cruveilhier, likewise, maintains that, in most cases, the primitive seat of cancer in general of the stomach, is, the submucous cellular tissue, the other coats being only consecutively affected. But this author has also assured himself, that "in a certain number of cancerous affections, the mucous membrane was the part primitively affected." Mucous membranes appear to him to be "essentially composed of a vascular, venous, areolar web—in a word, by a thin layer of erectile tissue. It is in this vascular web, wholly venous, that the phenomenon of inflammation takes place; it is, equally, here that ulcerating and encephaloid cancer is developed." He has easily been able to see, with the assistance of a powerful lens, the encephaloid matter squeezed out, by gentle compression, from the numerous venous areolæ, constituting the mucous membrane of the vagina, in the case of cancer of the neck of the uterus, propagated to the contiguous part of the vagina; and, on cutting the mucous membrane, he has been able clearly to discern the areolæ filled with the encephaloid matter. He sometimes found the alteration propagated even to the small veins issuing out of that capillary venous system, the veins being gorged with the same matter.

To sum up, then, it may be said, 1. that some of the excrescences under consideration appear to originate in the mucous membrane; and others, in the submucous cellular tissue: 2. that, when they originate in the mucous membrane, the subjacent tissues generally become implicated after the excrescences have

attained a certain volume: 3. that the affection is sometimes nothing more than simple hypertrophy of the mucous membrane: 4. that, in other instances, it constitutes soft or encephaloid cancer.

In substantiation of the third proposition it may be added, that it is consistent with general analogy to suppose that the mucous membrane, like any other, may sustain a partial hypertrophy;—further, when such is the nature of the excrescences, they are unattended by malignant symptoms. In substantiation of the fourth proposition it may be urged, that the excrescences occasionally yield encephaloid matter,* that they accompany cancer in other organs, (case 2, Fig. 174,) particularly in the liver, and that they are eventually attended with symptoms, more or less marked, of malignant cachexy.

Encephaloid excrescences of the stomach, when they have attained a considerable size, display a great tendency to become gangrenous. In Fig. 175, will be seen one in this condition, its crown being a mass of dark brown and intolerably offensive disorganization. This tendency to gangrene, which Cruveilhier considers to form, as it were, one of the necessary elements of cancerous affections, is by him thus explained. The primitive seat of cancer being, as he conceives, in the capillary venous system, (an “areolar erectile tissue,”) when this system is over-distended, and its circulation intercepted, by cancerous matter, the immediate result is rupture of the venous areolæ—whence ulceration and gangrene. These sometimes slowly wear down, in successive layers, the parts that they affect, which is the more ordinary case: and thus the cancerous ichor is produced, the horrible fetor of which results from the mixture of pus and putrefied matter. But in other cases, where the disease has obstructed

* Since writing the above, I have seen a macerated specimen, in which, at a part of the ileum adherent to a large encephaloid tumour of the kidney, the mucous membrane was thickened, and raised into ridges resembling those of Fig. 150, which my colleague, Dr. Sims, who saw the specimen when recent, considered to be of an encephaloid nature.

larger vessels, the gangrene attacks, at once, a great thickness of parts; and it is from such vessels that proceeds the hæmorrhage so common in cancer with or without gangrene. (Liv. iv. Planche i. pp. 3 and 4.)

Cruveilhier thinks that the circumstance of cancer being seated in the capillary venous system, throws great light on the question of the consecutive cachexy. For the disease continues local so long as the cancerous matter remains isolated in the portion of the venous capillary system, which, as a new organ, has furnished it; but, no sooner are these limits exceeded, than the cancerous matter circulates through the body, intermingled with the blood: it is presented to all the venous capillary systems in succession; the most predisposed receive it; it soon gives rise in them to the peculiar species of irritation which produces it; (for he does not think that the cancerous matter is deposited in substance;) and this new centre of disease soon becomes itself a source of general infection. He does not think it possible to explain, in a more satisfactory manner, the successive or simultaneous appearance of thousands of cancerous tumours in different organs.

This reasoning is undoubtedly true in reference to a great number of cases; but I must venture to differ from so high an authority in thinking it of universal applicability. It is certain that the cancerous matter exists, in some unknown elementary form, in the blood; and that, whenever it appears in organs, tissues, or in the blood-vessels themselves, it is a secretion or separation from the blood. Supposing, then, the taint of the blood to be universal, it is as easy to conceive the deposition taking place in numerous organs simultaneously, as in one. However, certain organs, as the uterus and mamma, the stomach and liver, being more predisposed than others, such are commonly the first to suffer. This predisposition is constituted by the more complex functions of the organs, in virtue of which they are subject to a greater variety of irritations of every kind. In this point of view, chronic inflammation, though cer-

tainly not a primitive cause of cancer, is a powerful predisposing agent.

B. *Hypertrophy, &c. of the Tissues subjacent to the Mucous Membrane.*—I shall first endeavour to illustrate that state of these tissues, which, though long indiscriminately ranged by writers under the general head of *scirrhus*, is properly regarded by Andral as mere hypertrophy; a state identical with the thickening and induration of the cellular tissue which surrounds chronic cutaneous ulcers; which is also seen affecting the interlobular pulmonary septa, and the sub-pleural cellular tissue, in cases of protracted peripneumony; (Fig. 3, *c*; and Fig. 4, *e f*;) and which presents itself, in a still more striking degree, in the same situations, in many instances of pulmonary phthisis (Fig. 28, *a, d d*). I shall afterwards endeavour to show under what circumstances the thickening in question is to be regarded as really *scirrhus* and cancer. First, then, of *hypertrophy*:—The primitive characters of hypertrophy of the submucous tissues are best seen in specimens where the disease has made only moderate steps of deviation from the healthy structure. Such a specimen is represented by Fig. 178, from the stomach. *a* is the mucous membrane, somewhat thickened by chronic inflammation; *b* is its adherent side, exhibiting inflammatory redness, still more apparent at *c*; *d* is the hypertrophous, sub-mucous cellular tissue, upwards of a line in thickness, of bluish-white colour, and slightly translucent like cartilage; *e* is the muscular coat, the greatly enlarged fasciculi of which are semi-transparent, of pinkish-grey colour, and are separated from each other by transverse lines of hypertrophous, white, fibro-cellular tissue connecting the submucous and the subperitoneal layers of cellular tissue; *f* is the subperitoneal layer of cellular tissue, only slightly thickened, but similar in its characters to the submucous layer *d*; *g* is the unchanged peritoneum itself.

It most commonly happens that we do not find all the coats hypertrophous in the distinct manner here represented. Sometimes one alone is hypertrophous, while another is atrophous; or

two are so blended together by hypertrophy as to be undistinguishable. Each may also present varieties in appearance, according to the duration and degree of the alteration. In order, therefore, to impart clear ideas on this subject, it will be necessary to illustrate the states of each coat or layer separately.

1. *Hypertrophy of the Submucous Cellular Tissue.*—Hypertrophy is far more frequent in this, than in any other part of the parietes, being found in a large proportion of cases of chronic diarrhoea in which the mucous membrane has become diseased, and especially in the vicinity of old ulcerations. The hypertrophy may vary in thickness from a line to half an inch or more; and it may either be circumscribed or extend over several feet of intestine. In Fig. 178 *d*, we have seen the appearance which it presents when forming a thin layer. Fig. 177 *a*, *a*, *b*, *b*, exhibits a thick and old layer, forming a stricture in the sigmoid flexure of the colon. It is semi-transparent, of bluish-white colour, is crossed by scarcely visible white lines of fibrous tissue, it grates under the scalpel, and has the density of pretty firm gristle. It is, in fact, a kind of fibro-cartilage. I have generally found high degrees of induration, like the present, connected with very protracted irritation, usually of a local nature. Accordingly, such induration is frequently seen in the pylorus.

When the hypertrophy is diffused along the intestines, it has generally a more lax consistence than when circumscribed, being, in fact, produced by a less permanent, and, as it were, concentrated irritation. A characteristic specimen of this kind is represented by Fig. 176, from the rectum. The submucous tissue *c* is half an inch thick, flabby, translucent, of dark greenish-grey colour, and crossed by very distinct white lines of fibro-cellular tissue.

When hypertrophy of the submucous cellular tissue is very recent, it is commonly not traversed by white lines, but, as in Fig. 178 *d*, presents a homogeneous appearance like lard, jelly, or size, the reason of which is, that the white lines are filaments of the original cellular tissue, between which the addi-

tional translucent matter is deposited; and the filaments become, *cæteris paribus*, more apparent in proportion as they become older and of a more fibrous nature.

2. *Hypertrophy of the Muscular Coat.*—In consequence of compression exercised upon it by hypertrophy of the cellular tissue, the muscular coat sometimes becomes atrophous, and even wholly disappears. The latter was the case in Fig. 177 *a a*, *b b*, where no trace of the coat could be found. It is more common, however, to find it more or less hypertrophous in connexion with hypertrophy of the cellular layers, as in Fig. 178 *e*, and Fig. 176 *d*. Sometimes, again, it is the only coat affected, as in Fig. 174 *d*, where its early stage is well characterized by a translucent greyish-pink colour, and by very delicate transverse fibro-cellular lines. As the disease advances, the pinkness decreases in connexion with a decrease of vascularity, and the fibro-cellular partitions become more apparent. Hypertrophy of the muscular coat is said by Cruveilhier to proceed to the great extent of seven or eight lines. I have never seen it exceed half an inch without having had reason to believe that the thickening was not mere hypertrophy, but of a carcinomatous nature.

3. *Hypertrophy of the Subperitoneal Cellular Tissue.*—This seldom exceeds a line or two in thickness, and it presents the same characters as hypertrophy of the submucous tissue. The thickening is often mistaken for that of the peritoneum itself; but the latter is extremely rare and always inconsiderable. Fig. 178 *g*, exhibits the peritoneum, and *f*, the thickened subjacent tissue.

Seats of Hypertrophy.—There is no part of the canal below the diaphragm in which hypertrophy of the submucous cellular tissue has not been observed; but it occurs principally in the parts most liable to chronic inflammation of the mucous membrane, namely, the stomach, the rectum, the colon, and the end of the ileum. Hypertrophy of the muscular coat is found principally where that coat is naturally of the greatest thickness,

namely, in the pylorus and pyloric third of the stomach, in the cardia, the rectum, and the colon.

Contraction of the pylorus is occasionally attended with enormous dilatation of the stomach, which has been known to reach even to the ossa pubis (Andral. Clin. Med.). Under these circumstances, the walls are sometimes attenuated, and sometimes of natural thickness. The dilatation arises from distension of the organ by accumulations of food which cannot pass through the pylorus. After the lapse of several days, the stomach, distended to the extreme, relieves itself by disgorging its contents; and hence, says Andral, arise those vomitings, so remarkable for their extreme copiousness, which supervene from time to time (every eight or ten days, for instance) in individuals labouring under contraction of the pylorus. When the contraction proceeds from carcinomatous tumours, the vomiting ceases when the ulceration of the tumour leaves the orifice free; but the symptom recurs in proportion as the tumour is regenerated. It occasionally happens that similar dilatation of the stomach takes place when the pyloric orifice is enlarged: an anomaly which is explained by the thickened walls of the viscus having lost their tonic contractile power; whence they allow accumulations to take place, as in an inert bag. When the pylorus is much thickened, a tumour may sometimes be felt externally; and when the whole stomach is diffusely thickened and contracted, without forming any particular tumour, an unusual resistance is, in some cases, perceptible over the whole epigastrium.

In the small intestines, hypertrophy of the submucous tissues is rare, and it is generally confined to a particular spot, of small extent. Sometimes the symptoms of stricture are produced by it, and increase from time to time to those of strangulation, of which the patient, after several relapses, usually dies. The intermittent nature of the symptoms of strangulation is ascribed by Andral to temporary tumefaction of the mucous membrane of the contracted portion; but it is also certain that the mere circum-

stance of distension of the gut above the stricture will, in contractions of a certain form, tend to close the passage; as, for example, in the stricture Fig. 177. In these cases the gut above the stricture is sometimes permanently dilated to three or four times its natural capacity.

In the colon, hypertrophy is more common at its two ends than in the middle, for the simple reason, that the mucous membrane and follicles are more subject to disease at the two ends. The thickening is in general attended with contraction of the gut; but sometimes the reverse takes place, and the walls, having lost their contractility, become dilated into a cyst with thick and hard parietes, forming adhesions with the contiguous parts, and presenting externally the feel of an abdominal tumour. (See case 105, by Abercrombie, on the Abdominal Viscera.)

Stricture of the rectum, or of the colon (Fig. 177), is in general nothing more than hypertrophy of the submucous cellular tissue, (*a a*), succeeding to irritation and thickening of the mucous membrane itself.

Condylomata around the anus are formed by hypertrophy of the submucous cellular tissue, covered with the thickened, and more or less injected mucous membrane, within the gut, and by the cuticle exterior to it. Fig. 179 represents a good specimen of the disease. The pale part *a* is a segment (about one-fourth) of the sphincter ani: all exterior to it is a triangular portion of one side of the nates. The alteration sometimes consists of distinct rounded tumours, like hæmorrhoids, with necks narrower than their heads, as seen at *b*, *c*, *d*; in other cases there is only a diffuse, granulated thickening around the anus, as at *e*, where the diseased skin is a third of an inch thick; but, most commonly, this thickening and the round tumours coexist, as in the present fig. The surface of the disease is highly vascular. During life the portion represented was universally red; but after death the blood gravitated away from the parts *a c*, leaving them lead-coloured, and stagnated in the large tumours *b*, and other dependent parts, rendering them of an intense violet hue.

On cutting them, blood oozed freely on pressure. When the thickened cuticle was peeled off, the surface had the granular appearance of a common wart, and the tumours grated like scirrhus when divided with the scalpel. Sooner or later, suppuration and ulceration take place, and the disease then assumes appearances often designated by the term *cancer*. In connexion with external condylomata, Andral once found similar globular bodies, of livid red colour, studding the whole internal surface of the rectum.

Hypertrophy of the intestinal canal occurs most frequently between the ages of thirty-five and sixty-five, and is very rare between puberty and thirty-five. It is not uncommon in children between the ages of four and twelve, when of unhealthy constitutions and subject to chronic diarrhœa.

There is reason to believe that the blood-vessels and nerves of the intestinal canal may become hypertrophous (Path. Anal. ii. 86). Hypertrophy of the lymphatic apparatus is a familiar affection, this being the nature of the enlargements of the mesenteric glands following protracted inflammation of the intestinal mucous membrane, as in figs. 154 and 155.

Having now examined hypertrophy of the several layers of the alimentary canal, we have next to turn our attention to scirrhus and cancer of these parts.

Scirrhus and Cancer.—Scirrhus, as its name imports (*σκιρρῶς*, & *σκίρος*, a fragment of marble), supposes an induration of the tissue which it affects. It constitutes the hard form of cancer, but it is not usual to give it the name of cancer until it has ulcerated and formed an open sore. By these two terms, therefore, scirrhus and cancer, we are here to understand merely different stages of the same lesion. I shall not at present stop to show that scirrhus and encephaloid disease are the extreme links of an identical chain.

According to the views of Andral, the lesion last described, or hypertrophy, is not scirrhus, because it is not a new tissue without anything analogous in the healthy state. Further, it has not

a necessary tendency to proceed to incurable ulceration, and it is not, any more than the induration around a chronic cutaneous ulcer, connected with a morbid state of the blood. When, however, there is more than mere thickening and induration; when there is a deposition of a morbid matter, which becomes solid, acquires a tendency to organization, and is often divided into regular lobules, or cells, by something like fibrous intersections;—under these circumstances, Andral is of opinion that the alteration is truly scirrhus.

Hypertrophy is apt to pass into scirrhus, because the local irritation, while it gives rise to an increase of the natural nutritive function, also favours the separation of cancerous matter from the blood, if a tendency to the disease pre-existed in the system. But the morbid deposition may likewise take place as a primitive lesion, wholly independent of previous hypertrophy; and the resulting appearances may be so similar, for a time, to those of hypertrophy, that the discrimination can only be effected by collateral evidence. Namely, in cancer, the disease is commonly of limited extent; in hypertrophy, many feet of the canal are often affected; cancer is more confined to the stomach and rectum than hypertrophy, it is attended with greater thickening of the walls, the muscular coat is more frequently implicated, and there is in many instances a coexistence of cancer in other organs, particularly the liver. When the morbid deposition has advanced so far as to become divided into lobules by fibrous intersections, or hollowed into cells or areolæ filled with gelatinous matter, these physical characters alone are sufficient to mark the cancerous nature of the disease.

Scirrhus presents different appearances according as there is more of the fibrous tissue, and less of the semi-transparent matter, or the converse; also, according as the matter, instead of being semi-transparent, presents various degrees of approximation to the opaque cream-like whiteness of encephaloid matter. It is unnecessary to illustrate all these varieties of appearance, and I shall

therefore confine myself to one of the most characteristic and remarkable, namely, that denominated by Cruveilhier *Areolar Gelatiniform Cancer*.

It consists, as its name indicates, of a transformation of the affected tissue into a fibrous areolar web, filled by a sort of transparent jelly. In the highest degree of the alteration, all kind of organization has disappeared: no trace of vessels is longer to be discovered, and all the tissues, however heterogeneous, seem brought to one uniform morbid type. The cellular tissue is, according to Cruveilhier, the primitive seat of the deposition, in conformity with a general law which he constantly inculcates, namely, "that all organic transformations and degenerations are the result of a successive deposition of morbid matter in the cellular element of organs exclusively; that the proper tissues are themselves insusceptible of organic lesion, except hypertrophy and atrophy; that these tissues, at first rendered hypertrophous by the irritation which surrounds them, finally disappear by atrophy consequent on compression." I find difficulty in subscribing to this law of Cruveilhier's; first, because it is not obvious to me how the proper tissue of an organ should be susceptible of increased, and yet not of morbid nutrition; secondly, because I believe I have seen cancerous matter deposited in the muscular fasciculi of the stomach.

Areolar gelatiniform cancer occurs in two forms: 1. in disseminated masses varying from the size of a millet-seed to that of a turkey-egg, or more; 2. uniformly infiltrated throughout the substance of the organ affected. The infiltrated form appears to me to be nothing more than a higher degree of the disseminated form, standing in the same relation to it, as tubercular infiltration does to round tubercle. The two forms will be illustrated by abstracts from Cruveilhier's own plates, exhibiting the disease in the stomach.

1. In the disseminated form, the disease sometimes presents a few detached prominent tumours, with heads broader than their

bases, as in Fig. 181, *f*; which tumours may attain the size of turkey-eggs: and sometimes it exhibits an infinite number of small, contiguous, and coalescing tumours, diffused over a greater or less extent of surface, as in the same fig., where the pyloric third of the stomach was thus affected. Towards the edges of the lesion, the tumours, being recent, are minute and entire; more towards the centre they are larger, and their summits are more or less truncated; further still, they have ulcerated away and left depressions, some of the larger of which are seen at *g*, Fig. 181. These tumours, whatever be their size and number, and whether isolated or coalescing, are soft, spongy, semitransparent, and, when examined attentively, are seen to consist of areolæ infiltrated with gelatiniform matter. They are considered by Cruveilhier to be nothing more than mucous papillæ prodigiously developed by the morbid deposition.*

2. In the infiltrated form, the gelatinous matter is deposited uniformly throughout the substance of the organ; in which case the part maintains its general shape, but undergoes a remarkable thickening, occasionally amounting to an inch or an inch and a half. Fig. 181 illustrates the manner and succession in which the several coats of the stomach become affected. The submucous cellular tissue suffers before the mucous membrane, as is seen under the pin, where the mucous membrane is still healthy. From below the pin to *c*, both the mucous and the submucous tissues are diseased, and together form one thick, greenish-grey, semi-transparent layer. Exterior to this, and separated from it by loose cellular tissue, readily admitting of being torn asunder, is a second layer, *a*, composed of the muscular coat, the peritoneum, and the intervening cellular tissue. Its colour is whiter and more opaque; but it consists, equally with the internal layer, of an areolar web, in the meshes of which a gelatiniform matter is deposited. The muscular fibres have

* Although the present head only professes to embrace the submucous tissues, yet, as the mucous membrane is implicated in this affection, its state must be described.

disappeared, vestiges of them being scarcely indicated by a few pale lines. In this case the cancerous degeneration had commenced at two distinct points, viz. the muscular coat and the submucous tissue. These, though at first independent of each other, ultimately coalesce, and form one homogeneous mass of disease, as seen at the section *d*.* More commonly, however, the disease is propagated from the submucous, to the muscular tunic by continuity of tissue; namely, according to Cruveilhier, the muscular coat, in consequence of irritation, becomes hypertrophous and divided into fasciculi by fibro-cellular partitions, as represented in Fig. 178 *e*. Along these partitions the disease extends from the submucous layer;† the fasciculi, compressed on all sides by the gelatinous deposition, become atrophous, and finally disappear; whence the parietes of the stomach are converted into one uniform areolar tissue, in which none of their original elements can be detected. Fig. 180, from Cruveilhier, exhibits a remarkably beautiful specimen of this kind in an advanced degree. The part is the interior of the stomach, of which *b* is the pylorus, and *a a* the cut edges. The mucous membrane and the layers immediately subjacent, have been worn away, so that the areolar character is universally visible. The areolæ are very irregular in size and shape; their walls are fibrous, and the contained transparent matter escapes, but not in a liquid form, from the openings made into the cells. At *c* it is seen still in the cells.

Areolar gelatiniform cancer, though found in the rectum, the cæcum, and occasionally in the ileum, is in no part of the alimentary canal so frequent as in the stomach. In this organ it exhibits, in common with the other varieties of cancer, a predilection for the pylorus; but it extends its ravages on each side, generally to a limited degree on the duodenal side, as in Fig.

* In the midst of the muscular layer are seen a few rounded osseous concretions.

† I have already stated my belief that the carcinomatous matter may be deposited in the muscular fibre itself.

181 *e*, but often over a large space on the side of the stomach, of which it may pervade a third, a half, and even the whole. After the pylorus, the lesser curvature is the part most liable to the first attack of the disease. The exterior of the organ often presents a lumpy surface from the unequal contraction of the muscular coat, and the absorbents are occasionally seen ramifying on it, charged with cancerous matter, and presenting the appearance of knotty cords of a whitish or translucent greyish colour. The veins also are sometimes charged with the same matter.

It not unfrequently happens that, when the stomach is affected, the two omenta participate in the disease; and they, likewise, present the two forms above mentioned, namely, 1. that of disseminated masses, either isolated, as in Fig. 183, or confluent, as in Fig. 184; 2. that of diffuse infiltration, in which case the omentum may be thickened from one to three or four inches. The thickening is attended with contraction, by which it is either drawn up into a thick girdle across the upper part of the abdomen, or, if adhesions have formed, it is torn below into longitudinal strips.

The present species of cancer is an extremely obscure disease, in reference both to its local and its constitutional symptoms. The only characteristic local signs which it offers are those of a mechanical obstacle to the passage of the food. In the absence of these, and of an external tumour or induration, the symptoms are such as cannot be distinguished from those of chronic inflammation or irritation; and patients are found to live and carry on digestion for a considerable period, when half, three-fourths, and even the whole of the mucous membrane is deficient! The constitutional symptoms, according to Cruveilhier, acquire the characters of cancerous cachexy more slowly than in any other variety of cancer; they exhibit less of general reaction and irritation, and the deposition itself seldom takes place, simultaneously or successively, in any considerable number of different parts.

The reason why areolar gelatiniform cancer is of so sluggish and chronic a nature appears to me to be that it possesses ex-

ceedingly little vascularity ; whence it has no intrinsic power of extension and propagation—in this respect forming a strong contrast with encephaloid cancer, which, by its high vascularity, effects its own reproduction with surprising celerity.

It is rare, according to my observation, to see well-marked encephaloid cancer affecting the submucous tissues of the alimentary canal, the ordinary form of the disease in these parts being scirrhus, under which term I include *areolar gelatiniform cancer*. Sometimes, however, we see an opaque whitish matter deposited in spots in the midst of hypertrophy of the submucous tissue or of the muscular coat. Thus it is seen in Fig. 174, *h*, in connexion with an encephaloid tumour, *g*, adherent to the peritoneum.

The observations which I have made on vomiting, in consequence of contraction of the pylorus by hypertrophy, apply equally when the obstacle is occasioned by cancer. But a mechanical obstacle is not the only cause of vomiting in cancer ; for, independent of any obstruction, it may result from the morbid irritability of the stomach in the advanced stage of the disease, and especially when the surface of the organ is denuded by ulceration. In this case, the vomiting, instead of being periodical and affording relief, comes on promptly after the introduction of ingesta, and the straining is attended with pain, sometimes of great severity. At this period of the disease the matter ejected is generally spotted, streaked, or freely intermixed with a substance resembling coffee or chocolate-grounds, or lees of wine. This is blood extravasated from the disorganized surface, and changed by exposure for a sufficient period to the action of the gastric juice. It generally augurs a near approach of the fatal termination. I have already shown that a similar matter may be a product of exhalation from the mucous membrane in cases of chronic gastritis, and that it even takes place in the vessels themselves when the mucous membrane is removed by softening. Fig. 132. The same dark matter may appear in the excretions when cancer has affected the intestines, and, by ulceration, led to

hæmorrhage. In this case, the discolouration of the blood is effected by the intestinal fluids and gases, which, like the gastric juice, have acid qualities.

DISEASES OF THE PERITONEUM.

THE ordinary effects of inflammation of the peritoneum differ little from those of the pleura and the pericardium; and I therefore refer the reader to those subjects for an account of false-membrane, and of the several varieties of effused fluid. The effects of chronic inflammation, however, and the morbid alterations of false-membrane under the influence of such inflammation, are more frequent and remarkable in the peritoneal, than in any other serous cavity. They therefore require a brief notice, though they are, with a few exceptions, of too intelligible a nature to stand in need of graphic illustrations.

False-membrane, when gradually accumulated by chronic peritonitis, sometimes forms immense masses of fibro-cellular and fibro-cartilaginous substance, by which the whole of the abdominal viscera are matted together in one complicated heap of confusion. By ulceration of the false-membrane in this state, communications may be established between one organ and another. Thus, when house-surgeon to the Edinburgh Infirmary, I had charge of a man, æt. 50, affected with a carbuncle six inches in diameter, in the umbilical region. It had several ulcerated orifices, yielding a green watery discharge, intermixed with sloughy cellular tissue. It had come on gradually during a year, and the patient died exhausted by irritation and hectic, in a state of extreme marcor. On examination it was found that the carbuncle had formed adhesions with all the surrounding viscera, and with them constituted an enormous confused mass of disease. A bougie, introduced into one of the orifices of the carbuncle, passed through a fistulous canal formed by the false-membrane and the agglutinated viscera, and emerged in the stomach through an aperture half an inch in diameter, surrounded by induration and green discolouration.

When chronic false-membrane ulcerates, its ordinary colour is a dirty green of disgusting appearance; but it may also present various tints of yellow, grey, and brown, the latter colour being mostly dependent on stagnant or extravasated blood, and being more considerable in proportion to the previous vascularity.

Sometimes chronic false-membrane never becomes organized, and it is then friable or rotten. I have seen a layer of this kind, two or three inches thick, overspreading the whole peritoneum, and of an appearance closely resembling mashed carrots. Sometimes lymph is deposited on the peritoneum in the form of granulations, at first small and transparent, afterwards becoming larger and white. The latter are represented by Fig. 189, in which the heads of the granulations are seen to be larger than the necks. The peritoneum is slate-coloured from chronic inflammation. The appearance was very striking, as the whole peritoneum was similarly affected. It is not uncommon to see granulations surrounded by an areola of black matter, often presenting a ramiform or stellated aspect. Sometimes the granulations themselves partake of the discolouration. It proceeds from stagnation of the blood in capillary vessels, the circulation through which has been impeded by the tumours. By the same process black matter is deposited in the vicinity of pulmonary tubercles. The discolouration may also proceed from melanosis.

False-membrane frequently becomes the seat of tubercles thickly disseminated in its substance, which, by keeping up the inflammatory irritation, cause those extensive accretions of the peritoneum described by Dr. Baron. They are principally found in the scrofulous and phthisical.

False-membrane occasionally presents the remarkable disease exhibited in Fig. 191,* namely, a yellowish-white matter, as dense as the fibrous coat of the aorta, in irregularly rounded masses of every size between a pin's-head and a bean. They are

* The Fig. is copied from a portion of a highly spirited drawing by Dr. Charles Williams, who also obliged me with the particulars of the case.

bedded in a pinkish-grey semi-transparent false-membranous matter. In the present instance they were found, not only in the false-membrane by which the intestines were, in numerous points, firmly agglutinated together; but also within the omentum and mesentery, under various other parts of the intestinal peritoneum, and principally beneath the peritoneum lining the anterior abdominal parietes. The specimen is from the region of the umbilicus. The disease was regarded by the French pathologists of La Charité as constituting the *cirrhosis* of Laennec. To me it appears to be allied to the genus cancer, and I shall revert to it hereafter when speaking of cancer of the mamma and some other external organs.

Peritoneal false-membrane, and the subperitoneal cellular tissue, are also subject to encephaloid cancer, such as I have exhibited it in the lungs. (Fig. 37.) As its growth in the abdomen is little opposed by compression, it often forms very voluminous masses. In connexion with them, the mesenteric, lumbar, and pelvic glands are usually affected. I recently deposited in the Museum of St. George's Hospital a specimen of a mass of lumbar glands as large as a foetal head, the individual glands of which were the size of pigeons' and hens' eggs.

The abdominal ramifications of the vena portæ may also be more or less filled and obstructed by encephaloid matter when similar disease exists in parts to which they are distributed. I have already adverted to the same matter as existing in the hepatic ramifications of the porta, in cases of cancerous depositions (tubera) in the liver, and I recently saw it in an extraordinary degree in the veins of an encephaloid kidney. The deposition in the great veins is usually subsequent to that in organs and tissues; but this is not necessarily the case; for, as the disease exists in the blood, the vessels themselves may sometimes be the primary seat of the deposition.

Melanosis is occasionally found on the peritoneum after chronic peritonitis. Andral is of opinion that, when in layers, it is nothing more than false-membrane infiltrated with melanotic matter.

Others contend that the discolouration of false-membrane does not proceed from melanosis, but from a blackening of the blood in the false-membrane by intestinal gases and acids,—a distinction which appears to me to be too refined; as the blackening ought, on this principle, to occur in all, or, at least, in many cases of chronic false-membrane. The same writers believe that genuine melanosis in layers on the peritoneum is an independent secretion, forming either a mere pigment on the serous surface, or a more substantial stratum, of elastic consistence like jelly, inclosed in a delicate web-like membrane of new formation, and capable of being dissected off without injury to the peritoneum.

Melanosis is also found adherent to the peritoneum in round pedunculated tumours, isolated or agglomerated, similar to those represented on the pleura in Fig. 39. They are covered by a fine membranous film of their own. Their most common situation is on the omentum. The appendices epiploicæ of the colon are sometimes infiltrated with melanosis, while all other parts of the peritoneum are exempt. This arises from the predilection which this disease exhibits for adipose tissue.

The distinction between melanosis and black discolouration of the blood occasioned by its stagnation, by gases, acids, &c., is, in many cases, as already pointed out, (p. 53,) very ill defined; and I agree with Andral in thinking that attempts to draw a positive line of demarcation anticipate the existing state of science.

EXTERNAL CANCER.

EXTERNAL cancer properly falls within the department of surgery; but as it occurs so frequently in connexion with internal cancer, and is calculated to throw a certain degree of light upon it, I have introduced a few Figures, in the hope that they may prove sufficient to answer this purpose.

For the anatomical characters of Fig. 185, representing a

most instructive specimen of cancer of the mamma,* the reader is referred to the description of the plates (p. 73.) Some of its physiological characters I shall here briefly notice.

At a certain period of its progress the scirrhus tumour softens in its interior. The softening is not the result of inflammation, but of an obstructed state of the circulation, resulting sometimes from congestion, and sometimes from partial compression of the vessels by the unequal developement of certain portions of the tumour, whereby the circulation through other portions is intercepted. The function of nutrition may thus be suddenly modified or wholly suspended over a large extent; and hence we sometimes see firm tumours undergo complete softening with surprising rapidity. The softened portion consists of sloughy matter, held loosely together by remains of cellular tissue and blood-vessels, and intermixed with a muddy serous fluid of variable consistence, and occasionally with blood. Hæmorrhage, however, is much less frequent in scirrhus, than in encephaloid tumours.

From the explanation now given, it will be apparent that softening does not necessarily commence in the centre of the tumour, but at any part, the circulation to which happens to be intercepted. The centre, in fact, occasionally presents a nucleus of such density as to be the last to undergo softening; for, not only is the vascularity of scirrhus less in proportion to its degree of induration, whence there is an inferior *direct* tendency to softening; but the circumstance of the density renders the circulation less liable to be intercepted by unequal compression.

At the most prominent part of the tumour, the circulation through the skin gradually becomes suspended by the subjacent pressure, which is indicated by a blush of red, progressively passing into purple, livid, and even black. Finally, a slough is detached, and the tumour next yields its disorganized contents. At first, the margins of the aperture resemble those of an ordi-

* I made the drawing for Mr. Keate of St. George's, who has obligingly allowed me the use of it.

nary abscess : namely, they are impending ; but in a short time they become expanded and everted. For, as cancer grows most rapidly in that direction where it is least opposed by pressure, its growth, in the present instance, is from all sides of the cavity towards the surface : whence the margins, whose external or cutaneous surface sustains no corresponding growth, become curled back, as seen in the Fig. at *f, f* ; while a new, rounded, and much thicker boundary, *b, e*, is formed by the eversion of the continually springing matter.

In Chimney-sweep's Cancer, eversion of the circumference of the tumour takes place by an analogous process. The disease first appears on the scrotum as a small hard tumour or wart, Fig. 186, which appears broken upon its surface. "Upon this wart," says Sir A. Cooper, (Diseases of the Testes, p. 227,) "an incrustation forms and continues to cover the surface. If this incrustation be rubbed away, or picked off, the papillæ on the surface of the wart appear excoriated, red, and broken, and issue a slight discharge upon the surface. An incrustation again appears upon the wart, which remains until accident, or the progress of ulceration, removes it, and then the surface appears highly vascular, and discharges a bloody serum. Still the surface becomes encrusted, until an ulcer of some extent forms under it. When the sore is carefully examined, it will be found hard, its edges indurated and everted, and its surface unequally vascular, so that it is yellow in some parts, red and vascular in others. It discharges a bloody serum, the smell of which is often very offensive ; but, still, a purulent discharge is sometimes observed." This account applies exactly to Fig. 187. (See description of the Fig. p. 74.) The principle of the eversion of the edges is seen in the internal structure of the tumour before us ; for, at its root *b*, the lobules are elongated—in other words *radiating*, in consequence of being most under the influence of compression ; but in proportion as the pressure decreases on advancing towards the surface, the lobules gradually become rounder, as seen at *a*.

Fig. 188 is introduced to show the wide difference which may be occasioned in the character of a scirrhus tumour by the circumstances of its developement. One who inseparably associates the idea of radiating and minutely lobulated or granulated structure with his conception of scirrhus, would scarcely refer the specimen before us to this class of morbid productions; yet its nature is fully proved by the anterior and subsequent existence of scirrhus in the same spot. (See case, p. 74.) The fact is, that, the mamma having already been extirpated, the tumour grew immediately beneath the integuments, the expansibility of which allowed it to enlarge freely in all directions without sustaining any particular compression at its root. Hence there is no appearance of radiation from this part. The rapidity of its growth, in connexion with the absence of compression, accounts for the large size of the lobules, as *a*, and for the unusual degree of vascularity and elastic softness. I have already endeavoured to show, when treating of tubera (cancer) of the liver, how greatly the physical characters of these tumours are dependent on the degree of compression and the rapidity of their developement. If the same circumstances, together with the structure of the organ or tissue affected, be taken into consideration in reference to cancerous formations in general, they will be found to bring many of the apparent inconsistencies and anomalies which perplex this subject, within the limits of a few simple principles.

Fig. 190 represents an external encephaloid tumour, the exterior of which, *a*, was of a livid violet colour before death. (See p. 75.) Its unrestricted growth in the subcutaneous cellular tissue accounts for the large and distinct lobules which it presents. The delicacy of their vessels renders congestion, rupture and extravasation very common in such tumours; accordingly, from the bleeding, fungoid appearance which they exhibit when sprouting through the integuments, the epithet *fungus hæmatodes* has been applied to them by Mr. Hey, (Pract. Observat. on Surg. 1803,) and Mr. Wardrop (Observat. on Fungus Hæmatod. 1809). The same epithet, according to Andral, has been applied to a de-

velopment of accidental erectile tissue—especially when it has become the seat of cancerous, melanotic or other morbid secretions. (Path. Anat. I. pp. 218 and 610.) The degree to which vascularity and extravasation may be carried in an encephaloid tumour is well displayed in Fig. 195, connected with the ovaria.

For further information on the subject of tumours, or, more correctly speaking, of *organizable morbid productions*, the reader may refer to the papers of Mr. Lawrence in the *Medico-Chirurg. Trans.* vol. xvii. p. 1, Mr. Travers, vol. xv. p. 195, and Dr. Hodgkin, vol. xv. p. 265. There is scarcely any subject in pathology beset with greater difficulties, and more imperfectly understood than this: nor does it appear to me possible, in the existing state of science, to give a complete general history of organizable morbid productions. The most acute and extended observation has not yet been able to define the line between malignant and non-malignant productions,* nor even to trace very distinctly the nature of the relations between malignant productions themselves. A relationship subsists, for instance, between the hardest scirrhus and the softest encephaloid matter, as is denoted by the simultaneous occurrence of the two in different parts, not only of the same subject, but of the same tumour. In most cases, differences in the structure of the parts affected, and in the rapidity with which the production is generated, appear to account, as already shown, for the occurrence of the one form or the other; but when the two present themselves, under apparently similar circumstances, in the same tumour, we cannot with any more certainty account for their co-existence, than we can for that of physiological secretion itself. Mr. Lawrence, after rejecting three proposed explanations of the mode in which tumours origi-

* To which class, for instance, is Fig. 191 (described at p. 224) to be referred? When it occurs in connexion with cancer of other organs, which is sometimes the case, it falls as legitimately into the class carcinoma, as do the productions represented in Figures 183 and 184. But when there is no evidence of carcinoma in other organs, we are left in doubt as to the nature of the affection.

nate, viz. 1, by effusion and organization of blood; 2, by effusion and organization of coagulating lymph; 3, by chronic inflammation; and after stating his inability to substitute an explanation more satisfactory, adds, "it seems to me that the circumstances, which determine the production of tumours generally, or of any particular kind of growth, are entirely unknown to us: nor ought we to feel surprised at our ignorance respecting these aberrations of nutrition, when we are quite in the dark as to the mode in which the process is accomplished in its natural or normal state—when we know nothing of the differences in arrangement or operation, which lead to the varied results of vascular action—when we are unable to explain how the capillary vessels of one part deposit muscle, of another bone, of a third fat; how one gland secretes bile, another urine, and a third saliva." (Medico-Chir. Trans. vol. xvii. p. 9.)

M. Andral has laboured under the same perplexity—and not without a degree of research and reflection seldom surpassed, as I can testify from my personal relations with him. At a loss to what lesions he can strictly apply the term *cancer*, he applies it to any or all that tend to incurable ulceration. "I have now," says he, "reviewed the principal varieties of appearance of organizable morbid productions, without enumerating *cancer* amongst them: neither have I included it amongst the other alterations of nutrition and secretion already treated of. Where then is cancer to be placed, and what is it? In my opinion, cancer is not a distinct morbid alteration, but the name is applied to every lesion, whether of nutrition or secretion, that has reached the period when it terminates in an ulcer constantly extending its ravages either in depth or surface. This metaphorical term, then, which, like that of inflammation, belongs to the infancy of science, expresses merely a termination happening in common to several very different kinds of alterations. I imagine that no one at the present day can maintain, with Bayle and Laennec, that cancer is an alteration *sui generis*, characterized by the presence of the scirrhus and encephaloid tissues, isolated or combined. In fact, the preternatural developement of a capillary

net-work on the surface or in the texture of the internal or external tegumentary membranes; a determination of long standing towards a portion of mucous membrane, without any real change of texture; a small portion of that membrane, or of the skin, in a state of hypertrophy; a pimple or an excrescence on the mucous or cutaneous surfaces, formed merely by an expansion of the proper tissue of the membranes, without any trace of a new formation; the thickening of the cellular tissue; the infiltration of its meshes by an albuminous or gelatinous matter; the red or white induration of the lymphatic ganglions, which has no more to do with accidental tissue than the red or grey hepatization of the lungs—these are all so many lesions, which, equally with encephaloid and scirrhus, may terminate in the destruction of the part in which they are developed, and in the production of an ulcer incessantly extending in every direction: all these lesions, though possessed of no anatomical character in common, may have this mode of termination in common: they all, in the last stage of their existence, become what is called *cancer*."

There are very few, I believe, in this country at least, who would accompany Andral to the bold extent of this generalization. Most would keep scirrhus and encephaloid more nearly in view, and would be inclined to suppose, when any of the varied lesions to which he refers really become malignant, that their local characters had been in some way modified by a morbid constitutional taint. From seeing and feeling the insufficiency of our data on this subject, I have made it my object throughout this work, when treating of cancer, rather to offer as accurate delineations and descriptions as possible, with the view of furnishing materials for future research, than to venture, without clearly discerning my path, into the misty regions of generalization. To bring under review, and balance the merits of the almost endless opinions that have been broached by others, would lead me far beyond the limits of a work which is restricted merely to principles. I must therefore refer the reader to original sources of information, strongly recommending the subject to his attention, as one whose obscurity is only surpassed by its importance.

DISEASES OF THE UTERINE SYSTEM.

CHAPTER I.

DISEASES OF THE OVARIA.*

IN Fig. 192 are seen the size and appearance of the ovaria soon after impregnation, in a female aged about 22; also their situation in the posterior duplicatures of the broad ligament, a little below the Fallopian tubes. (See Descrip. of the Plate.) They are observed to consist of a thick, white peritoneal capsule, *c*, and a tough fibro-cellular parenchyma, (here greatly congested,) in which are imbedded from twelve to twenty Graafian Vesicles, *e*, of various sizes, composed of a fine membrane, separable into two layers, and enclosing a clear coagulable fluid, with which the vesicle *f* is seen distended.

* My graphic resources on the subject of uterine diseases in general have been enriched by access to the invaluable portfolio of my friend and colleague Dr. Lee, executed principally by Mr. Perry. It would thus be in my power to extend the subject to several times its present length; but my limits forbid.

How much I regret this, will be understood when I state that the drawings illustrate the principal features of Dr. Lee's work "On some of the most important Diseases of Women"—more especially the doctrines of phlegmasia dolens, of which he has the distinguished merit of being the originator.

As I am under the necessity of submitting his drawings to the same Procrustean mutilation as my own, it is proper to say that no opinion of their real merits must be formed from their appearance in this work.

In the opinion of Dr. Lee, certain facts seem to prove that it is not to the influence of the uterus, but of the ovaria, that we are to attribute all the changes which take place in the female at the period of puberty : also, that it is to certain changes in the Graafian vesicles at the time of menstruation, that all the phenomena of that singular process are to be referred. (See Cyclopæd. OVARIA, by Dr. Lee.) These changes consist in distension of the vesicles with fluid, as at *f*, leading to rupture,—first, of the proper coat of some one vesicle,—and next, of the peritoneal capsule ; whence the fluid of the vesicle is discharged, but, whether the entire vesicle escapes, remains undetermined. There is, however, no proof whatever that an *ovum*—by which is usually meant an embryo enveloped in membranes—passes along the Fallopian tubes into the uterus during menstruation, as some have imagined ; and such a view is strongly discountenanced by the facts that an ovum is never formed but as a consequence of impregnation, and that conception does not take place at the menstrual period. It is not, indeed, clearly established that the passage of an ovum through the Fallopian tubes takes place even subsequent to conception. (Ibid.) A most careful search was made for an ovum in the case of Fig. 192 by Mr. Stanley, Mr. Lawrence, and myself, but without success ; though the open fissure, *k*, of the peritoneum, the corresponding corpus luteum, *m*, and the history of the case, afforded the strongest reasons for believing that the impregnation was very recent.

Fig. 193 illustrates the rupture of the peritoneum by a Graafian vesicle during menstruation. It is a portion of the drawing referred to by Dr. Lee, (Cyclopæd. Ovaria, p. 227,) in the following terms—“The peritoneal coat of the left ovarium was perforated at that extremity which was nearest to the uterus, by a circular opening, *c*, around which aperture, for several lines, the surface of the ovarium was elevated and of a bright scarlet colour, like extravasated injection. The margin of this opening was thin and smooth, and did not appear to have been produced

by laceration. Its centre was slightly depressed below the level of the edges, but there was scarcely the appearance of a cavity beneath." "Both ovaria were remarkably large." "Both Fallopian tubes were red and turgid, and the interior of the left *a, a*, was filled with menstrual fluid; but nothing in the form of a Graafian vesicle could be detected in the tube." When the catamenia cease, about the age of 46, the ovaria shrink, and the Graafian vesicles degenerate into thick, fibrous cysts.

It has appeared to me desirable to give this brief sketch of the natural functions of the ovaria, in order that the student may be fully impressed with the importance of the diseases of these remarkable organs. We now proceed to the diseases.

Acute inflammation of the ovaria will be noticed in connexion with inflammation of the uterus.

Chronic Inflammation is generally attended with little or no pain, and is therefore insidious. It occasionally converts the ovarium into a sac full of pus. In a case of Dr. Taylor's of Philadelphia, the quantity amounted to twenty pints! The sac in these cases sometimes becomes softened and perforated, and the pus is either discharged into the cavity of the peritoneum, exciting fatal peritonitis, as in a case of Dr. Bright's, cited by Dr. Lee; (Cyclopæd. Ovaries, p. 228;) or, what is more common, the sac forms adhesions with the uterus, vagina, bladder or intestines, and the pus is discharged into the cavities of these organs. In such cases, recovery is not uncommon. I saw a case in St. Bartholomew's, under Dr. Latham, where two pints were passed suddenly *per vaginam*: the tumour subsided at the same moment, and the patient recovered.

Alterations of Nutrition and Secretion. These are numerous and diversified, and may occur either as sequels of inflammation, or without any previous symptoms of it. The capsule may become thickened, fibrous, cartilaginous, and osseous. Thus a large bony plate invested a portion of the tumour, Fig. 195. The parenchyma may be increased in bulk and density by hypertrophy; or it may be reduced by atrophy to a small, shrivelled

and pale cellulo-fibrous mass;—a condition which is only morbid when premature, as it is physiological in the aged, when the catamenial function has ceased.

Fibrous Tumours are of common occurrence in the substance of the ovary, on its surface, and adherent to it by a long peduncle. They may commence no larger than a mustard seed, and attain the magnitude of an orange or more. They often co-exist with ovarian cysts, sometimes become cartilaginous and osseous, and occasionally soften in different parts of their interior, forming irregular cavities filled with a thick, dirty fluid. The texture of the fibrous tumours is very much the same as those of the uterus, presently to be described.

Cysts of the Ovaria. There is not any part of the body in which serous cysts are of so frequent occurrence, as in the ovaries and the folds of the broad ligament. In the latter situation, they are, according to my observation, most commonly simple; and I have seen the simple cyst attain the largest size without its walls becoming more than a line or two thick. Occasionally, one, two or more simple cysts become confluent. A tumour of this description, at least a foot in diameter, consisting of two cysts, recently presented itself to my colleague Dr. Sims, in the St. Marylebone Infirmary. I met with another case many years ago, in the Edinburgh Infirmary, in which there were eight or nine confluent cysts. The following are my notes:—"Connected with the left ovarium, but exterior to it, was an immense tumour containing two or three gallons of serous fluid, of coffee-colour. Its walls consisted in some parts of dense fibro-cartilaginous tissue, and they were laminated and rough internally—evidently from inflammation of the lining membrane, and successive depositions of lymph. Attached to the exterior of this great cyst, were seven or eight minor cysts, averaging two inches in diameter, thin and transparent, with one exception, and filled with a clear serum, slightly differing in colour and consistence in the several cavities.

It occasionally happens that cysts both of the broad ligament and the ovary produce secondary and even ternary cysts within

This subject has been very ingeniously developed by Dr. Hodgkin, (*Medico-Chir. Trans.* vol. xv. p. 276,) who contends that all multilocular ovarian cysts are thus formed; an opinion in which I must, with great deference, venture to differ with so high an authority.

There appears to me to be little doubt that ovarian cysts, both unilocular and multilocular, when not of a malignant nature, originate, in many instances, in the Graafian vesicles; which, becoming progressively distended and enlarged, are at length converted into cysts, presenting endless varieties with respect to their size, their number, the anatomical composition of their parietes, and the qualities of their contained fluid. Such also is the opinion of Andral.

Sometimes a single vesicle is developed at the expense of the whole ovary, which, rendered atrophous by compression, is found adherent to some part of the circumference of the tumour, while the vesicle itself may attain the capacity of several gallons, and fill the whole abdomen. In this case, viz., of a unilocular cyst, the contained matter is generally fluid.

More commonly, a certain number of Graafian vesicles are developed simultaneously, so as to form a multilocular tumour. Of this, an excellent specimen is presented by Fig. 196, which contained about thirty cysts, some thin and transparent, others thick, fibro-cartilaginous, and firm. (See *Descript. of the Plates.*) This specimen may be regarded as a miniature type of a great number of large ovarian tumours, some of which attain such a size as even to fill the whole abdomen, thrusting back the intestines, and ascending to the spleen, liver and diaphragm. We can easily understand from a glance at the drawing and its anatomical description, that such tumours may present a knobbed and uneven surface; that some parts may be soft and fluctuating, while others are as firm as bone; and that, when opened, their parietes may present every grade of fibrous, fibro-cartilaginous and osseous thickening and induration.

The cysts, whatever be the nature of their walls, are always

lined by the same thin, smooth, and more or less vascular membrane—evidently of the serous class. This may, however, inflame and become concealed by rough layers of coagulable lymph. Notwithstanding the identity of their lining membranes, the different sacs may present singularly different contents; a clear serum, a gelatinous matter, a white, ropy, albuminous liquid, pus, fluid or coagulated blood, a chocolate or coffee-like fluid, a matter like treacle or black oil-paint, a greasy or suety matter, sometimes intermixed with bone or hair. I have repeatedly found several of these in contiguous cysts of the same tumour. All the dark coloured matters are probably modifications of effused blood.

Greasy matter in the ovary is represented by Fig. 197; where it forms white and greenish grains, flakes and lumps, of the consistence of firm cream-ice, encrusting the interior of the sac; but a small quantity of the matter which has been evacuated was soft, and much resembled the impure, opaque honey of commerce. Fig. 194 represents the interior of an ovarian sac, from which similar grease has been removed, in order to display a rugged and spiculated piece of bone, *a*, with a dependent fragment *b*; and also a smaller portion *c*. They are based in firm fibro-cartilaginous tissue.

For an account of hairs and teeth in the ovaries, and the speculations on their causes, the reader is referred to Andral, *Path. Anat.* ii. p. 687; and to Meckel, *Journal Complementaire*, Nos. 14 and 15. The diseases hitherto described are not malignant: that is, they may exist without being either the cause or the effect of that class of constitutional symptoms, which we understand by the term cancerous cachexy.

Malignant Disease of the Ovaria. Encephaloid disease of this organ, or of the broad ligament in its vicinity, is of pretty frequent occurrence. Fig. 195 exemplifies the enormous size to which it may attain, and exhibits a well-characterized specimen of the diversified states of this kind of disease co-existent in the same tumour. (See Descrip. of the Plates.)

In its incipient condition, of which so advanced a tumour can convey little idea, the encephaloid matter presents itself sometimes in a lobulated, solid form ; with much the same general characters as are seen in Fig. 190 ; and in other cases it consists of a combination of cysts and tumours, soft, flabby, and in parts highly vascular—the cysts containing a gelatinous matter of various degrees of consistence.

This latter state runs into the variety well described and beautifully delineated by Cruveilhier (Livr. 5. Pl. 3) under the name of *areolar gelatiniform cancer* of the ovary, to which class he refers the disease, because, says he, it differs from areolar gelatiniform cancer of the stomach and other tissues only in the greater size of its meshes. The tumour, which may attain such a size as to fill nearly the whole abdomen, consists of a lumpy sac, from the internal surface of which rise mammiform excrescences of greater or less width and depth, formed by irregular fibrous cells filled with a ropy fluid, like white of egg, or with a concrete, trembling matter, like jelly. The cells are of all sizes, from a pea to an egg, and their walls are of an opal semitransparent white on the cells, and of a cartilage-white in the intermediate partitions.

Encephaloid disease of the ovary may occur at an early period of life, and it appears, in some instances, to be excited by pregnancy. Its symptoms and diagnosis are well described by Dr. Seymour. (Dis. of Ovaria, p. 61.)

I have never, within my recollection, met with well-characterized scirrhus of the ovary, and I therefore imagine that it is rare in this organ. Dr. Seymour, who appears to be of the same opinion, cites, however, (p. 59 of his valuable work,) a preparation of Dr. Baillie's in the College of Physicians, as affording an instance : the patient died of cancer of the stomach.

I have so frequently seen the results of paracentesis abdominis disappoint the operator, that it appears to me highly important to obtain a more accurate diagnosis, not only between ovarian dropsy and ascites, which is comparatively easy, but, especially,

between the varieties of ovarian tumours themselves—between the unilocular and the multilocular sac—between that containing serum, and that filled with gelatinous matter, or consisting of elastic encephaloid. For obvious reasons, paracentesis is worse than useless in the case of the multilocular, the gelatinous and the encephaloid tumours.

The diagnosis from ascites need not be mistaken. When the ovarian tumour is within a moderate size, its circumscription is conclusive. Its commencement *on one side* has been unnecessarily insisted upon, since, as its attachment is generally long and free, it soon passes towards the mesial line, where most latitude is afforded for its expansion.

When the tumour fills the whole abdomen, the diagnosis is more difficult: here, however, percussion affords excellent, and, with ordinary care, conclusive signs. In ascites, the intestines float upon the fluid, and the resonance on percussion is hollow in the most elevated situations—and invariably so in the umbilical and epigastric regions. (Piorry's ivory Plessimeter is here preferable to the hand.) On the contrary, the ovarian tumour being developed *in front* of the intestines, which it forces back, the most prominent part of the tumour is always dull on percussion. Further, to a practised ear, the dulness on percussion of an encysted dropsy is much greater than that of ascites; since, in ascites, the layer of fluid before the intestines is never so thick as to prevent a certain degree of resonance from being elicited by firm and smart percussion. Again, fluctuation is more distinct in ascites than in ovarian dropsy, unless much tympanitic tension coexist with the ascites—a very common case: but here, fortunately, the high degree of resonance affords an unequivocal diagnostic sign. In ovarian dropsy, the neck of the uterus is usually drawn up out of reach. The general symptoms also are different, ascites being almost always connected with some old organic disease of the liver, heart, or kidneys, and attended with infiltration in other parts; while ovarian dropsy may exist inde-

pendent of them, and may even be compatible with a perfect state of the general health.

The single gelatinous cyst cannot be physically distinguished from the single serous cyst—the feel and fluctuation of both being the same; but the multilocular cyst may often be distinguished from the unilocular, by its inferior degree of fluctuation, and, still more, by its uneven surface perceptible through the abdominal parietes or through the vagina and rectum. Encephaloid ovarian tumours may often be detected by their uneven, or unequally resisting surface, by the rapidity of their development, by frequent attacks of acute pain from local inflammation of the cyst, and by the general symptoms and appearance of cancerous cachexy.

For the introduction of greater precision into our diagnosis of ovarian tumours, we are much indebted to Rostin, Piorry, and Cruveilhier.

Scrofulous and tubercular disease of the ovary are of so rare occurrence, and so little importance, as scarcely to require notice.

CHAPTER II.

DISEASES OF THE UTERUS.

INFLAMMATION.

INFLAMMATION of the uterus is divided by Dr. Lee into the following principal varieties, which are as accurate and convenient as can be adopted.

1. Inflammation of the peritoneal covering of the uterus and of the peritoneal sac : 2. Of the uterine appendages : viz., the ovaria, Fallopian tubes, and broad ligaments : 3. Of the muscular and

mucous tissues of the uterus · 4. Inflammation and suppuration of the absorbent vessels and veins of the uterine organs.*

These varieties may occur independently of each other, but they are most frequently met with in combination. Peritonitis commencing on the uterus, almost always implicates the uterine appendages in a greater or less degree. It may also be propagated to the muscular substance of the uterus, in the same way that pericarditis causes carditis, and pleuritis peripneumony. It is, however, more common to find uterine peritonitis unattended with inflammation of the muscular tissue, the veins and the absorbents of the uterus, than these affections unattended with peritonitis. The importance of discriminating in practice between uterine peritonitis and inflammation of the deep-seated structures of the uterus cannot be too strongly or too frequently inculcated; as the former is a comparatively well-marked and tractable affection; whereas the latter is more or less insidious, accompanied with typhoid symptoms, and ranks with the most fatal maladies to which the human frame is obnoxious. With a view to the elucidation of this diagnosis, the above-mentioned varieties will now be reviewed and illustrated in succession.

1. It is unnecessary to dwell on the morbid appearances of uterine peritonitis, since the vascularity, the effused lymph and the serous, sero-flocculent, sero-sanguineous and sero-purulent fluids are similar to those of ordinary peritonitis. Fig. 198 exhibits in some parts a pink blush of the peritoneum, and in others a dim brownish and yellowish red; tints which supervene as the inflammation becomes more chronic. It is generally on the uterus, as might be expected, that the thickest masses of lymph are found. Serum and pus are occasionally effused in the subperitoneal cellular tissue of the organ.

2. The uterine appendages—the Fallopian tubes, ovaria and broad ligaments, when inflamed, are found red, vascular, and

* “On the most important Diseases of Women,” p. 18.

more or less imbedded in lymph or pus. The redness is seen in Fig. 199 *a*, and *b*. The loose extremities of the Fallopian tubes, says Dr. Lee, have been found of a deep red colour and softened, and depositions of pus, diffused or circumscribed, have taken place within the tubes, or in their subperitoneal tissue. Serous and purulent effusions are found between the layers of the broad ligament also. The ovaria are sometimes greatly swollen, as exhibited in Fig. 199, *c*; and on opening such an ovarium, it is found either to be gorged with a bloody fluid, effused around or within the Graafian vesicles; or, it is resolved by suppuration into a pulpy, disorganized mass, such as that seen in Fig. 200, *a*, which Dr. Lee aptly compares to a rotten pear. The peritoneal capsule *b* is, in this Fig., of a vivid red: in the preceding Fig. it was pale, perhaps from extreme tension. Occasionally, the ovarium is converted by acute inflammation into a large purulent cyst, which, like the chronic purulent cyst formerly described, may either burst into the peritoneal cavity, or into the interior of any adjoining organ with which it happens to form adhesions. In some cases adhesions form with the peritoneum along the brim of the pelvis, and the inflammation being propagated to the subperitoneal tissue of this part, purulent matter is generated; which, making its way over the psoas magnus and iliacus internus muscles, passes under Poupart's ligament, and escapes at the upper part of the thigh. From the researches of MM. Husson and Dance, it appears that this is a frequent, and often a fatal termination of inflammation of the peritoneal coat of the uterus and its appendages.

3. Inflammation and softening of the mucous membrane and muscular substance of the uterus present the following characters. The mucous membrane becomes soft, lacerable, flocculent, (Fig. 198, *a*), and sometimes completely disorganized; changes analogous to those of the gastro-intestinal mucous membrane already exhibited. Where the placenta has adhered, the mucous membrane sometimes sloughs away and leaves a foul, green, broken

surface, as in Fig. 198, *b*. In a few instances, pus is found in the cavity of the uterus, in connexion with inflammation of its mucous membrane.

The muscular tissue may be inflamed either to a certain depth only, or throughout its whole substance: sometimes the cervix alone is affected; in other cases, the part to which the placenta had adhered. If much charged with blood, the inflamed portion may be of a deep red or a violet colour: if less vascular, it may be greyish, yellowish, or even remarkably pale. With any of these hues, the texture of the organ may be so softened as to yield to the slightest pressure of the fingers. All the changes now described may exist without visible suppuration; but in other cases, the muscular parenchyma is found dripping with pus. Sometimes the suppuration forms circumscribed depositions or abscesses, which may be surrounded either by softening, or, what is more rare, by a natural consistence of the muscular substance. That destruction of the healthy organization of the proper and internal tissues of the uterus is the consequence of an inflammatory process, and not of any specific action, as some pathologists have maintained, Dr. Lee thinks may be inferred not only from the symptoms, and from the usual effects of inflammation of muscular tissue in other parts of the body; but from the frequent occurrence of this affection in combination with peritonitis, and the other varieties of uterine inflammation. (Dis. of Women, p. 39.)

Andral is at a loss how to account for the softening which sometimes occurs without any discoverable previous irritation. In women, for instance, who have died of some disease quite unconnected with the uterus, we are sometimes greatly surprised to find this organ remarkably pale and placid. It may be torn as easily as the tissue of the spleen, and in some parts it is even transformed into a kind of semi-fluid pulp. "As to the cause of this affection," says Andral, "we are quite in the dark: irritation and atony are equally hypothetical. All we can say of it is, that it bears a great resemblance to similar affections already described in the

heart, liver, stomach, and kidneys, the cause of which is equally inexplicable." (Path. Anal. ii. p. 666.)

Inflammation of the uterus may also be followed by induration.

This change takes place very slowly.

4. Inflammation and suppuration of the uterine absorbents, the receptaculum chyli and the thoracic duct, has been proved, by the researches of MM. Tovellè and Dupley, to be of not unfrequent occurrence in puerperal women, and to give rise to the same constitutional disturbance as uterine phlebitis, with which, indeed, it is usually associated. The reason of this identity of symptoms is obvious: namely, that the purulent matter, whether generated in the absorbents or in the veins, is equally carried into the general mass of the circulation.

Suppuration of the absorbents of the broad ligament is beautifully displayed by Fig. 202, from Dr. Lee's collection. Mr. Caesar Hawkins, in a communication to Dr. Lee, gives the following description of the first case of the kind noticed in this country, by himself, in 1829, at St. George's Hospital. The description applies very accurately to the drawing before us.

"In the broad ligaments, on each side, numerous large absorbent vessels were discovered passing up with the spermatic vessels to the receptaculum chyli, which was unusually distended. All these vessels, and the receptacle itself, were quite filled with fluid pus; but that in the receptacle was mixed with lymph, so as to be more solid: the vessels themselves were firmer and thicker than usual. The thoracic duct above this part was quite healthy." Dr. Lee has related the histories of four similar cases, which occurred to himself. (Med. Chir. Trans. Vol. XVI. p. 54.)

The local symptoms of inflammation of the absorbents, says Dr. Lee, are often so obscure as to escape detection during life; while the constitutional symptoms, which often resemble in a striking manner the effects produced by the introduction of specific poisons into the body, are so violent as to yield to no remedies, however early and vigorously employed.

Inflammation of the veins of the uterus, or *uterine phlebitis*,

when its frequency as well as its destructiveness is considered, may be regarded as the most formidable affection of the puerperal state. It appears to originate as follows :—

Coagula of the fibrine of the blood, often extending a considerable distance into the uterine veins, are formed in the orifices of these vessels after every labour, and are the principal means employed by nature for the permanent suppression of uterine hæmorrhage. Dr. Lee has observed distinct traces of these coagula, partially absorbed, four weeks after confinement, at the part where the placenta had adhered. (*Diseases of Women*, p. 52.) Now, when the placenta is detached, and the coagula first form, the veins are in the same relative circumstances as those of the stump after amputation; in the same way, therefore, their extremities may inflame, and the inflammation may be propagated upwards. Some have supposed that exposure to the air is the cause of the inflammation; but as it may also occur in veins arising from shut sacs, and likewise plugged with coagula, we cannot strictly go further than to say, that the inflammatory action originates in an ill-conditioned or unhealing state of the venous extremities and their coagula, of which the presence of atmospheric air may be one of the exciting causes. But a much more powerful cause is certainly to be found in the exposure of the lacerated ends of the veins to the putrid matter produced by decomposition of blood, or fragments of the placenta. Inflammation once established in the uterine veins is seldom confined to them; but runs along their continuous membrane to the spermatic and hypogastric veins, involving the Fallopian tubes, the ovaria and the broad ligament in its effects. Thence it may extend to the vena cava itself, (Fig. 203,) to its principal branches, returning the blood from the lower extremities, (Fig. 204,) and occasionally, even to the veins and substance of the kidney. Though the whole of the uterine veins may be inflamed, yet, in general, it is the spermatic veins alone which suffer, since these veins are invariably connected with the placenta, to whatever part of the uterus it may happen to be attached. Most commonly, however,

the vein of one side only—namely, that to which the placenta was attached, is inflamed; and the same observation applies to the hypogastric veins—probably on account of their contiguity to the spermatic veins, from which the disease is propagated to them.

The anatomical characters of uterine phlebitis are as follows.—The coats of the veins are thickened, and the cellular tissue investing them becomes hypertrophous and greatly condensed. Sometimes, the muscular tissue immediately around the vein, participating in the inflammation, is infiltrated with deep-red or chocolate-coloured blood, and is greatly softened. (See Fig. 212 and its descrip.) The circumference of this uterine apoplexy, as it might be called, is defined and abrupt.* On opening the veins, we find the following successive degrees of phlebitis, which, in the opinion of Cruveilhier, are constant in every case: 1. concretions of pure blood adherent to the venous parietes; 2. concretions more or less discoloured, (Fig. 198, *d* and *f*; and Fig. 203, *a, a, a*,) the centre of which contains pus, at first sanious, afterwards laudable; when the layer of concretion is thin, it has the appearance of false-membrane lining the tube; 3. absence of all concretion and pus, either sanious or laudable, is in immediate contact with the thickened and wrinkled vein; 4. erosion and laceration of the venous parietes, allowing the pus to escape all around and present the appearance of an ordinary abscess, in which the lacerated vein can with difficulty be detected.†

The cause of this series admits of a simple and satisfactory explanation. When a vein inflames, the first effect is, coagulation of the blood in the affected portion. If resolution takes place, which is by no means uncommon, the coagulum is absorbed, and the calibre of the vessel is either re-opened, or it remains permanently obliterated. But if suppuration is established, the pus shows itself first in the centre of the coagulum, because this

* At p. 127 is an account of similar apoplectic effusions, caused by the introduction of chemical and mechanical irritants into the veins.

† In connexion with this subject, the reader may peruse the description and case of Fig. 110.

part is less coherent than the circumference, and the pus more readily strains to it by capillary attraction. The pus is at first sanious, from intermixture with the colouring matter of the blood; and it becomes laudable when this matter disappears. The concretion, originally thick, gradually becomes thinner and finally suppurates away.

So long as the pus is contained within the interior of the concretion, the symptoms are local; but when, by the destruction of the concretion, the pus comes in immediate contact with the vein, one of two things happens: either, 1. the pus remains isolated by means of sanguineous concretions plugging the two ends of the inflamed portion of the vein—in which case the pus is sometimes absorbed and the vein obliterated, and sometimes it progressively accumulates, distends the vein, and causes erosion and rupture of its walls: or, 2. the portions of the concretion which operated as plugs, are slowly undermined by absorption, and at length carried away by the torrent of the surrounding liquids. The pus is then intermingled with the blood, and simultaneously appear typhoid and fatal symptoms.

It is under these circumstances that visceral abscess and sanguineous concretions take place in almost every organ and tissue, by a process already described (p. 125 et seq.). For the detail of symptoms attending these lesions—symptoms with which every practitioner should be minutely acquainted—I refer the reader to the invaluable work of Dr. Lee.

Crural phlebitis is illustrated by Figures 203 and 204, to the description of which the reader is referred for observations on this disease.

CORRODING ULCER OF THE OS UTERI.*

THIS appellation was employed by the late Dr. Clarke, and by Sir C. M. Clarke, to designate an affection which, from its fearful ravages, was often confounded, by less scientific practitioners, with carcinomatous ulceration of the cervix uteri. From this, however, it essentially differs in not being preceded by scirrhus or encephaloid depositions; in the pain which attends it not being of that acute, lancinating character which is characteristic of carcinomatous ulceration; and in its not tending so directly to a fatal termination, though it is to be lamented that, ultimately, it is scarcely less destructive than cancer itself.

The corroding ulcer originates in inflammatory action, which produces a slight tumefaction of the os uteri, and sometimes a little protuberant unevenness of its external surface, but never gives rise to that thickening and induration of the cervix which always exist in carcinoma, in consequence of a deposition of new matter. The corroding ulcer commences in the mucous membrane of the os uteri, and thence extending to the subjacent structures, destroys first the cervix, and, if the patient's life be prolonged, gradually consumes the body, as high even as the fundus,—ravages which do not take place to the same extent in carcinomatous ulceration, partly on account of the continual deposition of new matter, and partly because the patient is worn out previously by constitutional irritation.

I deem it unnecessary to offer delineations of the corroding ulcer, as its anatomical characters are simple and intelligible. Several cases have fallen under my observation within the last few years, and the appearances presented after death were,—a dirty-greenish and brownish, sloughy, and shreddy ulceration, with more or less adhesion and hypertrophy of the surrounding

* Called *malignant ulcer* by Dr. Baillie.

cellular tissue and other contiguous textures,—the products of chronic inflammation, propagated to them when the disease was far advanced. I have sometimes seen the ulceration penetrate into the bladder and rectum. On examining the corroding ulcer per vaginam, the erosion may be easily felt and its extent estimated, but no thickening or induration of the uterus can be distinguished. The latter circumstance, therefore, will materially assist in forming the diagnosis from cancer; and further assistance will be derived from the fact, that when slight pressure is made with the finger on the corroding ulcer, the patient does not suddenly shrink, as in cancer, but merely complains of a little soreness. The establishment of this diagnosis is important, because, with judicious management, the progress of the corroding ulcer may be retarded even for many years; and the practitioner is enabled to inform the patient that, if she will submit to a few privations, her sufferings will not be great. The disease usually takes place between the ages of forty and fifty-five, the period when the catamenial function ceases, and when there is a greater disposition to inflammatory action in the uterus, in consequence of the periodical determination of blood to it not being relieved by the accustomed secretion; a circumstance which often causes a temporary enlargement or hypertrophy of the uterus at this period of life, independent of ulceration.*

SCIRRHOUS AND ENCEPHALOID CANCER OF THE UTERUS.

THESE two varieties of cancer may here be considered in connexion, since they often co-exist in the same uterine tumour. The disease attacks, in the first instance, the cervix almost exclusively, probably in consequence of this being the most glan-

* An excellent account of the symptoms, progress, and treatment of the corroding ulcer is given by Sir C. Mansfield Clarke, in his "Observations on the Diseases of Females," Part II., p. 187.

dular part of the organ, cancer having a particular disposition to affect glandular structures.

Cancer of the uterus is characterised by a thickening and induration of the cervix, which is disposed to ulcerate. The thickening sometimes pervades the whole substance of the cervix, and sometimes forms a tumour at some particular part of it. The diseased structure, when divided, presents the usual characters of scirrhous, viz., an areolar arrangement, formed by more or less distinct white lines intersecting each other transversely.

A specimen of the disease is presented by Fig. 205, *b*, where it is of a mixed character, partaking both of the scirrhous and the encephaloid forms. At a distance, it has the yellowish-white aspect of encephaloid, but on close inspection the areolæ exhibited a degree of the bluish translucency of scirrhous. A livid remnant of the os uteri is seen at *e*, the rest having ulcerated away. Above this, is an ulcerated excavation *c, c*, in the substance of the carcinomatous matter, which has not yet opened its way into the vagina *g*. The fundus of the uterus is converted into a vascular, closed sac, *a*, as large as an egg, which was filled with a turbid greenish serum. The cancer extends to the walls of the bladder, of which the divided and thickened edges are seen at *d, d*.

Purely scirrhous cancer is of a more greyish-white colour than the specimen before us. I have not found it so translucent as in other textures, apparently in consequence of the close, fibrous texture of the uterus itself. For the same reason, encephaloid matter deposited in this texture is often so firm as to grate under the scalpel; but when it has increased so far as to have overcome the resistance offered by the uterine fibres, its consistence becomes softer, its lobules larger, its growth more rapid, and its volume sometimes five or six times greater than that of the whole uterus itself. Encephaloid tumours springing from the *surface* of the cervix uteri meet with comparatively little resistance to their development from compression.

It is not in the uterus alone, but occasionally also in the cellular tissue uniting it to the surrounding parts, particularly the

rectum and bladder, as well as in the walls themselves of these organs, (Fig. 205, *d, d,*) that encephaloid matter is deposited; and it may form tumours so large as, by pressing upon the organs, greatly or wholly to impede their functions. In the large majority of cases of cancer of the uterus itself, on the contrary, the enlargement is not so considerable as to cause the symptoms of compression of the pelvic viscera. Those of irritation, however, are seldom absent: thus strangury is of frequent occurrence, and is sometimes accompanied with chronic inflammation of the mucous membrane of the bladder and a copious mucous discharge. A similar discharge, often tinged with blood, is commonly yielded by the vagina: the rectum likewise, in most cases, exhibits symptoms of chronic inflammation; and the patient not unfrequently complains of aching pains following the tracts of the nerves derived from the sacral and lumbar plexus.

The history and occasional examination of patients with carcinoma uteri, afford reason to believe that a slight degree of the malady may sometimes remain in an indolent state even for many years, provided the individual adopt proper regiminal precautions. Eventually, however, the constitution becomes tainted, and the disease then tends unrelentingly to its fatal termination. Any violence done to the part appears greatly to hurry on this event. A stout, plethoric, and healthy-looking woman of fifty, subject for some years to a slight uterine affection, received a kick, which brought on hæmorrhage and pain. From this time the pulse rarely fell below 110, and there were constant lancinating pains, complete anorexia, vomiting of most ingesta, and, in four or five months, great emaciation. A thickened, ulcerated, and exquisitely painful state of the os uteri can be felt *per vaginam*.

In Fig. 205, we have seen one aspect of carcinomatous ulceration: in Fig. 206, we see a much more advanced state, the dirty-green, rugged, sloughing part *a* being a portion of the interior of the uterus, while the part *b* is the only remaining fragment of the cervix. Here also we have a beautiful instance

of the extension of encephaloid disease from the uterus to the vagina *c*, which is thickened and raised into soft, yellowish-white protuberances. I have already noticed a similar affection of the interior of the ileum, where the intestine adhered to an encephaloid tumour of the kidney.

In former times, scirrhus was confounded with the fibrous tumour of the uterus,—an error which, in the advanced state of pathological science, can scarcely be committed by a practitioner of education. It is here sufficient to say that the fibrous tumour seldom affects the cervix uteri, never ulcerates at its surface, produces no constitutional irritation, is unattended with pain even on pressure, and is generally harmless except from its mechanical effects on the contiguous organs,—circumstances which widely distinguish it from cancer.*

FIBROUS TUMOUR OF THE UTERUS.

THIS is the *Fleshy Tubercle* of Dr. Wm. Hunter and Sir C. M. Clarke, and the *Tubercle of the Uterus* of Dr. Baillie. Fig 209 presents a good type of one of a small size, which grew from the exterior of the uterus Fig. 211. It consists of parcels of fibres convoluted together and forming whitish lobules of irregularly rounded, oval, and elongated forms, and great density. These lobules are separated from each other by a compact cellulo-vascular tissue, pinkish and translucent, like the muscular fibre of veal. Hence the epithet *fleshy*, which the tumour has acquired. This tissue decreases in proportion as the fibrous lobules encroach upon it; and, at the same time, the tumour becomes denser and whiter. One in this state is seen in Fig. 214, where the cellulo-vascular tissue has almost disappeared. The

* For the clinical history and the treatment of cancer of the uterus, the reader may consult the work of Sir C. M. Clarke, on the Diseases of Females, with great advantage.

drawing is made from a specimen in spirits, in order to display more distinctly the direction of the convoluted fibres. Sometimes one or more broad white fibrous tracts run across the tumour, as at *b*, and subdivide it into large lobes.

Sometimes the fibrous tissue becomes fibro-cartilaginous, with a proportionate increase in density; and the latter state occasionally passes into the calcareous. Of this, a remarkably fine specimen is seen in Fig. 211, the great tumour *d* being so firmly ossified as to require the saw for its division. Its centre was hollow, as if the calcareous case had suspended the nutritive process within. Its surface is granular, and is invested with a transparent and highly-vascular production of the uterine mucous membrane *c*. In most cases, the cartilaginous and calcareous transformations take place in parts only of the tumour.

In some instances, the cellulo-vascular element of the tumour increases more than the fibrous; in which case the mass is somewhat soft and compressible, or elastic. In general the largest tumours, especially those approximating to the size of a foetal head, are of the softest consistence: probably because their nutritive process is the most free and their growth the most rapid.

Sometimes the cellulo-vascular tissue is so mixed up with the fibrous, as to present a homogeneous yellow appearance, like that of fibrine; the fibrous arrangement being discernible only on very close inspection, or after maceration. In the interior of a tumour of this kind I have seen a clot of extravasated blood.

Occasionally, serous cysts are developed in the cellulo-vascular tissue between the fibrous lobules, thus forming a sort of compound tumour. It has already been stated, that the co-existence of fibrous tumours with cysts is not uncommon in the ovaries. The size of fibrous tumours varies from that of a pea to the full dimensions of a foetal head. Their form is generally more or less spherical, but their surface is sometimes uneven or knobby, as seen in Fig. 211, *b*. They grow in three situations with respect to the uterine walls:—1. under the peritoneal coat, and exterior to the walls, as in Fig. 211, *e*; in which case their growth is outwards,

and, by elongating the peritoneum, they become pedunculated, as in Fig. 213, *d*. 2. In the substance of the walls. When near their external surface, they grow outwards; and sometimes, emerging from the uterine substance, they become pedunculated under the peritoneum. "When in the middle of the walls, it is remarked," says Andral, "that they remain much longer stationary than when situated near either surface," doubtless because their growth is impeded by compression. These tumours scarcely ever form in the cervix uteri,—a circumstance important to recollect, as it forms one of the most valuable diagnostic signs from cancer. When seated near the internal surface of the walls, they grow inwards, sometimes carrying a layer of the uterine substance before them into the cavity of the uterus, and sometimes making their way through this, and projecting immediately beneath the mucous membrane. 3. They form between the proper tissue of the uterus and its lining mucous membrane. In this and the preceding case, they tend to become pedunculated, as in Fig. 213, *b*; but this pedunculation is not, in general, complete, because the uterus closes upon the tumour as it increases, maintains it in its original situation, and thus prevents it from elongating the mucous membrane into a narrow neck. The neck, therefore, is most commonly broad and short, like that of Fig. 218, attached to the fundus *d*.

Fibrous tumours adhere to the uterine substance by a very lax cellular tissue, which admits of their being removed with great facility. When they attain any considerable size, either in the substance or within the cavity of the uterus, the organ undergoes hypertrophy and a diminution of consistence, exactly as in the gravid state; and in the case of several tumours, it is occasionally so deformed that its topography can with difficulty be ascertained.

Fibrous tumours do not ulcerate at their surface, but they are occasionally found softened, though without suppuration, in parts of their interior. When situated under the peritoneum of the uterus, they rarely produce any symptoms except those of mecha-

nical pressure on the adjacent organs; but when projecting into the interior of the uterus, they sometimes excite uterine contractions, attended with pains in the lumbar and hypogastric regions similar to those of labour. If these contractions should burst a layer of uterine tissue investing the tumour, and the layer should happen to contain large vessels, hæmorrhage may be the consequence, and may prove fatal, either immediately or by periodical recurrences. (Cruveilhier.) It occasionally happens that fibrous tumours are spontaneously expelled by uterine contractions, probably in consequence of their investments having been destroyed by previous inflammation consequent on their over-distension; for it is observed that such expulsions are generally attended with severe symptoms of inflammation and irritation. In the great majority of cases, however, no uterine contractions are excited by fibrous tumours within the organ: such is the difference of constitution. I have several times met with tumours in this situation in females between the ages of sixty and eighty, without being able to ascertain that they had ever produced even the slightest symptoms. This was the case with respect to Fig. 211.

Fibrous tumours are rarely seen before the age of thirty. Sir C. M. Clarke has never met with, or heard of, an instance before the age of twenty. In old women they are by no means uncommon—especially, it is thought, in the unmarried.*

POLYPUS OF THE UTERUS.

UTERINE Polypus is an insensible tumour springing from the mucous membrane of the uterus, and frequently descending into the vagina. With respect to the origin of polypi, Andral thinks that they are of two kinds; the one is at first merely a coagulum

* For a good account of the symptoms and treatment, see Sir C. M. Clarke on "Diseases of Females," Part I., p. 273.

of blood, which gradually assumes a determinate form and organization; the other appears to result from an alteration in the nutrition of the mucous membrane itself. The two classes, as they advance, become undistinguishable.

In shape, size, colour, and consistence, polypi present much diversity. Some are short and round; others are long and thin, and these occasionally become adherent at their free extremity. Some are less than peas; others are as large as the foetal head. Some possess a consistence not greater than that of the mucous membrane; others have an almost fibrous density. Some are pale and exsanguine; others are so vascular and pink as to resemble an erectile tissue.

Fig. 217 represents a polypus of the most ordinary kind. It is of a fleshy consistence, greyish-pink colour, and appears to be formed of concentric, laminated cylinders of cellulo-vascular tissue, which, when divided,—some transversely, others obliquely, and others longitudinally,—present the rude forms of spheres, ovals, and long tracts. At the most dependent part of the tumour *a*, is a quantity of black, concrete, extravasated blood, which gives a dark purple colour to the exterior *c*, and was probably the result of strangulation by the ligature. The investing mucous membrane was fine and transparent.

Fig. 215 represents a polypus of large size and great firmness. The drawing is taken from a preparation in spirits, in order to display the directions of the convoluted fibres and laminae. The white lines are composed of dense fibrous tissue, and the darker parts are composed of a compact cellulo-vascular tissue. In the centres of some of the cylindrical bundles of fibres, run large venous trunks, plugged with coagula. One part of the tumour *d*, is of a closer and firmer texture than the remainder *c*, and the centre is denser than the circumference. The colour of the recent specimen was a purplish-grey, two or three shades darker than Fig. 217, *b*,—the fibrous lines being grey, and the cellulo-vascular tissue, purple. The whole is invested by a thick and firm capsule *a, a, a*, apparently formed by the hypertrophous

mucous membrane and submucous cellular tissue. It is easily peeled off from the tumour. The peduncle was formed of the hypertrophous muscular tissue and mucous membrane of the uterus. The external surface, as represented in Fig. 216, is rendered rough by adherent flakes and fragments of coagulable lymph—the products of superficial inflammation. When the specimen was recent, blood oozed in abundance from the surface, and such, doubtless, was the source of the hæmorrhage during life.

There are other varieties of polypi of very different structure. Thus Fig. 218 represents a beautiful specimen of a vesicular polypus. The cut surface *c* displays a great number of vesicles, which contained a transparent, pale serum. The intermediate substance is a tough, but flexible, white, fibrous tissue. The exterior, *b*, is very vascular, and is studded with innumerable, prominent and transparent vesicles. The tumour adheres by a broad base to the fundus uteri *d*. Andral has described a similar, but smaller tumour; also one, the size of a walnut, composed of a “white semi-cartilaginous substance, divided into a great many cells, which contained a substance resembling thin, colourless jelly. It was attached to the uterus by a very narrow stalk. The cervix uteri was full of small cells containing the same jelly-like substance.”

In other cases, instead of a vesicular tumour, we find a crowd of separate vesicles, varying in size from a mustard-seed to a grape, filled with a transparent fluid, attached to each other by cellulo-vascular stalks in the manner of a bunch of grapes, and adhering to the interior of the uterus by a peduncle of variable breadth. These are usually called hydatids of the uterus.

Sometimes, again, a number of soft excrescences grow from the mucous membrane of a great part, or the whole of the uterus, and by their agglomeration form a tumour filling its cavity. As the excrescences have not long peduncles, the tumour seldom descends into the vagina. It produces the same symptoms as polypus, but is more fatal; since the excrescences are no sooner removed by ligature than they are regenerated.

Polypi of the uterus have occasionally been found to contain calcareous matter.

Polypi occur both in single and married women, and nothing certain is known respecting their cause, except when originating in coagula.

The most important symptoms are, a discharge of mucus and of blood, by which the circulating fluids are impoverished, dyspepsia induced and the patient gradually exhausted. There are also mechanical symptoms in proportion to the size of the tumour. In suspicious cases, an early examination should be strongly advised. When the tumour fills the cavity of the uterus, the os uteri dilates, and permits its descent into the vagina. In the latter situation, it is felt with its peduncle surrounded by the os uteri.

CAULIFLOWER EXCRESCENCE OF THE OS UTERI.

THIS species of excrescence springs, not from the interior of the uterus, but from the circumference of the os uteri exclusively; probably because this part possesses a glandular structure.

The tumour is composed of an exceedingly vascular erectile tissue; so that when the blood is withdrawn from it, either by the death of the patient or by exudation from the surface of the tumour after the application of a ligature, nothing remains of the mass but its cellular frame-work, in the form of a whitish, flaccid, slimy substance. Hence, it is extremely rare to find preparations of the cauliflower-excrescence in museums, and I have never been able to meet with a specimen for delineation. Sir C. M. Clarke has given an engraving of it, and he represents the surface to consist of a great number of small granular projections, various in size and regularity, like the head of the cauliflower. A membrane of very fine texture invests the surface; and the colour of the tumour, when seen *in situ* during life, is a bright flesh colour. When the surface is broken, the blood which escapes is florid.

In married women, in whom the vagina is very dilatable, the growth of the tumour is sometimes remarkably rapid ; whereas the less capacious, and more contractile vagina of single women, by compressing the mass, restrains its growth.

The tumour is insensible to the touch. It occurs at every period of life after the age of twenty, but rarely before.

The great and formidable symptom of the disease, is, the copious exudation of a watery fluid (the serum of the blood) from the surface of the tumour, sometimes sufficient in quantity to require twenty or thirty napkins daily. It is generally attended sooner or later with a discharge of blood, which, on any local excitement or corporeal exertion, as that of coughing, sneezing, straining, &c., may become profuse. The debility, emaciation, and other symptoms following such a discharge, terminate fatally, if the disease be not arrested.

CHAPTER III.

DISEASES OF THE FALLOPIAN TUBES.

THE diseases of these organs, though few, are important in reference to their effects on conception.

Acute inflammation seldom attacks the tubes, except in connexion with inflammation of the uterus and ovaries, already described : it may produce pus, and lead to adhesion and obliteration.

Obliteration of a part or the whole of the tubes may also arise from other causes, as chronic inflammation, congenital adhesion, an accidental membrane stopping the uterine orifice, disease of the fimbriæ, or their agglutination to the ovary or other parts.

When the two extremities of a tube are obliterated, serum or mucus may accumulate within, to the extent even of several pints. The fluid may also consist of pus.

Tuberculous matter filling the tubes is seen in Figs. 207 and 208. The latter is cut open at *a* to exhibit the dry, concrete appearance of the matter. Encephaloid matter, serous cysts, and calculous concretions may also obstruct the tubes.

DISEASES OF THE KIDNEYS.

THE kidney is one of the organs least liable to organic alterations—a circumstance which appears surprising when we consider the activity of its functions, and the facility with which its secretion is modified by the most trifling deviations from health. There is considerable difficulty in forming an arrangement of the diseases of the kidney, since both the structural alterations and the symptoms are often so uncertain as to breed doubt as to the position which certain lesions should occupy in an arrangement. The following arrangement of Andral can scarcely, I think, be considered exempt from this objection; provisionally, however, it may be adopted:—

LESIONS OF CIRCULATION.

- I. *Hyperæmia*.—A, from congestion; B, from inflammation.
- II. *Anæmia*.—A, general, after chronic disease, dropsy, &c.; B, partial, in the granular kidney.

LESIONS OF NUTRITION.

- I. *Hypertrophy*.—A, without change of structure; B, with the granular alteration, described by Dr. Bright.

II. *Atrophy*.—A, general, of one or both kidneys, either congenital or accidental; (under this head falls the single kidney, whether in its proper situation or in front of the vertebral column;) B, partial, almost always confined to the cortical substance.

III. *Softening*.—A, inflammatory; B, cause uncertain.

IV. *Induration*.—A, red; B, white.

LESIONS OF SECRETION.

I. Serum in cysts; II. fattiness of the cortical substance; III. pus—A, from ordinary inflammation; B, from phlebitis; IV. gelatiniform matter; V. encephaloid matter; VI. tubercular matter; VII. entozoa—A, hydatids; B, the strongylus.

I shall now attempt to consider the above alterations in reference, as far as is possible, to the diseases which appear to give birth to them, this plan being the most convenient in practice.

Inflammation of the Kidney.—Preternatural redness in connexion with softening, as in Figs. 225 and 226, affords strong evidence of acute inflammation; and this amounts to certainty if the patient had suffered pain in the loins, with fever, and had passed blood-tinged or purulent urine. The degree of redness may exceed that of Fig. 225, and even attain the deep chocolate tint of Fig. 229.

The softening also presents degrees, and may become so great that the parenchyma is converted into a pulp by the slightest pressure or tearing.

Acute inflammation may terminate in suppuration, and the pus may either be infiltrated generally or partially, or it may be collected into abscesses. In cases of infiltration, the pus oozes out muddy and blood-tinged on pressure; and when there is much softening, it sometimes forms, with blood, a pulpy matter resembling lees of wine.

Abscesses are sometimes small, and the intermediate substance appears little altered. In other instances they are large. I lately

saw a case under Mr. Brodie, at St. George's Hospital, in which there were five or six as large as walnuts. I have also seen the whole kidney converted into one immense purulent cyst. More frequently, however, it is converted into a multilocular cyst.

In cases of phlebitis, the pus, in this as in other organs, may either be infiltrated in spots, or form collections bounded by a cyst of lymph.

Hypertrophy and Atrophy.—I have seen the kidneys nearly double their natural size without any apparent change of structure. This preternatural development generally takes place in one kidney when the other is atrophous or absent; and it is, therefore, reasonable to suppose that it depends on the increased determination of blood to the sound organ. In corroboration of this view, a case, seen by Andral, may be quoted, in which an hypertrophous kidney had two renal arteries.

In other cases, chronic inflammation, irritation, and congestion, may be the causes of hypertrophy of the kidney, in the same way that we see them so frequently produce this effect in the liver and elsewhere. Thus, in diabetes, where we must, at least, admit the existence of irritation, hypertrophy of the kidneys is one of the most common alterations, and it is sometimes found accompanied with congestion, even of the deepest hue. It has been observed by authors, that the diabetic kidney is generally in the state of extreme anæmia. I greatly doubt, however, whether this is a primary alteration: it appears to me to be merely a consecutive effect of general anæmia and emaciation, just as we find the kidneys pale after protracted chronic disease, and particularly after old dropsy. Occasionally, the diabetic kidney retains its natural colour. Hypertrophy accompanying the granular alteration of Dr. Bright will presently be noticed.

Atrophy of the kidney may result from a deficient supply of blood to the organ, whether congenital or accidental. The latter may be occasioned by the pressure of a contiguous tumour, or by a process of increased or deranged nutrition in the neighbourhood

of the kidney, as that connected with an abscess, or a morbid growth, which, acting as a species of dirivant or counter-irritant, causes diminished nutrition in the kidney.

Atrophy of the kidney may also be a consequence of general atrophy. The cortical substance suffers much more from atrophy than the tubular cones.

Softening and Induration.—Softening from inflammation has already been described. There is another kind of softening, in which, says Andral, the substance of the kidney is remarkably pale, or of a peculiar grey tint: its nature and causes are uncertain.

Induration, when accompanied by hypertrophy, is generally red, but sometimes pale, and both appear to be, in most cases, results of chronic inflammation, the pale variety being, perhaps, of older date. Corresponding red and pale varieties of chronic induration (hepatization) are seen in the lungs. Induration, accompanied by diminution of size, is most commonly pale, and the structure may be either natural, granular, or so dense and white as to resemble cartilage. These states may be consequences of inflammation, and of structural changes in the organ impeding the circulation through it.

The Granular Kidney.—This disease has been excellently described by Dr. Bright. He has pointed out three varieties, but doubts whether they are not merely degrees of the same lesion,—a conjecture in which my own observation leads me to coincide with him.

Figs. 219, 220, and 221, exhibit the general aspects of the disease. In Fig. 219, from a girl æt. eight, it is not far advanced. Clusters of granules are seen at the surface *a*, from which the capsule *b* has been peeled off. Fig. 220 is the interior of the same, and small granules are seen forming in the cortical substance, along lines radiating from the vascular cones. This state was attended with softening and considerable congestion.

Fig. 221 exhibits a much more advanced degree, with greater softening, a paler colour, and with hypertrophy. On minute

inspection with a lens, uriniferous ducts are seen to be prolonged from the cones in a radiating direction towards the surface of the organ, and towards the adjoining cone, gradually becoming finer in proportion as they recede from the cones, till at length they die away insensibly. Between these ducts the pale granules are formed, and they become larger in proportion as the ducts recede from each other in their radiating course towards the surface. It is, therefore, near the surface and between the cones that the granules are most abundant and commence the earliest. The granules are speckled with a number of minute holes or pores. A more vascular and red tissue accompanies and surrounds the uriniferous ducts, as they diverge through the cortical substance, by which a more or less distinct appearance is produced of alternate red and pale lines or rows of spots diverging from the cones to the surface. This structure is rendered more apparent by the following Figs. :—

Fig. 225 is a portion of an inflamed and softened granular kidney, the granules, *a*, being disposed between the deeper red lines running to the surface. This surface is represented by Fig. 226, *a*, and is seen to consist of granules surrounded by a deeper red vascularity. The same kidney, after maceration in spirits for upwards of a month, presented the following appearances :— Fig. 224, *a*, represents its exterior, where are seen large, roundish granules, with an intermediate speckled vascularity. Fig. 225, *a*, represents a section parallel to the surface, and three lines distant from it. The red spots are the vascular tissue surrounding the uriniferous ducts, while the intermediate pale part is the morbid or granular alteration. The side *b* shows the radiating form which the disease assumes when the incision is made in the direction of the tubuli. This is still better seen in Fig. 222, *b*. The encroachment of the granules upon the vascular lines causes the latter to have a somewhat interrupted appearance.

This encroachment may ultimately intercept the circulation and cause atrophy with contraction and induration of the cortical

substance, as in Fig. 227, whence the surface is brought close to the cones.

The granular disease may be attended with an extreme degree of paleness, as in Fig. 228, or with an extreme degree of congestion, as in Fig. 229,—differences dependent on the general or local causes of anæmia and hyperæmia, but not constituting an essential feature of the granular disease itself.

It appears to me that the granular disease is merely a morbid development of the natural granules of the kidney, in consequence of some derangement of the circulation in the organ; and I imagine that the disease corresponds with the *nutmeg* and *granular* alterations of the liver. Should Mr. Kiernan extend to the kidney the masterly researches which have explained the minute anatomy of the liver, I entertain little doubt that the mechanism of the granular alteration of the kidney will be rendered perfectly intelligible.

Dr. Bright pointed out that albuminous urine was the characteristic symptom of the granular kidney; but the late Dr. James Gregory concluded, from extensive observation, that the sign was not certain unless the urine was also of less specific gravity than natural. In the absence of other manifest causes of dropsy, the granular disease of the kidney should always be suspected, and the urine should accordingly be tested.

Cysts in the Kidney.—It is remarked with great truth, by Cruveilhier, that there is not any organ more subject than the kidney to become transformed into, and to produce cysts. Cysts by *transformation* are formed, according to this author, by the following mechanism:—When the ureter is by any cause plugged up, urine, pus, or mucus accumulates within the pelvis of the kidney, and dilates it, as seen in Fig. 230, *d*. The dilatation is gradually propagated backwards into the calices; the tubular cones are, by compression, forced inwards upon themselves, and, by the atrophy resulting from this compression, are converted into fibrous cysts. The pressure operating next upon the cortical substance, this undergoes the same change, till the whole organ

is gradually converted into a multilocular sac, the several compartments of which communicate with each other by apertures of greater or less width, and usually of a circular form. It frequently happens that vestiges of the renal tissue may be discovered between the two fine layers of fibrous tissue constituting the partition between adjoining cysts. If, instead of the ureter being plugged up, the obstacle should be confined merely to one or more of the calices, the corresponding cones and lobules alone will be transformed into cysts,—a circumstance evincing the reciprocal independence of the cones. The matter within the cysts has always been found by Cruveilhier to be either a liquid still preserving some of the properties of urine, or a clear or purulent mucus.

Cysts by *production* are formed by a different mechanism. The cortical substance of the kidney is composed of glandular granules, each of which encloses a sort of cavity or lax web. When the communication of a granule with the tubular substance is obliterated, the granule dilates by the accumulation of the liquid which it secretes, and its walls soon undergo a transformation into fibrous membrane; for distension and compression cause atrophy of the proper tissues of organs, and development of the cellular element. Thus a cyst is formed; and, as the same cause generally operates on a number of granules at once, a number of cysts are the result: accordingly, though we occasionally find only one, two, or three, it is more common to find dozens, and even hundreds, scattered throughout the cortical substance, especially at the surface, the tubular substance remaining exempt from them. Their ordinary size is from a millet seed to a nut, but they sometimes become much larger, and augment the kidney to five or six times its natural volume. The contained matter is various: sometimes a limpid serum, variously tinted; sometimes a muddy, blackish, or yellowish fluid, and occasionally even cretaceous matter,—differences no doubt corresponding, says Cruveilhier, with the numerous modifications which the vitality of the walls undergoes.

When the cysts are numerous, the intermediate renal tissue becomes compressed and atrophous, sometimes to such a degree as to be undistinguishable. A slight quantity remaining, however, will often suffice to carry on the urinary secretion.

There is also another mode in which cysts are produced in this, as in all other glandular organs of granular structure, viz., at the expense of the serous cellular tissue existing in the organ. Cysts of this kind, seldom numerous, occasionally attain an enormous size. The contained fluid is serous, and is scarcely, if at all, coagulable by heat: it may become more or less purulent by inflammation of the cyst. Mr. Cæsar Hawkins met with a cyst containing about five pints of serum, and his account of it affords the best history of the affection in the kidney that has appeared.* He denominates it an *aqueous encysted tumour*, and believes it to correspond with the same tumour in the liver.

Hydatids occasionally occur in the kidney, and are, in some instances, expelled with the urine in great number and for a long period.

Encephaloid Disease.—This is pretty frequent in the kidney, and occasionally exists here when not found in any other organ in the body. The extent of the disease may be inconsiderable, or it may form a tumour as large as a fœtal head. The deposition may exist both in the parenchyma and in the great and small veins—a fine instance of which lately came under my observation at the St. Marylebone Infirmary. The disease presents the characters already frequently described in reference to other organs, its general type being the development of cellular filaments in an areolar form, the meshes of which are of variable density, and contain, some a cerebriform, and some a gelatiniform matter, and some a compound of the two. The symptoms of cancer of the kidney are exceedingly obscure.

Tubercle is rare in the kidney, especially when not existing simultaneously in other organs.

* Medico-Chir. Trans., vol. xviii.; where are also valuable cases of the same cysts in the liver.

DISEASES OF THE BLADDER.

DISEASES of the bladder are exceedingly rare, except as results of diseases of the urinary passages. In five hundred subjects, M. Louis found injection of the bladder in six only, and ulceration in but one.

Inflammation may produce ramiform, diffuse, patchy, and speckled redness of the mucous membrane, as in the intestines, and already described. Zones of red may also encircle the bases of the mucous follicles.

After chronic inflammation I have frequently seen the mucous membrane chocolate-coloured, green (Fig. 231), brown, and blackish; and these states are occasionally attended with adherent flakes of false membrane.

Hypertrophy.—By inflammation, the mucous membrane may become thickened and indurated, either diffusely or partially. In the latter case, excrescences of variable size, shape, consistence, and vascularity, may be the result, a fine specimen of which is represented by Fig. 231, *c, c, e*. The ramiform vascularity at the base of the incipient tumour *d*, shows that the tumour is a product of inflammation.

The mucous follicles become developed by hypertrophy, exactly as in the intestines, and the disease is usually attended with a protracted discharge of mucus or pus.

The submucous cellular tissue likewise becomes hypertrophous, and indurated, as in Fig. 231, *f*, where it forms the principal part of the tumour.

Hypertrophy of the muscular coat is seen at *b*. It sometimes affects detached fasciculi of fibres exclusively, thus forming the *vessie à colonnes* of French writers.

The bladder is subject to atrophy, softening, and ulceration, either of one or of all its coats.

The mucous membrane may secrete mucus, blood, pus, and

false-membranous matter; and the substance of the walls may produce pus, tubercle, encephaloid, and melanosis.

DISEASES OF THE SPLEEN.

THE diseases of the spleen are unintelligible without an accurate knowledge of the anatomical structure of the organ.

When the spleen is well cleansed from its blood by repeated washing, it is found to consist of the following anatomical elements, besides its nerves and lymphatics:—1. A fibrous tissue, forming, externally, the investing capsule, and, internally, divided and subdivided into innumerable septa, or cells, communicating with each other, into which the blood is effused; 2. A vein, which throughout its whole extent communicates with the splenic cells by an infinite number of holes pierced through its sides, and which ultimately has its cavity confounded with the cavities of the cells; 3. An artery which immediately subdivides into small branches that ramify on the septa of the cells, but of which the ultimate distribution as yet remains to be discovered.*

“ Since,” says Andral (*Path. Anat. II.*, p. 429), “ the parenchyma of the spleen may be resolved into two component parts,—the part contained, which is blood, and the parts containing, which is fibrous tissue,—it follows that the alterations to which this organ is liable should be sought for in one or other of these parts; in fact, its diseases ought to be the same as those of the veins; for, after all, what is the spleen but a vast venous network, in which the cellular is substituted for the vascular form?” Accordingly, the diseases of the spleen are—1. Those of the capsule and walls of the cells, corresponding with the diseases of the venous coats—a class of minor importance, and comparatively rare occurrence; 2. Those of the matter contained in the cells, corresponding with

* This description of Andral's coincides with that of the old anatomists, particularly Winslow.

the same in the veins—a class much more frequent and important. This matter, says Andral, in the splenic cells, which is in fact coagulated fibrine, although not possessed of any distinct organization, enjoys, perhaps, a greater sum of vitality than the fibrous tissue which contains it, and consequently is more prone to become irritated and altered in its nutrition.

CHAPTER I.

DISEASES OF THE FIBROUS TISSUE.

THE capsule is subject to inflammation, softening, rupture, thickening, and transformation into cartilaginous or osseous tissue.

The fibrous walls of the cells have been found softened, hypertrophous, and cartilaginous or osseous. Andral saw a spleen transformed, both externally and internally, into a mere osseous shell. I have found a calcareous mass as large as a filbert in the centre of the organ.

CHAPTER II.

DISEASES OF THE MATTER CONTAINED IN THE SPLENIC CELLS.

Softening and Induration.—These, says Andral, evidently depend on a change in the consistence of the blood or coagulated fibrine, which fills the splenic cells.

In softening, the blood is so thin as to admit of being thoroughly washed out of the cellular parenchyma. Sometimes it is

perfectly fluid, and gives an obscure feeling of fluctuation. Softening may be attended with diminution, or enlargement of volume: the latter is common after protracted typhoid fevers. Analogy leads us to believe that inflammation may be one of the causes of softening; but a more frequent cause probably is, an alteration of the whole mass of the blood, since it is principally in typhoid fevers, scurvy, &c., that softening is observed. Fig. 167 presents an instance of extreme softening of the spleen *e*, with enlargement, and a deep black colour *f*, in connexion with inflammation and gangrenous sloughing of the stomach *b*, *c*.

In induration of the spleen, the concrete blood in the cells is unusually dense, so that the viscus cuts and appears like liver. Induration is almost always attended with enlargement, but sometimes with contraction. Chronic inflammation may be one of its causes; but a more common cause—particularly when the induration is attended with enlargement—appears to be, protracted mechanical congestion, as that from disease of the liver obstructing the circulation through the vena portæ, from disease of the heart, from ague, &c.

Induration is sometimes attended with a deficiency of colouring matter in the concrete blood of the cells. This deficiency may exist—1. In detached points, and the organ then presents the beautiful mottled appearance represented by Fig. 234, the rich crimson hues of which are occasioned by the lighter ground being apparent through the blood, in the same way that dark venous blood assumes a brilliant crimson hue when on a white plate. The spleen in this case was double its natural size, and unusually solid and friable. 2. The discolouration may form masses of variable size, as that at Fig. 233, *a*, *b*. Five or six similar existed in the same spleen, which was thrice its natural size. The mass represented has abrupt edges, irregular within; its colour is a reddish yellow, finally becoming pale, like fibrine; its structure is obscurely granular, occasioned by the moulds of splenic cells; its consistence, at first firmer than the rest of the organ, gradually softens and eventually breaks up or suppurates.

These tumours appear to be nothing more than the fibrine of the blood, undergoing changes similar to what we see in the veins. In both the cases delineated, the alteration followed extreme venous obstruction—the former from disease of the liver—the latter from disease of the heart.

The alterations represented in Figs. 233 and 234 are sometimes distinctly referable to sub-acute inflammation, of which a fine instance is given by Cruveilhier. (Liv. II. pl. 5.) Deep reddish-black induration precedes the yellow induration. The former may be compared to incipient or red hepatization of the lungs, and the latter to complete or yellow hepatization, as that in Fig. 7, g.

Enlargement and Diminution.—Enlargement, according to Andral, depends either on the blood deposited by the arteries not being removed in sufficient quantity by the veins—whence there is enlargement by mere congestion; or the blood, being once deposited, and having become endowed with life, acquires the faculty of nourishing itself by intus-susception—whence there is enlargement by hypertrophy. Diminution of the spleen depends, of course, on some defect of nutrition. Andral has seen the organ as small as a walnut. Of the circumstances, says he, which tend to produce this atrophy of the spleen, we are totally ignorant.

New Productions.—*Pus* is occasionally found in the spleen—most frequently in connexion with phlebitis and visceral abscesses in other parts. The pus is either in isolated drops, oozing out here and there from the cut surface, or it forms collections, sometimes diffuse, and sometimes bounded by a cyst of false membrane. Diffuse suppuration occasionally pervades the greater part, and even the whole of the organ.

Tubercles in the spleen are not uncommon in children, but very rare in adults: in both they almost always exist in other organs at the same time. Fig. 232, from a child æt. 5, exhibits their usual form—that of minute bodies, here isolated, but sometimes confluent or clustered.

Fig. 235 represents a fine specimen of tubercles in the adult.

Each seems to be contained in a cyst,—probably the distended wall of a splenic cell,—which adheres slightly to the substance of the viscus by vessels ramifying on, and imparting a red colour to, its exterior. The interior of the cyst is lined with a curdy yellow matter, within which is a thick pus, even in the smallest of the tubercles.

Encephaloid matter is, I presume, to be found in the spleen, but I have not met with an instance.

Serous cysts are occasionally seen in the spleen—sometimes in great numbers, either isolated or congregated. Andral has found them not only in the splenic cells, but within the veins, some floating loose, others attached by peduncles to the sides of the veins, and others again lodged between their coats. Stronger cysts, containing suety matter with hairs, and melicerous matter, are also found.

Hydatids are rarer in the spleen than in the liver, but are in other respects similar.

The spleen is one of the organs least frequently affected with structural alterations.

The first of these is the fact that the United States is a young nation, and that its history is a history of growth and development. The second is the fact that the United States is a nation of immigrants, and that its history is a history of the struggle for a common identity.

The third is the fact that the United States is a nation of free men, and that its history is a history of the struggle for freedom and justice.

The fourth is the fact that the United States is a nation of opportunity, and that its history is a history of the struggle for a better life for all its people.

The fifth is the fact that the United States is a nation of progress, and that its history is a history of the struggle for a more advanced civilization.

The sixth is the fact that the United States is a nation of peace, and that its history is a history of the struggle for a more peaceful world.

The seventh is the fact that the United States is a nation of justice, and that its history is a history of the struggle for a more just society.

The eighth is the fact that the United States is a nation of hope, and that its history is a history of the struggle for a more hopeful future.

The ninth is the fact that the United States is a nation of faith, and that its history is a history of the struggle for a more faithful people.

The tenth is the fact that the United States is a nation of love, and that its history is a history of the struggle for a more loving world.

The eleventh is the fact that the United States is a nation of unity, and that its history is a history of the struggle for a more united people.

The twelfth is the fact that the United States is a nation of strength, and that its history is a history of the struggle for a more powerful nation.

DISEASES OF THE BRAIN AND SPINAL CORD.

"IF," says Andral, "the variety of the functional derangements of an organ bore any constant proportion to that of its derangements of texture, no part should present a greater variety of lesions than the nervous centres and the nerves: such, however, is not the fact; these lesions are few in number, and frequently bear no proportion to the nature and intensity of the symptoms." Even of these lesions, several do not admit of delineation; as, for instance, induration and slight degrees of softening, &c., in which the deviations from nature, in colour and form, are too delicate to be expressed by the graphic art. The same may be said of slight degrees of hypertrophy and atrophy: nor can congestion, inflammation, and serous effusion, in their first degrees, be decided upon, except by an eye exceedingly familiar with nature. It follows that, to acquire a knowledge of these lesions, connected as they often are with the most important functional derangements, nature itself must be sedulously appealed to, and minute comparisons must be frequently and carefully instituted.

The remaining lesions, which *do* admit of delineation, resolve themselves into a very few genera of a simple and intelligible nature; such as the effusions of blood, of serum, of lymph, and of pus, together with tubercle, encephaloid, cysts, &c. The species and varieties of these genera, though capable of being multiplied almost *ad infinitum*, and of affording a series of the most graceful and brilliant drawings in the whole range of morbid anatomy, are of less importance in an elementary work like the present, than the species and varieties of disease in most other organs; since, from the uniform, or, if I may be allowed the term, homogeneous nature of the cerebro-spinal substance, they consist more of differences in size, colour, and situation than in the essential characters of the lesion. I shall here, therefore, confine myself to the more important genera; and I entertain a

hope that, to the young student, there may even be an advantage in this; since it may possibly present to him a simple frame-work, on which he may, with less difficulty, arrange the more varied and complex stores furnished by his subsequent reading and observation.*

Notwithstanding the many admirable researches made in this country and abroad, on the subject of cerebro-spinal disease, the field is still widely and invitingly open. Violent symptoms sometimes occur, which cannot be traced to any structural lesion; though it is probable that a lesion, hitherto inappreciable by our senses, does actually exist as their cause: a lesion, apparently identical, may produce a certain train of symptoms in one case, a different train in a second, and no symptoms whatever in a third: finally, the seat of the structural lesion corresponds, in many cases, with the portion of the body exhibiting the functional derangements; but the exceptions to this rule are so numerous, that it cannot yet be ranked as a general law. Until these anomalies are more completely cleared up, a degree of uncertainty must hang over the diagnosis of a considerable proportion of the diseases of the brain and spinal cord.

The following arrangement of Andral's presents a synopsis of the diseases of the nervous centres:—

CHAPTER I.—GENERAL ARRANGEMENT.

LESIONS OF CIRCULATION.

I. *Hyperæmia*.—A, without effusion of blood, and resulting both from *congestion* and from *inflammation*; B, with effusion of blood (apoplexy).—II. *Anæmia*. A, of the brain alone; B, of the whole body.

* A work of which this country is justly proud, and which supersedes the necessity for my dwelling at length on the present subject, will richly supply the reader with the varieties which my narrow limits have compelled me to omit. Of few works may it be more justly said than of Dr. Bright's on the Brain,—“nocturnâ versate manu, versate diurnâ.” The drawings by Say have never been excelled, and seldom rivalled.

LESIONS OF NUTRITION.

I. *Hypertrophy*.—II. *Atrophy*.—III. *Softening*.—IV. *Induration*.—V. *Ulceration*, independent of any other alteration.

LESIONS OF SECRETION.

I. *Serum*.—II. *Pus*.—III. *Tubercle*.—IV. *Scirrhus* and *Encephaloid* productions.—V. *Fatty* productions.—VI. *Fibrous*, *Cartilaginous*, and *Osseous* productions.—VII. *Entozoa*.

Without following the above arrangement, I shall, in conformity with my general plan, consider the several morbid alterations, so far as is practicable, under the diseases to which they may be respectively referred.

CHAPTER II.

INFLAMMATION.

THIS is divided into inflammation ; 1. Of the Membranes (meningitis) ; 2. Of the Cerebral Substance (cerebritis).

I. MENINGITIS.—This is a generic term, applying to inflammation of the membranes of the brain in general. The term *arachnitis* is employed when it is wished to particularize inflammation of the arachnoid membrane ; and the French use the term sub-arachnoid meningitis to denote inflammation of the sub-arachnoid cellular tissue and pia mater.

The dura mater is less frequently inflamed than the other membranes, and its external or fibrous, less frequently than its arachnoid layer. Its fibrous layer, in fact, is seldom inflamed, except from external injuries. In several cases of fracture of the skull, and in some of injury of the scalp alone, I have found pus,

either liquid or of pasty consistence, between the bone and the dura mater, and adhering to both. The bone was usually discoloured, and presented a zone of redness around the purulent deposition; the dura mater exhibited a corresponding zone, and its arachnoid surface was vascular, had lost its polish, and appeared thickened. In such cases the disease is rarely more than a few inches in extent, corresponding with the external injury.

Inflammation of the arachnoid layer of the dura mater is not uncommon. Though most frequently partial, it is sometimes general, the base being the part last affected. Its first stage is characterised by ramiform vascularity, which, in further degrees, advances to uniform redness, sometimes even of intense scarlet hue. This hue, however, is seldom seen, as the inflammation usually makes further progress before the patient dies. Chronic spotted injection, in the vicinity of scrofulous tubercles, is seen in Fig. 260 *a*; and cloudy, mixed with ramiform redness, surrounds the tubercles adherent to the dura mater in Fig. 259.

Acute inflammation is soon followed by an effusion of serum, or of this and lymph conjointly. The lymph may become concrete, and form a consistent layer of pale greenish-yellow colour, which, becoming organized, may be converted into a perfect false membrane. In other cases, the lymph may be puriform and insusceptible of organization. False membranous layers, within the cavity of the arachnoid, I conceive to be rare, since an examination of several hundred cases has afforded me only a very few instances. The alterations now described, as affecting the dura mater, are so similar to those of other serous membranes, that they will easily be understood without further delineations than those illustrating pleuritis and pericarditis.

When the arachnoid is inflamed, its colourless vessels sometimes become finely injected, as in Fig. 238; but, more commonly, little or no vascularity is observable after death, though it probably existed before. A far more constant change is, a degree of milky or opalescent opacity, attended, after a time, with slight thickening and increased consistence and tenacity, so

that the membrane readily admits of being peeled off from the pia mater. The vertex and the base are the parts at which these changes are most common, the whole of the membrane being rarely affected.

In connexion with inflammation of the arachnoid, and of its subjacent cellular tissue, which is almost always simultaneously affected, the vessels of the pia mater are found preternaturally injected, an extreme degree of which injection, from a case of phrenitis, is presented by Fig. 237, and a minor degree by Fig. 236. The inflammatory injection in these, as in other inflamed membranes, is attended at first with preternatural dryness, but soon after, with an effusion of serum, either pure or mixed with lymph or with pus. Serum effused into the cavity of the arachnoid, gravitating during dissection to the inferior part, often escapes unnoticed when the dura mater is cut: that effused into the cellular tissue between the arachnoid and pia mater is retained, and presents, when turbid, the appearance delineated in Fig. 236; viz., accumulating in the interspaces between the convolutions, it imparts a haziness to their tracts, through which the outlines of the great veins are dimly seen. When the accumulation is great, a degree of haziness extends even over the summits of the convolutions, and the convolutions become widely separated and very rounded, as I notice in a recent specimen before me. On puncturing the arachnoid, the fluid, if purely serous, oozes out, though slowly, being somewhat detained by the sub-arachnoid cellular tissue; but if the fluid contain an intermixture of lymph, it has more or less of a gelatinous consistence, and often does not escape till pressure is employed. In proportion as the intermixture of lymph is greater, the consistence is more considerable, until it attains such a degree as to constitute real false membrane. In this case, the colour is a semi-opaque yellow, or greenish-yellow, the latter of which tints is well seen in Figs. 246 and 247.

These tints, particularly the yellow, are more decided, and are attended with greater opacity when the effused matter is of a

purulent nature. In such cases the surface of the brain presents a pale, dead-yellow tint along the interspaces between the convolutions, by which the great vessels are sometimes completely concealed. The vertex and the base are the parts where effusions on the exterior of the brain usually occur; in the ventricles, serous effusion is exceedingly common; but it is comparatively rare to find lymph or pus in these cavities.

In chronic meningitis the arachnoid acquires a greater thickness and opacity than in acute. A recent specimen before me, Fig. 248, *c*, is nearly as thick as a wafer, with which I compare it. Effusions of serum, lymph, and pus may attend it, as in the acute form: in addition, the free surface of the arachnoid may become studded and roughened with small, white, flaky, and knotty elevations, represented in Fig. 248. These are more abundant along the edges of the hemispheres contiguous to the falx major, and they often form the medium of firm adhesions between the arachnoid proper and its reflected layer on the dura mater. Though sometimes called *glandulæ Pacchioni*, they are not seen in infancy or in the perfectly healthy state of the membranes; and they must, therefore, be regarded as granulations of lymph, similar to what are seen after chronic inflammation on the pleura, the pericardium, and the peritoneum. It has appeared to me that they are more common in scrofulous and tubercular subjects.

Cruveilhier has given cases and drawings of minute tubercles, thickly and extensively disseminated in the sub-arachnoid cellular tissue, which he is inclined to believe were the results of acute arachnitis.

Inflammation of the Sinuses of the Dura Mater.—This affection is represented by Fig. 240, which affords an exceedingly fine instance of it (from Cruveilhier). The superior longitudinal sinus *aa* is filled with coagulated blood strongly adherent to the walls of the sinus. In the centre of the clots is a semi-concrete puriform matter, which was not anywhere in immediate contact with the walls. Almost all the cerebral veins emptying them-

selves into the superior longitudinal sinus, are full of concrete pus, which formed small yellowish-white cords, intermixed and continuous with black coagula. Some of these purulent veins, as *b*, have been opened, to afford a more distinct view of the arrangement of the small sanguineous and purulent cylinders. The torcular Herophyli, and the posterior half of the lateral sinuses, were in the same state as the longitudinal sinus. All the other sinuses were perfectly healthy. A kind of ecchymosis is seen on the surface of the hemisphere between *c* and *e*. A great quantity of serum existed in the cavity of the arachnoid. The interior of the brain was not examined.

It is unnecessary to say more on the general pathology of phlebitis than has already been said in treating of the liver, the uterus, and crural phlebitis; but it may be added that the disease is fatal in the brain at an earlier period than when affecting the system in general; because, when the sinuses, the great veins of the brain, are obliterated, the circulation through the organ is necessarily suspended, there being no collateral channels by which the reflux blood can be carried off. Accordingly, in many instances, death occurs in the very first stage—that of mere coagulation of the blood in the sinuses, when extensive and complete: others die in the second stage, namely, when pus occupies the centre of the clots, or when they become pale by the absorption of their colouring matter.

It might be anticipated *à priori*, and it has been proved by experiment on the extremities, that when the great venous trunks are obliterated, the continuing influx of arterial blood causes serous and sanguineous effusions. Accordingly, it is found that, when the sinuses of the dura mater are obliterated, the consequences are, not only stagnation of the blood in the cerebral veins, but exhalation of serum, and even of blood, into the cavity of the arachnoid, extensive ecchymoses in various parts, extravasations of blood in the sub-arachnoid cellular tissue,* with softening of the cerebral tissue of the convolutions; rupture of vessels in the

* Of this a beautiful drawing is given by Dr. Bright. Pl. 5.

substance of the brain, and apoplectic coagula in the midst of the hemispheres. All these different effects result, without doubt, from differences in the seat and extent of the venous obstruction, and still more, perhaps, from the rapidity with which the sinuses are obliterated—(Cruveilhier).

II. CEREBRITIS, OR INFLAMMATION OF THE SUBSTANCE OF THE BRAIN.—Considerable difficulty is experienced in ascertaining the existence of inflammation of the substance of the brain in its early stages, in consequence of the natural standard of vascularity being different at different ages, and in consequence of certain diseases, certain modes of death, and several other circumstances, giving rise to congestion, which may be mistaken for inflammation. It will, therefore, be desirable to premise the present subject with a brief sketch of the natural appearances of the brain, and of the aspects and causes of congestion.

Natural appearance of the Brain.—In adults, the colour of the cortical substance of the cerebral hemispheres is aptly compared to weak coffee, mixed with much milk, as in Fig. 241, from a female æt. 19. In infancy and early youth, the vascularity being greater, the colour is rather more purple, and resembles chocolate with milk. In elderly people, a diminution of vascularity, by withdrawing the pink intermixture, leaves the substance greyer and paler; and, in very advanced age, it acquires a slight yellowish tint, which, however, sometimes appears prematurely at a much earlier period.* When the pia mater is torn off, the surface of the grey substance is speckled over with red dots, arising from the rupture of the meningocephalic vessels, the dots being more numerous in proportion as the brain is more vascular: the interior of the grey substance also

* Andral, Path. Anat., vol. ii. p. 712., and Cazauvieill, *Recherches Anatomico-Physiologiques sur l'Encéphale, considéré chez l'Adolescent, l'Adulte, et le Vieillard.*

presents a few dots and streaks, which are less abundant, or, at least, less apparent, than those of the white substance.

The grey substance is composed of three distinct layers: the first, or external, of a whitish grey; the second, which is very thin, of a dirty white; and the third, which is the thickest, of a more leaden grey. Dr. Bright states that six layers may occasionally be discerned. The layers are marked by natural or accidental differences of colour.

The white substance of the cerebral hemispheres is usually called milk-white in young people and adults; but on repeatedly comparing it with white paper, I have found it to present a delicate pink tinge, which is deeper in proportion as the subject is younger, and also a faint yellow tinge, very much as in Fig. 241, produced by a very faint carmine wash, and, over it, an ochre wash. After the age of 50 the pinkness vanishes, leaving the white more pure than at any other period of life; in old age a yellower tint supervenes. On making a section, a few scattered dots of blood ooze out of the cut vessels, and are intermixed with a few short, capilliform streaks, as if from vessels cut longitudinally. The blood from a few of the larger vessels diffuses itself and forms small blotches. The number of these red specks, streaks and blotches is greater in children than in adults, and in these than in the aged.

Congestion.—Acute disease, attended with increased arterial action, augments the injection of the brain; while chronic disease, producing anæmia, diminishes it. Diseases attended with obstruction to the return of the blood from the head, as asthma, organic affections of the heart &c., augment cerebral congestion; and, on the same principle, it is augmented by death from asphyxia or convulsions. It is likewise increased by hypertrophy of the left ventricle, which causes a preternatural determination to the brain.

After death, if the head be placed in a dependent position, very considerable injection and even uniform redness may be occasioned by the gravitation of the blood, and its transudation

through the coats of the vessels. The same transudation may occur if the examination be delayed till putrefaction commences, especially when the weather is hot. Cerebral congestion is diminished by opening the chest before the head, and thus allowing the blood to drain off by the jugular veins. The French mode of opening the cranium by the hammer causes redness and ecchymosis along the line of the fracture. It is scarcely necessary to add the familiar fact, that, when the surface of the brain, divested of its membranes, is exposed for some time to air, its redness is greatly increased in consequence of the venous blood becoming oxygenized; and the same change is sustained, though in a less degree, by the interior when sliced and similarly exposed. Such are the causes of congestion before, and after death: we have now to examine the appearances which it presents.

The veins on the surface are preternaturally turgid, and their minute ramifications become unusually distinct. The interior (Fig. 242) exhibits an exaggerated degree of the natural red dotting, especially in the grey substance of the convolutions, the colour not being so bright a red as that from inflammation. In cases of great and old congestion, it is not uncommon for the vessels of the medullary substance to be so charged with dark blood as to impart a uniform dingy grey tinge to this substance, Fig. 243. Dr. Bright has shown that the vessels on which this colour depends are easily perceptible with a lens. In some instances, more especially those in which the circulation has been greatly retarded, the brain is marbled with a purple cloudiness, occasioned, perhaps, by a faint transudation through the gorged vessels. When the obstruction to the return of the blood from the brain has been extreme, as from obliteration of the sinuses by coagula, rupture of the minute vessels of the cerebral substance sometimes occurs and forms numerous petechial extravasations, which, when very close to each other, break down the texture of the part. They are most abundant in and near the grey substance of the convolutions. Similar extravasations are also very common in the vicinity of apoplectic effusions, as in Fig. 251, *a*; being

sometimes the result of violence done to the surrounding parts by the clot, and sometimes a product of the original tendency which led to the apoplectic effusion. Concussion of the brain often causes the same ecchymoses by laceration of the minute vessels. Ecchymosis on the surface from congestion is shown in a very remarkable degree in Fig. 239.

Congestive redness may not only be dotted, but uniform. This variety of redness, indeed, is most commonly a result of congestion, and is much less frequently the anatomical sign of inflammation than speckled redness. (Andral.) Uniform redness may vary in depth from a light rose-colour to a deep mahogany-hue. It is never general, being found only in patches in different parts. It occurs in either of the two substances, but principally in the grey, both of the convolutions, and of the *corpora striata* and *thalami optici*. In the white substance, where it is rare, it is usually found in the vicinity of apoplectic effusions, as in Fig. 245, *e*, though it may occur independent of hæmorrhage.

As in other organs, so in the brain, blood, whether extravasated or contained in its vessels, may, from decomposition, absorption of its colouring matter, &c., pass through a great variety of tints: namely, black, violet, purple, mahogany, chocolate, brown, slate-colour, green, amber, and various tinges of pale yellow; most of which colours may be seen in Figs. 249 to 257, inclusive.

Inflammation.—The substance of the brain, when sliced, presents a preternatural degree of scarlet dotting, which has been compared by M. Lallemand to a white surface sprinkled over with red sand ("*injection sablée*"). The dots are occasioned by blood circulating in the naturally colourless capillaries, from the larger of which it may be seen oozing for some seconds after the incision has been made. In young children, the injection is occasionally so great as to give a uniform pink tinge to the whole brain. Intermixed with the dots, are small red stains, probably occasioned by rupture of the capillaries and infiltration of blood into the surrounding pulp. These stains are various in number, size, form, and depth of colour: sometimes they give a marbled

aspect to the part, as in Fig. 244 ; and sometimes, by coalition, they form patches of red, the depth of which decreases from the centre towards the circumference of the patch. These marks of inflammation may either exist in scattered parts of the brain, or may affect a considerable portion of a hemisphere. The vascular turgescence imparts an increased degree of firmness to the part inflamed ; but, at the same time, it is more lacerable than natural. The diagnosis of inflammatory from congestive redness will be facilitated by retaining in recollection that the former, when recent, is of a more brilliant or scarlet hue ; that it is usually accompanied with anatomical vestiges of inflammation of the membranes, and with the symptoms of cerebral inflammation. When cerebritis is extensive, it may prove fatal without advancing beyond the degree now described, especially if accompanied by meningitis ; when limited, it commonly passes into the second degree, or that of softening, to be described in the next chapter.

Cerebritis is usually attended with an effusion into the ventricles either of serum, or, more rarely, of a sero-purulent or sero-albuminous fluid, the quantity of which is never very considerable from acute inflammation : from chronic, it may be enormous.

Cerebritis, though common at all ages, is most frequent in children, being connected with the high degree of cerebral vascularity which exists at that age.

CHAPTER III.

SOFTENING OF THE BRAIN.

WHEN inflammation of the cerebral substance has proceeded to a certain extent, it causes a diminution of consistence and tenacity ; at first, this is only appreciable by the touch ; in the next degree a pulpiness is perceptible to the eye ; in a further degree the part

is broken up into a diffuent matter, intermixed with the remains of the cellular and vascular tissues. These progressive stages exhibit many varieties of colour, dependent on the presence of blood and pus in different proportions. When the inflammatory injection is originally only slight, the dotted pink tinge which characterises it gives place to a pale yellow, or greenish-yellow, arising, as appears to me, partly from a stain left by the decomposed and absorbed blood, and partly from an intermixture of pus infiltrated into the affected part. The greenish-yellow colour is darker and dirtier in proportion as the previous redness was more considerable; if, however, the red be a deep colour, it is seldom wholly absorbed; but, mixed up with pus and dissolved cerebral pulp, it may pass through the several shades of claret, chocolate, brown, green, and grey. We can sometimes discern the three degrees of softening very distinctly in a single patch: the centre being a liquid pulp, beyond which is a zone of softened yellow substance, and this again is encircled by a halo of dotted or cloudy-red colour, the tenacity of which is diminished, while, from the vascular turgescence, it feels firmer than natural. It not unfrequently happens that extravasations of blood take place into softened portions of brain, in consequence of considerable vessels becoming disorganized. This fact should not be forgotten, since, before M. Lallemand pointed it out, it was too common to regard the softening as, in all cases, consecutive to the extravasation.

The cineritious substance is much more subject to inflammatory softening than the white, in consequence of its greater vascularity rendering it more prone to inflammation. Accordingly, the parts of the brain most frequently found softened, are, the *corpora striata* and *thalami optici*, with the medullary substance surrounding them (parts in which hæmorrhage likewise is the most common), and the grey substance of the convolutions. Softening of the latter often accompanies acute arachnitis, and it may be strictly confined to the grey matter, the white remaining totally exempt. "This partial ramollissement," says Andral,

“deserves the more attention, as it readily escapes detection when one is not previously aware of the possibility of its existence.”

There is another species of softening, which is not a result of inflammation, but appears to depend on causes obstructing the circulation through the brain, and producing, in the opinion of M. Rostan, an alteration something of the same nature as *gangrena senilis*. It occurs principally in the white substance, and the part affected even exceeds natural brain in whiteness, since it loses the pink and yellow tinge of health, and becomes a pure white. Its appearance is sometimes broken or curd-like, and it is moistened with a serous fluid in variable quantity. The grey substance becomes of a yellowish-fawn colour. No inflammatory blush is found in the vicinity of this species of softening; but the surrounding cerebral substance is not unfrequently in an oedematous state, and serum is effused in the ventricles and on the surface. It occurs principally in old people in whom the arteries of the brain are diseased. From its colour, it is commonly denominated *white softening*. It is not to be confounded with the soft, flaccid, and pale state of the brain which accompanies anæmia and emaciation after chronic or cachectic disease; nor with a variety of softening sometimes occurring, according to Dr. Abercrombie, in hydrocephalus, and affecting the *corpus callosum*, the *fornix*, and the *septum lucidum*, which parts are evidently infiltrated with serum. He believes this to be the result of inflammation; for he divides hydrocephalus into two species, the one attended with inflammatory softening of the above-named parts, and also of the cerebral substance forming the walls of the ventricles; the other depending on simple inflammation of the lining membrane of the ventricles, a species much less frequent than the preceding.

General softening of the brain is exceedingly rare in adults, but it occurs sometimes in new-born infants. In thirty cases of pultaceous softening of the brain observed by M. Billard, there were ten in which the affection extended to the whole of the spinal cord also; and in each of these ten the odour of sulphu-

retted hydrogen was perceptible. The infants in whom this alteration was observed, lived for some days after birth, but their respiration was laborious and imperfect, their limbs were flaccid and motionless, and the pulsations of the heart were scarcely perceptible.—(Andral. Path. Anat. II. p. 747.)

The spinal cord has been sometimes universally softened; but in general it is only so in some one part. Moreover, the two substances that enter into its composition may each be softened separately. When it is the internal grey substance that is affected, its liquefaction may produce accidental canals in the interior of the cord, which of course occupy the situation and present the form of that substance.

It appears from the researches of M. Billard, that softening of the nervous centres occurs at all ages, but is most frequent in old people, and, next to them, in adults. Between fifteen and twenty it is rather uncommon, but becomes less so between two and fifteen years of age: it may occur immediately after birth, and it is then more considerable and extensive than at any other period of life; it is probable, indeed, that in some cases it begins even before birth.

Authors have differed much in opinion respecting the nature of softening. Lallemand conceives it to be always an inflammatory affection, passing, like phlegmon, through the different stages of tumefaction, suppuration, &c. Rostan adopts a totally opposite opinion, viz., that it is a real gangrene of the brain, of the nature of *gangrena senilis*, depending on a diseased state of the blood-vessels. Laennec thought that one variety (the yellow, or red softening) was inflammatory, and the other (white softening) was œdema of the brain destroying its cohesion. Dr. Abercrombie considers softening of the brain as the death of the affected portion, and that, like gangrene, it may arise from two opposite causes:—1st, from excessive action, which includes the cases with appearances of vascular injection, suppuration, &c.; and 2nd, from a deficiency of action, owing to a failure of the circulation, which includes the cases of white softening with disease of the blood-vessels.

CHAPTER IV.

SUPPURATION, ABSCESS, AND ULCER.

INFILTRATION of the nervous centres with pus has been above adverted to, as being a result of inflammatory softening. The pus first makes its appearance in scattered drops, and this may occur within a very brief space of time; Laennec thinks within twenty-four hours: these drops gradually multiply, extend, and coalesce; the solid parts between them grow softer and softer, and at last appear as it were dissolved in the pus, leaving only a few filamentous fragments behind. The colour of the pus is yellow, greenish or brown, and it is sometimes partially concrete.

The collection becomes encysted by nearly the same process as in phlegmon: the sides of the cavity, at first ragged and undefined, are lined with successive layers of coagulable organized lymph, whose delicate vessels connect themselves with the circulation of the brain. The cyst, at first thin, finally becomes thick and firm, as in Fig. 257, and sometimes even fibrous, cartilaginous, and calcareous. The rudiments of cysts have been found formed within a week, but three or four weeks are requisite to complete their organization, and they sometimes continue increasing in thickness for years. It is highly probable that abscesses of the brain occasionally heal. The cerebral substance around a recent abscess is generally inflamed or softened: around a chronic one, it may be perfectly healthy, for a long period; but it may, at last, from irritation, undergo inflammation and softening, and bring on a new train of symptoms, which are attributable to these causes and not to the abscess itself. Softening is seen around the abscess in Fig. 257, and the history of the case presents a striking illustration of the principle in question.

It is not rare to find the spinal cord infiltrated with pus; but Andral states that he is not aware of an instance in which it contained an abscess.

Ulcer.—Independent of ulceration consequent on ramollissement, apoplectic effusions, &c., there is another ulcer of a more simple nature, though of rare occurrence. It affects the surface of the convolutions, and of the *thalami optici* and *corpora striata*, the nervous substance of which is superficially eroded, so as to form ulcers of various sizes and forms, mostly with uneven, ragged edges and a yellow albuminous surface, Fig. 258, *a*, but sometimes hard and dry. The surrounding cerebral substance may be either healthy or injected. Occasionally, the ulcer communicates with deep-seated abscesses. Sometimes it originates in the arachnoid and pia mater. This species of ulcer is mentioned by various writers, as Morgagni, Scoutetten, and in the *Archives de Médecine*.

CHAPTER V.

INDURATION.

CONTRA-DISTINGUISHED to softening, yet originating, in many instances, in the same inflammatory cause, (Abercrombie, Andral, Lallemand, Billard,) is induration of the nervous centres. Andral describes three degrees of induration: in the first, the affected part presents the consistence of brain that has been kept for some time immersed in diluted nitric acid; in the second, it is as firm as wax; and in the third, it is as firm and elastic as fibro-cartilage.

Induration may be general or partial. When general, it has never been observed to exceed the first degree. The medullary substance, in this degree, may contain little or no blood, and is of remarkable whiteness: it is firmer than the grey, especially in the central parts of the brain and at the origin of the nerves. General induration has been observed principally after ataxic

fever, and after convulsions from the poison of lead. It appears to be, in general, an acute affection.

Induration may affect the whole length of the spinal cord, being here also confined principally to the white substance. (Billard.)

Partial induration, which is more common than general, is usually a result of chronic inflammation. Of this, strong evidence is afforded by its occasionally surrounding old apoplectic clots, or other morbid productions, and by the thickened and infiltrated condition of the meninges often observed near an indurated part. In other cases, however, the existence of inflammation cannot be proved, and is merely inferred. Partial induration may exhibit various tints of red or yellow; or it may possess the colour, as well as the density of gristle. The disease has been observed in different parts of the nervous centres, and it sometimes affects the grey substance of the convolutions exclusively. After subsisting for a considerable time, it occasionally terminates in suppuration. Abercrombie and others are of opinion that partial induration is the origin of numerous organic tumours of the brain, the specific characters of which are subsequently determined by peculiarities of the constitution or other accidental circumstances.

CHAPTER VI.

APOPLEXY.

APOPLECTIC extravasations of blood have been found in almost every part of the nervous centres, but they are much more rare on the surface and within the ventricles than in the substance of the brain. Andral mentions that, of 392 cases of cerebral hæmorrhage which he has found described by authors, the seat of it

was in some part of the substance of the brain in so many as 386; in 202 of which it occurred in the part of the cerebral hemispheres on a level with the *corpora striata* and *thalami optici*, as well as in those parts themselves.

Effusion on the surface is represented by Fig. 249, a portion of the cerebellum. The blood is effused beneath the pia mater and arachnoid, and overspreads a wide surface, dipping between the convolutions, and, by its accumulation and coagulation, forming the beautiful black lines represented in Fig. 249. A similar effusion overspread a large portion of the cerebrum. In new-born infants, it not unfrequently happens that a whole hemisphere, or the whole spinal cord, is thus affected; but at other periods of life, extensive effusions on the surface are rare. When blood is found within the ventricles, it is almost always derived from an adjoining extravasation into the cerebral substance, making its way into the ventricles.

Extravasations in the cerebral substance may be of all sizes; some not larger than pins' heads, others occupying nearly the whole of a hemisphere. Copious effusions in one hemisphere usually rupture the walls of the lateral ventricles, and also tear or destroy the septum lucidum and fornix, filling the whole of these parts with coagula. Sometimes the blood bursts from the interior to the surface and overspreads the convolutions, as was the case in Fig. 249. It is rare for an effusion to exist in the cerebellum without one in the cerebrum also; but the converse of this is not true. Several extravasations may take place simultaneously in the same brain.

The appearance of the coagulum varies according to the time that has elapsed since the occurrence of the effusion; and it is not uncommon to discover several coagula, or their vestiges, in different stages of advancement, and corresponding with successive attacks of apoplexy or palsy. I have repeatedly found from four to six of these, and, in some of the cases, the corresponding attacks of apoplexy extended so far back as six or eight years. It is important to study these coagula, for by learning the pro-

cesses which Nature adopts of curing apoplexy and palsy, we likewise learn the most appropriate mode of seconding her efforts.

Fig. 245 represents a recent apoplectic effusion, which is a sufficient type of recent effusions in general, since they have all much the same characters, viz., a clot of a reddish black colour, and a consistence somewhat less than that of blood coagulated out of the body; an infiltration of blood into some portion of the cerebral substance adjoining, as into the *corpora striata*, *a*, *e*; and spots of ecchymosis, either in the midst of this red infiltration, *g*, or in the colourless substance around, *h*. Smaller recent coagula are represented by Fig. 251, *b*, in the *corpus dentatum*, *c*, of the cerebellum: dotted ecchymoses, *a*, are seen around. Fig. 250 represents a similar small effusion near the *corpus striatum*, which is seen below it, streaked with infiltrated blood. In ten days or a fortnight the coagulum is firmer, more defined, and of a dim red or chocolate hue. Fig. 252, *a*, represents a clot six weeks old, situated in the posterior part of the medulla oblongata immediately below the pons varolii. The clot is spherical, and is contained within a cavity, the walls of which are smooth, and lined by a delicate green-coloured membrane, exterior to which is an amber-coloured halo of indurated cerebral substance. Fig. 253, *e*, represents a coagulum seven months old: it consists of lax fibrine, two small spots of which are still red, the remainder being brown or orange, and adherent to the cerebral substance. The brown and yellow discolouration is seen to extend to the wall of the lateral ventricle, *f*. The whole of the discoloured part around was firmer than brain. Fig. 254 is another portion of the same effusion, from which the coagulum has been withdrawn for the purpose of exhibiting more distinctly the party-coloured membranous walls of the cyst. The brown, green, and orange colours are occasioned by the blood when its red particles are absorbed.

At a still more advanced period the colouring matter wholly disappears, and leaves either a solid whitish mass, surrounded by

a thickish and dense cyst, or a cavity lined by a kind of serous membrane, and containing a serous or gelatinous fluid. A cavity of this kind in the *corpus striatum* is represented by Fig. 255, and one in the medullary substance by Fig. 256. Sometimes the cavity contains a net-work of filamentous tissue, infiltrated with serum; and occasionally, the only vestige of the effusion is a puckered or even cicatrix. The time requisite for the formation of a cicatrix cannot be positively ascertained; but several months, at least, appear to be necessary.

Softening of the cerebral substance often occurs around apoplectic effusions, and is the result of inflammatory action, excited by the irritation of the clot, which operates as a foreign body. As the coagulum is absorbed, the inflammatory injection subsides, and the part affected either acquires its former consistence or becomes indurated. In Fig. 245, the part has passed from the red to the yellow softening; at *g*, it is brownish.

The softening, however, is not always consecutive, for Lallemand has proved that it often precedes, and is the cause of the effusion; and he has shown the possibility of tracing, in a softened portion of brain, all the degrees between simple injection and sanguineous effusion.

In most cases of cerebral and spinal effusion, the hæmorrhage appears to result from exudation, or from rupture of the capillaries, since no lesion can be discovered in the vessels of the part. In such cases, however, it is very common to find the large arteries at the base of the brain steatomatous, ossified or thickened and inelastic, as in Fig. 252, *g*,—alterations peculiarly incident to the aged, in whom apoplexy and palsy are most common. In a few cases, says Andral, the vessel from which the hæmorrhage took place has been discovered situated either on, or at some distance from, the walls of the cavity formed by the extravasation. Hæmorrhage at the base of the brain is sometimes occasioned by the rupture of aneurismal, dilated or otherwise diseased arteries of the part.

Cerebral hæmorrhage has been observed at all ages, even as

early as three days after birth (Billard) ; it is rare before the age of fifty, except in those who labour under organic disease of the heart; and it is most common between the ages of sixty and seventy.

Andral has seen the coincidence of hypertrophy of the heart and apoplexy or palsy sufficiently often to believe the truth of the assertion, that they are connected as cause and effect. According to Rostan, affections of the heart are by no means so frequent in persons that die of apoplexy, so far as his own experience goes; but it must be taken into consideration, that this experience refers principally to the Salpêtrière, an asylum for the aged, in which class apoplexy is most common from causes independent of disease of the heart. Within the last two years I have seen upwards of a hundred cases of apoplexy and hemiplegia, and in full two-thirds there was organic disease of the heart. The prevailing forms were hypertrophy with dilatation, and simple hypertrophy; but, in many instances, the cerebral affection was connected merely with dilatation or disease of the valves, impeding the return of the blood from the head.

CHAPTER VII.

HYPERTROPHY, ATROPHY, AND ANÆMIA OF THE BRAIN AND SPINAL CORD.

Hypertrophy of the brain is known by the following characters: the convolutions are crowded together and flattened,* the intervals between them disappear, and it seems as if the investing membranes of the brain had become too tight for it. The substance of the organ is firm, contains but little blood, and appears remarkably dry when cut into. The ventricles are, as

* A similar flattening may be occasioned by fluid in the ventricles.

it were, effaced, and the various surfaces of the brain deprived of their ordinary moisture; in other respects, its texture remains unaltered. The affection generally involves both hemispheres, but is sometimes partial.—(Andral, &c.) The symptoms are those of pressure, and the disease may be easily confounded with hydrocephalus internus. It is frequently attended with epilepsy or convulsions. I have observed it principally in children under the age of twelve, in some of whom the cranium was enlarged.

In the spinal cord, hypertrophy may be either general or partial. The part is firmer than natural, and it fills the whole cavity of the dura mater, being closely applied to the parietes of the vertebral canal. Hypertrophy must be carefully distinguished, both in the brain and the spine, from mere turgescence occasioned by hyperæmia.

Atrophy.—This may exist in various degrees, from a slight diminution to the total absence of the nervous centres. As the subject scarcely requires delineation, the reader is referred for an account of it to Andral, Path. Anat., vol. ii. 735.

Anæmia.—This has the same causes as anæmia in general, and it may either be confined to the head or extend over the whole body.

In certain acute diseases it may present the symptoms of inflammation. Abstraction of accustomed stimuli sometimes occasions delirium—possibly by giving rise to anæmia.

CHAPTER VIII.

TUBERCLE, SCIRRHOUS, ENCEPHALOID, FATTY, FIBROUS, CARTILAGINOUS AND OSSEOUS PRODUCTIONS, AND HYDATIDS.

Tubercle.—Tubercles of the nervous centres are found principally in children, being rare in infants, and still more so in

adults—even the most phthisical. Still tubercles are amongst the most common morbid growths in the nervous centres. They are few in number, and sometimes there is only one. Fig. 259, representing a group of tubercles adherent to the dura mater, gives a perfect idea of the appearance of these bodies. Their colour is a pale greenish-yellow, *a* and *c*; but when the centre softens, *b*, it becomes of an ochre-yellow. Their consistence is, I think, somewhat less than that of pulmonary tubercles; and, like the latter, they sometimes acquire a cretaceous composition, in colour and consistence resembling dryish putty. They present the same characters when seated in the substance of the brain, as are here represented on the membranes. Their most common size is about that of peas; but they may be as small as millet seeds, (Fig. 259, above *b*,) or may even exceed the size of hens' eggs; and, when grouped, may form still more considerable masses. The most common part in which they are generated, appears to be the pia mater. As they grow, they sometimes excite chronic inflammation, causing close agglutination of all the membranes and adhesion of the masses to the dura mater, as seen in Fig. 259, where the mass *d* is covered by the vascular arachnoid and pia mater, which have, with difficulty, been stripped off from the others, *a*, *b*, *c*. Fig. 260, *b*, displays lax adhesions of the dura mater to the arachnoid and pia mater, and also spotted injection of the former, around the tubercles, over nearly the whole extent of the parietal bone. The tubercles grow inwards, in consequence of meeting with least resistance in that direction, and it is probable that they sometimes become completely detached from the membranes. In other cases, the tubercles are generated in the nervous substance itself; yet, in the hemispheres, they are commonly seated in or near the grey substance of the convolutions, as if the greater vascularity of these parts was favourable to their production. The parts where they are oftenest found, after the hemispheres, are, successively, the cerebellum, the pons varolii, the medulla oblongata, various parts of the spinal cord, (especially about the cervical region,) the

crura cerebri, the crura cerebelli, the thalami optici, the corpora striata, and the pituitary gland.—(Andral.) Tubercles are often, if not always, enveloped in a membranous cyst, which is generally fine, but sometimes thick, and even fibrous, cartilaginous, or osseous. When the nervous substance around tubercles is healthy, as is often the case, there may be no symptoms; these being chiefly dependent on inflammation, softening, or wasting of the nervous substance, excited by the tubercles.

Scirrhus and Encephaloid productions exhibit the same general characters as in all other parts. Dr. Bright thinks, that when they are of a scirrhus nature, as inferred from appearances in other parts of the body, the membranes are more especially the original seat of the tumour; but that, in cases approaching to the fungous character, the disease is less obviously dependent on the membranes. Dr. Abercrombie thinks that partial inflammatory induration of the brain lays the foundation of most organic tumours, their specific character being determined by constitutional causes.

Fatty Productions.—A large mass, like adipocire, was found by Dr. Leprestre; and one as large as a hen's egg, and resembling spermaceti, was met with by M. Dalmas. The latter consisted of a large quantity of fatty matter, and another matter seeming to be cholesterine.

Melanosis attacks the brain, though rarely.

(Case by Mr. Fawcington, with drawings.)

Fibrous, Cartilaginous, and Osseous productions.—These generally grow from the membranes, particularly the dura mater. There may be few or many; and they may form masses from the size of mustard seeds to hen's eggs. I have seen the dura mater converted into a bony plate as large as the expanded hand. The productions in question appear, though very rarely, in the substance of the nervous centres.

Entozoa.—Acephalocysts and cysticerci have been occasionally found in the brain.

I N D E X.

A

ABSCCESS of lungs: (see LUNGS;) of heart, 75; of liver from phlebitis, 125: (see LIVER.—*Purulent depositions.*)

ALIMENTARY CANAL, arrangement of diseases of, 145; natural colour of, 147.—*Hyperæmia independent of disease*, 148; from digestion, 148; from venous retardation, 149; from cadaveric gravitation, 150; and transudation, 150; discolouration from gases and bile, 152.—*Hyperæmia from disease*, 152.—*Acute inflammation*; red colour, 154; viz., ramiform injection, 154; capilliform injection, 155; redness in patches, 155; diffuse redness, 156; speckled redness, 157; streaky redness, 156; hyperæmia of the villi, 159; of the follicles, 160; hyperæmia of the large veins exclusively, 160.—*Chronic inflammation*; brown colour, 161; slate colour, 162; black colour, 162; acute gangrene, 162.—*Softening*, 163; natural consistence of the mucous membrane, 164; softening from putrefaction, 165; solution by gastric juice, 165; softening from disease: 1st., of mucous membrane alone, 167; causes, 170: 2nd., of all the coats, 171; gelatiniform softening, 171.—*Healthy state of mucous glands*, 173; isolated glands, 174; patches of peyer, 176; causes of their unusual developement, 177; mucous glands in cholera, 179.—*Inflammatory enlargement of mucous glands*: 1st., from simple inflammation, 180; symptoms, 184: 2nd., from specific inflammation, 185; symptoms, 185.—*Ulceration of the mucous glands*: 1st., from simple inflammation, 186; mesenteric glands simultaneously enlarged, 190: 2nd., from specific inflammation, 190; intestines thickened, 192; mesenteric glands enlarged and tubercular, 192; summary, 193; ulcers from tubercle beneath mucous membrane, 194; from circumscribed softening of mucous membrane, 195; spontaneous perforation, 196; ulcers from inflammatory excoriation of mucous membrane, 197; diagnosis of advanced ulcerations, 198; symptoms, 199; solitary ulcers, 200; simple chronic ulcer of stomach, 200; ulcers from gangrene, 201; cicatrization of ulcers, 202; treatment of chronic ulceration, 203.—*Hypertrophy*, 204: 1st., of the mucous coat, 205; vegetations, &c., 206; their origin, 208; gangrene of, 209: 2nd., hypertrophy of the tissues subjacent to the mucous membrane, 211; viz., of the sub-mucous cellular tissue, 212; of the muscular coat, 213; of the sub-peritoneal cellular tissue, 213; parts of the canal affected, 213; condylomata, 215; stricture of the rectum, 215.—*Scirrhus*, 216; areolar gelatiniform cancer, 218; parts affected, 220; symptoms, 221.

ANEURISM, of heart (i. e. partial dilatation), 85.

APOPLEXY, pulmonary, (see LUNGS;) cerebral, 292.

AQUEOUS ENCYSTED TUMOURS (serous cysts) of liver, 136.

ATROPHY, of lungs, 43; of heart, 82; of liver, 134; of kidney, 263.

B

BLACK PULMONARY MATTER, 53.

BLADDER, disease of, 269.

BRAIN AND SPINAL CORD, disease of, 275; structural lesions few, but functional derangements numerous, 275; arrangement of diseases, 276. INFLAMMA-

TION.—*Meningitis*, 277; of dura mater, 277; of arachnoid, 278; of sub-arachnoid cellular tissue and pia mater, 279; chronic meningitis, 280; inflammation of the sinuses of the dura mater, 280.—*Cerebritis*, 282; natural appearances of the cerebral substance, 282; congestion of, 283; inflammation of, 285; diagnosis and symptoms, 286.—*Softening*, inflammatory, 286; non-inflammatory (white softening), 288; general softening, 288; softening of spinal cord, 289; opinions of authors respecting the nature of softening, 289.—*Suppuration and abscess*, 290; of spinal cord, 290.—*Ulcer*, 291.—*Induration*, 291.—*Apoplexy*, 292; on the surface, 293; in the substance, 293; appearance of clots at different ages, 294; softening around, 295; vessels diseased, 295; disease of the heart, a frequent cause, 296.—*Hypertrophy*, 296.—*Atrophy and Anæmia*, 297.—*Tubercle*, 297.—*Cancer*, 299; fatty productions, melanosis, fibrous, cartilaginous and osseous productions, and entozoa, 299.

C

CANCER, of alimentary canal, 216; areolar gelatiniform, 218; (see ALIMENTARY CANAL, also SCIRRHUS, and ENCEPHALOID;) external, 226; of the mamma, 227; chimneysweeper's cancer, 228; scirrhus with large lobules, 229; external encephaloid, 229; diagnosis of malignant productions, 230; opinions of Laurence, Andral, &c., 231; of ovaria, 238; of uterus, 250; of brain, 299.

CHOLESTERINE, of liver, 135; of brain, 299.

CIRRHOsis, of liver, 104; (see LIVER, *granulated*;) of peritoneum, 225.

CONSUMPTION, pulmonary; see LUNGS, *phthisis*.

D

DILATATION, of heart, 83.

DYSENTERY, chronic, 199.

E

EMPHYSEMA, of lungs; see LUNGS.

ENCEPHALOID CANCER, of lungs, 45; of heart, 87; of liver, 115 and 117; of stomach, 208; how the constitution is affected, 210; of peritoneum, 225; of lumbar glands, 225; of vena portæ, 225; external, 229, (see CANCER;) of ovaria, 238; of uterus, 251; of kidney, 268; of spleen, 274.

F

FALSE MEMBRANE, of lungs, 19; of larynx and trachea (croup), 62; of pericardium, 68: see HEART.

FALLOPIAN TUBES, diseases of, 260.

FIBROUS TUMOURS, of ovaria, 236: (see OVARIA;) of uterus, 253.

FLESHY TUBERCLE, of uterus: see FIBROUS TUMOUR.

FUNGUS HÆMATODES, of lungs, 45; of heart, 87; of liver, 113 and 117.

G

GANGRENE, of lungs, 13; of heart, 77; of colon, 162; gangrenous ulcers of intestines, 201.

GRANULATIONS, peripneumonic, 8 and 17.

H

HEART, arrangement of diseases of, 65.—*Pericarditis*, 67: 1st, redness, 67; 2nd, adherent lymph, 68; 3d, effused fluid, 70; chronic, 71.—*Carditis*, 71; inflammation of the lining membrane, 72; non-inflammatory redness of the

membrane, 72; suppuration of the heart, 73; softening, 73; abscess, 75; purulent depositions, 75; ulcers, 75; perforation, 76; rupture, 76; gangrene, 77; induration, 77; anæmia, 77.—*Hypertrophy*, three varieties of, 78; of the whole heart, 79; of the left ventricle, 80; of the right, 80; of part of a ventricle, 81; of auricles, 81.—*Atrophy*, 82.—*Dilatation*, 83; three varieties, 84; diagnosis from distention, 84; partial dilatation (real aneurism), 85.—*Morbid productions*: fattiness, 86; greasiness, 86; cartilage and bone, 86; tubercle, 87; scirrhus, 87; encephaloid, 87.—*Diseases of the valves*: hypertrophy of their fibrous tissue, 88; steatoma, 89; cartilage, 89; calcareous depositions, 89; illustrations of these, 91; valvular vegetations, 93.—*Serous cysts and hydatids*, 95; malformations, 96.

HYDATIDS, of lungs, 55; of heart, 95; of liver, 138; of uterus, 258; of kidney, 268; of spleen, 274.

HYPERTROPHY, of lungs, 43; of heart, 78; of fibrous tissue of the valves, 88; of liver, 133; of intestinal mucous membrane, 204 and 211: see **ALIMENTARY CANAL**.—Of kidneys, 263; of bladder, 269; of brain, 297.

I

INDURATION, of lungs, 15; of heart, 77; of liver, 134; of kidney, 264; of spleen, 272; of brain, 291.

INTESTINES: see **ALIMENTARY CANAL**.

KIDNEYS, arrangement of diseases, 261; inflammation, 262; hypertrophy and atrophy, 263; softening and induration, 264 and 262; granular kidney, 264; nature of, 266; symptoms of, 266; cysts: 1st, by transformation, 266; 2nd, by production, 267; contents of, 267; serous cysts and hydatids, 268; encephaloid, 268; tubercle, 268.

L

LIVER, arrangement of diseases, 97; structure of the parenchyma, 99.—*Nutmeg liver*, 103.—*Granulated liver*, (tuberculated, lobulated, mammellated, cirrhosis,) 104; opinions of authors, 104; researches of writers, 106; illustrations of granulated liver, 108; symptoms, 111.—*Cancer*, (tubera,) 113; their form, 113; number, 114; size, situation, consistence, and texture, 115; distinction between the hard or scirrhusous tuber, and the soft or encephaloid, 115; characters of hard tuber, 117; characters of soft tuber, 117; disorganization of tubera, 119; seat of tubera in the hepatic parenchyma, 119; origin of, and anatomical element first affected by tubera, 120; state of the hepatic tissue, 122; summary, 123; symptoms and their causes, 123; treatment, 124.—*Purulent depositions and abscess from phlebitis*, 124; origin and formation of, with opinions of authors, 125; experiments of Cruveilhier on phlebitis, 127; contamination of the blood by pus, and symptoms of, 130.—*Acute hepatitis*, 131; chronic, 132.—*Congestion*, 133.—*Hypertrophy*, 133.—*Atrophy*, 134.—*Induration*, 134.—*Softening*, 135.—*Adipose and cholesterine degenerations*, 135.—*Melanosis*, 136.—*Serous cysts and hydatids*, 136.—**DISEASES OF THE BILIARY APPARATUS**, 139.—*Alterations of the bile, and biliary calculi*, 141.

LUNGS, structure of, 1; arrangement of diseases, 2.—*Acute peripneumony*, 5; deg. 1, engorgement, 5; deg. 2, hepatization, 6; deg. 3, purulent infiltration, 8.—*Abscess*, 10; from phlebitis, 11.—*Gangrene*, uncircumscribed, 13; circumscribed, 14.—*Chronic peripneumony*, 15; three degrees of, 15; indurated hepatization, 15; tubercular hepatization, 16; vesicular induration, (pulmonary granulations,) 17 and 8.—*Pleurisy*, 18; false membrane, 19; liquid effusions, 23.—*Phthisis*, 25; tubercle, 25; miliary, 25; yellow crude tubercle, 26; growth of tubercle, 26; tubercular infiltration, 27; duration of tubercle, 28; terminations of tubercle, viz., 1st, cretaceous induration, 28;

2nd, softening by suppuration, 30; Lombard's theory of, 30.—*Vomica, or cavern*, 31; walls of, 32; internal surface of, 32; bronchi and blood-vessels near, 33; contents of, 33; healing of, 33; healed cavern, 33; Linear cicatrix, 34; fibro-cartilaginous cicatrix, 34; absorption of tubercle, 35; situations of, 35; state of the lung around, 35; "gelatiniform, and grey tubercular infiltration," probably erroneous terms, 35; inflammation, how far a cause of tubercle, 35; predisposition, innate or acquired, 36; tissues, organs and ages most liable to tubercle, 37.—*Pulmonary apoplexy*: 1st, by exhalation, 38; 2nd, by rupture, 40; causes of, 41.—*Emphysema*, 41; vesicular, 41; interlobular, 44.—*Encephaloid cancer*, 45; encysted, 46; without cysts, 47; infiltrated, 47; effects and symptoms, 48.—*Melanosis*, 49.—*Black pulmonary matter*, 53.—*Edema of the lungs*, 54.—*Ossification*, 55.—*Hydatids*, 55.—DISEASES OF THE AIR PASSAGES.—*Bronchitis*, 56; redness of mucous membrane, 56; thickening, from hyperæmia, 57; from hypertrophy, 58; softening of mucous membrane, 59; ulceration, 59; diseases of the sub-mucous tissues, 60.—*Dilatation of the bronchi*, 61; effects on the pulmonary tissue, 62; calcareous concretions, 62.—*Membraneous concretions*, 62; causes of, 64.

M

MELANOSIS, of lungs, 49; in masses, 49; infiltrated, 50; in layers on serous membranes, 51; liquid, 51; tissues affected by it, 52; symptoms, 53; of liver, 136; of peritoneum, 225.

O

OVARIA, 233; impregnated ovarium, 233; rupture of ovarium by a graafian vesicle, 234; chronic inflammation and suppuration, 235; fibrous tumours, 236; cysts, 236; origin of, 237; contents of, 238; malignant disease; viz., encephaloid, 238; areolar gelatiniform cancer, 239; scirrhus, 239; diagnosis of ovarian dropsy, 239.

P

PERIPNEUMONY: see LUNGS.

PERITONEUM, acute and chronic inflammation of, 223; chronic false membrane, 223; ulceration of, 224; unorganized, 224; granulations of the peritoneum, 224; tubercular accretions, 224; malignant depositions (cirrhosis) under, 224; encephaloid cancer, 225; melanosis, 225.

PHLEBITIS, of liver, 124; of uterus, 245; crural phlebitis: see Figs. 203 and 204, and their cases; of sinuses of dura mater, 280.

PURULENT DEPOSITIONS, in lungs, 11; in heart, 75; in liver from phlebitis, 125: see LIVER.

S

SCIRRHUS, of heart, 87; of liver, (hard tubera,) 117; of alimentary canal, 216: (see ALIMENTARY CANAL;) of mamma, 227: (see CANCER;) of ovaria, 239; of uterus, 251.

SEROUS CYSTS, (aqueous encysted tumours,) of liver, 136; of heart, 95; of kidney, 268; of spleen, 274.

SOFTENING, of bronchial mucous membrane, 59; of heart, 73; of liver, 135; of alimentary canal, 163: (see ALIMENTARY CANAL;) of uterus, 244; of kidney, 262 and 264; of spleen, 271; of brain, 286; of spinal cord, 289.

SPINAL CORD: see BRAIN, AND SPINAL CORD.

SPLEEN, diseases of, 270; of fibrous tissue, 271; of the matter in the splenic cells, 271; softening and induration, 271; enlargement and diminution, 273; suppuration, 273; tubercle, 273; encephaloid, 274; serous cysts, 274; hydatids, 274.

T

TUBERCLE, pulmonary : see LUNGS, *phthisis* ; of heart, 87 ; of mesenteric glands, 193 ; of intestinal mucous glands, 185 ; beneath mucous membrane, 194 ; tubercular accretions of peritoneum, 224 ; of kidney, 268 ; of spleen, 273 ; of brain, 297.

TUBERA, of liver : see LIVER, *Cancer*.

U

ULCER, of the larynx, trachea, and bronchi, 61 ; of heart, 75 ; of alimentary canal, 186 : (see ALIMENTARY CANAL, *Ulceration* ;) of os uteri, 249 ; of brain, 290 and 291.


UTERUS, inflammation, 241 : 1st., of the peritoneal covering of the uterus, 242 : 2nd., of the uterine appendages, 242 : 3rd., of the mucous membrane and muscular substance, 243 ; softening, 244 : 4th., of the uterine absorbents and veins, 245 ; anatomical characters of *uterine phlebitis*, 247 ; symptoms, 248.—*Crural phlebitis*, 248.—*Corroding ulcer of os uteri*, 249 ; diagnosis from cancer, 250.—*Scirrhus and encephaloid cancer of uterus*, 250 ; symptoms, 252 ; ulcerated cancer, 252.—*Fibrous tumour*, 253 ; structure of, 253 ; situation of, 254 ; softening of, 255 ; expulsion of, 256.—*Polypus of the uterus*, 256 ; ordinary, 257 ; vesicular, 258 ; hydatid polypus, 258 ; excrescences, 258 ; symptoms, 259 ; cauliflower excrescence of the os uteri, 259.—*Diseases of Fallopian tubes*, 260.

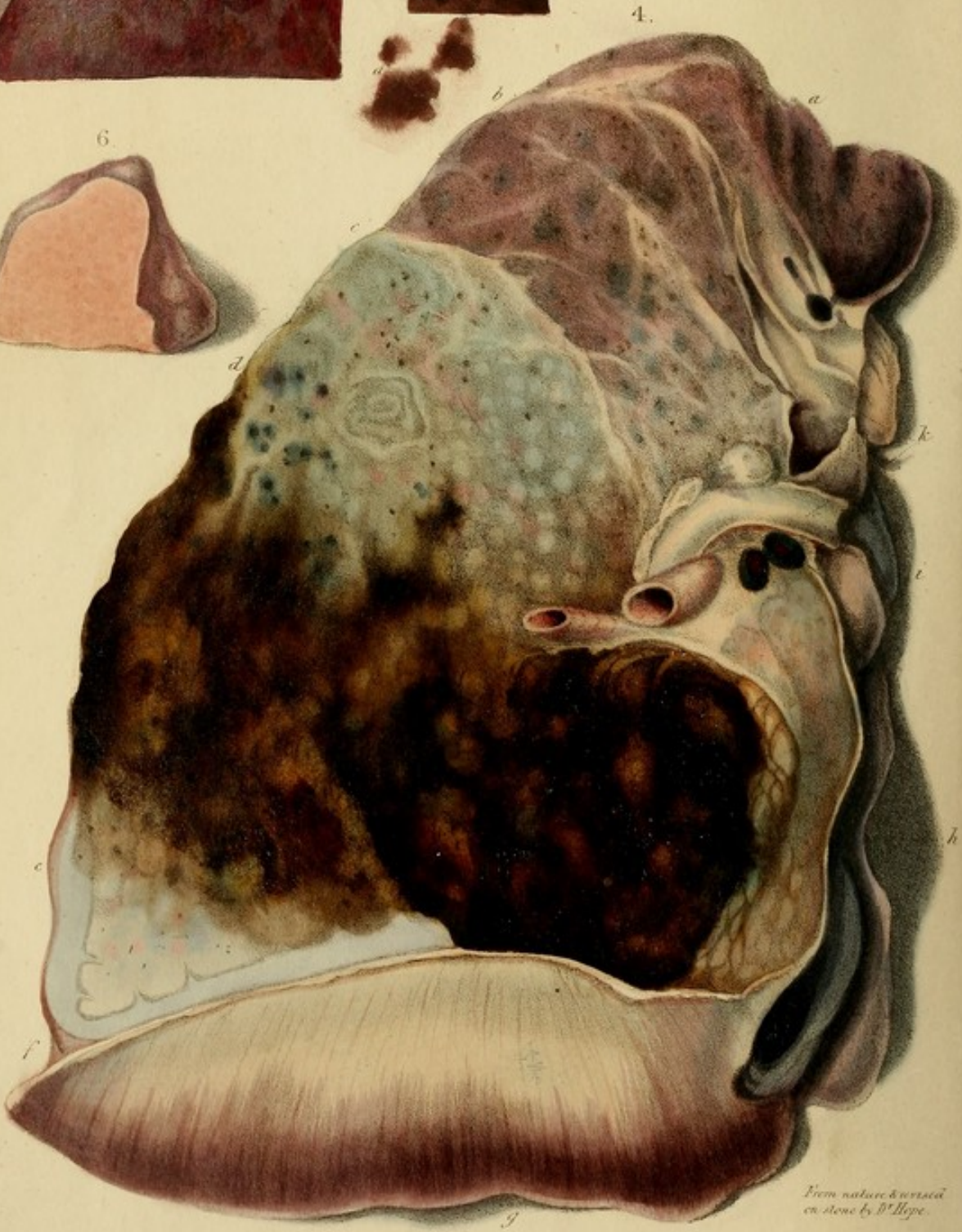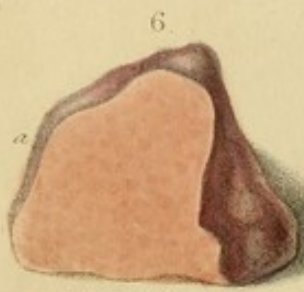
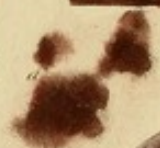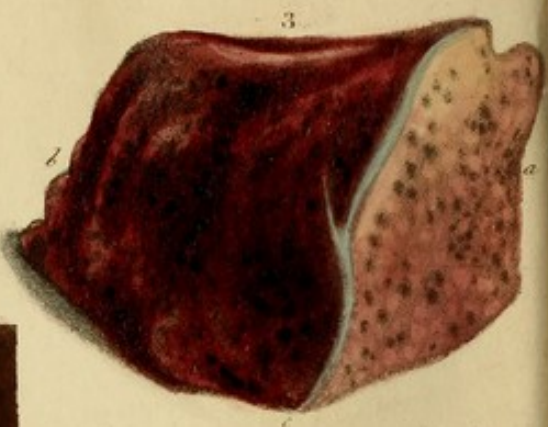
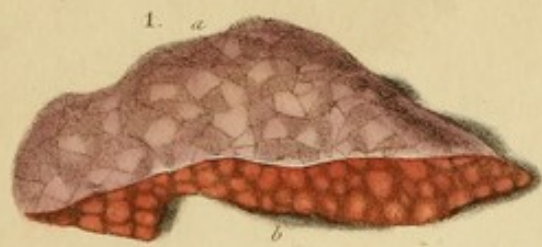
V

VEGETATIONS, in the heart, 93 ; of the alimentary canal, 206.

Printed by WILLIAM CLOWES,

Duke street, Lambeth.





From nature & versed
on stone by D^r Hope.

DESCRIPTION OF THE PLATES.

Fig. 1.—Lobular and vesicular peripneumonitis.

Case.—Pertussis, (et. 3.) fatal in five weeks. Suffocative cough; face livid; lips permanently violet. Finally, convulsions. Antiphlogistic treatment was neglected in the first instance.

Fig. 2.—Purulent infiltration, of deep, muddy, claret-red colour.

Case.—Fatal typhus in an old woman.

Fig. 3.—Chronic yellow and red hepatization, with consolidation.

Fig. 4.—A flat section of the anterior part of the right lung, (reduced a third,) displaying the three degrees of peripneumony, and uncircumscribed gangrene.

a, b. The first degree, (*engorgement.*)

b, c. The second degree, (*hepatization.*)

c, d. & e, f. The third degree, (*purulent infiltration.*)

d, e. Gangrene.

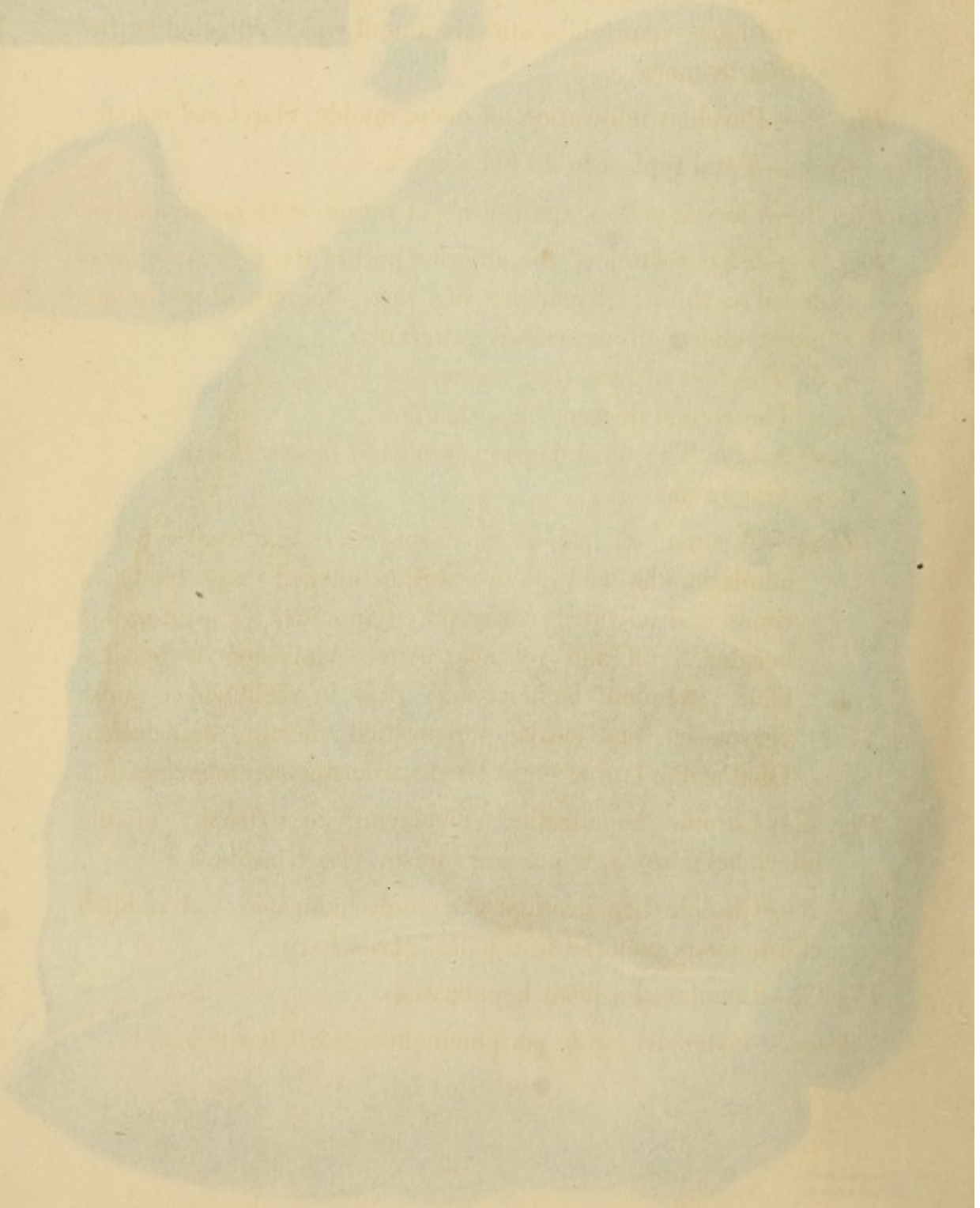


Case.—A man, et. 25, at St. George's. Six weeks before admission he had pleuro-peripneumony: was bled six times, and salivated; relief only temporary; expectoration became fetid and yellow. After admission it became black; frequent hæmoptysis; pain in right side; pulse very quick and weak; perspiration; hectic; emaciation. Died at the end of eight weeks from the commencement.

Fig. 5.—Chronic hepatization, displaying hypertrophy of the interlobular septa, which are bluish. (*La Charité.*)

Fig. 6.—Chronic hepatization, extremely indurated. A reddish substance is enclosed in a paler. (*La Charité.*)

Fig. 7.—Lobular and lobar hepatization.

Case.—Extensive acute peripneumony. (*La Charité.*)



DESCRIPTION OF THE PLATES.

Fig. 1.—Lobular and vesicular peripneumony.

Case.—Pertussis, (æt. 3,) fatal in five weeks. Suffocative cough; face livid; lips permanently violet. Finally, convulsions. Antiphlogistic treatment was neglected in the first instance.

Fig. 2.—Purulent infiltration, of deep, muddy, claret-red colour.

Case.—Fatal typhus in an old woman.

Fig. 3.—Chronic yellow and red hepatization, with consolidation.

Fig. 4.—A flat section of the anterior part of the right lung, (reduced a third,) displaying the three degrees of peripneumony, and uncircumscribed gangrene.

a, b, The first degree, (*engorgement.*)

b, c, The second degree, (*hepatization.*)

c, d, & e, f, The third degree, (*purulent infiltration.*)

d, e, Gangrene.

Case.—A man, æt. 25, at St. George's. Six weeks before admission he had pleuro-peripneumony: was bled six times, and salivated; relief only temporary: expectoration became foetid and yellow. After admission it became black; frequent hæmoptysis; pain in right side; pulse very quick and weak; perspiration; hectic; emaciation. Died at the end of eight weeks from the commencement.

Fig. 5.—Chronic hepatization, displaying hypertrophy of the interlobular septa, which are bluish. (La Charité.)

Fig. 6.—Chronic hepatization, extremely indurated. A reddish substance is enclosed in a paler. (La Charité.)

Fig. 7.—Lobular and lobar hepatization.

Case.—Extensive acute peripneumony. (La Charité.)

Fig. 8.—Purulent infiltration in its most advanced stage, and dipping into pus. A false membrane on the pleura.

Case.—Peripneumony fatal in a fortnight. The various stethoscopic signs accompanied and marked the progress of the disease. (La Charité.)

Fig. 9.—Lobular hepatization seen on the pleura.

Case.—Peripneumony at the close of typhus, in an old person. (St. Mary-le-bone Infirmary.)

Fig. 10.—Purulent and gangrenous depositions in the lungs after a surgical operation.

Fig. 11.—From the same case as *Fig. 10.*

Case.—(St. George's.) Compound fracture of the tibia, with sub-cutaneous cellular inflammation. Amputation above the knee. The wound went on well for a few days; then pleurisy supervened with great depression, and was fatal on the fourth day.

Section.—A little pus in the small veins near the centre. Extensive pleurisy. A part of serum turbid with lymph. Numerous depositions, especially under the pleura and at the edges of the lung.

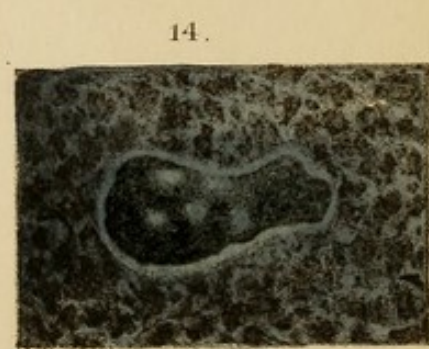
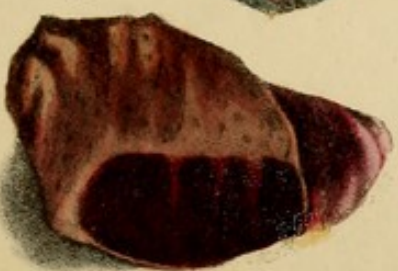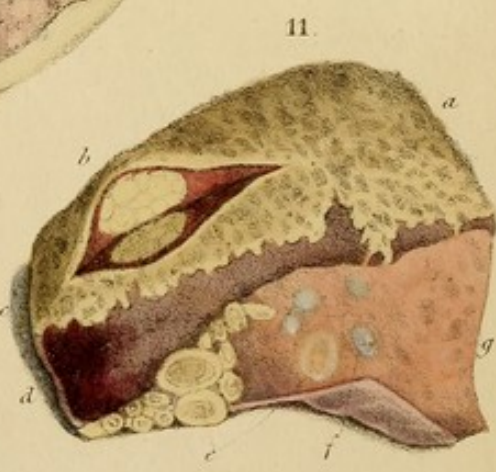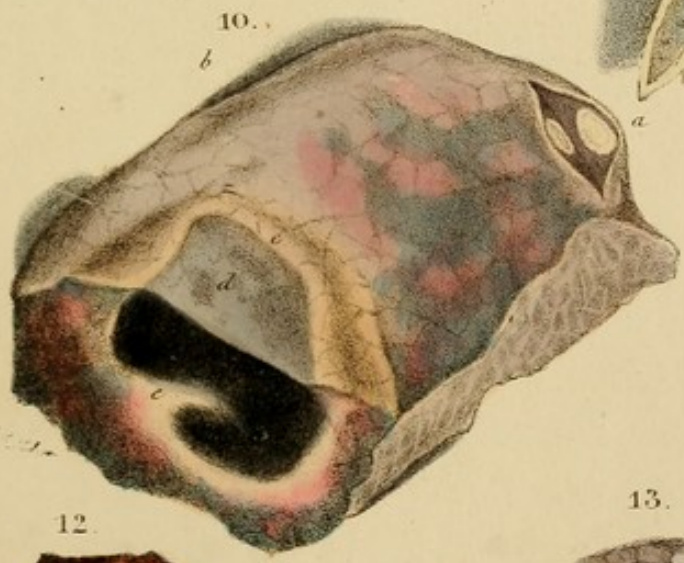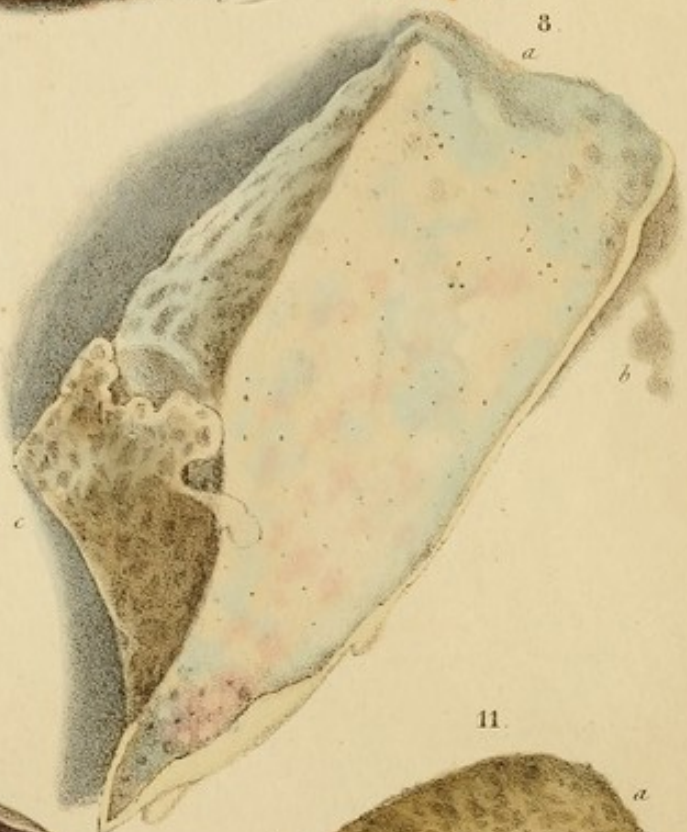
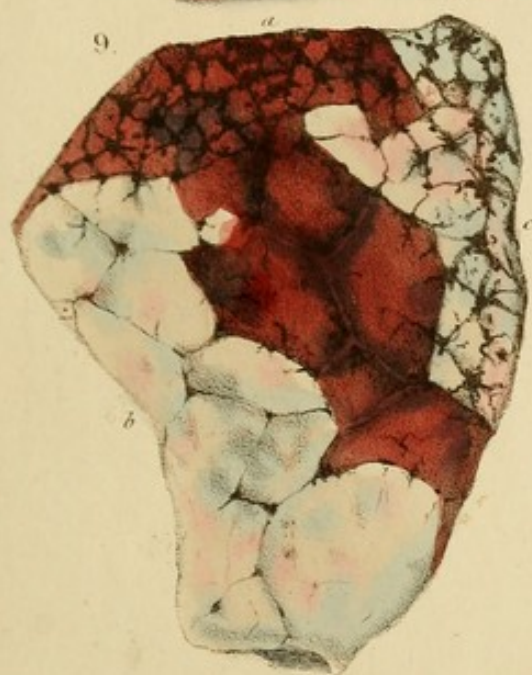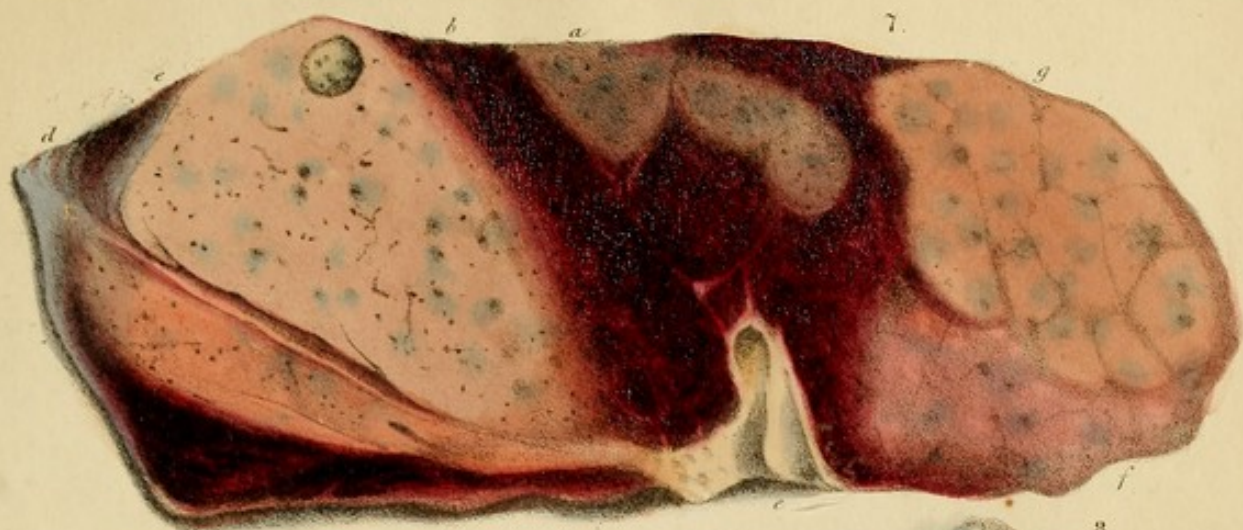Fig. 12.—Hepatization surrounding pulmonary apoplexy from transudation of blood into the air-passages.

Case.—Extreme disease of the heart with great pulmonary congestion and hæmoptysis of black blood. Several other circumscribed apoplectic masses were found, not bounded by cysts, but in healthy, though gorged, pulmonary tissue.

Fig. 13.—Purulent infiltration of detached lobules.


Fig. 14.—A circumscribed gangrenous abscess in the lung, bounded by a fibro-cartilaginous cyst, and surrounded by chronic grey induration.


Case.—A boy, æt. 15. (St. George's.) After a cough for two



From nature & revised on stone by D. Hope.

A. Smith Lithog. W. P. Martins Lane.

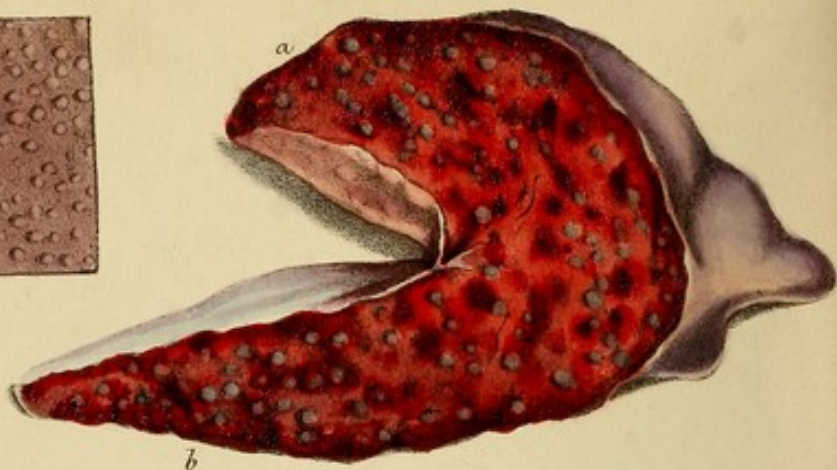




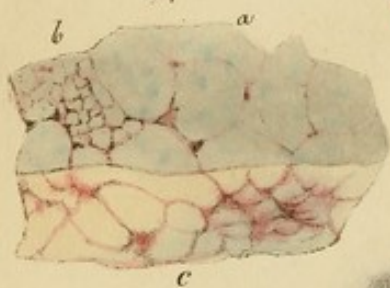
16.



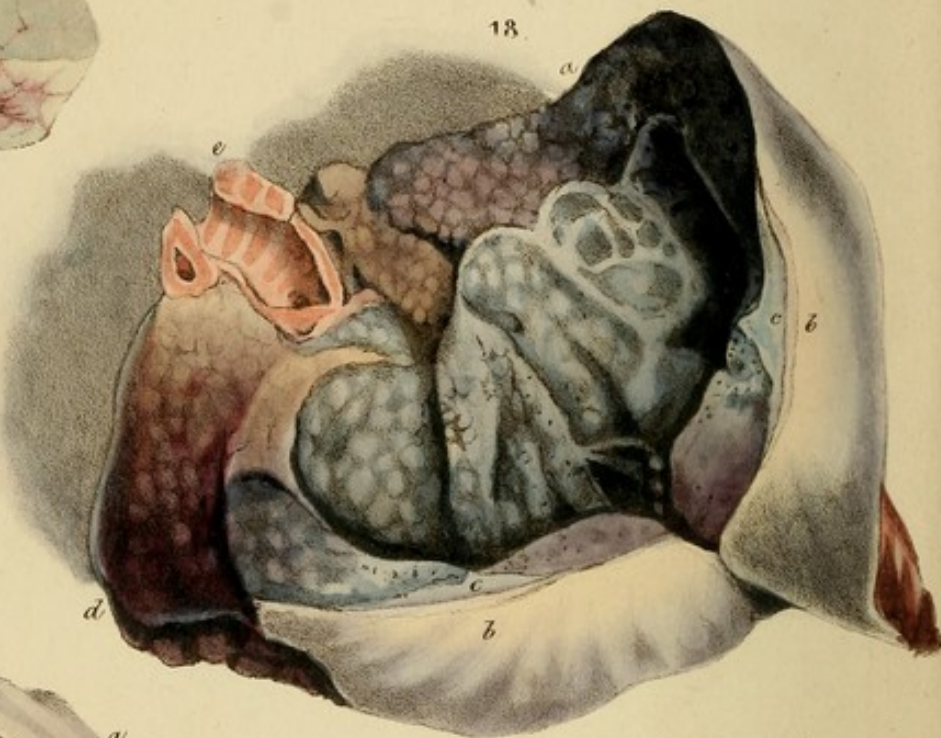15.



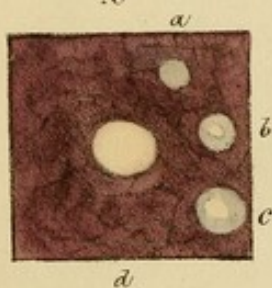
17.



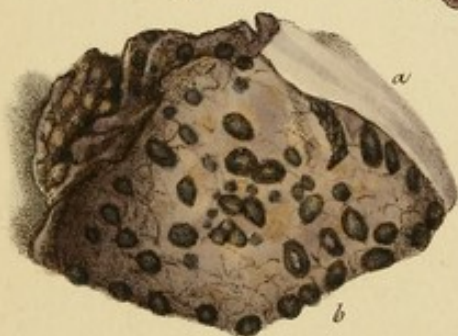
18.



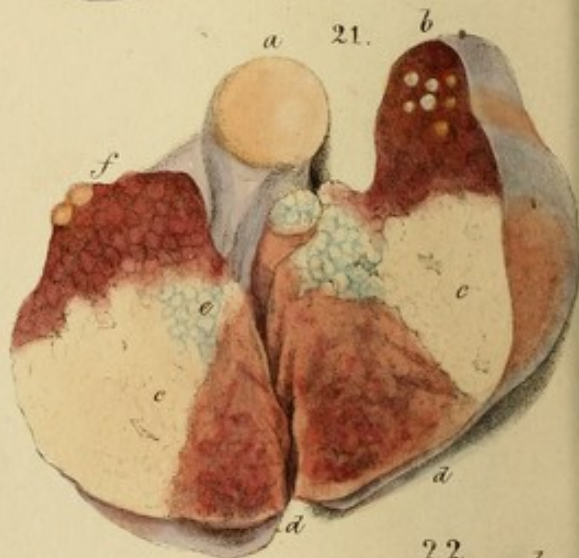
19.



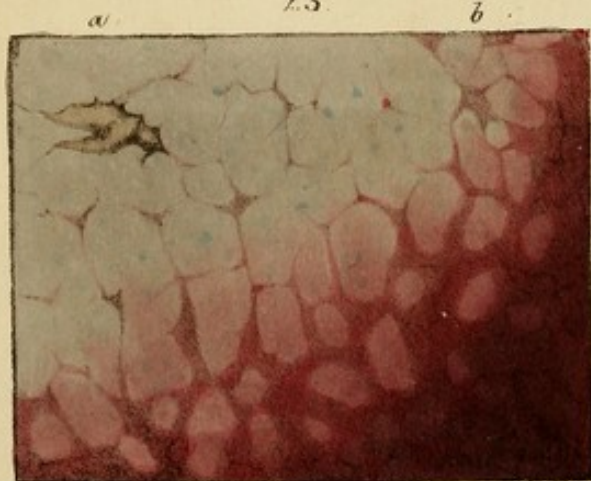
20.



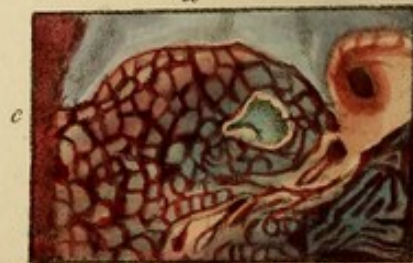21.



23.



22.



*From Nature & retouched in
tone by M. Leger.*

months, he had pain in the right side, and very offensive foetid sputa. The latter progressively increased, accompanied by colligative perspirations, and a quick small pulse, for four months, and were on his admission, of coffee-grounds colour, intermixed with dark blood, and doughy matter. They continued to be expectorated, with gradual sinking, for five days, when he expired.

Section.—Numerous gangrenous abscesses, some the size of a goose egg, occupied two-thirds of one lung.

Fig. 15.—Alveolar granulations of M. Bayle, considered by Andral to be air-vesicles inflamed and thickened. Lung congested.

Fig. 16.—Granulations of the same kind, but harder, from being more chronic. The surrounding inflammation has subsided, and left livid congestion.

Cases 15 & 16.—Both presented the symptoms of purpura-morosa. (La Charité. Specimens approved by Andral.)

Fig. 17.—Tubercular infiltration, increasing by juxta position.

Case.—Constitutional phthisis in a child, et. 7, who died of pneumonia. In other parts of the lungs the tubercular infiltration had softened, and it presented the appearance and consistence of cheese-cake. The bronchial glands were large, soft, tubercular masses.

Fig. 18.—A tubercular cavern, half divided, and thrown open. Its walls exhibit external and internal thickening of the pleura, chronic grey induration, and tubercles.

Fig. 19.—Tubercles in their progress from the grey to the yellow state, as described by Lacaze.

Fig. 20.—Dark tubercles, denser and semi-transparent like cartilage.

Case.—Chronic phthisis: caverns above.

Fig. 21.—Tubercular infiltration, forming masses by juxta position, in a child.

THE
THE
THE

THE
THE
THE

THE
THE
THE

THE
THE
THE

THE
THE
THE

THE
THE
THE

THE
THE
THE

THE
THE
THE

THE
THE
THE

months, he had pain in the right side, and very offensive foetid sputa. The latter progressively increased, accompanied by colliquative perspirations and a quick small pulse, for four months, and were, on his admission, of coffee-grounds colour, intermixed with dark blood, and sloughy matter. They continued to be expectorated, with gradual sinking, for five days, when he expired.

Sectio.—Numerous gangrenous abscesses, some the size of a goose-egg, occupied two-thirds of one lung.

Fig. 15.—Pulmonary granulations of M. Bayle, considered by Andral to be air-vesicles inflamed and thickened. Lung congested.

Fig. 16.—Granulations of the same kind, but harder, from being more chronic. The surrounding inflammation has subsided, and left livid congestion.

Cases 15 & 16.—Both presented the symptoms of peripneumony. (La Charité. Specimens approved by Andral.)

Fig. 17.—Tubercular infiltration, increasing by juxta-position.

Case.—Constitutional phthisis in a child, æt. 7, who died of pneumony. In other parts of the lungs the tubercular infiltration had softened, and it presented the appearance and consistence of cheese-curds. The bronchial glands were large, soft, tubercular masses.

Fig. 18.—A tubercular cavern, half divided, and thrown open. Its walls exhibit external and internal thickening of the pleura, chronic grey induration, and tubercles.

Fig. 19.—Tubercles in their progress from the grey to the yellow state, as described by Laennec.

Fig. 20.—Dark tubercles, dense and semi-transparent like cartilage.

Case.—Chronic phthisis: caverns above.

Fig. 21.—Tubercular infiltration, forming masses by juxta-position, in a child.

Case.—(Hôpital des Enfants.) The patient had chronic cough and died of confluent variola.

Fig. 22.—Tubercular infiltration, forming masses by juxtaposition in an adult. Intermediate lung is a deep red, and indurated.

Fig. 23.—Tubercular infiltration of lobules, by the juxtaposition of which a soap-like mass is formed. Peripneumonic engorgement around.

Case.—Phthisis. The two upper lobes, infiltrated as at *a*, contained numerous large and anfractuous caverns.

Fig. 24.—Cretaceous tubercles, some contracting and leaving their cysts. Two empty cysts. Much black pulmonary matter.

Case.—Chronic phthisis. One lung only affected, and not extensively.

Fig. 25.—Osseous formations in the centre of an enlarged bronchial gland spotted with black pulmonary matter.

Fig. 26.—A tuberculous cavern traversed by bands. Tubercles forming in chronic grey hepatization.


Fig. 27.—A dense hard tubercle of caseous appearance, in healthy lung. Such tubercles are generally cretaceous, and sometimes as large as an egg.

Fig. 28.—Tubercles and caverns in chronic grey induration. Thickening of the pleura by false membrane, and an albuminous deposition between the pleura and the lung.



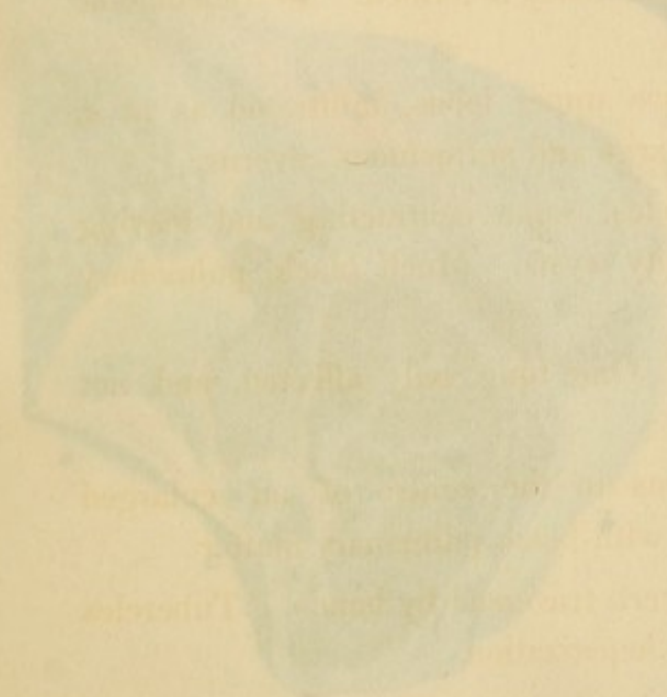
Case.—Phthisis with chronic pleuritis.

Fig. 29.—Yellow cretaceous tubercles. A cyst containing six loose bones. Recent grey tubercles, spotted with black pulmonary matter.


Fig. 30.—False membrane, deposited by inflammation on the lungs of a child, taking the form of tubercle and suppurating. (Drs. Alison and Gregory, Edinburgh.)



...the ...
...the ...
...the ...
...the ...
...the ...



...the ...
...the ...
...the ...
...the ...
...the ...



Case.—*Fulgid* (see *Rubens*). The patient had chronic cough and blood in sputum various.

Fig. 22.—Tubercular infiltration, forming masses by juxtaposition in an adult. Intermediate lung is a deep red, and indurated.

Fig. 23.—Tubercular infiltration of lobules, by the juxtaposition of which a soap-like mass is formed. Peripneumonic engorgement around.

Case.—*Phthisis*. The two upper lobes, infiltrated as at a, contained numerous large and anfractuous caverns.

Fig. 24.—Cremaceous tubercles, some contracting and leaving their cysts. Two empty cysts. Much black pulmonary matter.

Case.—*Chronic phthisis*. The lungs are white, and are extensively.

Fig. 25.—*Chronic phthisis*. In the lower a, an enlarged bronchial gland opened with black pulmonary matter.

Fig. 26.—A tuberculous cavern traversed by bands. Tubercles lying in chronic grey hepatization.

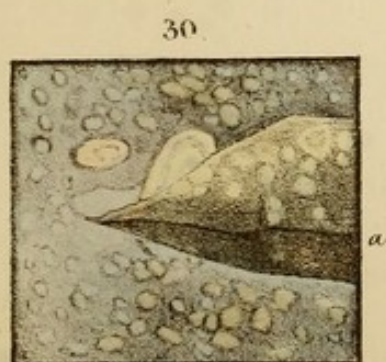
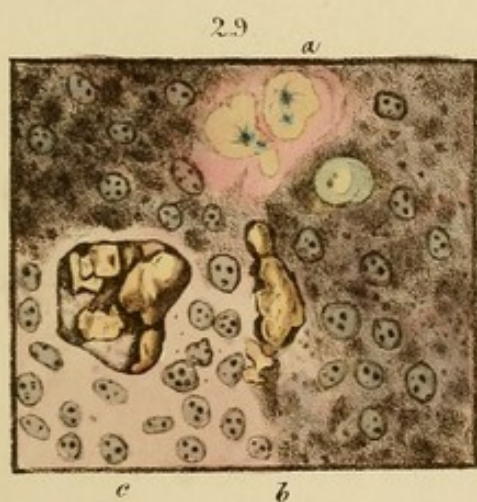
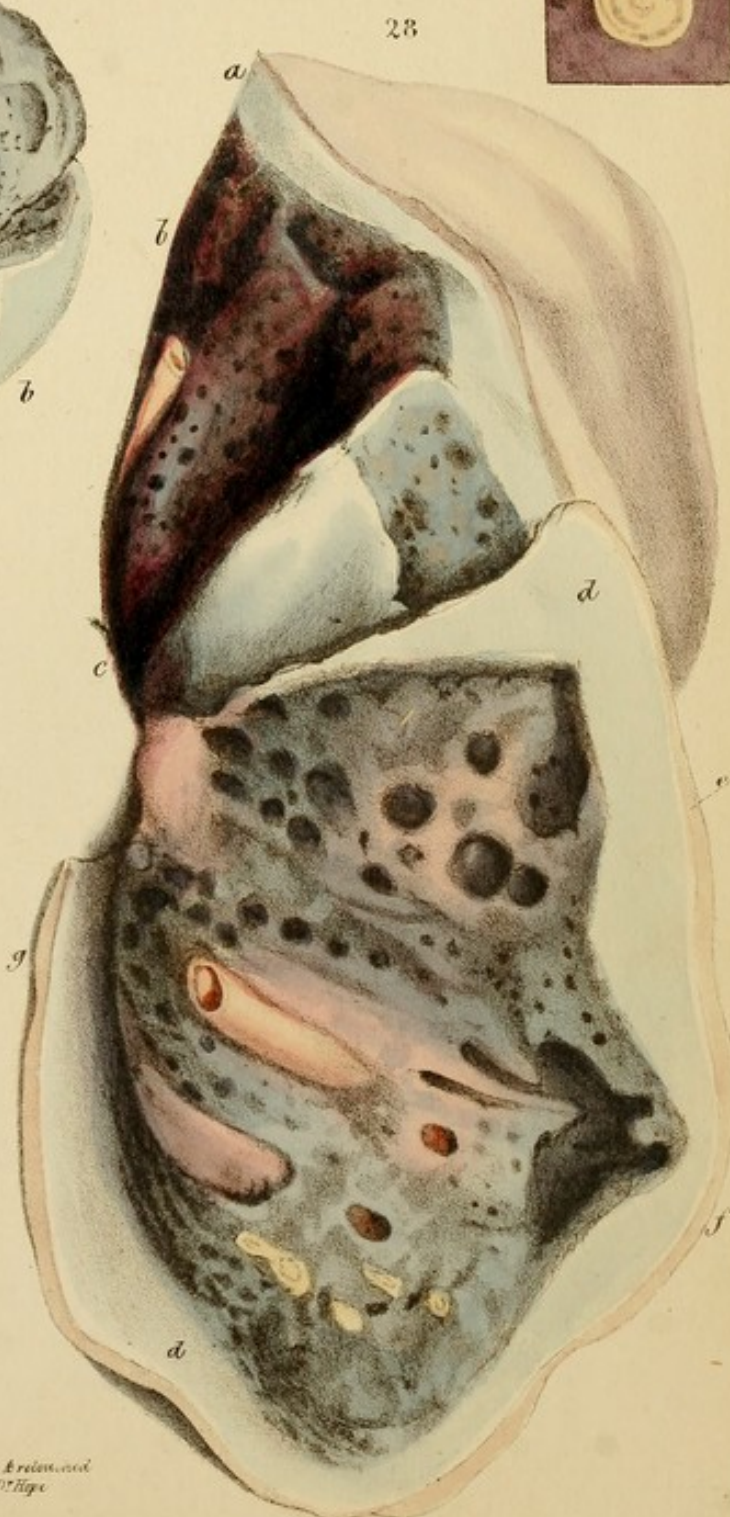
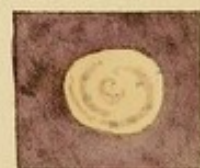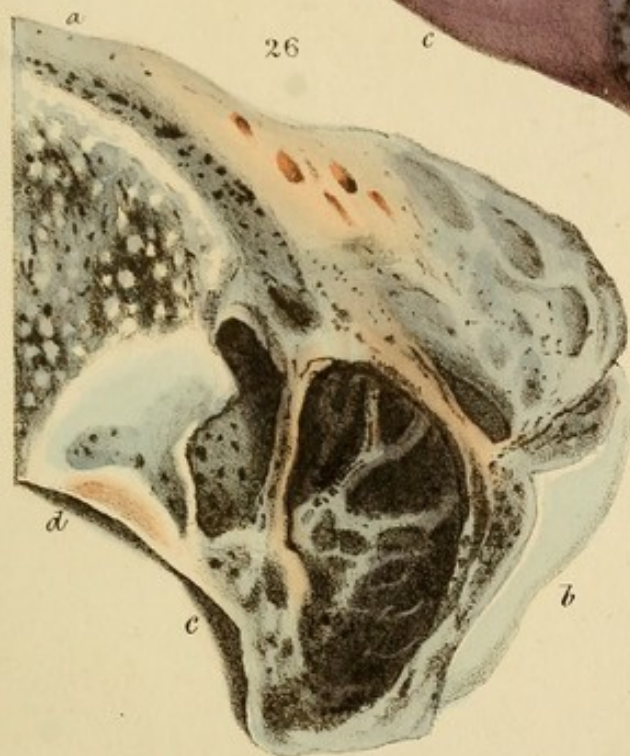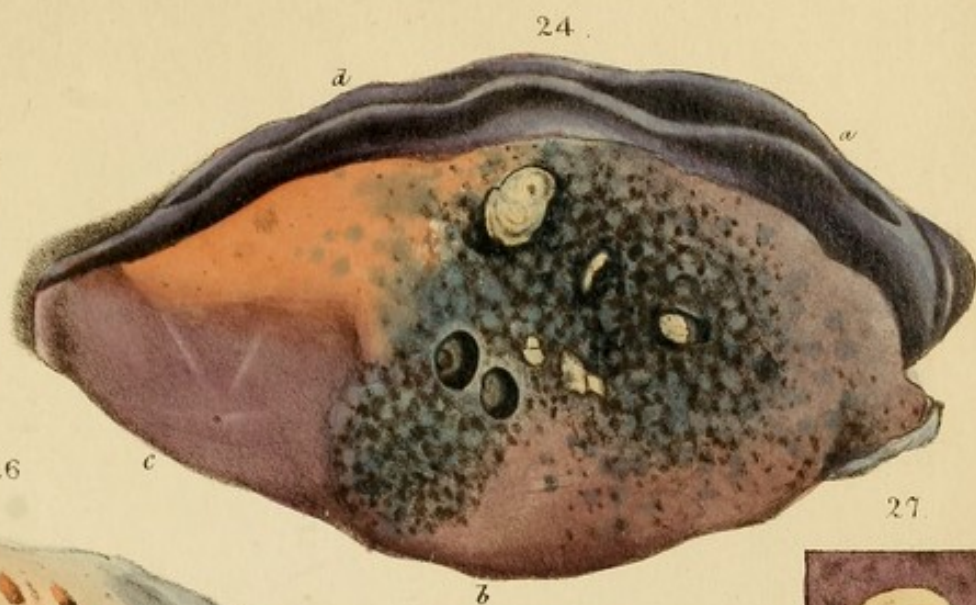
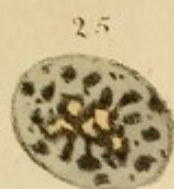Fig. 27.—A dense hard tubercle of cancerous appearance, in healthy lung. Such tubercles are generally cartilaginous, and sometimes as large as an egg.


Fig. 28.—Tubercles and caverns in chronic grey induration. Thickening of the pleura by false membrane, and an abundant deposition between the pleura and the lung.


Case.—*Phthisis with chronic pleurisy*.

Fig. 29.—Yellow cremaceous tubercles. A cyst containing a mass of case. Recent grey tubercles, opened with black pulmonary matter.

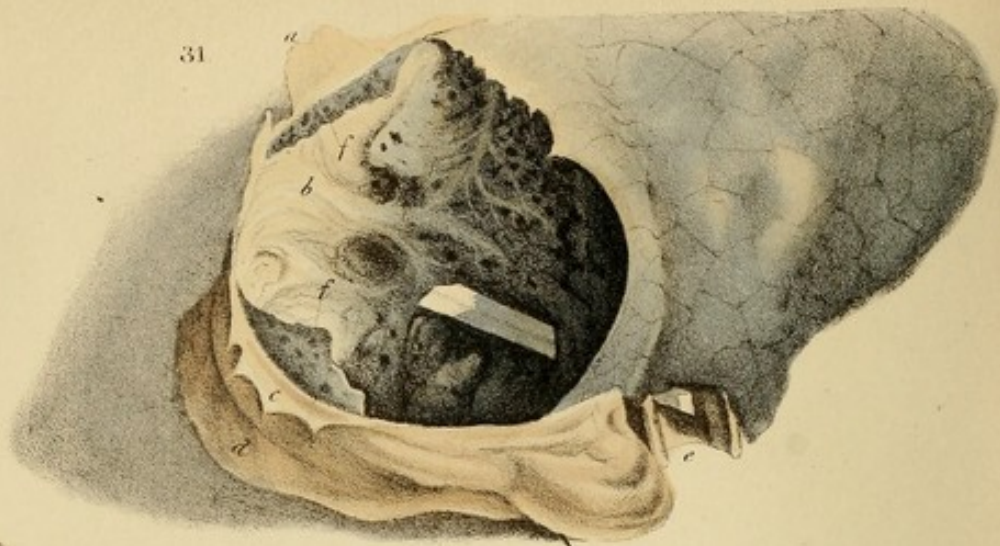
Fig. 30.—False membrane, deposited by inflammation on the lungs of a child, taking the form of tubercles and suppuration. (See *Alcock and Gregory, Edinburgh*.)



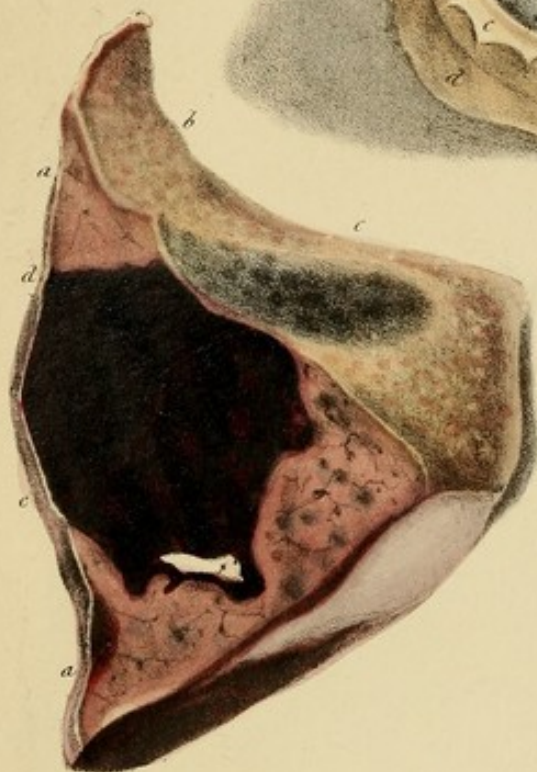




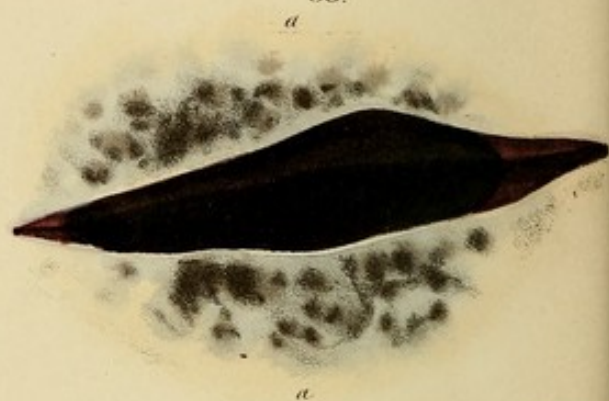
31



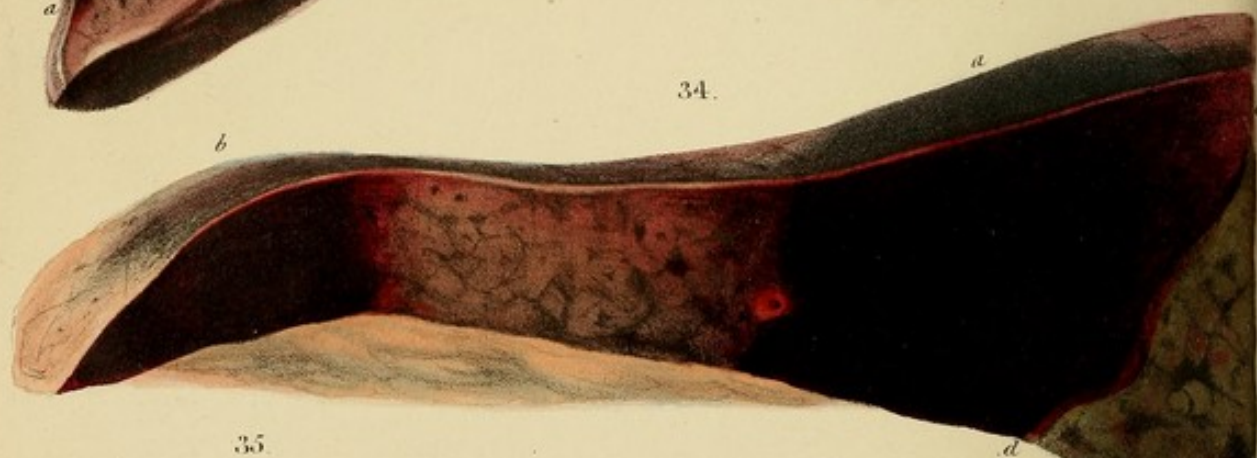
32.



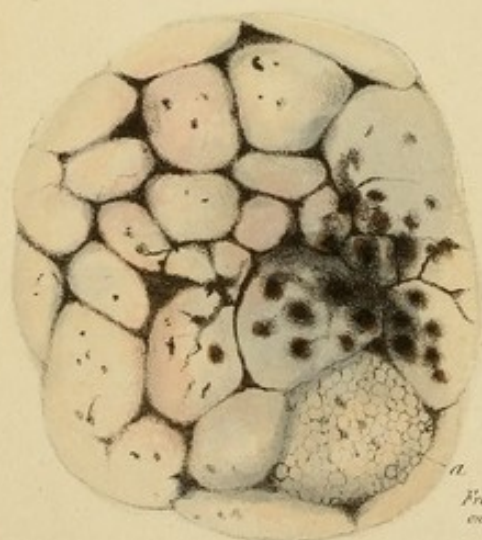
33.



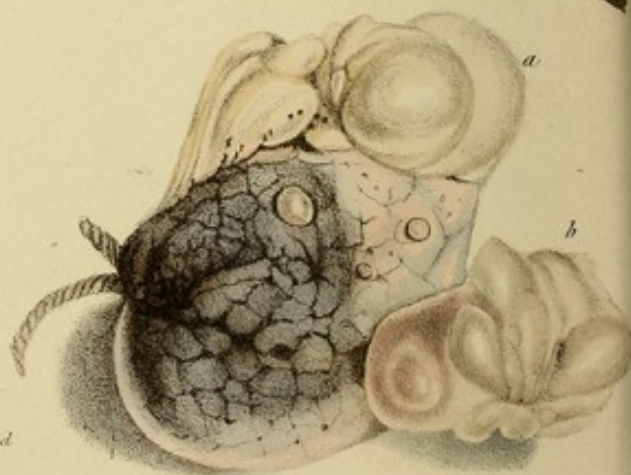
34.



35.




36.



From nature & revised
on stone by D. Hope.

Sculpsit L. Lloyd & W. Marshall.

DESCRIPTION OF THE PLATES

Fig. 31.—A relaxed view of a tuberculous cavern, the size of the largest orange, lined by a  and healthy mucous membrane, under which are blood-vessels. A pen passes through a large bronchus. Several smaller open into the cavity. The preparation had been a day in spirits: hence its grey colour.

Case.—A female, æt. 40, at St. George's, under Dr. Hewitt, presenting a remarkable instance of temporary recovery from consumption. Four years before admission she had hæmoptoe after a fall, followed by hectic, emaciation, and all the symptoms of confirmed phthisis. These subsided, and she was able to resume her accustomed avocations. They subsequently returned, and, on admission, she was emaciated, had cough, thick yellow opaque sputa, perspirations, and loud pectoriloquy over the whole upper lobe of the left lung. She had also the symptoms of organic disease of the heart, and died dropsical.

On dissection, the above described cavity was found, and the lung beneath it was dense, contained numerous small tubercles, and was deeply coloured with much black and grey pulmonary matter. A few tubercles in the apex of the opposite lung. The tubercular disease had probably recurred subsequent to the healing of the cavity.

Fig. 32.—Pulmonary apoplexy, by rupture of the pulmonary tissue, forming a clot, *d, e,* in a lacerated cavity. Pleura, *b, c,* covered with a thin, spotty layer of recent lymph, which imparts a mottled aspect to the blackness of the clot seen through it. Lung healthy, but compressed by hydrothorax, whence it has a solid appearance and feel.

THE HISTORY OF THE CHURCH

The history of the church is a subject of great importance and interest to all who are concerned with the progress of the human race.

The church has been the center of civilization and the source of all knowledge and wisdom.

The church has been the foundation of all laws and the source of all justice.

The church has been the source of all love and the source of all peace.

The church has been the source of all truth and the source of all life.

The church has been the source of all hope and the source of all faith.

The church has been the source of all charity and the source of all mercy.

The church has been the source of all grace and the source of all glory.

The church has been the source of all power and the source of all dominion.

The church has been the source of all wisdom and the source of all knowledge.

The church has been the source of all love and the source of all peace.

The church has been the source of all truth and the source of all life.

The church has been the source of all hope and the source of all faith.

The church has been the source of all charity and the source of all mercy.

The church has been the source of all grace and the source of all glory.

The church has been the source of all power and the source of all dominion.

DESCRIPTION OF THE PLATES.

Fig. 31.—A reduced view of a tuberculous cavern, the size of the largest orange, lined by a thin and healthy mucous membrane, under which ramify blood-vessels. A pen passes through a large bronchus. Several smaller open into the cavity. The preparation had been a day in spirits: hence its grey colour.

Case.—A female, æt. 40, at St. George's, under Dr. Hewitt, presenting a remarkable instance of temporary recovery from consumption. Four years before admission she had hæmoptysis after a fall, followed by hectic, emaciation, and all the symptoms of confirmed phthisis. These subsided, and she was able to resume her accustomed avocations. They subsequently recurred, and, on admission, she was emaciated, had cough, thick yellow opaque sputa, perspirations, and loud pectoriloquy over the whole upper lobe of the left lung. She had also the symptoms of organic disease of the heart, and died dropsical.

On dissection, the above described cavity was found, and the lung beneath it was dense, contained numerous small tubercles, and was deeply coloured with much black and grey pulmonary matter. A few tubercles in the apex of the opposite lung. The tubercular disease had probably recurred subsequent to the healing of the cavern.

Fig. 32.—Pulmonary apoplexy, by rupture of the pulmonary tissue, forming a clot, *d, e*, in a lacerated cavity. Pleura, *b, c*, covered with a thin, spotty layer of recent lymph, which imparts a mottled aspect to the blackness of the clot seen through it. Lung healthy, but compressed by hydrothorax, whence it has a solid appearance and feel.

Case.—A female with hypertrophy and dilatation of the heart and contraction of the mitral valve, of which she died.

Fig. 33.—An incision into another clot from the same lung as Fig. 32, with thickening of the pleura by dirty-yellow lymph, which transmits the blackness in different degrees according to its thickness, so as to present a mottled grey and black appearance.

Fig. 34.—Pulmonary apoplexy by exhalation into the air-vesicles. The mass *a* presents the usual abrupt edges. The edge of the mass *b* is blending, in consequence of a little liquid blood remaining in the lobules adjoining the coagulated portion. The blackness is seen through the pleura. (Presented by Dr. Alison.)

Fig. 35.—Vesicular emphysema, presenting an unusually brilliant appearance by the contrast of spotted and interlobular black pulmonary matter with the yellow parenchyma, rendered exsanguine by inflation. The lobules are more rounded and bulging than natural, from distension. In a single lobule, *a*, the various sizes of the enlarged air-vesicles are rudely represented. This Fig. is also an illustration of some of the characters of black pulmonary matter.

Fig. 36.—Vesicular emphysema, with prominent air-blebs. Three are small and spherical: two are large, and of irregular, lobulated form. All have necks narrower than the bodies. The larger are connected with spacious cavities in the lung, formed by the coalition of several lobules. The drawing is reduced one-third.

Case.—A woman, æt. 50, asthmatic for many years. Left ventricle was an inch thick: aortic, mitral, and tricuspid valves were cartilaginous and contracted. Extensive vesicular emphysema. Died of cholera.

Fig. 37.—Encephaloid tumour of the encysted form. The tumours *d*, *e*, and those below, are denuded of their cysts: the others are invested not only with them, but also with the

pleura: hence they are somewhat bluer, except *a* and *b*, where extravasation has taken place. The larger masses, particularly *c* and *d*, are lobulated. The smallest are greyer and firmer.

Case.—James Ricards, æt. 25, gardener, under Mr. Brodie, at St. George's, April, 1830, emaciated, exsanguine; has a round tumour on the right side of the chest, extending from the fourth to the eleventh rib, and from the angles to within an inch of the cartilages. It is firm, elastic, has an indistinct feel of deep fluctuation, and is not moveable on the ribs. It is painful on pressure, and at night there is an increase of deep seated pain. Integuments healthy. He lies on the back, as, when on the sides, the tumour is painful.

The right side of the chest expands imperfectly. The resonance is sonorous above the fifth rib anteriorly, but dead below it, and also over the whole right side of the back.

The respiratory murmur is puerile where the resonance is sonorous; elsewhere it is extinct. Indistinct œgophony about the sixth rib anteriorly, and very shrill bronchophony in the right axilla. Slight cough for a month; scanty expectoration of greyish mucus. Heart's action forcible; slight bellows-murmur; dulness of the præcordial region. Pulse frequent, small, and vibrating; tongue whitish; skin cool; perspiration at night; bowels open; aspect strumous.

About ten years ago he strained himself at cricket, and ever since has had tenderness in the situation of the tumour. Eighteen months ago the tumour first presented itself externally with a prominence not larger than a nut. During the last month it has increased with greater rapidity than at any previous period. Three weeks ago he had an attack of what appears to have been inflam-

mation of the affected side of the chest. It was relieved by a blister.


The pain in the side recurred, requiring leeches, cupping, and a blister. He died in ten days.

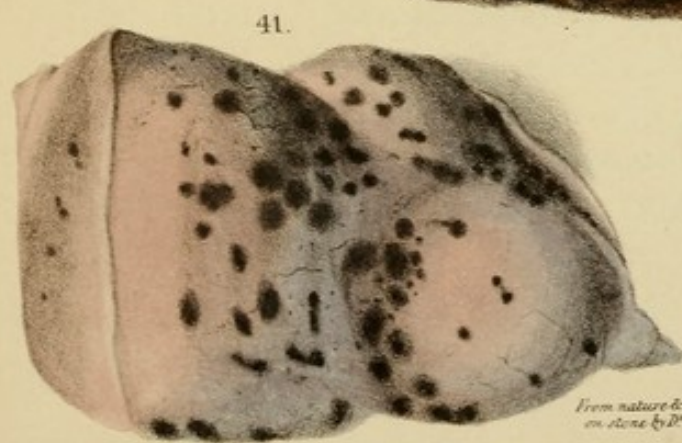
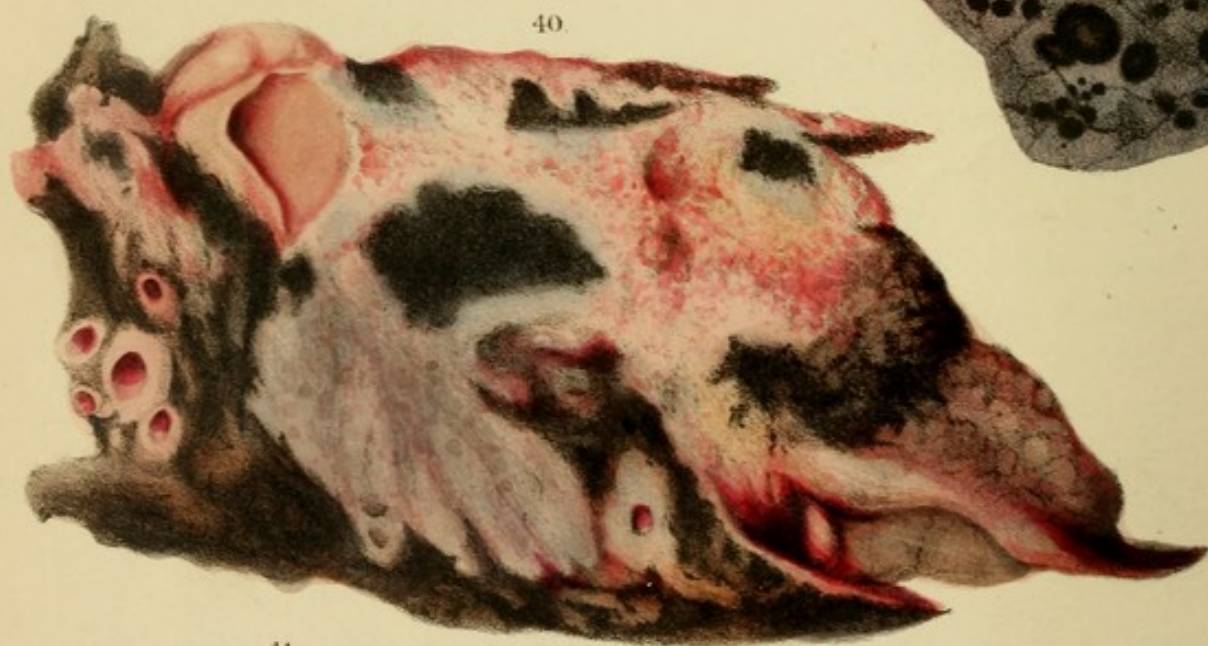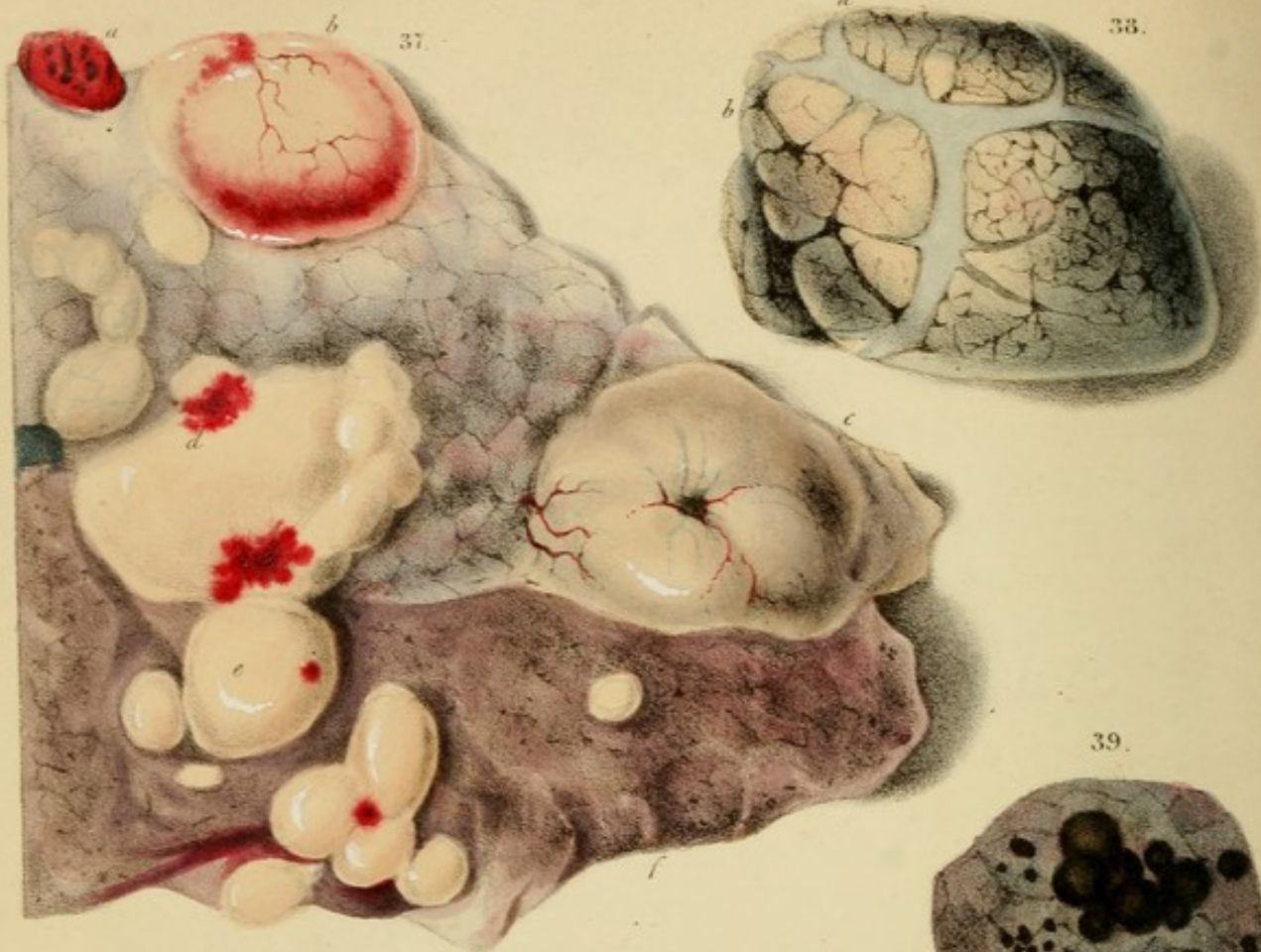
Sectio.—The external tumour was covered anteriorly by the integuments alone, but posteriorly, by the serratus magnus and latissimus dorsi also. It was invested by a thin, loose, cellular membrane. The central portions of the eighth and ninth ribs, which were forced widely apart, were destroyed by absorption, and through the interval the tumour emerged from the chest, of which it occupied the whole cavity except the space filled by about two-thirds of the upper lobe. The lower lobes were flattened, pressed against the mediastinum, and inextricably confused with the tumour. The heart was protruded far to the left side, and the pericardium was compressed on almost all sides.

The tumour, though forming one immense mass, was found to be separated by cellular tissue into several portions or lobes. Its colour resembled that of the cortical substance of the brain; its consistence was somewhat less. In some parts masses of the encephaloid matter were intimately mixed with recent soft coagula of extravasated blood, of deep claret-black colour. In other parts, especially near the external tumour, it was combined with firm, dryish, fibrinous concretions, laminated as in old aneurisms, and of dirty-brownish, yellowish, and reddish colours, the red being deepest between the laminae.

The portion of the upper lobe remaining pervious, was inflamed, and contained isolated, round, medullary tumours, from the size of a pea to that of a walnut.

The left lung contained numerous similar tumours, but some of larger size. From this lung Fig. 37 was taken.





*From nature & revised
on stone by D. Hope.*

A. Smith & Co. 70, St. Martin's Lane.

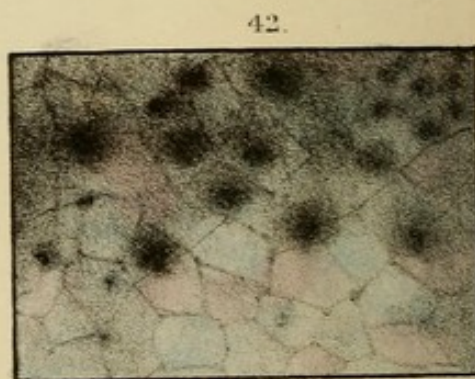


Fig. 10.—A view of the skull of the individual whose measurements are given in the preceding table. The lower jaw is shown in its natural position.

Fig. 11.—A view of the skull of the individual whose measurements are given in the preceding table. The lower jaw is shown in its natural position. The skull is shown in its natural position, and the lower jaw is shown in its natural position.

Fig. 12.—A view of the skull of the individual whose measurements are given in the preceding table. The lower jaw is shown in its natural position. The skull is shown in its natural position, and the lower jaw is shown in its natural position.

Case.—A man, of about 40 years of age, of the following measurements:—The measurements of the skull are given in the preceding table. The measurements of the lower jaw are given in the preceding table. The measurements of the lower jaw are given in the preceding table.

Fig. 13.—A view of the skull of the individual whose measurements are given in the preceding table. The lower jaw is shown in its natural position. The skull is shown in its natural position, and the lower jaw is shown in its natural position.

Fig. 14.—A view of the skull of the individual whose measurements are given in the preceding table. The lower jaw is shown in its natural position. The skull is shown in its natural position, and the lower jaw is shown in its natural position.

Fig. 15.—A view of the skull of the individual whose measurements are given in the preceding table. The lower jaw is shown in its natural position. The skull is shown in its natural position, and the lower jaw is shown in its natural position.

Fig. 16.—A view of the skull of the individual whose measurements are given in the preceding table. The lower jaw is shown in its natural position. The skull is shown in its natural position, and the lower jaw is shown in its natural position.

Fig. 17.—A view of the skull of the individual whose measurements are given in the preceding table. The lower jaw is shown in its natural position. The skull is shown in its natural position, and the lower jaw is shown in its natural position.

The first of these is the fact that the
the first of these is the fact that the

the first of these is the fact that the
the first of these is the fact that the

the first of these is the fact that the
the first of these is the fact that the

the first of these is the fact that the
the first of these is the fact that the

the first of these is the fact that the
the first of these is the fact that the

the first of these is the fact that the
the first of these is the fact that the

the first of these is the fact that the
the first of these is the fact that the

the first of these is the fact that the
the first of these is the fact that the

the first of these is the fact that the
the first of these is the fact that the

the first of these is the fact that the
the first of these is the fact that the

It was in other respects healthy. The liver was considerably enlarged.

Fig. 38.—Interlobular emphysema. Transparent bluish bands traverse the surface of the lungs and descend deep into its substance with a wedge-like convergence. They insulate some of the lobules. The portion is included in a ligature behind: hence its ovoid shape. (From La Charité.)

Fig. 40.—Melanosis of soot colour, in spherical and oval masses, in the cellular tissue beneath the pleura.

Case.—A man, æt. about 50, in the Edinburgh Infirmary. The disease affected the cellular tissue almost universally. A mass developed at the base of the orbits led to extirpation of the eye. The patient had also chronic bronchitis, and died worn out by cachectic emaciation.

Fig. 40.—Fibro-cartilaginous masses partially ossified, and more or less vascular, surrounded by infiltrated melanosis, of which they inclose several patches. The portion represented is a flat section through two lobes, the acute margins and interposed fissure of which are seen on the right side. For this drawing, by Syme, I am indebted to my friend, Prof. Monro of Edinburgh.

Fig. 41.—Beautiful spotted appearance of black pulmonary matter. Also old œdema; whence the tumid character and muddy pink and grey colour.

Fig. 42.—Small round melanotic masses, encircled by dark clouds, in the parenchyma of the lungs, and seen through the pleura.

Fig. 43.—Singularly brilliant appearance of black pulmonary matter, forming spots at the angles of the interlobular septa. The lung was healthy. (La Charité.)

Fig. 44.—Infiltrated melanosis, with dirty-white (*a*) and deep grey (*b*) induration from chronic inflammation. At *c* the lung is reddish, soft, and crepitant.

Case.—The patient had no material pulmonary symptoms, and died of cholera. Both lungs were, throughout, nearly as dark as at *c*, and contained numerous round melanotic masses as large as mustard-seeds and peas.

Fig. 45.—Pulmonary or melanotic matter, of blue-black colour, with tubercles seen through the pleura. At the upper part the lung is redder, and less charged with tubercles. An identical appearance was presented by the pleura in parts of the lung, *Fig. 49*, except that there were no tubercles. (*La Charité.*)

Fig. 46.—Ulceration of the fauces *a, a*, and epiglottis *b*, with vegetations extending into the larynx. Also hypertrophy of the mucous glands and papillæ, *c, c*.

Case.—Syphilis treated with excess of mercury.

Fig. 47.—Tubercular consolidation of blackish-grey colour, with a cavern. (The phthisis with melanosis of Bayle.) The pleura is thickened externally by vascular false membrane of a dense fibrous nature.

Fig. 48.—Ulceration of the larynx, which is laid open by an incision through the front. On and above the chordæ are cribriform ulcers covered with pus. Below, the mucous follicles are ulcerated, and present an external and internal zone of red. Still lower is a large deep ulcer penetrating to the cricoid cartilage. The integuments of the arytaenoid cartilages *a* are tumid with inflammatory œdema.

Case.—A female, æt. 45, who died of phthisis. Acute inflammation had supervened and caused the vivid redness.

Fig. 49.—A cauliflower excrescence springing from the œsophagus and partly from the larynx, into which it projects in front of the chordæ vocales *c*. The cricoid cartilage is ossified and held open by a piece of wood. (*Vid. BRONCHITIS*, hypertrophy of the mucous membrane.)

Case.—A woman, æt. 55. Voice croaking, inspiration rather

the first of these is the fact that the
the second is the fact that the

the third is the fact that the

the fourth is the fact that the

the fifth is the fact that the

the sixth is the fact that the

the seventh is the fact that the

the eighth is the fact that the

the ninth is the fact that the

the tenth is the fact that the

Case.—The patient had no material pulmonary symptoms, and died of cholera. Both lungs were, throughout, nearly as dark as *a*, and contained numerous round melanotic nodules as large as mustard-seeds and peas.

Fig. 42.—Pulmonary or melanotic matter, of blue-black colour, with tubercles seen through the pleura. *A*: the upper part the lung is redder, and less charged with tubercles. An identical appearance was presented by the pleura in parts of the lung, *Fig. 49*, except that there were no tubercles. (*Lé. Charc.*)

Fig. 43.—Elevation of the larynx *a*, *a*, and epiglottis *b*, with vegetation extending into the larynx. Also hypertrophy of the mucous glands and papillae *c*, *c*.

Case.—Syphilis treated with success of mercury.

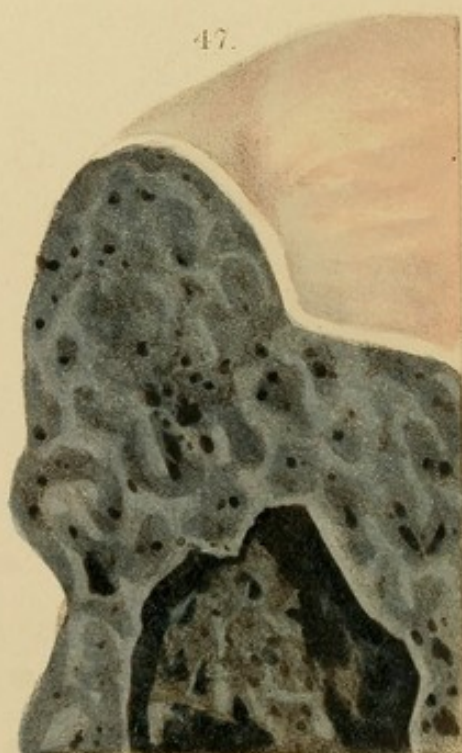
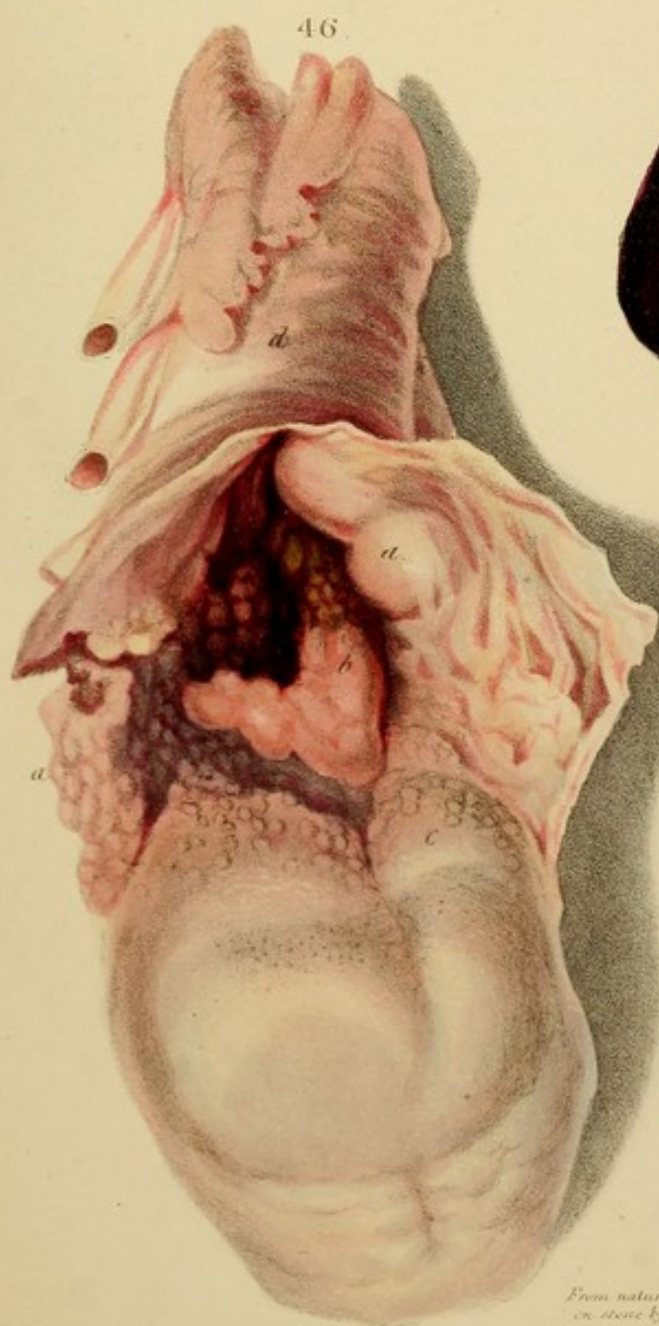

Fig. 44.—Cylindrical condensation of larynx, *a*, *a*, with a *c* *c* *c* *c*. (The patient with nodules of "larynx." The pleura is thickened externally by vascular false membrane of a dense fibrous nature.

Fig. 45.—Elevation of the larynx, which is laid open by an incision through the front. *bb* and *cc* show the arylean and aryepiglottic valves, covered with granules. Below, the mucous follicles are elevated, and project in external and internal rows of red. Still lower is a large deep ulcer penetrating to the cricoid cartilage. The integuments of the arytenoid cartilages *c* are tumid with inflammatory oedema.


Case.—A female, *æt.* 45, who died of phthisis. Acute inflammation had supervened and caused the fatal result.


Fig. 46.—A cauliflower excrescence springing from the oesophagus and partly from the larynx, into which it projects in front of the chordæ vocales *a*. The cricoid cartilage is outlined and held open by a piece of wood. (*Vid. Epithelioma*, hypertrophy of the mucous membrane.)

Case.—A woman, *æt.* 35. Voice croaking, inspiration rather



*From nature & revised
on stone by D. Hope.*





sibilous, emaciated. Complaints were of six months standing. Stated that late in life he had a "croup of the throat."

Fig. 50.—Dilatation of the bronchi, by which dilated cavities. A pin is passed through these which are of course. The walls are thickened and inflamed, and appear of a yellowish, purplish, and in some places of a brownish color. (See *Fig. 50*.)

Case.—A man, who had been subject to chronic cough for six years. When attended by Dr. J. C. W. for the first time, he was taken for the drawing, the specimen of the disease is now preserved.

Fig. 51.—A cross section of the bronchi, showing the dilated cavities of the bronchi, protected by a network of red.

Case.—The same as *Fig. 48*.

Fig. 52.—Dilatation of the bronchi, of which the walls, particularly of the cavities near *b*, are very thin and transparent. From the same case as *Fig. 50*.

Fig. 53.—Contraction of a bronchus by thickening of the mucous membrane.

Case from London. In which there was a similar, but greater contraction. A. Toynton, Esq., 37, had the symptoms of organic disease of the heart. Said that he had long experienced a sort of constriction in the chest above the right nipple; and that he did not breathe on the right side of the chest. The respiration behind was very strong, with a mixture of mucous rattle; in front, on the left, it was similarly loud, but on the right, under the clavicle, the inspiratory murmur, though pure, was much more feeble than on the left, yet there was no evidence of percussion. Hence emphysema was excluded. He recovered, from the disease of the heart, and was still.

Section.—The superior lobe of the right lung presented no

sibilous, emaciation. Complaint was of six months standing. Stated that her "father died of cancer of the throat."

Fig. 50.—Dilatation of the bronchi, forming rounded cavities. A pin is passed through three which communicate. The walls are thickened and indurated, and display various shades of yellowish, purplish, and brownish-red from chronic inflammation. (Varieties, ii. and iii. p. 61.)

Case.—An old soldier, who had been subject to chronic catarrh and asthma for ten years. When attended by Dr. Alison, to whom I am indebted for the drawing, the quantity of expectoration was enormous.

Fig. 51.—Acute inflammation with ulceration of the mucous follicles of the trachea, presenting an external and internal zone of red.

Case.—The same as *Fig. 48*.


Fig. 52.—Dilatation of the bronchi, of which the walls, particularly of the cavities near *b*, are very thin and transparent. From the same case as *Fig. 50*.

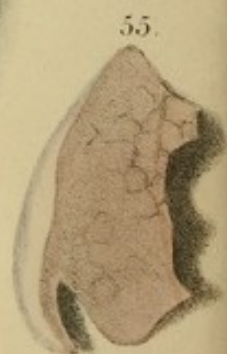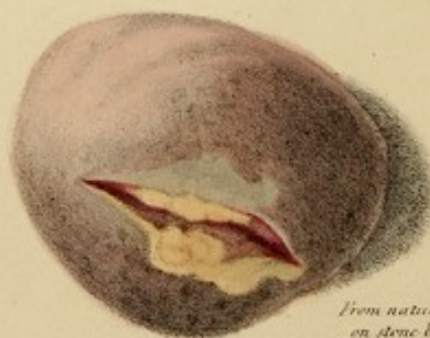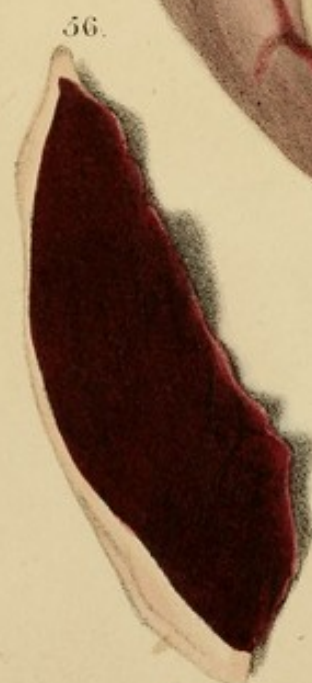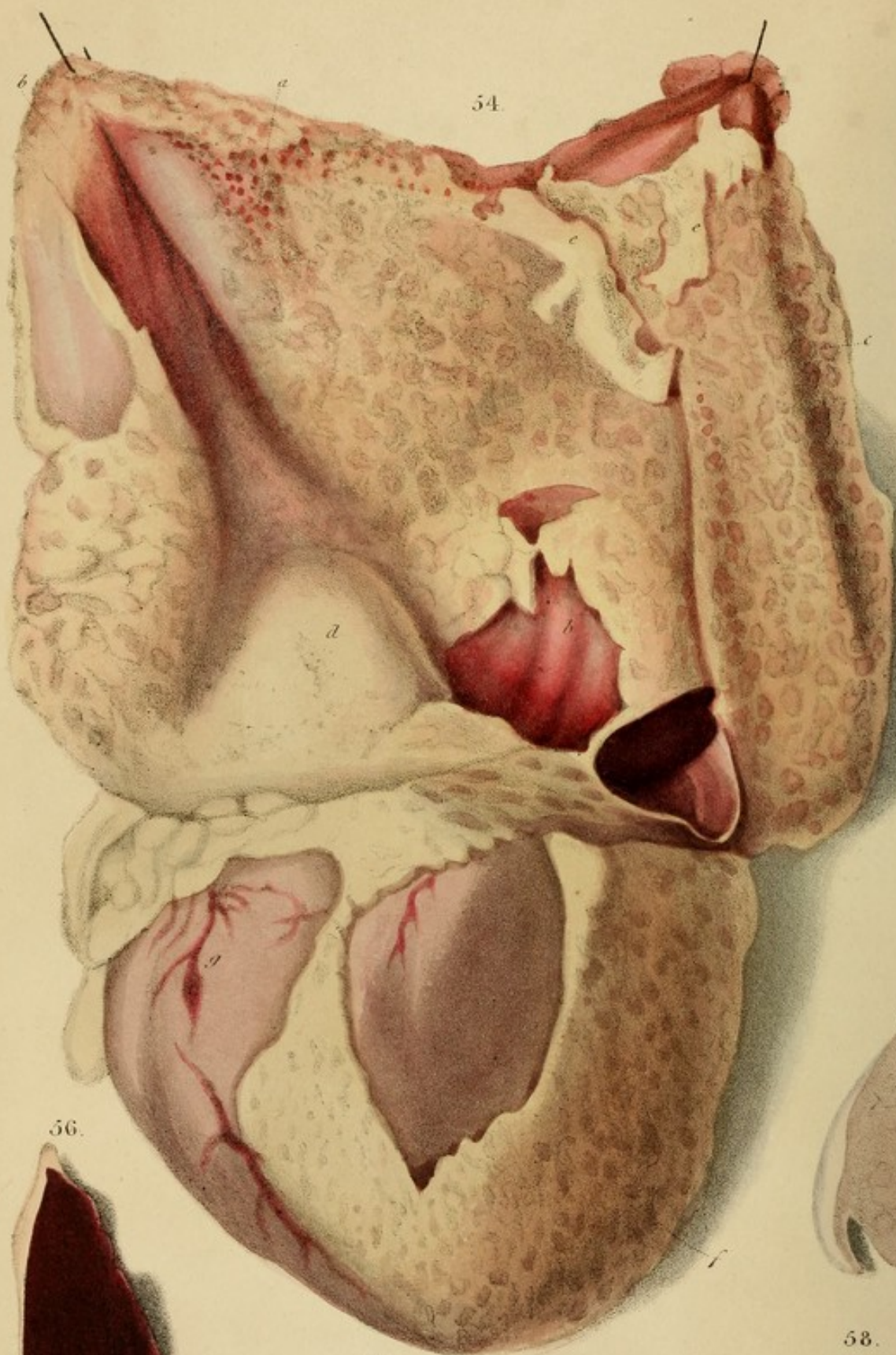
Fig. 53.—Contraction of a bronchus by thickening of the mucous membrane.

Case from Andral, in which there was a similar, but greater contraction. A toyman, æt. 31, had the symptoms of organic disease of the heart. Said that he had long experienced a sort of constriction a little above the right nipple; and that he did not breathe on the right side of the chest. The respiration behind was very strong, with a mixture of mucous ronchus: in front, on the left, it was similarly loud, but on the right, under the clavicle, the inspiratory murmur, though pure, was much more feeble than on the left, yet there was no dulness on percussion. Hence emphysema was expected. Hydrothorax, from the disease of the heart, supervened, and was fatal.

Sectio.—The superior lobe of the right lung presented no

emphysema, but its tissue was very deficient in crepitaney, though otherwise sound. The principal bronchus presented, a few lines from its origin, a contraction so great that a fine stiletto could scarcely pass through it. A little before dividing, the bronchus regained its usual calibre. Over the extent of the contraction, the fibrous coat was natural, but the mucous membrane was red and greatly thickened. The bronchi and lungs were otherwise healthy. Hydrothorax; hypertrophy with dilatation; contracted aorta. (Clin. Med.)





From nature & revised
on stone by R. W. H. G.

DESCRIPTION OF THE PLATES.

Fig. 54.—Acute pericarditis, with a very recent false membrane, beneath which the pericardium is of a vivid red. In parts, *a*, speckled; in other parts, *b*, *c*, diffuse, though mottled. On the heart it is usually thicker than natural, except to the extent of the vessels *g*.

The false membrane is soft, lacinate, and of pinnate colour. It is pinned in parts with remarkably regular regular elevations which stand in lines. At *a*, though the bases of which the subjacent red is apparent. At *b*, it is smooth and very thick. At *f*, it hangs in shaggy folds; *e*, *c*, are fragments torn from above and reflected downwards.


Case.—A man in La Charité, who had protracted peripneumony, in the last stage of which pericarditis supervened, and was assisted by Chomel, four days before death, by the pulse becoming very irregular, this being the only well-marked symptom. The pericardium contained eight ounces of turbid, flocculent, yellow serum.

Fig. 55.—Pale colour of the heart in a case of anæmia and atrophy. The portion *b* is transverse section through the middle of the organ, and it shows the comparative thickness of the right and left ventricles and the septum.

Case.—A man, æt. 70, who died of chronic bronchitis and anæmia. His complexion was singularly ashy, and all the internal organs were in a similar state.

Fig. 56.—Infarctory softening of the heart, of deep red colour. The exterior is fatty.

Fig. 57.—Pericarditis, with an abscess descending two lines and a half into the muscular substance of the left ventricle.



DESCRIPTION OF THE PLATES.

Fig. 54.—Acute pericarditis, with a very recent false membrane, beneath which the pericardium is of a vivid red,—in parts, *a*, speckled; in other parts, *b, b*, diffuse, though mottled. On the heart it is scarcely redder than natural, except in the tract of the vessels *g*.

The false membrane is soft, lacerable, and of primrose colour. It is pitted in parts with remarkably regular alveoli, especially at *c*, through the bases of which the subjacent red is apparent. At *d*, it is smooth and very thick. At *f*, it hangs in shaggy flocculi; *e, e*, are fragments torn from above and reflected downwards.

Case.—A man in La Charité, who had protracted peripneumony, in the last stage of which pericarditis supervened, and was suspected by Chomel, four days before death, by the pulse becoming very irregular, this being the only well-marked symptom. The pericardium contained eight ounces of turbid, flocculent, yellow serum.

Fig. 55.—Pale colour of the heart in a case of anemia and atrophy. The portion is a transverse section through the middle of the organ, and it shows the comparative thickness of the right and left ventricles and the septum.

Case.—A man, æt. 70, who died of chronic bronchitis and emphysema. His complexion was singularly exsanguine, and all the internal organs were in a similar state.

Fig. 56.—Inflammatory softening of the heart, of deep red colour. The exterior is fatty.

Fig. 57.—Pericarditis, with an abscess descending two lines and a half into the muscular substance of the left ventricle.

It consisted of a concrete and very pale curdy matter, inclosing in its centre a little liquid pus. A soft false membrane, as in Fig. 54, universally invested the pericardium. The drawing is a rude fore-shortened sketch of the ventricles, from which the lymph has been washed off.

Case.—A child, æt. 7, with rubeola, followed by left peripneumony, and finally by pericarditis. The pulse became very irregular, small, and weak, with stupor and asphyxia. The pericardium contained about four ounces of serum, turbid with flakes of lymph. The mesenteric glands were enlarged. It is probable that the abscess in the heart originated in a scrofulous predisposition.

Fig. 58.—Softening of the heart, of dirty fawn colour, like dead leaves.

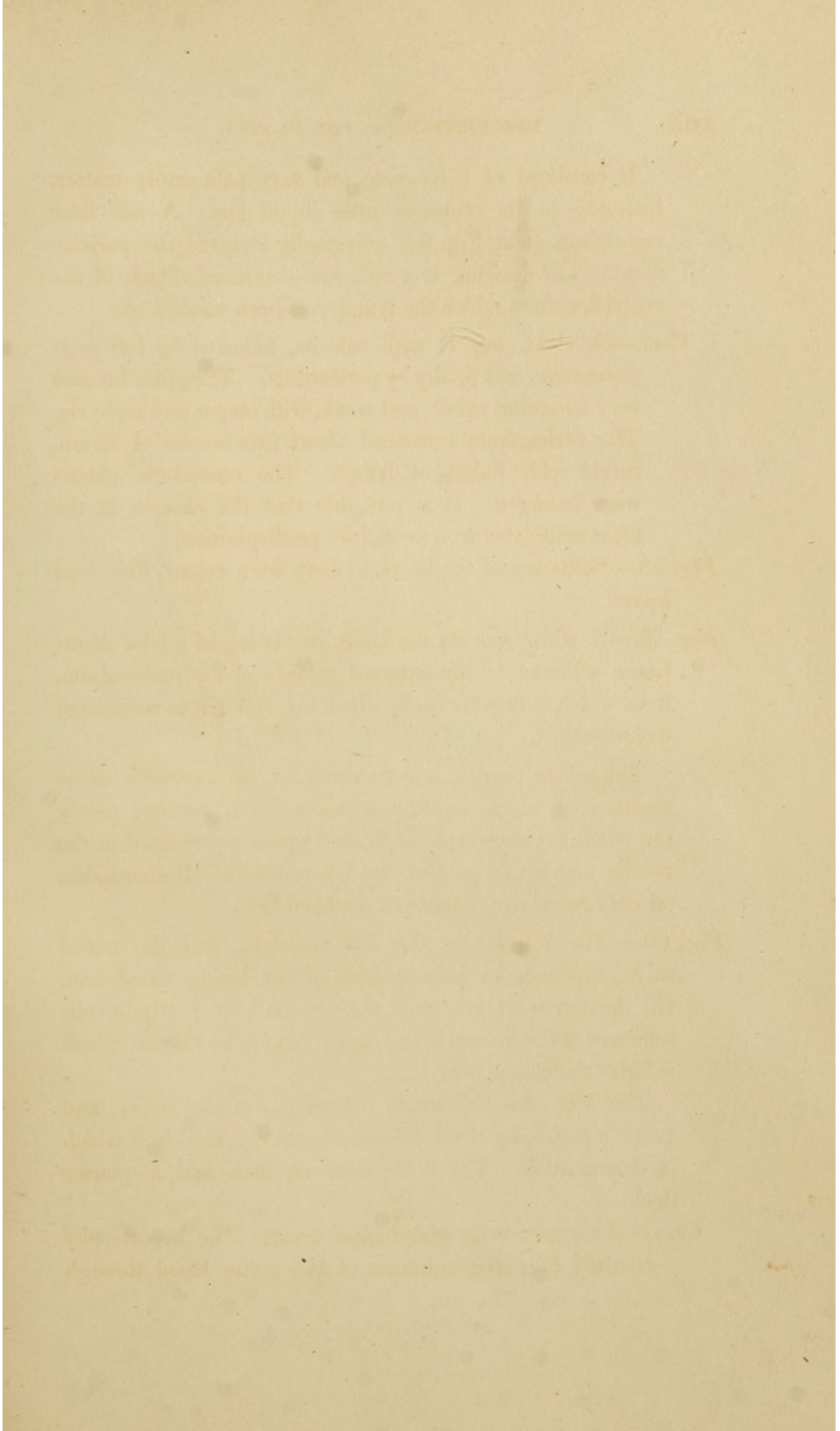
Fig. 59.—A white spot on the heart, consisting of a false membrane adherent to the external surface of the pericardium, from which it may be easily dissected. A pin is insinuated underneath it.

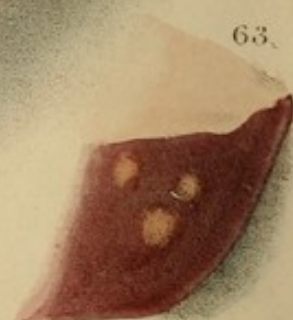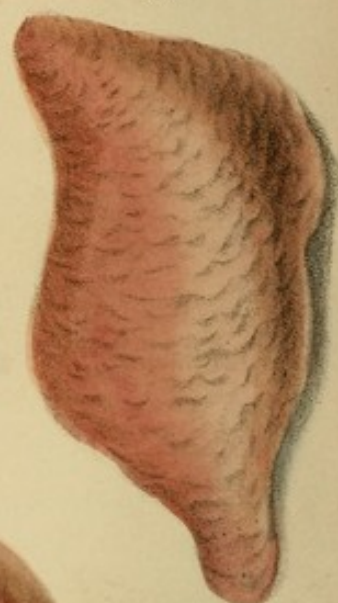
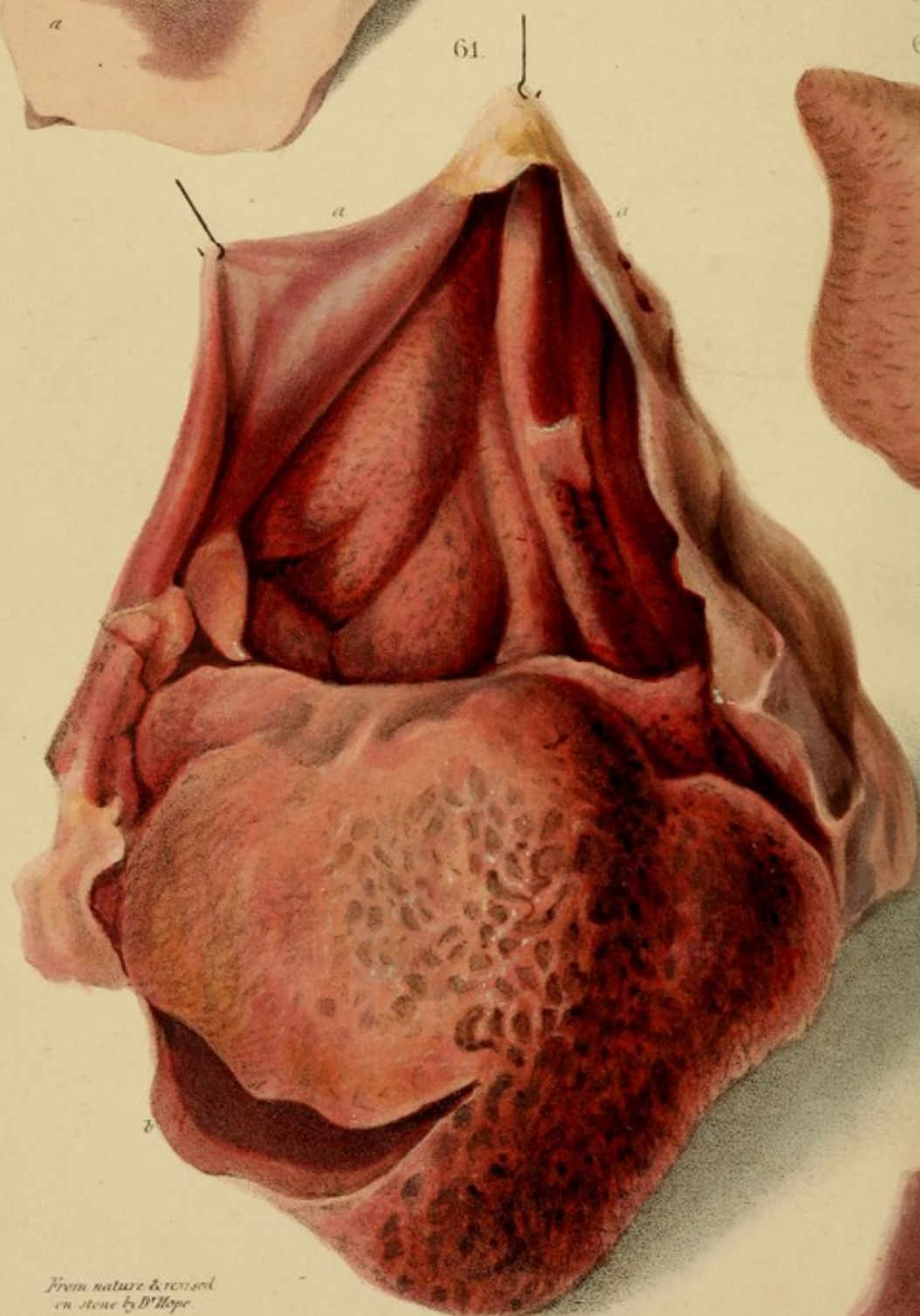
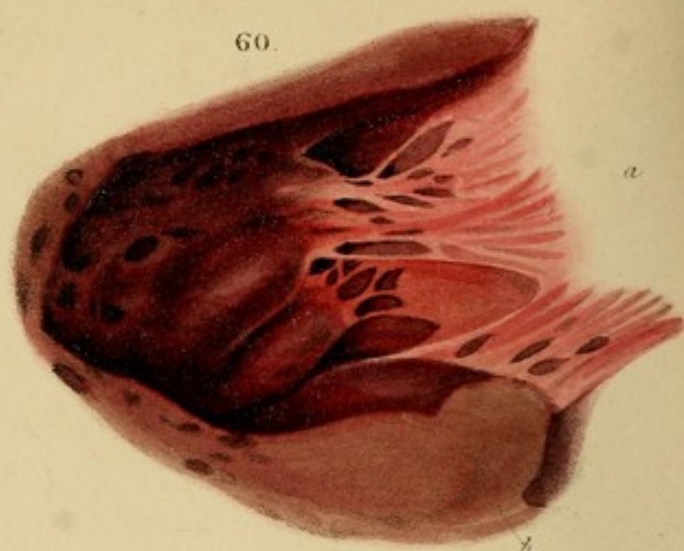
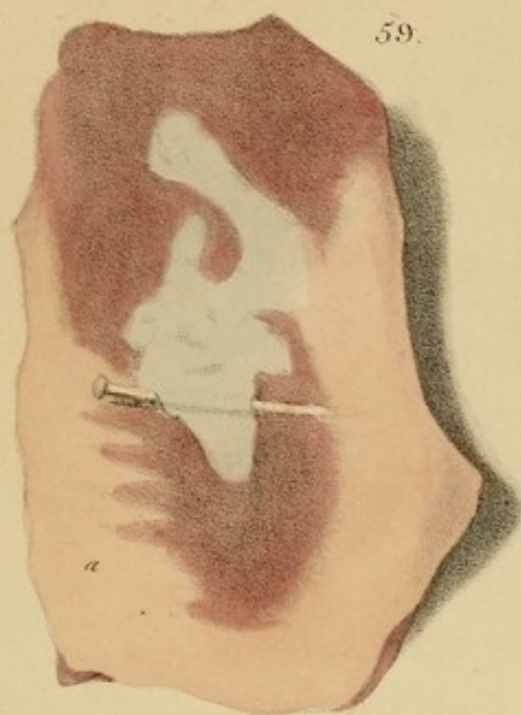The yellow portion, *a*, represents fat, an excessive accumulation of which, under the pericardium, covered nearly the whole organ except the limited space represented in the middle and upper part of the left ventricle. It encroaches on the muscular substance in a ribbed form.

Fig. 60.—The interior of the left ventricle, and the mitral valve, reddened by inflammation of the lining membrane. On the muscular substance the red is deep, partly in consequence of the ground being dark; but on the valve *a*, which is light, the colour is vivid.

The Fig. also represents contraction of the cavity, and great hypertrophy of the columnæ carneæ, a section of which is shown at *b*. The walls were an inch and a quarter thick.

Case.—An aged female who died of fever. The hypertrophy resulted from regurgitation of the aortic blood through





*From nature & revised
on stone by D. Hope.*

A. Leitch del. J. W. Smith sculp.

a ruptured vessel. She had formerly had apoplexy, and there were the remains of an old extravasation in the brain.

Fig. 61.—Chronic pericarditis, with a thickened false membrane effusing bloody fluid. From the part a, a, the membrane has been peeled off in *b, b*, which being reflected below, it is seen to show the deep bluish colour of the pericardium itself. The false membrane is tough and completely organized: its surface is variously wrinkled and pitted, on the least we observe the thick and smooth, somewhat like small worms.

At *b, b* is seen evident swelling of the muscular substance, two or three lines deep, a result of inflammation propagated from the pericardium.

Case.—A man, *et. 60*, in the Edinburgh Royal Infirmary, who three months before death, fell with the precardial region against a stone. Permanent pain ensued, attended with symptoms of organic disease of the heart, and with emaciation. He complained principally of "a heavy lump" in the epigastric region, which caused dyspnoea; and his right arm suffered from numbness and immobility. A part of bloody serum was found in the pericardium. *Pl. Fig. 61* removed one-third.

Fig. 62.—Chronic pericarditis, showing a pitted false membrane, like nodulations of sand on the surface. It is of a constant colour.

Fig. 63.—Thickening in the substance of the left ventricle, with thickening of the walls to the extent of an inch.

Fig. 64.—Chronic Pericarditis. The upper half of the heart, opened by *a, a*, and from which the membrane has been removed, showing the deep bluish colour of the pericardium, and the pale bluish colour of the pericardium, separated by a film of organized cellular tissue on its surface.

a ruptured valve. She had formerly had apoplexy, and there were the remains of an old extravasation in the brain.

Fig. 61.—Chronic pericarditis, with a blood-stained false membrane effusing bloody fluid. From the parts *a, a*, the membrane has been peeled off in flaps, which hang reflected below, in order to show the deep bluish-red colour of the pericardium itself. The false membrane is tough and completely organized: its surface is variously wrinkled and pitted: on the heart the elevations are thick and round, somewhat like small worms.

At *b*, is fawn coloured softening of the muscular substance, two or three lines deep,—a result of inflammation propagated from the pericardium.

Case.—A man, æt. 60, in the Edinburgh Royal Infirmary, who, three months before death, fell with the præcordial region against a stone. Permanent pain ensued, attended with symptoms of organic disease of the heart, and with emaciation. He complained principally of “a heavy lump” in the scrobiculus cordis, which caused orthopnoea; and his almost constant position was sitting with an inclination forwards. A pint of bloody serum was found in the pericardium. The *Fig.* is reduced one-third.

Fig. 62.—Chronic pericarditis, showing a plaited false membrane, like undulations of sand on the sea-shore. It is of a cinnamon colour.

Fig. 63.—Tubercles in the substance of the left ventricle; also thickening of the walls to the extent of an inch.

Fig. 64.—*Chronic Pericarditis.* The upper half of the heart, covered by a thin and firm, rugous false membrane, *a*, of reddish-yellow colour, which is peeled from the centre, *b, c*, to show the pale-bluish colour of the pericardium, occasioned by a film of adventitious cellular tissue on its surface.

When this is removed, the red nucleus is seen, the base of which is attached to the wall of the ventricle.

The internal wall of the ventricle is covered by a thin layer of endothelium, the surface of which is smooth and glistening.

Case.—Pericarditis. The pericardium was found to be inflamed and thickened. The heart was enlarged and the coronary arteries were dilated. The ascending aorta was dilated to three times its normal capacity. (La Charité.)

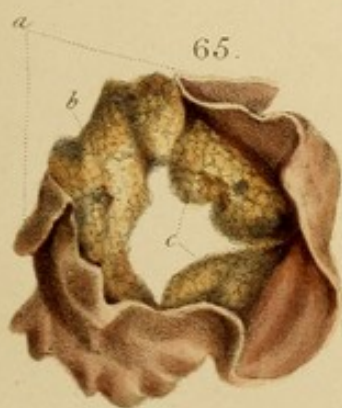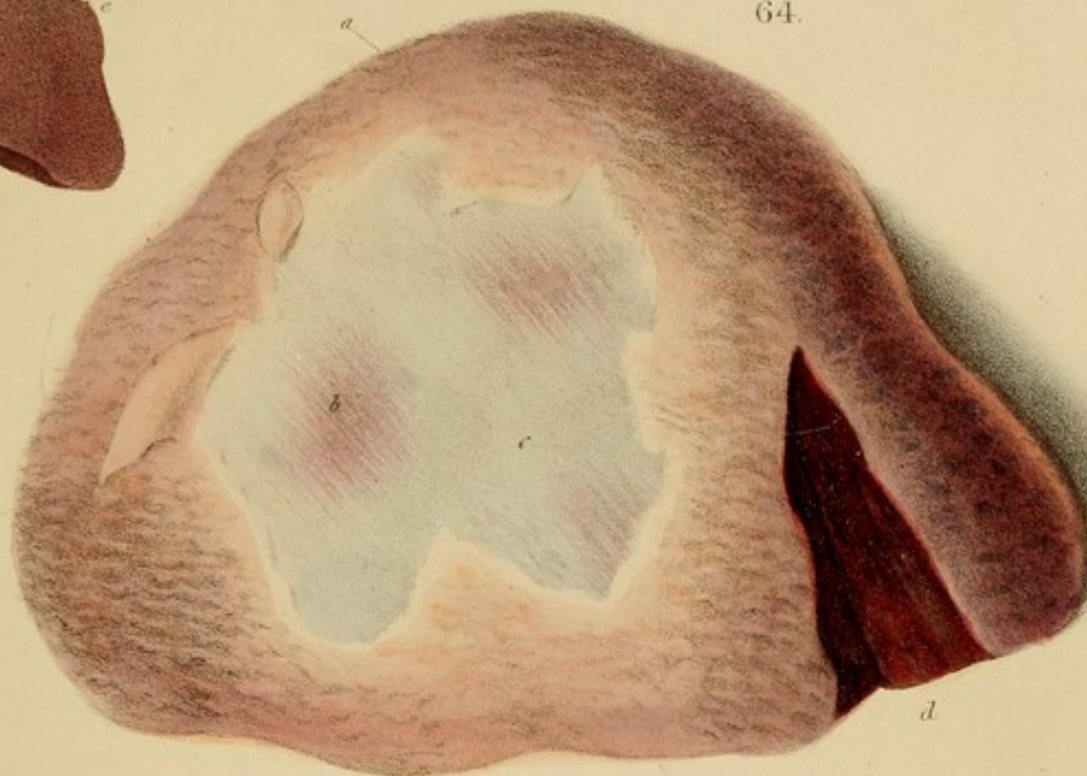
Fig. 63.—A dissection of the heart showing the pericardium and the heart itself. The pericardium is seen as a thin, white, glistening layer covering the heart. The heart is enlarged and the coronary arteries are dilated.

Fig. 64.—A dissection of the heart showing the pericardium and the heart itself. The pericardium is seen as a thin, white, glistening layer covering the heart. The heart is enlarged and the coronary arteries are dilated.

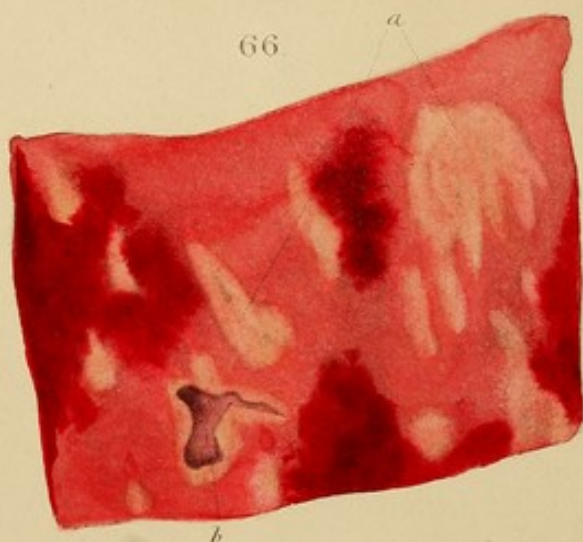
Fig. 65.—A dissection of the heart showing the pericardium and the heart itself. The pericardium is seen as a thin, white, glistening layer covering the heart. The heart is enlarged and the coronary arteries are dilated.



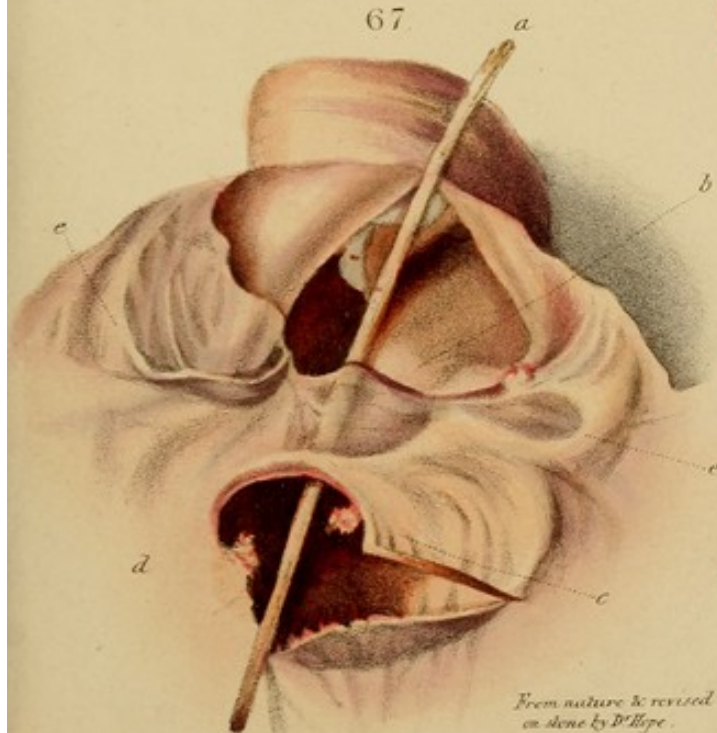
64.



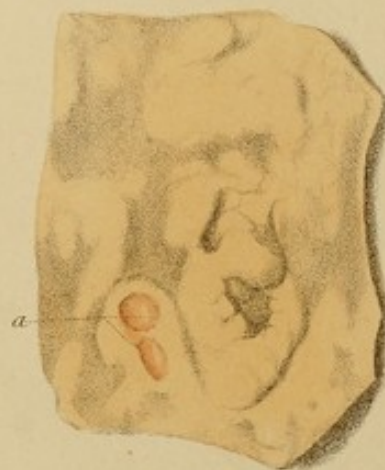66.



67.





68.

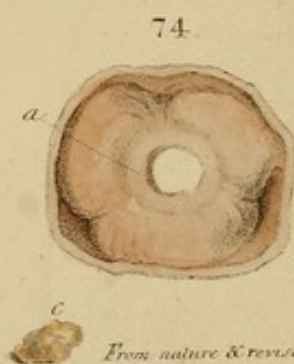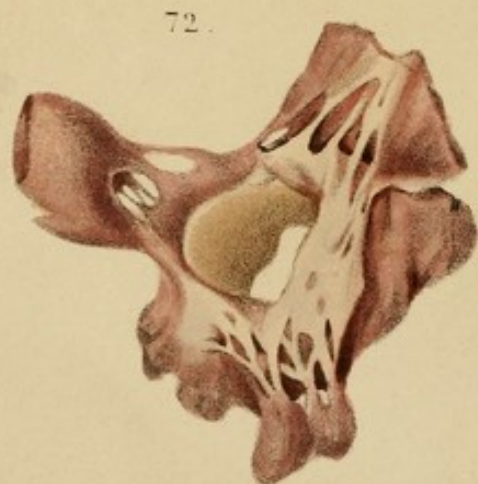
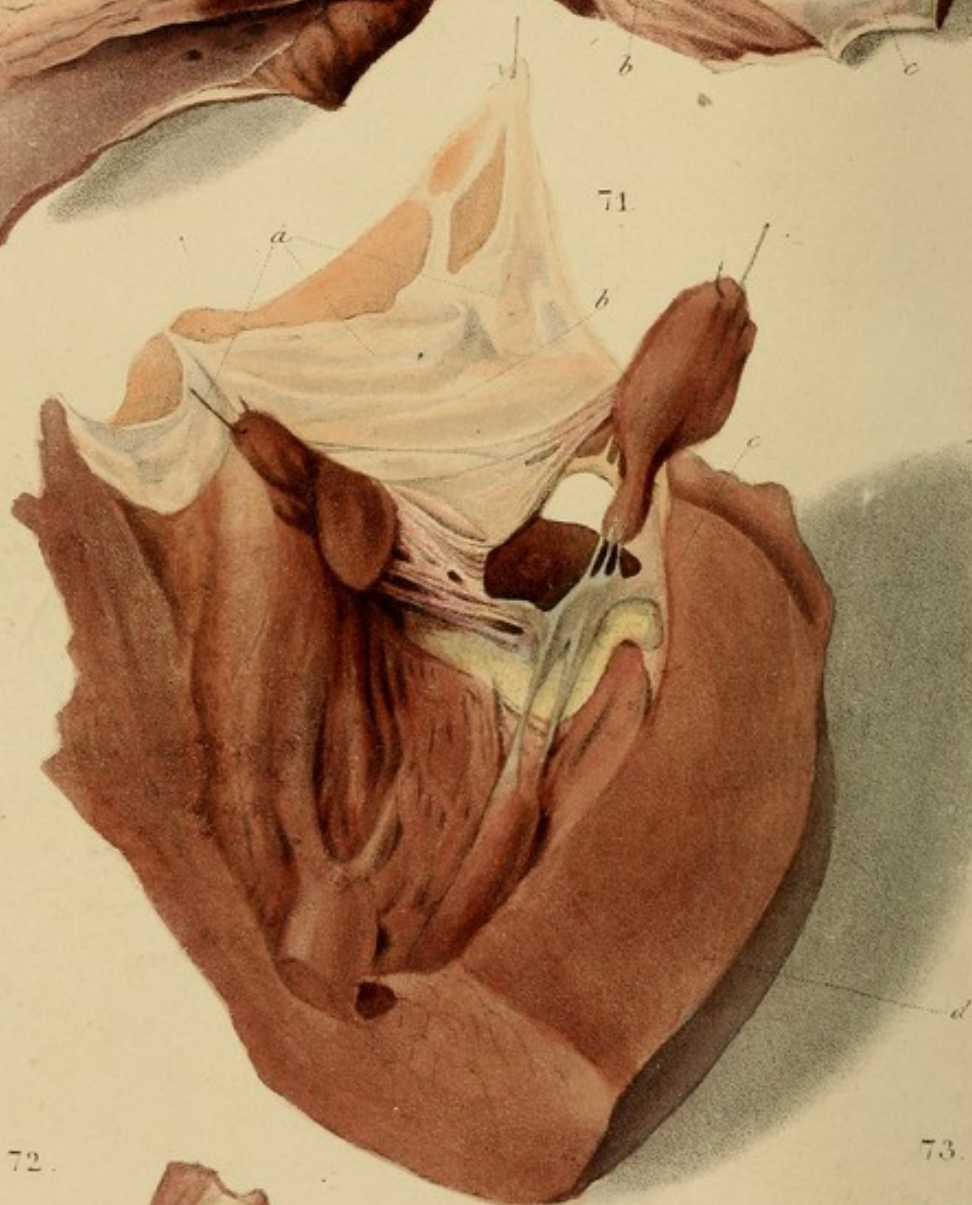
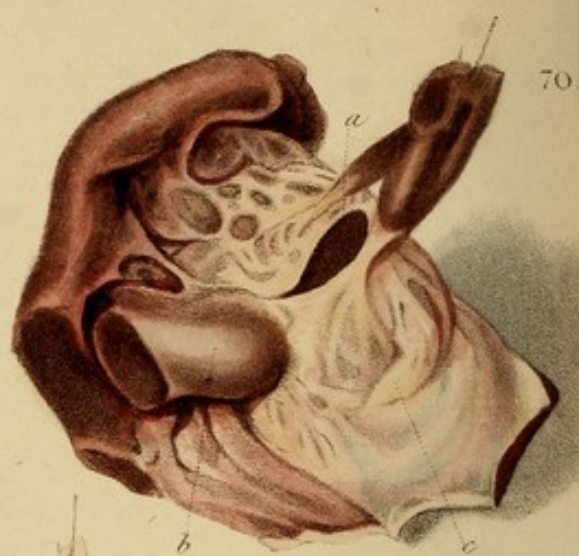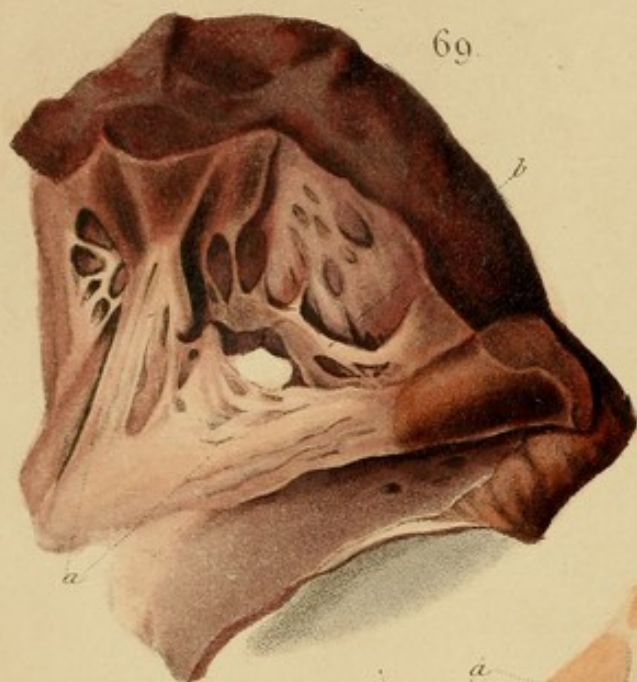


*From nature & revised
on stone by D. Hope.*

A. Smith & J. H. M. Martin & Co.







From nature & revised
on stone by D'Hope.

Case.—An old woman in the St. George's Infirmary who laboured under agonal symptoms of organic disease of the heart. The left ventricle was expanded and dilated. There were the usual signs of congestive enlargement in the lungs.

Fig. 69.—Section of the heart in the middle line beneath the internal pericardium. The right ventricle is dilated and yellow. It is closed, and contains fragments of coagulated blood of the colour. At a it has been converted into a red transparent mass of blood. The left ventricle is also dilated and contains a mass of blood.

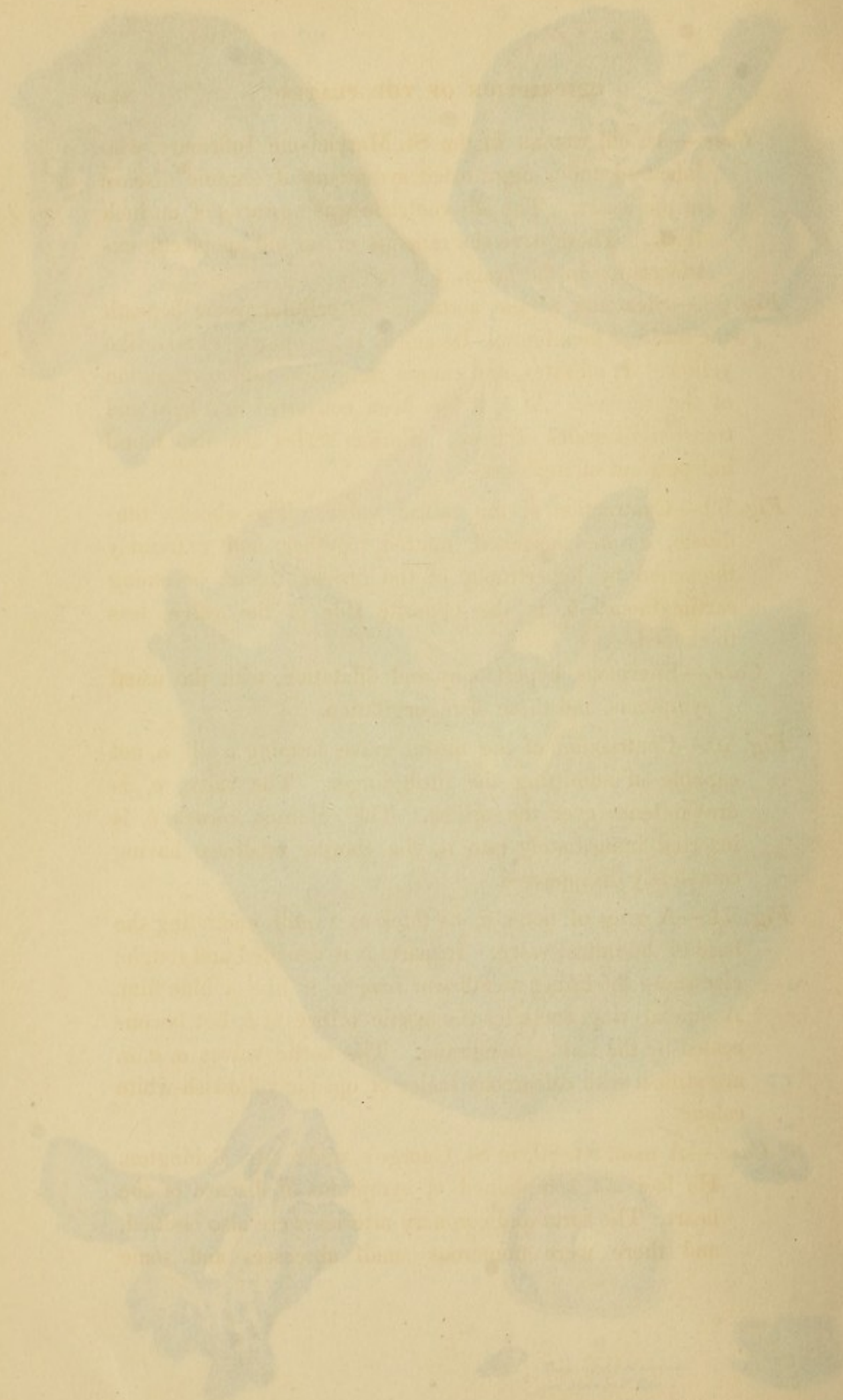
Fig. 70.—Diagram of the mitral valve. The chordæ tendineæ, a, are shortened, united together, and extremely thickened by hypertrophy of the fibrous tissue, becoming cartilaginous. b, is the opposite side of the valve, less thickened.

Case.—Extensive hypertrophy and dilatation, with the usual symptoms, and those of regurgitation.

Fig. 71.—Contraction of the mitral valve, forming a slit, a, not capable of admitting the little finger. The valve, b, is drawn down over the slit. The columnar carina, c, is bowed immediately over it, the chordæ tendineæ having completely disappeared.

Fig. 72.—A ring of bone, c, as thick as a ball, enclosing the base of the mitral valve. In parts it is rounded and rough; elsewhere the living membrane covers it like a blue film. A similar ring encloses the aortic orifice at d, but is concealed by the living membrane. The aortic valves, e, f, g, are studded with calcareous scales of opaque yellowish-white colour.

Case.—A man, æt. 50, in St. George's, under Mr. Richardson. He had no complaint of symptoms of disease of the heart. The aorta and coronary arteries were also calcified, and there were numerous small abscesses and aneurysms.



Case.—An old woman in the St. Marylebone Infirmary, who laboured under aggravated symptoms of organic disease of the heart. The left ventricle was upwards of an inch thick. There were the remains of an old apoplectic extravasation in the brain.

Fig. 68.—Steatoma in the aorta, in the cellular tissue beneath the internal membrane. Its colour is an opaque, cheese-like yellow. It elevates, and causes roughness and corrugation of the surface. At *a*, it has been converted into hard and transparent scales of bone. Similar scales are also found independent of steatoma.

Fig. 69.—Contraction of the mitral valve. The chordæ tendineæ, *a*, are shortened, matted together, and extremely thickened by hypertrophy of the fibrous tissue, becoming cartilaginous. *b*, is the opposite side of the valve, less thickened.

Case.—Enormous hypertrophy and dilatation, with the usual symptoms, and those of regurgitation.

Fig. 70.—Contraction of the mitral valve, forming a slit, *a*, not capable of admitting the little finger. The valve, *c*, is drawn tense over the orifice. The columna carnea, *b*, is inserted immediately into it, the chordæ tendineæ having completely disappeared.

Fig. 71.—A ring of bone, *c*, as thick as a quill, encircling the base of the mitral valve. In parts it is denuded and rough; elsewhere the lining membrane invests it like a blue film. A similar ring encircles the aortic orifice at *b*, but is concealed by the lining membrane. The aortic valves *a, a, a*, are stiffish with calcareous scales of opaque yellowish-white colour.

Case.—A man, æt. 80, in St. George's, under Mr. Babington. He had not complained of symptoms of disease of the heart. The aorta and coronary arteries were also ossified, and there were numerous small abscesses and some

hydatids in both kidneys. He died of disease of the urethra, with a false passage. (Vid. *Treatise*, p. 212.)

Fig. 72.—Contraction of the mitral valve, from hypertrophy of the fibrous tissue, with shortening and thickening of the tendinous cords, whence regurgitation and bellows-murmur.

Fig. 73.—*a* and *b* are rough calcareous concretions, from the aortic valves: *c*, was a smoother one. They projected into the vessel and caused loud rasping-murmur.

Fig. 74.—The aortic valves seen from the ventricular side. They are agglutinated together, and form a fibro-cartilaginous ring, *a*. From a preparation discoloured by spirits.

Case.—A boy, æt. 10, had sawing-murmur; P. 120, very small, weak, and unequal; respiration hurried; temporary pain and constriction in the præcordial region; pulsation of the heart over a preternatural extent; slight cough, œdema round the eyes; tongue thickly furred, moist; skin generally cold and clammy; bowels regular; urine scanty, dark, and thick. But his most remarkable symptom was an intermittent febrile paroxysm, coming on daily about noon, with pain in the heart, and consisting of chilliness for an hour, heat for half an hour, and perspiration till evening. He was affected with the pain and intermittent paroxysms for ten weeks, when he died.

Section.—In addition to the contraction of the aortic valves, both ventricles, but particularly the left, were affected with simple hypertrophy. Hydro-pericardium, two ounces; hydro-thorax, six ounces on each side. Lower lobes of the lungs congested and somewhat condensed.*

The signs of inflammation of the lining membrane of the heart producing constriction of the valves, being ob-

* For an account of the murmurs occasioned by the valvular diseases represented in the illustrations, see *Treatise on the Diseases of the Heart*, by the Writer, pp. 54 and 335; for the mechanism of their productions, see *ibid.* p. 56; and for the general symptoms, see p. 329.

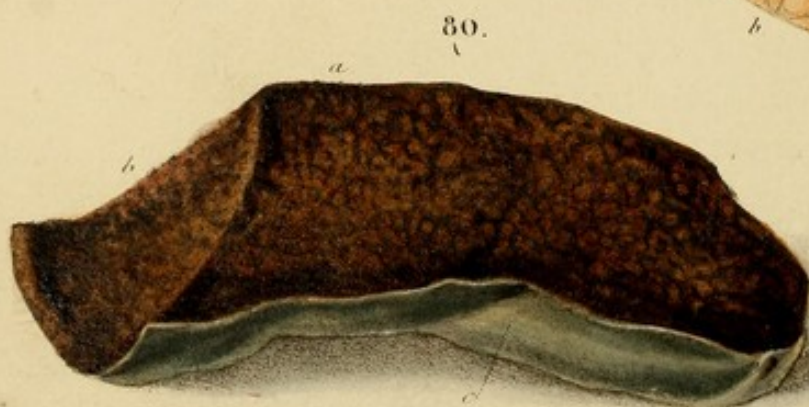
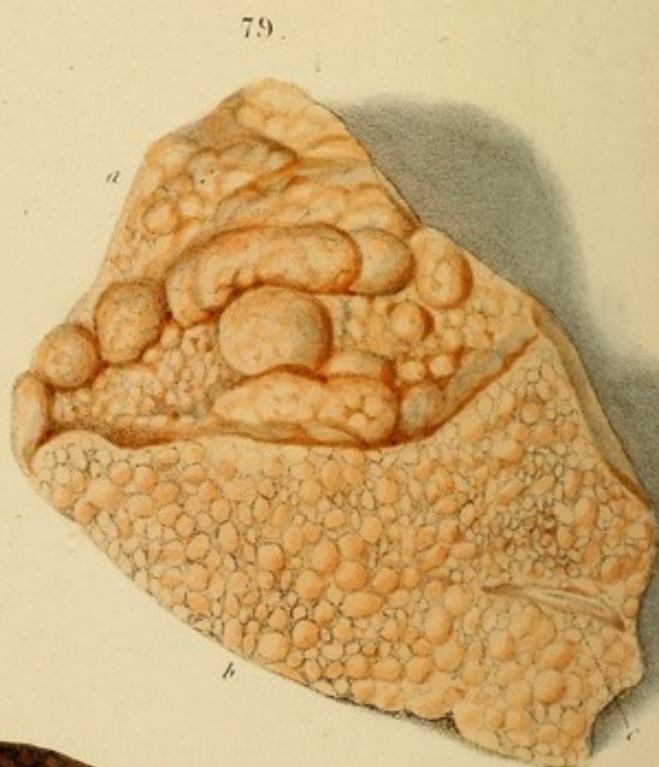
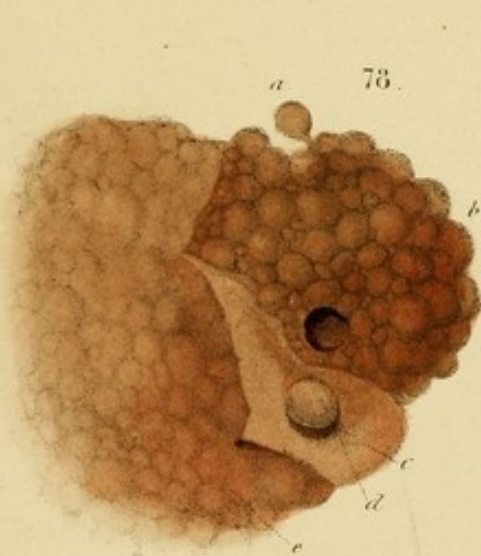
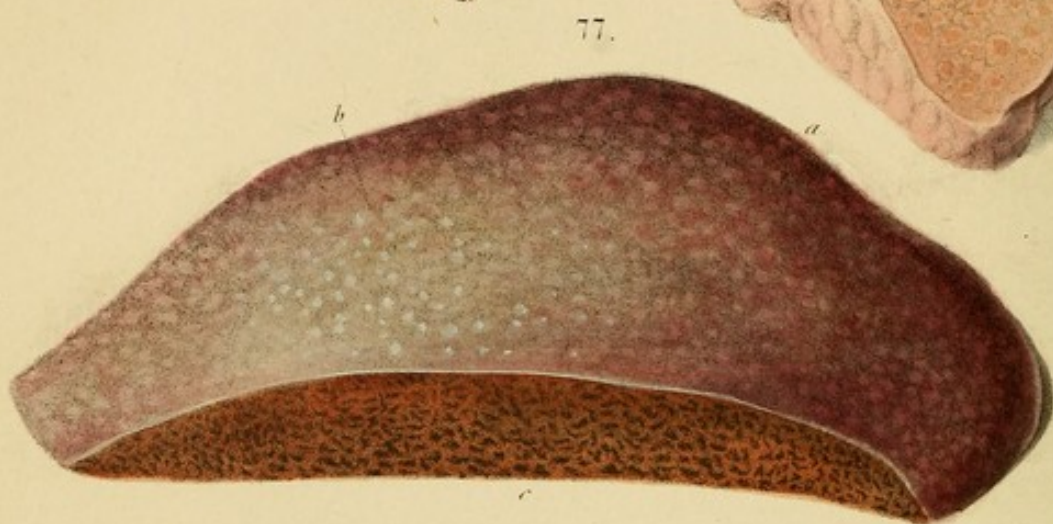
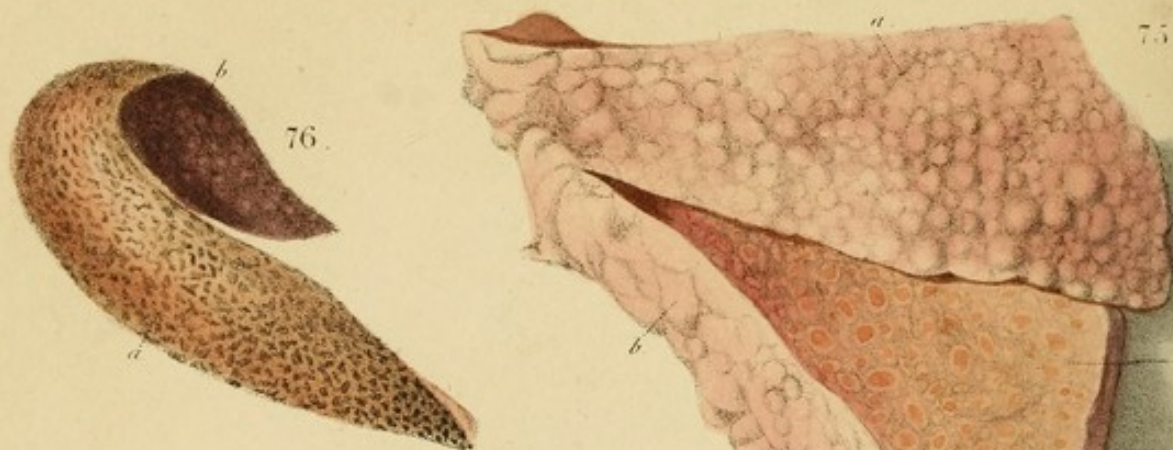
scure, the following cases are added as illustrative of that affection :—

Case I.—Constriction of the Aortic Valves. W. Bush, æt. 19, in the St. Marylebone Infirmary, when convalescent from severe chronic hepatitis and icterus, suddenly experienced a rise in the pulse from 70 to 110, with palpitation and accelerated respiration, the pulse and action of the heart being of a jerking or bounding character. The symptoms, which seemed to give him very little inconvenience, did not yield to purging and tartar emetic, and on the third day he complained of a slight pain in the heart. A sawing-murmur of the first sound was now heard. The nature of the affection being obvious, he was freely cupped in the præcordial region, purged, and promptly salivated, by which the pain was immediately removed, and the palpitation in the course of a week, but the murmur remained. Twice afterwards, at intervals of about a month, he had a recurrence of the same symptoms, which readily yielded to the same treatment, without salivation. But though his general health was gradually restored, the murmur over the aortic valves remained permanent, and symptoms of organic disease of the heart were subsequently developed.

In this case I imagine, from the mildness of the symptoms, that the inflammation was confined to the lining membrane, or that, if the pericardium participated, it was only partially and slightly affected. As inflammation of the lining membrane is so formidable in its consequences, it should be treated, however mild the existing symptoms, with uncompromising firmness.

Case II.—Constriction of the Mitral Valve. A boy, æt. 10, had acute pain at the heart, a jerking impulse and pulse, fever, anxiety, and a murmur with both sounds, that with the second being a prolonged sigh extending through the

whole 'interval of repose,' and completely superseding the second sound on the left side of the heart, but not on the right. He was immediately and repeatedly bled, cupped, and purged, and promptly salivated. In a week he was convalescent, but the sighing-murmur of the mitral valve continued, though with decreasing intensity. Nothing but the supposition of an inflammatory constriction could account for the second murmur being on the left side and not on the right also.



From nature & revised
on stone by D. Hope.

DESCRIPTION OF THE PLATES.

Fig. 75.—Granulated liver (cirrhosis) contracted, indurated, and deformed. Peritoneum pinkish.

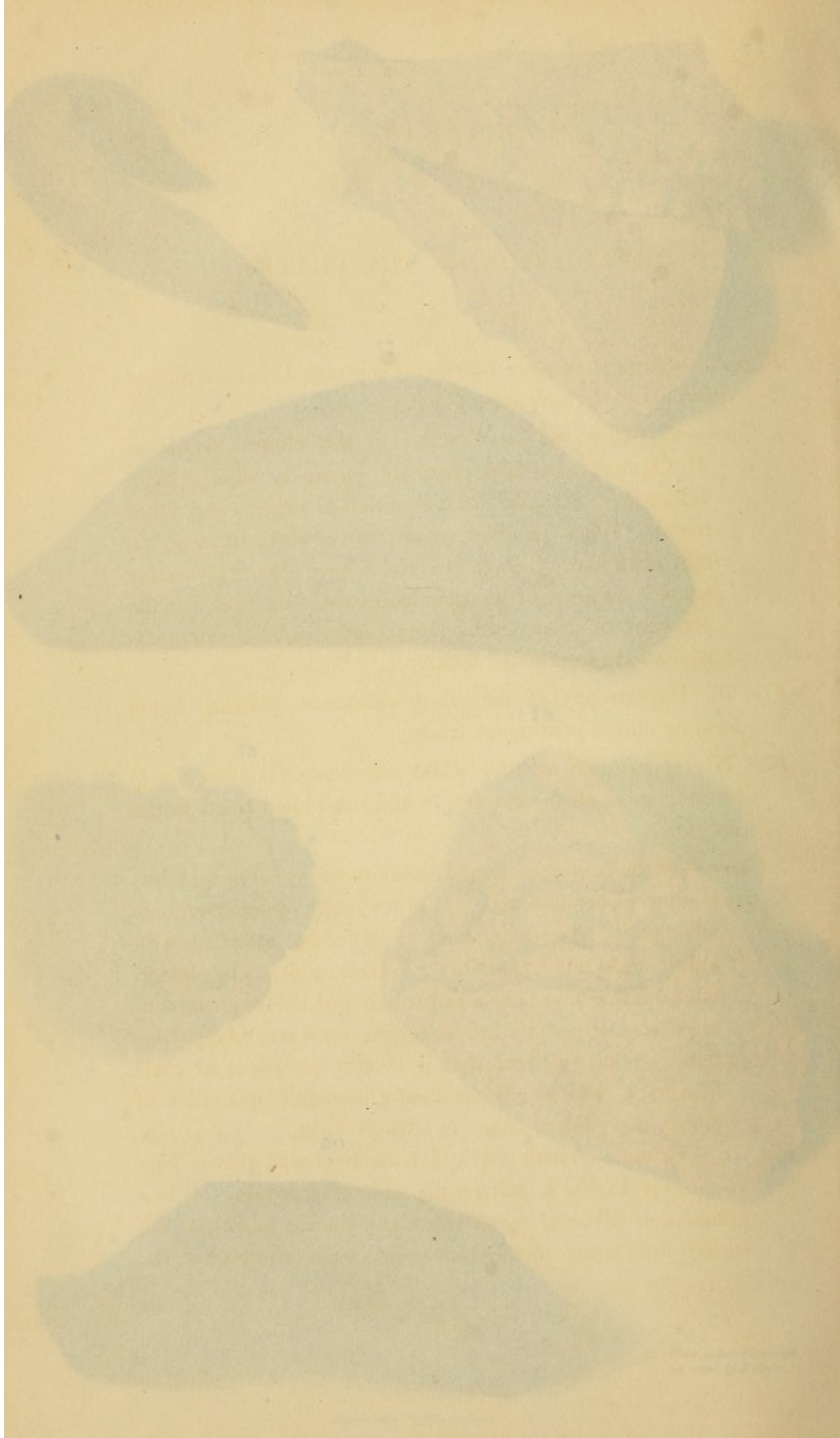
Case.—A patient at La Charité, in the clinical wards of M. Chomel, who had obstinate jaundice, with a deep yellow stain not only of the skin, but of almost every other tissue. When jaundice recurs two or three times in an individual above the age of sixty, I have almost invariably found it connected with organic disease of the liver, and the precursor of dropsy, emaciation, and a train of symptoms which have terminated fatally.

Fig. 76. Hypertrophy of the white substance (nutmeg liver) forming almost continuous tracts.

Fig. 77. Hypertrophy of the white substance (nutmeg liver) forming spots on the exterior *a*, and convoluted tracts in the interior *c*.

Case.—Of the nutmeg liver, I have numerous cases, which it is unnecessary to detail. It is the most ordinary organic affection of the organ, and is generally attended with enlargement and lacerability. *Fistulas*, *necrosis*, and *carcinomata*, often leading to a fatal termination, are its frequent consequences, especially in old persons or shattered constitutions. I have noticed that it is very prevalent in coal-broilers, a class who drink almost incredible quantities of spirit, and seldom attain an advanced age.

Fig. 78.—Granulated liver (cirrhosis), identical with that of Fig. 75, except that it is universally coated with bile. *a*, is a granulation adherent by its vascular peduncle *b* to the surface from which the peritoneum has been reflected; *c*, the



DESCRIPTION OF THE PLATES.

Fig. 75.—Granulated liver (cirrhosis) contracted, indurated, and deformed. Peritoneum pinkish.

Case.—A patient at La Charité, in the clinical wards of M. Chomel, who had obstinate jaundice, with a deep yellow stain not only of the skin, but of almost every other tissue. When jaundice recurs two or three times in an individual above the age of sixty, I have almost invariably found it connected with organic disease of the liver, and the precursor of dropsy, emaciation, and a train of symptoms which have terminated fatally.

Fig. 76. Hypertrophy of the white substance (nutmeg liver) forming almost continuous tracts.

Fig. 77. Hypertrophy of the white substance (nutmeg liver) forming spots on the exterior *a*, and convoluted tracts in the interior *c*.

Cases.—Of the nutmeg liver, I have numerous cases, which it is unnecessary to detail. It is the most ordinary organic affection of the organ, and is generally attended with enlargement and lacerability. Icterus, ascites, and marcor, often leading to a fatal termination, are its frequent consequences, especially in old persons or shattered constitutions. I have noticed that it is very prevalent in coal-heavers, a class who drink almost incredible quantities of porter, and seldom attain an advanced age.

Fig. 78.—Granulated liver (cirrhosis), identical with that of *Fig. 75*, except that it is universally stained with bile. *a*, is a granulation adherent by its vascular peduncle alone: *b*, the surface from which the peritoneum has been reflected: *c*, the

reflected peritoneum: *d*, a granulation entirely withdrawn from its cyst. The Fig. is an imitation from Cruveillier.

Fig. 79.—A granulated liver, double the natural size. Granulations elastic, and projecting above the level of the section *b*. Substance exsanguine, and of a remarkably rich yellow colour.

Case.—A coachmaker, at St. George's Hospital, under Dr. Chambers. Emaciation, intense yellowness, œdema peditum, ascites, dyspnœa, and other symptoms of great disease of the heart. Evacuations clay-coloured, urine scanty and dark. Ill two years. Jaundice for six weeks.

Sectio.—Heart immense. Liver universally as delineated.

When there is disease of the heart, the liver may become granulated at an earlier age than is common from other causes. This results from the obstruction of its circulation occasioned by the obstacle to the free passage of blood through the heart. From the great distensibility of the hepatic parenchyma, and the vicinity of the organ to the heart, it is peculiarly liable to suffer from this cause.

Fig. 80.—Hypertrophy of the white substance (nutmeg liver). The whole is deeply stained with bile.

Cases.—I have not notes of this case, but have met with several others of a similar nature. So deep a bilious impregnation is most frequently connected with an obstruction in the great biliary ducts, preventing the escape of the bile. The skin sometimes partakes of the green dye of the liver, constituting what is vulgarly called green jaundice. Such cases almost invariably terminate fatally, and that within a brief period.

Fig. 81.—Yellow granulated liver. The granulations are very large, and closely set; whence their slightly angular appearance. The interspaces are red from blood which has exuded and become oxygenized. *c, c*, are fissures occasioned by a fall. (From the collection of Dr. Alison, and

...the heart is found to be ...
...the heart is found to be ...
...the heart is found to be ...
...the heart is found to be ...
...the heart is found to be ...

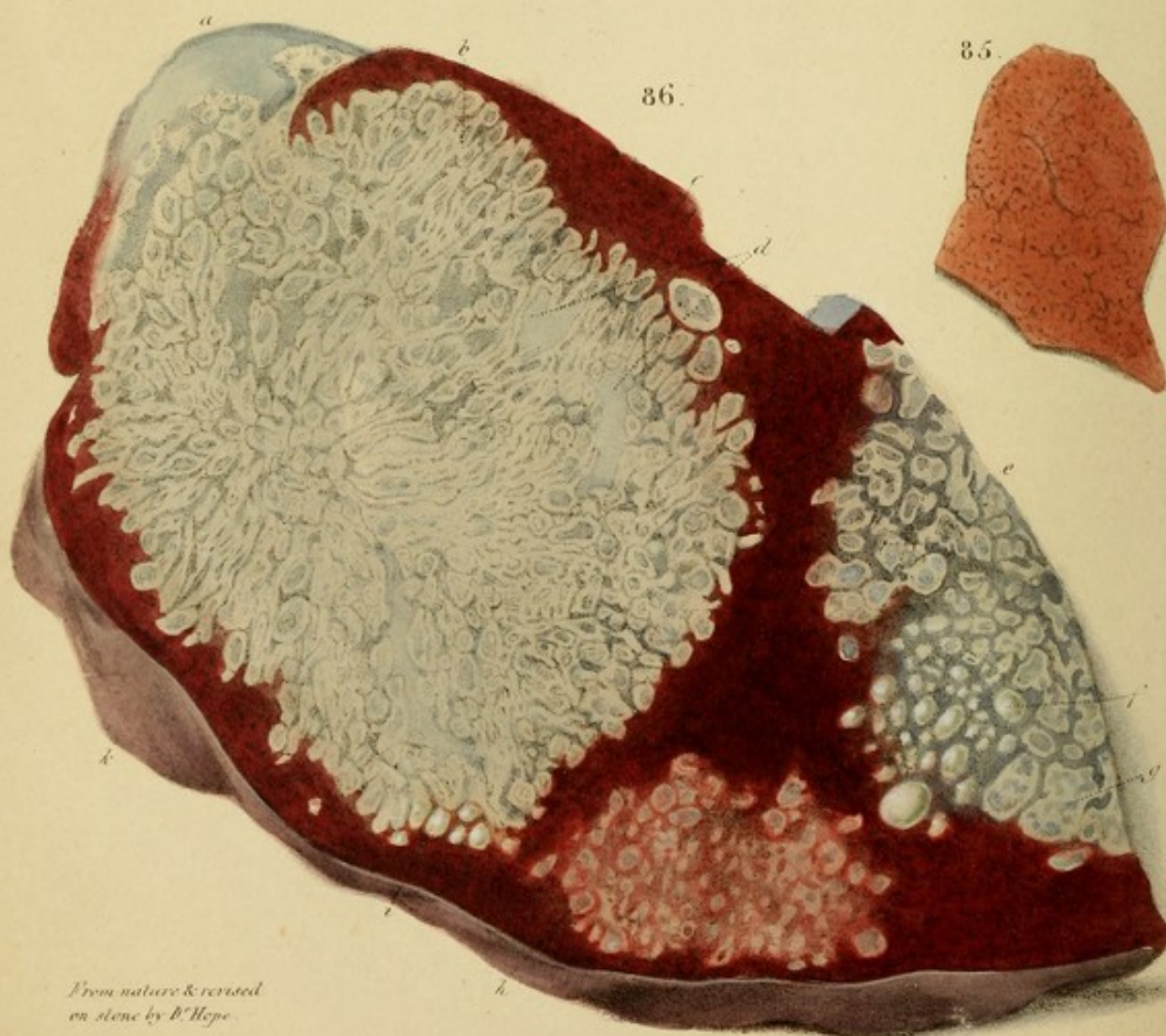
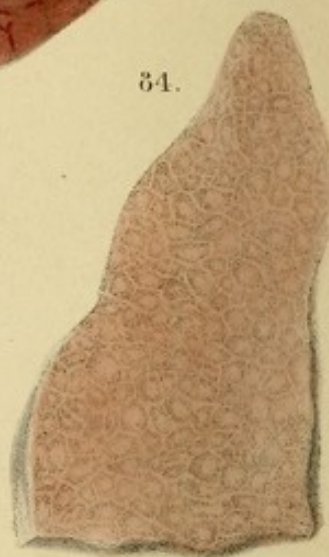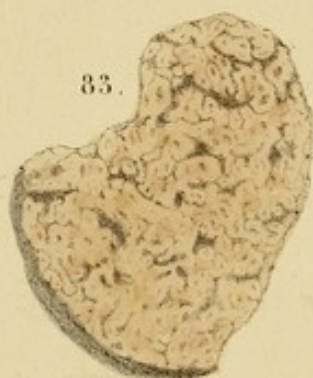
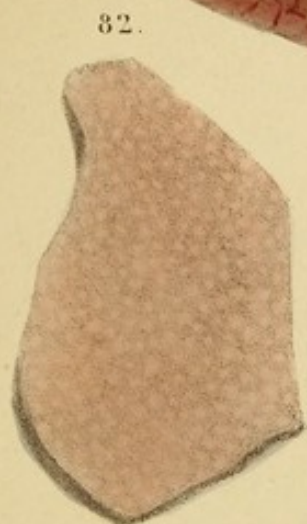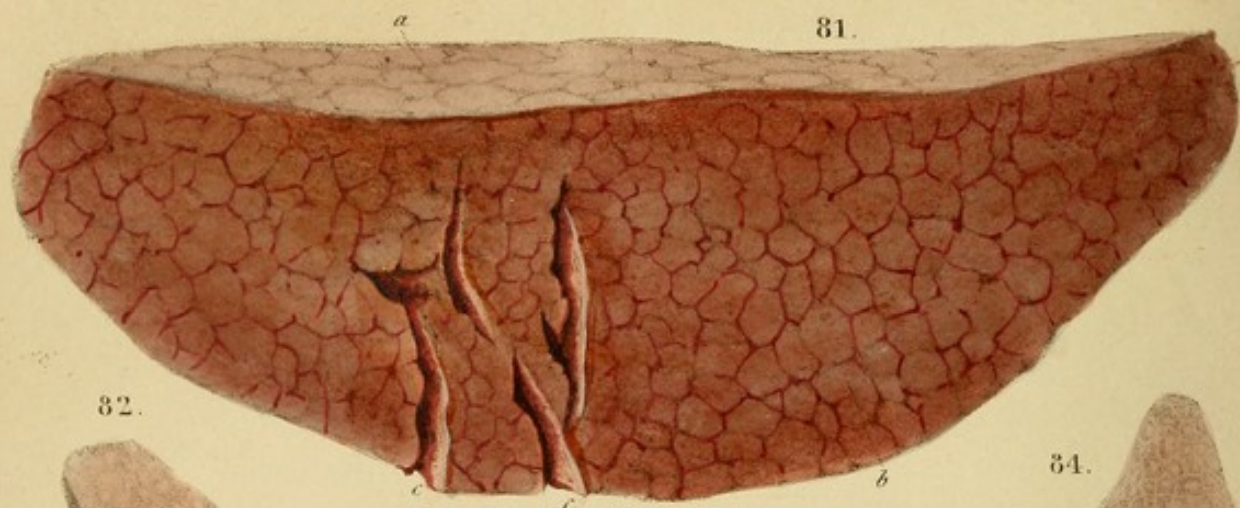
Case—A ...
...the heart is found to be ...
...the heart is found to be ...
...the heart is found to be ...
...the heart is found to be ...

When ...
...the heart is found to be ...
...the heart is found to be ...
...the heart is found to be ...
...the heart is found to be ...

The ...
...the heart is found to be ...
...the heart is found to be ...
...the heart is found to be ...
...the heart is found to be ...

...the heart is found to be ...
...the heart is found to be ...
...the heart is found to be ...
...the heart is found to be ...
...the heart is found to be ...

...the heart is found to be ...
...the heart is found to be ...
...the heart is found to be ...
...the heart is found to be ...
...the heart is found to be ...



From nature & revised
on stone by B. Hepe.

sent to me by my friend, the late Dr. J. Gregory, of Edinburgh.


Fig. 82.—Granulated liver, extremely dense, presenting a perfect flat section, and speckled with a brown yellow matter in the spaces of the granulation. On exposure to air for a few minutes it exhibited the appearance represented in *Fig. 84*.

Fig. 83.—Hypertrophy of the white substance (nutmeg liver), magnified by an ordinary lens to about double. The representation is a fac-simile of a portion macerated for about three days. The red substance is atrophied. The liver was enlarged.

Fig. 84.—The same specimen as *Fig. 82*, after exposure to air, by which the pale interspaces became developed. The granulations are angular from compression. The liver was enlarged to double.

Case.—A female, æt. 45, married, who died of a surgical affection. She was scrofulous, and had formerly had hemiplegia, but no distinct history was given of symptoms referable to the liver. The spleen was enlarged to double, and indurated, as if from a fibrous deposition. The ovaries were as large as pigeon's eggs, and contained depositions of early yellow scrofulous matter.

Fig. 85.—Remarkable paracystic depositions in the liver. The group *a* exhibits the early or incipient state of the depositions. They resemble concrete fibrine. A few of the larger are beginning to soften in the centre. These depositions correspond with those in the lungs, delineated in *Fig. 11, b* and *c*, following suppuration, the only difference being referable to the different structure of the two organs. The group *d, f, g*, is more advanced, each deposition being filled with a beautiful green pus, as at *f*. It has been washed away from the remainder to display the cysts, some of which are compound, as *g*. The hepatic tissue interposed between the cysts is purple and slightly granular.



sent to me by my friend, the late Dr. J. Gregory, of Edinburgh.)

Fig. 82.—Granulated liver, extremely dense, presenting a perfectly flat section, and spotted with a firm yellow matter in the centres of the granulation. On exposure to air for a few minutes it exhibited the appearance represented in *Fig. 84*.

Fig. 83.—Hypertrophy of the white substance (nutmeg liver), magnified by an ordinary lens to about double. The representation is a fac-simile of a portion macerated for about three days. The red substance is atrophous. The liver was enlarged.

Fig. 84.—The same specimen as *Fig. 82*, after exposure to air, by which the pale interspaces became developed. The granulations are angular from compression. The liver was enlarged to double.

Case.—A female, æt. 45, emaciated, who died of a surgical affection. She was scrofulous, and had formerly had hemiplegia, but no distinct history was given of symptoms referable to the liver. The spleen was enlarged to double, and indurated, as if from a fibrinous deposition. The ovaries were as large as pigeon's eggs, and contained depositions of curdy yellow scrofulous matter.

Fig. 86.—Remarkable purulent depositions in the liver. The group *h* exhibits the early or incipient state of the depositions. They resemble concrete fibrine. A few of the larger are beginning to soften in the centre. These depositions correspond with those in the lungs, delineated in *Fig. 11*, *b* and *e*, following amputation, the only difference being referable to the different structure of the two organs. The group *e*, *f*, *g*, is more advanced, each deposition being filled with a beautiful green pus, as at *f*. It has been washed away from the remainder to display the cysts, some of which are compound, as *g*. The hepatic tissue interposed between the cysts is purple and slightly translu-

cent, being, on the transition to the semi-transparent grey state, represented in the large tumour *b, d*.

The large tumour *b, d*, consists of a congeries of smaller and more closely set depositions, presenting a distinct appearance of radiation from a centre. Each was filled with green pus, which has been washed away except from a few at *i*. The blood has entirely disappeared from the intermediate hepatic tissue, which resembles grey gristle. *d* are the tracts of two obliterated vessels, of a paler grey. At *a*, the gristly transformation has occupied a portion of the liver itself, probably in consequence of the circulation to it being intercepted by the tumour.

In the upper part of the liver there were a few other depositions similar to those represented, and one had been completely disorganized and resolved into an abscess as large as the tumour *b, d*, filled with a foul greyish yellow pus, and opening, through the diaphragm, into a similar abscess in the substance of the right lung.

Case.—*Purulent depositions in the liver and lungs in connexion with an abscess near the bladder, and disease of the intestines.*

Henry Snelgrove, under Dr. Wilson, (to whom I am indebted for the specimen,) at St. George's Hosp. Sept. 9, 1829. Ill 18 months. Cough worse at night; sputa sometimes bloody. Full inspiration causes pain in the left hypochondrium. Diarrhoea; sweating; emaciation; pearly conjunctiva. (Hirud. viii. lateri sinistro. \mathcal{R} Plumbi Acet. gr. ii., Extr. Papav. gr. v. m. omni nocte sumend. \mathcal{R} Quinæ sulph. gr. i., Inf. Cuspar. \mathfrak{z} iss., Tinct. Cardam. C. \mathfrak{z} i. m. bis die sumend.) Died in a month.

Sectio.—In the angle formed by the reflection of the peritoneum from the abdominal parietes to the bladder was a large abscess, containing blackish-green matter and sloughy cellular membrane. Fifteen months previous to

admission, and three months subsequent to the date of his illness, it had burst above Poupart's ligament, and, since that time, had constantly yielded a purulent discharge.

Intestines.—The mucous membrane of the colon and rectum was of a greenish-claret colour, thickened, rough, and covered with flakes and sprouting granulations of dirty-yellow lymph. The lower portion of the ileum had contracted an adhesion with the sigmoid flexure of the colon, and a fistulous canal had formed, first, from the ileum into an abscess an inch in diameter, exterior to the intestine, and, next, from this into the colon.

Liver.—This organ, besides containing the depositions above described, was more than twice its natural size, remarkably dense, and of a deep, rich red colour.

Lungs.—Communicating through the diaphragm with the great abscess in the liver, was a similar one in the substance of the inferior lobe of the right lung. In each lung were three or four others, varying in size between a pea and a nut, perfectly isolated, and filled with a fluid, greenish-yellow pus. The walls of all were extremely thin and tender,—widely dissimilar from those of tubercular excavations; and the surrounding lung was healthy. A small abscess corresponding with this description, and following a surgical operation, is delineated in Fig. 10, *a*.

Remarks.—It cannot be doubted that these depositions in the liver and lungs originated in the absorption of pus from the abscess near the bladder. Fig. 86 (which is a fac-simile imitation, every spot being introduced which existed in nature) is admirably calculated to display the manner in which morbid depositions arrange themselves conformably to the structure of the organ. This subject will be more fully developed in the chapter on Tubera. A preparation of the specimen is in the possession of Dr. Hewett, late physician to St. George's Hospital.

Fig. 87.—A tuber of the liver, identical in structure with the great one *b, d*, *Fig. 86*, but the cysts contained a liquid encephaloid matter, like a mixture of cream and a thick solution of gum arabic. The cysts at *a* and *d* were not opened by the section, and their exterior is seen to be of a purplish cast. When divided, they yielded the same liquid encephaloid matter as the others, and the larger, *d*, contained minor or secondary cysts, as seen in various masses in the centre of the tumour, and at *g*, *Fig. 86*.

The intermediate tissue was a delicate, semi-transparent pink, forming several considerable intervals in the centre of the tuber, some of which contained red patches of extravasated blood. The substance of the liver was healthy.

Case.—A man, *æt.* 73, in the St. Mary-le-bone Infirmary, greatly emaciated. He had been affected for two months with hemiplegia, consequent on an apoplectic attack, which had left mental imbecility. No information could be obtained respecting any symptoms referable to the liver.

Sectio.—The brain contained a considerable clot, of old standing. In the liver were upwards of a dozen tubera of the same character, but some not larger than a nut. The one represented was eight inches long. These tubera are sometimes very rapidly developed; and, considering the advanced age of the patient, I suspect that such was the case in the present instance.

Fig. 88.—A lacerated portion of the same liver as *Fig. 90*, displaying the exterior of two recent tubera which were buried in its substance, and showing that their adhesion to the parenchyma is so slight as to admit of their being detached by laceration without injury to their texture. They are lobulated, and each lobule consists of a rather soft, semi-transparent encephaloid matter.

The *Fig.* also shows the granular appearance of the liver




Fig. 87.—A tuber of the liver, identical in structure with the great one, *A. c.* *Fig. 86*, but the cysts contained a liquid encephaloid matter, like a mixture of cream and a thick solution of gum arabic. The cysts at *a* and *b* were not opened by the section, and their exterior is seen to be of a purplish cast. When divided, they yielded the same liquid encephaloid matter as the others, and the larger *d* contained minor or secondary cysts, as seen in various masses in the centre of the tumour, and at *e*, *Fig. 88*.

The intermediate tissue was a delicate, semi-transparent pink, forming several considerable intervals in the centre of the tuber, some of which contained red patches of extravasated blood. The substance of the liver was healthy.

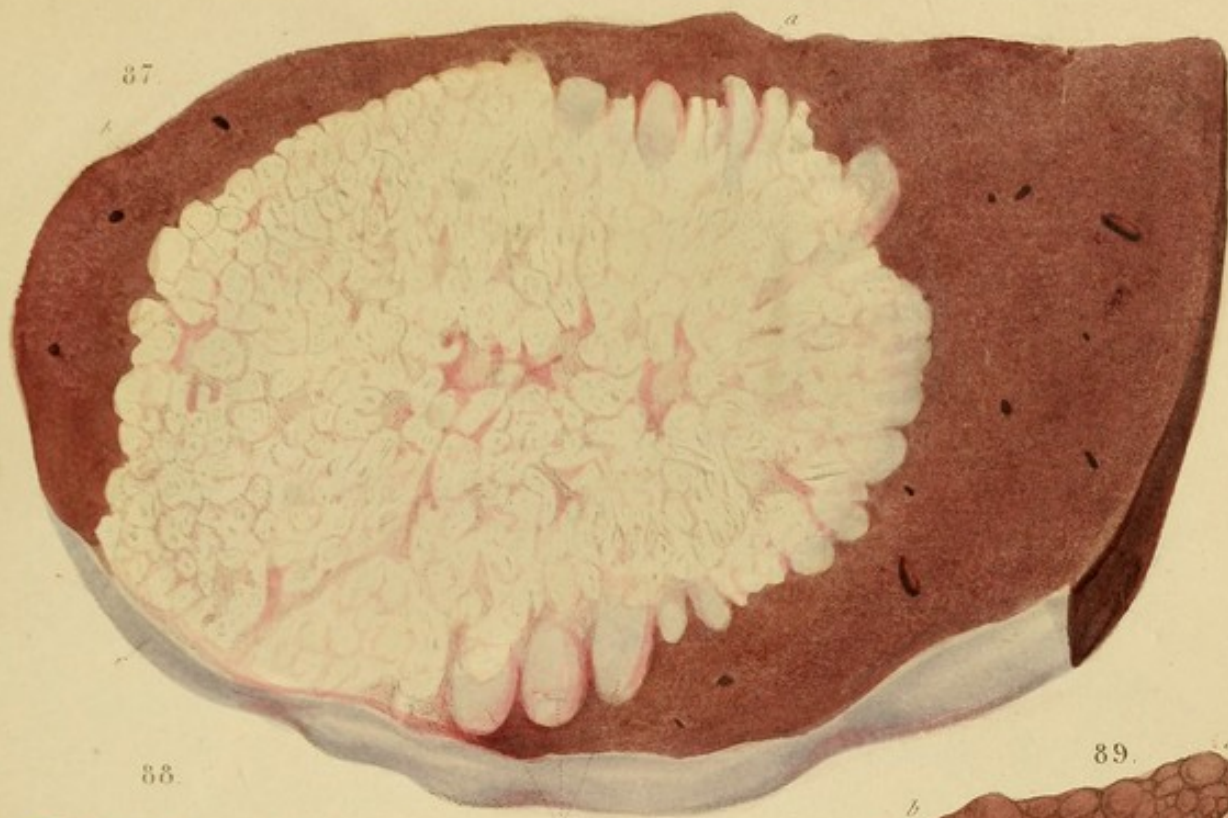Case.—A man, *æt.* 73, in the St. Mary-le-bone Infirmary, greatly emaciated. He had been affected for two months with hemiplegia, consequent on an apoplectic attack, which had left mental imbecility. No information could be obtained respecting any symptoms referable to the liver.

Section.—The brain contained a considerable clot of old blood. In the lower part of the brain were a dozen tubers of the same character, but some not larger than a nut. The one represented was eight inches long. These tubers are sometimes very rapidly developed; and, considering the advanced age of the patient, I suspect that such was the case in the present instance.

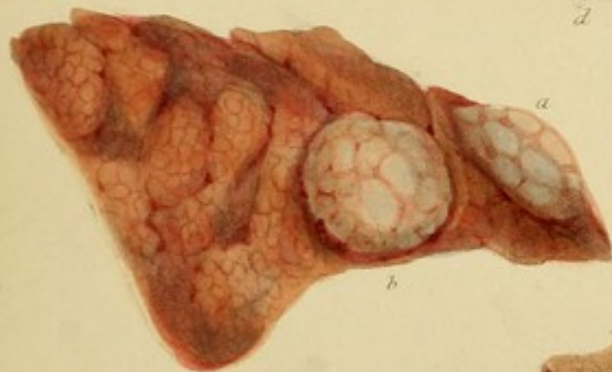
Fig. 88.—A lacerated portion of the same liver as *Fig. 87*, displaying the exterior of two recent tubers which were buried in its substance, and showing that their adhesion to the parenchyma is so slight as to admit of their being detached by laceration, without injury to their texture. They are lobulated, and each lobe consists of a rather soft, semi-transparent encephaloid matter.

The *Fig.* also shows the general appearance of the liver

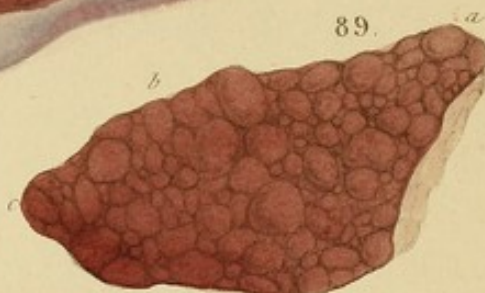87.



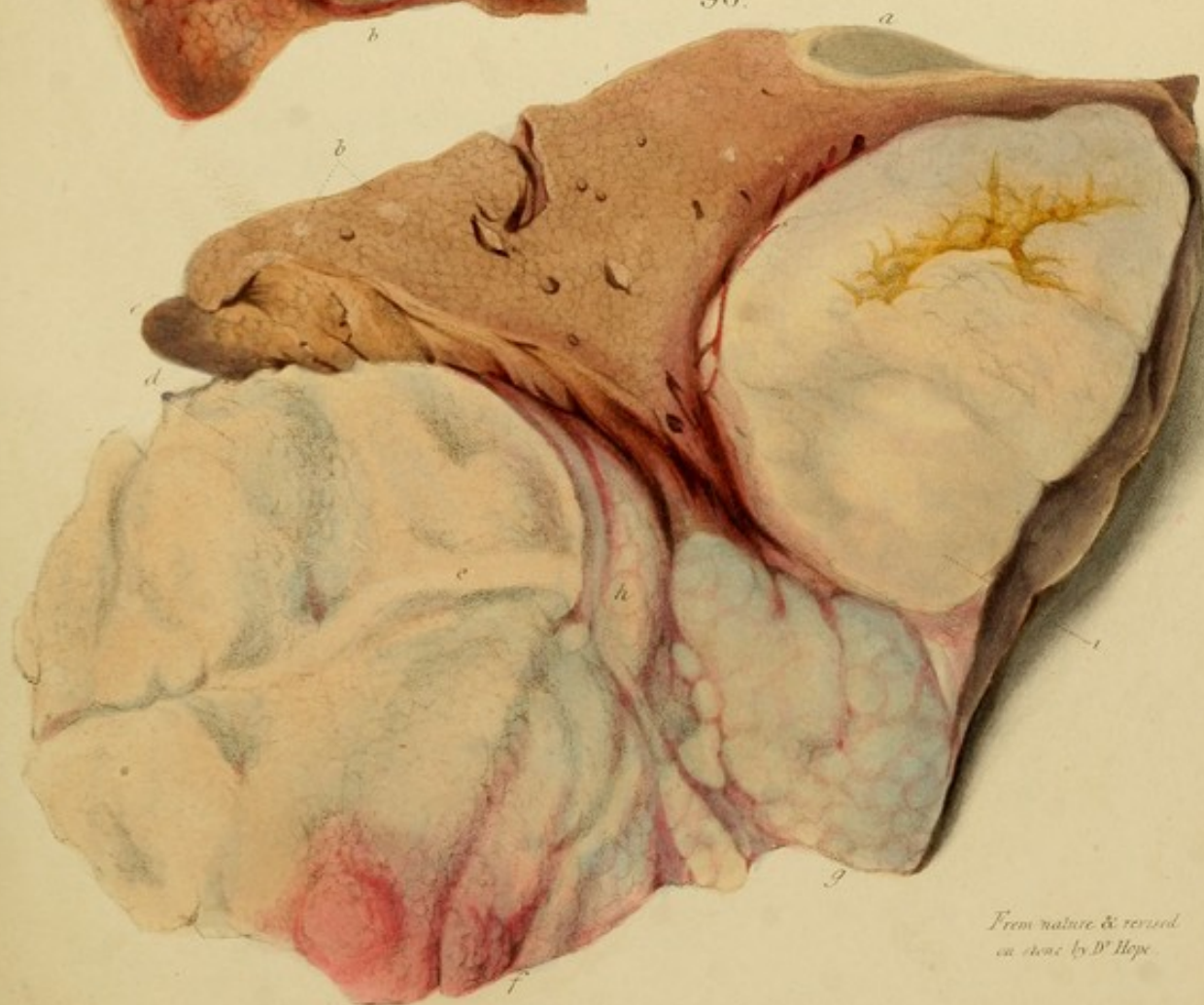88.



89.



90.



From nature & revised
on stone by D^r Hope.

When injected the animal is kept in a state of torpor, and the substance is deposited in the posterior extremity.

Fig. 50. - A. White, translucent, like oil, and colourless. The granulations are a few, and are deposited in the posterior extremity, from 6 to 8 days after the injection, being in number (7 or 8).

Case. - A female in the 12th day of pregnancy, at the extremely copious who died of haemorrhage on the 10th day.

Section. - The middle lobe of the right hemisphere was removed, and of a more muddy yellow colour than natural. The slight pressure it was resolved into a pulp. Black granulations of the substance. It was very soft, and very friable. The lower part of the brain, and the greater part of the muscular substance were stained of the deep red, with white colour, represented in Fig. 50. There was about one third smaller than natural, and of the same structure throughout. The substance was highly, and its surface was partially pitted, especially around a thickened fibrous cartilaginous portion of the posterior end.

The section of the body was not injected by the side of the liver. Could this be related to the circumstances that the organ was not injected, and consequently the circulation through it was not as depicted by the red colour? The case is well calculated to show that the granulations perform vicariously the function of the white or osseous substance, which they have replaced; whence it is to be inferred that they are fitted to form substance in their nature.

Fig. 50. - Tabern. soft, and of the spongy character. A. They are insipid and very much, being distinguishable from granules of the white substance only by their black transparency. A. is a mixture of recent blood, fibrin, and other soft, at the same time, but never advanced.

when lacerated, the granules being larger when the white substance is hypertrophous, as in the present instance.

Fig. 89.—A flabby, granulated liver, of dim-red colour. The granulations from *a* to *b* are rendered prominent by pressure beneath: from *b* to *c* they lie flat, the pressure being removed. (Vide p. 111.)

Case.—A female in the St. Mary-le-bone Infirmary, æt. 60, extremely corpulent, who died of hemiplegia on the left side.

Sectio.—The middle lobe of the right hemisphere was softened, and of a more muddy-yellow colour than natural. By slight pressure it was resolved into a pulp. Much congestion of the sinuses. *Heart* was softened and very lacerable. The lining membrane and the greater part of the muscular substance were stained of the deep, rich violet colour represented in Fig. 60. *Liver* was about one-third smaller than natural, and of the same structure throughout. Its consistence was flabby, and its surface was partially puckered, especially around a thickened, fibro-cartilaginous portion of the peritoneal coat.

The nutrition of the body was not impaired by the state of the liver. Could this be referable to the circumstance that the organ was not indurated, and consequently the circulation through it was free, as denoted by the red colour? The case is well calculated to show that the granulations perform vicariously the function of the white or secreting substance, which they have supplanted; whence it is to be inferred that they are allied to that substance in their nature.

Fig. 90.—Tubera, soft, and of the encephaloid character. At *b* they are incipient and very small, being distinguishable from granules of the white substance only by their bluish translucency. At *g* is a congeries of recent lobules, bluish, and rather soft: at *f* the same are seen, but more advanced,


and highly vascular. Above, the tuber *d*, *e*, is not only mature, but has undergone partial disorganization. It contained a thick pulpy fluid, and presented a broken, hilly, and indistinctly lobulated surface. The transverse tract, *e*, is an incision, to show the different appearance of the section and the disorganized surface. The exterior, *h*, has receded from the liver above, to which it feebly adhered by delicate vessels and fine cellular tissue.

The tuber, *i*, has the same characters, but its disorganization is less advanced. The fissures in the upper part are stained yellow with bile.

Fig. 91.—An external view of tubera, showing the lobular character, the vascularity of the intersections, the diminution of this vascularity as the tumours enlarge, and the central depression in some, *d*, and not in others, *b*, *e*.

Fig. 92.—An internal and external view of tubera in different stages. *b* exhibits the beautiful radiating structure of a firm tuber. The great tuber is disorganized and excavated in its centre, which contained a greenish-yellow pulpy fluid. The exterior opposite to the centre is depressed and intersected with gorged blood-vessels. *g* is the peritoneum seen by reflected light, on which are several small tubera. The larger one, *f*, has a slight central depression and is very vascular.

On dividing the tubera at any stage previous to their disorganization, as *b*, each lobule was seen to consist of a whitish, translucent matter like lard, surrounded by a more opaque yellow substance forming the intersections. On pressure or scraping, the surface yielded a small quantity of cream-like fluid.



and highly vascular. Above, the tuber *d*, *e*, is not only mature, but has undergone partial disorganization. It contained a thick pulpy fluid, and presented a broken, hilly, and indistinctly lobulated surface. The transverse tract, *c*, is an incision, to show the different appearance of the section and the disorganized surface. The exterior, *f*, has receded from the liver above, to which it feebly adhered by delicate vessels and fine cellular tissue.

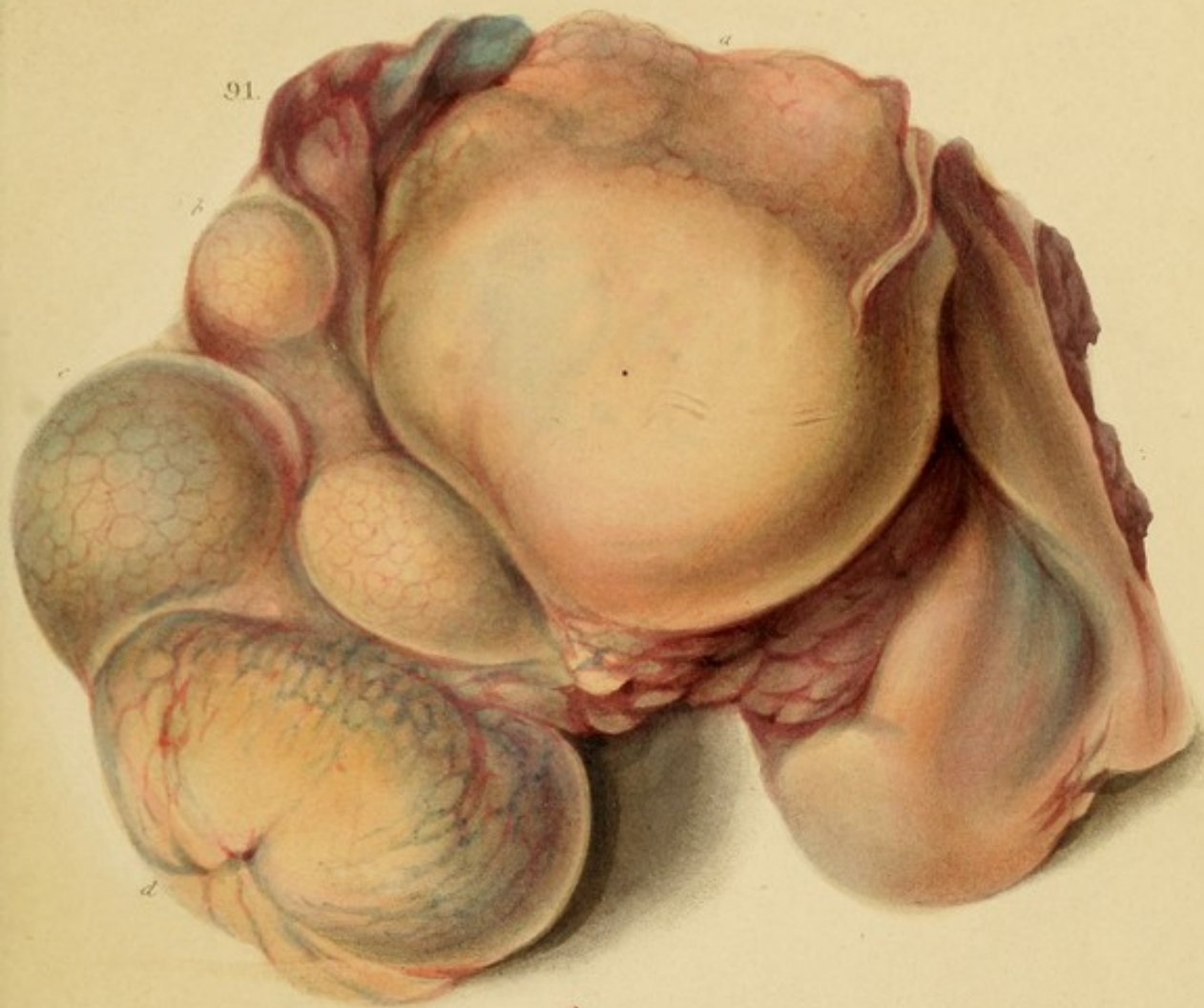The tuber, *i*, has the same characters, but its disorganization is less advanced. The fissures in the upper part are stained yellow with bile.

Fig. 31.—An external view of tubera, showing the lobular character, the vascularity of the intersections, the diminution of this vascularity as the tubers enlarge, and the central depression in some, *d*, and not in others, *f*, *e*.

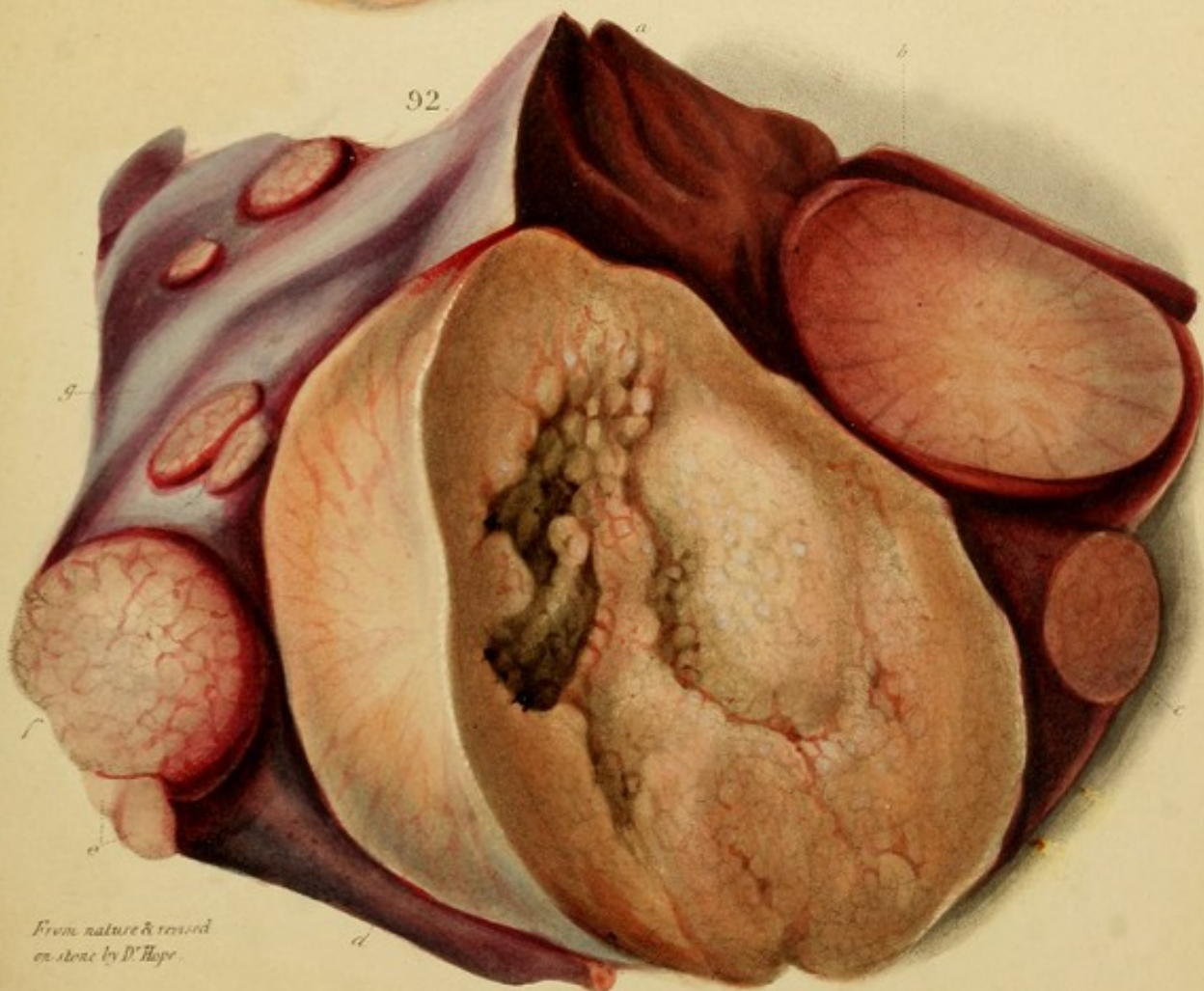Fig. 32.—An internal and external view of tubers in different stages. *b* exhibits the beautiful radiating structure of a new tuber. The great tuber is disorganized and excavated in its centre, which contained a greenish-yellow pulpy fluid. The exterior opposite to the centre is depressed and intersected with gorges, filled with a greenish-yellow fluid, and by some elevated by small tubers. The greenish-yellow fluid is reflected light, and shows no vessels. The larger one, *f*, has a slight central depression and is very vascular.

On dividing the tubers at any stage previous to their disorganization, as *b*, each lobule was seen to consist of a whitish, translucent matter like lard, surrounded by a more opaque yellow substance forming the intersections. On pressure or scraping, the surface yielded a small quantity of cream-like fluid.

91.





92.



From nature & removed
on stone by D. Hope.

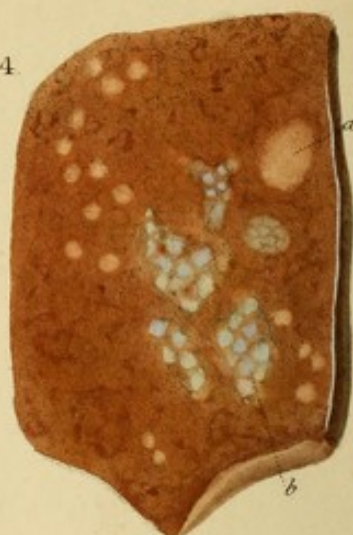A. Dauterive del. W. S. Martin sculp.



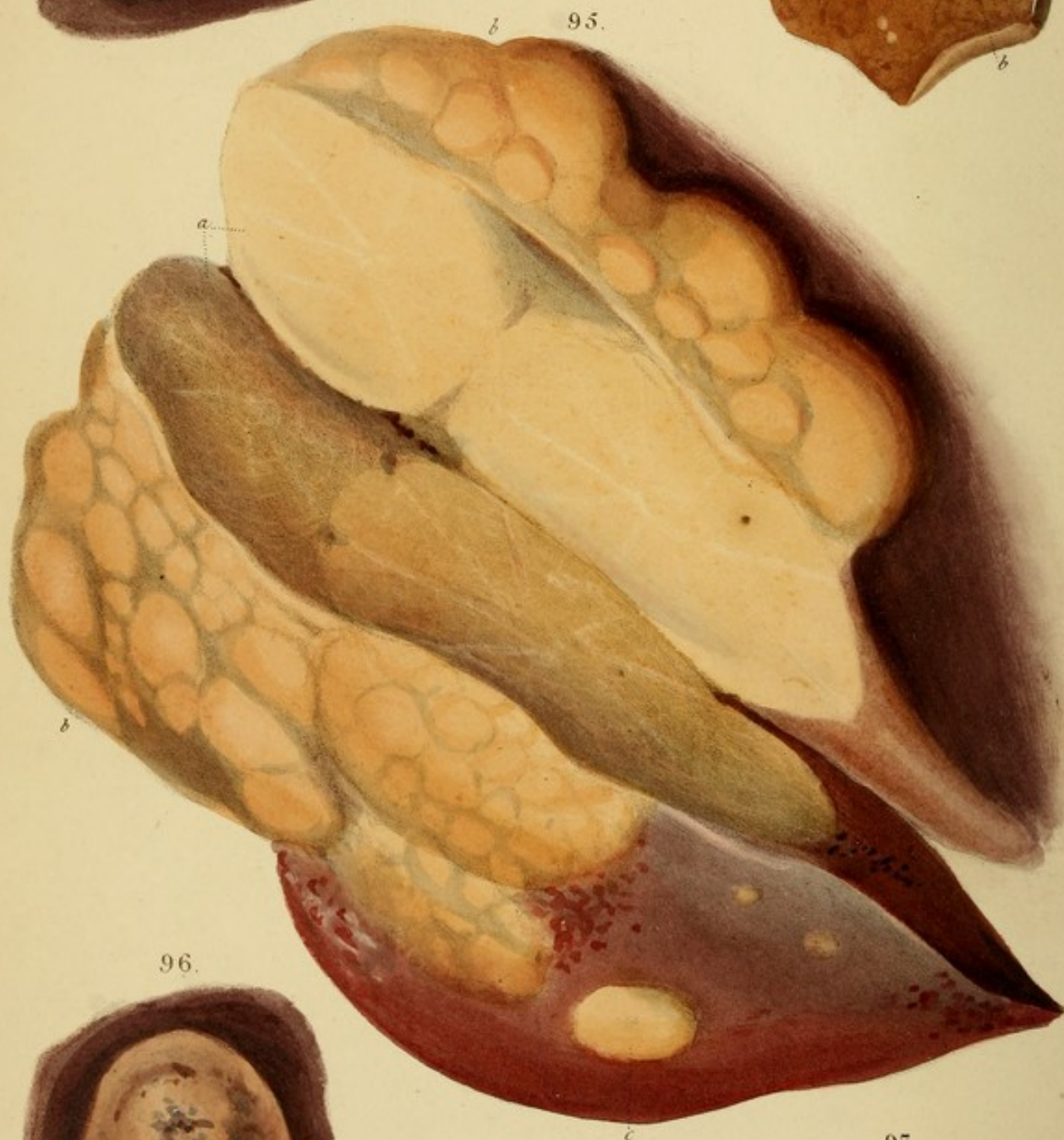



93.



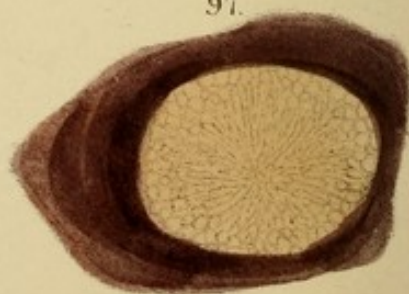
94.



95.



96.



97.

*From nature & reversed
on stone by P. Hays*

A. J. Smith Lithog. U.S. Marine Lane

DESCRIPTION OF THE PLATES.

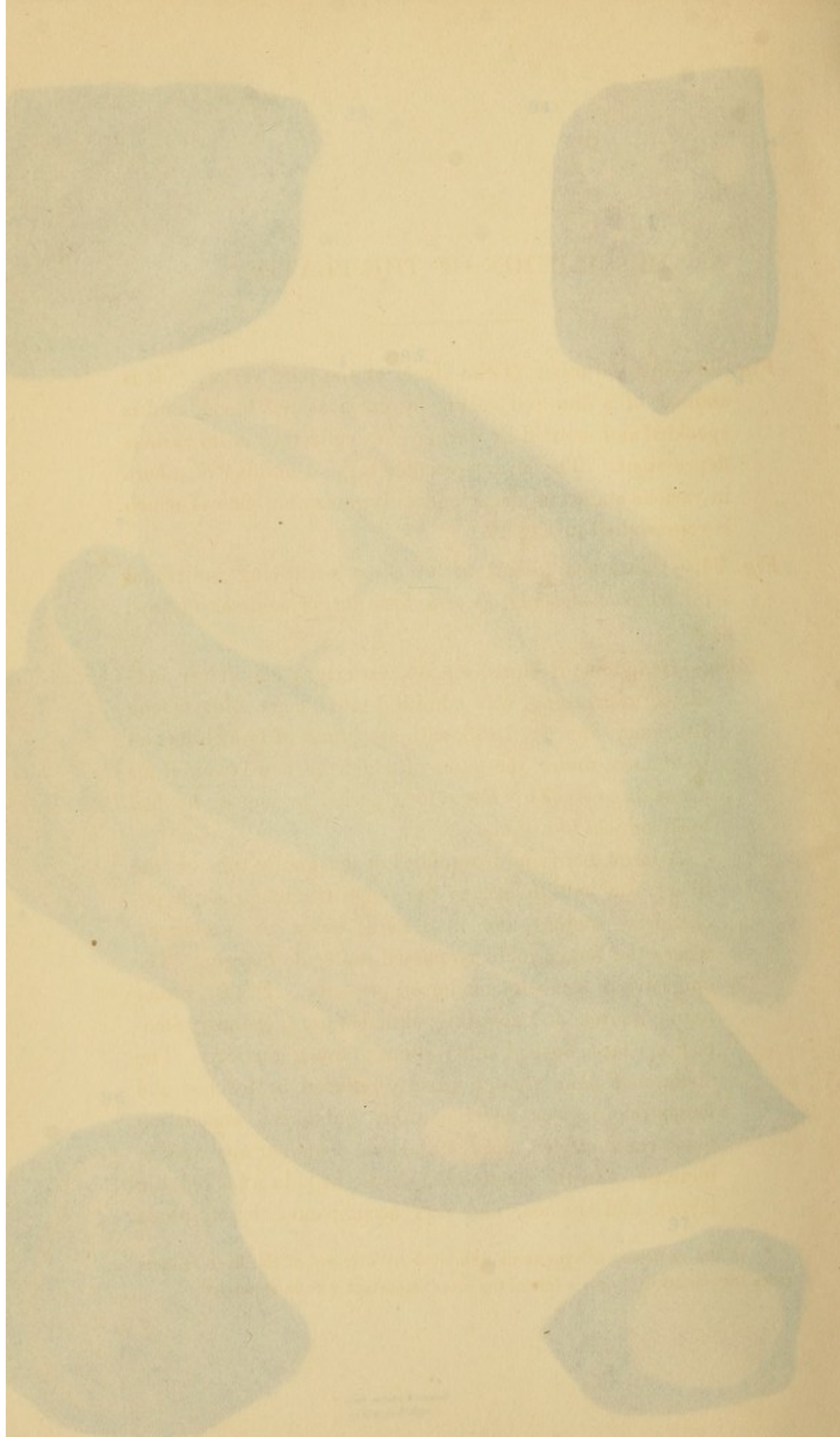
Fig. 12.—An old cancer of the breast of the hard variety. It is covered by a thin red colour by extravasated blood, and is speckled and mottled by darker clots collecting in its various depressions. The liver presented a great number of tubercles in various stages of decay and disorganization, one of which is represented in Fig. 13.

Fig. 13.—Tubercles taken from the liver overlying individual cords which pulsating, as it is, form large compact masses, as it is.

Case.—Benjamin Beckins, at 55, formerly a cab-driver, addicted to drinking, was admitted into the St. Marylebone Infirmary, Jan. 18, 1833, with symptoms of bronchitis and peritonitis, under the latter of which he had laboured for about three weeks. For a long period previously he had been subject to asthma.

A large, hard and irregular, but not knotty tumour (the liver), was felt to occupy the epigastric and right hypochondriac regions, and to descend below the umbilicus, where the finger could be passed under its margin. The epigastrum was very tender to pressure. P. 120, pulse hard; mucus and vomiting, skin hot and dry, and covered with clamour, face flushed and shining, great anxiety. The abdominal pain, though greatly relieved by pressure and hypodermic, was never entirely subdued. Respiration made rapid strides, and the abdominal circumference increased. In the course of a fortnight the tumour, the larynx and trachea, and was accompanied by dyspnoea.

* As the symptoms exhibited by this case, were not so common as those of the preceding, only a few of the more important are here noticed.



DESCRIPTION OF THE PLATES.*

Fig. 93.—An old tuber of the liver, of the hard variety. It is stained of a dim red colour by extravasated blood, and is speckled and mottled by darker clots collecting in its various depressions. The liver presented a great number of tubera in various stages of decay and disorganization, one of which is represented in *Fig. 96*.

Fig. 94.—Cancerous tubera of the liver occupying individual acini, which coalescing, as at *b*, form larger compact masses, as *a*.

Case.—Benjamin Berkins, æt. 55, latterly a cab-driver, addicted to drinking, was admitted into the St. Marylebone Infirmary, Jan. 18, 1833, with symptoms of bronchitis and peritonitis, under the latter of which he had laboured for about three weeks. For a long period previously he had been subject to asthma.

A large, hard and irregular, but not knotty tumour (the liver), was felt to occupy the epigastric and right hypochondriac regions, and to descend below the umbilicus, where the finger could be passed under its margin. The epigastrium was very tender on pressure. P. 110, rather hard; nausea and vomiting, skin hot and clammy, emaciation, face flushed and bilious; much anxiety. The abdominal pain, though greatly relieved by leeches and fomentations, was never entirely subdued; emaciation made rapid strides, and the abdominal tumour appeared to increase. In the course of a fortnight pain attacked the larynx and trachea, and was accompanied by dyspnoea

* As the sameness of symptoms exhibited by diseases of the liver renders cases less instructive, only a few of the more important will be appended.

and aggravation of cough. Antiphlogistic and counter-irritant remedies afforded little relief, and he sunk at the end of another week.

Sectio.—*Larynx* injected, but no apparent obstruction to the passage of air. Tracheal mucous membrane injected with purple blood, and covered with a viscid, jelly-like fluid. Bronchial mucous membrane, from the bifurcation of the trachea to the smaller bronchi, covered almost universally with a soft layer of yellow fibrinous matter, easily separable as a continuous membrane from the mucous lining of the tubes, which was highly and universally injected with blood of a venous colour. The smallest tubes and the air-cells seemed free, but the latter were perhaps emphysematous.

Liver enormous, being four or five times its natural size and weight. It was universally crammed with hundreds, perhaps thousands, of tubera, varying from the size of a single acinus of the liver, as delineated in the Fig., to that of an egg. Some were hard; others were much softer; all yielded a creamy fluid on pressure. The mode of growth of these tumours is described at p. 119. The liver was united to the anterior parietes of the abdomen by strong adhesions, and when the false membrane was peeled off, the surface of the viscus around the superficial tubera exhibited a vivid red vascularity.

Stomach.—About a quarter of an inch from the pyloric orifice was a fungoid excrescence about the size of a bean, and apparently of the same nature as the tubera the liver. The mucous membrane at the fundus was softened, and in parts completely dissolved.

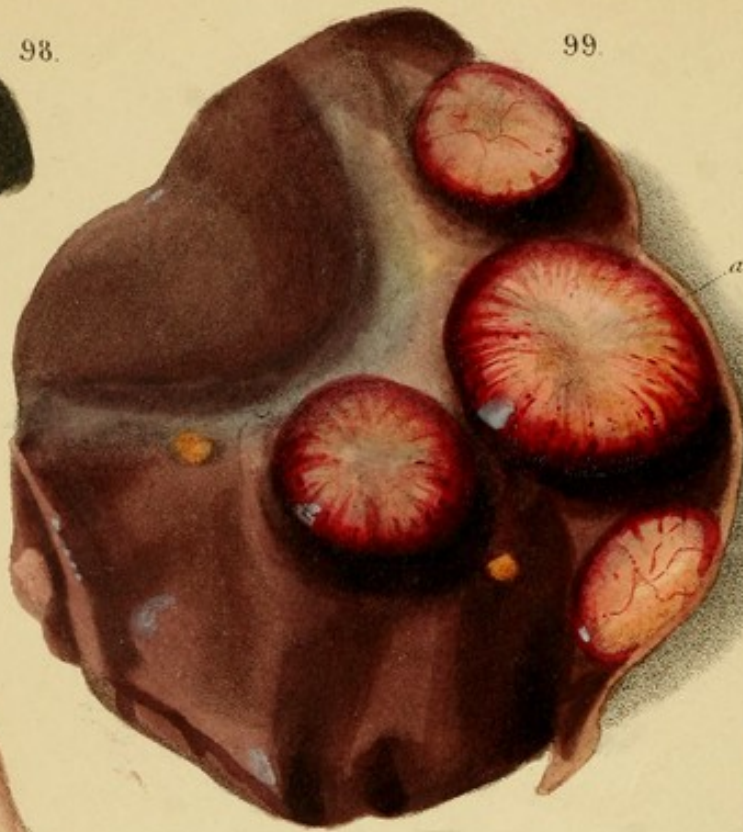Gall-bladder and *Great Ducts* healthy: bile apparently natural.

Kidneys and *Spleen* healthy.


Fig. 95.—Tubera coalescing and forming one large mass, the interior of which is displayed by the section *a*. The exterior



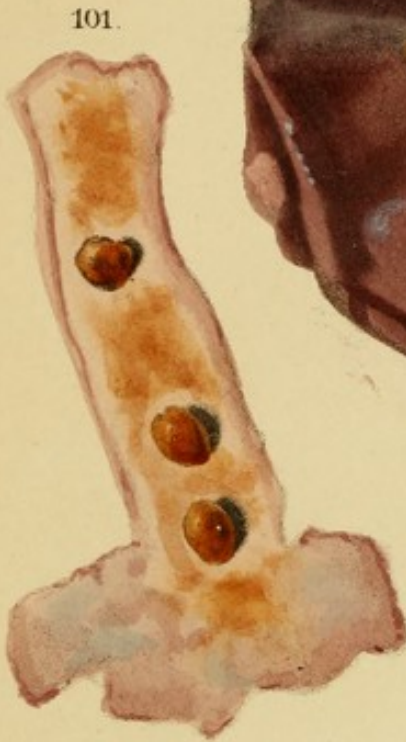98.



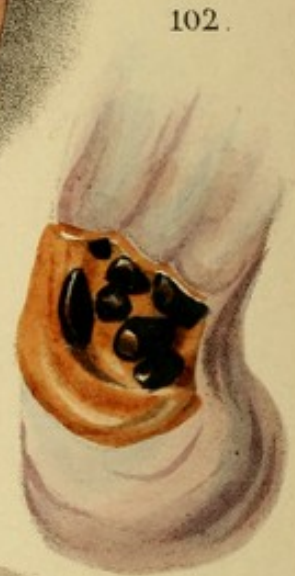99.



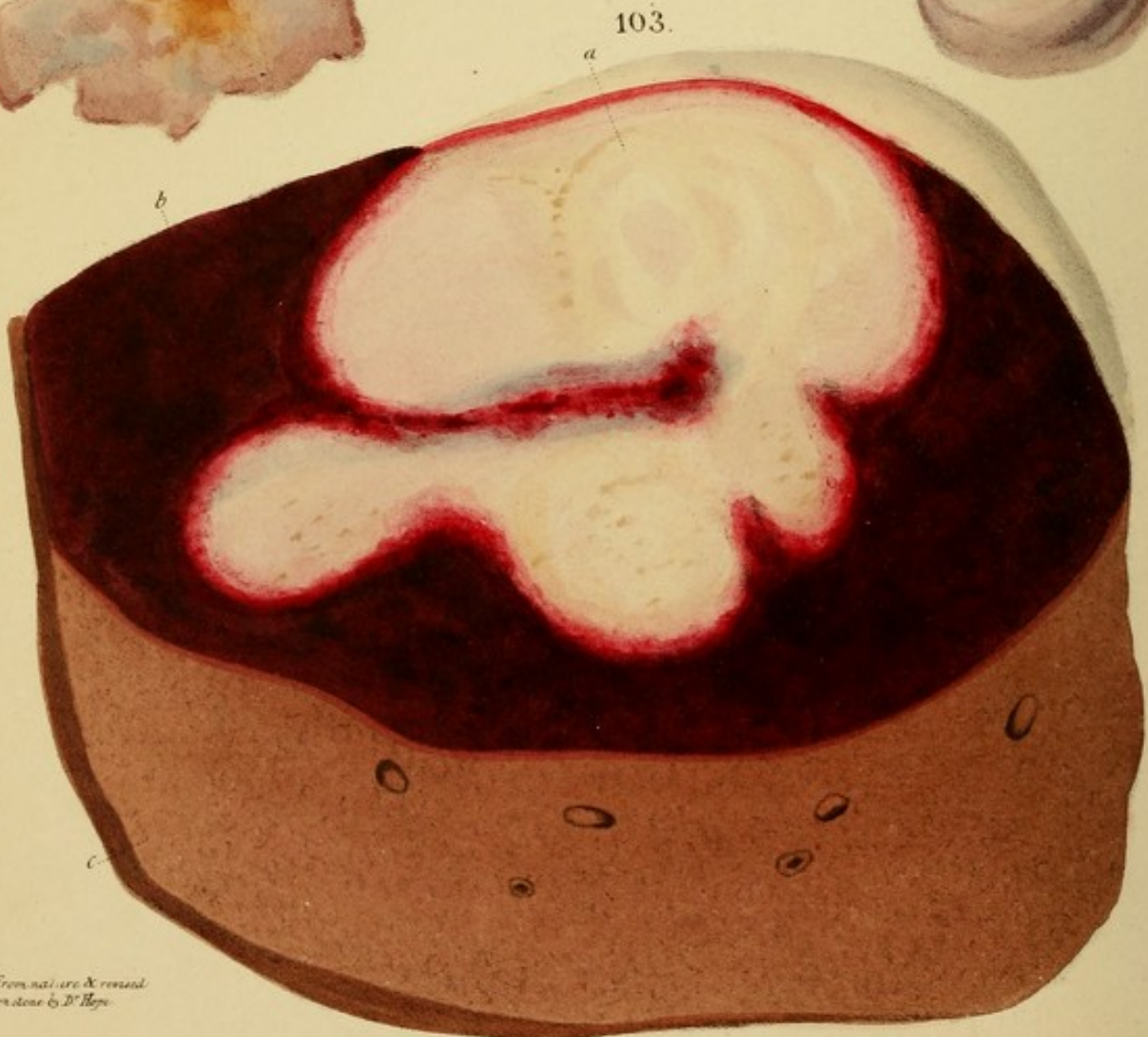100.



101.



102.



103.

From nature & revised
on stone by D. Hays.

6, 5, presents many irregular elevations. Numerous tumours existed throughout the organ. The interlobular hepatic substance was healthy.

Fig. 96.—An old hard tuber in progress of disorganization. Its colour is a dirty brownish yellow, ~~and in parts with dirty red.~~ It had become laterally or rotten, and its cavity contained a pulpy reddish fluid. Its areolar and radiating structure has entirely disappeared.

Fig. 97.—A tuber of the hard variety, on the decline. The milky fluid, and with it the radiated areolar structure, have disappeared from the centre, leaving the yellow fibro-cellular tissue disposed in radiating lines. These changes have not yet taken place at the circumference.

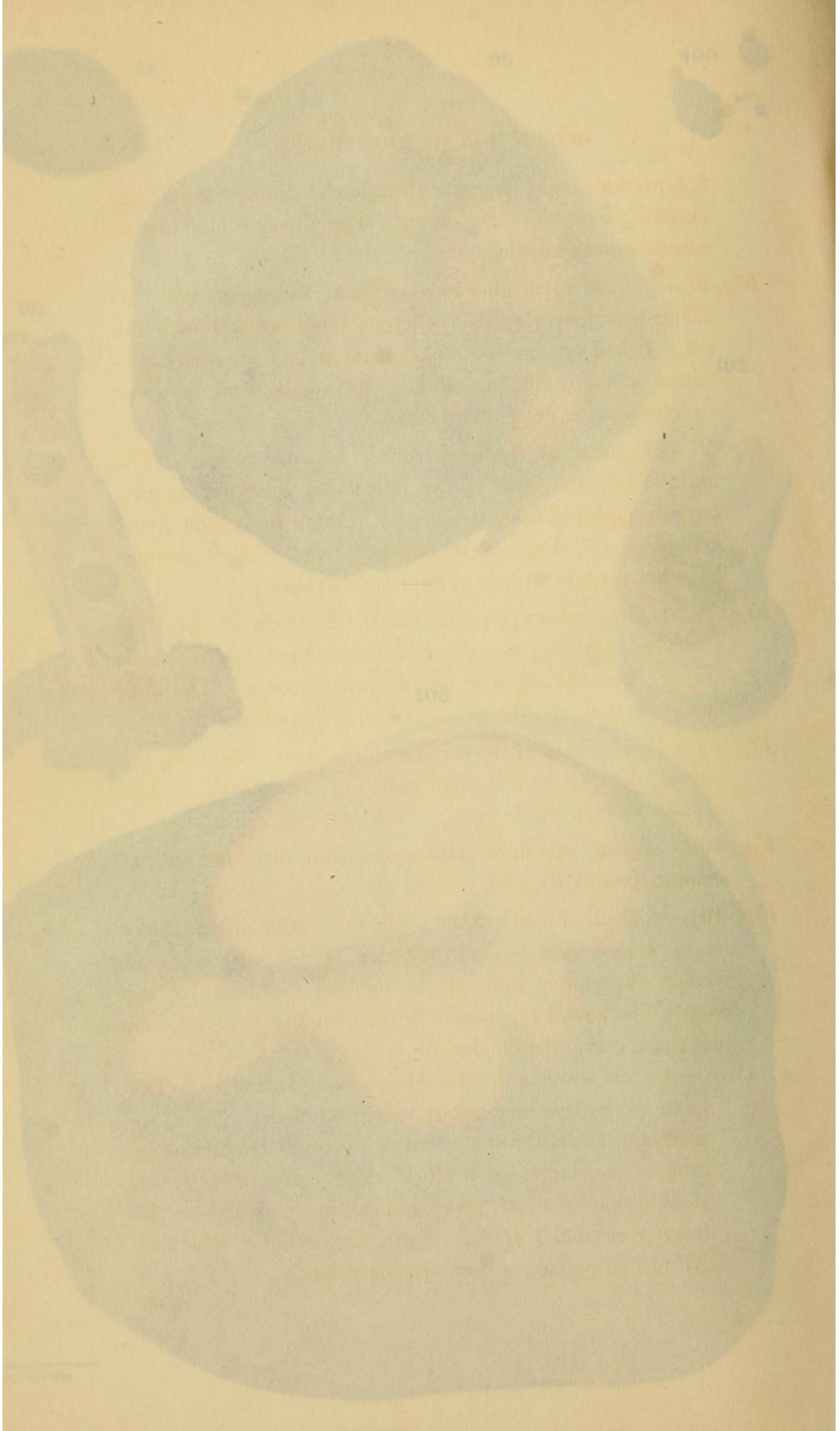
Fig. 98. A large binary calculus from the ductus hepaticus. It is composed of a congeries of smaller ones, the facets of which are agglutinated together by indurated mucus. The surface is rugged, and the colour is a greenish-black.

Fig. 99.—Hard tubers at the surface of the liver, exhibiting the central depression and the radiating vascularity. The hepatic parenchyma is highly congested, but healthy.

Fig. 100.—Binary calculi of various sizes from the ducts of the same subject as *Fig. 98.*

Fig. 101.—Calculi of a rich brown colour, in the ductus communis choledochus. Their exterior is soft and soluble: whence the yellow stain of the mucous membrane of the duct. The hardest calculus is in the mouth of the duct, and just passing into the duodenum.

Case.—An old woman in the Marylebone Infirmary. The liver presented the autologous degeneration. Near the pyloric orifice of the stomach was a fungoid cancerous tumour, as large as a duck's egg. Its exterior was fleshy, and of a dirty green and coffee-ground colour: its interior consisted of pale bluish fibro-cellular structure. An ulcerating cancer occupied the pylorus.



b, b, presents many irregular elevations. Numerous tumours existed throughout the organ. The intermediate hepatic substance was healthy.

Fig. 96.—An old hard tuber in progress of disorganization. Its colour is a dirty brownish-yellow, stained in parts with dim red. It had become lacerable or rotten, and its cavity contained a pulpy reddish fluid. Its areolar and radiating structure has entirely disappeared.

Fig. 97.—A tuber of the hard variety, on the decline. The milky fluid, and with it the reticulated areolar structure, have disappeared from the centre, leaving the yellow fibro-cellular tissue disposed in radiating lines. These changes have not yet taken place at the circumference.

Fig. 98. A large biliary calculus, from the ductus hepaticus. It is composed of a congeries of smaller ones, the facets of which are agglutinated together by indurated mucus. The surface is rugged, and the colour is a greenish-black.

Fig. 99.—Hard tubera at the surface of the liver, exhibiting the central depression and the radiating vascularity. The hepatic parenchyma is highly congested, but healthy.

Fig. 100.—Biliary calculi of various sizes from the ducts of the same subject as *Fig. 98*.

Fig. 101.—Calculi of a rich brown colour, in the ductus communis choledochus. Their exterior is soft and soluble: whence the yellow stain of the mucous membrane of the duct. The lowest calculus is in the mouth of the duct, and just passing into the duodenum.

Case.—An old woman in the Marylebone Infirmary. The liver presented the *nutmeg* degeneration. Near the pyloric orifice of the stomach was a fungoid carcinomatous tumour, as large as a duck's egg. Its exterior was sloughy, and of a dirty green and coffee-ground colour: its interior consisted of pale bluish fibro-cellular structure. An ulcerating cancer occupied the pylorus.

Fig. 102.—Calculi in the gall-bladder. Their exterior, while moist, is of a brilliant and highly polished black. Their interior is brown. Each has several facets, occasioned by contact and compression. The mucous membrane of the gall-bladder is stained with bile of a rich orange colour.

Case same as *Fig. 101*. It is thus seen that black and brown calculi may co-exist, and that the brown may acquire a coat of black.

Fig. 103.—An extravasation of blood, *b*, into the parenchyma of the liver; at *a*, a large coagulum is undergoing a kind of encephaloid transformation. (From the Collection of Professor Alison of Edinburgh.)

Fig. 104.—The acini, or white substance of the liver displayed with singular and unusual distinctness: from a case in which the vena portæ was plugged with coagula and fibrinous concretions. (Vid. *Fig. 110* and *Case*.) The acini were very small, pale, and collapsed, as if they had lost a portion of their supply of blood, thus allowing the red substance, which occupied a preternatural space, to encroach upon and compress them. Can it be inferred from this appearance, in connexion with the obstructed circulation through the vena portæ, that the principal part of the portal blood is distributed to the acini?

Fig. 105.—A section of the same liver as *Fig. 104*, but perpendicular to the surface there represented. It displays the elongated form of the acini when divided in this direction. Small puncta, or depressions in the centre of the acini, are seen in both *Figs.*

Fig. 106.—A soft, or encephaloid tuber of the liver, highly vascular, and infiltrated with extravasated blood, whence its deep red colour. The tumours, *b*, consist of fibrine of the blood, from which the colouring matter has been absorbed. They are firm, but friable, like mature tubercles, and appear




Fig. 102.—Calculi in the gall-bladder. Their exterior, while moist, is often brilliant and highly polished black. Their interior is brown. Each has several facets, occasioned by contact and compression. The mucous membrane of the gall-bladder is stained with bile of a rich orange colour.

Case same as Fig. 101. It is thus seen that black and brown calculi may co-exist, and that the brown may acquire a coat of black.


Fig. 103.—An extravasation of blood, *b*, into the parenchyma of the liver; at *a*, a large coagulum is undergoing a kind of encephaloid transformation. (From the Collection of Professor Alison of Edinburgh.)

Fig. 104.—The acini, or white substance of the liver displayed with singular and unusual distinctness. From a case in which the vena porta was occluded with thrombi and fibrinous concretions. (See *Fig. 105* and *106*.) The acini were very small, pale, and collapsed, as if they had lost a portion of their supply of blood, thus allowing the red substance, which occupied a preternatural space, to encroach upon and compress them. Can it be inferred from this appearance, in connexion with the obstructed circulation through the vena porta, that the principal part of the portal blood is distributed to the acini?

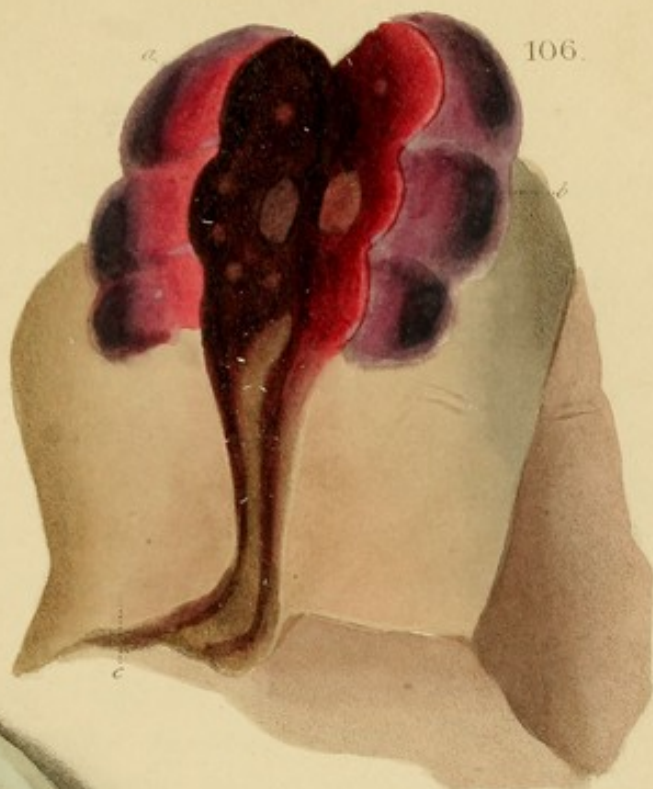Fig. 105.—A section of the same liver as *Fig. 104*, but perpendicular to the surface there represented. It displays the elongated form of the acini when divided in this direction. Small puncta, or depressions in the centre of the acini, are seen in both *Figs.*

Fig. 106.—A soft, or encephaloid tumor of the liver, highly vascular, and infiltrated with extravasated blood, whence its deep red colour. The tumour, *b*, consists of fibrine of the blood, from which the colouring matter has been absorbed. They are firm, but friable, like *strawberry cancer*, and appear

104.



106.



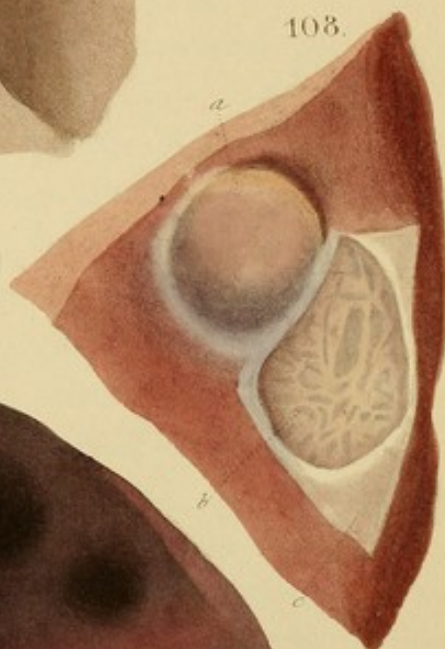105.



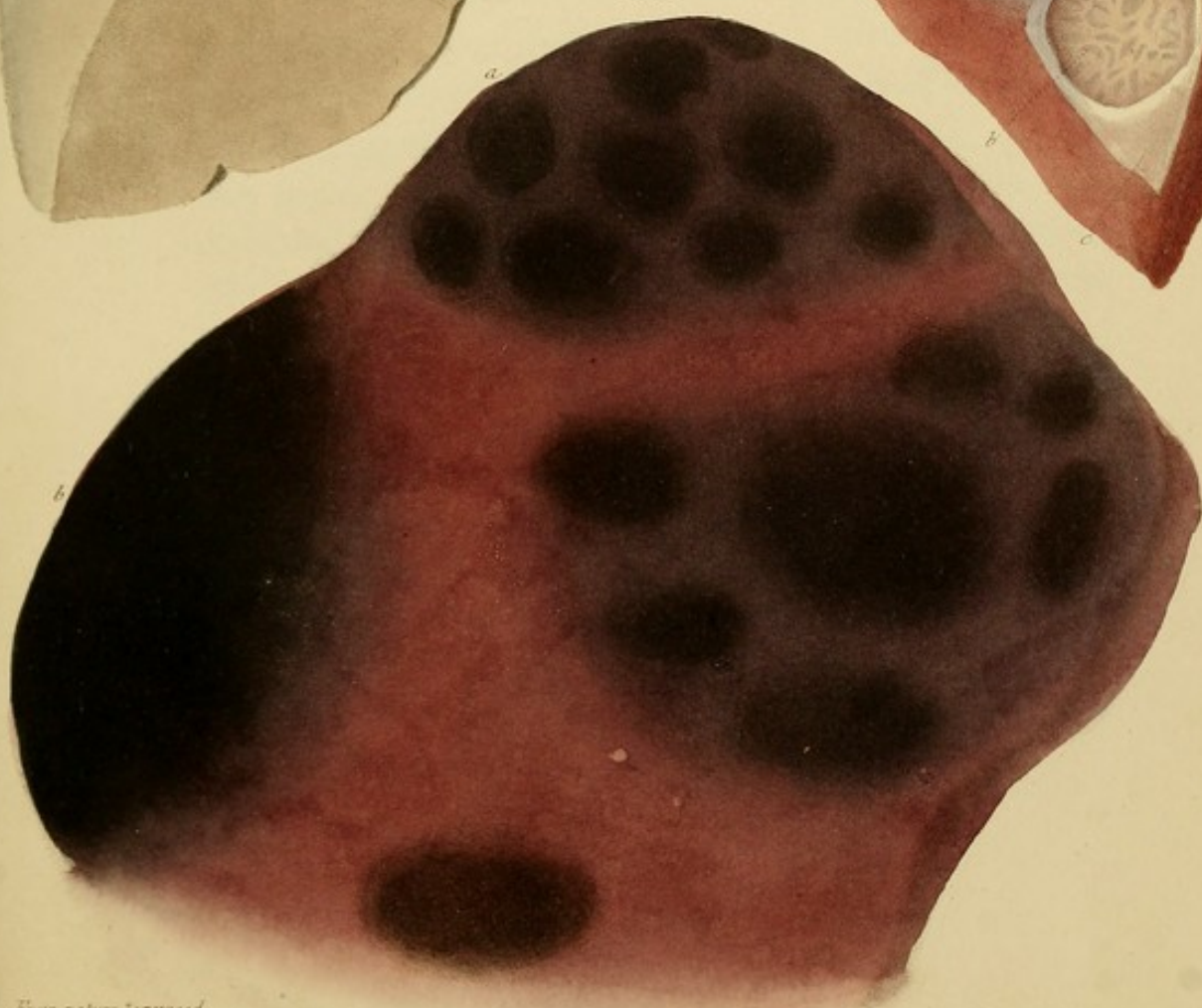
107.



108.



109.



From nature & revised
on stone by D. Hope

to be in progress of organization. The substance of the liver, *c*, is very pale and flabby.

Vascular and hæmorrhagic tubera, similar to this, are very rare. An examination of many hundred livers has only supplied me with the present case.

Fig. 107.—Greasy degeneration of the liver. It is of a pale yellowish grey colour, and much softened. The distinction between the red and white substances is lost, the appearance of the texture being almost homogeneous.

Fig. 108.—Serous cysts of the liver. The one *a*, denuded of its peritoneal coat, and containing a clear amber-tinted fluid, is almost as transparent as water. The empty cyst, *b*, displays a depression in the liver about a quarter of an inch deep. The base is reticulated with prominent filaments of cellular tissue. *c*. shows the thinness of the cyst and peritoneum united. The tumours produced no symptoms.

Fig. 109.—An external view of melanosis of the liver. Some of the tumours were slightly prominent. Both the red and the white substances were infiltrated by the black matter.

Fig. 110.—Fibrinous concretions, originally coagula, in the vena portæ. In the branch *a*, a deep red coagulum is seen gradually undergoing transformation into a pale concretion. The largest concretion is externally streaked and stained with blood; but immediately beneath a thin film investing its surface, the colour is perfectly pale. Nearly all the masses have made greater or less advances towards suppuration, and some contain liquid pus in their interior. In general they float loose in the vessel, and lodge in the orifices of the ramifications. A few only, which appear to have remained fixed in the spot where they were originally formed, as *a*, adhere very slightly to the vessel by extremely delicate cellular filaments, but no where do the coats of the veins present appreciable vestiges of phlebitis.

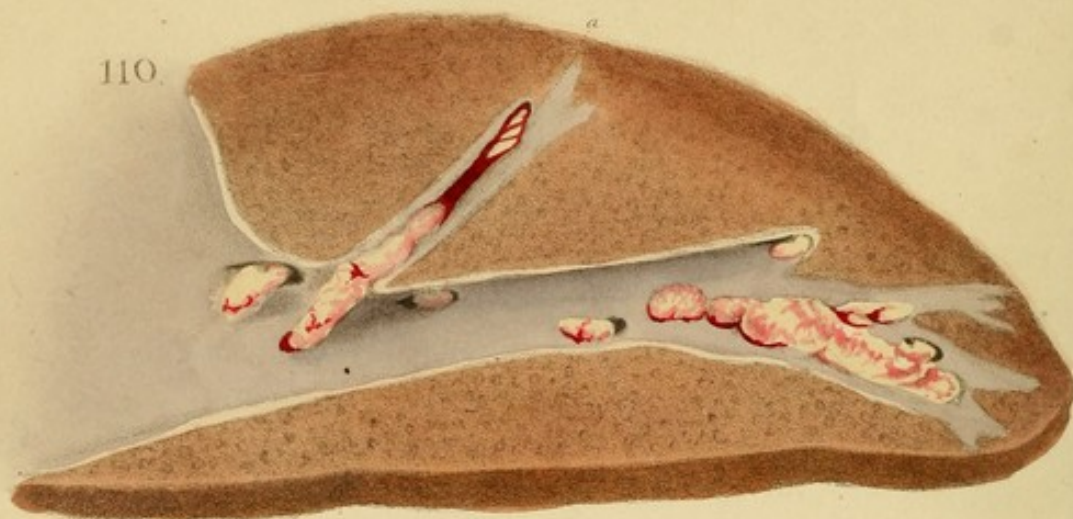
Case.—A female, æt. 30, at the St. Marylebone Infirmary.

For several years she had been delicate and hysterical, and during a residence of eighteen months in the Infirmary, she was subject to violent abdominal pains of a nervous character, became thin, exceedingly exsanguine, and finally so feeble as to be incapable of leaving her bed. In this condition she first came under my care affected with recent symptoms of crural phlebitis. The prompt employment of leeches, fomentations, aperients, and mercury, relieved the local pain and cord-like hardness of the vein in the space of three or four days. During the following week she slightly improved, but then fell into a sinking state, with a scarcely perceptible pulse of 130 to 140, clammy perspirations, intense headache, and intellectual torpor, with slight delirium. In this state she continued, unrelieved by ammonia, camphor, wine, &c., for a week, when she expired.

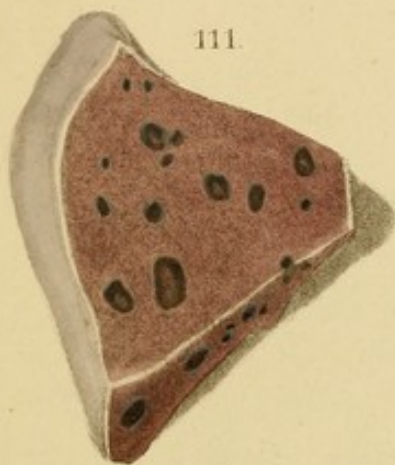
Sectio.—The left external iliac and femoral vein contained, over an extent of six inches, a series of concretions exactly similar to the large one in the Fig. They were slightly adherent by cellular filaments, and the internal surface of the vessel was a little roughened at the points of adhesion. Similar concretions, but in general loose, were found not only in the various branches of the vena portæ, but in the mesenteric, renal, and splenic veins, in the great sinuses of the brain, the vena azugos, and the pulmonary artery. In no organ was circumscribed inflammation (capillary phlebitis) found, except in the lungs, where it formed several masses of dim red hepatization passing into suppuration.

Remarks.—The most remarkable feature in this case was, that concretions should have existed in so many parts of the venous system without being accompanied by numerous visceral abscesses. Is this to be ascribed to a less degree

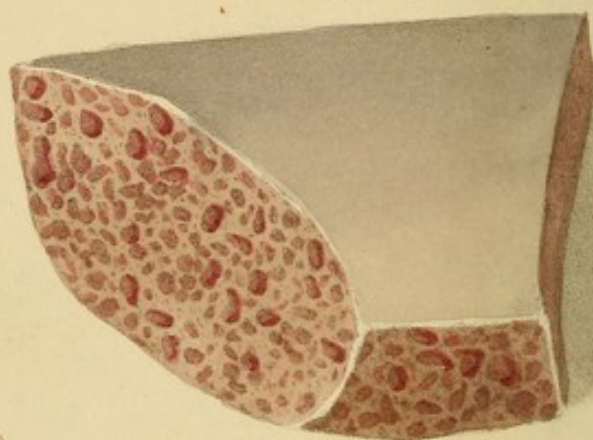
110.



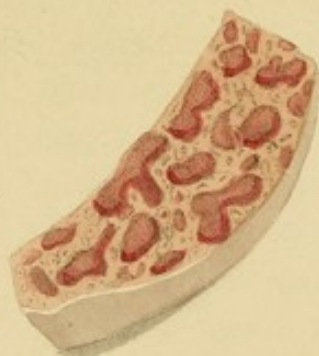111.



112.



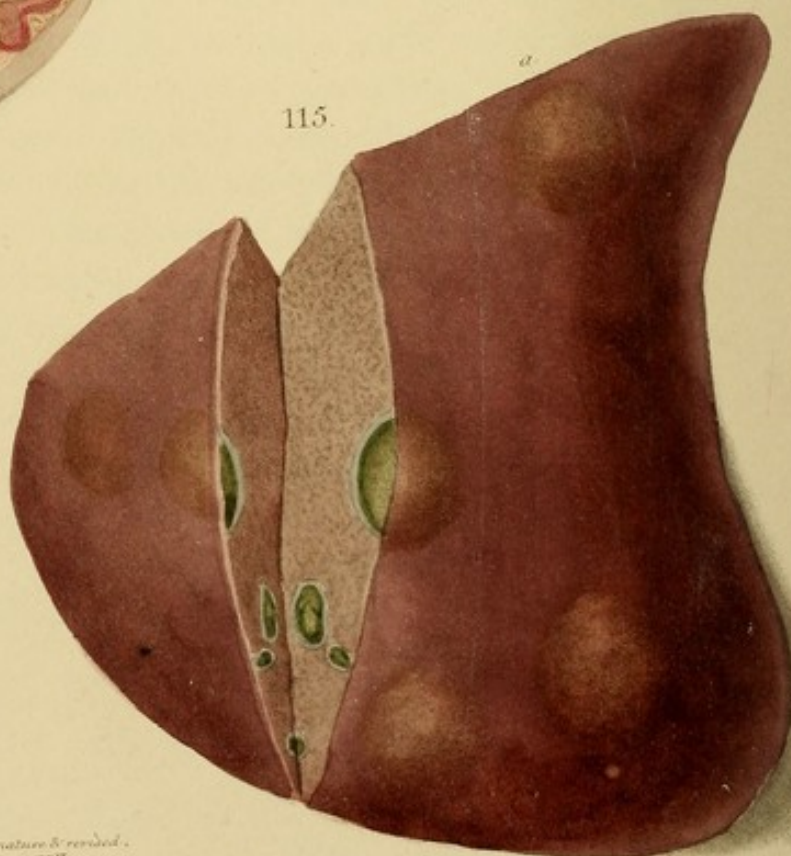
113.



114.



115.



*From nature & revised,
on stone by R. Hope*

A. Dainton lithog. to R. Martin & Co.

of contamination of the blood—a degree sufficient to cause its coagulation without being able to excite an inflammation! Further facts are necessary to answer this question.

Fig. 111.—Dark green gall-stones in the substance of the liver, probably formed either in the arteries or in the biliary canals springing from them. They are surrounded by dense cysts of a paler colour.

Fig. 112.—Hypertrophy of the red substance of the liver.* I imagine this remarkable and new form of disease to consist in an accumulation of blood in the red substance of the liver. The red substance is susceptible of a very remarkable kind of hypertrophy, which produces in the interior of the liver small hard red masses, that are distinguished from the surrounding parenchyma by their greater consistency and deeper colour." (Hall, Anat. II. p. 387.)


In the present case the red masses were of various sizes, and yielded, on pressure, an abundant exudation of blood, while the intermediate parts were unusually pale and sanguine, as if the circulation through them had been interrupted by the presence of the red tumours. On close inspection, particularly with an ordinary lens, it was easy to observe that the tumours consisted of portions of the red substance in the state of hypertrophy; and that the intervals were composed, partly of the white substance or acid, flattened and elongated by compression, yet still displaying their central puncta; and partly of a proportion of the red substance which had not undergone hypertrophy, but, on the contrary, had become pale and, perhaps, atrophic, in consequence of the encroachment of the red tumours. The substance of the liver was very firm, but more friable than natural. (For the case, see Fig. 113.)

* This Fig. should follow Fig. 85; but as the case occurred in one subject, and in the publication of Fig. 85, I was under the necessity of introducing it here.




111


112



113



114



of contamination of the blood—a degree sufficient to cause its coagulation without being able to occasion inflammation? Further facts are necessary to answer this question.

Fig. 111.—Dark green gall-stones in the substance of the liver, probably formed either in the acini or in the biliary radicles springing from them. They are surrounded by dense cysts of a paler colour.

Fig. 112.—Hypertrophy of the red substance of the liver.* I imagine this remarkable and rare form of disease to constitute what Andral alludes to in the following terms: —“The red substance is susceptible of a very remarkable kind of hypertrophy, which produces in the interior of the liver small, hard, red masses, that are distinguished from the surrounding parenchyma by their greater consistence and deeper colour.” (*Path. Anat.* ii. p. 587.)

In the present case the red masses were of various sizes, and yielded, on pressure, an abundant exudation of blood, while the intermediate parts were unusually pale and exsanguine, as if the circulation through them had been intercepted by the pressure of the red tumours. On close inspection, particularly with an ordinary lens, it was easy to discern that the tumours consisted of portions of the red substance in the state of hypertrophy; and that the intervals were composed, partly of the white substance or acini, flattened and elongated by compression, yet still displaying their central puncta; and partly of a proportion of the red substance which had not undergone hypertrophy, but, on the contrary, had become pale, and, perhaps, atrophous, in consequence of the encroachment of the red tumours. The substance of the liver was very firm, but more friable than natural. (For the case, see *Fig. 113.*)

* This *Fig.* should follow *Fig. 85*; but as the case occurred to me subsequent to the publication of *Fig. 85*, I am under the necessity of introducing it here.

Fig. 113.—A magnified view of the same disease as *Fig. 112*.


Case.—A girl, *æt.* about 8, of a strumous habit and conformation, in the St. Marylebone Infirmary. For many months she had been under the care of my colleague, Mr. Stafford, for an abscess in the groin. When transferred to me, the abscess was closed, but she laboured under excessive ascites, and considerable *œdema pedum*; the face was pale and leucophlegmatic, urine rather scanty, bowels regular, appetite tolerably good. The liver was felt to be enlarged.

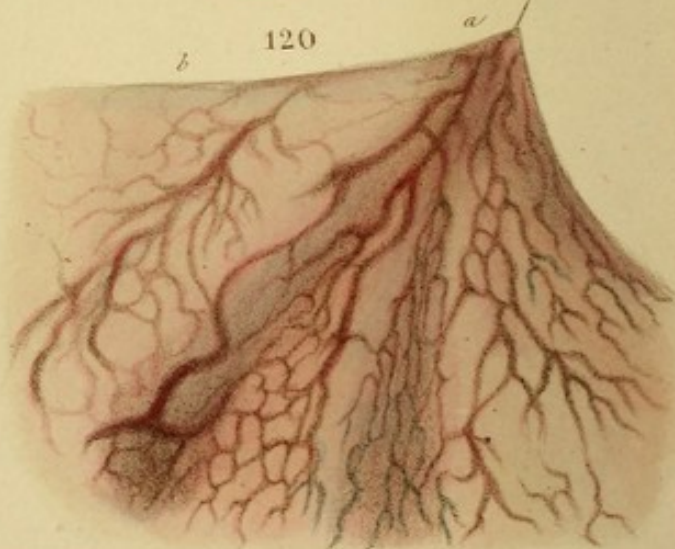
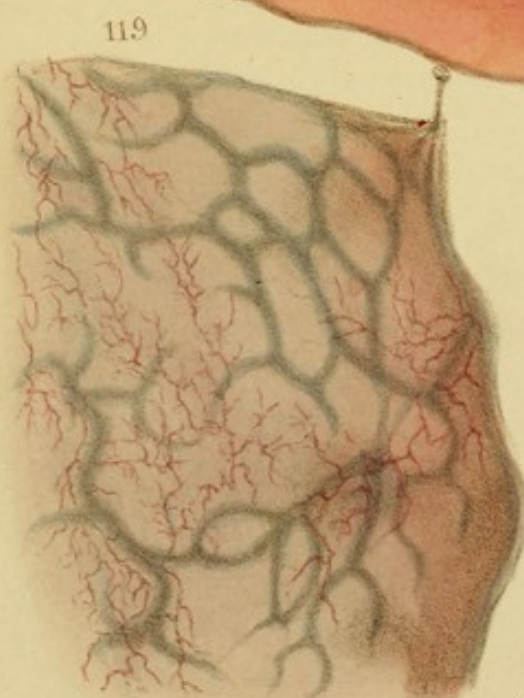
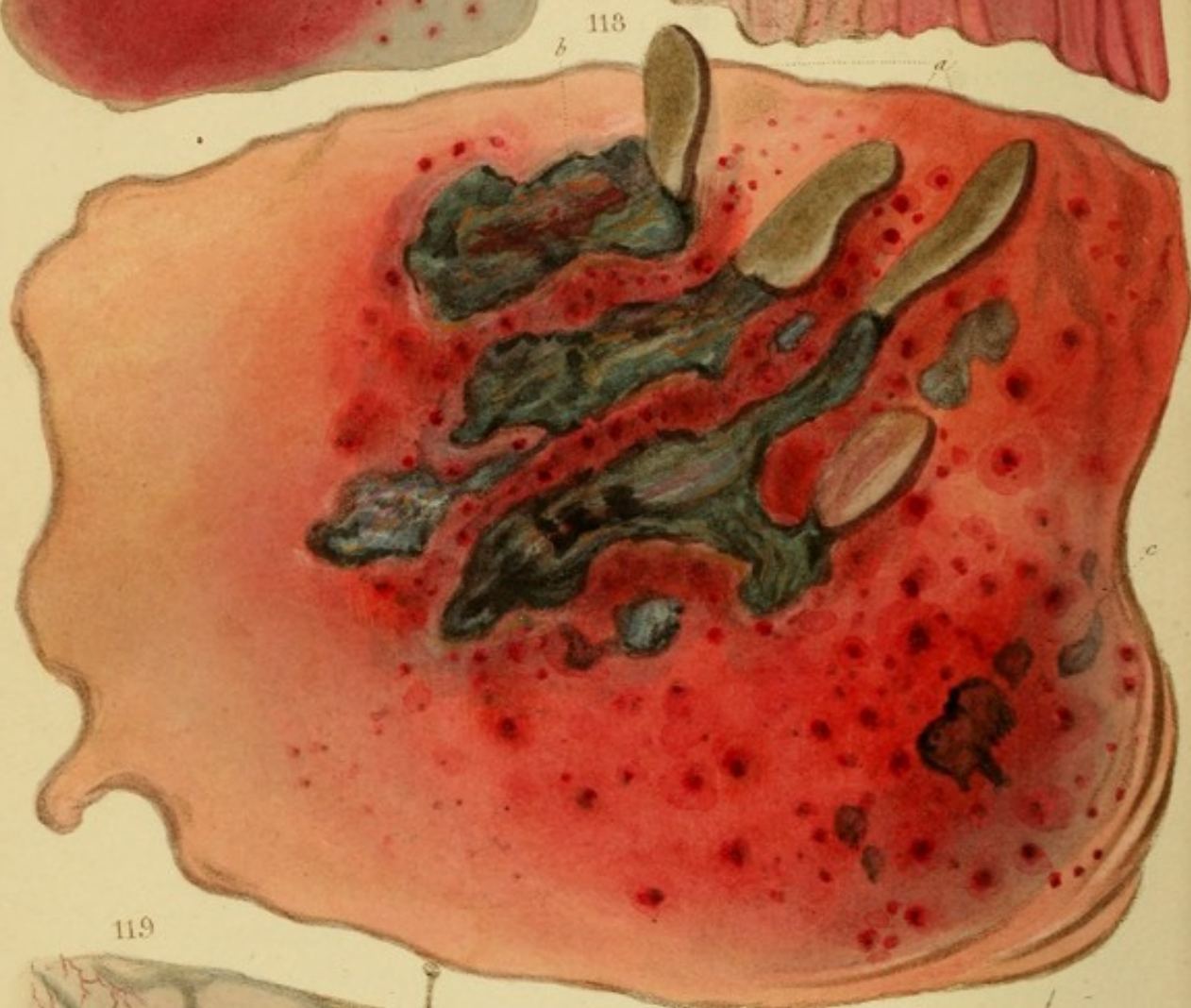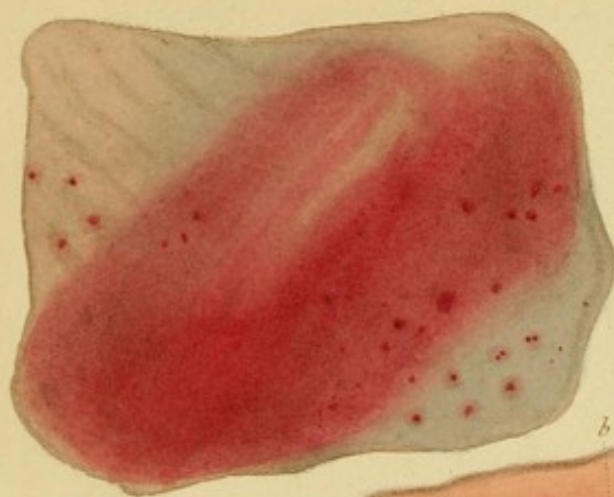Various combinations of mercury, purgatives, and diuretics failed to make any impression on the ascites, though they repeatedly removed the *œdema*. At the expiration of six months the abscess re-opened, and in three months more she died.

Sectio.—The abdominal cavity was filled with clear serum; the liver was more than twice its natural size, and universally diseased in the manner delineated; the inguinal abscess was deep, but did not reach the loins.

Fig. 114.—Biliary cysts and indurations, resembling tubercles, resulting, according to Cruveilhier, from inflammation of the biliary ducts. Some of the cysts, *c*, consisted of a single pouch; others presented several. The walls of the cysts were thick and dense, and their cavities were filled with inspissated bile or biliary concretions. The indurations were either isolated, as *b*, or agglomerated, as *a*: they were extremely dense, and were supposed by Cruveilhier to be formed by the obliteration of cysts. (This and the following *Fig.* are imitations from Cruveilhier.)

Fig. 115.—Biliary cysts, similar to those in *Fig. 114*, but larger. They elevate the surface of the liver, as at *a*, and their interior is deeply stained with bile.





*From nature & copied
in steel by B. Hope.*

A. Smith del. W. P. Martin sculp.

DESCRPTION OF THE PLATES

Fig. 116.—Circular spot of the fundus of the stomach, excited by arsenic. The intensity of the reaction is shown by the color of the spot.

Date—March 18, 1884. Subject—Male, aged 25.

Fig. 117.—Circular spot of the fundus of the stomach, excited by arsenic. The intensity of the reaction is shown by the color of the spot. The spot is of a deep red color, and is surrounded by a zone of lighter color.

Case—Intense gastro-enteritis in a female, aged 50. Continued vomiting, pulse 140.

Fig. 118.—Diffuse redness of the fundus of the stomach, excited by arsenic. It is of great intensity, and presents spots of a deeper color, mainly occasioned by extravasation of blood upon and beneath the mucous membrane. It is probable that other parts of the system gave rise to these extravasations, inasmuch as the patient gave rise to these extravasations in other parts of the system. The patient died on the 18th of March, 1884, at 11 o'clock, after a long and severe illness.

Case—A female, aged 25, who had been suffering from a severe attack of gastro-enteritis, and who had been treated with arsenic. The patient died on the 18th of March, 1884, at 11 o'clock, after a long and severe illness.

116

117

118

119

120

121

122

123

124

125

126

127

DESCRIPTION OF THE PLATES.

Fig. 116.—Capilliform injection of the mucous membrane from *a* to *b*: diffuse redness from *b* to *c*. From the duodenum. The valvulae conniventes are of a deeper red.

Case.—Gastro-enteritis, presenting the ordinary symptoms.

Fig. 117.—Redness in patches, seated in the stomach. Other patches pervaded the greater part of the organ, and were attended with softening, thickening, elevation and morbid facility of detaching the mucous membrane.

Case.—Intense gastro-enteritis in a female æt. 50. Constant vomiting; pulse 140.

Fig. 118.—Diffuse redness of the fundus of the stomach, excited by arsenic. It is of great intensity, and presents spots of a deeper colour, mostly occasioned by extravasation of blood upon and beneath the mucous membrane. It is probable that adherent particles of the poison gave rise to these extravasations by forming nuclei of vehement inflammation. In the centre are muddy-green gangrenous sloughs, *b*, from which flaps, *a*, in a rather less disorganized state, are reflected back. There is every reason to believe that these flaps were torn up by the stomach-pump, and that the other black and greenish spots, *c*, were occasioned by the same cause.

Case.—A young woman at St. Bartholomew's Hospital, who, in a fit of disappointment, swallowed a large quantity of arsenic. Several hours elapsed before the stomach-pump could be employed, and she died soon without having experienced much relief.

Remarks.—In similar cases, after such a period has elapsed as to admit of the complete establishment of inflammation, the stomach-pump should be used with great caution, as the softening of the sub-mucous cellular tissue, which attends the inflammation, allows the mucous membrane to be torn up with the greatest facility.

Fig. 119.—Ramiform injection in the stomach; also congestion of the great veins. The latter is seen more distinctly in consequence of the portion represented being stretched on a white plate. The congestion co-existed with general congestion of the great veins, and depended on the extreme age of the individual. Ramiform injection may exhibit any degree of closeness up to that point where it ceases to present the branch-like character.

Fig. 120.—Dilated veins of the stomach resulting from protracted chronic inflammation. The representation is made against a side-light.

Case.—Cancer of the stomach, to which the dilated plexus led. (La Charité.)

Fig. 121.—Streaky redness from inflammation, affecting the summits of wrinkles of the stomach, which are convoluted in an elegant manner. Also a few scattered patches of redness. (Presented by Dr. J. Bardsley of Manchester.)

Case.—An individual who died of fever, and manifested symptoms of inflammation of the stomach.

Fig. 122.—Speckled redness of the stomach. In some parts, intervals of several lines are interposed between the specks; in others, they are more or less confluent, as here seen. Some specks have abrupt, others softened edges.

Case.—Gastro-enteritis of a mild character.

Fig. 123.—Reddish-brown or chocolate colour of the ileum, from chronic inflammation. This, in various degrees of depth, is

Remarks.—In similar cases, after such a period has elapsed as to admit of the complete establishment of inflammation, the stomach-pump should be used with great caution, as the softening of the sub-mucous cellular tissue, which attends the inflammation, allows the mucous membrane to be torn up with the greatest facility.

Fig. 119.—Raniform injection in the stomach; also congestion of the great veins. The latter is seen more distinctly in consequence of the portion represented being stretched on a white plate. The congestion co-existed with general congestion of the great veins, and depended on the extreme age of the individual. Raniform injection may exhibit any degree of closeness up to that point where it ceases to present the branch-like character.

Fig. 120.—Dilated veins of the stomach, resulting from protracted chronic inflammation. The representation is made against a white light.

Case.—Cancer of the stomach, in which the dilated plexus led. (La Charité.)

Fig. 121.—Streaky redness from inflammation, affecting the summits of wrinkles of the stomach, which are convoluted in an elegant manner. Also a few scattered patches of redness. (Presented by Dr. J. Hardcastle of Manchester.)

Case.—An individual who died of fever, and manifested symptoms of inflammation of the stomach.

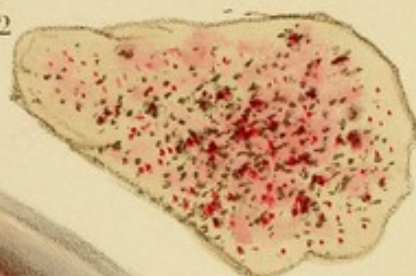
Fig. 122.—Speckled redness of the stomach. In some parts, intervals of several lines are interposed between the specks; in others, they are more or less confluent, as here seen. Some specks have abrupt, others softened edges.

Case.—Gastro-enteritis of a mild character.

Fig. 123.—Reddish-brown or chocolate colour of the interior, from chronic inflammation. This, in various degrees of depth, is

121

122





123

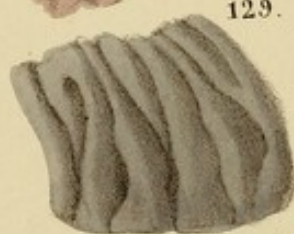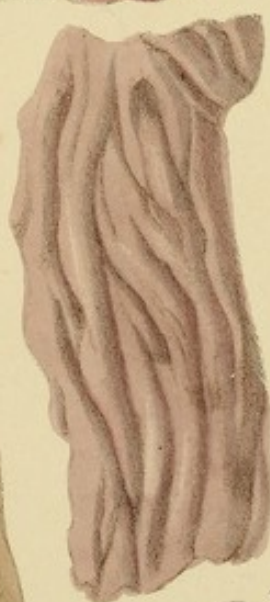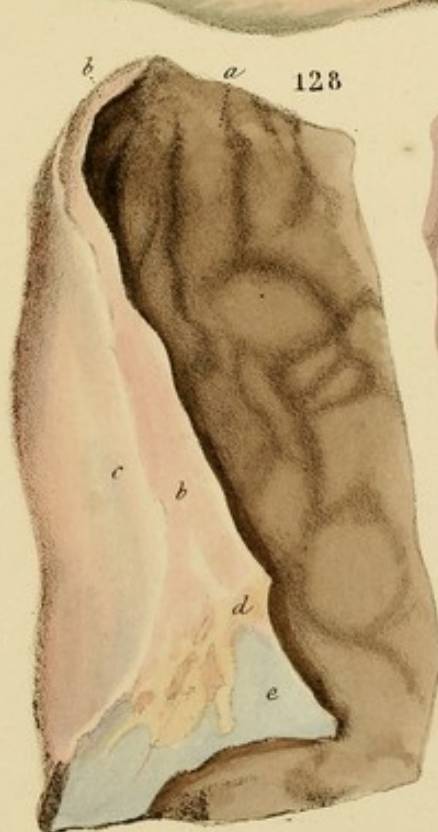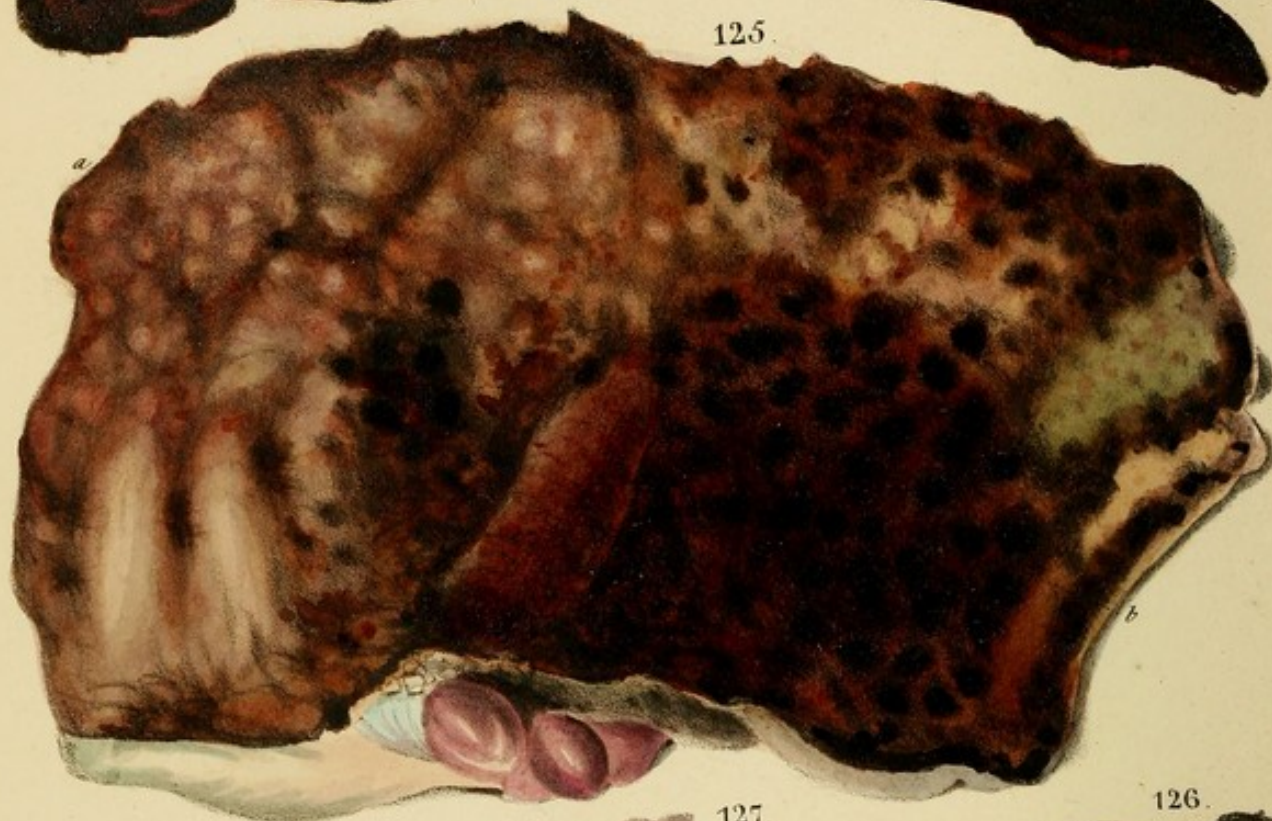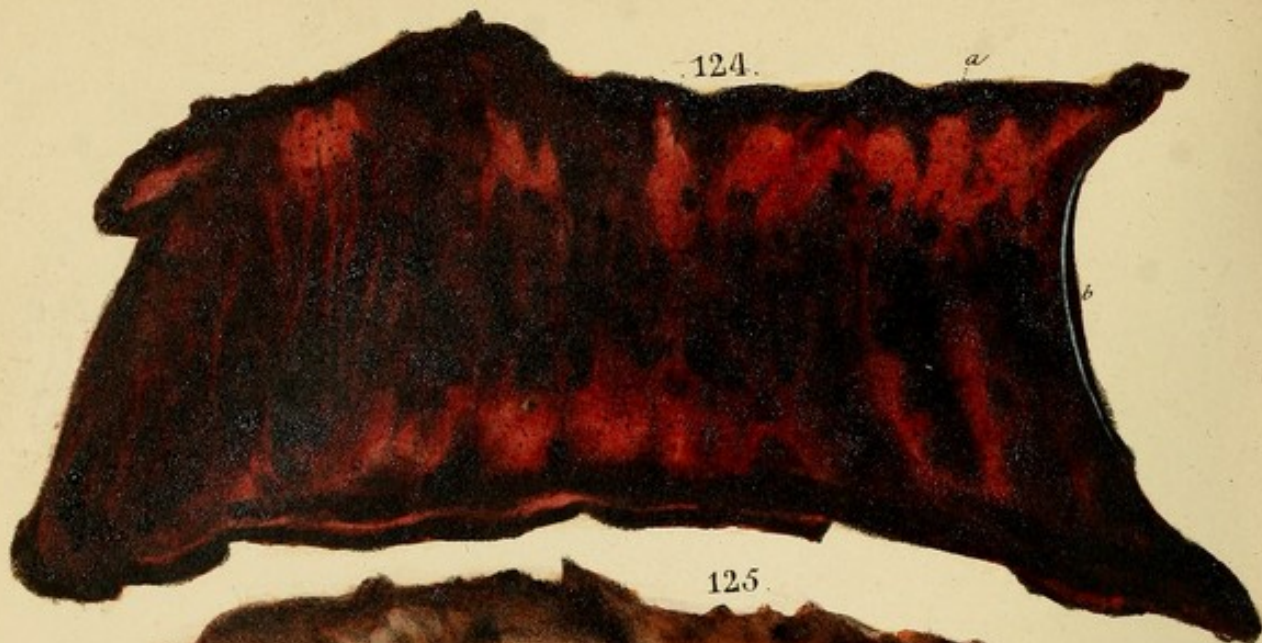


From nature & removed
on stone by Dr. Hope.

A. J. Smith Lithog. W. & M. Martin & Co.







*From nature & revised
on stone by D. Hope.*

very common in the vicinity of old ulcers, and in chronic inflammation in general.

Fig. 124.—A brilliant reddish-black colour of the mucous membrane of the ileum, from hyperæmia connected with protracted diarrhoea. The membrane was not detached. The blackness is seated mainly in the villi, which are partly concealed by the grain of the lithography. The intestine is stretched on a white plate, which throws out the brilliancy of the red; when doubled on itself, it has a uniform mulberry-black aspect.

Fig. 125.—Red-brown colour, running almost into black, at the head of the colon, resulting from gangrene following acute inflammation. The mucous membrane is softened at the side *a*, and is an almost disorganized pulp at *b*. The next *Fig.* is from the same subject.

Fig. 126.—Black gangrene of the mucous membrane of the lower half of the colon. The membrane is completely disorganized, and forms a thin pulp. The blackness extends to the muscular coat; the exterior is livid and greenish; the odor is extreme.

Case.—Acute dysentery of extreme severity and rapidity.
(*See Chapter.*)

Fig. 127.—A vivid red colour of the mucous membrane of the ileum, from chronic inflammation in the vicinity of old ulcers.


Fig. 128.—A pure marbled-brown colour, *a*, of the rectum, resulting from chronic inflammation below a stricture. All the intestinal coats were hypertrophied. *c* is the peritoneum; *b*, *d*, and *e* are hypertrophied cellular and adipose tissues beneath it. *f* is hypertrophied sub-mucous cellular tissue.

Fig. 129.—Slaty colour of the mucous membrane, from chronic inflammation in the vicinity of old ulcers of the ileum.


122




125




127



126



123



128

very common in the vicinity of old ulcers, and in chronic inflammation in general.

Fig. 124.—A brilliant reddish-black colour of the mucous membrane of the ileum, from hyperæmia connected with protracted diarrhœa. The membrane was not softened. The blackness is seated mainly in the villi, which are aptly represented by the grain of the lithography. The intestine is stretched on a white plate, which throws out the brilliance of the red; when doubled on itself, it has a uniform mulberry-black aspect.

Fig. 125.—Red-brown colour, running almost into black, at the head of the colon, resulting from gangrene following acute inflammation. The mucous membrane is softened at the side *a*, and is an almost disorganized pulp at *b*. The next *Fig.* is from the same subject.

Fig. 126.—Black gangrene of the mucous membrane of the lower half of the colon. The membrane is completely disorganized, and forms a thin pulp. The blackness extends to the muscular coat; the exterior is livid and greenish; the fœtor is extreme.

Case.—Acute dysentery of extreme severity and rapidity.
(La Charité.)

Fig. 127.—A livid-red colour of the mucous membrane of the ileum, from chronic inflammation in the vicinity of old ulcers.

Fig. 128.—A pure marbled-brown colour, *a*, of the rectum, resulting from chronic inflammation below a stricture. All the intestinal coats were hypertrophous. *c* is the peritoneum; *b*, *b* and *d* are hypertrophous cellular and adipose tissues beneath it. *e* is hypertrophous sub-mucous cellular tissue.

Fig. 129.—Slate-colour of the mucous membrane, from chronic inflammation in the vicinity of old ulcers of the ileum.

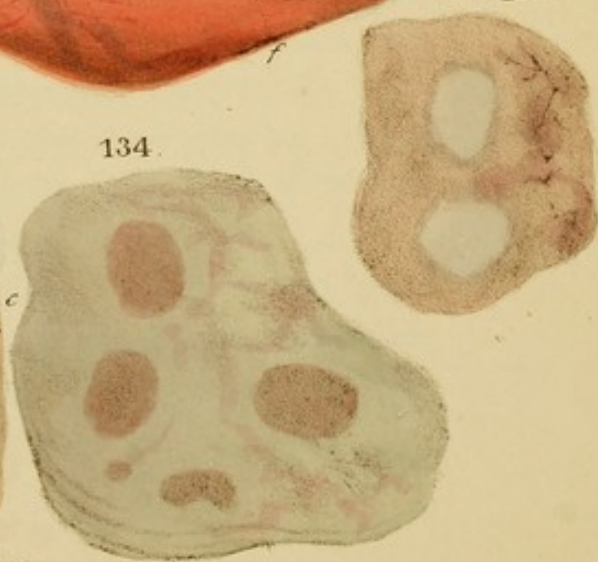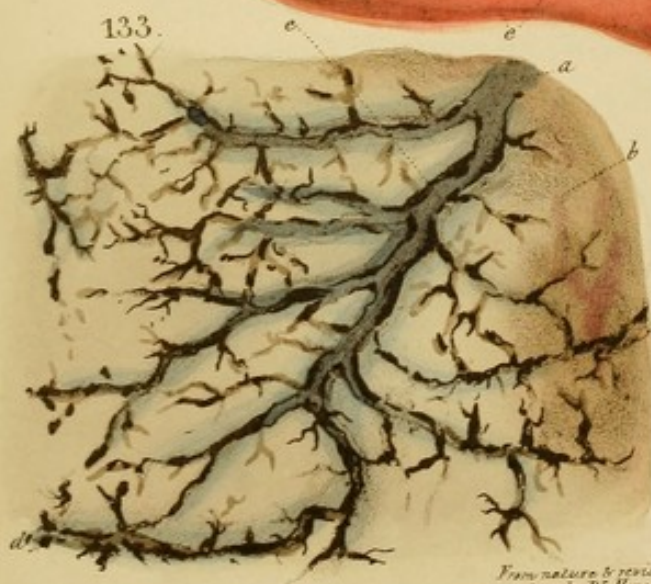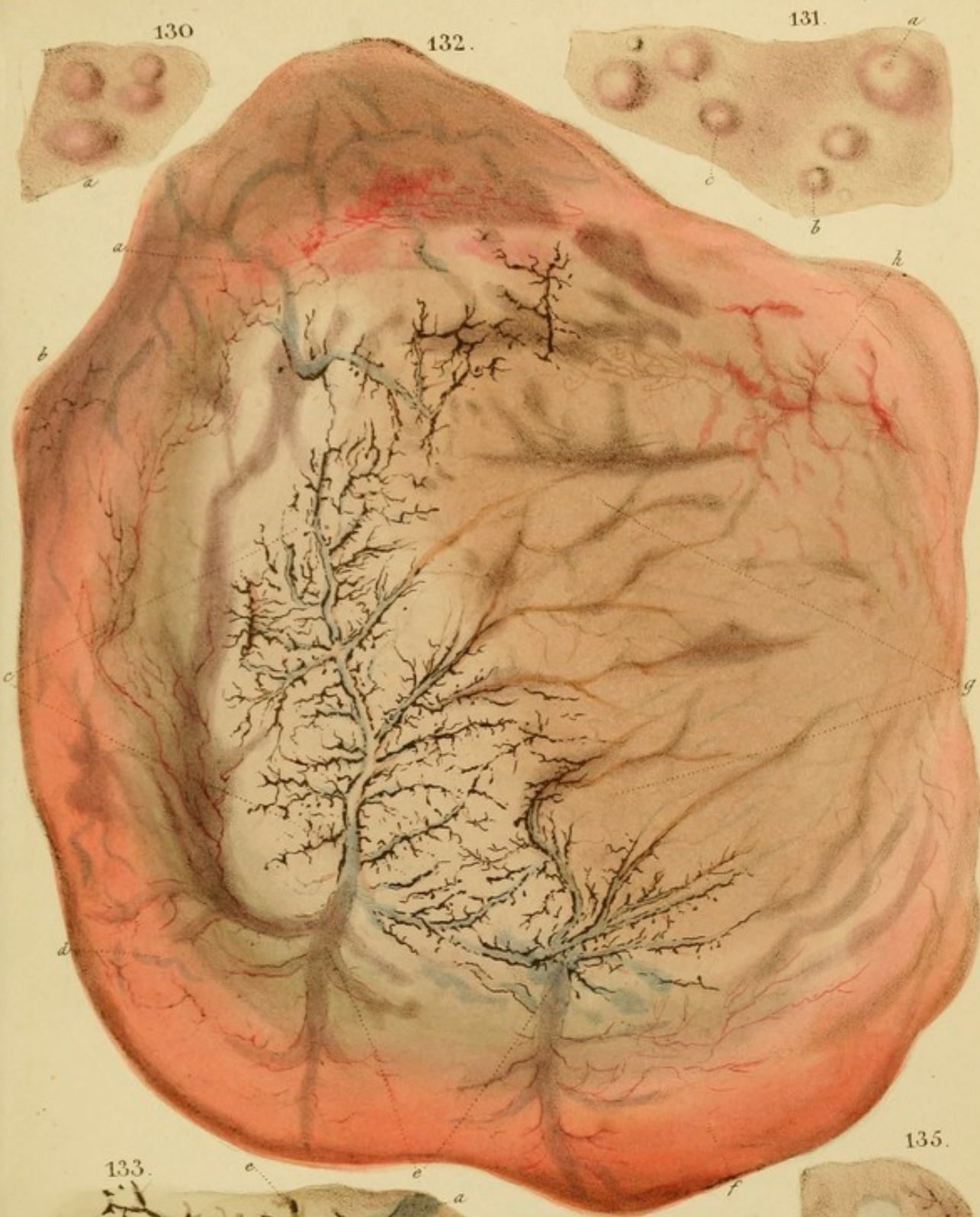Fig. 130.—Isolated follicles of the lower part of the ileum, enlarged by inflammation, and universally red, with an areola of a darker shade at the base.

Fig. 131.—Isolated follicles of the lower part of the ileum, enlarged by inflammation, with pale summits, and encircled by a red areola at their base. In the follicle *a*, a red areola also surrounds the central orifice.

Case.—Typhus, fatal in three weeks by extensive ulceration of the isolated and congregated glands of the ileum. (La Charité.)

Fig. 132.—Inflammatory softening of the stomach. In the red and the greenish parts the softening is incipient, and the mucous membrane immediately breaks when attempts are made to detach it in flaps. In the faintly coloured part *g*, the softening is far advanced, the mucous membrane being almost disorganised, and forming a mass of a pale yellow colour, which escaped with the rest of the stomach. At the moment of separating the border of the organ, the vessels were completely disappeared, leaving the submucous cellular tissue detached, and of the natural pinkish-white colour. The vessels being also detached, the blood has gushed out and accumulated in the veins, particularly at their free edges. In interrupted, dark-brown fragments like coffee-grounds; *c* and *e* are branches of these veins seen through the softened mucous membrane; other branches cistify over the part *g* and elsewhere, as indicated by the brown streaks. On each side of the vein runs a small artery, seen at *a*, but not visible over the detached part *c*, in consequence of being empty. *A* represents uniform arterial vascularity, in connexion with diffuse redness; the same is seen on the opposite side *b*.

Case.—Hydrophobia, at St. Bartholomew's Hospital, under Dr. Latham, in 1825. The man, aged about 40, had received a bite from a dog two or three weeks previous to the attack. On his admission he presented the symp-



From nature & revised
on stone by D^r Hope.
A Jacob's Lithog^r 70, St. Martins Lane.

toms of the malady in their most characteristic form, and was reported to have manifested them about twenty or thirty hours before. He lived two days in a state of great agitation, taking, in connexion with other remedies, two drachm doses of tinct. opii at moderate intervals.

Whether inflammation of the stomach had been excited by the tincture or by other causes, it is impossible to determine; but the vestiges of it exhibited by the Fig. are of a positive nature. A patient of M. Chomel's, under my charge as one of his clinical clerks, was affected with an inflammatory softening of the stomach, of which the present Fig. was a perfect fac-simile, except in outline. The patient died in the third week of typhus with a brown and parched tongue, and had taken wine in considerable quantity during the last week. Ulceration of Peyer's patches was also found.

Fig. 133.—Softening of the stomach of a chronic nature. At the side *b, c*, the mucous membrane is so soft as to come off in the form of a pulp when scratched with the nail or a scalpel. Elsewhere it is wholly deficient, and the sub-mucous tissue and vessels are exposed. The thick ramifications are veins, the blood in which is partly fluid and of a purple colour, and partly concrete and of a brown-black colour, the latter accumulating at the sides of the veins in broken detached coagula. At the ends of the ramifications, where the whole of the blood is concrete, it has lost the purple and acquired a yellow-brown colour. Transudation through the venous coats has taken place, and communicated a purple or a brownish stain to the contiguous parts. On each side of the veins runs an artery, *e*, much smaller, and containing so little blood as not to be visible without close inspection.

Case.—A man, æt. 60, pale, thin, in the St. Marylebone Infirmary, had universal dulness and absence of respiratory

murmur of the left lung, with slight pain in the side affected; little cough and no expectoration; little fever. His history, which dated several weeks back, was that of pleurisy. In the course of two months, by the use of repeated slight vesications of the side, a little blue pill and a light diet, he completely recovered the use of the lung, and was ordered a moderate quantity of animal food and porter daily, with great benefit to his general health and strength. In a month his appetite completely failed rather suddenly; he complained of weight at the stomach, with loathing of food, and gradually sunk in the course of ten days without complaining of any other symptom.

Sectio.—Left lung universally soft and permeable, but rather flaccid, as seen after recent compression by fluid. Adhesions of the pleuræ. Only two or three ounces of serum in the cavity. Stomach as delineated, the deficiency of the mucous membrane being almost universal.

Fig. 134.—Softening of the stomach in small, pale-red, circular patches, on a level with the surrounding membrane.

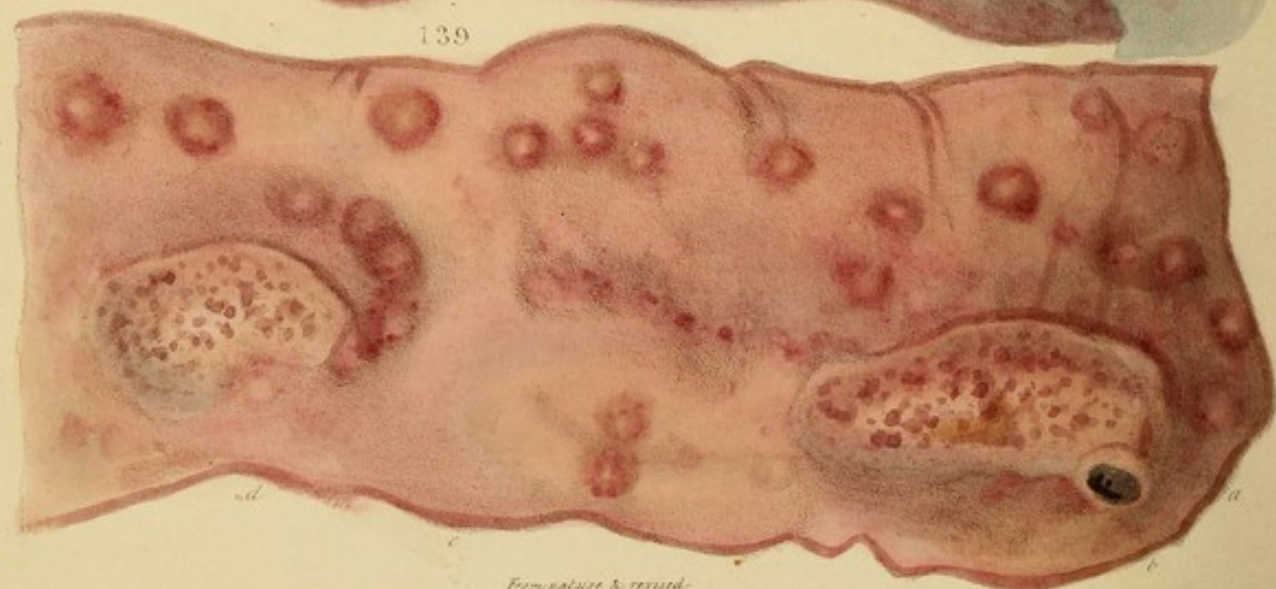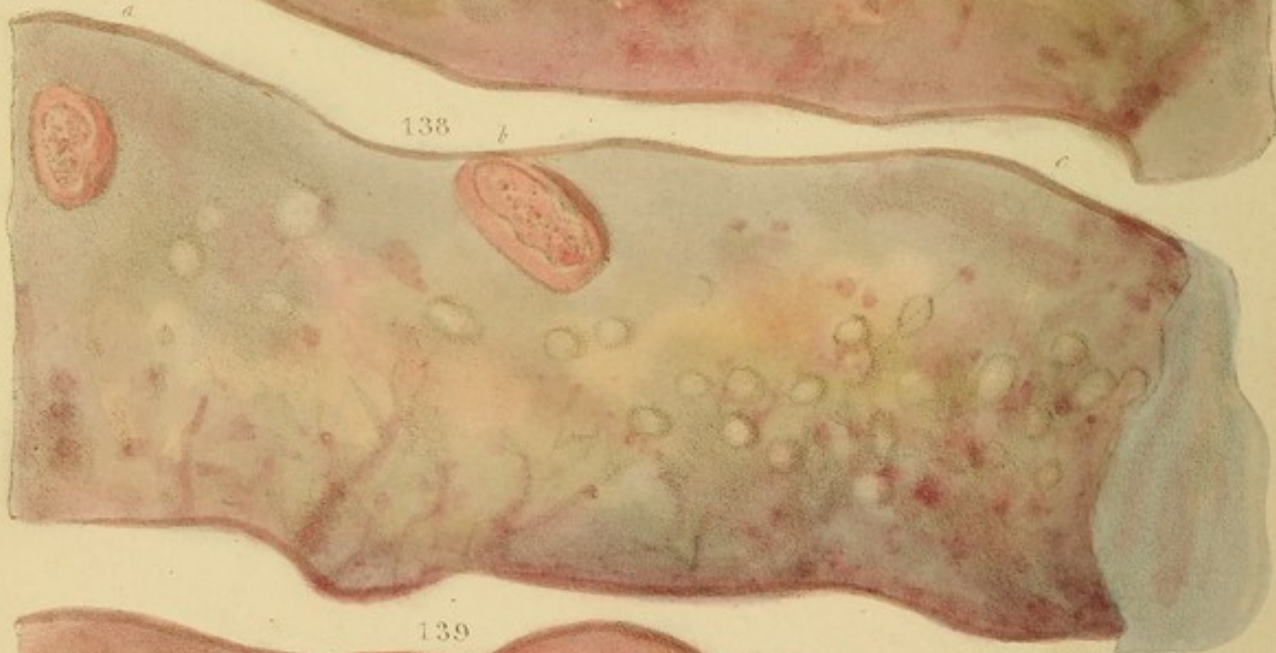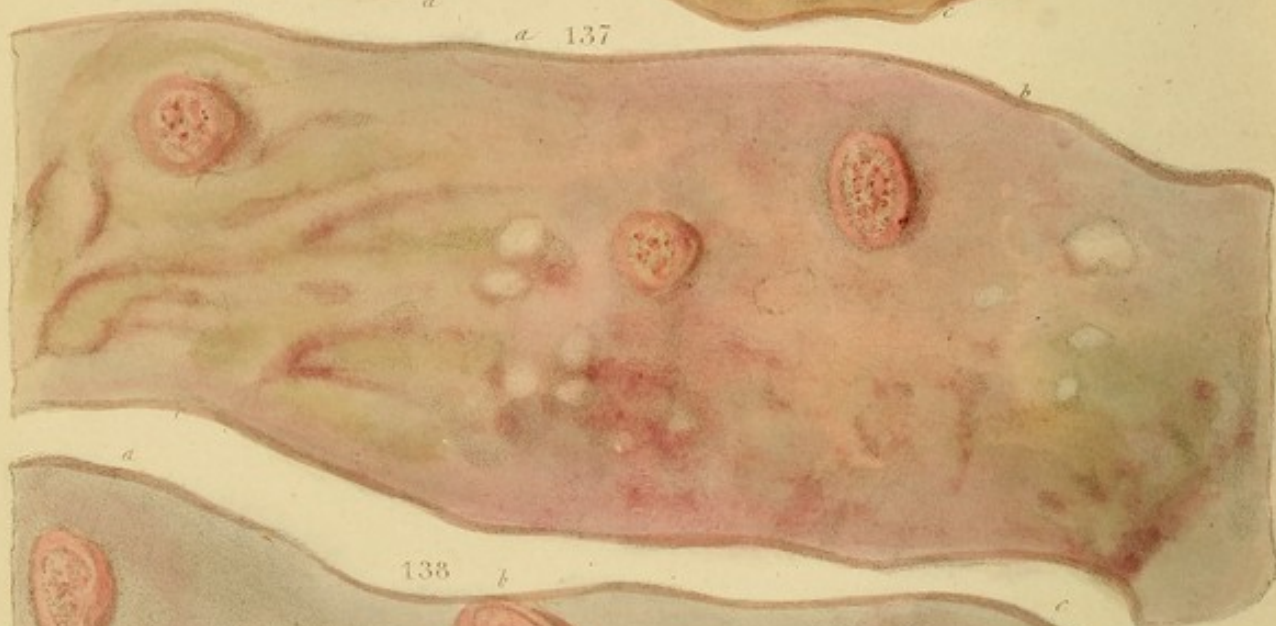
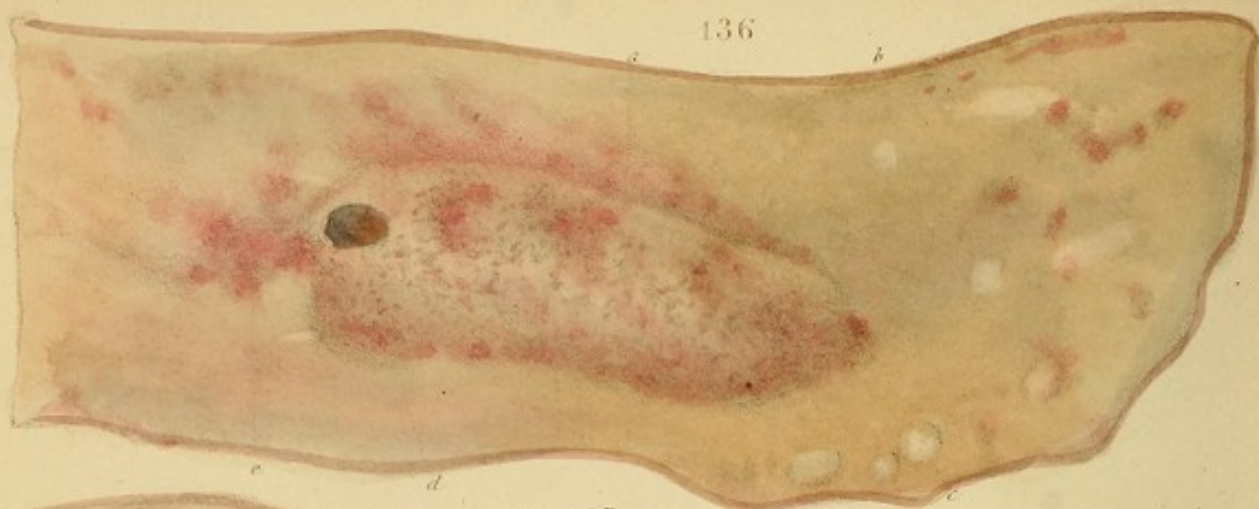Fig. 135.—Similar softened patches to the preceding, but whiter than the surrounding membrane. They are, in many cases, the cause of the perforations called *spontaneous*.

movement of the left lung, with slight pain in the side affected; little cough and no expectoration. Little fever. The history, which dated several weeks back, was that of pleurisy. In the course of two months by the use of repeated slight vesications of the side, a little blood was brought out, but it was completely reabsorbed, the use of the lung, and was ordered a moderate quantity of animal food as before. In a month his appetite completely failed rather suddenly; he complained of weight in the stomach, with burning of food, and gradually sank in the course of ten days without complaint of any other symptom.

Section.—Left lung universally soft and friable, but rather flaccid, as seen after recent compression by hand. Adhesions of the pleurae. Only two or three ounces of serum in the cavity. Stomach as described, the debility of the mucous membrane being almost universal.

Fig. 134.—Section of the stomach in small, pale red, circular patches on a bed with the surrounding membrane.

Fig. 135.—Similar sectioned patches to the preceding, but white, than the surrounding membrane. They are in many cases, the cause of the perforations called spontaneous.



DESCRIPTION OF THE PLATES.

*Figs. 136 to 140, inclusive, are taken from the same case, and represent portions of the lower third of the ileum, affected with inflammatory enlargement of the isolated glands, and of the patches of Peyer, with ulceration of the latter. The disease being of seven weeks' duration, the redness has in a great measure disappeared, and what remains, presents the dim, brownish cast of chronic inflammation. It exists principally in the vicinity of the glands, and along the tracts of great veins, as at *c*, Fig. 137. Many of the isolated glands have become perfectly pale, as *c*, Figs. 136 and 138; and they are in a state, not of mere tumefaction, but of actual hypertrophy.*

The patches of Peyer are ulcerated, and some of the most advanced, as Fig. 136, *a*, are much eaten down at the edges; while, in the more recent, the edges remain high, as *a* and *b*, Figs. 137 and 138. Blood oozed from them on pressure. They were partially covered by yellowish eschars of con-
crete pus; and, on peeling these off, two black, gangrenous sloughs were found at *d*, Fig. 136, and *b*, 139, penetrating down to the peritoneum.

In Fig. 140, of which the end *d* was bounded by the caecal valve, the isolated glands, *a*, *a*, are remarkably numerous and closely set. *c*, are very small patches of Peyer.

Case.—Typhus (fièvre grave), from the clinical works of M. Chomel.

A baker, æt. 20, of middle size, after leaving the country, had been resident in Paris four months. In the

DESCRIPTION OF THE PLATES.

Figs. 136 to 140, inclusive, are taken from the same case, and represent portions of the lower third of the ileum, affected with inflammatory enlargement of the isolated glands, and of the patches of Peyer, with ulceration of the latter. The disease being of seven weeks' duration, the redness has in a great measure disappeared, and what remains, presents the dim, brownish cast of chronic inflammation. It exists principally in the vicinity of the glands, and along the tracts of great veins, as at *c*, Fig. 137. Many of the isolated glands have become perfectly pale, as *c*, Figs. 136 and 138; and they are in a state, not of mere tumefaction, but of actual hypertrophy.

The patches of Peyer are ulcerated, and some of the most advanced, as Fig. 136, *a*, are much eaten down at the edges; while, in the more recent, the edges remain high, as *a* and *b*, Figs. 137 and 138. Blood oozed from them on pressure. They were partially covered by yellowish eschars of concrete pus; and, on peeling these off, two black, gangrenous sloughs were found at *d*, Fig. 136, and *b*, 139, penetrating down to the peritoneum.

In Fig. 140, of which the end *d* was bounded by the cæcal valve, the isolated glands, *a*, *a*, are remarkably numerous and closely set. *c*, are very small patches of Peyer.

Case.—Typhus (fièvre grave), from the clinical wards of M. Chomel.

A baker, æt. 20, of middle size, after leaving the country, had been resident in Paris four months. Imme-

diately on his arrival in that capital he was attacked with diarrhœa, which lasted eight days. During the two succeeding months he was well, with the exception of a slight relapse, of which he gives a confused account. At the expiration of this period, being seven weeks before his admission into La Charité, he was seized with his present attack.

It commenced with a cold, which, in a week, was followed by diarrhœa, producing five or six liquid evacuations per day. They were immediately excited by any ingesta, and he was soon compelled to leave work.

State on Admission.—Face pale; physiognomy more dejected than in mere diarrhœa; some emaciation. He can raise himself to the sitting posture with tolerable ease, but cannot walk. Only three evacuations during the last three days; but five or six liquid ones on all the days preceding. Abdomen a little tympanitic, but not painful on pressure. No nausea or vomiting. Cough has greatly diminished during the last three weeks. Mucous sputa, stained with a few streaks of blood. Epistaxis. Tongue dry, and red at the point; pulse 108, hard, but compressible; respirations 44; no head-ache nor giddiness, &c., but he scarcely sleeps at all, and his thoughts ramble much on the subject of his country.

Resonance of the chest, good; sibilant râle throughout, and respiratory murmur feeble; crepitant mucous râle above the right breast.

Has not undergone any treatment.*

(14th. Violet syrup of gum, iii pots. Gummy potion. Emollient fomentations on the abdomen. Leeches xx to the anus.)

15th. Delirium since last night, violent this morning;

* As this case affords a good exemplification of the French treatment of fièvre grave, I give it in full, as I took it, from the dictation of M. Chomel.

increased paleness; more stupor in the physiognomy; eyes almost motionless; articulation more difficult; P. 124, less hard; resp. 38; tongue dry, and brown in the centre; black crusts on the teeth and lips; urine and fæces passed involuntarily: urine lateritious; abdomen highly tympanitic; little cough; auscultation the same.

(Continue the syrup, potion, and fomentations. Solution of syrup of mallows, i pot. Half-lavement of linseed. Two blisters on the legs.)

16th. Remarkable stupor of the physiognomy; features collapsed and immoveable; complexion cadaveric; mouth open; conjunctivæ injected; has passed from xv to xx ounces of blood with the fæces; P. 136, small, unequal, and irregular; resp. 46, laborious; more confusion of ideas than yesterday; other symptoms the same.

(Add xx drops of muriatic acid to the violet syrup of gum; Extr. of cinchona ʒi, to the gummy potion; and camphor ʒi, to the half-lavement of linseed. Solution of syrup of currants, ii pots. Chamomile fomentations on the abdomen.)

17th. Physiognomy worse; eyes haggard and devoid of expression; convulsive twitching of the eyebrows, and jactitation of the arms; five or six bloody, fetid dejections, in bed; P. 148; R. 54; intellectual faculties gone; muttering all night; now, almost aphonia; other symptoms as yesterday.

(Infus. cinchon with muriatic acid, ij pots. Extr. cinchon ʒij with the gummy potion. Fomentation with camphorated alcohol on the abdomen. Half-lavement of chamomile, camphorated. Omit the rest.)

Died in the evening.

Sectio 36. h. p. m.—Little emaciation.—*Lungs*. Marked inter-lobular emphysema of the left lung, at its base. Good crepitation elsewhere. Bronchi of right lung, very red; those of left, rosy in parts. *Heart*, sound. *Blood* in it

and the great vessels, is liquid. *Stomach*, universally rosy. The mucous membrane is mamellated, especially at the smaller curvature, and is slightly thickened and softened. *Duodenum and ileum*, pale. In the middle third of the latter are seen some very distinct, yet not unhealthy, patches of Peyer. A little lower, the patches begin to present a crimped or stamped character, (gauffrées,) though pale; and, on descending, they become ulcerated, and exhibit the appearances represented in the Figs. The colon was stained in several parts by the blood which formed the enterorrhagy. *Brain* firm, and speckled with blood.

Fig. 141. Enlargement of the isolated mucous glands in malignant cholera. The part represented is the duodenum, above and below the head of the pancreas *b*.

The glands appear like mustard-seeds beneath the mucous membrane. Their colour is an opaque, yellowish white; and they easily break up on pressure.

The same appearances are sometimes seen in healthy children. (See p. 177.)

Case.—Malignant cholera at Clapham, nearly three years before the general irruption of the same disease in Great Britain. An old cesspool having been opened, and its contents thrown out immediately contiguous to the playground of a boys' school, twenty-two boys were, within two days, attacked with the disease.—*Symptoms.* Most alarming vomiting and purging, with prostration appearing, in many, to threaten instant death. Stools for the most part pale, consisting of mucus and muco-purulent matter, slightly streaked with scarlet blood. Matter vomited was, in the great majority of cases, colourless and inodorous. P., in the early stages of collapse, was very frequent, but scarcely perceptible. Skin cold and clammy. In a few, it was, for a short time, hot, with flushing in the

face. In some, slight tenderness and tension of the abdomen existed, but no pain was complained of beyond griping before the stools. Twitching, rather than cramp, of the muscles of the upper extremities. The stage of collapse was, in the most favourable cases, succeeded, under the use of stimulants, by a stage of warmth, gentle moisture, and general re-action. My friend Dr. P. M. Latham, (who, with Dr. Chambers and Mr. Pearson, was in attendance,) on seeing thirty children affected with the epidemic cholera in February, 1832, under my care at the St. Marylebone Infirmary, stated that, "from the identity of the symptoms, he could have imagined himself to be again in the midst of the scene at the boys' school."

Treatment.—Brandy and other stimulants with opium during collapse. Leeches to the heads of a few during re-action. Mustard poultices on the abdomen. Enemata; afterwards, full doses of calomel and opium.

Two died within twenty-five hours; the rest recovered in the course of a week.

Section of one.—Exterior of the viscera apparently natural. Stomach healthy. Duodenum as represented in Fig. 141, (the specimen being obligingly given to me by Dr. Chambers.) Jejunum exhibited few isolated glands at its upper part, but more below; while the ileum was universally studded with them; and also with patches of Peyer, somewhat enlarged. No glands were found in the great intestine; but its mucous membrane was, throughout, *uniformly* congested, pulpy, and very easily separable from the subjacent tissue. (In the other fatal case which was examined, the isolated glands of the ascending and transverse colon were universally enlarged, giving the whole interior an appearance of tuberculation.) Contents of the bowels were nearly colourless, and had no fæculent, or any other peculiar odour.

Remarks.—In the Med. Gaz. March 1832, I have given the dissections of one child that died, out of the thirty-one cases in the St. Marylebone Infirmary, and also of some others. The identity of the symptoms and *post-mortem* appearances with those of the present case, proves, if other proof were wanting, that the malignant cholera existed in England before 1832, and was not necessarily an importation from India.

Fig. 142.—Inflammatory enlargement of the mucous glands of the colon, near the caput cæcum. The redness has almost disappeared, the disease having subsisted upwards of six weeks.


Case.—The patient, in the clinical wards of M. Chomel, had been affected with chronic enteritis for forty days, when she was suddenly carried off by acute peritonitis, consequent on perforation of the intestines. This originated in ulceration of the mucous glands, which had proceeded to a remarkable extent in the lower part of the colon. The state will be exhibited in a subsequent plate.

Fig. 143.—Green discoloration of the mucous glands of the colon in a child. The glands are not appreciably enlarged. From the same case as the next.

Fig. 144.—Isolated glands of the duodenum, *b*, immediately below the pylorus, *a*, enlarged by inflammation. At *c*, those of the valvulæ conniventes only, are enlarged, and their orifices are stained green.

Case.—A cachectic child, æt. 5, at the Hôpital des Enfants. My notes of this case are defective; but I believe that the patient died worn out by infantile remittent fever.

Fig. 145.—Inflammatory enlargement of the mucous glands of the stomach. The central orifices are remarkably expanded, and present the appearance of ulcers. The redness results from intense acute inflammation.



Remarks.—In the *Med. Gaz.* March 1832, I have given the dissections of one child that died, out of the thirty-one cases in the St. Marylebone Infirmary, and also of some others. The identity of the symptoms and *post-mortem* appearances with those of the present case, proves, if other proof were wanting, that the malignant cholera existed in England before 1832, and was not necessarily an importation from India.

Fig. 142.—Inflammatory enlargement of the mucous glands of the colon, near the caput-cæcum. The redness has almost disappeared, the disease having subsisted upwards of six weeks.

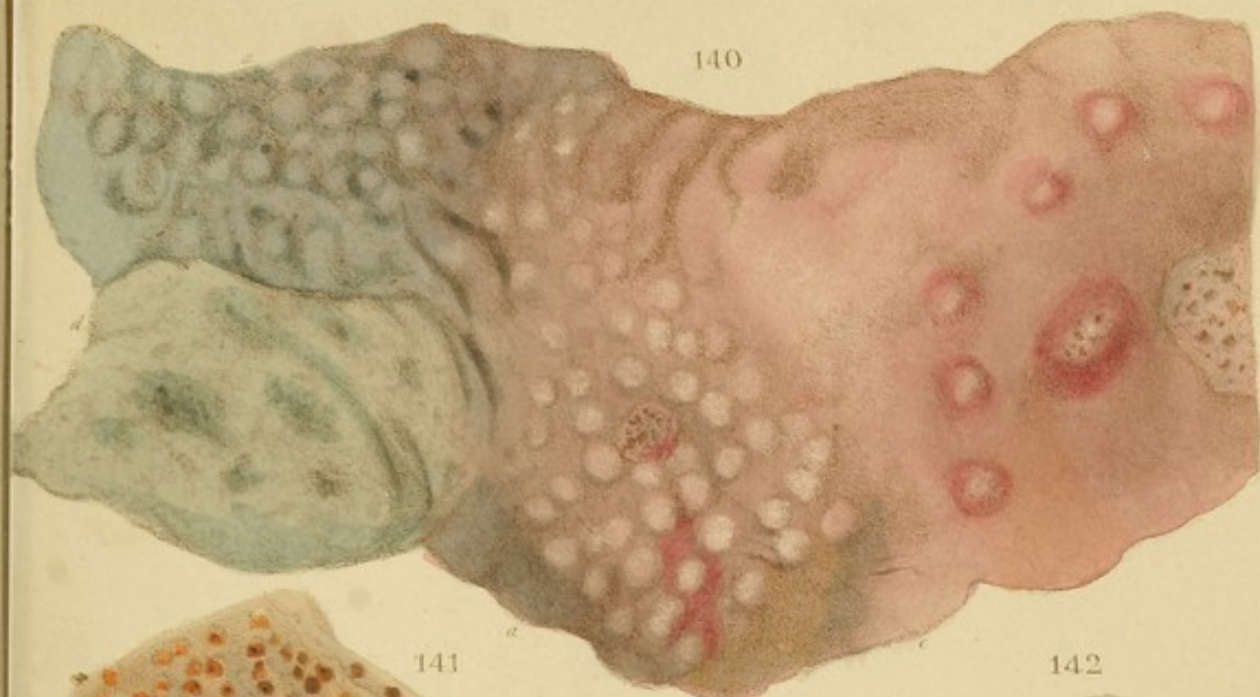Case.—The patient, in the clinical wards of M. Clotel, had been affected with chronic enteritis for fifty days, when she was suddenly carried off by acute peritonitis, consequent on perforation of the intestines. This originated in ulceration of the mucous glands, which had proceeded to a remarkable extent in the lower part of the colon. The state will be exhibited in a subsequent plate.

Fig. 143.—Green discoloration of the mucous glands of the colon in a child. The glands are not appreciably enlarged. From the same case as the next.

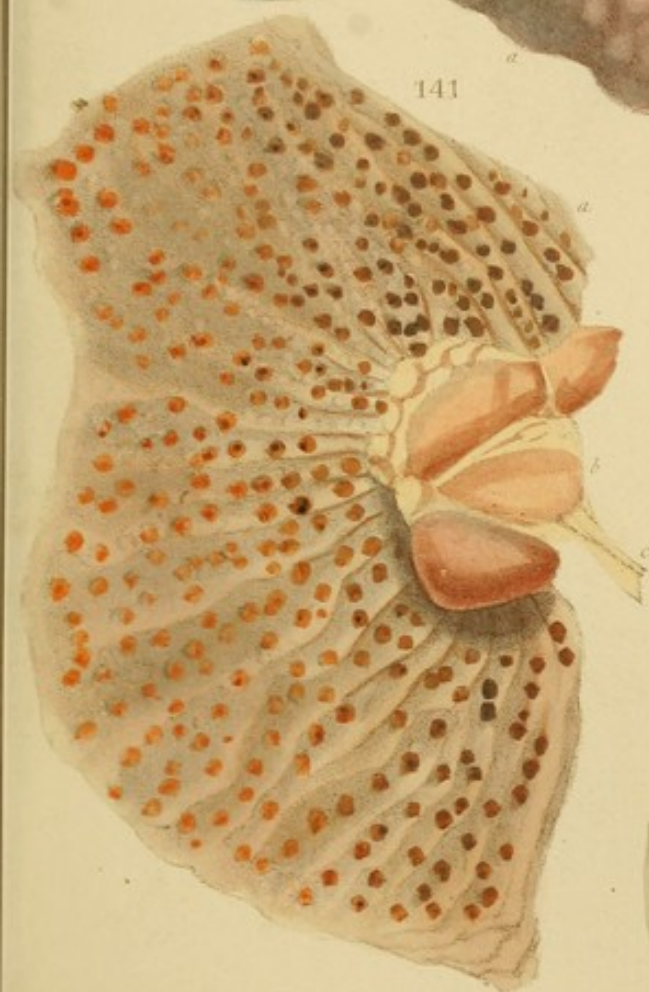Fig. 144.—Isolated glands of the duodenum, *b*, immediately below the pylorus, *a*, enlarged by inflammation. At *a*, those of the *valvula conniventes* only, are enlarged, and their orifices are stained green.

Case.—A cachectic child, æt. 5, at the Hôpital des Enfants. My notes of this case are defective; but I believe that the patient died worn out by infantile remittent fever.

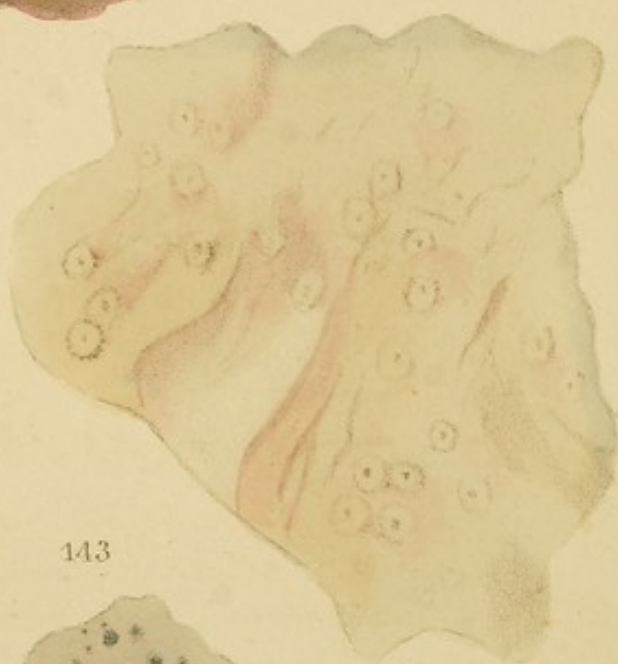Fig. 145.—Inflammatory enlargement of the mucous glands of the stomach. The central orifices are remarkably expanded, and present the appearance of ulcers. The redness results from intense acute inflammation.



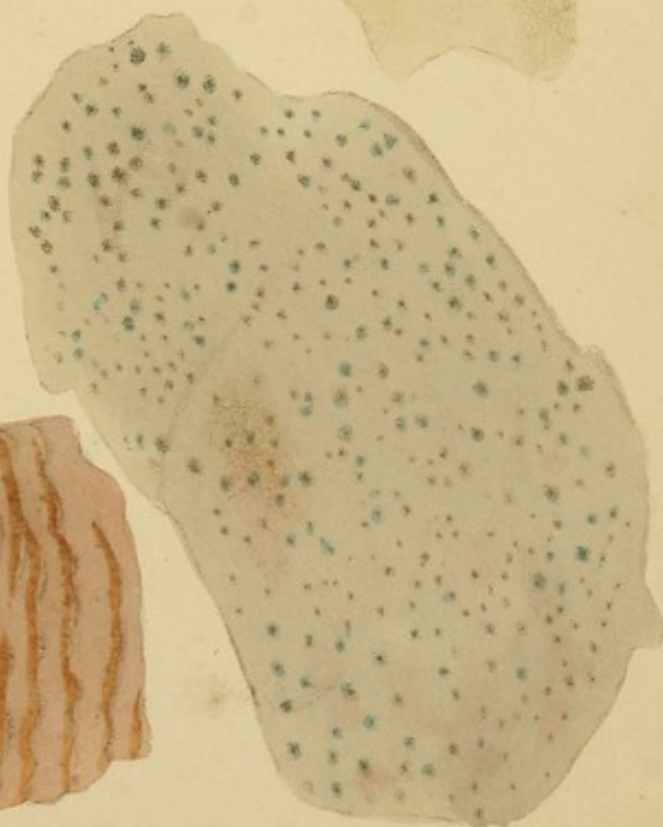140



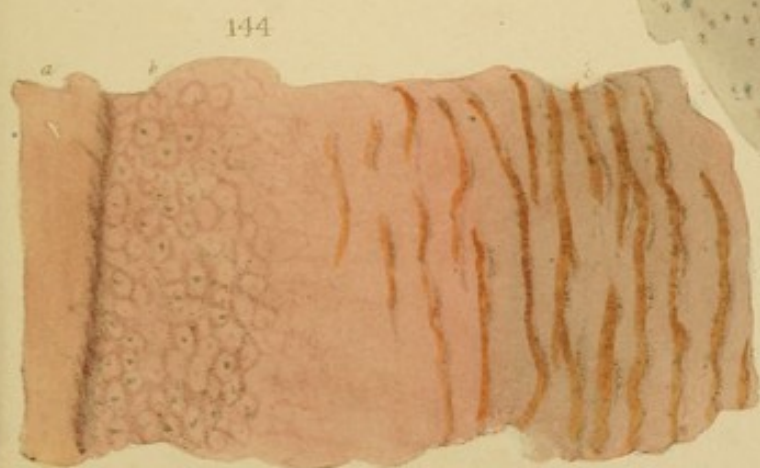
141




142




143



144





Case.—A female in the Edinburgh Infirmary æt. 50, emaciated. She had vomiting of all ingesta; thirst; heat of skin, with flushing of the face; great tenderness of the epigastrium; P. very small, quick, and weak; great anxiety of countenance. Died in two days after admission.

Section.—Stomach inflamed, and its glands enlarged, as here delineated. Its walls were thickened to the extent of a quarter of an inch, by œdema. The great extremity, where adherent to the spleen, had mortified, and sloughed completely through to this organ.

Fig. 146.—A patch of Peyer, greatly enlarged by acute inflammation, but not yet ulcerated.

Fig. 147.—A similar patch to the preceding, but advancing to ulceration. A little pus is seen in the centre.

Case.—Typhus fever.

Fig. 148.—Isolated glands of the ileum inflamed, enlarged, and ulcerated. The glands, *a, a, a, a*, are inflamed and red; those *b, b, b*, contain pus; in *c, c*, the pus is on the eve of bursting through; in *d*, the rupture has taken place; and in *e* and *f*, the ulcerated cavities are exposed to view.

Case.—Typhus fever.

Fig. 149.—Another view of isolated glands of the ileum greatly enlarged, and ulcerated. The glands *a* contain pus; those *b, b*, have ulcerated, and present a sloughy interior. The mucous membrane exhibits inflammation on the decline, and passing from the diffuse, to the circumscribed state.

Case.—Typhus fever. For the two last specimens, I am indebted to Dr. J. Baclesley of Manchester.

Fig. 150.—Inflammatory enlargement of the mucous glands of the valvula conniventes in the ileum. The glands were of a rich yellow colour, and presented a singularly beautiful appearance. The intermediate mucous membrane is inflamed, the inflammation having probably been excited by

Case.—A female in the Edinburgh Infirmary æt. 50, emaciated. She had vomiting of all ingesta; thirst; heat of skin, with flushing of the face; great tenderness of the epigastrium; P. very small, quick, and weak; great anxiety of countenance. Died in two days after admission.

Sectio.—Stomach inflamed, and its glands enlarged, as here delineated. Its walls were thickened to the extent of a quarter of an inch, by scirrhus. The great extremity, where adherent to the spleen, had mortified, and sloughed completely through to this organ.

Fig. 146.—A patch of Peyer, greatly enlarged by acute inflammation, but not yet ulcerated.

Fig. 147.—A similar patch to the preceding, but advancing to ulceration. A little pus is seen in the centre.

Case.—Typhus fever.

Fig. 148.—Isolated glands of the ileum inflamed, enlarged, and ulcerated. The glands, *a, a, a, a*, are inflamed and red; those *b, b, b*, contain pus; in *c, c*, the pus is on the eve of bursting through; in *d*, the rupture has taken place; and in *e* and *f*, the ulcerated cavities are exposed to view.

Case.—Typhus fever.

Fig. 149.—Another view of isolated glands of the ileum greatly enlarged, and ulcerated. The glands *a* contain pus; those *b, b*, have ulcerated, and present a sloughy interior. The mucous membrane exhibits inflammation on the decline, and passing from the diffuse, to the ramiform state.

Case.—Typhus fever. For the two last specimens, I am indebted to Dr. J. Bardesley of Manchester.

Fig. 150.—Inflammatory enlargement of the mucous glands of the valvulæ conniventes in the ileum. The glands were of a rich yellow colour, and presented a singularly beautiful appearance. The intermediate mucous membrane is inflamed, the inflammation having probably been excited by

tartrate of antimony, taken for pneumonia. *d*, is a considerably developed patch of Peyer, with its glandular orifices stained grey. It is surrounded by a fine elevated margin, *e*. Observe that the *valvulae conniventes* do not cross it.

Case.—A young man, at La Charité, in the clinical words of M. Chomel, had acute pain in the right breast, cough, mucous sputa, rigors followed by high fever, and the crepitant and mucous râles. *Diagnosis*. Pleuro-peripneumony and bronchitis. *Prognosis*, unfavourable. He was bled, ordered demulcent drinks, and tartar emetic gr. xxiv. daily. On the second day, diarrhoea was produced, (11 stools) and an opiate (syrup of Diacode) was, therefore, added to the tartrate of antimony. On the third day, the pulse became irregular, and the thoracic symptoms remained unabated. On the fifth day, M. Chomel suspected, from the irregularity of the P., that the inflammation had been propagated from the lungs to the pericardium; but, as the præcordial region did not sound dull, he inferred that there was not yet much effusion. On the following day, the irregularity and inequality of the pulse became extreme, and, on the day after, the præcordial region was dull, indicating effusion. On the eighth day the features were more collapsed. He had taken xxxvi. grains of Tart. Antim. without stool or vomiting. On the following day he died.

Sectio.—Peripneumonic engorgement of the lower lobes of the lungs. Pleuritis on the right. Bronchi red. Heart and pericardium were universally covered by a pale, canary-yellow, false membrane, which was soft, lacerable, pitted, and in some parts, three lines thick. The pericardium beneath was of a bright, spotted scarlet. The cavity contained eight ounces of opaque sero-purulent fluid, like sublimed sulphur and water.

Intestines.—The whole length of the ileum presented more or less of the appearance delineated in the Fig.

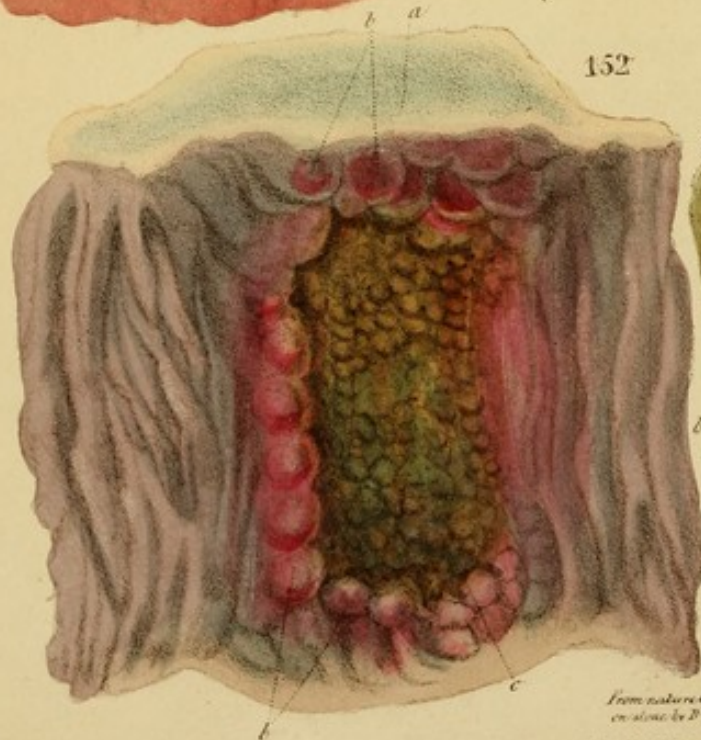
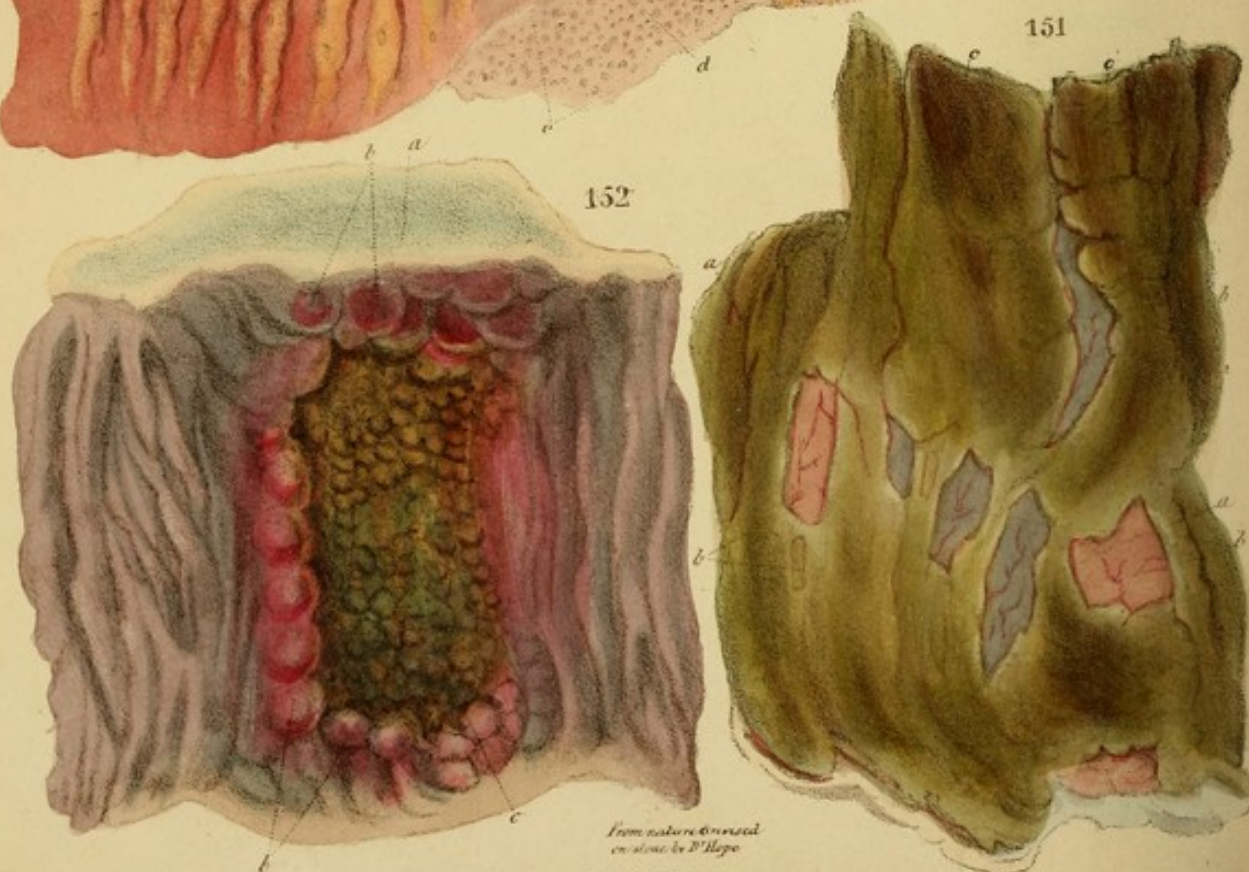
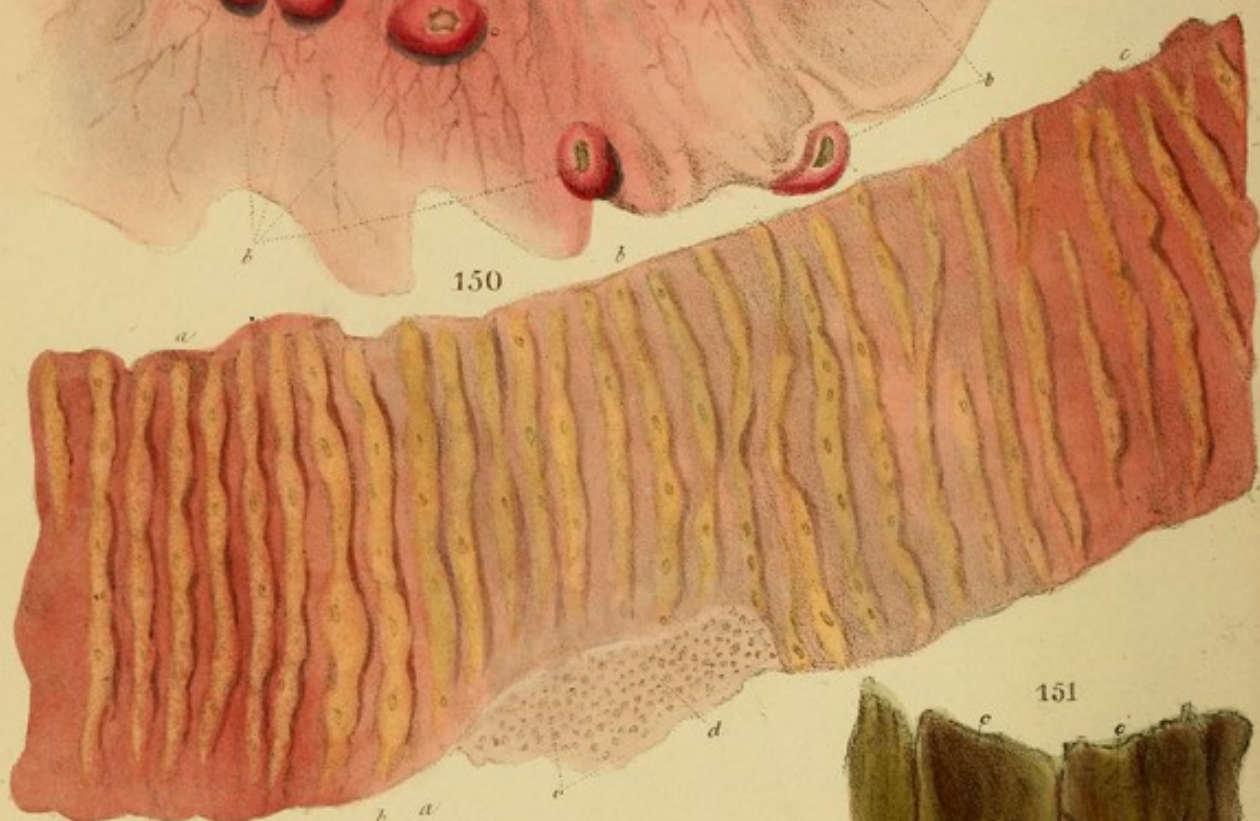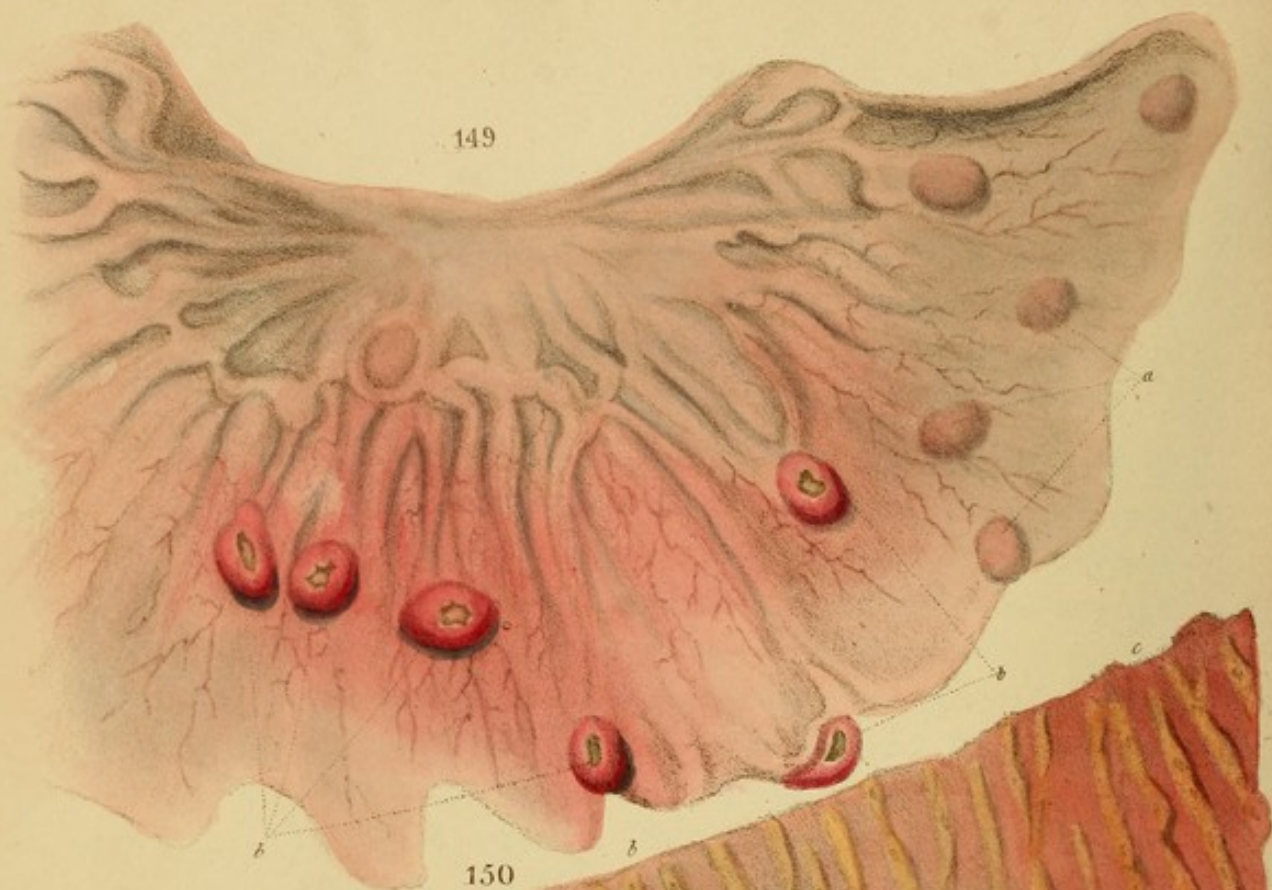


Fig. 131.—An advanced degree of the same affection as in the preceding Fig. It will be more intelligible by reference to the *Section* below.

Case.—Dinah Newman, æt. 20, under Dr. Chambers, at St. George's Hospital. Swelling and tenderness of both arms, especially at the wrists (acute rheumatism). Sore throat, with a deep ulcer in the left tonsil and ~~and~~ purple redness of the posterior fauces (scarlatina anginosa). Delirium; anxiety; P. 120, small; T. parched and brown; skin pungently hot; B. confined for two days; U. high coloured. The attack commenced eleven days ago, with rigors and sore-throat, followed by pyrexia. It is ascribed to cold, but scarlet fever was in the house. No eruption, however, had been observed on the patient. She had been thrice bled.

R Hydr. Subm. gr. v. opii gr. i. M. ft. pil. 4tis. horis, ad tertiam vicem, somnol. R Haust. semine statim. On the third day there was still much pain and tenderness of the limbs; the stools were green, and the throat was easier. She died in the evening.

Section.—Tongue extensively ulcerated.

Cutis.—At the end of the transverse arch, the intestine exhibited precisely the same appearance as in Fig. 130: namely, lines of enlarged glands, with open central orifices, occupied the edges of the valvula conniventes. A little further back, the glands were ulcerated; and, on proceeding still further, the degree of ulceration, and the number of the glands affected, progressively increased; until the disease assumed the appearance represented in the present Fig. and which may be thus described. The green parts *a, c, c*, &c. are layers of false membrane, thrown out by the ulcerated surface beneath, in ridges corresponding with the valvula conniventes; which ridges, a little lower down, were separate; but, here,




Fig. 151.—An advanced degree of the same affection as in the preceding *Fig.* It will be more intelligible by reference to the *Sectio* below.

Case.—Dinah Newman, æt. 20, under Dr. Chambers, at St. George's Hospital. Swelling and tenderness of both arms, especially at the wrists (acute rheumatism). Sore throat, with a deep ulcer in the left tonsil, and dark purple redness of the posterior fauces (scarlatina anginosa). Delirium; anxiety; P. 120, small; T. parched and brown; skin pungently hot; B. confined for two days; U. high coloured. The attack commenced eleven days ago, with rigors and sore-throat, followed by pyrexia. It is ascribed to cold, but scarlet fever was in the house. No eruption, however, had been observed on the patient. She had been thrice bled.

R Hydr. Submu. gr. v. opii gr. i. M. ft. pil. 4tis. horis, ad tertiam vicem, sumend. R Haust. sennæ statim. On the third day, there was still much pain and tenderness of the limbs; the stools were green, and the throat was easier. She died in the evening.

Sectio.—*Tonsils* extensively ulcerated.

Colon.—At the end of the transverse arch, the intestine exhibited precisely the same appearance as in *Fig. 150*: namely, lines of enlarged glands, with open central orifices, occupied the edges of the *valvulæ conniventes*. A little further back, the glands were ulcerated; and, on proceeding still further, the degree of ulceration, and the number of the glands affected, progressively increased; until the disease assumed the appearance represented in the present *Fig.* and which may be thus described. The green parts *a, a, c, c, &c.* are layers of false membrane, thrown out by the ulcerated surface beneath, in ridges corresponding with the *valvulæ conniventes*; which ridges, a little lower down, were separate; but, here,

they have partially coalesced by the extension of the disease. The false membrane is loose at its edges, and overlaps the scanty remains of the mucous membrane *b, b, b*, seen between the ridges. This membrane is a dim red, passing into slate-colour, and exhibits ramiform vascularity. When the false membrane is peeled off, a raw, ulcerated surface is exposed, the mucous membrane being completely destroyed. The false membrane is stained green by bile in the fæces.

Fig. 152.—Chronic ulceration of the intestine, of very old date. See the *Sectio*, below.

Case.—A mason, æt. 34, under M. Chomel at La Charité. Has often had cholic with diarrhœa during the last eight years, the attacks usually lasting three or four days. It has increased during the last year, and especially during the last four months. Three weeks ago an attack came on, attended with rigors and headache: the stools were watery and yellow. Slight cough for a year; no perspirations, nor hæmoptysis. P. not accelerated. Emaciation. *Diagnosis* of Chomel. Chronic inflammation of the intestines, on which acute has supervened: probably ulcerations. Chronic catarrh, and perhaps a few tubercles.

During ten days, the diarrhœa continued, and the emaciation made rapid strides. M. Chomel now referred the latter decidedly to ulceration; as there existed no other adequate cause for it. On the eleventh day, after fifteen stools, sudden collapse came on, and he died in two days more.


Sectio.—*Lungs.* An extraordinary quantity of black pulmonary matter, with induration, and dense tubercles like cartilage, very similar to those in Fig. 24. A few had small cavities, and yielded a little pus.


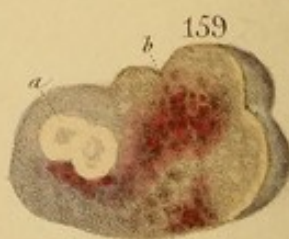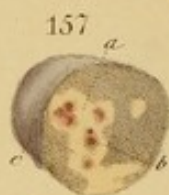
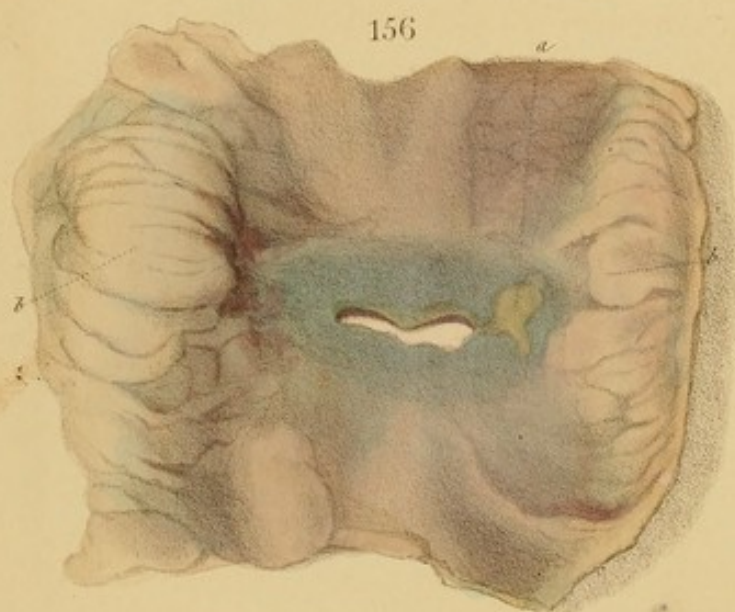
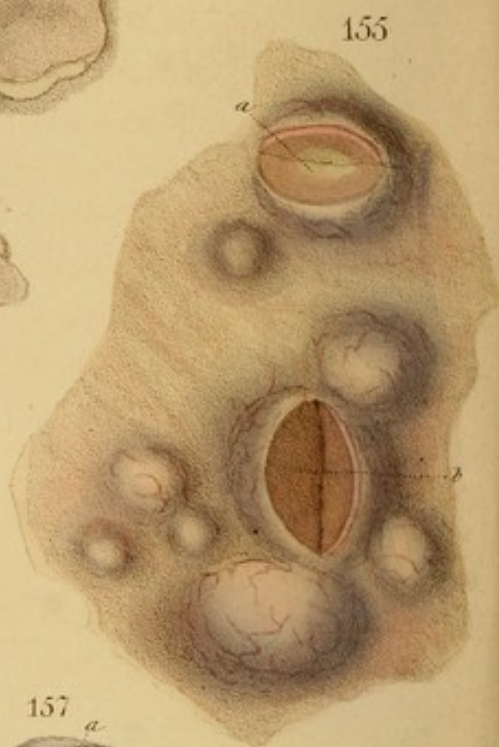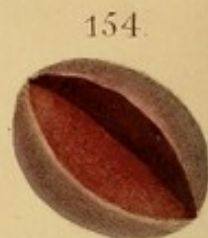
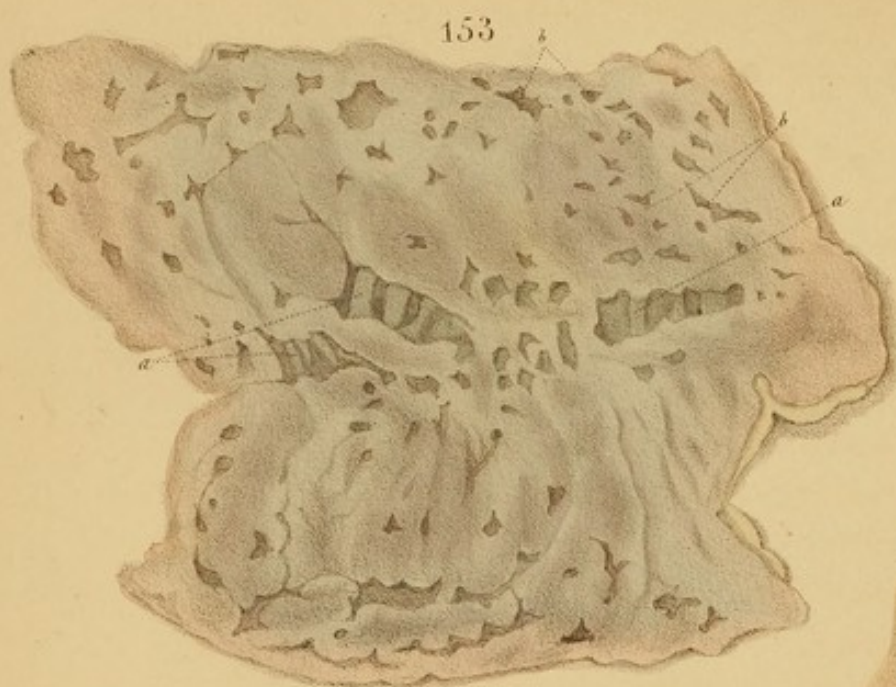Intestines.—Eight or ten ulcerations, at intervals of about as many inches, occupied the lower part of the

small intestine, and the whole of the large. They were from half an inch to two inches broad ; many formed complete rings round the intestine, and several penetrated to the peritoneum. The one delineated exhibits the general characters of the others. Its base is of a deep yellowish-green colour, ragged, knotty, and extremely friable or rotten, so that the slightest violence causes a rupture through the intestine. The circumference is elevated into irregular, hard knobs of deep lake colour. The redness occupied a breadth of about half an inch around most of the ulcers. The intermediate portions of intestine were either of a deep, purplish, uniform red, or of a slate-colour—changes resulting from chronic inflammation.

In another ulceration the peritoneum was destroyed, and the perforation was obstructed by layers of the green matter alone, which consisted of fibrine stained with bile. The exterior of the peritoneum presented a yellow eschar, surrounded by a deep slate-colour.

Remarks.—I introduce this case at length, as being highly characteristic of chronic ulcerations. The frequent recurrence of diarrhœa during a long period, and emaciation, not referable to any other cause, (particularly if conjoined with a red, tense, glistening tongue, like raw beef,) are symptoms which I have seldom found fallacious. Great numbers of such cases occur at the St. Marylebone Infirmary, amongst the lowest classes of poor, who are not only ill fed and much exposed, but are habitually inattentive to the state of the bowels.





*From nature & finished
on stone by P^r Hope.*

A. Tricolor Ishog. W.S. Macrinalane


DESCRIPTION OF THE PLATES.

Fig. 153.—Ulceration of the mucous glands of the lower part of the colon, from the same case as *Fig. 142*, which was taken from the head of the colon. The intestine is perfectly riddled with small ulcers, most of which penetrate to the peritoneum, and a few perforate it. Remnants of the muscular coat, *a, a*, are seen traversing the bases of some. The mucous membrane is exceedingly tanned, so as to contract the mouths of the ulcers, giving them a narrow angular shape, *A, B, C*, &c. The greater part of the colon was in the same state. The specimen was drawn under water. For Case, see *Fig. 142*.

Fig. 154.—An enlarged and inflamed mesenteric gland, denuded of its peritoneum.

Case.—A boy, *æt.* 14, in the St. Marylebone Infirmary, affected with typhus, *P.* 120, very small and weak; *T.* and lips covered with dry, brown scales; diarrhoea; great tenderness of abdomen; collapse of features; stupor, from which he could scarcely be roused. In a month. Died a few hours after admission.

Section.—The isolated and aggregated glands of the lower third of the ileum presented successive grades of enlargement and ulceration. The last five inches of the ileum were deeply disorganized, the muscular coat being partly destroyed. Twenty or thirty mesenteric glands, corresponding to the part diseased, were enlarged to various sizes between a pea and a filbert, and were of the red colour



DESCRIPTION OF THE PLATES.

Fig. 153.—Ulceration of the mucous glands of the lower part of the colon, from the same case as *Fig. 142*, which was taken from the head of the colon. The intestine is perfectly riddled with small ulcers, most of which penetrate to the peritoneum, and a few perforate it. Remnants of the muscular coat, *a, a*, are seen traversing the bases of some. The mucous membrane is exceedingly tumid, so as to contract the mouths of the ulcers, giving them a narrow angular shape, *b, b*, &c. The greater part of the colon was in the same state. The specimen was drawn under water. For *Case*, see *Fig. 142*.

Fig. 154.—An enlarged and inflamed mesenteric gland, denuded of its peritoneum.

Case.—A boy, æt. 14, in the St. Marylebone Infirmary, affected with typhus, P. 130, very small and weak; T. and lips covered with dry, brown sordes; diarrhœa; great tenderness of abdomen; collapse of features; stupor, from which he could scarcely be roused. Ill a month. Died a few hours after admission.

Sectio.—The isolated and aggregated glands of the lower third of the ileum presented successive grades of enlargement and ulceration. The last five inches of the ileum were deeply disorganized, the muscular coat being partly destroyed. Twenty or thirty mesenteric glands, corresponding to the part diseased, were enlarged to various sizes between a pea and a filbert, and were of the red colour

represented in the Fig. The brain, the bronchial membrane and the great vessels were congested.

Fig. 155.—Enlarged and inflamed mesenteric glands, connected with acute follicular enteritis. Some are red; (like Fig. 154;) others, *b*, being more advanced, are of a pinkish-yellow colour internally, and yield a blood-tinged pus on pressure; others, *a*, are still yellower and more purulent, but not disorganized.—*Case.* Typhus.

Fig. 156.—Perforation of the colon, viewed externally. It corresponded with a patch of ulceration similar to that represented in Fig. 152, and from the same subject. The perforation had been preceded by conversion of the peritoneum into a dirty-yellow, friable, and disorganized matter, as seen at *a*, and round the edge of the aperture. The part corresponding with the internal ulcer is slate-coloured. The parts *b, b*, consist of adipose matter. For *Case*, see Fig. 152.

Figs. 157, 158, 159.—Chronic, tubercular enlargement of the mesenteric glands. For particulars, see p. 193.

Case.—A scrofulous child in the St. Marylebone Infirmary, affected with tabes mesenterica, chronic diarrhoea, and disease of the intestinal mucous membrane. It was carried off suddenly by variola.

Fig. 160.—Tubercle, *a*, in the submucous cellular tissue, forming ulcers, *b*, and causing a thickened, knotty, and highly disorganized state of the mucous membrane. At all the dark parts, *c*, the membrane is deficient.

Case.—Ellen Drinkwater, in the St. Marylebone Infirmary. She had tubercles of the dura mater, and of the lungs, with chronic dysentery, and finally anasarca.

Fig. 161.—Ulcers of the isolated glands of the ileum, from chronic inflammation, in a phthisical subject. The margins are rounded and very callous. The large veins are con-

occurred in the lake. The water was somewhat warm and the great vessels were somewhat enlarged.

Fig. 100.—Illustration of the anterior end of the larva, showing the head, antennae, and the first pair of legs. The head is small and rounded, with a few setae. The antennae are short and thick. The first pair of legs is small and simple.

Fig. 101.—Illustration of the middle part of the larva, showing the thorax and the second pair of legs. The thorax is small and rounded, with a few setae. The second pair of legs is small and simple.

Fig. 102.—Illustration of the posterior end of the larva, showing the abdomen and the third pair of legs. The abdomen is small and rounded, with a few setae. The third pair of legs is small and simple.

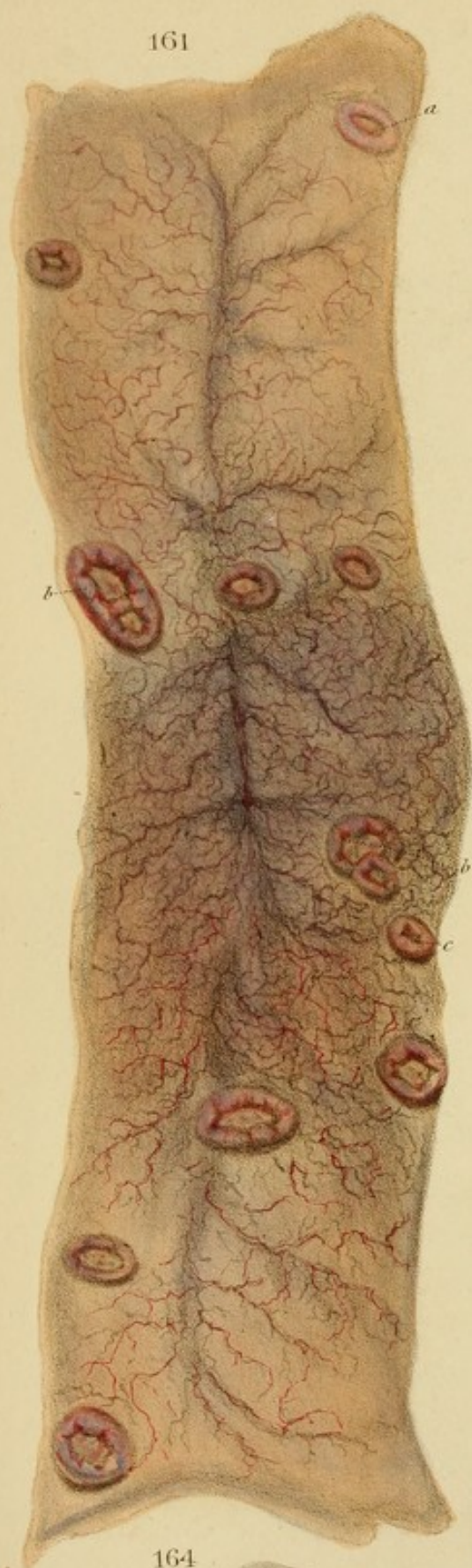
Fig. 103.—Illustration of the head of the larva, showing the antennae and the first pair of legs. The head is small and rounded, with a few setae. The antennae are short and thick. The first pair of legs is small and simple.

Fig. 104.—Illustration of the thorax of the larva, showing the second pair of legs. The thorax is small and rounded, with a few setae. The second pair of legs is small and simple.

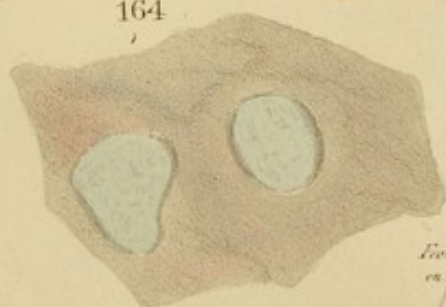
Fig. 105.—Illustration of the abdomen of the larva, showing the third pair of legs. The abdomen is small and rounded, with a few setae. The third pair of legs is small and simple.

Fig. 106.—Illustration of the head of the larva, showing the antennae and the first pair of legs. The head is small and rounded, with a few setae. The antennae are short and thick. The first pair of legs is small and simple.

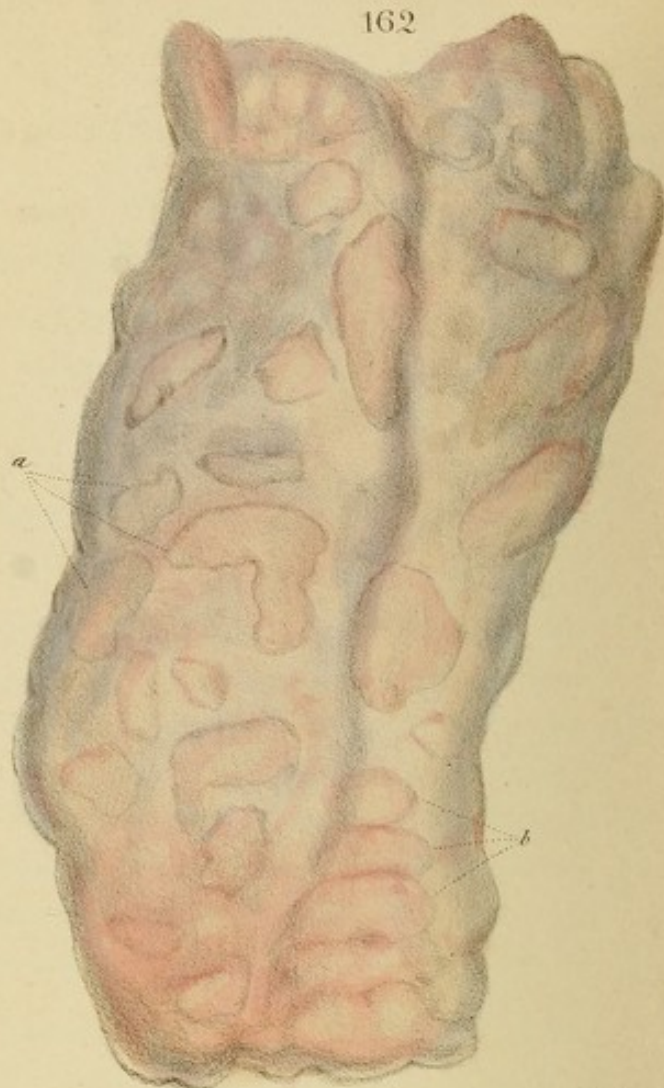161



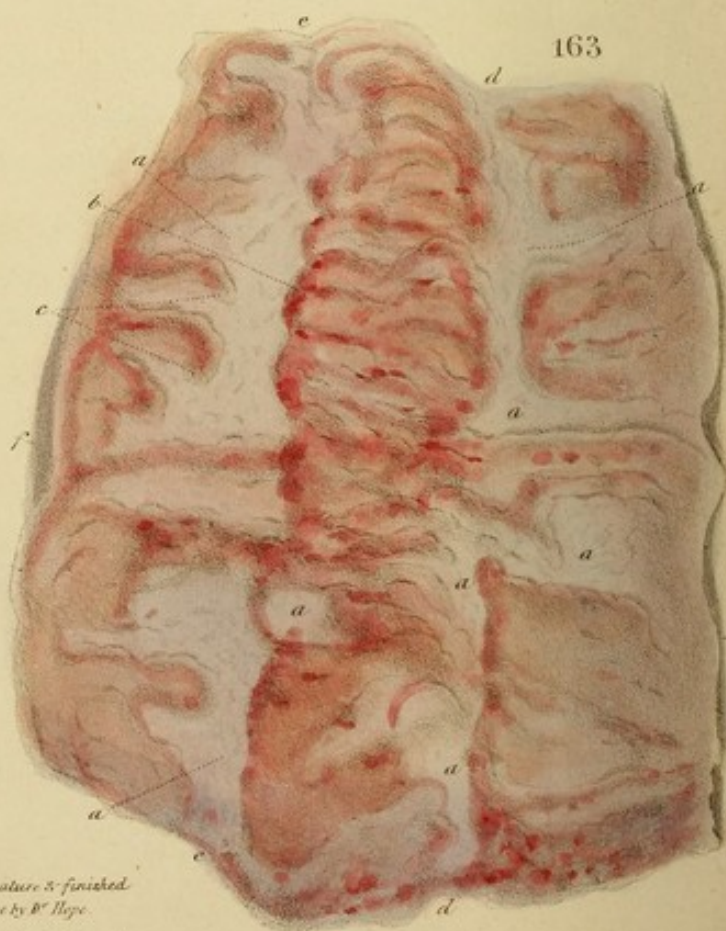164



162



163



From nature & finished
on steel by B. Hope.
A. D. 1800. L. 10. 10. 10.

gested, and the smaller vessels exhibit a beautiful capillary injection.

Case.—Pulmonary tubercular phthisis, attended with chronic diarrhoea. From the Clinique of M. Chenevix.

Fig. 162.—Rounded zones of inflammation, with softening of the included mucous membrane, tending to form ulcers. From the upper part of the colon. (See p. 192.)

Figs. 163 and 164.—*Fig. 164* exhibits two ulcers, formed by detachment of the softened mucous membrane of *Fig. 163*. Their edges are flat and sharp, as if cut out by a punch; and their bases are formed by bluish-white, submucous cellular tissue.

Fig. 163 exhibits the same disease in the lower part of the colon, after the ulcers have coalesced by extension, and formed long irregular patches, *a*, of denuded, bluish-white submucous cellular tissue. In the direction, *d*, *d* and *e*, *e* run the longitudinal bands of the colon. (See p. 196.)

Case of the three preceding *Figs.* Chronic dysentery, in La Charité. The whole colon was diseased, and its lower part was deeply and extremely disorganized.

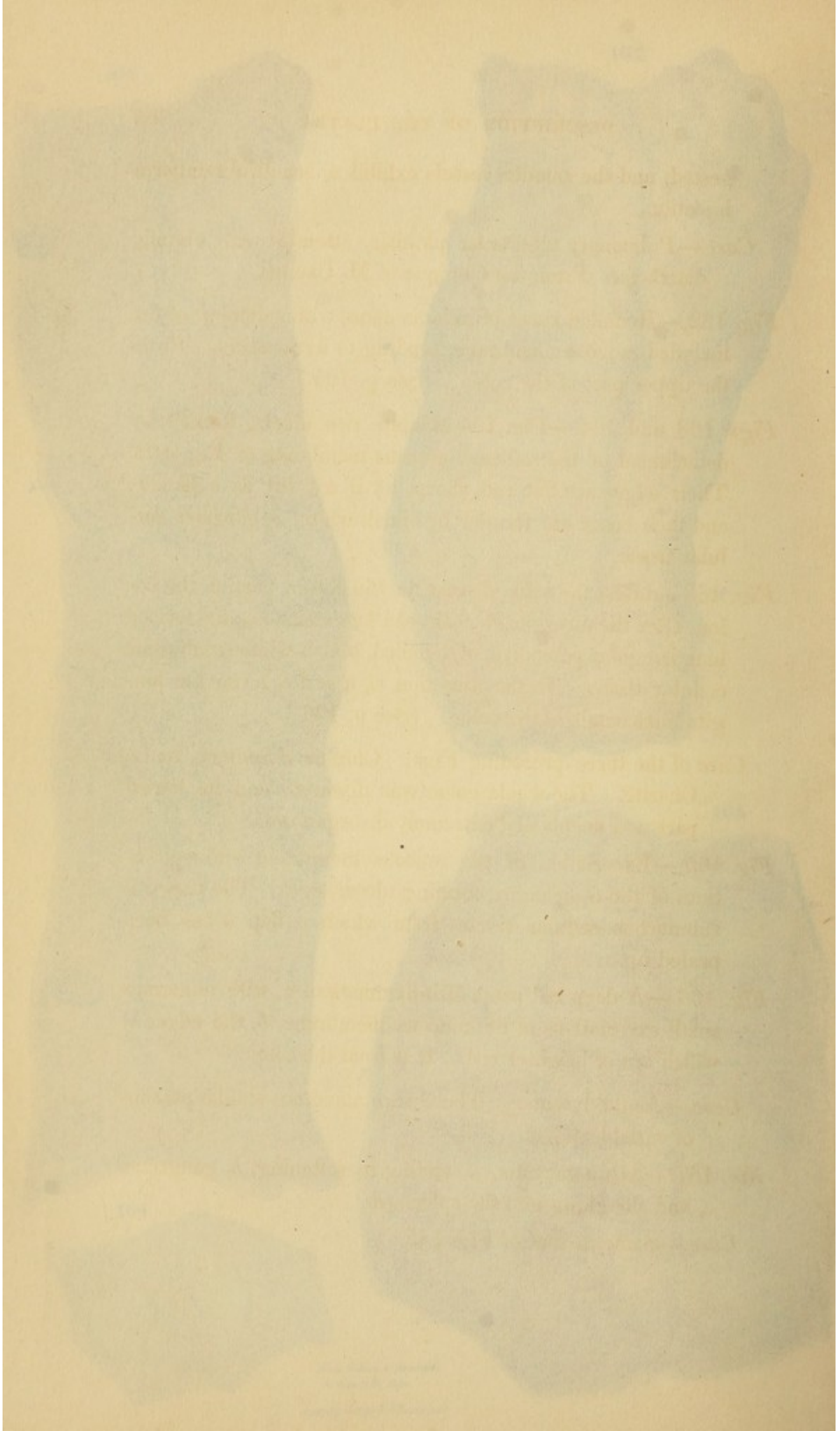
Fig. 165.—Excoriation of the mucous membrane and epithelium of the oesophagus, forming ulcers, *c*, *d*. The part *a* is submucous cellular tissue, from which a flap *b* has been prised up.

Fig. 166.—A deep red patch of inflammation, *a*, with numerous small excoriations of the mucous membrane, *b*, the edges of which are of brighter red. It is from the colon.

Case.—Acute dysentery. There were numerous similar patches of variable extent.

Fig. 167.—Acute gastritis, *a*, ending in softening, *b*, gangrene, *c*, and sloughing into the spleen, *d*.

Case.—Same as that of *Fig. 145*.



gested, and the smaller vessels exhibit a beautiful ramiform injection.

Case.—Pulmonary tubercular phthisis, attended with chronic diarrhoea. From the Clinique of M. Chomel.

Fig. 162.—Rounded zones of inflammation, with softening of the included mucous membrane, tending to form ulcers. From the upper part of the colon. (See p. 195.)

Figs. 163 and 164.—*Fig. 164* exhibits two ulcers, formed by detachment of the softened mucous membrane of *Fig. 162*. Their edges are flat and sharp, as if cut out by a punch; and their bases are formed by bluish-white, submucous cellular tissue.

Fig. 163 exhibits the same disease in the lower part of the colon, after the ulcers have coalesced by extension, and formed long irregular patches, *a*, of denuded, bluish-white submucous cellular tissue. In the direction, *d, d* and *e, e* run the longitudinal bands of the colon. (See p. 196.)

Case of the three preceding *Figs.* Chronic dysentery, in La Charité. The whole colon was diseased, and its lowest part was deeply and extremely disorganized.

Fig. 165.—Excoriation of the mucous membrane and epithelium of the œsophagus, forming ulcers, *c, d*. The part *a* is submucous cellular tissue, from which a flap *b* has been peeled up.

Fig. 166.—A deep red patch of inflammation, *a*, with numerous small excoriations of the mucous membrane, *b*, the edges of which are of brighter red. It is from the colon.

Case.—Acute dysentery. There were numerous similar patches of variable extent.

Fig. 167.—Acute gastritis, *a*, ending in softening, *b*, gangrene, *c*, and sloughing into the spleen, *d*.

Case.—Same as that of *Fig. 145*.

Fig. 168.—A half-healed intestinal ulcer. (See p. 202.)

Fig. 169.—A completely cicatrized intestinal ulcer, with contraction, and puckering towards its centre.

Case of Figs. 168 and 169. Chronic diarrhœa. The ulcers were in the colon. Others were in progress, and others, again, in a state of great disorganization.

Fig. 170.—Knobby and undulating, but smooth cicatrix of a deep ulcer, affecting the muscular coat.

Case 1.—A boy, æt. 11, in the St. Marylebone Infirmary, long affected with chronic enteritis and diarrhœa. Extreme emaciation; P. 130, very small and weak; frequent vomiting of a matter like lees of wine; a week before death, a lumbricus teres, six inches long, was ejected from the stomach.

Sectio.—Mucous membrane of the stomach was red, softened, and coated with thick adherent slime. In the lower third of the ileum, the mucous coat was thickened, and of dark-grey colour; Peyer's patches were enlarged, and a few ulcerated. Some of the isolated glands were in the same state. The cicatrix delineated was found immediately above the cæcal valve; where, also, two small lumbrici were discovered.

Case 2.—This affords an instructive instance of recovery from a miserable state, apparently dependent on intestinal ulceration. A gentleman, æt. about 21, stout and athletic, after an over-exertion in walking several hundred miles, followed by free, though not intemperate living, became subject to recurrent diarrhœa, with slimy dejections, tormina, and tenesmus. After nearly a year, he consulted me. He had lost two or three stone weight, and was extremely emaciated. Pain in the umbilical region, increased on pressure; enlarged mesenteric glands could be felt. P. 50, extremely small and weak; general coldness;

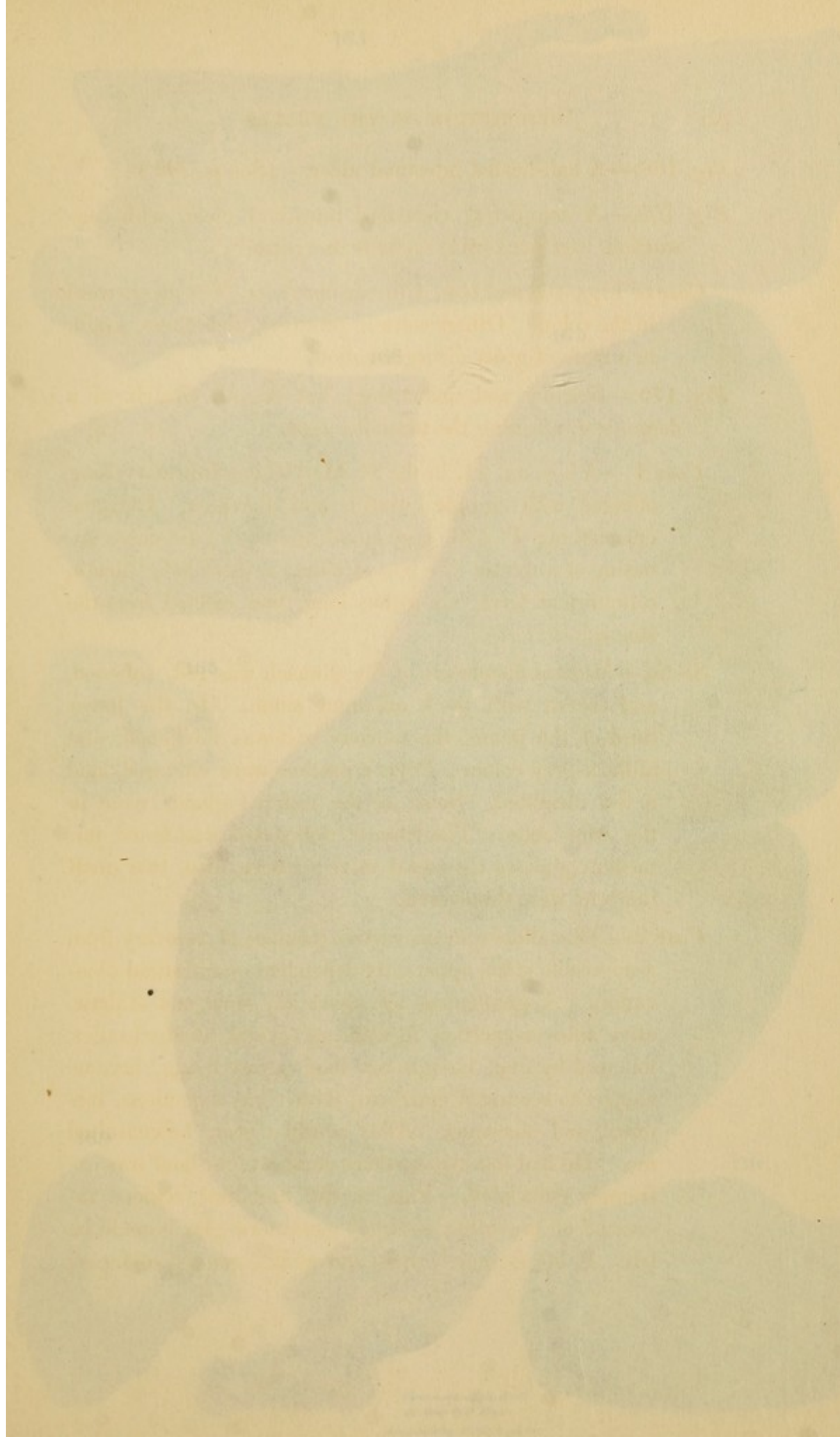


Fig. 168.—A half-healed intestinal ulcer. (See p. 202.)

Fig. 169.—A completely cicatrized intestinal ulcer, with contraction, and puckering towards its centre.

Case of Figs. 168 and 169. Chronic diarrhoea. The ulcers were in the colon. Others were in progress, and others again, in a state of great disorganization.

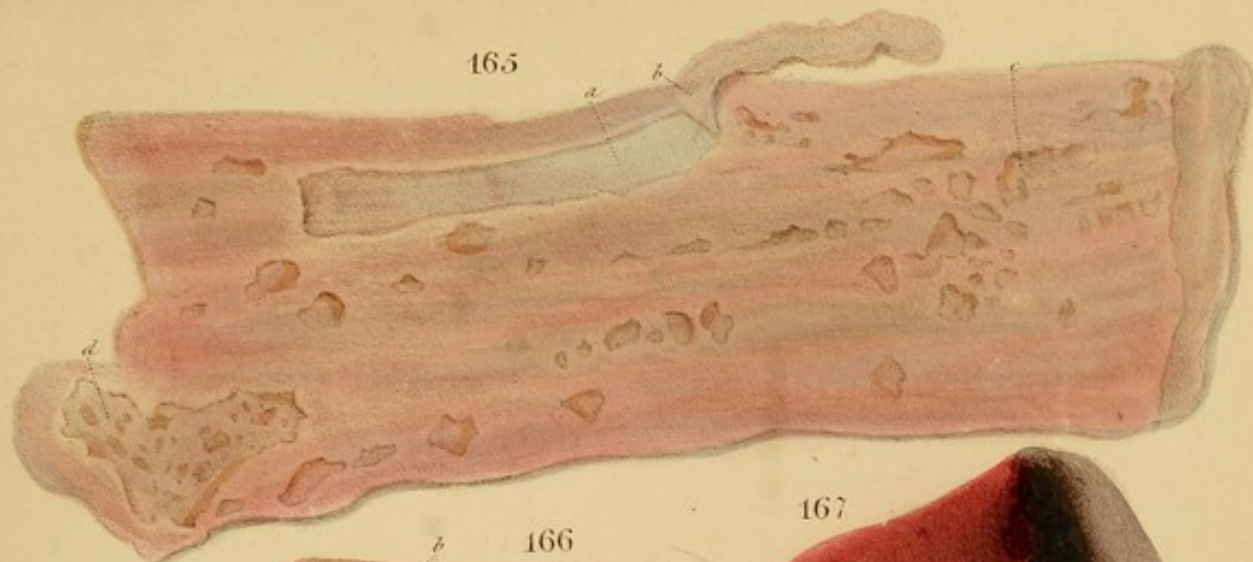Fig. 170.—Knobby and undulating, but smooth surface of a deep ulcer, affecting the muscular coat.

Case 1.—A boy, æt. 11, in the St. Mary's Hospital, long affected with chronic enteritis and diarrhoea. Extreme emaciation, P. 130, very small and weak; frequent vomiting of a matter like lees of wine; a week before death, a limbricus terrestris, six inches long, was ejected from the stomach.

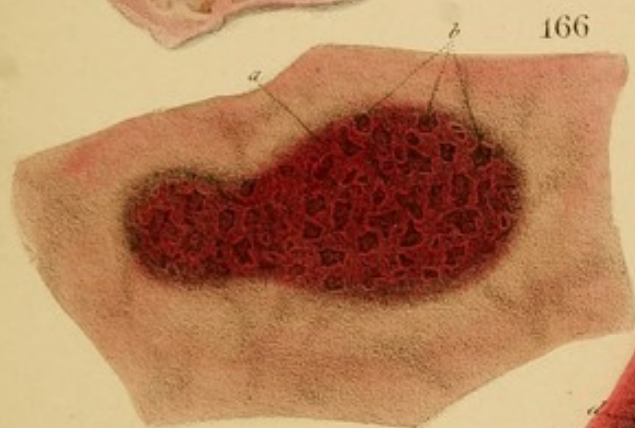
Section.—Mucous membrane of the stomach was red, softened, and coated with thick adherent slime. In the lower third of the stomach, the mucous coat was thickened, and of a dark grey colour; Peyer's patches were enlarged, and a few ulcerated. Some of the isolated glands were in a raw bloody condition. The cæcum was found immediately above the caecal valve; where, also, two small hæmorrhoids were discovered.

Case 2.—This affords an instructive instance of recovery from a miserable state, apparently dependent on intestinal ulceration. A gentleman, æt. about 21, stout and athletic, after an over-exertion in walking several hundred miles, followed by free, though not intemperate living, became subject to recurrent diarrhoea, with slimy dejections, tormina, and tenesmus. After nearly a year, he consulted me. He had lost two or three stone weight, and was extremely emaciated. Pain in the umbilical region, increased on pressure; enlarged mesenteric glands could be felt. P. 50, extremely small and weak; general coldness;

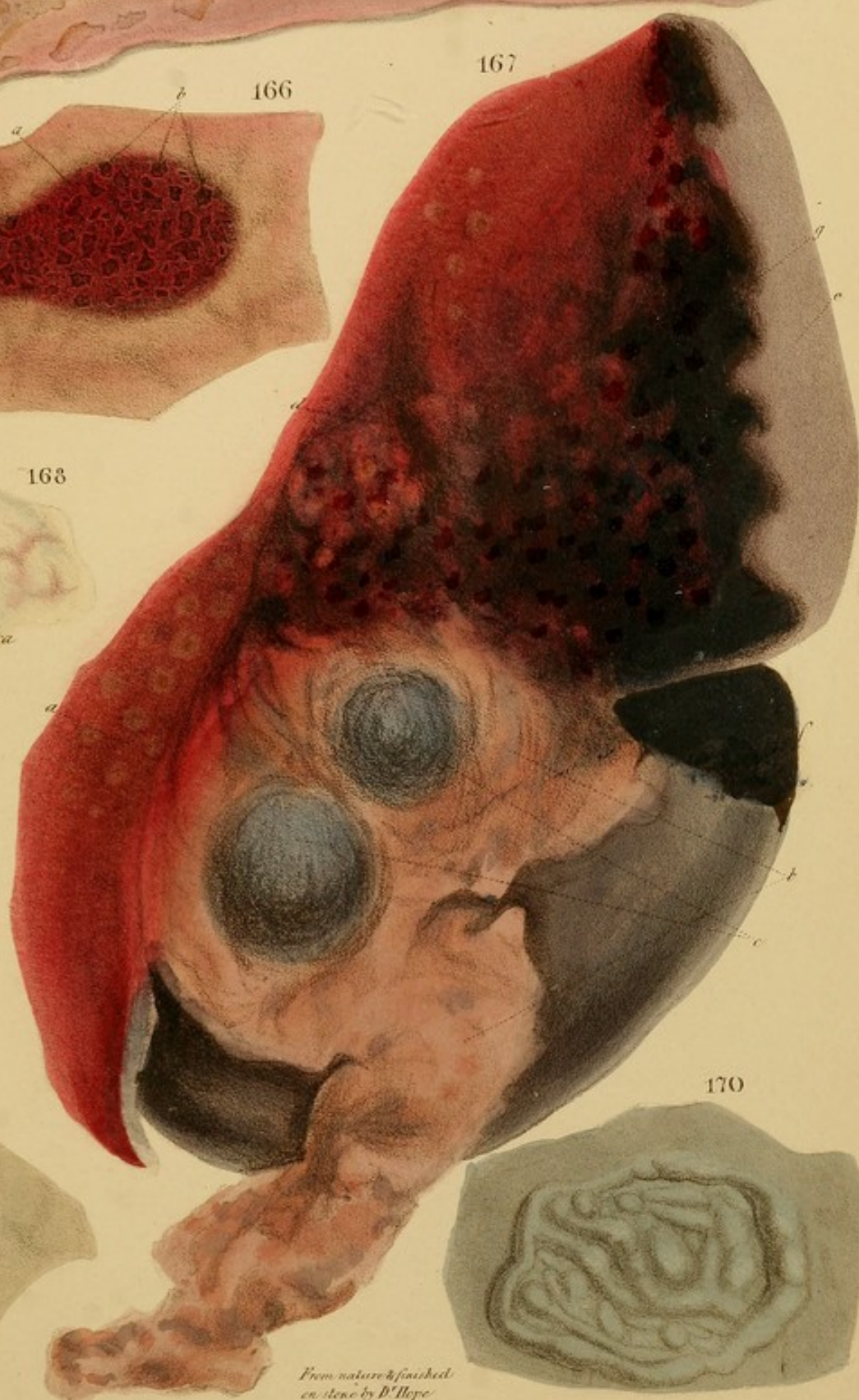
165



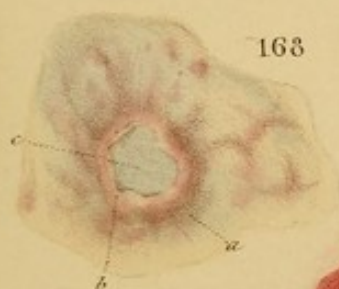
166



167



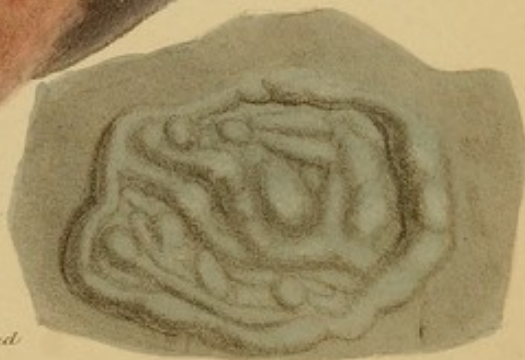168



169



170



*From nature & finished
en steel by D. Hope
A. Duval Lithog. 105 N. 3rd St. N. C.*

can only digest the smallest quantities of light food ; heart-burn ; eructation ; diarrhoea as above, alternating with constipation ; distressing flatulence and distension. He went, by my advice, to the country, lived principally on farinaceous gruels with a third of weak animal broth, took a light infusion of cascarilla twice a day, and applied a succession of mild blisters to the abdomen. In three or four months he was convalescent, and had gained greatly in bulk and strength. He was now induced, while at sea, to take burnt brandy as a preventive against cholera, by which the diarrhoea was again brought on. He fell into other hands in the country, and was put upon a stimulant treatment, viz., animal food, wine, &c., under which he progressively deteriorated. He returned in about six months to London, where, by a smart attack of bronchitis, super-added to his original complaint, he was reduced almost to a skeleton, and became dropsical and bedridden. After the bronchitis had yielded, I put him on an extremely scanty, milk, farinaceous and broth diet, and prescribed the inf. cascaril. also half a tea-spoonful of Gregory's powder every other night, without which the abdominal distension become intolerable. On this plan, he got rid of the dropsy and diarrhoea, and improved in strength and substance. Subsequently, as he became impatient and discouraged, it was determined, in consultation, to try a more nutritious diet : viz., rum and milk, turtle, porter, jellies, &c. The diarrhoea recurred, and he finally retrograded. He was now sent, early in spring, to the country, under circumstances of great mental encouragement, and was again put upon the mild diet. Under this, he steadily improved, and, in a few months, was enabled to sail for a foreign clime, after an illness of more than two years.

Remarks.—This appears to me to be a well-characterized history of ulceration of the intestines, probably above the

cæcal valve. The enlarged state of the mesenteric glands, so frequent a concomitant of ulceration, corroborates this view of the case. The good effects of a mild diet, thrice alternated with a stimulant one, evince very strikingly the advantages of the former. His final recovery seemed to be much promoted by a good air and a cheerful state of mind. To humour a fancy, he took a mild vapour bath about twice a week.

Fig. 171.—Hypertrophy of the mucous membrane of the stomach, with a mammelated surface (*muqueuse mammelonée*). Colour dim red and slate-grey, from chronic inflammation: *a* shows the thickness of the membrane, about two lines; *b* is the submucous cellular tissue; *c*, the flap torn up.

Case.—A man in the Clinical wards of Chomel, whose history I could not obtain. The following is a remarkable case of the same affection:—Martha Lock, æt. 36, widow, at the St. Marylebone Infirmary, January, 1829, under Dr. Hooper. Four years ago, menstruation was checked by a fright; mucous diarrhœa followed, and was succeeded by intense gastrodynia, for which she took brandy and water. By this, inflammation was excited: vomited incessantly for a week; was blooded, leeches, &c., and recovered in three weeks. From this time, the catamenia were seldom more than a mere show; and, at each period, she experienced a recurrence of gastrodynia and vomiting, the three first attacks of which were attended with hæmatemesis, and this symptom recurred occasionally for two years. For the first two years and a half, the monthly paroxysm of gastrodynia and vomiting lasted about four days and nights without intermission, on each occasion. During the next year, the catamenia having wholly ceased, the attacks became irregular and shorter; and during the last six months, they have recurred every two or three days, and lasted twenty-four hours.

The paroxysm commences with flatulent distension of the stomach, which brings on the gastrodynia and vomiting; and these symptoms are incessant, until the flatus is discharged freely upwards and downwards. The matter vomited is a clear, sour fluid, which, after much straining, becomes greenish, yellowish, brownish, and of bilious taste. The quantity ejected sometimes amounts to two or three pots de chambre at a single attack. It is remarkable that solid ingesta, though taken immediately before the attack, are never, as she affirms, expelled. So long as the vomiting continues, she experiences a sensation of burning heat in the stomach.

Cold water is her sovereign and sole remedy for the paroxysm. So great is the relief derived from fomenting the epigastrium with it, that she never goes to bed without a quantity at hand. She also takes copious draughts, which expel the flatus downwards, and thus finish the attack.

After the attack she requires food in small quantities and often. Meat, thus taken, agrees better than light food, because the latter occasions flatulence—her greatest enemy. Wine and fermented liquors excite an intense burning pain in the stomach, and immediately cause a relapse.

There seems to be a very slight diffuse induration deep under the left hypochondrium. Decubitus on the left side excites the paroxysm; she is also uneasy on the right, and therefore always lies on the back. B. regular and evacuations natural, except after the bilious vomiting, when they are almost white: U. natural, but very copious and pale during the attack: T. whitish, but clean: P. 96, rather weak; though thin and pale, she is not emaciated.


Blisters, leeches, stomachics, aperients, and every variety of narcotic, were tried by Dr. Hooper without permanent relief; but for one three months, while in the country, she had total exemption from every symptom except amenorrhœa. *Diagnosis.* Dr. Hooper did not

regard the case as one of cancer, but formed no other decided opinion. I was inclined to suspect the existence of a simple chronic ulcer.

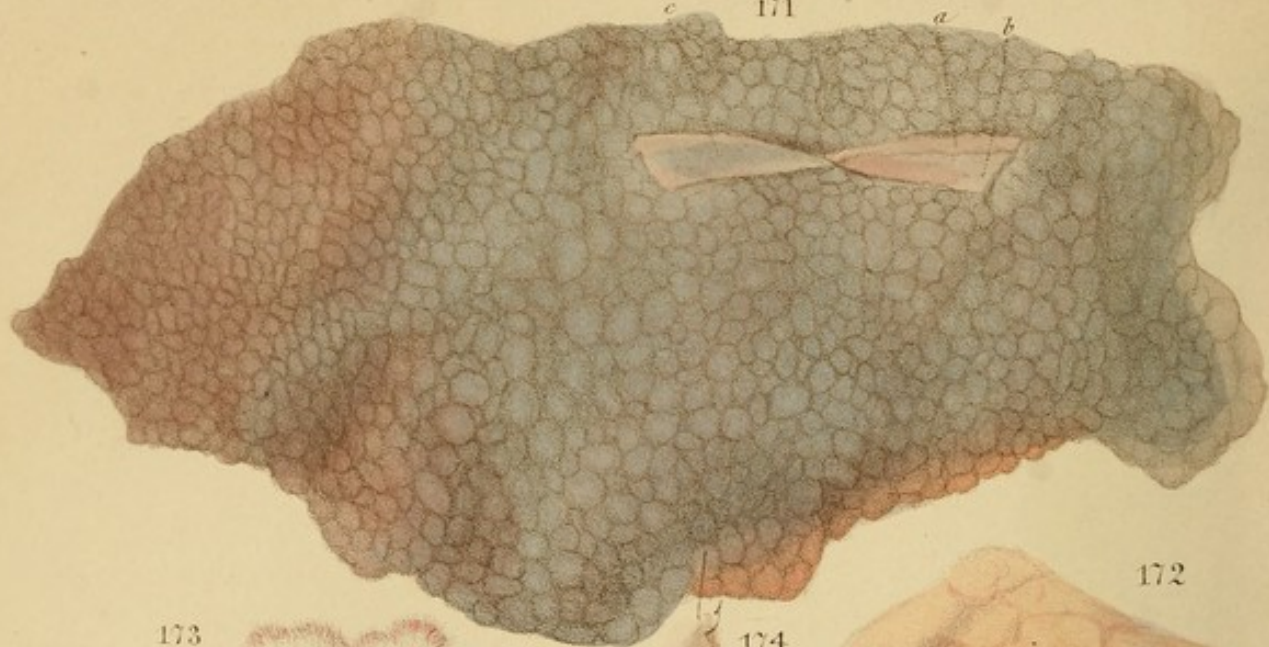
The patient remained three years and a half, more or less, under my eye, and occasionally under my care. The symptoms presented, throughout, little variation, except that the matter vomited was occasionally dark, like treacle (decomposed blood). During the last year, emaciation made some advances. Died June 9th, 1832.

Sectio.—The mucous membrane of the stomach was universally thickened to the extent of about two lines; it was also indurated, so as to admit of being torn up in large flaps. Its surface was mammelated, (as in the Fig.,) and covered by a thick layer of adherent, slimy, transparent mucus. The colours were dim red and slate-grey, with yellowish-white in parts. The submucous cellular tissue was thickened to the extent of a line or two. The other viscera were healthy.

Reflexions.—This case affords much practical instruction in several points of view:—1. It illustrates the well-known connexion between the stomach and the uterus, by the occurrence of gastrodynia at the menstrual periods, when the discharge was defective. 2. The case shows how complex a series of symptoms, and how much of a spasmodic character, may be produced by chronic gastritis. Had a strictly abstinent, antiphlogistic and counter-irritant plan been perseveringly employed, it is probable that this patient would have derived much greater benefit, if not complete relief. 3. The case shows that the lightest diet is not always the most useful in inflammatory dyspepsia; since the flatulence to which it may give rise, more than countervails its superiority, in other respects, over animal food. 4. Did the flatulence excite gastrodynia by stretching and irritating the thickened, and therefore inelastic, walls of the stomach? 5. The dark,



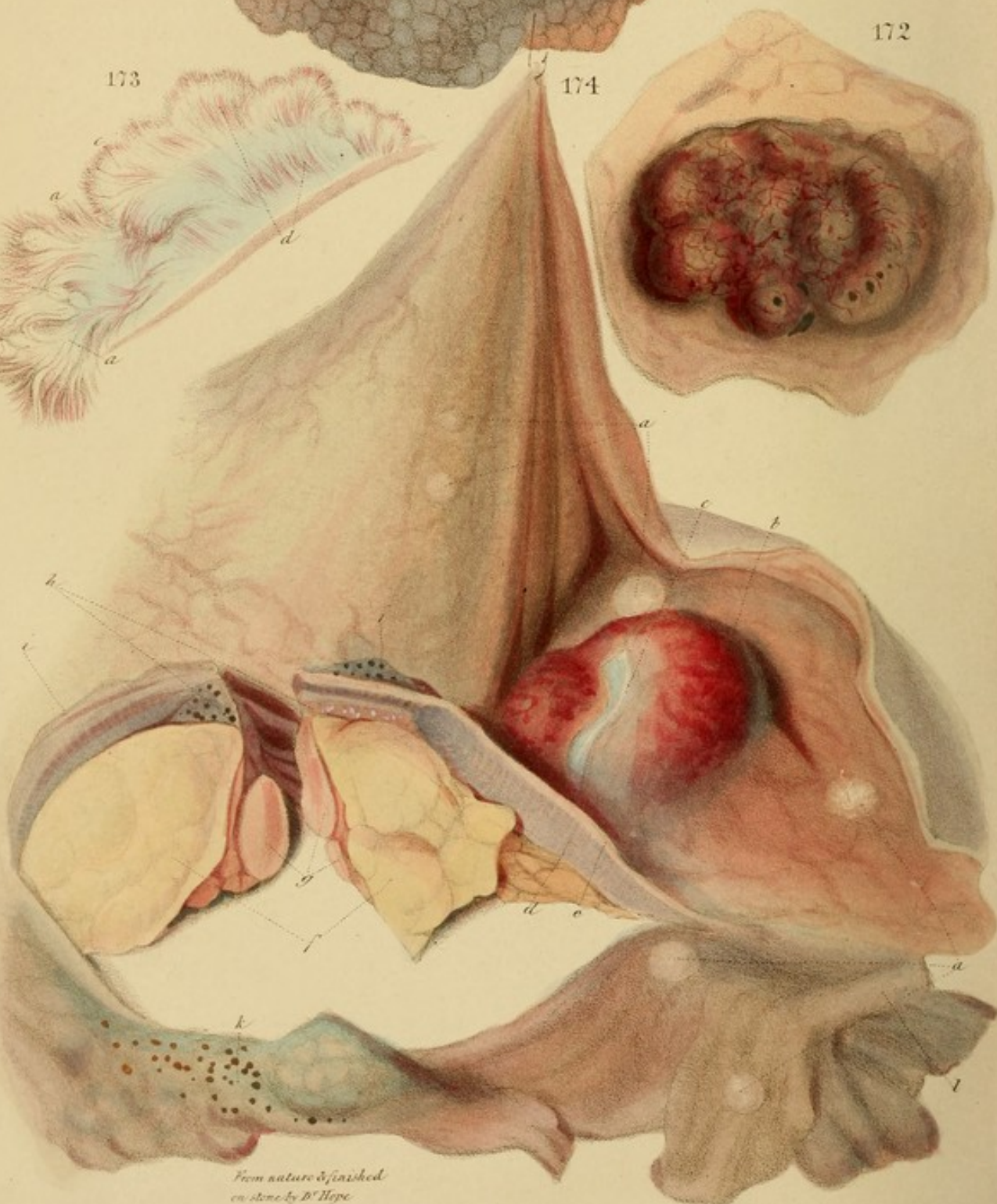171



172

174

173



From nature & finished
on stone by D. Hope

A. T. Smith del. & P. W. Morgan sculp.

...under
... ..
... ..

... ..
... ..
... ..
... ..
... ..
... ..
... ..
... ..
... ..
... ..


Fig. 172.—Excretory duct of the stomach. The root is less, by half or more, than the crown, which hangs over like a umbel-like, with a pale substance. The redness is increased partly by galled blood vessels and partly by spots of extravasation from them. A section of the fungus exhibits a pulpy filamentous structure, (similar to that in Fig. 173,) springing upwards from the mucous membrane and subjacent cellular tissue, in the manner of a cauliflower-head. The section is of a reddish-grey colour. The surrounding mucous membrane is healthy.

Case.—A female, at 70, in the St. Marylebone Infirmary, where Henry I could not learn.

Fig. 173.—A section of a fungus. (See p. 100.)

... ..
... ..
... ..
... ..
... ..
... ..
... ..

The centre of the Fig. exhibits a
... ..
... ..
... ..
... ..
... ..
... ..



treacly matter vomited was blood, which had slowly exuded, and been decomposed in the stomach. The symptom is not rare in chronic inflammation.

I had formerly under my charge, in the Edinburgh Infirmary, a case precisely similar to the present, except that, as the catamenia were wholly suppressed, the attacks of gastrodynia were irregular. The patient could not tolerate any but an abstemious, antiphlogistic and counter-irritant plan; and after this had been steadily pursued for nine months, she left the Infirmary convalescent.

Fig. 172.—Excrescence from the surface of the stomach. Its root is less, by half an inch, than its crown, which hangs over like a mushroom, and is of pulpy consistence. The redness is occasioned partly by gorged blood-vessels and partly by spots of extravasation from them. A section of the fungus exhibits a pulpy filamentous structure, (similar to that in *Fig. 173*,) springing upwards from the mucous membrane and subjacent cellular tissue, in the manner of a cauliflower-head. The section is of a reddish-grey colour. The surrounding mucous membrane is healthy.

Case.—A female, æt. 70, in the St. Marylebone Infirmary, whose history I could not learn.

Fig. 173.—Internal structure of a fungus. (See p. 207.) Copied from Cruveilhier.

Fig. 174.—Excrescences, and cancer of the stomach. The excrescences *a, a*, are small and incipient; the one, *b*, is large, and red externally from congestion and extravasation. The submucous cellular tissue is seen at *c*, thickened and blue.

The centre of the *Fig.* exhibits a section through the thickened walls of the stomach, displaying a bisected tumour, *f*, adherent to the peritoneal surface. It is as large as an egg, and consists of a congeries of enlarged, cancerous glands, *g*,

covered by lobulated adipose tissue, *f*. The irritation of this tumour had led to hypertrophy (scirrhus) of the muscular coat, *d*, ending in carcinomatous ulceration, *h, i*. The pylorus is at *l*; the cardia near *h, i*.

Case. 1.—A female, æt. 50, in La Charité, who had been subject to vomiting, but not to such an extent as to fix the attention of her physicians. This was the only characteristic symptom manifested by the cancer and excrescences of the stomach. On admission she was universally dropsical, and had enlarged liver, in which condition she died.

Section.—In addition to anasarca, two pints of fluid were found in the chest, and as much in the abdomen. The liver was double its natural size, granulated, and of deep dingy yellow colour. The external tumour and corresponding cancer of the stomach were situated along the lesser arch, and one-third nearer to the cardiac orifice, at *h, i*, than to the pyloric, *l*. By causing the approximation of the two orifices, the disease had diminished the capacity of the organ.

Remark.—The symptoms were slight in this case, from the circumstance of the orifices being exempt from disease.

Case. 2.—A female, in La Charité, had an encephaloid excrescence of the stomach, in connexion with universal cancer, namely, an enormous ulcerating cancer occupying the whole of the left mamma; axillary and subclavian glands on both sides, enlarged,—some to the size of pigeons' eggs; liver crowded with encephaloid tubera, of all sizes, from a pea to a billiard-ball. All the other viscera of the thorax, abdomen, and pelvis, without exception, contained analogous tumours.

Remark.—It cannot be doubted that, in such a case, the tumour of the stomach was cancerous.

The first of these is the fact that the
... of the ... is ...

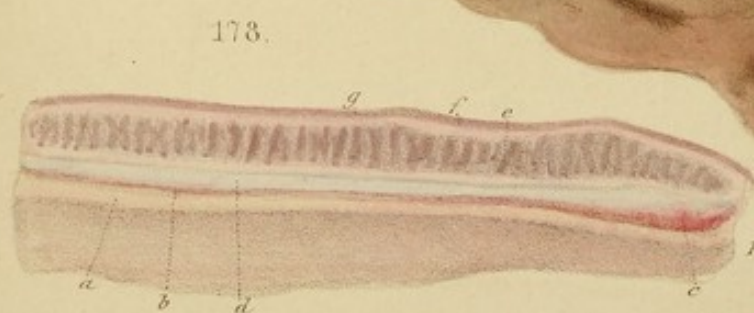
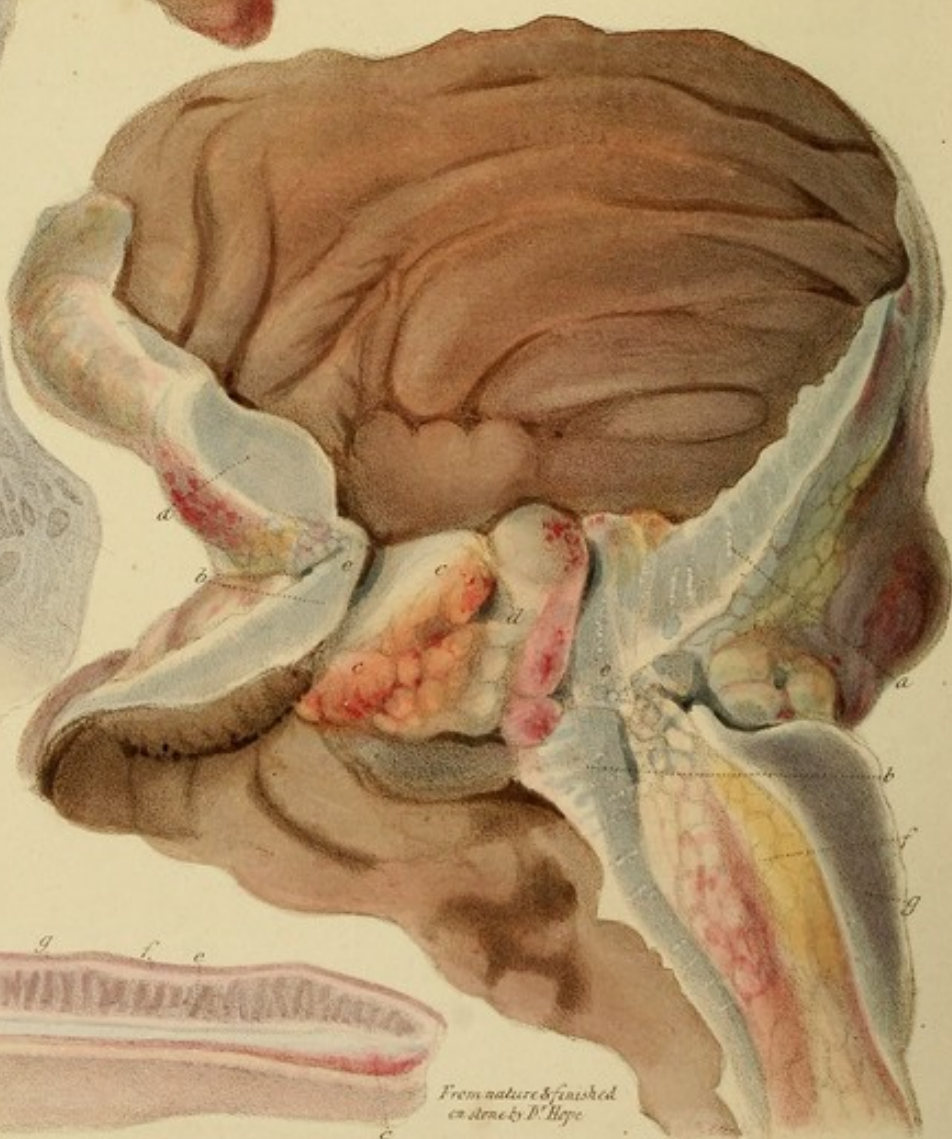
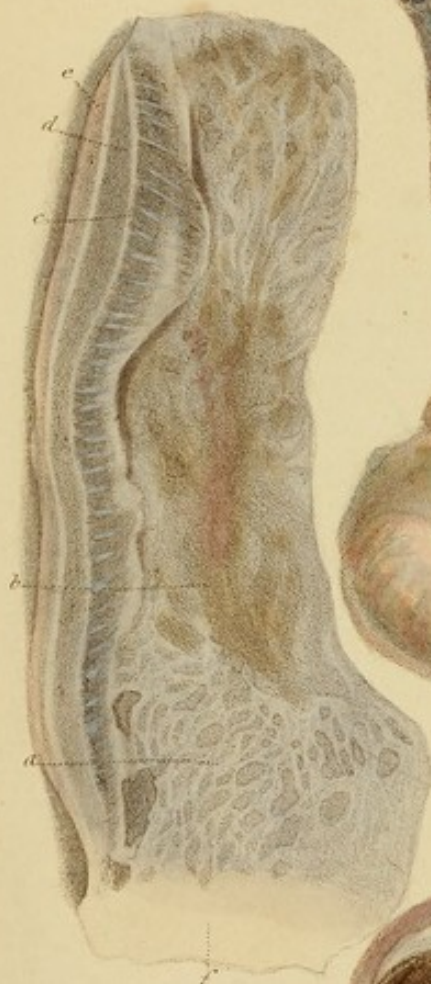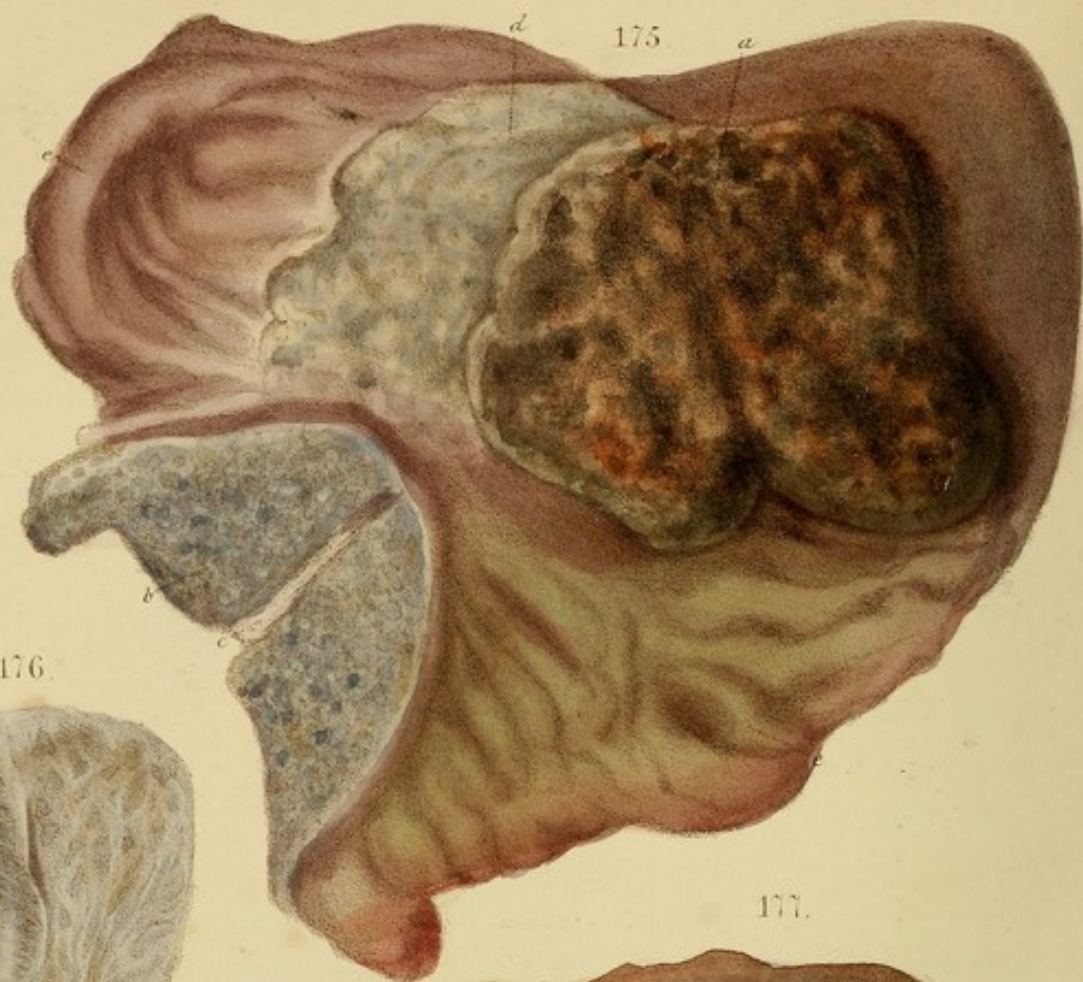The second is the fact that the
... of the ... is ...

The third is the fact that the
... of the ... is ...

The fourth is the fact that the
... of the ... is ...

The fifth is the fact that the
... of the ... is ...

The sixth is the fact that the
... of the ... is ...



From nature & finished
by P. Hope

DESCRIPTION OF THE PLATES.

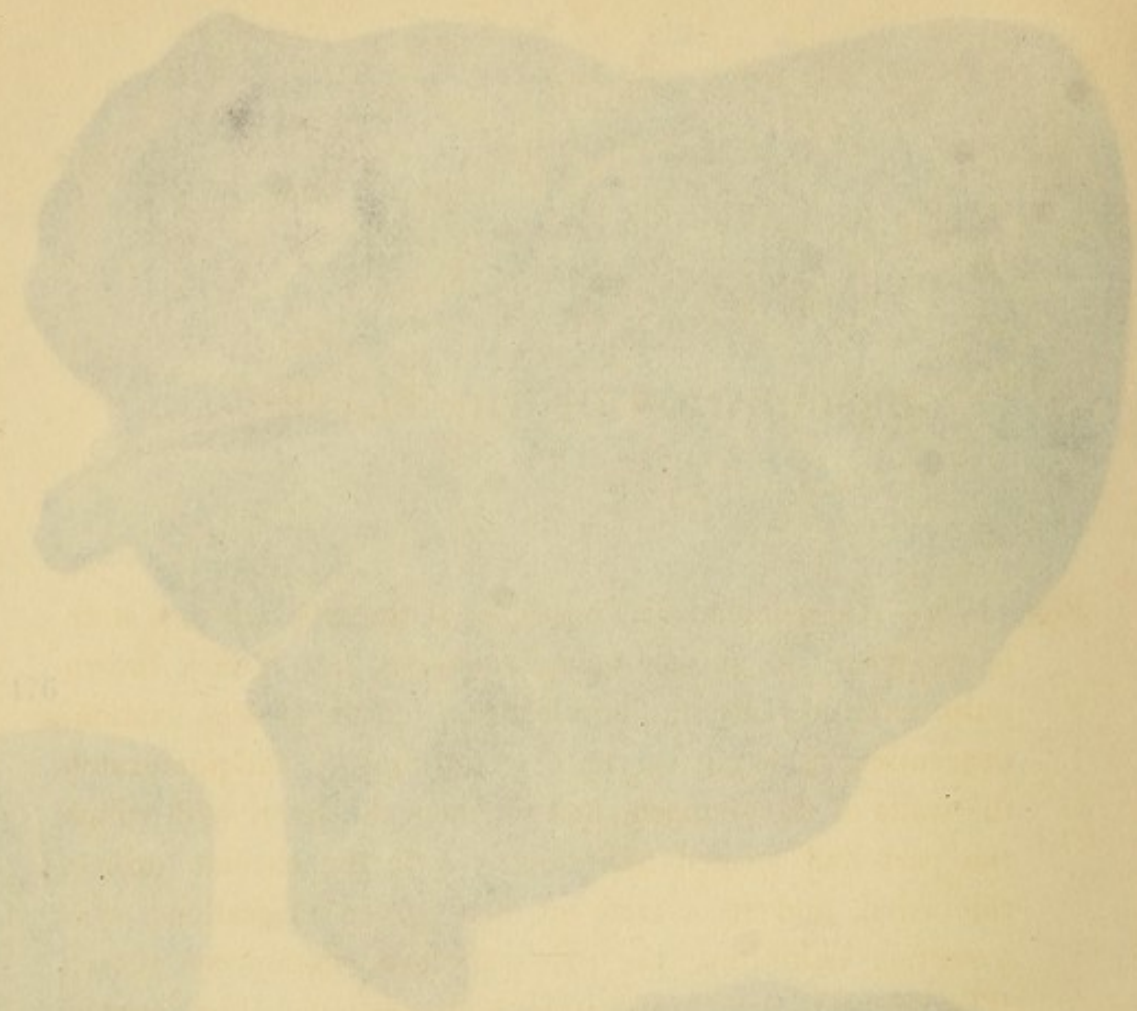Fig. 175.—An enccephaloid fungus, *a*, of the stomach in a state of gangrene, its surface being converted into a dark brown pulp, exhaling an intolerable fetor. The disorganization, descending through the centre of the fungus, had penetrated the walls of the stomach, and reached the liver, with which the part had formed adhesions. *b* is the cardiac orifice, thickened, and in a state of dirty green ulceration; *c* is a section exhibiting the pale scirrhous submucous tissue. The part *d* is in a similar state of ulceration. The mucous membrane *e, e*, is thickened and of green and livid colours from chronic inflammation. The stomach was greatly contracted and shortened. The lymphatic glands on its outside were enlarged by enccephaloid disease to the size of pigeon's eggs.

Case.—An old woman, in the St. Marylebone Infirmary, Feb. 1832; whose history I could not learn.

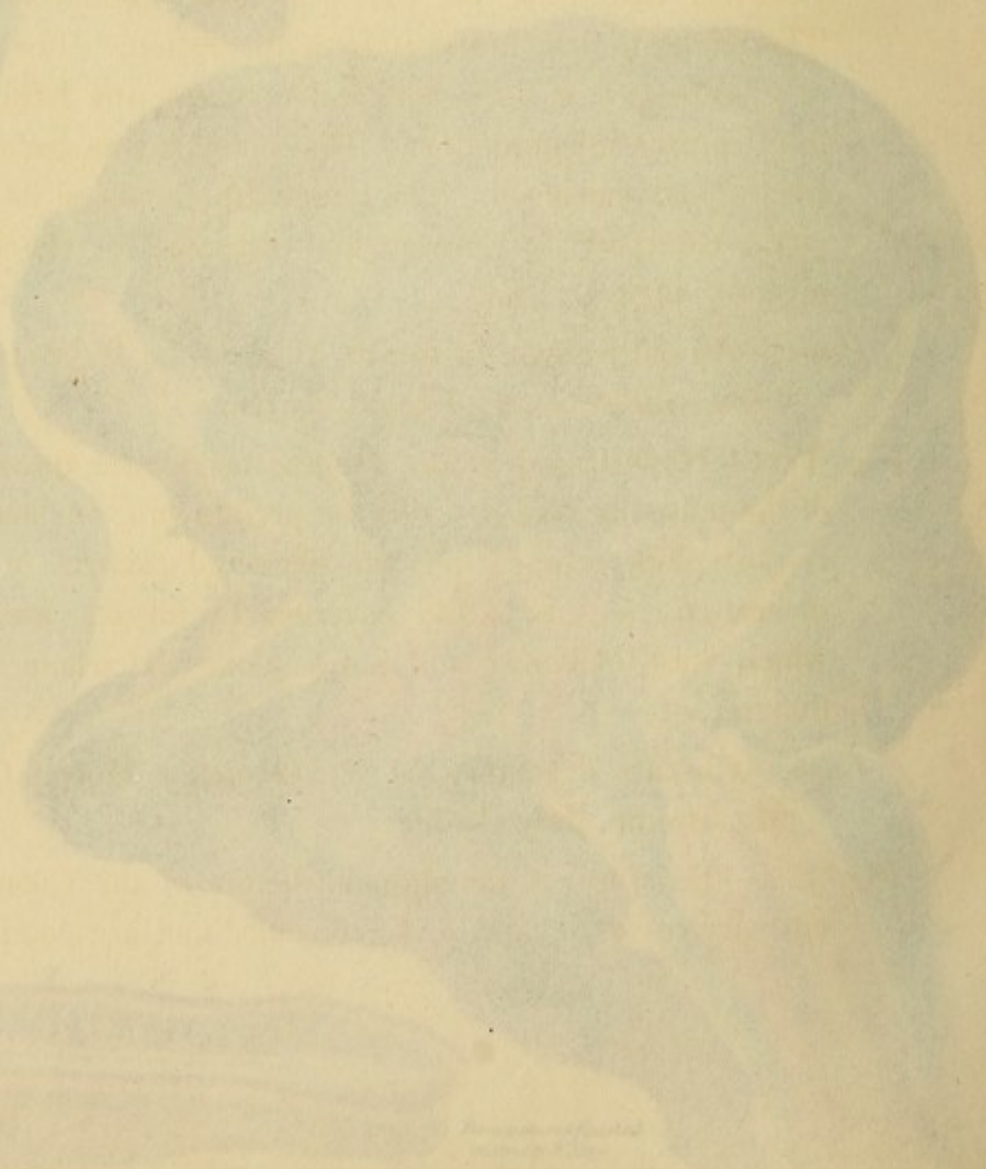
Fig. 176.—Hypertrophy of the submucous cellular tissue *e*, and of the muscular coat *d*. *c* is the peritonæum, unchanged; *f* is the sphincter ani; *a* is the puckered cicatrix of an old ulceration. *b* is a partial covering by mucous membrane, which was thickened and pulpy along the whole sigmoid flexure.

Case.—Chronic dysentery, at St. George's Hospital, under Mr. Brodie, July, 1832.

Fig. 177.—Stricture of the sigmoid flexure of the colon. The gut surfaces *a, a*, and *b, b*, coincide, and are composed of



176



Handwritten text, possibly a signature or date, located at the bottom right of the page.

DESCRIPTION OF THE PLATES.

Fig. 175.—An encephaloid fungus, *a*, of the stomach in a state of gangrene, its surface being converted into a dark brown pulp, exhaling an intolerable fœtor. The disorganization, descending through the centre of the fungus, had penetrated the walls of the stomach, and reached the liver, with which the part had formed adhesions. *b* is the cardiac orifice, thickened, and in a state of dirty green ulceration; *c* is a section exhibiting the pale scirrhus submucous tissue. The part *d* is in a similar state of ulceration. The mucous membrane *e, e*, is thickened and of green and livid colours from chronic inflammation. The stomach was greatly contracted and shortened. The lymphatic glands on its outside were enlarged by encephaloid disease to the size of pigeons' eggs.

Case.—An old woman, in the St. Marylebone Infirmary, Feb. 1832, whose history I could not learn.

Fig. 176.—Hypertrophy of the submucous cellular tissue *c*, and of the muscular coat *d*. *e* is the peritoneum, unchanged; *f* is the sphincter ani; *a* is the puckered cicatrix of an old ulceration; *b* is a partial covering by mucous membrane, which was thickened and pulpy along the whole sigmoid flexure.

Case.—Chronic dysentery, at St. George's Hospital, under Mr. Brodie, July, 1832.

Fig. 177.—Stricture of the sigmoid flexure of the colon. The cut surfaces *a, a*, and *b, b*, coincide, and are composed of


a gristly substance resulting from hypertrophy of the sub-mucous cellular tissue. The two coinciding points, *e, e*, formed the narrowest part of the stricture, which only allowed the introduction of a bougie one-third of an inch in diameter, in the direction *d*. The mucous membrane *c, c, d* was thickened, tumid, lumpy, and vascular, filling up the passage so as to prevent the descent of water through it by its own gravity. *f* is lax, vascular, adipose tissue in great abundance beneath the peritoneum *g*. The mucous membrane above and below the stricture is of brown colour from chronic inflammation.

Case.—Mrs. Webb, æt. about 40, at St. George's Hospital, June, 1829, under Dr. Seymour; she was emaciated, and had had no alvine evacuation for a month. Intestinal tympanitis: severe bearing-down pains in the hypogastrium for two months; obstinate constipation for two years. A considerable tumour was felt projecting into the vagina between the cervix uteri and the rectum, and the same could be felt in the rectum. It suddenly disappeared when pressure was exercised upon it simultaneously per vaginam et rectum.

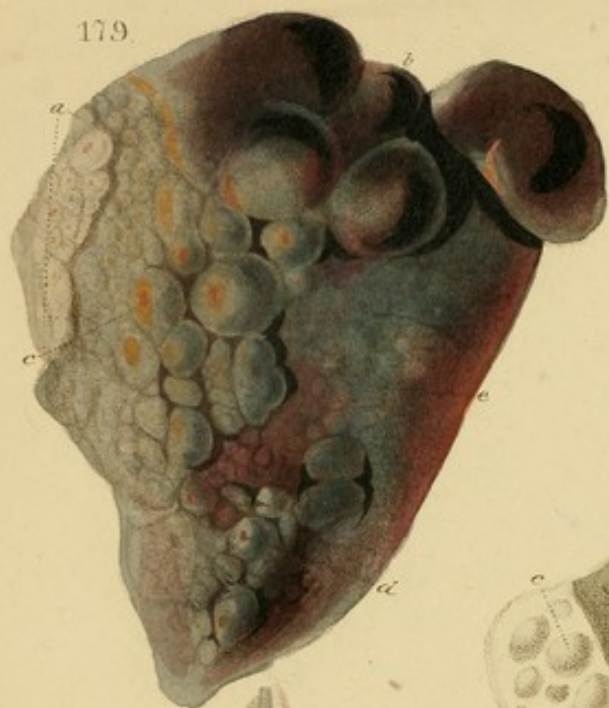
Ol. Croton. &c., had no effect, and enemata could not be forced above the obstacle, even with the aid of a stomach-pump tube. Increase of pain and tympanitis; pulse very quick; anxiety; incoherence; death on the fifth day.

Sectio.—The tumour felt per vaginam et rectum was the right ovary, as large as a kidney, which had probably been forced into that situation by the inflated intestines, and was driven back again by the pressure with the fingers. The intestinal obstruction was occasioned by the stricture delineated in the Fig. seated about ten inches up the gut.

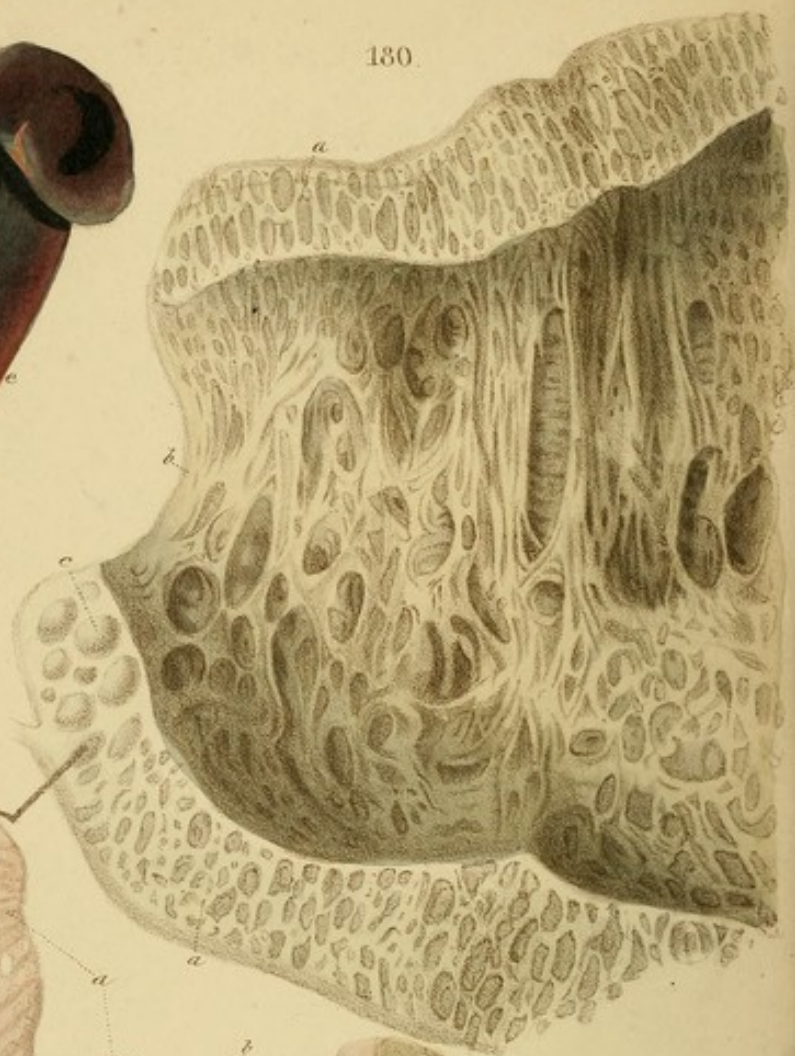
Fig. 178.—Hypertrophy of all the coats of the stomach:—*a*, the mucous coat; *b, c*, vascularity under it; *d*, submucous



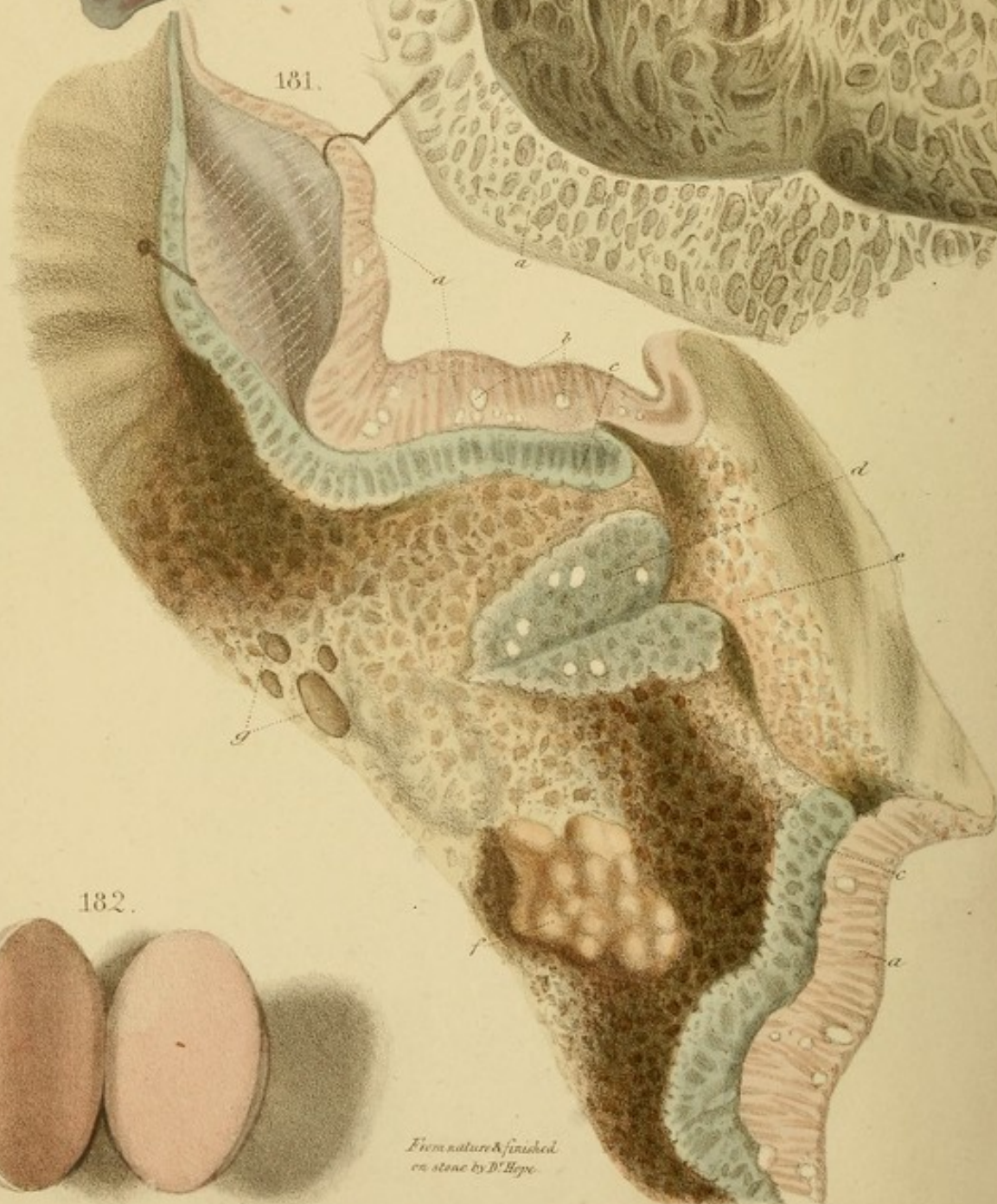
179.



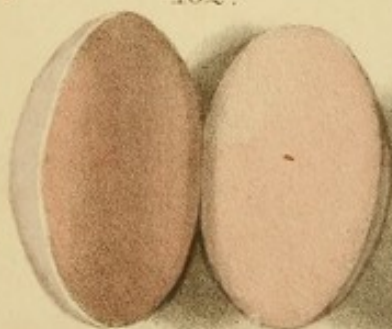
180.



181.



182.



*From nature & finished
on stone by D. Hoge.*

A. Dantel Lithog. 709 Martin Lane.

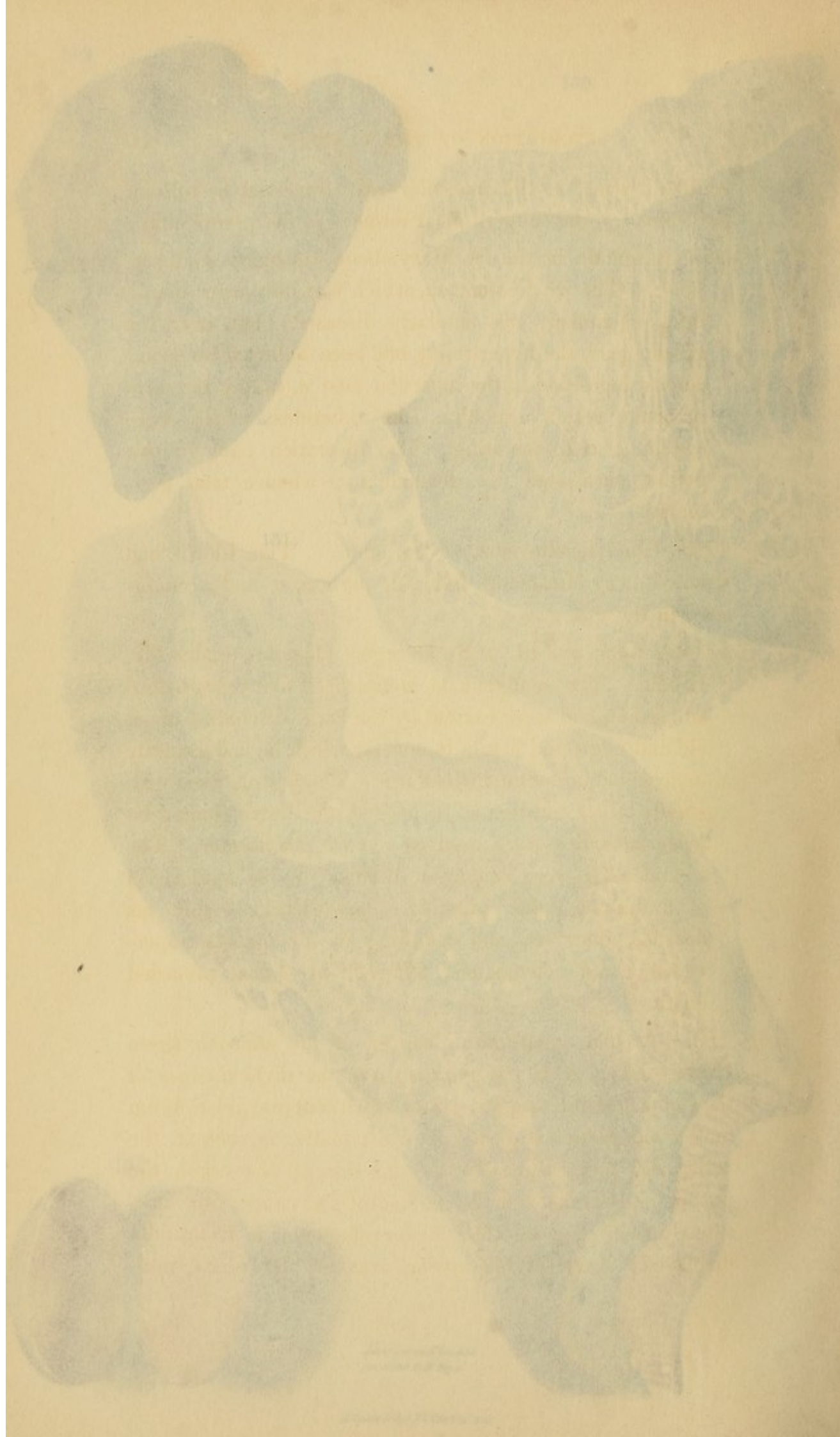
cellular tissue; *e*, the muscular coat traversed by cellular partitions; *f*, the subperitoneal tissue; *g*, the peritoneum.

Case.—A female in the St. Marylebone Infirmary, October 1831. The whole stomach, which was not larger than a thick cucumber, was uniformly diseased; but over the greater part of its surface had been followed by a cancerous deposit, which appeared as a *condyloma* taking the form of many small, rounded, like tubercles, which were soft, and bleeding. The ulceration had, in two places, perforated the peritoneum; whence fatal peritonitis.

Fig. 172.—*Condylomata* around the anus. The blood had streamed away after death from the parts *a, c*, and accumulated in those *b, d, e*.

Case.—A man, *æ* 40, in St. George's Hospital, under Mr. Brodie. The condylomata commenced five years before admission, and were excited by the scral discharge of an old and neglected fistula in ano, for which he had formerly undergone an operation in Paris. The bowels were constantly either constipated or purged, the latter coming on when opium was used to remove the former. The condylomata were somewhat reduced by the application of leeches and by the use of the *liquor plumbi*. Three weeks before his death, he was seized with a violent dysentery, which was followed by a profuse hæmorrhage, and ultimately terminated in coma, preceded by delirium.

Fig. 173.—*Condyloma* of the stomach (from *Condyloma*). *b*, the pylorus; *a a*, the divided edges of the stomach, from which concrete gelatiniform matter has partly escaped. At *c* the matter is seen in the cells, and prominent. In the interior of the organ the mucous membrane and the surface of the cancer has ulcerated away; whence the areolar character is beautifully displayed: some of the areole are very large and multi-



cellular tissue; *e*, the muscular coat traversed by cellular partitions; *f*, the subperitoneal tissue; *g*, the peritoneum.

Case.—A female in the St. Marylebone Infirmary, October, 1832. The whole stomach, which was not larger than a thick cucumber, was similarly diseased; but, over the greater part, the hypertrophy had been followed by a cancerous deposition in the muscular coat *e*, taking the form of opake yellow granules, like tubercles, which were softening and ulcerating. The ulceration had, in two points, perforated the peritoneum; whence fatal peritonitis.

Fig. 179.—Condylomata around the anus. The blood had strained away after death from the parts *a*, *c*, and accumulated in those *b*, *d*, *e*.

Case.—A man, æt. 40, in St. George's Hospital, under Mr. Brodie. The condylomata commenced five years before admission, and were excited by the acrid discharge of an old and neglected fistula in ano, for which he had formerly undergone an operation in Paris. The bowels were constantly either constipated or purged, the latter coming on when remedies were used to remove the former. The condylomata were somewhat reduced by the application of undiluted liquor plumbi. Three weeks before his decease, diarrhœa and vomiting of all ingesta supervened; and convulsions, followed by coma, preceded death.

Fig. 180.—Areolar gelatiniform cancer of the stomach (from Cruveilhier). *b*, is the pylorus; *a a*, the divided edges of the stomach, exhibiting cells, from which concrete gelatiniform matter has partly escaped. At *c* the matter is seen in the cells, and prominent. In the interior of the organ the mucous membrane and the surface of the cancer has ulcerated away; whence the areolar character is beautifully displayed: some of the areolæ are very large and mul-

tilocular. The drawing is as fine, as the specimen is remarkable, for which reasons I am induced to offer it here.

Fig. 181.—Areolar gelatiniform cancer of the pyloric third of the stomach (from Cruveilhier). *a, a* is the cancerous muscular coat; *b* are numerous calcareous concretions in it. *c, c* is a layer formed by the mucous membrane and submucous cellular tissue together; it is separated from the muscular layer by healthy cellular tissue, which is torn open between the pin and hook. At *d* the two layers have coalesced and formed one homogeneous state. The mucous membrane is affected with the same gelatiniform disease, which it has also extended to the duodenum *e*; *f* is a considerable tumour; *g* are ulcerated pits.

Case.—A woman, æt. 40, had dyspepsia with eructations and sometimes vomiting, for two years after the cessation of the catamenia. Three days before death she was almost in a state of marasm; face yellowish, and vomiting of all ingesta. A superficial tumour was felt to extend from a little above the umbilicus to the epigastrium, on the right side of the linea alba.

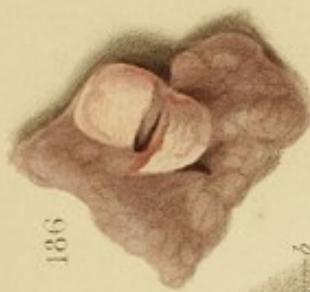
Sectio.—No disease but in the stomach. (Cruveilhier, liv. x. p. 4.)

Fig. 182.—An enlarged cancerous gland from the axilla. It is dense, though springy, and consists of minute translucent lobules separated by fibrous partitions. The structure is too delicate to be represented, as it can scarcely be seen but by reflected light.

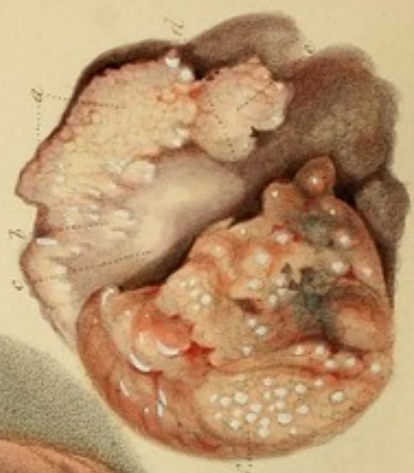Case.—Cancer in the mamma, the axillary glands, the lungs, liver, spleen, stomach, and intestines.

Fig. 183.—*Areolar gelatiniform cancer* in disseminated masses between the layers of the omentum.

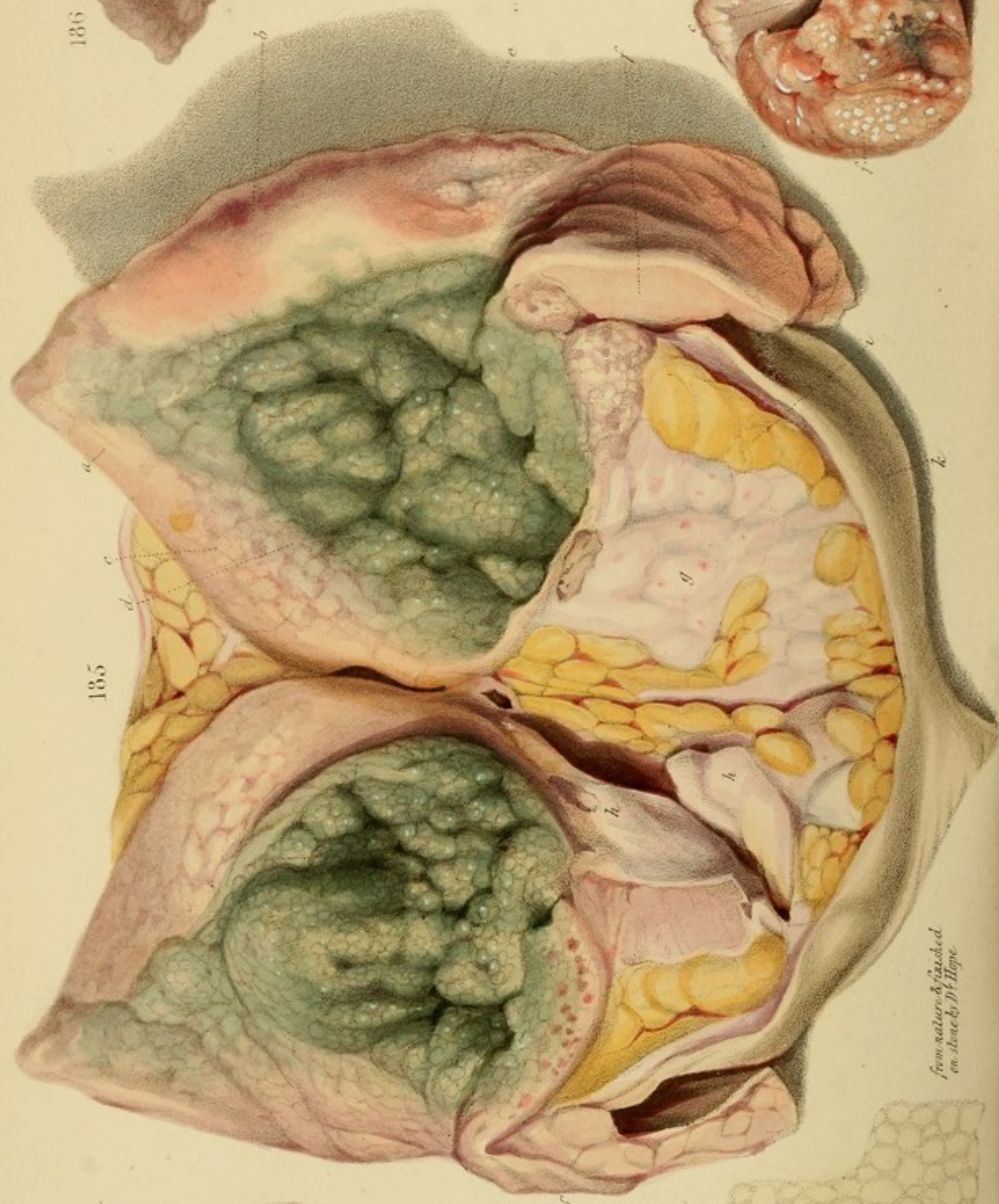
Fig. 184.—The same as the preceding, but confluent, and attended with considerable thickening of the omentum.



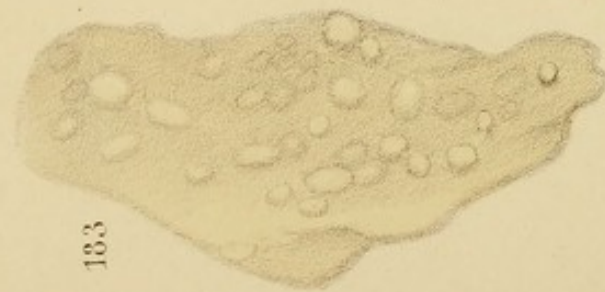186



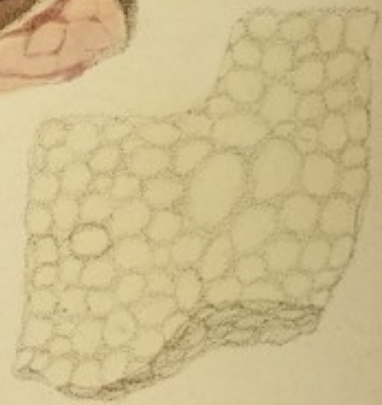
187



185



183



184

from nature & finished
on stone by Dr. Hope

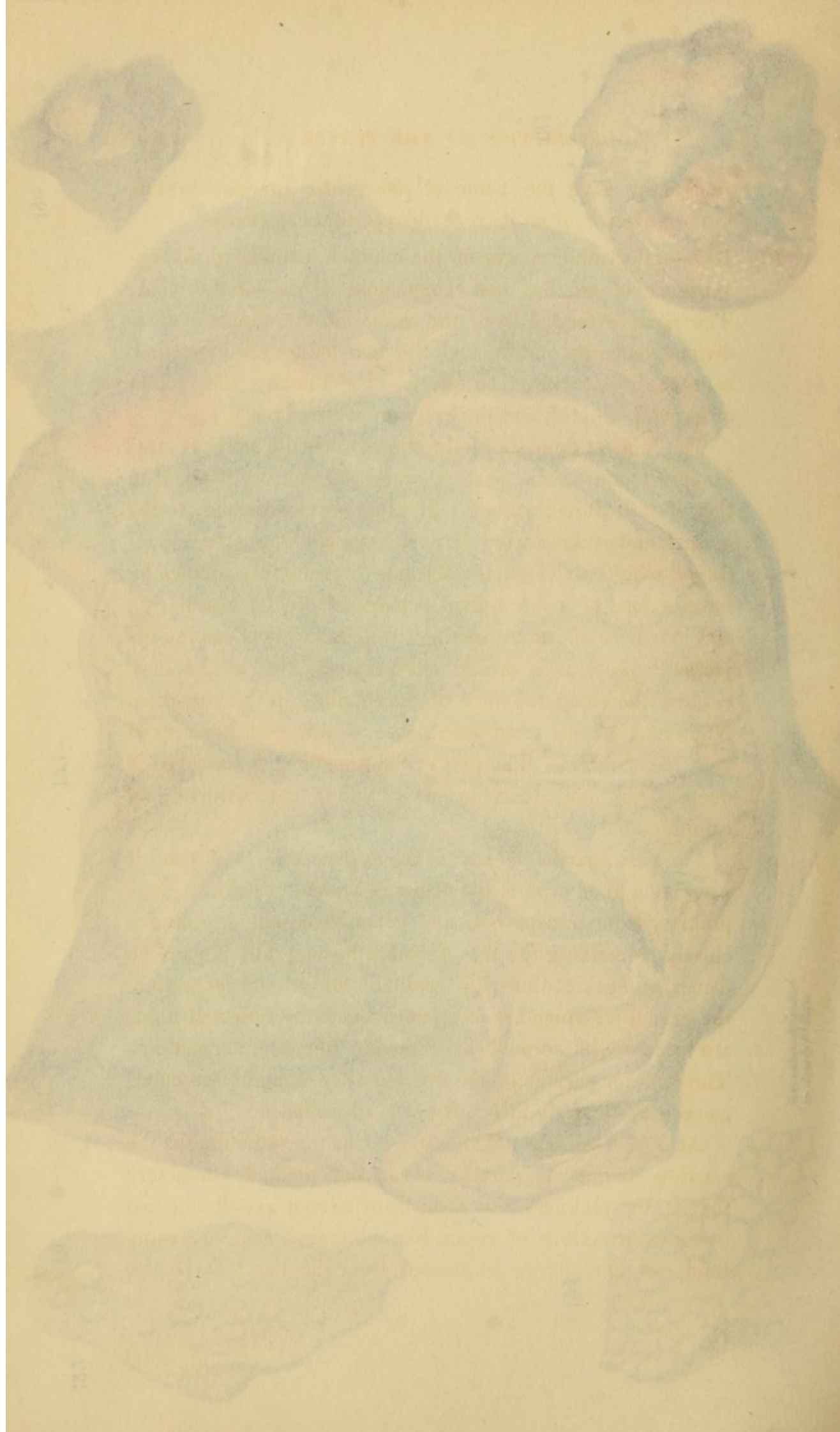
Abernethy gave the name of *pancreatic carcinoma* to this form of disease, from its resemblance to the pancreas.

Fig. 185.—Ulcerating cancer of the mamma, exhibiting the co-existence of scirrhus and encephaloid in the same tumour. The mass extended from the axilla to the nipple. It is divided down its middle and the two halves are expanded, so as to display the greater density of the scirrhus, the section of its walls *a, a, d*, and the eversion of its edges *f, f*.

The highest degree of induration which the scirrhus presents is found at the part *g*, where its density is equal to that of firm fibro-cartilage. It offers great resistance to the scalpel, and grates during the cut; its colour is an opake lilac-tinged white; it is subdivided into considerable lobules by intersections of a more livid colour and greater vascularity, and it is here and there mottled by delicate spots of pink injection. *h, h*, is a second cut perpendicular to the first, to show the elongated form of the lobule *h* in this direction. Numerous masses of adipose tissue, *i*, are seen intermixed with the scirrhus. The part of the tumour now described is deep-seated, and therefore most under the influence of compression.

The part next in density is the everted edge *f, f*; and it presents a good type of the ordinary form of scirrhus. It is pinkish, semi-transparent, and granulated—as appearance closely resembling the fat of boiled bacon; but it is much firmer, and grates under the scalpel. On minute inspection, the granules (which are most conspicuous by reflected light) are seen to be formed by reticular fibrous intersections. The anterior surface of the everted edge is highly vascular, as seen particularly at *b*; at *c* it is ulcerated.

At *a* (and all around the tumour at the same depth) the scirrhus begins to partake of an encephaloid character: that is, the pinkness and semi-transparency are diminished by an intermixture of cream-like whiteness, and a creamy fluid can actually be expressed from the part: it is also



Abernethy gave the name of *pancreatic sarcoma* to this form of disease, from its resemblance to the pancreas.

Fig. 185.—Ulcerating cancer of the mamma, exhibiting the co-existence of scirrhus and encephaloid in the same tumour. The mass extended from the axilla to the nipple. It is divided down its middle, and the two halves are expanded, so as to display the green interior of the cavity, the section of its walls *a, c, d*, and the eversion of its edges *f, f*.

The highest degree of induration which the scirrhus presents is found at the part *g*, where its density is equal to that of firm fibro-cartilage. It offers great resistance to the scalpel, and grates during the cut; its colour is an opaque lilac-tinged white; it is subdivided into considerable lobules by intersections of a more livid colour and greater vascularity, and it is here and there mottled by delicate spots of pink injection. *h, h*, is a second cut perpendicular to the first, to show the elongated form of the lobule *h* in this direction. Numerous masses of adipose tissue, *i*, are seen intermixed with the scirrhus. The part of the tumour now described is deep-seated, and therefore most under the influence of compression.

The part next in density is the everted edge *f, f*; and it presents a good type of the ordinary form of scirrhus. It is pinkish, semi-transparent, and granulated—an appearance closely resembling the fat of boiled bacon; but it is much firmer, and grates under the scalpel. On minute inspection, the granules (which are most conspicuous by reflected light) are seen to be formed by reticular fibrous intersections. The anterior surface of the everted edge is highly vascular, as seen particularly at *b*: at *e* it is ulcerated.

At *a* (and all around the tumour at the same depth) the scirrhus begins to partake of an encephaloid character: that is, the pinkness and semi-transparency are diminished by an intermixture of cream-like whiteness, and a creamy fluid can actually be expressed from the part: it is also

softer, and its fibrous intersections are more vascular than in pure scirrhus.

At *c*, an inch deeper, the encephaloid character is complete, the part being soft and white, like cerebral substance, and presenting, between its lobules, the high vascularity peculiar to encephaloid cancer.

At *d*, the disease is becoming livid, from obstruction of the circulation preparatory to ulceration.

The ulcerated cavity has a broken lobulated surface of greyish-green colour, yielding pus of the same tint.

Case.—A female, in St. George's Hospital, under Mr. Keate, November, 1829. The tumour was extirpated by that gentleman with his usual address, but the patient did not rally from the shock of the operation, and died in a week.

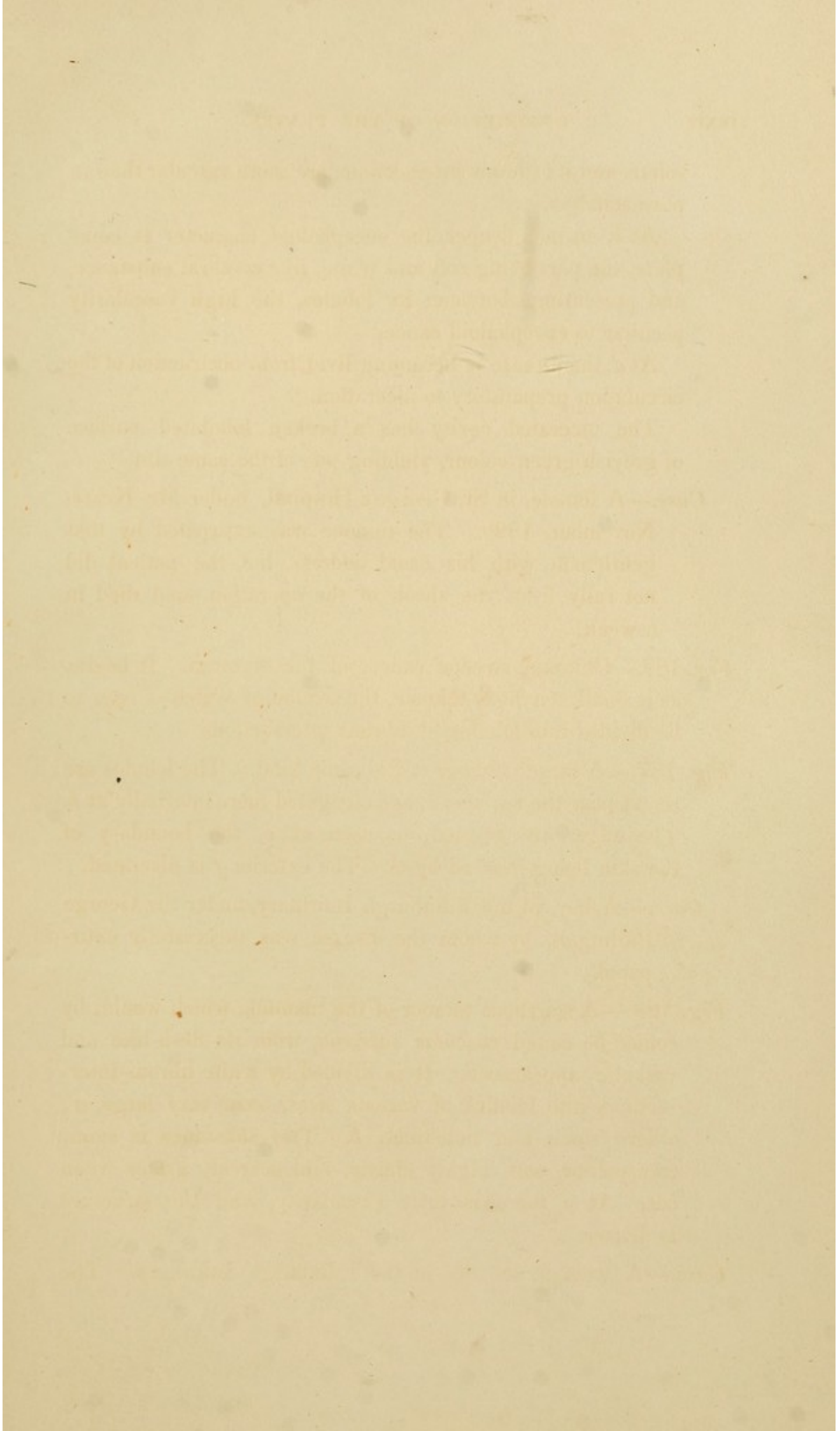
Fig. 186.—Chimney-sweeps' cancer of the scrotum. It begins as a small scirrhus tumour, the section of which is seen to be divided into lobules by fibrous intersections.

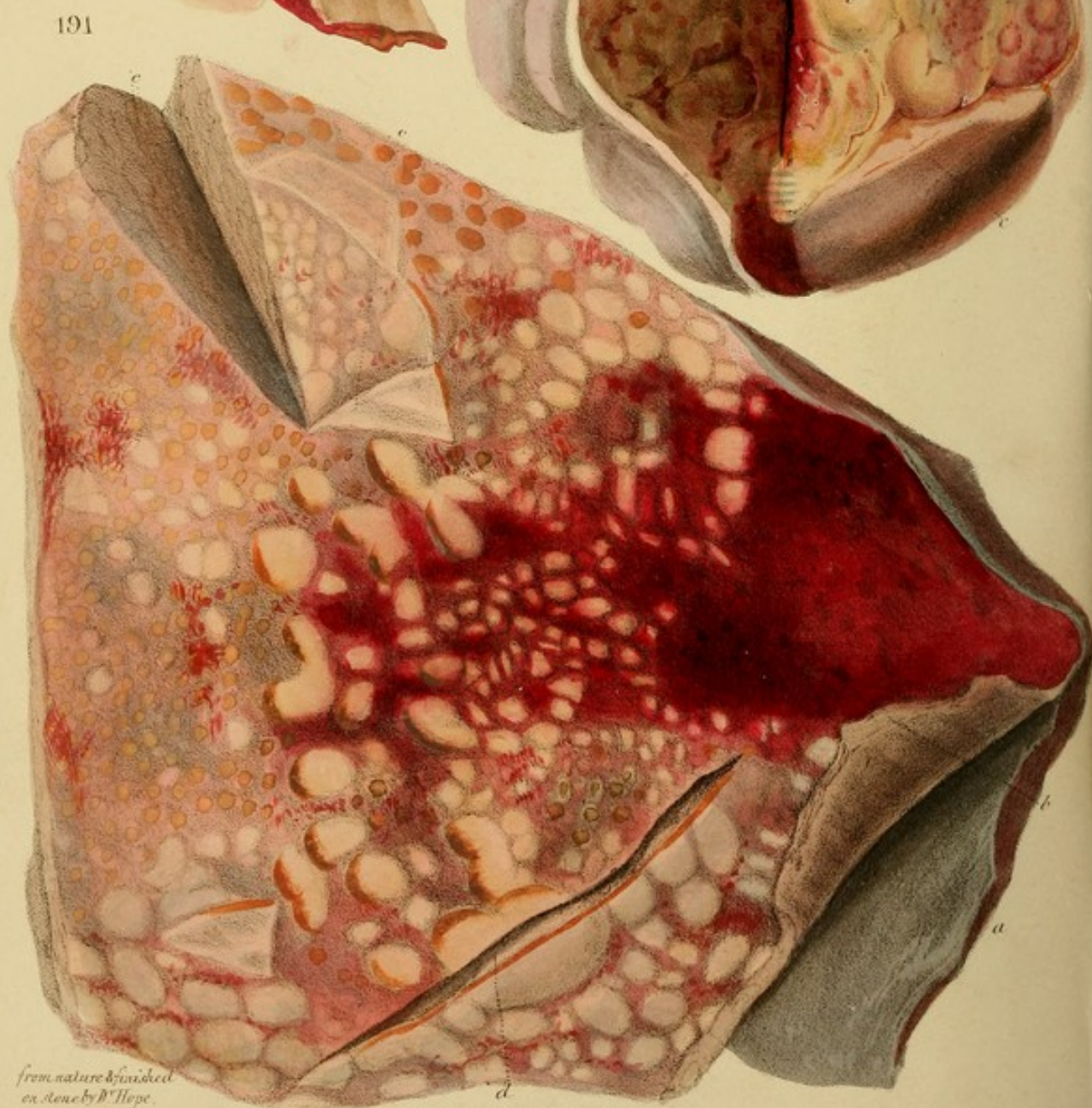
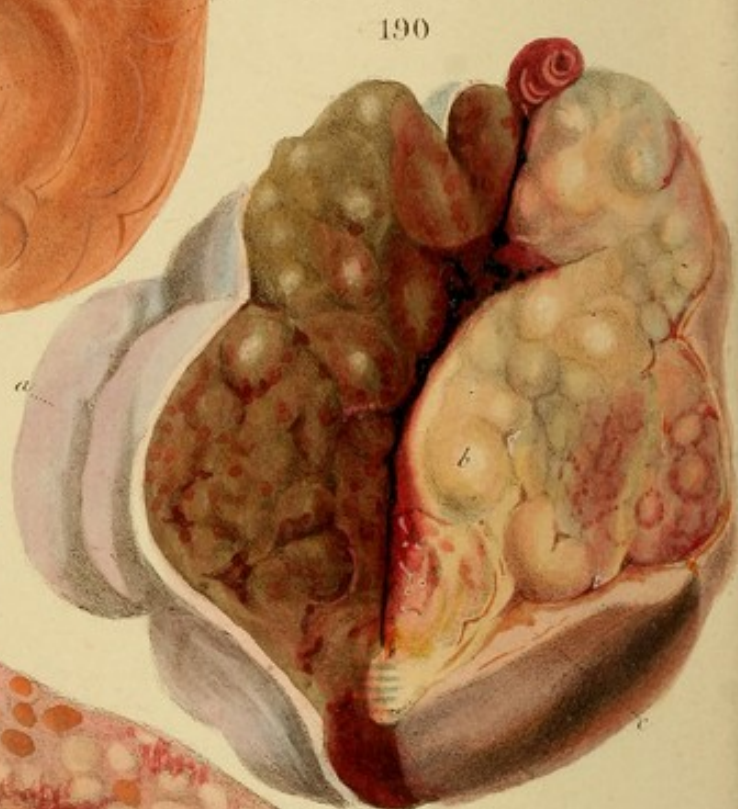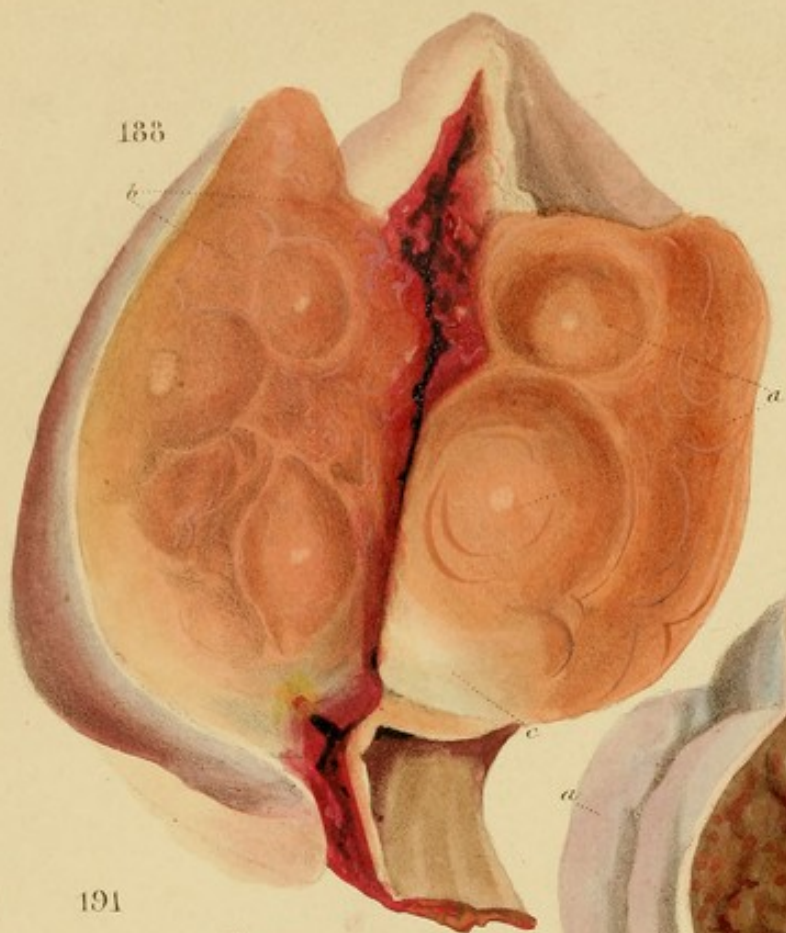
Fig. 187.—A larger tumour of the same kind. The lobules are round near the surface, *a*, and elongated more internally at *b*. The edges are everted, as seen at *c*, the boundary of the skin being marked by *d*. The exterior *f* is ulcerated.

Case.—A boy, in the Edinburgh Infirmary, under Sir George Ballingall, by whom the disease was successfully extirpated.

Fig. 188.—A scirrhus tumour of the mamma, which would, by some, be called *vascular sarcoma*, from its flesh-like and vascular appearance. It is divided by white fibrous intersections into lobules of various sizes, some very large, *a*; others small and indistinct, *b*. The substance is semi-transparent, soft, highly elastic, and scarcely grates when cut. At *c* there is little vascularity, and the structure is denser.

Case.—A woman, æt. 60, in the Edinburgh Infirmary. The





from nature & finished
on stone by W. Hope.

A. Inverdale & W. B. Martineau sculp.

tumour was seated in the middle of a scattered cicatrix, from which my friend, the late Mr. George Bell, informed me that he had removed a large ulcerating cancer fourteen years before. The present tumour, which had grown rapidly, was removed by Sir George Ballingall. Two years subsequently, when travelling in the Highlands, I accidentally met my old patient, and was sorry to find that a new tumour had recently begun to show in the same spot.

Fig. 189.—Granulations of lymph on the peritoneum, from chronic inflammation.

Fig. 190.—An encysted tumour from the testes, near the anus. It is soft, lobulated, vascular, and inclosed in a capsule, exterior to which the cellular tissue at *c* is thickened and indurated. The surface, *a*, was livid before death.

Case.—A man in the Edinburgh Infirmary, under Sir George Ballingall. He had two or three similar tumours in the same situation. An operation was not performed, as similar disease was expected and found internally. He died from irritation and exhaustion.

Fig. 191.—The disease called *cirrhosis*, by Laennec, situated beneath the peritoneum *a*. See p. 224.

Case.—A man in Laennec's Clinical Wards, who for many weeks presented symptoms of chronic peritonitis, taking on, from time to time, the character of acute disease. Tympanitis some days before death.

Section.—The same deposition existed under the peritoneum in many other parts, and in false-membranes, by which the intestines were agglutinated together.

125

126

127

128

tumour was seated in the middle of a puckered cicatrix, from which my friend, the late Mr. George Bell, informed me that he had removed a large ulcerating cancer fourteen years before. The present tumour, which had grown rapidly, was removed by Sir George Ballingall. Two years subsequently, when travelling in the Highlands, I accidentally met my old patient, and was sorry to find that a new tumour had recently begun to form in the same spot.

Fig. 189.—Granulations of lymph on the peritoneum, from chronic inflammation.

Fig. 190.—An encephaloid tumour from the nates, near the anus. It is soft, lobulated, vascular, and inclosed in a capsule, exterior to which the cellular tissue at *c* is thickened and indurated. The surface, *a*, was livid before death.

Case.—A man in the Edinburgh Infirmary, under Sir George Ballingall. He had two or three similar tumours in the same situation. An operation was not performed, as similar disease was expected and found internally. He died from irritation and exhaustion.

Fig. 191.—The disease called *cirrhosis*, by Laennec, situated beneath the peritoneum *e*. See p. 224.

Case.—A man in Laennec's Clinical Wards, who for many weeks presented symptoms of chronic peritonitis, taking on, from time to time, the character of acute disease. Tympanitis some days before death.

Sectio.—The same deposition existed under the peritoneum in many other parts, and in false-membrane, by which the intestines were agglutinated together.

It is a well-known fact that the United States has a large and increasing population. This is due to many causes, such as the immigration of people from foreign countries, the increase in the birth rate, and the decrease in the death rate. The population of the United States in 1900 was about 76 million, and it is estimated that it will reach 100 million by the year 1920.

The population of the United States is distributed unevenly over the country. The most densely populated areas are the Eastern States, particularly the New England States, the Middle States, and the Southern States.


The population of the United States is also distributed unevenly according to race and color. The white race is the most numerous, followed by the negro race, and then the Chinese and Japanese.

The population of the United States is also distributed unevenly according to sex. The male population is slightly larger than the female population. This is due to the fact that the male population is more numerous in the older age groups.

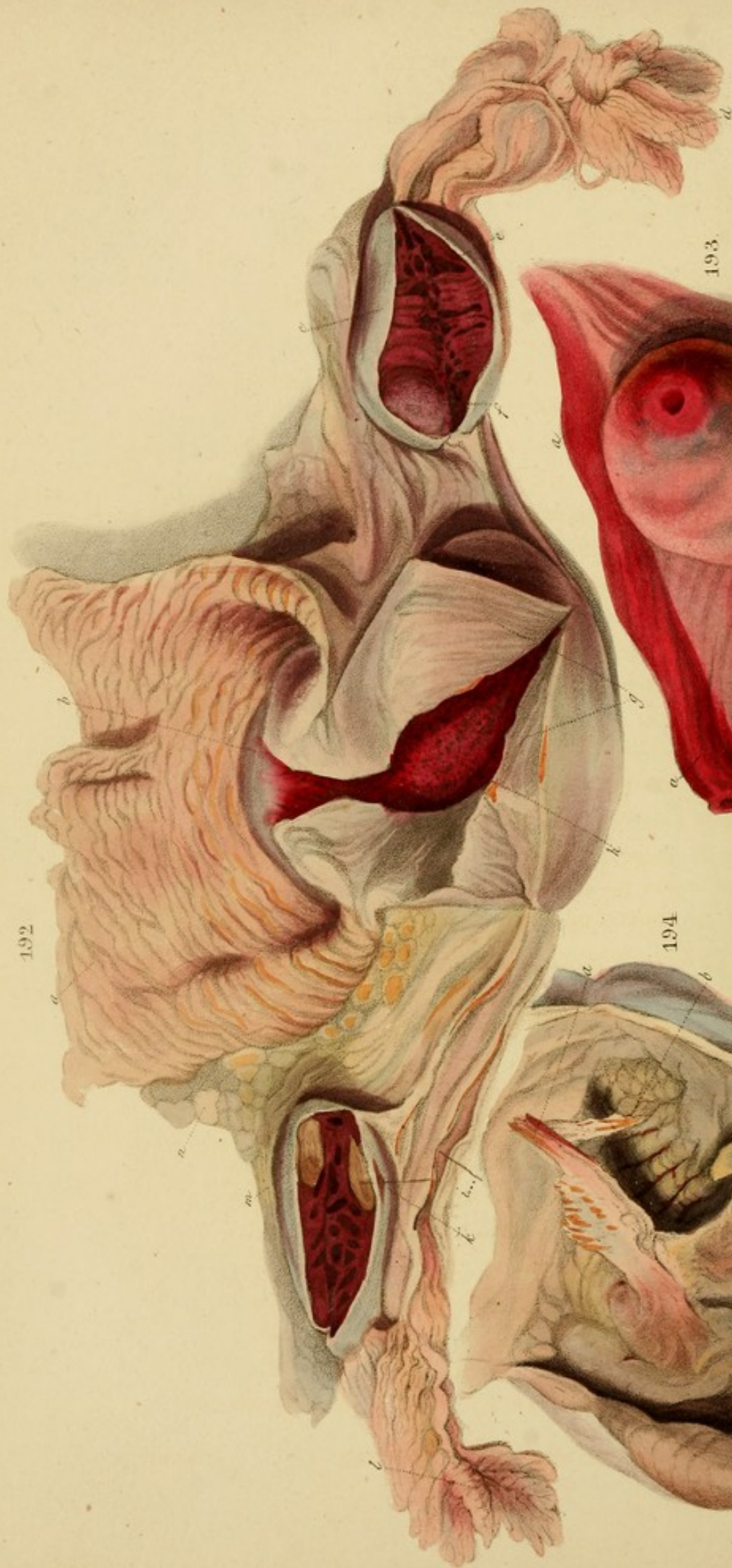
The population of the United States is also distributed unevenly according to education. The population with a college education is the smallest, followed by the population with a high school education, and then the population with a common school education.

The population of the United States is also distributed unevenly according to occupation. The population engaged in agriculture is the largest, followed by the population engaged in manufacturing, and then the population engaged in commerce.

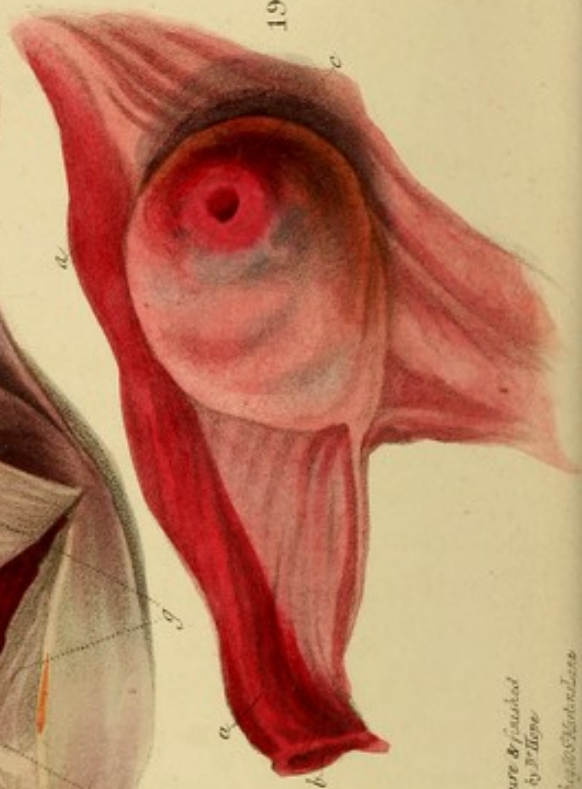The population of the United States is also distributed unevenly according to income. The population with a high income is the smallest, followed by the population with a middle income, and then the population with a low income.



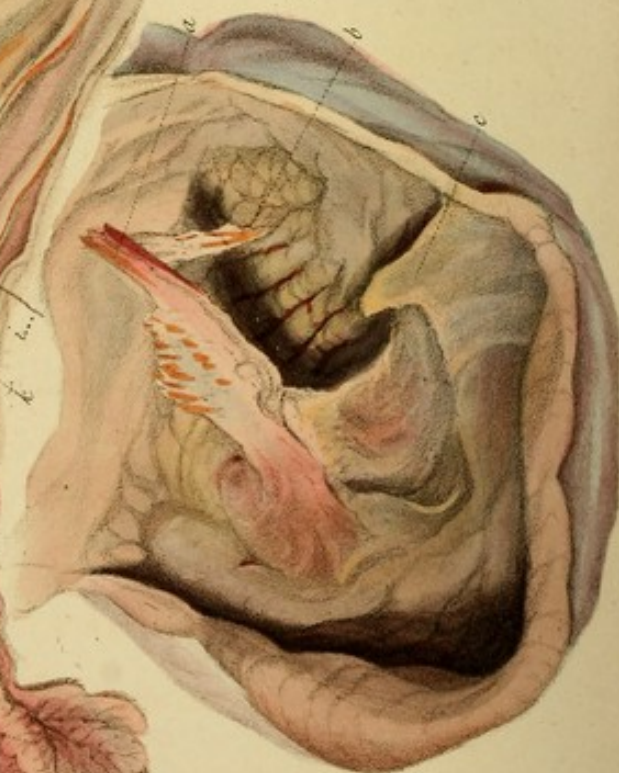192



193



194



From nature & painted
on three by J. Haye
A. D. 1714. 1715. 1716.

DESCRIPTION OF THE PLATES

Fig. 132.—The uterus and its appendages in a female aged about 22, within a short period after impregnation.

The uterus is laid open by a longitudinal incision from its fundus *h* to its border *g*, and another incision divides its left half transversely. The walls are thicker and paler than in the unimpregnated state. Its cavity *k* is filled with a gelatinous matter, between which and the inner membrane is a quantity of dark coagulated blood in small flakes. This condition is described by John Hunter as characteristic of incipient胎毒.

a is the expanded vagina in its natural state of contraction. On each side are the ovaries, which, before being opened, were swollen with dark blood to the size of the ovary *e*, Fig. 133. *c* are Graafian vesicles; *f* is one unopened, and distended with a muddy serous fluid. *m* is a corpus luteum, into the other half of which a bristle has been passed, through a purple fissure *h* in the peritoneal capsule. *i* is a bristle, the point of which rests in the opened fallopian tube. Both tubes were filled with a white watery fluid. *l* and *g* are the fimbriated extremities.

Case.—A female in St. Bartholomew's Hospital, June 1844, who poisoned herself with arsenic. From several accounts in the history, and from a post-mortem examination which was judged to be recent, it is probable that the poison had taken place within a short period.

Fig. 133. (From the same Collection.)—Tumid state of the ovaries, and fallopian tubes, with perforation of the per-

DESCRIPTION OF THE PLANT

The plant is a small, upright, herbaceous perennial, growing to a height of about 1 foot. It has a thick, fleshy, horizontal rootstock, from which several upright stems arise.

The leaves are alternate, ovate-lanceolate, with a long petiole and a acuminate apex. They are glaucous above and pale beneath, with a distinct midrib and secondary veins.

The flowers are small, tubular, and arranged in a terminal raceme. They are white or pale pink, with a long, slender corolla tube and a slightly flared lobes.

The fruit is a small, globose capsule, which is green when young and becomes brownish when ripe. It contains several small, dark seeds.

The plant is native to the mountains of the Himalayas, where it grows in rocky, open places. It is also cultivated in some parts of India for its medicinal properties.

The plant is a member of the family *Scrophulariaceae*, and is closely related to the genus *Androsace*. It is a very common plant in the mountains of the Himalayas, and is often found growing in the same places as the *Androsace*.

The plant is a very common plant in the mountains of the Himalayas, and is often found growing in the same places as the *Androsace*. It is a very common plant in the mountains of the Himalayas, and is often found growing in the same places as the *Androsace*.

The plant is a very common plant in the mountains of the Himalayas, and is often found growing in the same places as the *Androsace*. It is a very common plant in the mountains of the Himalayas, and is often found growing in the same places as the *Androsace*.

The plant is a very common plant in the mountains of the Himalayas, and is often found growing in the same places as the *Androsace*. It is a very common plant in the mountains of the Himalayas, and is often found growing in the same places as the *Androsace*.

The plant is a very common plant in the mountains of the Himalayas, and is often found growing in the same places as the *Androsace*. It is a very common plant in the mountains of the Himalayas, and is often found growing in the same places as the *Androsace*.

The plant is a very common plant in the mountains of the Himalayas, and is often found growing in the same places as the *Androsace*. It is a very common plant in the mountains of the Himalayas, and is often found growing in the same places as the *Androsace*.

The plant is a very common plant in the mountains of the Himalayas, and is often found growing in the same places as the *Androsace*. It is a very common plant in the mountains of the Himalayas, and is often found growing in the same places as the *Androsace*.

The plant is a very common plant in the mountains of the Himalayas, and is often found growing in the same places as the *Androsace*. It is a very common plant in the mountains of the Himalayas, and is often found growing in the same places as the *Androsace*.

The plant is a very common plant in the mountains of the Himalayas, and is often found growing in the same places as the *Androsace*. It is a very common plant in the mountains of the Himalayas, and is often found growing in the same places as the *Androsace*.

DESCRIPTION OF THE PLATES.

Fig. 192.—The uterus and its appendages in a female aged about 22, within a short period after impregnation.

The uterus is laid open by a longitudinal incision from its tumid orifice *b* to its fundus *g*, and another incision divides its left half transversely. The walls are thicker and pinker than in the unimpregnated state. Its cavity *h* is filled with a gelatinous matter, between which and the mucous membrane is a quantity of dark coagulated blood in small flakes. This condition is described by John Hunter as characteristic of incipient infestation.

a is the expanded vagina in its natural state of corrugation. On each side are the ovaries, which, before being opened, were swollen with dark blood to the size of the ovary *c*, *Fig. 193.* *e* are Graafian vesicles; *f* is one unopened, and distended with a muddy serous fluid. *m* is a corpus luteum, into the other half of which a bristle has been passed, through a purple fissure *k* in the peritoneal capsule. *i* is a bristle, the point of which rests in the opened fallopian tube. Both tubes were filled with a white semi-gelatinous fluid. *l* and *d* are the fimbriated extremities.

Case.—A female in St. Bartholomew's Hospital, June 14th, 1826, who poisoned herself with arsenic. From certain circumstances in the history, and from a laceration of the hymen which was judged to be recent, it is probable that impregnation had taken place within a short period.

Fig. 193. (From Dr. Lee's Collection.)—Tumid state of the ovary during menstruation, with perforation of the peri-

toneum, *c*, in consequence of rupture of a Graafian vesicle. The fallopian tube *a a* is red, turgid, and filled with menstrual fluid.

Case.—A young woman who died suddenly when the catamenia were flowing.

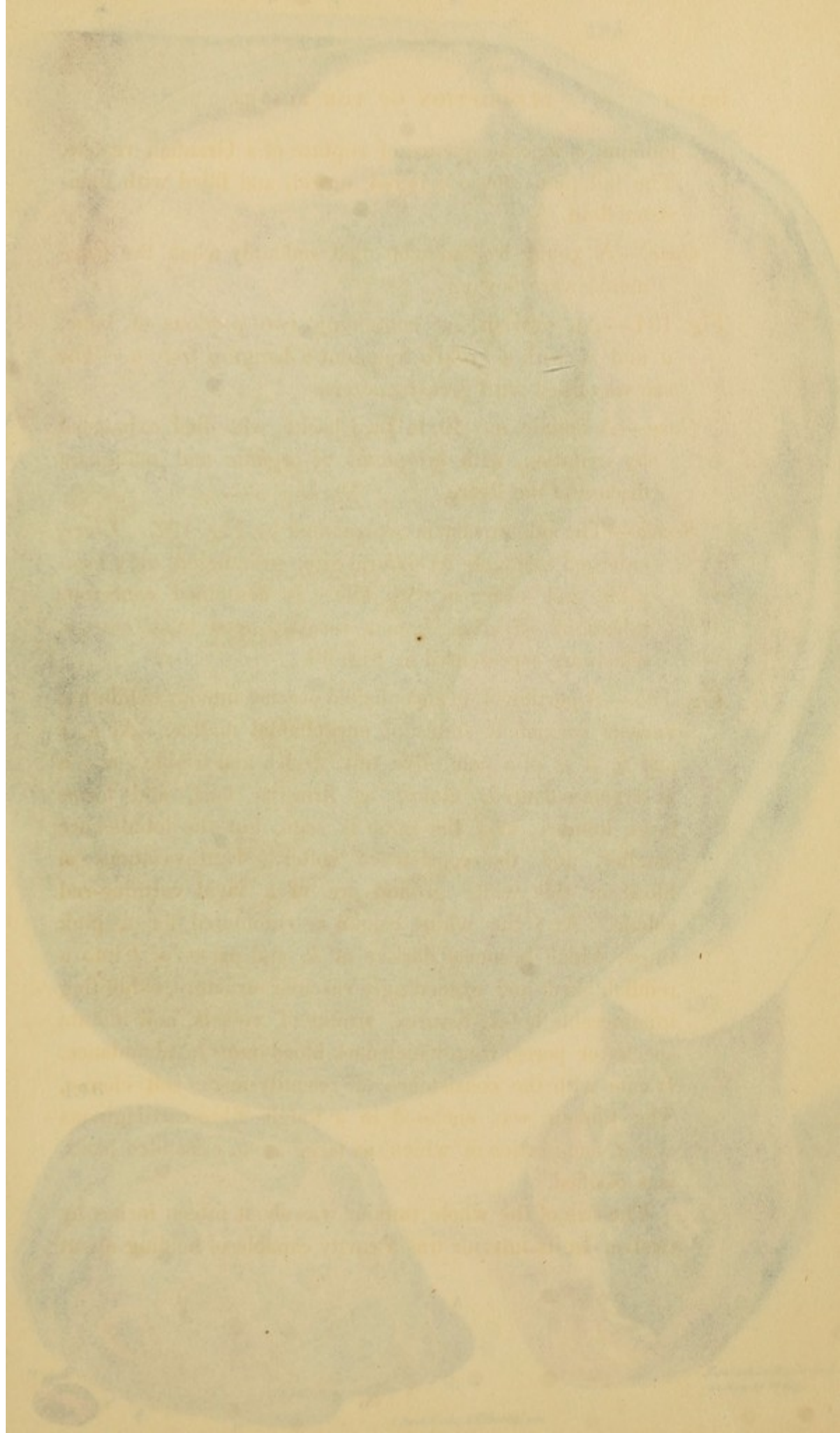
Fig. 194.—An ovarian sac containing two portions of bone, *a* and *c*, with a broken fragment *b* hanging from *a*. The sac was filled with greasy matter.

Case.—A female, æt. 40, in La Charité, who died exhausted by irritation, with symptoms of organic and malignant disease of the liver.

Sectio.—The other ovary is represented by *Fig. 197*. *Liver*, enlarged to double its natural size, granulated, very lacerable and charged with bile. It contained cancerous tubera of all sizes, from a mustard seed to an orange, which are represented in *Fig. 90*.

Fig. 195.—A portion of an encephaloid ovarian tumour exhibiting various coexistent states of encephaloid matter. At *a*, *b* and *h*, it is of a pale olive tint, dryish and friable: at *e* it is cream-coloured, almost as firm as lard, and forms large lobules: at *g* the same is seen, but the lobules are smaller, and the consistence softer. Extravasations of blood on this white ground are of a vivid carmine-red colour. At *i* the white colour is commuted for a pink tinge, which becomes darker at *k*, and passes at *l* into a reddish black and exceedingly vascular structure, exhibiting innumerable holes, fissures, trunks of vessels, and minute specks or pores, from which dark blood oozes in abundance. It cuts with the consistence of recently-made soft cheese. The tumour was enclosed in a tough fibro-cartilaginous cyst *d*, one portion of which, as large as an expanded hand, was ossified.

The size of the whole tumour was about fifteen inches by twelve. In its interior was a cavity capable of holding about



ionem, in consequence of rupture of a Graafian vesicle. The fallopian tube *a c* is red, turgid, and filled with menstrual fluid.

Case.—A young woman who died suddenly when the catamenia were flowing.

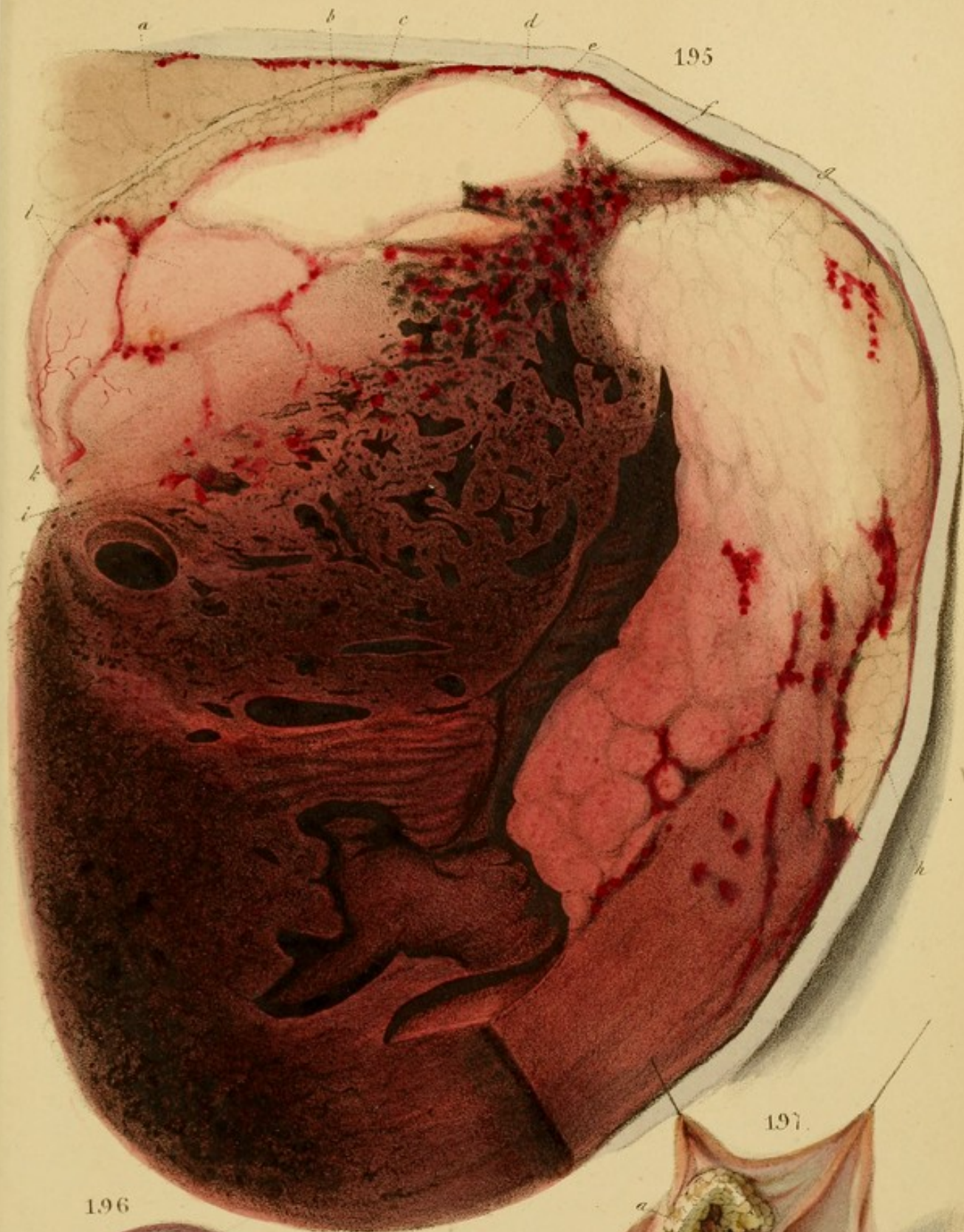Fig. 194.—An ovarian sac containing two portions of bone, *a* and *c*, with a broken fragment *b* hanging from *a*. The sac was filled with greasy matter.

Case.—A female, æt. 40, in La Charité, who died exhausted by irritation, with symptoms of organic and malignant disease of the liver.

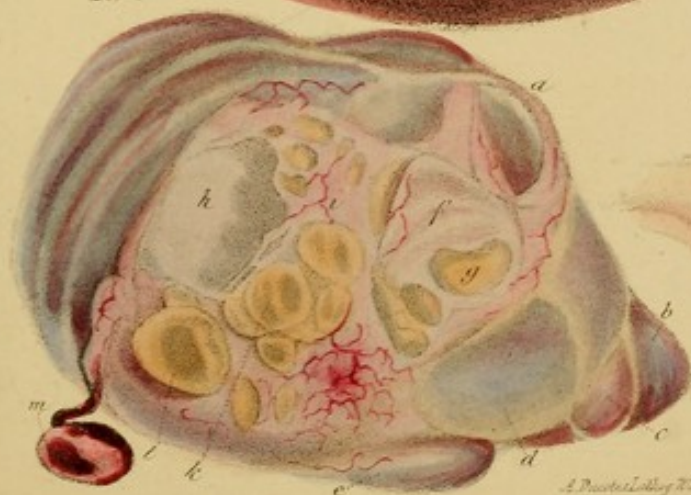Section.—The other ovary is represented by *Fig. 197*. It was enlarged to double its natural size, granulated, very lacerable and charged with bile. It contained cancerous tubercles of all sizes, from a mustard seed to an orange, which are represented in *Fig. 90*.

Fig. 195.—A portion of an encysted ovarian tumour exhibiting various coexistent states of development. At *a*, *b* and *c*, it is of a granular, firm, and brittle nature; it is cream-colored, and when cut is hard, and forms large lobules. At *d* the colour is rose, but the lobules are smaller, and the substance softer. Extravasations of blood on this white ground are of a vivid carmine-red colour. At *e* the white colour is commuted for a pink tinge, which becomes darker at *f*, and passes at *g* into a reddish black and exceedingly vascular structure, exhibiting innumerable holes, fissures, trunks of vessels, and minute specks or pores, from which dark blood oozes in abundance. It cuts with the consistence of recently-made soft cheese. The tumour was enclosed in a tough fibre-cartilaginous cyst *h*, one portion of which, as large as an expanded hand, was ossified.

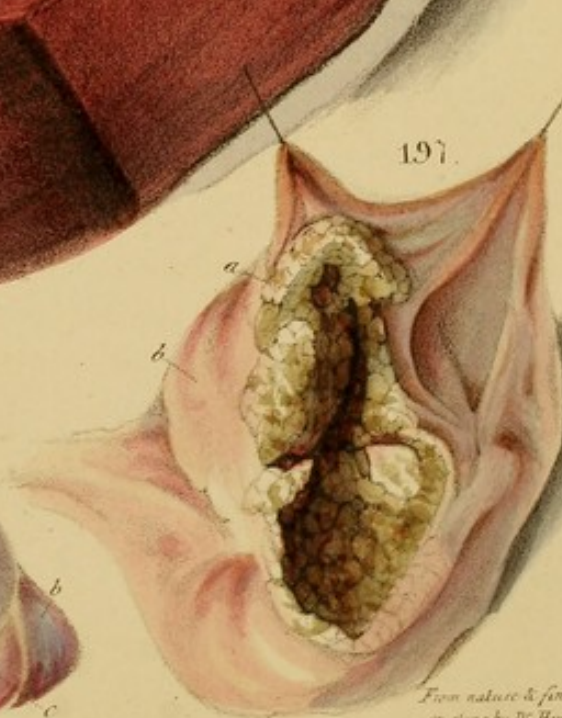
The size of the whole tumour was about fifteen inches by twelve. In its interior was a cavity capable of holding about



196



197



From nature & finished
on stone by Dr Hope.

A. P. D. 1800. By J. S. Martin. Linc.

two parts, the sides of which were ragged, sloughy, and of a dirty smoky-brown colour. The contained fluid was thick brownish, and somewhat bloody.

The portion represented in a nearly flat section of the walls on one side, though not of their entire thickness by about an inch. Applied to one side of the exterior of the tumor were found the remains of the ovary and fallopian tube; but whether the tumor was an excrescence from the ovary or an independent growth in the broad ligament could not be clearly ascertained. It presented, discoloured and knotty with coarse encephaloid matter, mottled beautifully on the surface.

Case.—Elizabeth Taylor, æt. 55, under my colleague Dr. Sims at the St. Mary's Hospital, Nov. 1853. 17. History of swelling of abdomen, with an exceedingly tense, polished surface, elastic, but distinct fluctuation; absence of the umbilical region on percussion; no fluctuation of surface was detected till after tapping, when about a pint only of bloody fluid escaped, and a hard nodular mass was then found in the left iliac region, corresponding to the situation of the twisted plate.

The swelling commenced two years before death. The patient suffered little throughout the course of the disease except from occasional sudden attacks of syncope, attended with distressing palpitation, and immediately relieved by expulsion of flatus. In one of these attacks she died.

Fig. 196.—An ovarian tumor consisting of about thirty cysts. Those on the surface, as A and the group, have thin transparent walls, separable into two layers by the removal of the exterior of which, they acquire an almost watery transparency. One, as B, is filled with blood, and is attached by a long, slender peduncle. Some of the internal cysts likewise have thin transparent walls, as C and D, which have and

two quarts, the sides of which were rugged, sloughy, and of a dirty snuff-brown colour. The contained fluid was thick, brownish, and somewhat bloody.

The portion represented is a nearly flat section of the walls on one side, though not of their entire thickness by about an inch. Applied to one side of the exterior of the tumour were found the remains of the ovary and fallopian tube; but whether the tumour was an excrescence from the ovary or an independent growth in the broad ligament, could not be clearly ascertained. Absorbents, distended and knotty with concrete encephaloid matter, ramified beautifully on the surface.

Case.—Frances Taylor, æt. 55, under my colleague Dr. Sims, at the St. Marylebone Infirmary, Nov. 12th, 1833. Pyriform swelling of abdomen, with an exceedingly tense polished surface; elastic, but distinct fluctuation; dulness of the umbilical region on percussion; no inequality of surface was detected till after tapping, when about a pint only of bloody fluid escaped, and a hard nodular mass was then found in the left iliac region, corresponding to the situation of the ossified plate.

The swelling commenced two years before death. The patient suffered little throughout the course of the disease, except from occasional sudden attacks of syncope, attended with distressing flatulence, and immediately relieved by expulsion of flatus. In one of these attacks she died.

Fig. 196.—An ovarian tumour consisting of about thirty cysts. Those upon the surface, as *l* and the group *k*, have fine transparent walls, separable into two layers, by the removal of the exteriors of which, they acquire an almost watery transparency. One, *m*, is filled with blood, and is attached by a long, slender peduncle. Some of the internal cysts likewise have thin transparent walls, as *i* and *g*, which parts, and

several smaller, are seen through intervals in the opaque white ovarian capsule *i f*, the over-distention of which has caused its rupture. The cysts *b*, *c*, *d*, and *e*, are covered by the capsule, and are therefore opaque, and more or less purple according to the degree of vascularity of the capsule. When, however, the capsule is peeled off, their proper walls are fine and transparent. On bisecting the tumour, the walls of most of the internal cysts were found in a very different state: namely, they were composed of fibrous and fibro-cartilaginous tissues, were from one to two lines thick, and so firm as to resist strong compression. Two or three cysts were much larger than the rest, and a few communicated together by smooth, rounded apertures, apparently formed by their bursting into each other; the fluid in most of them was a limpid lemon or amber tinted serum: in others it was more or less turbid.

Case.—The patient, æt. 60, had not experienced any symptoms from the tumour. She died of peripneumony in the St. Marylebone Infirmary.

Fig. 197.—An ovarian sac encrusted with grease, described p. 239. For *Case*, see Fig. 194.

Fig. 198.—Uterine phlebitis. *d* and *f* are suppurating concretions in the veins; *e*, a deposition seen through the peritoneum; *b* the sloughy surface to which the placenta was attached; *a* the inflamed and flocculent mucous membrane. The peritoneum is inflamed.

Fig. 199.—Inflammation of the broad ligament *a*, the fallopian tube *b*, and the ovary *c*, which is greatly swollen. From the same case as the preceding Fig., and both from the collection of Dr. Lee.

Fig. 200.—Suppuration of the ovarium from acute inflammation. It is reduced to a disorganized vascular and shreddy pulp, in appearance not unlike a rotten pear.

several smaller, are seen through intervals in the opaque white capsular capsule *b*, the outer distention of which has caused its rupture. The cysts *b*, *c*, *d*, and *e*, are covered by the capsule, and are therefore opaque, and more or less purple according to the degree of vascularity of the capsule. When, however, the capsule is peeled off, their proper walls are fine and transparent. On dissecting the tumour, the walls of most of the internal cysts were found in a very different state: namely, they were composed of fibrous and fibro-cartilaginous tissues, were from one to two lines thick, and so firm as to resist strong compression. Two or three cysts were much larger than the rest, and a few communicated together by smooth, rounded apertures, apparently formed by their bursting into each other; the fluid in most of them was a limpid lemon or amber tined serum, in others it was more or less turbid.

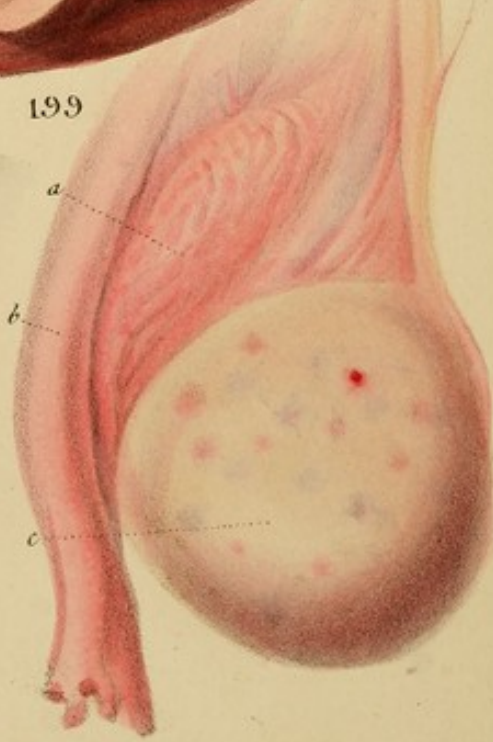
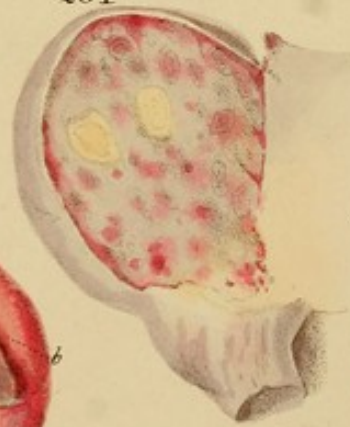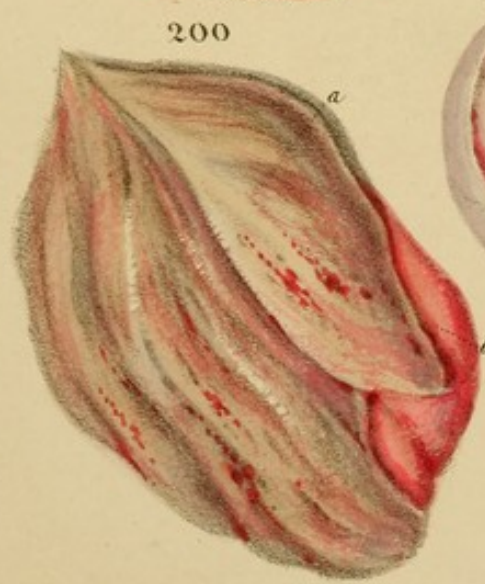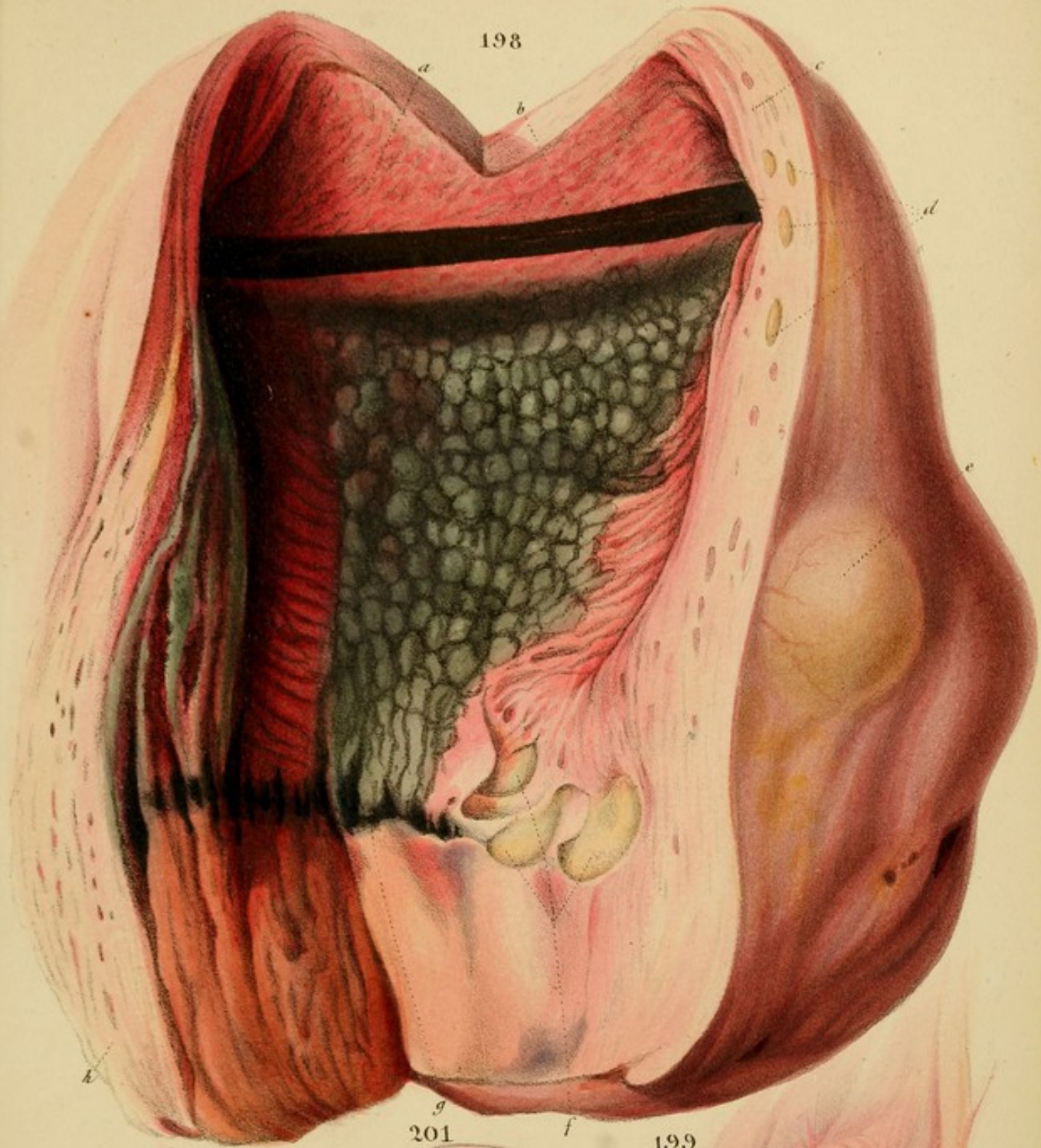
Case.—The patient, æt. 60, had no very marked symptoms from the tumour. She died of peripneumony in the St. Marylebone Infirmary.

Fig. 197.—An ovary encased with germ, described p. 339. *For Case, see Fig. 194.*

Fig. 198.—Uterine phlebitis. *d* and *f* are suppurating concretions in the veins; *e*, a deposition seen through the peritoneum; *b* the sloughy surface to which the placenta was attached; *a* the inflamed and flocculent mucous membrane. The peritoneum is inflamed.


Fig. 199.—Inflammation of the broad ligament *a*, the fallopian tube *b*, and the ovary *c*, which is greatly swollen. From the same case as the preceding Fig., and both from the collection of Dr. Lee.


Fig. 200.—Suppuration of the ovary from acute inflammation. It is reduced to a disorganized vascular and shaggy pulp, its appearance not unlike a rotten pear.



*From nature & finished
on stone by D. Hope*

A. Ducote Lith. 70 St. Martins Lane



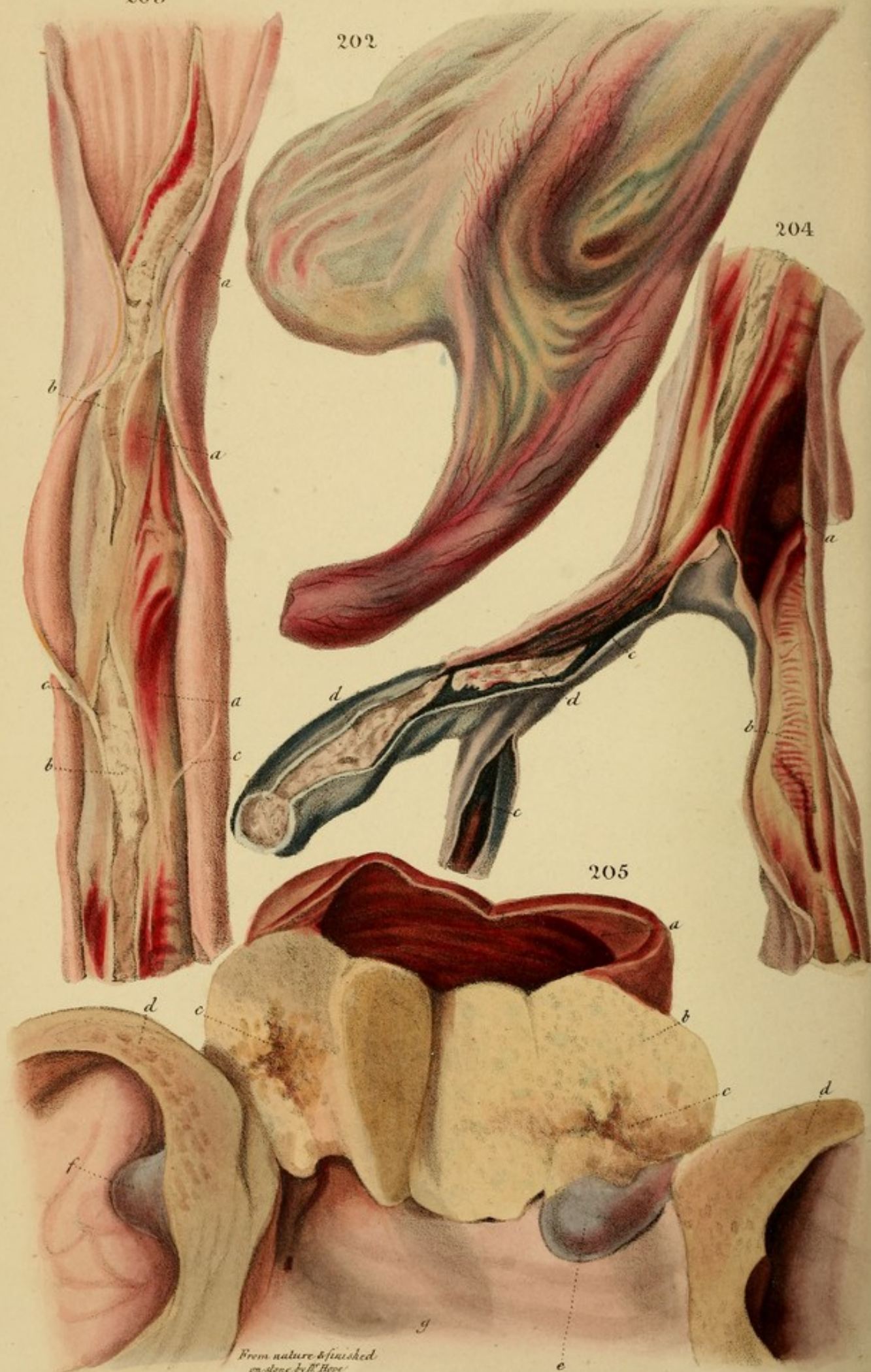


203

202

204

205



Case.—Inflammation of the uterus and its appendages, and of the intestinal peritonæum, fatal on the fourth day after parturition. (Lee, on Dis. of Women, p. 31.)

Fig. 201.—An ovary containing a yellow friable deposition, like scrofulous lymph, partly in the vesicles, and partly in the parenchyma. The latter is grey, tough, and spotted with vascularity.

Case.—Patient, æt. 40, had soap-bubble induration with enlargement of the liver (see Fig. 89); also enlargement and induration of the spleen. She had had hemiplegia, and died worn out by a surgical affection.

Fig. 202.—Absorbent vessels of the broad ligament filled with pus. They form yellow, irregular, knotty lines, more or less distinctly seen through the peritonæum.

Case.—Inflammation of the uterus fatal on the third day after delivery. The left ovary was colored as a liver-down, flocculent pulp; and, on the same side, the absorbents of the broad ligament and uterus were filled with pus. The veins and muscular structure were healthy. (Dr. Lee, on Dis. of Women, p. 84.)

Figs. 203 and 204.—Crural phlebitis, or inflammation of the iliac and femoral veins, extending to the vena cava.

Vena Cava. Fig. 203.—Coats of the vessel considerably thickened, and the internal, where visible, of a rose colour; its whole cavity is occupied by a coagulum, distending it to its utmost, and terminating in a loose pointed extremity about an inch below the entrance of the vena cava hepatica. The coagulum, *b, b*, is covered with a membranous-like substance *a, a, a*, of a bright red colour in parts, and throughout adhering firmly, and in many places inseparably, to the inner lining of the vein. The substance within it varied in consistence and colour: in some parts it presented the appearance of coagulable lymph; in others, it was a pulraceous dull yellow mass.

DESCRIPTION OF THE VILLAGE

The village of the name of the village is situated on the left bank of the river, about 10 miles from the mouth of the river. The village is a small one, with a few houses and a few shops. The houses are built of mud and are very small. The shops are also small and are situated on the bank of the river. The village is very quiet and peaceful. There are no schools or hospitals in the village. The people of the village are very poor and live in a very simple way. They are very friendly and hospitable. They are very kind to the strangers who come to the village. They are very helpful and are always ready to assist the strangers. The village is a very beautiful one. It is situated on a very fertile land. The land is very green and is very productive. The people of the village are very happy and content. They are very satisfied with their life and are very proud of their village. The village is a very important one. It is a very good example of a small village in the country. It is a very good example of a village that is very friendly and hospitable. It is a very good example of a village that is very helpful and is always ready to assist the strangers. The village is a very beautiful one. It is situated on a very fertile land. The land is very green and is very productive. The people of the village are very happy and content. They are very satisfied with their life and are very proud of their village. The village is a very important one. It is a very good example of a small village in the country. It is a very good example of a village that is very friendly and hospitable. It is a very good example of a village that is very helpful and is always ready to assist the strangers.

Case.—Inflammation of the uterus and its appendages, and of the intestinal peritoneum, fatal on the fourth day after parturition. (Lee, on Dis. of Women, p. 31.)

Fig. 201.—An ovary containing a yellow friable deposition, like scrofulous lymph, partly in the vesicles, and partly in the parenchyma. The latter is grey, tough, and spotted with vascularity.

Case.—Patient, æt. 40, had soap-like induration with enlargement of the liver (see Fig. 82); also enlargement and induration of the spleen. She had had herniplegia, and died worn out by a surgical affection.

Fig. 202.—Absorbent vessels of the broad ligament filled with pus. They form yellow, irregular, knotty lines, more or less distinctly seen through the peritoneum.

Case.—Inflammation of the ovaria fatal on the third day after delivery. The left ovarium was reduced to a broken-down, flocculent pulp; and, on the same side, the absorbents of the broad ligament and uterus were filled with pus. The veins and muscular structure were healthy. (Dr. Lee, on Dis. of Women. p. 84.)

Figs. 203 and 204.—Crural phlebitis, or inflammation of the iliac and femoral veins, extending to the vena cava.

Vena Cava. Fig. 203.—Coats of the vessel considerably thickened, and the internal, where visible, of a rose colour: its whole cavity is occupied by a coagulum, distending it to its utmost, and terminating in a loose pointed extremity, about an inch below the entrance of the vena cava hepatica. The coagulum, *b, b*, is covered with a membranous-like investiture *a, a, a*, of a bright red colour in parts, and throughout adhering firmly, and in many places inseparably, to the inner lining of the vein. The substance within it varied in consistence and colour: in some parts it presented the appearance of coagulable lymph; in others, it was a pultaceous dull yellow mass,

made up apparently of pus and lymph blended together. The exterior of the firmer portions were separated into layers, which gradually disappeared as they approached the centre. The mouths of all the veins emptying themselves into the cava were sealed up, the emulgents excepted, the coagulum near the entrance of these vessels hanging loosely within the cava.

Left common iliac and its branches.—*Fig. 204. b.* Its interior was plugged up with a continuation of the coagulum from the cava, and differing in no respect from it: it was continued beyond the entrance of the internal iliac (which it completely closed) and terminated in a pointed extremity about the middle of the external iliac. The internal iliac was much contracted and lined with a thick adventitious membrane.

Right common iliac and its branches.—This vessel *c* was contracted to more than one-half its natural size: it was firm to the touch, and of a greyish-blue colour: to its internal coat adhered an adventitious membrane of the same colour, containing within it a firm coagulum, *d*, made up of thin layers of dense lymph. The internal iliac was rendered quite impervious by dense, dark-coloured, bluish membranes, and at its entrance into the common iliac, it was converted into a solid cord.

The contracted external iliac contained a soft yellowish coagulum, similar to that in the cava; its coats were three or four times their natural thickness, and lined with dark-coloured membranous layers. The *femoral vein*, from Poupart's ligament to the middle of the thigh, was diminished in size, and almost inseparable from the artery. Its tunics were thickened, and its interior coated with a dense membrane, surrounding a solid purple coagulum strongly adherent to it. The superficial and deep femoral veins were in a similar condition. The cellular mem-

brane and other textures of the limb were in a perfectly healthy state.

Thorax.—Pleurisy, peripneumony and purulent depositions in the lungs.

Case.—The above description is almost a transcript from the work of Dr. Lee, where the details of this most interesting case may be found—(p. 124). It is sufficient for my present purpose to say, that Mrs. Edwards, æt. 35, was suddenly attacked, a fortnight after delivery, with pain in the calf of the right leg, followed by pale, glistening swelling of the whole extremity, and great tenderness along the inner surface of the leg and thigh, from the ankle to the groin, where the femoral vein was felt enlarged and indurated. Some of the superficial veins of the calf were also indurated. The invasion of the disease was not attended with rigors or pyresia.

In a fortnight the local symptoms had declined, but she then became affected with rigors, quick pulse, loaded tongue, thirst, and intermittent pains in the umbilical region, loins, and back. These symptoms, after temporary fluctuations, had declined by the end of the next three weeks, and she appeared recovering; when she was again seized with a long and violent fit of rigors, which were succeeded, during the following four weeks, by an extremely rapid and feeble pulse, deep anxiety of countenance, vomiting, pleuritic pain, delirium, great prostration of strength, a peculiar sallow tinge of the body, conjunctivæ of deep-red colour and extremely swollen, corneæ dull, shreds of lymph on the left iris, surface cold and clammy; black, dry sordes of mouth, diarrhœa, eyes swollen and pushed forward from the orbits, vision lost, a puffy red swelling over the right elbow-joint, constant wandering, hurried and laborious respiration, death nine weeks from the first attack.

Observations on Crural Phlebitis.—This case, together with the case of Fig. 110, form a good epitome of the multifarious consequences of this fearful malady. In the latter case, the coagula differed from those of Figs. 203 and 204, in the single circumstance of their being *loose*. One circumstance in the case of Fig. 110, I accidentally omitted to mention: viz., that a coagulum existed in the pulmonary artery. Another fine specimen of this kind Dr. Lee recently invited me to see at the St. Martin's Infirmary.

Crural Phlebitis occurs not only in puerperal women, but also in others suffering from suppressed menstruation, malignant ulceration, and other organic diseases of the uterine organs. A valuable series of cases of these kinds will be found in the work of Dr. Lee. p. 152 et seq.

The disease may also occur in males, its cause being inflammation or organic disease of some of the pelvic viscera, by which inflammation is excited in the hæmorrhoidal, vesical, pudic or other branches of the internal iliac veins. More commonly it originates in some of the superficial veins of the leg, being occasioned by ulcers, injuries, cold, amputation, &c.

Uterine and crural phlebitis is of much more frequent occurrence than is generally supposed. Since its nature was fully pointed out by Dr. Lee, a single Institution, of 350 beds, (the St. Marylebone Infirmary, which includes a puerperal department,) has furnished instances of most of its varieties. The exceedingly obscure and anomalous character of its symptoms in many cases, leads me to believe that, in former times, it was frequently overlooked; and I can now recall to memory cases in which I feel assured that this oversight was committed. Phlebitis cannot be too deeply studied.

Fig. 204.—Encephaloid cancer of the cervix uteri *b, c*, and of the walls of the bladder *d, d*.

The first of these was the establishment of the

second of these was the establishment of the

third of these was the establishment of the

fourth of these was the establishment of the

fifth of these was the establishment of the

sixth of these was the establishment of the

seventh of these was the establishment of the

eighth of these was the establishment of the

ninth of these was the establishment of the

tenth of these was the establishment of the

eleventh of these was the establishment of the

twelfth of these was the establishment of the

thirteenth of these was the establishment of the

fourteenth of these was the establishment of the

fifteenth of these was the establishment of the

sixteenth of these was the establishment of the

seventeenth of these was the establishment of the

eighteenth of these was the establishment of the

nineteenth of these was the establishment of the

twentieth of these was the establishment of the

twenty-first of these was the establishment of the

twenty-second of these was the establishment of the

twenty-third of these was the establishment of the

twenty-fourth of these was the establishment of the

twenty-fifth of these was the establishment of the

twenty-sixth of these was the establishment of the

twenty-seventh of these was the establishment of the

twenty-eighth of these was the establishment of the

twenty-ninth of these was the establishment of the

thirtieth of these was the establishment of the

thirty-first of these was the establishment of the

thirty-second of these was the establishment of the

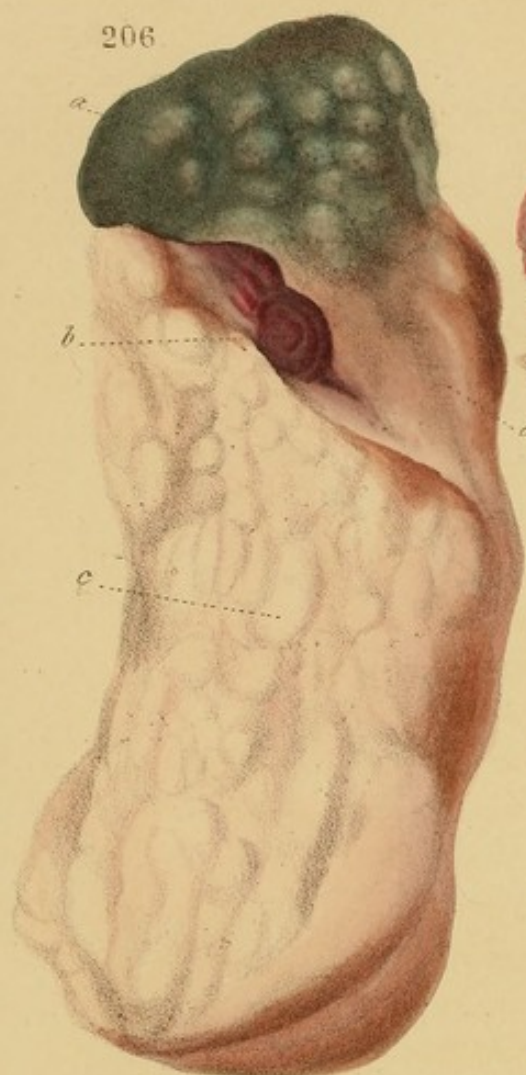
thirty-third of these was the establishment of the

thirty-fourth of these was the establishment of the

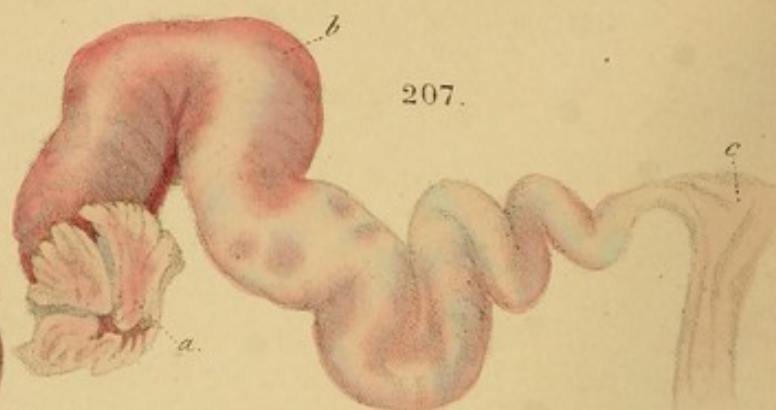
thirty-fifth of these was the establishment of the

thirty-sixth of these was the establishment of the

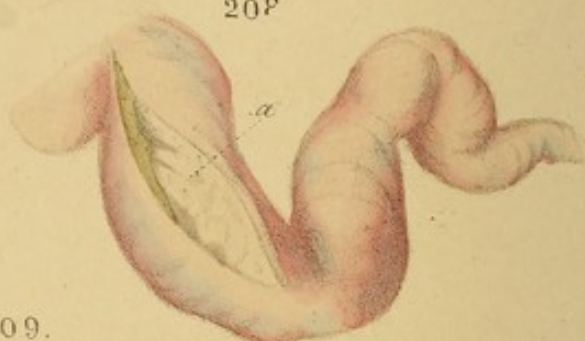
206



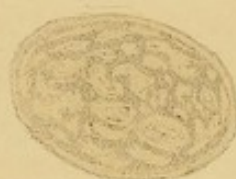207.



208



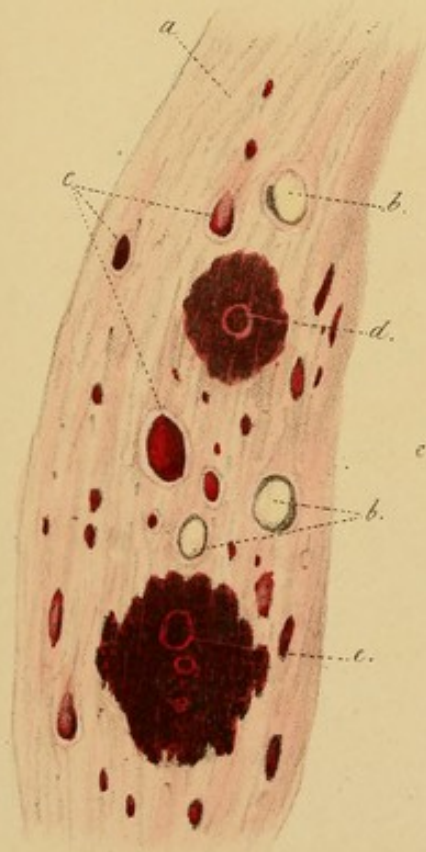
209.



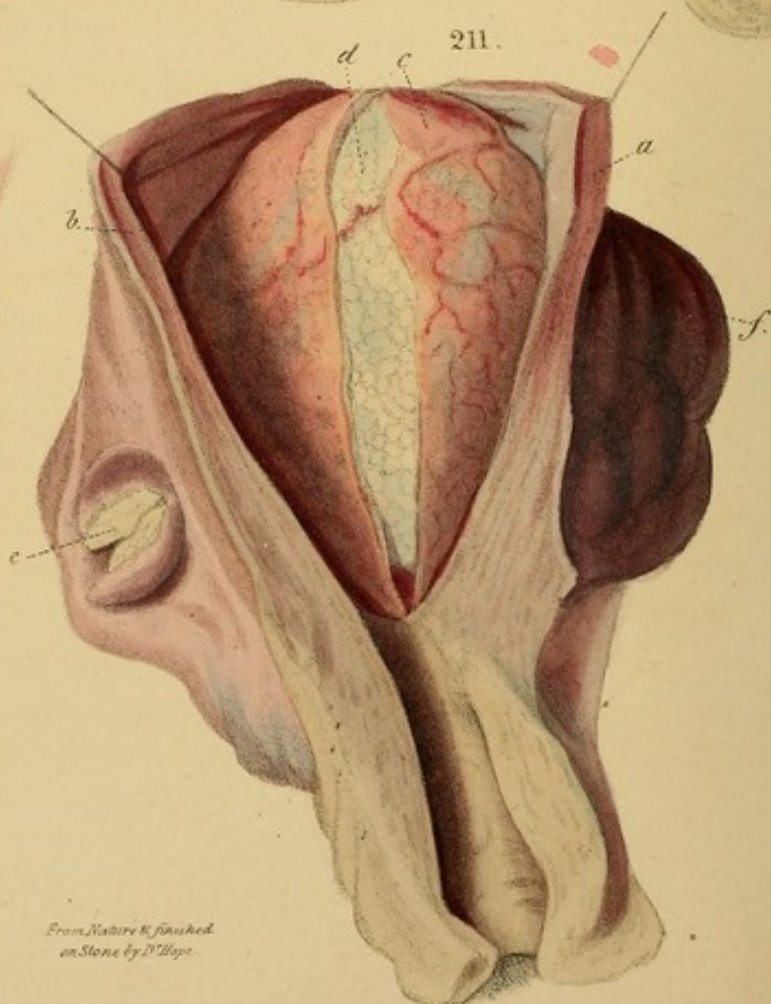
210.



212.



211.



From Nature & finished
on Stone by D. Hope.

DESCRIPTION OF THE PLATES.

Fig. 206. Monoploid cancer of the uterus and vagina. The Fig. represents a longitudinal section of both. *a a* is the interior of the uterus in a green, doughy state; *b* is the only remaining fragment of the os and cervix; *c* is the vagina thickened and bulging with monoploid matter. (Portion of a drawing from Dr. Lee's collection.)

Fig. 207.—A Fallopian tube distended with tubercular matter at the fimbriated extremity; *b* the middle; *c* the uterine extremity.

Fig. 208.—The Fallopian tube of the opposite side, cut open to show the tubercular matter *a*.

Fig. 209.—Section of a fibrous tumour of the uterus, showing the convoluted fibrous lobules and the intervening cellular-vascular tissue.

Fig. 210.—One of the same, but smaller.

Fig. 211.—Fibrous tumours of the uterus. The tumour *d* is completely ossified, and is covered by the perimetrium, thickened, and vascular mucous membrane *c*. *e* is a vessel under the perimetrium tending to become pedunculated. *f* are other tumours, with uneven surfaces, under the perimetrium. *g* is the hypertrophied and softened uterine substance. There were eight or nine tumours associated with this uterus.

Case.—A very aged female in the St. Marylebone Infirmary who had not complained of any uterine symptoms.

Fig. 212.—Section of the uterine walls in uterine phlebitis fol-

DESCRIPTION OF THE PLATES.

Fig. 206. Encephaloid cancer of the uterus and vagina. The Fig. represents a longitudinal portion of both. *a, a* is the interior of the uterus in a green, sloughy state: *b* is the only remaining fragment of the os and cervix: *c* is the vagina thickened and bulging with encephaloid matter. (Portion of a drawing from Dr. Lee's collection.)

Fig. 207.—A Fallopian tube distended with tubercular matter. *a* the fimbriated extremity; *b* the middle; *c* the uterine extremity.

Fig. 208.—The Fallopian tube of the opposite side, cut open to show the tubercular matter *a*.

Fig. 209.—Section of a fibrous tumour of the uterus, showing the convoluted fibrous lobules, and the interposed cellulovascular tissue.

Fig. 210.—One of the same, but smaller.

Fig. 211.—Fibrous tumours of the uterus. The tumour *d* is completely ossified, and is covered by the transparent, thickened, and vascular mucous membrane *c*. *e* is a tumour under the peritoneum tending to become pedunculated. *b* are other tumours, with uneven surfaces, under the peritoneum. *a* is the hypertrophous and softened uterine substance. There were eight or nine tumours connected with this uterus.

Case.—A very aged female in the St. Marylebone Infirmary who had not complained of any uterine symptoms.

Fig. 212.—Section of the uterine walls in uterine phlebitis fol-

lowing parturition. *a*, the tissue of the uterus ; *b, b*, veins plugged with yellow concretions of the fibrine of the blood, tending to suppuration. *c*, veins plugged with coagula of blood. *d, e*, veins surrounded by inflammatory extravasations of blood, attended with softening and ending in suppuration.

Fig. 213.—Diagram of fibrous tumours of the uterus. *b*, one which grew beneath the mucous membrane, and had become pedunculated. *d*, one which grew beneath the peritoneum and had become pedunculated. *e*, one growing in the uterine substance, of which it had caused the hypertrophy.

Fig. 214.—A fibrous tumour, from a specimen in spirits, to show the directions of the fibres. (From the Museum of Dr. Lee.)

Fig. 215.—A large and firm uterine polypus, from a preparation in spirits, to show the directions of the fibres. *a, a, a* is its capsule, held back by bristles.

Fig. 216.—The surface of the preceding tumour, rough with fragments of lymph from inflammation.

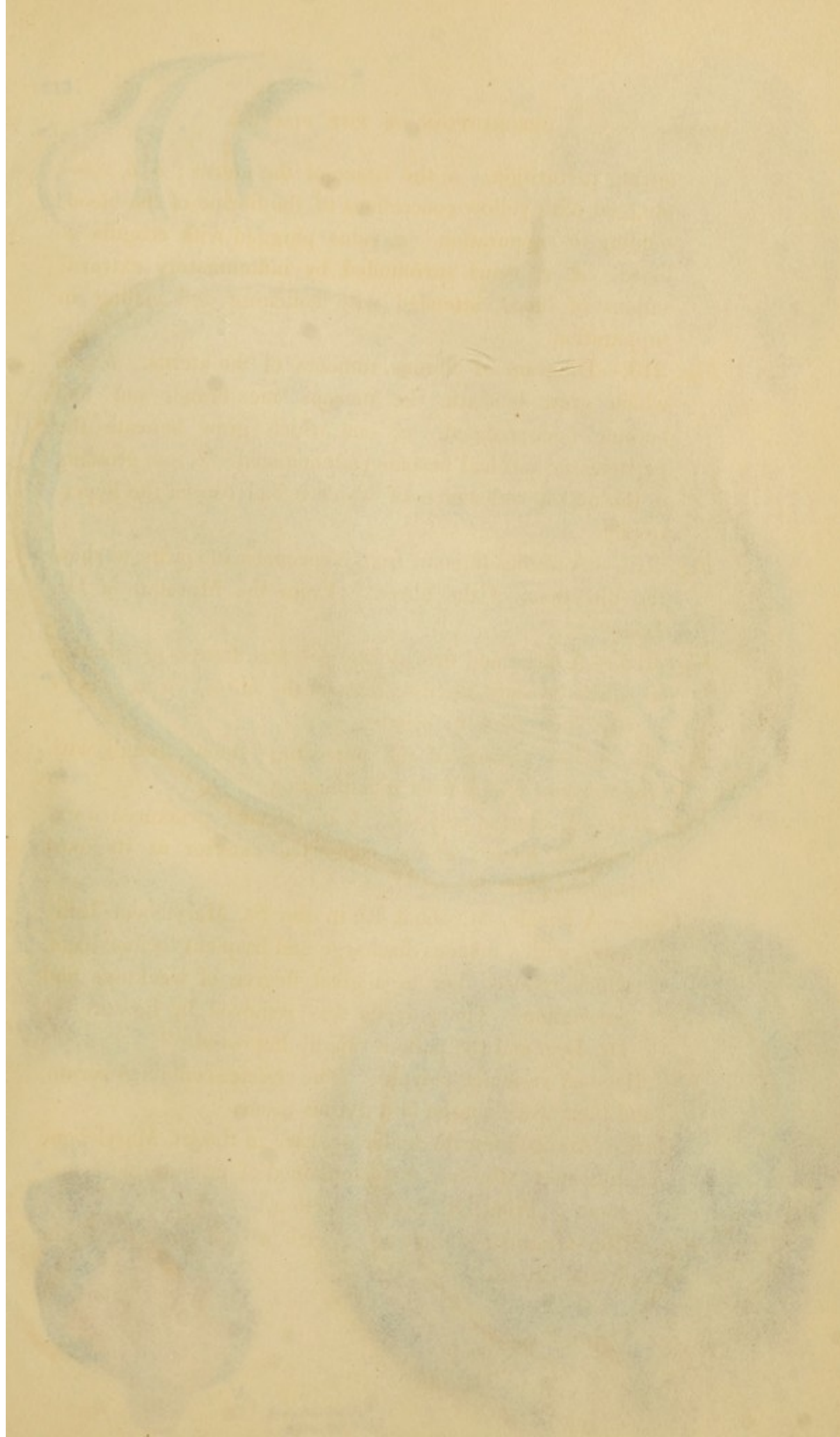
Fig. 217.—A uterine polypus. *b* its internal structure ; *a* extravasated blood ; *c* the congested exterior at its most dependent part.

Case.—A female, æt. about 40, in the St. Marylebone Infirmary, with a mucous discharge and frequent hæmorrhage, which reduced her to a great degree of weakness and emaciation. The polypus was removed by ligature by Dr. Lee, and the patient rapidly improved.

Fig. 218.—A vesicular polypus. The vesicles contained serum, and their walls consist of a fibrous tissue.

Case.—An aged female under my care in the St. Marylebone Infirmary, who had not complained of any uterine symptoms. (From Dr. Lee's collection.)

Fig. 219.—Granular kidney of a girl. *a*, the surface ; *b*, the reflected capsule.



lowing pectoration. *a*, the tissue of the uterus; *b, b*, veins plugged with yellow concretions of the fibrine of the blood, tending to suppuration; *c*, veins plugged with coagula of blood. *d, e*, veins surrounded by inflammatory extravasations of blood, attended with softening and ending in suppuration.

Fig. 213.—Diagram of fibrous tumours of the uterus. *b*, one which grew beneath the mucous membrane, and had become pedunculated. *d*, one which grew beneath the peritoneum and had become pedunculated. *c*, one growing in the uterine substance, of which it had caused the hypertrophy.

Fig. 214.—A fibrous tumour, from a specimen in spirits, to show the directions of the fibres. (From the Museum of Dr. Lee.)

Fig. 215.—A large and firm uterine polypus, from a preparation in spirits to show the directions of the fibres. *a, a, a* is its capsule, held back by bristles.

Fig. 216.—The surface of the preceding tumour, rough with fragments of lymph from inflammation.

Fig. 217.—A uterine polypus. *b* its internal structure; *a* extravasated blood; *c* the congested exterior at its most dependent part.

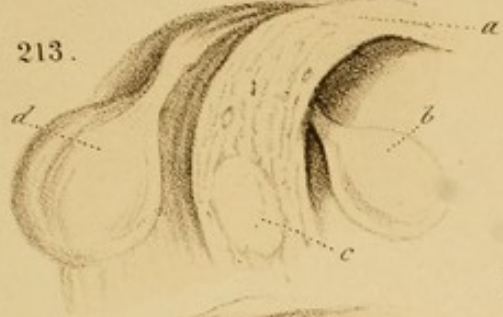Case.—A female, æt. about 40, in the St. Marylebone Infirmary, with a mucous discharge and frequent hæmorrhage, which reduced her to a great degree of weakness and emaciation. The polypus was removed by ligature by Dr. Lee, and the patient rapidly improved.

Fig. 218.—A vesicular polypus. The vesicles contained serum, and their walls consist of a fibrous tissue.

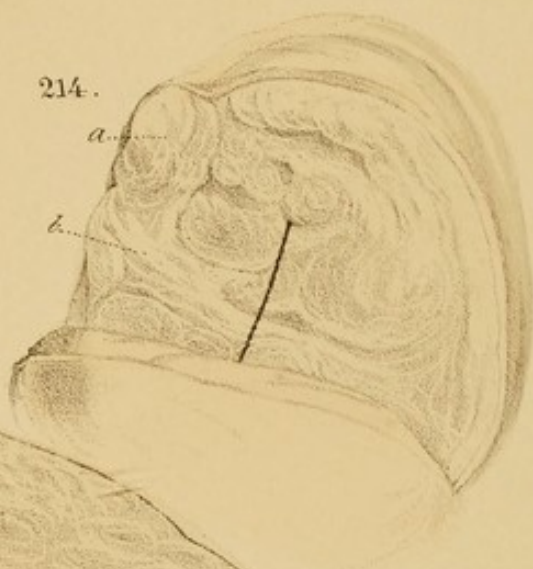Case.—An aged female under my care in the St. Marylebone Infirmary, who had not complained of any uterine symptoms. (From Dr. Lee's collection.)

Fig. 219.—Granular kidney of a girl. *a*, the surface; *b*, the reflected capsule.

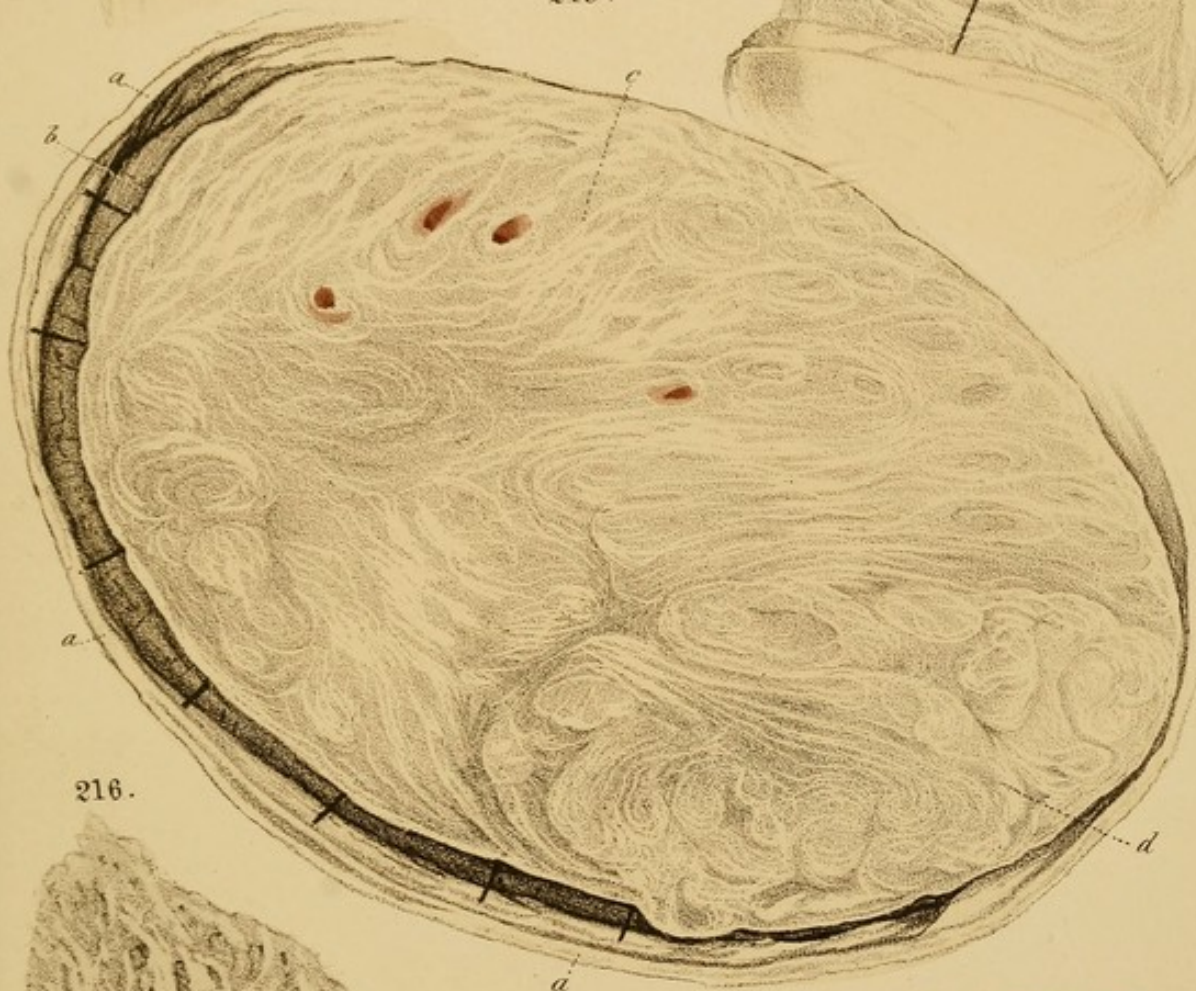213.



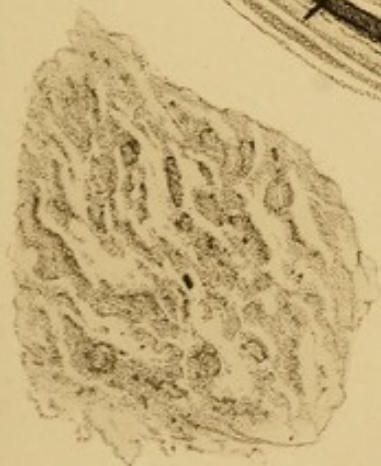214.



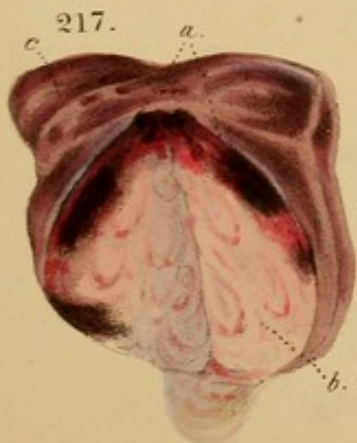215.



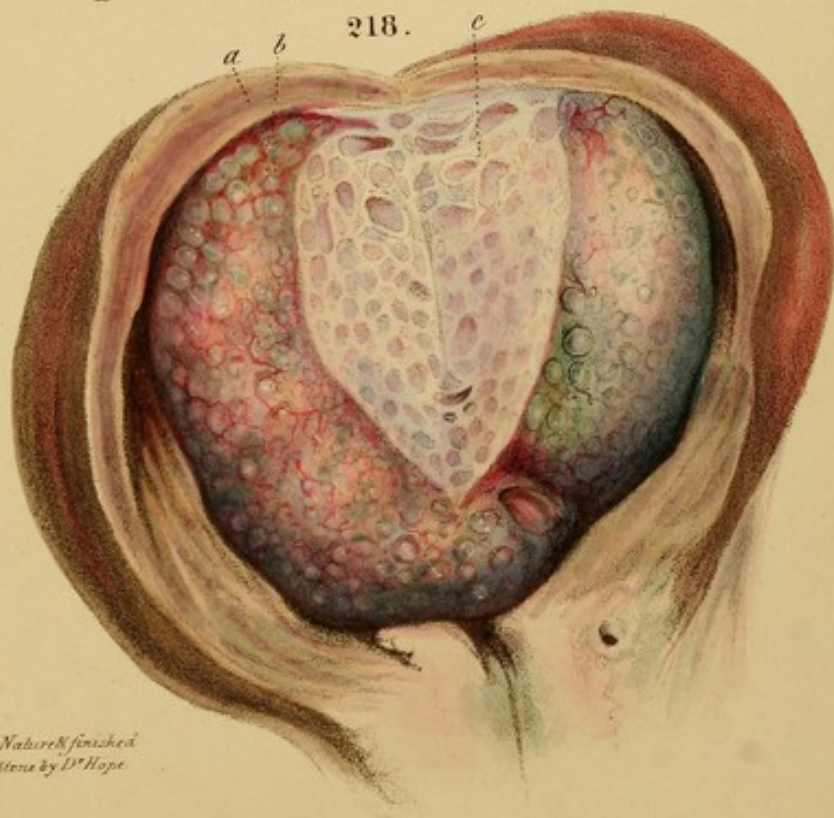
216.




217.




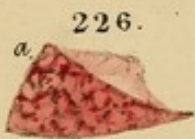
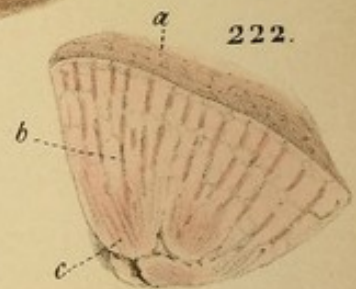
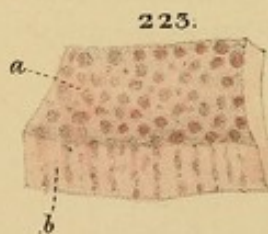
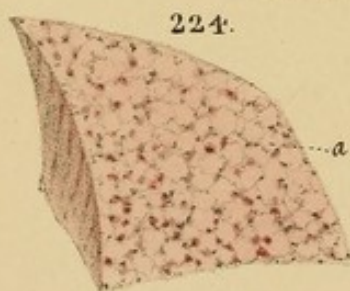
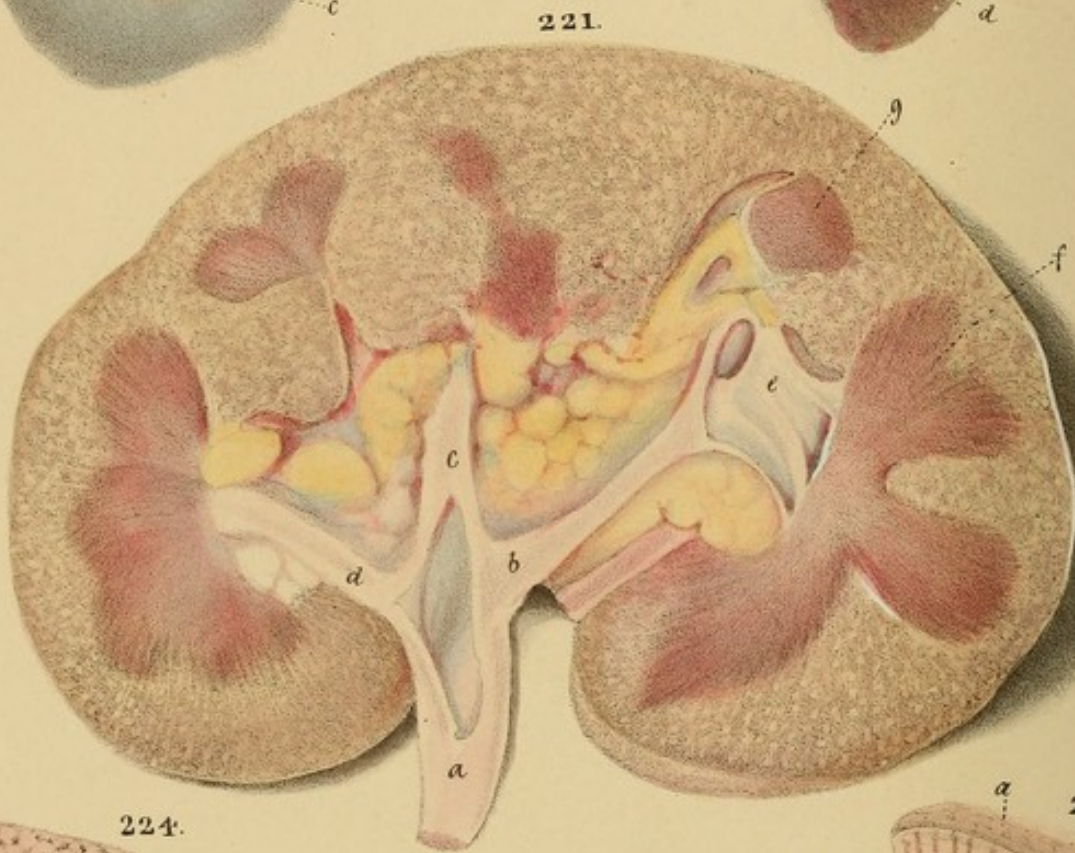
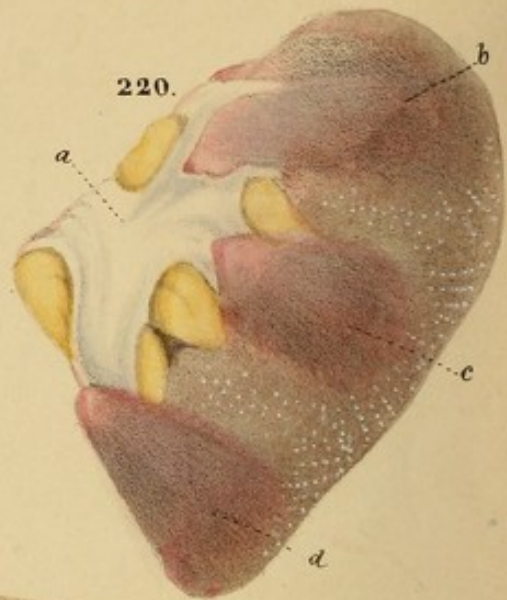
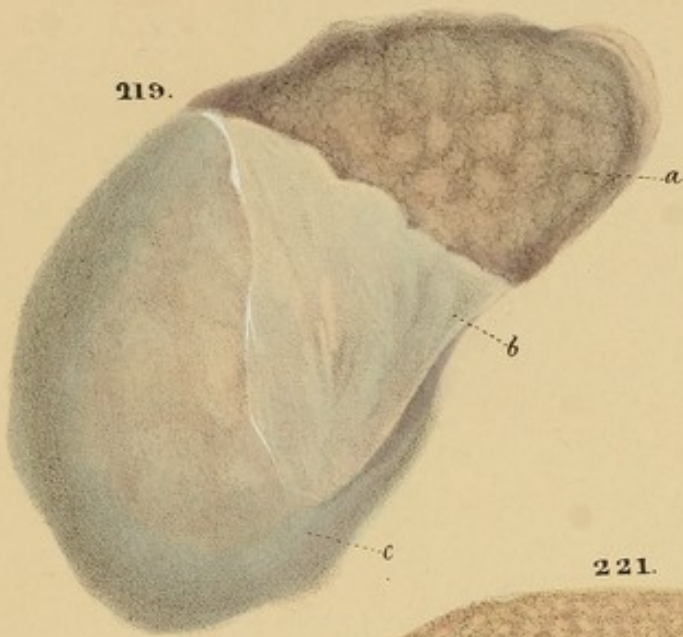
218.



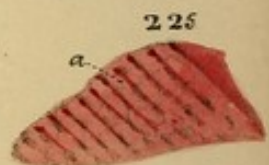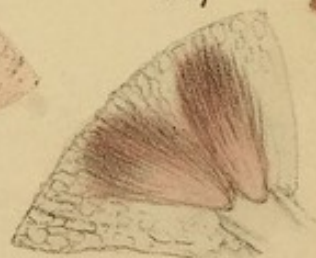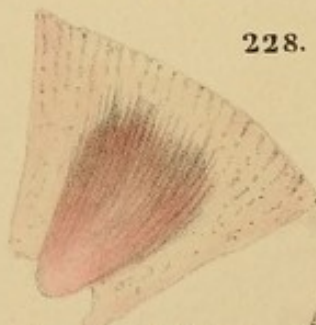
From Nature & finished
on Stone by D. Hope







229.



From Nature & finished
on Stone by D^r Hope

Fig. 220.—Interior of the same. *a*, the pelvis; *b*, *c*, *d*, vascular cones. Granules are seen in the cortical substance.

Case.—A girl, *æt.* 8, six months under my care in the St. Marylebone Infirmary, with great and obstinate ascites, which resisted all remedies. The urine was scanty. Died exhausted. *Section.* Both the kidneys were diseased, as represented. The liver was enlarged to double, and presented the very rare alteration delineated in Figs. 112 and 113.

Fig. 221.—A granular kidney, pale, softened, and enlarged. *a*, the pelvis, with three branches, *b*, *c*, *d*, leading to the cones; *e*, one branch opened; *f*, the cones; *g*, a cone cut transversely.

Case.—A man, *æt.* 56, eight months under my care in the St. Marylebone Infirmary, who had great ascites and finally anasarca; occasional pain in the region of the kidneys, relieved by cupping and blisters; urine albuminous and obstinately scanty; bowels costive. Diuretics produced only temporary relief: gradual emaciation. *Section.* Both kidneys as delineated. Liver contracted, wrinkled, and of the mummified character. (Vide Fig. 80.) Much ascites; peritoneum universally studded with semi-transparent grey granules of old lymph.

Fig. 222.—Granulated kidney macerated in spirits.

Fig. 223.—Section of the same parallel to the surface.

Fig. 224.—Surface of the same.

Fig. 225.—Section of the same, while recent. It is inflamed, red, and softened.

Fig. 226.—Exterior of the same, while recent.

Case.—A female, *æt.* 30, with general dropsy, attacking suddenly and recurring frequently. Died comatose. *Section.* Both kidneys inflamed, softened, and granulated. No disease elsewhere.

Fig. 227.—Granulated kidney with contraction and induration, drawing the surface to the cones.

The plant is a small, upright, perennial herb, with a single stem, and a few leaves at the base. The leaves are lanceolate, with a serrated margin, and a prominent midrib. The flowers are small, and are borne in a terminal raceme. The fruit is a small, round, capsule, which is covered with a fine, reticulate, or net-like pattern.

221

The plant is a small, upright, perennial herb, with a single stem, and a few leaves at the base. The leaves are lanceolate, with a serrated margin, and a prominent midrib. The flowers are small, and are borne in a terminal raceme. The fruit is a small, round, capsule, which is covered with a fine, reticulate, or net-like pattern.

The plant is a small, upright, perennial herb, with a single stem, and a few leaves at the base. The leaves are lanceolate, with a serrated margin, and a prominent midrib. The flowers are small, and are borne in a terminal raceme. The fruit is a small, round, capsule, which is covered with a fine, reticulate, or net-like pattern.

The plant is a small, upright, perennial herb, with a single stem, and a few leaves at the base. The leaves are lanceolate, with a serrated margin, and a prominent midrib. The flowers are small, and are borne in a terminal raceme. The fruit is a small, round, capsule, which is covered with a fine, reticulate, or net-like pattern.

The plant is a small, upright, perennial herb, with a single stem, and a few leaves at the base. The leaves are lanceolate, with a serrated margin, and a prominent midrib. The flowers are small, and are borne in a terminal raceme. The fruit is a small, round, capsule, which is covered with a fine, reticulate, or net-like pattern.

The plant is a small, upright, perennial herb, with a single stem, and a few leaves at the base. The leaves are lanceolate, with a serrated margin, and a prominent midrib. The flowers are small, and are borne in a terminal raceme. The fruit is a small, round, capsule, which is covered with a fine, reticulate, or net-like pattern.

The plant is a small, upright, perennial herb, with a single stem, and a few leaves at the base. The leaves are lanceolate, with a serrated margin, and a prominent midrib. The flowers are small, and are borne in a terminal raceme. The fruit is a small, round, capsule, which is covered with a fine, reticulate, or net-like pattern.

The plant is a small, upright, perennial herb, with a single stem, and a few leaves at the base. The leaves are lanceolate, with a serrated margin, and a prominent midrib. The flowers are small, and are borne in a terminal raceme. The fruit is a small, round, capsule, which is covered with a fine, reticulate, or net-like pattern.

The plant is a small, upright, perennial herb, with a single stem, and a few leaves at the base. The leaves are lanceolate, with a serrated margin, and a prominent midrib. The flowers are small, and are borne in a terminal raceme. The fruit is a small, round, capsule, which is covered with a fine, reticulate, or net-like pattern.

Fig. 220.—Interior of the same. *a*, the pelvis; *b, c, d*, vascular cones. Granules are seen in the cortical substance.

Case.—A girl, æt. 8, six months under my care in the St. Marylebone Infirmary, with great and obstinate ascites, which resisted all remedies. The urine was scanty. Died exhausted. *Sectio.* Both the kidneys were diseased, as represented. The liver was enlarged to double, and presented the very rare alteration delineated in Figs. 112 and 113.

Fig. 221.—A granular kidney, pale, softened, and enlarged. *a*, the pelvis, with three branches, *b, c, d*, leading to the cones; *e*, one branch opened; *f*, the cones; *g*, a cone cut transversely.

Case.—A man, æt. 56, eight months under my care in the St. Marylebone Infirmary, who had great ascites and finally anasarca; occasional pain in the region of the kidneys, relieved by cupping and blisters; urine albuminous and obstinately scanty; bowels costive. Diuretics produced only temporary relief: gradual emaciation. *Sectio.* Both kidneys as delineated. Liver contracted, wrinkled, and of the nutmeg character. (Vide Fig. 80.) Much ascites; peritoneum universally studded with semi-transparent grey granules of old lymph.

Fig. 222.—Granulated kidney macerated in spirits.

Fig. 223.—Section of the same parallel to the surface.

Fig. 224.—Surface of the same.

Fig. 225.—Section of the same, while recent. It is inflamed, red, and softened.

Fig. 226.—Exterior of the same, while recent.

Case.—A female, æt. 30, with general dropsy, attacking suddenly and recurring frequently. Died comatose.

Sectio. Both kidneys inflamed, softened, and granulated. No disease elsewhere.

Fig. 227.—Granulated kidney with contraction and induration, drawing the surface to the cones.

Fig. 228.—Granulated and softened kidney, very pale.

Fig. 229.—The same gorged with blood.

Fig. 230.—Pelvis *d* and ureter *e f* distended with urine, from encephaloid disease of the bladder obstructing the mouth of the ureter. *b*, adipose tissue; *c*, a vein; *a*, the kidney transformed into bulging cysts.

Fig. 231.—Thickening of all the coats of the bladder, with excrescences, *c, c*, of the mucous membrane, and submucous cellular tissue.

Fig. 232.—Spleen of a child containing tubercles; *a* seen within, *d* seen at the surface.

Case.—The child, æt. 5, had also tubercles of the bronchial glands and the intestines, and died with hectic and marcor.

Fig. 233.—A mass, *a, b*, of pale, concrete fibrine in the spleen.

Case.—Regurgitation through the mitral valve of the heart, causing extreme venous retardation. The spleen was thrice its natural size.

Fig. 234.—A mottled spleen from formations of pale concrete fibrine in the bright red spots.

Case.—Extreme induration of the liver, represented in *Fig.* 82, which see.

Fig. 235.—Spleen containing tubercles; some unopened, *a*; others opened, *b*; others seen through the peritoneal capsule, *d*. All enclosed thick pus. The splenic cells, *c*, were unusually distinct in this specimen.

Case.—Wm. Perryman, æt. 20, at St. George's Hospital 1829, was carried off by acute abdominal inflammation followed by coma.

Section.—The peritoneum lining the diaphragm was tuberculated. The spleen contained about 30 of the tubercles delineated, and the lungs contained tubercles and a few small vomicae.

Fig. 100.—Ovarian and uterine tubes, very long.

Fig. 101.—The same, enlarged with black.

Fig. 102.—Tarsus and claw, very long, with black.

Fig. 103.—Tarsus and claw, very long, with black.

Fig. 104.—Tarsus and claw, very long, with black.

Fig. 105.—Tarsus and claw, very long, with black.

Fig. 106.—Tarsus and claw, very long, with black.

Fig. 107.—Tarsus and claw, very long, with black.

Fig. 108.—Tarsus and claw, very long, with black.

Fig. 109.—Tarsus and claw, very long, with black.

Fig. 110.—Tarsus and claw, very long, with black.

Fig. 111.—Tarsus and claw, very long, with black.

Fig. 112.—Tarsus and claw, very long, with black.

Fig. 113.—Tarsus and claw, very long, with black.

Fig. 114.—Tarsus and claw, very long, with black.

Fig. 115.—Tarsus and claw, very long, with black.

Fig. 116.—Tarsus and claw, very long, with black.

Fig. 117.—Tarsus and claw, very long, with black.

Fig. 118.—Tarsus and claw, very long, with black.

Fig. 119.—Tarsus and claw, very long, with black.

Fig. 120.—Tarsus and claw, very long, with black.

Fig. 121.—Tarsus and claw, very long, with black.

Fig. 122.—Tarsus and claw, very long, with black.

Fig. 123.—Tarsus and claw, very long, with black.

Fig. 124.—Tarsus and claw, very long, with black.

Fig. 125.—Tarsus and claw, very long, with black.

Fig. 126.—Tarsus and claw, very long, with black.

Fig. 127.—Tarsus and claw, very long, with black.

Fig. 128.—Tarsus and claw, very long, with black.

Fig. 129.—Tarsus and claw, very long, with black.

Fig. 130.—Tarsus and claw, very long, with black.

Fig. 228.—Granulated and softened kidney, very pale.

Fig. 229.—The same gorged with blood.

Fig. 230.—Pelvis *d* and ureter *e f* distended with urine, from encystoid disease of the bladder obstructing the mouth of the ureter. *b*, adipose tissue; *c*, a vein; *a*, the kidney transformed into bulging cysts.

Fig. 231.—Thickening of all the coats of the bladder, with excrescences, *c, c*, of the mucous membrane, and submucous cellular tissue.

Fig. 232.—Spleen of a child containing tubercles; *a* seen within, *d* seen at the surface.

Case.—The child, *æt.* 5, had also tubercles of the bronchial glands and the intestines, and died with hectic and marcor.

Fig. 233.—A mass, *a, b*, of pale, concrete fibrine in the spleen.

Case.—Regurgitation through the mitral valve of the heart, causing extreme venous retardation. The spleen was thrice its natural size.

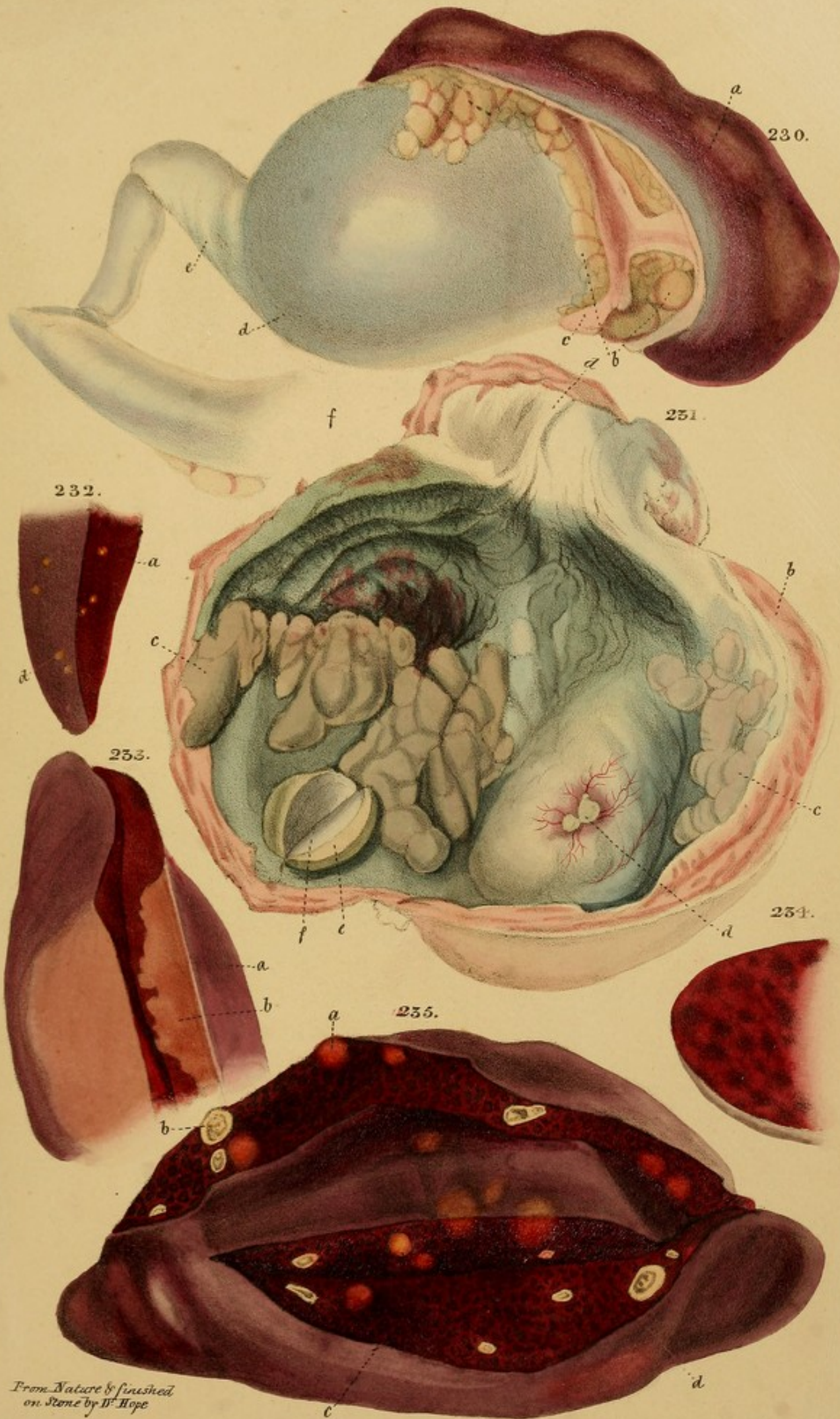Fig. 234.—A distended spleen from formation of pale concrete fibrine in the bright red spots.

Case.—Extreme induration of the liver, represented in *Fig. 32*, which see.

Fig. 235.—Spleen containing tubercles; some unopened, *a*; others opened, *b*; others seen through the peritoneal capsule, *d*. All enclosed thick pas. The splenic cells, *c*, were unusually distinct in this specimen.


Case.—Wm. Perryman, *æt.* 30, at St. George's Hospital 1829, was carried off by acute abdominal inflammation followed by coma.


Section.—The peritoneum lining the diaphragm was tuberculated. The spleen contained about 30 of the tubercles delineated, and the lungs contained tubercles and a few small vomice.

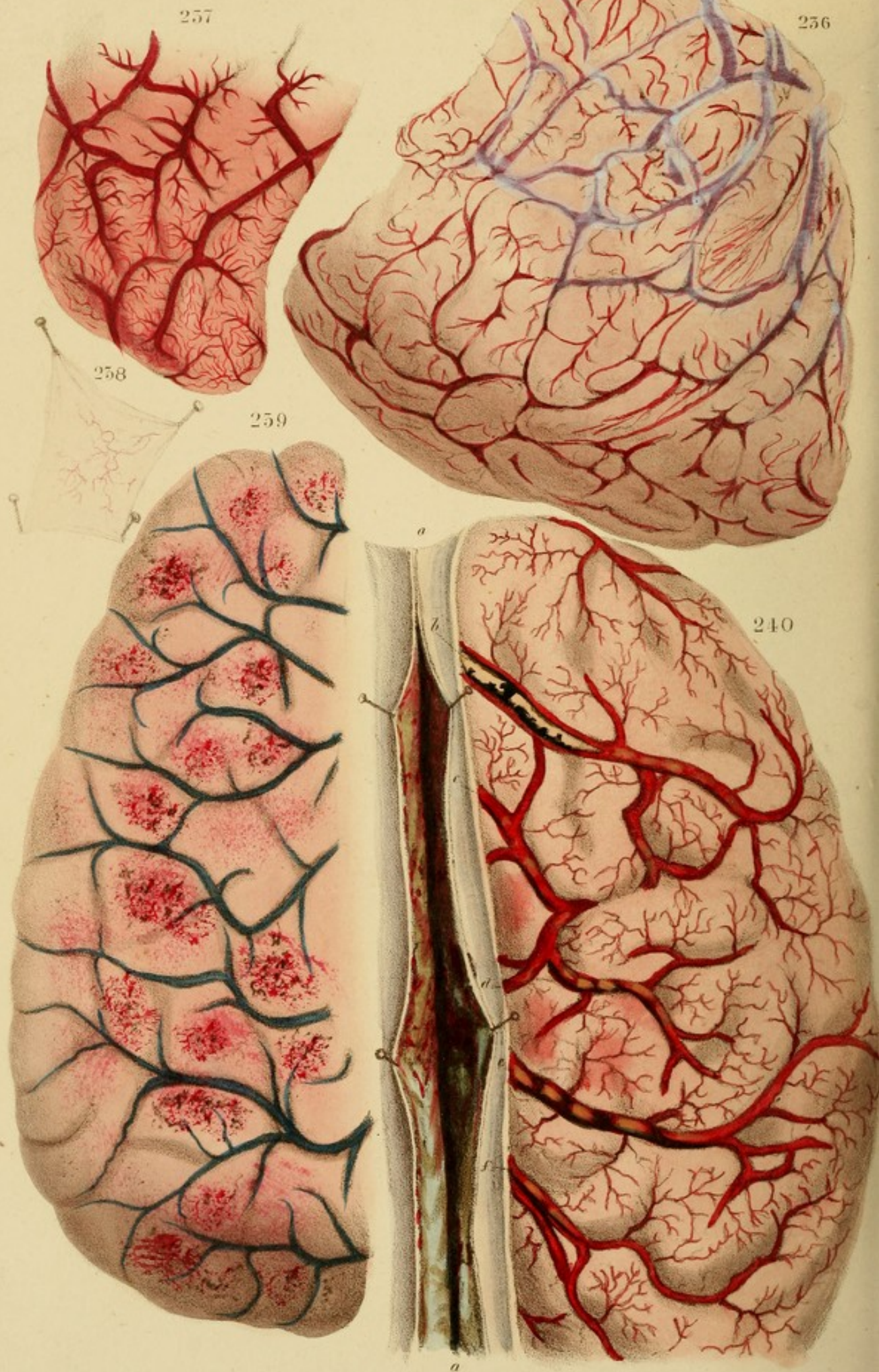


From Nature & finished
on Stone by W. Hope

A. Ducote's Litho & 70, St. Martins Lane.







From *Anders* and revised
on *Bois* by D. Buge.

DESCRIPTION OF THE PLATES.

Fig. 206.—Acute arachnitis with serous effusion. The small vessels of the pia mater are preternaturally congested, the general tint is rufous than in the healthy state, and serum is accumulated under the arachnoid in the intervals between the convolutions, giving their tracts a hazy bluish appearance, which obscures the great veins.

Case.—I know not the particulars of this case, but have repeatedly seen these alterations after acute meningitis.

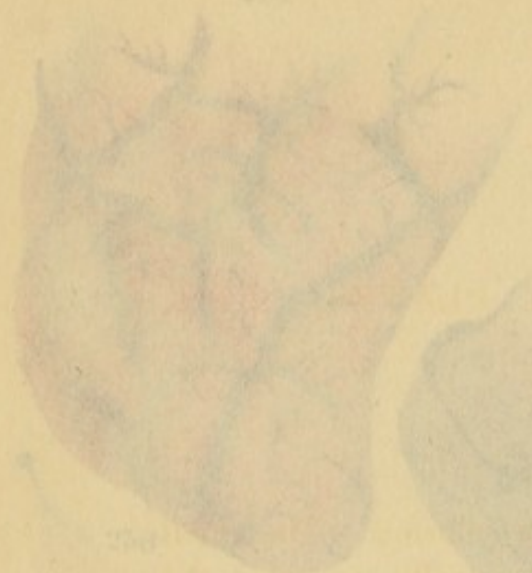Fig. 207.—Arachnitis with extreme vascularity. Dr. J. Bardeley, of Manchester, to whom I am indebted for this Fig., (a portion only of a large drawing,) says, "I have seen several hundred cases, but never met with one in which the pia mater was so minutely injected."

Case.—"This patient," says Dr. Bardeley "was admitted under my care into the Peter Ward with symptoms of meningitis. She was extremely violent and required the most constant attendance day and night. She died thirty-six hours after admission, when the highly vascular state of the pia mater is represented in the drawing, was noticed." Small portions of serum were effused in some parts along the intervals between the convolutions.

Fig. 208.—Supposed meningitis.

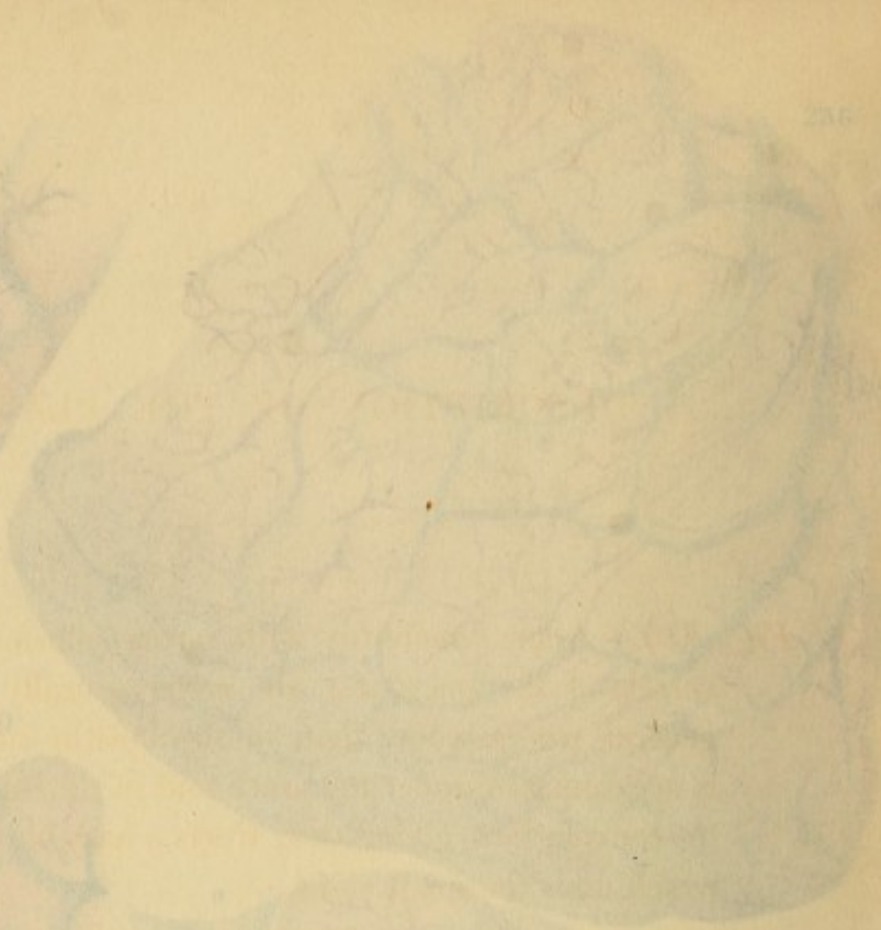Fig. 209.—Nervous system, as it appears on the surface of the brain. Dr. J. Bardeley, to whom I am indebted for this drawing, says, "I believe that there is no place in any pathological condition, in which the state is such."

Case.—"The patient was a female, at all of her character

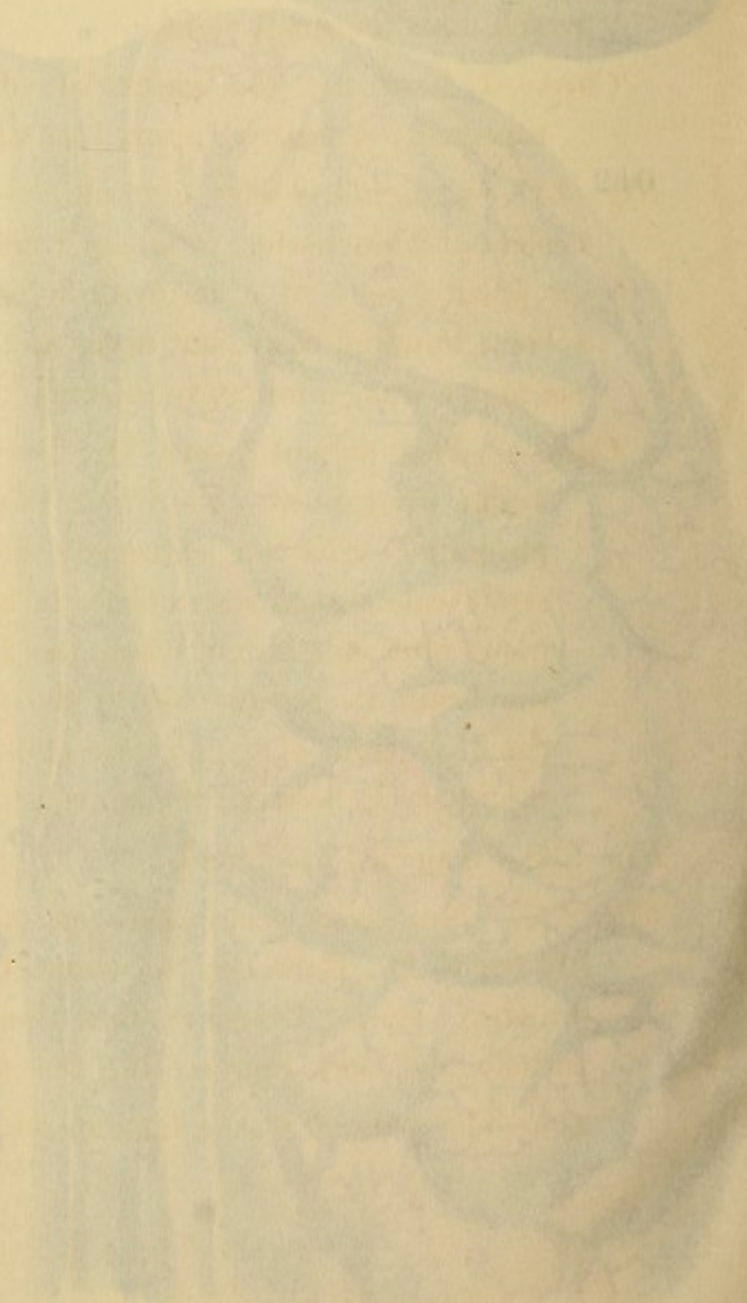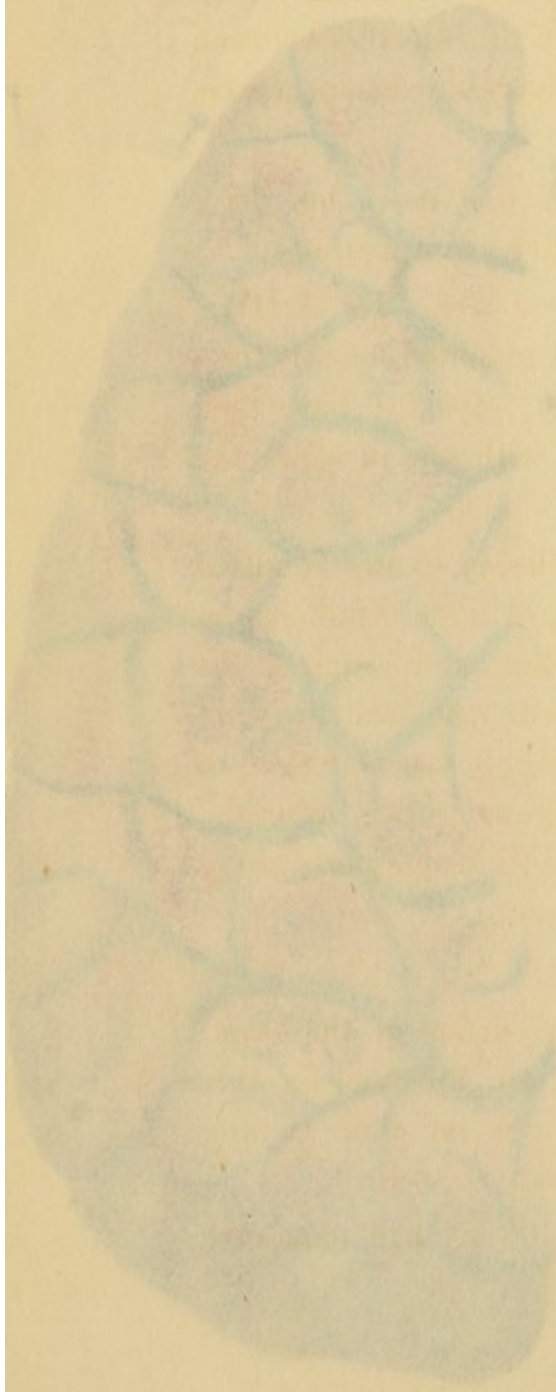


236

237



238



DESCRIPTION OF THE PLATES.

Fig. 236.—Acute arachnitis with serous effusion. The small vessels of the pia mater are preternaturally congested, the general tint is redder than in the healthy state, and serum is accumulated under the arachnoid in the intervals between the convolutions, giving their tracts a hazy bluish appearance, which dims the great veins.

Case.—I have not the particulars of this case, but have repeatedly seen these alterations after acute meningitis.

Fig. 237.—Arachnitis with extreme vascularity. Dr. J. Bardesley, of Manchester, to whom I am indebted for this Fig., (a portion only of a large drawing,) says, "I have seen several hundred cases, but never met with one in which the pia mater was so minutely injected."

Case.—"This patient," says Dr. Bardesley, "was admitted under my care into the Fever Wards with symptoms of phrenitis. She was extremely violent and required the strait waistcoat to restrain her in bed. She died thirty-six hours after admission, when the highly vascular state of the brain, as represented in the drawing, was noticed." Small portions of lymph were effused in some parts along the intervals between the convolutions.

Fig. 238.—Injected arachnoid.

Fig. 239.—Numerous ecchymoses on the surface of the brain. My friend Dr. Bardesley, to whom I am indebted for this drawing, says, "I believe that there is no plate in any pathological work representing this state so well."

Case.—The patient was a female, æt. 63, of bad character

and much addicted to intoxication. She was found one evening in the streets, in a state of insensibility, and was brought into the Royal Infirmary. She lived several days, and, though she somewhat recovered from deep stupor, she never became capable of speaking or expressing her wants by signs. Deglutition was impaired, and the whole frame seemed to be paralysed. No decided coagulum of blood was found.

Fig. 240.—Phlebitis of the superior longitudinal sinus *a a*, and the veins *b c d e f* falling into it: the whole are distended with coagula, described at *p*, 280. The drawing is copied from Cruveilhier.

Case.—A girl, *æ*t. 4, whose principal symptoms were, dilated pupils, cries and groans, rigidity of the limbs, tongue white, dulness of the summit of the left lung (peripneumony); a few days before, she had passed by the mouth eight ascarides lumbricoides. Died on the fifth day after admission.

Fig. 241.—A portion of healthy brain from a female, *æ*t. 19, to show the colours. The medullary substance differs from white paper in having a faint pink and yellow tinge. See *p*. 282 et seq.

Fig. 242.—Appearance of congestion: viz. an increased number and more venous colour, of the red dots, lines and spots.

Fig. 243.—Excessive congestion, giving a leaden tinge to the brain.

Case.—Disease of the heart obstructing the return of the venous blood.

Fig. 244.—Inflammation of the substance of the brain, in one part presenting a cloudy appearance, and a pretty deep red colour of the cortical substance.

Case.—Phrenitis.

Fig. 245.—A recent apoplectic effusion partly in, and partly

and much addicted to intoxication. She was found one evening in the streets, in a state of insensibility, and was brought into the Royal Infirmary. She lived several days, and, though she somewhat recovered from deep stupor, she never became capable of speaking or expressing her wants by signs. Deglutition was impaired, and the whole frame seemed to be paralysed. No decided coagulum of blood was found.

Fig. 240.—Phlebitis of the superior longitudinal sinus *a a*, and the veins *b c d e f* falling into it: the whole are distended with coagula, described at *p*, 280. The drawing is copied from Cuvillier.

Case.—A girl, æt. 4, whose principal symptoms were, dilated pupils, cries and groans, rigidity of the limbs, tongue white, dulness of the summit of the left lung (peripneumony); a few days before, she had passed by the mouth eight scarious humors. Died on the fifth day after admission.

Fig. 241.—A portion of healthy brain from a female, æt. 19, to show the colours. The medullary substance differs from white paper in having a faint pink and yellow tinge. See *p*. 282 et seq.

Fig. 242.—Appearance of congestion: viz. an increased number and more venous colour, of the red dots, lines and spots.

Fig. 243.—Excessive congestion, giving a leaden tinge to the brain.

Case.—Disease of the heart obstructing the return of the venous blood.

Fig. 244.—Inflammation of the substance of the brain, in one part presenting a cloudy appearance, and a pretty deep red colour of the cortical substance.

Case.—Phrenitis.

Fig. 245.—A recent apoplectic effusion partly *m*, and partly

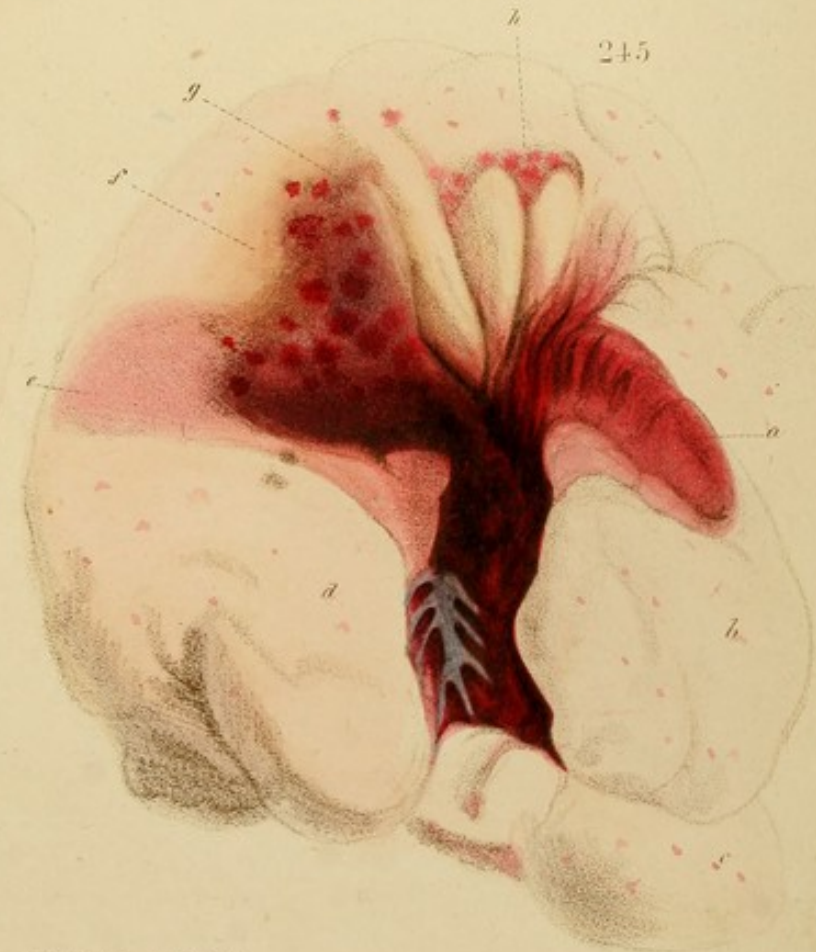241

242


243


244

245

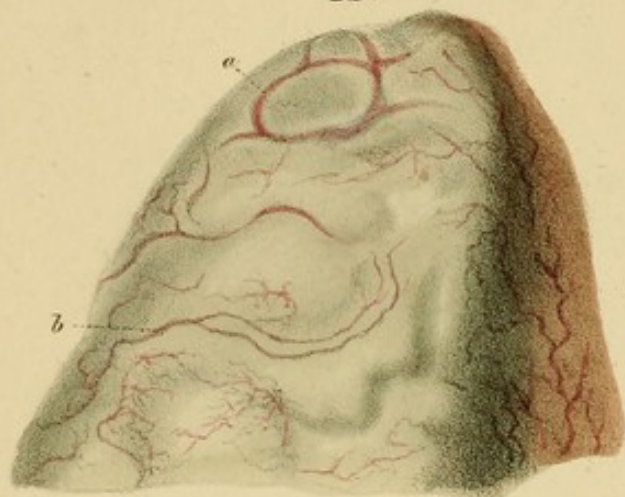

*From Nature, and Revised
on Stone by D. Hope.
A. Ince's Lithog. 76 St. Martin's Lane.*

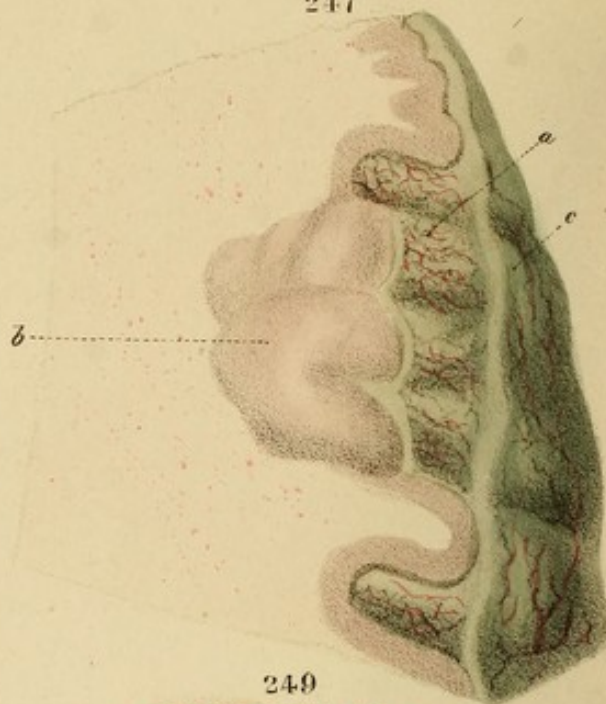




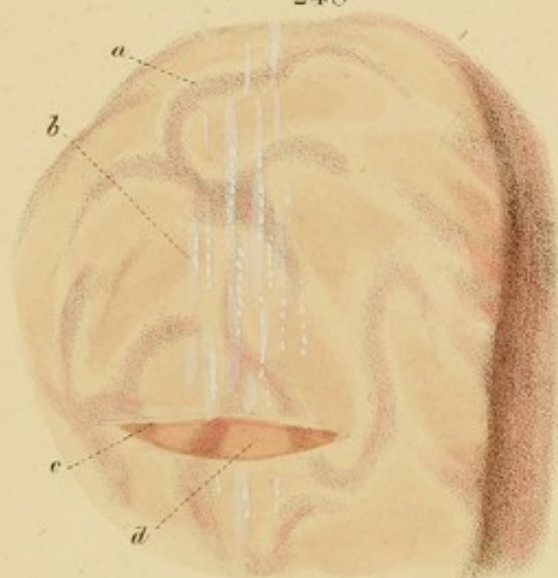
246



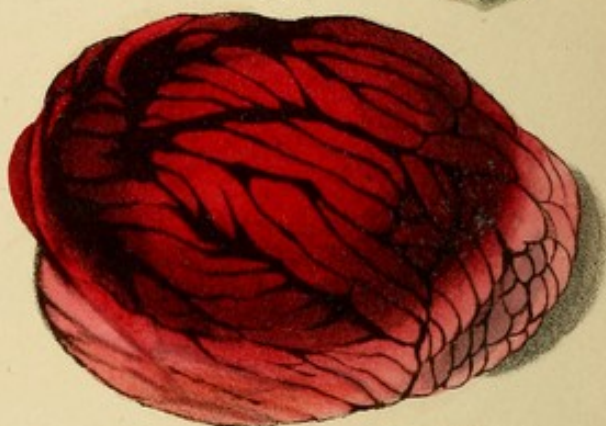247



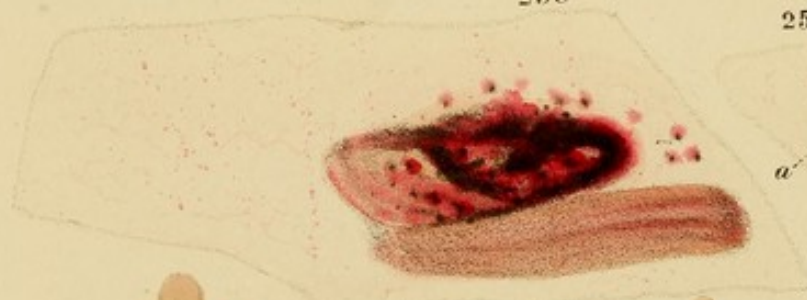
248



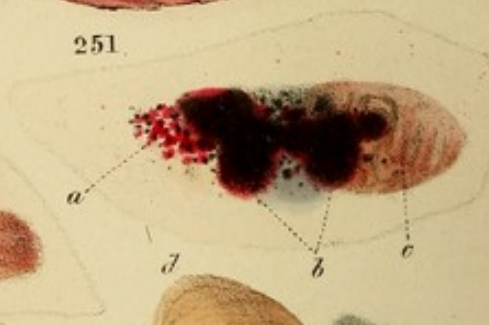249



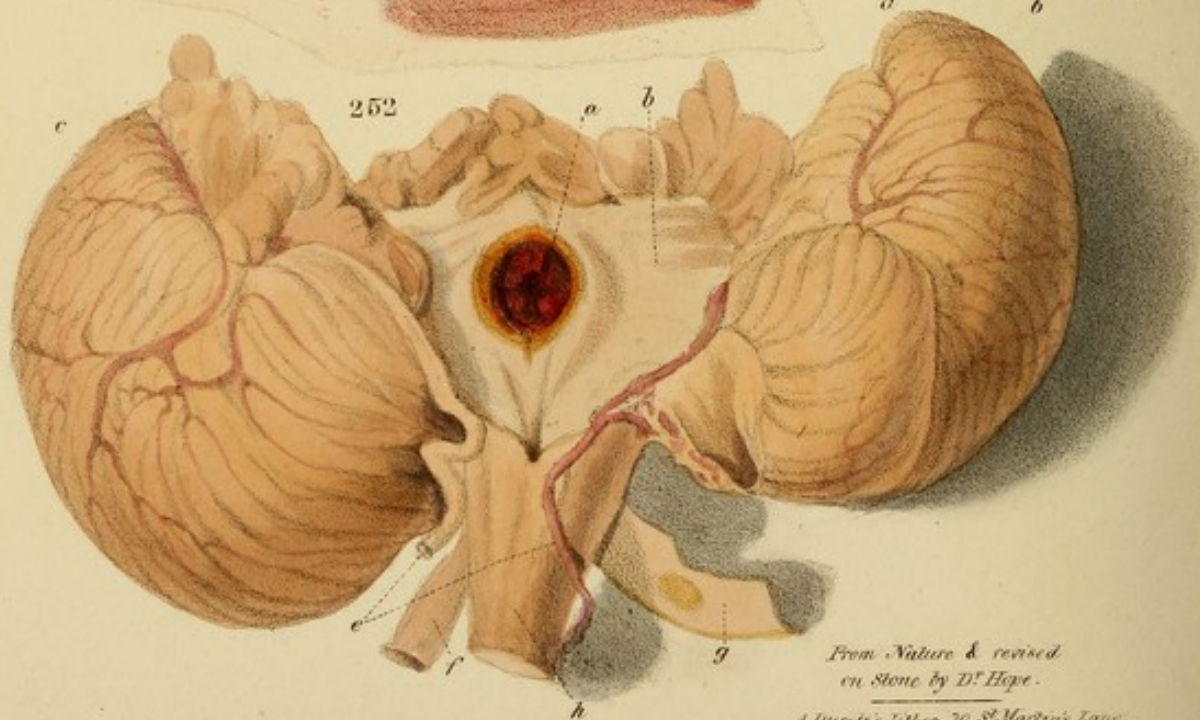
250



251



252



From Nature & revised
on Stone by D^r Hope.

A. Ducrot's Lithog. 76, St. Martin's Lane.

below the left corpus striatum *a, c*, which has been divided horizontally, and the upper half *a* reflected over to the right, together with the left thalamus opticus *b* in order to display the clot beneath.

Case.—Apoplexy fatal in three days.

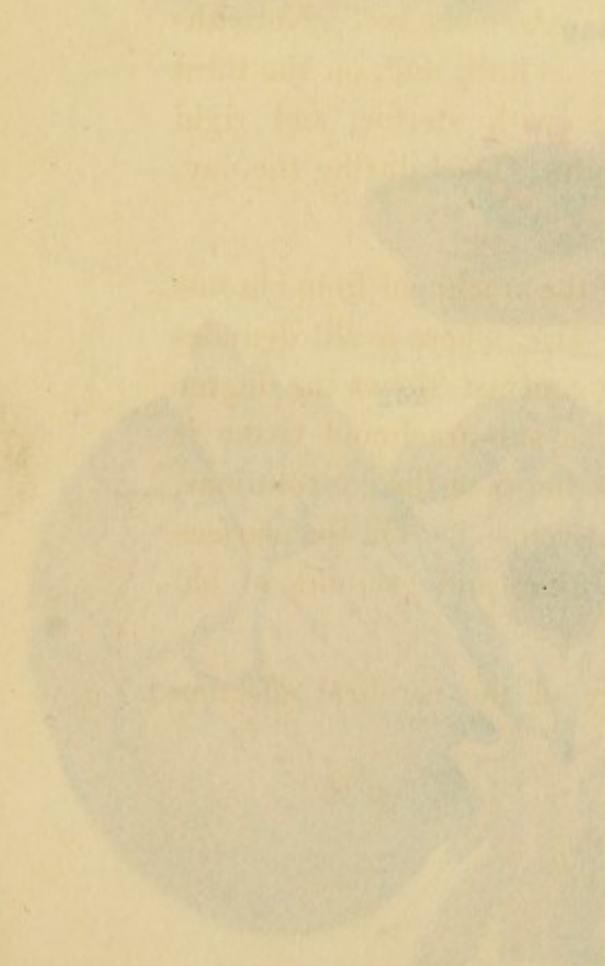


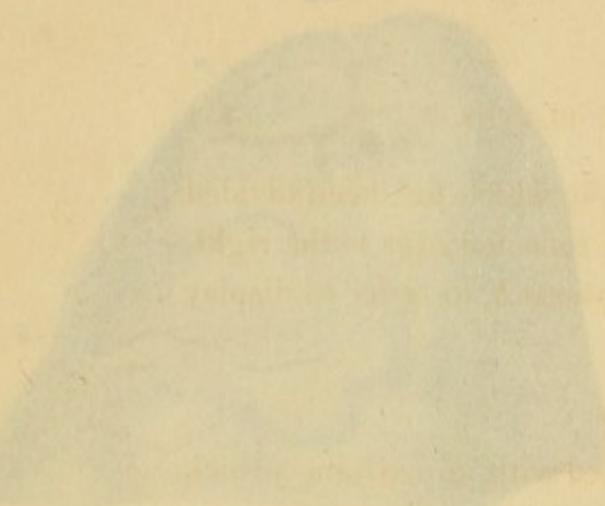
Fig. 246.—A portion of brain enveloped with an extremely thick layer of greenish yellow false-membrane, situated between the arachnoid and pia mater, the gorged vessels of which are partially seen through the semi-transparency of the layer. (From Cruveilhier, *Liv. viii. pl. 4.*)

Fig. 247.—A portion of the same, showing that the false-membrane follows the pia mater deep between the convolutions, which it widely separates. Injected vessels of the pia mater are seen as the prolongations of false membrane. The whole brain and a great part of the cerebellum was in a similar state. (From Cruveilhier, *Ibid.*)

Case.—A man, *æt.* 70, at the Bicêtre. Flushed face; extreme and furious loquacity; pulse frequent, full and hard; throbbing of temporals; head extremely hot. Notwithstanding bleeding, &c., he became dull, and, on the third day, fell into profound coma, with stertor, and rigid tremulous flexion of the right arm. Died during the day. He was a great spirit-drinker.

Fig. 248.—Thickening and opacity of the arachnoid from chronic inflammation. The edge is seen at *c*, where a slit denudes the perical convolutions, and by contrast shows the degree of opacity of the arachnoid. The sub-arachnoid tissue is also thickened along the intervals between the convolutions, obscuring the tracts of the great veins *a*. On the surface are seen opaque, white, flocculent lines and granules of old lymph.

Case.—Phthisis. No clear history of the cerebral affection was obtained.



below the left corpus striatum *a*, *e*, which has been divided horizontally, and the upper half *a* reflected over to the right, together with the left thalamus opticus *b*, in order to display the clot beneath.

Case.—Apoplexy fatal in three days.

Fig. 246.—A portion of brain enveloped with an extremely thick layer of greenish yellow false-membrane, situated between the arachnoid and pia mater, the gorged vessels of which are partially seen through the semi-transparency of the layer. (From Cruveilhier, Liv. viii. pl. 4.)

Fig. 247.—A portion of the same, showing that the false-membrane follows the pia mater deep between the convolutions, which it widely separates. Injected vessels of the pia mater are seen on the prolongations of false membrane. The whole brain, and a great part of the cerebellum was in a similar state. (From Cruveilhier, *ibid.*)

Case.—A man, æt. 70, at the Bicêtre. Flushed face; extreme and furious loquacity; pulse frequent, full and hard; throbbing of temporals; head extremely hot. Notwithstanding bleeding, &c., he became dull, and, on the third day, fell into profound coma, with stertor, and rigid tremulous flexion of the right arm. Died during the day. He was a great spirit-drinker.

Fig. 248.—Thickening and opacity of the arachnoid from chronic inflammation. The edge is seen at *c*, where a slit denudes the cerebral convolutions, and by contrast shows the degree of opacity of the arachnoid. The sub-arachnoid tissue is also thickened along the intervals between the convolutions, obscuring the tracts of the great veins *a*. On the surface are seen opake, white, flocculent lines and granules of old lymph.

Case.—Phthisis. No clear history of the cerebral affection was obtained.

Fig. 249.—Effusion on the surface of the cerebellum beneath the pia mater and arachnoid. The black lines are coagula between the convolutions.

Case.—A man, æt. 66, in the Marylebone Infirmary with fatal apoplexy. There were also several internal effusions in the brain and cerebellum. Left ventricle of heart an inch thick, and foramen ovale open.

Fig. 250.—A small, recent apoplectic effusion near the *corpus striatum*, which is seen below it, streaked with infiltrated blood.

Case.—Same as the preceding.

Fig. 251.—Small, recent effusions, *b*, in the *corpus dentatum*, *c*, of the cerebellum, and dotted ecchymoses, *a*, around.

Case.—Same as the two preceding.

Fig. 252.—A clot six weeks old in the posterior part of the medulla oblongata, with amber-coloured induration around. The specimen had been immersed in spirits: hence its unnatural colour. *c* and *d* are the lobes of the cerebellum, separated; *f*, *g*, are the vertebral arteries, the latter of which is cut open and expanded to show a patch of opaque yellow steatoma; *e* are the vertebral veins; *h* is the medulla oblongata. The specimen is in the possession of Dr. Hewett, late Physician to St. George's Hospital, to whose kindness I was indebted for being allowed to make the drawing.

Case.—Prudence Campin, æt. 50, stout, in St. George's, under Dr. Hewett. Paralysis of the *right* side of the body and the *left* side of the face; the tongue is protruded towards the left. Strabismus; speech slow but distinct; incoherence. Three weeks before admission, she had a fit attended with tinnitus, loss of vision, and finally, coma; from which she was relieved by bleeding, cupping and leeching. Died at the end of six weeks, from inflammation of the kidney and bladder.

Sectio.—The brain presented the extravasation seen in the Fig. situated on the left side of the mesial line, *which is pushed aside to the right.* The arteries at the base of the brain were of opake yellow and green colour, and very lacerable. Left ventricle of heart, hypertrophous, being three fourths of an inch thick. Left kidney contained pus; bladder was ulcerated from chronic inflammation.

Remark.—Having the pleasure of M. Foville's acquaintance, I requested his explanation of the circumstance that opposite sides of the face and the body were paralyzed, a circumstance of which this is by no means a solitary instance. He replied that the effusion on the left side of the mesial line of the pons varolii compressed the origin of the 5th nerves of the opposite side. This explanation is ingenious, and apparently correct.

Fig. 253.—An apoplectic effusion, *e*, seven months old, in the corpus striatum, *d*, (see p. 294,) *b*, is the thalamus opticus, from which a slice, *a*, has been cut off, to show the grey substance. *c* is the choroid plexus.

Case.—Alexander Cleaver, æt. 45, in the Marylebone Infirmary, August 1832, had a mild apoplectic attack from which he recovered, but was carried off a month afterwards by acute laryngitis. Three years before, at which time he was subject to headaches, he had apoplexy, which left him affected with mental imbecility. He subsequently had occasional attacks—the last, seven months before death. An occasional increased impulse of the heart.

Sectio.—No recent coagulum was found in the brain; whence the last apoplectic attack appears to have been merely congestive. The old clot, *e, f*, represented in the Fig., was found in the right corpus striatum, and must have corresponded with the fit seven months before. The arteries of the base were slightly thickened and opaque.

Heart enlarged; left ventricular walls nearly an inch thick. Oedema of the glottis closing the passage.

Fig. 254.—Another portion of the same cyst from which the coagulum has been withdrawn, so as to show the walls of the cyst.

Fig. 255.—A cavity in the corpus striatum, &c. left by an apoplectic coagulum.

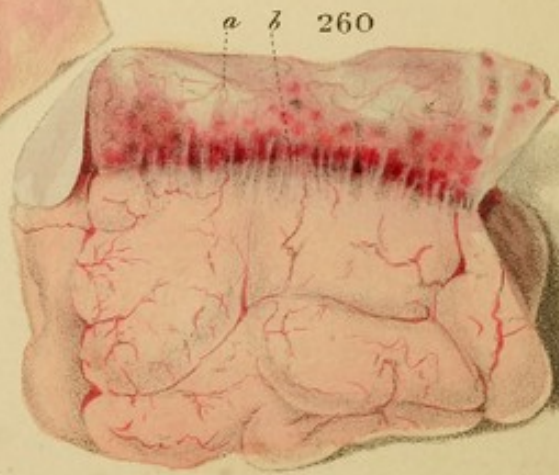
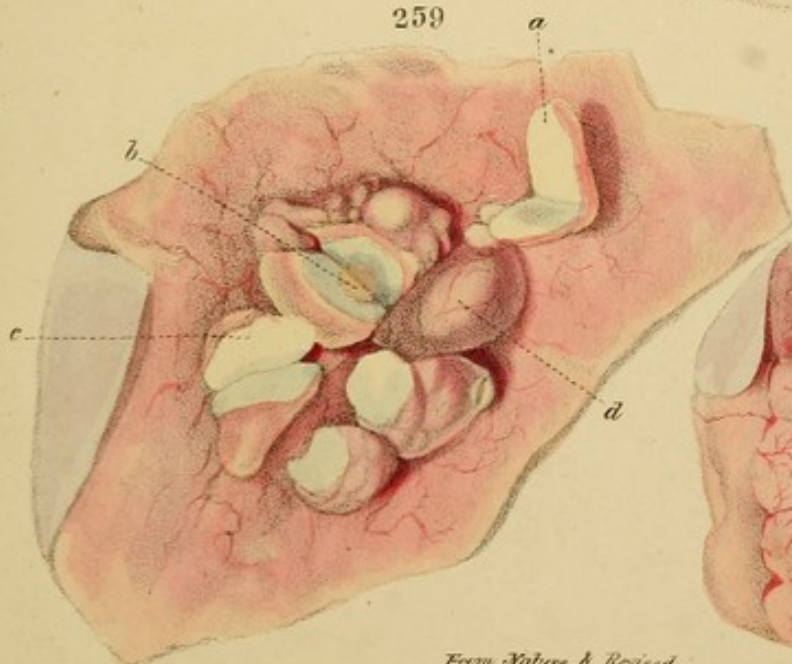
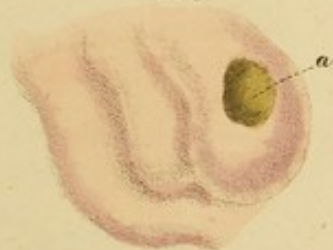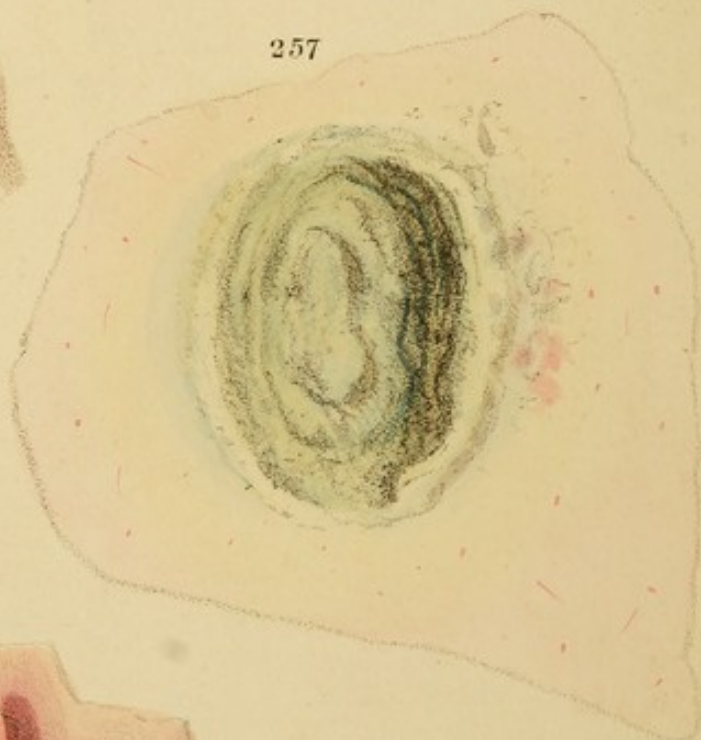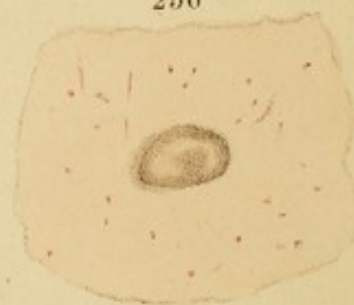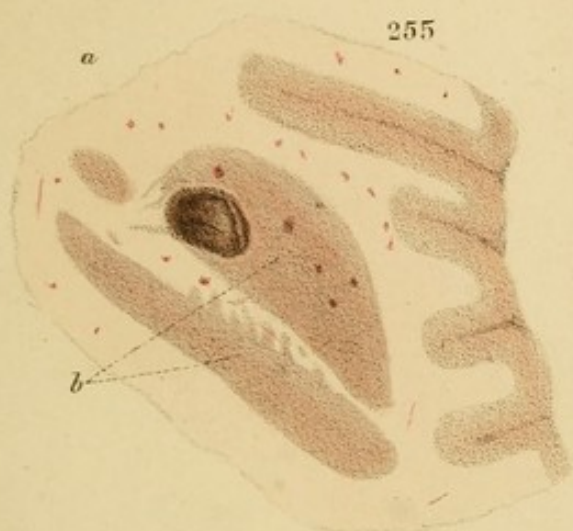
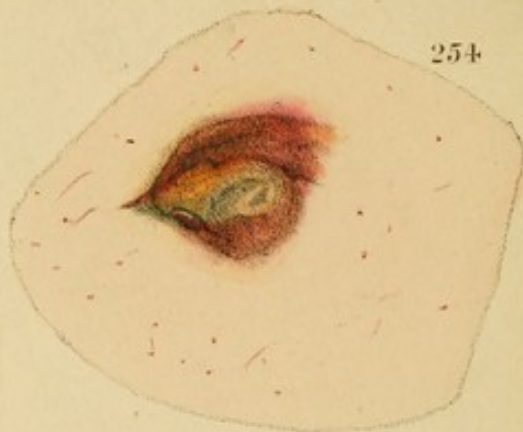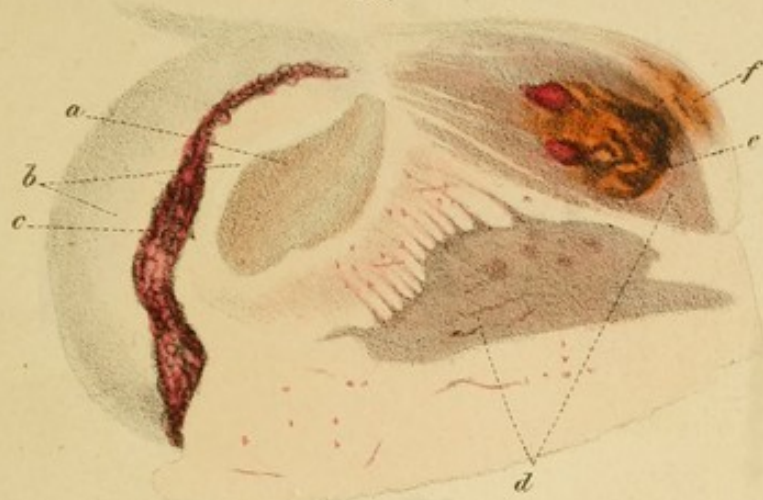Fig. 256.—A similar cavity in the medullary substance. Both these specimens were from a man who had had five attacks of apoplexy: the first, eight years before death. There were three other coagula apparently corresponding with more recent attacks.

Fig. 257.—A chronic ulcer of the brain, situated in the posterior part of the left hemisphere. It has a thick, tough, and ragged cyst of dirty greenish-yellow colour. The medullary substance around is softened from acute inflammation, and is greenish near the cyst and yellow beyond.

Case.—Mary Collins, æt. 8, labouring with epansia. She suddenly became affected with the symptoms of acute hydrocephalus, without having previously complained more of the head than she had done for two or three years. The attack was attended with pain in the left occipital region, on which part she constantly lay. Strabismus and coma, without paralysis, supervened, and she died in a week.*

Section.—The principal cerebral lesion was, the abscess and surrounding softening, rudely delineated in the Fig. As the cyst was manifestly old, it must have existed long before the acute attack, without occasioning any particular symptoms; and there can be no doubt that the patient died of the acute inflammatory action excited

* This case is described in the author's Treatise on the Diseases of the Heart, p. 468.




around it, and terminating in softening. The meningocephalic vessels were gorged, and the general tint of the cerebral substance was dark.


Fig. 258.—A superficial ulcer or erosion in the grey substance of the convolutions.


Fig. 259.—Scrofulous tubercles between the thickened and inflamed dura mater and arachnoid, and adhering to both by an abundance of strong, vascular cellular tissue. This, together with the arachnoid and pia mater, has been peeled off from all the tubercles, except the one, *d*. The others, *a*, *c*, &c., are invested by a very delicate proper capsule. The mass *b* is softened in the centre, and yields a thick, curdy pus; the other masses are almost as firm as gristle, but more friable, and are of homogeneous appearance. The membranes and cellular tissue around the mass *b* were soft, and of dirty-brown, and the brain contiguous to it was softened and yellow. There were a few other similar tumours.


Fig. 260.—Adhesion of the dura mater *a* to the arachnoid by cellular filaments *b*, around the tubercles in *Fig. 259*, over an extent nearly equal to the parietal bone. Also, spotted inflammatory redness of the dura mater.


Case.—A middle-aged female, in the St. Marylebone Infirmary, subject to chronic headaches, with occasional acute inflammatory attacks, by one of which she was carried off.




















HARVARD UNIVERSITY
Library of the Medical School



THE WARREN LIBRARY

Dr. John Warren
1753-1815

Dr. John Collins Warren
1778-1856

Dr. Jonathan Mason Warren
1811-1867

Dr. John Collins Warren
1842-1927

Dr. John Warren
1874-1928

COUNTWAY LIBRARY OF MEDICINE

RB
33
H77

RARE BOOKS DEPARTMENT

1. Mu. 1834.7

